



THE LIBRARY
OF
THE UNIVERSITY
OF CALIFORNIA
LOS ANGELES

GIFT OF

Robert Huebert

To U. C. L. A. Library
From Robert Huebner



Digitized by the Internet Archive
in 2007 with funding from
Microsoft Corporation

DISEASES OF THE THYROID GLAND

DISEASES OF THE THYROID GLAND

BY

ARTHUR E. HERTZLER, M.D., F.A.C.S.

PROFESSOR OF SURGERY IN THE UNIVERSITY OF KANSAS SCHOOL OF MEDICINE;
SURGEON TO THE HALSTEAD HOSPITAL, HALSTEAD, KANSAS; SURGEON
TO ST. LUKES HOSPITAL AND ST. MARYS HOSPITAL, KANSAS
CITY, MO., AND TO PROVIDENT HOSPITAL,
KANSAS CITY, KANSAS.

WITH A CHAPTER ON

HOSPITAL MANAGEMENT OF GOITER PATIENTS

BY VICTOR E. CHESKY, A.B., M.D.
ASSOCIATE SURGEON TO HALSTEAD HOSPITAL.

ONE HUNDRED SIX ORIGINAL ILLUSTRATIONS

ST. LOUIS
C. V. MOSBY COMPANY

1922

COPYRIGHT, 1922, BY THE C. V. MOSBY COMPANY

(All rights reserved)

(Printed in U. S. A.)

*Press of
The C. V. Mosby Company
St. Louis*

WK

200

H447d

1922

PREFACE

It is a new departure for the small country hospital to present to the profession the result of studies of any particular disease. The disadvantages detached workers labor under are many, but the advantages also are worth noting. The isolation makes the investigators more free to follow their own ideas uninfluenced by the opinion of associates. The small country hospital drawing its patrons from the immediate community is better able to study the end results. It is only by frequent examination of the patient that one can obtain an accurate idea of the subsequent course in disease of the thyroid gland.

The material obtained at operations has been carefully studied and compared with the clinical history. Each time information has been obtained as to the subsequent course of the disease the specimen and slide have been re-examined and compared with the sum total of information available to date. This study has brought convincing evidence that the activity of the interstitial cells is associated with a definite clinical type of thyroid intoxication. It is the desire to bring this evidence before the profession that has prompted the publication of this monograph at this time.

The presentation of statistics has been designedly avoided. The study of our cases has brought evidence that statistics as now published are of little value. They present the disease in an entirely too optimistic light and the permanent value of any treatment is entirely overestimated. Statistics can be of value only when the entire subsequent life span of the individual is taken into account. This obviously is not within the range of any individual observer but falls within the province of an institution and particularly within the province of the small community hospital which serves a relatively stable population. It is to be hoped that the pursuit of this policy may in time present a true picture of the life history of the disease. It is to be

hoped other institutions may engage in the collection of similar data.

I am fortunate to be able to present a series of drawings made by Tom Jones illustrating the topographic anatomy and the operative technic of the operations on the thyroid gland as done in this hospital. The preliminary sketches were made beside the operating table and present the various steps with more than the average degree of accuracy.

A. E. H.

Halstead, Kansas.

CONTENTS

CHAPTER I

	PAGE
ETIOLOGY AND PATHOGENESIS OF GOITER	17
Age, 17; Sex, 18; Heredity, 20; Endemiology, 21; Infection, 22; Previous and Associated Diseases, 23; Neurogenic Theories, 23; Thyrogenic Theory, 25.	

CHAPTER II

NORMAL AND PATHOLOGIC ANATOMY OF THE THYROID GLAND	28
Normal Morphology, 28; Pathological Anatomy, 41; Colloid Goiter, 43; Adenomatous Goiter, 59; Interstitial Proliferative Goiters (Forme Fruste), 76; Pathology of Other Organs Associated with Goiter, 79; General Summary, 84.	

CHAPTER III

SYMPTOMATOLOGY OF DISEASES OF THE THYROID GLAND	85
Goiter, 85; Degree of Enlargement, 85; Consistency, 87; Sensitiveness, 88; Mobility, 88; Eye Symptoms, 88; Exophthalmia, 89; Imperfect Movement of the Upper Lid, 90; Graefe's Sign, 91; Lessening of Involuntary Winking, 91; Disturbance of Convergence, 92; Uncommon Eye Signs, 93; Pupil sign, 93; Field of Vision, 93; Tear Secretion, 93; Nystagmus, 93; Involvement of the Muscular System, 94; Tremor, 94; Muscular Fatigue, 94; The Heart in Thyroid Disease, 95; Tachycardia, 96; Blood Pressure, 97; Heart Sounds, 99; Goiter Heart, 99; Thyrotoxic Heart, 100; Mechanical Goiter Heart, 100; Digestive Disturbance, 102; The Appetite, 102; Diarrhea, 102; Vomiting, 102; Constipation, 103; Icterus, 103; Intestinal Hemorrhages, 104; Changes in the Skin, 104; Blood Changes, 105; Anemia, 105; Leucocytosis, 106; Changes in Coagulation Time, 108; The Goetsch Test, 108; The Adrenalin Test, 109; Basal Metabolism, 110.	

CHAPTER IV

DIAGNOSIS OF THYROID DISEASE	112
Colloid Goiter, 112; Adolescent Goiter, 112; Simple Colloid Goiters, 113; Secondary Toxicity, 114; Malignant Degeneration, 114; Affections of Other Organs, 115; Toxic Goiter, 116; Secondary Toxic Goiter, 117; Atypical Forms, 119; Hyperacute Forms, 119; Forme Fruste, 120.	

CHAPTER V

PROGNOSIS IN DISEASE OF THE THYROID	125
Malignancy, 131; Mortality after Operation, 131.	

CHAPTER VI

	PAGE
GOITERS IN UNUSUAL PLACES	133
Abnormal Expansion of the Normally Situated Thyroid Gland, 133; Substernal and Intrathoracic Goiter, 138; Aberrant Goiters, 149.	

CHAPTER VII

HOSPITAL MANAGEMENT OF GOITER PATIENTS. BY DR. VICTOR E. CHESKY	156
Preoperative Treatment, 156; Nontoxic Goiter, 156; Toxic Goiters, 156; Postoperative Treatment, 161; Postoperative Complications, 166; Collapse of the Trachea, 165; Hemorrhage, 167; Hoarseness, Loss of Voice, Paralysis of Vocal Cords, 168; Shock, 169; Acidosis, 169; Infection, 170; Disfiguring Scars, 171; Bronchitis and Pneumonia, 172; Tetany, 172; Myxedema, 173; Instructions at Dismissal, 174.	

CHAPTER VIII

TREATMENT OF DISEASES OF THE THYROID GLAND	175
Adolescent Goiter, 176; Colloid Goiter in the Adult, 179; Primary Toxic Goiter, 181; Secondary Toxic Goiter, 181; Forme Fruste (Interstitial), 183.	

CHAPTER IX

TOPOGRAPHIC ANATOMY OF THE THYROID GLAND	185
The Overlying Soft Parts, 185; The Skin Covering, 185; The Platysma Myoides, 186; The Superficial Veins, 186; The Muscles of the Neck, 188; The False Capsule, 190; The Nerve Supply of the Skin and Muscles, 190; The Nerve Supply of the Thyroid Gland, 193; The Sympathetic Nerves, 193; The Superior Laryngeal Nerves, 193; The Recurrent Laryngeal Nerves, 193; Topography of the Gland, 194; The Blood Supply of the Thyroid Gland, 194; The Arteries of the Thyroid Gland, 196; The Superior Thyroid Arteries, 196; The Artery to the Suspensory Ligament, 196; The Inferior Thyroid Arteries, 198; The Thyroidea Ima Artery, 198; Disturbance of the Site of the Vessels by Thyroid Hypertrophy, 200.	

CHAPTER X

TECHNIC OF OPERATIONS ON THE THYROID GLAND	205
The Anesthetic, 206; The Skin Incision, 214; Incision of the Platysma, 214; Incision of the Deep Muscles of the Neck, 215; Isolation of the Superior Pole, 217; Separation of the Lateral Border and Ligation of the Lateral Vessels, 220; Dislocation of the Lower Pole, 221; Dislocation of the Lobe, 224; Excision of the Lobe, 224; Disposal of the Pole Stumps, 229; Management of the Second Lobe, 229; Closure of the Wound, 230; Sutures Used, 233; Drainage, 236; Pole Ligation, 236.	

ILLUSTRATIONS

FIG.	PAGE
1. Slide of a normal thyroid gland showing the thin fibrous tissue capsule	29
2. High power of the preceding slide showing the large nucleated cells lying between the fiber bundles which compose the capsule	29
3. Slide of a normal thyroid gland from which the superficial layer of the fibrous capsule has been teased off to show its endothelial-like character	30
4. Slide of a normal thyroid gland showing the septa which separate the gland into secondary lobules	30
5. Slide showing the sustentacular tissue between the acini teased apart. The thin planes of tissue with small spindleform cells are shown	31
6. Cross section of a superior thyroid artery just below the surface of the gland, showing the thick walls	31
7. Injected gland showing the network of capillaries in the interacinal spaces	32
8. Slide showing a superficial vein of a normal thyroid gland	33
9. Slide from a normal thyroid gland showing the variation in size and form of the acini	35
10. High power of the preceding showing the form and relation of the acinal cells	36
11. Slide from an old colloid goiter showing the thin interacinal septae and the low endothelial-like acinal cells	37
12. Slide of a thyroid gland taken from a boy aged four, showing interstitial cells and their relation to the acinal cells	38
13. Slide from a slightly toxic goiter (forme fruste) showing the acinal cells inactive while the interstitial cells are active	39
14. Slide obtained from a boy aged four years made from tissue removed during an operation for intratracheal growth	40
15. Section of a small recent colloid goiter showing the uniform granular surface	44
16. A colloid goiter of medium size showing the translucent masses of colloid and the mildly bosselated surface showing the position of the chief colloid masses	44
17. Section of a large colloid goiter of long duration showing degeneration with secondary hemorrhages	45
18. Section of a colloid goiter of 45 years' duration which has undergone extensive fibrous degeneration	46
19. Section of a large colloid goiter showing uniform enlargement of the thyroid lobe with the retention of the original lobulations	46
20. Section of an old colloid goiter showing the unequal development of the lobules	47
21. Slide of an early colloid goiter showing the uniform increase of the colloid without changes of the acinal epithelium or retraction or vacuolization of the colloid	48

FIG.	PAGE
22. Slide showing the flat, inactive cells of a quiescent colloid goiter	49
23. Slide from a clinically inactive goiter	50
24. Slide of a supposedly inactive goiter	51
25. Section of an old colloid goiter	52
26. Sections of cysts of the thyroid showing an old clot indicating an ancient process, and a recent hemorrhage	53
27. Section of a thyroid showing many degeneration cysts which collapsed during the operation, and the more recent lobe showing beginning colloid degeneration	54
28. Slide of a goiter which has undergone fibrous degeneration	55
29. Section of a large goiter of long duration showing extensive calcareous degeneration	56
30. Slide of an old goiter showing activity of the interstitial cells with fibrosis and secondary hyaline degeneration	57
31. Slide of an "innocent" goiter of forty-five years' duration	57
32. Slide of an adenomatous goiter which caused extensive bone metastasis	58
33. Photograph of a fetal adenoma showing its smooth ovoid contour and the uniform fine granular character of the cut surface	60
34. Section of an old fetal adenoma which has undergone complete degeneration with secondary hemorrhage and cyst formation	60
35. Slide of a fetal adenoma showing the small acini with little colloid	61
36. Slide of a toxic fetal adenoma showing the presence of colloid in many of the acini	62
37. Section of a large colloid goiter enclosing within itself a small fetal adenoma	62
38. Slide of the preceding showing the structure of the fetal adenomatous nodule, and that of the colloid part	63
39. Section of a recent acutely toxic adenomatous goiter showing fine granular appearance	63
40. Section of an adenomatous goiter of a year's duration	64
41. Slide showing a typical picture of toxic goiter without eye signs	65
42. Slide of a toxic nonexophthalmic goiter showing the development of secondary acini	66
43. Slide from a goiter of extreme toxicity	67
44. Slide from a typical exophthalmic goiter	67
45. Slide from a goiter in which the eye signs developed after the appearance of the toxicity	68
46. High power photograph of the acinal cells of an exophthalmic goiter	69
47. Slide showing extensive secondary degeneration in a primary toxic adenomatous goiter	69
48. Slide showing the exfoliation of the acinal cells in an acutely fatal case of toxic goiter	70
49. Slide showing degeneration of the acinal cells and the colloid in a secondary toxic goiter	72
50. Slide showing separation of the acinal cells from the connective tissue in a secondary toxic goiter	73
51. Slide from a secondary toxic goiter showing the acinal cells in the midst of the colloid substance	73

FIG.	PAGE
52. Slide from a secondary toxic goiter showing the rejuvenescence of the acinal cells	74
53. Slide from a secondary toxic goiter showing papillary formation	75
54. Slide from a forme fruste goiter showing activity in the interstitial cells with little change in the acinal cells or in the colloid	76
55. Slide from a forme fruste showing marked increase in the interstitial cells with degeneration of the colloid substance	77
56. Slide from a forme fruste showing extensive proliferation of the interstitial cells with little evidence of colloid substance	77
57. Slide from a forme fruste showing extensive proliferation of the interstitial cells, and round-cell infiltration	78
58. Section of two cases of forme fruste showing the fine granular surface	78
59. Showing the trachea as being compressed between the lobes of the goiter producing the so-called sword sheath trachea	134
60. Diagram showing the manner in which a lobe may grow between the trachea and esophagus, compressing both these tubes	134
61. Photograph of a specimen in which the rounded lobe on the right lay between the trachea and the esophagus producing dyspnea and dysphasia	135
62. X-ray picture showing the trachea pushed far to the left by a medial lying substernal goiter	136
63. X-ray of a goiter in which the calcareous plaque caused misjudgment as to the location of the trachea	137
64. Diagram showing the difference between a substernal and an intrathoracic goiter	139
65. Photograph of a patient who had a typical exophthalmic goiter with no apparent thyroid enlargement	141
66. Intrathoracic goiter in a patient with dysphagia and cough	146
67. Diagram showing the possibilities in aberrant goiters	149
68. An aberrant goiter near the angle of the jaw	152
69. Intratracheal goiter	154
70. Musculature of the neck	187
71. The relation of the anterior and the external jugular veins	189
72. Musculature of the neck	191
73. The nerve supply of the neck	192
74. The general topographic relations of the thyroid gland	195
75. The arterial supply of the thyroid gland	197
76. The arteries of the thyroid gland and the recurrent laryngeal nerve	199
77. Aberrant locations of the thyroid arteries	201
78. Veins of the thyroid gland	203
79. Typical sites for ligation of the thyroid vessels	204
80. The preliminary needle prick	210
81. The line of primary infiltration	211
82. Intramuscular infiltration	212
83. Periglandular infiltration	213
84. The preliminary incision	215
85. Exposure of the anterior jugular veins	216
86. Ligation of the anterior jugular veins	217
87. Incision of the short muscles covering the gland	218
88. Ligation of the vessels to the isthmus	219

FIG.	PAGE
89. Separation of the superior pole from the trachea	220
90. Ligation of the upper pole	221
91. Ligation of the lateral veins	222
92. Ligation of the inferior thyroid artery and veins	223
93. Topography of the lateral veins	223
94. Wrong method of managing the lateral veins	225
95. Diagram showing the appearance after the resection of both lobes	226
96. Resection of the gland	226
97. Completed resection of the right lobe	227
98. The folding downwards of the upper pole	228
99. The folding of the poles completed; resection of the remaining lobe	230
100. Wedge resection of the opposite lobe	231
101. The resection completed	232
102. The closure of the capsule	232
103. The restoration of the sternohyoid muscles	233
104. The coaptation of the platysma muscle	234
105. The coaptation of the subcutaneous fat	234
106. The closure of the skin	235

DISEASES OF THE THYROID GLAND

DISEASES OF THE THYROID GLAND

CHAPTER I

ETIOLOGY AND PATHOGENESIS OF GOITER

As is true of many chronic diseases, we do not know the cause of goiter and we can but detail some of the conditions and circumstances under which it arises. The knowledge we possess relative to the causation is a matter of general interest only. It is quite useless in the practical consideration of a concrete case. There is an obvious difference between the onset and most likely the causes of the various kinds of goiters. The simple colloid and the frankly exophthalmic type bear little resemblance to each other at the outset. There are so many transitional types, however, that it seems best to consider all types together. By this means it is possible to emphasize the very obvious fact that there are no "innocent" goiters. This may not apply to all regions and countries but it surely does to Kansas.

Age

Congenital goiters have been reported, but they are rare and are often associated with other developmental anomalies. I have seen one in a baby of three days, otherwise normal. Occasionally patients of a very early age are met. I have seen a simple goiter in a girl of two and a half years, and typical exophthalmic goiter in a girl of eight years, and many about the age of puberty.

The adolescent colloid goiter occurs usually between the tenth and twentieth year. It is only in regions where the endemic goiters are rare that the age onset can be accurately observed. The endemic goiters usually appear in early life because the patients are born in the goitrous regions. The adolescent type often disappears after full maturity, possibly to recur during the child-bearing years.

The true degenerative toxic goiter usually appears in middle or later life. The common age of the primary toxic type, according to Sattler, is between twenty and forty years with more than half coming between twenty and thirty (55.7 per cent). The most violently toxic forms predominate in the fourth decade. The secondary toxic type is most common after thirty. The true degenerative type is seen most often after the fiftieth year. The sudden appearance of the secondary type after the sixtieth year is distressingly common though numerically the more cases occur between forty and sixty. The forme fruste is commonly seen in early life though it may appear at any age. Stern found 45.1 per cent between ten and twenty, and 29.4 per cent between forty and sixty, and but 9.8 per cent between twenty and forty. Usually the time of onset is hard to determine, for they give a history of a long enduring nervousness and are unconscious of the existence of a goiter.

Goiters producing pressure symptoms and the malignant degenerations occur in the latter part of life. However, I have seen bone metastases in a patient twenty-three years of age.

Sex

Women are much more prone to be affected by goiter. The proportion is variously given as from 1:6 to 1:10. The disproportion is less in the more severe forms than in the milder types. The reason goiters are more common in women than in men was formerly based on the knowledge that there was a close association between the genital function and the thyroid gland. This association is indicated in the slight enlargement often seen during menstruation, and still more during pregnancy. The adolescent goiters of girls are so closely associated with the advent of the menses that a relationship has been assumed. The observation has been made that the reason women are more often affected by goiter is that they are females, that is to say, that in the complex adjustment of their horizon to the horizon of the world in general certain irritative products are produced which stimulate the thyroid gland to development. Such speculations do not account for the well-known geographic distribution of goiter. At any rate in this time of intensive ductless gland study, it is well to remember that the ovary is not the

sole possible factor in the preponderance of goiter in women. The whole physiologic metabolism is upset periodically at the menstrual periods and during pregnancy and its significance we cannot now estimate.

Genital disturbances of a more indistinct physiologic nature are sometimes operative, possibly more often than we know. This disturbance may be due to a conscious or unconscious lack of proper functional exercise or to overindulgence or sometimes to an improper exercise of that function. We need not be dependent upon the patient's viewpoint alone. When we suspect that one of these factors is influencing the condition, improvement may follow its correction. Not infrequently a toxic goiter improves by marriage and childbirth. Conversely toxic goiter may arise during pregnancy or be made worse by it. (Barrett: *Am. Jour. Obst.*, 1914, lxx, 637.) Correction of surgical conditions of the pelvic organs often are followed by improvement in the goiter. (Hertzler: *Jour. Am. Med. Assn.*, 1911, lvii, 2076.) Cases have been reported by Himmelhaber (*Zentralbl. f. Gynäk.*, 1909, xxxiii, 1225), Leuf (*Am. Med.*, 1907, n. s. ii, 222), Wells (*Med. News*, 1903, lxxxiv, 1209), and others in which simple goiters have become toxic following simple operations on the pelvic organs. I have experienced two such calamities. It is interesting to note that the relation between the genital organs and the thyroid must be due to disturbance of factors other than inflammatory. Acute infections of the genitalia are not followed by thyroid dysfunction. Conversely, it is rare to find a thyroid patient who has pus tubes. In the ordinary toxic goiters the ovaries as ductless glands seem to play a relatively slight part. In the forme fruste, however, the ovaries seem to be more closely associated. There is usually a pronounced dysmenorrhea. Frequently the ovaries are very small, wrinkled and contain but few follicles. These findings are common whether the patient is near the beginning or the end of the menstrual epoch. The symptomatology of the forme fruste is very like the complaints of oophorectomized women.

Much is yet to be learned as to the relation of the sexual function to goiter, but the interrelation should not be allowed to rest by the mere statement of fact. The relation should be sought for in each case. No examination of a goiter patient

should be regarded as complete without an examination of the generative organs. It is the surgeon who has the best opportunity to develop our knowledge along this line. Now that roentgenologists have learned to castrate women with radium, we have a new material in which we may study the loss of ovarian function on the nervous system and the thyroid gland. It may also be noted that in severely toxic cases amenorrhœa is by no means uncommon.

Some of these cases are still further complicated by obvious signs of pituitary disturbances. Such combinations have given license to the expression "polyglandular disease" which term has become the synonym of all that is weird in speculative pathology or, perhaps better stated, pathologic speculation.

Why goiters long inactive become toxic is not known. These often give a history of long existent simple goiter which show no evidence of toxicity. Sooner or later they present the usual symptoms of thyroid intoxication, most often without eye signs. Very commonly pelvic disease of a character requiring the service of a surgeon is found. In fact it is uncommon to find such cases without some pelvic lesion. Not uncommonly this type shows toxic symptoms at the genital involution period. This may be regarded as indicating gonoidal deficiency. On the other hand, often the signs of toxicity do not appear until long after the menopause. This makes it doubtful whether the genital lesions so often found play any etiologic rôle. If they do not, then we are forced to confess that we have no clew as to why the goiter begins to cause trouble. Commonly the symptoms of intoxication develop slowly but sometimes the onset is sudden.

Heredity

The familial occurrence of goiter is a common observation. Whether this is due to heredity of environment or a biological heredity is another question. It is common to see a number of members of a family affected. I have had the grandmother, the mother, and three daughters consult me at the same time. They came from a goitrous region. Most likely heredity plays a prominent part. I have noted numerous instances where three or more daughters became goitrous long years after each had left the parental roof. Not infrequently there is a family type

in that all members affected become so at the same age. Some families do so at an early age, say below fifteen, others, again, at a late age, say after thirty. The determination of the question of heredity is important. If the mother had a goiter and it disappeared, there is better prospect that the daughters' also will disappear, than if the mother got hers at twenty and has it still at fifty.

In the forme fruste type there is very obvious the neurotic substratum which characterizes the type. In fact frequently some members will have the nervous manifestations without any symptoms that can be ascribed to a thyroid disturbance. These usually suffer from ovarian dysfunction.

The typical exophthalmic goiters seldom give a history of numerous cases in the same family or any family characteristics that would indicate a familial predisposition, either organic or functional.

Endemiology

It has been known that there are regions in which goiter is very common and others where it occurs but seldom. Limestone and lime-bearing rocks are most frequently associated with endemic goiters. The active influences were for a long time ascribed to geological or chemical causes. Bircher (*Ergebnisse der Chirurgie und Orthopädie*, Sprunger, Berlin, v, 133) believed the remains of extinct flora and fauna provided the noxious material. These regions where goiters are most commonly found were noted to be mountainous while in the low lying regions it was less frequently observed. This does not apply to the valley of the Arkansas river where goiter is quite common. This river contains no rock and but little water. If this stream is culpable it must be due to sand and sunflowers. It was observed that when a pure or at least a different water supply was produced in goiterous regions the frequency markedly decreased. Bircher (*loc. cit.*) notes one town in which in 1885, 59 per cent of the inhabitants had goiters. The water supply was then obtained from another source and in 1907 there were but 2½ per cent goitrous. It has not been satisfactorily established whether the suspected water contains a deleterious substance or lacks something essential for the proper functioning of the thyroid. Kim-

ball and Marine (*Arch. Int. Med.*, 1918, xxii, 41) have shown that a small amount of iodine will prevent the development of goiter in children. Kocher observed that those who drank rain water, though living in goiterous regions, did not develop goiter. Similar observations might be many times multiplied from the Swiss literature.

The department of agriculture has determined that in certain regions myxedematous pigs are born. When food from a nongoitrous region is fed to sows in regions where they previously had farrowed myxedematous pigs normal pigs are born. This indicates clearly that the disturbance of the thyroid is due to some lack in the food. If iodine is fed to the pregnant sows, normal pigs are born. It seems, therefore, that Marine has done the same service for the human race that governmental machinery has done for pigs.

Infection

Numerous investigators, notably McGarrison (*The Thyroid Gland and Its Diseases*, Wm. Wood & Co., 1917, p. 91) have ascribed the influence to infectious organisms, probably bacterial. He sums up the argument in favor of the infection theory; (1) Goiter decreases in prevalence as the water supply increases in purity. (2) Goiter has been produced by injection of residue in a Berkefeld filter through which goitrogenous water has been passed. (3) Exhibition of intestinal antiseptics causes disappearance of recent goiters, etc. Adami (*Montreal Med. Jour.*, 1900, xxix, 1) had previously pointed out that if an infection is active, it must be of a peculiar sort because it comes on at a particular age and if the patient removes from the region before permanent changes occur, the goiter disappears. Therefore, the infection would remain operative only so long as the patient remained in the goitrous region.

The infectious theory led naturally to the search for foci and the teeth and tonsils were diligently searched. One of my former assistants (Dillingham) followed out this theory with wholly negative results. More recently influenza has been blamed by several writers and a number have been observed in this clinic who dated their trouble from the flu, but there was no evidence obtainable which would warrant such an assump-

tion. Rheumatism and tuberculous infections have been reported as preceding the origin of the goiter. After reviewing the literature designed to establish the infectious character of goiter, one can readily subscribe to the statement of Professor Dock that "Whether sporadic, epidemic or endemic, the cause of goiter is unknown."

Previous and Associated Diseases

Obviously the relation of a chronic disease of one organ to an acute affection of another organ is difficult to determine. Many authors have noted the appearance of goiter soon after the patient recovered from an acute disease. Almost all the acute diseases have been mentioned. The tonsils, of course, were at one time vociferously proclaimed to be the archenemy of the thyroid. Be this as it may, the removal of the tonsils does not appease the angered thyroid. Shurlenge, however, believes that he has seen improvement in goitrous patients following the removal of tonsils. Syphilis, of course, has been blamed. Engel-Reimers (*Zentralbl. f. Chir.*, 1895) has observed a swelling of the thyroid in 50 per cent of cases in secondary syphilis. Tuberculosis also has been blamed. In diseases so common as goiter and tuberculosis a simultaneous occurrence in some instances must be expected. It has been assumed that the toxin of tuberculosis acts directly on the thyroid gland. In this region where tuberculosis is rare it is very exceptional for the diseases to coexist. I have not seen such a case. One should not be too hasty in assuming a relationship. Moreover, the differentiation between the fruste type and tuberculosis is the most difficult problem the student of goiter encounters, and often a diagnosis is not possible.

Neurogenic Theories

In toxic goiters only need the nervous system be seriously considered as an etiological factor. Because of the symptom-complex, exophthalmos, tachycardia and goiter, the sympathetic system was early considered to be at fault. The lesion responsible could not be decided on. The exophthalmos and tachycardia appeared to be due to a stimulation while the dilated

vessels of the thyroid could be explained only by accepting a paralysis of this nerve. Trousseau met this difficulty by assuming a neurosis in which he believed the nerve could act in part as an excited and in part as a paralyzed one. The vagus, likewise, was accused. The lesion hypothesized was a pressure from the goiter (Gros) or enlarged lymph glands (de Mussy). Others hypothesized a lesion in the medulla. Many attempts were made to prove this theory experimentally. Other centers were experimented with but no investigator has succeeded in producing a lesion that in any way imitated a toxic goiter. That the nervous system plays an important part cannot well be denied, however. In the typical exophthalmic goiter there is in isolated cases a definite history of nervous trauma. In these the patients relate definitely that their disease began following a severe nervous shock. I recall one patient whose disease followed a fall from a sidewalk on a dark night, another followed the receipt of news of the unexpected death of her mother; one developed after being struck lightly on the hand by a wrench which fell from the top of an oil tower. Mackenzie related a case which developed following the meeting of a drunken man. A generation from now this will sound more plausible. Chvostek presses our credulity when he ascribes one case to the discovery of an anal fissure. The literature is replete with similar instances.

Crile has pointed out that the general symptoms of toxic goiter and the phenomena of fright are so similar that they may be regarded as almost parallel. Why in some instances the phenomena of fright continue into the symptoms of the disease has not been explained. Saying that metabolism or catabolism of the nerve cells is increased by the stimulus of the excitement which produces a toxic substance which breaks down the nerve cells, thus producing a vicious circle, sounds plausible but no proof can be offered to substantiate it. The cases in which such a definite relationship to nervous shock can be traced are relatively few however. The onset is as often insidious, frequently under the guise of intestinal or even febrile diseases. In such evidently the perverted toxic secretion antedates the disturbance in the nervous system. These cases which develop after gynecological operations may be explained

either as a nervous trauma or a disturbance of the genital functions or both.

We are yet too far from the truth to be able to define the physiologic relationship of psychic trauma and toxic goiter. Many patients have a susceptible nervous system, but many do not give any such history. The defenders of the neurogenic theory contend that these patients remain nervous during the remainder of their lives. There is much truth in this, but it is equally true that many fully recover.

Thyrogenic Theory

It is easy to appreciate the arguments in favor of the thyrogenic nature of the disease. Changes in structure of the thyroid gland are found in all cases of toxic goiter; by the removal of a part of the gland the disease is favorably influenced and by these means only. These statements may be elaborated without adding strength to the argument. A. Kocher (*Arch. f. klin. Chir.*, 1911, xev, 1007) believes that the varying course of each disease is expressed in corresponding changes in the histology. This is true in a very broad way. However, the severity of the disease is by no means parallel with the degree of anatomic change. As a matter of fact in some of the severest cases the gland is but little enlarged and the histologic changes, while definite, are relatively restricted. In many the removal of goiter tissue is not followed by a subsidence of the symptoms. The blood changes noted by Kocher (*loc. cit.*) are not always present and by no means always parallel with the severity of the disease. Furthermore, in the degenerative type there is a destruction of thyroid tissue without in many instances any proliferation at all. These, it is true, may be excluded from true thyrotoxic cases, but they show clearly enough that the problem is something besides over-production of thyroid secretion.

The argument that like changes in structure may occur without any toxic symptoms has often been advanced. It is true that in many long standing goiters one finds areas of epithelial proliferation. Usually in such cases if the clinical history, the blood picture, and also perhaps, the metabolic rate, are carefully studied, the supposition that there was no evidence

of thyrotoxication will be unsupported. The more careful the study, the less common are the disharmonious observations. The *forme fruste*, it must be admitted, often shows but little change in the gland structure. It is a question, however, just what relation this type bears to the typical thyrotoxic goiter. One may mistake a neurosis for a *forme fruste*.

Likewise the argument that cases of thyrotoxicosis are observed without any specific changes in the colloid falls when the gland is carefully searched. In the large secondary goiters considerable search may be necessary before one finds such areas. It cannot be too much emphasized that a thyrotoxicosis without changes in the thyroid gland has never been demonstrated. The thyroid gland changes are the one constant, demonstrable factor.

It must be remembered, too, that in other parenchymatous organs there is also a variation in structure as compared to function. In nephritis one sometimes finds marked disturbance of function with comparatively little structural changes to account for them, and, conversely, one may find extensive anatomic changes with a relatively normal urine. Yet who argues on these grounds against the "nephrogenic" origin of nephritis?

We may gain from this that the physiologic and the anatomic so far as our crude means of study admit of, do not always run parallel. Or in other words, our anatomic knowledge does not enable us in all cases to gap the physiologic. Then, too, the state of the other organs may in a measure compensate or aggravate the local function. The adrenals, as well as the thymus and pancreas, have been assumed to act as intermediaries in magnifying the action of nerve trauma. The action of the adrenals particularly have been invoked to explain the action of fright.

On the other hand, the evidence in favor of extraneous influences active on the thyroid is largely of a circumstantial nature. These are all more or less subject to the errors incident to the personal equation of the observer. The most commonly advanced antagonistic argument against the thyrogenic nature of toxic goiter is the relation of nervous shock to the origin of the disease. As before stated instances are not uncommon in which the disease began a short time after pronounced nervous shock. These cases are so numerous that it does not seem that

coincidence can be considered in the argument. If the nervous shock is the primary exciting factor how does it bring about the anatomic changes in the thyroid? It has been assumed that a vascular dilatation takes place which results in the parenchymatous proliferation. There is no evidence for this because there may be very marked proliferation without vascular dilatation. We may assume that some noxious agent is liberated by the nervous excitement. Possibly the adrenals perform this act. It has been stated that grief or fright may cause a mother to secrete poisonous milk for her suckling infant. We may assume some such interaction in order to explain the changes that take place in the thyroid during menstruation and pregnancy.

When all the factors are sifted, one does not get beyond the simple fact that the one constant factor in goiter is the enlargement of the thyroid gland. Surgeons should remember that the pathology of this organ does not explain all the phases of the disease, and while removal of a part of the diseased gland does most to remove the symptoms, it is fundamentally unscientific and the endeavor should be to discover the fundamental problem in its etiology.

CHAPTER II

NORMAL AND PATHOLOGIC ANATOMY OF THE THYROID GLAND

In an organ which is normally labile, the dividing line between the normal range of variability and the abnormal must be very close. It seems best, therefore, to consider both in the same chapter.

NORMAL MORPHOLOGY

Preliminary to an appreciation of the changes that occur in the diseased thyroid gland it is necessary to understand its normal structure. Embryologically we may remember that it is formed from a budding out of the areas which afterward become the pharynx. Valuable as this knowledge is in enabling us to understand the various aberrant lobules, it is of no aid in the understanding of its histology. It resembles no other structure in the body, and, for the most part, comparisons confuse rather than aid in the understanding of its formation. Like all organs containing cells which perform a specific function, it is made up of stroma and epithelial parenchyma. We must be prepared, however, to see the epithelial cells present a variety of changes not comparable to those seen in any other organ, because it has a function not comparable to any other.

The Capsule.—The gland has a thin capsule composed of white connective tissue (Fig. 1). The fibrils are flat and laminated. When teased apart, large ovoid cells are seen (Fig. 2). These on section appear spindle-form but when the cells are isolated they are seen to be flat with ovoid nuclei. The surface laminae are covered by a more or less complete layer of such cells (Fig. 3). This peritoneum-like structure accounts for the ease with which the gland glides about under the overlying structure on movement and deglutition and also for the facility with which it reacts to irritative changes of the gland parenchyma. It contains no elastic fibers but the connective tissue

takes on a glossy refraction like that of the peritoneum indicating an elasticity not possessed by ordinary connective tissue and permits it to expand to meet the changing requirements of the parenchyma.

From the capsule sustentacula extend into the interior dividing the gland into more or less distinct lobulations (Fig. 4). From these heavier septae fiber bundles extend, forming the

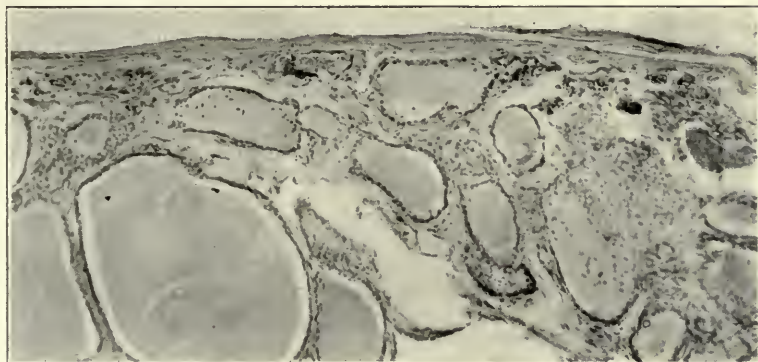


Fig. 1.—Slide of a normal thyroid gland showing the thin fibrous tissue capsule.

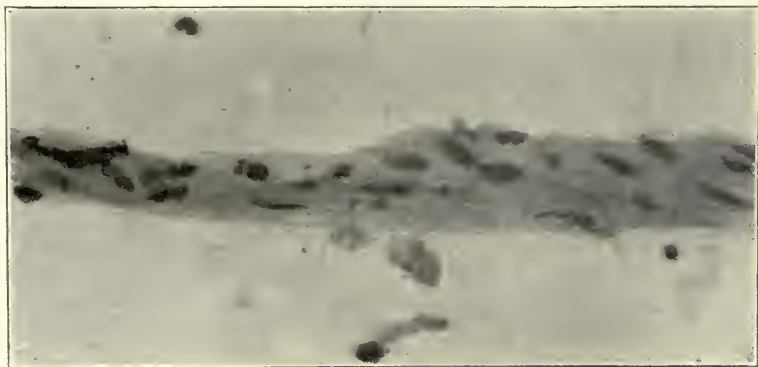


Fig. 2.—High power of the preceding slide showing the large nucleated cells lying between the fiber bundles which compose the capsule.

walls of individual acini. These terminal fasculi are very fine, being composed of thin bundles of reticular tissue (Flint: Bull. Johns Hopkins Hosp., 1903, xiv, 32) in which are a few spindle cells with long, narrow nuclei. In most places it forms a thin plane of tissue on which the cells rest (Fig. 5). This sustentacular tissue has much in common with the subendothelial conec-

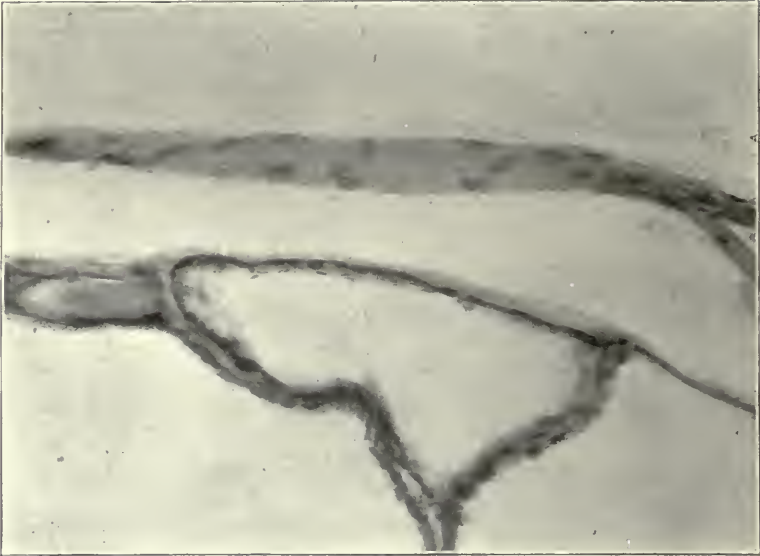


Fig. 3.—Slide of a normal thyroid gland from which the superficial layer of the fibrous capsule has been teased off to show its endothelial-like character.

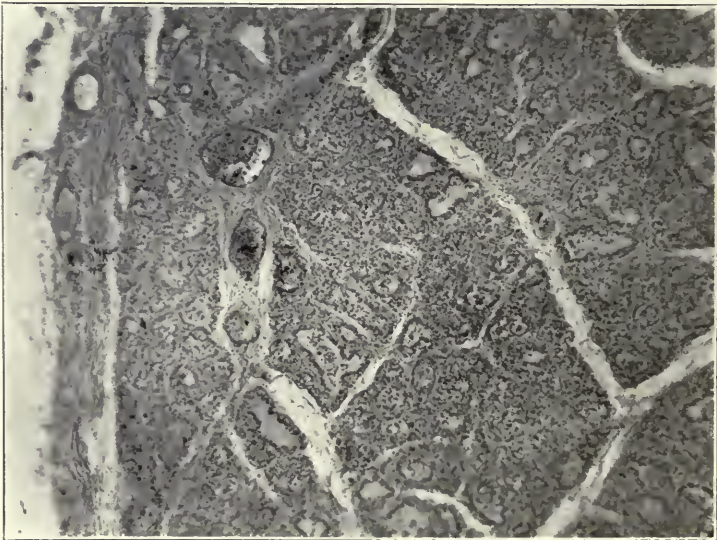


Fig. 4.—Slide of a normal thyroid gland showing the septa which separate the gland into secondary lobules. The specimen was obtained from a child.

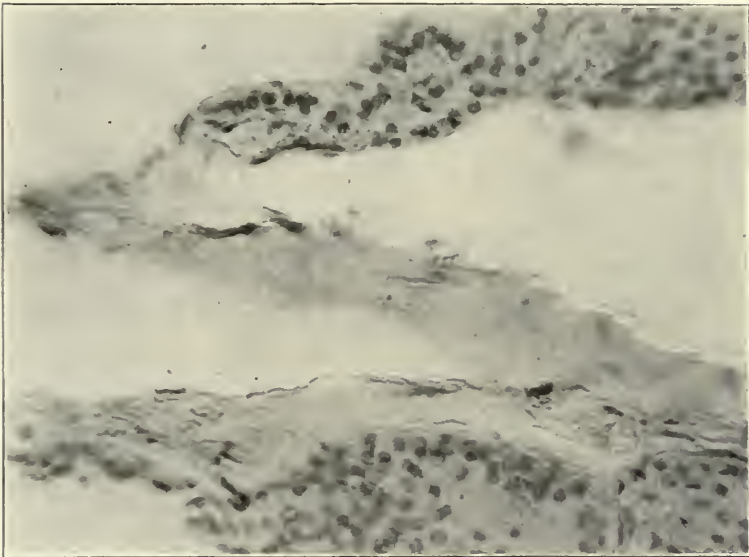


Fig. 5.—Slide showing the sustentacular tissue between the acini teased apart. The thin planes of tissue with small spindleform cells are shown.

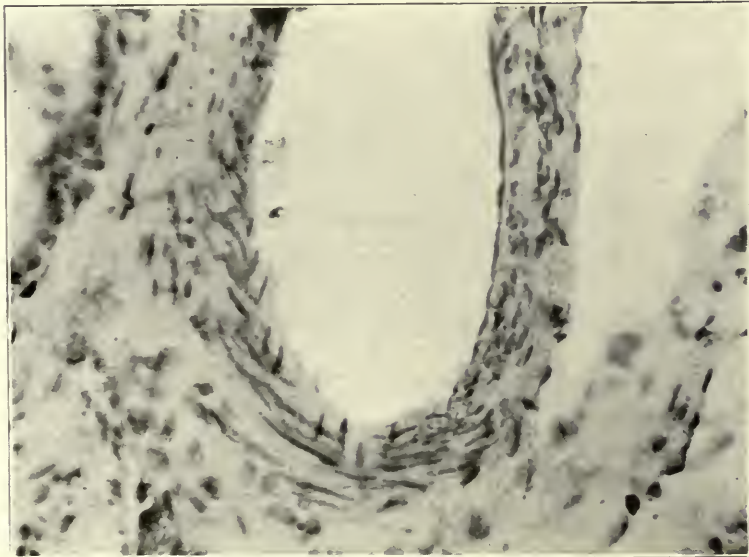


Fig. 6.—Cross section of a superior thyroid artery just below the surface of the gland, showing the thick walls.

tive tissue of the peritoneum. The upper lamellae are covered by cells containing large ovoid vesicular nuclei very similar to the endothelial cells of the peritoneum. They do not seem to differ from the capillary endothelium. In fact there is no sharp dividing line between them. Both may be composed of long sheets of protoplasm like the capillaries in the potential vessels of the peritoneum (compare Hertzler: *The Peritoneum*, i, Fig. 15, p. 75).

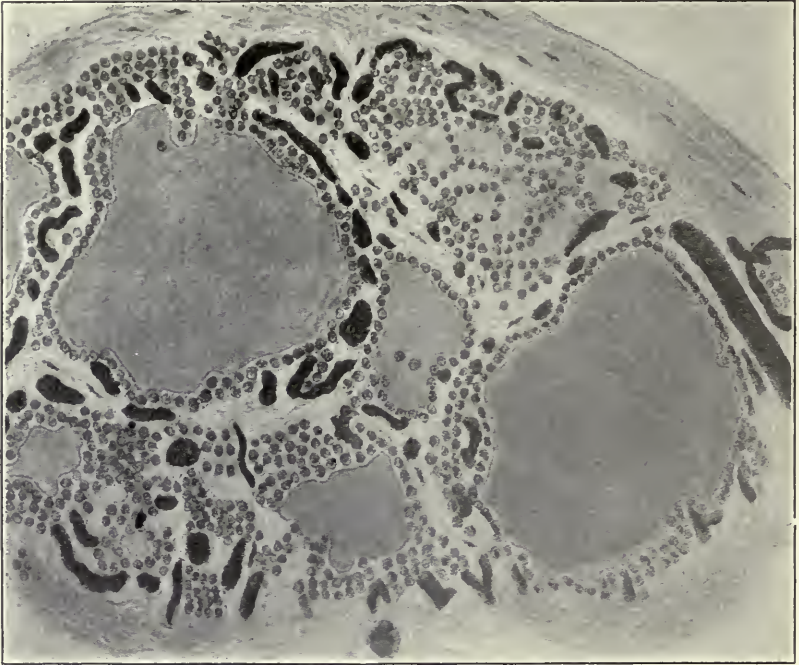


Fig. 7.—Injected gland showing the network of capillaries in the interfollicular spaces (Major).

Blood Vessels.—Because of the great vascularity of the thyroid gland the study of the circulation has received considerable attention both because of its theoretical and technical interest. The earliest important study was by Baber, (*Philoi. Trans. Roy. Soc.*, London, 1876 and 1881) and Hürthle (*Deutsch. med. Wehnschr.*, 1894, xx, 267). More recently Major has studied the subject (*Am. Jour. Anat.*, vol. ix, 475) and has also collected the literature.

The blood supply of the thyroid gland is derived from su-

perior and inferior thyroid arteries (to be described in the chapter on Anatomy). They form abundant anastomoses both between the upper and lower vessels of the same side and between those of the opposite side. Major doubts that there is anastomosis between the more deeply lying arteries. Experience at the operating table would convince one that they must do so. In the capsule the vessels have well formed walls (Fig. 6), but these rapidly lessen as the vessels reach the interior of the gland. As soon as the vessels reach the gland they branch, following the septae to the individual acini. Here they break up in a fine

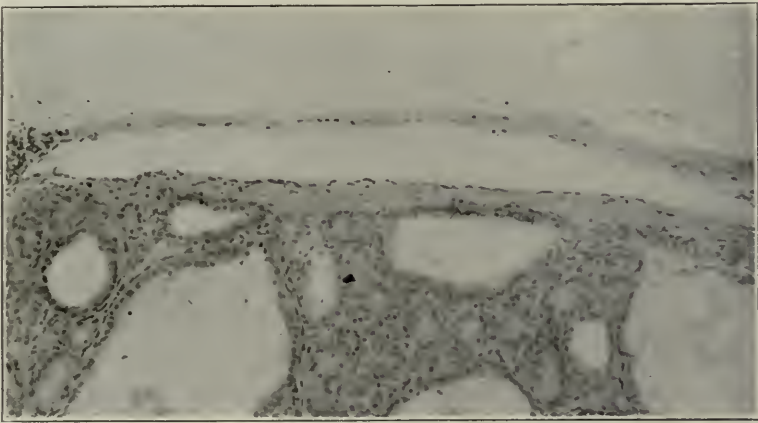


Fig. 8.—Slide showing a superficial vein of a normal thyroid gland. It appears as a broad, narrow slit just below the capsule.

capillary network which surrounds the acini (Fig. 7). The return blood is taken up here by a rich plexus of veins which follows the septae to the surface where they are collected by a complicated plexus of veins.

The veins are characterized by their delicate walls (Fig. 8). In rapidly developing goiters the vein wall may be reduced to a few fine lamellae while in old goiters the walls may be quite thick due to the proliferation of the fibrous tissue walls. The adventitia, even in larger ones, is very sparse. Their tendency to tear on manipulation in goiter operation is, however, due less to their delicate structure than to the reactive changes the walls undergo as a result of the thyroid changes. According to Major, about the acini the capillaries lie just outside the cells in the

connective tissue. The capillaries compared to the cells are very large.

Lymph Vessels.—The lymphatic circulation of the thyroid gland has not been satisfactorily worked out. According to Baber and Petijean (*Bibliographie Anat.*, xiv, 1905) the capillary network surrounds the acini filling the interstices between them. These collect into larger trunks in the capsule, from whence they reach the lymph glands of the lower cervical region, and in addition, according to Major, one trunk passes toward the submaxillary gland. It has been accepted that the colloid is absorbed by way of the lymphatics, but Hunt and Seidell (*Jour. Pharmacol. and Exper. Ther.*, 1910, xxvi, 32) deny the truth of this. It is true that in the interacinal connective tissue clefts may be seen filled with colloid, but there is no evidence to show that these clefts are connected with the lymphatic system. On the contrary the cells surrounding these colloid masses are indistinguishable from the cells lining the acini. I conclude, therefore, that the interstitial cells have the power of producing new acini and what has been mistaken for lymph spaces containing colloid is but gland formation in the early stages.

Nerves.—The nerve supply of the thyroid gland is derived from the sympathetic system and reaches the gland through its upper pole and lateral surface. The endings have been traced to the acinal cells.

Acini.—The acini have no basement membrane in a true sense. A basement membrane has been described by some histologists, notably Flint (*Bull. Johns Hopkins Hosp.*, 1903, xiv, 32) but unless a structureless plasma-like substance which cements the epithelial cells to the connective tissue stroma be called the basement membrane, none exists. The important point consists in that there is no structure which resists the invasion of the surrounding stroma by the acinal cells. In the absence of a basement membrane the thyroid acini resemble the uterine glands. This is the most important point in their histology, for it is dependent on this fact that the interacinal connective tissue becomes so readily infiltrated by gland cells or assumes the morphology of acinal cells.

The acini are variously shaped being more or less spherical or polyhedral (Fig. 9). They average in size from .3 to 1 mm.

Reconstruction sections according to Streiff (*Arch. f. Mik. Anat.*, *xlvi*, 579) show the acini may be irregularly shaped with various accessory pockets and intercommunicating openings with neighboring acini. The colloid contained in the acini is a homogeneous acidophilic substance which stains with eosin about the same shade as red blood cells. The similarity is most readily seen in specimens which contain blood clots. One sees then the blood clot and the acini side by side. The colloid in various parts of the gland or even in adjacent acini shows varia-

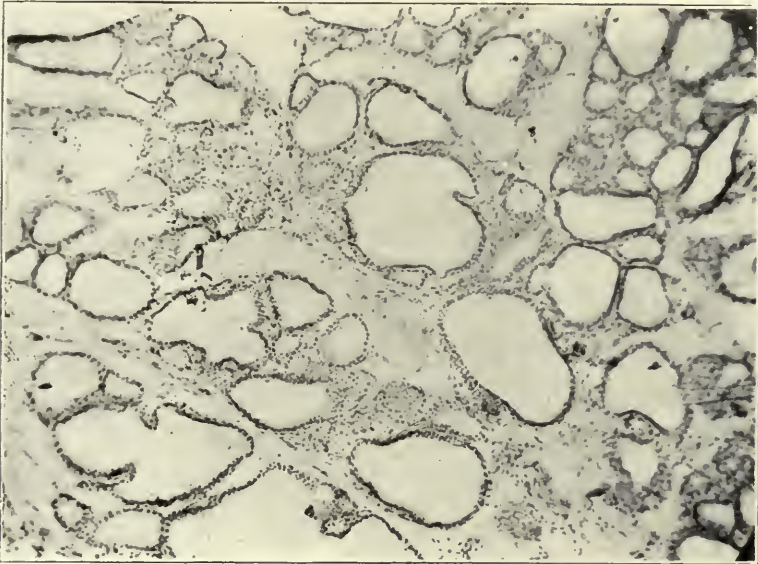


Fig. 9.—Slide from a normal thyroid gland showing the variation in size and form of the acini.

tions in staining intensity. The colloid is attached to the cells by fine processes which become apparent when from any cause there is a shrinking of the colloid. When the retraction is pronounced the whole border is serrated or dentated. In some glands, supposedly normal, there is some vacuolization. This is quite constant in alcohol hardened specimens. In the normal gland there are a few empty acini when frozen sections are studied, but they are fewer in number in paraffin slides. The colloid may fall out during the manipulation of the sections in any technic, but this is particularly likely to occur in frozen sections. The more careful one is in his technic, the fewer the empty acini, so

it may be that empty acini indicate only rough manipulation of the section.

The essential cells of the gland line the acini. Some histologists recognize two types of cells, the chief and the colloid. Hürthle (*Arch. f. d. ges. Physiol.*, 1894, lvi, 1) and Langendorf (*Biolog. Centralbl.*, 1880-90, ix, 136) using Ehrlich-Biondi stain, found one type of cell which stained lightly (the chief) and the other stained deeply due presumably to the contained colloid. These colloid cells are probably but the functioning stage of the

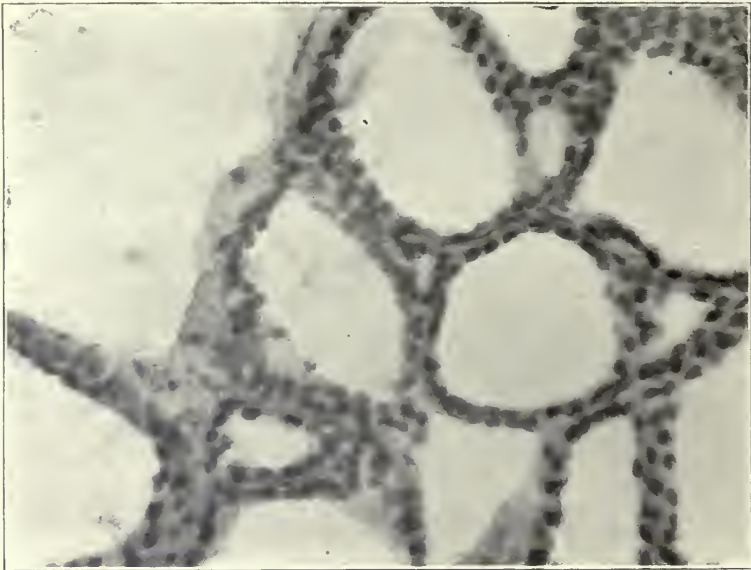

Fig. 10.—High power of the preceding showing the form and relation of the acinal cells.

chief cell. These cells are usually described as being cuboidal with variations between the flat and columnar (Fig. 10). They are not comparable to cuboidal cells lining the acini of duct glands in that they are more irregular and the intercellular lines are not so definitely formed. On the contrary, the protoplasm may be continuous, forming syncytia-like masses resembling like tissue in the placenta more than they do the ordinary type of gland epithelium. In a state of compensatory hypertrophy, as after partial resection of a gland and in pathologic proliferation, they assume a more pronounced cuboidal or columnar form and may then be compared morphologically with the common

type of gland cells. The epithelium is taller in young subjects and in acini containing little or no colloid. Conversely, in old persons it is more flat, and in much distended follicles in goiters of long standing the endothelium is flat, closely resembling endothelium (Fig. 11). The nuclei are ovoid with vesiculated nucleoli. In old, degenerated glands they are often deeply staining with little evidence of vacuolization. In order to understand this varying phase of cell morphology, it is necessary to study the teased and macerated sections. One may profit-

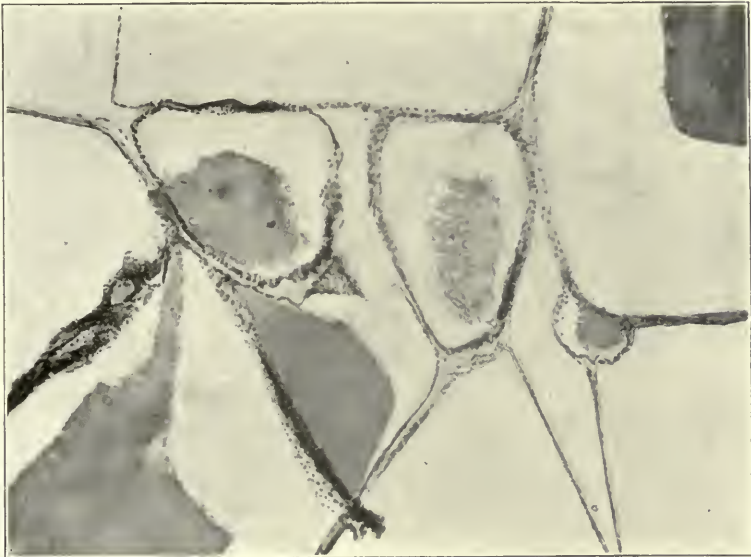

Fig. 11.—Slide from an old colloid goiter showing the thin interacinal septae and the low endothelial-like acinal cells.

ably study the structure of the thyroid by treating fresh frozen sections by the silver nitrate technic commonly employed in the study of the peritoneum. When so studied the irregularity of the cells becomes more impressive. The intercellular canaliculi described by Hürthle do not appear with this technic. I believe they are artefacts.

The Interacinal Cells.—Between the acini are regularly found collections of cells which in morphology and tinctorial reaction do not differ from those lining the acini (Fig. 12). Their constant presence and great variability in certain types of thyroid intoxication proclaim them to be elements of im-

portance. The interstitial cells likely differ from the colloid as the Langerhans of the pancreas differ from the acinal cells of the pancreas, except that the relation is closer since apparently the interstitial cells may under certain conditions form acini. These cells obviously have a different significance, for when these are in the ascendancy, the symptoms are different from those when the acinal cells dominate; when both are damaged a polyglandular disturbance results—all within the thyroid gland.

It is in the midst of these interstitial cells that masses of

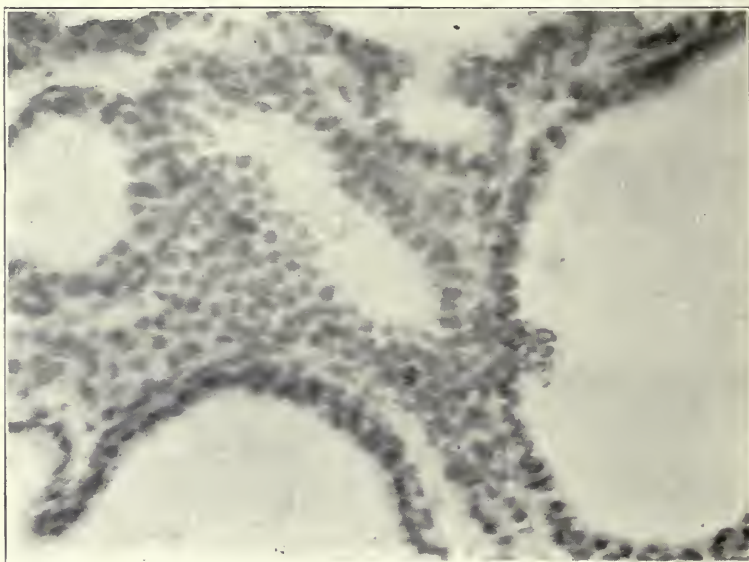


Fig. 12.—Slide of a thyroid gland taken from a boy aged four which shows the interstitial cells and their relation to the acinal cells.

colloid collect and from these new glands are formed (Fig. 12) much as new vessels form in adhesions of the peritoneum. The theory that the accessory acini develop from preexisting acini by a budding-out process does not seem to have been demonstrated. On the contrary these are often seen in old glands in which the acini are lined with flattened atrophied epithelium (Fig. 13) while the small glands and, from the tinctorial reaction presumably new glands, show much more intense staining reaction (Fig. 13). In toxic glands in which the acinal epithelium is high and well staining, small acini in proc-

ess of formation can be traced. In these it is sometimes impossible to distinguish between acinal cells and interstitial cells.

It is important to note that there is no definitely established normal. Theoretically we may assume that the thyroid gland should be composed entirely of acini lined with a single layer of cells. As a matter of fact such a simple arrangement extending over the whole gland is not found. In some areas there is a piling up of cells in the interacinal spaces and often some papillary formation into the lumen. Marine and Lenhart (*Arch. Int. Med.*, 1911, xii, 506) are of the opinion that any

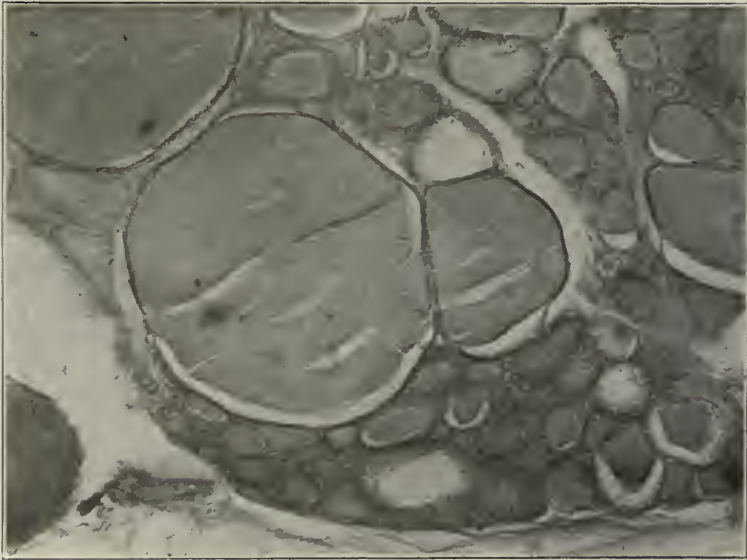

Fig. 13.—Slide from a slightly toxic goiter (interstitial type) showing the acinal cells inactive while the interstitial cells are active.

papillary formation is an indication of a departure from the normal state. Naturally in human material these points are difficult to establish, for operations are done on glands supposedly diseased, hence the specimens procured are supposedly abnormal and material obtained at autopsy is naturally obtained from subjects that are dead supposedly from some disease. The latter obviously have been subjected to possible changes due to the disease which caused the death of the patient. Observations of value on this point, therefore, can be obtained only by the study of thyroid glands obtained from bodies in which

death had been caused by violence or in biopsy material obtained during the course of other operations, as on the trachea for tumors or strictures. In the two glands obtained after violent deaths which I have been privileged to study, neither of them was "normal" in a textbook sense; that is to say, many areas showed cellular infiltration of the interstitial tissue (interstitial cells) and some indication of papillary formation. These changes were particularly marked in the slides obtained from the gland following a legal execution. It may be argued that the mental excitement incident to the tragic end may have been in

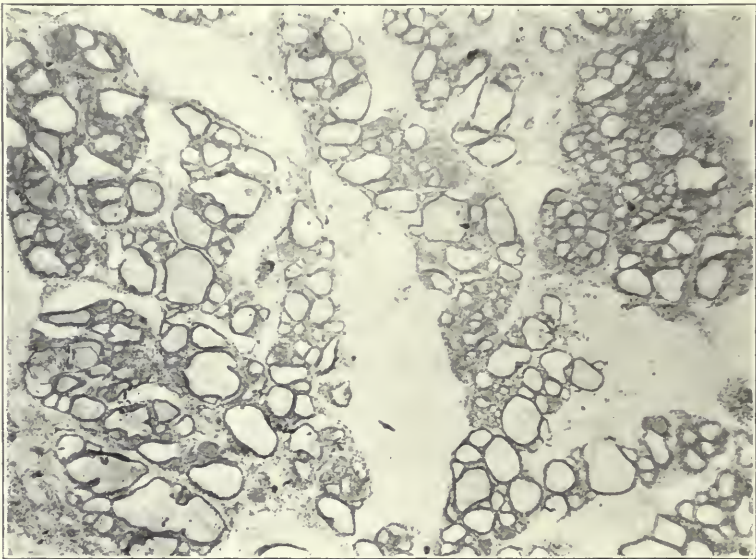


Fig. 14.—Slide obtained from a boy aged four years made from tissue removed during an operation for intratracheal growth. The interstitial cells are more abundant than in the adult gland.

part responsible for the changes noted. There are some changes, however, in material obtained by biopsy where no excitement has existed, or at least no more than might be excited by the anticipation of the operation and during the exhibition of the anesthetic, be it general or local. Even these exciting factors are absent in a sudden accidental death. In all such tissues there are interstitial collections of cells and such complications must be regarded as within the range of the normal.

In the infant and in young children the presence of inter-

stitial cells is much more pronounced (Fig. 14). The epithelium is piled up in many places and in some areas there is a lack of lumen extending over large areas. It is said this piling up of cells in the acini is in a measure a compensatory process and is capable of being influenced by diet and the use of drugs. The thyroid organ is exceedingly labile in its function, and quite likely in some of the wider excursions of its physiological responses, structural changes as well accompany them. The rapidity with which changes in the structure of the gland can take place has been studied by Marine and Lenhart (*Arch. Int. Med.*, 1909, iv, 253). They describe notable changes in five days and complete involution in twenty-six days.

It is important to recognize the range of variability of the normal, for on this variable normal the pathological shades without any sharp dividing line, giving ample reason why the normal and abnormal, from the clinical aspect, is so hard to determine. All the available evidence must be concentrated on the question of normality or abnormality, microscopic study alone is not sufficient.

PATHOLOGICAL ANATOMY

In a malady so protean as goiter there is always difficulty in correlating the physiological and pathological changes with the clinical. The pathological anatomists at best can but study a state of a given specimen. It is only by studying many of these with constant comparison with the clinical manifestation that the process can in a measure be charted. In goiter, fortunately, most of the tissues offered for study are obtained at biopsies so that it is possible to compare the course of the disease before, with that after the tissues are removed. Often secondary operations furnish further material for the study of a given case.

The study of such material makes it possible to divide the pathology of the thyroid into four great groups. (1) The colloid, in which there is an accumulation of the specific secretion of the cells, either because of lessened absorption or increased secretion. (2) Adenomatous proliferation including increase in the activity of the normally situated cell, increased intracinal proliferation, including both adenomatous proliferation

and papillary proliferation of the acinal cells. (3) Those in which the changes are predominatingly in the interstitial cells. (4) Degeneration, including degeneration of the colloidal contents, degeneration of the acinal cells and degeneration of the interstitial connective tissue. These, in brief, are the groups in which the majority of goiters may be placed preliminary to a more minute study.

Any combination of these may be detected in a single specimen. A concrete example will illustrate this; a woman of twenty-three has had a goiter for six years. Six months ago she began to manifest distinct toxic symptoms, with exophthalmos. Four weeks before operation she began rapidly to lose weight and presented other evidences of extreme toxicity. The gland shows areas of colloidal goiter, albeit with some evidence of colloidal degeneration, distinctive of the early "innocent" stage of the disease. Other areas show exquisite papillary proliferation distinctive of exophthalmic goiter. Finally other areas show distinctive degeneration of acinal epithelium characteristic of the extreme toxic state.

The adoption of such a grouping is doubly advantageous since it serves, not only the pathologist, but the clinician as well, for the disease as he sees it falls into one or the other of these great groups.

It is well for the surgeon constantly to keep in mind that there is no sharp dividing line in pathology any more than there is in the clinical course. He should not expect more of the pathologist than the pathologist may expect of him, an error surgeons habitually make. The attempt at division into certain pathological types does not seek to provide a series of hooks upon which the surgeon can hang definite disease pictures, but rather to aid him in visualizing the changes which have occurred in a gland which has given rise to certain manifestations which he of all others must be most able to recognize. Anatomic study is of less value than the careful clinical observation, but the surgeon grasps a clinical state much more clearly if he can visualize the anatomic state of the organ he contemplates attacking. This is important for sometimes the more marked pathological changes are confined to certain portions of the gland and the surgeon should be able to recognize the

part most nearly representing the normal in order that this may be preserved. The operating room diagnosis is as important in goiter surgery as it is in the operative treatment of tumors, and it requires as much careful study.

With the classification of goiters as already mentioned, only group types are indicated. Within each group are endless variations which can be comprehended only by the study of a large number of specimens. The group "carcinoma" represents a vast variation. The appreciation of this variation becomes to the student a sort of subconscious thing to be employed in his clinical work but which he is not able to express in abstract discussion.

It has already been stated that the majority of goiters may be placed in one of the four classes already mentioned, the colloid, the adenomatous, the interstitial and the degenerative. This holds in a general way, both for the laboratory and the clinic, but the more one searches for detail the more complex the problem becomes. There are variations in the clinical pictures which cannot be accounted for in anatomic study. It is possible that this variation is accounted for by the influence of other endocrine organs and the general nervous characteristics of the individual. The variation is no greater, however, than we find in carcinoma. We know in general from the examination of a given tumor what the nature and clinical tendency is, though in concrete instances they may surprise us in the rate of their growth and the points of metastasis.

In goiter more than in any other disease the clinician has to do, not only with a disease, but also with a patient, because general conditions react so constantly against the thyroid gland, that not to study the two together is not to study the disease at all.

Colloid Goiter

The colloid type is so characterized because it is distinguished by an increased collection of colloid in the acini. The increase of the colloid present may be due to an increased production or a decreased absorption. The general opinion seems to lean toward the assumption that some change in the colloid takes place which makes it less readily absorbable than

the normal colloid. This is the type usually found in early life and is the type usually observed in endemic goiter. I am disposed to believe that the picture generally accepted as that



Fig. 15.—Section of a small recent colloid goiter showing the uniform granular surface.

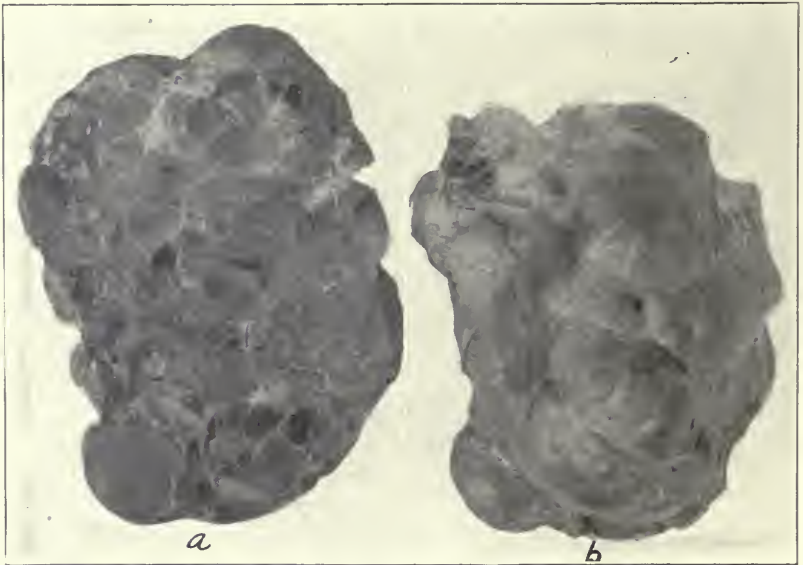

Fig. 16.—A colloid goiter of medium size showing (a), the translucent masses of colloid, and (b), the mildly bosselated surface showing the position of the chief colloid masses.

of colloidal goiter is really that of a *resting* colloid goiter. In those cases in which operation was done early in simple cases there has always been evidence of cell change. As a matter of

fact no developing colloid goiter is without some evidence of cellular activity. If the patient is carefully observed during the period of rapid development some increased nervousness and increase of pulse rate will be discovered though the patient



Fig. 17.—Section of a large colloid goiter of long duration showing degeneration with secondary hemorrhages.

may declare herself perfectly well. When the gland has reached its maximum size these phenomena subside and the gland may remain stationary many years without producing untoward symptoms.

Gross Pathology.—Colloid goiters usually present a considerable increase in size, frequently both lobes are nearly uni-

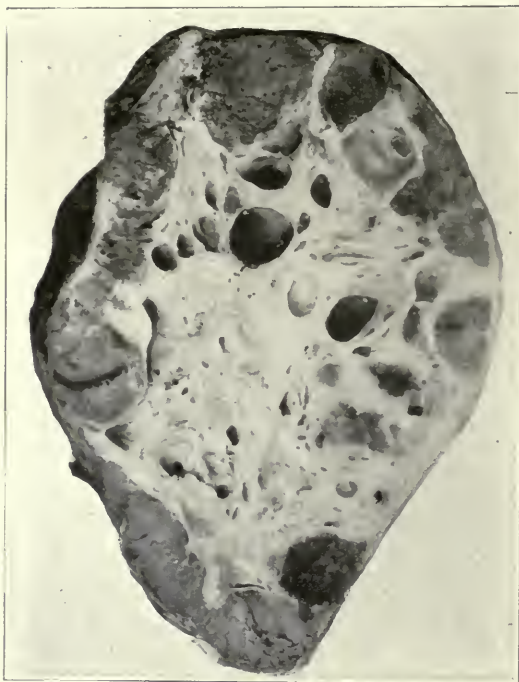

Fig 18.—Section of a colloid goiter, of 45 years' duration, which has undergone extensive fibrous degeneration.

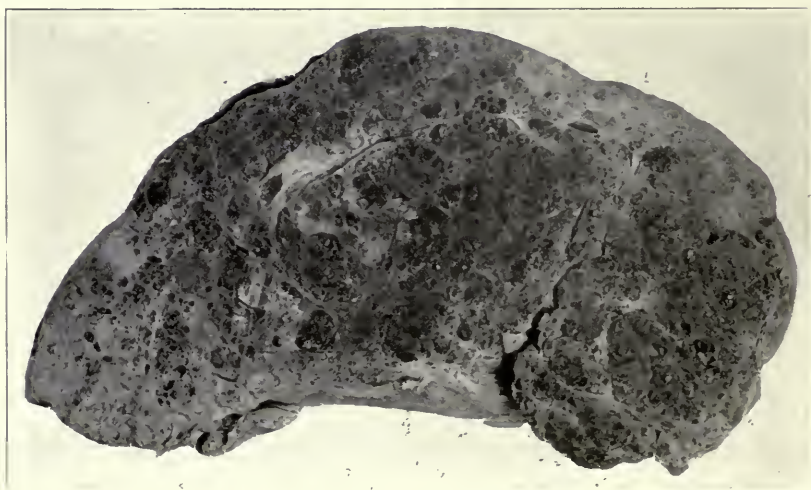


Fig. 19.—Section of a large colloid goiter showing uniform enlargement of the thyroid lobe with the retention of the original lobulations.

formly enlarged but in some cases one lobe is chiefly enlarged. They are elastic, soft in the early developmental stages, firmer as they reach the resting stage. When degeneration takes place, hemorrhages may take place into their substance or

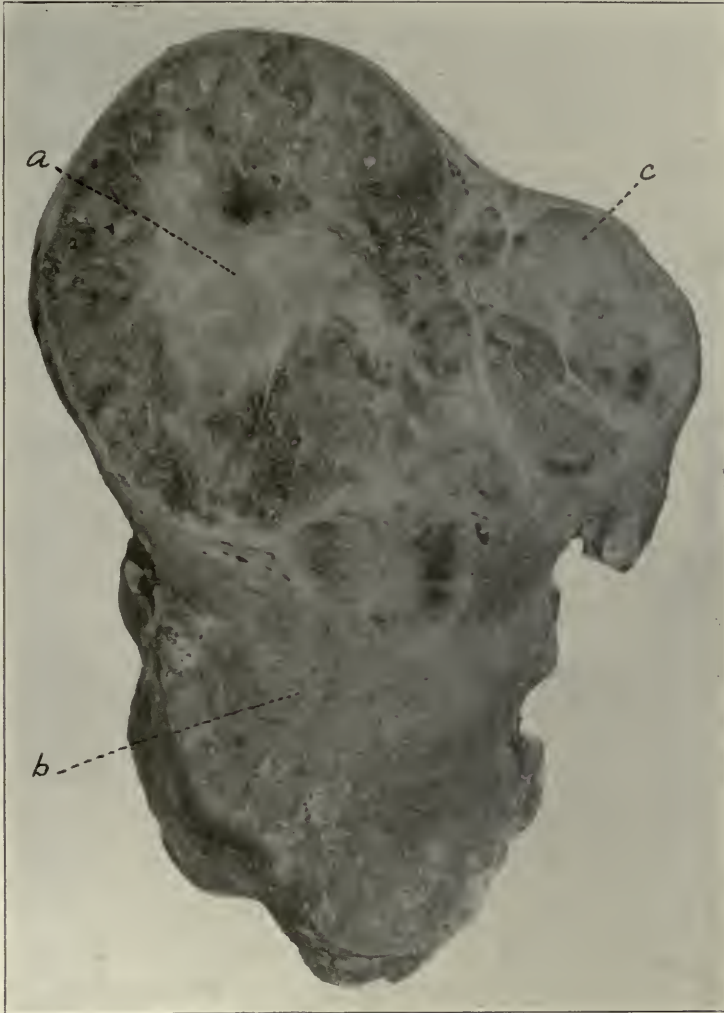

Fig. 20.—Section of an old colloid goiter showing the unequal development of the lobules. (a) Extensive fibrous degeneration; (b) calcareous infiltration; (c) complete degeneration of the acinal elements.

cystic or calcareous areas may sometimes develop. On section they are deep red in color presenting a fine granular surface when small (Fig. 15), paler as they become larger, and when

fully developed may be translucent over large areas (Fig. 16) with hemorrhagic infiltration and cyst formation in older goiters. Mass degeneration with hemorrhage usually occurs only in those which have attained some size (Fig. 17). Extensive fibrous degeneration (Fig. 18) is usually seen only in the very old ones. In some of them the original lobulation is maintained (Fig. 19) while in others certain lobules develop more than others, giving rise to very irregular tumors (Fig. 20). In this way secondary lobules may extend in various directions beyond the confines of the goiter.

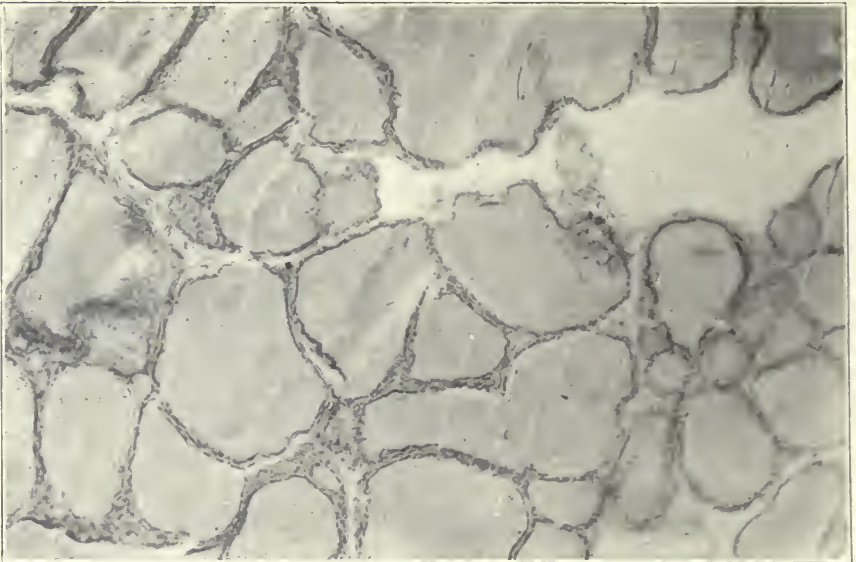


Fig. 21.—Slide of an early colloid goiter showing the uniform increase of the colloid without changes of the acinal epithelium or retraction or vacuolization of the colloid. The interstitial cells show no activity.

Histology.—In the average run of colloid goiters there is a general increase in the colloid differing but little from normal colloid save that the acidophilic character is not so uniform (Fig. 21). The cells are not notably changed in the early cases. The cells are flat or cuboidal and stain evenly and remain adherent to the acinal walls (Fig. 22). In older areas they may become somewhat flattened while still retaining their integrity. The cells when teased from their acinal walls appear wholly like endothelium (Fig. 11) with the flat ovoid nuclei and

the irregular protoplasmic areas between. Still later they suffer degenerative changes.

The colloidal increase does not involve all acini alike. In some areas the increase may be so marked that the individual acini are visible to the naked eye. In others there may be but a slight or no increase. In some apparently simple goiters there is, here and there, some vacuolization, lack of tinctorial reaction or retraction of the border, factors indicating that all is not well in the gland. In some there may be considerable degeneration in the colloid, vacuolization, retraction and tinc-

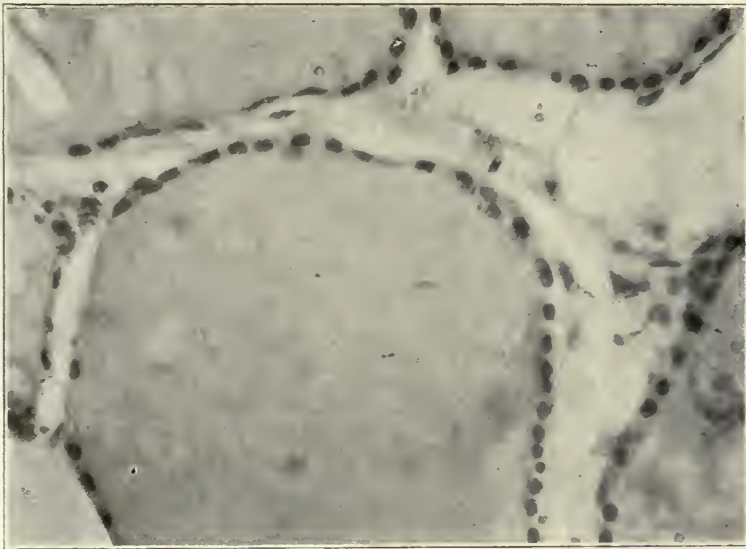


Fig. 22.—Slide showing the flat, inactive cells of a quiescent colloid goiter. The colloid shows slight vacuolization.

torial changes, factors ordinarily indicating a toxic degeneration, yet there are apparently no clinical symptoms to correspond to these changes (Fig. 23).

In some parts of the gland there is always more or less increase in the cells in the sustaining tissue. In some of them this is the dominant picture (Fig. 24). In these there is usually an accompanying nervousness. These cells are structurally like those lining the acini. The cell clusters may form lumens and colloid may be found in them or they may be found empty after the most careful technic.

Some changes in the cells and the colloid, suggestive of pernicious activity can be, on search, found in the most orthodox and innocent colloid goiter. It is possible that these cells may in some way injure the general bodily economy though there is not evident any definite sign or deficiency of secretion or absorption. Myocardial changes are most often found associated with goiters which show changes in the colloid.

The changes in the vessels are often marked. There may be some increase in the size of the interracinal vessels but it

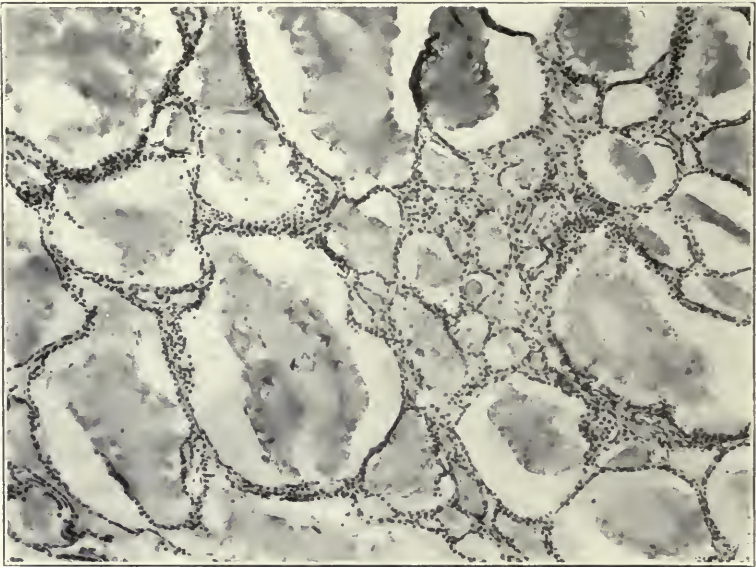


Fig. 23.—Slide from a clinically inactive goiter. The colloid is markedly retracted and vacuolated. The interstitial cells show some activity.

is not marked. The chief supplying vessels may be increased in proportion to the size of the goiter; I have seen the superior thyroidal vessels larger than a normal radial at its origin. The vessels often show extensive atheromatous degeneration, a factor of importance in ligation of the vessels.

There is a type of goiter seen especially in girls and young women in which there is no notable increase of epithelial elements but which is associated with definite toxic symptoms. They are soft and turgid but not tender. The changes in the colloid are exactly parallel with the changes in the colloid in the

secondary toxic goiters but much less marked. The colloid changes its reaction to dyes, retracts from the cell, is vacuolated and in the more pronounced cases the colloid contains within some destroyed cells. There is sometimes round-celled infiltration. Aside from an increase of the pulse rate, there is little evidence of toxicity. They do not bear iodine and its administration may produce nervous symptoms. This is obviously a close approach to a toxic goiter and it is the clinical symptoms rather than the microscopic picture that enables one to properly place them.

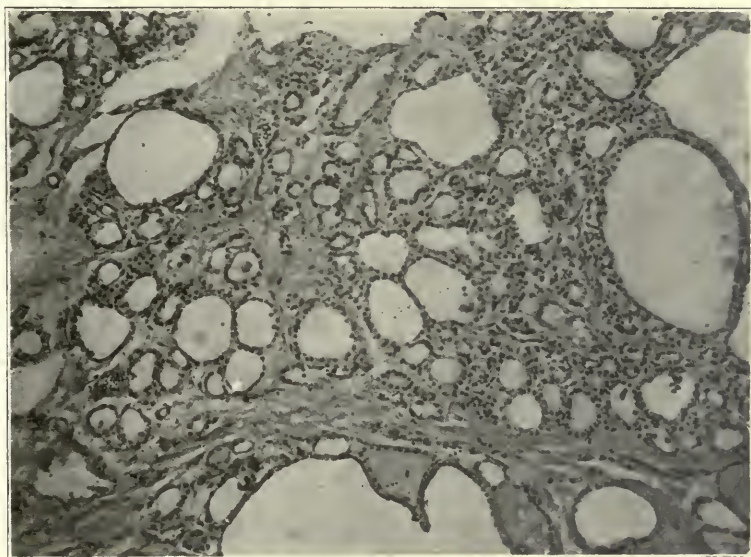


Fig. 24.—Slide of a supposedly inactive goiter. The interstitial cells are increased and there has been absorption of the colloid.

Secondary Changes.—As already noted, it is only in the recent goiters that the simple changes characteristic of colloid goiter are found. In old glands secondary changes are numerous and often important, and may be regarded as representing only the normal life history of the gland. In other instances such changes take on added importance and for this reason require special emphasis.

Cystic Degeneration.—By the coalescence of a number of large acini a veritable colloid cyst may be formed. The contents may be predominantly colloidal or a variable amount of

hemorrhage may have occurred in them (Fig. 25). Sometimes these cysts containing fluid blood are ruptured during the course of the operation. The sudden appearance of so large a volume of blood is apt to scare the wits out of the young operator. In most old colloidal goiters, because of the varying de-

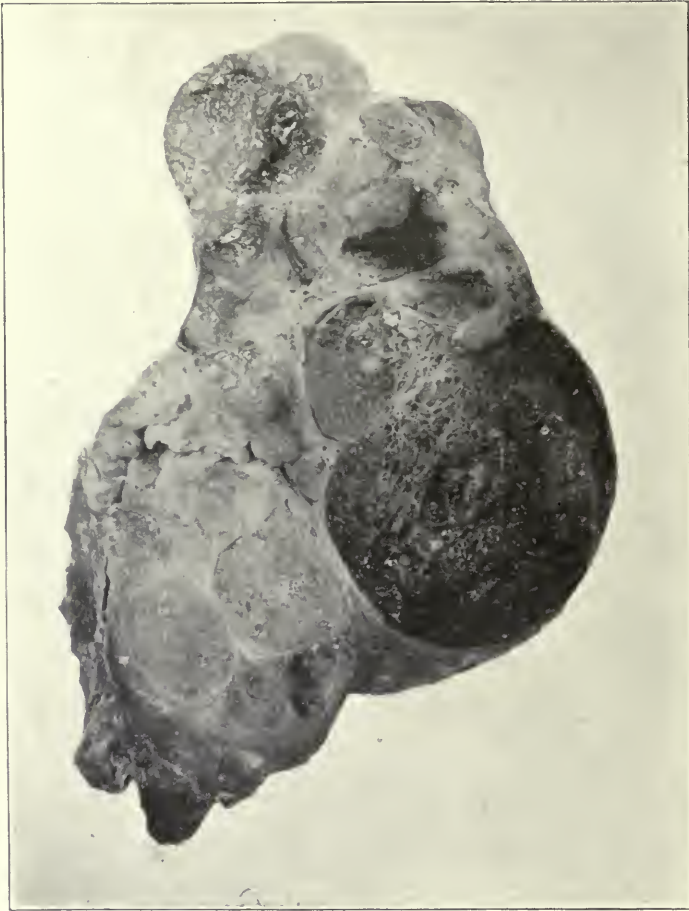

Fig. 25.—Section of an old colloid goiter. To the left at the bottom of the figure are lobules developing independently, imitating fetal adenomas. At the right is a degeneration cyst in which hemorrhage occurred with disastrous results. At the very bottom of the figure is an inverted pyramid of nearly normal colloid tissue.

gree of hemorrhage and degeneration that has taken place, the cut surface as a whole presents a mottled appearance. Often too, large areas of gland, interstitial tissue as well as colloid contents, may undergo degeneration which results in a mass of

structureless gummous material which escapes if the gland capsule is ruptured by the rough manipulation of the surgeon. These secondary cysts when small may be lined by a flat epithelium which in many instances is so flattened that it resembles the endothelium of serous surfaces and exhibits a tinctorial reaction which characterizes that tissue. More often the epithelial lining is lost and when there is much degeneration the wall is made up of tags of interstitial septae in a greater or less degree of degeneration.

Cysts find their chief practical interest in that extensive

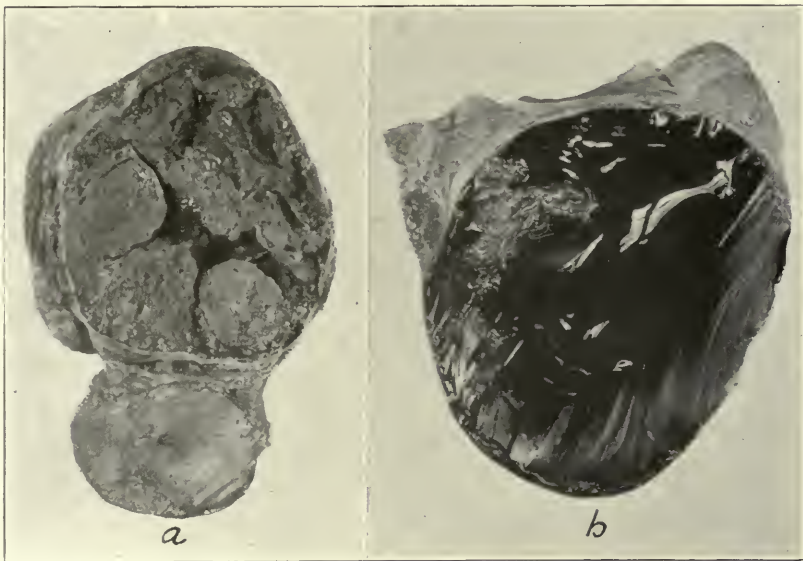


Fig. 26.—Sections of cysts of the thyroid showing (a) an old clot indicating an ancient process and (b) a recent hemorrhage.

hemorrhage into them may so increase the volume of the gland that the trachea may be suddenly compressed and asphyxiation of the patient occur. Whether or not the large solitary cysts found in otherwise unchanged glands are the product of a degenerative process has not been definitely established. Since they are usually located in the lower poles or isthmus, the anlage likely is congenital. Furthermore, they develop progressively, indicating that they are neoplastic in character. Hemorrhage rarely takes place in them.

Simple cysts are among the rarer tumors of the thyroid

gland. They usually contain a straw-colored fluid. When hemorrhage takes place in them, the fluid is red and it may coagulate after removal of the cyst (Fig. 26-b) or the clotting may take place before the operation is done (Fig. 26-a).

Fibrous Tissue Degeneration.—As this type of goiter becomes older, the connective tissue may become markedly increased. So great may this become that whole areas appear

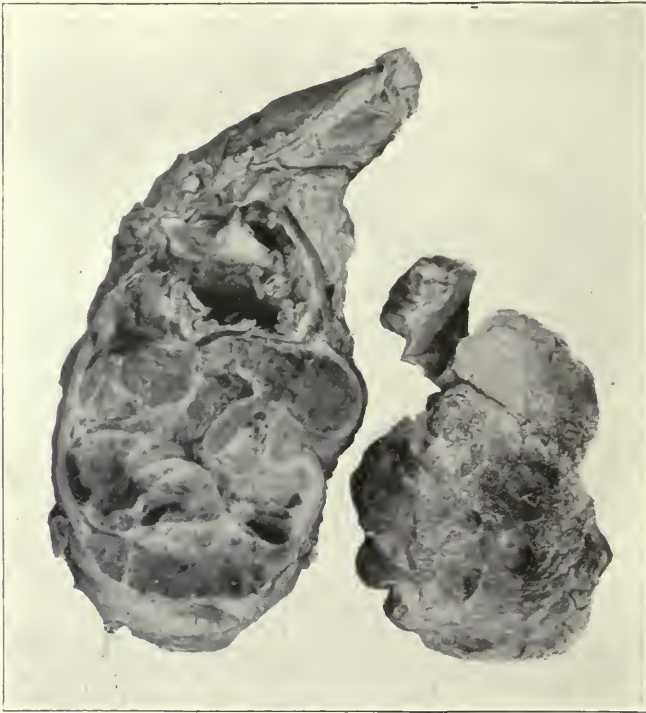

Fig. 27.—Section of a thyroid showing at the left many degeneration cysts which collapsed during the operation, and at the right the more recent lobe showing beginning colloid degeneration.

macroscopically as fibrous (Fig. 27). The epithelium may entirely disappear or become degenerated and is exfoliated into the colloid. The cells may become pressed together and because of the disappearance of the colloid they appear as cell-nests surrounded by connective tissue (Fig. 28). Such areas are sometimes regarded as malignant by credulous pathologists. As a matter of fact, if the microscopist does not note that the cells are degenerated and that the fibrous tissue has undergone a de-

gree of hyaloid or myxomatous degeneration, the error of judgment may seem to have a measure of justification. Whether the increase in connective tissue is responsible for the disappearance of the colloid or the disappearance of the colloid is followed by increase of connective tissue cannot be stated. As a matter of fact malignancy does not develop from such tissue. These are really the only truly "innocent" goiters. When the degeneration involves a large proportion of the thyroid tissue, a hypofunction, a myxedema, develops despite the fact that the patient has a goiter.




Fig. 28.—Slide of a goiter which has undergone fibrous degeneration. Below is shown the degenerated acinal epithelium with increase of the interstitial cells. Above is abundant fibrous tissue increase compressing the cells, giving rise to a superficial imitation of a malignant process.

Calcareous Degeneration.—In very long-standing goiters, calcareous deposits may form in or about degenerated areas. Usually the deposit forms a shell in some part of the tumor, but complicated partitions and septae of calcareous material may be formed (Fig. 29). Sometimes a whole lobule may become encased in a lime shell. These calcareous plaques not infrequently become attached to the trachea, making separation difficult during operation and because of their firmness may cause exten-

sive erosions of the tracheal rings. When these plaques extend over the upper pole upon the vessels the surgeon may feel keen embarrassment because the ligature may cut through the vessel wall. In intrathoracic goiter the unyielding form these masses impart to the goiter may make operation difficult and hazardous. Bone formation within colloid goiters has been described. In many of the reported instances the description is

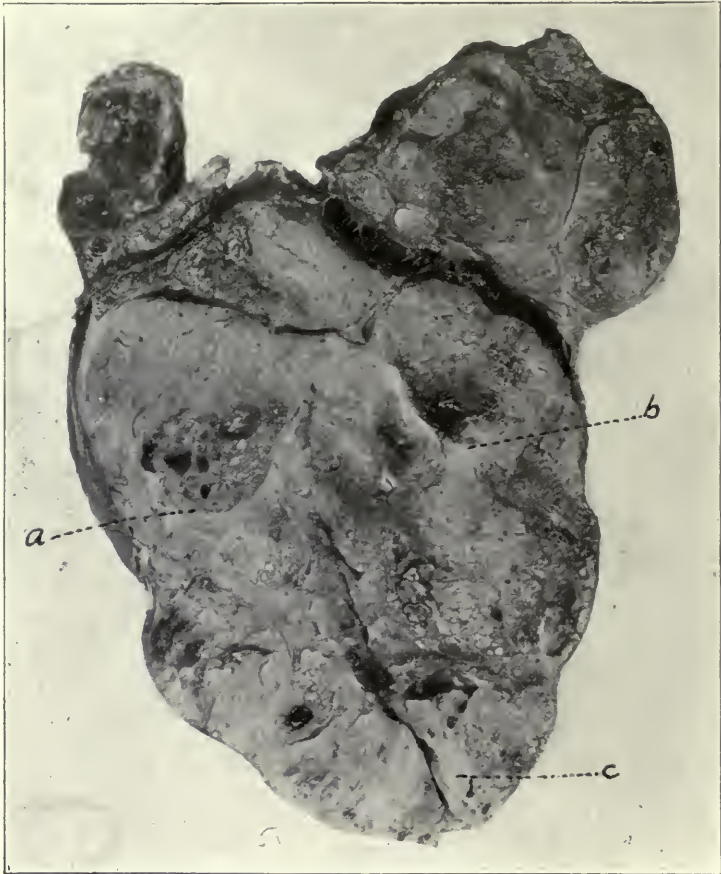


Fig. 29.—Section of a large goiter of long duration showing extensive calcareous degeneration which at the lettered points forms heavy plates of stony material.

far from satisfactory and in view of the common confusion between bone and calcareous infiltration, one must demand a careful histological demonstration of bone before it can be accepted as such. I have never encountered bone in a thyroid. A number

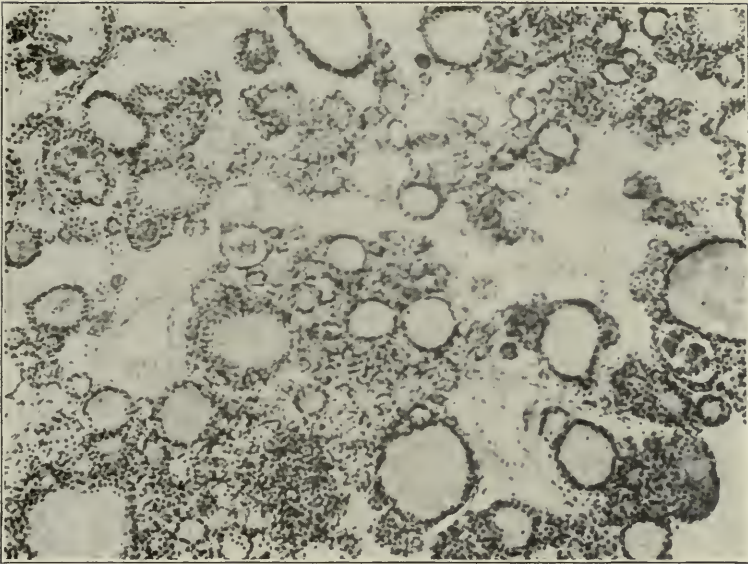


Fig. 30.—Slide of an old goiter showing activity of the interstitial cells with fibrosis and secondary hyaline degeneration.

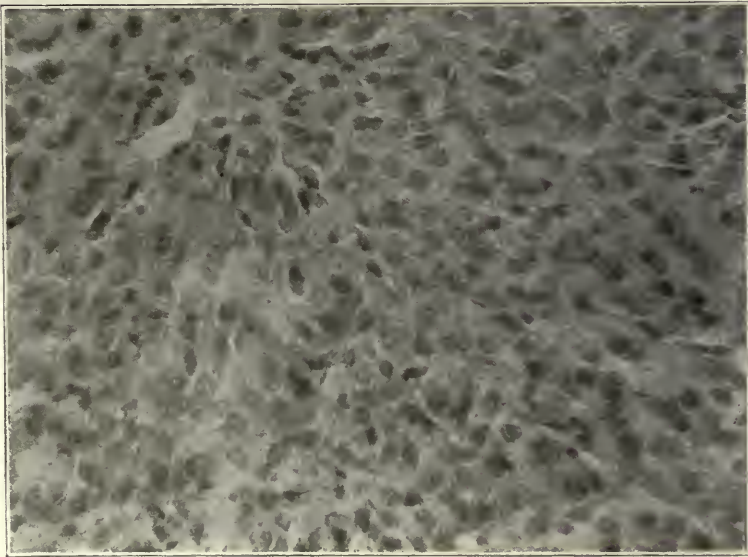


Fig. 31.—Slide of an "innocent" goiter of forty-five years' duration. Carcinomatous degeneration has taken place.

of undoubted instances have been recorded by Meyer (Proc. New York Path. Soc., 1919, n. s., xix, 70) Seahrt (Centralbl. f. Chir., 1905, xxxii, 337) and Pennel (Lancet, 1917, i, 454).

MALIGNANT DEGENERATION.—As already mentioned often the fibrous proliferation causes a disappearance of the acinal cells or they may be so distorted that malignancy is imitated. Sometimes many new acini form in such tissue which gives the impression that they are invading the surrounding tissue (Fig. 30). It is questionable whether malignancy ever supervenes on any goiter showing secondary fibroses. Malignancies in my experience always resemble the interstitial glandular prolifera-

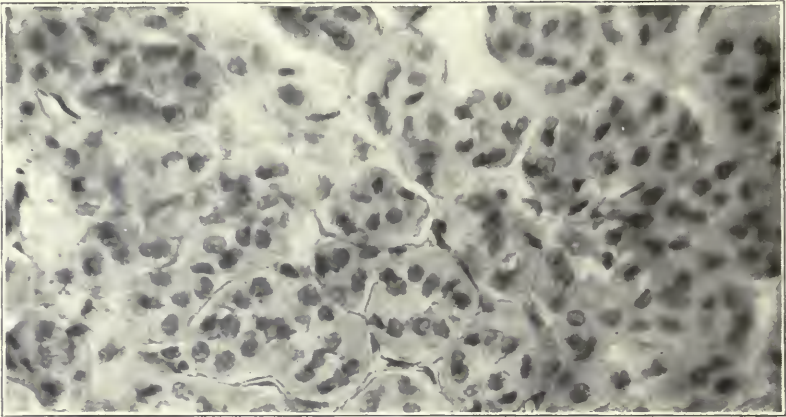


Fig. 32.—Slide of an adenomatous goiter which caused extensive bone metastasis. This slide was made from tissue removed from a bone.

tions of lumenless acini, and it is such areas that must be scanned for dangerous areas. When malignancy occurs, the cells are noted to be larger and to stain more deeply and form solid masses (Fig. 31) or the acini form solid cell columns (Fig. 32). Usually the thyroid manifests malignancy by active acinal proliferation and not as a scirrhous or even a simple carcinomatous formation. Therefore the consistency of the thyroid is not of the same value in the determination of malignancy as it is in carcinomas of most situations, though in many cases the consistency is very suggestive.

As is well known, the thyroid may exhibit evidences of malignancy without showing corresponding structural alteration

and the thyroid structure may be easily recognizable in the metastasis. On the other hand the statement that metastases may go out from normal glands is without warrant. There are always changes to be found if they are diligently searched after. Berard and Durnet have recently (*Rev. de Chir.*, 1921, xl, 521) collected a large number of cases and have come to the conclusion that in none of them was the thyroid normal. In fact to speak of the metastasis of any normal organ is to deny the validity of our fundamental notions of malignancy. The metastases are particularly likely to occur in bone but may form secondary nodules in any tissue, not uncommonly in the gut tract.

Malignancy is diagnosticated more often than it exists. If the patient recovers, the gland most likely was not malignant, yet recoveries are often reported after even a partial removal of the gland. The surgeon who cures a carcinoma of the thyroid places a heavy burden on his pathologist. If ever a patient of mine, in whom a diagnosis of malignancy has been made, remains well, I shall renounce the diagnosis.

Adenomatous Goiter

The term adenomatous goiter is used in its general sense, that is to say, it is a goiter that is gland-like, which implies that it is made up of the proliferation of the acinal cells. Because of this active proliferation of the epithelial elements, this type stands out in marked contrast with the preceding. In colloid goiters the primal disturbance has to do with secretion or absorption, while in the adenomatous type, there is a fundamental cell multiplication. As one might suspect, this increase in cell elements is apt to be attended by a hyperfunction. As a matter of fact this phase dominates the picture clinically and the term "adenomatous" is of use only to fix the attention on the fundamental anatomic change. Clinically it is the perverted function of the proliferated cells that fixed attention and the clinical synonym is, broadly speaking, thyrotoxicosis.

There are certain modifications in the hypertrophy which made possible a certain sub-classification. (1) The *fetal adenomas* in which definitely encapsulated areas of thyroid tissue are easily distinguished. These may or may not be toxic. (2)

The *diffuse adenomas* in which more or less of the whole gland is involved. The glandular proliferation in this class takes place in two more or less definite directions; (a) the one shows

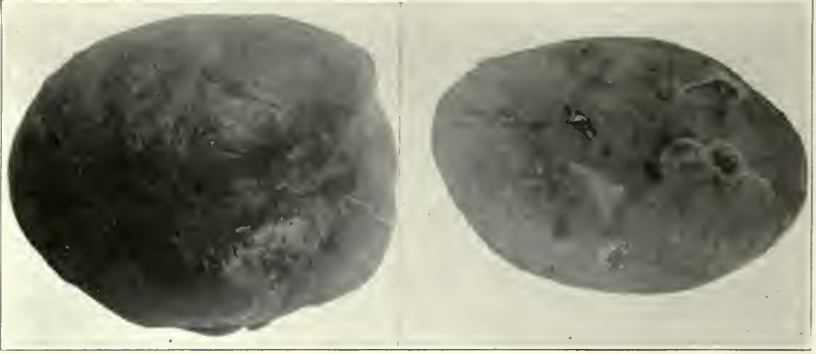

Fig. 33.—Photograph of a fetal adenoma showing its smooth ovoid contour and the uniform fine granular character of the cut surface.

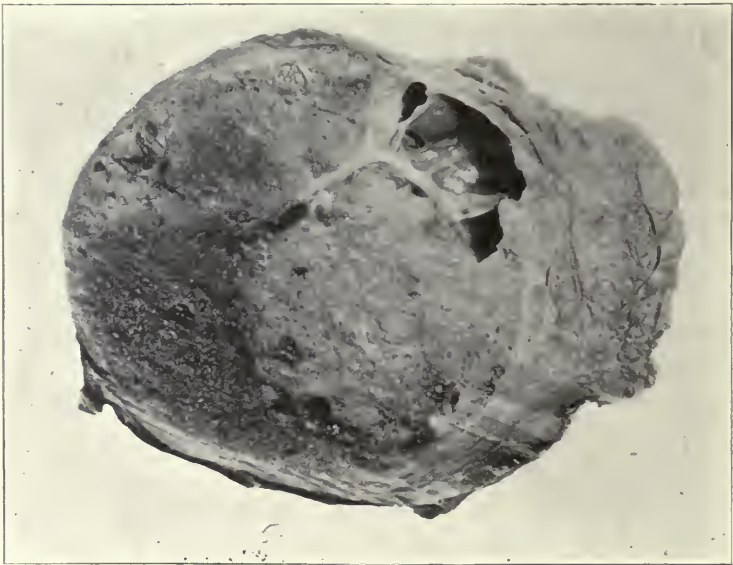

Fig. 34.—Section of an old fetal adenoma which has undergone complete degeneration with secondary hemorrhage and cyst formation.

definite multiplication of acini producing a true adenoma; and (b) the other in which the epithelial elements pile up forming more or less definite papillary projections into the lumen of the acini, producing a papillary adenoma; and, possibly a third

group, (c) in which the interstitial cells dominate. It may be stated at the outset that broadly speaking Group a, corresponds with toxic goiters without exophthalmos; b, toxic goiters with exophthalmos and possibly, c, to the forme fruste in which general neurotic symptoms are prominent.

Fetal Adenomas.—This type is formed by a complete encapsulation of a portion of the gland. The gross appearance pre-

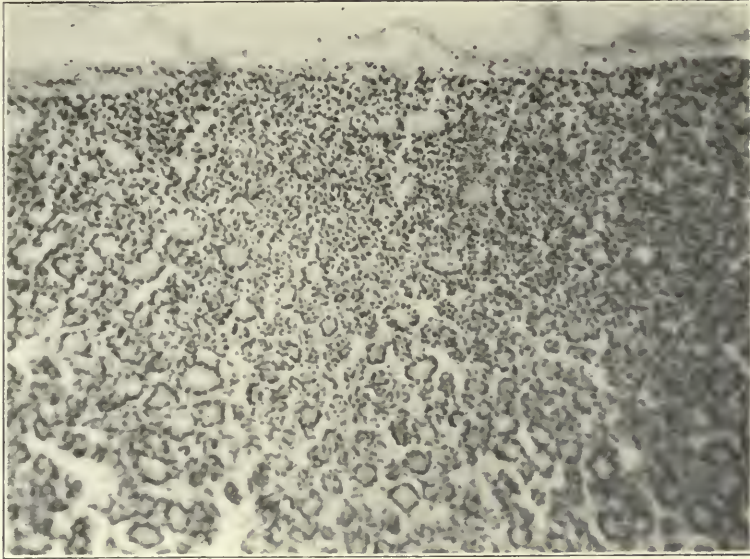


Fig. 35.—Slide of a fetal adenoma showing the small acini with little colloid. This one had recently undergone marked increase in size.

sents an ovoid mass, thoroughly encapsulated, which permits of easy separation from the surrounding gland tissue. On section the gland is deep red and finely punctiform (Fig. 33). In rapidly growing types colloidal areas may be detected and in old regressive areas serous or hemorrhagic cysts may be formed (Fig. 34). The structure is that of an adenoma, being made up of closely packed glands formed of small cells. The colloid content is very small and may be absent. The structure indicates immature development closely resembling in structure the gland in the fetus (Fig. 35), hence the name. Ordinarily these acini contain no colloid, but when toxic symptoms develop there may be a variable amount of colloid present (Fig. 36) which shows the usual changes found in toxic goiters. Cellular changes are

not common, but increase in number of acini is responsible for the growth of the tumor. These tumors may not infrequently form the sole lesion and their removal rids the patient of her disease, but as often a general glandular hypertrophy is present

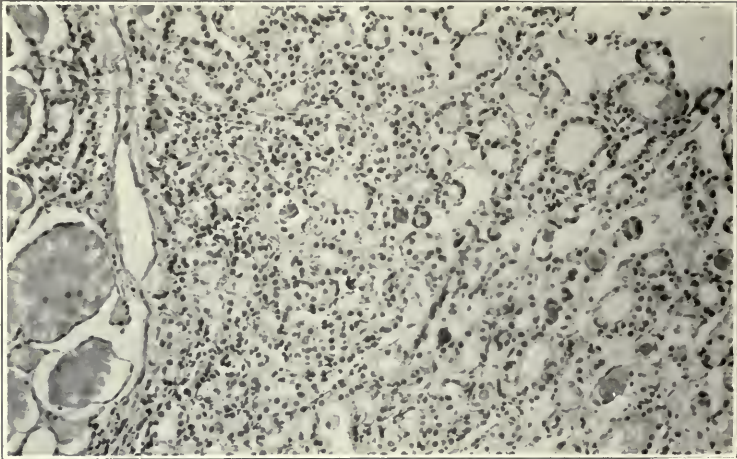


Fig. 36.—Slide of a toxic fetal adenoma showing the presence of colloid in many of the acini. At the extreme left of the figure are a few acini of the adjacent colloid goiter. A thin capsule divides the two portions.




Fig. 37.—Section of a large colloid goiter enclosing within itself a small fetal adenoma.

and the adenoma represents but a part of the disease, and is found embedded in the general adenomatous mass (Fig. 37). Usually these tumors are solitary and are easily palpable. When these smaller masses are discovered with the microscope, the examiner is apt to think of malignancy (Fig. 38). The usual

site for these adenomas is in the lower pole of the right lobe, less often in the isthmus but may be found anywhere in the gland. In rare instances they are compound tumors being formed in part of thymus and lymphoid tissue.

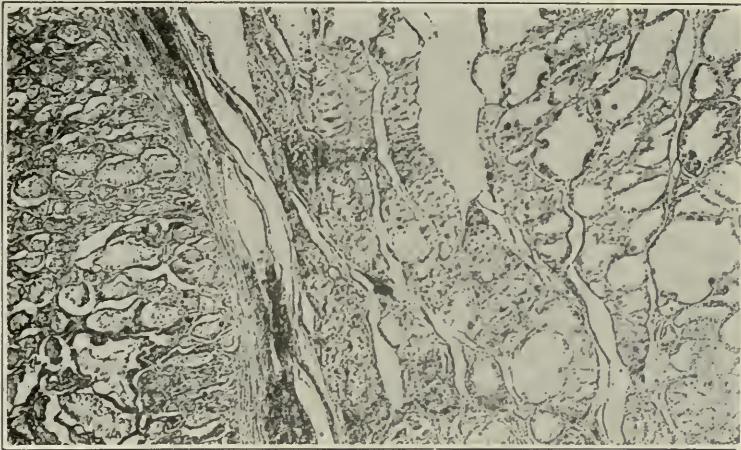

Fig. 38.—Slide of the preceding showing the structure of the fetal adenomatous nodule at the left and that of the colloid part to the right of the picture. Both show extensive secondary degeneration.

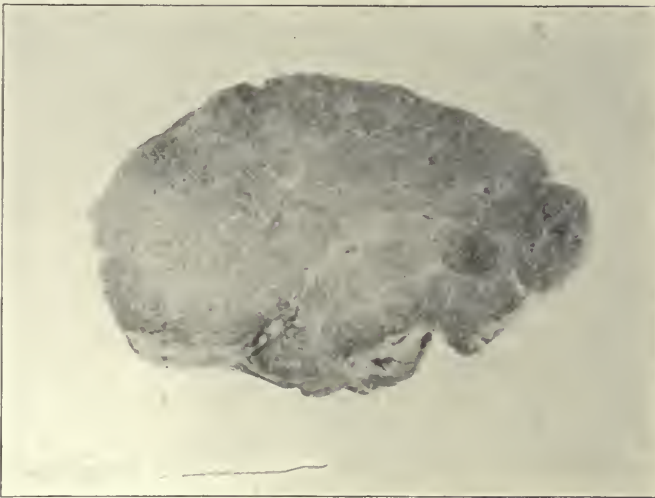

Fig. 39.—Section of a recent acutely toxic adenomatous goiter showing fine granular appearance. Its dark red color cannot be reproduced.

Diffuse Adenomatous Goiters (Glandular Proliferations).—

There is no macroscopic difference between the glandular and

papillary types. They vary greatly in size and the degree of glandular increase bears little relation to the severity of the intoxication they produce. When small they may be firm and elastic, while the larger ones are usually soft and pulsating. In many, however, and these are often the severest cases, the gland is very firm giving the general feel of a subacute inflammation. The larger ones are soft in the beginning and tend to become firm as they develop. On section the early ones are red with or without translucency (Fig. 39). The older ones are greyish red and may even have the color of boiled liver (Fig. 40). This



Fig. 40.—Section of an adenomatous goiter of a year's duration. The fine granular surface within distinct lobules is shown. Its liver-like consistency and grayish-red color cannot be reproduced.

change in color presents a degeneration of the interstitial tissue as well as of the colloid. This type is extremely friable, tearing on the least tension, making ligation or suture very difficult. The firm areas usually show some reaction on the surface, as indicated by the adhesions between the gland capsule and the surrounding tissue, which likewise adds materially to the technical difficulty on their removal. The endothelial-like character of the superficial layers of the capsule seems to facilitate the development of adhesions.

As already indicated, glandular proliferation may involve predominatingly a production of new acini, while the other type presents the formation of papillary epithelial proliferation within the lumen of the acini. The former is seen in the toxic goiters without eye signs, while the latter is characteristic of the classical exophthalmic goiter. In both types there is often a diffuse infiltration of the interstitial tissue, with gland cells with ovoid nuclei without definite gland formation.

THE GLANDULAR TYPE.—In this type the chief change is in the cells lining the acini; they become higher, stain more deeply,

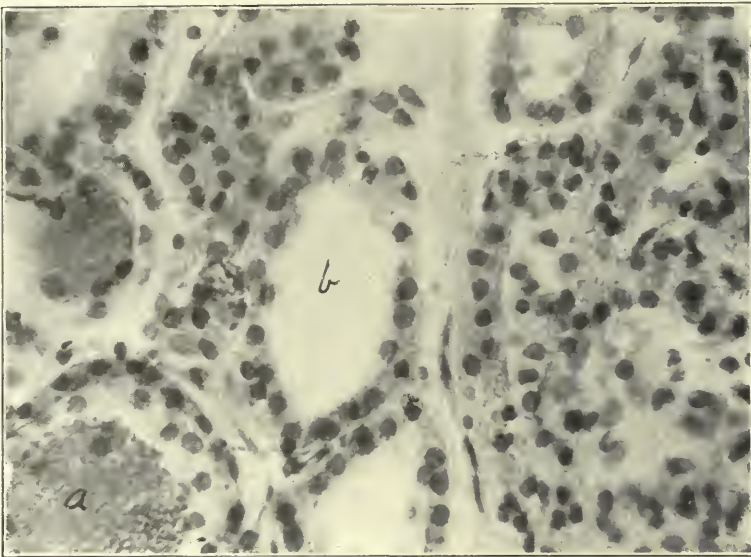


Fig. 41.—Slide showing a typical picture of toxic goiter without eye signs. At *a* the colloid has undergone granular degeneration and at *b*, it has disappeared. At the right of the picture there is marked increase of the interstitial cells.

and present every evidence of overactivity (Fig. 41). In this type there is also a marked proliferation of the acinal cells within the interstitial tissue from which are formed secondary acini. There has been astonishingly little effort made to determine the true nature of the cells in question or to determine the process by which new acini are formed (Fig. 42). These secondary acini may contain little or no colloid. In my judgment it is a mistake to confuse the interstitial cells which are found in all glands, normal and abnormal, and the round cells gen-

erally recognized as indicative of inflammation. The interstitial tissue may be infiltrated with round cells and in some instances these become so numerous as to simulate lymphoid tissue. Some pathologists have even described germinal centers in such areas. In my judgment these are not germinal centers but represent extensive round-celled infiltration about young acini.

THE PAPILLARY TYPE.—In this type there is a proliferation of the cells of the preexisting acini producing the projections

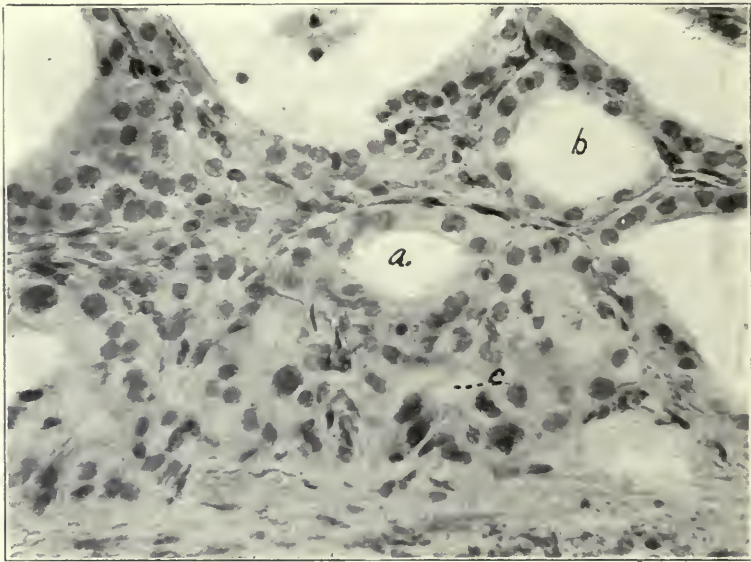


Fig. 42.—Slide of a toxic nonexophthalmic goiter showing the development of secondary acini. At *b*, is a well-formed one, at *a*, one in which one wall is made up of interstitial cells and at *c*, is a space containing colloid which is surrounded by interstitial cells.

of papillary formations into the lumen of the gland (Fig. 43). This is the most constant and striking picture seen in the study of the pathology of goiter. It is distinctly associated with exophthalmic goiter. It is very rare to find eye signs without finding the characteristic changes and on the other hand, these changes are often found when no eye signs can be demonstrated. In this type more than any other, the glands present evidence of overactivity. A look at these cells suggests at once the idea of overfunction. When the papillary formation is extensive the picture may resemble a malignant adenoma (Fig. 44), as of the

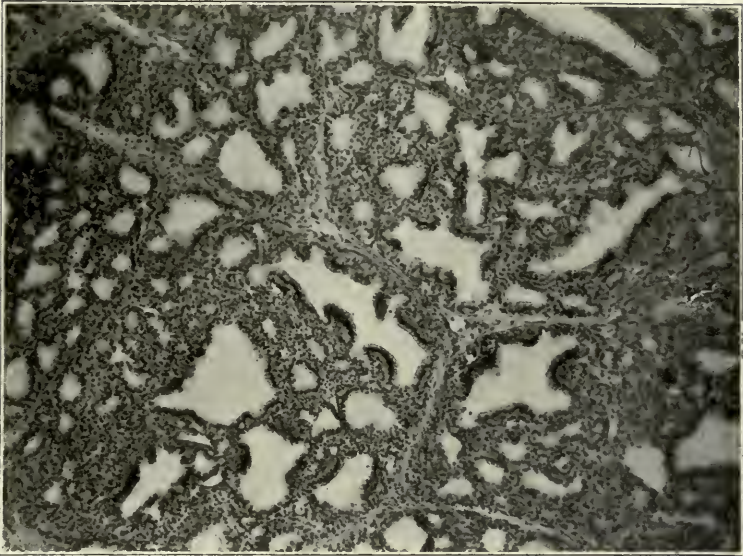


Fig. 43.—Slide from a goiter of extreme toxicity. There is extensive papillary formation, but the interstitial cells are also much increased.

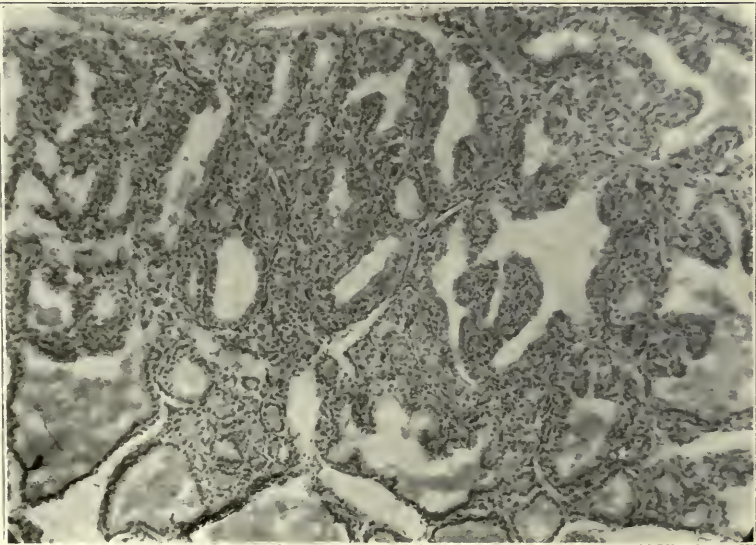


Fig. 44.—Slide from a typical exophthalmic goiter. There is extensive papillary formation with but little participation of the interstitial cells. In some of the acini the degenerated colloid is still present.

fundus of the uterus. In such cases there is usually a complete absence of colloid. Where the proliferation is less marked there is often degenerated colloid (Fig. 45). In this form the cells are apt to be high columnar and deeply staining (Fig. 46).

In long-standing cases there may be more degeneration than actual proliferation. This is noted chiefly in those cases where the acute stage has long passed. The cells exfoliate into the lumen of the gland and often extensive areas become degenerated and lose their ability to absorb stains (Fig. 47). The colloid if any is present is degenerated and granular. As the

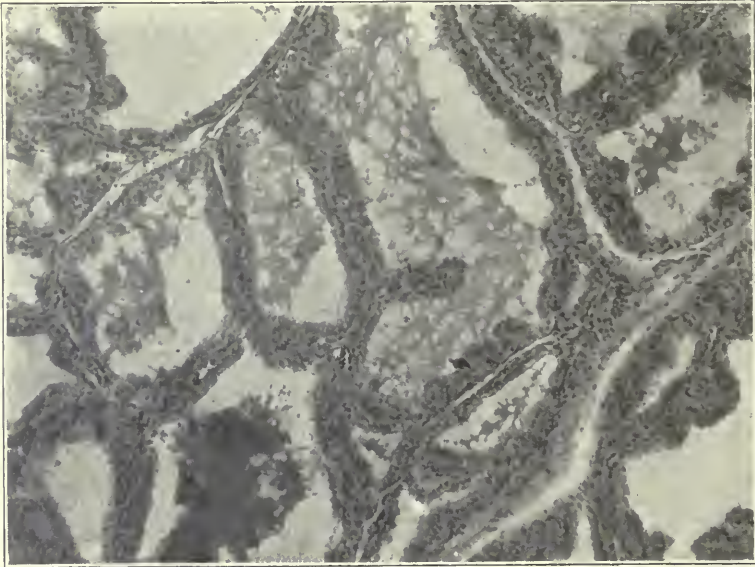


Fig. 45.—Slide from a goiter in which the eye signs developed after the appearance of the toxicity. The papillary formations project into the degenerated colloid.

degeneration increases they come more and more to resemble the secondary degenerated cases with secondary proliferation. In extremely toxic acute cases the cells are exfoliated giving the appearance as if the slide had been treated with some destructive chemical (Fig. 48).

Each of these forms of active cell proliferation is commonly associated with thyrotoxicosis. While there are no sharply defined lines between the pathological pictures of the various types of intoxication, one may predict in a general way from the clinical symptoms what the slide will show and one

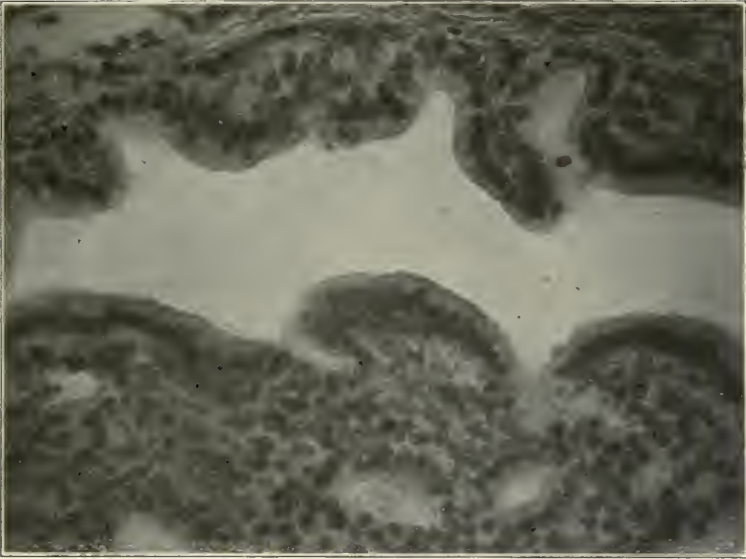


Fig. 46.—High power photograph of the acinal cells of an exophthalmic goiter. They appear as tall columnar cells.

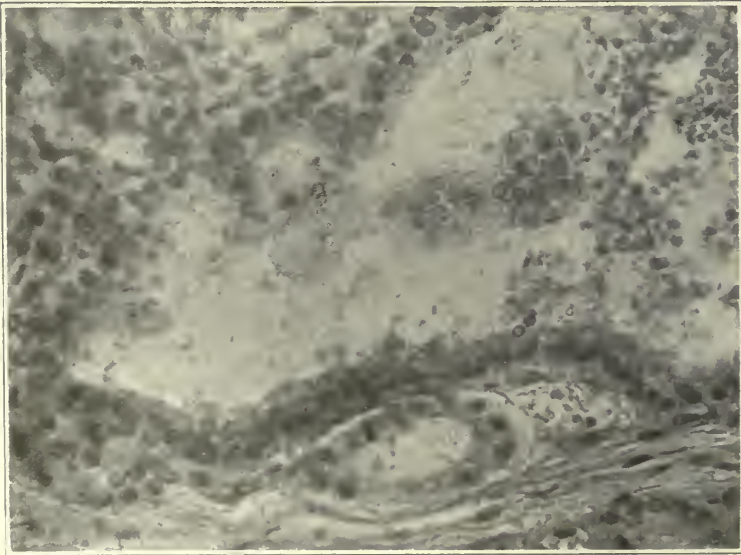


Fig. 47.—Slide showing extensive secondary degeneration in a primary toxic adenomatous goiter.

may judge from the slide what the clinical symptoms and prognosis may have been. It must be constantly kept in mind that all parts of the gland are not equally affected and one may find in the various parts of the gland several types of disease. Enough of the gland must be examined to insure an average picture of the dominant lesion. The more thoroughly the glands are studied the fewer exceptions will there be to this rule.

Recessions in toxicity of the goiters are not always ex-

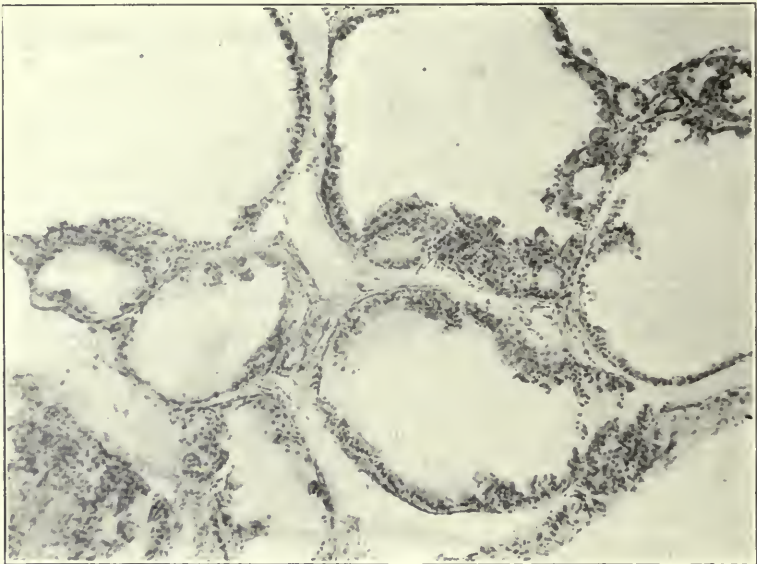


Fig. 48.—Slide showing the exfoliation of the acinar cells in an acutely fatal case of toxic goiter.

pressed by anatomic changes in the gland. Usually the density of the gland lessens if it has been firm, and expansile pulsations cease if it has been pulsating. Probably there is a decrease in the round-cell infiltration and the serous exudate in the one and a lessening of the stimulation of the vasodilators in the other. This inference seems warranted because of the differences observed when one lobe is resected in the stage when the goiter is firm and sensitive to pressure and the other resected when the remaining lobe has softened as the one type and in the other there is a lessened vascularity observed at the op-

eration when the operation is done after the pulsations have ceased.

In order to make the pathologic findings harmonize with the clinical observations it is necessary, therefore, to take into account the stage of the disease as learned from the history of the case. If the microscopic findings indicate a very intense intoxication and the patient does not present evidence of it the history likely will reveal that the disease has passed its peak.

Glandular Degeneration (Secondary Toxic Goiter).—This condition is usually implanted on a long pre-existing colloid goiter and is therefore properly called “secondary Basedow.” Two forms may be distinguished. In the first there is a general degeneration without reaction either on the part of the defensive forces of the body or by proliferation of the acinal cells. In the other type there is a proliferation of the acinal cells associated with the general degeneration. One may call the former a secondary degenerative toxic goiter and the latter a secondary proliferative toxic, being, therefore, not strictly speaking a toxic goiter but an adenomatous one implanted on a pre-existing goiter.

DEGENERATIVE TOXIC GOITER.—The degenerative type should really have been appended to the degenerative changes in colloid goiter, but since it is attended by grave toxic symptoms it adds to clinical clarity to discuss it here. In this type the onset of toxic symptoms is usually sudden, occurring chiefly in old women. After being for many years the serene host of an “innocent” goiter the patient rapidly loses weight and becomes nervous. The gross appearance does not differ from old colloid goiters. They may show any of the types of secondary degeneration mentioned under that type. The chief changes are usually found in the colloid. The gross changes are those of any long existing colloid goiter. Even when toxicity is extreme, the gland remains firm but may be sensitive. It has no pulsation of its own but may throb with the much excited carotids. That part of the gland responsible for the intoxication is the part which previously approached the stationery colloid goiter. Those portions which have previously undergone the usual degenerative changes of colloid goiter do not seem to take

part. The colloid shows marked vacuolization (Fig. 49.). The colloid is granular and is largely indifferent to any stain. It usually shows complete retraction from the acinal cells. The cells show a lessened tinctorial reaction, are often flattened and sometimes are loosened from their basement membrane (Fig. 50) or may lie free in the colloid substance (Fig. 51). In these, large areas of gland sometimes seem to have undergone necrobiosis.

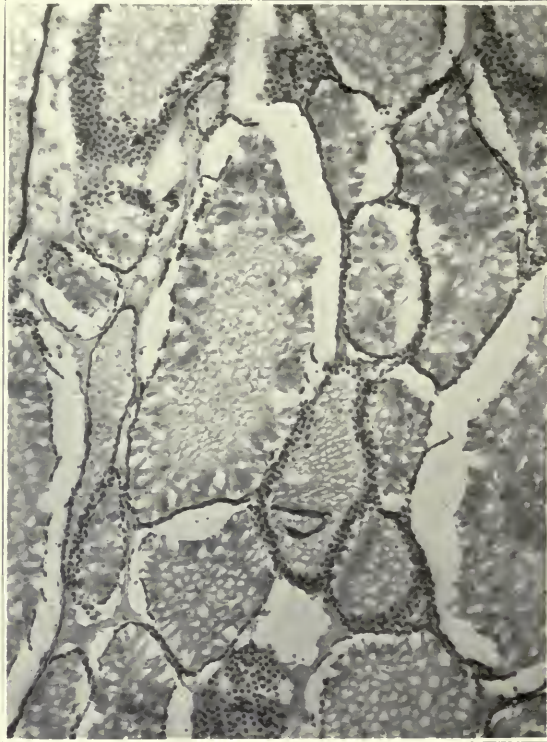


Fig. 49.—Slide showing degeneration of the acinar cells and the colloid in a secondary toxic goiter.

This same process may begin in a thyroid not previously enlarged or in the portion of gland remaining after a partial lobectomy. That the symptoms are due to dysfunction is suggested by an autopsy Halsted (Johns Hopkins Hosp. Rept., 1896, i, 373) made on a dog in which a complete removal of the thyroid was done a year previously. This dog became emaciated, weak, and lost its hair during the year following the removal of the thyroid gland. Following thyroidectomy there may be a




Fig. 50.—Slide showing separation of the acinar cells from the connective tissue in a secondary toxic goiter.

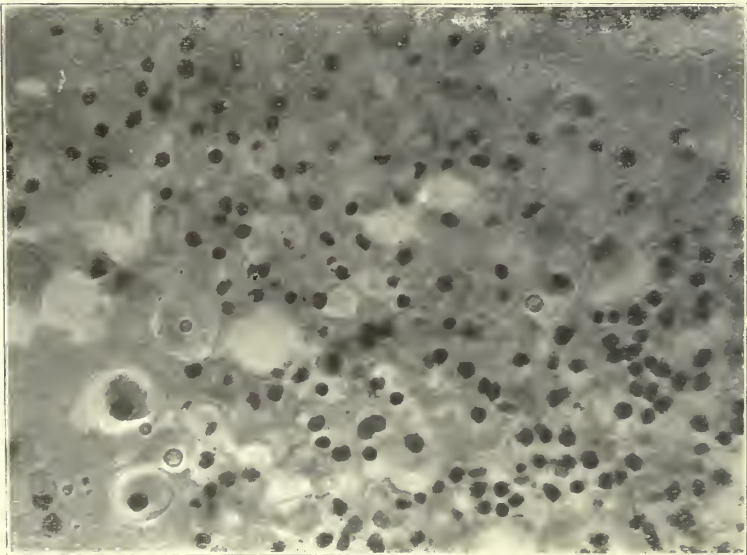


Fig. 51.—Slide from a secondary toxic goiter showing the acinar cells in the midst of the colloid substance.

return of the symptoms of tremor, rapid pulse, rapid loss of weight and death, yet at autopsy there may be all but a complete loss of all thyroid gland tissue. In severely toxic cases with increase of the gland, the enlargement may disappear and a fatal issue ensue without any change in symptoms though the gland undergoes complete disintegration. There is nothing in our present theory of things to explain this extreme anatomic variation.

SECONDARY ADENOMATOUS GOITER.—This form usually occurs in younger women than the preceding. The metabolic changes

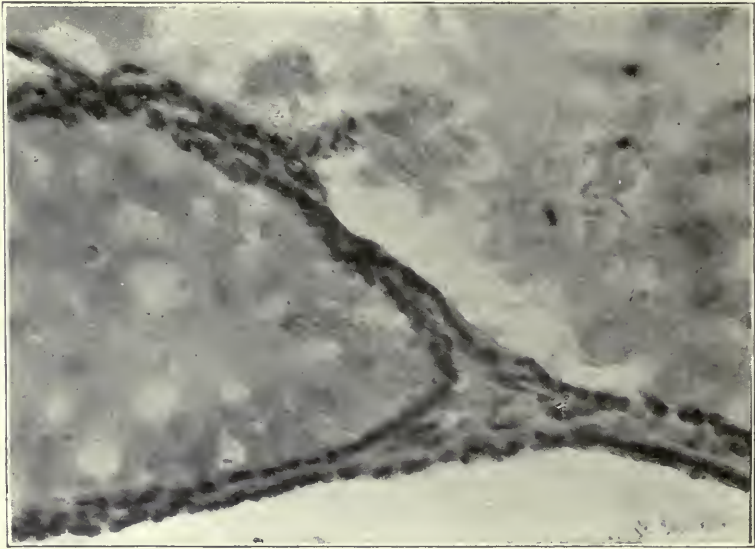


Fig. 52.—Slide from a secondary toxic goiter showing the rejuvenescence of the acinar cells. The colloid has undergone extensive granular degeneration.

are less pronounced and the ordinary symptoms of toxic goiter, even to the eye signs, may be noted.

The gross sections of this form also are often those of an ordinary colloid goiter with the secondary changes this type is prone to undergo if long existent. In persons who have had an “innocent” goiter many years all the secondary changes incident to colloid goiter may be found. Often the goiter is very firm and sensitive to the touch. The slides do not show infiltration which one naturally expects to find. The tenderness evidently is due to a noncellular infiltration. Instead of there being a

degeneration of the cells there is usually somewhere in the gland a rejuvenescence of the cells (Fig. 52). Usually the acinal cells are increased and sometimes there is an increase of gland formation. When exophthalmos is present papillary formation will be found (Fig. 53). In this type there is often more or less round-cell infiltration in the connective tissue. These areas are often so pronounced as to resemble lymph follicles and some writers have described germinal areas in them as was described for the primary adenomas. The colloid is vacuolated, often granular, and frequently contains much debris of epithelial cells as described for the preceding type. The retraction from the cells

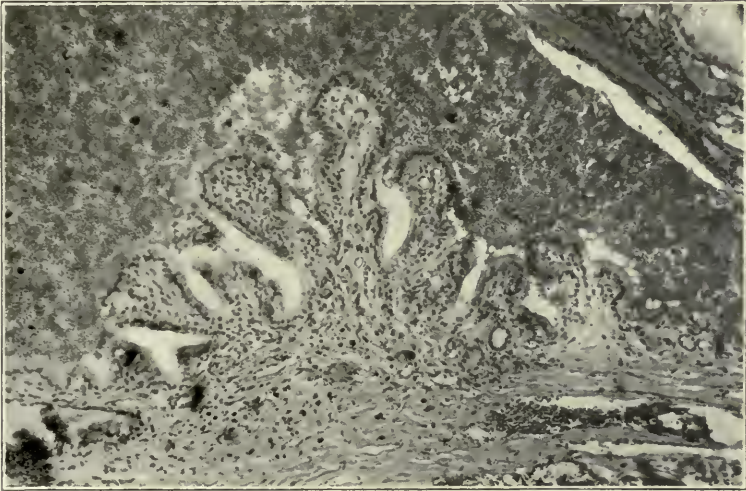


Fig. 53.—Slide from a secondary toxic goiter showing papillary formation.

is apparently the earliest and mildest change. The proliferation of gland acini in the areas where gland degeneration is the most pronounced gives the impression of a compensatory development of gland tissue. It is not a normal reaction, however, because these newly formed glands do not, usually, contain colloid. These hyperactive cells may subside and the goiter again assume its "innocent" state. —

In this type of goiter sometimes relatively normal areas of gland tissue can be detected at the operating table. These areas are commonly found near the upper pole and to a lesser extent at the lower pole. It is important to recognize these areas at the operating table.

Interstitial Proliferative Goiters (*Forme Fruste*)

In many goiters there are relatively slight changes in the acinal cells or in the colloid but the increase in the cells in the interstitial spaces is marked. These changes may consist of a mere multiplication of these cells, sometimes in the formation of colloid-containing spaces resembling young acini. The acini are but little enlarged (Fig. 54) and the colloid but little changed. The interstitial cells show an abundant increase, widening the spaces between the acini quite materially (Fig.

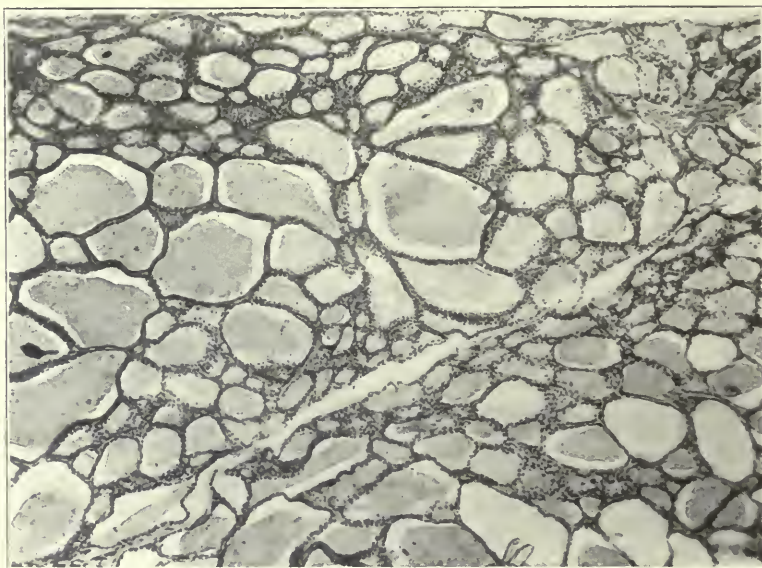


Fig. 54.—Slide from a forme fruste goiter showing activity in the interstitial cells with little change in the acinal cells or in the colloid.

55). In other sections large areas may be dominated by these cells, the acini apparently having suffered injury by compression (Fig. 56).

These cells do not differ greatly from the acinal cells. They differ from the cellular exudate as seen in inflammations, but when they are diffusely scattered, one cannot tell when the interstitial cells end and the acinal cells begin. This is sometimes seen in the typical Basedow cases of a very acute type. This, however, would not exclude them from a separate category. Little can be judged of a cell's function by its appearance as an

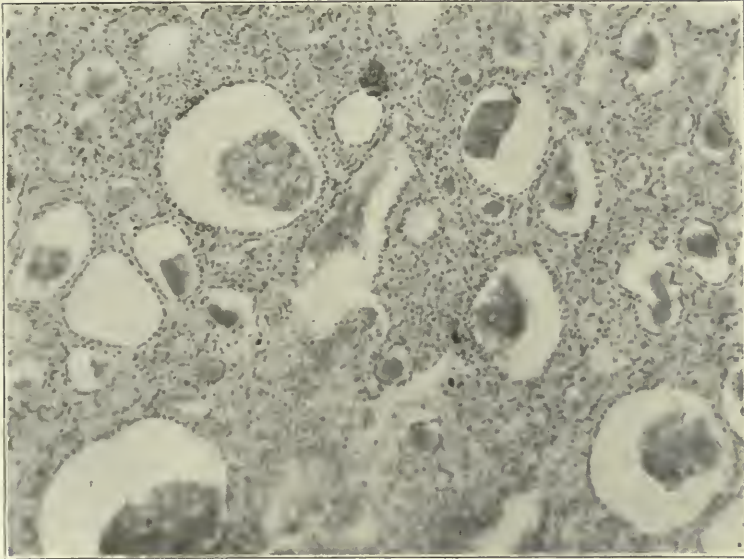


Fig. 55.—Slide from a forme fruste showing marked increase in the interstitial cells with degeneration of the colloid substance.

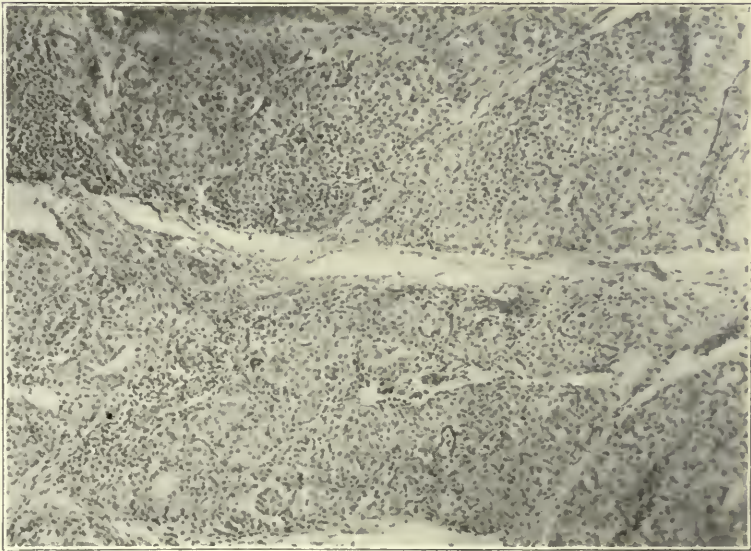


Fig. 56.—Slide from a forme fruste showing extensive proliferation of the interstitial cells with little evidence of colloid substance.

isolated cell. These cells do not represent a reactive product for in glands the site of active reaction has the interstitial tissue infiltrated with leucocytes and lymphocytes (Fig. 57) in ad-

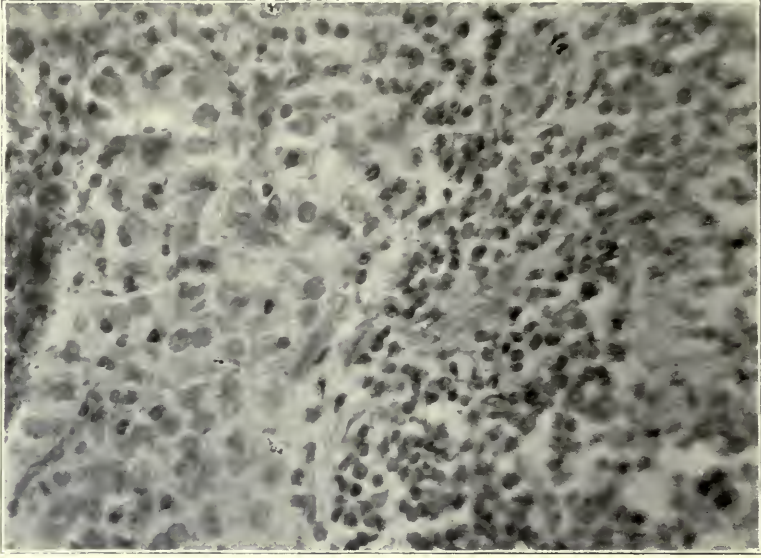


Fig. 57.—Slide from a forme fruste showing on the left of the figure extensive proliferation of the interstitial cells and on the right of the figure, round-celled infiltration.



Fig. 58.—Section of two cases of forme fruste showing the fine granular surface.

dition to the interstitial cells but these present the classical appearance and are not to be confused with the cells now under discussion.

The source and significance of these cells is an unexplored

field. I have been struck, however, with the very constant association of these changes with the forme fruste type. Since this type of disease differs essentially from the typical Basedow type it appears possible that the thyroid like the testicle and ovary, may be really a compound gland, the interstitial cells representing one function, the acinal cells another. If this were true, the thyroid might have a "polyglandular" disturbance all by itself. The thyroid in this type of the disease is small, fine, granular (Fig. 58) usually firm elastic and is never fragile like the true toxic goiters often are.

Before any headway can be made along this line the histology and histogenesis of the gland must be investigated anew. That colloid in the interacinal spaces lies in the lymph channels has not been proved, and that this material is the product of acinal cells and found its way into the interstitial spaces, either as colloid or "precolloid," has not been demonstrated.

There are many curious and inexplicable mixtures of disturbances in the thyroid gland both clinically and anatomically and it is quite possible that a closer morphological study may reveal much of interest.

Pathology of Other Organs Associated with Goiter

Unquestionably too great a proportion of attention has been centered on the changes within the thyroid gland and too little on associated changes. This finds its explanation in the fact that most of the material obtained is from biopsies and in the second place that outside of the thyroid gland there is little or nothing that is tangible. Since, however, there is a close association of the thyroid with other organs this very fact should be a stimulus to intensive study.

What little there is known may be referred to here which at least is impressive in its paucity.

Pathology of the Nervous System.—Surgeons happily have little opportunity to study lesions other than those of the tissue removed at operation, hence I am obliged to depend on the recorded autopsy findings of the internists. The most constant finding in the brain is petechial or larger hemorrhages. If one remembers the usual death scene of these cases one would hardly wonder at this. Klein in 37 autopsies found fresh hemor-

rhage in 24 cases, obviously terminal changes. In 19 there were changes in pons and medulla, 6 times, in the cerebrum, and 3 times in the cerebellum. In 20 there was a fresh hemorrhage, 5 times a leucocyte infiltration, 3 times fresh degeneration, in 2 old hemorrhages, in 5 atrophy of ganglion cells of the fibre bundles and in 3 areas of acute softening. The most constant changes are in the medulla, particularly in the floor of the fourth ventricle. Hemorrhage in the floor of the fourth ventricle may be responsible for the terminal hyperpyrexia. Admittedly the hemorrhages are recent and therefore cannot be used as explaining causative factors. White believes there are preliminary changes in his region which may be softened and the hemorrhages occur here because of the previous degeneration. Müller suggests that these may account for the bulbar symptoms sometimes noted. How or by what agent these areas become injured White does not say.

Crile found some pronounced changes in the ganglion cells. Wilson (*Jour. Lab. and Clin. Med.*, 1917, ii, 295) has described changes in the sympathetic ganglion. He notes the presence of functioning and nonfunctioning cells in immediate proximity. Such changes are not found in patients on whom a complete lobectomy has been done. He compares the changes with those seen in the ganglion cells in the cord in poliomyelitis. These changes consisted for the most part of leucocyte infiltration and hyperemia as well as degeneration of the ganglion cells.

The findings in the spinal cord and peripheral nerves have been even less impressive. For instance Cheadle found hyperemia and White some isolated hemorrhages. Joffoy and Achard found slight degenerative changes in the anterior spinal nerves.

On the whole it may be safely stated that the pathologic changes in the nervous system are few, inconstant, and unimpressive. On the whole, they represent terminal changes. They remind one very much of the autopsy findings in cases of eclampsia. Those who argue for the neurogenic origin of thyrotoxicosis must depend on clinical observation, for no anatomic confirmation is available.

The Thymus.—The relation of the thymus to toxic goiter has been much discussed. Halsted particularly emphasized the importance of a careful consideration of this gland. On the

whole it may be said that in recent years interest has lagged, perhaps because so few have found this gland enlarged, either because of its absence or of faulty technic. Mikulicz was perhaps the first to sound a word of discouragement. As a source of possible danger in operative prognosis it looms larger. McCordie in 35 cases of sudden death in goiter patients found hyperplasia of the thymus in 18 cases. Mackenzie (*Brit. Med. Jour.*, 1897, i, 333) in 1897 described two cases of Graves' disease with persistent thymus and (*Am. Jour. Med. Sc.*, 1897, cxiii, 132) advised the use of the extract of this gland as a therapeutic agent. Capelle thinks there is a persistence of the thymus in nearly half of the cases of Graves' disease and is present in 85 per cent of the cases of death from this disease and in 95 per cent of cases which died following operation. Slightly lower figures but still impressive are given by Schultze (87 per cent), Rehn (87.5 per cent) Gebele (80 per cent), and Kocher (60 per cent).

That the thymus is not a direct factor is attested by the fact that it is absent in a considerable number of cases. The size of the persistent thymus is not given in the impressive figures above quoted. I have regularly failed to find the gland for reasons not clear to me. At any rate, the very large glands mentioned by some (Symmonds, 65 gm., Schlagerhauser, 45-90 gm., etc.) have not been present in my patients. It is possible that the enlargement of the thymus may be but a secondary, possibly a terminal, process, for it is generally believed this gland may undergo hyperplasia in infections and in cases of starvation.

The histologic findings likewise are inconstant, or at least the interpretation of them is. Most authors note that the infantile type is retained. Kocher believes a medullary hypertrophy is characteristic of the Graves' disease thymus. Schridde is in general agreement with this. Hassels corpuscles are diminished according to most authors but according to Saupault there is a marked increase and Mönckueberg found the same thing. Some found them remarkably large, others small. Various degenerations, notably hyaline and calcareous, have been noted. Fat infiltration has been observed in a number of cases.

Lymphatic hypertrophy has been found by a number of observers. It is a rare occurrence in my experience.

The relation of hypertrophy of the thymus and lymph glands to Graves' disease is probably that of general intoxication. The great variability, and the inconstant occurrence precludes the possibility of a direct relationship.

Suprarenal Gland.—The changes found in this organ seem to be irrelevant for the most part, no two investigators finding the same changes. Kocher found hyperplasia of the suprarenal when there was hyperplasia of the thymus. Pettenvel found lymph follicles in two cases. Parode found proliferation in the medullary portion while Pettenvel found a hyperplasia of the cortical portion. In one patient, who died in this clinic, we found the suprarenal capsule generally degenerated, approaching a state of necrobiosis.

Hypophysis.—This gland has been but little studied. Benda found the cells small in all portions, while Farners found a general enlargement, having found a hyperemia in five cases.

Parathyroids.—McCallum found these glands unchanged. Humphrys in two cases found an infiltration of fat. Stune found tuberculosis in one gland.

Pancreas.—Askanagy found nothing; Pettenvel in two cases found the pancreas atrophied in one, in one an atrophy of Langerhans' bodies with leucocyte infiltration and areas of necrosis. In coincident cases of Graves' disease with diabetes the characteristic pancreatic changes of the latter were found by several observers.

The Genital Tract.—The changes in the genital tract coincident with goiter are numerous. What the relationship is to goiter is another matter. The changes are of two types, those of the mid-child-bearing age in which there are lacerations and displacements of the uterus and in the adolescent period where there are hypoplasias. The former are associated with typical thyrotoxic goiters, while the latter are associated with the formes frustes. The lacerations and displacements and other gross surgical lesions cannot have a direct relation whatever influence they may have on the nervous system. In the latter type the relation is such that a direct association is indicated. The most constant finding is a hypoplasia of the ovaries. The

organs are small, hard and contain few graafian follicles. Often the uterus likewise is hypoplastic. Hetzel reported a case in which the cervix was larger than the body. I have seen several such. Pettenvel found the ovaries large but containing few follicles and Farner also found few follicles.

Circulatory Apparatus.—From the symptomatology of toxic goiters one would expect extensive changes. Many such have been reported. For the most part these consist of dilatation and hypertrophy, chiefly of the left ventricle. There are considerable variations noted of degree and combination as one might expect from the varying duration of the disease. Various pigmentations and degenerations of the heart muscle have been noted and in some cases marked fatty degeneration. It is difficult to separate out lesions due to some pre-existent disease and those due to the goiter itself, if such there be. There is constantly an increase of blood pressure sufficient to make some difference in the heart muscle. Possibly the increased rate may add to the work-hypertrophy if it is such. The fact that there are degenerative changes in the skeletal muscles makes the assumption plausible that there is some direct effect on the heart.

Digestive Tract.—Collections of lymph nodules in the gut walls have been noted and naturally various hyperemias have been observed.

Liver.—Aside from congestion and fatty degeneration, few liver changes have been noted.

Kidneys.—Hyperemia and degeneration represent the few recorded findings. The changes all are such as are found in the usual routine autopsies.

Muscular System.—Askanazy (Deutsch. Arch. f. klin. Med., 1896, lxi, 118) found extensive degeneration in the skeletal muscles. He believed they are due to toxic substances circulating in the blood vessels and have nothing to do with the nerves. He found the degeneration in the skeletal muscles, diaphragm, esophagus and eye muscles. He describes the changes as an interstitial lipomatosis. These observations have been confirmed by most observers but a few have failed to find any such changes. A possible specific relationship is rendered doubtful by the fact that Langhans found like changes in the muscles of cretins.

Osseous System.—Osteomalatic symptoms have been noted as have lymphocyte infiltrations of the marrow of some of the long bones. Unusually thick bones of the skull have been noted. The known relation of the ovaries to osteomalacia has been used as an argument for the theory of direct relationship between the ovaries and the thyroid gland. Be this as it may, there is nothing in the pathology of the bones in patients dead of goiter to give it weight.

In considering the findings in the various organs above quoted, it is interesting to note that most of the general findings are such as might be accounted for by the fact that the patient was long seriously ill. There is nothing in the whole category that might rightfully be ascribed a relationship either causative or as a result of the thyroid change. It should be noted that those authors who find changes in one organ find changes in many other organs, while those who report negative findings in one organ do not find anything in any of them. The suspicion is raised, therefore, that the personal equation plays a considerable rôle.

General Summary

When one collects the opinion and observations on the pathology of the other organs of the body the fact remains that the only definite and constant pathologic changes are found in the thyroid gland itself. While the variations from the normal are not always commensurate with the clinical symptoms, the same may be said in reference to the kidneys and Bright's disease as Wilson has well pointed out. The variations between the normal and abnormal are very close it has been noted. The same is true of the symptoms. Transition cases occur in the one as well as the other. Kocher's statement that a normal thyroid has not yet been demonstrated in a case of goiter still holds. While it must be admitted that our knowledge of the pathology of goiter is very meager and unsatisfactory, the fact remains that what we do know points to the thyrogenic nature of the disease.

CHAPTER III

SYMPTOMATOLOGY OF DISEASES OF THE THYROID GLAND

The clinical signs and symptoms of goiter are so protean and the dividing line so narrow that it seems unwise to separate the different forms in treating this phase of the subject. It is particularly desirable to warn against the complacent regard of any goiter as simple. There is no simple goiter. One had best think of the group usually considered under this head as not yet toxic. Unless one does this, his treatment may very quickly convert it into a toxic one. In harmony with this view the symptoms which may be found in any goiter will be discussed in turn. This is eminently practical for the whole list of symptoms must be considered in every case of demonstrable or suspected goiter.

Goiter

An enlargement of the thyroid gland is present in the vast majority of patients suffering from thyroid diseases. There are rare instances in which the gland is not enlarged. In those instances in which there is no enlargement there can always be demonstrated some definite anatomic change. In every case which I have sectioned there have been distinct changes, wholly like those of the enlarged gland. There may be a thyrotoxicosis without goiter as some contend, but there is no thyrotoxicosis without disease of the thyroid gland. Furthermore, when there seems to be no enlargement to palpation, when the gland is exposed at operation, it may be found to be markedly enlarged. Those who contend that there are patients showing the thyrotoxic syndrome without change in the gland have yet to exhibit normal glands.

Degree of Enlargement.—Because of the location of the thyroid gland there is no satisfactory method of determining whether it is enlarged at all or not. If enlarged there is no

scheme whereby we can compare it with the size of other glands. This is obvious when it lies substernally, but the difficulty may be nearly as great when the neck muscles are well developed and the adipose deposit generous.

Ordinarily in average necks the normal thyroid gland is just palpable to experienced hands. If easily palpable, it is probably slightly enlarged. If palpable in the plump patient, it may be regarded as being enlarged. Often an increase in consistency is as valuable as evidence as increase in volume. Increase of sensitiveness, likewise, may be evidence of increased activity. During pregnancy these statements must be modified, for during this state not infrequently the thyroid gland is easily palpable in the normal state.

When the isthmus is present it is usually easily detected lying over the trachea just below the cricoid cartilage. The lateral lobes can best be detected by placing a finger on either side of the trachea and pressing gently downward and backward. This is usually facilitated by inclining the patient's head gently forward. If the patient is asked to swallow, the excursions which the gland makes with the trachea may bring it into contact with the examining finger. If the goiter is located behind the sternum or the clavicle, coughing may cause it to appear or to transmit an impulse to the examining finger. In the latter situation the x-ray may aid. This is particularly true if the goiter is an old one which has undergone fibrous or calcareous degeneration. In small soft goiters the x-ray picture may be unsatisfactory or misleading. One should not depend on the x-ray examination alone. I have repeatedly operated on patients under the assurance of the x-ray man that there was a goiter under the sternum only to meet disappointment and I have much oftener operated on patients whose chests were negative to x-ray only to find large masses. Both these experiences were humiliating. Percussion also in large ones gives positive evidence, but in small ones, because of the bone conduction, this method too leaves one in doubt. In such cases the question of the vocal cords, the deviation of the trachea, the subjective symptoms must be taken into account. All the arts known in the diagnosis of mediastinal tumors must be invoked.

Once the presence of goiter is determined, a means of comparative record is desired. There is no satisfactory way. Mensuration is unsatisfactory because of the varying shapes of necks. It is impossible to place the tape in the same position each time a measurement is taken. Many clinicians, however, employ this method. If one desires to depend on measurements, McGarrison's scheme (*The Thyroid Gland in Health and Disease*, Wm. Wood Co., 1917) is as good as any. In necks measuring 13 to 16 inches, he assumes an increase of an inch represents a doubling and an additional increase of $\frac{1}{2}$ to $\frac{3}{4}$ a quadrupling of the gland.

My experience has been that one does as well to employ more general terms, such as palpable to indicate the normal; easily palpable to indicate a suspected enlargement; small when the gland is the size of an egg; medium when the size of a turkey egg, and large when the size of a goose egg. For the very large ones usually a suitable adjective suggests itself when the examiner first sees it. Usually the interne attends to the designation in a satisfactory manner.

In determining the progress or regress of the goiter one's memory is as good as a measurement. Men and elderly women may estimate the increase or decrease by the tightness of the collar. As a matter of fact, the size of the gland is of minor importance, progress of the disease is measured better by other symptoms than by the size of the gland.

Consistency.—The normal thyroid is soft and elastic. When it is enlarged it may be soft, pulsating, firm or even hard. Many early large toxic goiters are very soft, almost semi-fluctuating. As they grow older they are prone to become harder. The toxic type when rapidly developing, when soft, is usually pulsating as well. The pulsations are detected by placing the flat hand over the goiter, when a gentle expansion is felt with each pulse beat. Expansion must be distinguished from a transmitted impulse from the carotid or thyroid arteries. Colloid goiters when old are firm and when firm are usually sensitive as well. This firmness may equal, particularly in severely toxic cases, the feel of cancer. In these often as the disease subsides somewhat the hardness gives way to a peculiar liver-like elasticity. In these cases an impulse is imparted to the examining finger which may

be mistaken for expansion of the goiter but it is due to the movement of the whole gland in response to the impulse of the carotid and thyroid vessels. A goiter cannot be expansile and hard at the same time. When fibrosis has developed, particularly if calcareous deposits are present, bosselations and angulations of positively stone-like hardness are felt.

Sensitiveness.—The normal thyroid and the colloid goiters are not sensitive to ordinary manipulation. Toxic goiters, on the other hand, are often sensitive to touch. This may be true when the gland is yet too small to be positively identified. Severely toxic goiters are often as sensitive as acutely infected goiters. In these very sensitive glands the subcutaneous tissues may be somewhat edematous.

Mobility.—A nontoxic goiter usually is freely movable under the overlying muscles. Cysts sometimes are so mobile that they may give the impression of lying beneath the subcutaneous fat. Mildly toxic goiters may be equally mobile. Those which have been markedly toxic and regressed may seem mobile but may nevertheless be closely attached to the surgical capsule. Acutely toxic goiters may be so firmly fixed that they are but slightly mobile to manipulation and follow the trachea but indifferently during deglutition or more correctly speaking, limit the excursion of the trachea. The importance in determining the mobility consists in that thereby the difficulties of an operation may in a measure be judged. In a measure only, for not infrequently a goiter may seem freely movable and yet be firmly fixed and present many difficulties in operation. When they are firmly fixed the problem is simple—the operation will undoubtedly be difficult and the surgeon may prepare his field accordingly.

Aberrant Goiters.—Goiters or parts of them may lie at situations other than the normal places. The more common sites are in the thorax, at the angle of the jaw and at the base of the tongue. (See Chapter VI.)

Eye Symptoms.—It is the symptoms manifest by the eyes that distinguish between the simple toxic goiter and the exophthalmic goiters, or true Graves' disease. It is the least constant of the triad of symptoms counted as pathognomonic of Graves' disease, but when it is present it is all but infallible.

The eye signs are present in less than 10 per cent of all toxic goiters.

Exophthalmia.—The most striking of the eye signs is prominence of the eyeball. In some cases other eye symptoms are present without exophthalmos, but the two usually go hand in hand with the protrusion preceding the development of the other signs.

The protrusion of the eyeball is usually noticed by the patient's friends before a physician is consulted. Less often it appears late in the disease. This is true particularly in the degenerative type. In mild cases the expression is best described as that of surprise but in more pronounced cases it is more that of terror. It is never that of anger as it is sometimes described. The facial contour of the patient may emphasize or suppress the prominence of the protrusion and the degree of lid retraction also influences the apparent prominence. The degree of vascular compensation plays a rôle. When there is decompensation, it may be increased. Increasing toxicity and emaciation may act in the same way.

Exophthalmos is bilateral in about 80 per cent of the patients, but one side only may be affected; in such instances it is usually the right that is involved and not infrequently remains dominant though the other eye may protrude later. Sometimes the most prominent eye is on the side of maximum thyroid development but not always. The degree of protrusion of the eyeball varies from time to time and is most apt to be pronounced at the menstrual period. The cause of the protrusion has been discussed. The most generally accepted explanation is that the protrusion is due to the contraction of the muscle of Müller. This muscle extends in the upper lid from the palpebral insertion of the superior levator palpebrae muscle and extends to the tarsal cartilage. In the lower lid it extends from the fovia of the conjunctiva to the lower border of the tarsal cartilage. Though this muscle is scarcely 1 cm. in length to it is ascribed the power of giving the staring look. Schmitt-Rimpler (Nothnagles Handb., xxi, 1898) denies that this weak muscle is capable of producing the dislocation of the eyeball. The sympathetic system has been held responsible, presumably by stimulating Müller's muscle to contraction, and to counter-

act its influence removal of the superior sympathetic ganglion has been advised. There seems to be some evidence that section of the sympathetic is followed by regression of the eyeball in some cases. The operation is no longer done which may be taken as evidence that the previous observations were erroneous or that the results are uncertain or indefinite. The overfilling of the vessels of the orbit has been ascribed an important part. The fact that the exophthalmos disappears after death has been pointed to as an argument for this theory. Later on, no doubt, the orbital fat proliferates and adds its part. The evidence of this is found in that in early cases the prominence of the eye can be reduced by gentle pressure while later on this is not possible. Earhardt (*Deutsch. Chir.*, Lief. 38, s. 232) believes the protrusion is facilitated by the degeneration of the ocular muscles which lessens the resistance offered the overdistended vessels of the orbit.

Exophthalmos is usually the last symptom to disappear after cure by operation, and it is not at all uncommon for it to persist to some extent. This persistence may be ascribed to anatomic changes in the orbital tissues. Operations have been devised for the removal of the excess fat, but the results do not seem to warrant imitation.

The degree of prominence varies. Sometimes it is scarcely measurable but in not rare instances it is so protuberant that the lids do not close and in very rare cases the eye is said to be actually forced from its socket. A number of instruments have been devised to measure the degree of exophthalmos. They can be of use only in measuring the progress of a case. Since there is no constant relation of the cornea to any fixed point, it cannot be used as a means of diagnosis. When the exophthalmos is so great that the lids do not close over the eye, the cornea is much endangered. Jessop (*Ophthalmic Review*, November, 1895) collected 25 cases in which blindness occurred from ulceration. In a general way only the degree of exophthalmos bears a relation to the severity of the disease. A graphic record of the degree of exophthalmos is difficult to obtain. As much as 31 mm. protrusion has been recorded, usually it amounts to between 5 and 20 mm.

Imperfect Movement of the Upper Lid.—Despite the

marked displacement of the eyeball, there is seldom a limitation in the range of movements of the eyeball. The protrudent eyes are usually symptomless. The eye signs other than those of exophthalmos have to do with the movements of the eyelids. They are usually more or less associated. When one is present, the others are quite sure to be sooner or later.

Graefe's Sign.—This is the best known and most important of the eye signs. It is best elicited by placing the finger above the horizontal line of vision and after the patient fixes her gaze on the finger gradually lowering it. It is seen then that the upper lid follows the downward movement but imperfectly and may allow an area of sclera to appear. The lid may follow the eye downward for a time and then remain stationary while the eyeball continues its journey unattended, or the lid may lag behind but follows with a jerking motion. As the eye is moved upward again, the lid may travel the faster and expose a considerable area of the cornea until the eye catches up and then the two may continue upward together. It has occurred several times in my experience that when the patient was engaged in very exciting conversation so that his attention is closely fixed and interest excited, one or both lids will slowly rise exposing a rim of cornea, then slowly descend again, when the regular tests for von Graefe's sign were negative.

A pseudo-Graefe symptom may be present in some cases where there is disturbance in the innervation of the eye muscle due to some central nerve lesion as in Thompson's disease and in some intrinsic eye diseases. Orbital tumors may cause a protrusion of the eye and a Graefe sign may be simulated so far as exposure of the sclera goes, but there is never the cogwheel movement of the lid.

The cause of this sign has not been established. Contraction of Müller's muscle (Remak) and congestion of its palpebral muscle (Terry) have been blamed. Because of its constant association with exophthalmos the same cause likely is operative in both symptoms.

Lessening of Involuntary Winking.—One of the earliest symptoms is that first described by Stellwag (Wiener Jahrbücher, 1869, xvii, 25). It consists of a prolongation of the interval between involuntary winking. It is best observed when

the patient is engaged in relating her history or when the examiner is counting her pulse. At any rate, the patient should not be conscious of being observed. The rate of normal winking as given by Stellwag is from 3 to 5 per minute while in Graves' disease it may be reduced as much as to one per minute. This symptom often gives the examiner the first hint as to the nature of the disease. It is associated with the widening of the palpebral fissure. This phenomenon was first observed by Dalrymple and first recorded by W. White Cooper (*Lancet*, 1849, i, 551). This symptom is sometimes observed in other nervous diseases, notably in hysteria. The excitement incident to the first meeting with the examiner in susceptible persons often gives these nervous patients a staring look. Even this may be in itself an important sign. If a person accustomed to meeting strangers stares out of nervousness it should suggest thyrotoxicosis. On the contrary rapid blinking may occur particularly in very toxic cases especially if the patient has learned of this eye sign from previous examiners.

These lid symptoms are seldom present when there is no exophthalmos but in some instances they are present and in such cases are of the greatest diagnostic value. They are by no means always present even if exophthalmos is present (Marie). They sometimes vary from day to day being present sometimes and absent at others, or are present in varying degree of prominence on successive days.

Disturbance in Convergence.—Möbius first noted the disturbance in convergence. If the patient is asked to fix his vision on a distant object the eye is unable to follow it to as near a point as is possible in the normal eye. In testing for this symptom Möbius advises that the patient be told to look at the ceiling and then quickly at the end of his nose. One of the eyes ceases to fix the object and turns outward. It is interesting to note that double vision does not result, but the patient complains of an unpleasant tension. This sign does not maintain a relationship to the signs previously mentioned and it is usually not present until there is a pronounced exophthalmos. This symptom may be noted in nervous affections; is one which can be used only by those familiar with the exact examination of the eye;

and is of relatively little importance because when it is present other more characteristic signs are easily elicited.

Uncommon Eye Signs.—Gifford's Sign.—Gifford (*Ophthalm. Rec.*, 1906, xv, 249) described a symptom occasionally present. It consists in a marked difficulty in everting the eyelid. It is not due to a thickening of the tissues but to a spasm of the levator muscle. It is observed early and tends to disappear later in the disease. It is a curiosity rather than a symptom of much diagnostic value because when it is present the other symptoms are pronounced.

Pupil Sign.—The pupils are usually not affected, occasionally one pupil is larger than its fellow. This is usually noted in large thyroids which press on the sympathetic nerves. Occasionally patients come with this as their chief complaint. If there is any disturbance in the size or motility of the pupil some other cause should be diligently sought. The reaction to light is normal.

Field of Vision.—In some instances the field of vision is contracted (Kost, Wilbrand). These symptoms may be due to complications, notably that of hysteria (Möbius).

Tear Secretion.—The secretion of tears may be much increased, even to such a degree as to cause the patient annoyance. On the other hand, the conjunctiva may be so dry as to greatly harass the patient. Corneal ulcer is a rare complication, but when it does occur, is a serious one, and not infrequently results in the loss of the eye. Liability to ulceration does not run parallel with the degree of exophthalmos. Some of the most pronounced degrees of ulceration occur in cases with relatively slight protrusion. In some cases there is an anesthesia of the cornea. This may predispose to ulceration.

Nystagmus.—A rare sign is an oscillatory movement of the eyeball. It is sometimes present while gazing in certain directions. Kocher saw it only in a few instances.

The eye signs above enumerated are all but pathognomonic of thyrotoxicosis. Usually there are symptoms which will permit a diagnosis without them. Too great emphasis of this member of the triad has caused many cases of thyrotoxicosis to be overlooked. On the other hand, obscure cases without goiter are sometimes first recognized by the presence of the eye signs.

Involvement of the Muscular System.—The voluntary muscular system is affected by tremor and weakness. The former resembles an overstimulation and the latter a loss of control of the nerve supply.

Tremor.—A fine tremor of the hands, less often of other parts of the body, is one of the most constant symptoms of thyroid intoxication. Charcot and Pierre Marie seem to have been the first to emphasize the importance of this symptom. The latter measured the rate and degree of the tremor by means of tracings on a carbon sheet. He found the rate varies from 8 to 10 to the second. He discovered furthermore, that the normal individual shows a very fine tremor of the same rate.

The tremor is often observed even before the rapid heart or other signs of thyroid intoxication. On the other hand it is present in many nervous states as in hysteria and neurasthenia and in alcoholic tremor. Generally speaking, in nervous states it is not so constantly present as in thyroid intoxication. On the other hand it is likely that many patients classed as hysteric and neurasthenic were really suffering from thyrotoxicosis.

In many instances patients have not noticed that they had a tremor before the test was applied while in others it is so great as to constitute the chief complaint.

It is noted that the trembling of anger and fear is very similar to that in thyroid intoxication. Such consideration suggests that the tremor is closely related to hypertension or overstimulation. I have frequently noted that beginners in pistol shooting impart the tremor to the end of the barrel which resembles in rate the tremor of thyroid intoxication. This tremor is due to a too tight grip on the stock of the gun while under the mental strain of securing a bull's eye.

The sign is best elicited by having the patient stretch out her hand with the fingers spread out to the maximum degree. It is then usually visible to the naked eye and is palpable by the examining finger. The direction is vertical in the pronated hand.

The lower extremities, particularly the knees, often tremble. Other parts, notably the hand and tongue, are apt to show the tremor. These tremors are usually present only in the severer cases. Occasionally the tremor is intermittent.

Muscular Fatigue.—One of the constant accompaniments of

thyrotoxication is a sense of muscular weakness. The patient feels tired, particularly in the morning, and when she attempts to exert herself she discovers that she is tired—that is to say, it is impossible for her to undergo the former physical exertion no matter how she may try. Early this seems to be but a nervous exhaustion state, for a few doses of bromides may restore to a great extent the former vigor. The weakness is usually ascribed to associated suprarenal dysfunction. In some of the deeply pigmented cases one might think of disturbances of the adrenal. The color is more that of an argyria, however, than that of an Addison's disease. Be this as it may, bromides do more to counteract it than does epinephrin. Later when their is emaciation the weakness must be due to actual muscle changes.

One of the earliest and most striking phenomena of motor weakness, in a small proportion of cases, is a weakness of the knees. Quite unawares the knees give way, particularly in going down stairs. Sometimes this is the symptom that causes the patient to seek advise. I once had a carpenter consult me because he was unable to go down a ladder. He had a goiter and marked tachycardia, but these symptoms had not been noticed. This weakness is sometimes associated with or preceded by cramps in the calves.

Usually in thyrotoxication the tendon reflexes are exaggerated when the disease is well developed. In the beginning and in milder cases they are normal. Late in the disease the reflexes are sometimes lost. When the reflexes are absent other causes for their absence should be sought.

The Heart in Thyroid Disease.—It is on the proper interpretation of the mechanical and functional state of the heart that the surgeon's accuracy of operative prognosis depends. The most obvious sign is naturally the rate of the beat, but the state of the heart muscle is the more important. This state is in part only expressed in the form and size of the heart and in the working capacity as determined by ordinary clinical means. The state of the heart in goiter assumes the greater importance to the surgeon because the examination of this organ falls without the pale of his ordinary clinical investigations and his medical consultant does not grasp the full importance of es-

timating the exact working capacity of the organ under the added toxic and mechanical insult incident to the operation. Hence, though he may have the aid of a competent internist, the responsibility of the final judgment rests on the surgeon.

Tachycardia.—The most constant single sign in toxic goiter is the tachycardia. Not uncommonly the sense of increased heart activity is the factor that sends the patient in quest of medical advice. All other signs may occasionally be absent but rapid heart is nearly always present. There are marked exceptions to this rule. I observed one patient with the other classical signs very pronounced whose pulse did not exceed eighty. After operation the pulse increased to 100-120. Nothing appeared to explain this anomaly. The rate is usually between 100 and 150 with 90 and the limit of accountability, 200 or more, as the extreme limits. The pulse rate is a fair measure of the intensity of the symptoms. The rate is habitually more rapid in the morning than later in the day when the patient is up and about. This point sometimes helps to distinguish between a toxic and a myocardial rapid heart. It is commonly increased by nervous excitement, but is influenced by drugs with difficulty. In some cases there are attacks of extremely rapid pulse, often without apparent provocation. Pure tachycardia is not markedly affected by exercise. If it is increased by exercise there is most likely some cardiac muscle degeneration already present. Often the patient is unable to lie on her left side. This points to cardiac dilatation. Sometimes the patient is aware of the rapid pulse, but quite as often the patient is oblivious of any trouble. So long as there is no myocardial degeneration the rate is regular. Sometimes there is a subjective sensation of pulsation in the peripheral vessels. Throbbing in the ears may be the symptom most complained of. The large arteries show a pulsation similar to pulsation in the water-hammer pulse in aortic regurgitation. The aorta and large vessels of the neck, particularly the superior thyroid, pulsate visibly and even pulsation of the parenchymatous organs is said to occur. Epigastric pulsation may be pronounced and may constitute the chief disturbing element.

The rate of the heart is an indication of the severity of the disease, provided the heart muscle is intact. If there is a de-

generation of the muscle, the heart may be relatively slow and yet the patient be a poor operative risk. Usually the slow heart presents evidence of fibrillation and dilatation or other danger signals of cardiac decompensation, as well as edemas and dyspnea on exertion. If there is in addition to dyspnea on exertion some other sign of weak heart muscle, operation is prohibited no matter what the rate. The Mayos place the safe operative rate limit at 130 and this is as good a conclusion as one may express on paper, but applies only when the heart muscle is intact.

The duration of the disease gives a valuable clue in estimating the resistance of the heart. Slight signs are of graver significance in a disease of some years' standing than in a recent case. A decreasing rate is of more favorable import than an increasing one. For instance, given a mean rate of 130 it is safer to operate on one whose rate was 150 a month or two ago than one of the same rate who had a rate of 110 a like period preceding. A rate which has remained constant for a long time, without signs of cardiac degeneration is less serious than one recently developing the rapid rate. Other factors also enter. Given a mean rate if the patient is gaining in weight the prognosis is better than the same rate in one who is losing weight. A labile nervous equilibrium also increases the gravity in the presence of like heart states.

The sensitiveness to adrenalin is a valuable determinative test of the irritability of the heart. If much excitement is produced by adrenalin, the patient will react badly to operation even in the absence of cardiac degeneration. This is a valuable point in operating under local anesthesia. If, for instance, one has decided to do a lobectomy and discovers after the injection of the novocain epinephrin that the patient is markedly excited by it, he may conclude to change his plan and do a pole ligation instead.

Blood Pressure.—The blood pressure varies much in toxic goiter, often varying in relatively short intervals of time. Strickland-Goodall (*The Practitioner*, July, 1900) classifies the pressure phenomena into three stages; (a) a state of hypertension, appearing in the primary stages and is probably the result of the exciting stimulus on the suprarenal capsule; (b)

stage of hypotension. At this stage it is 10 to 20 per cent below the physiologic normal and is due to peripheral dilatation. This state is due to the action of a depresser substance produced by the gland; (c) stage of secondary rise and is dependent on the reduction of the superactivity of the gland and to secondary changes in the cardiovascular system, such as cardiac hypertrophy.

It may be readily conceded that there is an early primary rise if the disease begins with a previously normal circulatory system. However, in long pre-existing colloid goiters to which has been added a myocarditis, and secondary toxicity develops, there may begin at once a marked depression in the blood pressure. This is most typically noted in women past the menopause who have developed a "goiter heart" along with adiposity and high blood pressure. The stage of hypertension may come early. In the hyperacute cases the stage of preliminary rise must be very short. I have noted a depression within a few weeks after the onset of the disease. The lessened peripheral resistance no doubt has something to do with the fall but usually there is also a cardiac dilatation or at least a diffuse, widened apex beat with a sharp pulmonary click. The final rise of pressure presages a spontaneously developing recovery.

Strickland-Goodall recommends operation in the stage of depressed blood pressure, while Kocher recommends operation during the period of high pressure. My experience has been that the *state* of the pressure is of little value, it is the *tendency* alone which is of value. A rising low pressure may indicate a favorable stage and a maintained high pressure may indicate a safe time, but a pressure may be high and yet be *falling*, in which event it may represent a highly improper time to operate. If there is a failing heart, operation is dangerous irrespective of the state of the blood pressure. A single observation of the blood pressure is without value unless it be very low, say below a hundred. Yet patients with a long existing stationary goiter stand operation very well with a pressure as low as 90. Dyspnea on exertion is a more valuable sign than blood pressure, for the ability of the heart to stand an increased demand is what we need to determine. Here also, one must individualize. A patient may appear dyspneic when she is only excited. The

emotional state preceding the dyspneic state may be the best guide. Dyspnea from pressure is relatively unimportant as compared to dyspnea from cardiac weakness. The two are often combined. This point is likely to be overlooked in patients who have long had an "innocent" goiter who become toxic and dyspneic. Pressure dyspnea is usually increased by assuming certain positions, while cardiac dyspnea is increased by exertion. Edemas often show the dyspnea to be cardiac when the displaced and compressed trachea seems the obvious explanation. Ocular inspection of the degree of tracheal stenosis is an interesting but misleading stunt.

However favorable the cardiac state may be such as a rising pressure early in the disease and a decreasing rate, the operation may add so much to the toxicity that the heart muscles may be overwhelmed by the load. If the metabolic destruction is great no matter what the apparent rate of the heart, operation is interdicted.

Heart Sounds.—The heart sounds are usually loud and sharp. Often in primary thyroid intoxication, they are clicking. It is the heart beat of excitation. Sometimes the apex beat both on palpation and auscultation is diffuse when percussion and the x-ray show an absence of any enlargement. This is due to the increased force of the beat. The beat is often so violent that the whole chest heaves. Not infrequently the beat may be heard some distance from the chest. This is not uncommonly observed soon after the injection of novocain-epinephrin solution. There are sometimes murmurs particularly over the base without the presence of anemia or demonstrable enlargement. They are often ephemeral. Reynolds (*Lancet*, 1890, i, 1055) found it in two-thirds of his cases. It is difficult to say when one should designate the tones as sharp and when as murmurs. Real murmurs, as one heard them in valvular disease, are rare. In many cases, of course, there are organic lesions which existed before the development of the thyroid trouble. In these there are usually the signs and symptoms that make a diagnosis possible. That there is no organic lesion present can only be determined with certainty by their disappearance as the patient recovers from the thyroid disease.

The Goiter Heart.—The cardiopathies associated with thy-

roid enlargement have been much discussed under the general caption of "Goiter heart". Under this head must be considered only organic lesions of the heart and apart from the mere increase of the rate. Some authors have clouded the discussion by discussing under the title diseases characterized chiefly by rapid heart with minor thyroid changes and with incompletely developed clinical picture. There has been much discussion as to the genesis of the cardiac state as observed in goiter. For the purposes of this discussion but two factors need be considered; the conditions due to excitation dependent on the activity of the thyroid gland, the thyrotoxic heart, and that due to mechanical hindrance to respiration or the circulation.

The Thyrotoxic Heart.—Obviously there are many cardiopathies in which there are no mechanical factors operative. These must be ascribed to the toxic action of the goiter. That such toxicity is capable of influencing the heart is indicated by the fact that it can be artificially produced by the exhibition of gland substance. It is maintained by some that the increased rate of the heart beat may be in part due to pressure by the goiter on the heart regulating nerves. These nerves by changing the vascularity of the muscle influence the nutritional state of the muscle and hence the work capacity of the heart.

There is no direct connection with the degree or duration of the tachycardia and the extent of the heart muscle change. A toxic goiter may exist many years and yet the heart appear normal. Since there is no relation between the degree of compression exerted by the goiter and the degree of cardiac disturbance, compression, believed to be active in colloid goiters, cannot be operative. If we assume that the goiter elaborates a toxic substance capable of affecting the heart muscle, all known factors are employed and the explanation is simple—though we do not know the method of action.

An actual widening of the heart's diameter in toxic goiter is due mostly to an increase in the size of the cavities which may in turn be due to a weakening of the muscle, as seen in acute Graves' disease or to a muscular degeneration as seen in long-existing goiter. Commonly the enlargement is apparent only due to the increased violence of the beat.

Mechanical Goiter Heart.—Rost was the first to ascribe

the goiter heart to the mechanical hindrance to respiration. He explained that the forced inspiration increased the negative pressure which results in an overfilling of the right ventricle; the increased expiratory effort tended to increase the diameter of the air passages with increase in the interstitial connective tissue with subsequent disturbance of the circulation. This is plausible but incapable of proof.

That the patient may suffer much from tracheal stenosis is obvious. Often the patients do not realize how much they do suffer until relieved of their obstruction, and no doubt the surgeon often fails to appreciate the degree of their suffering. The disturbances due to tracheal compression are in direct degree to the tracheal compression. No doubt such stenosis tends to cause emphysema. The goiter hearts are by no means confined to those cases where there is pronounced tracheal compression. On the contrary, they are as often seen in those prominent goiters in which the local disturbance is wholly cosmetic. That mere compression does not produce a goiter heart is indicated by the fact that mediastinal obstruction from other tumors may exist for many years without producing any lesion comparable to goiter heart. We may assume, therefore, that the simple colloid goiter may elaborate a substance inimical to the normal functioning of the heart muscle.

Many complicating factors may enter. This type is observed only in goiters capable of causing compression. These patients are often beyond the midperiod of life. Often they have developed some cardiac lesion independent of goiter. When the long existent goiter becomes toxic the already diseased heart acts badly to the stimulus of the goiter. It acts badly just as it would to any other acute disease. To ascribe all heart lesions in goitrous patients to the influence of the goiter but confuses the clinical picture. The common picture is as follows: a patient beyond the age of fifty who has borne many children and in the course of years has developed a large colloid goiter. She has gained in weight, the blood pressure has ascended to around 200. She is dyspneic on exertion. Suddenly she develops a tremor, she loses rapidly in weight, she becomes weak and dyspneic. The heart becomes rapid and is widely dilated. This is a mechanical goiter heart. There is no relation to the degree

of compression of the trachea and the likelihood of the development of such a heart. It seems on the contrary to be dependent on abnormal thyroid secretion and the old overworked crippled heart just cannot stand the pace.

Digestive Disturbance.—In a disease so closely associated with the nutritional state, digestive disturbance assumes a double importance. There is no symptom which varies more in cases of like severity. Though expressive of the goitrous state, it must be remembered that a patient may suffer from diseases of the gastrointestinal tract which have no relation to the goiter. Any existing digestive disorder should, therefore, be considered on its own merits before it is ascribed to the thyroid disease. Hyperacidity and ulcer are most commonly observed.

The Appetite.—Loss of appetite to complete anorexia is sometimes noted, particularly in those severe cases in which the climax has been passed and improvement has begun or is about to begin. So long as appetite is excessive, disaster is not imminent even though the patient is still losing weight. In some cases anorexia and excessive appetite alternate or the patient may feel excessive even painful hunger, but becomes nauseated at the sight of food. When a patient admits of an excessive appetite it is important to inquire as to the actual amount of food eaten, for the amount consumed may be relatively small. If such be the case, frequent meals may be desirable.

Diarrhea.—Diarrhea is not infrequently noted, particularly in severe cases. They are usually painless, watery, grayish or yellow stools which repeat 4 to 8 times in a short period, then cease for some hours or even days only to recur. In rarer instances they may persist for many months and may then seriously menace the patient. This is particularly true of those made worse by psychic excitement. A true nervous colitis, capable of independent treatment, may exist. These are usually seen in patients in whom extreme nervousness antedates the development of the thyrotoxic state. I have never observed it in the true exophthalmic type.

Vomiting.—Vomiting is a more serious complication. In many of the fatal cases persistent vomiting is the signal of approaching dissolution. The vomitus is usually clear fluid but may be mucus and in extreme cases may be bloody. It occurs

irrespective of ingestion of food, and is most apt to occur in the morning, but may continue throughout the day. Sometimes recurring morning vomiting is followed by excessive appetite during the rest of the day. Most of my cases of vomiting with anorexia died within a few days, while those with intermittent vomiting recovered. The vomiting is evidently central and toxic because it is not attended by nausea and during the remissions, when such occur, the digestion may not be impaired. A combination of vomiting and purging seems to be very rare. Both seem to be due to a hyperperistalsis. There may be persistent nausea without vomiting. Miesowicz (Wien. klin. Wchnschr., 1904, xvii, 1205) examined the stomach contents in such cases and found the secretion to be neutral.

Constipation.—This condition is often associated with Graves' disease. Sometimes it is particularly obstinate before the beginning of the disease. This observation has led some authors to assume an etiologic relationship between the constipation and the goiter. More likely the constipation so noted is an early sign of the disease, since atony of other muscles is often noted as the initial sign. Naturally the presence of constipation may be but the continuation of the patient's previous habits. This is the explanation in the majority of cases. In rare instances there may be obstinate constipation with vomiting simulating an intestinal obstruction. Such crises may precede the recognition of the goitrous manifestations.

Icterus.—Icterus is a rare but very significant symptom. In some cases it is a part of the terminal symptom-complex particularly when associated with vomiting. Even in cases in which it occurs early or even precedes definite thyrotoxic symptoms, it is indicative of severe affections. I operated on one such patient who seemed otherwise a good risk, with fatal results. All writers are agreed that the icterus is a degenerative and not a retention icterus. In such cases the autopsy shows definite anatomic changes. Egier (Deutsch. med. Wchnschr., 1880, vi, 153) saw one in which there was marked atrophy of the right lobe of the liver and marked fatty degeneration. However, Haberehron (Lancet, 1874, i, 510) reported one autopsy in which the icterus seemed to be due to a swelling of the common duct. Even in cases in which there appears to be a primary

anemia the liver has been found atrophic. Of course other causes of icterus may be present. Eder (*Lancet*, i, 1765) saw icterus disappear after the patient passed gallstones. As might be expected gallstones and toxic goiter may be coincident, though they rarely are so associated.

Intestinal Hemorrhages.—Bloody stools are sometimes noted. These are believed to be associated with vasoneuroses. Possible independent sources of hemorrhage should always be sought before such an explanation is accepted, however. Metrorrhagia is sometimes noted and bleeding from the nose is common. I saw one patient in whom there was a vicarious hemorrhage from the nose during the period of existing amenorrhea. Pagoff (*Neurologisches Centralbl.*, 1899, xviii, 1068) saw hemorrhage from the bowels with metrorrhagia and bleeding from the gums. Intestinal hemorrhages, therefore, likely are an expression of general vessel changes and not of local disease. In such cases there is most likely a polyglandular disturbance and not truly a thyrotoxic manifestation.

Changes in the Skin.—In myxedema the skin is much thickened and the subcutaneous tissue much increased so that the natural contour of the body is lost. When the skin is picked up in folds the skin is felt to be thick and inelastic. The increase seems to be myxomatous rather than edematous.

As one might expect from the excited circulation in toxic goiter, the patient is often subject to sensations of heat and to excessive perspiration. These attacks sometimes simulate like sensations incident to the menopause. The hands and feet often are alone affected and in such cases unpleasant odors are encountered. These symptoms are sometimes most pronounced at night. Usually they are but incidental to the general course of the disease, but sometimes they bring the patient to the physician before the underlying cause has been diagnosed.

Localized, more permanent erythemas have been observed. They not infrequently precede the not uncommon vitiligo spots. The vitiligo spots are commonly surrounded by deeply pigmented areas. Pigmentation may be increased to extend over large areas and may then suggest the pigmentation of Addison's disease. That the pigmentation is directly associated with the thyroid disturbance is evidenced by the fact that when the pri-

mary disease improves the abnormal pigmentation disappears. That the disturbance is not dependent on the hypersecretion is evident from the fact that pigment disturbances attend myxedema.

Under excitement thyrotoxic patients may flush, sometimes in localized areas and not infrequently show themselves subject to urticaria. Urticarial lesions may be produced by mechanical irritation and according to Peyrou and Nair irritation from an electrical current may act in the same way.

There does not seem to be any sharp line of demarcation between these urticarial lesions and more enduring edemas. These are most commonly seen about the eyelids and the extremities. These may simulate the edema of myxedema. Scleroderma and Raynaud's disease have been reported. The former may be associated with the localized edemas. Abdominal dropsies I have noted in a number of instances in hyperthyroidism as well as in myxedema. In rare instances the hair becomes much thinned. This is more likely to occur in myxedema than in hyperthyroidism. When there are changes in the hair in thyrotoxic cases a transition to a hypofunction should be suspected and the surgeon should guard his operative procedures with this possibility in mind.

Blood Changes.—Basedow in his original paper noted the resemblance of goiter patients to the chlorotics. Bigelow (Boston Med. and Surg. Jour., 1859-60, lxi, 37) noted "pale, anemic girls with goiter and staring eyes." More recently the white cells have been studied closely which has resulted in determinations of some practical value.

Anemia.—As above noted the suspicion was early expressed that there were blood changes in toxic goiter. More recently Roth (Deutsch. med. Wchnschr, 1910, xxxvi, 259) has studied this subject and found moderate degrees of chlorotic changes in some instances. On the other hand, cases have been reported as chlorotics in which there was thyroid enlargement and prominent eyes. Immermann in fact thought there was a close relationship.

The observations in this hospital seem to show that there is no relation between toxic goiter and the hemoglobin and red cells of the blood. There is generally a slight reduction, the

hemoglobin averages between 75 and 80 per cent, the red count between three and a half and four million. These are about the findings one would expect in persons somewhat under par in general health. If anemia exists, diligent search should be made for some complication, for be it remembered, the existence of goiter does not insure the patient freedom from other diseases. The common causes for anemia are gynecologic complications, next gastrointestinal affections presenting the symptoms of ulcer and mucous colitis, and finally tuberculosis. Cases have been reported in which crises of pernicious anemia have antedated the goiter (DeCostello) and of splenic anemia (Variot and Ray). In pronounced secondary degeneration in long existing goiter in old women there is often a more pronounced general anemia. On the contrary, in some of the acute cases with hyperemia or in the time of remission when the gain in weight is rapid, the red count may go as high as six or seven million and the hemoglobin to 110.

Generally speaking, when a patient with anemia is encountered, the cause of the anemia should be determined before she is accepted as a surgical risk, not so much because the goiter operation will be made more hazardous, but because the cause of the anemia will not be relieved by the cure of the goiter.

Leucocytosis.—It was Kocher's studies that brought the relation of the leucocyte to goiter to the front. He believed that in the relative increase in the lymphocytes was to be found a valuable diagnostic and prognostic aid. Unfortunately, while true in the abstract, for use in the consideration of a concrete case the exceptions are too many to permit the use of this change. Generally speaking there is a general leucopenia of from 3,500 to 6,000 but the reduction is at the expense of the polynuclear leucocytes, though there may be also an actual increase of the lymphocytes. It is known that there is a decrease of leucocytes in starvation and the leucopenia in goiters is most marked where loss of weight is most pronounced. Perhaps the dependence of the leucopenia on the toxic goiter is indirect only. Be this as it may, in our experience these changes do appear in a considerable proportion of cases. Generally speaking the lymphocytes amount to 25 to 45 per cent but may reach 50 per cent or beyond. Sometimes the lesser percentage of the lympho-

cytes is compensated for by an increase in the large mononuclears, leaving the polynuclears low in percentage. The variations, however, are frequent and important. In some cases there is an actual leucocytosis of moderate degree. In many of the severer cases the lymphocytes are actually reduced. In one of our severest cases they were but 6 per cent. Various writers have sought to iron out the discrepancies. Bracherdt found in the transitional cells a balancing factor, while Caro found by taking altogether all the mononuclear forms the results were more constant. This seems to me an important observation, for no doubt when the lymphocytes are fewer than one would expect the large mononuclears may show an increase. Kocher believed that the lymphocyte count gave a valuable prognostic help in that within a few days following operation the relative proportionate count approaches normal. It is in fact a common observation that the lymphocytes become reduced in percentage on the second or third day. This does not help us in a practical way, for if the patient survives the operation so long, we may be confident of her recovery. The changes in the leucocytes are interesting but not important. The decrease in the proportion of the lymphocytes is due more to the increase in the polynuclears than in the decrease of the lymphocytes. It has been argued that this increase of the polynuclears is due to a reaction of the operation per se and not to the fact that the thyroid has been operated on. If this were true, this should subside when the reaction has ceased, but this is not true. There is a permanent readjustment toward the normal. The presence of the toxic substance of the thyroid must therefore play the determining rôle.

Kocher believed the determining cause of the increase of the lymphocytes was the toxic substance in the blood stimulating the spleen to give up its leucocytes. Others, notably Klose and Schumacher, and Roth believed the interaction on the thymus played a determining part. That the thyrotoxic elements are not the determining factor is shown by the fact that the same blood picture is found in endemic goiter and even in myxedema. It should be emphasized, however, that the findings are much less constant in these diseases than in the toxic type. One should be slow in concluding that colloid goiter is exerting no toxic in-

fluence and that a myxedema is not a mixed affair. The hope that the leucocyte count would give some help in determination of an existing status thymolymphaticus has been shattered by the study of Kohler. He showed that the same blood pictures are found in a variety of diseases, noteworthy, pseudoleukemia, Mikulicz's disease, diabetes, mumps, hysteria and neurasthenia, psychoses, and during the menstrual period. It may also be remarked that it is the normal state in children and is found not infrequently in perfectly healthy adults.

If one sums up the available evidence obtainable from a study of the leucocytes, one is forced to the conclusion that there is some factor active in toxic goiter which produces certain changes in the leucocytes but at the present time they are not yet sufficiently determined to aid the clinician in a diagnostic or prognostic way. The findings to date are so suggestive that a further study is much to be desired.

Changes in Coagulation Time.—Lidsky believes the lengthening of the coagulation time is of diagnostic moment since he found this change in 29 out of 39 cases studied, but in a few cases the time was shortened. Kottmann likewise found it shortened. In this connection it should be remembered that Kuster found the coagulation time in women shorter than in men. An attempt to use this finding as a differential sign has further been upset by the fact that the same findings were demonstrated in myxedema. The viscosity of the blood likewise is inconstant. Kaes found it normal in 19 per cent, reduced in 50 per cent and increased in 31 per cent.

The Adrenalin Test.—The increased sensitiveness of thyrotoxic patients to adrenalin has been known for some time. Cannon observed that after stimulation of the sympathetic, animals were more sensitive to adrenalin. Levy (*Am. Jour. Physiol.*, 1916, xli, 492) after stimulating the cervical sympathetic, found the animals more susceptible to the stimulation of adrenalin as measured in terms of blood pressure. Since such stimulation is known to increase the thyroid secretion, this agent was believed to be the intermediary factor. Barker and Sladen (*Tr. Assn. Am. Physicians*, 1912, xxvii, 471) applied this principle to patients with goiter and discovered a considerable degree of hypersensitiveness to adrenalin.

The credit of developing this test in its workable form is due to Goetsch (New York State Jour. Med., 1918, xviii, 259). He used 7.5 minims (0.5 c.c.) of a 1:1000 of adrenalin hypodermically and noted the effect on the blood pressure and the general reaction. In positive cases there is a rise in blood pressure of from 10 to 50 mm. The normal state is again reached in 1½ hours. The general symptoms of the thyrotoxic state are augmented at the same time. A much smaller dose (1 minim of 1:4000) injected endermically produces a blanched area at the site of injection with a peripheral zone of reddening. This lasts in the thyrotoxic patient from 1½ to 2½ hours while in the normal individual it disappears in 30 to 40 minutes.

The endermic test just mentioned I have found inconstant or at least it is present in nervous asthenic individuals who present no other reason for suspecting hypersecretion. It is possible that many neuroses may ultimately be proved to be thyrotoxic and this test is more valuable than we now suspect.

The hypodermic injection of the larger amount does, no doubt, augment the usual symptoms of thyrotoxicosis. One sees this regularly in operation with local anesthetics containing adrenalin. It should not be used as a diagnostic test in patients in whom the diagnosis is evident because the increase of the symptoms excites the patient and makes her unduly apprehensive of subsequent manipulations and in a few the symptoms seem permanently increased. In slightly toxic or doubtful cases it may be of use as a means of differential diagnosis, particularly in those in whom there is no apparent thyroid enlargement.

The chief value of the knowledge of this test is in the course of operations. If the patient is found to be excessively sensitive to the adrenalin in the local anesthetic the surgeon had best do as little in the way of operation as possible. Experience will teach him the relation of the reaction to operative resistance.

Value of the Goetsch Test.—The Goetsch test may add a link to the chain of evidence. Standing alone it is a curious phenomenon. It can be at most but relative and relative signs can never stand alone. Many persons not thyrotoxic are susceptible to adrenalin; some toxic goiters are not. When the diagnosis is evident as it nearly always is when operation is in question, it should not be used. Its use may frighten the patient to the ex-

tent that she will not return to the surgeon. This is always unfortunate for the surgeon and may be bad for the patient.

As an aid in determining the indication for an operation or as a guide in judging its safety, it is fallacious and as an aid in determining the existence of thyrotoxicosis it must be judiciously considered along with all the other signs and symptoms. In the consideration of toxic goiters there are always two factors, the disease and the patient and in the use of adrenalin it is not always easy to determine whether the disease is reacting or the patient. The surgeon's powers are limited to the attacking of the disease and the management of the patient.

The chief value of the test lies in the fact that it may give one the first clue in patients who appear to be simply nervous. Sometimes positive evidence of goiter does not appear until some years after this test appears positive. In borderline cases it can be used to advantage.

Basal Metabolism.—Much labor has been expended in recent years in perfecting apparatus for the determination of the metabolic rate in toxic goiters and in the determination of the relation of this to the clinical course and operative risk. Among these workers may be mentioned Means and Aub (*Jour. Am. Med. Assn.*, 1917, lxi, 33); Boothby (*Boston Med. & Surg. Jour.*, 1916, clxxv, 564); Boothby and Sandiford (*Saunders Co.*, 1920) and many others. By means of gas apparatus it is sought to determine the rate of the bodily tissue change, and by this means determine the severity of the disease. In general it may be said that there is a direct relation demonstrable in many cases. Unfortunately there are many secondary factors which enter, such as damage done to other organs, notably the heart.

Taking it as a whole, the test becomes at once a relative one, say for instance like the Wassermann reaction. It is of value if taken as an adjunct to a careful clinical examination and if done by thoroughly competent hands. Unfortunately the test is a difficult one to make properly and error of technic too often comes in to confuse the results.

In severely toxic cases the patients are often too nervous to submit to the restraint necessary to the test. An attempt to apply the mask in such cases may be attended by permanent

damage to the patient. This is unfortunate, for it is in just this class of patients that the surgeon is most urgently in need of aid.

On the whole, it appears to be of value in inverse ratio to the clinical experience of the surgeon. A good laboratory man may be of much help to the inexperienced clinician but to the experienced surgeon the aid is relatively little and a poor laboratory man is a nuisance to both.

To make the test the sole tribunal in the question of the presence or absence of thyrotoxicosis is unquestionably wholly wrong. I have seen a number of discharged soldiers with the diagnosis of irritable heart or some such diagnosis when the patient was typical Basedow, eyes hanging on their faces, eye signs, tremor, tachycardia, goiter, and whose goiter after operation showed the typical histologic changes. Because there was no notable increase in metabolic rate, thyrotoxicosis was declared to be absent.

It is my judgment that the truth lies somewhere between the views of the skeptic and the enthusiast, with the skeptic perhaps rather nearer the truth. The work along this line should be indulgently encouraged, but critically analyzed and the results accepted only when they harmonize with the general clinical findings.

CHAPTER IV

DIAGNOSIS OF THYROID DISEASE

In considering the diagnosis of goiter, it must always be regarded as a constitutional disease. Even in the endemic colloid goiter, though it is essentially a local process, no doubt the general economy suffers. The thyroid is a guardian of the body, and though the effect of disturbance of it on the general system may not be apparent in many cases, a broad view must convince one that the influence is always present. In the toxic forms the systemic effect is apparent. In no case of thyroid disease should a careful general examination be omitted. A good diagnosis does not consist in placing the patient in one or the other of the groups of any classification of thyroid diseases, but the ability to comprehend the deviation from the normal, not only of the thyroid, but also of every function of the body. This viewpoint is particularly important for the surgeon because from the nature of his work, he is apt to concentrate his attention on a lesion he can attack in an operative way.

Each general group will be considered in turn ever mindful, however, that in many, no one group will satisfy all the symptoms the patient presents. Furthermore, there is often a fringe of symptoms that refuses to be placed anywhere in any scheme of classification.

Colloid Goiter

Under this head may be considered the adolescent goiter, which in general signifies that the patient is having some trouble in adjusting her endocrine system and the endemic colloid goiter which tends in general to progress and persist. The dividing line is not a sharp one but the separation of the two types is helpful in deciding the treatment.

Adolescent Goiter

Strictly speaking, perhaps, the adolescent goiters are those which appear only at the developmental period of life and then

disappear again. However, often these continue to develop and assume a permanent place. These appear to differ in no wise from the endemic. In fact, it may be open to question whether we can rightfully speak of any of the goiters indigenous to this region as "endemic." At any rate, it prejudices nothing to refer to them as simple colloid goiters.

The adolescent goiters are observed in young persons before the period of maturity and are most commonly observed at the period of puberty. The recognition of the presence of an enlargement of the thyroid gland constitutes the diagnosis. Fetal adenomas appear as encapsulated nodules in the substance of the gland and as such form a separate disease.

Simple Colloid Goiters

In this type there is enlargement of the thyroid gland confined to a part or it may involve more or less the entire gland. Seldom in fact is any part of the gland wholly normal. The gland is elastic, freely movable, and not tender. When they have existed for a long time they may be dense because of fibrous tissue, or hard, due to calcareous infiltration, or soft, due to cystic degeneration of some part of the gland. They may be lobulated or bosselated, due to the independent proliferation of some part of the gland. The diagnosis is established by determining that the enlargement represents the thyroid gland, that there are no toxic symptoms, and that no secondary changes have occurred. If secondary changes have taken place, the proper amendment to the diagnosis must be made.

It is usually easy to determine that the tumor represents the thyroid gland. The tumor is attached to the trachea and moves with it in deglutition. Dermoids, cysts and lipomas in rare instances occur in the thyroid or are attached to it and may be mistaken for an enlargement of the thyroid gland.

The commoner forms of degeneration discussed in the section of pathology, notably, the cystic, hemorrhagic and the calcareous, are so common as to constitute a part of the disease. The solitary cysts usually present isolated, smooth, freely movable lobules which are very elastic or definitely fluctuating. The fetal adenomas are equally encapsulated but are firmer than the cysts.

Secondary Toxicity

To determine the presence of secondary toxicity of a long existing goiter, the symptoms detailed for primary toxic goiter are to be sought. Usually the patient complains of loss of weight and increased nervousness. The eye signs may be present and tremor usually is. In many the lymphocyte count is markedly increased. If there is progressive loss of weight, the metabolism rate will be increased and the determination of it is of confirmatory value. The Goetsch test will confirm the presence of nervousness. It is important to remember that patients with a colloid goiter may have complicating diseases which may cause a loss of weight, and may make them nervous. Therefore other cases should be sought for these symptoms. An insipient tuberculosis most often causes confusion, there is usually a rise of temperature which never occurs in toxic goiters mild enough to be mistaken for tuberculosis. If the physical signs of tuberculosis are demonstrable, the matter is simplified. The two diseases may coexist. The presence of tuberculosis seems in fact to have a disturbing influence on the thyroid.

Malignant Degeneration

In rare instances malignant degeneration of an old colloid goiter takes place. This is manifest (1) by a peculiar hardness which characterizes cancer anywhere; (2) by the invasion of surrounding structures; (3) by the formation of metastases elsewhere in the body. The hardness is seldom pathognomonic because the nonmalignant gland is often hard. It is only when small nodular protrusions, apparently of recent growth, appear that the suggestion becomes impressive. Often the gland may manifest malignancy by forming metastases when its consistency and the anatomic structure do not show any decided change from the normal, therefore clinical examination often leaves us nothing more tangible than a suspicion. The invasion of the surrounding tissue, when definite and pronounced, is impressive and certain. The muscles are the first to become involved, but the esophagus and trachea may become invaded. In order that one may make a diagnosis of invasion, tumor nodules must be felt beyond the confines of the goiter if one is to be cer-

tain. Mere attachment to the surrounding tissue may be simulated by a perithyroiditis. If there is complete fixation of the trachea without definite symptoms of inflammatory reaction, malignancy is suggested. Pronounced enlargement of the skin veins, particularly if unilateral, presents additional evidence in favor of malignancy. If suspicions of local malignancy are coupled with metastasis elsewhere the probability is increased. If such metastasis shows thyroid structure, the malignant character of the thyroid is proved no matter what the local findings in the thyroid may be. In a number of instances of metastatic tumors in my experience the thyroid was not suspected, even the presence of a goiter was not noted, until the supposedly primary tumor elsewhere proved to be of thyroid origin. The bones most frequently show such metastases, notably the humerus, the iliac, and the skull bones are most likely to be invaded. The intestinal tract has been the seat in a number of instances.

Affections of Other Organs

In colloid goiters other organs, notably the heart and lungs, may show involvement. The heart may present the usual symptoms of fibrillation and myocardial degeneration. These symptoms likely are the result of an intoxication from the "innocent" goiter. When the rapid pulse is associated with nervousness, the goiter may erroneously be regarded as toxic. Loss of weight and tremor may aid in the differentiation. In many of the secondarily toxic goiters the lesions characteristic of myocardial degeneration may coexist with the tachycardia of thyrotoxicosis. In such combined disturbances the relative part each plays can best be determined by putting the patient in bed and treating the heart as a myocardial lesion. As this improves, the extent of the actual tachycardia becomes more apparent. An irregular heart from primary myocardial lesion stands operation better than one which has become irregular following the toxic changes in the goiter.

The lungs often are involved in simple goiter because of pressure on the trachea or large vessels of the neck. This is said to lead to emphysema, possibly to bronchiectasis and particularly to secondary involvement of the heart, the so-called

goiter heart. It seems a bit far fetched to ascribe the heart involvement to pressure of the goiter on the vessels. One sees the heart involved when there is no evidence of interference with the vessels and it may be absent when there is obvious pressure on the vessels. This leads me to the opinion that the "simple" goiter may poison the heart. This seems doubly so because when the heart is affected the goiter shows marked cellular and colloidal degeneration.

Toxic Goiter

In harmony with the preceding remarks in the consideration of toxic goiter it is well for the surgeon to consider well whether he has a goiter which developed along with the general symptoms of thyrotoxicosis or whether the general symptoms were implanted on a long existing goiter. In the former in the beginning he likely has the cooperation of a normal bodily function affected only by the toxic material of the goiter, while in the latter he may have pre-existing changes in addition to those produced by the toxic goiter.

Primary toxic goiters may be separated into the exophthalmic and the nonexophthalmic type. In the former the eye signs form the important chain in the symptomatology. The various eye signs detailed in the chapter on symptomatology are pathognomonic of toxic goiter. The nonexophthalmic type may present like symptomatology in other respects and when goiter, tremor and tachycardia are present, the diagnosis offers no difficulty.

The present tendency to exclude cases as not genuine if there is a lack of metabolic disturbance that can be shown by the machine, is to be deprecated. There have been examples enough of the fallacy of allowing scientific refinements to upset clinical experience without adding this to the list. If the typical symptoms are present the diagnosis is made irrespective of the metabolic rate. Toxic goiter is notoriously a disease of waves, and if the observation is made in a quiescent period or when the disease is regressive, the metabolic rate will not show the extent or even the presence of the disease. The patient is a thyrotoxic one albeit one in the stage of remission.

In rarer instances the goiter may be absent. In the pres-

ence of eye signs, tachycardia and tremor the diagnosis is certain. In the absence of eye signs the problem is more difficult. The tremor, tachycardia, and loss of weight are suggestive, but a probable diagnosis can be arrived at only by a careful consideration of the various diseases that may cause each of these symptoms singly or collectively.

Neuropathic tachycardia is intermittent, the periods of remission being attended by a normal pulse rate. There is an absence of tremor and loss of weight. The tachycardia may usually be controlled by proper remedial measures which have no influence on the thyrotoxic tachycardia.

The neurogenic tremors are coarser and not so fast as the tremor of thyrotoxicosis and they are not attended by a rapid heart or loss of weight.

Rapid heart and loss of weight are often the accompaniments of incipient tuberculosis. When there is a palpable enlargement of the thyroid, the differentiation is often difficult. The presence of rise of temperature is the most valuable differential sign as has already been mentioned. In toxic goiters of mild degree there is no rise of temperature. One may find physical signs of tuberculosis, the muscle signs, loss of vesicular breath sounds or the increase of them, particularly if râles can be discovered, the problem is then simplified. Cough is not an early sign of tuberculosis and its absence should not be considered as a negative sign of value. The various tests are of little value; among these may be considered the von Pirquet for tuberculosis and the Goetsch for thyrotoxicosis. If relied upon, standing alone, they are more apt to mislead than to aid. If after careful physical examination there is doubt, the case had best be considered as one of tuberculosis. It will be an error on the side of safety and the guess will nearly always be right. At any rate, the proper treatment in each case is rest. The surgeon can find comfort in the fact that a goiter patient with fever is not a fit subject for operative treatment and the knottier problem of lung diagnosis may be left for the lung specialist.

Secondary Toxic Goiter

The diagnosis rarely offers great difficulty. The borderland cases have already been discussed. The patient nearly al-

ways presents an evident goiter of many years' duration. Added to this are the toxic symptoms. These consist of nervousness both subjective and objective. Eye signs are rarely present, never in the pure degenerative forms. Tremor is a marked sign and tachycardia and loss of weight are prominent. The thyroid often is hard and elastic and very often is sensitive to pressure and may show a degree of fixation. These local signs are of great value in deciding the degree of responsibility that should be ascribed to the goiter. Often there is pain in the region of the mastoid and occasionally dilatation of the corresponding pupil. Not infrequently the local reaction on the part of the goiter may amount to a veritable nonsuppurative thyroiditis. Fever and delirium frequently are present. These severer forms are most commonly observed in women past the menopause.

In the milder types a careful general examination must be taken into account. This is particularly true of those who are in the mid-child-bearing period. Here pelvic lesions, particularly those resulting from child-bearing, must be carefully considered. Loss of weight and nervousness are often pronounced, but the nervousness is usually subjective and the tachycardia if present is ephemeral and disappears on rest in bed. The neurotic may present a tremor particularly if the sign is often sought after, giving her the impression that it will add to the general interest if she has one, but it is not the fine tremor of the thyrotoxic patient.

Unfortunately this type of thyrotoxic patient usually has some genital lesion and it requires fine judgment to determine how much each disease adds to the sum total of the patient's complaint. This is necessary in order to determine how much improvement will follow the correction of either evil. A vertex or occipital headache, a lumbar backache or a leucorrhœa will not be cured by the removal of a part of the thyroid gland. The dominant lesion may often best be judged by noting the patient's viewpoint. If she voluntarily offers at the first meeting that she is suffering from a chain of symptoms which the surgeon recognizes as of pelvic origin this should be regarded as likely the dominant disease, even though she be carrying a goiter that the surgeon covets. If the surgeon operates for the

relief of one ailment and the patient expects relief from another, misunderstanding may arise.

Atypical Forms

In some cases some of the dominant symptoms are lacking. In most cases, as a matter of fact, the eye signs are absent. In such cases, some care may discover eye signs otherwise regarded as absent. One eye alone may be affected. The eye signs may be positive when the patient is under excitement, as after the administration of adrenalin, either during the operation or in the use of the Goetsch test. In some the goiter is absent, in rare instances the pulse rate is slow and very rarely the tremor is absent. These atypical forms have been erroneously classified with the forme fruste. In the atypical forms, the symptoms that are present do not vary in any essential manner from the true form. The character of the apex beat when tachycardia is the only symptom is very suggestive. If it is more rapid in the morning than in the afternoon when the patient is left quietly in bed, this fact is in itself enough to warrant a presumptive diagnosis. This is particularly true of the tremor. It is very fine and is constantly present. When the tachycardia and the tremor both are present, a diagnosis may be hazarded. The heart may be slow but the heart outline may be increased, the neck vessels full and pulsating, in fact all the usual symptoms of the circulatory disturbance of toxic goiter except the rate. The goiter may appear to be absent while it really is present though substernal or aberrant. It may appear for a short time then recede without there being any notable change in the symptomatology. These atypical forms may be very severe, even to the development of delirium and high fever. Because of these symptoms a general infection such as malignant endocarditis may be suspected.

Hyperacute Forms

In rare instances toxic goiters come on with amazing suddenness. Nervousness, delirium and fever and often vomiting may set in within the first few days. They may even have the violent symptoms of an acute mania. If eye signs are present and the thyroid is enlarged, the diagnosis is fairly easy. One must be careful in judging the eye symptoms, for febrile, de-

lirious patients have a staring look and one is not able to satisfactorily test out the finer movements of the eyes and the eyelids because of the mental state. The tremor is usually marked and the neck vessels violently throbbing. There is rapid emaciation though this sign may be of little use because the fever and vomiting may appear to account for it. When there is no thyroid enlargement one may not suspect the possibility of a toxic goiter and will consider only acute mental excitation and the general symptoms of intoxication. If the heart signs dominate or the excitation be slight, one may suspect an inflammatory cardiac lesion. However, the tumultuousness of the cardiac activity should cause one to suspect the true nature of the trouble. Usually there is the characteristic tremor which gives one the clew. If the sign is searched for often one finds the thyroid region sensitive even if the goiter is not definitely palpable. Nearly always sooner or later the thyroid enlargement appears.

These cases usually run their course in ten days to three weeks which is more rapid than the diseases it simulates usually run their course. Sometimes one only suspects the disease and an extremely degenerated state of the thyroid furnishes the final point in diagnosis.

Interstitial Type (Forme Fruste)

By the forme fruste is understood a type of thyroid disturbance which differs from the regular form by the predominatingly nervous symptoms, usually of an indefinite nature, and by its little tendency to remit or recover or to become progressively worse. This type is to be sharply separated from the atypical forms already discussed.

This type was named *Forme Fruste* by Charcot (*Gaz. d. Hosp.*, 1885, No. 15) and by G. Marie (*Contribution a l'étude et an diagnostic des formes frustes de la Maladie de Basedow*, Paris, 1883) because they believed it represented an incomplete type of Graves' disease. This assumption has led to endless embarrassment to the operating surgeon. According to Charcot forme fruste represents a type of the disease made up of one or more of the chief triad symptoms (exophthalmos, goiter, tachycardia and to these he added tremor) with a number of

secondary symptoms, such as digestive disturbances, nervous symptoms, disturbances in respiration, disturbances in the genital sphere and in the urinary secretion. In drawing the analogy Charcot was guided only by symptoms present at a given time. He ignored entirely the fact that the onset, the inherent physical substratum and the final course were without definite similarity to the typical Basedow's disease. There are any number of instances in medical history where like error in logic ended in confusion. Chancre and chancroid, typhus and typhoid may be cited as instances.

Whatever may be the ultimate solution of the question of relation, however, the classic Basedow and the forme fruste, surgical experience has emphatically proved that the prognosis is wholly different and so far as the surgeon's activities are concerned the relationship between the two diseases is not very close.

There is a wide divergence of opinion among neurologists as to the relation of this disease to Graves' disease on the one hand and unrelated neuroses on the other. To neurologists it is largely an academic question, but to surgeons it is more vital. Nevertheless there is a constancy in the symptomatology and course which bespeaks a fundamental pathologic defect but regarding it we are yet in the dark. Unfortunately we cannot attack the problem as yet on the only certain basis, that of etiology, consequently the prognosis is the most reliable guide.

The most constant phenomena found in this class of patients is that they are primarily nervous, irritable, sleepless, often showing definite neuropathic manifestations, as epilepsy or mental aberration. The disease begins in early adult life; often there are a number of cases in the same family, not infrequently representatives of both sexes. They are usually long and thin of build. Their chief symptom is nervousness. They are hyperesthetic and often the reflexes are increased. They have a fine tremor which becomes worse under excitement. They present small, fairly firm, uniformly enlarged smooth goiters which are often sensitive to touch. The patient often complains of choking sensations, particularly if she knows of the presence of an "inward goiter." These often resemble the symptoms of globus hystericus and quite possibly they are synonymous.

These symptoms are wholly different from those in which there is actual compression of the trachea by the goiter. When actual tracheal compression exists, so slow has been its development that the patient is inclined to minimize its extent.

These patients are apprehensive of everything and observe their multitudinous symptoms with the minute care of a sympathetic scientist. Often they come armed with a manuscript copy of their various complaints, apprehensive that in their recitation of symptoms some of them might inadvertently be overlooked.

They are sensitive to everything. They respond to the Goetsch test and are hypersensitive to thyroid extract and, according to Chareot, they have a lessened resistance to the electrical current, but they react badly to nerve sedatives.

The loss of weight varies, but usually amounts to 10 to 25 pounds. Usually the normal weight exceeds a hundred pounds but slightly, so that the loss of a few pounds is an important matter to them. The weight usually fluctuates a few pounds up and down from year to year.

Associated with these symptoms there is usually evidence of ovarian hypoplasia. The menses usually begin late. The patient has a scanty menstruation; generally there are cramps in the beginning and the patient is often obliged to take to her bed during the first few hours. The genital organs are hypoplastic and frequently the small uterus is displaced backwards or the small flat cervix points in the axis of the vagina. The ovaries are small, hard and the surface puckered and contain few or no follicles. Often these phenomena exist for years before a thyroid enlargement and rapid pulse manifest themselves. *Forme fruste* with normal pelvic organs is unusual, to say the least. The belief that there is a relationship to the ovaries is strengthened by the fact that many of the symptoms of this disease are simulated in the complaints of the castrated.

One must differentiate these patients from those who have adolescent goiter with neuropathic symptoms. However, the menstrual disturbance is not scant, not delayed, and the pain if any, is definitely spasmodic in the adolescent form. Moreover their nervousness is of the vulgar type while the true *forme fruste* has raised her nervousness to an art. The course also de-

finer the difference. The adolescent goiters recover with or without treatment and often respond quickly to sedative treatment; or if not, when they gain the rank of matrons their symptoms lessen.

The loss of weight accompanied by marked weakness often raises the question of tuberculosis, and if the observer is inclined to a specialty in that disease, he is apt to render this as the probable diagnosis. Seldom does the tuberculous patient show the nervous apprehension of the goiter patient, and the tremor is not present in tuberculosis. Tuberculosis specialists have a neat way of escaping, when later developments indicate a positive diagnosis of thyroid disease, by declaring an association of the two diseases, the tuberculosis having healed as the thyroid disease grew worse.

The most constant symptom in the forme fruste disease is the rapid heart. The increase in rate does not approach that of the real toxic goiter. The rate is usually 90 to 110. The pulse is small and the neck vessels do not pulsate. The blood pressure, instead of being increased as in thyrotoxicosis, is diminished; usually it varies between 95 and 110. This has led some observers to designate this disease as a "Basedow heart." This is unfortunate because a rapid heart is no more a specific symptom in disease involving the thyroid, than is pain in the differentiation of abdominal diseases. As a matter of fact, the heart other than its rate is little affected. Dilatation is uncommon and murmurs even more so.

Rarely this type develops into a more pronounced type of thyroid intoxication, having the classical symptoms. I recently observed a patient who had suffered from the milder type of the disease for many years, suddenly develop a pronounced goiter, cardiac dilation, and nervousness. She died spontaneously three months later. This patient had, however, a large colloid goiter which ran the course of a secondary toxic goiter after the menopause. She had two sons and a daughter victims of forme fruste. This fact makes one somewhat reserved in expressing a prognosis.

The chief difficulty in the diagnosis of this type is that typically neurotic persons may develop any of the common types of goiter. As a matter of fact, many neurologists main-

tain that all toxic goiters have a neuropathic substratum. When a change in type occurs the heart rate may become more rapid and the apex become broader and the neck vessels pulsate.

Evidence of metabolic disturbance in these cases is usually wanting and is never pronounced. The blood changes, notably the lymphocytosis is within a possible normal for such individuals, generally hypoplastic.

The chemistry of this is the important element in the diagnosis. The more pronounced the symptoms of a goitrous nature, the better the prospect of improvement. Usually after years the thyroid enlargement disappears, but the nervous symptoms continue, years without end. There are many who have the symptom-complex without goiter and in all of them one gets the impression that the affair is dominantly neurotic. This supposition is heightened by the fact that operation influences the course but little. The more pronounced the nervous elements, the less the prospect of any improvement. In this, Nature has been kind: underdeveloped, they are unfit for motherhood and they dote on their symptoms with the same care they might a brood of offspring. Some who bear children seem to be improved by it, the ovarian function seems in a measure to gain a balance of power. Quite as commonly the burdens of motherhood add new features of irritation, and pelvic disease is added to the complex.

CHAPTER V

PROGNOSIS IN DISEASE OF THE THYROID

No phase in the discussion of a disease is so difficult as the abstract consideration of prognosis. It implies the use of statistics, yet the use of statistics is doubly difficult in a disease like that of goiter in which the question of cure cannot be definitely determined and the estimate of the degree of improvement is always colored by the personal equation of both patient and surgeon. The question of mortality after operation likewise cannot be stated in general terms. The results of the tyro and the expert, as regards operative results, are more divergent than after any other surgical procedure. The results of one operator cannot be used in the slightest degree in estimating the probable operative risk in the hands of another operator.

Even in the study of one's own results the difficulties are many. I am becoming more skeptical as to the prognosis the more closely I study my patients. Like operating on malignant disease, the operative recovery is only a part of the story. Nearly all patients operated on show postoperative improvement. In some instances the patient thinks herself well and writes glowing accounts of her improved condition. Reports by correspondence are of limited use. Often those that report by letter that they are quite well will be found on examination to have still some of their old symptoms. For purposes of comparison, therefore it is necessary that the clinician, or one who employs the same language, should check up the results from time to time by actual examination of the patient. When the patient declares herself quite well and the examiner finds evidence of the former symptoms, whose opinion shall prevail in the formulation of statistics?

Statistical records correct today may be all wrong at some future date. Frequently the improvement lasts many years and then a relapse comes. One of my patients remained symptomatically well more than ten years, then died of an acute thyro-

toxicosis. The longer one observes his patients, the less the percentage of cures. One by one, in the lapse of years, step from the cured group. I have seen many patients operated on by other surgeons who come after several years of improvement with a relapse. They state that their surgeon does not know of their renewed trouble. Therefore, that surgeon has her on his records as a cure. No doubt some of my "cures" are telling of their renewed trouble to some sympathetic surgeon.

It is questionable whether one should ever speak of a cure. Usually the whole gland is affected. Taking a part of the bad away does not leave a good. It is only in the removal of fetal adenomas and the solitary cysts that we can speak of a complete cure, anatomic and symptomatic.

The best that can be said of the operative treatment is that it is the best we have to offer the patient. Aside from active interference our efforts are not brilliant; surgeons can well afford to be truthful in their statements and conservative in their estimates for they alone can speak with confidence of having rendered aid. By taking away a part of the disease, the patient can better cope with the part that remains than with the whole. Fewer patients succumb from the operation than from the disease untouched. Of this much we may speak with confidence.

Aside from operation we can only aid the patient in her effort to overcome the disease. Much can be done to make the struggle less uncomfortable. The irritation can be lessened, the strength conserved, and the hope maintained. In the estimation of cure by medical treatment one cannot separate the spontaneous improvement so often noted from that produced by the exhibition of drugs or other curative means.

The best service that can be rendered, therefore, in the discussion of prognosis is to point out in a general way the usual life history of the disease and with it the general influence our therapeutic effort is apt to have. Such a consideration is facilitated by the discussion in turn of the various types of disease.

Colloid Goiter.—In colloid goiter much depends on the age of the patient and the duration of the goiter.

Adolescent Colloid Goiter.—In growing children the goiters disappear in most cases after treatment with iodine in some form. Many disappear spontaneously it is true, yet the influ-

ence of iodine in bringing about or expediting the result cannot be doubted. Some continue to develop, however, in spite of such treatment, developing either into large colloid or into toxic goiters.

Colloid Goiter in the Adult.—Those that disappear in early life may reappear, most often during a pregnancy. Those that remain from childhood and those that appear in later life may persist unchanged for many years. Once maturity of the individual has been reached there is little tendency for the goiter to disappear, either spontaneously or with treatment. The goiter remains unchanged in size for many years. They remain unchanged in size but not unchanged in structure. During this so-called innocent period changes in structure are taking place as indicated in the chapter on pathology. Sudden hemorrhage into a cyst may as suddenly destroy the life of the patient. During the innocent period pressure symptoms may harass her, injure her lungs and damage her heart. If operated before secondary symptoms develop the deformity is removed. Just how much this contributes toward protecting the patient against mischievous activity of the remaining portion of the gland cannot be stated. It will require close observation of a large series during the period of the patient's lifetime to determine this point.

Many of the simple goiters become toxic, slightly so, only to subside again. Others repudiate their innocence and assume a state of pronounced toxicity requiring surgical treatment. A few develop into typical exophthalmic goiters but the most of them present toxicity without exophthalmos. The results of surgical treatment in these cases are usually better than the primary toxic so far as the control of the toxicity is concerned. One can usually anticipate pronouncedly favorable results from operation. The permanency of the improvement is greater than after operation on other toxic types.

If marked myocardial degeneration has taken place, this is not restored by the removal of the goiter. Lung changes may have taken place and remain more or less permanently damaged. The extent of these, both before and after operation, can be but approximately determined.

In some of these cases a more rapid degeneration begins. They lose markedly in weight, the heart previously damaged,

dilates and beats rapidly. Usually the course goes uninterruptedly to a fatal termination. These are the simple annals of a "simple goiter." In my experience a patient long the host of a goiter dies of it sooner or later.

Toxic Goiter.—Toxic goiters vary much in intensity and in rapidity of onset and in a measure on the area of tissue involved.

Fetal Adenomas.—The toxic fetal adenoma, without involvement of the remaining gland, rarely becomes pronouncedly toxic, shows little influence to general measures and is cured by removal.

The Primary Toxic Goiters.—The life history of the primary toxic goiter is that of rapid ascent, the maintenance of a high point for a period of six months to two years, then a remission. A recrudescence often takes place. Complete recovery seldom is met with, but a symptomatic cure is not infrequently observed. In my early practice it was my privilege to observe a considerable number of these patients who ran their course untreated. Many of these, now a quarter of a century later, find their state tolerable, many regard themselves as well. Those that had eye signs have traces of them still. There is in some a constantly rapid heart, and most are easily excited to a markedly rapid heart. A few have died of myocardial degeneration with attendant dropsy. Several whose disease began in girlhood improved during the child-bearing years only to suffer a relapse at the menopause. Only one passed into a marked myxedema. There remains usually a state of nervousness and general bodily lability. The hyperacute cases usually terminate in death in a course of weeks or months. The more chronic ones begin slowly, reach a state of moderate severity, and retain their state for many months or years unchanged.

Such patients when operated on, usually show a pronounced improvement beginning soon after operation. This is marked first of all, Kocher pointed out, by a fall in the lymphocytes. The nervousness decreases and the weight begins to increase. In the average case this improvement continues and the patient declares herself quite well, and physical examination confirms her opinion. In many instances, however, the patient, if examined, will be found to still have many of her former symptoms, particularly a degree of rapid heart; and if there has been

exophthalmos, this quite certainly will be found to still persist to some extent. Operation has accomplished in a month what would have required many years to take place in the natural course of regression. What is more, there is less likely to be a rapidly fatal recrudescence after operation than after spontaneous improvement.

When improvement does not take place after operation, one of two factors will be found operative. Either not enough of the gland has been removed or there is some other condition present which cannot be influenced by operation on the goiter. In the former instance reoperation is in place. Usually the proper estimate of the amount of gland to be removed will produce a favorable result. One should not hesitate to operate again should it appear that not sufficient gland tissue has been removed. Not uncommonly a portion of the gland not previously involved begins to develop with a renewal of the symptoms. A reoperation will again produce favorable results in these cases. On the other hand, a general nervous state or some other source of ill health may underlie the complaint. Whenever operation fails to produce the desired result the entire problem should be studied again.

In some instances a marked recrudescence of the symptoms takes place without any renewed increase in size of the gland. It is useless to reoperate for this; it is a degeneration and not a proliferation that is causing the trouble. I have received more of these from other surgeons than of my own making. Some of them die. Because of the fear of such results I seldom do a complete bilateral resection at the first sitting, preferring to operate again rather than face such possibilities. We know too little of the late results of operation of a bilateral lobe resection to follow this practice with confidence. These unfavorable late results are more apt to follow operations on patients with pronounced toxicity who have small goiters. Generally speaking, the smaller the goiter, in proportion to the intensity of the symptoms, the less satisfactory the results from operation.

Secondary Degeneration.—The insidiousness with which a toxic state may be implanted on a simple colloid goiter has already been considered. In many of them the toxic state develops suddenly and definitely resembling in symptomatology the

primary toxic type. The prognosis is dependent almost wholly on the degree of metabolic disturbance. This is usually definitely proportional to the loss of weight. If the weight remains stationary or begins to definitely increase, the operative prognosis is good. It is one of the safest operations in surgery as a matter of fact. The symptomatic results are almost uniformly satisfactory and the lingering symptoms are much less conspicuous than after operation for primary toxic goiter.

Those secondary goiters when they begin hyperacutely, carry a graver prognosis than the primary type. They carry a greater operative risk and more of them die without treatment. The gravity is partly expressed by the degree of emaciation. The addition of fever adds materially to the gravity of the prognosis. When delirium is added, the outlook is very bad indeed. The gravity mounts as the fever and delirium increase. A few recover, however, in whom fever and delirium have developed. I have never seen a nonoperated patient recover whose temperature has reached as high as 104°.

These hyperacute secondary toxic goiters make up by far the greater number of fatal cases. They are most common in old women who have had a goiter since young womanhood. To die from such a toxic state may be said to be the natural cause of death in these old goiter patients.

Interstitial Form (Forme Fruste).—This type does not assume a severe form. The prognosis is more that of the patient's general condition and less that of the disease. Sooner or later the patients will improve and resume the state of health they had before the goiter manifested its activity.

A reservation must always be made because the diagnosis is not to be made with certainty in many cases. What may seem to be a pure type of this disease may later show a dominance of thyroid disturbance. That is, an adenoid disturbance becomes implanted on the interstitial changes characteristic of this type of the disease. Then the prognosis becomes that of the type and degree of thyroid disturbance presented. If the adenoid disturbance is markedly dominant, much may be expected from operation.

Not much can be expected from operation in the pure interstitial type because the thyroid gland usually represents but a

part of the disease. There is commonly a pelvic disturbance that is not amenable to treatment. The results to be expected from operation may be judged by the state of the patient's health before the goiter developed. One cannot hope to exceed this state. I hesitate to operate on these patients because they seldom receive the benefit they expect. I have seen a number of these, who have been operated on by surgeons of the highest standing, made worse by the operation. Many of these receive temporary improvement, it is true, following operation, but they quite as regularly lapse into their former state sooner or later. It is, therefore, the selection of the case and not the technical skill that was at fault.

Malignancy

There are those who speak of curing malignancy of the thyroid. Our knowledge of histopathologic diagnosis is not yet exact enough to permit us to speak positively in many cases. When we have to do with suspected malignancy we may be pretty sure that either our diagnosis is wrong or there will be a recurrence. It is too much to expect that we may cure a condition where we do little more than remove the suspected lesion with little attention to the environment. Much less may we credit those cases where a resection of the malignant gland is alleged to have produced a cure. In those cases in which a diagnosis can be positively made, I refuse operation. The suspected cases that remain well after operation one may be fairly sure were not malignant.

Mortality after Operation

The operative risk in colloid goiter comes from pneumonia, tracheal collapse, hemorrhage and infection. Each of these are factors of the rarest occurrence. There are few diseases of like magnitude in which the operative prognosis is so good. In long existing cases the heart may become much affected and this may invite complications, but heart failure per se is but little to be feared following operation for simple goiter. Hemorrhage and infection can be prevented as certainly as anything in surgery. Tracheal collapse is rarely troublesome and pneumonia

following operations under local anesthesia is a disaster wholly foreign to my experience.

In the toxic type the risk is directly proportionate to the degree of metabolic disturbance. In extreme emaciation or in the presence of a rise of temperature the risk is definite despite every care the surgeon may invoke. The risk from operation is greater than from expectant treatment. One should wait for a remission and then operate.

There is no disease that is so largely dependent on the skill and judgment of the surgeon. Every operative death must be regarded as an impeachment of his ability and should be a signal for the careful reconsideration not only of the factors underlying the case in question but also of his whole viewpoint of the disease. To justify itself, operation for goiter must be without mortality.

It is interesting to note that while the technics of the various operators differ much in detail, some simple, some elaborate, the operative prognosis is about the same. It seems fair to presume, therefore, that the determining factor is skill in operating, born of experience, and not any particular procedure, that counts in the operative results.

CHAPTER VI

GOITERS IN UNUSUAL PLACES

Under this head may be grouped all those conditions which because of their topographic relationship cause some disturbance by virtue of such location. For the most part they do this mischief as tumors and the goitrous element is unimportant or incidental. The most common conditions to be considered are those in which the trachea is displaced or compressed by the abnormal expansion of the gland. Next in frequency come the growths into or extension into areas not normally occupied by the thyroid gland. These comprise the substernal, in which the lower pole grows into the thoracic cavity leaving a part only to occupy the normal situation of the gland, then the intrathoracic goiters in which the entire enlargement lies within the thorax, leaving no part of the enlargement at the normal site of the gland. Next are the aberrant goiters which from some trick of development remain at some unusual situation. These lie usually at the angle of the jaw or at the base of the tongue. Finally the intratracheal goiters, though rare, deserve consideration.

Abnormal Expansion of the Normally Situated Thyroid Gland

Under this awkward heading all those conditions in which the expanding gland produces mischief may be grouped. The gradual symmetrical growth of both lobes may compress the trachea between them (Fig. 59). This is most likely to happen in old calcareous goiters. This compression flattens the trachea so that it becomes a mere slit giving rise to the old expression "saber sheath" trachea. If one lobe expands chiefly the trachea may be widely displaced or displaced and compressed. Sometimes secondary or irregular bosselations may produce unusual conditions. The most common are those in which a nodule grows medially between the trachea and esophagus (Fig. 60). Hemorrhage into a cavity remaining after the removal of such

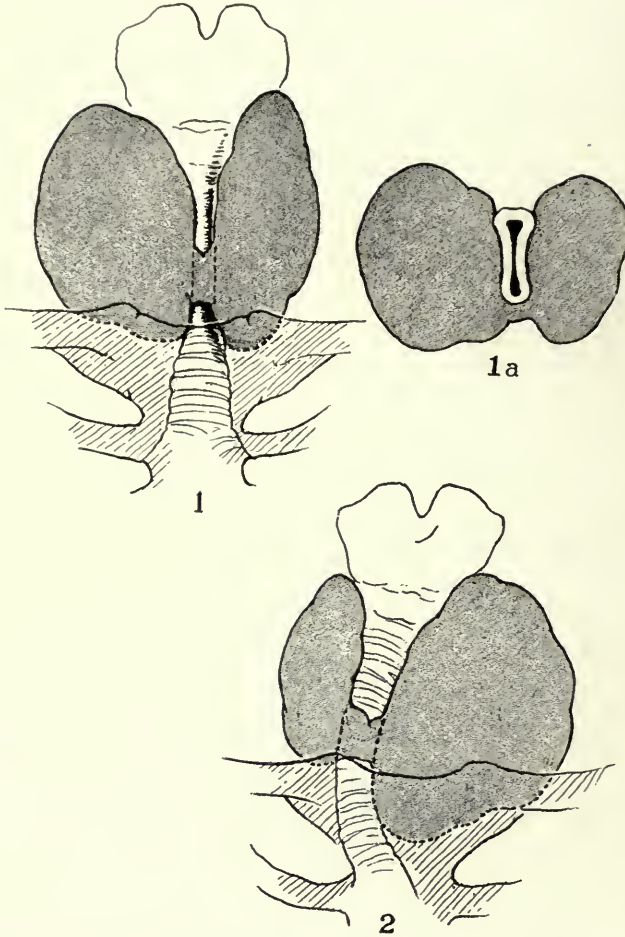


Fig. 59.—The trachea is shown as being compressed between the lobes of the goiter producing the so-called sword-sheath trachea. 1, the trachea being compressed by bilateral lobe enlargement; 1a, the same showing in cross section the result of such compression; 2, the trachea is shown as being both compressed and displaced by unequal lobe hypertrophy.

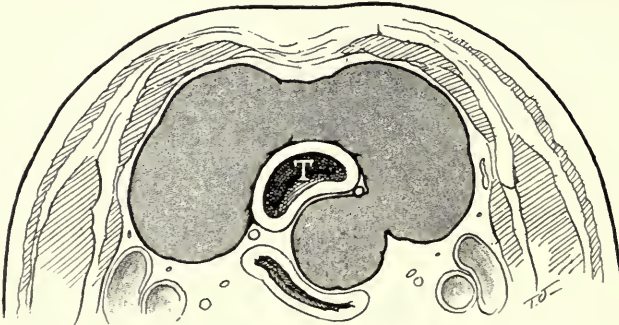


Fig. 60.—Diagram showing the manner in which a lobe may grow between the trachea and esophagus, compressing both these tubes. The right recurrent nerve lies in a groove between the right and the aberrant lobes.

a lobe may cause sudden death by compression of the trachea (Fig. 61).

Compression of the Trachea.—The effect of the compression of the trachea may be dyspnea or secondary affections of the lungs. Often the dyspnea is facultative; that is to say, in certain positions the patient has difficulty in breathing, in others,

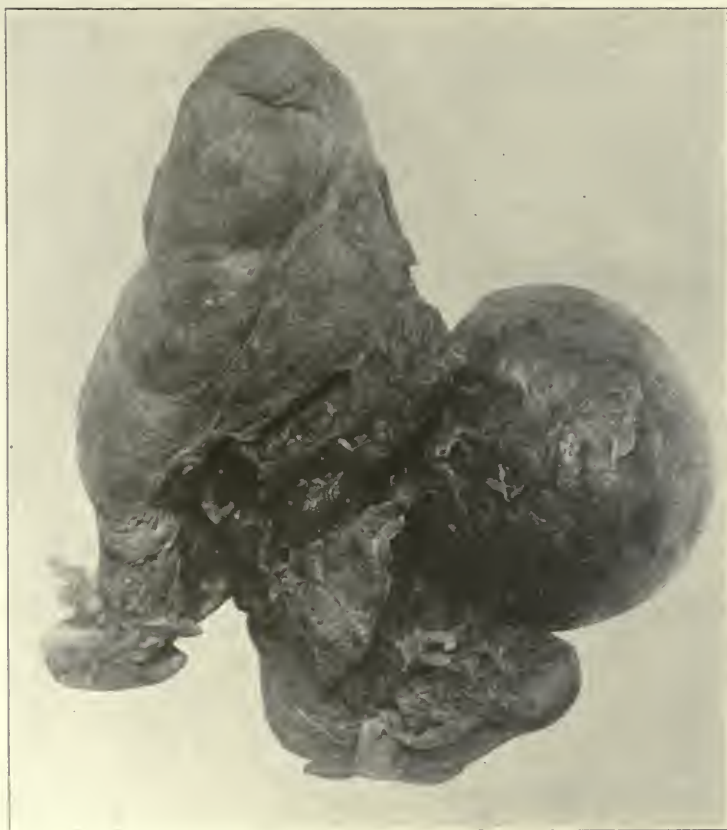

Fig. 61.—Photograph of a specimen in which the rounded lobe on the right lay between the trachea and the esophagus producing dyspnea and dysphasia. Secondary hemorrhage into the cavity occupied by this lobe produced dangerous tracheal obstruction after the operation.

not. This is particularly noted when the patient is in bed. The pillows must be arranged in a particular way. When sudden changes take place in the gland, the situation may be more serious.

Compression of the Vessels.—Besides the tracheal compression, the neighboring vessels may be compressed, producing sec-

ondary affections of the heart. Though it is well established in the literature, in my experience the degree of cardiac disturbance bears no or at least very little relation to the degree of disturbance of the circulation. It is just as easy to believe the "innocent" goiter has gradually poisoned the heart.

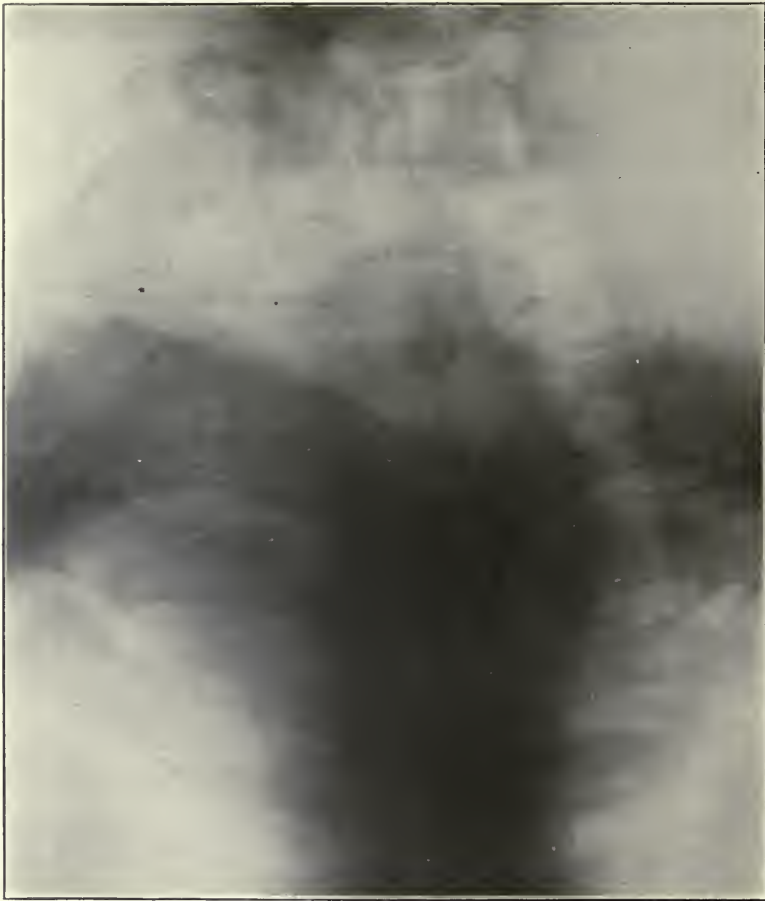

Fig. 62.—X-ray picture showing the trachea pushed far to the left by a medial lying substernal goiter. The trachea is represented by a broad light band to the right of the picture.

Dysphasia.—Difficulty in swallowing is sometimes complained of by goiter patients. Only occasionally is there an actual impingement on the esophagus. In most cases the sense of constriction is a nervous manifestation.

Compression of the Nerves.—Compression on the surround-

ing nerves is frequently noted. In large old goiters there is often a paralysis of one of the vocal cords. This may be indicated by the disturbance of the voice, but it is usually not so announced. The vocal apparatus should be examined in each case lest the discovery of it after operation might lead to the



Fig. 63.—X-ray of a goiter in which the calcareous plaque caused misjudgment as to the location of the trachea. The light area at the extreme top of the picture was taken to be the trachea. This was a calcareous deposit and the trachea was found displaced far to the left.

opinion that the paralysis was due to the operation. A knowledge of its presence before operation would be a source of satisfaction to the surgeon in case of a damage suit, but it is a fictitious hope that such a record would have any influence on the court or jury.

One of the sympathetic nerves is sometimes compressed producing dilatation of the pupil on the affected side.

Not uncommonly, pain in the mastoid region is complained of, caused by compression of the deep sensory nerves of the neck.

Diagnosis.—The recognition of disturbances caused by the abnormal development of goiters is not always easy. Usually the displacement of the trachea can be readily palpated or it may be demonstrated by the x-ray (Fig. 62). Sometimes when the gland is hard and calcareous, neither of these means is of help (Fig. 63). In such cases the laryngoscopic examination may show a narrowing of the trachea. In some cases one cannot prove that a narrowing of the trachea exists, but there being a goiter and dyspnea the one may be assumed to have followed the other. Other possible causes of dyspnea, of course, must be kept in mind lest the patient be disappointed if the operation does not relieve the symptoms.

Nerve compressions when coexistent with the goiter may be assumed to be due to it but other causes for the condition should always be excluded.

The importance of a careful diagnosis of the conditions here considered lies in the fact that especial caution is required in the preparation for the operation. Those particularly who operate under general anesthesia will do well to have a tracheotomy tube at hand and to locate the trachea as early as possible after the operation is begun. Further details may be found in the chapter on technic.

Substernal and Intrathoracic Goiter

Strictly speaking, an enlargement of the thyroid gland is a "goiter" (that is to say a "big neck") only when it is situated in the normal position. However as is so often the case, inaccuracy is most expressive, for in the more common type, the substernal, the displaced portion migrated because of the pressure from the "goiter" above. Therefore, while physiologically incorrect, it expresses the pathogenesis very well so far as it concerns the substernal but the intrathoracic cannot be so explained. The thyroid gland is situated just above the superior opening of the thorax. It follows naturally that if a certain de-

gree of enlargement is surpassed, the projecting poles must needs enter the thoracic cavity. When this takes place, that portion projecting into the thoracic cavity is called substernal or if located to one side, retroclavicular. The extension from above downwards usually involves the lateral lobes and consequently the displaced portion may be located to one or the other side. However, since the midline offers the least resistance, usually no matter from which lobe they arise, they tend to reach the midline (Fig. 64).

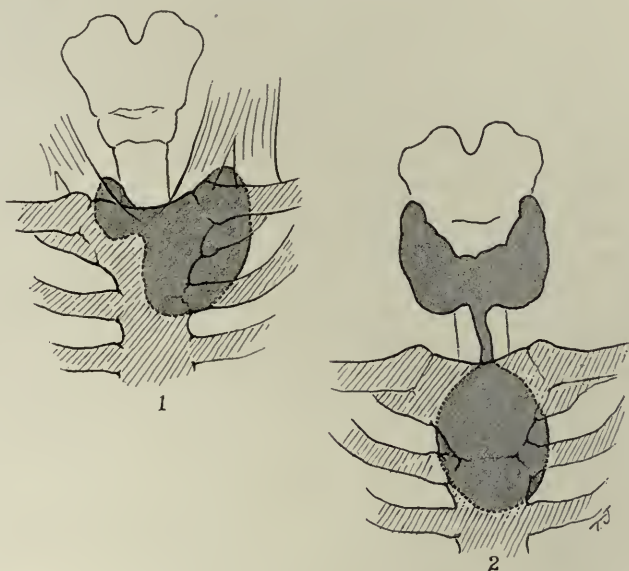


Fig. 64.—Diagram showing the difference between a substernal and an intrathoracic goiter. 1, Substernal, being a prolongation into the thorax of a normally situated goiter, and, 2, an intrathoracic being attached to the isthmus by a fibrous cord only.

In those instances in which the whole enlargement lies within the thoracic cavity, without there being any goiter in the neck, they are then called intrathoracic, for they are actually so. Kleinböck (*Med. Klin.*, 1908, iv, 488-495) divides the intrathoracic goiters again as to their relation to the vessels of the neck. When they lie laterally they are situated between the vertebral column and esophagus behind, lateral to the trachea, medial to the apical pleura and behind the common carotid and anonymous arteries and their veins. The medial intrathoracic goiter lies in front of the large vessels and in front

of or immediately to one side of the trachea. In front is the sternum and below, the arch of the aorta. Generally speaking, those derived from the lateral lobes lie behind the vessels, those arising from the isthmus lie in front. Whether they come to lie substernally because of accident of growth or developmental anomalies is not always clear. Some are attached to the remainder of the gland by a narrow pedicle when the remainder of the gland is normal in size and situation. In addition these nodules are ovoid in form and the attaching pedicle reminds one forcibly of the aberrant goiters in other situations. This type, it is fair to assume, are really aberrant goiters and in contradistinction to the following may be called primary intrathoracic. The secondary type is usually attached to a lateral lobe, generally by a broad pedicle. However, the primary intrathoracic type is attached to one of the lower poles and its definite pedicle often a direct extension of the isthmus. Lahey (*Jour. Am. Med. Assn.*, 1920, lxxv, 163) has recently emphasized the fact that a substernal goiter may become an intrathoracic one if the mass is pear-shaped. As it grows in size, its wedge shape pulls it down, like a growing uterus pulls itself up into the abdomen. Those in contradistinction to the preceding may be called secondary intrathoracic goiters.

Some goiters have the faculty of spending a part of the time above the sternum and part beneath it. These are called wandering goiters. They sometimes can be made to appear at will by coughing. As they grow larger, they can no longer be expelled and they remain permanently behind the sternum, or commonly they remain above the clavicle. I had one patient who wore the goiter above the clavicle when about her household duties, but pushed it below the clavicle when she went out into society. She nearly died in a fit of coughing at a social function. She then had it removed.

Incidence.—Substernal goiters, those that are for the most part above the sternum and extend below only in part, are quite common in colloid goiters, being so in about one-fourth of the cases. Intrathoracic goiters are much less common, representing not more than a fourth per cent of all goiters. This type is much less frequent in primary toxic goiters and in typical Basedow patients. I have seen a number in which the entire enlarged

lobe was hidden beneath the sternum. Not infrequently toxic goiters are pear-shaped with the big end of the pear nested in the supra-clavicular fossa, while the gland in the normal situation seems but little enlarged. This type occurs in some 5 per cent of



Fig. 65.—This patient had a typical exophthalmic goiter with no apparent thyroid enlargement. The goiter lay behind the sternum.

cases. One is apt to regard these as “Graves’ disease without goiter” (Fig. 65), unless one uncovers the prolonged pole by operation. Both the substernal and intrathoracic occur most

frequently in midlife or beyond, most likely because the larger goiters appear in more advanced years. However, I have seen the substernal as early as seventeen years and the intrathoracic at the age of twenty-two. The intrathoracic are said to occur most frequently in the male, a statement entirely in accord with my own experience.

Symptoms.—The disturbances caused by abnormally situated thyroid lobes are dependent almost entirely upon the mechanical displacement of organs native to this region. These are the trachea, the esophagus, the blood vessels, and the nerves. The symptoms do not differ materially from those already detailed for compression by the normally situated goiters. Herein lies the importance: one may think he has removed the cause of the trouble when the normally situated goiter has been removed, yet the chief trouble may lie within the thorax.

The trachea is naturally in most intimate contact with the goiter and any considerable compression of it is registered by a lessened facility of the interchange of air. Dyspnea may be produced either by compression or displacement. Often this dyspnea develops so gradually that there may be no objective evidence of it and the obstruction may reach a considerable degree before the patient registers complaint, just as in the normally situated goiter. Because of the change in position of the tumors and trachea by the different position of the head, the dyspnea may be increased or lessened by holding the head in a certain position. It is indicative of this type of the substernal goiter if elevating the chin or depressing it or holding it to one side increases or lessens the respiratory difficulty. Therefore, if the patient desires high pillows or is compelled even to maintain a sitting position, a substernal lobe likely exists. If change of position makes no difference, one should think of an intrathoracic lobe.

Disturbances of deglutition are much less common than disturbances of respiration, because the esophagus glides out of the way more easily and its patency is not an unremitting necessity. When this is present, either the tumor is very large or a smaller lobe is insinuating itself between the trachea and esophagus. Disturbance of deglutition is most apt to occur in the retrovascular type. Occasionally the disturbance is so great

as to simulate a malignant process, but it usually is only marked enough to excite the attention of the patient sufficiently to make it a matter of record.

The patient may be harassed by a constant cough. This may be due to a direct irritation of the trachea, but more often is caused by displacing or compressing the recurrent laryngeal nerve. Occasionally the "goose cough" due to recurrent irritation gives the first clue to the nature of the trouble and suggests an intrathoracic goiter. Not infrequently there is a paralysis of a cord without the patient's being aware of any difficulty of any sort. A laryngoscopic examination, therefore, should always be made when a hidden goiter is suspected.

Usually compression of the veins causes a dilatation of the superficial veins over the sternum and the base of the neck. Less common pressure on the anonymous artery may produce an inequality of the pulse. Swelling of the face and edema of the arm have been noted (Bard: *Rev. med. de la Suisse*, 1905, xxv, 204).

Diagnosis.—When there is dyspnea with the presence of a goiter in the neck, in the absence of other causes, compression of the trachea may be assumed. When there is a goiter in the usual situation, one should first determine whether this is compressing the trachea. If not, a substernal goiter must be sought. A deviation of the trachea may be palpated and if not accounted for by the normally situated goiter, suggests a prolongation into the thorax. When such can be demonstrated, the diagnosis is usually completed. There are exceptions. I once examined a patient who had had a goiter for many years. She developed a dyspnea, and a substernal tumor apparently continuous with the goiter was demonstrated by the x-ray. The substernal tumor proved to be a metastatic carcinoma from a breast removed many years before.

When there is narrowing of the trachea the question arises whether this is due to compression by the normally situated goiter or to pressure of an abnormally situated lobe. Sometimes displacement of the trachea, shown by palpation or by the x-ray, not accounted for by the size and situation of the goiter in the neck gives a clew. Under favorable conditions the laryngoscope will reveal the actual situation of

the narrowing. Percussion of the upper end of the sternum will show dullness if the displaced lobe be large. The larynx may not make the usual excursions in deglutition and it may be situated abnormally low. Both these signs are significant. The x-ray is the most valuable aid in showing the presence of a tumor of the upper mediastinum. It is most valuable when the gland is old, particularly if it contains calcified areas. The x-ray usually adds valuable evidence, but it may also mislead. I have failed to find substernal goiter when the x-ray seemed to indicate its presence and more often I have found it when the plate showed no shadow. If a shadow can be detected under the sternum by means of the fluoroscope and this shadow moves with the trachea with deglutition, the diagnosis is certain. The surgeon should verify this evidence whenever possible, however. Mobility may be reported from the x-ray laboratory when none exists. The play of shadows during deglutition is often confusing and slight changes may be magnified by those who are not to assume the responsibility of the operative procedure. Sometimes the tumor itself prevents this excursion. This occurs usually in tumors of large size or those fixed by secondary changes. Generally speaking, all the factors must be taken together before a conclusion is hazarded and then the surgeon should approach the operation with the feeling that the operation alone can clear up the final doubt.

Interference of deglutition is less valuable as evidence than is disturbance of the trachea. Its presence without evidence of respiratory disturbance should cause one to proceed with caution. I was once sent a patient for the removal of a suppositious substernal goiter which it was alleged was responsible for a dysphasia. The x-ray had demonstrated its presence, it was said. As I approached the patient, already on the operating table, he burst out weeping. Since patients do not usually weep so copiously on making my acquaintance, I retired and signaled a neurologist. A diagnosis of bulbar paralysis was made.

The diagnosis of intrathoracic goiter is much more difficult than the recognition of the substernal. They are missed because one does not think of the possibility of their presence. Sometimes cough is the chief or only sign. Since intrathoracic goiters are most common in the emphysematous, one may pass

over this complaint lightly. The goiter by pressure on the trachea, or in rare instances on the bronchi, may add materially to the emphysema. In such cases emphysema may exist without the classical barrel-shaped chest commonly associated with this syndrome and thus give a clew. Extensive emphysema may obliterate substernal dullness. As a matter of fact, substernal dullness is a sign of uncertain value because of the associated changes above noted. Wohrmann (*Deutsch. Ztschr. f. Chir.*, 1906, xliii) was able to demonstrate it in but 10 of 75 cases. This corresponds to my experience. The dilatation of the veins of the skin, referred to as a sign of substernal goiter, may be somewhat vitiated by a generalized phlebeetasis of the chronic asthmatic. In such cases the study of the excursions or the position of the trachea as it disappears into the thorax may be of the greatest value. Its deviation from the midline often is a hint of great value. Sometimes a finger placed in the suprasternal notch may receive an impulse when the patient swallows or coughs. A pulsation on coughing in the supraclavicular space once enabled one of my assistants (Olsen) to catch the clew after I had gone over the patient repeatedly and found nothing but a recurrens paralysis (Fig. 66). Only after all the signs have been carefully studied should an opinion be hazarded. In rare instances the presence of the usual symptoms of toxic goiter without there being any goiter visible will lead to the successful search for one behind the sternum.

When the intrathoracic goiter becomes malignant shooting pains and bloody sputum are added to the usual picture. Fixation of the trachea is apt to be absolute, and deglutitory disturbances progress rapidly. Metastatic mediastinal masses from goiters normally situated sometimes occur. In the only instance of this kind in my experience, the normally situated goiter, because of its hardness and fixity, was obviously malignant, and since the mediastinal symptoms were of recent origin, a secondary relation was probable. The x-ray showed not only a tumor in the mediastinal space, but others in the lungs thus settling the small element of doubt that remained.

Hemorrhage into a substernal goiter may suddenly increase the volume of the tumor. One of my patients, known to have a

substernal goiter, suffocated during a night from what was probably a hemorrhage into the tumor.

When a mediastinal tumor, supposedly goitrous, has been

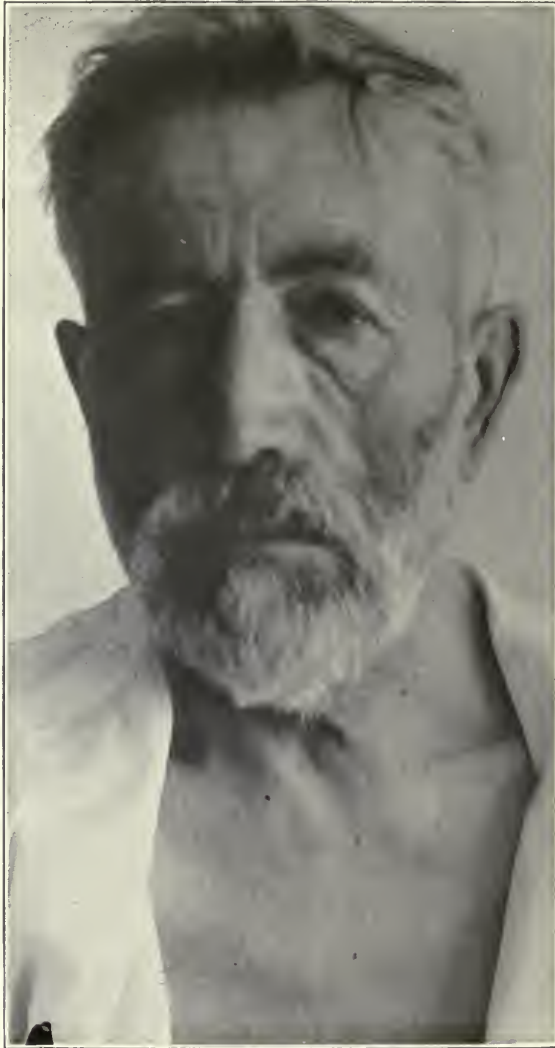

Fig. 66.—Intrathoracic goiter in a patient with dysphagia and cough. The goiter lies substernal. During efforts at coughing it could be seen bulging behind the left sternoclavicular articulation.

hypothecated, a differentiation from other mediastinal growths must be made.

Thymus tumors have been observed, but are rare. In the

adult they are usually malignant and the duration is less than in intrathoracic goiters. The trachea is less apt to be compressed and is usually neither displaced nor fixed. Lymphosarcomas are the commonest mediastinal tumors. They often show dullness on percussion and the x-ray shows them some distance below the sternal notch. The top is more rounded and does not extend up so high. The trachea is not fixed until late and then there are usually several tumors present. Sometimes there are lymphomas elsewhere. Metastatic tumors, from primary tumors situated at a distance, are sometimes encountered. Sarcomas are the most common. Usually there is no difficulty in discovering the primary tumor, but sometimes the patient does not volunteer the information. Aneurysm is usually sufficiently demonstrated by the x-ray. It is interesting to know that a goiter may pulsate, but it is not the expansile pulsation of aneurysm and there is no bruit. Goiters may disturb the synchronicity of the carotids or the two radials. Usually too, intrathoracic goiters are encountered at an age when aneurysms are not found, that is to say, beyond fifty years. Still rarer tumors are sometimes encountered. I once encountered a substernal dermoid. It presented in the sternal notch, was semifluctuant and did not disturb the excursions of the trachea. Lipomas are rare substernal tumors, and usually do not occupy the upper mediastinal space alone.

Treatment.—Once a substernal or intrathoracic goiter has caused the patient trouble, it must be removed. The substernal goiters give but little trouble because the suprasternal portion gives a good handle and furnishes a good guide. All that is needed is the careful determination of the line of cleavage. This found, one can raise the offending mass by gentle traction. Fortunately the vessels supplying it have gone down with the progressive development of the lobe and as it is withdrawn the vessels become more accessible. It is only when the submerged lobe is very large that it is necessary to reduce the size by evisceration. This is best done by exposing the top of the tumor, which can usually be done by making a long transverse incision just above the sternum, separating the sternal insertions of the clavicle if necessary, making an incision into the goiter and by grasping the capsule with forceps it can be held while the finger

scoops out the colloid material within. By continued traction and the scooping manipulation the mass can be brought forth. As the vessels entering the gland appear they should be caught and ligated. By this technic I have removed a mass as large as two fists. Should the capsule be calcified, new difficulties would be encountered because in addition to being incompressible there would likely be a firm union with the trachea. Jacques and Michel (*Rev. med. de l'est Nancy*, 1910, xiii, 233) report a calcified intrathoracic goiter. Fortunately the size of the tumor was not great enough to offer difficulties. Retrosternal goiters not infrequently have calcified areas. These can be crushed and delivery effected. This can usually be done without exciting any considerable hemorrhage.

The substernal masses sometimes lie so deeply that they are difficult to grasp. Sometimes if the patient coughs violently, the gland may be so much elevated that it may be grasped. A husky ranchman once aided me by this means. The gland was so deeply situated that I could not grasp it. A violent cough, made at my request, fairly shot the offending lobe up into the neck and it remained perched above the sternoclavicular articulation and its removal was effected with the greatest ease.

In exceptionally difficult cases, the natural avenue of approach is not sufficient. I have employed a lateral method of approach by removing the costochondral cartilage of the first and second ribs and then biting away the adjacent sternum with a ronguer. This gives good access to the gland. However, I believe Milton's method, which consists of the longitudinal splitting of the sternum as employed by Lilienthal (*Surg. Gynec. and Obst.*, 1915, p. 389) is preferable in some respects in that it gives better access to the lower extremity of the tumor. In any of these very difficult cases it is well to remember that if the hemorrhage becomes threatening it is best to pack with gauze and finish at another sitting.

When the apparent cause of tracheal obstruction has been found, one must assure himself that the whole trouble has been relieved. I once came near overlooking an intrathoracic lobe after a substernal one had been removed. One patient had been operated on and an enlarged right lobe with a prolonged lobe extending well behind the clavicle had been removed. I found

a complete intrathoracic lobe going out from the left lobe. She subsequently developed a goiter on the thyroglossal duct just above the hyoid bone. This also was removed.

Aberrant Goiters

Owing to the failure of the thyroglossal duct to become atrophic or to the displacement of thyrogenic tissue, it is possible to find accessory thyroids anywhere between the foramen cecum and the normally situated thyroid gland and even as low as the aortic arch. A diagram from v. Enselsberg's book

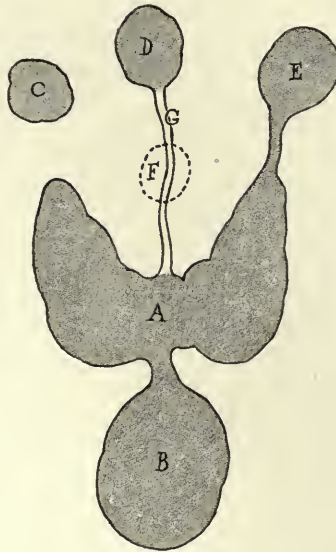


Fig. 67.—Diagram showing the possibilities in aberrant goiters. *A*, the normally situated gland; *B*, intrathoracic lobe; *C*, detached lobe near the angle of the jaw; *D*, sublingual lobe; *E*, lobe near the angle of the jaw but attached to the upper pole by a fibrous band; *F*, pre-tracheal lobe (which is most often cystic); *G*, thyroglossal duct.

helps to visualize the usual distribution of aberrant goiters (Fig. 67).

Accessory thyroid glands are most common in the lateral regions of the neck. These evidently are displacements from the normally situated lateral anlagen for in many instances they retain fibrous attachments to the lateral lobes. However, in a case reported by Reynier (*Bull. et mém. de la Soc de Chir.*, 1906, xxxii, 901) a laterally situated cystic thyroid seemed to have attachment to the thyroglossal duct. Thyroid tissue alleged to

have been found in remote parts of the body must be ascribed to other influences.

Lingual Goiter.—Thyroid nodules at the base of the tongue are among the rarer anomalies of displacement. About 50 cases have been recorded in the literature according to Jorge and Layern (*Rev. de la Asoc.*, Buenos Aires, August, 1918, Vol. 29). These figures give an erroneous idea of the frequency of its occurrence. I find on inquiry that most surgeons of considerable experience have seen one or more. In two instances it appears that the lingual was the only thyroid tissue the individual possessed. In order to avoid depriving the patient of the only thyroid tissue she possessed, it would be advisable to make an incision at the site of the normal thyroid and demonstrate its presence, or absence. Myxedema followed the removal of a large lingual goiter in Seldowitch's case. On the contrary the patient may be unduly well provided. I once removed a very large colloid goiter from a patient who had a lingual goiter the size of a hulled walnut. The lingual goiter gave her no trouble and she preferred to keep it. After the removal of the normally situated goiter the lingual one shrank and has given her no trouble, now ten years since the operation. This anomaly is present more often in women than in men, in the proportion of 6:1. It has been observed in all ages from birth to seventy-seven years, but is most common between the ages of fifteen and forty.

SYMPTOMS.—Lingual goiters develop gradually and exercise an unfavorable influence only by interfering with the function of deglutition and speech. When the growth is rapid or when some accident befalls it, such as acute inflammation or hemorrhage into its substance, respiration may be seriously interfered with. In some instances thyrotoxic symptoms have attended the enlargement of lingual goiters. They vary in size from a small marble to that of a walnut or even a hen's egg. When large, they may be palpated in the hyoid region (Berger, *Bull. et mém. Soc de Chir.*, 1906, xxxii, 1161). They are rounded or somewhat lobulated, the mucous membrane covering them contains large veins. The tumor is elastic, but not fluctuating unless secondary changes have taken place. They are situated at the base of the tongue and may project upward so that they are plainly visible, but sometimes they are deeply situated

so that especial effort is required to see them and if small, a laryngeal mirror must be employed.

DIAGNOSIS.—Dermoids at the base of the tongue are most apt to be mistaken for lingual goiters. The dermoids grow more rapidly, fluctuate or pit on pressure and the covering mucosa is not vascular and the color is whitish or yellow. Cysts in this region are situated usually in the midline, the surface is bluish, sometimes translucent, and they are tense, elastic, or fluctuating. Gummas are deeply imbedded in the substance of the tongue and the duration is not so long as in lingual thyroids. Tuberculomas are fungoid, and lung involvement can be demonstrated in most instances.

TREATMENT.—**Excision** is the best treatment. Because of the great tendency to bleed, a preliminary tracheotomy is performed as done by some surgeons (Sterling, *Ann. Surg.*, 1907, xlii, 826) or the anesthesia is given by intratracheal insufflation. Berger operated on his patient under chloroform anesthesia, but had much trouble with hemorrhage and cyanosis. Mass ligation about the tumor controls hemorrhage. Harsha (*Surg. Clinics of Chicago*, 1918, ii, 312) and Berger made an incision under the jaw and drew the tongue down through the incision. This made the tumor readily accessible. This seems to me to be the safest procedure.

Aberrant Tumors of the Submaxillary Region.—These are the most common of the aberrant tumors. They are usually found most frequently in the midperiod of life. I have seen none before twenty-five or after fifty-five. All that I have seen have been in women.

SYMPTOMS.—They appear as ovoid tumors between the anterior border of the sternomastoid and the border of the lower jaw (Fig. 68). They vary in size from that of a bean to that of an orange. They cause no disturbance except from their size and the disturbance is cosmetic rather than physical. They are well encapsulated and move freely in all directions and are quite painless on pressure.

DIAGNOSIS.—Aberrant goiters in this situation must be differentiated from a great variety of tumors. Their long history differentiates them from malignant growths and their great mobility distinguishes them from most other tumors in this region.

Carotid tumors are not movable in a vertical direction. Thyroglossal cysts are more elastic and usually can be made to bulge into the floor of the mouth when pressed upon. They are differentiated from mixed tumors of the submaxillary gland by the fact that the latter are firmer than goiters. When the aberrant lobe is attached to the upper pole of the normally situated goiter, a tugging on the aberrant lobe can be felt during deglutition. If the diagnosis is not made before operation, they are



Fig. 68.—An aberrant goiter near the angle of the jaw. This lobe was the sole cause of a thyrotoxicosis.

differentiated from carotid tumors by the fact that they are not associated with the carotid vessels.

TREATMENT.—They are more easily removed than any other tumor of the neck. They have no attachment and but little blood supply.

Intratracheal Struma.—Thyroid tissue within the trachea has been described in some 16 cases. Whether these shall be regarded as embryonal displacements or secondary growth into the trachea from a normally situated gland has not yet been

determined. They have been noted all the way from beneath the vocal cords (Paltouf) to the tracheal bifurcation (Radistock, *Beitr. z. path. Anat.*, 1888, iii, 288). The majority have been noted about the level of the first tracheal ring. The usual situation relative to the circumference of the trachea has been in the posterior or lateral wall or the posterolateral. Paltouf (*Beitr. z. path. Anat.*, 1892, ii, 71) was able to trace a direct connection between the intratracheal and the normally situated gland, and he reasons from this that there must be a like connection in the other cases. As Grunenwald (*Beitr. z. klin. Chir.*, 1905, xlv, 711) points out, such a connection would be hard to hypothecate for the tumors located in the posterior wall of the trachea, and even more difficult of explanation is Rodestrak's case in which the tumor was situated at the tracheal bifurcation. All things considered, it seems safe to classify these intratracheal masses along with the aberrant thyroids.

SYMPTOMS.—As might be anticipated, women are more commonly affected than men. The proportion of 1:4 is given. They are most frequently noted in early adult life. The reported cases range in age from twelve to thirty-four years, though my patient was fifty-eight years old. Most generally there is a prodromal difficulty of respiration for months or years with a more or less sudden onset of threatening dyspnea which in Paltouf's case required an emergency tracheotomy. In Rodestock's case a bronchiectasis with suppuration developed following the drainage, of which the patient died. The tumor was found at the bifurcation. Six of the reported cases were located on the posterior wall, six on or near both sides, two exclusively on one side and one was attached to the anterior wall. In my case the base of attachment was to the lateral wall (Fig. 69). The thyroid lobe had previously been removed for malignancy and no attachment to the trachea at this point was noted.

DIAGNOSIS.—In most of the cases a rounded tumor mass covered with normal mucosa has been observed with the laryngoscope. When deeply lying they may escape observation, or in very dyspneic patients satisfactory observation may not be possible. In my patient (Hertzler: *Clinical Surgery by Case Histories*; Mosby, St. Louis, i, p. 205) a corpulent woman of fifty-eight, it was not possible to see below the vocal cords. Two of

the cases reported were autopsy findings. These tumors are often associated with normal thyroids though in several there was a moderate struma and in my case the patient had already been operated twice for thyroid enlargement. Usually there is a history of gradual onset.

Paltouf's case was mistaken for a syphilitic and Rodestock's for a tuberculous perichondritis. This error is more

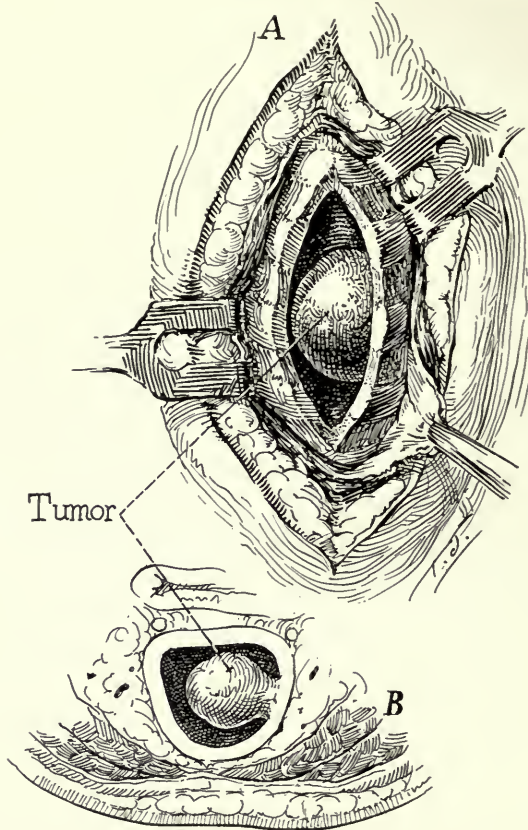


Fig. 69.—Intratracheal goiter. *A*, as it appeared at operation; *B*, diagrammatic presentation of a cross section, showing the lateral attachment of its base.

likely to be made when the tumor is situated just below the vocal cords than when it is located more deeply. In my patient the tumor was 4 or 5 cm. below the cords and its nature could be easily determined.

Intratracheal strumas must be differentiated from a number of equally rare conditions. Fibromas are lighter in color and

are pedunculated, while strumas are attached by a broad base and are red in color. Papillomas have a distinctive surface characterizing these tumors elsewhere. Chondromas are firm and lighter in color. Still more rare tumors are lymphomas and lipomas. Inspection does not make it possible to make the differentiation. Syphilis is usually attended by symptoms elsewhere in the body. In case of doubt the therapeutic test may be applied. It must be remembered that thyroid tissue may respond to iodine therapy. In Neumeyer's cases (*Monatsch. f. Ohrenh.*, 1904, xxxviii, 388) the tumor rapidly shrank under iodine treatment. A goiter in the normal situation also lessened. Neumeyer argued because of this that the intratracheal tumor likewise must have been thyrogenic.

TREATMENT.—My patient was treated by performing a tracheotomy and excising the tumor with a thermocautery and the trachea closed. No difficulty followed. Grünwald's case was treated by excision with ligation of bleeding points. A granuloma sprang up requiring a secondary ligation. Two of the cases were treated by partial destruction, both resulting in failure to cure. Paltouf's case was treated by compression. Infection and acute thyroiditis followed and despite drainage the patient died. Freer (*Jour. Am. Med. Assn.*, 1901) punctured a tumor with an electrocautery. Swelling followed, necessitating a tracheotomy. In two cases (Neumeyer's) iodine and thyroid extract were given with good results. This treatment would be permissible when the diagnosis is made early before threatening dyspnea has developed, a desideratum only rarely met. On the whole, laryngofissure with excision with the electric cautery as practiced in my case seems to be the most rational treatment.

CHAPTER VII

HOSPITAL MANAGEMENT OF GOITER PATIENTS

By Dr. Victor E. Chesky

The hospital management of the patient includes the care from the time she enters the hospital until dismissal. It includes the preoperative treatment, both of the goiter itself and associated diseases, the postoperative treatment and the treatment of any complications that may arise.

PREOPERATIVE TREATMENT

The preoperative treatment of the nontoxic and the toxic goiter is essentially different.

Nontoxic Goiter

The preoperative treatment of the nontoxic goiter patient is that accorded any ordinary surgical patient that comes in for operation. The history and physical examination are made with the view of discovering any contraindications for operation or any factor that may complicate it. The region of the goiter is x-rayed to discover whether there are any substernal prolongations, or any deviations of the trachea from its normal site. The vocal cords are examined to note the presence of a preoperative paralysis. If there is a myocardial disturbance, rest and heart tonics are given.

Toxic Goiters

With the thyrotoxic cases much more careful and elaborate preparation is necessary. Each patient must be managed according to her needs.

Preliminary Examination.—When the thyrotoxic patient enters the hospital, if the toxicity is at all pronounced, she is told she will be placed under observation for a short time before the date of the operation can be determined. During this period the

extent of toxicity is determined as nearly as possible. From the history it can be learned in a general way whether the patient is on the downward curve headed toward a toxic crisis, whether her symptoms are spontaneously subsiding or whether they have reached a stationary plane. The history shows the length of time the toxemia has existed, the number, and to some extent the severity, of the toxic crises she has passed through. The patient's variations in weight are carefully gone into, her normal weight, her estimate of her present weight and she is then weighed to test the accuracy of her judgment. The extent of damage done the parenchymatous organs by previous crises is determined by a general physical examination. The toxic status having been determined, the preparation for operation is begun.

Rest.—Rest, as complete as is possible to obtain, is by far the most important part of the preoperative treatment. By rest both mental and physical rest is implied; the former being much more difficult to obtain. Apprehension, distrust, and worry over domestic or financial affairs are only a few of the conditions of mind encountered in thyrotoxic cases. Sometimes patients enter only at the insistence of relatives thus adding another element to the obstacle in the way of securing mental repose. One should always remember that he is dealing not alone with a physical condition but also with a type of neurosis which at times amounts to a mild mania.

Kindness and patience on the part of doctor and nurses will go a long way toward allaying mental unrest. Kindness on the part of the surgeon should, however, be backed up by an unobtrusive firmness which makes the patient realize that he expects to have his instructions carried out. Correction of the patient by doctors or nurses should never amount to scolding or abuse. One should always remember the high nervous tension of the patient. Crotti puts it admirably when he says "It must never be forgotten that thyrotoxic patients are highly sensitive and often react with a veritable thyrotoxic explosion to some trivial annoyance." It has been a common observation with us to have patients come in looking the picture of an extreme thyroid intoxication who after a few hours' rest during which they are kindly treated by their nurses and receive the assurance

from their doctor that all will be well, lose their initial hospital fear and present an entirely different appearance.

The patient should be placed in a comfortable room and things arranged as far as possible to her liking. Quiet should prevail both within the room and in proximity to it. Loquacious relatives and friends should be excluded. A few chosen relatives or friends may be allowed to visit, for they can often aid materially in making the patient satisfied with her enforced rest and help allay her apprehension for the coming operation. The duration of their visits should stop short of exhausting the patient. Toxic patients do not need entertainment and very little reading should be indulged in by them.

The patient should be in bed most of the time and the severe cases should not be allowed to leave the bed at all. No hard and fast rules can be made, however, in regard to rest in bed. One must study the type of patient. Some are satisfied to lie in bed and do better on a back rest elevated from 30 to 45 degrees for several hours during the day while others are allowed a chair for two or three hours at a time to take the edge off their nervousness. Every patient should be cautioned against making any sudden physical movements such as springing from a reclining to a sitting posture, a type of calisthenics I have frequently seen indulged in by these patients.

By tact and care most patients can be made to take the required amount of rest. There are a few who are, because of excessive nervousness, entirely beyond the surgeon's control. They continually chafe under the restraint and after weeks of rest in the hospital are no better, or are even worse, than at the time of entrance. Some of the severe, acute intoxications respond to no treatment and rapidly progress to a fatal termination.

Diet.—A toxic goiter patient must have the greatest amount of food possible to counteract the excessive oxidation the disease causes. This increase in katabolism is shown by the basal metabolic test and the metabolic rate is a fairly true index of the extent of the toxemia. It is estimated that a severely toxic patient at rest in bed requires as much food as a man at hard manual labor, that is 3,500 to 4,000 calories per day.

These patients do better on a preponderatingly carbohy-

drate diet. If the diet is largely protein they are apt to lose their appetite. The food must not be of the heavy indigestible character, with a large amount of residue, if we are to get the patient to take the requisite number of calories.

If the patient does not take enough food at mealtime, drinks of lemonade containing 50 gm. of lactose to the glassful may be given between meals. This gives the patient 200 calories per glass and the amount of sugar does not make the drink nauseatingly sweet. In some cases 60 gm. or 240 calories may be given. It may also be given occasionally in hot peppermint water.

Fortunately the patients usually have a good appetite, sometimes a ravenous one, which aids materially in solving the feeding problem. Feeding should be continued day and night up to the time of operation together with the forced giving of liquids and especially the lactose drinks. This is the surest prophylactic treatment of postoperative acidosis.

Drugs.—No attempt will be made to discuss the various drugs used in the medical treatment of goiter but only those which are useful after operative procedure has been determined upon.

The principal drugs used are the sedatives which insure the patient rest and sleep.

Sodium bromide, gr. xv to gr. xx three times daily, or in some patients a single large dose as gr. xxx to xl once daily is about the required amount to take the edge off the patient's nervousness and to secure sleep.

If the patient sleeps poorly despite the above treatment several gr. x doses of veronal or sodium bromide gr. xx with chloral hydrate gr. x given in a glass of hot water or hot milk an hour before bedtime will usually correct the insomnia. In some extremely nervous cases, who do not react well to these drugs, codeine gr. ss to gr. 1 hypodermically often acts very well.

About one hour before operation the patient should receive morphine sulphate gr. $\frac{1}{4}$ hypodermically if the work is to be done under a local anesthetic as is the practice in this hospital; if under a general anesthetic a small dose as gr. $\frac{1}{8}$ to $\frac{1}{6}$ will insure the patient's taking the anesthetic with a minimum of excitation.

Vomiting and Diarrhea.—Some of the cases of toxic goiter at one time or another during their toxic crises suffer from a diarrhea. Increased metabolism causes an excessive secretory activity of both the stomach and intestines. This stimulates the intestines to the production of copious watery, grayish appearing stools. They appear to be devoid of bile but the volume of bile is not decreased. A powder consisting of a half grain each of calomel and opium given every 4 hours will often check the diarrhea while in some cases opium and belladonna suppositories help quiet the irritable intestine.

The hyperchlorhydria together with the general irritability and spasticity of the stomach musculature often produces persistent vomiting. In that event fluids by mouth should be discontinued allowing only a little cracked ice. Water should be given by proctoclysis. Gastric lavage should be used only as a last resort.

Management of Constipation.—Mild laxatives are given if necessary during the period of preoperative care, and a soap suds enema is given the night before operation. Even this is unnecessary if the bowels move well with laxatives. It is important that the patient be not disturbed by an enema a short time before operation.

Time of Operation.—Thyrotoxic patients constantly harass the surgeon with questions as to the time they will be operated on. As a rule they wish to get it over with regardless of their condition. It is best that no date for operation be set as many grow more nervous as the time approaches. I have also seen a marked increase of the toxic symptoms follow the disappointment incident to a postponement of operation.

The patient should be told that all of the preparation is for the purpose of making operation a safe procedure and that no one can tell the length of the preparation necessary. The surgeon should never set a limit on that time until he is absolutely sure. When the time for operation has been determined on, the patient is told the time in a simple, confident way. The personality of the operator and the consequent confidence he can inspire is a large factor in securing the desired tranquillity on the part of the patient.

POSTOPERATIVE TREATMENT

The postoperative treatment of goiter varies according to the type of goiter for which the patient has been operated on. In the purely nontoxic type the treatment resolves itself into that accorded any clean operative wound, in which the operation is not followed by any marked reaction and in which the probability of complications is rather remote.

On the other hand, the patient suffering from the exophthalmic type requires a great deal of postoperative care because the toxicity is increased after the operation and the tendency to complications is much greater.

The purpose of this section is to discuss the treatment of the toxic type after operation, together with the treatment of complications which may arise.

General Nursing Care.—The patient should be under the care of a special nurse, preferably one who has been with the patient a day before the operation. This allows the patient to become accustomed to the nurse and permits the establishment of confidence on the part of the patient in the nurse. This aids materially in allaying the nervousness incident to the operation. The nurse should be quiet, even-tempered, and able to control her patient without friction.

After operation, the patient should be placed in a partly darkened, cool room and made as comfortable as possible. Quiet should be maintained both within the room and in the proximity of it. Noise that the ordinary operative patient would not notice, produces a marked impression on a patient suffering from a thyroid intoxication. After the needs of the patient have been attended to she should be left undisturbed. Nothing so irritates a highly toxic patient as a nurse who thinks that she must be constantly doing something in order to best serve the interest of her patient.

Conversation, reading, or any other form of entertainment is not only unnecessary, but detrimental at this time. Relatives and friends should be excluded from the room until the postoperative toxicity is markedly reduced.

Vomiting.—Postoperative vomiting is rarely severe except in cases of acidosis. Most patients operated on under local

anesthesia do not vomit at all, while a few do vomit, probably because of the preoperative dose of morphine. Some surgeons believe that novocaine also causes nausea and it is true we occasionally see instances of nausea after almost any type of operation in which novocaine is used. After general anesthesia the vomiting is usually more severe.

If the patient vomits, but little water by mouth should be given, but if the nausea persists, the stomach should be washed. If the vomiting still continues, which is extremely rare, fluids should be withheld by mouth and water given by proctoclysis, or by hypodermoclysis.

Pain.—Severe pain does not usually follow thyroidectomy. Many complain of only a rather intense soreness on swallowing. Occasionally a patient complains of extremely severe pain in the wound region which radiates upward toward the ears. Such patients should have opiates for their relief. Codeine gr. ss given hypodermically is usually sufficient, but when the pain is especially severe, morphine gr. $\frac{1}{6}$ to $\frac{1}{4}$ should be given.

Restlessness and Nervousness.—These symptoms are the measure of toxicity. Their severity depends on the extent of the thyroid intoxication which existed previous to operation. They are increased by the operation possibly, as many surgeons believe, by the increased absorption of toxic substances from the manipulation of the thyroid during the operation or from the cut surface exposed by the excision. To combat the toxemia one keeps the patient as comfortable as possible and in general carries out the suggestions given under the heading of General Nursing Care.

Codeine or morphine hypodermically are often necessary. If the restlessness is not accompanied by severe pain, codeine gr. ss is usually sufficient but when it is severe or extreme restlessness develops, morphine gives better results.

I have not found other sedatives very efficient in these cases. The large doses necessary to get results, the slowness of their action, and their depressing after-effects make them objectionable. These patients are also sometimes nauseated and any medicine by mouth increases the disturbance.

Control of Temperature.—Toxic goiters almost without exception have a fever after operation. The height of the tem-

perature seems to be in direct proportion to the toxicity of the goiter. The temperature often goes to 102° or to 103° and may go even higher. The patient becomes very restless and seems fairly to radiate heat. Reducing the temperature helps allay the restlessness and so conserves the patient's strength.

The temperature is best controlled by placing an ice bag on her head or the whole body may be sponged with cool water, or a number of ice bags may be placed about the patient. The patient should be under constant observation, and if any cyanosis develops, the ice bags should be immediately removed.

Treatment of Toxemia.—Toxic goiters soon after operation pass through a period during which there is a marked exacerbation of their toxic symptoms. This is noticed within a few hours. By 36 to 48 hours the toxic symptoms are at their height and soon begin to subside. The prognosis is grave if the symptoms continue beyond this time.

The patient at the height of her toxemia tosses about the bed; the eyes are open wide, even the exophthalmos seeming to be increased; the skin is flushed and feels hot to the touch; the arms and legs are in almost constant motion and sometimes there is a delirium during which the patient mutters and talks incessantly. The pulse is rapid, sometimes irregular, and the respiratory rate is increased.

The treatment of the toxemia consists of increasing the elimination by the giving of large quantities of fluids. Often these are well taken by mouth, but the total intake may be increased by giving fluids by proctoclysis. An almost continuous proctoclysis may be given, stopping for a few hours if the patient begins to expel it. Water may also be given subcutaneously and this should be done if not enough fluid can be given by the other avenues. The only objection to this method is the amount of disturbance which it sometimes causes. A preliminary hypodermic of morphine often quiets the patient enough to overcome this objection. The giving of lemonade sweetened with lactose often is much appreciated immediately after operation and serves the double purpose of giving fluids and also an easily assimilated carbohydrate to burn.

Tracheitis and Laryngitis.—Trauma in such close proximity to the trachea almost always produces some reaction within it.

The more closely and extensively the goiter is adherent to the trachea, the greater will be this reaction. This manifests itself in an accumulation of viscid mucus in the trachea and larynx. It makes breathing difficult, annoys the patient, and increases the nervousness. Much can be done at the operation to lessen this complication by leaving the tissue intact immediately surrounding the trachea.

Drinks of lemonade, orangeade or of water will relieve the pharynx and steam inhalations with compound tincture of benzoin added lessens the viscosity of the mucus and renders its expulsion less difficult.

Care of the Wound.—The care of the wound following a thyroidectomy is in general that accorded any other clean operative wound. If the wound is closed without drainage, as is the practice in this hospital, the dressings should be left undisturbed until the fourth day unless some complication arises.

In most cases there is a little oozing of blood through the line of incision immediately after operation which causes the gauze dressing to adhere to it. Because of this every subsequent turn of the patient's head exerts a little pull on the incision or sutures, which is annoying to her. If the dressing is raised and this piece of bloodsoaked gauze is gently separated and removed and clean gauze is allowed to come into contact with the wound she is much relieved. This appears to be a small matter to consider, but it is always appreciated by the hypersensitive patient.

After about four days the skin is completely healed and the sutures are removed. The early removal of the sutures precludes the possibility of puncture scars where the sutures pass through the skin.

If the wound has been drained, the drains are removed twenty-four to forty-eight hours after operation. If the tissue removed is large in amount and the drainage correspondingly greater, the drain may be left in several days longer.

In the wound that is not drained, there is sometimes seen a marked edema of the tissues both above and below the incision. This does not cause much pain and usually subsides in about two or three days. If the swelling is excessive, so that the patient complains of pain or of a feeling of pressure on the trachea, several layers of gauze soaked in equal parts of glycerine and

alcohol and applied to the swollen area for ten to twelve hours will cause a marked reduction of the swelling.

From about the fourth to the seventh day, small blebs, due to the iodine used for sterilizing the skin, may appear in the skin in the line of incision, which contain an almost clear or brownish serum. If not treated, they finally rupture and drain out. As soon as they are discovered they should be pricked open with a sharp-pointed, narrow-bladed knife and the fluid expressed. They have a tendency to close and refill and should be opened daily until they disappear.

Sometimes there is an accumulation of fluid in the wound. This is partly from the cut surface of the gland and partly from capillary oozing. It often gives no visible evidence of its presence even for as long as a week after operation. If a portion of the incision remains indurated and tender to slight pressure, its presence should be suspected and the patient not discharged from the hospital until its ultimate fate is determined. The indurated area will often fluctuate as late as two weeks after operation and finally open spontaneously and the fluid drain out. If this occurs after the patient has gone home, it causes considerable anxiety to the patient and annoyance to the surgeon. As soon as any fluctuation is noticed, a very small opening made in the line of incision will allow this to drain out. A large opening is not necessary because the exudate is sterile.

Treatment of the Heart.—Patients who had cardiopathies before operation may require continuation of treatment after operation. Myocardial degeneration may result from a long period of thyroid intoxication, or from a goiter which has existed for twenty-five or thirty years and with toxic symptoms of recent origin. Whatever be the cause of the cardiac disturbance, these patients should be kept in bed and given digitalis in some form until compensation is restored.

In those patients with a damaged heart muscle and without signs of heart failure but where a severe toxic reaction after operation is anticipated, digitalis should be given for a few days before operation and kept up until the toxemia has subsided. When nausea continues some days after operation, digitalis in the form of tincture, using from four to six mils may be placed in a pint of normal solution and given by the Murphy drip.

Some suitable form of digitalis may also be given hypodermically in cases where urgency exists or where the gastric condition contraindicates its being given by mouth. Morphine or codeine to quiet the restlessness does much to save the heart. Ice caps over the cardiac area are indicated when the heart rate is extremely rapid.

Diet.—Feeding should be begun immediately after operation; nourishing drinks, lactose lemonade, 50 gm. to the glass, and soups which have milk as the vehicle and have a real caloric value should be the first nourishment. Hospital customs die a lingering death and if one does not specify the fluids to be given, surgeons are likely to find their patients getting that ancient fraud, broth, which consists of water with a trace of albumin in the form of extractives. Lactose may be used as the sweetening in any liquid, thus greatly increasing its nutritive value. Glucose may also be given in the proctoclysis.

The day after operation the patient may be given soft, easily digested foods, and the diet steadily increased from this time. The food should be largely carbohydrates without much cellulose residue but protein and fats in the form of milk and dairy products should be given. Meat should not be given until the patient is entirely recovered from the operation and then only fish or white meat and these very sparingly.

POSTOPERATIVE COMPLICATIONS

Since the principles of the operative technic have become common knowledge, there are few operations so little liable to complications as are the operations on the thyroid gland. Pneumonia has all but disappeared with general anesthesia; tetany with the preservation of the parathyroids; myxedema with the proper preservation of sufficient functioning gland and vocal cord paralysis since resection has supplanted lobectomy. However, notwithstanding the greatest technical care, complications still appear at times. These will be discussed in the following paragraphs.

Collapse of the Trachea

Collapse of the trachea is extremely rare, but if it occurs at all, it is one of the earliest complications, occurring either during

the operation or immediately following it. It occurs in those cases in which the trachea has been subjected to pressure by a hard, or usually a large goiter for such a period of time that the cartilages are eroded. During the operation, collapse usually occurs when a partially resected thyroid is rotated subjecting the thinned-out trachea to torsion. Later it may be caused by the thinned-out portion being sucked down into the trachea at inspiration, acting as a valve, or by edema or hemorrhage around it causing it to collapse.

The symptoms are increasing dyspnea and cyanosis, the extent of each depending on the degree of occlusion. The collapse is apt to come with extreme suddenness, the patient dying with scarcely a struggle. If the fact that the trachea is compressed before operation is determined, measures should be taken to prevent trouble by the careful manipulation of the gland. A tracheotomy tube should be at hand. If there is a tendency for the walls of the trachea to fall together, this may be prevented by passing a suture from the side of the trachea to the edge of the sternomastoid muscle. If the trachea falls together despite this precaution, tracheotomy should be done at once. If one is not sure as to the permanence of the patency, it is advisable to pack the wound down to the trachea so that tracheotomy may be done without delay should disaster impend.

In doing a tracheotomy the cut edge of the trachea should be sutured into the overlying muscles or skin to prevent a second collapse should it be necessary to remove the tube. An experienced nurse should be in constant attendance. In a few days the peritracheal adhesions fix it so that the danger of renewed collapse is past. The tube should be removed as early as possible in order to prevent erosion of the tracheal mucosa which is more liable to occur in these cases than in ordinary tracheotomies. If tracheotomy does not relieve the symptoms at once, one should think of a substernal lobe that may have been partially pulled up and severed from the rest of the goiter during the operation.

Hemorrhage

Serious hemorrhages are usually due to the slipping of a ligature from the stump of a large vessel, such as the superior

thyroid artery. Cases are on record in which hemorrhage followed the tearing of an atheromatous vessel ruptured after ligation. When such a large vessel becomes patent, there is a rapid swelling of the neck with a rapidly developing dyspnea and cyanosis, but without the sudden appearance of symptoms of tracheal collapse. The symptoms are due to tracheal pressure. Not sufficient blood can escape into the tissues to produce any considerable anemia. The wound must be opened and the bleeding vessel caught and ligated.

Hemorrhages may also occur from small vessels being overlooked during the operation, from their ligatures slipping, by crushed vessels starting to bleed again after the forceps have been removed, and by extensive capillary oozing. Hemorrhages from these sources may or may not cause respiratory difficulty. It is most likely to happen in those cases where the tracheal wall is thinned or where a lobule has been removed from behind the trachea, leaving a cavity that is not obliterated by wound closure but which subsequently fills with a clot. If the wound has been drained, these slow hemorrhages seldom give trouble, if it has not been drained the neck may gradually enlarge and the dyspnea, cyanosis and restlessness appear. Frequently oozing will stop spontaneously and treatment is not needed. If respiration is interfered with, the wound must be opened at some point and allowed to drain. It may be even necessary to insert the finger to remove a clot which may be exerting pressure on the trachea.

Hoarseness, Loss of Voice, Paralysis of Vocal Cords

Hoarseness or loss of voice coming on gradually in from a few hours to a few days after operation need cause no alarm. When coming on secondarily, it is due to pressure on the recurrent laryngeal nerve caused by edema and infiltration of the tissue, a slow capillary oozing, or combinations of these. Nothing need be done as the condition usually clears up by the time the patient is ready to leave the hospital. In some instances three, six or even nine months may be required before the difficulty disappears.

If vocal cord irritation is observed during the course of the operation, as is possible when using a local anesthetic, the ma-

nipulations which cause it must be avoided. If the irritation first becomes noticeable immediately after operation under general anesthesia, there is a likelihood that actual injury of the recurrent laryngeal nerve has occurred. The nerve may be crushed, stretched, torn, cut or tightly ligated. If crushed, ligated or stretched there is a possibility of spontaneous restoration of function after some months, depending on the degree of injury. If cut or torn the corresponding vocal cord is paralyzed and the damage beyond repair. The only consolation in this case is the fact that the uninjured vocal cord has a tendency to compensate for the loss of its fellow, and after some time and in some cases the voice is practically restored to normal. If the paralysis of the cord was known to have existed before the operation it will be a source of comfort to the surgeon though this evidence may fail to convince the jury.

Shock

The earlier papers on after-course gave much space to the discussion of shock. Marked shock following thyroidectomy is now, however, an unusual occurrence. Inhalation anesthesia is being rapidly replaced by local anesthesia for goiter surgery, as the excessive loss of blood incident to it was probably responsible for much of the shock then seen. In addition to the use of local anesthesia, better judgment as to the time to operate, more thorough preparation of the patient for operation, and the increase in technical skill, all tend to minimize the cases of shock.

Real shock has not been observed following goiter operations. I have frequently noticed toward the close of a goiter operation the patient's face becomes pale and covered with beads of perspiration. When they reach their room the pulse is somewhat rapid and weak. These are cases of mild degree of shock. On being placed in a warm bed, surrounded with hot-water bottles and quieted with a little codeine or morphine these symptoms soon passed away without further treatment.

Acidosis

In the extremely toxic cases of degenerative goiter, acidosis is sometimes observed. The symptoms appear in from one to six days after operation. The patient complains of being des-

perately sick without making any definite complaint. He looks desperately ill, restless and irritable; the face and lips are pale, the skin cold and moist, but the face may be flushed, with a hot dry skin. The eyes are sunken, pulse rapid and weak, temperature elevated. Vomiting is usually present at some time and there are often intervals of apathy alternating with restless, or even active delirium. The breath has a distinct acetone odor. Finally the patient passes into coma with Cheyne-Stokes respiration and dies.

The prophylactic treatment consists of avoiding the use of drastic hydragogue cathartics before operation, and continuing the feeding and fluid intake of the patient up to the time of operation. When an acidosis is imminent 6 to 12 gm. of soda bicarbonate should be given daily for two to three days preceding the operation and carbohydrates may be pushed by giving 150 to 200 gm. daily of lactose in lemonade or peppermint water for several days preceding operation.

A minimum amount of anesthetic should be used and as little trauma as possible inflicted at operation. Carbohydrate food and fluids should be started immediately after operation even if there is some vomiting. The patient should be given a 5 per cent sodium bicarbonate and 10 per cent glucose solution in normal saline by proctoclysis.

When the symptoms are well developed, a 2 per cent soda bicarbonate solution and 2 per cent glucose in normal saline solution should be given subcutaneously, and where the case is urgent, 1 gm. each of soda bicarbonate and glucose and .3 gm. of noncrystalline calcium chloride in 1000 c. c. of normal saline solution may be given intravenously and repeated as needed. Morphine should be given hypodermically partly to conserve the patient's strength and also because it seems to have some specific action. Sodium bicarbonate should be constantly pushed by mouth, 12 to 20 gm. daily until the condition improves.

Infection

With the present day operating room conditions and technique, infection is not common. When it does occur it is slight and merely delays healing and results in more disfiguring scars.

Infection may be simulated by blebs which appear a day or

two after operation in the line of incision. These are due to the irritation of the iodine on the delicate skin of the neck. These blebs may be opened and drained.

If drainage was instituted at the time of operation, this may prove sufficient if the wound has not closed after removal of the drainage material. If no drainage was placed after operation, the wound edges should be gently separated with forceps. The infection is nearly always confined to the subcutaneous fat.

Deep infection may not show up early, in fact areas of fluctuation may not appear for a week or more. It should be suspected whenever a part of the incision remains swollen, indurated and tender and the temperature remains elevated. I have seen low grade infections overlooked and open spontaneously on the day set for the patient to leave the hospital. This is embarrassing, and when the above conditions are present, the prognosis as to the date of discharge from the hospital should be guarded. Whenever the drainage of deep infection is made the incision should be spread at the point nearest the infection and drainage provided. Hot moist dressings applied to the wound after drainage has been established, hasten the evacuation of the pus and speed healing.

Sometimes there is a thickening of the skin and subcutaneous tissue due to irritation of the anesthetic. This is most likely to appear when the adrenalin used has become decomposed as may be noted by the pink color of the solution. This thickening should not be confused with an infection. It disappears after a number of weeks without treatment. The disappearance may be expedited by the application of hot compresses.

Disfiguring Scars

Scars may be unsightly because of their breadth or because of their attachment to underlying structures, causing annoyance to the patient.

Bad scars may be caused by poor approximation of the skin at operation, but more frequently result from wound infection and subsequent drainage of abscesses or because of the necessity for draining the wound at time of operation. There are a certain number of cases which develop thick red keloid-

like scars when approximation has been perfect and healing by primary union.

Scars attached to the trachea or larynx often cause a sense of pulling whenever the patient swallows, which is in some cases extremely annoying to the patient. It also produces a dimpling in the skin or a pulling upward of the scar which a sensitive patient dislikes.

The preventive measures are accurate approximation of the skin edges, careful asepsis, removal of the drainage in twenty-four to forty-eight hours and accurate hemostasis to avoid the necessity for drainage.

The use of fine suture material and its removal by the fourth day after operation prevents scarring from the cutting in of sutures.

Bronchitis and Pneumonia

Pulmonary complications have in our experience proved one of the rarest complications, even bronchitis being seldom encountered.

Tetany

Tetany is a definite clinical syndrome resulting from a suspension or disturbance of parathyroid function. No case has been observed in this hospital. It was much more common as a complication in those days of complete lobectomy. As it is now most commonly seen, it is due to a disturbance of the nerve or vascular supply of the parathyroids, the symptom lasting from a few hours to a few days. As there is some variation in the size, number and location of these glands, there is still always a possibility of tetany even when the posterior capsule and some thyroid tissue is left at operation. Anything interfering with the inferior thyroid arteries might affect the parathyroids as this is the source of their blood supply.

The symptoms usually appear from 1 to 3 days after operation. Stiffness of the fingers is the first thing noticed, and later, tonic and intermittent contractions of the flexor muscles of the upper extremities, and later still in a lesser degree of the lower extremities. In the more severe cases contraction becomes general, involving the muscles of the esophagus, masseter muscles,

tongue, larynx, and diaphragm. Death is caused by spasm of the diaphragm or glottis. Heart and respiratory rate are increased before and during the convulsion, and the patient is pale due to vasoconstriction until the cyanosis of diminished respiratory function appears.

On the other hand, the symptoms may disappear spontaneously in a few hours, or in a few days, if the function of the parathyroids is restored by compensatory blood supply, or other conditions affecting them are removed. In rare instances the condition becomes chronic.

Calcium lactate given orally, rectally, subcutaneously, or intravenously is a specific; 0.6 gm. in 100 c.c. of normal saline gives rapid results, and it should be given so in severe cases. In others the slower method of administration suffices. The treatment should be repeated if the symptoms return. This treatment only tides the patient over until parathyroid function is restored.

Myxedema

Myxedema is a rare complication after thyroidectomy. It is caused by too much of the thyroid tissue being removed or by a later disappearance of what at the time of operation was entirely sufficient amount of normal tissue. It has been repeatedly proved that only a very small amount of normal thyroid tissue with sufficient blood and nerve supply is adequate to carry on the normal function of the gland.

A mild myxedema may not be recognized, in fact well-developed cases have been overlooked for a long time. The subcutaneous swelling which does not pit on pressure, the thick, dry, rough, pale skin, and dull listless mental state, the obliteration of the facial lines of expression and the thick lips and nostrils, are symptoms. There is a progressive gain in weight. The temperature is usually subnormal and the pulse slow. The patient complains of cold when others are comfortable.

The treatment is the giving of thyroid extract. The patient should be started at gr. i doses three times daily and this soon increased to gr. ii. It may have to be still further increased. The effect is seen in the loss of weight, the increased rate of the pulse, increase in temperature to normal and the different facial

appearance. The treatment usually has to be carried throughout life with intermissions.

Boothby, of the Mayo Clinic, says that 1 mg. of thyroxin given hypodermically every other day will soon bring the metabolic rate, which is below normal, up to normal and that after that 1.6 mg. daily by mouth will keep it so.

Instructions at Dismissal

The operation of thyroidectomy in toxic goiter but removes a part of the tissue that is producing an abnormal secretion. The removal but gives nature a chance to repair the damage done, thus the cure is only started by operation. The patient should be made to understand that she should not expect to be well in a few weeks, but that it will take months or a year or more and that the rate of improvement will now depend almost entirely on her own conduct in the future. She should take regular moderate exercise, preferably in the open air, but always stop short of fatigue. She must avoid the excitement of society and anything else that produces mental excitement or emotion. Abundant rest is necessary; from eight to ten hours sleep every night and a nap during the day is desirable for the first few months. A plain diet, consisting of vegetables, cereals, fruits, milk and milk products is best. Meat should be eaten very sparingly; a little fish, poultry or game occasionally is most to be recommended. Milk, buttermilk, abundance of water is advised, but avoid tea, coffee, and alcohol.

CHAPTER VIII

TREATMENT OF DISEASES OF THE THYROID GLAND

Diseases of the thyroid gland cover such a wide range of possibilities that in determining the results of therapeutic measures it is necessary to proceed with the most rigid self-criticism. The fundamental difference between recovery and cure is nowhere better illustrated. The vast number of measures for its cure advanced from time to time, and the results alleged to have been obtained, are proof of this statement. In order to judge the effect of a therapeutic measure the therapist must have a thorough knowledge of the life history of the disease. The disease varies so much that it is exceedingly difficult to obtain a clear notion of its natural course. An approximate picture can be obtained by dividing the cases in their several clinical groups, then following them throughout the life history of the individual, a requirement obviously difficult to fulfill.

In the young the gland is often enlarged, and often disappears again without any remedial measures having been applied. In many of these the enlargement hardly seems beyond the physiologic and the cycle might be regarded as a normal one; but taken as a group, we know that the disappearance is expedited by certain measures. Though they are without notable symptoms, their disappearance is desired lest they form the basis of more serious disturbances in later life. Obviously it is of importance in all cases in the adult to record carefully the various changes the goiter has undergone up to the time of observation.

Goiter in the adult is a dangerous disease, and unless cured tends to destroy the life of the patient. The so-called innocent goiters, which frequently exist for ten to forty years, usually, sooner or later kill by undergoing toxic or malignant degeneration. When a patient is first observed in extremis a carefully worked out history gives the observer the life history and he is then enabled to determine how far along this path a less serious case has traveled.

The cardiac degenerations associated with this type of goiter are generally underestimated; in fact, they are but imperfectly understood. It is difficult to determine whether an existing cardiac condition is due to the goiter or to some co-existent or preexisting cardiopathy. Often only by observing the course of the disease under treatment can this point be determined.

There is no other disease in which it is so necessary to individualize as in the treatment of goiter. A close and usually a protracted study is necessary, for it is frequently necessary to shift the diagnosis as the disease progresses, or does not progress, and often to change the treatment accordingly. At the first meeting the plan of campaign can be outlined in the most general terms only. Even after the treatment has been conducted to an apparently successful end, observation must be continued. The need for this is obvious when we remember that at most we modify or annihilate but a part of the disease. It is necessary, therefore, that every therapist follow his cases and construct for himself a series of experiences, for by this means alone can he develop the niceties of judgment so necessary to the successful treatment of goiter.

After operation when the usual improvement follows, the patient is apt to believe that she is cured and too often the surgeon shares in this delusion. It should be remembered that the part of the gland the surgeon left is diseased and the patient is not cured until this has been restored to normal.

In the following account only the broadest outline for treatment can be constructed, one which I could not myself follow without the aid of multitudinous experiences and impressions impossible to commit to paper.

Adolescent Goiter

In this type there is but a mild dysfunction, characterized by a diffuse enlargement, usually moderate in degree. These nearly always respond to treatment by iodine. Many of these disappear spontaneously, hence one must regard the results of this therapeutic measure with a certain degree of skepticism but a large experience by countless observers has established that iodine is of definite value. The drug may be given in the

form of a solution of iodine, or as the syrup of iodide of iron or as potassium iodine. The form selected seems to be of no moment. The dose required is small. Because of the more pleasant nature of the drug my preference is for the syrup of iodide of iron of which five minims may be given several times a day.

Iodine must be given over long periods of time in most instances; months or even a year or more are often required. In young children the result is usually much more prompt.

Iodine externally is only another way of giving the drug and is an unnecessary though harmless adjunct. If the patient or her mother feels that it is necessary to do penance the tincture of iodine may be smeared on externally.

Thyroid extract works more promptly than iodine, but its action must be more carefully controlled since it is a more powerful agent. The dosage must be small, not more than a grain or two per day may be given.

In many of the adolescent goiters, there is a tendency to hyperthyroidism, hence it is necessary to use the above named agents with caution so that if toxic symptoms appear the drug can be promptly discontinued. They may be given iodine until they become nervous and the heart rate increases. Then the iodine should be discontinued and sedatives given until the nervousness and rapid heart subside. Hyocine and bromides give the best results. From 4 to 6 minims of the Fluid Extract of the former and 10 to 15 grains of the latter three times a day usually gives good results. With this the excitement is quieted and the iodine may be resumed. It has seemed to me that it is possible that bromide like iodine may have a direct specific influence on the gland function. By following this plan of alternating iodine and sedatives, many may be conducted to recovery without operation.

These youngsters are often impatient of results and clamor for operation rather than undergo the prolonged treatment necessary for a medical cure. However, one should not be moved by these pleadings, for if a cure can be obtained without operation the patient likely is more secure from future difficulty than if a part of the gland is removed.

In some of the adolescent goiters medical treatment does not avail and operative treatment comes into question. If the

goiter is large and does not respond to treatment, particularly if the family is predisposed to goiter, operation should be advised.

Those which tend to become toxic when iodine is given even though a prolonged treatment has not yet been tried should be considered as possibly requiring operation. In smaller goiters which are very sensitive to iodine, early operation may be required. One can judge only by noting the sensitiveness to the drug. Some complain of nervousness and congestion in the neck with the very first dose of iodine. Such should be operated on at once.

In deciding an operation for adolescent goiter the previous state of the patient's health must be taken into account as well as the general neuropathic possibilities in the family. In the neurotic the disturbance from the exhibition of iodine has less significance than those of a more plethoric heredity. In such cases one is warranted in compromising much longer than in previously robust cases. In the neurotic the result of operation is not satisfactory for even if they are cured of their goiter they will be neurotic still. If there is a neurotic mother the unwarranted anticipation of a regeneration of the nervous system is apt to be annoying to the surgeon. The patient after operation will be no better than she was before the advent of the goiter. That is the standard upon which we must judge our therapeutics and not the average normal. George Ade makes the wise observation that if the young swain desires to know what shape the daughter will have at fifty to study the profile of mother. Equally so if one desires to know what one will have left after curing a goiter it is well worth while to study the mother. Not only heredity but environment may be determined from such observation.

Any patient who is taking iodine in any form, or the thyroid extract, must be carefully watched. If she becomes more nervous or the pulse becomes rapid, this line of medication must be stopped and a sedative substituted.

It is not advisable, therefore, to give the patient a prescription and allow her to take it indefinitely without observing the course.

Often these patients have menstrual disorders which ag-

gravate both the nervous system and the goiter and vitiate the results of treatment. Usually these individuals are substandard and usually slow to develop. Something may be done by general treatment, hygienic and medicinal, but any sort of operation on the pelvic organs but makes them worse. When there is marked menstrual disturbance in young girls who have goiters *hydrastis canadensis* with iron often produces excellent results. Ten minims of the former and a dram of the elixir iron, quinine and strychnine is a convenient form of giving it. Often they marry, and, while industriously pushing a perambulator, become forgetful of their previous complaints. One is often asked as to the advisability of the patient's marrying under such conditions. Advice is never heeded, of course, and it is equally obvious that one must advise against marriage in substandard individuals, but it is a comfort to know that since the advice will be ignored the patient is generally improved by marriage. Hence it is well to make his proscription of marriage in a minor key.

Colloid Goiter in the Adult

It is the exception to secure any noteworthy results by medication in the colloid goiter of the adult. It happens only in the transitional type between the adolescent and the colloid. Occasionally there is spontaneous fluctuation in size, particularly when influenced by pregnancy, and in rare instances some improvement follows iodine medication. On the other hand, many of these patients are made markedly worse by the use of iodine or thyroid extract. One cannot too emphatically warn against the use of agents in long existent stationary goiter. Many patients are started on their downward course by these agents and no sedative, operation or any other agent can rescue them from a fatal termination. In the vast majority of cases, operative removal is the only measure that avails anything. Personally, I categorically refuse to treat colloid goiter, even when under constant observation, other than by operation. To do so achieves nothing, and it but encourages those patients to regard their trouble lightly.

In planning an operation on a goiter of this type, usually there is a mechanical factor to be considered. Pressure symp-

toms must be relieved as a first consideration. It is not always easy to know how much may safely be removed. A considerable portion of each lobe should be removed. The operator must judge with the goiter in hand how much it is safe to remove. Sometimes relatively normal tissue is found near one pole (usually the upper). When this is the case, a mass the size of the normal lobe is all that is required. In some old glands there is extensive colloid deposit in all parts of the gland. In such one should leave a larger piece, even up to the size of a turkey egg, preferably at the left upper pole. The posterior border of each lobe should be left whenever possible, because this usually represents the portion of the gland that is nearest normal. Besides, by this means the parathyroids are most certainly protected. In old, very much calcified, glands it sometimes is necessary to do a complete lobectomy on one side because the calcareous infiltration makes a resection impossible. The parathyroids are particularly endangered in a lobectomy of a calcareous gland. However, if the parathyroids are certainly preserved on one side, the patient is safeguarded.

Early operation in colloid goiter is desirable in order to avoid the consequences of degenerations of the heart and obstruction to the respiratory passages. The chief difficulty we wish to avoid is the subsequent degeneration into a secondary toxic goiter. If we remove a part, is the remaining portion less likely to undergo mischievous change? It may be confidently said that it is. One reason for this is that the most pronouncedly degenerated portion is removed. Possibly the removal of a large part allows that remaining to become restored to the normal more readily. Medical treatment should be continued after the operation with the idea of aiding such restoration. Our knowledge on this point is painfully meager, and any statement one may make is purely hypothetical, to say the least.

Unfortunately on this fundamentally important problem of subsequent anatomic change we are without trustworthy information. What the anatomic state of the remaining part may be years after an operation for colloid goiter seems not to have been investigated. Whether malignancy or secondary toxic goiter develops from these stumps seems not to have been determined. That they may go on to myxedema is well known. Per-

sonally I have not seen malignancy or secondary toxic goiter develop after resection of simple colloid goiter. I have repeatedly seen, after the resection of one lobe for a mildly toxic goiter, the other lobe develop rapidly and produce a greater toxicity than the one previously removed. It is well to warn the patient, in cases where there is one large lobe that is toxic, that after the removal of this the other may develop and produce symptoms and that this in turn may require removal. If one does not thus fortify himself, the patient is very apt to seek advice elsewhere when the relapse comes.

Primary Toxic Goiter

In considering the treatment of primary toxic goiter it is necessary to distinguish between the various types. The fetal adenomatous toxic goiter is always a surgical disease and should be attacked as soon as the patient is in a proper condition for operation, which usually is as soon as the toxicity is recognized. Generally speaking, the larger the goiter the better the results from operation.

In the frank Basedow with goiters of considerable size the operation is necessary and satisfactory. In the very toxic in which the goiter is very small the results after operation are unsatisfactory. If the patient is very toxic, preliminary treatment is necessary. Rest in bed and bromidés constitute the chief treatment. In the expansile type, pole ligation gives good results.

After the operation the patient should be carefully observed from time to time. Often bromides must be continued. If other portions of the gland enlarge reoperation may be necessary. A toxic goiter history is complete only at the death of the patient. In the intervening period symptoms must be anticipated and sought for.

Secondary Toxic Goiter

It has already been stated that operation should be advised in all colloid goiters in adults. When these show evidence of toxicity, operation should be urged. Operation is indicated whenever it can be safely employed. If there has been marked

emaciation, preliminary treatment must be instituted until the patient begins to regain weight. In some instances there may be a widely dilated heart, requiring rest and digitalis, that delays the operation.

If there is not a gain in weight, often after a period of stationary weight, operation may be safe. In the presence of a constantly decreasing weight, operation is not safe. Such declines cannot be halted by operation.

In general the preliminary treatment is the same as for the primary toxic goiter, but usually a longer period of treatment is required.

The amount of gland to be removed depends upon the severity of conditions. The object of operative treatment is to remove as much as possible of the toxic material. The removal of one lobe was formerly generally done, later the removal of a part of both lobes was advised. The objection to the complete removal of one lobe is that the recurrent nerve is more frequently injured. The removal of one lobe leaves a deep depression over the site of the removed lobe and the hump of the remaining lobe is still in position. The removal of a part of both lobes preserves the posterior part of each which protects the nerve and parathyroid glands and makes the removal of a larger amount of gland tissue possible. However, I believe that in very toxic goiters where the preservation of life is the one factor in mind, one had best do a lobectomy. This gets rid of a maximum amount of toxic material and leaves a minimum of oozing tissue and inflicts a minimum of trauma in comparison to the amount of tissue removed.

The amount of tissue it is desirable to remove in this type is the same as in the primary toxic. In general it may be said that a piece as large as the normal lobe should be left. When too much is removed, deficiency symptoms may result. The deficiency apparently does not always result in myxedema but pronounced general disturbances of a character but poorly understood are not infrequently noticed.

Generally speaking the removal of a part of the gland results in a marked improvement of the symptoms. The improvement is usually more marked than after operations for primary

toxic goiters. If improvement does not occur, it is an indication that not enough of the gland has been removed. When a part of the gland has been removed and the improvement is but slight and transitory, the removal of an additional part may produce a benefit that is pronounced and permanent. If one lobe only apparently is enlarged and the resection of this does not produce satisfactory results, one should search for a sub-sternal or intrathoracic lobe. The hidden lobe may be the real offender. An aberrant lobe in rare cases is the part at fault. When patients have been operated on, the presence of enlargement may be masked by the scar tissue. This is particularly true when the operation has been badly done or infection has followed operation. In these cases I know of no other way of finding out what has been left than to look under the scar and see. Often pressure symptoms may give one a lead.

In the very toxic patients pole ligation may be done, but it is less likely to do good than in the primary toxic goiter. In fact save to test the patient's reaction to operative procedures, I believe ligation is quite useless.

Interstitial (Forme Fruste)

In this type general management is the mainstay. The avoidance of factors which tax the nervous system should be advised. General hygienic surroundings are desirable, but these patients do not stand physical exercise well. They tend to spontaneous improvement in most instances. In many cases they marry, have a few children, then lapse into semi-invalidism even though their little goiters have long disappeared. Usually some form of a sedative is desirable. Small doses of bromides 10 to 15 grains after meals with or without hyoscyamus (3 to 4 minims of the fluid extract), are as good as anything.

Usually there is disturbance of menstruation. Measures which improve this trouble are in order. Sometimes there is marked retroflexion of the uterus the definite cure of which by operation is advisable. The various "local treatments" are to be condemned. In a number of instances I have noted an improvement in both the goiter and the menstrual disturbance in patients who were taking pituitary extract (anterior lobe) in small doses (2 to 5 grains). These results are not constant. A

few have improved with corpus luteum, but both of these preparations are usually disappointing.

These cases are combined disturbances most likely, the ovaries and possibly other organs being involved as well as the thyroid gland. Usually the one is as incurable as the other. In my early experience I tried to remedy the condition by conservative operations on the ovaries. The results were not reassuring. Operation on the goiter I have found disappointing. If there is a combination with adenomatous goiter, operation may be done with confidence of success. If the goiter becomes of some size or if there are eye signs one may be sure that the acini have multiplied along with the interstitial cells and operation is indicated.

With the various nonoperative procedures for the destruction of gland substance I have had no experience. Among them may be mentioned the x-ray, radium, cauterization, hot water and quinine injections. Each of these has had its warm advocates. I do know that each of these often fail and that they render operation more hazardous. They may be used to entertain the patient while she is securing the necessary rest. In order to accomplish this purpose it is not necessary, however, to employ them vigorously enough to increase the difficulties of operation.

CHAPTER IX

TOPOGRAPHIC ANATOMY OF THE THYROID GLAND

The region of interest in operations on the thyroid gland involves the most complicated region, anatomically, of the body. It is bounded above by the border of the lower jaw, laterally by the sternomastoid muscles and below by the clavicles and the upper border of the sternum. Adjacent regions, likewise, are sometimes invaded by the gland, and the surgeon's interest and activities must follow. The range of possibilities is so great that there is no structure in the neck proper, the submaxillary and substernal regions, but that may at some time become the field of operation for goiter.

Anatomical points will be considered here only in so far as it is necessary to the presentation of the typical thyroidectomy as performed in this hospital.

The Overlying Soft Parts

Before the gland itself can be discussed, it is necessary to consider the skin, fascias and muscles overlying it.

The Skin Covering

The skin covering the neck is traversed by a varying number of folds which are of interest to the operator because by following them with his incision he can place his scissor so that the natural folds will cover it. These folds consist of two groups; an upper group, varying in number from one to three, which run from above, medially and downward about the level of the carotid bifurcation, following in a general way the direction of the lower border of the jaw. These lines can conveniently be followed in the incision for ligation of the upper poles. When there are several of these lines the one most completely hidden may be selected. The second group of folds encircle the neck at its lower part just above the sternum and clavicle. The lower

lines, if several exist, can be used for the collar incision which is the one now most generally made. In the necks of old women there are other folds higher up which may be followed conveniently in large goiters. If these folds do not lie just at the most advantageous point for the incision of the deeper structures, the mobility of the skin is such that it may be easily displaced to make the deeper field easily accessible.

The Platysma Myoides

The platysma myoides covers, in a radiating manner from above downward and outward, the anterior surface of the neck (Fig. 70). It is lost above over the border of the jaw in the muscles of the face and below it passes out of the field of interest by losing itself in the pectoral fascia over the second rib. It lies just beneath the skin and is rather intimately attached to the superficial fascia. The chief interest of the platysma to the surgeon is that it serves as a guide to important veins. In closing the wound it must be coapted lest its traction cause an undesirable widening of the scar.

The Superficial Veins

Just beneath the skin and in front of the superficial fascia a number of small veins are found. These are variable in number and each subject is wholly to be analyzed for itself. They are for the most part small and rarely require ligation during operation. The platysma often contains small veins that require ligation.

Just beneath the cervical fascia the jugular veins are found. They consist of the external jugular veins, which do not usually fall in the field of goiter operations, and the anterior jugular veins which regularly require ligation (Fig. 71). These chief veins are united by a subsidiary plexus inconstant in arrangement. The external jugular veins extend from near the angle of the jaw downward and lateralward to disappear beneath the clavicle crossing the sternomastoid muscle near its middle. In very large goiters the skin incision may reach these vessels. The anterior jugular veins usually lie a fingersbreadth medial to the anterior border of the sternomastoid muscle, but may be



Fig. 70.—The fan-shaped radiation of the platysma from the borders of the jaws to the clavicles is shown. Between the medial borders of these muscles the sternohyoid muscles appear. The cervical nerves, lying between the sternomastoid and platysma muscles, pass downward and medially. The relation of the thyroid gland to these structures is shown by the dotted figure.

found in other situations. They are typically two in number but sometimes six or more may require ligation. When numerous they are found at irregular points between the borders of the two muscles above mentioned. They are readily seen shimmering through the fascia as soon as the skin, subcutaneous fat, and platysma have been severed. There is usually a short branch connecting the two veins just above the clavicle. When the vessels are numerous, connecting branches may form a plexiform network. If care is exercised, all these veins can be recognized and clamped before they are cut. This is particularly easy when local anesthesia is used.

The Muscles of the Neck

The sternomastoid muscles, extending from the inner end of the clavicle and the sternum to the mastoid process, bound laterally the field of the goiter operations. In very large goiters, particularly in malignant ones, it may be necessary to incise these muscles, but ordinarily they can be retracted out of reach of the knife. Just beneath the platysma already described and between the two sternomastoids, the sternohyoid and the sternothyroid muscles (Fig. 72) lie. Both these muscles arise from the posterior surface of the upper border of the sternum. The former is inserted into the body of the hyoid bone and the latter into the oblique line of the thyroid cartilage. This arrangement brings the latter to lie beneath the former. When the thyroid gland is small, these muscles are unchanged, but when the gland is large they are flattened into ribbon-like structures. The superficial ones, the sternohyoid, have intimate fascial attachments along their lateral border to the anterior border of the sternomastoid muscle. It is the severing of this attachment that does much to give free access to the gland at the moment of dislocation. The sternothyroid muscle lies just over the gland, being separated from it only by a layer of connective tissue, the false capsule of the gland. A small muscle is sometimes given off the sternothyroid which extends to the isthmus of the thyroid gland and is given the dignified name of levator glandulae thyroideae. It assumes importance because it harbors a small artery which may annoy the operator if it is severed.

These muscles obtain their blood supply from twigs of the cricothyroid arteries. These vessels are small, rarely requiring ligation in operations done under local anesthesia. There

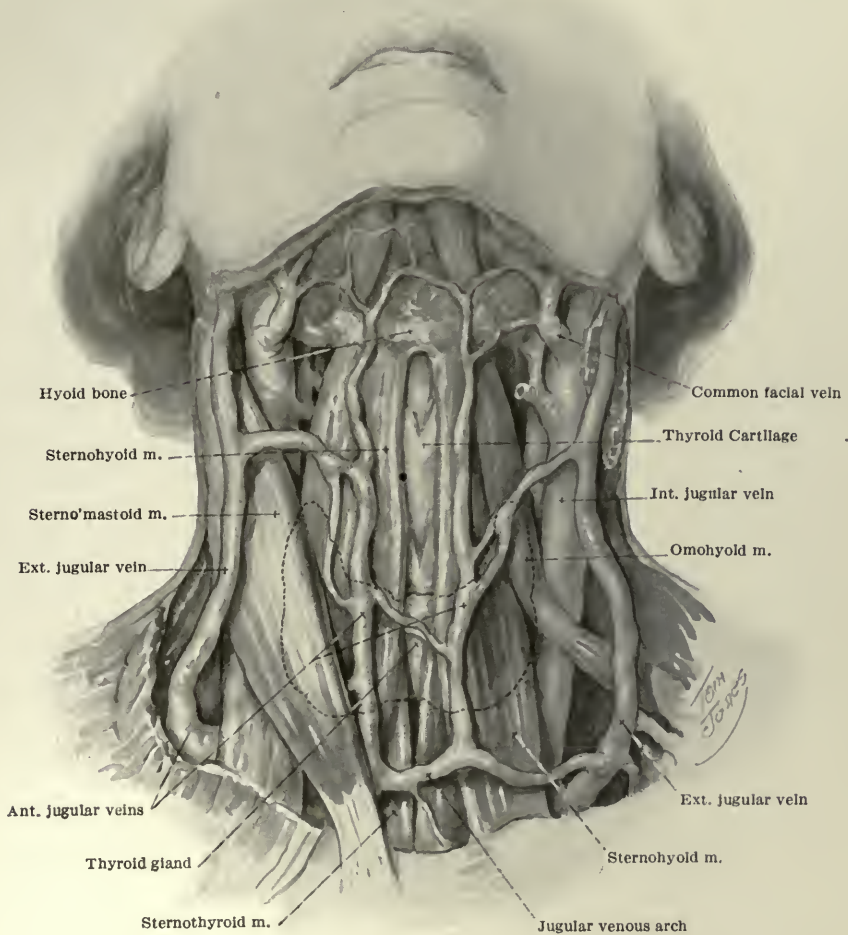


Fig. 71.—The relation of the anterior and the external jugular veins is shown. The external lie over the sternomastoid muscles crossing them from within outward. The anterior veins lie medially to the medial border of the muscles. These veins lie superficial to the short muscles of the neck. The position of the thyroid gland is shown by the dotted line.

is an artery which courses downward at the median edge of the sternomastoid which may be severed when the sternohyoid is separated from the sternomastoid muscles.

The False Capsule

In contradistinction to the true capsule, mentioned in the section on histology, the false capsule must be distinguished. This capsule is made up of a plane of fibrous tissue interposed between the true capsule of the gland and the surrounding structures. In front it is a more or less definite plane lying between the true capsule and the posterior surface of the sternothyroid muscle. Sometimes it is so intimately blended with the sheath of these muscles that it cannot be separated from them. Lateral to the gland it leaves this muscle and at the insertion of the middle veins divides into two planes (See Fig. 94, Chapter X). The one follows the posterior surface of the gland to the tracheal surface, forming attachments for the gland to the trachea, imbeds the parathyroid bodies and the recurrent nerve and below is continuous with the prevertebral fascia. The other layer passes outward to the carotid sheath and is lost in the fascia of the sternomastoid muscle.

The Nerve Supply of the Skin and Muscles

The skin in the anterior surface of the neck is supplied by branches of the superficial cervical nerves (Fig. 73). These nerves, derived from the second and third cervical roots, curve first backward around the posterior border of the sternomastoid muscle hence forward and at about the middle of this muscle pass between it and the external jugular veins, perforate the platysma about the anterior border of the sternomastoid and supply the skin covering the anterior surface of the neck.

The skin of the lower portion of the neck, at the site where the usual collar incision is made, is supplied in part by the sternal branches of the supraclavicular nerves. These nerves pass behind the posterior border of the sternomastoid muscle and passing under the jugular vein reach the supraclavicular region over the clavicular portion of the sternomastoid muscle.

The platysma is supplied by the lower branches of the facial nerve. The sternomastoid muscles are supplied by branches from the spinal accessory nerve while the sternohyoid and sternothyroid muscles are supplied by branches from the descending branches of the hypoglossal nerves and from deep

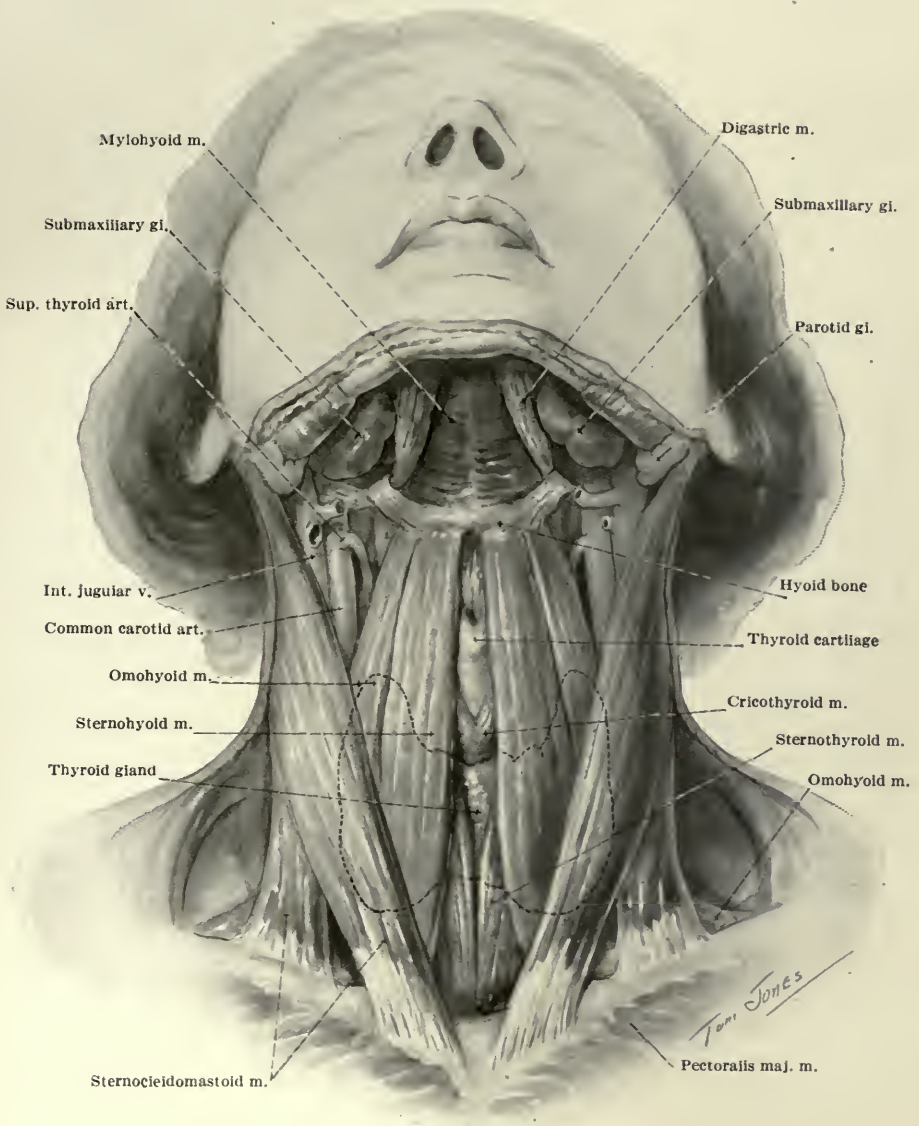


Fig. 72.—The sternomastoid muscles pass obliquely upward and outward from the region of the sternoclavicular articulation to the tip of the mastoid process. Arising from the posterior surface of the upper border of the sternum and extending to the hyoid bone are the sterno-hyoid muscles. Beneath the lower end of these the sternothyroid muscles are seen. The isthmus of the thyroid gland appears between the diverging upper extremities of these, and the cricothyroid muscles appear just above the isthmus.

branches of the first three cervical nerves forming the ansa cervicalis.

In nerve-blocking the point selected is where the nerves

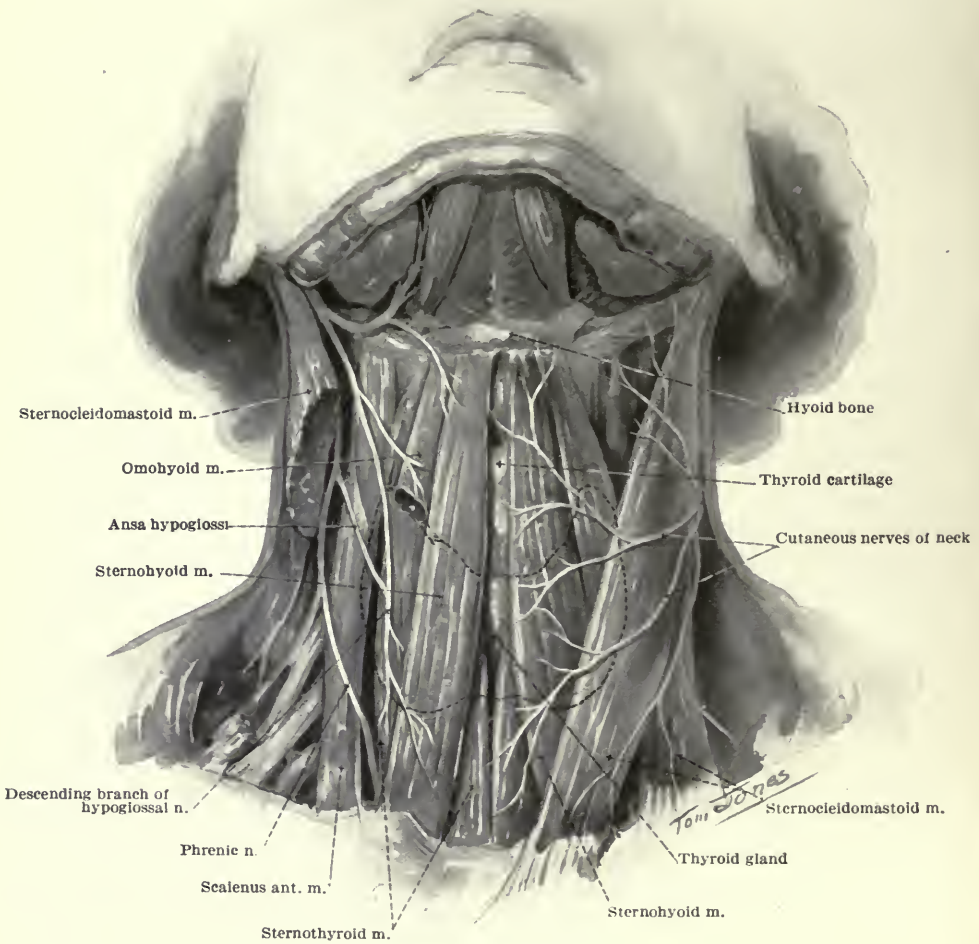


Fig. 73.—The nerve supply of the neck. The anterior cervical nerves are seen on the right looping around the posterior border of the sternomastoid muscle and radiate medially and downwards. These nerves supply the skin. On the left of the figure the descending branches of the hypoglossal nerves are seen. These nerves supply the deep muscles of the neck.

curve around the posterior border of the sternomastoid muscle. This point is usually about on the plane of the Adam's apple.

It may be noted that blocking these nerves does not affect the nerve supply of the region of the clavicles nor the nerves supplying the deep muscles of the neck.

The Nerve Supply of the Thyroid Gland

The nerves supplying the thyroid gland have not been satisfactorily determined. In a general way the sympathetic, the superior laryngeal and the recurrent laryngeal nerves may be said to be distributed to the gland.

The Sympathetic Nerves

Luschka (*Anatomie des menschlichen Halses*, p. 306) believed these nerves reached the gland only by following the superior thyroid artery. Drobnik (*Arch. f. Anat. u. Entwicklungsgesch.* Jahrg., 1887, S. 339) believes that nerves are given off from the second cervical ganglion uniting with the first cardiac nerves and then sending branches to the gland along the inferior thyroid arteries. The position of these nerves is of interest because some surgeons think the destruction of this nerve supply is the factor of importance in pole ligations.

The Superior Laryngeal Nerves

These are branches of the 10th cervical ganglia of the sympathetic and supply the mucous membrane of the larynx. Whether the thyroid gland receives any branches from them has not been satisfactorily demonstrated. Lindeman (*Centralbl. f. allg. Path. u. path. Anat.*, 1891, ii, 321) believes both the superior and recurrent nerves send branches to the thyroid gland.

The Recurrent Laryngeal Nerves

These nerves ascend from the thorax, the right passing around the subclavian artery, the left around the aorta, and approach the cleft between the trachea, esophagus and lower pole of the thyroid gland (Fig. 76). As they approach this region they cross the inferior thyroid vessels, sometimes in front, sometimes behind and sometimes between its branches, when division takes place some distance before the gland is reached. They enter the larynx at the level of the hyoid bone and supply all the

muscles of the larynx except the cricothyroid. Drobnik believes the recurrent nerves receive branches of the sympathetic nerves. The interest in this nerve lies chiefly in the fact that it is liable to injury in lobectomy or in careless ligation of stumps in lobe resections.

Topography of the Gland

The thyroid gland is a bilobed gland joined by a narrow isthmus. Each lobe is pear-shaped and lies on either side of the trachea. The lobes are two inches long and extend from the lower border of the thyroid cartilage to the third tracheal ring (Fig. 74). The lateral lobes are united in most cases by an isthmus which covers the second and third tracheal rings. The isthmus is said to be absent in 10 to 20 per cent of the cases. I have rarely found it absent. The isthmus is united to the trachea by abundant connective tissue bands, the ligaments of the thyroid gland. Often there is a fascial band extending from the thyroid cartilage to the isthmus. This is the suspensory ligament. Sometimes it contains a few muscular fibers as already noted. Often an elongated mass extends upward from one of the lobes, usually the left and may reach as high as the hyoid bone. This is called the pyramidal lobe (Fig. 78). The median borders of the lateral lobes are united to the trachea by fascial bands. These sometimes contain small arteries. At the posterior inner border of the gland there is considerable loose areolar tissue which harbors the recurrent laryngeal nerve. At the point where the thyroid comes in close contact with the trachea lime salts may become deposited uniting the goiter firmly to the trachea by a calcareous bridge. The separation of such bridges may cause some difficulty and result in annoying hemorrhage.

The Blood Supply of the Thyroid Gland

Descriptions of the thyroid gland generally begin with the statement that it is a very vascular organ. This is usually the first fact the young surgeon verifies when he begins to operate. A thorough knowledge of the paths through which this gland receives and dispels its blood does much to lessen the pain of this first lesson.

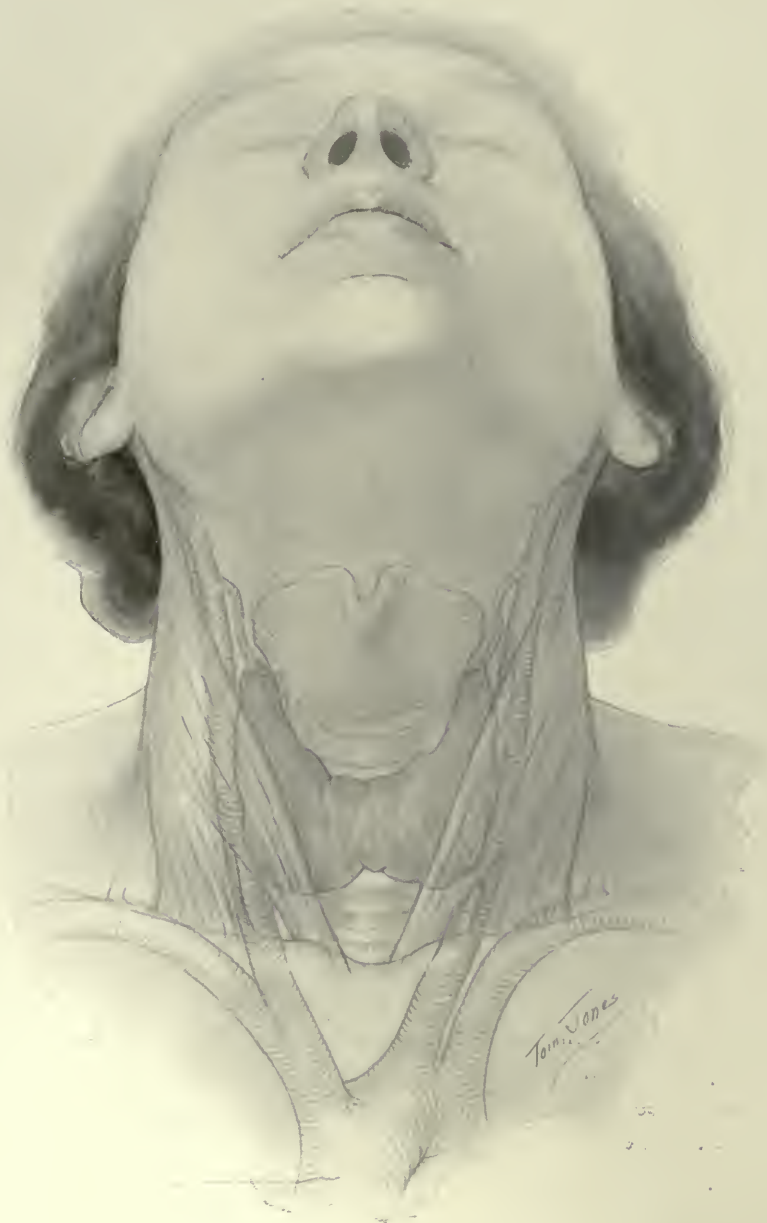

Fig. 74.—The general topographic relations of the thyroid gland. It straddles the upper portion of the trachea covering the upper three tracheal rings. The upper poles overlie the lower edges of the thyroid cartilage. The carotid vessels lie lateral to the lateral lobes. The medial borders of the sternomastoid muscles cover the lateral borders of the lateral lobes.

Generally speaking, the thyroid gland is supplied by two pairs of arteries and drained by corresponding veins. The number of veins, however, varies considerably.

The Arteries of the Thyroid Gland

The principal arteries are the superior and inferior thyroid arteries. The lesser are the artery to the suspensory ligament and the thyroidea ima arteries.

The Superior Thyroid Arteries

The most constant vessels are the superior thyroid arteries. They arise from the external carotid arteries just above the bifurcation of the common carotid arteries. They course first upward to near the greater cornu of the hyoid bone, then curve downward and medially and enter the upper pole of the gland just anterior to the summit (Fig. 75). Near their origin they give off branches which course along the medial border of the sternomastoid muscle, and more medially other branches which form a plexus in front of the thyroid cartilage and the cricoid membrane. The superior thyroid artery is usually about the size of a knitting needle. The comparison is apt because the size of a knitting needle varies. When there is a large goiter the vessel may be much enlarged. I have seen it larger than a normal radial. It is only occasionally that it is small, due either to a maldevelopment of the lobe or to the presence of a large branch of the superior laryngeal artery.

The Artery to the Suspensory Ligament

The superior laryngeal artery, itself a branch from the superior thyroid, sends a small branch to the suspensory ligament or the pyramidal lobe as the case may be (Fig. 75). Sometimes it extends downward as a considerable branch and anastomoses with the posterior branch of the inferior thyroid artery. The cricothyroid arteries are branches which come off the superior thyroid arteries at the level of the cricothyroid membrane and by uniting form an arch. Somewhere from this arch there is usually a small artery which descends in the suspensory ligament or on the pyramidal lobe if one exists. This is the artery to the suspensory ligament.

This small vessel deserves the attention of the surgeon. Though small, when the tissue in which it lies is cut, it tends to retract and may be the source of considerable hemorrhage, particularly delayed hemorrhage.

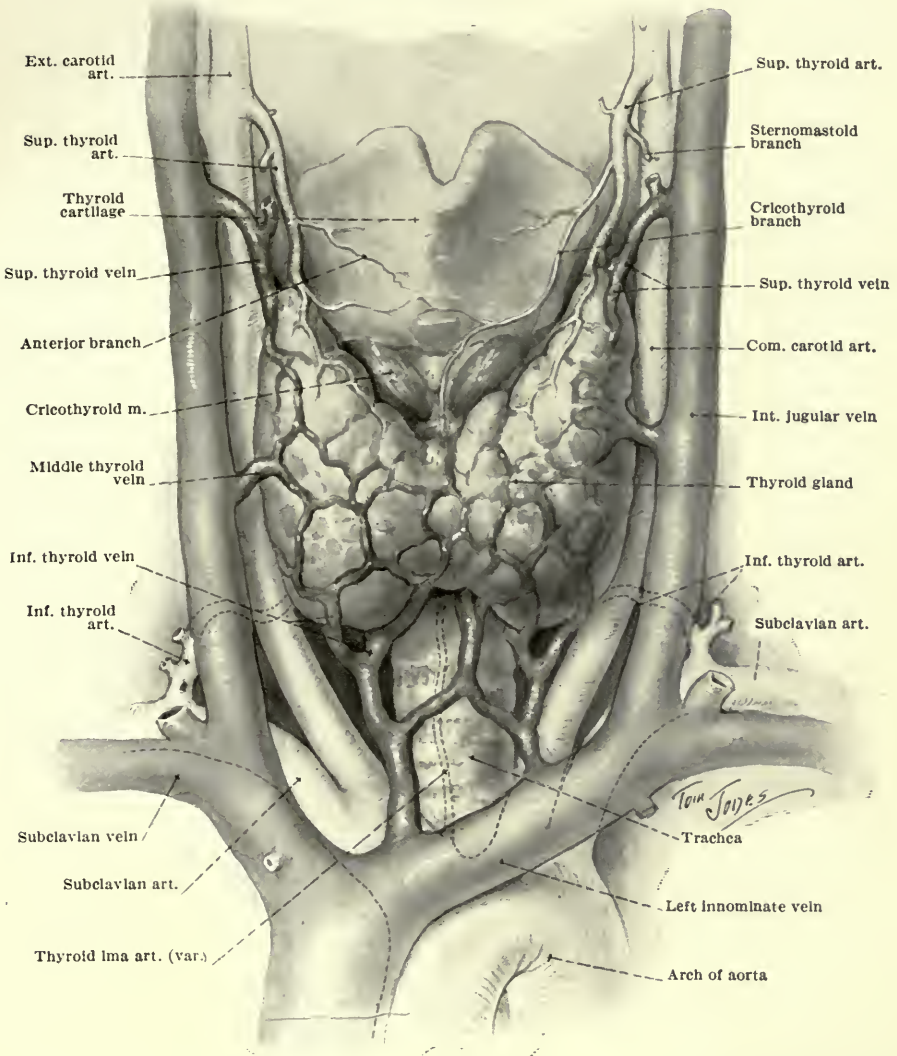


Fig. 75.—The arterial supply of the thyroid gland. The superior thyroid arteries enter the superior poles at the anterior surface. From these vessels branches extend across the thyroid cartilage, the cricothyroid arteries, to anastomose with their fellows of the opposite side. From these a branch is given off which follows the pyramidal lobe, the suspensory ligament or suspensory muscle, as the case may be, to the isthmus of the thyroid gland. The inferior thyroid arteries are derived from the celiac axis and passing behind the carotid vessels, enter the lower pole of the thyroid gland. (See the next figure.)

The Inferior Thyroid Arteries

The lower pole is supplied by the inferior thyroid arteries. They arise from the thyroid axis, together with the suprascapular and the transverse cervical and ascend upward and inward behind the sheath of the common carotid artery and internal jugular vein and approach the lower poles of the thyroid gland at the point of maximum convexity. They divide before they enter the gland; the one following the lateral border plunges at once into the depth of the gland (Fig. 76). The other, the inferior branch, remains more superficial and continues upward just within the substance of the gland in its posteromedial border. From this branches are sent forward into the substance of the gland and anastomose with branches of the arteries of the other side through the isthmus and possibly with branches from the superior laryngeal arteries (Fig. 76). Some anatomists believe there is a direct anastomosis between the superior and inferior thyroid arteries. Hyrtle denies such anastomosis. There is reason to believe that this is correct, for when the superior thyroid arteries are ligated, the upper pole can be cut across without causing hemorrhage. There is no doubt but that by far the larger part of the gland is supplied by the inferior thyroid arteries. The vessel sometimes divides some distance before the thyroid gland is reached, in which event the recurrent laryngeal nerve may pass between the two branches. The inferior thyroid arteries vary more in size than do the superior. The artery of the opposite side may compensate for a diminutive one. The site of division and the number of branches vary considerably. It is even more prone to displacement by the vagaries of enlargement of the gland than is the superior. It is by the posterior branch of these vessels that the nutrition to the parathyroid glands is conveyed. These vessels likewise give off the branches to the trachea which sometimes are of sufficient size to annoy the operator.

The Thyroidea Ima Artery

The thyroidea ima artery is a small vessel which, according to Gruber, occurs in one case in ten, springs directly from the arch of the aorta between the anonymous and the common

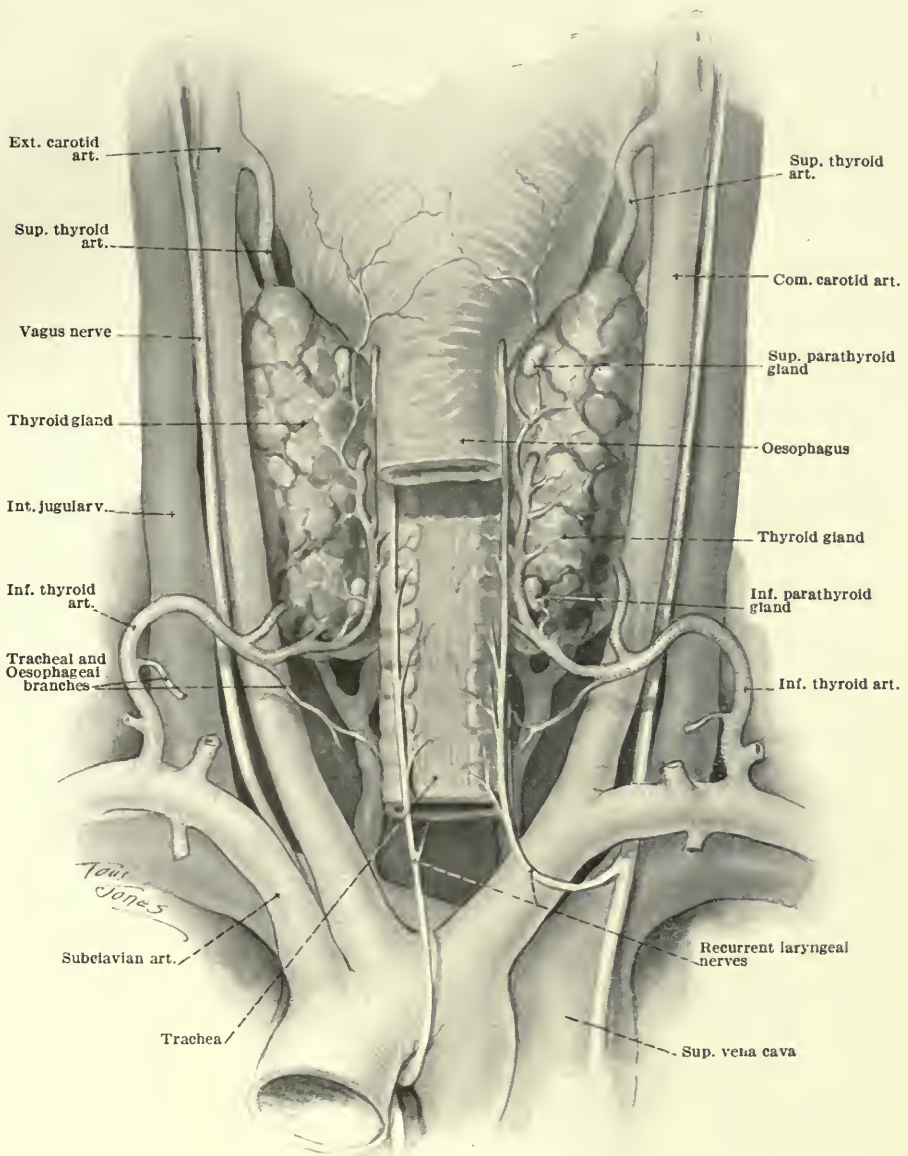


Fig. 76.—The arteries of the thyroid gland and the recurrent laryngeal nerve. The superior thyroid artery is seen to enter the superior pole anterior to its apex. The inferior thyroid arteries arise from the thyroid axis, ascend first upward and then medially behind the common carotid arteries. As they approach the gland, they divide into two branches. The one enters the lower lateral border. The second branch passes behind the lower pole and enters the gland near the medial border. It ascends to the midpoint of the gland and then enters deeply into it. The recurrent laryngeal nerves ascend along the lateral surface of the trachea to the cricothyroid membrane.

carotid artery. It reaches the isthmus of the thyroid gland by traveling in front of the trachea verging slightly from left to right.

Disturbance of the Site of the Vessels by Thyroid Hypertrophy

As the lobes enlarge, the gland is subject to a great variety of disturbances in position, particularly when the enlargement of the gland is irregular and bosselated. Because of this the relation to the various adjacent structures may be very materially altered. Enlargement toward the medial line may compress the trachea, producing a flattening, the so-called "saber sheath" trachea, or if there is irregular enlargement of the adjacent lobe, the trachea may be curved to accommodate itself to such enlargement. Because of such deformities the lumen of the trachea may be very much lessened.

The growth of the lobulations in directions other than toward the trachea leads to displacement of vessels. When this occurs at the upper pole the superior thyroid vessels are displaced. When a lobulation occurs lateral to the vessels they are displaced toward the median line (1, Fig. 77). This displacement may be so great as to push the vessels beyond the median line. If a lobe develops medial to the vessels they may be pushed far laterally (2, Fig. 77) and sometimes carried high upon the neck. Such wide deviations may cause the surgeon to miss the main vessel in the ligation and tie a minor one.

Lateral lobulations may extend beyond the site of entrance to the median vein leaving a constriction of fibrous tissue at the site of the vein, which partly subdivides the lobes into lobuli (4, Fig. 77). The failure to recognize the importance of these septae will cause the surgeon to lose the line of cleavage. The septae often carry vessels of importance and if severed and allowed to contract may give rise to troublesome hemorrhages.

The lower pole more than the upper is liable to marked displacement. The vessels are often displaced, the veins medially and the artery downward (3, Fig. 77). The displacement downward behind the clavicle constitutes the most common displacement and produces the common substernal goiter. Because of the close relation of this to the intrathoracic and other aberrant lobes, these are discussed in a separate chapter.

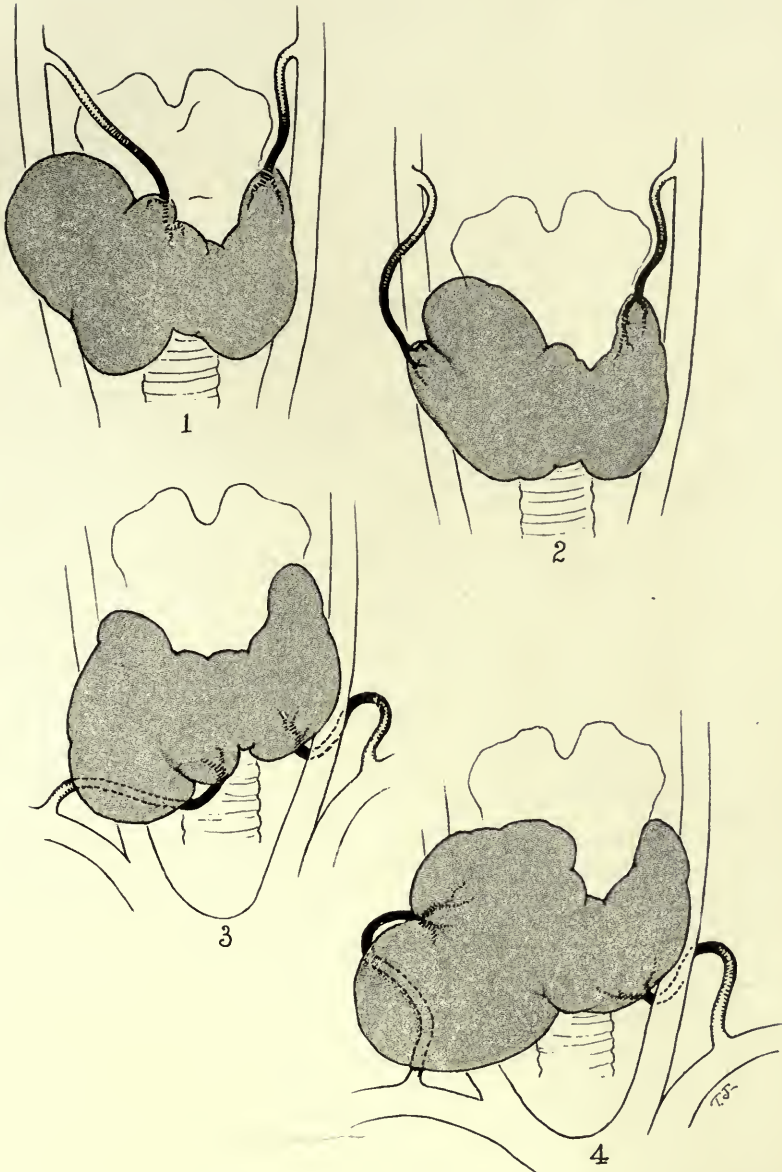


Fig. 77.—Aberrant locations of the thyroid arteries. (1) The superior thyroid artery is displaced medially by an unusual development of the superior pole. (2) The superior thyroid artery is displaced laterally by the medial development of the superior lobe. (3) The inferior thyroid artery is displaced medially by a massive development of the lower pole. (4) The inferior thyroid artery is displaced upward by a marked hypertrophy of the lower pole.

The Thyroid Veins.—The efferent channels of the thyroid gland are numerous and thin walled. They leave the gland at three chief points, the upper pole, the middle of the lateral surface, and the lower pole.

Superior Thyroid Vein is usually single and leaves the gland usually at the level of the upper pole along with the artery (Fig. 78).

The Middle Thyroid Veins arise from the lateral border of the lobes and pass directly lateralward and empty into the internal jugular veins (Fig. 78). Often there are two or more. If there are several the supernumerary ones usually come off nearer the upper pole. These middle thyroid veins are often torn by the surgeon in enucleating the gland. This is the most common source of troublesome hemorrhage.

The Inferior Thyroid Veins come off from the lower pole near the median border. In the beginning they are three or four or more in number but usually collect into two main trunks, the inferior thyroid and the thyroidea ima veins (Fig. 78). The first passes downward and lateralward and empties into the internal jugular, the other into the innominate vein just in front of the origin of the common carotid artery. On the left side both veins pass downward and to the left and empty into the left innominate vein. If there is a pronounced enlargement of one lower lobe only, these veins may be carried in front of the trachea or even to the opposite side. The veins arising from the lower pole often form a considerable plexus. Because of this the size and situation of the veins is very variable. These vessels are often closely attached to the false capsule of the gland, making careful dissection at this point very important.

The Thyroidea Ima Vein, when present, arises in the venous plexus over the isthmus and passes downward in front of the trachea and empties in the left innominate vein.

Typical Sites of the Ligation of Vessels.—There are several points of election in the ligation of the veins (Fig. 79). The first point is at the superior pole. By ligating the vessels just above the superior pole, or by ligating the point of the gland itself, the upper pole is made bloodless. The lateral veins if double-clamped permit the rotation medially of the lobe without the loss of blood. The inferior thyroid artery can usually be

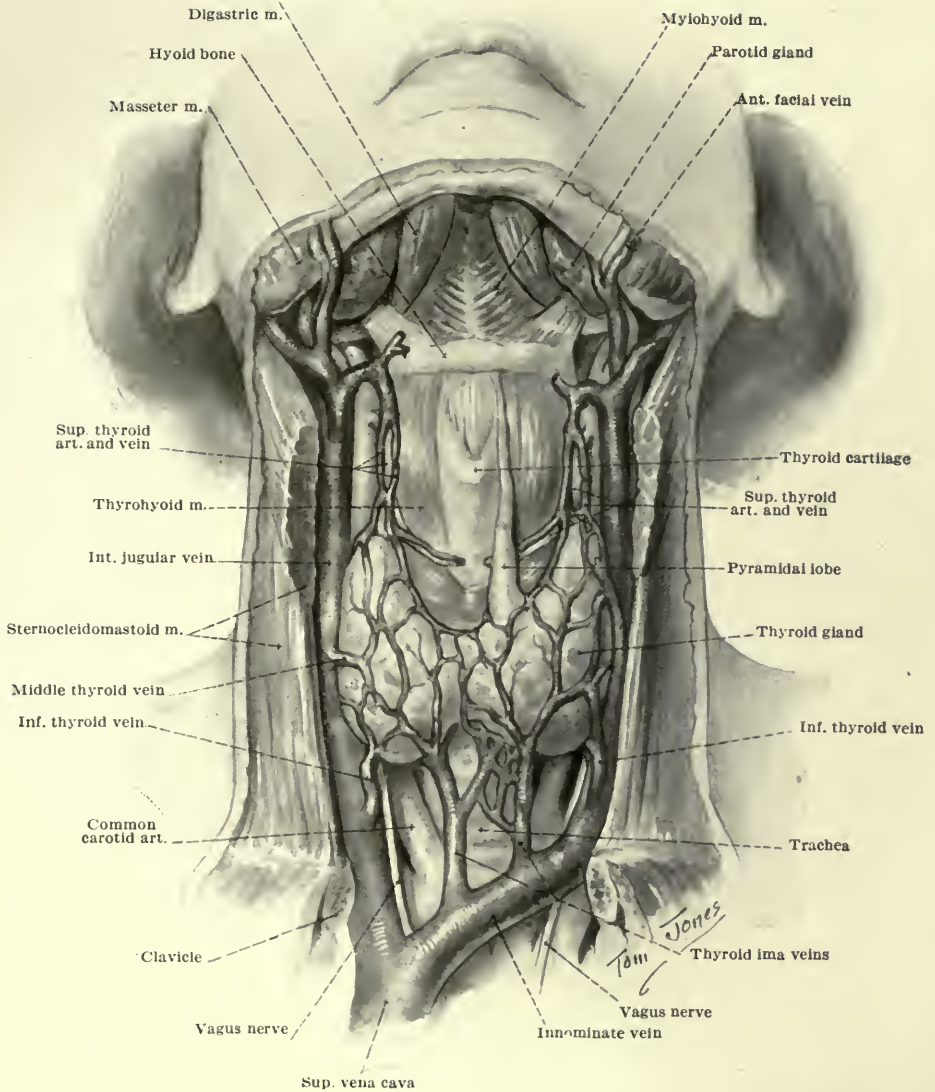


Fig. 78.—The veins of the thyroid gland. The veins of the upper part of the gland collect at the upper pole and leave as a single trunk. At the lateral border the median veins empty into the internal jugular veins. At the lower pole the inferior jugular veins empty into the internal jugular and the thyroidea ima veins empty into the innominate vein.

seen at the lateral border of the lower pole. By passing a suture through the gland this vessel can be occluded. The veins arising in the lower pole can be controlled by a single ligature. The medial branch of the inferior thyroid artery can be clamped at the moment it is cut within the substance of the gland. This

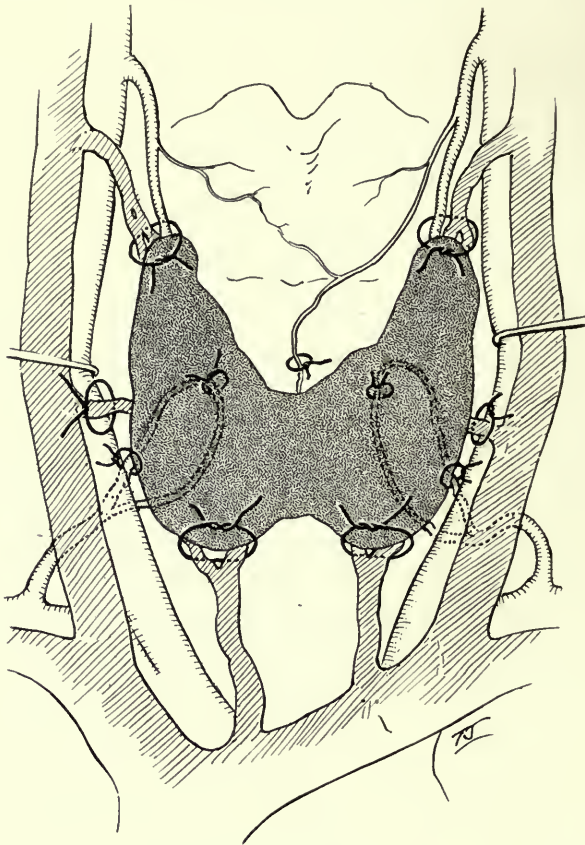


Fig. 79.—Typical sites for ligation of the thyroid vessels. The superior thyroid vessels are ligated *en masse* with the tip of the upper pole. The lateral veins are ligated between the gland and the internal jugular veins. The inferior thyroid arteries are ligated, when they divide before entering the gland, the upper as it enters the gland, and the lower in the middle of the gland after being cut in the resection of the gland. The inferior veins may be ligated separately or *en masse* depending on their relation to each other.

preserves that portion of the artery which supplies the parathyroid glands. By following this scheme the greater part of the blood supply can be excluded before the substance of the gland is cut into. This simplifies the technic and lessens the hemorrhage materially.

CHAPTER X

TECHNIC OF OPERATIONS ON THE THYROID GLAND

Operations on the thyroid gland involve many of the finer points in surgical technic. The thinness and abundance of the vessels and the proximity of important nerves are the chief factors which demand accuracy and delicate technic. The gland is separated by delicate layers of connective tissue from the surrounding structures, therefore an accurate determination of the line of cleavage makes for a good operation. Patency of the tracheal lumen must be maintained and when this structure is compressed and displaced, by the irregular growth of the gland, careful manipulation and constant observation of the patient's respiratory function are demanded. Accurate approximation is required to retain the symmetry of the neck and to avoid an unsightly scar.

Like all major operations on the neck, a constant attention to hemostasis is demanded. A vessel that will eventually require ligation should be tied at once. It requires no more time to do it at once than to do it later and the possibility of tearing off a vessel by an unintentional pull on a clamp is removed and the field of operation is not obstructed by a lot of artery clamps; besides the forceps are released for use again. A dozen forceps are enough for any operation. The safest cutting instrument to use in dangerous areas is a sharp knife. The scissors have no place in goiter operations except for the cutting of ligatures.

Many complicating factors may appear in goiter surgery which in like number are not encountered in any other operation. In the first place the surgeon is dealing not only with the disease for which he is operating, but there may be many complications not directly involved in the malady in question. In the second place, particularly in toxic goiters, the management of the patient may be the important part of the procedure. This may necessitate a variety of things in the preliminary treat-

ment, but during the course of the operation the plan may need to be shifted because the preoperative estimate of the patient's resistance has been found to be incorrect. For this reason it may be necessary to diagnose the case as the operation proceeds. No more may be done than the patient can stand.

The Anesthetic

The choice of the anesthetic in operations for goiters depends on a great variety of factors. Generally speaking but two, ether and novocaine, need be considered though a few surgeons employ nitrous-oxide-oxygen anesthesia. With the last named I have had no experience.

Ether.—The advantage of ether is chiefly that it gives the operator a free hand. He does not need to consider the whims and vagaries of the patient. He can work without any annoying consideration as to the ability of the patient to stand a complete anesthesia for he will not know until the operation is completed whether or not she can. It does not limit the surgeon to any refinement of technic. If he spills a lot of blood it is best that the patient does not know of it.

It is a question in the case of very nervous patients who in spite of every care in preliminary treatment still are afraid of the operator and the operation, whether the shock from the fright or the shock from the anesthetic will be the greater. If the operator by his personality cannot bring the patient to favor local anesthesia, or accept in full confidence the judgment of the operator, ether is the best anesthetic. The only alternative is to postpone the operation. This is the one I elect. If the patient cannot be calmed for the local anesthetic, rest and sedatives will in time bring about such a state of tranquility in nearly every case. To soak a frightened patient with ether is to court all but certain disaster.

Many patients stand ether very well and the beginner should select only such cases as will take ether without danger. He then is free to consider only the technic. He will find out later whether he has done more than the patient can stand.

Against ether may be counted the increased hyperemia of the field of operation which it causes. The operation is more bloody and more difficult, though this is in part offset by the

freedom the surgeon has in that it is possible to grab anything in any way. Packs can be applied with a degree of vigor that the patient under local anesthesia would not bear.

The patient being asleep, interference or impending compression of the trachea are not recognized early and disaster is first announced by the asphyxiation of the patient demanding a hasty tracheotomy. If the recurrent laryngeal nerve is endangered, the surgeon has no way of finding out until the patient salutes him the next morning with a cracked-pot voice. The danger of pneumonia is greater after ether, a matter of great importance in old patients who have suffered from tracheal obstruction from pressure of the goiter.

The action of ether on the hypertoxic patient may be open to debate. I believe the resources of the patient are tried more by the general anesthetic than by the nervous tension when operated on under local anesthesia. I use ether only in the very young and the obstreperous, who except for their disposition, depart but little from the normal, that is to say, simple colloid or slightly toxic goiters.

Novocaine.—This drug may be regarded as the prototype of all local anesthetics. Other chemicals may be as good; to date, none is better. It is efficient and only a small fraction of the amount that may be safely administered is required for any goiter operation. The question of safety, therefore, does not enter. It is efficient because complete anesthesia can always be secured. The sense of traction or compression of the trachea is all that can appear as unpleasant sensation for the patient to bear. Usually two or three grains of novocaine, with 5 to 8 minims of epinephrine to the ounce makes up the standard solution. From one to two ounces of the solution is all that is required for any operation. Four times this amount would fall within the limits of safety. Highly toxic goiters are sensitive to the adrenaline and such cases may require the lesser amount of epinephrine while very vascular goiters make the larger percentage desirable.

The advantages of local anesthesia are numerous. It makes a bloodless field which permits exact work to be done. This not only saves blood at the operation, but lessens the liability of secondary hemorrhage because the vessels are accurately caught

up before they are cut and they can be then accurately and securely ligated. Impending compression of the trachea is observed at once in the breathing of the patient and the gland can be so manipulated as to give relief. If the recurrent laryngeal nerve is approached, the patient at once responds by irritation of the larynx. There is no vomiting after operation to test the efficiency of the hemostasis. The ill-effects of the anesthetic on the respiratory tract are avoided. The excitement incident to the administration of a general anesthetic also is avoided. Perhaps the most valuable feature of local anesthesia consists in that the surgeon can gauge the type and extent of the operation he is to perform. If he plans a lobectomy but discovers that his patient shows a greater degree of toxicity than he had anticipated, he can do a ligation instead, leaving the more radical operation for some future sitting. If a double resection seems more than the patient can safely stand, one lobe only can be operated on leaving the other for a future sitting.

The disadvantages of local anesthesia are that the operator must plan accurately exactly what he wants to do. His technic must be painstaking. He must control not only himself, but the patient as well. The whole environment must be regulated so that the patient is not unduly excited. Local anesthesia is not suited for the inexperienced goiter operator and the difficulties are much increased if the operating room assistants do not know how to comport themselves.

The excitation adrenaline produces in very toxic patients must be considered a disadvantage. The excitement incident to the adrenaline subsides in from ten to twenty minutes and in nervous patients it is well to wait until it does subside.

The disadvantages of local anesthesia may be minimized by developing an accurate, gentle technic. Everything pertaining to the operation must be quiet and simple. Noise, loud conversation and the like must be prohibited.

Anesthetization.—Inasmuch as a general anesthetic is rarely used in this hospital, the following description of technic presupposes the employment of local anesthesia.

The most important factor in the anesthesia is a proper relation between patient and the surgeon. The patient must feel assured of the success of the procedure. If the patient is sent

by a friend who has had an operation done under local anesthesia she brings this attitude with her. For others the method of approach must depend on the personality of the surgeon. If one is an expert in the art of deception it may be an advantage to "steal" the gland. If one is not, it is best to tell the patient simply that one will remove a part of the gland at a given time or whenever she is in proper condition. The disadvantage of stealing the gland lies in that the patient will tell her friends that she did not know when she was to be operated on and this second patient will believe every manipulation of the surgeon or nurse presages the operation. Instead of the strain being lessened, it will be multiplied with every manipulation. The man who believes he is stealing anything from a woman is only fooling himself.

Before beginning the anesthesia it is desirable that the patient receive at the outset a good impression. She should be placed on the operating table in a comfortable position. The surgeon should assure himself that the patient is relaxed, contented and satisfied that all is well. If she is nervous a few words of encouragement from the surgeon may allay her fears.

The Infiltration of the Anesthetic.—The gland may be gently palpated to accustom the patient to the pressure of the operator's fingers. The initial prick of the needle is likely to try the patient's nerves more than any other step of the operation. This first pain can be materially lessened by picking up a fold of the skin at the point where the initial puncture is to be made and by compressing it half a minute between the thumb and index finger cause an acute anemia (Fig. 80.) The preliminary prick can be made with very little pain at the point of maximum compression. A new sharp needle causes much less pain than a dull, rusty one. The initial wheal should be made slowly lest the sudden expansion of the tissue cause pain.

A row of wheals is made along the line of the proposed incision, this being usually along one of the natural folds of the skin on a line where a string of beads would naturally fall (Fig. 81). The injection must be made endermically which is indicated by the prompt blanching of the skin. The entire extent of the proposed incision is infiltrated as the first step of the operation. If the solution is injected below the skin, anesthesia

is not instantaneous and the anesthesia is apt to disappear before the time for suturing the skin has arrived. After the skin has been infiltrated the platysma should be infiltrated by passing the needle parallel with the skin infiltration but deeply enough to reach the muscle.

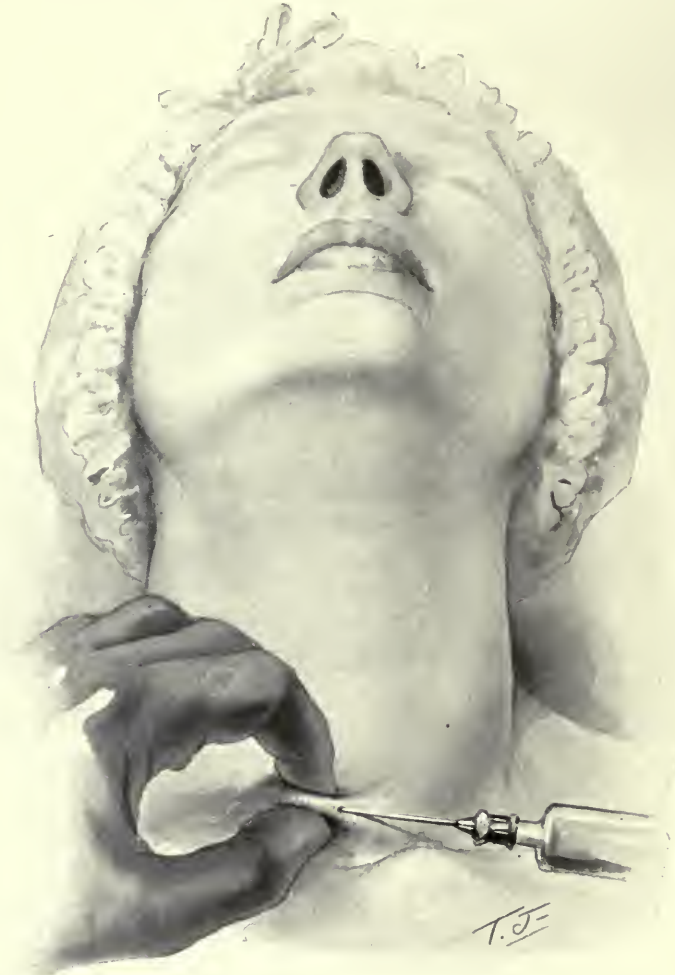

Fig. 80.—The preliminary needle prick. The skin is pinched firmly between the forefinger and thumb of the left hand as the needle is inserted. Note the sterile cap made by passing a drawstring about the edge of a loose cap. A rubber bathing cap covers the hair before the sterile cap is put on. (Devised by Dr. Chesky.)

After the site of the incision has been anesthetized, the muscles of the neck should then be infiltrated. The sternomastoid and the sternohyoid and sternothyroid muscles must be anesthe-

tized. These muscles receive their nerve supply from the hypoglossal nerve, a different source than the skin and platysma. The operator can readily tell when his needle has entered the proper plane by noting when the needle passes through the

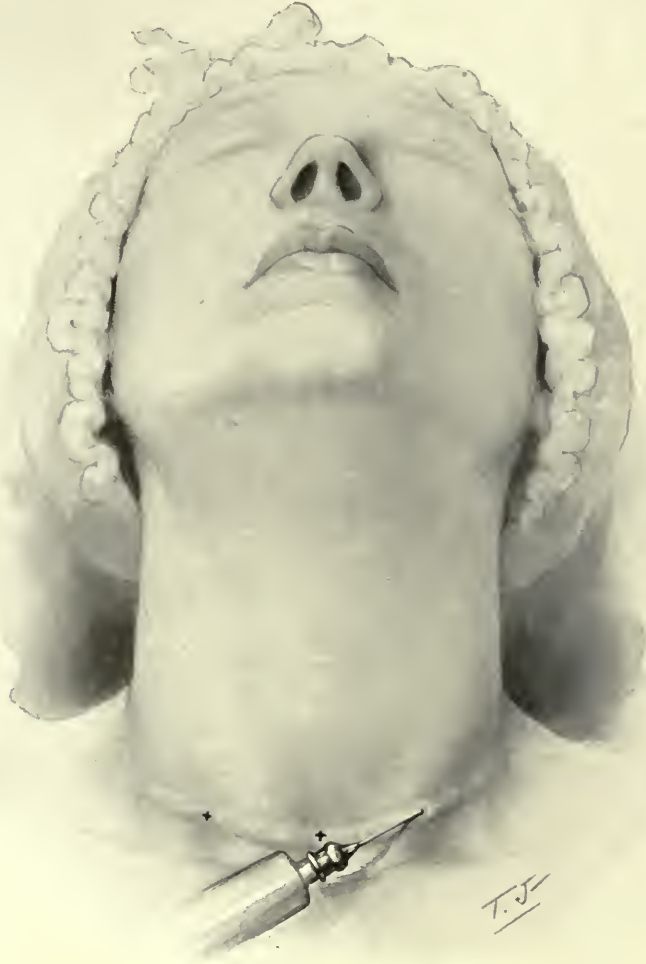

Fig. 81.—The line of primary infiltration. A line of wheals is made just above the sternoclavicular border. The infiltration is endermic.

platysma muscle. By moving the skin and platysma one can readily prove whether the needle lies in the proper place. Care should be taken that the needle does not pass too deeply, thus wounding the superficial veins of the gland proper.

In anesthetizing the muscles it is convenient to inject the anesthetic solution in the muscle covering the gland over the entire site of the operation. This not only assures anesthesia



Fig. 82.-Intramuscular infiltration. From the primary line of infiltration the needle is passed between the platysma and the more deeply lying muscles. At 2 and 3 the anterior cervical and the supraclavicular nerves are blocked. At 4 and 5 the peritracheal tissues are infiltrated.

but facilitates enucleation by producing a mild edema and by constricting the small vessels everywhere in the field of operation. The whole area can be reached by passing the needle through the original line of infiltration. The mobility of the

skin and platysma make it possible to reach every part of the field of operation (Fig. 82).

It is likewise advantageous to inject deeply about the poles

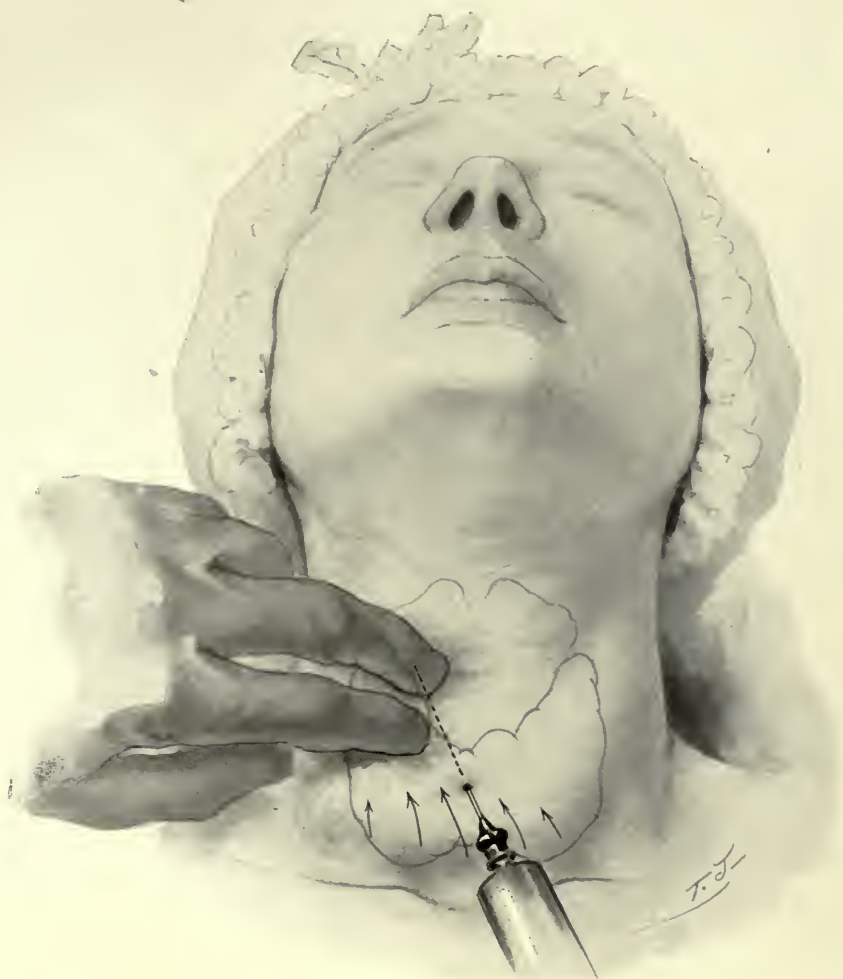

Fig. 83.—Periglandular infiltration. The needle is passed between the gland and the overlying muscles. By pressing over the soft parts as the needle is being passed the point may be made to reach the space between the trachea and superior pole of the gland. A like maneuver at other parts of the gland makes it possible to infiltrate the entire periglandular tissue.

of the gland and at the isthmus, because it assures anesthesia if any nerve trunk has escaped the previous infiltration. It also facilitates enucleation. By depressing the needle with the index

finger of the left hand one can make the needle follow any of the planes without danger of injuring any of the neighboring structures (Fig. 83).

If the operator desires, the needle may be passed over the top of the sternomastoid, at the level of the carotid bifurcation, with the idea of blocking the cervical nerves at the point where they curve over that muscle (2 and 3, Fig. 82). If it succeeds it but anesthetizes the skin, subcutaneous tissue and platysma but the deeply lying muscles, supplied by the hypoglossal nerves, are not influenced. The objection to the blocking of the cervical nerves at this origin as a means of anesthetizing the skin area is that anesthesia does not appear at once and the vessel-constricting effect at the site of operation is lost. The plan above advised, on the other hand, gives instant anesthesia, is unailing in its results, and the maximum degree of constriction of the vessels is secured. Besides if the various nerves are blocked at their roots several stabs must be made through the unanesthetized skin.

The Skin Incision

The injection of the anesthetic having been completed, the incision is begun at once. The skin is incised throughout the entire length of the field it is desired to expose. The initial incision should extend through the skin and subcutaneous tissue down to the platysma muscle. This skin flap is dissected upward off the platysma for the distance of an inch or two (Fig. 84). This is done in order that the platysma may be incised at a higher level than the skin incision. This gives more room in which to find the anterior jugular veins and makes a careful coaptation of the platysma easy in the closing of the wound. A few oozing points may be encountered at this stage. These are caught up and ligated at once.

Incision of the Platysma

The platysma is then incised carefully watching for the anterior jugular veins which lie beneath the fascia. The platysma is dissected up from the fascia to permit easy access to the veins (Fig. 85). The extent of this dissection is exaggerated in the figure in order to show the relation of the veins to each other.

Four are shown in the figure. Usually from two to six are found. The veins after being exposed by cutting the fascia parallel to the wall of the vessels, are caught up between two forceps, cut and ligated (Fig. 86). The ends of the veins should be undercut (Fig. 86) so that the ligature can be securely placed. If this undercutting is not done, the retracting vein may slip its ligature like a frightened pup slips its collar. The fascia is cut from one end of the wound to the other, exposing the sternomastoid muscles and the short muscles covering the gland. When the fascia is cut, it retracts, exposing these muscles.

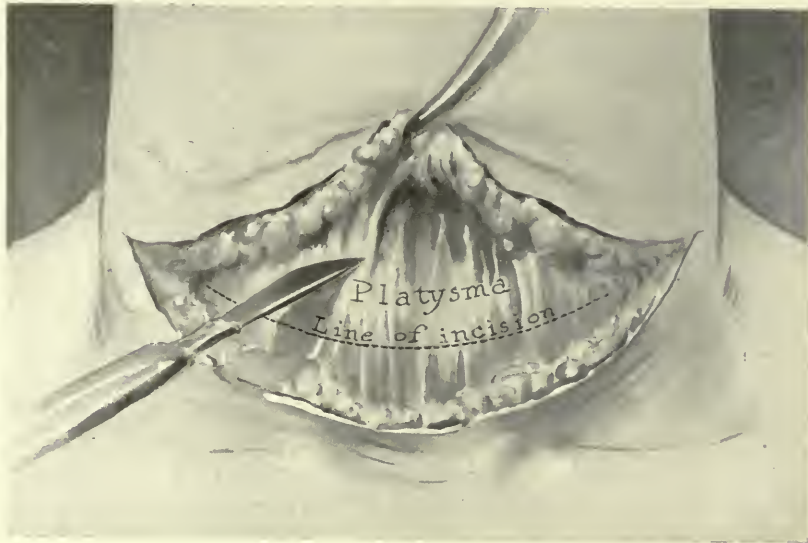

Fig. 84.—The preliminary incision. The incision is made along the line of the primary infiltration (Fig. 81) down to the platysma muscle. The skin and subcutaneous tissue is then dissected off from the platysma so that the incision through this muscle can be made at a higher plane than the skin incision. (Note dotted line.)

Incision of the Deep Muscles of the Neck

The sternohyoid muscles being thus exposed are divided from the edge of one sternomastoid to the other. This maneuver is facilitated by picking up the muscle with tissue forceps (Fig. 87). By doing this the muscle can be quickly cut with a knife without endangering the vessels of the thyroid gland. It is well to separate these muscles from the sternomastoid muscles for an inch or more. A small vessel requiring ligation may be severed in this procedure. This increases the space sufficiently

without the necessity of incising the sternomastoid muscles. After the sternohyoid muscles are cut the sternothyroid muscles are exposed. The gland lies just below these muscles and they must be gently lifted from the gland before they are cut. When there has been much reaction, these muscles may be quite firmly attached to the gland requiring care in their separation. The sternohyoid muscles are incised only as far laterally

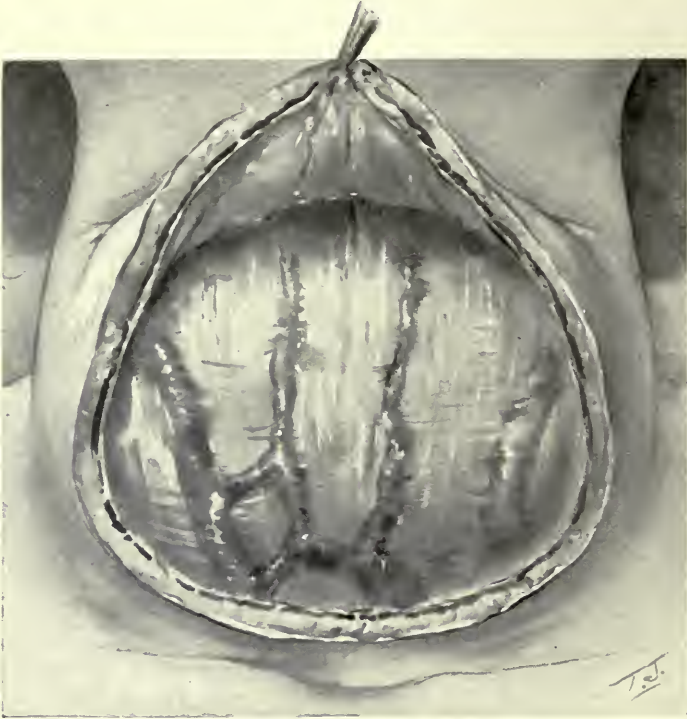

Fig. 85.—Exposure of the anterior jugular veins. The platysma is incised along the line indicated in the preceding figure. The platysma is then dissected from the fascia underneath. This exposes the anterior jugular veins. (The area exposed is double that ordinarily performed in order to show the venous plexus to better advantage.)

as is needed to reach the outer border of the gland. In small glands they need to be incised but little.

In some instances the false capsule exists as a separate plane of fascia easily separated from the muscle and gland. When this is the case it is elevated with the forceps and incised. Often the fascia is so closely attached to the muscles that it is elevated and cut with them.

By lifting the muscle flap so mobilized, additional delicate

planes of fibrous tissue covering the gland may be identified and all above the true capsule must be lifted upward. By so doing, the suspensory ligament, or the pyriform lobe, as the case may be, becomes accessible and may be double clamped, ligated, and divided (Fig. 88). This step is important because a small artery is found here, too small to bleed much when cut and readily hidden by the muscle flap covering it, but which may cause troublesome late hemorrhage. By dividing the suspensory liga-

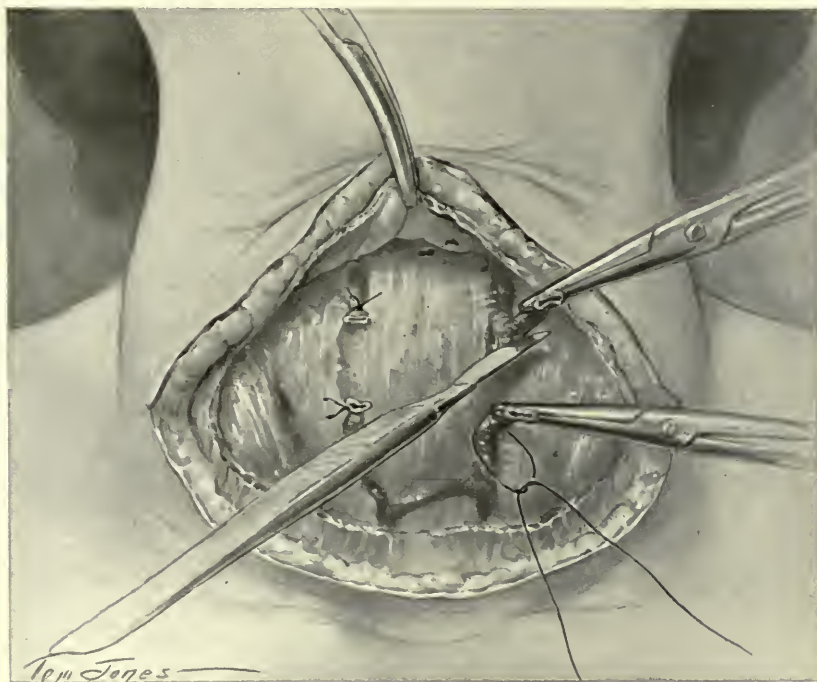


Fig. 86.—Ligation of the anterior jugular veins. The fascia is then incised parallel to the walls of the veins and the vessels caught between two forceps and the vessel is cut between them. The end of the vessel is dissected loose for a quarter of an inch in order to give a better hold for the ligature.

ment so early in the operation the trachea, as far as the isthmus, is exposed and the cleft between the superior pole and the trachea is made more accessible.

Isolation of the Superior Pole

Isolation of the superior pole can best be done by gently pushing the knife handle between the trachea and the gland tis-

sue (Fig. 89). This can be readily done without danger of injuring any structure. This procedure is much facilitated if the tissue uniting the pole to the trachea was edematized during the infiltration of the anesthetic. This area can be infiltrated after the gland has been exposed if it has not been already done. The aid in separation rendered by edematization of the line of separation applies to all other borders as well. If the tip of the lobe extends high up, it may be drawn downward by grasping

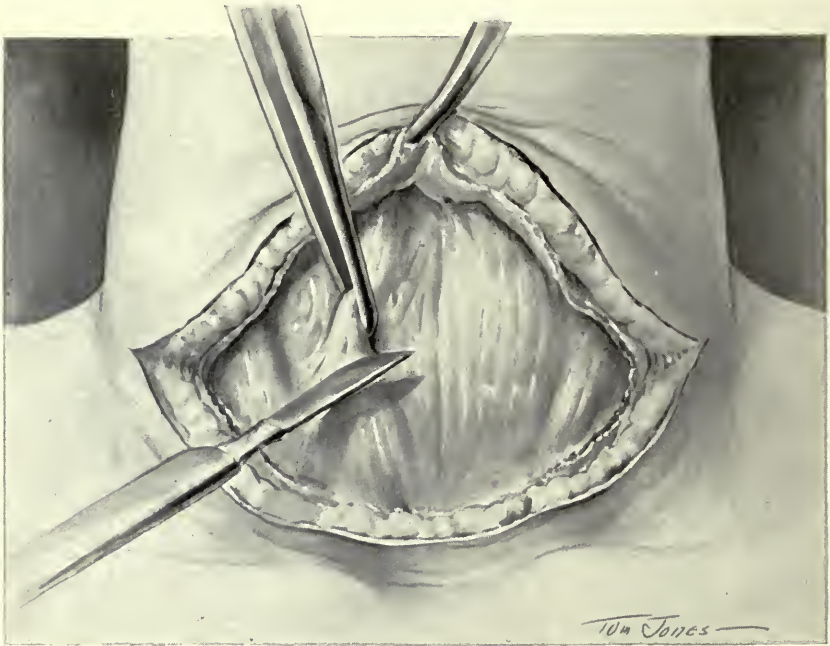


Fig. 87.—Incision of the short muscles covering the gland. After the vessels have been tied and the fascia incised, the short muscles alone cover the gland. These are lifted off from the gland with thumb forceps and cut with a knife.

the pole with forceps and making gentle traction keeping up meanwhile the manipulations of the scalpel handle. The outer surface of the pole is then freed from adjacent muscles and vessels.

After the pole is dislocated the vessels are identified either by sight or palpation. These are secured by passing a ligature about them or about the extreme upper end of the pole of the gland. This may be done by passing a threaded needle eye end

first (Fig. 90) or by lifting up the pole with forceps, grasping the ligatures and pulling them under the pole as the forceps are withdrawn (Insert *A*, Fig. 90). The separation of the pole and the passing of the ligature is much facilitated by grasping the gland near the upper pole and making gentle traction downward as the pole is being gradually separated.

If the vessels are much displaced by the irregular develop-

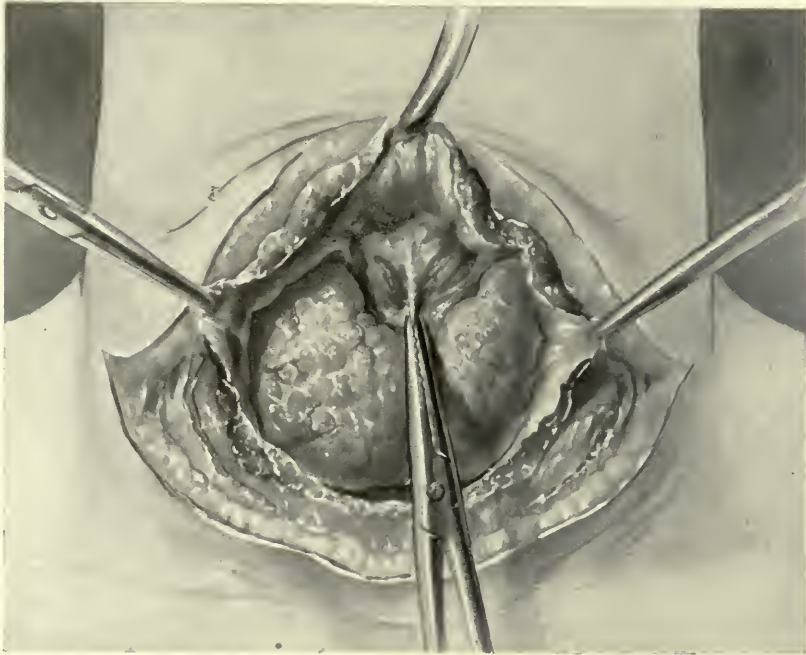

Fig. 88.—Ligation of the vessels to the isthmus. The short muscles and the capsule have been incised and elevated from the gland. The three forceps are used to retract the muscles and capsule. The central forceps is making traction on the suspensory ligament. A suture-armed needle is passed around the ligament securing the vessel.

ment of the gland the uppermost point may not represent the pole and hence the vessels may be missed. The vessels should, therefore, be identified by sight or touch. These unusually developed lobes sometimes contain small vessels, which may cause confusion with the proper vessels, but they are never so large as a normal superior thyroid vessel. (Compare Fig. 77, Chapter IX.)

Separation of the Lateral Border and Ligation of the Lateral Vessels

The superior vessels having been ligated, the lateral surface of the gland is separated by means of the handle of the scalpel. Usually it is easiest to separate the lateral surface down to the highest point of its concavity and then proceed to a partial separation of the lower pole. When the lateral wall is being freed,

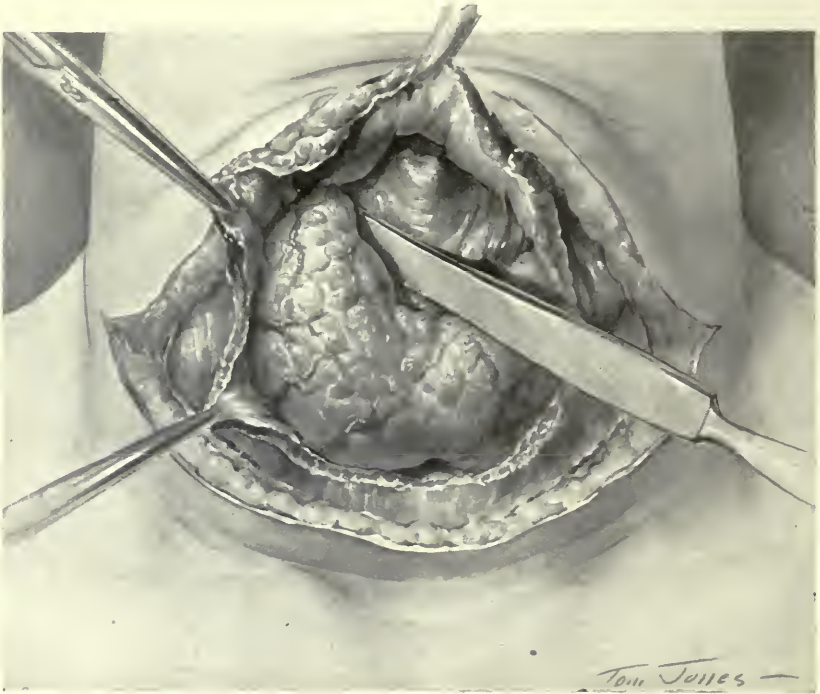


Fig 89.—Separation of the superior pole from the trachea. The trachea has been freed as far as the isthmus. The upper pole is being separated from the trachea with the handle of the scalpel.

the lateral veins should be sought for. If the field is free from blood these veins are readily identified by pulling on the edges of the sternothyroid muscles at the lateral end of the incision. (See Chapter on Anatomy.) These veins should be double clamped and tied (Fig. 91); care must be used in locating these veins for they are thin walled and are easily pulled from their union with the internal jugular veins, which produces a very troublesome hemorrhage. Care must now be exercised to follow

the fascia close to the gland, for at this point the fascia divides. By following close to the gland the tissue enclosing the parathyroid glands and recurrent nerves can be avoided even if it is necessary to completely dislocate the thyroid gland from its bed.

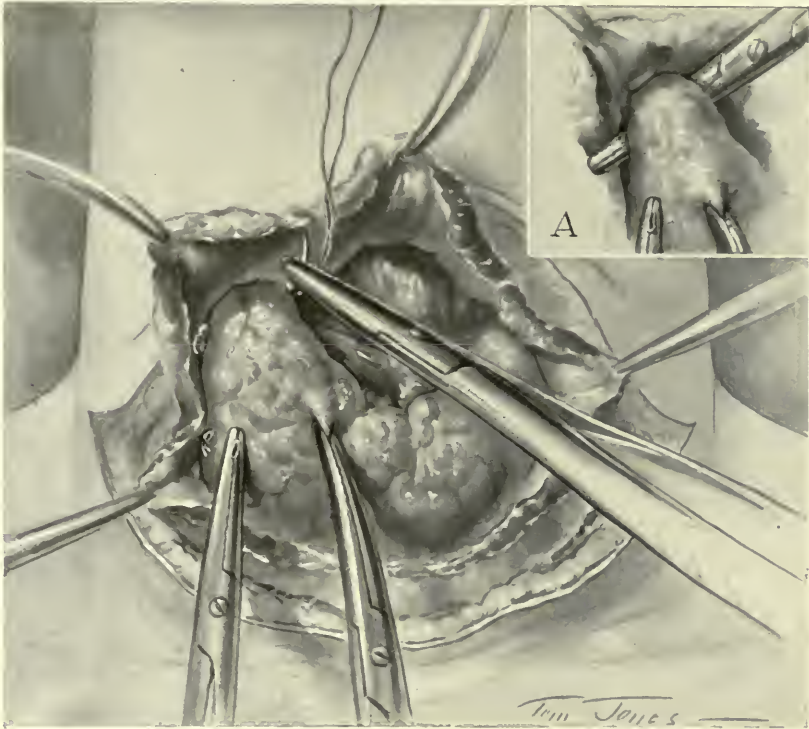


Fig. 90.—Ligation of the upper pole. The upper pole has been freed from the surrounding tissue and a suture-armed needle is being passed, eye end first, about the pole. The gland has been grasped with forceps and by traction the pole comes into the wound. The insert shows a forceps passed under the pole ready to grasp a ligature. When the pole is very long this is more convenient than the needle.

Dislocation of the Lower Pole

If the lower lobe is not large, the capsule may be gently lifted from it with the handle of the scalpel. If this lobe extends behind the clavicle, traction must be made on the gland with forceps as the capsule is carefully stripped from the gland. Care must be taken lest the veins be torn.

After the pole has been dislocated the inferior thyroid artery is located in the lower end of the lateral border. The ves-

sel is ligated by passing a needle armed with a suture through the substance of the gland, in such a way that the artery is included (Fig. 92). In this way the recurrent nerve is most surely avoided.

Some operators advise the ligation of the inferior vessel at some distance from the gland. If this is done at a perfectly safe distance to insure safety of the nerve, the incision and exposure is unnecessarily large. If one ties close to the gland,

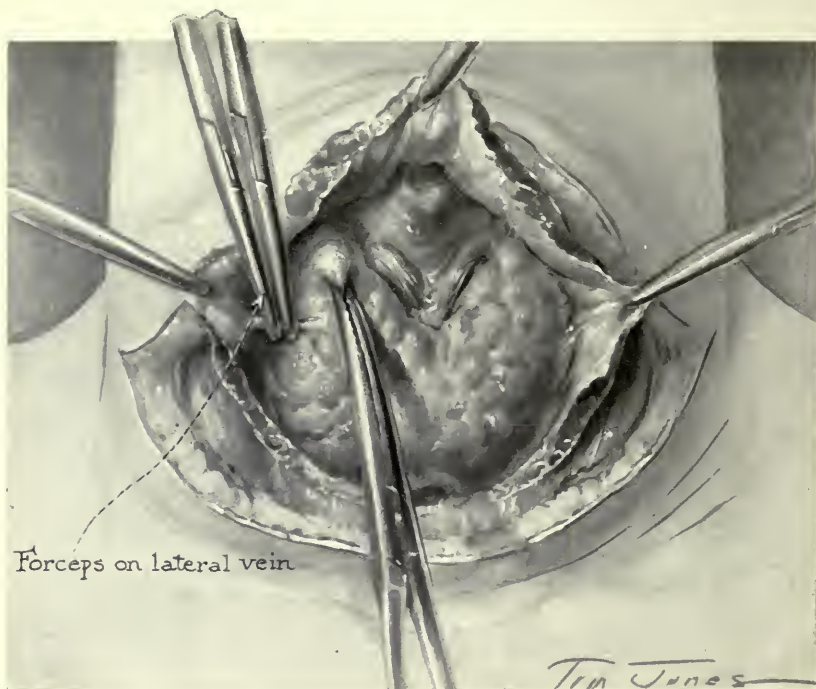


Fig. 91.—Ligation of the lateral veins. The lateral vein has been grasped between two forceps and is ready for section and ligation.

the nerve may be caught in the ligature and destroyed, or if the tie is made close to the nerve, the distortion may disable it temporarily or even permanently, even though the nerve is not actually included within the ligature. Furthermore, the posterior portion of the gland and the parathyroid glands secure their nutrition from the posterior branch and if the main trunk is ligated the blood supply to these glands may be endangered. Sometimes small branches of the artery may be discovered

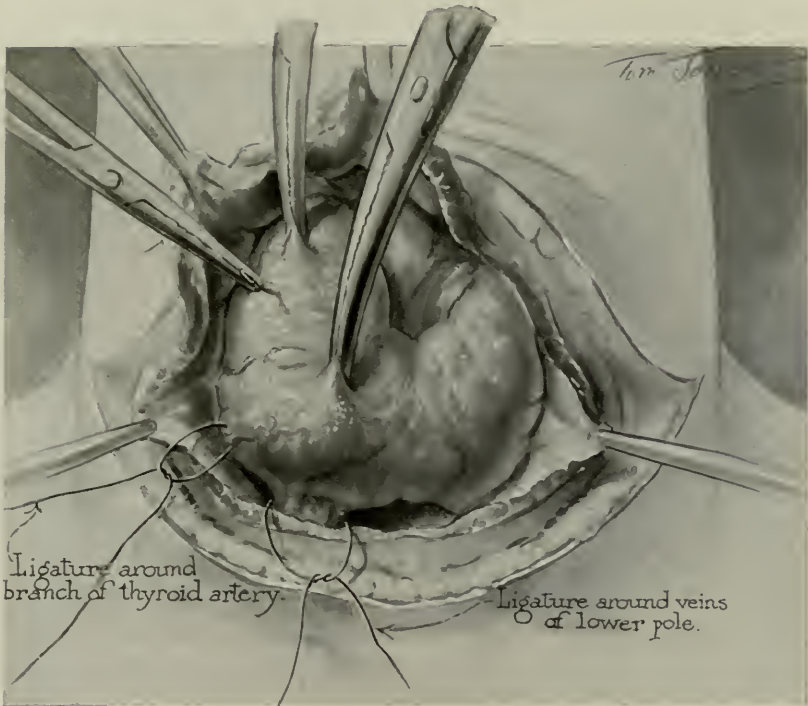


Fig. 92.—Ligation of the inferior thyroid artery and veins. The lower pole is being pulled upwards with forceps. A ligature has been passed about the lateral branch of the inferior thyroid artery at the left of the figure. At the bottom a ligature has been passed about the veins at the lower pole.

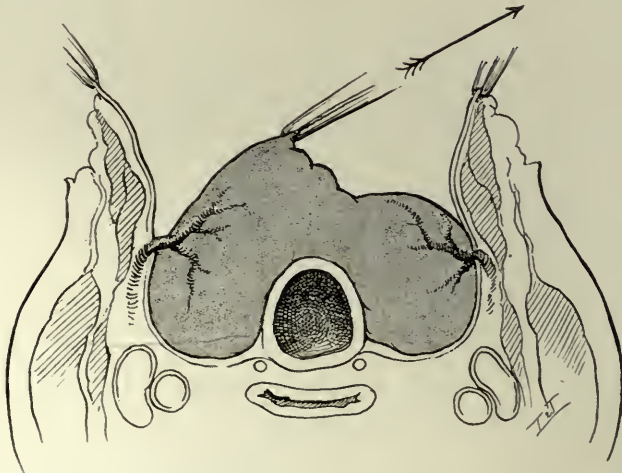


Fig. 93.—Topography of the lateral veins. At the left of the figure forceps are making traction on the capsule of the gland. The forceps on the right are making traction on the gland itself. The relation of gland and vein thus becomes apparent.

higher up the side of the gland. These may be ligated by passing a needle about them.

By following the lower pole medially the inferior thyroidal veins are exposed. These are secured by passing a ligature through the superficial part of the gland (Fig. 92). If the veins are numerous several ligature-sutures must be passed. If the thyroidea ima artery is present it should be ligated separately.

In ligating any of these vessels it is well to pass the ligature with a needle in such a way as to include a portion of the true capsule of the gland; this prevents the ligature from slipping or cutting through the walls of the vessels.

Dislocation of the Lobe

The lateral vein is made prominent by pulling the capsule lateralward and the gland medially (Fig. 93). After the lateral veins have been clamped, cut, and ligated, the lobe is dislocated by gently rolling it toward the trachea. At the point where the median vein enters the gland, the fascia divides. The one plane follows the gland toward the trachea, passing behind the parathyroid glands (Fig. 94). The other plane passes outward and is lost in the sternomastoid sheath. If the middle vein is ignored and the separation attempted blindly with the finger (*A*, Fig. 94) the outer plane will be followed and the operator will attempt to lift the capsule with the gland together with the parathyroid glands (*B*, Fig. 94).

If the middle vein is tied at the proper time and the gland is properly separated from its false capsule, the separation need not be carried so far as to endanger the parathyroid glands or the recurrent laryngeal nerves. This relation is shown in Fig. 95.

Excision of the Lobe

After the superior pole, the lateral veins, the lateral branch of the inferior thyroid artery, when it can be located, and the inferior thyroid veins have been ligated and the gland dislocated medially, the severing of the gland is begun. The incision near the upper pole will not bleed (Fig. 96) because these vessels do not anastomose with the inferior vessels. As the incision extends downward, small bleeding points may be found

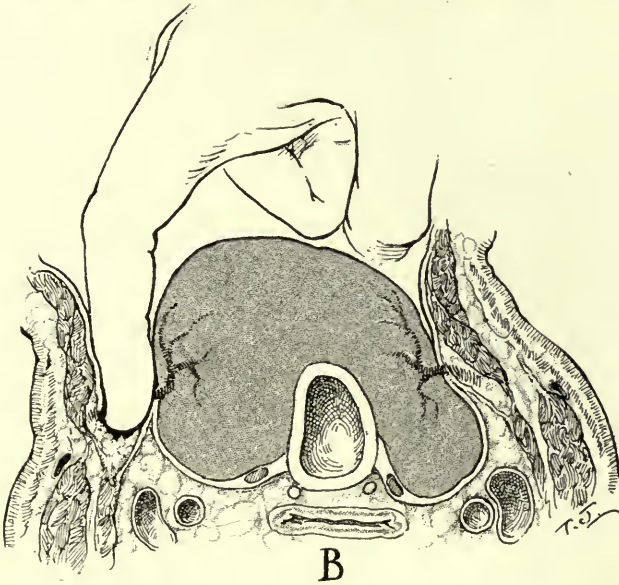
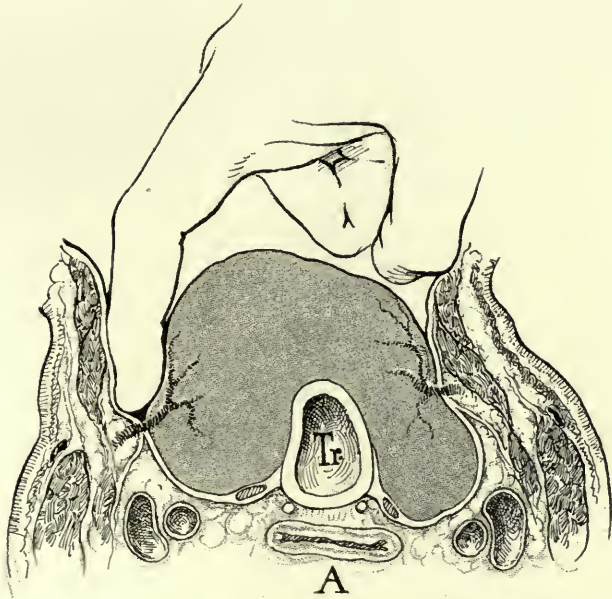


Fig. 94.—Wrong method of managing the lateral veins. *A*, The finger is shown separating the gland from its capsule without preliminary ligation of the vein. *B*, The finger is shown as having ruptured the vein and is following the fascia going to the sheath of the vessels instead of following between the gland and capsule.

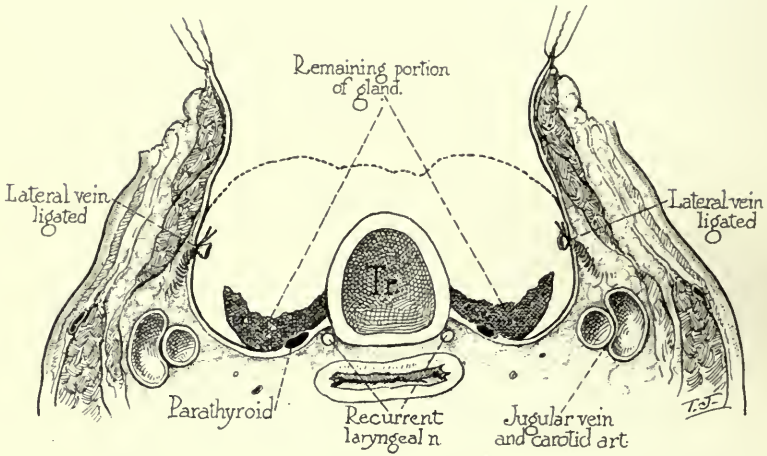


Fig. 95.—Diagram showing the appearance after the resection of both lobes. The lateral veins have been ligated and the remnant of the lobe separated to near the parathyroid glands. The topographic relation of these glands is not disturbed. Note the location of the recurrent laryngeal nerves.

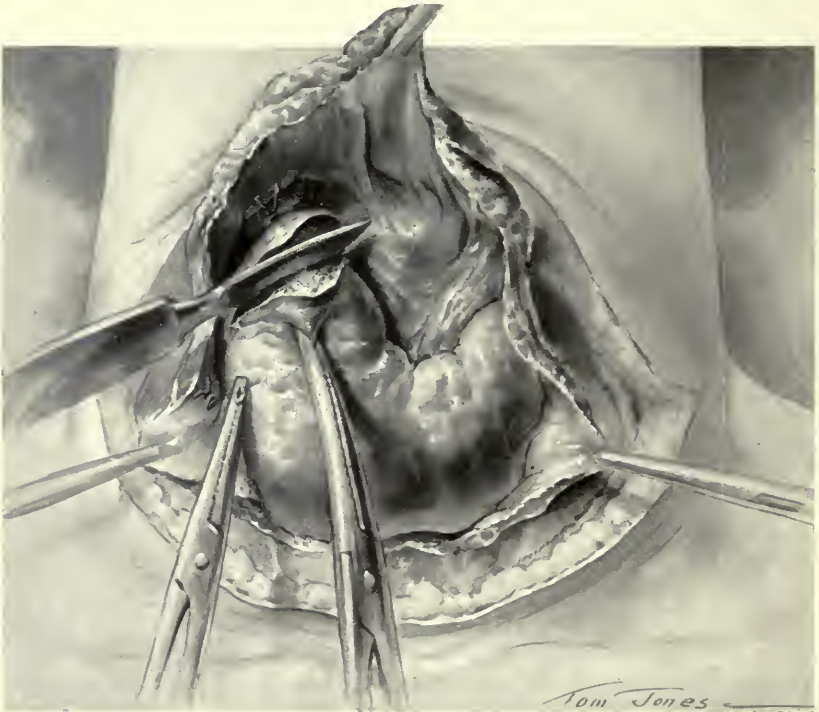


Fig. 96.—Resection of the gland. After the vessels have been ligated as shown in Figs. 90, 91, and 92 the gland is resected. While making traction downward with forceps the gland is cut below the ligature about the upper pole. The first inch of the incision is bloodless.

anywhere in the interior of the gland. Near the midportion a short distance from the median surface, a smart bleeder will be invariably encountered. This vessel is the continuation of the posterior branch of the inferior thyroid artery (Fig. 97). By catching up the bleeding points as they are encountered, the gland can be rapidly removed without any considerable loss of blood.

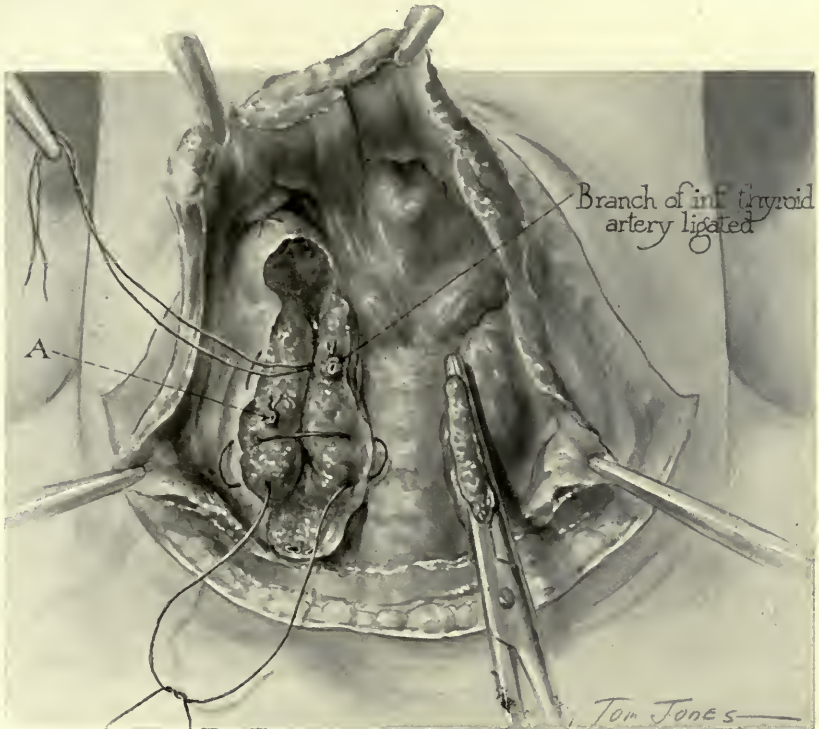


Fig. 97.—Completed resection of the right lobe. As the incision from the point shown in Fig. 96 is extended downwards, vessels in the substance in the gland are encountered. These are caught up and are shown ligated. Two staple sutures approximate the cut edges. The upper has been tied, the lower passed but not tied.

The bleeding points above mentioned are ligated by stitching around them through the stump of the gland with a needle (Fig. 97). An ordinary ligature should not be trusted because the vessels tend to retract and may slip a ligature unless it is secured by passing it into the gland tissues as above indicated.

In toxic goiters the gland is so fragile that hemostasis may be secured with difficulty. Mass ligatures, taking in as much

as possible of the gland, are usually successful. These may be passed from one capsule to the other, bringing one edge of the gland toward the other as much as possible (Fig. 97). In these cases the problem of hemostasis is the same as that in wounds of the liver. I have not found open packing of the wound necessary or the suturing of the muscle stump to the cut surface. Neither have I found the leaving on of clamps, as recently rec-

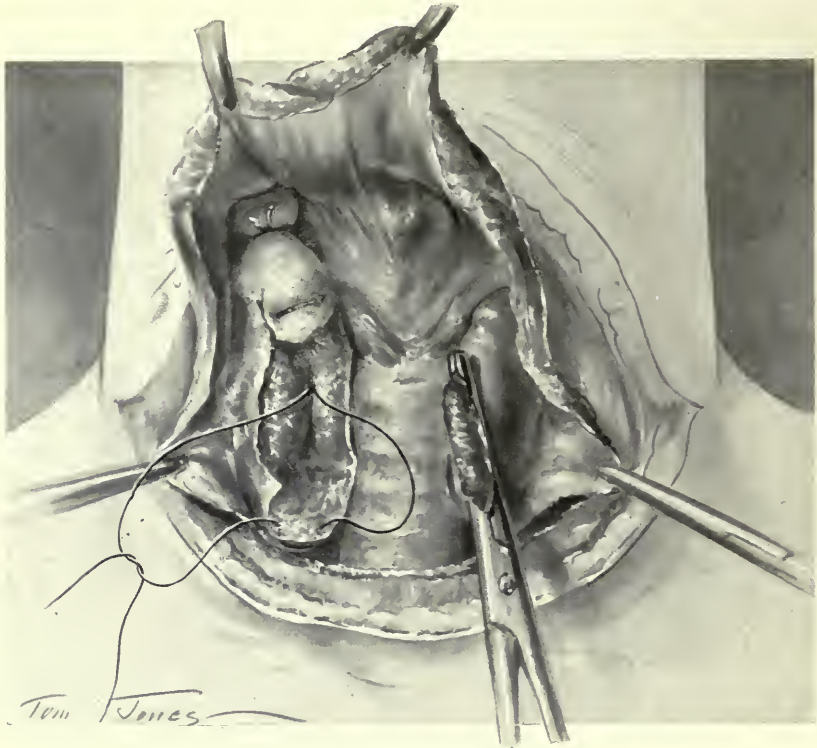


Fig. 98.—The folding downwards of the upper pole. The cut edge of the upper pole is folded downwards by means of a staple suture. A suture is passed through the lower pole but has not been tied.

ommended by Bartlett, necessary. At the same time, I should not hesitate to employ any of these means should occasion arise. I did find it necessary once to pack because of tearing off the lateral vein during the stage of enucleation. Both patient and operator recovered in two days and the operation was successfully completed. It is well for the young surgeon to remember that should alarming hemorrhage occur packing may be resorted to, and if need be, the completion of the operation de-

ferred to a later date. I would again elect anything in preference to death from hemorrhage on the table.

Disposal of the Pole Stumps

When all bleeding points have been secured, ligatures are passed through the stump of the superior pole and through the body of the gland (Fig. 98). The stump of the inferior pole is pulled upward in like manner (Fig. 99). This brings these cut ends to lie on the cut surface of the body of the gland and prevents the muscle and fascia from adhering to the underlying gland. This technic exposes a smoother surface over which to unite the capsule and it shortens the long axis of the gland to more nearly that of the normal gland.

Management of the Second Lobe

The next step depends on the amount of tissue the operator deems it desirable or safe to remove. The operation may be terminated at this point or one of two courses may be pursued. If the major portion of the opposite lobe is to be removed, the technic just described may be carried out on the other side also. If the removal of less gland tissue is deemed sufficient, a partial resection may be done. It is probably true, as many surgeons believe, that the more tissue removed the surer the results. However, we do not as yet know the end results of such radical procedures. Hence I frequently elect to obliterate only a part of the lesser lobe, leaving enough to insure an unimpaired circulation in the least affected lobe.

When it is desirable to destroy but a part of the lobe a V-shaped piece of the gland is removed. This is done by passing a ligature deeply through the gland some distance from the lower pole (Fig. 99). A like suture is passed through the gland near the upper pole. Any amount of tissue may be removed depending on where these mass ligatures are placed. A large V is then cut from the gland between these ligatures (Fig. 100). The cut surfaces thus remaining are approximated by sutures (Fig. 101). In very fragile glands, as in very toxic goiters, this method is not suited because of the tendency of the ligatures to cut through the soft tissue. In such cases the operator had

better be satisfied with the removal of the major part of one lobe.

Closure of the Wound

The operation is now completed and the wound is ready for closure (Fig. 101). When the capsule has been separated from the sternothyroid muscle, it may be closed separately over the

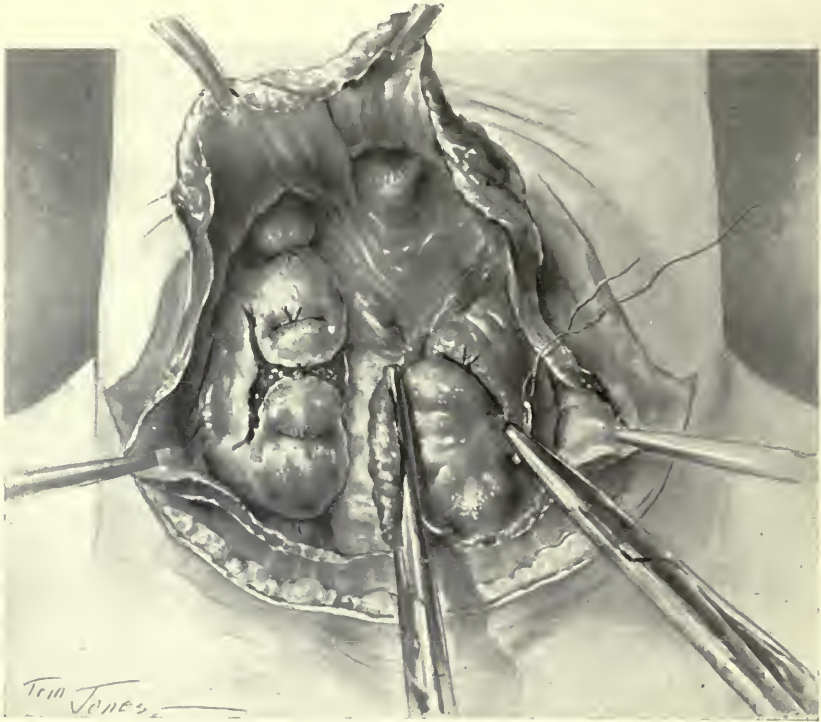


Fig. 99.—The folding of the poles completed; resection of the remaining lobe. The folding in of the lower pole is shown completed by the tying of the suture noted in the preceding figure. A wedge resection of the opposite lobe is begun by ligating en masse near the upper pole. The needle is being passed through the gland near the lower pole.

gland. Often it makes up the posterior sheath of these muscles. In this event the muscle is pulled over the cut surface of the gland and united in a longitudinal line (Fig. 102).

The ends of the sternohyoid muscles are then identified and brought into apposition. When the operation is done under local anesthesia, it is rarely that bleeding vessels are encountered in the muscle stumps. If such should be encountered they are caught with a clamp and when the muscle ends

are coapted a figure-of-eight suture is used. If there has been no bleeding, a simple running suture or staple suture may be used and is preferable because it causes less rolling up of the ends of the muscles (Fig. 103). Care should be exercised to bring the muscle ends in good coaptation. The lateral border of the sternohyoid muscles are then sutured to the medial bor-

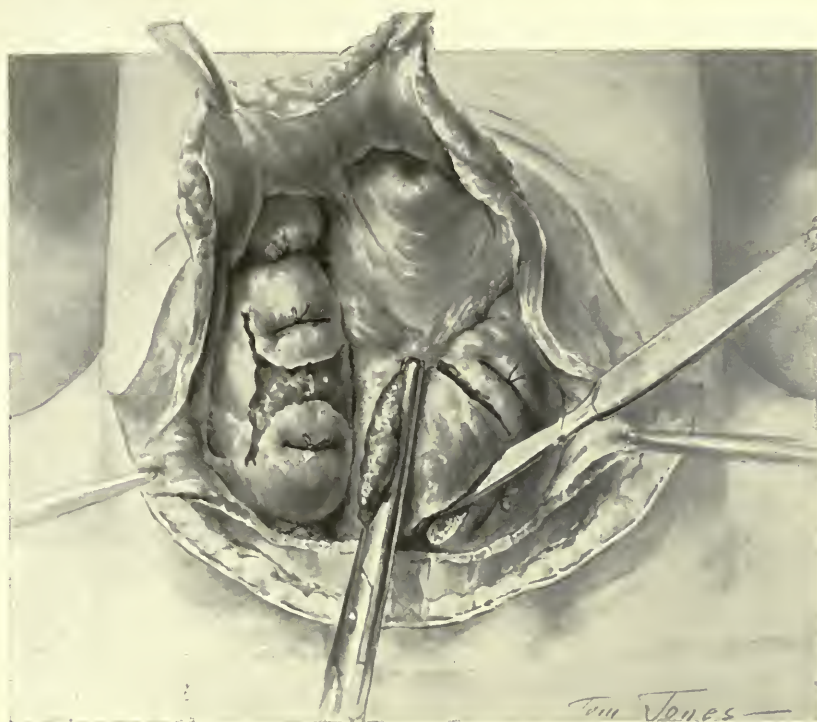


Fig. 100.—Wedge resection of the opposite lobe. The ligatures mentioned in the preceding figure have been tied and the wedge of tissue is being excised.

ders of the sternomastoid muscles in order to obliterate any dead spaces at this point.

The platysma is then united throughout its extent by a running suture (Fig. 104). A careful coaptation of this muscle does much to prevent attachment of this line of sutures to the deeper structures of the neck. If this is not done the platysma may become adherent to the deeper structures and the skin will make excursions with the trachea in deglutition. This annoys the patient and brings chagrin to the surgeon.

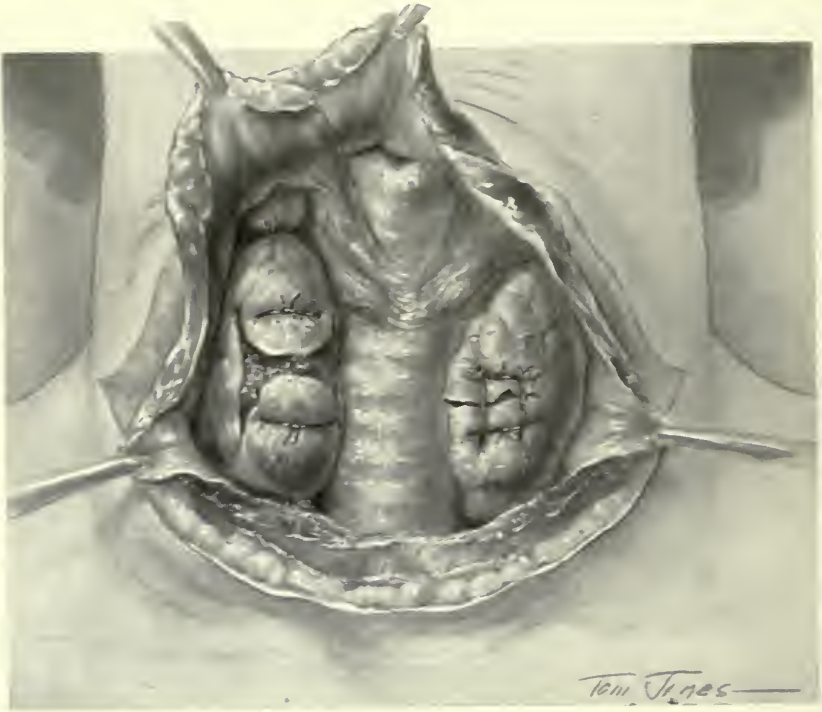


Fig. 101.—The resection completed. The wedge excision shown in the preceding figure has been completed and the cut surfaces coapted by sutures.

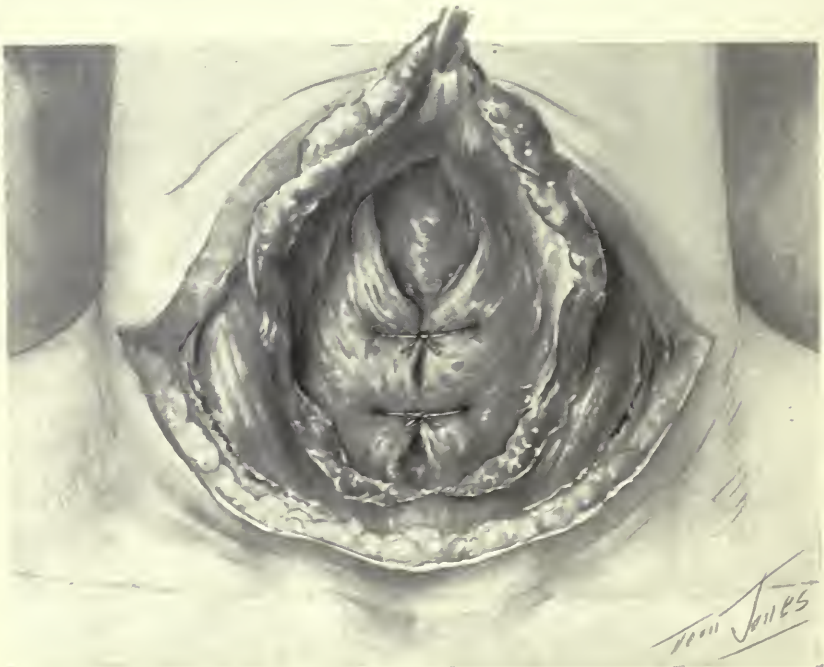

Fig. 102.—The closure of the capsule. The operation having been completed as in the preceding figure the false capsule is closed over the stumps of the lobes. If the fibrous capsule is identified it may be used. If not the borders of the sternothyroid muscles are brought together.

Usually after the platysma has been united, there remains the gapping subcutaneous fat. The extent of this is dependent on the adiposity of the patient. In thin subjects, particularly in old women, it may be neglected, but in plump ones, especially when a fine scar is desired, a subcutaneous layer of sutures should be passed (Fig. 105). This is done with a straight sharp needle.

If the subcutaneous sutures have been properly placed,

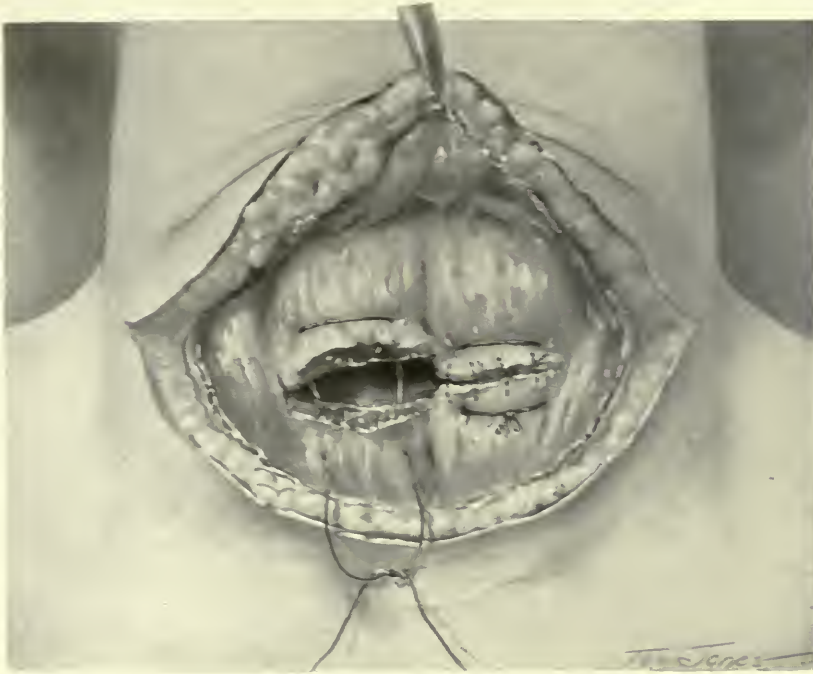

Fig. 103.—The restoration of the sternohyoid muscles. The cut ends of the muscles are identified and coapted either by a staple suture or by a figure-of-eight suture. If there is an eversion of the edges these may be united by secondary sutures.

little is needed to coapt the skin. The finest available suture is desired. Horse hair is perhaps the best material available. A staple suture is used in order that the epidermal layer may be brought into more accurate coaptation (Fig. 106).

Sutures Used

Pyocetanin No. 2 is used for ligation of the poles. Pyocetanin No. 0 for all other ligatures and sutures. Horse hair or "dermal suture" is used in the skin.

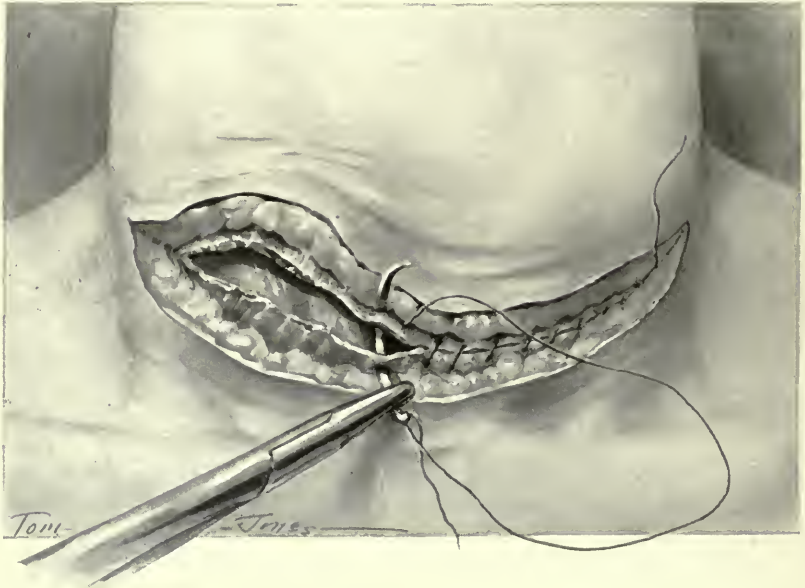


Fig. 104.—The coaptation of the platysma muscle. The cut edges of the platysma muscle are brought together with a running suture.

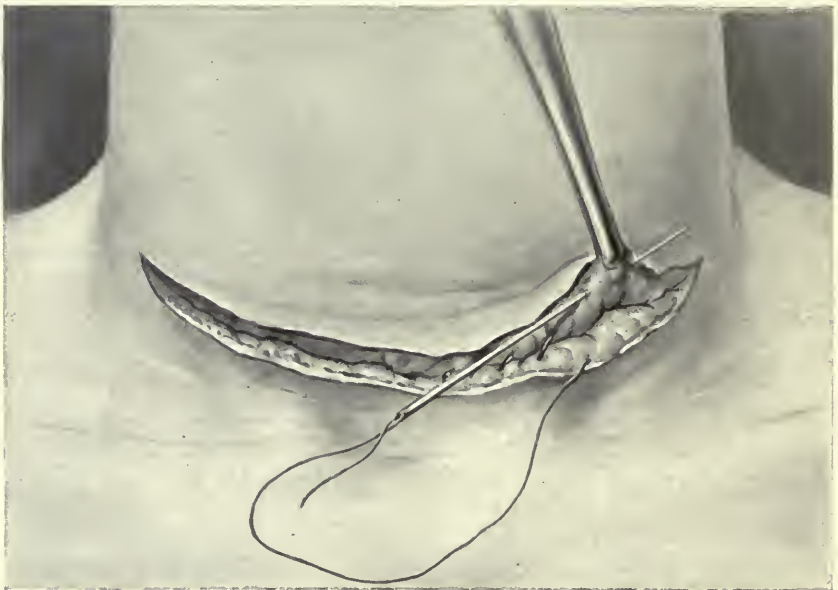

Fig. 105.—The coaptation of the subcutaneous fat. After the platysma muscle has been united a subcutaneous suture is placed in the fat so that the edges of the skin fall together. The suture likewise obliterates the dead space. This is important in fat patients.



Fig. 106.—The closure of the skin. After the edges have been brought together by the subcutaneous suture the edges of the skin are brought into exact apposition by staple sutures of horse hair.

Drainage

Drainage is not used except in special cases. If one elects to close without drainage the surgeon must be sure of his hemostasis. The beginner had better drain. In very fragile glands where the hemostasis is not satisfactory, a gauze drain is used, the end being passed down to the offending surface. This performs the double purpose of aiding coagulation, should hemorrhage occur, and it permits the blood to escape from the wound should there be considerable bleeding. In large intrathoracic goiters, where a cavity is unavoidably left, drainage is always placed. Here a rubber tube is preferable to gauze, for it is desirable that any hemorrhage that may occur be at once conducted to the surface. In the substernal lobes, the capsule can be drawn up and the cavity obliterated, thus obviating the need for drainage. In old women and men where scarring is of minor importance, drainage may be placed with less hesitation than in persons in whom a fine scar is desirable.

Pole Ligation

In patients too toxic to permit lobectomy, ligation of one or more vessels may be resorted to. In vascular goiters this seems sometimes beneficial. At any rate it assures rest in bed and it is a rehearsal for the patient for the main operation to come, and it gives the surgeon a means of judging the patient's reaction to operation. The reason so little is to be expected from superior pole ligation is that the superior thyroid artery supplies but a small part of the gland and the blood supply of the greater portion is not materially influenced.

Some operators have recommended the ligation of all four of the principal arteries. This is quite a serious undertaking, quite as serious as lobectomy. I fear to do this lest too great a part of the circulation be cut off thus not only endangering the remaining part of the thyroid gland, but the parathyroid bodies as well. I fear it because I have seen conditions years after operation which I did not understand and the possibility of too great a part of the gland being deprived of its blood supply seems a possibility.

The ligation of the superior poles is a relatively harmless

procedure and may be done in the hope that it may do some good. It should not be forgotten, however, that death has followed pole ligation and even in this simple operation the grounds should be carefully considered. Pronounced rise of temperature, extreme emaciation, and delirium are the symptoms that contraindicate it. Pole ligation is most apt to be of benefit in large, soft glands which show expansile pulsation; in such cases ligation sometimes produces brilliant results.

The technic is relatively simple. A line two inches long is anesthetized along one of the wrinkles of the skin nearest the superior pole. The platysma and the deeper muscles are then infiltrated. Next the tissue about the pole is abundantly infiltrated both to secure the anesthesia and anemia but also to facilitate dissection. The skin, subcutaneous fascia, and platysma are then incised throughout the length of the infiltrated line. The pole is then palpated, and the deeply lying muscles are split and retracted. The vessel can now usually be palpated. It is further freed until its pulsations can be seen. A silk thread is then passed around the vessels and tightly tied. If one elects the upper end of the pole may be ligated instead of the artery and veins. I do not ligate the inferior thyroid arteries. The results obtained do not warrant an operation of such magnitude, in my judgment.

INDEX

A

- Abdominal dropsies, 105
- Aberrant goiters, 88, 149
 - locations of thyroid arteries, 201
 - tumors of the submaxillary region, 151
- Accessory thyroid glands, 149
- Acidosis, postoperative, 169
- Acinal cells of exophthalmic goiter, 69
- Acini of thyroid gland, 34
- Adenoma, diffuse, 60
 - fetal, 59, 61
- Adenomatous goiter, 58, 59
 - diffuse, 64
 - glandular type, 65
 - papillary type, 66
- Adolescent colloid goiter, prognosis in, 126
 - goiter, diagnosis of, 112
 - treatment of, 176
- Adrenaline, in goiter operations, 208
 - test, 109
- Age in relation to goiter, 17
- Amenorrhea in toxic goiter cases, 20
- Anatomy, of thyroid gland, normal and pathological, 28
- Anemia in goiter, 105
- Anesthesia, intramuscular infiltration, 212
 - periglandular infiltration, 213
- Anesthetic, infiltration of, 209
 - in goiter operation, 206
- Anesthetization, in goiter operations, 208
- Appetite, 102
- Arteries of the thyroid gland, 196
- Artery to suspensory ligament, 196
- Asphyxiation in goiter operation under ether, 207
- Atypical forms of goiter, diagnosis of, 119

B

- Basal metabolism, in goiter, 110
- Basedow heart, 123
- Basedow's disease, 121
- Blood changes in goiter, 105
 - pressure in goiter cases, 97
 - supply of the thyroid gland, 194
 - vessels of the thyroid gland, 32
- Bone formation within colloid goiters, 56

- Brain hemorrhages in goiter, 79
- Bronchitis, postoperative, 172

C

- Calcareous areas in colloid goiters, 47
 - degeneration in colloid goiter, 55
- Carcinomatous degeneration in colloid goiter, 57
- Carotid tumors, 152
- Capsule, closure of, 232
 - false, 190
 - morphology of, 28
- Circulatory apparatus, pathology of, in goiter, 83
- Coagulation time, changes in, 108
- Collapse of the trachea, postoperative, 166
- Colloid goiter, 37, 42
 - bone formation within, 56
 - calcareous degeneration in, 47, 55
 - carcinomatous degeneration in, 57
 - cystic degeneration in, 51
 - degeneration with secondary hemorrhages in, 45
 - diagnosis of, 112
 - early operative treatment, 180
 - endemic, 44
 - fetal adenoma in, 61
 - fibrous degeneration in, 46
 - tissue degeneration in, 54
 - gross pathology, 45
 - histology of, 48
 - hyaline degeneration in, 57
 - in adult, prognosis in, 127
 - treatment of, 179
 - malignant degeneration, 58
 - myocardial changes in, 50
 - operative treatment, 179
 - prognosis in, 126
 - resting, 44
 - secondary changes, 51
 - substance in toxic goiter, 73
- Complications, postoperative, 166
- Compression of trachea by goiter, 134, 135
- Congenital goiters, 17
- Consistency of thyroid gland in goiter, 87
- Constipation in goiter, 103
 - management of, in toxic goiter, 160
- Cough, constant, as symptom of abnormally situated goiter, 143

Cystic degeneration in colloid goiters, 51

Cysts of the thyroid, 53

D

Degeneration, mass, with hemorrhage in colloid goiter, 48

secondary, prognosis in, 129

Degenerative toxic goiter, 71

Diagnosis of abnormal location of goiter, 138

of abnormally situated goiter, 143

of thyroid disease, 112

Diarrhea and vomiting in toxic goiter, 160

in goiter, 102

Diet in preoperative treatment of toxic goiter, 158

postoperative, 166

Diffuse adenoma, 60

adenomatous goiters, 63

Digestive disturbances, 102

tract, pathology of, in goiter, 83

Drainage, 236

Drugs in preoperative treatment of toxic goiter, 159

Dysphasia in goiter, 136

Dyspnea as symptom of abnormally situated goiter, 142

E

Endemic goiter, usually colloid type, 44

Endemiology, 21

Ether in goiter operation, 206

Etiology and pathogenesis of goiter, 17

Exophthalmia, in goiter, 89

Exophthalmic goiter, nervous trauma in etiology of, 24

papillary formation in, 67

Eye signs in pupillary type of adenomatous goiter, 66

Graefes' sign, 91

Möbius' sign, 93

symptoms, disturbance in convergence, 92

Gifford's sign, 93

imperfect movement of upper lid, 90

in goiter, 88

nystagmus, 93

pupil sign, 93

tear secretion, 93

F

False capsule, 190

Fetal adenoma, 59, 61

in colloid goiter, 61

adenomas, prognosis in, 128

Fibrous tissue degeneration in colloid goiter, 54

Forme fruste, diagnosis of, 120

differentiation from Graves' disease, 121

goiters, 76

interstitial treatment of, 183

ovarian hypoplasia associated with, 122

pelvic organs in relation to, 19

prognosis in, 130

rapid heart most constant symptom, 123

G

Genital disturbances in goiter cases, 19

lesions associated with secondary toxic goiter, 118

tract, pathology of, in goiter, 82

Gifford's sign, 93

Glandular degeneration, 71

proliferations, 63

type of adenomatous goiter, 65

Goetsch test, 108

Goiter, aberrant, 88, 149

abnormally situated, diagnosis of, 143

symptoms, 142

acidosis postoperative, 169

adenomatous, 59

adolescent, diagnosis of, 112

treatment of, 176

adrenaline test, 109

age in relation to, 17

amenorrhea in cases of, 20

anemia in, 105

appetite in, 102

atypical forms, diagnosis of, 119

basal metabolism in, 110

blood changes in, 105

pressure in, 97

brain hemorrhages in, 80

bronchitis postoperative, 172

care of wound, 164

changes in coagulation time, 108

circulatory apparatus, pathology in, 83

classification of pathology of, 41

collapse of trachea, postoperative, 166

colloid, 43 (*see* colloid goiter)

compression of trachea by, 135

consistency of, 87

constipation in, 103

degenerative toxic, 71

degree of thyroid enlargement, 85

diagnosis of, 112

abnormal location of, 138

diarrhea in, 102

diet in preoperative treatment of, 158

Goiter—Cont'd.

diet, postoperative, 166
 digestive disturbances, 102
 digestive tract, pathology in, 83
 drugs in preoperative treatment of, 159
 dysphasia in, 136
 epidemiology of, 21
 etiology and pathogenesis of, 17
 examination for, 86
 exophthalmia in, 89
 eye symptoms in, 88
 genital disturbances accompanying, 19
 genital tract, pathology in, 82
 glandular degeneration, 71
 Goetsch test, 108
 Graefe's sign, 91
 heart in, 95, 99, 116
 postoperative care of, 165
 hemorrhage postoperative, 167
 heredity as factor in, 20
 hoarseness postoperative, 168
 hyperacute forms of, diagnosis of, 119
 hypophysis pathology in, 82
 icterus in, 103
 in pigs, 22
 infectious theory of, 22
 intestinal hemorrhages, 104
 proliferative, 76
 iodine in prevention of, 22
 kidney pathology in, 83
 laryngitis, postoperative, 163
 leucocytosis in, 106
 lingual, 150
 liver pathology in, 83
 malignant degeneration, diagnosis of, 114
 management of constipation in preoperative treatment, 160
 mania in hyperacute forms, 119
 muscular fatigue as symptom of, 94
 system in, 83
 myxedema postoperative, 173
 nerve compression in, 136
 nervous shock in etiology of, 24
 system, pathology in, 79
 nervousness postoperative, 162
 neurogenic theories, 23
 nontoxic, preoperative treatment, 156
 nursing care, postoperative, 161
 operation, anesthetic, 206
 anesthetization, 208
 closure of wound, 230
 complications, 205
 dislocation of lower pole, 221
 of the lobe, 224
 disposal of pole stumps, 229
 drainage, 236
 ether in, 206

Goiter, operation—Cont'd.

excision of lobe, 224
 hemostasis in, 205
 incision of deep muscles of the neck, 215
 of the platysma, 214
 infiltration of anesthetic in, 209
 intramuscular infiltration, 212
 isolation of superior pole, 217
 jugular veins exposed, 216
 ligation of lateral veins, 222
 local anesthesia in, 207
 management of bleeding points, 227
 mortality after, 131
 novocaine in, 207
 periglandular infiltration, 213
 pole ligation, 236
 resection of gland, 226
 second lobe, management of, 229
 separation of lateral border and ligation of lateral vessels, 220
 skin closure, 235
 skin incision, 214
 sutures used, 233
 time of in toxic goiter, 160
 operations, adrenaline in, 208
 operative mortality, 131
 osseous system in, 84
 pain, postoperative, 162
 pancreas pathology in, 82
 parathyroid pathology of, 82
 pathology of other organs associated with, 79
 patients, hospital management of, 156
 instructions at dismissal, 174
 pituitary disturbances in, 20
 pneumonia postoperative, 172
 postoperative complications, 166
 treatment, 161
 previous and associated diseases, 23
 primary toxic, treatment of, 181
 prognosis of, 125
 rest in treatment of, 157
 scars following operation, 171
 secondary adenomatous, 74
 toxic, 71
 diagnosis of, 117
 genital lesions associated with, 118
 treatment of, 181
 toxicity, diagnosis of, 114
 sensitiveness of, 88
 sex in relation to, 18
 shock postoperative, 169
 size and rapidity of growth, 87
 skin changes in, 104
 substernal and intrathoracic, 138
 suprarenal gland pathology in, 82
 symptomatology of, 85

Goiter—Cont'd.

- tachycardia in, 96
 - temperature, postoperative control of, 162
 - tetany postoperative, 172
 - thymus pathology in, 80
 - thyrogenic theory, 25
 - time of operation, 160
 - toxemia, postoperative, 163
 - toxic (*see* also toxic goiter)
 - diagnosis of, 116
 - differentiation of, from tuberculo-
sis, 117
 - preoperative treatment of, 156
 - prognosis in, 128
 - tracheitis postoperative, 163
 - treatment of, 175
 - tremor in, 94
 - vomiting in, 102
 - and diarrhea in, 160
 - postoperative, 161
 - wandering, 140
 - x-ray examination, 86
 - unusual locations, 133
- Goose cough in abnormally situated goiter, 143
- Graefé's sign, 91
- Graves' disease, relation of forme fruste to, 121

H

- Laryngeal nerves, recurrent, 193
 - postoperative treatment, 165
 - rapid, as constant symptom of forme fruste, 123
 - sounds in goiter, 99
 - thyrotoxic, 100
- Hemorrhage into substernal goiter, 145
 - management of, in goiter operation, 227
 - postoperative, 167
- Hemorrhages, brain, in goiter, 80
 - in colloid goiters, 47
- Hemostasis in goiter operation, 205
- Heredity as factor in goiter, 20
- Histology of colloid goiter, 48
- Hoarseness, postoperative, 168
- Hospital management of goiter patients, 156
- Hyaline degeneration in colloid goiter, 57
- Hyperacute forms of goiter, diagnosis of, 119
- Hypertoxic patient, effect of ether on, 207
- Hypophysis, pathology of, in goiter, 82

I

- Ieterus, symptom of goiter, 103
- Infection following operation, 170

- Infectious theory of goiter, 22
- Inferior thyroid arteries, 198
- Infiltration of anesthetic, 209
- Instructions to goiter patients at dismissal, 174
- Interacinal cells in thyroid gland, 37
- Interstitial proliferative goiters, 76
- Intestinal hemorrhages, as symptom of goiter, 104
- Intramuscular infiltration, 212
- Intrathoracic goiter, 138
 - diagnosis of, 144
 - treatment, 147
 - struma, 152
 - diagnosis, 153
 - symptoms, 153
 - treatment, 155
- Iodine in prevention of goiter, 22

J

- Jugular veins, exposure of, in goiter operation, 216
 - ligation of, in goiter operation, 217

K

- Kidneys, pathology of, in goiter, 83
- Kindness in preoperative treatment of toxic goiter, 157

L

- Laryngeal nerves, recurrent, 193
 - superior, 193
- Laryngitis, postoperative, 163
- Leucocytosis in goiter, 106
- Levator glandulae thyroideae, 188
- Ligation of jugular veins, 217
 - of upper pole, 221
 - of vessels, typical sites of, 202
- Limestone associated with endemic goiter, 21
- Lingual goiter, 150
 - treatment, 151
 - goiters, diagnosis, 151
 - differentiation from dermoids, 151
 - symptoms, 150
- Liver, pathology of, in goiter, 83
- Lobe, dislocation of, in goiter operation, 224
 - excision of, in goiter operation, 224
- Local anesthesia in goiter operation, advantages of, 207
- Lower pole, dislocation of, 221
- Lungs, involvement of, in goiter, 115
- Lymph vessels of the thyroid gland, 34

M

- Malignancy in substernal goiter, 143
 - in intrathoracic goiter, 145
 - prognosis in, 131

Malignant degeneration, diagnosis of,
114
in colloid goiter, 58
Mechanical goiter heart, 100
Mediastinal tumor, 146
Medical treatment of adolescent goiters,
177
Menstrual disorders complicating ado-
lescent goiter, 179
disturbance in forme fruste, 183
Metabolic disturbances as aid in goiter
diagnosis, 116
Metastatic thyroid tumors, 147
Morphology of the thyroid gland, 28
Mortality after operation, 131
Muscular fatigue in goiter, 94
system in goiter, 83, 94
Muscles, anesthetization of, 211
of the neck, 188, 191
incision of, 215
Myocardial changes in colloid goiters,
50
Myxedema in colloid goiter, 55
postoperative, 173

N

Neck muscles, 188
Nerve compression in goiter, 136
supply of neck, 192
of skin and muscles, 190
of thyroid gland, 193
Nerves of the thyroid gland, 34
superior laryngeal, 193
sympathetic, 193
condition in forme fruste, 121
Nervous system, pathology of, in goiter,
79
Nervousness and restlessness, postop-
erative, in goiter, 162
Neurogenic theories, 23
Neuropathic tachycardia in diagnosis
of toxic goiter, 117
Nontoxic goiter, preoperative treat-
ment, 156
Novocaine in goiter operation, 207
Nystagmus, 93

O

Operation (*see* goiter operation)
Operations on the thyroid gland, tech-
nic of, 205
Operative treatment for adolescent goi-
ter, dependent on patient's
general health, 178
Organic disturbances in relation to goi-
ter, 115
Osseous system in goiter, 84
Ovarian hypoplasia associated with
forme fruste, 122

P

Pain, postoperative, in goiter, 162
Pancreas, pathology of, in goiter, 82
Papillary type of adenomatous goiter, 66
Paralysis of vocal cords, postoperative,
168
Parathyroids, pathology of, in goiter,
82
Pathogenesis of goiter, 17
Pathologic anatomy, 41
Pathology of goiter, classification of,
41
of other organs associated with goi-
ter, 79
Pituitary disturbances in goiter, 20
Platysma, incision of, 214
myoides in relation to thyroid gland,
186
Pneumonia, postoperative, 172
Pole ligation, 236
stumps, disposal of, 229
Polyglandular disease, 20
Postoperative complications, 166
toxemia, 163
treatment of goiter, 161
Preoperative treatment, 156
Primary toxic goiters, prognosis in, 128
Prognosis in disease of the thyroid, 125
Pupil sign, 93

R

Rest, part of preoperative treatment of
toxic goiter, 157
Resting colloid goiter, 44
Restlessness and nervousness, postop-
erative, in goiter, 162

S

Saber sheath trachea, 133
Sears following operation, 171
Secondary adenomatous goiter, 74
Basedow, 71
degeneration, prognosis in, 129
toxic goiter, 71
diagnosis of, 117
treatment of, 181
toxicity, diagnosis of, 114
Sensitiveness of goiter, 88
Sex in relation to goiter, 18
Shock in etiology of goiter, 24
postoperative, 169
Simple colloid goiters, diagnosis of, 113
Skin changes in goiter, 104
closure of, 235
covering thyroid gland, 185
incision, in goiter operation, 214
Sternohyoid muscles, restoration of, 233
Sternomastoid muscles, 188
Sternothyroid muscle, 188

Submaxillary region, aberrant tumors of, 151
 Substernal goiter, differentiation from Graves' disease, 140
 hemorrhage into, 145
 incidence, 140
 treatment, 147
 Superficial veins, 186
 Superior pole, isolation of, 217
 Suprarenal gland pathology in goiter, 82
 Suspensory ligament, artery to, 196
 Sutures used in goiter operation, 233
 Sympathetic nerves, 193
 Symptomatology of goiter, 85
 Symptoms of abnormally situated goiters, 142

T

Tachycardia and tremor in diagnosis of toxic goiter, 117
 in goiter, 96
 Tear secretion in goiter, 93
 Temperature, control of, postoperative, 162
 Tetany, postoperative, 172
 Thymus, pathology of, in goiter, 80
 tumors, 146
 Thyroglossal cysts, 152
 Thyrogenic theory in goiter, 25
 Thyroid arteries, inferior, 198
 and veins, inferior, ligation of, 223
 artery, superior, 31
 cysts of the, 53
 disease, diagnosis of, 112
 prognosis in, 125
 symptomatology of, 85
 diseases (*see also* goiter), 86
 gland, abnormal expansion of normally situated, 133
 accessory, 149
 acini, 34
 adenomas of, 59
 anatomy of, 28
 arteries of, 196
 superior, 196
 blood supply of, 194
 vessels of, 32
 capsule, 28
 consistency of, 87
 disease, degree of enlargement, 85
 false capsule in relation to, 190
 interacinal cells in, 37
 lymph vessels, 34
 morphology of, 28
 muscles of neck in relation to, 188
 nerve supply of, 193
 of skin and muscles, 190
 nerves of, 34

Thyroid gland—Cont'd.

 platysma myoides in relation to, 186
 relation of, to genital function, 18
 resection of, 226
 skin covering, 185
 superficial veins, 186
 symptomatology of disease of, 85
 technic of operations on, 205
 topographic anatomy of, 185
 topography of, 194
 treatment of diseases of, 175
 hypertrophy, disturbance of site of vessels by, 200
 nodules at base of tongue, 150
 veins, 202

Thyroidea ima artery, 198

 ima vein, 202

Thyrotoxic heart, 100

Topographic anatomy of thyroid gland, 185

Topography of lateral veins, 223

Toxemia, postoperative, treatment of, 163

Toxic goiter, 39

 classification of, 116
 diagnosis of, 116
 diet in preoperative treatment, 158
 drugs in, 159
 papillary formation in, 67
 preliminary examination, 156
 preoperative treatment, 156
 primary treatment of, 181
 prognosis in, 128
 rest in preoperative treatment, 157
 time of operation, 160
 vomiting and diarrhea in, 160

Toxicity of goiters, recessions in, 70

Trachea, collapse of, postoperative, 166
 compression of, by goiter, 134, 135
 displacement of, by goiter, 136
 disturbance as aid in diagnosis of abnormally situated goiter, 144

Tracheitis, postoperative, 163

Treatment of diseases of the thyroid, 175

Tremor as symptom of goiter, 94

Tuberculosis, differentiation of, from toxic goiter, 117

U

Urticarial lesions, 105

V

Vasularity of the thyroid gland, 32

Veins, thyroid, 202

Vessels, compression of, by goiter, 135
disturbance of site of, by thyroid
hypertrophy, 200
to isthmus, ligation of, 219
typical sites of ligation of, 202
Vision, field of, 93
Vocal cords, paralysis of, postoperative,
168
Voice, loss of, postoperative, 168
Vomiting in goiter, 102
and diarrhea in toxic goiter, 160
postoperative, in goiter cases, 161

W

Wandering goiter, 140
Water in relation to goiter, 21
Winking, lessening of involuntary, 91
Worry, influence of, in toxic goiter
cases, 157
Wound, care of, 164
closure of, 230

X


X-ray examination in goiter, 86



NY 100

CALIFORNIA LIBRARY
Los Angeles

200
#447d
922



3 1158 01208 3696

UC SOUTHERN REGIONAL LIBRARY FACILITY



A 000 400 709 2

