



This is a digital copy of a book that was preserved for generations on library shelves before it was carefully scanned by Google as part of a project to make the world's books discoverable online.

It has survived long enough for the copyright to expire and the book to enter the public domain. A public domain book is one that was never subject to copyright or whose legal copyright term has expired. Whether a book is in the public domain may vary country to country. Public domain books are our gateways to the past, representing a wealth of history, culture and knowledge that's often difficult to discover.

Marks, notations and other marginalia present in the original volume will appear in this file - a reminder of this book's long journey from the publisher to a library and finally to you.

### **Usage guidelines**

Google is proud to partner with libraries to digitize public domain materials and make them widely accessible. Public domain books belong to the public and we are merely their custodians. Nevertheless, this work is expensive, so in order to keep providing this resource, we have taken steps to prevent abuse by commercial parties, including placing technical restrictions on automated querying.

We also ask that you:

- + *Make non-commercial use of the files* We designed Google Book Search for use by individuals, and we request that you use these files for personal, non-commercial purposes.
- + *Refrain from automated querying* Do not send automated queries of any sort to Google's system: If you are conducting research on machine translation, optical character recognition or other areas where access to a large amount of text is helpful, please contact us. We encourage the use of public domain materials for these purposes and may be able to help.
- + *Maintain attribution* The Google "watermark" you see on each file is essential for informing people about this project and helping them find additional materials through Google Book Search. Please do not remove it.
- + *Keep it legal* Whatever your use, remember that you are responsible for ensuring that what you are doing is legal. Do not assume that just because we believe a book is in the public domain for users in the United States, that the work is also in the public domain for users in other countries. Whether a book is still in copyright varies from country to country, and we can't offer guidance on whether any specific use of any specific book is allowed. Please do not assume that a book's appearance in Google Book Search means it can be used in any manner anywhere in the world. Copyright infringement liability can be quite severe.

### **About Google Book Search**

Google's mission is to organize the world's information and to make it universally accessible and useful. Google Book Search helps readers discover the world's books while helping authors and publishers reach new audiences. You can search through the full text of this book on the web at <http://books.google.com/>

HC 19E3 D

BOSTON UNIVERSITY

School of Medicine.



LIBRARY.


No. ....

~~Stack~~ 162 No. 1,

Presented by

.....

.....





















DISEASES  
OF  
THE PANCREAS  
AND  
THEIR SURGICAL TREATMENT

A. W. MANDRILLON, F.R.C.S.

Senior Surgeon to the General Hospital, Manchester; Professor of Surgery, Manchester  
College of Physicians; Lecturer in Surgery, University of Manchester; Surgeon  
Royal Infirmary, St. Mary's Hospital, Manchester; Surgeon  
Royal Victoria Infirmary, Manchester; Lecturer

AND

R. G. A. MOYNE, F.R.C.S. (GL.), F.R.C.S.


Assistant Surgeon to the General Hospital, Manchester; Lecturer in Surgery,  
University of Manchester; Surgeon, St. Mary's Hospital, Manchester; Surgeon,  
Royal Victoria Infirmary, Manchester; Lecturer,  
Royal Infirmary, Manchester; Lecturer,  
Royal Victoria Infirmary, Manchester

ILLUSTRATED

THE PUBLISHERS  
WILLIAMS AND WILKINS & COMPANY

BOSTON

BOSTON MEDICAL LIBRARY  
WITH  
FRANCIS A. CUNTYWAY  
LIBRARIAN



DISEASES  
OF  
THE PANCREAS  
AND  
THEIR SURGICAL TREATMENT

BY

A. W. MAYO ROBSON, F.R.C.S.

Senior Surgeon, Leeds General Infirmary; Emeritus Professor of Surgery, Yorkshire College, Victoria University; Member of Council and Hunterian Professor Royal College of Surgeons of England; Honorary President, Surgical Section, International Medical Congress 1900

AND

B. G. A. MOYNIHAN, M.S. (LOND.), F.R.C.S.

Assistant Surgeon, Leeds General Infirmary; Consulting Surgeon to the Skipton Hospital and to the Mirfield Memorial Hospital; Arris and Gale Lecturer, and Member of the Board of Examiners in Anatomy for the Fellowship, Royal College of Surgeons of England

16.L.1.

ILLUSTRATED

PHILADELPHIA AND LONDON  
W. B. SAUNDERS & COMPANY

1903

BOSTON MEDICAL LIBRARY  
IN THE  
FRANCIS A. COUNTRYMAN  
LIBRARY OF MEDICINE

Copyright, 1902, by W. B. Saunders & Company

Entered at Stationers' Hall, London, England

TO  
THE SURGEONS OF AMERICA  
IN CORDIAL RECOGNITION OF  
THEIR WORK





## PREFACE.

---

It is only within recent years that any material progress in regard to our knowledge of the functions and diseases of the pancreas has been made. The admirable works of Körte and Oser, the fruitful researches of Opie and others into the functions and significance of the islands of Langerhans, the observations lately made as to the causation and treatment of acute and chronic pancreatitis,—have all attracted much attention from the profession, and have excited a keener interest in the pathology and treatment of the diseases of this gland.

The publication of a work dealing with the surgical aspects of pancreatic disease may therefore be held to have a twofold object: to record and to review the work done in the past, and to indicate, so far as is possible, the scope and trend of future research. This has been our intention, and these have been our aims in the present work; and though we recognize fully its incompleteness, we venture to think that this is, in no small measure, inevitable in the present state of our knowledge.

We desire to express our thanks for permission to reproduce the following illustrations: For figures 4 and 5, to Professor Leith, of Birmingham; for figures 6, 7, 8, 9, and 10, to Dr. Eugene Opie; for figures 15, 22, 23,

24, and 25, to the Royal College of Surgeons of England; for figure 16, to the Clinical Society of London.

Figure 3 has been drawn for us by Mr. W. C. Mayo; the remainder of the drawings are by Dr. McGregor Young, to both of whom we are indebted for their careful work.

A. W. M. R.

B. G. A. M.

*October, 1902.*

# CONTENTS.

---

## CHAPTER I.

ANATOMY OF THE PANCREAS, ETC. . . . .	17
Abnormalities, 22—Development of the Pancreas, 23—Structure of the Pancreas, 24—Movable Pancreas, 26—Methods of Obtaining Access to the Pancreas for the Purposes of Operation, 27.	

## CHAPTER II.

EXPERIMENTAL WORK ON THE PANCREAS . . . . .	29
Pancreatic Diabetes in Man, 34.	

## CHAPTER III.

INJURIES OF THE PANCREAS . . . . .	45
Prolapse of the Pancreas, 56	

## CHAPTER IV.

PANCREATITIS . . . . .	58
------------------------	----

## CHAPTER V.

ACUTE PANCREATITIS . . . . .	81
------------------------------	----

## CHAPTER VI.

SUBACUTE PANCREATITIS . . . . .	134
---------------------------------	-----

## CHAPTER VII.

CHRONIC PANCREATITIS . . . . .	147
--------------------------------	-----

## CHAPTER VIII.

PANCREATIC CALCULUS . . . . .	178
-------------------------------	-----

## CHAPTER IX.

PANCREATIC CYSTS . . . . .	188
Retention Cysts, 189—Proliferation Cysts, 197—Hydatid Cysts, 204—Congenital Cystic Disease, 207—Hæmorrhagic Cysts, 208—Pseudo-Cysts, 210.	

CHAPTER X.		PAGE
NEW GROWTHS OF THE PANCREAS . . . . .		260
Carcinoma, 269—Sarcoma, 274—Adenoma, 276—Tubercular Disease of the Pancreas, 277—Syphilis, 278—Treatment of Solid Tumours of the Pancreas, 280.		

---

INDEX . . . . .	289
-----------------	-----

## CHAPTER I.

### ANATOMY OF THE PANCREAS.

*Movable Pancreas—Method of Obtaining Access to the Pancreas.*

THE pancreas is an elongated gland (from 15 to 20 cm. in length and  $2\frac{1}{4}$  to  $2\frac{1}{2}$  ounces in weight) lying behind the stomach at the level of the first and second lumbar vertebræ. For the purposes of description it is divided into head, neck, body, and tail.

The **head** is a rounded disc-shaped mass lying in the concavity formed by the second and third portions of the duodenum, whose walls it partially embraces. In a well-developed gland one-third of the circumference of the duodenum may be in intimate contact with the pancreas. The lower portion of the anterior surface is crossed by the transverse mesocolon. A vascular loop is formed by the superior and inferior pancreaticoduodenal vessels on the anterior surface near the line of contact with the duodenum. To the left lie the superior mesenteric vessels; the part of the gland upon which they run may be separated from the rest, and is then known as the **lesser pancreas**. The posterior relations of the head are the inferior vena cava, the left renal vein, and the aorta. The common bile duct passes down in a groove, sometimes in a canal, on the posterior surface.

The **neck** is thick and stunted and is rarely more than one inch in length. It springs from the anterior surface of the body at the upper part and arches forwards, slightly upwards and to the left to join the body. Its posterior surface forms a sulcus in which lies the commencement of the portal vein, as it is formed by the fusion of the superior mesenteric and splenic vein.

The **body** passes to the left and slightly upwards and

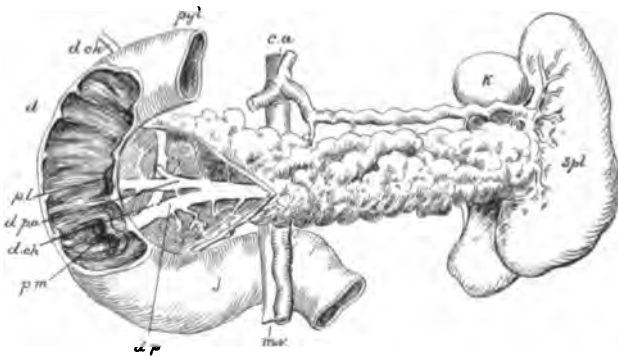


FIG. 1.—Pancreas dissected to show (*d. p.*) pancreatic duct; *d. p. a.*, accessory duct; *d. ch.*, bile duct. Duodenum laid open to show (*p. m.*) papilla major; *p. l.*, papilla minor; *spl.*, spleen; *k.*, kidney; *j.*, jejunum; *m. v.*, mesenteric vessels; *c. a.*, coeliac axis.

ends in the splenic portion or tail. The body and tail together are about 10 to 12 cm. in length. Three surfaces—anterior, posterior, and inferior—are defined. The anterior is covered closely and intimately by the posterior layer of the peritoneum of the lesser sac, which can only with great difficulty be stripped from it. In front lies the stomach. The posterior surface rests upon the aorta, the pillars of the dia-

phragm, the splenic vein, the left kidney and its vessels, and the suprarenal capsule. The inferior surface rests upon the duodeno-jejunal flexure, and at its extremity upon the transverse colon just before the splenic flexure.

**Ducts.**—The pancreas possesses normally two ducts, which open separately into the duodenum. The main

duct—the canal of Wirsung—begins in the tail and, passing from left to right, increases gradually in size as it receives its tributaries. At the neck of the gland the duct alters its course, turning downwards and slightly backwards. Just before reaching the duodenum it unites with the common bile duct to form the ampulla or diverticulum of Vater. The ampulla of Vater narrows to an opening, which is

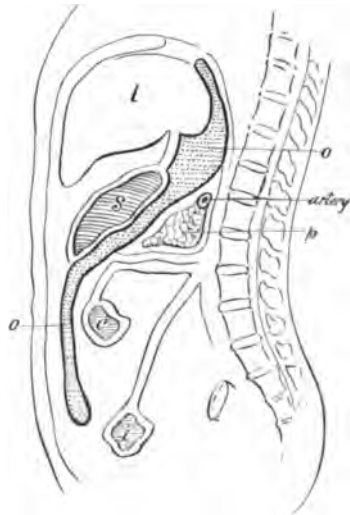


FIG. 2. — Diagrammatic section through the pancreas, etc., to the left of the duodeno-jejunal flexure: *p*, Pancreas; *o*, omentum.

placed on a longitudinal fold of mucous membrane,—the “*plica longitudinalis*,”—and is rather nearer the posterior than the anterior wall of the gut. At the point where the canal of Wirsung changes its direction a second smaller duct—the duct of Santorini—is continued forwards, maintaining the horizontal direction of the canal in the body of the gland, and opens into the



duodenum about an inch above and slightly ventral to the opening of the ampulla of Vater. A small papilla, felt as a shot-like thickening,—the *caruncula minor* of Santorini,—bears the orifice. The duct of Santorini—the accessory duct, as it is sometimes called

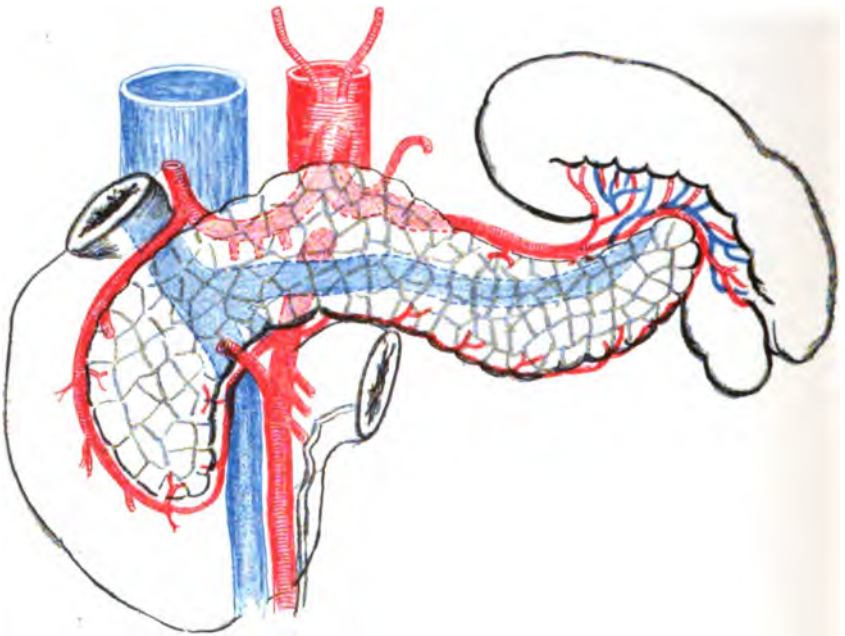


FIG. 3.—Arteries and veins of the pancreas.

—communicates with the canal of Wirsung in the great majority of cases, by a wide opening.

The wall of the main duct is thin, smooth, and white; the widest diameter, just before fusion with the common bile duct, is about three millimetres.

**Vessels.**—The arterial supply of the pancreas is derived from—

(a) The splenic, which sends a large number of small branches as it lies above the gland.

(b) The hepatic, which not infrequently sends a large branch downwards to the dorsal surface. From this small offshoots are given also to the head of the gland, and an anastomosis is established with the middle colic artery.

(c) From the superior (or anterior) pancreatico-duodenal a branch of the gastro-duodenal from the hepatic, which forms a vascular arch with—

(d) The inferior (or posterior) pancreatico-duodenal from the superior mesenteric. Rarely this vessel arises from the middle colic from which in some few instances a branch may be sent to the head of the gland. It runs upwards and to the right across the back of the head of the pancreas, and sends branches to it and to the duodenum.

(e) The inferior pancreatic branch of the superior mesenteric is a large branch running along the lower border of the gland, often as far as the tail.

The veins are (1) an *anterior* (or inferior) *pancreatico-duodenal*, which passes down and to the left on the front of the head, and joins the superior mesenteric; (2) a *posterior pancreatico-duodenal*, which crosses the back of the head and opens into the portal; (3) several small pancreatic veins, which join the splenic.

The lymphatic vessels terminate in glands lying on the head of the pancreas, along the superior mesenteric artery and in the hilum of the spleen. A complete intricate network is formed in and around the gland substance.

**ABNORMALITIES.**

That portion of the gland lying behind the superior mesenteric vessels may be isolated, forming the lesser pancreas. The superior mesenteric vessels may be embraced by the gland, lying in a canal in its substance.

The gland may completely encircle the second part of the duodenum. Ecker, Symington, Genersich ("Tenth Intern. Med. Congr."), and Tieken ("American Medicine," Nov., 1901) record cases of annular pancreas causing constriction of the duodenum with dilatation of the stomach and the portion of the duodenum above the point of narrowing.

The tail of the organ may be separated from the body, or may be bifid.

In one case (Hyrtl) the head of the gland was separated from the body.

**Accessory Pancreas.**—Pancreatic tissue in larger or smaller isolated masses, forming an accessory gland, is found chiefly in four positions—in the wall of the stomach, of the duodenum, of the jejunum, and of the ileum.

Klob found an accessory gland in the stomach near the greater curvature; Wagner, in the anterior wall of the stomach just below the lesser curvature. Gegenbaur described an accessory pancreas 14 mm. by 6 mm. on the lesser curvature about one inch from the pylorus. Weichselbaum described an accessory pancreas on the right side of the duodenum, isolated completely from the main gland.

Similar masses have been observed in the jejunum by Klob and Zenker, and in the ileum by Zenker and Nauwerck. According to all observers, Klob alone excepted, a duct can be found opening into the adjacent portion of the alimentary canal.

**Abnormalities of the Ducts.**—The accessory duct may be absent.

There may be three openings on the plica longitudinalis—two from ducts of the pancreas, one from the common bile duct.

There may be four openings into the duodenum—one from the common bile duct, one from the accessory duct, one from the main duct, and one, lowest of all, from an abnormal duct lying in the head of the pancreas (Oser).

There may be only one duct, running transversely through the gland, and opening into the duodenum at the caruncula minor. The terminal portion of the duct then represents the accessory duct. The common bile duct in such a case opens alone at the usual point.

The canal of Wirsung may open into the termination of the common bile duct.

#### DEVELOPMENT OF THE PANCREAS.

The following account is given by Schäfer in Quain's "Anatomy," vol. III, part IV, page 142:

"From the observations of Zimmermann and Hamburger it appears that in the human subject the pancreas is formed from two distinct outgrowths from

the wall of the duodenum. One of these, the smaller, is in close relation with the duodenal end of the common bile duct; the other, which is situated near the pylorus, is much larger and forms the greater part of the pancreas. About the sixth week of embryonic life the two processes join, and their contained ducts subsequently communicate with one another. The portion of the upper duct on the duodenal side of the point of union grows less rapidly than the lower duct. It becomes the duct of Santorini, while the lower duct, with the peripheral portion of the upper one, forms the main channel for the pancreatic secretion, and is generally known in the adult as the main pancreatic duct or canal of Wirsung."

#### THE STRUCTURE OF THE PANCREAS.

The pancreas is an acino-tubular gland. Its ducts are lined by columnar epithelium, the cells being longer in the larger ducts, shorter and in proportion thicker in the smaller ducts. The intercalary ducts, those connected with the alveoli, are lined with flattened cells. The secreting cells are characteristic in appearance. "They frequently, if not constantly, contain, besides the ordinary nucleus, a *paranucleus* (Neben-kern), a spherical mass staining more readily than the rest of the protoplasm and said to be formed by extrusion of material from the nucleus (Gaule, Nicolaides). In shape they are columnar, in some parts approaching the polygonal form, and they show very distinctly, even in the loaded condition of the gland,

two parts or zones—an inner granular zone next the lumen, and an outer clean and finely striated zone next the basement membrane” (Schäfer).

P. Langerhans (“Beitr. zur mikros. Anatomie der Bauchspeicheldrüse,” Inaug. Diss., Berlin, 1869) described certain masses or groups of cells lying in the interalveolar tissue, and differing markedly from the ordinary secretory cells of the pancreas. These groups, rounded in form, are made up of small, irregularly polygonal cells with a round nucleus and homogeneous refractive cell body. These structures are now known as the “**islands of Langerhans.**” It is possible that these cell-islets have an independent origin, as suggested by Schulze (“Arch. f. mikros. Anat.,” Bd. LVI, S. 491-509). In Merkel and Bonnet’s “Ergebnisse der anat. Entwickl.” (Bd. IX, 1900, S. 150) the following is the concluding summary as to the origin of the islands: “In vertebrates two distinct types of pancreas are found, both arising from the intestinal epithelium. Of these, one, the primitive pancreas, is found as an independent organ in the cyclostomata. In selachians, and probably also in reptiles, the primitive pancreas is represented by the intertubular cell-islets which still maintain a connection with the duct system of the pancreas proper. In the higher vertebrates this connection is lost and the pancreas proper becomes ultimately predominant, while the primitive pancreas remains as the so-called Langerhans cell-islets.”

**Pancreatic juice** obtained from a pancreatic fistula in man is a clear, slightly viscid liquid, alkaline in reaction, having a specific gravity of approximately

1030. For experimental work the pancreatic secretion from the dog, obtained by Pawlow's method, is usually employed. After a few days the secretion is found to become more limpid, to contain fewer salts, and to be less active.

The ferments contained in the pancreatic juice are—

I. A proteolytic, proteid-digesting ferment, *trypsin*.

II. An amylolytic, starch-converting ferment, *amyllopsin*.

III. A lipolytic, fat-splitting ferment, *steapsin*.

IV. A milk-curdling ferment.

The juice contains almost 10 per cent. of solid matter, chiefly proteids.

#### MOVABLE PANCREAS.

A degree of mobility in the tail of the pancreas is not unusual. The whole organ may, however, be displaced. A falling forwards of the gland was described by Hertz in 1844. When the spleen is unduly movable the tail of the pancreas may be dragged with that organ in its wanderings.

The displacement of the pancreas may occur into a diaphragmatic hernia, either congenital or acquired. In 276 cases of diaphragmatic hernia collected by Lacher the pancreas formed a hernial content in 27. Claessen records a case of rupture of the diaphragm with prolapse of the pancreas through the rent.

Rarely the pancreas may be found in congenital umbilical herniæ, and in one case, recorded by Rose,

the gland has been found in the umbilical hernia of a woman of sixty-four.

#### METHODS OF OBTAINING ACCESS TO THE PANCREAS FOR THE PURPOSES OF OPERATION.

The pancreas may be approached from the front or from behind.

**From the Front.**—After opening the abdomen by an incision in or near the middle line above the umbilicus there are three routes to the pancreas.

(a) *Above the Stomach.*—It is not infrequent in case of gastropotosis to find that the pancreas can be seen above the lesser curvature of the stomach. (See "Diseases of the Stomach and Their Surgical Treatment," page 240.) In such cases the pancreas can be reached by tearing through the gastro-hepatic omentum. This route was used by Sendler and Franke.

(b) *Below the Stomach.*—The gastro-colic omentum may be divided immediately below the greater curvature of the stomach between the vessels given off from the left and right gastro-epiploic arteries. A small rent may be enlarged so as to expose the whole of the pancreas lying on the posterior abdominal wall covered by the posterior layer of the lesser sac. This is the route generally employed.

(c) *Through the Transverse Mesocolon.*—The omentum is turned upwards and the transverse mesocolon at a place bare of vessels is torn through and the lesser sac opened. Care has to be taken to avoid the middle and left colic arteries or their branches. This route is advised by Krönlein.



**From Behind.**—The pancreas may be exposed from behind by an incision beginning at the tip of the twelfth rib and passing obliquely forwards towards the umbilicus. A hydatid cyst of the gland has been evacuated in this way by Peters.

## CHAPTER II.

### EXPERIMENTAL WORK ON THE PANCREAS.

IN the earlier operative work on the pancreas it was the experience of every observer that a complete extirpation of the organ was followed speedily by the death of the animal either from shock, hæmorrhage, injury to the duodenum, or peritonitis. The first investigator to demonstrate the possibility of successful removal of the pancreas was Martinotti, in 1888. In a report to the Academy of Medicine of Turin in that year he related his experiences of operations upon 16 animals,—6 dogs and 10 cats,—and formulated the following as his conclusions:

1. Partial extirpation of the pancreas is an operation which is well borne by dogs.

2. Contrary to the assertion of a large number of physiologists and surgeons, it is possible to extirpate the whole of the pancreas of dogs without, of course, those small portions of the gland which are devoid of physiological significance.

3. After total extirpation of the pancreas the dogs have no digestive disturbances, and they are able, therefore, to increase in weight and in size.

4. The causes of failure of earlier experimenters can be avoided with care: They are chiefly peritonitis, avoided by adopting scrupulous antisepsis; hæmorrhage, avoided by careful ligature and clamp-

## 30 Experimental Work on the Pancreas

ing of all vessels; and gangrene of the duodenum, avoided by carefully preserving intact the vascular loop of supply.

5. After an operation rigorously carried out the death of the animals results often from adhesion and twisting of the intestinal loops in the operation area.

In 1889 appeared the memorable work of von Mering and Minkowski. The observations of these investigators established the physiology and the surgery of the pancreas upon a new basis, and was so complete as to leave little for their successors to do.

**Total Extirpation of the Pancreas.**—In 1889 von Mering and Minkowski discovered that extirpation of the pancreas in dogs produced, in addition to certain profound digestive disturbances, all the symptoms of diabetes, glycosuria, polyuria, polyphagia, and gradual wasting unto death. They found also that diabetes never occurred as a permanent disease unless the whole gland was removed. If any portion, even the tip, were left, diabetes did not occur. They suggested thereupon that diabetes was the result of the absence, not of the pancreatic juice, but of some secretion, analogous to those known as “internal” in the thyroid and other glands.

**Partial Extirpation of the Pancreas.**—Glycosuria fails absolutely when any portion of the gland—head, body, or tail—is left, and appears at once if the remnant be subsequently removed. Hédon confirms this opinion of von Mering and Minkowski. He has removed portions of the gland at three successive operations at long intervals. If a very small portion

## Subcutaneous Transplantation of Pancreas 31

only of the gland remains, a gradually increasing glycosuria develops, the sugar increasing concomitantly with the atrophy of the fragment (Minkowski, Sandmeyer, Hédon).

**Ligature of the duct of the pancreas** gives rise to a chronic interstitial inflammation in the gland. The duct does not dilate behind the ligature and become the wall of a cyst. The islands of Langerhans are unaffected by the ligature (Ssobolew).

**Destruction of the gland *in situ*** after the method of Claude Bernard, by injection of sterile oil or fat into the duct, does not produce glycosuria, or, at the most, a transient and very trivial attack. The animals, however, suffer from polyuria, polyphagia, phosphaturia. The absence of glycosuria after destruction of the gland *in situ* is paradoxical, and may possibly be explained by one of two alternative theories: (a) The whole pancreas is not destroyed. (b) As the atrophy takes some months to be complete, some other organ or organs take on as a vicarious function the work of the pancreas. The latter hypothesis receives the support of Hédon.

**Subcutaneous Transplantation of the Pancreas.**—The descending portion of the pancreas is rendered mobile, its blood-vessels being left intact, and is grafted into the subcutaneous cellular tissue of the abdominal wall. The secretion is passed through a fistula. If after a time the vasculo-nervous pedicle be divided, the graft thrives and continues to secrete for a time, but generally atrophies. If the graft remains active the intra-abdominal portion of the gland can be re-

## 32 Experimental Work on the Pancreas

moved without invoking diabetes; but if, after removal of the intra-abdominal portion, and after an interval of a few days, the graft be removed, glycosuria immediately develops (Minkowski, Hédon, Thiroloix). Hédon and Thiroloix have shown that if the intra-abdominal portion be removed, and the graft severed from all nerve connections, and left subcutaneous, diabetes does not appear at once, proving that the nervous mechanism of the gland has no influence upon the production of diabetes. Minkowski has ligatured the efferent veins of the graft to ensure that all the returning blood has passed into the general circulation. Diabetes did not then develop, showing that the special function of the gland, the destruction of which entails diabetes, does not necessitate the transmission of the efferent blood into the portal circulation.

Extirpation of the pancreas produces diabetes in the dog, cat, and pig (Minkowski). Bull has recorded a fatal case of diabetes in man after depancreatisation. After extirpation, sugar is found in the urine in all cases, generally within a few hours. The glycosuria increases progressively and attains its maximum in three or four days. It is found in animals fed up and in animals starved. The animals have a voracious appetite and devour all food within their reach; thirst is unquenchable. Such enormous ingestion does not prevent a very rapid loss in weight, and the animal is speedily reduced almost to a skeleton. During the few hours that precede death glycosuria may disappear (Hédon). The extreme wasting is

## Subcutaneous Transplantation of Pancreas 33

largely due to the glycosuria, for if the secretion of the gland be diverted and intestinal digestion prevented, then wasting, though marked, is much less profound than after extirpation. Acetone, according to Azémar, is present in the urine with sugar, and its amount is directly proportioned to the amount of sugar.

The length of life after extirpation depends entirely upon the intensity of the diabetes. If every particle of the gland has been removed the animal dies in twenty to thirty days. If a small fragment gradually undergoing atrophy has been left, then the life may be prolonged a few weeks.

At a post-mortem examination extreme wasting is found and fatty degeneration of the liver. The animals that have survived long enough show a dilatation of the stomach and intestines, with hypertrophy of the mucosa (and according to Martinotti and Boccardi, abnormal development of the glands of Lieberkühn). The kidneys are hypertrophied and also the bladder. In dogs completely depancreatized and diabetic, glycogen disappears rapidly from the liver and from the muscles.

Certain experimenters—Dominicis, Martinotti, and later the brothers Cavazzani—have stated that diabetes does not necessarily follow after complete extirpation of the pancreas. Whether the two former observers performed a total ablation of the organ is open to doubt. The Cavazzanis, however, knowing the results of the experiments of von Mering and Minkowski, and of their statement that a leaving behind

## 34 Experimental Work on the Pancreas

of even a small fragment of the pancreas is sufficient to prevent diabetes, performed "extirpation with the greatest care, without leaving any trace of the pancreas." Of fourteen dogs so treated only three became diabetic. These observers believe that the onset of diabetes is to be attributed solely to an increased production of glucose. They admit that the liver alone is the seat of the formation of glucose, and they infer, therefore, that diabetes produced by extirpation of the pancreas is caused by a profound influence on the nervous system—on the coeliac plexus—that is, which is injured by the operation.

### PANCREATIC DIABETES IN MAN.

For a century before the experimental investigations of von Mering and Minkowski clinical observers had recognized the association between diabetes and pancreatic disease. In the year 1788 Cawley, in the "London Medical Journal," recorded the existence of calculi in the duct of an atrophied pancreas in a case of diabetes. In 1833 Bright described the pancreas in a patient who had died from diabetes as hard, cartilaginous, and adherent to surrounding organs; and in 1821 Chopart and many subsequent observers—Frerichs (1862), von Recklinghausen (1864), Klebs, and others—discovered atrophy, fatty degeneration, and sclerosis of the pancreas in diabetes. In 1877 Lancereaux emphasized the connection between diabetes and diseases of the pancreas. Lancereaux and his pupil Lapiere showed that in a certain type of

case, "diabète maigre,"—diabetes with wasting,—characterised by brusqueness of onset, the gravity of the symptoms, and the rapid progress of the disease, an atrophy or other profound alteration in the pancreas could be found. In his work "Traité des maladies du foie et du pancreas" Lancereaux describes the following conditions as having been found in cases of "diabète maigre":

1. Aplasia of the pancreas—that is, a simple diminution in the gland elements, without alteration in their character.

2. Atrophy, with sclerosis and fatty changes in the gland.

3. Atrophy consecutive to inflammation and obliteration of the ducts.

4. Tumours of the gland, notably cancer of the head obstructing the ducts, and producing changes in the whole secreting tissue of the organ.

Hansemann has collected and criticised many of the recorded cases and concludes:

Firstly, that there are, indubitably, cases of diabetes without any change in the pancreas.

Secondly, that there are examples of profound alteration in the pancreas without diabetes. All are explicable by assuming an incomplete destruction of the gland. In cases of acute necrosis of the pancreas speedily terminating fatally no trace of sugar may ever be discovered in the urine. So in the dog if, after complete extirpation of the pancreas, an acute affection such as gangrene of the duodenum, or peritonitis, appears, no glycosuria is observed. In diffuse car-



### 36 Experimental Work on the Pancreas

cinoma of the pancreas glycosuria is absent, due, as Hansemann believes, to the possibility of internal secretion from the cells of the growth. The post-mortem records quoted by Hansemann from the Berlin hospitals show in the space of ten years: 8 cases of diabetes without disease of the pancreas; 6 cases of diabetes without any note of the condition of the pancreas; 40 cases of diabetes with disease of the pancreas; 19 cases of disease of the pancreas without diabetes.

The 40 examples just mentioned include 36 cases of simple atrophy, 3 of sclerosis and atrophy, and 1 of complex change.

Among 72 cases of diabetes associated with pancreatic disease recorded in the literature in which the lesion of the pancreas was mentioned were 14 cases of lithiasis, 5 cases of carcinoma with blockage of the ducts, 38 cases of simple atrophy with interstitial inflammation, and 15 of various other changes. Dieckhoff, in an analysis of 53 cases, found recorded:

Acute pancreatitis	in	10	per	cent.
Chronic	"	"	36	"
Carcinoma	"	7	"	"
Atrophy	"	40	"	"
Cysts	"	7	"	"

R. T. Williamson gives the following table to show the condition of the pancreas in 23 consecutive cases of diabetes:

1. Extensive changes:	CASES.
Very marked cirrhosis .....	2
Cancer .....	1

2. Fairly well-marked changes:	CASES.
Cirrhosis .....	2
Lipomatosis .....	1
Atrophy, fatty degeneration and inflammation ..	1
Very advanced atrophy.....	1
3. Slight Changes:	
Atrophy with slight fatty degeneration .....	1
Atrophy (without any other changes) out of proportion to the general wasting .....	2
4. Atrophy, but only in proportion to general wast- ing; no other changes .....	4
5. Pancreas normal macroscopically and microscop- ically.....	8

In 12 out of 23 cases, therefore, the pancreas was either normal or only atrophied in proportion to the general wasting.

The relations of the pancreas to diabetes may be thus briefly stated:

1. Extirpation of the whole pancreas produces diabetes. Extirpation of almost the whole pancreas, the fragment left undergoing atrophy, gradually induces diabetes. Extirpation of a part of the pancreas does not produce diabetes.

2. Diabetes in a large number of cases is associated with, or accompanied by, diseases of the pancreas, the most frequent of which is a chronic interstitial inflammation and sclerosis. There are, however, cases of diabetes in which there is no demonstrable affection of the pancreas and cases of chronic interstitial inflammation without diabetes.

Certain observers have attempted to discover a definite type of pancreatic disease associated with diabetes. Hoppe-Seyler and Fleiner (quoted by Opie)

## 38 Experimental Work on the Pancreas

have described cases of diabetes in which chronic interstitial pancreatitis accompanied general arterial sclerosis. Lemoine and Lannois have studied pancreatitis in four cases of diabetes and have thought that the new growth of interstitial tissue has its seat of origin in the perivascular tissue whence fibrous processes extend between the parenchymatous structures. They describe the penetration of fibrous strands into the acini, separating the cells and producing what they designate unicellular sclerosis. Hansemann has attempted to define a variety of pancreatitis always associated with diabetes. The organ is diminished in size and is flattened from before back. Its interstitial tissue is in continuity with that of adjacent structures, and consequently the removal of the organ is more difficult than usual. The microscope demonstrates an atrophy of the parenchymatous elements which are in part replaced by new fibrous tissue. He thinks that the lesion is similar to certain forms of granular atrophy of the kidneys.

There are, as we have seen, embedded in the substance of the pancreas certain groups of polygonal cells, arranged in columns, known as the *islands of Langerhans*. It has been suggested by Laguesse ("Compt. Rend. Soc. de Biol.," 1893), Schäfer ("Lancet," 1895, vol. 11), Diamare, and others that these islands are concerned in the production of the "internal secretion" of the pancreas. Ssobolew states that when animals are overfed with carbohydrates the cells in the islands become more granular than normal. He finds also that the chronic interstitial pancreatitis

which, in dogs, follows ligation of the pancreatic ducts spares the islands of Langerhans. Schulze has recently shown that the same observation holds good when guinea-pigs are used for the experiment. If the suppression of the "internal secretion" of the pancreas produces diabetes, and if the secretion is the product of the islands, then in a case of pancreatic diabetes we should expect these islands to show some pathological condition.

Opie ("Journ. of Experimental Med.," Jan., 1901), in a paper on the relation of chronic interstitial pancreatitis to the islands of Langerhans and to diabetes, describes two forms of interstitial pancreatitis:

(a) **Interlobular pancreatitis**, in which the inflammatory process is localised chiefly at the periphery of the lobule and implicates the islands of Langerhans only when the sclerotic process has reached a very advanced grade. When pancreatitis has followed obstruction of the ducts, the islands long remain unaltered though embedded in dense scar-like tissue.

(b) **Interacinar pancreatitis** in which the process is diffuse, invading the lobules and separating individual acini. The inflammatory change invades the islands of Langerhans.

In one of eleven cases of interlobular pancreatitis diabetes of mild intensity occurred. The sclerosis, which in this case followed obstruction of the ducts by calculi, was far advanced and affected the islands of Langerhans. In two of three cases of interacinar pancreatitis diabetes was present. The third case was associated with a condition hæmochromatosis, which

at a later stage is associated with diabetes, the result of pancreatic lesion. In a fourth case of diabetes hyaline deposit between the capillaries and the parenchymatous cells had so altered the islands of Langerhans that they were no longer recognisable.

Opie further describes, in a very important paper in the "Journal of Experimental Medicine," vol. v, No. 5, March, 1901, a case of diabetes in which the causal relation of a lesion of the islands of Langerhans to the disease is demonstrable. These islands are the seat of a degenerative change which has left unaltered the secreting parenchyma of the gland.

The patient was a female negro fifty-four years of age, suffering from phthisis and diabetes. Death occurred on the seventh day after admission to hospital. At the autopsy the pancreas was found to weigh 80 grammes and to measure 23 by 5 by 1 cm. It was readily dissected from surrounding structures. It was soft in consistence and on section had a grey-yellow colour. The following is the account of the *microscopical examination*:

"In sections of the pancreas prepared for histological study is found no generalised increase of the interstitial tissue, but here and there, particularly in the tail of the organ, the fibrous stroma shows some proliferation, and there are occasional irregular strands of tissue between the acini, though these are almost universally separated by delicate septa. This scanty, new-formed interstitial tissue, where it occurs, is poor in cells; about some of the medium-sized interlobular blood-vessels are small accumulations of scattered lymphoid

cells, together with an occasional plasma cell. Mononuclear cells with eosinophile granulations are not infrequently seen in the interlobular and interacinar tissue. In the head and the body of the organ are small areas of post-mortem self-digestion, where nuclei no longer stain and the tissue takes with hæmatoxylin a diffuse blue tint. The glandular tissue elsewhere is well preserved. In many acini, centro-acinar cells are numerous. The ducts are not dilated and appear to be normal. There are no alterations of the veins or arteries.

“The islands of Langerhans are the seat of a very remarkable change. In varying amount within almost every island is a homogeneous material which stains with eosin. Only rarely is found an unaltered island. Those which are least changed contain a few scattered masses of hyaline material, of which the smallest are irregularly polygonal in shape and correspond in size to the cells of the island. The larger particles are rounded. This hyaline substance at times lies in the midst of groups of cells, but is usually in contact with the walls of the capillaries penetrating the island, or next the peripheral fibrous tissue, and is therefore usually between the remaining cells and the capillary walls. Increasing in amount, it replaces the cells, and, where it is abundant, the cells which still persist are small and contain small nuclei, staining deeply with hæmatoxylin. They do not appear compressed or distorted.

“Where hyaline material is abundant it forms conspicuous masses in contact with capillaries, the endothelium of which is well preserved. It does not form

## 42 Experimental Work on the Pancreas

a uniform zone about them, but it occurs as scattered groups of irregular, rounded, often globular masses. The cells of the island have been in large part replaced, and between the hyaline particles is seen only an occasional compressed, fusiform, or irregular nucleus.

“The hyaline substance may occupy almost the entire area of the island, and besides a few endothelial cells are found only small scattered groups or rows of atrophic epithelial cells. The island is represented by a sharply circumscribed, hyaline structure, composed of particles of homogeneous material, giving the impression of broken, twisted columns, between which are the capillary walls. The nuclei of the capillary endothelium persist after destruction of the epithelial cells, but finally disappear. The lumen of the capillary remains patent and red blood-corpuscles are seen between the hyaline masses, although the endothelium no longer contains nuclei. The hyaline metamorphosis is limited strictly to the islands of Langerhans, the glandular acini remaining intact.

“The staining reactions of this homogeneous substance present in the islands of Langerhans, interpreted with reserve, indicate its epithelial origin. Finding it in irregular masses in contact with the cells, I was at first inclined to believe that it was formed by a process resembling secretion. It was pointed out to me by Dr. Welch, who examined my specimens, that transitions occurred between the cells and the hyaline masses. In slightly altered islands one finds small masses of material which resemble the hyaline substance, but, like the cell protoplasm, have a granu-

lar aspect. They correspond in size to the adjacent cells of the island, but contain no nuclei.

“By the use of certain stains—phosphomolybdic acid, hæmatoxylin by the method of Ribbert for white fibrous tissue, or aniline blue, as employed by Mallory, for the demonstration of white fibres and reticulum—the hyaline material acquires a deep blue colour and becomes very conspicuous. In the islands are not infrequently found slightly enlarged cells which, though still containing nuclei, exhibit a reaction similar to that of the hyaline material. The cell protoplasm, though granular, has assumed a diffuse blue colour.

“The degenerative process first manifests itself by an increase in the size of the cell and an alteration of its protoplasm. With the death of the cell its nucleus disappears and the protoplasm which stains with acid dyes remains for a time granular, but subsequently becomes homogeneous. The small particles of hyaline fuse with one another and form larger masses which lie in contact with the fibrous septa of the island. After complete transformation of the cells the island is represented by a hyaline mass penetrated by the remains of altered capillaries.”

Opie concludes that destruction of the pancreas in animals and in man is accompanied by diabetes; in the present case destruction of the islands of Langerhans has been accompanied by this disease. Since diabetes is absent when, as the result of duct obstruction, the secreting portion of the gland undergoes great alteration, though the islands are spared, the conclusion is justified that it is those structures which



#### 44 Experimental Work on the Pancreas

influence carbohydrate metabolism. What has been learned concerning the relation of the pancreas to diabetes is the relation of the islands of Langerhans to this disease.

Weichselbaum and Stangl ("Wien. klin. Wochenschr.," Oct. 10, 1901) describe the changes observed in the pancreas in 18 cases of diabetes. Atrophy of the parenchyma was noted macroscopically in 17 cases. In 7 cases the interlobular and intralobular connective tissue had become lipomatous; in 1 case there was hyperplasia of the connective tissue. The islands of Langerhans were fewer in number and much smaller than under normal conditions. These observers conclude that the changes described are not due to pancreatitis or granular atrophy, but to a genuine atrophy, from some unknown cause, especially affecting the islands of Langerhans.

## CHAPTER III.

### INJURIES OF THE PANCREAS.

INJURIES of the pancreas are rare. The depth of the organ within the abdomen, the protection it receives from the viscera beneath which it lies, and its partial shelter by the costal margin all render its injury unlikely. When the pancreas is wounded, the force producing the laceration is of such severity that other organs within the abdomen are generally damaged also. A rent in the liver, a fracture of the kidney or the spleen, a tearing at the duodeno-jejunal flexure or in the duodenum, a rupture of the stomach, or extensive lacerations in the peritoneum have all been observed. In the great majority of instances the force producing the injury has been directed from before backwards at the epigastrium; the patient has been kicked by a horse, or run over by a cart.

The following cases of laceration of the pancreas proving fatal have been recorded:

1. *Travers* ("Lancet," 1827).—A drunken woman was knocked down by a coach; death occurred from internal hæmorrhage. The pancreas was torn transversely, the liver was rent, and the ribs were broken.

2. *Störck* ("Annus Medicus," 1836).—A woman was run over by a coach and lived only a few hours. The pancreas was completely torn in two and lay in a large mass of semi-fluid blood. Several ribs were fractured and the liver was torn.

3. *Cooper* ("Lancet," 1839).—A man, aged thirty-three, was run over by a cart, and died in two hours from internal hæmorrhage. The pancreas was bruised to a pulp and embedded in clotted blood. The spleen, kidney, and liver were torn and several ribs were broken.

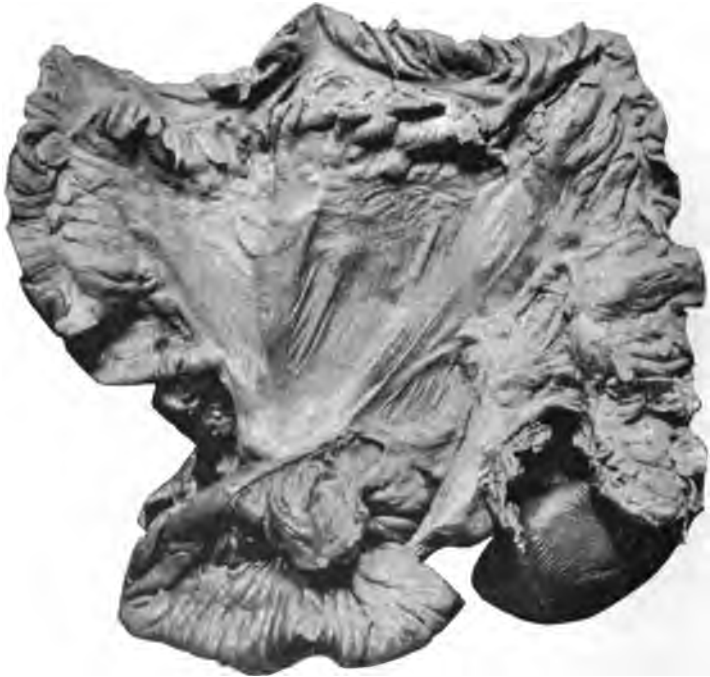

FIG. 4.—Showing the rupture in the duodenum. The ends have been filled with cotton wool and separated from one another for the purpose of demonstration.

4. *Wandesleben* ("Wochenschr. f. d. gesam. Heilk.," Berlin, 1845).—The pancreas and lungs were injured. A pancreatic abscess formed.

5. *Faun* ("Indian Ann. Med. Sci.," 1855).—A male, aged fifty, died after an assault in which he was kicked in the abdomen. The pancreas was torn vertically

and everywhere bruised. The peritoneum contained a little blood-stained fluid; no other sign of injury.

6. *Wilks and Moxon* ("Path. Anat.," second and third editions).—An adult was run over in the street. "The pancreas is so crushed in its middle as to be divided into two parts. The injury affects the part



FIG. 5.—Shows the rupture in the pancreas and its peritoneal covering.

opposite the spinal column, whose prominence no doubt afforded the counterpressure in the crushing action."

7. *LeGros Clark* ("Lect. on Surg. Diagnosis," 1870).—A lad showed rupture of the pancreas and other severe injuries which rapidly proved fatal.

8. *Leith* ("Ed. Med. Journ.," 1895).—A child, aged four, was kicked in the abdomen by a horse and fell, fracturing the left humerus. Death occurred in ten hours. On opening the abdomen a quantity of fluid (about one pint) was seen lying free in the peritoneum; it was clear and dark brown and had a peculiarly pungent odour. A rupture of the duodenum, close to the termination of the third part, was found. The rupture in the pancreas ran vertically from above downwards, passing through the whole thickness at the upper border, but through a part only towards the lower border. The main duct and the splenic vessels were uninjured. The rupture was at the junction of the right with the middle third of the gland and was directly over the aorta. The gaping wound in the gland opened directly into the lesser sac. There was practically no blood in the lesser sac.

9. *Goldmann* (*Leith, loc. cit.*).—A man received a blow in the abdomen from a heavy packing case, and death occurred in a few hours. At the post-mortem the pancreas was found to be transversely ruptured. Profuse hæmorrhage had occurred into the lesser sac and has caused an epigastric tumour. The spleen was also torn.

10. *Wagstaff* ("Lancet," 1895, vol. 1).—A man jumped from a cart and fell on his left side. On examination two hours after a fracture of the left femur was found. No other injury observed; there was an entire absence of shock. On the second day vomiting set in; there was no abdominal pain, no dullness or distention of abdomen. Died on the fourth day. On opening the abdomen no peritonitis was found. The stomach, intestines, kidney, liver, and spleen were healthy. A large retroperitoneal hæmatoma was discovered in connection with the pancreas. It was impossible to define its precise origin, as the whole organ

was so bruised and lacerated as to break up on handling.

11. *Villière* ("Bull. d. l. Soc. Anat. Paris," 1895).—A man received a heavy blow on the abdomen. Operation discovered blood free in the peritoneum, welling up from near the liver. The source of the hæmorrhage was not discovered. At the post-mortem the pancreas was found cut in two as with a knife. The spleen and the splenic artery and vein were also torn across.

12. *Pressel* (Inaug. Dissert., Berlin, 1895).—Analyzed the records of 200 post-mortems upon persons killed by being run over. In two of these lacerations of the pancreas were found.

13. *Groeningen* (Report of Berlin Garrison Hosp., 1890) published 19 cases of abdominal injury, in one of which the pancreas was wounded by the kick of a horse. The patient was a Hussar, who died of peritonitis two days after the injury. The duodenojejunal flexure was also torn.

14. *Hale White* ("Guy's Hosp. Rep.," vol. LIV) records four examples of rupture found in the post-mortem room at Guy's. Two were in patients who had been run over, and two in patients struck on the abdomen. All were males.

From these records it will be seen that a rupture of the pancreas apart from other abdominal injuries has only been observed in the cases related by Jaun, Wilks and Moxon, and Wagstaff.

It is probable that injuries of the pancreas are not so rare as the paucity of recorded examples would seem to indicate. When liver, spleen, or kidneys are ruptured, the hæmorrhage is so profuse as rapidly to fill the peritoneal cavity. At the post-mortem of such

a case the simultaneous laceration of the pancreas might readily escape observation.

The injury has generally been followed by a rapid onset of the symptoms of shock; in the cases of Jaun, Wagstaff, and Leith an interval of an hour or more occurred between the receipt of the injury and the oncoming of collapse. When the pancreas alone is injured, the bleeding is comparatively slight; when associated with an injury to the spleen or the liver, the blood has chiefly escaped from these organs and not from the pancreas.

A diagnosis was not achieved in any of the cases. The symptoms were those of collapse and internal hæmorrhage, and the source of the bleeding was only traced at the necropsy.

In addition to these instances of severe and fatal injury to the pancreas there is a class of cases in which the injury has been less severe, the damage done less profound, and in which recovery after operation has occurred.

The following is recorded by Rose: A man twenty-four years of age was struck by a brick and fell with his left side against a plank, breaking several ribs. Soon afterwards vomiting of blood occurred, and a tumour gradually formed in the epigastrium. Fourteen days after the accident he was admitted to hospital with a large, smooth, spherical tumour in the epigastrium. At the operation the tumour was seen to press the stomach upwards; the gastro-colic omentum was incised and four and a half litres of reddish-yellow fluid evacuated, with old blood coagula. A

rent in the posterior wall of the stomach and another in the pancreas were found. Drainage; recovery. This case seems to form an intermediate stage between such a one as that of Goldmann just recorded, and those cases in which, within a few days or a few weeks, tumours in the epigastric region have formed—tumours which on exploration have proved to be examples of distention of the lesser sac with highly blood-stained fluid. Such tumours have generally been spoken of and described by their recorders as cysts of the pancreas, and weight has been given to this view by the discovery of ferments either in the fluid found in the sac, or in that issuing later from the drainage opening. The sequence of events is probably this: The traumatism causes a laceration of the posterior layer of the lesser sac, and of the pancreas to which it intimately adheres; blood (and possibly pancreatic secretion) is poured into the lesser sac, and a peritonitis results; the foramen of Winslow is sealed by adhesion, and the lesser cavity of the peritoneum, now a closed sac, is distended with the serous outpouring, mixed with blood and pancreatic secretion. When the fluid is evacuated, the pancreas continues to pour its secretion into the lesser bag through the rent in its peritoneal investment. The distinguishing clinical feature of cystic tumours formed in this manner is the great rapidity of their enlargement. A tumour from which several pints are evacuated may form within a few days. Hadra records the case of a boy aged nine who was struck in the abdomen by the handle of a bicycle. Faintness, vomiting, and severe abdominal



pain followed. Twenty-four hours after the accident a swelling was noticed in the region of the stomach, and within three days a fluctuating tumour was discovered. The lesser sac was opened and a large quantity of clear fluid containing sugar was evacuated. Drainage was employed and the patient recovered. The absence of blood from the fluid makes it doubtful whether the pancreas was torn, but the history well illustrates the rapidity with which the lesser bag can be shut off from the general peritoneal cavity and distended with fluid. In Lloyd's second case, quoted fully in the chapter on pancreatic pseudo-cysts, a tumour was noticed ten days after the accident. As characteristic examples of dilatations of the lesser sac associated with laceration of the pancreas, we may quote the following cases, recorded as "pancreatic cysts":

*Cathcart's Case* ("Edin. Med. Journ.," July, 1890).—The patient was run over on May 4th. On July 20th was readmitted to hospital with a swelling occupying the left hypochondriac, lumbar, and umbilical regions. An exploratory puncture caused rupture of the cyst and peritonitis from leakage. The cyst was opened after laparotomy and posterior drainage adopted.

*Littlewood's Case* ("Lancet," vol. 1, 1892, page 871).—Male, thirty, was thrown from a horse which stamped upon him in the epigastrium. Thirteen days afterwards a swelling was noticed in the left upper umbilical and lower epigastric regions. The swelling was explored and a syringe full of dark blood withdrawn. The abdomen was opened above the umbilicus and the

cyst was at once seen, having displaced the stomach upwards and the colon downwards. It was covered by omentum which was torn through, the cyst opened, and the cyst wall stitched to the peritoneum. Forty ounces of fluid were removed. The fluid from the cavity was examined later and was found to contain all the usual pancreatic ferments.

*W. H. Brown's Case* ("Lancet," 1894, vol. 1, page 21).—Male, aged seventeen, was crushed between a locomotive and a trunk, the buffers striking his abdomen. A swelling gradually formed in the abdomen and was tapped, seventy ounces being removed. Six weeks later sixty ounces were drawn off. On admission to the Leeds Infirmary, the abdomen was generally distended and dull on percussion. An incision was made below the umbilicus and three pints of fluid escaped. Drainage was adopted. As the symptoms continued an incision was made above the umbilicus. The stomach presented in the wound with the omentum below it. This was drawn upwards and the wall of a tense cyst exposed; it was punctured with a trocar and about three pints of dark-coloured fluid with a peculiar odour withdrawn. The cyst wall was stitched to the abdominal wall and drainage employed. The fluid first discharged was alkaline and contained no digestive ferments. Later the fluid contained all the pancreatic ferments.

The first case of this kind was recorded by Kühlenkampff, who was followed by Senn, Küster, Treiberg, Karewski, and others. Coombs and Nash ("Lancet," vol. 1, 1901, page 1826) have tabulated the records of twenty-five cases, all traumatic in origin.

**Treatment.**—In cases of extensive rupture of the pancreas successful surgical intervention can be but

rarely possible. In all the cases except those of Jaun and of Wagstaff (possibly also the case recorded in Wilks and Moxon's work, though details are lacking) the injury to the gland was but a part of a widespread destruction involving the liver, kidneys, spleen, stomach, or intestines. In the cases of less extensive rupture, involving the overlying and adherent peritoneum, the symptoms and signs are those of effusion into the lesser bag of the peritoneum.

Experimental work has shown that wounds of the pancreas can be sutured, and that healing speedily takes place. All bleeding from the cut surfaces must be stopped as completely as possible, and sutures introduced must secure accurate coaptation of surfaces and avoid puncturing the main duct of the gland.

**Sequelæ.**—Wounds of the pancreas may be followed by inflammatory changes, as recorded by Wandersleben, Rolleston, and others who have described cases of pancreatic abscess of traumatic origin. The following is an example (Rolleston, "Brit. Med. Journ.," vol. II, 1892, page 895): A woman, aged fifty, received a blow on the abdomen, which was followed at once by pain, and the next day by severe vomiting, inaction of the bowels, and collapse simulating intestinal obstruction. Death took place in eighty days, after the formation of an abscess in the right hypochondrium. At the post-mortem an abscess in the head of the pancreas and fat necrosis in the subperitoneal cavity were observed.

Hansemann, Fitz, and Prince have related cases of necrosis of the pancreas after injury.

Chronic pancreatitis and stenosis of the canal of Wirsung may follow bruising or tearing of the gland.

*Gunshot wound of the pancreas* has been recorded in several instances. Otis, in his surgical report on the American Civil War, relates three cases. In the first the pancreas and spleen were both lacerated and the splenic artery was divided; the patient lived one month. In the second the stomach and pancreas were wounded; the patient lived fifteen days. In the third the lung, left lobe of the liver, diaphragm, and pancreas were perforated; death followed on the twelfth day. A case similar to this occurred in the Franco-Prussian War. The late President McKinley was wounded in the stomach, pancreas, and left kidney. In all these cases and in the few others found scattered in surgical literature the wound of the pancreas was never unaccompanied by gross lesions of the viscera around or in front of it.

*Ninni* ("Brit. Med. Journ. Supp.," June, 1901, No. 376) relates a case of revolver wound of the abdomen in a man aged twenty-seven. The patient had run more than 500 yards after the wound had been inflicted, but was brought to hospital collapsed, almost unconscious, with thready pulse and abdomen painful and tympanitic. The bullet had entered close to the second lumbar vertebra, and after passing through the pancreas had made six wounds in the small intestine, and one in the colon at the hepatic flexure, and come out in the right epigastric region. An incision was made from the xiphisternum to halfway between the umbilicus and pubes, giving vent to blood and gas.

Having sutured the seven intestinal wounds, while making the peritoneal toilette he found blood and fluid oozing from between the stomach and transverse colon on the right. Making a transverse incision from the umbilicus to the right axillary line, and tearing through the gastro-colic omentum, he found a wound of the pancreas at the junction of the head and body, which he closed by two deep sutures, thus arresting all extravasation of blood and pancreatic juice. The after-progress was normal. The patient left the hospital after thirty-five days.

The author discusses the principles hitherto laid down, and holds (1) that punctured or incised wounds of the pancreas should be sutured; if the duct is cut, suture as in intestine, leaving no thread in the lumen, so as to avoid risk of calculi forming. (2) In gunshot wounds, if there is not much laceration, suture in bulk; if lacerated, resect; if the laceration is total, one can only plug, for removal of the whole gland is difficult and fatal. (3) To contused wounds the same rules apply. (4) In rupture, there being usually not much laceration, suture. In all cases, if suture does not stop the hæmorrhage, ligature.

#### PROLAPSE OF THE PANCREAS.

The possibility of a protrusion of the pancreas through a wound of the abdominal wall has been disputed. The examination of certain records, however, removes any doubts that may, not unnaturally, be felt as to the likelihood of such an accident. The first case,

one very widely quoted, of "prolapse of the pancreas" was recorded by Laborderie, but the worth of this record is destroyed when we discover that in a later number of the same periodical, after a microscopical examination, Laborderie described the prolapsed tissue as omentum ("Gaz. des Hôpitaux," 1856, Nos. 2 and 9). Otis related the history of two cases of prolapse from perforating bullet-wounds in the American Civil War. In all, eight well-investigated cases are recorded (Kleberg, Otis (2), Caldwell, Dargan, Adevoine, Earl, Allen). In Otis's second case (seen by Dr. Cheever) the prolapsed viscus was recognised as pancreas at the necropsy.

## CHAPTER IV.

### PANCREATITIS.

**History.**—Although we now know that pancreatitis is far from uncommon, yet it is astonishing that the attention of the profession was not prominently drawn to it until the publication of the classical monograph on the subject by Fitz, of Boston, in 1899, and this is the more astounding from the facts that so early as 1641 Tulpius found an abscess of the pancreas, and that Greisel (quoted by Portal) described a case of gangrenous pancreatitis in 1673.

In 1804 Portal gave a good description of pancreatitis and described both the suppurative and gangrenous varieties. He speaks of the subject as if he had seen a number of cases verified by autopsy.

Neumann, of Berlin, drew attention to the possibility of a fatal metastasis from parotitis to pancreatitis.

Claessen in 1842 collected six cases from various sources.

In 1865 Rokitansky and in 1870 Klebs described hæmorrhagic pancreatitis, and in 1870 Kenker prominently drew attention to the significance of hæmorrhage within the gland or its vicinity, his observations being confirmed by Prince, Draper, and others.

In 1882 Boldt collected eleven cases of pancreatitis out of 140 cases of disease of the pancreas.

Moore in the same year saw four cases of thrombosis of the veins around the pancreas, and gave it as his opinion that pancreatitis commenced always in the veins.

The same year was signalised by Balser's description of fat necrosis as a sign of pancreatic disease.

Senn's classical work in the surgery of the pancreas, in 1886, showed the lines on which surgery might follow.

Since Fitz's lecture on acute pancreatitis in 1889 there have been numerous contributions on the subject, and we would especially refer to the monograph of M. Antoin Page on suppurative and gangrenous pancreatitis and the theses of Stojanovitz, in 1893, and of Durand, in 1895, on the hæmorrhagic form.

Although acute pancreatitis has thus been before the profession since the middle of the seventeenth century, chronic pancreatitis was not described until 1895 when Birch-Hirschfield drew attention to the frequency with which the pancreas is affected in congenital syphilis and described the condition very accurately, the disease having been further and systematically investigated by Schlesinger, whose observations were published in "Virchow's Archives" (CLIV, page 501) in 1898. The significance of chronic pancreatitis and its important surgical bearings had, however, received very little notice before a lecture given by one of us at the London Polyclinic in January, 1900, as the result of observations extending over a period from 1892; but since attention has been drawn to the subject, numerous surgeons in various parts of the world have confirmed those observations and estab-



lished the subject on a firm basis, both with regard to its pathology and its treatment.

**Etiology and Pathological Considerations.**—It is a curious fact that, although surgeons have been removing gall stones from the common duct for a little over ten years,—that is, since Courvoisier's first successful choledochotomy in 1890,—and that although the subject of jaundice dependent on obstructed common bile duct received great attention from physicians many years previously, yet until comparatively recently it never seemed to dawn on the minds of clinical observers that whatever obstructs the common bile duct at the ampulla of Vater must also of necessity lead to an obstruction in the pancreatic duct; and although since the description of the disease by Charcot as "intermittent hepatic fever," infective and suppurative cholangitis have been well recognised by pathologists, yet infective and suppurative catarrh of the pancreatic ducts have even yet received no place in the medical text-books, which means in reality that all diseases of the pancreas except those producing gross organic changes such as cancer, acute pancreatitis, cysts, and calculi have been practically ignored; yet we know, both by post-mortem observation and by surgical experience, that under similar conditions the pancreatic ducts participate in the same inflammatory processes as the bile ducts.

When the common bile duct is obstructed, the objective sign of jaundice at once demonstrates the fact; hitherto, however, no pathognomonic sign has been discovered which will show conclusively that the pan-

creatic ducts are occluded, unless it be the extremely rapid loss of weight. As is now well known, the presence of fat necrosis does afford a clue, and a very important one, which has, however, hitherto only been of use from a diagnostic point of view, when the abdomen is opened. But, even for fat necrosis to take place, there must have been some escape of the fat-splitting ferment from the gland; the affection of the pancreas must therefore be somewhat advanced before the sign is evident. Glycosuria, lipuria, and fat in the stools occur too seldom to be of much use in the diagnosis of pancreatic disease, though when present they are of great diagnostic importance.

The most satisfactory evidence at present of deficient pancreatic juice in the bowel is afforded by the abundance of undigested muscle fibre in the motions of a patient, not suffering from diarrhoea, after a meat diet; and by the absence of carbolic acid and salicin in the urine when sixty grains of salol are taken in divided doses during the day.

Physiological chemistry may, perhaps, help us in the diagnosis, and though our observations are not yet by any means complete, we hope that some researches at present being conducted on cases under our care, by Mr. P. J. Cammidge, may prove of practical use. We have some grounds for hope that by an examination of the urine alone, or of the urine, the blood, and the fæces, we may have some assistance in the diagnosis of these difficult cases.

The pancreas is a racemose gland well supplied with blood, and, unlike the parotid, the lobules of which

are well supported by fibrous partitions, its tissues are comparatively soft and easily bruised, so that although it is placed in the most favourable position for protection from direct injury, yet a slight injury takes more effect on it than on many other firmer organs, and we have experience of pancreatitis resulting from blows in the epigastrium apparently trifling in character, as in a case seen by one of us several years ago:

A butler slipped and fell forward against a knife-board projecting from the end of the table at which he was working. The blow was comparatively slight and the man did not even fall to the ground, but acute, so-called hæmorrhagic pancreatitis followed and the patient died; an exploration for peritonitis, followed by a necropsy, revealing the true cause of death.

Probably slight injury to the pancreas often occurs in abdominal operations for gall stones in the common duct, when it is sometimes necessary to manipulate, and rather forcibly to draw the parts in the neighborhood of the pancreas forward in order to view the common duct when sutures are applied. Such a case has, indeed, been related recently.

When it is borne in mind that the pancreatic duct opens along with the common bile duct into the second part of the duodenum, a channel usually containing septic organisms, especially when it is the seat of catarrh, to which it is especially liable, it is not a matter for surprise that pancreatitis should be met with, but rather that it should not occur more frequently. As in the liver we may have simple, infective, and suppu-

rative catarrh of the excretory ducts, as well as inflammation of the interlobular tissues, so in the pancreas we undoubtedly have similar diseases which are only awaiting our recognition when we shall have achieved greater diagnostic skill. As bearing on this, the pathologist of a large hospital has told us that, in cases of obstruction of the common duct by gall stones, he has noticed that pus can usually be expressed from Wirsung's duct, and this has been confirmed by others. We feel sure that, as our means of diagnosis becomes more perfected, diseases of the pancreas, both functional and organic, will be more frequently recognised and awarded their deserved positions in medicine.

Since Claude Bernard and Dr. Walker, of Peterborough, showed that the absence of the pancreatic secretion from the intestine, even though bile was present in the intestinal canal, led to pale-coloured motions, very little attention has been paid to this sign, although much has been written about the presence of sugar in the urine in pancreatic disease; yet glycosuria is, in our experience, a very rare phenomenon in this relationship, and, in fact, it only occurs when there is great destruction of pancreatic tissues, as in extensive cirrhosis or in extensive malignant disease. The work of Opie has clearly shown the fact that, so long as the islands of Langerhans remain intact, glycosuria is absent, but that when they become affected either by lardaceous or other disease, glycosuria follows. Fat in the stools is more common, but not by any means universal, and lipuria is still more uncommon.

We have seen cases of discomfort, with some swelling of the epigastrium, associated with dyspepsia and ague-like attacks, but without jaundice, or with only very slight jaundice, which it was thought might be explained on the hypothesis of infective inflammation of the pancreatic duct, the cases having cleared up under general treatment. We have also seen the same symptoms associated with more pain, irregular fever, more marked swelling and tenderness over the pancreas, and discharge of pus by the bowel from time to time, but without any collection sufficiently large to form a distinct abscess. The case related on page 136, we think may have been of this nature, but the recovery of the patient made the absolute certainty of the diagnosis impossible, though an examination under an anæsthetic enabled a swelling of the pancreas to be felt, and this was confirmed by palpation of the abdomen at a later stage, when tenderness was less marked. This case was probably a subacute pancreatitis associated with suppurative catarrh of the pancreatic ducts analogous to suppurative cholangitis.

The essential and immediate cause of the various forms of pancreatitis is bacterial infection, this having been positively proved both clinically in the human subject and experimentally in the lower animals; but as in inflammatory affections of the liver and bile ducts we look for extrinsic causes, so in pancreatic diseases we find biliary and pancreatic lithiasis, injury, gastro-duodenal catarrh, ulcer and cancer of the stomach, pylorus, or duodenum, and zymotic diseases,

such as typhoid fever, mumps, and influenza, to be determining factors, though in some cases pancreatitis has come on suddenly in persons in robust health, and the determining cause has been beyond recognition.

Though the infection may arise from the blood, as in pyæmia, or by direct extension from the neighbouring tissues, as in ulcer of the stomach, yet the most usual channel is through the duct, as in cases arising from gall stones in the common duct, and from gastro-duodenal catarrh.

A possible cause of the disease is, as Halsted and Opie suggest, retrojection of bile into the pancreas produced by the impaction of a very small calculus in the ampulla of Vater. As is well known, the common bile duct usually joins the pancreatic duct (duct of Wirsung) a short distance from the duodenum, and the two channels form a slightly dilated ampulla before opening on the mucous surface of the second portion of the duodenum. This orifice, Hyrtl ("Handbuch der topographischen Anatomie," Vienna, 1882) states, is narrower than the lumen of the gall duct at any point and is not distensible, so that gall stones often remain impacted at this point.

The conditions necessary for the production of acute hæmorrhagic pancreatitis by a calculus are set forth by Halsted as follows:

1. In order that bile may be retrojected into the pancreatic duct the calculus must be (*a*) too small to occlude the pancreatic duct or to interfere with the force of the jet, and at the same time (*b*) too large to pass the ampulla.

2. One calculus would be more likely to cause the pancreatitis than several, for other stones in the duct, unless very small, would weaken the force of the bile-spurt which drives the ball-valve against the papillary orifice.

3. The gall bladder must be normal or nearly so and not thickened, shrunken, or weakened by inflammation.

Thus a small calculus in the ampulla of Vater converts the two ducts into a continuous channel, while a large stone might simultaneously obstruct the duodenal orifice of the diverticulum and the orifices of the ducts which enter it, thus damming back bile and pancreatic juice upon their respective glands. Opie, who performed the necropsy on Halsted's case, made a series of experiments on dogs; in five instances the duodenum was opened and the duct was injected with bile, varying from 2.5 to 5 cubic centimetres. In two other cases the duct was opened, injected with bile, and ligated. In all, hæmorrhagic pancreatitis and fat necrosis were produced and verified by examination post-mortem.

Seeing that we have noted pancreatitis in a number of cases where the gall stone or stones in the common duct were large or numerous, we think that Dr. Halsted has overrated the importance of the gall stone being small.

The knowledge of the association of gall stones with chronic pancreatitis was absolutely forced upon us by the frequency with which inflammatory enlargement of the head of the pancreas was found when

operating for gall stones in the common duct. The first instance observed by us was in 1892, in a case on which we operated for deep jaundice supposed to be due to common bile duct obstruction, but in which cirrhosis of the head of the pancreas was found. Since that time we have operated on a considerable number of cases, and though only one patient has died directly from the operation, in two others, one a cholecystenterostomy, death occurred in a few months, and the correctness of the diagnosis was verified both by necropsy and by microscopical section of the diseased pancreas. It is a simple matter to infer that if common duct cholelithiasis can give rise to chronic pancreatitis, it will also be likely to induce the sub-acute and acute forms of the disease, and this is now clearly proved. Dr. Kennan ("British Medical Journal," November 14, 1896) described a case of acute pancreatitis ending fatally on the second day, in a woman aged thirty-eight, and at the post-mortem examination a large number of gall stones were found in the common duct, one being partly extruded into the duodenum.

Körte notes that the lesions of the pancreas are frequently associated with diseases of the bile ducts.

Lancereaux ("Traité des Maladies du Foie et du Pancreas," 1898) mentions the possibility that a gall stone impacted in the diverticulum of Vater may occlude the pancreatic duct and produce conditions favouring the entrance of organisms into the duct.

Dr. Opie, in a very instructive and interesting paper ("American Journal of the Medical Sciences," January,



1901, page 27), relates cases, one of Dr. Osler and several from various sources, showing the relation between pancreatic and gall stone troubles.

Mr. Gilbert Barling ("British Medical Journal," December 22, 1900) has given several interesting cases bearing out very fully the views expressed above.

In some of our cases gall stones were not found, but only old and firm adhesions, with an antecedent history of paroxysmal attacks, followed by jaundice, which afforded strong presumptive evidence that cholelithiasis had been present at some time; and it seems quite possible that temporary occlusion of the common duct, with the damming back of infected secretions, or with injury to the ducts, may set up pancreatitis, which may itself then cause compression of the common bile duct, and so lead to a perpetuation of the obstructive jaundice and other troubles, started in the first instance by impacted gall stones.

*Fat Necrosis.*—By fat necrosis is understood a splitting up of the fat into fatty acids and glycerin; the latter is absorbed, but the acids, being insoluble, remain in the cells and unite with calcium salts, forming yellowish-white patches of various sizes in the sub-peritoneal fat and in the omentum and mesentery and even in more distant parts. It was first described by Balser, in 1882, and has been since investigated by Langerhans, Hildebrand, Dettmer, Milisch, Williams, Flexner, Opie, Oser, Hlava, Körte, and others.

Fat necrosis is commonly found in association with hæmorrhagic and gangrenous pancreatitis, and the relation between the two conditions has given rise to

## Etiology and Pathological Considerations 69

much speculation; but the facts that fat necrosis is not found in all acute pancreatic diseases, and that it has been noted during abdominal operations for other ailments, and in necropsies where there was no suspi-

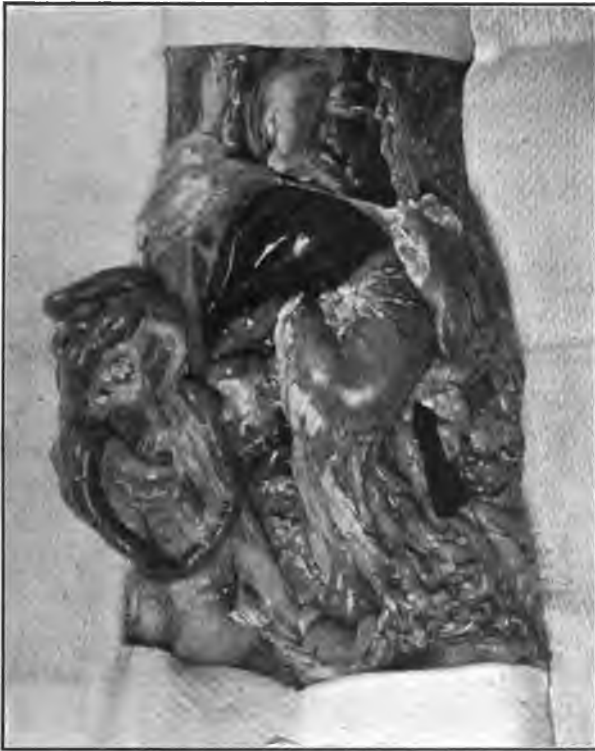

Fig. 6.—Administration of pilocarpin after ligation of pancreatic ducts. Foci of necrosis in omental and mesenteric fat, in fat below parietal peritoneum, and in fat of parietal pericardium (Opie).

cion of pancreatitis, appear to show that the condition giving rise to it is not essentially a pancreatitis, as suggested by certain authors, though these facts do not disprove the fact that fat necrosis is essentially

due to interference with the discharge of pancreatic secretion, and so to an escape of pancreatic fluid into the tissues, whence it may be taken up by the lymphatics or blood-vessels. Langerhans, and more recently Flexner ("Contributions to the Science of Medicine," Johns Hopkins Press, Baltimore, 1900), and others regard the fat necrosis as the effect of the fat-splitting ferment of the pancreatic fluid which has in some way escaped from the duct into the surrounding tissues. It is difficult at first sight to explain the patches of fat necrosis occurring at a distance from the pancreas,—for instance in the pericardium, —unless it be by absorption of the ferment and its diffusion by means of the lymphatics, though it is easy to understand, and it undoubtedly does explain, the disintegration of the fatty tissues immediately surrounding the pancreas, and extending by continuity first to adjoining and then even to distant parts in the abdomen and thorax.

Numerous instances of multiple fat necrosis have been found to be associated as a rule with some well-marked lesion of the pancreas. In the majority of cases, a hæmorrhagic infiltration of the organ is present and is accompanied by a greater or less degree of degeneration and necrosis of the parenchyma—the so-called hæmorrhagic pancreatitis. Necrosis of the pancreas—"gangrenous pancreatitis"—occurs with somewhat less frequency, the black necrotic organ often lying dissected almost entirely free from the surrounding tissue in a cavity containing fluid and solid necrotic particles. Such sequestration of the

organ, Langerhans ("Arch. f. Path.," Berlin, 1890, Bd. CXXII, S. 252) thinks, may be the result of extensive necrosis of the fat surrounding it. More rarely other pathological conditions are present. Chronic suppurative pancreatitis is at times accompanied by fat necrosis, and in a few instances chronic interstitial inflammation has coexisted with it. Occasionally, however, the organ has been apparently normal.

After numerous experiments Dr. Opie's conclusions on fat necrosis are as follows:

1. The condition essential to the production of focal fat necrosis is the penetration of the fat-splitting ferment of the pancreas into living adipose tissue.

2. By causing the entire secretion of the pancreas in cats to penetrate into the tissue surrounding the organ, wide diffusion takes place and necrosis results, not only in the abdominal fat, but in that of the pericardium and subcutaneous tissue as well, thus reproducing the widespread distribution of the lesion occasionally observed in man and in the lower animals.

3. Lesions of the pancreas associated with focal fat necrosis are such as permit the diffusion of the pancreatic ferment into the surrounding tissue.

*Hæmorrhage in Pancreatic Disease.*—It is well known that local hæmorrhages into the pancreas may occur apart from injury and apart from any general hæmorrhagic tendency, and that although they may be recovered from, as shown by the remains of extravasated blood in the gland in persons dying from other diseases, yet such spontaneous hæmorrhages may lead to death from collapse either immediately or after

some hours. Curiously, this may occur in persons apparently in good health, and without any premonitory signs on which a diagnosis can be based, the only symptoms at the time being those of collapse, with dyspnoea and feeble pulse. It is also well recognised that a hæmorrhagic condition coexists with cancer of the head of the pancreas. . Some years ago we thought this to be altogether dependent on the cholæmia, until increased experience in operations on deeply jaundiced subjects taught us that there is much less danger of serious hæmorrhage in patients jaundiced from gall stones than in those where the jaundice depends on pancreatic disease. In several cases of cancer of the pancreas on which we have operated, the bleeding has been the immediate cause of death; in one aged subject especially was this well marked, after cholecystotomy for the relief of jaundice. Death occurred on the third day from collapse, and at the necropsy there was found effusion of blood away from the site of operation and behind the peritoneum, extending into the loins around the kidneys, and into the cellular tissues beneath the diaphragm, the blood being in sufficient quantity to account for death; and though the bleeding had evidently arisen from the pancreas, there was no manifest vascular lesion to account for the hæmorrhage. In another case, sent to one of us in 1888 by Professor Clifford Allbutt, a cholecystotomy was followed by persistent oozing of blood from the interior of the gall bladder and from the stitch punctures, which resisted all then known remedial measures in the way of styptics, pressure, transfusion, etc., and

which proved fatal on the ninth day. In neither of the cases was there any peritonitis or other cause than the hæmorrhage to account for death. Now, in another patient, equally jaundiced, that one of us saw with Dr. Churton, in 1889, where the disease was dependent on cancer of the common bile duct above the entrance of the pancreatic duct, there was no hæmorrhage, although the patient survived several weeks and died from exhaustion due to the disease and to the suppurative cholangitis accompanying it. We could give many similar comparisons showing the difference between the behaviour of the blood in the two classes of cases. Before operating on these cases we now always administer calcium chloride in thirty-grain to sixty-grain doses thrice daily for from twenty to forty-eight hours previous to operation, and by enema in sixty-grain doses thrice daily for at least forty-eight hours afterwards; this is nearly always successful in correcting the hæmorrhagic tendency. The following case illustrates, as well as any case could, how the failure to give it after operation led to hæmorrhage and how its administration in heroic doses apparently saved the patient:

Cholelithiasis; deep jaundice; chronic pancreatitis; duodeno-choledochotomy; hæmorrhage; recovery.

Reported by Dr. W. Gough, house surgeon.

Mrs. M. E. G., aged thirty-eight, was admitted to the Leeds General Infirmary on January 23, 1901.

*History.*—She had had typhoid fever in September, 1899, and she had never been quite well since. Shortly afterwards she began to suffer from biliary colic, though she had never been jaundiced till six months before

admission, from which time jaundice had never left her. On December 24, 1900, she became much worse, had very severe paroxysmal pain, accompanied by shivering and profuse sweats. From that time she lost weight very rapidly and the jaundice deepened. On admission, the liver could be felt below the ribs, and there was a distinct fullness on deep palpation in the region of the pancreas. From January 21st to 31st she took calcium chloride in twenty-grain doses thrice daily.

Duodeno-choledochotomy was performed on January 31st. There was very little bleeding. A stone nearly as large as a pigeon's egg was removed from the ampulla of Vater, which was laid open over a director introduced through the papilla at its opening into the duodenum. The head of the pancreas was felt to be much enlarged and hard. The incision into the ampulla was not sutured, but through it the common bile duct, very much dilated, was explored by the finger. The anterior wound in the duodenum was then sutured and the abdominal wound closed. A drainage tube was inserted through a stab-wound in the right loin. The patient inadvertently did not have calcium chloride given in the nutrient enemata as is usual in these cases.

*After-history.*—She did well till the morning of February 2d, when the nurse noticed at 3 A. M. that the dressings were soaked with bright red blood. The drainage-wound was exposed, but no hæmorrhage was occurring there. On examining the abdominal incision, blood was seen to be slowly oozing from it and from the stitch punctures. One drachm of calcium chloride was at once administered by the mouth, and three stitches were removed; the surface of the wound was then seen to be oozing all over. It was packed with gauze soaked in tincture of hamamelis, and a

firm dressing applied. One drachm of calcium chloride was given again in two hours, and it was afterwards repeated in thirty-grain doses every two hours for six times, it being then given thrice daily. There was no recurrence of hæmorrhage, and the patient made an uninterrupted recovery. The drainage tube was removed on February 4th, and she returned home within the month.

In this case Mr. Cammidge found the characteristic crystals in the urine, and an examination of the blood showed a very marked diminution in the blood plates.

These arguments are brought forward to show that there is some, as yet ill-understood, relation between pancreatic disease and serious hæmorrhage, but we cannot help thinking that it is a mistake to allow this fact to influence our views on the pathology of inflammation by adopting permanently the name "hæmorrhagic pancreatitis" in cases where there has been no bleeding, or no more than occurs frequently in inflammation of other parenchymatous organs, though it may be useful to retain the name for those cases of pancreatitis associated with well-marked interstitial hæmorrhage, in which the disruption of the gland by bleeding may be the direct cause of the inflammation.

We recently read a very interesting paper ("Boston City Hospital Report" for December, 1900) by Dr. F. B. Lund, entitled "Acute Hæmorrhagic Pancreatitis and its Surgical Treatment, with a Report of Six Cases"; yet, in remarking on the second case, the author says: "This case is notable for the absence of pancreatic hæmorrhage." In the fifth case there was the



evacuation and drainage of a small abscess of the pancreas, and no evidence of hæmorrhage, and in the sixth case also there was apparently no evidence whatever of hæmorrhage. The title of the paper is surely a misnomer, yet other authors adopt the same nomenclature in the same indefinite manner.

Dr. Flexner produced an inflammation of the pancreas associated with hæmorrhage within forty-eight hours, by injecting the *Bacillus pyocyaneus* and the *B. diphtheriæ* into the pancreatic duct in animals (*loc. cit.*, page 743).

Hlava also produced hæmorrhagic pancreatitis by injecting the *B. diphtheriæ* into the pancreas.

Hildebrand ("Centralbl. f. Chir.," 1894, Bd. xxii, S. 297) suggested that the hæmorrhage in acute pancreatitis was due to trypsin.

The facts concerning hæmorrhage in diseases of the pancreas, and the conclusions we have come to after carefully considering the whole subject, are:

1. That in certain diseases of the pancreas there is a general hæmorrhagic tendency which is much intensified by the presence of jaundice.

2. That hæmorrhage may apparently occur in the pancreas unassociated with inflammation or with jaundice, or with a general hæmorrhagic tendency.

3. That acute, subacute, and chronic pancreatitis can and do frequently occur without hæmorrhage.

4. That acute pancreatitis is so frequently associated with hæmorrhage into the substance of the gland as to establish the need for the name "hæmorrhagic pancreatitis" as a variety of the acute inflammation.

It seems to be worth while taking into account the fact that the glycerin set free in the tissues by the fat necrosis may possibly be the real cause of the local hæmorrhagic tendency in pancreatic affections, though our observations are not yet sufficiently far advanced to say that this is an adequate explanation. There are certain very important facts bearing on the question. If glycerin in very small amount be injected into mice, it rapidly produces hæmaturia (Cambridge) or hæmoglobinuria, due to destruction of the blood-corpuscles; and in certain cases in which glycerin has been used by gynæcologists for the purpose of inducing abortion, and in others in which it has been injected along with iodoform for the treatment of tuberculous disease in the human subject, blood has also been noticed in the urine, sometimes in large quantities.

The blood conditions about to be mentioned may possibly serve to explain the general hæmorrhagic tendency in cases of chronic pancreatitis associated with jaundice, but behind that there must be some other cause not yet discovered. Can it be due to something absorbed from the pancreas into the blood, which only acts when the absorption has been occurring over a prolonged period of time? This matter seems to be worth attention, and it should be possible to prove or disprove it by experimental work.

Against this theory, Mr. Cambridge suggested that only a small amount of glycerin could obtain access to the blood as the result of fat necrosis. When the glycerin is set free and the fatty acids are saponified, it would become oxidised just like any other alcohol,

and the oxidation product for which one would look would be an aldehyd, but the tests employed failed to demonstrate this.

In the course of these investigations, however, it was found that if the urine was boiled for a short time with an oxidising agent, and then the phenyl-hydrazin test performed, an abundant crop of delicate yellow needles arranged in sheaves and rosettes was produced. The untreated urine gave no such result; normal urine, morbid urines from gout, etc., and, most important, bilious urine from patients suffering from simple catarrhal jaundice, gave also negative results; moreover, some experiments performed on bile and bile salts yielded none of the crystals.

The number of cases is too few to allow one to do more than suggest that it may prove useful as a diagnostic test in this class of cases; but it is also interesting to note that on one day one of us operated on two patients deeply jaundiced, in one of which there was chronic pancreatitis; whereas in the other, although there was a small gall stone in the common duct, there was no manifest enlargement or disturbance of the pancreas. Both urines were submitted to Mr. Cammidge, and without his knowing the history of either case, he sent word that the urine in the latter case (where there was no pancreatitis) gave negative results so far as the crystals were concerned, and that in the former case he was able to obtain abundant crystals.

An examination of the blood has also been made in a number of cases, with a view to ascertain if any information can be found to explain the hæmorrhagic

tendency. Although glycerin may be present, Mr. Cammidge knew of no test sufficiently delicate to demonstrate its presence in the blood, but a histological examination of the blood showed in two of the cases a very striking diminution in the number of blood plates as compared with the normal blood. This diminution of the blood plates, whatever may be its cause, may possibly explain the general hæmorrhagic tendency and the great delay in the coagulation period.

**Classification of Pancreatitis.**—It is convenient to consider pancreatitis clinically under the headings of (1) acute, (2) subacute, and (3) chronic, which does not interfere with Fitz's pathological classification of acute pancreatitis into hæmorrhagic, suppurative, and gangrenous.

An analysis of recorded cases gives three distinct classes:

1. Cases in which death occurs within forty-eight hours of the onset. Here hæmorrhagic pancreatitis is frequently found and fat necrosis, if present, is not widely distributed.

2. Those in which death does not occur for several weeks after the onset. In these the pancreas may be dry, black, and necrotic, or abscesses may occur from secondary infection by the *Bacillus coli communis*, the diplococcus of Fraenkel, or streptococcus, and the fat necrosis is widely disseminated.

3. Where the attacks are long-continued or repeated, a chronic inflammation or cirrhotic change is found in the pancreas.

**Symptoms.**—The symptoms of pancreatitis are very

variable and differ in the separate forms. It is a disease without pathognomonic signs, and a correct diagnosis is usually only arrived at by a careful study of the history, mode of onset, and combination of symptoms.

## CHAPTER V.

### ACUTE PANCREATITIS.

THIS is usually ushered in by a sudden pain in the superior abdominal region, accompanied by faintness or collapse, and followed sooner or later by vomiting. It is almost constantly accompanied by constipation, so that it is quite usual for these cases to be mistaken for intestinal obstruction at first. The obstruction, however, is not absolute, flatus passes, and a large enema may secure an evacuation; if the patient survive for several days, diarrhoea may supervene. The pain may be so severe as to produce syncope or collapse, and though the pain does not quite pass away, it has a tendency to be paroxysmal and to be increased by movement; it is associated with well-marked tenderness just above the umbilicus or between it and the ensiform cartilage. The pain is soon followed by distention in the superior abdominal region, which may become general and usually does so in the later stages, and by vomiting, first of food, then of bile. The vomiting may be severe and each seizure may aggravate the pain, but at times vomiting may not be a prominent symptom. Slight icterus, from associated catarrh of the bile ducts, is usually present and deepens the longer the patient survives. The aspect is anxious and the face is pinched, resembling the facies of peritonitis, which in fact is usually present.

The pulse, which is rapid and small, is a better guide than the temperature, which may be normal, sub-normal, irregular, or high. Hiccough sometimes occurs and the urine may contain albumin and casts. Delirium comes on in the later stages. The distention, pain, and tenderness, with rigid recti, prevent an exact examination of the pancreas, which would otherwise be found enlarged. Death frequently supervenes, from the second to the fifth day from collapse, though in the less acute cases life may be more prolonged and recovery sometimes occurs. Acute infective pancreatitis thus takes on the form of acute peritonitis starting in the superior abdominal region. If life be prolonged, the case comes under the category of subacute pancreatitis, and in that case the onset is usually less grave, though often equally sudden.

**Diagnosis.**—The diagnosis of acute pancreatitis is at first difficult, as the symptoms are only characteristic of peritonitis starting in the upper part of the abdomen.

*Fitz's rule* is worth bearing in mind: "Acute pancreatitis is to be suspected when a previously healthy person or sufferer from occasional attacks of indigestion is suddenly seized with violent pain in the epigastrium, followed by vomiting and collapse, and in the course of twenty-four hours by a circumscribed epigastric swelling, tympanitic or resistant, with slight rise of temperature." Should a tumour rapidly form, it is difficult to palpate without the aid of an anæsthetic, on account of great tenderness and rigid recti. After a few days, when the symptoms are less acute, the site of the swelling may be ascertained by distending

the stomach with CO<sub>2</sub>, and its relation to the colon by distending it with air introduced through the rectum.

In case of laparotomy, the presence of extensive fat necrosis is almost pathognomonic.

At first the differential diagnosis must be made from intestinal obstruction, perforating duodenal or gastric ulcer, ruptured gall bladder or bile ducts, phlegmonous cholecystitis, and gangrenous appendicitis.

In considering the difficulty of diagnosing between acute pancreatitis and intestinal obstruction, it has to be borne in mind that the two may coexist, as the swollen pancreas may embrace and strangle the duodenum, or a collection of inflammatory material may seriously compress it. The swelling will, however, be usually less general in pancreatitis than in obstruction, and even if the bowels will not move, flatus can generally be passed. In case of doubt, exploration may reveal fat necrosis.

In perforation of a duodenal or gastric ulcer, there will generally have been premonitory symptoms pointing to the disease before the perforation actually occurs, and almost immediately an absence of liver dullness will usually be found.

In phlegmonous cholecystitis the symptoms are usually preceded by a swelling and well-marked tenderness beneath the right costal margin, at first distinctly localised and only later extending to the epigastrium and umbilical region, where the tenderness is generally found in acute pancreatitis; moreover, the history of gall stones or of typhoid fever will be elicited.

In gangrenous appendicitis the tenderness below



and to the right of the umbilicus and the swelling in that region take away the difficulty created by the pain in both appendicitis and pancreatitis being frequently felt at first just above the umbilicus.

In acute pancreatitis the excruciating pain, at first epigastric, but later general, the extremely rapid loss of weight, the irregular temperature, and the tender swelling in the abdomen opposite to and above the umbilicus are usually characteristic. Halsted ("Johns Hopkins Hospital Bulletin," 1901, Nos. 121, 122, and 123) lays stress on two symptoms—the excessive pain and cyanosis of the face and of the abdominal wall. The former symptom is universal, but the latter is not always present in our experience.

**Treatment of Acute Pancreatitis.**—In acute infective pancreatitis, treatment practically resolves itself into that of peritonitis commencing in the superior abdominal region; and as the only diseases which acute pancreatitis is likely to simulate are such as can only be relieved by surgical treatment, if we can prove that operation is beneficial in this class of cases, we shall have established the advisability of operating in all cases of peritonitis starting in the upper part of the abdomen.

We must not lose sight of the probability that many of the milder cases of pancreatitis or peripancreatitis recover, as in those reported by Drs. Osler and Manges ("Practice of Medicine," page 459), where the abdomen was opened and the diagnosis established without anything further being done. Nor should we forget that there is another class where neither medical nor

surgical treatment can do any good, for the patients die rapidly of shock or hæmorrhage before any diagnosis can be established. There is, however, an intermediate series, which, though acute, survive the initial shock and go on for days or in some cases for several weeks, ending in necrosis of the pancreas or in suppuration and abscess formation; but in either case death is the usual termination. In some of these cases it seems not improbable that an early operation, after recovery from the initial collapse and as soon as a diagnosis can be established, might be beneficial, by draining away the blood and inflammatory fluids, or removing the cause of inflammation and so putting an end to the inflammatory process.

The pain at the onset is so acute as to necessitate the administration of morphine, and the collapse will probably demand stimulants, which, on account of the associated vomiting, may have to be given by enema. In the early stages the symptoms are usually so indefinite that the indications for surgical treatment are not clear enough to warrant operation, and until the collapse has passed off no surgical procedure would generally be justifiable. The simulation of intestinal obstruction will probably lead to efforts to secure an evacuation of the bowels and relief to the distention.

Just as in perforative or gangrenous appendicitis an early evacuation of the septic matter is necessary to recovery, so in this equally lethal affection an early exploration from the front, through the middle line above the umbilicus, or from behind through the left costo-vertebral angle, is indicated, in order to evacuate

septic material, secure free drainage, and arrest the hæmorrhage, which in some cases leads to disintegration and necrosis of the pancreas.

The after-treatment will be chiefly directed to combating shock and keeping up the strength until the "materies morbi," both local and general, can be thrown off. Even if no pus be found, no harm should accrue by such an exploration, which can be made in a few minutes through a very small incision in the middle line above the umbilicus, if necessary with the aid of cocaine anæsthesia. After establishing the diagnosis by the anterior small incision, a posterior incision, which must be a free vertical one in the left costo-vertebral angle, so as to permit the insertion of the whole hand, if thought necessary, will enable the diseased organ to be very freely examined, and if necessary drained for the evacuation of pus and gangrenous material, thus involving no risk to the general peritoneal cavity and little danger of retained septic matter, as the drainage will be a dependent one.

**Pathology.**—After the full preliminary discussion of the pathological conditions prevailing in pancreatitis, we purpose to describe the pathological conditions found in the various forms of pancreatitis in connection with the clinical histories of the cases to be described.

The following cases are examples of acute gangrenous, hæmorrhagic, and suppurative pancreatitis, but it is our purpose to exemplify suppurative pancreatitis more fully under the subacute form of the disease.

CASE.—Report of a case of acute hæmorrhagic pancreatitis by Mr. Charles R. Keyser, Surgical Registrar at St. George's Hospital ("Lancet," October 19, 1901):

A man, aged twenty-six years, was admitted into St. George's Hospital on September 9th, under the care of Mr. H. W. Allingham. The history was as follows: On September 8th he was seized with a sudden and severe attack of vomiting, followed almost immediately by excruciating pain in the abdomen, chiefly on the left side, which had continued until admission. The vomiting had also persisted and was almost constant. The bowels were absolutely constipated, neither flatus nor fæces having been passed; there was also pain on micturition. The bowels were opened for the last time on September 6th. The patient stated that one year previously he had suffered from a similar, though milder, attack. The temperature was  $98.6^{\circ}$  F. and the pulse was 120, and he looked very ill. There was no cyanosis of the face or of the abdominal wall. The abdomen was slightly distended, chiefly around the umbilicus, was quite soft, and moved slightly on respiration and on palpation, especially on the left side of the umbilicus, where some resistance was felt. There was no tenderness in the right iliac region and there was no jaundice. A diagnosis of acute intestinal obstruction was made and immediate operation advised.

Gas and ether, and subsequently chloroform, having been given, Mr. Allingham opened the abdomen in the middle line below the umbilicus. On opening the peritoneum some blood-stained fluid escaped, but no other abnormal condition could be felt. There was no peritonitis and the intestines were but slightly distended. The skin incision was enlarged upwards and the intestines were examined from the jejunum to the rectum; there was no obstruction. Acute hæmor-

rhagic pancreatitis was immediately thought of, but the patient was not in a condition to stand any prolongation of the operation; before closing the abdomen it was noticed that the omentum was much redder than normal. On the next day the patient was distinctly better, the pain being less and the vomiting having stopped, but the pulse was 156 and the temperature was 97.8°. He complained of thirst and was unable to pass his urine. The abdomen was slightly distended and did not move on respiration; the bowels had not acted nor had any flatus been passed in spite of enemas and the passage of a rectal tube, etc. It was obvious, therefore, that the improvement, if any, in his condition was only in relation to subjective symptoms. He gradually became worse and died early next morning.

*Necropsy.*—Dr. R. S. Trevor, Assistant Curator of the Museum, who made the post-mortem examination, thus describes the condition found after death: There were ten ounces of blood-stained fluid in each pleural cavity. Both lungs were sodden with blood and serous fluid and there was much frothy mucus in the tubes. The pericardium was healthy. There was a small amount of blood-stained fluid in the peritoneal cavity and there were a few clots in the pelvis. There was no obstruction or strangulation of the intestines. In the neighbourhood of the pancreas the fat around and in the mesentery was very blood-stained. The pancreas was much enlarged and there were a few hæmorrhages in the liver. The gall bladder contained no stones and the bile was very fluid and escaped freely from the papilla duodenalis. The pancreas was increased in thickness to nearly four times its usual size; this increase mainly affected the body. The surrounding fat was deeply blood-stained and in places was softened into red masses of a jelly-like consistency

with a very offensive odour. There was much matting together of the parts, the pancreas being firmly adherent to the stomach, as well as to the spleen and left kidney, by a mass of tissue much infiltrated with blood. There were numerous areas of fat necrosis in the vicinity of the pancreas, as well as in the omental fat. On cutting into the pancreas the gland substance was seen to be much altered, more particularly in the body of the organ; in the head and tail lobulation was still present. The tail on section was uniformly red in colour; the head looked nearly normal, but there were a few darker areas to be seen. In the body the normal lobulation was absent and the gland substance was here of a greyish-black tint. It was softened and pulpy; the duct of Santorini opened into the duodenum by a separate papilla situated just above the biliary papilla. There was no calculus in the ampulla of Vater, but on squeezing the head of the pancreas white cheesy material escaped from the biliary papilla and the papilla for Santorini's duct. The splenic vein was dilated, and as it crossed the tail of the pancreas there was adherent ante-mortem clot in it, but the lumen was not completely occluded by clot. Dr. H. R. Spitta, assistant bacteriologist to the hospital, reported that cultures taken from the substance of the most affected area of the pancreas grew typical *Bacillus coli communis*.

CASE.—Opie ("American Journal of Medical Science," January, 1901) records the case of a patient who was seized with colic eighteen days before admission into hospital. On examination, slight jaundice, irregular fever, and leucocytosis were observed. There was a prominent fluctuating swelling in the right hypochondriac and epigastric regions. Laparotomy was performed and an abscess opened, which occupied the lesser peritoneal cavity. The patient

died from exhaustion. At the necropsy many gall stones were found in the gall bladder, and one 7 mm. in diameter situated in the common bile duct and compressing the duct of Wirsung. The pancreas was found moderately firm, studded with hæmorrhagic foci and opaque yellow areas. Opaque white patches were seen in the fat of the omentum, mesentery, etc. The pancreatic ducts were not dilated, and this fact, together with slightness of the jaundice, tends to show that the obstruction was not absolute.

CASE.—Hæmorrhagic necrosis of the pancreas. R. Morian ("Munch. med. Woch.," March 14, 1899; "Brit. Med. Journ. Suppl.," April 29, 1899) records the case of a woman, aged forty-four, with a good previous history, excepting that in the preceding year she is said to have had a short attack of biliary colic with jaundice. On April 2, 1898, she suddenly became ill with vomiting and severe pains in the abdomen. The vomit was green and the fæces natural. The urine was bilious and free from albumin or sugar. There was slight fever. On the fourth day Morian was called in and found the patient jaundiced and cyanosed, with dry tongue, superficial breathing, and a pulse of 112. The abdomen was distended, and its walls soft. The region of the gall bladder was tender, though the gall bladder itself could not be distinctly felt. On April 9th some gall stones were removed by operation, and cholecystotomy was performed. An irregular intermittent fever, however, persisted, together with other constitutional symptoms. On April 20th an abscess in the right elbow-joint was opened. On April 22d some of the contents of the stomach were evacuated by the cholecystotomy wound, and a day or two afterwards dullness and bronchial breathing were noted at the base of the left lung. The patient died on April 29th, exactly four weeks from the commencement of the

illness. Post-mortem examination showed hæmorrhagic necrosis of the greater portion of the pancreas (the head only of the gland remaining healthy), with multiple patches of fat necrosis in the omentum and peripancreatic tissues. The blood-vessels were not diseased. The spleen was double its natural size. Morian considers the case a typical example of pancreatic necrosis, in which the sudden commencement of the symptoms can simulate cholelithiasis, peritonitis (from perforation), and intestinal obstruction.

Two cases of acute hæmorrhagic pancreatitis reported in the "Lancet," November 10, 1900, by J. H. Bryant, M.D. "I publish these two cases as they present some curious features which I have not been able to find recorded before. If perchance I have missed any case in which similar changes have been noted, I take this opportunity of apologising to the author or authors for claiming them as new. In case I, when performing the necropsy, I found marked fat necrosis of the mediastinal and pericardial fat, and in both cases at the time of the operation the peritoneal cavity was found to be distended with large quantities of bile-stained serous fluid."

CASE I.—The patient, a bandmaster, aged thirty-six years, was admitted into Luke Ward at Guy's Hospital on May 31, 1899, under the care of Mr. L. A. Dunn, for excruciating pain in the abdomen. On Sunday evening, May 28th, he was playing in a band at Portsmouth and felt quite well and later in the evening he partook of some pigeon pie for supper. On coming up to London in the train on the same night he was seized with violent pain in his abdomen and was sick. He went to a medical man, who gave him an injection of morphia, and he passed a very fair night. On the 29th the pain was just as bad and the medical man gave him another morphia injection,



but he had a bad night. His bowels were fairly well opened. On the 30th the pain had much increased. He was very sick; he brought up a quantity of gas, and he passed a very bad night. On the 31st he was in a very collapsed condition; he was in great pain and was unable to take any food. He was removed to the hospital in the evening.

On admission the patient was found to be very collapsed. The pulse was 144 and feeble. He was in great pain and could not bear to be touched. He was soon afterwards seen by Mr. Dunn and myself. We ascertained that for some years he had suffered from attacks of abdominal pain and sickness, points which materially influenced our diagnosis. An examination of the abdomen showed it to be rather distended, especially in the upper part between the umbilicus and the ensiform cartilage. There was no pain, tenderness, or tumour in the right iliac fossa. The abdomen was most tender between the umbilicus and the ensiform cartilage, and the wall in this part was resistant. The abdomen was dull on percussion. He vomited some bile-stained matter and brought up a lot of foul-smelling gas. We came to the conclusion, taking into consideration the previous history of abdominal pain and vomiting, the sudden onset, and the position of the pain and tenderness, that the most likely diagnosis was one of perforating gastric ulcer. The possibility of acute hæmorrhagic pancreatitis was mentioned, but we thought that perforating gastric ulcer was more likely to be correct.

At 8.30 P. M. on May 31st Mr. Dunn performed laparotomy. The stomach and duodenum were found to be quite healthy. Patches of fat necrosis were discovered in the subperitoneal fat and in the mesenteric and omental fat. A large hard mass was felt in the region of the pancreas and a diagnosis of acute hæmor-

rhagic pancreatitis was made. On exploring the pancreas a large quantity of clear, dark-brown, bile-stained serous fluid escaped from the lesser peritoneal cavity and later from the general peritoneal cavity. The abdominal cavity was flushed out with hot saline solution, a drainage tube one inch in diameter was inserted, and the abdomen was closed. During the night he became very restless. On June 1st in the morning he appeared to be better and was able to take some nourishment. On the 2d he was worse; at two o'clock on that day the pulse was 126 and was very feeble in character. He took nourishment up to 1 P. M., but after that he refused it. At 6 P. M. his temperature rose to 102.2° F. and he died.

At the necropsy, which was performed by me on June 3d, the body was found to be very well nourished. The complexion was dark. There was no anasarca. The brain was not examined. The thyroid was much larger than normal, but on section it had a perfectly normal appearance. There was no pleurisy. The lungs were engorged with blood, but there was no pneumonic change. The mucous membrane of the trachea and bronchi was much congested. The mediastinal fat and the intrapericardial fat showed a number of opaque, milky-looking spots of undoubted fat necrosis. There was no direct communication between the peritoneal and pericardial cavities. There was no pericarditis. The heart weighed eight ounces. The myocardium was soft and flabby. The left ventricle was dilated. The endocardial lining was stained a deep red on both sides. Frothy blood was found in the right ventricle. The valves were healthy except for their colour. The mucous membrane of the œsophagus was deeply stained with bile. The stomach was congested. The duodenum presented a normal appearance and there were no signs of catarrh. Areas of

fat necrosis, varying in size from minute, almost perceptible spots to others one-sixth of an inch in diameter, some a dead white, some a golden yellow, others a greyish-yellow, and some a milky white, were seen throughout the peritoneal cavity wherever fat was situated. The peritoneal cavity contained a good deal of blood-stained fluid. There was no peritonitis. In the position of the pancreas a large hard mass about three or four times as large as a normal pancreas was found, which appeared to be chiefly made up of blood of a dark chocolate colour. On section, very little trace of any normal-looking pancreatic tissue could be seen; the whole organ was infiltrated with, and appeared to be tightly distended with blood. In places, dark-brownish breaking-down necrotic areas were seen, the largest being about a quarter of an inch in diameter. The interacinous, interlobular, and peripancreatic tissues appeared to be infiltrated with blood. The head of the pancreas appeared to be the most thickened part of that organ; it measured 4.2 centimetres in the antero-posterior diameter. The gall bladder was thickened; it contained several gall stones and a thick brownish fluid. The liver weighed sixty ounces and was normal. The spleen was also normal; it weighed four and a half ounces. An examination of the pancreas and its adjacent tissues some time after it had been lying in formalin solution showed some reddish areas of hæmorrhage in the fat of the mesentery similar in size and form to the areas of fat necrosis, and suggested that the earliest change which took place in the fat was that of hæmorrhage. The kidneys were normal; they weighed ten ounces. There was a considerable amount of hæmorrhage into the perinephric tissues, and in the fat numerous points of fat necrosis were seen.

On microscopical examination sections of the pan-

creas showed marked inflammatory changes. The outlines of the acini were just visible. The nuclei of the cells lining the acini were, however, unstained and were almost indistinguishable from the protoplasm of the cells, which was granular and cloudy in appearance. In places no traces whatever of the normal pancreatic structure could be seen, it being replaced by a structureless granular débris. No marked blood extravasations were visible; the blood-vessels generally were very distended with blood. The fat in the interlobular tissue showed many areas of fat necrosis. The increase in the size of the pancreas was more apparent than real, as the blood was almost entirely effused into the peripancreatic tissues. The mediastinal and pericardial fat showed typical fat necrosis.

CASE II.—The patient, a man, aged twenty-two years, was admitted into John Ward, Guy's Hospital, under my care on September 16, 1899, suffering from abdominal pain. The patient had had an attack of jaundice on the previous Christmas. He had frequently had attacks of abdominal pain since, which he ascribed to indigestion, and for a few days he had noticed that his urine was very dark in colour. Two days before admission into the hospital he had a severe attack of abdominal pain. He went to a medical man, who noticed that he was slightly jaundiced and thought that the case was one of biliary colic. The bowels had been opened regularly. As he became worse he was sent to the hospital and admitted.

The following was his condition on admission: The pulse was 140 and was very soft and compressible, and the temperature was 97.6° F. He complained of pain in the abdomen, but did not appear to be much distressed. His colour was good and he was not jaundiced. The tongue was slightly furred. There was some distinct fullness in the upper part of the abdomen

between the umbilicus and the ensiform cartilage. There was also a little fullness in the left hypochondriac region. The abdomen moved hardly at all on respiration. There was tenderness over the upper part of the abdomen, but it was not very intense. There was a curious area of dullness extending from the ensiform cartilage to the umbilicus and on each side to a point about an inch outside the nipple lines. The heart and lungs were normal. I saw him very soon after his admission and thought the diagnosis rested between acute hæmorrhagic pancreatitis and perforating gastric ulcer. Mr. Dunn was called in to see him and he agreed with the diagnosis, but as he was rather collapsed, he decided not to operate until some stimulants had been administered. Tincture of digitalis (fifteen minims) and solution of strychnia (five minims) were given hypodermically and a saline enema of one pint was injected, with the result that the patient's pulse improved in rate and volume, being 128 per minute just before the operation. A. C. E. was administered and he took the anæsthetic well.

After the patient had been carefully prepared to prevent any risk of sepsis, Mr. Dunn made an incision in the middle line of the epigastrium and opened the peritoneal cavity. Some bulging was found in the region of the small omentum. Mr. Dunn therefore opened the lesser sac, when a large amount of clear bile-stained fluid flowed out. The gall bladder was felt to be full, but no rupture of that organ or of the ducts could be discovered, nor was there any perforation of the duodenum or of the stomach. The pancreas did not appear to be enlarged. Some parts of the small intestine appeared to be a little collapsed. Fat necrosis was carefully looked for, but none was found. It was at first thought that the bile-stained fluid was confined to the lesser peritoneal cavity, but

a second incision was made below the umbilicus and bile-stained fluid flowed away from here also. Two drainage tubes were inserted into the upper opening and one into the lower opening, and the upper wound was partially closed with a double row of sutures. The operation did not clear up the diagnosis. As the pancreas did not feel enlarged, and as there was no fat necrosis visible, the diagnosis of acute hæmorrhagic pancreatitis was given up. The cystic duct was intact, but the bile duct and hepatic ducts could not be satisfactorily examined.

The patient was put back to bed and was placed on his left side. A port wine enema was given immediately and about one and a half pints of saline solution were infused into the axilla. He came round well from the anæsthetic and was very little sick. The pulse was almost imperceptible at 11.20 P. M. and the hands were cold. Twenty minims of brandy were given hypodermically and the saline enema was repeated. This caused a decided improvement in the pulse. The dressings were changed at this time. He subsequently became very restless, and one-sixth of a grain of morphia was given hypodermically, but had no effect, and at 2 A. M. on the 17th the pulse again became very bad. The dressings were changed. The pulse continued very rapid in the early morning, but improved later. He was of a good colour and the tongue was clean. The hands were cold, but other parts were warm. He was again very restless, and at 12.10 P. M. an injection of a quarter of a grain of hydrochlorate of morphia was given. This gave him about half an hour's sleep, and another injection of hydrochlorate (one-sixth of a grain) was given at 9.50 P. M. He was dressed twice, the dressings on both occasions being saturated with bile-stained fluid. On the 18th the abdomen became more distended and

was tender. Sickness commenced in the morning and the patient complained very much of flatulency. He was fed on albumin-water. He was very restless and could not keep still. The sickness increased in the afternoon, and at 4 P. M. he became very collapsed and he died at 5.30 P. M. The cause of death was considered to be peritonitis and the primary condition was thought to be rupture of the common bile duct or of one of the hepatic ducts. The fluid obtained at the operation contained a large quantity of bile. Cultures were taken and proved to be sterile both under aerobic and anaerobic conditions. No micro-organisms could be detected on microscopical examination of the fluid.

The necropsy was made twenty hours after death, when rigor mortis was well marked. The body was anæmic, but it was not wasted. The conjunctivæ were slightly tinged with yellow. The brain was not examined. There was no pleurisy, but there were numerous subpleural petechiæ. The lungs were normal. The heart weighed nine ounces and was normal. General acute peritonitis was found, the peritoneum being injected and covered with flakes of yellow bile-stained lymph. At the time of the operation there was no peritonitis, so that it must have followed the draining of the peritoneal cavity. The coils of intestine were found adherent to each other. There was a good deal of turbid bile-stained fluid in the peritoneal cavity. The peritoneal blood-vessels were much congested. The stomach and duodenum were quite normal; there was no ulceration or perforation, and the mucous membrane presented quite a healthy appearance. The small and large intestines were also quite normal in appearance. The pancreas was much enlarged, feeling about one and a half times as large as it should have been under normal conditions. It was

adherent to the adjacent structures and it was covered with lymph which was deeply stained with bile. The under surface of the liver was covered with lymph, and the connective tissue in the portal fissure had a sodden appearance and was deeply stained with bile. Bile could be squeezed from the gall bladder into the duodenum. The gall bladder was abnormally large, but its walls were œdematous. The common duct was patent and its mucous membrane was bile-stained; it was not ulcerated and there was no fistulous opening. The hepatic ducts were normal; so also was the cystic duct. A small calculus of about the size of a pea was found in the common duct, resting in a fold of mucous membrane just where the cystic duct joined it. The fat in the neighbourhood of the pancreas showed spots and patches of fat necrosis. The pancreas was firm and hard. There were many little infiltrations of blood either into the tissues of the pancreas or into the adjacent tissues. The parenchyma had a swollen, pink, and sodden appearance. I could not trace any direct cause for the bile-stained peritoneal fluid. There certainly was no fistulous communication between the gall bladder, the cystic duct, the common or hepatic ducts, and the peritoneal cavity, but the tissues in the neighbourhood of the bile passages and pancreas had a sodden appearance and were all deeply stained with bile. There were no signs of general biliary pigmentation, although the urines contained a large amount of bile, a condition that was noted before death. The liver weighed fifty-one ounces. A depressed, wedge-shaped, dull yellowish-looking area was found at the edge of the left lobe extending upwards for about half an inch and being about a quarter of an inch in thickness. In appearance it resembled an infarct more than anything else. The kidneys weighed eight ounces. The left kidney was normal. The perinephric fat sur-



rounding the right kidney was bile-stained and showed numerous opaque, milk-white, and orange-yellow spots and patches of fat necrosis. The spleen weighed three and a half ounces. It was quite healthy. The suprarenals were normal.

Sections from different parts of the pancreas were examined under the microscope. It was found that the pancreas was not involved throughout. All the sections examined showed areas where the acini and their cells appeared to be quite normal. Irregular-shaped areas were also seen, the central parts of which appeared to be made up of a granular débris, no outline at all of the acini or their epithelial cells being visible. Dotted about in this granular débris were a number of polymorphonuclear leucocytes. There were also several patches where this granular débris was stained a bright golden colour (bilirubin?). In places effusion of blood could be seen into the interlobular tissue. The blood-vessels generally were distended with blood and some of the smaller ones were filled with thrombi partially organised. At the periphery of the necrosed areas the outline of the acini and their cells had a very granular appearance and their nuclei were not stained. Some of these cells were stained a bright golden colour and contained granules of this pigment. Outside these the cells were faintly stained, and outside these again the acini appeared to be normal. There was undoubted parenchymatous inflammation, necrosis of the glandular tissue, pigmentation, and blood effusion and infiltration. Numerous patches of fat necrosis were seen also in the interlobular connective tissues. Sections stained with carbol thionin blue and examined with a one-twelfth oil immersion did not show the presence of micro-organisms. Cultures were taken and a pure growth of the *Bacillus coli communis* was obtained.

CASE.—A case of acute hæmorrhagic pancreatitis simulating intestinal obstruction; necropsy. Under the care of Dr. E. Deanesly at the Wolverhampton and Staffordshire General Hospital, reported in the "Lancet," July 1, 1899.

A man, aged thirty-nine years, was admitted into the Wolverhampton and Staffordshire General Hospital on April 10, 1899, with the history that for several years he had suffered from constipation, but he had never had any previous attack of actual obstruction of the bowels. Three days before admission he was seized suddenly with intense cramp in the abdomen, which increased and became agonising pain. The bowels had not been opened for three days before this. After about twenty-four hours the pain began to lessen and vomiting set in and became incessant up to the time of his admission to the hospital. The vomited material consisted of dark bile-stained fluid with no fæcal odour. Enemata had been administered by the medical man who attended the patient, but had only succeeded in bringing away a few scybala.

On admission the temperature was normal and the pulse was rather small, but not much accelerated. The facial aspect was free from any trace of the sunken and pinched appearance characteristic of grave abdominal mischief. The patient was a big, fat man, and was said to have consumed much beer. The abdomen was large and fat, but not much distended, and moved perfectly with respiration. The pain complained of could not be precisely located, but was said to be all over the abdomen. No abnormal swelling could be felt anywhere. There was no hernia. The diagnosis was intestinal obstruction, but there was no guide as to its nature or position.

On opening the abdomen by a median hypogastric incision a considerable quantity of fluid escaped, being

at first nearly clear and afterwards turbid, but not purulent or offensive. It lay in the iliac and pelvic parts of the peritoneal cavity. The small intestines were moderately distended and slightly reddened, but after a thorough search with the whole hand introduced, no constricting band, volvulus, or collapsed coil could be found. One of the most distended coils was chosen and a Paul's glass tube was tied into it. It was then returned inside the abdomen and surrounded by a few turns of gauze and the abdominal wound was closed. The operation, which lasted about an hour, was borne well. On the following day (April 11th) the patient appeared to be rather better, but vomiting had not ceased and no fæces had escaped through the Paul's tube. Water was poured into the latter through a funnel and tubing raised about eighteen inches above the bed; the water entered the bowel freely, but on lowering the funnel below the bed nothing returned, nor could any water or fæces be withdrawn from the tube by suction with a syringe. Advantage was taken of this fact to administer peptonised milk and brandy by pouring it directly into the small intestine in preference to the rectum. On the 12th there was no improvement in the patient's condition. The vomiting continued and the vomited material became rather offensive, but not really stercoraceous. Several large enemata brought away small but increasing quantities of clay-coloured motion. No fæces or flatus had escaped from the Paul's tube in spite of repeated irrigation and suction. On the other hand, it served well for the administration of nourishment. The heart was only kept going by regular doses of strychnia administered hypodermically. The anomalous features of the case now for the first time suggested its true nature, as it afterwards proved; but as it was thought that possibly the opening in the small intestine was below the as-

sumed obstruction, a second enterostomy was made in the left flank in order to reach the upper part of the bowel. From this there escaped a pint or two of dark brown fluid similar to the vomited material. In spite of this no improvement resulted and death occurred about sixteen hours later.

*Necropsy.*—At the post-mortem examination the peritoneum was found to contain a good deal of serum, but no lymph. The duodenum and the following few feet of small intestine were greatly distended. The distention grew gradually less on descending, until at the junction with the cæcum the bowel was quite collapsed and empty. The Paul's tube first inserted was twelve feet above the ileo-cæcal valve, and the second tube was seven and a half feet above this. The failure of the fluid to escape from the first tube appeared to be due to the mucous membrane of the intestine opposite its mouth having been pressed by the underlying coils against the tube so as to occlude it. Suction applied to the tube would then merely draw the mucous membrane more tightly against it, although a small amount of positive pressure from without would disengage it and allow fluid to enter the bowel. The omentum and parietal peritoneum were studded with very numerous small, yellowish-white, circular spots from one-eighth to one-quarter of an inch in diameter. They closely resembled miliary tubercles, but were flat and soft to the touch. They were most numerous about the root of the transverse mesocolon and the immediate neighbourhood of the pancreas and spleen, as well as on the portal fissure. The spleen was not much altered. The liver was very large and fatty, weighing sixty ounces. The pancreas was embedded in a dense mass of the small white patches, which were afterwards shown to be areas of fat necrosis. The pancreas was enlarged to quite twice the natural size and on section showed

to the naked eye the typical red-and-yellow mottled appearance of acute hæmorrhagic pancreatitis. The kidneys appeared to be healthy, but subsequent microscopical examination demonstrated well-marked interstitial nephritis. As regards the microscopical appearance of the pancreas, Mr. J. H. Targett, of the Clinical Research Association, reported that there were large areas of necrosis, congested vessels, and widespread extravasation of blood, with a striking absence of true inflammatory changes, especially in the vicinity of the necrotic areas. Hence the necrosis looked as if it had been produced by some chemical agent. The case was one of simple hæmorrhagic pancreatitis associated with or producing fat necrosis.

CASE of acute pancreatitis reported by E. S. Reynolds, M.D., F.R.C.P., in the "Medical Chronicle," August, 1900, page 328:

A hotel proprietor, aged twenty-nine, said to be temperate, had in May, 1897, an attack of pain in the epigastrium, followed by incessant vomiting, which lasted three or four days. In June, 1897, he had a more severe attack, but the pains were situated higher, over the cardiac region, and shot down the left arm; the heart's action was irregular. The attacks were thought to be due to angina pectoris. The patient was a heavy smoker. Another attack occurred in December, 1897, but the pain was more epigastric; it lasted four days, and was, like the previous ones, relieved by morphia and atropin. On February 6, 1898, whilst in good health, the pains in the epigastrium suddenly returned; they were very acute, and followed by vomiting. He was relieved by hypodermic injections, which were increased to four-fifths of a grain of morphia and one forty-fifth of a grain of atropin; but symptoms resembling those of atropin-poisoning followed. The pupils were dilated and did

not react to light; the mouth, throat, and skin were dry; there was a scarlatiniform rash on the chest; the pulse was 120 and weak. He was delirious and had visual hallucinations; but the effect was greater than was to be expected from the dose, and he had had similar doses without these symptoms. He recovered from this condition. The abdomen was rather resistant, especially in the epigastrium, where it was somewhat prominent and tender on deep pressure. The symptoms resembling atropin-poisoning recurred, and he died about sixty hours after the beginning of the attack. A necropsy showed a slightly enlarged cirrhotic liver and early interstitial nephritis. The pancreas was enlarged and hard, and there were gangrenous patches and recent hæmorrhages, as well as dark pigment patches, probably due to old hæmorrhages.

CASE.—Two cases of gangrenous pancreatitis with disseminated fat necrosis, published by Brennecke ("Journ. Amer. Med. Assoc.," Chicago, June 4, 1898).

The first case was a woman, aged forty-seven, for years addicted to alcohol, who was suddenly seized with severe cramps in the abdomen and fell to the ground. She had to be carried home, and the pain was only relieved by morphia. She vomited several times. The bowels were constipated for the first few days. The sharp piercing abdominal pain recurred several times. They were located in the epigastric region and did not radiate. On admission the abdomen was distended, tympanitic, and tender. There was an area of increased resistance in the right hypochondriac region. The tenderness, though general, was most marked in the epigastric region. The urine showed a slight amount of albumin and a few hyaline casts. Laparotomy was performed on the eighth day. The intestinal coils were found matted together by

fibrinous exudation. The omentum was thickened, hyperæmic, and studded with small greyish areas, varying in size from a pinhead to a pea. These were foci of typical fat necrosis. The peritoneal cavity, which contained considerable clear, straw-coloured fluid, was walled off with iodoform gauze; drainage was established. The pain was much less for a time after the operation. The discharge was at first clear, but soon contained shreds of fibrin. Death occurred twenty-five days after the operation, with symptoms of a slow form of sepsis.

The necropsy showed the omentum, and, to a lesser extent, the parietal peritoneum studded with foci of fat necrosis, surrounded by a narrow hyperæmic zone. The intestinal coils were adherent to each other and to the omentum, but easily separated. A considerable quantity of bloody fluid was found in the peritoneal cavity. The pancreas was represented by a mass of grey, granular, necrotic tissue, easily torn. The consistence was more liquid in the head and right half. The left half was studded with numerous greyish areas, which fused together in places, forming larger greyish or yellowish masses. These areas were distinctly cheesy and soft, and in places appeared to be formed of retained and inspissated pancreatic secretion.

The second case was that of a man, aged forty-three, who had also been much addicted to alcohol. He was taken ill one month before admission to the hospital. He began to have severe pains in the abdomen, which required morphia. He vomited constantly. The pains were located chiefly in the epigastrium, but sometimes in the right and left iliac regions. On admission the abdomen was much distended, there was dullness in the flanks and in the right iliac region. His abdomen was diffusely tender, most in the iliac fossa. The pulse varied between 116 and 120, and was very

weak; the temperature was usually normal, rising at times to 101° F.; respirations were 28 to 36. An exploratory incision was made six days after admission. As soon as the peritoneal cavity was opened, a grey turbid fluid, containing shreds of necrotic tissue and fibrin, escaped. The omentum was much reddened, and studded with white areas. The intestines and omentum were matted together by fibrinous adhesions. The patient died soon afterwards.

The necropsy revealed well-marked peritonitis. In the omental fat, and to a lesser degree in the abdominal wall, were greyish-white patches. The abdominal cavity contained a turbid, greyish-red fluid. A large cavity was found in the region of the pancreas. It contained fluid of a dirty yellowish-grey colour, mixed with shreds of disintegrated material. The fluid had escaped into the abdominal cavity through a rupture, whose margins were necrotic and of a bluish-grey colour. Stretching across the cavity were remnants of the pancreas, much softened. The entire pancreas was involved in the cavity and contents. The fat tissue around the pancreas contained numerous white areas, like those found in the omentum. A bacillus, corresponding to the cultural and other characteristics of the *Bacilli coli communis*, was found in the blood from the heart, in the spleen, liver, kidney, and in the necrotic areas in the subperitoneal fat.

CASE.—Mr. A. D. Fripp and Dr. J. H. Bryant ("Lancet," Dec. 17, 1898) related a case of acute hæmorrhagic pancreatitis.

The patient was a man, aged forty-two years, admitted to Guy's Hospital on September 18, 1898. He was seized with pain two days before and was admitted in a state of collapse. The pain was chiefly above the umbilicus. An exploratory laparotomy was performed at once. No obstruction was found. There was a



good deal of blood-stained peritoneal fluid; the omentum had a shotty feel, but no necrotic nodules were found. There was extreme contraction of the small intestine in places. The abdomen was closed and the patient died forty-eight hours later. The necropsy was performed eleven and a half hours after death. The abdominal wall was very thick owing to the great increase of subperitoneal and subcutaneous fat. The omentum was large and thick. Extensive fat necrosis was found in the omentum, mesocolon, fat around the pancreas, and the subperitoneal fat both visceral and parietal. There was extensive hæmorrhage into the fatty tissue around the pancreas in the gastro-splenic omentum. The pancreas was of about twice its normal size; it was of a dull dark, purplish colour, and on section appeared to be infiltrated with blood. Patches of fat necrosis were also visible in the interlobular tissue of this organ. The stomach, duodenum, and the rest of the intestine presented a normal appearance except for a little ecchymosis around the cardiac orifice of the stomach. The heart weighed thirteen ounces; the valves and blood-vessels were normal in appearance. On microscopical examination the most striking change noticed in all the sections was the enormous amount of blood present, which could be seen in large quantity beneath the capsule of the pancreas, in the interstitial tissue between the lobules, between the acini themselves around the ducts, and in the fat cells and intercellular spaces of the periglandular tissues. A good many patches of fat necrosis were seen in the interlobular and periglandular tissues. The glandular acini immediately adjacent to these areas were in various stages of necrosis, and beyond these again the cells of the acini showed cloudy swelling and their nuclei were faintly stained and indistinct. Apart from these areas there was very little evidence of any parenchymatous

inflammation, the nuclei and protoplasm of the cells staining well with the various reagents. The pancreatic ducts were not obstructed; the cells presented a normal appearance. In the fibrous tissue of and around the ducts a good deal of blood was seen. The fat necrosis presented the usual features characteristic of that condition. Sections stained with methylene-blue showed a few rod-shaped bacilli in the blood throughout the organ. There were no bacilli in the pancreatic ducts. Sections of the nerves and ganglia from the pancreatic duodenal plexus were examined, but nothing abnormal was found. Cultivations were taken from the centre of the body of the pancreas, with strict precautions to prevent the possibility of any accidental contamination, and a pure culture of the *Bacillus coli communis* resulted. The pathological process in this case appeared to be a primary acute interstitial inflammation associated with the presence of the *Bacillus coli communis* and characterised by extensive hæmorrhage, as stated above, and by secondary necrosis and inflammation of the parenchyma in the immediate vicinity of areas of fat necrosis. The distribution of the bacilli suggested the blood-vessels as the probable channel of infection.

CASE.—Five cases of acute pancreatitis reported by Dr. Newton Pitt and Mr. Jacobson ("Medical Press and Circular," Dec. 14, 1898, page 619).

1. *Acute Hæmorrhagic Pancreatitis*.—A corn chandler, aged forty-two, temperate, had three attacks of severe abdominal pain with vomiting, each lasting about an hour, in August and September, 1898. On November 12th he had another attack of intense pain, with vomiting and constipation. The pulse was 120, and abdomen rigid. On the 14th severe diarrhoea, temperature 100°, and a swelling in the upper part of the abdomen. He was seen by Dr. John Young, of

Stamford Hill, who brought him up to Guy's Hospital. The man was extremely ill and difficult to examine. A retroperitoneal tumour with impaired resonance was found above the umbilicus, the motions were normal in colour, but the man was so ill that it was thought better to defer any operative interference. Under examination the urine was found to contain albumose; there was marked leucocytosis (22,500 per c.mm.), and the tumour lay behind the stomach, pushing forward the duodenum and greatly distending the former. The evidence pointed to a pancreatic cyst of an abscess in connection with either pancreas, gall bladder, or gastric ulcer, or a rapidly growing sarcoma. As the tumour was increasing in size, Mr. Jacobson decided to open the abdomen, and found extensive fat necrosis, and the tumour with the lesser omentum, intestines, and stomach matted to it. The oozing from every part when disturbed was excessive, and the firm feel of the mass prevented any radical treatment. The abdomen was closed and the patient died next day. At the inspection there was an abscess cavity some four inches across, in front of which was the stomach and lesser omentum and behind lay the sloughy pancreas.

2. *A Retrogastric Pancreatitis Abscess.*—A middle-aged lady was seen by Dr. Pitt some years ago for intense abdominal pain and vomiting. She was found to have a large abscess behind the peritoneum to the right loin, where it was opened. Most of the pancreas had disappeared, the abscess occupying its site. It is now clear that this was a case of acute pancreatitis.

3. *Acute Hæmorrhagic Pancreatitis.*—A woman, aged seventy, was seen by Mr. Leedham Fuller, of Streatham, on October 16, 1898, for intense epigastric pain with sickness and collapse after an unusually good breakfast. The pain was not relieved by the vomiting.

There was a constant desire to defecate, which was not relieved by an enema which brought away a constipated motion containing particles of fat. There was slight tympanites, which steadily increased until death, forty-eight hours later. She was said to have had a similar attack eighteen months previously. Post-mortem: Fat necrosis of the omentum. There was an acute hæmorrhagic pancreatitis.

4. *Acute Suppurative Pancreatitis*.—Mr. G., aged fifty-three, alcoholic. November 12, 1863, at 2 A. M., he took a draught of cold water; at 3 A. M. he was seized with intense epigastric pain with vomiting. The symptoms quieted down on the 17th. On the 24th a pulsating tumour imperfectly resonant on percussion was noticed above the umbilicus; this became less distinct in the knee-elbow position. The pain ceased. The vomiting returned at the end of January, and he died on February 8th from exhaustion.

Post-mortem: The omentum formed a black, puckered mass, the stomach was greatly distended; the lesser sac of the omentum contained a well-defined abscess above and behind the stomach. The greater part of the pancreas was healthy, but some distended ducts communicated with the abscess.

5. Man, aged sixty, a publican, had had severe abdominal pain and vomiting for three months, the attacks recurring every three or four days. For four years he had had attacks of gastric pain from time to time. On admission under Dr. Habershon's care there was a tender pulsating tumour in the upper part of the abdomen. He vomited frequently and died of exhaustion.

Post-mortem: Some early peritonitis; a minute opening was found in the mesocolon leading to an abscess cavity behind the stomach and filled with a brown fluid. At the posterior part of the abscess two and a half inches of necrotic pancreas was found. There

were numerous nodules of yellow concrete matter in the wall of the cyst (probably fat necrosis).

CASES reported by Dr. F. B. Lund, "Boston City Hospital Reports," December, 1900:

1. *Acute Pancreatitis with Fat Necrosis*.—History of previous attacks: Operation one month after onset. Median laparotomy, and lumbar incision for drainage. Immediate improvement. Second operation for drainage of pus pockets through lumbar incision five weeks later. Recovery.

Clinical History: Mrs. S., aged thirty-six, was seen by Dr. Henry Jackson, in consultation with Dr. Flanders, on March 4, 1899. As a girl she had had various symptoms suggestive of hysteria or a highly neurotic condition. Two years previously she had had three attacks of pain in the epigastrium, running through to the back. This pain she described as boring in character, as accompanied by vomiting, but not by jaundice. Three weeks before she was seen by Dr. Jackson she had had an attack of severe pain in the epigastrium and left hypochondrium, accompanied by vomiting, and relieved only by morphine. There was no interference with the action of the bowels. The vomiting persisted for one week. She had had moderate fever since the beginning of the attack, and a pulse of 90 to 100.

On March 7th she was seen by Dr. J. C. Munro, from whose notes the following account is abstracted.

Examination showed a very corpulent woman suffering from pain, general abdominal tenderness and spasm, especially marked in both hypochondria and epigastrium. Tumour, especially in left renal region and hypochondrium and over gall bladder. Leucocytosis. Pulse 120. Urine negative.

Diagnosis: Probable rupture of gall duct with retroperitoneal abscess. Pancreatitis, and possibly abscess

or tumour of kidney complicating gall stones, were considered.

March 8th, operation. A long median incision was made through the very thick abdominal walls in the epigastrium. The omentum, which was lightly adherent to the abdominal parietes, contained nodules of fat necrosis, which were also noted on the parietal peritoneum. On freeing the omentum the pancreas was found swollen in the median line, and on the left enlarged so as to form a tumour, which felt hard and nodular. The finger was pushed into the tumour in various directions, in the hope of finding pus. The patient's condition at this time became alarming; the pulse rose to 180, and she became cyanotic. There was moderate bleeding from the fresh adhesions about the pancreas. An opening was made in the left lumbar region, using the finger as a guide, and the anterior wound closed with deep sutures of silkworm-gut. Through the lumbar opening the tumour was broken up by pushing the finger in various directions, and a nodule removed, together with some omentum and fat necrosis. The wound was packed with iodoform gauze around a glass drainage tube, and a baked gauze dressing applied. The patient was in a very poor condition at the close of the operation, and was stimulated freely. During the night she rallied somewhat, though vomiting continually. At 10 A. M. on March 9th the vomiting ceased and the bowels moved. On March 12th, on removal of the gauze drains, there was a free discharge, with fine fat globules. On March 20th there was still considerable greenish discharge from the lumbar wound; the anterior wound had healed by first intention. There was no albumin or sugar in the urine. The patient continued to improve, the wound discharging freely until April 8th, one month after operation, when a rise of temperature to 103° took

place, with vomiting and prostration. During the next four days the temperature ran between  $101^{\circ}$  and  $105^{\circ}$ , and the patient was nervous, restless, and discouraged. On April 11th tenderness and a tumour were noted in the left renal region. While probing the sinus the probe passed through a thin wall into a cavity, with evacuation of several ounces of sweet, greenish pus of molasses odour, containing particles of broken-down pancreas and fat necrosis. On April 15th, under ether, the sinus was enlarged, and its posterior wall broken through, admitting the finger into several pockets containing greenish, sweet-smelling pus. These pockets reached to the median line, downwards along the posterior abdominal wall for two and a half inches, and upwards along the latter for five and a half inches, passing behind the stomach towards the epigastrium. A counter opening on a level with the floor of the pockets was made posteriorly in the left lumbar region, and drainage with rubber tubes and gauze wicks was provided. Following this operation there was a very free discharge from the sinuses. Subsequently this discharge became fæcal, and was noted to contain certain particles of food eaten the day before it appeared in the discharge. This discharge ceased in about ten days, and the patient steadily improved, and went on to complete recovery, leaving the house for a ride on June 10, 1899. Her health ever since has been excellent.

CASE reported by Dr. F. B. Lund:

Summary: Acute hæmorrhagic pancreatitis. Operation one week after onset. Evacuation through median and right lateral incision of blood and necrotic fat. Relief of symptoms followed by rise of pulse, temperature, and respiration, with cyanosis. Dullness and râles over bases of both lungs. Exploratory incision in left lumbar region. Death eight weeks after opera-

tion, from hæmorrhage from erosion of an artery in wall of splenic flexure. Autopsy: Abscess in lesser peritoneal cavity, with perforation of diaphragm above spleen. No retroperitoneal or lumbar pockets. Perforating ulcer of splenic flexure of colon, with hæmorrhage from an eroded artery. Perforating ulcer of jejunum.

Clinical History: N. G., aged thirty, dressmaker, entered the City Hospital July 26, 1900. Service of Dr. H. W. Cushing. Three years ago had "indigestion" for about a year, followed by attack like present, but less severe; associated with abdominal pain, running into left shoulder; fever; vomiting. No jaundice; bowels regular; sick in bed two weeks. Has been well since. Gaining in weight. One week ago woke up with abdominal pain and vomiting. Says she was not feverish. No chill then or since. Pain was crampy, and not localised. Vomiting better. No blood. Bowels moved with enemata and laxatives; dejecta just after onset were very light-coloured; since then dark; no blood noted, vomited day after onset, but not since. Two days after onset abdomen was distended and tender. Urine has been high-coloured, never bloody. Since onset there has been shortness of breath, and deep breath has been painful. No cough or expectoration. Pain has remained about the same since onset; some pain in left shoulder.

Physical Examination: Corpulent. Pupils equal and react. Scleræ yellow. Tongue fairly clean. Temperature 100.8°; pulse 128; respirations 40. Heart's action somewhat irregular. Aortic sound occasionally reduplicates. The first pulmonic is replaced by a soft murmur; pulmonic second not accented.

Lungs: Fine moist râles in right back and axilla. On left back near angle of scapula, there is dullness,



diminished broncho-vesicular respiration; increased voice sounds; fine crackling râles.

Liver: Dullness begins at fifth space.

Abdomen: There is muscular spasm and tenderness in the upper abdomen, especially on left. A firm, smooth, resistant mass is felt occupying the epigastrium, mostly to the right of the median line and extending down to the level of the umbilicus, where edge of mass is apparently felt. Percussion note is tympanitic over this mass. There is slight distention. No free fluid could be demonstrated. No tenderness in lower abdomen. There is slight pitting of the ankles.

July 27th: Seen in consultation by Drs. Post and Jackson, who advise operation at once. The diagnosis was an abscess or inflammatory tumour in epigastrium, due to pancreatitis or localised abscess from perforating gastric ulcer. Operation, by the writer, under local anæsthesia with 1 : 1000 cocaine solution. Incision five inches long, median line above umbilicus.

On entering the abdomen a tumour was felt just to the right of the median line, adherent by light fresh adhesions to the abdominal wall. Tumour could be felt to fluctuate. The patient was then etherised to the primary stage, and a second incision made just outside the outer border of the right rectus muscle. Finger was passed into the centre of the tumour, which was found to consist of necrotic tissue and blood clot. A considerable amount of blood clot was scooped out, and the cavity freely irrigated from one incision to the other. The finger reached the region of the pancreas. Gauze packing was attempted, but profuse hæmorrhage required immediate removal and repacking of the cavity, which controlled the bleeding. Incisions partially closed with silkworm-gut. Patient stood operation very well.

July 28th: Fairly comfortable night. No vomiting;

no cough. Bowels moved this morning. Pulse 148; respiration 52. In the evening abdomen was slightly distended, and patient complained of pain in lower abdomen. Analysis of urine: Trace of albumin. Few blood globules. Hyaline and fine granular casts.

July 29th: General condition improved. Pulse 124; respiration 40. Bowels moved freely. First dressing done; gauze soaked with bloody discharge, odourless; no evidence of suppuration.

Pathological Report: Probably hæmorrhagic pancreatitis or peripancreatitis, with fat necrosis.

July 31st: All wicks removed, except one in each incision. Considerable dark liquid followed removal of packing from lateral incision; quickly stopped. Wounds irrigated with salt solution. New wicks inserted.

August 1st: Remaining wicks removed. Irrigated from one incision through to other. Rubber drainage tubes applied. Discharge less. Continues to improve.

August 4th: Pulse 124; temperature 101; respiration 35. There is a free discharge of brownish, thick fluid, with numerous shreds from both incisions; odourless. Wound irrigated and dressed twice daily. Patient complains of some pain in left hypochondrium. Takes nourishment well, and is receiving free stimulation. Oxygen s.o.s. cyanosis.

August 6th: Twice since last date has had periods of delirium and unconsciousness, with rapid pulse and respiration. This morning respiration is laboured; patient cyanotic; tracheal râles. Temperature 101; pulse 140; respiration 50. Signs of consolidation remain in the left lower lobe. Coarse râles in both chests. In left lumbar region there is tenderness, slight bulging, and dullness. On account of these signs an exploratory incision was made under cocaine in the left lumbar region. No pus was found in the retroperitoneal space. Incision was packed.

August 13th: Condition rather better. Colour good. Temperature 99.8; pulse 124; respirations 36. Discharge from abdominal incision is more free, and consists of a thick brownish material with numerous sloughs. Lumbar incisions clean and healing.

August 20th: Several large masses of sloughing tissue were washed out to-day.

Pathologist's Report: Necrotic fat tissue with considerable hæmorrhage.

August 24th: Pulse and respirations continue elevated. No cyanosis. No expectoration. Signs continue in left lower lobe. To-day there is biliary fluid on the dressing. A piece of bowel in the lower angle of the right-hand incision has perforated, allowing the escape of intestinal contents. Closed with Lembert's sutures.

August 28th: Attempt to close fistulous opening unsuccessful, and a second one has appeared just above the first. Discharge from incisions is diminishing in amount.

September 3d: Tube omitted from median incision. Lumbar incision healed. Third incision presents deep sinus above and two openings in exposed knuckle of gut below. Discharge is less in amount, stained with bile and mixed with intestinal contents which escape from the fistulæ. General condition slightly improved.

September 5th: There is some digestion of the skin about the intestinal fistulæ.

September 10th: Patient appeared as well as usual this morning. Temperature 99; pulse 120; respirations 44. Binder had just been unpinned preparatory to dressing, when blood was noted gushing from incision in right side. Patient became quickly blanched. Active bleeding stopped quickly. As soon as preparation could be made, light ether was given, incision enlarged, and cavity packed with gauze. Foot of bed

elevated. Salt infusion and stimulants were given subcutaneously. Patient reacted somewhat, but pulse gradually failed, and patient died at 1.45 P. M., eight weeks after the operation.

Autopsy: Dr. Steensland, three hours post-mortem. Body of a well-developed, very well nourished woman, thirty years old. Healed operation incision in epigastric region in median line, and one in left lumbar region. Longitudinal incision 12 cm. long in epigastric region to right of median line.

Peritoneal Cavity: Extensive, firm, fibrous adhesions about the two epigastric incisions, involving chiefly the omentum between the transverse colon and the pyloric end of the stomach. From the skin incision a passage leads into the lesser peritoneal cavity. The walls of this passage and of the lesser peritoneal cavity have a dirty blackish appearance. The lower lobe of the left lung is firmly adherent to the parietal and diaphragmatic pleura. When these are separated, a hole in the diaphragm 6 cm. in diameter, surrounded by blackish necrotic borders, is revealed. Through this is projecting a perfectly free blackish mass about the size and shape of a normal pancreas. It probably passed up into the pleural cavity after the adhesions of the lung to the diaphragm were separated. On section it is blackish in colour, and shows a few greyish markings, suggesting the lobulation of pancreatic tissue. The mass is soft, and of a somewhat pasty consistence. The cavity contains no fresh blood clot. The spleen is completely concealed by firm adhesions. When the splenic flexure of the colon is separated from its relation with the lesser peritoneal cavity, its external surface appears blackish necrotic, and a hole in the wall 1 cm. in diameter with blackish necrotic borders is found.

In the region of the operation incision over an area

4 cm. in diameter the same blackish appearance of the external surface is seen. The wall is here much thinned, leaving practically nothing but mucosa. The pancreas is concealed by the same blackish discolouration. The left border of the liver is bound to the anterior wall of the stomach by firm fibrous adhesions. The general peritoneal surface is smooth and glistening, presenting no evidence of inflammation. Numerous fat necroses in the tissue surrounding the lesser peritoneal cavity, the largest 6 cm. in diameter. Some are considerable harder than the surrounding fat.

Pleural Cavities: Upper lobe of left lung free. Few fairly firm fibrous adhesions over lateral and posterior surfaces of middle and lower lobes of right lung.

Lungs: On section, lower part of left lung darker in colour than surrounding tissue, lax, and apparently collapsed. Upper portion of left lung and all of right lung pink and downy. No nodules at apices. On section, some colour presented. Mucosa of bronchi pale. Bronchial lymph nodes not enlarged.

Spleen on section, pale red, soft. Lymph nodules distinct, trabeculæ indistinct. Considerable increase of pulp.

Gastro-intestinal Tract: Mucosa, except as described above, pale. Small intestine contains little bile-stained fluid material with no evidence of blood. Transverse colon contains 50 gm. of fresh blood clot. Perforating ulcer of splenic flexure and another of upper part of jejunum.

Pancreas: Probe readily introduced into pancreatic duct, which passes through the centre of practically the whole length of the pancreatic tissue. Mucosa of duct smooth and pale. Its orifice is in common with the bile duct. Pancreas extends from the duodenum to spleen and adrenal. It is apparently slightly smaller than normal. Pancreatic tissue is lax. On

section, colour is more yellowish than normal, and the lobular markings are somewhat indistinct. In the intestinal tissue are a few fat necroses, the largest 5 mm. in diameter.

Liver weight, 1280 grammes. Very pale, smooth, and normal consistency. On section very pale, lobular markings distinct. Gall bladder filled with small gall stones and a small amount of normal bile. Mucosa normal. Mucosa of common bile duct pale. No gall stones present in the duct.

Microscopical: Subsequent careful examination, by Drs. F. B. Mallory and H. C. Lowe, of the mass so closely resembling necrotic pancreas projecting through the diaphragm showed that it consisted of nothing more than necrotic fat tissue.

Anatomical Diagnosis: Hæmorrhagic peripancreatitis; fat necroses of pancreas; general subperitoneal fat necroses; necrotic mass in lesser peritoneal cavity (fat necrosis); aperture connecting left pleura and lesser peritoneal cavity; atelectasis of left lung; hæmorrhage into colon; localised chronic adhesive peritonitis; cholelithiasis; perforating ulcer of splenic flexure of colon; perforating ulcer of upper part of jejunum.

Remarks: This case presents many points of interest, and though resulting fatally, there can be no doubt that life was prolonged by the operation, and might have been saved had the abscess extended into the left lumbar region instead of perforating the diaphragm into the pleura.

The patient's condition on entering the hospital was so bad that a very grave prognosis was given, and on account of the condition at the base of the left lung it was decided to dispense with general anæsthesia. When,

owing to the necessity for a second incision and extensive manipulation, ether had to be given, the operation was performed as rapidly as possible, and on account of a really alarming hæmorrhage the cavity had to be rapidly stuffed with gauze. A fatal prognosis was given immediately after the operation. The course of the abscess upwards through the diaphragm points to an early infection extending probably to the left pleura, and perhaps accounting for the signs which were noted at entrance over the lower left back. The walling off of this process may have accounted for the process thought to be a pneumonia, which followed the operation. If the lower left pleura had been drained by resecting a rib, it is possible that the patient might have been saved. Pocketing was expected, and looked for in the left lumbar region, but naturally not found. The abscess cavity lay well up under the diaphragm, and the mass of necrotic tissue extended through the hole in the diaphragm above the spleen.

The fact that enough nearly normal pancreas was left at the time of the autopsy to raise a doubt whether the disease was not almost entirely a peripancreatitis, with no permanent injury to the pancreas other than an extension inwards from its periphery of a few areas of fat necrosis, would indicate that in case of recovery there would have been no permanent interference with the functions of the pancreas. The presence of gall stones in the case is noteworthy. The fact that the mass found at autopsy projecting through the diaphragm, and thought at first to be sloughing pancreatic tissue, proved on careful examination to be

nothing more than necrotic fat tissue, points to the case having been one of peripancreatitis rather than pancreatitis. The normal condition of the ducts renders it difficult to account for the disease by the escape of pancreatic fluid. The discovery that this mass so closely resembling necrotic pancreas was really necrotic fat tissue casts a doubt on the reported cases in which patients have recovered after passing a necrotic pancreas by rectum (Trafoyer, quoted by Chiari). May not the so-called necrotic pancreas have been merely a mass of necrotic fat?

CASE.—Summary: Acute hæmorrhagic peripancreatitis. On the fourth day, operation, in spite of severe prostration, on account of symptoms of epigastric peritonitis. Pancreas dark in colour and surrounded by areas of fat necrosis. Incision and gauze drainage. Gall bladder and ducts noted to be full of gall stones. Death three and a half hours after operation. Pancreas removed after death. Duct of Wirsung and central portion of pancreas normal. The connective tissue surrounding the pancreas infiltrated with blood. Areas of fat necrosis numerous over the surface of the pancreas, and diminishing rapidly towards the central portion, which was normal in appearance.

Clinical History: M. W., aged thirty-one, housewife, entered July 11, 1900, at 11 P. M., service of Dr. H. W. Cushing. Has had three attacks which patient says were "similar to present"; the first, five years ago; the second, eight months ago; the third, three months ago. Not one of these attacks ever so severe as present. Previous attacks were associated with abdominal pain, vomiting, and fever; in one attack, at least, patient was jaundiced. (Patient too sick to give an accurate account of symptoms.) In interval, since last attack,



has been well; able to eat anything; bowels regular; no pain.

The present attack began on July 6th, in the afternoon, with sudden sharp pain, which started in the back, between the shoulders, and ran round to the epigastrium. Feverish, but no chill. No vomiting. Bowels moved naturally. The next two days was more comfortable; slept fairly well; went to a dispensary for treatment. On July 9th pain became much more severe. Fever continued. No chill. Vomited twice. Bowels moved a number of times following castor oil. Vomitus yellow and bitter. Dejecta loose, brownish, not particularly offensive; not bloody. Unable to sleep on account of pain. No cough; no pain in chest. Yesterday, pain continued. Vomited once. Bowels moved once. Abdomen began to distend. Motions of breathing became painful. Obligated to lie on back, as every motion aggravated the pain. To-day symptoms have continued. Distention has increased, but there has been no nausea or vomiting. Bowels have not moved to-day, but patient has passed gas. Frequent eructations, also, of gas. Pain is a dull ache in back and abdomen; not localised in any particular spot at any time, but in upper rather than in lower abdomen. Very restless; unable to sleep; mouth dry. Urine has been darker than normal, but not bloody; passed normally. Has noted no yellowness as in previous attack.

Corpulent; face dusky; eyes bright; pupils equally contracted. Tongue dry, with white coat. Whole surface of body covered with cold sweat. Hands and feet cold. Pulse 128, weak. Temperature 101.4°. Respiration 38, shallow. Slight yellowness of conjunctivæ. Lungs negative. No œdema of ankles. Abdomen markedly distended; generally tender, espe-

cially in epigastrium and left hypochondrium. Marked spasm in these regions. Slight tenderness and spasm over rest of abdomen. Distinct resistance in epigastrium as of a prominent tumour, which was tympanitic, as was the rest of the abdomen. Operation under cocaine proposed, but refused. Ether was therefore given at 3.30 A. M., July 12th. Operation by the writer. Incision five inches long, median line, above umbilicus. General peritoneal cavity normal. Transverse colon greatly distended. On tearing through transverse mesocolon, at the bottom of the lesser peritoneal cavity there was felt the much-thickened pancreas. Seen to be dark in colour and studded with areas of fat necrosis. A small amount of turbid fluid lay in the bottom of the cavity. Gall bladder and ducts contained a large number of small gall stones. On account of the serious condition of the patient nothing further was done than to insert rubber tube and three strips of gauze down to necrotic pancreas. Incision partly closed with silk. Patient left table in great shock. Duration of operation fifteen to twenty minutes. During and after operation free stimulation by brandy, strychnia, atropine, digitalis, and salt solution. Patient rallied slightly, but the pulse gradually failed and she died three and a half hours after the operation.

Remarks: This case was operated upon for the reason that the symptoms suggested a general peritonitis, beginning in the epigastrium, and incision, irrigation, and drainage in this event were thought to give a possible chance to the patient.

The operation showed that the prostration of the patient was not due, as thought probable, to a general peritonitis, but to a pancreatitis. This marked tendency to collapse and shock in this disease has been

explained by various writers as due to the close relation of the organ to the solar plexus.

The result of the examination of the pancreas agreed with that of the autopsy on Case 2, as showing that the case was a peripancreatitis, so to speak, and indicating that if recovery had taken place the pancreas would not have been sufficiently damaged to interfere seriously with its functions.

CASE.—Summary: Acute hæmorrhagic pancreatitis in a male thirty-seven years of age, who had had previous attacks of epigastric pain. Seen by surgeon, Dr. W. P. Bolles, two weeks after onset of attack. Operation contra-indicated by poor condition of patient. Death on third day after admission to hospital.

Autopsy: Hæmorrhagic pancreatitis with necrosis of pancreas and abscess in lesser peritoneal cavity. Extensive disseminated necrosis of subperitoneal fat. Cholelithiasis.

Clinical History: G. L. S., aged thirty-seven, married, bookkeeper, was admitted to the service of Dr. W. P. Bolles on January 11, 1899. Four months before entrance he had an attack of epigastric pain, vomiting, and jaundice lasting five days. Two months later a similar attack, lasting one week. Two weeks before entrance the present attack began with a dull ache in the right hypochondrium and vomiting, with prostration. After a week the pain and vomiting ceased, but retching continued. During the five days preceding his entrance he had two chills.

Examination: Well-developed, rather than thin. Abdomen somewhat distended and tympanitic, except for slight dullness in the flanks. Temperature 103.2°; pulse 124, weak. Slight tenderness to pressure in the right hypochondrium. The upper border of the liver

was slightly higher than normal and the lower border, though somewhat masked by tympany, was apparently somewhat lower than normal. The facial expression was dull and apathetic, and the patient looked very sick. On January 12th the bowels moved freely without cathartics. The patient was dull and slightly delirious at times. Movements semi-solid in consistency. He was seen by Drs. Jackson, Thorndike, and the writer in consultation, and operation advised against owing to the weakness of the patient. After a fairly comfortable night, with slight fall in temperature, the patient had a severe chill followed by collapse, requiring free stimulation, on January 13th, the second day after entrance. He did not rally under stimulation, sank into coma, and died at 11 P. M. The diagnosis in this case lay between abscess of the liver and pancreatitis, inclining to the former. At no time during the patient's stay in the hospital was his condition good enough to permit of operation.

At the autopsy by Dr. F. B. Mallory, on making the first incision there were found small yellow opaque areas in the fat tissue of the abdominal wall just beneath the peritoneum. Similar spots from 1 to 4 or 5 cm. in diameter were found all over the surface of the great omentum. They were slightly raised above the surrounding fat tissue, more or less circular in outline, with edges usually irregular. Similar areas were found in enormous numbers in the fat tissue beneath the lining peritoneum, everywhere in the abdominal cavity, being especially numerous in the mesentery. The lesser peritoneal cavity was found to be much distended and filled with clotted blood and hæmorrhagic fluid, almost a litre in quantity. At the bottom of the lesser peritoneal cavity was a dark, reddish-brown, friable mass—all that remained of the pancreas. The cavity had extended beyond the ordinary limits of the

lesser peritoneal cavity on the left side over the kidney and apparently ruptured into the general peritoneal cavity, a reddish-grey fluid oozing up on carefully drawing up the coils of small intestine on the right side. In the general peritoneal cavity was a small amount of reddish-yellow exudate, most abundant in the pelvis. On opening the duodenum there was a thin place in the wall below the pylorus, at which point the contents of the lesser peritoneal cavity seemed just on the point of breaking into the duodenum. The papilla of the common bile duct appeared normal, and no obstruction of any sort could be found in or near it. In the gall bladder there were numerous small stones. The pancreas seemed to be destroyed right up to the wall of the duodenum. The fat capsule of the left kidney formed a part of the wall of the lesser peritoneal cavity. Yellowish areas similar to those already described were found throughout this fat tissue both in front of and behind the kidney. In the fat tissue on the left side below the kidney, along the outer border of the psoas muscle, was a great mass of necrotic fat. At the middle of the seventh rib on the right side and along the lower border of the tenth rib beneath the costal pleura were areas of necrosis.

Anatomical Diagnosis: Necrosis of pancreas with hæmorrhage; acute peritonitis; cholelithiasis.

Remarks: In this case, the only one in the series of a male patient, we have the presence of gall stones and history of previous attacks. In the two weeks which elapsed before the patient entered the hospital, necrosis of the entire pancreas, with diffusion of patches of fat necrosis over the entire peritoneal cavity and extensive suppuration in and about the lesser peritoneal cavity, had occurred. It does not seem impossible that if

operation had been performed early after the primary shock of the beginning of the attack, but before the process had become so extensive, and if adequate drainage had been provided and maintained, a fatal issue might have been averted. Certainly, if operation is to be of avail in these cases it must be performed before the process has become as extensive as it had in this case when he first came under observation.

CASE.—Summary: Localised necrosis of pancreas with fat necrosis. Exploratory laparotomy on third day of disease. Diagnosis of appendicitis or epigastric peritonitis of unknown origin. Evacuation and drainage of small abscess of the pancreas. Death on third day after operation. No autopsy.

Clinical History: K. T., aged forty-five, a widow, was admitted to the service of Dr. H. W. Cushing on April 20, 1899. Her previous history showed that she had had eight normal deliveries and suffered from a hernia. During the last six years she had had repeated attacks of abdominal pain, constipation, and vomiting, lasting several days. Two days before entrance she was seized with severe abdominal pain and vomiting. The second day of the attack the pain had become more on the right side and the vomiting was severe and continuous; the abdomen became tender and she had a chill.

On entrance she was found to be fairly well nourished, sick and apathetic in appearance. The temperature was 99° and pulse 100. Tongue slightly coated. Constant vomiting of greenish material. Abdomen distended and generally tender, though this symptom was most marked in the region of the gall bladder and the left iliac fossa. There was muscular spasm on deep pressure. No tumour was made out. Vaginal and

rectal examinations were negative. The following night the bowels were moved by an enema and considerable gas was passed. On April 21st, the third day of the attack, there was slight tenderness in the epigastrium, and percussion in this region showed a tympanitic area suggesting a dilated stomach. The patient was seen in consultation by Dr. C. F. Withington, and operation advised. Exploratory laparotomy was performed by Dr. J. C. Munro. Through a short median incision below the umbilicus the appendix was found apparently somewhat thickened, lying high under the border of the liver, slightly adherent. It was ligated and removed. Then a careful examination of all the intestines was made for constriction, during which a smooth tumour, pulsating with the aorta, was found in the position of the head of the pancreas. An incision was then made in the epigastrium, by which the adherent colon was accidentally opened and closed at once with silk. Then the omentum and intestines were packed off to allow a view of the posterior peritoneum and a grey diphtheritic patch found on the peritoneum over the tumour, which was punctured with a director allowing the escape of a little sero-purulent material and fat necrosis. A cavity in the pancreas the size of an English walnut, which lay beneath this patch, was cureted and drained with a glass tube. The epigastric wound was packed with gauze around the tube and the other wounds sutured. The operation was borne well. Free stimulation and cathartics were the line of treatment after the operation, and the following day the patient's condition made marked improvement and the bowels moved. The second day after operation vomiting began and the general condition grew worse. Death occurred at noon on the third day following the operation. Cultures from the abdomen at the time of the operation

were sterile. Examination of the material removed from the cavity in the pancreas showed fat necrosis.

Remarks: This case is interesting as presenting grave symptoms depending on a localised necrosis rather than a general inflammation of the pancreas. It is unfortunate that no autopsy was obtained, as much light might have been thrown on the condition of the pancreas and surrounding organs.

The following cases, though reported briefly, are of historical interest:

Tulpius, so far back as 1672 (Nicolai, "Observationes medicæ," ed. nova, Amstelodami; ap. Danielem Elzevirum, 1672, "Pancreas suppuratum," lib. iv, p. 328), reports the case of a young man from whom an enlarged testicle had been removed and who some years later died of fever and abdominal pain. At the autopsy attention was at once arrested by the condition of the pancreas, which was distended with thick pus, the tissues around the vena cava and aorta being infiltrated with pus.

Portal in 1804 ("Cours d'anatomie médicale," t. v, p. 352) describes the case of a man who died from an acute attack of gout in the feet. He was thought to be convalescing steadily when he had two or three attacks of vomiting, followed by syncope, in one of which he died. An examination revealed the pancreas completely broken down by acute suppuration.

Portal also reported another case clearly pyæmic—an abscess around the pancreas, following on castration with ligature of the cord.

Percival in 1818 ("Trans. Ass. K. and Q. Phy. Ire-



land," 1818) described an abscess of the pancreas in a young man who had jaundice with bilious vomiting and foetid and bloody stools. There was a tumour formed in the epigastrium and the patient died three months later. The pancreas was found to be very much enlarged and contained a large purulent cavity.

Baillie in 1833 ("Morbid Anat.") mentions a case in which a young man of twenty suffered from severe abdominal pain; with a sense of weight at the epigastrium, vomiting, diarrhoea, and polyuria. The pancreas was found very much increased in size, containing a large quantity of pus.

Perle ("De pancreate ejusque morbis," Diss. Beorlini, 1837) described the case of an adult man who was weakly and anæmic. For several weeks he had severe pain in the epigastrium accompanied by vomiting and foetid diarrhoea. The pulse was rapid, the skin dry, and there was tenderness on pressure in the epigastrium. Improvement for a time, but the fever returned, accompanied by vomiting, and he rapidly became worse. Death at the end of four months. The pancreas was indurated and suppurating. The abscess had opened into the peritoneum. The other organs were healthy.

Fletcher in 1848 ("Prov. Med." and "Surg. Journ. London," 1848, in Fitz, page 228) describes the case of a very stout man, who both ate and drank to excess. He was seized with intense pain in the epigastrium, which spread over the whole abdomen. He gradually became worse to the end, suffering from foetid and purulent stools. He died at the end of

nine months. The pancreas was enlarged, the whole being infiltrated with pus. The abscess had opened at the head of the pancreas into the duodenum and there was pus in the intestine.

Kilgour ("London Journ. of Medicine," 1860, page 1052) reports the case of a man, aged forty-one, who suffered from dyspepsia, and who for six months had never been free from attacks, after which he had frequent vomiting with a sense of fullness at the stomach, accompanied by great feebleness and loss of weight. He had ague-like attacks and persistent fever. Death occurred in the eleventh month. The pancreas was found very much enlarged, the interior being occupied by a cavity filled with creamy pus with small caseous masses in it. The duodenum close to the pancreas was gangrenous and the spleen slightly enlarged.

Further cases are reported by Riboli ("Gaz. de Sard.," 1858), Klob ("Oester. Zeitschr. f. prakt. Heilk.," 1860), Drasche ("Ber. der kl. k. Krankenanst. in Wien," 1886), Roddick ("Canada Med. Journ.," 1869, t. v., p. 385; Seitz, page 208), Smith ("Dublin Journ. of Med. Sci.," 1860, page 201; Seitz, page 208), Frison ("Pancréatite suppurée," "Recueil de Med. militaire," mai, juin, 1876; "Marseille méd.," 1875, page 257), Friedreich ("Die Krankheiten des Pankreas," Ziemssen's "Handbuch der spec. Path. und Ther.," 1878, Bd. VIII), Shea ("Lancet," 1881, page 791), Moore ("Trans. Lond. Path. Soc.," 1882, xxxiii, page 186), and others.

## CHAPTER VI.

### SUBACUTE PANCREATITIS.

BETWEEN subacute pancreatitis and acute pancreatitis no hard-and-fast line can be drawn. The former has usually a sudden onset with acute pain and vomiting associated with constipation, but the collapse is not so marked as in the more acute form, and may even be absent. The upper abdominal region does not become so rapidly swollen, and vomiting is less severe and less prolonged. At other times the onset is more gradual, though the symptoms may be similar. Tenderness over the pancreas is well marked, and on account of the tympanites being less than in the acute form, it may be possible to feel the swollen gland, especially under an anæsthetic. Constipation gives place to diarrhœa, and pus or blood may be noticed in the stools which have a very foetid odour. The pulse is less rapid and less thready than in the acute form, and the temperature is more irregular. We have seen the temperature reaching  $104^{\circ}$  and  $105^{\circ}$  F., and yet the pulse to vary between 90 and 110. The morning temperature may be normal and the evening temperature high for several days or even weeks. Rigours may occur and may be repeated from time to time. The pain occurs in paroxysms, but there is also a constant dull pain at the epigastrium. The patient may lose the more urgent symptoms and appear to be really

improving, but the loss of flesh and feebleness continue and relapses usually occur, leaving the patient each time more and more feeble until death supervenes from asthenia. Albuminuria is pretty constant, but glycosuria is rarely present, and lipuria is an unusual symptom.

If an abscess develop, the pus may form a tumour projecting in the superior abdominal region and forming a tender swelling behind the stomach, or perhaps coming to the surface above or below that viscus; or it may burrow into either loin, forming a perirenal abscess, or, passing under the diaphragm, it may form a subphrenic abscess. Occasionally the pus may follow the psoas muscle and form a subperitoneal abscess in the iliac region, or even passing over the brim of the pelvis it may collect in the left broad ligament. We have seen the several terminations in cases either under our care or under the care of colleagues, and we have operated five times for abscess of the pancreas. Sometimes the abscess bursts into the stomach and is vomited, or into the bowel and is voided per anum, after which diarrhoea may continue and pus may be seen from time to time as each fresh collection forms and bursts. We have seen both of these modes of evacuation of the pus. With the emptying of the abscess relief occurs for a time and the temperature improves, but relapses usually follow and a mild form of septicæmia persists with a hectic temperature. Death is the usual termination, but recovery may occur after a tedious and prolonged illness, as in the following case:

CASE.—On March 17, 1900, one of us was asked by Dr. J. Glen, of Middlesborough, to see Miss W., aged twenty-six years, when the following history was given: The patient was first attended the last week of December, 1899. Her symptoms then indicated a chronic form of dyspepsia with recurrent attacks of diarrhoea, the latter associated with indurated *faeces*. No relief from treatment resulted. The main symptoms at this time were general tympanitic condition of abdomen with tenderness over the sigmoid flexure, no acceleration of pulse, and no rise of temperature. About the second week in January, 1900, the diarrhoea still persisting, a good deal of fresh blood was present with each evacuation, these giving one the idea of dysentery. Then retching and vomiting set in, but this condition was probably set up by the free exhibition of powder of ipecacuanha. This condition continued more or less for upwards of a fortnight, when improvement took place. The tympanites disappeared, the tenderness of the left groin became less, there was less sickness, and a desire for food returned. The diarrhoea abated, there being only one or two evacuations in the twenty-four hours, the motions being formed. The improvement continued till the second week in February. The patient at this time, having gained flesh, was daily gaining strength and was able to sit up in her dressing-gown for a time each day. A relapse took place, accompanied with much pain in the epigastric region, constant sickness, return of diarrhoea, and blood in the stools, with rapid emaciation, quick pulse, and rise of temperature. This condition persisted in spite of all treatment. There had never been blood in the vomited matter except once, when there was a slight streak as if it might have come from the pharynx during the act of severe retching. Since the relapse there had developed a dull area with ten-

derness over the pancreas, but the degree of tenderness varied from day to day. At one time there was retention of urine, afterwards incontinence; no albumin or sugar was present. Hæmorrhage was profuse, the blood being gruel-like and mixed with stools which were very offensive. Dr. Glen had obtained the report of the Clinical Research Association of an examination of the fæces, which contained some blood and pus, but no cells suggestive of growth and no tubercle bacilli. When we saw her the patient was looking very ill and emaciated, with feeble, quick pulse; there was tenderness in the superior abdominal region, with rigid recti, but not along the course of the colon either on the right or left side. Examination under an anæsthetic revealed a swelling in the situation of the pancreas, but no fluctuation could be made out. As there was resonance in front of it, it was clearly behind the stomach, and from its position it was above the colon. The patient said there was very great tenderness on pressure over the swelling in the epigastrium. The rectal examination was negative, except that there was ballooning. A diagnosis was made of suppurative pancreatitis, the abscess having discharged into the bowel. A cachet of five grains of salol, two grains of quinine, and half a grain of opium was advised to be given thrice daily. Plasmon and somatose, dissolved in broth, tea, etc., were ordered, as the patient could not take milk. The question of operation was raised and dismissed, to be further considered in about a week or ten days, as she was at the time too feeble to bear even an exploratory incision. From this time improvement steadily occurred, and when seen again in a fortnight she was picking up distinctly, though there was still well-marked tenderness over the pancreas. In June she had gained nearly a stone and a half in weight, looked much better, and could take her food well;

there was, however, still a little rigidity of the recti and some tenderness, though no distinct tumour of the pancreas. The diarrhoea had disappeared and there was neither pus nor blood in the motions. A year later she was quite well.

**Treatment of Subacute Pancreatitis.**—The subacute form of pancreatitis is more amenable to treatment, as the indications are so much more definite and there is more time for careful consideration. Though it has usually only been attacked when an abscess has formed, and is manifestly making its way to the surface, yet there is no reason why in some cases surgical treatment should not be adopted at an earlier stage. As in the acute condition, morphine may be required to relieve the pain and lessen the collapse.

Distention, if present, demands attention, and may have to be relieved by lavage of the stomach and turpentine enemata, or by the administration of calomel by the mouth. Calomel is also of benefit as an intestinal antiseptic, for which purpose it may be given in small repeated doses or in doses of five grains followed by a saline aperient. As soon as the constipation is relieved, diarrhoea is apt to supervene, when salol and bismuth, with small doses of opium, may be given. If surgical treatment is decided on, a median incision above the umbilicus, as suggested by Senn, will enable the operator to palpate the pancreas and locate any incipient collection of pus, which, if practicable, should then be evacuated by a posterior incision in the left or right costo-vertebral angle. If the

posterior incision be thought impracticable, however, the collection of pus may be removed by aspiration and the cavity opened and packed with gauze, which may be brought forwards through a large rubber tube, which procedures will in the course of from twenty-four to forty-eight hours establish a track isolated from the general peritoneal cavity. In one case we were able to do this, but the operation was undertaken at too late a stage to be successful; and though the patient lived two or three days afterwards, the evacuation of the pus seemed to make very little difference to the general septic condition previously existing, and death occurred on the fourth day, from increasing debility. The method adopted had, however, been successful from the point of view of drainage, and the track of the gauze and tube had been isolated from the general peritoneal cavity. If a definite abscess form and approach the surface in front or in either loin, the treatment will be that of incision and drainage, as in the case of any other abdominal abscess. Of five cases on which we have operated, three recovered completely, one recovered from the operation, but died a few weeks later from chest complications and debility, and the fifth case is the one just referred to. The strength must be maintained by careful feeding and the administration of stimulants, and it will be necessary to keep a sharp lookout for further collections of pus and for subphrenic abscess or empyæma, which on recognition will need treatment.

The following case of pancreatitis is exceptional both with regard to course and treatment:



**CASE.**—Chronic gastric ulcer eroding pancreas; pancreatitis; abscess of pancreas bursting into stomach; vomiting; impending death. Posterior gastro-enterostomy; recovery.

On November 12, 1900, one of us was asked by Dr. Mercer, of Bradford, to see Mr. R., who was extremely ill, and supposed to be suffering from pancreatic disease.

Condition when first seen: We found the patient, aged thirty-five, extremely emaciated, lying in a typhoid condition, vomiting extremely offensive dark-coloured pus and mucus mixed with blood. He was extremely feeble, and had a rapid, weak pulse, and a slight icteric tinge in the conjunctivæ. A tumour could be felt above the umbilicus, which was tender to pressure. On distending the stomach with CO<sub>2</sub>, great pain was produced and vomiting followed. The stomach was slightly dilated, reaching on the left side to the level of the umbilicus. There was a little sugar in the urine with a trace of albumin, and the fæces contained free fat.

History: There had been an elevated temperature for a few weeks, but this had become subnormal after the vomiting of pus. Pain after food and indigestion had existed for some months, during which time there had been steady loss of flesh; but recently, especially during the last month, the wasting had been very considerable. No medicine had done any good either for the relief of the vomiting or in controlling the horrible odour, which permeated the whole house.

Diagnosis: A diagnosis of chronic gastric ulcer of the posterior wall of the stomach, with secondary ulcerative pancreatitis and abscess of the pancreas, was made, and gastro-enterostomy proposed as the only means likely to produce any chance of relief, but even that seemed hopeless. He was removed to a Surgical Home

by ambulance, and the stomach was washed out carefully. As showing the nature of the stomach contents, both the attendant nurses were made sick by the odour of the material evacuated by the tube.

Operation: On November 18th, after enveloping the patient in cotton wool and administering strychnine subcutaneously, posterior gastro-enterostomy was performed, a bone bobbin being used. The operation was done as quickly as possible in order to save shock. The tumour felt before operation was found to be formed by stomach and pancreas firmly fixed together towards the pylorus, but leaving the cardiac end of the stomach free, so that no difficulty was found in doing a satisfactory operation, which was completed in twenty minutes.

After-history: Saline subcutaneous injections and rectal enemata were given and strychnine was freely administered, but for two days we had a great fight with death, apparently due to poisoning by the foul stomach contents. Hot water was freely given to induce vomiting on the second day, as the patient could not bear the stomach tube being used. This gave relief, and afterwards progress to recovery was uninterrupted. He rapidly gained strength and put on flesh, returning home five weeks after operation. His friends, who had despaired of his recovery, were astonished to find him so well. In April he was in such good health that he married. A year later he was in perfect health.

CASE.—Some years ago one of us saw a gentleman, aged twenty-two, near Stockton-on-Tees, whose case at the time was to us incomprehensible, but in the light of further knowledge we believe it to have been one of subacute pancreatitis ending in abscess. The patient had been in poor health for some months and had suffered from dyspeptic symptoms, which were followed by a serious and prostrating illness accom-

panied by great loss of flesh and characterised by severe epigastric pain and irregular fever tending to become hectic. In the course of a month from the onset of the acute symptom a swelling formed in the right loin, which was diagnosed as a perirenal abscess, although there were no renal symptoms either at the time or subsequently. On evacuating the abscess, which contained very offensive grumous and greasy pus, through a lumbar incision, an exploration failed to discover anything wrong with the kidney, but showed the pus to come from the situation of the pancreas. A large drainage tube was inserted and remained in for about a month. Ultimately complete recovery occurred and the normal weight was regained after a long convalescence.

We saw another case similar to the foregoing, but in a woman of twenty-three. The treatment was by incision in the right loin and drainage, which was followed by complete recovery.

CASE.—Subacute pancreatitis with abscess associated with gall stones; cholecystotomy; relief; death four months later from exhaustion; necropsy.

Mr. H., aged forty, was seen by one of us with Dr. Woods, of Batley, on October 11, 1900.

Condition when first seen: The patient was then deeply jaundiced and extremely ill, suffering from continuous fever, with exacerbations, great debility, and extreme emaciation. A large tumour in the region of the pancreas could then be felt, as well as a distended gall bladder.

History: He had been failing in health for nine months, and gave a history of gall stone attacks and painful indigestion for some time before that, but, although he had had frequent attacks of abdominal pain for three

or four months, the jaundice had only supervened a fortnight before seeing him.

Operation: He was too ill to bear a prolonged search, and there were numerous adhesions around the tumour, which was made out to be a swelling of the pancreas; the gall bladder was simply opened and drained of a quantity of muco-pus. A quantity of pus was discharged from the drainage tube several days after operation, and this was repeated on two or three occasions, as if it came from a deeply-seated abscess. A large drainage tube having been used, there was a free discharge of bile, and a considerable number of gall stones were evacuated through it—thirty-three in all.

After-history: Previous to the attack the patient was suffering from shivering attacks and a persistently elevated temperature, which subsided immediately after drainage was effected, and the temperature kept nearly normal throughout the remainder of his illness, it being normal in the morning, though there was usually a hectic rise each evening. He made slow, though apparently steady, recovery from the operation, and the pancreatic tumour diminished so rapidly that it was confidently believed to be entirely disappearing, it being only one-third as large as at the time of operation. He returned home on December 14th, but he never really picked up strength, and, though there was no further elevation of temperature, he got gradually weaker, and died in February, four months later.

Necropsy: At the post-mortem examination, made by Dr. Woods, a tumour of the pancreas was discovered which was carefully examined by Mr. Cammidge and pronounced to be a chronic inflammatory tumour, the centre being occupied by pulpy material where the abscess had originally been. Nothing else was discovered and there were no gall stones left either in the gall bladder or ducts.

Mr. Paul emptied over a pint of pus out of a pancreatic abscess. Pieces of disintegrated glandular tissue floated about in the pus, and at the bottom of the cavity the head and tail of the pancreas could be felt. Yet, though the entire organ seemed broken up, the patient recovered from the operation and was restored to health.

Thayer's case was similar. The patient was a man, aged forty-four, with all the symptoms of suppurative pancreatitis. The abscess was opened on Senn's principle. A thick orange-brown pus, mixed with greasy tissue, came away. The abscess cavity opened into the substance of the pancreas. Within three months the patient was well again.

CASE.—Abscess of pancreas due to calculus. Dr. Gallaudet reported ("Annals of Surgery," Aug., 1899) the case of a man, aged thirty-seven years, who first came under his observation in September, 1897. For a period of two months there had been present continuously severe epigastric pain of sudden onset, more or less constipation, loss of appetite, flesh, and strength. No vomiting.

Examination showed marked emaciation; temperature 100° F., pulse 90. No fatty matter found in pus nor sugar in urine. In the epigastrium was a tumour, size of a small apple, hard and tender to the touch, immovable, and apparently adherent to the anterior abdominal wall. No signs of aneurism could be made out. A vertical incision, three inches long, over the tumour and carried down to it, showed a normal abdominal wall and fully exposed the tumour. On retracting the edges of the incision, strong adhesions

were found, between the swelling and posterior surface of the abdominal wall, extending above and below and on both sides of the growth, thus completely walling off the peritoneal cavity. An incision into the tumour was then made, and a quantity of thick, greenish pus was evacuated. Sponging revealed the fact that the pus was exuding from various small foci. The intervening tissue was soft and could be broken down by the finger. The incision was then carried deeper into the abscess and more tissue broken down. More pus came away, and as the finger could distinctly feel the aorta pulsating directly beneath it, no further incisions were made, and the cavity was packed with gauze. His general condition improved rapidly thereafter, and the wound healed by granulation, the pus of the original inflammation ceasing to appear after the third or fourth day. Cicatrisation was complete at the end of six weeks. About three weeks after the incision a calculus, rough, rounded, and about half an inch in diameter, was removed from the bottom of the wound.

Morian ("Prager med. Wochenschr.," No. 1, 1899) reports a case in which, judging from clinical symptoms, he operated for cholelithiasis. Some coils of intestine exposed during the operation bore small yellow growths which made him suspect that tuberculous peritonitis was the real malady from which the patient was suffering; nevertheless, he opened the distended gall bladder. Many calculi were extracted, with much serous fluid. The patient continued to show symptoms of sepsis, as before the operation. On the fourth day a swelling developed in the neighbourhood of the ensiform cartilage; it was punctured without any result. On the fifth day a coffee-ground substance with air escaped

suddenly from the opening made into the gall bladder, giving rise to a suspicion of perforation of the gall bladder. The patient lived a month after the operation. At the necropsy, necrosis of the pancreas was discovered, and a retroperitoneal abscess reached to the psoas.

CASE.—The following case, related in a thesis by Dr. B. C. Stevens (original reference not given), was probably one of subacute pancreatitis occurring as a metastasis from parotitis:

Boy, aged ten. Severe mumps. Temperature 101.4°. Third day unable to open mouth. Fourth day, vomiting, pain in stomach; later, violent pain in epigastrium. Temperature 103.8°; pulse 120, furred tongue, dry skin, not much distention; anxious face. Liver edge tender; not enlarged. Sausage-shaped tumour in epigastrium and left hypochondriac region, behind stomach.

Treatment: Turpentine fomentations; calomel and Dover's powder given. Vomiting stopped by bicarbonate of sodium in sips of hot water. Castor oil produced two copious and offensive motions. Temperature fell to 100.2° next day, and the glands subsided, but pain in region of pancreas continued severe. Sixth day, no pain, but tenderness over pancreas. Eleventh day all had cleared up.

Dr. Hale White ("Guy's Hospital Reports," 54) found only three cases of abscess in the pancreas in 6708 autopsies; one in a case of general pyæmia in a woman suffering from appendicitis, and another in a patient who died from cancer of the sigmoid flexure; in the latter case the pancreatic duct was much dilated and no cause could be found for either the abscess or the dilated duct. The third was a case of acute pancreatitis.

## CHAPTER VII.

### CHRONIC PANCREATITIS.

CHRONIC pancreatitis, at first hypertrophic, but later cirrhotic, is usually considered to be a very rare disease, but experience would lead us to believe it to be a much more common affection than the acute or subacute forms, and we believe that many cases put down as malignant disease of the head of the pancreas and terminating fatally may be cases of chronic interstitial pancreatitis. Our reason for this belief is shown in the cases related below, selected out of thirty cases on which we have operated. Our experience has resulted from having operated on a large number of cases of jaundice depending on obstruction to the common bile duct; the obstructive jaundice, wasting, paroxysmal attacks of pain and ague-like seizures having given rise to the suspicion of gall stones, and the absence of relief by medicinal treatment having rendered surgical treatment necessary. Our first case of this nature was in 1892. The patient was extremely ill before the operation, which was, in fact, undertaken too late; and as there was the opportunity of a post-mortem examination, the absence of malignant disease or of other cause than the chronic pancreatitis and associated jaundice to account for the death was directly proved.



This form of pancreatitis is quite distinct from the acute or subacute form, though it is probable that some of the latter cases end in chronic interstitial pancreatitis. As clinically seen it probably usually arises by extension of the inflammation from a chronic catarrh of the pancreatic duct extending from a gastro-duodenal catarrh, though it is frequently associated with biliary or pancreatic lithiasis, or with gastric, pyloric, or duodenal ulcer. Its course varies. The onset may be quite gradual and painless, or may be ushered in by a severe pain at the epigastrium, followed by jaundice resembling a gall stone attack and associated with nausea and vomiting, and perhaps followed by a feeling of chilliness or even a rigour. The pain, however, is not over the gall bladder and does not pass around the right side to the subscapular region, but is central and passes backwards to the midscapular region or around the left side, thus resembling stomach rather than gall bladder pain. The tender spot is usually an inch above the umbilicus in the middle line and not over the gall bladder, as in cholelithiasis. When once jaundice has come on, it tends to deepen with each attack, until it becomes continuous and chronic. The paroxysms of pain may be repeated more or less frequently, or there may be no paroxysmal pain, merely a dull ache deeply seated, burning and boring in character. A swelling of the pancreas may sometimes be made out, but as the recti are rigid because of the pain and tenderness in the epigastrium, it can usually only be discovered under anæsthesia.

Loss of flesh and strength are well-marked symptoms

in all cases. Vomiting may in some cases be absent, but there are usually a want of appetite and flatulent dyspepsia, and always a sense of fullness and weight at the epigastrium for some time after food. Jaundice is not necessarily present at first, though it is usually present at some stage of the disease and is often well marked; but, as was pointed out some years ago by Claude Bernard and by Dr. Walker, of Peterborough, the stools are white even when the pancreatic fluid alone is absent from the intestine. Diarrhoea is often present and the stools are offensive and may be fatty. Albuminuria is common and glycosuria may occur, but the latter is probably only present in cases where the whole gland is affected or where the islands of Langerhans are involved. Fever may be absent, but in some cases the temperature runs a hectic course, always rising in the evening and falling in the morning. This is especially the case where ague-like paroxysms occur. These varieties probably depend on the character of the infection in the pancreatic and bile ducts and also on the amount of obstruction present. Where jaundice is present the pulse may be abnormally slow, and even when the temperature is raised, the pulse-rate is not much elevated, though its character may be poor. In the later stages, especially if the disease be associated with jaundice, hæmorrhages from the nose and the bowel, vomiting of blood and petechiæ in the skin show marked blood degeneration, and death ensues from increasing weakness.

In the more chronic cases, especially when there is contraction or cirrhosis of the head of the pancreas,

there may be a tumour, formed by the distended gall bladder, just as there frequently is in cancer of the head of the pancreas, for which disease chronic interstitial pancreatitis is then apt to be mistaken and a hopeless prognosis given. In such cases the gall bladder will be distended with mucus, the bile which first filled it having become gradually absorbed, the backward pressure preventing fresh bile. This may occur so gradually as to be painless, and then the gall bladder is free from tenderness, seldom the case when the distention is due to gall stones.

There is a form of chronic pancreatitis occurring during foetal life in syphilitic subjects. Birch-Hirschfeld ("Arch d. Heilkunde," 1875, XVI, p. 174) first drew attention to this and described the lesion very fully, but more recently Schlesinger ("Virchow's Arch.," 1898, CLIV, p. 501) has made a systematic study of the subject of congenital syphilitic chronic pancreatitis. He found in six instances the enlarged, firm organ the seat of a diffuse interstitial inflammation characterised by proliferation of the interlobular and interacinar tissues penetrating at times between the cells of the acini. This inflammatory overgrowth is followed by contraction and atrophy of the parenchymatous elements. The process is essentially a syphilitic peri-arteritis and the adventitia is infiltrated with lymphoid cells. As the disease progresses the capillary network about the acini disappears. The disease has been observed as early as the fifth month of foetal life. Schlesinger has observed that the islands of Langerhans are not affected.

The following cases by Dr. Eugene L. Opie ("Journal of Experimental Medicine," vol. v, No. 4, Jan. 15, 1901) give the complete description of the histology, and by Dr. Opie's kind permission we have been able to reproduce these microphotographs.

CASE I.—Infant, lived three hours. Length of body 40 cm.

Anatomical Diagnosis: Congenital syphilis; interstitial pneumonia; interstitial pancreatitis; splenic tumour; chronic perisplenitis.

Microscopical Examination of Pancreas: The interstitial tissue is greatly increased at the expense of the parenchyma. The lobules, composed of a few acini scattered irregularly in dense cellular stroma, form groups separated by looser cellular tissue in which are situated the small veins and arteries. The smallest ducts, beset with acini along their course, terminate in a group of acini which, though much less numerous than those ordinarily forming a lobule, are of normal size and are composed of cells showing no evidence of degeneration. The interstitial tissue, particularly that between the groups of lobules and hence about the smaller vessels, is very rich in cells, which often form foci of dense cellular infiltration. Cells of lymphoid and of epithelioid type are numerous, but in even greater number, particularly about the blood-vessels, are round, oval, or polygonal cells with eccentrically situated nucleus. They have the characteristics of the plasm cells of Unna. Cells with eosinophilic granules are also abundant and are of two types: (a) mononuclear cells whose protoplasm is closely packed with large conspicuous eosinophilic granulations; (b) small cells whose nucleus is usually bilobed or trilobed. Eosinophilic granulations of smaller size scattered throughout the

cell body are most abundant about the nucleus. A conspicuous feature of the histological picture is the presence of compact round masses of cells embedded in the interstitial tissue, which is usually concentrically arranged immediately about them. By the character of the cells, which, polygonal in shape, are stained bright pink with eosin and by their arrangement in columns between which are capillary vessels, these structures are identified as the islands of Langerhans. Though they are embedded in the stroma, which separates widely the neighboring acini, they are not invaded by the inflammatory change. At times it is demonstrable, most conveniently in serial sections, that these islands are in continuity with the ducts and acini of the gland. At the periphery of the island one of the columns projects beyond the circular outline and is continuous with epithelial cells which, staining less brightly with eosin, are arranged about a lumen and are in turn continuous with adjacent acini. In many instances, however, an island traced through a series of sections is found completely isolated in the fibrous tissue.

CASE 2.—Infant, lived four hours. Length of body 50 cm.

Anatomical Diagnosis: Congenital syphilis; pemphigus neonatorum; interstitial pneumonia; interstitial hepatitis and pancreatitis; splenic tumour.

Microscopical Examination of the Pancreas: The interstitial tissue is greatly increased and the parenchyma is in very great part replaced by it, acini and groups of acini being widely separated. The new tissue is very cellular, but the cells are for the most part of the epithelial type and accumulations of round cells are not found. Plasma cells and cells with eosinophilic granulations are but rarely seen. The acini form small groups which may be regarded as primary lobules,

though the acini composing them are much less numerous than those of a normal lobule. Islands of Langerhans are conspicuous as compact round masses of epithelial cells and are scattered abundantly throughout the organ. The fibrous tissue is often concentrically arranged about them and at times they lie completely isolated. Not infrequently, however, as in Case 1, they are in continuity with the neighbouring acinar tissue; a double row of cells is found to be continuous on the one hand with a cell column of the island, on the other with a small duct.

The preceding cases apparently represent different stages of the syphilitic lesion. In Case 1 proliferating fixed tissue cells are very abundant, while cells, in part at least of vascular origin—namely, plasma cells and eosinophiles—are numerous and the condition may be interpreted as the active stage of a chronic inflammatory process. In Case 2, though interstitial tissue is more abundant and the persistent parenchymatous elements are more scattered, cells of the lymphoid type are few in number, while plasma cells and eosinophiles are almost absent. The process here is more advanced and is no longer active.

A conspicuous feature in both cases is the presence of numerous islands of Langerhans surrounded by newly formed stroma, but uninvaded by it. In many instances the islands are found to be in continuity with the secreting structures of the gland (Fig. 7). A cell column of the island is continuous with a small duct-like structure, which is in turn continuous with glandular acini. The lumen of the duct does not penetrate into the island.

Quite a number of types of interstitial pancreatitis have been described as affecting the fully developed gland.

Lemoine and Lannois ("Arch. de Med. Exper.," 1891, III, p. 33) have described perivascular intersti-

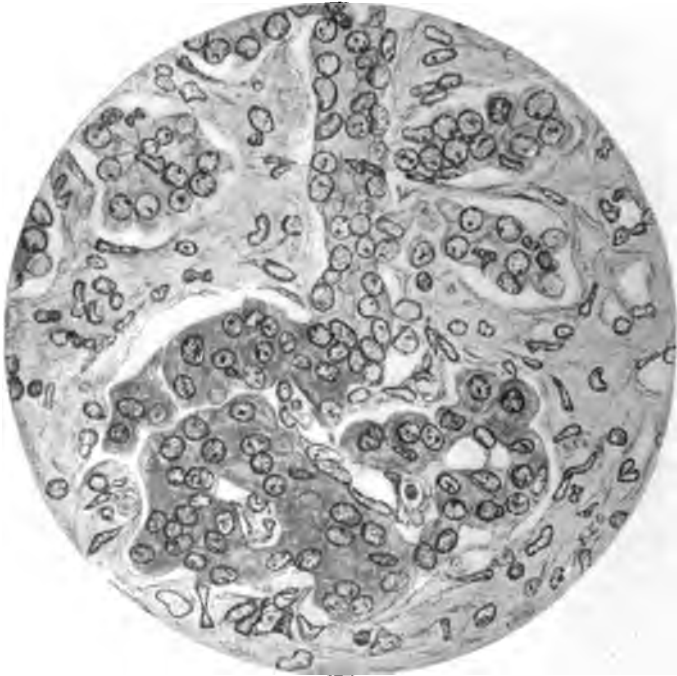


FIG. 7.—Congenital syphilitic pancreatitis. Case 1, showing a cell column of an islet of Langerhans in continuity with a small duct (Opie).

tial pancreatitis, and in four of these cases the process had been associated with diabetes.

G. Hoppe-Seyler ("Deutsch. Arch. f. klin. Med.," 1893, III, p. 171) described interstitial changes the result of arterial sclerosis, there being no anatomical

connection between the vessels and the new-formed tissue.

Rosenthal ("Zeitschr. f. klin. Med.," 1892, XXI, p. 401) described a case in which he believed the inter-

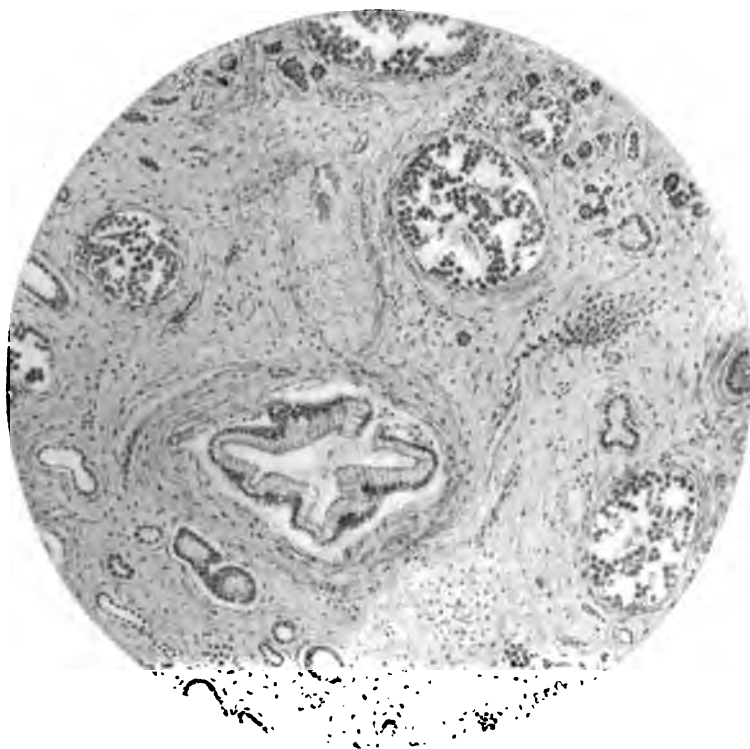


FIG. 8.—Chronic interstitial pancreatitis following duct obstruction, showing islands unchanged though embedded in sclerotic tissue (Opie).

stitial changes arose from the lymph-vessels, "lymphangitis proliferans," the essential cause being probably syphilis.

Were it practicable, it would be desirable to make



an etiological classification of chronic pancreatitis, but the same difficulties arise here as in cirrhosis of the liver. Our own personal experience would lead us to think that though the disease may arise from the blood-vessels or from the lymphatics in some cases, in by far the greater number it arises from the ducts

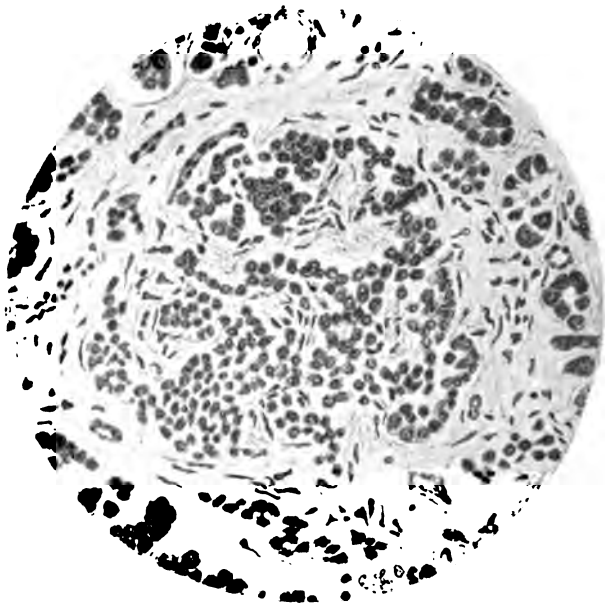


FIG. 9.—Chronic interstitial pancreatitis of interacinar type, showing the invasion of an island of Langerhans by the inflammatory process (Opie).

either by an extension of a catarrhal process from the duodenum, or by obstruction of the ducts by biliary or rarely pancreatic calculi. According to Opie, who has devoted considerable time to the study of chronic interstitial pancreatitis, two types are distinguishable.

## Forms of Chronic Interstitial Pancreatitis 157

1. Interlobular pancreatitis, where the increase of fibrous tissue is well marked between the lobules, but the intralobular or interacinar tissue is but slightly or not all affected and the islands of Langerhans are unaffected until the disease has attained a very advanced stage.

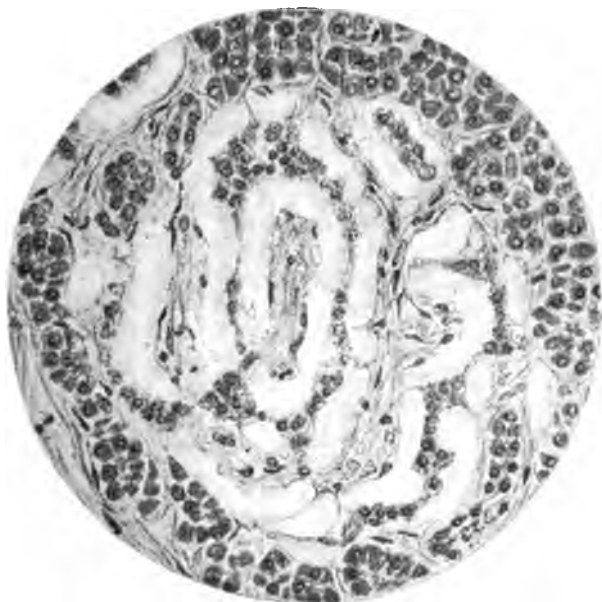

FIG. 10.—Hyaline degeneration of the pancreas (Opie).

This form follows an obstruction in the duct, as from cancer of the papilla, pancreatic calculi, or biliary calculi, and it may also occur from unknown causes where the ducts are quite free from obstruction. It is only in the later stages that diabetes is found. This form is more common than the interacinar variety.

2. Interacinar pancreatitis is characterised by the

presence of new-formed tissue within the lobules, the interlobular tissues being not at all or only slightly affected, but the islands of Langerhans being invaded by the new tissue. This type is much less common and is associated with glycosuria, but not commonly with obstruction in the ducts.

**Pathological Appearances.**—Whenever there is obstruction of the common bile duct by gall stones, with associated infective cholangitis, the pancreatic duct may be subject to backward pressure and to the same infective dangers as the liver; hence the association of infective and suppurative inflammation of the pancreatic duct is quite common. If this irritative process is kept up for some time, the substance of the pancreas participates in the inflammatory process and an interstitial pancreatitis results. There may be uniform swelling of the gland or only of certain lobules. Effusion into the interlobular and into the periglandular cellular tissues is associated with proliferation and detachment of the epithelium lining the acini and the tubes, and there is a crowding together of the cells, with an accumulation of inflammatory fluid containing round cells and blood-corpuscles in and around the affected parts of the gland, leading to tension. This simple pancreatitis is known by examining the parts of the pancreas less severely affected when death has occurred from abscess or other disease affecting a limited portion of the gland, and we have also seen it in cases of common bile duct obstruction where the pancreatitis only proved a secondary and not the fatal disease. In the greater number, if not in all cases of

obstruction of the common duct where the obstruction is close to the duodenum, the pancreatic duct participates in the infective process which usually follows, and when death occurs it will be found that pus can usually be squeezed from the duct of Wirsung. This has been observed independently by Dr. A. R. Ferguson, of Edinburgh.

If resolution takes place, complete recovery may occur or the interstitial effusion may organise and lead to irregular contraction of the tissues and to cirrhosis or chronic interstitial pancreatitis that may either end in diabetes if the whole gland be affected or may lead to pressure on, or distortion of, the common bile duct, and so to chronic jaundice, thus simulating cancer of the head of the pancreas. If, on the other hand, the inflammation be too acute for resolution, it may pass on to suppuration which may be general or localised. In all cases of chronic pancreatitis on which we have operated we have found numerous and firm adhesions around the duodenum, pylorus, and hepatic flexure of the colon, all of which have been adherent to the liver and gall bladder, and on several occasions occlusion of the foramen of Winslow has been found. Where there has not been associated cholelithiasis, the gall bladder will usually be found distended, and if the obstruction of the common duct be complete, it may be very large and filled with mucus. The lymphatic glands usually participate in the inflammatory process and may suppurate. If the patient survive there may be abscesses in the liver, enlargement of the spleen, pressure on, or thrombosis of,

the portal vein with ascites, or even obstruction to the flow of blood through the vena cava and œdema of the legs.

**Diagnosis.**—The diagnosis of chronic interstitial pancreatitis has to be made from gall stones in the common duct, cancer of the head of the pancreas, cancer of the liver and bile ducts, and chronic catarrh of the bile ducts. From gall stones the diagnosis is of no importance, since the two diseases are often associated and the treatment is in both cases surgical; nevertheless it may be possible to make a diagnosis of gall stones by the sequence of long antecedent history of spasms without jaundice, then by a severe attack of pain followed by jaundice, and after a time by recurring pains with increase of the icterus associated with ague-like attacks. The absence of tumour is more common in gall stones than in chronic pancreatitis, though in the latter the gall bladder may be found contracted. Although in pancreatitis there is usually less pain, at times the paroxysmal attacks may be equally as severe as in gall stone seizures. The tenderness in the latter case, however, will be over the gall bladder, and in the former at the middle line where the swollen gland can sometimes be felt, especially if the examination is made under anæsthesia; moreover, the radiating pain in chronic pancreatitis is towards the left or to the midscapular region. In cancer of the head of the pancreas the onset is usually gradual and painless, and the disease generally occurs later in life, usually after forty years of age. It is preceded by general failure of health, and when the

jaundice supervenes it becomes absolute and unvarying, and is nearly always associated with a tumour of the gall bladder, which generally attains a large size and shows no tenderness on manipulation. The liver enlarges from the biliary stasis, but there are no nodules to be felt. In some cases of cancer of the head of the pancreas a hard nodular tumour may be found on the inner side of the distended gall bladder. Extremely rapid loss of flesh and strength with increasing anæmia, but without ague-like seizures, is very characteristic, and it is common for there to be an absence of fever with a slow, feeble pulse and later ascites with œdema of the lower limbs.

Cancer of the common bile duct is rare, but when present may resemble, and in fact is usually associated with, gall stones. In cancer of the liver, the irregular enlargement, the nodular feel, the rapid deterioration of health, the less intense jaundice, and the absence of fever and paroxysmal pains will usually enable a diagnosis to be made. Chronic catarrh of the bile ducts is usually associated with an absence of symptoms, except jaundice and some loss of flesh. The entire absence of pain and fever with the relief by treatment usually give rise to little difficulty in establishing a diagnosis. In many cases a diagnosis will only be made by an exploratory incision, when the enlargement of the pancreas can readily be felt, or, if the tumour be small, the head of the pancreas may be found to be hard and perhaps nodular, like scirrhus. If ascites be present the tumour will probably be malignant. The lymphatic glands in the lesser omentum

may be enlarged in both cancer and chronic pancreatitis, but in the latter they will be discrete and soft, in the former hard and perhaps infiltrating. Adhesions are usually associated with chronic pancreatitis, but are generally absent in cancer.

**Prognosis.**—The disease may last for months or even years, and it is not improbable that some of the cases of jaundice persisting for several years and called chronic catarrh of the bile ducts may be of this nature. If glycosuria supervene it makes the outlook more grave, as it shows that the degenerative process has extended to the greater part of the pancreas, and that the islands of Langerhans have become involved in the disease. Increasing weakness and the super-vention of hæmorrhagic tendencies usually show the near approach of a fatal termination. Under surgical treatment the prognosis is very favorable, as out of twenty-two cases one of us had operated on at the time of giving a paper before the American Surgical Association, twenty-one had recovered from operation, and in nearly every case complete restoration of health had occurred.

**The Treatment of Chronic Pancreatitis.**—Chronic pancreatitis must be treated by abdominal section and drainage, but in this case the drainage is indirect and obtained by draining the gall bladder by cholecystotomy or cholecystenterostomy, or the pancreatic and common bile duct together by duodeno-chole-dochotomy. The exact line of treatment cannot be determined until the abdomen is opened, and for this purpose we prefer, as in all gall bladder operations,

a vertical incision through the upper part of the right rectus and splitting that muscle to whatever extent is necessary in order to obtain a good view of the diseased region, and to afford plenty of room for manipulation. If a mere cholecystotomy on a distended gall bladder is necessary, an incision through the parietes of one or two inches will usually suffice; but if the gall bladder be contracted, or if the ducts have to be attacked, an incision of four to six inches will be required, and if the several layers of the abdominal wall are sutured separately there is no fear of subsequent hernia; this we can affirm by ample experience. It saves much time and much unnecessary dragging on the parts, when operating on the common duct or duodenum, to have a free incision, and there is no retractor equal to the hand of a skilful assistant, who, with a flat sponge interposed between the spread-out fingers of his left hand and the viscera, will at the same time afford the operator a good view of the field of operation and with his right hand help in the further steps of the operation. If the right costal margin or the edge of the liver be obstructing the view, another assistant may with advantage retract it, either by digital manipulation or by means of a wide retractor with a long handle, so that he can stand back a little and avoid embarrassing the operator. As a matter of experience we seldom find a second assistant necessary. A sponge in the pouch to the right of the common duct and one pushed down over the right kidney help to catch all escaping fluids and to keep the peritoneum clear. When the ducts or duodenum are opened, sterilised gauze pads



are employed to mop up the fluid as it escapes, but none of these are allowed to remain even temporarily in the abdomen. When there are gall stones present they should be removed, unless the patient is too ill to permit of the complete operation; but in every case drainage must be secured—if possible, by cholecystotomy; moreover, the drainage must not be stopped before the bile has become healthy and not before the greater amount of bile is being passed by the bowel, which will be certain to occur as soon as the swollen pancreas has subsided, if the duct be otherwise clear of obstruction.

It might be thought that cholecystenterostomy would be an ideal operation in the treatment of these cases, but experience says it is not. For instance, in one of the cases the operation brought about so much relief that a cure was being anticipated, yet in the third month relapse occurred and death ensued, apparently simply owing to closure of the new opening between the gall bladder and duodenum.

In one of Mr. Barling's cases, where the gall bladder was joined to the duodenum, he stated that, although the symptoms were relieved, enlargement of the pancreas persisted.

The course and treatment of chronic interstitial pancreatitis are exemplified in the cases related. Possibly in some of these the manipulation of the indurated tumour may have detached calculi impacted in the pancreatic duct, though unconsciously to the operator, but in others the relief of tension as the result of draining the bile ducts by cholecystotomy or cholecysten-

terostomy, indirectly drained the pancreatic duct, and thus led to a subsidence of the pancreatitis, then to an opening of the common duct by the relief of tension, and so to a cure of the patient. The simulation of malignant disease of the head of the pancreas by chronic interstitial pancreatitis would make us hesitate to decline operation in any case of distended gall bladder, where the patient is in a condition to bear it, or even in any case of chronic jaundice without distention of the gall bladder where the general health is deteriorating; as, though it should be recognised that if the disease be really malignant, very little good will be done and life may even be shortened or only prolonged for a short time, yet, if the disease prove to be chronic pancreatitis, a real and permanent cure may be brought about. If a calculus be felt embedded in the head of the pancreas or impacted in the pancreatic duct, it may be reached through the second part of the duodenum by laying open the papilla and exploring the duct, or by dividing the peritoneum passing between the duodenum and the hepatic flexure of the colon and then cutting through the overlying pancreas on to the concretion. If the papilla common to the bile and pancreatic ducts be incised in the duodenum, it does not require suture, and in the cases in which we have explored the ducts by the duodenal route there has been no serious hæmorrhage; the anterior duodenal opening only requires closing by a mucous and serous suture. Drainage of the right kidney pouch for from twenty-four to forty-eight hours is advisable, though not always necessary, and this

is best done by a stab-wound at the most dependent part.

The results of treatment in this class of cases have been most encouraging, as out of twenty-four cases operated on, only one died directly from operation, and in that case the patient's life was only very slightly shortened, since he was reduced to the last stage of exhaustion before a surgical opinion was sought. Of those recovering from operation, with the exception of two that died a few months later, complete and perfect recovery ensued. These results contrast very markedly with the surgical treatment of cancer of the pancreas, where nearly half of the cases operated on have died directly as the result of operation, and in those who have survived, life has only been prolonged for a comparatively short time.

CASE I.—Chronic pancreatitis; cholecystotomy; cure.

A man, aged forty-five years, was sent to one of us on October 25, 1898, by Dr. J. B. Berry, of Keighley. The patient was very deeply jaundiced and said that he had lost a stone in weight since the onset of his illness five weeks before. He gave the history of having had attacks of pain, referred to the region of the gall bladder, nine years previously, but they were unaccompanied by jaundice and passed off after prolonged treatment. From that time onwards he had been free from attacks of pain up to the onset of the present illness five weeks before, when he was suddenly seized with severe pain at the pit of the stomach and became jaundiced. The pain had recurred daily and had been so severe as to necessitate his taking morphia. Dr. Berry noticed a swelling in the region

of the gall bladder a fortnight after the onset of his illness, and there was all along well-marked tenderness at the epigastrium, with gradually increasing enlargement of the liver. The patient's general health rapidly failed and the loss of flesh was well marked. When we saw him he looked pinched and ill; he was very deeply jaundiced and the urine was loaded with lithates, but contained neither albumin nor sugar. There were well-marked tenderness at the epigastrium and a smooth tumour, which was not very tender, in gall bladder region; the liver was enlarged and the edge was smooth and could easily be felt an inch below the costal margin. A diagnosis of gall stones in the common duct was made, and the patient was admitted into the Leeds General Infirmary. The operation was performed on September 27, 1898. On opening the abdomen numerous adhesions between the gall bladder and liver and the pylorus, colon, omentum, and duodenum were found. The gall bladder was slightly distended, but no gall stones were felt either in it or in the cystic or common duct. There was, however, a hard nodular swelling of the head of the pancreas, which at the time was thought to be malignant. In order to give relief the adhesions were detached and the gall bladder was drained by cholecystotomy. On October 28th we wrote to Dr. Berry telling him that we feared that the disease of the pancreas might be malignant, but that there was a possibility of its being a chronic pancreatitis. On November 5th a letter to this effect was written: "I am pleased to be able to tell you that your patient has improved very much and the jaundice has nearly disappeared. I hope, therefore, the tumour of the head of the pancreas may have been inflammatory and not malignant. At the time of operation it occurred to us that it was not quite hard enough for a malignant tumour, but under the circumstances felt it our duty

to give you our suspicions." From that time onwards recovery was uninterrupted and the patient left the hospital with the wound closed within the month. In December, 1899, the patient, at the kind suggestion of Dr. Berry, called to report himself. He looked perfectly healthy and had gained over a stone in weight since his return home. He had neither pain nor tenderness, and he said that he felt as well as if he had never ailed anything. The scar was firm, the liver was normal, and there was not the slightest tenderness in the epigastrium or in the gall bladder region.

CASE 2.—Chronic pancreatitis; cholecystotomy; cure.

The patient was a man, aged forty-five years, residing at Pickering. On March 19, 1898, he was brought to Leeds by Mr. G. V. Robertson, of Pickering, the history being that he had been well up to twelve months before, when he began to have painful attacks at the pit of the stomach, ending in vomiting, but not followed by jaundice until an attack on January 1, 1898, since which time he had been deeply and continuously jaundiced. He had also from that time onwards had ague-like attacks, and two days before coming he had had within twenty-four hours three of these seizures, each accompanied by pain. Within a twelve-month he had lost two stones eight pounds, in weight. On examining him there was some swelling in the gall bladder region, but no tenderness. The liver was a little enlarged, but the margins felt smooth. There was decided tenderness in the middle line just above the umbilicus, and on deep pressure the pain was considerable and an indefinite fullness could be felt. The diagnosis of gall stones in the common duct was made, and an operation was advised. The patient was operated on at a surgical home on March 30th, when the gall bladder was found to be slightly distended and surrounded by adhesions to the pylorus, duodenum,

colon, and omentum. No gall stones could be discovered, but there was a well-marked swelling of the head and the first two inches of the pancreas, which, though nodular and irregular, was not very hard. This extended further to the right than normal, so as to cover in the lower end of the common bile duct. Cholecystotomy was performed. Within twenty-four hours of the operation nearly four pints of very offensive bile were discharged through the tube. A specimen was examined by the Clinical Research Association and their report was as follows: "The bile contains both staphylococci and streptococci, but no *Bacillus coli communis* could be found either under the microscope or in the culture." Fearing that the disease might be malignant and the patient being so extremely weak and ill, I gave a poor prognosis, but in a few days we were able to write: "(The patient) is progressing very satisfactorily, though he is still profoundly weak. Bile has appeared in the motions, so that the obstruction is evidently overcome. The bowels have been moved naturally and the patient is less deeply jaundiced and looking better generally." On April 5th we were able to report that he was taking food well and that bile was passing freely in the motions. He had had no recurrence of the shivering attacks. The drainage was continued for fourteen days. On the 20th the patient returned home. The urine was then free from bile and the motions were assuming a natural colour; he was taking food well, gaining flesh, and looking better generally. We still, however, gave a guarded prognosis, though we said that we hoped the tumour would prove to be inflammatory and not malignant. From that time onwards his progress to recovery was extremely rapid. A report of his condition from Mr. Robertson a few months later said that he was perfectly well in every respect and that he had fully re-

gained his lost weight. We heard of this patient two years after his operation and he was still in perfectly good health.

CASE 3.—Chronic pancreatitis associated with gall stones; cholecystotomy; cure.

On October 20, 1899, one of us was asked by Dr. T. C. Squance, of Sunderland, to see a female patient, aged fifty-one years, who had been suffering for three years from attacks resembling those of gall stones, each attack being followed by jaundice. During the past fourteen weeks the seizures had been more frequent and severe and jaundice had never quite cleared away before another attack came. She had lost flesh and strength considerably and had vomited from time to time between the attacks. Her digestion was much impaired and there was a want of appetite. She had had no rigours, and had only slight fever at the time of each seizure. The urine contained abundant lithates and a slight trace of albumin, but no sugar. On examination the abdomen showed no manifest enlargement of the liver or gall bladder, but some tenderness over the gall bladder and at the epigastrium, where there was an indefinite sense of fullness. An operation was performed on the 23d, when, after detaching numerous adhesions, fifteen gall stones were removed from the cystic and common ducts; but as a large nodular mass was occupying the head of the pancreas and partly obstructing the common duct, it was deemed advisable to perform cholecystenterostomy so as to make a permanent opening between the fundus of the gall bladder and the duodenum. The tumour gave the impression both to myself, to Dr. F. Macrae, and to Dr. Squance that it was malignant. Recovery was, however, interrupted, the button was passed on the tenth day, the wound healed by first intention, and the patient immediately began to put on flesh. She returned

home within the month and has since been perfectly well in every respect. It is now nine months since the operation, and her health, I am informed, is perfect.

CASE 4.—Chronic pancreatitis; cholecystendysis; cure.

The notes of the following case have been kindly furnished by my friend Mr. Peter MacGregor, of Huddersfield. The patient was a female, aged fifty-one years, married, and the mother of several healthy children. "Her previous history was unimportant, but for two or three years she had been dyspeptic and during the past nine months she had been more or less continuously under medical treatment for dyspepsia and recurring attacks of cramp in the stomach. . . . I first saw her on August 19, 1899, when I got the above history, and a careful physical examination elicited nothing beyond tenderness in the pyloric region. On the 28th I was telegraphed for to see her and found her suffering from a severe attack of gall stone colic. She was seen at intervals from August 28th to October 16th. On the latter date I found her emaciated and in more or less constant pain, with frequent attacks of colic and distress after every particle of food had been tried, predigested and otherwise, but all with the same result—constant pain and frequent vomiting. Dr. Williams told me that he could feel a tumour in the pyloric region, but the patient was so very ill and examination caused her so much distress I did not satisfy myself of the fact. No jaundice on this date, but previous attacks of colic had been followed by jaundice. On November 25th the patient came into a nursing home for operation. She was then in constant pain, with frequent retching, deeply jaundiced, and a perfect skeleton. Operation (November 28th). On examining the patient under chloroform, a hard, rounded, irregular tumour was found between the umbilicus and



the ribs. On opening the abdomen the stomach, much dilated, was found extensively adherent to the under surface of the liver, and, on stripping it off, a healthy gall bladder in the normal position came into view. The right kidney, which had been diagnosed as 'floating,' was examined and the diagnosis verified, but the rounded, hard, irregular mass behind the duodenum appeared to be so undoubtedly a malignant tumour of the pancreas that the abdomen was closed and the friends were informed that the case was malignant and hopeless.

"After-history: The temperature never went above normal; stitches were removed on the ninth day. On the fifth day after operation patient had a chop for dinner. Within a fortnight the jaundice had gone, the appetite rapidly improved, and she went home at the end of three weeks, feeling much better, although the four medical men who were present at the operation felt, and said, she would die within six weeks. On March 15, 1900, she was plump and fat, ate anything, had had neither pain, retching, nor vomiting since the operation. Her tumour had quite disappeared, and her medical man had discharged her as cured many weeks since."

CASE 5.—Chronic pancreatitis; cholecystotomy; cure.

A woman, aged thirty-five years, was admitted to the Leeds General Infirmary under the care of Dr. A. G. Barrs, on September 11, 1899, and transferred to the care of one of us a few days later, with the history of having been subject to attacks of spasm in the upper abdominal region for twelve years, the intervals between the seizures having varied from a few days to several months, but of late they had become much more frequent, and during the week before admission she had had four attacks, all severe ones. The seizures began with pain in the epigastrium, accompanied by cold

sweats and faintness; the pain passed through the mid-scapular and to the right subscapular region, and lasted from two to six hours, having to be relieved at times by morphia. Jaundice followed the seizures, and if the attacks recurred frequently it was intensified with each; but if there was a long interval, only an icteric tinge remained.

Palpation revealed a point of tenderness in the mid-line one and a half inches above the umbilicus, where there was a sense of resistance with an abnormal fullness, but there was no tenderness over the gall bladder, nor could any swelling of the gall bladder or liver be discovered. On September 21st a vertical incision through the right rectus exposed adherent viscera, and on the separation of the adhesions a thickened gall bladder was exposed, but there were no gall stones in it or in the ducts. The lower part of the common duct was surrounded and overlaid by a well-marked swelling of the pancreas which was harder than usual, but not sufficiently hard to be mistaken for cancer, though it was somewhat nodular. Cholecystotomy was performed and drainage was carried out for a fortnight. Recovery was uninterrupted and the patient returned home within the month, and she has remained well since.

CASE 6.—Chronic pancreatitis with gall stone in the common duct; cholecystenterostomy; relief; relapse.

A man, aged forty-five years, from Queensbury, was admitted into the Leeds General Infirmary under the care of one of us on November 3, 1899, suffering from jaundice with repeated attacks of pain and ague-like seizures. He had been well up to thirteen months before his admission, when the attacks began, and since their onset he had lost 6 stones in weight. Jaundice followed the first seizure and persisted, but after each attack of pain it was more intense. He was so weak

and ill that it was feared he could not bear an operation. An enlargement of the right lobe of the liver could be felt, and on its inner side in the mid-line just above the umbilicus there was another tumour situated behind the stomach. On November 9th an operation was performed on a heated table with the patient enveloped in wool, an injection of ten minims of solution of strychnia having been previously given. On opening the abdomen an enlargement of the right lobe of the liver was seen, the gall bladder was found shrunken under adhesions, a floating gall stone too hard to crush was felt in the common duct, and a hard nodular tumour of the head of the pancreas was discovered. As the latter was thought to be malignant and the patient was extremely feeble, choledochotomy was not performed, but the gall bladder was connected to the duodenum by a Murphy's button in order to give temporary relief to the jaundice, fever, and pain. He had a severe rigour on the night of operation, but afterwards progressed satisfactorily and recovered from the operation. The button passed on the twelfth day, and as he had gained some weight and was taking his food well, it was thought that the operation was going to be of real benefit to him. The subsequent history of the case was as follows: On December 8th (a month and a day after operation) he had a feeling of chilliness, and a temperature of  $101^{\circ}$  F. followed for two days, his temperature being afterwards normal for twelve days, when he had a rigour and a return of the jaundice; from this time, although he got up every day, he gradually became weaker, and in January, 1900, he developed bronchitis, which ushered in the final scene. At the post-mortem examination the peritoneum was found to be free from inflammation and the gall bladder was found to be connected to the duodenum one and a half inches beyond the pylorus, but the opening had con-

tracted so that it would only admit a fine probe. The common bile duct was dilated and ulcerated and it contained a gall stone of the size of a filbert. The liver was considerably enlarged and the right lobe was occupied by an abscess containing thick, slimy muco-pus. The walls of the abscess cavity were ragged and ill defined, and it reached nearly to the surface both in front and behind. It was doubtless the result of the suppurative cholangitis which was present. The pancreas was much indurated about the head, and together with the indurated tissues in the small omentum presented on palpation the sensation of a tumour. On section it presented to the naked eye the appearance of chronic inflammation rather than growth, and on microscopical examination this view was confirmed, there being a great excess of interstitial fibrous tissue, but no sign of cancer.

CASE 7.—Chronic pancreatitis with cirrhosis of the head of the pancreas; cholecystotomy.

On January 28, 1901, Mr. E. R. H., aged twenty-six, was sent to one of us from Malvern.

History: He was deeply jaundiced, and told us that he had had jaundice since the age of seventeen, it having supervened upon a severe attack of what appeared to be biliary colic, he having had numerous seizures since the age of fourteen. For two or three years he had had severe ague-like seizures; and during that time lost very seriously in weight and strength; but during the past two years there had been no shivers, and he had also been free from the severe paroxysms of pain, though he had had slighter seizures, after all of which the jaundice became more intense. The patient only weighed 9 stones, and all the bile was apparently passing in the urine and none in the motions. There was also some swelling in the region of the pancreas,

slight enlargement of the liver, and a very decided enlargement of the spleen.

Operation: Four days later the abdomen was opened by a vertical incision through the right rectus. The gall bladder was found contracted and surrounded by numerous adhesions. After the separation of these the ducts were carefully explored, but without discovering any gall stones. The head of the pancreas was found to be enlarged and very hard. As the obstruction appeared to be entirely due to the pressure exercised by the pancreas on the common duct, the gall bladder was drained.

After-history: For a few days the jaundice was deeper. It then became gradually less until it almost disappeared. In ten days the stools became bile-stained, and have since retained their colour, though there has never been complete freedom from a tinge of jaundice in the skin. He returned home on April 16th, having gained nearly half a stone in weight. He looked and felt much better, and as a small quantity of bile was still coming from the tube, it was felt desirable to retain it until the last tinge of jaundice had disappeared. From the first week of operation up to the present he has had no further pain, and has been able to take ordinary food and to digest it well. On September 14, 1901, he returned to the Infirmary to have the biliary fistula treated and cholecystenterostomy was performed. He was well except for a slight icteric tinge when he returned home in October.

The following case is taken from the "Annals of Surgery" for January, 1902:

Interstitial pancreatitis; cholecystenterostomy.

Dr. Charles L. Gibson presented a woman, aged thirty years, who entered St. Luke's Hospital on August

20, 1901. Her previous history was negative, with the exception of an attack of peritonitis, of obscure origin, from which she suffered several years ago. Her present illness began about four weeks previous to the date of her admission to the hospital. It was ushered in with gastric disturbance; there was considerable epigastric pain and frequent attacks of vomiting. For several weeks she had been deeply jaundiced. A physical examination disclosed only a moderately enlarged gall bladder, which could be distinctly felt on pressure. Under ether, however, a large transverse tumour above the umbilicus was made out. The gall bladder was cut down upon and opened; it contained no stones. The large transverse tumour proved to be the pancreas, which was symmetrically enlarged throughout, the condition being due to a general hyperplasia of that organ. An anastomosis was made between the first part of the jejunum and the gall bladder with a Murphy button.

The patient's convalescence was quite uneventful, and her symptoms improved at once. It is now about six weeks since the operation, and she is beginning to be restored to health and to take on flesh, although she has had one or two attacks of vomiting and epigastric pain since her convalescence. A small fragment of the enlarged pancreas was removed, and the clinical diagnosis of interstitial pancreatitis was confirmed by microscopical examination.

## CHAPTER VIII.

### PANCREATIC CALCULUS.

THE occurrence of stone in the pancreas was first recorded by Graaf in 1667. Morgagni, in 1765, and in England Cawley, in 1788, refer to instances observed by them. In 1883 Johnston collected thirty-five cases from the literature. The fullest account was given in 1896 by Giudiceandrea ("Il Policlinico"). The stones are generally white, greyish-white, or yellowish-white in colour, rounded, ovoid, or elongated like a date stone. They are found in all parts of the duct of the pancreas, though very much more commonly in the head; in the tail of the gland they are very rarely seen. The calculi may be branched, the trunk of the stone lying in the main duct, its offshoots in the secondary ducts. The largest stone (two and a half inches by half an inch) was seen by Schupmann. A fine sand has been frequently noticed. Calculi may be single or multiple. One of the most striking examples of the latter is in the Museum of the Royal College of Surgeons (Curnow's case), specimen 2834. In one case 300 stones were found.

The stones are chiefly composed of phosphorus and carbon salts. One case of oxalate of lime stone is reported by Shattock. Johnston ("Amer. Journ. Med. Sci.," 1883) gives two analyses.



FIG. 11.—A pancreas, with calculi of various sizes in its ducts. The larger ones have been removed, but some remain at the termination of the main duct and in the accessory ducts. The orifices of some of the ducts are blocked and all are dilated. The calculi are composed of carbonates and phosphates of calcium, magnesium, and sodium, with organic matter. The cystic duct was obliterated, the gall bladder being of normal size. The hepatic and common bile ducts were patent, and the smaller branches of the hepatic duct were occupied by many microscopical calculi. From a dissecting room subject. (Museum R. C. S., specimen No. 2833.) The case is recorded in the "Transactions of the Pathological Soc.," XXIV, page 136 (Dr. Curnow).



## Pancreatic Calculus

I.	
Phosphorus salts . . . . .	72.30
Carbon salts . . . . .	18.90
Organic matter . . . . .	8.80
II.	
Carbon salts . . . . .	91.65
Magnesium carbonate . . . . .	4.15
Organic matter . . . . .	3.00

It is clear from this analysis that the pancreatic secretion during or before the formation of a stone



FIG. 12.—Some of the larger calculi from the preceding specimen; others are placed in the series of calculi (Museum R. C. S., specimen No. 2834) (Dr. Curnow).

is altered in quality, for carbon salts are not normally present. Schmidt, quoted in Schäfers text-book, gives the following as the composition of the ash obtained from the pancreatic juice flowing from temporary and permanent fistulae:

## Composition

181

	FROM TEMPORARY SECRETION.	FROM PERMANENT SECRETION.
Soda ( $\text{Na}_2\text{O}$ ) . . . . .	0.58	3.31
Sodium chloride . . . . .	7.35	2.50
Potassium chloride . . . . .	0.02	0.93
Earthy phosphates with traces of iron, . . . . .	0.53	0.08
Trisodic phosphate . . . . .		0.01
Lime ( $\text{CaO}$ ) and Magnesia ( $\text{MgO}$ ) . . . . .	0.32	0.01

The antecedent condition necessary for the deposit of stone is probably retention of the secretion. This may be produced by inflammation of the canal of Wirsung, extending upwards from the duodenum, or by a chronic interstitial pancreatitis, however arising.

Many attempts have been made, by partial obstruction of the duct by ligature, by the injection of paraffin, and in similar ways, to give rise to an artificial lithiasis. So far as we are aware, the only attempt that has succeeded was made by Thiroloix. He injected sterilised soot into the duct of Wirsung. At the post-mortem the pancreas was found to be atrophied, and in the tail a cystic swelling containing clear watery fluid surrounded by chronic inflammatory tissue had developed. In the cyst, and in the duct also, small concretions had formed.

Nimier attributes to micro-organisms a causative influence in the production of calculi. Galippe, on examining a stone, found numerous organisms distributed throughout, and Giudiceandrea discovered an organism very similar to, if not identical with, the *Bacterium coli commune*.

Associated with calculi are found, at times, certain more or less profound alterations in the pancreas. Of such are chronic interstitial inflammation, atrophy,

dilatation of the duct, cyst, abscess, fatty degeneration, and carcinoma.

**Symptoms.**—So few carefully observed cases of pancreatic lithiasis have been recorded that it is impossible to give any close or accurate portrayal of the symptoms. In the majority of examples pain, or at the least a sense of great discomfort, has been felt in the upper part of the abdomen, generally at or near the middle line, and but rarely, as in Minnich's case, under the left costal margin. The pain frequently comes in sharp colicky attacks, similar to, but less severe than, those due to gall stones. A sense of soreness or stiffness is noticed for a day or two after the attack. When the pain is at its height, vomiting, hiccough, rigours, cold sweats, or collapse may be noticed. After the attack some fragments of stone may be found in the motions (Minnich, Leichtenstern). Diabetes has been often observed. Hansemann, in seventy-two cases of diabetes associated with pancreatic disturbances, found that in twelve stone was present. Oser, in seventy cases of lithiasis, observed that diabetes was recorded twenty-four times. The probability is that the onset of diabetes is due to the chronic inflammatory changes instituted in the gland by the calculus; but it must be remembered that such inflammatory alterations produce in the gland and its duct precisely those changes which are most likely to cause the deposit of calculous material. Fatty stools have been occasionally observed, and in one case Lichtheim saw an abundance of fat-crystals in the *fæces*. Rarely jaundice may be caused, as related by Giudice-

andrea, by the pressure of the stone upon the common duct. Lancereaux ("Journ. de médecine interne," Feb., 1899) states that in each attack of pancreatic colic a temporary diabetes is produced by an inhibition of the secretion, analogous to the inhibition observed when one ureter is obstructed by a calculus.

The cardinal symptoms of pancreatic calculus, then, are: pain, colicky in character, similar to, but of lesser intensity than, gall stone colic; pain or tenderness over the pancreas; the passage of fragments of stone; fat diarrhoea and diabetes. It is rarely that all these are seen in association.

**Treatment.**—There is but little to say with regard to treatment. It is, with one exception, only when cyst or abscess has resulted from calculous impaction in the duct that treatment has been adopted. Caparelli records the case of a woman who developed, after many attacks of acute epigastric colic, an abscess above the umbilicus. The abscess burst and discharged some pus and gritty material. Through the fistula which persisted for six years over one hundred small stones were expelled. After the spontaneous closure of the fistula, diabetes developed and the patient died.

According to the results of the experimental work of Kühne and Lea, the subcutaneous injection of pilocarpin incites the flow of the pancreatic juice. A case is reported from Eichhorst's clinic of "undoubted pancreatic lithiasis" in which the subcutaneous injections of pilocarpin were tried. "The attacks of colic disappeared completely and the patient was better than for many months before."

The following case of removal of a pancreatic calculus is related by Mr. Pearce Gould. The patient was a man aged forty-six, whose only previous illness was an attack of influenza four years before. In September, 1895, he noticed some failure in health, and in November he suffered for a few days from severe pain referred to the umbilicus, chiefly felt on walking uphill. He became jaundiced and this persisted until February, 1896, when he came under observation. The liver was then enlarged nearly down to the umbilicus, the gall bladder could be felt distended as a cylindrical swelling in the right lumbar region, and there was no ascites. The motions were clay-coloured. On February 14th the abdomen was explored. Through the vertical incision to the right of the rectus muscle, half a pint of fluid was withdrawn from the gall bladder by aspiration. A lump was felt at the back of the small omentum, which proved to be a coral-like stone in the dilated duct of Wirsung, and other smaller calculi were found and removed. The operation did not relieve the obstruction to the flow of bile, and on March 3d he had an attack of agonising pain in the right hypochondrium. Mr. Pearce Gould reopened the abdomen, and with some difficulty was able to feel a stone in the head of the pancreas close to the duodenum, which he removed by incising the pancreas from the front, and he was then able to pass a probe through the duct into the duodenum. Soon after the operation the patient vomited bile, the stools became coloured, and bile ceased to flow from the incision in the gall bladder. Notwithstanding this, vomiting per-

sisted and he died of exhaustion the twelfth day after the second operation. Post-mortem: A little pus was found underneath the gall bladder and also behind the ascending colon. The pancreatic duct was found to be dilated and ulcerated. There was a hydatid cyst at the back of the liver. The calculus was composed of phosphate and carbonate of lime.

A CASE OF MULTIPLE PANCREATIC CALCULI.—Case under the care of Mr. W. H. Brown. Notes by Dr. Maxwell Telling. The patient, a well-built man of fifty-three, was admitted suffering from a cut throat, the act having been performed in a fit of alcoholic depression. The wound was fatal in about two days, and the following history was obtained from his wife: He had been extremely alcoholic (mostly spirits) for over twenty years. For the last eight years he had suffered from what he called attacks of "severe indigestion." In these attacks he would be suddenly seized with the most severe abdominal pain, which was referred to the epigastric region: during the attack he would often writhe in agony, getting out of bed, rolling on the floor, etc., in order to ease the pain. He would sweat profusely, and frequently vomited: occasionally the pain was relieved by this vomiting. Apparently these "indigestion attacks" were always ushered in by this sudden pain, which would cease as suddenly as it began. The attacks came on any hour of the day or night: they had no constant relation to food, often starting many hours after a meal. On one point the wife was most positive—that any exercise or violent exertion was liable to bring on an attack. They had increased in frequency until, for the last three months, they had occurred almost daily. They commenced eight years previous to death. After con-

tinuing for six years, they stopped altogether (with no alteration in his habits), to recur with increased

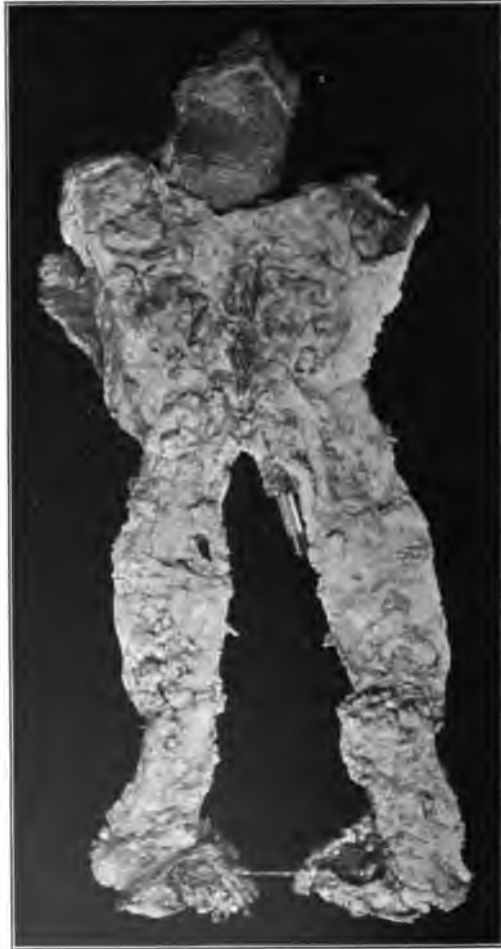

FIG. 13.—Photograph showing pancreas opened and displaying numerous stones.

severity for the last three months of his life. About the beginning of the latter period he was brought up

to the Casualty Department for abdominal pain and hæmatemesis, but no definite diagnosis appears to have been made. This was the only attack of hæmatemesis that he had had. There was some history of polyuria, but this was almost certainly due to his alcoholic excesses. The latter, his wife was distinctly of opinion, aggravated the colic attacks.

Post-mortem Examination: The stomach was dilated and adherent to the spleen. The liver was pale, but there was no cirrhosis. The spleen was adherent to some extent. The pancreas was surrounded by an excess of fibrous tissue. On removing it from the body and removing the fibrous tissue from its surface it was seen to be considerably atrophied, especially in its middle two-fifths, where it was extremely thin. Its tail was firmly adherent to the spleen. Numerous calculi could be felt in its substance, of various sizes, and a milky fluid could be squeezed from the ducts. The organ was hardened for some time in spirit and then a mesial section was made throughout its whole length. It was then seen to possess numerous loculi, which were filled with calculi of all sizes from minuteness up to a hazelnut. For the most part they were rough and granular, and white or pale yellow, and quite hard; some of the larger ones were much yellower, and quite soft and friable in consistence. There were no gallstones. The kidneys were a little granular.

While these pages have been going through the press a case of pancreatic calculus has been diagnosed and successfully treated by Moynihan. The stone was removed through the duodenum ("Lancet," Aug. 9, 1902).



## CHAPTER IX.

### PANCREATIC CYSTS.

AT the outset of a description of pancreatic cysts, one is met by considerable difficulties. The material upon which investigations have been founded has been scanty. In the great majority of cases dealt with by the surgeon the cyst has been opened, stitched to the abdominal wall, and drained; the fluid may have been examined, but no close investigation of the exact position, origin, or connections of the cyst has been prudent or desirable. The rarity of finding a pancreatic cyst on the post-mortem table is shown by the paucity of museum specimens. Moreover, it is indisputable that in some cases, when all the signs, physical and chemical, of pancreatic cyst have been elicited, the cystic tumour has only a secondary connection with the pancreas. Of such are certain peri-pancreatic cysts, and those effusions into the bursa omentalis which Körte has termed "pseudo-cysts." And to make confusion worse confounded, a cyst described as pancreatic by the operator is refused acceptance by a critical reviewer. Treves's case, for example, it is suggested by Tilger, was in reality a case of cyst of the suprarenal body.

The term "pancreatic cyst" has without question been used to describe any fluid tumour in, or asso-

ciated with, the pancreas, though such tumours differ widely in causation, position, and clinical features.

The following classification is as precise as our present knowledge permits:

1. Retention cysts.
2. Proliferation cysts { Cystic adenoma.  
Cystic epithelioma.
3. Hydatid cysts.
4. Congenital cystic disease.
5. Hæmorrhagic cysts.
6. Pseudo-cysts.

From the pathological standpoint the inclusion of the last form is not permissible. As, however, the clinical features tally precisely with those of true pancreatic cysts, the academic objection must give way to considerations of convenience.

#### I RETENTION CYSTS.

Virchow ("Die krankhaften Geschwülste," 1863, vol. 1, page 276) described two forms of retention cyst of the pancreas. In the one the whole duct is widened, and a "rosary-like" dilatation occurs. In the other the duct is blocked at its outlet, and becomes distended into a cyst, which may reach the size of a fist, and may contain mucoid, hæmorrhagic, or calculous matter. With the smaller cysts there can generally be little or no difficulty in determining their origin; with the larger cysts, with such as the surgeon is destined to meet, the differentiation may be difficult or impossible. Virchow himself has expressed his inability to determine the origin of a

large cyst attached on the one side to the pancreas and on the other to the stomach.

The **causes** of retention cyst are:

- (a) The impaction of a calculus, or calculi.
- (b) Cicatricial stenosis.
- (c) Pressure upon the duct from without.
- (d) Dislocation of a part of the gland.

(a) *The Impaction of a Calculus.*—A gall stone impacted in the ampulla of Vater blocks the duodenal outlet both of the common bile duct and of the duct of Wirsung. Such a block may result, so far as the pancreas is concerned, in chronic pancreatitis or the dilatation of the duct. Pancreatic calculi may be single or multiple. A specimen was shown by Curnow at a meeting of the Pathological Society of London. "The gland had greatly atrophied, and its ducts were much dilated and studded with calculi even in the smaller radicles. From the main duct and the accessory duct which was a little lower, fifteen calculi, varying in size from one-third of an inch to one inch in length, were removed, and three or four still remain *in situ*. It would seem as if the duodenal orifices of the ducts had been closed by catarrhal inflammation and the retained pancreatic secretion had been then inspissated, and its less soluble salts had crystallised out." The pancreas and the calculi are in the Museum of the Royal College of Surgeons. Drs. George Harley and C. H. Ralfe examined the calculi. The organic matter formed 24 per cent., the fixed organic salts (chiefly carbonate of lime) 76 per cent. Probably the explanation of

Curnow that some obstruction to the outlet precedes the formation of a calculus is frequently acceptable.

The museum specimens of pancreatic cyst due to a block by a stone furnish no large examples. The largest is recorded by Gould (Catalogue of the Anatomical Museum of the Boston Society, 1847). A pancreatic calculus may become blocked in the ampulla of Vater, and will then cause symptoms referable to a stone in the common bile duct. Such a case is recorded by Meckel (1763).

(b) *Cicatricial Stenosis*.—A stricture may be found at any part of the duct. When placed at the orifice it may be due to the healing of a duodenal ulcer, or to the encroachment of malignant disease. In Perry and Shaw's paper ("Guy's Hosp. Reports," 1893) four examples are quoted of healed duodenal ulcers causing constriction of the ducts at the bile papilla. Hoppe-Seyler and others have recorded similar cases.

A chronic interstitial pancreatitis, the healing of an ulcer caused by the rubbing of a calculus, and possibly rupture, partial or complete, of the duct from a blow, are all competent to produce such a stenosis of the duct as to impair seriously the escape of the gland secretion.

Wyss ("Virchow's Archiv," vol. xxxvi, page 455) relates a case in which a chronic interstitial inflammation of the head of the pancreas had so narrowed the duct as to cause a dilatation of the portion behind the constriction. In this case the patient had died from icterus produced by pressure upon the common bile duct. Bécourt has described a similar specimen

in the Pathological Museum at Strassburg. The gall bladder and bile ducts were distended; the pancreas was converted into a dense tissue, which on section presented a chalky deposit four to eight inches in length and of a yellowish colour. The duct of Wirsung was dilated to such an extent as to form a large cyst, which occupied the whole length of the pancreas.

In a very large proportion of the specimens that have been examined carefully, the presence of a chronic sclerosing interstitial pancreatitis has been revealed.

Hagenbach found a connective tissue proliferation on the surface and in the interstices of the gland. In the portions of the pancreas closely abutting on the cyst, a fatty degeneration had occurred.

In Churton's case the patient dying thirteen months after operation, a dense, hard mass of fibrous tissue, containing numerous vessels, had replaced the head of the pancreas. In the midst of this a small cavity was found, the remains of the large cyst.

Chronic interstitial inflammation of the organ is also described by Dieckhoff, Merigot de Treigny, Kühnast, Pepper, Klob, and several others.

The fullest account of this sclerosis of the pancreas as an antecedent to cyst formation is contained in a very able article by Tilger ("Virchow's Archiv," vol. cxxxvii, page 348). He considers that all cysts of the pancreas, with the exception of cysts associated with new growths, depend upon direct or indirect hindrance to the outflow of the pancreatic secretion, through chronic inflammatory troubles. There is a

retrogressive metamorphosis in the gland epithelium, which permits the secretion to be brought into contact with the altered gland substance, and to destroy it, by autodigestion, and thus to lead to the formation of a cavity.

Dieckhoff relates the findings in a case operated upon about six years before by Madelung. In the earliest beginning, from unknown causes, a slowly progressive chronic indurating inflammation existed in the head of the pancreas. In consequence partly of the pressure of hypertrophied interstitial tissue, and partly of the retention of the gland secretion, a distention of the ducts resulted. Numerous small cystic cavities were formed, and by the enlargement of several of these and the concomitant thinning of the intervening partitions, a single large cyst resulted. An extremely interesting case of pancreatitis followed by cyst of the pancreas is recorded by McPhedran.

An examination of recorded cases is sufficient to convince one that chronic interstitial pancreatitis is the first and weightiest factor in the series of events which determine cyst formation. The inflammatory change, however, is not invariable, for Stieda (*"Cent. f. path. Anat.,"* 1893, No. 12), after an exhaustive examination of his case, was able to say that the whole of the pancreas, up to the point in the tail in which the cyst lay, was perfectly normal, without trace of inflammation or fat necrosis.

A rupture of the duct, partial or complete, as a precursor of cyst development, has never been satisfactorily attested. Senn (*"Amer. Journ. Med. Sci.,"*



FIG. 14.—A pancreas, the duct of which is widely dilated throughout its entire length. Near the duodenal extremity the duct measures three-quarters of an inch in diameter, and shows two or three saccular protrusions into the substance of the head of the gland. Beneath the wall of the intestine there is a small abscess cavity, indicated by a black bristle. From a man aged fifty-seven, who was admitted for constipation and abdominal pain. Colotomy was performed a fortnight before death. At the autopsy it was found that there was a carcinomatous stricture of the sigmoid flexure. The liver contained a few secondary deposits of growth, and a small abscess was found in the connective tissue at the head of the pancreas. The cause of the dilatation of the duct was not discovered. (Museum R. C. S., specimen No. 2832 A) (Guy's Hospital, 1891).

1885, page 37) says: "I am quite convinced that in the case which I have reported, the retention was the direct result of traumatic stricture of the duct." Post-mortem evidence on the point is lacking.

A narrowing of the duct may result from the spread of inflammation upwards through the ampulla of Vater from the duodenum. Durante has recorded a unique case, in which a pancreatic cyst originated from the obstruction of the canal of Wirsung by an ascaris. Of this case Fitz remarks that "it is possible that the lesion in this patient may have been an inflammation of the lesser peritoneal pouch secondary to a pancreatitis."

(c) *Pressure upon the Duct from Without.*—Various forms of tumour growing in the duodenum or neighbouring structures may in their enlargement press upon and so obstruct the canal of Wirsung. A case of dilated pancreatic duct resulting from carcinoma of the duodenum is related by Hale White. The patient was a male, aged forty-one; he had had jaundice, much abdominal pain, and ascites, for which repeated tapplings were necessary. The post-mortem examination revealed carcinoma of the duodenum, which pressed upon the orifices of the bile and pancreatic ducts, which were so dilated that they would take a No. 12 catheter. Cruveilhier recorded a similar case, where a mass of duodenal scirrhus pressed upon and obstructed the pancreatic duct; and Virchow and Friedreich have both met with examples. Hoppe found the canal of Wirsung obstructed by a tumour originating in the lymphatic glands near the head of



the pancreas. Phulpin, Engel, and Horrocks and Morton have described cases in which a stone lodged in the lower end of the common duct above the ampulla of Vater had pressed upon the pancreatic duct and partially occluded it.

(d) *Dislocation of a Part of the Gland.*—This condition was the cause of a retention cyst in a case related by Engel. The patient was a woman sixty years of age; the tail of the pancreas formed a right angle upwards with the normal axis of the gland. The kink thus produced led to retention of the contents and cystic dilatation of the duct. A dislocation of the gland of this kind can occur, according to Senn, in one of the following ways:

1. Abnormal relaxation of the connective tissue attachments of the gland permitting a portion of the organ to descend, by its own weight, lower in the abdominal cavity.

2. Pressure upon the gland by tumours or exudations.

3. Cicatricial contraction in the substance of the organ or the peripancreatic space.

Retention cysts have been recognised as such during the course of the operation by several observers. In Ludolph's case (Inaug. Dissert., Bonn, 1890) the cyst was excised and the opening of the duct clearly seen. Hagenbach found two dilated radicles of the main canal, opening into the cyst. Dixon ("Medical Record," March, 1884) found the duct opening into the larger of two cysts. Richardson's case was considered by him to be a cystic dilatation of the duct.

As it is rarely possible to make an exhaustive inspection of the parts during an operation, it is perhaps remarkable that so many observations have been recorded.

On the post-mortem table specimens have been recognised by Virchow, Klebs, Gould, and many others. Virchow applied the term "ranula pancreatica" to a general distention of the whole duct. For the condition in which numerous small engorgements of the minute ducts are present, Klebs suggested the name "acne pancreatica."

## II. PROLIFERATION CYSTS.

Proliferation cysts may be either simple or malignant. The exact differentiation is not infrequently difficult, and is at times impossible from the pathological standpoint. One has in some cases to await the course of events after the removal of a cystic tumour before deciding as to the class in which to include it. Thus, Fitz, of Boston, in relating his case, says: "The tumour, from its histological appearances, is to be regarded as essentially a multilocular cystoma, but on the borderline between a proliferating cystoma or cystadenoma and a cystomatous carcinoma, a distinction which the subsequent history of the patient may be expected to make clear."

(a) **Cystadenoma**, or cystic simple tumour of the pancreas. These tumours are almost always multilocular, having a lining membrane of cylindrical epithelium, which is sometimes seen to dip down in the wall of the cyst in the form of a gland, and at times

covers masses projecting, polypus-like, into the cavity of the cyst. In many of the cases the simulation of multilocular cystoma of the ovary has excited remark.

The following cases are recorded (see Fitz, "Amer. Journ. Med. Sci.," August, 1900):

*Zukowski* ("Wien. med. Presse," 1881). Woman, thirty-six years of age. For two and three-quarter years a gradually increasing abdominal tumour, diagnosed by v. Rokitansky, who operated, as ovarian. The tumour was excised; it contained five litres of brownish-red albuminous fluid. The inner wall of the cyst was generally smooth, but at one part was roughened, and several small papillary masses projected into the cavity.

*Bozeman and Garrigues* ("Med. Record," 1882). The tumour consisted of a principal cyst holding two and a half gallons of brown fluid. The wall was trabeculated, the partitions contained large holes, and it bore several secondary cysts, the size of small hen's eggs. The walls were lined with cylindrical or polygonal epithelium, and the hardened section showed that the formation of the secondary cysts took place as in an ovarian cyst.

*Riedel* ("Archiv f. klin. Chir.," 1885). A woman, forty-five years of age. The cyst had been opened after laparotomy, and ten litres of brown fluid escaped; the tumour was then removed. The cysts had an adenoid projection from the wall, several globular spaces communicated directly with the interior, the spaces being lined with cylindrical epithelium, and others had papillary elevations, as in ovarian cystoma.

*Salzer and Paltauf* ("Zeitschr. f. Heilk.," 1886). The tumour was twice the size of a man's fist, and apparently continuous with the pancreas. Its con-

tents were a thick, slimy, greyish-brown fluid. From the anterior and lower portions of the cyst projected two globular, lobulated masses, the one as large as an apple, the other the size of an egg. They were separated from the main cavity by widely perforated septa, and were composed of an aggregation of smaller cysts. The walls were lined with cylindrical epithelium, and the pancreatic duct was found within the gland.

*Kühnast* (Inaug. Diss., Breslau, 1887). The pancreas of a man, fifty-one years old, was found, after death, to be made up of cysts, one as large as a medium-sized apple. All the cysts were filled with blood in various stages of metamorphosis, almost the entire gland was transformed into fibrous tissue, and the dilated duct was to be traced here and there through the cystic portion.

*Martin* ("Virchow's Archiv," 1890). A cystic tumour was successfully removed from the region of the pancreas; fifteen litres of thick brown fluid escaped from the cyst. A portion of the wall contained a large number of cysts, varying in size from a hazelnut to a goose egg. All were lined with cylindrical epithelium. The pancreatic duct was not found. (Roux describes this case as one of "cystic epithelioma.")

*Gussenbauer* ("Prag. med. Woch.," 1891) drained a cyst in the pancreas of a woman twenty-eight years of age. Several months later the patient died of phthisis. At the post-mortem (Chiari) a fistula extended from the abdominal incision to the pancreas, and the left half of the latter was replaced by a collection of cysts, the largest the size of a hen's egg. The smaller cavities were lined with a cylindrical epithelium. The pancreatic duct was opened from the duodenum to the cysts.

*Thirolaix and du Pasquier* ("Bull. de la Soc. Anat.,"

1892) found nearly the whole pancreas of an old woman of ninety-three transformed into a mass of cysts, the size varying from that of a hen's egg to that of a pea. The tumour was twice as large as the fist. The duct of Wirsung was not constricted.

*Poncet and Cibert* ("Gazette des Hôpit.," 1896). The tumour was successfully removed by Poncet, and was approximately the size of a man's head. A large cyst was found, in the wall of which were similar smaller cysts, no larger than hazelnuts. These were lined with cylindrical epithelium, and the wall of the main cyst was traversed by long ridges inclosing communicating spaces. Dor, who examined the tumour, considered it a teratoma or a foetal adenoma.

*Fitz* ("Amer. Journ. Med. Sci.," 1900, page 186). Two hundred and fifty cubic centimetres of fluid was removed from the cyst. The fresh specimen was examined by Dr. Whitney, who reported as follows:

"Hæmorrhagic cystadenoma. A cystic mass, the size of a squash, of a dark red colour, indicating extensive hæmorrhages, with a very soft necrotic tissue mingled with dark red fluid. No definite pancreas could be made out, though some of the hæmorrhagic masses suggested a piece of the pancreas, and another an *infiltrated adrenal gland*. A little piece of the tissue was soft, greyish, and rather malignant-looking to the eye. On microscopical examination of hardened and stained sections, rounded and irregularly sinuous cavities of various size were to be seen, some with incomplete septa, others with projecting papilliform growths. Some of the cavities contained granular, fibrillated, or hæmorrhagic material; others were filled with papilliform growths grouped in a somewhat irregular manner. The contents were occasionally cellular, the cells being free or clumped, at times in tufts. Many of the cavities were lined with a cylindrical epithelium, which was more

or less stunted in the larger cysts. Some of the papilli-form growths bore a cylindrical epithelium, while others were covered with cuboid cells. Occasionally the distribution of the epithelial cells suggested the acini of the pancreas, but the normal structure of this gland was not seen in any of the sections examined. The connective tissue between the cysts in places was densely fibrous, while elsewhere it contained numerous cells and was composed of interlacing fibrils, the latter forming a mesh-work inclosing a more or less homogeneous intercellular substance. Large and thin-walled blood-vessels were numerous. In places granules of blood-pigment and agglomerated red blood-corpuscles gave evidence of old and recent hæmorrhages, while extensive areas of necrosis, in which the structural details were well preserved, were not infrequent. It was in their vicinity particularly that the thin-walled blood-vessels and the hæmorrhages predominated. Although the above-mentioned characteristics prevailed in the sections examined, in a few of the latter a tendency to the atypical growth of epithelioid cells was apparent. The cells were of a cylindrical character, but by no means of a uniform shape, size, and arrangement, and were grouped in a tubular form, but the tubules often were so closely approximated as to present an irregularly alveolate appearance."

*G. Heaton* ("Brit. Med. Journ.," 1901, vol. 11). The tumour measured ten inches by seven inches, and was removed with the body of the pancreas. The mass was composed of a number of cysts, varying in size, and separated from one another by septa of fibrous tissue and a varying amount of apparently normal pancreatic tissue. The cysts were larger at the tail end of the organ than at the head. One cyst held one and a half pints of dark brown fluid, containing altered blood.

The fluid in the smaller cyst was light coloured, and, in some, colourless and watery.

The microscopical section shows in places fairly normal pancreatic tissue, the acini being separated by rather thicker bands of fibrous tissue than are usually found. In the main parts of the tumour the microscopical appearances are very different. Scattered throughout a connective tissue framework, which in places dense and thick, are masses of small epithelial cells. These cell masses have in most cases an irregular lumen towards the center. In some of the larger masses the most central cells are seen enlarged and undergoing vacuolation. In this way apparently small cysts lined by several layers of irregularly-shaped cells are formed. The larger cysts have a lining of several layers of similar cells, though somewhat flattened. The microscopical appearance in no way resembles that of normal pancreatic tissue.

It cannot be said that our knowledge of the pathology of cystadenoma is either accurate or complete. Some of the cases are certainly open to the objection that the origin of the growth from the pancreas is supposititious. Such are Martin's case and Fitz's case (one of the masses suggested an "infiltrated adrenal gland"). Unless a very careful post-mortem examination is made, the origin of the tumour in the pancreas cannot be positively proved; for if the growth begins in the suprarenal capsule, an adhesion to the pancreas is probably formed very early on the left side, and at the operation a portion of the pancreas may have to be removed.

(b) **Cystic Epithelioma.**—*Hartmann* (Cong. Franc. de Chir., 1891) was the first to operate upon a case of

cystic epithelioma. The patient was a woman, fifty-three years of age, who had an abdominal tumour of rapid growth. Wasting was very marked. Laparotomy was performed; 200 grammes of chocolate-coloured fluid were removed from a cystic tumour, which lay behind the stomach. The cyst was drained. Death occurred in six weeks. The post-mortem was performed by Gilbert. The entire body and tail of the pancreas were found to form a polycystic mass, through which the pancreatic duct could be followed. Cancerous nodules were found in the liver; these were regarded by Gilbert as representing a cystic epithelioma with the new formation of glandular cul-de-sacs presenting a cystic dilatation.

*Gilbert* ("Etudes sur les Maladies du Foie," Hanot and Gilbert, 1888) relates a case in which a series of cysts of various dimensions were found in the pancreas. The tumour was generalised in the liver, and was considered by Gilbert to be a pancreatic tubular epithelioma.

*Rotter and Orth* record a case of cystic tumour of the pancreas submitted to operation by the former surgeon. The examination showed carcinomatous tissue in the cyst wall.

The case of a woman aged sixty-nine is recorded by *Ménétrier*, in which, as in *Hartmann's* case, secondary nodules were found in the liver. The specimen was described as "tubular epithelioma." There were growths in the pancreatic glands, the duodenum, and the common bile duct, as well as in the liver.

The formation of cysts in cancer of the pancreas



has been described by Roux (Paris Thesis, 1891, part III).

### III. HYDATID CYSTS.

Hydatid cysts of the pancreas are extremely rare. Massèron (Thèse de Paris, 1881) was able to collect the records of only five cases, and these were first recognised on the post-mortem table. Graham, of Sydney ("Hydatid Disease in its Clinical Aspects," 1891), writes: "The hydatid is sometimes found in the pancreas. I have observed it as a cyst about three inches in diameter replacing the head of the organ." Tricomi states, without giving references, that seven cases have been recorded.

In a series of 986 cases of hydatid disease collected by Neisser, the distribution was:

Liver . . . . .	451
Lungs and pleura . . . . .	84
Kidneys . . . . .	80
Muscles and subcutaneous tissue . . . . .	72
Brain . . . . .	68
Spinal cord . . . . .	13
Female organs and mammae . . . . .	44
Male organs . . . . .	6
Pelvis . . . . .	36
Organs of circulation . . . . .	29
Spleen and bones . . . . .	28
Eye . . . . .	3
Pancreas . . . . .	0

*Hale White* records one case of hydatid disease of the pancreas. The patient was a boy aged six, under the care of Dr. Pye-Smith. The following is the history: "In January, 1894, was sick. In March became jaundiced, and has remained so. About six weeks before admission his abdomen distended. On

admission, November 6th, the liver could be felt most distinctly. It was uniformly enlarged, and extended almost to the crest of the ilium. The gall bladder was felt as a smooth, round swelling. Jaundice; bile in urine; motions clay-coloured. December 6th, paracentesis; three pints withdrawn. He began to be frequently sick, and died December 25th. Post-mortem: Liver very tough, hard, and cirrhotic; bile ducts much dilated; gall bladder very distended. There was a hydatid cyst in the head of the pancreas, three and a half inches by eight and a half inches; pancreatic tissue could be seen around it. It was pressing on and stretching the duodenum and bile duct. It contained 250 c.c. of fluid, and before it was opened the common bile duct was quite occluded, but after it was opened bile flowed freely."

*George Peters* ("Canadian Practitioner and Review," Feb., 1901) relates a case of hydatid disease successfully operated upon by him. The following is a brief abstract:

"E. I., aged twenty, seen by Peters in October, 1900. The condition made out was as follows: Patient rather thin; confined to bed. Suffering from fever, with evening temperature reaching  $104^{\circ}$ . Pulse generally over 100. Some sweating. The urine is normal.

"Local Conditions: A rounded tumour, about as large as a cocoanut, can be felt below the ribs on the left side, with its centre about midway between the nipple and sternal lines. The mass is tense to the feel, and elastic, but no distinct sense of fluctuation can be elicited.

"Its relations to the pancreas are determined by the

easy detection of stomach resonance above the tumour, and between it and the liver, and of colon resonance below. For the purpose of clearly making out the line of the colon, air was injected into it, per rectum, as recommended by Kocher.

“Stomach resonance can also be detected between the tumour and the normal situation of the spleen, while the kidney is excluded as the seat of the disease by the presence of colic resonance in the flank below the last rib, as well as between the normal area of renal dullness and the tumour.

“By pressing the tumour very firmly from the front, it can be felt at the back, below the twelfth rib. The mass descends very slightly on deep inspiration, but is clearly attached to the posterior abdominal wall. No pulsation can be felt.

“Operation: An incision, about three inches long, was made from the margin of the erector spinæ forward, about parallel to the twelfth rib, and curving slightly upwards around its end in the direction of the margin of the costal cartilages. On rapidly deepening the wound, the lumbar fascia was divided, the colon displaced forwards with the peritoneum, and the kidney, surrounded by its fat, was found lying in its normal position, and obviously quite healthy. The further dissection was done largely by the finger and the handle of the scalpel, keeping in front of the kidney and well clear of its vessels.

“On pressing the finger upwards, forwards, and inwards, the cyst could now be reached when very firm pressure was made from the front. A long hypodermic needle was inserted, and a very peculiar, dirty grey fluid was withdrawn. With the needle as a guide, the cyst was incised, with some difficulty, owing to its depth from the surface and the toughness and resistance of its wall. To one accustomed to dealing

with hydatids I have no doubt that this condition of toughness would immediately have suggested the true nature of the cyst; but as hydatid disease is very rare in this country, this being our first experience of it, we did not recognise the parasitic character of the neoplasm until the hooklets were discovered subsequently under the microscope.

“On opening the cyst, some three or four ounces of sero-purulent fluid escaped, in which were suspended shreds of yellowish-grey matter, which were, as we now know, probably disintegrated daughter cysts.

“On passing the finger into the cavity it was found to have a thin but very dense and resistant wall, which was roughened by the presence of broken-down material similar to that which escaped. A microscopical examination of the contents showed numerous brood-cysts, with their attached embryos in varying degrees of disintegration, as well as multitudes of the characteristic hooklets. It is highly probable that the process of tapping three weeks previously had resulted in the death of the parasite, as frequently occurs.”

#### IV. CONGENITAL CYSTIC DISEASE.

Similar to the congenital cystic disease of the liver and kidneys, and has been observed on rare occasions. Dr. Pye-Smith recorded (“Path. Soc. Trans.,” 1885, page 17) a case of cyst of the cerebellum, with numerous small cysts in the pancreas and kidneys. The patient was a man, aged twenty-seven. “The pancreas contained eight or nine thin-walled cysts, varying in size from a hemp-seed to a bean. Some of them projected from the surface. All contained a clear fluid, and looked, when recent, like so many vesicles or

small bullæ. The duct of Wirsung was not dilated, and the tissue of the gland was neither indurated nor in any way abnormal. No communication with one another or with the ducts could be discovered, yet their appearance was more like retention cysts than accidental bursa-like dilatations of the connective stroma of the gland."

Richardson has recorded a cyst of the pancreas occurring in a child fourteen months old; and in one case, related by Shattuck, a tumour had been noticed since birth.

#### V. HÆMORRHAGIC CYSTS.

That bleeding may occur into the substance of the pancreas as the outcome of acute or chronic inflammation is well proved.

Of the influence of these or other hæmorrhages, traumatic or spontaneous, upon the building up of a cyst, no positive opinion can be expressed. Hagenbach distinguishes between *hæmatoma*, in which bleeding occurs into pre-existing cysts, and *apoplectic cysts* resulting from hæmorrhage into softened, degenerate gland substance. In favour of the hæmorrhagic origin of cysts are the writings of Kühnast, Schröder, and Friedreich.

Gussenbauer conjectured that the origin of the cyst in the case operated upon by him was due to a central hæmatoma of the pancreas. In discussing the case, Senn remarks: "This assumption lacks demonstration, and it is just as logical to assume that the cyst originated in the usual way from an obstruction, and

that the blood in the cyst contents was an accidental product." A comment with which Körte seems in accord.

Dr. Theodore Fisher, in an article in the "Guy's Hospital Reports" (vol. xxxiv), brings forward evidence, based upon the records of cases, which he thinks establishes the hæmorrhagic origin of pancreatic cysts. He says: "We should be inclined to suppose that the cyst may arise from blood effusion, either within or without the gland. It is at least certain that hæmorrhage may occur into the substance of the pancreas, as in the cases collected by Fitz; in the neighbourhood of the pancreas, as in one of Dr. Rolleston's cases and in that of Frerichs; and at some distance from the gland, as in several cases quoted in this paper." And again: "We may conceive it to be possible that the pancreas may be secondarily affected by a blood effusion in its neighbourhood. The presence of blood in a pancreatic cyst is commonly explained by hæmorrhage into a cyst already present, which perhaps owes its existence to blockage of the duct; but I propose to take the opposite view, that an effusion primarily sanguineous may soon fail to give marked evidence of the presence of blood, and that the pancreatic cyst originates in a blood effusion not necessarily arising in the gland itself."

The origin of the pancreatic cysts in extravasated blood is not accepted by the majority of observers. Küster, and especially Tilger, combat the suggestion very strenuously.

It may be stated with emphasis that there is no

valid or acceptable evidence in favour of the hæmorrhagic origin of these cysts. The tendency to bleeding in greater or less degree is observed in all pancreatic cysts, and the presence, therefore, of blood in predominant quantity is not sufficient to establish a hæmorrhagic onset.

#### VI. PSEUDO-CYSTS.

Körte has proposed the term "pseudo-cysts" for those fluid tumours found in more or less close proximity to the pancreas, but not originating in the substance of the gland. The accurate distinction of a true pancreatic cyst from a pseudo-cyst is not always possible during life, for a cyst primarily peripancreatic may originate in a trauma, which implicates the gland at the same time, so that the pancreatic juice may in small quantity escape into the pseudo-cyst and make its mimicry of a true cyst so complete that a distinction is impossible. I am indeed strongly inclined to believe that many cases of so-called pancreatic cysts, especially those of traumatic origin, are in reality peripancreatic, or pseudo-cysts, effusions into the lesser cavity of the peritoneum, localised extravasations of blood, and so forth. In some recorded examples the origin of a cyst in the pancreas is purely hypothetical, and in these the tumour may be a "pseudo-cyst" of the pancreas or a true cyst of a neighbouring organ, such as the suprarenal, or the kidney.

The most frequently occurring form of "pseudo-cyst" is that first described by Mr. Jordan Lloyd

("Brit. Med. Journ.," November, 1892). In this very important paper attention is drawn to *effusions into the lesser peritoneal cavity*, as the result of injury to the pancreas, and two cases are fully reported. The first is perhaps open to the criticism that the report of the pathologists does not support the belief that the effusion was in the lesser sac. The blood-cyst is said to have been "removable with the stomach," and the extravasation may therefore have occurred between the muscular coat of the stomach and its peritoneal investment derived from the anterior wall of the lesser sac. Case II seems much clearer. The following are the notes and comments:

"CASE II.—G. D., aged twenty-seven years, labourer, was admitted into the Birmingham Workhouse Infirmary on December 9, 1891. On November 7th he was drinking in a public house, when a quarrel arose; he was thrown on the floor by a man, who kept him down by kneeling on his abdomen during the time a policeman was being sent for to remove him from the house. He was taken to the police station, and during the night complained of feeling ill, and was sick. Next morning a doctor was called in to see him. The patient stated he had then a swelling in his abdomen. On November 8th he was taken before the magistrates, and sent to prison for a month. The prison surgeon, Dr. Price, who was away on leave at the time of admission, writes me that 'shortly after his reception he vomited freely, and on November 10th was admitted into the prison hospital, a provisional diagnosis of pyloric obstruction being made.'

"On November 27th Dr. Price saw him for the first time, and noted that 'he alternately vomited and



retched after food, and had rapidly emaciated. The epigastric, left hypochondriac, and upper part of umbilical regions were occupied by a large solid tumour, which did not decrease in size after vomiting. There was no material increase in size up to the date of his discharge (December 9th), although it appeared to be more tense; but he rapidly lost flesh, and became very anæmic. I thought it was a blood tumour connected with the spleen.'

"I am indebted to Dr. J. O. Tunstall, formerly senior resident medical officer at the Workhouse Infirmary, for the following notes made at the time of his admission on December 9th:

"'Whilst in prison was sick after almost every meal; had pain in abdomen, striking through from front to back, but never very severe; had not vomited blood at any time; no trouble with bowels or bladder. He is a short, well-built man. In the abdomen is a large protruding swelling, occupying nearly the whole umbilical, the lower part of the epigastric, and the left hypochondriac regions, tense on palpation, fairly well defined, dull on percussion, the dullness not continuous with that of the liver or spleen. A resonant area can be percussed out all round the swelling. There is a dull area in the back, extending from the level of the angle of the left scapula to the lowest ribs, where the breath sounds and the vocal fremitus are diminished, but not absent. The apex beat is raised to the fourth left intercostal space, just internal to the nipple. Temperature, 96°; urine acid, 1025, faint traces of albumin and phosphates.'

"On December 12th Dr. Tunstall aspirated the swelling in the middle line, almost midway between the umbilicus and the ensiform cartilage, and drew off twenty ounces of dark brown, turbid fluid. The needle moved up and down synchronously with respira-

tion. The fluid had a specific gravity of 1010, was rich in albumin, and deposited a thick layer, consisting of blood cells, débris of cells, and linear-like crystalline bodies. A second puncture was made at a lower point, and a further small quantity of fluid withdrawn. The tumour reappeared in a few days, and he was transferred to the surgical wards. From what I had learned from my previous case I at once diagnosed the condition as an effusion into the cavity of the lesser peritoneum secondary to injury of the pancreas.

“On December 18, 1891, under chloroform, I opened the abdomen by an incision two and a half inches long in the middle line above the umbilicus. The cavity of the peritoneum was quite healthy. The greater curvature of the stomach lay across the upper end of the opening, with a red and thickened great omentum passing downwards from it; the omental vessels were abnormally large and tortuous, and were engorged with blood, the veins being as thick as penholders. A fine needle was pushed through the omentum and fluid found; the omentum was then stitched carefully to the skin, the parietal peritoneum not being included in the sutures. An opening was then made through the omentum, and eighty-four ounces of a brownish turbid fluid were caught in receivers. A finger passed into the opening entered a cavity situated behind the stomach, in front of the pancreas, above the colon, below the left lobe of the liver, limited to the right, but passing deeply backwards to the left, beyond reach of the finger. A double rubber drain tube was inserted and the parts dressed with dry boracic dressings.

“On the fourth day the edges of the wound were red and irritated by the discharge. The patient made an uninterrupted recovery, the tubes being discharged six weeks after the operation. The temperature was sub-

normal throughout. He grew stout and strong, and left the Infirmary in absolute health a short time later.

"I examined the fluid immediately after its removal, and made the following notes: Turbid; brownish pink colour; viscid; 1013; slightly alkaline; tasteless and odourless. On standing, a one-third pink flocculent precipitate goes down, and the upper layer remains turbid and of a yellow colour. On the following day Professor Allen, of the Mason College, examined the fluid, and appended is his report:

"Fluid received from Mr. Jordan Lloyd, on December 21, 1891. A turbid fluid of reddish-grey colour; specific gravity 1012; reaction slightly alkaline. Under microscope shows great quantity of blood corpuscles, many small crystals (probably phosphates, as being the most likely to exist in an alkaline fluid), a few globules of fat, and a few fine filaments resembling fibrin, but possibly adventitious material from the vessels used.

"Proteids: Fluid gives coagulum on boiling, which is greatly augmented on acidifying the boiling fluid. Thus there is present a small amount of albumin or globulin, and a much larger quantity of alkali albuminate. The coagulum, after standing twelve hours, amounts to two-thirds, representing 1 per cent. of dry proteids. The estimate is confirmed by Esbach's method. The filtrate, after coagulation, gives a faint rose colour, with  $\text{NaHO}$  and  $\text{CuSO}_4$ , indicating a trace of albumose or peptone, or both, but the quantity is too small to separate them. The albumose is insufficient to give a perceptible precipitate with ferric acetate.

"Sugar: Another portion of the same filtrate gives a slight yellow colour when heated with  $\text{NaHO}$ ; therefore sugar is probably present in minute quantity.

(Other tests are not applicable, owing to presence of trace of proteids.)

“Digestive Properties: When mixed with an equal quantity of starch paste it converts the starch rapidly into sugar in five or ten minutes. Fibrin left in the fluid for twenty-four hours at body temperature is not perceptibly dissolved, and the fluid scarcely shows any increase of albumose or peptone after the process; therefore trypsin is absent, or nearly so. As might be expected of a fluid containing so much alkali-albuminate, it forms an emulsion with olive oil on shaking; but its emulsive power is very weak, being only about one-fifth that of a 1 per cent. solution of sodium carbonate.

“Remarks: The hypothesis that the fluid was derived from a cavity in connection with the pancreas is favoured by the presence of (1) abundant amyolytic ferment, (2) a peculiar preponderance of alkali-albuminate, and (3) traces of albumose or peptone. It is not, however, normal pancreatic juice, as shown by the absence of trypsin. If trypsin had been present the alkali-albuminate would not have remained as such, but would have been mostly converted into albumose and peptone while the fluid was still in the body. It must be remembered, too, that amyolytic ferments occur in various fluids besides the digestive juices. The emulsive action is not a special feature of pancreatic juice, but belongs to any fluid containing a fair amount of alkali-albuminate.—F. J. ALLEN.’

“The points to which I desire to call attention here are, first, the nature of the injury received. The patient was held on the ground by a heavy man kneeling on his belly; in this position the pancreas might easily be squeezed between the knee and the body of the first lumbar vertebra, upon which it lies; secondly, the early onset of frequent vomiting; thirdly, the rapid

development of a large tumour in the umbilical, the epigastric, and left hypochondriac regions, which was looked upon as the distended sac of the lesser peritoneum before operation; fourthly, the displacement of the heart's apex beat upwards; fifthly, the area of dullness and impaired breath sounds in the left back; sixthly, the removal by puncture of brownish fluid; seventhly, the details of the operation and the verification of the diagnosis by digital exploration of the cavity; eighthly, the perfect recovery which followed; and, lastly, the examination of the fluid made by an experienced physiologist and chemist."

From this observation and a study of the recorded cases of pancreatic cyst, Mr. Jordan Lloyd suggests that some of the latter may be of the nature of effusions into the lesser sac. He writes further: "The diagnosis of pancreatic cyst appears to me often to have been made upon insufficient evidence. The fact that a cavity within the abdomen contains pancreatic secretion is no proof whatever that the cavity is within the pancreas; it tells us nothing more than that the cavity is connected with this organ. Neither is the fact that the pancreas can be felt by an examining finger from within an intra-abdominal sac, for if the lesser peritoneal cavity is opened from below by an incision in the transverse mesocolon, a finger passed through this opening enters a large space, at the back of which the pancreas is found. Similarly, too, if the lesser peritoneal cavity is opened by an incision in the great omentum below the stomach. Through either opening the deepest part of this space is found to the left, and cannot be reached by the examining finger."

The lesser peritoneal cavity is situated behind and below the whole of the stomach, the gastro-hepatic omentum, and the anterior layers of the great omentum. Owing to the varying extent of the process of "physiologic fusion" between the opposing layers of peritoneum in the great omentum, the cavity of the lesser sac is of widely different capacity in different individuals. It lies in front of the whole of the body of the pancreas, to which it is closely adherent, and from which it is never separated by a layer of fat even in the stoutest persons. Its lower boundary forms the upper layer of the transverse mesocolon, and reaches laterally from the hepatic to the splenic flexure of the colon. Its right limit is formed by the folding of the membrane into the foramen of Winslow, and its left limit corresponds to the hilum of the spleen. Its upper limit is determined by the groove in the liver to the right of the lobus Spigelii, by the transverse fissure of the liver, and by the under surface of the diaphragm, covered by the lower layer of the right ligament of the liver. The under surface of the Spigelian lobe is the only part of the liver which lies bare in this cavity. When the sac is opened by a transverse incision through the great omentum, close to the lower border of the stomach, it can be seen that the deep part of the cavity is arranged in at least three distinct hollows—one to the right of the Spigelian lobe, one at the bottom of which this lobe lies, and one reaching deeply backwards to the left of the lumbar vertebra as far as the back of the abdomen opposite the lower four ribs.

An effusion into this cavity will clearly produce a swelling of the exact shape, size, and position of many of those tumours recorded as "pancreatic cysts." In most of the records that I have consulted, no mention is made of the condition of the lesser sac, and I can therefore only speak with some reservation. My opinion is, however, strongly in favour of accepting Mr. Jordan Lloyd's suggestion that "pseudocysts" of this type have been not infrequently regarded as true glandular cysts, and I should consider this explanation the more acceptable in cases where the tumour is sudden in onset and rapid in development.

Mr. Jordan Lloyd summarises his conclusions as follows:

1. That contusions of the upper part of the abdomen may be followed by the development of a tumour in the epigastric, umbilical, and left hypochondriac regions.
2. That such tumours may be due to fluid accumulations in the lesser peritoneal cavity.
3. That when the contents of such tumours are found to have the property of rapidly converting starch into sugar, we may assume that the pancreas has been injured.
4. That many such tumours have been regarded as true retention "cysts of the pancreas," and that this opinion has been formed upon insufficient evidence.
5. That the diagnosis of distention of the lesser peritoneal cavity before operation can usually be made by the characteristic shape of the swelling.

6. That early median abdominal incision and drainage is the safe and proper treatment.

The following most interesting case is recorded by McPhedran ("Brit. Med. Journ.," 1897, vol. 1, page 1400):

"G. A. B., male, fifty-three. In 1891 had an attack of biliary colic, with well-marked jaundice and pale motions. Had two or three similar attacks every year. Condition became gradually worse; there was almost constantly some epigastric discomfort, indigestion, flatulence. One severe attack of pain lasted three days; the epigastrium was tender, and pain radiated in several directions. Was losing flesh. On examination on a certain date there was an increase in the thickening in the deep part of the epigastrium; three days later a large, smooth, cyst-like tumour was found in the epigastrium, extending from the right parasternal line to the left mammary line and down to the umbilicus. The upper boundary was ill defined; the stomach resonance was above and to the left. A cystic collection in the bursa omentalis was diagnosed, and the abdomen was opened. The cyst was emptied; at the bottom lay the pancreas, irregularly enlarged and firm, but somewhat elastic. The peritoneum over it was smooth and healthy looking. There was no sign of hæmorrhage anywhere. Five months after a tumour was again found in the epigastrium; this tumour extended down to the level of the anterior superior spinous processes and laterally to the mammary line on the right and the anterior axillary line on the left. It forced the diaphragm upwards, so that the cardiac impulse was in the fourth intercostal space. The abdomen was again opened and a cyst exposed lying behind the stomach;



the cyst wall was about 2 mm. thick; the fluid was opaque, whitish, and contained many flocculi and fibrin masses. The fluid was alkaline, contained albumin, but no digestive ferment. The cavity contracted rapidly, but a fistula persisted. The discharge from this irritated the skin. On examination it was found to possess marked action on albuminoids, fats, and starches, leaving no doubt as to the presence of pancreatic secretion. The condition causing the repeated attacks of colic lay in the pancreas, and may have been a calculus or a localised inflammatory deposit, causing mechanical obstruction. In the most acute attack the symptoms were those of acute pancreatitis."

This case is especially interesting from the fact that it is, so far as we know, the only one recorded in which a pseudo-cyst and a true cyst have been observed in the same individual.

Other forms of pseudo-cyst are mentioned in the article by Fisher, to which reference has already been made. They are found in the lesser omentum, in the great omentum, between the layers of the transverse colon, or behind the parietal peritoneum. All are the remnants of large extravasations of blood, the result of traumatism.

The consideration of these cases opens up the whole question of the relation of trauma to cysts of the pancreas. Körte describes two classes of traumatic pancreatic cyst, the one in which, after long-continued feelings of discomfort in the epigastrium, indigestion, and so forth, a tumour gradually forms; and the other in which, within a very brief period, a tumour already

of large size is noticed. It may be that in the former class the injury sustained has led to a chronic interstitial inflammation of the pancreas, as described by Tilger, a condition which we have seen to be the weightiest factor in the causation of true pancreatic cysts. Such a sclerosis of the gland after trauma has not been observed in the human; but Körte, experimenting upon dogs, has thus produced a "marked proliferation of the interstitial tissue." And he adds: "It is not at all improbable that in man also, as the result of injury, a chronic interstitial pancreatitis may develop and lead to the gradual formation of a cyst." This mode of origin is possible in the cases related by Küster, Lindner, Steele, Riegner, and Pitt, though Tilger is inclined to consider them as examples of effusions into the bursa omentalis. In the latter class—those in which the fluid tumour is very rapid in its onset—it is highly improbable that the pancreas is solely involved. It is more than probable that the injury to the gland is associated with an injury to its peritoneal covering, the posterior wall of the lesser sac. Blood and pancreatic secretion pour into the bursa omentalis, a low-grade inflammation is established, the foramen of Winslow is sealed, and the lesser peritoneal cavity is consecutively distended. The most rapid formation of a tumour under these circumstances is recorded by Hadra; twenty-four hours after a blow on the epigastrium some fullness was felt, and within three days a fluctuating tumour lying behind the stomach was readily palpable. The fact that in this and similar cases the effusion rapidly

increases until it obtains a certain bulk, and then remains stationary, suggests convincingly the distention of a pre-existing cavity.

#### PATHOLOGICAL ANATOMY.

Cysts of the pancreas are rather more frequent in men than in women. Of 121 cases collected by Körte, 60 were males, 56 females; in the remaining 5 no mention of sex is made.

The youngest patient affected was a child thirteen months old, whose case is recorded by Shattuck. Richardson has operated upon a child fourteen months old. Stiéda's patient was a man of seventy-six. In the 121 cases mentioned, the following was the age distribution:

Between	1	and	10	years	there	were	7	patients.
"	11	"	20	"	"	"	11	"
"	21	"	30	"	"	"	30	"
"	31	"	40	"	"	"	36	"
"	41	"	50	"	"	"	16	"
"	51	"	60	"	"	"	11	"
"	61	"	70	"	"	"	4	"

In 6 the age is not given.

The cystic tumour may be situated at any part of the gland, from the duodenal margin of the head to the tip of the tail. The body is more commonly affected than the head, and the tendency to implication seems, roughly, to increase as the tail is approached.

In 22 cases collected by Hagenbach, the cyst arose in the tail 10 times, 4 times in the head, once in the body, and in 7 the site is not indicated. Nimier gives the following: 21 times in the tail, 6 times on the body,

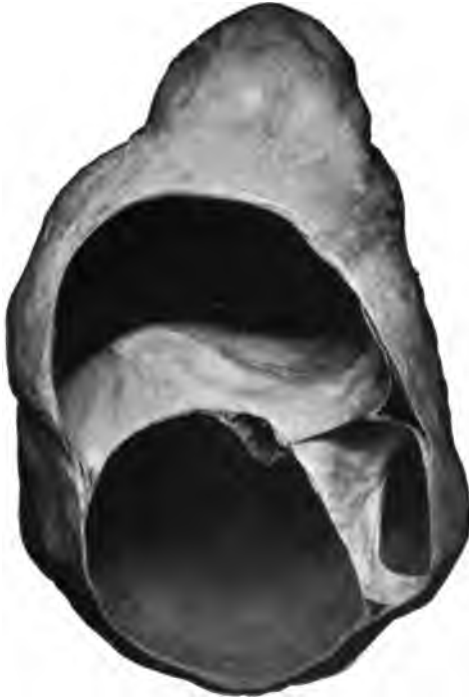

FIG. 15.—A thin-walled cyst which was removed from the pancreas. It measures about six inches in its chief diameter and is multilocular; some of the larger compartments communicate with certain of the lesser by circular, sharply-defined apertures, due probably to the atrophy of the intervening partitions. The interior of many of the cavities is blood-stained from hemorrhage. During the operation much of the fluid was withdrawn by aspiration from two of the chief loculi; that from one was quite clear, that from the other blood-stained. The somewhat ropy, dull-brown mixture of the two was found to be strongly amylolytic when tested on starch solution. The patient, a middle-aged lady, had noticed the growth about seven months, having discovered it first from a slight pain felt on leaning the abdomen against some article of furniture. The swelling was thought to be a cystic kidney at the operation; the tail of the pancreas came out of the wound and had to be dissected off. About an inch and a half or two inches from the end of the tail the connections of the cyst were most intricate, certain vessels occasioning much trouble in this situation (Museum R. C. S., specimen No. 2834 A) (J. D. Malcolm, Esq.).

4 times in the head, once in the head and the body, and in 1 the whole organ was implicated.

Cysts may be single or multiple, unilocular or multilocular. Two cysts may be simultaneously observed of almost equal size; or, after the healing of one cyst, a second may develop in a distant portion of the gland, and necessitate further operation. One small cyst may be found with a large number of smaller ones packed in its walls.

As the cyst enlarges it encroaches upon and stretches and destroys the substance of the gland, or, growing away from the pancreas, it may become narrowly pedunculated. When growing in the middle of the organ the gland may seem divided into two lateral halves. In size they vary within the widest limits. The gland may show innumerable tiny points of fluid, a condition described by Klebs as "acne pancreatica," or a tumour capable of holding enormous quantities of fluid may be formed. In Martin's case 15 liters of fluid were removed. In Stapper's case 20 liters were present; in others the tumour has been said to be of the size of a man's head, as large as a full-term pregnancy, and so forth.

The cysts are generally smooth and rounded; they are elastic, and rather tense. The inner surface of the cyst wall is commonly smooth, and lined throughout by cylindrical epithelium; trabeculæ or incomplete septa may at times be present. Intracystic polypoid masses are found in cases of proliferation cyst. In the great majority of recorded cases blood in greater or less quantity has been observed.

**CHARACTER OF THE FLUID.**

The fluid found in pancreatic cysts has been of vastly different quality in different cases. The colour is generally dark-reddish brown, but it may be clear, whitish, milky, yellow, dark coffee colour, green, or almost black. In Bull's case the fluid was dichroic, dark green by reflected light, dark red by transmitted light. The variations in colour are due to the amount of blood which has been extravasated and mixed with the contents. The fluid is generally thick and viscid; it is alkaline in reaction, and of specific gravity 1010 to 1020. Gussenbauer, in one case, found the specific gravity 1160. Albumin is always present; in Kraske's case 5.2 per cent. was found. Serum-albumin, paraglobulin, mucin, and urea have been noted. On microscopic examination, blood cells, fat cells, and epithelial cells may all be present, and cholesterin is frequently seen.

Ferments may be found,—an albumin-digesting ferment, a fat-emulsifying ferment, and a starch-converting ferment. The exact value of the discovery of one or more of these ferments is still a matter of dispute. Von Jaksch, in examining the fluid from various forms of abdominal cyst, and in ascites, found a starch-converting ferment; as affecting the question of a localising diagnosis, he considers that the presence of this ferment is valueless. Boas considers that the most important ferment in establishing a pancreatic origin is the albumin-digesting. Zeehuisen considers the discovery of a fat-emulsifying ferment important

as indicating pancreatic disease. Körte considers that a powerful starch-converting ferment, of great diagnostic value as such, proceeds only from the pancreas. The absence of ferments in cases of undoubted pancreatic cyst has been observed. In Gussenbauer's second case no ferments were found in the cyst or in the discharge from a persisting fistula. On the death of the patient five months later, from phthisis, the origin of the cyst from the pancreas was demonstrated. Similar instances are recorded by Heinricius and others. Körte concludes a full discussion of this subject with the following paragraph: "As characteristic of pancreatic cyst is a blood-stained, reddish-brown, or dark fluid, slightly viscid, alkaline, rich in albumin, of specific gravity 1010 to 1020. Ferments are frequently present, and, when in pronounced quantity, establish the diagnosis; their absence allows no conclusion against the pancreatic origin of the cyst to be drawn."

The cyst is, in most of the cases, more or less firmly adherent to surrounding structures. Zukowski found the tumour, in Rokitansky's case, surrounded by adhesions to the posterior wall of the stomach, the transverse colon, the great omentum, and the descending colon. In attempting to free the cyst the colon was torn for nearly an inch; fifty ligatures were applied in dividing adhesions. In stripping off the great omentum, the cyst wall was torn and the contents escaped. Rosenthal, Karewski, and others have found adhesions to the stomach of such firmness as to prevent extirpation of the cyst. In a case of

## Symptoms and Signs of Pancreatic Cysts 227

Hartmann's the cyst wall and the stomach were fused, the portal vein was firmly buried in the wall, and adhesions to the duodenum and liver were also present. Mikulicz has abandoned an attempt at extirpation, on two occasions, on finding tough, inseparable adhesions.

In other cases no adhesions of any kind have been observed. The cyst has been freely movable in the abdomen and excision has been readily performed, as in Clutton's case and in Bozemann's.

### **SYMPTOMS AND SIGNS OF PANCREATIC CYSTS.**

The symptoms produced by a pancreatic cyst are chiefly referable to the pressure exerted by the tumour upon surrounding viscera. In the earlier stages, while the tumour is yet small, the symptoms are absent, or so trivial as to attract but little attention. Almost imperceptibly the feelings of discomfort, weight, and fullness in the epigastrium increase. Pain is noticed towards the end of, and for some time after, a meal, and vomiting becomes gradually established as a distressing symptom. To these earlier, less pronounced symptoms Friedreich has given the name "coeliac neuralgia." The pain is generally confined to the upper half of the abdomen, but it may radiate to the back, especially on the left side, and has been said to strike downwards into the testes. The intensity of the pain is liable to wide variation; it may resemble that of "indigestion," or may be acute and almost intolerable, and suggest intestinal obstruction. Vomiting is inconstant and variable, but generally bears a



close relationship to the amount of pain suffered. In one case, related by Kocher, pain and vomiting occurred in paroxysmal outbursts every two or three months. Salivation is rarely noticed; the vomiting of clear, colourless fluid—"salivatio pancreatica"—is recorded by Zielstorff.

The functions of the bowels are generally sluggish; obstipation is the rule, but may give place to diarrhoea at times; a blood-stained liquid motion has been occasionally remarked. In one case, recorded by Indemans, a bloody diarrhoea constantly recurred.

Jaundice is noticed in a small proportion of cases. It depends upon a pressure exerted by the tumour upon the common duct, and is therefore associated almost always with a tumour in the head or neck of the pancreas. Körte finds the occurrence of jaundice noted in 9 out of 121 cases.

In these few recorded examples of giant cyst, the usual concomitant disabilities of largely distended abdomen are noticed. Dyspnoea is mentioned by Zielstorff, Filipoff, Stapper, and Shattuck.

In almost every case the general health of the patient suffers seriously. Wasting is rapid and continuous. In one of our cases the patient lost three stones of weight in seven weeks. Weakness is very pronounced, and in appearance the patient ages quickly, looking sallow, pinched, shrunken, and profoundly ill. According to Friedreich, wasting is more serious when affections of the bile passages are associated with disease of the pancreas.

There are certain symptoms and signs which depend

## Symptoms and Signs of Pancreatic Cysts 229

upon an absence of the pancreatic secretion from the bowel. These are the presence of fat in the stools, and the presence of sugar in the urine.

**Fatty Stools.**—The appearance of fat in excess in the fæces was first observed in connection with pancreatic disease by Kuntzmann in 1820. In cystic disease fatty stools are rarely observed, for in only very few cases is the whole gland involved, or even the head or neck to such a degree as seriously to impede the passage of pancreatic juice into the duodenum. The fat found in the stools is the unemulsified fat taken as food. Bull mentions that in his case the stools contained free fat. Fenger says that the motions were whitish. Stapper found that in his case there was 51.5 per cent. of fat in the stools before operation, and 14.6 per cent. after.

Claude Bernard and Walker ("Trans. Royal Med.-Chir. Soc.," 1889) have shown that when the pancreatic secretion is absent from the intestine, the stools are decolourised. The normal colour of the fæces is due to the action of the pancreatic juice upon the bile pigments. The presence of *undigested muscle-fibre* in unusual quantity in the fæces has been remarked by Küster, Riegner, Mikulicz, and Ogata.

The presence of sugar in the urine is, also, but rarely (in nine cases) observed, and for the same reason, that fatty stools are infrequent. It is only in three cases recorded that the patient died of diabetes; these cases are related by Churton, Bull, and Pagensteher. As the case related by our colleague, Dr.

Churton, is, so far as our knowledge goes, the only one yet recorded in which, when diabetes has been present, a post-mortem examination was obtained, we consider it deserving of quotation.

G. A., aged thirty-five, male. Complains of pain in back and abdomen, worse at night, and of intestinal rumbling. Temperature  $97.4^{\circ}$ ; some wasting of muscles; great loss of energy of all kinds; slow in apprehension and reply; appetite good; tongue furred on dorsum, edges clean, rather dry; flatulence, but no pain, after food; constipation; no hæmorrhoids; no jaundice now, but he states that four months ago he was jaundiced, and passed a gall stone; gall cyst not distended. At first sight the stomach seemed to be dilated, the epigastrium being markedly prominent; but closer examination showed that it was not dilated, but displaced, pushed forwards by something behind it, so that the contents of the pyloric third could be made to splash by palpation. The area of resonance varied, and the transverse colon was clearly separated from the stomach by a dull area varying in width from one to two inches. The left hypochondrium was dull also. Urine, specific gravity 1033; daily quantity not great, contained much sugar, but no acetone, diacetic acid, or albumin. The fæces were of palish colour, of normal consistence, not greasy; microscopically no fat crystals or needles could be found.

Pancreatic cyst was diagnosed, and the case was transferred to Mr. E. Ward. Having made an incision in front, Mr. Ward drew off the fluid by a trocar, and then, having enlarged the opening in the cyst, passed his finger through the cavity to its posterior wall below the last rib, made an incision at that part

## Symptoms and Signs of Pancreatic Cysts 231

for drainage, and then stitched up the incision in front. Dr. Arthur Clarkson, Demonstrator of Physiology in the Yorkshire College, kindly analysed the fluid, and reported as follows: "Reaction slightly alkaline, specific gravity 1015; colour dark, sanguineous; deposit whitish, heavy, flocculent. Microscopically, leucocytes and red blood-cells, the former in excess of the latter; some colourless plates of ill-formed or broken crystals, apparently not cholesterol; spectroscopy spectrum of methæmoglobin. Chemical testing showed presence of serum-albumin, peptone, blood, pus, and mucin; no sugar, no bile. Analysis for ferments: no trypsin, no fat-splitting nor milk-curdling ferments; a starch-converting (amylase) ferment is present." Possibly the last-mentioned ferment was derived from leucocytes.

The patient returned to the medical ward on January 30, 1893. On January 20th it had been observed in the surgical ward that he passed only 58 ounces of urine, though he drank 120 ounces of fluid. Next day he passed 71 ounces of urine and drank 110 ounces of fluid. On January 30th he passed 110 ounces of urine of specific gravity 1038, free from acetone. The patient died on January 7, 1894. The following is the report of the post-mortem, made by Dr. T. Wardrop Griffith:

"Owing to adhesions, the exact relation of the omentum, lesser sac, peritoneum, etc., could not, even with much care and patience, be demonstrated. The liver, duodenum, pancreas, and spleen were removed in one mass. Suppuration was traced behind the peritoneum; it had invaded both kidneys and ureters; the left ureter was blocked, and had ruptured. The body of the pancreas consisted of merely fibrous tissue and vessels. The head was a firm, fibrous mass, in which a small

cavity, apparently the remains of the large cyst, was found.

“On further dissecting the pancreas, I found the orifice of the duct a quarter of an inch above the papilla. A probe passed readily for an inch. Slitting the duct with scissors, it was found to end abruptly at a thick, fibrous wall of a cyst which had occupied the head of the pancreas. There was no calculus. Three branch ducts opening into the inch slit up could be traced for a quarter to half an inch, but the tissue to which they led was merely fibrous stroma; no gland-cells could be found. Dr. Trevelyan kindly searched in sections from various parts of the organ for gland tissue, but could find none. The head was converted into thick, contracted cyst-wall. The body of the organ was composed merely of vessels and fibrous tissue.

“The cyst seems to have been formed in the duct near its termination; but whether it was preceded by acute pancreatitis is uncertain. Possibly the rigours, nausea, and epigastric pain, lasting for some days, six months before admission, may have been due to that disease.”

The absence of the pancreatic secretion from the intestine may be ascertained by the test known as the “*signe de Sahli*.” Under normal conditions salol is decomposed in the duodenum into carbolic and salicylic acids, which may be recognised in the urine. The failure of this reaction indicates an absence of the pancreatic juice.

The cystic tumour developing in the pancreas lies behind the posterior layer of peritoneum forming the lesser sac. As the swelling increases it bulges into

## Symptoms and Signs of Pancreatic Cysts 233

the lesser sac and is covered, whatever direction it may take, by this layer of the serous membrane. The tumour is at first placed behind the stomach (Fig. 16), but in its gradual enlargement it displaces the viscus. It may pass in one of three directions:

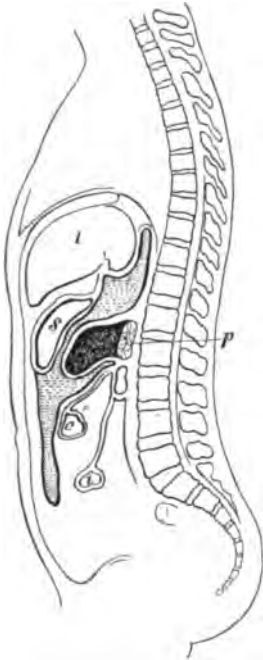

FIG. 16.—Tumour of pancreas. Stomach in front, colon below it.

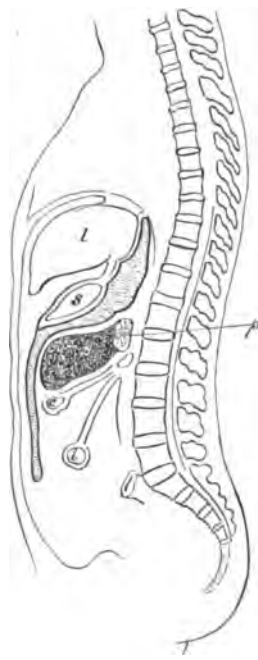


FIG. 17.—Tumour of pancreas pushing forward between the posterior layer of the great omentum and the transverse mesocolon. Stomach above, colon beneath it.

(a) In the great majority of cases the stomach is pushed upwards and to the right, and the transverse colon is pushed downwards, the cyst coming to the surface below the greater curvature of the stomach (Fig. 17). In order to reach the cyst through the

abdominal wall, the parietal peritoneum, the two layers of peritoneum forming the great omentum, and the posterior layer of peritoneum of the lesser sac have all to be divided. The amount of pressure and displacement to which the stomach and the transverse colon are subject depends entirely upon the bulk of

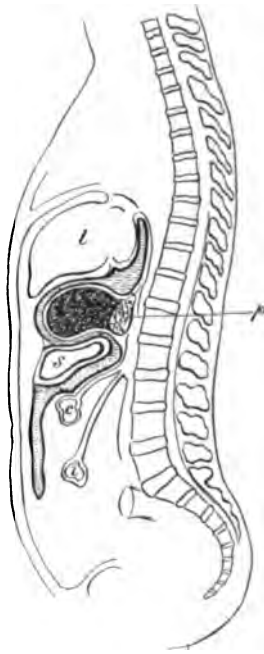


FIG. 18.—Tumour of pancreas. Stomach and colon both below it.

the cyst. The stomach may be jammed tightly under the liver, and the transverse colon may, as recorded by von Riedel, Salzer, Heinricius, and others, be pushed down as low as the symphysis pubis.

(b) In certain cases the enlarging tumour may push its way forwards above the upper border of the stom-

## Symptoms and Signs of Pancreatic Cysts 235

ach, and there present (Fig. 18). In order to reach the cyst in this position, the following layers of peritoneum must be divided: parietal, two layers of the gastro-hepatic omentum, posterior layer of the peritoneum of the lesser sac. The stomach is pushed downwards and the liver forced upwards and to the right. The most prominent part of the cyst presses against the anterior abdominal wall. In one case Albert saw a bulging of the cyst through the foramen of Winslow into the greater cavity of the peritoneum. The presenting of the cyst above the lesser curvature of the stomach has been observed in ten cases (Albert, Indemans, Zielstorff, Riegner, Swain, Hahn, Karewski, Doran, Herman, Finotti). Riegner and Finotti diagnosed the position before operation. In some persons, even in conditions of health, the pancreas may be seen above the lesser curvature through the thinned gastro-hepatic omentum. When a prolapse of the stomach is present, the pancreas may be felt above the stomach, or during an operation the whole breadth may be seen. It is probably under circumstances of this kind that the position of the cyst now described obtains.

(c) If the cyst spring from the lower portion of the head of the pancreas, or from the inferior border of the body or tail, it will be at the lower limit of the lesser sac. As it then increases in size it will push its way between the layers of the transverse mesocolon (Fig. 19), or bulge downwards the inferior layer (Fig. 20). If the former, the transverse colon will run directly across the front of the cyst; if the latter, the



transverse colon and the stomach will both be pressed upwards.

Cases in which the transverse mesocolon was invaded are recorded by Zukowski, von Petrykowski, Lardy, Salzer, Riegel, Treves. The tumour then

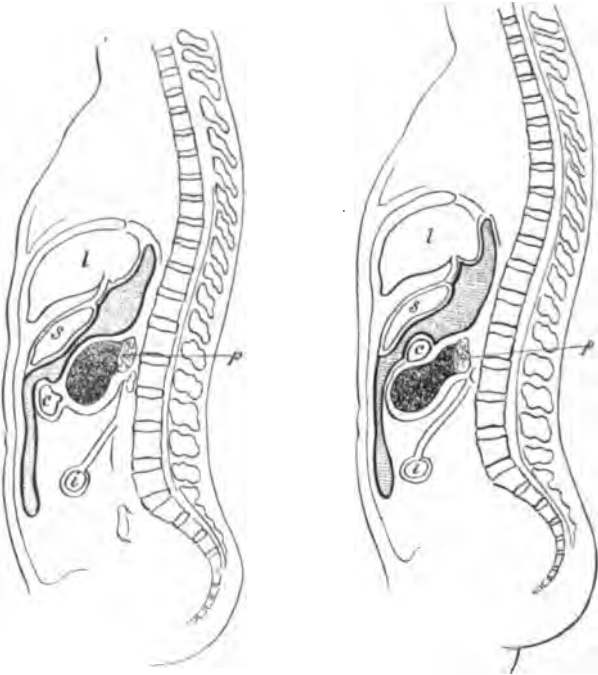


FIG. 19.—Tumour of pancreas. Stomach and colon both in front of it.

FIG. 20.—Tumour of pancreas. Stomach and colon both above it.

presents as a smooth rounded mass, crossed at or near its middle by the stretched colon.

The bulging of the lower layer of the transverse mesocolon is recorded by Hersche, Lindh, and Heinrichus. The great omentum may be stretched over the cyst, and thinned by its enlargement, or it may be

pushed aside. If the former, the parietal peritoneum, the great omentum, and the inferior layer of the transverse mesocolon have to be cut to reach the cyst, and in the latter the parietal peritoneum and the inferior layer of the transverse mesocolon only. In one instance, recorded by Bernard Pitts and Shattock, the enteric mesentery invested the front of the cyst. Martin found the descending colon in front of the cyst in his case, and Schwartz the cæcum; in both the tumour was of large size, and occupied the larger part of the abdomen.

The position of the large vessels with respect to the tumour has not been generally observed. The splenic artery and vein have been found running in front of or behind the tumour. The superior mesenteric vessels have been seen crossing the anterior surface of a cyst. A dilated coronary vein has been mentioned on some few occasions.

The tumour thus developing presents the following features: It lies at the first, generally to the left of the middle line, between the umbilicus and the left costal margin. Sometimes the swelling is accurately in the mid-line, sometimes it is almost completely under the cover of the ribs, and in rare instances its chief prominence has been to the right. It is smooth, spherical, elastic though resistant, and gives the impression to the hand of a tightly filled cyst. As enlargement progresses, the tumour may occupy the left, then the right flank, and finally may fill the whole abdomen to the symphysis pubis, and tempt a diagnosis of ovarian or parovarian cystoma. The tumour is generally im-

mobile, but in at least three cases (Heinricius, Poncet, and Clutton) has been freely movable, both vertically and laterally, as a result of the attachment of the cyst to the body or tail of the pancreas by a rather narrow pedicle. If one hand be placed over the front of the tumour and the other in the loin, the cyst can be felt to fill the abdominal cavity between them. If pressure be applied in front, the tumour transmits the pressure to the hand placed behind, a sign to which the apt term "ballottement" was applied by Hartmann. Respiratory movements are rarely present, and are then but of the slightest. The tumour generally has a transmitted aortic pulsation, which may suggest aortic aneurysm. The smaller the tumour, the closer the resemblance there is to a solid growth; the larger it is, the more obvious is its fluid nature. In the largest a clear wave of fluctuation is readily elicited. In a small minority of records it is stated that the surface was roughly nodulated or bossy. The skin over the prominence is soft, smooth, and supple, but more or less tightly stretched according to the bulk of the cyst.

The tumour is dull on percussion where it reaches the anterior abdominal wall. The stomach lies in front of the cyst above, the transverse colon in front and below. If the dull percussion area be marked out and the lower limit of the stomach carefully outlined, the stomach area of resonance will be found to descend over the front of the tumour when the viscus is distended with CO<sub>2</sub>. If the tumour be comparatively small, the distention of the stomach may

hide it, and a hyper-resonant note will be obtained where before the note was dull. The ascent of the colon over the front of the tumour may be demonstrated by inflating it with air pumped in *per rectum* by means of an ordinary Higginson syringe, with a vaginal tube well introduced into the bowel. The colon should be inflated gradually, and a constant percussion kept up at the lower margin of the tumour; the area of colic resonance then can be shown to creep slowly over the formerly dull area.

This description applies to the majority of cases. In those unusual forms in which the cyst presents above the stomach or below the transverse colon, the signs will, of course, be different. In the former class the stomach resonance will be below the tumour, overlapping the dull area from below. The area of absolute dullness is then continuous with that of the left lobe of the liver, the area of impaired resonance extending a short distance beyond. In the latter class—those in which the cyst lies below the transverse colon—the dullness may reach almost down to the pubes. The colon on distention overlaps the tumour from above. In both classes the diagnosis from physical signs alone is impossible.

#### **COURSE AND TERMINATIONS.**

As a general rule the symptoms and the signs of pancreatic cysts tally with one another. While yet the cyst is small, the symptoms are trifling, insignificant and of no serious concern to the patient. With increasing size come increasing difficulties, pain, diges-

tive troubles, and epigastric uneasiness. The clinical course is as a rule steadily and quietly progressive, though variations in the size of the cyst have been noticed; but it may be brusquely interfered with when acute and almost overwhelming catastrophies occur. Such are the pressure of the cyst upon intestine causing intestinal obstruction, the bursting of the cyst, and hæmorrhage into the cyst, and its sudden enlargement. The temporary disappearance and re-filling of a pancreatic cyst are well authenticated. Though the tumour may vanish entirely, it has always, with one single exception (Stiller), reappeared.

Cysts have been known to burst into the general peritoneal cavity (Gullois and Peabody), and to empty into the bowel. Dixon ("Med. Record," 1884) records a case in which, thirty-four days after puncture, the patient was overwhelmed with agonising abdominal pain, collapsed, and died. A post-mortem examination showed a large cyst, in the head of the pancreas, which had ruptured. Emptying into the bowel occurred in Bull's case ("New York Med. Journ.," 1887), in which a disappearance of the tumour occurred concomitantly with the passage of the dark-coloured contents of a cyst *per rectum*, and in a case recorded by Pepper, in which the bursting of the cyst invoked hæmatemesis and melæna. Reddingius reports the case of a patient twenty years of age, who died suddenly. At the post-mortem a brownish fluid was found in the peritoneal cavity. A cyst the size of a child's head was present in the pancreas; it had ruptured into the duodenum. A

similar catastrophe—death from the rupture of a pancreatic cyst—is related by Janeway. In a case recorded by Schmid (quoted by Körte), where a tumour diagnosed as a pancreatic cyst was present, a rupture may have occurred into the stomach, inasmuch as a piece of “necrotic fleshy” material, supposed to be pancreatic, was vomited.

The frequency with which blood is found in cysts of the pancreas has already been pointed out. In some few cases a sudden enlargement of the tumour, accompanied by intense pain, faintness, and collapse, has been due presumably to a large hæmorrhage from the cyst wall into the cavity.

There are not a few cases on record in which tumours, subsequently discovered to be cysts of the pancreas, have persisted for many years, even up to twenty, without causing any suffering or discomfort.

#### DIAGNOSIS.

The signs and symptoms warranting a diagnosis of pancreatic cyst are as follows: A patient ill, with indefinite symptoms of epigastric uneasiness, weight, pain, and occasional vomiting, begins to lose weight, and on examination a swelling of the upper part of the abdomen is discovered; or, a patient suffers an injury of some severity to the upper part of the abdomen—the kick of a horse, a heavy blow, or while lying on the ground the abdomen is trampled upon; within a brief period of days or weeks a tumour forms, with or without symptoms, in the epigastric region. As the tumour enlarges, the symptoms be-

come more acute, or, less commonly, remain stationary. Jaundice, intestinal hæmorrhages, or diarrhœa may be observed.

The tumour which forms lies generally in the epigastric region, with its most prominent aspect at or near the middle line or between the mid-line and the left costal margin. The tumour is rounded, generally smooth, elastic or fluctuating. It may vary in size from time to time. It is dull on percussion in the center, but above percussion demonstrates the stomach resonance, and below that due to the transverse colon. Inflation of these viscera, as first suggested by Gussenbauer, increases the area of their tympany and lessens the central dull area of the tumour. The tumour is fixed; the skin over it, smooth and unwrinkled.

In the urine sugar may be found; in the fæces an excess of fat, and of undigested muscle fibre.

In order to establish a diagnosis an exploratory puncture has been frequently made. This procedure need only be mentioned to be condemned. The risk of leakage from the puncture in the cyst, or of subsequent rupture from the point of puncture, is not small, and the information derived from an examination of the fluid has rarely been of value. The risks of the method outweigh the advantages, and we strongly discountenance the procedure.

**Differential Diagnosis.**—The differential diagnosis of pancreatic cyst may be a matter of insurmountable difficulty. It is more than probable that many cases recorded as pancreatic cyst were in truth examples of disease of neighbouring viscera. Thus, Tilger con-

siders that a case recorded by Treves was not pancreatic, but suprarenal, and the same criticism might be applied to a case recorded by Fitz.

Gussenbauer, in 1882, was the first surgeon to diagnose tentatively a cyst, upon which he was about to operate, as pancreatic in origin. In 1885 Senn's famous paper was published, and since this date many examples have been correctly diagnosed before operation. According to Körte, up to 1898 fifty-three cases had been diagnosed—thirty in men, twenty-three in women.

The following are the chief conditions from which pancreatic cysts must be distinguished:

1. *Ovarian Cystoma*.—In typical, early cases of pancreatic and ovarian cyst there cannot be the least difficulty in achieving a correct diagnosis. It is only when the tumour assumes giant proportions that a real difficulty may be encountered. In eight of the recorded cases a diagnosis of ovarian disease has been made before operation, and it is only necessary to mention the names of Billroth and von Hacker among those who have erred, to illustrate the impossibility at times of an accurate discrimination. The pelvic organs must be carefully examined, and the condition of the ovaries investigated. This is perhaps rendered simpler by adopting the Trendelenburg position for the patient, as suggested first by Hartmann; the tumour then moves away from the pelvis, and an examination of the uterus and its adnexa is thereby facilitated. The ovaries will in practically all cases be easily felt. The distention of the colon with air will show that a



pancreatic tumour lies above the transverse colon, and an ovarian cyst below. Those rare cases in which the pancreatic cyst bulges the under surface of the transverse mesocolon downwards and forwards, and comes to lie below the colon, will be the most difficult to diagnose. The history of the case may reveal the fact that the swelling has made its first appearance in the epigastrium or in the pelvis. An error in diagnosis has resulted probably from the exact resemblance of the appearance of the abdomen to that of ovarian cyst, and from the fact that ovarian tumours are so frequent. Had a suggestion been made that the tumour was anything but ovarian, it is probable that an examination on the lines mentioned would have disclosed the true nature of the tumour.

2. *Cysts of the Liver.*—Hydatid cyst of the liver may cause a hemispherical bulging in the epigastrium, which, so far as appearances go, is strikingly similar to that produced by a cyst of the pancreas. In the typical cases, however, no difficulty can arise, for a band of resonance separates a pancreatic cyst from the liver, and this band becomes a broad area on inflation of the stomach. Quènu has related a case of echinococcus cyst of the left lobe of the liver connected by only a narrow tongue to the body of the liver. Such a case is extremely rare, but it might lead to an incorrect diagnosis. In the form of pancreatic cyst which projects above the stomach, no diagnosis, based upon physical signs alone, can be made with certainty. This is probably the only condition under which an exploratory puncture would be helpful, for hydatid

fluid is unmistakable; but even here an exploratory incision is safer, and brings more certain information.

3. *Distended Gall Bladder*.—An enormously distended gall bladder may in rare cases simulate a pancreatic cyst, as it has been known to simulate ovarian cystoma. It is only in the giant cases that any difficulty can arise, and in them the continuance of the tumour dullness with the liver dullness is almost always noticeable.

4. *Cyst of the Suprarenal Capsule*.—The resemblance between a cyst of the pancreas and one of the suprarenal is exact. In Gussenbauer's first case, to which reference has been made, an alternative diagnosis of adrenal cyst was made. An adrenal tumour enlarges in one of three directions—above the transverse mesocolon, between the layers of the transverse mesocolon, or below the transverse mesocolon. The first position is the most frequent, and the likeness to a pancreatic cyst is therefore readily understood. Routier relates a case of a firmly adherent cyst, supposed to be of pancreatic origin, which he opened and drained, dividing the omentum just below the greater curvature of the stomach in order to obtain access to the cyst. The patient died of peritonitis five days after the operation, and at the post-mortem the origin of the cyst from the adrenal was disclosed. Pawlik has related an example of a cyst, with hæmorrhagic contents, springing from the left adrenal and giving all the physical signs of a pancreatic tumour. Indeed, an examination of recorded cases shows that the distinction between a pancreatic cyst and a supra-

renal cyst, from the physical signs alone, is not possible. Pancreatic cysts are the more common form of tumour, but some examples so recorded are almost certainly adrenal in origin, and others supposed to be pancreatic at the operation were found at the post-mortem to spring from the suprarenal capsule.

5. *Fluid Tumours of the Kidney* (Cysts, Hydro-nephrosis, Pyonephrosis).—A large fluid tumour fills the lumbar region of the abdomen, and when examined between a hand over the abdomen and a hand behind in the loin, is felt to move to some extent as respiration, and to have its chief bulk between the hands so placed. The descending colon lies generally to the left of a kidney tumour on both sides, and the transverse colon crosses above it. These may both be mapped out by percussion with simultaneous inflation. In the great majority of cases some very pronounced symptom—pain, renal ache, frequent micturition, disappearance of the swelling with the passage of a large quantity of urine, or hæmorrhage—will have attracted attention to the kidney. The following case is recorded by van Kleef: The whole left side of the abdomen down to a hand's breadth above Poupart's ligament was filled by a cyst which extended back to the vertebral column, and in front crossed the mid-line. The colon lay in front of the tumour. An exploratory puncture evacuated some turbid brown fluid, which contained albumin and blood. A hydronephrosis was diagnosed. The day after the puncture some clear fluid escaped from the fistula. Eight days later the

shrunkn cyst was extirpated, and was found to have its origin in the tail of the pancreas.

If any uncertainty as to the functional activity of the kidney exists, catheterism of the ureter may be employed.

6. *Mesenteric Cysts*.—The characteristic signs of a mesenteric cyst are: Prominence of the fluctuating tumour towards the umbilicus; great mobility, especially in the transverse direction, and the possibility of rotation round a central axis; the presence of a zone of resonance around, and a belt of resonance across the cyst. It is, therefore, only possible to make a fallacious diagnosis when the mesenteric cyst is large, and little, if at all, movable. If a pancreatic cyst grow between the layers of the transverse mesocolon, the transverse band of resonance will be given by the colon. A cyst growing in the transverse mesocolon, from remnants of the Müllerian or Wolffian ducts, is sometimes, as stated by Dowd, attached to, or in opposition to, the pancreas. A differential diagnosis is then impossible.

7. *Omental Cysts*.—A cyst springing from the omentum immediately below the greater curvature of the stomach would precisely resemble a pancreatic cyst. It would push the stomach upwards, the transverse colon downwards. Ris has recorded a case in which the signs and symptoms were identical with those caused by a pancreatic cyst.

8. *Cysts in the posterior wall of the stomach* have been recorded by Kosinski and Ziegler. They enlarge towards and into the lesser sac, and imitate the con-

ditions of pancreatic cysts very closely. It is possible that the first case in Jordan Lloyd's paper, already quoted, was an example of cyst in the posterior wall of the stomach.

9. *Cysts of the spleen*, especially hydatid cysts, form prominent tumours emerging from the left subcostal region. As the spleen is free in the peritoneal cavity, its enlargements push before them and displace the viscera with which they come into contact. The relations of the stomach and the transverse colon are not those found in cases of pancreatic cyst. In pancreatic cysts an area of resonance between the tumour and the spleen may be mapped out.

10. *Retroperitoneal cysts* of uncertain or undetermined origin may present signs closely allied to those of pancreatic cysts. Narath ("Ueber retroperitoneale Lymphcysten," "Arch. f. Chir.," L, Heft 4) describes a case of cyst in the upper left quadrant of the abdomen, which was indistinguishable from a cyst of the pancreas. Przewoski and Pawlik ("Arch. f. Chir.," Bd. LIII, S. 571) both record retroperitoneal cysts simulating pancreatic cysts. The former attributed the origin of the cyst he found to the remains of the Wolffian or Müllerian ducts; the latter's case was one of adrenal cyst. As the line of growth taken by these cysts may be precisely that taken by a cyst of the pancreas, the distinction is hardly possible, by physical signs alone.

We have made no mention, in discussing the question of differential diagnosis, of cystic collections in the lesser sac, for we cannot but think that many of

the recorded examples of pancreatic cyst were primarily effusions into the lesser sac. Even in those cases where pancreatic secretion has issued from a fistula left after operation, it is not improbable that a rent in the pancreas has caused the canal of Wirsung to communicate with the cavity of the lesser sac. In the majority of the records we have studied, no mention is made of the condition of the lesser peritoneal cavity, and therefore a differential diagnosis cannot be achieved. The great probability is that the cysts of rapid formation, which speedily attain a large size and then remain stationary, are serous, or sero-sanguineous, effusions into the lesser sac, the foramen of Winslow being blocked by the inflammatory outpouring of lymph. In a case recorded by McPhedran, a pseudocyst—serous effusion into the lesser sac—was operated upon; five months later a second cyst formed in the epigastric region, and this proved at a second operation to be a true pancreatic cyst. Both cysts occupied the same area, but differed in shape, the peritoneal effusion extending less to the right and further downwards, being somewhat irregular in shape, with its longest diameter nearly vertical, while the pancreatic cyst was somewhat quadrilateral in shape, with the long diameter transversely. The peritoneal effusion took place within a few days, more rapidly than a cyst could form in so firm and friable a structure as the pancreas, while the pancreatic cyst formed comparatively slowly, increasing steadily in dimensions.

**TREATMENT.**

The **operative treatment** of pancreatic cysts is limited to three methods:

1. Aspiration.
2. Evacuation and drainage, the cyst being stitched to the abdominal wall.
3. Extirpation, partial or complete.

1. *Aspiration*.—This method may be dismissed in a few words. It is unscientific, unsatisfactory, and redolent of mediævalism. We have pointed out the risks and the drawbacks attending exploratory puncture in cases of cyst of the pancreas. The same disadvantages attach to the method of aspiration. The method, moreover, is futile. It has never been attended with success. In Lynn's case ("Lancet," 1894) it is practically certain that the tumour was due to a fluid effusion into the lesser sac, with perhaps a rupture of the pancreas as well. In fact, all our knowledge of pancreatic cyst disproves the possibility of cure by aspiration, however often repeated.

If the cyst be emptied it will refill. The risks during refilling are leakage from the point of puncture, and laceration of the cyst starting from the small opening, both of which have been recorded.

If the patient is seriously ill from diabetes, or suffering acutely from pressure symptoms, and unable to withstand the shock of an abdominal operation, an aspiration may be resorted to in the hope of tiding the patient over an acute crisis, so that the subsequent

operation may safely be borne. Under no other conditions can it be considered desirable.

2. *Evacuation and Drainage.*—The method which has been the most frequently adopted is that of stitching the cyst to the skin, and opening and draining its cavity. The operation may be done in one or two stages, the opening of the cyst being delayed until adhesions have formed, which protect the peritoneal cavity. The operation at two sittings has rarely been adopted in recent years. Of seventeen cases collected by Takayasu, death occurred in one.

The abdomen is opened by a median or slightly lateral incision. The cyst is exposed by tearing gently through the omentum just below the greater curvature of the stomach. A careful exploration and examination are made in order to determine the source of the cyst, the condition of the pancreas, the presence of adhesions, and so forth. An aspirator needle is then thrust into the cyst, and the contents are evacuated. As the needle is withdrawn, a clip is placed over the puncture. By gentle traction on the clip, the cyst can be lifted well up into the wound. With a curved intestinal needle, threaded with strong catgut, or fine silk, or Pagenstecher thread, a continuous suture unites the peritoneum, covering the cyst to the parietal peritoneum. When the stitching is secure, the clip may be removed, the puncture which it guarded enlarged into an opening, and a large rubber drain introduced.

Drainage may be secured by an opening through the loin, as advised by Cotterell and Pearce Gould.



This may be done after the exposure of the cyst and its evacuation through an abdominal incision. In cases where the diagnosis is difficult this method permits of a certain diagnosis. After the emptying of the cyst a finger is pressed to the back of the cavity, and by pressure is made to present below the last rib, where an incision is made down on to it and a drainage tube is passed through.

Peters, in a case of hydatid cyst of the tail of the pancreas, made no abdominal incision, but cut directly down from the loin, through an incision three inches in length, made from the margin of the erector spinæ forward, about parallel to the last rib, and curving slightly upwards around its end in the direction of the margin of the costal cartilages. The lumbar fascia was divided, the colon displaced forwards with the peritoneum, and the cyst reached by pressing the finger upwards, forwards, and inwards.

The exposure of the cyst from the front is not seldom a matter of difficulty; adhesions may be numerous and dense, and the vessels in the omentum may be greatly enlarged, swollen, and easily lacerable. As bloodless a spot as possible must be found in the great omentum, and as few vessels interfered with as is consistent with adequate exposure of the cyst wall. Any vessels needing division should be doubly ligatured before being severed.

Hagen ("Archiv f. klin. Chir.," Bd. LXII, H. 1) reports a case of abdominal tumour in a boy thirteen years of age. Laparotomy was performed, and after opening the abdomen a cyst about the size of a child's

head was found, posterior to the stomach, firmly surrounded by adhesions, so that it was impossible to bring the cyst wall in contact with the abdominal wall, and equally impossible to remove the cyst as a whole. The only hope of saving the child's life, however, was in the evacuation of the cyst. Approach to the cyst was finally gained by first incising the anterior gastric wall, and then, through the cavity of the stomach, the posterior gastric wall was reached and the cyst opened. The contents of the cyst were easily removed. A finger passed in through the openings found the least external resistance on the left side of the cyst, and with difficulty the stomach was here displaced a little towards the right, so that, pushing firmly on the abdominal wall, the cyst could be brought in contact with the parietal peritoneum. The two wounds in the stomach were sutured, first that in the posterior wall, and afterwards that in the anterior wall. In order to allow the abdominal wall to fall in to a sufficient extent to come in contact with the cyst, it was found necessary to resect a part of the ninth and tenth rib cartilages. The cyst was then sutured to the abdominal wall and opened. Examination of the cyst showed that it was evidently the result of a chronic intestinal inflammation of the pancreas. The patient stood the operation well, and two months afterwards the cyst had disappeared and the pancreatic fistula had closed, and the patient had gained twenty pounds in weight.

If the cyst is not of a large size there may be some difficulty in dragging its wall up to the parietal peri-

toneum in order to suture it there. Under these circumstances a tube surrounded by gauze may be passed down to the cyst, the tube projecting beyond the gauze into the cavity; or a purse-string suture may be passed round the opening into the cyst and a tube introduced. On tying the suture the tube is held firmly in position, and will so remain until lymph has been thrown around it to wall off the general peritoneum; or, again, a fold of the great omentum may be brought round, to form a barrier to the escape of fluid into the peritoneal cavity. If none of these devices seems desirable, then, after exposure of the cyst and its evacuation by means of an aspirator needle, gauze packing may be introduced and left for three days. On removing it, it will generally be found that a water-tight channel from the abdominal wound to the cyst has been formed, and that the cyst may then be safely opened without the risk of peritoneal contamination.

The mortality of this method has been carefully computed from the records of published cases by Körte.

From Gussenbauer's case, the first one so treated, there have been 84 patients submitted to operation. Of these, 1 died of sepsis (Ogston), 2 died of peritonitis (Durante, P. Gould), and 1 died of shock and peritonitis (Mérigot de Treigny). Two patients who suffered from diabetes subsequently died (Churton and Pagenstecher); 2 patients who were operated upon for cystic epithelioma died soon after operation (Labbée and Hartmann); and 1 (Reeve) died of secondary in-

fection from the fistula. This last case and the first four may be considered as deaths from the operation—5 deaths in 84 patients, a comparatively small mortality. Takayasu, in a tabular list of 64 cases, found 8 which proved fatal.

3. *Extirpation*.—The extirpation of a pancreatic cyst is seldom necessary, and is rarely capable of being carried out successfully. The adhesions formed by the tumour are often of the densest character; blood-vessels of large size run in and around the cyst wall, and the tissues are very readily lacerable. An attempt at extirpation under such conditions is very hazardous, and may prove impossible. Mikulicz on two occasions has abandoned attempts at removal, finding the physical difficulties insuperable. In 2 cases (Billroth, Mikulicz) the splenic vessels have had to be tied in liberating the cyst from adhesions.

If, as may rarely be the case, the cyst is rather narrowly pedunculated, and the adhesions are of no great density, then extirpation may properly be attempted. In all, 15 cases of complete excision have been recorded, with 13 recoveries. In 7 additional cases the extirpation has been only partial, some of the cyst wall being irremovable; 4 of these patients died.

The pedicle has been ligatured (Clutton and others), clamped with forceps (Poncet), or divided with the thermo-cautery (Kosinski). In almost all the cases the cyst presented between the stomach and omentum. The most favourable case for excision was that related by Sharkey and Clutton. The patient was a female, aged thirty-five, who had noticed an abdominal en-

largement for sixteen or twenty years. The tumour was remarkably movable in all directions. At the operation the tumour "shot out of the wound with the greatest facility," with the tail of the pancreas attached to it. The splenic artery and vein had to be dissected off the tumour, which was removed entire, without being opened. The pedicle bled freely, and was packed with gauze. The wound for some time after the operation discharged pancreatic juice. The contents of the cyst were fluid, canary yellow in colour, of specific gravity 1024; albumin was present in large quantity; the fluid was turbid and iridescent with cholesterin.

#### CYSTS OF THE PANCREAS UNDER OUR CARE.

OPERATION I.—Omental pseudo-cyst in a man *æt.* thirty-eight. Groom. Crushed by a horse. Admitted under our care and operated on by Mr. Littlewood, August 12, 1891. Drainage; recovery. Case fully reported elsewhere.

OPERATION II.—Annie M. A., *æt.* thirty-nine, admitted early in 1892. Pain and tenderness associated with cystic tumour above the umbilicus. Abdomen opened in middle line above umbilicus and cyst drained. The tube passed to the back of the abdomen in the pancreatic region. Drainage for some weeks until secretion appeared to have ceased, when tube was left out and the wound rapidly healed, and she was discharged apparently cured. (Notes of case imperfect.) For further history see next record.

OPERATION III.—Excision of cyst apparently forming from near head of pancreas. Annie M. A., *æt.* thirty-nine, readmitted to the Infirmary September 12,

1892, three months after the drainage opening had closed, on account of pain and recurrent tumour in region of old operation wound. It caused so much distress that she asked for its removal. Operated September 16th. Old wound reopened. The transverse colon was turned up, exposing the cyst, which was partly enucleated and partly dissected out; it contained about half a pint of fluid. Lumbar drainage was effected through a stab wound. The patient was discharged cured.

OPERATION IV.—Traumatic cyst of pancreas (effusion into lesser sac bursting into greater); peritonitis; death. A butler, æt. twenty-eight, fell forward against his knife board, hurting the abdomen, but he did not fall to the ground. After a few days symptoms of intestinal obstruction developed, for which he was admitted to Infirmary. Abdomen swollen and tender; great tension in upper abdomen; vomiting; collapse. On opening abdomen much bloody fluid in general cavity seen to be escaping through rent in great omentum below stomach. Lesser sac full of the same fluid. Abdomen washed out and drained by tube passing from front through lesser sac to left loin above the top of the kidney. Death from collapse. (Case referred to under hæmorrhagic pancreatitis.)

OPERATION V.—Cyst; drainage; recovery. David G., aged thirty-seven, warehouseman, admitted October 23, 1897. Pain on left of abdomen extending down left thigh, for three months; tumour noticed by doctor in upper abdomen on left side. Four years previously he fell off a pair of steps and hurt himself, but had no subsequent trouble. Tumour dull on percussion. Tense; no tenderness except in left loin. Abdomen markedly distended. Operated November 10, 1897. Incision in left semilunar line above umbilicus. Tumour tapped and four and a half pints of greenish-

yellow, turbid fluid withdrawn. Opening enlarged and stitched to parietes. Drainage by rubber tube. Fluid contained large amount of albumin, spherical granular masses, a few leucocytes, cholesterin crystals. No tubercle bacilli found. Out-patient December 18th, with wound closed.

OPERATION VI.—Pancreatic cyst; drainage; cured. Mr. H. H., æt. thirty-six, seen with Dr. Kershaw, of Pudsey. Loss of flesh and general failure of health since English cholera two years ago. Vomiting after food nearly every day for three months. Great pain, which was relieved by vomiting. A year ago jaundice for six weeks, accompanied by little shivering. Tumour only noticed the day before seeing us. Only slight movement on respiration. Dull on percussion. Aspirated by Dr. Kershaw and grumous fluid withdrawn. Smooth, fluctuating. Operated May 21, 1897. Incision through right rectus vertically. Stomach was spread out over tumour. Stomach drawn up and cyst incised through great omentum above transverse colon. Edges of incision in cyst fixed to surface and drainage by rubber tube. The drainage was continued for a month, and when last heard of the patient was well.

OPERATION VII.—Recurrence of Case V. David G., æt. thirty-seven, was quite well subsequent to the operation in 1897 and remained so up to three weeks before admission, October 4, 1898, when he began to have pain and numbness in the left thigh, much worse during the past ten days. (N. B. This symptom is worth noting; it was marked on the previous occasion.) He said he felt tired and weary and was quite done up by night. A tumour was noticed, but on this occasion it was so far up and extended so far under cover of the ribs that it was suspected to be splenic.

Operation: The abdomen was opened and the cyst

thoroughly explored; it was found to spring from the pancreas. An attempt at enucleation failed on account of bleeding and other difficulties. It was therefore incised and drained as before. Three and a half pints of light brown turbid fluid evacuated.

He made a steady recovery, and although in the following June there was a fistula still present, he had gained thirteen pounds in weight and was well. Irrigation with a weak solution of iodine diminished the secretion very much, and when last heard of he was quite well.

OPERATION VIII.—W. G., aged thirty-seven, seen with Dr. Exley, April, 1901. Six months' history of abdominal pain, commencing suddenly. The acuteness and intensity of shock suggested perforation of a gastric ulcer. A tumour gradually formed in upper abdomen between the stomach and colon, hemispherical in shape and very smooth and tense. On opening the abdomen an hour-glass stomach with ulcer adherent to anterior abdominal wall was found. Gastroplasty was performed. The great omentum was torn through and a large cyst was found springing from the pancreas, broadly pedunculated. This was opened and drained. The patient made a great recovery, but a small pancreatic fistula remains.



## CHAPTER X.

### NEW GROWTHS OF THE PANCREAS.

THE new growths met with in the pancreas are carcinoma, sarcoma, adenoma, lymphoma.

#### CARCINOMA.

Carcinoma is the most common of the neoplasms found in the pancreas. Its frequency may be gaged from the following series of statistics:

Biach ("Wien. med. Wochenschr.," 1883) tabulated the post-mortem records of three of the Vienna hospitals: In 18,069 post-mortems at Wien. allg. Krankenh. were 1270 cases of carcinoma; of these, 22 affected the pancreas. In 5065 post-mortems at Wiedener Krankenh. were 514 cases of carcinoma; of these, 6 affected the pancreas. In 477 post-mortems at Rudolfspital Krankenh. were 221 cases of carcinoma; of these, 1 affected the pancreas.

In a total of 23,611 were 29 cases of pancreatic carcinoma.

*Segré* ("Ann. univers. della med. e chir.," vol. CCLXXXIII) collected the post-mortem records for nineteen years (1868-1886) in Milan. Out of a total of 11,472 post-mortems there were 132 examples of pancreatic disease; 127 carcinoma, 2 sarcoma, 2 cyst, 1 syphilis. Of the 127 specimens of cancer, in

only 12 had the disease remained limited to the pancreas.

*Oser* found in the records in Vienna, from 1885 to 1895, 32 cases of primary carcinoma of the pancreas.

*Rohde* (Inaug. Diss., Kiel, 1890) examined the records of 5952 post-mortems. In 13 pancreatic carcinoma was found; in 1 only of these was the growth restricted to the gland.

*Soyka* ("Prag. med. Wochenschr.," Oct., 1876), in 3950 post-mortems, found 313 cases of carcinoma, 3 of them pancreatic.

*Hale White* ("Guy's Hosp. Rept.," 1897, page 20), among 6708 post-mortems, found 31 cases of primary carcinoma, 11 cases of secondary growth, and 13 in which a growth of some other organ became secondarily adherent to the pancreas.

Carcinoma may be primary or secondary. The majority of authors consider that the latter is the more frequent, though *Hale White's* experience (see above) is different from this. The frequency of secondary carcinoma is accounted for by the fact that, according to *Oser*, 10 per cent. of all cases of primary gastric carcinoma affect the pancreas.

*Olivier* and *Dieckhoff* are disposed to doubt whether some of the cases related as primarily pancreatic are genuine. The former says: "It can happen that a tumour, which to the naked eye seems to arise in the pancreas, springs in reality from the duodenum and has all the microscopical attributes of an intestinal cancer." *Hale White* upon this remarks: "Judg-

ing by the naked eye appearances of cases I have seen, I should say this is very unlikely."

**Site of the Tumour.**—A malignant growth is most commonly found in the head of the pancreas. Segré, in the tabulated record already mentioned, states that in 57 of the 127 cases of carcinoma of the pancreas the position of the growth is given. In 35 it was in the head, in 19 it was diffuse, in 2 in the body, and in 1 in the tail. Oser, in 78 cases, found the distribution to be: head, 39 times; the whole organ, 19 times; the tail, 4 times; the head and body, 3 times; the body and tail, once; the body, once; the head and tail, once. In 10 cases no details were given. In the 32 cases observed by him in the Vienna Hospital from 1885 to 1895, the head was affected in 20, the body in 2, the tail in 3, the whole gland in 1. In the remainder no mention of the exact site is made.

**Pathological Anatomy.**—The frequency with which the head is affected accounts for certain of the distinguishing symptoms. Courvoisier, in 66 cases of obstruction of the common bile duct due to diseases of the pancreas, found that carcinoma was present in 55. The narrowing produced by the pressure of malignant disease on the ampulla of Vater or on the common bile duct may also affect the canal of Wirsung, and by so doing may produce a distal distention. According to Boldt, in one-third of the examples of malignant disease of the head of the pancreas there is found a dilatation of the duct in the body and tail.

The growth in its enlargement may narrow the duodenum and produce symptoms of obstruction. The general increase in size of the tumour may cause compression of the pylorus (Bardleben), the cardiac end of the stomach (Rahn), of the whole stomach by forcing it against the anterior abdominal wall (Petit), of the colon, the ureter, the portal vein, the aorta, the vena cava, the splenic artery and vein, and the superior mesenteric vein. Thrombosis of the portal vein is recorded by Wesener.

The breaking down of the growth may cause perforation of the abdominal wall, of the stomach, of the portal vein, of the celiac axis, and of the duodenum.

Secondary nodules are found most commonly in the liver, but may be found anywhere in the body. According to Oser, a general carcinomatosis may be found, but in such cases the origin of the disease in the pancreas is open to doubt.

Males are more frequently affected than females.

Oser gives the following quotations:

Da Costa, in 37 cases . . . . .	24 men, 13 women.
Ancelet, " 161 " . . . . .	102 " 59 "
Biggsby, " 28 " . . . . .	16 " 12 "
Boldt, " 56 " . . . . .	35 " 21 "
Mirallié, " 106 " . . . . .	69 " 37 "

The proportion is, therefore, roughly, 60 per cent. males to 40 per cent. females. Hale White gives the ratio as 3 to 1.

The ages of patients who have died from the disease are generally between 40 years and 60 years.

In Hale White's cases, 5 were between 30 and 40, 10 between 40 and 50, 10 between 50 and 60, 4 between 60 and 70, and 1 was over 70. In 73 cases examined by Oser the following were the ages:

Under 1 year . . . . .	1 case	(Bohn, 7 months).
From 1 to 10 years . . . . .	1 "	(Kühn, 2 years).
" 11 " 20 " . . . . .	1 "	(Dutil, 14 years).
" 21 " 30 " . . . . .	3 cases.	
" 31 " 40 " . . . . .	14 "	
" 41 " 50 " . . . . .	19 "	
" 51 " 60 " . . . . .	20 "	
" 61 " 70 " . . . . .	10 "	
" 71 " 80 " . . . . .	4 "	

The **varieties** of carcinoma in the order of frequency are scirrhus, encephaloid, columnar-epithelioma, and colloid. Adeno-carcinoma has been described by Seebohm and Ruggi. The condition of "cystic epithelioma" has been discussed in the chapter on Pancreatic Cysts. The great majority of malignant tumours are examples of scirrhus.

**Symptoms.**—The symptoms of cancer of the pancreas are sometimes so subdued, or even lacking, that the patient dies without any diagnosis of his ailment having been made, and carcinoma is revealed only at the autopsy. In the majority of cases, however, a certain group of symptoms will be present. The earlier symptoms refer almost invariably to disturbances of the digestive organs: There are loss of appetite, heaviness after meals, feelings of fullness and weight in the epigastrium, heart-burn, and occasional vomiting.

*Pain* in the epigastrium radiating round one or both

sides of the back is sometimes excessive, wearing, almost intolerable. In the lancinating, burning, and instantly overwhelming character the pain in certain cases is probably only equaled by that caused by tabes. It is both continuous and intermittent; the continuous pain is rather a dull, persistent ache; the intermittent is sudden in onset, apparently causeless, and brief in duration. In one-half the cases, at least, the suffering is exquisite, and is not infrequently worse at night. In a certain number of cases pain may be entirely absent.

*Faundice* is present in the greater number of cases. It is always present in cancer of the head of the pancreas, but usually absent in cancer of the body and tail. Mirallié found it recorded in 82 out of 113 cases, Oser in 21 out of 36 cases. It is due to the gradual narrowing of the common bile duct as it traverses the head of the pancreas (the part of the gland usually affected), and is therefore slight when first observed and slowly progressive. In a few patients it has appeared suddenly and has rapidly attained a high degree; it is in all cases persistent. The usual concomitants of biliary retention are observed, a general feeling of lassitude, want of energy, slow pulse, pale stools, and high-coloured urine. The gall bladder is frequently distended and can in some instances be felt as a smooth, rounded tumour below the rib-margin. Lachmann has recorded a case observed in the Greifswald clinic in which the gall bladder became overdistended and ruptured. Enlargement of the liver is frequently observed. Courvoisier, Mayo

Robson, and Terrier pointed out that in obstruction of the common duct by stone the gall bladder was generally shrunken and contracted, whereas in the obstruction by pressure of cancer of the head of the pancreas the gall bladder was distended. In the former, obstruction is sudden, but seldom complete, and cholangitis is almost invariable; in the latter, obstruction is gradual, but rapidly complete, and cholangitis, as a rule, absent.

*Tumour.*—When the growth has attained a certain size, and some degree of wasting is present, a tumour may be felt in the epigastrium. In Mirallié's series of cases it was present in about one-fourth or one-fifth of the whole number. In 52 cases collected by Boldt a tumour was present in 20; in 7 cases observed by Bard and Pic, in 1 only. It may be smooth or roughly nodular, rounded or transversely elongated in form, and is deeply seated in the epigastric or upper umbilical region. Not seldom it is described as resembling a pyloric tumour, only more deeply placed; it is almost always fixed, though in cases related by Stein and Klemperer it was movable. Being placed over the aorta, a transmitted pulsation will often be present, and a diagnosis of aortic aneurysm may be suggested.

Rarely two tumours may be present, the one produced by the growth, the other by the distended gall bladder. Frerichs has related a case in which he achieved a correct diagnosis by observing a hard, uneven, immovable, deep-lying tumour below and to the left of a smooth, rounded, mobile swelling. When

these three chief symptoms—pain, jaundice, and tumour—are established, the disease runs a swift course. Wasting is rapid; the appetite may remain good or even be excessive, and constipation is frequent. The stools are bulky, as a result of imperfect intestinal digestion, and may contain fat or fatty acids. The presence of undigested muscle fiber in the stools in large quantity, in the absence of diarrhoea, is a sign of importance. Vomiting of stomach contents, occasionally mixed with blood, free fat, or fatty acids, is an inconstant symptom. Hale White considers that authors “hardly lay stress enough upon the importance of vomiting”; in his own series of cases it was, however, present in less than one-third.

If pancreatic juice be prevented from entering the bowel the “*signe de Sahli*” may be present. This sign depends upon the fact that salol is decomposed in the duodenum by the pancreatic juice into salicin and carbolic acid, which are soon found in the urine. If the decomposition does not take place it is an indication that the pancreatic juice does not gain access to the intestinal canal. Polyuria may be noticed, and sugar may, though rarely, be found in the urine (in 13 cases out of 50, Mirallié); albumin is frequently present. Mirallié believes that an early examination of the urine would discover sugar in a larger proportion than that quoted, for in the cases recorded by Marston, Frerichs, Collier, Macaigne, and Mirallié sugar was found at the beginning of the illness, but vanished when jaundice became well established. In 35 cases of which he had record and in which sugar



was not found, no examination of the urine was made until a late stage in the disease. Ewald and Hansemann have recorded cases in which a complete destruction of the pancreas was found post-mortem and yet repeated examination of the urine failed at any time to discover a trace of sugar. Lipuria is rarely observed.

In a very few cases the symptoms of diabetes—polyuria, polyphagia, polydipsia, glycosuria, and wasting—may be noted.

The gradual enlargement of the growth may produce pressure upon the portal vein and ascites, or upon the vena cava and oedema of the lower extremities. Chylous ascites has been observed.

A subnormal temperature is considered a sign of value by Bard and Pic. Gallaudet has recorded a case in which a scirrhus mass in the head of the pancreas constricted the duodenum, without interfering with the common bile duct. Gastro-enterostomy was performed.

**Diagnosis.**—The typical clinical picture of malignant disease of the pancreas may thus be drawn: A patient suffers for a time from indefinite symptoms of digestive disturbance, then jaundice appears, coming gradually, but persistently increasing; the gall bladder is usually distended, the liver normal or slightly enlarged. A tumour may be found in the neighbourhood of the head of the pancreas. Cachexia rapidly develops and in some cases pain, characteristically severe, almost unendurable, becomes more frequent and disturbs the patient's rest. There is soon a feeling

of intense prostration and weakness. At times there are certain alterations in the urine and fæces. The fæces are massive, contain fat or fat-acids, and an undue proportion of undigested muscle fibre. The urine contains albumin frequently, and sugar and fat rarely. The whole clinical course is run, as a rule, within twelve months.

*Differential Diagnosis.*—In malignant disease of the pancreas the symptoms are not constant.

The cases may be divided into three chief types:

1. Where the tumour extends to the right and compresses or occludes the common bile and the pancreatic ducts. This is the typical condition just described.

2. Where it takes an upward and forward direction and besides compressing the bile duct leads to pyloric stenosis. In this case, to the typical symptoms are added those of dilated stomach.

3. Where the extension is backwards, causing compression of the vena cava and of the portal veins, thus leading to an early onset of ascites and, later, to œdema of the lower extremities.

When the body and tail of the pancreas are involved, the symptoms are atypical, and the forming of a tumour with steady loss of strength and increasing anæmia are such as might be due to any malignant tumour outside the pancreas.

In the differential diagnosis of cancer of the head of the pancreas we must consider common duct cholelithiasis, interstitial pancreatitis, cancer of common

bile duct, cancer of liver, cancer of the pylorus, and chronic catarrh of the bile ducts.

Whenever, in a patient at or past middle age, jaun-



FIG. 21.—Section of a pancreas, in the middle of which is a large oval mass of hard cancer. Scarcely any trace of the pancreas can be discerned around the tumour. The head, or right end of the pancreas, appears healthy, but the left end is very small, atrophied, and apparently in a state of fatty degeneration (Museum R. C. S., specimen No. 3835) (Sir James Paget).

dice comes on painlessly and becomes absolute, at the same time that the gall bladder gradually enlarges so as to form a perceptible tumour and the patient rapidly

loses flesh and strength, a diagnosis of cancer of the head of the pancreas will probably be correct.

The diagnosis will be made more certain if there is an absence of tenderness below the right costal margin associated with a tumour opposite to or above the umbilicus, having communicated pulsation and not moving with respiration.

On distending the stomach with CO<sub>2</sub>, it will be found that the tumour, at the best rather indefinite, becomes hidden behind the resonant stomach, and that the distended gall bladder becomes pushed to the right. If cholelithiasis has preceded the onset of cancer, the gall bladder will not be enlarged, but the rapid deterioration of health and the presence of anasarca and ascites will, as a rule, leave no doubt of the nature of the disease.

In common duct cholelithiasis there is practically always a preliminary history of gall stone attacks, though it may have been years previously. The jaundice will have come on after pain and is probably never absolute, for some bile nearly always escapes past gall stones into the duodenum. The bile soon becomes infected and then ague-like seizures follow and an irregular temperature, at times almost resembling pyæmia. In place of distended gall bladder a rigid right rectus will be felt which often makes it difficult to examine the parts beneath.

A tender spot will usually be found an inch above and to the right of the umbilicus and the pain will be found to pass backwards to the mid-scapular region or to a spot beneath the right shoulder-blade. Whereas

in cancer of the head of the pancreas the disease is only a question of months, in cholelithiasis it may be one of years.

Chronic pancreatitis frequently accompanies gall stones in the common duct and clears up after their removal, but it may persist after the cause has passed away. Whenever a tumour of the head of the pancreas is felt during a gall stone operation, especially if before middle life, hope may be always felt that the disease may be simple and clear up by the drainage of the ducts.

A long history is in favour of the simple disease, as are the presence of adhesions, the history of painful attacks, and the presence of tenderness above the umbilicus.

In chronic pancreatitis it is not uncommon to find enlarged glands in the free border of the lesser omentum, but they are discrete when the disease is simple and generally confluent in cancerous affections. The jaundice may be absolute, but as a rule, it is not complete.

Infective cholangitis and infection of the pancreatic ducts are commonly present, as shown by the temperature and by ague-like seizures.

Although the loss of flesh is marked, it is less evident than in cancer of the head of the pancreas, and until the disease has existed for a longer time than cancer gives its victim there is no sign of anasarca or ascites or of enlarged abdominal veins. The gall bladder is seldom distended, though this is not an absolute rule, as we have seen it much enlarged on three occasions.

Between gall stones in the common duct and chronic pancreatitis it is often difficult to determine, but this is of no moment from a practical point of view, as surgical treatment is, as a rule, demanded in both conditions.

Anæmia is much more marked in cancer of the head of the pancreas than in chronic interstitial pancreatitis.

Cancer of the common bile duct is rare and is usually associated with gall stones; if the disease involves the papilla, the symptoms are undistinguishable from those of cancer of the head of the pancreas; but if it be situated above the opening of the pancreatic duct, it will not interfere with the functions of the pancreas and therefore the loss of flesh will not be so rapid. In one case on which we operated, suppurative cholangitis was present, but this is not a constant event.

Cancer of the liver is distinguished by the jaundice being absent or much less intense and by the enlargement of the liver with irregular nodules on its surface and edges.

In simple catarrhal jaundice the symptoms are almost negative except for the jaundice and loss of appetite; and the way in which it yields to treatment shows the slighter nature of the ailment.

In cancer of the pylorus the predominance of gastric symptoms and the dilatation of the stomach, with absence of free HCl and presence of blood in the vomit, usually enable a diagnosis to be made, but it should not be forgotten that cancer of the pylorus and of the head of the pancreas frequently coexist.

**SARCOMA.**

Primary sarcoma of the pancreas is rare; secondary sarcoma, especially of the melanotic type, is not uncommon. A very good example of the latter is in the Museum of the Royal College of Surgeons. The first generally accepted case of primary sarcoma is recorded by Paulicki ("Allgemein. medicin. Centralzeitung," 1868, No. 90). The patient, a young man, died of pulmonary and intestinal tuberculosis; during life no symptoms referable to the pancreatic disease had been observed. The tumour was a "small round-celled sarcoma." In view of the fact that tubercular lesions were widespread, it seems not improbable that the supposed growth was a tuberculous lesion in the substance of the gland. Sidney Martin, in a discussion at the Pathological Society in 1900, mentioned a case of primary sarcoma of the pancreas with secondary deposits in the liver and lungs.

The following case is recorded by Hale White ("Guy's Hosp. Rep.," vol. LIV): Male, aged twenty-eight. Pain first experienced one month before admission. On admission, very pale liquid motions, containing blood. A lump felt 3 inches by  $3\frac{1}{2}$  inches, deeply seated below and to the left of the umbilicus. Death occurred in three weeks. At the post-mortem a large retroperitoneal, small, round-celled sarcoma of the pancreas, involving the duodenum. Pancreas wasted; head deeply involved in a growth, so that it could not be distinguished; tail contained a secondary



FIG. 22.—Section of a pancreas, in which there are numerous melanotic growths of various sizes and shapes. The texture of the gland around and between the growths appears healthy. The specimen was taken from a girl, twenty years of age, whose eye, containing a melanotic growth, was removed three years before her death. There were great masses of melanosis in her liver, and melanotic deposits in the skull, skin, and many other parts. The other section of the pancreas, the melanotic eye, and some other parts are preserved in the museum of St. Bartholomew's Hospital. (Museum R. C. S., specimen No. 2836.) The case is related by Mr. Lawrence in the "London Medical Gazette," vol. XXXVI, page 951, London, 1845 (Sir Wm. Lawrence).



growth. Secondary deposits in omentum, mesentery, kidneys, and lungs.

Litten reports a case of primary sarcoma of the pancreas in a child four years old. There were enormous secondary deposits. The origin of the growth in the pancreas was established by Virchow.

Routier has removed a primary "lympho-sarcoma" from the tail of the pancreas. Krönlein extirpated an angio-sarcoma from the body of the gland; the middle colic artery was wounded and gangrene of the transverse colon followed. Lubarsch also records a case of angio-sarcoma.

In some of the earlier recorded cases the microscopical appearances are so poorly and inadequately described that we hesitate to accept them as genuine. In all, certainly less than one dozen examples are recorded.

Michelsohn (Dissert., Wurzburg, 1894) records a case of von Rindfleisch's, of sarcoma of the pancreas, in the newly-grown parts of which an atypical epithelial proliferation was found.

A similar case of *sarco-carcinoma* is reported by Baudach (Dissert. Freiburg, 1885).

#### ADENOMA.

Adenoma of the pancreas has been recorded by Thierfelder, Biondi, Cesaris-Demel, and Neve.

Thierfelder's specimen was found as a definitely encapsulated, but easily shelled-out, tumour in the

head of the pancreas of a man who had died of general tuberculosis.

Biondi ("Ref. Med.," 1896) excised a "fibro-adenoma" from the head of the pancreas. Two years later the patient was in good health.

#### TUBERCULAR DISEASE OF THE PANCREAS.

The pancreas is said by Kudrewetzki to be involved in approximately one-third of the cases of general miliary tuberculosis.

In a series of 128 post-mortems on tuberculous subjects the pancreas was affected in 12—a percentage of 9.37. In Hale White's series of 142 post-mortems there were 4 examples; 3 of the patients suffered from general tuberculosis and 1 from tubercular peritonitis.

Multiple tubercular deposits may be found irregularly distributed through the gland, or single large masses undergoing caseation may be found. It is probable, as suggested by Virchow and by Klebs, and more recently by Lefas, that in the latter class of cases the tumour may have had its origin in one or more of the lymphatic glands buried in the substance of the pancreas.

A case of successful removal of a tubercular mass in the head of the pancreas (or more probably in a lymph gland) is recorded by P. Sandler ("Deut. Zeit. f. Chir.," 1896).

Kudrewetzki ("Prag. Zeit. f. Heilk.," 1892) relates the occurrence of the bursting into the stomach of a

tuberculous caseous mass in the body of the pancreas.

Charles W., æt. forty-two, an overlooker, residing at Keighley. Admitted for abdominal swelling and general failure of health September 3, 1895. He had been in the Infirmary three years before for tubercular disease of right testicle, which was excised. He had suffered from indigestion and pain in the region of the stomach, but had only vomited once, and that in August. A tumour had been noticed in the region of the stomach for some months, but it had not materially increased in size.

On admission, a tumour about three inches in diameter could be felt in the right of the middle line just below the costal margin. The mass was dull on percussion and moved only slightly with respiration. The liver could be felt to glide over the swelling on deep inspiration. There was distinct pulsation, evidently communicated by the aorta.

At the operation a caseating mass was found behind the stomach and a number of caseating glands were felt and seen in the lesser omentum. The patient became so collapsed on manipulating the tumour, which was occupying the site of the head of the pancreas, that nothing further could be done. The wound healed and he was discharged on September 28th.

#### **SYPHILIS.**

Syphilis of the pancreas is seen in two forms, interstitial and gummatous, which occur separately or together. The former is the more frequent. Both may depend upon congenital syphilis as well as upon the acquired form.

Syphilis of the pancreas may be congenital or acquired.

**Acquired syphilis** is decidedly uncommon. Schlagenhafen has related ("Archiv f. Derm. und Syphilis," 1895) a case of chronic indurating pancreatitis with gummata. Petersen ("Monatsheft f. prakt. Derm.," 1891) in 88 post-mortem examinations of patients who had suffered from tertiary syphilis, found that in one only was the pancreas affected. H. Betham Robinson ("Brit. Med. Journ.," 1900, page 1004) gives details of a case of obstructive jaundice due to a gummatous infiltration involving the head of the pancreas, in which cholecystocolostomy was successfully performed.

**Congenital syphilitic disease of the pancreas** was first described in 1875 by Birch-Hirschfeld ("Arch. d. Heilk.," xvi). The most recent exhaustive account has been given by Schlesinger ("Virch. Arch.," vol. CLIV, page 501). The pancreas is not commonly affected in congenital syphilis, less commonly than the spleen and liver. The inflammatory deposits may be noted as early as the fifth month. As a rule, a diffuse interstitial overgrowth commencing around the vessels is observed, but in rare cases minute or even large gummata may be found. Adhesions to the duodenum or liver or gastro-hepatic omentum may be present. Schlesinger and Opie have shown that the islands of Langerhans are neither invaded by the new growth of interstitial tissue nor implicated in the atrophy which affects the cells of the acini. For further details the reader is referred to the chapter on Chronic Pancreatitis.

**TREATMENT OF SOLID TUMOURS OF THE PANCREAS.**

Certain solid tumours—carcinoma, sarcoma, adenoma—of the pancreas have been treated by removal of the portions of the gland affected. The following cases are recorded:

1. *Trendelenburg* ("Deut. Zeit. f. Chir.," 1886). Woman, aged forty-four. A large tumour was observed on the left side of the abdomen. Lateral abdominal section. The tumour was found to be retroperitoneal, and was covered with large blood-vessels. The growth involved the tail of the pancreas; in removing it the hæmorrhage was free. The spleen was torn and had to be removed with the tumour. Recovery from the operation, but the patient died shortly after her return home. The tumour was a spindle-celled sarcoma.

2. *Ruggi* (*Körte*, page 133). Woman, aged fifty. Two abdominal tumours, the lower a fibroma uteri; the upper was above the umbilicus to the left. An incision made parallel to the rib-margin, and tumour, together with the body and tail of the pancreas, removed; adeno-carcinoma. Recovery, but recurrence later.

3. *Routier* ("Rev. de Chir.," 1892) removed a "lympho-sarcoma" from the tail of the pancreas, through an incision in the transverse mesocolon. The patient died two days later from anuria.

4. *Terrier* ("Nimier. Rev. de Chir.," 1893 and 1894). A tumour on the left side of the abdomen was removed through a median incision. Adhesions were numerous and vascular. The tumour was isolated and an India-rubber tourniquet applied round the base. The pedicle was divided with the cautery. "Cystic epithelioma." Death the same evening from shock.

5. *Biondi* ("Clinica chirurgica," Nr. 4, 1896). Woman, aged forty-five. A tumour on left side of abdomen. The abdomen was opened and the gastro-colic omentum torn through. The tumour involved the head and body of the pancreas, the lower two-thirds of the head being implicated. The growth was removed and the pancreas remaining was stitched to the duodenum. Two days after the operation bile was discharged from the wound, but ceased in four days. On the twenty-fifth day pancreatic juice escaped and a fistula remained for a short time. After its closure all progressed well, and one and a half years after the operation the patient was well and had gained considerably in weight. The specimen showed "fibro-adenoma."

6. *Krönlein* ("Beitr. z. klin. Chir.," Bd. xiv). Woman, aged sixty-three. A movable tumour the size of the fist in the umbilical region. The tumour was reached by dividing the gastro-colic ligament; to it the stomach, pylorus, and duodenum were adherent. The patient died of peritonitis on the sixth day.

7. *Malthé* ("Festschrift f. Prof. Heiberg," Kristiania, 1895). Woman, aged forty-nine. Tumour reached by dividing gastro-colic omentum and by splitting the enteric mesentery. The tumour, and the tail of the pancreas from which it sprang, removed. "Carcinoma giganto-cellulare." Recovery.

8. *Sendler* ("Deut. Zeit. f. Chir.," Bd. XLIV). A woman, fifty-four years of age. A hard tumour in middle line above the umbilicus was reached by splitting the lesser omentum, above the lesser curvature. The pancreas was drawn forwards. In the head a tumour of the size of a walnut was found and was removed, the gap being closed by sutures. Recovery. An examination and report were made by Thoma—"tuberculous lymphoma."

9. *Tricomi* ("Cent. f. Chir.," 1898) removed almost the whole pancreas successfully, for "adeno-carcinoma." The patient died five months later, of "carcinoma of other viscera."

10. *Franke* ("Archiv f. klin. Chir.," Bd. LXIV, 1901) relates three cases of carcinoma of the pancreas operated upon by him. The first patient was a man aged fifty-nine. The tumour involved almost the whole gland. It was approached by dividing the lesser omentum. It was seen that the growth embraced the vena cava and strangled it. A small portion of the constricting mass was removed. The patient died suddenly fifteen days later.

11. The second patient was a man, aged sixty-two. The tumour was again approached by dividing the lesser omentum. The left half of the gland was removed. Free bleeding. Death from peritonitis.

12. The third patient was a woman, aged sixty-eight. A tumour the size of an apple was found in the head of the pancreas, and two other hard nodules in the body. The adhesions were numerous and extremely vascular. The whole pancreas is said to have been removed, but a careful reading of the account leaves this point in doubt. The patient lived from May 1st to October 16th. Sugar was found in the urine from the fifth to the nineteenth day after operation.

13. *B. Codivilla* ("Rendiconto statistico della Sezione chirurgica dell'ospedale di mola," 1898). Epithelioma of the pancreas. The head of the pancreas, the duodenum, and part of the stomach were removed. The cut end of the common bile duct was closed and cholecystenterostomy was performed. Gastro-enterostomy in Y. Death in twenty-four days.

These thirteen operations are all that are recorded.

## Treatment of Solid Tumours of Pancreas 283

They show very forcibly the extreme difficulties of any attempt at the removal of a solid growth of the pancreas. These difficulties are the risk of shock, of gangrene of the duodenum, of hæmorrhage, and of peritonitis. During the operation very large vessels are continually encountered. The splenic vessels on two occasions have been ligatured. The vascular loop between the superior and inferior pancreaticoduodenal arteries is in danger of being wounded. All the tumours are densely adherent, and their removal is seldom practicable.

The following case is recorded by Malcolm ("Lancet," March, 1902):

"The patient was a female child and was born on March 9, 1894. Her father and mother are both alive and well; they have one other child, a healthy girl, born in 1897. One of the patient's grandfathers was said to have died from an internal cancer at the age of sixty-five years. The patient had whooping-cough when she was three weeks old. It was not known that she had suffered from any lung trouble. The bowels were very constipated whilst she was under immediate observation. There was no albumin in the urine, which was scanty (sometimes only twelve ounces in twenty-four hours), and deposited urates, its specific gravity being usually about 1030. An abdominal swelling was first noticed in April, 1898, and Dr. R. L. Guthrie sent the patient to a well-known surgeon, who diagnosed a tumour of the left kidney, but advised that no operation should be performed. Dr. Guthrie asked me to see the patient in May of the same year. She had then an obvious swelling in the upper part of the left side of the abdomen. It was firmly held in



the position of a renal tumour, but the attachments seemed sufficiently lax to allow of the growth being shelled out of its bed. The patient was, however, extremely emaciated and anæmic, having a cachectic appearance which seemed to contraindicate surgical interference, and I therefore agreed with the opinion and advice already given.

“Dr. Guthrie treated the child with iron and laxatives, and in October, 1898, he asked me to see her again. She then had improved very much in her general condition, had quite a good colour, and was not thinner. The tumour had increased in size, but not to any great extent. It distended the hollow of the left loin, pushing the lower ribs upwards and forwards, bulging the side outwards, extending across the abdomen as far as the outer edge of the right rectus muscle and downwards to below the level of the anterior superior iliac spines. The greatest girth of the body was twenty-three and three-quarter inches a little above the level of the umbilicus. On palpation the mass was smooth and elastic. It could be grasped between a hand in front of the abdomen and the other hand behind the loin, and although it was firmly held, there was still a slight mobility of the tumour, sufficient to make me think that I could remove it. There were some easily felt glands in both axillæ and in both groins, but they were not enlarged. The veins over the upper part of the abdomen were distended. No disease of the heart or lungs was detected. In view of the greatly improved condition of the child's general health I told the parents that she had a tumour of the kidney and explained that an operation would involve extreme risks. I also told them that I knew of only three cases in which after the successful removal of a tumour of this kind from a child the patient had survived more than a few months. On the other hand, I pointed out

## Treatment of Solid Tumours of Pancreas 285

that death must occur soon if nothing were done. It was decided to accept the risks of an operation.

“On November 4, 1898, chloroform was administered and the tumour then seemed decidedly more mobile. I opened the abdomen through the upper part of the left linea semilunaris, and exposed the growth, with the splenic flexure and adjacent portions of the colon fixed in front of it. The most convenient place to open the retroperitoneal space, in which the tumour lay, was



FIG. 23.—Tumour removed from the tail of the pancreas. The figure is about half the actual size of the tumour, which measured five inches in its longest diameter. (No. 2836 A, Royal College of Surgeons of England Museum.)

above the transverse colon, and when the peritoneum in that situation was divided, I had no difficulty in separating the tumour from the connective tissue in which it was loosely embedded. Some firm adhesions to the lower end of the spleen were separated and the new growth was then easily drawn out of the abdominal cavity, the tail of the pancreas being dragged out with it. The tumour was then only attached to the pancreas and it was impossible to separate them without

cutting through pancreatic tissue. In doing this large vessels were divided, but hæmorrhage from them was easily controlled by ligatures. No ureter was seen during the operation. There was a second new growth, of about the size of a bantam's egg, to the right of the cavity from which the tumour had been removed. I thought that this was a collection of glands affected by malignant disease, but the patient was in such a serious state of collapse that it was out of the question to attempt an investigation of the nature and connections of this second abnormal condition. I therefore ligatured all bleeding points, having much trouble in securing those on the spleen. I washed out the abdominal cavity with warm sterilised salt and water, leaving as much as possible inside, when the wound was sewn up, with a view to counteracting the shock of the operation, which, however, was not survived by the patient.

“At the necropsy, which was conducted by Dr. Cuthbert H. J. Lockyer, caseating glands were found near the bifurcation of the bronchi and in the anterior mediastinum. There were extensive old pleuritic adhesions on the right side. There was no sign of peritonitis or of union of the lips of the wound. The peritoneal cavity was full of fluid (the salt and water introduced at the operation), which at first flowed away clear, but that from the loin pouches was deeply blood-stained. The kidneys were healthy and were normal in position. Part of the transverse colon was separated from its attachments, its mesocolon having been completely divided, and the omentum had been removed from all but the left one and a half inches of the stomach. The left pleuro-colic fold was intact. The spleen had a wound on the lower end of its inner surface one and a half inches long. The left half of the pancreas was absent, its cut surface presenting

many ligatured points. There was a smooth encapsulated growth situated in the gastro-hepatic omentum with the bile duct and some vessels in front of it.

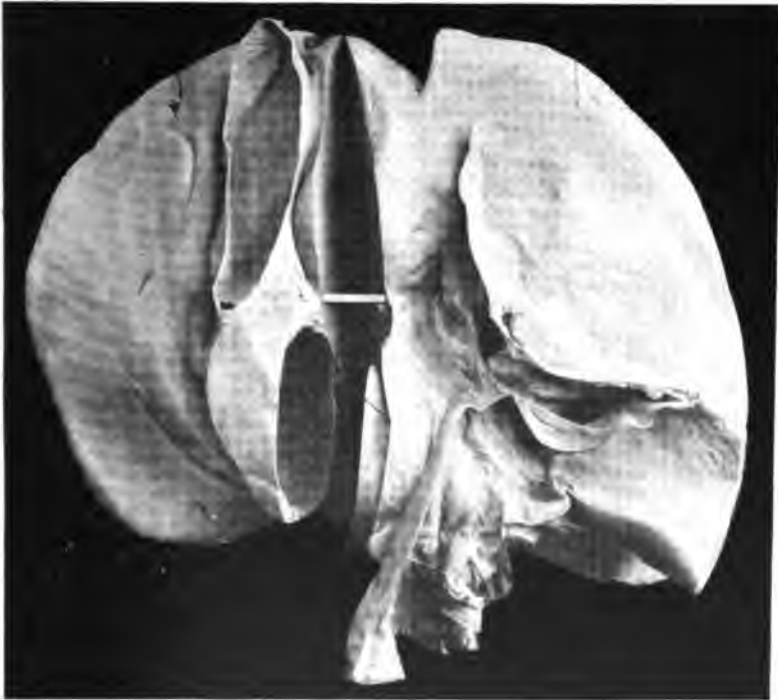


FIG. 24.—Under surface of the liver, parts of the stomach, duodenum, gall bladder and the divided portal vein greatly distended. In dividing the vein the tumour also was divided into two unequal parts, the larger of which, nearer the liver end of the vein, was found to be quite unattached and has been removed; a considerable portion of the remaining part of the tumour is also obviously unattached. The vein was not occluded; a bristle is seen passing by the side of the tumour through the lower portion of the vessel. (Half size.) (No. 2836 B, Royal College of Surgeons of England Museum.)

The neck of the gall bladder and the transverse fissure of the liver were above it. The foramen of Winslow was behind and the new growth seemed to be con-

nected with the head of the pancreas below, the connection between the two being much constricted.

“The parts were sent to the Royal College of Surgeons of England, and when they had been dissected it was found that the mass in the lesser omentum was a new growth inside the portal vein and widely distending it. Mr. Shattock has examined the tumours and both are fibro-sarcomatous in structure. The specimens are preserved in the museum of the College, and the accompanying illustrations (Figs. 23 and 24), which are reproduced from photographs taken by Mr. H. George, give a very faithful representation of their appearance.”

## INDEX.

- ABSCSS**, retrogastric pancreatitis, case of, 110  
**Accessory pancreas**, 22  
**Adenoma of pancreas**, 276  
**Ampulla of Vater**, 19  
**Amylopsin**, 26  
**Apoplectic cysts of pancreas**, 208  
**Arterial supply of pancreas**, 20  
**Aspiration in cysts of pancreas**, 250
- CALCULUS**, multiple pancreatic, case of, 185  
pancreatic, 178  
symptoms of, 182  
treatment of, 183
- Carcinoma of pancreas**, 260  
diagnosis of, 268  
differential, 269  
pathological anatomy of, 262  
site of, 262  
symptoms of, 264  
varieties of, 264
- Cystadenoma of pancreas**, 197  
cases of, 198
- Cystic disease, congenital, of pancreas**, 207  
epithelioma of pancreas, 202
- Cystoma, ovarian, and cysts of pancreas**, diagnosis of, differential, 243
- Cysts, apoplectic, of pancreas**, 208  
hæmorrhagic, of pancreas, 208  
hydatid, of pancreas, 204  
mesenteric, and cysts of pancreas, diagnosis of, differential, 247  
of liver and cysts of pancreas, diagnosis of, differential, 244  
of pancreas, 188  
and cysts of liver, diagnosis of, differential, 244
- Cysts of pancreas and cysts of spleen**, diagnosis of, differential, 248  
of stomach, diagnosis of, differential, 247  
of suprarenal capsule, diagnosis of, differential, 245  
and distended gall bladder, diagnosis of, differential, 245  
and fluid tumors of kidney, diagnosis of, differential, 246  
and mesenteric cysts, diagnosis of, differential, 247  
and omental cysts, diagnosis of, differential, 247  
and ovarian cystoma, diagnosis of, differential, 243  
and retroperitoneal cysts, diagnosis of, differential, 248  
of pancreas, aspiration in, 250  
cases of, 52, 256  
course and terminations of, 239  
diagnosis of, 241  
differential, 242  
evacuation and drainage in, 251  
extirpation of, 255  
fatty stools in, 229  
fluid of, character of, 225  
operative treatment of, 250  
pathological anatomy of, 222  
sugar in urine in, 229  
symptoms and signs of, 227  
terminations of, 239  
treatment of, operative, 250  
under care of authors, 256  
of spleen and pancreatic cysts, diagnosis of, differential, 248

- Cysts of stomach and pancreatic cysts, diagnosis of, differential, 247
- of suprarenal capsule and cysts of pancreas, diagnosis of, differential, 245
- omental, and cysts of pancreas, diagnosis of, differential, 247
- proliferation, of pancreas, 197
- retention, of pancreas, 189
- cicatricial stenosis as cause of, 191
- dislocation of a part of gland as cause of, 196
- etiology of, 190
- impaction of a calculus as cause of, 190
- pressure upon duct from without as a cause of, 195
- retroperitoneal, and pancreatic cysts, diagnosis of, differential, 248
- DESTRUCTION of pancreas in situ, effect produced by, 31
- Diabetes, pancreatic, 34
- relation of pancreas to, 37
- Distended gall bladder and cysts of pancreas, diagnosis of, differential, 245
- Diverticulum of Vater, 19
- Duct of pancreas, ligature of, effect produced by, 31
- of Santorini, 19
- of Wirsung, 19
- Ducts of pancreas, 19
- abnormalities of, 23
- EPITHELIOMA, cystic, of pancreas, 202
- Evacuation and drainage in cysts of pancreas, 251
- Extirpation of cysts of pancreas, 255
- partial, of pancreas, effect produced by, 30
- Extirpation, total, of pancreas, effect produced by, 30
- FAT necrosis in pancreatitis, 68
- Fatty stools in cystic disease of pancreas, 229
- Fitz's rule for diagnosis of acute pancreatitis, 82
- Fluid tumours of kidney and cysts of pancreas, diagnosis of, differential, 246
- GALL bladder, distended, and cysts of pancreas, diagnosis of, differential, 245
- Gangrenous pancreatitis with disseminated fat necrosis, cases of, 105
- Gunshot wounds of pancreas, 55
- HÆMORRHAGE in pancreatic disease, 71
- Hæmorrhagic cysts of pancreas, 208
- necrosis of pancreas, case of, 90
- pancreatitis, acute, cases of, 87, 91, 101, 107, 109, 110, 114, 126
- production of, by a calculus, conditions necessary for, 65
- peripancreatitis, acute, case of, 123
- Hydatid cysts of pancreas, 204
- Hydronephrosis and cysts of pancreas, diagnosis of, differential, 246
- INJURIES of pancreas, 45
- sequels of, 54
- treatment of, 53
- Interacinar pancreatitis, 39, 157
- Interlobular pancreatitis, 39, 157
- Islands of Langerhans, 25, 38
- KIDNEY, fluid tumours of, and cysts of pancreas, diagnosis of, differential, 246

- LACERATION of pancreas, fatal cases of, 45
- Lesser pancreas, 17
- Ligature of duct of pancreas, effect produced by, 31
- Liver, cysts of, and cysts of pancreas, diagnosis of, differential, 244
- MESENTERIC cysts and cysts of kidney, diagnosis of, differential, 247
- Milk-coagulating ferment of pancreatic juice, 26
- Movable pancreas, 26
- NECROSIS, hæmorrhagic, of pancreas, case of, 90
- New growths of pancreas, 260
- OMENTAL cysts and cysts of pancreas, diagnosis of, differential, 247
- Ovarian cystoma and cysts of pancreas, diagnosis of, differential, 243
- PANCREAS, abnormalities of, 22
- abscess of, due to calculus, case of, 144
- accessory, 22
- acquired syphilis of, 279
- adenoma of, 276
- anatomy of, 17
- apoplectic cysts of, 208
- arterial supply of, 20
- body of, 18
- carcinoma of, 260
- diagnosis of, 268
- differential, 269
- pathological anatomy of, 262
- site of, 262
- symptoms of, 264
- varieties of, 264
- chronic gastric ulcer eroding, case of, 140
- congenital cystic disease of, 207
- syphilis of, 279
- Pancreas, cystadenoma of, 197
- cases of, 198
- cystic epithelioma of, 202
- tumour of, 232
- cysts of, 188
- and cysts of liver, diagnosis of, differential, 244
- of spleen, diagnosis of, differential, 248
- of stomach, diagnosis of, differential, 247
- of suprarenal capsule, diagnosis of, differential, 245
- and distended gall bladder, diagnosis of, differential, 245
- and fluid tumours of pancreas, diagnosis of, differential, 246
- and mesenteric cysts, diagnosis of, differential, 247
- and omental cysts, diagnosis of, differential, 247
- and ovarian cystoma, diagnosis of, differential, 243
- and retroperitoneal cysts, diagnosis of, differential, 248
- aspiration in, 250
- cases of, 52, 256
- course and terminations of, 239
- diagnosis of, 241
- differential, 242
- evacuation and drainage in, 251
- extirpation of, 255
- fatty stools in, 229
- fluid of, character of, 225
- operative treatment of, 250
- pathological anatomy of, 222
- sugar in urine in, 229
- symptoms and signs of, 227
- terminations of, 239
- treatment of, operative, 250
- under care of authors, 256
- destruction of, in situ, effect produced by, 31
- development of, 23



- Pancreas, ducts of, 19**  
   abnormalities of, 23  
   experimental work on, 29  
   extirpation of, partial, effect produced by, 30  
   total, effect produced by, 30  
   gunshot wounds of, 55  
   hæmorrhagic cysts of, 208  
   necrosis of, case of, 90  
   head of, 17  
   hydatid cysts of, 204  
   injuries of, 45  
     sequels of, 54  
     treatment of, 53  
   laceration of, fatal cases of, 44  
   lesser, 17  
   ligature of duct of, effect produced by, 31  
   methods of obtaining access to, for purposes of operation, 27  
     from behind, 28  
     from front, 27  
       above stomach, 27  
       below stomach, 27  
       through transverse mesocolon, 27  
   movable, 26  
   neck of, 18  
   new growths of, 260  
   paranucleus of, 24  
   prolapse of, 56  
   proliferation cysts of, 197  
   pseudo-cysts of, 210  
   relations of, to diabetes, 37  
   retention cysts of, 189  
     cicatrical stenosis as cause of, 191  
     dislocation of a part of gland as cause of, 196  
     etiology of, 190  
     impaction of a calculus as cause of, 190  
     pressure upon duct from without as cause of, 195  
   sarcoma of, 274  
   solid tumours of, treatment of, 280
- Pancreas, structure of, 24**  
   subcutaneous transplantation of, effect produced by, 31  
   syphilis of, 278  
   tubercular disease of, 277  
   tumours of, solid, treatment of, 280  
   veins of, 21  
   vessels of, 20  
   wounds of, treatment of, 56  
**Pancreatic calculus, 178**  
   multiple, case of, 185  
   symptoms of, 182  
   treatment of, 183  
   diabetes, 34  
   disease, hæmorrhage in, 71  
   juice, 25  
     absence of, from intestine, method of ascertaining, 232  
     ferments contained in, 26  
**Pancreatitis, 58**  
   abscess, retrogastric, case of, 110  
   acute, 81  
     after-treatment of, 86  
     cases of, 104, 109  
     diagnosis of, 82  
       differential, 83  
       Fitz's rule in, 82  
     hæmorrhagic, cases of, 87, 91, 101, 107, 109, 110, 114, 126  
       production of, by a calculus, conditions necessary for, 60  
     pathology of, 86  
     suppurative, case of, 111  
     symptoms of, 81  
     treatment of, 84  
       with fat necrosis, case of, 112  
   chronic, 147  
   congenital syphilitic, 150  
     cases of, 151, 152  
   diagnosis of, 160  
     differential, 160  
   pathological appearances in, 158  
   prognosis of, 162  
   symptoms of, 147

- Pancreatitis, chronic, treatment**  
of, 162  
classification of, 79  
etiology of, 60  
fat necrosis in, 68  
gangrenous, with disseminated  
fat necrosis, cases of, 105  
hæmorrhage in, 71  
history of, 58  
interacinar, 39, 157  
interlobular, 39, 157  
pathology of, 60  
subacute, 134  
  case of, 136  
  treatment of, 138  
with abscess associated with  
gall stones, case of, 142  
symptoms of, 79
- Paranucleus of pancreas, 24**
- Peripancreatitis, acute hæmor-  
rhagic, case of, 123**
- Prolapse of pancreas, 56**
- Proliferation cysts of pancreas, 197**
- Pseudo-cysts of pancreas, 210**
- Pyonephrosis and cysts of pan-  
creas, diagnosis of, differential,  
246**
- RETENTION cysts of pancreas, 189**  
  cicatricial stenosis as cause  
  of, 191  
  dislocation of a part of  
  gland as cause of, 196  
  etiology of, 190  
  impaction of a calculus as  
  cause of, 190  
  pressure upon duct from  
  without as cause of, 195
- Retrogastric pancreatitis abscess,  
case of, 110**
- Retroperitoneal cysts and cysts of  
pancreas, diagnosis of, differen-  
tial, 248**
- SANTORINI, duct of, 19**
- Sarcoma of pancreas, 274**
- Signe de Sahli, 232**
- Spleen, cysts of, and pancreatic  
cysts, diagnosis of, differential,  
248**
- Steapsin, 26**
- Stomach, cysts of, and pancreatic  
cysts, diagnosis of, differential,  
247**
- Stools, fatty, in cystic disease of  
pancreas, 229**
- Subacute pancreatitis, 134**  
  case of, 136  
  treatment of, 138  
  with abscess associated with  
  gall stones, case of, 142
- Subcutaneous transplantation of  
pancreas, effect produced by, 31**
- Sugar in urine in cysts of pan-  
creas, 229**
- Suppurative pancreatitis, acute,  
case of, 111**
- Suprarenal capsule, cyst of, and  
cysts of pancreas, diagnosis of,  
differential, 245**
- Syphilis, acquired, of pancreas, 279**  
  congenital, of pancreas, 279  
  of pancreas, 278
- TRANSPLANTATION, subcutaneous,  
of pancreas, effect produced by,  
31**
- Trypsin, 26**
- Tubercular disease of pancreas, 277**
- Tumours, fluid, of kidney, and  
cysts of pancreas, diagnosis  
of, differential, 246**  
  solid, of pancreas, treatment of,  
280
- URINE, sugar in, in cysts of pan-  
creas, 229**
- VATER, diverticulum of, 19**
- Veins of pancreas, 21**
- Vessels of pancreas, 20**
- WIRSUNG, duct of, 19**
- Wounds, gunshot, of pancreas, 55**  
  of pancreas, treatment of, 56







---

---

**SAUNDERS' BOOKS**

— on —

**SURGERY**

and

**ANATOMY**

---

**W. B. SAUNDERS & COMPANY**

**925 WALNUT STREET**

**PHILADELPHIA**

**London: 9, Henrietta Street, Covent Garden**

---

---

**T**HE books advertised in this Catalogue as being *sold by subscription* are usually to be obtained from traveling solicitors, but they will be sent direct from the office of publication (charges of shipment prepaid) upon receipt of the prices given. All the other books advertised are commonly for sale by booksellers in all parts of the United States; but books will be sent to any part of the world, carriage prepaid, on receipt of the price herein given.

Money may be sent at the risk of the publishers in any of the following ways: A postal money order, an express money order, a bank check, and in a registered letter. Money sent in any other way is at the risk of the sender.

**SPECIAL  
OFFER**

To physicians of approved credit any book or books on our list will be sent, carriage paid, on the following terms: \$5.00 cash upon delivery of the books, and monthly payments of \$5.00 thereafter; payments to be made free of all expense to the publishers.

**A Complete Catalogue of Our Publications will be Sent upon Request**

---

---

# American Text-Book of Surgery

**American Text-Book of Surgery.** Edited by WILLIAM W. KEEN, M.D., LL.D., F.R.C.S. (Hon.), Professor of the Principles of Surgery and of Clinical Surgery, Jefferson Medical College, Philadelphia; and J. WILLIAM WHITE, M.D., PH.D., John Rhea Barton Professor of Surgery, University of Pennsylvania. Handsome octavo, 1230 pages, with 496 wood-cuts in the text and 37 colored and half-tone plates. Cloth, \$7.00 net; Sheep or Half Morocco, \$8.00 net.

## THIRD EDITION, THOROUGHLY REVISED AND ENLARGED

Of the two former editions of this book there have been sold over 36,000 copies. This and its adoption as a text-book in eighty-five medical colleges have furnished a stimulus to the authors to keep the work abreast of the times by another careful revision. This has been accomplished by a vigorous scrutiny of all the old matter, by the enlargement of several sections, by the addition of new illustrations, and by the introduction of the many new topics that have come to the front in the surgery of to-day. Among the new topics introduced are a full consideration of serum-therapy; leucocytosis; post-operative insanity; Krönlein's method of locating the cerebral fissures; Hoffa's and Lorenz's operations of congenital dislocations of the hip; Allis' researches on dislocations of the hip-joint; lumbar puncture; the forcible reposition of the spine in Pott's disease; the use of Kelly's rectal specula; the use of eucaïn for local anesthesia; Krause's method of skin-grafting, etc.

## PERSONAL AND PRESS OPINIONS

### Edmond Owen, F.R.C.S.

*Member of the Board of Examiners of the Royal College of Surgeons, England.*

"Personally, I should not mind it being called **The Text-Book** (instead of **A Text-Book**), for I know of no single volume which contains so readable and complete an account of the science and art of surgery as this does."

### The Lancet, London

"If this text-book is a fair reflex of the present position of American surgery, we must admit it is of a very high order of merit, and that English surgeons will have to look very carefully to their laurels if they are to preserve a position in the van of surgical practice."

### Boston Medical and Surgical Journal

"This book marks an epoch in American book-making. All in all, the book is distinctly the most satisfactory work on modern surgery with which we are familiar. It is thorough, complete, and condensed."

# International Text-Book of Surgery

SECOND EDITION, THOROUGHLY REVISED AND ENLARGED

**The International Text-Book of Surgery.** In two volumes. By American and British authors. Edited by J. COLLINS WARREN, M.D., LL.D., F.R.C.S. (Hon.), Professor of Surgery, Harvard Medical School; and A. PEARCE GOULD, M.S., F.R.C.S., of London, England.—Vol. I. *General and Operative Surgery*. Royal octavo, 975 pages, 461 illustrations, 9 full-page colored plates.—Vol. II. *Special or Regional Surgery*. Royal octavo, 1122 pages, 499 illustrations, and 8 full-page colored plates.

Per volume: Cloth, \$5.00 net; Half Morocco, \$6.00 net.

## ADOPTED BY THE U. S. ARMY

In this new edition the entire book has been carefully revised, and special effort has been made to bring the work down to the present day. The chapters on Military and Naval Surgery have been very carefully revised and extensively rewritten in the light of the knowledge gained during the recent wars. The articles on the effect upon the human body of the various kinds of bullets, and the results of surgery in the field are based on the latest reports of the surgeons in the field. The chapter on Diseases of the Lymphatic System has been completely rewritten and brought up to date; and of special interest is the chapter on the Spleen. The already numerous and beautiful illustrations have been greatly increased, constituting a valuable feature, especially so the seventeen colored lithographic plates.

## OPINIONS OF THE MEDICAL PRESS

### **Annals of Surgery**

"It is the most valuable work on the subject that has appeared in some years. The clinician and the pathologist have joined hands in its production, and the result must be a satisfaction to the editors as it is a gratification to the conscientious reader."

### **Boston Medical and Surgical Journal**

"The articles as a rule present the essentials of the subject treated in a clear, concise manner. They are systematically written. The illustrations are abundant, well chosen, and enhance greatly the value of the work. The book is a thoroughly modern one."

### **The Medical Record, New York**

"The arrangement of subjects is excellent, and their treatment by the different authors is equally so. . . . The work is up to date in a very remarkable degree, many of the latest operations in the different regional parts of the body being given in full details. There is not a chapter in the work from which the reader may not learn something new."



# Senn's Practical Surgery

**Practical Surgery.** A Work for the General Practitioner. By NICHOLAS SENN, M.D., PH.D., LL.D., Professor of Surgery in Rush Medical College, Chicago; Professor of Surgery in the Chicago Poly-clinic; Attending Surgeon to the Presbyterian Hospital, etc. Handsome octavo volume of 1133 pages, with 650 illustrations, many of them in colors. Cloth, \$6.00 net; Sheep or Half Morocco, \$7.00 net. *Sold by Subscription.*

## DR. SENN'S GREAT WORK

### Based on His Operative Experience for 25 Years

This work represents the practical operative experience of the author for the last twenty-five years. The book deals with practical subjects, and its contents are devoted to those sections of surgery that are of special interest to the general practitioner. Special attention is paid to emergency surgery. Shock, hemorrhage, and wound treatment are fully considered. All emergency operations that come under the care of the general practitioner are described in detail and fully illustrated.

The section on Military Surgery is based on the author's experience as chief of the operating staff in the field during the Spanish-American War, and on his observations during the Greco-Turkish War. Intestinal Surgery is given a prominent place, and the consideration of this subject is the result of the clinical experience of the author as surgeon and teacher of surgery for a quarter of a century. The text is profusely illustrated.

---

## OPINIONS OF THE MEDICAL PRESS

### **Annals of Surgery**

"It is of value not only as presenting comprehensively the most advanced teachings of modern surgery in the subjects which it takes up, but also as a record of the matured opinions and practice of an accomplished and experienced surgeon."

### **Quarterly Medical Journal, England**

"We cannot speak too highly of this valuable contribution to the literature of practical surgery. . . . The present work more than sustains the high reputation of its author."

### **Buffalo Medical Journal**

"As an intelligent exposition of the science of surgery as practiced to-day it is deserving of commendation, and it will be particularly welcomed by the general practitioner."

# Scudder's Treatment of Fractures

**The Treatment of Fractures.** By CHARLES L. SCUDDER, M.D., Assistant in Clinical and Operative Surgery, Harvard Medical School; Surgeon to the Out-Patient Department of the Massachusetts General Hospital, Boston. Handsome octavo volume of 485 pages, with 645 original illustrations.

Polished Buckram, \$4.50 net; Half Morocco, \$5.50 net.

## THE THIRD LARGE EDITION IN TWO YEARS

In this edition several new fractures have been described, and an excellent chapter on Gunshot Fractures of the long bones has been added. The reports of surgeons in the field during the recent wars have been carefully digested, and the important facts regarding fractures produced by the small caliber bullet have been here concisely presented. In many instances photographs have been substituted for drawings, and the uses of plaster-of-Paris as a splint-material have been more fully illustrated. In the treatment the reader is not only told, but is *shown*, how to apply apparatus, for as far as possible all the details are illustrated. This elaborate and complete series of illustrations constitutes a feature of the book. There are 645 of them, all from new and original drawings and reproduced in the highest style of art.

---

## PERSONAL AND PRESS OPINIONS

### William T. Bull, M.D.,

*Professor of Surgery, College of Physicians and Surgeons, New York City.*

"The work is a good one, and I shall certainly recommend it to students."

### Joseph D. Bryant, M.D.,

*Professor of the Principles and Practice of Surgery, University and Bellevue Hospital Medical College, New York City.*

"As a practical demonstration of the topic it is excellent, and as an example of bookmaking it is highly commendable."

### American Journal of the Medical Sciences

"The work produces a favorable impression by the general manner in which the subject is treated. Its descriptions are concise and clear, and the treatment sound. The physical examination of the injured part is well described, and . . . the method of making these examinations is illustrated by a liberal use of cuts."

# DaCosta's Modern Surgery

**Modern Surgery—GENERAL AND OPERATIVE.** By JOHN CHALMERS DACOSTA, M.D., Professor of the Principles of Surgery and of Clinical Surgery in the Jefferson Medical College, Philadelphia; Surgeon to Philadelphia Hospital and to St. Joseph's Hospital, Philadelphia. Handsome octavo volume of 1117 pages, copiously illustrated.

Cloth, \$5.00 net; Sheep or Half Morocco, \$6.00 net.

## THIRD REVISED EDITION

**Enlarged by over 200 Pages, with over 100 New Illustrations**

The remarkable success attending DaCosta's Manual of Surgery, and the general favor with which it has been received, have led the author in this revision to produce a complete treatise on modern surgery along the same lines that made the former editions so successful. The book has been entirely rewritten and very much enlarged in this edition. It has been increased in size by new matter to the extent of over 200 pages, and contains more than 100 handsome new illustrations, making a total of 439 beautiful cuts in the text. The old editions of this excellent work have long been favorites, not only with students and teachers but also with practising physicians and surgeons, and it is believed that the present work, presenting, as it does, the latest advances in the science and art of surgery, will find an even wider field of usefulness.

---

## OPINIONS OF THE MEDICAL PRESS

### **The Lancet, London**

"We may congratulate Dr. DaCosta in the success of his attempt. . . . We can recommend the work as a text-book well suited to students."

### **The Medical Record, New York**

"The work throughout is notable for its conciseness. Redundance of language and padding have been scrupulously avoided, while at the same time it contains a sufficient amount of information to fulfil the object aimed at by its author—namely, a text-book for the use of the student and the busy practitioner."

### **American Journal of the Medical Sciences**

"The author has presented concisely and accurately the principles of modern surgery. The book is a valuable one, which can be recommended to students, and is of great value to the general practitioner."

---

# McClellan's Art Anatomy

**Anatomy in its Relation to Art.** An exposition of the Bones and Muscles of the Human Body, with Reference to their Influence upon its Actions and external Form. By GEORGE MCCLELLAN, M.D., Professor of Anatomy, Pennsylvania Academy of the Fine Arts. Handsome quarto volume, 9 by 11 ½ inches. Illustrated with 338 original drawings and photographs, with 260 pages of text.

Dark Blue Vellum, \$10.00 net; Half Russia, \$12.00 net.

## Just Issued

This is an exhaustive work on the structure of the human body as it affects the external form, and although especially prepared for students and lovers of art, it will prove very valuable to all interested in the subject of anatomy. It will be of especial value to the physician, because nowhere else can he find so complete a consideration of surface anatomy. Those interested in athletics and physical training will find reliable information in this book.

**Howard Pyle,**

*In the Philadelphia Medical Journal.*

"The book is one of the best and the most thorough Text-books of artistic anatomy which it has been the writer's fortune to fall upon and, as a text-book, it ought to make its way into the field for which it is intended."

---

# McClellan's Regional Anatomy

**Regional Anatomy in its Relations to Medicine and Surgery.** By GEORGE MCCLELLAN, M.D., Professor of Anatomy, Pennsylvania Academy of the Fine Arts. Two handsome quartos, 884 pages of text; 97 full-page chromolithographic plates, reproducing the author's original dissections. Cloth, \$12.00 net; Half Russia, \$15.00 net.

## Fourth Revised Edition

This well-known work stands without a parallel in anatomic literature, and its remarkably large sale attests its value to the practitioner. By a marvelous series of colored lithographs the exact appearances of the dissected parts of the body are reproduced, enabling the reader to examine the anatomic relations with as much accuracy and satisfaction as if he had the actual subject before him.

**British Medical Journal**

"The illustrations are perfectly correct anatomical studies, and do not reproduce the inaccuracies which experience has taught us to look for in works of a similar kind. Some of the plates, especially those of the anatomy of the chest, are of great excellence."

GET THE BEST **American** THE NEW STANDARD  
**Illustrated Dictionary**

SECOND EDITION, REVISED

**The American Illustrated Medical Dictionary.** A New and Complete Dictionary of the terms used in Medicine, Surgery, Dentistry, Pharmacy, Chemistry, and kindred branches; together with new and elaborate tables of Arteries, Muscles, Nerves, Veins, etc.; of Bacilli, Bacteria, Micrococci, etc.; Eponymic Tables of Diseases, Operations, Signs and Symptoms, Stains, Tests, Methods of Treatment, etc. By W. A. N. DORLAND, M.D. Large octavo, 770 pages.

Flexible leather, \$4.50 net; with thumb index, \$5.00 net.

**LARGE FIRST EDITION EXHAUSTED IN EIGHT MONTHS**

In this edition the book has been subjected to a thorough revision. The author has also added upward of one hundred important new terms that have appeared in medical literature during the past few months.

**Howard A. Kelly, M.D.,**

*Professor of Gynecology, Johns Hopkins University, Baltimore.*

"Dr. Dorland's Dictionary is admirable. It is so well gotten up and of such convenient size. No errors have been found in my use of it."

**Roswell Park, M.D.,**

*Professor of Principles and Practice of Surgery and of Clinical Surgery, University of Buffalo.*

"I must acknowledge my astonishment at seeing how much he has condensed within relatively small space. I find nothing to criticise, very much to commend, and was interested in finding some of the new words which are not in other recent dictionaries."

## American Year-Book

**Saunders' American Year-Book of Medicine and Surgery.** A yearly Digest of Scientific Progress and Authoritative Opinion in all branches of Medicine and Surgery, drawn from journals, monographs, and text-books of the leading American and foreign authors and investigators. Arranged, with critical editorial comments, by eminent American specialists, under the editorial charge of GEORGE M. GOULD, A.M., M.D. In two volumes: Vol. I—*General Medicine*, octavo, 715 pages, illustrated; Vol. II—*General Surgery*, octavo, 684 pages, illustrated. Per vol.: Cloth, \$3.00 net; Half Morocco, \$3.75 net. *Sold by Subscription.*

In these volumes the reader obtains not only a yearly digest, but also the invaluable annotations and criticisms of the editors. As usual, this issue of the Year-Book is amply illustrated.

**The Lancet, London**

"It is much more than a mere compilation of abstracts, for, as each section is entrusted to experienced and able contributors, the reader has the advantage of certain critical commentaries and expositions . . . proceeding from writers fully qualified to perform these tasks."

# Helferich and Bloodgood's Fractures and Dislocations

**Atlas and Epitome of Traumatic Fractures and Dislocations.** By PROFESSOR DR. H. HELFERICH, Professor of Surgery at the Royal University, Greifswald, Prussia. Edited, with additions, by JOSEPH C. BLOODGOOD, M.D., Associate in Surgery, Johns Hopkins University, Baltimore. *From the Fifth Revised and Enlarged German Edition.* With 216 colored illustrations on 64 lithographic plates, 190 text-cuts, and 353 pages of text. Cloth, \$3.00 net. *In Saunders' Atlas Series.*

## A New Volume—Just Issued

A book accurately portraying the anatomic relations of the fractured parts, together with the diagnosis and treatment of the condition, has become an absolute necessity. This work is intended to meet all requirements. As complete a view as possible of each case has been presented, thus equipping the physician for the manifold appearances that he will meet with in practice. The illustrations are unrivaled for accuracy and clearness of portrayal of the conditions represented, showing the visible external deformity, the X-ray shadow, the anatomic preparation, and the method of treatment.

# Zuckerkindl and DaCosta's Operative Surgery

ADOPTED BY THE U. S. ARMY

**Atlas and Epitome of Operative Surgery.** By DR. O. ZUCKERKANDL, of Vienna. Edited, with additions, by J. CHALMERS DACOSTA, M.D., Professor of the Principles of Surgery and Clinical Surgery, Jefferson Medical College, Philadelphia. 40 colored plates, 278 text-cuts, and 410 pages of text. Cloth, \$3.50 net. *In Saunders' Atlas Series.*

## SECOND EDITION, THOROUGHLY REVISED AND GREATLY ENLARGED

In this new edition the work has been brought precisely down to date. A number of chapters have been practically rewritten, and of the newer operations, all those of special value have been described. Sixteen valuable lithographic plates in colors and sixty-one text figures have been added, thus greatly enhancing the value of the work.

**New York Medical Journal**

"We know of no other work upon the subject in which the illustrations are as numerous or as generally satisfactory."

# Macdonald's Diagnosis and Treatment

**A Clinical Text-Book of Surgical Diagnosis and Treatment.** By J. W. MACDONALD, M.D. Edin., F.R.C.S. Edin.; Professor Emeritus of the Practice of Surgery and of Clinical Surgery in Hamline University, Minneapolis, Minn. Octavo, 798 pages, handsomely illustrated. Cloth, \$5.00 net; Sheep or Half Morocco, \$6.00 net.

This work aims to furnish a guide to surgical diagnosis. It sets forth in a systematic way the necessity of examinations and the proper methods of making them. The various portions of the body are then taken up in order and the diseases and injuries thereof succinctly considered and the treatment briefly indicated. Practically all the modern and approved operations are described. The work concludes with a chapter on the use of the Röntgen rays in surgery.

**British Medical Journal**

"Care has been taken to lay down rules for a systematic and comprehensive examination of each case as it presents itself, and the most advanced and approved methods of clinical investigation in surgical practice are fully described."

# Warren's Pathology and Therapeutics

**Surgical Pathology and Therapeutics.** By JOHN COLLINS WARREN, M.D., LL.D., F.R.C.S. (Hon.), Professor of Surgery, Harvard Medical School. Octavo, 873 pages; 136 relief and lithographic illustrations, 33 in colors. With an Appendix on Scientific Aids to Surgical Diagnosis and a series of articles on Regional Bacteriology. Cloth, \$5.00 net; Sheep or Half Morocco, \$6.00 net.

**SECOND EDITION, WITH AN APPENDIX**

The volume is for the bedside, the amphitheatre, and the ward. It deals with diseases not as we see them through the microscope alone, but as the practitioner sees their effect in his patients; not only as they appear in and affect culture-media, but also as they influence the human body; and, following up the demonstrations of the nature of diseases, the author points out their logical treatment.

**Roswell Park, M.D.,**

*In the Harvard Graduate Magazine.*

"I think it is the most creditable book on surgical pathology, and the most beautiful medical illustration of the bookmakers' art that has ever been issued from the American press."

---

# Golebiewski and Bailey's Accident Diseases

**Atlas and Epitome of Diseases Caused by Accidents.** By DR. ED. GOLEBIEWSKI, of Berlin. Edited, with additions, by PEARCE BAILEY, M.D., Attending Physician to the Almshouse and Incurable Hospitals, New York. With 71 colored figures on 40 plates, 143 text-cuts, and 549 pages of text. Cloth, \$4.00 net. *In Saunders' Hand-Atlas Series.*

This work contains a full and scientific treatment of the subject of accident injury ; the functional disability caused thereby ; the medicolegal questions involved, and the amount of indemnity justified in given cases. The work is indispensable to every physician who sees cases of injury due to accidents, to advanced students, to surgeons, and, on account of its illustrations and statistical data, it is none the less useful to accident insurance organizations.

## **The Medical Record, New York**

" This volume is upon an important and only recently systematized subject, which is growing in extent all the time. The pictorial part of the book is very satisfactory."

---

# Sultan and Coley's Abdominal Hernias

**Atlas and Epitome of Abdominal Hernias.** By PRIVATDOCENT DR. GEORG SULTAN, of Göttingen. Edited, with additions, by WILLIAM B. COLEY, M.D., Clinical Lecturer on Surgery, Columbia University (College of Physicians and Surgeons). With 119 illustrations, 36 of them in colors, and 277 pages of text. Cloth, \$3.00 net. *In Saunders' Hand-Atlas Series.*

During the last decade the operative side of this subject has been steadily growing in importance, until now it is absolutely essential to have a book treating of its surgical aspect. This present atlas does this to an admirable degree. The illustrations are not only very numerous, but they portray most accurately the conditions represented.

## **Robert H. M. Dawbarn, M.D.,**

*Professor of Surgery and of Surgical Anatomy, New York Polyclinic.*

" I have spent several interesting hours over it to-day, and shall willingly recommend it to any classes at the Polyclinic College and elsewhere."



# Grant's Surgery of Face, Mouth, and Jaws

**A Text-Book of the Surgical Principles and Surgical Diseases of the Face, Mouth, and Jaws.** For Dental Students. By H. HORACE GRANT, A.M., M.D., Professor of Surgery and of Clinical Surgery, Hospital College of Medicine; Professor of Oral Surgery, Louisville College of Dentistry, Louisville. Octavo volume of 231 pages, with 68 illustrations. Cloth, \$2.50 net.

## FOR DENTAL STUDENTS

This text-book, designed for the student of dentistry, succinctly explains the principles of dental surgery applicable to all operative procedures, also discussing such surgical lesions as are likely to require diagnosis and perhaps treatment by the dentist. Whenever necessary, for the better elucidation of the text, well-selected illustrations have been employed. For the dental student the work will be found an invaluable text-book, and, indeed, the medical beginner also will find its perusal of more than passing benefit.

---

# Robson and Moynihan on the Pancreas

**Diseases of the Pancreas and Their Surgical Treatment.** By A. W. MAYO ROBSON, F.R.C.S., Senior Surgeon, Leeds General Infirmary; Emeritus Professor of Surgery, Yorkshire College, Victoria University, England; and B. G. A. MOYNIHAN, M.S. (Lond.), F.R.C.S., Assistant Surgeon, Leeds General Infirmary; Consulting Surgeon to the Skipton and to the Mirfield Memorial Hospitals, England. Octavo of 293 pages, illustrated. Cloth, \$3.00 net.

## JUST ISSUED

This work, dealing with the surgical aspect of pancreatic disease, has been written with a two-fold object: to record and to review the work done in the past, and to indicate, so far as possible, the scope and trend of future research. Besides containing a very commendable exposition of the various diseases and injuries of the pancreas, the volume includes an accurate account of the anatomy, abnormalities, development, and structure of the gland.

---

# Senn's Tumors

**Pathology and Surgical Treatment of Tumors.** By NICHOLAS SENN, M.D., PH.D., LL.D., Professor of Surgery, Rush Medical College, Chicago. Handsome octavo, 718 pages, with 478 engravings, including 12 full-page colored plates.

Cloth, \$5.00 net; Sheep or Half Morocco, \$6.00 net.

## SECOND EDITION, REVISED

Books specially devoted to this important subject are few, and in our text-books and systems of surgery this part of surgical pathology is usually condensed to a degree incompatible with its scientific and clinical importance. The author spent many years in collecting the material for this work, and has taken great pains to present it in a manner that should prove useful as a text-book for the student, a work of reference for the general practitioner, and a reliable, safe guide for the surgeon.

### Journal of the American Medical Association

"The most exhaustive of any recent book in English on this subject. It is well illustrated, and will doubtless remain as the principal monograph on the subject in our language for some years. The author has given a notable and lasting contribution to surgery."

---

# Stoney's Surgical Technic for Nurses

**Surgical Technic for Nurses.** By the late EMILY A. M. STONEY, Superintendent of the Training School for Nurses, Carney Hospital, South Boston. 12mo, 200 pages, profusely illustrated.

Cloth, \$1.25 net.

The work is intended as a modern text-book on Surgical Nursing in both hospital and private practice. The first part of the book is devoted to Bacteriology and Antiseptics; the second part to Surgical Technic, Signs of Death, and Autopsies. The matter in the book is presented in a practical form, and will prove of value to all nurses who are called upon to attend surgical cases.

### Trained Nurse and Hospital Review

"These subjects are treated most accurately and up to date, without the superfluous reading which is so often employed. . . . Nurses will find this book of the greatest value both during their hospital course and in private practice."

# Haynes' Anatomy

**A Manual of Anatomy.** By IRVING S. HAYNES, M.D., Professor of Practical Anatomy, Cornell University Medical College. Octavo, 680 pages, illustrated with 42 diagrams and 134 full-page half-tones from photographs of the author's dissections. Cloth, \$2.50 net.

In this book the great practical importance of a thorough knowledge of the viscera and of their relations to the surface of the body has been recognized by according to them a prominent place in illustration and description.

**The Medical Record, New York**

"This book is the work of a practical instructor—one who knows by experience the requirements of the average student, and is able to meet these requirements in a very satisfactory way. The book is one that can be commended."

# Beck's Fractures

**Fractures.** By CARL BECK, M.D., Professor of Surgery, New York Post-graduate Medical School and Hospital. With an Appendix on the Practical Use of the Röntgen Rays. 335 pages, 170 illustrations. Cloth, \$3.50 net.

In this book particular attention is devoted to the Röntgen rays in diagnosis. The work embodies in a systematic treatise the important essentials of this subject, based on the extensive experience of the author in X-ray work.

**The Medical Record, New York**

"The use of the rays with its technic is fully explained, and the practical points are brought out with a thoroughness that merits high praise."

# American Pocket Dictionary

**The American Pocket Medical Dictionary.** Edited by W. A. NEWMAN DORLAND, A.M., M.D., Assistant Obstetrician, Hospital of the University of Pennsylvania, etc. 518 pages. Full leather, limp, with gold edges, \$1.00 net; with patent thumb index, \$1.25 net.

## THIRD EDITION, REVISED

This is an absolutely new book. It is complete, defining all the terms of modern medicine, and forming an unusually full vocabulary. It makes a special feature of the newer words and contains a wealth of anatomical tables.

**James W. Holland, M.D.,**

*Professor of Medical Chemistry and Toxicology, and Dean, Jefferson Medical College, Philadelphia.*

"I am struck at once with admiration at the compact size and attractive exterior. I can recommend it to our students without reserve."

## Warwick and Tunstall's First Aid

**First Aid to the Injured and Sick.** By F. J. WARWICK, B.A., M.B. Cantab., Associate of King's College, London; and A. C. TUNSTALL, M.D., F.R.C.S. Edin., Surgeon-Captain Commanding the East London Volunteer Brigade Bearer Company. 16mo of 232 pages and nearly 200 illustrations.

Cloth, \$1.00 net.

"Contains a great deal of valuable information well and tersely expressed. It will prove especially useful to the volunteer first aid and hospital corps men of the National Guard."—*Journal American Medical Association.*

## Beck's Surgical Asepsis

**A Manual of Surgical Asepsis.** By CARL BECK, M.D., Professor of Surgery, New York Post-graduate Medical School and Hospital. 306 pages; 65 text-illustrations and 12 full-page plates. Cloth, \$1.25 net.

"The book is well written. The data are clearly and concisely given. The facts are well arranged. It is well worth reading to the student, the physician in general practice, and the surgeon."—*Boston Medical and Surgical Journal.*

## Pye's Bandaging

**Elementary Bandaging and Surgical Dressing.** With Directions concerning the Immediate Treatment of Cases of Emergency. By WALTER PYE, F.R.C.S., late Surgeon to St. Mary's Hospital, London. Small 12mo, over 80 illustrations. Cloth, flexible covers, 75 cts. net.

"The author writes well, the diagrams are clear, and the book itself is small and portable, although the paper and type are good."—*British Medical Journal.*

## Senn's Syllabus of Surgery

**A Syllabus of Lectures on the Practice of Surgery.** Arranged in conformity with "American Text-Book of Surgery." By NICHOLAS SENN, M.D., PH.D., LL.D., Professor of Surgery, Rush Medical College, Chicago. Cloth, \$1.50 net.

"The author has evidently spared no pains in making his Syllabus thoroughly comprehensive, and has added new matter and alluded to the most recent authors and operations. Full references are also given to all requisite details of surgical anatomy and pathology."—*British Medical Journal.*

## Keen's Operation Blank, Second Edition, Revised Form

**An Operation Blank, with Lists of Instruments, etc.,** Required in Various Operations. Prepared by WM. W. KEEN, M.D., LL.D., F.R.C.S. (Hon.), Professor of the Principles of Surgery and of Clinical Surgery, Jefferson Medical College, Philadelphia. Price per pad, blanks for fifty operations, 50 cts. net.

"Will serve a useful purpose for the surgeon in reminding him of the details of preparation for the patient and the room as well as for the instruments, dressings, and antiseptics needed."—*New York Medical Record.*

## Keen on the Surgery of Typhoid

**The Surgical Complications and Sequels of Typhoid Fever.** By WM. W. KEEN, M.D., LL.D., F.R.C.S. (Hon.), Professor of the Principles of Surgery and of Clinical Surgery, Jefferson Medical College, Philadelphia, etc. Octavo volume of 386 pages, illustrated. Cloth, \$3.00 net.

"Every surgical incident which can occur during or after typhoid fever is amply discussed and fully illustrated by cases. . . . The book will be useful both to the surgeon and physician."—*The Practitioner, London.*

## Moore's Orthopedic Surgery

**A Manual of Orthopedic Surgery.** By JAMES E. MOORE, M.D., Professor of Clinical Surgery, University of Minnesota, College of Medicine and Surgery. Octavo of 356 pages, handsomely illustrated. Cloth, \$2.50 net.

"The book is eminently practical. It is a safe guide in the understanding and treatment of orthopedic cases. Should be owned by every surgeon and practitioner."—*Annals of Surgery*.

## Nancrede's Anatomy and Dissection. Fourth Edition

**Essentials of Anatomy and Manual of Practical Dissection.** By CHARLES B. NANCREDE, M.D., Professor of Surgery and of Clinical Surgery, University of Michigan, Ann Arbor. Post-octavo; 500 pages, with full-page lithographic plates in colors, and nearly 200 illustrations.

Extra Cloth (or Oilcloth for the dissecting-room), \$2.00 net.

"The plates are of more than ordinary excellence, and are of especial value to students in their work in the dissecting-room."—*Journal of the American Medical Association*.

## Nancrede's Principles of Surgery

**Lectures on the Principles of Surgery.** By CHAS. B. NANCREDE, M.D., LL.D., Professor of Surgery and of Clinical Surgery, University of Michigan, Ann Arbor. Octavo, 398 pages, illustrated. Cloth, \$2.50 net.

"We can strongly recommend this book to all students and those who would see something of the scientific foundation upon which the art of surgery is built."—*Quarterly Medical Journal, Sheffield, England*.

## Nancrede's Essentials of Anatomy. Sixth Revised Edition

**Essentials of Anatomy**, including the Anatomy of the Viscera. By CHAS. B. NANCREDE, M.D., Professor of Surgery and of Clinical Surgery, University of Michigan, Ann Arbor. Crown octavo, 388 pages; 180 cuts. With an Appendix containing over 60 illustrations of the osteology of the body. Based on *Gray's Anatomy*. Cloth, \$1.00 net. *In Saunders' Question Compend.*

"The questions have been wisely selected, and the answers accurately and concisely given."—*University Medical Magazine*.

## Martin's Essentials of Surgery. Seventh Edition Revised

**Essentials of Surgery.** Containing also Venereal Diseases, Surgical Landmarks, Minor and Operative Surgery, and a complete description, with illustrations, of the Handkerchief and Roller Bandages. By EDWARD MARTIN, A.M., M.D., Professor of Clinical Surgery, University of Pennsylvania, etc. Crown octavo, 338 pages, illustrated. With an Appendix on Antiseptic Surgery, etc. Cloth, \$1.00 net. *In Saunders' Question Compend.*

"Written to assist the student, it will be of undoubted value to the practitioner, containing as it does the essence of surgical work."—*Boston Medical and Surgical Journal*.

## Martin's Essentials of Minor Surgery, Bandaging, and Venereal Diseases. Seventh Revised Edition

**Essentials of Minor Surgery, Bandaging, and Venereal Diseases.** By EDWARD MARTIN, A.M., M.D., Professor of Clinical Surgery, University of Pennsylvania, etc. Crown octavo, 166 pages, with 78 illustrations.

Cloth, \$1.00 net. *In Saunders' Question Compend.*

"The best condensation of the subjects of which it treats yet placed before the profession."—*The Medical News, Philadelphia*.

1. 1976  
2. 1977

3. 1978

4. 1979

5. 1980  
**Four  
Educ  
on.**

6. 1981

7. 1982

8. 1983

9. 1984

10. 1985

11. 1986

12. 1987

13. 1988

14. 1989

15. 1990

16. 1991

17. 1992

18. 1993

19. 1994

20. 1995

21. 1996

22. 1997

23. 1998

24. 1999

25. 2000

26. 2001

27. 2002

28. 2003

29. 2004

30. 2005

31. 2006

32. 2007

33. 2008

34. 2009

35. 2010

36. 2011

37. 2012

38. 2013







SPECIAL LOAN

