

Biomed.  
WW  
210  
J381e  
1868

JEFFRIES — ENUCLEATION OF THE EYEBALL

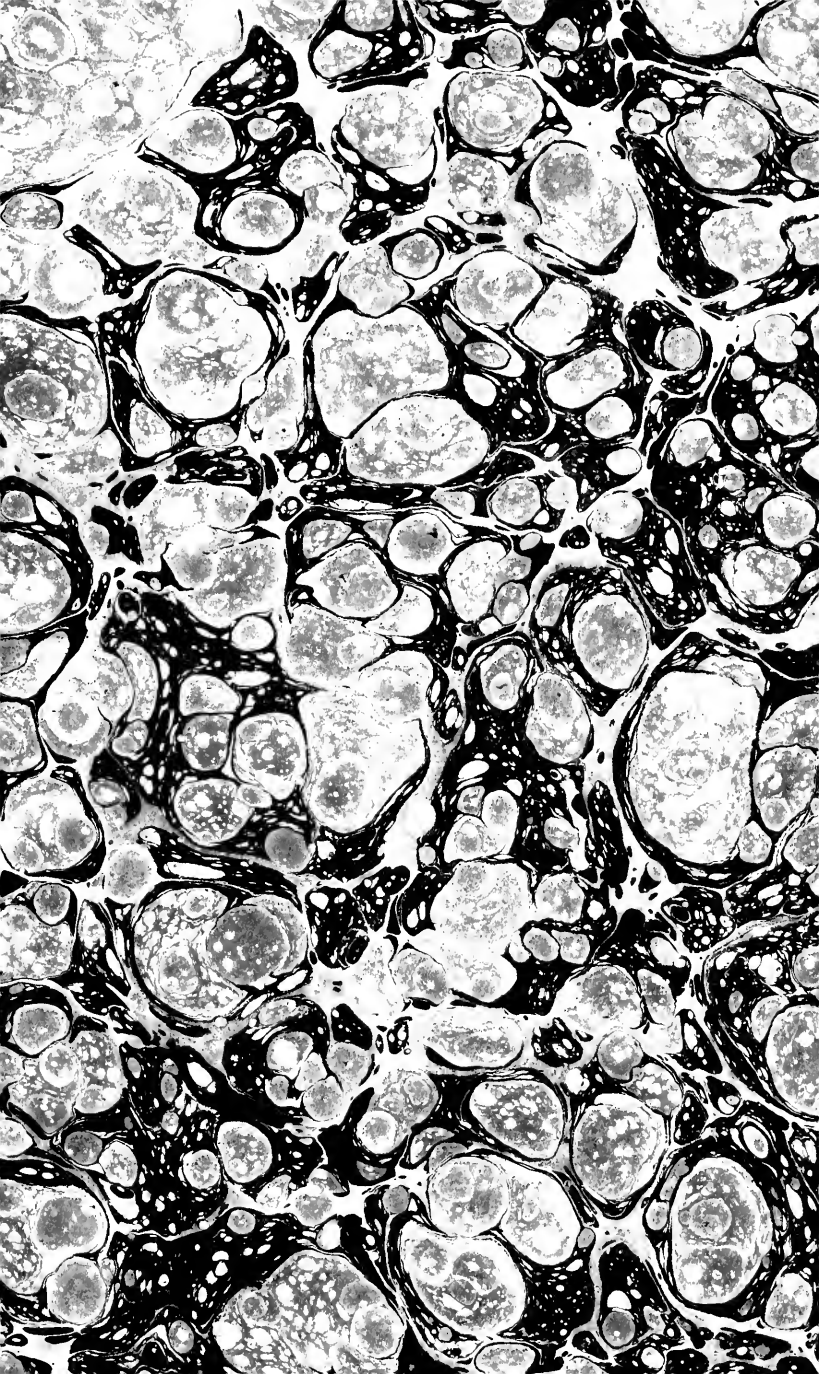
UC SOUTHERN REGIONAL LIBRARY FACILITY



G 000 005 870 1



THE LIBRARY  
OF  
THE UNIVERSITY  
OF CALIFORNIA  
LOS ANGELES





# ENUCLEATION OF THE EYEBALL. /

One of the selected papers read before the Mass. Medical Society, June 2d, 1868. /

# 21  
286

---

Section of the Ciliary Nerves and Optic Nerve.

Communicated to the Boston Medical and Surgical Journal.

---

Some Unnecessary Causes of impaired Vision.

Communicated to the Boston Medical and Surgical Journal.

---

BY B. JOY JEFFRIES, A.M., M.D.

FELLOW OF THE MASS. MED. SOCIETY.    OPHTHALMIC SURGEON MASS. CHARITABLE EYE AND  
EAR INFIRMARY.    MEMBER OF THE AMERICAN OPHTHALMOLOGICAL SOCIETY.  
LECTURER ON DISEASES OF THE SKIN, BERKSHIRE MED. COLLEGE.

v.  
18.772

---

BOSTON :

DAVID CLAPP & SON, PRINTERS, 334 WASHINGTON STREET.

1868.

FROM conversation with some of my fellow members of the American Ophthalmological Society at our recent meeting at Newport, R. I., I am induced to circulate these papers among my professional brethren in the New England States.

Respectfully,

B. JOY JEFFRIES,  
15 Chestnut Street, Boston, Mass.

Donned  
WW  
210  
J381e  
1868

## ENUCLEATION OF THE EYEBALL.

---

I HAVE found among my patients a perhaps natural horror in reference to removal of the eyeball, no matter how useless this organ may have become as respects sight, and even when it has been the seat of severe or lasting pain; and I have also found my medical brethren, when bringing their patients to the specialist, shrinking from advising them to submit to the removal of a sightless globe. There seems to be a sort of vague sensation among the laity, and I have found it also among physicians, that enucleation of the eyeball is a formidable and dangerous operation, only to be resorted to in malignant disease, and as a dernier resort. The laity also do not distinguish between the comparatively trifling operation of enucleation of the globe, and the, at present, rarely necessary and more formidable one of evacuation of the contents of the orbit. I propose, therefore, to fully explain the anatomy of the operation, prove its simplicity and show its application, and thus, I trust, place before the members of the Society some of the advances of my specialty, which may not have been brought to their immediate notice.

The foundation of surgery rests, of course, on pure anatomy, and the instance before us is one of the many where anatomical points have been forgotten and only recalled when the requirements of surgery have brought them again into notice. The capsule of the eyeball, which now bears the name of Tenon, was known to the students of anatomy

hundreds of years ago. Galen knew it but imperfectly, for he says (*De usu part.*, cap. 2), "Sexta quædam tunica extrinsecus prope accedit, in duram tunicam inserta." Reald. Columbus, in his "*De re Anatomica*" (Venet. 1559, lib. 10), calls it *tunica innominata*. The first correct anatomical description, however, of this, to us ophthalmologists so important membrane, was given by Tenon,<sup>1</sup> before the French Institute in 1804, and the capsule is now known by his name. Hyrtl<sup>7</sup> calls it *tunica vaginalis bulbi*. Richet,<sup>6</sup> *aponeurosis orbiti ocularis*. Budge<sup>8</sup> and Arnold make some further subdivisions of this fascia, not affecting, however, our present operation. A most careful subdivision and description is given by Henle.<sup>10</sup> I would refer also to Linhart,<sup>32</sup> Hélie<sup>13</sup> and to Richet,<sup>14</sup> and of course to the various recent compendiums on ophthalmology, particularly Pilz.<sup>31</sup> Mr. Dalrymple,<sup>2</sup> of London, described it in 1834 as the cellular capsule of the eye. Malgaigne has the credit of first pointing out its surgical importance; he considered it an aponeurosis, and called it *albuginea*. In 1840 Mr. Lucas,<sup>9</sup> of London, and in 1841 O'Ferrall,<sup>4</sup> in Dublin, and Bonnet,<sup>3</sup> of Lyons, re-described this membrane, each independently of the other, and therefore naturally individually considered themselves the discoverer. This was one of those circumstances still too often occurring, where anatomical and physiological truths are claimed as novelties, without a previous thorough search through medical literature, which would often prevent the critic from the disagreeable necessity of showing that there is in reality nothing new under the sun.

I will here give, in order, a brief account from each of these last three authorities mentioned, because their investigations were made in special reference to the pathology and treatment of affections of the eye, and lead directly to the substitution of enucleation of the globe for extirpation of the contents of the orbit.



Mr. Lucas called Tenon's capsule the *submuscular fascia*, and thus explains its demonstration:—"The eye and its appendages, with half an inch of the optic nerve, should be removed from the orbit and placed upon a plate, the cornea being downwards. The masses of fat, together with the loose cellular tissue and bloodvessels, should be carefully dissected away, and the muscles be turned forward towards their insertions, not dissected as if with a view of exposing their appearance, but merely expanded on the surface of the plate. If the neurilemma of the optic nerve be now examined, it will be found covered with a fine fascia, which can be easily raised with the forceps, and with little difficulty can be traced off the neurilemma to the sclerotic coat at the point where the nerve enters. It will now be found to cover the posterior aspect of the sclerotica, and to advance as far as the insertions of all the muscles of the eye; at these points it turns upon itself, lines the ocular surfaces of the muscles, and passes backwards along them to where they surround the optic nerve. This fascia possesses a high degree of elasticity, and forms rather a membranous sheath for the sclerotica than an expansion for the muscles; it takes the form of the eyeball, and acts the part of a membranous cup for the organ to move in, separating it from the bellies of the recti muscles, and covering the ciliary nerves as they pass onwards to pierce the sclerotica. In the dead eye, more or less fluid will be found to exist between this cup-like membrane and the eyeball, which always enables the anatomist to separate one from the other with the greatest facility."

Dr. O'Ferrall has the merit of a pathological application of the capsule. Mr. Haynes Walton<sup>11</sup> gives a print of his own dissection, and a condensed account from O'Ferrall, who says, "It is a distinct tunic of a yellowish white color and fibrous consistence, continuous in front with the posterior

margin of the tarsal cartilages, and extending backwards to the bottom or apex of the orbit, where its consistence becomes less marked; the sharp end of a probe or a director will be sufficient to separate it from the eyeball, by breaking the fine cellular tissue which connects them. Within, where the eye glides over it, the surface is smooth, the external or orbital part loose and cellular. The muscular portions of the recti muscles lie outside of this tunic, which isolates and protects the eye in the most perfect manner possible. Half an inch posterior to its anterior margin are six well defined openings, through which the tendons of the muscles pass to their insertions in the sclerotic coat, and over which they play as through a pulley."

Bonnet, in his treatise on "Section of tendon and muscles," says, "When I meet with a case favorable to the application I would thus proceed to enucleate the globe. Distending the lids with suitable instruments which I employ, I would cut the internal rectus with the same precautions as for the operation for strabismus. Then sliding the scissors along the wound I have made, between the sclerotic on one side and the subconjunctival fascia and muscles on the other, I would cut in turn all the recti muscles near their ocular insertion. We need then only divide the obliqui as near as possible to the globe, and afterwards the optic nerve. The globe will then be removed without my interfering with any vessel or nerve, and without penetrating the orbital fat." By not touching vessel or nerve, of course he means as in the old operation for extirpation of the contents of the orbit.

Stöber,<sup>5</sup> of Strasbourg, first performed this operation in 1841.

Here I think it worth while to go back to Tenon's description, which, as it has been so often misquoted, I translate from his own words:—

“ A little behind the tendon of each of the recti muscles around the eye, there is formed a tendinous fascia, which proceeds from the fleshy fibres of each of the recti muscles and the membranous sheath surrounding and penetrating them. These tendinous fasciæ separate from the tendinous muscles which they arise from; they are a continuation of the fleshy fibres of the muscles, and spring from the membranous sheath enveloping each of the muscles. The largest and thickest belongs to the *abductor* muscle. It springs from the external side of the muscle, and is attached to the external angle of the orbit near the lower edge of the lachrymal gland. It acts as a counter brace on the muscle, and prevents it while contracting from pressing on the eye. The fascia of the *adductor* (*rectus internus*) is shorter and not so thick as that of the *abductor* (*rectus externus*). It commences at the point of termination of the fleshy fibres, and is implanted on the inner angle of the orbit at the edge of the nasal canal. It acts also as a counter brace. The tendinous fascia of the *elevator* of the eye (*rectus superior*) forms an aponeurotic band extending from one side of the orbit to the other, to the depth of the upper lid. The tendinous fascia of the depressor (*rectus inferior*) is lost in the lower lid.” Tenon called it, “the new tunic of the eye.”

For the surgical purposes of our operation we may regard it as a membranous sac on which the globe rolls, and which is pierced by the tendons of the muscles, the cutting of which tendons in front of the capsule at their insertion into the globe will leave this membranous sac as a basis or support for an artificial eye, and the muscles being still attached to this capsule will therefore move it and the glass eye lying on it in nearly as great degree as when an artificial eye lies against a stump of the globe left by disease or surgical interference.

This so simple operation, recommended by Bonnet, is in

such contrast to the former one, really to be dreaded, of extirpating the whole contents of the orbit, muscles, nerves, fasciæ, gland, &c., that it is a wonder that ophthalmic surgeons did not sooner practise it, but not more wonderful than that even to this day, perhaps, unfortunate patients are undergoing extirpation of their orbital contents, much as certain bivalves are their contents, and with not very dissimilar instruments.

I would dwell upon this, because one of the purposes of this paper, as I have said, is to prove to you how simple and little to be dreaded this present operation is, and that it has no relation with extirpation of the orbital contents, an operation only applicable to certain tumors in the orbit. The method of operating for enucleation of the globe, taught me by Prof. Arlt, in Vienna, is the following:—

Dilating the lids with a speculum and holding in one hand a pair of toothed forceps and in the other a small pair of curved scissors, the tendinous insertion of the rectus internus muscle on the globe is seized and cut through. Retaining the grasp with the forceps the conjunctiva is cut around the cornea, and the tendons of the other three recti divided at their insertion. The scissors are now passed in behind and the optic nerve severed close to the globe, which will then start forward, and we have only to cut the tendons of the two obliqui muscles to free the eye from the orbit and leave intact the capsule of Tenon with the muscles attached to it.<sup>35</sup> This operation I have done, and it is comparatively easy, when inflammation has not bound down the conjunctiva or fastened the globe to the capsule, but under anæsthetics, at least, I would advise the following:—Raise with forceps a piece of conjunctiva near the corneal edge, pass in the curved scissors and separate the conjunctiva all round the cornea. With strabismus hook lift up and cut all four recti tendons as carefully as in operating for squint. Steady the

globe with fingers and thumb, and pass a large pair of curved scissors behind it and divide the optic nerve, which releases the globe from the orbit, and then we can sever the obliqui attachments. There will be but little bleeding. A piece of ice in the orbit is all that is required, and filling the latter with sponge or charpie and applying pressure is not only absolutely useless, but apt to be painful. A glass eye may be inserted, often within a week, and always should be as soon as possible to avoid shrinking of the soft parts, which it certainly does.

Perhaps some one will here say to me, there must be something wrong about all this, for I certainly was taught and learned, that removal of the eye was a severe and dangerous operation. Moreover, I remember the first proceeding was to enlarge the palpebral aperture in order to have room to work in. My reply is, I desire only to remove the useless and now offending organ, namely, the eyeball, and would as soon think of slitting up the lids, as a dentist would of enlarging a man's mouth to extract a molar tooth.

Yet the following is from the American Edition of Erichsen's Surgery, 1866. "Extirpation of the eyeball is also occasionally called for, when in consequence of injury or disease one eye has become disorganized and the vision of the other is sympathetically affected, and can only be preserved by the removal of the globe that is already useless. The operation may be performed in the following way:—The surgeon standing in front of the patient, makes an incision through the outer commissure of the lids as far as the edge of the orbit. The eyelids are then well everted and held apart with a wire speculum. The surgeon next passes a double hook into the globe and draws it well forward; then with a curved, broad pair of scissors he divides the conjunctiva at its upper part, and then proceeds to cut

across the several muscles of the orbit, and lastly the optic nerve."

The operation of enucleation has been found so simple, so effective when needed, and so perfectly adapted to its ends, that we may well wonder at its having been neglected so many years after Bonnet proposed and Stœber performed it. What was called *sinking the eye*, namely, cutting out a piece and letting the contents of the globe escape, was formerly the operation practised where now enucleation is in place. Pathology and experience soon taught that in the operation of sinking the eye, exactly that portion of the globe was left which was most often the source of trouble, namely, some part of the ciliary region. Hence soon came from one and another the improved method of removing the anterior part of the globe up to the edge of the retina or *ora serrata*, leaving the rest to form a stump. Dr. E. Williams, of Cincinnati, especially, proposed at the Ophthalmic Congress, at Paris, 1862,<sup>15</sup> to remove a portion of the anterior part of the eye instead of enucleation, for the purpose of having a better stump for the eye to move on. He cut *through* the ciliary body, the only part of his operation I would object to, as we must remove all of the ciliary region to avoid sympathetic trouble of the other eye, as time has since proved. This operation, when done with stitches passed behind the portion to be removed, now has Mr. Critchett's name attached to it, as he introduced it for *staphylomata*.<sup>16</sup> Four or five curved needles are passed through the globe just behind the part to be cut off, and the wound brought together, an operation which might be in place in certain cases, rather than enucleation, and we must then decide between the two. The disadvantages are the long time consumed in recovery, the probable subsequent pain, great swelling during suppuration, and the possibility that even *then* enucleation of the stump must be practised, as I

have been obliged to do where I have found traumatic or artificial sinking has occurred. On the other hand, we may get good union of the sclerotic and no great pain or swelling. But the stump remains a doubtful source of irritation.

Prof. Knapp,<sup>36</sup> of Heidelberg, has quite recently proposed a modification of this operation which may prove of very great service. He passes the needles through the conjunctiva *alone*, above and below, and by drawing it together closes the sclerotic wound, thus avoiding any chance of sympathetic irritation of the other eye, which the continued presence of stitches in the sclerotic may produce.

I will at once answer the question which may arise, by saying the false eye will move nearly if not quite as well and sometimes even better, bedded on Tenon's capsule, than if resting on a stump *which it may possibly irritate*. I may say, I have seen the muscles move the capsule sufficiently to deceive at first glance, even an oculist, as to whether the eye was false or not. But the point is just here, and it must be kept steadily in mind. The capsule will move the artificial eye well enough, and the stump, if composed of any part of the cornea or ciliary region, is never safe from the danger of producing sympathetic irritation.

In the adult, when the features, the bones and soft parts have reached their fullest development, an objection to enucleation does not apply to the same extent as in the young. The objection is this, and I would dwell upon it because little if anything will be found in regard to it in the ophthalmic literature which you will meet. After enucleation of the globe by the method proposed by Bonnet, the orbital fat seems to become absorbed, allowing the muscles and Tenon's capsule to sink in more than natural, and more than when a stump or portion of the globe remains. When done in youth before the bones are perfectly formed, or perhaps even afterwards, the osseous tissue about the orbit seems also to

shrink, giving a different outline and feature to this compared with the other side of the face. The expression is peculiar, making the patient on that side look as if thinner or not in good health, to which the bright cheek and lips give the denial. This I have seen so marked, that it always arises to my mind in deciding whether to enucleate the globe or abscise the anterior portion of it, and I have in the young chosen the latter simply on these cosmetic grounds, otherwise enucleation is greatly to be preferred, removing as it does all source of irritation which has called for the operation.

That the laity may better understand the necessity, simplicity and effectiveness of enucleation, by being taught through you to no longer dread it as something terrible, to be avoided till the last, is, as I have said, the purpose of this paper. It remains, therefore, to show when and why we ophthalmologists employ it.

Enucleation may be needed simply to get rid of an enlarged or staphylomatous globe which the lid will not cover, or which we desire to remove to give place to a false eye; or, as a prophylactic operation, to subdue or prevent sympathetic inflammation in the other eye. Years ago (1802) Beer, and afterwards especially Himly in 1843, noticed and laid stress upon the fact, that continued irritation or chronic inflammation of one eye caused its fellow to sympathize. Graefe,<sup>18</sup> Arlt,<sup>19</sup> Bader,<sup>20</sup> Muller,<sup>21</sup> and Augustine Prichard<sup>22</sup> of Bristol, have since then given us their special studies of sympathetic irido-choroiditis, so that at present it is as recognized as dreaded by the ophthalmologist. Trouble in the sound eye does not commence, as you might suppose, in the retina or nerve or choroid, but in the uveal tract, and gradually extends back from there towards the posterior part of the globe. A patient with an injured or inflamed eye will have, in the other sound one, intolerance of light, sensation of fulness, even perhaps perceptible to the touch,



inability to use the eye, fatigue of accommodation and contraction of the range of accommodation, long before he may apply to the surgeon, who at once recognizes this insidious sympathetic irritation from the other eye. I do not propose here, however, to discuss sympathetic inflammation, except so far as regards the removal of the injured or inflamed eye, to control or avoid it.

It is rather curious that the idea of destroying an injured or inflamed eye to prevent its acting on the other, comes from veterinary surgery. This in the horse was at first done by pushing a nail into the globe or putting lime between the lids; afterwards by Wardrop, in a less cruel manner, by opening the globe. Credit is due the English for first having proposed destruction of one eye to save the other from sympathetic trouble, and formerly the same method was used as in the horse by Barton,<sup>23</sup> Crompton and others. Græfe destroyed the eye by passing a thread through the sclerotic and cornea, or through the ciliary body. Walton and Taylor, as Dr. E. Williams, of Cincinnati, above quoted, preferred to cut away more of the cornea, to remove if necessary an old cataract, results of exudations, foreign bodies, &c. Now it is curious to see, that notwithstanding the knowledge which then existed of Tenon's capsule, its being repeatedly brought into notice, and even enucleation within this membrane having been distinctly proposed and to a small extent practised, yet ophthalmic surgeons did not commence the employment of this method of removing an injured or inflamed eye to save its fellow, till Mr. Critchett<sup>25</sup> in 1851, probably from seeing how successful enucleation was when practised for tumors, staphylomata, &c., and how well the false eye set and moved in the cup of the capsule, proposed and carried out this operation in preference to others for sympathetic irritation, and, as Prof. Græfe said in 1857, its practicability and success were at once established.

Again, in 1860, he says, practitioners ought to understand enucleation better than they do, for they seem to have a sort of dread of it, as if dangerous to the other eye, and as though it was a severe and bloody operation. The success attending Mr. Critchett's operation of course led other English ophthalmic surgeons to follow him, and enucleation soon became so frequent in London practice as to astonish the French and German schools, and naturally excite their opposition, which was perhaps fortunate, as the whole subject of enucleation for sympathetic trouble has in consequence been now thoroughly discussed, and the results carefully weighed and considered, so that we already have some definite laws to guide our decision.

The more this operation has been used by surgeons at the great centres of ophthalmic practice and clinical study and teaching, the more strongly do they speak of its value, simplicity and necessity. A few quotations from the highest authorities in the English, French and German ophthalmic schools will here be directly in place, and probably have their due weight.

Dr. Bader,<sup>26</sup> of London, says, "The facility with which enucleation is performed, its great freedom from risk, and the adaptability of an artificial eye, ought to make us consider a disorganized eye, which is the seat of pain or annoyance, as a foreign body whose removal the sooner it is accomplished the better. If not painful at the time it is a deformity, and is liable at any time of ill health to become the seat of inflammation, and affect sympathetically the opposite organ. It is not only unwise, but incorrect to bring before the patient's imagination the idea of 'taking the eye out,' and omitting the scientific advantage of excising; medical men must soon learn to value the operation."

Mr. Jonathan Hutchinson<sup>27</sup> says, in regard to enucleation of the eyeball even during the acute stage of traumatic pan-

ophthalmitis, "Whenever I am satisfied that an injured globe is utterly lost, I always advise its excision without loss of time. By adopting this course the patient's suffering, often extreme, is at once put an end to, and I think, also, the risk of sympathetic inflammation of the other eye is avoided. I have excised globes in all stages of inflammation, and have never seen the slightest ill consequence, whilst the patients have invariably been most grateful for the complete relief afforded."

Mr. Critchett, at the Ophthalmic Congress at Heidelberg, in 1863, says:—1st. That injuries which cause sympathetic ophthalmia are those which occur in the ciliary region. 2d. The effects of such inflammations differ in important points from those dependent on the other forms of iritis. 3d. Local or constitutional remedies have as little beneficial effect on the eye as surgical interference. 4th. Operation must be suspended till all inflammation is gone by, and even then a doubtful prognosis must be given. 5th. In view, therefore, of the uncontrollable inflammation and the danger of total blindness, it may be perhaps safer, when injuries have affected the ciliary region and threaten long irritation, to enucleate the injured eye before signs of trouble appear in the other."

From the Franco-German school Wecker<sup>28</sup> says, "It is vain to attempt to substitute iridectomy or section of the optic nerve for enucleation. There is no longer any doubt of the necessity of removing an eye which is lost, as soon as it becomes dangerous to the other. The only question arising is in reference to the case itself and the time when recourse must be had to enucleation. We are forced to enucleate: 1st. Whenever one eye remaining sound, the other is the seat of intolerable pain which, not yielding to remedies, makes us fear for the sound one. 2d. In every case where a lost eye has given rise to sympathetic irido-choroiditis in the other, no matter how slight, for this is our only means

of controlling it. 3d. In every case where the eye, till now sound, has become in any degree amblyopic, its range of accommodation rapidly diminished, intolerant of light, or incapable of prolonged use; these symptoms often being the precursors of irido-choroiditis. Enucleation will be all the more urgent when careful examination cannot find for these troubles, either in the eye itself or in the general condition, other cause than this sympathetic influence in question. Under all circumstances when in doubt, it is better to operate too early than too late, for we may find enucleation useless after sympathetic irido-choroiditis is fully established."

From the various ophthalmic clinics of Germany we also have concurrent testimony. Græfe's<sup>18</sup> and Arlt's<sup>19</sup> results and observations I have already quoted. Pagenstecher, at Wiesbaden, found enucleation necessary from the following causes:—

- 1st. Traumatic irido-choroiditis occasioned by
    - (a) Lesion of the iris, resulting from its being nipped between the edges of the wound.
    - (b) Lesion of the choroid.
    - (c) Suppurative choroiditis, or suppuration in the vitreous.
    - (d) Presence of a foreign body in the eye.
    - (e) Lesion of the capsule of the lens.
    - (f) Choroiditis after reclination, or depression of the lens.
  - 2d. Incipient exudative irido-choroiditis and hæmorrhage from the choroid.
  - 3d. Processes leading to staphyloma (choroiditis serosa).
  - 4th. Extensive separation of the retina.
  - 5th. Tumor developing from the choroid or sclerotic.
  - 6th. Formation of bone within the choroid.
- Let me here add one more testimony from Dr. Mooren's<sup>30</sup>

clinical experience for eleven years with 32,000 patients in Düsseldorf. He says, "The causes of sympathetic disease, according to my observation, may be divided into three distinct groups. 1st. Direct injuries of the ciliary region. 2d. Mechanical irritation of the ciliary body, whether by the action of a foreign body (wearing an artificial eye), or by the lens turned into a foreign body by displacement, re-clination, luxation, staphyloma, etc. 3d. Every inflammation of any part of the uveal tract, when by cyclitis it has reached its culminating point." And finally, as do all other authorities, Dr. Mooren gives, "pain upon pressure in the ciliary region as the never-failing symptom which pointed to and proved danger from sympathetic disease. When this is present, the only possibility of saving the second is by enucleation of the first affected eye."

To the above I would add the testimony of my own experience in ten years of ophthalmic practice in this community. In the medical literature of this country you will find reports of successful cases of this operation, coming from the scientific ophthalmologists of our larger cities, who strive to avail themselves of the sound sense of the English, the élan of the French, or the patient industry and scientific attainments of the German surgeons in this specialty.

I trust, therefore, my efforts have succeeded in proving to you that enucleation of the eyeball from within the capsule of Tenon, is an anatomical possibility, a surgical necessity and a powerful prophylactic remedy.

**NOTE.** This paper having been intended for a large State Medical Society, will explain to my brother ophthalmic surgeons why no comparison is made with simple iridectomy, section of the optic nerve, or of the ciliary nerves.

THE accompanying wood cuts are from photographs of a diagram and dissection exhibited to the Society when the paper was read.

Fig. 1. The lids are slit up vertically, and the four flaps turned back. The conjunctiva dissected off and strings passed under the tendinous insertion into the sclerotic of the external, internal and inferior recti muscles, just as they would be lifted on the hook to be cut in operating for squint. A needle is passed under the tendon of the superior rectus, which is seen to pass to the capsule of Tenon, showing itself between the upper half of the globe and the upper lid, from both of which it is freed. In a single wood cut it is of course difficult to give a more definite view of a minute dissection.

Fig. 2. Represents in *diagram* a vertical section through the orbit and eyeball. The heavy dotted line shows the fibrous lining of the orbit, which at the anterior upper and lower edge passes off to the lids, and also backwards to the globe which it surrounds to the optic nerve, thus forming Tenon's capsule. A layer behind runs over the nerve to form its sheath, and in front a prolongation extends forward to the conjunctiva. The superior and inferior recti muscles are represented, and where their tendons pierce Tenon's capsule to become attached to the globe. It will thus be seen that cutting the tendons of the muscles at their insertions, and the optic nerve, releases the globe and leaves Tenon's capsule like a cup for an artificial eye to rest on and be moved by the muscles.

Fig. 1.

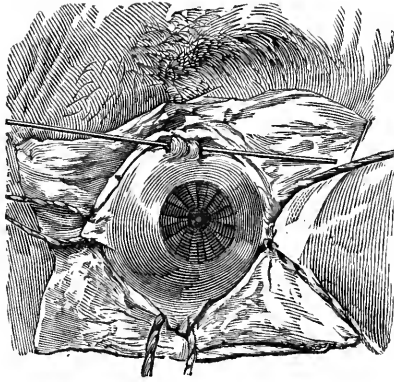
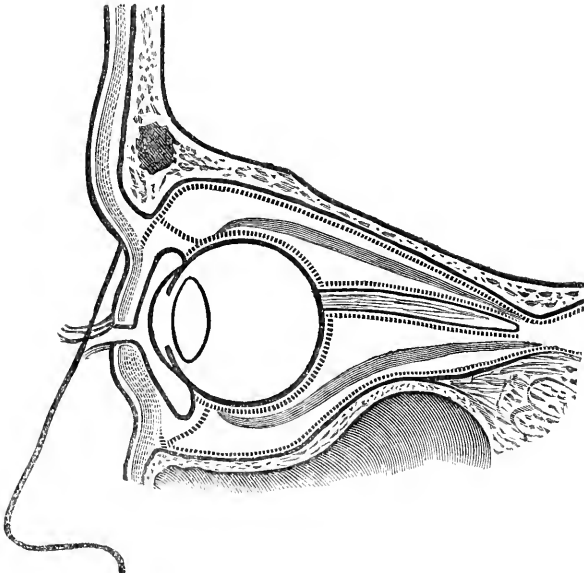


Fig. 2.








## BIBLIOGRAPHIC REFERENCES.

- 
- |   |    |
|---|----|
| <i>Tenon.</i> Mémoires et Observations sur l'Anatomic, la Pathologie et la Chirurgie, et principalement sur l'Organe de l'Œil. p. 193. Paris, 1816.   | 1  |
| <i>Dalrymple.</i> Anatomy of the Human Eye. London, 1834.   | 2  |
| <i>Bonnet.</i> Read at Paris Academy of Sciences, Feb. 1, 1841. Gazette Méd. de Paris, Feb. 13, 1841. Dublin Med. Press, March 3, 1841, p. 133. Annales d'Oculistique, t. v. p. 27, and t. vii. 1842, pp. 141, 237. | 3  |
| <i>O'Ferrall.</i> Dub. Med. Press, March 10, 1841, p. 158. Dub. Jour. Med. Sci. Vol. 19, p. 336.  | 4  |
| <i>Stöber.</i> Annales d'Oculistique. Tome vii. p. 31.  | 5  |
| <i>Richet.</i> Traité pratique d'Anatomie Médico-chirurgicale. Paris, 1857.   | 6  |
| <i>Hyrtl.</i> Handbuch der topographischen Anatomie. Wien, 1853.  | 7  |
| <i>Budge.</i> Ztschr. für rat. Med. 3 R. vii. p. 273.   | 8  |
| <i>Lucas.</i> Practical Treatise on the Cure of Strabismus. London, 1840. American Journal Medical Sciences, Oct. 1841.   | 9  |
| <i>Henle.</i> Handbuch der Anatomie des Menschen. Vol. 2, Prt. 3.   | 10 |
| <i>Walton.</i> Treatise on Operative Ophthalmic Surgery. London, 1853.  | 11 |
| <i>Bonnet.</i> Traité des Sections Tendineuses et Musculaires. 1841.  | 12 |
| <i>Hélie.</i> Thèses de Paris. 1841.  | 13 |
| <i>Richet.</i> Anat. Chirurg. Paris. 1860. 2d edit. p. 324.   | 14 |
| <i>E. Williams.</i> Congrès Internationale d'Ophthalmologie. Paris, 1862, p. 139.   | 15 |
| <i>Critchett.</i> Royal London Ophthalmic Hosp. Reports. Vol. 5. Part 1. 1863.  | 16 |
| <i>Pagenstecher.</i> Klinische Beobachtungen aus der Augen heilanstalt zu Wiesbaden. 1862. p. 42 et sequitur.   | 17 |
| <i>Gräfe.</i> Archiv f. Ophth. B. 3. Abth. 2. B. 12. Abth. 2. B. 6. Abth. 1.  | 18 |
| <i>Arlt.</i> Zeitschrift der Gesellschaft der Aertze zu Wien. 1859. Nr. 10.   | 19 |
| <i>Bader.</i> Prager Med. Vierteljahrsschrift. 57. Band.  | 20 |
| <i>Muller.</i> Archiv. f. o. B. 4. Abth. 1.   | 21 |
| <i>Prichard.</i> "Association Journal." Oct. 6, 1854.   | 22 |
| <i>Barton &amp; Crompton.</i> London Medical Gazette, 1837.   | 23 |

<i>Walton &amp; Taylor.</i> Annales d'Oculistique. t. 34, p. 256.	24
<i>Critchett.</i> Allgemeine Wiener Zeitung. Feb. 14, 1860. Lancet, 1851, p. 368.	25
<i>Bader.</i> Royal Lond. Opth. Hosp. Reports. No. 1, 1857.	26
<i>J. Hutchinson.</i> Roy. Lond. Opth. Hosp. Reports. Vol. 5, Part 4.	27
<i>Wecker.</i> Traité theorique et pratique des Maladies des Yeux.	28
<i>Blodig.</i> Zeitschrift der Gesellschaft der Aertzte zu Wien. 1860.	29
<i>Moorcn.</i> Ophthalmiatische Beobachtungen. Berlin. 1867.	30
<i>Pilz.</i> Compendium der Operativen Augenheilkunde. Prag. 1860, p. 3.	31
<i>Linhart.</i> Würzburger Verhandlungen. Bd. 9. Heft. 2 et 3, 1859.	32
<i>Lenoir.</i> Thèse sur la Strabisme.	33
<i>Demarquay.</i> Traité des Tumeurs de l'Orbite. Paris, 1860.	34
<i>Liebreich.</i> Eine Modification der Schiel Operation. Archiv f. Opth. 12. 2.	35
<i>Knapp.</i> Staphylomabtragung und Vereinigung der Wunde durch Bindehautnähte. Archiv. für Opth. 14. 1.	36
<i>Hart.</i> London Laneet, Jan. 1863.	37
<i>Carter.</i> Br. Med. Jour., Nov. 1864.	38
<i>Wecker.</i> Gazette des Hospitaux, 93. 1864.	39
<i>Hulke.</i> British Med. Journal, Jan., 1866.	40
<i>Lawson.</i> London Laneet, Jan., 1863.	41
<i>Lawson.</i> London Laneet, Aug., 1864.	42
<i>Wolf.</i> Gazette des Hospitaux, 100. 1864.	43
<i>Calderini.</i> Jahrb. 135. p. 356.	44



UNIVERSITY OF CALIFORNIA LIBRARY

Los Angeles

This book is DUE on the last date stamped below.

Form L9-Series 4939

