

UC-NRLF




\$B 172 992

RK
61
H4

Everyday Mouth Hygiene


—
JOSEPH HEAD, M.D., D.D.S.

61.5179



EX LIBRIS

BIOLOGY LIBRARY



Digitized by the Internet Archive
in 2007 with funding from
Microsoft Corporation

Everyday
Mouth Hygiene

By

Joseph Head, M. D., D. D. S.

Dentist

*to the Jefferson Hospital
Philadelphia*

Illustrated

Philadelphia and London

W. B. Saunders Company

1921

UNIVERSITY OF CALIFORNIA
LIBRARY

TK 61

H 4
BIOLOGY
LIBRARY

Copyright, 1920, by W. B. Saunders Company

Reprinted February, 1921

add

PRINTED IN AMERICA


PRESS OF
W. B. SAUNDERS COMPANY
PHILADELPHIA

PREFACE

DECAY is not a normal condition of the mouth. Cleanliness of the teeth and gums will absolutely prevent decay, and may sometimes cure it. Up to the present all methods of cleansing the mouth have been failures, as they have not thoroughly removed the mass of infection from between the teeth and the surface of the gums. Mouth disease spreads throughout the body, causing prolonged sickness and death.

It is hoped that this little book will be an inspiration to loving mothers and conscientious nurses, so that future generations will acquire the correct principles of mouth cleansing, and thus the terrible disease of mouth infection will be banished from the human race.

JOSEPH HEAD.





EVERYDAY MOUTH HYGIENE

INFECTION of the teeth and gums causes directly or indirectly one-half of the fatal diseases. This infection exists because the teeth and gums are not kept clean. Five minutes a day properly expended will really cleanse the teeth and gums if the disease has not progressed beyond the superficial stage, and if the disease is within the possibility of actual contact of the tooth-brush and dental floss. The daily cleansings cause the gums to heal and render them less likely to receive infection in the future.

The film or scum that ordinarily collects upon the teeth and gums is not food deposit, it consists of masses of bacteria that attack the tissues, and if undisturbed, break down the vital resistance and form lodgments which send constant streams of poison and bacteria throughout the body.

Figure 1 represents two lower teeth at approximately the age of ten. The shading shows the healthy bone around the roots. The line *A* at the neck of the teeth shows the normal gum line. The space between the teeth and around the gum is clean because the mother of the child has used the dental floss to wipe out the space each day, and then the tooth-brush to scrub

the teeth and gums so that they are clean. If all the teeth can be kept as clean as shown in Fig. 1, decay will not occur, gum infection will be prevented, and the chances against rheumatism, heart disease, ulcer of the

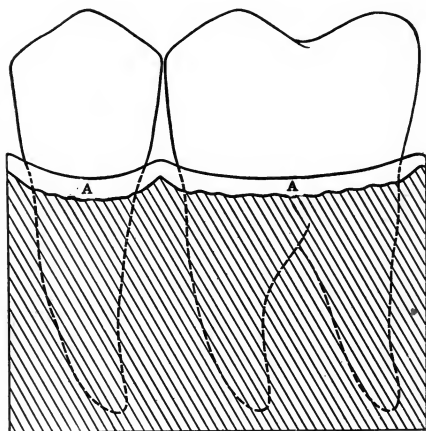


Fig. 1.—Shows two normal clean teeth. The line *A* represents the gum margin; the shading, the bony sockets supporting the teeth in the jaw.

stomach, and many other fatal diseases will be reduced 50 per cent.

Figure 2 represents similar teeth in another child aged ten, where efficient cleansing has not been performed. The mass of small worm-like lines around the gum margins and the space between the teeth, rep-

resents the disease-spreading infection covering the gums that are now outlined by a dotted line. This mass at the exposed sides of the teeth can be cleansed by the brush, but the mass at *B*, between the teeth, can

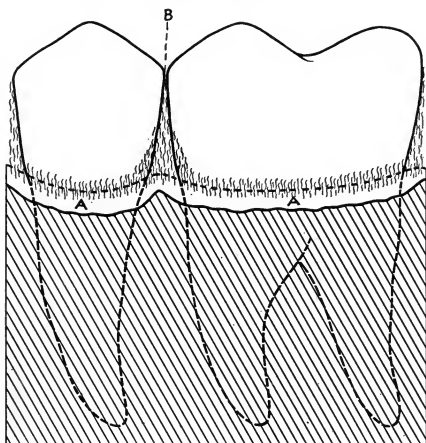


Fig. 2.—Shows the same teeth as in Fig. 1, except that they are dirty through lack of proper cleansing. The little worm-like lines represent the infection. Note the mass of bacteria in the space *B* that can only be cleansed by the dental floss.

only be cleansed by dental silk, and unless dental silk is used daily and unless a small brush skilfully used scrubs the necks of the teeth clean each day, the gums and bone will be progressively diseased as is shown by the following series of illustrations.

Figure 3 illustrates the condition of the gum and bone between and around the teeth at approximately the age of fifteen years when the infection between the teeth has been growing undisturbed for at least five years. This is the critical time for the health of the

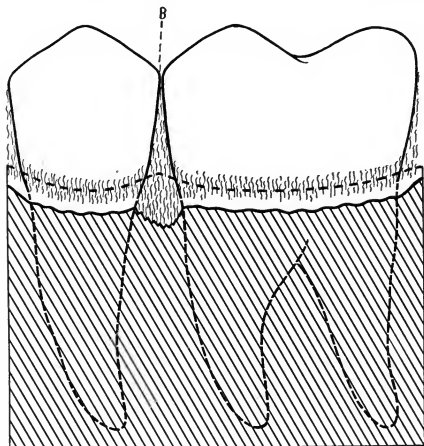


Fig. 3.—The beginning of a pyorrhea pocket starting between the teeth. Note the absorption of the bone at the bottom of the space *B*.

child's teeth and gums. Even yet, if the dental floss is ruthlessly swept along the triangle *B*, the space between the teeth can be restored to health. The gums by this time are swollen and red, while the slightest touch to the tissue between the teeth will cause pain

and a free flow of blood. The absorption and roughness of the bone between the teeth show the beginning of the infected spot that is to grow into a pyorrhea pocket.

The curative action of the dental floss is twofold: It mechanically removes the mass of infection, and it rubs the germs into the gums so that the tissues are stimulated to form a protective ferment that will destroy any individual germ that attempts further advance, and at the same time the ferment increases the resistance of the gums to any further infecting attack. In plain words, it vaccinates the gums.

Of course some infections are much more aggressive and poisonous than others, and therefore this crisis may come much more quickly to some teeth than others; it may come as early as twelve or as late as twenty-five years of age, just as there is or is not protective action of the saliva or of the tissues. When the infection has really become entrenched in the substance of the gum and bone, as in the triangle *B*, it penetrates with great rapidity along the roots. This makes the much-talked of pyorrhea pocket. The gums on the sides being partly swept by the food, recede more slowly, so that external observation may reveal the gums at almost their normal size, while deep pockets may have formed as shown in Fig. 4.

Figure 4 is now drawn as a cross-section with the outer bony plate removed from the roots. Thus we can see the progress of the pocket beneath the gum as revealed by the area of little worm-like lines that even

now have dissolved the bone and have worked along the root membrane of the molar, so that the nerve is beginning to be infected. There may be no decay in the crown of the tooth, and externally the tooth may appear quite normal except for a slight tender-

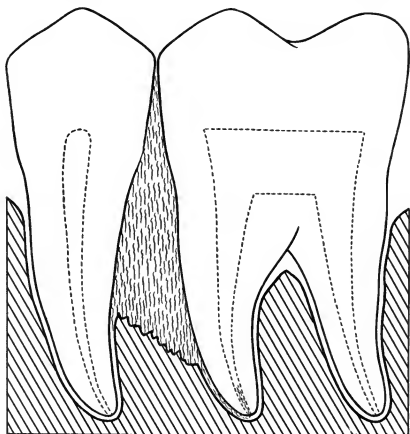


Fig. 4.—The further progress of the pyorrhea pocket which is now well established. The picture shows the cross-section of the teeth and gum. The outer bony plate has been removed, showing the bone only on the side.

ness to pressure and an extra sensibility to heat or cold. Such a pocket may form here and there in the mouth where the infection has found exceptional opportunity for growth, while the gums on either side of the pocket may be as high as the gums shown on the outer sides

of the teeth in Fig. 4. Such a pocket appears between the ages of twenty-five and forty years, and can only be cured by radical surgery and long treatment. But all of this destruction and toxic poisoning could

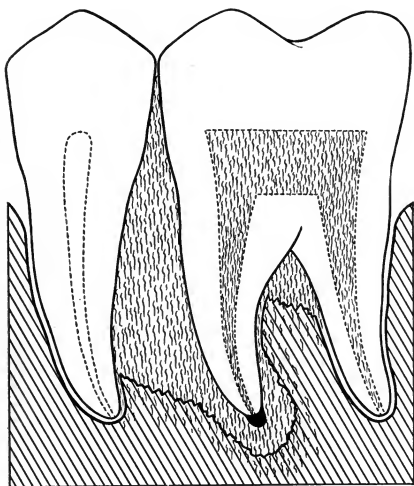


Fig. 5.—A fully established pyorrhea pocket with an abscess at the tip of the molar. The black spot represents the abscess.

have been prevented by the skilful daily use of the tooth silk and brush. The destructive enlargement of the pocket from now on is extremely rapid, as is shown in Fig. 5.

The bone around the tip of the adjacent molar root is

completely diseased and is replaced by a spongy mass of infection. The germs have penetrated the tip of the molar root, destroying that portion of the nerve and causing the acute abscess sac to form, as is shown by the black spot. Thus we have a dead nerve in one root while the nerve in the other root is alive. The tooth is painful and loose. Each time the tooth is used in chewing food the infected root is jammed on the spongy infection beneath, so that the poison and germs are driven into the bone substance, where the circulation carries them to all portions of the body to lodge and form new areas of infection.

Those portions of the body that have the weakest resistance receive this injected material, whether it be the joints, the heart, the stomach, the nerve centers, or the liver, and thus a tooth externally undecayed and apparently normal in appearance may be the cause of a crippling disease, and all because the teeth were not cleansed for a period of five minutes once or twice a day. It will be noted in Fig. 5 that the worm-like lines of infection have almost reached the tip of the other tooth.

Figure 6 shows a further progressive stage. One root of the molar has become absorbed and roughened with sharp, needle-like points, while abscess sacs have formed on the other two roots, so that all three of the roots during the process of chewing now act like pistons of a syringe, forcing the infection into the blood-stream. At first the body resists the poison, but as it is driven in day by day, week by week, year by year, the systemic

health resistance is broken down, and the patient becomes permanently diseased. Such teeth at first may be sore or sensitive to cold or heat, but as the disease becomes chronic the pain disappears and the teeth seem almost normal in their functions. The greatest

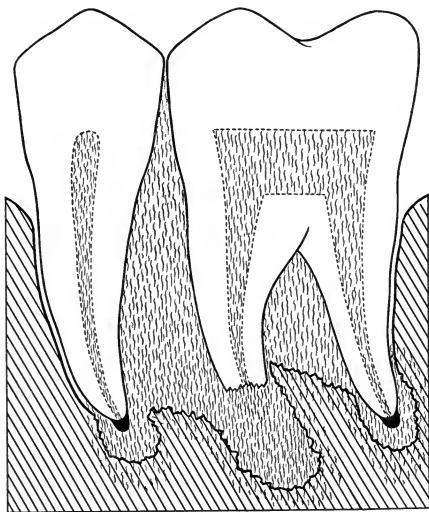


Fig. 6.—A pocket that is spreading infection to the other teeth.

infection may come from a tooth that has become abscessed and apparently recovered, since the fact that a tooth is comfortable, normal in appearance, and useful for chewing food is no guarantee that it may not be the spreader of infection, which within a compara-

tively short time will cause crippling neuralgias or death-dealing abscesses in the vital organs of the body.

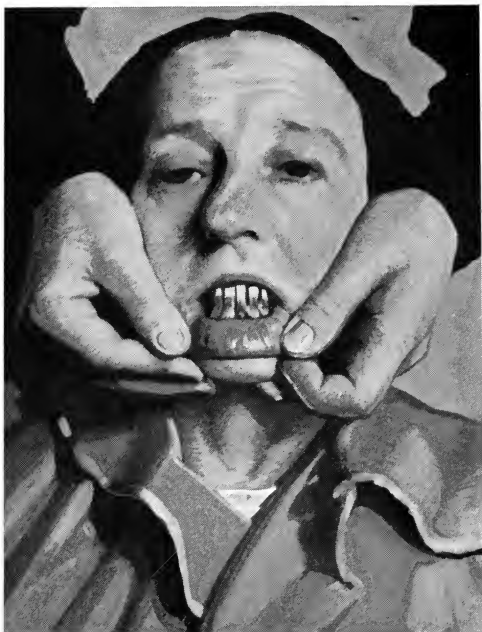

Fig. 7.—Teeth that have never been properly cleansed.

Figure 7 shows the mouth of a woman who did not cleanse her teeth and gums, and Fig. 8 shows the deformity of her hand which was typical of a disease

that resulted in her becoming a complete cripple and led eventually to her death.

Let us again remember that this terrible source of disease would be eliminated by proper mouth cleansing. We have seen how the deadly pus pocket can form in



Fig. 8.—Deformity due to unclean teeth.

the jaw bone when there is no tooth decay; let us now examine how the same type of bone abscess can be formed by decay in the crown of the tooth.

Figure 9 shows two such cavities forming.

Figure 10 shows a further progress of infection where the nerve is reached.

Figure 11 shows a putrescent nerve with the same type of bone abscess at the root tip as we have already seen in Figs. 5 and 6.

Cleanliness would have prevented all of this trouble. If the space between the teeth had been kept clean the cavity on the side of the tooth would not have oc-

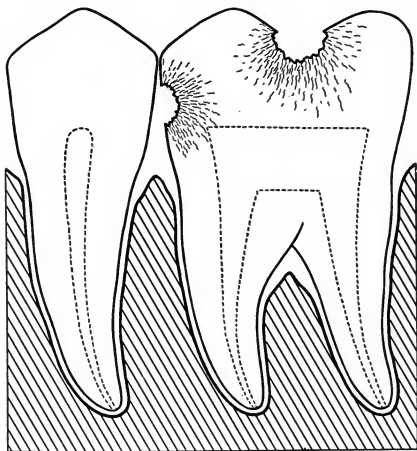


Fig. 9.—Spots of tooth decay due to lack of cleanliness.

curred, and if the fissure on the crown of the tooth had been polished by the dentist so that food could not jam into it, the grinding surface would have been self-cleansing; thus the cavities would not have formed and the infection-spreading bone abscesses at the tips of the roots would have been prevented.

Thus we see how easy it is for a dentist and a patient to prevent decay before it starts, and how difficult, and finally how impossible, it is to remedy the trouble except by the extraction of the teeth and the scraping away of the diseased jaw bone. This warns us not only to see

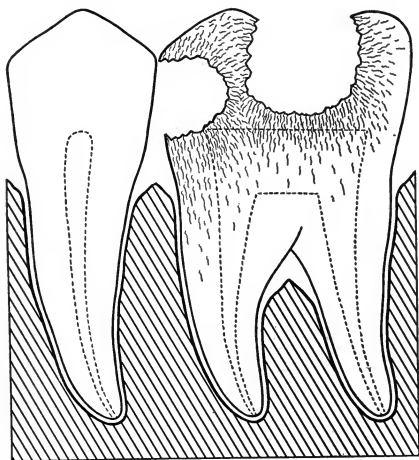


Fig. 10.—Tooth decay advanced to the point of nerve infection.

that our teeth and gums are kept clean, it also urges us to visit the dentist so that any defects of tooth development may be remedied. For when that is done skillfully and the teeth have erupted so that they can be kept clean, thorough cleansing of the teeth and gums

with brush and tooth silk will prevent mouth infection with all of its consequent systemic diseases.

Let us now consider the proper method of cleansing the teeth and gums: In a large majority of cases the

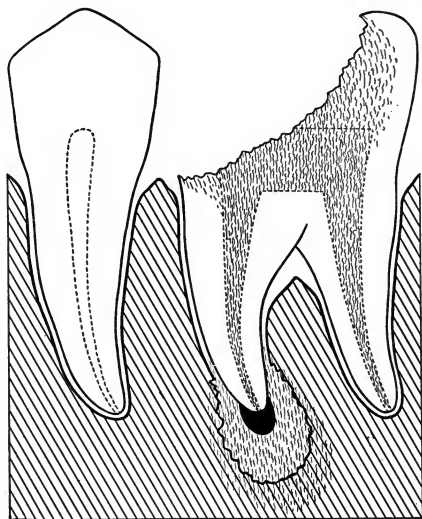


Fig. 11.—Tooth decay that has attacked the dental nerve and formed an infection-spreading bone abscess at the root-tip.

pyorrhoea pocket of infection starts between the teeth, and as the tooth silk alone can cleanse the tooth spaces, the efficient use of this important and much neglected agent of mouth hygiene will now be discussed.

Figure 12 shows the space between the teeth packed with a bacterial mass that is always present if the dental silk is not used properly. Dental silk heretofore has been supposed to be used solely for the purpose of removing particles of food from between the teeth, and

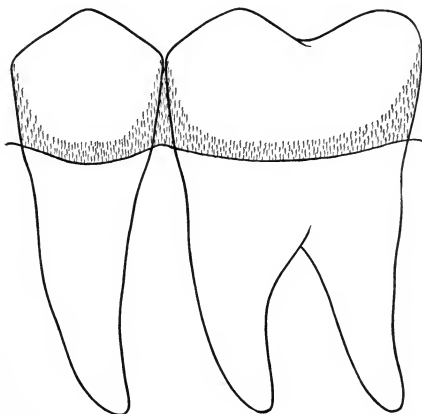


Fig. 12.—The small worm-like lines indicate the mass of infection usually found around or between the teeth unless dental floss and a small tooth-brush have been properly used.

while this is unquestionably important, it is far more important that the mass of bacteria shall be thoroughly removed before it can gain lodgment in the teeth and the gum. But because the dental silk has been used solely with the idea of removing food particles, where food did not pack between the teeth the dental silk has

not been used at all, and where it has been used it has been slipped in and out in a straight line to the gum, making only a cut in the bacterial mass as in Fig. 13, leaving the gum and tooth surface as much covered as before it was used. The silk when used should extend well around the contours of the tooth surface (see Fig.

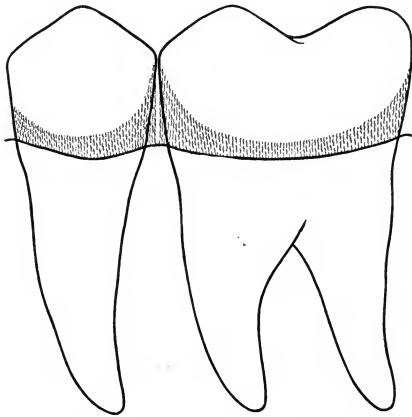


Fig. 13.—Bacterial mass between the teeth cut but not removed by the wrong way of using the dental floss.

14), for the bacteria are very adhesive and stick to the infected tooth and gum surfaces with all the tenacity of glue. No mouth-wash can kill or remove a mass of bacteria. It is, therefore, essential that the dental silk should be scraped along the rounded contours of the three sides of the triangular space between the teeth,

so that only the slightest film of bacteria will be left. The mass of bacteria will come out on the tooth silk. It is particularly important that the mass of infection should be thoroughly removed from around the curving sides of the tooth so that the tooth-brush can readily

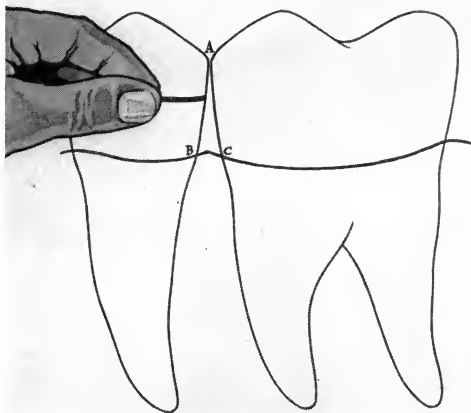


Fig. 14.—Shows the way the dental floss should extend around the contours of the teeth during the process of cleansing.

remove all of the remaining film, and so render the mouth free from *masses* of bacteria, for a thin film of germs cannot produce an amount of poison or acid sufficient to harm either the gums or the teeth.

Figure 15 shows the space cleaned by the removal of

the mass through its adherence to the dental silk. It will be noted that at the sides of the teeth near the gum a considerable portion of the germ deposit has been scraped away by the encompassing sweep of the silk. To make it quite simple, let the triangle, Fig. 16, represent the space between the teeth. The lines *A-B* and

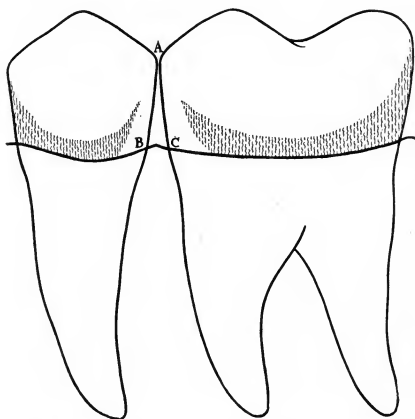


Fig. 15.—The extent of cleansing that properly used dental floss can effect.

A-C represent the sides of the teeth. The line *B-C* represents the gum line between the teeth. The dental silk should start at the grinding surface *A*, scrape down to *B*, then scrape from *B* to *C*, and finally from *C* to *A*, and out, carrying the bacteria away on the silk.

Properly used, the dental silk is far more important

as a means of cleansing and preserving the teeth and gums than the tooth-brush. When this use of the dental silk has been performed on all the tooth spaces, and especially on the gum margins back of the back teeth, three-fourths of the bacterial mass in the mouth will have been removed, and the remainder can readily be cleansed by a small brush properly used.

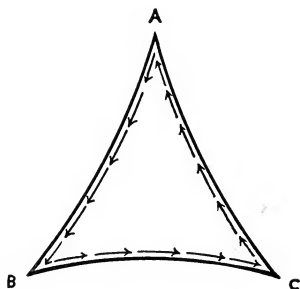


Fig. 16.—A diagrammatic representation of the space between the teeth. The arrows indicate the path which should be followed by the dental floss.

Let us now take up the handling of the dental floss with the fingers in detail, so as to readily and effectively reach all portions of the mouth. Many instruments for holding dental floss have been devised, but there is no instrument equal to the finger-tips properly instructed and used. In fact, the finger-tips are the only instruments up to the present time that have accomplished this function satisfactorily. And they

require the most careful training if the bacterial films are to be effectively removed.



Fig. 17.—Preliminary position of the dental floss.

Figure 17 shows the first position taken for holding the dental floss. The piece of silk should not be less than 18 inches long and the ends should first of all be

twined around the little fingers of each hand, leaving a space as shown in the picture of about $\frac{1}{2}$ inch between



Fig. 18.—Position of floss for cleansing the left upper side of the mouth.

the ends of the thumbs. Then for cleansing the teeth on the upper left side the dental silk should be taken thus, Fig. 18, with only $\frac{1}{2}$ inch of silk span being left

between the left thumb and right first finger. If more free silk is left the cramped position in the mouth will




Fig. 19.—The position of the floss when inserted in the mouth for cleansing the left upper side. Note that the thumb is well inside the cheek.

cause the silk to slacken and pivot, so that the scraping, cleansing action will be lost. Then, as in Fig. 19, slip-

ping the thumb and finger-tip well within the corner of the mouth, the thread should be passed back of the



Fig. 20.—The incorrect way of inserting the silk.

third molar and well up into the fold of the gum around it, and the gum and tooth surface should be well scraped of its slimy covering. Figure 20 shows the incorrect way,

where the cheek is pushed back by the thumb, making it most difficult to reach the back teeth. The silk should



Fig. 21.—Further progress in the cleansing of the left upper teeth.

then be passed into the next space and continued forward (see Fig. 21), the triangular motion previously

described being carried out. When the central division of the teeth has been reached, the silk should be shifted



Fig. 22.—Position of floss for cleansing the right upper side of the mouth.

as in Fig. 22, for the work on the upper right side, and inserted as in Fig. 23. Note that the right thumb must

be on the outside of the dental arch for the right side cleansing, just as the left thumb should be on the outside



Fig. 23.—Position of fingers for cleansing the right upper back teeth.

of the dental arch for cleansing the left upper teeth. Then, as was done on the left side of the cheek, the right

side is pushed out by the right thumb, the silk inserted back of the right third molar, and the procedure repeated until the upper front teeth are again reached.



Fig. 24.—Position of silk for cleansing the lower teeth.

For starting to cleanse the lower right teeth the dental silk should be supported by the tips of the two index-

fingers (see Fig. 24), and then, as in Figs. 25, 26, and 27, the silk should be passed back of the lower third molar



Fig. 25.—Position for cleansing the right lower back teeth.

on the right side, well down into the fold of the gum, and the bacteria scraped out from between the teeth as previously described. The triangular motion should

invariably be carried out in all the dental spaces to the front middle section. The silk should then be passed



Fig. 26.—Note the curve of the silk when cleansing the back of a tooth.

back of the left lower third molar, and the process repeated on that side. (See Figs. 28 and 29.) Note again in cleansing the right lower teeth the right index-finger

is always on the outside, and with the left teeth the left index-finger is always on the outside.



Fig. 27.—Note the curve of the silk when cleansing the front surface of a tooth.

This is not an easy performance to execute efficiently so that the deposits will be thoroughly removed. The gums will bleed at first and will be sore for a period of

ten days to two weeks, but a trial of this procedure during the time mentioned will give a feeling of cleanliness

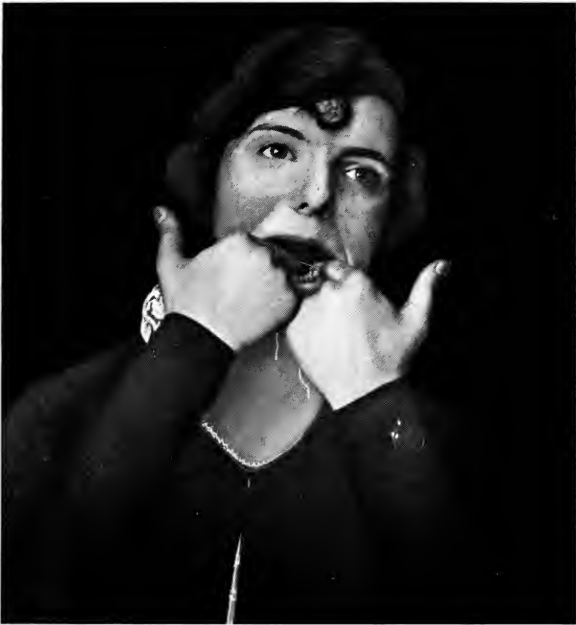

Fig. 28.—Cleansing the spaces between the left lower teeth.

never before experienced, and the gums, ceasing to bleed, will become pink, firm, and comfortable.

Let us now consider the use of the tooth-brush as a

means of removing the bacterial masses from the exposed surfaces of the teeth and the gums. Just as those



Fig. 29.—Finish of cleansing the spaces between the left lower teeth.

who never use dental silk never cleanse between the teeth, so do the great majority of those who brush the teeth never really cleanse them. The cleansing action

of a tooth-brush can only lie in bristle friction, and most well-meaning people either use strokes of the brush that never get beyond a pivoting of the long bristles, or they use brushes so large that there is neither room to move them nor to effectively place them against the back teeth. With all the talk that there has been about tooth brushing since Adam delved and Eve span, the wisdom teeth have never been brushed. The dirty, neglected wisdom tooth has been as badly treated as the near-sighted child of fifty years ago who was relegated to the dunce cap because he could not see the letters of the book that he was blamed for not understanding. The wisdom-tooth enamel is, in structure, just as sound as that of any other tooth, and it has its bad name simply because it is never cleansed. And because the back molars are badly cleansed they are usually the first to become infected and loosen.

The great test of a tooth-brushing method is, does it cleanse where it is designed to cleanse? In plain words, the way to brush the teeth and gums is to *brush* them. Obviously, too large a brush is useless. To use a 2-inch brush with bristles $\frac{1}{2}$ -inch long where there is only $2\frac{1}{2}$ inches for free action means that there will be practically no bristle friction, which is what occurs in most mouths during the process of brushing the teeth. The usual brush being about 2 inches long generally reduces the possible movement of the brush to about $\frac{1}{2}$ inch, and this half-inch is entirely taken up by the spring and pivoting of the bristles, so that with any such attempt

at brushing there is very little bristle friction at all. Therefore we should avoid the use of the ordinary large tooth-brush and use a narrow bristle brush not over $1\frac{1}{2}$ inches long, with bristles not over $\frac{1}{4}$ inch in length. This will allow sufficient room for genuine motion of the brush in the mouth, and if the bristles are too stiff, the brush should be placed in hot water for a minute each time before using, until the gums have become accustomed to genuine cleansing. Healthy gums can bear the same scrubbing as the flesh around the fingernails, and with the same benefit. In fact, the exposed surfaces of unhealthy inflamed gums when given a vigorous scrubbing with a stiff brush twice a day, in the course of a week or ten days will become firm and healthy, and no other single treatment will accomplish the same result. This generally unknown fact was utilized some years ago by a certain charlatan who was trying to sell his tooth-paste. He forced his way into the office and immediately began, "Doctor, this tooth-paste is most useful for the cure of the small canker sores that so often come on the cheek and gums. All you have to do is to put a little of this paste on the tooth-brush and brush it thoroughly into them." "But," I interposed, "won't the sores get well if they are brushed with the tooth-brush and water?" "Why, yes," he replied, with a sickly smile, "but that is not usually known."

The brushing of the gums, as before stated, is of prime importance, but the intense pain occasioned by

the first week's work is as severe as the pains in the back of an athlete when he first starts to get himself into condition. The trainer tells the athlete to go on with his work and that it will be all right, and in the same way the poor patient, though he fears that he is injuring his gums when he uses the brush vigorously, must be encouraged by his dentist to continue, with the assurance that the pain in his gums will soon disappear. The author once showed a young lawyer how to brush his teeth and gums. He went away and the next day the author received a letter from him threatening suit for having ruined his face. Amusing as this incident is, it has a very serious bearing. The gums, to be healthy, must be scrubbed so as to remove the bacterial masses, and also the dead epithelial scale, which will act as a bacterial food. Scrubbing infected gums cannot result at first in anything but further infection, that may, and frequently does, cause a slight fever, and yet the bacteria cannot be removed and the gums will not heal unless this severe ordeal is endured. The systemic reactions caused at times by brushing infected gums must be explained as a process of vaccination, for under no other supposition is it possible to explain why, under the newly inaugurated thorough brushing day by day, the gums should continue to be sore and inflamed, and then suddenly, between the seventh and tenth day, become healthy, hard, and firm, thereafter standing with complacency any amount of brushing.

The brushing of the teeth will now be discussed in

detail. As before stated, the tooth-brush should not be over $1\frac{1}{2}$ inches long, the bristles not over $\frac{1}{4}$ inch long, and the handle long and large enough to afford a firm grip to the hand (Figs. 30, 31). The principal thing to be avoided is too great bristle length, since long bristles, by increasing the pivoting arc of each bristle, just so much reduce the bristle friction produced by the general movement of the brush. It is bristle friction alone

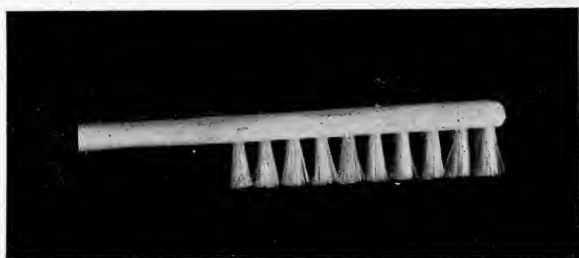


Fig. 30.—Actual size of brush that can properly cleanse the teeth and gums.

that cleanses the teeth and gums during the process of brushing. Bristles $\frac{1}{2}$ inch long can pivot $\frac{3}{8}$ inch each way without bristle friction. If, therefore, there is a 1-inch stroke, the bristle friction stroke is only $\frac{1}{4}$ inch, and if, as frequently happens, the tooth-brush stroke is only $\frac{3}{4}$ inch, there is no bristle friction stroke at all. The $\frac{1}{4}$ -inch bristle, under the same conditions, would have a play each way of $\frac{3}{16}$ inch, which theoretically

would cause only $\frac{3}{8}$ -inch loss of bristle friction, but, in reality, it would be less, since the further the bristle extends from the back of the brush, the more readily it bends under pressure. But granting that there was $\frac{3}{8}$ inch loss in bristle friction to each stroke, this would still leave a real cleansing friction stroke of $\frac{5}{8}$ inch, when

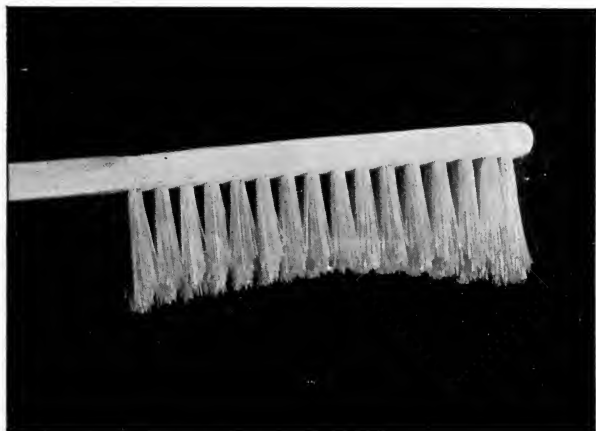


Fig. 31.—Actual size of brush ordinarily used.

the $1\frac{1}{2}$ -inch brush was moved through a $2\frac{1}{2}$ -inch stroke, the amount of space for tooth-brush motion usually found in the average adult mouth.

So much for the mechanics of tooth-brushing; now as to the actual motions as applied to the human mouth. There are three motions: First, the rotary motion,

whereby all the gums and teeth anterior to the second molars are cleansed with vigorous whirling action;

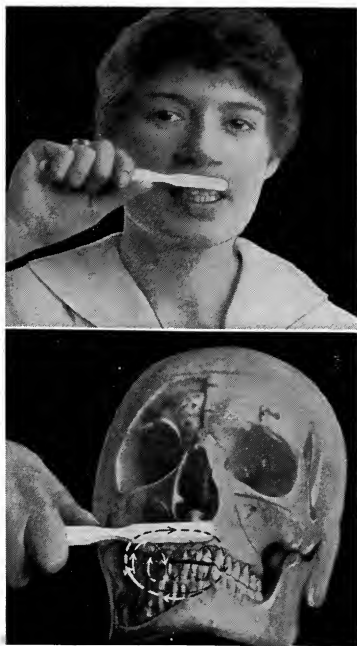

Fig. 32.—Motion of brush for cleansing front teeth and gums.

second, the drawing motion; wherein the middle of the brush is placed behind the last molar and drawn vigorously across the outside gum margins of the teeth;

third, the drawing motion, wherein the brush is placed back of the last molar inside of the mouth and drawn sharply forward along the gum margins and the teeth. In each stroke care should be used to follow the curve of the arch with the entire face of the brush.

Let us now discuss motion No. 1 in its minute details. The upper and lower front teeth should be placed edge on edge to avoid the lapping of the upper teeth over the lower. The brush should then be placed against the teeth and rubbed upward to the junction of the upper gum and lip, forward for a distance of a full inch or more, downward to the lower gum and lip margin, then back to the original position, and end with three small inner circular motions on the teeth as shown in Fig. 32. This should be done at least five or six times. The brush should then be placed between the cheek and teeth on the left side. Here the same general motions should be carried out. The brush should be rubbed upward to the juncture of the cheek and gum, back to where the end of the brushing is stopped by the overhanging curve of the lower jaw, down to the juncture of the cheek and lower gum, then back to the start, and three circular motions, as in Fig. 33. This same motion should be repeated on the right side and the three movements of motion No. 1 are finished. If, after this motion has been thoroughly performed, the second and third molars, upper and lower, are examined, they will still be found covered with bacterial masses. And the reason for these undisturbed deposits is easily discov-

ered. The curving side of the lower jaw lies so close to the upper teeth that no tooth-brush can effectively

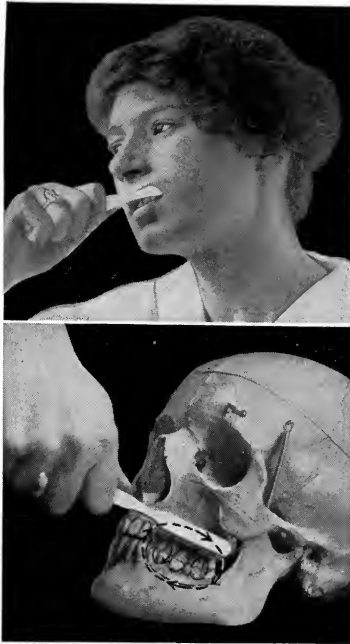


Fig. 33.—Motion of brush for cleansing side teeth and gums.

get at them while the jaws are closed, and in the same way the last two lower teeth are excluded from the action of the brush by the fact that they lie behind and

within the curving angle of the lower jaw. When the jaws are closed there is not $\frac{1}{8}$ inch of room remaining for tooth-brush cleansing, but when the jaws are partly opened, the lower jaw swings back, leaving a space of a full $\frac{1}{2}$ inch in which the brush can thoroughly do its work behind the third molars. Therefore, as just intimated, in performing motion No. 2 for the upper teeth the mouth should be about half open and the lips and cheek held relaxed. The middle of the bristles of the $1\frac{1}{2}$ -inch brush should be placed at the back of the third molar and drawn briskly forward along the gum margins, care being taken to follow the curve of the gum with the entire face of the brush (Fig. 34). To place the brush behind the third molar the relaxed corner of the mouth should be stretched back by the back of the brush until the middle of the brush is directly back of the wisdom tooth. When this is done correctly the brush will be pointing directly at the wisdom tooth on the other side of the arch. The middle of the brush should be placed behind the third molar, not thrust in place by the point, as by thrusting the bristles will be so bent that the resulting pivoting of the bristles will cause the back of the upper third molar to get no bristle friction at all, and so the back of the third molars will not be cleansed. Motion No. 2 in its action on the lower molar teeth is exactly the same as with the upper, except that instead of placing the bristles on the back of the lower third molar, the bristles are directed downward on the gum back of the third molar, and then with a curving, down-

ward sweep are brought sharply along the gum and cheek

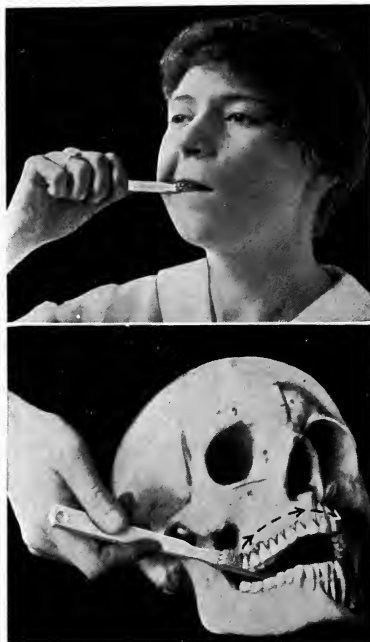

Fig. 34.—Position of brush preparatory to cleansing upper wisdom teeth. Dotted line shows direction in which the brush should be drawn.

margins and the necks of the lower teeth (Fig. 35). This motion should be carried out on the upper and

lower jaws, right and left, and not less than five or six times each.

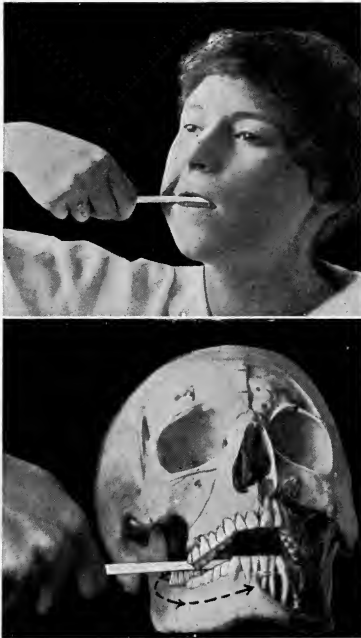

Fig. 35.—Position of brush preparatory to cleansing back of lower wisdom teeth. Dotted line shows the proper downward sweep.

Motion No. 3 is comparatively simple. The brush is placed on the gum and tooth line behind the third

molars and drawn sharply forward and out of the mouth over the insides of the central incisors, care being taken to follow the curve of the arch with the entire face of the brush. The brush should be placed so as to extend back of the last molars, it should not be thrust back of them, as the thrusting will cause a counterbending of the brush bristles and result in a pivoting that again will leave the back molars without bristle friction, and consequently dirty (Fig. 36). Motion No. 3 should be done five times on the upper and lower jaws, right and left, and when this has been properly done the surfaces of the teeth and gums will be free from bacterial masses.

After so much minute explanation it may not be inadvisable to review once more just what the daily cleansing of the mouth should be. The surfaces between the teeth should be thoroughly swept by dental floss to remove all food and bacterial deposits. The teeth and gums should then be thoroughly brushed, as described, with dentifrice or antiseptic mouth-wash, and the saliva and mouth-wash vigorously swashed in between the teeth for a period of not less than two minutes, so that the thin coating of bacterial film left by the dental floss on the sides of the teeth may be discouraged from growth until the next cleansing. Where there is marked gum infection a saturated solution of sodium silicofluorid or 1 per cent. peroxid solution should be held in the mouth for at least two minutes after the procedure just described. This cleansing should be

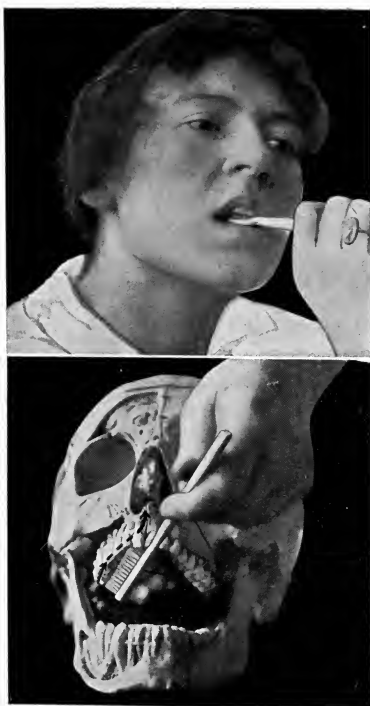

Fig. 36.—Position of brush preparatory to cleansing inside of dental arches. The brush must extend well back of the back tooth and be drawn briskly forward along the edge of the gum and teeth, and finally out across the median line, as is shown by the dotted line.

carried out morning and evening. It must not be forgotten, however, that each mouth is a separate problem and must be treated as such. If teeth are missing, the brush must be inserted vigorously in the vacant spaces, and if certain abnormal rotations are necessary the dentist must train the patient to see that these abnormalities are met and the parts are thoroughly cleansed by especially devised strokes of the brush.

The following is the history of a pronounced case of mouth infection. An examination revealed the fact that the infection was superficial in the gum and had not penetrated along the teeth so as to be beyond the reach of the dental floss and tooth-brush. A systemic examination proved the patient to be in good general health. The patient was accordingly told that if he would scrub his teeth and gums according to the author's directions, and also use dental floss as described, he could cure himself without any other treatment. The patient came back in four days. There was a wonderful change in color, showing that the gums had become almost normal. He was told to keep up the flossing and gum-brushing, and not to use any dentifrice or mouth-wash. He came back in a week, and while his mouth showed considerable improvement, there was a large ulcer still present. The author told him that by this time he expected the mouth to be entirely well. He said, "I don't know what more I can do, doctor, for I brush my gums thoroughly three times a day." "Brush them once a day," was the

reply, "and give the poor ulcer a chance to get well." In this instance the patient had been over strenuous in carrying out instructions. He went away, and when, after four days, he returned his mouth looked and felt entirely normal. When the author first saw the patient, two weeks before, his gums were dark red, and would bleed at the touch of dental floss or a brush. Two weeks later, merely through proper cleansing, he could brush them as vigorously and as painlessly as he could brush his finger-nails. There was no bleeding, his mouth was healthy, and it not only looked clean, but it felt clean. Mouth antiseptics and dentifrices have unquestionable value at times, but for ordinary service their value is inconsiderable when compared to efficient cleansing.

In summing up it might be wise to emphasize the fact that a brush softened in hot water is a valuable instrument with which to commence to cleanse and harden infected gums. As the gums become hard and firm the patient will naturally be less careful about the use of hot water on the brush and very soon the stiff bristles can be fearlessly used. This precaution is especially valuable in the preliminary training of children in their daily mouth hygiene.

When green stains come on the teeth and the ordinary brushing will not remove them, a drop or two of tincture of iodine on a wet brush will usually prove efficacious. A drop or two of aromatic spirits of ammonia on the brush immediately after the iodine has been used will re-

move any remaining dark stains and will heighten the bleaching effect. This may also be followed by a rinsing of a 1 per cent. peroxid solution. The iodine can be used two or three days in succession, and for a child of six years of age can be repeated as often as twice a week. For an adult the iodine can be used every day, especially if the iodine is not swallowed. Where the previous directions have been followed such iodine applications will be quite sufficient to keep the mouth clean.

Tooth pastes and powders have not been accentuated, as ordinarily they contain precipitated chalk as a basis, and the chalk when used in any quantity for any length of time cuts the enamel, so that in the course of twenty or thirty years the enamel is worn away, leaving the tooth bone exposed to the saliva. Liquids or a powder that is extremely soluble are, therefore, to be preferred. Of these, table salt, for those who do not object to the taste, is most admirable. It can be sprinkled on the brush and swashed in between the teeth after the cleansing has been completed. As above stated, a solution of 1 per cent. peroxid of hydrogen is most effective after the bacterial masses have been removed. Perborate of soda is also excellent. It can be flavored with wintergreen and makes an agreeable antiseptic froth that gives out large quantities of free oxygen, and in the presence of acid secretions makes an alkaline peroxid of hydrogen mixture that is highly pleasing and beneficial.

For those who really desire a dentifrice the following

formula is most agreeable, and practically non-corrosive, being free from chalk:

Peroxid of magnesia 60 parts.

Perborate of soda 30 “

Pulverized soap 10 “

Mix thoroughly in 200 mesh sieve and flavor to taste.



REMARKS ON IRREGULARITY IN CHILDREN'S TEETH

DURING the last twenty years the straightening of children's teeth has undergone a great revolution and has developed from a haphazard, hit-or-miss procedure to a delightfully scientific method that produces permanent results in a surprisingly large percentage of cases. But as these permanent results should ordinarily be remedied between the ages of six and twelve years of age, it would be perhaps useful to point out a few of the obvious defects in order that they may be remedied as soon as they appear.

It has been discovered that the teeth do not grow to fit the face, but the face grows to fit the teeth. If the teeth can be made to assume their true, normal arch, the rest of the face develops in corresponding symmetry and beauty. The arch of the teeth is the keystone on which the development of the upper bones of the face and forehead depend. If the arch is constricted the openings in the nose are correspondingly lessened or even closed. This prevents breathing through the nose. The passage of air through the nose being cut off, air pressure is not exerted in the various hollow bones of the face, and thus, to a serious extent, this important stimulant to facial development is missing. This being

the case, it is quite apparent that the future health and development of the child depend largely on the early formation of a normal dental arch, and it is, therefore, important for the mother or nurse to be acquainted with the first tendencies toward malformation. When it is realized that before a child is six or seven years old all of the full-sized crowns of the permanent teeth, except the wisdom teeth, are packed away in the small face; and then without disturbing mastication or nutrition, the roots of the first teeth must be absorbed, and the large replacing second teeth must emerge into graceful lines from their crowded positions as the face develops sufficient room for them, the marvel of it is simply overwhelming. Having grasped the idea that the process of dentition is a wonderful engineering plan, it can then be appreciated that a little extra resistance of the bone caused by inflammation may readily result in producing serious disarrangement and discord.

Therefore it is especially important that the first teeth should be kept clean and free from decay. This should be carefully looked to after the fourth year has been reached, and dental floss should be slipped between the first and second temporary molars at least once a day. The small baby brush will keep the rest of the teeth clean, as the first teeth with the exception of the molars rapidly separate during the development of the jaw, causing large spaces into which the tooth-brush bristles can be easily inserted with a cleansing effect.

In addition to keeping the teeth clean and free from

decay it is especially important that the parents or nurse should understand the law that governs the correct development of the dental arches. For instance, Figs. 37 and 38 represent the normal arch of a boy of eight. Note particularly that the lower four incisor teeth inclosed in a bracket should always occupy their full space

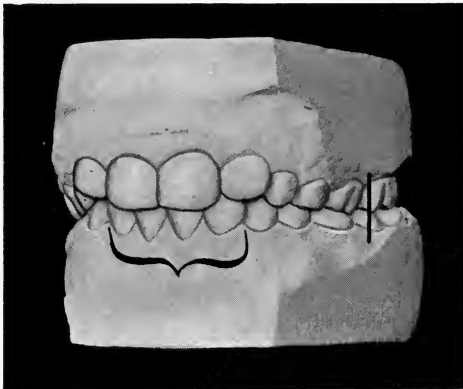


Fig. 37.—Normal relation of a child's teeth between the ages of seven and ten. The permanent incisors have successfully replaced the temporary.

in the gradual curve of the arch, so that the permanent canines can come in at the age of eleven, and thus make the full arch in the lower jaw. For, if the lower teeth are straight and of full width the upper teeth are bitten and hammered into the proper position. This is especially the case if the lower first permanent molar on

either side bites in front and within the upper first permanent molar, as is shown by the connecting line in Fig. 37. It is especially necessary to note during erup-

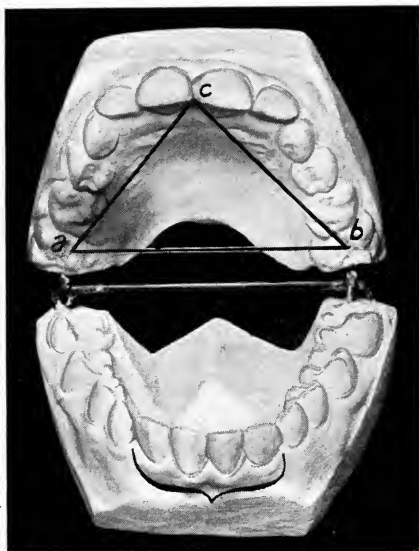


Fig. 38.—Normal arches of a child between the ages of seven and ten

tion of the teeth that the upper teeth, especially those in front, should never slip inside of the lower arch. The parent or nurse may also notice, after the age of eight, if the arch is contracted. (See the triangle, Fig. 38.)

The distance between the anterior pits in the first permanent molars should always greatly exceed either side of the triangle drawn to the junction of the cutting edges of the central incisors. If there is any question in the mind of the nurse or parents on these points the advice of the dentist should immediately be obtained. It should be especially remembered that all temporary teeth erupt before the age of three. The first permanent molars just mentioned erupt at the age of six years, sometimes at five, and it is especially necessary that these teeth should be kept clean and never extracted under the impression that they are temporary teeth. This has at times occurred.

And now let us sum up the points to be especially noted during dentition. The lower front teeth should be straight and untwisted in their arch. The lower first permanent molars should always bite inside and in front of the upper first permanent molars, as shown by the cross line in Fig. 37. The arch should have sufficient width. (See Fig. 38.) The upper teeth should never bite inside of the arch of the lower teeth; and, above all, the temporary teeth should be kept clean and free from decay, so that until absorbed at the proper time they will maintain the necessary space in the jaw for the permanent teeth to emerge from the gum in their normal position.

The loss of a temporary tooth through decay or premature extraction is a serious misfortune for the child, and usually results in deformity of the permanent

teeth; but proper care of the temporary teeth in a surprising number of cases will result in a perfect alignment of the permanent teeth.

The dentist, of course, must always be the final judge of what is or is not correct, but a few remarks on the subject of crowns and bridges may not be out of order. Any permanent bridgework placed in the mouth in a way that cannot be kept as clean as the natural teeth, is a menace to health and should not be tolerated. If the dental floss and brush cannot be used to cleanse all sides of a fixture, both those that rest on the gum and those that are exposed to the action of the saliva, it had better far be removed and a dental plate worn instead. Removable bridgework that can be taken out and scrubbed during the cleansing of the teeth and then slipped back securely into place, is now possible almost anywhere; and should always be preferred to fixtures that cannot be cleansed.

Crowns that are persistently associated with bleeding during the process of flossing and cleansing the teeth should be considered a possible source of systemic infection, and if they cannot be made wholesome they should be removed.

Here is the picture of a man with healthy teeth and gums, biting on an instrument that shows how much pressure he can exert between his back teeth. (See Fig. 39.) The pointer shows that he is creating a force equal to 340 pounds. He surely will have no difficulty in chewing his food. He can only exert such force because

he has kept his teeth clean and his gums healthy, and while you may not all be able to bite so hard, it is advisable for the sake of chewing your food to keep your



Fig. 39.—Gnathodynamometer. For measuring the force exerted by the closing of the jaws. This represents a man exerting a pressure equal to 340 pounds—over twice his weight.

teeth clean, for ordinary food will sometimes require over a hundred pounds pressure before it is thoroughly prepared for digestion by the stomach.

INDEX


	PAGE
ABSCESS from decay of teeth.....	17-20
Arches, dental, brushing inside of.....	51
proper development of.....	59
BACK teeth, instrument for measuring strength of....	63
Beginning pyorrhea.....	10
Bridgework, dangers from.....	62
Brush, tooth.....	39
Brushing front teeth and gums.....	44
gums.....	40
inside of dental arches.....	51
lower wisdom teeth.....	48
side teeth and gums.....	44
teeth.....	37
drawing motion.....	47
mechanics of.....	42, 43
rotary motion.....	45
wrong way.....	38
upper wisdom teeth.....	48
CHILDREN'S teeth, care of.....	50
irregularity in.....	57
Cleansing teeth and gums.....	20
time necessary for.....	7
Crowns, dangers from.....	62
DECAY of teeth, abscess from.....	17-20
Dental arches, brushing inside of.....	51
proper development of.....	59

	PAGE
Dental floss, curative action.....	10
improper use of.....	21
incorrect way of inserting.....	29
position of, for cleansing back of tooth.....	35
front of tooth.....	36
left lower teeth.....	37, 38
upper side.....	27, 28, 30
right lower teeth.....	34
upper side.....	31, 32
positions, preliminary.....	26, 33
proper method of application.....	22
Dentifrice, formula for.....	55
FLOSS, dental. See <i>Dental floss</i> .	
Front teeth, brushing of.....	44
GNATHODYNAMOMETER.....	63
Green stains on teeth, removal.....	52
Gums, brushing.....	40
cleansing of.....	20
infection of, brush treatment.....	40
disease from.....	7
INFECTED gums, brush treatment.....	40
Irregularity in children's teeth.....	57
MOUTH infection, early treatment.....	52
wash, peroxid solution.....	50
sodium silicofluorid solution.....	50
PEROXID solution mouth wash.....	50
Pyorrhea, beginning.....	10
infection of system from.....	14, 16, 17
pocket.....	10-15
advanced.....	13, 15

INDEX

67

	PAGE
SODIUM silicofluorid solution mouth wash.....	50
System, infection of, from pyorrhea.....	14, 16, 17
TEETH, back, instrument for measuring strength of. . .	63
brushing of. See <i>Brushing teeth</i> .	
children's, care of.....	58
irregularity in,	57
cleansing of.....	20
time necessary for.....	7
decay of, abscess from.....	17-20
front, brushing of.....	44
green stains on, removal.....	52
infection of, disease from.....	7
left upper, position for cleansing.....	27, 28, 30
lower, position for cleansing.....	33, 34, 37
wisdom, brushing of.....	48
normal clean.....	8
right upper, position for cleansing.....	31, 32
side, brushing of.....	44
unclean.....	8, 9
upper wisdom, brushing of.....	48
wisdom, neglect of.....	39
with beginning pyorrhea.....	10
Tooth brush, improper	39, 43
proper.....	40, 42
pastes.....	54
powders.....	54
UNCLEAN teeth.....	8, 9
WISDOM teeth, neglect of.....	39



UNIVERSITY OF CALIFORNIA LIBRARY,
BERKELEY

**THIS BOOK IS DUE ON THE LAST DATE
STAMPED BELOW**

Books not returned on time are subject to a fine of 50c per volume after the third day overdue, increasing to \$1.00 per volume after the sixth day. Books not in demand may be renewed if application is made before expiration of loan period.

SEP 16 1925

NOV 10 1926

MAR 14 1936

17
100

[Faint, illegible text]

1

