CONTENTS.

THE OWENS COLLEGE

COURSE OF ELEMENTARY BIOLOGY.

PART I.

THE FROG:

AN INTRODUCTION TO

ANATOMY AND HISTOLOGY.

BY

A. MILNES MARSHALL, M.D., D.Sc., M.A., F.R.S.,

FELLOW OF ST. JOHN'S COLLEGE, CAMBRIDGE;
BEYER PROFESSOR OF ZOOLOGY IN OWENS COLLEGE.

SECOND EDITION.
REVISED AND ILLUSTRATED.

MANCHESTER:
J. E. CORNISH, 33 PICCADILLY.
LONDON:
SMITH, ELDER, & CO., WATERLOO PLACE
1885.

PREFACE TO THE FIRST EDITION.

The Owens College Course of Elementary Biology, which forms part of the scheme of study prescribed by the Victoria University, is of a rather more extended and comprehensive nature than the courses held elsewhere under the same name; and experience has shown me that there is want of a book that will guide and direct the student through the practical part of his work, the whole ground of which is covered by no one of the existing manuals. It is to meet this want that the present little work has been prepared.

This first instalment of the work consists of an Introduction containing practical instruction in the methods employed in biological investigation; followed by the application of these methods to the examination, both anatomical and histological, of an actual animal. For this purpose the frog has been selected as being convenient to dissect, easy to obtain, and a fairly typical example of the great group of Vertebrate animals. Where, from its small size or for other reason, the frog proved unsuitable, other animals have been substituted for it.

For convenience of reference, and in order to definitely stamp the practical character of the work, directions for dissection, etc., have throughout been printed in italics.

It is not expected that the student should do the whole of the work here given the first time he goes over it. The dissection of the muscles and of the cranial nerves should only be attempted if time remain after the other work is completed.

In preparing this first part I have received very valuable assistance from Dr. Hartog, Demonstrator of Biology in the College, and from my friend and pupil Mr. C. H. Hurst. I am also much indebted to Prof. Gamgee and to Mr. Waters for the important help they have given me in the Histological portions.

Owens College,

August, 1882.

PREFACE TO THE SECOND EDITION.

In preparing the present edition I have again received valuable help from Mr. C. H. Hurst, Assistant Lecturer in Zoology in the College.

The illustrations are, with the exception of figs. 1, 11, 12, and 14, original; and will, I hope, add to the usefulness of the book. They have been carefully selected in order to aid the student in his work without in any way replacing the drawings he must make from his own dissections.

The second instalment of the work, containing directions for the examination and dissection of a number of animals chosen as types of the principal zoological groups, is in active preparation, and will be published shortly.

Owens College,

July, 1885.

INTRODUCTION.

I.—LABORATORY RULES.

1. The Laboratory is open daily throughout the session from 10 to 1.30 and from 2 to 5; on Saturdays from 10 to 1.

2. Each student has a definite seat assigned him in the Laboratory, which he is not allowed to change without permission.

3. Each student has the free use of the locker belonging to his seat; the key may be obtained on payment of a deposit of half a crown, which will be returned if the key is given up before the end of the term, but otherwise will be forfeited.

4. All necessary reagents and specimens for dissection are provided by the Laboratory, but each student is required to furnish himself with dissecting instruments, note book, and pencil, as explained in the next section.

5. Paper and solid refuse from dissections must not be thrown into the sinks, but into the pails provided for the purpose.

II.—LIST OF APPARATUS REQUIRED.

Each student is required to provide himself with the following:—

1. Two scalpels or dissecting knives, one large and one small.

2. Two pairs of forceps, one large and one small. Both pairs should have the tips roughened in order to secure a firmer hold.

3. Two pairs of scissors; one pair large and strong, for cutting bone and other hard tissues; the other pair small, for fine dissections. The latter pair should have the blades either bent at an angle (elbow scissors), or else curved. In selecting scissors be careful to see that they cut quite up to the points of the blades.

4. Three needles, mounted in handles; two round and one triangular.

5. A seeker, *i.e.* a blunt needle mounted in a handle, and with the end bent at an angle.

7. A pocket lens.

8. Slides and coverslips, for mounting microscopical specimens.

9. A blank note book, for drawing in; an HB pencil, and a piece of india-rubber.

III.—ON DISSECTION.

The object of dissection is to separate the several parts and organs from one another, so as to define their boundaries and display clearly their relations to one another. Dissection consists, therefore, mainly in removing the "connective tissue" which binds the several parts to one another.

The following rules should be carefully attended to:—

1. Always pin down the animal you are dissecting firmly to the dissecting board. Never attempt to dissect a specimen that is not so fixed.

2. In pinning out a dissection stick the pins in, not vertically, but obliquely, so that their heads do not get in the way or obscure the dissection.

3. Never cut away anything until you are quite certain what it is you are removing.

4. Always put the part you are dissecting slightly on the stretch; *e.g.* when dissecting the bloodvessels or nerves of the throat, distend it by passing a small roll of paper or the handle of a seeker down the œsophagus; or when dissecting the muscles of the leg, pin out the leg in such a position as to stretch the muscles you are cleaning.

5. In cleaning bloodvessels or nerves always dissect along them and not across them; and avoid laying hold of them with the forceps. Similarly when cleaning muscles, dissect along their fibres and not across them.

6. Fine dissections should always be done under water, which supports the parts and greatly facilitates the operation. A stream of water allowed to play gently on the dissection from time to time is often a valuable aid.

7. The dissection of muscles, and still more of nerves, is greatly aided by placing the specimens in spirit for a day before dissecting.

8. Always keep your instruments clean and sharp. Be careful not to blunt your fine scissors or scalpel by using them for cutting hard parts.

IV.—ON DRAWING.

It is absolutely essential to draw your dissections, and this must on no account be omitted. Keep a separate book for your drawings, and draw every dissection you make. Do not be discouraged if you find it difficult at first: you will never regret time spent on it.

The following rules will be useful to those who have not learnt drawing systematically:

1. Always make your drawing to scale, *i.e.*, either the exact size of the natural object, or half or double or treble that size as the case may be.

2. In commencing a drawing, first determine by careful measurement the positions of the principal points, and sketch in lightly the whole outline before finishing any one part.

3. If the object you are drawing is bilaterally symmetrical, draw a faint line down the middle of your paper, and sketch in the left hand half first; by measuring from your median line it will be very easy to make the two halves symmetrical.

4. Always name the several parts shown in your drawing, and mark also the scale adopted. Thus, if your drawing be of the natural size mark it thus— × 1; if it be double the size of the object mark it × 2; if half the size, × $\frac{1}{2}$, and so on.

5. Coloured pencils are very useful, and water-colour paints still better. Always keep certain colours for particular organs or tissues; *e.g.*, when drawing the skeleton colour the cartilage blue, the cartilage bones yellow, and the membrane bones either red or white; when drawing the bloodvessels colour the arteries red and the veins blue.

V.—THE USE OF THE MICROSCOPE.

The microscope consists essentially of a *stand* and a *body*, the latter of which bears at each end the *lenses* by which the magnifying power is obtained.

The stand is an upright pillar, the lower end of which is attached to a heavy foot to ensure steadiness. A little way above the foot the stand supports a horizontal plate—the *stage*—on which the object to be examined is placed. The stage is perforated in the middle by a hole, the size of which can be varied by means of diaphragms. Through this hole light is directed on the object to be examined by means of a mirror

attached to the stand below the stage. Above the stage the stand supports a vertical tube, in which the body of the microscope slides up and down.

The body is a tube, in the upper end of which is placed a combination of lenses, known as the *eyepiece*, while to the lower end is screwed another combination of lenses—the *objective*.

Each microscope is provided with a couple of eyepieces and a couple of objectives of different magnifying power. An objective magnifying only a small number of times is called a *low power*; one magnifying many times (200 diameters or more) a *high power*. Similarly eyepieces are spoken of as high or low according to their magnifying power.

In order that an object may be seen clearly the objective must be at a certain definite distance from the object, the distance varying with different objectives, and to a slight extent with different observers. The higher the power employed the closer must the objective be brought to the object. As the position of the object on the stage of the microscope is a fixed one this distance is regulated by moving the body of the microscope up and down in the tube in which it slides.

This process of *focussing* is effected in two ways: (1) by simply sliding the body up and down by hand: this is known as the *coarse adjustment*; it should always be performed with a slight screwing motion, and can only be used when low powers are being employed.

(2) With high powers the distance between the objective and the object examined is so small that a more delicate method of adjustment is necessary. This *fine adjustment* is effected by a screw with a milled head placed at the top of the vertical pillar forming the stand. By turning the head from left to right, in the direction of the hands of a watch, the body of the microscope is lowered and the objective brought nearer to the object: by turning in the reverse direction the objective is raised.

In using the microscope attend to the following rules:—

1. Always examine an object first with the low power. Having adjusted the eyepiece and objective, direct the light up the tube of the microscope by means of the mirror, and then place the object on the stage. Twist down the body until the objective is about a quarter of an inch from the object; look down the microscope, and gradually twist the body up until the

object becomes visible. Focus accurately by means of the fine adjustment.

2. When using a high power, start with the objective the same distance from the object as before, and very gradually twist down the body until the object becomes dimly visible; then complete the focussing by the fine adjustment. It will facilitate the process if, while twisting down the body with the right hand, you move about the object slightly with the left hand.

3. Take extreme care never to let the objective touch the object; and never to touch or allow any dirt to get on the face of the objective. The face of an objective cannot be cleaned without doing harm to it.

4. Should by any chance a drop of glycerine get on the face of the objective, stream it gently with water from a wash-bottle, and wipe it very carefully with a silk handkerchief or piece of chamois leather. Should Canada balsam be allowed to get on the objective, do not attempt to clean it yourself, but give it at once to the assistant.

5. See that the body of the microscope slides smoothly in its tube. If it does not, remove it, and clean it by rubbing with a few drops of olive oil.

6. Keep the eye you are not using open; a very little practice will enable you to do this, and it will save you much fatigue. Also get into the habit of using either eye.

7. With a high power, use a small diaphragm: the amount of light will be somewhat diminished, but the clearness and definition of the object much increased.

8. When examining an object, use your left hand to move the object about on the stage, and keep your right hand on the fine adjustment.

9. If the object appears dim or dirty, find out where the fault lies, in this way:—

While looking down the microscope, turn round the eyepiece with your right hand: if the dirt turns round too, remove and clean the eyepiece. If the fault is not in the eyepiece, move the slide about gently; if the dirt moves with the slide remove the slide and clean it. If the dirt does not move with either the eyepiece or the slide the fault is almost certainly in the objective, which should be removed and examined; if dirty, it must be cleaned very carefully with a piece of silk or chamois leather.

VI.—THE PREPARATION OF MICROSCOPIC OBJECTS.

In mounting microscopic objects be careful that your slides and coverslips are thoroughly clean. Slides should be labelled as soon as they are prepared, and should be kept in a box or cabinet in which they can lie flat.

A. Methods of Mounting.

There are various media in which objects may be mounted. The method of procedure is much the same with all. Put a small drop of the fluid in the middle of the slide, place the object in the middle of the drop, and arrange it with needles in any position that may be desired. Then place the coverglass carefully on the top, letting it rest by one edge on the slide and supporting the opposite edge by a needle, which is gradually withdrawn so as to let the coverglass down slowly and drive out any air-bubbles there may be in the fluid. If any air-bubbles still remain, leave them alone, as they will probably work out by themselves. Be careful not to use too large a drop of your mounting medium, and above all things be careful not to let any of it get on the top of the coverglass; should this happen, the cover must be removed at once and the specimen mounted again with a clean coverglass.

The most important mounting media are :—

1. Normal Salt Solution. A 0·75 per cent. solution of common salt in water. This is very useful for the examination of fresh specimens of animal tissues, as, unlike water, it has practically no action whatever on them. It cannot be used, however, for making permanent preparations.

2. Glycerine. Can be used either pure or diluted with its own bulk of water. If the preparations are intended to be permanent, a narrow ring of cement must be painted round the edge of the coverglass to fix it to the slide.

3. Canada Balsam. The most generally useful; requiring no cement. Specimens that are to be mounted in balsam must first be deprived of all water they may contain by placing for an hour or so in absolute alcohol, and should then, before mounting, be soaked for a few minutes in a mixture of creosote and turpentine in order to clear them, *i.e.*, render them permeable by the balsam. Canada balsam, if too thick, may be diluted with chloroform, turpentine, or benzole.

B. Teasing.

The object of teasing is to separate the several parts of a tissue or organ from one another as completely as possible, in order to show their minute structure.

The fragment to be teased should be placed on a slide in a drop of the medium in which it is to be mounted, and then torn up into as minute particles as possible by means of a couple of needles held one in each hand. The process is often greatly facilitated by placing the slide on a piece of black paper, which renders the particles easier to see. When torn up as finely as possible, a coverglass is placed on as before. The two rules to be borne in mind in teasing are—

1. Take a *very small* fragment to commence with.

2. Tease it as finely as you possibly can. Your object is to separate the component cells from one another.

C. Maceration.

The process of teasing is in many cases very greatly facilitated by previously macerating the specimen, *i.e.*, soaking it in some fluid, which, while preserving the individual cells, tends to loosen their connections with one another. The most important macerating fluids are—

1. **Ranvier's Alcohol.** A mixture of one part of strong spirit with two parts of water. The specimens should be put fresh into this preparation and allowed to remain twenty-four hours.

2. **Baryta Water.** Very useful for isolating the individual cells of tendons.

3. **Müller's Fluid.** A solution of bichromate of potash with a little sodic sulphate in water.

D. Staining.

Various reagents are employed for the purpose of staining preparations; some of these merely colour the whole preparation more or less uniformly, but the most useful ones are those which stain certain parts of the cells only, or at any rate stain these much more strongly than the other parts. The most important are:

1. **Hæmatoxylin.** There are various preparations of hæmatoxylin, or logwood, used in microscopical work: the best is that proposed by Kleinenberg and called by his name. It is prepared thus:—

(*a*) Make a saturated solution of crystallized calcium chloride in 70 per cent. alcohol, and add alum to saturation.
(*b*) Make a saturated solution of alum in 70 per cent. alcohol, and add (*a*) to (*b*) in the proportion of 1 to 8.
(*c*) To the mixture of (*a*) and (*b*) add a few drops of a saturated solution of hæmatoxylin in absolute alcohol.

The specimens, which must be perfectly free from all trace of acid, should be left in the hæmatoxylin in a covered vessel or stoppered bottle for from one to twenty-four hours, according to the size of the specimen and the depth of staining desired, and then placed in strong spirit for some hours before mounting. Hæmatoxylin stains the nuclei of cells much more strongly than the other parts.

2. Borax-carmine. This, which is perhaps the most generally useful of all the stains in ordinary use, is prepared as follows: Dissolve 2 parts of carmine and 4 of borax in 100 parts of water: add an equal volume of 70 per cent. alcohol; let the mixture stand for a couple of days, and then filter.

Specimens may be left in borax-carmine for from one to twenty-four hours, or even for two or three days: on removal they should be placed in **acid-alcohol**—*i.e.*, 70 per cent. alcohol to which a few drops of hydrochloric acid have been added—until they become a bright scarlet colour, when they should be transferred to 70, and then to 90 per cent. alcohol, in which latter they may be left till required. The time of immersion in acid alcohol will vary according to the nature and size of the specimen from a quarter of an hour up to a day or more.

3. Picro-carmine. A very useful, and to a certain extent a differential stain, as it colours the several tissues different tints. It may be prepared thus: Dissolve 1 gramme of carmine in 4 cc. of liquor ammonia and 200 cc. of distilled water. Add 5 grammes of picric acid; shake the mixture well for some minutes, and then decant from the excess of acid. Leave the decanted liquid for some days, stirring it occasionally: then evaporate it to dryness, and to every 2 grammes of the dried residue add 100 cc. of distilled water.

Picro-carmine answers best with specimens preserved in 70 per cent. alcohol. They should be left in the stain for a day, and then placed in 70, and afterwards in 90 per cent. alcohol. Some specimens give better results by washing freely with water on

removal from the picro-carmine, and then placing in 1 per cent. acetic acid for an hour before transferring to alcohol.

4. Magenta. Stains very rapidly, but diffusely: the colour also is not permanent. Useful for fresh specimens of infusoria, hydra, and some other of the lower animals.

5. Silver nitrate. A 1 per cent. solution in water stains the intercellular substance, which binds together the several cells of a tissue, much more strongly than the cells themselves, and is therefore chiefly used when we wish to render prominent the outlines of the individual cells. The specimens should be placed fresh in the silver solution for from two minutes to a quarter of an hour, then washed thoroughly with distilled water and exposed to the light until stained sufficiently deeply, when they may be mounted in glycerine. Such preparations are rarely permanent, as the reduction of the silver, to which the staining is due, continues until the specimens ultimately become too dark to be of any use.

6. Osmic Acid. A 1 per cent. solution of osmic acid in water forms an extremely useful staining reagent. It is especially useful for the detection of fat which is stained by it a dark brown or black colour. Specimens, which must be quite fresh, should only be left in it a few minutes, and may then be mounted in glycerine or else dehydrated and mounted in balsam.

7. Acetic Acid. Although not strictly a staining agent inasmuch as it does not colour the specimens, acetic acid may conveniently be mentioned here as it is used for the same purpose as the true stains, *i.e.*, for the sake of rendering certain parts of the cells especially distinct. Acetic acid, of which a 1 per cent. solution is employed, causes the protoplasm of cells to swell up and become transparent, and brings the nuclei into special prominence. It is used with fresh specimens.

VII.—ON SECTION CUTTING.

Many tissues and organs can only be studied satisfactorily by cutting them into thin sections, and this method of investigation is of such importance as to require special notice. There are three chief stages: Hardening, Imbedding, and Cutting, which will be noticed in succession.

A. Hardening.

Before the object can be cut into sections it is necessary to

harden it: this may be effected by freezing, but the more usual plan is by means of reagents. The general action of these hardening reagents is to coagulate the protoplasm of the tissues; and the objects to be attained are to effect this coagulation quickly, before the tissues can undergo any alteration; and thoroughly, *i.e.*, throughout the whole thickness of the object to be hardened. To ensure the latter result it is always advisable to use small pieces of the substance to be cut.

The hardening reagents in most common use are:

1. Osmic Acid. For this purpose a 1 per cent. solution in water is used: it acts almost instantaneously, and so allows no change to occur in the tissues; it has also the merit of staining the tissues as well as hardening them. It can, however, only be employed when the specimens are very small, as it hardens the surface layers so rapidly that it is unable to penetrate beyond a very slight depth. A few minutes immersion is usually sufficient.

2. Corrosive Sublimate. A saturated solution in water is employed, in which the object is placed for half an hour or more. After removal it is thoroughly washed with water or weak alcohol, and then transferred to 70 per cent. alcohol before staining.

3. Chromic Acid. A 0·25 to 0·5 per cent. solution of chromic acid in water is a useful hardening reagent; it acts much more slowly than osmic acid, but is thereby enabled to penetrate to greater depths. Specimens should usually be left in the solution for 24 hours.

4. A Mixture of chromic acid with a few drops of osmic acid is often very useful, as it combines the advantages of both reagents.

5. Picric Acid. A very valuable hardening reagent, of which the best preparation is Kleinenberg's. Specimens should be left in it from 12 to 24 hours. It is prepared thus: with 100 cc. of water make a cold saturated solution of picric acid: add 2 cc. of concentrated sulphuric acid: filter, and add to the filtrate three times its volume of water.

6. Absolute Alcohol. Often a useful hardening reagent.

B. Dehydration.

Specimens that have been hardened in any of the preceding reagents, with the exception of the last, should, on removal,

be placed for a few hours in 30 per cent. alcohol, and then transferred to 50 per cent. alcohol: on the following day they should be transferred to 70 per cent. alcohol, which should be changed daily until the specimens are colourless: they may then be left in 90 per cent. alcohol until required.

C. Staining.

The hardened specimens, if not too large, may now be stained with either hæmatoxylin, borax-carmine, or picro-carmine; they should then be placed back in 90 per cent. alcohol and transferred from that to absolute alcohol immediately before imbedding. If too large to stain whole, the sections must be stained after cutting.

D. Imbedding.

The preparation of sections is greatly facilitated by imbedding the specimen in some waxy substance. For this purpose various materials have been employed, but by far the most useful is paraffin, which is used in the following manner:—

The stained specimen is placed in absolute alcohol for an hour or two in order to completely dehydrate it. It is then transferred to turpentine, in which it is left for half an hour or more until completely saturated. From the turpentine it is transferred to paraffin, which is kept by means of a water bath at a temperature just above its melting point. In this it is left for several hours, or even for a whole day, in order that it may be thoroughly permeated. It is then placed in a small box of paper, or other material, filled with melted paraffin. By means of hot needles it can readily be arranged in any desired position; and then the paraffin should be allowed to cool.

E. Section-Cutting.

When thoroughly set the block is removed from the box, and the paraffin pared away with a knife until the specimen just comes into view.

The block is then placed in a microtome, and cut into thin sections. These may be transferred one by one to a slide, but a great saving of time is effected by the method of cutting continuous ribbons devised by Mr. Caldwell.

This depends on the fact that if the paraffin is of proper consistency the successive sections, as they are cut, will stick

together at their edges, so as to form a ribbon. To ensure this the razor should be placed at right angles to the direction of stroke, and the edges of the block of paraffin cut parallel to one another, and to the edge of the razor. If for any reason it is desirable to imbed the specimens in a paraffin too hard to form ribbons, the block should, before cutting, be coated with a layer of soft paraffin, by dipping it for a moment in a dish of melted soft paraffin. This outer coating should be left on the sides of the block parallel to the edge of the razor, but cut away from the sides at right angles to it.

The razor should be used dry: and the sections, when cut, placed on slides painted, just before they are used, with a thin layer of a mixture of collodion and oil of cloves in equal parts. The slide is then heated by a water bath to a temperature not exceeding 55°—60° C., so as to melt the paraffin and evaporate the oil of cloves. The melted paraffin should then be washed off by turpentine, when the sections will remain fixed to the slide by the collodion, and may be mounted in balsam in the usual manner.

Instead of the mixture of collodion and oil of cloves, a solution of shellac in absolute alcohol may be used: this should be spread over the slide in a thin layer by means of a glass rod and allowed to dry. Immediately before being used the slide should be brushed over with oil of cloves.

Chap. I.—GENERAL ANATOMY OF THE FROG.

Fig. 1. The Common Frog *(Rana temporaria)*: (from Ecker.)

A. External Characters.

Lay the frog on a board before you, and note the following points:—

1. The division into head, trunk, and limbs; and the absence of neck and tail.

2. The two great surfaces;—

a. The dorsal surface, or back, directed upwards when the frog is in the natural position.

b. The ventral surface, or belly, directed downwards towards the ground.

3. The skin: moist and smooth: devoid of hairs, scales, or claws. The colour of the skin is variable in different specimens

and at different times: mottled on the dorsal surface, paler on the ventral.

4. The head: flat and triangular, with a blunt apex directed forwards.

At the sides of the head are the eyes, which are large and prominent. Each eye has two eyelids of which the upper is thick, pigmented, and almost immoveable, while the lower is semi-transparent and freely moveable.

Behind the eye on either side is an obliquely placed elongated patch of a dark colour, in the middle of which is a circular area—the **tympanic membrane**—supported by a firm marginal ring.

5. The limbs: two pairs, fore and hind, each composed of three segments—

- **a. Fore limb**:
  - **i. Arm.**
  - **ii. Forearm.**
  - **iii. Hand,** with four digits corresponding to the four fingers of man; the thumb being very small and inconspicuous. In the male frog at the breeding season there is a thickening along the inner edge of the first digit.
- **b. Hind limb**: much longer than the fore limb: composed of:—
  - **i. Thigh.**
  - **ii. Leg.**
  - **iii. Foot,** with five toes, webbed together. The shortest toe corresponds to the big toe of man, and the longest to his fourth toe.

6. External apertures: or openings on the surface of the body.

- **a. Median apertures.**
  - **i. Mouth**: a wide horizontal slit.
  - **ii. Cloacal aperture**: a small hole at the posterior end of the body between the legs: placed slightly on the dorsal surface, just behind the bony projection formed by the posterior end of the urostyle.
- **b. Paired apertures.**
  - **i. Nostrils** or **anterior nares**: two small openings on

the dorsal surface of the head, close to its anterior end.

B. The Buccal Cavity.

Open the mouth to its full extent: note the wide buccal or mouth cavity, of which the hinder part or pharynx is continued back into the œsophagus. Note also the following structures:—

1. On the Roof of the Mouth.

   a. **Teeth.**

      i. **Maxillary teeth**; a row of fine teeth attached round the edge of the upper jaw.

      ii. **Vomerine teeth**: two small patches of sharp teeth in the fore part of the roof of the mouth and near the middle line.

   b. **The posterior nares.** Two small holes lying to the outer sides of and slightly in front of the two patches of vomerine teeth.

      Pass bristles through the nostrils, and see that they come out through the posterior nares into the buccal cavity.

   c. **The Eustachian tubes or recesses.** A pair of much larger holes at the sides of the posterior part of the buccal cavity. Each hole opens into a slightly dilated chamber—the tympanic cavity—which is closed externally by the tympanic membrane already seen on the surface of the head.

      Perforate the tympanic membrane on one side with a needle, and pass a bristle through the hole and down the Eustachian tube into the mouth.

   d. Two rounded prominences at the sides of the roof of the mouth caused by the eyeballs.

      Press down one of the eyes with your finger, and note that it can be made to project very considerably into the buccal cavity,

2. On the Floor of the Mouth.

   a. **The lower jaw,** devoid of teeth, and forming a bony margin to the floor of the mouth: the rest of the floor is soft and fleshy, but is slightly stiffened by a cartilaginous plate—the body of the hyoid.

b. The tongue: thin and fleshy: attached to the front part of the floor of the mouth, and with its free bilobed end turned backwards toward the throat.

Turn the tongue forward with the forceps to see:—

c. The glottis: a longitudinal slit in the floor of the posterior part of the mouth: its sides are stiffened by the arytenoid cartilages.

Pass bristles through the glottis into the lungs.

C. The Abdominal Viscera.

Lay the frog on its back under water, and fasten it down to the dissecting board by pins through the limbs. Cut through the skin along the middle line the whole length of the ventral surface. Separate the skin from the underlying parts, noticing its very loose attachment to these parts, and the large space—lymph cavity—beneath it. Turn the flaps of skin outwards and pin them back. Notice:—

a. The muscles forming the body wall.

b. The sternum, or "breast-bone," in the middle line, opposite the fore-limbs.

Pinch up with forceps the muscular body wall, and cut through it into the body cavity with scissors a little to the right of the median line, being careful not to injure the anterior abdominal vein which runs along the inner surface of the body wall in the middle line.

Continue the cut backwards to the hinder end of the body and forwards to the jaw, cutting through the sternum with strong scissors, and taking care not to injure the parts beneath.

Note on the inner surface of the left flap the anterior abdominal vein, and carefully dissect this from the flap. Pull the two flaps apart, cutting through them transversely at their posterior ends to facilitate the process, and pin them out so as to display the viscera.

Inflate the lungs with a blowpipe through the glottis, and inflate the bladder through the cloacal aperture.

Note and draw the general arrangement of the viscera, showing:—

1. The heart: enclosed in the pericardium: situated in the middle line in front, and in the natural condition of the parts covered by the sternum

2. **The liver**: a large reddish-brown bilobed organ just behind the heart.

3. **The lungs**: two thin-walled elastic sacs at the sides of the heart: they lie dorsal to the liver, and are often hidden by it.

Note the bristles already passed into the lungs through the glottis.

4. **The corpora adiposa,** or **fat bodies**: two bright yellow tufts of flattened processes attached to the dorsal wall of the body cavity: they vary much in size, and usually come to the surface just behind the liver.

5. **The small intestine**: a light coloured convoluted tube: in the middle line behind is the much wider **large intestine.**

6. **The bladder**: a thin-walled bilobed sac at the posterior end of the body cavity.

7. *In the female frog note, in addition to the above parts,*
   a. **The ovaries**: two large bodies of irregular shape, each consisting of a mass of spherical black and white eggs, like small shot.
   b. **The oviducts**: two long very much convoluted tubes with thick white walls, lying at the sides of the body cavity.

8. *In the male frog note,*
   a. **The testes**: a pair of ovoid bodies of a pale yellow colour, attached to the dorsal wall of the body cavity.

D. The Peritoneum.

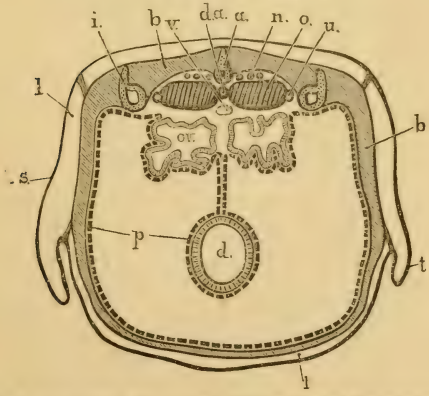

Fig. 2. A diagrammatic transverse section across the posterior part of the body of the female frog.

a, urostyle: *b*, muscles of body wall: *d*, large intestine: *d.a*, dorsal aorta: *i*, ilium: *l*, lymph space between the skin and the muscular body wall: *n*, spinal nerves: *o*, kidney; *o.v*, oviduct: *p*, peritoneum: *s*, skin: *t*, fold of skin at groin: *u*, ureter: *v*, vena cava inferior.

Notice the thin pigmented membrane—the **peritoneum**—which lines the body cavity. Trace this to the mid-dorsal line where it is reflected downwards as a double layer—the **mesentery**—which embraces at its edge the alimentary canal.

Notice also that all the abdominal viscera are really outside the peritoneum, which forms a closed sac into which the viscera are as it were pushed from without.

E. The Digestive Organs.

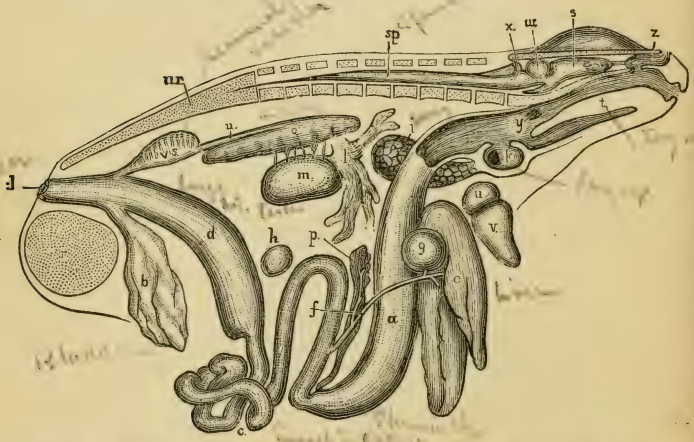

Fig. 3. General view of the viscera of the male frog, from the right side.

a, stomach: *b*, bladder: *c*, small intestine: *cl*, cloacal aperture: *d*, large intestine: *e*, liver: *f*. bile duct: *g*, gall bladder: *h*, spleen: *i*, lung: *k*, larynx: *l*, fat body: *m*, testis: *n*, ureter: *o*, kidney: *p*, pancreas: *r*, pelvic symphysis: *s*, cerebral hemisphere: *sp*, spinal cord: *t*, tongue: *u*, auricle: *ur*, urostyle: *v*, ventricle: *v.s*, vesicula seminalis: *w*, optic lobe: *x*, cerebellum: *y*, Eustachian recess: *z*, nasal sac.

Turn the liver forwards, and note the stomach lying beneath its left lobe. Pass the handle of the seeker through the mouth and down the œsophagus into the stomach.

[*If the specimen be a female, remove the ovaries and oviducts completely.*]

1. The Alimentary Canal.

a. The œsophagus: a short wide tube leading from the buccal cavity to

b. The stomach: a wide tubular sac about an inch and a half in length: narrowed behind, and separated by a distinct **pyloric constriction** from the duodenum.

Cut open the stomach longitudinally along its left hand edge: note the handle of the seeker already inserted through the mouth; also the longitudinal folds of the mucous membrane lining the stomach, which serve to increase the extent of its surface.

c. The duodenum: the first part of the small intestine; rather more than an inch in length: beyond the pylorus it is bent back so as to lie parallel to the stomach. At its further end it passes without any sharp boundary into

d. The small intestine: a slender convoluted tube about four and a half inches long, opening at its distal end by a small orifice into

e. The large intestine: a short straight tube about an inch and a quarter long: very much wider than the small intestine, and opening behind to the exterior at the cloacal aperture.

f. The cloaca in the frog is the last half inch of the large intestine into which open the renal and genital ducts as well as the bladder: it will be described more fully when considering the urinary and reproductive organs.

2. The Liver.

A large reddish-brown organ, divided into right and left lobes, connected together by a narrow bridge of liver-tissue. Of the two lobes the left one is much the larger, and is again subdivided into two.

a. The gall-bladder: a small spherical sac lying between the right and left lobes of the liver.

b. The bile duct: a slender tube leading from the liver and gall bladder to the duodenum, into which it opens about half an inch beyond the pylorus, and on the inner or concave side of the loop formed by the duodenum and stomach. The lower half of the bile duct has rather thick white walls and is easy to see, but the upper half is more slender and more difficult to trace.

To see the opening of the bile duct, slit up the first three quarters of an inch of the duodenum along its convex border: wash out its contents: note the point at which the bile duct enters: find its actual opening, and insert a bristle through it into the duct. Notice also the strong wavy transverse folds of the mucous membrane of the duodenum.

3. The Pancreas.

A whitish irregularly lobed mass lying in the loop between the stomach and duodenum, and seen best by turning the whole loop forwards. The pancreatic ducts, which are numerous, open into the bile duct, which passes through the pancreas to reach the duodenum.

Cut through the mesentery along its attachment to the intestine: uncoil the intestine and spread it out on your dissecting board: measure the lengths of the several portions and draw them to scale.

F. Other Abdominal Viscera.

1. The Kidneys: two flat elongated oval bodies of a red colour attached to the dorsal body wall, close to the middle line, one on each side of the back bone or vertebral column. They lie in the large lymph space behind the peritoneum. (See fig. 2, p. 17.)

a. The Ureters, or ducts of the kidneys: two white tubes arising from the outer edges of the kidneys at about a quarter of their length from their hinder ends, and running back to open into the dorsal wall of the cloaca, opposite the opening of the bladder.

b. [In the male frog notice a sac-like dilatation—the **vesicula seminalis**—on each ureter, close to its opening

into the cloaca: notice also the **testes**—a pair of yellow ovoid bodies attached to the ventral surface of the kidneys.]

2. The Spleen: a small round dark-red body lying in the mesentery, opposite the commencement of the large intestine.

Chap. II.—THE VASCULAR SYSTEM OF THE FROG.

The vascular system is a closed system of tubes or vessels filled with blood, and ramifying throughout all parts of the body: its main parts are (1) the **heart,** which by its contractions is continually driving the blood round and round the system of vessels: (2) the **arteries,** which are the vessels taking the blood from the heart to all the different parts of the body: (3) the **veins,** which return the blood from those parts back to the heart: and (4) the **capillaries,** a system of very small vessels connecting the arteries and veins together.

A. The Heart.

Pin down the frog on its back and open the body cavity as before, taking especial care to preserve the anterior abdominal vein. Dissect the vein carefully from the body-wall, and pin out the flaps.

Open the pericardial cavity: examine and draw the heart in situ, showing

1. The divisions of the heart.

i. **The auricles:** anterior, thin-walled and dark coloured owing to the blood being seen through their walls. On close examination the division into right and left auricles can be seen.

ii. **The ventricle:** posterior: paler in colour owing to the greater thickness of its walls: conical in shape, with the apex pointing backwards.

iii. **The truncus arteriosus:** a cylindrical body arising from the right anterior border of the ventricle, and running obliquely forwards across the auricles.

Lift up the ventricle and turn it forwards so as to expose

iv. **The sinus venosus:** a thin-walled sac lying on the dorsal side of the auricles and ventricle, and receiving the three large **venæ cavæ.**

2. The pulsation of the heart.

a. Note that the contractions of the heart continue some time after the frog has been killed, or even after the heart is completely removed from the body.

b. Note the character of the heart's pulsations—a regularly alternating series of contractions and dilatations.

c. Note further that in each contraction or systole of the heart all four divisions of the heart contract, but not simultaneously. The sinus venosus contracts first, then the two auricles, then the ventricle, and finally the truncus arteriosus.

B. The Veins.

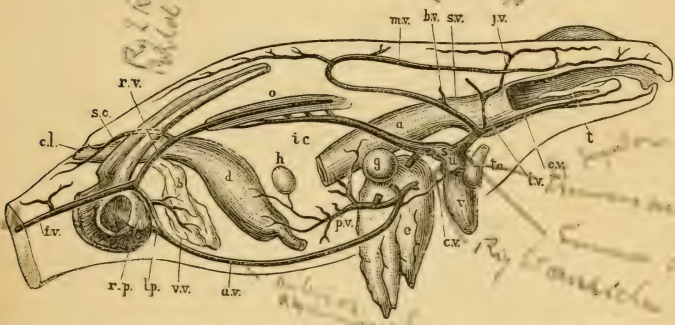

Fig. 4. Diagrammatic figure of the venous system of the frog, from the right side.

a, stomach: *a.v*, anterior abdominal vein: *b*, bladder: *b.v*, brachial vein: *c.l*, cloaca: *c.v*, cardiac vein: *d*, large intestine: *e*, liver: *e.v*, external jugular vein: *f.v*, femoral vein: *g*, gall bladder: *h*, spleen: *i.c*, inferior vena cava: *i.v*, innominate vein: *j.v*, internal jugular vein: *l.p*, left pelvic vein: *m.v*, musculo-cutaneous vein: *o*, kidney: *p.v*, hepatic portal vein: *r.p*, right pelvic vein: *r.v*, right renal portal vein: *s*, sinus venosus: *s.c*, sciatic vein: *s.v*, subclavian vein: *t*, tongue: *t.a*, truncus arteriosus: *u*, right auricle: *v*, ventricle: *v.v*, vesical veins.

The veins should be dissected before the arteries because, as a rule, they lie nearer the surface and are therefore met with first. The veins are further distinguished from the arteries by their larger size, thinner walls, and darker colour, due to the blood being seen through their walls.

Dissect from the ventral surface. In cleaning a vein take hold with the forceps, not of the vein itself but of the tissue surrounding it: and take especial care not to prick the vein, as by doing so you allow the blood to escape and obscure the dissection, and also

render the vein itself difficult to see owing to the loss of colour. Always dissect along and not across a bloodvessel, and pin out the parts so as to stretch it slightly.

I. Veins opening into the Sinus Venosus.

a. **The right superior vena cava**: a large vein opening into the right side of the sinus venosus, and returning to it the blood from the right side of the head and body, and from the right fore-limb. It is formed by the union of three veins :—

1. The **external jugular vein**: formed by

   i. The **lingual vein**: from the floor of the mouth and the tongue.

   ii. The **mandibular vein**: from the margin of the lower jaw.

2. The **innominate vein**: formed by

   i. The **internal jugular vein**: returning blood from the interior of the skull, which it leaves by an aperture at the posterior border of the orbit.

   ii. The **subscapular vein**: a small vein from the back of the arm and shoulder.

3. The **subclavian vein**: the largest of the three: formed by

   i. The **brachial vein**: from the fore-limb.

   ii. The **musculo-cutaneous vein**: a very large vein returning blood from the skin and muscles of the side and back of the body, and of the head as far forwards as the nose.

b. The **left superior vena cava**: its course and branches are the same as those of the right.

c. The **inferior vena cava**: a median vein which, commencing between the kidneys, runs forward to open into the posterior end of the sinus venosus. It returns to the heart blood from the liver and from the kidneys,

and indirectly from other viscera and from the hind limbs. It receives the following veins :—

i. The **right and left hepatic veins**: from the liver: these open into the vena cava inferior just before it joins the sinus venosus.

ii. The **renal veins**: from the kidneys: of these there are four or five on each side which open into, or rather form by their union, the inferior vena cava. The most anterior of these receive the veins from the fat bodies.

iii. The **ovarian veins** (in the female), or **spermatic veins** (in the male); returning blood from the ovaries or testes. They are usually four or five in number on each side, and open into the vena cava inferior between the renal veins.

II. Vein opening into the Left Auricle.

a. The **pulmonary vein**: formed by the union of the right and left pulmonary veins, returning to the heart the blood from the right and left lungs respectively. Each pulmonary vein runs along the inner side of its lung.

III. The Portal Systems.

A portal vein is one which, returning blood from the capillaries of some part, breaks up before reaching the heart into a second set of capillaries within some other organ; these again unite to form a vein which carries the blood to the heart. In the frog there are two portal systems, one supplying the kidneys, and the other the liver.

a. The renal portal system.

Trace back the anterior abdominal vein to the hinder end of the body, where it will be seen to be formed by the union of the two **pelvic veins.** *Follow back the pelvic vein of the right side to the base of the hind limb; here it will be seen to be one of two branches into which the* **femoral vein** *(the large vein returning blood from the hind limb) divides. The other branch of the femoral vein is the* **renal portal vein,** *which is to be followed to the outer side of the kidney*

1. The **right renal portal vein**: the dorsal branch of the right femoral vein: it runs forward along the outer side of the kidney and ends in numerous branches in its substance. It receives the following branches:—
   i. The **right sciatic vein**: from the muscles and skin of the back of the thigh: it joins the renal portal vein close to its commencement, and before it reaches the kidney.
   ii. The **right dorso-lumbar veins**: small veins from the dorsal wall of the body, and (in the female) from the oviduct: they join the renal portal vein opposite the kidney.
2. The **left renal portal vein**: its course and branches correspond to those of the right vein.

b. The hepatic portal system.

Formed partly by the anterior abdominal vein, which brings to the liver blood from the hind-limbs; and partly by veins returning blood from the alimentary canal.

1. The **anterior abdominal vein**: a median vein formed by the union of the two pelvic veins—the ventral branches of the femoral veins. It runs up the middle line of the ventral body-wall to the level of the liver, where it leaves the body-wall and divides into right and left branches, which enter the right and left lobes of the liver respectively. During its course it receives the following veins:—
   i. **Vesical veins**: from the bladder.
   ii. **Parietal veins**: from the ventral body-wall.
   iii. A **cardiac vein**: from a network of vessels on the truncus arteriosus.
2. The **hepatic portal vein**: a wide vein which runs in the mesentery and joins the anterior abdominal vein at its point of division into right and left branches; giving off, before doing so, a branch to the left lobe of the liver. It carries to the liver the blood from the walls of

the alimentary canal, and is formed by the union of the following veins :—

i. The **gastric vein**: from the stomach.

ii. **Intestinal veins**: from the whole length of the intestines, both small and large.

iii. The **splenic vein**: from the spleen: usually joins one of the intestinal veins.

C. The Arteries.

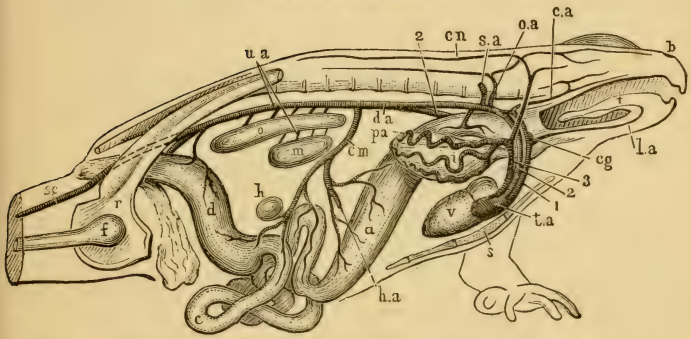

Fig. 5. Diagrammatic figure of the arterial system of the male frog, from the right side.

a, stomach: *b*, nostril: *c*, small intestine: *c.a*, carotid artery: *c.g*, carotid gland: *c.m*, cœliaco-mesenteric artery: *c.n*, cutaneous artery: *d*, large intestine: *d.a*, dorsal aorta: *f*, femur: *h*, spleen: *h.a*, hepatic artery: *i*, right lung: *l.a*, lingual artery: *m*, testis: *o*, kidney: *o.a*, occipito-vertebral artery: *p.a*, pulmonary artery: *r*, pelvic girdle: *s*, sternum: *s.a*, subclavian artery: *s.c*, sciatic artery: *t*, tongue: *t.a*, truncus arteriosus: *u.a*, urinogenital arteries: *v*. ventricle: 1, carotid arch: 2, systemic arch.: 3, pulmo-cutaneous arch.

Dissect as for the veins. Pass a small cork or roll of paper down the œsophagus, so as to distend it and stretch the aortic arches. Clean carefully the aortic arches, commencing at the truncus arteriosus; and follow the several arteries to their distribution, removing the veins and other structures when necessary. Note the division of the truncus arteriosus in front into right and left branches, each of which again divides into three aortic arches:— the **carotid arch,** *the* **systemic arch,** *and the* **pulmo-cutaneous arch.**

I. The Carotid Arch (the third embryonic arch; the two anterior ones disappearing in the adult): the most anterior of the three persistent arches: it runs round the side of the œsophagus, and is connected above with the second or **systemic arch**: its chief branches are—

1. The **lingual artery**: a small artery supplying the tongue. Immediately beyond the origin of the lingual artery there is a small spongy swelling, the **carotid gland**, on the carotid arch.

2. The **carotid artery**: runs forward beneath the base of the skull, and divides into

   i. The **external carotid artery**: supplying the roof and sides of the buccal cavity, and the orbit.

   ii. The **internal carotid artery**: which enters the skull and supplies the brain.

II. The Systemic Arch (the fourth embryonic arch): the middle arch of the three that persist in the adult. Runs somewhat obliquely round the œsophagus to the dorsal surface, and unites with its fellow of the opposite side about the level of the anterior ends of the kidneys to form the **dorsal aorta**: near the posterior ends of the kidneys it again divides into the two **iliac arteries.** Its branches are :—

a. Branches given off before the union of the two arches :

1. The **laryngeal artery**: to the larynx.
2. The **œsophageal arteries**: to the œsophagus.
3. The **occipito-vertebral artery**: dividing into

   i. The **occipital artery**: supplying the side of the head and jaws.

   ii. The **vertebral artery**: a large artery which runs back alongside of and above the vertebral column, and gives off branches to the muscles of the body-wall and to the spinal cord.

4. The **subclavian artery**: arises from the arch immediately behind the occipito-vertebral artery, and supplies the shoulder and fore-limb.

b. Branches given off after the union of the two arches to form the dorsal aorta :—

1. The **cœliaco-mesenteric artery**: a large median artery arising immediately beyond the point of union of the two arches (or sometimes from the left arch, just before the union), and supplying the stomach and intestines. Its branches are:

   i. The **cœliac artery**: which divides into

      α. The **gastric artery**: supplying the stomach.

      β. The **hepatic artery**: supplying the liver and gall-bladder.

   ii. The **mesenteric artery**: which divides into

      α. The **superior mesenteric artery**: supplying the upper part of the intestine.

      β. The **inferior mesenteric artery**: supplying the lower part of the intestine.

      γ. The **splenic artery**: supplying the spleen.

2. The **urinogenital arteries**: from four to six small arteries which arise from the ventral surface of the aorta between the kidneys, and immediately divide into right and left branches, supplying the kidneys, the reproductive organs and ducts, and the fat bodies.

3. The **lumbar arteries**: small paired lateral branches supplying the body-walls.

4. The **hæmorrhoidal artery**: a small median artery arising from the lower end of the aorta, and supplying the large intestine.

c. Branches formed by the division of the aorta :—

1. The **iliac arteries**: two large arteries formed by the division of the aorta, and supplying the hind-limbs. Each gives off a **hypogastric artery**, which supplies the bladder, giving **epigastric** branches to the ventral body-wall, and then continues as the **sciatic artery** down the leg, giving off branches to the muscles and skin of the thigh, and dividing at the knee into **peroneal** and **tibial arteries** supplying the leg and foot.

III. The Pulmo-cutaneous Arch (the fifth embryonic arch): the hindmost of the three persistent arches: it divides about the level of the carotid gland into:—

1. The **cutaneous artery**: a large artery which at first runs forwards and upwards and then turns backwards, supplying the skin of the back along the whole length of the body, and sending smaller branches to the sides of the head and the skin of the ventral surface.
2. The **pulmonary artery**: runs in a somewhat sinuous manner along the outer side of the whole length of the lung, giving off branches into its substance.

D. The Structure of the Heart.

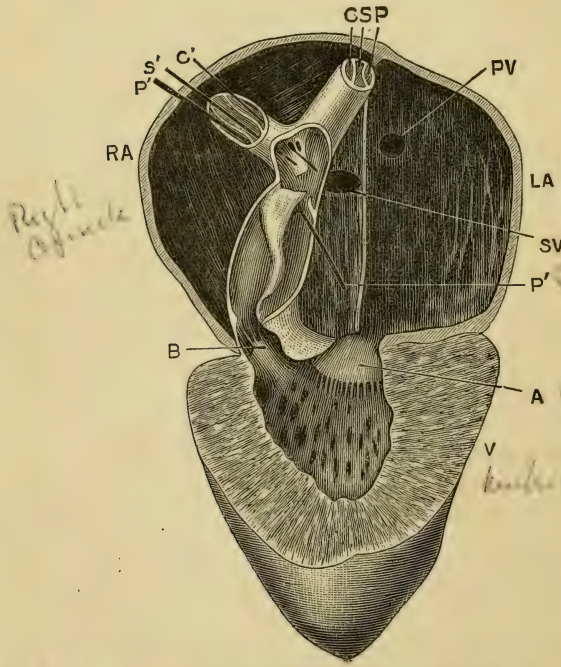

Fig. 6. The frog's heart seen from the ventral surface, and dissected so

as to show its structure. The ventral walls of the truncus arteriosus, and of the auricles and ventricle have been removed. (From a drawing by Mr. Hurst.)

A, auriculo-ventricular aperture and valve: **B**, aperture leading from ventricle to truncus arteriosus, with its valve: **C**, left carotid arch: **C′**, style passed down right carotid arch into the truncus arteriosus: **LA**, left auricle: **P**, left pulmo-cutaneous arch: **P′P′**, style passed down right pulmo-cutaneous arch into the truncus arteriosus: **PV**, opening of pulmonary vein into left auricle: **RA**, right auricle: **S**, left systemic arch: **S′**, style passed down right systemic arch into the truncus arteriosus: **SV**, opening from sinus venosus into right auricle: **V**, ventricle.

Having completed the dissection of the blood vessels, remove the heart completely, and dissect it carefully under water so as to display its structure more fully.

a. *Cut open the ventricle from the ventral surface: note its thick spongy walls, and the small size of its central cavity.*

b. *Pass a seeker from the ventricle*

i. *Into the truncus arteriosus.*

ii. *Into the right and left auricles.*

c. *Open the auricles from the ventral surface; wash out the contained blood, and note the very thin inter-auricular septum dividing the right and left auricles from one another.*

d. *Open the sinus venosus, and pass a seeker from it into the right auricle.*

e, *Trace carefully the pulmonary vein, and see its opening into the left auricle.*

f. *Cut away the ventral wall of the truncus arteriosus with fine scissors, to see the valves in its interior.*

g. *Cut across the aortic arches just beyond the division of the truncus into right and left branches, and note that though each branch is apparently a single vessel, its internal cavity is really divided into three vessels corresponding to the three aortic arches. Pass bristles down these aortic arches, and note the points at which they severally open into the truncus arteriosus.*

E. Microscopic Examination of Blood.

I. Frog's Blood.

1. Normal.

Place on a slide a small drop of blood from the heart of a frog: dilute it with a drop of normal salt solution (0·75 *per cent.*)*: put on a thin coverglass and run a ring of oil round the edge to prevent evaporation: examine with high power, and note:—*

The **blood corpuscles** floating in the colourless **liquor sanguinis** or **plasma.** The corpuscles are of two kinds.

i. **Red corpuscles**; very numerous: pale reddish or yellowish red colour: flattened oval shape, with rounded edges and a central bulging—the **nucleus.** The flattened shape is best seen when a corpuscle turns edgeways. Size $\frac{1}{1000} \times \frac{1}{1700}$ of an inch.

ii. **White corpuscles**: much fewer in number and of smaller size: colourless: granular: subspherical in shape: exhibiting "amœboid" movements. *Sketch one half a dozen times at intervals of half a minute.*

2. Action of acetic acid on blood.

Place a fresh drop of blood on a clean slide: add a drop of acetic acid: cover, and examine with high power: note the changes produced:—

i. **Red corpuscles**: the nuclei become much more apparent than before: the red colour disappears.

ii. **White corpuscles**: become clearer: show nuclei, sometimes more than one in a single corpuscle.

II. Human Blood.

1. Normal.

Prick the tip of your finger and place a small drop of the blood on a slide: add a drop of normal salt solution, cover, and examine as before. Note:—

i. **Red corpuscles**: much smaller than in frog's blood: in form of circular biconcave discs with

rounded edges, but no nuclei. Note the tendency of the red corpuscles to run together into rouleaux, like piles of coins. Average diameter about $\frac{1}{3200}$ of an inch.

ii. **White corpuscles**: much as in frog: slightly larger than the red corpuscles, averaging about $\frac{1}{2500}$ of an inch in diameter; amœboid movements not well seen unless the slide is warmed.

2. **Action of acetic acid.**

Treat with acetic acid as before: note that unlike the frog's no nuclei are visible in the red corpuscles.

F. Circulation of the Blood in the Web of a Frog's Foot.

The Web uniting together the toes of the frog's foot is so thin and transparent, that with the microscope the blood can readily be seen coursing along the capillaries.

Examine a frog prepared to show the circulation in the web of the foot. Note:

1. With a low power:

a. The irregularly branched **pigment cells** to which the colour of the frog's skin is due.

b. The fine meshwork of bloodvessels along which the blood can be seen flowing. These bloodvessels are of three kinds:—

i. The **arteries**: carrying blood to the web: distinguished by the fact that when they divide the direction of flow of the blood is from the larger trunk to its branches.

ii. The **capillaries**: a close network of very small, very thin-walled vessels, along which the blood flows from the arteries to the veins.

iii. The **veins**: carrying the blood away from the web back towards the heart: distinguished from arteries by the fact that the blood flows from smaller to larger vessels.

2 With a high power: *note the following points:*

a. The walls of the arteries and veins; much thicker than

those of the capillaries, which latter are often difficult to see.

b. The tendency of the white corpuscles to creep along the sides of the vessels, while the red corpuscles rush far more rapidly along the middle of the stream: seen best in the small arteries.

c. The variations in calibre of the small arteries and capillaries: whilst under observation an artery or capillary may be seen to change its size to a considerable extent.

d. The indefinite character of the capillary circulation. Owing to changes of size in adjacent vessels, the direction of flow of the blood in a given capillary may become reversed.

e. The elasticity of the red corpuscles: seen best when they are turning the corners of the capillary network.

f. The tendency of the white corpuscles to migrate through the walls of the capillaries into the tissues outside. This is much increased by the application of some irritant substance, as a drop of weak acid, to the web.

Chap. III.—ELEMENTARY HISTOLOGY.

When examined under the microscope all the different tissues and organs of the body are found to consist of elementary bodies called **cells,** and of an **intercellular substance** connecting the several cells together. These cells, of which a white blood corpuscle is a typical example, vary much in shape, size, and structure in different tissues, but are to be considered as fundamentally equivalent to one another. The intercellular substance varies very much in quantity; it may be almost absent, so that the several cells are practically in contact with one another; or may be so abundant as to separate them widely: it is to be viewed as formed by the cells, and therefore as secondary in importance to them.

A. Epithelium.

Epithelium consists of cells placed side by side so as to form layers, which cover the surface of the body (epidermis) and line the alimentary canal and the various internal cavities of the body. At the external apertures of the body the epidermis becomes directly continuous with the epithelial lining of the internal cavities.

The layers may be one or more cells in thickness: in the former case the epithelium is said to be **simple,** in the latter **stratified.**

Epithelium is of different kinds, according to the shape and structure of its component cells.

I. Squamous Epithelium: the component cells are flattened parallel to the surface they cover: if the epithelium is stratified the flattening is most marked in the most superficial cells.

a. Isolated cells.

Scrape gently the inside of your cheek with the handle of a scalpel, and put the scrapings on a slide; cover and examine with a high power: draw, showing:—

i. **Shape**: large flattened scale-like cells, often slightly curled up at the edges.

ii. The **nucleus**: oval and granular: near the middle of the cell: rendered more distinct by acetic acid or magenta.

b. Cells in situ: cast skin of newt.

Take a small piece of the prepared specimen, which has been stained in hæmatoxylin, and then, after treatment with alcohol, cleared with creosote and turpentine. Mount the specimen in balsam; cover, and examine with high power: note

i. Flattened cells fitted together at their edges to form a continuous layer. Each cell has a large nucleus near its centre.

II. Columnar epithelium: Consists of elongated rodlike cells placed vertically to the surface on which they rest. If the epithelium is stratified the columnar character is most marked in the most superficial cells.

a. Isolated cells: From small intestine of frog: isolated by maceration for 24 hours in Ranvier's alcohol, and stained with picro-carmine.

Mount a small drop of the prepared specimen in glycerine: paint a ring of cement round the coverglass; and examine with high power: note:—

i. The columnar shape of the cells: their nuclei. The cells often remain side by side in little groups.

b. Cells in situ.

Take prepared section of stomach of dog which has been stained and then cleared in creosote and turpentine. Mount in balsam and examine with high power: note:—

i. The superficial layer of long narrow columnar cells packed together side by side; with nuclei at their inner or deeper ends.

III. Ciliated epithelium: the cells, which are usually columnar, bear at their free ends tufts of exceedingly fine hair-like processes—**cilia**—which, when living, exhibit active lashing movements.

a. Isolated cells. From trachea of rabbit: isolated by maceration for 24 hours in Ranvier's alcohol; stained with picro-carmine, and scraped into glycerine.

Mount a small drop of the prepared specimen in glycerine: paint a ring of cement round the coverglass; examine with high power, and note:—

i. The shape of their cells: their nuclei; and the tuft of cilia at one end.

b. Cells in situ: ciliary movement.

Snip off a small piece of the epithelium from a freshly killed frog, either from the tongue or from the roof of the mouth near the eyeball: mount in normal salt solution, and add a small drop of gamboge water to render the movements more clearly visible: examine with high power; note:—

i. The currents due to the ciliary motion.

ii. The movements of the individual cilia: best seen when the specimen is beginning to die, and the movements to slacken in speed.

IV. Stratified epithelium: cells arranged in several layers.

Take prepared section of œsophagus of rabbit, or of conjunctiva of rabbit or pig, which has been hardened in chromic acid, stained, and cleared in creosote and turpentine. Mount in balsam, examine with high power, and note:—

i. The stratification of the epithelium.

ii. The transition from the deeper spherical or columnar cells to the superficial squamous cells.

B. Glands.

A gland consists essentially of a layer of epithelial cells secreting some special fluid. The epithelial surface may be flat, but is more usually folded, often in a very complicated manner, in order to increase the extent of the secreting surface.

a. Simple Glands. In simple glands the epithelial surface is increased by simple pit-like depressions, whose mouths serve to discharge the secretion on the free surface.

Take prepared section of large intestine of rabbit which has been hardened in chromic acid, stained, and cleared in creosote and turpentine. Mount in balsam, and examine first with low power, then with high. Note:—

i. The shape of the glands: simple tubular depressions of the surface.

ii. The characters of the glandular epithelium lining the pits: a single layer of short columnar granular cells.

b. Compound glands. In compound glands each depression instead of being a simple pit is itself subdivided or branched, often in a very complicated manner. There are two chief varieties: (1) **tubular glands,** in which the several sub-divisions are tubular, and of tolerably uniform diameter throughout: and (2) **racemose glands,** in which the ends of the pits are dilated into globular chambers or alveoli, to which the special glandular epithelium is usually confined.

Compound tubular glands. *Take prepared section of kidney of frog: mount in balsam, and examine with both low and high powers. Note:—*

i. The **tubular gland-cavities,** cut at various angles. If cut transversely a tube will appear as a circular ring: if cut obliquely as a more or less elongated elliptical ring: if cut longitudinally as two parallel rows of epithelial cells.

ii. The characters of the **gland cells:** a single layer of cubical granular cells.

iii. The **Malpighian bodies:** spherical dilatations on the tubes, into which project little knots of capillary bloodvessels. Their structure is most readily made out in specimens in which the bloodvessels have been injected with a coloured substance to make them more distinct.

c. Glands of stomach.

The glands of the stomach are well adapted for a more minute examination of the histology of glands.

Examine again with a high power the section of cardiac end of dog's stomach already used for columnar epithelium: note:—

1. **Characters of the glands:** tubular glands, either simple or very slightly branched.

2. **Characters of the gland cells:** three distinct kinds of cells.

   i. **Columnar cells:** arranged in a somewhat radiate manner round the mouths of the glands.

   ii. **Cubic cells:** or peptic cells: lining the deeper parts of the glands: cubical granular cells with centrally placed nuclei.

iii. **Ovoid cells**: large oval cells with large nuclei: they are less numerous than the other two forms, and occur most abundantly a short way below the mouths of the glands: they are said to secrete the acid of the gastric juice.

C. Muscle.

In muscular tissue the component cells are much elongated and, in the higher forms, very greatly modified. Muscular tissue is of two kinds: (1) **striated**, or **voluntary**; of which all muscles that are under the control of the will consist: and (2) **non-striated**, or **involuntary**; forming those muscles over whose contractions the will has no direct control. The muscular tissue of the heart, which though involuntary is striated, forms the chief exception to this rule.

I. Striated, or voluntary muscle.

a. **Crab's muscle.** *Tease in glycerine a small piece of crab's muscle that has been hardened in alcohol; cover, and examine with both low and high powers: note:—*

i. The elongated fibres of which the muscle consists. Each fibre is a single cell, and is enclosed in a delicate sheath—the **sarcolemma**—which will be visible in but few cases; it is most readily seen at places where the fibre has been torn across.

ii. The alternate light and dark bands with which the muscle fibres are marked transversely, and from which the name striated muscle is derived.

iii. The readiness with which the fibres split up longitudinally into **fibrils**,

b. **Frog's muscle.** *Tease gently a piece of fresh frog's muscle in normal salt solution, cover, and examine with high power: note*

i. The **transverse striations.**

ii. The **sarcolemma**: best seen by slightly crushing the specimen.

iii. The **nuclei** in the fibres: seen on addition of acetic acid.

II. Non-striated, or involuntary muscle.

Take specimen of frog's bladder prepared by maceration in Ranvier's alcohol for 24 hours, and removal of the epithelium of the inner surface by pencilling with a fine brush: stained, and cleared with creosote and turpentine. Mount in balsam, and examine with low and high powers: note:—

i. The bands of muscular fibre.

ii. The formation of each band by a number of elongated, fusiform, nucleated muscle-cells.

iii. The absence of transverse striation in the muscle.

D. Connective Tissues.

Under the name "connective tissue" are included various tissues whose functions are mainly passive, and which serve to support, strengthen, and bind together the various organs and parts of the body. Histologically the connective tissues consist of elements of four kinds, united together in very varying proportions in different situations: (1) white fibrous tissue; (2) yellow elastic tissue; (3) connective tissue corpuscles, which are comparatively little altered cells, usually branched; and (4) ground substance, or intercellular substance.

I. White fibrous tissue. Consists of a number of fine transparent fibres of a more or less cylindrical shape, and with a very characteristic wavy outline. The fibres are usually arranged side by side in bundles, and each fibre presents a number of longitudinal fibrillar striations. The cellular character of white fibrous tissue is difficult to recognise; but each fibre is formed from a single fusiform cell of which the nucleus disappears during development.

a. **Tendon of rat's tail**: *pull out a small piece of tendon from the tail of a rat: place it on a slide in a drop of normal salt solution: spread it out with needles, cover and examine with high and low powers: note*

i. **fibres**; with wavy outlines.

ii. **fibrillæ**: longitudinal wavy striations within the fibres.

Add a drop of acetic acid to the preparation: note that

iii. The fibres swell up and become transparent.

iv. Rows of connective tissue corpuscles with nuclei become visible between the fibres.

b. Isolated fibres and fibrillæ: *take a small piece of tendon that has been macerated for 24 hours in baryta water or picric acid to dissolve the cementing ground substance: tease it in a drop of glycerine: cover and examine with high power: note:—*

i. Isolated fibres and fibrillæ.

II. Yellow elastic tissue. Consists of fine branched homogeneous fibres, with great power of resisting chemical reagents: the fibres are formed from branched cells which lose their nuclei completely during development.

a. Ligamentum nuchæ of ox: *tease finely a small shred in water: examine with low and high powers: note:—*

i. The branching fibres, with very sharp outlines.

ii. The tendency of the branches to anastomose with one another and so form networks.

iii. The tendency of the fibres and branches to curl up at their broken ends.

Add a drop of acetic acid: note that

iv. No alteration whatever is produced in the fibres.

v. No nuclei appear.

III. Areolar tissue: a meshwork composed of both white fibrous and elastic tissues.

a. Subcutaneous tissue of mammal: *Take a freshly killed rat, and snip off a small piece of the loose fibrous tissue which connects the skin with the subjacent parts: spread it on a slide: add a drop of normal salt solution: cover, and examine with low and high powers: note*

i. Meshwork composed of white fibrous tissue with wavy outlines, mingled with which are branched elastic fibres.

Add acetic acid: note that

ii. The white fibrous tissue swells up and becomes transparent.

iii. The elastic tissue is unaltered.

iv. Connective tissue corpuscles with nuclei become visible.

IV. Adipose tissue. Consists of a network of vascular connective tissue, in the meshes of which are fat cells, *i.e.*, connective tissue corpuscles in which large quantities of fatty matter have accumulated.

a. Omentum of rabbit or kitten: *mount a small piece of fresh omentum in normal salt solution; examine with low and high powers: note:—*

i. The vascular connective tissue meshwork, in which lie the

ii. **Fat cells:** large spherical, or from mutual pressure, polyhedral, cells: distended with fatty matter, and with nucleus at one side.

b. Osmic acid specimen.

Note the reduction of the osmic acid by the fat, which becomes stained a dark brown or black colour.

E. Cartilage.

In cartilage or gristle the intercellular substance, which in most other tissues is only present in small quantity, is greatly increased so as often to far exceed in bulk the cells which it connects together. The intercellular substance forms a dense translucent matrix resembling an extremely stiff jelly, in which are imbedded the cartilage cells, either singly or in groups. In young cartilage the intercellular substance is much less abundant, and the cells consequently closer together than in older or more mature specimens.

I. Hyaline cartilage. *Take a small piece of cartilage from the shoulder girdle of a newt: scrape away gently any muscle or other tissue that may adhere to it: mount in normal salt solution, and examine with low and high powers: note:—*

i. The **intercellular matrix:** hyaline or faintly granular.

ii. The **cartilage cells**: imbedded in the matrix: each cell nucleated, and occupying a cavity or lacuna in the matrix. In places the cells are in groups of twos or fours owing to recent division.

Wash the specimen thoroughly in water: stain with hæmatoxylin, and mount as a permanent preparation in glycerine: examine with high power, and note that

iii. The cell nuclei are stained deeply, and the matrix very slightly: the layer of matrix immediately surrounding each cell—the **capsule**—stains more deeply than the other parts.

II. Articular cartilage. Forms caps covering the ends of those bones which fit together to form moveable joints: these caps act as elastic cushions to break the force of shocks.

Mount in balsam prepared section of articular cartilage from the head of the femur, the section being made perpendicular to the articular surface: examine with low and high powers: note:—

i. The **matrix**: hyaline or faintly granular.

ii. The **cartilage cells.** Towards the free surface the cells and cell groups become gradually flattened and arranged parallel to the surface.

F. Bone.

Bone consists of a dense fibrillar intercellular matrix, in which are imbedded cells which lie in cavities connected with one another by fine branching canals. The matrix is richly impregnated with inorganic salts, chiefly phosphate and carbonate of lime, which form about two-thirds by weight of the substance of the bone and give it its great hardness and strength. The matrix, with its contained bone-cells, is arranged in concentric layers or lamellæ, formed in succession one within another around central canals in which lie the bloodvessels, which penetrate the bone in great numbers. A bloodvessel with its surrounding layers of matrix and cells is spoken of as a **Haversian system.**

1. *Examine with both low and high powers prepared transverse sections of a long bone: note:—*

i. The **Haversian systems**: concentric layers surrounding the Haversian canals.

ii. **Incomplete Haversian systems**: filling up the spaces between the complete systems. These are the remains of systems which were formerly complete but have been removed in part by the process of absorption which is continually going on in bone.

iii. The **lacunæ**: or spaces in the matrix in which the bone cells lie.

iv. The **canaliculi**: very fine branching canals connecting the lacunæ together: probably occupied while the bone is living by branching processes of the bone-cells.

v. The large central **medullary cavity** of the bone: occupied during life by the **marrow,** which consists of adipose tissue, with very numerous bloodvessels and large nucleated reddish coloured marrow cells.

vi. The **peripheral or circumferential lamellæ**: forming the most superficial layer of the bone: a series of concentric lamellæ parallel to the surface.

vii. The **perimedullary lamellæ**: a series of concentric lamellæ lining the central medullary cavity of the bone.

Chap. IV.—THE SKELETON OF THE FROG.

The skeleton, which forms the hard internal parts of the frog, is composed partly of cartilage and partly of bone. It forms a framework giving definite shape to the body, and precision to the movements; and serves also to protect from injury some of the more important and delicate organs, notably the central nervous system, the sense organs, and the heart. In the early stages of its development the skeleton consists entirely of cartilage: in the adult this primary cartilaginous skeleton is replaced to a greater or less extent by bone. Bone may also be developed in places where there was no pre-existing cartilage, and is then called **membrane bone,** in contradistinction to the former kind, or **cartilage bone,** which replaces cartilage. Membrane bones arise in the first instance as ossifications in the dermis or deeper layer of the skin: in many fish they retain this primitive position, but in the frog and most higher vertebrates they sink below the skin and graft themselves on to the more deeply placed cartilaginous skeleton. Cartilage may also become calcified, *i.e.*, have calcareous salts deposited in its matrix, without in any way taking on the character of true bone.

The skeleton may be conveniently divided into (1) the **axial portion,** including the skull and the vertebral column: and (2) the **appendicular portion,** including the limbs and the limb-girdles which attach them to the body.

Examine the prepared skeletons and make careful drawings to scale of the several parts. Colour, in your drawings, the cartilage blue, the cartilage bones yellow, and the membrane bones white or red. Prepare skeletons for yourself by soaking the parts in hot water, and carefully brushing away the soft tissues until the skeleton is clean.

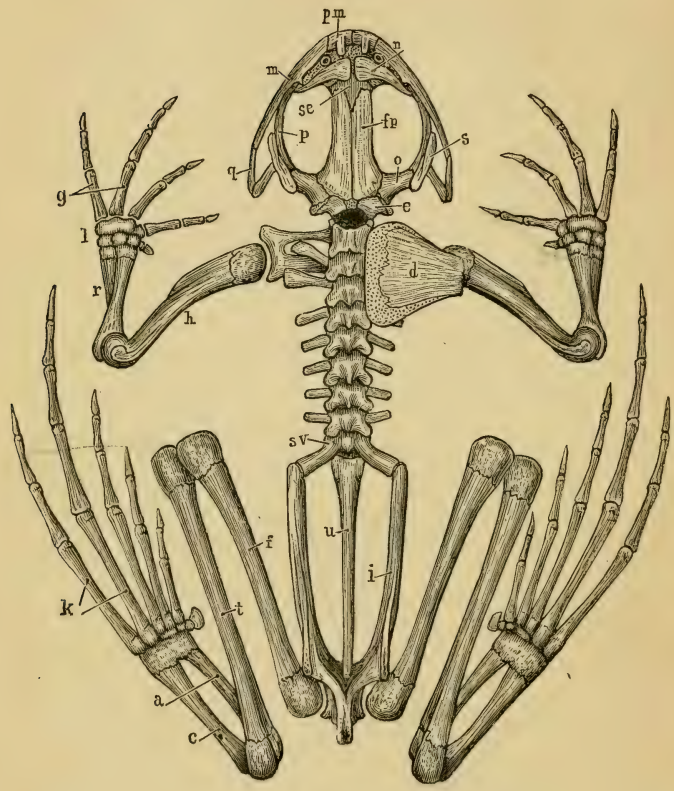

Fig. 7. The skeleton of the frog, seen from the dorsal surface: the left suprascapula and scapula have been removed.

a, astragalus: *c*, calcaneum: *d*, suprascapula: *e*, exoccipital: *f*, femur: *fp*, frontoparietal: *g*, metacarpals: *h*, humerus: *i*, ilium: *k*, metatarsals: *l*, carpus: *m*, maxilla: *n*, nasal: *o*, pro-otic: *p*, pterygoid: *pm*, premaxilla: *q*, quadratojugal: *r*, radio-ulna: *s*, squamosal: *se*, sphenethmoid: *s.v*, sacral vertebra: *t*, tibio-fibula: *u*, urostyle.

A. The Axial Skeleton.

I. The vertebral column or "back bone." A bony tube which surrounds and protects the spinal cord: divisible into an anterior part which is divided transversely into nine rings or **vertebræ,** and a posterior unsegmented portion of about equal length—the **urostyle.** At the sides of the tube between the successive vertebræ are the **intervertebral foramina** through which the nerves pass out from the spinal cord to the various parts of the body.

a. Structure of a vertebra. *Examine one of the vertebræ, say the third, more closely: draw it, showing:—*

i. Its ring-like shape: the central **neural canal** in which the spinal cord lies.

ii. The **centrum** or **body**: the thickened ventral portion of the ring: it articulates with the centra of the vertebræ in front of and behind it; and forms the floor of the **neural canal.**

iii. The **neural arch**: the lateral and dorsal portions of the ring: forming the sides and roof of the neural canal.

iv. The **spinous process** or **neurapophysis**: a small blunt median process projecting upwards and backwards from the top of the neural arch.

v. The **transverse processes**: a pair of large lateral processes projecting horizontally outwards from the sides of the neural arch.

vi. The **articular processes** or **zygapophyses**: on the anterior and posterior borders of the neural arch: they articulate with corresponding processes on the vertebræ in front and behind, and so serve to link the vertebræ together.

α. The **anterior articular processes** or **præzygapophyses**: look upwards and slightly inwards.

β. The **posterior articular processes** or **postzygapophyses**: look downwards and slightly outwards.

b. Peculiar vertebræ.

i. The **atlas** or first vertebra: articulates in front with the posterior end of the skull: has no transverse processes. Note the large gap on the dorsal surface between the skull and the neural arch of the atlas: through this gap, which is closed by the strong **occipito-atlantal membrane,** the central nervous system is divided and destroyed in the operation of pithing a frog.

ii. The **sacrum:** the ninth vertebra; has very stout backwardly directed transverse processes, which support at their outer ends the pelvic arch.

c. The **urostyle.** The unsegmented posterior portion of the vertebral column; probably equivalent to two or more vertebræ fused together. It articulates in front with the body of the sacral vertebra by two surfaces. Along its dorsal surface runs a prominent vertical ridge, highest in front and gradually diminishing posteriorly: the neural canal is continued down the anterior part of this ridge. At the sides of the urostyle, and about the length of a vertebra from its anterior end, are a pair of small holes through which nerves pass out, and which therefore correspond to inter-vertebral foramina.

II. The skull. Consists of (1) an axial portion, the **cranium proper,** enclosing the brain and forming an anterior continuation of the vertebral column: (2) the **olfactory capsules** and the **auditory capsules,** which are fused with the anterior and posterior ends of the cranium respectively: (3) the bony framework of the **jaws,** and the **hyoid apparatus.**

In the skull the original cartilage is not so largely replaced by bone as in the vertebral column, large tracts of unossified cartilage persisting in the adult. Besides the cartilage bones the skull is further strengthened by the addition of numerous membrane bones.

1. The **cranium proper.** An unsegmented cartilaginous tube whose cavity forms the anterior part of the neural canal and lodges the brain. The roof of the tube is imperfect, there being one large **anterior fontanelle,** and two smaller **posterior fontanelles,** which are closed by membrane only. In the cartilage are developed cartilage bones, and around it membrane bones.

To study the cranium satisfactorily, the membrane bones should be stripped from one of the skulls you have prepared as directed above.

a. Cartilage bones of cranium proper.

i. The **exoccipitals:** two irregular bony masses at the sides of the posterior end of the skull. They almost completely surround the **foramen magnum** or entrance to the cranial cavity; and bear on their posterior surfaces the **occipital condyles,** two oval convex processes which articulate with the first vertebra or atlas.

ii. The **sphenethmoid** or **girdle-bone:** a bony tube which encircles the anterior end of the cranial cavity, and extends forwards into the olfactory region: in front it is divided by a vertical partition into right and left cavities, in which lie the olfactory nerves.

b. Membrane bones of cranium proper.

i. The **fronto-parietals:** two long flat bones on the top of the brain-case; covering the fontanelles, and overlapping the hinder end of the sphenethmoid.

ii. The **parasphenoid:** a ⊥ shaped bone on the ventral surface of the cranium: its lateral processes underlying the auditory capsules.

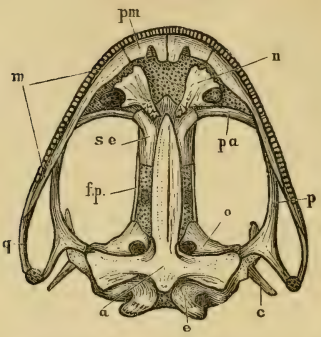

Fig. 8. The frog's skull, from the ventral surface.

a, parasphenoid: *c*, columella: *e*, exoccipital: *f.p*, frontoparietal: *m*, maxilla: *n*, vomer: *o*, pro-otic: *p*, pterygoid: *pa*, palatine: *pm*, premaxilla: *q*, quadratojugal: *se*, sphenethmoid.

2. The **sense capsules:** cartilaginous and bony capsules which surround and protect the olfactory and auditory organs; and are fused with the cranium proper so as to form parts of the skull.

a. The **auditory capsules** are fused with the sides of the posterior end of the cranium, to which they form wing-like projections: they consist largely of cartilage.

α. **Cartilage Bones of auditory capsules.**

i. The **pro-otics:** a pair of irregular shaped bones in the anterior walls of the capsules, and forming also parts of their roof and floor.

b. The **olfactory capsules** are fused with the anterior end of the cranium, and also with one another. They consist very largely of cartilage, which is produced in front into the **rhinal processes.**

α **Cartilage bones of olfactory capsules.** The **sphenethmoid** as already noticed extends forwards so as to invade the olfactory region, but does not properly belong to the olfactory capsules.

β. Membrane bones of olfactory capsules.

i. The **nasals**: two triangular bones on the dorsal surface of the anterior end of the head: the bases of the triangles are turned towards the middle line and meet one another in front, while their posterior ends diverge from one another and enclose, with the anterior ends of the fronto-parietals, a diamond shaped patch in which the sphenethmoid is visible from the dorsal surface.

ii. The **vomers**: two triradiate bones on the ventral surface of the fore part of the head: each vomer bears at its inner and posterior angle a small group of pointed teeth, and forms the inner boundary of the posterior narial opening of its side.

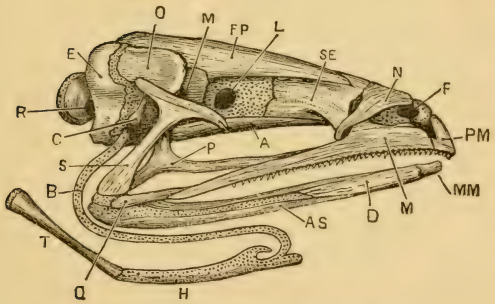

Fig. 9. The frog's skull from the right side.

A, parasphenoid: AS, angulosplenial: B, anterior cornu of hyoid: C, columella: D, dentary: E, exoccipital: F, nostril: FP, frontoparietal: H, body of hyoid: L, aperture for exit of optic nerve: M, maxilla: MM, mento-meckelian: M′, aperture for exit of fifth and seventh nerves: N, nasal: O, pro-otic: P, pterygoid: PM, premaxilla: Q, quadratojugal: R, aperture for exit of ninth and tenth nerves: S, squamosal: SE, sphenethmoid: T, posterior cornu of hyoid.

3. The **jaws**: consist of two cartilaginous arches on each side, maxillary and mandibular, in connection with which cartilage and membrane bones are developed. Each arch meets and fuses with its fellow in the middle line in front; and the maxillary arches, forming the

upper jaw, are firmly connected with the cranium by anterior and posterior bony struts.

a. The **maxillary arch.**

α. **Cartilage bones of maxillary arch.**

i. The **pterygoid**: a large triradiate bone, the inner limb of which is connected with the auditory capsule; while the posterior limb runs back to the angle of the mouth, and the anterior limb forwards along the upper jaw to the palatine bone.

ii. The **palatine**: a slender transverse bone connecting the upper jaw with the anterior end of the sphenethmoid.

iii. The **quadratojugal**: a short bone forming the posterior part of the margin of the upper jaw.

β. **Membrane bones of maxillary arch.**

i. The **maxilla**: a long thin bone forming the greater part of the margin of the upper jaw: it bears teeth along its whole length which are anchylosed with the bone. It is connected behind with the quadratojugal; about the middle of its length with the anterior limb of the pterygoid and with the palatine; and in front with the premaxilla.

ii. The **premaxilla**: a small bone which meets its fellow in the middle line in front, and so completes the margin of the upper jaw: like the maxilla it bears teeth. It gives off on its dorsal surface a backwardly projecting process which forms part of the inner boundary of the nostril.

b. The **mandibular arch**: the upper part of the arch remains unossified as the **quadrate cartilage,** which forms the **suspensorium,** *i.e.*, serves to connect the lower jaw with the skull. It is a rod of cartilage which is fused above with the auditory capsule, and runs downwards and backwards to the angle of the mouth, where it is connected with the hinder end of

quadratojugal bone. The lower part of the arch also persists in part unossified as **Meckel's cartilage**, which forms the base of the lower jaw, but is ensheathed by cartilage and membrane bones.

α. **Cartilage bones of mandibular arch.**

i. The **angulosplenial**: ensheaths the inner and lower surfaces of Meckel's cartilage along the greater part of its length: near its hinder end it is produced upwards into the coronary process.

ii. The **mentomeckelian**: a small ossification in Meckel's cartilage at the symphysis, *i.e.*, the union of the arches of the two sides at the chin.

β. **Membrane bones of mandibular arch.**

i. The **squamosal**: a T shaped bone, the body of which is closely applied to the outer surface of the quadrate cartilage. The posterior limb of the T is attached to the outer surface of the auditory capsule, and with the body of the squamosal helps to support the **tympanic cartilage**, a ring of cartilage surrounding the tympanic membrane.

ii. The **dentary**: a flat bone covering the outer surface of the distal half of Meckel's cartilage, as far forward as the mentomeckelian bone.

4. The **hyoid apparatus** (fig. 9). Consists of the hyoidean arch and the remains of the branchial arches of the two sides, together with a median ventral plate—the **body of the hyoid**—which unites their lower ends together, and lies in the floor of the mouth. The hyoid apparatus consists almost entirely of cartilage.

a. The **hyoid arch.**

i. The **columella** (figs. 9 and 10): the top of the hyoid arch: forms a small rod, partly bone and partly cartilage, the inner end of which is inserted into the **fenestra ovalis**—an aperture in the outer wall of the auditory capsule—, while the outer end is attached to the tympanic membrane rather above its middle.

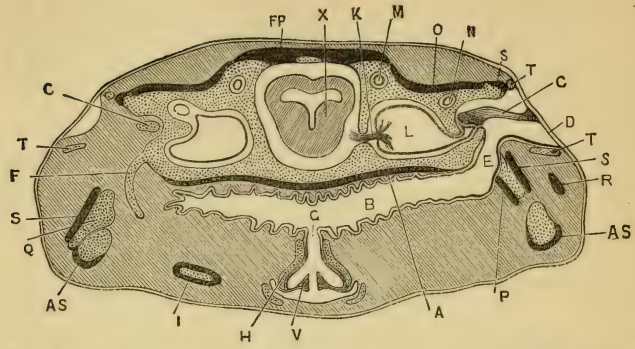

Fig. 10. A transverse section across the posterior part of the frog's head, to show the position and relations of the auditory organs, Eustachian tubes, and hyoid apparatus. On the right side the section passes through the tympanic cavity and the columella; on the left side through the anterior cornu of the hyoid. The cartilage is dotted, and the bones represented black.

A, parasphenoid: AS, angulosplenial: B, buccal cavity; C, columella: D, tympanic membrane: E, Eustachian tube: F, anterior cornu of the hyoid: FP, frontoparietal: G, glottis: H, arytenoid cartilage: I, posterior cornu of hyoid: K, auditory nerve: L, vestibule: M, anterior vertical semicircular canal: N, horizontal semicircular canal: O, pro-otic: P, pterygoid: Q, quadrate cartilage: R, quadratojugal: S, squamosal: T, tympanic cartilage: V, vocal cord: X, mid-brain.

ii. The **anterior cornu of the hyoid**: a long slender curved rod of cartilage: attached above to the auditory capsule just below the fenestra ovalis, and curving at first backwards and then forwards and downwards to be attached to the anterior outer angle of the body of the hyoid.

b. The **body of the hyoid**: a flat squarish plate of cartilage formed by the fused ventral ends of the hyoid and branchial arches, and lying in the floor of the mouth: short processes are given off from its angles.

c. The **posterior cornua of the hyoid**: a pair of stout bony processes diverging from the hinder border of the body of the hyoid.

B. The Appendicular Skeleton.

Consists of the limbs and the limb-girdles. As in the case of

the axial skeleton it consists at first entirely of cartilage, which becomes afterwards replaced to a greater or less extent by cartilage-bone. Membrane bones, *i.e.*, bones developed independently of cartilage, are very rare, the clavicles being the only examples met with in the frog. (Fig. 7.)

1. The pectoral girdle.

Consists originally of two half rings of cartilage, one on each side of the body, which they encircle a short way behind the head; the dorsal ends of the half rings are attached by ligaments and muscles to the vertebral column, while the ventral ends are united together in the median line by the **sternum** or "breast bone."

Each half ring bears in the middle of its outer surface a cup-shaped cavity, which forms with the first bone of the fore-limb the shoulder joint. The part of the arch above the joint is the **scapular portion**; and the part below, which is divided into anterior and posterior portions, the **coracoid.**

a. The **scapular portion**: divided into

- i. The **suprascapula**: the upper portion: a thin expanded plate of cartilage overlapping the first four vertebræ; partly calcified and partly ossified, though very imperfectly.
- ii. The **scapula**: an oblong bony plate, constricted in the middle: it forms the upper half of the **glenoid cavity,** the cavity of the shoulder joint.

b. The **coracoid portion**: forms the lower half of the glenoid cavity; it is divided into anterior and posterior portions, separated from each other by the **coracoid foramen.**

- i. The **precoracoid**: a slender horizontal bar of cartilage connecting the anterior edge of the scapula with the sternum.
- ii. The **clavicle**: a slender membrane-bone, closely applied to the anterior border of the precoracoid: its outer or scapular end is bent forwards almost at a right angle. Noteworthy as being the only membrane-bone in the appendicular skeleton.

iii. The **coracoid**: a stout bone, wider at its inner than its outer end: it connects the posterior edge of the scapula with the sternum.

c. The **sternum**: lies in the mid-ventral line: it consists originally of two lateral halves which fuse completely in front and behind, but remain distinct in the median portion. It presents from before backwards the following parts:—

i. The **episternum**: a flat circular plate of cartilage.

ii. The **omosternum**: a slender bony rod projecting forwards in front of the clavicles.

iii. The **epicoracoids**: a pair of narrow strips of cartilage closely applied to one another, and lying between the ventral ends of the precoracoids and coracoids.

iv. The **sternum proper**: a rod of cartilage ensheathed in bone projecting backwards behind the coracoids.

v. The **xiphisternum**: a broad expanded plate of cartilage.

2. The fore-limb.

The bones, which are all cartilage bones, are elongated with enlarged ends, excepting the small bones of the wrist. The enlarged ends or **epiphyses** ossify independently of the shaft of the bone, with which they do not unite until late in life: the extremities are capped with articular cartilage. The end of a bone which, when the limb is extended, is nearer to the body is called its **proximal** end, the opposite extremity the **distal** end.

a. The **arm**: in the arm there is only a single bone.

i. The **humerus**: the proximal end or **head** is enlarged, and articulates with the glenoid cavity of the pectoral girdle: below the head is the strong **deltoid ridge** extending along the proximal half of the anterior surface. At the distal end is a spheroidal articular surface for the bone of the fore-arm: and at either side of this a

prominent **condylar ridge,** the inner or postaxial one being the larger of the two, especially in the male frog.

b. The **fore-arm.**

i. The **radio-ulna:** corresponding to two bones, **radius** and **ulna,** in other animals: it is single at its proximal end, but in its distal half is imperfectly divided by a groove into anterior or radial, and posterior or ulnar portions. Its proximal end is hollowed out to articulate with the lower end of the humerus, and so form the elbow joint, behind which it forms the backwardly projecting **olecranon process.**

c. The **wrist;** consists of six small **carpal** bones arranged in two rows, proximal and distal, each row having three bones.

d. The **hand;** has four complete digits and a rudimentary **pollex** or thumb. Each digit consists of a proximal **metacarpal** bone, beyond which are a variable number of **phalanges.**

i. The **pollex:** the anterior or preaxial digit: consists simply of a small metacarpal bone.

ii. Corresponding to the fore-finger of man: consists of a metacarpal and *two* phalanges.

iii. Corresponding to the middle-finger of man: consists of a metacarpal and *two* phalanges.

iv. Corresponding to the ring-finger of man: consists of a metacarpal and *three* phalanges.

v. The postaxial digit, corresponding to the little-finger of man: consists of a metacarpal and *three* phalanges.

3. The pelvic girdle.

Consists primitively, like the pectoral girdle, of a couple of half-rings of cartilage, fused together below and attached above to the tips of the transverse processes of the sacrum. In the adult frog the girdle is placed very obliquely so as to be nearly parallel with the vertebral column instead of at right angles to it.

Each half presents on its outer aspect a cup-shaped cavity—the **acetabulum**—forming with the thigh bone, the hip-joint: we accordingly distinguish an **iliac portion** above the acetabulum, and an **ischio-pubic portion** below it, corresponding respectively to the scapular and coracoid divisions of the pectoral girdle.

i. The **ilium**: forms the anterior and upper half of the acetabulum, and extends forwards as an elongated laterally-compressed bar, which is attached in front to the transverse process of the sacrum and bears along its dorsal surface a prominent vertical ridge of bone, the **iliac crest**, ending behind in an abrupt vertical border. Posteriorly the two ilia meet one another and are united together in the median plane to form the **iliac symphysis.**

ii. The **pubes**: consists entirely of cartilage: forms the anterior portion of the ventral division of the girdle, and therefore corresponds to the pre-coracoid in the pectoral girdle. The two pubes are completely fused together in the median plane, and form only a very small portion, about one-sixth, of the acetabular cavities.

iii. The **ischium**: the posterior portion of the ventral division; corresponding therefore to the coracoid in the shoulder girdle. Forms the posterior third of the acetabulum. The two ischia are completely fused together in the median plane.

4. The hind-limb.

The bones have the same general characters as those of the fore-limb, to which they correspond very closely.

a. The thigh.

i. The **femur**: a long slender bone expanded at both ends, and curved slightly in a sigmoid manner. The proximal end or head is spheroidal, and fits into the acetabulum to form the hip joint: the distal end is somewhat expanded laterally.

b. The **leg.**

i. The **os cruris** or **tibio-fibula**: a single bone rather longer than the femur, slightly curved, and expanded laterally at both ends. It presents along the greater part of its length a distinct groove indicating its correspondence with two bones, **tibia** and **fibula,** which in man and many other animals remain distinct from one another.

c. The **ankle.** Corresponding to the wrist in the fore-limb: consists of two rows of tarsal bones.

a. **Proximal row of tarsal bones:** consists of two elongated bones united together at both ends, but widely separated in the middle.

i. The **astragalus**: on the preaxial or tibial side.

ii. The **calcaneum**: on the postaxial or fibular side: the larger of the two bones.

β. **Distal row of tarsal bones**: consists of two very small bones.

d. The **foot.** Has five complete digits, and a supernumerary toe as well. Each digit consists of a proximal **metatarsal** bone, beyond which are a variable number of **phalanges.**

i. The **hallux,** corresponding to the great toe of man: the preaxial digit, and the smallest of the series. Consists of a metatarsal and *two* phalanges.

On the inner side of the hallux is the **calcar,** supposed to be an additional or supernumerary toe.

ii. Consists of a metatarsal and *two* phalanges.

iii. Consists of a metatarsal and *three* phalanges.

iv. The longest of the toes: consists of a metatarsal and *four* phalanges.

v. The postaxial digit, corresponding to the little toe in man: consists of a metatarsal and *three* phalanges.

Chap. V.—THE MUSCULAR SYSTEM OF THE FROG.

The muscles, or flesh, are the direct means by which the various movements of the body and of its several parts are brought about. A muscle usually consists of a fleshy belly which is attached at each end by means of tendons to some hard part, very commonly to bone. Motion is effected by the muscle **contracting,** *i.e.*, shortening, and so bringing its two ends, and consequently the parts to which the ends are attached, nearer together. Of the two attachments of a muscle one is usually to a more fixed and central part, the other to a more moveable and peripheral part: the former attachment is called the **origin** of the muscle, the latter its **insertion.**

Muscles are of two kinds: (1) **voluntary muscles,** *i.e.*, those which are under the control of the will, as the muscles of the arm: and (2) **involuntary muscles,** *i.e.*, those over which the will has no direct control, as the muscles of the heart and bloodvessels, or of the alimentary canal.

Voluntary muscles, which are the only ones dealt with in this chapter, are usually attached at both ends to bone; but one or other end, or both, may be attached to **aponeuroses,** strong connective tissue membranes, which ensheath the muscles and other parts, and separate them from one another.

For the dissection of the muscles, take a frog that has been in spirit for a day or more. When cleaning a muscle be careful to put it on the stretch, and to dissect along and not cross its fibres: define the origin and insertion of the muscle very clearly, and test its action by pulling it gently with the forceps in the direction of its fibres. Always have the skeleton in front of you so as to see accurately the origins and insertions of the muscles.

A. Muscles of Trunk.

1. Muscles of ventral body wall.

Pin out the frog on its back, remove the skin, and clean the muscles.

i. The **rectus abdominis**: runs longitudinally along the midventral wall, the muscles of the two sides being separated from one another in the middle line by the **linea alba,** a longitudinal band of connective tissue, immediately dorsad of which lies the anterior abdominal vein. Each **rectus** muscle is divided into bellies by five transverse tendinous intersections.

The muscle arises from the pubes, runs forward and is inserted into the dorsal surface of the sternum and coracoid.

ii. The **pectoralis**: a large fan-shaped muscle consisting of a thoracic portion, which arises from the whole length of the ventral surface of the sternum: and an abdominal portion arising from the aponeurosis along the outer side of the **rectus abdominis** almost as far back as the pubes. From this extensive origin the fibres converge to the deltoid ridge of the humerus into which they are inserted, the line of insertion extending down almost to the elbow.

iii. The **obliquus externus**: a thin sheet of muscle which arises from the aponeurosis of the back, a short distance on either side of the vertebral column, and covers the whole of the side of the body, the fibres running obliquely downwards and backwards to end in an aponeurosis which passes dorsad of the **rectus abdominis** to be inserted into the linea alba.

iv. The **obliquus internus**: lies beneath the **obliquus externus,** which must be removed in order to see it. It arises from the transverse processes of the vertebræ from the fourth backwards, and from the ilium. The fibres run downwards and forwards, and are inserted in front into the coracoid and sternum: some of the fibres surround and are inserted into the œsophagus and pericardium. The hinder two-thirds of the muscle pass dorsad of the tendon of the **obliquus externus** and are inserted like it into the linea alba.

2. Muscles of Back.

Pin out the frog on its belly: remove the skin, and clean the muscles in order.

i. The **depressor mandibuli**: a broad triangular muscle which arises from the fascia covering the dorsal surface of the suprascapula: the fibres run downwards behind the tympanic membrane, and converge to be inserted into the angle of the lower jaw. The muscle by its contraction opens the mouth.

ii. The **cucullaris**: a small oblong muscle which, arising from the exoccipital near the middle line, runs backwards and outwards, and is inserted into the dorsal border of the suprascapula.

iii. The **latissimus dorsi**: a triangular muscle lying behind the **depressor mandibuli**: it arises from the fascia dorsalis just behind the shoulder girdle, its origin being partly covered by the obliquus externus. The fibres run forwards and outwards, converging to be inserted by a long tendon into the deltoid ridge of the humerus.

Dissect away the **depressor mandibuli** *and* **latissimus dorsi** *from their origins, and turn them down.*

iv. The **infraspinatus** arises from the dorsal surface of the suprascapula, partly overlapped by the **latissimus dorsi**: it runs outwards to be inserted into the deltoid ridge of the humerus; its action is to elevate the arm.

Lift up the suprascapula and note the muscles attaching it to the body, viz.:

v. The **retrahens scapulæ**, behind.

vi. The **levator anguli scapulæ**, in front.

Remove the suprascapula on one side, and clean the median longitudinal muscles of the back.

vii. The **extensor dorsi communis**: a longitudinal mass of muscle arising from the urostyle, and running forwards and slightly outwards: it is inserted into the ilium, into the transverse processes of

the vertebræ, and in front into the posterior end of the skull. The anterior part is divided by transverse tendinous intersections.

viii. The **intertransversales**: small muscles running between the transverse processes of the vertebræ and lying beneath the **extensor communis.**

ix. The **glutæus**: arises from the outer side of the posterior two-thirds of the ilium, and runs backwards to be inserted into the trochanter of the femur.

B. Muscles of Head.

1. Muscles of the ventral surface of the head.

i. The **mylohyoid** or **submandibular** muscle: a flat sheet of muscle running across from one ramus of the mandible to the other, and divided down the middle line by a tendinous intersection. A narrow strip along the posterior border is commonly separated by a slight interval from the major or anterior part of the muscle.

Remove the **mylohyoid** *muscle, and the sternal portion of the* **pectoralis.**

ii. The **geniohyoid**: a narrow longitudinal band a short distance from the middle line: it arises from the lower jaw close to the chin, runs back on the ventral surface of the body of the hyoid, and divides posteriorly into two portions which are inserted respectively into the bony and the cartilaginous posterior processes of the hyoid.

iii. The **sternohyoid**: is practically the anterior continuation of the **rectus abdominis.** It arises from the dorsal surface of the coracoid and clavicle, and is inserted into the ventral surface of the body of the hyoid, the tendon passing between the two divisions of the **geniohyoid.**

iv. The **hyoglossus**: arises on either side from the posterior bony horn of the hyoid: the two muscles converge and meet each other in front of the larynx. In front of the larynx the muscle runs

forward in the middle line as a stout band nearly to the chin: it then enters the tongue, and runs back along it to its tip.

v. The **petrohyoid**: a set of four muscular bands which arise close together from the outer surface of the auditory capsule, and diverging from one another in a fan-like manner, pass round the floor of the pharynx and œsophagus to be inserted in front into the median ventral line of the pharynx, and behind into the side of the hyoid. The first or most anterior band is a wide thin sheet of muscular tissue, while the three posterior portions are very narrow slips.

2. Muscles of the side of the head.

Remove the skin carefully from the side of the head and jaws, noticing how much more closely it is attached to the underlying parts than was the case in the body.

a. **Depressors of the lower jaw**: opening the mouth.

i. The **depressor mandibuli**; has been already seen and dissected.

b. **Elevators of the lower jaw**: shutting the mouth: these lie in the space between the auditory capsule and the eye.

ii. The **temporalis**: arises from the upper surface of the auditory capsule, and passes outwards and downwards between the pterygoid and maxillary bones and in front of the cartilaginous ring supporting the tympanic membrane, from which some of its fibres arise: it is inserted into the coronoid process of the lower jaw.

iii. The **pterygoideus**: a slender muscle placed just in front of the **temporalis** and partly covered by it: it arises from the side wall of the skull, and is inserted into the mandible further back than the temporalis and very close to the joint.

iv. The **masseter**: a small muscle placed behind the **temporalis**: it arises from the quadratojugal and

runs downwards and slightly backwards to be inserted into the outer surface of the mandible, just in front of the joint.

To see the insertions of these last three muscles the mouth should be opened widely.

3. Muscles of the eyeball.

Remove the temporal and pterygoid muscles carefully, dissecting them away from their origins, and then turning the muscles down and cutting them short close to their insertions. Remove also the lower jaw: pin the frog out on its back and dissect away carefully the mucous membrane of the roof of the mouth: note

i. The **levator bulbi**: a thin sheet of muscle lying between the mucous membrane and the eye. Its fibres arise from the side of the skull, run outwards underneath the eye and are inserted into the upper jaw. The muscle by its contraction serves to lift up the eyeball and so make it more prominent. Some of its fibres are inserted into the lower eyelid which they serve to depress, acting as a **depressor palpebræ inferioris.**

Remove the **levator bulbi** *and clean the remaining muscles, dissecting them partly from the dorsal and partly from the ventral surface.*

a. The **recti muscles**: a group of four small muscles which arise close together from the inner and posterior angle of the orbit close to the optic foramen, and run forwards and outwards, diverging from one another, to be inserted into the bulb of the eye.

i. The **rectus superior**: inserted into the dorsal surface of the eyeball: seen best from above.

ii. The **rectus externus**: the most posterior of the four: inserted into the posterior surface of the eyeball: seen best from the side or from below.

iii. The **rectus internus**: the longest of the four: runs forward between the skull wall and the eyeball, and is inserted into the inner or median surface of the eyeball: seen best from below.

iv. The **rectus inferior**: inserted into the under surface of the eyeball: seen best from below.

b. The **obliqui muscles**: a group of two small muscles which arise close together from the palatine bone at the anterior end of the orbit, and run backwards to be inserted into the eyeball.

i. The **obliquus superior**: inserted into the dorsal surface of the eyeball just in front of the **rectus superior**: seen best from above.

ii. The **obliquus inferior**: passes backwards beneath the **rectus internus**, and is inserted into the eyeball between it and the **rectus inferior**: seen best from below.

c. The **retractor bulbi**, or choanoid muscle: a funnel-shaped muscle which lies within the four **recti** and embraces the optic nerve: it arises from the parasphenoid, and is inserted into the eyeball. It is best seen from below by carefully removing the **recti** muscles.

C. The muscles of the Hind-limb.

If the frog's leg be stretched back parallel to the longitudinal axis of the body, as in the act of swimming, we distinguish in it ventral and dorsal surfaces, an outer border in which is the projection of the knee, and an inner border along which is the bend of the knee. The outer border, which corresponds to the front of the leg in man, is called the **extensor surface**, inasmuch as the muscles which extend or straighten the leg lie along this edge: the inner border is the **flexor surface**. The "ventral" and "dorsal" surfaces only appear to be such in consequence of the extreme obliquity of the pelvic girdle: they are really anterior and posterior, and are better called **preaxial** and **postaxial**: they correspond respectively to the inner and outer surfaces of the human leg. If the foot be examined carefully, it will be seen that the first digit or "big toe" is on the preaxial side, and hence may be called the **preaxial digit**: while the fifth or "little toe" is on the postaxial side, and is therefore the **postaxial digit**.

1. Muscles of the thigh.

Remove the skin from one of the legs of the frog and clean the muscles first of the preaxial and then of the postaxial surfaces.

a. Superficial muscles of preaxial (apparent ventral) surface.

i. The **sartorius**: a long narrow muscular band which crosses the thigh somewhat obliquely from the outer to the inner side. It arises from the iliac symphysis below the acetabulum, and is inserted into the inner side of the head of the tibia.

ii. The **adductor magnus**: a large muscle lying along the inner border of the **sartorius,** but passing beneath it at its distal end. It arises from the pubic and ischial symphyses, and passes under the **sartorius** to be inserted into the distal third of the femur.

iii. The **adductor longus**: a long narrow muscle lying along the outer side of the **adductor magnus,** and almost completely hidden by the **sartorius**: it arises from the iliac symphysis beneath the **sartorius,** and unites a little way beyond the middle of the thigh with the **adductor magnus.**

iv. The **rectus internus major**: a large muscle lying along the inner side of the **adductor magnus** and the **sartorius.** It arises from the ischial symphysis and is inserted into the head of the tibia.

v. The **rectus internus minor**: a narrow flat band of muscle running along the inner (flexor) margin of the thigh: it arises from a tendinous expansion connected with the ischial symphysis, and is inserted into the inner side of the tibia just below its head.

b. Superficial muscles of extensor surface of thigh.

i. The **triceps extensor femoris**: the great extensor muscle of the thigh: it arises by three distinct origins, which may be described separately, and is inserted into the tibia just below its head.

α. The **rectus anticus femoris**: forms the middle head of the **triceps**: it arises from the ventral border of the posterior third of the ilium, in front of the acetabulum: about half way down the thigh it joins

β. The **vastus internus**: the preaxial division of the **triceps**: a large muscle arising from the ventral and anterior border of the acetabulum, and lying in the thigh between the **sartorius** and the **rectus anticus.**

γ. The **vastus externus**: the postaxial division of the **triceps**: it arises from the posterior edge of the dorsal crest of the ilium, and joins the other two divisions of the **triceps** about the junction of the middle and distal thirds of the thigh.

c. Superficial muscles of the postaxial (apparent dorsal) surface of the thigh.

i. The **glutæus**: has been already noticed: it lies in the thigh between the **rectus anticus** and **vastus externus.**

ii. The **biceps**: a long slender muscle which arises from the crest of the ilium just above the acetabulum: it lies in the thigh along the inner border of the **vastus externus,** and is inserted by a flattened tendinous expansion into the distal end of the femur and the head of the tibia.

iii. The **semimembranosus**: a stout muscle lying along the inner side of the **biceps,** between it and the **rectus internus minor.** It arises from the dorsal angle of the ischial symphysis just beneath the cloacal opening, and is inserted into the back of the head of the tibia. It is divided about its middle by an oblique tendinous intersection.

iv. The **pyriformis**: a slender muscle which arises from the tip of the urostyle, passes backwards and outwards between the **biceps** and the **semimembranosus,** and is inserted into the femur at the junction of its proximal and middle thirds.

d. Deep muscles of the thigh.

Lay the frog on its back so as to dissect the thigh from the preaxial surface. Separate the **adductor magnus** *and* **rectus internus major** *with blunt instruments so as to expose :—*

i. The **semitendinosus**: a long thin muscle which arises by two heads; an anterior one from the ischium close to the ventral angle of the ischial symphysis and the acetabulum; and a posterior one from the ischial symphysis. The anterior head passes through a slit in the **adductor magnus** and unites with the posterior head in the distal third of the thigh. The tendon of insertion is long and thin, and joins that of the **rectus internus minor** to be inserted into the tibia just below its head.

Divide the **adductor magnus** *and the* **sartorius** *in the middle and turn the cut ends backwards and forwards, so as to expose*

ii. The **adductor brevis**: a short wide muscle lying beneath the upper end of the **adductor magnus.** It arises from the pubic and ischial symphyses, and is inserted into the preaxial surface of the proximal half of the femur.

iii. The **pectineus** : a rather smaller muscle, lying along the outer (extensor) side of the **adductor brevis.** It arises from the anterior half of the pubic symphysis in front of the **adductor brevis,** and is inserted like it into the proximal half of the femur.

iv. The **ilio-psoas**: arises by a wide origin from the inner surface of the acetabular portion of the ilium : it turns round the anterior border of the ilium, and crosses in front of the hip joint, where for a short part of its course it is superficial between the heads of the **vastus internus** and **rectus anticus femoris** : it then passes down the thigh beneath these muscles, and is inserted into the back of the proximal half of the femur.

v. The **quadratus femoris** : a small muscle on the back of the upper part of the thigh : it arises from the ilium above the acetabulum, and from the base

of the iliac crest: it lies beneath the **pyriformis** and behind the **biceps**, and is inserted into the inner surface of the proximal third of the femur between the **pyriformis** and the **ilio-psoas.**

vi. The **obturator**: a deeply situated muscle which arises from the whole length of the ischial symphysis and the adjacent parts of the iliac and pubic symphyses, and is inserted into the head of the femur close to the **glutæus.**

2. Muscles of the leg.

As in the thigh, we distinguish extensor and flexor surfaces, corresponding to the front and back of the leg in man; and also preaxial and postaxial surfaces, corresponding to the inner and outer sides of the human leg.

Lay the frog on its belly and commence the dissection from the postaxial surface.

i. The **gastrocnemius**: the large muscle forming the calf of the leg: it has two heads of origin, whereof the larger one arises by a strong flattened tendon from the flexor surface of the distal end of the femur; while the smaller head, which joins the main muscle about one-fourth of its length below the knee, arises from the edge of the tendon of the **triceps extensor femoris** where it covers the knee. The muscle is thickest in its upper third, and tapering posteriorly ends in the strong **tendo Achillis,** which passes under the ankle joint, being much thickened as it does so, and ends in the strong plantar fascia of the foot.

ii. The **tibialis posticus**: arises from the whole length of the flexor surface of the tibia: it ends in a tendon which passes round the internal malleolus, lying in a groove in the lower end of the tibia, and is inserted into the dorsal surface of the astragalus.

iii. The **tibialis anticus**: lies on the extensor surface of the leg: it arises by a long thin tendon from the lower end of the femur, and divides about

the middle of the leg into two bellies which are inserted into the proximal ends of the astragalus and calcaneum respectively.

iv. The **extensor cruris brevis**: lies along the preaxial side of the **tibialis anticus,** partly covered by it and partly by the strong fascia of the leg. It arises by a long tendon from the preaxial condyle of the femur, runs in a groove in the upper end of the tibia, and is inserted into the extensor surface of the tibia along nearly its whole length.

v. The **peroneus**: a stout muscle which lies along the postaxial surface of the leg, between the **tibialis anticus** and the **gastrocnemius.** It arises from the distal end of the femur, and is inserted into the external malleolus of the tibia and the proximal end of the calcaneum.

Chap. VI.—THE NERVOUS SYSTEM OF THE FROG.

The nervous system consists of—

i. A central portion—the **brain** and **spinal cord**—which lies in the cartilaginous and bony tube formed by the cranium and vertebral column, and which is the centre where sensations are felt, and whence motor impulses causing the muscles to contract take their origin: and

ii. A peripheral portion—the **nerves** themselves—which connect the central portion with the skin, sense organs, muscles, viscera, etc., and serve to convey sensory impulses from these parts to the brain and cord, or motor impulses from the central organs to the muscles.

Fig. 11. The nervous system of the edible frog (*Rana esculenta*), from the ventral surface. (From Ecker.)

F, facial nerve: G, ganglion of pneumogastric nerve: He, cerebral hemisphere: Lc, optic tract: Lop, optic lobe: M, boundary between medulla oblongata and spinal cord: M 1–10, the spinal nerves: MS, connection between fourth spinal nerve and sympathetic chain: N, nasal sac: Ni, sciatic nerve: No, crural nerve: o, eyeball: S, trunk of sympathetic; S 1–10, the sympathetic ganglia: Sp, continuation of sympathetic into head.

I, olfactory nerve: II, optic nerve: III, motor oculi: IV, trochlear nerve: V, trigeminal and facial nerves: Va, ophthalmic branch of trigeminal: Vc, maxillary branch of trigeminal: Vd, mandibular branch of trigeminal: Ve, hyomandibular branch of facial: Vg, Gasserian ganglion: Vs, upper end of sympathetic trunk, in connection with Gasserian ganglion: VI, abducens nerve: VII, facial nerve: VIII, auditory nerve: X, glossopharyngeal and pneumogastric nerves: X1, ramus anterior of glossopharyngeal: X 2, ramus posterior of glossopharyngeal: X 3–4, branches of pneumogastric.

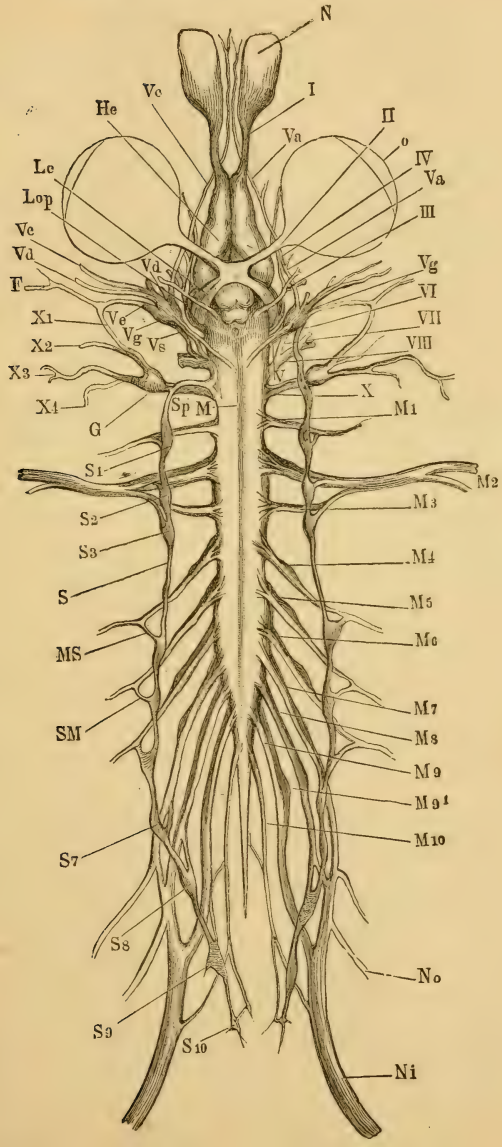
N
Vc
I
He
II
Va
o
IV
Lc
Va
Lop
III
Vc
Vd
Vd
Vg
F
VI
X1
Ve
VII
Vg
Vs
X2
VIII
X3
X
X4
Sp
M
M1
G
S1
M2
M3
S2
S3
M4
S
M5
M6
MS
M7
SM
M8
M9
M9'
M10
S7
S8
No
S9
S10
Ni

These two functions are fulfilled by different nerves, which may accordingly be distinguished as (*a*) **afferent** or **sensory nerves,** conveying impulses *to* the central parts, and (*b*) **efferent** or **motor nerves,** conveying impulses *from* the brain or cord.

A special set of nerves in connection with the bloodvessels and viscera form the **sympathetic nervous system.**

For the dissection of the nervous system specimens should be taken which have been in strong spirit for two or three days, and in which the brain has been exposed to the action of the spirit by removal of the roof of the skull.

A. The Central Nervous System.

Divisible into an anterior portion—the **brain**—lying in the cavity of the cranium; and a posterior portion—the **spinal cord**—which lies in the neural canal of the vertebral column. There is no sharp line of demarcation between the two portions, which are directly continuous with each other.

The central nervous system appears at a very early period in the development of the frog as a longitudinal groove extending the whole length of the dorsal surface. By fusion of its lips the groove becomes converted into a tube, which soon separates from the skin. This tube, which at first consists of almost unmodified epidermis, becomes converted by thickening of its walls and by further changes into the central nervous system; the modifications being greater at the anterior end or brain than in the posterior part or spinal cord, but the tubular character being retained throughout life along the whole length.

If the brain and spinal cord have not been already exposed, clear away the dorsal muscles from both sides of the spine: cut through the occipito-atlantal membrane, flexing the frog's head slightly to make the membrane tense, and being careful not to injure the brain beneath it. Introduce one blade of the scissors into the cranial cavity, with the flat surface of the blade parallel to the back of the frog, and keeping as close to the roof of the skull as possible. Cut carefully through the side walls of the skull, first on one side and then on the other. Turn the roof of the skull forwards with forceps, and remove it altogether.

Similarly cut through and remove the neural arches of the vertebræ one by one from before backwards.

Examine and draw the central nervous system in situ, showing

I. The brain.

a. The dorsal surface of the brain: *note from before backwards the following parts, removing the pigmented membrane—***pia mater***—covering the several parts as you come to them.*

i. The **olfactory lobes**: united together in the median plane by a commissure: they give off the olfactory nerves from their anterior ends, and are separated behind by slight constrictions from the hemispheres.

ii. The **cerebral hemispheres**: smooth ovoid bodies which touch one another in the median plane but are not fused together.

iii. The **thalamencephalon**: lozenge-shaped: lies immediately behind the hemispheres and between their diverging posterior ends: it is covered by a thick vascular membrane—the **choroid plexus**—through which passes the stalk of the **pineal gland**, a small body adherent to and removed with the roof of the skull. On removing the **choroid plexus** a small hole is seen in the roof of the thalamencephalon, connecting the hollow stalk of the pineal gland with the third ventricle. The thickened sides of the thalamencephalon are the **optic thalami.**

iv. The **optic lobes**: two prominent ovoid bodies touching one another in the median line; forming the widest part of the brain.

v. The **cerebellum**: a narrow transverse band immediately behind the optic lobes.

vi. The **medulla oblongata**: the part of the brain behind the cerebellum: it is widest in front and gradually tapers towards its posterior end, where it is continuous with the spinal cord. It is

covered by a very vascular triangular membrane, beneath which lies the fourth ventricle.

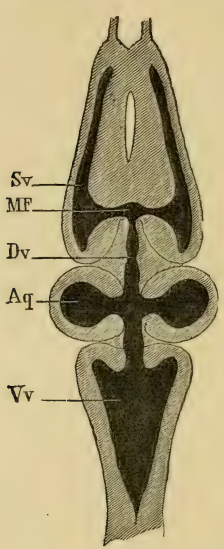

Fig. 12. A horizontal section through the brain of the frog, to show the internal cavities. (From Ecker.)

Aq, ventricles of the optic lobes, and Sylvian aqueduct: Dv, third ventricle: MF, foramen of Monro: Sv, lateral ventricle; Vv, fourth ventricle.

b. The cavities of the brain.

Slice off the upper surface of the brain horizontally so as to expose the several cavities or ventricles, which are merely parts of, or outgrowths of, the original central canal of the neural tube of the embryo.

i. The **lateral ventricles**: extend through the whole length of the cerebral hemispheres and a short way into the olfactory lobes.

ii. The **third ventricle**: situated in the thalamencephalon: it opens in front through the **foramina of Monro** into the lateral ventricles: the stalk

of the pineal gland opens into it above; and in the hinder part of its floor is a conical depression, the **infundibulum.**

iii. The **aquæductus sylvii** or **iter a tertio ad quartum ventriculum**: a narrow passage leading from the third to the fourth ventricle: it communicates above with the cavities or ventricles of the optic lobes, which are hollow.

iv. The **fourth ventricle**: the large triangular cavity in the medulla already exposed by removal of the vascular membrane covering it.

c. The ventral surface of the brain.

Cut through the medulla at the level of the hinder end of the skull: carefully remove the brain from the cranial cavity, noting the several nerves arising from it, and cutting through these as close to the skull wall as possible. Lay the brain on its dorsal surface, and examine and draw the ventral surface, showing:—

i. **The optic chiasma**: formed by the decussation of the roots of the optic nerves; the point of crossing being opposite the hinder ends of the hemispheres, and immediately in front of the infundibulum.

Trace back the optic nerves behind their point of crossing to their origins from the optic lobes.

ii. The **tuber cinereum**: a small median swelling immediately behind the optic chiasma, and caused by the depression of the floor of the third ventricle to form the infundibulum.

iii. The **pituitary body**: a flattened sac, placed behind and continuous with the tuber cinereum. It is very liable to be left behind in the skull on removing the brain.

iv. The **crura cerebri**: two dense white columns of nervous matter, lying at the base of the optic lobes, and partly hidden by the pituitary body: they serve to connect the hemispheres with the medulla and spinal cord.

v. The **anterior fissure of the brain**: a median longitudinal groove on the ventral surface of the hinder part of the brain: continuous with a similar groove on the ventral surface of the spinal cord.

II. The spinal cord.

A somewhat flattened band presenting brachial and lumbar enlargements opposite the points of origin of the nerves for the fore and hind limbs respectively, and slightly constricted between these two points. About the level of the sixth or seventh vertebra the cord narrows rapidly to form a fine thread, the **filum terminale,** which extends back into the canal of the urostyle. Besides the **anterior** or **ventral** fissure the cord presents a **dorsal fissure,** a median longitudinal groove starting from the hinder angle of the fourth ventricle and extending to the commencement of the **filum terminale.**

The tubular character of the spinal cord is best seen on making transverse sections of it. These will be described further on in the present chapter.

B. The Peripheral Nervous System.

I. The Spinal Nerves: Ten pairs of nerves arise from the sides of the spinal cord; each nerve arising by two roots, a ventral or "anterior," and a dorsal or "posterior," which unite together at their point of exit from the vertebral canal through the intervertebral foramen: just before their union the posterior root bears a ganglionic swelling.

Within the vertebral canal the roots of the anterior spinal nerves run nearly transversely outwards, so as to leave the canal opposite their points of origin from the spinal cord. The roots of the middle and posterior nerves, owing to the vertebral column being of greater length than the part of the cord belonging to it, pass obliquely backwards to their points of exit: and in the case of the hindmost nerves, the roots run backwards within the vertebral canal some distance before reaching their foramina of exit: the bundle formed by these roots, together with the filum terminale, is spoken of as the **cauda equina.**

a. The spinal nerves within the vertebral canal:

To expose the nerves either cut away with scissors the neural

arches of the vertebræ one by one, according to the directions given for the dissection of the central nervous system; or else lay the frog on its back and cut away with stout scissors the bodies of the vertebræ so as to expose the spinal cord and nerves from the ventral surface. Note:—

i. The roots of the nerves: dorsal and ventral.

ii. The obliquity of the middle and posterior roots.

iii. The **cauda equina**: formed by the roots of the hinder nerves together with the **filum terminale.**

iv. The **ganglia** on the posterior roots as they pass through the intervertebral foramina: they are best seen from the ventral surface, where they are covered by whitish calcareous patches, which form conspicuous objects on either side of the vertebral column. *Remove these patches carefully to see the ganglia.*

b. The spinal nerves outside the vertebral canal:

Lay the frog on its back: cut through and pin out the body-walls, and remove the abdominal viscera. Note the spinal nerves, seen as white cords at the sides of the vertebral column. Clean the nerves on one side and follow them to their distribution. Each nerve divides directly after the union of its two roots into a small dorsal branch and a much larger ventral branch.

1. The **hypoglossal** or first spinal nerve: leaves the vertebral canal between the first and second vertebræ, and then runs forward on the under surface of the head beneath the mylohyoid and in the substance of the geniohyoid muscle to the chin, where it enters the tongue in which it ends. It supplies the muscles of the tongue and floor of the mouth, and also some of the muscles of the back and shoulder. (Fig. 13.)

2 and 3: the second and third spinal nerves leave the canal between the second and third, and third and fourth vertebræ respectively: they unite together to form the **brachial nerve,** which gives off a large **coracoclavicular** branch to the shoulder muscles and then runs down the arm, supplying it with muscular and cutaneous

branches, and divides just above the elbow into the **radial** and **ulnar nerves** which supply the forearm and hand.

4, 5, and 6: the fourth, fifth, and sixth spinal nerves are small, and supply the muscles and skin of the body-wall. They leave the vertebral canal between the fourth and fifth, fifth and sixth, and sixth and seventh vertebræ respectively.

7, 8, and 9: the seventh, eighth, and ninth spinal nerves together form the **sciatic plexus.** The roots of these three nerves within the vertebral canal form the main part of the **cauda equina.** The seventh nerve leaves the canal between the seventh and eighth vertebræ, the eighth nerve between the eighth and ninth vertebræ, and the ninth nerve between the ninth or sacral vertebra and the urostyle. Outside the vertebral canal the three nerves unite together opposite the middle of the urostyle to form the sciatic plexus, from which branches are given to the large intestine, bladder, oviducts, etc. Just before joining the plexus the seventh nerve gives off the **ileohypogastric** and **crural nerves** supplying the muscles and skin of the abdomen and thigh. Beyond the plexus is the large **sciatic nerve,** which runs down the thigh, giving branches to it, and dividing a short distance above the knee into the **tibial** and **peroneal nerves** supplying the leg and foot.

10: The **coccygeal** or tenth spinal nerve emerges through a small hole in the side of the urostyle near its anterior end. It gives branches to the bladder, cloaca, and other adjacent parts.

II. The Sympathetic Nervous System. Consists of a longitudinal nervous band on each side of the body connected by branches with the several spinal nerves. The two main sympathetic trunks lie in front close to the dorsal surface and alongside the vertebral column: further back they are in close relationship with the dorsal aorta alongside which they run.

Each trunk receives a branch from each of the spinal nerves of its side, and at the junction of each of these branches with the main trunk there is a ganglionic enlargement.

The coccygeal or tenth spinal nerve, unlike the others, is connected with the sympathetic by more than a single branch: the actual number of these branches is not constant, but is said to vary from two up to as many as twelve.

From the sympathetic ganglia nerves are given off to the bloodvessels and viscera, the chief ones being:—

i. The **cardiac plexus**: formed by nerves arising from the first sympathetic ganglion: the plexus is a meshwork of nerves on the auricles and around the great vessels at their openings into the heart.

ii. The **solar plexus**: on the dorsal surface of the stomach: the nerves are derived mainly from the third, fourth, and fifth ganglia. Hepatic, renal, genital, hæmorrhoidal, and vesical plexuses also exist in connection with the liver, kidney, reproductive organs, large intestine, and bladder respectively.

III. The Cranial Nerves. There are ten pairs of cranial nerves in the frog, which are numbered in order from before backwards.

To dissect the cranial nerves expose the brain by removing the roof of the skull as already described, and then follow the special instructions given in the case of the more important nerves.

1. The **olfactory nerve**: the special nerve of smell: arises from the anterior end and outer side of the olfactory lobe, and is distributed to the membrane lining the nasal cavity.

To see its course and distribution dissect from the dorsal surface removing the roof of the anterior part of the skull, including the nasal bone.

2. The **optic nerve**: the nerve of sight: arises from the side of the brain just below the optic lobe, crosses over partially at the optic chiasma on the under surface of the brain, and then runs outwards to the eyeball.

The course of the optic nerve has been fully seen in previous dissections.

3. The **motor oculi**: a small nerve arising from the ventral surface of the brain close to the median line and between the crura cerebri. It supplies four of the muscles moving the eyeball; *viz.*, the rectus superior, rectus internus, rectus inferior, and obliquus inferior.

Owing to its small size the third nerve is not easy to dissect in the frog.

4. The **pathetic** or **trochlear nerve**: a very slender nerve, arising from the dorsal surface of the brain between the optic lobes and the cerebellum, and supplying the obliquus superior muscle of the eyeball.

The nerve is too small to be dissected satisfactorily in the frog.

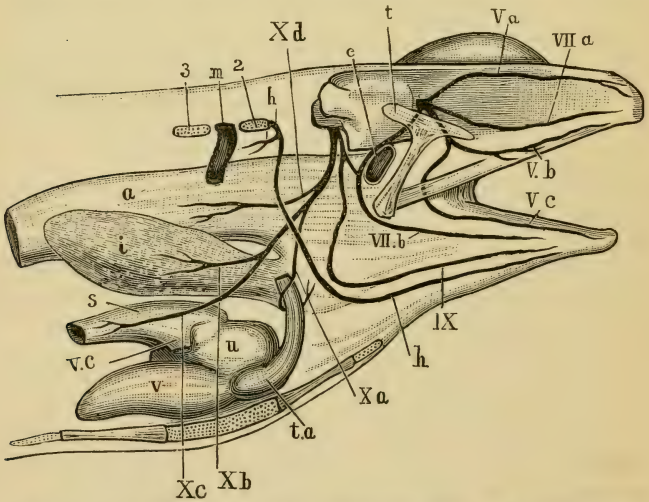

Fig. 13. The trigeminal, facial, glossopharyngeal, and pneumogastric nerves of the frog, dissected from the right side.

a, stomach: *e*, Eustachian tube: *h*, hypoglossal nerve: *i*, lung: *m*, second spinal nerve: *s*, sinus venosus: *t*, squamosal: *t.a*, truncus arteriosus: *u*, right auricle: *v*, ventricle: *v.c*, right vena cava superior: Va, ophthalmic branch of trigeminal: Vb, maxillary branch of trigeminal: Vc, mandibular branch of trigeminal: VII a, palatine branch of facial; VII b, hyoidean branch of

facial: IX, glossopharyngeal: Xa, laryngeal branch of pneumogastric: X b, pulmonary branch of pneumogastric: Xc, cardiac branch of pneumogastric: X d, gastric branch of pneumogastric: 2, transverse process of second vertebra: 3, transverse process of third vertebra.

5. The **trigeminal**: the largest of the cranial nerves in the frog. Arises from the side of the anterior part of the medulla, and runs outwards and forwards to the skull wall; just before reaching this it expands into a large swelling—the **Gasserian ganglion.** It then passes through the skull wall immediately in front of the auditory capsule, and divides at once into two main branches:—

   i. The **ramus ophthalmicus**: runs forward through the orbit lying close to its inner side, between the skull wall and the eye. It lies beneath the rectus superior, but above all the other muscles of the eyeball and the optic nerve. At the anterior end of the orbit it divides into two branches which passes through the walls of the nasal capsule, and supply the skin of the fore part of the head.

To trace this branch dissect from the dorsal surface: cut away carefully with scissors the side wall of the cranium; cut through and turn aside the rectus superior, and find the nerve running close alongside the skull wall, between it and the eyeball. Trace it forwards to the nose.

   ii. The **ramus maxillo-mandibularis**: runs directly outwards behind the eyeball, in front of the auditory capsule and between the temporal and pterygoid muscles. After a very short course it divides into the maxillary and mandibular nerves.

To trace this nerve and its branches remove the squamosal bone carefully, and find the nerve lying on the pterygoid muscle and immediately behind the eye. Follow the nerve between the pterygoid and temporal muscles to the skull, removing the muscles if necessary; and then trace the branches outwards to their distribution.

      a. The **ramus maxillaris**: runs forwards and outwards in the floor of the orbit, behind and below the eyeball, to the margin of the upper jaw which it reaches about midway

along its length : it then ends in branches which run along the jaw, some forwards and some backwards, supplying the skin of the upper lip, the lower eyelid and other neighbouring parts.

β. The **ramus mandibularis**: runs parallel to and behind the **ramus maxillaris** as far as the outer border of the eyeball, giving branches to the temporal and pterygoid muscles : it then turns backwards, outwards, and downwards, and passing across the inner side of the upper jaw, reaches the outer surface of the mandible just behind the insertion of the temporal muscle : it then runs forward along the outer side of the lower jaw to the chin, supplying the lower lip and the muscles of the floor of the mouth.

6. The **abducens**: a very slender nerve which arises from the ventral surface of the medulla close to the median line, and a short way behind the pituitary body. It passes either through, or in very close contact with, the Gasserian ganglion, and entering the orbit supplies the retractor bulbi and the rectus externus muscles.

The nerve is too small to be dissected satisfactorily in the frog.

7. The **facial nerve**: arises from the side of the medulla immediately behind the trigeminal nerve, and passes forward to the skull wall where it is very closely connected with the Gasserian ganglion. It passes through the skull wall immediately behind and in close company with the trigeminal nerve, and divides at once into its two main branches.

i. The **ramus palatinus**; runs forward in the floor of the orbit a short distance from the side wall of the skull, and immediately beneath the mucous membrane of the floor of the mouth. Near the anterior end of the orbit it divides into two branches, one of which runs outwards and anastomoses with the ramus maxillaris of the trigeminal nerve, while the other runs for-

wards to the anterior part of the roof of the mouth. It supplies the mucous membrane of the roof of the mouth.

Dissect this nerve from the ventral surface: cut away the lower jaw: carefully remove the mucous membrane of the roof of the mouth, and find the nerve lying on the ventral surface of the eyeball and its muscles, and running parallel to and a short distance from the skull wall. Trace it backwards and forwards.

ii. The **ramus hyomandibularis**: runs outwards and backwards round the front end of the auditory capsule; it then crosses over the inner end of the columella and turns downwards in the posterior wall of the Eustachian tube to the angle of the mouth, giving branches to the tympanic membrane and to the articulation of the mandible. It then divides into two branches.

The dissection of this nerve, which is not easy, may be performed thus:—remove the shoulder-girdle of one side; also the depressor mandibuli and temporalis muscles: open the cranial cavity as before, to expose the brain; remove the tympanic membrane and clean the outer end of the columella. Cut away carefully the roof of the auditory capsule by a horizontal cut, just above the level of the columella: find the facial nerve running round the front end of the auditory capsule and in close contact with it, and trace it back over the columella and down to the angle of the mouth.

α. The **ramus mandibularis**: runs forward in the floor of the mouth, lying along the inner edge of the lower jaw and between the mylohyoid muscle and the skin, as far forward as the chin.

Dissect from the ventral surface; remove the skin from the under surface of the floor of the mouth and find the nerve running along the inner border of the mandible.

β. The **ramus hyoideus**: the posterior and larger of the two branches: runs forward in the floor of mouth along the anterior cornu of the hyoid, supplying its muscles.

8. The **auditory nerve**: the nerve of hearing: arises from the side of the medulla immediately behind and in close

contact with the root of the facial nerve: it enters the auditory capsule and ends in the internal ear.

9. The **glossopharyngeal nerve**: arises from the side of the medulla behind the auditory nerve, by a root common to it and to the tenth nerve: leaves the skull by an aperture immediately behind the auditory capsule, and divides behind the capsule into two branches:—

   i. The **ramus anterior**: runs downwards and forwards round the hinder border of the auditory capsule and beneath the depressor mandibuli muscle to join the facial nerve just after it has crossed over the columella.

The dissection already made for the ramus hyomandibularis of the facial nerve will show also the above branch of the glossopharyngeal.

   ii. The **ramus posterior**: runs downwards and forwards to the ventral wall of the pharynx, passing beneath the fourth division of the petrohyoid muscle but superficial to the others; it runs just behind and parallel to the anterior cornu of the hyoid. On reaching the floor of the mouth it crosses obliquely dorsad of the hypoglossal or first spinal nerve, and then runs forwards in a peculiarly sinuous course, close to the middle line and between the geniohyoid and hyoglossus muscles, to the base of the tongue which it enters and in which it ends. It supplies the petrohyoid muscle, and the mucous membrane of the pharynx and tongue.

The dissection of the first part of the nerve is best performed from the side, and is much facilitated by distending the œsophagus and pharynx with a cork or roll of paper. Its course along the floor of the mouth to the tongue should be dissected from the ventral surface.

10. The **pneumogastric or vagus nerve**: arises, as already noticed, in common with the glossopharyngeal. It leaves the skull by the same aperture as the ninth nerve, and immediately outside the skull presents a ganglionic enlargement: it gives off dorsal branches to the muscles

of the back, and then runs backwards and downwards round the side wall of the pharynx, running along the hinder border of the fourth division of the petrohyoid muscle: behind this muscle it divides into its main branches.

i. The **ramus laryngeus**: loops round the posterior cornu of the hyoid and round the pulmocutaneous artery close to its origin from the aortic trunk: passes inwards dorsad of the artery to the middle line where it ends in the larynx.

ii. The **ramus cardiacus**: passes dorsad of the pulmonary artery to the interauricular septum of the heart, and to the sinus venosus.

iii. The **rami pulmonales**: follow the course of the pulmonary artery to the lung, in which they end.

iv. The **rami gastrici**: usually two in number: run through the partial diaphragm formed by the anterior fibres of the obliquus internus muscle, and end in the walls of the stomach.

The dorsal portions of the several branches of the vagus are best dissected from the side: to see them properly, the shoulder girdle and fore-limb must be removed and the œsophagus well distended: the terminal branches must be dissected from the ventral surface.

IV. The Cranial Portion of the Sympathetic Nervous System.

The main sympathetic trunk of each side extends forwards in front of the first ganglion, and enters the skull at the foramen in the exoccipital bone through which the glossopharyngeal and vagus nerves pass out: it is connected with the vagus nerve, and then runs forwards within the skull to the Gasserian ganglion of the trigeminal nerve, in which it ends.

C. Histology of Nerves.

Nervous matter consists histologically of elements of two kinds, **nerve cells** and **nerve fibres.** The nerve cells are branching nucleated cells connected by their processes with one another and with the nerve fibres. The nerve cells are the

centres whence impulses originate, while the nerve fibres serve to convey those impulses from one part to another. A local accumulation of nerve cells is called a ganglion.

1. **Nerve Fibres**: are of two kinds, medullated and non-medullated.

   a. **Medullated nerve fibres**; these form the greater part of the cranial and spinal nerves.

Take a small piece of the sciatic or some other nerve from a freshly killed frog: spread out and tease in a drop of normal salt solution: examine with low and high powers: note

i. The **nerve fibres**: unbranched.

ii. The **perineurium**, or connective tissue binding the nerve fibres into bundles or "nerves."

In each nerve fibre note

iii. The **primitive sheath**, or **sheath of Schwann**: a very delicate external investment, seen with difficulty, and only in certain places.

iv. The **medullary sheath**: a thick fatty layer within the primitive sheath.

Tease in glycerine a small piece of nerve that has been treated with osmic acid: examine with high power a single nerve fibre: note

i. The **medullary sheath**: stained black in consequence of its fatty nature: interrupted at intervals by

ii. The **nodes of Ranvier**: spots where the medullary sheath is absent, and the primitive sheath forms constrictions touching

iii. The **axis cylinder**: a central cylindrical rod, the essential part of the nerve fibre: visible at the nodes: much less deeply stained than the medullary sheath.

iv. **Nuclei**: project into the medullary sheath about midway between the nodes.

Tease a small piece of fresh nerve in chloroform: this will partially dissolve the fatty medullary sheath and so render clearly visible:—

i. The **primitive sheath,** or **sheath of Schwann.**

ii. The **axis cylinder.**

b. Non-medulated nerve fibres.

Examine mounted preparation of frog's cornea stained with chloride of gold: note the fine varicose nerve fibres with no medullary sheath.

2. **Nerve cells:** *Tease in glycerine a small fragment of the anterior cornu of the spinal cord of the ox (lumbar region): cover, and examine with low and high powers: note*

i. The **nerve cells;** large nucleated cells with many branching arms.

ii. The **nerve fibres.**

iii. The fine connective tissue binding the several parts together.

3. **Structure of the Spinal Cord.**

Take one of the prepared transverse sections of spinal cord of frog: mount in balsam, and examine with low and high powers: note:—

a. With low power.

i. **Shape:** bilaterally symmetrical; considerably wider than it is deep.

ii. The **ventral** or **anterior,** and **dorsal** or **posterior fissures:** of these the anterior is broad and shallow, the posterior narrow and deep.

iii. The **white matter:** forming the outer part of the cord, and composed of medullated nerve fibres.

iv. The **grey matter:** forming the central part of the cord, and composed of a dense network of non-medullated nerve fibres, in which are imbedded numerous nerve cells.

v. The **cornua**: anterior or ventral, and posterior or dorsal, into which the grey matter is produced on either side.

vi. The **central canal** of the cord: in the median line, nearer the ventral than the dorsal surface.

vii. The **nerve roots**; only seen if the section happens to pass through their points of origin.

α. The **posterior** or **dorsal root**; connected with the posterior cornu of the grey matter: a single thick band of nerve fibres.

β. The **anterior** or **ventral root**; connected with the anterior cornu of the grey matter: a number of very slender bands of nerve fibres.

b. With high power.

i. The **ganglion cells**; large nucleated branched cells lying in groups in the grey matter: largest and most numerous in the anterior cornua.

ii. The **neuroglia**: a delicate network of connective tissue fibres and cells penetrating and supporting all parts of the cord, and continuous at the surface with the pia mater.

iii. The **pia mater**: the delicate connective tissue membrane ensheathing the cord and extending into the fissures.

iv. The **bloodvessels** of the cord: small and numerous: enter from the pia mater.

v. The **ciliated epithelium** lining the central canal.

Chap. VII.—THE EYE AND EAR.

A. The Eye of the Frog.

1. *Remove the eye from a freshly killed frog : snip off with scissors the muscles of the eyeball : note*

i. The shape of the eyeball : flattened on the outer side : more convex on the inner or deeper side.

ii. The **sclerotic**; the firm outer wall of the eyeball, formed of dense white connective tissue strengthened by hyaline cartilage.

iii. The **cornea**: the transparent patch on the outer side of the eye through which the light enters : continuous at its margin with the sclerotic.

iv. The **iris**: a pigmented ring placed behind the cornea and seen through it : it acts as a diaphragm, limiting the amount of light that enters the eye.

v. The **pupil**: the aperture surrounded by the iris, which serves to admit the light to the interior of the eye.

vi. The **optic nerve**: seen piercing the sclerotic to enter the eyeball on its inner side.

2. *Place the eye under water and divide it with scissors into two halves by a cut passing through the middle of the cornea and through the sclerotic close to the optic nerve, so as to lay open completely the interior of the eye : note :—*

i. The **lens**: a firm solid transparent body, just behind the iris and attached to its outer margin : more convex on its inner than its outer surface.

ii. The **anterior chamber of the eye**: between the lens and cornea : small : contains the **aqueous humour.**

iii. The **posterior chamber of the eye**: the large space behind the lens : filled by the **vitreous humour,** a gelatinous body.

iv. The **choroid**: the black pigmented layer lining the sclerotic, and continuous in front with the iris.

v. The **retina**: a delicate transparent membrane lining the posterior two-thirds of the eye: it is readily detached from the choroid, except at the entrance of the optic nerve with which it is continuous.

B. The Eye of the Sheep or Ox.

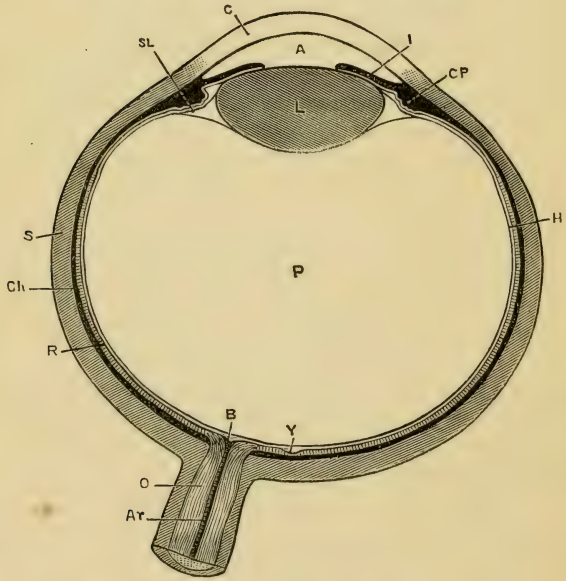

Fig. 14. A diagrammatic section through the eye of a mammal passing through the centres of the cornea and lens, and through the yellow spot and point of entrance of the optic nerve.

A, anterior chamber: Ar, central artery of retina: B, blind spot: C, cornea: Ch, choroid: C P, ciliary processes: H, hyaloid membrane, enclosing the vitreous humour: I, iris: L, lens: O, optic nerve: P, posterior chamber: R, retina: S, sclerotic: SL, suspensory ligament: Y, yellow spot.

1. *Dissect off the muscles of the eyeball and the fat which surrounds the optic nerve: note:—*

i. The shape of the eyeball.

ii. The **sclerotic,** covering about five-sixths of the eyeball; tough, white, and opaque.

iii. The **cornea:** covering the outer sixth of the eyeball: circular, transparent: continuous at its margin with the sclerotic: more convex than the sclerotic.

iv. The **conjunctiva:** a delicate epithelial layer, covering the front of the cornea and part of the sclerotic.

v. The **iris:** a pigmented ring seen through the cornea.

vi. The **pupil:** the central aperture surrounded by the iris.

vii. The **optic nerve:** piercing the sclerotic at the back of the eye.

2. *Cut all round the cornea close to its margin with fine scissors: remove the cornea: note:—*

i. The **aqueous humour:** the transparent watery fluid filling the **anterior chamber of the eye,** and escaping when the cornea is removed.

ii. The **lens.**

3. *Make four radial cuts equidistant from one another through the margin of the cornea and the sclerotic, taking care not to injure the deeper parts; and extend the cuts back towards the optic nerve. Carefully peel off the four flaps into which the sclerotic is now divided from the underlying black choroid coat: turn them down, and pin them to the dissecting board so as to fix the eye with the iris upwards: note:—*

i. The **ciliary muscle:** a whitish ring of unstriped muscle connecting the outer margin of the iris with the junction of the cornea and sclerotic: this must be detached with the handle of the scalpel to allow the flaps of the sclerotic to be turned back.

ii. The **choroid**: the dense black coat exposed by the removal of the sclerotic.

iii. The **ciliary vessels**: these pierce the sclerotic to convey blood to and from the choroid, which is extremely vascular.

iv. The **ciliary nerves**: seen passing through the sclerotic to the choroid while the flaps are being turned down.

4. *Make a couple of radial incisions a short distance apart through the iris and ciliary muscle, and turn back the portion of the iris between the two cuts: note:—*

i. The **ciliary processes**; a series of radial folds on the under surface of the outer margin of the iris: they fit into corresponding folds in the ligament which surrounds and supports the lens.

5. *Make a circular incision with scissors all round the eye about half an inch behind the ciliary muscle, cutting through the choroid and retina, but taking care not to injure the delicate membrane enclosing the vitreous humour. Gently detach and remove in one piece this front ring of iris, choroid, and retina: pin it on the dissecting board with the posterior surface upwards: note:—*

i. The **ciliary processes.**

ii. The **uvea**: the layer of dense black pigment at the back of the iris.

iii. The **ora serrata**: the indented anterior boundary of the part of the retina sensitive to light: in front of this the retina becomes extremely thin, but really extends forwards as far as the free edge of the iris.

6. *Examine the front of the eyeball from which the ring has been removed as described above: note:—*

i. The **capsule of the lens**: transparent and elastic.

ii. The **suspensory ligament of the lens,** or **zonule of Zinn**: the outer margin of the capsule of the lens: marked with radiating folds into which the ciliary processes fit.

iii. The **hyaloid membrane**: the delicate elastic membrane enclosing the vitreous humour, and continuous in front with the posterior layer of the capsule of the lens.

iv. The cut edges of the retina and choroid.

7. *Remove the lens from its capsule: note its shape, more convex behind than in front: harden it with spirit, or by boiling for a few minutes in water.*

8. *Remove the vitreous humour in the hyaloid membrane: note:—*

i. The **retina**; a delicate pulpy membrane between the hyaloid membrane and the choroid.

ii. The **blind spot**: the point of entrance of the optic nerve: to this spot the retina adheres firmly, though it can be readily removed from the choroid at all other parts.

iii. The **retinal vessels**; radiating from the blind spot.

C. Histology of the Eye.

1. The **frog's eye.**

Mount in balsam one of the prepared sections of the posterior part of the frog's eye: examine with low and high powers: note:—

a. The **sclerotic**; consisting chiefly of hyaline cartilage.

b. The **choroid**: a vascular plexus with much pigment.

c. The **retina**: composed of the following layers from without inwards:—

i. Layer of **pigment cells,** sending processes between

ii. The **rods and cones**: a single layer of columnar bodies placed vertically to the surface: the rods are far more numerous, and much larger than the cones: each consists of an inner and an outer segment.

iii. The **outer nuclear layer**: a moderately thick layer, well stained.

iv. The **outer molecular layer**; a very thin layer, not stained.

v. The **inner nuclear layer**: thick, and well stained.

vi. The **inner molecular layer**; thick, but not stained.

vii. The layer of nucleated **nerve cells.**

viii. The layer of **nerve fibres.**

ix. The **internal limiting membrane.**

x. The **radial fibres** or **Müller's fibres**: commencing with expanded ends in the ninth layer and stretching outwards: can easily be traced through the inner molecular layer.

2. The **choroid**; *spread a small piece of fresh choroid on a slide in normal salt solution: examine with low and high powers · note :—*

i. The **network of bloodvessels**; invested by

ii. **Pigment cells**; irregularly branched: with clear nuclei.

3. The **lens**; *tease in glycerine a small piece of lens hardened by boiling: examine with low and high powers: note :—*

i. The elongated cells of which the lens is composed.

ii. The serrated edges of many of the cells.

D. The Ear of the Frog.

The frog's auditory organ is too small to dissect satisfactorily, and is best studied by making transverse sections of the entire head, in the following manner :—

Kill a frog with chloroform, cut off the head with stout scissors and decalcify it by placing in a 5 to 10 per cent. solution of nitric acid, or a mixture of chromic acid with a few drops of nitric acid. When the bones are thoroughly soft, which will take from a few hours to 3 or 4 days or more according to the strength of acid employed, remove it from the decalcifying solution and transfer to weak alcohol and thence to strong alcohol. Then stain with borax carmine, imbed in paraffin, and cut into transverse sections with a microtome. Mount the sections in series; examine, and draw them showing :—

1. The **periotic capsule**: consists mainly of cartilage, and is firmly fused with the hinder part of the cranium.

2. The **vestibule**: a membranous sac lying in the cavity of the periotic capsule, and filled with a watery fluid the **endolymph**: it is partially divided by a constriction into two main divisions:—

   i. The **utriculus**; the upper and larger one.

   ii. The **sacculus**; the inferior and smaller division: from it arise three small saccular dilatations supposed to represent the cochlea of higher animals.

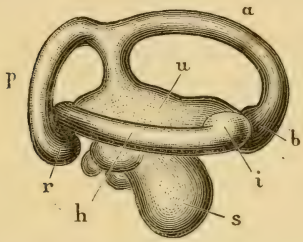

Fig. 15. The right internal ear of the frog, removed from the periotic cartilage and drawn from the outer surface.

a, the anterior vertical semicircular canal: *b*, its ampulla: *h*, the horizontal canal: *i*, its ampulla: *p*, the posterior vertical canal: *r*, its ampulla: *s*, the sacculus: *u*, the utriculus.

3. The **semicircular canals**; three tubular offsets of the vestibule into which they open at both ends. They lie in canals in the periotic cartilage, and are placed in planes at right angles to one another: each has at one end, close to its opening into the vestibule, a dilatation or **ampulla.**

   i. The **anterior vertical canal** has its ampulla at its anterior end.

   ii. The **posterior vertical canal** has its ampulla at its outer end, while its inner end joins the posterior end of the anterior vertical canal to open into the vestibule by a common orifice.

   iii. The **horizontal** or **external canal** has its ampulla at the anterior end.

4. The **auditory nerve**: the auditory or eighth nerve leaves the cranial cavity through a hole in the inner wall of the periotic capsule, and divides into branches distributed to the sacculus and its diverticula, and to the ampullæ of the semicircular canals.

5. The **accessory auditory apparatus.** The essential organs of hearing:—*i.e.*, the vestibule and its offsets, and the auditory nerve—are enclosed in the periotic cartilage, deeply placed in the side of the head: the communication with the surface is brought about by the accessory apparatus, which consists of the following parts (Fig. 10):—

   i. The **Eustachian passage** and **mpanic cavity**: really the hyomandibular gill cleft, which having lost its original respiratory purpose persists with modified function as an accessory organ of hearing.

   ii. The **tympanic membrane**; closing the tympanic cavity on its outer side.

   iii. The **columella**: a rod of bone and cartilage, whose outer end is attached to the tympanic membrane, while its inner end is inserted into a hole in the outer wall of the periotic capsule so as to lie in close contact with the vestibule. It serves to communicate the auditory vibrations from the tympanic membrane to the vestibule.

Chap. VIII.—THE REPRODUCTIVE ORGANS AND THE CLOACA OF THE FROG.

A. The Male Frog.

1. The Reproductive Organs. (Fig. 3.)

Pin the frog on its back under water: open the body cavity from the ventral surface: turn aside or remove the alimentary canal and liver.

i. The **testes**; a pair of yellow oval bodies about a quarter of an inch long, lying on the ventral surface of the kidneys: within these are developed the essential male elements or spermatozoa.

ii. The **vasa efferentia**: a number—usually 10 to 12—of slender ducts, connecting the testis of each side with the inner or median border of the corresponding kidney: they serve to convey the spermatozoa from the testis into the tubules of the kidney, from which they escape by the ureter which acts as vas deferens.

iii. The **vas deferens or ureter**: runs along the outer side of the posterior part of the kidney and then back to the cloaca.

iv. The **vesicula seminalis**; a large pouch-like dilatation on the outer side of the vas deferens, just below the kidney and before reaching the cloaca.

2 The Cloaca.

Lay the frog on its back: cut through the femur on each side with strong scissors just below its head: cut also through the two ilia at their necks just in front of the acetabula. Carefully dissect away the pelvic symphysis, which is now isolated, from the muscles attached to it and from the cloaca, and remove it completely, taking care not to injure the cloaca.

i. The **cloaca**: really the terminal portion of the large intestine into which open the ureters, the genital ducts, and the bladder.

ii. The **bladder**: a thin-walled bifid muscular sac, lying on the ventral surface of the large intestine and cloaca, its two lobes communicating freely with each other. It is invested by peritoneum and attached to the sides of the body by special peritoneal folds.

Inflate the bladder with a blow pipe through the cloacal aperture: pass a seeker up the cloaca to determine the exact position of the opening from the bladder to the cloaca. Cut up the cloaca along one side: wash out its contents and examine the opening into the bladder.

iii. The **ureter** or **vas deferens** behind the vesicula seminalis forms a very short tube opening into the dorsal wall of the cloaca almost exactly opposite the opening of the bladder on the ventral surface. The openings of the two ureters are close together on the apices of two small papillæ, overhung by a slight valvular projection of the mucous membrane of the cloaca.

B. The Female Frog.

1. The Reproductive organs.

Dissect as in the male.

i. The **ovaries**: a pair of black masses lying in folds of the peritoneum in front of the kidneys, in very much the same position as the testes in the male. Their shape and size vary much at different seasons of the year. On their surfaces are numerous rounded projections, like small shot; these are ova in various stages of development: the smaller and younger ones are white; the larger and more mature ones black in one half, and white or yellowish in the other.

ii. The **oviducts**: a pair of white much convoluted tubes with thick gelatinous walls. They commence with open mouths at the extreme front end of the body cavity, close to the outer side of the roots of the lungs; and run back increasing

in size, and becoming much convoluted. The lower ends are much dilated, but have thinner walls. Unlike the male the female has genital ducts distinct from the ureters.

2. The cloaca:

Dissect as in the male.

i. The **cloaca**: very similar to that of the male.

ii. The **bladder**: like that of the male.

iii. The **oviducts**: open separately into the dorsal wall of the cloaca just above the bladder by two wide apertures separated by a narrow median partition.

iv. The **ureters**: open by two small apertures placed close together into the dorsal wall of the cloaca just behind the oviducts.

J. E. Cornish's Publications.

Roger Bacon. The Philosophy of Science in the Middle Ages. By R. Adamson, M.A., Professor of Logic and Mental and Moral Philosophy in the Owens College, Victoria University. 1*s.*

Greek Exercises for Beginners. Translated from the Greek Grammar of Prof. George Curtius. By Edwin B. England, M.A., Lecturer in Greek and Latin in the Owens College, Victoria University. 1*s.*

The Present Aspect of the Antiseptic Question. By Edward Lund, F.R.C.S., Prof. of Surgery in the Owens College, Victoria University. 2*s.*

Engineering Syllabus of the Lectures at the Owens College, together with a series of examples relating to the various subjects included in the course. By Osborne Reynolds, M.A., F.R.S., Prof. of Engineering in the Owens College, Victoria University. Arranged by Mr. J. B. Millar, Assistant Lecturer in Engineering. 2nd Edition. 3*s.*

Description of the Chemical Laboratories at the Owens College, from the plans of Alfred Waterhouse, R.A. By Sir H. E. Roscoe, F.R.S., Professor of Chemistry in the Owens College, Vic-University. With lithographed copies of the original plans and elevations. 5*s.*

Notes on the Diagnosis of the various forms of Paralysis of the Muscles of External Relation. By James Ross, M.D., LL.D. 1*s.*

Histological Notes for the use of Medical Students. By W. Horscraft Waters, M.A., Lecturer on Histology in the Owens College, Victoria University. 2*s.* 6*d.*

J. E. CORNISH,
33 PICCADILLY,
MANCHESTER.

Marshall, Arthur Milnes, 1852-1893.

The frog : an introduction to anatomy and histology.