

Exhibit 2

CHRONIC TRAUMATIC ENCEPHALOPATHY IN A NATIONAL FOOTBALL LEAGUE PLAYER

Bennet I. Omalu, M.D., M.P.H.

Departments of Pathology and Epidemiology, University of Pittsburgh, Pittsburgh, Pennsylvania

Steven T. DeKosky, M.D.

Departments of Human Genetics and Neurology, University of Pittsburgh, Pittsburgh, Pennsylvania

Ryan L. Minster, M.S.I.S.

Department of Human Genetics, University of Pittsburgh, Pittsburgh, Pennsylvania

M. Ilyas Kamboh, Ph.D.

Department of Human Genetics, University of Pittsburgh, Pittsburgh, Pennsylvania

Ronald L. Hamilton, M.D.

Department of Pathology, University of Pittsburgh, Pittsburgh, Pennsylvania

Cyril H. Wecht, M.D., J.D.

Departments of Pathology and Epidemiology, University of Pittsburgh, Pittsburgh, Pennsylvania

Reprint requests:

Bennet I. Omalu, M.D., M.P.H., Departments of Pathology and Epidemiology, University of Pittsburgh, 7520 Penn Bridge Court, Pittsburgh, PA 15221. Email: bennet.omalu@verizon.net

Received, August 30, 2004.

Accepted, February 10, 2005.

OBJECTIVE: We present the results of the autopsy of a retired professional football player that revealed neuropathological changes consistent with long-term repetitive concussive brain injury. This case draws attention to the need for further studies in the cohort of retired National Football League players to elucidate the neuropathological sequelae of repeated mild traumatic brain injury in professional football.

METHODS: The patient's premortem medical history included symptoms of cognitive impairment, a mood disorder, and parkinsonian symptoms. There was no family history of Alzheimer's disease or any other head trauma outside football. A complete autopsy with a comprehensive neuropathological examination was performed on the retired National Football League player approximately 12 years after retirement. He died suddenly as a result of coronary atherosclerotic disease. Studies included determination of apolipoprotein E genotype.

RESULTS: Autopsy confirmed the presence of coronary atherosclerotic disease with dilated cardiomyopathy. The brain demonstrated no cortical atrophy, cortical contusion, hemorrhage, or infarcts. The substantia nigra revealed mild pallor with mild dropout of pigmented neurons. There was mild neuronal dropout in the frontal, parietal, and temporal neocortex. Chronic traumatic encephalopathy was evident with many diffuse amyloid plaques as well as sparse neurofibrillary tangles and τ -positive neuritic threads in neocortical areas. There were no neurofibrillary tangles or neuropil threads in the hippocampus or entorhinal cortex. Lewy bodies were absent. The apolipoprotein E genotype was E3/E3.

CONCLUSION: This case highlights potential long-term neurodegenerative outcomes in retired professional National Football League players subjected to repeated mild traumatic brain injury. The prevalence and pathoetiological mechanisms of these possible adverse long-term outcomes and their relation to duration of years of playing football have not been sufficiently studied. We recommend comprehensive clinical and forensic approaches to understand and further elucidate this emergent professional sport hazard.

KEY WORDS: Chronic traumatic encephalopathy, National Football League, Retired professional football players

Neurosurgery 57:128-134, 2005

DOI: 10.1227/01.NEU.0000163407.92769.ED

www.neurosurgery-online.com

Several professional players of the National Football League (NFL) have retired prematurely because of postconcussion syndrome (29), a possible outcome of repeated concussion of the brain. The NFL Committee on Mild Traumatic Brain Injury, which was formed in 1994 to study this trend, has replaced the terminology *postconcussion syndrome* with *mild traumatic brain injury* (MTBI). MTBI is defined as a "traumatically induced alteration in brain function that is manifested by a) alteration of awareness or

consciousness, including but not limited to loss of consciousness, sensation of being dazed or stunned, sensation of wooziness or foggy, seizure, or amnesic period; and b) signs and symptoms commonly associated with postconcussion syndrome, including persistent headaches, vertigo, lightheadedness, loss of balance, unsteadiness, syncope, near-syncope, cognitive dysfunction, memory disturbance, hearing loss, tinnitus, blurred vision, diplopia, visual loss, personality change, drowsiness, lethargy, fatigue, and inability to

CHRONIC TRAUMATIC ENCEPHALOPATHY IN A FOOTBALL PLAYER

perform usual daily activities" (29). In 1995, the committee recommended that the NFL should fund independent scientific research to understand the causes of MTBI and elucidate ways of preventing MTBI. Despite this recommendation, which was made many years ago, the possible long-term cognitive and neurodegenerative sequelae of professional football as well as the underlying histological changes and pathobiological cascades associated with and likely induced by the trauma of professional football are little understood. This is especially true for the neuropathological changes, because no cases have come to autopsy.

We herein report the first documented case of long-term neurodegenerative changes in a retired professional NFL player consistent with chronic traumatic encephalopathy (CTE). This case draws attention to a disease that remains inadequately studied in the cohort of professional football players, with unknown true prevalence rates. Although clinical assessments can determine encephalopathy and dementia, and new neuroimaging methods may aid in the detection of amyloid plaques (23), autopsy examination is required to confirm the neuropathological basis of these changes. Autopsies aimed at diagnosing long-term central nervous system (CNS) sequelae of repeated brain concussions in NFL players are virtually nonexistent. Our case represents an extremely rare scenario whereby a complete autopsy was performed on a retired NFL player with a comprehensive neuropathological examination, which revealed changes consistent with CTE.

CASE REPORT

Premortem History

Our patient was a 50-year-old professional football player who died approximately 12 years after retirement from the NFL. He began playing football in high school and played for 3 years in college, where he was a team's most valuable player and a multiyear starter as a lineman in a Division I college. Drafted into the NFL at the age of 22 years, he played in 245 games in the NFL during 17 seasons. For 10 of those years, he played 177 consecutive games, principally as an offensive lineman. He was in the starting lineup in 150 consecutive games and played in 19 playoff games (15). After his retirement, he presented with a medical history that included atrial fibrillation and coronary atherosclerotic disease, which were treated with intraluminal stenting. Telephone interviews of surviving family members revealed a neuropsychiatric history that resembled a dysthymic disorder according to the criteria of the *Diagnostic and Statistical Manual of Mental Disorders*, 4th edition (2). Other medical history included a deficit in memory and judgment as well as parkinsonian symptoms. He died suddenly from clinically documented myocardial infarction. There was no known history of brain trauma outside professional football.

Autopsy Findings

General

External examination revealed the body of an adult Caucasian man who weighed 244 lb and measured 69 inches (body mass index, 36 kg/m² [Class II obesity]). There was no external evidence of recent trauma. The pericardium revealed diffuse fibrocalcific and adhesive pericardioepicarditis. The cardiovascular system revealed dilated cardiomyopathy with severe cardiomegaly (855 g), severe bilateral atrioventricular dilation; biventricular hypertrophy; and patchy subendocardial, endocardial, and valvular fibrosis. There was evidence of cardiogenic shock with centrilobular hepatocellular coagulative necrosis. There was chronic sinusoidal hepatic congestion with trabecular atrophy. There was severe atherosclerosis of the proximal and distal right coronary artery and the left anterior descending coronary artery, with approximately 95% multifocal intraluminal occlusion. The proximal left circumflex coronary artery revealed moderate atherosclerosis with 50 to 75% focal intraluminal occlusion. A metal intraluminal surgical stent was identified in the proximal right coronary artery. The myocardium revealed moderate interstitial and perivascular fibrosis. The respiratory system revealed moderate acute pulmonary edema and congestion with patchy, acute, and terminal bronchopneumonia.

Gross CNS Findings

The dura mater and dural sinuses appeared unremarkable. The formalin-fixed whole brain weighed 1565 g, whereas the cerebellum and brainstem weighed 220 g. The leptomeninges were unremarkable. There was no cerebral atrophy. There were no cortical contusions, infarcts, or hemorrhages. There was moderate cerebral edema but no evidence of uncal or cerebellar tonsillar herniation. The cerebral blood vessels and circle of Willis revealed focal mild eccentric atherosclerosis of the left vertebral artery without aneurysms or other anomalies. The cranial nerves were normal.

Coronal sections of the cerebral hemispheres revealed no significant gross pathological changes of the cortex, white matter, or deep gray structures. The ventricles were not enlarged, and there was no atrophy of the hippocampi or the corpus callosum. The amygdala and piriform cortex demonstrated no atrophy. The mamillary bodies and hypothalamus appeared unremarkable.

The midbrain, pons, and medulla oblongata were grossly unremarkable, except for the pigmentation of the substantia nigra, which was attenuated for age, but the locus ceruleus appeared adequately pigmented. There were no infarcts in the cerebellum. There was mild atrophy of the anterior superior vermis. The dentate nucleus appeared normal. The pituitary gland and spinal cord were unremarkable.

CNS Histomorphology

Primary hematoxylin and eosin stains were performed on all tissue sections. After they were reviewed, a panel of spe-

OMALU ET AL.

cialized histochemical and immunohistochemical stains was applied. These specialized stains included β -amyloid protein (Beta-A4; Dako, Carpinteria, CA), neurofilament (Dako), α -synuclein (Zymed Laboratories, South San Francisco, CA), and τ -protein (Dako) immunostains as well as Bielschowsky's silver impregnation histochemical stains.

The frontal, parietal, and temporal neocortex revealed normal laminar and columnar organization, with mild neuronal dropout and astrogliosis. The penetrating parenchymal vessels revealed patchy perivascular hemosiderin-laden macrophages in the Virchow-Robin spaces. There was moderate cerebral edema. The centrum semiovale revealed no white matter rarefaction or perivascular pallor but demonstrated focal mural mineralization of deep penetrating blood vessels. There was no periventricular leukomalacia, and the subependymal white matter was nongliotic. The basal ganglia and subcortical white matter tracts were unremarkable. There was mild to moderate neuronal dropout of the nigral pars compacta and pars reticularis, accompanied by mild extraneuronal pigment and astrogliosis. There were no Lewy bodies. There was no mineralization of pallidal vessel walls. The hippocampus revealed mild neuronal dropout of the pyramidal neurons of Sommer's sector (CA-1) without selective neuronal necrosis. There were no Hirano bodies and no granulovacuolar neuronal degeneration. The subiculum, entorhinal cortex, and alveus were unremarkable, as were the amygdala and basal nucleus of Meynert. There were no lesions in the remaining brainstem structures. The cerebellar cortex revealed mild neuronal dropout and Bergmann astrogliosis of the Purkinje cell layer. This was accentuated in the superior anterior vermis, which also revealed mild atrophy of the internal granule cell layer. The cerebellar white matter and dentate nucleus were unremarkable. The adenohypophysis and neurohypophysis were normal. The cervical, thoracic, and lumbar segments of the spinal medulla were normal and demonstrated no signs of anterior horn cell dropout or degenerative changes.

Specialized Stains

The battery of immunohistochemical stains revealed frequent diffuse extracellular amyloid plaques (Fig. 1A), sparse τ -positive neuritic threads (Fig. 1B), and sparse intraneuronal band-shaped and flame-shaped neurofibrillary tangles (NFTs) (Fig. 1C) in the frontal, temporal, parietal, occipital, and cingulate cortex and the insula. Cortical Lewy bodies were absent. Many neocortical perikarya revealed diffuse cytoplasmic immunopositivity for neurofilament protein. The hippocampal formation was spared of these pathological changes; the dentate gyrus, cornu ammonis, and subiculum demonstrated no diffuse amyloid plaques (Fig. 1D), NFTs, neuritic threads, or Lewy bodies. The subcortical nuclei and brainstem, including the substantia nigra, contained no diffuse amyloid plaques, NFTs, neuritic threads, or Lewy bodies. There was no histological evidence of cerebral amyloid angiopathy.

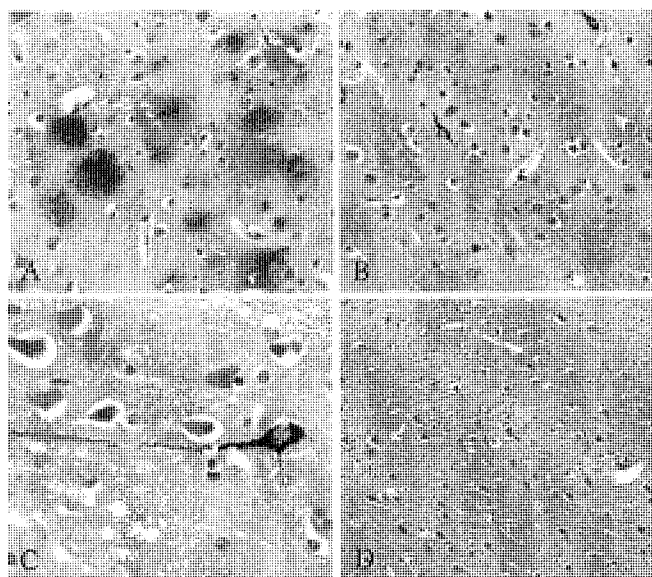


FIGURE 1. A, β -amyloid immunostain of the neocortex (original magnification, $\times 200$) showing frequent diffuse amyloid plaques. B, τ immunostain of the neocortex (original magnification, $\times 200$) showing sparse NFTs and many τ -positive neuritic threads. C, τ immunostain (original magnification, $\times 400$) showing an NFT in a neocortical neuron with extending τ -positive dendritic processes. D, β -amyloid immunostain (original magnification, $\times 100$) of the Sommer's sector (CA-1 region of the hippocampus) showing no diffuse amyloid plaques.

Apolipoprotein E (ϵ) Genotyping

Genomic deoxyribonucleic acid (DNA) was extracted from 25-mg formaldehyde-fixed brain tissue with the QIAamp DNA Mini Kit (Qiagen, Valencia, CA) using the protocol for isolation of genomic DNA from formaldehyde-fixed tissues. Representative whole-genome amplification of the extracted DNA was accomplished using the GenomiPhi DNA Amplification Kit (Amersham Biosciences, Piscataway, NJ). Restriction fragment length polymorphism analysis was completed using previously published protocols (20). The genotype of the sample was determined to be E3/E3 (Fig. 2).

DISCUSSION

Although head injury (repeated mild concussive brain injury or a single episode of severe diffuse brain injury) may increase the risk of sporadic Alzheimer's disease (AD), (14, 25) importantly, this case did not meet criteria for AD but met criteria for CTE. Cortical amyloid plaques and NFTs were unaccompanied by tangles in the entorhinal cortex or hippocampus, which is the usual starting point for neuropathological changes of sporadic AD. The first neuropathological report on the long-term effects of contact sport (boxing) was written by Brandenburg and Hallervorden (8) in 1954, in a 51-year-old retired boxer who manifested delayed posttraumatic dementia with AD pathological changes. In 1973,

CHRONIC TRAUMATIC ENCEPHALOPATHY IN A FOOTBALL PLAYER




FIGURE 2. Polyacrylamide gel electrophoresis showing DNA from decedent's brain under ultraviolet light. Lanes 1 and 2 contain duplicate samples of the DNA extracted from the brain sample amplified as described in the text and digested with HhaI to reveal the restriction fragment length polymorphism. Lane 3 is a sample known to be E2/E4 prepared in parallel with the samples from Lanes 1 and 2. Lane 4 is a negative template control. Lane 5 contains a 50- to 2000 base-pair (bp) ladder.

Corsellis et al. (8) described the neurohistological substrate of CTE in the brains of 15 retired professional and amateur boxers. These reports and other subsequent reports (12–14, 34–36, 39, 41) have described characteristic neuropathological findings for CTE, especially in boxers, which comprise: 1) sparse to many τ -positive NFTs in the neocortex concentrated around penetrating parenchymal vessels, 2) neocortical τ -immunopositive neurites in the neuropil (neuropil threads), and 3) neocortical diffuse amyloid plaques with or without neuritic plaques. Neocortical changes seem to spare the hippocampus. The NFT distribution is notably different from that observed in normal aging and AD, in which there is early involvement of the entorhinal cortex and hippocampus with later involvement of the neocortex in advanced stages. Other reported delayed gross neuropathological changes in the brains of retired boxers have included cerebral atrophy, cerebral amyloid angiopathy, communicating hydrocephalus, fenestrations of the septum pellucidum, cavum septi pellucidi, cerebellar cortical atrophy, and degeneration of the substantia nigra (8, 10, 12, 34, 38, 39, 41). After an extensive search of the medical literature, we could not identify any study on the neuropathological substrate of delayed neurodegeneration in professional football players.

The pathological mechanisms for these delayed posttraumatic changes are thought to be biochemical cascades that are induced by cumulative effects of repeated low-grade concussive brain injury, especially changes like hyperphosphorylation of neuronal microtubule-associated protein and aberrant metabolism of amyloid precursor protein (13, 34, 38, 39). It has been suggested that repeated axonal injury, vascular injury, and ischemia trigger a cascade of molecular events involving derangement of neuronal cytoskeletal metabolism and accumulation of abnormal cytoskeletal proteins; increased expression of amyloid precursor protein; and a subsequent increase in the β -amyloid fragment, which is deposited in amyloid plaques.

The sport of American football has a high probability of impact to the head and concussion of the brain. There are up to 300,000 cases per year of MTBI or brain concussion in contact sports in the United States (29–32). There are approximately 0.41 concussions per NFL game of American football: 67.7% of concussions involve impact by another player's helmet, 20.9% involve impact by other body regions (e.g., a knee), and 11.4% involve impact on the ground (29, 31, 32, 40). It has been reported that 9.3% of the concussions involved loss of consciousness and 2.4% of the concussions resulted in hospitalization. Most (92%) of the players who sustain a concussion return to practice in less than 7 days; fewer (69%) of the players who experience loss of consciousness return to practice in less than 7 days. The relative risk of brain concussion in NFL players is associated with player position. Although every player position is at risk of brain concussion, quarterbacks, wide receivers, tight ends, and defensive backs have the highest relative risks (1.62, 1.23, 0.94, and 0.93 concussions per 100 games, respectively) (30–32). The most frequent position played by the patient was an offensive lineman. In a 17-year career as an offensive lineman, he sustained numerous episodes of mild traumatic and/or concussive brain injury, which is supported by the histological evidence of remote hemorrhages into the Virchow-Robin spaces of penetrating parenchymal vessels, with multiple perivascular hemosiderin-laden macrophages. These histological findings indicate microvascular injury that may be sustained from repetitive concussive brain injury.

Concussions in professional football are related to translational acceleration-deceleration, with considerable head impact velocity and velocity changes. The injury potential of these transferring inertial forces is ameliorated by the use of protective helmets. Since 1978, there has been a remarkable reduction in fatal head injuries (51%), concussions (35%), and cranial fractures (65%) in youth football, after the voluntary adoption of set standards for protective helmet manufacturers by the National Operating Committee on Standards for Athletic Equipment (29, 31, 32). The NFL has aggressively pursued the prevention of traumatic brain injury during play by the modification of play and rules of play as well as the introduction of improved standardized helmets, which have generated a marked reduction in the incidence of fatal and nonfatal head injuries (6). Although the technology and safety of football helmets have advanced in the past decades, this player's career spanned earlier decades in which helmets were not as protective as the ones in use today.

The acute sequelae of brain injury in professional football players have been elucidated and ameliorated, although there is less information about the chronic long-term sequelae of brain injury in retired football players. A variety of delayed clinical outcomes have been studied by radiological and neuropsychiatric testing, although without neuropathological evaluation. Such studies have suggested long-term impaired cognitive functioning (memory, planning, and visuosperceptual processing), electroencephalographic abnormalities, and cerebral atrophy in professional boxers, soccer players, football players, ice hockey players, karate players, lacrosse players, and rugby players (1, 3, 5, 7, 11, 22, 24, 33, 39, 42, 43). Possible symptoms of CTE may include recurrent headaches,

OMALU ET AL.

irritability, dizziness, lack of concentration, impaired memory, and mental slowing; mood disorders, explosive behavior, morbid jealousy, and pathological intoxication and paranoia; tremor, dysarthria, and parkinsonian movement disorders (9, 18, 19, 26, 37). Postmortem telephone interviews of close family members of the patient in this case indicated a long-standing mood disorder that resembled a dysthymic disorder according to the criteria of the *Diagnostic and Statistical Manual of Mental Disorders*, 4th edition (2).

Apolipoprotein E (ϵ) and CTE

We analyzed the apolipoprotein E (APOE) genotype of the patient in this case, because genotypic variation of APOE predisposes to or mitigates the development of AD and posttraumatic AD-like pathological changes (4, 16). The possession of the APOE4 allele by professional football players and boxers has been associated with chronic neurological deficits, lower scores in overall cognitive performance, and lower scores in cognitive domains (17, 21). The three APOE isoforms differ by only one or two amino acids but confer a three- to ninefold increase in the risk for developing these diseases (APOE4 > APOE3 > APOE2). Individuals who inherit one or two copies of APOE4 have an earlier age of onset for late-onset and sporadic AD and increased long-term sequelae of brain trauma (4). The presence of the APOE4 allele does not confer absolute predisposition to CTE and/or other sporadic or posttraumatic AD pathological changes, and absence of the APOE4 allele does not confer absolute protection from these diseases (4). Geddes et al. (12) reported the E3/E3 APOE genotype in two patients with repetitive head injury in contact sports who demonstrated neuronal cytoskeletal changes and CTE. The authors concluded that CTE can occur in the absence of APOE4 (12, 13). Our finding of the E3/E3 APOE genotype in our patient appears similar to the findings in the cases reported by Geddes et al. (12, 13).

CONCLUSION

This case study by itself cannot confirm a causal link between professional football and CTE. However, it indicates the need for comprehensive cognitive and autopsy-based research on long-term postneurotraumatic sequelae of professional American football. Empirical, cognitive, and postmortem data on CTE are currently unavailable in the population cohort of professional NFL players. Our report therefore constitutes a forensic epidemiological sentinel case that draws attention to a possibly more prevalent yet unrecognized disease because of the rarity of CNS-targeted autopsies in the cohort of retired NFL players.

REFERENCES

1. Abreau FTD, Schuyler BA, Hutchison HT: Neuropsychological assessment of soccer players. *Neuropsychology* 4:175-181, 1990.
2. American Psychiatric Association, American Psychiatric Association Task Force on DSM-IV: *Diagnostic and Statistical Manual of Mental Disorders: DSM-IV-TR*. Washington, DC, American Psychiatric Association, 2000.
3. Aotsuka A, Kojima S, Furumoto H, Hattori T, Hirayama K: Punch drunk syndrome due to repeated karate kicks and punches [in Japanese]. *Rinsho Shinkeigaku* 30:1243-1246, 1990.
4. Bales KR, Dodart JC, DeMattos RB, Holtzman DM, Paul SM: Apolipoprotein E, amyloid, and Alzheimer disease. *Mol Interv* 2:363-375; 339, 2002.
5. Barth JT, Macciocchi SN, Giordani B, Rimel R, Jane JA, Boll TJ: Neuropsychological sequelae of minor head injury. *Neurosurgery* 13:529-533, 1983.
6. Cantu RC, Mueller FO: Brain injury-related fatalities in American football, 1945-1999. *Neurosurgery* 52:846-852, 2003.
7. Collins MW, Grindel SH, Lovell MR, Dede DE, Moser DJ, Phalin BR, Nogle S, Wasik M, Cordry D, Daugherty KM, Sears SF, Nicolette G, Indelicato P, McKeag DB: Relationship between concussion and neuropsychological performance in college football players. *JAMA* 282:964-970, 1999.
8. Corsellis JA, Bruton CJ, Freeman-Browne D: The aftermath of boxing. *Psychol Med* 3:270-303, 1973.
9. Dikmen SS, Bombardier CH, Machamer JE, Fann JR, Temkin NR: Natural history of depression in traumatic brain injury. *Arch Phys Med Rehabil* 85:1457-1464, 2004.
10. Editorial: Brain damage in sport. *Lancet* 1:401-402, 1976.
11. Erlanger DM, Kutner KC, Barth JT, Barnes R: Neuropsychology of sports-related head injury: Dementia Pugilistica to Post Concussion Syndrome. *Clin Neuropsychol* 13:193-209, 1999.
12. Geddes JF, Vowles GH, Nicoll JA, Revesz T: Neuronal cytoskeletal changes are an early consequence of repetitive head injury. *Acta Neuropathol (Berl)* 98:171-178, 1999.
13. Geddes JF, Vowles GH, Robinson SF, Sutcliffe JC: Neurofibrillary tangles, but not Alzheimer-type pathology, in a young boxer. *Neuropathol Appl Neurobiol* 22:12-16, 1996.
14. Gentleman SM, Graham DI, Roberts GW: Molecular pathology of trauma: Altered β APP metabolism and the etiology of Alzheimer's disease, in Kogure K, Hossmann K-A, Siesjö BK (eds): *Progress in Brain Research*. New York, Elsevier, 1993, pp 237-246.
15. <http://www.footballresearch.com/articles>. February 20, 2004.
16. Jin ZQ, Fan YS, Ding J, Chen M, Fan W, Zhang GJ, Zhang BH, Yu SJ, Zhang YS, Ji WF, Zhang JC: Association of apolipoprotein E 4 polymorphism with cerebral infarction in Chinese Han population. *Acta Pharmacol Sin* 25:352-356, 2004.
17. Jordan BD, Relkin NR, Ravdin LD, Jacobs AR, Bennett A, Gandy S: Apolipoprotein E ϵ 4 associated with chronic traumatic brain injury in boxing. *JAMA* 278:136-140, 1997.
18. Jorge R, Robinson RG: Mood disorders following traumatic brain injury. *Int Rev Psychiatry* 15:317-327, 2003.
19. Jorge RE, Robinson RG, Moser D, Tateno A, Crespo-Facorro B, Arndt S: Major depression following traumatic brain injury. *Arch Gen Psychiatry* 61:42-50, 2004.
20. Kamboh MI, Aston CE, Hamman RF: The relationship of APOE polymorphism and cholesterol levels in normoglycemic and diabetic subjects in a biethnic population from the San Luis Valley, Colorado. *Atherosclerosis* 112:145-159, 1995.
21. Kutner KC, Erlanger DM, Tsai J, Jordan B, Relkin NR: Lower cognitive performance of older football players possessing apolipoprotein E ϵ 4. *Neurosurgery* 47:651-658, 2000.
22. Maddocks D, Saling M: Neuropsychological deficits following concussion. *Brain Inj* 10:99-103, 1996.
23. Mathis CA, Wang Y, Klunk WE: Imaging β -amyloid plaques and neurofibrillary tangles in the aging human brain. *Curr Pharm Des* 10:1469-1492, 2004.
24. Matser JT, Kessels AG, Jordan BD, Lezak MD, Troost J: Chronic traumatic brain injury in professional soccer players. *Neurology* 51:791-796, 1998.
25. McKenzie JE, Gentleman SM, Roberts GW, Graham DI, Royston MC: Increased numbers of β APP-immunoreactive neurones in the entorhinal cortex after head injury. *Neuroreport* 6:161-164, 1994.
26. Mendez MF: The neuropsychiatric aspects of boxing. *Int J Psychiatry Med* 25:249-262, 1995.
27. Millar K, Nicoll JA, Thornhill S, Murray GD, Teasdale GM: Long term neuropsychological outcome after head injury: Relation to APOE genotype. *J Neurol Neurosurg Psychiatry* 74:1047-1052, 2003.
28. Nicoll JA, Roberts GW, Graham DI: Apolipoprotein E ϵ 4 allele is associated with deposition of amyloid β -protein following head injury. *Nat Med* 1:135-137, 1995.
29. Pellmar EJ: Background on the National Football League's research on concussion in professional football. *Neurosurgery* 53:797-798, 2003.

CHRONIC TRAUMATIC ENCEPHALOPATHY IN A FOOTBALL PLAYER

30. Pellman EJ, Powell JW, Viano DC, Casson IR, Tucker AM, Feuer H, Lovell M, Waeckerle JF, Robertson DW: Concussion in professional football: Epidemiological features of game injuries and review of the literature—Part 3. *Neurosurgery* 54:81–96, 2004.
31. Pellman EJ, Viano DC, Tucker AM, Casson IR: Concussion in professional football: Location and direction of helmet impacts—Part 2. *Neurosurgery* 53:1328–1340, 2003.
32. Pellman EJ, Viano DC, Tucker AM, Casson IR, Waeckerle JF: Concussion in professional football: Reconstruction of game impacts and injuries. *Neurosurgery* 53:799–812, 2003.
33. Porter MD: A 9-year controlled prospective neuropsychologic assessment of amateur boxing. *Clin J Sport Med* 13:339–352, 2003.
34. Roberts GW: Immunocytochemistry of neurofibrillary tangles in dementia pugilistica and Alzheimer's disease: Evidence for common genesis. *Lancet* 2:1456–1458, 1988.
35. Roberts GW, Allsop D, Bruton C: The occult aftermath of boxing. *J Neurol Neurosurg Psychiatry* 53:373–378, 1990.
36. Roberts GW, Whitwell HL, Acland PR, Bruton CJ: Dementia in a punch-drunk wife. *Lancet* 335:918–919, 1990.
37. Ryan LM, Warden DL: Post concussion syndrome. *Int Rev Psychiatry* 15:310–316, 2003.
38. Smith DH, Chen XH, Nonaka M, Trojanowski JQ, Lee VM, Saatman KE, Leoni MJ, Xu BN, Wolf JA, Meaney DF: Accumulation of amyloid β and τ and the formation of neurofilament inclusions following diffuse brain injury in the pig. *J Neuropathol Exp Neurol* 58:982–992, 1999.
39. Sortland O, Tysvaer AT: Brain damage in former association football players: An evaluation by cerebral computed tomography. *Neuroradiology* 31:44–48, 1989.
40. Tagliabue P: Tackling concussions in sports. *Neurosurgery* 53:796, 2003.
41. Tokuda T, Ikeda S, Yanagisawa N, Ihara Y, Glenner GG: Re-examination of ex-boxers' brains using immunohistochemistry with antibodies to amyloid β protein and τ protein. *Acta Neuropathol (Berl)* 82:280–285, 1991.
42. Tysvaer AT, Storli OV: Soccer injuries to the brain: A neurologic and electroencephalographic study of active football players. *Am J Sports Med* 17:573–578, 1989.
43. Tysvaer AT, Storli OV, Bachen NI: Soccer injuries to the brain: A neurologic and electroencephalographic study of former players. *Acta Neurol Scand* 80:151–156, 1989.

COMMENTS

This is the first publication of chronic traumatic encephalopathy (CTE) in a retired National Football League (NFL) player. It should come as no surprise, though, as a number of NFL players have had to retire from sequelae of multiple mild traumatic brain injuries. It also is consistent with the findings of studies of Kevin Guskiewicz, Julian Bailes, and others at The Center for the Study of Retired Athletes at the University of North Carolina. These researchers found retired NFL players with three or more concussions had a fivefold prevalence toward mild cognitive impairment and a threefold prevalence toward significant memory problems compared with retirees with no history of concussion. Hopefully, in the years ahead, the center will be able to study these retirees so a better idea of the incidence of CTE in former NFL players becomes known, as well as how many years of participation may lead to this risk. I fully support the conclusions of Omalu et al.

Robert C. Cantu
Concord, Massachusetts

In this case report of CTE in a retired NFL player, the authors provide an in-depth description of the deceased player's neuropathological findings. The authors assert that the individual's premortem cognitive decline, depression, parkinsonian symptoms, and neuropathological findings were a manifestation of traumatic encephalopathy resulting from his many years of professional football. Although this is an interesting hypothesis and it is

likely he sustained several mild traumatic brain injuries over the course of his NFL career, this assertion appears to be somewhat presumptuous because they are only reporting associated findings in a single individual. It is notable that no mention is made of any concussions, mild or otherwise, in his premortem history, and that he played predominantly as an offensive lineman which is one of the player positions associated with the lowest frequency of concussion in the NFL. Additionally, this individual's apolipoprotein E genotype was not E4 which has been more strongly associated with the development of Alzheimer's disease. Ideally, the causal link suggested here between a career in professional football and CTE would result from postmortem assessments of a group of similar individuals from the NFL compared with another group of otherwise well-matched individuals whose careers did not involve repetitive contact sports. I encourage the authors to continue their investigations.

Daniel F. Kelly
Los Angeles, California

The authors provide a detailed analysis of the central nervous system histopathology in an offensive lineman who played for 17 seasons in the NFL and died from a myocardial infarction 12 years after retirement. The autopsy findings were consistent with CTE. This article complements the series of articles by Pellman et al. that have previously appeared in this journal regarding the neuropsychological abnormalities suffered by NFL players, and provides an important anatomic underpinning for those abnormalities. Unfortunately, Omalu et al. did not provide specific information about the neuropsychological deficits experienced by this athlete, other than to state that he met criteria for dysthymic disorder, had deficits in memory and judgment, and had parkinsonian symptoms. It is unlikely that detailed neuropsychological testing was routinely performed during his career, so such data was probably not available. The increasing use of detailed pre- and post-traumatic neuropsychological testing by the NFL and amateur football groups should provide an invaluable database of information that will allow for clinical-anatomic correlations not previously possible. Together with information obtained from functional magnetic resonance imaging studies, this data will significantly advance our understanding of the cellular and physiologic mechanisms of traumatic brain injury.

Donald W. Marion
Boston, Massachusetts

This article raises some interesting questions. However, in this case report, the scientific validity of the putative association between suspected repetitive mild traumatic brain injury in professional football players and histological findings consistent with chronic neurodegenerative processes is, at the very least, questionable. This report highlights the potential value of a prospectively administered database that might include athletes' medical histories and, when available, postmortem findings and results of cognitive testing. More abundant and more rigorously collected data of this type might enable us to provide better answers to the questions posed here.

Alex B. Valadka
Houston, Texas

Omalu et al. have added to our knowledge of neuropathological correlates of sports-related head injury. They provide a detailed postmortem analysis of a retired player who spent 17 years in the NFL. It is clear that we are just beginning to understand the myriad of biomechanical, physiological, neurogenetic, and neurocognitive sequelae of this condition. By providing the first reported case of autopsy-confirmed traumatic encephalopathy in a professional football player, these authors provide an initial

OMALU ET AL.

window to structural changes of this condition. It is noted that the authors indicate that the player's encephalopathy occurred as a result of long-term repetitive concussive brain injury. However, they did not indicate the frequency of concussive events or the numbers of years over which concussive events occurred. Because concussive events were not recorded systematically at the time of this player's career, we cannot be sure that his encephalopathy was caused by either repetitive or long-term events.

Kenneth C. Kutner
Neuropsychologist
Hackensack, New Jersey

Omalu et al. have reported a sentinel case of a 50-year-old retired NFL player with 17 years experience as a professional football player. It provides a glimpse, for the first time, into the gross and microscopic pathological changes of this relatively young brain, which had extensive exposure to repetitive head impacts in football. These findings, which are not consistent with Alzheimer's disease or aging, but rather CTE, have been observed previously in autopsy material of retired boxers. These consist predominantly of markers of neuronal and axonal injury to the neocortex with relative sparing of the hippocampus, as well as hemorrhagic markers in the Virchow Robin spaces.

Despite attempts to enact rule changes and to improve helmet design, naturally there are still regular episodes of traumatic brain injury in contact sports such as football. Irrespective of design modifications in the football helmet, there still exists the regular occurrence of rapid acceleration-deceleration mechanisms of brain injury which are difficult to ameliorate or eliminate. In addition, recent reports have suggested that the true incidence of concussion in football, recognized or subclinical in nature, is higher than previously believed. Although earlier research has shown that contact athletes may later develop mental and cognitive impairment, this case report documents cerebral histopathological abnormalities and adds to our knowledge as we further study the long-term consequences of repetitive traumatic brain injury.

Julian E. Bailes
Morgantown, West Virginia

This article raises controversial questions concerning the potential risk of CTE in retired NFL players. The authors provide detailed and compelling neuropathological evidence supporting the presence of CTE in this particular case, but there is no documentation of concussion history during the athlete's sports career. As the authors openly note, this is a single case report and does not establish an empirically substantiated causal relation between participation in professional football and the development of CTE, even if previous concussion history had been recorded in this case. Clearly, further investigation with multiple subjects and a controlled experimental design is needed.

By reporting their case, the authors lay a solid groundwork for pursuing further neuropathology studies in professional football players. Based on the potential association between CTE and boxing, it is certainly conceivable that there is a link between the activities inherent in professional football and CTE. However, the rate at which a typical player sustains head injuries and the severity of those injuries are important factors that may differentially affect the likelihood of developing CTE. Thus, it will be important to note not only the length of career and the number of athlete exposures, but to also include reliable concussion history data in future studies. Empirical studies that include this information would portray a more complete picture of the risks of professional football, contribute knowledge of the possible etiologic factors of CTE, and convey precautionary measures, if needed, to minimize its occurrence.

The postmortem finding of CTE in a retired football player raises

the possibility that some of the cognitive, emotional, and neurological symptoms observed in retired NFL athletes may be manifestations of disease processes other than Alzheimer's disease, which has been more extensively documented in recent literature. The relation of CTE, Alzheimer's disease, and the Apolipoprotein E genotype in retired athletes is also fuel for future research. Although this article raises more questions than it answers, it provides a foundation indicating that these questions are important and worth pursuing.

Joseph Bleiberg
Neuropsychologist
Washington, District of Columbia

This article represents the first documented case of long-term neurodegenerative changes in a retired professional NFL player. The case report describes the comprehensive autopsy and laboratory findings of a retired professional football player showing neuropathological changes consistent with long-term repetitive concussive brain injury. The report states that the deceased athlete "sustained numerous episodes of mild traumatic and concussive brain injury . . ." during his 17-year career as an offensive lineman. Although the report does not indicate an approximate number of suspected concussions, we are left to assume that it was well above the average of two concussions reported to the Center for the Study of Retired Athletes by retired NFL players with an average of 6.5 years in the league (1). Given that the deceased athlete played approximately three times longer than the retired NFL players in that study, we might predict that he experienced at least six concussions, and probably many more subconcussive impacts to the head during his professional football career.

The authors indicate that the deceased player demonstrated long-standing mood disorders that resembled a dysthymic disorder. This report parallels findings from the Center for the Study of Retired Athletes which suggest there is an association between recurrent concussions sustained during the professional playing years, and the likelihood of being diagnosed with clinical depression (1). As the authors state, the case study by itself cannot confirm a causal link between professional football and chronic neurodegenerative diseases such as CTE, however, it indicates the need for a more comprehensive study of both active and retired professional football players.

Furthermore, this case report calls to team physicians and athletic trainers for improved injury surveillance of concussions and other brain related traumas so future studies may be able to better understand the relationship between these injuries and the neurodegenerative changes described. For years there has been speculation of an increased risk for late life cognitive impairment in athletes with a history of multiple concussions. While this well written case report provides a good starting point for answering these important questions, future prospective studies implementing genetic testing, more rigorous diagnostic criteria, historical documentation, and extensive serial evaluations (e.g., neuropsychological testing and functional neuroimaging) will be necessary to clarify the direct or mitigating effects of head trauma on lifetime risk of such neurological disorders. The authors should be commended for providing the medical community with a very interesting paper that will make significant contributions to the literature on the topic of sport-related concussion and neurodegenerative disease, and will likely serve as an impetus for future study in this area.

Kevin M. Guskiewicz
Chapel Hill, North Carolina

1. <http://www.csr.unc.edu/statistics.htm>. Accessed June 13, 2005.