

App. Tab 43

ORIGINAL ARTICLE

Chronic traumatic encephalopathy in a professional American wrestler

Bennet I. Omalu, MD, MBA, MPH¹, Robert P. Fitzsimmons, JD², Jennifer Hammers, DO³, and Julian Bailes, MD⁴

1 San Joaquin General Hospital, French Camp, California/Chief Medical Examiner, San Joaquin County, California

2 Fitzsimmons Law Offices, Wheeling, West Virginia

3 Office of the Chief Medical Examiner, New York, New York

4 Department of Neurosurgery, School of Medicine, West Virginia University, Morgantown, West Virginia

Keywords

Chronic traumatic encephalopathy; forensic nursing; professional wrestling; world wrestling entertainment.

Correspondence

Bennet I. Omalu, MD, MBA, MPH
1132 Junewood Court
Lodi, CA 95242.
Tel: 412-759-3597;
E-mail: bennetomalu@comcast.net

Received: January 18, 2009; accepted: June 2, 2009

doi: 10.1111/j.1939-3938.2010.01078.x

Abstract

We present in this case report the tissue substrates and forensic evidence for chronic traumatic encephalopathy (CTE) in a professional American wrestler with Apolipoprotein E (apoE) genotyping. Professional wrestling is a contact-sport, with an integral risk for players to sustain repeated concussions over their careers. This case provides the first autopsy evidence of neuropathological abnormalities that accompany CTE in professional American wrestlers. A complete autopsy was performed on a 40-year-old Caucasian male, after he died unexpectedly by suicidal hanging after he had killed his wife and son. The brain showed no atrophy and no recent or remote contusions or necrosis. There was a mild to moderate neocortical neuronal dropout without any amyloid plaques. There were diffuse, sparse to frequent tau-immunoreactive Neurofibrillary Tangles and Neuropil Threads in the neocortex, subcortical ganglia, and brainstem nuclei including the substantia nigra consistent with CTE. The apoE genotype was determined to be E3/E3. Other autopsy findings included cardiomegaly, left ventricular hypertrophy, and bilateral atrioventricular dilatation; toxicologic analyses showed alprazolam and hydrocodone in the blood, and evidence of exogenous testosterone in the urine. Longitudinal studies of professional contact-sport athletes are needed to identify the differentiating characteristics of athletes who develop CTE and devise strategies for intervention.

Introduction

We present the first reported case of chronic traumatic encephalopathy (CTE) in a professional American wrestler confirmed by an autopsy, accompanied by Apolipoprotein E (apoE) genotyping. CTE represents the cumulative, long-term cognitive, intellectual, and neuropsychiatric sequelae of repetitive concussive and subconcussive blows to the brain, which may be sustained in contact sports such as boxing, ice hockey, martial arts, American football, and wrestling (Cantu, 2007; Rabadi & Jordan, 2001). We have previously reported the neuropathologic tissue substrates of CTE and apoE genotypes of deceased professional American football players who were autopsied (Omalu et al., 2006; Omalu et al.,

2005; Omalu, Hamilton, Kamboh, DeKosky, & Bailes, 2010).

Case report

Early childhood history of this deceased professional wrestler revealed a normal development with no medical or mental illnesses. At the age of 6 years, he was involved in a motor vehicle accident when his head struck the windshield of the automobile in which he was a passenger. He was hospitalized for 3 days, felt to have had a mild traumatic brain injury (MTBI), but went on to have no known deleterious effects and no permanent injury. He was interested in wrestling from an early age and

B. I. Omalu et al.

began serious exercise and weightlifting regimen when he was about 12 years old. He participated in organized football for 5 years, sustaining no known instances of MTBI, and never missed practices or games due to injury. He had no known drug or substance abuse as a child.

He began his professional wrestling career in 1985 at the age of 18. He traveled regularly at that time seeking the best training, and ultimate performance venues. A cornerstone of his career was spending 2 years in Japan, studying with whom he felt were some of the most progressive and knowledgeable wrestling coaches. Upon his return to North America, his career blossomed, and he became a successful and popular professional wrestler both in the United States and Canada. He was known, however, for his aggressive and rough style of performance, enjoying the contact aspects of the sport.

He traveled to Japan under contract between 15–20 weeks per year between 1989 and 1995, and subsequently wrestled in Canada, Mexico, and Europe. He continued to have a busy career, wrestling for approximately 250 days annually. He sustained a cervical fracture in the ring in 2001 while working for the World Wrestling Entertainment [WWE], which was treated with cervical fusion. Professional wrestling evolved to having bigger performances with more theatrics, including the use of multiple props, such as tables, ladders, and chairs. Using these objects, wrestlers jump, strike one another, and have various methods of sustaining multiple and repeated head impacts. He once remarked to his father, that he had sustained at least 15 concussions during his career.

The first indications of mental problems occurred in 2003 when he was 36 years old, with trouble involving his home life. Although to some his behavior may have been unusual, there were no obvious warning signs for his impending violent behavior. He did have periods of depression, beginning in 2005 following the death of his best friend and wrestling colleague. His 2005 diary offers a glimpse of his mental state including numerous references to depression and to memory lapses. He was believed to have used anabolic steroids for a prolonged but undocumented period during his adult life. Following his spinal surgery and in combination with a myriad of musculoskeletal injuries, it is believed that he developed a usage of narcotic prescription drugs up until the time of his death. He struggled with depression for the ensuing years, even taking time off work in 2006 for herniorrhaphy and reportedly for treatment of depression.

In 2007, at the age of 40 years, our deceased professional wrestler, his son, and his wife were found dead in their home. Allegedly, he had killed his wife by strangulation and killed his son by compression of the neck, before he committed suicide by hanging.

Chronic traumatic encephalopathy in a professional American wrestler

Autopsy

At autopsy, the decedent was a well-developed, well-nourished, muscular, 5 foot 11 inch man whose appearance was consistent with the stated age of 40 years. There were multiple abrasions of all four extremities. There was a tight single looped rope ligature around the neck slipped through a white metal carabiner. Adjacent to the carabiner was a black ball attached to the rope. The carabiner and ball were on the right lateral neck. Underneath the rope ligature was a white towel, which was wrapped around the neck twice and taped to itself.

There was a 0.6–1.3 cm in width dry, leathery, and tan ligature indentation circumferentially situated around the neck. The ligature indentation was situated in a transverse fashion on the anterior neck, and was situated in a transverse-oblique ascending fashion on each side of the neck, before ascending behind the ears to the rostral mid posterior neck. There were three 0.6 cm in diameter dry abrasions of the anterior neck. There were few, scattered petechial hemorrhages in both palpebral conjunctivae.

Internally, there were no fractures of the hyoid bone or thyroid cartilage or hemorrhage in the soft tissues of the anterior or posterior neck. The brain appeared grossly normal, was sectioned in the fresh state, discarded, was later retrieved from the body and saved in formalin. There was evidence of surgical hardware in the cervical spine. There was cardiomegaly (620 g) with left ventricular hypertrophy and bilateral atrioventricular dilatation. The liver and spleen weighed 2,620 g and 300 g, respectively. Grossly, the testes appeared normal in size and shape, however microscopic examination of the testes revealed atrophy of the seminiferous tubules, thickened basement membranes, and interstitial edema with arrest of germ cell maturation.

Toxicologic analyses of his blood revealed Alprazolam (50 µg/L) and Hydrocodone (45 µg/L). Postmortem toxicologic analyses of his urine revealed an elevated level of Testosterone (207 µg/L) with an elevated Testosterone to Epi-testosterone ratio (59), which indicated an exogenous source of Testosterone. The underlying cause of death was determined to be asphyxiation due to hanging and the manner of death was determined to be a suicide.

Forensic neuropathology

The brain was initially cut in the fresh state during the autopsy and placed back into the truncal cavity for cremation. Following efforts made by the authors, consent was obtained from the next-of-kin and partially decomposed brain pieces were later retrieved from the truncal cavity by the forensic pathologist and submitted for

neuropathologic analyses. Cut sections of the brain containing the mesial temporal lobe, amygdala, and hippocampus were not identified and were not submitted for neuropathologic examination. These sections most probably were inadvertently left inside the body and possibly were cremated with the body.

One irregular piece of dorsal dura mater and 29 irregularly cut coronal, transverse, and oblique sections of the formalin-fixed brain were retrieved. The fragment of dorsal dura mater revealed smooth epidural and subdural surfaces without xanthochromia, membranes, or hemorrhages. The dural venous sinuses were patent without thromboemboli. The 29 irregular sections of the brain measured from 3.0 × 3.0 × 1.0 cm to 14 × 11.5 × 2.7 cm, weighed over 1,510 g in aggregate and comprised of five irregular pieces of cerebellum, three irregular and incomplete pieces of brainstem, and 21 irregular pieces of cerebral hemispheres.

There were no meningeal or parenchymal hemorrhages. There was no parenchymal necrosis or infarcts. Diffuse early parenchymal decompositional changes were present without Swiss-cheese cavitations. The cortical gyri were not thinned out. The cortical sulci were not widened. There was no gross atrophy of the subcortical/basal ganglia. There were diffuse, prominent, congested penetrating parenchymal vessels in the centrum semiovale.

Representative topographically targeted sections of brain tissue were submitted for histochemical and immunohistochemical stains in 22 tissue cassettes as follows: frontal cortex, middle gyrus; cingulate gyrus and corpus callosum; insula cortex, putamen, and globus pallidus; random section of neocortex; thalamus; irregular fragment of brainstem; irregular fragment of brainstem; random section of neocortex; cerebellum; dura mater; parietal cortex; superior temporal gyrus; calcarine cortex; caudate nucleus, internal capsule, and putamen; random section of neocortex; small irregular fragments of brainstem and anterior perforated substance; random section of neocortex; basal ganglia, thalamus; random section of neocortex; random section of neocortex; irregular piece of brainstem; irregular pieces of brainstem/basis pontis.

The following histochemical and immunohistochemical stains were performed on all the 22 submitted sections of the brain: Hematoxylin and Eosin stains [H/E]; Bielschowsky silver impregnation stains; immunostains for Tau protein; immunostains for Beta-A4 Amyloid protein; immunostains for Glial Fibrillary Acidic Protein [GFAP]; immunostains for Alpha-Synuclein protein; immunostains for CD-68.

Microscopic examination of the submitted tissue sections revealed early postmortem autolytic changes with scattered amphophilic neurons and scattered basophilic

clusters of bacteria in the leptomeninges. The dura mater revealed intradural congestion without epidural or subdural hemorrhages, hemosiderin-laden histiocytes, or fibrocytic/fibroblastic membranes. There was mild to moderate neocortical neuronal dropout. Superficial laminar cortical spongiosis was absent. There was diffuse vascular congestion of the leptomeninges and arachnoidal blood vessels as well as marked congestion of penetrating parenchymal vessels with perivascular microextravasations. Focal confluent arachnoidal microextravasations were also noted.

Neuronal cytomegaly, achromatic, or ballooned neurons were absent. The corpus callosum showed no rarefaction or cavitating infarcts. There was no demyelination of the lateral periventricular white matter. The basal ganglia did not reveal any lacunar infarcts, hemorrhages, necrosis, Charcot-Bouchard microaneurysms, or mineralization of vessel walls. The internal, external, and extreme capsules revealed no infarcts or rarefaction. Very sparse perivascular infiltration of some Virchow Robin spaces by lymphocytes and hemosiderin-laden histiocytes was noted.

Few subpial corpora amylacea were noted. Neuronal cytoplasmic lipofuscin was not markedly increased. Fragments of the substantia nigra was identified and showed mild neuronal dropout and mild incontinencia pigmenti. There were no nigral pale bodies or inclusions. Fragments of brainstem showed some ventral and tegmental brainstem nuclear groups without cytomegaly, achromasia, or ballooned neurons. The pontine nuclei, transverse, and descending white matter tracts appeared unremarkable. An incidental capillary telangiectasia was however noted.

The Purkinje cell layer of the cerebellum showed mild Bergmann astrogliosis, mild neuronal dropout and scattered empty basket cells. No Purkinje torpedoes were noted. The internal granule cell layer and dentate nucleus were not noticeably atrophic.

There were no diffuse or neuritic amyloid plaques in all regions of the brain examined. Cerebral amyloid angiopathy was absent. There were sparse to frequent (Gearing et al., 1995; Heyman, Fillenbaum, & Mirra, 1990; Mirra et al., 1991), randomly situated Neurofibrillary Threads, band-shaped, flame-shaped, small, and large globose perikaryal Neurofibrillary Tangles and Ghost Tangles [Figure 1A and B] in the neocortex, subcortical ganglia, and brainstem nuclei including the substantia nigra. Table 1 summarizes the immunohistochemical findings in the brain, which essentially confirm a diffuse cerebral tauopathy comprising diffuse Neurofibrillary Tangles (NFTs) and Neuritic Threads (NTs).

Globose Neurofibrillary Tangles were found in the subcortical ganglia and brainstem, but were absent in the

B. I. Ormalu et al.

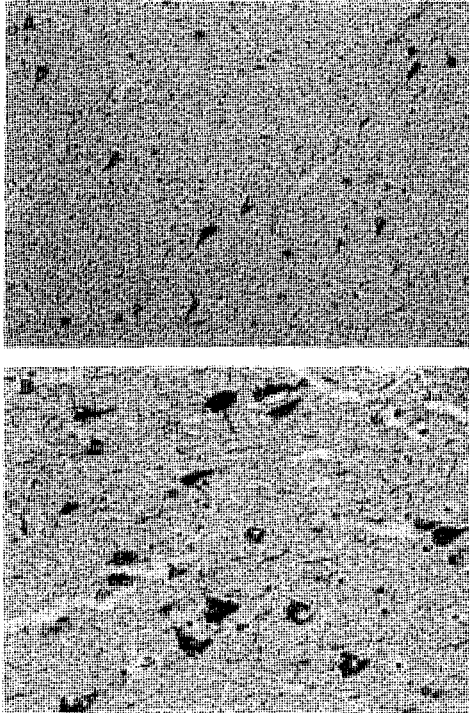


Figure 1. (A) Photomicrograph of a section of the frontal neocortex [$\times 200$ magnification] immunostained with polyclonal tau antibodies showing many Neurofibrillary Tangles and Neuritic Threads. (B) Photomicrograph of a section of the temporal neocortex [$\times 400$ magnification] immunostained with polyclonal tau antibodies showing many Neurofibrillary Tangles and Neuritic Threads.

neocortex. The calcarine cortex showed no neuronal inclusions. Tau positive glial inclusions, tufted astrocytes, thorn astrocytes, and astrocytic plaques were absent. Lewy bodies, Lewy-related neuritis, oligodendroglial inclusions, or Glial Cytoplasmic Inclusions (GCI) were absent. Microglial proliferation, histiocytic parenchymal infiltration, microglial nodules, multinucleated giant cells, and neuronophagia were absent.

Few scattered perivascular histiocytes were noted in the Virchow Robin spaces. There was prominent GFAP staining of the subcortical white matter and plexiform layer of the frontal, parietal, and temporal cortex, and of the thalamus, internal capsule, external and extreme capsules, of the deep cerebellar white matter, and Purkinje cell layer.

Chronic traumatic encephalopathy in a professional American wrestler

Table 1 Summary of topographic distribution of Neurofibrillary Tangles and Neuritic Threads

Region of the brain	Density of Neurofibrillary Tangles	Density of Neuritic Threads
1. Frontal, temporal, and parietal cortex	+++	+++
2. Calcarine cortex	0	0
3. Cingulate cortex	++	++
4. Insula cortex	+++	+++
5. Caudate	+	+
6. Putamen	+	+
7. Claustrum	+	+
8. Thalamus	++	++
9. Substantia nigra/ tegmental brainstem nuclei	++	++
10. Pontine nuclei	+	+
11. Cerebellum	0	0
12. Anterior perforated substance	+	+

(+ : sparse density; ++ : moderate density; +++ : frequent density. These criteria for quantifying the density of Neurofibrillary Tangles and Neuritic Threads is based on the CERAD [The Consortium to Establish a Registry for Alzheimer's Disease] criteria for quantifying the density of neuritic plaques).

Apollipoprotein E genotyping

Genomic deoxyribonucleic acid (DNA) was extracted from peripheral blood leukocytes using the QIAamp DNA Blood Mini Kit (Qiagen, Valencia, CA). The APOE genotype was ascertained from the amplified DNA by fluoro-genic 5' nuclease assays (TaqMan SNP genotyping assays [Applied Biosystems, Foster City, CA]). The genotype was determined to be E3/E3.

Discussion

We present for the first time the tissue substrates of CTE in a professional American wrestler. Professional wrestling is a contact sport, which may be associated with repeated concussions and subconcussions. Our case suffered numerous concussions and subconcussions during his wrestling career. Repeated concussions and subconcussions sustained while playing high-impact contact sports can result in CTE in amateur and professional athletes (Cantu, 2007; Rabadi & Jordan, 2001).

The association between a contact sport and chronic neurodegeneration was reported as early as 1928 by Dr. Harrison Stanford Martland, a Newark, New Jersey pathologist who was the first medical examiner of Essex County, New Jersey (Martland, 1928). In this landmark paper, Dr. Martland introduced the term "punch drunk" to describe "the tendency for experienced boxers to

become unsteady on their feet and to move and think more slowly" [Dementia Pugilistica].

The nature and existence of structural changes in the brains of boxers in 1928 could be confirmed only by examining the brains of deceased boxers (Corsellis, Bruton, & Freeman-Browne, 1973) and the same scenario remains today since CTE can only be confirmed by direct tissue examination of the brain. In 1969, a report by the Royal College of Physicians of London (Royal College of Physicians of London. Committee on Boxing, 1969) and a book by Roberts A.H. (Roberts, 1969) established that there was a danger of chronic brain damage occurring in boxers as a result of their careers.

CTE is the term applied to chronic cognitive, intellectual, and neuro-psychiatric symptoms of chronic neurodegeneration following a single episode of severe traumatic brain injury or (more commonly) repeated episodes of MTBI. Currently there are two recognized subtypes of CTE associated with contact sports: (1) Dementia pugilistica [punch-drunk syndrome] as seen in boxers; and (2) CTE associated with other contact sports like rugby, ice hockey, football, wrestling etc. CTE represents the cumulative, long-term neurodegenerative consequences of repetitive concussive and subconcussive impacts to the head.

Abnormal accumulations of tau protein in the form of NFTs and NTs, which we have observed in our case, have been confirmed to be consequences of repetitive head injuries (Allsop, Haga, Bruton, Ishii, & Roberts, 1990; Geddes, Vowles, Nicoll, & Revesz, 1999). NFTs and NTs are principally composed of abnormally hyperphosphorylated, paired helical filaments of tau protein, which is a microtubule associated protein [MAP]. Tau is a phosphoprotein, the gene of which is mapped to Chromosome 17q, and occurs normally in axons of neurons in the central and peripheral nervous system, where it binds to and stabilizes microtubules in their polymerized state (Greenfield, Graham, & Lantos, 2002).

Microtubules are neuro-axonal cytoskeletons composed of alpha and beta tubulins, and are important in the maintenance of cell shape, motility, transport, and mitosis. MAP's such as tau regulate the transport of vesicles or organelles in microtubules, support axonal outgrowth, and anchor enzymes. Gene induction, increased synthesis, and upregulation of tubulins occur during neuro-axonal regeneration following neuro-axonal injuries and axotomies (Greenfield et al., 2002).

Experimental models of traumatic brain injuries have also shown that proteolytic cleavages, disintegration, abnormal metabolism, and accumulation of neuronal cytoskeletal and transmembrane proteins, including amyloid precursor protein and tau protein, may follow severe or repeated MTBIs both acutely and chronically

(DeKosky et al., 2007; Gabbita et al., 2005; Ikonovic et al., 2004). Repeated MTBIs may also initiate progressive widespread neuronal loss in selectively vulnerable brain regions for months to years after the initial insult. The mechanisms underlying these delayed neuronal injuries are believed to result from the activation of endogenous auto-destructive biochemical pathways induced by traumatic brain injuries (Gabbita et al., 2005; Omalu et al., 2010).

CTE may manifest with a broad spectrum and varying severities of cognitive, intellectual, and neuro-psychiatric impairment (Omalu, 2008; Omalu et al., 2010). The underlying anatomic pathology of these impairments may be the impairment by NFTs and NTs of normal neuronal functioning, interneuronal communications and transmissions, and axonal transport and transmissions; as well as the destruction and loss of neurons in the centers and nuclei of the brain responsible for specific domains of neural functioning like the limbic cortex and the frontal cortex. We expect the brains of individuals with CTE to suffer an imbalance of neurotransmitters like serotonin, nor-adrenalin, and acetyl-choline since the anatomic pathology of CTE involves and destroys the nuclei, which secrete these neurotransmitters for example, the locus ceruleus and Basal Nucleus of Meynert, which secrete nor-adrenalin and acetyl-choline, respectively. Involvement and destruction of the hypothalamus may also manifest with a wide spectrum of hormonal imbalances.

As we have alluded to in our previous reports (Omalu et al., 2006; Omalu et al., 2005; Omalu et al., 2010), the neuropathology of CTE in athletes may in part resemble the neuropathology of the Tangle-Only Dementia [TOD]. The underlying neuropathologic tissue substrates of TOD are sparse to frequent tau-immunoreactive NFTs and NTs primarily in the limbic cortex and possibly in the neocortex and subcortical ganglia, with or without diffuse amyloid plaques (Jellinger & Bancher, 1998; Noda et al., 2006). However, the topographic spread of NFTs and NTs in our CTE cases is broader than the topographic spread of NFTs and NTs that is typically seen in TOD. TOD is a rare type of dementia with a reported prevalence of 0.7–7.7% in several autopsy series (Jellinger & Bancher, 1998) and occurs in the oldest old people in their 80s and 90s. The total duration and clinical course of dementia in TOD is from 1 to 15 years and the initial symptom is usually memory disturbance (Noda et al., 2006).

The apoE genotype of our reported case was E3/E3. As we have alluded to in our previous reports, there seems to be an overrepresentation of the E3 allele in athletes who suffer from CTE (Omalu et al., 2006; Omalu et al., 2005; Omalu et al., 2010). Similarly, there is an overrepresentation of the E3 allele in patients who suffer from TOD

B. I. Omalu et al.

with lower prevalences of E4 alleles than in Alzheimer's Disease patients (Jellinger & Bancher, 1998; Noda et al., 2006). ApoE is a circulating 34-KDa glycosylated protein, the gene for which is mapped to chromosome 19q (Bales, Dodart, DeMattos, Holtzman, & Paul, 2002). In the central nervous system, apoE is synthesized and secreted primarily by astrocytes and microglia, and its importance is underscored by the absence of most other plasma apolipoproteins in the brain. It is the primary cholesterol transporter in the brain, where it is proposed to function as a ligand directing the delivery of lipids for neuronal repair and remodeling after injury (Bales et al., 2002; Greenfield et al., 2002). In humans, there are three apoE isoforms, E2, E3, and E4, with three corresponding apoE alleles, E2, E3, and E4. Although the underlying mechanism remains poorly defined, the alleles for apoE represent important genetic risk factors for late-onset forms of Alzheimer's Disease and adverse outcomes following traumatic brain injury (Jordan et al., 1997; Kutner, Erlanger, Tsai, Jordan, & Relkin, 2000), with the E4 allele increasing the risk for developing Alzheimer's Disease by 19-fold for E4/E4 homozygotes (Bales et al., 2002; Ellison & Love, 2004).

Most disease models are multifactorial in pathobiology and pathogenesis. CTE is not an exception. While there may be multiple factors involved in the pathobiology and pathogenesis of CTE, the primary, underlying causal, and initiating factor is traumatic brain injury. Other secondary factors like specific genotypes, endogenous steroids (Rissman, Lee, Vale, & Sawchenko, 2007), and possibly exogenous steroids may play indirect roles in modifying or regulating the mechanisms and cascades of disease development but do not constitute the primary, underlying causal, or initiating factor of CTE.

In summary, there is a danger of CTE occurring in professional contact-sport athletes as a result of their careers, and their cumulative exposure to repeated head trauma of varying severity. While not every professional athlete develops CTE, some do; and the varying predisposing factors (in addition to trauma itself) need to be defined. A prospective, longitudinal study of large numbers of professional contact-sport athletes, with varying amounts of career experience, is needed to clearly define this disease, identify the differentiating characteristics of the athletes who develop it, and develop prophylactic and interventional therapies.

Forensic implications

This case establishes the first reported case of CTE in a professional American wrestler for the evidence-based practice of establishing the denominators and characteristics of a trauma-induced disease in athletes. Since the definitive diagnosis of CTE, like all types of dementias

Chronic traumatic encephalopathy in a professional American wrestler

and brain degeneration, can only be made by direct tissue examination of the whole brain, this case underscores the invaluable role of forensic nurses and physicians in the forensic surveillance and diagnosis of cases of CTE. Medico-legal questions concerning CTE may not be answered without full autopsies and comprehensive brain examinations/analyses. Medico-legal procedures may not be initiated without the required evidentiary and diagnostic tissue findings of CTE, which will provide a reasonable degree of medical certainty.

References

- Allsop, D., Haga, S., Bruton, C., Ishii, T., & Roberts, G. W. (1990). Neurofibrillary tangles in some cases of dementia pugilistica share antigens with amyloid beta-protein of Alzheimer's disease. *American Journal of Pathology*, *136*(2), 255–260.
- Bales, K. R., Dodart, J. C., DeMattos, R. B., Holtzman, D. M., & Paul, S. M. (2002). Apolipoprotein E, amyloid, and Alzheimer disease. *Molecular Interventions*, *2*(6), 363–375, 339.
- Cantu, R. C. (2007). Chronic traumatic encephalopathy in the National Football League. *Neurosurgery*, *61*(2), 223–225.
- Corsealis, J. A., Bruton, C. J., & Freeman-Browne, D. (1973). The aftermath of boxing. *Psychological Medicine*, *3*(3), 270–303.
- DeKosky, S. T., Abrahamson, E. E., Ciallella, J. R., Paljug, W. R., Wisniewski, S. R., Clark, R. S., et al. (2007). Association of increased cortical soluble abeta42 levels with diffuse plaques after severe brain injury in humans. *Archives of Neurology*, *64*(4), 541–544.
- Ellison, D., & Love, S. (2004). *Neuropathology: A reference text of CNS pathology* (2nd ed.). Edinburgh, New York: Mosby.
- Gabbita, S. P., Scheff, S. W., Menard, R. M., Roberts, K., Fugaccia, I., & Zeman, F. P. (2005). Cleaved-tau: A biomarker of neuronal damage after traumatic brain injury. *Journal of Neurotrauma*, *22*(1), 83–94.
- Gearing, M., Mirra, S. S., Hedreen, J. C., Sumi, S. M., Hansen, L. A., & Heyman, A. (1995). The Consortium to Establish a Registry for Alzheimer's Disease (CERAD). Part X. Neuropathology confirmation of the clinical diagnosis of Alzheimer's disease. *Neurology*, *45*(3 Pt 1), 461–466.
- Geddes, J. F., Vowles, G. H., Nicoll, J. A., & Revesz, T. (1999). Neuronal cytoskeletal changes are an early consequence of repetitive head injury. *Acta Neuropathologica*, *98*(2), 171–178.
- Greenfield, J. G., Graham, D. I., & Lantos, P. L. (2002). *Greenfield's neuropathology* (7th ed.). London; New York: New York, NY: Arnold; Distributed in the U.S. by Oxford University Press.
- Heyman, A., Fillenbaum, G. G., & Mirra, S. S. (1990). Consortium to Establish a Registry for Alzheimer's Disease (CERAD): Clinical, neuropsychological, and neuropathological components. *Acta Neuropathologica*, *2*(4), 415–424.

- Ikonomic, M. D., Uryu, K., Abrahamson, E. E., Ciallella, J. R., Trojanowski, J. Q., Lee, V. M., et al. (2004). Alzheimer's pathology in human temporal cortex surgically excised after severe brain injury. *Experimental Neurology*, 190(1), 192–203.
- Jellinger, K. A., & Bancher, C. (1998). Senile dementia with tangles (tangle predominant form of senile dementia). *Brain Pathology*, 8(2), 367–376.
- Jordan, B. D., Relkin, N. R., Ravdin, L. D., Jacobs, A. R., Bennett, A., & Gandy, S. (1997). Apolipoprotein E epsilon4 associated with chronic traumatic brain injury in boxing. *Journal of American Medical Association*, 278(2), 136–140.
- Kurzer, K. C., Erlanger, D. M., Tsai, J., Jordan, B., & Relkin, N. R. (2000). Lower cognitive performance of older football players possessing apolipoprotein E epsilon4. *Neurosurgery*, 47(3), 651–657; discussion 657–658.
- Martland, H. S. (1928). Punch drunk. *Journal of the American Medical Association*, 91, 1103–1107.
- Mirra, S. S., Heyman, A., McKeel, D., Sumi, S. M., Crain, B. J., Brownlee, L. M., et al. (1991). The Consortium to Establish a Registry for Alzheimer's Disease (CERAD). Part II. Standardization of the neuropathologic assessment of Alzheimer's disease. *Neurology*, 41(4), 479–486.
- Noda, K., Sasaki, K., Fujimi, K., Wakisaka, Y., Tanizaki, Y., Wakugawa, Y., et al. (2006). Quantitative analysis of neurofibrillary pathology in a general population to reappraise neuropathological criteria for senile dementia of the neurofibrillary tangle type (tangle-only dementia): The Hisayama Study. *Neuropathology*, 26(6), 508–518.
- Omalu, B. (2008). *Play hard, die young: Football depression, dementia, and death* (1st ed.). Lodi, CA: Neo-Forensis Books.
- Omalu, B. I., DeKosky, S. T., Hamilton, R. L., Minster, R. L., Kamboh, M. I., Shakir, A. M., et al. (2006). Chronic traumatic encephalopathy in a national football league player: Part II. *Neurosurgery*, 59(5), 1086–1092; discussion 1092–1083.
- Omalu, B. I., DeKosky, S. T., Minster, R. L., Kamboh, M. I., Hamilton, R. L., & Wecht, C. H. (2005). Chronic traumatic encephalopathy in a national football league player. *Neurosurgery*, 57(1), 128–134; discussion 128–134.
- Omalu, B. I., Hamilton, R. L., Kamboh, M. I., DeKosky, S. T., & Bailes, J. (2010). Chronic traumatic encephalopathy (CTE) in a National Football League Player: Case report and emerging medico-legal practice questions. *Journal of Forensic Nursing*, 6(1), 128–134.
- Rabadi, M. H., & Jordan, B. D. (2001). The cumulative effect of repetitive concussion in sports. *Clinical Journal of Sport Medicine*, 11(3), 194–198.
- Rissman, R. A., Lee, K. F., Vale, W., & Sawchenko, P. E. (2007). Corticotropin-releasing factor receptors differentially regulate stress-induced tau phosphorylation. *Journal of Neuroscience*, 27(24), 6552–6562.
- Roberts, A. H. (1969). *Brain damage in boxers: A study of the prevalence of traumatic encephalopathy among ex-professional boxers*. London: Pitman Medical & Scientific Publishing Co., Ltd.
- Royal College of Physicians of London. Committee on Boxing. (1969). *Report on the medical aspects of boxing*. London: Royal College of Physicians of London.