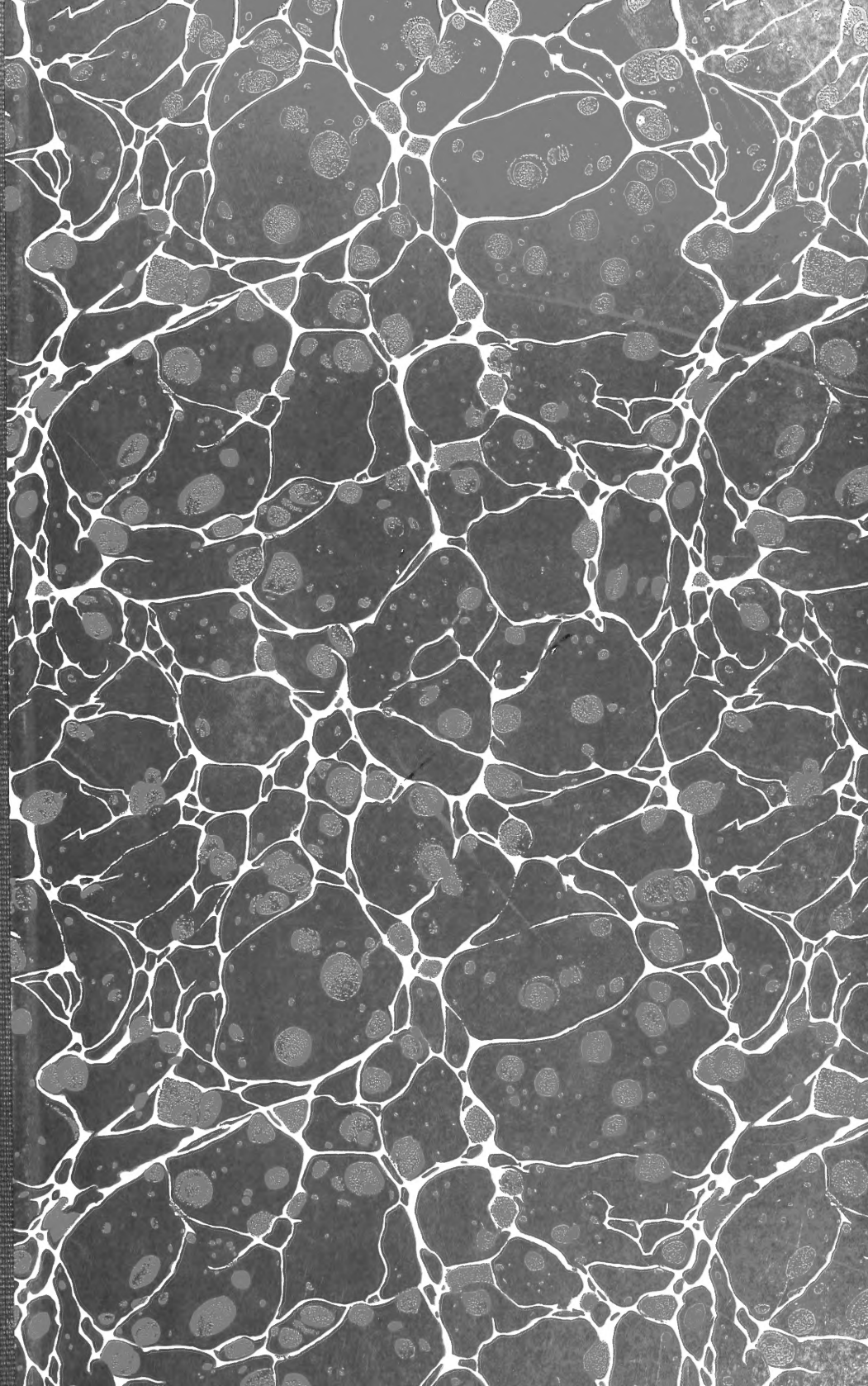


SF
765
.H6
1922





Class _____.

Book _____.

COPYRIGHT DEPOSIT


GUIDE
TO THE
Dissection and Study
OF THE
CRANIAL NERVES AND
BLOOD VESSELS
OF
THE HORSE

BY
GRANT SHERMAN HOPKINS
New York State Veterinary College
Ithaca, N. Y.

SECOND EDITION

Geneva, N. Y.
F. W. Hummel, printer

51923



SF765
H6
1922

GUIDE
TO THE
Dissection and Study
OF THE
CRANIAL NERVES AND
BLOOD VESSELS
OF
THE HORSE

SECOND EDITION

COPYRIGHT 1922
BY GRANT SHERMAN HOPKINS

THE CRANIAL NERVES.

<i>NAME</i>	<i>Real or Deep Origin</i>	<i>Apparent or Superficial Origin</i>	<i>Foramen of Exit</i>	<i>Function</i>
I. N. olfactorius.	Olfactory epithelium.	Olfactory bulb.	Foramina in the cribriform plate.	Sensory.
II. N. opticus.	Ganglion cells of the retina.	Optic chiasma.	Fm. opticum.	Sensory.
III. N. oculomotorius.	Floor of the aqueduct of Sylvius.	Crus cerebri.	Fm. lacerum orbitale.	Motor.
IV. N. trochlearis.	Floor of the aqueduct of Sylvius.	Anterior medullary velum.	Fm. patheticum.	Motor.
V. N. trigeminus	<div style="display: flex; align-items: center;"> <div style="font-size: 2em; margin-right: 5px;">{</div> <div style="margin-right: 5px;">Motor root.</div> <div style="margin-right: 5px;">{</div> <div>Floor of 4th ventricle and the pons.</div> </div> <div style="margin-left: 5px;">Sensory root.</div> <div style="margin-left: 5px;">{</div> <div>Ganglion semilunare. (Gasserian ganglion.)</div>			

© A661564

MAY -3 1922

The Cranial Nerves and Blood Vessels of the Horse

According to the usual enumeration there are twelve pairs of cranial nerves. The first or olfactory nerve, on either side, consists of numerous soft, gray, non-medullated fibers which are not united into a single nerve trunk but pass through the cribriform plate of the ethmoid bone as numerous small bundles; these several bundles taken together are considered as one nerve.

Of the twelve pairs of cranial nerves three are sensory, viz., the olfactory, the optic and the acoustic nerves. Five are motor, viz., the oculomotor, trochlearis, abducens, accessory and hypoglossal nerves. The remaining four nerves, viz., the trigeminal, facial, glossopharyngeal and vagus, are mixed nerves.

The relation of the motor and the sensory nerves to the brain and spinal cord is radically different. The motor nerve fibers originate from nerve cells that lie within the gray matter of the brain and spinal cord and are distributed principally to the skeletal and visceral musculature. The sensory nerve fibers, on the other hand, originate from nerve cells that are situated in the sensory ganglia or the end organs lying wholly outside of the central nervous system. The sensory nerve fibers enter the brain and spinal cord and terminate either directly or indirectly in the respective sense areas and reflex centers of the central nervous system. Under normal conditions the motor fibers are stimulated only at their central origin, i. e., through the nerve cells in the brain and spinal cord from which the fibers originate. The sensory fibers are stimulated only at their endings in the peripheral tissues, the skin, the mucous membrane and the sense organs.

Of the purely sensory nerves the first or olfactory originates from the olfactory cells of the nasal mucous membrane and passes in the form of numerous soft, gray, non-medullated fibers through the lamina cribrosa of the ethmoid to the olfactory bulb of the brain. The connections established by the nerve fibers that connect the olfactory bulb with the cerebral hemispheres are complicated and in part incompletely known. The optic nerve arises from the ganglion cells of the retina of the eye. From these cells the nerve fibers pass through the optic nerve and thence to the primary optic centers of the brain.

The origin of the acoustic nerve is from two ganglia in the internal ear. The acoustic nerve consists of two parts, the cochlear and vestibular branches. The cochlear branch arises from the ganglion spirale of the cochlea and the vestibular branch from the ganglion vestibulare of the internal ear. From these sensory ganglia of origin the nerve fibers pass through the internal acoustic meatus to their respective acoustic and equilibrium centers in the brain.

The twelve pairs of cranial nerves as commonly enumerated are given in the preceding table. The part or region of the brain to which the respective nerves are attached is often spoken of as the place of origin of the nerve. It should be kept in mind, however, that the real origin of the respective motor nerves is from a group or nucleus of nerve cells situated within the central nervous system and that the real origin of the sensory nerves is from their respective ganglia or end organs situated outside of the central nervous system. The sensory fibers of the fifth, seventh, ninth and tenth cranial nerves originate from the cells of the ganglia of these nerves. A short distance from the ganglion nerve cells the sensory fibers divide into two branches of which one branch passes into the brain while the other passes to the peripheral tissues as the skin, mucous membrane, teeth, etc., the two branches together constituting a sensory nerve fiber.


PREFACE

This dissection guide is designed to meet the needs of the student for an orderly and systematic guide to the dissection of the cranial nerves and blood vessels. By exercising a little care nearly all of the parts may be left intact for study and demonstration after the dissection is completed. After completing the dissection of a part, as a nerve or blood vessel, which often must be done piecemeal, it is essential that the student get a comprehensive idea of the structure as a whole. This idea should be got from the specimen itself. Most students need encouragement to study and to learn the actual object rather than to memorize text-book descriptions of it. Too often the student is unable to identify on the dissected specimen a given structure although he may be able to repeat practically everything that is said of it in the book.

The dissection of the nerve supply to the larynx preferably should be done on another larynx. Otherwise the vessels and nerves already dissected, in this region of the head, will be so mutilated as seriously to interfere with their subsequent demonstration.

After completing the dissection and study of the head the student should demonstrate his dissection.

A satisfactory demonstration necessitates the presentation of visual evidence confirmatory of all oral statements.



will be dissected later. The nerves auricularis medius and auricularis posterior and also the three small nerves to the muscles digastricus, stylo-mandibularis, occipito-styloideus and stylohyoideus originate from the N. facialis at the stylomastoid foramen, Pl. II, 52, 53, 57. The two auricular nerves are readily found but the other three small nerves are covered by a thin aponeurosis and cannot be demonstrated satisfactorily at present. Usually a nerve loop encircles the A. auricularis posterior, Pl. II, 58.

N. auricularis posterior.

Carefully remove the skin of the external ear. The N. auricularis posterior originates from the N. facialis at the stylomastoid foramen and accompanies the peripheral portion of the A. auricularis posterior as shown in Pl. II, 52. The nerve, covered by the parotid gland, passes dorsally across the base of the styloid process of the occipital bone and is distributed to the posterior auricular muscles. Turn aside the overlying structures and trace the nerve as far as possible.

A. auricularis posterior. Pl. II, 46.

The superficial branches of this artery should now be dissected. The origin of the artery and its deep branch cannot be seen at this stage of the dissection. Of the two superficial branches the larger, posterior branch passes to the posterior part of the ear, near its base, and divides into two branches both of which extend to near the tip of the ear where they anastomose with each other; one of these anastomosing branches runs along near the middle of the posterior surface of the external ear and the other near the inner or medial border of the ear.

The much smaller of the two superficial branches of the A. auricularis posterior passes along the lateral or external border of the ear and anastomoses with the middle branch. A small branch accompanies the N. auricularis medius through the foramen near the base of the styloid process of the conchal cartilage to the inner surface of the ear, Pl. II.

N. auricularis medialis or internus.

This nerve originates from the N. facialis close to the stylomastoid foramen, Pl. II, 53. Surrounded by gland tissue, it passes along the styloid process of the conchal cartilage to the foramen near the base of this process through which the nerve passes to the inner surface of the ear.

N. auricularis anterior or auriculo-palpebraris.

This nerve, as already indicated, originates from the dorsal edge of the N. facialis immediately posterior to the V. temporalis superficialis, Pl. II, 54.

Transect and turn aside the thin *M. zygomatico-auricularis* and carefully remove the gland tissue which surrounds the nerve. Before the nerve crosses the zygomatic process of the temporal bone it gives off several small branches which supply the anterior auricular muscles.

The main portion of the *N. auricularis anterior* passes anteriorly across the zygomatic process of the squamous temporal bone a little posterior to the mandibular articular surface; here it intermixes somewhat with a branch of the *N. lacrimalis*, from the 5th cranial nerve, and with it forms a plexus known as the **plexus auricularis anterior**, Pl. II, 55. The larger portion of the nerve, however, continues anteriorly to the inner canthus of the eye and is distributed to the muscles *corrugator supercillii*, *orbicularis palpebrarum* and *levator naso-labialis*. (The branch to the last mentioned muscle may be traced 10 to 15 cm. below the eye). The branch of the *N. lacrimalis* which helps to form the *plexus auricularis anterior* passes through a small groove on the zygomatic process of the temporal bone immediately posterior to the suture between this process and the supraorbital process of the frontal bone and is distributed to the skin at the base of the ear.

Ramus colli.

This small nerve arises from the *N. facialis* almost directly opposite the *N. auricularis anterior*, Pl. II, 59, or occasionally in common with the anterior end of the nerve loop encircling the *A. auricularis posterior*. It passes obliquely through the parotid gland and then extends along its surface, close to the *V. jugularis*, immediately beneath the aponeurosis which covers the superficial face of the gland. The *M. parotido-auricularis* receives a filament either from the *ramus colli* or directly from the *N. facialis*. The *ramus colli* receives communicating branches from the second to the sixth spinal nerves.

The parotid gland should now be removed in order to expose the small nerves to the muscles *occipito-styloideus*, *digastricus*, *stylo-mandibularis* and *stylohyoideus*. In removing the gland, if the handle of the scalpel be used pretty largely the danger of injury to the veins and underlying structures will be greatly diminished. Interposed between the deep face of the parotid gland and the subjacent structures is an aponeurosis which is attached principally to the tendons of the *sterno-mandibularis* and *brachio-cephalicus*. The three small nerves to the muscles *occipito-styloideus*, *digastricus*, *stylo-mandibularis* and *stylohyoideus* originate from the ventral edge of the *N. facialis*, near the *stylomastoid foramen*. The filament to the *M. stylohyoideus* can not be readily demonstrated until after the removal of the mandible.

Dissection of the Cranial Nerves and Blood Vessels

Make an incision in the skin on the median plane from near the free margin of the lower lip to a point opposite the third or fourth tracheal ring. The anterior end of this incision should now be continued dorsally along the margin of the lips as far as to the median plane of the upper lip. A second incision should now be made from the tip of the ear along its lateral margin to its base; continue this incision along the parotid gland and prolong it to the first incision. Reflect the skin. Care should be taken in reflecting the skin not to include the thin *M. cutaneous faciei*. This muscle is fairly well defined in the submaxillary space and on the lateral face of the horizontal portion of the mandible (Pl. I, 19; Pl. II, 17) but the portion which covers the greater part of the *M. masseter* is largely aponeurotic. Upon the removal of the skin two large branches of the *N. facialis* will be seen extending across the *M. masseter*, covered only by the thin *M. cutaneous faciei*. To dissect this latter muscle, begin at its more or less clearly defined border in the submaxillary space and dissect it from the underlying parts. This may be done the more readily if the muscle be transected a little posterior to the large nerve which is supplied to it and the overlying skin by one of the branches of the *N. facialis* (Pl. I, nerve just below 36). Over a large part of the *M. masseter* the *cutaneous faciei* is mostly aponeurotic and this portion of the muscle may be entirely removed.

N. facialis, VII. Mixed.

This nerve is usually classed as a mixed nerve. The facial nerve proper, however, is purely motor at its nucleus of origin in the dorsal part of the pons. The nerve emerges from the base of the brain immediately caudal to the pons, Pl. VI, 14.

The *N. facialis* passes from the cranial cavity through the internal acoustic meatus and the facial canal of the petrous temporal bone. Closely associated with the facial nerve in its course through the facial canal are a sensory nerve—**N. intermedius**—and a ganglion—**Gang. geniculatum**—which are often regarded as the sensory part of the facial nerve. This sensory nerve and ganglion however have no nerve connection with the facial nerve and form no integral part of it. The nerve fibers from the geniculate ganglion to the brain constitute the nerve *intermedius*; the peripheral fibers from the ganglion

large nerve with which the N. labialis dorsalis intermixes some distance anterior to the infraorbital foramen is the N. infraorbitalis, a branch of the 5th cranial nerve.

Before proceeding farther with the dissection of the nerves the following structures should be demonstrated.

Submaxillary lymph gland.

Remove the connective tissue from the submaxillary space and note the location, form and size of the submaxillary lymph gland. The gland is V shaped, each arm being from 10 to 12 cm. in length.

Parotid duct and the V. maxillaris externa.

Trace the V. maxillaris externa to the place where it passes from the submaxillary space across the border of the mandible. Refer to Pl. II for an idea of the relations of the parotid duct, the artery and the vein shortly after they cross the margin of the mandible. At this stage of the dissection, veins 28, 29, 30, 31 cannot be seen, as they are covered by the M. masseter; they will be exposed later. Cut the two branches of the N. facialis (dorsal and ventral labial nerves) about 5 cm. anterior to the parotid gland and reflect them from the M. masseter. Now continue the dissection of the parotid duct and the adjacent portions of the A. and V. maxillaris externa. Trace the parotid duct to its termination in the oral cavity opposite the third superior premolar tooth. Note that the duct is somewhat enlarged just before it opens into the oral cavity. Demonstrate by inserting a probe into the duct a few centimeters from its termination.

A. labialis ventralis or inferior.

This artery originates from the A. maxillaris externa about 2 cm. ventral to the M. depressor labii inferior, Pl. II, 40; Pl. VII, 10. It passes obliquely across the deep face of this muscle and continues to the lower lip where it anastomoses with its fellow of the opposite side. It gives off a branch to the angle of the mouth (A. anguli oris) which may anastomose with the A. labialis superior. The A. labialis inferior supplies the M. depressor labii inferior, the inferior molar glands and the lower lip and skin of this region.

A. labialis dorsalis or superior.

The A. labialis superior is the next large branch of the A. maxillaris externa. It originates near the level of the maxillary or facial crest, Pl. I, 37; Pl. II, 41. It passes beneath the muscles zygomaticus, levator nasolabialis and dilator naris lateralis all of which have previously been turned aside. Trace the artery into the upper lip and demonstrate its anas-

tomosis with its fellow of the opposite side; and also its anastomosis with the palatine arteries, by means of a branch which passes through the foramen incisivum of the premaxilla, Pl. VII, 16.

A. lateralis nasi.

This vessel arises from the maxillaris externa a little peripheral to the A. labialis superior, Pl. II, 42. It extends nearly parallel to the A. labialis superior and enters the nasal fossa near the angle formed by the nasal and premaxillary bones.

Aa. dorsalis nasi and angularis oculi.

These two small vessels may be considered as the terminal branches of the A. maxillaris externa. They arise on the M. levator labii superioris proprius and pass under the M. levator nasolabialis, the first to the dorsum nasi and the second to the vicinity of the inner canthus of the eye.

A. & V. transversa faciei, Pl. I, 32, 33; Pl. II, 31, 48.

Note the relation of this artery and vein to the zygomatic process of the temporal bone and to the facial crest. Note also the small nerve which accompanies the superficial portion of the artery and vein; this small nerve is a branch of the N. temporalis superficialis, as will be demonstrated later. After a short course the artery and vein dip into the M. masseter, a portion of which must be removed in order to demonstrate the course of the vessels, Pl. II, 31, 48. Just after the A. transversa faciei crosses the posterior border of the mandible and gains its lateral face, it gives off a deep branch which, accompanied by a large vein, passes ventrally between the bone and the deep face of the M. masseter (Pl. II, immediately below 61). To expose the vessels just mentioned and also the N. massetericus, proceed as follows: Reflect the proximal portion of the N. facialis from the M. masseter and remove enough of the muscle to expose for a distance of 2 or 3 cm. the deeply situated branches of the A. & V. transversa faciei. The N. massetericus is deeply embedded in the muscle and lies from 3 to 4 cm. anterior to the vessels just exposed, Pl. II, 63. To uncover the nerve, make an incision 8 to 10 cm. in length and about one and one-half centimeters in depth, in the M. masseter just ventral of, and parallel to, the A. & V. transversa faciei and carefully turn aside the overlying portion of the muscle until the nerve is uncovered. Demonstrate the distribution of the nerve to the M. masseter and then cut it 5 to 8 cm. from the sigmoid notch of the mandible. (The origin of the nerve from the mandibular division of the 5th cranial nerve cannot be demonstrated until after the removal of the mandible, Pl. III, 62). The dissection of the deep branches of the A. & V.

transversa faciei, already partially exposed, should now be completed. The artery almost immediately divides into two branches of which the larger is distributed to the *M. masseter*. The smaller branch is covered by the vein and can be traced for only a short distance, at present. It runs beneath the *V. transversa faciei* and the zygomatic process of the temporal bone, enters the temporal fossa and anastomoses with the *A. temporalis posterior*. Each of the above mentioned arterial branches is accompanied by a vein.

A. & V. masseterica.

The *V. masseterica* joins the jugular opposite the *V. auricularis posterior*, Pl. II, 35. It is formed, at the posterior border of the mandible, by two branches one of which comes from the *M. masseter* and the other from the *M. pterygoideus internus*. Trace the masseteric branch and its accompanying artery as far as possible. The vein usually anastomoses with the *V. buccinatoria*. The origin of the *A. masseterica* and the pterygoid branch of the vein will be demonstrated after the mandible is removed. The *M. masseter* should now be removed as shown in Pl. II, but in doing this be careful not to injure the large veins which lie beneath the muscle, Pl. II, 29, 30. These vessels, **Vv. buccinatoria** and **alveolaris**, and also the small artery that lies just dorsal to the *V. buccinatoria*, should be cleaned up as shown in Pl. II.

N. ramus transversus faciei.

This small nerve accompanies the *A. & V. transversa faciei*, as already demonstrated. Trace the nerve to its place of origin from the *N. temporalis superficialis*, Pl. III, 74. At this stage of the dissection the latter nerve usually is not clearly distinguishable from the *N. facialis*, as the two nerves unite at the place of origin of the *ramus transversus faciei* and also from this point to its place of origin the *N. temporalis superficialis* is covered by the surrounding structures.

Removal of the mandible.

Cut the *A. & V. maxillaris externa*, the parotid duct, the *A. & V. transversa faciei*, and the *A. & V. masseterica* at their respective places of crossing the margin of the mandible. All of the horizontal portion of the mandible, except the part anterior to the mental foramen, should now be completely denuded as follows: Begin at the ventral margin of the horizontal portion of the mandible and dissect up en masse all of the overlying structures so that when these are turned dorsally both the upper and lower rows of teeth are exposed. With the saw and chisel cut the ramus of the mandible a little

posterior to the mental foramen and also cut it near the place of crossing of the N. facialis. With strong pliers abduct the ramus of the mandible just enough to expose the artery, vein and large nerve that enter the mandibular foramen. All three of these structures should now be cut. Note the small N. mylohyoideus, Pl. III, 72, which lies just posterior to the above mentioned vessels and nerve, and close to the surface of the bone. Continue to abduct the mandible and at the same time detach from it, as completely as possible, the muscles pterygoideus internus and stylomandibularis; also transect the M. mylohyoideus near its attachment to the mandible. Detach the M. digastricus from the ramus of the mandible and remove the latter. The remaining proximal portion of the mandible, i. e., the coronoid process and the condyle, are best removed by first detaching, with saw and chisel, the coronoid process from the condyle, but in doing this some care is necessary not to injure the N. massetericus, which passes through the corono-condyloid or sigmoid notch. Now cut the M. pterygoideus externus close to its attachment to the mandible and disarticulate and remove the condyle. The zygomatic arch and the coronoid process of the mandible should now be removed. With saw and chisel cut the zygomatic process of the temporal bone near the middle of the condyle and glenoid fossa and at right angles to their long axis; cut the orbital process of the frontal bone just peripheral to the supraorbital foramen and also the malar bone at the level of the maxillary tuberosity of the maxilla. Sever the palpebrae and the periorbital or orbital sheath, to within about 2 cm. of the inner canthus, from their attachments to the rim of the orbit, taking care not to cut the nerve and artery that pass through the supraorbital foramen. Remove the detached portion of the zygomatic arch and also the coronoid process of the mandible; in removing the latter, however, disturb as little as possible the overlying **plexus auricularis anterior** and the M. temporalis, whose insertion completely surrounds the coronoid process. Slit the M. temporalis down to the bone and carefully detach the muscle from the coronoid process and remove the latter.

Before proceeding with the dissection of the nerves, the large V. maxillaris interna and certain other veins should be noted.

V. masseterica (continued).

The deep branch of this vein should now be traced into the M. pterygoideus internus.

A little peripheral to the points where the veins masseterica and auricularis posterior open into the V. jugularis, the latter vessel is formed by the union of two large branches, the V. temporalis superficialis and the V. maxillaris interna, Pl. II, 37, 38.

V. temporalis superficialis.

The V. temporalis superficialis is formed by the union of the veins auricularis anterior and transversa faciei. The course of the vein and its relation to the N. facialis are shown in Pl. II, 37. Occasionally the N. facialis lies superficial to the temporal vein.

V. auricularis anterior.

This vein arises from the anterior face of the external ear and unites with the transversa faciei to form the V. temporalis superficialis. Demonstrate the large branch, **V. cerebralis dorsalis**, which emerges from the parieto-temporal canal posterior to the postglenoid process of the squamous temporal bone, and joins the auricularis anterior shortly before the latter unites with the transversa faciei.

The V. transversa faciei has already been traced.

V. maxillaris interna.

Trace the large V. maxillaris interna, Pl. II, 38, from the V. jugularis along the ventral border of the M. pterygoideus externus. At the alveolar border of the mandible it makes an abrupt S shaped curve and is continued by the large V. buccinatoria, Pl. II, 29. The principal radicles of the V. maxillaris interna are as follows:

(1) **V. temporalis profunda.** This is a large vessel which receives smaller branches from the M. temporalis and from the parieto-temporal canal. Its dissection should be deferred until after the temporal nerves have been dissected.

(2) **V. dorsalis linguae.** This large vein is a satellite of the N. lingualis; it enters the V. maxillaris interna near the alveolar margin of the mandible.

(3) **V. buccinatoria**, Pl. II, 29. This is the direct continuation of the V. maxillaris interna, as mentioned above. It may communicate with the V. alveolaris in the vicinity of the maxillary tuberosity. Its communication with the V. maxillaris externa is shown in Pl. II.

(4) **V. alveolaris**, Pl. II, 30. Push aside the orbital fat and trace the vein to the periorbita. Its connection with the ophthalmic vein cannot be seen until after the periorbita has been removed.

Venae labiales, Pl. II, 25, 26, 27, 28.

Trace the V. labialis communis (Pl. II, 25) from its place of union with the maxillaris externa to the venous plexus near the middle of the cheek. From this plexus, trace the respective labial veins to the lips; also trace the branch which communicates with the V. buccinatoria as shown in Pl. II, 28. In tracing the latter do not cut the nerve which lies in close proximity to the dorsal surface of the vein, Pl. II, 65.

V. angularis oculi, V. dorsalis nasi and V. lateralis nasi. Pl. I, 27, 28, 29.

These branches have already been exposed while tracing the corresponding arteries.

Cut the various veins that enter the maxillaris interna and turn aside or remove the latter.

N. trigeminus, V. Mixed.

The apparent origin of the N. trigeminus is from the side of the pons by two roots, of which the larger is sensory and the smaller motor; the fibres of the sensory root, however, really originate from the large **ganglion semilunare** of the 5th cranial nerve. The fibers of the smaller motor root originate in the pons and mid brain. Within the cranial cavity, the trunk of the N. trigeminus divides into three large branches or divisions, viz., the **N. ophthalmicus**, the **N. maxillaris** and the **N. mandibularis**, Pl. VI, 12', 12"; 12". All of the nerve fibres of the motor root enter the N. mandibularis; a large number of sensory fibres also enter this portion of the 5th nerve thus making it a mixed nerve. The ophthalmic and maxillary divisions of the trigeminus are purely sensory nerves. The N. ophthalmicus passes from the cranial cavity through the foramen lacerum orbitale; the N. maxillaris passes through the foramen rotundum and the N. mandibularis through the foramen lacerum basis cranii.

N. mandibularis. Mixed.

The N. mandibularis is made up of both sensory and motor nerve fibres. The nerve, which has a very short course, leaves the cranial cavity by the foramen lacerum basis cranii and, under cover of the M. pterygoideus externus, divides into several terminal branches as shown in Pl. III, 61. To demonstrate these branches of the N. mandibularis first identify the two large nerves, **N. lingualis** and **N. alveolaris inferior**, Pl. III, 69, 71, which extend across the outer surface of the M. pterygoideus internus, and trace them towards the base of the skull as far as to the edge of the M. pterygoideus externus from beneath which the two nerves emerge. The M. pterygoideus externus must not be removed but simply pushed aside just sufficiently to expose clearly the origin of the nerves.

Branches of the N. mandibularis.

(1) **N. alveolaris inferior.** Sensory.

This nerve arises from the N. mandibularis in common with the N. lingualis, Pl. III, 69, 71. It passes through the alveolar canal of the mandible and upon emerging at the mental foramen it divides into several branches known as the mental nerves, which are distributed to the chin and

the lower lip, Pl. II, 64a. With a chisel, expose the nerve, artery and vein alveolaris inferior in their course through the alveolar or mandibular canal. As already mentioned, the Nn. mentales are simply the terminal branches of the N. alveolaris inferior. Trace them into the lower lip. Just before emerging from the mental foramen the N. alveolaris inferior gives off a branch that extends through a small osseous canal to the roots of the canine and incisor teeth. To demonstrate this small branch, medisection the lip and chin and remove the one half from their attachment to the mandible and turn them aside. Now carefully chisel away the bone and trace the nerve to the roots of the teeth.

(2) **N. mylohyoideus.**

This small nerve was noted when removing the mandible. Trace it to its origin from the N. mandibularis and to its termination in the M. mylohyoideus, the anterior portion of the M. digastricus and the skin of the anterior part of the submaxillary space, Pl. III, 72. The filament to the M. digastricus is given off near the posterior border of the M. mylohyoideus.

The N. mylohyoideus may appear to originate from the N. alveolaris inferior; the fibres, however, can readily be separated from this nerve and traced back to the N. mandibularis.

Gl. sublingualis.

Reflect the M. mylohyoideus and identify the sublingual salivary gland, Pl. III, 35; Pl. VIII, fig. 1, 8. It is from 12 to 15 cm. in length and from 2 to 3 cm. in width. Note the sublingual crest and the 20 to 30 small openings of the ducts of the sublingual gland.

(3) **N. lingualis.** Sensory.

The N. lingualis arises from the mandibularis in common with the N. alveolaris inferior, Pl. III, 69. The two nerves pass between the muscles pterygoideus externus and internus and soon diverge from each other, the lingual nerve lying to the inner side and somewhat anterior to the N. alveolaris inferior. Near the place where the N. lingualis diverges from the alveolaris inferior, it is joined by the **chorda tympani**, a small nerve which originates within the facial canal of the petrous temporal, from the **geniculate ganglion** of the N. intermedius. Demonstrate as much of the chorda tympani as possible. At the anterior border of the M. pterygoideus internus the lingual nerve passes between the muscles mylohyoideus and styloglossus between which it extends as far as to the posterior end of the sublingual salivary gland where it passes beneath the gland and the M. styloglossus deep into the tongue. Dissect up the ventral edge of the sublingual

gland and turn it dorsally. Trace the nerve to the point where it dips between the muscles styloglossus and genioglossus. Further dissection should be deferred until after the N. sublingualis has been dissected. The N. lingualis gives off several small branches to the region of the maxillary tuberosity, Pl. III.

(4) **N. sublingualis.** Sensory.

This small nerve arises from the dorsal edge of the N. lingualis opposite, or a few centimeters from, the anterior edge of the M. pterygoideus internus, Pl. III, 70. Upon reaching the sublingual gland the nerve dips beneath it and accompanied by the sublingual artery and vein and the duct of the submaxillary salivary gland, all of which should now be studied, runs the whole length of the sublingual gland and terminates in the mucous membrane of the anterior portion of the floor of the mouth. Numerous small branches are given off from the N. sublingualis to the mucous membrane of the tongue and oral cavity. Demonstrate the termination of the submaxillary duct at the **caruncula sublingualis**.

The N. lingualis, after giving off the sublingual, passes between the muscles mylohyoideus and styloglossus to the posterior extremity of the sublingual gland, as already mentioned. Here it turns obliquely across the ventral border of the M. styloglossus and extends along the inner surface of the muscle to the tip of the tongue. Demonstrate the numerous branches given off from the dorsal edge of the lingual nerve in its course between the muscles of the tongue. These branches extend to the mucous membrane of the anterior two-thirds of the dorsum of the tongue.

(5) **N. massetericus** (continued).

This nerve should now be traced from the point where it was cut, 5 to 8 cm. from the sigmoid notch of the mandible, to its place of origin from the N. mandibularis, close to the base of the skull, Pl. III, 62. From its place of origin it extends laterally, immediately anterior to the temporo-mandibular surface of the temporal bone and through the sigmoid notch of the mandible as already noted.

Near its origin it usually gives off two branches, the **Nn. temporales profundi**, both of which should be traced into the temporal muscle, Pl. III, 63. The mass of fatty tissue in the orbit should now be removed after first demonstrating the small artery supplied to it.

(6) **N. buccinatorius.** Sensory.

The N. buccinatorius may be readily found at the antero-internal surface of the V. buccinatoria, Pl. II, 65. Opposite the last molar tooth the nerve

passes between the *M. depressor labii inferioris* and the mucous membrane of the cheek and accompanies the inferior labial artery and vein to the lower lip. In this part of its course numerous branches are given off to the inferior molar glands and to the mucous membrane of the cheek and lower lip; one or more small branches may be traced to the upper lip in the immediate vicinity of the commissure. Now trace the nerve toward its place of origin from the *N. mandibularis*. Opposite the maxillary tuberosity it gives off several small branches to the superior molar glands and to the mucous membrane of the cheek. The *N. buccinatorius* passes between the maxillary tuberosity and the anterior border of the *M. pterygoideus externus* and thence through the *M. pterygoideus externus* which must be divided longitudinally in order to expose the nerve; do not, however, disturb the muscle more than is necessary clearly to expose the nerve, Pl. III, 64.

(7) **N. temporalis profundus anterior.**

This small nerve originates from the *N. mandibularis*. It lies on the dorsal surface of the *N. buccinatorius* along which it extends to near the anterior border of that portion of the *M. pterygoideus externus* which is dorsal to the nerve, Pl. III, 8. It then bends dorsally, as shown in Pl. III, 65, and immediately enters the temporal muscle.

(8) **N. pterygoideus externus.**

This small nerve originates from the *N. mandibularis* and almost immediately enters the inner or deep surface of the external pterygoid muscle. Very frequently the nerve consists of two nearly parallel portions, Pl. III, 67.

(9) **N. pterygoideus internus.**

The nerve to the *M. pterygoideus internus* is much larger than the one to the *M. pterygoideus externus*. It originates from the *N. mandibularis* and is partly covered by the dorsal edge of the common trunk of the nerves *lingualis* and *alveolaris inferior*. The nerve enters the muscle at its posterior border, Pl. III, 68.

(10) **N. temporalis superficialis.** Sensory.

This is a large sensory branch which originates from the *N. mandibularis* and joins the facial nerve at the posterior border of the mandible, Pl. III, 74. It gives off several small branches one of which, **ramus transversus faciei**, accompanies the artery and vein of the same name for some distance across the *M. masseter* as has already been demonstrated; one small branch, **ramus auricularis**, accompanies the anterior auricular artery and vein to the ear. Numerous small filaments go to the parotid gland and to the external ear.

N. ophthalmicus. Sensory.

The N. ophthalmicus is the smallest of the three principal branches of the N. trigeminus. It originates from the semilunar ganglion and, for a short distance, is closely joined to the N. maxillaris but within the orbital hiatus the two trunks are separated by the thin osseous plate that separates the foramen lacerum orbitale from the foramen rotundum. Within this osseous canal the nerve divides into three branches, viz., **N. lacrimalis**, **N. frontalis** or **supraorbitalis**, and the **N. nasociliaris**, all of which are sensory.

To expose the nerve proceed as follows: With the handle of the scalpel, free from its attachment to the bone the portion of the temporal muscle that intervenes between the orbit and the M. pterygoideus externus, taking care not to break the artery that emerges from the temporal foramen; also similarly detach the portion of the M. pterygoideus externus that is attached to the region between the orbital hiatus and the alar or pterygoid foramen. Slit open the periorbita a little posterior to its point of connection with the V. alveolaris. Note on a prepared skull the relations to each other of the foramen patheticum, the foramen lacerum orbitale and the foramen rotundum. With a small chisel carefully remove enough of the bony plate that forms the lateral wall of the orbital hiatus to expose clearly the Nn. ophthalmicus and maxillaris; care should be taken not to disturb the small N. trochlearis which emerges from the foramen patheticum. Upon drawing aside the periorbita three nerves are visible, viz., the **lacrimalis**, the **frontalis** or **supraorbitalis** and the **orbitalis**.

[The N. orbitalis is a branch of the N. maxillaris and will be dissected with that nerve.]

(1) **N. lacrimalis**, Sensory. Pl. IV, 27.

This consists of several small branches which pass directly to the lacrimal gland and the upper eyelid. One of the larger branches, however, pierces the periorbita, passes posterior to the orbital process of the frontal bone and helps to form the plexus auricularis anterior. This branch of the N. lacrimalis supplies filaments to the skin of the temporal region and the base of the ear, as already noted when dissecting the N. auricularis anterior.

(2) **N. frontalis**. Sensory.

This nerve is of about the same size as the lacrimal and for some distance from its origin lies immediately dorsal to the N. lacrimalis, Pl. IV, 25. Within the orbit it is enclosed by the periorbita until within 2 to 4 cm. of the supraorbital foramen when it pierces the periorbita and then lies between this membrane and the bone, Pl. IV. After passing through the

supraorbital foramen the nerve divides into several small branches which join with the terminal filaments of the N. auricularis anterior, and are distributed to the skin of the forehead and upper eyelid.

(3) **N. nasociliaris.** Sensory, Pl. IV, 26; Pl. V, 28.

The N. nasociliaris has the same general course as the A. ophthalmica and lies close to either the dorso-lateral or convex side, Pl. V, 28, or frequently at the concave side of the artery. At its origin it is covered by the Nn. lacrimalis and frontalis. To expose the nerve, dissect up the muscles rectus dorsalis and levator palpebrae dorsalis and transect them at about one or two centimeters from their attachment to the globe of the eye, Pl. V, 7, 8. Beneath the M. rectus dorsalis the nerve divides into two main branches, Pl. V, 29, 30, of which one branch, **N. ethmoidalis**, accompanies the ophthalmic artery through the ethmoid foramen into the cranial cavity and thence passes through the cribriform plate and is distributed to the mucous membrane of the nasal fossa. The other branch, **N. infratrochlearis**, is of about the same size as the ethmoidal branch. It extends along the ventral surface of the M. trochlearis or obliquus dorsalis as far as to the trochlea or pulley through which the muscle passes. Before attempting to trace the nerve farther first expose the terminal tendon of the muscle trochlearis or obliquus dorsalis and transect it close to the trochlea. The nerve may now readily be traced to the nasal canthus of the eye where it is distributed to the skin, the membrana nictitans and the lacrimal apparatus in this region. Some of the filaments extend several centimeters beyond the nasal canthus of the eye. A small branch extends from the N. nasociliaris to the ciliary ganglion constituting the long or sensory root of the ganglion (**radix longa ganglii ciliaris**), Pl. V, 32.

N. maxillaris. Sensory.

The origin of this division of the trigeminus from the semilunar ganglion of the fifth cranial nerve and its position immediately ventral to the N. ophthalmicus have already been noted. Carefully free the nerve and adjoining arteries, Pl. IV, 30, and Pl. V, 25, of surrounding fatty tissue noting meantime the three or four small nerves extending to the region of the maxillary tuberosity. The N. maxillaris divides into three branches, viz., **N. orbitalis**, **N. infraorbitalis**, and **N. sphenopalatinus**.

(1) **N. orbitalis.** Sensory, Pl. IV, 28.

The nerve orbitalis arises from the N. maxillaris before the latter passes through the foramen rotundum. It enters the periorbita or ocular sheath

and soon divides into two or more branches which extend between the periorbita and the M. rectus externus to the lateral canthus of the eye and are distributed to the lower eyelid.

(2) **N. infraorbitalis.** Sensory.

The N. infraorbitalis is simply the continuation of the greater portion of the N. maxillaris through the infraorbital canal. With saw and chisel expose the nerve by opening the maxillary sinus and the osseous canal through which the nerve passes. At the infraorbital foramen the nerve divides into three portions, a dorsal, a middle and a ventral, Pl. II, 68, 69, 70. The small dorsal portion, **N. nasalis dorsalis** or **N. nasalis externus**, consists of one or more branches which accompany the M. levator labii superioris proprius and are distributed to the skin on the dorsum of the nose and the nasal diverticulum. The middle portion, **N. nasalis anterior**, is much larger than the preceding. It enters the anterior portion of the nasal fossa usually by two branches as shown in Plate II. The smaller of these two branches is distributed to the mucous membrane of the anterior part of the nasal fossa; the larger branch is continued to the skin of the upper lip. The ventral portion, **ramus labialis dorsalis**, is the largest of the three portions. It divides into numerous branches which intermix with the fibres of the N. labialis dorsalis of the facial nerve and are distributed to the skin and tactile hairs of the upper lip. The small branch, **ramus alveolaris maxillae incisivus**, supplied to the canine and incisor teeth, arises from the N. infraorbitalis in the anterior part of the infraorbital canal. Two to four centimeters before reaching the infraorbital foramen the ramus enters a small canal in the superior and premaxillary bones and runs in this canal to the roots of the canine and incisor teeth. With a small chisel expose the nerve throughout its intraosseous course, or see laboratory specimen already exposed. The small nerves to the maxillary sinus and the superior molar teeth also arise from Nn. maxillaris and infraorbitalis. Transect the N. infraorbitalis near its entrance to the infraorbital canal and turn aside the proximal part.

(3) **N. sphenopalatinus.** Sensory.

The N. sphenopalatinus arises as a large somewhat flattened nerve from the ventral side of the N. maxillaris and passes directly to the sphenopalatine foramen, Pl. V, 41. Closely attached to the dorso-medial surface of the nerve are numerous ganglia (**ganglia sphenopalatina** or **Meckel's ganglion**) which are scattered along the nerve for a distance of 2 to 4 cm, Pl. V, 42. A magnifying glass may be necessary to bring out clearly these small ganglia.

Note the numerous small filaments, a score or more, extending from the dorsal side of the ganglia to the periorbita. Some of these filaments pass through the periorbita to the structures within. Numerous filaments from the sphenopalatine ganglia join the Nn. sphenopalatinus, palatinus major and palatinus minor. Immediately after passing through the sphenopalatine foramen the N. sphenopalatinus divides into two nearly equal branches, a lateral or external branch and a medial or internal branch (see laboratory specimen). The lateral branch runs along the inferior turbinated bone and is distributed to its mucous membrane and to that of the middle and ventral nasal meati. The medial branch, **N. septi narium**, leaves the main trunk at nearly a right angle and passes to the posterior end of the nasal septum and then extends anteriorly towards the prenares. It lies near the ventral edge of the nasal septum and is distributed to the mucous membrane of the septum and also to the mucous membrane of the anterior portion of the hard palate.

(4) N. palatinus anterior or major. Sensory.

This large nerve arises from the N. sphenopalatinus and accompanies the anterior palatine artery through the palatine canal and groove, Pl. V, 43. Expose from within the maxillary sinus the nerve and artery in their course through the palatine canal. In the palatine groove the nerve forms a kind of plexus around the artery. It is distributed principally to the mucous membrane of the hard palate but also sends some filaments through small foramina in the bones of the hard palate to the mucous membrane of the nasal fossa.

(5) N. palatinus posterior or minor.

This small nerve arises from the ventral edge of the sphenopalatine nerve in common with some of the fibres of the N. palatinus anterior. It passes through the groove formed by the maxillary tuberosity and the palatine bone and is distributed to the soft palate, Pl. V, 44.

N. canalis pterygoidei (Vidii).

First demonstrate on a cleaned skull the two foramina of the pterygoid or vidian canal. Now lift up the A. maxillaris interna and the N. sphenopalatinus a little from the bone and note the vidian nerve extending from the anterior foramen of the canal to the posterior part of the sphenopalatine ganglion. (The N. canalis pterygoidei is formed by the union of the superficial petrosal branch of the N. facialis with a sympathetic filament).

Summary of the Branches of the N. Trigemini or 5th Cranial Nerve

The N. trigeminus divides into three principal branches, viz., the N. ophthalmicus, the N. maxillaris and the N. mandibularis. The first two are sensory and the last is a mixed nerve. The N. mandibularis supplies the muscles of mastication, viz., the masseter, the temporal and the two pterygoids; also the mylohyoid and the anterior belly of the digastric; it also supplies sensory branches as follows: the temporalis superficialis, the buccinatorius, the lingualis and sublingualis, the rami dentales and mentales. The N. ophthalmicus divides into three branches, viz., the N. frontalis, the N. lacrimalis and the N. nasociliaris. The N. maxillaris supplies the following branches: N. orbitalis, N. infraorbitalis, Nn. palatinus major and minor and the N. sphenopalatinus.

N. oculomotorius. III. Motor.

This nerve supplies all the extrinsic muscles of the eye except the obliquus dorsalis or trochlearis, the rectus externus and the retractor oculi. The superficial origin of the nerve is from the crus cerebri. It passes from the cranial cavity through the foramen lacerum orbitale and is here covered by the three branches of the N. ophthalmicus. At the apex of the orbit the nerve divides into a small dorsal branch and a much larger ventral branch, Pl. V, 33, 34. The dorsal branch is short and supplies the muscles rectus dorsalis and levator palpebrae dorsalis. It enters the rectus dorsalis about two centimeters from the origin of the muscle and near its lateral border. The very small filament to the levator palpebrae dorsalis may be found best by raising somewhat the latter muscle from the rectus dorsalis and carefully removing the intervening connective tissue. The filament enters the muscle at its inner or deep face near the middle of the muscle. By using a magnifier the filament may easily be recognized and traced to its place of origin from the dorsal branch of the N. oculomotorius. Usually it is more or less embedded in the M. rectus dorsalis. The ventral branch of the N. oculomotorius is much larger and longer than the dorsal branch. Before attempting to follow this ventral branch, which passes between the tendons of origin of the rectus dorsalis and rectus externus, first dissect the branch of this nerve that supplies the M. obliquus ventralis. This branch lies between the adjacent borders of the external and ventral recti muscles, Pl. IV, 29. Trace it to its termination in the ventral oblique muscle. Transect the M. rectus externus near its middle and reflect the proximal end. Now follow the branch that supplies the M. obliquus ventralis to its place of origin from the ventral branch of the oculomotor, taking care not to disturb

the small ciliary ganglion which lies close to the place of origin of this branch from the oculomotor, Pl. V, 38. Usually the ciliary ganglion is so small that it cannot be seen clearly with the unaided eye; by using a magnifying glass, however, it can be seen satisfactorily. Near the origin of the branch to the M. obliquus ventralis the ventral branch of the N. oculomotorius terminates in several large short branches of which two or three enter the rectus ventralis and one or more equally large branches enter the rectus internus, Pl. V. No special dissection is necessary to demonstrate the large branches just mentioned.

Ganglion ciliare (Ophthalmic ganglion).

This small ganglion lies directly against the ventral branch of the N. oculomotorius and is connected to it by one or more very short branches from that nerve, which branches constitute the motor or short ciliary root of the ganglion (radix brevis ganglii ciliaris). The sensory or long ciliary root of the ganglion (radix longa ganglii ciliaris) is formed by a branch from the N. nasociliaris, Pl. V, 32. From the ciliary ganglion and its sensory root are given off the several ciliary nerves which accompany the optic nerve to the globe of the eye. [The ganglion is more easily demonstrated in the cat than in the horse.]

N. abducens, VI. Motor. Pl. VI, 13.

The superficial origin of the N. abducens is from the medulla, immediately posterior to the pons. It passes from the cranial cavity into the orbit through the foramen lacerum orbitale and divides into two branches the larger of which enters the M. rectus externus at its inner face, near the origin of the muscle. The smaller branch enters the M. retractor oculi, a short distance from its origin, and is the only nerve supplied to this muscle, Pl. V, 36.

N. trochlearis or patheticus, IV. Motor.

The superficial origin of the N. trochlearis is from the anterior medullary velum immediately posterior to the quadrigemina. It passes through the smallest of the three suprasphenoidal grooves and emerges from the cranial cavity through the foramen patheticum, Pl. IV, 24, and Pl. V, 31. The nerve extends from this foramen directly to the M. trochlearis or obliquus dorsalis which it enters at its dorso-lateral border at a point about half-way between the place of origin of the muscle and the trochlea or pulley through which the muscle passes.

N. acusticus, VIII. Sensory.

The apparent origin of this nerve is from the side of the medulla immediately caudal to the N. facialis, Pl. VI, 15. Its real origin, however, is from the spiral and vestibular ganglia of the internal ear. It passes through the internal auditory meatus with the N. facialis.

Submaxillary salivary gland.

To expose this organ, transect the M. pterygoideus internus just ventral to the N. lingualis and remove the detached portion of muscle. Turn the M. stylomandibularis dorsally. The submaxillary salivary gland extends from beneath the wing of the atlas to the basihyoid or body of the hyoid bone. It is from 20 to 25 cm. in length and from 2 to 4 cm in width, although the cervical or posterior end is sometimes much wider. The gland is somewhat crescent shaped and is surrounded by a thin fibrous capsule. Turn the gland dorsally noting meantime any small arteries supplied to it. Trace its duct, which extends along the deep face of the gland nearly the whole length of the organ and is continued anteriorly to the caruncula sublingualis where it opens into the oral cavity.

Nerve filament to the M. stylohyoideus.

This very small filament extends along the outer face of the proximal portion of the M. stylohyoideus for a distance of several centimeters. Trace the filament to its place of origin from the N. facialis, Pl. III, 77.

Exposure of the A. carotis communis.

Remove the aponeurosis covering the V. jugularis and the adjoining muscles. Turn aside the M. sterno-mandibularis taking care not to cut the nerve that enters its deep face at the level of the V. maxillaris externa. Now turn aside the M. subscapulo-hyoideus in order to expose the trachea, the oesophagus (if on the left side), the thyreoid body, the A. carotis communis and the common trunk of the vagus and sympathetic nerves, Pl. III, 28, 29, 30, 36, 89. Spend some time in studying the relations to each other of the parts just mentioned. Note the relation of the thyreoid body to the angle formed by the jugular and external maxillary veins and also the relation of the jugular vein to the carotid artery.

V. thyroidea.

This large vessel arises from the thyreoid body principally, but also from the superior cervical lymph gland and the posterior pharyngeal region, and terminates in the V. jugularis at nearly the same level as the V. maxillaris externa. Another vein from the muscles of the dorsal part of the neck enters the jugular at about this same level.

V. occipitalis.

This large vein emerges from beneath the wing of the atlas and opens into the jugular about 5 cm. peripheral to the V. maxillaris externa.

Anterior cervical lymph gland.

This gland is situated in the triangular space formed by the jugular and external maxillary veins and the posterior border of the submaxillary salivary gland. The gland may form two or more separate masses the larger of which, six or more cm. in length in this specimen, lies at the side of the carotid artery; the smaller mass, 2 to 3 cm. in length, lies between the thyroid body and the submaxillary salivary gland. This lymph gland is supplied with blood by a small branch from the A. thyroidea superior.

A. carotis communis, Pl. III, 36.

Trace this artery to the point where, under cover of the submaxillary salivary gland, it divides into its three terminal branches, viz., **A. occipitalis**, **A. carotis interna** and **A. carotis externa**, Pl. III. 38, 39, 40.

Collateral branches of the A. carotis communis.

(1) Several small branches to the oesophagus, the trachea and to some of the ventral muscles of the neck.

(2) **A. thyroidea superior, Pl. III, 37.**

This is the largest collateral branch of the A. carotis communis. It arises near the level of the thyroid gland, bends over its cephalic end and terminates by several branches in the ventral surface of the gland; several large branches also enter the dorsal surface of the gland. It gives off a small pharyngeal branch to the posterior part of the pharynx and a larger laryngeal branch which passes between the cricoid and thyroid cartilages to the interior of the larynx.

(3) **A. thyroidea accessoria.**

In this specimen, the artery arises from the carotis communis 5 cm. posterior to the A. thyroidea superior (10-12 cm. posterior to the trifurcation of the carotid). It soon divides into three or four branches of which the largest enters the posterior end of the thyroid body; the other small branches go to the muscles subscapulo-hyoideus, sterno-thyro-hyoideus and to the trachea.

(4) **A. parotidea.**

This artery is about the same size as the accessoria. It arises from the carotid at the same level as the thyroidea superior and divides into two

branches of which one goes to the parotid gland and to the muscles brachiocephalicus and rectus capitis anterior major; the other branch goes to the submaxillary salivary gland and to the muscles sterno-mandibularis and subscapulo-hyoideus and also supplies twigs to the cervical lymph gland.

A. occipitalis.

The origin of the A. occipitalis is from the carotis communis usually immediately peripheral to that of the A. carotis interna, Pl. III, 38. Occasionally, however, these two arteries arise by a common trunk of variable length. The general course of the occipital artery is in nearly a direct line to the alar foramen of the atlas. Beneath the wing of the atlas the artery divides into two branches of which one passes through the alar foramen to the region of the poll and the other through the foramen transversarium of the atlas and anastomoses with the A. vertebralis. To expose the A. occipitalis turn aside the structures that cover the M. obliquus capitis posterior. Cut the latter muscle along its attachment to the wing of the atlas, taking care not to injure the arteries that pass through the foramen transversarium and the foramen alare. Free the muscle from its attachment to the atlas and the axis. Transect the M. obliquus capitis anterior close to its attachment to the wing of the atlas and also close to the styloid process and the crest of the occipital bone and turn it aside. Remove a portion of the wing of the atlas in order fully to expose the artery.

Branches of the A. occipitalis.

(1) A small branch to the posterior extremity of the submaxillary salivary gland (**A. glandulae submaxillaris dorsalis**).

(2) Small branches to the ventral recti muscles of the head and to the parotid gland.

(3) The **A. condyloidea** is a very small branch which can be traced, at present, for only a short distance. It divides into very small muscular and meningeal branches. The former go to the muscles rectus capitis anterior major and minor. The two very small meningeal branches enter the cranial cavity by the foramen lacerum basis cranii and the hypoglossal foramen respectively, and are distributed to the dura.

(4) **A. meningea posterior.**

This branch is much larger than any of the preceding branches. It runs along the posterior edge of the styloid process of the occipital bone, passes through the mastoid foramen (trace it only to this foramen) and is distributed to the dura. Near the base of the styloid process it gives off a branch to the region just posterior to the occipital tuberosity.

(5) **Ramus caudalis** (retrograde).

This large branch leaves the A. occipitalis at nearly a right angle, passes through the foramen transversarium of the atlas and anastomoses with the A. vertebralis.

(6) **Ramus occipitalis**.

This large branch of the A. occipitalis passes through the alar foramen of the atlas and supplies the muscles and the skin in the region of the poll. In the alar groove it gives off the **A. cerebrospinalis** which passes through the intervertebral foramen of the atlas, penetrates the dura and divides into two branches, **ramus cerebrialis** and **ramus spinalis**. These two branches will be demonstrated after removing the brain, Pl. VI.

Pharyngeal lymph glands, Pl. III, 31.

These glands lie directly ventral to the M. stylohyoideus and are covered laterally by the muscles stylo-mandibularis and digastricus. They often consist of two groups: The larger and more compact group lies on the lateral surface of the pharynx along the course of the A. carotis externa. The smaller group, posterior or **retropharyngeal** lymph gland, is situated between the posterior face of the pharynx and the eustachian or guttural air sac. It consists of more or less isolated or scattered lymph nodules.

A. carotis interna, Pl. III, 39; Pl. VI, 27.

This artery is one of the three terminal branches of the carotis communis. It extends to the foramen lacerum basis cranii through which it passes into the cranial cavity. Its distribution to the brain will be demonstrated after the removal of that organ.

A. carotis externa, Pl. III, 40.

The A. carotis externa is the largest of the three terminal branches of the carotis communis. It crosses the lateral wall of the pharynx at the caudal border of the eustachian or guttural air sac and is covered by the submaxillary salivary gland, the muscles stylo-mandibularis, digastricus, stylohyoideus and the N. hypoglossus. Upon emerging from beneath these structures the artery passes more or less obliquely across the stylohyoid or great cornu of the hyoid, and near its dorsal border divides into two terminal branches: **A. temporalis superficialis** and **A. maxillaris interna**, the latter being much the larger, Pl. III, 48, 51. The collateral branches of the carotis externa are three in number, viz., **A. maxillaris externa**, **A. masseterica**, and **A. auricularis posterior**, Pl. III, 41, 46, 47.

(1) **A. maxillaris externa.**

The *A. maxillaris externa* rises from the *carotis externa* either on the inner surface of the posterior belly of the *M. digastricus* or on the inner surface of the *M. stylohyoideus*. In the first part of its course the artery crosses the lateral wall of the pharynx nearly parallel to the stylohyoid bone and is covered by the muscles *digastricus* and *stylohyoideus*. The *N. hypoglossus* lies immediately ventral to the artery, Pl. III. After giving off the large *A. lingualis* from its dorsal side (Pl. III, 43) the vessel inclines ventrally, crosses the *N. hypoglossus*, the intermediate tendon of the *digastricus* where the latter plays through the tendon of the *stylohyoideus*, the submaxillary duct and often the end of the submaxillary gland itself, and enters the submaxillary space near the posterior end of the submaxillary lymph gland. In the submaxillary space the artery lies between the *V. maxillaris externa* and the submaxillary lymph gland. The remaining or facial portion of the *A. maxillaris externa* has already been dissected (p. 12). Three collateral branches arise from the *A. maxillaris externa* between its point of origin and the anterior extremity of the submaxillary salivary gland, viz., **A. palatina ascendens**, **A. lingualis** and **A. sublingualis**. In addition to these three collateral branches several small twigs are supplied to the *M. pterygoideus internus*, the anterior extremity of the submaxillary salivary gland and the pharyngeal lymph gland.

(a) **A. palatina ascendens**, Pl. III, 42.

This artery arises from the dorsal side of the *A. maxillaris externa* 2 to 4 cm. from the *A. carotis externa*; sometimes, however, it arises in the angle formed by the *carotis externa* and the *maxillaris externa*. It passes beneath the stylohyoid bone, a short section of which should be removed, and is distributed to the lateral wall of the pharynx, the soft palate and the tonsil.

(b) **A. lingualis**, Pl. III, 43.

This large artery diverges from the *maxillaris externa* at the tip of the thyroid cornu of the *basihyoid*, extends along the ventral edge of the *stylohyoid* for a short distance and then dips under the *M. hyoglossus*. Before exposing the artery first trace the large *N. hypoglossus*, which lies just ventral to the *A. maxillaris externa*, across the lateral face of the *M. hyoglossus*. Now push aside the *M. styloglossus*, Pl. III, 12, in order more fully to expose the *M. hyoglossus* (Pl. III, 13), and transect the latter muscle one to two centimeters dorsal to the *N. hypoglossus*. Separate the *M. hyoglossus* from the more deeply lying *genioglossus* and trace the artery to the tip of the tongue. (Occasionally the *A. lingualis* lies on the superficial face of the *M. hyoglossus* as in the specimen from which Plate III was made).

(c) **A. sublingualis**, Pl. III, 44.

This is a smaller vessel than the preceding. It arises from the maxillaris externa at the anterior or cephalic extremity of the submaxillary salivary gland, passes anteriorly on the inner face of the anterior belly of the M. digastricus, and between the ramus of the mandible and the M. mylohyoideus to near the middle of the latter muscle; here it pierces the mylohyoideus, runs along the inner surface of the sublingual gland and terminates in the mucous membrane of the anterior portion of the floor of the mouth. Just as the artery passes through the mylohyoideus it gives off a branch, **A. submentalis**, which runs on the outer surface of the M. mylohyoideus towards the lower lip and chin. The A. sublingualis supplies small branches to the mylohyoideus and digastricus, the sublingual gland and the submaxillary lymph gland. Occasionally a branch of considerable size arises from the maxillaris externa, near the place of origin of the A. sublingualis, crosses the lower border of the mandible and is distributed to the M. masseter.

(2) **A. masseterica**.

This artery originates from the A. carotis externa at the dorsal border of the M. stylohyoideus, Pl. III, 46. One or two centimeters from its origin it divides into a superficial and a deep branch. The superficial branch is distributed to the parotid gland and the M. masseter; the deep branch to the muscles pterygoideus internus, stylomandibularis and the posterior belly of the digastricus.

(3) **A. auricularis posterior** (continued).

The A. auricularis posterior arises at a very acute angle from the A. carotis externa about one centimeter peripheral to the A. masseterica, Pl. III, 47. It extends dorsally towards the base of the ear and is deeply covered by the parotid gland to which it sends numerous small branches. The two superficial branches have already been dissected (p. 9). The deep branch arises 1 to 2 cm. from the origin of the parent trunk, and after giving off a small branch to the tympanum or middle ear, passes between the external auditory canal and the mastoid process of the petrous temporal. Transect the conchal cartilage and trace the artery as far as possible.

A. temporalis superficialis.

This is the smaller of the two terminal branches of the A. carotis externa, Pl. III, 48. After a course of 1 or 2 cm. it divides, under cover of the parotid gland, into two branches, the **A. auricularis anterior** and the **A. transversa faciei**, Pl. II, 47, 48; Pl. III, 49, 50.

(1) **A. auricularis anterior.**

The artery auricularis anterior is accompanied by the vein and nerve of the same name and is deeply covered by the parotid gland to which it sends numerous small twigs. The vessel runs posterior to the capsule of the temporo-mandibular articulation and is distributed to the temporal and auricular muscles and the overlying skin. It sends a small branch to the inner surface of the conchal cartilage and also a branch which accompanies the N. auriculo-palpebraris to the supraorbital foramen where it anastomoses with the A. supraorbitalis.

(2) **A. transversa faciei.**

This artery has already been dissected. (See p. 13.)

A. maxillaris interna, Pl. III, 51.

The A. maxillaris interna is much the larger of the two terminal branches of the carotis externa and is the direct continuation of it, Pl. III, 51. It begins on the outer surface of the stylohyoid bone and extends in a tortuous course to the pterygoid or alar foramen of the sphenoid bone, passes through this foramen and the pterygo-palatine fossa, to the maxillary hiatus where it is continued by the A. palatina major. For convenience, the artery may be divided into three parts of which the **first part**, the longest and most tortuous, extends from the stylohyoid bone to the pterygoid or alar foramen of the sphenoid. The **second part** extends through the pterygoid or alar canal. The **third part** extends from the anterior extremity of the pterygoid or alar canal to the maxillary hiatus. The **first part** of the vessel describes an S-shaped curve and is covered by the M. pterygoideus externus. Beneath this muscle the artery is crossed superficially by the Nn. mylohyoideus, alveolaris inferior, lingualis, pterygoidei, buccinatorius, and deeply by the chorda tympani. Note the relation of the artery to the eustachian or guttural air sac. The **first part** of the A. maxillaris interna gives off the following branches:

(1) **A. alveolaris inferior**, Pl. III, 52.

This arises from the convexity of the first curve of the A. maxillaris interna and with the vein and nerve of the same name passes through the alveolar canal of the mandible. At the mental foramen the artery anastomoses with the A. labialis inferior and is continued to the lower lip as the **A. mentalis**. The alveolaris inferior supplies twigs to the pterygoid muscles and to the teeth and gums of the mandible; the branch to the canine and incisor teeth accompanies the nerve that supplies these structures, as has already been demonstrated.

(2) **A. tympanica**, Pl. III, 53.

This small vessel arises a little peripheral to the preceding but from the opposite side of the A. maxillaris interna. It lies close to the common trunk of the nerves alveolaris inferior and lingualis (at the side of the chorda tympani) and enters the tympanum or middle ear.

(3) **Aa. pterygoideae**.

There are two or three of these small arteries. They arise from the concavity of the second curve of the maxillaris interna, Pl. III, 55, and are distributed to the pterygoid and tensor palati muscles.

(4) **A. meningea media**, Pl. III, 54.

The A. meningea media is a small artery which arises from the convexity of the second curve of the maxillaris interna, nearly opposite the pterygoid arteries and close to or even beneath the N. buccinatorius, Pl. III, 54. Sometimes it arises in common with the A. temporalis profunda posterior. It can be traced but a short distance. It enters the cranial cavity by the foramen lacerum basis cranii and is distributed to the dura.

(5) **A. temporalis profunda posterior**, Pl. III, 56.

This vessel arises from the dorsal side of the A. maxillaris interna a little before the latter enters the pterygoid or alar foramen. It is covered by the M. temporalis to which it is mainly distributed. (For some distance the artery accompanies the N. temporalis profunda posterior).

The **second part** of the A. maxillaris interna, i. e., the part in the pterygoid canal, gives rise to two branches, **A. temporalis profunda anterior** and **A. ophthalmica**. These two arteries commonly originate by a very short common trunk, Pl. V, 17.

(1) **A. temporalis profunda anterior**, Pl. III, 57; Pl. IV, 14; Pl. V, 18.

This artery, as just mentioned, arises from the **second part** of the A. maxillaris interna in common with the ophthalmica. It leaves the pterygoid canal by the temporal or alar parvum foramen and is distributed to the M. temporalis and the skin of the forehead.

(2) **A. ophthalmica**, Pl. V, 17.

This artery originates from the A. maxillaris interna within the pterygoid canal in common with the A. temporalis profunda anterior. Upon emerging from the canal it enters the apex of the periorbita. Beneath the M. rectus dorsalis it makes a sharp curve and upon reaching the ethmoid fora-

men is continued by the *A. ethmoidalis*. (See laboratory specimen for the distribution of this artery.) The branches of the *A. ophthalmica* are as follows:

(a) ***A. lacrimalis***, Pl. IV, 23.

This small artery accompanies the *N. lacrimalis* to the lacrimal gland and upper eyelid.

(b) ***A. supraorbitalis***.

This vessel arises either from the *A. temporalis profunda anterior* or the *A. maxillaris interna*. It pierces the periorbita between which and the osseous wall of the orbit it extends directly to the supraorbital foramen through which it passes and is distributed to the muscles *orbicularis palpebrarum* and, *corrugator supercilii* and the skin of the forehead.

(c) **Rami musculares.**

The numerous muscular branches that supply the muscles of the eye.

(d) **Aa. ciliares.**

The numerous small ciliary arteries arise from the *ophthalmica* and its muscular branches. They are distributed to the ciliary body, the iris and the choroid coat of the eye.

(e) ***A. centralis retinae***.

This is a small artery which supplies the retina.

(f) ***A. ethmoidalis***. (Trace this only to the ethmoid foramen).

The *A. ethmoidalis* is the continuation of the *ophthalmica*. It passes through the ethmoid foramen into the cranial cavity and divides into meningeal and nasal branches, Pl. VIII, fig. 2. The meningeal branch is distributed to the dura and anastomoses with the branches of the *A. corporis callosi*. The nasal branch passes through the cribriform plate into the nasal fossa and is distributed to the nasal mucous membrane.

The **third part** of the *A. maxillaris interna* is shown in Pl. IV. It extends from the anterior opening of the pterygoid canal to the maxillary hiatus. It gives off the following branches:

(a) ***A. buccinatoria***, Pl. IV, 19; Pl. II, 50; and Pl. III, 58.

The *A. buccinatoria* arises from the ventral side of the parent trunk soon after the latter emerges from the pterygoid canal. It crosses the maxillary tuberosity with the *N. buccinatorius*, and is distributed to the dorsal molar

glands and the muscles pterygoidei and buccinator. Near its origin the A. buccinatoria gives off a long slender branch (Pl. IV, 16) to the large mass of orbital fatty tissue in the temporal fossa, posterior to the periorbita.

(b) **A. infraorbitalis**, Pl. IV, 17.

The A. infraorbitalis arises from the dorsal side of the maxillaris interna, Pl. IV, 17. It extends to the infraorbital canal, through which it passes, and continues to the canine and incisor teeth through the small osseous canal (canalis alveolaris incisivus) in the maxillary and premaxillary bones. Before entering the infraorbital canal it gives off the **A. orbitalis**, Pl. IV, 18, which extends between the periorbita and the anterior wall of the orbit to the inner or nasal canthus of the eye and is distributed to the lower eyelid, the M. obliquus ventralis and the lacrimal sac. Within the infraorbital canal the A. infraorbitalis gives off small branches to the teeth and, at the infraorbital foramen, a branch of variable size which anastomoses with either the A. labialis dorsalis or the A. lateralis nasi.

(c) **A. palatina minor**.

This is a very small vessel which arises from the maxillaris interna, passes through the groove at the inner side of the maxillary tuberosity and is distributed to the soft palate, Pl. IV, 20. The N. palatinus posterior and the palatine vein also pass through this groove with the artery.

(d) **A. sphenopalatina**, Pl. IV, 21; Pl. V, 24.

This vessel arises from the A. maxillaris interna at the extreme anterior part of the pterygo-palatine fossa, close to the orifice of the palatine canal, and passes through the sphenopalatine foramen into the nasal fossa where it divides into two branches. (See laboratory specimen). One of these branches is distributed to the mucous membrane of the nasal septum and the other to the mucous membrane of the inferior turbinal, the inferior meatus, the posterior nares and the maxillary and frontal sinuses.

(e) **A. palatina major**.

This artery is the direct continuation of the maxillaris interna. It passes through the palatine canal and groove with the N. palatinus anterior. At the incisive foramen it anastomoses with its fellow of the opposite side. From the arch formed by this anastomosis a branch passes through the incisive foramen and anastomoses with the dorsal labial arteries, Pl. VII.

N. glossopharyngeus, IX. Mixed.

The superficial or apparent origin of the N. glossopharyngeus is from the medulla, Pl. VI, 16. The deep or real origin of its motor fibers is from

two nuclei in the medulla. The sensory fibers arise from the cells of the ganglion petrosum of the nerve trunk. The centrally directed sensory fibers extend from the ganglion into the medulla. The peripherally directed sensory fibers supply in part the mucous membrane of the tongue, pharynx, the tympanic cavity and the eustachian tube. The glossopharyngeus passes through the foramen lacerum basis cranii with the Nn. vagus and accessorius, Pl. III, 78. The nerve is readily found at any point along its course between the stylohyoid or great cornu of the hyoid and the A. maxillaris externa, Pl. III, 84. It should not be mistaken for the much larger N. hypoglossus which runs parallel to it but which lies on the ventral side of the artery. Expose, as follows, the proximal portion of the nerve. With a chisel cut the paramastoid or styloid process of the occipital bone close to its base (Pl. III, 3) and reflect it, with the portions of muscles attached to it, onto the stylohyoid. Trace the N. glossopharyngeus towards the base of the skull, noting its relation to the A. carotis externa and to the great N. hypoglossus, with which it is in close contact in this part of its course. Near the base of the skull these two nerves, together with the trunk of the vagus and sympathetic, are bound together by connective tissue into one large cord which is partially surrounded by a fold of the eustachian or guttural air sac. In exposing the nerves of this region it is not necessary to cut or tear the thin wall of this sac; it may simply be pushed from around the nerves with the handle of the scalpel. At the base of the skull note the enlargement of the N. glossopharyngeus, the **ganglion petrosum**, Pl.

III, 79. A small nerve, **N. tympanicus**, originates from the antero-lateral face of the ganglion and extends dorsally, closely applied to the surface of the ganglion, into the tympanum or middle ear. Not infrequently some difficulty is experienced in demonstrating this small nerve; by using a magnifier, however, it can usually be seen without much difficulty, Pl. III, 80. The next branch of the N. glossopharyngeus is given off anywhere from 2 to 6 cm. before the main trunk crosses the A. carotis externa. This branch passes directly to the carotid nerve plexus at the trifurcation of the A. carotis communis. Very frequently this branch of the glossopharyngeus is joined by a branch from the superior cervical ganglion (Pl. III, 93) of the sympathetic nerve shortly before reaching the plexus. As the N. glossopharyngeus crosses the medial surface of the A. carotis externa it divides into two nearly equal branches, **ramus pharyngeus** and **ramus lingualis**.

(a) **Ramus pharyngeus**, Pl. III, 82.

Trace this branch to the place where it crosses, at a right angle, the stylohyoid bone and the M. stylopharyngeus. Note the small filament to

the M. stylopharyngeus, Pl. III, 83; this filament may originate from either the pharyngeal or the lingual branch of the N. glossopharyngeus. Opposite the place where the nerve crosses the stylohyoid and the M. stylopharyngeus, remove a section of the bone as shown in Plate III. Near the dorsal edge of the M. stylopharyngeus the nerve turns sharply and divides into numerous small branches which intermix with one of the pharyngeal branches of the vagus, as will be seen later, to form the pharyngeal plexus. The numerous branches of this plexus are distributed to the pharyngeal muscles and mucous membrane.

(b) **Ramus lingualis**, Pl. III, 84.

This branch of the N. glossopharyngeus is somewhat larger than the pharyngeal branch and lies between the stylohyoid bone and the A. maxillaris externa as already mentioned. Turn aside the stylohyoid bone and trace the nerve peripherally. It gives several small branches to the isthmus of the fauces and the tonsil and terminates in the mucous membrane of the posterior third of the dorsum of the tongue.

N. vagus, X. Mixed.

The apparent or superficial origin of the vagus is from the ventro-lateral side of the medulla, Plate VI, 17. The deep or true origin, however, is as follows. The motor fibers arise within the medulla from the same mass of nerve cells that gives rise to the motor fibers of the glossopharyngeus. The sensory fibers arise from ganglion cells of the nerve trunk. The centrally directed sensory fibers terminate in the medulla. The peripherally directed sensory fibers are distributed to the mucous membrane of the larynx, trachea, lungs, oesophagus, stomach, intestines, gall bladder and gall ducts. The vagus passes through the foramen lacerum basis cranii in company with the N. accessorius or the eleventh cranial nerve. The two nerves appear as a single trunk for a distance of 2 to 5 cm. from the base of the skull; they then separate and the great N. hypoglossus passes between them, Pl. III, 92, the vagus being medial and the N. accessorius lateral to the hypoglossus, Pl. III, 85. Trace the vagus for some distance along the course of the carotis interna and carotis communis noting that near the trifurcation of the carotis communis the vagus becomes closely united to the **N. sympathicus**, Pl. III, 95.

(1) **Pharyngeal branch of the N. vagus**, Pl. III, 86.

The pharyngeal branch of the vagus is given off opposite the superior cervical ganglion of the sympathetic (Pl. III, 86, 93) and soon divides into two nearly equal branches. Upon drawing the carotid artery and the vagus and

the sympathetic nerves somewhat ventrally, one of these branches may be traced to its place of distribution to the pharyngeal muscles and the pharyngeal extremity of the oesophagus. The other branch of the pharyngeal nerve passes deeply between the eustachian or guttural air sacs, and is more difficult to follow; however, by pushing aside the walls of the sacs the nerve may be traced to the dorso-lateral wall of the pharynx near to the insertion of the *M. stylopharyngeus*, Pl. III, 10, where it divides into numerous branches some of which intermix with the pharyngeal branch of the *N. glossopharyngeus*, the two together forming the pharyngeal plexus, as already mentioned.

(2) ***N. laryngeus superior***, Pl. III, 87; Pl. IX, 25. Sensory.

The large *N. laryngeus superior* arises from the vagus about 6 cm. from the point where the vagus and hypoglossus cross each other, Pl. III, 87. At the place where the *laryngeus superior* leaves the trunk of the vagus is sometimes an indistinctly marked network called the **ganglion nodosum**. The *N. laryngeus superior* crosses the medial face of the *Aa. carotis externa* and *interna*, near their origin, and enters the larynx through the foramen near the cephalic border of the thyreoid cartilage. The nerve is distributed to the mucous membrane of the larynx, the floor of the pharynx and the entrance to the oesophagus. A very small branch, sometimes called the ***N. laryngeus externus*** or ***medius***, is given off either from the plexiform enlargement of the vagus (ganglion nodosum) or more commonly from the *N. laryngeus superior* and extends directly to the *M. cricothyreoides*; it also supplies a small filament to the *M. cricopharyngeus*.

(3) ***N. laryngeus inferior*** or ***recurrens***.

The origin and course of the *N. laryngeus inferior* can not be seen until the thoracic portion of the vagus is dissected. Its distribution to the muscles of the larynx will be taken up later.

N. accessorius, XI. Motor.

The nucleus of origin of this nerve is very elongated. It begins near the middle of the medulla and extends caudally nearly the whole length of the cervical portion of the spinal cord. The radicles of the nerve emerge from the spinal cord and medulla and together make up the nerve trunk. The nerve trunk begins between the sixth and seventh cervical spinal nerves and extends cephalad along the immediate lateral face of the spinal cord. It passes between the dorsal and ventral roots of the first six spinal nerves and is enclosed by the dura and arachnoid of the spinal cord, Pl. VI, 18. In this ascending course the nerve gradually increases in size as it at in-

tervals receives additional filaments from the spinal cord. After entering the cranial cavity the nerve receives some filaments from the medulla. The N. accessorius accompanies the vagus to the foramen lacerum basis cranii and for a short distance from the base of the skull, as already noted, Pl. III, 90. After leaving the vagus the nerve passes across the lateral surface of the eustachian or guttural air sac and the ventral surface of the wing of the atlas and finally gains the dorsal border of the M. brachiocephalicus along which it extends nearly the entire length of the neck. The distribution of this portion of the nerve is principally to the thoracic portion of the muscle trapezius; one or more small branches, however, are supplied to the cervical portion of the trapezius and to the muscle brachiocephalicus. Shortly after crossing the A. occipitalis the N. accessorius sends off a large branch to the muscle sterno-mandibularis, Pl. III, 91. In its course along the neck the nerve is joined by branches from the ventral divisions of the first six cervical nerves.

N. hypoglossus, XII. Motor.

The superficial origin of the N. hypoglossus is from the medulla, Pl. VI, 19. It passes through the hypoglossal foramen and between the vagus and accessorius, Pl. III, 92. The hypoglossus crosses the lateral face of the A. carotis externa, at the place of origin of the A. maxillaris externa, and then extends along the ventral side of the latter vessel as far as to the ceratohyoid of the hyoid; from this point it extends between the muscles mylohyoideus and hypoglossus to about opposite the tip of the lingual prolongation of the basihyoid, a distance of 8 to 10 cm., where it divides into a superficial and a deep branch. The smaller superficial branch supplies the muscles styloglossus and hyoglossus. The larger deep branch of the hypoglossus crosses the ventral edge of the M. hyoglossus and extends obliquely between this muscle and the M. geniohyoglossus toward the tip of the tongue. In this intermuscular course the nerve divides into many branches which are distributed to the muscles of the tongue. Near the point where the N. hypoglossus divides into superficial and deep branches it gives off a small filament to the M. geniohyoideus. The N. hypoglossus communicates with the ventral division of the first cervical nerve by a small threadlike ramus which joins the hypoglossus just before the latter crosses the A. maxillaris externa or at any point intermediate to this and the base of the skull (Pl. III, nerve just below 31). The N. hypoglossus also gives off one or more small filaments which join the carotid plexus.

N. laryngeus inferior (continued). Pl. IX, 26.

The N. laryngeus inferior, of the left side, arises from the vagus within the thorax. It recurves around the arch of the aorta and in the first part of its

course lies on the ventro-lateral face of the trachea; nearer the larynx the nerve lies on the dorso-lateral face of the trachea. In order to trace the terminal portion of the nerve, the pharyngeal muscles of the left side (or right side as the case may be) must be transected and turned aside. Near the posterior end of the *M. cricoarytenoideus posterior* is given off the branch to this muscle, entering at its deep face and near the lateral border of the muscle. Carefully trace the main trunk of the *N. laryngeus inferior* to the point where it passes beneath the thyreoid cartilage. Disarticulate the posterior cornu of the thyreoid from the cricoid and abduct the former sufficiently to expose the muscles *crico-arytenoideus lateralis* and *thyro-arytenoideus*. Near the middle of the lateral border of the *M. crico-arytenoideus posterior* a small branch is given off to the *M. arytenoideus*. This branch passes beneath the *M. cricoarytenoideus posterior* which should be transected and turned aside, Pl. IX. Beneath the thyreoid cartilage the laryngeal nerve terminates in branches which supply the muscles *cricoarytenoideus lateralis*, *thyro arytenoideus* and also one or more branches that anastomose with the *N. laryngeus superior*, Pl. IX. All of these respective branches should be traced to their proper muscles. The *N. laryngeus inferior* of the right side recurves around the *A. dorsocervicalis* and is similarly distributed to the muscles of the right side of the larynx.

PLATE I

- | | | | |
|-----|--|-----|--|
| 1. | M. splenialis. | 24. | V. jugularis. |
| 2. | M. brachiocephalicus. | 25. | V. maxillaris externa. |
| 3. | M. sterno-mandibularis. | 26. | V. labialis communis. |
| 4. | M. subscapulo-hyoideus. | 27. | V. lateralis nasi. |
| 5. | M. auricularis inferior or parotido-auricularis. | 28. | V. dorsalis nasi. |
| 6. | Mm. cervico-auricularis. | 29. | V. angularis oculi. |
| 8. | M. zygomatico-auricularis. | 30. | V. masseterica. (This vein and artery are incorrectly represented as lying on the surface of the M. masseter; they are really embedded in the muscle.) |
| 9. | M. parieto-auricularis. | 31. | V. auricularis posterior. |
| 10. | M. masseter. | 32. | V. transversa faciei. |
| 11. | M. orbicularis oculi. | 33. | A. transversa faciei. |
| 12. | M. corrugator supercillii. | 34. | A. masseterica. |
| 13. | M. lacrimalis (or malars). | 35. | A. maxillaris externa or facialis. |
| 14. | M. levator naso labialis. | 36. | A. labialis ventralis or inferior. |
| 15. | M. levator labii superioris proprius. | 37. | A. labialis dorsalis or superior. |
| 16. | M. dilator naris lateralis. | 38. | A. lateralis nasi. |
| 17. | M. zygomaticus. | 39. | A. angularis oculi. |
| 18. | M. buccinator. | 40. | N. labialis dorsalis or superior. |
| 19. | M. cutaneous faciei (facial panniculus). | 41. | N. labialis ventralis or inferior. |
| 20. | M. depressor labii inferioris. | 42. | N. transversus faciei (a branch of the N. temporalis superficialis). |
| 21. | M. orbicularis oris. | 43. | Second spinal nerve. |
| 22. | Gf. parotis. | 44. | Ramus colli, a branch of the N. facialis. |
| 23. | Ductus parotidis. | | |




PLATE II

- | | | | |
|-----|---|------|--|
| 2. | M. splenius | 38. | V. maxillaris interna. |
| 3. | M. brachiocephalicus | 39. | A. maxillaris externa. |
| 4. | M. sternomandibularis. | 40. | A. labialis ventralis or inferior. |
| 5. | M. subscapulo-hyoideus. | 41. | A. labialis dorsalis or superior. |
| 6. | M. cervico-auricularis. | 42. | A. lateralis nasi. |
| 7. | M. stylomandibularis. | 43. | A. dorsalis nasi. |
| 8. | M. masseter (partially removed). | 44. | A. angularis oculi. |
| 9. | M. orbicularis oculi. | 45. | A. masseterica. |
| 10. | M. corrugator superciliaris, turned aside. | 46. | A. auricularis posterior. |
| 11. | M. malaris or lacrimalis. | 47. | A. auricularis anterior. |
| 11. | M. levator labii superioris proprius. | 48. | A. transversa faciei. |
| 13. | M. dilator labii superioris. | 49. | A. alveolaris inferior. (inferior dental). Some of the bone has been cut away to show a portion of the alveolar canal. |
| 14. | M. zygomaticus. | 50. | A. buccinatoria. |
| 15. | M. buccinatorius, showing cut edge. | 51. | N. facialis. |
| 16. | M. orbicularis oris. | 52. | N. auricularis posterior. |
| 17. | M. cutaneous faciei (facial panniculus). | 53. | N. auricularis medius (or internus). |
| 18. | M. depressor labii inferioris. | 54. | N. auricularis anterior. |
| 19. | Gf. parotis. | 55. | Plexus auricularis anterior. |
| 20. | Ductus parotidicus. | 56. | Small nerve from the N. temporalis superficialis. |
| 21. | Gf. molaris superior. | 57. | N. (or ramus) digastricus. |
| 22. | Gf. molaris inferior. | 58. | Nerve loop around the A. auricularis posterior. |
| 23. | V. jugularis. | 59. | Ramus colli. |
| 24. | V. maxillaris externa. | 60. | N. temporalis superficialis. (A branch of the 5th cranial nerve). |
| 25. | V. labialis communis. | 61. | N. labialis dorsalis or superior. |
| 26. | V. labialis superior. | 62. | N. labialis ventralis or inferior. |
| 27. | V. labialis inferior. | 63. | N. massetericus. |
| 28. | Communicating branch between V. buccinatoria and the V. labiales. | 64. | N. alveolaris inferior (inferior dental) or (N. alveolaris mandibularis). |
| 29. | V. buccinatoria. | 64a. | N. mentalis. |
| 30. | V. alveolaris. | 65. | N. buccinatorius. |
| 31. | V. transversa faciei. | 66. | Branches of the N. supraorbitalis. |
| 32. | V. lateralis nasi. | 67. | N. infraorbitalis. |
| 33. | V. dorsalis nasi. | 68. | N. nasalis dorsalis. |
| 34. | V. angularis oculi. | 69. | N. nasalis anterior. |
| 35. | V. masseterica. | 70. | N. labialis dorsalis. |
| 36. | V. auricularis posterior. | 71. | Second spinal nerve. |
| 37. | V. temporalis superficialis. | | |

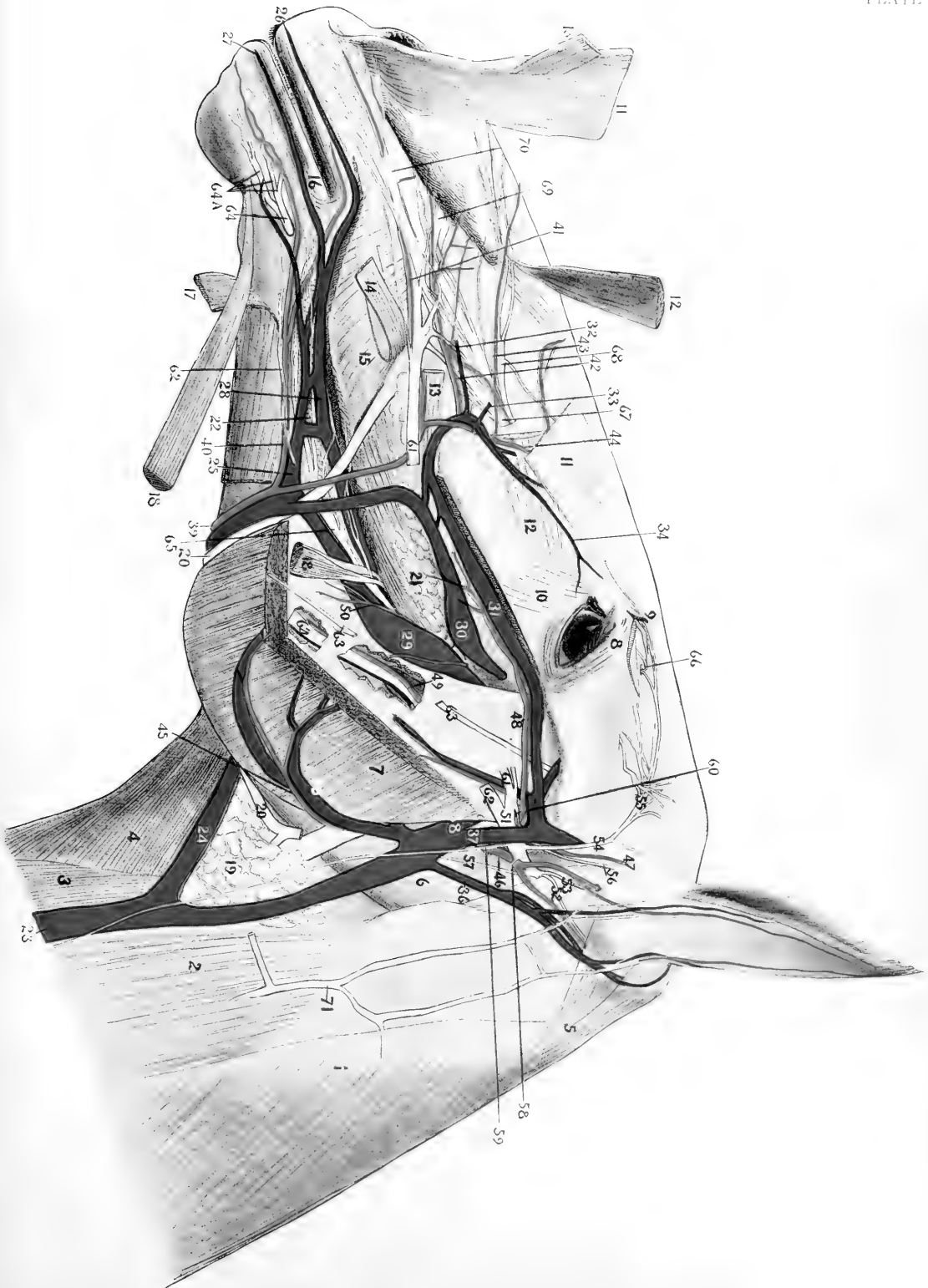


PLATE III

1. Supraorbital process.
2. Zygomatic process.
3. Styloid process of occipital.
3. Cut surface of malar bone.
5. Stylohyoid. (A portion has been removed).
6. Mandible.
7. M. temporalis.
8. M. pterygoideus externus.
9. M. pterygoideus internus.
10. M. stylopharyngeus.
11. M. stylohyoideus.
12. M. styloglossus.
13. M. hyoplossus partially reflected.
14. M. genioGLOSSUS.
14. M. geniohyoideus.
15. M. mylohyoideus.
16. M. digastricus (anterior belly).
17. M. rectus capitis anterior major.
18. M. recto-pharyngeus.
19. M. crico-pharyngeus.
20. M. hyo-pharyngeus.
21. M. hyo-thyroideus.
22. M. cerato-thyroideus.
23. M. crico-thyroideus.
24. M. sterno-mandibularis.
25. M. subscapulo-hyroideus.
26. M. sterno-hyroideus.
27. Trachea.
28. Oesophagus.
29. Cl. thyreoidea.
30. Pilo-thyroideus.
31. Parathyroid lymph gland.
32. Submaxillary lymph gland.
33. Submaxillary serous gland. (Anterior end).
34. Ductus submaxillaris.
35. Sublingual gland (greater portion has been removed).
- 35a. O. lacrimalis.
36. A. carotis communis.
37. A. thyroidea.
38. A. occipitalis.
39. A. carotis interna.
40. A. carotis externa.
41. A. maxillaris externa.
42. A. palatina ascendens.
43. A. lingualis.
44. A. sublingualis.
45. A. maxillaris externa.
46. A. masseterica.
47. A. auricularis posterior.
48. A. temporalis superficialis.
49. A. transversa faciei.
50. A. auricularis anterior.
51. A. maxillaris interna.
52. A. alveolaris inferior.
53. A. tympanica.
54. A. meningea media.
55. A. pterygoidea.
56. A. temporalis profunda posterior.
57. A. temporalis profunda anterior.
58. A. buccinatoria.
59. V. transversa faciei.
60. V. alveolaris.
61. N. mandibularis.
62. N. massetericus.
63. Nn. temporales profundi posterior.
63. N. buccinatorius.
64. N. temporalis profundus anterior.
65. N. maxillaris.
66. N. maxillaris.
67. N. pterygoideus externus.
68. N. pterygoideus internus.
69. N. lingualis.
70. N. sublingualis.
71. N. alveolaris inferior.
72. N. mylohyoideus.
73. N. chorda tympani.
74. N. temporalis superficialis.
74. N. facialis.
75. N. digastricus.
76. N. digastricus.
77. N. stylohyoideus.
77. N. glossopharyngeus.
79. G. bellion petrosus.
80. N. tympanicus.
81. Branch to carotid plexus.
82. Ramus pharyngeus.
83. Branch to the 1st. stylopharyngeus.
84. Ramus lingualis.
85. N. vagus.
85. Ramus pharyngeus.
86. Ramus laryngeus superior.
87. N. laryngeus externus.
88. N. laryngeus internus.
89. Commoned trunks of the Nn. vagus and sympathicus.
90. N. accessorius.
91. Branch to XI. sterno-mandibularis.
92. N. hypoglossus.
93. Superior cervical ganglion of the sympathetic nerve.
94. N. sympathicus, accompanying the internal carotid.
95. N. sympathicus.
96. Plexus carotidus.
97. Eustachian pouch or air sac (guttural pouch).
98. Branch of first spinal nerve.

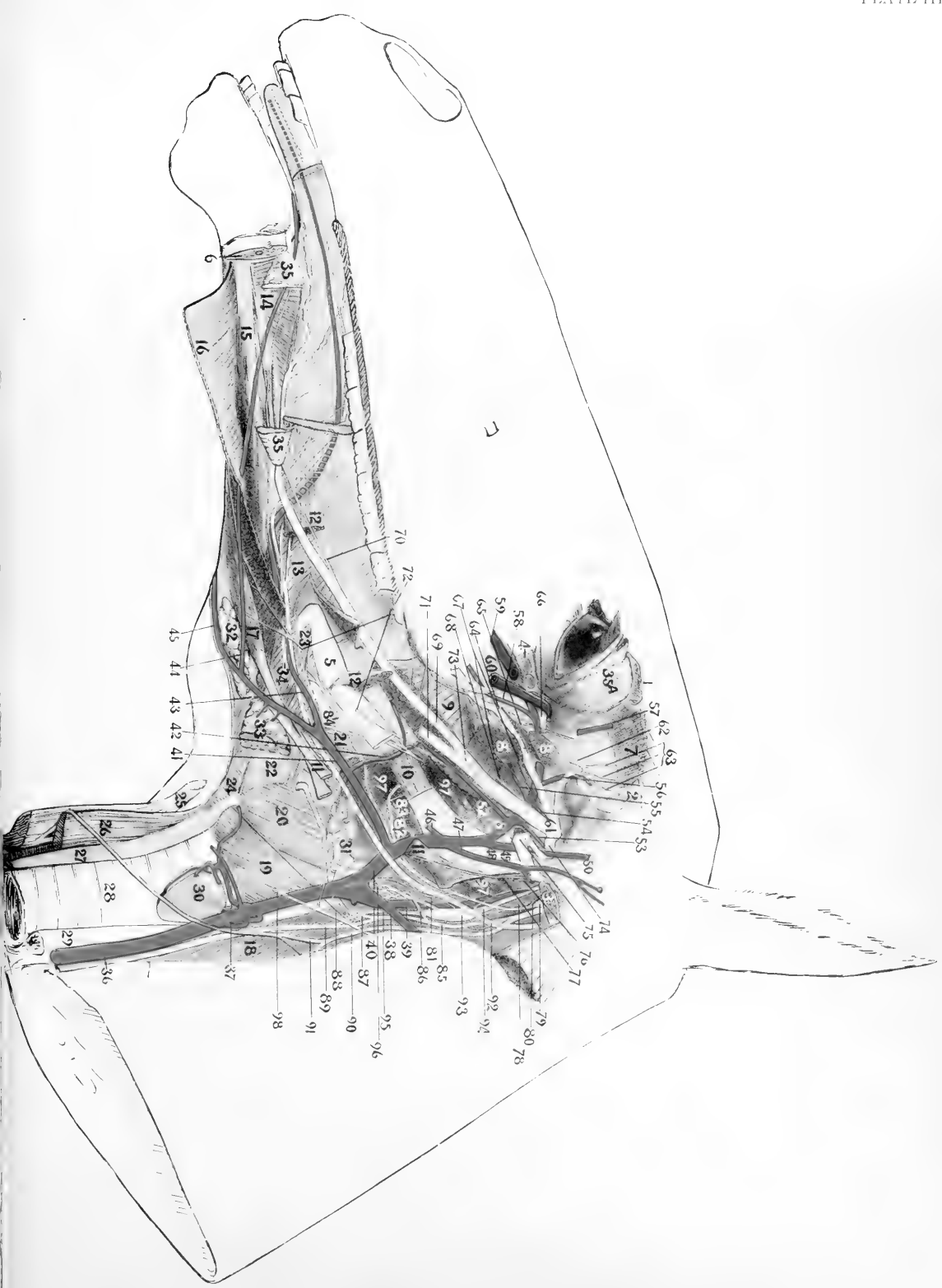




PLATE IV

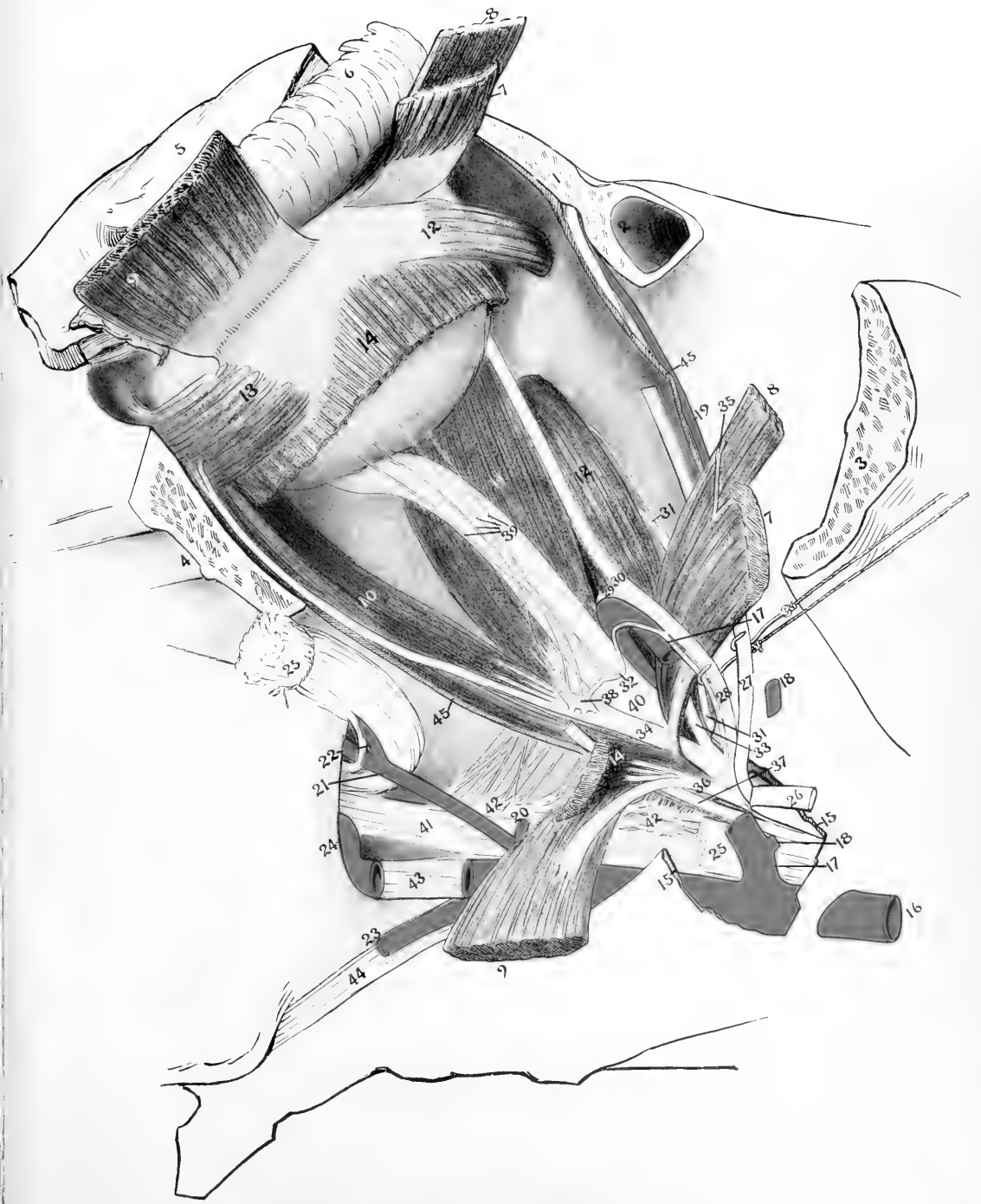
1. Cut surface of the supraorbital process.
2. Frontal sinus.
3. Cut surface of the zygomatic process of the temporal.
4. Cut surface of the malar.
5. Palpebræ.
6. Gl. lacrimalis.
7. M. rectus dorsalis or superior.
8. M. levator palpebrae dorsalis or superior.
9. M. rectus lateralis.
10. M. rectus ventralis or inferior.
11. M. obliquus ventralis or inferior.
12. M. retractor oculi or bulbi.
13. A. maxillaris interna.
14. A. temporalis profunda anterior.
15. A. supraorbitalis.
16. Small artery to the mass of adipose tissue in the temporal fossa.
17. A. infraorbitalis.
18. A. orbitalis or malaris.
19. A. buccinatoria.
20. A. palatina posterior.
21. A. sphenopalatina.
22. Muscular branch of the A. ophthalmica.
23. A. lacrimalis.
24. N. trochlearis.
25. N. supraorbitalis or frontalis.
26. N. nasociliaris (palpebronasal).
27. N. lacrimalis.
28. N. orbitalis or zygomaticus.
29. Branch of the N. oculomotorius to the M. obliquus ventralis.
30. N. maxillaris.
31. N. sphenopalatinus.
32. N. palatinus anterior or major.
33. N. palatinus posterior or minor.
34. Cut edge of the periorbita or ocular sheath.





PLATE V

1. Cut surface of supraorbital process.
2. Frontal sinus.
3. Cut surface of the zygomatic process of the temporal.
4. Cut surface of the malar.
5. Palpebrae.
6. Gl. lacrimalis (somewhat reflected).
7. M. rectus dorsalis or superior.
8. M. levator palpebrae dorsalis or superior.
9. M. rectus lateralis.
10. M. rectus ventralis or inferior.
11. M. rectus medialis.
12. M. obliquus dorsalis or superior.
13. M. obliquus ventralis or inferior.
14. M. retractor oculi or bulbi.
15. Cut edge of sphenoid.
16. A. Maxillaris interna.
17. A. ophthalmica.
18. A. temporalis profunda anterior.
19. A. supraorbitalis or frontalis.
20. Small artery to the mass of adipose tissue in the temporal fossa.
21. A. infraorbitalis.
22. A. orbitalis or malaris.
23. A. buccinatoria.
24. A. sphenopalatina.
25. N. Maxillaris cut and one end turned aside.
26. N. lacrimalis, cut and turned aside.
27. N. supraorbitalis or frontalis.
28. N. nasociliaris or palpebronasal.
29. N. ethmoidalis.
30. N. infratrochlearis.
31. N. trochlearis.
32. Sensory root of Gang. ciliare.
- 33 and 34. N. oculomotorius, dorsal and ventral branches.
35. Small branch from the N. oculomotorius to the M. levator palpebrae dorsalis.
36. N. abducens.
37. N. orbitalis or zygomaticus (the peripheral portion has been removed).
38. Ganglion ciliaris.[Represented too large]
39. Nn. ciliares.
40. N. opticus.
41. N. sphenopalatinus.
42. Ganglion sphenopalatinum showing many small nerves leaving it.
43. N. palatinus anterior or major.
44. N. palatinus posterior or minor.
45. Cut edge of the periorbita or ocular sheath.




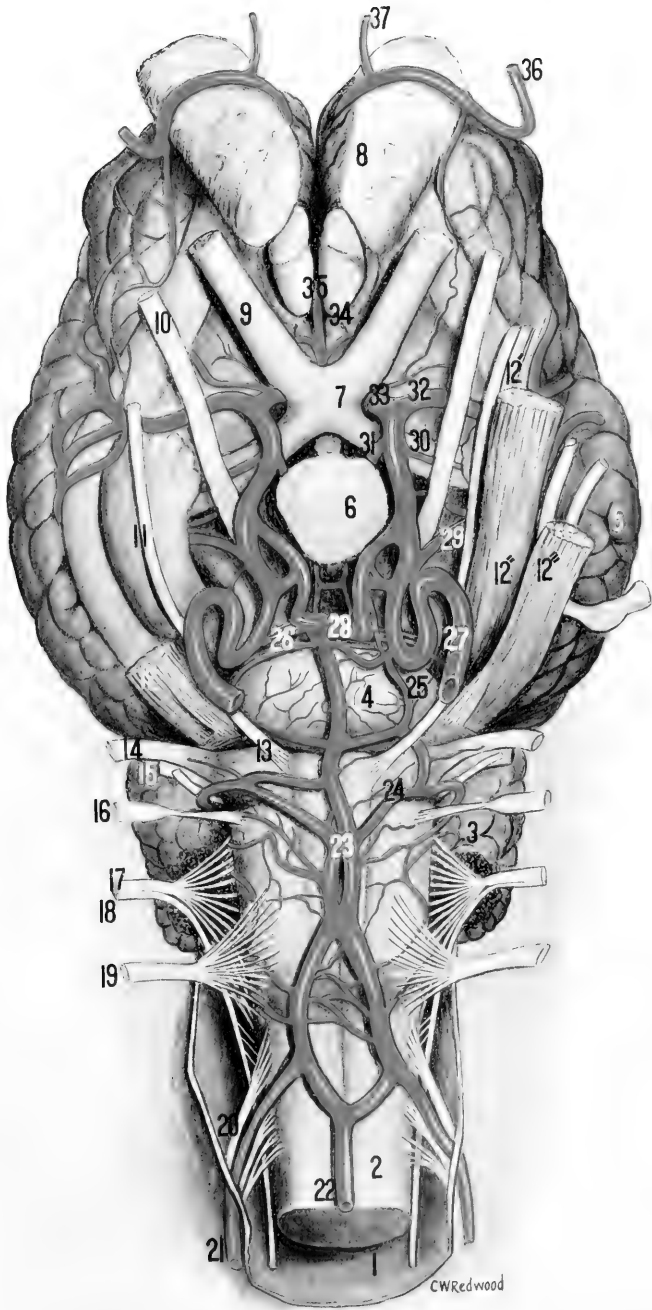


PLATE VI

1. Dura.
2. Medulla.
3. Cerebellum.
4. Pons.
5. Cerebrum.
6. Hypophysis.
7. Chiasma opticum.
8. Bulbus olfactorius.
9. N. opticus.
10. N. oculomotorius.
11. N. trochlearis.
12. N. trigeminus. This trunk divides into three subdivisions, viz.,
- 12' N. ophthalmicus.
- 12'' N. maxillaris.
- 12''' N. mandibularis
13. N. abducens.
14. N. facialis.
15. N. acusticus.
16. N. glossopharyngeus.
17. N. vagus.
18. N. accessorius.
19. N. hypoglossus.
20. First spinal nerve.
21. A. cerebrospinalis.
22. A. spinalis ventralis.
23. A. basilaris.
24. A. cerebelli posterior.
25. A. carotico-basilaris.
26. A. cerebelli anterior.
27. A. carotis interna.
28. A. intercarotica.
29. A. cerebri profunda.
30. A. choroidea anterior.
31. A. communicans posterior.
32. A. cerebri media.
33. A. cerebri anterior. This either fuses with its fellow of the opposite side as in the present case, or is joined to it by a transverse branch called A. communicans anterior.
34. A. meningea anterior.
35. A. corporis callosi.
36. A. ethmoidalis See Pl. VIII, fig. 2.
37. Nasal branch of the A. ethmoidalis. See Pl. VII, fig. 2.



CWRedwood

PLATE VI a.

- 1 (Pl. VI, 21) A. cerebrospinalis.
- 2 (" ", 22) A. spinalis ventralis.
- 3 Rami medullares.
- 4 (Pl. VI, 23) A. basilaris.
- 5 (Pl. VI, 24) A. cerebelli posterior.
- 6 (" " 25) A. carotico-basilaris.
- 7 (" " 27) A. carotis interna.
- 8 (" " 28) A. intercarotica.
- 9 (" " 30) A. choroidea anterior.
- 10 (" " 31) A. communicans posterior.
- 11 (" " 32) A. cerebri media.
- 12 (" " 33) A. cerebri anterior.
- 13 (" " 34) A. meningea anterior.
- 14 (" " 35) A. corporis callosi.
- 15 (" " 29) A. cerebri profunda.
- 16 A. cerebri posterior (Not named in Pl. VI but are represented by the two small arteries immediately posterior to the hypophysis, No. 6).
- 17 (Pl. VI, 26) A. cerebelli anterior.

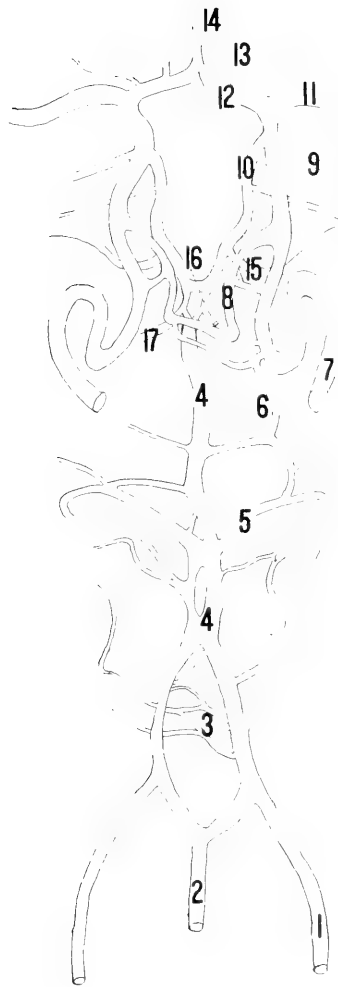




PLATE VII

FACIAL REGION IN PERSPECTIVE

1. P. M. levator nasolabialis, cut and turned aside.
2. M. levator labii superioris proprius.
3. 3'. M. dilator naris lateralis, cut and turned aside.
4. 4'. M. zygomaticus, cut and turned aside.
5. M. masseter.
6. M. buccinator.
7. M. depressor labii inferioris.
8. M. cutaneous faciei.
9. A. maxillaris externa.
10. A. labialis ventralis or inferior.
11. A. labialis dorsalis or superior.
12. A. lateralis nasi.
13. Small artery to nasal region.
14. A. dorsalis nasi.
15. A. angularis oculi.
16. Terminal branches of the A. palato-labialis. These branches anastomose with the dorsal nasal and the superior labial; they also give off branches to the upper lip and the nostrils.
17. V. maxillaris externa.
18. N. facialis.
19. N. infraorbitalis.
20. Ductus parotideus.
21. Tongue.
22. Caruncula sublingualis.

B. Bell. 21

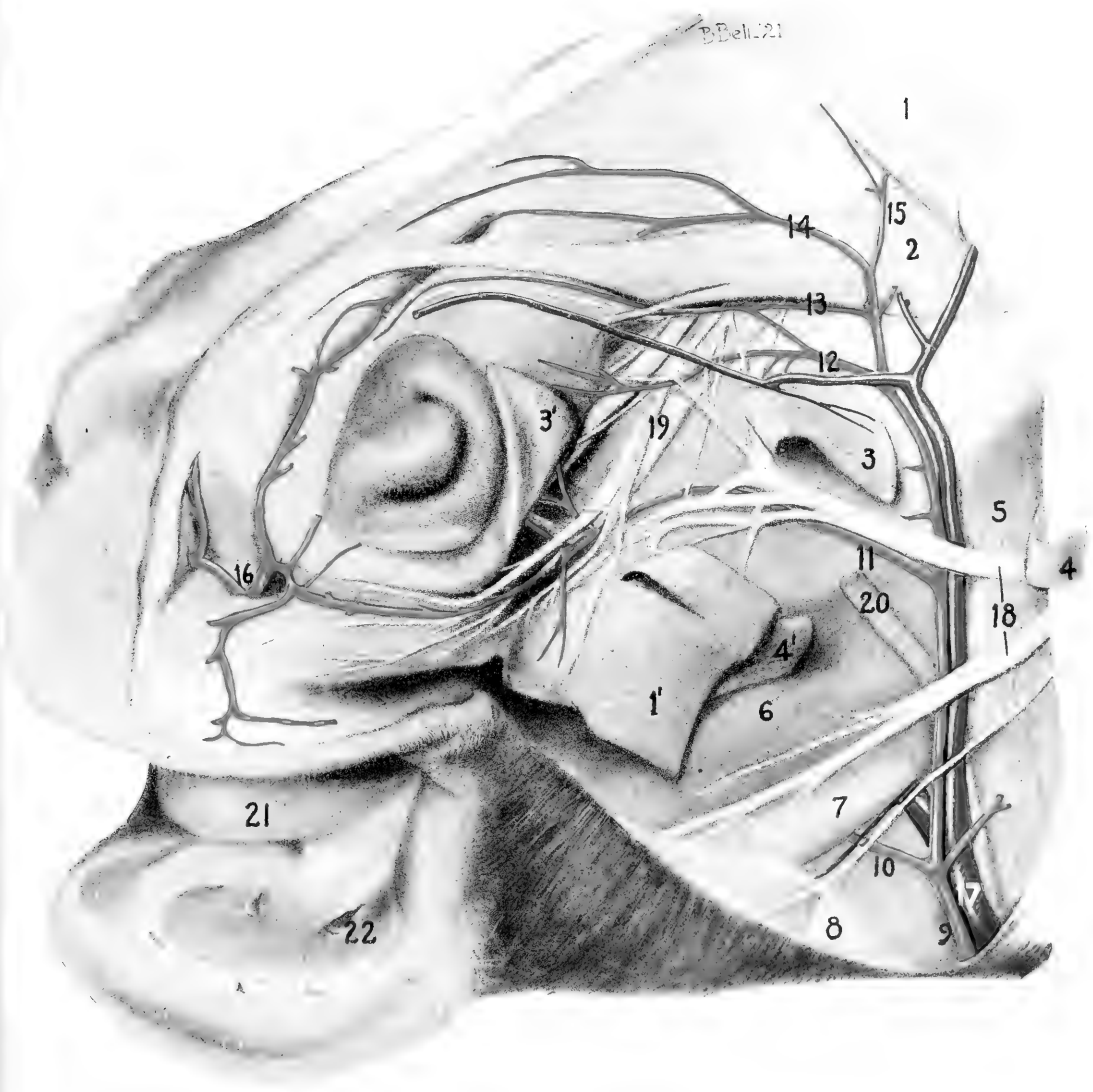




PLATE VIII

FIGURE 1.

1. Naris.
2. Tongue.
3. Mandible.
4. M. zygomaticus.
5. M. buccinator (a portion of this muscle has been removed to show the sublingual salivary gland).

6. M. masseter.
7. 7'. M. depressor labii inferioris.
8. Glandula sublingualis with its numerous ducts which open into the oral cavity.
9. A. maxillaris externa.
10. A. labialis ventralis or inferior.
11. A. angularis oris.
12. V. maxillaris externa.
13. 13', 13". Vv. labiales.
14. Ductus parotideus.
15. N. buccinatorius.
16. N. alveolaris inferior.

FIGURE 2.

1. Frontal sinus.
2. Ethmoid bone.
3. Fossa ethmoidalis. On the right side a portion of the frontal bone has been removed in order to show the extent of the ethmoid fossa and the blood vessels in it.
4. Portion of falk cerebri.
5. A. communicans posterior.
6. A. cerebri media.
7. A. cerebri anterior.
8. A. corpus calosi.
9. A. meningea anterior.
10. A. ethmoidalis.
11. 11', Rete ethmoidale.
12. Nasal branches of A. ethmoidalis.
13. Chiasma opticum.
14. Part of hypophysis.

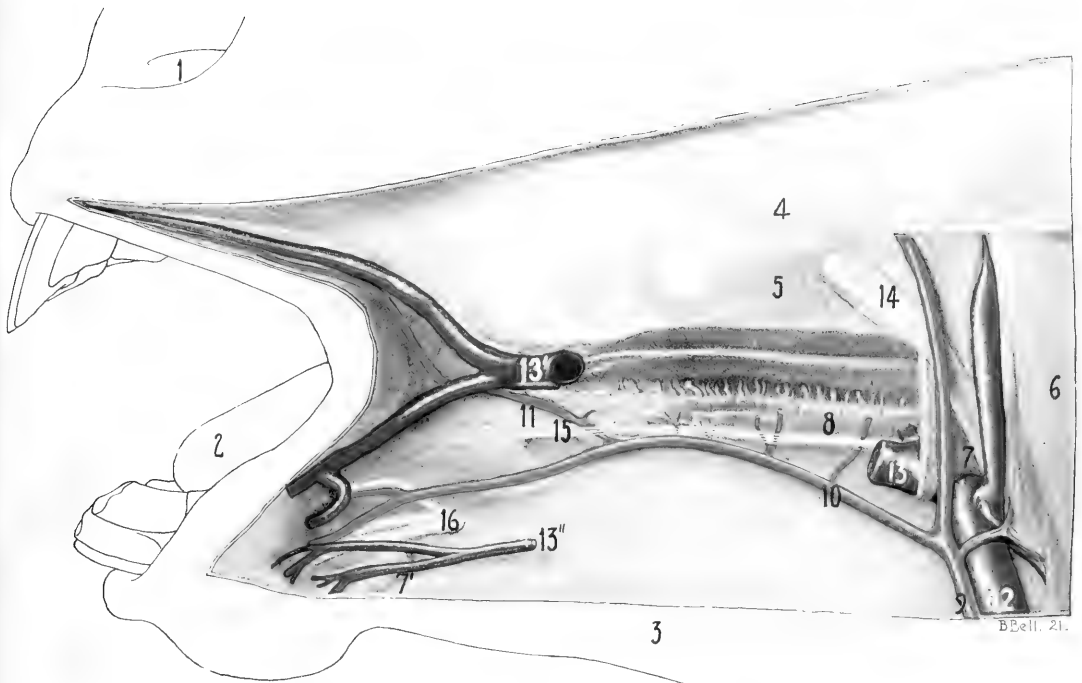


FIG. I

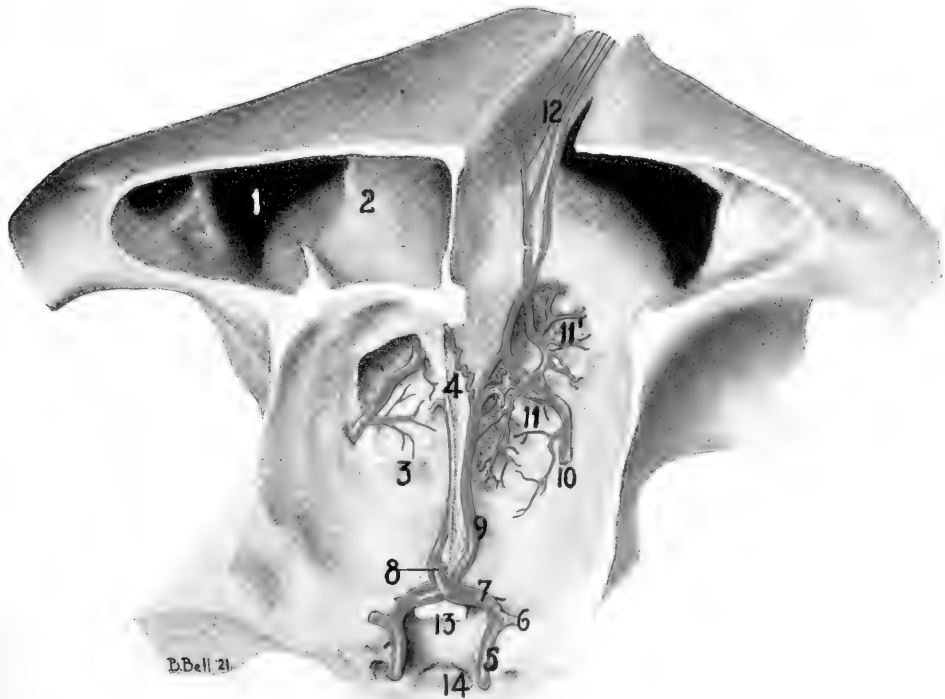
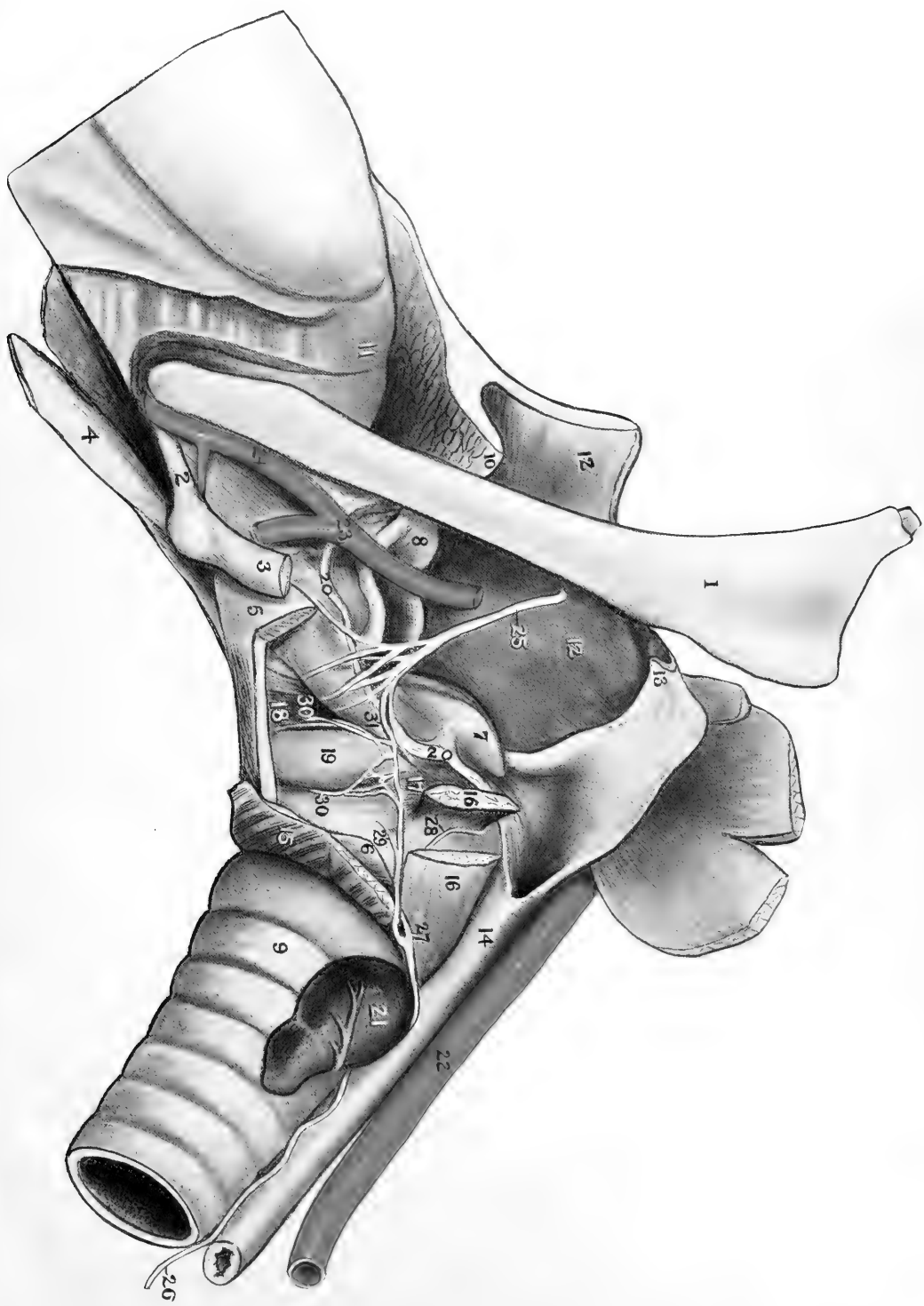


FIG. II

PLATE IX

1. Stylohyoid (great cornu).
 2. Ceratohyoid (small cornu).
 3. Thyrohyoid, end cut off (thyroid cornu).
 4. Glossohyoid (lingual process).
 5. Thyroid cartilage partially cut away.
 6. Cricoid cartilage.
 7. Arytenoid cartilage.
 8. Epiglottis.
 9. Trachea.
 10. Soft palate.
 11. Root of tongue.
 12. Pharyngeal wall turned back.
 13. Posterior pillar of soft palate.
 14. Oesophagus.
 15. M. cricothyroideus, cut.
 16. M. cricoarytenoideus dorsalis, cut and one end turned aside.
 17. M. cricoarytenoideus lateralis.
 18. M. ventriculatus (or part of the M. thyroarytenoideus).
 19. Laryngeal sacculæ.
 - 20, 20. Cut edge of pharyngeal mucous membrane.
-
21. Thyroid body.
 22. A. carotis communis.
 23. A. maxillaris externa.
 24. A. lingualis.
 25. N. laryngeus superior (sensory).
 26. N. laryngeus inferior (recurrent laryngeal) (Motor).
 27. Branch of the N. laryngeus inferior which supplies the cricoarytenoideus dorsalis and the arytenoideus transversus. The branch to the M. cricoarytenoideus dorsalis is not shown in the drawing. It is given off beneath the cricoarytenoideus dorsalis and immediately enters the deep face of the muscle. The branch to the M. arytenoideus transversus is No. 28.
 28. Branch of the N. laryngeus inferior to the M. arytenoideus transversus.
 29. Branch of the N. laryngeus inferior to the M. cricoarytenoideus lateralis.
 - 30, 30. Branches of the N. laryngeus inferior to the Mm. ventriculatus and vocalis.
 31. Communicating branch between the superior and inferior laryngeal nerves. (represented somewhat too large).






102



11-V-01142



LIBRARY OF CONGRESS



0 002 829 174 7