



This is a digital copy of a book that was preserved for generations on library shelves before it was carefully scanned by Google as part of a project to make the world's books discoverable online.

It has survived long enough for the copyright to expire and the book to enter the public domain. A public domain book is one that was never subject to copyright or whose legal copyright term has expired. Whether a book is in the public domain may vary country to country. Public domain books are our gateways to the past, representing a wealth of history, culture and knowledge that's often difficult to discover.

Marks, notations and other marginalia present in the original volume will appear in this file - a reminder of this book's long journey from the publisher to a library and finally to you.

Usage guidelines

Google is proud to partner with libraries to digitize public domain materials and make them widely accessible. Public domain books belong to the public and we are merely their custodians. Nevertheless, this work is expensive, so in order to keep providing this resource, we have taken steps to prevent abuse by commercial parties, including placing technical restrictions on automated querying.

We also ask that you:

- + *Make non-commercial use of the files* We designed Google Book Search for use by individuals, and we request that you use these files for personal, non-commercial purposes.
- + *Refrain from automated querying* Do not send automated queries of any sort to Google's system: If you are conducting research on machine translation, optical character recognition or other areas where access to a large amount of text is helpful, please contact us. We encourage the use of public domain materials for these purposes and may be able to help.
- + *Maintain attribution* The Google "watermark" you see on each file is essential for informing people about this project and helping them find additional materials through Google Book Search. Please do not remove it.
- + *Keep it legal* Whatever your use, remember that you are responsible for ensuring that what you are doing is legal. Do not assume that just because we believe a book is in the public domain for users in the United States, that the work is also in the public domain for users in other countries. Whether a book is still in copyright varies from country to country, and we can't offer guidance on whether any specific use of any specific book is allowed. Please do not assume that a book's appearance in Google Book Search means it can be used in any manner anywhere in the world. Copyright infringement liability can be quite severe.

About Google Book Search


Google's mission is to organize the world's information and to make it universally accessible and useful. Google Book Search helps readers discover the world's books while helping authors and publishers reach new audiences. You can search through the full text of this book on the web at <http://books.google.com/>

HC 2V6F /

HUMAN ANATOMY FOR ART STUDENTS

SIR ALFRED FRIPP & RALPH THOMPSON





t. 2968



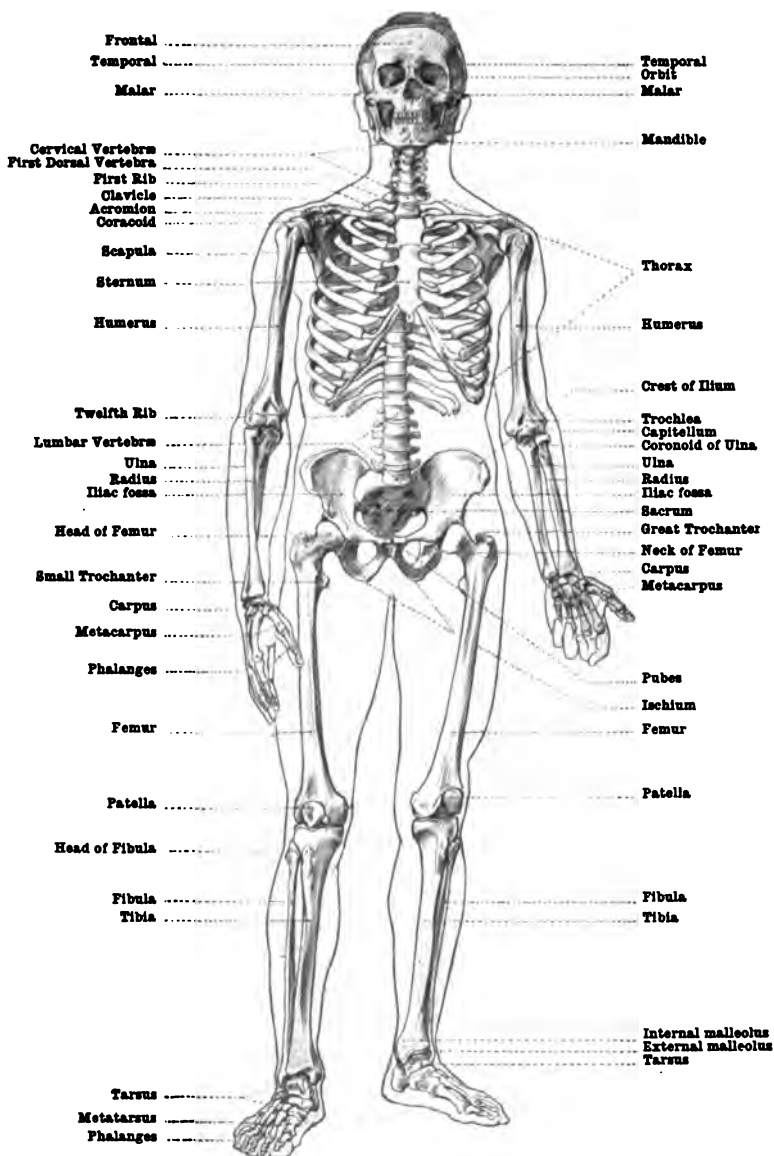


THE NEW ART LIBRARY

Edited by M. H. SPIELMANN, F.S.A., & P. G. KONODY

HUMAN ANATOMY FOR ART STUDENTS

*



FRONT VIEW OF MALE FIGURE

Human Anatomy

FOR

Art Students

BY

SIR ALFRED D. FRIPP, K.C.V.O., C.B.,

M.B., M.S. (LOND.), F.R.C.S. (ENG.)

Surgeon-in-Ordinary to H.M. the King.

Surgeon to, and lately Lecturer upon Anatomy at, Guy's Hospital.

AND

RALPH THOMPSON, M.B., CH.M., F.R.C.S. (ENG.)

Senior Demonstrator of Anatomy, Guy's Hospital.

WITH DRAWINGS BY

INNES FRIPP, A.R.C.A. (LOND.)

Life-Master, South London Technical Art School, City Guilds.

AND AN APPENDIX ON COMPARATIVE ANATOMY BY

HARRY DIXON, M.S.B.S.

With 151 Illustrations

PHILADELPHIA

J. B. LIPPINCOTT COMPANY

LONDON: SEELEY AND CO. LIMITED

1911

INTRODUCTION

THE object of this book is to give the shortest description of human anatomy compatible with the interests of the artist and essential for his work, and to burden his mind as little as possible with names, with technicalities, and with those details which do not bear directly upon the surface forms.

It is, unfortunately, impossible to save the art student from the difficulties of the nomenclature employed in anatomy. Attempts made from time to time to simplify it have been found to impair the accuracy and clearness of the necessary descriptions, and have by common consent of teachers been abandoned.

Further, inasmuch as the subject-matter is to a large extent made up of hard facts, the task of remembering a string of these confronts the student as soon as he has mastered the nomenclature, with the result that the beginner usually finds the study of anatomy dull and prosaic as well as difficult. The superficial knowledge required for use in the studio seldom leads the student into those higher realms where the study of anatomy becomes fascinating and suggestive, as indicated in some of the later chapters and in the Appendix upon Comparative Anatomy.

The names allotted to many of the structures, especially to the muscles, are long and cumbrous;

INTRODUCTION

and many of the expressions used, *e.g.* "above," "below," "internal," "external," are employed in a more precise or more technical sense than that attributed to them by the layman. For instance, nobody but an anatomist would take exception to the common description of an overcoat as being worn "outside" the other clothes, or of the husk as lying "outside" the nut. The anatomical purist, on the other hand, would in each case substitute the term "superficial to," and the student, if he would keep his mental view of anatomy clear, however limited, must be urged to become a purist in the application of such technical terms as he is called upon to use.

In anatomical description the subject is always supposed to be standing in the position of "attention," the face looking straight towards the student, the upper limbs hanging by the side, with the palms of the hands to the front. Whatever may be the actual position of the subject under study, the terms **Above** or superior to, **Below** or inferior to, **Anterior** or in front, **Posterior** or behind, **Internal** or medial, **External** or lateral, **Proximal** or nearer to the axis, in distinction from **Distal** or further removed from the axis, are applied in such a way that they would be true if the "attention" position were resumed by the subject or model.

The human body is divided, for purposes of anatomical description, into various parts; and each of these is made up of several tissues or systems.

After giving an account of the skeleton, with its joints and ligaments, we shall proceed to a description of the various soft structures which clothe the skeleton.

Then the four **parts** into which the body is divided

INTRODUCTION

will each claim a chapter, and these will be taken in the following order :—

1. *The upper extremity*, including shoulder, axilla, arm, elbow, forearm, wrist, hand, and digits or fingers.

2. *The lower extremity*, including buttock, groin, thigh, knee, leg, ankle, foot, and digits or toes.

3. *The trunk*, including back, thorax, abdomen, and pelvis.

4. *The head and neck*.

The systems of which these parts are built up are the *osseous* system or *skeleton*; the *ligamentous* system of fibrous tissue, whose chief function is to bind the bones together; the *muscular* system; the *nervous*, the *blood-vascular*, and the *epithelial* systems. Of the last two examples may be readily seen without dissection, namely, the skin which covers the body generally, and the mucous membrane which lines the internal surface of all the hollow viscera, such as the lungs, stomach, and intestines, but is modified in its appearance in different organs, and is notable only in the undissected subject as the covering of the red part of the lips and mouth and of the eyeball and nostrils.

A full knowledge of anatomy embraces all these parts and all the systems which build them up, and much more besides, such as embryology or the study of development from the embryo, histology or microscopical anatomy, and comparative anatomy or the science which compares the anatomy of all the different members of the animal kingdom, and of this branch a short sketch is given in the Appendix.

Physiology, the science of the functions of each organ in health, and pathology, the science of disease, will also occasionally call for notice in any such

INTRODUCTION

attempt as this book makes to rivet the attention of the artist upon those details in structure and function upon which depends the external appearance. The chief objects of his study will be the bones, muscles, skin, and hair, with the variations of form and colour which may take place in these systems under different conditions of age, sex, race, activity or repose, occupation, and emotion.

The latter is a very important subject and claims a chapter to itself. To deal at all adequately with its intricacies would need a volume. Though the expression of the emotions is chiefly apparent in the face, yet all the other parts of the body, and especially the limbs, may contribute appropriate movements or gestures. We recognise, for instance, the tottering lower limbs of the fear-stricken, the swagger of the arrogant, and the crouching gait of the coward, as gestures which indicate the condition of the affected person almost as much as, and indeed sometimes more than, does the facial expression.

In other words, certain attitudes of the anatomical parts are liable to be associated with, and so to convey to the observer, the various mental and physical states of the individual, whence the claim of the subject to be included in the science of anatomy.

For the assumption of any attitude is consequent upon the passing into action or repose of some definite muscles or groups of muscles. The contraction of any muscle causes a difference in the contour of the skin covering it; usually, but not always, the skin becomes prominent over those muscles which are in action, and *vice versa*. For instance, when the elbow is forcibly bent, the shape of the front of the upper arm is considerably altered in comparison

INTRODUCTION

with its appearance in the passive position. The alteration is due to the fact that the large Biceps muscle has contracted and has produced a rounded prominence.

At the joints, again, there is great variation in shape in the different positions assumed by the limbs. This is well seen in the case of the knee. When the model forcibly straightens the leg the patella or knee-cap is seen very distinctly, and so are the component parts of the quadriceps extensor muscle in its neighbourhood. When the knee is bent, the patella, having sunk between the condyles of the femur, is scarcely visible, though it may still be easily felt; and while the flexor tendons or hamstrings now stand out prominently, the component parts of the quadriceps can no longer be clearly identified.

But however noteworthy the effects of muscular action upon the surface-form of the body, there are, as already indicated, other factors to be studied.

The alterations that take place with advancing years are due to several causes, and to these a separate chapter has been devoted. Such conditions as are associated with premature old age are akin to those of disease, and are of greater interest to the student of medicine than to the artist. The artist, however, at times depicts his subjects in age or infirmity, and therefore an attempt will be made to indicate the more obvious of these conditions.

At the end of the book we have included a short series of photographic reproductions. These are designed to demonstrate points mentioned in the text, and it is hoped that they will be particularly useful to those students who find themselves prevented from attending at a life school while studying anatomy.

INTRODUCTION

Constant reference from the text to the illustration and to the actual model is most desirable. Such knowledge and appreciation of the details of this laborious science as is evinced by the work of Leonardo da Vinci and Michael Angelo, to mention only two of the greatest among the many great depicitors of the beauty of the human form, can only be acquired by many years of close and devoted study. Yet even these great ones must have experienced, during their novitiate, as we do nowadays, that sense of dejection in the presence of unexpected difficulties which bars the threshold of the study of each of the sciences.

Let the student be cheered by the realisation that such dejection is unreasonable, in that the same difficulties have appeared just as great to, and yet have been overcome successfully by, countless numbers of students before us. And it is worth while to overcome them; for the more knowledge we have of anatomy, the greater will be our appreciation of the beauties of the human form, and the greater our possibilities of portraying those beauties; to appreciate all that is conveyed in a work of art, one must know what to look for.

CONTENTS

INTRODUCTION	ix
I. THE SKELETON	33
II. THE COVERINGS OF THE BODY	65
III. THE REGIONS OF THE BODY	70
IV. THE UPPER EXTREMITY	73
V. THE LOWER EXTREMITY	103
VI. MOVEMENTS OF THE JOINTS OF THE UPPER EX- TREMITY	146
VII. MOVEMENTS OF THE JOINTS OF THE LOWER EX- TREMITY	153
VIII. THE TRUNK	157
IX. THE HEAD AND NECK	179
X. EXPRESSION AND GESTURE	234
XI. DIFFERENCES OF SIZE AND PROPORTION IN THE SEXES	252
XII. GROWTH, DEVELOPMENT, AND MEASUREMENTS	259
APPENDIX	267
INDEX	287

LIST OF ILLUSTRATIONS

PLATES

FRONT VIEW OF MALE FIGURE . . .	<i>Frontispiece</i>
I. FRONT VIEW OF MALE SKELETON	24
II. FRONT VIEW OF FEMALE SKELETON	25
III. BACK VIEW OF MALE SKELETON	26
IV. LATERAL VIEW OF MALE SKELETON	27
V. MUSCLES OF THE BODY (FRONT VIEW)	28
VI. MUSCLES OF THE BODY (BACK VIEW)	29
VII. MUSCLES OF THE BODY (LATERAL VIEW)	30
VIII. MUSCLES OF THE FACE, HEAD, AND NECK	31

REPRODUCTIONS FROM PHOTOGRAPHS TAKEN FROM LIFE

These will be found at the end of the book after the Index

IX. FRONT VIEW OF MALE FIGURE, STANDING ALERT AND READY	3
X. FRONT VIEW OF FEMALE FIGURE	7
XI. BACK VIEW OF MALE FIGURE AT "ATTENTION"	11
XII. BACK VIEW OF FEMALE FIGURE	15
XIII. FIGURE OF A MAN STRAINING HIS MUSCLES	19

LIST OF ILLUSTRATIONS

XIV. FIGURE OF A WOMAN IN SLIGHTLY FLEXED POSITION	23
XV. CHILDREN	27
XVI. FRONT VIEW OF MALE FIGURE STRETCHING	31
XVII. BACK VIEW OF MAN LOOKING UPWARDS	35
XVIII. FIGURE OF A WOMAN STOOPING	39
XIX. FIGURE OF A MAN CROUCHING	43
XX. FIGURE OF MAN RESTING ON OUTSTRETCHED ARM	43
XXI. FIGURE OF A MAN IN THE "READY" POSITION	47
XXII. FIGURE OF A MAN WITH BOWED HEAD	51
XXIII. BUST OF WOMAN WITH CHIN DEPRESSED	55
XXIV. FRONT VIEW OF MAN STRAINING HIS NECK BACKWARDS	59
XXV. SIDE VIEW OF MAN STRAINING HIS NECK BACK- WARDS	59
XXVI. FIGURE OF THE LEGS OF MAN	63
XXVII. THREE STUDIES OF THE MALE LOWER EX- TREMITIES	67
XXVIII. THREE STUDIES OF THE MALE LOWER EX- TREMITIES FROM BEHIND	71
XXIX. OUTSTRETCHED ARM, BACK VIEW IN STATE OF STRAIN	75
XXX. OUTSTRETCHED ARM, FRONT VIEW IN STATE OF RELAXATION OF MUSCLES	75
XXXI. FIGURE OF A WOMAN SITTING	79

LIST OF ILLUSTRATIONS

FIGURES AND DIAGRAMS

1. THE CLAVICLE AND SCAPULA OF THE RIGHT SIDE, WITH THE STERNUM. FROM THE FRONT . . .	35
2. THE SCAPULA AND CLAVICLE OF THE RIGHT SIDE. FROM THE BACK	36
3. THE RIGHT HUMERUS. FRONT VIEW	38
4. THE FRONT OF THE UPPER EXTREMITY, SHOWING THE "CARRYING ANGLE" BETWEEN ARM AND FORE- ARM	39
5. THE BONES FORMING THE ELBOW JOINT. BACK VIEW	40
6. THE RIGHT ULNA AND RADIUS. FRONT VIEW	40
7. THE BONES OF THE WRIST AND HAND. FRONT VIEW	43
8 AND 9. MALE AND FEMALE PELVIS	45
10. RIGHT FEMUR. FRONT VIEW	48
11. RIGHT FEMUR. BACK VIEW	48
12. THE LOWER END OF THE FEMUR	51
13. BONES OF RIGHT FOOT. INNER SIDE	53
14. BONES OF RIGHT FOOT. OUTER SIDE	53
15. ANTERO-LATERAL VIEW OF SKULL (ADULT)	55
16. SKULL OF YOUNG CHILD	56
17. FRONT VIEW OF SKULL (ADULT)	56
18. SIDE VIEW OF SKULL (ADULT)	58
19. THE BACK OF THE NECK, UPPER PART OF THE TRUNK AND ARM	74
20. THE MUSCULAR PROMINENCES ON THE BACK OF THE TRUNK, BUTTOCK, AND NECK	75
21. THE MUSCLES ON THE BACK OF THE TRUNK, BUTTOCK, AND NECK	76
22. THE OUTER SIDE OF THE UPPER EXTREMITY	77

LIST OF ILLUSTRATIONS

23. THE MUSCLES OF THE SHOULDER	78
24. THE MUSCLES OF THE INNER SURFACE OF THE ARM AND OF THE ARMPIT	79
25. THE MUSCLES ON THE FRONT OF THE TRUNK AND NECK	80
26. THE MUSCLES AND SUPERFICIAL VEINS ON FRONT OF ARM AND ELBOW	81
27. THE MUSCULAR PROMINENCES ON THE FRONT OF THE TRUNK AND NECK	83
28. THE FRONT AND INNER SIDE OF THE UPPER EX- TREMITY	84
29. THE OUTER SIDE OF THE RIGHT UPPER EXTREMITY .	85
30. MUSCLES ON THE BACK AND OUTER SIDE OF THE ELBOW JOINT	86
31. THE OUTER SIDE OF THE UPPER EXTREMITY, WITH INDICATION OF THE VARYING SHAPE OF TRANS- VERSE SECTIONS AT DIFFERENT LEVELS	88
32. THE BACK OF THE FOREARM AND HAND	89
33. MUSCLES AND SUPERFICIAL VEINS ON FRONT OF FORE- ARM	89
34. MUSCLES ON BACK OF FOREARM	90
35. RIGHT UPPER EXTREMITY. SURFACE MARKINGS OF MUSCLES, TENDONS, AND SUPERFICIAL VEINS	91
36. THE CREASES UPON THE FRONT OF THE HAND AND DIGITS	93
37. THE DEEP PALMAR FASCIA	94
38. THE SHORT MUSCLES OF THE HAND	94
39. SHOWING FORMATION OF CREASES OR "LINES OF FLEXION" IN THE SKIN OF THE HAND AND DIGITS	96

LIST OF ILLUSTRATIONS

62. THE MUSCLES ON THE BACK OF THE TRUNK, BUTTOCK, AND NECK	158
63. THE MUSCULAR PROMINENCES ON THE FRONT OF THE TRUNK AND NECK	159
64. THE MUSCLES ON THE FRONT OF THE TRUNK AND NECK	165
65. MUSCULAR AND BONY SURFACE MARKINGS OF NECK, TRUNK, AND ARM	166
66. THE MUSCLES OF THE INNER SURFACE OF THE ARM AND OF THE ARMPIT	167
67. LATERAL VIEW OF NECK. MASSIVE TRAPEZIUS	180
68. THE SURFACE MARKINGS OF THE SIDE AND FRONT OF THE NECK	181
69. FURROWS AROUND MOUTH. THIN LIPS. DOUBLE CHIN	182
70. THE SURFACE MARKINGS ON THE NECK OF AN OLD MAN. FRONT VIEW	183
71. THE SURFACE MARKINGS ON THE NECK OF AN OLD MAN. SIDE VIEW	183
72. THE LARGE THYROID GLAND IN A GIRL'S NECK	185
73. THE MUSCLES OF THE SIDE AND FRONT OF THE NECK	187
74. NECKLACE-LIKE CREASES IN FRONT OF NECK OF YOUTH	188
75. HEAD AND FACE OF AN OLD MAN	190
76. BACK OF BOY'S NECK, SHOWING MEDIAN FURROW	196
77. CREASES SEEN ON BACK OF EXTENDED NECK	197
78. MUSCLES OF SIDE OF HEAD, FACE, AND NECK	205
79. TEMPORAL MUSCLE. ZYGOMA CUT AWAY	206
80. SURFACE MARKINGS UPON A THIN FACE AND NECK	207
81. FIGURE TO SHOW PROPORTIONS OF FACE AND NECK	207
82. THE PALPEBRAL APERTURE, EYELIDS, AND EYEBROWS	210

LIST OF ILLUSTRATIONS

83. THE ANGLE FORMED BY THE COLUMNA NASI WITH THE UPPER LIP	220
84, 85, 86. VARIOUS TYPES OF NOSE	221
87. NOSTRILS AND MOUTH	224
88. DIMPLED FACE OF SMILING CHILD	224
89, 90. MOUTH AND CHIN	226
91. FURROWS AROUND MOUTH, CHIN, AND NECK	227
92. HEAD AND NECK OF BABY	228
93. CHILD SUCKING THUMB	228
94. DIFFERENT TYPES OF EAR	229
95. MUSCLES OF SIDE OF HEAD, FACE, AND NECK	233
96. SORROW	243
97. DEJECTION	244
98. TERROR	245
99. ANGER	247
100. SELF-APPRECIATION	248
101. SUSPICION	249
102. ANTICIPATION	250
103. FIGURE OF A FEMALE SKELETON	253
104. TO SHOW THE PROPORTIONS OF THE MALE BODY	255
105. TO SHOW THE CHARACTERISTIC POSITION OF THE HEAD, BODY, AND LIMBS OF A CHILD WHO IS LYING DOWN	256
106. CHILD. SIDE VIEW.	257
107. TO SHOW THE ATTITUDE AND PROPORTIONS OF AN INFANT WHO IS LEARNING TO WALK	263
108. THE GAIT OF AN OLD MAN	265
109-131. COMPARISON OF THE STRUCTURE OF MAN AND THE LOWER ANIMALS	267-284

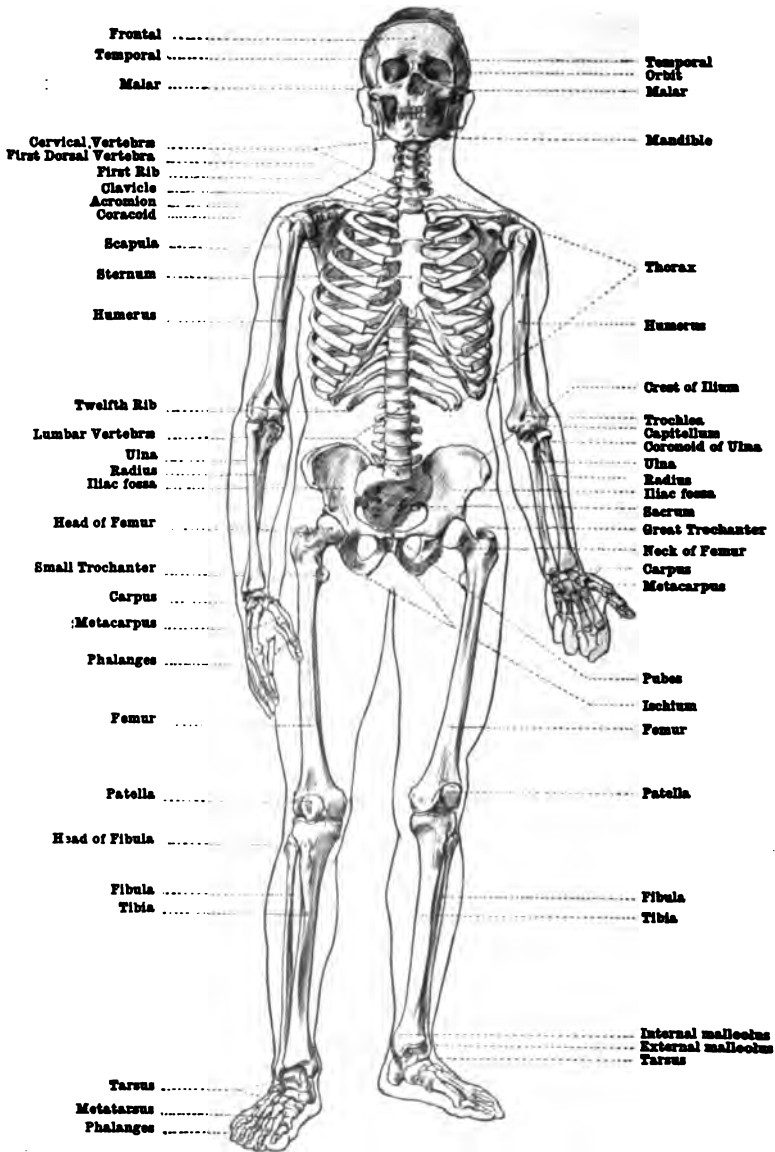


PLATE I.—FRONT VIEW OF MALE SKELETON
 Right Forearm Pronated ; Left Forearm Supinated

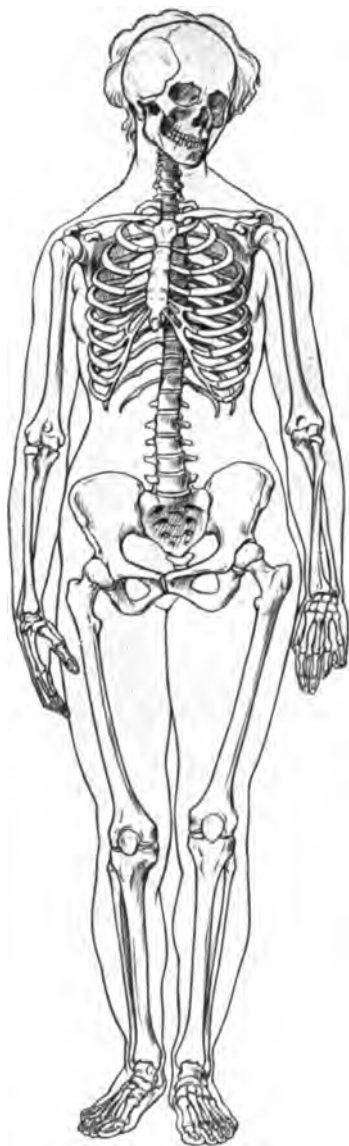

PLATE II.—FRONT VIEW OF FEMALE SKELETON

Figure of a Female Skeleton, showing the characteristic narrow thorax, broad pelvis, and increased degree of "knock knees," as compared with the Male.
The general slenderness of the bones should also be noted.

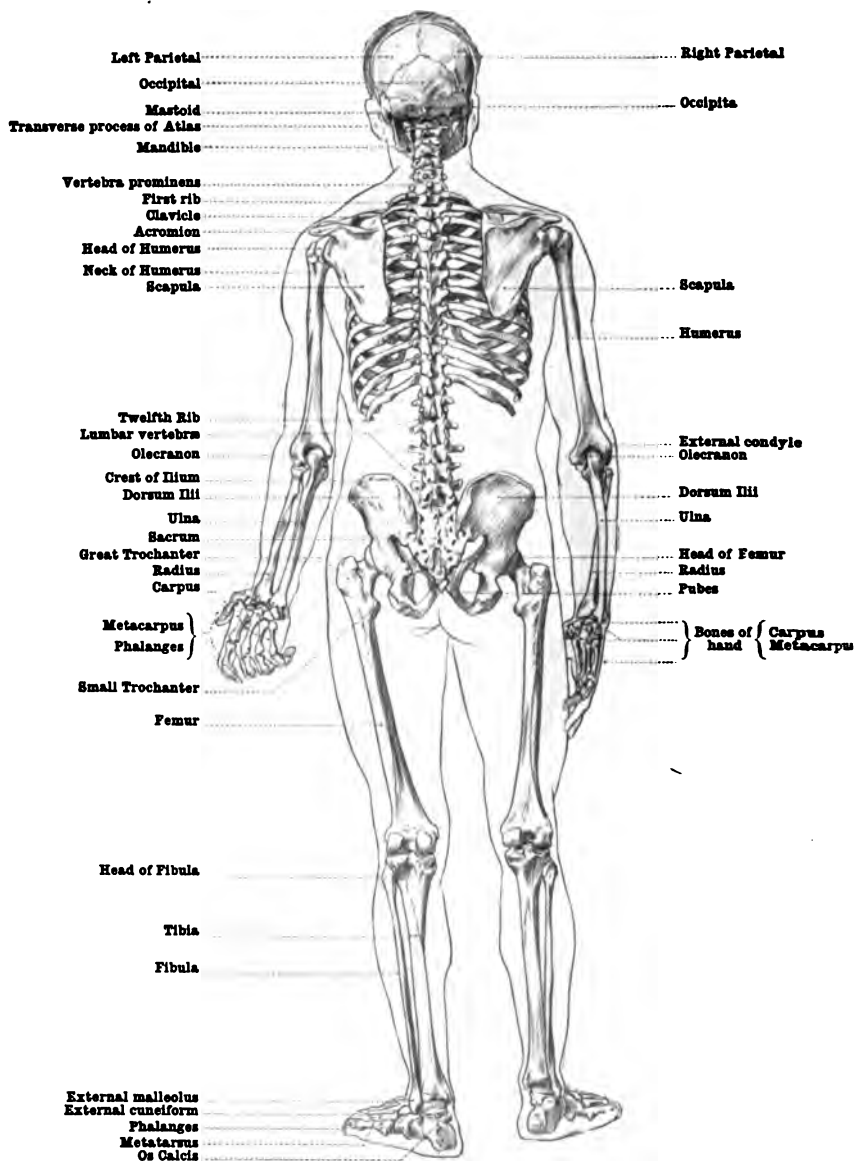


PLATE III.—BACK VIEW OF MALE SKELETON

Right Forearm Pronated; Left Forearm Supinated

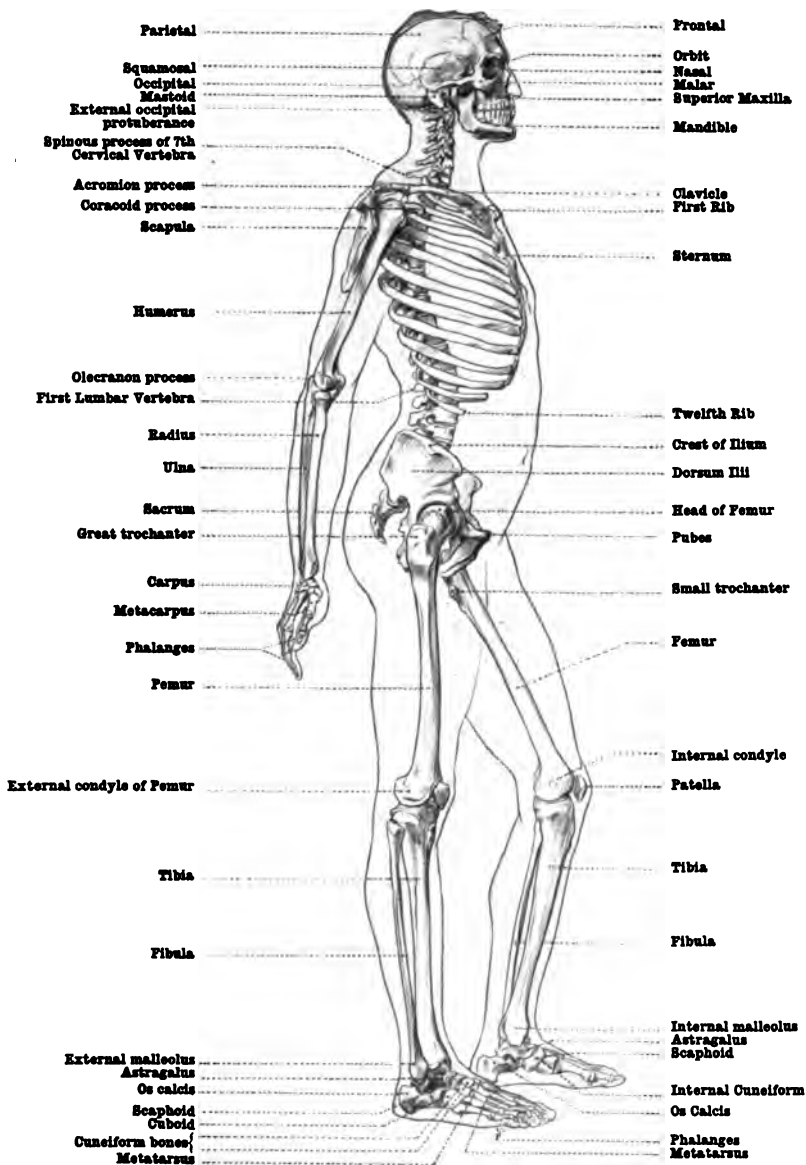


PLATE IV.—LATERAL VIEW OF MALE SKELETON

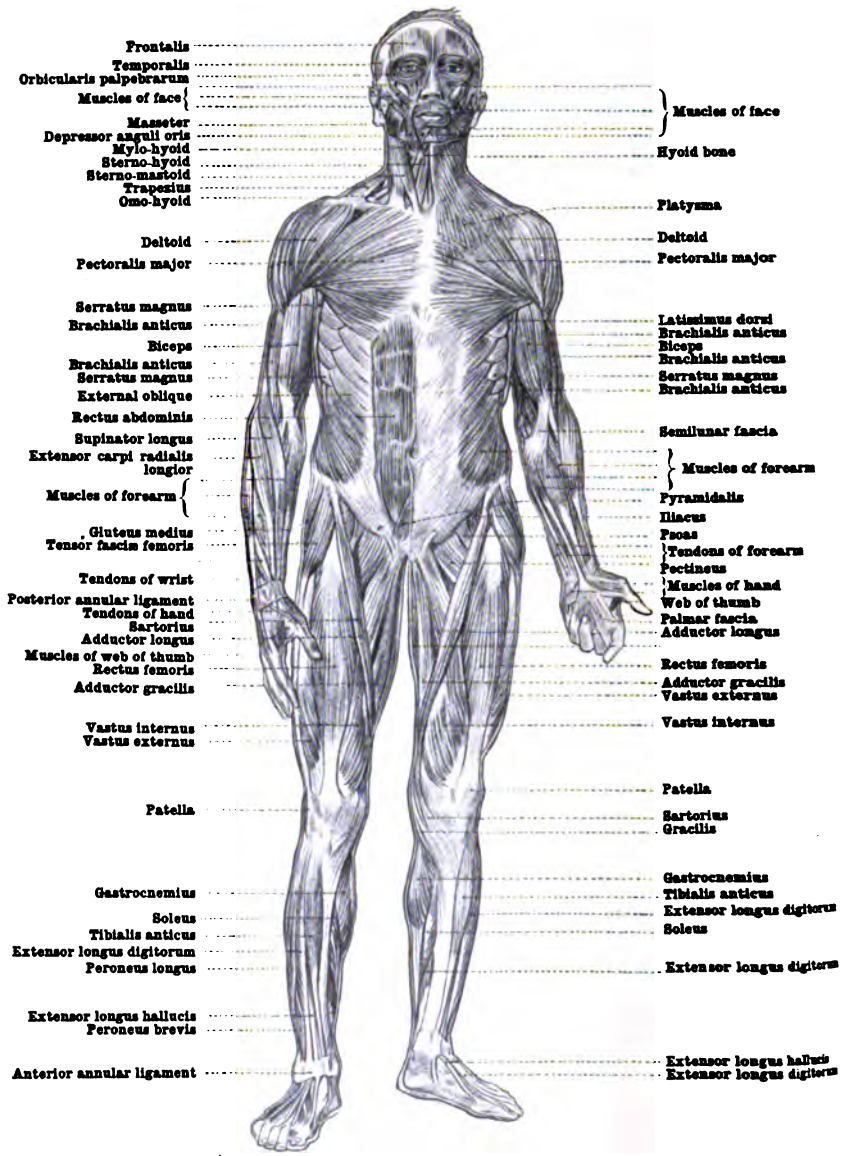


PLATE V.—MUSCLES OF BODY (Front View)

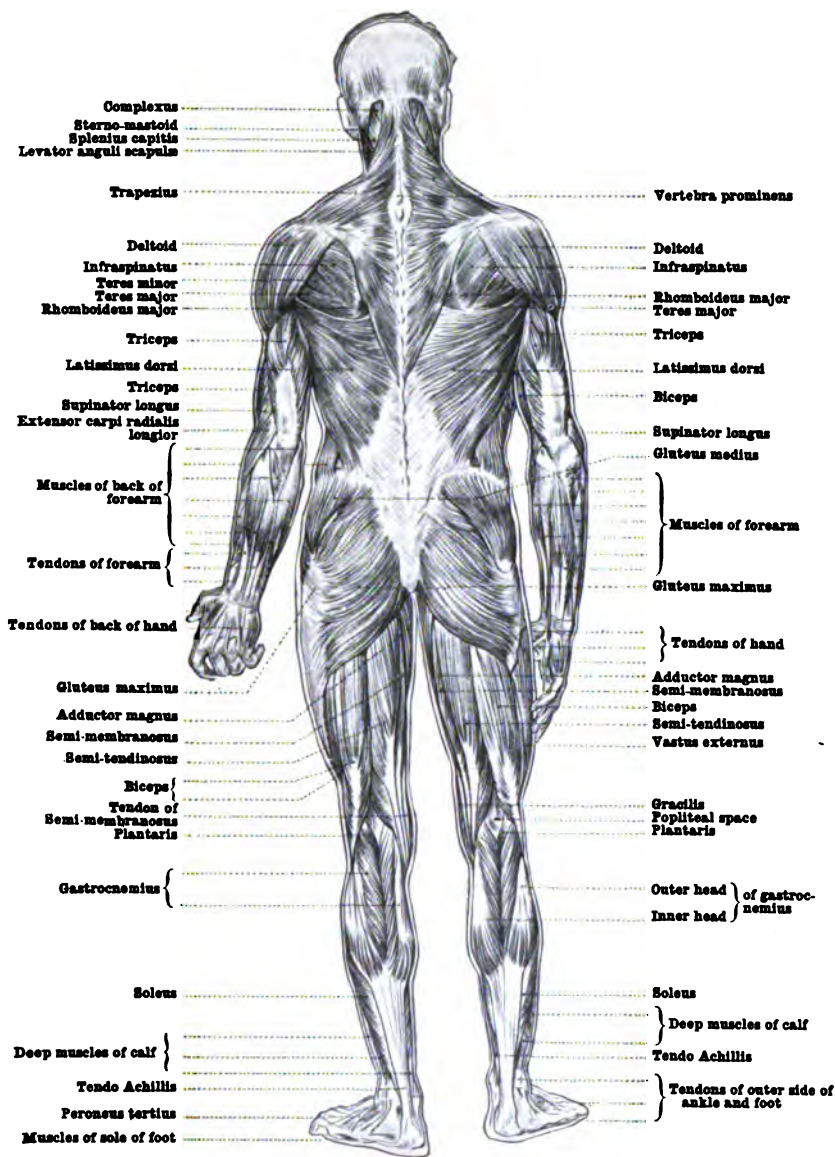


PLATE VI.—MUSCLES OF BODY (Back View)

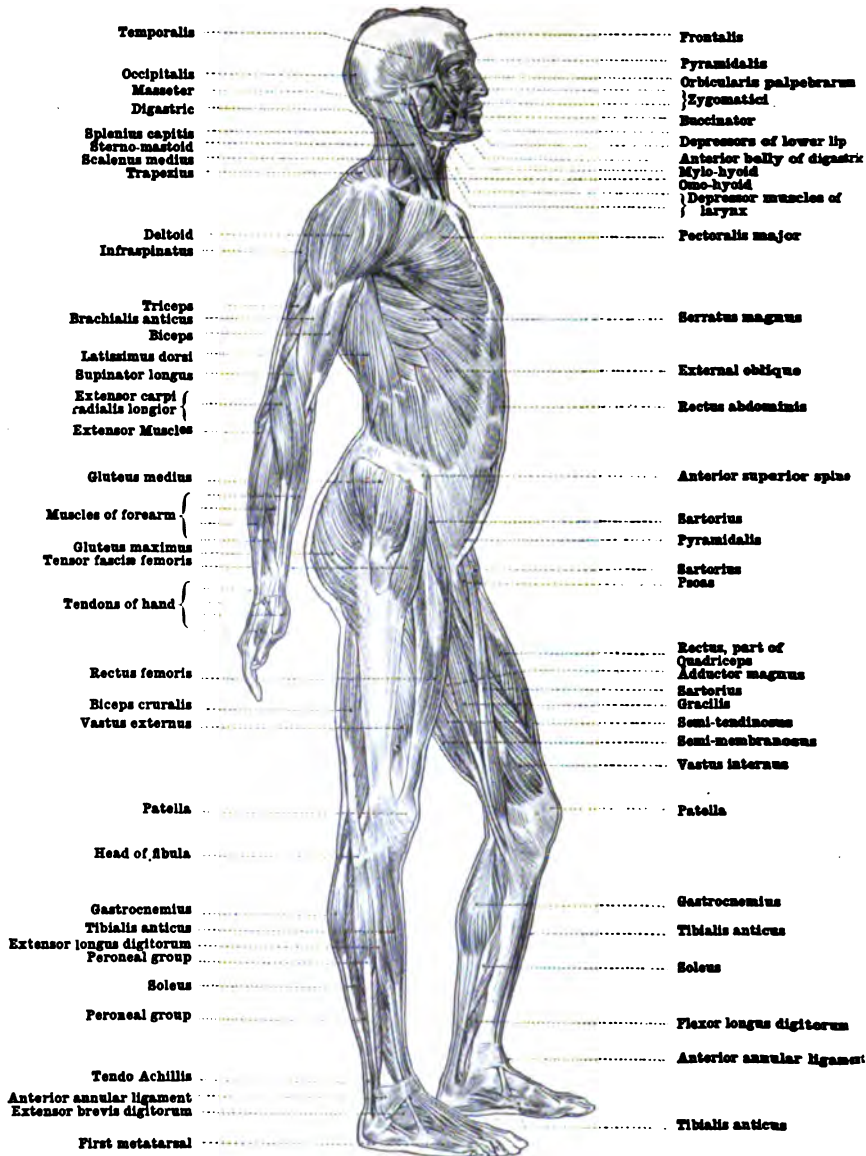


PLATE VII.—MUSCLES OF BODY (Lateral View)

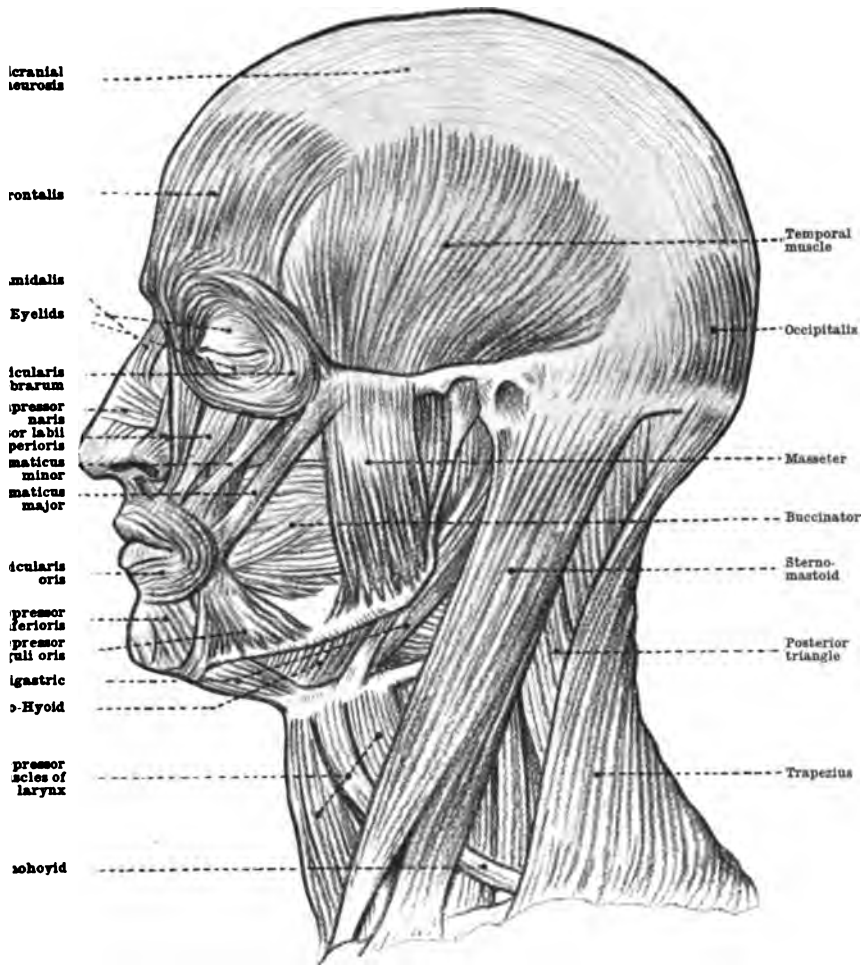


PLATE VIII.—MUSCLES OF THE FACE, HEAD, AND NECK

HUMAN ANATOMY FOR ART STUDENTS

CHAPTER I

THE SKELETON

No bone is either quite rigid or quite straight. The elasticity (which is greater in the young) and the curves found in every bone are obviously adapted to increase its strength.

The skeleton of the adult is built up of almost rigid bones, and the length of each bone is slightly increased by a layer of less rigid cartilage, forming a kind of buffer at each end. In addition, within certain of the joints, actual cushions of fibro-cartilage intervene between the ends of the bones.

There are various forms of bone. The femur, or thigh-bone, may be taken as an example of the *long bone*, while the spine, wrist, and ankle are composed of *short bones*. The scapula, or shoulder-blade, and the frontal, or forehead bone, are good examples of the *flat bone*.

The stature of any individual depends chiefly upon the length of the long bones of the lower limb and of the short bones of the spinal column.

1. The long bones should be regarded as mechanical "*levers*"; every muscular action may be interpreted as a power or force applied to such a part of the bar or bone as to overcome a definite weight or resistance, and so to produce movement about a fixed point or fulcrum.

THE SKELETON

2. The short bones will plainly be less liable to fracture, and the multiplication of the cartilaginous and articulating surfaces will, of course, result in the better breaking of jars and increased mobility. Thus, if the spine were a single rigid long bone, its relation to the cranium would be that of the broom-handle to the broom-head, and the effect of a blow upon the other end, as when one sits down with a jerk, would be to drive the neck into the base of the skull, just as the handle of the broom is driven into the broom-head.

3. The flat bones are generally protective; thus the flat bones of the vault of the skull protect the delicate brain which lies in the cranium, and the flat bones on each side of the pelvis, known as the hip-bones or ossa innominata, afford protection to important viscera. In addition, flat bones provide an extensive attachment for strong muscles. Chewing or mastication, which is one of the most powerful and one of the most fundamentally important movements in the body, is brought about by the very strong muscles inserted into the jaw, which have an extensive origin from the flat bones of the cranium. In like manner the movements of the humerus are partly caused by muscles which arise from broad areas of the scapula.

A muscle is said to "arise or take origin" from that end which usually is fixed when the muscle acts, and its "insertion" is that end which usually moves most.

The femur is the longest bone in the body; the next longest are the bones of the leg and arm and forearm, some of the ribs, and then the clavicle.

The bones of the upper limb comprise:—

1. The clavicle, or collar-bone.
2. The scapula, or shoulder-blade.

THE SKELETON

3. The humerus, or bone of the arm.
4. The ulna, the inner bone of the forearm.
5. The radius, the outer bone of the forearm.
6. The carpals or bones of the wrist.
7. The metacarpals or bones of the palm of the hand.
8. The phalanges or bones of the digits.

1. The clavicle (Fig. 1) is situated in the front part of the thorax or chest, where the trunk merges into the neck.

At its inner extremity it is joined to the sternum (breast-bone) by the sterno-clavicular joint. The inner ends of the right and left clavicles are about an inch apart. The outer extremity of the clavicle touches the acromion process of the scapula in the acromio-clavicular joint, and is situated

at a somewhat higher level than the inner end (Fig. 1). This is the case even with people whose shoulders slope in a very marked degree.

The clavicle has its curves so arranged that there is a convexity forward in the inner part, for rather more than half the length of the bone, and a concavity forward in the outer part, for rather less than half. It is thicker and more prominent internally than externally: a cross section made through the internal half is triangular; through the external half it is flattened from above downwards.

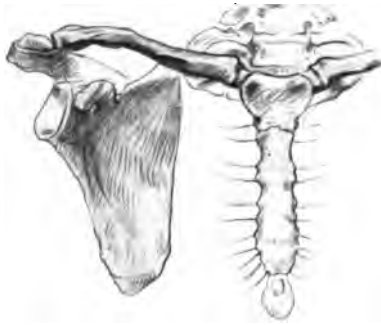

Fig. 1.—The Clavicle and Scapula of the Right Side, with the Sternum. From the front.

THE SKELETON

In the clavicle, as in all other long bones, the degree of its roughness gives a fair indication of the muscularity of the individual.

The clavicle is a bone of high importance to the student of anatomy. It forms a very prominent landmark, easily seen in thin people. In well-covered and muscular subjects, however, it lies at the bottom of a furrow, a situation common in many other parts of the body, *e.g.* the external condyle of the humerus and the great trochanter of the femur, a dimple indicating the position of a bone which in the skeleton appears to be prominent.

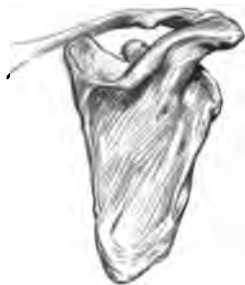

Fig. 2.—The Scapula and Clavicle of the Right Side. From the back.

The clavicle, unlike the other long bones, continues to increase much in length between the ages of twenty and twenty-five years, and thus produces, during this period, a great increase in the breadth of the shoulders, an increase which constitutes one of the chief characteristics distinguishing the adolescent boy

from the adult man.

2. The scapula (Fig. 2) is chiefly visible upon the upper part of the back of the trunk, but two of its “processes” are apparent from the front of the skeleton, namely, the acromion, which makes the point of the shoulder, and the coracoid, which is covered by thick muscles, but in the wasted subject can be seen under the skin below the outer part of the clavicle.

It is a triangular flat bone having *two surfaces* :—

a. The front or ventral surface, applied to the ribs

THE SKELETON

over the back of the thorax, from the second to the seventh.

b. The hinder or dorsal surface, overlaid by the muscles and skin of the back.

Three borders :—

a. The upper.

b. The mesial, vertical, or vertebral.

c. The external, oblique, or axillary (lying in relation to the axilla or armpit).

And three angles :—

a. The superior.

b. The inferior, which is prominent in persons who are "round-shouldered."

c. The external, sometimes called the head of the scapula, which, with the head of the humerus and the connecting ligaments, forms the shoulder-joint.

The three processes of the scapula are :—

a. The spine or spinous process (Fig. 2, p. 36). This is a well-marked bony ridge which projects backwards from the dorsal surface. It begins internally at the junction of the upper and second quarter of the vertebral border, and becomes more prominent externally, where it terminates in the second process.

b. *The acromion process.* This is flattened and directed forwards, upwards, and outwards, to form the point of the shoulder. The acromion process has two borders, of which the inner one enters, with the external end of the clavicle, into the formation of the acromio-clavicular joint.

c. *The coracoid process* is curved upon itself, and tapers rapidly to its apex, which is directed forwards and outwards just below the forward concavity of the outer third of the clavicle (Fig. 1).

3. The humerus (Fig. 3), or bone of the arm

THE SKELETON

proper, is described, like all the long bones, as consisting of a shaft and two extremities, upper and lower. (The extremities of the clavicle only are known as outer and inner, and the extremities of the ribs are called anterior and posterior.)

The humerus articulates above with the head of the scapula, to form the shoulder-joint, and below with the ulna and radius, where it forms the elbow-joint.



Fig. 3.—The Right Humerus. Front view.

The upper extremity, or head of the humerus, forms a small segment of a large globe. It is directed upwards, inwards, and backwards, and the size of it greatly influences the prominently convex shape and outline of the shoulder. When the arm is outstretched, the head of the humerus may be felt, or even seen, in the axilla, especially in thin people.

The tuberosities of the humerus are flattened projections which are separated from the head by the anatomical neck, to which the capsule of the shoulder-joint is attached. The vertical bicipital groove divides the greater and lesser tuberosities from each other, the groove running downwards, inwards, and slightly forward, and lodging the tendon of the long head of the biceps muscle. The greater tuberosity lies outside and behind the lesser.

The shaft of the humerus begins below the tuberosities and head at a decidedly narrower part, which is known as the surgical neck on account of the frequency with which the bone is broken in this region. Below the neck the shaft becomes a little thicker, and is twisted, not bent, outwards through

THE SKELETON

an angle of fifteen or twenty degrees. In its lower third it is slightly flattened from before backwards, and is concave forwards.

The lower extremity of the humerus is very wide from side to side.

The condyles of the humerus lie on each side of the lower extremity. The internal, which is larger and lies at a lower level than the external, is directed chiefly inwards but also slightly backwards, while the external is directed outwards.

The condyles serve the usual purpose of bony prominences, namely, the attachment of muscles in this case, and of some of the ligaments of the neighbouring joint, the elbow. They form the lower limits of correspond-

ing ridges, called the supra-condylar ridges, which descend on each side of the shaft of the humerus.

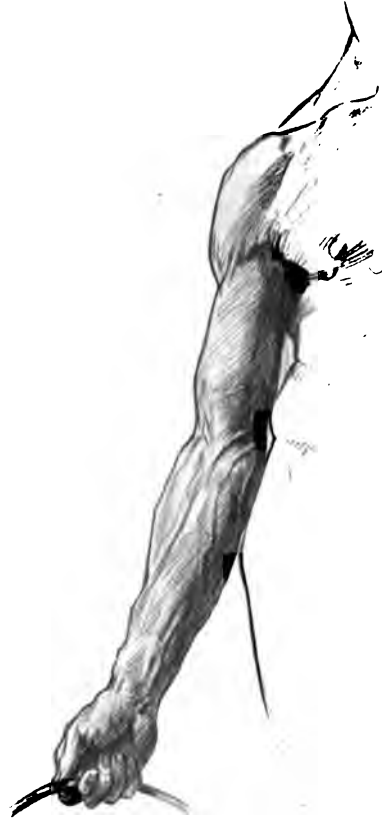

Fig. 4.—The Front of the Upper Extremity, showing the "Carrying Angle" between Arm and Forearm.

THE SKELETON

The trochlea is a broad, smooth articular surface at the lower end of the humerus, grooved obliquely, so that behind the groove it is directed downwards and inwards, and in front it runs upwards and outwards. The inner lip of the trochlea is more prominent than the outer, especially towards its lower part. This lip, by its large size, is responsible for the maintenance of the carrying angle (Fig. 4). The articulation of the trochlea and the ulna forms the main part of the elbow-joint (Fig. 5).

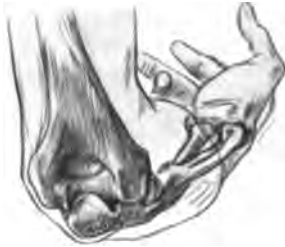

Fig. 5.—The Bones forming the Elbow Joint. Back view.

The capitellum lies between the trochlea and the external condyle and articulates with the radius in the elbow-joint. It is a rounded surface, and is not so well seen from behind as from in front.

The capitellum lies between the trochlea and the external condyle and articulates with the radius in the elbow-joint. It is a rounded surface, and is not so well seen from behind as from in front.

The bones of the forearm (Fig. 6) are the radius and the ulna. The two bones lie nearly parallel to each other in the position of "attention," which is that of "supination" of the forearm; but the ulna begins higher up the limb and does not reach so far down as the radius. In pronation the radius crosses obliquely downwards and inwards over the ulna.

They taper in different directions, the ulna being larger at the elbow end and the radius at the wrist. The elbow-joint is in great part formed by the ulna, while the radius is the more important constituent of the wrist.

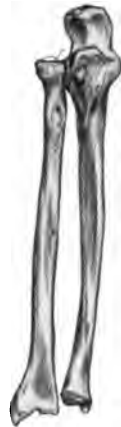

Fig. 6.—The Right Ulna and Radius. Front view.

THE SKELETON

4. The ulna, the longer bone, lies to the inner side of the radius. The greater sigmoid cavity of the ulna is a deep hollow at its upper end, the concavity of which is directed forwards and articulates with the trochlea of the humerus. This cavity is overhung above and behind by the prominent olecranon process. The strong portion of bone known as the coronoid process projects forwards below the greater sigmoid cavity.

The lesser sigmoid cavity lies on the outer side of the upper part of the coronoid process, and receives the head of the radius.

The posterior surface of the olecranon process is triangular in shape and very easily felt, because subcutaneous. Its upper part forms the point of the elbow. The triangular area, with its apex below, is continuous with the sinuous posterior border of the shaft, which is also subcutaneous in the whole length of the bone.

The shaft tapers towards the wrist where the lower end of the ulna presents two prominences separated by a deep groove. The larger, the head of the ulna, is very obvious on the back of the wrist in the pronated position. The slenderer styloid process is detected with more difficulty by the examining finger.

Notice that the ulna tapers from elbow to wrist in about the same delicate graduation as does the undissected forearm, and that its shaft is not only concave forwards throughout its whole length, but also, when viewed from before back, it is concave outwards towards the radius.

5. The radius has a head with a saucer-like depression at its upper end. The constriction below the head is the neck, from which the shaft gradually

THE SKELETON

swells out till it reaches the very large lower extremity at the wrist.

The bicipital tuberosity lies just inside and below the neck, and its posterior part gives attachment to the biceps tendon.

The shaft is convex outwards, and concave towards the ulna. At the most prominent part of the curve is a noticeable rough area, into which an important muscle known as the "pronator radii teres" is inserted.

The styloid process of the radius can be felt in the "anatomist's snuff-box" (*vide* p. 101); it is more massive, and situated at a lower level than the corresponding process of the ulna. The back of the lower end of the radius is marked by four grooves, the deepest of which lies on the inner side of a prominent tubercle, and lodges the tendon of the extensor longus pollicis muscle.

The sigmoid cavity, lying on the inner side of the lower end of the radius, receives the head of the ulna.

The radius is joined by ligaments to the ulna. The chief of these are the collar-like orbicular ligament which surrounds the head of the radius, the triangular fibro-cartilage which unites the lower ends of the two bones, and the interosseous membrane, the fibres of which pass downwards and inwards from the shaft of the radius to that of the ulna.

This membranous ligament is a very important factor in the mechanics of the forearm. When a thrust with the hand is made, pressure is transmitted, from the object pushed to the lower end of the radius, and this bone tends to be displaced upwards. But the direction of the fibres of the interosseous membrane is such that they are at once made tight,

THE SKELETON

and so they pull upon the ulna. The thrusting force is thus transferred to the ulna, distributed throughout its whole length, but changed into a pulling one, and so shock is diminished.

6. There are eight bones of the wrist or **carpus** (Fig. 7). They are so articulated with each other that there is a distinct general concavity of the anterior aspect of the carpus. This concavity is bounded on the inner side by the pisiform bone, the smallest of the series, and by the well-marked hook of the unciform bone, which lies more deeply and is just below the pisiform.

The corresponding eminences which bound the concavity to the outer side are the tubercle of the scaphoid and the ridge on the trapezium. The latter bone is on the outer side of a deep groove that receives the flexor carpi radialis tendon. It possesses a very special importance in that it has a small process of bone which is directed downwards and inwards and throws the thumb away from the finger. The great range of movement in the thumb is characteristic of the human hand, and is of vital importance to man in the performance of many of the finer movements which in the process of civilisation he has acquired, such as are for instance essential to the proper use of pen and pencil. This range is so free that the palmar surface of the thumb's terminal phalanx can be opposed to the palmar surface of any part of the other digits.

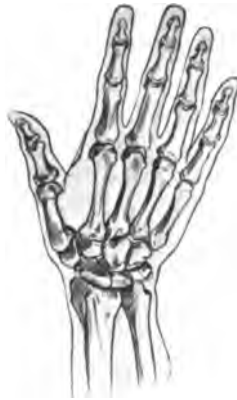

Fig. 7.—The Bones of the Wrist and Hand. Front view.

THE SKELETON

7. The metacarpal bones (Fig. 7, p. 43) are five, one to each digit. Their posterior surfaces form longitudinal ridges on the back of the hand, more obvious in the aged or emaciated, and their heads form the first or proximal set of knuckles.

8. The phalanges (Fig. 7) are fourteen in number—three to each finger, but only two to the thumb. They diminish in size from above downwards, and are described as long bones, in that each has a shaft and two extremities. The heads of the proximal¹ and middle phalanges form the middle and distal rows of knuckles.

The bones of the lower limb comprise:—

1. The os innominatum, or hip-bone. The bony basin of the pelvis is formed of the two ossa innominata together with the sacrum and coccyx, which are the two lowest bones of the spinal column.

2. The femur, or thigh-bone.

3. The patella, or knee-cap.

4. The tibia, or large bone of the leg.

5. The fibula, or small bone of the leg.

6. The tarsals.

7. The metatarsals.

8. The phalanges.

1. The hip-bone belongs to the class of flat bones. Its functions are:—

To give attachment to the strong muscles which maintain the erect position (Figs. 8 and 9, p. 45).

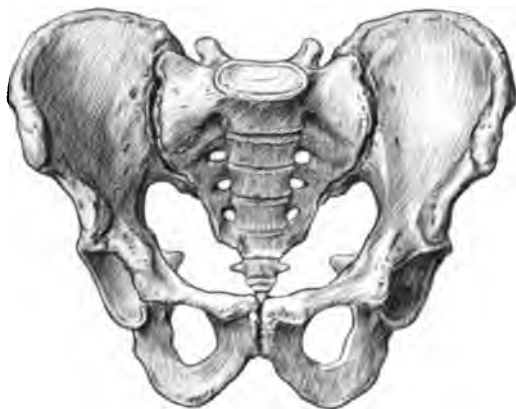To support the weight of the head, trunk, and upper limbs, and to transmit this weight to the lower limb.

To protect the important viscera which lie in the lower part of the abdominal cavity and in the pelvis.

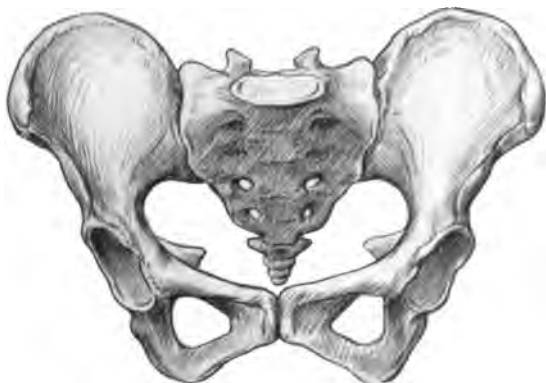¹ The term "proximal" refers to that part which is nearer to the centre of the body; the term distal, to that part which is farther removed.

THE SKELETON

The relation of the os innominatum to the sacrum



Male Pelvis.



Female Pelvis.

FIGS. 8 AND 9.—These two figures should be compared with one another. They show the characteristic features of the male and female pelvis. The bones forming the male pelvis are more massive, and the muscular prominences are better marked, than those of the female. In the female, on the other hand, the pelvic cavity is broader: the subpubic angle wider: and the thyroid foramen more triangular and set more horizontally than in the male. The increased breadth of the pubic bones, in the female, should also be noted.

in the constitution of the pelvic cavity will be described later.

THE SKELETON

Although the hip-bone is responsible to a great extent for the configuration of the lower part of the trunk and the region of the buttock, and although many of its prominences can easily be felt, and indeed form important anatomical landmarks, yet few of them form projections visible in the undissected model, as do the clavicle, the tibia, and other thinly covered bones. The bone is developed in three separate parts which unite at puberty, viz. :—

- a. The ilium, the flat upper portion.
- b. The ischium, the tuberous lower portion.
- c. The pubes, the anterior part.

The ilium presents two surfaces, an inner and an outer. The inner surface is smooth and hollow in front for the attachment of the iliacus muscle. Behind there is a smooth ear-shaped surface for articulation with the sacrum, and above a rough area to which are fixed the very strong posterior sacro-iliac ligaments, to be described later.

The outer surface is generally convex, and affords origin to the three gluteal muscles, which are of great importance in attaining the erect position. Each of these surfaces is bounded above by the sinuous crest of the ilium. The crest forms the brim of the false pelvis; it terminates in front in the oval anterior superior spine of the ilium, and behind in the posterior superior spine. The latter spine lies, in the living subject, at the bottom of a shallow dimple, and corresponds to the middle of the sacro-iliac joint.

The tubercle of the ilium is a thickened portion of bone situated upon the outer lip of the crest some $2\frac{1}{2}$ inches behind the anterior superior spine. It is the highest part of the iliac crest, and forms the extreme lateral portion of the bone.

THE SKELETON

The *ischium* and *pubes* surround a large oval orifice, the thyroid foramen. The most important part of the ischium is its massive tuberosity, which forms to a large extent the prominence of the buttock, and is the resting point of the body in a sitting position.

The *pubes*, lying in front of and above the ischium, is a flatter and less massive bone. It articulates with its fellow in the middle line at the *symphysis pubis*. The crest of the *pubes* extends outwards from the symphysis for about an inch, and has the *rectus abdominis* attached to it. It ends in a palpable eminence called the spine of the *pubes*.

The acetabulum. The three parts of the *os innominatum* converge at the deep cup-shaped hollow, the *acetabulum*, situated upon the outer surface of the bone, for the reception of the head of the femur. The margin of the hollow is deficient, at a point below and in front, which is known as the *cotyloid notch*.

The *ilium* forms less than two-fifths of the *acetabulum*.

The *ischium* forms more than two-fifths.

The *os pubis* forms about one-fifth.

The Pelvis (Figs. 8 and 9, p. 45), which is formed of four bones—viz. the two hip-bones, the sacrum, and the coccyx—is of very great importance in determining the shape of the skeleton, and differs in the two sexes, most markedly, of course, in the adult, but also to some extent in the young.

The pelvis forms an expanded, basin-like cavity for the reception, support, and protection of the viscera contained in the lower part of the abdomen, and for the attachment of large and powerful muscles. As it is open both above and below, it would be more

THE SKELETON

correct to liken it to a funnel, which is broad above and narrow below. The expanded wings, which are formed on either side by the iliac portions of the hip-bones, constitute *the false pelvis*; whilst *the true pelvis*, which lies below this, is formed by the sacrum and coccyx, and the ischial and pubic portions

of the hip-bones. In the female pelvis the bones, as elsewhere, are much lighter in texture than in the male, and the muscular prominences are not so well marked. The iliac wings are more widely expanded, so that much more of their inner surfaces can be seen from the front. The diameters of the true pelvis are greater, as is also the subpubic angle.



Fig. 10. — Right Femur. Front view.



Fig. 11. — Right Femur. Back view.

2. The femur, or thigh-bone (Figs. 10 and 11), is the longest bone in the body. As a general rule its length may be considered as equal to

a quarter of the total length of the body from the vertex of the skull to the heel. It articulates above with the acetabulum to form the hip-joint, and below with the patella and tibia in the knee-joint.

The femur presents for examination a shaft and an upper extremity consisting of head, neck, and two trochanters, and a lower extremity.

The head is smooth, in shape rather more than

THE SKELETON

half a sphere, and is received into the cup-shaped acetabulum.

Just below is the long *neck*, broader and flatter externally, where it is continuous with the shaft of the bone at an angle of about 120 degrees. Some authorities consider that the angle diminishes with advancing age, but Sir George Humphry, to whom every student of anatomy owes so much, came eventually to the conclusion that no such diminution takes place.

The *great trochanter* is above and external to the neck, and into it several strong and important muscles are inserted—*e.g.* the glutei. The external surface of the great trochanter is painfully well known to skaters, among whom it has acquired the name of the “two-turn bone.” It may be easily felt three or four inches below the crest of the ilium. In the thin subject it forms a visible prominence at that point; in the well covered it lies at the bottom of a slight depression, best marked in the female.

The *lesser trochanter* is a smaller tubercle lying deeply embedded in the muscles on the inner and posterior aspect of the upper part of the shaft. To it is attached the powerful Ilio-psoas.

The *shaft* of the femur is generally cylindrical, and swells out as it is traced downwards. It is marked usually by a slight forward convexity; the concavity of the posterior aspect is greatly strengthened by a thick ridge of bone known as the *linea aspera*.

The *inferior extremity* presents large internal and external swellings known as condyles, the former larger than the latter. They are separated by a hollow which is more pronounced below and behind, the intercondyloid notch.

On the upper part of the postero-internal aspect

THE SKELETON

of the internal condyle is the adductor tubercle for the insertion of the adductor magnus muscle. Both condyles are smooth behind, below, and in front. The smooth surfaces behind and below articulate with the tibia, and in complete flexion of the joint the latter articulates with the patella also, but the smooth surface on the front of each condyle, and the smooth surface between the condyles, articulate only with the patella.

Inclination and torsion of the femur. In the erect position of the subject there is a distinct inclination of the shaft of the femur inwards as it approaches the knee. The angle of inclination from the vertical is about nine degrees, and is greater in the female, in consequence of the larger pelvis, than in the male. The shaft of the femur is also rotated inwards through an angle of about ten degrees, so that the inner end of the axis of the head and neck lies in front of the inner end of the transverse axis of the lower extremity. In other words, the neck of the femur is directed not only upwards and inwards, but also a little forwards.

3. The patella, or knee-cap (Fig. 12), is a small, somewhat triangular bone having the apex pointed downwards. To its upper and lateral borders is attached the quadriceps extensor cruris, which is chiefly muscular at the superior border of the bone, and ligamentous at the sides. From the pointed lower end of the patella the thick ligamentum patellæ passes to the tubercle of the tibia, and so transmits to the leg bones the force of the quadriceps extensor muscle. The posterior surface of the patella is smooth; it articulates with the femur, and not at all with the tibia.

4. The tibia, or large bone of the leg (Fig. 12), has

THE SKELETON

a thick upper extremity for articulation with the femur by a wide upper surface forming a generally horizontal plane, on which there are two slight concavities for the femoral condyles. The upper end of the bone is slightly recurved, and made up of two tuberosities, and the internal one forms a marked prominence on the inner side of the knee.

On the anterior surface, about two inches below the upper end, is the prominent "tubercle of the tibia," into which the ligamentum patellæ is inserted. This tubercle transmits the weight of the body in the kneeling posture. It is continuous below with the sinuous anterior border of the shaft. This border bounds, in front and externally, the subcutaneous anterior surface of the tibia, which looks not only forwards but inwards. As no muscles intervene between them and the skin, both border and surface are easily felt and seen, and are commonly known as "the shin." The surface is bounded internally and behind by the internal border of the bone, and both here and at the anterior border a prominent mass of muscle is seen when the well-developed leg is thrown into muscular activity (Plate XXI.).

The lower extremity of the tibia is considerably larger than the shaft, but is only prominent at its internal aspect, where it projects downwards on the inner side of the ankle-joint as the internal malleolus. Through the groove at the back of the internal



Fig. 12.—The Lower End of the Femur, with the Patella, Tibia, and Fibula of the Right Side. Front view.

THE SKELETON

malleolus the tibialis posticus tendon may be always felt and, in positions of strain, seen as it passes down into the sole of the foot.

5. The fibula, or small bone of the leg (Fig. 12, p. 51), lies on the outer side of the tibia, and is directed downwards and forwards from above in a slightly oblique position. It is almost completely covered by muscles. The posterior part of its head, however, projects upwards, and can be seen and felt just below the level of the knee (into which it does not enter) as the styloid process, for the attachment of the external lateral ligament of the knee-joint, and also of the biceps flexor cruris. The neck is a slightly constricted part just below the head.

Similarly, the inferior extremity of the fibula, expanded and a little flattened from side to side, can be felt and seen as it forms the external malleolus. This is the prominence on the outer part of the ankle, and it reaches a lower level than does the internal malleolus of the tibia. It articulates with the tibia and with the astragalus, one of the bones of the foot.

The Bones of the Foot (Figs. 13 and 14).—These form a composite arch, concave downwards, not only in a sagittal direction (*i.e.* from behind forwards), but also in a transverse direction, so that the term "dome" would be more accurate than "arch." The arch has one pier behind, formed by the os calcis, but two in front formed by the heads of the first and fifth metatarsal heads.

6. The tarsus is made up of seven bones; the os calcis is much the largest, and the middle cuneiform much the smallest.

The os calcis, or heel, forms the single posterior pillar of the arch. It articulates with the astragalus

THE SKELETON

above and with the cuboid in front. Placed in the position it occupies in the body when the subject is standing upright, its long axis is directed backwards

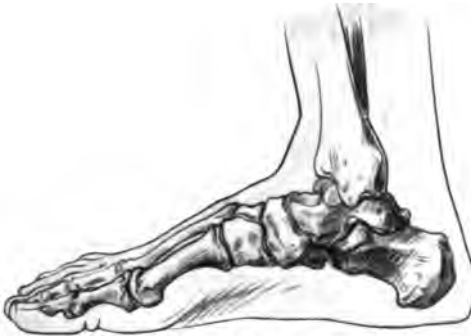

Fig. 13.—Bones of Right Foot. Inner side.

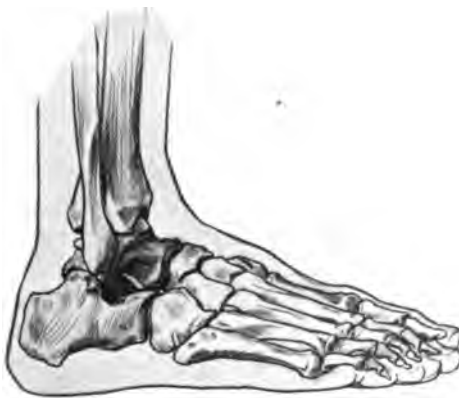

Fig. 14.—Bones of Right Foot. Outer side.

and downwards. Its posterior surface is convex and rough, unlike its anterior surface, which is smooth and slightly concave.

THE SKELETON

The convex posterior surface of the os calcis may be divided into three parts. The middle part gives attachment to the Tendo Achillis, the large tendon running to the heel; the lowest part first receives the impact of the body when the foot is placed upon the ground in the action of walking.

The sustentaculum tali is a prominent tubercle on the inner side of the bone, smooth above for articulation with the astragalus or talus, and grooved below for the transmission of the tendon of the flexor longus hallucis muscle.

On the outer aspect is a small prominence called the *peroneal tubercle*, separating the tendons of the two *peroneal muscles*.

The astragalus is the keystone of the arch, and transmits pressure from the tibia to the foot. It possesses a convex, smooth articular facet for the tibia, broader in front than behind, with the result that when the foot is flexed, *i.e.* brought as far as possible into a straight line with the leg, a certain amount of lateral movement is allowed at the ankle-joint.

A strong interosseous ligament fixes the astragalus very firmly to the os calcis.

In front the astragalus articulates with the scaphoid, a bone situated on the inner side of the foot and prolonged internally and below into a prominent tuberosity which can be seen and felt.

The scaphoid, or navicular, is flattened from before backwards, and articulates in front with the three cuneiform bones. Only the internal cuneiform requires mention here, as its lower border forms a well-marked ridge directed downwards.

The cuboid, on the outer side of the foot, articulates behind with the os calcis, and in front with the fourth and fifth metatarsal bones. Its under

THE SKELETON

surface is marked by a deep groove directed inwards and forwards for the transmission of the peroneus longus tendon.

7. The metatarsal bones are five in number. The first is much the largest. It presents a noticeable tuberosity at its base, or extremity nearest the heel. The head forms the "ball of the toe," and constitutes the base of the anterior pier of "the arch of the foot" (Fig. 13, p. 53).

8. The phalanges of the foot, fourteen in number, are much smaller than the corresponding bones of the hand.

As has been stated, the astragalus is the keystone of the arch of the foot, and the os calcis is the posterior single pillar. There are two pillars supporting the arch in front, an internal and an external. The scaphoid, the three cuneiform bones, and the three innermost metatarsals form the internal pillar, and the external is built up of the cuboid, and the two outer metatarsal bones.

The Bones of the Skull.

The skull (Fig. 15), with the exception of the inferior maxillary bone, appears in the adult to be made up of a continuous bony structure, whose various parts are inseparably and immovably united.

However, if a young child's skull is examined (Fig. 16, p. 56), it will at once be obvious that there are in reality many bones, easily distinguishable from one another, and, at any rate in a newly born infant,

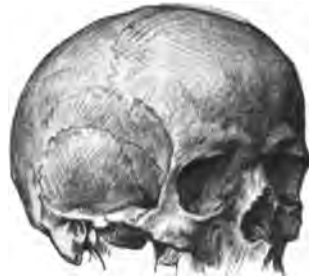

Fig. 15.—Antero-lateral View of Skull (adult).

THE SKELETON

each bone is capable of being moved to some extent relatively to its neighbours. This mobility of the bones enables the head to be moulded in the process of birth to the shape of the maternal passages.

In the adult, each bone is intimately articulated to its neighbours by means of tortuous and often deeply serrated "sutures."

"The skull" means the entire skeleton of the head.

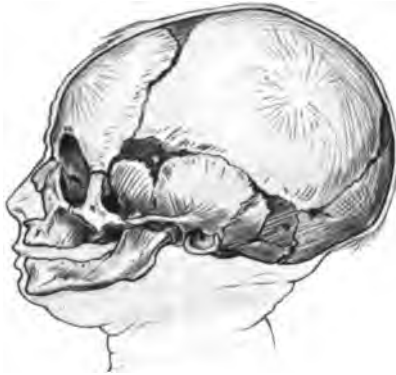


Fig. 16.—Skull of Young Child.

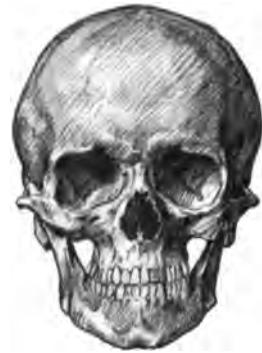

Fig. 17.—Front View of Skull (adult).

"The cranium" is the term reserved for the skull without the mandible.

"The calvarium" is that part of the skull which remains after the bones of the face have been removed.

The "cranial bones" are eight in number :—

1. One frontal.
2. One sphenoid.
3. One ethmoid.
4. One occipital.
5. Two parietal.
6. Two temporal.

1. **The frontal bone** (Fig. 17) is situated on the

THE SKELETON

anterior aspect of the cranium. It is responsible for the form of the forehead; it provides the roof of the orbits, or cavities which contain the eyes, and of the nasal fossæ.

The "supra-orbital margin" is curved strongly with its concavity downwards; it carries the eyebrows, and in common with all the cranial prominences it varies much in different individuals, both in its curve and in its degree of prominence. The broad but low "superciliary ridge" lies above rather more than the inner half of each supra-orbital margin. Above this again is the "frontal eminence," lying on a vertical line drawn through the middle of the supra-orbital margin.

On each side of the orbit the frontal bone is prolonged downwards both externally and internally, but the external of these two angular processes does not reach so far down as the internal.

The anterior aspect of the frontal bone is convex, while its posterior surface is concave, and lodges that portion of the brain which is known as the frontal lobe, and which is associated with intellect.

Above the bridge of the nose the frontal bone may be very prominent. There is here an air-chamber, the frontal sinus, of very variable dimensions, between the two dense plates which constitute the chief structure of all the cranial bones. This air cavity constitutes one of the many resonating chambers which largely determine the quality of the voice.

The median nasal spine supports the two small nasal bones, and upon them the shape of the bridge of the nose chiefly depends. It is a slender process prolonged downwards and forwards from the inferior and anterior part of the frontal bone.

2 and 3. The ethmoid and sphenoid bones

THE SKELETON

scarcely come to the surface of the articulated skull, and therefore a full understanding of them is not necessary for the art student. They play, however, an important part in the determination of the size and shape of the nasal cavity and of the face, and even of the skull, and like the frontal bone they contain large resonating air-chambers.

4. The occipital bone (Fig. 18) forms the posterior and lower part of the cranium. It is roughly

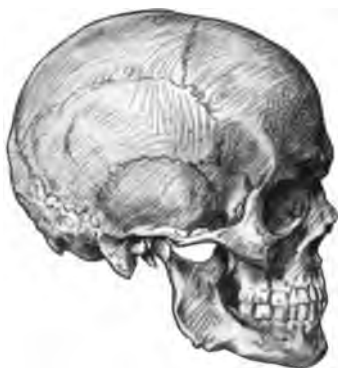

Fig. 18.—Side View of Skull (adult).

diamond-shaped, and in it is the large foramen magnum for transmission of the spinal cord to the cranial cavity. The foramen is directed downwards and forwards, the forward inclination being peculiar to the human.

In the middle line, about the centre of the bone, on its posterior convex aspect, is the external occipital protuberance, from which the external occipital crest may be traced downwards to the foramen magnum, while outwards on each side from the protuberance there runs a curved ridge for the posterior portion of the occipito-frontalis muscle to be attached above, and the trapezius and part of the sterno-mastoid below. Below this again some of the strong muscles of the back of the neck are inserted.

5. The parietal bone (Fig. 18) lies on each side of the middle line between the frontal and occipital bones. It is quadrilateral in shape, with a convex

THE SKELETON

outer surface giving attachment in its lower half to the temporal muscle. A little above and behind the centre of each is the increased convexity or prominence known as the parietal eminence. Under this bone lies the part of the brain chiefly concerned with the motor and sensory functions.

6. The temporal bone (Fig. 18) lies on each side below the parietal bone. It contains the organ of hearing, and supports the cartilaginous auricle or external ear. It shows on its external aspect a deep hole or canal called the external auditory meatus. Behind this is a nipple-like projection directed downwards, called the mastoid process, and giving origin to the very important sterno-mastoid muscle.

The mastoid process is not fully developed till the age of seven years, by which time an air sinus is formed in its interior. It is relatively much smaller in the infant and young child, in whom the air cavity is yet to be developed, than in the adult. The flattening of the auricular region so obvious in young children is thus explained by a reference to the deep anatomy of the region. The part of the temporal bone above the meatus articulates with the parietal bone, and is called *squamous*, because of its likeness to a fish scale.

The zygomatic process is a prolongation forwards from the outer surface of the temporal bone, just above the external auditory meatus. It forms, together with a similarly named process of the malar bone, the zygomatic arch, under which the temporal muscle passes to its insertion, and from which the masseter muscle arises.

The Bones of the Face (Figs. 15, 17, 18, pp. 55, 56, 58).—Besides the ethmoid and sphenoid, which

THE SKELETON

determine the width between the eyes, the bones chiefly responsible for the shape of the face are the superior and inferior maxillary bones, the malar and the nasal. With the exception of the single inferior maxillary bone, these are all in pairs and are symmetrical.

1. The nasal bones lie close to, and articulate with, each other in the middle line. They are very small, forming the bridge of the nose only, and being assisted in this by the nasal spine of the frontal bone, which lies behind in the middle line, and by the nasal processes of the superior maxillæ, which are on each side behind them.

2. The superior maxillary bone, or *upper jaw*, underlies that part of the lips and cheek which is above the mouth, and it forms a great part of the inferior margin of the orbit. It also enters into the formation of the nasal chambers and of the buccal cavity, contributing the greater portion of the hard palate. It is a hollow bone, and besides containing the large air sinus known as the antrum of Highmore and the sockets for eight teeth, it gives attachment to numerous small facial muscles.

The upper jaw articulates with its fellow below the nasal orifice.

3. The malar or cheek-bone forms one-half of the lower margin of the orbit, and three-quarters of its outer margin. It causes a flat prominence below and external to the orbit, the so-called cheek-bone, of which the degree of development varies so enormously in different types of face. The malar has a zygomatic process prolonged backwards to form part of the zygomatic arch.

4. The mandible (Figs. 17, 18, pp. 56, 58), *inferior maxillary bone*, or *lower jaw*, supports the teeth of the

THE SKELETON

lower jaw, sixteen in number, eight on each side in the adult; but nearly twice that number before the deciduous or temporary set have been shed. It is the most massive bone of the face, and articulates only with the temporal bone, by a transversely placed "condyle" playing, when the mandible is raised or lowered, in a hollow on the under surface of that bone known as the glenoid cavity. Its shape is that of an arch, with the convexity directed forwards and its pillars turned upwards. Its lower margin is very prominent, especially in front, where it forms the mental protuberance, which supports, and is in great part responsible for the shape of, the chin.

The angle of the jaw is situated behind, where the pillar of the arch turns upwards to change the name of "body" (horizontal part) for that of the "ramus" (or vertical part).

The masseter muscle is attached to the outer surface of the angle, and is prominent in muscular individuals when the teeth are clenched.

The ramus is set on to the body at an angle which approaches a right angle in the prime of adult life, but which is much more open or obtuse at both extremes of life.

The hyoid bone will be described in connection with the neck.

The Bones of the Vertebral Column or Vertebræ.

The spinal column consists of twenty-six separate bones: seven "cervical" vertebræ in the neck; twelve, called "dorsal," in the back; and five "lumbar," in the loin. Two conglomerate masses of vertebræ, the sacrum and the coccyx, help to form the pelvis.

Each vertebra surrounds a central spinal canal for

THE SKELETON

the transmission of the spinal cord and its coverings. The anterior part of the bone is called its "body," and is absent in the case of the first cervical or atlas. The superincumbent weight is transmitted through the column of the bodies. A spinal nerve passes out on each side beneath each vertebra. The lateral part of the vertebra has a transverse process on each side, and the posterior part projects backwards as the spinous process, which in most regions can be felt and even seen on the model (Plate II.), especially when the spine is flexed.

The spinous processes are especially prominent in the lower cervical and upper dorsal region, the seventh cervical having the name of the *vertebra prominens*; but the first dorsal is almost, if not quite, as prominent.

The lumbar vertebræ are the most massive, and the buffer-like discs of cartilage separating them are much thicker than those between the other vertebræ, so that although there are less than half the number of lumbar vertebræ when compared with the dorsal vertebræ, the total length of the lumbar portion of the spinal column is considerably more than half the length of the dorsal portion.

The sacrum (Figs. 8 and 9) is concave downwards and forwards, and convex above and behind. It is triangular in shape, base upwards, and continues the lumbar spine, and articulates on each side with the hip-bone. It is wider in the female.

The coccyx is the involuted tail.

The Curves of the Spine.—The spinous processes of all the vertebræ lie very nearly in the middle line of the back, but their line is, in right-handed persons, deflected by the stronger muscles to form a slight convexity to the right. Nowhere in anatomy is

THE SKELETON

strict symmetry, or absolute similarity of the two sides, to be found.

There are other curves to be noticed in a profile view, viz. the cervical and lumbar curves having their convexity forwards, and the dorsal curve with a backward convexity. The object of these curves is to increase greatly the elasticity of the spinal column.

The thorax consists of the twelve dorsal vertebræ, the twelve ribs on each side, and the sternum in front.

The seven upper **ribs** articulate in front by the intervention of costal cartilages with the sternum. The eighth, ninth, and tenth ribs articulate in a similar way with those immediately above them, and the eleventh and twelfth, lipped with cartilage, do not articulate in front with any bone, and are called "floating ribs."

The first rib (Fig. 1, p. 35) is flattened from above downwards, lies very obliquely, so that its posterior end is two inches or more above its anterior end, and unites with the first dorsal vertebra behind to form, with the sternum in front, the inlet of the thorax. This rib is partially concealed and protected by the clavicle.

The succeeding ribs gradually increase in length as far as the eighth, and then they begin to decrease. Thus the cavity of the thorax, which they enclose, is considerably more roomy below than above.

The sternum, or breast-bone (Fig. 1, p. 35), is flattened from before backwards, and lies in the middle line between the clavicles above and the seven upper ribs on each side. It is divided into three parts, of which the middle, or *gladiolus*, is the longest. The upper part, or *manubrium*, is the broadest, and makes

THE SKELETON

a very distinct angle, the sternal angle, on the front of the chest, with the middle part.

The ensiform or lower part is frequently retracted, and lies in the pit of the stomach.

The thorax differs in the two sexes. In the female it is relatively shorter, and less flattened from before back, than in the male. Its capacity also is not so great.

CHAPTER II

THE COVERINGS OF THE BODY

The Skin covers the whole body. On the face it is continuous with the **mucous membrane** lining the alimentary canal at the red margin of the lips, and also with the mucous membrane of the nasal cavities, and with the conjunctiva or membrane covering the front of the eyeballs.

It is elastic, and varies greatly in thickness, both in different individuals and in different parts of the same individual. Thus it is thick over the scalp, the back of the trunk, the palms of the hands, the soles of the feet, and the extensor surfaces of the limbs; and thin over the face, the neck, the abdomen, and the flexor surfaces of the limbs, but perhaps thinnest of all in the eyelids.

Its surface presents numerous fine but permanent ridges and furrows, best marked on the palmar surface of the hand, the fingers, and the thumbs; a fact which has been turned to account by the palmist, and to a more useful purpose by the criminologist, since the discovery that it is possible to register the finger-prints, and so to identify suspected individuals.

Additional, but usually temporary, furrows are often caused by the action of underlying muscles. Sometimes even these tend to become permanent, as in the furrows on some foreheads and most necks.

Numerous minute pits on the surface of the skin

THE COVERINGS OF THE BODY

indicate the orifices of the sweat and sebaceous (or grease) glands and the hair follicles, but, as a lens is necessary for their accurate study, they hardly call for the notice of the artist.

Moles are pigmented patches, usually small and flat, but sometimes large and hairy, and are liable to occur on any part of the skin.

The colour of the skin varies enormously in different individuals and in different circumstances. The ruddy colour of health is chiefly due to a good circulation; the pallor of cold, of collapse, and of death; the deep blush; and the whiteness associated in certain persons with anger, are examples of the variation in colour resulting from altered blood supply.

Pigment may be developed in the deep layers of the skin, not only in the negro races, but in white skins when afflicted with certain diseases, or when lately sunburnt. Certain parts become pigmented more readily than others, *e.g.* the flexure of the limbs, the eyelids, and the areola immediately around the nipple of a woman who has, or is about to, become a mother.

The skin is marvellously well adapted to the multitudinous purposes it has to serve. It is tough, yet pliable and elastic; smooth and moist, yet not messy; sensitive, yet very resisting, and quick in repairing when damaged.

The Nails are appendages specially developed from the skin. Each one is embedded by its root in the skin, and near the root is the crescentic *lunula*, which is responsible for its growth, opaque white, and offering a contrast to the pinkish hue of the rest of the nail.

The nails are grooved longitudinally. In old

THE COVERINGS OF THE BODY

persons they are apt to become very brittle. If allowed to grow long they become bent over the digit.

Hair is demonstrable all over the skin, except upon the palms of the hands, the soles of the feet, and the dorsal surface of the distal phalanges of the fingers and toes.

There is, of course, great variety in quantity, quality, and colour in different individuals. White hair is due to the presence of air spaces, and dark hair to the presence of pigment, within the cells of which each hair is composed.

In many parts it is hardly visible without the aid of a magnifying glass. On the scalp and on the face of the male it is apt to grow long, while on the armpits, the pubes, the front of the chest, and in the eyebrows and eyelashes it seldom attains much length. Like the straws on a thatched roof, all hairs, whether in the human or the lower species, have that direction which is best calculated to carry off any rain that may fall on the part.

The hairs, especially those of the trunk, are capable of being erected to some extent upon the surface of the skin by minute muscles. Such a condition, commonly called "goose-skin," is associated with fear or cold.

The hair of the head may feel as if it were being erected, and without doubt actual bristling does occur in the lower animals, *e.g.* the cat and the dog, but it is doubtful whether this ever actually happens in man. The upturned moustache, so commonly affected by men, including those of the most equable temperament, is an artificial, even if unintentional, mimicry of the involuntary raising of the hair of the head and face in an animal aroused to anger.

When puberty approaches the skin is particularly

THE COVERINGS OF THE BODY

active. Pustules on the face, in association with increased formation of hair, are a common condition in youths who have just reached this time of life.

Blushing and Pallor.—Blushing consists in a diffuse reddening of the skin of the face, and may extend to the forehead, neck, shoulders, or even the whole body. It is due to the determination to the surface of a larger quantity of blood than usual, and is not under the control of the will. Certain involuntary nervous impulses act upon the superficial blood-vessels and dilate them.

Pallor is the opposite condition to that of blushing, and it is less evanescent. Temporary pallor may be associated with fear or anger, but is more frequently due to a feeling of fatigue or faintness.

The waxy appearance of anæmic subjects and the yellow tinge of jaundice are phenomena of disease.

In *albinos* the usual deposits of pigment are wanting. The skin is wax-like, the hair flaxen, and the irides of the eyes are pink, while the pupils appear red.

Beneath the skin is a layer of **Subcutaneous or Superficial Fascia or Tissue**, the loose meshes of which are more or less loaded with fat (except under the skin of the eyelids, the scrotum, and the penis, which parts never in any circumstances have any fat). This layer of fat is known as the *panniculus adiposus*; it rounds off angles and hollows, and fills up spaces; it represents a storehouse of nourishment, and it protects against exposure to cold. The deposit of fat is apt to be especially marked over the buttocks and the breasts and the thighs, and over as well as within the abdominal cavity.

The *sub-mental pad* of fat provides the familiar double chin of the corpulent, while the *sucking pad*

THE COVERINGS OF THE BODY

makes the cheek of the infant prominent. There are other pads around the eyeballs and in the temporal fossæ, which are very early absorbed *in wasting illnesses*, and so allow the prominences of the bones to give the *appearance of emaciation*. Old age is perhaps most difficult to conceal where the skin becomes baggy from absorption of fat, and especially in those regions of the neck which lie over and below the mastoid process and the hyoid bone.

In certain regions—viz. the front of the neck, the face, the scrotum, and the inner side of the palm of the hand—muscular fibres are developed into definite sheets known by the name of the *panniculus carnosus*. Such sheets are remnants of a much more complete system in some of the lower animals, enabling them to move the skin of the body, but in man the facial part of the *panniculus carnosus* attains special importance as the **Platysma**, a thin but strong and extensive sheet of muscle which contributes largely to the various movements of the face involved in different expressions (Plates XXIV., XXV.).

Everywhere under the superficial fascia is the **deep fascia**, a much firmer fibrous sheet. It acts as a closely investing membrane bracing the muscles more or less tightly to the bones. In many regions it is connected deeply with the joints, and it is also frequently continuous with the periosteum or membrane covering the bones. In a few places it is thickened to form either very definite tendon-like bands—*e.g.* the ilio-tibial band in the thigh—or transversely disposed tunnels for the transmission of tendons past joints—*e.g.* the annular ligaments at the wrist and the ankle.

CHAPTER III

THE REGIONS OF THE BODY

The form of the subject or model depends upon:—

1. The shape of the skeleton, which varies with age, race, sex, condition of health, &c.

2. The relative position of the various parts of the skeleton.

3. The condition of the muscles, whether active or passive, and whether well or ill developed.

4. The quantity and quality of subcutaneous fat.

5. The condition of the other coverings—the skin and the hair.

It is necessary for the student to understand various terms used in connection with muscles.

When a muscle contracts it becomes broader, thicker, and shorter: individual bundles of fibres may become prominent, and its tendon, or leader, may stand out as a prominent ridge.

Most muscles are attached to at least two bones. The place of attachment to the more movable bone is called the muscle's *insertion*, and to the more fixed bone, its *origin*.

In the limbs the more movable bone is usually, but not always, distal, *i.e.* more removed from the centre of the body. A very good example of the application of these terms is to be found in the *latissimus dorsi*. This muscle's chief action is to pull the arm down to the side, and therefore it is said to be *inserted into* the humerus; but it may be put

THE REGIONS OF THE BODY

to quite another use, viz. to pull the side up to the arm, as in climbing.

The skeleton having been dealt with already, let us proceed to examine such of the muscles as are responsible for surface form, and are found in the various regions of the body as soon as the skin and superficial and deep fasciæ have been dissected away. In this examination we will note some of the modifications observable in the normal surface form under varying conditions of activity and rest of these same muscles.

For the purposes of anatomical description the regions of the body are classified as follows:—

The upper extremity.

The lower extremity.

The trunk.

The neck.

The head.

Each of these parts presents certain generally recognised subdivision.

The upper extremity includes:—

The shoulder, the axilla, the arm, the elbow, forearm, wrist, hand, and fingers.

The lower extremity includes:—

The thigh, the buttock, the groin, knee, leg, ankle, foot, and toes.

The trunk includes:—

The spine, the thorax, abdomen, pelvis, and perineum.

The head includes:—

The cranium and the face.

The neck includes all the parts which intervene between the head and the thorax.

Some difficulty arises in fixing the boundaries between the various regions of the body, and between

THE REGIONS OF THE BODY

the subdivisions of those regions. Unfortunately for precision of anatomical classification, several important features lie on these boundaries, or cross a boundary and so occur in two or more adjacent regions, but the difficulty thereby created need not trouble the artist.

CHAPTER IV

THE UPPER EXTREMITY

THIS, as has just been indicated, is made up of the arm joined to the trunk and neck by the region of the shoulder and armpit; of the forearm joined to the arm by the elbow; and of the hand joined to the forearm by the wrist.

When any limb is considered as a whole, it is at once seen to be more massive in the neighbourhood of the joints than in the parts between them, and in the upper parts than the lower. The reasons for this are (1) that in the regions of the joints the ends of the bones are larger than the shafts; (2) that muscles often take their origins in fleshy groups, while their insertions are usually tendinous and widely divergent; (3) that in the upper regions of the limbs the muscles have harder work to do, and are therefore larger, than the muscles lower down, which have less powerful but more delicate tasks to perform.

The Shoulder.

A description of this region must trespass upon and overlap that of the trunk and neck.

In the upper part of the back, and lying on each side of the vertebral column, is a flat eminence, roughly triangular in shape. It is formed by the *scapula* or shoulder-blade and the muscles which cover it (Figs. 19, 20; Plates XI., XII., XIII., XVII., XXIV.).

The eminence is divided into two parts by a trans-

THE UPPER EXTREMITY

verse furrow if the subject be well covered, or ridge if he be wasted, indicating the position of the *spine of the scapula*, which is continuous externally with the acromion process. The *acromion* is directed upwards and forwards from the spine to articulate

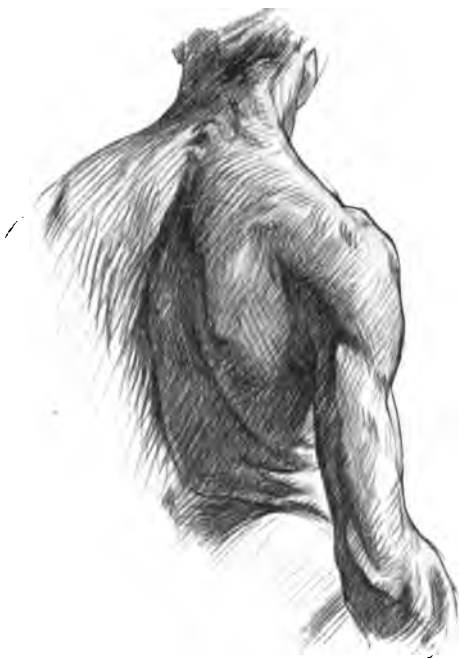

Fig. 19.—The Back of the Neck, Upper Part of Trunk, and Arm.

with the clavicle, and so to form the point of the shoulder.

The part above the ridge or furrow is the smaller, lodges the supra-spinatus muscle, and is obscured by the flat *Trapezius* (Figs. 20 and 21) muscle as the latter passes to its insertion into the spine, acromion pro-

THE UPPER EXTREMITY

cess, and posterior border of the outer third of the clavicle.

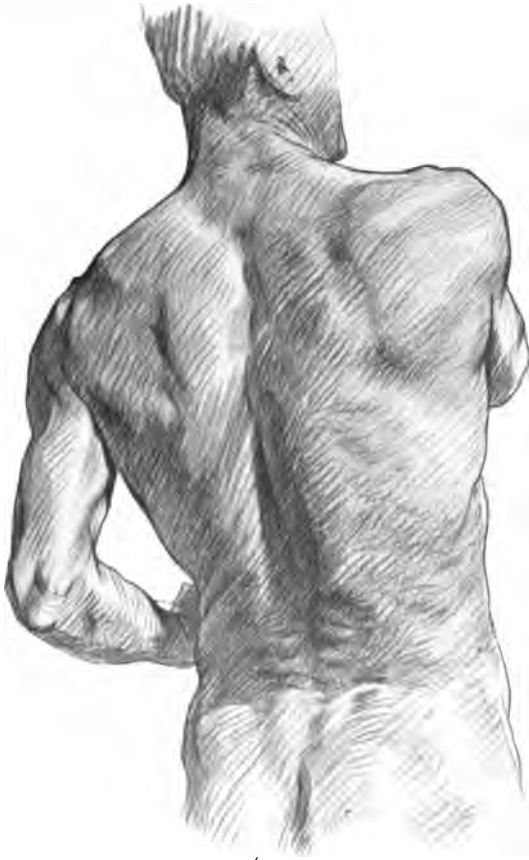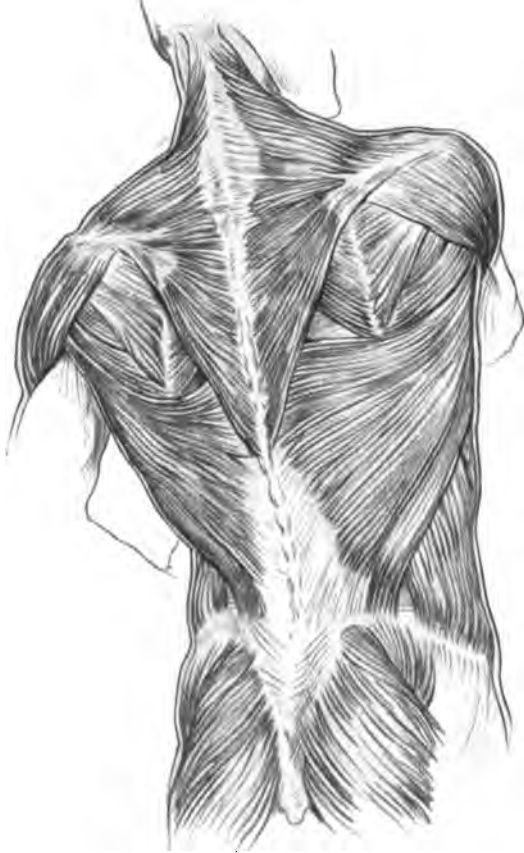


Fig. 20.—The Muscular Prominences on the Back of the Trunk, Buttock, and Neck.

The lower part of the trapezius also conceals, over somewhat less than its inner quarter, the infra-

THE UPPER EXTREMITY

spinatus muscle, which, as its name implies, occupies the hollow in the scapula below its spine (Fig. 21).



**Fig. 21.—The Muscles on the Back of the Trunk,
Buttock, and Neck.**

The inner limit of this flat triangular eminence is, of course, the vertebral border of the scapula, which

THE UPPER EXTREMITY

lies parallel with the vertebral column and is made more obvious by the subject placing the hand upon the opposite shoulder.

The rounded inferior angle of the eminence is concealed by the upper edge of the *Latissimus dorsi* (Fig. 21) on its way from the vertebral column to the upper part of the humerus. This inferior angle

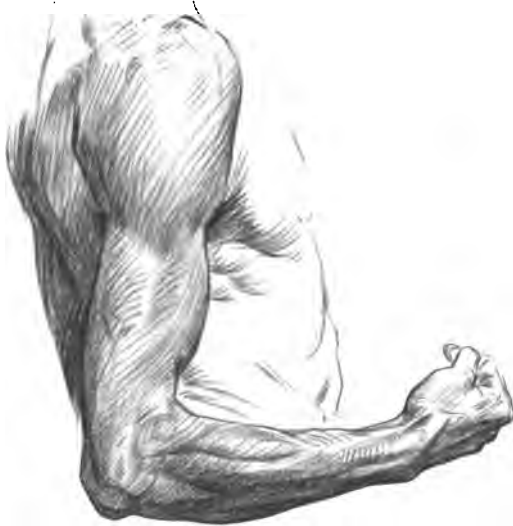

Fig. 22.—The Outer Side of the Upper Extremity.

stands out when the subject places his hand behind his back.

The upper part of the infra-spinatus is obscured by the thick posterior border of the *Deltoid* muscle.

The posterior edge of the deltoid passes from the spine of the scapula near its root or inner part downwards and outwards, and, in the dependent position of the arm, also slightly forwards, to its humeral attachment.

THE UPPER EXTREMITY

It is owing to the great development of the trapezius and deltoid muscles that the position of the spine of the scapula is often actually indicated by a furrow in the living subject.

The lower angle of the scapula is directed downwards when the arm is hanging by the side or is raised to form a right angle, or less, with the side.

If the angle formed by arm and side exceeds 90° , the inferior angle of the scapula moves outwards, owing to the rotation of the scapula upon the thorax around an antero - posterior axis, and it then becomes obvious in the back part of the armpit.



Fig. 23.—The Muscles of the Shoulder.

Together with the head of the humerus it determines the rounded form of the shoulder.

The curved and conspicuous *clavicle* is a useful landmark on the front of the upper part of the trunk, as it is subcutaneous and easily traced by eye or hand. It is joined to the sternum near the middle line of the root of the neck, and curves first forwards and outwards, then backwards and outwards, and finally a little forwards again to join the acromion process just above the shoulder-joint (Fig. 25).

THE UPPER EXTREMITY

Viewed from the front, the outer end of the clavicle is narrower, and is always situated on a higher plane than its inner end.

The remaining part of the deltoid—viz. its anterior part—arises from this thin anterior border of the

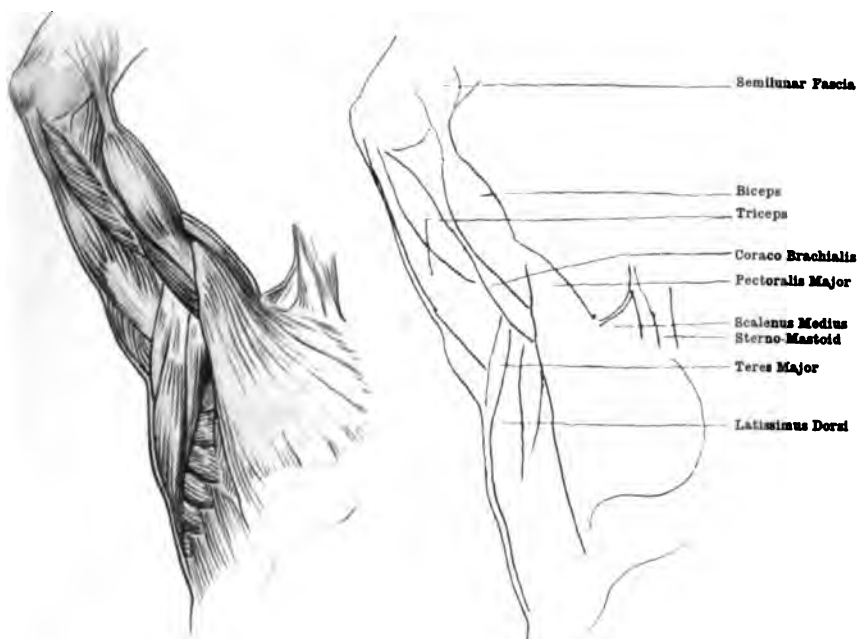


Fig. 24. — The Muscles of the Inner Surface of the Arm and of the Armpit.

outer third of the clavicle, also from its upper surface, and from the outer border of the acromion.

The anterior border of the deltoid is directed downwards, outwards, and slightly backwards as it converges upon the posterior border, the muscle being inserted by the apex of its delta into the middle of the outer surface of the shaft of the humerus.

THE UPPER EXTREMITY

The deltoid raises the arm at the shoulder, and it also has an important function in keeping the parts of the shoulder-joint in apposition.

Notice the tendinous intersections—four of origin

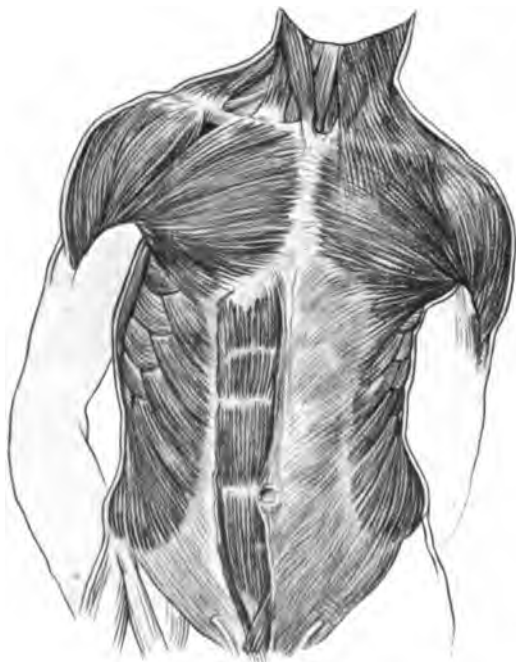

Fig. 25.—The Muscles on the Front of the Trunk and Neck.

and three of insertion—which groove the surface of the muscle longitudinally when in forcible action (Fig. 23, p. 78; Plate XX.).

The Pectoralis Major (Figs. 24 and 25).—Arising from the anterior surface of the inner half of the clavicle, the clavicular portion of this fan-shaped

THE UPPER EXTREMITY

muscle passes outwards and slightly downwards to the upper part of the humerus.

The inclination of its upper border is less than that of the anterior border of the deltoid, so that the contiguous edges of these two muscles bound a narrow groove, which opens out above under the middle of the clavicle to form the infra-clavicular fossa.

In very thin persons the apex of the *coracoid process* may be seen projecting forwards in this fossa. It is situated below the anterior border of the clavicle in the outer part of the infra-clavicular fossa, and is in close contiguity, if not in actual contact, with the under surface of the clavicle at the junction of its outer and middle thirds.

The large *median cephalic vein* (Fig. 26) runs in the groove between the deltoid and pectoralis major muscles, and disappears in the infra-clavicular fossa. It is especially noticeable when hard manual labour is being performed.

So far we have only spoken of the thick clavicular head of the pectoralis major. There is, however, another and more extensive but thinner fan-like origin from the sternum and rib cartilages, the fibres of which passing outwards, and with increasing degrees upwards, converge to add to the thick mass of muscle whose tendon is inserted into the humerus, under cover of the deltoid muscle.

The thick rounded lower border is directed from

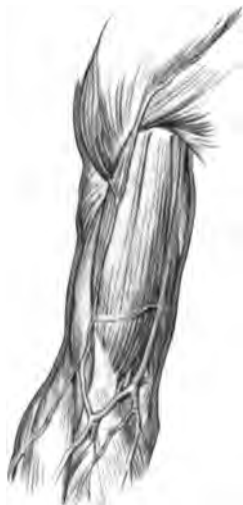

Fig. 26.—Muscles and Superficial Veins on Front of Arm and Elbow.

THE UPPER EXTREMITY

the bone of the seventh rib in its anterior part upwards and outwards to the humerus. About the middle of this border the inner part of the *pectoralis minor* may sometimes be seen as a slight ridge when the arm is raised above the head (Fig. 24).

Emerging from the under surface of the outer part of the *pectoralis major* is a ridge formed by the *biceps* and *coraco-brachialis* muscles (Fig. 24, p. 79). The *pectoralis major* in its extreme outer part passes under the anterior part of the deltoid.

The Axilla or armpit (Fig. 24).

This is a pyramidal space with its base directed downwards and outwards, and its apex directed upwards and inwards behind the clavicle. In the adult the skin covering its base bears long, coarse hairs.

The armpit is bounded *in front* by the *pectorales major* and *minor*; *behind*, by the front of the scapula—or rather the *sub-scapularis* muscle, which arises therefrom, but is unimportant to the art student—and by the *latissimus dorsi*, which winds from behind forwards and outwards in a spiral manner round the lower portion of another muscle in this region named the *teres major*. Both of these muscles are attached to the humerus near the *pectoralis major*.

The *pectoralis major* from the front, and the *latissimus dorsi* from behind, thus converge upon the humerus, a small width only of which forms the narrow *outer wall*, while the wider *inner wall* of the unequally four-sided pyramidal armpit is formed by the thoracic wall covered by the *Serratus magnus*.

This important muscle arises by “digitations,” which are very obvious on the side of the chest when the muscle is in action (Figs. 24, 25, pp. 79, 80), from the nine upper ribs, half-way between the vertebral column and the sternum. Passing horizontally

THE UPPER EXTREMITY

backwards in front of the scapula, the sheet which is constituted of these digitations is attached to the front of its inner or vertebral border.

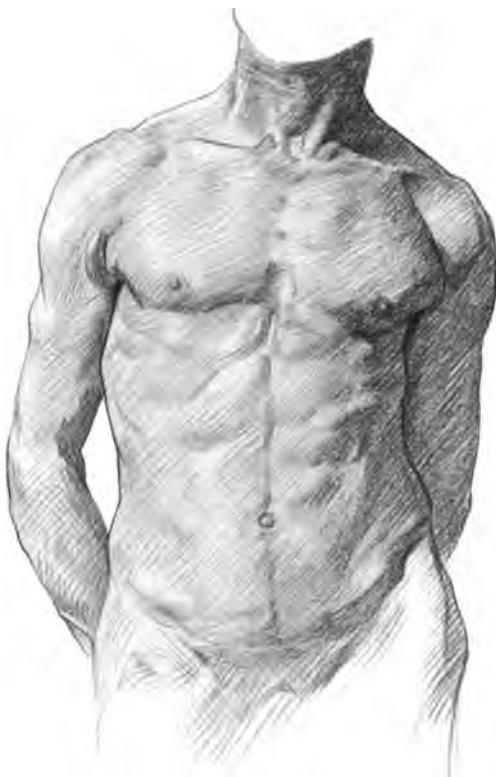

Fig. 27.—The Muscular Prominences on the Front of the Trunk and Neck.

The muscle is brought into use when the upper limb is outstretched, because it fixes the scapula, and so gives the muscles which arise from the latter a fixed origin from which to act.

THE UPPER EXTREMITY

The *Coraco-brachialis muscle* lies on the inner side of the short head of the *Biceps*. It passes from above downwards on the outer wall of the armpit (Fig. 24).

The Arm denotes anatomically only that part of the subject which extends from the shoulder to the elbow (Figs. 4, p. 39; 19, p. 74; 22, p. 77).

The two last-mentioned muscles form a distinct ridge on the front of the limb, which is more prominent when the arm is lifted up from the side, and which is seen emerging from under cover of the outer part of the *pectoralis major*.



Fig. 28.—The Front and Inner Side of the Upper Extremity.

The *coraco-brachialis* (Fig. 24, p. 79) terminates half-way down the arm, where it is inserted into the humerus.

The short head of the *Biceps* joins with the long head, which also emerges from underneath the *pectoralis major*, to form a fusiform mass of muscle,

thicker in the middle than at its extremities, and very prominent upon the front of the arm when thrown into action.

Even when it is not in a contracted condition, as it is in Fig. 28, an obvious ridge, extending the whole distance of the lower two-thirds of the arm, may be observed (Fig. 29).

As the tendon passes to its insertion in the tuberosity on the radius, it becomes narrow and tendinous. The tendon may be traced as a sharp ridge vertically

THE UPPER EXTREMITY

across the hollow in front of the elbow nearly to its insertion.

The Semilunar fascia (Figs. 24, 26, 28) is a thin but strong fibrous expansion from the biceps in the upper part of the front of the forearm, extending from the inner border of the tendon of the biceps downwards and inwards to join the deep fascia of the

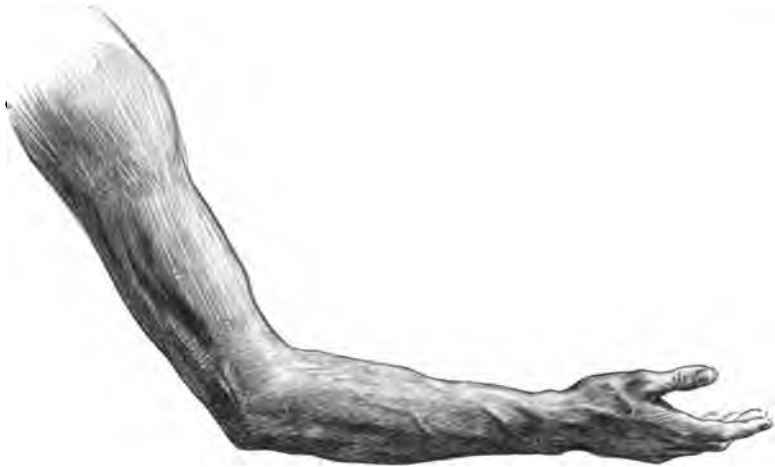

Fig. 29.—The Outer Side of the Right Upper Extremity.

forearm, and indenting transversely the mass of muscles which arises from the internal condyle of the humerus.

On each side of the biceps is a groove (Fig. 26); in the outer lies the *cephalic vein*, in the inner the *basilic vein* and *brachial artery*, the latter more deeply situated, but visible sometimes in thin old persons, and especially if it is tortuous.

Lying behind the biceps on the inner side of the arm is the inner head of the *Triceps*, which arises from the humerus all the way from the lower border

THE UPPER EXTREMITY

of the pectoralis major to the internal condyle of the humerus (Figs. 24, 28, 30).

To the outer side of the biceps in the upper half of the arm is the great mass of the deltoid muscle (Figs. 22, 23, 26), and in the lower half, arising from the external supra-condylar ridge, are the *Supinator longus*, a muscle which is chiefly important as a flexor of the elbow joint, and forming when in the contracted condition a very obvious swelling; and the *Extensor carpi radialis longior*, a smaller and very similarly arranged muscle lying below and behind the supinator longus (Figs. 19, 22, 30).

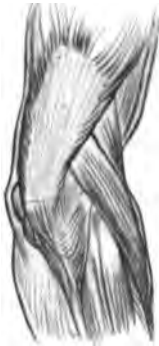

Fig. 30.—Muscles on the Back and Outer Side of the Right Elbow-Joint.

The furrows which lie on each side of the biceps converge below where the mass of the muscle narrows, and terminate in a hollow on the front of the elbow called the *Ante-cubital fossa*. This fossa is triangular, with its base, directed upwards, opposite the elbow-joint (Figs. 26, 31, 34, 35).

An important vein lies in the lower half of the groove upon the inner side of the biceps. It is known as the *basilic vein*. At the centre of the arm it passes through the deep fascia, and disappears from view to join the deep veins of the arm accompanying the brachial artery (Figs. 26, 33, 35).

The back of the arm presents for examination two large muscles, the deltoid and the triceps.

The posterior border of the deltoid runs from the inner part of the spine of the scapula downwards and outwards to the insertion of the muscle a little above the centre of the outer surface of the humerus. This ridge of muscle bounds a deep and obliquely placed

THE UPPER EXTREMITY.

groove which lies parallel to and immediately below it, and is succeeded again by the mass of the *Triceps* (Figs. 22, 23, 29), which passes downwards with a slight inclination inwards, to terminate below by being inserted into the upper part of the *Olecranon process*, or point of the elbow (Fig. 30).

A second groove, passing similarly downwards and inwards, across the inner part of the back of the arm but nearer to the elbow, separates the upper and outer humeral head from the inner and lower humeral head of the triceps (Figs. 19, 22, 29).

When the arm is abducted from the side against resistance, three other features are to be noted upon the posterior aspect of the arm.

First, below (*i.e.* in the present abducted position of the arm) the posterior deltoid border, the scapular, or long, head of the triceps forms a slightly elevated ridge, passing from the back of the shoulder-blade to the arm (Fig. 24; Plates XIII., XVI.).

Secondly, above the triceps, the biceps muscle may be seen, producing a marked prominence (Plate XVI.).

Thirdly, the skin over the deltoid presents some longitudinal grooves, which indicate the position of some tendons within that muscle (Plate XX.).

Thus it is to be noticed that, although the biceps is situated on the front of the arm, so prominent is it that a portion of it may be seen from the back on the outer side of the arm; and similarly we have already pointed out (p. 85) that the triceps, although situated upon the back of the arm, can be seen also, in part, from the front.

The Elbow.—The bony landmarks are very obvious. The “point of the elbow” is formed by the posterior part of the upper surface of the *olecranon process* (Fig. 5, p. 40). It bounds above a triangular

THE UPPER EXTREMITY

subcutaneous area of bone, the sides of which converge below to form the posterior border, which is also subcutaneous, of the ulna.

The *internal* and *external condyles* of the humerus lie a little above the bend of the elbow. The internal condyle is the more prominent, partly because of its actual size, and partly because the muscles arising from the external supra-condylar ridge of the humerus obscure the external condyle (Fig. 30). The two condyles lie on the same level, and the olecranon just

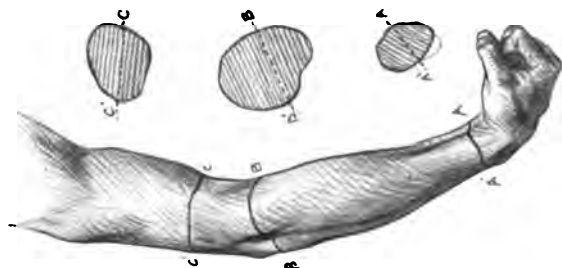


Fig. 31.—The Outer Side of the Upper Extremity, with indication of the varying shape of transverse sections at different levels.

comes up to this level in the extended position of the elbow-joint, but in the acutely flexed position these three bony eminences form the apices of an equilateral triangle.

A transverse section of the arm above the elbow is nearly circular. The forearm just below the elbow is flattened from before backwards and bulges laterally. It tapers towards the wrist, but remains more flat in males, while in females it has a more circular outline (Fig. 31).

The Carrying Angle.—The extended forearm makes with the arm an angle of 160° or thereabouts, open outwards (Fig. 35). This “carrying angle,” as it is called,

THE UPPER EXTREMITY

diminishes progressively as the arm is flexed until it completely disappears in full flexion (Fig. 32). Indeed, by the time the elbow is fully flexed, the hand will be seen to have been carried over actually on to the inner side of the arm. The presence of the carrying angle is independent of supination or pronation of the hand, and is of great importance mechanically; indeed, it looks very much as if it was designed to allow weights which are being carried, *e.g.* a bucket, to swing clear of the pelvis and lower limbs, thus saving much muscular effort. The carrying angle is due to the large size of the inner lip of the trochlea of the humerus (Figs. 3 and 4, pp. 38, 39).

The Forearm.—The triangular *ante-cubital fossa* is bounded on each side by prominent ridges of muscles (Figs. 26, 33, 34).

On the inner side is the ridge formed by the *super-*

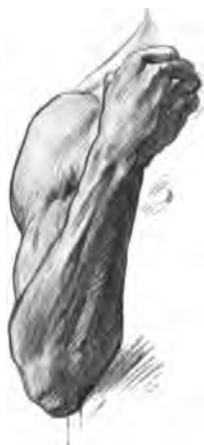

Fig. 32.—The Back of the Forearm and Hand, showing surface markings of muscles and tendons. Notice the disappearance of "carrying angle," when arm is flexed at elbow.

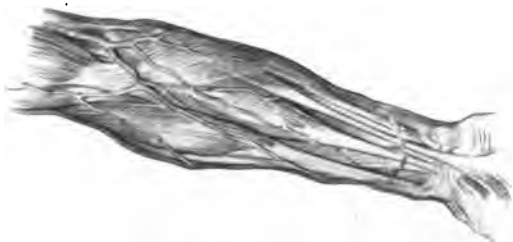

Fig. 33.—Muscles and Superficial Veins on Front of Right Forearm.

ficial flexor muscles of the hand and the *pronator radii teres*. The latter is inserted into the middle of

THE UPPER EXTREMITY

the outer surface of the radius. Notice the wisp of *semi-lunar fascia* springing off the inner side of the tendon of the biceps and passing inwards over, and indenting, the mass of muscle just below the internal condyle (Figs. 24, 26). The indentation is most obvious when a muscular subject strongly flexes and supinates the forearm. The ridge which bounds the triangle externally is formed by the *supinator longus* muscle (Fig. 26). Under this the pronator radii teres passes to its insertion, and it is by the convergence of these muscles that the apex of the fossa is formed at

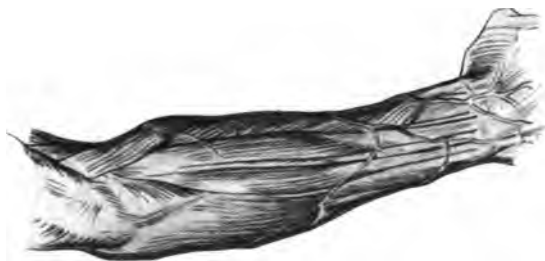

Fig. 34.—Muscles on Back of Right Forearm.

a point which lies under cover of the largest of the superficial veins depicted in Fig. 33, p. 89.

Lower down the limb tapers gradually, because the muscles give place to tendons, only two of which are prominent on the surface, viz. the *palmaris longus* and the *flexor carpi radialis*. These two tendons lie one on each side of the mid point at the wrist (Fig. 33).

[A slight prominence which affords no evidence of extensive muscular development may occasionally be seen on the front of the forearm two or three inches above the wrist in the middle line. It is due to an extra muscular belly formed in connection with the *palmaris longus*.]

THE UPPER EXTREMITY

The “*pulse*” in the radial artery may sometimes be seen, and nearly always felt, just external to the flexor carpi radialis tendon.

On the inner side of the tendons previously mentioned is the *flexor carpi ulnaris*. This does not produce any external form, but internal to it is a small shallow depression (Fig. 28).

The Veins of the Forearm (Figs. 26, 29, 33, 34, 35).—The main superficial veins of the forearm are found chiefly upon the front. They may be made to stand out much more clearly than usual if the fist be repeatedly clenched, especially if some constricting band is lightly applied meanwhile just above the elbow. Under these circumstances the veins will be dilated at intervals in bead-like eminences, due to the presence of valves within them.

These veins drain the hand. The *median vein* passes from the radial border of the lower part of the forearm to the ante-cubital fossa, where it divides into two branches, viz. :—

1. The *median cephalic*, which joins with some veins passing from the radial side of the upper two-thirds of the forearm, to form the *cephalic vein*, and to pass upwards in the groove on the outer side of the biceps

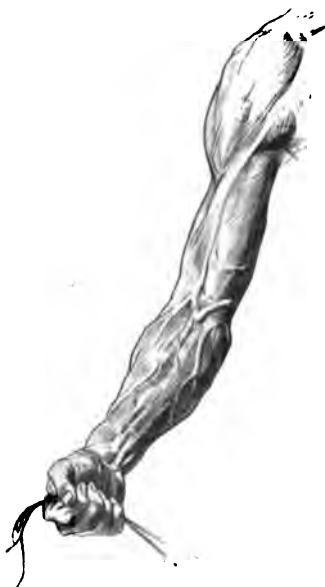

Fig. 35.—Right Upper Extremity.
Surface markings of Muscles,
Tendons, and Superficial Veins.

THE UPPER EXTREMITY

muscle, afterwards entering the groove between the pectoralis major and the deltoid, where it has already been alluded to.

2. The *median basilic*, which passes over, or superficial to, the semi-lunar fascia and joins with some veins draining the ulnar side of the forearm to form the *basilic*, and then up the arm on the inner side of the biceps. This vein is not seen when it reaches the middle of the arm, as it then ceases to be superficial.

The median basilic is the vein which is most conveniently opened for the purpose of blood-letting, a practice quite fashionable a few decades ago, and still resorted to occasionally.

If we now study the back of the forearm (Figs. 29, 30, 32, 34), the first thing to be noticed is the triangular subcutaneous area of the ulna below the olecranon process, continuing downwards into the posterior border of the shaft of the ulna, and easily traceable by the examining finger right down to the prominent little head of the same bone near the wrist. This border of bone lies close to the inner aspect of the forearm, being as a rule at the bottom of a small but distinct furrow, because it is subcutaneous all the way and therefore easily felt. The furrow is bounded by two ridges; that on the inner side is due to the *flexor carpi ulnaris*, and that on the outer side, less well marked, to the *extensor carpi ulnaris* muscle.

External to the olecranon is a slight fossa (Figs. 30, 31), in which the *head of the radius* lies, and can be felt and sometimes seen. A distinct furrow runs downwards and inwards from this fossa, and to its outer side is a ridge due to the muscular mass of the *extensor communis digitorum*, which when it contracts draws the fingers backwards (Figs. 31, 32, pp. 88, 89, and Fig. 34, p. 90).

Another slight groove to the outer side of the

THE UPPER EXTREMITY

extensor communis separates this muscle from the *extensor carpi radialis brevis* above and from the *extensor ossis metacarpi pollicis* below.

The *anconeus* (Fig. 34, p. 90) is a very short muscle which forms a triangular mass extending from the external condyle towards the posterior border of the ulna.

The tendons of the extensor muscles (Fig. 34) passing to the fingers are placed in deep grooves on the back of the radius and ulna, and cannot be seen through the skin till they get below the wrist, being hidden above by dense deep fascia.

It is probably a very common rule that when any muscle in the limbs is thrown into voluntary action its opponent undergoes a simultaneous but slighter contraction, so as to steady the moved part. A pretty illustration of this rule is found in the fact that if you watch the back of the forearm while you *flex* your fingers, however slightly, you will see the *extensor communis digitorum* become more prominent.

The Wrist (Figs. 36 *et seq.*).—This is the region which connects the hand with the forearm. On the inner side of the *Dorsum* or back of the wrist is a bony prominence formed by the *head of the ulna* (Plate XXXI.). The styloid processes of the ulna and radius, that of the latter being placed a little lower, can be easily felt, but, except in very thin persons, they cannot be seen.

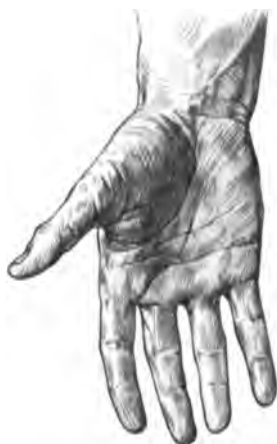

Fig. 36.—The Greases upon the Front of the Hand and Digits.

THE UPPER EXTREMITY

Although a large number of tendons pass from the extensor muscle bellies in the forearm to become obvious on the dorsum of the hand, none of them is visible at or above the wrist, because they are bound down and obscured by a transverse, or rather a

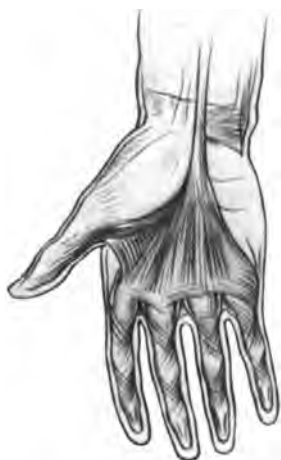

Fig. 37.—The Deep Palmar Fascia.

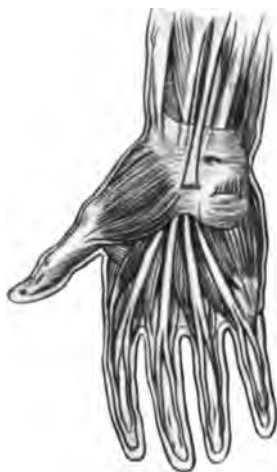

Fig. 38.—The Short Muscles of the Hand, and the Tendons passing under the Anterior Annular Ligament.

The Palmaris longus is cut as it passes over the annular ligament.

slightly oblique, band of the deep fascia, known as the *posterior annular ligament* (Fig. 34). It may be traced by dissection from the region of the lower end of the ulna to the outer surface of the radius on a rather higher level. This special thickening of the deep fascia bridges the grooves on the lower end of the radius and ulna, which transmit the extensor tendons from the back of the forearm to the dorsum of the hand.

THE UPPER EXTREMITY

The Hand (Figs. 31, 32, 35, *et seq.*) presents for examination the palm and the dorsum, and the fingers and thumb collectively known as digits.

The hand is broader and flatter than the wrist, the increased breadth being due in great part to the thumb. When this is bent into the palm—or, as the technical expression goes, when the thumb is “opposed”—the hand becomes much narrower, and its breadth approximates to that of the wrist.

The palm of the hand (Fig. 36 *et seq.*) is continuous with the front of the forearm, but its general surface is raised from that of the forearm by the thenar and hypo-thenar eminences, composed of small muscles. Between these two eminences is a hollow lined by a thick fibrous structure, *the palmar fascia*, which succeeds to a fibrous transverse arch, the *anterior annular ligament*, whose function is to form the roof of a tunnel through which the flexor tendons pass on their way from the front of the forearm to the front of the fingers. The walls and floor of the tunnel are formed by the carpal bones (Fig. 38).

The skin over the palm is very thick, and in persons accustomed to hard manual work it is horny. It is plentifully supplied with sweat-glands, but devoid of hairs and sebaceous glands. Certain lines or skin folds found on the palm will be described later.

The palm of the hand forms a shallow, saucer-like hollow, bounded above and at the sides by the *thenar and hypo-thenar eminences*, and below by the prominences at the bases of the fingers. When the fingers are forcibly extended, these prominences can be seen, and in every position of the fingers they can be felt, to be due to the heads of the metacarpal bones.

Between the four metacarpal heads there are easily seen, when the fingers are semi-flexed, three little

THE UPPER EXTREMITY

soft eminences—caused really by pads of fat. The slight depressions between these three eminences are due to the prolongations from the base of a triangular sheet of fibrous structure (Fig. 37), which is attached by its apex above to the anterior annular ligament. Below, at the root of the fingers, the base of the triangle is split into four processes, each of which is

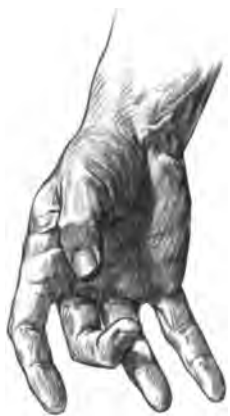

Fig. 39.—Showing Formation of Creases or "Lines of Flexion" in the Skin of the Hand and Digits.

attached to the tendon sheath on the front of a finger. The structure is dense and fibrous, and is known as the *palmar fascia*. It is continuous above with the *palmaris longus* (cut short in Fig. 38, p. 94). The *anterior annular ligament* is a strong fibrous bridge springing across from the base of the thenar eminence to the base of the hypothenar eminence. Its superficial surface is about the size of a postage stamp placed transversely, and under it the flexor tendons pass from the front of the forearm into the palm of the hand.

The *lines on the palms*, upon which "palmistry" is founded, are due to the varied and frequent movements of the fingers and thumb and the presence of underlying muscles. Their actual position and length undoubtedly vary in different individuals.

A very brief description of these lines must suffice (Fig. 36, p. 93, and Fig. 39).

There are three main lines. The first passes from the inner side of the upper end of the thenar eminence and curves downwards and outwards to

THE UPPER EXTREMITY

a point on the outer border of the palm, situated half an inch below its centre, and on a level with the distal part of the outstretched thumb. This line is due to the movement of the thumb in "opposition" (p. 95), an action brought about by the short muscles of the thumb which form the thenar eminence.

The second line passes from the inner border of the palm, three-quarters of an inch above the little finger, to the cleft between the index and middle fingers, but to the outer part of the cleft. It is made obvious by flexing the inner three metacarpophalangeal joints while the index and thumb are extended.

The third main line passes outwards from the lower part of the hypo-thenar eminence between the other two main lines, and reaches the outer border of the hand one inch above the index finger, on about the same transverse level as the point at which the second line begins. It is made obvious by flexing the four inner metacarpophalangeal joints.

The thenar eminence at the base of the thumb is especially scored by numerous smaller lines.

The fingers are not attached to the palm on an exactly transverse plane. Their line of attachment is slightly curved, so that the cleft between the middle and ring fingers is one-third of an inch further from the wrist than the clefts between the other fingers.

The Back of the Hand.—The skin on the back of the hand is rougher, looser, and thinner than that of the palm. It is covered with fine hair, and immediately beneath the skin lies an irregular *venous plexus* which receives the veins from the digits. There is usually discernible a more or less well

THE UPPER EXTREMITY

marked venous arch, with convexity towards the digits, which receives these digital veins.

In delicately nurtured hands the veins appear as thin blue lines; in the horny hand of the labourer they are tortuous, dilated, and bulging; in old age they become more obvious, and so do the spaces between the metacarpal bones, owing to the wasting of the soft tissues.

Upon the back of the hand, and situated underneath the veins, are various ridges corresponding to the *tendons* of the extensor muscles of the fingers. (The thumb is not now being described.) These ridges are seen to great advantage when the wrist is extended, *i.e.* bent backwards, and the metacarpo-phalangeal joints extended and the interphalangeal joints flexed, and the hand kept tight in this position (Fig. 40).

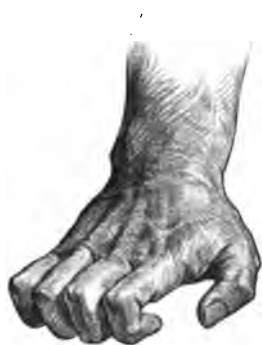

Fig. 40.—The Hand in the best position for demonstrating the Extensor Tendons.

Certain tendons make more obvious and constant ridges than others. Thus, in most subjects, the tendons passing to the middle and ring fingers stand out distinctly as compared with those passing to the index and little fingers. The tendons passing to the index and little fingers are duplicated, a fact which doubtless is associated with their freer movements.

The innermost tendon of the index finger sends a slip to join the tendon passing to the middle finger, and the tendon of the ring finger sends a slip on each side to the adjacent tendons of the middle and little

THE UPPER EXTREMITY

fingers. These slips lie subcutaneously, and may occasionally be seen close to the base of the fingers. They are probably responsible for the difficulty the pianist experiences in raising the ring finger independently of the others.

The Thumb.—It is chiefly the extraordinary mobility of the thumb that distinguishes the hand of man from the paw of the lower animals, including the anthropoid apes.

When it is in its natural position of rest its surfaces look inwards and outwards—an important fact, for the surfaces of the other digits look directly forwards and backwards. It follows from this that when the limb is extended with the palm looking to the front, the nail of the thumb can be seen, whereas the nails of the fingers are not visible—except, of course, in those Eastern races, and their rare Western mimics, who cultivate extraordinary length of nails.

The thumb rises from the surface of the palm in a distinct rounded prominence called *the thenar eminence*, oval, with its long axis directed downwards and outwards, and its skin scored by numerous transverse lines. Through this skin one or two veins may show, and occasionally in old persons the *superficialis volæ artery* may be observed pulsating as it pursues a vertical course across the thenar eminence, but it disappears suddenly before it reaches the palm.

The upper and outer free border of the thenar eminence is formed by the metacarpal bone of the thumb, and is straight, and inclined from the outer border of the forearm, with which it is continuous, at an angle of 45° , when the hand is in a position of rest with the palm forwards. This angle may, however, be increased to 60° or 70° by powerful abduction.

THE UPPER EXTREMITY

or by adduction of the thumb it may be wiped out altogether.

This outer border of the thenar eminence, if traced on to the two phalanges, becomes the outer surface of the thumb. The metacarpo-phalangeal joint is rather less than half-way from the base of the thenar eminence to the tip of the thumb, and is nearly always kept slightly flexed. It is not a joint which permits of much mobility, but such as it has is extremely important to the function of this most important digit. Near the termination of this outer surface, the thumb-nail breaks into its continuity; but short of this, in the part which corresponds to the first phalanx, the surface is concave.

The internal surface of the thumb (Fig. 40) is also concave opposite the first phalanx, convex opposite the second. It is united by a web to the outer border of the palm, a little above the centre of a line drawn from the upper limit of the thenar eminence to the base of the index finger.

The thumb is the shortest digit with the exception of the little finger. It is, however, much more massive than the other digits. Its shape is roughly cylindrical; at its root it is thicker from before back, and distally where the nail comes it is thicker from side to side. On its palmar aspect the skin presents the same characteristics as that of the palm. Its surface is broken at the joints by one or two lines of flexion; and shows multitudes of very fine lines, especially on the terminal phalanx, which, if studied with a hand lens, are seen to be arranged concentrically, but never exactly alike in any two individuals—a fact which has in recent years been used for the registration of criminals and others by taking and preserving their “finger-prints.”

THE UPPER EXTREMITY

These finer lines are seen over the whole palmar aspect of the hand and digits, and are associated with the high development in these regions of the sense of touch. On the outer, inner, and posterior aspects of the thumb the skin is similar to that on the back of the hand. On the distal knuckle of the thumb are numerous transverse lines.

The anatomical snuff-box is the name given to a depression on the back of quite the upper part of the thumb. Its boundaries are two ridges that are particularly obvious if the thumb is actively extended. The outer ridge is formed by the *extensor ossis metacarpi pollicis* and *extensor primi internodii pollicis* tendons; on the inner side the snuff-box is bounded by the ridge of the tendon of the *extensor secundi internodii pollicis* (Plate XXX.).

By waggling the thumb slightly while keeping it extended, each of these three tendons can be traced to the base of the bone indicated in its name.

The Fingers.—The middle finger is the longest, and the ring and index fingers are commonly of equal length. The bases of the three inner fingers are of about equal breadth, but the base of the index is broader than the others in the proportion of 11 to 10. With these figures as a guide, the base of the first phalanx of the thumb would be represented by the figure 12.

The fingers, as a rule, taper to their extremities, and the more they taper the more beautiful they are supposed to be; but the ends of the ring and middle fingers are frequently a little expanded. The fingers widen across the plane of the middle knuckles, but contract slightly across the plane of the distal knuckles.

Transverse lines are seen on the palmar surface

THE UPPER EXTREMITY

of the joints. The upper set lies three-quarters of an inch below the knuckle, the middle set exactly opposite, and the lowest set one-quarter of an inch above the corresponding knuckle (Fig. 39, p. 96).

The individual variations of the hand are considerable, and indeed second only in importance and interest to the variations in type and character of the head and face. Sir Charles Bell and Sir George Humphry have written most able accounts of this fascinating subject, and the student should turn to their books if he would fathom its interest. But even the most casual observer sees at the first glance the essential difference between the tapering fingers and small supple hand of the lady of ease, the large horny and rigid fist of the manual worker, the clubbed and bluish fingers of the chronic pulmonary invalid, the chubby "braceletted" hand of the infant, the podgy, smooth, insensitive hand of the well-fed successful man of sedentary habit, and the bony, dry hand of old age with its fingers all tending to lean their tips towards the ulnar side.

CHAPTER V

THE LOWER EXTREMITY

THE lower extremity comprises :—

1. The buttock.
2. The groin.
3. The thigh.
4. The knee.
5. The popliteal space.
6. The leg.
7. The ankle.
8. The foot.
9. The toes.

The buttocks are the massive parts of the body which lie at the bottom of the back on each side of the middle line. With the exception of the breast in females, there is no part of the healthy body in either sex which owes less of its shape to bone, and more to fat and muscle, than the buttock (Figs. 20, 21, 41, 42, 106, 107, 108, and Plates).

The great size of the region is peculiar to the human species. The maintenance of the erect position in bipeds is rendered possible by the development of the great gluteal muscles, but the thick layer of subcutaneous fat prevents their contours from being seen as well as they would be otherwise.

Without the powerful development of these muscles the erect position could never have been attained by man, yet once actually adopted, the maintenance of the attitude is facilitated by the ligaments on the

THE LOWER EXTREMITY

front of the hip-joint, and economy of strength is observed by this relegation of constant duty to in-extensible ligaments.

If these muscles were dissected away from the underlying bones, a deep and broad groove would be found between the great trochanter of the femur and the prominent portion of bone known as the tuberosity of the ischium, upon which we sit and from which the hamstring muscles arise. Now, this groove in the living body is not only completely filled up by muscles and fat, but it is overfilled, so that its position is marked by a massive prominence which prevents the bones from forming obvious landmarks in this region.

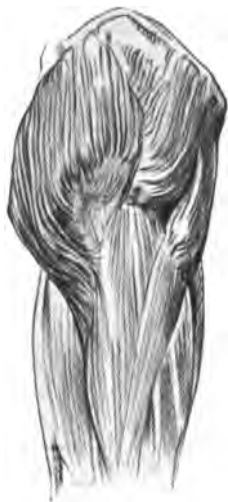

Fig. 41.—Gluteal Muscles and Ilio-tibial Band. Outer side of upper part of thigh.

The skin is thick and coarse, and the fat, even in ordinary individuals, is nearly an inch thick.

The *boundaries* of the buttocks are as follows:—

The *upper* limit is formed by the crest of the ilium, from which several large muscles arise—some passing upwards to the abdominal wall, some downwards to the thigh. The prominences formed by these muscles when well developed are separated by a groove, which does not accurately correspond, though it does roughly, to the iliac crest (*vide* Chap. VII.).

Internally the two buttocks are separated from each other above by the flattened termination of the spinal furrow, which is here supported by the upper

THE LOWER EXTREMITY

part of the sacrum, or, more precisely, by the upper three sacral vertebræ, the individual spines of each of which are easily felt, and sometimes seen. Below the sacral vertebræ the two buttocks are separated by a deep narrow cleft, continuous between the thighs with the perineum.

The *lower* limit of the buttock is formed by a well-marked furrow, *the natal fold*, sloping outwards and downwards from the median cleft, and running just below the level of the tuberosity of the ischium. The natal fold does not pass much beyond the middle line of the back of the thigh, for it then tapers rapidly away and turns slightly upwards, and leaves the outer half of the lower limit of the buttock quite ill defined. The natal fold does not correspond to, but crosses more horizontally, the very oblique lower border of the gluteus maximus (Fig. 42). Further, it becomes less and less well marked as the thigh is flexed (Plates XI., XIV., XXXVIII.). It is very important to grasp and bear in mind these two facts.

The *outer* boundary of the buttock is ill defined, but corresponds to a vertical line through the great trochanter of the femur.

On each side of the sacrum the buttocks are supported by the os innominatum, especially by the iliac part of that bone and by the tuberosity of the ischial part, which is easily palpable beneath the lower margin of the gluteus maximus.

The two tuberosities of the ischia form oval prominences upon which the body is directly supported in the act of sitting, no muscle actually intervening between the bones and the superficial fascia and skin. It follows that when the subject bends the hip beyond the right angle which is employed in sitting, the tuberosity emerges from under cover of

THE LOWER EXTREMITY

the gluteus maximus and becomes visible, and from it the hamstring muscles can then be seen to arise (Fig. 42).

The position of the tuberosity of the ischium, although it cannot in all positions be seen, can always be felt. Not far away are two other bony landmarks of great importance, with which the student is already familiar—the anterior superior spine of the ilium, and the tip of the great trochanter of the femur. If a rule be laid upon the anterior superior spine and also upon the tip of the great trochanter, its continuation will pass through the most prominent part of the tuberosity. This line is absolutely constant in the normal individual; it is called "*Nélaton's line*," and is obliquely placed, being directed from the front round the side of the buttock, backwards, downwards, and finally a little inwards.

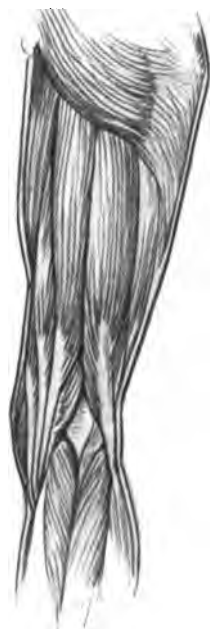

Fig. 42. — Muscles of the Back of the Right Thigh and Popliteal Space.

It is only in fat persons that the buttocks are pendulous, and in such case their most prominent part is a little below and internal to the tuberosity of the ischium.

It has already been pointed out that the fat in this neighbourhood is usually thick, and the outlines of the muscles consequently obscured; but if the body is bent forwards and then slowly raised, the gluteus maximus coming into vigorous action may generally be demonstrated.

THE LOWER EXTREMITY

The buttock is relatively larger in the female, because the pelvic skeleton is larger, and it is more rounded, because in this part, as in the thigh and chest, the female is apt to have a thicker covering of fat.

The gluteus maximus (Figs. 41 and 42, pp. 104, 106, and 20 and 21, pp. 75, 76) is one of the largest muscles in the body. It is made up of exceptionally coarse and thick muscle fibres, between the bundles of which lie quantities of fat and fibrous tissue. It forms a regular quadrate mass, which is directed obliquely from near the middle line at the base of the spine to the upper part of the femur, and that well-marked portion of the deep fascia of the thigh known as the *ilio-tibial* band.

The muscle has its origin from the back part of the crest of the ilium, from the sides of the sacrum and coccyx, and from the adjacent ligaments. Its upper and lower borders are parallel with each other. The upper border passes forwards and outwards, and somewhat rapidly downwards from the crest of the ilium; the lower border does not correspond accurately to, but rather cuts across, the outer part of the natal fold, and is continued onwards to the back of the upper extremity of the shaft of the femur.

The upper part of the insertion is into fascia forming the *ilio-tibial* band (Fig. 41, p. 104), and is not quite so prominent as the lower part, which is inserted into the femur.

In that part of the buttock which lies above the upper sloping border of the *gluteus maximus* and below the crest of the ilium, there is an extensive but shallow depression. This is occupied by the fibres of the *gluteus medius*, a fan-shaped muscle passing

THE LOWER EXTREMITY

from the outer surface of the iliac bone to the outer part of the great trochanter of the femur.

The chief action of the gluteus medius is to draw the lower limb away from the middle line of the body; of the gluteus maximus, to extend the hip-joint, as in raising the body from the position of the quadruped to that of the biped. By its attachment to the ilio-tibial band it also steadies the knee-joint. When it is in action, the ilio-tibial band is rendered taut, and produces a flattening, or even a furrow, upon the outer side of the thigh (Fig. 44).

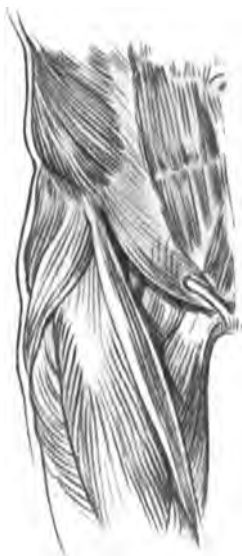

Fig. 43.—The Muscles in the Region of the Groin.

The Groin (Figs. 25, 27, 43, 44, 45, 46, 47) is a shallow oblique furrow which separates the abdomen above from the thigh below. It may, in fat persons, be obscured, or indeed overhung, by the fat of the abdominal wall (*vide infra*). This shallow furrow is continuous with the iliac furrow, which nearly corresponds to the crest of the ilium, on the side of the body. Its extent is from the anterior superior spine of the ilium to the pubic region, and its general direction is downwards and inwards. The furrow has a very slight convexity downwards and outwards, corresponding to the underlying and very important thickening of the tendon of the external oblique muscle named "*Poupart's ligament*."

The anterior superior spine of the ilium (Figs. 8, 9, 43 to 47), from which the ligament passes, is a small oval

THE LOWER EXTREMITY

prominence of bone on the side of the front of the body. The long axis of the oval is directed downwards and inwards.

The Thigh extends from the groin and buttock to the knee and popliteal space. It tapers considerably from above downwards, especially in the female (*vide* Plates), and becomes more circular as it approaches the knee. It is slightly constricted just above the knee, so that at the joint the limb slightly expands again (Fig. 44).

The outer side of the thigh is flattened; the inner side slopes from the inner end of the fold of the groin downwards and slightly outwards. Immediately below the furrow of the groin several important muscles are grouped in a region known as Scarpa's triangle, and some of them form very obvious surface markings.

The chief ridge is due to the long *tailor's muscle*, or *sartorius* (Figs. 43, 44, 45). Its course is very long and somewhat sinuous, reaching from an origin at the anterior superior spine of the ilium to an insertion at the upper end of the inner surface of the tibia, just below the knee, so that it passes over and acts upon two joints—the hip and the knee.

At its beginning the sartorius is directed downwards and inwards across the front part of the thigh, here forming the outer boundary of a slight hollow

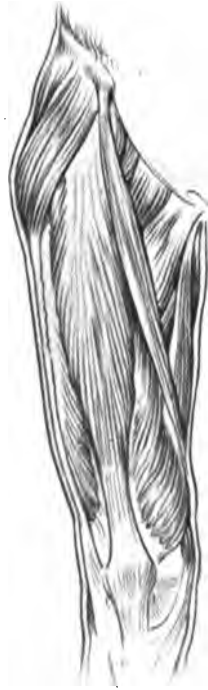

Fig. 44.—Muscles on the Front of the Right Thigh.

THE LOWER EXTREMITY

called *Scarpa's triangle*. At the junction of the upper and middle thirds of the thigh it reaches the inner side, and is directed downwards with a slight inclination backwards. It then passes down on the inner

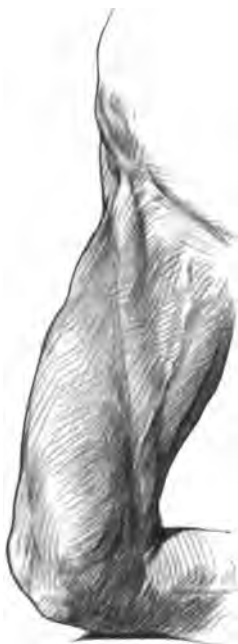

Fig. 45.—Inner Side of Thigh, showing Ridge formed by the Sartorius Muscle.

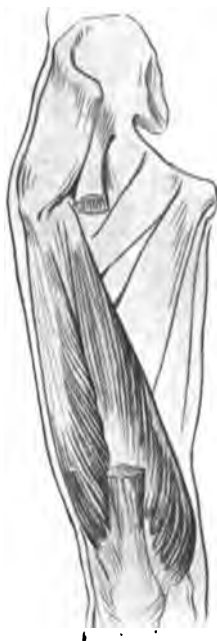

Fig. 46.—Vasti Muscles (shaded), Adductor Muscles (outline). Front of Right Thigh.

side of the knee, and finally turns forwards to reach its insertion into the tibia.

The outline of this muscle will usually be seen, even in fat persons, if the subject holds his limb so that the knee is flexed, and the hip flexed and strongly abducted, and rotated outwards (Fig. 45). This is

THE LOWER EXTREMITY

the old-fashioned tailor's customary position while sitting on his bench; hence the name of the muscle. It should, however, be understood that several other muscles are concerned in producing this movement.

Of the *adductor muscles* on the inner side of the thigh only the adductor longus needs mention here (Figs. 46 and 47). It passes from the front part of the pubic bone to the back of the middle of the femur. It starts above as a tendon and becomes much broader as it passes down. It lies in a doubly oblique plane—*i.e.* not only does it slope from above downwards and outwards, but also from before backwards, so that its inner and lower margin is much more prominent than its outer and upper margin. The adductor longus passes behind the sartorius and bounds Scarpa's triangle internally.

Poupart's ligament bounds this triangular hollow above. The apex of the triangle is formed below by the meeting of the adductor longus and the sartorius. The inner part of the hollow is deeper than the outer, where the head of the femur pushes the muscular floor of the triangle forwards.

The upper end of the large superficial internal or *long saphenous vein* passes upwards in the inner half of the triangle to within an inch and a half below the inner end of Poupart's ligament, where it dips

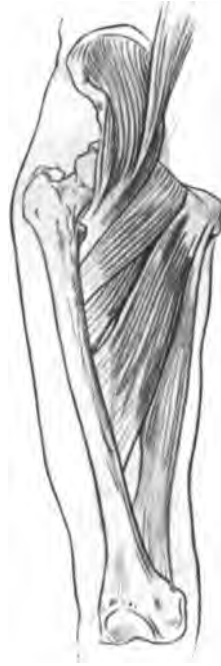

Fig. 47.—Ilio-psoas and Adductor Muscles of Thigh.

THE LOWER EXTREMITY

down among the deep structures to join the main vein of the limb, the common femoral vein. It is rarely visible unless abnormally large, or the subject very thin.

The quadriceps muscle (Figs. 43 to 46, and Plates) is a great mass lying deep to the sartorius on the front and sides of the thigh. It consists of four parts: the first three, the *vastus internus*, *vastus externus*, and *rectus femoris*, all produce obvious surface markings; but the *crureus*, which forms the fourth head of the muscle, although responsible in great part for its bulk, producing the general anterior convexity of the thigh, which is well seen in Fig. 45, is completely covered up by the other three heads.

The quadriceps mass emerges from under cover of the sartorius and passes to the knee. Its three visible constituents are:—

1. *The rectus femoris* (Fig. 44), forming the superficial anterior part of the mass. It pursues, as its name implies, a nearly vertical course, starting from the anterior superior spine of the ilium with a slight inclination inwards, and reaching to the upper border of the knee-cap.

2. *The vastus internus* (Figs. 44, 46), giving rise to a large prominent mass on the inner side of the lower half of the thigh. Good development of this muscle is one of the characteristics of great strength. In some positions of the limb its surface presents an oblique groove, some two or three inches above and internal to the knee-cap, best demonstrated perhaps when the subject stands on both legs but leans most of his weight on one. The groove will be noticed in the limb upon which the greater pressure is made, and it is directed downwards, inwards, and backwards (Plates XXVI., XXVII.).

THE LOWER EXTREMITY

3. *The vastus externus* (Figs. 44 and 46, pp. 109, 110), on the outer side of the thigh, extending from the great trochanter above to the patella below. On the general prominence formed by this muscle there is a shallow longitudinal groove or flattening produced by the *ilio-tibial band* (Plates XXII., XXVI., XXVIII. C), a longitudinal thickening in the deep fascial envelope of the thigh (the fascia lata), into which two muscles are inserted above, viz. the *gluteus maximus* and the *tensor fasciæ femoris* (Figs. 41, 44).

As a rule this groove is not obvious at a higher level than the middle third. Near the knee the band becomes more obvious as a ridge which terminates below in the external tuberosity of the upper end of the tibia, and lies a short way behind the tendon of the biceps muscle.

The *tensor fasciæ femoris* muscle, so called because it is inserted into (the front of) the ilio-tibial band, which is only a very strongly developed part of the deep fascia of the thigh, forms a prominent ridge running downwards from the anterior superior spine, with a decided inclination backwards (Figs. 43, 44).

Into the top end of the ilio-tibial band is also inserted the *gluteus maximus* muscle, but from behind. The band is very frequently taut and obvious, because

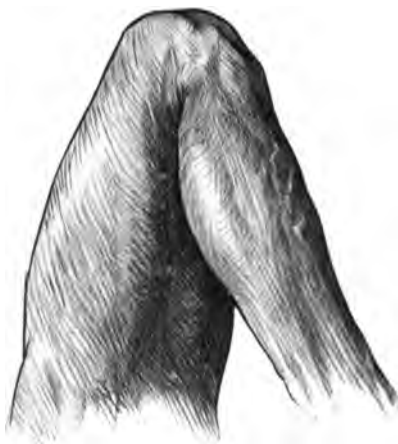


Fig. 43.—The Flexed Knee.

THE LOWER EXTREMITY

in most positions of the limb the muscles inserted into it have to be thrown into action in order to maintain the erect posture.

In the middle third of the thigh, and on its inner side, where the sartorius is passing nearly vertically downwards, this part of the muscle may not (as indicated in Fig. 45, p. 110) form a definite ridge, but may lie at the bottom of a groove which separates the adductor group of muscles behind from the quadriceps mass in front (Plates IX. and XXI.).

The adductor magnus muscle is chiefly responsible for the mass of the adductor group, although very little of it can be seen to produce a distinctive ridge. In its lower part the tendon of the muscle is capable of demonstration, forming a small ridge which ends just above the internal condyle of the femur in the *adductor tubercle*. This can always be felt, and can in some spare limbs be seen (Fig. 47, p. 111).

The great trochanter of the femur is easily felt in the upper part of the outer side of the thigh, covered to a certain extent, and therefore obscured, by the insertion of the great gluteal muscle. The actual position of the bone is marked by a slight hollow, yet the surrounding muscles form a pronounced general convexity in this region (*vide* Plates).

The back of the thigh is, as we have already seen, marked off from the buttock by the deep fold of the nates, which is the lateral and inferior continuation on each side of the deep median groove passing downwards from the coccyx and lying between the two buttocks.

Starting from the middle line, the two natal folds diverge, and each one curves at first downwards and outwards, then directly outwards, and finally even a little upwards and outwards, to terminate by gradu-

THE LOWER EXTREMITY

ally fading away at a point usually a little external to the middle line of the thigh (Plates XI. and XII.).

The bulk of the prominent muscularity of the back of the thigh is due to the *hamstring muscles*, along its whole length. They are three in number, and lie close together in the upper part of the thigh, where their superior attachments to the tuber ischii are concealed beneath the gluteus maximus, and they form when in action a single wide ridge (Fig. 42, p. 106).

The biceps, the largest, so called from its having a second head of origin from the femur.

The semi-membranosus, so called because it forms in its upper and lower parts a flat membranous band.

The semi-tendinosus, so called from its long thin tendon below, which is almost, if not quite, as long as the muscular portion.

These three muscles pass down the back of the thigh and, forming the "strings" of the "ham" or popliteal region (Figs. 42, 49, and 50), reach the bones of the leg below the back of the knee. It is of great importance to observe the manner in which they descend from their upper to their lower attachments.

Just before reaching the middle of the back of the thigh, the single ridge formed by their combined origin from the tuber ischii splits into two; the outer and larger and more prominent is the biceps, while

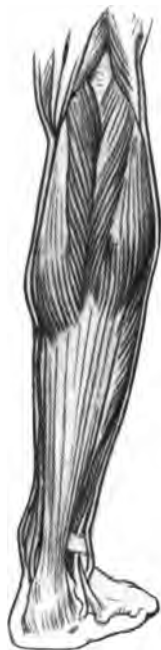

Fig. 49. — Muscles of the Popliteal Space and Calf of the Leg.

THE LOWER EXTREMITY

the inner is the semi-tendinosus, lying upon the semi-membranosus.

The two heads of which the biceps is composed cannot be distinguished from each other without dissection; the ridge it forms is single.

Not so, however, the inner ridge. Although it is true that in the upper part of the thigh the semi-tendinosus cannot be distinguished from the underlying semi-membranosus, this is by no means the case in the lower part; for here a secondary ridge or crest, sharp and prominent and formed by the tendon of the semi-tendinosus, lies upon the main eminence, which is broader and is formed by the semi-membranosus (Fig. 42, p. 106).

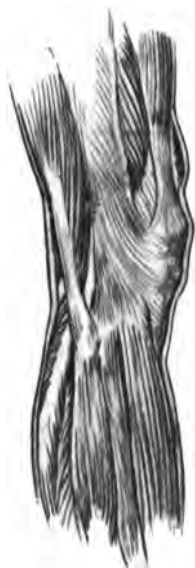

Fig. 50. — The Outer Side of the Knee.

These two main ridges, one on each side of the middle line of the back of the thigh, diverge as they travel down the thigh, till the biceps, passing to the outer side of the popliteal space, gains its lower attachment in the head of the fibula; while the other two muscles, passing the popliteal space well to the inner side, gain their insertions on the inner surface of the upper end of the tibia with the sartorius.

These ridges differ, then, in constitution and direction, but there is yet another difference to be carefully studied. The biceps muscle is inserted into the fibula by a moderately long, rope-like tendon (Fig. 50). The ridge produced by the biceps muscle itself therefore narrows rapidly into this tendon as it

THE LOWER EXTREMITY

travels down past the middle of the back of the thigh, and it is not obscured by any other structure. This point is one of great importance.

Similarly, the semi-tendinosus muscular belly rapidly gives place to its much smaller tendon as it is traced downwards.

But the main inner ridge, formed by the semi-membranosus, narrows comparatively little. The semi-tendinosus stands out much less conspicuously than the biceps.

Upon the outer side and in front of the bicipital ridge is a well-marked groove, succeeded by the ilio-tibial band, stretching from the gluteus maximus to the knee. In front of this band, again, lies the flattened outer side of the thigh, the muscular bulk of which is chiefly contributed by the vastus externus.



Fig. 51.—Muscles on Inner Side of Lower Half of Thigh.

The Region of the Knee (Figs. 45, 48, 49, 50, 51, and 52).

It will have been observed that in the thigh the general shape of the limb is chiefly due to the large and important muscles. But very different causes influence the shape of the knee, for the chief prominences are formed not by muscles, but by the underlying bones. These are the *patella*, the lower end of the *femur*, and the upper portions of the *tibia* and *fibula*.

When the knee is viewed from the front it will be observed that the inner side is much more prominent than the outer, and shows, especially in women, a marked convexity, while the outer side

THE LOWER EXTREMITY

is generally flat, but may even present a slight concavity (Fig. 52).

The upper and lower limits of this concavity, or flattening, lie wider apart than the limits of the internal convexity. In other words, the external concavity occupies a considerable length of the limb, while the internal convexity is short and sharp. It is produced by the *internal condyle of the femur* and the *internal tuberosity of the tibia*. The eye will not tell you where the femur ends and the tibia begins unless the knee is flexed. In a sitting position when one knee is crossed over the other, the internal tuberosity of the tibia is seen to be slightly more prominent than the internal condyle of the femur. In muscular subjects the prominence of the vastus internus very much obscures the bold outline of the internal condyle (Fig. 51), but the internal tuberosity of the tibia is not similarly obscured by superjacent muscles. In thin persons, of course, the bony prominences are much more obvious, and in them the internal condyle may be observed to begin abruptly, about the point at which the adductor tubercle, for the insertion of the tendon of the adductor magnus, is found on the inner side of the knee, half-way between the anterior and posterior surfaces.

In fact, it is the absence of great muscle-masses which allows the bony prominences about the knee to be so clearly recognised.

Although the external condyle of the femur may easily be felt upon the outer side of the limb, it is not usually seen as a marked prominence; nor is the external tuberosity of the tibia, and chiefly because of the biceps tendon and the ilio-tibial band (Fig. 50).

The most prominent bony point upon the outer side of the knee is that produced by the *head of the*

THE LOWER EXTREMITY

fibula. Like many other prominences this one lies, in well-covered persons, at the bottom of a slight depression. But if the knee is bent it forms almost always a definite prominence below the external tuberosity of the tibia and indeed well below it, so that the fibula is excluded from the knee-joint (Fig. 50).

The tendon of the biceps accounts for the well-marked ridge when the forcibly flexed knee is examined from the outer side, and will guide the finger down to the head of the fibula. In front of the bicipital ridge, notice the longitudinal groove, and in front of that again, the longitudinal prominence formed by the ilio-tibial band.

On the front of the knee, *the patella* or knee-cap is most obvious when the knee is extended or semi-flexed. It is the oval eminence which lies opposite the upper two-fourths of the convexity of the inner surface of the knee and the middle two-sixths of the concavity of the outer surface (Fig. 52).

The patella is much less noticeable when the joint is completely flexed. This is due to the fact that as the knee is bent the patella shifts from its position on the front of the femur to the inferior surface of that bone, here to lie in a groove and so to bury itself not only between the condyles of the femur, but also in the triangular space between the lower end of the femur and the upper end of the tibia (Fig. 48, p. 113).

The upper and lower edges of the patella are not so obvious as its lateral margins. The quadriceps muscle of the thigh is attached to the upper border,

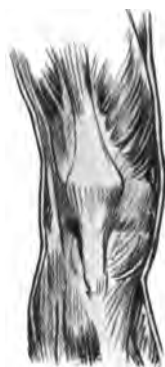

Fig. 52. — Muscles on the Front of the Right Knee.

THE LOWER EXTREMITY

and the *ligamentum patellæ* is fixed to the lower border, which is more pointed than the upper. The patella thus forms a connecting link between the quadriceps muscle and the *ligamentum patellæ*. The latter produces a well-marked ridge, and narrows as it descends to terminate in the tubercle of the tibia, upon which bone it acts as the tendon of insertion of the quadriceps muscle. The patella is the largest of the sesamoids, or little bones specially formed in tendons at the places where they glide over bony prominences. The *ligamentum patellæ* stands out conspicuously as the knee is extended, *i.e.* straightened out (Fig. 52).

The tubercle of the tibia, the *ligamentum patellæ*, and the pointed lower part of the patella receive the body weight when the kneeling posture is assumed, and the skin over them is very coarse. The front of the knee is marked by numerous transverse furrows, analogous to the wrinkles of the face, and to the lines of flexion upon the fingers and upon the palm of the hand.

When the leg is forcibly straightened, the loose fat which lies between the *ligamentum patellæ* and the tibia is squeezed and forms a slight bulging on each side of the ligament.

The *vastus internus* forms a much more obvious muscle-mass, just above the patella level, than does the *vastus externus*, and presents in the muscular a curious groove directed downwards, inwards, and backwards (*vide p. 122*). The maintenance of the erect posture depends both at hip and knee rather upon ligaments than on muscles, so that the Quadriceps is often off duty, and then the patella falls somewhat forward.

The ham, or popliteal space (Figs. 42 and 49, pp.

THE LOWER EXTREMITY

106, 115), is the hollow behind the knee. But it must be remembered that it is a hollow only when the knee is bent, for when the limb is straightened out a prominence takes the place of the hollow. This is chiefly caused by the shape of the lower end of the femur and of the upper end of the tibia, both of which, but especially the former, are prominent, and press backwards the soft fat and other contents of the popliteal space, such as the main artery and vein and nerves of the lower limb.

The hollow of the ham proves on dissection to be diamond-shaped, with its vertical axis at least three times the length of the horizontal. The apices of the diamond may as a rule be easily seen without dissection, but the more obvious one is the upper.

The upper sides of the diamond are longer than the lower; thus there is more length in the part lying above the horizontal line joining the lateral angles of the diamond than there is in the part lying below.

It will be remembered that the hamstring muscles, as they pass down the thigh, form two ridges which diverge from each other. At the angle of divergence is the upper apex of the popliteal space. This is situated at the junction of the middle with the lower third of the back of the thigh. It will be quite plain that the biceps forms the upper and outer boundary, and the semi-membranosus and semi-tendinosus the upper and inner boundary of the diamond.

The lower sides of the diamond are formed by the two heads of the *gastrocnemius muscle*, and are much less prominent than the upper sides; in fact, they lack definition until dissected. The upper parts of the *gastrocnemii* are overlapped by the muscles which form the upper boundaries of the popliteal space.

THE LOWER EXTREMITY

There is yet another muscular ridge to be noticed in connection with the inner side of the knee. This is obliquely placed and directed from behind the prominence which is formed by the internal condyle of the femur, downwards and forwards, to terminate on the inner surface of the tibia, at or about the level of its tubercle (Fig. 42; Plate XXVI.).

The ridge is due to the tendons of the gracilis, sartorius, and semi-tendinosus muscles, all three of which have a common insertion, though they arise from the os innominatum at very different points nearly equidistant from each other. The gracilis arises from near the symphysis pubis, the sartorius from the anterior superior spine, and the semi-tendinosus, from the tuber ischii.

The external concavity and the internal convexity mentioned above in connection with the sides of the knee will repay close and careful examination, as they differ considerably in young children and adults of both sexes (*vide* Plates). The difference between the male and female is nowhere more pronounced in the limbs than in the region of the knee. The inward convexity is much more marked in the female than in the male, and in the child than in the adult, and is due in both sexes, first, to the inclination inwards of the femur as it extends downwards from the hip to the knee, and secondly, to the large size of the internal condyle.

Owing to the larger relative, and, frequently, absolute, distance between the acetabula of the pelvis, which is an exact indication of its breadth, the femoral inward slant is more pronounced in the female than in the male.

The line of the knee-joint itself is transverse; the legs lie parallel to each other, but the thighs incline

THE LOWER EXTREMITY

towards one another, and so some slight degree of that condition which, when exaggerated, is called "*knock-knee*" is apparent even in the normal subject.

By **the Leg** (Figs. 48, 49, 50, 53, and Plates) is meant anatomically only that part of the subject which extends from the knee to the ankle.

It is thicker and more circular in the upper part or calf, owing to the relatively large size of those muscles, which are usually well developed because in constant use. Legs vary more in extent of muscular development than appears to correspond with their variation in strength. Very extensive muscular development, such as appears to be aimed at by some exponents of so-called "physical culture," is no more necessary or desirable from the point of view of health, strength, or efficiency than from the point of view of beauty.

The leg is smaller in its lower half, and oval in cross section. The decreased calibre is due to the replacement of the muscles by their tendons, and the level at which this takes place varies in different types or nationalities; the negro has a high calf, just as the Scandinavian has a high cheek-bone.

Immediately below the knee the leg is not so thick as it is a little lower down, and again after rapidly and gracefully tapering below the calf it increases

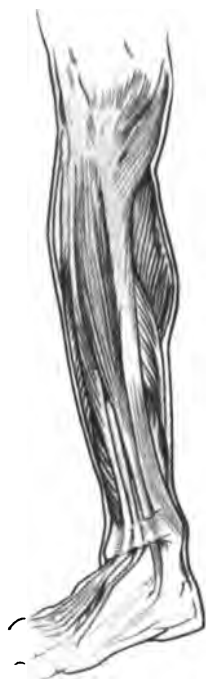

Fig. 53.—The Inner Side of the Right Leg.

THE LOWER EXTREMITY

a little in thickness when the actual ankle-joint is reached (Fig. 53).

The Bony Landmarks of the Leg.—*The shin* is formed by the inner surface of the tibia (Fig. 53), which is directed forwards as well as inwards, and by the sharp anterior border of the same bone. The anterior border of the tibia is named *the crest*; it pursues a sinuous course down the front of the leg, and is easily felt all the way from the tubercle of the tibia to the ankle-joint.

The crest is, in its upper two-thirds, slightly concave forwards, and in its lower third slightly convex.

The inner surface of the tibia, which extends subcutaneously along the whole length of the bone, tapers somewhat as it is traced downwards, but becomes expanded again in the region of the ankle-joint.

The crest and inner surface, which together form the shin, are for the most part immediately subcutaneous. In the upper part of the leg, however, the thin spreading tendons of the sartorius, gracilis, and semitendinosus muscles cover the inner surface as they come forwards below and inside the knee (Figs. 44, 51); and in the lower part of the leg, the crest of the tibia is obscured by the passage of the dorsal extensor tendons from the leg to the foot.

As an analysis of these tendons can readily be made without dissection, their relative positions will be described in more detail later (p. 127).

The bony prominences of the tibia and fibula in the region of the knee have already been noticed (p. 117); and with the exception of the shin, nothing more can be felt or seen of the bones till the region of the ankle is approached. Here the expanded lower portions of the tibia and fibula become again subcutaneous, and form two well-marked promi-

THE LOWER EXTREMITY

nences, the malleoli, situated one on each side of the ankle.

The internal malleolus of the tibia (Fig. 56), is more massive, but shorter and less prominent, than the external malleolus of the fibula (Fig. 57). The relative positions of these pointed lower extremities of the leg bones are as follows:—

The tip of *the external malleolus* is situated a full half-inch below and half an inch behind the corresponding point of the tibia. The external surface of the fibula is immediately subcutaneous for nearly three inches above the tip of its malleolus, but above this it is buried by the adjacent tendons and muscles.

The internal malleolus can be traced up into the subcutaneous shin.

Although the inner border of the tibia may be identified by the sense of touch, it is obscured from view by the bulging of the subjacent calf muscles on the back of the leg (Fig. 53).

In addition to the bony, muscular, and tendinous prominences, a careful inspection of the leg, which has habitually less fat than the thigh, will reveal three superficial structures, viz. the internal saphenous vein, the external or posterior saphenous vein, and the musculo-cutaneous nerve. They are all difficult to see except in thin subjects—and especially difficult is the nerve.

The internal, or *long saphenous vein* has already been described in the thigh (p. 111). In the leg it forms a blue line or ridge, just in front of the internal malleolus, and passes up the limb, just behind the shin, to the inner side of the knee, near the posterior aspect of which it lies. This vein receives several tributaries from the front and sides of the leg, and is liable to

THE LOWER EXTREMITY

be dilated at intervals, or to pursue a very tortuous course in those who are the subject of varicose veins.

The short, or *posterior saphenous vein* passes behind the external malleolus and reaches the back of the leg, where it occupies the middle line. Its course is straight to the back of the knee, and as it passes in this upward direction it lies between the two bellies of the gastrocnemius muscle.

If the foot is strongly bent downwards and inwards, the *musculo-cutaneous nerve* may occasionally be demonstrable as a faint, obliquely longitudinal ridge in the lower half of the front and outer side of the leg.

The prominences made by muscles in the leg are numerous, and fall into three groups. The first group comprises four muscles, three of which can usually be identified, and lies between the tibia and fibula on the front of the leg. The tendons of these muscles may be traced in favourable circumstances for their entire course as they pass to the upper surface of the foot.

The second group, which is made up of two muscles, lies on the outer side of the fibula, and its tendons also pass to the foot, but behind and below the external malleolus. This group is the smallest of the three.

The third group, which lies on the posterior aspect of the leg, may be further subdivided into the superficial massive muscles, which are inserted by the tendo Achillis into the heel, and the deep muscles and tendons which pass onward behind the inner malleolus to reach the sole of the foot, where for the most part they cannot be detected without dissection.

The first or anterior group of leg muscles are the *extensors* of the foot and toes. They comprise, from

THE LOWER EXTREMITY

within outwards, the *tibialis anticus*, the largest; the *extensor longus hallucis*; the *extensor longus digitorum*, the longest; and the *peroneus tertius*, the smallest, which may be regarded as part of the *extensor longus*.

The tibialis anticus (Figs. 50, 53) forms a prominent muscular mass on the outer side of the crest of the tibia, in the upper two-thirds of the leg, best seen when the toes are forcibly raised. The inner border of the muscle is separated, except in fat persons, by a groove from the crest of the tibia, and its outer border by another groove from the adjacent *extensor longus digitorum*. The *tibialis anticus* is often sufficiently bulky to endow the front of the leg with a longitudinal convexity, so that its contour viewed from the side is curved distinctly forwards when the muscle is in action (Fig. 48 and Plate XXI.).

This curve, due to a muscular prominence, must be carefully distinguished from any forward bowing of the tibia, which may be present, but only as a deformity. It has already been pointed out that the upper half of the normal tibial crest is slightly concave forwards.

In the lower third of the front of the leg, the muscular belly of the *tibialis anticus* gives place to a strong tendon, which may be rendered so prominent by forcible action of the muscle (as in raising and inverting the foot) that the ridge which it produces may be seen through the boot (Fig. 59).

As the tendon passes downwards to the foot, this ridge is found to be directed slightly inwards, and to pass over the lower end of the shin and part of the ankle-joint, slightly internal to the mid-point between the two malleoli. When the body is raised on tiptoe, both muscle and tendon stand out well.

THE LOWER EXTREMITY

The extensor longus digitorum (Figs. 50, 53) lies upon the outer side of the tibialis anticus in the upper third of the leg, in close relation to the fibula. The two muscles are separated by a groove which ends above in the head of the tibia, and not in the interval between the fibula and tibia. As this groove is traced downwards, it is interrupted or filled by the tendon of the *extensor longus hallucis*, coming to the surface and appearing to the outer side of the tibialis anticus (Fig. 53).

The ridge formed by the extensor longus digitorum muscle broadens out just above the ankle-joint previous to dividing into four tendons. This ridge is external to the mid-point between the two malleoli.

The peroneus tertius (Fig. 53, p. 123) is a small muscle which forms a slight elevation on the front of the leg in its lower third; but as its muscle is continuous with the ridge formed by the extensor longus digitorum, it has no defined limit above.

The muscle, in passing towards the foot, diverges a little from the extensor longus digitorum, and its tendon passes to the outer part of the dorsum of the foot (Fig. 54).

The second or external group of leg muscles comprises the two *peronei*—*longus* and *brevis*—as they run down the outer surface of the fibula.

The peroneus longus (Figs. 49, 50) lies behind the *brevis* and obscures its outline. Both *peronei* become tendinous in the lower third of the leg, and pass behind and below the external malleolus to the sole of the foot. The two tendons may usually be demonstrated, and they preserve the same relative position as the muscular bellies (Fig. 54).

The third or posterior group of leg muscles is the largest and the most characteristic of the three

THE LOWER EXTREMITY

groups. Its great size is due chiefly to the two superficial members of the group, though there are four other deeper and much smaller members. The gastrocnemius and soleus are very large, and lie upon the other muscles, the gastrocnemius being most superficial of all. This is the group that forms the calf of the leg.

The gastrocnemius (Figs. 48, 49, 53) has two prominent heads, an inner and an outer, both extending about half-way down the leg and separated by a deep vertical groove; the inner head is longer and broader than the outer.

The most prominent part of the calf of the leg lies at about the junction of the upper and middle thirds. The explanation of this is, that while the gastrocnemius arises from the lower end of the femur between the upper and diverging boundaries of the ham, the soleus (Figs. 49, 50, 53), at least in its main part, arises from the tibia and fibula considerably below the knee-joint. And although the gastrocnemius is responsible, so to speak, for the superficial expression of the calf of the leg, it is the soleus which chiefly influences its size and its general shape.

The gastrocnemius, in the lower half of the leg, tapers rapidly as it is traced downwards, and a very prominent longitudinal ridge is formed, which passes to the back of the os calcis or heel. The ridge is due to the presence of the thickest and strongest tendon in the body, the *Tendo Achillis* (Fig. 49, p. 115), which is the name applied to the conjoined tendons of insertion of the soleus and the gastrocnemii. It is about one inch broad at its lowest part, convex from side to side, and slightly concave from above downwards. The skin covering it is scored by transverse furrows, caused by the movement of the ankle-

THE LOWER EXTREMITY

joint; few and deep and striking in the infant (Fig. 58), more numerous and more superficial in the adult.

The edges of *the soleus* become prominent on each side of the *gastrocnemius*, and are seen to melt away completely into the *tendo Achillis* about three or four inches above the heel (Fig. 49).

The lateral parts of the calf, which, as has been pointed out, are formed by the *soleus* muscle, may easily be distinguished (even in the front view of a muscular leg), as they bulge outwards beyond the inner border of the *tibia* on the inner side of the leg, and the *peroneus longus* muscle on the outer side (Plate XXVI.). The four deep muscles of the calf are completely covered by the *gastrocnemius*, the *soleus*, and their *tendo Achillis*, and cannot be seen without dissection.

On each side of the *tendo Achillis* there is a marked hollow. These hollows are continuous with depressions lying behind and below each *malleolus*, and gradually disappear as they are traced upwards.

The functions of these two large muscles, viz. the *gastrocnemius* and the *soleus*, are of great interest. By raising the back part of the *os calcis*, which lies behind the axis of the ankle-joint, they forcibly depress the foot, and are thus, as will be seen later, of great use in the act of walking (Fig. 60). Further than this, the *gastrocnemius* assists in maintaining the erect attitude by means of its action upon the knee-joint, and so is in constant use. This explains why the muscle is so membranous compared with the *soleus*, as, for constant use, membrane, which is a lowly organised but elastic tissue, is much more economical than muscle, which is very highly organised.

It is important to notice that the *tendo Achillis* does not extend as far as the lowest level of the back

THE LOWER EXTREMITY

part of the os calcis, but only to its middle (Fig. 49). The lowest level of the backwardly projecting os calcis forms the actual heel, and is obscured by a very thick pad of fat, upon which the weight of the body is received when the heel is brought to the ground in the act of walking or jumping.

When the leg is viewed from the side, the calf of course presents a marked convexity occupying the upper two-thirds of the leg in white races—decidedly less in negroes.

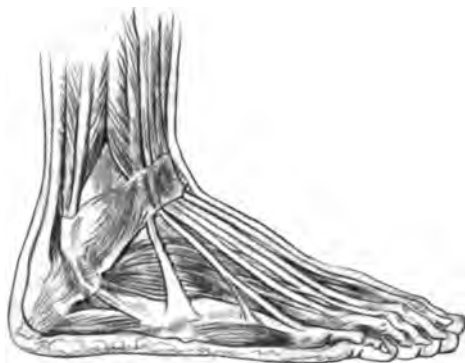


Fig. 54.—Extensor and Peroneal Muscles and Tendons of Foot. Outer surface and Dorsum.

The Ankle is the joint at which the foot is set on to the leg at about a right angle. The malleolar prominence on each side, the several tendons on the front of it, and the one large tendo Achillis at the back, with hollows on each side of it, have already been described with the lower part of the leg.

There is a marked, and not easily explicable, difference in individuals in the girth of the limb at, and just above, the ankle.

The Foot (Fig. 55), although constructed in much

THE LOWER EXTREMITY

the same way as the hand from the scientific anatomist's point of view, differs from it in many respects, all of which are of great importance to the student of art.

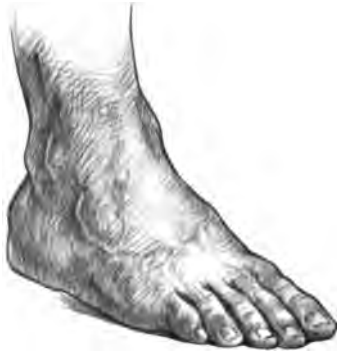

Fig. 55.—The Dorsum of the Foot.

Thus the angle which the main axis of the foot makes with the leg is rather more than a right

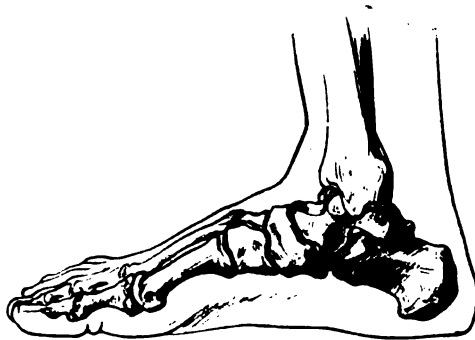

Fig. 56.—Bones of Right Foot. Inner side.

angle. Further the foot is usually turned outwards at an angle of about ten degrees from the strictly antero-posterior line. This angle of torsion of the

THE LOWER EXTREMITY

foot upon the axis of the leg varies, however, very much. It may amount to nothing at all, or it may be very much greater than usual.

Formerly drill instructors commonly taught that the outward pointing of the toes was essential to powerful walking and running; further observation has, however, demonstrated that the athlete in making a big effort is prone to invert rather than evert his toes (Plate XXVII. C, XXVIII. B).

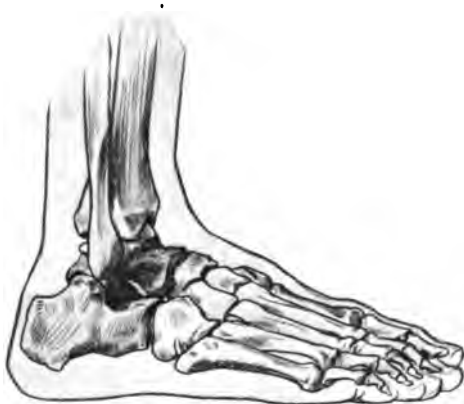

Fig. 57.—Bones of Right Foot. Outer side.

The foot is broader and flatter in front than behind, where it is thicker and more cylindrical. The comparatively great breadth in the neighbourhood of the toes is the characteristic feature of a natural and beautiful foot, and it is a thousand pities that this fact is not recognised by the genius which directs the fashions emanating from the boot factories.

The great breadth of the foot is especially well seen in infants, partly because there is less arching of the foot than in an older subject (Fig. 58).

THE LOWER EXTREMITY

In the natural state the foot is broadest at the root of the toes, or perhaps a little behind this level. The breadth is a little less at the points of the toes, unless the body is raised on tiptoe, when the broadest part

is at the level of the toes (Plate XXVII. C). As indicated before, the foot becomes narrower as it is traced backwards.

Various bony prominences mark the surfaces and borders of the foot. A description of these must presuppose a knowledge of the relative positions of the internal and external malleoli, which have already been described.

On the inner surface (Figs. 56, 58, 59) of the foot the following bony points may be recognised:—

The tubercle of the scaphoid or navicular bone produces a prominence one inch



Fig. 58.—To show the attitude and proportions of an infant who is learning to walk.

below the tip of the internal malleolus and one inch and a half in front of it. Though actually situated chiefly upon the under surface of the bone, this tubercle cannot be felt so well upon the sole of

THE LOWER EXTREMITY

the foot, owing to the thickness of the structures there lying superficial to it.

If the upper and lower levels of the inner surface of the foot be observed, the tubercle of the scaphoid

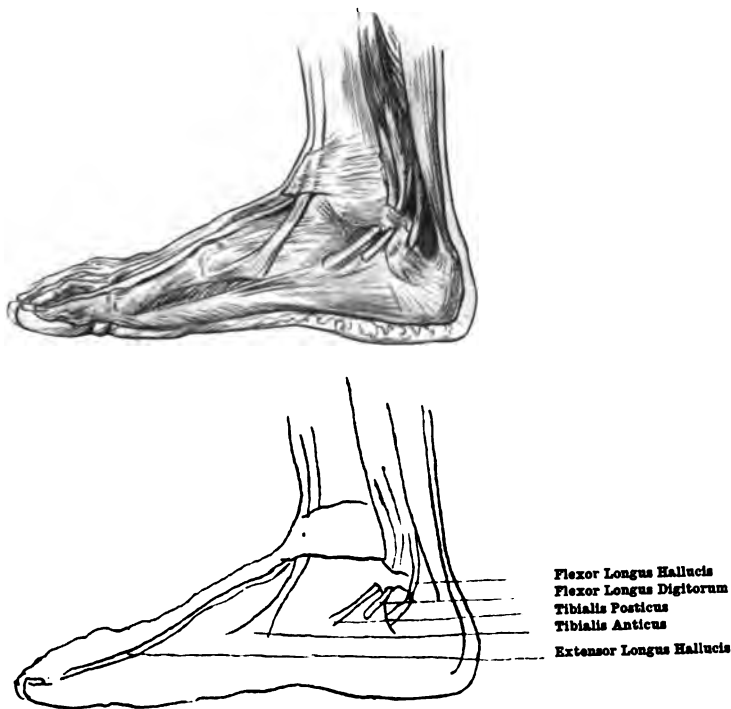


Fig. 59.—Tendons on Inner Side of Ankle and Foot.

will be found to lie half-way between them. One inch and a half in front of the tubercle of the scaphoid, and about a finger's breadth below it, is the projection formed by the *base of the first metatarsal bone*, much more easily felt than seen (Fig. 56).

THE LOWER EXTREMITY

Three fingers' breadth in front of this is a better marked prominence, made by the head of the same bone. Inclined almost directly forwards from it, but also slightly outward, *i.e.* towards the middle line of the foot, the inner border of the great toe shows a projection a little beyond its centre, due to the base of the terminal phalanx.

Upon the outer border (Figs. 54, 55, 57, 58, 60) of the foot the chief prominence is made by the *tuberosity of the fifth metatarsal bone*, some two inches below and two inches in front of the external malleolus.

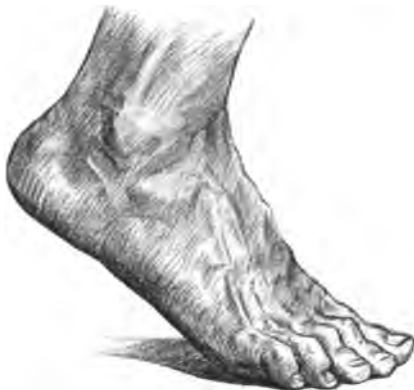

Fig. 60.—The Dorsum of the Foot.

From the tuberosity of the fifth metatarsal bone the outer border is continued forwards, with a very slight inclination outwards. It is interrupted at the level of the root of the little toe by a small prominence, caused by the presence of the head of the same metatarsal bone.

On the upper surface of the foot, when in an easy position, no prominences are noticeable, except the knuckles of the toes, and occasionally that portion of the astragalus which lies immediately below and a little in front of the ankle-joint.

The heads of all the metatarsal bones, but especially that of the first, may be observed forming a ridge near the roots of the toes. This ridge is

THE LOWER EXTREMITY

directed obliquely from within outwards and slightly backwards. Near the toes it may occasionally be found broken up into five separate prominences, formed by the individual heads of the metatarsal bones, with slight intervening grooves.

Many important points may be demonstrated by the study of an imprint of the sole of the foot. This may be done in sand, as Crusoe discovered, or by taking two pieces of brown paper, one wet and the other dry, and stepping from one to the other so that as much of the wetted sole as possible shall press upon the dry paper.

The imprint is broadest at the line of the metatarsal heads, and quite narrow at the heel; but between these two it is even narrower and confined to the outer side of the foot, because the middle part of the inner side of the sole does not touch the ground at all. This is of great importance, for it indicates that the foot is arched from before backwards.

The arch of the foot is by no means a simple one. We have just demonstrated that it is much more pronounced on the inner than the outer side of the foot. Moreover, dissection reveals the fact that in addition to the longitudinal arch there is a transverse one. Strictly speaking, therefore, it would be more correct to call the "arch" of the foot its "dome."

A complete examination and understanding of these arches can only be gained by dissection; but it is obvious that their integrity is of great value in the artistic "set" of the foot. If they give way, the result is a very unsightly deformity, with flatness and spreading out and eversion of the whole foot.

The posterior pier of the arch is formed by the os calcis, and the anterior piers by all the bones of the tarsus and metatarsus, except the astragalus. The

THE LOWER EXTREMITY

astragalus forms the keystone. This antero-posterior arch projects the dorsum upwards as the convex "*instep*," while to the corresponding concavity in the sole the name of "*waist*" is given (Fig. 56).

The pier or pillar in front of the keystone is much longer than the pier at the back, and, moreover, it is made up of several constituents, whereas the posterior pillar has only one, viz. the os calcis. This anatomical fact explains why a person prefers when jumping from a height to land upon the fore or mobile part of the foot, rather than upon the heel or single and rigid part, as the resulting jar to the body is much less.

Again, though the anterior pillar is made up of many bones, it may be resolved into two halves, outer and inner. The inner half was shown by the wet and dry brown-paper test to be the more pronouncedly arched. There is more spring and elasticity about this inner half of the antero-posterior arch.

The surface form of the foot must be studied in greater detail. The student must all the time be careful to bear in mind the various bony landmarks already described; otherwise he will get into difficulties.

The surfaces of the foot may be taken as four in number, viz. the upper, lower, inner, and outer, though the last is so narrow as to be little more than a border. The surfaces are not distinctly demarcated from each other except at this outer border.

The upper surface of the foot will be described first, as it is in many ways the most characteristic portion (Figs. 54, 55, and 60). It is set somewhat obliquely, so that it runs from the ankle downwards, forwards, and outwards. This surface presents the convexity already alluded to as the "*instep*," which,

THE LOWER EXTREMITY

be it remarked, is more pronounced in women than in men.

There are slight depressions below and above the actual instep, very shallow, and continuous with each other on the outer side of the dorsum of the foot, where the instep is not present.

Then there are blue lines, or faint ridges, due to subcutaneous veins, to be noticed. A very easy and excellent way to make these veins more apparent than usual is to put the foot in hot water, rubbing meanwhile the leg with the palm of the hand in a downward direction.

It will be found in many cases that there is little regularity in the arrangement of these veins at or near the toes, yet as they are traced backwards towards the ankle they form an irregular arch, convex forwards, whose two extremities give origin to the two saphenous veins. One of these, usually the larger of the two, passes upwards on the leg in front of the internal malleolus, and will be readily recognised as the beginning of the long or internal saphenous, which has already been described, in the regions of the leg, knee, and thigh. The external saphenous vein is usually smaller, and passes upwards on to the leg behind the external malleolus.

Beneath these veins other structures may be seen, but before any further consideration is given to the foot, the toes must be briefly described.

The toes, or digits of the foot, are shorter and less slender than those of the hand. They are numbered one to five from within outwards, whereas the digits of the hand are numbered from without inwards. In the process of evolution the foot has undergone rotation inwards and the hand rotation outwards.

The great toe corresponds closely to the thumb. It

THE LOWER EXTREMITY

has much less range of movement, however, partly because its evolution has been impeded by the wearing of boots, but chiefly because in man the foot is associated with standing and progression rather than with prehension.

This toe is usually the longest of all from base to tip, although, like the thumb, it has only two phalanges; but the second toe tip may project further. It is always much more slender than the first.

The second toe is frequently bent and crowded on to or under the great toe, in those who have been accustomed to wear tight and pointed boots.

The third, fourth, and fifth toes are progressively smaller in every dimension.

The toes, numbering from one to five, spring from the front of the foot at progressively diminishing distances from the ankle. In other words, the foot is shorter on the outer than the inner side, and the line of the base of the clefts between the toes is curved backwards as it proceeds outwards.

Each of the four outer toes possesses three bones or phalanges, except that it is not rare to find the terminal and middle phalanges of the little toe conjoined—an indication probably of its commencing involution. The knuckles are very similar in number and constitution to those of the hand, though they are not nearly so prominent.

The first row lies at the root of the toes, and can only be well made out by forcibly flexing the toes.

The line made by joining the second row is curved from within outwards and backwards, and runs parallel with the line of the clefts; and if this line be continued inwards, it will pass through the second knuckle of the great toe.

THE LOWER EXTREMITY

The line of the third row of knuckles, confined, of course, to the four outer toes, passes similarly from within outwards, and decidedly more backwards than the line of the second row. A continuation of this line inwards would pass across the base of the nail of the great toe.

There are transverse lines on the under surfaces of the toes that correspond with the knuckles.

The club-like ends of the four inner toes are larger than the bases; the fifth toe usually tapers to a pointed extremity.

The nail of the great toe is four times as large as the next, and the succeeding nails progressively diminish in size.

Returning now to the foot, the tendons of the muscles which have already been described as forming the anterior group in the leg are as a rule very plainly seen, as they run forward in the dorsum of the foot, and are easily demonstrated and studied by making the toes strain to assume different positions. The degree of voluntary control over the movements of the individual toes varies considerably in different people.

There is a small but conspicuous soft mass on the outer part of the dorsum, just in front of the external malleolus and outside the tendons of the extensor longus digitorum (Figs. 54, 60). It is bluish, and has been likened in size and shape to an oyster. It is due to a small muscle known as the *extensor brevis digitorum*, but it has often been mistaken, even by those who should know better, for a bruise. Four tendons proceed from the front of this small muscle and pass to the four inner toes. The innermost tendon may be seen passing to the great toe. When a person is standing upon tiptoe the other tendons

THE LOWER EXTREMITY

may with some difficulty be seen lying a little to the inner side of the ridges formed by the large tendons and passing to the upper surface of the toes.

The extensor brevis is the only muscle on the dorsum of the foot; all the other and larger tendons come down from the muscles of the leg.

It will be remembered that the muscles of the leg are divided into three main groups. The anterior group passes in front of the ankle-joint, and its

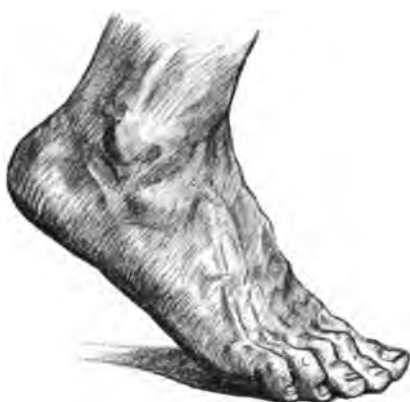

Fig. 61.—The Dorsum of the Foot.

tendons are found on the upper surface or dorsum of the foot; the external group passes behind the external malleolus; the posterior group passes chiefly into the os calcis as the tendo Achillis, but also the deeper tendons behind the internal malleolus, to be lost to view in the sole

of the foot, where their precise arrangement is unimportant to the art student.

The various groups are enclosed on their way to the foot in sheaths or tubes of soft tissue, containing an oily fluid, and are kept in place by bands of fascia, specially developed to tie the tendons down tightly at the ankle and to form tunnels for them to run through. The most important of these so-called *annular ligaments* (Figs. 53, 54, 59) is situated on the front of the ankle-joint. This pulley arrangement ties the tendons tight to the bones, and so at once

THE LOWER EXTREMITY

obscures them from view and enables them to alter their direction, while the oiled sheaths reduce to a minimum the friction of their play in the tunnels.

Of the anterior group, the thickest tendon, and one which produces a very prominent ridge, is the *tibialis anticus*. This can easily be traced by eye and finger as it passes inwards to the base of the metatarsal bone of the great toe, and terminates at a point midway between the tip of the internal malleolus and the head of the first metatarsal bone (Fig. 54).

On its outer side the tendon of the *extensor longus hallucis* passes slightly inwards to the terminal small bone of the great toe, producing a distinct ridge in the concavity already described between the summit of the instep and the great toe. On the outer side of this tendon a faint ridge, widening out and eventually dividing into four, may be detected passing to the four outer toes. This is the *extensor longus digitorum*. The tendon of the *peroneus tertius* may be detected, in favourable cases only, passing to the region of the tuberosity of the fifth metatarsal bone.

The outer surface of the foot shows the tendons of the muscles of the outer group which lie behind and below the tip of the external malleolus. If the foot be depressed and turned inwards, they will be found to be two in number and to diverge gradually from each other, that of the *peroneus brevis* passing forwards to the tuberosity of the fifth metatarsal, and lying above the tendon of the *peroneus longus*, which inclines more downwards to disappear in the sole of the foot.

The oyster-like *extensor brevis digitorum* muscle is visible on this aspect of the foot. Below its prominence and that of the external malleolus there is a longitudinal valley, and below this again the outer

THE LOWER EXTREMITY

edge of the sole touches the ground throughout its entire length, and presents the prominence of the styloid process of the fifth metatarsal about half-way.

The inner surface of the foot is wide at the back part, but gradually tapers to a border in front. It contains in its concavity the tendons of the posterior deep group of muscles which come from the leg. They are too deeply placed to be identified by the eye, though they may be felt just below the tip of the internal malleolus (Fig. 59).

Below and behind the internal malleolus is a deep fossa; another fossa below and in front is limited in front again by the tendon of the tibialis anticus. The inner edge of the sole, which bounds this surface of the foot below, is arched all the way from the heel to the head of the first metatarsal bone, and at the highest point of this arch the tubercle of the navicular can be distinctly felt and even seen. In front of the large rounded head of the metatarsal bone the first phalanx of the great toe presents somewhat of a waist, which hardly touches the ground, until the terminal phalanx buried in a massive pulp or "ball," and covered again by denser skin, is reached.

The sole is provided, for the purpose of resisting pressure, with a skin so thick, and a superficial and deep fascia so dense that few landmarks can be seen or felt; it will be observed that the skin of those parts which have had to adapt themselves to the habitual reception of the weight of the body—or, in other words, of those parts which our imprint experiment showed to touch the ground—is the thickest of all. Thus, the balls of the toes, the bases of the toes, and the heel, with the outer part of the sole, are covered with very thick skin, whereas comparatively thin skin covers the waist of the foot on the inner side.

THE LOWER EXTREMITY

The heel and the bases of the toes receive the chief impact in walking, and form marked prominences.

One longitudinal furrow may be observed in the skin of the sole. This is a broad one lying in the middle line.

The lines of flexion in the toes are arranged as in the fingers, but are less obvious, owing to the fact that the toes are not used for grasping as are the fingers.

CHAPTER VI

MOVEMENTS OF THE JOINTS OF THE UPPER EXTREMITY

THE mechanism of the joints in the upper extremity is adapted more particularly to the easy performance of two actions which are of equal and fundamental importance to the preservation of the life of the individual, viz. the assumption of the positions necessary for his own defence, and for the prehension and conveyance in the direction of his mouth of articles of food. In the lower limb, on the other hand, the shape of the bony surfaces at the joints, and the strength and tightness of the ligaments which connect them, are modified in such a manner as to confer great strength and rigidity upon this member as the weight-bearer in the erect attitude. Thus, though there are many points of similarity between the shoulder and the hip joint, the elbow and the knee joint, the wrist and the ankle joint, important differences exist in each of these comparisons. The hip-joint is a more secure ball-and-socket joint than the shoulder, because of the comparative smallness of the head of the femur, and its more complete envelopment by the cup-shaped acetabulum; while the shoulder presents a large ball applied to, but hardly at all received into, the slight cup of the glenoid cavity, so that the range of movement is much more free. Further, the innominate bone, which forms the acetabulum,

JOINTS OF THE UPPER EXTREMITY

is fixed almost immovably to the spine, whilst the scapula, which provides the glenoid cavity, is only secured to the trunk by elastic muscles and the movable collar-bone. Again, the great length of the collar-bone throws the centre of the shoulder-joint farther away from the spine than is the centre of the hip-joint, and the freedom and mobility in the small joints at each end of the clavicle permit of the shoulder being raised or lowered, brought forwards or backwards, so that the glenoid cavity is capable of being pointed in almost any direction, in the same way as the muzzle of a gun with modern mountings.

The **shoulder-joint** is thus endowed with almost universal movement. If the arm is carried forwards we speak of *flexion*; backwards, of *extension*; lifted away from the body, of *abduction*; carried towards the body, of *adduction*. *Rotation* is a twisting of the arm upon its own axis at the shoulder-joint. *Circumduction* is a describing, by means of the arm, of a cone, the apex of which is at the shoulder-joint, while the hand sweeps round the circular base. The result of this greater range of movement in the shoulder-joint is seen at once in the fact that the individual can touch practically any part of his body, including the back, with his fingers, whereas there are few parts which the toes can be made to explore, even when the lower limb reaches its maximum of mobility, as in the case of the acrobat.

Similarly, if one compares the movements at the elbow with those at the knee, it is at once obvious that, while both of them are checked in extension when the limb reaches a straight line, in the case of the knee flexion is a purely antero-posterior hinge movement, but in the case of the elbow it is accompanied, owing to the bevelling of the trochlear

MOVEMENTS OF THE JOINTS

surface of the humerus, by a sweeping inwards of the hand, towards the middle line of the body, in order to facilitate its approximation to the mouth. And again, in the case of the wrist there is a considerable amount of lateral movement, and of rotation between the radius and ulna, in addition to flexion and extension, whereas at the ankle there is hardly any movement permitted except flexion and extension, and even these movements are much more limited than they are at the wrist.

The muscles chiefly concerned in the production of these several movements at the shoulder-joint are seen to make prominences under the skin of the model when the particular movement they cause is performed with considerable force, *i.e.* when any resistance has to be overcome. These are in *Flexion*—the *pectoralis major* and the anterior part of the *deltoid*; in *Extension*—the *latissimus dorsi*, the *supra* and *infra spinatus*, and the posterior part of the *deltoid*; in *Abduction*—the *entire deltoid*, the prominent belly of which may then be seen, especially in the thin, to be grooved longitudinally by the three or more intra-muscular tendons of origin, and the two or more intra-muscular tendons of insertion; in *Adduction* when performed with force the *pectoralis major* and the *latissimus dorsi* muscles together with the long head of the *triceps*. *Rotation inwards*—calls into action the *pectoralis major* and the *latissimus dorsi*.

At the **elbow-joint** *flexion* is, of course, the movement which brings out the familiar prominence of the *biceps* and also the *supinator longus*, which, it is to be noticed, has not been happily named, for it is very little of a supinator and very much of a flexor. *Extension* makes prominent the *triceps*

OF THE UPPER EXTREMITY

muscle. *Pronation* and *supination* are the terms applied to that rotation of the forearm upon its own axis which results in the back of the hand or the front of the hand respectively being made to look forwards (in the subject standing in the position of attention). By means of this rotation of the forearm alone, the hand is capable of being rotated through a half-circle. But if the shoulder-joint is also brought into play so that the elbow is first abducted and then adducted, another half-circle is added to the play of the palm, enabling it to be made to face any point of a complete circle. These movements of pronation and supination take place at the radio-ulnar articulations, two small joints situated one at the upper and one at the lower end of the ulna and radius. The ulna in the motion now being described moves scarcely at all. The radius describes a cone around it. The apex of this cone is at the upper end, and the base of the cone at the transverse measurement between the styloid processes of the radius and ulna. Notice that when the hand is supinated the radius lies parallel with the ulna, whereas when the hand is pronated the radius crosses obliquely over the ulna.

It has already been pointed out that the supinator longus is ill-named, because it is much more of a flexor than a supinator. Observe now that neither of the pairs of muscles whose names indicate that they help to produce the movements under consideration makes any obvious prominence when in action. The pronator quadratus and the supinator brevis are quite undemonstrable without dissection, and the pronator radii teres and supinator longus can only be demonstrable with difficulty, unless their flexing effect upon the forearm is also

MOVEMENTS OF THE JOINTS

brought into play. The biceps muscle, powerful flexor that it is, has also a very great use as the chief supinator. It is, in fact, much stronger than either of the pairs of supinators and pronators which have just been mentioned, and its great strength is responsible for the fact that supination is a more powerful movement than is pronation, a fact which is acknowledged and turned to account by the direction in which hand-driven screws are planned to work, viz. by a supinating movement. Notice, before leaving this subject, that if you want to demonstrate on your own arm the semi-lunar fascia coming off the inner edge of the tendon of insertion of the biceps (and so giving to this muscle an attachment into the deep fascia in the region of the ulna), you must not only flex your elbow, but also supinate powerfully; by so doing you evoke each of the actions of the biceps, and then a gutter or depression will be seen running obliquely downwards and inwards across the prominent belly formed by the flexor group of the forearm, and the tip of your thumb can be thrust under the semi-lunar fascia.

At the **wrist-joint** *flexion*, or the bending of the palm towards the forearm, is produced by that powerful *group of muscles just alluded to which arise from the internal condyle*; *Extension*—by a considerably less powerful *group of muscles at the back of the forearm which arise from the external condyle*, and in neither case can the individual members of the group be at all clearly differentiated without dissection. *Adduction*—or movement of the hand towards the ulna in the extended position of the wrist—is more free than abduction, because the styloid process of the ulna is less prominent than the similar process of the radius. Powerful radial

OF THE UPPER EXTREMITY

abduction is largely brought about by those tendons which bound the "anatomist's snuff-box" (p. 101), which therefore is best demonstrated in this action.

Coming now to the **movements in the joints of the hand**, it is to be noted that flexion, together with opposition into the palm, of the thumb makes prominent the muscular form of the thenar eminence or ball of the thumb. Extension or straightening, together with radial abduction of the thumb, brings into play, and so makes obvious, three tendons chiefly concerned in the production of the "snuff-box," and on a spare wrist each of these is easily identified. The extensor ossi metacarpi pollicis, as its name implies, runs to the base of the metacarpal bone, and can be traced by the finger. The extensor primi internodii pollicis is seen to extend over the whole length of the metacarpal bone to its insertion into the base of the first phalanx. The extensor secundi internodii pollicis, which forms the inner limit of "the snuff-box," can similarly be seen and felt as it extends along the dorsum of the metacarpal bone and the first phalanx to its insertion into the base of the second phalanx.

Before leaving the thumb we must notice that circumduction, or making its extended bones describe a cone with the apex at the wrist, is very free, and that the freedom of this movement at the carpo-metacarpal joint results in the capacity to approximate the flexor surface of the tip to the flexor surface of any part of the four fingers. This approximation of flexor to flexor surface is called opposition. Its great development is a characteristic of the human thumb, and is obviously of the greatest possible use in all prehensile movements of accuracy. There is no corresponding movement in the great

JOINTS OF THE UPPER EXTREMITY

toe, or in any of the other digits in the hand or foot.

In the fingers flexion and extension are practically the only movements permitted, though at the metacarpo-phalangeal joints, which are at the junction of the fingers and the palm, a certain amount of adduction and abduction movement is possible, which facilitates greatly the widening of the span in such actions as piano-playing. This *adduction* and *abduction* of the fingers is chiefly brought about by the short muscles called the *interossei*, a curious group of muscles, too deep to be visible without dissection, which account to a large extent for the filling up of the gaps between the bones, making the hand roundly moulded when they are well developed, and skeleton-like when they and the superficial tissues are wasted in disease or old age. If the tip of the thumb is forcibly approximated to the tip of the forefinger, the first of this series of *interossei* forms a hard muscular prominence between the first and second metacarpal bones. It is known as the "abductor indicis," and, like the thenar and hypothenar muscular eminences, it is especially well marked in such people as masseurs, who have to cultivate strong development of the muscles which move the digits.

Enough has now been said to exemplify the truth of the remark with which this chapter opened, to the effect that in the upper limb the bones and joints have become modified upon a plan calculated to attain wide range of movement, with great delicacy and precision, rather than extreme strength. For the latter characteristic we shall have to look to the bones and joints of the lower extremity.

CHAPTER VII

MOVEMENTS OF THE JOINTS OF THE LOWER EXTREMITY

THE mechanism of the three large joints of the lower limb is chiefly subservient to the maintenance of the erect posture and to the act of progression.

The Hip, which is the articulation between the pelvis and the femur, is the only joint of the lower limb which permits free movement in any and every direction; and it is a very perfect example of that type of joint which is known as a "*ball and socket*," the globe-shaped head of the thigh fitting into the cup-shaped hollow of the acetabulum, and being kept in position by the accurate fitting of the two articular surfaces, aided by powerful ligaments and muscles.

The movements permitted by the hip-joint, the subject starting from the position of "attention," are:—

1. *Flexion*, when the thigh is raised and knee brought forward.
2. *Extension*, when foot is placed again on the ground.
3. *Abduction*, when the thigh is raised outwards from the middle line.
4. *Adduction*, when it is drawn inwards towards the middle line.
5. *External rotation*, which occurs round a vertical axis when the toe is turned out.

MOVEMENTS OF THE JOINTS

6. *Internal rotation*, when the toe is turned inwards.

7. *Circumduction*, by a combination of all these movements, inwards or outwards, may be performed; *i.e.* the parts of the lower limb which are further away from the hip-joint move round a larger circle than do the parts nearer the hip-joint.

1. The important *flexor* of the joint is the *ilio-psoas*, a large muscle which does not form a definite ridge, and which is invisible except on dissection. Other flexors are the *sartorius* and the *rectus femoris*, which can be seen when in strong action.

2. The important *extensor* of the hip is the *gluteus maximus*, which, when it is in action, forms a very well-marked prominence upon the buttock. The general direction of its fibres is from the middle line downwards and outwards. The *hamstring* muscles also extend the joint, and may stand out when in action.

3. The *abductors*, with the exception of the *gluteus medius* and *minimus*, cannot be observed, for they lie under cover of the *gluteus maximus*. The *gluteus medius* is a fan-shaped muscle, part of which is subcutaneous on the buttock between the front half of the crest of the ilium and the antero-superior border of the *gluteus maximus*, which overlies and hides the rest of the *medius*.

4. The *adductors* of the joint are the three adductor muscles on the inner side of the thigh.

5. The *external rotators* are the same as the adductors of the joint for the most part.

6. The only muscles which *rotate* the hip inwardly are the front part of the *gluteus medius* and the *tensor fasciæ femoris*. The student must remember that in the recumbent position the lower limb rotates

OF THE LOWER EXTREMITY

itself outwards, as it were, owing to its own weight, unless the internal rotators are kept in action. The lower limb of a corpse, therefore, assumes the position of external rotation, unless prevented by some force greater than its own weight.

The Knee.—Although the movements of this joint are really very complicated, only two—flexion and extension—are of importance to the artist. *Extension* is brought about by the large mass of the quadriceps muscle, *flexion* by the hamstring muscles. It has already been pointed out that the hamstrings act as extensors of the hips; similarly, the rectus femoris, which flexes the hip, assists in extending the knee.

The movements at the **ankle-joint** are flexion, when the toes are depressed, and extension when they are raised. These definitions are gathered from morphological anatomy, and the nomenclature presents difficulty to some students, which may be obviated by speaking of plantar-flexion and dorsal-extension.

Flexion, or dropping of the foot, is brought about by the muscles attached to the tendo Achillis, and so to the os calcis; *extension*, by the muscles on the front of the leg. It is frequently said that there is some lateral movement permitted in the ankle when flexed. This is very doubtful.

The movements of the toes are *flexion* and *extension*, and each muscle which effects one of these movements proclaims the fact in its name.

Internal and external rotation of the foot are also allowed at a transverse joint between the os calcis and astragalus behind, and the cuboid and scaphoid in front. The rotation takes place around a nearly horizontal axis, directed mainly forwards but slightly downwards.

JOINTS OF THE LOWER EXTREMITY

Outward rotation at this joint, when the sole looks a little outwards, is brought about by the peroneal muscles. Rotation inwards, which is a rather freer movement, is due to the action of the tibiales, anticus and posticus, muscles.

The joints between the other small bones of the foot possess a limited degree of movement, but are more important in that they largely diminish shocks to the feet; thus a "jar" loses much of its force before being transmitted to the leg, thigh, and trunk.

CHAPTER VIII

THE TRUNK

THE trunk, as understood by the artist, differs somewhat in its extent from that described by the scientific anatomist.

It will be considered here to include the back, chest, abdomen, and their immediately adjacent parts. The shoulders have been described to some extent (p. 73), but they will be mentioned again now with the trunk. A description of the neck will be found on p. 180.

The **back of the trunk** (Figs. 19, 20, 62) consists really of two parts—the back of the thorax, and the loins, or back of the abdomen. The distinction between these two regions is not so obvious behind as it is in front, where the chest is marked off from the abdomen by the margin of the ribs; and as these are covered behind by exceedingly thick and strong muscular and ligamentous structures, the last rib is usually completely hidden from sight, and in most subjects is only palpable with difficulty.

The *dorsal vertebræ* are those which carry the thorax, while the *lumbar vertebræ* support the loins.

The *spine*, when seen in profile, has been explained in a previous section to be convex backwards in the dorsal region, concave in the lumbar; and these curves contribute much to the elasticity, and therefore to the strength, of the back. There is no visible line of demarcation between these two curves or regions.

THE TRUNK

A prominent feature of the back is the deep furrow which extends in the middle line for nearly its

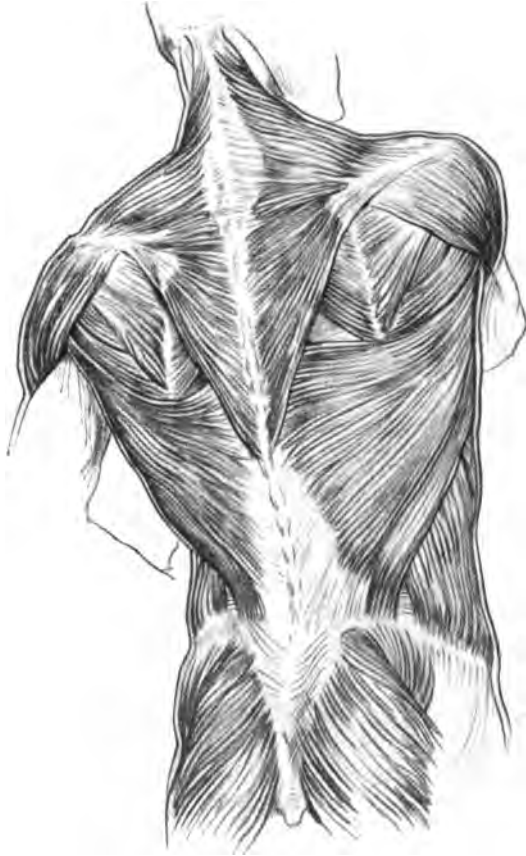

Fig. 62.—The Muscles on the Back of the Trunk, Buttock, and Neck.

whole length (see Plates). The depth of this furrow is caused by the large mass of the erector spinae muscle

THE TRUNK

which projects on each side of it, and gradually increases in width but diminishes in prominence as it is traced upwards. At the upper part of the buttocks

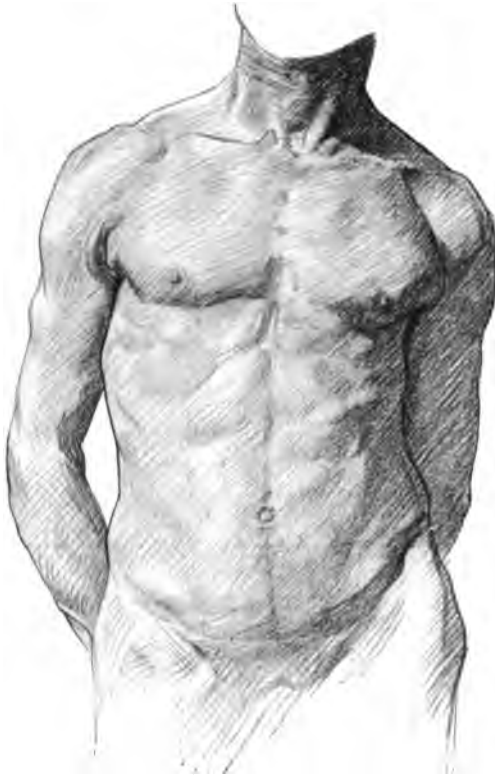

Fig. 63.—The Muscular Prominences on the Front of the Trunk and Neck.

the furrow gives place to a slightly depressed flat area, to which again there succeeds the deep and narrow furrow which separates the two buttocks and passes forwards into the perineum.

THE TRUNK

The furrow is deepest below the middle of the back. If the distance from the lowest part of the back of the neck—*i.e.* at the level of the seventh cervical vertebra, or *vertebra prominens*—be measured to the termination of the furrow between the buttocks and divided into fifths, it will be found that the deepest part of the furrow lies in the third and fourth fifths, counting from above.

This increased depth of the furrow is due to two causes: first, to the concavity of the vertebral column, which in this region is directed backwards; secondly, to the great height of the sides of the furrow. The sides are formed by the powerful and prominent mass of muscle lying on each side of the middle line, known as *the erector spinæ*, a name which sufficiently explains its action. In the dorsal region the backward projection of the ribs makes the erector spinæ prominent, and so accentuates the furrow.

At the bottom of this median furrow all the projecting spines of the dorsal and lumbar vertebræ can either be felt or seen.

The first dorsal vertebra lies immediately below the *vertebra prominens* (the seventh cervical), and its spine is the most prominent of any. All the spines can be seen more clearly when the back is bent and the distance between each one is thus slightly increased. It can then be noticed that the dorsal spines are single processes, unlike those of the cervical region, which are double. Frequently, especially in wasted subjects, circles of superficial veins may be seen around the spines.

When the back is straightened it is not unusual or abnormal for a slight side-to-side curve to be demonstrable in the dorsal region, the convexity of which is, except in left-handed subjects, directed to

THE TRUNK

the right. This curve is the result of the greater development of the muscles of the right side, in association with the freer and stronger movements of the right upper extremity in connection with right-handedness.

In left-handed persons the curve is found in the opposite direction. Since the normal slight curve is produced by muscular over-development, it naturally is the rule for it to be more pronounced in men than women, but its exaggeration owing to weakness or disease is more common in women.

The art student will do well to remember that such a lateral curve may develop as a result of tilting of the pelvis, *e.g.* when the subject is standing on one leg. It may also be pointed out that any lateral curve in the dorsal spine must present also some prominence of the shoulder-blade on the convex side.

It is important to notice that although the posterior convexity of the dorsal region of the back is much increased when the body is bent forwards, it never entirely disappears, even in the most erect Guardsman. Any apparent diminution of the curve as the erect position is assumed is due to an increase in the lumbar concavity backwards and to hyper-extension of the hip-joint.

Note also that although the lumbar vertebræ number only five to the dorsal vertebræ twelve, the former are so much larger individually that the lumbar portion measures nearly two-fifths of the total length of the back, and the dorsal portion only the remaining three-fifths.

The erector spinæ muscle, which forms a thick mass below, where it is attached to the iliac crest, breaks up above into numerous smaller portions which go to the vertebræ and ribs. Marked pro-

THE TRUNK

jections on each side of the middle line are formed by two comparatively thin sheets of muscle which lie superficial to the erector spinæ, passing from the trunk to the upper limb. The lower of the two is the *latissimus dorsi*; the one lying above is the *trapezius* (Fig. 62). The trapezius forms also a conspicuous landmark in the neck, which will be described in a later section. The lower two-thirds of the trapezius belong to the thorax, and this portion passes from the dorsal region of the spinal column, where it is attached to the spines of all the dorsal vertebræ. The cervical and dorsal parts of this triangular sheet of muscle converge upon, and are attached to, the concavity of the horseshoe of bone which is formed by the clavicle and the spine of the scapula (Figs. 21, 23).

The lower fibres of the trapezius are more vertical than those in the middle of the triangular sheet of muscle. They form a straight edge, passing from the spine of the lowest dorsal vertebra to the root of the spine of the scapula, which is on a level with the third dorsal vertebra.

In the middle line of the back the origins of the two trapezius muscles are separated only by the line of spinous processes, so that the two triangles form together a diamond-shaped sheet under the skin, which from its position, size, and shape has been likened to a collapsed monk's hood; hence the alternative name of the "musculus cucullaris."

The *latissimus dorsi* (Fig. 62, p. 159) is a muscle of great importance, and has a large share in pulling the body after the arm as in the act of climbing. It has three visible edges when in action—inner, upper, and outer. By the inner border it arises from the spine opposite the lumbar and the lower

THE TRUNK

six dorsal vertebræ. The upper border emerges from under cover of the trapezius in such a direction that it is curved with its concavity upwards. The lower border passes upwards and outwards from the back part of the crest of the ilium, and the two latter borders converge upon one another so that the muscle eventually forms a comparatively narrow thick band, the upper part of which overlaps the lower angle of the shoulder-blade. It then winds in a spiral manner round a thick muscle, only to be identified in muscular subjects, the *teres major*, and with it forms the thick and rounded posterior fold of the axilla or armpit (Fig. 24).

Between the outer or lowest borders of the trapezius, the upper border of the *latissimi dorsi*, and the inner border of the scapula, a triangular interval is formed which lies over a portion of the space between the sixth and seventh ribs. The floor of this triangle is formed by a flat muscle called the *rhomboideus major* (Fig. 62).

External to the inner border of the scapula, and below its spine, two thick muscles with a dividing groove may be seen in muscular subjects, passing under the posterior border of the deltoid muscle. The upper one is the *infra-spinatus*, and the lower the *teres major*. The *teres major* conceals the scapular head of the triceps from view.

Just as in connection with the upper border of the *latissimus dorsi* a triangular interval is displayed between it and the muscle which lies above and internal to it, viz. the trapezius, so frequently there is to be observed another but much smaller triangular space between it and the muscle lying below and external to it on the abdominal side, which is the *external oblique*. The edges of this triangle,

THE TRUNK

only demonstrable on dissection, are bordered by the latissimus dorsi internally, the external oblique externally, and by the crest of the ilium below. The triangle is floored by the internal oblique.

The external oblique muscle forms a distinct prominence upon the lateral part of the small of the back, which is concealed, however, by the latissimus dorsi in its upper part. In a very muscular subject the origin of the external oblique from the lowest ribs may appear in digitations, one arising from each rib.

All these muscles of the back produce hardly any prominence in persons who are well covered with fat, as, being flat sheets, their outlines may be completely obscured by the more superficial coverings.

Only in a very emaciated subject can *the ribs* be seen on the back, and there is difficulty even in feeling them clearly enough to count them. Their convexity makes the erector spinæ prominent on each side of the furrow in the middle line.

Frequently, in persons who are well covered with fat, the only obvious landmark in the general convexity of the back is the median furrow. In such cases the back forms a gentle uninterrupted curve on each side of the furrow.

In muscular subjects a further groove may be noticed, which is directed round the side of the body from the lower part of the lumbar spinal furrow. The groove separates the loins and abdomen above from the buttocks below, and is replaced in thin persons by a slightly sinuous ridge. In fat persons neither groove nor ridge can be detected. The ridge is due to the presence of the *crest of the ilium*, which is the expanded wing of the pelvis; the groove, when present, arises from the massing of muscles above and below it.

THE TRUNK

Anteriorly the groove is traceable into the deep cruro-scrotal fold, and as it runs forwards it lies a little below Poupart's ligament. Note that the groove is somewhat curved, and more horizontal than Poupart's ligament.

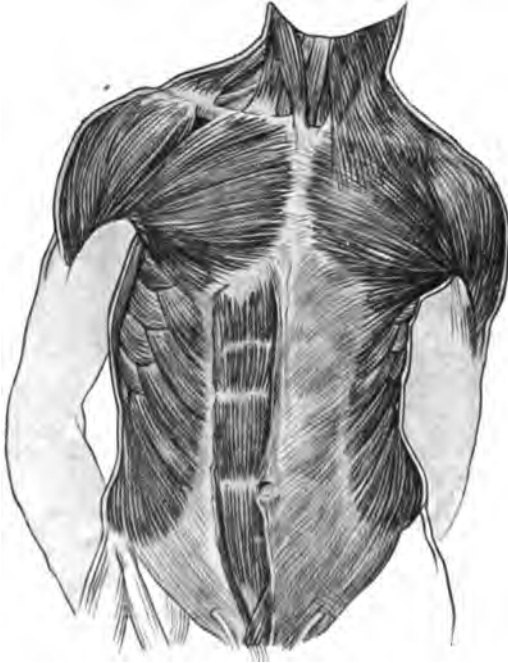

Fig. 64.—The Muscles on the Front of the Trunk and Neck.

In either case, whether ridge or groove, it may be traced posteriorly by the fingers into a slight elevation on the innominate bone, known as the *posterior superior spine of the ilium* (Fig. 62, p. 158), which in nearly all cases lies at the bottom of a dimple or depression in the skin. The situation of

165

THE TRUNK

the dimple is an inch and a half from the middle line, and a little above the prominence formed by the spine of the fourth sacral vertebra, which is the last spine of the vertebral column to be seen or felt.

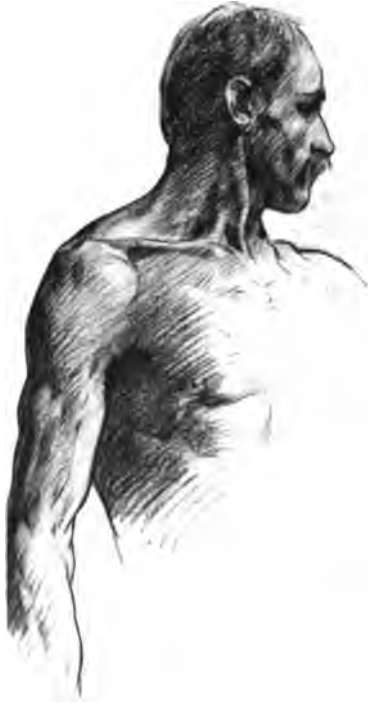

Fig. 65.—Muscular and Bony Surface Markings of Side of Neck, Trunk, and Arm.

When the crest of the ilium is traced forwards from this dimple round the side of the body, it is found to become thickened into a tubercle which marks the highest part of the crest. Some two or three inches farther forward the crest terminates a little below its highest level in the large and conspicuous bony prominence of the *anterior superior spine of the ilium* (Figs. 8, 9, 44).

Laterally, between the last rib and the crest of the ilium, the *ilio-costal space* is unsupported by bone. The height of this space varies much, according

to the stature of the subject, but perhaps two or three inches is the average measurement from the tip of the rib to that portion of the crest of the ilium which lies immediately below it. Here lies the narrowest part of the body, the *true waist* (Fig. 103).

THE TRUNK

The chief superficial landmarks of the back have now been mentioned, and attention must next be directed to the side of the body (Fig. 65).

In order that as many points as possible may be studied, it is better for the student to raise the arm of the subject from the side. It will be observed that the armpit lies at the highest level of the side of the trunk. The skin is here covered with numerous coarse hairs, and is often moist, owing to the secretion of perspiration (Fig. 66).

But the armpit is not only the highest part of the side of the trunk, it is also the narrowest. This is because it is encroached upon by two large muscular masses, viz. the pectorales forming the anterior "fold of the axilla," the latissimus dorsi and teres major forming the "posterior fold." The side gradually increases in breadth below the armpit as the ribs which support it become longer, and as these muscular folds of the axilla diverge forwards and backwards.

Most of the ribs can easily be felt on the side of the chest even in the fattest, and they lie at the

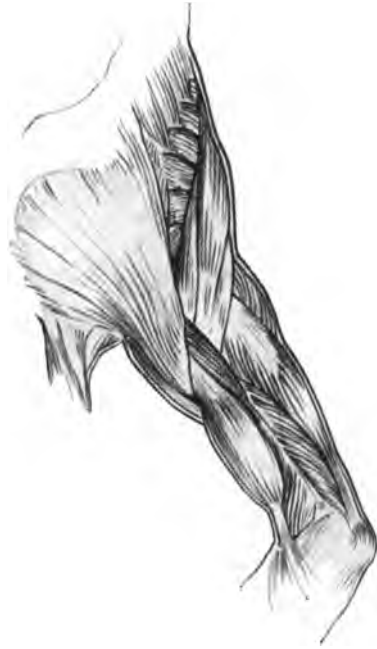

Fig. 66.—The Muscles of the Inner Surface of the Arm and of the Armpit.

THE TRUNK

bottom of furrows between well-marked digitations of certain muscles. Although there are twelve ribs, only those between the fourth and the tenth (and exceptionally the eleventh) can be seen on the side. The upper three lie so deeply covered by muscles and bones that they cannot be seen; the twelfth is not long enough to reach the side. The muscles which produce the inter-digitating prominences on the side are the *serratus magnus* above, and the *external oblique* of the abdomen below.

There is a distinct decrease in the breadth of the side below the level of the tenth rib, except in prominent abdomens.

The groove or ridge which separates the side of the body from the region of the hip has been described on p. 164. In front of this ridge the lower part of the abdomen is rather more prominent than the portion which lies above it; below and behind the prominence of the buttocks is obvious.

The Front of the Trunk (Figs. 63 and 64).—The lateral parts of the front view of the body pass insensibly into the side view which has just been described. Above, however, the bony ridge produced by the horizontally lying *clavicle* clearly marks off the trunk from the neck, and below, the front of the body is very obviously demarcated from the thighs and the pubic region by three surface markings from without inwards, viz. :—

1. *The crest of the ilium*, which terminates in front in the *anterior superior spine*.

2. *Poupart's ligament*, underlying the slight groove of the fold of the groin, which is more horizontal in the female than in the male, and relatively more pronounced when the abdomen is protuberant,

THE TRUNK

passing downwards and inwards from the anterior superior spine.

3. *The spine of the pubes.* This bony prominence can be felt, but cannot be seen, one and a quarter inches from the middle line which here is formed by the symphysis of the pubic bones. Poupart's ligament is a very important structure, for to it many muscles are attached.

Between the clavicles above and Poupart's ligament below, the front of the body (even in fat persons) is obviously divided into two parts by the margin of the thorax. The chest or thorax is the part of the body which is surrounded on all sides by a bony framework; the abdomen or belly lies below it, and is surrounded for the most part by soft structures only.

The clavicles form well-defined ridges which approach closely to each other in the middle line, but without meeting. Between the prominent inner ends of the clavicles there is a deep depression, which, as it lies above the breast-bone, is called the *supra-sternal fossa*. It is very deep and conspicuous, the two tendinous heads of the sterno-mastoid muscles converging as they bound it laterally. In its depth the main vessels of the neck and limb diverge from each other, occasionally allowing pulsation to be observed in the fossa. The windpipe also lies very deeply at the bottom of the hollow, and here, or a little higher, it is opened in the frequent operation of tracheotomy (Fig. 68).

Below the supra-sternal fossa is *the sternum*. Its borders, which are separated by a space of, roughly, two inches, are overlaid by the long margin of origin, in muscular subjects somewhat knotted, of a large fan-shaped muscle passing to the arm, and called the *pectoralis major* (Fig. 64, p. 165). This origin

THE TRUNK

extends from the clavicle to the seventh rib, and is a little arched, presenting a convexity towards the middle line, and leaving rather more of the anterior surface of the sternum exposed in its upper and lower than in the intermediate parts.

Indeed, in muscular subjects the area left between the prominent muscles of the two sides may amount to little more than a deep median groove at the level of the second and third ribs, though more expanded above and below.

When a skeleton is examined in profile it is seen that the sternum does not lie in a purely vertical plane. It not only slopes decidedly forwards, as it is traced downwards, but it is also bent so as to present a curved surface, or rather two surfaces, inclined at an angle to each other. This "*sternal angle*" is the most prominent part of the bone; it is situated at the level of the second rib, two inches below the supra-sternal fossa, and is continued on each side into the ridge produced by the second rib, the most easily identified of all the ribs, and therefore the one from which any enumeration of the ribs should be made. The first rib lies deeply beneath the clavicle in such a way that it can neither be seen nor easily felt.

Above this projecting sternal angle lies the expanded part of the median groove, already described as separating the two pectoral muscles, and supported by the upper portion of the sternum or *manubrium*.

The second part of the sternum which lies below the angle is called the *gladiolus*; it is more than twice as long as the part above it. It extends downwards, with a distinct inclination forwards, until it reaches the level of the seventh costal cartilage. At this level the bone is somewhat expanded.

THE TRUNK

Below this second part of the sternum, in what is popularly known as the "pit of the stomach," called by anatomists the *infra-sternal fossa*, is the somewhat recurved *ensiform cartilage*, which forms the lower end of the sternum. Its point may occasionally be distinctly projected forwards; it is always much narrower than the rest of the sternum.

Below the *infra-sternal fossa* a groove occupies the centre of the body, fading away as it approaches the pubic bone. It lies between the two wide strap-like muscles, the *recti abdominis*. The *linea alba*, a strong fibrous band, supports the groove, which is broken in its line by the *umbilicus*, or navel, the pitted scar of the vascular cord which connected the mother and the foetus *in utero*.

This scar lies a little below the centre of a line drawn from the *infra-sternal fossa* to the *symphysis pubis*, or junction of the two pubic bones. It is a circular, and usually depressed, area, with the surrounding skin raised and wrinkled, and it lies opposite the disc between the third and fourth lumbar vertebræ. Some hair may be found in the course of the middle line, even quite high up; this fact will be referred to later.

Three muscles should next be studied on each side of the middle line, viz. the *pectoralis major*, *serratus magnus*, and *rectus abdominis* (Figs. 63 and 64, pp. 159, 165, and Plates).

The *pectoralis major* is large and fan-shaped, converging from a wide origin from the inner half of each clavicle and from the margin of the sternum (Fig. 64), which it frequently obscures, to its narrow insertion into the upper part of the arm. The clavicular and sternal parts are separated by a groove which is nearly as distinct as that which

THE TRUNK

separates the adjacent borders of the deltoid and pectoralis major (Fig. 64). Sometimes the groove is not easy to identify, but even then the clavicular part of the muscle may be distinguished from the sternal. If the subject be instructed to lift the outstretched arm against some resistance, the clavicular portion will be noticed to stand out. If, on the contrary, he be instructed to depress the outstretched arm against resistance, the lower or sternal part will be put into action, and will become prominent.

There is a groove between the upper margin of the pectoralis major and the deltoid. The inner end of this groove opens out just below the clavicle into a depression known as the infra-clavicular fossa (Fig. 64, p. 165). Immediately below and external to the lower margin of the pectoralis major may be observed the lower digitations of the *serratus magnus* and the upper digitations of the *external oblique* muscle. The serratus magnus pulls the scapula forwards, and is thus used in stretching out the arm, as in shaking hands.

The *rectus abdominis* is the flat muscle lying upon each side of the middle line of the abdomen, and its effect upon the surface form of the abdomen is great. Even in fat persons it forms a definite ridge when in action. Its upper limit stretches as high as the fifth rib, close to the sternum, and here the muscle is somewhat narrower. Tracing it down, as it reaches the sixth and seventh ribs it widens, and continues of the same breadth until a point is reached a little below the umbilicus, whence it rapidly tapers to its lower end, which is quite narrow, on the front of the pubic bone. The narrowing of the lower part of the muscle is brought about by the incurving of its outer edge.

THE TRUNK

There are three or four horizontal lines, or rather grooves, dividing it into several parts or segments. The grooves lie in very constant positions—One at the level of the umbilicus, one at the level of the ensiform cartilage, and another midway between these points. Sometimes also a groove may be seen dividing the portion of muscle which lies below the navel into two nearly equal parts.

In the muscular subject, therefore, the rectus abdominis forms a very striking object. The inner edge is not so prominent as the outer border, which is known as the *linea semi-lunaris*, owing to the marked curving towards the middle line, below the umbilicus, already noted. There is an inclination on the part of some artists to make the rectus a little too broad, and to accentuate rather much the prominence of its individual segments, and it is not very rare to see too many segments of this muscle and of the serratus magnus depicted, especially in sculpture.

The rectus acts by drawing the chest and pelvis together, and in forcible bending forwards of the body its shape and actions may be demonstrated. It has other important functions; it helps to keep the viscera in position, and, like the pectoralis major and the serratus magnus, it is an accessory muscle of respiration. The linea alba is sometimes stretched to such a degree, especially in fat women, that the two recti become widely separated.

The vertical height of the chest wall is greater behind than in front; the abdominal wall, on the contrary, is more extensive in front than at the sides and back. The chest contains the heart and lungs, and other important structures, protected by the dorsal vertebræ, ribs, and sternum. The abdomen contains the alimentary canal and its great glands the liver and

THE TRUNK

pancreas, the urinary and the genital viscera (with the exception of the testicle and a part of its duct, which are contained in the scrotum), but they have no bony protection in front and at the sides. Both cavities also contain many large blood-vessels and nerves.

These two great cavities of the body are well adapted for their several purposes.

Respiration chiefly depends upon the action of the *diaphragm*, the thin dome-shaped muscular sheet intervening, inside the body, between the chest and abdomen. This muscle cannot be seen without deep dissection, but it produces such an effect upon the general shape of the chest and abdomen that it must be mentioned here. A series of little muscles essential to the full action of respiration must also be described, viz. the intercostals, which line and pass between the adjacent ribs.

When the diaphragm contracts, its dome becomes flatter and less rounded, with the result that the capacity of the chest, whose floor it forms, is increased and air rushes in through the windpipe to fill the cavity. The abdominal viscera are at the same time pushed downwards, thus producing a bulging of the abdomen. This type of respiration, "the abdominal type," occurs in both sexes, but is especially deep in men.

The little intercostal muscles raise and evert the ribs, and again the chest capacity is increased and air inspired. This "costal type" of breathing is more marked in women.

We have seen that the costal margin indicates the boundary line between chest and abdomen, and forms an obvious landmark on the front surface of the body, and that only the seven upper ribs arti-

THE TRUNK

culate with the sternum by means of their cartilaginous ends. The eighth, ninth, and tenth ribs articulate with the cartilage which lies immediately above each of them.

The costal margin may be traced, either by sight or by palpation, from the sternum to the vertebral column. Near the middle line of the sternum the seventh costal cartilage passes downwards and outwards from the expanded part of that bone which lies just above the infra-sternal fossa. This part of the costal margin is a little curved, so as to present a convexity pointing inwards and downwards. Below this the margin is directed outwards and downwards along a line which has a slight concavity open inward and downward; this part of the costal margin corresponds to the eighth, ninth, and tenth costal cartilages. If a vertical line be dropped from the middle point of the clavicle, it passes through the junction of the eighth and ninth costal cartilages.

The tenth cartilage is the lowest part of the costal margin, and lies at the side of the body. From it the costal edge passes upwards and backwards along the eleventh and twelfth ribs to the last dorsal vertebra.

The last two ribs can only be felt with difficulty, and are very rarely visible through the skin. They are called "floating ribs," because they do not join up by their tips with the cartilage of the rib above.

The greatest transverse diameter of the thorax lies between the seventh, eighth, and ninth ribs.

The tenth, eleventh, and twelfth ribs are separated by rather narrower intercostal spaces than the others.

Owing to the obliquity of the first rib, the upper aperture of the barrel-like thorax, or chest cavity,

THE TRUNK

slopes from the sternum upwards and backwards, the supra-sternal fossa lying opposite the cartilaginous disc between the second and third dorsal vertebræ, some two inches lower than the first dorsal, which bounds the aperture behind.

Although the ribs are the support of the thoracic or chest wall, it is clear that the greater breadth of the upper part of the trunk cannot be due to them; for the first rib is quite short, and the length of the ribs increases from above downwards till the seventh is reached. The greater width at the top of the trunk is, in fact, entirely the result of the length of the clavicle.

The function and formation of the chest having now been briefly explained, the student's attention should be turned to the position of the *nipples*. They lie one on each side of the middle line. In the male they are little pigmented nodules, surrounded by a pinkish area, and raised upon a somewhat elevated base from the general surface of the chest. They lie in the fourth intercostal space, four inches from the middle line.

Very different is the appearance of this part in the female. In the adults of this sex the nipple is much larger, and surmounts a large prominent mass known as the *breast*, which contains the milk-secreting "mammary" gland, embedded in a layer of fat which varies enormously in different individuals.

The female nipple has a less uniform position on the front of the chest, as the breast is very often pendulous, and so the nipple may hang considerably below the fourth intercostal space.

The fat which is present around the breast is responsible for the gentle curves of this part. Each breast lies upon the pectoralis major and the

THE TRUNK

serratus magnus, two-thirds upon the former and one-third upon the latter muscle.

The nipple is light brown in colour in the virgin, in whom it is surrounded by a pink areola. The nipple becomes browner and the areola more pigmented in the pregnant woman, and these tints remain in the matron.

The saucer-shaped mammary gland extends from the level of the second as far as the sixth rib, and from the margin of the sternum to the anterior fold of the axilla. These limits are the boundaries of the actual mammary gland when fully developed, but in the young it is less extensive, and in the old it is usual for it to become much smaller, though in both the young and the old there may be such a development of fat as to make the breast appear large.

Blue lines, which mark the presence of veins, may be seen on the surface of the fully developed breast, and these become much larger during pregnancy and lactation.

Notice that the shape of the breast varies not only with its consistence, but with the position of the trunk, and even with the position of the arm.

Notice also that while the nipple is in the middle of the breast, the contour of the upper half of the organ is less convex than the lower half, which makes with the chest wall a well-marked *thoraco-mammary* fold (Plates X., XVIII., XXIII., XXXI.).

The abdomen is usually, even in muscular men, rather more prominent in its lower than in its upper part. In women who have borne children a change is demonstrable in the skin throughout the lower part of the abdomen. Numerous pink, silvery lines are seen. In the old the lines become distinctly brown and pigmented, and are known as "*lineæ atrophicæ*."

THE TRUNK

The abdomen is apt to increase in size with advancing age, especially in elderly and sedentary men. This is the consequence of a great increase of fat, which causes the protuberant abdomen to hang downwards over the upper part of the thighs.

Three layers of muscle-sheets support the abdomen, viz. the *external and internal oblique*, and the *transversalis*. They are so arranged that their fibres cross each other, thereby adding very greatly to the strength of the abdominal wall.

The external oblique muscle is a flat sheet on the side of the abdomen. The anterior limit of its muscular portion is prominent along a curved line slightly convex towards the middle of the body, and nearer to the middle at the level of the costal margin, than below, where again it is very obvious just above and in front of the anterior superior spine of the ilium. Therefore its aponeurosis or spread-out tendon is broader below than above (Plate XVI.).

Just above the two pubic bones, the lower limit of the abdominal wall contains a pad of fat, which is covered with hair and marked off from the abdominal wall just above by a well-marked furrow in the skin, not quite transverse, but concave upwards. In the fat subject a similarly disposed furrow crosses at the umbilicus (Plate X.).

The hair upon the front of the trunk varies much in amount. The pubic hair extends up the middle line towards the umbilicus.

CHAPTER IX

THE HEAD AND NECK

IN the previous sections the trunk and extremities have been considered. The student must now devote his attention to the most difficult, and yet in many ways the most interesting, part of anatomy, viz. the head and neck. It will be convenient to take the neck first.

Close attention, assisted by repeated observation, is absolutely necessary, as it is by the narrowest scrutiny only that certain details can be understood.

For example, one frequently hears some such expression as "a beautiful light in the eye." But the explanation of such an expression is beset with great difficulties. In the first place, the light is not in the eye at all, but is reflected from it. Secondly, the manner of the reflection of the light depends to a large extent upon the curvature of the reflecting surface of the eyeball itself and of the surrounding lids and prominences. Thirdly, not only the surface of the eyeball, made up of the transparent cornea and the opaque white sclerotic, but also its internal parts, and in particular the iris, reflect and modify the light which falls upon it. And again, the expression, dependent upon the movements of the facial muscles surrounding the organ, is a very important factor in modifying "the light of the eye."

In expression one part of the face seldom acts alone; almost always there is a correlated action

THE HEAD AND NECK

of other sets of facial muscles. The student has to study and to learn how to indicate the associated actions involved in such expressions, *e.g.* of the eye and mouth; and further, he must also learn to correlate the expression of the face generally with the movements of the limbs and trunk; to learn, in other words, to combine *expression* with appropriate *gesture*.



Fig. 67.—Lateral View of Neck. Massive trapezius.

The Neck is the narrow part of the body between the head and the trunk. It supports the head upon the trunk, and it is based upon the two shoulders, and so connected with the upper limbs. The shape of the neck varies much in different individuals: it may be long or short; it may show well-marked muscular prominences, especially in males; it may be gently rounded, especially in the female, owing to the presence of a normal quantity of healthy fat

THE HEAD AND NECK

and the absence of any great muscular development; or it may present pendulous rolls of unhealthy fat.

The neck displays perhaps its most striking features in front.

If the student looks at the subject in profile (Figs. 67 and 68), he will observe that the upper part of the neck in front lies considerably behind the point of the chin.

As the profile is traced downwards towards the front of the chest, it is seen to incline a little forwards. In the natural easy position of the head the angle made by the lower jaw with the front of the neck is about ninety degrees, but of course it varies with changing positions.

When the head is bent backwards so that the face looks up, the angle is opened out (Fig. 77); when, on the contrary, the head is bent forwards, the angle is much diminished (Fig. 75). A greater range of movement is allowed in a downward than in an upward direction.

The angle also depends upon the extent of fulness in the submaxillary and submental regions. The surface here is gently rounded in youth (Fig. 72), while later in life it may be divided into two or even more rolls by transverse furrows, giving rise to the popular expression "double-chin" (Fig. 69).

These extra chins are the result of the presence of

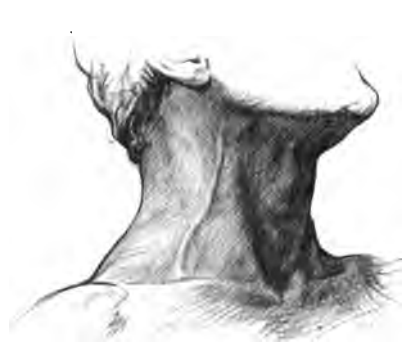

Fig. 68.—The Surface Markings of the Side and Front of the Neck.

THE HEAD AND NECK

fat in large quantities, and of the subdivision of the fat by folds in the skin, which are primarily caused by some fibres of the platysma muscle (Fig. 25) crossing to the other side, and by the movement of the head upon the neck; but they are secondarily perpetuated by the formation of fascial, or fibrous, bands under the skin.

Note that in the case of a well-marked double chin

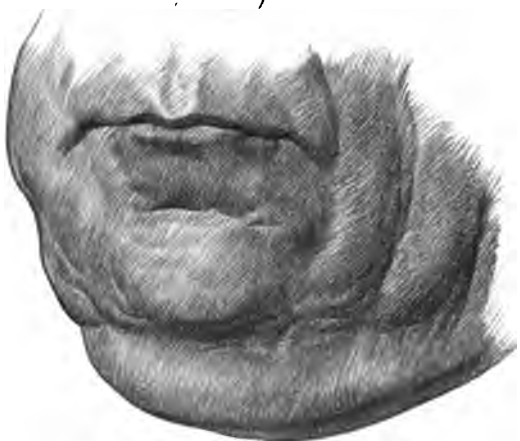

Fig. 69.—Furrows around Mouth. Thin lips. Double chin.

the intervening furrow is prolonged on to the lower part of the side of the face.

Immediately under cover of the lower jaw, never visible, and but very rarely even palpable until the head is bent backwards, is the slight median body of the *hyoid bone*. So small is this that it would hardly be worth noticing in a study of surface form were it not for the fact that from the hyoid many muscles pass to the lower jaw and tongue, and to the thyroid

THE HEAD AND NECK

cartilage, muscles which assist in the acts of talking, mastication, swallowing, etc. (Fig. 73), and become prominent during some of these actions. Moreover, since the hyoid bone is arched just like the body of the lower jaw, and is smaller, and placed just below it in the neck, it follows that the muscles which pass between these two bones must converge upon the smaller bone from the mandible. The general sloping

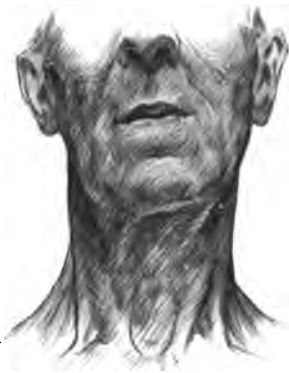

Fig. 70.—The Surface Markings upon the Neck of an Old Man. Front view.

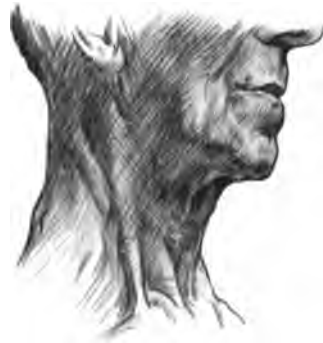

Fig. 71.—The Surface Markings upon the Neck of an Old Man. Side view.

inwards and backwards of the skin from the lower jaw to the upper part of the neck is thus explained; its direction is backwards in the submental region, best seen in profile, and downwards and inwards in the submaxillary regions, best seen from in front (Figs. 70, 71, 72).

The first prominent landmark which makes itself apparent in the profile below the lower jaw is due to the largest cartilage of the *larynx*, as the voice-box or upper part of the air-tube is called (Fig. 68).

THE HEAD AND NECK

This *thyroid cartilage* consists of two wings or *alæ*, which lie in a vertical plane, one on each side of the middle line. The *alæ* converge and are united to form a sharp though not straight edge, which is palpable in the middle line in front in both sexes, though more easily visible, because larger, in the male; it is called the *pomum Adami*, or "Adam's apple."

The adult male, then, has a prominent thyroid cartilage, and a much deeper voice than the female; the student will rightly anticipate that the two facts may be associated with each other.

It is in the upper part of the larynx that the *vocal cords* lie. The vibration of these by air during expiration produces phonation. Owing to the large size of the thyroid cartilage, to which in part they are attached, the vocal cords are much longer in the male than the female—indeed the proportion is 3 to 2—and thus a deeper sound is produced when they vibrate.

There is little or no difference in size between the young girl and the boy. In the latter, however, a great increase takes place at puberty, and accounts for the "breaking" of the voice.

The *alæ* are flat, and can be easily felt as they diverge backwards from the *pomum Adami*.

The thyroid cartilage is separated from the hyoid bone by a shallow and broad groove which is obliterated by the superficial coverings. The groove is supported by the thyro-hyoid membrane and thyro-hyoid muscle.

The *Cricoid cartilage*, in shape like a signet-ring, lies below the *pomum Adami*, and can be felt in the middle line of the neck. It is broad behind and narrow in front. It is partly by the movements of

THE HEAD AND NECK

the thyroid upon the cricoid cartilage that alterations in the pitch of the voice are brought about, by causing different states of tension in the vocal cords.

The thyroid and cricoid cartilages are separated by a transverse furrow, and are connected with each other in two ways: first, by a membrane which is continuous with the vocal cords, and which is known as the crico-thyroid membrane; and secondly, by a small joint on each side.

The cricoid cartilage is directly continuous below with the *trachea* or windpipe, which passes down behind the supra-sternal fossa into the upper part of the chest and so to the lungs.

The windpipe may generally be felt, but is only seen in very thin subjects. It would be legitimate to indicate it, or at least its first ring, as visible through the skin in a man suffering from starvation. It consists of alternate rings of fibrous tissue and cartilage. The more prominent rings are the cartilaginous, which are not quite complete, being deficient behind, where they are replaced by fibrous tissue.

The second, third, and fourth rings are obscured by the isthmus of the thyroid body (Fig. 72); the lower rings are not seen, because as the trachea is traced downwards towards the chest, it lies much more deeply, *i.e.* further away from the surface, until, in a fat adult male, it may be an inch and a half

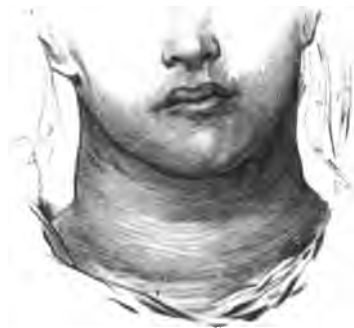

Fig. 72.—The large Thyroid Gland in a Girl's Neck.

THE HEAD AND NECK

from the floor of the supra-sternal fossa. This increased depth of the trachea from the surface is partly due to the fact that the neck, as seen in profile, slopes slightly forwards again just above the sternum (Fig. 77).

The larynx and trachea can be seen to move upwards during the act of swallowing, and downwards when the action is completed.

Just above the sternum lies the *supra-sternal fossa*, which has already been alluded to in the description of the trunk. Occasionally a small blue vein may be seen passing across this fossa in a transverse direction; it connects the lower parts of two veins which lie close to the middle line. They are the anterior jugular veins, and pass from the region beneath the chin to the lower part of the neck. There they diverge outwards on each side, under cover of the sternomastoid muscle. These veins are only obvious when enlarged in cases of asphyxia.

If the neck of a young female is thrown forcibly backwards a distinct bulging will be noticed in its lower part—in a very thin subject the bulging may reveal the shape of an H. The swelling, which is quite distinct in this position, and often obvious in any position, is due to the presence of an important structure known as the *thyroid gland*. This gland is very frequently enlarged, giving rise to a "goitre," a comparatively common condition amongst the inhabitants of some of the Swiss and Tyrolese valleys. In England the condition sometimes bears the name of "Derbyshire neck."

There are fashions in appreciation and portrayal of beauty, and the neck has in two very different periods been the part selected for exaggeration. Rossetti and Burne-Jones often endowed the lower

THE HEAD AND NECK

part of the side and back of the neck with extraordinary muscular development (Fig. 67), while in the Renaissance women the thyroid was often depicted as verging on a goitre (Fig. 72, p. 185).

Some of the landmarks hitherto referred to in the

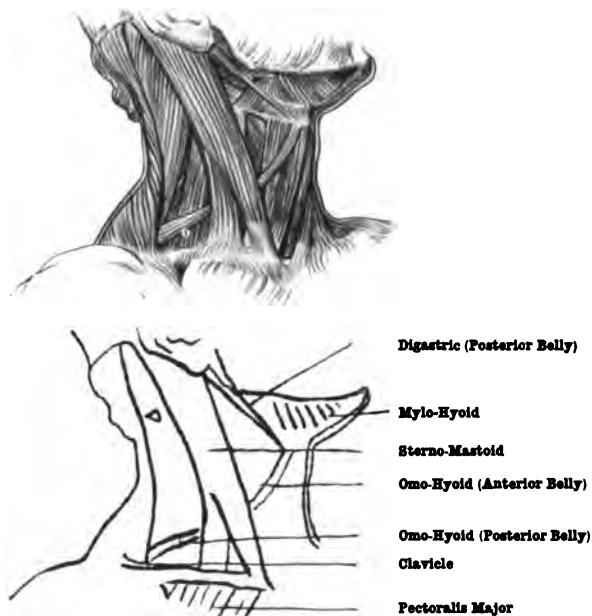


Fig. 73.—The Muscles of the Side and Front of the Neck.

neck can only be demonstrated with difficulty, and all are of little importance when compared with that to which the student's attention will now be called. This is the most marked muscular feature of the neck, in either sex, an oblique ridge formed by the *sterno-mastoid* on each side (Figs. 68, 70, 71, 73, 74).

This muscle is very thick and strong, and passes downwards from the mastoid process of the skull,

THE HEAD AND NECK

which is situated behind the external ear or auricle, as well as from a part of the occipital bone continued backwards from it (Fig. 73).

From this origin, where the ridge it forms is hardly so pronounced as elsewhere, the muscle passes downwards, forwards, and inwards, becoming progressively more prominent. It is attached below to



Fig. 74. —Necklace-like Creases in Front of Neck of Youth.

the inner two inches of the upper surface of the collar-bone, and, by an independent tendon, to the front of the upper part or manubrium of the sternum. The clavicular portion is broad, flat, and fleshy; the sternal portion round, cord-like, and tendinous. The two parts of the muscle become separated from each other at only a short distance above the clavicle; in this way a small and variable triangular interval is left between them.

THE HEAD AND NECK

Although the sterno-mastoid muscle runs obliquely when the head is directed forwards, its position is very different when the head is turned on one side. Then the sterno-mastoid of the side opposite to that towards which the face is turned assumes a vertical position, and stands out well, because it is in action, while the sterno-mastoid of the other side becomes more oblique and less prominent, because it is not in action.

Whatever position the head may occupy the prominence formed by the sterno-mastoid is always obvious, although naturally it is more pronounced when the muscle is in forcible action.

This large and important muscle has a complicated action. When the muscles of the two sides act together and the thorax is fixed, they bend the head forward. But when the head is fixed, they raise the chest, and can thus be used as accessory muscles of respiration. This happens when there is difficulty in breathing, as in a case of asphyxiation, or in a man suffering from asthma.

When one muscle acts alone the face is rotated to the opposite side, and the head is depressed on the shoulder of the side of the acting muscle. This composite movement results in a slight elevation of the chin, and a corresponding upward inclination of the face. The exercise of rowing displays it in vigorous action.

The sterno-mastoid muscle forms the boundary of certain regions of the neck, viz. the slightly hollow areas known as the **triangles of the neck** (Figs. 68, 73).

There are two chief triangles, anterior and posterior, so called from their position relative to the sterno-mastoid. They are of course bi-lateral,

THE HEAD AND NECK

and in the "attention" position of the head are symmetrical.

The anterior triangles are immediately adjacent to each other, the boundary being the anterior middle



Fig. 75.—Head and Face of an Old Man.

line of the neck, the various points of which have just been described.

The apex of each anterior triangle points downwards, and is formed by the convergence upon the middle line at the lower part of the neck of the sterno-mastoid muscle as it passes to its sternal attachment.

The base of the anterior triangle is directed up-

THE HEAD AND NECK

wards, and is formed on each side by the lower margin of the jaw, and by a line drawn backwards from this to the tip of the mastoid process.

The sides of the triangle are formed by the middle line of the neck and the anterior border of the sterno-mastoid muscle.

During the act of coughing, in a well-developed muscular subject who has very little fat, three ridges, or perhaps furrows, may occasionally be observed converging upon the hyoid bone. These indicate the presence of small subjacent muscles.

One of the ridges or furrows is more obscure than the others, and passes from the hyoid bone downwards, outwards, and backwards, beneath the sterno-mastoid. This is the anterior portion of a slender, long, tape-like muscle, the *omo-hyoid*, which passes downwards across the anterior triangle in its lower part, and subsequently across the base of the posterior triangle, to find attachment on the scapula (Fig. 73).

The other two ridges are due to the two portions of one muscle, the *digastric*, the anterior part of which passes to the hyoid bone from the chin, while the posterior part passes to the same bone from the mastoid process, in company with a small muscle, the *stylo-hyoid*, which cannot be separately distinguished without dissection (Fig. 73).

These three ridges divide the anterior triangle into three smaller ones, of which the upper, or *digastric triangle*, is the most obvious. It lies beneath the lower margin of the jaw, and contains the sub-maxillary salivary gland, which produces a fulness in this region, and a part of the parotid gland, which, except in the glutton, forms no prominence, but merely fills up what would otherwise be a hollow between the ramus of the lower jaw and the ear.

THE HEAD AND NECK

The posterior triangle lies behind the posterior border of the sterno-mastoid.

This is a much smaller area than the anterior triangle, and differs from it in having its base directed downwards and its apex upwards.

The base of the posterior triangle is formed by the middle third of the upper border of the clavicle. The sides are formed in front by the posterior border of the sterno-mastoid, and behind by the anterior border of the upper or cervical portion of the trapezius. The apex of the triangle is at the point where these muscles meet, or nearly meet, at the middle third of the superior curved line of the occipital bone. That is, the apex is about the midpoint of a line drawn between the tip of the mastoid process and the external occipital protuberance.

Occasionally the base of this triangle may be narrowed by the attachments of the sterno-mastoid and trapezius muscles to the clavicle approaching each other more nearly than usual.

Such decreased breadth is not necessarily due to excessive muscular development. Such development would merely cause the boundaries to be more prominent and the triangle to be deeper, and therefore more pronounced.

The apex of the triangle may, on the other hand, be replaced by a short line in those subjects in whom the attachments of the same two muscles to the occipital bone fail to meet.

The basal part of the area behind the sterno-mastoid may show pulsation, owing to the presence of the subclavian artery which lies deeply in this region just above the clavicle.

The neck, as it reaches the trunk, becomes rather thicker. The increased thickness is due to certain

THE HEAD AND NECK

deep muscles which pass from the neck to the upper ribs, but they will not repay the artist for an attempt at differentiation.

In persons who have not much superficial fat the *external jugular vein* is easily discerned, but it is seldom as striking an object in nature as in art (Fig. 68, p. 181). It is one of the largest of the superficial veins in the whole body. Its course is indicated by a line drawn from the mid-point between the angle of the lower jaw and the tip of the mastoid process to the middle of the upper border of the clavicle. Just above the clavicle it disappears from view by passing deeply under the outer margin of the sterno-mastoid, to join the subclavian vein. There is no such thing as a "jugular artery." The main artery in the neck is the carotid, and the vein which runs with it, too deep to be seen, is the internal jugular.

Expiratory effort, as in singing, makes the external jugular vein full and prominent, and then it may show one or two dilatations in its course, the result of valves within its lumen.

There is a very interesting thin, but wide, muscle on each side of the neck, called the *platysma myoides* (Fig. 25), the best example in the human being of the superficial sheets of muscular fibres similar to those which cover a great part of the body of some of the lower animals, *e.g.* the horse. A very good representation of this is to be found in the hall of the Royal College of Surgeons. The *platysma* lies in the superficial fascia of the neck and upper part of the chest. Sweeping downwards from the face, it covers both anterior and posterior triangles, and obtains a weak attachment to the margin of the lower jaw and of the clavicle as it passes with a slight inclination backwards over the latter bone, to terminate in the skin

THE HEAD AND NECK

of the upper part of the chest and shoulder. When the platysma acts, it pulls the skin of the chest upwards and the angle of the mouth downwards and outwards. Some of the muscles of the face are derived from the same subcutaneous muscular sheet, but have become specially developed in connection with the expression of the emotions. The platysma is sometimes very strongly marked, and the individual bundles of muscle fibres which form the sheet may even be seen through the skin. Being concerned in expression, it is innervated to a large extent by the facial nerve (Plates XXIV., XXV.).

Notice the double destiny of this subcutaneous muscle sheet, so useful to certain animals for starting away, by the sudden movements it can give to the skin, any irritating insects which are out of reach of the tail. Over the greater part of the human body the muscle has degenerated; it has, in other words, undergone involution. The facial part of it, however, has become evoluted and differentiated, and is of great importance in the expression of the emotions.

Notice also that it is the anterior borders of the two platysma muscles which account for those two vertical cord-like folds of baggy skin in the pre-hyoid and pre-thyroid region of the aged and withered neck. Here, and about the apex of the posterior triangle of the neck, are the two places where are earliest shown the effect of age in withering the subcutaneous structures and rendering the skin baggy (Fig. 70).

The superficial fat of the neck, as of the rest of the subject, is relatively more abundant in the female than the male, and fills up the hollows and rounds off the prominences, so that in the female the muscles, and especially the sterno-mastoids, are not nearly so conspicuous as in the male.

THE HEAD AND NECK

We must now concentrate our attention upon the *trapezius muscle*, which forms a flat sheet situated on each side of the cervical and dorsal vertebræ.

The *trapezius* (Fig. 62, p. 158) has the most extensive attachment of any muscle in the body. Its origin lies in and near the middle line, and embraces attachments above to the external occipital protuberance, and to an inch or more of the superior curved line of the occipital bone; below this to the *ligamentum nuchæ*, a strong, deep, elastic ligament which bridges the backward concavity formed by the cervical spine as seen in the profile view of the skeleton; and below this again to all the dorsal spinous processes.

The ligamentum nuchæ, from which this muscle arises in the neck, is a broad band of fibrous material containing some elastic tissue, and extending from the external occipital protuberance to the spine of the seventh cervical vertebra. It is attached to all the cervical spines, and gives origin to several layers of muscles situated on the back of the neck. It helps to keep the head erect, and so diminishes, but does not abolish, the need for continued muscular activity in order to maintain the poise of the head; in quadrupeds it is enormously hypertrophied, because, their spine being disposed horizontally, its task is increased. But for the *ligamentum nuchæ*, any quadruped with a heavy head would have to hang it vertically from the shoulder as in the position of grazing, or to develop some stronger muscles in the back of the neck; muscular tissue becomes tired, while ligaments do not.

If the student will now examine that border of the *trapezius* which bounds the posterior triangle (Fig. 62, p. 158), he will observe that it is not nearly so vertical as the lower border which lies upon the back. The

THE HEAD AND NECK

cervical outer border is curved somewhat forwards, so that the back part of the side of the neck is gently rounded. The shape and bulk of the trapezius will be better realised if the model shrugs his shoulders, while the student examines the part just above the scapula (Figs. 67, 77).

In a muscular subject it can be appreciated that in the greater part of the dorsal region, and in the upper part of the cervical region, the muscular fibres of the trapezius extend right up to the middle line; but in the lower cervical and upper dorsal regions a short flat tendon of origin, or aponeurosis, is developed on each side, which produces a slight flattening or depression on either side of the vertebra prominens (Fig. 62, p. 158).

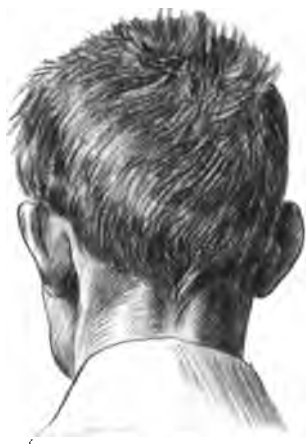

Fig. 76.—Back of Boy's Neck, showing Median Furrow.

In the middle line of the neck between the two trapezii there is a deep furrow, frequently obscured by fat, and best seen perhaps in the boy's neck (Fig. 76), continuous with that already described in the account of the trunk. At the bottom of this nuchal furrow lie the ligamentum nuchæ and the spines of the vertebræ. Although the trapezius makes the longitudinal elevation on each side of this furrow, it is by no means entirely responsible for its prominence, the thick *complexus muscle* contributing largely though its outline is obscured by the trapezius.

The complexus lies under the trapezius and pushes

THE HEAD AND NECK

it up. The ridge it forms is narrower and more prominent above than below (Fig. 76).

If the student now adds to what he can see that which he can feel by pressing his finger down this furrow, he will make acquaintance with the spine of the axis, or second vertebra.

The axis forms a massive, though not prominent, eminence below the occipital protuberance. The spines of the first, third, fourth, and fifth vertebræ cannot be felt, but the sixth and seventh are quite distinct. The spine of the *vertebra prominens* is, however, hardly more conspicuous than that of the first dorsal vertebra, which lies below it and is almost if not quite as obvious.

These spinous processes of the vertebræ are best observed when the skeleton spine is bent forwards. In this position they are also separated by wider intervals than when the head is erect (Plate XXII.).

When the head is bent backwards (Fig. 77), transverse superficial folds may be seen running across the back of the neck. Hair is found in the upper part of the neck, and especially in the median nuchal

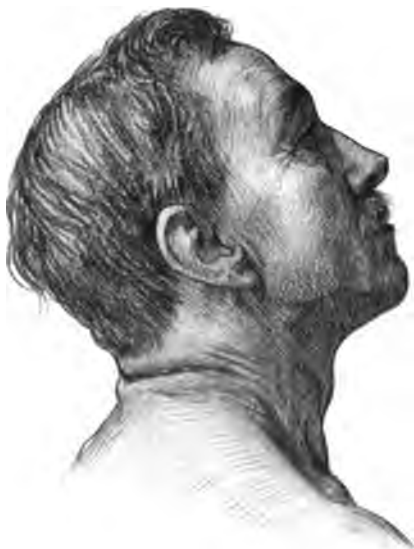

Fig. 77.—Creases seen on Back of Extended Neck.

THE HEAD AND NECK

furrow (Fig. 76, p. 196). In the muscular subject the back of the head is often nearly, but seldom quite, flush with the back of the neck (Figs. 65, 67), a very different condition from that seen and described in the front part of the same region.

The Head and Face.

The skull, or skeleton of the head, is divided by anatomists into (a) **the Cranial Bones**, concerned chiefly with the protection of the brain, and therefore dense and strong; and (b) **the Facial Bones**, designed for the accommodation of the organs of special sense and of mastication and expression, and therefore comparatively light.

The Scalp, as the soft parts covering the cranium are collectively called, is, with the exception of the forehead, covered with hair. The scalp is very dense and tough and mobile, but quite thin, so that the shape of the cranium is dependent upon the bones, which vary much in different skulls, and are rarely exactly similar even on the two sides of any individual—in fact, no human being is in any part strictly symmetrical. Two main types of skull may be mentioned—the “dolichocephalic” or long head, and the “brachycephalic” or broad head. Between these two main types is an intermediate one, to which belong the higher races of mankind.

The various relations of length and breadth of the skull in its different parts are dealt with in the science of anthropology.

We will study first the skull with its coverings, and later the face.

The Hairy Scalp.—The hair throughout the body varies in many qualities—*e.g.* colour, texture, thickness, and moisture—but it never varies in the direction of its slope, which as a general rule is such that if

THE HEAD AND NECK

one goes down on all-fours, rain falling on one's back would be directed to the ground by the hairs. The hair of the scalp slopes downwards from a point situated rather behind the vertex of the skull. Possibly the direction of the slope of the hair may be to some limited extent determined, or even altered, by habitual brushing in a definite direction. The frequent early disappearance of hair at the upper part and sides of the forehead is in all probability due partly at least to the wearing of some form of hard head-gear. Readers of Scott will recall his description of Marmion.

Hair also often disappears and produces baldness in the mid-line of the head, behind and around the vertex. From this "tonsure" the area of disappearing hair spreads forward, laterally, and backwards, until finally only the sides of the head are left covered. In the majority of persons becoming bald the area immediately surrounding the patch of baldness is poor not only in quantity, but also in the size of the individual hairs.

The scalp has no definite boundaries except in front, where it is separated from the face by the curved upper margin of the bony orbit, a line corresponding with the *eyebrows*. Laterally the boundary is that arch of bone, the *zygomatic arch*, which forms a flying buttress on each side of the head, and is composed of a slender process of the temporal bone, called the zygomatic process, at the back of the arch, and of the malar bone at the front.

Behind this arch the mastoid process, the superior curved line, and the external occipital protuberance mark the boundary between head and neck.

The *auricle*, or ear, ought properly to be considered as a part of the cranium. For various reasons, and

THE HEAD AND NECK

especially for the art student, it will be more conveniently considered with the anatomy of the face.

The part of the **Cranium** which is not covered with hair, and which is known as the forehead, is as liable to show variety of shape as any part of the skeleton. Any eminences which may be present upon it are due chiefly to the surface form of the underlying *frontal bone*. On each side of the middle line the student will notice the *frontal eminence*. This is situated some two inches above the orbit, and as a rule is smooth and rounded, and only slightly elevated.

The frontal eminences are said to be well marked in high types of intellect, as the intellectual nerve centres are specially developed in the frontal lobes of the brain. But it is only right to state that these eminences are also particularly well developed in feeble children suffering from rickets.

It is necessary to distinguish the frontal eminences from those others which are situated much nearer to the middle line, just above the root of the nose. These *superciliary ridges*, which, owing to the absence of any intervening furrow, occasionally run into one another, are due to the development of air spaces within the frontal bone connected with the nasal cavity, and are probably useful as resonating chambers for the modulation of certain qualities of voice. They are hardly developed at all until after the age of seven years, and afford little, if any, indication of the intellectual power of the individual.

They lie above and parallel to the *supra-orbital margins*, being separated from them by a distance of one-third of an inch. These ridges can always be felt, but not always seen.

The root of the nose, where the forehead becomes

THE HEAD AND NECK

continuous with the face, will be described with the latter.

The skin of the forehead is usually smooth and frequently shiny; it is liable, as in the act of raising the forehead to express surprise, to be thrown into a series of slightly curved folds, or furrows, some of which, to a varying extent in different individuals, are permanent.

Three or four such *frontal furrows* are demonstrable. The upper ones run across the middle line, but the lower are interrupted there. They are concavo-convex, the convexity lying on each side of the middle line and the concavity lying across it, and both ends being directed downwards (Fig. 75).

The upper furrows, as well as being larger and more complete, are deeper. All the furrows are prolonged outwards on each side to the margin of the hairy portion of the scalp. They occupy usually only the lower half of the forehead.

The furrows are due to the contractions of the underlying *frontalis muscle*, which is the anterior muscular portion of a musculo-membranous sheet called the occipito-frontalis. The muscle is connected above with the aponeurosis, while below it is inserted into the skin of the forehead, and passes down into the nose. It also blends with the muscle chiefly concerned in the opening and shutting of the eye, viz. the *orbicularis palpebrarum*.

In the act of frowning, additional grooves are to be noticed placed vertically or obliquely near the middle line just above the nose. These important grooves are formed by the contraction of a tiny muscle known as the *corrugator supercilii*.

The upper border of the frontalis muscle corresponds to the limit of the transverse furrows on the forehead.

THE HEAD AND NECK

The two frontales muscles lie immediately adjacent to one another in the middle line, and their upper edges, where they blend with the aponeurosis, are sharply convex. The outline of these muscles is particularly well seen in young subjects.

On the side of the forehead a tortuous, pulsating ridge may be seen in the old, or even in those who are prematurely old; and, be it remembered, a man's age is rarely so correctly ascertained at Somerset House as by an examination of his blood-vessels. The condition of this heaving and pulsating ridge, due to the presence of the subjacent superficial temporal artery, is a far better indication of senility than the records of a registrar (Fig. 75).

Its conspicuousness in old persons is a consequence partly of that wasting of the superficial tissues which occurs with age, but chiefly of the deposit of a lime salt within the walls of the artery. The deposit renders the artery more rigid, so that it stands out much more distinctly than it would do otherwise. The artery is at the same time lengthened, which causes it to become tortuous.

The forehead varies very much in expanse and shape. The low forehead, which is considered by some to be a point of beauty in the female, to others suggests chiefly the criminal taint with which it is often associated in the male.

The high forehead is thought to be a characteristic feature of intellect; notice, for instance, the busts of Shakespeare, or the portraits of Walter Scott. Certainly the height of forehead may be due to actual expanse of cranium, but beware of the false impression conveyed by baldness or the brushing back of the hair.

THE HEAD AND NECK

The forehead may bulge forwards, or it may be decidedly "retreating."

The prominences noticeable upon that part of the head which is covered with hair are symmetrically placed, like those of the forehead.

The parietal eminences are seen at the broadest part of the head on each side, above and behind the ear. They indicate the spots at which the ossification of those bones originally started.

Immediately behind the ear is the nipple-shaped *mastoid process* (Figs. 15, 16, and 18, pp. 55, 56, 58), a bony eminence which is better developed, actually as well as relatively, in the adult than in the child. The reason for this difference is, that after the age of seven years air spaces are developed in the substance of the temporal bone in connection with the middle ear, a part of the organ of hearing buried deep in that bone. The air spaces are in direct continuity with the middle ear, as the box which has the drum of the ear in its outer wall is called. All vibrations entering through the passage of the external ear disturb the drum which lies at the bottom of it. The drum transmits the disturbance or vibration by means of three small bones, advantageously placed for this special purpose, to the internal ear, which is the actual organ of hearing.

The external occipital protuberance can be more easily felt than seen, but its position should be observed, as it forms an important landmark. It lies just above the nuchal furrow in the middle line of the back. The superior curved line, and therefore the boundary between the head and the back of the neck, is continued outwards on each side from this protuberance.

In young children who have not yet obtained a

THE HEAD AND NECK

covering of hair, and to a less extent in older persons who may have lost it, the posterior muscular part of the epicranial musculo-aponeurotic sheet will be noticed, forming a flat, slightly raised eminence of thin muscle called the occipitalis. This corresponds behind to the frontalis already described as a landmark of the forehead.

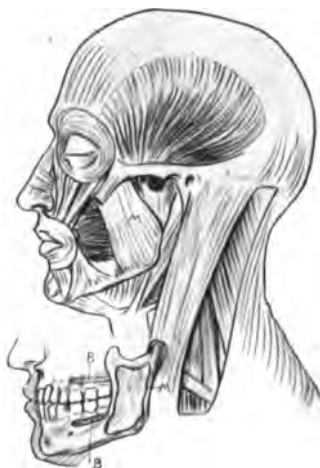The whole sheet is called the occipito-frontalis muscle. The posterior part is known as the occipitalis muscle, and arises from the superior curved line of the occipital bone. The origins of the two occipital muscles are separated, unlike the frontales, by a distinct interval, measuring at least an inch.

The *occipito-frontalis* muscle (Fig. 78) is not capable of throwing the skin of the scalp into folds except in the forehead, where it accounts for the transverse grooves so obvious in the expression of surprise. The extent to which these folds can be voluntarily produced varies much in different individuals, and in a few, especially after youth is past, the grooves are permanently impressed upon the skin. Similar differences are found in the degree of voluntary control possessed by individuals over the movement of the scalp and of the external ear.

On the side of the skull, but chiefly in front of the ear, a fan-shaped, slightly elevated region, broad with convex border above, and narrow below, is due to the subjacent *temporal muscle* (Figs. 79, 80). This is one of the immensely powerful closers, or elevators, of the lower jaw. It arises from the *temporal fossa* of the skull, and is inserted into the coronoid process of the mandible. When vigorously contracted, as in grinding the teeth, the belly of the muscle can be felt as a rounded eminence above the zygomatic arch. The muscle descends deep to this arch (which has been

THE HEAD AND NECK

cut away in Fig. 79 to show the tendon) as it passes to its destination. The facility with which this muscle may be felt, or even seen, to contract when the jaw is clenched has been utilised by fraudulent thought-readers as a means of communicating with the confederate by a sort of Morse code.



**Fig. 78.—Muscles of side of Head,
Face, and Neck.**

M—Masseter. Inset of Jaws showing:—
R. Origin of Buccinator.
M. Insertion of Masseter.

The Superficial Anatomy of the Face.—Even in the more vacant countenance, which has been said to bespeak the empty mind, there are variations in expression from moment to moment. When the subject of our study is an active-minded and intelligent person, the difficulties which confront us are complex and varying in the extreme.

The Face, for the purposes of convenient descrip-

THE HEAD AND NECK

tion, includes the chin, cheek, mouth, nose, eyes, and ears.

The ordinary anatomist is content to consider all faces to be as much alike as a row of pins, yet in reality there is as much difference between any two faces as there is between any two finger-prints; no two faces are exactly alike, and no face is strictly symmetrical. Even as a doctor must be a student all his life, so a portrait-painter finds that the longest

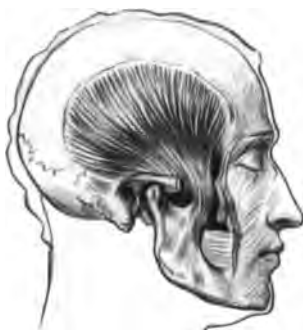

Fig. 79.—Temporal Muscle.
Zygoma cut away.

life is too short to fathom all the depths and difficulties presented by facial expression.

Let us attempt a brief account of the anatomy of the face and its component parts, in order that the student may begin to understand something of its various movements and resultant expressions.

When the face is viewed from the front (Fig. 81), the outline of the forehead (as high as the vertex) and face may be seen to resemble that of an egg, the broad part of the head being situated above and the narrow part below.

THE HEAD AND NECK

Let the ovoid be quartered or divided by a vertical median line and by a horizontal line through the middle of the vertical one (Fig. 81).

The eyeballs lie on a level with the line drawn



Fig. 80.—Surface Markings upon a Thin Face and Neck.

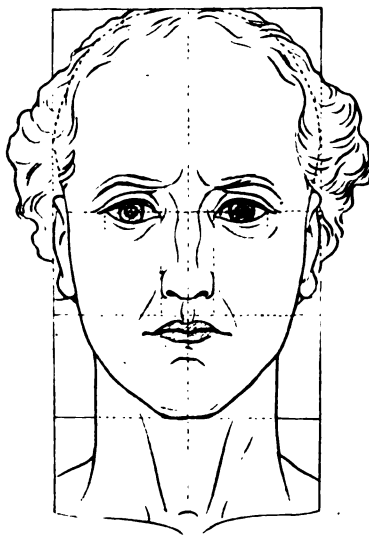


Fig. 81.—Figure to show Proportions of Face and Neck.

horizontally through the middle of the ovoid, or even slightly below this level. This is a most important point to realise, for if the eyes are placed too high, it becomes at once manifest that the head belongs to that microcephalic type which is usually associated with the criminal class.

THE HEAD AND NECK

Most of the face therefore lies in the lower half of the ovoid; only a small part, indeed, passes into its upper half, which is chiefly occupied by the forehead.

If the lower half of the vertical median line be bisected by another horizontal line so as to subdivide the lower half of the ovoid, the mouth and chin will be found to lie in the lowest quarter of the face, and the nose in the quarter above this.

If the horizontal line through the eyeballs be continued outwards it will pass a little below the highest points of the ears.

If a horizontal line be drawn between the tips of the ears, and the face be still viewed from the front and considered as if it were flat, and this line be divided into fifths, the middle fifth corresponds to the root of the nose, and the fifths on each side of the middle, to the eyes; and the fifths to the side of this again correspond to the foreshortened temples.

The eyeballs are the organs of vision by which light waves are received and transmitted to the brain. They are well protected from injury by surrounding bony ridges, *orbital margins*, which bound the anterior part of the bony cavities in the skull, known as the orbits.

Above the eyeball is the particularly well-marked ridge formed by the supra-orbital margin (Fig. 82, p. 210) of the frontal bone. This is sharp and concave downwards, and terminates externally in the well-marked external angular process to which the temporal muscle nearly reaches, and internally in the less noticeable internal angular process on the side of the root of the nose.

Externally to the eyeball, the antero-internal part

THE HEAD AND NECK

of the malar bone forms a protecting ridge. Below the eye the infra-orbital margin of the malar and superior maxilla forms a ridge which, though less prominent than the supra-orbital, yet projects enough to bring this margin also in front of the eyeball.

Internally, the boundary of the orbit is formed by the nasal process of the superior maxilla and part of the frontal bone.

It is the prominence of the nose, however, that is responsible in the main for the protection of the eyeball from blows directed on its inner side. Owing also to this same prominence, vision is more obscured on the inner or nasal side of the eye than on the outer or temporal side; so that when the eyes are directed to an object situated on the left side, the left eye sees much more of the object than does the right eye.

The supra-orbital margin is covered by closely set and rather coarse hairs, forming the eyebrows. The line of the eyebrows, in the inner half of its length, lies on a nearly horizontal plane, but in the outer half it is prolonged somewhat downwards.

The inner ends of the two eyebrows sometimes meet in the middle line of the root of the nose, running somewhat downwards to do so, and producing a "beetling brow."

The individual hairs of the eyebrows are directed for the most part upwards and outwards, but externally the outward or even a downward direction may be more apparent (Fig. 82, p. 210).

In some people the eyebrows project directly forwards, and are very long; in some the outer part may be almost wanting, or may be directed upwards and outwards.

The upper and lower soft fleshy curtains or *eyelids*

THE HEAD AND NECK

form an additional protection to the delicate organ of vision, upon which they move almost without friction because of the sac of the conjunctiva, which is lubricated by tears.

The conjunctiva covers the apposed surfaces of the

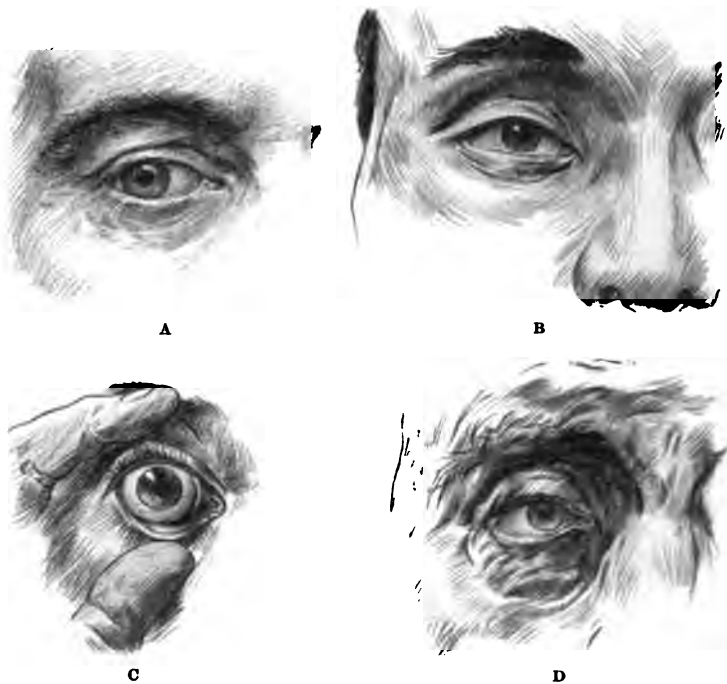


Fig. 82.—The Palpebral Aperture, Eyelids, and Eyebrows.

lids and eyes. It is a transparent sheet of mucous membrane, and allows the colour of the tissues lying beneath it to show through; so that the inner surface of each lid is ruddy, while the fibrous coat of the eyeball, or *sclerotic*, shines white through the

THE HEAD AND NECK

ocular conjunctiva. The transparency of this membrane is further proved by the fact that, although it covers the *cornea*, or clear part of the eyeball, it does not obstruct vision.

The chink between the two lids is known as the *palpebral fissure* (Fig. 82). When the eyelids are separated from each other and the eye open, this fissure is oval or almond-shaped, with the outer corner sharp and angular, and the inner corner rounded or punched out. At this inner corner the edges of the lids run for a space parallel with each other, and thus a little bay is formed, in which is to be seen the *caruncle*, a small pink fleshy structure.

In certain races, *e.g.* in the Chinese, the inner end of the upper eyelid is prolonged on the face, over the inner end of the lower eyelid (Fig. 82 B).

Naturally the shape and appearance of the palpebral fissure vary according as the eye is open or shut; and the fissure, when the eyelids are approximated, is generally transverse, with a slight convexity downwards and forwards. When the eye is open, the edge of the upper lid is convex forwards and concave downwards. The edge of the lower eyelid is convex forwards and slightly concave upwards. Both these edges become straighter when the eye is closed.

Near the entrance of the punched-out bay at the inner angle of the fissure, a black spot will be noticed on each eyelid at the summit of a very small eminence. This is *the punctum*, and is the entrance to the *lachrymal canaliculus*. It is by the apposition of the lids to the globe of the eyeball that the tears are enabled to enter these puncta, and to be thence transmitted along the canaliculi to the lachrymal duct, and so to the nose.

THE HEAD AND NECK

The lids act not only as curtains, but also as brushes; they move the tears along, and they also sweep away the particles of dust which constantly enter the conjunctival sac.

Increased formation of tears, in certain emotional states, leads to their accumulation in the conjunctival sac till they overflow the lower eyelids and run down the face, the canaliculi being too small to deal with such an increased flow.

As age advances, the lids, which are normally kept in close apposition with the eyeball, fall away a little (Fig. 82 D, p. 210), owing to loss of tone in the muscle controlling the movements of the lids. As a consequence the tears are very apt to flow over the face, and the eyes to become "blear"—*i.e.* the ruddy inner surface, especially of the lower lid, becomes visible as in most hounds and some other dogs.

The free edge of each eyelid is thicker than the rest of the lid, and is very slightly everted. Each free edge also carries a row of short, coarse, curved hairs, the eyelashes, which are not very numerous, vary greatly in thickness, in length, and in curve, and are directed forwards. They afford protection against small foreign bodies, which otherwise would enter the eye more frequently.

The Movements of the Eyelids.—Both lids are capable of an upward and downward movement, but the upper lid moves much more freely and extensively than the lower. For this reason the palpebral fissure, when closed, lies below the level of the pupil of the eye.

Within each lid there is a crescentic plate of cartilage, which gives rigidity to the curtain without impairing its mobility.

THE HEAD AND NECK

Two muscles bring about the movements of the lids, viz. *the orbicularis palpebrarum* and the levator palpebræ superioris. The former is a flat sheet of muscular fibres, arranged in parallel and concentric circles around the margin of the palpebral fissure. This muscle is not visible through the skin, but when the skin has been dissected away it may be seen to spread outwards in the temporal and malar regions; inwards, upon the nose; and downwards, upon the face.

A part of the orbicularis palpebrarum lying actually upon the eyelids may be distinguished from the main part, which lies wide of these curtains. The nerve supply, as is the case with all the muscles of expression, comes from the seventh cranial, *i.e.* the facial, nerve.

The upper eyelid is distinguished from the lower by having an additional muscle which assists in performing and controlling its movements. This is the *levator palpebralis superioris*. It runs forwards in the cavity of the orbit, as do most of the muscles which move the eyeball. By the contraction of this muscle the upper eyelid is raised, and owing to it the upper eyelid has more active movements than the lower.

Forcible closure of the lids is brought about by the contraction of the orbicularis palpebrarum, and the eye is opened by the relaxation of this muscle, together with the contraction of the levator.

Blinking is a quick forcible action of the orbicularis, resulting in momentary closing of the eye. It occurs at periodic intervals, and assists in the moistening of the surface of the eyeball itself, as well as in the circulation of the tears and the removal of small

THE HEAD AND NECK

foreign bodies from the conjunctiva. Blinking also occurs with any sudden shock, especially one of a visual nature.

Winking is a slower movement, is purely voluntary, and is dependent upon the action of the orbicularis, especially in connection with the lower lid, which is raised in the process. Winking does not take place without the will and knowledge of the subject, and it is not given to everybody to have the necessary amount of voluntary control over each orbicularis independently of the other; blinking, on the contrary, is usually as much an involuntary act as breathing, and the agent is not conscious of either unless it is performed under the influence of some unusual stimulus. Another essential distinction between these two actions is that in winking only one eye is involved at a time, while it is usual for both eyes to blink together—in the human being, at least, though the closing of a single eye in cats and other animals is probably of the nature of an unconscious blink rather than a conscious wink.

Ptosis, or drooping, is a condition of the upper eyelid which the art student should notice. It is sometimes due to paralysis of the facial nerve, which of course supplies the orbicularis; and sometimes to paralysis of the third cranial nerve, which supplies the levator. In either of these cases it is generally unilateral. It may, however, be congenital, and is then more frequently bilateral. Ptosis is an exaggerated degree of the condition known as drooping of the eyelids, which is of considerable interest as indicative of certain emotional states (*vide infra*).

Some of the various means by which very efficient protection is afforded to the eyeball have now been

THE HEAD AND NECK

considered, and the student should direct his attention next to the organ itself.

The eyeball is the organ of vision, and is connected with the brain by means of the optic or second cranial nerve. It is contained in the orbit, which is a cavity developed in the skull in special adaptation to the important structures which it contains.

The expression "globe of the eye" almost exactly describes its shape. It is a little over one inch in diameter, almost as large in the infant as in the adult, and about the same size in all adults. When we say that "the eye is large," we really mean "the palpebral fissure is large."

Only that part of the eyeball which lies in front can be seen without the aid of dissection, or the use of the ophthalmoscope, an instrument devised by Helmholtz, by means of which the interior of the eyeball can be illuminated and examined.

The wall of the eyeball consists of three coats. The inner coat, or *retina*, contains the terminals of the optic nerve, or rods and cones, which are the only structures in the body capable of receiving and transmitting to the brain for interpretation the vibrations of light; the middle, or *choroid*, is remarkably rich in blood-vessels for the supply of the component parts of the eyeball; and the outer coat, or *sclerotic*, is protective.

The sclerotic is fibrous and firm, and to it are attached the various small muscles which bring about the movements of the eyeball. It is white in colour, with a faint tinge of blue, and forms the "white of the eye."

The front part of the sclerotic presents a nearly circular window, filled in by a thick membrane, as transparent as glass and bulging slightly more than

THE HEAD AND NECK

the sclerotic. This is the *cornea*, and through it rays of light pass to the interior of the eye. In addition to its transparency, the cornea differs in certain other respects from the sclerotic. It is, in the first place, thinner; in the second place, it bulges from the surface of the sclerotic because it is a segment of a smaller globe. It would not be quite correct to say that the cornea is circular, for it is slightly longer horizontally than it is vertically.

The colour of the eye, which varies in different individuals, depends upon the presence of a pigmented circular membrane behind the cornea, known as *the iris*.

The iris might properly be described as a circular disc perforated in its centre. The perforation, however, presents a most remarkable peculiarity; it is capable of alterations in size. If the student brings a light suddenly in front of the eye he will notice that the aperture becomes smaller. If, on the contrary, he places his hand partially over the eye so as to cut off some light, he will observe that the perforation becomes larger.

The perforation or aperture is known as the *pupil* of the eye. The iris, in addition to being responsible for the colour of the eye, produces also alterations in the size of the pupil, which are of supreme importance to the subject.

The iris contains muscular fibres which are so disposed, in both a radiating and a circular manner, as to cause increase or decrease of the size of the pupil by their action. There are certain definite conditions which cause dilatation—*e.g.* when the surrounding light is obscured, when a distant object is being observed, and when the subject is under the influence of certain drugs. Belladonna is one of

THE HEAD AND NECK

these, and no doubt it received its name from the dark large pupils it produces, which are commonly considered beautiful, and which result from the contraction of the radiating fibres in the iris or the paralysis of the circular fibres.

The pupil is contracted and small during sleep; also, when an object close at hand is being observed, and when the subject is under the influence of certain other drugs, of which opium is one.

The iris contains pigment, which is variable in quantity and not in quality. If there is little pigment the eyes are lighter and bluer; if there is much pigment the eyes are dark. Occasionally there is no pigment at all, in which case the red colouring matter of the blood alone colours the iris. This condition of pink eyes, occurring in *albinos*, is associated with an absence of pigment elsewhere. The hair of such individuals is white, and the skin has a pinkish tinge. Owing to the absence of pigment their irides are too transparent, so that they do not like a bright light, and hide from it as far as they can.

A large pupil will make the whole eye appear larger than usual.

There is another cause, though a less important one, for the varying colour of eyes, namely, that the iris being thrown into folds radiating from the pupil the rays of light which strike it are reflected and refracted from it. Refraction implies the splitting up of white light into the various primary colours, and it will be clear that this must be responsible for much of the variation in the colour of irides and for some factors in that interesting and obscure subject "light in the eye."

The student, if he make a close observation, will

THE HEAD AND NECK

observe that the iris is not a flat surface, but is slightly curved forwards.

Behind the iris, and filling up the pupil, is the *lens of the eye*, a transparent structure shaped like an ordinary magnifying glass. It is capable of alteration in its convexity, by means of the action of the small *ciliary muscle* situated within the eye.

By alteration in the shape of the lens distant as well as near objects can be focussed upon the retina without the necessity for any change in the other parts of the eyeball. The power of thus altering the shape of the lens lessens with advancing years, so that old persons find they can read print more readily when it is held well away from the eyes. The explanation of this phenomenon is as follows: In the old, the lens tends to become set for distant vision only, *i.e.* for parallel rays of light. Only parallel rays fall upon the lens in such a manner as to be accurately focussed on the retina; and it is in the effort to produce as much parallelism as possible that the old man holds his paper as far off as the length of his arm will allow, and sometimes increases the distance yet more by the backward bending of his head and spine.

Between the lens and the cornea is the anterior chamber, filled with transparent *aqueous humour*.

Behind the lens lies a second and larger chamber, which contains the transparent *vitreous humour*.

All these parts, which go to make up the internal structure of the eye, would be useless if the eyeballs could not be moved. Their movement is brought about by six tiny muscles in each orbit. They all, with the exception of the smallest, arise from the back part of the orbit, and pass forwards to their destinations in the white sclerotic coat.

THE HEAD AND NECK

The *four recti muscles, superior, inferior, external, and internal*, are attached to these aspects of the eyeball a little beyond its centre of rotation. The smallest, or *inferior oblique* muscle, passes from the inner side of the front of the floor of the orbit, and is attached behind the centre of rotation. The fifth, or *superior oblique* muscle, passes from the back of the orbit to a little sling or pulley situated at the junction of the inner wall and roof of the orbit in front. The tendon of this muscle passes round the pulley, and is attached to the upper surface of the eye behind its centre of rotation.

The individual actions of the internal and external rectus are simple. The internal rectus rotates the eyeball inwards, while the external rectus turns it outwards. When the eyeballs move together to one side, the external rectus of the same side and the internal rectus of the opposite eye are acting together. Such a system of interaction between two muscles of different sides is called "co-ordination." This particular co-ordinated movement is controlled by a special collection of nerve cells in the brain.

The other muscles have a more complicated action, but it will be sufficient to state here that the eyeball is rotated upwards by the simultaneous action of the superior rectus and the inferior oblique, and is rotated downwards by the inferior rectus and the superior oblique acting together.

The co-ordination of these groups of muscles acting on each eyeball must be a very complicated matter. How much more complicated, then, the familiar and well-known action of making limbs and eyes act together in games or other actions of precision, *e.g.* shooting, cricket, and golf. The popular phrase, "a good eye," implies almost perfect co-ordination

THE HEAD AND NECK

between, and cerebral control of, the movements of very many muscles in the limbs, trunk, and eyes.

Squinting is a consequence of independent action of the muscles of the eye, their proper co-ordination being temporarily or permanently suspended. Many persons are incapable of turning both eyeballs simultaneously outwards, though most persons can turn them both inwards, and indeed do so frequently.

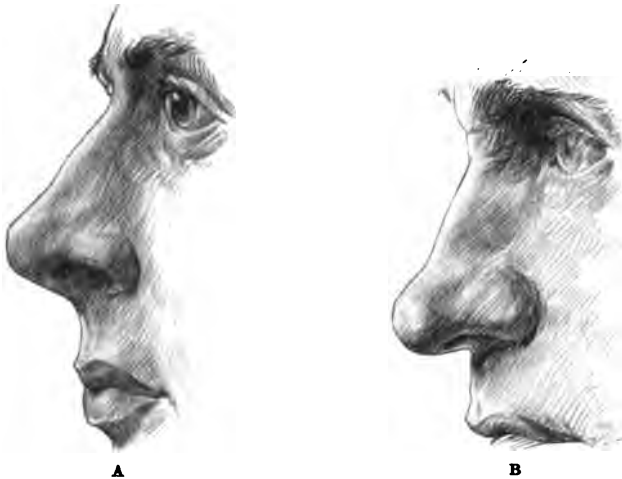


Fig. 83.—Compare these two drawings. The angle formed by the Columna nasi with the upper lip is very different.

When the eyes are accommodated for very near vision, they look decidedly inwards, as in reading small print held close to the eyes.

It may be added that in sleep the eyeball is rotated on a transverse axis upwards; the eyelids are slightly separated from each other, and only a small lower part of the cornea can be seen through the palpebral fissure.

In death the eyelids are widely separated, the cornea becomes dull, and the pupil semi-dilated.

THE HEAD AND NECK

The Nose is the most prominent part of the face. Its root is situated between the two eyes and is continuous with the forehead. Its varying shape in different individuals is due to several factors, which will be described later (Figs. 83 to 88).

The nose is narrower and depressed at its *root*, and more prominent at its lower end, the front part of

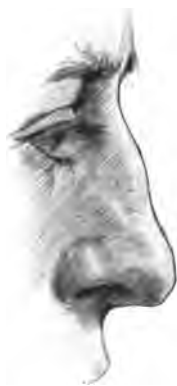

Fig. 84.



Fig. 85.

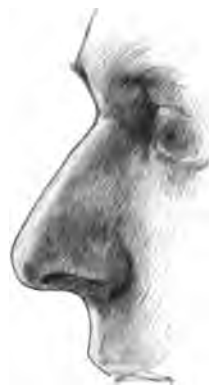

Fig. 86.

Various Types of Nose.

which is named the *tip*, while the lateral parts are called the *ala*.

The broadening at the lower end is due to the opening of the nostrils, or *anterior nares*, bilateral orifices through which air passes into the nasal cavity and thence to the windpipe.

The nose is supported by both bone and cartilage—or rather by either bone or cartilage, for where the bone supports the nose there is no cartilage, and *vice versa*. The bony framework lies chiefly at the root of the nose, the cartilaginous nearer the tip.

Thus the support of the *bridge* is formed by the

THE HEAD AND NECK

nasal bones and the nasal process of the superior maxilla, assisted by the spine of the frontal bone. This part of the nose, being fixed to the skull, is immovable.

The lower part of the nose is supported by cartilages, and is movable, and in the skeleton it is absent. The cartilages, just under the skin, are four in number, two on each side. They lie in apposition with each other in the mid-line, and the median groove between them can often be seen on the front of the tip.

In addition to these cartilages, the *nasal septum*, which divides the cavity of the nose into two parts, is also partly cartilaginous. It is cartilaginous where it forms the substance of the *columna nasi*, separating the two nostrils, and is covered by superficial fat and skin. By the presence of these stiffenings of cartilages the nostrils are kept open. The lateral cartilages are attached only by fibrous tissue to the adjacent superior maxillary bone, and are responsible for the slight bulge at the lower part of the lateral aspects of the nose.

The orifices of the nasal chamber, known as the *nostrils* or anterior nares, look almost directly downwards.

Sometimes the nostrils are much narrower than is usual or natural; in such cases the subject will be found to breathe almost entirely through his mouth, which he keeps constantly open.

The nostrils produce a bulging on each side of the lower part of the nose, and owing to the action of some tiny muscles these bulgings become more prominent during the action of respiration, especially if at all forced, as in distress of breathing.

There is always a slight depression, or fossa, to

THE HEAD AND NECK

be felt at the junction of the root of the nose with the forehead. Below this fossa the nasal bones may descend almost vertically from the frontal bone; or they may be inclined more obliquely forwards, when the result is a prominent bridge (Figs. 84, 85, p. 221); or the nasal bone may be sunk in, either as a congenital defect or following upon accident or disease, in which case the bridge is very much depressed and the nose is said to be "snub."

The nostrils are separated by a median partition or *columna*, which is the anterior end of the septum dividing the right and left nasal chambers from each other. It is also continuous with the central part of the upper lip, which may by its means communicate slight movement to the tip of the nose.

Hairs project from each nostril, especially, it is said, in the very strong. Those in front are directed backwards as well as downwards; those behind have a forward as well as downward direction. This arrangement produces a very efficient filter, which guards against the entrance of some gross impurities from the air.

The tip of the nose is sometimes red, rough, and blotchy, owing to cold, indigestion, or other causes. It varies much in shape—pointed, flattened, bulbous, and almost bifid varieties frequently running in families (Figs. 83 to 88). Age often has much to do with the shape of the nose; a prominent bridge is rare in childhood, but a cunning tip-tilt is common. Note also another characteristic which runs in families, and that is the extent to which the *columna nasi* is visible in profile (Fig. 83 A and B, p. 220).

The Mouth is as important an object in the study of expression as the eye. Just as the anterior nares form the entrance to the large nasal

THE HEAD AND NECK

cavities, so the mouth, surrounded by the lips, is the entrance to the large buccal cavity which contains the tongue and teeth (Figs. 87 to 92).

There is a great distinction between the shapes of the upper and lower lips.

The lips of a well-formed mouth that is unspoiled by bad usage exhibit curves which are certainly among the most beautiful features of the face, and as certainly they are among the most difficult to describe adequately. It is not too much to say that



Fig. 87.—Nostrils and Mouth.

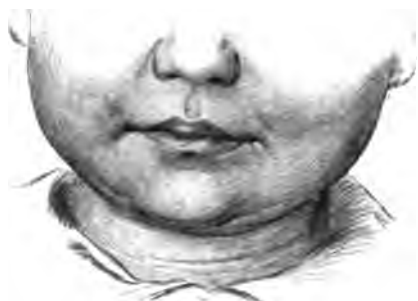

Fig. 88.—Dimpled Face of Smiling Child.

a child's mouth, which has not been pulled out of shape, is that part of the face which best repays close inspection (Fig. 88).

The two lips occupy rather different planes, the upper one, as a rule, projecting farther forwards than the lower (Figs. 89, 90).

The lips consist of muscle and a little fat, with a covering of skin and red mucous membrane.

The cutaneous surface of the upper lip shows a central vertical depression, beginning above at the septum of the nose, and terminating, after expanding a little, below, immediately above the middle

THE HEAD AND NECK

of the red margin of the lip, which here is rather prominent (Fig. 87).

On each side of the depression is a ridge passing vertically downwards from the inner side of each nostril towards the upper lip.

The curved *line of demarcation* between the skin and the mucous membrane of the upper lip may be traced on each side from the middle line, where it is slightly depressed. It then turns upwards, and with a magnificent sweep downwards, nearly reaches the corner of the mouth, before it again passes somewhat upwards for a brief space. This lateral part is well seen in profile to lie below and behind the central part (Figs. 89 to 91).

The edge of the red margin, which actually bounds the oral fissure or chink between the closed lips, begins in the mid-line at the papilla, and passes outwards and upwards, then slightly downwards, and then upwards again, to reach the angle; but the curves here are not so pronounced as in the upper line of demarcation between skin and mucous membrane. The visible red area of the lightly closed lips is broadest in the middle, and dwindles away to nothing at the angle.

The line of demarcation between the skin and red mucous membrane in the lower lip lies in a nearly horizontal plane, but as it projects forwards in profile it is directed slightly downwards (Fig. 90). The edge which bounds the chink between the closed lips is concave upwards, and consequently *the oral fissure* is convex downwards in the middle third, and concave downwards on each side of this (Fig. 88). Lips vary very greatly in different races, and even in different ages and sexes, and are valuable exponents of character. We expect more fulness in

THE HEAD AND NECK

youth, and are not surprised if in old age vertical wrinkles occur from wasting and withdrawal of support by loss of teeth (*cf.* Figs. 89, 90, and 75, 91).

The Chin.—The face terminates below in the chin, which is peculiar to the human being, but varies much in shape.

The chin is supported by the front part of the lower jaw, or *mental protuberance*, and like it may be pointed or square, prominent or retreating; occa-

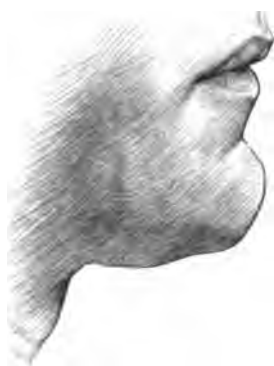

Fig. 89.

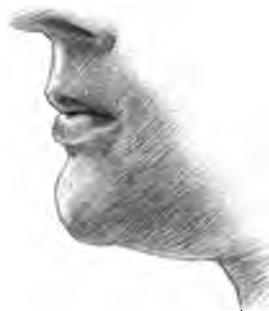

Fig. 90.

Mouth and Chin.

sionally, especially in broad chins, it may be surmounted by a central small pit of varying depth.

A deep transverse furrow separates the chin from the mouth (Fig. 90).

Very often, although not by any means always, the chin is a good indication of character.

Many men lack a good development of chin, and grow a beard to cover this deficiency. With their beard on they may have a strong face; without it, a weak one.

It may interest the student to consider the association of a small chin and weak character. If he will

THE HEAD AND NECK

take the trouble to notice a man who has recently passed through a great physical struggle, he will find that the jaw is dropped, as if even the facial muscles, and the muscles of mastication, were tired. He is so tired and breathless that he cannot even keep his mouth shut. He is not in a position now to force home arguments, even to a child. His appearance of strength has gone. Depression of the jaw, then, is associated with great physical exertion and fatigue, so that the man is no longer quite himself. Depression of the jaw leads to an apparent retraction of the chin. The small chin is, therefore, associated in our minds with the man who is wanting in decision and in strength of character, because the depressed jaw is seen in the man who has not the physical force to make his will prevail.

The hair of the face deserves more than the passing consideration which can be given in these pages. First, be it observed, the man who can grow a good beard cannot necessarily grow a good moustache. The moustache varies very much. Sometimes it curves downwards, sometimes forwards, sometimes upwards. Sometimes it may appear asymmetrical. Sometimes, even in a young person, it may be different in colour from the beard.

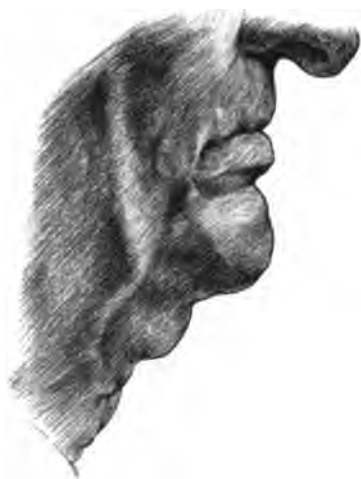

Fig. 91.—Furrows around Mouth, Chin, and Neck.

THE HEAD AND NECK

Below the eyes, that part of the face known as **the Cheek** bulges a little forward in the average well-nourished adult. In the infant the bulging is more pronounced, owing to the presence of a mass of fat called the "*sucking pad*" (Figs. 92 and 93).

The emaciated may actually become "hollow-cheeked," and then the zygomatici and other facial muscles may be identified when in action.

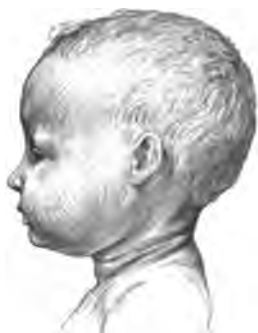

Fig. 92.—Head and Neck of Baby.

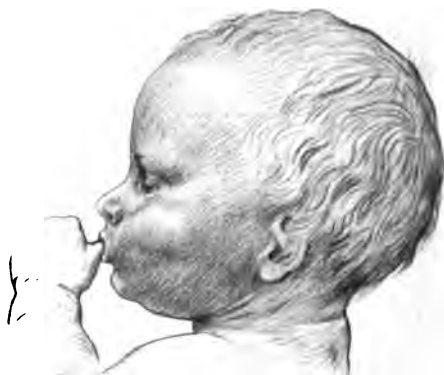

Fig. 93.—Child Sucking Thumb.

In edentulous or toothless persons the alveolar margins of the jawbones, which formerly contained the teeth, waste and the cheeks fall in (Fig. 75). The changes which the face undergoes with advancing age will be dealt with more fully in a succeeding chapter (p. 264).

The ear, the organ of hearing, consists of special sense as well as transmitting parts. The former or *inner ear*, and half the transmitting part or *middle ear*, lie deeply buried in the bones at the base of the skull, and fortunately the study of these is not

THE HEAD AND NECK

expected of the art student, for they are extremely complicated.

The remaining half of the transmitting part, namely, *the auricle and meatus*, together constituting the *external ear*, forms a prominent object on the side of the head, and claims the attention of the art student (Fig. 94).

It should be noticed how well adapted the auricle is for collecting the waves of vibration which, when

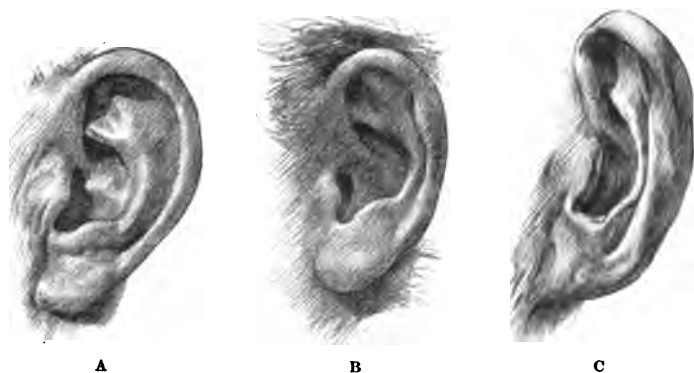

Fig. 94.—Different Types of Ear.

transmitted to, and interpreted by, the end organs of the auditory nerve in the inner ear, constitute sound. In respect of this function, however, the human auricle falls below that of certain of the lower animals, to whom hearing is of even greater importance than it is to man. They have not only larger but also more mobile auricles.

There is a little eminence on the curled-over edge of the auricle which is known as *Darwin's tubercle* (Fig. 94 B), after the great naturalist who was the first to explain its significance. It is said to be more

THE HEAD AND NECK

marked in members of the criminal classes. It is held to represent the extreme point of the auricle in the long-eared horse and ass, and thus to form one of the indications of the descent of man and beast from a common ancestor.

If the student will further observe the auricle of such an animal—for example, the horse—he will notice that it is capable of extensive movement. Owing to this great range of mobility, the open orifice of the funnel can be directed towards the back, side, or front of the animal, and thereby sounds can be collected from all quarters much more efficiently than by the fixed human organ. These movements are brought about by muscles which, in man, having undergone involution, are very tiny, and indeed quite rudimentary. Upon only a few members of the human species is the power of moving the auricle bestowed. Yet small muscles can be found by dissection of any auricle in exactly the situations to be expected.

One lies above the auricle, another behind it, and another in front of it. There are also some minute muscles lying on the auricle itself. All of them are, as one would expect, supplied by the seventh or facial nerve, because that is the nerve specially destined for the supply of all the muscles of expression. The student will quickly call to mind the very obvious influence produced by the movements of its ears upon the expression of a horse or a donkey.

The rigidity of the auricle, and the fact that when it is forcibly bent down it will recover its shape as soon as the pressure is released, indicate that it has some form of strong framework which is not bony. The support is afforded by a strip of cartilage folded upon itself and fixed within a bony orifice upon the

THE HEAD AND NECK

outer surface of the temporal bone, known as the *external auditory meatus*.

The cartilaginous support of the ear is immediately under the skin, which is very thin in this region, there being no fat except in the lower extremity or lobule. For this reason, and because it is apt to get compressed against the hard skull, bruising is peculiarly frequent upon the ear. An unsightly swelling results, and has been depicted in ancient statues of boxers.

The external ear varies very much in size, in degree of prominence, in shape, in quality of skin, and even in colour.

Maltreatment during development is prejudicial to the beauty of any feature, and the auricle suffers perhaps as often and as much as any.

The bony parts in immediate relation to the external ear are as follows:—

Behind it is the *mastoid process*; in front of it is the *ramus of the mandible*, while below there is a deep hollow, which is to some extent filled up by the upper part of the sterno-mastoid muscle.

The auricle has various named parts. Thus the part hanging downwards, which is thicker and softer than the rest of the ear, is known as the *lobe* or *lobule*. Its substance is fatty, and it contains no cartilage. The lobule usually hangs free at its posterior and inferior edges, but is attached in front to the cheek and above to the auricle. It may be very large (Fig. 94 A and B), and may then have a free anterior edge as well; or it may be very small (Fig. 94 C), and hardly separable from the rest of the auricle.

This is the part of the ear which is perforated for ear-rings, and certain races specially cultivate it for supposed æsthetic reasons, hanging weights upon it

THE HEAD AND NECK

for the purpose of increasing its length. Ear-rings have been considered a relic of this barbarous practice.

Above the lobule is the *concha*, a wide open depression which leads to the external auditory meatus.

The incurved margin of the ear, which begins below and behind at the lobule and curves round the ear to the middle of its anterior border, is the *helix*. "Darwin's tubercle" is situated in the upper and back part of this margin.

The *concha* is bounded at its upper and back part by a ridge known as the *antihelix*. The ridge bifurcates at its upper extremity, and is separated from the *helix* by a depression, somewhat in the shape of an elongated pear bent upon itself, called the *scaphoid fossa*.

The *concha* is prolonged downwards into a little bay, whose boundaries are the *tragus* anteriorly, and the *antitragus* situated at the back. The little bay has the name of the *incisura intertragica*.

Just above the *tragus*, and slightly in front of it, the *crus helicus* forms a prominence directed backwards into the *fossa* of the *concha*. There is no cartilage between this part of the *helix* and the *tragus*.

The auricle is apt to become red in cold weather, and it takes a part in the general reddening of the face known as blushing.

Large ears are often prominent. Ears may be nearly triangular in shape, broad above and narrow below. There may be hardly any lobule developed at all, and it may be closely attached to the side of the head.

Upon the back part of the side of the face a massive quadrated swelling is formed by the *masseter muscle*

THE HEAD AND NECK

(Fig. 95), lying on the angle of the jaw. Its prominence is much more noticeable when the jaws are clenched, and it can then be seen passing between the mandible near its angle and the zygomatic arch.

The outline of the contracted muscle may be sometimes obscured in the glutton by the over-development of a tongue-like lobe of the parotid gland, which lies horizontally upon the surface of the masseter.

In a face which has clearly cut and well-marked features, the following points should be noted by the student. There is a well-marked furrow, running from a point just below the inner angle of the eye, downwards and outwards, well on to the cheek. There is a second furrow below, and nearly parallel, continuous above with the fossa above the ala of the nose, and curved downwards below to pass just outside the angle of the mouth. Between these two furrows is the naso-labial fold. There is a third furrow passing in a curved direction downwards and outwards from the angle of the mouth. The furrows, or wrinkles, best seen in old people at the sides of the eyes, lie at right angles to the fibres of the orbicularis palpebrarum, and thus are disposed in a radiating manner.

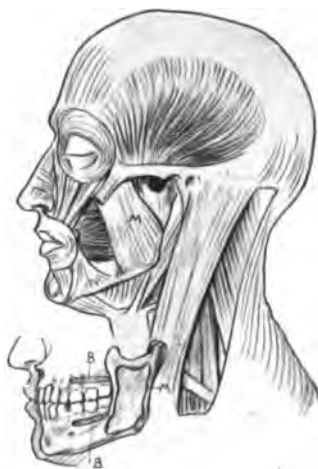

Fig. 95.—Muscles of side of Head, Face, and Neck.

M—Masseter. Inset of Jaws showing :—
B. Origin of Buccinator.
M. Insertion of Masseter.

CHAPTER X

EXPRESSION AND GESTURE

THE important subject of **Expression and Gesture** must now engage the student's attention.

Those who are intimate with the habits and in sympathy with the affections of the lower animals will be aware of the great part which is played, not only by the face but by the whole body, in the expression of various emotions. A very familiar example of this is the attitude and actions of the tail and the ears in the dog, and the different positions they assume according to whether the animal is pleased or otherwise. In the human species few except actors make much use of the possibilities we still possess, in spite of clothes, for the expression of our emotions by gestures of the head, trunk, and limbs, so that the body has come to play a much smaller part in emotional expression than it does in some animals. But the variations in the form of the face which betray different mental conditions are greatly in advance, both in variety and degree, of those of most of the lower animals, possibly for a similar reason—viz. that our face is not covered with hair as theirs is.

Figure 96 and Figure 100 exemplify better perhaps than words can explain some of the minutiae which produce the obvious differences in expression. The

EXPRESSION AND GESTURE

one shows depression and grief, perhaps long continued; the other, pride and good health.

In the space at our disposal only a very short account can be given of this complicated subject. To begin with, we must surely recognise that while there is infinite variety, and no two faces are exactly alike, yet there are very definite and distinct *types of face*. Next, that, given any particular face, its expression will vary much from time to time. And lastly, that each variation of expression will depend upon alterations of the surface form, and that these alterations are caused by the contraction or relaxation of the facial muscles. The facial muscles are small, because they have not got to move heavy bones, therefore they are rarely capable of being identified through the skin, and they are supplied by the facial, or seventh pair of cranial nerves. Of these muscles there is an exceedingly good dissection in the Hunterian Museum at the Royal College of Surgeons. These muscles are developed in connection with, and are capable of pulling upon and so altering the shape of, one or other of the orifices of the face—the ear, the nose, the eye, but especially the mouth—and so influencing the expression.

The muscles which converge upon and surround **the mouth** may first be considered.

The *orbicularis oris* (Fig. 95, p. 233) surrounds the oral fissure much in the same way that the *orbicularis palpebrarum* lies disposed around the palpebral fissure. This muscle forms in great part the mass of each lip, and has its fibres arranged in parallel and concentric circles. But it has an intimate connection with other smaller muscles whose fibres blend with its own. Not only do these muscles pass into the *orbicularis*, but they send a variable

EXPRESSION AND GESTURE

number of their fibres into the overlying skin, and so contribute materially to the infinity of small differences which characterise each individual face. They are very numerous, twenty in all, ten on each side of the face. Their insertions, either to muscle or skin, are extremely movable, whilst their origins are fixed to bone. They are as follows:—

1. Levator labii superioris.
2. Levator anguli oris.
3. Levator labii superioris alæque nasi.
4. Zygomaticus major.
5. Zygomaticus minor.
6. Buccinator (the largest).
7. Risorius.
8. Depressor labii superioris.
9. Depressor anguli oris.
10. Levator menti.

If the name is long there is this compensation, that in most cases it tells you the attachments or action of the muscle.

The buccinator (Fig. 95, p. 233), the sixth muscle on the list, is a thin sheet which blends in front with the muscles at the angle of the mouth. It arises behind from a \supset -shaped area of the jawbones corresponding to the three molar teeth.

The muscles numbered from 1 to 5 on the above list lie above and in front of the buccinator, the others below and in front.

The levator labii superioris (Fig. 95, p. 233) passes from just below that part of the infra-orbital margin which is formed by the superior maxillary bone to the upper lip.

The levator anguli oris lies chiefly under cover of the last-named muscle, and passes from the superior

EXPRESSION AND GESTURE

maxilla to the angle of the mouth. The two latter muscles are those which raise the angle of the mouth and the upper lip. If the student makes this observation himself, he will notice that this action is invariably accompanied by the raising of the nostril on the same side. This is due to the fact that there is a small muscle with a long name (No. 3 on the list), which passes from the side of the nasal process of the superior maxilla, and which is inserted not only into the upper lip, but also into the ala of the nose.

The zygomaticus minor passes from the anterior part of the outer surface of the malar bone to the upper lip. The *zygomaticus major* passes from the posterior part of the outer surface of the malar bone to the angle of the mouth.

The buccinator, as has been mentioned, passes to the corner of the mouth. The student should notice that it lies on a deeper plane than the other muscles. It supports the cheek and prevents food from collecting between the teeth and the inside of the cheek.

The risorius (Fig. 95, p. 233) passes from the side of the cheek to the angle of the mouth, and lies in a slightly curved horizontal plane. By its contraction it draws the angle of the mouth backwards.

The depressor anguli oris passes from the inferior margin of the mandible to the angle of the mouth. The *depressor labii inferioris* passes from under cover of this muscle to the lower lip.

The levator menti has only an indirect action upon the shape of the mouth, for it passes from that part of the mandible which lies below the incisor teeth to the skin on the chin. Its action is to raise the chin, and so it helps to protrude the lower lip.

Two of the muscles which surround **the eye** have

EXPRESSION AND GESTURE

already been described (p. 213), viz. the *orbicularis palpebrarum* and the *levator palpebræ superioris*. A third, the *corrugator supercilii*, lies under the inner portion of the upper part of the *orbicularis palpebrarum*. By its contraction the skin of the lower and middle part of the forehead is thrown into vertical or oblique folds.

The muscles of the nose are as follows:—

The pyramidalis nasi lies on the upper part of the nose, and is really a part of the *orbicularis palpebrarum*.

The compressor naris passes from each side over the lower half of the nose.

The depressor alæ nasi passes from the superior maxilla above the incisor teeth to the septum and alæ of the nose.

There are also two feeble muscles known as *dilatores naris*, placed on the outer side of each nostril.

The expression of the emotions is chiefly effected by varied combinations of these facial muscles. But there are other factors, such as the state of contraction or relaxation of the blood-vessels in the skin, and the secretion of certain glands, such as tears or perspiration.

Blushing.—This is due to the increased flow of blood through the superficial vessels, especially of the face, external ear, forehead, and neck. The shoulders and chest, and even the whole body, may participate in the general flush of the skin.

Blushing must be distinguished from *hectic*, in which the face is usually drawn and pale, with a scarlet flush on each cheek; it must also be distinguished from the rubicund face associated with good health, sunburn, or chronic alcoholism, when

EXPRESSION AND GESTURE

the nose especially is red and bloated, and small superficial veins appear on the skin, chiefly at the margin of the nose.

Secretion of Tears.—The tears, the popular name for the lachrymal secretion, come in regular, never-ceasing supply from the lachrymal gland, situated under cover of the outer and upper angle of each orbit. This lachrymal secretion enters the upper and outer part of the conjunctival sac, and when the quantity is not excessive it is conducted by the movements of the lids to each punctum, and from thence into the nasal cavity *viâ* the canaliculi and the lachrymal canal. The secretion of the lachrymal gland, and probably of all glands in the body, never quite comes to a standstill, but any normal amount is carried away by the lachrymal canal, and evaporates in the nasal cavity, an important function of which is to moisten and warm the inspired air before it reaches the lungs.

An abnormally brisk secretion, however, is apt to prove more than the lachrymal canals can carry away, and then, as in exposure to high winds or other irritation, or the presence of a foreign body in the eye, the tears roll out of the palpebral fissure and down over the face in drops of various size; and similarly in grief.

Secretion of Sweat.—Cold-blooded animals are not provided with the means of maintaining an even body temperature in the face of considerable alterations in the temperature of their surroundings. Warm-blooded mammals, on the other hand, are so provided, and the complex co-ordination of functions which is necessary to achieve this very desirable end is more efficient in the human than in any other species. Energy is defined as the power to do work,

EXPRESSION AND GESTURE

and no organ in the body—indeed, no living cell, whether of nerve, gland, muscle, or bone—can do any work without setting free some heat. Every living body is therefore constantly generating heat, sometimes less, as during rest and starvation, sometimes more, as during exercise and plethoric feeding. The surrounding medium is sometimes so much colder than the body that much heat is abstracted from the surface of the body—as in the case of prolonged immersion in a cold bath, or of exposure to cold air. This condition is promptly met by the withdrawal of blood from the surface, with resulting pallor and dryness of the skin. Sometimes, on the other hand, the air is so much hotter than the body that the latter would actually be raised to fever heat, or even to boiling (*e.g.* in a Turkish bath), if blood was not promptly supplied in excess to the skin, and the sweat-glands stimulated to pour forth moisture, the evaporation of which cools the surface. A dog cannot sweat, and therefore exposes as much moist surface as he can to evaporation on a hot day by hanging out his tongue and “panting” air to and fro over it.

The average temperature of the body of a large number of human beings in health is found by observation to be 98.4° F.—rather lower in the morning and rather higher in the evening. And within a degree or two of this normal we are enabled, by a very delicate nervous adjustment between the heat-producing (especially the muscular) and the heat-losing (especially the cutaneous) systems, to maintain an equilibrium in spite of very considerable extremes of tropical heat and arctic cold. Only when so much sweat is secreted that it cannot evaporate off the surface of the skin as quickly as it oozes from the millions of mouths of the sweat-glands, does it

EXPRESSION AND GESTURE

accumulate into visible drops and the subject is commonly said to "perspire" or "sweat," though as a matter of fact we are unconsciously perspiring every minute from our birth to our death, and cannot live many days if this function of the skin is abolished. Visible sweating occurs also in certain mental states, *e.g.* the fainting condition, and great fear, and that is why some explanation of the phenomenon has been offered here.

The phenomena of blushing and its opposite, pallor, the escape of tears, and the accumulation of sweat on the skin of the face, are associated with many and various expressions, but the actual production of these expressions is chiefly brought about by the action, or want of action, of the small muscles of the face, of which the attachments have just been considered, together with the action, or want of action, of those larger muscles, and especially the masseter and the platysma, which move the lower jaw.

The student's attention has already been drawn to the fact that the form of the body and limbs in man differs from that of the lower animals in the following essentials:—

(1) The relatively large size and arched shape of the foot, because of its increased importance in the erect attitude.

(2) The large size of the buttocks, which has a similar explanation.

(3) The breadth of the chest.

(4) The extent of the movement permitted in the joints of the upper limb.

(5) The power of opposition of the thumb, and

(6) The large size of the head.

But these characteristics of the human form are not more marked than the differences which exist in the

EXPRESSION AND GESTURE

capacity for variation of expression, by means of the facial muscles, between man and the lower animals. And for him who would master the finer gradations of those expressions a careful and detailed study of the origins of the small muscles of the face will well repay the labour involved.

The facial muscles can be divided into groups surrounding the various orifices, viz. the palpebral, buccal, and nasal apertures. Each group may be subdivided into those muscles which by their action close the particular orifice and those which open it. Let us take as an instance the expression of mirth or **laughter**. We see at once that the lips and the angles of the mouth are widely separated, and thus the shape of the buccal orifice tends to assume a quadrilateral form as in the Mask of Comedy. The teeth are exposed unless, perchance, the individual happens to have very bad ones, when the natural expression will be vitiated by an unnatural and conscious and constrained effort to attempt to conceal this blemish, revealing at once some element of self-consciousness in the expression of mirth, an expression which in its ideal form is entirely unconscious, or at least involuntary. Some wrinkling will occur round the eyes, and the eyelids be drawn upwards owing to the action of "orbicularis palpebrarum," and there will be some drawing upwards of the angles of the mouth and of the whole of the side of the face, caused by the action of the zygomatici; and indeed, if the expression stops at a smile short of laughter, the characteristic upward pulling of the angles of the mouth is due chiefly to these muscles.

In the expression of **grief** (Figs. 96 and 97) the opposite of each of the actions which produce laughter is seen; the angles of the mouth, and indeed the whole

EXPRESSION AND GESTURE

of the substance of the cheek, is drawn downwards. The corrugator supercilii draws the eyebrows inwards and produces a vertical wrinkling at the root of the nose; the lower jaw droops, and so do the eyelids; the lips are slightly separated from each other. To take



Fig. 96.—Sorrow.

one more instance, viz. the expression of **pain**, the mouth is either slightly opened or firmly closed; its angles are either drawn together or retracted; the jaws and gums are firmly clenched; and some frowning is produced again by the corrugator supercilii. In the case of **fear** the chief play of the muscles is seen in the parts surrounding the eyes and the mouth. The eyes are widely opened, fully exposing the “white

EXPRESSION AND GESTURE

of the eye"; the eyelids are raised by the occipito-frontalis, and the forehead is wrinkled transversely. The mouth is opened, but in a somewhat expressionless way; and, be it noted, this opening of the mouth is not as great as the separation of the jaws, so



Fig. 97.—Dejection.

that the teeth are hardly, if at all, uncovered, whereas in the expression of grief or pain the upper teeth are apt to be shown. **Terror** (Fig. 98) is a higher degree of fear, and is indicated by a knitting of the forehead concurrently with an elevation of the inner or median part of the eyebrows, and the pupils are widely dilated. **Despair** expresses itself by re-

EXPRESSION AND GESTURE

laxation not only of the muscles of the face, but also those of the whole body. Many other expressions will occur to the student as worthy of study and description, but our attempt has been rather to select typical ones and to remember that, as Darwin said, "In our estimate of any particular expression we



Fig. 98.—Terror.

are often guided to a much greater extent than we suppose by a previous knowledge of the person or the circumstances." Indeed, the subject is a very complex one, and its full consideration would involve an examination of the personality of the individual concerned in each instance. It has often been said, for instance, that guilt is rarely unassociated with some degree and expression of fear. There are, how-

EXPRESSION AND GESTURE

ever, children who certainly have no sense of fear, yet present quite a guilty expression when reproved. Conversely, even the partial lowering of the eyelids, the shifty travelling of the eyes, and the blushing of the face must not convince us of their guilt, for it may well be that they are only afraid. **Shyness** is associated with a curious tendency to lateral movements either of the face alone or of the whole trunk. The question may be asked, Is this based upon an attempt on the part of the individual to avoid looking any facts or individuals in the face?

The shaking of the head from side to side which indicates the word "no," and the upward and downward movement of the head to express the word "yes," are familiar and interesting phenomena. These are the movements associated in infants with the refusal or acceptance of food, and it looks as if nature had stereotyped these movements to save herself from having to invent fresh expressions for dissent and assent in the adult.

Professor Cleland gives an admirably concise description of the expression of **deceit**. "The culprit sheltering himself by a lie hangs his head over his secret, while he steals upward glances to see the effect which he distrusts." **Scorn, disdain, sneering, and defiance** have, as Darwin has pointed out, much in common. There is a slight raising of one side of the mouth so that the canine tooth is exposed; the side of the nose is also slightly elevated, and this expression may easily pass into a smile. A young child's smile is always delightful to watch, and especially when talking with a "grown up," for then there is often just a trace of derision in it. In derision as in other expressions, many other parts of the muscular system besides the face are called into play,

EXPRESSION AND GESTURE

to aid in the depiction of the mental state of the subject.

The subject of "**gesture**," as these various secondary movements of the different parts of the skeleton are called, is a very large one, and can but be hinted at here. Notice the aversion of the face by



Fig. 99.—Anger.

turning of the head in derision; the shrugging of the shoulders in doubt, indecision, or depreciation; the erect head of candour; the bowed head of shame or great grief; the confident and decisive step and action of the whole body in conscious rectitude; the shuffling gait of the Uriah Heap, and even the spitting of the affronted and slighted Shylock. Blushing, and the inability to keep the limbs quiet, particularly

EXPRESSION AND GESTURE

the hands, are two characteristics of shyness or self-consciousness; the eyes, too, are then turned downwards. Self-conceit is quite different from self-consciousness, and has totally different expressions and gestures, though both may be considered to be

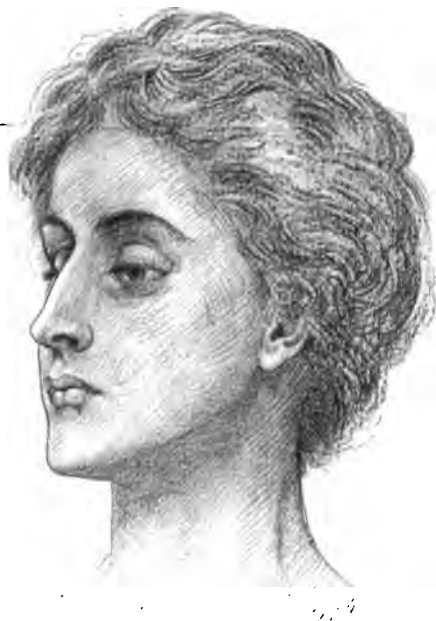

Fig. 100.—Self-appreciation.

due to an over-estimation of the Ego. Sulkiness is generally indicated by pouting and frowning. Decision by firm closure of the mouth; though, as we have seen, it is an open question how far there is any ground for the popular impression that a massive chin goes with a strong nature. Sir Charles Bell drew attention to the rôle which the muscles of respiration play in the

EXPRESSION AND GESTURE

production of certain expressions; those which are dependent upon the firm closing of the mouth are usually associated with fixation of the chest in the position of full inspiration. The deep, long-drawn breath known as a sigh and associated with grief or despair, and the convulsive movement of the



Fig. 101.—Suspicion.

diaphragm, together with some degree of spasm of the laryngeal muscles, causing audible laughter, are notable instances; and so, probably, is the slightly increased rapidity of breathing, together with distinct raising of the *alæ nasi* and compression of the mouth, so that the breathing takes place through the nose, in the expression of anger.

The Teeth.—Voltaire has said that no woman can

EXPRESSION AND GESTURE

be really good-looking who has bad teeth, and no woman who has good teeth can be considered ugly.

The condition of the teeth is, indeed, an important factor in the appearance. The shape of the jaws and



Fig. 102.—Anticipation.

the play of the facial muscles is largely dependent upon their physiological perfection, and so in no less degree is the health, and the appearance of health, in the individual. It is therefore desirable that the art student should consider a few points in their development and anatomy. There are two sets of teeth which erupt from the gums at two distinct periods of

EXPRESSION AND GESTURE

life. The temporary or milk teeth begin to appear at about the sixth month, and are complete by the end of the second year. They are pearly white and translucent, but smaller of course than the permanent teeth, and as a general rule more narrow at the bases than at the cutting edge. There are five of them on each side in both jaws, and they are named from the middle line outwards: (1) central incisor, (2) lateral incisor, (3) canine or eye tooth, (4) first molar, and (5) second molar. There should be a distinct gap between each of them. The temporary teeth are pushed out and loosened by the eruption of the permanent set, the first of which to appear is one of the molars, usually at about the sixth year. There are more permanent teeth than temporary, viz. thirty-two instead of twenty, or eight instead of five in each half of each jaw, and named from the middle line outwards: central incisor, lateral incisor, canine, first and second premolars, or bicuspids, and first, second, and third molars, of which the last is given the nickname of wisdom tooth because it does not erupt until about the eighteenth year. The most striking demonstration of the effect of the teeth upon the appearance of the face is, of course, to be found when they are shed, and when, following upon their loss, the alveolar or tooth-bearing margin of the two jaws is absorbed. The edentulous stage is then reached and the lower jaw has to modify its form considerably, so that its toothless gum may be approximated to the upper jaw, as seen in the elderly nutcracker type of face, a change in the skeleton which obviously must leave the soft parts covering the jaws in a baggy and wrinkled state.

CHAPTER XI

DIFFERENCES OF SIZE AND PROPORTION IN THE SEXES

THE average female is smaller than the average male, and the only part of the skeleton which does not conform to this general rule is the pelvis. The muscles are usually not nearly so well marked, owing partly to their less vigorous use, but chiefly to the presence of a larger quantity of superficial fat, which is especially thick over the chest, the buttocks, the hips, and the thighs.

The outline of the body of the female differs very much from that of the male. (Compare Fig. 103 and Frontispiece.) The narrow part of the body, or waist, of the female is situated at the level of the tenth or eleventh rib, and is therefore rather higher up than the narrow part of the male. Owing to the greater breadth of the female pelvis, the femora are more inclined towards each other at the knee than are those of the male. Hence the normal slight degree of "knock-knee," or *genu valgum*, is more obvious in females than in males. The limbs generally are more rounded and "shapely" in women than in men. The calves are more pronounced, the ankles and wrists more slender, and the instep more markedly convex in the female.

The face is smaller in females than in males, and the comparatively small development of the occipital

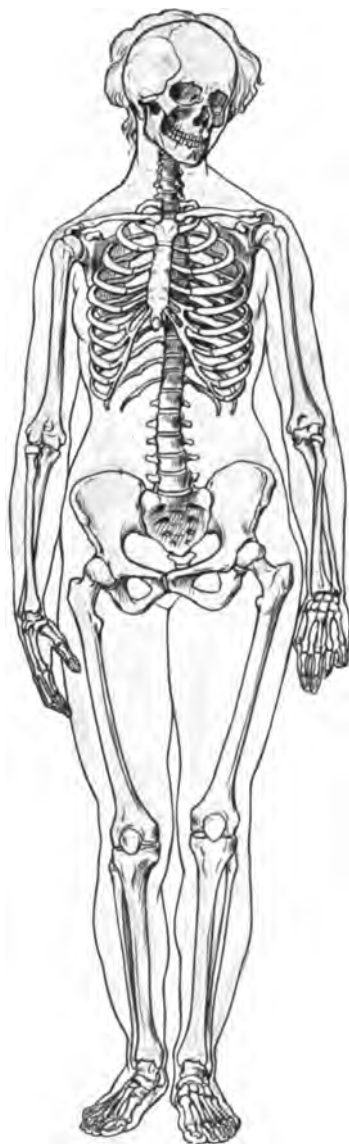

Fig. 103.—Figure of a Female Skeleton, showing the characteristic narrow thorax, broad pelvis, and increased degree of "knock-knee," as compared with the Male. The general slenderness of the bones should also be noted.

DIFFERENCES OF SIZE AND

and frontal regions of the skull in females is also to be noticed.

But a comparison of the Plates at the end will demonstrate that the three most obvious differences between the male and female form are to be found at the waist, the pelvis, and the thigh. With regard to the waist, it will be remembered that between the costal margin and the pelvis the body has no bony support except that of the vertebral column at the back, the rest of the circumference at this level being composed of the soft tissues of the abdominal wall. In every normal subject, whether male or female, there is a distinct narrowing at this part of the trunk, which is named the waist, or the "true waist." In the female, owing to the greater width of the pelvic bones, it happens that the narrowest girth is in the upper rather than the lower part of this unsupported interval, and therefore the waist is, or should be, at about the level of the costal margin; the figure of the Venus of Milo is often named as an example of the correct proportion which the female figure should possess.

The *anatomical waist* is found to be about equal to one and a half times the breadth of the head in either sex. It appears to be less than this in the female, because relatively and absolutely the breadth of the pelvis is greater in the female, and also because the concavity backwards of the lumbar spine is greater in the female profile. This increased tilting of the pelvis as seen in the female profile, besides making the waist more obvious, also makes the buttocks more prominent below. Further, the increased width of the pelvis separates the femoral trochanters more from one another and increases the width across the hips, and this increased massive-

PROPORTION IN THE SEXES

ness is observable all down the upper two-thirds of the thigh; it is contributed to, not by increased muscular development, but by a thick deposit of subcutaneous fat, so that while the greatest breadth of the male hips is at the level of the great trochanters, the greatest breadth of the female hips is at a slightly lower level.

Relative Measurements in Children and in Male and Female Adults. — Although there may be a great fascination for some minds in formulating elaborate rules for the accurate measurement and comparison of various parts of the body, the student of art anatomy will do well to remember that the more exact the measurements which are made upon one special individual, the more liability to error is there if you attempt to lay down general rules therefrom. One cannot measure the parts of the human skeleton in millimetres or quarters of an inch. The prominences and fossæ which are taken for landmarks are not

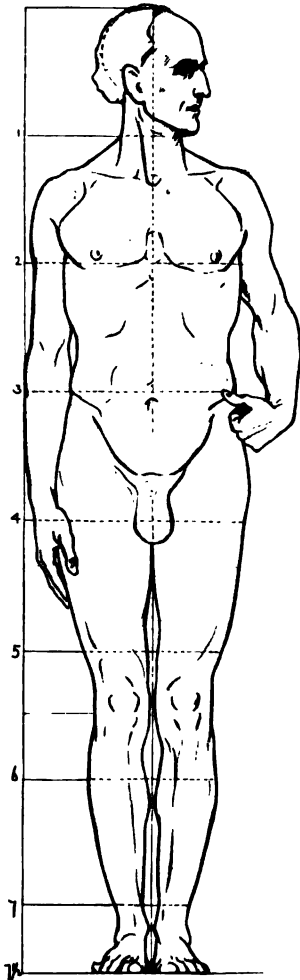


Fig. 104. — To show the Proportions of the Male Body.

DIFFERENCES OF SIZE AND

“points,” but surfaces too large to yield incontestably accurate observations. The position of a limb will alter its apparent length; and the two limbs, moreover, may be, and frequently are, even in a normal individual, of unequal length, just as every face, every cranium, and every trunk is to some slight degree asymmetrical.

It has already been pointed out that differences in the height of individuals are due chiefly to the



Fig. 106.—To show the characteristic position of the head, body, and limbs of a child who is lying down.

length of the trunk or to the length of the lower limbs.

Professor Marshall took for his measurements a unit of nearly one inch, rather more than an inch in the male, rather less than an inch in the female.

In the lower limb of a male subject the thigh measures 18, the leg 14, and the foot 9 units (Fig. 104).

In the female the thigh is still 18 and the leg 14, but the foot is only 8 units.

In the male upper limb the arm is 13, the forearm 9, and the hand $7\frac{1}{2}$ units. In the female the corresponding figures are $12\frac{1}{2}$, 9, and $7\frac{1}{2}$.

The stature of the adult is equal to $7\frac{1}{2}$ heads.

PROPORTION IN THE SEXES

The axial part of the body equals 4 heads, viz. :—

1. From vertex to below chin.
2. From below chin to lower end of the breastbone.
3. From lower end of breastbone to crest of ilium.
4. From crest to below the tuberosity of the ischium (Fig. 104, p. 255).

Other measurements which will be found useful are as follows :—

The head in both sexes is $6\frac{1}{2}$ units wide.

The face in both sexes is 6 units wide.

Breadth of the shoulders in the male is 18 units.

Their breadth in the female is 17 units.

Breadth of the neck in the male is 5 units.

Breadth of the neck in the female is $4\frac{1}{2}$ units.

The stature of the newly born child is equal to a little more than 4 heads.

The mid point of the stature is situated—

1. At birth, a little above the navel (Fig. 105).
2. At two years, at the navel.
3. At ten years, on a level with the upper part of the femoral trochanters (Fig. 106).
4. In the adult, on a level with the arch of the pubes.

These levels emphasise the large relative size of the head of a child compared to that of an adult.

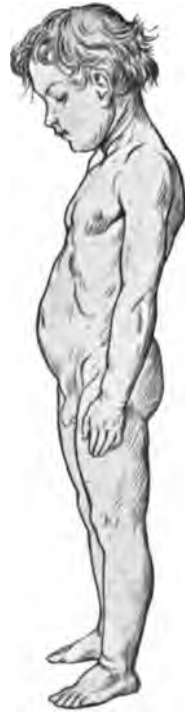

Fig. 106.—Child.
Side view.

DIFFERENCES IN THE SEXES

The student will do well to remember this point, and should never make the mistake, as has frequently been made, in the portraiture of the mother and her child, of drawing the head of the child too small. Nor should he make the child's face intellectual; full of expression, if he likes, may be the face he draws, but of intellect there is no indication at such an early age.

CHAPTER XII

GROWTH, DEVELOPMENT, AND MEASUREMENTS

ALTHOUGH special points about growth and development have already been alluded to in the chapters upon the anatomy of the adult, many others which will interest the art student yet remain.

The somewhat lengthy dependence of the human infant upon his elders is noteworthy. Owing to the large size of the head, it is unusual for him to be able to sit up much before he is nine months old, to stand much before he is twelve months, or to toddle much before fifteen months.

The new-born infant is frequently jaundiced, and his head bears the impress of the maternal passages through which he has passed. His head is often long and triangular, and markedly asymmetrical, and altogether not a very beautiful object.

The infant, even when not being fed, purses up his lips and sucks as if his life depended on the sucking—as indeed it does—and to this end nature develops the cartilage of his lower jaw into bone earlier than anywhere else in the skeleton.

At first he hardly notices anything, not even a bright light. The arms are long, compared with the legs; the abdomen is large in comparison with the chest; the buttocks are small, and the thighs somewhat flexed upon the trunk. The nails, which are fully developed before birth, are of a beautiful pink tinge.

GROWTH, DEVELOPMENT

The measurements of the foot are very characteristic in an infant. Its greatest breadth is nearly, if not quite, half its length. The foot is a little flexed, and is turned inwards at the ankle, and presents no obvious arch of the sole.

The statement sometimes made that there is no bony arch is inaccurate. The bony arch of the young child is as well developed as that of the adult. But, owing to the large amount of subcutaneous fat, the external features of the arch are obscured.

As the days pass the child pays a little more attention to external objects, and is fascinated especially by a bright light.

In the early days of infancy the child is, or should be, continually either sleeping or feeding. Later on he will begin to amuse himself by sucking his thumb or fingers. The child either sucks the thumb or two fingers. Nature has provided that the object sucked should be sufficiently large to fill up the orifice of the mouth. Thus the ball of the thumb is engaged in the mouth, and by this happy provision no air is sucked in by the side of the thumb. When the child sucks two fingers, the groove between them exactly corresponds to the portion of the central papilla of the lip, so that a minimum amount of deformity of the lip is produced.

As yet no teeth are present. The cheeks are prominent with fat, forming the "sucking pad." The lips are full, and deep red in colour. The back is straight; no secondary curves are yet developed in the spine; only a generally convex one directed backwards is present in the first year of life.

Constant motion, while awake, is the characteristic feature of the infant. Tears and laughter are rarely

AND MEASUREMENTS

seen. He may wail, he may yell, but it is not till he is over two months old that he will begin to smile or actually to drop tears. He may very readily be made to smile after this age by placing the tip of the index finger upon both upper and lower lip at the same time.

The muscles generally do not stand out well ; they have had little opportunity yet of developing, and there is an extraordinarily thick covering of fat under the skin.

Later the child begins to take an interest in things generally, and his anatomy undergoes a development which is the necessary preliminary to the assumption of the erect attitude.

It is a general belief that girls adopt the erect attitude earlier than do boys. This belief may be founded on correct statistics, but it is difficult to explain on anatomical grounds. The pelvis, differing considerably in the two sexes, differs not only in the adult but also in the infant and in the child. The pelvis even at birth shows well the sexual differences which have been described in the adult. Now the pelvis of the female is not nearly so well adapted for the assumption of the erect position as is that of the male, but the more forward mental development of the female child may possibly get over this difficulty.

The infant cannot at first sit upright. By the time, however, that he reaches the age of eighteen months, he would be considered backward if he were not able to walk without assistance.

Let us trace the development of the power to stand upright. To begin with, the upper limbs are relatively larger than in the adult, the lower limbs relatively smaller. But as the baby begins, very soon after birth, to kick his legs about, and to use

GROWTH, DEVELOPMENT

them more than his arms, they grow faster (*vide* Plate XV.). The child next sits up with a little support. Then he desires to get about from place to place. He may begin by crawling, or, as often happens, he may prefer to walk, clinging on to the furniture or other supports with his hands, always leaning a little forward.

The baby's crawl is not quite the same as that which is often practised by adults to please the young. It is a far superior performance. A young, strong, and vigorous baby can make almost a trot of his crawl, and progresses upon hands and feet, only occasionally using the knees. The adult always puts his knees on the ground in this method of progression.

Skill comes with age, and the child depends less and less upon his upper limbs for support, until finally he is able to stand, without their aid, by himself. It is to be noticed that the buttocks increase in size, partly, and perhaps chiefly, because in the effort to stand the gluteal muscles are developed (Fig. 107).

But there is another reason. The student will remember that there are four curves in the spinal column, viz. cervical, dorsal, lumbar, and sacral.

The sacral and dorsal concavities forwards are present and merged into one at birth, and the thighs are slightly flexed upon the abdomen. This means that when the child attempts to stand upright, the abdomen, or, to be more accurate, the pelvis, finds itself slightly flexed upon the thighs. In order that the child may not fall forwards, the spine above the pelvis has to be carried backwards, and thus the concavity backwards in the lumbar region is produced. And the production of this curvature, in addition

AND MEASUREMENTS

to some forward rotation of the sacrum, very much increases the prominence of the gluteal region.

When the infant has adopted the erect attitude, the legs continue to grow at a greater rate than the upper limbs, till in the adolescent who is not yet fully developed the lower limbs may appear almost ridiculously long.

The rather prominent abdomen, due to the very great size of the liver, and the small chest of the quite young child give place to the prominent chest and somewhat retracted abdomen of the youth. It may interest the student to know that, although the young child is commonly said not to have a very big chest, yet we have seen, not once nor twice, but many times, young children with magnificent development of the upper



Fig. 107.—To show the attitude and proportions of an infant who is learning to walk.

part of the trunk. Though increase of stature ceases as a rule well before twenty, proportional increase of massiveness does not usually supervene till five, ten, or even fifteen years later, except that the shoulders

GROWTH, DEVELOPMENT

become broader, owing to increase in the length of the clavicle by growth at its inner extremity.

Between the ages of twenty and thirty the muscular system is at its best, and the individual muscles are best seen and felt. After thirty they tend, especially in dwellers in civilised countries, to become obscured by the presence of fat, unless special care is taken to keep them in condition. The fat which thus becomes obvious on the surface of the body is associated with a deposit of the same material in the deeper parts, notably in the abdominal cavity, and especially in that portion of it known as the great omentum. This is a structure which hangs down like an apron in front of the bowels and protects them to a material degree from exposure to cold, and to a lesser degree from injury. Thus arises that "lower chest" which is so much dreaded by men who are particular about their figure.

As old age advances the skin usually becomes paler, and the face, neck, limbs, especially the shoulders and buttocks, and trunk, with the possible exception of the abdomen, thinner. A general forward curve of the back, as seen in the infant, develops again, and in fact the old man returns to some of the anatomical, as well as other, characteristics of childhood; he is compelled to re-enlist his upper limbs as aids to his withering legs, and when he loses his teeth he must take once more to baby-food and almost to sucking. He loses that control which is the hall-mark of the prime of life, he totters and shakes once more, and is easily pleased, and as easily vexed, in his second childhood as he was in his first.

The changes from birth to old age in the curvatures of the spine, as seen in profile, are thus remarkable. The infant, as already stated, presents only a single

AND MEASUREMENTS

primary curve, convex backwards. As he grows older secondary curves appear; the sacrum becomes more deeply concave downwards and forwards; then the lumbar and cervical curves, concave backwards, develop, and the original primary convexity backwards persists only in the dorsal region; this persists until senility brings a diminution again in the lumbar and cervical concavities backwards, with that stooping shoulder and drooping head which are so characteristic of old age.

We have seen already that at birth and in the young child the skull differs from that of the adult in being much larger in proportion to the trunk and limbs. Notice also that the frontal and occipital regions are small, the frontal eminences are relatively higher and wider apart in the child, the lower jaw is small, and the mastoid process is hardly developed at all.

The differences which exist in the size, shape, and appearance of the jaw, at varying ages, may be considered as entirely due to the presence or absence of teeth.

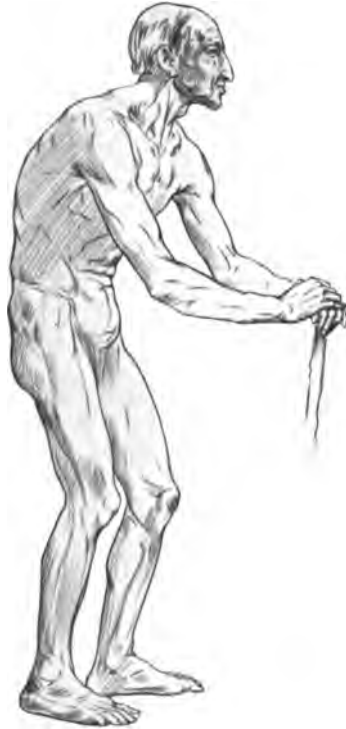

Fig. 108.—The Gait of an Old Man

GROWTH, MEASUREMENTS

The jaw of the adult has been described as having the shape of a horseshoe, whose two free ends are bent upwards at a right angle to form the rami. In infancy and old age these rami are less abruptly bent upwards, with the result that the angle of the jaw is less marked. In the infant the muscles of mastication have not been used to any great extent; in the old, when the teeth have gone, the muscles, which perhaps act too powerfully, tend to straighten out the jaw. The "nutcracker" appearance of the aged is familiar, and is thus explained. The small size of the jaw in a child is due to the small number and size of the teeth. The fangs of the teeth are surrounded on all sides by bone, and when the teeth are removed, the sides of the bone, which surround the empty sockets, drop together, and that which was formerly a broad margin, supporting and filling out the face, now becomes a narrow edge. In fact, the hollow face, retracted mouth, and thin lips of the old man are chiefly caused by the loss of his teeth (Fig. 75).

In Fig. 108 the student should notice the tottering attitude of the old man, the flattened foot, the bent knees, the prominent and "baggy" lower part of the abdomen, and the curved back—factors which all tend to shift the centre of gravity forwards, so that the man has to support himself with his arms by means of a stick.

APPENDIX

COMPARATIVE ANATOMY

It is not proposed in this chapter to deal in any way minutely or scientifically with the subject, necessarily a large one, of comparative anatomy, but rather to put forward some at least of the more salient points of resemblance and difference between the structure of man and the animals.

On looking at the subject, we quickly realise that there is, to a considerable extent, a relationship of construction running through all the mammalia, including man. They may, indeed, be almost regarded as modifications of a single form. The possession of a head, trunk, and four limbs is of course (except in the case of certain entirely aquatic mammals) a common link; but the resemblance is deeper than that, and is to be traced not only through the mammalia, but also through the birds, and even to the quadrupedal reptiles.

The head, trunk, and limbs are modified and adapted to meet the varied requirements of the different orders and species, whether for predatory purposes or for defence, for simple progression on land or for swimming, climbing, digging, seizing, and so forth. These modifications go, indeed, sometimes as far as practical eliminations, as in the case of the hind-limbs of the whales (mammals), which are merely rudimentary and invisible, in no way affecting the

APPENDIX

external form of the animal, the largely developed and adapted tail supplying their place as a power of locomotion. Or, the modification may be in the direction of increased development, as in the case of the bat, where the metacarpus and phalanges are very greatly lengthened, forming a wing, by means of a membrane stretched between them, this membrane extending to the hind-leg, which, as the animal is non-terrestrial, is very small and useless for locomotion on the ground. But such extreme forms as these need hardly be considered in the present chapter.

With regard to the quadrupeds, it will be found that, in common with man, they possess skull, spine, ribs, and sternum, scapula, pelvis, humerus, and femur. The clavicle, important in man, and in such animals as have free lateral movement of the forelimbs, is absent in many cases—in the horse or the ox, for instance—or it may be rudimentary, as in the cats.

It is below the humerus and femur that the variation in the number of bones in the limbs of the different creatures commences, and towards the extremities the differences are very great: for instance, between the foot of the bear—with five digits, and plantigrade like man—and of the horse, which consists of a single digit, enclosed within a rigid nail, the hoof—or the forefoot of one of the cats, with five digits, each with a retractile claw and a pad beneath, a foot silent and powerful, and, unlike the horse's, an instrument of more than mere progression.

A common purpose of the limbs in all terrestrial or partly terrestrial animals is to sustain the weight of the body (except, of course, in the case of the arms in man, and to a considerable extent of the monkey) and,

APPENDIX

more particularly in the case of the hind-limbs, to propel that weight forward. Without doubt, the main design to be traced through such a variety of forms is the one best suited for that purpose.

The accompanying drawings will show at a glance the resemblances as well as the differences between a human leg and the hind-legs of several animals

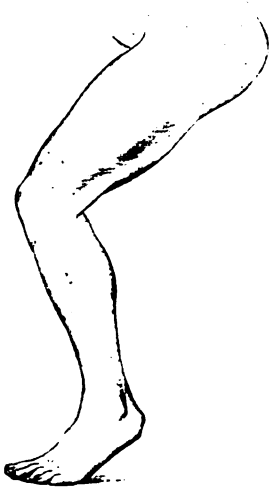


Fig. 109.



Fig. 110.

of different types; man, the gorilla, and the bear (plantigrades when standing at rest) being shown with the calcaneum raised from the ground as in movement, whereby the limb is pulled more into the position of those of the habitually digitigrade animals which follow.

It is seen that all these limbs are divided by two joints into three principal lengths, corresponding to the thigh, leg, and foot in man (though this

APPENDIX

division is certainly least apparent in the case of the elephant), and that there is also a similarity in the relative direction of the angles, one with another, formed by these lengths.

Each foot of the gorilla and bear, like that of man, has five digits, and when standing the whole of it is placed upon the ground. The foot of the



Fig. 111.

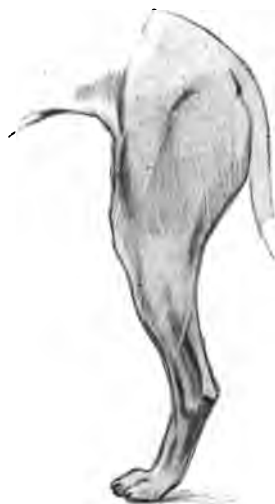

Fig. 112.

bear has a strong resemblance to man's, much more than that of the ape, which more resembles a hand. In the bear the toes are short as compared with the metatarsus, as in the human foot.

The dog and the lion (*digitigrades*), which may be taken as types of the *canidæ* and *felidæ*, have each four digits on the hind-foot, though the dog occasionally has five. Both have five on the fore-foot, the innermost being of little importance with the

APPENDIX

dog, but in the cats the “thumb,” with its well-developed claw, is a powerful instrument for seizing and holding, and is capable of being bent to a right angle with the other claws. When “sitting”—the familiar attitude of the cat or dog—these animals are for the time being plantigrade, the whole of the foot being upon the ground. The limb is then

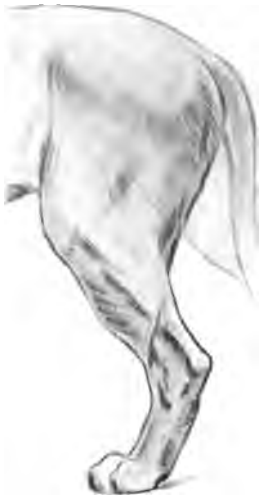

Fig. 113.



Fig. 114.

in much the same position as the leg of an Indian or African native when “squatting.”

The deer (digitigrade) has the calcaneum (the “point of the hock” in the horse and the heel in man) high above the ground; the digits are two in number, enclosed one on each side of the divided hoof. The length of foot—that is, from the calcaneum to the hoof—gives the animal great springing power. It is a limb built for sustained speed; the foot is very

APPENDIX

light, and the sinew corresponding to the "Achillis" is as powerful as the haunch.

The greyhound has, in proportion to the rest of the limb, a shorter foot than the deer, but the femur is longer and more free from the body, which is much lighter in build than the deer's. This, then, is a different type of limb to that of the last-named animal, but it is also designed for speed.

The lion's is relatively a heavier type of limb than the deer's or the greyhound's, and is more adapted for strength and sudden spring than for sustained rapid motion.

The elephant, even more pronouncedly digitigrade than the dog, has a hind-limb which can hardly be likened to that of any other mammal. The femur and tibia make a slighter angle than in other quadrupeds, the calcaneum ("hock") is very near the ground, and the bones of the metatarsus, five in number, are short. It is the shortness of these bones which gives the peculiar and distinctive character to the animal's hind-leg. The toes are not separated, and are supported behind by a large pad of fleshy substance; and there are in the African species three stout short nails, the Indian having four. The general appearance of the limb suggests that there is but one joint, viz. the knee. The foot has, indeed, but little power of movement at the ankle, and when kneeling to receive its load, the elephant rests upon the knee, with the limb below that point stretched along the ground to the rear. A similar disposition of the hind-limb may be observed in a quadrupedal reptile, the tortoise, which also has the calcaneum low and the metatarsus short—indeed the two limbs are not dissimilar in character. As with the tortoise, the elephant's limb is designed for weight-bearing.

APPENDIX

and not for rapid movement, for the animal progresses mainly by the mere swing of the leg from the pelvis. The elephant must, in proportion to his size, be considered as a slow mover. This lack of speed is due to the straightness of the limbs. It is true that man, when standing erect, has the femur and tibia more in line, one with the other, than is the case with

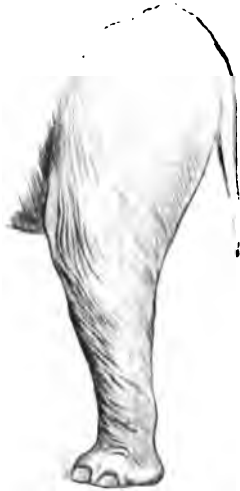

Fig. 115.

any quadruped ; but the entire length of the femur is free from the trunk, the leg is capable of great flexion, and the elasticity and length of the foot, worked by the well-developed soleus and gastrocnemius, afford that spring which in the elephant is practically absent. He is therefore, in proportion to size, a much more speedy mover than the elephant, which, according to Sir Samuel Baker (when speaking of the longer limbed of the two varieties, the African), is only "capable of a speed of fifteen miles an hour,

APPENDIX

which it could keep up for two or three hundred yards, after which it would travel at about ten miles an hour." This is a very moderate rate of speed for an animal of the elephant's size and length of limb, when compared with that of many vastly smaller creatures.

A great contrast to the elephant's leg may be seen in the frog's. The thigh, leg, and foot are still here, but differently proportioned. The thigh is free of



Fig. 116.

the body, the leg muscular, the joints extremely flexible, the foot and digits long. It is a limb for leaping and swimming.

In the fore-limbs the same general resemblance in the three principal lengths, humerus, ulna, and metacarpus, is again apparent. A man's arm is here compared with the fore-limbs of two widely differing animals—the lion and the deer. The inner side of the limb is shown in each case; the "wrist" in man and the lion corresponds to the "knee" in the deer. The five metacarpal bones in man and the lion are reduced to two, closely united and greatly lengthened

APPENDIX

in the deer. The two digits enclosed in the divided hoof are of very limited use in comparison with the five digits of the lion. The deer's limb is designed for support and locomotion alone, the lion's, in addition, for striking, seizing, and pulling. In the lion, as in man, the flexors of the forearm and wrist are well developed, and it will be seen that on the outside of

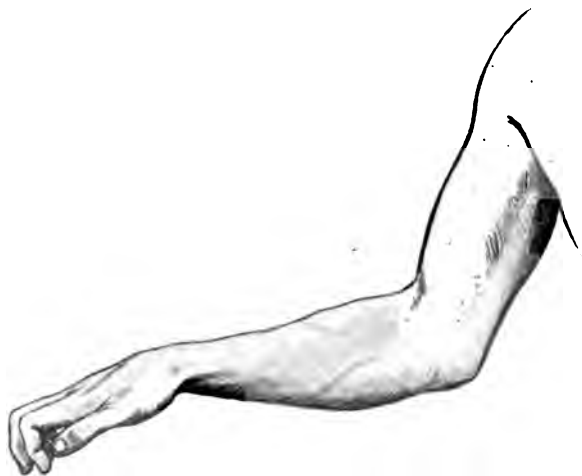

Fig. 117.

the limb the olecranon is more developed than in man, and that the extensors of the forearm are very powerful. The lion is able to strike down by a blow from the paw, and to drag away his prey, which often consists of animals of great weight. The lion, like the *felidæ* in general, possesses power of supination in the forearm, though not to the same extent as man. The deer, in common with all hoofed animals, is devoid of that power.

It will be noticed that the humerus in man is free

APPENDIX

from the body. This is not so with the lion or deer, the former having a limited power of lateral movement of the limb, the latter none. This characteristic will also apply generally to the two classes which these animals represent.

Compared with the arm in man, the fore-limb of the lion, deer, or indeed of any animal, splendidly adapted as it may be to that animal's special require-

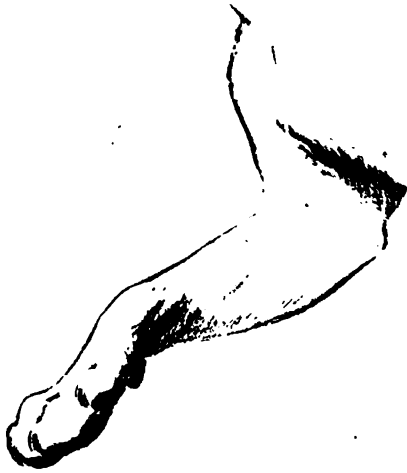

Fig. 118.

ments, is restricted in its appointed movements and uses. It would be, for instance, impossible for one of the *felidæ*, creatures with exceptionally supple limbs, to place the forearm across the back—an action perfectly easy in man.

The monkeys and apes come nearest to man in freedom of arm movement, though even they are probably not capable of such a variety of action, while in the hand they are very deficient, owing to the poor development of the thumb. In one

APPENDIX

species, the Spider monkey, this member is entirely absent.

It is a curious fact, which has been provocative of much speculation, that the primary apes, Gorilla, Chimpanzee, and Orang-utan—the creatures most nearly approaching man in organisation and structure (indeed, from a strictly natural history point



Fig. 119.

of view, there is little to separate them from man)—should be amongst the least beautiful of animals; and though certain of the monkeys have considerable grace of form (apart from their colouration, which is often beautiful), yet they can hardly be compared for beauty of shape with many less highly classed animals, such, for instance, as the horse, greyhound, or almost any member of the *felidæ*.

The superiority of man's form, from an artistic standpoint, over that of the apes is due to the fact

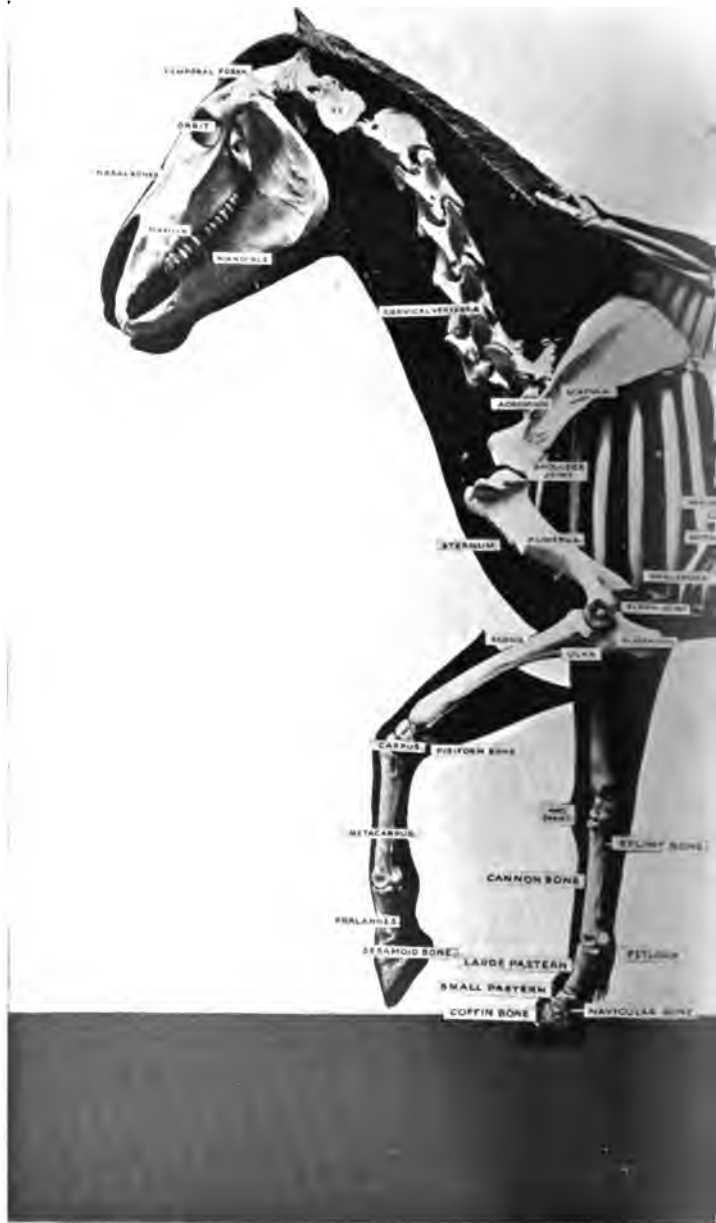APPENDIX

that he habitually stands and moves supported only upon the legs, thus accounting for the fine development of those limbs, which are ungraceful and poor in the primary apes, and of the trunk, with its distinctive curve of the spine.

It is perhaps in the development of the trunk that man, in the higher human types, is pre-eminent in beauty of form over any of the animals, many of which, particularly amongst graminivorous classes, though they may possess finely shaped head, neck, and limbs, have no great beauty in the form of the trunk, the abdomen being often large and barrel-like.

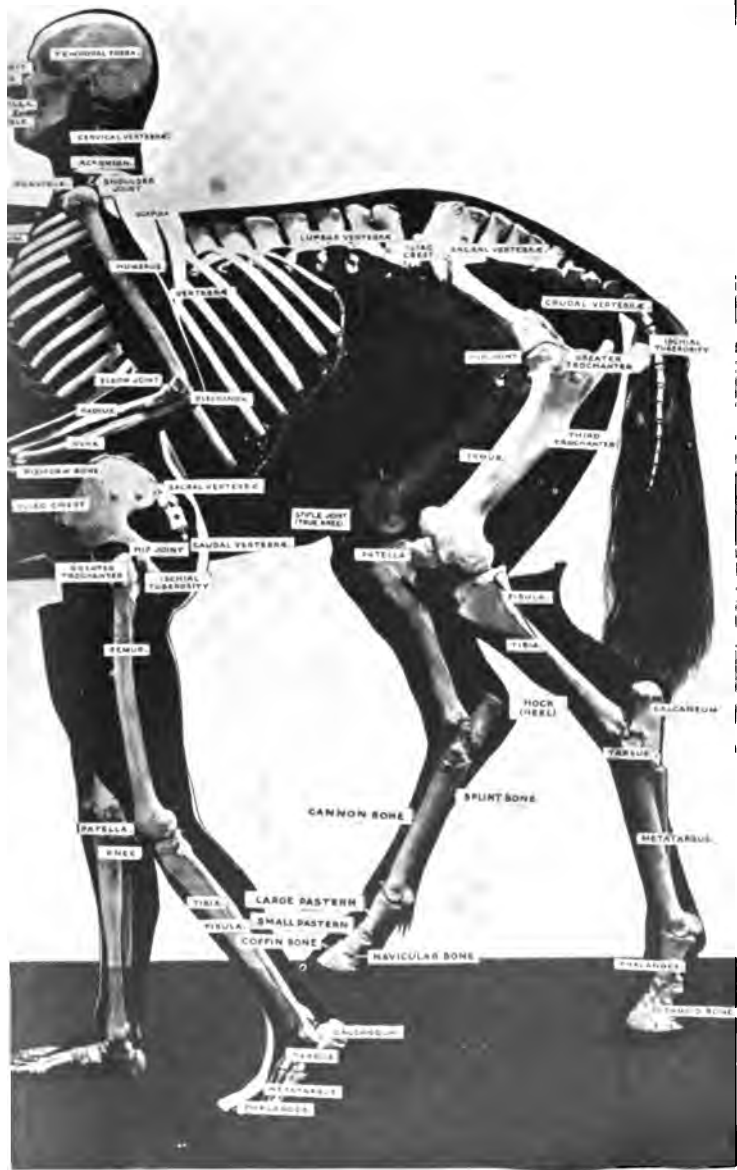
Man's arms are shorter, and his legs longer, in relation to the trunk than is the case with the apes—a significant step in the direction of beauty. He also possesses an important feature in the neck, in which respect the apes are very deficient. The differences in the formation of the head and features are too obvious to need comment. The foot is another point in which the ape compares unfavourably with man. It has not the arch of the human foot, and the toes are much longer. The innermost of these toes project at an angle from the others, and are better developed as a serviceable thumb than the corresponding member on the hand of the animal.

It may be claimed that man, in his structural development, is capable of a greater variety of position and action than any of the animals, and to this is doubtless due the fact that in him is found the highest type of beauty of form. Though plantigrade in standing or walking, he becomes digitigrade, or nearly so, in swift running; indeed, it requires but little effort for him to remain for a considerable time with the heels raised from the ground. He



Photo

FIG. 120.—THE SKELETONS OF A HORSE



L. Barnard

AND A MAN COMPARED

APPENDIX

is capable of rapid movement in water (the apes and monkeys cannot swim), and he is able to climb and to leap; his spine is supple. The contortionist and the gymnast show what the human figure is capable of under special training, and the "strong man" to what a degree of development the muscular system may be brought. In the hand man has, of course, an instrument such as no animal possesses.

There is here reproduced a photograph from a group of the skeletons of man and the horse, in the Natural History Museum, London.

If we begin a brief comparison of these skeletons at the heads, we recognise at first sight that the two skulls are very differently attached to the neck, though this difference is as much apparent as real, being partly caused by the great difference in the shape of the skulls, and the fact that man's neck is upright while the horse's inclines to the horizontal. Man has a "back" to the skull, which is entirely wanting in the horse, and his head is poised upon the neck with a fair distribution of weight before and behind.

The horse has a great elongation of the nasal and maxillary bones. Finding his food upon the ground, length is necessary. For the same reason, the neck is required to be long, and although there is the same number of cervical vertebræ as in man, seven, they are each much greater in relative length. The giraffe, with its elongated neck, has still only seven, which is the almost invariable number of cervical vertebræ throughout the mammalia.

To sustain the weight of the head and neck, there must be much power above the cervical vertebræ, which, it will be seen, run downward from an imaginary straight line drawn from the occiput to the

APPENDIX

highest part of the shoulder (the "withers"), thus affording a large triangular space. In addition to the muscles, there is in this space a special provision for sustaining the great weight of the head, which is hung on the more or less horizontal neck. This is a strong elastic ligament which proceeds from the occiput to the high processes of bone on the dorsal vertebræ. This ligament acts automatically, and the head is sustained without fatigue. The droop of the head in an old horse is due to its weakening. Although this ligament sustains the head without effort, it is apparent that it must also be capable of relaxation, as when tired, or sleeping whilst standing, as a horse will often do, the head is hung down, while the action is not produced by muscular exertion.

It is the great height of the processes from the spine at the "withers," just referred to, together with the fact of the actual vertebræ being somewhat higher at the pelvis than where they pass between the scapulæ, which gives the hollow appearance to the horse's back. The spine is in reality somewhat arched, and is therefore the better capable of sustaining the weight of the rider.

The horse has eighteen ribs (while man has twelve), and seven or eight of these are attached to the sternum. The equine sternum is very unlike the corresponding bone in man, which has a flattish face, the ribs attached flush with the face; in the horse it nearly resembles the keel of a boat, with the ribs attached to the sides of the keel.

There is no clavicle; the limbs are restricted practically to "fore and aft" movement, and the forelimbs are relatively less widely separated than are the arms in man, where they have the whole width

APPENDIX

of the trunk between them. The inner faces of the scapulæ are opposed, whereas in man they face in the same direction. The horse possesses no power of pronation or supination, for the ulna and radialis are closely united and, as the animal ages, become actually one bone.

The scapula is a bone of great strength, and is longer than the humerus, contrasting strongly with man in this respect. The last-named bone is completely hidden by muscle, and in a sense is joined on to the body—another marked difference. In the living animal the humerus is only visible at the point of the shoulder, where its head is conspicuous. The scapula is not attached to any other bone (there being no clavicle), and it is very strongly muscled, having to sustain the greater part of the shock when the horse alights on the ground after leaping, at which moment the limb is straightened out. The supple pastern (corresponding to the phalanges in man) take a certain part of the shock.

Below the carpus (the "knee" in the horse), the metacarpus consists of one principal bone (as against five in man), with two much smaller bones, the heads of which are opposed to the carpus, but which taper downward to a point, and cease before the next joint is reached. These small bones also become one with the principal bone as the horse becomes aged. Fossil remains show that these bones, now evidently in the course of disappearance, were once fully developed, and that the ancestor of the horse was not supported upon a single digit as is the animal of the present time.

It will be noticed that the olecranon is much more developed in the horse than in man, affording hold for two strong and very conspicuous muscles in the

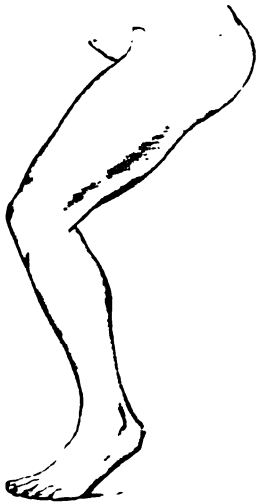


Fig. 131. Leg of Man.



Fig. 132.—Leg of Gorilla.



Fig. 123.—Hind-leg of Bear.



Fig. 124.—Hind-leg of Dog.

**COMPARISON OF THE STRUCTURE OF MAN
AND THE LOWER ANIMALS.**

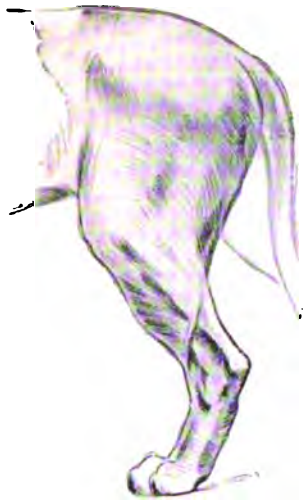

Fig. 125.—Hind-leg of Lion.



Fig. 126.—Hind-leg of Deer.

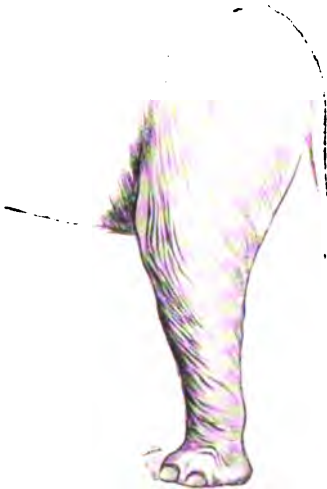


Fig. 127.—Hind-leg of Elephant.



Fig. 128.—Hind-leg of Frog.

**COMPARISON OF THE STRUCTURE OF MAN AND THE
LOWER ANIMALS.**

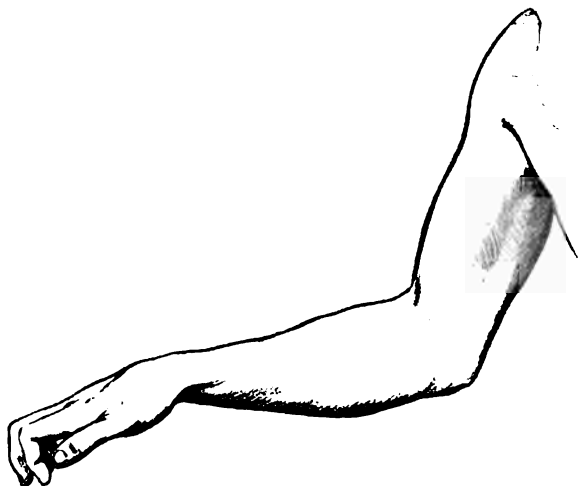


Fig. 129.—Arm of Man.

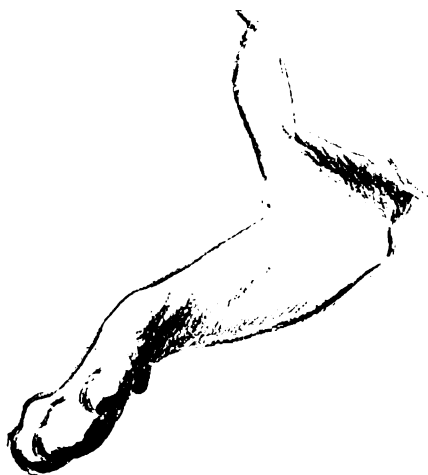

Fig. 130.—Fore-leg of Lion.



Fig. 131.—Fore-leg of Deer.

**COMPARISON OF THE STRUCTURE OF MAN AND THE
LOWER ANIMALS.**

APPENDIX

horse, the anconæus muscles, which are used to straighten the limb, as does the human triceps.

The pelvis is very unlike man's, and the femur is shorter in proportion. This bone is also much covered with muscle, and is very strongly made. The horse has a patella. The tibia is of great strength, while the fibula is reduced to insignificance.

As with the metacarpus, the metatarsus is reduced to a single important bone, with two smaller ones dwindling downward to a point, and, as in the fore-limb, there is a single toe.

Although the principal bones of the human frame are represented in the horse, the differences in the proportional sizes and shapes of the bones, and the uses to which the limbs are put, necessitate a great modification of the muscular system. Whereas, for instance, the deltoid is the most noticeable muscle on the man's shoulder, where it is the means of raising the arm from the side, an action impossible for the horse, any equivalent to this muscle is not prominent in the latter. But the anconæus, already referred to, is very apparent. The pectoral muscle is present in the horse, but as it has a more restricted use and covers a narrower space it is smaller than in man, and differently shaped.

The muscles of the trunk are, as compared with man, not very conspicuous. In man, the trunk is not only self-supporting, but carries, in addition to its own weight, that of the head and arms, the latter being in the horse a source of support instead of a burden. The horse's trunk is also capable of but little movement independent of the limbs. There is therefore no necessity for such development.

In the case of animals (such as the larger *felidæ* or the dog) which may be in the habit of pulling at

APPENDIX

weight held by the jaws, the muscles of the loin are well developed. These, along with the decreased size of the abdomen, give to these creatures a more gracefully shaped trunk than that of the horse, ox, deer, or animals of kindred classes.

There is much muscle about the thigh and between the knee ("stifle") and the carpus ("hock"). The muscles on the outer side of the limb, with the comparatively concave form of the limb on the inner side, help to endow the leg with a very beautiful shape.

If the student, when drawing or modelling any animal, will, instead of regarding it as an altogether new form, rather consider it as one approximating in a greater or less degree to the human form with which he is familiar, he will find the difficulties of his task lessened, and will be able to avoid many of the errors which are often to be noticed in the depiction of animal forms by those who have not given the subject special attention.

**Plate IX.—Front View of Male Figure
standing alert and ready**

Plate X.—Front View of Female Figure

PLATE X.

The student should observe in this figure, as in the other female figures, the general absence of muscular prominences. On the front of the left elbow the hollow known as the Antecubital Fossa is obvious ; the position and shape of the breast are seen to vary with the position of the upper limb. The furrow corresponding to Poupart's ligament is not nearly so deep as in the male. Often the female shows a greater degree of "knock knee" than is represented here. Notice that the umbilicus is on a level which falls considerably below the waist line. The Supra-sternal depression is well marked, and the outline of the left Sterno-Mastoid is prominent. The left foot is rather flat. The great toes are somewhat displaced by wearing pointed boots.



Plate X.—Front View of Female Figure

**Plate XI.—Back View of Male Figure
at “attention”**

PLATE XI.

The proportions of this figure are good throughout. Note that the width of the thorax and shoulders is greater than the pelvis, and compare with the back view of female figure (Plate XII).

There is a massive Trapezius, and the Erector Spinæ shows well on each side of the spinal furrow. The Gluteal, or Natal, folds show well, but the Latissimus Dorsi does not; and, indeed, few of the muscles can be identified because the model is in a restful pose (compare, for instance, with Plate XVI).



**Plate XI.—Back View of Male Figure
at “attention”**

Plate XII.—Back View of Female Figure

PLATE XII.

The general absence of muscular prominences is noticeable. In the ham a pad of soft tissue is seen projecting backwards between the inner (or Semi-membranosus) and the outer (or Biceps) hamstrings. The ridge produced by the Tendo Achillis is well seen; also the spinal furrow, the true waist, the gluteal fold, and the fact that the thighs are widest a little below the level of the great trochanter. The moulding of the back of the lower extremities is particularly worthy of study. The massive pelvis is considerably wider than the thorax (compare this with the male figures, Plates IX and XI).



Plate XII.—Back View of Female Figure

**Plate XIII.—Figure of Man straining his muscles
as he rests his weight upon a pole**

PLATE XIII.

In this figure the student will be able to identify many of the muscular prominences on the back of the arm; the back and inner side of the forearm; the back and side of the trunk, and the side of the buttock; and lower limb.

On the back of the arm, below the muscular prominence of the shoulder, which is formed by the Deltoid muscle, the outline of the Triceps is faintly apparent. In the region of the elbow, the prominence of the Olecranon process of the ulna, and the deep depression, external to this, at the bottom of which lies the external condyle, are marked features. The groove formed by the muscles converging upon the crest of the Ilium is well shown. The depression in the buttock which lies above and behind the great trochanter, the hollow behind the knee, the ridges formed by the tendons on the outer side of the ankle and by the dorsal venous arch upon the foot, are very apparent.



Plate XIII.—**Figure of Man straining his muscles as he rests his weight upon a pole**



**Plate XIV.—Figure of a Woman, in slightly flexed position,
resting her weight upon a pole**

PLATE XIV.

Notice once more how in the female figure the prominences due to muscles are apt to be obscured by superficial fat. Note again the greater relative size of the pelvis and buttocks and the position of the true waist. Compare this with the next plate. The gluteal, or natal, fold is just discernible, and the dimpling around the olecranon.



Plate XIV.—Figure of a Woman, in slightly flexed position,
resting her weight upon a pole

Plate XV.—Children

Plate XV.—Children

PLATE XV.

These figures show particularly well the slight degree of "knock knee" which is present in the majority of children; also the rather prominent abdomen, making the thorax look poorly developed, and the absence of well-marked muscular prominences, owing to the general covering of fat. The absence of any "waist" should be observed, and the great development of the legs in comparison with the arms.



Plate XV.—Children

Plate XVI.—Front View of Male Figure stretching

PLATE XVI.

The boundaries of the armpits are well seen in this figure; also the connection of the costal cartilages with the sternum; the digitations of the Serratus Magnus; the thoracic margin; the outlines of the Rectus Abdominis; the external oblique of the abdomen; and the Tensor Fasciæ Femoris. The position of the true waist is seen to correspond to about the tenth costal cartilage. The two furrows bounding the Rectus Abdominis are very clearly seen. The moulding of the upper extremities and of the front of the neck will repay close study. The Pomum Adami shows well, and also the prominence of the Cricoid cartilage below it. The subject is a thin, but very muscular one.



Plate XVI.—Front View of Male Figure stretching

**Plate XVII.—Back View of Man looking upwards
with strained gesture of alarm**

PLATE XVII.

The muscles of almost every part are in a condition of strain. The fingers are semi-clenched. The posterior borders of the Deltoids show unusually well. The spine, as indicated by the well-marked spinal furrow, is somewhat curved. The thighs being slightly flexed, the gluteal folds do not show well; but the Biceps tendon in the left thigh and the Gastrocnemius muscle in the right leg are obvious.



**Plate XVII.—Back View of Man looking upwards
with strained gesture of alarm**

Plate XVIII.—Figure of a Woman stooping

PLATE XVIII.

Notice the transverse creases on the front of the abdomen ; also the altered shape of the breast when dependent. The flattening of the outside of the thigh, and the outline of the muscles of the back of the neck, should be observed. The back is generally arched, but particularly so in the dorsal region. With the exception of the calf, and of the Biceps tendon in the thigh, hardly any muscular prominences can be identified.



Plate XVIII.—Figure of a Woman stooping

**Plate XIX.—Figure of Man crouching, as at the
start for a race**

**Plate XX.—Figure of Man resting on
outstretched arm**

PLATE XIX.

In this figure the following "surface markings" should be particularly noticed : the thick and rounded outer border of the Latissimus Dorsi muscle, the great mass formed by the Pectoralis Major, and between them the serrations of the Serratus Magnus. The flattening of the outer side of the thigh is due to the tightening of the ilio-tibial band. The general convexity of the vertebral column, except at its two extremities, should be noted. Several of the muscles in the arm, forearm, and leg can be identified, as well as the Trapezius in the neck. The arch in the left foot is almost obliterated by the weight thrown upon the great toe.

PLATE XX.

Note the prominent masses formed by the Trapezius, Deltoid, Latissimus Dorsi, Supinator Longus, and the extensor muscles of the forearm. The fossa, at the bottom of which lies the acromion process of the scapula, is well seen ; so is the projection formed by "Adam's apple."



Plate XIX.—Figure of Man crouching, as at the start for a race



Plate XX.—Figure of Man resting on outstretched arm

**Plate XXI.—Figure of a Man in the “Ready”
position for wrestling**

PLATE XXI.

Note the vertical position of the right Sterno-Mastoid muscle, which is powerfully contracted ; the fainter oblique ridge which is produced by the anterior margin of the Trapezius muscle ; and the depression which corresponds to the anterior triangle of the neck between these two. The pit of the stomach, the umbilicus, the Median furrow between the Recti Abdominis, are noticeable features on the front of the abdomen. The outline of the Quadriceps muscle is faintly visible in the front of the right thigh ; and the student should note, in association with the contraction of this muscle, the tapering ridge, continued downwards from the patella to the shin in the right limb, which is due to the underlying and taut Ligamentum Patellæ. The great toe has not been displaced by boot-pressure. The well-developed Tibialis Anticus makes the shin-bone look convex forwards. The Pectoralis Major is well developed, and so is the Biceps in the right arm.



**Plate XXI.—Figure of a Man in the “Ready” position
for wrestling**

Plate XXII.—Figure of a Man with bowed head

PLATE XXII.

In this figure notice—

1. The large mass of the contracting **Latissimus Dorsi** muscle.
2. The vertebra prominences at junction of **dorsal** convexity with the straight cervical spine.
3. The **Gluteus Maximus** prominent in action.
4. The fossa between it and the great trochanter.
5. The **Erectores Spinæ** muscles separated by
6. The spinal furrow, at the bottom of which **some** of the spinous processes of the vertebræ can be detected.
7. The hamstring muscles on the back of the thigh separated by
8. The ilio-tibial band from
9. The prominent mass of the **Quadriceps Extensor** on the front of the thigh.



Plate XXII.—Figure of a Man with bowed head

Plate XXIII.—Bust of Woman with chin depressed

PLATE XXIII.

The convexity forwards of the erect cervical spine has in this pose been obliterated, so that the dorsal concavity forwards is continued upwards into the bent neck. The position of the clavicle is well seen. The right breast is somewhat dependent, accentuating the thoraco-mammary fold. Notice what a wide extent of the thorax is covered by the breast; also how much more convex the lower half of each breast is than the upper half, so that the nipples are slightly tilted upwards.



Plate XXIII.—Bust of Woman with chin depressed

**Plate XXIV.—Front view of Man straining neck
backwards**

**Plate XXV.—Side view of Man straining neck
backwards**

PLATE XXIV.

This illustration shows the appearance of the abnormally developed and actively contracting *Platysma* from the front. Observe how it lies superficial to the clavicles and to the oblique ridge of the *Sterno-Mastoid* muscle, and how it pulls the angles of the mouth downwards.

PLATE XXV.

The outline of the posterior border of the *Platysma* muscle is well shown, but in this subject it is decidedly exaggerated. The head is extended, and transverse folds are developed in the skin of the back of the neck (compare Fig. 77, p. 19.).



**Plate XXIV.—Front view of Man straining
neck backwards**



**Plate XXV.—Side view of Man straining
neck backwards**

**Plate XXVI.—Figure of the legs of Man—muscles
in contraction**

PLATE XXVI.

On the right lower limb above the knee are two furrows ; the upper and front one is due to the posterior border of the ilio-tibial band ; the lower and back one to the tendon of the Biceps. The prominence of the calf is due to the Gastrocnemii, just in front of which is seen the Soleus. The next ridge, in the right leg, is formed by the peroneal group of muscles, and is very pronounced. Note the hollow above the heel, and the depression above the external Malleolus in front of the peroneal tendons. On the left lower limb the Internal Saphenous vein and the oblique groove mentioned in the text as due to a band of fascia passing over the Vastus Internus muscle are well seen. The inner head of the Gastrocnemius is bigger than the outer.



Plate XXVI.—Figure of the legs of Man—muscles in contraction

**Plate XXVII.—Three studies of the male lower
extremities from the front**

PLATE XXVII.

The figure A shows the Quadriceps Extensor of the thigh in vigorous contraction, and three anatomical features are exceedingly well seen. These are (1) the relation of the furrow, which nearly corresponds to Poupart's ligament, but is seen in the figure to really lie somewhat above the anterior superior spine and Poupart's ligament; (2) the individual parts of the Quadriceps muscle on the front of the right thigh; (3) the fossæ around the patella. The two other figures show the difference in outline of the lower limbs in various positions. The band of deep fascia is producing a very definite groove across the slack Vastus Internus just above the patella in both limbs in B and in the left limb in C.



A B C
Plate XXVII.—Three studies of the male lower extremities from the front

**Plate XXVIII.—Three studies of male lower
extremities from behind**

PLATE XXVIII.

Note in B the straightness of the spine, the prominent Erectores Spinæ, the transverse gluteal folds and the definition of the Gastrocnemii (inner head larger) and Tendo Achillis, the subject standing symmetrically on tiptoe.

In A the subject is standing at ease on the right leg. The Gastrocnemii are not so defined, the left side of the pelvis is raised ; consequently the left hip is slightly flexed and the gluteal fold is less marked ; while a convexity of the spine to the right is developed, with inequality of the shoulder-blades. In the left ham the Biceps tendon shows.

In C the vertebral groove or Spinal furrow is well seen, the Erector Spinæ being well developed. The thighs are more flexed, so that the gluteal folds have disappeared. The Biceps Cruris tendon shows well in the left limb. The buttock and thigh are very massive.



A B C

Plate XXVIII.—Three studies of male lower extremities from behind

**Plate XXIX.—Outstretched arm, back view,
in state of strain**

**Plate XXX.—Outstretched arm, front view,
in state of relaxation of the muscles**

PLATE XXIX.

The prominences formed by muscles of the arm and forearm are strongly marked in such an action as clenching the fist of the outstretched arm. The Deltoid and the Triceps in the upper arm, and the following muscles in the forearm, should be identified : The Supinator Longus, the Extensor Carpi Radialis Longior, the Extensor Communis Digitorum, and the Extensor Carpi Ulnaris. Some of the tendons, and the hollows between the metacarpal bones, on the back of the hand are also seen.

PLATE XXX.

The Antecubital Fossa, the "Anatomist's Snuff Box," and the vein of the front of the forearm should be observed, also the axilla, the lower border of the Pectoralis Major muscle, and the relation of the nipple thereto, the Median furrow on the front of the chest, the navel, the outline of the Rectus Abdominis and external oblique muscles, and the iliac furrow. The student will also observe the difference between the outline of the Biceps on the right side, where it is long and narrow, and that on the left side, where it is broader. The muscle is in action in the left arm, but not in the right.



Plate XXIX.—Outstretched arm, back view, in state of strain



Plate XXX.—Outstretched arm, front view, in state of relaxation of muscles

Plate XXXI.—Figure of a Woman sitting

PLATE XXXI.

The right arm in a restful pose ; the Antecubital Fossa is just discernible, but is better seen in the left arm. The margin of the Pectoralis Major and the relation to it of the breast is well seen. The head of the ulna is prominent at the left wrist. The folds of the groin are very obvious. Compare with Plate XVIII (" Figure of a Woman stooping ").



Plate XXXI.--Figure of a Woman sitting

INDEX

A

ABDOMEN or belly, 169, 173, 177
 " of the infant, 263
" "Abdominal type" of breathing,
 the, 174
Abdominal wall, the, 173
Abduction, of the arm, 147
Abductor indicis, the, 132
Acetabulum, the, 47
Acromio-clavicular joint, 37
Acromion, the, 74
 " process, the, 35
" "Adam's apple," 184
Adduction of the arm, 147
Adductor magnus muscle, the,
 50, 114
 " muscles, 111
 " tubercle, the, 50
Air-cavity or frontal sinus, 57
Air sinus of the mastoid process,
 59
Alæ of the nose, 221
 " or wings of the thyroid car-
 tilage, 184
Albinos, 68, 217
Anæmic subjects, 68
Anatomical waist, the, 254
"Anatomist's snuff-box," the, 42,
 101, 151
Anconeus muscle, 93
Angle of torsion of the foot, 132
Angles of the scapula, 37
Ankle, the, 33, 131
Ankle-joint, movements of the,
 155

Annular ligament, the, 95
 " ligaments of the foot,
 142
Ante-cubital fossa, the, 86
Anterior superior spine of the
 ilium, 166
Antrum of Highmore, the, 60
Aponeurosis, the, 178
Aqueous humour of the eye, 218
Arch or "dome" of the foot, the,
 52, 137
Arm, the, 84
 " the human, 278
 " and leg compared, 147
Armpit, the, 82, 167
Astragalus, the, 52, 54
Auricle or ear, 199, 229
Axilla or armpit, 38, 82

B

BACK of the hand, the, 97
Baldness, 199
"Ball and socket" joint, 153
Ball of the toe, the, 55
Basilic vein, 86
Bat, limbs of the, 268
Bear, the foot of the, 268, 270
"Beetling brow," the, 209
Biceps flexor cruris, 52
 " muscle, the, 38, 82, 115,
 150
 " the tendon of the, 119
Bicipital groove, the, 38

INDEX

Bicipital tuberosity, the, 42
" Blear," 212
Blinking, 213
Blushing, 238
Blushing and pallor, 68
" Body" or horizontal part of the
maudible, 61
Bones of the foot, the, 52
 ,, of the forearm, 40
 ,, of the lower limb, the, 44
 ,, of the skull, the, 55
 ,, of the vertebral column, 61
 ,, of the wrist, 43
 ,, various forms of, 33
Borders of the scapula, 37
Brachial artery, the, 85
Brachycephalic or broad head,
198
" Breaking" of the voice, 184
Breast, the female, 176
Breast-bone, the, 63
Bridge of the nose, 221
Buccal cavity, the, 60
Buccinator muscle, 236
Buttocks, the, 103

C

CALCANEUM, the, 271
Calvaria, the, 56
Capitellum, the, 40
Carotid artery, the, 193
Carpals, or bones of the wrist,
35, 95
Carpus or wrist, 43
Carrying angle, the, 88
Cartilage of the nose, 221
Cartilaginous auricle, the, 59
Caruncle, the, 211
Cat, the foot of the, 268
Cephalic vein, the, 85
Cervical vertebrae, 61
Cheek, the, 228
Cheek-bone, the, 60
Chest or thorax, the, 169
Chin, the, 61

Chin, the, as an indication of
character, 226
Choroid of the eye, the, 215
Ciliary muscle, the, 218
Circumduction of the arm, 147
Clavicle, the, 34, 35, 78, 169
 ,, in quadrupeds, the, 268
Coccyx, the, 44, 62
Colour of the skin, 66
 ,, of the eye, the, 216
Columna nasi, the, 222
Comparative Anatomy, 267
Complexus muscle, the, 196
Compressor uaris, 238
Concha of the ear, the, 232
Condyles, 49
 ,, internal and external,
 88
 ,, of the humerus, the
 39
Conjunctiva or membrane of the
eyes, 65, 210
Contraction of the muscles, 70
 ,, of the pupil of the
 eye, 217
" Co-ordination" of muscles, 219
Coraco-brachialis muscles, 82, 84
Coracoid process, the, 36, 41, 81
Cornea, the, 211, 216
Corrugator supercillii muscle, 202,
238
" Costal type" of breathing, 174
Cotyloid notch, the, 47
Cranial bones, the, 56, 198
Cranium, the, 56
 ,, in relation to the spine,
 34
Crest of the ilium, the, 164, 168
 ,, of the tibia, the, 124
Cricoid cartilage, the, 184
Crico-thyroid membrane, the, 185
Criminology and the skin, 65
Crureus, the, 112
Crus heliis, the, 232
Cuboid, the, 53
Cuneiform bones of the foot, the,
54
Curve in the spine, 161

INDEX

D

Dark hair, 67
Darwin's tubercle, 229
Deceit, 246
Decision, 248
Deep fascia, the, 69
Deer, the foot of the, 271
Defiance, 246
Deltoid muscle, the, 77, 86
Depressor alæ nasi, 238
 " **anguli oris**, 237
Despair, 244
Diaphragm, the, 174
Digastric muscle, the, 191
 " **triangle**, the, 191
Digitations, 82
Digitigrade animals, 269
Digits, the bones of the, 35
Dilatores naris, 238
Disdain, 246
Distal, 44
Dog, the foot of, 270
Dolichocephalic or long head,
 198
Dorsal surface of the scapula, 37
 " **vertebræ**, 61, 157
Dorsum of the foot, 138
"Double chin," the, 181

E

EAR, the, 199, 228
Elbow, the, 87
 " **and knee compared**, 147
Elbow-joint, the, 40
Elephant, the foot of the, 272
Emaciation, the appearance of, 69
**Ensiform or lower part of the
 sternum**, 64
Ensiform cartilage, 171
Erector spinæ muscle, 158
Ethmoid bone, the, 56
**Expression dependent on corre-
 lated action of facial muscles**,
 180

Expression and Gesture, 234
Extension of the arm, 147
Extensor brevis digitorum, 141
 " **carpi radialis brevis**, 93
 " **[carpi radialis longior
 muscle**, 86
 " **communis digitorum**, 92
 " **internodii pollicis**, 151
 " **internodii pollicis ten-
 dons**, 101
 " **longus digitorum**, 128
 " **longus hallucis**, 127
 " **longus pollicis muscle**,
 the, 42
 " **ossis metacarpi pollicis**,
 93, 151
Extensors of the foot and toes,
 126
External auditory meatus, 59
 " **malleolus**, the, 52
 " **oblique muscle**, the, 163
Extremities, divisions of the, 71
Eye, the light in the, 179
Eyeballs, the, 208
Eyebrows, the, 57, 209
Eyelashes, the, 212
Eyelids, the, 209

F

FACE, the, 206
 " **types of**, 235
Facial bones, the, 198
 " **nerve**, the, 213
False pelvis, the, 46
Fascia lata, 113
Fat, the deposit of, 68
Fear, 243
Female waist, the, 254
Femur, the, 33, 34, 45, 48, 117
Fibula, the, 44, 52, 117
Fingers, the, 101
 " **flexion and extension of
 the**, 152
Flat bones, the, 33
Flexion of the arm, 147

INDEX

Flexor carpi radialis tendon, the,
 43, 90
 „ longus hallucis muscle, 54
 "Floating ribs," 63, 175
 Fold of the axilla, 167
 Foot, the bones of the, 52, 131
 „ the human, 278
 „ of the infant, the, 260
 Foramen magnum, the, 58
 Forearm, the, 89
 „ the bones of the, 35, 40
 „ veins of the, 91
 Forehead, the, 57, 200
 „ types of, 203
 Form of the model, the, 70
 Frog, the leg of a, 274
 Frontal bone, the, 33, 56, 200
 „ eminence, the, 57, 200
 „ furrows, 201
 „ sinus, the, 57
 Frontalis muscle, the, 202

G

GASTROCNEMIUS muscle, 121, 129
 Gesture and expression, 180
 Gladiolus, part of the sternum,
 63, 170
 Glands of the skin, 66
 Glenoid cavity, the, 61, 146
 Globe of the eye, the, 215
 Gluteal muscles, the, 46, 49, 103
 Gluteus maximus, the, 105, 107,
 154
 „ medius, the, 107
 "Goitre" or "Derbyshire neck,"
 186
 "Goose-skin," 67
 Gracilis muscle, the, 122
 Great omentum, the, 264
 „ toe, the, 139
 „ trochanter, the, 36, 49,
 114
 Greyhound, the foot of the, 272
 Grief, 242
 Groin, the, 108

H

HAIR, the, 67, 178
 „ direction of the, 199
 „ follicles, 66
 Ham or popliteal space, 120
 Hamstring muscles, the, 106, 115,
 154
 Haud, the, 95
 Head, divisions of the, 71
 Hectic, 238
 Heel or os calcis, the, 52, 130
 Helix of the ear, 232
 Hill, Sir Charles, 102
 Hip-bones, the, 34, 44, 146, 153
 Hip-joint and shoulder compared,
 146
 Horse, the foot of the, 268
 Humerus, or bone of the arm, 35,
 37
 „ movements of the, 34
 „ in man and quadrupeds,
 276
 Humphrey, Sir George, 102
 Hyoid bone, the, 61, 182

I

ILIAC crest, the, 46
 „ wings, the, 48
 Ilio-costal space, the, 166
 Ilio-psoas flexor, the, 154
 Ilio-tibial band, the, 107
 Ilium, the, 46, 104
 Imprint of the foot, 137
 Inclination and torsion of the
 femur, 50
 Infancy and old age, 264
 Infant, the development and
 measurements of, 259
 Infants, male and female, com-
 parison of, 261
 Infant's skull, 55
 „ smiles and tears, 261
 Inferior angle of the scapula, 37
 Infra-clavicular fossa, the, 81, 172

INDEX

Infra-spinatus muscle, the, 76, 163
Infra-sternal fossa, or "pit of the stomach," 171
"Insertion" of a muscle, the, 34, 70
Instep, the, 138
Intercondyloid notch, 49
Intercostals, the, 174
Internal malleolus, the, 51
Interossei muscles, 152
Interosseous membrane of the arm, 42
Iris of the eye, the, 216
Ischium, the, 46

J

JAUNDICE, the yellow tinge of, 68
Jaw, the movements of the, 34
Jugular veins, the, 186, 193

K

KEYSTONE of the arch of the foot, the, 55
Knee, the, 117, 155
"Knee" of the deer, the, 274
Knee-cap, the, 44, 119
"Knock-knee," 123, 252
Knuckles, the, 44, 102
" of the toes, 140

L

LACHRYMAL canaliculus, the, 211
" gland, the, 239
Larynx, the, 183
Latissimus dorsi, the, 70, 162
Laughter, 242
Leg, the, 123

Lens of the eye, the, 218
Lesser trochanter, the, 94
Levator anguli oris, 236
" labii superioris, 236
" menti, 237
" palpebralis superioris, 213
Ligaments joining the radius to the ulna, 42
Ligamentum nuchæ, the, 195
" patellæ, the, 50, 120
"Light in the eye," the, 179
Linea alba, the, 171
" aspera, the, 49
" semi-lunaris, the, 173
Lineæ atrophicæ, 177
Lines on the palms, the, 96
" of the thumb, 100
Lion, the foot of the, 270
Lips, the, 224
Lobe or lobule of the ear, 231
Loins, the 157
Long bones, the, 33
"Lower chest," the, 264
Lower jaw, the, 60
Lumbar vertebræ, 61, 157
Lunula of the nails, 66

M

MALAR or cheek-bone, the, 60
Male and female outlines, 252
" pelvis, 45
Malleolus, the, 51, 125
Man, the leg of, 273
Man and horse compared, skeletons of, 279
Man and lower animals, essential differences between, 241
Mandible, the, 60
Manubrium, part of the sternum, 63, 170
Masseter muscle, the, 59, 232
Mastoid process, the, 59, 203
Maxillary bones, the, 60
Meatus, the, 229

INDEX

- Median basilic vein, 92**
 „ cephalic vein, the, 81, 91
 „ nasal spine, the, 57
 „ vein, the, 91
Membranous ligament of the fore-arm, 42
Mental protuberance, 226
Mesial border of the scapula, 37
Metacarpal bones, the, 44, 95
Metacarpo-phalangeal joint, the, 100
Metatarsal bones, the, 44, 55, 136
Moles, 66
Monkey compared with man, the, 277
Motor and sensory functions, the, 59
Moustache and beard, the, 227
Mouth, the, 223
Movements of the ankle-joint, 155
 „ of the bones, 34
 „ of the hip-joint, 153
 „ of the knee, 155
 „ of the toes, 155
Mucous membrane, the, 65
Muscle, anconeus, 93
 „ adductor magnus, 114
 „ biceps, 84
 „ the coraco-brachialis, 84
 „ the deltoid, 77, 86
 „ erector spinæ, 158
 „ extensor communis digitorum, 92
 „ „ carpi radialis breviar, 93
 „ „ carpi radialis longior, 86
 „ „ ossis metacarpi pollicis, 93
 „ the gastrocnemius, 121
 „ the gracilis, 122
 „ the infra-spinatus, 76
 „ pectoralis major, 80
 „ pronator radii teres, 89
 „ quadriceps, 112, 119
 „ supinator longus, 86
Muscle, the supra-spinatus, 74
 „ tailor's, 109
 „ the tensor fasciæ femoris, 113
 „ the trapezius, 74
 „ the triceps, 85
Muscles, adductor, 111
 „ attached to flat bones, 34
 „ contraction of the, 70
 „ of the back of the neck, 58
 „ of the ear, 230
 „ of the eye, 219
 „ of the fingers, 152
 „ the hamstring, 106, 115
 „ of the hip-joint, 154
 „ of the leg, 126
 „ of the mouth, 235
 „ of the nose, 238
 „ of the shoulder-joint, 148
 „ superficial flexor, 89
 „ tibialis anticus, extensor longus hallucis, extensor longus digitorum, peroneus tertius, 127
Musculo-cutaneous nerve of the leg, 125
 „ *Musculus cucullaris*, 162

N

- NAIJS, the, 66**
 „ of the toes, 141
Nasal bones, the, 57, 60
 „ fossæ, the, 57
 „ septum, the, 222
Naso-labial fold, the, 233
Natal fold, the, 105, 114
Navicular or scaphoid, the, 54, 135
Neck, the, 71, 180
Nélaton's line, 106
Nipples, position of the, 176
Nose, the, 221
Nostrils, the, 221

INDEX

O

- OCCIPITAL bone, the, 56
- " protuberance, the, 204
- Occipitalis muscle, the, 204
- Occipito-frontalis muscle, the, 58
- Old age, 69, 264
- Olecranon process, the, 41, 87
- Omo-hyoid muscle, the, 191
- Opposition, of the thumb, 151
- Orbicularis oris, 235
- " palpebrarum muscle, 202
- Orbital margins, 208
- Orbits of the eyes, the, 57
- Origin of the muscle, the, 70
- Os calcis or heel, 52, 129
- " pubis, the, 47
- Ossa innominata, 34, 44, 46, 105

P

- PAIN, 243
- Palate, the, 60
- Pallor, 68
- Palm of the hand, the, 95
- Palmar fascia, 95
- Palmaris longus tendon, 90, 96
- Palpebral fissure, the, 211
- Panniculus adiposus, 68
- " carnosus, the, 69
- Parietal bones, the, 56
- " eminence, the, 59, 203
- Parotid gland, the, 191
- Patella, the, 44, 50, 117, 119
- Pectoralis major muscle, 80, 169, 171
- " minor, the, 82
- Pelvis, the, 44, 47
- Peroneal tubercle, the, 54
- Peronei, the, 128
- Peroneus longus tendon, the, 55
- "Perspiration" or "sweat," 241
- Phalanges or bones of the digits, the, 35, 44
- " of the foot, the, 55, 140
- Pigment of the skin, 66

- Pisiform bone, the, 43
- "Pit of the stomach," the, 171
- Plantigrade animals, 268
- Platysma, the, 69, 182, 193
- Popliteal space, the, 120
- Posterior annular ligament, the, 94
- " superior spine of the ilium, 165
- Poupart's ligament, 108, 168
- Processes of the scapula, 37
- Pronation of the forearm, 40
- " and supination, 149
- Pronator quadratus, the, 149
- " radii teres, the, 42, 89
- Proportions, male and female, 252
- Protective bones, 34
- Proximal, 44
- Ptosis or drooping of the eyelids, 214
- Puberty, 67
- Pubes, the, 46
- Pulse, the, 91
- Punctum, the, 211
- Pupil of the eye, the, 216
- Pyramidalis nasi, 238

Q

- QUADRICEPS extensor cruris, the, 50
- " muscle, the, 112, 119

R

- RADIO-ULNAR articulations, 149
- Radius, the, 40, 41, 93
- "Ramus" or vertical part of the mandible, 61
- Rectus abdominis, the, 47, 171
- " femoris, the, 112, 154
- Relative measurements, 255
- Resonating air-chambers, 58
- Retina of the eye, the, 215

INDEX

Rhomboides major, the, 163
 Ribs, the, 63, 167, 175
 „ of man and horse compared,
 the, 280
 Ridges and furrows of the skin, 65
 Risorius, the, 237
 Root of the nose, the, 221
 Rotation of the arm, 147
 “Round shoulders,” 37

S

SACRAL vertebrae, the, 105
 Sacro-iliac ligaments, 46
 Sacrum, 44, 62
 Saphenous vein, 111, 125
 Sartorius or tailor's muscle, 109,
 154
 Scalp, the, 198
 Scaphoid, the, 54
 „ fossa of the ear, 232
 „ tubercle of the, 43, 135
 Scapula, the, 33, 34, 36
 „ of a horse, the, 281
 Scarpa's triangle, 109
 Sclerotic, the, 210, 215
 Scorn, 246
 Sebaceous glands, 66
 Self-conceit, 248
 Semilunar fascia, the, 85, 90
 Semi-membranosus, the, 115
 Semi-tendinosus, the, 115
 Serratus magnus muscle, the, 82,
 171
 Sesamoids, the, 120
 Shaft of the humerus, 38
 Shape of the nose, 223
 Shin, the, 51, 124
 Short bones, the, 33
 Shoulder, the, 73
 Shoulder-blade or scapula, 34
 Shoulder-joint, the, 147
 Shyness, 246
 Sigmoid cavity, the, 41
 Skeleton, the shape of the, 70
 Skin, the, 65

Skin of the forehead, the, 201
 „ of the palm, the, 95
 Skull of an adult, the, 55
 „ of an infant, the, 55
 „ divisions of the, 198
 Sneering, 246
 “Snub” nose, 223
 Sole of the foot, the, 144
 Soleus, the, 129
 Sphenoid bone, the, 56
 Spinal column, the, 61
 „ cord, 62
 „ nerve, 62
 Spine, the, 33, 157
 „ in relation to the cranium,
 the, 34
 „ of the pubes, the, 47, 169
 „ of the scapula, the, 74
 Spinous process, the, 62
 „ „ of the scapula, 37
 „ processes of the vertebrae,
 197
 Squamous part of the temporal
 bone, 59
 Squinting, 220
 “Sternal angle,” the, 170
 Sterno-mastoid muscle, the, 58,
 187
 Sternum or breast-bone, 63, 169
 Stylo-hyoid muscle, the, 191
 Styloid process, the, 41, 52, 93
 Subcutaneous tissue, 68
 Sub-mental pad, the, 68
 Sucking pad of the infant, 68, 228
 Sulkiness, 248
 Superciliary ridge, the, 57, 200
 Superficial fascia, 68
 „ flexor muscles, 89
 Superficialis volæ artery, the, 99
 Superior angle of the scapula, 37
 Supination and pronation, 149
 „ of the forearm, 40
 Supinator longus muscle, 86, 149
 Supra-condylar ridges, the, 39
 Supra-orbital margin, the, 57, 200
 Supra-spinatus muscle, the, 74
 Supra-sternal fossa, the, 169
 Surface form of the foot, 138

INDEX

"Surgical neck," the, 38
 Sutures of the bones of the skull, 56
 Sweat glands, 66
 ,, secretion of, 239
 Symmetry in anatomy, the absence of strict, 63
 Symphysis pubis, the, 47, 171

T

TAILOR'S muscle or sartorius, 109
 Talus, the, 54
 Tarsus, the, 44
 Tears, 211, 239
 Teeth, the, 249
 Temporal bones, the, 56
 ,, muscle, the, 205
 Tendo Achillis, the, 54, 126, 129
 Tendon, flexor carpi radialis, 90
 ,, " " ulnaris, 91
 Tendons of the foot, 141
 ,, of the hand, 98
 ,, of the thumb, 101
 Tensor fasciæ femoris, 113
 Teres major, the, 163
 Terror, 244
 Thenar eminence, 95
 Thigh, the, 109
 Thigh-bone, the, 44
 Thoraco-mammary fold, the, 177
 Thorax or chest, the, 35, 63, 157
 Thumb, the, 95, 99, 151
 ,, movement of the, 43
 Thyroid cartilage, the, 184
 ,, foramen, the, 47
 ,, gland, the, 186
 Tibia, the, 44, 50, 117
 Tibialis anticus, the, 127
 Tip of the nose, the, 221
 Toes, the, 139, 155
 Tortoise, hind limbs of the, 272
 Trachea or windpipe, the, 185
 Tragus of the ear, 232

Transversalis muscle, the, 178
 Trapezium, ridge of the, 43
 Trapezius muscle, the, 74, 162, 195
 Triangles of the neck, 180
 Triceps, the, 85
 Trochanters, the, 48
 Trochlea, the, 40, 89
 Trunk, the, 157
 ,, divisions of the, 71
 ,, of man and horse compared, 285
 Tubercle of the ilium, 46
 ,, of the scaphoid, 135
 ,, of the tibia, the, 51, 120
 Tuberosities of the humerus, 38
 Tuberosity of the ischium, the, 104

U

ULNA, or bone of the forearm, the, 35, 40, 93
 Umbilicus or navel, 171
 Unciform bone, the, 43
 Upper extremity, the, 73
 ,, jaw, the, 60

V

VASTUS internus and externus, 112, 120
 Ventral surface of the scapula, 36
 Venus plexus, 97
 Vertebra prominens, the, 62, 160
 Vertebrae, the, 61, 160
 ,, or quadrupeds, 279
 Vertebral border of the scapula, 37
 Vertical border of the scapula, 37
 Vitreous humour of the eye, 218
 Vocal cords, the, 184

INDEX

W

- W_AIST, the true, 166
,, of the foot, the, 138
Wasting illnesses, effect of, 68
W_HALE, rudimentary limbs of the,
267
W_HITE hair, 67
,, of the eye, the, 215
W_INDPIPE, the, 169, 185
W_INKING, 214
W_ITHERS of a horse, the, 280

- W_RIST, the, 33, 43, 93
,, the bones of the, 35
,, and ankle compared, 148
,, man's, 274
W_RIST-JOINT flexion, 150

Z

- Z_YGOMATIC arch, the, 59, 199
,, process, the, 59
Z_YGOMATICUS, the, 237

THE END

Printed by BALLANTYNE, HANSON & Co.
Edinburgh & London

202

COUNTWAY LIBRARY



HC 2V6F /

t. 2968
Human anatomy for art students, 1911
Countway Library BFK6713



3 2044 046 282 109

t. 2968
Human anatomy for art students, 1911
Countway Library BFK6713



3 2044 046 282 109