



This is a digital copy of a book that was preserved for generations on library shelves before it was carefully scanned by Google as part of a project to make the world's books discoverable online.

It has survived long enough for the copyright to expire and the book to enter the public domain. A public domain book is one that was never subject to copyright or whose legal copyright term has expired. Whether a book is in the public domain may vary country to country. Public domain books are our gateways to the past, representing a wealth of history, culture and knowledge that's often difficult to discover.

Marks, notations and other marginalia present in the original volume will appear in this file - a reminder of this book's long journey from the publisher to a library and finally to you.

Usage guidelines

Google is proud to partner with libraries to digitize public domain materials and make them widely accessible. Public domain books belong to the public and we are merely their custodians. Nevertheless, this work is expensive, so in order to keep providing this resource, we have taken steps to prevent abuse by commercial parties, including placing technical restrictions on automated querying.

We also ask that you:

- + *Make non-commercial use of the files* We designed Google Book Search for use by individuals, and we request that you use these files for personal, non-commercial purposes.
- + *Refrain from automated querying* Do not send automated queries of any sort to Google's system: If you are conducting research on machine translation, optical character recognition or other areas where access to a large amount of text is helpful, please contact us. We encourage the use of public domain materials for these purposes and may be able to help.
- + *Maintain attribution* The Google "watermark" you see on each file is essential for informing people about this project and helping them find additional materials through Google Book Search. Please do not remove it.
- + *Keep it legal* Whatever your use, remember that you are responsible for ensuring that what you are doing is legal. Do not assume that just because we believe a book is in the public domain for users in the United States, that the work is also in the public domain for users in other countries. Whether a book is still in copyright varies from country to country, and we can't offer guidance on whether any specific use of any specific book is allowed. Please do not assume that a book's appearance in Google Book Search means it can be used in any manner anywhere in the world. Copyright infringement liability can be quite severe.

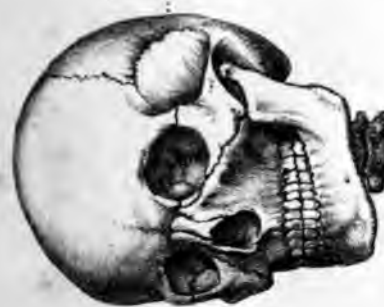About Google Book Search

Google's mission is to organize the world's information and to make it universally accessible and useful. Google Book Search helps readers discover the world's books while helping authors and publishers reach new audiences. You can search through the full text of this book on the web at <http://books.google.com/>



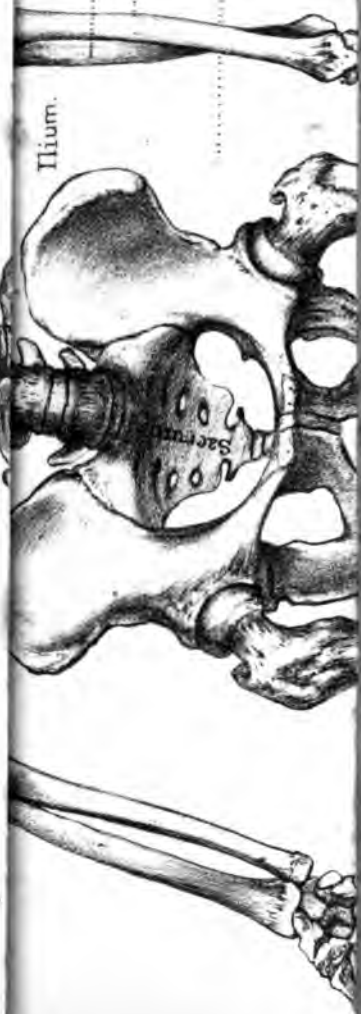HUMAN OSTEOLOGY





Cranium.

7 Cervical vertebrae.



Hium.

Ulna.

Radius

Pelvis.

Sacrum

HUMAN OSTEOLOGY

COMPRISING

A DESCRIPTION OF THE BONES

WITH DELINEATIONS OF THE ATTACHMENTS OF THE MUSCLES
THE GENERAL AND MICROSCOPIC STRUCTURE OF BONE
AND ITS DEVELOPMENT

BY

LUTHER HOLDEN

EX-PRESIDENT AND MEMBER OF THE COURT OF EXAMINERS
OF THE ROYAL COLLEGE OF SURGEONS OF ENGLAND
CONSULTING SURGEON TO SAINT BARTHOLOMEW'S AND THE FOUNDLING HOSPITALS

ASSISTED BY

JAMES SHUTER, F.R.C.S. M.A. M.B. CANTAB.

ASSISTANT SURGEON TO THE ROYAL FREE HOSPITAL
LATE DEMONSTRATOR OF PHYSIOLOGY, AND ASSISTANT DEMONSTRATOR OF
ANATOMY, AT SAINT BARTHOLOMEW'S HOSPITAL


With numerous Illustrations

SIXTH EDITION

LONDON

J. & A. CHURCHILL, NEW BURLINGTON STREET

1882



165. e. 91.

PREFACE
TO
THE SIXTH EDITION

IN THE SIXTH EDITION a few brief Notes on Comparative Osteology have been added, with the object of facilitating the intelligent study of the human skeleton ; and these have been made practically illustrative by reference to specimens in the Museum of the Royal College of Surgeons.

Several of the Plates have been re-drawn.

The order in which the Bones were described in previous Editions has been slightly altered ; and it is hoped that the arrangement in the present edition will be found more systematic and convenient.

The Author has been assisted by Mr. JAMES SHUTER, late Demonstrator of Practical Physiology, and Assistant Demonstrator of Anatomy, at St. Bartholomew's Hospital.

January 1882.

PREFACE

TO

THE FIFTH EDITION



IN preparing the present Edition the Author has been assisted by Mr. ALBAN DORAN, late Anatomical Assistant to the Museum of the Royal College of Surgeons of England.

In revising the Attachments of Muscles, note has been taken of the highly instructive dissections,—made by Mr. W. PEARSON in the work-rooms of the College,—which are now in the Physiological Series of the Museum.

Most of the Plates have been re-drawn. Numerous woodcuts have been added, in illustration of the Development of Bone—for which, as well as for other collateral work, the author is indebted to Mr. JAMES SHUTER, Assistant Demonstrator of Anatomy at St. Bartholomew's Hospital.

Grateful acknowledgments are due to Professor FLOWER, F.R.S. and to the Demonstrators of St Bartholomew's Hospital, for valuable suggestions in special details.

September 1878.

CONTENTS.



	PAGE	PLATE
GENERAL OBSERVATIONS ON THE STRUCTURE OF BONE	1	. . I. to IV.
MICROSCOPIC STRUCTURE OF BONE	13	
STRUCTURE OF CARTILAGE	22	
DEVELOPMENT OF BONE	23	
BONES OF THE SKULL	37	
Occipital Bone	37	. . v.
Parietal Bone	42	. . VI.
Frontal Bone	46	. . VII.
Temporal Bone	52	. . VIII., IX.
Sphenoid Bone	63	. . X., XI.
Ethmoid Bone	71	. . XI.
BONES OF THE FACE	76	
Superior Maxillary Bone	76	. . XII.
Malar Bone	85	. . XIII.
Nasal Bone	87	. . XVI.
Lachrymal Bone	88	. . XIII.
Palate Bone	90	. . XIII., XIV.
Inferior Spongy or Turbinated Bone	93	. . XV.
Vomer	94	. . XVI.
Inferior Maxillary Bone	96	. . XVII.
THE SKULL AS A WHOLE	102	
Sutures	102	. . XVIII.
Skull-cap	103	. . XVIII.
Base of the Skull as seen from above	107	. . XIX.
Base of the Skull as seen from below	109	. . XX., XXI.
Temporal, Zygomatic, Spheno-max- illary Fossæ	114	. . XVI., XXII.
The Orbits	115	. . XXII.
Nasal Fossæ	118	. . XXIII., XXIV.
General Observations on the Skull . .	121	

	PAGE	PLATE
VERTEBRAL COLUMN	128 XIV. to XVII.
SACRUM	145 XVIII., XIX.
COCCYX	150	
BONES OF LOWER EXTREMITY	152	
Os innominatum	152) XXX. to XXXII.
Ilium	153	
Pubes	156	
Ischium	157	
Pelvis in general	161	
Femur	166 XXXIII., XXXIV.
Patella	174) XXXV.
Tibia	176	
Fibula	180	
BONES OF FOOT	184	
Astragalus	185) XXXVI. to XXXVIII.
Os Calcis or Calcaneum	188	
Scaphoid Bone	191	
Cuboid Bone	192	
Cuneiform Bones	193	
Metatarsus	195	
Phalanges	198	
Sesamoid Bones	199	
OBSERVATIONS ON THE FOOT AS A WHOLE	199	
INTEROSSEOUS MUSCLES OF THE FOOT	204	
THE THORAX	205	
Sternum	206) XXXIX. to XLI.
Ribs	209	
MUSCLES OF THE BACK	218) XLI. to XLVII.
Muscles of the back of the Neck	220	
Muscles in front of the Spine	221	
BONES OF THE UPPER EXTREMITY	222	
Clavicle	222) XLVIII., XLIX.
Scapula	225	
Humerus	230 LI.
Radius	237) LII., LIII.
Ulna	241	

CONTENTS.

xi

	PAGE	PLATE
BONES OF THE HAND	246	
Carpus	246	} . . LIV. to LVI.
Metacarpus	252	
BONES OF THE FINGERS	256	
Sesamoid Bones	258	
Interosseous Muscles	258	
GENERAL SURVEY OF THE SKELETON	260	
Os HYOIDES	264	. . XXIVIII.
THE LARYNX	266	. . LVII.
THE ANATOMY OF THE EAR	276	. . LVIII. to LXI.
NOTES	297	
INDEX	305	

HUMAN OSTEOLOGY.

Importance and Interest of Osteology.—Whoever would become a good anatomist and a skilful surgeon must make himself master of Human Osteology. It must be, not only his first, but his principal and constant study. He cannot understand his dissections without continually referring to the skeleton. Nor can he fail to be interested from the first in the science, if in studying each bone he will compare it with the corresponding bone in his own body, in order that he may become familiar with what he can feel of it in the living subject. He will thus see in osteology, not death, but life. In discovering and reducing the simplest dislocation, how important it is to have a competent knowledge of the feel of the bony parts and their relations to one another! A little progress will convince him that, far from being dry, osteology is attractive, not only as conducive to professional success, but for its own sake. Undertaken in a right spirit, the study of it becomes, with many, a favourite pursuit, and creates a natural longing to know something of the skeleton of the lower animals, that we may the better judge of the advantageous construction of our own; for it is only by comparison that we can judge. When the great truth unfolds itself, that our own structure appears to be but a modification of the ‘one common pattern’ upon which all vertebrate animals are formed, we cannot but feel with the philosophic poet, that—

’Tis the sublime of man,
Our noontide majesty, to know ourselves
Parts and proportions of a wondrous whole.

COLERIDGE.

Uses of the Bones.—The bones form the framework which supports the soft parts of the body. All the bones, either separately or in conjunction with others, form levers upon which the attached muscles act and give rise to our various movements. Take a few examples. If the biceps muscle contracts the forearm becomes flexed; this shows that the radius is a lever (see fig. 61). It will likewise be seen that the other bones are levers, as the lower jaw in opening and shutting the mouth; the skull as a whole in nodding the head; the vertebræ in balancing and flexing the trunk; the pelvis as a whole (see fig. 29); the ribs when raised and depressed in respiration; the clavicle in shrugging or depressing the shoulders; the scapula and the humerus in raising the arm; the ulna and the radius in flexing or extending the forearm; the carpus and metacarpus as a whole in the movements of the wrist joint; the phalanges in the actions of the fingers. In like manner the bones of the lower extremities are levers, which, when acted upon by the various muscles attached to them, give rise to locomotion.

The bones contribute to the formation of the joints, which admit of more or less movement, depending in direction and extent upon the shape of the articular surfaces and the attachments of the muscles. Besides this, the bones of the head and trunk lodge and protect delicate organs; thus, in the skull and spinal canal we find, respectively, the brain and spinal cord; in the orbits are the eyes; in the temporal bone are the internal parts of the ear; and in the bony framework of the chest are the heart and lungs, which, as well as the upper abdominal viscera, it protects.

The fact that the long bones are curved in their long axes increases their elasticity, gives them some amount of spring similar to that of a bow, and helps to diminish shocks.

Composition of Bone.—Bone is composed of a basis of animal matter impregnated with earthy salts. The analysis is easily made. If a bone be boiled in water for a few hours it loses its elasticity and its animal matter. The animal matter is found in solution in the water and is called jelly or 'gelatin.' The residual bone is white and brittle, and consists only of earthy salts. A like result may be obtained by burning or calcining the

bone: it first becomes black from the charring of the animal matter and then white, the animal matter having been completely burnt off and nothing left but the 'earthy salts.' If, on the other hand, a bone be soaked for a few days in a solution of hydrochloric acid (about one part of the dilute acid to six of distilled water), it loses its earthy salts, becomes soft, and may be bent in any direction. Bones are used in making soup for the gelatin they yield on boiling. Notwithstanding their antiquity, fossil bones are found to contain nearly as much animal matter as recent bones. Gimbernat made soup from the gelatin of the mastodon's tooth, as Dr. Buckland afterwards did from the fossil bones of the hyæna.

Animal and Earthy Matter.—From the above experiments bone is found to contain about one-third of animal matter, the rest being earthy salts, i.e. about 33 of animal matter and 67 of earthy salts in a hundred parts. Bones of children are softer, more elastic and less likely to be broken by slight injuries than those of the aged. This is due to the sponginess and great vascularity of children's bones, as well as to the fact that in them the shafts of the bones are united to the epiphyses by a layer of cartilage. Bone when pure, i.e. when entirely divested of fat or marrow and blood-vessels, is probably a definite compound of constantly the same composition, whether it be from a child or from an old person, but it varies in compactness and arrangement, and on these variations the differences in the strength and elasticity of bones depend.¹

The following is a percentage analysis of adult human bone:—²

Animal matter	33·30	
Earthy salts {	Tribasic phosphate of calcium	51·04
	Carbonate of calcium, Ca CO ₃	11·30
	Fluoride of calcium, Ca F ₂	2·00
	Phosphate of magnesium	1·16
	Soda and chloride of sodium	1·20
	100·00	

¹ For this and other references see the end of the book.

Rickety Bones.—In the disease of early life called ‘rickets,’ in which the bones grow bent and distorted, from deficiency of earthy matter, the proportions of animal and earthy matter have been found to be—³

Animal matter	79·75 per cent.
Earthy matter	20·25 „

Of all animals, the bones of birds (especially of the predaceous kind) contain the largest proportion of earthy matter. Hence their great compactness and white colour. The bones of mammalia come next; then those of reptiles; and last of all those of fishes.

As in the birds of prey, so in the carnivora, the bones have a hard and compact structure. The tympanic bone of the whale is extremely hard; but the skeleton most remarkable for hardness and weight is that of the manatee, which may be seen in the Osteological Series of the Royal College of Surgeons of England. When the late articulator to the College was taken to task for having charged the enormous sum of £15 (instead of about £5) for articulating the manatee, he pleaded, in justification, that the bones were so hard that it had taken him unusual labour to put them together, and had spoilt many of his tools. The truth of this assertion is at once clear to any one who takes in his hand the weighty rib of a manatee. (See sections of ribs, No. 2,653).*

Phosphate of Lime: its Importance.—Of the earthy ingredients of bone the phosphate of lime holds by far the first rank; hence it is commonly called ‘bone earth.’ Adult bone contains 51 per cent. of it, and about 11 per cent. of the carbonate of lime. Carbonate of lime is the principal ingredient in the hardening of shells. The phosphate of lime forms a harder compound with animal matter than the carbonate. What can be harder than the enamel of the teeth? And this consists of a very large proportion of phosphate of lime combined with animal matter. There is only 2 per cent. of animal matter in the enamel, and of the remaining 98 parts, 88½ consist of phosphate of lime.

Phosphate of lime enters not only as the principal earthy

* Throughout the work the numbers refer to specimens in the Osteological Series in the Museum of the Royal College of Surgeons of England, unless otherwise stated.

ingredient into the composition of bone, but is contained, more or less, in nearly all the tissues of the body. Of all inorganic materials it appears to be the most essential both for vegetable and animal life. Therefore it is not only a most important article of diet, but a necessary manure. ‘Those parts of plants which experience has taught us to be the most nutritious, contain the largest proportion of the phosphates—such as bread-corn, peas, beans, and lentils.’⁴ It has been ascertained by experiment, that if animals have their entire supply of phosphate of lime cut off, after some weeks of illness, they are attacked with diarrhœa, which soon kills them. Their bones are found to be very soft; and it is not unlikely that the phosphates are absorbed from their bones and supplied to other structures, such as the nerves and muscles.

It is the quantity of phosphate of lime in the bones which makes them so valuable as manure. The bones are boiled to obtain the gelatin or glue; afterwards they are crushed in a mill, and, as ‘bone dust,’ form an extensive article of commerce.

Strength of Bone.—The strength of bone, contrasted with other substances, is remarkable. The following materials stand in point of strength to each other thus:—

Fine freestone, as	1·0
Lead	6·5
Elm and ash	8·5
Box, yew, oak	11·0
Bone	22·0

Hence bone is twice as strong as oak. A cubic inch of bone will support 5,000 lbs. weight.⁵ Besides this, we shall presently see that bone is so constructed that it gives great strength with but little expenditure of materials. The specific gravity of bone is from 1·87 to 1·97.

Elasticity of Bone.—In consequence of the animal matter they contain, bones possess a certain amount of elasticity. If a skull be thrown upon the ground, it will rebound. The degree of elasticity varies in different bones, according to their form and texture. The clavicle, for instance, owing to its curved

form, is remarkably elastic—a property which enables it to break the shock of a fall upon the hand. If one end of a clavicle be placed at a right angle against a hard substance, and the other end struck smartly with a hammer, the bone will rebound to a distance of nearly two feet. The ribs, too, are exceedingly elastic. The Arab children are said to make excellent bows with the ribs of camels. Perhaps the best instance of elasticity in bone is the clavicle (merry-thought) of the bird. It acts as a spring, and restores the base of the wings to their proper position after the action of the muscles of flight. All the long bones are more or less curved, which gives them the benefit of elasticity.

Classification of Bones.—Though the bones present every variety of form and size, yet, for convenience of description, anatomists divide them into three classes:—1. The long and round; 2. The broad and flat; 3. The short and cubical, or irregular. The long and round form the great levers of the limbs, and are moved by muscles. The broad and flat are found chiefly in the skull and pelvis, and protect the viscera. The short and irregular allow more limited motion combined with great strength, as the bones of the spine, the carpal and tarsal bones.

Nomenclature.—In describing the different parts of a bone, we use terms—Latin, Greek, or English—which denote either the form of the part, or its fancied resemblance to some natural object, or the purpose it serves. We soon become familiar with such terms as ‘eminences,’ ‘depressions,’ ‘processes,’ ‘tuberosities,’ ‘spines,’ ‘foramina,’ ‘notches,’ ‘canals,’ ‘sinus,’ ‘fossæ,’ ‘trochanters,’ ‘condyles,’ etc. Again, there are parts of bones named after some celebrated anatomist, who first described them: for instance, the ‘aqueduct of Fallopius,’ ‘the antrum of Highmore,’ ‘the fissure of Glaser,’ the ‘canal of Vidius.’ These memorials of anatomists, though interesting to historians, are rather encumbering to anatomical nomenclature, and are therefore very much to be deprecated.

Structure of Bone: Naked Eye.—Let us examine, first, the structure of bone, as it can be seen with the naked eye; afterwards, its minute structure with the microscope. Lastly, we will study the development and growth of bone.

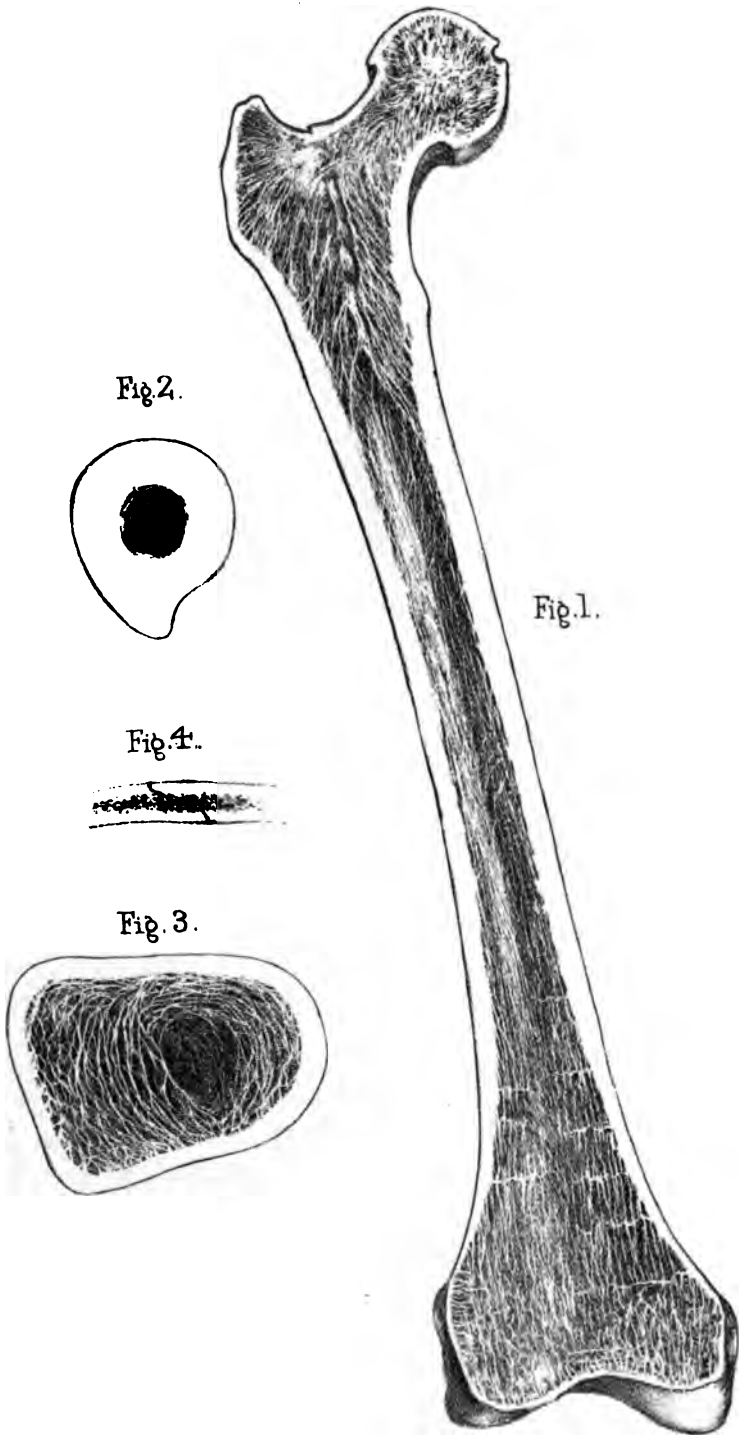


Fig. 2.



Fig. 4.




Fig. 3.

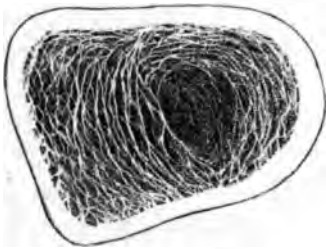

Fig. 1.

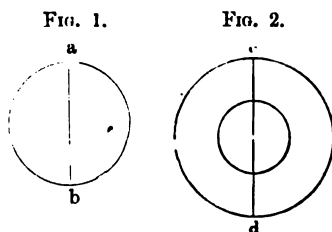


The best way to obtain a rough idea of the structure of bone is to make a vertical section through one of the long bones—say the femur—all the way down (Plate I.). We then see that the outer part, or ‘wall,’ of the bone is compact like ivory; the interior is hollow, forming the ‘medullary canal,’ or cavity containing the marrow. The ends, which expand to form the joints, are composed of a beautiful network of plates and tubes of bone, forming what is called ‘cancellous or spongy tissue,’ which in the recent state is also filled with marrow.

Shaft of Bone hollow.—What are the advantages of bones being hollow? The amount of material being the same, a hollow cylinder is much stronger than a solid one. It is proved that the crushing pressures of two cylinders of equal weight and length, of which one is hollow and the other solid, are, respectively, as the diameters of their transverse sections; provided always that the diameter of the tube be within certain dimensions. Thus, let $a b$, $c d$ (figs. 1 and 2) represent the sections of two cylinders; then the strength of the tube $c d$ is to that of the solid $a b$ as the line $d c$ is to the line $a b$.⁶

In some animals which seldom or never leave the water, the bones have no medullary cavities, but are completely filled by cancellous tissue. This is the case in the penguins (Nos. 1138 to 1140), the whales, and amphibia, whose solid bones appear to act as ballast.

In the early part of the seventeenth century, Galileo observed in nature a variety of instances in which the strength of bodies was made very great consistently with lightness by the arrangement of their structure. This most profound philosopher, when accused of atheistical opinions, and interrogated before the Inquisition as to his belief in a Supreme Being, picked up a straw from the floor of his prison, and replied, ‘If there were nothing else in nature to teach me the existence of a Deity, even this straw would be sufficient.’



Air Cells in Bone.—Strength and lightness are thus combined in the economy of bones. This principle is carried to the extreme in the bones of birds, which are filled with air instead of marrow. There is a communication between the lungs and the cavities in the bones of birds (Nos. 1107-8); and the air which fills the bones being warm, renders them still lighter. The extent to which air is admitted into the bones of birds is generally in proportion to their powers of flight. The ostrich (No. 1114), which never flies, has air only in the bones of his legs. The great beak of the hornbill forms one large air cell (No. 1492); even the thin columns of the cancellous tissue in the interior are hollow and filled with air. In this bird, as well as in the toucan, every bone of the skeleton, down to the little bones of the claws, is filled with air. In the little ‘apteryx’ of New Zealand, which has no available wings, and in the penguin, which rarely leaves the water, no bones of the skeleton except those of the skull receive air. In the bones of the chick there are no medullary cavities; as the bird grows its bones become hollowed out, and filled with marrow, which is subsequently, in the mature bird, removed and replaced by warm air. In mammalia there are no air cells except in the bones of the head. There are large air cells (sinuses) in the frontal, sphenoid, ethmoid, palate, maxillary and mastoid bones in man.

Bone divisible into Layers.—Although the compact tissue of bone seems hard and solid as stone, yet it is made up of layers placed so close together, that there is no apparent interval between

FIG. 3.



them. Towards the articular ends (Plate I. fig. 3), the layers gradually separate to form the cancellous tissue, and the compact tissue becomes thinner in proportion. In bones long weather-beaten in a church-yard, these layers may be peeled off one after another; or if the earthy matter be removed by acid, the animal matter admits of being stripped off like so many leaves. It is essential to bear in mind this lamellar structure of bone, because it explains what is observed in cases of inflammation of bone—namely, that the enlargement of the blood-vessels together with the in-

flammatory deposit separates the layers from each other, and thus causes the bone to expand and be perceptibly increased in diameter, as seen in the adjoining wood-cut (fig. 3), taken from a preparation in the museum of St. Bartholomew's Hospital.

Cancellous Tissue: Arrangement.—The cancellous tissue occupies the interior of bones, and chiefly the articular ends. It is formed by the separation of the component layers of the bone, and these are connected by cross plates and fine tubes, which form a kind of lattice-work with a most delicate and elegant arrangement. The cancellous architecture of bones is arranged upon this principle:—its columns always run along the lines of greatest pressure, thus combining the greatest strength and elasticity with lightness. A beautiful example of this is seen in the section of the cancellous tissue of the thigh-bone (Plate I.). At the lower part, towards the knee, the layers run vertically—that is, in the direction of the axis of the shaft, this being the line of pressure when the body is erect. But in the neck of the thigh-bone the layers are arranged in decussating curves like Gothic arches, one within the other, and sustain with the greatest mechanical advantage the weight transmitted on to the heads of the thigh-bones. (Norm. Hum. Ost., Nos. 211 to 222.)

Cancellous Tissue: Properties.—Though so light and spongy, the cancellous tissue is able to support a great weight without giving way. We may form some idea of its strength from the following experiment:⁷—A cubic inch of cancellous texture was taken from the lower end of the femur, and placed with its principal layers upright. Four cwt. was then placed upon it, but it did not give way in the least. Six cwt. made it sink half an inch. Yet the cubic inch of bone itself did not weigh more than 54 grains. Not only is cancellous tissue strong as well as light, but it possesses another advantage—that of diminishing shocks. When a ball of ivory strikes another, as in the game of billiards, the whole force of the shock is transmitted from one to the other; but let a ball made of the cancellous tissue be interposed, and then see how the shock will be broken. This property of diminishing shocks is of course greater when the bone is in its natural state and filled with marrow.

The spaces formed by the cancellous tissue vary in size and shape, but freely communicate with each other, and with the holes on the surface of the bones. This is easily proved by boring a hole at one end of a bone, and pouring mercury into it:—we shall find that the mercury will run out freely through the natural holes at the other end.

Marrow, Yellow.—The interior of the shaft of a long bone is filled with yellow marrow; a substance composed almost entirely of fat (96 per cent.); that is, in bones that are healthy. Like all other fat, it is removed in cases of great emaciation—in general dropsy, for instance; and its place is supplied by an albuminous fluid. Hence the bones of a dropsical subject are always the least greasy, and the best adapted for skeletons.

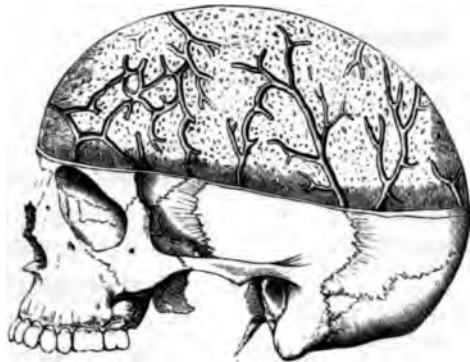Marrow, Red.—The cancellous tissue of the articular ends of long bones, and of the bodies of the vertebræ, the sternum, the ribs, and the bones of the cranium, contain another kind of marrow of a red colour. This red marrow differs from the yellow, in that it contains little or no fat—not more than 1 per cent. It consists of 75 per cent. of water and 25 per cent. of solid matters, chiefly albumen. It is this kind of marrow which is found in all the bones of the fœtus, and in infants. Hence it is sometimes called foetal marrow. Examined with a high magnifying power, it is found to contain a number of oval, many-nucleated cells (Plate IV. fig. 9). Cells of this form are found in most rapidly growing tumours and are called ‘myeloid’ cells. They form the greater part of the so-called myeloid tumours.⁹

Blood supply of Bones.—At the articular ends of any long bone, or on the body of a vertebra, we observe a number of holes. Near the lower end of the thigh-bone we might soon count as many as 200 or more. What are these holes? The smaller transmit the articular arteries which nourish the vascular cancellous tissue. The larger contain veins which run by themselves. These veins of the cancellous tissue are large and numerous. They traverse and ramify through this tissue in various directions in special canals with thin walls of bone. They are well seen in a section through the body of a vertebra (Plate XXV. fig. 7), also in the cancellous tissue (termed ‘diploe’) of the cranial bones. From

a surgical point of view these 'diploic' veins are interesting, on account of their liability to inflame after severe injuries of the head: such inflammation may lead to suppuration in the diploe, which is often fatal. The adjoining figure (4) shows the large venous canals in the 'diploe' of the skull-cap.

Again, on the outside of the shaft of a long bone there are a number of minute grooves, which run for the most part parallel to the shaft, and lodge blood-vessels. At the bottom of these grooves lie a multitude of still more minute holes, barely visible to the naked eye, but easily seen through a small pocket - lens. These holes transmit the blood-vessels from the 'periosteum,' or membrane covering the bone, to the compact tissue.

FIG. 4.



VEINS IN THE DIPLOR OF THE SKULL.


Artery of the Marrow.—The marrow in the interior of the bone is supplied with blood by the 'medullary artery.' This artery reaches the marrow through a very distinct canal (canal for the nutrient artery of the medulla), which runs obliquely through the shaft, near its middle. In a long bone like the femur there are generally two of these, situated at the back part. As soon as the artery reaches the medullary cavity, it divides into two branches, an ascending and a descending, which ramify in and supply the marrow, and finally communicate with the 'articular' arteries already described.

Thus the several parts of a long bone are supplied with blood as follows:—The compact wall of the shaft by blood-vessels from the periosteum; the marrow in the interior by a special medullary artery; and the cancellous tissue of the ends by the articular arteries. The blood-vessels of these several parts are not exclusive, but communicate more or less with each other when the parts of

the bone have united with the shaft. Hence they readily reciprocate their morbid actions, and inflammation arising in the one part may spread to the other. Now, although these three orders of blood-vessels do communicate in the bone, yet we cannot be surprised to find that when a bone is broken below the canal for the nutrient artery of the marrow, the lower fragment, being deprived of part of its supply of blood, in some cases becomes atrophied and thinner.⁹

Periosteum : its use.—A fibrous membrane, termed the periosteum, invests the bones everywhere except at the insertion of strong tendons, and where covered with cartilage. This periosteum consists of two layers, an external one, tough and fibrous, and an internal one (osteogenetic), soft and cellular, in

FIG. 5.



BLOOD-VESSELS OF PERIOSTEUM.

which the blood-vessels break up into minute branches before penetrating the pores on the surface of the bones. The adjoining figure shows the arrangement of the blood-vessels of the periosteum. The periosteum likewise provides each of the vessels entering the bone with a fibrous covering. It assists in the formation of bone, and afterwards in its nutrition. If, therefore, the periosteum be torn from the surface of a bone, there is

a risk that a layer of the subjacent bone will lose its vitality and be cast off.

Medullary Membrane.—The medullary canal and the cells (marrow spaces) of the cancellous tissue are lined by an extremely delicate membrane, termed the ‘endosteum.’ It is much more delicate than the periosteum; nevertheless, it supports the marrow, and provides a stratum for the subdivisions of the medullary artery, before they penetrate the contiguous bone.

Nerves in Bone.—Periosteum and bone unquestionably possess nerves. This is proved by absolute demonstration, and by disease. Nerves may be traced into some of the minute foramina on the shaft of a long bone, and into the articular ends.

A nerve also enters the medullary canal with the nutrient artery of the medulla, and divides like the artery into an ascending and a descending branch. Of all the bones, the tibia presents the largest canal for the nutrient artery of the marrow; in this bone also it is easy to trace the entrance of the nerve with the artery. Though bone in health has but little feeling, when diseased it becomes highly sensitive. There is such a thing as 'neuralgia' of bone. Every surgeon must have witnessed how sensitive are granulations from bone. Indeed, it is probable that the severe pain attendant on the ulceration of articular cartilage is occasioned by the pressure of the cartilage on the bone granulations beneath it.

Lymphatics of Bone.—The lymphatics of bone have been actually demonstrated by injecting the lymphatics of the body of a vertebra.¹⁰ It has been recently proved by injections that the blood-vessels of Haversian canals are surrounded by perivascular lymphatic vessels.¹¹ This accounts for the fact that ivory pegs introduced into bones, for the purpose of consolidating ununited fractures, are in some instances absorbed.

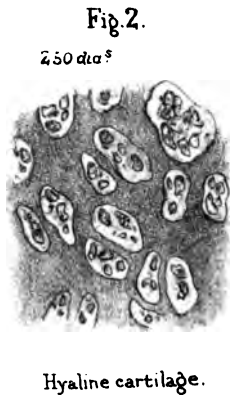
MICROSCOPIC STRUCTURE OF BONE.

This is a most interesting and instructive study. It reveals to us that bones are as minutely provided with blood-vessels and nerves as the softer parts of the body. Being as fully organised as other parts, we cannot wonder that they are subject to like diseases. We have to investigate how the bones are formed in early life, how they grow to maturity, how their health is maintained, how their injuries are repaired. Would anyone, looking at a solid bone, expect to find that even its hardest parts are tunnelled out by a network of minute canals containing blood-vessels; and that from these canals other tubes, infinitely more minute, and connected with a series of reservoirs, radiate in all directions and convey nutritious fluids?


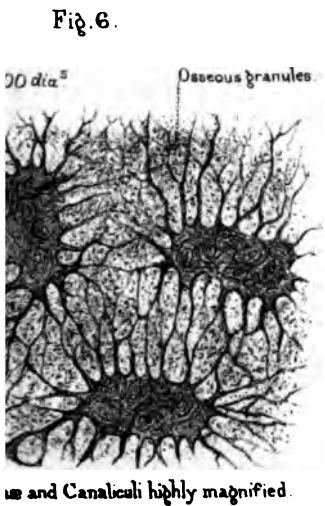
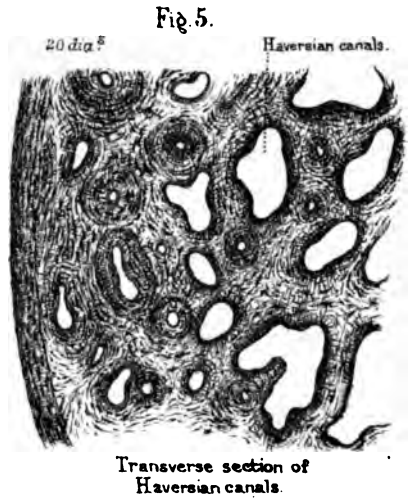

General Idea: Haversian Canals.—Let us first get a general idea of the microscopic structure of bone, and go into details afterwards. If a transverse section from the shaft of a long bone be ground extremely thin, and examined with a power of about 20 diameters (Plate II. fig. 5), we see a number of

holes, with dark spots grouped around them, in a series of tolerably concentric circles. These holes are sections of the canals (termed 'Haversian')¹² which transmit blood-vessels into the substance of the bone. The dark spots are minute reservoirs, called 'lacunæ.' They look like solid bodies, but they are cavities and are occupied during life by soft 'bone corpuscles,' concerning which more will be said hereafter. Different parts of the section show that the Haversian canals vary considerably in size and shape. They are generally round or oval. Those nearest to the circumference of the bone are very small; but towards the medullary cavity they are seen to be larger, and at last open out into the cells of the cancellous texture.

Haversian Lamellæ.—The same section examined with a higher power (Plate II. fig. 7) shows that the Haversian canals are surrounded by a series of concentric lines, resembling the transverse section of the branch of a tree. These lines are termed the 'lamellæ.' They are so many layers or rings of bone that have been developed within the Haversian canal. Even the smallest Haversian canal was, when originally formed, a much wider space, and circumscribed by only a single layer of bone; but in process of growth the canal becomes gradually contracted by the deposit of successive layers of bone. The dark spots, before alluded to as the 'lacunæ,' are situated between the lamellæ; under a higher magnifying power (Plate II. fig. 6), they look like insects. The central part or the lacuna, representing the body of the insect, is hollow, and the dark filaments which run out from it, representing the legs, are minute tubes termed 'canaliculi.' These are exceedingly numerous, and radiate from all parts of the 'lacuna,' through the lamellæ. Now, since the canaliculi of one circle of lacunæ communicate most freely with those of the next circle, and the canaliculi nearest to the Haversian canal open directly into it, it follows that by means of this system of radiating tubes a complete communication is established between the Haversian canal in the centre, and the successive circles of bone which surround it. The nutrient material of the bone proceeds from the perivascular lymphatics in the central canal, and is transmitted through the canaliculi from one lacuna to another.



BONE.



Drawn on stone by H. Gruber.
Printed by West, Newman & Co.

Haversian System.—Every Haversian canal taken in conjunction with its concentric layers of bone, lacunæ, and canaliculi, is termed an ‘Haversian system.’ (Plate II. fig. 7.)

Almost all the compact substance of bone is made up of a multitude of these ‘Haversian systems.’ Each system is, to a certain extent, independent of its neighbour, since the lacunæ of one system communicate very sparingly with those of another. In consequence of this isolation, we sometimes find, in favourable sections, that each system is more or less circumscribed by a tolerably distinct white line, which is transparent bone with but few canaliculi.

Haversian Interspaces.—As the Haversian systems are for the most part circular, and arranged like sticks in a faggot, it is clear they cannot touch each other in all parts of their circumference; so that here and there triangular portions of bone fill up the gaps between them. Such portions are termed ‘Haversian interspaces.’ (Plate II. fig. 7.) These ‘outlying’ portions of bone are also provided with lacunæ and canaliculi, and they derive their nourishment from the surrounding Haversian systems, of which they are dependencies.

The section we have hitherto been examining was a transverse one. We must now make an equally thin section in the longitudinal direction of the shaft, and we then have quite a different appearance. (Plate II. fig. 4.) We cut in the course of the Haversian canals, not across them; and we find that, as a general rule, they run parallel to the surface of the bone (no matter whether long or flat), and that they communicate very frequently by transverse or more or less oblique canals. If the section be large enough to include the Haversian canals near the circumference, we find that many open on the outer surface and admit blood-vessels from the periosteum; others, again, open into the medullary canal, and admit blood-vessels from the interior. In this way the Haversian canals permeate the compact substance of the bone, and establish a free communication between the blood-vessels of the periosteum and those of the medulla. These canals may, in fact, be regarded as so many multiplications of surface for the ramifications of blood-vessels, whereby every part of the bone substance is brought within the range of nutrition.

In this longitudinal section, the lamellæ, instead of being arranged concentrically, are seen running in lines parallel with the Haversian canals to which they belong.

Bone Tissue.—At this stage of the investigation, a question naturally arises—Where is the earthy material, the phosphate and carbonate of lime? To see this, the transverse section must be magnified about 1,200 diameters. (Plate II. fig. 6.) We then discover that the earthy ingredient consists of an infinite multitude of minute osseous granules, which are deposited in a ‘matrix’ or bed of animal matter. This mixture of earthy granules and animal matter is called ‘bone tissue.’ It occupies all the space between the lacunæ and their canaliculi. If the specimen were steeped for a time in dilute hydrochloric acid, the osseous granules would be dissolved out of it, and the little pits in the matrix in which the granules were imbedded would become apparent.

So far we have acquired a general notion of the minute structure of bone; that is to say, of the ‘Haversian canals,’ the ‘lacunæ’ and their ‘canaliculi,’ the ‘lamellæ,’ and the ‘osseous granules.’ We must now speak of these several parts a little more in detail; and first, of the Haversian canals.

Haversian Canals.—As said before, the Haversian canals are tunnels in the compact substance of the bone, which contain the blood-vessels. Observe, they form no part of the *essential* structure of bone. Wherever bone is so thin as to be able to derive its nutrition from the vascular membrane covering its surface, we do not find Haversian canals in it, nor does it require any. For instance, the delicate plates of bone composing cancellous tissue, the paper-like bones in the interior of the nose, have no Haversian canals in them; but they have plenty of lacunæ, which send out their canaliculi to open on the surface and imbibe the requisite nutrition. Bone so thin as to need no Haversian canals is called ‘non-vascular’ bone. Such bone lives upon the blood which flows through the minute vessels of its periosteum. Bone has, therefore, like all other living structures, a *self-formative* power, and draws from the blood the materials for its own nutrition.

The Haversian canals vary in diameter from $\frac{1}{1000}$ to $\frac{1}{200}$ of an inch, the average being about $\frac{1}{800}$. The smallest are found near the outer surface, where the bone is the most compact; but they gradually become larger towards the interior, where they open out into the cancellous tissue, or into the medullary cavity. All, whatever their direction may be, are surrounded by concentric lamellæ of bone; but the number of the lamellæ varies around different canals from 5 to 15 or more; a smaller number in young bone, and a larger in old. All are lined by a very delicate membrane, continuous with the periosteum. The smallest canals contain only a single capillary blood-vessel; the larger contain a network of vessels, while the largest, which gradually merge into the cancellous tissue, contain marrow as well as blood-vessels.

Here it may be as well to mention a fact concerning the minute structure of bone, which should never be lost sight of. It is this:—that everywhere underneath the membrane in contact with the surface of bone, whether it be the periosteum covering the exterior, the prolongation of it lining the Haversian canals, or the medullary membrane (endosteum) lining the cancelli, there is a delicate layer of soft connective tissue, with a multitude of small corpuscles in it, termed ‘osteoblasts.’ Now, it has been ascertained that these osteoblasts, and the soft tissue in which they are imbedded, are mainly concerned in the formation and the growth of the bone; and that by the successive ossification of these tissues, the concentric layers of bone are produced within the Haversian canals.

Haversian Canals dilated by Inflammation.—The knowledge of the free circulation of blood through the substance of bone gives us the key to some of the effects produced by inflammation in it. For example, as inflammation in soft parts is attended by dilatation of the blood-vessels, so is it in the case of bone. When bone is actually inflamed, the blood-vessels in the Haversian canals become greatly enlarged, and cause the canals themselves to become larger by absorption of the bone

FIG. 6.

SEPARATION OF LAYERS
BY INFLAMMATION.

tissue—so much so as to give the bone, sometimes, a reddish colour. In operations where the surgeon has to cut through inflamed bone, one may see the blood flowing from the cut surface of the bone, as it would from the soft parts. More than this, the distended blood-vessels may occasion not only a gradual enlargement of the Haversian canals, but their inflammatory deposit may cause even a general swelling of the compact substance of the bone and a natural separation of its component layers, so that it becomes light and spongy, as seen in the adjoining figure.¹³

Haversian Canals obliterated by Inflammation.—On the other hand, in some cases, *e.g.* in chronic inflammation, we sometimes find that bones become harder and thicker than natural. They may become as hard as ivory, and can take a polish. Here the Haversian canals are nearly filled up by successive layers of bone. Indurated bone is therefore less vascular than healthy bone. A good example of ‘eburnation’ of bone is occasionally seen as the result of chronic osteo-arthritis, where the articular ends of bone lose their cartilage and become hard and polished like ivory, owing to the blocking up of the Haversian canals by osseous tissue.

Lacunæ and their Contents.—The ‘lacunæ’ are the insect-like cavities which we find between the lamellæ, arranged in concentric circles around the Haversian canals. They are characteristic of true bone, and distinguish it from ‘calcifications,’ sometimes met with as products of disease. Formerly the lacunæ and canaliculi, in consequence of their dark colour, were considered to be solid; but later observations have proved them to be hollow spaces. Each lacuna in the living bone contains a soft nucleated substance termed a bone corpuscle, which sends its soft processes or ‘outrunners’ along the canaliculi. The bodies in the lacunæ and canaliculi circulate nutritious matter through the bone. The lacunæ and canaliculi can be filled with Canada balsam. It is curious that in the bones of Egyptian mummies these minute cavities are filled with the bituminous material. Such a bone corpuscle, with its processes highly magnified, is shown in Plate III. fig. 5.

As a rule, the lacunæ are oval and flattened, so that one of

their broad sides is turned towards the Haversian canal. The first ring of lacunæ sends some of its canaliculi directly into the Haversian canal, while others communicate with the canaliculi of the second ring, and so on throughout the whole system. The nutrient fluid in the perivascular lymphatics in the Haversian canal enters the nearest canaliculi, and then the inhabitants of the nearest row of lacunæ, and is gradually passed on to all the others in the Haversian system. One may say, then, that the inhabitants of the lacunæ are parts of the machinery of the circulation and nutrition in the bone.

Size and Shape.—In man, the lacunæ measure about $\frac{1}{2000}$ of an inch in their long diameter, and about $\frac{1}{3000}$ in their short. It has been shown that they vary in size and shape in the four great classes of animals, so that by means of this test it can be ascertained with certainty whether a given fragment of bone be part of a mammal, a bird, a reptile, or a fish. As this test is equally applicable in the case of fossil bones, it has an important bearing upon the study of geology. Another interesting fact is, that the size of the lacunæ bears very little relation to the size of the animals to which they belong. They are nearly as large in the bones of the little lizard as they are in those of the enormous extinct lizard, the *Iguanodon*. But their size *does* bear an exact proportion to that of the blood corpuscles in the several classes of animals. Therefore, as amphibia have the largest blood corpuscles, so have they the largest lacunæ.¹⁴

Canaliculi: Size and Office.—Respecting the ‘canaliculi’ (Plate II. fig. 7), observe how exceedingly minute they are; that they run off from all parts of the circumference of the lacunæ and communicate most freely with the canaliculi of the adjoining lacunæ. Their diameters range from $\frac{1}{14000}$ of an inch to $\frac{1}{20000}$ of an inch; but there are some even smaller. Soft nucleated corpuscles, ‘bone corpuscles,’ lie in the lacunæ, and have many delicate branching processes, by means of which they intercommunicate and pass lymph from one to another. These branching processes lie in the canaliculi.

Lamellæ.—The ‘circumferential’ lamellæ encircle the shaft of the bone (Plate II. fig. 5), and result from the bone growing

jected, may then be seen shooting up through the heretofore non-vascular layer of bone, into the cartilage on its surface.

STRUCTURE AND VARIETIES OF CARTILAGE.

Varieties of Cartilage.—Cartilage, commonly called ‘gristle,’ is tough, flexible, and more or less elastic. There are several kinds of it, which have functions varying with their position and structure. It consists of nucleated cells embedded in a matrix or intercellular substance.

Hyaline Cartilage.—Where the matrix is translucent and structureless it is called hyaline cartilage. Nearly the entire skeleton of the foetus has this structure at some time or another as well as the white cartilage covering the articular ends of bones.

White Fibro-Cartilage.—The intercellular substance may be white and fibrous, then it is called ‘white fibro-cartilage.’ This variety is but slightly elastic, and the cells are small and scattered (Plate II. fig. 1). The intervertebral substance consists mainly of this variety as well as the interarticular fibro-cartilages.

Yellow Fibro-Cartilage.—The gristle of the ear, epiglottis, and the Eustachian tube is of a yellow colour, is very elastic, and its intercellular substance consists of long interlacing wavy fibres. It is therefore named ‘yellow fibro-cartilage.’ The cells in this variety are large and arranged in fusiform rows, each row containing from 4 to 6 cells.

Cellular Cartilage.—As early as the fourth week of foetal life, when the embryo is but $\frac{1}{4}$ of an inch long, the principal part of the skeleton is mapped out by the formation of firm masses of cells called ‘cellular’ cartilage. (Plate II. fig. 3.)

Cartilaginous Skeleton.—A week later an intercellular substance has developed in this cellular cartilage, converting it into ‘hyaline’ cartilage, and giving it greater solidity. Thus, the whole foetal skeleton, with the exception of the skull-cap and the bones of the face, consists at one time of hyaline cartilage.

At the fifth week bony substance begins to be deposited in the middle of the clavicle; at the sixth week in the lower jaw;

and by the seventh week, when the fœtus is about an inch long (Norm. Hum. Ost., No. 1), a small deposit of bone has made its appearance in the middle of nearly every bone in the body. The points at which the bony deposit commences in a bone are called its 'centres of ossification.' It will therefore be understood that the deposition of bone does not take place at the same time in all parts of the cartilage, but only about these 'centres of ossification.'

Meaning of Centres of Ossification.—Every bone has a definite number of these centres, which always appear in the same place; and from these centres the ossification extends according to a regular plan. The number of centres varies in different bones. Some bones have only a single centre; others two, three, five, seven, etc.; and the bone called the 'sacrum' has as many as thirty-three centres from which its ossification is completed.

Observe, the centres of any given bone do not all appear at once; some appear before birth, others after it, but all in regular succession, and at stated periods, according to the degree of importance of the bone, and the function which it has to perform; *e.g.* the lower jaw and the ribs ossify early, because suction and respiration are brought into play at birth. As a general rule, each centre appears first in the middle of the cartilage; and thence the ossification extends towards the circumference in the flat bones, and towards the extremities in the long bones. Almost all the bones, then, in infancy and childhood are made up of so many distinct bony pieces united together by cartilage; and these several pieces remain distinct until the stature of the individual is complete, after which they are all consolidated.

Perichondrium.—All kinds of cartilage, with the exception of that which covers the ends of the bone (articular cartilage), are invested with a white fibrous membrane, termed 'perichondrium.' This, like the periosteum of the bones, contains plexuses of blood-vessels ramifying all over the cartilage.

Cartilage contains no blood-vessels. But when diseased, it has been proved by injection that blood-vessels do shoot into the cartilage through the layer of articular bone beneath it.¹⁹

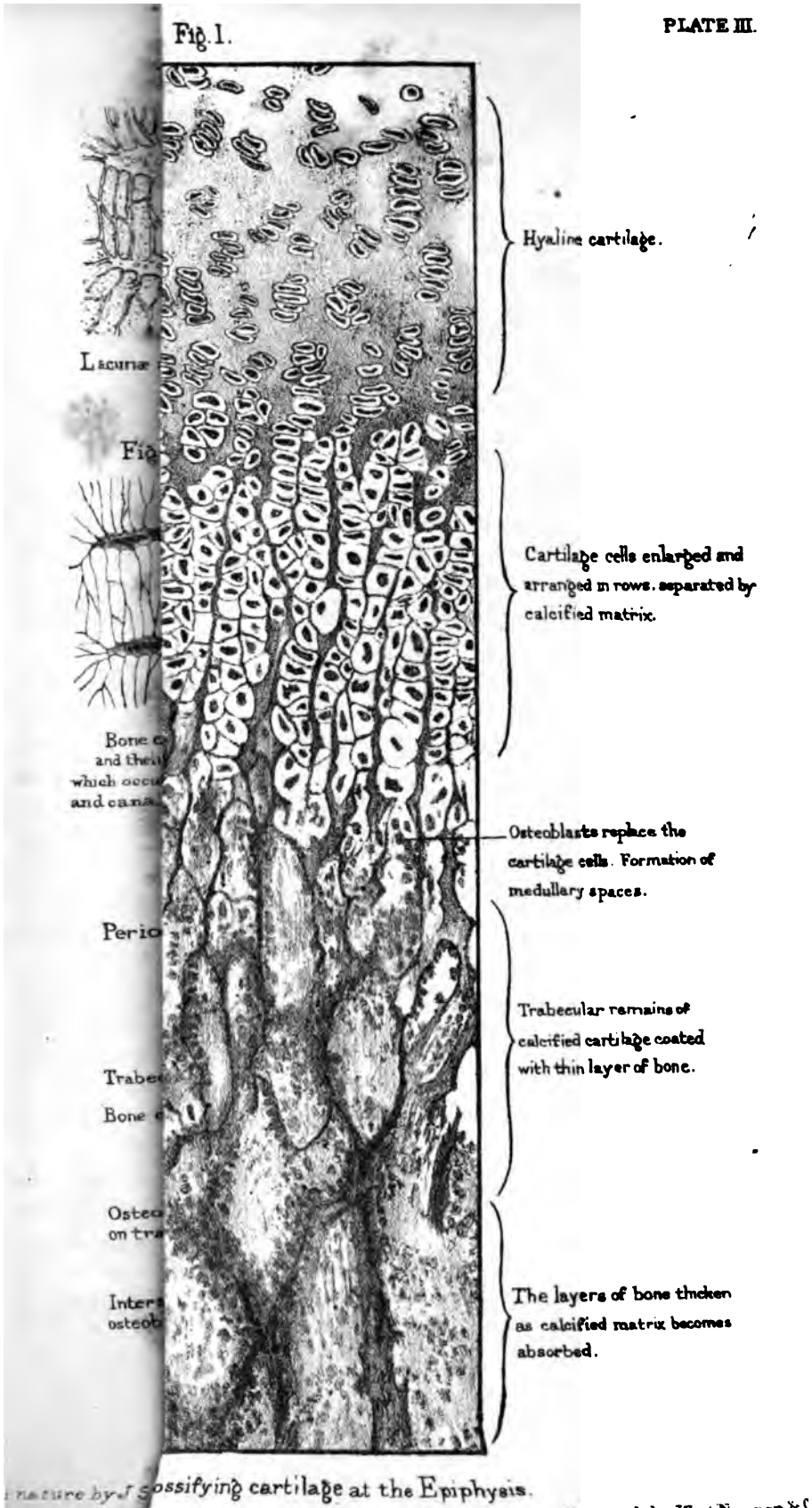
Ossification of Femur.—As an example of what can be seen of the process of ossification with the naked eye, let us follow out that of the thigh-bone (Plate IV. figs. 1 to 6). The future bone is at first sketched out in hyaline cartilage. About the seventh week after conception, the first centre of ossification appears in the middle of the shaft—as is the case in all the long bones (fig. 1). From this point ossification gradually extends up and down the shaft, which is all ossified before the other centres appear. About the last month of foetal life, a second centre appears in the lower end, which forms the knee (fig. 3). About the end of the first year after birth, a third centre appears at the upper end or head of the bone (fig. 4). In the course of the fourth year, a fourth centre appears in the projection termed the ‘trochanter major’ (fig. 5). In the course of the fourteenth or fifteenth year a fifth and last centre appears in the ‘trochanter minor’ (fig. 6).

‘Diaphysis’ and ‘Epiphysis.’—Thus, then, the thigh-bone has five centres of ossification. The shaft or body of the bone, which ossifies first, is called the ‘diaphysis;’ the other parts are termed ‘epiphyses.’ As these epiphyses, during the period of growth, are only united to the shaft by a layer of cartilage, the separation of an epiphysis by violence is not an unfrequent accident in childhood. When growth is complete, all the epiphyses are consolidated with the rest of the bone, and no cartilage remains except at the articular surfaces, where there is a thin layer of it which breaks the shocks at the joints. An ‘epiphysis,’ therefore, is a portion of bone growing *upon* another, but separated from it by cartilage.

Order of Union of Epiphyses to Shaft.—It is worth observing, in the long bones, that the epiphyses of that end towards which the canal for the medullary artery runs, are the last to commence to ossify.

It is a curious fact, also, that the order in which the epiphyses unite to the shaft of a bone is just the reverse of that in which they begin to ossify. Thus, the epiphysis of the trochanter minor, though ossifying last, unites first. The same may be said of the trochanter major, of the head of the femur, and, lastly, of

Fig. 1.



Hyaline cartilage.


Cartilage cells enlarged and arranged in rows, separated by calcified matrix.

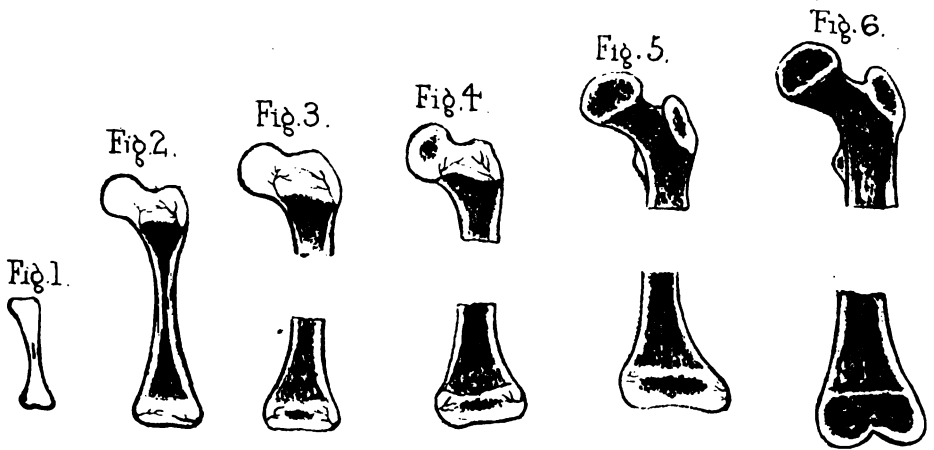
Osteoblasts replace the cartilage cells. Formation of medullary spaces.

Trabecular remains of calcified cartilage coated with thin layer of bone.

The layers of bone thicken as calcified matrix becomes absorbed.

...nature by ossifying cartilage at the Epiphysis.





Diagrams showing the formation of the Thigh bone




Fig. 7.

Parietal bone of a Foetus.




Fig. 9.

Cells from Foetal marrow.

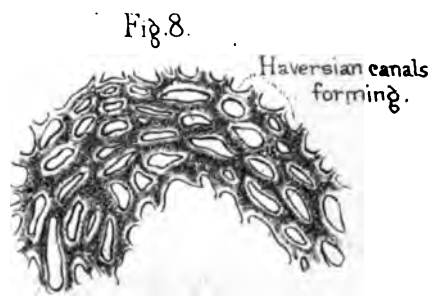


Fig. 8.

Section of Foetal bone.

the lower end. At the age of twenty-one, or near it, they have all united to form a single bone. The fibula is the only exception to the above rules, its lower epiphysis ossifying first and uniting first to the shaft.

In Sauropsida, the place of the epiphyses is taken by thick pads of cartilage, which gradually ossify from the shafts. These are, therefore, not true epiphyses. Birds, however, have a centre of ossification which appears in the upper projection of cartilage on the tibia. This may be seen in the leg of a common fowl.

Advantages of several Centres.—The fact that bones are developed from several ossific centres, separated by layers of cartilage, is advantageous to the growing animal. For example, it is necessary to have the shaft of a bone ossified to support weight, while other parts remain cartilage and diminish concussion, thus acting as buffers. ‘The young lamb or foal,’ to use the words of Professor Owen, ‘can stand on its four legs as soon as it is born; it lifts its body well above the ground, and quickly begins to run and bound. The shock to the limbs themselves is broken and diminished at this tender age by the division of the supporting long bones—by the interposition of the cushions of cartilage between the diaphyses and the epiphyses.’

We see, moreover, a definite use in separate centres of ossification for the bones of the head, not only as facilitating growth, but also the process of birth. The bones of the skull-cap, being connected only by membrane, overlap each other a little during parturition, and thus a large head is admitted through a comparatively small pelvis.

Bones developed in Membrane.—Most of the bones in the human body pre-exist in the shape of cartilage, and form what is called the ‘cartilaginous skeleton,’ which supports the embryo. But there are some bones which do not pre-exist as cartilage, and are formed directly in membrane, namely, the bones of the skull-cap (the frontal bone, the parietal, the upper half of the occipital, the squamous and tympanic parts of the temporal); also, the bones of the face; and lastly, the inner plate of the pterygoid process of the sphenoid. In short, none of the bones of the skull pre-exist as cartilage, except those which form the base

of the skull. The base is sketched out in cartilage at a very early period of foetal life, and forms a support to the young brain. The cap of the skull, at the time we are speaking of, is simply membranous.

Ossification in Membrane.—We will examine first what can be seen of the formation of bone in membrane with the naked eye, taking the parietal bone as an example. In the early embryo (Norm. Hum. Ost., Nos. 1 to 43) the covering of the brain is composed of two closely united membranes—an outer, termed the ‘pericranium’; and an inner, termed the ‘dura mater’: between these the bone is laid down. About the end of the second month after conception, a centre of ossification appears in the middle of the space which is to be occupied by the parietal bone. From this point the deposition of bone spreads in radiating fibres (Plate IV. fig. 7). Similar centres of ossification appear simultaneously in other parts of the soft covering of the brain, and, radiating in the same manner, sketch out the rudiments of the several bones of the skull-cap. For some time the individual bones are connected simply by membrane; and even at birth they can overlap each other a little, and so facilitate parturition. Long after birth, indeed, there are parts of the skull-cap closed in by membrane only, as everyone knows who has felt the head of an infant (Plate XVIII. fig. 4). These unossified parts are called the ‘fontanelles,’ from the visible pulsations of the brain beneath them, like the welling up of a spring. As the child grows, the rays from the edges of the bones meet and dovetail so as to form what are called the ‘sutures’ (Plate XVIII. fig. 2). For a long period of life the sutures may be separated; indeed, a thin film of animal matter is left unossified between the interlocking teeth of the bone, which considerably diminishes the shock to the brain from a blow on the cranium. As old age creeps on, even this film of animal matter ossifies, and the cap of the skull becomes a solid dome of bone, with all trace of the sutures lost.

Microscopic Examination.—Let us now study what can be learned with the microscope of the process of ossification in membrane, taking that of the parietal bone as an example.

The membrane or animal basis to be ossified is composed of


fibres like those of common connective tissue. The fibres interlace freely and the meshes between them are filled with blood-vessels and closely packed granular corpuscles termed 'osteoblasts.' These are all the materials required for bone building.

Changes in the Membrane.—The centre of ossification is at the (future) parietal eminence. Just before the appearance of the bone salts, the membrane becomes thicker and more vascular. Its component fibres radiate in thicker bundles from the centre towards the circumference, sketching in advance the lines in which the bone is to be laid. Meantime the 'osteoblasts' have enormously multiplied.

Osteoblasts: their Function.—The 'osteoblasts' (bone buds or germs) are granular nucleated corpuscles about the size of the colourless corpuscles of the blood. They are so named because they and their descendants appear to take most important parts in the actual formation of bone. It is probable that they are not all destined to a like future. But one of their chief functions appears to be to abstract from the blood the bone salts, to deposit them in and around the fibres of the membrane, and to become themselves ossified, and buried in the fabric of the bone, as the bricks of a building are in the mortar.

From the centre of ossification the deposit of bone shoots out in needle-like rays (trabeculæ) towards the circumference, as shown in the annexed wood-cut (fig. 8). Under a high power the rays of bone can be seen covered with layers of osteoblasts, which successively ossify, and thus the trabeculæ grow in thickness. The best place to study the process is at the points of the rays where the membrane is more or less transparent. The dark rays may be seen lying amongst the crowd of osteoblasts, and some of the osteo-

FIG. 8.



DIAGRAMMATIC SKETCH OF PART OF AN OSSIFYING PARIETAL BONE OF A FOUR MONTHS' FETUS. (FROM A PREPARATION IN THE MUSEUM OF THE R. C. OF SURGEONS.)

blasts in various stages of ossification upon the rays. We may thus infer how the bone grows in extent.

To see how the bone grows in thickness, a section should be made across the rays where they are a little thicker. Such a section (fig. 9) shows that the rays become connected by cross

FIG. 9.

- A. Periosteum.
- B. Trabeculae of bone.
- C. Osteoblasts with blood-vessels.



VERTICAL SECTION THROUGH AN OSSIFYING PARIETAL BONE.

arches, and thus form channels in which the blood-vessels and bone-building materials lie. These channels are the Haversian canals. Some of them remain as cancellous tissue; others are gradually filled by the ossification of concentric layers of osteoblasts and become Haversian systems. (Plate IV. fig. 8.)

Bone Corpuscles: Origin.—The interesting but difficult question as to the origin of the bone corpuscles and their connecting processes has been for many years under discussion. But the now generally accepted doctrine is, that they are developed from some of the osteoblasts. It has been already observed that the osteoblasts have probably not all the same future. It is the destiny of some to become ossified. It may be the destiny of some to become marrow cells: while others are destined to be developed into bone corpuscles, and perform their allotted functions shut up in their bony crypts (*lacunæ*) and their connecting processes in bony tubes (*canaliculi*). The evidence of this development of osteoblasts into bone corpuscles is derived from the fact that some of them can be seen in the successive stages of their transformation.

Ossification in Cartilage.—We will now endeavour to explain that the process of ossification in cartilage, rightly understood, is essentially like ossification in membrane. In both cases the materials for bone-building are similar, namely, connective tissue, blood-vessels, and the little corpuscles termed ‘osteoblasts.’ The old school used to teach that the cartilage was

directly transformed into bone tissue. But this is not the modern doctrine. The microscope has proved that the cartilage is only a temporary structure, that, having answered a temporary purpose, it is removed, and that true bone tissue, of which the materials are derived from the periosteum, is substituted in its place as a new product.

Previous to its removal the cartilage undergoes remarkable structural changes, which prepare the way and shape the direction in which the bone is afterwards laid down. These preparatory changes are—the enlargement of the cartilage cells, and the calcification of the intervening matrix. If we examine the calcified portion of the epiphysial cartilage we find there that the cells are arranged in rows which are parallel to the axis of the bone. It is this appearance which is familiarly known as ossifying cartilage (fig. 11*b*).

As the term calcification might be taken in a wrong sense, it should be clearly understood that it is not the same thing as ossification. Calcification is the infiltration of an animal tissue with earthy salts, as in the case of shells, or in the cranium of cartilaginous fishes. Ossification means the formation of true bone—a highly organized structure. Calcification, in the process before us, is the forerunner of ossification.

Thus much premised, let us examine the process of ossification as observable in the cartilaginous shaft and at the epiphysial ends of what is to be a long bone.

Calcification of Cartilaginous Matrix.—The process begins by the appearance of an opaque spot in the centre of the miniature shaft. This opacity is occasioned by the enlargement of the cartilage cells, and the calcification of the matrix. These changes spread gradually from the centre up and down the shaft, but stop short of the ends, which are continually growing in advance.

Ingrowths of Periosteum.—At the same time and to the same extent that the preceding changes are taking place in the cartilage, the deep layer of its surrounding perichondrium (future periosteum) sends off vascular shoots (periosteal ingrowths) of connective tissue charged with osteoblasts which penetrate the calci-

fied cartilage and soon make it hollow; the enlarged cartilage cells disappearing one after another, and their places being taken by the 'osteoblastic tissue' from the periosteum (see fig. 10).

FIG. 10.

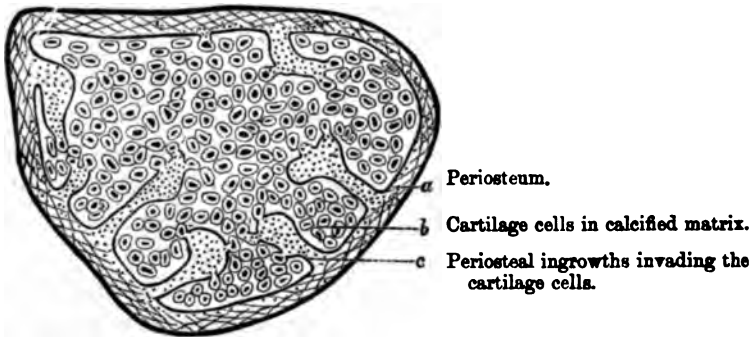


DIAGRAM OF PERIOSTEAL INGROWTHS FROM THE FIRST PHALANX OF GREAT TOE OF A FETUS. (TRANSVERSE SECTION.)

Crust of Bone around Shaft.—*Pari passu* with this tunnelling of calcified cartilage by the ingrowths, the deep layer of the periosteum is at work laying down a gradually thickening crust of true bone around the shaft (fig. 11, *d*). This process is not preceded by cartilage, but is direct membranous ossification, as in the tabular bones of the skull.

Summing-up.—To form a correct idea of these separate processes, the mind must grasp them as going on all together, not one after the other. Their general results may be summed up as follows (fig. 11):—1. The cartilage at the middle is hollowed into a cavity (general medullary) and filled by osteoblastic or bone-building tissue and blood-vessels (*e*). 2. The shaft is surrounded by a circumferential crust of porous bone; the first rudiment of the true wall (*d*). 3. The cartilage towards the ends is tunnelled (by periosteal ingrowths) into irregular tubular (medullary) spaces, also filled with osteoblastic tissue (*c*). These spaces freely communicate with the general medullary cavity, but are blocked towards the growing ends by a boundary line of cartilage (*b*). It is in these spaces that blood-vessels in injected preparations can be seen running up to the cartilage cells.

4. The walls of these tubular spaces are formed by the slender remains (trabeculæ) of the calcified matrix. These slender remains serve as the foundation upon which the true bone is laid and by which its cancellous architecture is directed.

For the more minute observation of the process of ossification in cartilage, it is best to take the 'line of ossification' at the epiphysis of a long bone. The enlarged diagram (fig. 12) is intended to illustrate it.

FIG. 11.

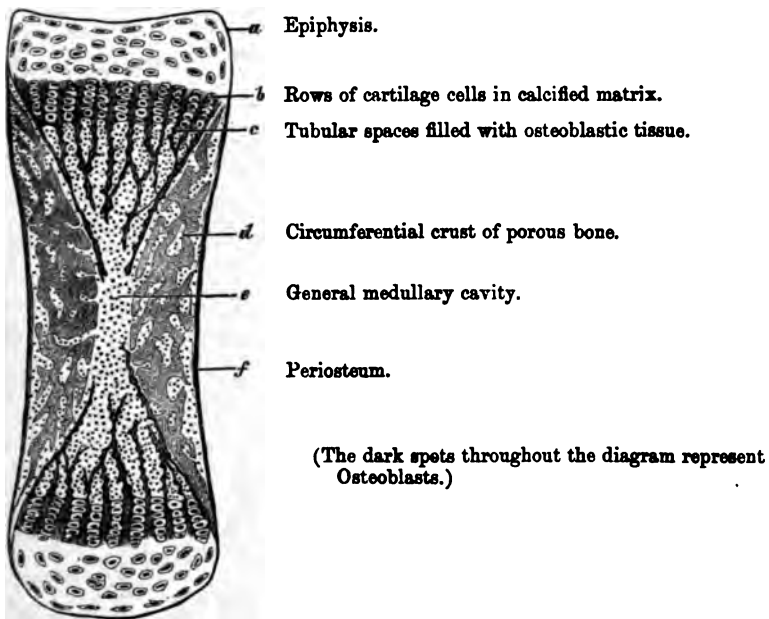
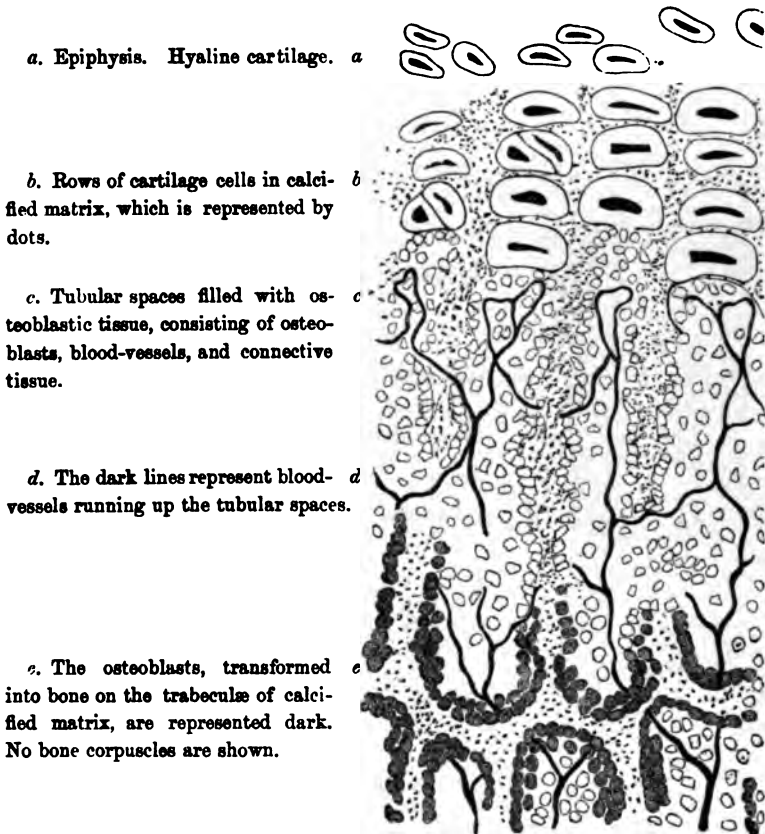


DIAGRAM OF A LONGITUDINAL SECTION OF FETAL LONG BONE.

Near the top of the diagram the cartilage cells are seen enlarged and arranged in rows (*b*). The calcified matrix, represented by dots, lies not only between the rows, but between the cells, so that it makes transverse as well as vertical septa between them. A little lower, we see the tubular spaces, filled with the bone-building materials, namely, osteoblastic tissue and blood-vessels (*c* and *d*). The blood-vessels form loops along the line of ossification, where the osteoblasts, having absorbed the transverse septa of

calcified matrix, are invading the cartilage cells which disappear. We see how the tubular spaces are formed by the vertical remains (trabeculæ) of the calcified matrix; how these spaces communicate here and there with each other where osteoblasts

FIG. 12.



a. Epiphysis. Hyaline cartilage. *a*

b. Rows of cartilage cells in calcified matrix, which is represented by dots. *b*

c. Tubular spaces filled with osteoblastic tissue, consisting of osteoblasts, blood-vessels, and connective tissue. *c*

d. The dark lines represent blood-vessels running up the tubular spaces. *d*

e. The osteoblasts, transformed into bone on the trabeculæ of calcified matrix, are represented dark. No bone corpuscles are shown. *e*

EPIPHYSIAL END OF THE SHAFT OF A LONG BONE.

(ENLARGED FROM *a*, *b*, *c*, FIG. 11, WITH THE ADDITION OF THE BLOOD-VESSELS.)

have absorbed their walls; how the remains (trabeculæ) of the calcified matrix form a basis upon which the osteoblasts are deposited and transformed into bone (*e*). The ossified osteoblasts are represented dark at the bottom of the diagram.

The actual appearances of the process of ossification at the

epiphysis, as seen under the microscope, are represented in Plate III. figs. 1 and 2.

Experiments with Madder.—That bones grow in thickness by additions to their surface, and not by interstitial deposit, is proved from the interesting experiments made with madder. It was accidentally discovered by Mr. Belchier, that madder tinges the bones red. He gives the following account of the circumstances under which the discovery was made.³⁰ He happened to be dining with a calico-printer on a leg of fresh pork, and was surprised to observe that the bones, instead of being white, as usual, were red. On making inquiry, he found that the pig had been fed on the refuse of the dyeing vats, which contained a large quantity of the colouring substance of madder. This fact naturally attracted the attention of physiologists. The red tinge was found to be communicated much more quickly to the bones of growing animals than to those full grown. The bones of a young pigeon were tinged a rose colour in twenty-four hours. In the adult bird it took fifteen days to do it. The effect of madder upon bones depends upon this:—The colouring principle of the madder (*Rubia tinctorum*) has a strong affinity for phosphate of lime. It appears, however, that the vegetable dye does not combine with the phosphate of lime already formed, but only with that which is actually forming and being deposited in the bones. Therefore, since the dye tinges only the most recent deposit of bone, it is possible to produce alternate rings of white and red bone, by periodically administering and withholding the madder as an article of diet. These rings will be observed not only at the circumference of the bone, but also within the Haversian systems.

Growth in Length of Bones.—Bones increase in length, not so much by interstitial deposit, as by addition to their ends; that is, by progressive ossification of the layers of cartilage which intervene between the ends of the shaft and the epiphyses. These layers of cartilage furnish the animal basis of ossification, by constantly growing, while they ossify on their upper and lower surfaces. When the cartilage ceases to grow, ossification still goes on till the component parts of the bone are all united by bony matter; and thus the stature of the individual is determined. If

from inflammation or other cause the epiphyses unite sooner than they ought to do, then one limb may be shorter than the other. That bones grow chiefly by addition to their ends was proved by Hunter. He introduced shots at definite distances into the shaft of a growing bone of a common fowl, and examined them a fortnight or three weeks afterwards. The distance between the two shots was found only half as much increased as the distance between a given shot and the end of the bone. (Phys. Ser. Nos. 188, 189.)


Value of Periosteum.—Such is an outline of the structure and formation of bone. It is a subject interesting not only for its own sake, but because it helps us towards the explanation of what we are every day seeing of the progress of disease, and the repair of injuries in bone; and what is more, it helps us towards a rational treatment of them. To give a few examples. Look at the value of the periosteum. Suppose a portion of periosteum to be detached by injury or disease from the surface of a bone, a part of the subjacent bone will run great risk of dying. It will not *necessarily* die, because its blood-vessels may still be filled from within, owing to the free communication between the blood-vessels of the periosteum and those of the marrow. In a case of compound fracture, where there are loose fragments of bone, we ought not to remove any that are still connected to their periosteum. Or, when a portion of the skull-cap sliced off by a sabre cut adheres firmly to a flap of the scalp, the flap with the bone should be re-applied, and the cure will frequently be effected without death of bone. In the Hunterian Museum are several skulls which have suffered from severe sabre cuts. The portions of bone thus sliced off were once detached, and afterwards re-united a little out of their proper places, so that the lines of original separation and subsequent union can be distinctly seen. (Path. Ser. Nos. 2892 to 2899.) Again, there are cases in which, either from exposure to cold or from direct injury, acute inflammation of the periosteum of the shaft of a bone ensues, effusion of fluid takes place beneath it, and severs the connection between it and the bone. The death (necrosis) of the entire shaft may be the consequence. Then, what happens? As the inflammation subsides, the bone-

secreting layer of the periosteum forms new bone around that which is dead, and by degrees encloses it in a bony case. The dead bone lies loose in this new case, having been detached from the articular ends, which do not die like the shaft, and for the reason that the epiphysial ends receive sufficient blood for their nutrition from the articular arteries, independently of what they receive from the shaft. The articular ends of the old bone become in time the articular ends of the new. Thus, the periosteum has formed a new shaft with a capacious cavity in its interior, in which the old bone is enclosed, and will remain so, and be a source of irritation for years, unless removed by a surgical operation.

Although the periosteum holds the first rank of all the structures which repair bone, still we are not to suppose that it is absolutely essential to the process. Under certain circumstances we find various other structures becoming transformed into bone. For example: In a case of compound fracture of the leg, where a portion of the entire circumference of the tibia, including its periosteum, was taken away, the vacancy in the bone was filled up by new osseous substance secreted by the surrounding soft tissues, and there was no shortening of the limb.²¹ Again, we occasionally see the intervening soft tissues forming bridges of bone, and so repairing a fracture where the broken ends themselves are widely apart.

Material which Repairs Fracture.—Fractures are repaired by a material similar to that out of which bone was originally formed. The animal matter which is first laid down is of a fibrous or cartilaginous nature—or a mixture of both, as the case may be—and then earthy salts are deposited in it. In the case of a simple fracture, where the broken ends are kept in contact and perfectly immovable by surgical appliances, the bones unite almost like an incised wound of soft parts. After all the effused blood is absorbed from between the broken ends, a soft fibrous substance (blastema) full of osteoblasts is thrown out from the ends of the broken bone, which forms a thin layer of animal matter (intermediate callus) between them. This gradually hardens, and the bone earth is then deposited in the blastema and

cells. So the ends are united. This occupies a period varying from four to ten weeks, according to the bone broken; e.g. the clavicle and the ribs unite more quickly than other bones, probably from their greater vascularity. The process is simply an excess of nutrition. Apparently more new bone than is necessary is formed. The excess fills up the medullary cavity, at the seat of fracture, and rounds off corners if there be any. But when the *permanent* uniting medium is strong, all that is seemingly superfluous is gradually absorbed, and the medullary canal is restored to its original condition, after a period varying from six to twelve months. On the other hand, if the fracture be not kept steady—for instance, in the case of animals—a kind of temporary splint is formed in the shape of a broad and thick ferule of cartilage, which ossifies around the ends of the broken bone, and keeps them almost immovable, while the permanent process of repair is going on between them. This ferule, termed the provisional callus,²³ does not disappear until the fracture has been thoroughly repaired.



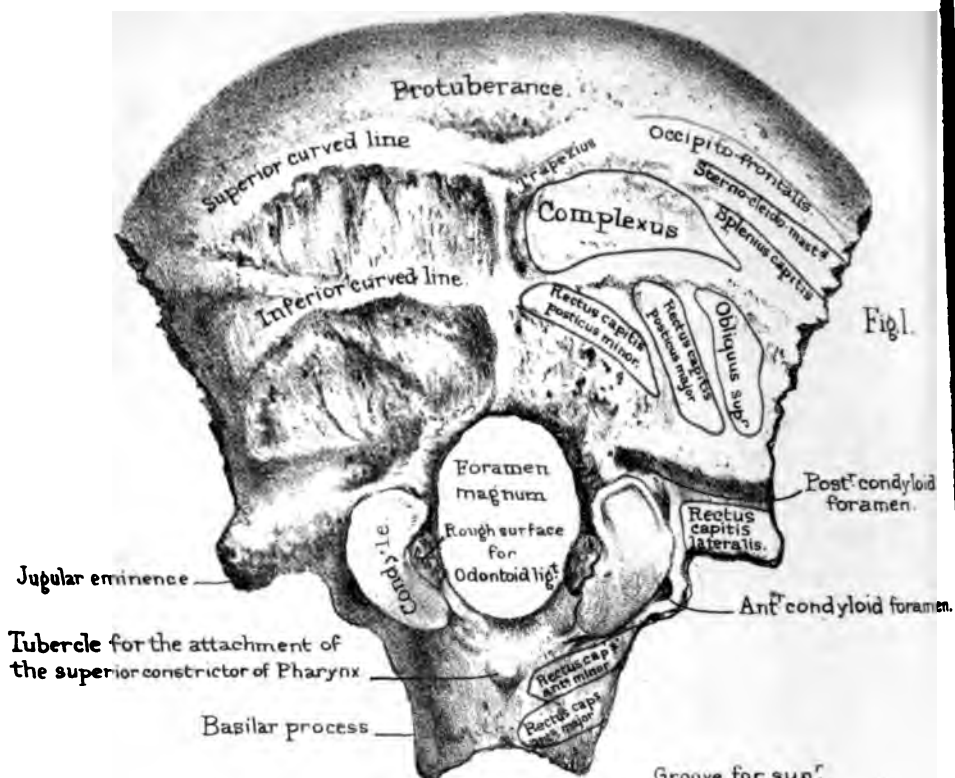


Fig. 1.

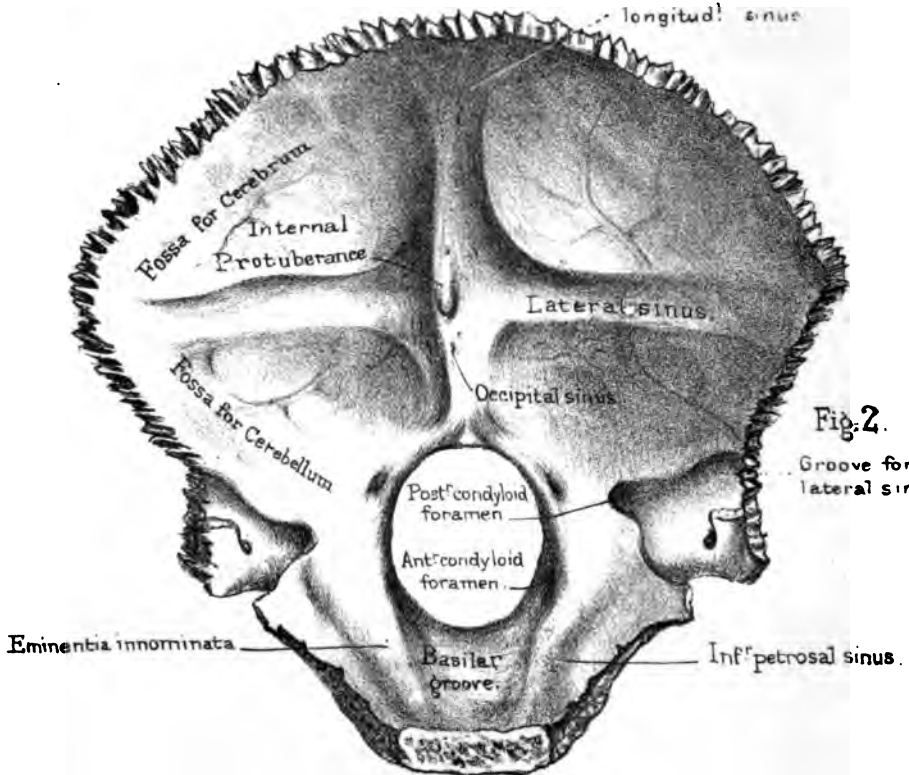


Fig. 2.

BONES OF THE SKULL.

FOR convenience of description the bones of the skull are generally divided into those which form the 'cranium' or brain case, and those which form the skeleton of the face. Each of these will first be described separately, and afterwards the skull will be examined as a whole.

8 BONES OF THE CRANIUM.	{	Occipital, Frontal, 2 Parietal 2 Temporal, Sphenoid, Ethmoid.	}	14 BONES OF THE FACE.	2 Superior Maxillary, 2 Malar, 2 Nasal, 2 Palate, 2 Lachrymal, 2 Inferior Turbinated, Vomer, Inferior Maxillary.
-------------------------------	---	--	---	-----------------------------	---

THE OCCIPITAL BONE.

(PLATE V.)

Foramen Magnum: Basilar Process.—The occipital bone contributes to form part of the base of the skull, as well as the back of the head. There is a large oval hole in it, called the 'foramen magnum,' which transmits the spinal cord and its membranes, the two vertebral arteries, and the two spinal portions of the spinal accessory nerves. The hole is very much larger than the parts which pass through it: all the intervening space is occupied by the cerebro-spinal fluid which supports and protects the cord. The narrow part of the bone, in front of the hole, projects, with a considerable inclination upwards, when the bone is held in its proper position—that is, with the foramen magnum horizontal; it is called the 'basilar process,' because it is wedged into the base of the skull. It is at the top of the

pharynx. This relation is of practical importance. It is well to know that the basilar process is within reach of the finger when introduced deeply into the mouth, and that, consequently, we can explore it satisfactorily, so as to ascertain how far a polypus may be connected to it. The end of the basilar process is joined to the body of the sphenoid bone, in early life, by cartilage; but in the adult this cartilage becomes ossified. On its under surface (Plate V. fig. 1) we notice a tubercle, exactly in the middle line, to which the aponeurosis of the pharynx is attached; and laterally, rough surfaces for the attachment of the 'rectus capitis anticus major' and 'minor.' On the upper surface (Plate V. fig. 2) of the basilar process there is a gently sloping groove (basilar groove), which supports the 'medulla oblongata.' The medulla is not in actual contact with the bony groove; a thin layer of fluid is interposed, which, like a water-bed, protects this important part of the nervous system from concussion. On each side of this groove is another, but much smaller (petrosal) groove, which lodges the inferior petrosal sinus, by which some venous blood is returned from the brain.²³

Occipital Part.—The expanded and vaulted part behind the foramen magnum contributes to form the skull-cap. On the convex or cutaneous surface, about the middle, we notice a rough prominence, called the 'occipital protuberance,' plainly to be felt at the back of the head. From this we trace down to the foramen magnum what is termed the 'crest' of the occiput, which gives attachment to the ligamentum nuchæ at the back of the neck. From this middle protuberance and crest trace outwards, towards the borders of the bone, two lines on either side, termed the 'superior and inferior curved lines.' These lines, as well as the rough surfaces between them, more or less evident in different instances, indicate the attachments of muscles at the back of the neck. The precise attachments of these muscles are mapped out on the right side of the drawing; and in examining them, understand, once and for all, that the blue outline denotes the *insertion* of a muscle; the red, the *origin*. It is right to explain that the *origin* of a muscle is the term applied to its most generally *fixed* attachment; the *insertion* of a muscle is the attachment which

is usually the more movable. However, it should be understood that a precise rule cannot be laid down with regard to these terms as applied to muscles, since the origin or fixed attachment, and the insertion or movable one, may under altered conditions be reversed.

Thus, the bone near the superior curved line gives origin to the 'trapezius' and 'occipito-frontalis,' and insertion to the 'sterno-cleido-mastoideus' and 'splenius capitis.' The surface between the two lines gives insertion to the 'complexus.' Below the inferior line are the insertions of the 'rectus capitis posticus major,' the 'rectus capitis posticus minor,' and the 'obliquus superior.'

Condyles and Condyloid Foramina.—The articular processes called the 'condyles' are placed one on either side of the foramen magnum along its anterior half. They are kidney-shaped and convex, with their anterior ends converging. Moreover, they slant so that their inner margins are lower than their outer; and they thus fit into the 'cups' of the 'atlas' or first cervical vertebra. Owing to this arrangement, and the great strength of the connecting ligaments, dislocation of the head from the atlas is exceedingly rare. More than this, by fitting together the two bones, you find that the condyles of the occiput are much longer than the cups which receive them; this permits the backward and forward motion of the head. On the inner side of each condyle is a rough surface or 'tubercle,' to which are attached the 'odontoid' or 'check ligaments' which limit the rotation of the head. Outside each condyle is the 'anterior condyloid foramen.' The direction of this foramen is outwards and forwards. It gives passage to the 'hypoglossal' or ninth nerve, which, proceeding from the medulla oblongata, is distributed to the muscles of the tongue. Immediately above the 'anterior condyloid foramen,' or canal, as it should be called, there is a heaping-up of bone, which, not having received a name, may be termed the 'eminentia inno-minata.' It looks like a strong bony bridge over the canal, and strengthens the base of the skull like a flying arch just over the condyle. Behind each condyle is a deep depression or 'fossa,' at the bottom of which is mostly found a 'posterior condyloid fora-

men.'²⁴ The fossa, by making room for the cups of the atlas, enables us to move our heads further backwards than we otherwise could have done; and the foramen at the bottom of it is the opening of a canal which runs horizontally forwards into the 'groove for the lateral sinus' (Plate V. fig. 2), and transmits a vein from the lateral sinus to the vertebral vein outside the skull.

Immediately external to the condyles, the bone forms on each side a projection, termed the 'jugular eminence.' On its under surface (Plate V. fig. 1) there is a roughness for the insertion of the 'rectus capitis lateralis.' On its upper or cerebral surface is a deep 'groove for the lateral sinus,' one of the large venous canals which return the blood from the brain. Trace this groove forwards, and observe that it turns suddenly downwards, forming a kind of gulf, sometimes termed the 'jugular fossa' which lodges the commencement of the internal jugular vein. Looking at the base of the skull (Plate XIX.) observe further, that it contributes, with the petrous part of the temporal bone, to form the 'foramen lacerum posterius.'

Cerebral Surface.—On the concave surface (Plate V. fig. 2) observe two deeply grooved thick ridges of bone, crossing each other,—the one vertical, the other horizontal: these grooves contain the sinuses of the brain. The groove of the vertical ridge contains the 'superior longitudinal sinus' above, and the 'occipital sinus' below the crossing. Near the foramen magnum, the groove for the occipital sinus generally subdivides into two smaller ones, which gradually lose themselves around its margin. The horizontal groove contains the great 'lateral sinus.' By referring to Plate XIX. this great groove may be traced in its winding course along the occipital bone across the posterior inferior angle of the parietal bone, the temporal, and then on to the occipital again, down as far as the 'foramen lacerum posterius.' The grooves for the lateral sinuses are seldom of equal size on both sides of the skull. Generally, the right is larger than the left; hence the larger size of the right internal jugular vein. Besides being grooved for the sinuses, the ridges give attachment to processes of the 'dura mater,' which support the lobes of the brain. The horizontal ridge gives attachment to the 'tentorium cere-

belli,' the longitudinal ridge to the 'falx cerebri' above, and the 'falx cerebelli' below the crossing.

Where the ridges cross each other, there is a heaping-up of bone, termed the 'internal occipital protuberance.' This is by far the strongest part of the bone, and protects the back of the cranium; besides which, at this protuberance, no fewer than six sinuses of the brain meet, viz. the superior longitudinal, the two lateral, the two occipital, and the straight. The meeting of these sinuses is termed the 'torcular Herophili.' Herophilus fancied that the blood flowing in here would be 'twisted' or 'pressed.'

Between the ridges there are four 'fossæ' which receive the lobes of the brain—the two upper, the posterior lobes of the cerebrum, the two lower, the lateral lobes of the cerebellum. Hold the bone to the light, and see how thin are the walls of the fossæ for the cerebellum; this is well protected by the mass of muscles at the back of the neck.

Connections.—The occipital bone is connected with six other bones; namely, with the two parietals by the remarkably serrated 'lambdoid' suture, with the two temporals, with the sphenoid, and with the atlas; the latter being articulated to the condyles by movable joints. The sutures are simply named after the bones which they connect: for instance, we speak of the 'occipito-parietal' suture, the 'petro-occipital,' the 'occipito-mastoid,' and the 'spheno-occipital.' All these connections are well serrated, except the 'spheno-occipital,' which is quite effaced in the adult skull, and the 'petro-occipital.'

Ossification.—The occipital bone is developed from four distinct centres, which appear about the seventh week of foetal life—one for the basilar part, one for the occipital, and one for each condyloid part (Nor. Hum. Ost. No. 35). These segments are, respectively, the 'basi-occipital,' the 'supra-occipital,' and the two 'ex-occipital' foetal elements of the bone. They all meet and form the foramen magnum, and all are distinct at birth. The occipital and condyloid parts unite about the fourth year; the basilar and condyloid about the fifth.

In very few skulls, there projects from the lower surface of the jugular eminence a more or less prominent tubercle, the '*par-*

occipital process.' It is the analogue of a transverse process. It is quite a deviation from the human type, but is very constantly developed in the mammalian series. There is a good specimen of the process in the Nor. Hum. Ost. Ser. (No. 747), in a skull from an aboriginal of one of the Philippine Islands. The process is even longer than the mastoid process, and presents an articular surface for joining the transverse process of the atlas. There is a similar process in a skull in the museum of St. Bartholomew's Hospital. There are also two specimens of it in the Museum of Anatomy, in Richmond Street, Dublin.

Comparative Osteology.—In all mammalia, as in man, there are two occipital condyles, fitting into two corresponding articular surfaces on the atlas. In birds and reptiles (Sauropsida), however, there is but a single occipital condyle, in front of the foramen magnum, in the middle line. This should be seen and noted, as it is one of the distinctive features of the above-named classes. (See separate series in the Mus. Roy. Col. Surg.)

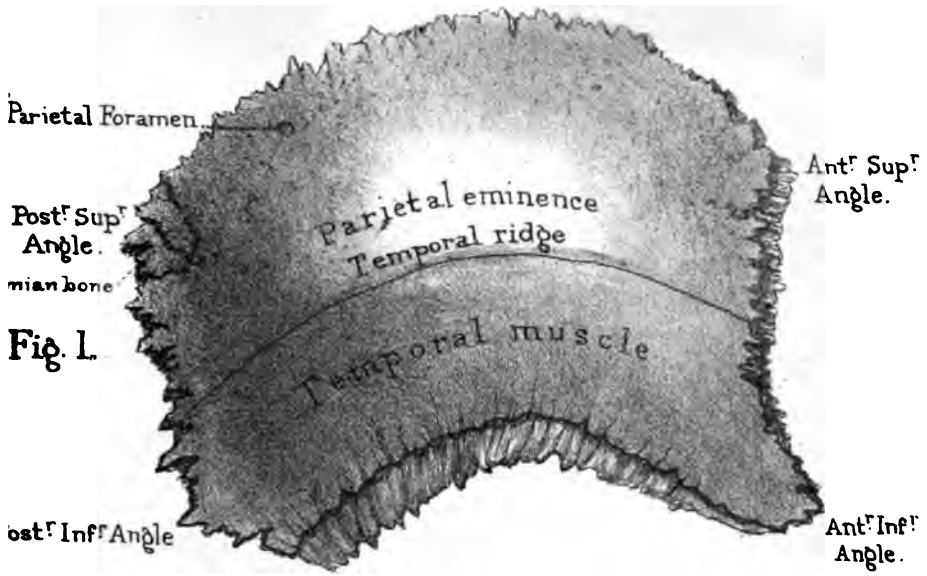
The cells which contain air and separate the inner and outer tables of the skull in the frontal bone of man extend as far back as the occipital bone in elephants. See sections of the elephant's skull (No. 2657).

In quadrupeds the prominence of the crest and external occipital protuberance bears a direct relation to the development of the ligamentum nuchæ which supports the head, and is usually in proportion to the weight of the head and its appendages. Compare the head of a deer, elephant, and tiger with that of a man in these particulars. In the moles the ligamentum nuchæ will be seen to be nearly all ossified.

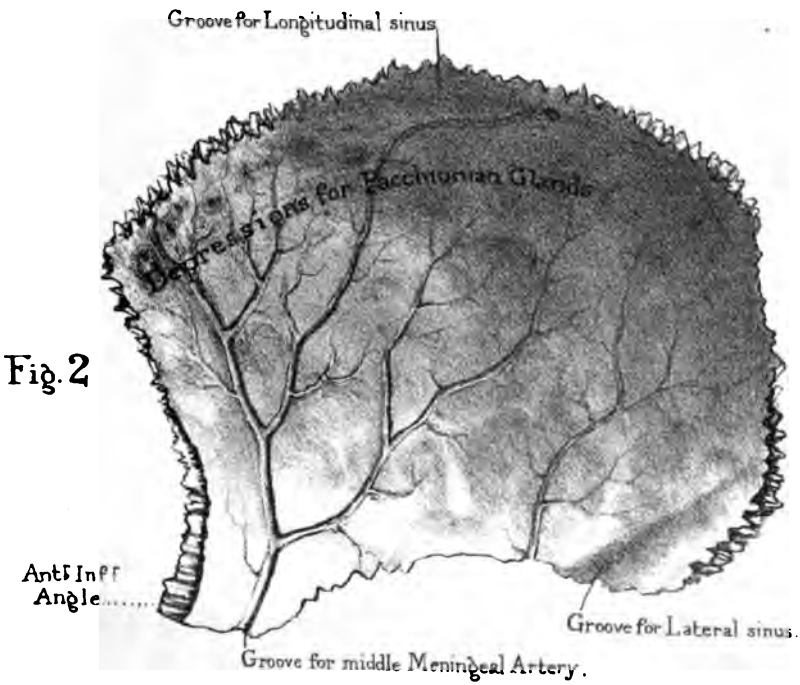
PARIETAL BONE.

(PLATE VI.)

This broad, roof-like bone derives its name from *paries*, a wall, as it forms so much of the wall of the skull-cap. It is the only bone belonging exclusively to the vault of the cranium. With its



Parietal Bone



fellow of the opposite side it makes the keystone of the arch which spans the brain. The two pillars of the arch are the squamous portions of the temporal bones (fig. 23, skull as a whole). It is convex on the outer surface, concave on the inner, and four-sided.

Outer Surface.—On the outer or convex surface (fig. 1), notice the ‘parietal eminence.’ This is the spot in which the ossification of the bone began. Below the eminence is a curved line, termed the ‘temporal ridge,’ which gives attachment to part of the ‘temporal aponeurosis.’ The surface below this line forms part of the ‘temporal fossa,’ which gives origin to the ‘temporal muscle.’ The four angles of the bone are ‘anterior superior,’ ‘anterior inferior,’ ‘posterior superior,’ and ‘posterior inferior.’

Cerebral Surface.—The concave cerebral surface has four kinds of marks or impressions upon it. Firstly, over the general surface there are large shallow grooves corresponding to the convolutions of the brain. Secondly, along the upper border is a half groove for the superior longitudinal sinus, and across the posterior inferior angle is a complete groove for the lateral sinus on its way from the occipital to the temporal bone. This should be borne in mind in articulating these bones with the parietal. Thirdly, running close to and parallel with the anterior border is the groove for the middle meningeal artery, from which ramify over the rest of the bone a number of smaller channels. Fourthly, near and along the upper border are seen a number of rounded depressions, which in the recent state contained the so-called Pacchionian bodies. Towards the back part of the upper border is mostly seen a foramen (‘parietal foramen’) which transmits a vein from the superior longitudinal sinus to the outside of the skull, and often an artery from the middle meningeal to the temporal artery.

Connections.—The parietal bone is connected by sutures with five bones (Plate XVIII.), as follows:—With the opposite parietal bone, by the interparietal or ‘sagittal’ suture; with the frontal bone, by the fronto-parietal or ‘coronal’ suture; with the temporal bone, by the temporo-parietal or ‘squamous’ suture; with the occipital bone, by the occipito-parietal or ‘lambdoid’ suture, and with the sphenoid bone, by the spheno-parietal

suture. In all adult skulls the sagittal suture, though for the most part extremely serrated, is much less so near the parietal foramina. When obliteration of this suture takes place in age, it always begins opposite these holes. Do not fail to notice the beautiful arrangement of the sutures of the parietal bone: the sutural edges are bevelled on alternate sides, so that the bone cannot be driven in without previous fracture.

Ossification.—It is developed from one centre, which makes its appearance at the parietal eminence, about the seventh week of fetal life.

Fontanelles.—The term 'fontanelles' is given to those membranous intervals in the fetal skull which are seen at the four angles of the parietal bone. These unossified parts are so called from the pulsations of the brain beneath them, perceptible in infants, like the welling up of water in a spring. They are produced in the following manner. Ossification commences in the centre of the bone, and advances towards the circumference; therefore, the most distant parts of the bone are the last to be ossified. These points are the angles where the several bones eventually meet. There are in all six 'fontanelles' (Plate XVIII. figs. 4 and 5). Observe the shape of the anterior and posterior 'fontanelles,' and of the two lateral. The *anterior*, situated between the adjacent angles of the parietal bones and the ununited halves of the frontal, is lozenge-shaped, and remains open for some time after birth; indeed, it is not (as a rule) entirely obliterated till the fourth year. The *posterior*, situated between the parietals and the apex of the occipital bone, is triangular and nearly closed at birth. These 'fontanelles' are of especial importance to the accoucheur, as by the feel of them the finger can detect, during parturition, the position of the head of the child. The *lateral* 'fontanelles' are of less importance, and generally obliterated before birth.

Right or Left?—In studying osteology the student must learn to hold each bone in a similar position to the corresponding one in his own body. Now in order to do this in the case of single bones, such as the occipital or frontal, all that it is necessary to know is (1) either the top or the bottom, and (2) either the front or the

back of the bone. But in all bones which occur in pairs (i.e. of which there is a right and left) six aspects must be considered, viz. a top and bottom, a front and back, an inner and outer side, and it becomes necessary in them to know three points instead of two, in order to place them in the required position, viz. (1) the top or the bottom; (2) the front or the back; and (3) the inner or the outer side. It is best to choose the most striking or obvious characters of a bone by which to determine these points, as being the quickest way of arriving at the conclusion. Thus, taking the parietal bone: (1) the inner side is recognised by its concave surface, which fits on to the brain, and is marked by its convolutions; (2) the bottom is known by its arched edge for articulation with the squamous portion of the temporal bone; (3) the front is known by the groove for the middle meningeal artery which runs up close to its edge. Bearing in mind these points, it is impossible to mistake a right for a left; and with anything less than these three points, it is equally impossible to know one from the other.

Comparative Osteology.—In Carnivora the temporal muscles are so extensive that they meet in the middle line of the skull, where they are attached to a dense median crest of bone, which represents the temporal ridges coalesced. This is conspicuous in the skeleton of the tiger. It is interesting to note that the dog is not born with this median ridge; at birth the temporal muscle extends only partly up the side of the head. As the dog grows the muscle rises further up the head until it meets its fellow in the middle, and then the ridge begins to be developed. This progressive increase of the muscle may be due to the habit puppies have of worrying everything they meet with, or it may be the result of an hereditary tendency.

In elephants and owls the inner and outer tables of the parietal bones are separated by enormous air cells.

In man the two originally distinct halves of the frontal unite and form one bone. In bats the two parietals, which in us remain distinct, unite and form a single bone; this is also the case in many rodents, as the hare, but in the rabbit they remain separate. In Ruminants and Solidungula the parietals are united.

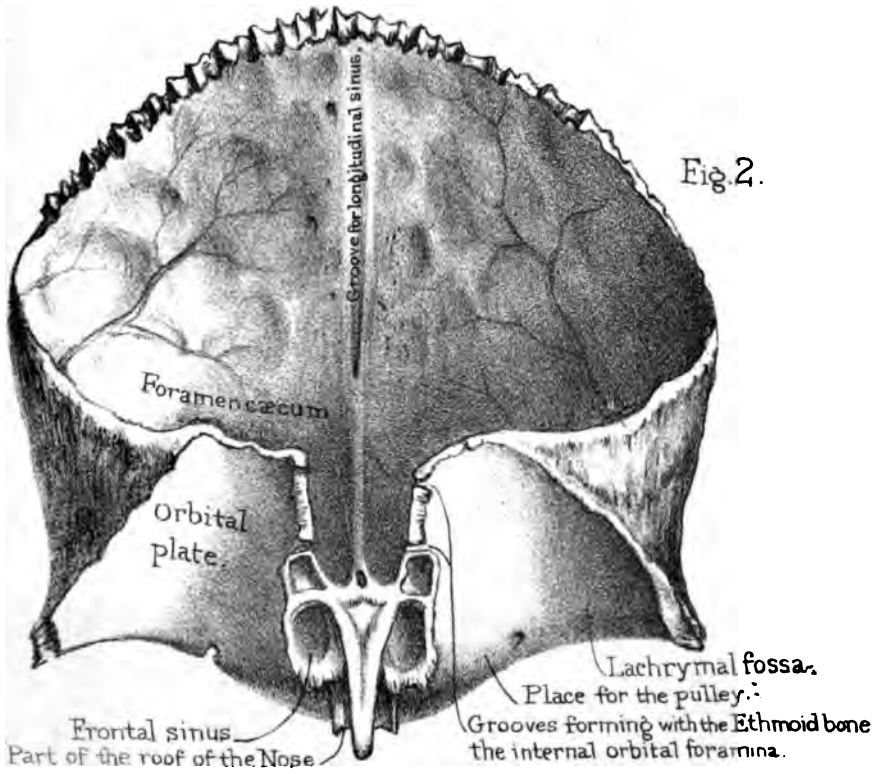
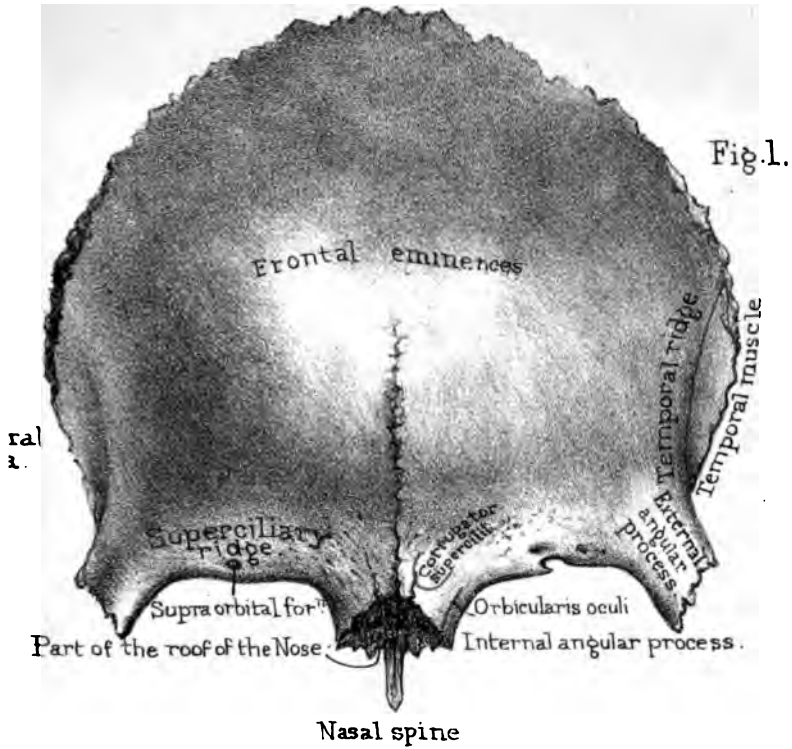
FRONTAL BONE.

(PLATE VII.)

The situation of the frontal bone is implied by its name. As it forms not only the forehead, but the roof of the orbits, we naturally divide it into a 'frontal plate' and an 'orbital.'

Frontal Plate.—The anterior surface of the 'frontal plate' is smooth and convex, and gives breadth and height to the forehead. Observe, first, the two 'frontal eminences,' one on each side, familiarly called the 'bumps' of the forehead. They are the two points from which the bone was originally formed, and their greater or less prominence indicates to a certain extent the amount of brain behind them. Not so the two projections lower down, termed the 'superciliary ridges:' these do not correspond to prominences of the brain, but are occasioned by air-cavities termed the 'frontal cells' or 'sinuses,' situated between the two 'tables' of the skull. And here it may be well to mention, that the cap of the skull consists of two layers of compact bone, called, respectively, the outer and inner 'tables' of the skull, and separated by an intermediate cancellous tissue termed the 'diploe.' We shall allude to the advantage of this structure hereafter (skull as a whole, fig. 20); meantime, observe that the frontal cells are formed by the separation of these tables. To see the extent of the cells, one ought to make vertical sections as shown in Plate XXIII.

The Frontal Sinuses.—There are some points of interest about the frontal sinuses. 1. They communicate freely with each nostril through a canal termed the 'infundibulum' (fig. 2); therefore it is possible for insects to reach them.²⁵ A lady had a kind of centipede (*Scolopendra electrica*) for a year in one of her frontal cells. It gave her intense pain, and was expelled at last, alive, during a fit of sneezing.²⁶ It is by no means uncommon to find the larvæ of insects in the frontal cells of animals. Sir C. Bell states that a man, having slept in barns, was afflicted with pains in the forehead, 'which were relieved after he had discharged from his nose a worm belonging to that class which spoils the corn.' 2. As



they are lined by a continuation of the same mucous membrane which lines all the other passages of the nose, we have a ready explanation of the aching pain in the forehead in cases of influenza, or a common head cold. 3. In cases of fracture of the base of the skull involving the walls of the cells, it is possible for fragments of the brain to escape from the nose. The author has seen a case of this kind where the patient recovered without any permanent ill effects except partial loss of smell. 4. If the outer wall of the cells be injured by violence or disease, the air, in sneezing or coughing, is liable to escape under the skin of the forehead; this condition is called 'surgical emphysema.'²⁷ A boy was kicked by a horse on the forehead, so that the frontal cells were exposed. There resulted a fistulous opening, through which, when the nose was held, he could blow out a candle. 5. They not only contribute to the lightness of the skull, but increase the resonance of the voice. They are not developed until about the age of puberty, and steadily increase in size afterwards. In some tribes—for instance, in the native Australians—they are but slightly developed;²⁸ and hence arises that want of resonance for which their voice is remarkable.²⁹ Even in Europeans their size and extent vary exceedingly. A good idea may be formed of their size in some persons, by the fact that they may lodge a musket-ball. A soldier was wounded at the battle of Talavera by a ball which struck him on the forehead and lodged in the frontal sinus. It was readily removed by enlarging the opening, and the man recovered.³⁰ The author has seen a case precisely similar, in a soldier who was wounded in the Crimea. The sinuses are commonly separated by a bony partition, often incomplete.

The 'bumps' are not prominent in children, because the tables of the skull do not begin to separate to any extent before puberty. From an examination of more than 100 skulls, it appears that the absence of the external prominence, even in middle age, does not necessarily imply the absence of the sinus itself, since it may be formed by a retrocession of the inner table of the skull. In old persons, as a rule, when the sinuses enlarge, it is by the inner table encroaching on the brain case. The skull wall follows the shrinking brain. The range of the sinuses may extend even

more than half-way up the forehead, and backwards for an inch or more along the orbital plate of the bone. Sometimes one sinus is larger than the other, and consequently the 'bump' on one side of the forehead may naturally be more prominent than that on the other. In the *Nor. Hum. Ost. Ser.* (Nos. 153 to 155) in the Museum of the Royal College of Surgeons, there is an instructive collection of horizontal sections through the frontal bone at the level of the sinuses. In a specimen from a man *æt.* 32, it may be observed that though the sinuses are very extensive, there is no external protuberance. In another from a man *æt.* 47 there are no sinuses, yet there is a great external protuberance. One obvious conclusion from all this is, that the 'bumps' on the forehead mapped out in this situation by phrenologists, under the heads of 'Locality,' 'Form,' 'Time,' 'Size,' &c., do not necessarily coincide with any convolutions of the brain.

Orbital Margin.—The margin of the orbit, termed the 'supra-orbital arch,' is composed of thick and massive bone,—as is, indeed, the entire circumference of the orbit. But the 'internal and external angular processes'—in other words, the piers of the arch—are remarkably strong, and form buttresses for its support. Near the inner third of the arch is the 'supra-orbital foramen,' or it may be a 'notch,' for the transmission of the supra-orbital nerve and artery. It is this nerve which is affected in 'brow ague.' At the external angular process is the starting-point of the 'temporal' ridge,' to which the temporal aponeurosis is attached (Plate XV. fig. 2); and just below this is a little surface of bone which contributes to form the 'temporal fossa' for the origin of the temporal muscle.

Cerebral Surface.—On its cerebral surface (Plate VII. fig. 2), the 'frontal plate' is concave, and mapped out by the convolutions of the brain and the grooves of the anterior meningeal arteries (small vessels given off from the ethmoidal branches of the ophthalmic), and the ramifications from the middle meningeal artery, on either side. In the middle line is the groove for the commencement of the superior longitudinal sinus. Trace the groove downwards, and observe that its margins gradually approximate, and lead to a small hole, the 'foramen cæcum.' The foramen cæcum sometimes

leads into the frontal sinus, sometimes directly into the nose; or it may open on the posterior or anterior surface of the nasal bones. It sometimes contains a small artery. Though called 'blind,' it generally transmits a small vein from the longitudinal sinus into the frontal cells; and this is one of the anatomical reasons assigned why bleeding from the nose relieves congestion of the brain, and why the old practitioners were in the habit of leeching the nose.

Very often the margins of the groove for the longitudinal sinus coalesce, so as to form a small ridge, before they reach the foramen cæcum. They give attachment to a perpendicular sheet of the dura mater (termed, from its shape, the 'falx cerebri'), which separates the hemispheres of the brain. Therefore, when we see a frontal bone with a well-marked ridge along the beginning of the longitudinal groove, it is but the ossification of part of this fibrous membrane. Pieces of bone occasionally occur in the falx cerebri, which remind us of the tentorium cerebelli in some *Carnivora*, as tigers, seals, and cats, in which the tentorium is for the most part bony instead of membranous (Nos. 4608 and 4483).

Orbital Plates.—The 'orbital plates' (Plate VII. fig. 2) extend horizontally backwards, and form a concave roof for the orbit, and a part of the anterior fossa of the cranium. Hold them to the light, and observe how thin they are. In extreme old age, when the diploe of the skull becomes absorbed, the orbital plates have sometimes large holes in them. At any time of life their thinness renders them liable to be perforated by sharp instruments thrust into the orbit. Wounds of the brain from such accidents are sometimes met with. Sir C. Bell speaks of a young man having been killed by the thrust of a foil which had lost its guard, and passed through the orbital plate into the brain. Their 'cerebral surface' is slightly convex, and generally ridged and furrowed by the impressions of the brain. The orbital plates of the frontal bone are more or less arched in different skulls. Of course the more they are arched the more they encroach on the cranial space, and therefore the less room there is for the anterior lobes of the brain. Contrast the skull of a monkey with that of

a man, and you will observe a marked difference. Their lower surface is concave, more especially near the external angular process, where there is a depression ('lachrymal fossa') which lodges the lachrymal gland. Again, near the internal angular process there is a trace of a slight depression, indicating the attachment of the cartilaginous pulley of the 'superior oblique' muscle of the eye.

Ethmoidal Notch.—The orbital plates are separated by a wide gap, called the 'ethmoidal notch,' because it receives the cribriform plate of the ethmoid bone, which here fits into the base of the skull. (Plate XIX.) On each side of the irregular margins of the notch observe the incomplete cells with thin walls. These cells correspond with, and are closed by, the ethmoidal cells (Plate XI. fig. 2). The largest cell of all is in the front; and this, as seen in Plate VII. fig. 2, leads into the frontal sinus. All of them are filled with air, and lined by mucous membrane continuous with that of the nose. At the front part of the notch is the 'nasal spine' of the frontal bone. This little perpendicular projection—generally broken off in taking the skull to pieces—supports the proper nasal bones (Plate XXIII. fig. 1), and helps to form the septum of the nose, by uniting with the perpendicular plate of the ethmoid bone. On either side of it is a little groove which forms part of the roof of the nose (Plate VII. fig. 1). Immediately in front of the nasal spine is the jagged surface which receives the nasal bones, and the nasal process of the superior maxillary bone (Plate XVI. fig. 2). Lastly, on the margin of the ethmoidal notch, notice two grooves which, with the ethmoid bone, form the 'anterior and posterior ethmoidal foramina.' The anterior transmits the 'nasal' branch of the ophthalmic division of the fifth nerve, and the anterior ethmoidal artery and vein; the posterior, the posterior ethmoidal artery and vein.

Connections.—The frontal is connected with twelve bones, of which two, the sphenoid and ethmoid, are single. It is united to the two parietal bones by the 'fronto-parietal' or '*coronal suture*' (Plate XVIII. fig. 2). Concerning this suture, see how admirably it locks the bones together, and secures the arch of the skull. The margin of the frontal bone is bevelled at the expense

of its inner table above, of its outer table below; and the parietal bone is adapted accordingly. The lower half of its temporal margin unites with the greater wing of the sphenoid. Its external angular process is connected to the malar bone; its internal angular process, to the nasal bone and nasal process of the superior maxillary. Its orbital plate is connected to the sphenoid, ethmoid, and lachrymal bones. Look well into the orbits and see these several connections. They form a continuous suture from one external angular process to the other. This is called the 'transverse frontal suture.'

Ossification.—The frontal bone is developed from two centres, which appear one on each side, in the situation of the frontal eminence, about the seventh week of foetal life. These lateral halves meet and form a vertical suture down the middle of the forehead, termed the 'frontal' suture; so that in children the two halves of the bone are easily separated. Generally this suture becomes obliterated during the second year; but sometimes traces of it persist, as seen in the skull, Plate XVIII.; hence the practical rule not to mistake it for a fracture.³¹

The frontal bone gives attachment to three muscles; namely, to part of the 'temporal,' part of the 'orbicularis oculi,' and the 'corrugator supercilii.'

Comparative Osteology.—In some animals, such as the Carnivora (see skull of tiger) the temporal muscle extends so far forwards that there is no room for articulation between the malar bone and the external angular process of the frontal. Thus, in these skulls the temporal fossa and the orbit are not separated by bone as in man. This character runs throughout the Carnivora, Rodentia, Edentata, and Pachydermata. In some animals the air cells are very numerous and large. Let any one who, admiring the intelligence of the elephant, imagines him to have a huge brain, put his hand into the foramen magnum of the skull which stands on the pedestal in the Mus. Roy. Coll. Surg. and explore the cranial cavity. He will find that this forms but a small portion of the size of the head. And now looking at the sections of the skulls in the case behind it, he will see that the larger part of the skull is formed by cells or air spaces between

the tables of the frontal, parietal, and occipital bones, which often separate the inner and outer tables of the skull to the extent of a foot. These make a vast increase in the size of the skull—an increase of advantage, however, as it affords additional leverage for those muscles which are inserted into the back of the skull, and raise the massive head, including the trunk, tusks, and jaws. The place to aim at in this animal is just above the root of the trunk, where the case of the brain is not much thicker than a shilling. These sinuses are also well developed in the owl and the giraffe. In the great extinct sloths the upper, back, and side walls of the cranium were thus inflated with air; so that in these instances the brain is protected by a double skull, with air between the two. This modification not only lightened the skull, but protected the brain from the falling trees uprooted for food by these animals.

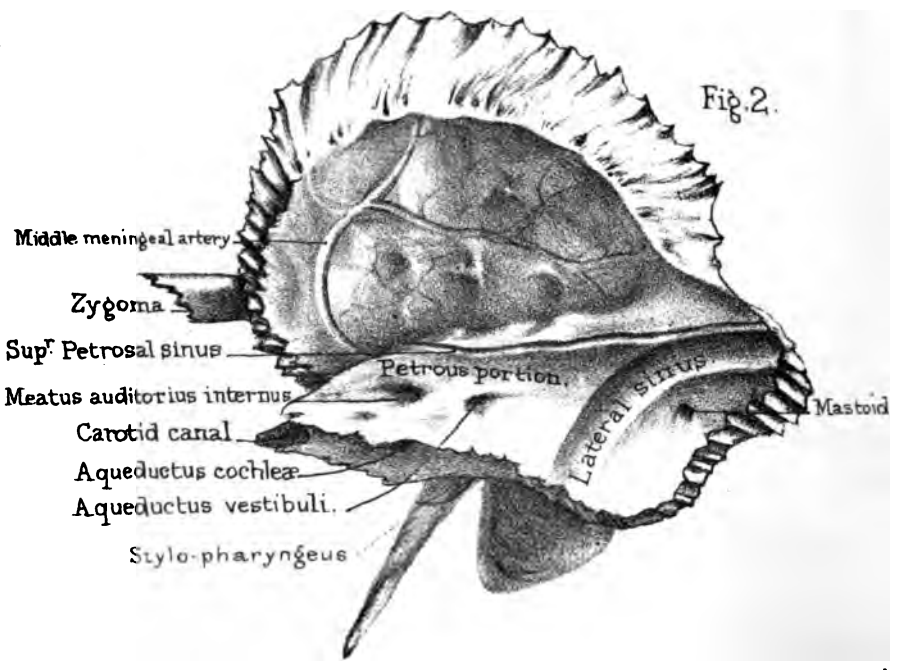
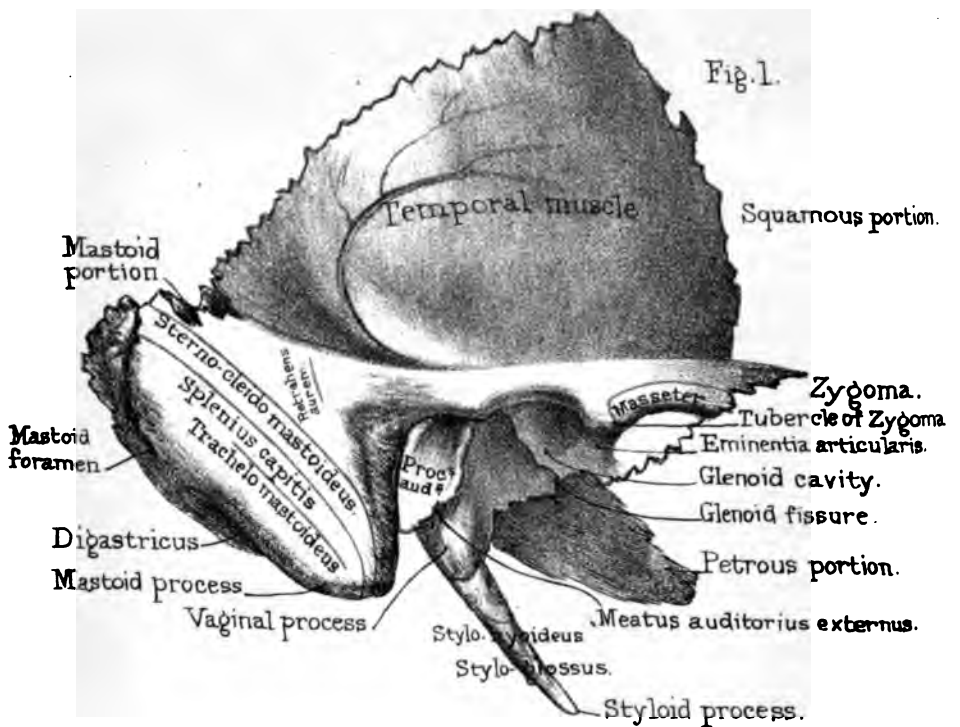
The horns of animals such as oxen, sheep, and antelopes, consist of a horny sheath supported upon a long mass of bone which grows from the surface of the frontal bone. These horns last the lifetime of the animal, excepting, indeed, in the case of the prong-horned antelope at the Zoological Gardens, which has twice shed its horns (No. 3713). The antlers of the deer consist entirely of bone, and grow from a projection on the frontal bone, and are shed annually; even the Wapiti deer sheds its huge antlers every year, and the extinct Irish elk formed no exception to this rule. Antlers are very vascular, and are covered by a vascular membrane, termed the 'velvet,' until the full growth, when they lose the 'velvet,' and are themselves ultimately shed. The horn of the rhinoceros is simply horny, and has no shaft of bone in its interior.

TEMPORAL BONE.

(PLATE VIII.)

Three Parts.—This bone occupies the temples. It is a complicated bone, even on the surface; much more so in its interior, because it includes the organ of hearing. It consists of three





Drawn on Stone by T. Godart
 From Nature by L. Holder
 Printed by Nestlé & Newman & Co.

parts,—a *squamous* portion, situated in the temple; a *mastoid*, forming the little projection behind the ear; and a *petrous*, which contains the organ of hearing, and projects like a wedge into the base of the skull. This division is very convenient: but the natural divisions of the bone are—1. The squamous; 2. the petrotic, comprising the petrous and mastoid; and, 3, the tympanic, or small ring of bone which surrounds the membrana tympani, and by its outward growth comes to form the external auditory passage. These parts are separate in the human foetus, and permanently so in many of the lower animals.

Squamous Portion.—The squamous portion, named from its scale-like appearance, forms part of the wall of the temple. It is very thin; hence the danger of a blow here. Its smooth outer surface is entirely covered by the temporal muscle, to which it gives origin. Its inner surface is marked by the convolutions of the brain, and by a narrow groove which sweeps, in a curved direction, from before backward, indicating the course of the posterior branch of the middle meningeal artery. (Plate VIII. fig. 2).

Zygoma.—At the lower part of the squamous portion there is an outgrowth of bone, termed the ‘zygoma’ (ζύγωμα, a bolt or bar). It projects horizontally forwards, and can be easily felt on the side of the face. It is connected by a strongly serrated suture with a similar projection from the malar bone; so that the two together form an arch (‘zygomatic arch’) beneath which the temporal muscle plays. (Plate XV. fig. 2.) The base of the zygoma is very broad, and appears to spring from two roots,—an anterior and a posterior: in the space between them is the ‘glenoid cavity,’ which forms the socket for the lower jaw. The *posterior* root (supra-mastoid ridge) runs backwards in the same line with the zygoma, and forms the upper boundary of the glenoid cavity: after that, it passes over the meatus auditorius externus, and then it gradually fades away, marking the line of separation between the squamous and the mastoid divisions of the bone. In the negro race, this supramastoid ridge is strongly marked, and is characteristic of a degraded type of skull (see two Tasmanian skulls, Nor. Hum. Ost. Nos. 1096–1097). The

anterior is the main root; it is very broad and strong, runs transversely inwards and forms the front boundary of the glenoid cavity. It is called the 'eminencia articularis.' This is crusted with cartilage in the recent state, and forms additional surface for the play of the lower jaw. Under ordinary circumstances, the 'condyle' of the jaw is in the glenoid cavity; but while the mouth is opening widely, the condyle can be felt sliding so far forward that the finger can be placed into the socket behind it. In fits of laughter or of yawning, the condyles may be suddenly dragged in front of the articular eminences by the muscles; and then the jaw is dislocated into the zygomatic fossa. Under such circumstances a person presents a very ridiculous appearance, since the mouth remains wide open until the dislocation is reduced. At the base of the zygoma we notice a little tubercle ('tubercle of the zygoma'), to which is attached the external lateral ligament of the lower jaw. Lastly, the upper edge of the zygoma gives attachment to the temporal aponeurosis; the lower edge gives origin to the masseter muscle.

Glenoid Cavity.—The 'glenoid cavity' (γλήνη, a socket), or socket for the lower jaw, is concave and oval, with the long diameter transverse, or nearly so. At the bottom of it notice a fissure, termed the 'fissura Glaseri,' or 'glenoid fissure,' the remains of the original separation between the squamous and tympanic portions of the bone. The part in front of the fissure is the socket for the jaw: the part behind it is occupied by a lobe of the parotid salivary gland. Pass a bristle up the fissure, to see that it leads to the tympanum of the ear. The glenoid fissure contains the 'processus gracilis' of the 'malleus,' the tympanic artery, the 'laxator tympani' muscle, and is usually said to transmit the 'chorda tympani' nerve; but this nerve, strictly speaking, runs through a little canal, close by the fissure termed 'Canal of Huguier.' Between the glenoid cavity and the meatus auditorius there is a slight process which affords support to the lower jaw, and guards against dislocation backwards. This 'postglenoid process' is generally well marked in African skulls, and always so in the gorilla, the animal which approaches man so nearly.

Mastoid Portion.—The ‘mastoid portion’ forms the prominence of bone which is felt behind the ear termed the mastoid ‘process’ (*μαστός*, a nipple). This process gives insertion and great leverage to some of the muscles which move the head round, viz. the ‘sterno-cleido-mastoideus,’ under that the ‘splenius capitis,’ and still deeper the ‘trachelo-mastoid.’ Beneath all these muscles the occipital artery runs to the back of the head, along a slight groove in the bone, internal to the digastric fossa. These muscles, as seen in Plate VIII. fig. 1, are also inserted into the rough surface above and behind the mastoid process. If a section be made through the process, it is found to contain large and freely communicating cells, termed ‘mastoid,’ which open into the back part of the tympanum. These cells, like the tympanum itself, contain warm air, which is admitted from the back part of the nostrils through ‘the Eustachian tube.’ They not only make the bone light, but are useful to the sense of hearing, by allowing more space for the vibration of the air. Like the frontal cells, and indeed all the air-cells in the bones of the skull, they are not developed till the approach of puberty. In cases of deafness, arising from obliteration of the Eustachian tube, it was formerly the practice to make an opening into the mastoid cells, in order to admit free access of air into the tympanum. The success attending this proceeding induced Just Berger, physician to the King of Denmark, to have the operation done upon himself; but he died twelve days afterwards from extension of inflammation to the membranes of the brain; and the death of this illustrious man brought the operation into disrepute. Internal to the mastoid process is a deep fossa, termed the ‘digastric fossa,’ where the ‘digastric’ muscle arises. Behind the process is a hole, called the ‘mastoid foramen,’ through which a vein runs from the lateral sinus to the outside of the head. This explains why leeches, applied behind the ears, relieve congestion of the brain. Lastly, on the cerebral aspect of the mastoid portion, notice the ‘groove for the lateral sinus.’

Petrous Portion.—The ‘petrous portion’ derives its name from the hardness of its constituent bone (*πέτρος*, a rock). It projects horizontally into the base of the skull (Plate XIX.),

and so carries far out of harm's way the delicate organ of hearing which it contains. Its shape is like a triangular pyramid with the apex inwards; so that, for descriptive purposes, it may conveniently be divided into three surfaces,—an anterior, a posterior, and an inferior: then there is a base and an apex. Our best plan is to examine each of these parts separately, that we may be able to answer the question, what is seen on the anterior, what on the posterior surface, and so forth. Take the base first.

Meatus Auditorius Externus.—At the *base* of the petrous portion is the orifice of the passage to the ear, termed the 'meatus auditorius externus.' It is situated immediately behind the glenoid cavity, and its boundaries are chiefly formed by a curved plate of bone, called the 'processus auditorius.' Observe, first, that the edge of it is very jagged, for the attachment of the cartilage of the ear; and then look carefully down the passage to see that this curved plate of bone forms its boundary wall all round, except at the uppermost part. This inspection will probably suggest that the whole plate is something superadded to the rest of the bone,—a sort of after-growth; which is precisely the case. In the fetus there is no meatus, but simply a ring of bone forming three-fourths of a circle, the deficiency being at the upper part. This ring is ossified independently about the third month, is quite distinct from the other parts, and to it is attached the membrane of the drum of the ear (*membrana tympani*); so that at this early period it might be rudely compared to a hoop with a membrane stretched across it. In many animals this remains permanently a distinct bone, under the name of the 'tympanic bone.' (Plate XVIII. fig. 5.) In process of time, however, the hoop begins to grow out on its external side, and thus becomes a canal or meatus, which, as it grows longer, gradually coalesces with the other constituents of the bone.

Respecting the shape of the passage, observe that it is oval, with the long diameter nearly vertical; therefore all specula used for examining the ear ought to be of the like shape. The narrowest part of the passage, in the recent state, is about the middle; hence if a foreign body, such as a pea, happen to get into the ear, it is generally pushed through the narrow part by clumsy

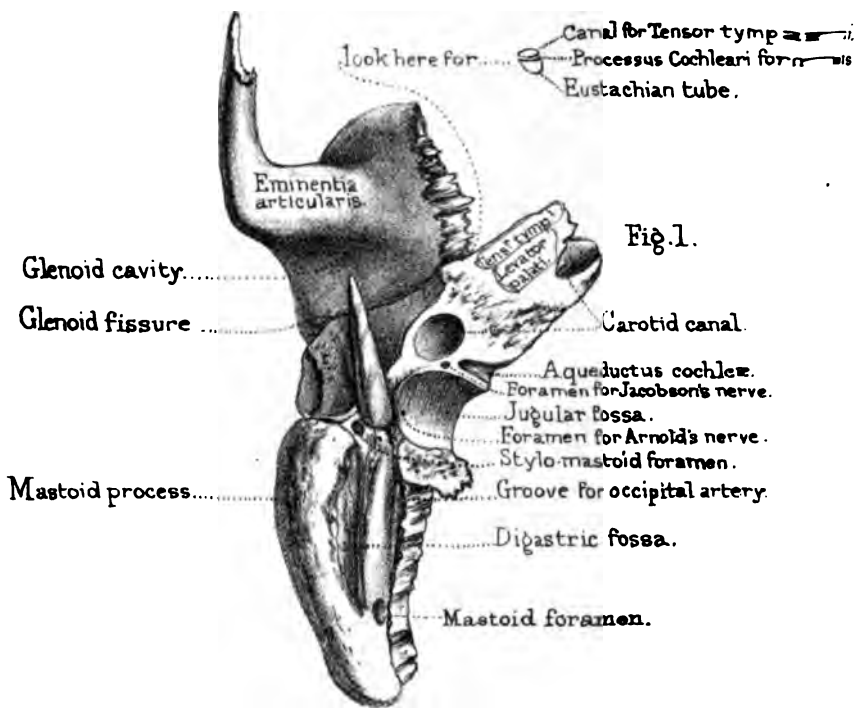


Fig. 1.

TEMPORAL BONE.

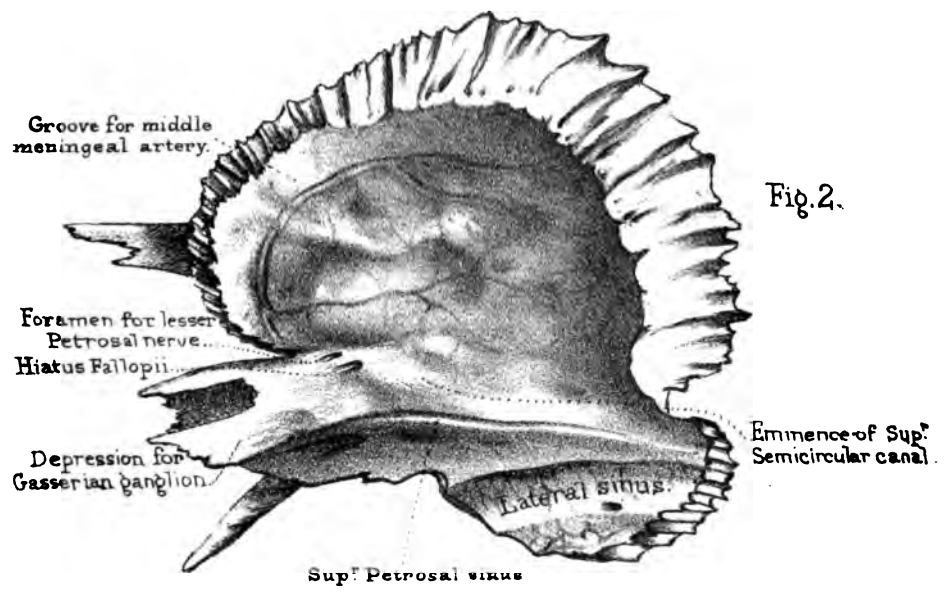


Fig. 2.

Drawn on Stone by H. Gumpert
 From nature by L. Holden
 Printed by West Newman & Co.

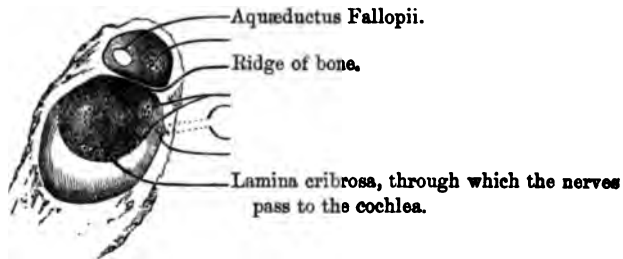
efforts to extract it, and then the moisture of the ear causes it to swell, and makes its extraction most difficult and painful. A boy, eight years of age, had a grain of Indian corn thrust into his ear by one of his schoolfellows. The schoolmaster, in his wisdom, endeavoured to remove it by attaching a piece of wax to the end of a stick, and thrusting it into the passage. Four days afterwards, the boy was brought, with his ear in a state of acute inflammation, to the doctor, who eventually succeeded in extracting the grain by means of a 'curette,' with the point bent to a right angle. The grain of corn had increased to one-third more than its natural size.³²

Petrous Portion : Anterior Surface.—The *anterior* surface (Plate IX. fig. 2) of the petrous portion forms part of the middle cerebral fossa which lodges the middle lobe of the brain, and bears more or less marks corresponding to the convolutions. About the middle of it is a little eminence, indicating the position of the 'superior semicircular canal' (a part of the internal ear). More forward, is a small furrow leading to an opening termed the 'hiatus Fallopii,' which transmits the 'great petrosal' nerve. Immediately to the outer side of this is a smaller furrow and opening, which gives passage to the 'lesser petrosal nerve.' Near the apex is a depression for the 'Gasserian ganglion.' External to this is the termination of the 'carotid canal.' Lastly, at the angle where the squamous and petrous portions meet (Plate IX. fig. 1), you will observe two tubes running backwards parallel to each other, like a double-barrelled gun (except that they lie one above the other): they both lead to the tympanum. The upper of the two is the canal for the 'tensor tympani' muscle; the lower, which is by far the larger, is the Eustachian tube, or passage which conducts the air from the pharynx to the tympanum. The thin partition separating the two barrels is called the 'processus cochleariformis.'

Petrous Portion : Posterior Surface.—The *posterior* surface of the petrous portion forms part of the posterior fossa of the base of the skull. (Plate XIX.) The most prominent object upon it is the 'meatus auditorius internus' (Plate VIII. fig. 2), a large canal which runs nearly horizontally outwards, and transmits the

'seventh pair' of nerves, consisting of the auditory nerve (*portio mollis*), and the motor nerve of the face (*portio dura*). It also transmits the auditory artery, a branch of the basilar. The meatus is much larger than the nerves which it transmits, the space between them and the bony canal being filled by a fluid (cerebro-spinal), which surrounds and supports the brain. In fractures through the base of the skull involving the meatus, the fluid sometimes oozes out through the external ear: this, therefore, is regarded as a very grave symptom in cases of injuries to the head. A transverse section near the bottom of the meatus would show that it is divided by a small ridge of bone into two unequal parts, as seen in fig. 13. In the upper and smaller of the two is the commencement of a special canal (*aquæductus Fallopii*)

FIG. 13.



for the motor nerve of the face; in the lower there are several minute apertures arranged in a spiral form (*lamina cribrosa*), through which the fibres of the auditory nerve reach the internal ear. About a quarter of an inch behind the meatus is a slit-like opening which looks backwards, and is termed the '*aquæductus vestibuli*.' This, though about a quarter of an inch long, soon contracts so much that it will barely admit a bristle. It leads to the vestibule of the internal ear. Immediately below the meatus there is a *conical* pit, which is wide at first, but gradually contracts to a minute canal, leading to the cochlea, termed the '*aquæductus cochleæ*.' These minute 'aqueducts' leading to the internal ear sometimes transmit small blood-vessels.

Petrous Portion: Inferior Surface.—The *inferior* surface of the petrous portion presents an irregular aspect, and has

many holes in it (Plate IX. fig. 1). Beginning near the base, notice, first, the 'styloid process,' so called from its resemblance to an ancient 'style,' or pen. It is, originally, distinct from the rest of the bone, but gradually coalesces with it at the end of the third year. This long 'process' descends with a slight inclination forwards, and gradually tapers to a sharp point. Its length varies in different skulls; generally it is about half an inch long. In old skulls it is sometimes longer: there is a skull in the Museum of St. Bartholomew's Hospital which has a styloid process three inches long. It gives origin to three muscles and two ligaments. The muscles are for the movement of the tongue and pharynx; they arise as follows:—the 'stylo-pharyngeus,' from the inner side of the base; the 'stylo-hyoideus,' from the middle and outer aspect; and the 'stylo-glossus,' from the front of the process (Plate VIII. fig. 1). To the tip itself is attached the 'stylo-hyoid ligament,' which runs downward and forward to the lesser cornu of the os hyoides. The styloid process is nothing more than ossification of part of this ligament. The other ligament attached to the process is the 'stylo-maxillary,' which separates the sub-maxillary from the parotid gland. Lastly, the fore part of the root of the styloid process is surrounded by a kind of bony sheath, termed the 'vaginal process,' about which there is nothing to be remarked except that it is a continuation of the plate of bone which forms the hinder part of the glenoid cavity.

Between the mastoid and styloid processes is a hole termed the 'stylo-mastoid foramen.' (Plate IX. fig. 1.) It gives exit to the motor nerve of the face (portio dura), which entered the bone at the meatus auditorius internus. The stylo-mastoid artery, a branch of the posterior auricular, enters at this foramen, and supplies the tympanum. If you introduce a stiff bristle into the hole, you will probably succeed in passing it through the bony canal traversed by the nerve from its entrance to its exit. The canal is a complete tube of bone, called the 'aquæductus Fallopii' ³³ after the anatomist who first described it. (Plate LIX.) The passage of this nerve through the temporal bone renders it liable to be injured in fractures of the base of the skull, or in disease of

the ear; and this explains the paralysis of one side of the face which sometimes occurs under these circumstances.

On the inner side of the stylo-mastoid foramen is a deep depression termed the 'jugular fossa.' This, with a corresponding part of the occipital bone, forms the 'foramen lacerum posterius.' (Plate XX.) Here the lateral sinus pours its blood into the commencement of the internal jugular vein, which forms a great bulge and fills the fossa. Here also the eighth pair of nerves leaves the skull (through a little notch in the front part of the foramen lacerum); and here, one of the posterior meningeal arteries, a branch of the occipital, enters it. On the outer wall of the jugular fossa, near the root of the styloid process, we find the minute foramen which transmits the auricular branch of the pneumogastric nerve. In front of the jugular fossa is the large circular commencement of the canal in the petrous bone, through which the carotid artery enters the skull ('carotid canal'). The canal mounts nearly perpendicularly for a short distance, and then, turning forward and upward, emerges at the apex of the bone. On the plate of bone which separates the jugular fossa from the carotid canal, there is a minute foramen which transmits the tympanic branch of the glosso-pharyngeal nerve.³⁴ Near the apex is a rough surface which gives origin to the 'tensor tympani' and 'levator palati' muscles. The apex itself presents nothing more than the termination of the carotid canal, and helps to form one of the boundaries of the jagged hole at the base of the skull, termed the 'foramen lacerum medium.' (Plate XX.)

Along the sharp border between the anterior and posterior surfaces of the petrous portion remark the groove for the 'superior petrosal sinus,' which discharges itself into the lateral sinus. The faintly indicated groove along the fore part of the lower border of the posterior surface is for the 'inferior petrosal sinus.' The nearness of these venous channels to the cavity of the tympanum explains the bleeding from the ear which sometimes occurs in fractures running through the petrous portion of the temporal bone.

Connections.—The temporal is connected with five bones. The squamous portion is connected to the parietal bone and the great wing of the sphenoid bone by the 'temporo-parietal' and

'temporo-sphenoidal' sutures, concerning which the following mechanism must be noticed; namely, that the squamous part overlaps the parietal above, but is itself overlapped by the sphenoid below—an arrangement which greatly contributes to the security of the arch of the skull. The mastoid part is connected, above, to the posterior inferior angle of the parietal by the 'masto-parietal' suture, and, behind, to the occipital by the 'masto-occipital' suture. The petrous part is wedged into the base of the skull between the sphenoid and occipital bones. (Plate XIX.) The zygomatic process is connected to the malar bone by a strong suture, the 'zygomatic,' which slopes downwards and backwards. Lastly, the glenoid cavity articulates with one of the condyles of the lower jaw. In the living subject, an inter-articular fibro-cartilage, lined above and below by synovial membrane, separates the two articular surfaces, and protects this part of the skull from the effects of a blow under the lower jaw.

Ossification.—The temporal bone is developed from four centres of ossification; namely, one for each of the following parts:—the squamous, including the zygoma; the petrous and mastoid, or periotic bone; the tympanic or processus auditorius; and lastly, the styloid process. Some of these remain permanently distinct bones in many of the lower animals; and it is worthy of remark, that even in the human subject traces of the union of all are visible even in advanced age. The most curious development is that of the tympanic part; it is a simple ring of bone in the fœtus, grooved inside for the attachment of the membrana tympani, which eventually grows out so as to form the meatus auditorius. (Nor. Hum. Ost. Nos. 34 and 43.) In the fœtus, the mastoid part is very small, and gradually enlarges towards puberty by the formation of the mastoid cells. The styloid part is for a long time cartilaginous after birth, and ossifies slowly with age. The ossification of the squamous part commences about the eighth week of foetal life; of the petrous and mastoid, between the fifth and sixth months; of the tympanic ring, about the third month; of the styloid process, after puberty.

Right or Left?—The bone will be in the same position as the corresponding one in the student's body if he hold the petrous

portion (on which part of the brain lies) inwards; the zygoma (which articulates with the malar) forwards, and the glenoid cavity downwards.

Comparative Osteology.—In white men the temporal bone very rarely articulates with the frontal, but this abnormality appears to be less rare in some coloured races. In the Hum. Ost. Ser. it may be seen in four skulls of natives of New Caledonia, Nos. 1159, 1160, 1161 and 1146; in two Australian skulls, Nos. 1088, 1071, as well as in two remarkably long skulls in the General Ost. Ser. Nos. 126, 127. Some of these abnormalities may be explained, by referring to Plate XVIII. fig. 5, in which it will be seen that where these bones meet, is the anterior lateral fontanelle. Here there is occasionally developed a small Wormian bone called the 'Epipteric bone.' (General Ost. Ser. No. 116.) If the epipteric bone unite to either the sphenoid or parietal, the articulation is normal, but if to the frontal or temporal, it is abnormal; in the Orang Outan the temporal bone articulates with the frontal normally, and this is also the case in nearly all the monkeys.

It seems curious that the Howling Monkey (*Mycetes laniger*) has these articulations similar to those of man.

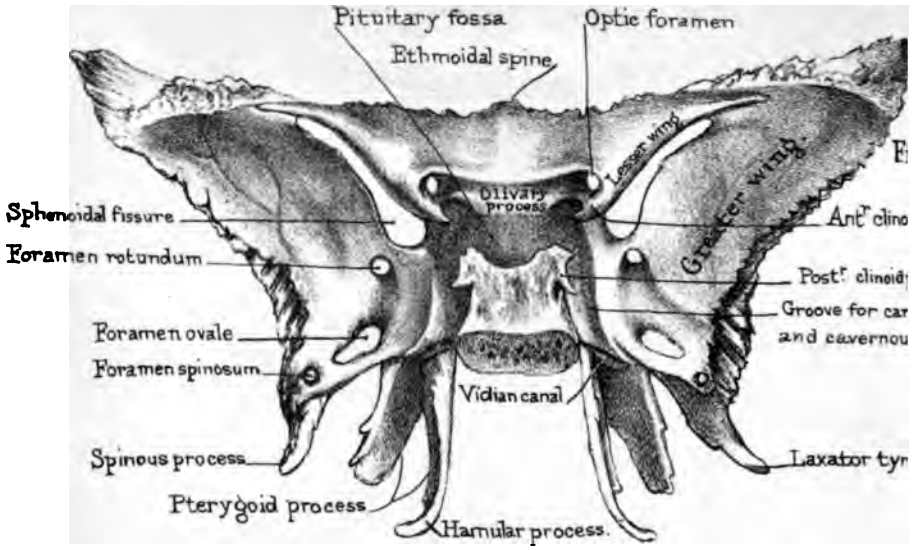
Notice the immense zygomatic arch in the skeleton of the manatee. (No. 2647.)

In crocodiles the tympanic cavity is completely walled in by bone; so that they hear by vibrations communicated through bony substance.


In all the Mammalia, and in them alone, the lower jaw articulates directly with the temporal bone. By referring to No. 12 in the Nor. Hum. Ost. the tympanic bone and membrane in the foetus may be seen at the base of the skull. The fissura Glaseri is open widely, and the processus gracilis of the malleus lies in it. In all Mammalia the malleus remains very small and becomes cut off from the glenoid cavity by the outgrowth of the tympanic bone; but in birds (see Sep. Ser.) the malleus becomes largely developed, projects between the squamous and tympanic bones, and, under the name of 'quadrate bone,' comes to support and form the articulation for the lower jaw.

Sphenoid Bone.

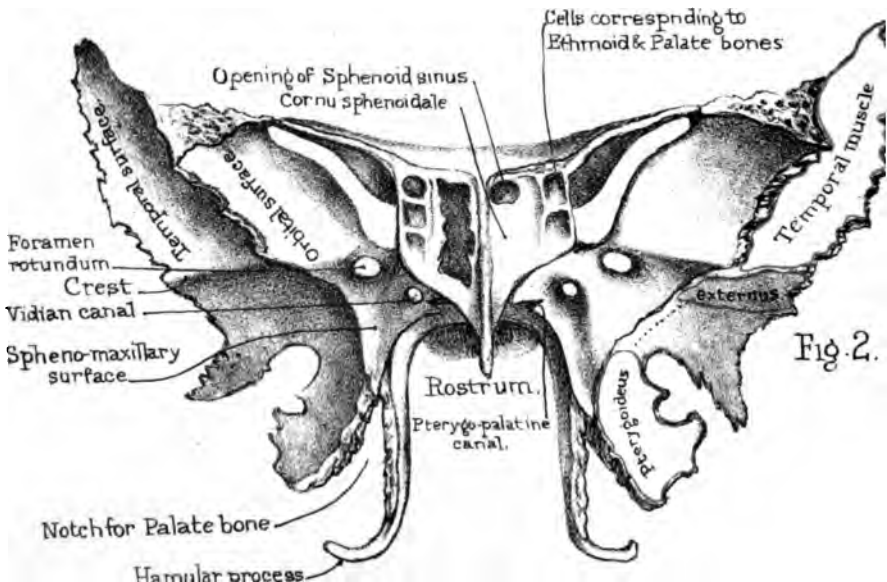
PLATE X



Posterior aspect



Muscles arising round the Foramen opticum.



Anterior aspect.

Fig. 2.

SPHENOID BONE.

(PLATES X., XI.)

Constituent Parts.—The sphenoid bone is so called because it is wedged in at the base of the skull between all the other bones of the cranium (*σφήν*, a wedge, *εἶδος*, form). As it not only enters into the formation of the base of the skull, the orbits, the temples, and the nasal passages, but is connected with all the bones of the cranium, and many of those of the face, one cannot be surprised that it is a difficult bone to understand. Fortunately, it bears a remarkable resemblance to a bat with extended wings; so that we can shape our description accordingly. It presents, then—1. A body, or central part; 2. The two greater wings; 3. The two lesser wings; 4. The pterygoid processes, which make the two legs of the bat.

Body: four Surfaces.—Commencing with the body, we must examine its four surfaces—a ‘superior,’ and ‘inferior,’ an ‘anterior,’ and a ‘posterior.’

The *superior* surface of the body (Plate X. fig. 1) comprises what is seen of the body on the inside of the base of the skull. There is a deep depression in it, termed the ‘pituitary fossa,’ which lodges the ‘pituitary’ body.³⁵ Another name given to it is the ‘*sella turcica*,’ from its resemblance to a Turkish saddle. In front of it is an eminence, termed the ‘olivary process,’ from its olive-like shape. This process supports the commissure of the optic nerve which makes a slight transverse groove (the ‘optic groove’) upon it, leading on each side to the ‘optic foramen’ through which the nerve enters the orbit. In front of the olivary process is a smooth and slightly concave surface, which supports the roots of the olfactory bulbs, and terminates in the middle line in the ‘ethmoidal spine,’ which articulates with the ethmoid bone.

Each side of the ‘body’ is more or less distinctly marked by a broad groove which winds upwards in a gentle curve, and lodges the internal carotid artery as it passes through the ‘cavernous

sinus' after entering the skull; generally, a little tubercle, called the 'middle clinoid process,' rises from the side of the groove. In some skulls this tubercle is long enough to unite with the apex of the anterior clinoid process, so that the artery, in emerging from the groove, passes through a ring of bone. The two 'clinoid' processes on each side give attachment to the 'tentorium cerebelli.' The pituitary fossa is bounded behind by a square plate of bone, which, as it represents the back of the saddle, is termed the 'dorsum sellæ.' The corners of this plate project and form what are called the 'posterior clinoid processes,'—thus named from their fancied resemblance to bed-posts. These are directly opposite to the 'anterior clinoid processes,' of which we shall speak presently. The posterior surface of the plate slopes very obliquely backwards, is continuous with the basilar process of the occipital bone, and forms an inclined plane which supports the 'pons Varolii.' Lastly, in the side of the plate there is generally a notch which transmits the sixth nerve.

The *posterior* surface of the body is connected with the basilar process of the occipital bone, in young subjects by cartilage, in adults by bone, so that after a certain age it is impossible to separate the 'basilar suture' without the saw. The section shows well the structure of this part of the base of the skull; namely, two plates of compact bone separated by about $\frac{3}{16}$ of an inch of cancellous tissue or 'diploe.' Thus the bone is light and shocks transmitted to the base of the skull are broken. (Plate XI. fig. 1.)

Cornua Sphenoidalia.—The *anterior* surface of the body (Plate X. fig. 2) fits the posterior part of the ethmoid bone. It presents in the middle line a perpendicular plate of bone termed the 'rostrum.' This forms part of the bony septum of the nose, and is connected in front with the perpendicular plate of the ethmoid bone, and below with the vomer; as may be seen in Plate XXIII. fig. 1. The surface of bone on each side of the rostrum is completed by two plates of bone, one on each side, termed the '*cornua sphenoidalia*' or 'sphenoidal turbinated bones.' Although apparently integral parts of the sphenoid, yet these little bones are formed each from a special centre of ossification, are

distinct in early life, and remain separable till adult age. The annexed drawing (fig. 14) shows the 'cornua sphenoidalia' removed in a perfect state. The rostrum of the sphenoid would fit into the gap between them. Each cornu is triangular with the apex downwards. Each completely walls in the sphenoidal cell of its own side, except at the upper part, where there is a round opening in the base of the cornu which admits air from the upper meatus of the nose. Fig. 15 represents one of the cornua seen from the surface towards the sphenoidal cell. It shows the thin scales of bone which project into the cell and assist in lining its walls. However, it is right to state that these cornua sphenoidalia are rarely met with perfect. In consequence of their coalescence with the sphenoid, ethmoid, and palate bones, they are generally broken in the process of separation, so that there appears in most sphenoid bones a large irregular hole leading into the cell; as shown on one side of Plate X. fig. 2.

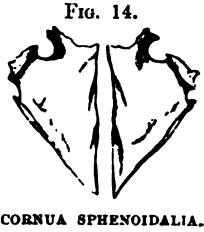

FIG. 15.



Sphenoidal Cells.—Next come the 'sphenoidal cells' or sinuses. These are large air cavities in the body of the sphenoid, generally two in number, and separated by a more or less complete perpendicular partition. (Plate XXIII. figs. 1 and 2.) Like the other air-cells in the bones of the skull, they are not developed in young subjects; but in the adult they gradually become large enough to excavate the whole body of the bone. The air is admitted freely into them from the upper meatus of the nose through an opening in the front wall of each sinus; and they are lined with a prolongation from the nasal mucous membrane. This communication of the sphenoidal cells with the nasal cavities explains how bleeding from the nose may occur as a symptom of fracture through the base of the skull,—that is, through the body of the sphenoid.

Lastly, the sides of the anterior surface of the body are hollowed out into two or three small air-cells, one below the other. (Plate X. fig. 2.) Of these, the upper, one or more, are roofed

in by corresponding cells of the ethmoid bone; and the lower by a corresponding cell in the orbital process of the palate bone.

The *inferior* surface of the body (Plate XI. fig. 1) assists in forming the roof of the nasal fossæ; and the posterior part of this surface, continuous with the basilar process of the occipital bone, looks towards the upper part of the throat, and may therefore be called the 'guttural' surface. A portion of the vertical plate or 'rostrum' is seen here also. Observe that it is expanded a little towards its base. Now it is this lower part of the rostrum which is connected with the vomer, and the mode of connection is rather singular. The rostrum fits into a deep cleft between the two plates or 'wings' of the vomer, and thus serves as a foundation from which this bone passes forwards and forms the septum of the nose. But the chief thing to notice on this surface is a process or scale of bone which projects horizontally inwards, on each side, from the base of the internal pterygoid plate. These are termed the 'vaginal processes,' and their free edges rise just enough to allow the edges of the vomer to slide beneath them. This is another contrivance which fixes the vomer. Lastly, each of these plates is traversed by a small groove, or perhaps a complete canal, termed the 'pterygo-palatine canal,' which transmits the pterygo-palatine artery, and a posterior branch (the pharyngeal nerve) from the sphenopalatine ganglion. The artery is a branch of the internal maxillary, runs from before backwards, and supplies the top of the pharynx and the Eustachian tube.

So much for the anterior, posterior, superior, and inferior surfaces of the body of the sphenoid. All that we have to remark concerning the sides of the body is, that they are grooved for the carotid artery, and that the smooth plate of the body in front of the sphenoidal fissure contributes to form a part of the inner wall of the orbit. (Plate XXII.)

Lesser Wings.—The lesser wings (or orbito-sphenoids) project transversely from the upper part of each side of the body. (Plate X. fig. 1.) Their upper surface is smooth and flat, and supports the anterior lobes of the brain; their lower surface overhangs the sphenoidal fissure, and forms the back part of the roof of the orbit: hence they are sometimes called the 'orbital wings.'

Their anterior margins are serrated and articulate with the orbital plates of the frontal bone ; their posterior margins are free, and in life fit into the great fissure (of Sylvius) between the anterior and middle lobes of the cerebrum. Their base is traversed by the 'foramen opticum,' through which pass the optic nerve and ophthalmic artery into the orbit. This foramen should be described rather as a short canal directed outwards and forwards. Towards the 'sella Turcica' each wing projects considerably in the form of a blunt angle, termed the 'anterior clinoid process ;' and between this and the body of the sphenoid there is either a deep notch or a complete ring for the internal carotid artery.

Greater Wings.—The 'greater wings,' sometimes called the 'temporal' (or alisphenoids), project from the lower part of each side of the body. Each wing presents three surfaces, which respectively enter into the formation of the base of the cranium, the orbit, and the temple. The 'cerebral surface' is concave, and marked by the convolutions of the middle lobe of the brain. The 'orbital surface' is a smooth quadrilateral plate which forms more than half of the outer wall of the orbit. (Plate XVI. fig. 2.) Of the four borders of this plate, notice that the superior articulates with the frontal bone, and the anterior with the malar bone ; while the posterior enters into the formation of the 'sphenoidal fissure' and the inferior into the 'sphenomaxillary' fissure. The 'temporal surface' is divided into two unequal parts by a transverse 'crest' of bone ; of these, the upper and larger one forms part of the temporal fossa, and gives origin to part of the temporal muscle : the lower one, which is more horizontal, forms part of the zygomatic fossa, and gives origin to one head of the 'pterygoideus externus.' The posterior angle of the great wing terminates in a sharp process termed the 'spinous process,' which fits into the angle between the squamous and petrous portions of the temporal bone, and gives attachment to the internal lateral ligament of the lower jaw, as well as origin to the 'laxator tympani' muscle.

Sphenoidal Fissure.—The greater wings are separated from the lesser by a broad and long fissure, termed the 'sphenoidal fissure,' which leads from the cranial cavity into the orbit, and

transmits nerves to the eye and its appendages. The sphenoidal fissure gives passage to the third and fourth nerves, to the first or ophthalmic branch of the fifth, the sixth, a few filaments of the sympathetic nerve, and also to the ophthalmic vein. Immediately below the inner end of this fissure is the 'foramen rotundum,' which transmits the superior maxillary division of the fifth nerve. Farther back and more external is the 'foramen ovale,' which transmits the inferior maxillary division of the fifth nerve, the lesser petrosal nerve, and the small meningeal branch of the internal maxillary artery. Near the spinous process is the 'foramen spinosum,' through which the 'arteria meningea media' enters the skull. Besides the foramina in the greater wing, there is often one (near the outer edge of the sphenoidal fissure) which leads into the orbit, and transmits a branch of the middle meningeal artery. There is often another between the foramen spinosum and the foramen ovale, through which a small vein passes; this is termed the 'foramen Vesalii.'

Pterygoid Processes.—The 'pterygoid processes' descend nearly perpendicularly from the under part of the bone,—one on either side, and act as buttresses which support the upper jaw bones. Each process consists of two parts termed the 'internal' and 'external pterygoid' plates. These are united in front, but diverge from one another behind, forming a deep interval called the 'pterygoid fossa.' At its lower part the 'pterygoid fossa' presents a deep notch which in the complete skull is filled up by the tuberosity of the palate bone. The external plate is broader than the internal and gives origin to the 'pterygoideus externus' and the 'pterygoideus internus' muscles on its external and internal surfaces respectively. These muscles cause the grinding movement in mastication. Its outer surface also forms the floor of the zygomatic fossa. Respecting the internal pterygoid plate, observe that it forms the lateral and part of the superior boundary of the posterior opening of the nose, and that it has a crescent-shaped margin above, leaving room for the cartilage of the Eustachian tube. At the root of this plate is a shallow groove called the 'scaphoid fossa,' which gives origin to the 'tensor palati' muscle, the tendon of which plays round a notch on the

‘hamular’ process at the end of the internal pterygoid plate. Behind the last molar tooth of the upper jaw we can distinctly feel this hamular process. Lastly, through the base of the internal pterygoid plate, a long canal, the ‘pterygoid’ or ‘Vidian,’ runs from before backwards, and transmits the ‘Vidian’³⁶ (‘great petrosal’) nerve and artery.

Look now at the anterior aspect of the pterygoid process, and observe a plate of bone, standing off like a side buttress which connects it with the greater wing. The plane of this plate forms a smooth surface, termed the ‘spheno-maxillary,’ and nearly corresponds in direction with that of the ‘orbital surface’ of the greater wing. (Plate X. fig. 2.) We draw special attention to this plate, and give it the special name of spheno-maxillary surface because it constitutes the posterior wall of a deep fossa, termed the ‘spheno-maxillary,’ which, in the perfect skull, intervenes between the sphenoid and superior maxillary bones.

Connections.—The sphenoid is connected with twelve bones, including all those of the cranium and five of the face. The ‘body’ is connected behind with the occipital bone by the basilar suture; in front with the ethmoid bone, the two palate bones, and the vomer. The ‘lesser wing’ is connected to the orbital plate of the frontal bone: the ‘greater wing’ is connected to the orbital plate of the frontal by a rugged surface of considerable extent, to the anterior inferior angle of the parietal bone, to the squamous and petrous parts of the temporal bone; and to the malar bone. Lastly, the pterygoid processes are connected with the palate bones.³⁷

Ossification.—In the early foetus the sphenoid bone consists of several parts. The posterior part of the body, termed by scientific anatomists the ‘basisphenoid’ or ‘post-sphenoid,’ is ossified from two centres, placed side by side in the sella Turcica. Later on another pair of centres (one on each side of the former) appear, making in all four for the basisphenoid part.

The greater wings, termed ‘alisphenoids,’ have each a distinct centre, from which the external pterygoid plates are also ossified.

The front part of the body, termed ‘presphenoid,’ has two

centres; its lesser wings (orbito-sphenoids) each have one ossific-nucleus.

Lastly, the internal pterygoid plates and the sphenoidal turbinated bones have each their separate nucleus of ossification. The bone then as a whole has fourteen centres.

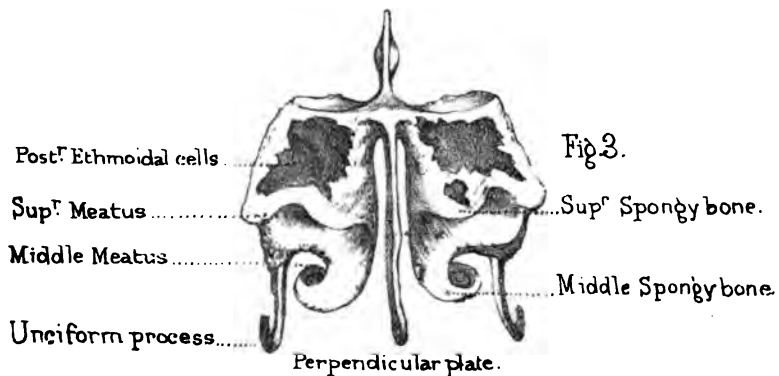
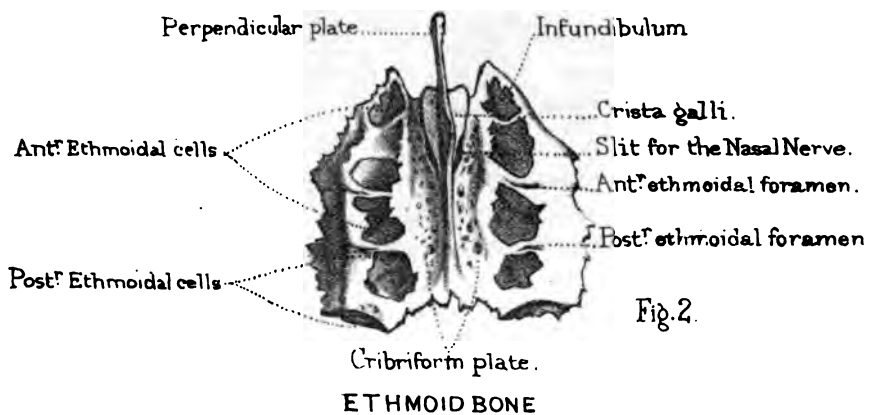
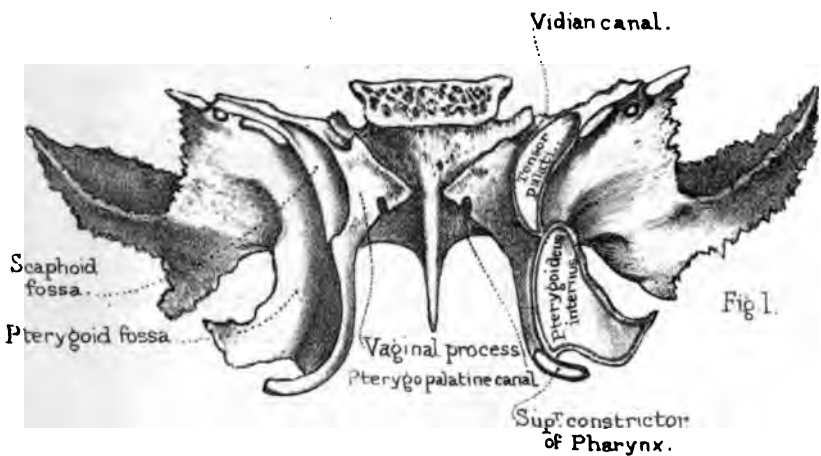
As the preceding description may appear a little confusing to a beginner, the following plan will explain it better, and at the same time refresh the memory on the chief elements of the entire bone.³⁸

PLAN OF THE OSSIFIC CENTRES OF THE SPHENOID BONE.

CORNU SPHENOIDALE <i>(Sphenoidal turbinated).</i> 1	CORNU SPHENOIDALE <i>(Sphenoidal turbinated).</i> 1	
LESSER WING <i>(Orbito-sphenoid).</i> 1	FRONT OF BODY <i>(Presphenoid).</i> 1	LESSER WING <i>(Orbito-sphenoid).</i> 1
BACK OF BODY <i>(Basisphenoid).</i>		
GREATER WING 2 <i>(Alisphenoid)</i> <i>and external pterygoid plate.</i> 1	2	GREATER WING <i>(Alisphenoid)</i> <i>and external pterygoid plate.</i> 1
INTERNAL PTERYGOID PLATE <i>(Pterygoid).</i> 1	INTERNAL PTERYGOID PLATE <i>(Pterygoid).</i> 1	

Comparative Osteology.—The top of the great wing of the sphenoid, passing up between the frontal and temporal bones, articulates with the anterior inferior angle of the parietal bone. The union of these two bones separates the temporal from the frontal. In those types of men where the forehead slopes backwards, these bones approximate, and in some cases actually articulate with





each other. (Nor. Hum. Ost., Nos. 1159, 1160, 1161, and 1146.) The size and strength of the external pterygoid plate bear a direct relation to the development of the pterygoid muscles which cause the grinding movements of mastication; consequently, it is highly developed in ruminants (see skulls of the deer and ox).

In old skulls the sphenoidal cells often extend into part of the basilar process of the occipital bone. In the chimpanzee the sphenoidal cells extend far into the alisphenoid and pterygoid bones.

THE ETHMOID BONE.

(PLATE XI. figs. 2 and 3.)

Constituent Parts.—This remarkably light and spongy bone contains the organ of smell. It occupies the interval between the orbital plates of the frontal bone, and enters into the formation of the cranium, the orbit, and the nose. It appears, at first sight, complicated; but it is simple when one understands the plan of it. It consists of a horizontal plate, which forms part of the base of the skull; of a central perpendicular plate which forms part of the septum of the nose; and of two 'lateral masses' containing the air-cells. Each of these must be examined separately.

Cribriform Plate.—The horizontal plate fits into the 'notch' between the orbital plates of the frontal bone; and completes the anterior fossa of the base of the skull. (Plate XIX.) It is called the 'cribriform plate' (*cribrum*, *ἰθμός*, a sieve), because it is perforated by holes for the passage of the olfactory nerves. High above it rises a crest of bone, termed, from its resemblance to a cock's comb, the 'crista galli.' This, which is a continuation of the perpendicular plate, gradually rises from behind, swells out as it proceeds, and stopping suddenly short, presents a broken edge which is connected to the frontal bone.

The 'crista galli' serves for the attachment of the 'falx cerebri.' It varies in size, and has often a slight lateral inclination. Sometimes it contains an air-cell. The cribriform plate does not

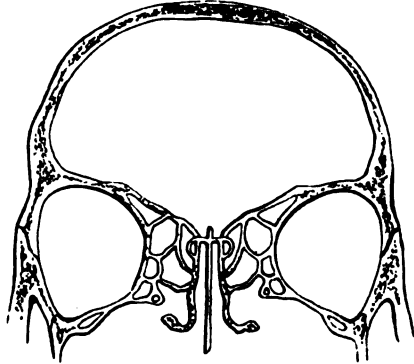
come up to the level of the lateral masses, but lies at the bottom of a deep groove ('olfactory groove'), which, being divided by the crista galli in the middle, forms in the perfect skull two recesses which lodge and support the olfactory lobes of the brain. The foramina at the bottom are arranged on each side in three somewhat irregular rows,—an outer, an inner, and a middle. Pass bristles down these holes, and you will find that the inner and the outer rows lead respectively to the 'olfactory canals' on the perpendicular plate and the upper spongy bones; while the middle holes run simply through the cribriform plate. These three rows of holes correspond to the three sets of olfactory nerves: namely those that ramify on the septum, those that ramify on the spongy bones, and those that supply the roof of the nose. (Plate XXIII. figs. 1 and 2.) Close to the front of the 'crista galli' is a long 'slit,' rather than a hole, which gives passage to the 'nasal nerve' (a branch of the first division of the fifth pair), which confers common sensation upon the mucous membrane as well as the skin of the nose.

Perpendicular Plate.—The perpendicular plate descends from the cribriform plate and assists in forming the septum of the nose. Notice the numerous grooves and canals on its surface, for the passage of the olfactory nerves. Its connections are well shown in Plate XXIII. fig. 1. Behind, it is connected along a sloping line with the 'rostrum' of the sphenoid and the vomer: in front, it is connected with the nasal spine of the frontal and the crest of the two nasal bones, of which it mainly supports the arch. The triangular gap in the septum in the dry skull is filled up, in the recent state, by the central cartilage of the nose.

Lateral Masses.—The 'lateral masses' of the ethmoid (fig. 16) are made up of irregular air-cells, surrounded by paper-like walls of bone, lined by mucous membrane continuous with that of the nose. The cells are divided into two sets,—an anterior and a posterior; and the cells of one set do not communicate with those of the other. In the separated bone many of the cells are necessarily opened, because their walls, in the perfect skull, are completed by the adjoining bones. Thus, the front cells on the upper surface are roofed in by corresponding cells in the orbital

plate of the frontal; those at the back of the bone are closed by the body of the sphenoid and the orbital process of the palate bone; those in front of the bone are walled in by the lachrymal; those below, by the superior maxillary bone. On the outer side of each lateral mass the cells are closed by a smooth and square plate of bone, termed the 'os planum,' belonging entirely to the ethmoid. This forms a large share of the inner wall of the orbit (Plate XXII.), where it is easy to learn its connections with the surrounding bones, by tracing the sutures between them.

FIG. 16.



TRANSVERSE SECTION, TO SHOW THE LATERAL AIR CELLS OF THE ETHMOID BONE.

Lastly, notice the two notches on its upper border, which, with the frontal, form the 'anterior and posterior ethmoidal foramina.' The 'anterior' transmits the nasal nerve and the anterior ethmoidal vessels; the 'posterior' gives passage to the posterior ethmoidal vessels.

Turbinated Bones and Meatus.—On the inner aspect of the lateral mass we observe two thin plates of bone standing out, one below the other, and slightly curled, like a turbinated shell. These are the 'turbinated' or 'spongy' bones of the ethmoid (Plate XI. fig. 3), and can be properly seen only in a divided skull. The 'superior' is the smaller of the two, and does not reach so far forward as the other, which is called the 'middle,' because there is a third or 'inferior turbinated' bone, still lower down in the nose; but this does not belong to the ethmoid. Now the spaces left between these turbinated bones and the lateral masses are called respectively the superior and middle 'meatus,' or passages of the nose. Each is distinct from the other, and leads to its own particular cavities, and to no other. The superior meatus, being farther back than the middle, leads into the sphenoidal cell, and into the posterior ethmoidal cells. The middle meatus

leads into the anterior ethmoidal cells, and also to the frontal cells, along a funnel-shaped canal ('infundibulum') which traverses the foremost of the ethmoidal. (Plate XXIII. fig. 2.)

Unciform Process.—Lastly, from the anterior part of each lateral mass an irregular plate of bone descends almost perpendicularly, and terminates in a kind of hook; hence it is called the 'unciform³⁹ process' (Plate XI. fig. 3). By referring to Plate XXIII. fig. 2, it is seen that this process is connected with the inferior spongy bone, and with the thin walls of the 'antrum' of the superior maxillary bone; it chiefly assists in narrowing the orifice of this great air-cavity.

Connections.—The ethmoid is connected with thirteen bones, namely,—behind, with the sphenoid and two palate bones; above, with the frontal; below, with the two superior maxillary; in front, with the two lachrymal bones. The perpendicular plate is connected behind with the vomer, and in front with the two nasal bones. Lastly, the unciform process on each side is connected with the inferior spongy bone and the superior maxillary.

Ossification.—Until the middle of foetal life the ethmoid is all cartilage. Ossification begins about the fifth month, by a centre for each of the lateral parts, and gradually extends into the two upper turbinated bones (ethmo-turbinals). Within a year after birth another centre appears for the perpendicular and cribriform plates (mesethmoid). An arrest in the progressive ossification of the perpendicular plate occasions a 'pug nose.' In the foetus at birth there are no ethmoid cells; these are not formed until the fourth or fifth year.

Comparative Osteology.—In man the rule is that there are three turbinated bones on each side; sometimes there is a fourth, smaller than the rest, and higher up at the back part. This fourth bone is more frequently met with in some coloured races where the sense of smell is notoriously acute.

The curled plates of the turbinated bones are covered by a very vascular membrane. The upper ones afford an extensive surface upon which the olfactory nerves are distributed after their passage through the cribriform plate. By the variation of the extent of surface of these bones it will be seen that the acuteness

of the sense of smell and the capability of warming the air on its way through the nose to the lungs are regulated.

The sense of smell is remarkably keen in the deer tribe and carnivora, and their spongy bones are developed in proportion. It is curious that they should both in a measure depend for a living upon the development of the same sense, the one to avoid its enemies, and the other to find its prey.

The spongy bones on which the nerves of smell are distributed and those which are only covered by a vascular membrane, are widely differentiated in their conformation in the lower animals. In the seal, for instance (Nos. 3934, 3935A), which inhabits the arctic regions and necessarily breathes intensely cold air, the inferior spongy bones subdivide into a multitude of plates and afford a vast surface on which is distributed a profusion of blood-vessels which warm the air before entering the lungs. The surface of these bones has been estimated at about 120 square inches in each nostril; a longitudinal section of such a nostril has the appearance of being completely plugged by the convoluted warming plates of the lower spongy bone; while those on which the olfactory nerves are distributed have a different form and are further back and separated by a slight interval from the others.

There is no ethmoid bone in serpents, but the olfactory filaments are spread out on a plicated mucous membrane.

BONES OF THE FACE.

THERE are fourteen bones of the face ; namely, the two superior maxillary, the two malar, the two nasal, the two lachrymal, the two inferior spongy, the two palate, the vomer, and the inferior maxilla.

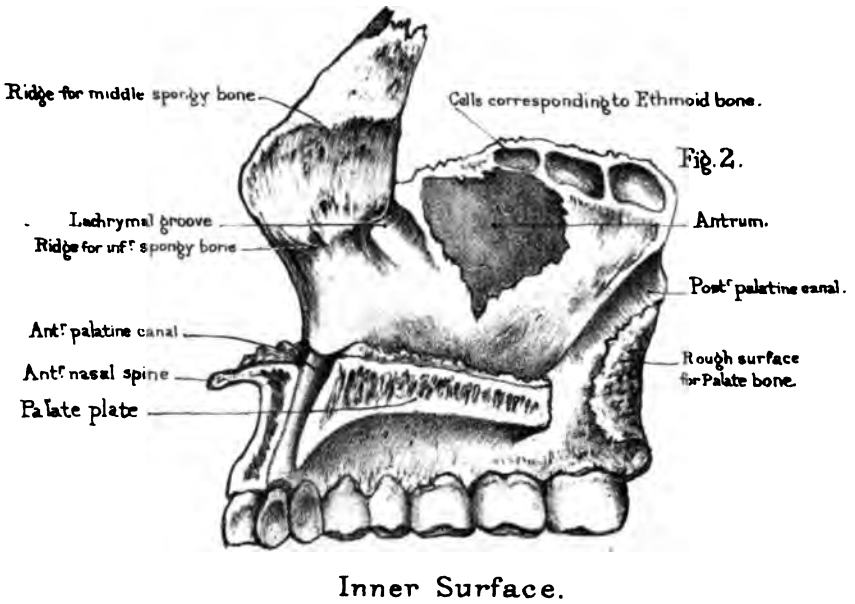
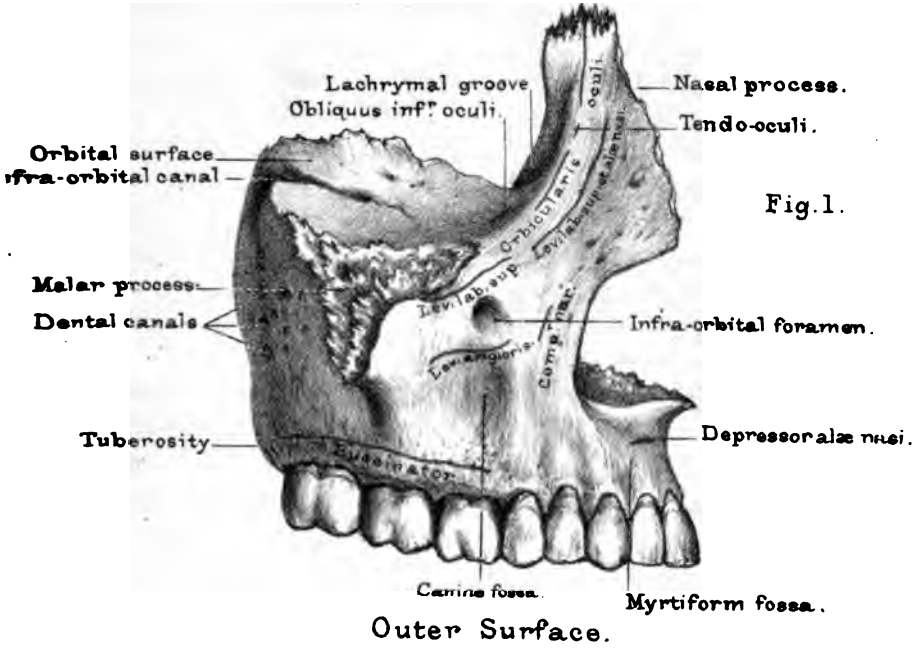
SUPERIOR MAXILLARY BONE.

(PLATE XII.)

Constituent Parts.—This bone gives much character to the human face, and forms the greater part of its framework. It is exceedingly irregular in shape, and, besides forming sockets for the teeth, enters into the composition of the nose, the orbit, the cheek, and the palate. For convenience of description, we divide it into a ‘body,’ which is hollowed out into a large air-cavity, called the ‘antrum,’ and four outstanding ‘processes ;’ namely, the ‘alveolar,’ which holds the teeth ; the ‘palatine,’ which forms part of the hard palate ; the ‘nasal,’ which assists in forming the nose ; and the ‘malar,’ which helps to form the prominence of the cheek.

Body: Walls of Antrum.—Let us take the ‘body’ first, and learn its various relations well, for it is a part of great surgical interest, being liable to many diseases requiring surgical operations. The first thing to observe is, that the walls which bound its cavity have *four* aspects : one—namely, the front—looks towards the cheek ; another, the upper, looks towards the orbit ; a third, the inner, looks towards the nose ; and a fourth, behind, looks towards the zygomatic fossa. Therefore, when a morbid growth forms in the antrum, and distends it, any one or more of

SUPERIOR MAXILLARY BONE.



Drawn on Stone by T. Godart.
 From nature by L. Holden

Printed by West, Newman & Co.

these walls may be protruded. They are all very thin, the orbital especially; but it is worth remembering that they are thicker in the child than in the adult.

Antrum: Anterior Wall.—The anterior wall of the ‘antrum’ is that which is generally removed to take out a morbid growth from the interior, and through which we tap the antrum to let out pus, or any fluid that may have accumulated there; cysts in the antrum being by no means uncommon. There is a depression in it, called the ‘canine fossa’ a little outside the eminence of the canine tooth; and above this is the ‘infra-orbital foramen,’ or termination of the ‘infra-orbital canal,’ which transmits the ‘infra-orbital’ nerve and artery. The canine fossa gives origin to the ‘levator anguli oris.’ Above the infra-orbital foramen arises the ‘levator labii superioris,’ and more internally the ‘compressor naris.’

Antrum: Posterior Wall.—The posterior wall of the antrum is convex, and bulges into the zygomatic fossa.⁴⁰ There are several small holes in it, leading to canals (‘dental canals’) which transmit the posterior dental branches of the superior maxillary nerve, and the superior dental branches of the internal maxillary artery. Lower down it has a very rough surface, just behind the wisdom tooth, called the ‘tuberosity,’ by which it is firmly connected to the palate bone; and along the inner edge of this surface (Plate XII. fig. 2) is a groove, which, with the perpendicular plate of the palate bone, forms the ‘posterior palatine canal,’ for the passage of the descending palatine nerve and artery.

Antrum: Superior Wall.—The superior wall of the antrum slopes downwards and outwards, and forms the floor of the orbit. Like the other walls of the antrum, it is thin enough to be translucent. Notice here the ‘infra-orbital canal,’ for the passage of the superior maxillary nerve and infra-orbital artery. It commences behind as a groove, but soon becomes a canal, which terminates on the front wall of the antrum, just below the edge of the orbit. A little before its termination, the main canal gives off one or sometimes two smaller ones, not always visible, termed the ‘anterior dental canals.’ These run down in the very substance of the front wall of the antrum, and transmit blood-vessels and nerves to the

two incisor, the canine, and the first bicuspid teeth. To see these canals it is necessary to introduce a bristle as a guide, and then to rasp away the front wall of the bone. Near the lachrymal groove may sometimes be seen a small depression, indicating the spot where the 'inferior oblique' muscle of the eye arises. This is the only muscle of the orbit which takes origin from the front; all the others arise from the back part, around the optic foramen. In the perfect skull (Plate XVI.) observe that the upper wall or 'orbital plate' of the antrum is connected on its inner side with the lachrymal, ethmoid, and palate bones; but that on its outer side it forms one of the margins of the 'spheno-maxillary fissure,' at the back of the orbit.

Antrum; Internal Wall.—On the inner or 'nasal wall' of the antrum, the first thing to notice is the orifice of the antrum itself. (Plate XII. fig. 2.) In the separate bone, this orifice is very irregular, and large enough to admit the end of a finger⁴¹; but in the perfect skull (Plate XXII.) it is very much closed in by thin plates from the ethmoid, the palate, and the inferior spongy bones. In the recent state the orifice is generally so contracted by a fold of the mucous membrane of the nose, that it will only admit a crow-quill. The orifice is not near the bottom of the antrum, but very high up: the consequence of this is, that when fluid collects in the antrum it cannot run out until the antrum is nearly full, or until the head is inclined horizontally with the opposite cheek downwards.

Antrum, Cavity of.—The 'maxillary sinus,' or 'antrum,'⁴² is by far the largest of the air-cells in the bones of the head. It is lined by mucous membrane continuous with that of the nose, and is large enough to hold a musket-ball with ease. A ball has been known to lodge in the antrum for months, and even for years, before it was removed.⁴³ A ball once lodged for eleven years in the antrum, and finally made its way out through the roof of the mouth.⁴⁴ However, it varies in size, and somewhat in shape, in different persons; but, as a rule, it has the form of a triangular pyramid, with the base towards the nose, and the apex towards the malar bone. Thin plates of bone often project into the antrum, making a kind of recess or pocket here and there⁴⁵;

and the fangs of one or more of the molar teeth generally project into it, either quite bare, or covered by a thin scale of bone. Hence the practice, adopted by some surgeons, of drawing one of these teeth, say the first or second molar, to let out matter from the antrum. Again, the fangs of decayed or otherwise injured molar teeth are liable to set up disease in the antrum; and this is the explanation commonly given why morbid growths arise in the antrum more frequently than in any other of the air-cavities of the nose.

The following case gives a good idea of the extent of the antrum:—‘A lady suffering from tooth-ache submitted to the extraction of the canine tooth of the upper jaw, with which a portion of the alveolar process was removed, making an aperture in the antrum, from which a watery fluid constantly issued. The patient, desirous of ascertaining the source of the discharge, took a pen, and having stripped off the barbs from the feathered part, found that the whole of it, full six inches long, could be introduced into the cavity. At this she was greatly terrified, believing it must have gone into the brain. She consulted Highmore, who explained to her that the pen had turned spirally within the sinus, and he, besides, counselled her to submit with patience to the inconvenience of the discharge from the cavity.’⁴⁶

Alveolar Process and Teeth.—The alveolar process is a thick and strong ridge of bone, curved so as to form with that of the other side the dental arch. It consists of two plates, an outer and an inner, connected by numerous septa which form the sockets (alveoli) of the teeth. The inner plate is the stronger; therefore, in drawing a tooth, care should be taken to incline it a little outwards. The outer plate is marked by eminences corresponding to the fangs of the teeth; the eminence of the canine tooth being especially marked.

In a child, from the end of the second to the end of the sixth year, the half of each jaw contains sockets for five teeth, i.e. for two incisors, one canine, and two molars.

The formula for the ‘milk dentition’ is therefore—

$$i. \frac{2+2}{2+2}, \quad c. \frac{1+1}{1+1}, \quad m. \frac{2+2}{2+2} = 20 \text{ in all.}$$

The half of each jaw contains, in the adult, sockets for eight teeth; namely, two 'incisors,' one 'canine,' two 'bicuspid (or præ-molars)' and three 'molars.' Thus the dental formula of the adult human skull is—

$$-i. \frac{2+2}{2+2}, \quad c. \frac{1+1}{1+1}, \quad p. \frac{2+2}{2+2}, \quad m. \frac{3+3}{3+3} = 32 \text{ in all.}$$

The eruption of the second or permanent set of teeth commences about the end of the sixth year. The first to appear is the first permanent molar, which is therefore called the six-year-old tooth, and is the oldest tooth in an adult's head. The presence of this tooth has been used as a test of age by medical inspectors in giving certificates as to the fitness of children to work in factories.⁴⁷

Generally speaking, the twenty milk teeth are cut between the 6th and 24th months, and the thirty-two permanent teeth between the 6th and 24th years.⁴⁸

Sockets of Teeth.—The sockets correspond in number and size to the fangs of the teeth they receive. They vary in depth in different instances. The deepest of all is the socket of the canine tooth: this is often $\frac{1}{10}$ of an inch in depth in the dry bone. The first two molars of the upper jaw have three fangs each, and as many sockets. Of these fangs, two are external, one internal. In the last molar, or wisdom tooth, the fangs are generally consolidated into one. Irregularities in the shape and the direction of the fangs, whether diverging too much or converging, lead to unavoidable evils when it is necessary to extract them. Either a fang breaks, or part of the alveolus must be extracted with the fang. One cannot foresee this. Hence it follows that, now and then, even the most skilful operators break teeth or extract portions of bone. At the bottom of each socket is a minute hole, through which the vessels and nerve come up and supply the pulp cavity; and there are also numerous holes in the bony partitions between the sockets, through which vessels supply the gums and the periosteum. These are the sources of the bleeding after the extraction of a tooth. The teeth are fixed, not only by the closely fitting socket, but also by the very vascular mem-

brane, the periosteum, which lines the socket and adheres closely to the fang. This periosteum not only retains the teeth in their places, but helps to maintain their vitality, and, being elastic, breaks shocks which would otherwise be communicated to the jaws. When the dental periosteum inflames, the tooth is partly lifted out of its socket, and the teeth cannot be clenched without pain. If the inflammation goes on to the formation of matter, the periosteum quits its hold of more or less of the fang, and abscess in the socket is the result. The matter then makes its way out by the side of the tooth, or through a small hole formed by ulceration in the alveolar wall; that is, a gumboil is the result. In the dry bones, most of the teeth fall out, because the periosteum shrinks, and thus the sockets become too large.

The alveolar process gives origin to two muscles (Plate XII. fig. 1), namely, to the 'buccinator' above the three molar teeth, and to the 'depressor alæ nasi' above the incisor teeth, where there is a little depression, termed the 'myrtiform fossa.'

Nasal Process.—The nasal process ascends nearly perpendicularly, in a line with the canine tooth, and abuts, by means of a very rough suture, upon the internal angular process of the frontal bone. It supports the true nasal bones, and contributes to form the inner margin of the orbit. The principal point concerning the nasal process is the deep groove which runs almost vertically behind its orbital margin. It is called the 'lachrymal groove.' In the perfect skull it is converted into a complete canal by a corresponding groove in the lachrymal bone and a small portion of the inferior spongy bone. The canal thus completed lodges the 'lachrymal sac' and 'nasal duct,' which convey the tears into the inferior 'meatus' of the nose. It is about the size of a common goose-quill. When, from inflammation or other cause—such as a tumour—the canal becomes obstructed, the tears necessarily flow over and run down the cheek. To obviate this, it is often requisite to slit up one of the lachrymal canaliculi, and introduce a probe into the nasal duct. Therefore one must know well the direction of the lachrymal canal. It runs from above downwards, and slightly backwards. On the outer surface of the nasal process is the prominent

ridge which forms the inner margin of the orbit. This gives origin to the 'tendo oculi' or 'palpebrarum' and the 'orbicularis oculi.' A little in front of this the 'levator labii superioris et alæ nasi' arises. On the inner surface are the two ridges to which the inferior and middle spongy bones are attached, and also the smooth surfaces between the ridges which respectively form part of the inferior and middle 'meatus' of the nose. Near the top the nasal process often closes in one of the anterior ethmoidal cells at the lower half. In front the nasal process presents a sharp crescent-shaped margin, which, with the similar one on the opposite bone and the nasal bones, bounds the anterior opening of the nose, and gives attachment to the lateral cartilage.

Palatine Process.—The palatine process extends horizontally inwards, and forms the anterior two-thirds of the hard palate, and the floor of the nose; the posterior third being completed by the palate bone. It is slightly arched from before backwards, and is thicker in front, near the alveolus, than behind. On the palatine surface (Plate XX.) can be seen—1, the palatine groove for the descending palatine vessels and nerve; 2, the numerous foramina which transmit vessels into the bone; and 3, the pits made by the palatine glands. The upper or nasal surface is smooth and slightly concave. By adjusting the two superior maxillary bones together, you find that the palatine processes are connected in the middle line by a very rough suture (palatine suture); and that they rise towards the nose in a crest, which articulates with the vomer, and forms the base of the bony septum of the nose. (Plate XXIII. fig. 1.) This crest projects in front in the shape of a sharp spine (the 'anterior nasal spine'), to which is attached the cartilaginous part of the septum. In this palatine suture, immediately behind the middle incisor teeth, we see the 'anterior palatine canal.' (Plate XX.) Towards the palate this canal has, at first sight, only one large orifice; but if we look to the bottom of it, we shall probably find four minute openings. Two of these⁴⁹ lie in the middle line, one behind the other, and transmit the nasopalatine nerves; the other two much larger, are situated one on each side of the middle line; they lead into the floor of each nostril, and transmit the anterior palatine arteries.⁵⁰

Malar Process.—The malar process stands off from the outer side of the antrum. It is remarkably thick and strong, and is connected, by a very rugged triangular surface, with the malar bone. The malar process is situated just over the first and second molar teeth, and is therefore well calculated to resist pressure in mastication. When we crack a nut, we instinctively place it under these teeth.

Connections.—The superior maxilla is connected with nine bones, as follows:—With the malar, the frontal, the nasal, the lachrymal, the vomer, the inferior spongy, the palate bone, its fellow, and lastly, the ethmoid. We mention this bone last of all, because we wish to direct attention to a fact which we have hitherto omitted to notice, that some of its cells are closed in by half cells usually seen along the orbital plate of the superior maxillary bone. (Plate XII. fig. 2.)

Ossification.—The ossification of the upper jaw begins about the seventh week of foetal life, and proceeds so quickly, that the number of its independent centres has not yet been accurately determined. It appears to have five distinct centres: one for the alveolus behind the incisors, one for the palatine process, one for the floor of the orbit and malar process, a fourth for the portion in front of the antrum with the nasal process, and lastly, a very distinct centre,⁵¹ which includes the sockets of the two incisor teeth. In most human skulls, if not very old, one can trace the remains of the ‘pre-maxillary’ suture. (Plate XX.) It runs outwards from the anterior palatine canal, and then through the alveolar border of the jaw, invariably between the second incisor and the canine tooth; and here we lose all trace of it. This is interesting surgically. In cases of double hare-lip, where the fissure is not confined to the lips, the pre-maxillary bones on each side fail to unite with the rest of the upper jaw, and often project in a hideous manner through the fissure of the lip. When removed by operation, these bones are always found to contain the capsules of the four incisor teeth.⁵²

Right or Left?—This bone will be in the same position as the corresponding one in the student’s body, if he hold the nasal

process (which articulates with the frontal) upwards, the opening of the antrum inwards, and the incisor teeth forwards.

Comparative Osteology.—The teeth which grow from the pre-maxillary bones are called incisors. On a close inspection of the narwhal hanging in the Mus. Roy. Coll. Surg. the sharp spiral tusk will be found to spring from the left pre-maxillary bone. It is therefore the left incisor tooth. The right one usually remains undeveloped; but there is a specimen in the Cambridge Museum where both are of full length. Evidence of the narwhal's power of offence or defence is given by the tusks having been found buried to a depth of ten or twelve inches in the timbers of ships. The female narwhal has no such extraordinary growth of the incisor tooth. It is interesting to notice in the skull of the elephant that the suture between the superior maxillary and pre-maxillary bones is visible, and that his tusks grow from the pre-maxillary bones, and are therefore also incisor teeth. The tusks of the walrus have their origin externally to the pre-maxillary bone, and are therefore canine teeth, and this animal belongs to the carnivora. (No. 3864A.)

Examine the bull, and it will be seen that there are no incisors in the upper jaw. This is the case in all the Ruminants, excepting the camel, which loses the central incisors early in life. In the bull, deer, and other Ruminants also notice that the so-called canines in the lower jaw are in a regular series with the six incisors, and much resemble them. They seize their food between this even row of teeth and the prehensile upper lip, and then chew it with the molars.

In the order Monotremata, the one member, *Echidna* has no teeth, and the other, *Ornithorhynchus paradoxus*, has but horny plates to represent them. (See Sep. Ser.)

In many of the lower animals teeth are not confined to the alveolar margins of the jaw, but are found scattered about the upper part of the alimentary canal. Thus, in the Labroid fishes (No. 96), large teeth may be seen developed upon the palate. In the perch there are teeth in the pharynx. (No. 197.) In the lobster there are horny teeth in the stomach, where the food is ground.

In birds the superior maxillary, with the inter-maxillary bones, are prolonged forwards, and when covered with the appropriate horny material, constitute the beak; the lower jaw also projecting forms the lower half of the beak. (Nos. 1678, 1678A.)

The upper jaw is movable in parrots (No. 1438), and has a broad transverse articulation with the frontal. It consists of the coalesced nasal, maxillary, and pre-maxillary bones.

In Primates there are never more than four incisors above, and the same number below.

In the Rodents the incisors continue to grow throughout life and are long and curved. See the Canadian beaver (No. 2165).

In Cetacea the pre-maxillæ, which are small in proportion to the maxillæ, are prolonged far in advance of the nasal aperture, as may be seen in the skeleton of the great sperm whale in the Mus. Roy. Coll. Surg.

Examine the poison fang in a serpent from New Holland (No. 650). It is situated in the upper jaw and has a bristle passed through it, showing that it is tubular. This tube contains the duct of the poison gland.

Look at the plates of whalebone hanging from the upper jaw of the whalebone whale. It is by means of these plates that he entangles the small molluscs on which he feeds.

M A L A R B O N E.

(PLATE XIII. fig. 3.)

Three Surfaces.—The malar bone forms the prominence of the cheek, a part of the margin and wall of the orbit, and the greater portion of the zygomatic arch. It is remarkably thick and strong, and resists injury, to which the face, in this situation, is so exposed. We divide it into an anterior or *subcutaneous* surface, a superior or *orbital*, and a posterior or *zygomatic*.

On the *subcutaneous* surface there is nothing to observe except the orifice of one of the ‘malar canals,’ and that it gives origin to the ‘zygomaticus major’ and ‘minor’ muscles.

The *superior* surface forms part of the outer wall of the orbit, a small part of its floor, and, generally speaking, the corner only of the spheno-maxillary fissure.⁵³ There are usually two 'malar canals' to be seen on it. By introducing bristles, it will be found that one of these leads to the subcutaneous surface; the other, to the zygomatic surface. These malar canals transmit cutaneous nerves which proceed from the orbital branch of the superior maxillary nerve to the cheek, and the zygomatic fossa respectively.

The *posterior* surface is very concave, and forms the anterior wall of the zygomatic fossa.

Three Borders.—The malar bone has three free borders. One forms at least a third of the margin of the orbit, and reaches as far inwards as the infra-orbital canal, giving origin to a few fibres of the 'levator labii superioris'; a second forms the upper edge of the zygomatic arch, and running upwards becomes continuous with the temporal ridge at the external angular process of the frontal bone—this border gives attachment to the 'temporal fascia'; a third forms the lower edge of the arch, and gives origin to the 'masseter' muscle. (Plate XV. fig. 2.)

Connections.—The malar bone is connected with four bones: namely, by a broad and very roughly serrated surface, with the superior maxillary; by suture, with the external angle of the frontal, the orbital plate of the sphenoid, and the zygomatic process of the temporal. These several connections are so strong that the bone cannot be driven inwards towards the orbit, and fractures of it are very rare.

Ossification.—It is developed from a single centre of ossification, which appears about the seventh week of foetal life.

Right or Left?—The cheek bone will be in the same position as the corresponding one in the student's body if he hold it with the subcutaneous surface forwards (and outwards); the orbital surface upwards; and the articulation for the zygoma backwards.

Comparative Osteology.—The upper process of the malar bone does not articulate with the frontal in the carnivora (Nos. 4561, 4562).

In the Great Kangaroo and Wombat the zygomatic process of the malar bone extends backwards so far that it forms part of the glenoid cavity and articulates with the lower jaw.

N A S A L B O N E.

(PLATE XVI. fig. 3.)

The nasal bones, situated one on either side, occupy the space between the nasal processes of the superior maxillary bones, and, together, complete the bridge of the nose. Their length, breadth, and degree of inclination, determine the shape of the nose. We have to examine their anterior and posterior surfaces, and their four borders.

Surfaces.—Their *anterior* surfaces are subcutaneous, convex, and present the orifices of one or more canals, which transmit blood-vessels. Their *posterior* surfaces are concave, form part of the roof of the nose, and each is marked by a groove for the passage of the external branch of the nasal division of the fifth nerve.

Borders.—Their *upper* borders are broad, serrated, and firmly articulated with the frontal bone. Their *lower* borders are thin and free in the dry bone, but connected in the recent subject with the lateral cartilages of the nose. Each has, generally, a little notch in it, through which the external branch of the nasal nerve comes and supplies the skin at the tip of the nose. Their *outer* borders are serrated, slightly sloped, and rest upon the nasal processes of the superior maxillary bones. Their *inner* borders articulate with each other, in the middle line, along the ‘nasal suture.’ From the under surface of this suture a high ‘crest’ of bone projects. By putting the bones together, it is seen how their crests form the beginning of the bony septum of the nose, and how they articulate with the nasal spine of the frontal bone, and the perpendicular plate of the ethmoid. (Plate XXIII. fig. 1.) Hence, with a depressed fracture of the nasal bones, there must

be a fracture of the perpendicular plate of the ethmoid. In some rare instances, the injury extends through the perpendicular plate of the ethmoid to the base of the brain. Observing the great strength of the nasal bones and the massive arch they form, how the sides of this arch are supported by the nasal processes of the superior maxillæ, while the centre is propped up by the nasal spine of the frontal bone, and the perpendicular plate of the ethmoid (Plate XXIV. fig. 2), one can readily understand what makes the arch so strong, and why the bones are so seldom broken. A pretty good proof is given of the strength of the arch, when one sees a mountebank support upon it, with impunity, a ladder, with the additional weight of a man upon the steps.

Connections.—The nasal bone articulates with four others, namely, its fellow, the superior maxillary, the frontal, and the perpendicular plate of the ethmoid.

Ossification.—Each nasal bone is developed from a single centre of ossification, which appears about the seventh week of foetal life.

Right or Left?—This bone will be in the same position as the corresponding one in the student's body if he hold the thick border (which articulates with the frontal bone) upwards, the convex surface forwards and outwards, and the short side (for articulation with its fellow) inwards.

Comparative Osteology.—The only difference between the skulls of a tiger and a lion is that in the lion the upper ends of the nasal bones and the nasal processes of the superior maxillary bones are on the same level, whereas in the tiger the nasal bones run up considerably beyond the nasal processes.

L A C H R Y M A L B O N E .

(PLATE XIII. fig. 4.)

Surfaces.—The lachrymal bones are situated, one on each side, on the inner wall of the orbit. They are exceedingly thin and delicate, and shaped somewhat like a finger-nail; hence the

name 'os unguis.' In old skulls, they are often as thin as silver paper, and sometimes perforated. One surface is directed towards the orbit; the other towards the nose. One of these bones is seen *in situ* in Plate XVI. fig. 2.

The external or *orbital* surface has a vertical ridge upon it which terminates below in a small hook-like process or tongue, termed 'hamulus,' which fits into the angle between the inferior turbinated and the superior maxillary bones (Plate XXIII. fig. 2). In front of this is a groove ('lachrymal groove'), which, together with the groove on the nasal process of the superior maxilla, forms the commencement of the canal for the passage of the tears from the lachrymal sac into the nose. The ridge itself gives origin to the 'tensor tarsi.' The bone behind the ridge is smooth, slightly concave, and forms part of the inner wall of the orbit.

The internal or *nasal* surface presents a slight furrow corresponding to the external ridge. The surface in front of this forms part of the middle meatus of the nose; that behind it always covers the anterior cells of the ethmoid bone, and sometimes a small cell or two in the frontal bone.

Connections.—By examining the orbit (Plate XVI. fig. 2), you observe that the lachrymal bone is somewhat square, and that it articulates by suture with the frontal above, the ethmoid behind, the superior maxillary in front and below. But this is not all. The hook-like process (hamulus) at the lower edge of the bone articulates with what is called the 'lachrymal process' of the inferior turbinated bone. (Plate XXIII. fig. 2.) So, then, it articulates with four bones.

Ossification.—It has one centre of ossification, which appears about the eighth week of foetal life.

Right or Left?—This bone will be in the same position as the corresponding one in the student's body, if he hold the concave orbital surface outwards, the lachrymal groove forwards, and the small tongue-like process (which articulates with the lachrymal process of the inferior turbinated bone) downwards.

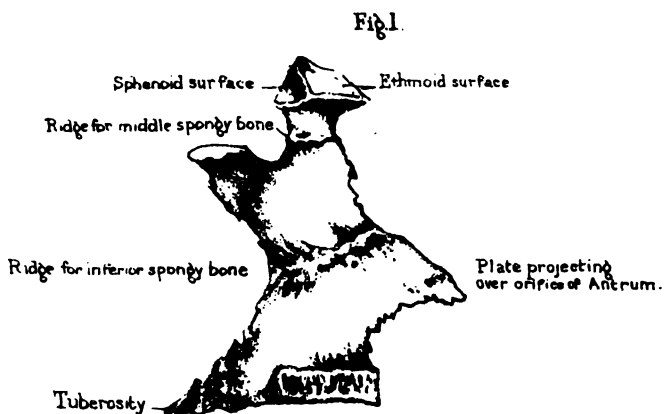
PALATE BONE.

(PLATES XIII. and XIV.)

Each 'palate bone' is wedged in between the pterygoid process of the sphenoid and the superior maxillary bone. Each forms part of the nasal fossa, of the orbit, and of the palate. As the palate bone somewhat resembles the letter L in shape, we can divide it, for convenience of description, into a horizontal and a vertical plate.

Horizontal Plate.—The horizontal plate completes the bony palate by fitting on to the palate plate of the superior maxillary bone. Its under surface (Plate XIV. fig. 2) presents a transverse ridge for the insertion of the aponeurosis of the 'tensor palati.' In front of this ridge and towards its outer end we observe the orifice, more or less complete, of the 'posterior palatine canal,' for the transmission of the descending palatine vessels and the larger palatine nerve from the sphenopalatine ganglion. The anterior edge of this plate is serrated and cut obliquely, so as to articulate with, and be supported by, the palate plate of the superior maxilla. The posterior edge is smooth and concave, and gives attachment to the soft palate. The inner edge firmly articulates with its fellow, by means of a 'median crest' raised up towards the nose, precisely like the corresponding parts in the superior maxillary bones (see Plate XXIII. fig. 1): this crest supports the vomer, and forms a basis for the septum of the nose. Behind it terminates in a pointed process, termed the 'posterior nasal spine' (Plate XX.), which gives origin to the 'azygos uvulæ' muscle. The upper surface of the plate is smooth and slightly concave, thus forming part of the floor of the nose.

Vertical Plate.—The vertical plate of the palate bone contributes to form the outer boundary of the nasal fossa. On its inner surface (Plate XIII. fig. 1) is a 'ridge' to which is attached the inferior turbinated bone. The surfaces above and below this ridge, respectively, form part of the middle and inferior 'meatus'



INTERNAL VIEW OF PALATE BONE.

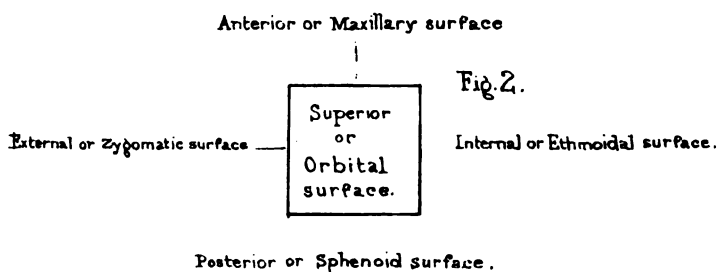
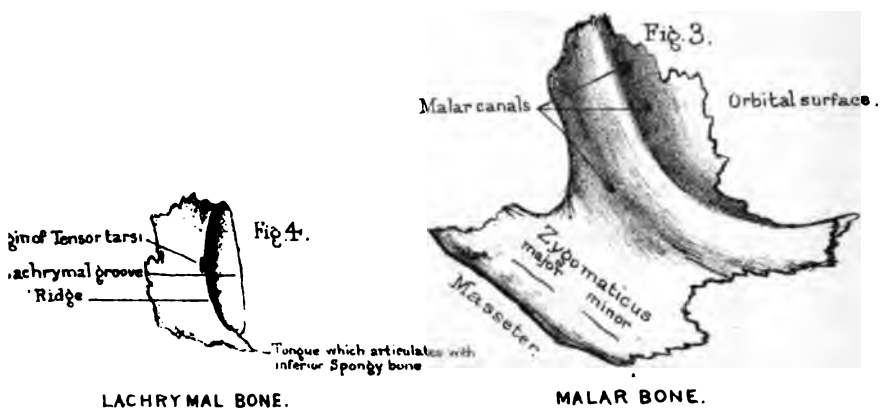
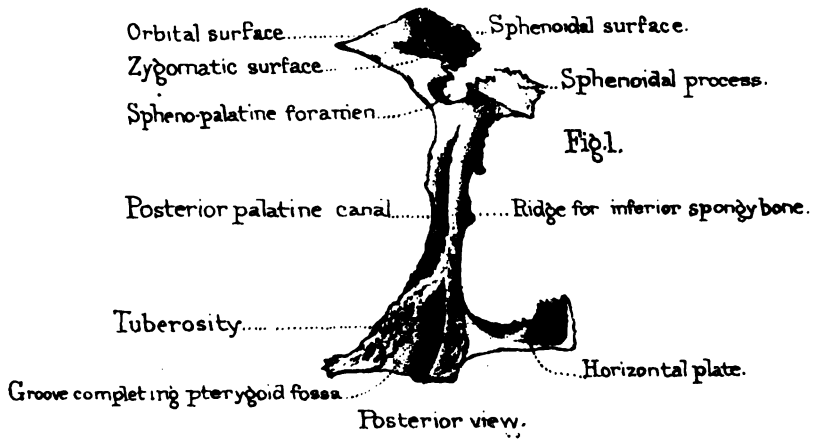


Diagram of the orbital process of the Palate bone.

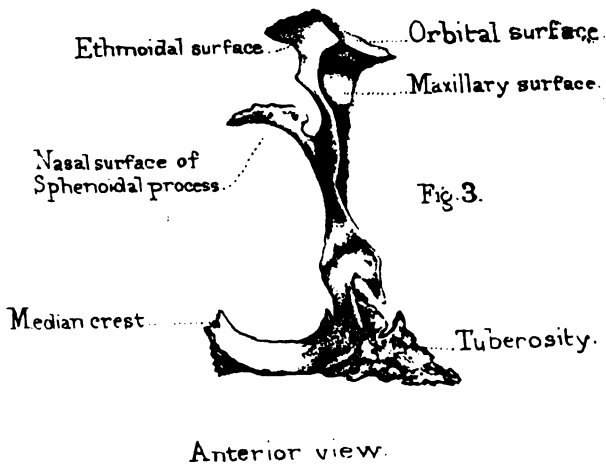
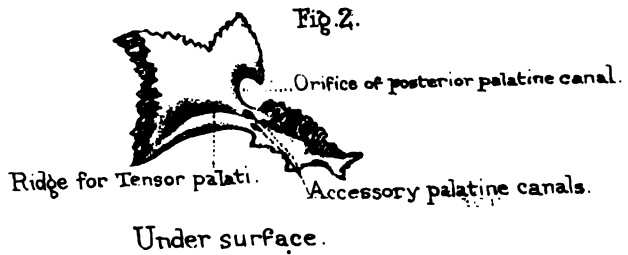


LACHRYMAL BONE.

MALAR BONE.



PALATE BONE.



of the nose. Still higher is a ridge for the middle turbinated bone. On its outer surface we observe a vertical groove, which either alone, or in conjunction with the superior maxilla, forms the 'posterior palatine canal,' which transmits the descending palatine vessels and the large palatine nerve. The front part of the vertical plate fits along the inner wall of the antrum of the superior maxilla, and helps to close the lower and back part of the orifice of the antrum. This part, however, is very fragile, and is generally broken in separating the bones.

Tuberosity.—From the angle formed by the horizontal and vertical plates projects backwards what is called the 'tuberosity.' This is the thickest and strongest part of the whole bone, and it fits into and fills up the 'notch' which is seen between the pterygoid plates of the sphenoid. Notice also that its posterior aspect presents a groove which completes the pterygoid fossa, and gives origin to a part of the 'pterygoideus internus.' The groove is bounded by two rough surfaces, which diverge from each other like the letter V reversed, and fit into the borders of the notch itself. (Plate X. fig. 2.) The anterior aspect of the tuberosity presents a very rugged surface, which articulates with the tuberosity of the superior maxillary bone. Behind this rough surface is a smooth portion continuous with the plane of the external pterygoid plate; this smooth part gives origin to some of the fibres of the external pterygoid muscle. The inferior aspect has nothing remarkable on it, except the orifices of one or two canals large enough to admit a pin. They are the 'accessory palatine canals,' and transmit the external and the small palatine nerves to the soft palate.

Turn now your attention to the upper part of the palate bone, and observe that at the top of the vertical plate there are two processes separated by a deep notch, which forms the greater part of the 'spheno-palatine foramen.' One of these processes is called the 'orbital,' because it fills up a little corner at the back part of the orbit; the other is called the 'sphenoidal,' because it fits under the body of the sphenoid bone.

Orbital Process.—The 'orbital process' springs from the top of the bone by a narrow 'neck,' and is hollow, so that it forms a

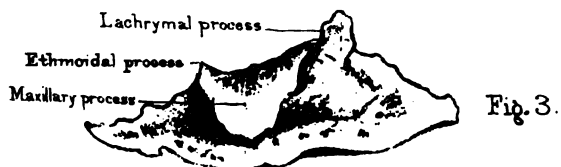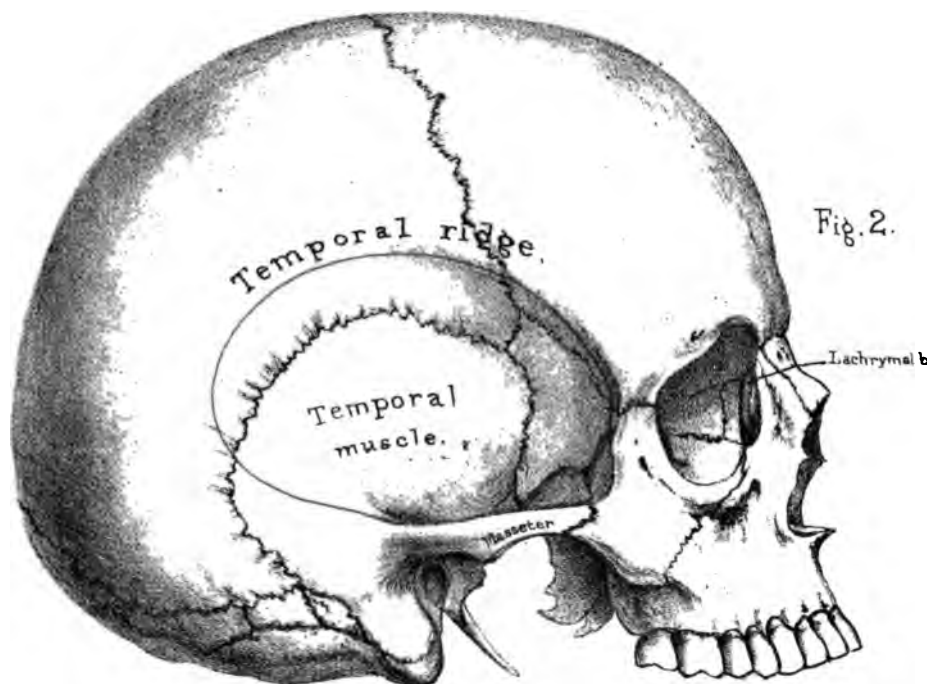
cell. The cell contains air, admitted through one of the posterior ethmoidal cells. This little process has *five* surfaces, unequal in extent, and looking in different directions. If you hold the bone before you, precisely as it is in your own person, and remember that it is interposed between the maxillary in front and the sphenoid behind, you will have no difficulty in recognising the direction of the surfaces to be as follows (see Plate XIII. fig. 2):—the *superior* looks into the orbit and contributes to form its floor; the *external* looks into the spheno-maxillary fossa; the *posterior* is connected with the body of the sphenoid; the *internal* with the ethmoid; and the *anterior* with the superior maxillary bone. Thus, then, we have a superior or orbital surface, an external or zygomatic, a posterior or sphenoidal, an internal or ethmoidal, and an anterior or maxillary: of these five two only are free, namely, the orbital and the zygomatic—the other three are attached to the respective bones with which they are contiguous. Plate XXII. shows the little corner at the inner and back part of the orbit, which is filled up by the palate bone, and also the relative positions of the bones with which the orbital process is connected. It likewise shows that the ‘zygomatic surface’ forms that part of the floor of the spheno-maxillary fossa which lies above the spheno-palatine foramen.

Sphenoidal Process.—The ‘sphenoidal process’ is a thin plate of bone, which arches inwards beneath the body of the sphenoid, and forms part of the roof of the nasal fossa. As it is generally broken in the separate bone, one can see it best in the perfect skull. (Plate XX.) The arch which it forms has three surfaces,—an upper or convex surface, which closes in the pterygo-palatine canal; an under or concave surface, which is seen in looking into the nasal fossa; and, lastly, an outer, which is seen in looking at the bottom of the spheno-maxillary fossa.

Spheno-Palatine Foramen.—Respecting the ‘spheno-palatine foramen,’ we need, for the present, merely observe, that it is an opening which leads from the spheno-maxillary fossa into the cavity of the nose, and transmits the nasal or spheno-palatine branch of the internal maxillary artery and nasal branches of the spheno-palatine ganglion. (Plate XXII.)



Inferior Spongy bone, inner surface.



Inferior Spongy bone outer surface

Connections.—The palate bone articulates with six bones,—namely, its fellow, the sphenoid, the ethmoid, the inferior spongy bone, the vomer, and the superior maxilla.

Ossification.—It is developed from a single centre of ossification, which appears at the angle of the horizontal and vertical portions, about the seventh week of foetal life.

Right or Left?—This bone will be in the same position as the corresponding one in the student's body if he hold the notch (which forms with the sphenoid the spheno-palatine foramen) upwards, the orbital process forwards, and the palatine plate inwards.

INFERIOR SPONGY OR TURBINATED BONE.

(PLATE XV. figs. 1 and 3.)

In each nasal cavity there are three spongy or turbinated bones—an upper, a middle, and a lower. The upper and middle form part of the ethmoid bone, and have been already described, p. 73. We have now to examine the lower one.

Its Position and Use.—This thin plate of bone is well called 'spongy,' from its structure, and 'turbinated,' from its curved form. By referring to Plate XXIII. fig. 2, you see it *in situ*, and observe how much longer it is than either of the others. Its internal surface, forming the convex part of the roll, looks towards the septum of the nose; its external surface forms the concave part, and bounds the inferior meatus of the nose. Both surfaces are covered with little ridges and furrows, and more or less horizontal canals, which lodge numerous plexuses of arteries, but chiefly of veins. This quite accords with the function served by the bone, namely, of affording an additional extent of surface which warms the air on its passage to the lungs. It has nothing to do with the sense of smell. The olfactory nerves have not been traced lower than the middle spongy bone.

Connections.—By its upper edge it is attached along the outer wall of the nose to four bones as follows—Beginning from

the front, we find it attached, 1, to a ridge along the nasal process of the superior maxilla; 2, by means of a little 'tongue' ('lachrymal process') to just such another 'tongue' of the lachrymal; it is this part of the bone which completes the lachrymal canal; 3, to the orifice of the antrum by means of a triangular plate termed the 'maxillary process' (Plate XV. fig. 3), which turns down like a dog's ear, and helps to narrow the lower part of the orifice of the antrum; 4, to the unciform plate of the ethmoid by means of a little tongue, called the 'ethmoidal process'; 5, and lastly, to a ridge along the vertical plate of the palate bone. Notwithstanding these numerous connections, the bone is by no means strongly fixed in its position: in the dry skull it often falls out; and in the operation of extracting a polypus from the nose, it is quite possible to pull out part of the bone or even the entire bone with the polypus.

Its lower edge is free, and generally about half an inch from the floor of the nose, so that there is just room enough to introduce the tube of a stomach-pump through the nose.

Ossification.—The bone has one independent centre of ossification, which appears about the fifth month of foetal life.

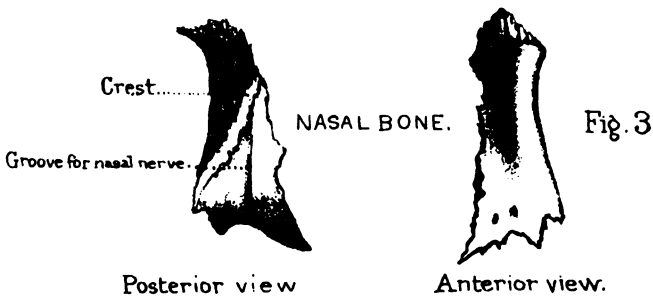
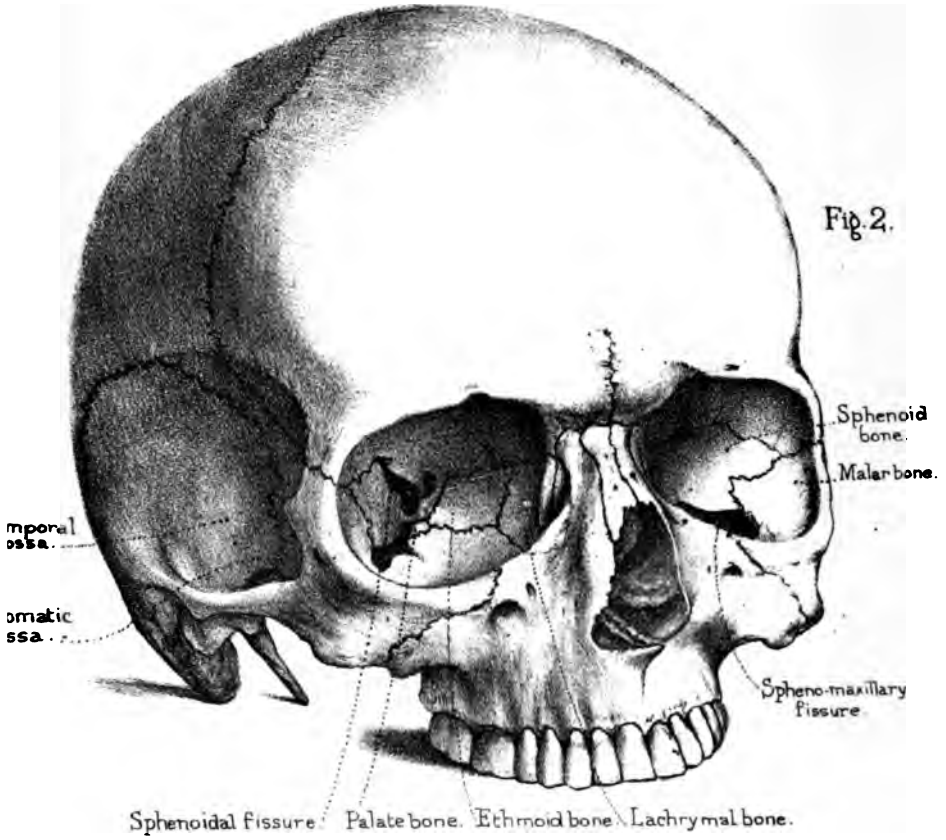

Right or Left?—This bone will be in the same position as the corresponding one in the student's body if he hold the convex surface inwards towards the septum of the nose; the maxillary process hanging downwards; and the large lachrymal process in front of the smaller ethmoidal process.

Comparative Osteology.—See the remarks at the end of 'the Ethmoid bone.'

THE VOMER.

(PLATE XVI. fig. 1.)

The 'vomer' is so named from its resemblance to a ploughshare. It is a thin and delicate plate, situated perpendicularly in the middle line, and, together with the perpendicular plate of the ethmoid bone, forms the bony septum of the nose. (Plate XXIII. fig. 1.)





Two Plates.—Thin as it is, the vomer consists of two plates, united in the middle, but separated above, where they become stronger, diverge from each other, and form a deep fissure which receives the ‘rostrum’ of the sphenoid. The diverging edges of the fissure, called the ‘wings,’ fit into the little furrows beneath the ‘vaginal processes’ of the sphenoid. (Plate XI. fig. 1.) Concerning the other connections of the vomer, we have to observe that the two plates of which the bone is composed separate from each other at every articular edge of it; and as the vomer receives the other bones into its grooves, so it is locked in on all sides.

Connections.—The vomer is connected with six bones. Below, it articulates with the crest of the maxillary and palate bones; above, with the lower edge of the rostrum of the sphenoid; in front, with the perpendicular plate of the ethmoid, and the median cartilage of the nose; behind, its edge is sharp and free, and, in the perfect skull, is seen as the septum between the posterior openings of the nasal fossæ.

Both surfaces of the vomer are marked by grooves for blood-vessels and nerves: but the only groove deserving notice is that which descends obliquely and transmits the ‘naso-palatine nerve.’

It is necessary to know that the direction of the vomer is not, in all persons, perpendicular. In 100 skulls the vomer was found to be perpendicular only in 24. There are instances in which it projects into one side of the nose to such an unusual extent, that when covered by its vascular and swollen mucous membrane, the projection might easily be mistaken for a polypus. Such mistakes are alluded to in surgical works.⁵⁴

Ossification.—The vomer is developed from one centre of ossification, which appears about the seventh week of foetal life, at the upper part, and from it each lateral plate is developed.

THE INFERIOR MAXILLARY BONE.

(PLATE XVII.)

For convenience of description we divide the lower jaw into the arched part in front, the 'body,' and the ascending part behind, the 'ramus.' At the top of each ramus are the 'condyle' or articular surface, the 'coronoid' process for the insertion of the temporal muscle, and the 'sigmoid notch.'

Body and Symphysis.—The convex part of the body presents, exactly in the centre, a slight ridge, the 'symphysis,' which is the strongest part of the bone, and indicates where the two halves of the bone grew together. Its direction is vertical, or even projects forwards: this is one of the characteristics of man, who alone has a chin. The 'symphysis' terminates, below, in the triangular 'mental process.' On each side of the symphysis is a slight depression, the 'mental fossa,' which gives origin to the 'levator menti.' More externally, and generally in a line with the first præ-molar tooth, is the 'mental foramen,' which transmits the 'mental branch' of the inferior dental nerve and artery. From the lower part of the symphysis we trace the beginning of the 'external oblique line' or ridge, which curves backwards towards the root of the coronoid process. This line gives origin to the 'depressor labii inferioris' and 'depressor anguli oris.' A little below both these, is the insertion of the 'platysma-myoides' of the neck. Along the alveolar border adjacent to the three molar teeth is one origin of the 'buccinator.'

Four Tubercles.—On the concave surface of the body (fig. 2), at the symphysis, are four small tubercles, i.e. two on each side, one above the other; the upper give origin to the 'genio-hyo-glossi': the lower, to the 'genio-hyoidei.' These four tubercles in some instances are confluent, and appear as one. Beneath these is a well-marked depression on each side, for the insertion of the 'digastricus' muscle, which opens the mouth. On this surface is an oblique line, faint near the symphysis, but more prominent as it ascends backwards below the last molar tooth.

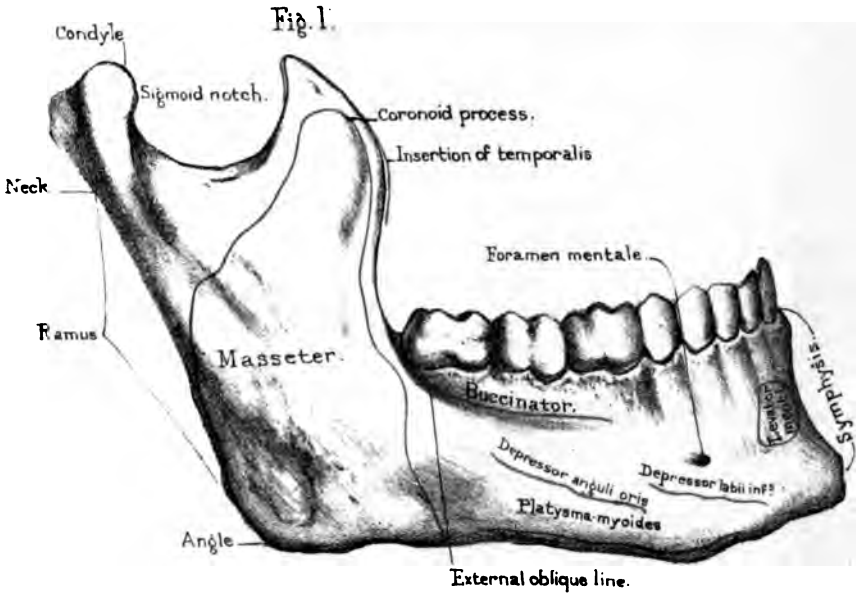
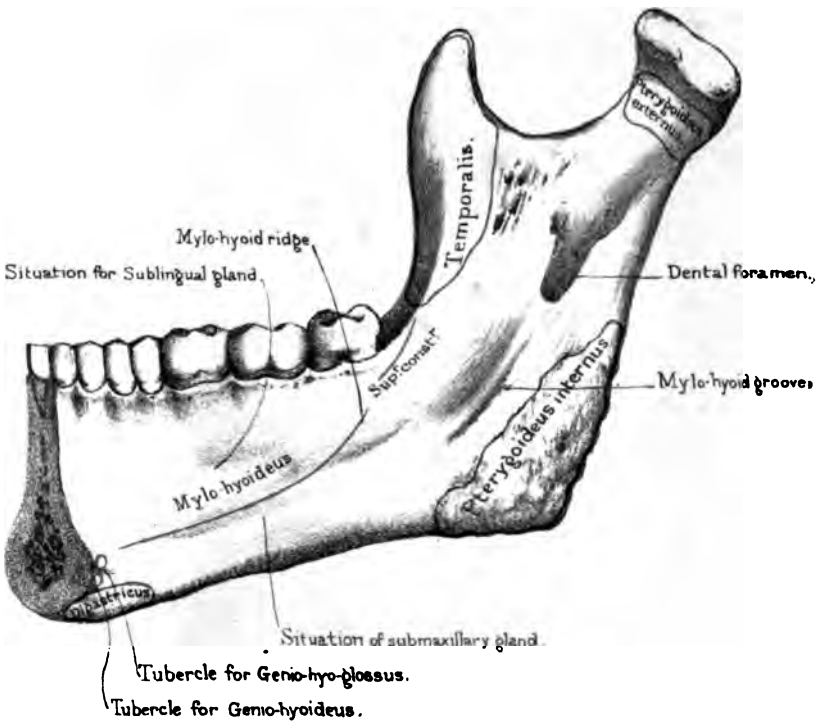



Fig. 2





It is called the 'mylo-hyoid ridge,' because it gives origin to the 'mylo-hyoideus.' Behind and a little above this ridge, near the last molar tooth, is the origin of part of the 'superior constrictor' of the pharynx. Below the ridge is a slight depression, indicating the position of the sub-maxillary salivary gland. Above the ridge is the place for the sub-lingual gland; but this is not well marked.

Oblique Lines.—These oblique lines or ridges on the two surfaces of the body are something more than mere muscular impressions. They indicate the limit between the 'alveolar' part which contains the teeth, and the lower or 'basilar' part of the jaw. These distinctions are made because these parts come and go at different periods of life. In infancy there is only the alveolar part; towards puberty the basilar part slowly grows to perfection: in old age when the teeth fall out, and their sockets are absorbed, the basilar part alone remains, and the chin gradually approximates the nose. The absorption of the sockets (alveoli), which is natural in old persons, often occurs prematurely. It is apt to arise from long salivation, scurvy, or purpura, and is frequently hereditary.

Teeth.—The teeth in the lower jaw correspond in number (eight on each side) with those in the upper, but differ from them in these particulars:—1. The first two lower molars have only two fangs, an anterior and posterior, while the upper molars have three. In the third molar or wisdom tooth the fangs are often consolidated into one; 2. When the mouth is closed the teeth of the lower jaw shut within those of the upper jaw which form a larger arch; 3. The external tubercles or cusps of the teeth of the lower jaw fit into the hollows between the external and internal cusps of the teeth of the upper jaw; by which arrangement we are enabled to use the entire surface of the opposing teeth in grinding the food. When the jaws are closed, each tooth in one jaw is opposed by two in the opposite jaw; one good result of this is, that when we lose a tooth, the corresponding tooth in the other jaw being still more or less opposed, is still of service in mastication.

Ramus.—The ramus of the jaw mounts up from the body nearly at a right angle in adult age, when the upper and lower

jaws are kept well apart behind by the molar teeth. But in infancy, before the development of the molars, and in age when they are lost, the 'angle' of the jaw becomes obtuse. Excluding its outstanding processes, the ramus is nearly square. Nearly the whole of its outer surface gives insertion to the powerful 'masseter,' which closes the jaw (fig. 1). On its inner surface (fig. 2) is the 'dental foramen,' or the orifice of the canal for the transmission of the inferior dental nerve and artery. Its inner margin is raised into a short 'spine' for the attachment of the internal lateral ligament of the jaw. Leading down from the orifice is the 'mylo-hyoid groove,' which contains the mylo-hyoidean vessels and nerve. Below the groove is the rough surface for the insertion of the 'pterygoideus internus.' The muscles inserted on each surface of the angle of the jaw are so thick that fractures through this part of the bone sometimes escape detection.

Condyle.—The 'condyle' projects from the upper and back part of the ramus to form the joint of the jaw, and fits into the glenoid cavity of the temporal bone. It is oblong in form, and convex both from without inwards and from before backwards. The long axis is directed horizontally inwards and slightly backwards, so that, if prolonged, the axes of the two condyles would meet near the front of the 'foramen magnum.' Just outside the condyle is a 'tubercle' for the attachment of the external lateral ligament. The condyle is supported on a contracted part termed the 'neck' of the jaw. This neck is flattened in the same direction as the condyle, and is slightly excavated in front for the insertion of the 'pterygoideus externus.'

The oblique direction of the condyles of the jaw renders easy the rotatory movement necessary in mastication. In masticating we can readily feel that one condyle advances towards the anterior margin of its glenoid cavity, while the other recedes to the posterior.

Coronoid Process.—The 'coronoid' process is a triangular, lofty plate of bone, which ascends beneath the zygomatic arch and increases the leverage of the temporal muscle which closes the mouth. The insertion of this muscle occupies the inner surface, the apex, and front border of the process down to the

last molar tooth : the greater part of the outer surface is occupied by the masseter. The 'sigmoid notch' transmits the 'masseteric' nerve and artery.

The walls of the lower jaw, particularly at the basilar part, are exceedingly compact and tough. In operations for removal of this part of the bone, it is necessary to use the saw freely, before the bone forceps can be of any service. The interior assumes the form of 'diploe,' and is traversed by the 'inferior dental canal,' which carries the vessels and nerves to the teeth (Nor. Hum. Ost. No. 234). This canal begins on the inner side of the ramus, curves forwards, beneath the sockets of the teeth, and, towards the front, divides into two, of which one ends at the 'foramen mentale,' the other, much diminished in size, runs on through the diploe nearly to the symphysis, and conveys vessels and nerves to the canine and incisor teeth.

Ossification.—The lower jaw has two centres of ossification, which appear about the sixth week of foetal life, one for each lateral half. Their junction at the symphysis takes place about the close of the first year after birth. In the lower animals the symphyseal suture often remains throughout life.⁵⁵

Comparative Osteology.—In the order Monotremata, observe that there is scarcely any bend or inflexion in the lower jaw (No. 1699). The jaw of the anteater is also straight, thus greatly resembling that of the pelican (see Sep. Ser.).

In snakes (Ophidia) the two halves of the lower jaw are not united by bone, but held together by an elastic ligament, which permits the two halves of the jaw to be separated from each other sideways to a considerable extent. This is one of the many arrangements by which the boa is enabled to swallow its prey though larger than its own body. This is shown in the specimen of the tiger-boa (No. 602).

In the lower animals the two halves of the jaw generally remain separate throughout life. In all mammalia each half of the lower jaw consists of a single piece which articulates with the squamosal bone of the skull. In all below the mammals it articulates with a modified malleus called the quadrate bone. This is

well seen in the skull of the ostrich and other birds in the Separate Series.

[For some interesting points as to the relation between the size of the coronoid process and the temporal fossa the student should read the Comparative Osteology paragraph at the end of the chapter on 'The Skull as a Whole.']

It has been said that man is the only creature which has a chin. It is most distinct in the Caucasian race, becomes faintly marked in the Negro, and does not exist in the Apes.

Rodentia have never more than two incisors in the lower jaw ; and usually only two, but sometimes four, in the upper. When there are four incisors in the upper jaw, as in hares and rabbits, there are two small ones behind the two large ones (No. 1916). These incisors have a persistent pulp, and continue to grow in adult life. They have no canines.

Carnivora have milk and permanent teeth, which are enamelled, and always consist of incisors, canines, and molars.

In elephants the teeth consist of tusk-like incisors, growing from persistent pulps, and molars.

Look at the lower jaw of the crocodile (No. 717 D) and see how greatly the angle projects backwards. This projection is for the insertion of the digastricus, the muscle which opens the mouth, and which acts upon the jaw as a lever of the first order. In man it acts as a lever of the second order, as it is inserted near the symphysis.

To appreciate the mechanism of the lower jaw, look at the form of the joint in animals. In them it varies according to the

FIG. 17.



structure of their teeth and the food they eat. There are three principal types of it: the *carnivorous*, the *ruminant*, and the *rodent*. The *carnivorous* type is a simple transverse hinge: this form is well seen in the badger (No. 4412), where the condyle of the jaw is mechanically locked in its socket. It is shown in fig. 17, where G represents the shape of the glenoid cavity, and C the shape of the condyle which fits into it. The *ruminant* type presents a socket and a condyle nearly flat, so as to admit of the

lateral movement necessary for grinding the food. This form is seen in fig. 18, which is taken from the sheep (No. 3767 B). In the *rodent* type there is a longitudinal groove in the temporal bone in which the condyle plays from before backwards like a plane. Fig. 19 shows the corresponding surfaces of the glenoid cavity (G), and the condyle (C), in the capybara (No. 1974).

The joint of the lower jaw in man partakes somewhat of the nature of these three types: we can move our jaw in the vertical direction, from side to side, and from before backwards. The teeth of man are likewise intermediate in structure between those of carnivorous and those of ruminant animals. Man is adapted, by his dentition, to eat animal or vegetable food, and is said to be omnivorous. But the presence of grinding, tearing, and cutting teeth, equally developed, in the jaws of any animal, is no proof that he is omnivorous. Monkeys have large canines, yet live on vegetables; all bats possess well-formed incisors, canines, and molars, yet some are purely frugivorous, whilst the British species live entirely on insects.

FIG. 18.



FIG. 19.



THE SKULL AS A WHOLE.

THE examination of the Skull as a whole is easy and intelligible, provided the individual bones have been carefully studied.

Course of Sutures.—A knowledge of the course of the sutures is of practical value—1, because it enables us to say with precision in what direction the head of the child is presenting during labour; 2, because in injuries of the skull we must not commit the error of mistaking a suture for a fracture.⁵⁶

Coronal Suture.—The ‘coronal suture’ (Plate XVIII.) (fronto-parietal) connects the frontal with the parietal bones. It extends transversely across the top of the skull, from the great wing of the sphenoid on one side to the other. In the middle the frontal overlaps the parietal bones, but at the sides the parietals overlap the frontal, by which arrangement the bones are locked together.

Sagittal Suture.—The ‘sagittal suture’ (inter-parietal) connects the two parietal bones. It runs backwards, in the middle line, from the frontal to the occipital bone. This suture is much serrated, except near the parietal foramina, where it is always much straighter than elsewhere.⁵⁷

Frontal Suture.—The ‘frontal suture’ is formed by the union of the two halves of the frontal bone. It runs down the middle of the forehead, from the sagittal suture to the root of the nose. It always exists in infancy and childhood, but is generally obliterated in the adult (p. 51).

Lambdoid Suture.—The ‘lambdoid suture’ (Greek letter Λ) (occipito-parietal) unites the two parietals to the occipital bone.

Occipito-Mastoid Suture.—‘The occipito-mastoid suture,’⁵⁸ apparently a continuation of the lambdoid, connects the occipital with the mastoid portion of the temporal bone.



Fig. 3.

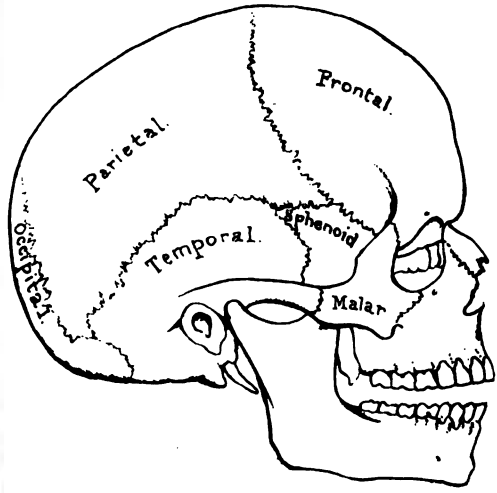
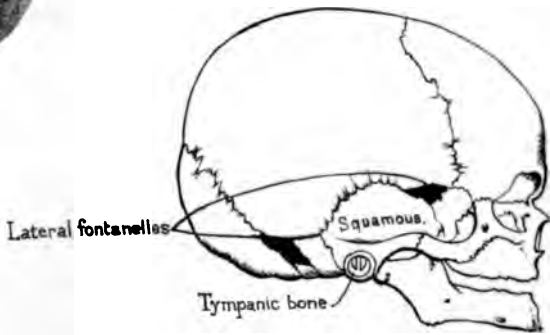


Fig. 5.



Fœtal skull full term.

7
7

7

Masto-Parietal Suture.—The mastoid part of the temporal is connected to the posterior inferior angle of the parietal bone by the ‘masto-parietal suture.’

Squamous Suture.—The squamous part of the temporal is connected to the parietal bone by the ‘squamous suture’ (squamo-parietal); and to the great wing of the sphenoid by the ‘squamo-sphenoidal’ suture. The squamous bone so overlaps the parietal as to strengthen the arch of the skull at the sides, and prevent the lateral expansion of the buttresses.

Wormian Bones.—In the mastoid suture more frequently than in any other, we meet with what are termed ‘Wormian⁵⁹ bones,’ or ‘ossa triquetra.’ They are little islands of bone, developed from distinct centres, in the membrane which connects the cranial bones. They vary in number and size. In the Museum of the College of Surgeons there is the hydrocephalic skull of an adult (Path. Ser. No. 3489) in which there are upwards of one hundred of these little bones. Specimens of Wormian bones may be seen in the Gen. Ost. Ser. Nos. 103 to 110.

Transverse Frontal Suture.—Of the sutures which connect the bones of the cranium with the face, the chief one is the ‘transverse frontal suture.’ It extends from the external angular process of the frontal bone, from one side to the other, across both orbits and the root of the nose (Plate XVI.). It connects the frontal with the malar, sphenoid, ethmoid, lachrymal, superior maxillary, and nasal bones. Other short sutures, such as the ‘spheno-malar,’ ‘spheno-parietal,’ ‘zygomatic,’ etc., speak for themselves.

A knowledge of the sutures is of practical value in midwifery. Thus when we feel the meeting of the three sutures at the top of the occipital bone, we know the back of the head presents; if, again, we feel the ‘anterior fontanelle,’ or lozenge-shaped space where four sutures meet (page 44), we know it is a forehead presentation.

THE SKULL-CAP.

Skull-cap: Outer Surface.—The skull-cap forms an oval dome which protects the brain with its greatest breadth about

the parietal protuberances. In a well-formed European head, if we look at the skull-cap from above (the beginning of the sagittal suture being in the centre of the perspective plane), we see scarcely anything but the smooth expanded vault of the cranium. But in the Negro and the Australian, the narrowness of the temples allows the zygomata to come into view, and, in the most 'prognathous'⁶⁰ examples, the incisor teeth appear in front of the frontal sinuses.

Foramina.—On the outer surface of the skull-cap are a multitude of small foramina, which transmit blood-vessels from the pericranium into the substance of the bone. Hence, if this membrane be torn off during life, the bone bleeds through minute pores. On each side of the sagittal suture is the 'parietal foramen,' which transmits a vein from the superior longitudinal sinus to the outside of the skull; sometimes a small artery runs with it, and communicates with a branch of the middle meningeal.

Temporal Ridge.—Along the side of the skull-cap is a curved line, the temporal ridge (Plate XV.), which indicates the attachment of the temporal aponeurosis to the frontal and parietal bones.

Temporal Fossa.—The ridge circumscribes the 'temporal fossa,' which is formed by the frontal, parietal, temporal, sphenoid, and malar bones. The fossa gives origin to the temporal muscle, of which the tendinous rays, converging beneath the zygoma, are inserted into the coronoid process of the lower jaw. The size of the temporal fossa in all animals depends upon the size of the temporal muscle. Hence it is largest in the carnivora.

Skull-cap: Inner Surface.—On the inner surface of the skull-cap we observe—1, the groove in the middle line, which gradually becomes broader as we trace it backwards, for the superior longitudinal sinus; 2, on either side of this, especially in old skulls, are a number of irregular excavations, occasioned by the 'Pacchionian bodies'⁶¹; 3, grooves for the ramifications of the middle meningeal artery. The main groove, at first sometimes a complete canal, is seen at the anterior-inferior angle of the parietal bone; from thence it spreads widely over the frontal and parietal bones, one branch of considerable size often traversing

the posterior-inferior angle of the parietal above the groove for the lateral sinus. In fractures of the skull, the arteries running in these grooves are liable to be injured, and thus occasion an effusion of blood, producing compression of the brain.

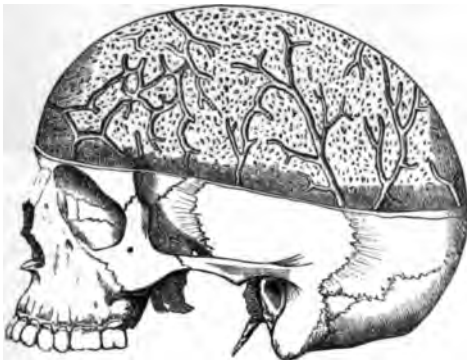Thickness of the Skull-cap.—The skull-cap differs in thickness in different parts. This is easily ascertained by holding it to the light. As a rule, it is thicker in parts which were the centres of ossification—as at the frontal and parietal eminences. It is thinnest in the temporal region. The ordinary thickness of an adult skull is about one-fifth of an inch, though it varies very much at different periods of life. In the anatomical museum at Pavia there is the skull-cap of a child, in which a hole was pecked by the beak of an angry cock. Whoever is in the habit of making post-mortem examinations soon observes how much skulls vary in thickness, even in persons of the same age, and this without any obvious reason. Generally speaking, any cause which produces a chronic congestion of the vessels of the head,—such as habits of intemperance,—will increase the thickness of the skull. For the same reason constant exposure to the action of the sun will thicken and indurate the skull-cap. The observation of Herodotus⁶² is probably correct, when he says that ‘the Egyptians have thick skulls because they expose their shorn heads to the heat of the sun; whereas the Persians have thin and soft skulls, because they cover them with turbans from infancy.’ A severe blow may thicken the skull. The late Mr. Quekett had in his possession part of a skull-cap nearly an inch in thickness. It belonged to a gentleman who received a blow on his head some years before his death. He recovered perfectly, to all appearance, from the effects of the injury. By-and-by, however, his head began to grow larger; but this, strange to say, was first discovered by his hatter, who found it necessary from time to time to give him a larger hat. In very old persons, the skull-cap, owing to the absorption of the diploe, becomes in some parts as thin as a shilling. Not only the skull, but all the bones become much lighter in old age. Soemmering says the skull of a centenarian is two-fifths lighter than in middle age.

Cerebral Impressions.—The inner surface of the skull-cap

is marked by the cerebral convolutions, so that it takes, to a certain extent, an impression of the brain. But it cannot be said that a particular impression on the inner surface has a corresponding bump outside. A glance at any skull-cap is sufficient to prove this. The depressions occasioned by the convolutions take place at the expense of the diploe; and the external bumps are often caused by a mere thickening of the outer table. On the other hand, it holds good, as a general rule, that the external form and dimensions of the cranium may be taken as a *general* expression of the corresponding lobe of the brain, whether in the frontal, the parietal, or the occipital region. The general characters of the brain, then, may be ascertained by external examination, but not the individual detail.

Veins of the Diploe.—The diploe of the skull-cap is traversed by numerous venous canals. These (fig. 20) are of considerable size, and are

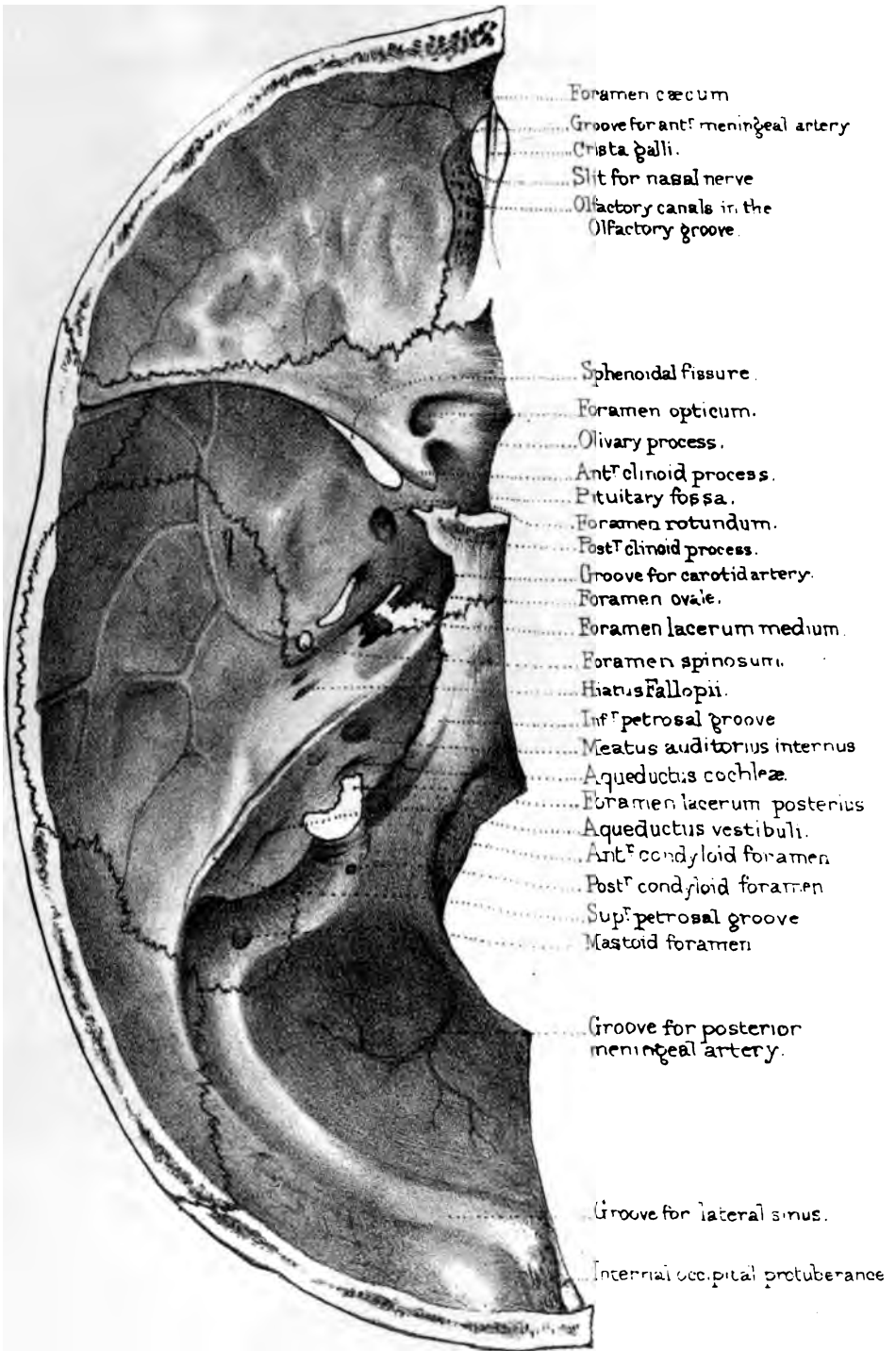
FIG. 20.



VENOUS CANALS IN THE DIPLOE.

best displayed by filing off the outer table. Their course is by no means so regular as they are commonly drawn; but, in a general way, we may speak of the frontal, temporal, and occipital 'diploic' veins. The two former discharge their blood into the veins on the outside of the

cranium; the occipital generally open into the lateral sinus. After injuries of the head, these veins are liable to inflammation, which may give rise to pus in the diploe and pyæmia. Hence the occasional occurrence of visceral abscesses, especially hepatic, after injuries of the head,—a circumstance which had not escaped the notice of the old surgeons.



Drawn on Stone by H. Grise.
 From nature by L. Holden. Prints by Geo. N. ...

BASE OF THE SKULL AS SEEN FROM ABOVE.

By referring to Plate XIX. it is seen that the base of the skull presents, on each side, three fossæ,—an anterior, a middle, and a posterior,—respectively lodging the anterior and middle lobes of the cerebrum, and the cerebellum. The posterior lobe of the cerebrum rests upon the ‘tentorium cerebelli,’ and not upon bone. These several fossæ are marked by the cerebral convolutions just as much as the skull-cap; but phrenologists take no notice of *these* convolutions, and have omitted to assign any office to them. All their ‘organs’ are placed at the top and sides of the brain;—why are there none at the base?

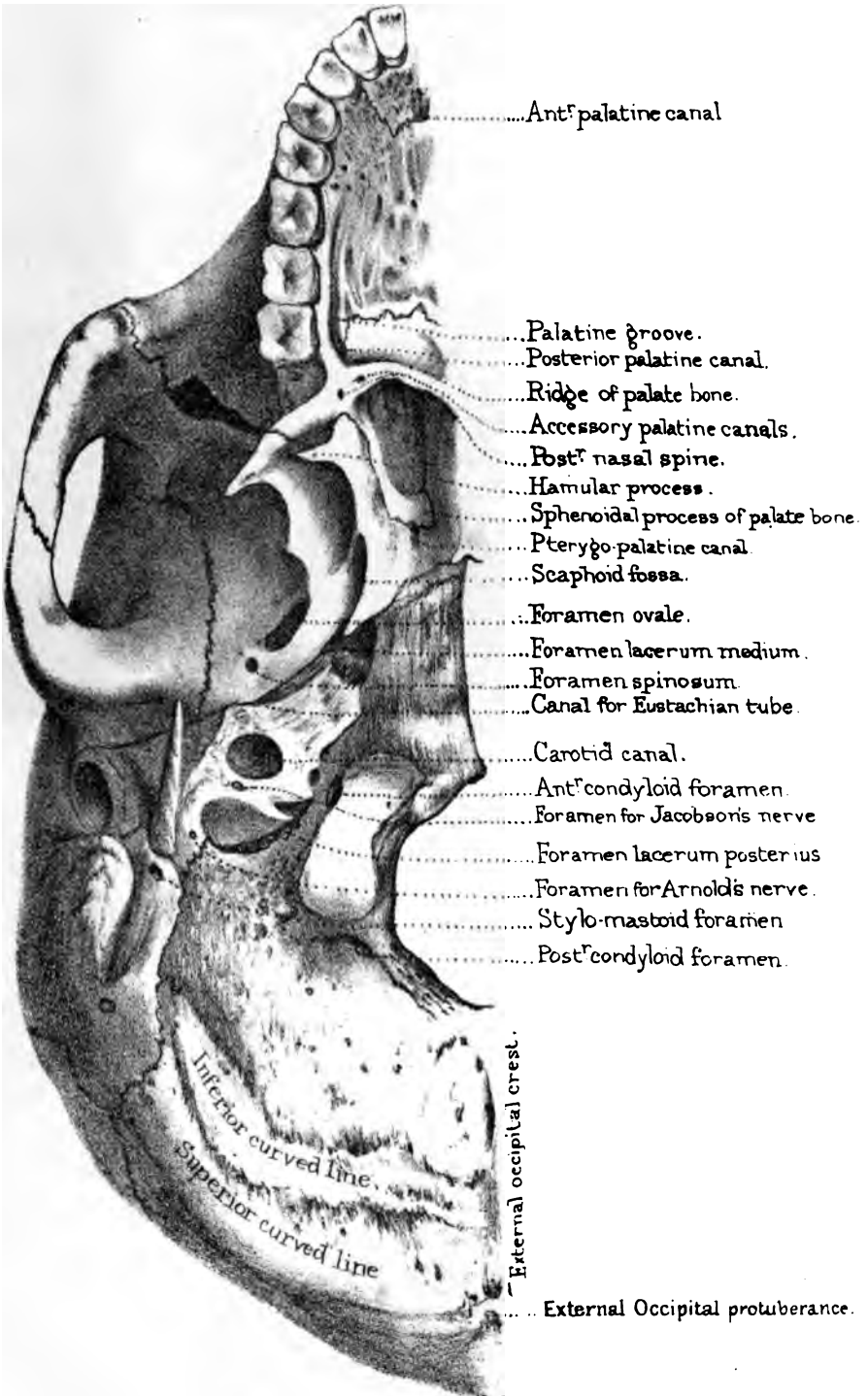
Anterior Fossa of the Cranium.—The anterior fossa of the cranium is formed by the orbital plates of the frontal, the cribriform plate of the ethmoid, with the front part of the body and the lesser wings of the sphenoid. The points to be noticed in this fossa are as follows: 1. The ‘foramen cæcum,’ which, if pervious, generally transmits a vein from the superior longitudinal sinus into the nose. 2. The groove for the ‘anterior meningeal artery,’ one of the secondary branches of the ophthalmic. 3. The ‘crista galli,’ which gives attachment to the falx cerebri. 4. The slit for the ‘nasal nerve,’ a branch of the first division of the fifth nerve. 5. The ‘olfactory groove,’ perforated by foramina, which give passage to the filaments of the olfactory lobes. 6. The ‘anterior ethmoidal foramen’ on the outer side of the olfactory groove, for the transmission of the nasal nerve and anterior ethmoidal vessels. 7. The ‘posterior ethmoidal foramen,’ at the hinder extremity of the olfactory groove, immediately in front of the body of the sphenoid transmits the posterior ethmoidal vessels. 8. The ‘foramen opticum,’ which transmits the optic nerve and ophthalmic artery. 9. The ‘olivary process,’ which supports the commissure of the optic nerves. 10. The ‘anterior clinoid process,’ which gives attachment to the tentorium cerebelli.

Middle Fossa of the Cranium.—The middle fossa of the cranium supports the middle cerebral lobe, and is formed by the

great wing of the sphenoid, the squamous and petrous portions of the temporal bone. The points to be noticed in this fossa are—

1. 'The sphenoidal fissure' between the wings of the sphenoid, leads to the orbit, and transmits the 3rd, the 4th, the first division of the 5th, and the 6th nerves, also filaments of the sympathetic nerve and the ophthalmic vein.
2. The 'foramen rotundum' gives passage to the superior maxillary, or second division of the 5th nerve.
3. The 'foramen ovale' gives passage to the inferior maxillary, or third division of the 5th nerve, and to the arteria meningea parva, and sometimes to the lesser petrosal nerve.
4. The 'foramen spinosum' gives passage to the arteria meningea media and its two veins—the main trunk of this artery grooves the squamous part of the temporal and the anterior-inferior angle of the parietal bone.
5. The 'foramen lacerum medium' is blocked up, in the recent state, by fibro-cartilage; the Vidian (great petrosal) nerve runs through this cartilage. The internal carotid artery also passes through it.
6. At the apex of the petrous portion of the temporal bone is the termination of the 'carotid canal' through which the carotid artery enters the skull: the artery then winds along the groove on the side of the body of the sphenoid.
7. On the front surface of the petrous portion of the temporal bone is the 'hiatus Fallopii,' which transmits the great petrosal nerve, and external to it is the opening of the canal for the lesser petrosal nerve. Further back, on the same surface, we may observe the eminence for the superior semicircular canal.
8. In the centre of the sphenoid is the 'pituitary fossa,' for the reception of the pituitary body.
9. The 'posterior clinoid process,' like the anterior, gives attachment to the 'tentorium cerebelli,' a process of the dura mater which supports the posterior lobes of the brain.

Posterior Fossa of the Cranium.—The posterior fossa is the largest and deepest of the cranial fossæ, and is formed by the occipital bone, the petrous and mastoid parts of the temporal bone. It supports the cerebellum. Proceeding from before backwards, we observe, in the middle line: 1. The 'basilar groove,' which supports the medulla oblongata and the pons Varolii. 2. On each side of this is the groove for the 'inferior petrosal



Drawn on Stone by T. Cobden.

From nature by L. Hoiden.

Printed by Wood, Newman & Co.

sinus.' 3. Along the top of the petrous bone is the groove for the 'superior petrosal sinus.' 4. Both these sinuses terminate in the great 'lateral sinus,' which grooves successively the occipital, posterior-inferior angle of the parietal, mastoid part of the temporal, and, last of all, the jugular process of the occipital bone. A line drawn on the outside of the head, from the occipital protuberance to the front border of the mastoid process, corresponds with the lateral sinus. On the posterior aspect of the petrous part of the temporal bone is—5. The 'meatus auditorius internus,' for the facial and auditory branches of the 7th nerve and the little auditory artery. 6. Some distance behind, and rather below the meatus, is the 'aqueductus vestibuli,' somewhat concealed by an overhanging ridge of bone. This 'so-called aqueduct' transmits, if anything, a small vein from the vestibule of the ear.

Behind the basilar process is—7. The 'foramen magnum,' which transmits the spinal cord and its membranes, the vertebral arteries, and the spinal part of the spinal accessory nerves. 8. On each side of the foramen magnum are the 'condyloid foramina,' of which the 'anterior' transmits the hypoglossal or 9th nerve (motor nerve of the tongue); the 'posterior,' a vein from the lateral sinus to the outside of the skull. 9. The 'mastoid foramen' also transmits a vein from the lateral sinus to the outside of the skull. 10. Lastly, the 'foramen lacerum posterius' transmits the three divisions of the 8th nerve and also the blood from the lateral sinus into the internal jugular vein. The nerves pass through the anterior part of the foramen, which is separated from the posterior by a bony ridge.

BASE OF THE SKULL AS SEEN FROM BELOW.

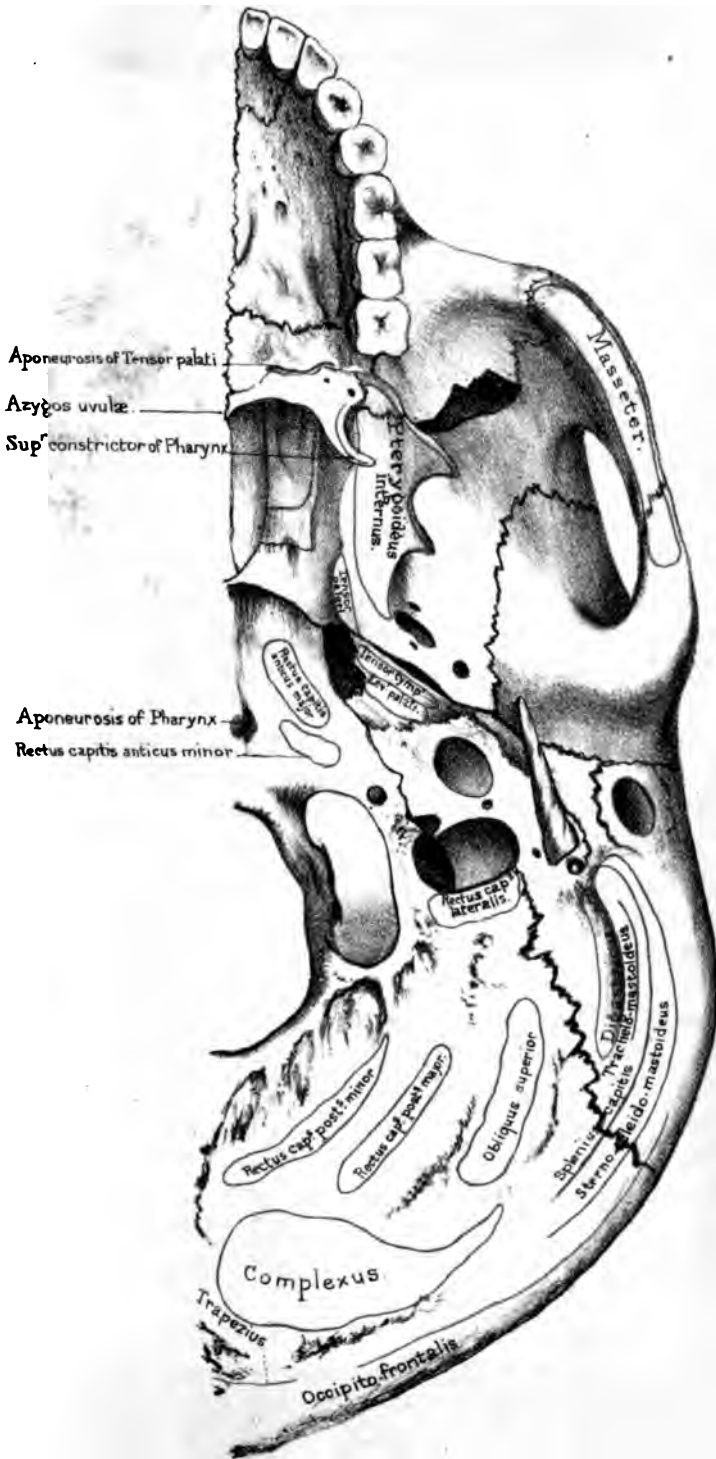
(PLATES XX., XXI.)

The base of the skull comprises such a wide area, that it is desirable to draw certain limitary lines. If, then, a line be drawn from the first incisor tooth on each side, backwards to the mastoid

process, and another transversely, from one mastoid process to the other, we shall describe a triangle within which are contained all the parts usually spoken of as at the base of the skull.

Arch of the Palate.—In front is the arch of the ‘hard palate,’ formed by the superior maxillary and palate bones: its ‘middle’ and ‘transverse’ sutures cross each other at right angles. A pin introduced at the point of crossing would touch five bones, the 5th being the vomer. Generally speaking, when the palate presents a fine arch, free from contraction in any direction, the voice is clear and sonorous. The best singers have always well-formed palates. Its surface is rugged for the lodgment of the palatine glands, and it is riddled with minute holes for the passage of blood-vessels. Behind the incisor teeth is the ‘anterior palatine canal’; a single orifice below, but double above, so as to open separately into each nostril. It transmits the anterior palatine vessels and ~~naso~~-palatine nerves (see also p. 82). Near the last molar tooth is the orifice of the ‘posterior palatine canal,’ formed conjointly by the palate and superior maxillary bones: and from this we trace forwards the ‘palatine groove’ for the lodgment of the descending palatine vessels and the large palatine nerve. Lastly, there is the ‘ridge’ on the palate bone for the attachment of the ‘tensor palati,’ and the ‘posterior nasal spine,’ to which is attached the ‘azygos uvulæ.’

Posterior Openings of Nose.—Behind the palate are the posterior openings of the nasal fossæ, separated by the sharp edge of the vomer. Each opening is somewhat oval, about one inch in the [long diameter and half an inch in the transverse. We should remember this in plugging the nostril. It is bounded, above, by the body of the sphenoid and the sphenoidal process of the palate bone; below by the horizontal plate of the palate; outside, by the internal pterygoid plate of the sphenoid; and inside, by the vomer. On the roof of each are the expanded ‘wings’ of the vomer, which receive between them the ‘rostrum’ of the sphenoid; and also the ‘pterygo-palatine canal.’ This, as its name implies, is formed conjointly by the pterygoid plate of the sphenoid and the sphenoidal process of the palate bone. It transmits a branch of the internal maxillary artery, and a pharyngeal



Drawn on Stone by T. Goert
 From nature by L. Holden

Printed by West, Newman & Co.

nerve from the sphenopalatine ganglion to the top of the pharynx.

Pterygoid Region.—On each side of the nasal openings are the ‘pterygoid processes’ of the sphenoid. These pterygoid processes bound the posterior openings of the nose: act as buttresses to support the upper jaw-bones behind; and serve for the origin of the powerful pterygoid muscles which grind the food. From the pterygoid fossa, or, more strictly, from the *inner* surface of the external pterygoid plate and the back of the tuberosity of the palate bone which fits into the gap between the pterygoid processes, arises the ‘pterygoideus internus’; while the *outer* surface of the same plate and the adjacent outer aspect of the tuberosity of the palate bone give origin to the ‘pterygoideus externus.’ At the base of the internal plate is the scaphoid fossa, for the origin of the ‘tensor palati’; and at the apex is a pulley, termed the ‘hamular process,’ around which the tendon of this muscle plays. Besides this, the hamular process gives origin to part of the ‘superior constrictor’ of the pharynx. Immediately above the ‘scaphoid fossa’ is the posterior orifice of the Vidian canal.

Proceeding backwards from the base of the pterygoid processes, we come next upon the great foramina at the base of the skull, most of which have already been seen in the examination of the base from above. In the great wing of the sphenoid there is the ‘foramen ovale.’ The foramen rotundum cannot be seen at the inferior part of the base of the skull: look for it at the back of the orbit. Behind the foramen ovale is the ‘foramen spinosum’; and still farther back is the apex of the wing, termed the ‘spinous process,’ which is wedged between the squamous and petrous bones, and gives attachment to the internal lateral ligament of the lower jaw and the ‘laxator tympani.’ From the spinous process we trace outwards the ‘glenoid fissure,’ which runs across the glenoid cavity of the temporal bone. Between the sphenoid and petrous bones is the canal for the ‘Eustachian tube’ (running in the same line as the Glaserian fissure), which is completed in the recent state by fibro-cartilage.

Petrous Region.—The petrous portion of the temporal bone is wedged in between the sphenoid and the basilar process of the

occipital. Observe that the apex of the wedge is cut short, so that an irregular opening remains between the three bones, termed the 'foramen lacerum medium.' In the recent skull this space is filled with cartilage, through which pass the internal

FIG. 21.

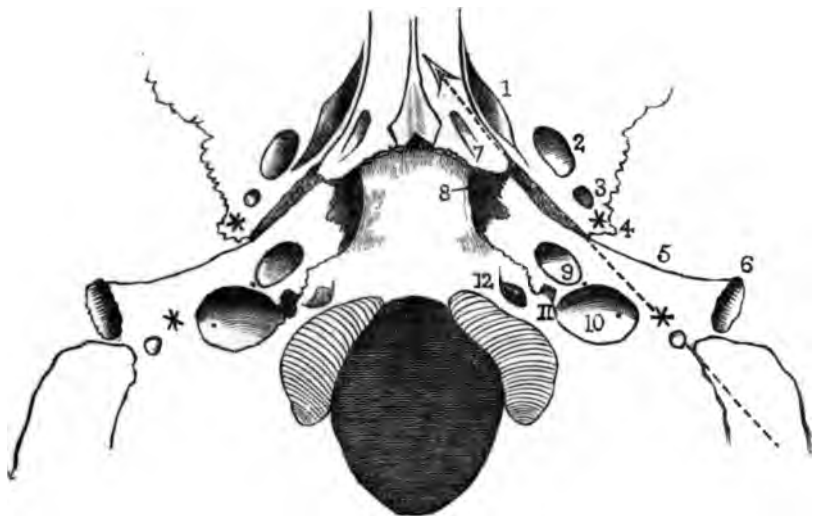


DIAGRAM OF THE RELATIVE POSITIONS OF THE MORE IMPORTANT PARTS AT THE BASE OF THE SKULL.

The dotted arrow shows that the mastoid process, the stylo-mastoid foramen, the styloid process, and the spinous process of the sphenoid (represented by stars), and the Eustachian tube are pretty nearly in a line.

Outside the arrow arc—

1. Scaphoid fossa.
2. Foramen ovale.
3. Foramen spinosum.
4. Spinous process.
5. Fissura Glaseri.
6. Meatus auditorius externus.

Inside the arrow arc—

7. Pterygo-palatine canal.
8. Foramen lacerum medium.
9. Carotid canal.
10. Foramen jugulare.
11. Notch for 8th pair of nerves.
12. Anterior condyloid foramen.

carotid artery, surrounded with filaments of the sympathetic nerve, and the Vidian nerve. The apex of the petrous bone gives origin to the 'tensor tympani' and 'levator palati.' In the middle of the petrous bone is the wide orifice of the carotid canal which transmits the carotid artery. Trace this canal, and you will find that

it does not enter the cranial cavity directly, but that it ascends for a short distance, and then runs horizontally forwards and inwards through the petrous bone, till it opens at the apex into the foramen lacerum. Thus the carotid artery makes two curves, like the letter S, before it enters the cranium—the first curve in the bony canal, and the second through the cartilage which fills up the foramen lacerum. This disposition of the great arteries at the base checks the force of the blood on its passage to the brain.

Behind the carotid canal is the ‘foramen lacerum posterius,’ or ‘foramen jugulare,’ another opening left between the petrous and occipital bones. The size and shape of it are subject to great variety. The right jugular foramen is usually larger than the left, but it is generally divided by a projecting tongue of bone into an anterior part, which transmits the eighth pair of nerves, and a posterior, which is by far the larger, for the passage of the blood from the lateral sinus into the commencement of the internal jugular vein. The posterior meningeal arteries (from the occipital and ascending pharyngeal branches of the external carotid) also enter the cranium through this aperture.

Outside the foramen lacerum posterius is the ‘styloid process,’ projecting, more or less, beyond the ‘vaginal process’ at its root. Behind this is the ‘stylo-mastoid foramen,’ through which the facial nerve emerges from, and the stylo-mastoid artery enters, the skull. Still farther back is the mastoid process, and the digastric fossa for the origin of the digastric muscle. Internal to this fossa may generally be seen a groove for the occipital artery.

Basilar Process.—The basilar process of the occipital bone projects into the base of the skull, and joins the body of the sphenoid: here it forms the roof of the pharynx. This relation is of practical importance, because the basilar process is within reach of the finger introduced into the mouth, and can be explored so as to determine how far a polypus may be connected with it. It affords insertion to the ‘rectus capitis anticus major’ and ‘minor,’ and (by means of a little tubercle) to the aponeurosis of the pharynx. Behind the basilar process is the ‘foramen magnum.’ On each side of this are the ‘condyles’ of the occiput, with the

‘anterior’ and ‘posterior condyloid’ foramina; and on the outside of each condyle is the jugular eminence, which gives insertion to the ‘rectus capitis lateralis.’

Occipital Foramen.—In a well-formed European skull, the plane of the occipital foramen is horizontal when the body is erect, and its anterior extremity is about half way between the tuberosity of the occipital bone and the incisors of the upper jaw. This central position of the occipital foramen and the condyles is one of the great peculiarities of man, who stands erect. His head, therefore, is almost equally balanced on the top of the spine. In monkeys, who hold a middle rank between man and quadrupeds, the foramen magnum is placed farther back: in the orang-outan, it is about twice as far from the foramina incisiva as from the back of the head. Consequently, although monkeys can stand erect for a time, they cannot do so long. In quadrupeds, again, the foramen magnum is still nearer to the back of the head, and its plane forms a considerable angle with the horizon. The weight of the head in quadrupeds is sustained, not only by the spine, but by an elastic ligament of great strength (ligamentum nuchæ), which arises from the lofty spines of the dorsal vertebræ, and is fixed to the crest of the occiput.

TEMPORAL, ZYGOMATIC, AND SPHENO-MAXILLARY FOSSÆ.

The temporal fossa (see page 104) leads into the zygomatic fossa, the boundary between them being the crest of the sphenoid bone.

Zygomatic Fossa.—The ‘zygomatic fossa’ is bounded externally by the zygomatic arch, which serves as a strong buttress to support the bones of the face, and gives origin to the powerful ‘masseter’ muscle which closes the mouth. In front of the fossa there is the back part of the superior maxilla, and at the bottom of it, the outer pterygoid plate of the sphenoid, which gives origin to the external pterygoid muscle. At the deepest part of the fossa are two wide fissures at right angles to each other: one, nearly horizontal, leads into the orbit, and is called the ‘sphenomaxillary fissure,’ through which the infra-orbital nerve and artery

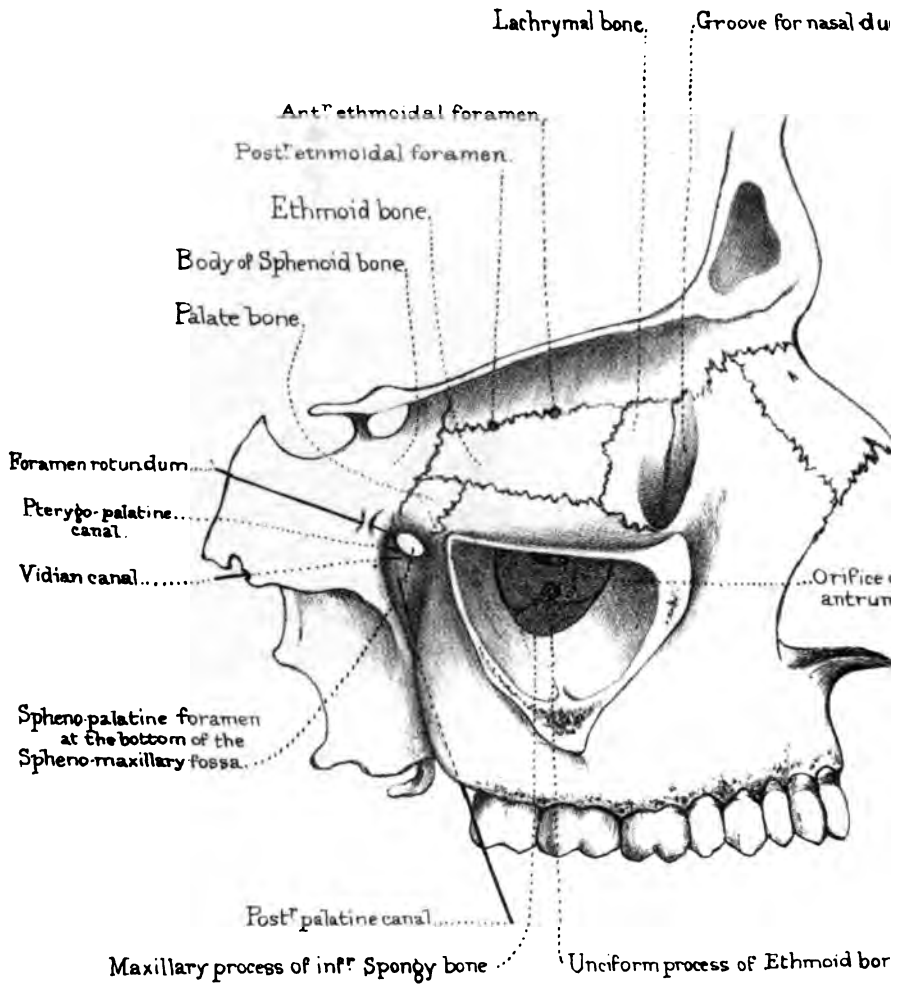


Diagram of the Bones and Foramina
 on the inner wall of the Orbit, the five openings into the
 Spheno-maxillary fossa, the Antrum and bones contracting its orifice

enter the floor of the orbit to reach their canal in the superior maxillary bone.

Spheno-maxillary Fossa.—The other fissure, nearly vertical, leads to the ‘spheno-maxillary fossa,’ in which the third part of the internal maxillary artery breaks up into terminal branches. This fossa is bounded in front by the back of the superior maxilla; behind, by a smooth surface at the base of the pterygoid process; internally, it is separated from the nasal fossæ by the perpendicular plate of the palate bone.

There are five openings into the spheno-maxillary fossa (see Plate XXII.), as follows:—

FIVE OPENINGS INTO SPHENO-MAXILLARY FOSSA.

1. Spheno-palatine foramen	{ transmits into the nasal fossa .	{ Internal or nasal branches of spheno- palatine ganglion. Nasal or spheno-palatine branch of internal maxillary artery.
2. Posterior-palatine canal	{ transmits to the palate . .	{ Descending palatine artery and large palatine nerve.
3. Foramen rotundum	transmits	{ Superior maxillary nerve, or second division of fifth pair.
4. Vidian canal	transmits	Vidian artery and nerve.
5. Pterygo-palatine canal	transmits	{ Pterygo-palatine branch of internal maxillary artery, and pharyngeal nerve from Meckel's ganglion.

THE ORBITS.

The orbits, or sockets for the eyes, are like crypts excavated beneath the cranium. (Plate XVIII.) To use the words of Sir Charles Bell, ‘these under arches are groined;’ that is to say, they are provided with strong ribs of bone, so that there is no need of thick bone in the interstices of the groinings. The plate between the eye and the brain is as thin as parchment: but look how strong is the arch forming the orbital margin, and what a strong ridge of bone runs up from the zygoma, like a buttress to support the side of the arch. When the eye is threatened and somewhat retracted in its socket, the margin of the orbit is more than strong enough to protect it from the effects of violence.

Each orbit is pyramidal, with the apex behind. Their axes, if prolonged, would pass through the optic foramina, and meet behind the pituitary fossa of the sphenoid. This divergence gives a greater range of vision. The anterior opening of the orbit is quadrilateral and consists of an upper, a lower, an inner and an outer margin. In the higher types of man these openings are more rounded.

Upper Wall of Orbit.—The upper wall of the orbit is slightly arched, and formed by the frontal bone and lesser wing of the sphenoid. On this wall are—1, the optic foramen; 2, the fossa beneath the external angular process for the lachrymal gland; 3, the little depression for the pulley of the ‘superior oblique’ muscle; 4, the supra-orbital foramen or notch, situated at the junction of the inner with the middle third of the orbital margin.

Lower Wall or Floor of Orbit.—The lower wall of the orbit slopes downwards and outwards, and is formed by the orbital plate of the superior maxilla, by part of the malar bone, and behind by the orbital plate of the palate bone. On this wall is the groove for the infra-orbital nerve.

Inner Wall of Orbit.—The inner wall (Plate XXII.) is formed by the nasal process of the superior maxilla, by the lachrymal, the os planum of the ethmoid, and the side of the body of the sphenoid bone. Here we observe the groove for the nasal duct, formed conjointly by the nasal process of the superior maxilla, the lachrymal, and the inferior spongy bone. Its direction is downwards, backwards, and a little outwards, and it leads into the inferior meatus of the nose. Besides this, there are the ‘anterior and posterior ethmoidal foramina.’

Outer Wall of Orbit.—The outer wall of the orbit is formed by the malar bone and the orbital plate of the great wing of the sphenoid. Here there are one or two small foramina (malar canals), which transmit small nerves from the orbit to the skin of the cheek and temple. (See p. 86.) The outer wall of the orbit recedes more than the other parts of its circumference, giving so great a range of vision externally, that by rotating the head on each side of the spine, we can see all round.

Bones Composing Orbit.—Look into the orbit and examine two four-sided plates, one on the inner side belonging to the ethmoid, and one on the outer belonging to the great wing of the sphenoid. The four-sided plate of the ethmoid articulates above with the frontal; below with the superior maxillary bone, in front with the lachrymal and behind with the sphenoid. Besides these the orbital process of the palate bone here comes up between the sphenoid and superior maxilla (articulating with both of them) and joins the posterior inferior angle of this plate. The four-sided plate of the sphenoid articulates likewise with the frontal bone above which arches over from the top of the aforesaid plate of the ethmoid; below, its edge is separated from the superior maxillary bone by the speno-maxillary fissure; in front, it articulates with the malar bone, and behind, its edge is separated from the rest of the sphenoid by the sphenoidal fissure. These articulations should be traced on the bones and thoroughly mastered. Thus, seven bones enter into the composition of each orbit: namely—the frontal, ethmoid, and sphenoid, the superior maxilla, the malar, the lachrymal, and the palate; but there are only eleven bones in the two orbits, since the first three bones are common to both.

Sphenoidal and Speno-maxillary Fissures.—At the back of the orbit are two wide fissures for the admission of blood-vessels and nerves. The upper one is the ‘sphenoidal fissure,’ formed between the greater and lesser wings of the sphenoid bone. It leads into the cranium, and transmits the third and fourth nerves, the ophthalmic branch of the fifth, the sixth nerve, some filaments of the sympathetic nerve, and the ophthalmic vein. The lower one, the ‘speno-maxillary fissure,’ leads into the zygomatic fossa. The borders of this fissure are formed internally by the superior maxillary and palate bones, externally by the sphenoid. It is completed in front by the malar.⁶³ Through this fissure the infra-orbital artery and the superior maxillary nerve enter the groove along the floor of the orbit.

There are some points of practical interest about these two fissures. 1. In blows on the temple, blood is apt to make its way

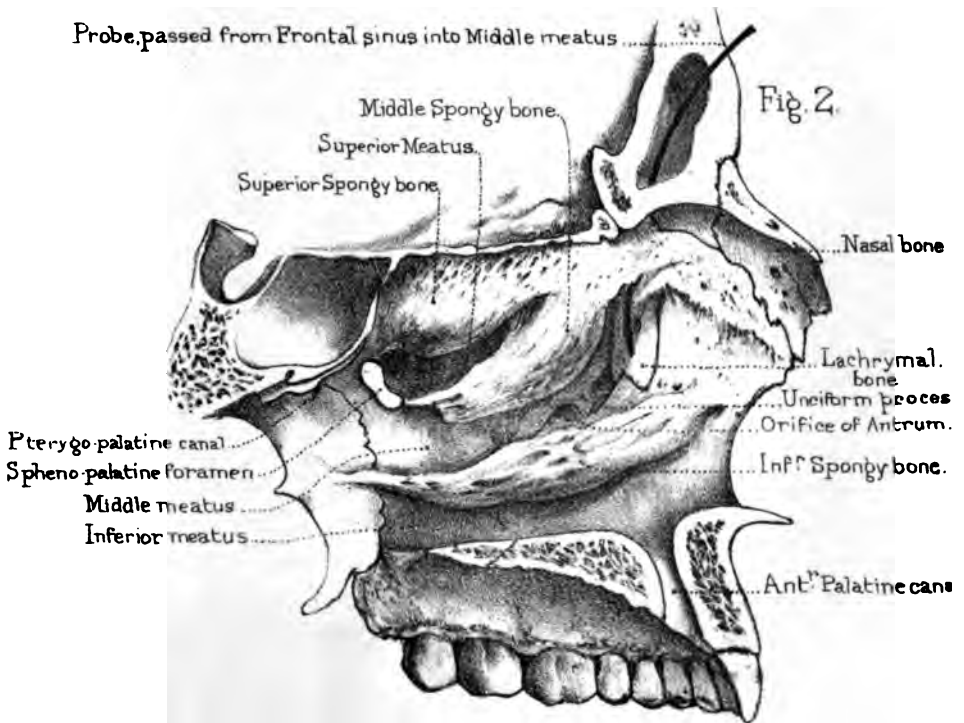
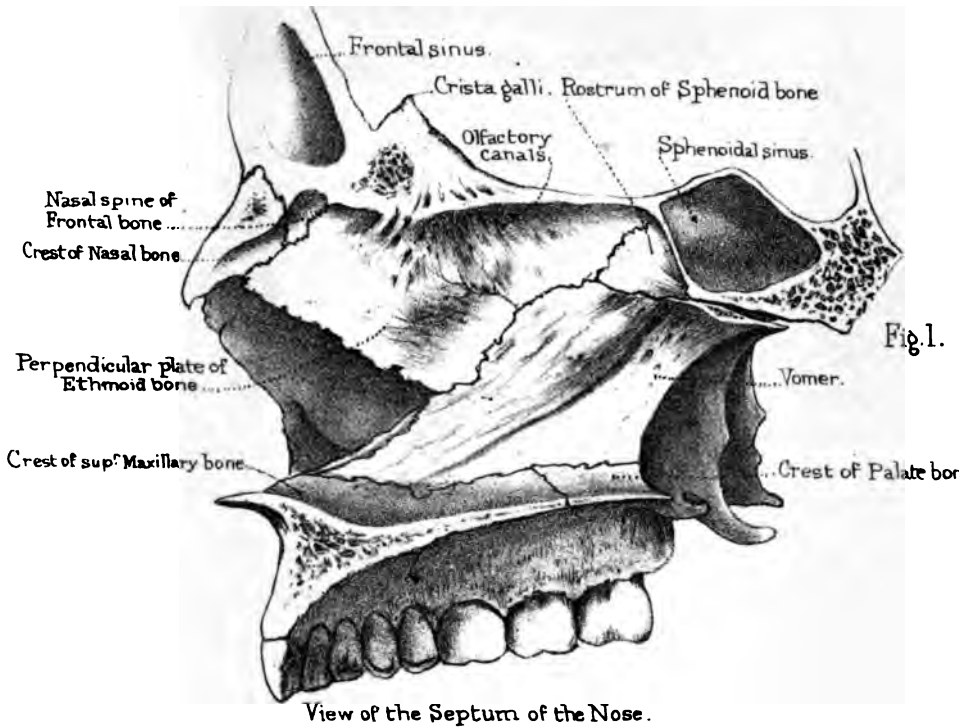
through the *spheno-maxillary fissure* into the orbit, and produce ecchymosis under the conjunctiva. 2. In the operation for the removal of the superior maxillary bone, we saw through the orbital wall into the fissure, so that it is requisite to know its precise position. Concerning the *sphenoidal fissure*, we should know that: 1. In fracture through the base of the skull, involving this fissure, the effused blood may make its way into the orbit and produce ecchymosis of the conjunctiva. 2. A sharp instrument might penetrate through this fissure into the brain. Surgery has such cases on record. Here is one. Henry II. of France, one of the last princes of the House of Valois, was mortally wounded by Montgomery, captain of the body guard, in a tournament held in 1559, on the occasion of the marriage of Philip II. with Elizabeth of France. A splinter from a lance entered through the sphenoidal fissure, stuck fast, and could not be extracted. The king died on the eleventh day.

N A S A L F O S S Æ .

(PLATE XXIII.)

These cavities open widely in front, and admit the air through the nostrils, and behind into the top of the pharynx. To study them properly it is indispensable to have a skull divided longitudinally on one side of the septum, so that we can examine the roof, the floor, the outer and inner surfaces of the cavities.

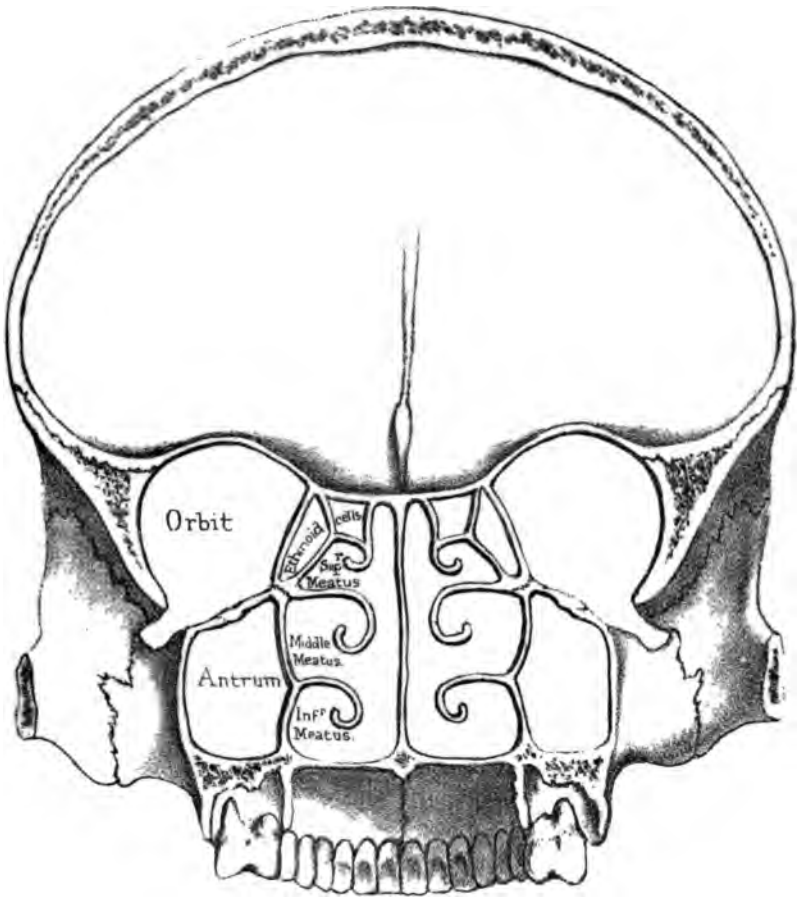
Boundaries of Nasal Fossæ.—The ‘roof’ of the nasal fossæ is formed by the nasal bones, by the nasal spine of the frontal, the cribriform plate of the ethmoid, and the body of the sphenoid. It does not form a horizontal plane from before backwards. It is only the cribriform plate which is horizontal; from this, the roof slopes forwards towards the nose, and backwards towards the pharynx: therefore the vertical depth is much greater in the middle than elsewhere. Notice the greater thinness of the cribriform plate, and how easily an instrument might be thrust through this part of the roof into the brain. Herodotus,⁶⁴ in his excellent



View of the three Meatus' of the Nose.

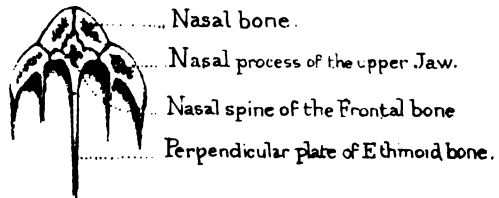
Drawn on Stone by J. G. Fisher
From nature by L. Holden
Engraved by West Neumann and Co.

Fig. 1.



Section showing the Meatus of the Nose.

Fig. 2.



Section, showing the Nasal arch.

Drawn on Stone by T. Godart.
From nature by L. Holden. Printed by West Newman & Co.

description of the process of embalming the dead, as practised by the ancient Egyptians, mentions that they drew out the brain through the nostrils with an iron hook, and filled up the void by injecting drugs. In the fine series of ancient Egyptian skulls, brought from the great necropolis of Thebes by Professor Flower, and now in the Museum of the Royal College of Surgeons (Nor. Hum. Ost., Nos. 584 to 593), it may be seen that in every one of them the cribriform plate is broken away, and the bones of the nasal fossæ more or less damaged; an interesting proof of the veracity of the ancient historian.

The 'floor' is nearly horizontal, and is formed by the palate plates of the superior maxillary and palate bones. In the dry bones can be seen, on each side of the septum, the orifice of the 'anterior palatine canal' (p. 82).

Meatus of the Nose.—The outer wall of the nasal fossæ is made irregular by the 'meatus' or passages in the nose, and the numerous openings leading to the air-cells, in the neighbouring bones. It is formed by the ethmoid (including its two turbinated bones), the nasal, the superior maxillary, the lachrymal, the inferior turbinated, the palate, and the internal pterygoid plate of the sphenoid. It is important to observe the position of the turbinated bones and the three 'meatus' or passages of the nose. (Plates XXIII. and XXIV.)

Superior Meatus.—Beneath the superior turbinated bone lies the 'superior meatus,' into which open the posterior ethmoidal cells and the sphenoidal cells. At the back part of this meatus is the sphenopalatine foramen, which leads into the sphenomaxillary fossa.

Middle Meatus.—Below the middle turbinated bone is the 'middle meatus.' Into this open—1, towards the front, the frontal sinus (or cell), along a passage termed the '*infundibulum*'; 2, the anterior ethmoidal cells (distinct from the posterior); 3, the antrum or maxillary sinus. The orifice of the antrum is large and irregular in the dry bones; but in the recent state it is so narrowed by mucous membrane that it will just admit a crow-quill.

Inferior Meatus.—Below the inferior turbinated bone is

the 'inferior meatus.' No air-cells open into this meatus: there is only the termination of the nasal duct or channel which conveys the tears into the nose: this cannot be seen without removing part of the turbinated bone.

The openings into the several 'meatus' of the nose may be thus tabulated:—

Into the SUPERIOR MEATUS	open	{	The sphenoidal cells.
			The posterior ethmoidal cells.
Into the MIDDLE	open	{	The anterior ethmoidal cells.
			The frontal cells.
			The antrum.
Into the INFERIOR	opens		The nasal duct.

The two upper turbinated bones (belonging to the ethmoid) are delicately channelled for the lodgment of the olfactory nerves. The lower or third turbinated bone has nothing to do with the sense of smell, and is coarser in its texture. It is traversed by several canals and grooves, which run from before backwards, and in the recent state contain large veins. The turbinated bones do not extend throughout the whole length of the outer wall. All the surface in front of a perpendicular line let fall from the nasal spine of the frontal bone is smooth, as is also all the surface behind a perpendicular line from the sphenopalatine foramen.

Bones forming Septum of Nose.—The bony septum of the nose, one of the principal supports of the nasal arch (Plate XXIII.), is formed chiefly by the perpendicular plate of the ethmoid and the vomer. (Plate XXIV. fig. 2.) The formation of the septum is assisted by the nasal spine of the frontal, the crests of the nasal, superior maxillary, and palate bones; also by the rostrum or crest of the sphenoid, making ten bones in all. The triangular interval left in the septum in the dry skull is filled up in the perfect one by the middle cartilage of the nose, which fits into a fissure in the bone.

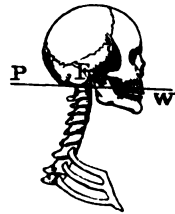
The posterior openings of the nasal fossæ have been already described in the 'base of the skull' (p. 118). The anterior opening is heart-shaped, with the broad part below. It is bounded on either side by the nasal bone, and by the nasal process of the

superior maxilla; below it is bounded by the palatine process of this bone, which terminates in front by a sharp projection, termed the 'anterior nasal spine,' the prominence of which is a marked feature in the higher races of mankind. It is very diminutive in some of the lower races, and absent in monkeys.

GENERAL OBSERVATIONS ON THE SKULL.

Skull a Lever of the First Order.—The entire skull represents a lever of the first order. The fulcrum or point of support F (see fig. 22) is at the occipito-atlantoid articulation; the resistance is the weight of the head W; the power P is the mass of muscle attached to the occiput. The skull is nearly balanced on the spine, and the muscles moving it have but small leverage. Contrast this, however, with that of the elephant (see p. 42), the massive appendages of whose head have proportionally strong muscles and ligaments for their movements and support.

FIG. 22.



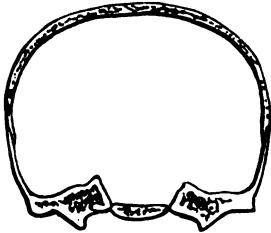
Three Layers or Tables of the Skull.—The cranial bones consist of three layers—an outer, an inner, and an intermediate 'diploe.' The outer is formed of compact and tough bone; the inner is harder, but more brittle (hence called 'tabula vitrea'); while the diploe is softer and spongy, and diminishes the effects of shocks. Altogether, then, this structure may be coarsely compared to a case composed of wood outside, porcelain inside, and soft leather between the two.

The different structure of these three layers or 'tables' of the skull is interesting practically. In blows on the head, the inner table, in consequence of its great brittleness, is likely to be broken more extensively than the outer. Cases indeed have occurred, where the inner table has been broken without any fracture of the outer. In sabre cuts penetrating the skull-cap as deep as the inner table, although the cut through the outer table may be only a simple incision without any depression, yet the inner table will be broken almost always to a greater extent than the outer:

indeed, it may be separated from it, and driven into the membranes if not into the substance of the brain.⁶⁵ Hence the necessity of examining these cases very carefully, to ascertain if there be any parts of the inner table depressed, and to remove them. Another reason why the inner table is often more extensively splintered than the outer is, that it is the last table reached by the force which inflicts the damage. The aperture of exit of a bullet is larger than that of its entry.⁶⁶ (See injuries and diseases of bone, No. 2901 E.)

Locking of the Bones.—The bones are mechanically locked together by the sutures; and in the recent state there is a thin

FIG. 23.



layer of animal matter between their edges, which diminishes the effects of blows. Whoever knows the strength of an egg-shell, can understand what hard blows the cranium will bear. Most of the bones mutually support each other, by having their edges bevelled alternately on opposite sides, as in the frontal suture; or by one overlapping the other, as in the squamous suture, where the temporal prevents the ‘starting’ of the parietal bone (see fig. 23). The effect of this is, that no single bone can be taken out of the cranium without separating the whole fabric. (Nor. Hum. Ost., No. 175.) When we wish to separate the bones, we do so, not by force from without, but by force from within the skull; that is, by introducing peas, which, when moistened with water, swell, and by pressing equally in all directions disjoint the bones.

Groins along the Sinuses.—Notice how the interior of the dome is strengthened by ‘ribs’ or ‘groins’ of bone, which run in the line of the principal sinuses. One rib extends from the centre of the frontal bone to the foramen magnum, and spans from before backwards the whole arch of the cranium. Another crosses transversely the back part of the occipital bone; the point of intersection of these two ribs being at the occipital protuberance, which is the thickest and strongest part of the skull.

Buttresses of the Skull.—Like all other arches, the cranium

transmits shocks towards its buttresses; these are firmly wedged into the base, and all meet at the centre, that is, at the body of the sphenoid. The frontal part of the arch is supported by the wings of the sphenoid and the malar bones, the parietal part by the temporal bones, and the occipital part supports itself by running, wedge-like, into the base, and abutting on the sphenoid. A knowledge of the buttresses which support the respective parts of the skull-cap affords an explanation of the direction which fractures generally take along the base of the skull, according as the injury has been received on the frontal, the parietal, or the occipital region of the cranium.

Power of resisting Shocks.—The older French school generally advocates the doctrine that the cranium resists shocks after the manner of other spheres, namely, that a blow struck on one side is transmitted to the opposite one; as when a glass tumbler, struck smartly with the finger nail, is made to crack on the opposite side. This they call fracture by '*contre-coup*.' But the modern school contends that the cranium resists shocks like all architectural arches; and that vibrations, instead of going round to the base direct, are lost upon the supporting pillars. The frontal pillars are the malar and sphenoid bones—the parietal pillars are the temporal bones—the occipital pillars are the ribs of the occipital bone itself. When the head is struck, the parietal region is most often the seat of injury. The bone breaks at the part struck, and the fracture runs on through the temporal bone, and most frequently through the tympanum—the weakest part. There are many excavations in the bone which weaken it about this part; 1, there is the '*meatus auditorius externus*'—2, the cavity of the tympanum itself—3, the jugular fossa—4, the carotid canal—5, the Eustachian tube. This accounts for the frequency of hæmorrhage from the ear in cases of fracture of the base of the skull.

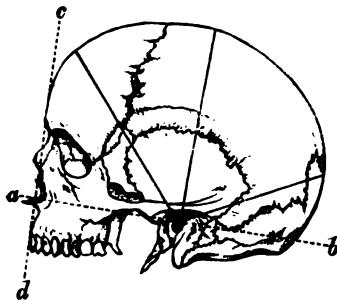
Buttresses of the Upper Jaw.—In the bones of the face there are two points to be noticed—1st, the great strength of the nasal arch (Plate XXIV.); 2nd, the extreme firmness of the upper jaw, fixed by its three buttresses on each side—namely, the nasal, the zygomatic, and the pterygoid. The *nasal* buttresses

rest against the internal angles of the frontal bone, and between them is the heart-shaped opening of the nose. The *zygomatic* buttresses are exceedingly strong; they are supported by the external angles of the frontal bone and the zygomatic processes of the temporal, and correspond to the molar teeth, which have to sustain the greatest pressure. The *pterygoid* buttresses descend perpendicularly from the base of the skull, and support the upper jaw behind.

Male and Female Crania.—The capacity of the cranial cavity varies, as a general rule, with the intelligence of the individual or of the race. It has been shown that in almost all races the capacity of the cranial cavities of the women is to that of the men as 9 is to 10. The mastoid and the other processes for the attachment of muscles are less pronounced in women than in men. The orbital margins, and especially the external angular processes, are thinner and sharper in females' skulls. In women's skulls the glabella and frontal sinuses are but slightly developed. The digastric groove is better marked in males than in females. The masticatory apparatus is more massive in the males' skulls. The development of the frontal, parietal, and occipital regions may be taken as a general expression of the development of the corresponding lobes of the brain. Upon this is founded the study of Craniology.⁶⁷

Facial Angle.—The best method of determining the proportions between the cranium and face in man, and the vertebrate

FIG. 24.



FACIAL LINE AND ANGLE.

animals generally, is by taking what is called the 'facial angle.' Let a line (see fig. 24) be drawn from the external auditory meatus along the floor of the nostrils, and be intersected by another line touching the most prominent parts of the forehead and upper jaw: the intercepted angle is generally in proportion to the size of the cranial cavity, and is a measure of the degree of

intelligence of the individual. In the dog this angle is 20° ; in

the chimpanzee, it is 40°; in the Australian native, 85°; in the European, 95°. The ancients, in their impersonation of the beautiful and intellectual, adopted an angle of 100°.⁶⁸

Comparative Osteology.—A student may, with careful observation, discover slight points of difference between opposite sides of the same skull. For instance, the posterior condyloid foramen of one side may be wanting, the mastoid process of one side may be larger than that of the other, or the digastric fossæ may be of unequal size; one nasal passage may be larger than the other; the lateral sinus may be much deeper on the one side than on the other, or there may be a middle clinoid process on one side only. Asymmetry may occur in men highly gifted, as in the celebrated French anatomist Bichat. This is no more than one might expect, seeing the difference often existing between features of the two sides of the same face. Such want of symmetry is greatly exaggerated in many of the lower animals, as may be seen in the Cetacea, in the head of the great sperm-whale or in that of the narwhal (*Mus. Roy. Coll. Surg.*), for the details of which, see the comparative osteology of the superior maxillary bone. But the most striking example of asymmetry is seen in those flat fish which lie usually on their left sides, viz., soles and plaice (*Pleuronectidæ*, Nos. 179 to 190). For in them both eyes are on the right or upper side of the skull, and one orbit only is completed, the eyes being directed away from the ground on which they lie. The teeth are chiefly developed on the left side of their jaws—away from the side on which their eyes are—that is, on the white side. It is interesting to note that in these fish, when very young, the skulls are symmetrical. When the turbot is just hatched, it has an eye on each side of the head, and it is only by subsequent development that the asymmetry occurs. The turbot, unlike soles and plaice, lies on its right side.

Different habits develop different muscles; and these muscles give rise to modifications in the form of the bones as well as of the bodily configuration. It will therefore be extremely interesting to contrast the skulls of the Carnivora with those of the Ungulata, or hoofed animals. Take, for example, a tiger's skull and that of

a deer. The skull of the tiger is in perfect adaptation to his enormous temporal muscle. It has a high median ridge, to which the muscles are attached, great arches of the zygoma, under which they pass, and broad and lofty coronoid processes, into which they are inserted. But his masseters are comparatively small, therefore the zygomata and the angles of the jaw are not specially strong. Now, the sole action of this temporal muscle is to clench the teeth together as on a hinge; so we find that his jaw articulation is hinge-like, and allows no other motion. This mechanism is admirably fitted for cutting purposes, but is quite unfit for grinding; so his teeth are cutters. He has no grinders. Exactly the converse of all this is true of the deer: his temporals are small, he has no median ridge, the passage under the zygoma is small, and his coronoid process is delicate and scarcely deserves notice. On the other hand, his masseters and pterygoid muscles are very large, his zygomata broad, the external pterygoid plates greatly expanded, the angles of the jaw massive and extensive. The masseters acting with the internal pterygoids cause the grinding action; so here the articulation of the jaw is nearly flat, allowing of a free grinding movement; and in accordance with this, we find the teeth are flattened on the surface, and good grinders. It will be seen how clearly this conformation is in keeping with the habits and nature of each animal.

From what has been said of the temporal muscles of the tiger, as well as from what will be said of the pectoral muscles of the flying birds (*Carinatae*), it appears that those sets of muscles by which an animal gets its living are the most largely developed, and that their bony attachments are large in proportion. Thus the history of the animal is always written on its bones clearly enough for any careful student to read. He who learns to love osteology will soon feel that it is far from dry, and that beauty finds indelible expression even in the bones; for he will see that low degraded types have skeletons which cannot be mistaken, while the healthy, intelligent, and upright carry their characters in their skeletons as much as they do in their faces.

In the ant-eater, which has no teeth, the zygomatic arch is incomplete (No. 2336).

In reptiles the cranial cavity is remarkably small. In a Nilotic crocodile (No. 717 D) nearly fifteen and a half feet long, the cranial cavity is only just large enough to admit the thumb.

Some heads are long, some are broad, and others round. These different forms are determined by the varying extent of growth of bone either in the transverse or the longitudinal sutures, or by the early union of one or other of them, as may be readily understood by a reference to the Gen. Ost. Ser. (Nos. 126—127), where, the parietal bones uniting early, the skull was unable to accommodate the growing brain by increasing in breadth, and therefore could only increase in length by growing at the fronto-parietal and the occipito-parietal sutures, thus giving rise to these extraordinarily long skulls.

The great and heavy skull of the crocodile contains large nasal passages and air cavities which float it, so that its body can lie under water while its eyes and nostrils alone appear just above the surface (No. 712).

One of the first-fruits of the study of comparative anatomy was the discovery of the law, 'That an invariable co-relation exists not only between the different parts of an animal's body, but likewise between the parts of his body and his mode of life.' The discovery was made by Cuvier, and would of itself have been sufficient to immortalise his name. He was led to the detection of this law by the study of a number of fossil bones which were found in quarries in the neighbourhood of Paris. The following is his own account:—⁶⁹

'I found myself in the position of a man who had received a confused heap of the mutilated and incomplete remains of some hundreds of skeletons belonging to a score of different kinds of animals; each bone had to search for those with which it should articulate—it seemed almost a resurrection in miniature. I had not at my command the all-powerful trumpet, but the immutable laws prescribed to living beings answered its purpose, for at the voice of comparative anatomy every bone, every fragment of bone, resumed its natural position. I am at a loss for words to describe my delight when so soon as I discovered any characteristic feature, I saw all the sequences of this character,

more or less foreseen, develop themselves in succession. I found the teeth conformed to what the feet had foretold, and the feet to what the teeth foretold, and all the bones between the feet and the teeth conformed as could be judged beforehand; in a word, each of these species sprang up again out of one of its elements. Those who will have the patience to follow me will be able to form an idea of the sensations I experienced in thus restoring by degrees these antique monuments of fearful revolutions. Subsequent discoveries of fossils have hardly ever contradicted my earlier conclusions.'

THE VERTEBRAL COLUMN.

(PLATES XXV. TO XXIX.)

The vertebral column, or spine (Plate XXVI.), consists of a series of bones articulated together so as to describe three slight and graceful curves, the bend being forward in the loins, backward in the chest, and again forward in the neck. These bones are called 'vertebræ,' because they permit the bending and rotation of the body (*verto*, I turn). They are 33 in number: of which 7 constitute the cervical region, 12 the dorsal, and 5 the lumbar. Below the lumbar vertebræ, the spine is supported upon a bone termed the 'os sacrum,' which consists of five vertebræ firmly coalesced into a single bone. Below the sacrum is the little bone termed the 'coccyx,' from its resemblance to the beak of a cuckoo (*κόκκυξ*). This also contains the rudiments of four, sometimes only three, vertebræ. The vertebral formula of man, therefore, is —7 cervical, 12 dorsal, 5 lumbar, 5 sacral, and 4 coccygeal, or caudal: that is, 33 in all.

Constituent Parts of a Vertebra.—The vertebræ have certain general characters which are common to all. These are modified in the different regions of the spine, according to the functions they perform. (See separate series, Mus. Roy. Coll. Surg.) Therefore, first obtain a general knowledge of a vertebra,

1
2

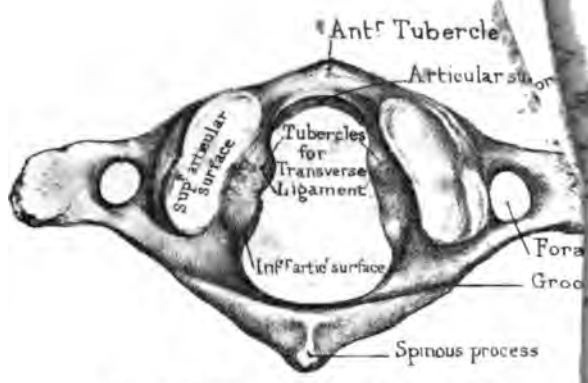
3

4

5

6

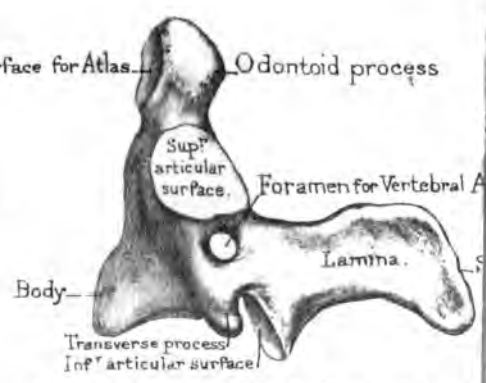
Fig. 5



First Cervical Vertebra or Atlas.

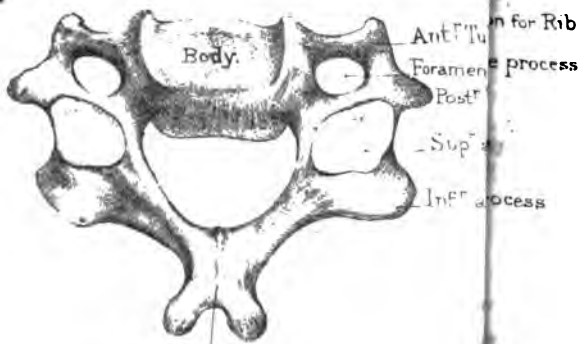
Articular surface for Atlas

Fig. 6.



Second Cervical Vertebra or Axis

Fig. 4.



Spinous process
Cervical Vertebra.

(From Nature by J. Holmes)

and of the names given to its several parts; afterwards examine the characteristics of the vertebræ in each region.

Taking the first lumbar vertebra as a pattern (Plate XXV.), it is seen to consist of a 'body,' or 'centrum,' which forms the columnar part, and supports the weight of the spine. The body is convex in front from side to side, but slightly concave behind, where it assists in the formation of the 'vertebral foramen,' which transmits and protects the spinal cord. The upper and lower surfaces of the body present a disc of solid bone at the circumference (Plate XXV. fig. 2), and a slight cup in the centre which lodges the elastic 'intervertebral fibro-cartilage,' found in the recent subject, and acting as a 'buffer' between the vertebræ. These discs or rings of compact bone deserve notice, not only because they strengthen the spongy bodies, but because they have separate centres of ossification, and remain until about the 25th year, as 'epiphyses.' A section through the body of a vertebra shows it to be composed of cancellous tissue, which makes it light compared to its bulk. (Nor. Hum. Ost., Nos. 175 to 185.) This tissue is traversed by large 'venous canals,' of which the orifices are observable on the surface, but chiefly on the back part of the body, towards which the larger canals converge (Plate XXV. fig. 7). Behind the body is the 'vertebral foramen.' Now this foramen is formed by two thick processes of bone, which proceed, one from each side of the posterior part of the body, and gradually converging, unite and form an arch (vertebral or neural arch). The spring of the arch, where it joins the body, is called the 'pedicle'; the converging plates are termed the 'laminae.' The arch sends off seven 'processes.' Of these, three—namely, the 'spinous' and the two 'transverse'—give attachment to muscles. The 'spinous process' arises from the top of the arch; the two 'transverse processes' pass off, nearly horizontally, one from each side of it, near the junction of the 'pedicle' with the 'lamina.' The remaining four are termed 'articular processes'—two superior articulating with corresponding processes of the vertebra above and two inferior articulating with corresponding processes of the vertebra below; they are situated on the point of union of the pedicles with the laminae. Their articular surfaces are covered

with cartilage in the fresh state, and project beyond the bodies, so that the joints are on a level with the intervertebral fibro-cartilages. Lastly, on the pedicles, we observe two 'notches' on either side,—an upper and a lower, the lower being always the larger. When the vertebræ are together, these notches make what are called the 'intervertebral foramina,' in which the spinal nerves lie. (Plate XXVII.) The 'pedicle,' or the part of the arch between the notches, is the weakest part of a vertebra, and consequently it is the principal seat of torsion in curvatures of the spine.

Such, then, are the constituent parts of a vertebra: namely, a body, an arch, a vertebral foramen: seven outstanding processes, of which four are articular, and three give attachment to muscles; lastly, the notches which transmit the spinal nerves.

In examining a single vertebra it is necessary first to ascertain to which region it belongs, and then which vertebra it is of that region. We will therefore describe first the distinctive characters of the region, and then the peculiar characters of the individual vertebræ, as far as they can with certainty be distinguished.

Cervical Vertebræ—Distinctive Character.—All the cervical vertebræ, and they alone, have a foramen in the base of each transverse process, which (excepting that in the 7th) transmits the vertebral vessels and a plexus of sympathetic nerves.

General Characters of the Cervical Vertebræ.—There are seven cervical vertebræ. The 'bodies,' excepting the first and second, are broader from side to side than from before backwards, and a lateral ridge projects from each side of their upper borders, and fits into a corresponding depression on the sides of the vertebra above (Plate XXV. fig. 4). Each 'body' slopes a little forward, and overlaps the one below. (Plate XXVII.) By all this interlocking, lateral displacement is prevented; this mechanism compensating for the apparently insecure connections of the articular processes. Their 'spinous processes' are horizontal, and give attachment to the ligamentum nuchæ as well as to the muscles which maintain the head erect. But the spinous processes of the third, fourth, and fifth are especially short, and permit the free extension of the neck, and are very distinctly

bifurcated ; they overlap each other a little in extension, as any one may see in the dry bones by moving them backwards over each other. There is a groove on the upper surface of each transverse process in which lodges the spinal nerve ; and this groove bifurcates the summit, so that there are two 'tubercles' formed, an anterior and a posterior (in the lower five), both for the attachment of muscles. Observe especially the large size of the anterior tubercle of the sixth cervical vertebra. It is called the carotid tubercle, being a guide to the carotid artery. Strictly speaking, we ought to say that the transverse process of a cervical vertebra arises by two roots or bars, an anterior and a posterior, which subsequently join, and so form the foramen which transmits the vertebral artery, vein, and a plexus of nerves : the anterior root springs from the side of the body : the posterior springs from the arch. Their 'articular processes' are flat, oblique, and inclined, so that their planes make an angle of about 45° with the horizon. The upper processes look backward and upward, the lower forward and downward. Their obliquity permits the requisite flexion and extension of the neck, as well as slight lateral inclination of it. A dislocation of one of these vertebræ may happen without fracture of the articular processes. Such a dislocation is exceedingly rare ; but there are specimens of it in the Museum of St. Bartholomew's Hospital. It may be produced by sudden and forcible rotation of the neck. Baron Boyer⁷⁰ speaks of an advocate who dislocated one of his cervical vertebræ by suddenly turning his head round to see who was coming in at a door behind him.

1st and 2nd Cervical Vertebræ.—The 1st and 2nd cervical vertebræ differ most remarkably from the rest, as they respectively permit the nodding and the rotation of the head.

1st Cervical Vertebra: Atlas.—The 1st cervical vertebra (Plate XXV. fig. 5) is called the 'atlas,' because it supports the head. This is the only vertebra which has no body. The odontoid process of the axis (the 2nd cervical vertebra) is the body of the atlas, and is thus transferred and fixed to the second vertebra, forming a pivot or axis upon which the atlas rotates. It seems, at first sight, rather far-fetched to say that the atlas rotates

round its own body (detached); but it is nevertheless true, and borne out by the facts of philosophical anatomy. The 'spinous process' is a mere tubercle (the posterior tubercle) to which the 'rectus capitis posticus minor' is attached. A large spine here would interfere with the free backward movement of the head. This vertebra is like a ring, wider behind than in front, and thickened on each side, forming the 'lateral masses' and the articular surfaces. In front there is a small 'anterior tubercle,' into which is inserted a portion of the 'longus colli.'

Now the form of the atlas is adapted to the rotatory movement of the head. In the first place there is a little articular surface, the odontoid articulation, on the back of the anterior part of the ring of the atlas. The 'transverse processes' are thick and strong, and project far beyond those of the other cervical vertebræ, and give great leverage to the inferior oblique muscles which assist in rotating the head from side to side. Its 'inferior articular' processes look downwards and slightly inwards; they are nearly horizontal, flat and circular, like the upper ones on the axis on which they slide, in the movement of rotation of the head. The 'superior articular surfaces' are concave, and articulate with the convex condyles of the occipital bone, and are similarly oval, converge anteriorly, and lie near the front of the foramen. The outer edges being the highest, they form two little cups looking upwards and inwards, which receive the occipital condyles, sustain the whole weight of the head, and permit its nodding movement. On the inner side of each articular process is a tubercle which gives attachment to the strong 'transverse' ligament, which confines the odontoid process in its position. The 'arch' formed by the laminae is wider than in other vertebræ, and leaves such ample space that lateral displacement of the atlas has occurred without compression of the spinal cord.⁷¹ On the upper surface of each lamina is a groove (sometimes a complete bony canal) for the vertebral artery and suboccipital nerve; this corresponds to the superior notch in the other vertebræ. Lastly, the 'notches' for the nerves are placed behind the articular processes, while in all the other vertebræ (except the upper notch in the axis) they are in front of them.

2nd Cervical Vertebra: Axis.—The 2nd cervical vertebra or ‘vertebra dentata’ (Plate XXV. fig. 6) is called the ‘axis’ because it is the axis upon which the atlas (with the head) rotates. The pivot, termed the ‘odontoid process’ from its resemblance to a tooth, rises vertically from the ‘body’ of the axis, and fits into a ring formed in front by the atlas, and behind by the strong ‘transverse’ ligament which passes between the lateral masses of the atlas, and divides the vertebral foramen of that bone into two parts, an anterior for the reception of the odontoid process, and a posterior for the passage of the spinal cord. It is a mechanism resembling a tenon and mortise.⁷² The odontoid process has a smooth surface in front, which articulates with the atlas; another behind, on which plays the ligament. There is a distinct synovial membrane and a layer of cartilage on each surface, so that they possess all the apparatus of a joint. Moreover, it is slightly constricted at its lower part (forming what is called ‘the neck’), which the ‘transverse’ ligament clasps securely. Lastly, its summit or ‘head’ is rough and sloped laterally. From these lateral slopes proceed the ‘check’ or ‘odontoid’ ligaments, which fasten the odontoid process to the occipital bone. Notwithstanding the strength of its ligaments, the odontoid process does sometimes slip out of its ring. The following is an instance:—A lady was carrying her child on her shoulders. Losing its balance, the child clung to its mother’s head, and drew it suddenly and forcibly backwards. The lady fell dead. It is more liable to dislocation in children, because the ligaments are weaker than in the adult. Petit relates the case of a child who was instantaneously killed by being lifted by the head. Considering the importance of the odontoid process, we are not surprised that its internal structure is much more compact than that of the body of the axis. The upper ‘articular processes’ are placed, partly on the body and partly on the root of each transverse process; they are nearly flat and circular, and slope a little downward and outward. Like those of the first vertebra, they have a very strong base, and transmit to the ‘body’ the weight of the head. The ‘notch’ is behind them. The lower ‘articular processes’ are oblique, and placed

considerably behind the upper, and correspond with the line of the articular processes of the succeeding vertebræ which they resemble. The intervertebral 'notch' is in front of them, as in all the vertebræ below. The 'transverse processes' are comparatively small, and not grooved or bifurcated; but the hole at their base is inclined obliquely outwards, corresponding to the curve of the vertebral artery. The 'laminæ' of the arch are remarkably strong. The 'spinous process' stands well out, and bifurcates widely, giving great leverage to the inferior oblique muscles which rotate the head. The great size and projection of this *spinous* process is one of the distinguishing characters of the axis; and with this we should associate the large size of the *transverse* processes of the atlas, these being the respective attachments of the inferior oblique muscles.

3rd, 4th, and 5th Cervical Vertebræ.—The 3rd, 4th, and 5th cervical vertebræ can be easily distinguished from the rest, although not from one another, by the following points:—Their spinous processes are spread out horizontally, and are thin, bifid, and short (Plate XXV. fig. 4), thus allowing the neck to be bent backwards very considerably before the spines come into contact.

6th Cervical Vertebra.—The spine of the 6th is short, it is not bifid (or rarely so), and runs nearly horizontally backwards, but is not spread out like the 3rd, 4th, and 5th.

7th Cervical Vertebra.—The 7th cervical is called the 'vertebra prominens' on account of its long and prominent spine, which can be easily felt at the back of the neck. It slopes downwards, and thus somewhat resembles those in the dorsal region, and gives attachment to the 'ligamentum nuchæ.' The foramen in the transverse process is never traversed by the vertebral vessels, and is in some rare cases absent. Moreover, the transverse processes, though so long and broad as to suggest a rudimentary rib, are but slightly grooved, and have no distinct tubercles. This vertebra in some rare instances has two little (cervical) ribs attached to it, one on either side, in form and situation resembling the cervical ribs of animals. A cervical rib may be mistaken for a bony tumour if

the surgeon does not bear in mind that such an anomaly may exist in the skeleton. It is sometimes united with the first rib.

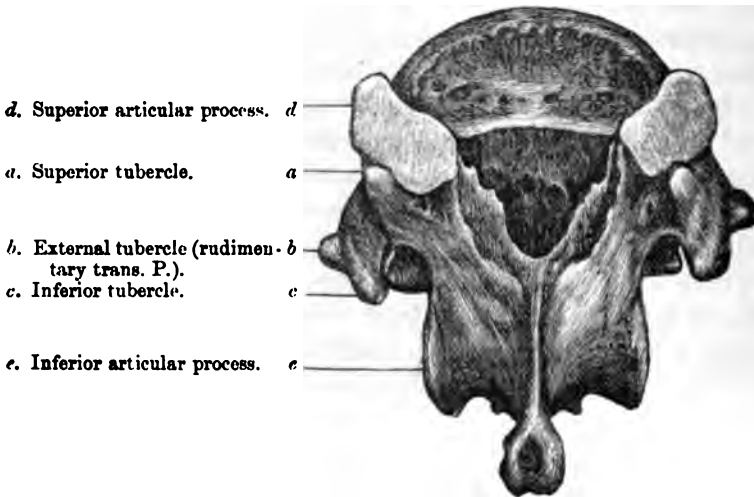
Dorsal Vertebrae: Distinctive Character.—All the dorsal vertebrae, and they alone, have facets on the sides of their bodies with which the heads of the ribs articulate.

Dorsal Vertebrae: General Characters.—The general characters of the twelve dorsal vertebrae are as follows:—Their ‘bodies’ are heart-shaped, and smaller than those of the lumbar, and they have less weight to bear. Their vertical depth is less in front than behind, especially near the middle of the back, in adaptation to the dorsal curve. They have two little cup-like facets on each side for the articulation of the heads of the ribs, the lower cups being the larger. By referring to the spine (Plate XXVI.), we observe that the socket for the head of the rib is formed by the articular facets of two vertebrae with the intervening fibro-cartilage. Their ‘spinous processes’ are long, clubbed at the end and slant downwards, so that they overlap each other, especially near the middle of the back, and prevent extension of the spine in this region. Their ‘transverse processes’ are thick and strong, and each has in front, near its end, an articular surface for the tubercle of a rib, which it supports like a buttress. Observe that the transverse processes of the seven upper dorsal vertebrae are very thick and strong, and support the seven true ribs, whilst the five lower gradually diminish in size; those of the eleventh and twelfth are the smallest of all, and they do not support ribs; these lower ones present three tubercles, of which more will be said hereafter. The ‘laminæ’ are broad and flat, and slope one over the other. Of the ‘articular processes’ the upper look backward, the lower forward, and the planes of both are so nearly vertical that it is manifest there can be but little movement between any two dorsal vertebrae. The ‘vertebral foramen’ is nearly round.

1st, 9th, 10th, 11th, and 12th Dorsal Vertebrae.—The FIRST dorsal vertebra has on the side of its ‘body’ an articular surface for the whole of the head of the first rib, and a smaller one at the lower border for half of that of the second rib. Again, the upper surface of its body has lateral ridges like the cervical

vertebræ. The NINTH dorsal has usually only half a facet on the upper part of the body. The TENTH dorsal has generally an entire facet for the tenth rib. The ELEVENTH and TWELFTH dorsal have each a single articular facet for the eleventh and twelfth ribs respectively, and their 'transverse processes,' much reduced in size, do not articulate with the ribs. Moreover, they are smaller than in the upper dorsal region, and they resolve themselves into three tubercles (seen in fig. 25). The TWELFTH dorsal may be distin-

FIG. 25.



TWELFTH DORSAL VERTEBRA, SHOWING THE THREE TUBERCLES ON THE TRANSVERSE PROCESSES.

guished from the ELEVENTH by the fact that its lower articular processes look outward, like the corresponding processes in the lumbar vertebræ. Its spinous process is short and square, and more like those of the lumbar vertebræ. The tubercles of its transverse process are always well-marked. (Plate XLV. fig. 2.)

Lumbar Vertebræ: Distinctive Characters.—The lumbar vertebræ have neither holes in their transverse processes nor articulations for ribs.

General Characters of the Lumbar Vertebræ.—The general characters of the five lumbar vertebræ are as follows:—

The 'bodies' are large and oval, with their broad diameters transverse, and firmly support the trunk. The vertical measurement of the bodies is greater in front than behind, in adaptation to the lumbar curve. Their sides are slightly excavated, which economises weight and bulk. Their 'spinous processes' are broad, in their vertical measurement, thickest at the lower border, and give good leverage to the extensor muscles of the spine: they stand out horizontally, and so do not interfere with the extension of the back. Their 'transverse processes' are thin and long, and appear like stunted ribs, but are not true ribs. Their 'articular processes' are vertical, and very strong: the upper, slightly concave, look towards each other; the lower, slightly convex, are nearer together, and fit in between the upper ones of the succeeding vertebra. Thus, these articulations are so shaped that they admit, not only of extension and flexion of the loins, but of a certain amount of rotation, which is useful in progression. The 'vertebral foramen' is triangular, with the angles rounded.

Characters of the last Lumbar Vertebra.—The last lumbar vertebra is distinguished (1) by the slope on the lower surface of its body, in adaptation to the slope of the sacrum; (2) by the great thickness of the root of its transverse process which springs more from the body, the ilio-lumbar ligament being attached to this additional massiveness; (3) by its lower articulating processes being placed so widely apart; and (4) by its spinous process being somewhat reduced in size, thereby leaving room for the free extension in this part of the back.

Tubercles on the Lower Dorsal and Lumbar Vertebrae.—An observant eye looking at the back of a well-marked spinal column will find that the transverse processes of the lower dorsal vertebrae have a tendency to resolve themselves into three bony prominences at their extremities. The twelfth (often the eleventh) transverse process actually terminates in three such prominences or tubercles; one being superior, a second inferior, and a third external (see fig. 25). The 'superior tubercle' is close behind the superior articular process. The 'inferior tubercle' is in a straight line immediately below the superior; the 'external' projects in front of the other two tubercles, and is seen to be in a line with

that part of the transverse processes of the upper dorsal vertebræ which bears the ribs. Now the superior and inferior tubercles gradually fade away in the lumbar vertebræ; but the external tubercle increases in size, and forms the transverse process of the lumbar region. Hence the transverse process of a human lumbar vertebra is homologous to that part of the transverse process of a typical dorsal vertebra which articulates with the tubercle of a rib. The tubercles are shown in Plate XLV. fig. 2.

In the human subject these 'tubercles' ⁷³ serve only as attachments for muscles; but in some animals they attain extraordinary size, and have other functions. For instance: in the armadillo (No. 2335 B), the superior tubercle is as long as the spinous process itself, and helps to support the armour. In the Carnivora the inferior tubercles gain a conspicuous development in the lower dorsal and upper lumbar regions, and contribute to the lateral security of the spine.

TABLE CONTRASTING THE IMPORTANT PARTS OF THE VERTEBRÆ IN THE DIFFERENT REGIONS.

We have shown how the vertebræ of the different regions of the spinal column may be distinguished, within certain limits, by the examination of any one of their constituent parts. These important parts are contrasted in the annexed table.

BODIES OR CENTRA.	{	<p><i>Cervical.</i>—Always broadest transversely. Lateral ridges on upper surface.</p> <p><i>Dorsal.</i>—Transverse and antero-posterior measurements nearly equal, except in two or three uppermost. Facets or parts of facets on sides for heads of ribs.</p> <p><i>Lumbar.</i>—Always broadest transversely, somewhat kidney-shaped, no ridges, no facets.</p>
LAMINÆ.	{	<p><i>Cervical.</i>—Long, thin and flattened.</p> <p><i>Dorsal.</i>—Short, very broad vertically.</p> <p><i>Lumbar.</i>—Very short and stout.</p>
SPINES.	{	<p><i>Cervical.</i>—Bifurcated, grooved underneath.</p> <p><i>Dorsal.</i>—Long, very oblique, tubercle at summit.</p> <p><i>Lumbar.</i>—Broad and square.</p>
TRANSVERSE PROCESSES.	{	<p><i>Cervical.</i>—Bifurcated, grooved on upper surface. Foramina for vertebral artery.</p> <p><i>Dorsal.</i>—Large and strong; facets for tubercles of ribs, except eleventh and twelfth.</p> <p><i>Lumbar.</i>—Thin, long and narrow.</p>





SUPERIOR ARTICULAR PROCESSES.	{	<i>Cervical.</i> —Surfaces plane, inclined at angle of 45°, look backward and upward.
		<i>Dorsal.</i> —Surfaces plane, almost vertical, look backward and outward.
		<i>Lumbar.</i> —Surfaces concave, vertical, look backward and inward.

Vertebral Column as a Whole.—The spine is a most wonderful piece of mechanism, and has excited the admiration of anatomists in all ages, from the various and apparently incompatible offices it serves (Plate XXVI.). It forms a column, at once strong and firm, which supports the body in the erect position; it is flexible, and so admits the bending of the trunk in various degrees; it is elastic, diminishing concussion of the head. It forms a continuous canal at the back of the column, which contains and protects the spinal cord, a basis for the origin of the muscles which spread over the trunk, and a lever for the muscles which keep the body erect. All these offices are performed by it with so much safety, that even the feats of a mountebank rarely injure the spine.

Strength of the Spine.—The main strength of the spine depends upon this,—that it consists of a chain of bones so locked together, that the degree of motion between any two is limited, though the sum of the whole is extensive. Another reason of the strength of the spine is its arrangement in alternate curves. Mathematicians have calculated that it is many times stronger, and more adapted to resist vertical pressure, than if it were straight, the force being decomposed by the curves.⁷⁴ Look at the enormous weight which a man can carry with ease and safety on his head. Moreover, the curves convert the spine into so many elastic springs, which prevent the jarring of the brain. Besides this, the curves are admirably disposed for the lodgment of the internal organs, and the transmission of the weight of the head and trunk in the line of gravity. They are so regular and gentle withal, that the spinal cord runs no risk of compression; and lastly, they give the body that graceful form which has been the ‘line of beauty’ in every age.

The weakest part of the spine is about the last dorsal vertebra: firstly, because it is the narrowest part of the column; secondly, because it is not supported by the ribs like the higher dorsal vertebræ; thirdly, because it is the centre of the spine and the

centre of motion in the back, and therefore exposed to the powerful leverage of the spine above and below it. Again, at the articulation between the last dorsal and the first lumbar vertebræ, the pliable lumbar part of the spine suddenly joins the comparatively rigid dorsal region.

Curves of the Spine.—The curves of the spine are produced partly by the relative thickness of the bodies of the vertebræ in the different regions, but *chiefly* by the relative thickness of the intervertebral fibro-cartilages and the tension and elasticity of the ‘ligamenta subflava’ which connect the laminae.

Extent of Motion in Different Regions.—From common observation, as well as from experiments, it appears that flexion and extension, as well as lateral movement of the spine, are freest in the neck, less free in the loins, and least free in the dorsal region. Now the component parts of the vertebræ are shaped accordingly. Thus, in the *neck* the articular processes are oblique, the spinous processes of the third, fourth, and fifth vertebræ are short and spread out horizontally, and the intervertebral substances thick. In the *back* these substances are thin, the articular processes nearly vertical, and the spinous processes are long and overlap each other, particularly about the middle of the back, where the heart lies, from the fourth to the eighth dorsal vertebra; so that there cannot be much movement between the bones. In the *loins*, the thickness of the intervertebral substances, the horizontal and wide-apart spines, and the shape of the articular processes combined, allow more motion than in the back, but less than in the neck.

The movements of which the spine is capable are threefold: (1) Flexion and extension; (2) Lateral inclination; (3) Torsion. Flexion and extension are freest between the third and sixth cervical vertebræ, owing to their short and horizontal spines; between the eleventh dorsal and second lumbar; and, again, between the last lumbar and the sacrum. This is well seen in cases of tetanus (‘opisthotonos’), where the body is supported on the back of the head and the heels; or when a mountebank bends backwards and touches the ground with his head. The lateral movement is freest in the neck and in the loins. The articulations of the lum-

bar vertebræ admit of a certain amount of rotation or torsion, as proved by the following experiment: Sit upright with your head and shoulders well applied against the back of a chair; the head and neck can be rotated to the extent of 70°. Lean forwards so as to let the lumbar vertebræ come into play; you can then turn your head and neck 30° more.

Intervertebral Fibro-Cartilage.—The intervertebral fibro-cartilage provides for the elasticity as well as the flexibility of the spine. The solidity of this substance gradually diminishes from the circumference towards the centre, where it forms a soft and almost incompressible pulp, permitting, to a limited extent, the motions of a ball-and-socket joint; namely, a gentle bend in every direction, with a small amount of rotation. Its great elasticity breaks the force of jars by gradually yielding, and always tends to restore the column to its erect form. Long-continued pressure during the day will, indeed, make the intervertebral substances yield, so that a man loses in height perhaps $\frac{1}{3}$ or even $\frac{1}{2}$ an inch; but this is recovered after a night's rest. At the same time it should be remembered, that a habit of leaning too much on one side will make the yielding of the intervertebral substance *permanent*. Even the bones themselves, while they are growing, will yield under such circumstances. There may be considerable distortion without actual disease.


Shape of the Column from the Front.—As to the form of the column in front, we observe that it is pyramidal, and that the bodies of the vertebræ gradually increase in size from above, and form a broader and broader base of support as the weight to be supported by each one in succession becomes greater. The atlas, in consequence of the great projection of its transverse processes, necessary for the rotation of the head, tops the pillar like a 'capital.' It is, however, necessary to remark, that there is a partial enlargement of the column about the lower part of the cervical region, which gives a broader base to the neck; and again a slight decrease in its breadth, about the third and fourth dorsal vertebræ, which allows more room for the lungs. Moreover, we commonly observe a very gentle lateral curve in the dorsal region, particularly about the third, fourth, and fifth

vertebræ, with the concavity towards the left side. The cause of this curve has been much discussed. Some anatomists attribute it to the more frequent use of the right arm; others to the presence of the aorta. The solution of the question is of no practical value; all we need remember is, that the curve is natural.

Back of the Column.—At the back of the column, we observe the long row of spinous processes forming the vertical crest which gives the name to the ‘spine.’ The spines of the vertebræ should be examined on the living subject when the head is bent forwards and the arms folded. At the risk of repetition we will again direct attention: 1. To the suppression of the spine in the atlas, which permits the free extension of the head. 2. To the great projection and bifurcation of the spine of the axis which gives attachment to the inferior oblique muscles which rotate the head and atlas. 3. To the shortness and horizontal position of the spines of the third, fourth, and fifth, which allows of free extension. 4. To the spine of the ‘vertebra prominens,’ where the ligamentum nuchæ is attached. 5. To the overlapping of the long spines of the dorsal vertebræ which limits movement in the region of the heart and lungs. These organs could not resist stretching or compression like the abdominal viscera. 6. To the square lumbar spines, the planes of which are vertical.

Vertebral Groove.—On either side of the spine is a deep furrow, termed the ‘vertebral groove,’ and formed by the laminae. It is bounded in the neck and back by the transverse processes, in the loins by the articular processes. The groove is narrowest about the junction between the last dorsal and first lumbar vertebræ (the weakest part of the back), and widest at the sacrum. The groove is occupied by the strong muscles of the back. The crest, being all that we can either see or feel of the spine during life, is the part we immediately examine in cases of injury or disease. In making this examination, we ought to be aware that the spines of the several vertebræ do not always succeed each other in a precisely straight line, but that one, here and there, may deviate to the right or the left, even in persons of the strongest frame.

Throughout the spine the intervertebral foramina are in front



of the articular processes. But it is worth observing that the transverse processes vary in position. In the cervical region they lie between the foramina and are grooved by nerves. In the dorsal region they lie further back between the articular processes in accommodation to the ribs which lie between the foramina. In the lumbar region the transverse processes lie between the articular processes and the intervertebral foramina.

Vertebral Canal.—Respecting the vertebral canal (shown throughout in Plate XXVII.), remark how well it is protected from injury by the breadth of the arches of the vertebræ. The arches overlap each other, so that it would be difficult for a cutting instrument to penetrate anywhere, except perhaps in the lumbar region, and, again, between the arch of the atlas and the occiput, where animals are usually ‘pithed.’ The area of the canal is larger in the lower cervical and in the lumbar region than elsewhere, for the reason that the spinal cord itself presents corresponding enlargements in those parts where the great nerves of the limbs proceed from it. Observe well the relative size and mode of formation of the intervertebral foramina by the notches (Nor. Hum. Ost. No. 73).

Ossification.—As a rule, each vertebra is ossified in cartilage from eight centres, of which three are ‘principal,’—namely, one for the body and one on each side for the arch and its processes (Nor. Hum. Ost. No. 35): the remaining five are ‘epiphyses,’ and appear, soon after the age of puberty, as follows:—one in the cartilaginous end of the spinous process, one in the cartilaginous end of each of the transverse processes, and one for each of the discs which form the articular surfaces of the body. The five epiphyses become united to the vertebra by bone about the twenty-fifth year.

Ossification usually commences at the sides of the arch just before it begins in the body of the vertebra,—viz. about the seventh week after conception. The sides of the arch unite first at the base of the spinous process, so that the ossification of the arch is complete in the first year after birth. During the third year the bases of the arch unite with the independently ossified ‘centre’ or ‘body.’

It must be borne in mind that the sides of the bodies are ossified from the arches; the line of junction is the 'neuro-central suture' of scientific anatomists.

Exceptions to the General Rule.—Where vertebræ undergo great modifications of form, we meet with exceptions to the above rule. Thus the atlas has only two 'primary' centres,—one for each of its lateral halves; and two 'epiphyses,' one for the anterior tubercle, the other for the posterior. The odontoid process of the axis has two additional centres placed side by side and unites to the body in the third year. It has also two small epiphyses, one at the tip, and another between the centres for the process and the centre for the body of the axis. These epiphyses are homologues of the discs of ordinary vertebræ, and help to justify the general opinion that the odontoid process is really the body of the atlas; although, if it be so, it is remarkable that this body should have a pair of centres.

There is a separate ossification for the 'superior tubercles' or 'mammillary processes' of the lumbar vertebræ.

Comparative Osteology.—In all known mammalia there are seven cervical vertebræ, with the following exceptions: Hoffmann's two-toed sloth—*Cholœpus Hoffmannii* (No. 2387 F) has six; the Three-toed sloth—*Bradypus Tridactylus* (No. 2367) has nine. In *Bradypus*, however, the ninth, and sometimes the eighth, bears a pair of short movable ribs; the manatee, again—*Manatus Americanus* (No. 2647 a)—has only six cervical vertebræ. The number of cervical vertebræ bears in no case any relation to the length of the neck. The short neck of the whale and the long neck of the giraffe (No. 3617) contain each seven cervical vertebræ. The Greenland fin-whale in the Mus. Roy. Coll. Surg., appears to have but one cervical vertebra. An inspection of the transverse processes, however, shows that it has seven, and that they have become anchylosed. The lesser fin-whale, next to it, has the seven vertebral bodies perfectly distinct.

The bifurcation of the spines of the cervical vertebræ is almost peculiar to the human skeleton. It affords more room for the insertion of the powerful muscles which maintain the neck, and therefore the head, erect.

In the gorilla, the spines of the five lower cervical vertebræ (No. 5178) are longer in proportion than those of any other known animal. They measure from three to four inches in length, and form one of the most striking features of difference between this skeleton and that of man.

The whale (Cetacea) has no odontoid process, and thus differs from the manatee (Sirenia), which has a well-marked one. See Series of Separate Bones, Mus. Roy. Coll. Surg.

In the chameleon each of the two lower cervical vertebræ bears a pair of cervical ribs (Nos. 664 *a*, 665 *a*); and in the snakes all the vertebræ, excepting those of the tail, carry movable ribs. Cervical ribs may also be seen in crocodiles (see Nilotic Crocodile, No. 717 D).

When mammalian vertebræ are very numerous, the great number is made up of caudal vertebræ; but when a bird's vertebræ are numerous, the number is made up of cervical. There are nine in the neck of the sparrow, and twenty-three in that of the swan.

In the wading birds (Grallatores), whose long legs raise the body some two feet or more above the water in which they wade, the neck is long enough to enable their beaks to reach the ground. Thus their necks are in proportion to the length of their legs. See the flamingo.

In swimming birds, as ducks and swans, the length of the neck is in no relation to the length of their short legs, but is in proportion to the depth to which they have to reach for food.

In man the upper and lower surfaces of the bodies of the vertebræ are slightly cup-shaped, and receive in their depressions the convex surfaces of the discs of fibro-cartilage, which are placed between the bodies of the vertebræ, and give the spinal column its elasticity. In most fishes the bodies are so deeply cupped above and below, that there is a perforation in the centre through which the intervertebral substances are continuous (Nos. 433 to 437). In man the soft central part of this intervertebral substance is the remains of the chorda dorsalis, which persists in fishes, and is continuous through the central perforations. See the central cavities for the chorda dorsalis in the blue shark, No. 413; also No. 13. In

the mud fish (*Dipnoi*) all the notocord is persistent, and there are no centra to the vertebræ whatever. This may also be seen in the *Amphioxus Lanceolatus* (No. 8).

The epiphyses on the upper and lower surfaces of the bodies of the vertebræ should be especially examined in the whale (Separate Series). They form complete plates of great size, and being separable from the bodies of the vertebræ in many of these animals, are very abundant on the sea-shore in northern climates. It is interesting that when H.M.S. 'Hecla' was wrecked, the crew used these discs as plates.

In serpents (*Ophidia*) the body of each vertebra is cup-shaped in front, and receives the rounded head of the one in front of it (Nos. 604 to 609), and this is the same in many of those of the crocodiles in which the upper surfaces of the bodies are cup-shaped, and each receives the convex projection from the lower surface of the vertebra above.

In many flying birds, the dorsal vertebræ are fixed to one another by fusion of the spines, and often of the transverse processes and bodies. In birds that do not fly, such as the cassowary and the ostrich, they retain their mobility (Nos. 1633, 1633 A—B and 1634).

The vertebræ, which vary in number so widely throughout the animal kingdom, attain in the tiger boa (*Python tigris*, No. 602) the enormous number of 291 in all.

In tortoises (*Chelonia*) the dorsal vertebræ are immovably connected, and have no transverse processes. The proximal ends of the ribs unite directly with the vertebræ, and are also immovable.

THE SACRUM.

(PLATES XXVIII., XXIX.)

Situation and Inclination.—The 'sacrum'⁷⁵ is situated at the back of the pelvis, and wedged in between the two innominate bones. It forms the 'keystone' of the arch which supports the spine, and transmits the weight of it to the lower limbs.

SACRUM.

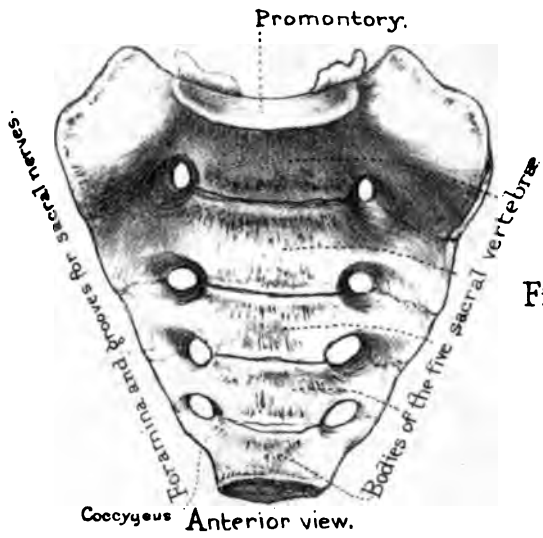


Fig. 1.

Anterior view.

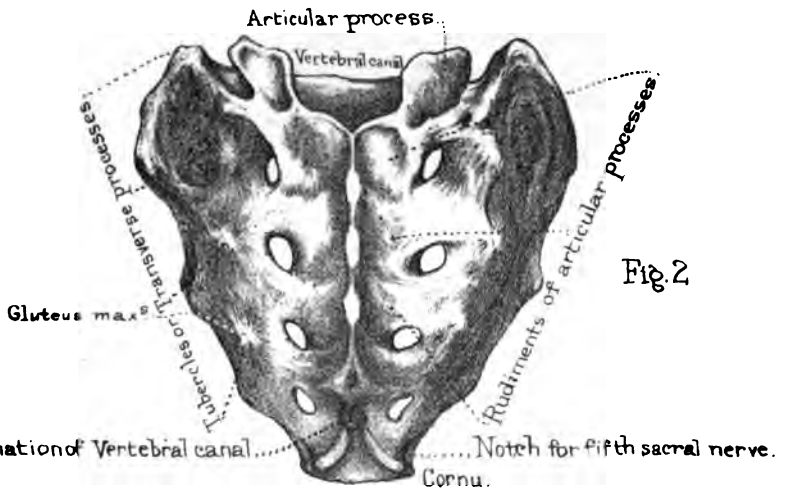


Fig. 2.

Posterior view.

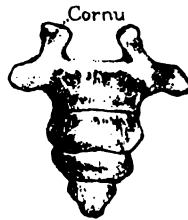

Fig. 3.

COCCYX.

Observe that it inclines backwards, and forms, with the last lumbar vertebra, a rounded angle, termed the 'promontory' of the sacrum. This inclination answers a double purpose: it not only makes the pelvis capacious, but breaks the force of shocks transmitted from the pelvis to the spine.

Composed of five Vertebrae.—Its general shape is triangular. It plainly consists of five vertebrae,⁷⁶ with their bodies and processes all consolidated into a single bone. Examine its anterior and posterior surfaces, its sides, its base, and its apex.

Anterior Surface.—Its *anterior* surface is concave from above downwards, and from side to side, in adaptation to the pelvic cavity. The curvature of the bone forwards, inferiorly, not only assists in supporting the pelvic viscera, but permits us to sit, which we could not have done had the bone projected like a tail. In the middle, are the anchylosed bodies of the five sacral vertebrae decreasing in size from above downwards, and the four transverse ridges indicating their union. On each side of the ridges are the four anterior sacral foramina, with grooves leading from them for the passage of the anterior branches of the sacral nerves.

The bone exterior to the foramina, on each side, is made up of parts which in the three upper sacral vertebrae are homologous to ribs. These are united to the bodies, to each other, and to the transverse processes behind, so as to form a solid lateral mass. Here the 'pyriformis' arises. (Plate XLVII.)

Posterior Surface.—The *posterior* surface of the sacrum is convex, and presents, in the middle line, the spines of the four upper sacral vertebrae, usually coalesced into a vertical crest, for the origin of the 'erector spinæ.' The last sacral vertebra, and sometimes the last two, have no spines, and even their arches are more or less deficient, so that the termination of the vertebral canal is here left unprotected in the dry bone; and in the recent state it is covered only by a fibrous membrane. This explains the serious effects that are apt to follow an injury to this part. Sloughs from bed-sores are sometimes deep enough to expose the vertebral canal. On each side of the crest is the vertebral groove; and here are the faint traces of the anchylosed

articular processes of the sacral vertebræ. The most conspicuous of these processes are those of the last vertebra: they project like two knobs of bone, and are called the 'cornua' of the sacrum: they correspond with the cornua of the coccyx, with which they are connected by ligaments.

Posterior Foramina and Tubercles.—Next to the articular processes are the four foramina which transmit the posterior sacral nerves. These posterior foramina are directly opposite the anterior. Bécларd, in his lectures, relates the case of a sharp instrument running through both into the pelvic cavity. The fifth sacral nerve emerges through the little 'notch' beneath the sacral cornu. Still more externally are the 'tubercles,' indicating the anchylosed transverse processes. These, like the crest, give origin to the tendon of the 'erector spinæ.' (Plate XLIII.)

Base of Sacrum.—The *base* or upper end of the sacrum presents the oval surface of the body of the first sacral vertebra, which articulates with the last lumbar, a thick fibro-cartilage intervening. When the bone is in its proper position, this upper surface slants downwards and forwards, forming, with the lumbar vertebra, the sacro-vertebral angle, or 'promontory,' before referred to (page 147). On each side of the body are its thick and strong lateral masses, expanded like wings, which transmit the weight of the trunk to the iliac bones. Each wing has a rounded edge in front, which forms part of the brim of the true pelvis. Behind the body is the triangular opening of the vertebral canal formed by the vertebral arches. Lastly, on each side of the canal are the articular processes for the last lumbar vertebra. They are set very wide apart, giving a broad base of support to the spine; they look backwards and inwards, are slightly concave from side to side, and thus permit a slight rotatory movement. In front of each articular process is the indication of the notch for the passage of the last lumbar nerve.

Apex.—The *apex* of the sacrum is formed by the diminutive body of the last sacral vertebra, and has an oval articular surface for the coccyx.

Sacro-iliac Symphysis.—At the sides of the sacrum, notice the surface which is connected to the ilium, forming what is

called the 'sacro-iliac' symphysis. Three sacral vertebræ concur to form it. The connection is effected, partly by cartilage, partly by ligament. The cartilaginous part is in front, and is mapped out on the dry bone in the shape of a little ear, hence it is called the 'auricular' surface of the sacrum. Behind this is the rough and deep excavation denoting the attachment of the strong interosseous ligament connecting the two bones. Separation of the 'sacro-iliac' symphysis does sometimes, though rarely, take place as the result of injury. It is an accident of the gravest kind, and one rarely sees recovery in such a case, since it is almost sure to be accompanied with other injury to the pelvic viscera. Lastly, the side of the sacrum below the auricular part gives origin to some of the fibres of the 'gluteus maximus.'

Ossification.—The sacral vertebræ are ossified like the others, with the addition of an independent centre on each side of the first three for the formation of the lateral mass. Now, since every vertebra has three primary centres (one for the body and two for the laminæ, or arches), and two secondary centres for the body (the discs on the upper and lower surfaces), the number of centres for the five sacral vertebræ stands thus:—

$3 \times 5 = 15$ centres for the bodies.

$2 \times 5 = 10$ centres for the arches.

$2 \times 3 = 6$ additional centres for the lateral masses of the
— first three vertebræ.

that is 31.

To these add four epiphysial plates, two on each side, the upper for the auricular surface, the lower for the outer margin of the sacrum beneath that surface—making in all 35 centres.

The component parts of each vertebra unite together first. Thus complete, the vertebræ remain separate until about the 15th year, when they begin to unite; not all at once, but in regular succession from below upwards. The lateral masses unite before the bodies. The 'auricular' discs do not appear till about the 20th year, and the whole bone is not consolidated before the 26th year, or thereabouts. However, even in ad-

vanced age, one sometimes finds the bodies of the upper sacral vertebræ still united in the centre by cartilage only.

Comparative Osteology.—Animals with well-developed hind-legs, which articulate with a pelvis, have a more or less developed sacrum, formed by one or more vertebræ. Supple animals, such as the tiger, will be seen to have a very rudimentary sacrum; the component parts are not welded together into a confused mass like that of man.

Snakes (Ophidia) have no sacrum, although there are rudimentary hind limbs in Typhlops, Python Regius and Tortrix. In the dugong and manatee (No. 2647, Sirenia) the sacrum is wanting as well as the hind limbs.

There is no sacrum in the whales (Cetacea).

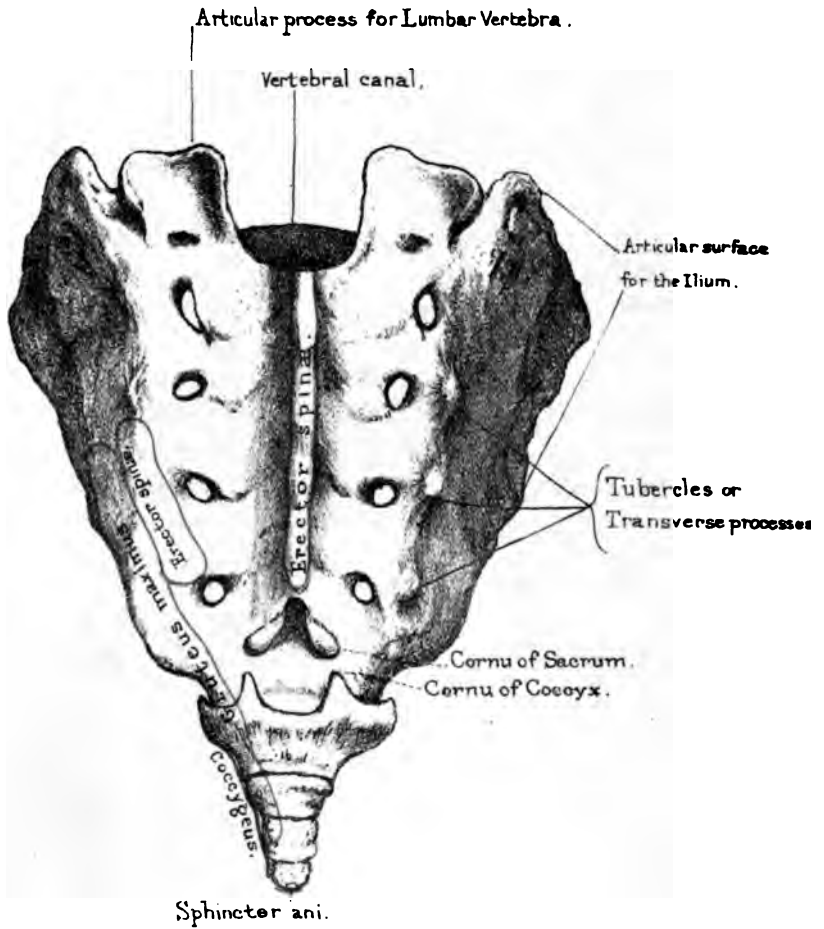
The simplest form of sacrum is seen in the frog. It consists of one vertebra only, the transverse processes of which are expanded to articulate with the ilia.

THE COCCYX.

(PLATES XXVIII., XXIX.)

Constitution and Shape.—The coccyx derives its name from a fancied resemblance to the beak of a cuckoo (κόκκυξ). It consists of four or sometimes five rudimentary vertebræ, articulated (or anchylosed) together, and successively decreasing in size, the last being a mere nodule of bone. As a whole, it is triangular. The body of the first coccygeal vertebra articulates by an oval surface with that of the last sacral: and it has two little articular processes termed 'cornua' which are connected with the 'cornua' of the sacrum, either by fibrous tissue or cartilage. The first vertebra has also two rudimentary transverse processes, and two 'notches' (one beneath each cornu) for the last sacral nerves.

The first coccygeal vertebra articulates with the lower end of the sacrum by an intervening fibro-cartilage, and the succeeding ones are also separated by a fibro-cartilage. Thus the coccyx admits of being bent backwards and forwards, which is of great advantage in parturition, and gives as much as one inch more space in the antero-posterior diameter of the outlet of the pelvis. About the age of 45 or 50, and indeed sometimes earlier, these



Posterior surface of Sacrum:
with muscles attached

little bones become ankylosed to each other and to the sacrum. This condition is one of the causes of difficult labour, and is generally met with in women bearing a first child late in life, and in those who have been accustomed to sit during the greater part of the day, as in the case of milliners.⁷⁷ Under these circumstances, the bone will sometimes break in labour. It is a most distressing accident, and causes great pain when the bowels are acting.

Dr. Hunter says that ankylosis of the sacrum and coccyx is common in females who ride much on horseback, and thus explains the comparative frequency of hard labours in English ladies. Father Dobritzhofer, who lived a long time a missionary among the Abiponians, speaks of the difficult labours of the women there, who spend the greater part of their time on horseback.

Ossification.—Each bone of the coccyx is ossified from a single centre. The first begins to ossify soon after birth; the second about the fifth year; the third about the tenth; and the fourth about the fifteenth or twentieth year.

Comparative Osteology.—The coccyx in man corresponds to the tail of other animals. It now and then happens that the end of the coccyx projects somewhat, and is enclosed in a tube of integument; the man is then said to have a tail, and is looked upon by the vulgar with great suspicion.

In Mammalia the number of caudal (or coccygeal) vertebræ mostly far exceed those of any other region. This may be seen in the tail of the great ant-eater, which has forty, and that of the long-tailed Manis, which has forty-five. The Barbary ape (No. 4919) has but three caudal vertebræ. The gibbon (No. 5026) has two. The vampire bat (No. 2416, *g*) is the only mammalian animal which has no coccyx.

In all birds, except the extinct Archæopteryx, the caudal region of the spine is shorter than the body, and numbers only eight or nine at most. In nearly all birds the terminal vertebræ will be seen to be ankylosed into a ploughshare-shaped bone, as in the ostrich and the vulture (No. 1674). In No. 70, A (the sheat-fish and the halibut) the last caudal vertebra is triangular and flat, and to the posterior edge of it articulate the rays forming the tail.

BONES OF THE LOWER EXTREMITY.

Constituent Bones.—The bones of the lower extremity consist of the ‘femur,’ the ‘patella,’ the two bones of the leg, namely, the ‘tibia’ and ‘fibula,’ the bones of the ‘tarsus,’ the ‘metatarsus,’ and the ‘phalanges’ of the toes.

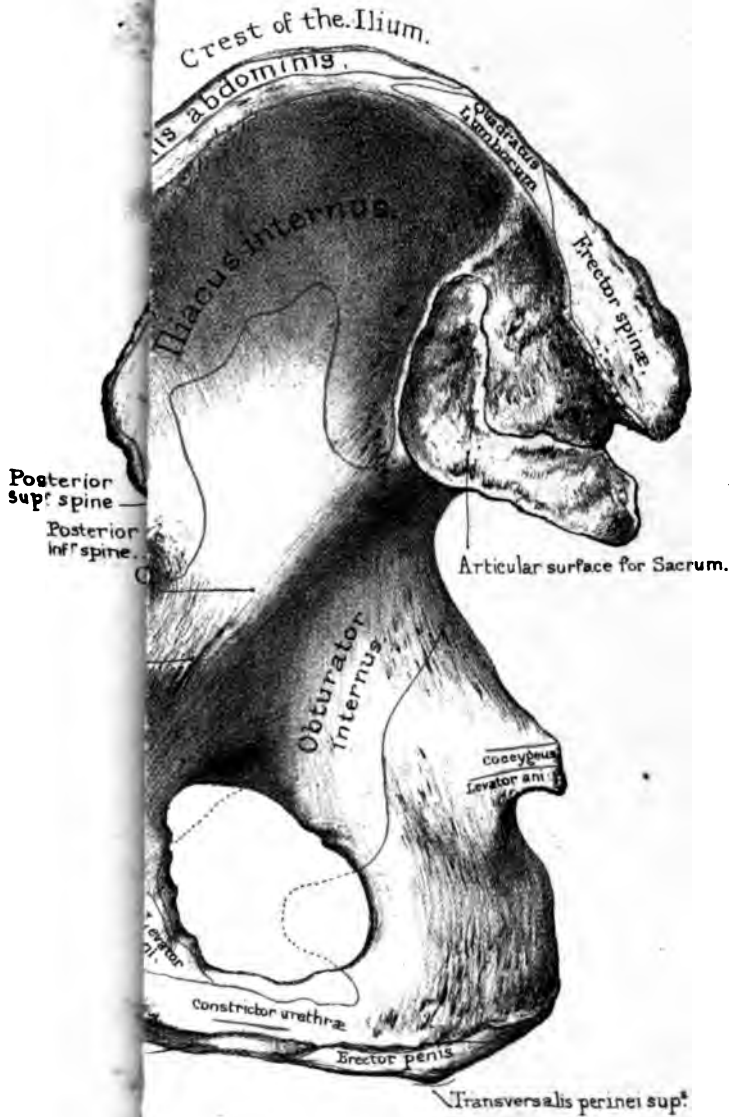
The femur articulates with the pelvis. The pelvis consists of the ‘os sacrum,’ the coccyx, and the two ‘ossa innominata.’ These bones form an arch, of which the sacrum is the keystone, and the innominate bones are the pillars. (Plate XXXII.) The weight of the spine is supported on the top of the sacrum, and the pressure is communicated down the pillars of the arch to the thigh bones which articulate with the innominate bones. It is in this way that the weight of the body is supported by the lower extremities.

 OS INNOMINATUM.

(PLATE XXX.)

General Description.—The ‘os innominatum,’ so named by Galen, is made up of three bones, distinct in childhood, but united in the adult, and termed the ‘ilium,’ ‘ischium,’ and ‘pubes.’ Thus its constituents have received appropriate names, but the bone, consolidated, remains ‘nameless.’ The ‘ilium’ is the expanded part which supports the flank (ilia); the ‘ischium’ supports the body in the sitting posture (*ισχία*, the buttocks); the ‘pubes’ is the front part—so called from its being covered with hair. All three contribute to form the ‘acetabulum,’ or socket for the head of the femur, and in the following proportions (Plate XXX. fig. 3):—the ischium contributes rather more than two-fifths, the ilium rather less than two-fifths, and the pubes

OS INNOMINATUM.



Inner surface.



about one-fifth. Until the age of puberty they are separated at the bottom of the acetabulum by a piece of cartilage shaped like the letter Y; in the adult, however, little trace is left of the original division, so that, for practical purposes, it is better to consider the bone as *one*, and to describe successively its iliac, pubic, and ischial portions.

In studying the relative bearings of these several parts in the erect position of the body, it is necessary that the bone be held at such an inclination that the 'notch' in the margin of the acetabulum directly faces the ground.

Ilium.—The 'ilium' (os ilii) forms a broad expanse for the support of the abdominal viscera, and gives a powerful leverage to the great muscles which balance the pelvis on the head of the femur. Examine its outer and inner surfaces, and its borders.

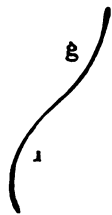
Outer Surface of Ilium.—The outer surface of the ilium (dorsum ilii) is slightly undulating, being convex on its anterior half, and concave on its posterior. In a well-marked bone there are distinct traces, termed the 'superior and inferior curved lines,' which map out the origins of the gluteal muscles. These lines commence, the one at the 'anterior superior spine,' the other at the 'anterior inferior spine,' and extend backwards to the 'greater ischiatic notch.' The surface above the superior line gives origin to the 'gluteus medius'; that between the lines to the 'gluteus minimus.' A rough surface further back indicates the origin of a part of the 'gluteus maximus.'⁷⁸ Just above the acetabulum is one origin of the 'rectus femoris,' the other being at the 'anterior inferior spine.'

Inner Surface: Iliac Fossa.—The inner surface of the ilium is slightly excavated, forming the 'iliac fossa.' This fossa is one of the characteristics of the human skeleton; it supports the abdominal viscera, and gives origin to the 'iliacus.' Hold the bone to the light, and observe that the bottom of the fossa is the thinnest part of the ilium: it is out of the line of the weight of the body. The fossa is bounded below by the 'linea ilio-pectinea,' which forms the true '*brim of the pelvis*.' This brim is the thickest and strongest part of the bone, since it is the 'line of the pelvic arch,' along which the weight of the trunk is trans-

mitted to the head of the thigh bone. No one can form an adequate idea of the massive architecture of this part of the pelvis without inspecting a vertical transverse section such as is shown in Plate XXXII. Behind the iliac fossa is the articular surface for the sacrum (sacro-iliac symphysis). The front part of this is shaped like a little ear, and, in the recent state, crusted with cartilage, which acts as a 'buffer' to the joint, while the hinder part is exceedingly rocky for the attachment of the strong 'interosseous' ligament which secures it. Lastly, on the inner surface is the foramen, which transmits nutrient blood-vessels and a nerve into the cancellous texture.

Crest and Spines of Ilium.—The upper border of the ilium is termed the 'crest.' Looking at it from above, we observe that its outline is alternately concave and convex, like the adjoining figure (26), in adaptation to the general surface of the ilium, which

FIG. 26.



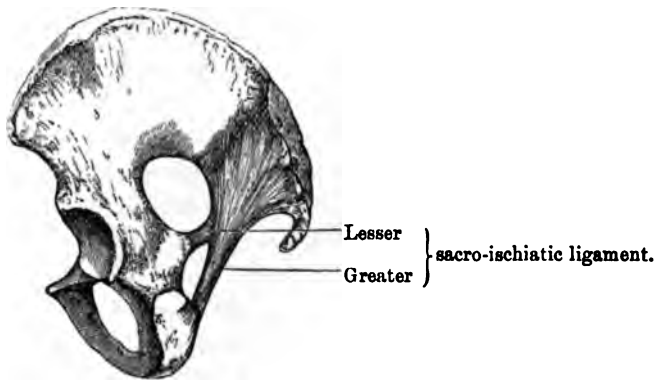
CURVES OF
RIGHT ILIUM.

undulates at the one part, forming the 'iliac fossa' (i), and at the other forming what may be termed the 'gluteal fossa' (g), which lodges the muscles of the buttock. The crest is rough and broad, and is spoken of as presenting three 'lips'—an 'outer,' an 'inner,' and a 'middle'—giving origin to the muscles which form the lateral walls of the abdomen. The outer lip gives origin to the 'tensor fasciæ femoris,' the 'obliquus externus abdominis' and the 'latissimus dorsi'; the middle lip gives origin to the 'obliquus internus'; and the inner lip to the 'transversalis abdominis,' the 'quadratus lumborum,' and a part of the 'erector spinæ.'

Anterior Spines.—Along the front border of the ilium are the 'anterior-superior' and 'anterior-inferior spines,' with the shallow notch between them. The superior spine, with the edge of the notch below, gives origin to the 'sartorius,' and the inferior spine to one head of the 'rectus.' Below this spine is another notch, for the passage of the iliacus and psoas muscles, and then comes the 'ilio-pectineal eminence,' where the ilium and pubes join. This eminence is the part over which the femoral artery passes into the thigh, and against which it can be effectually compressed.

Posterior Spines and Ischiatic Notches.—Along the posterior border of the ilium are the ‘posterior-superior’ and ‘posterior-inferior spines,’ with the little notch between them. These spines are for the attachment of ligaments. Below the spines is the ‘greater ischiatic notch,’ which transmits the great vessels and nerves from the pelvis to the buttock and back of the thigh. Lower still is the ‘spine of the ischium,’ and then the ‘lesser

FIG. 27.



ischiatic notch.’ In the recent state the notches are converted into complete holes by the ‘sacro-ischiatic ligaments,’ greater and lesser respectively, as shown in fig. 27. These ligaments answer three important purposes: 1. They mainly contribute to the fixation of the sacrum, which is the keystone of the pelvic arch; 2. They afford an extensive surface for the origin of the great muscle of the buttock (gluteus maximus); 3. They help to form the floor of the pelvis, and support the pelvic viscera, without adding much to the weight of the cavity. The ischiatic notches transmit the following objects:—

The GREATER ISCHIATIC NOTCH	transmits . . .	{	Gluteal vessels and nerve. Pyriformis muscle. Greater and lesser ischiatic nerves. Ischiatic vessels. Pudic vessels and nerve (out of pelvis). Nerve to obturator internus (out of pelvis).
The LESSER ISCHIATIC NOTCH	transmits . . .	{	Tendon of the obturator internus. Nerve to obturator internus (into pelvis). Pudic vessels and nerve (into pelvis).

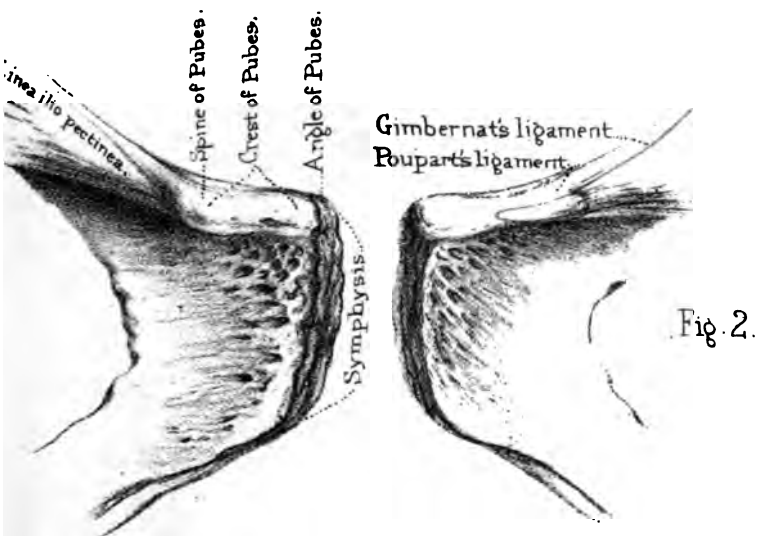
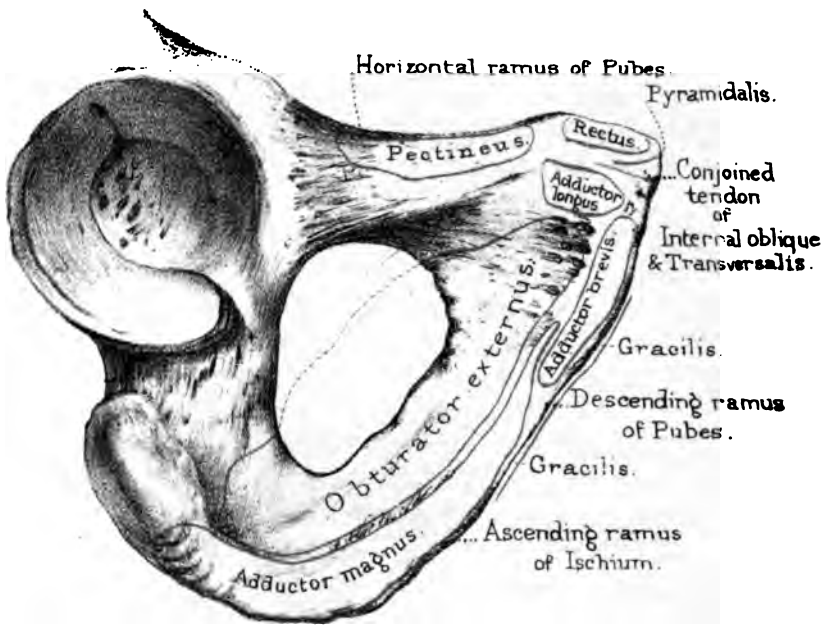
Pubes, Body, and Rami.—The ‘pubes’ (Plate XXXI. fig. 1) is usually described as having a ‘body’ and two branches: one of which, called the ‘horizontal ramus,’ joins the ilium at the iliopectineal eminence; the other, called the ‘descending ramus,’ joins the ascending ramus of the ischium. These terms ‘horizontal’ and ‘descending,’ as descriptive of the direction of the ‘rami,’ are likely to mislead. They have come into general use from the pelvis having been described as if it were horizontal, which it is not. Look at a properly articulated skeleton, or hold the pelvis inclined at its proper angle to the horizon, and you soon see that the pelvic rami run in a direction almost the reverse of that which is implied by their names.

The ‘horizontal ramus’ of the pubes is somewhat triangular. Its upper surface gives origin to the ‘pectineus,’ and is marked by the continuation of the true brim of the pelvis, or ‘*linea iliopectinea*,’ which gives insertion to the ‘*psoas parvus*’ when there is one, and also to that part of the ‘crural arch’ termed ‘Gimbernat’s ligament.’] The inner surface forms part of the wall of the true pelvis, while its lower surface bounds the obturator foramen, and is grooved for the passage of the obturator vessels and nerve.

Pubic Arch.—The ‘descending ramus’ of the pubes inclines outwards and backwards, and forms, with its fellow of the opposite side, what is called the ‘arch of the pubes.’ The margin of the arch slopes a little outwards, and has a groove for the attachment of the ‘*crus penis*’ in the male, or ‘*crus clitoridis*’ in the female. This shelving of the arch is greater in women, and facilitates the passage of the child. Behind the groove is the origin of the ‘*constrictor urethræ*.’

Body and Symphysis of the Pubes.—The ‘body’ of the pubes (Plate XXXI.) is connected along a rough and somewhat oval surface to the corresponding part on the opposite bone. This union is termed the ‘*symphysis pubis*.’ Observe the bones are not here in immediate apposition, but united by fibro-cartilage of at least $\frac{3}{8}$ ths of an inch in thickness in front, which is elastic, like that between the bodies of the vertebræ, and, while it completes the pelvic arch below, serves also to obviate the effects of

Fig. 1.



Front view of body of Pubes.



concussion. The summit of the pubes is a most important part in relation to the anatomy of hernia. *The chief point of interest here is the 'spine.'* This is for the attachment of the 'crural arch' (Poupart's ligament), and is, surgically, of great importance as the guide to the external abdominal and femoral rings. From the spine we trace outwards the beginning of the 'linea ilio-pectinea,' where 'Gimbernat's ligament' is attached. Between the spine and the symphysis is the part called the 'crest,' with which so many muscles are connected. These are, proceeding from the front, the insertion of the conjoined tendon of the 'internal oblique' and 'transversalis,' the origin of the 'pyramidalis,' and that of the 'rectus abdominis.' The posterior surface of the body forms part of the wall of the pelvic cavity; its angle of inclination, as well as that of the 'symphysis,' is such as to present (in the erect position) a gently sloping plane for the support of the pelvic viscera. Lastly, its anterior surface is rough for the origin of muscles: viz. the 'adductor longus,' the 'adductor brevis,' and part of the 'adductor magnus,' also the 'obturator externus' and the 'gracilis.'

Ischium.—The ischium completes the lower part of the innominate bone. (Plate XXX.) It supports the trunk in sitting, and projects for the origin of the hamstring muscles. Regarded separately for purposes of description, it is formed of a 'body,' which is the most bulky part of it, for the formation of the acetabulum: from this, the bone drops vertically to form the 'tuberosity' upon which we sit; and then, curving forwards like a hook, it forms the 'ascending ramus,' which unites with the corresponding part of the pubes, and thus completes the 'foramen ovale.' Leaving the acetabulum for separate study, notice the 'spine of the ischium,' which separates the 'greater' from the 'lesser ischiatic notch.' Its outer side gives origin to the 'gemellus superior'; its inner surface to the 'coccygeus' and a part of the 'levator ani': the front part of the 'levator ani,' observe, arises from the body of the pubes, while the intermediate part arises from a tendinous arch thrown across from one point of bone to the other. Attached to the spine is the lesser sacro-ischiatic ligament; the internal pudic artery crosses over its outer surface. In case of severe hæmor-

rhage after lithotomy, it would be possible in a thin subject to compress the artery against the bone.

Foramen Ovale, or Obturatum.—The ‘foramen ovale,’ or ‘obturatum,’ is a wide opening of an oval form in the male, but triangular, with rounded angles, in the female. It is closed in the recent state by the ‘obturator membrane,’ everywhere except at the top, where there is a small aperture for the passage of the obturator vessels and nerve into the thigh. The membrane serves for the origin of the obturator muscles just as well as if it had been a plate of bone: besides which, it gives a little during the passage of the head of the child: it also materially lightens the pelvis. Externally, the border of the hole gives origin to the ‘obturator externus.’ Between the lips of the acetabulum and the upper part of the tuberosity is a groove, in front of which the obturator externus passes to its insertion into the femur.

Behind the foramen ovale (Plate XXX.), the ischium presents a smooth and extensive surface which, with the corresponding part of the ilium, forms much of the lateral wall of the pelvic cavity. Observe that this surface inclines so as to form a gentle slope towards the lower opening of the pelvis. Now it is this ‘slope of the ischium’ which guides the head of the child after it has entered the brim of the pelvis, and makes it turn so that the longest diameter of the head corresponds with the widest part of the outlet. The greater part of the slope gives origin to the ‘obturator internus,’ which also arises from the margin of the obturator foramen, as well as the membrane closing it; and with this muscle we associate the lesser ischiatic notch, because it forms the pulley (crusted in the recent state with cartilage) round which the four tendons of this muscle turn, in order to reach the thigh bone.

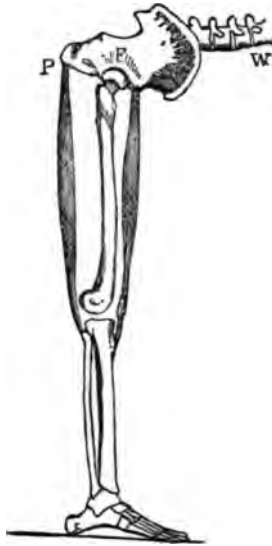Tuberosity of the Ischium.—The tuberosity of the ischium answers a double purpose—1. It serves to support the trunk in the sitting position; 2. It forms a lever for the action of the hamstring muscles, of which one important function is to restore the body to the erect position after stooping, as seen in the annexed fig., 28. Here we have a lever of the first

order. The fulcrum *F* is at the hip joint; the weight *W* is the trunk of the body; and the power *P* is at the tuberosity of the ischium, where the hamstring muscles arise. On the 'tuberosity' itself are the rough impressions made by the strong muscles attached to it. (Plate XXX.) Its well-marked outer border gives origin to the 'quadratus femoris'; behind this margin is a slightly concave surface, narrowest below, for the origin of the 'semi-membranosus'; more internally, and separated by a ridge from the attachment of the last-named muscle, is an almost plane surface, from which arise, together, the 'semitendinosus' and 'biceps.' The 'gemellus inferior' arises from its upper border. At its lowest part, anteriorly, begins the origin of the 'adductor magnus,' which is continued a long way up the ramus, nearly to the body of the pubes. Along the inner side of the tuberosity is a rough ridge to which the greater sacro-ischiatic ligament is attached: anterior to this, but in the same line, is the origin of the 'erector penis,' and that of the 'transversalis perinei superficialis.'

The pudic vessels and nerves run along the inner side of the ischium, not quite one inch and a half from the inner margin of the tuberosity.

Acetabulum. Its Direction. Notches.—Lastly, we come to the 'acetabulum,' so named from its resemblance to an ancient vinegar cup. Its great depth and hemispherical form securely lodge the head of the femur, and yet allow more or less movement in any direction. It looks *downwards* and *outwards* (in the erect position), transmitting the weight of the trunk directly on to the head of the thigh bone; the upper or iliac portion of it has to support the whole weight of the trunk, and is by far the thickest and strongest part. As before stated (p. 152) it is formed

FIG. 28.

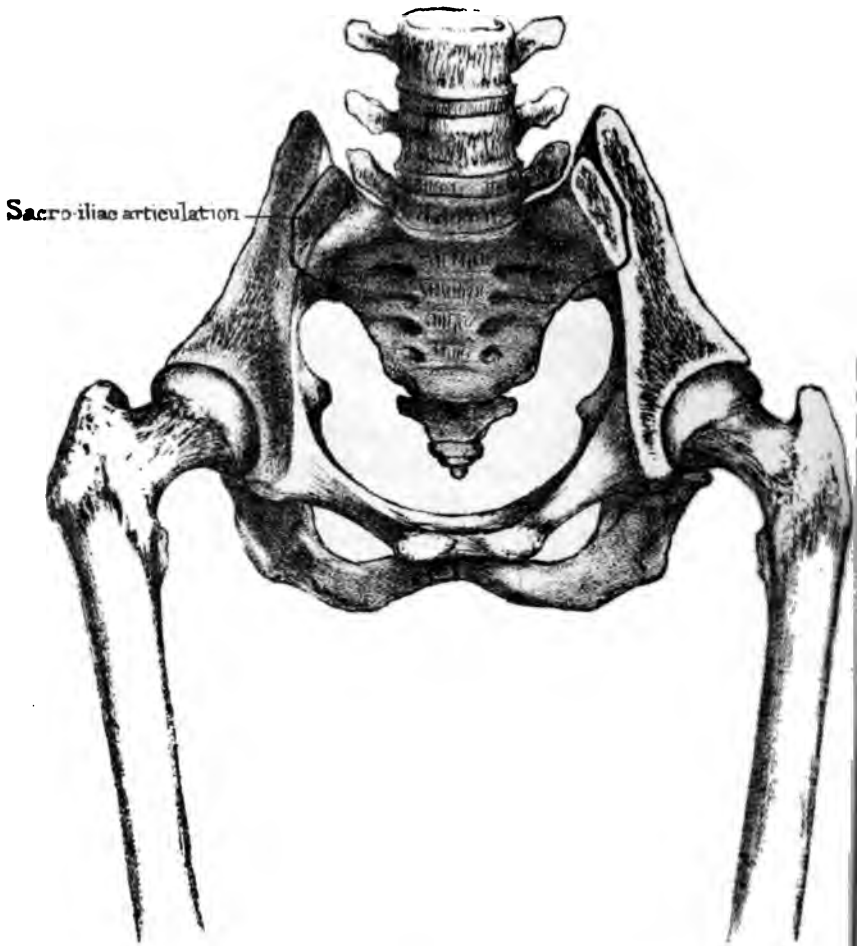


THE TUBEROSITY OF THE ISCHIUM, A LEVER OF THE FIRST ORDER.

partly by the ischium (more than two-fifths), partly by the ilium (less than two-fifths), and the remainder by the pubes. There are two notches in the margin or 'brim' of the acetabulum. The upper and smaller one is near the ilio-pectineal eminence, and permits the free bending of the thigh towards the abdomen. The other and larger, specially called '*the* notch,' is at the lowest part of the margin. It permits the 'adduction' of the thigh, as when we cross the legs, and also lets blood-vessels run into the acetabulum to supply the ligamentum teres, and the fat at the bottom of it. Besides which, there is no need of bone at the lowest part of the socket, which never has to support weight. Two ligaments are attached to the borders of the notch: one is the 'ligamentum teres'; the other is the 'transverse ligament' which runs across it to complete the margin of the acetabulum. The transverse ligament is sometimes ossified in extreme old age. (See Nor. Hum. Ost. No. 733.) Deep as it is, even in the dry bone, the acetabulum is made still deeper in the recent state by a broad rim of fibro-cartilage, called the 'cotyloid ligament,' which, besides increasing its depth, serves as a 'sucker' to keep the head of the bone in the socket.

Excavation at Bottom of Acetabulum.—The socket is smooth everywhere (in the recent state crusted with cartilage), except at the bottom, where there is an irregular excavation continuous with the notch below. This allows the free play of the ligamentum teres within the joint; it is partly occupied by fat and synovial fringes. If the socket be held to the light, the bottom of it will be found translucent. This thinness explains why, in some cases of hip-joint disease, the matter makes its way through the socket into the pelvic cavity. (See St. Bartholomew's Hospital Mus., Diseases of Joints, No. 601.) It likewise explains why a fall on the trochanter major is able to fracture the bottom of the acetabulum. There is a preparation (Injuries of Bones and Joints, Nos. 936, 937) in St. Bartholomew's Hospital Mus. in which a fracture, caused by a fall on the trochanter a few months before death, extended in several directions from the centre of the acetabulum to its circumference.

Ossification.—Besides the three pieces of which it is origin-



Section through the upper part of the Sacrum and Iliæ,
so as to exhibit the construction of the
PELVIC ARCH.

Drawn on Stone by T. Godart
From nature by L. Holden
Printed by West, Newman & Co.

ally formed, the os innominatum has four 'epiphyses,' which begin to appear about the age of puberty. One, the marginal epiphysis, skirts the crest of the ilium. There is a second for the anterior-inferior spine; a third along the tuberosity of the ischium; and a fourth, which forms a thin plate, at the symphysis pubis. (See Nor. Hum. Ost., Nos. 64, 65.) The Y-shaped cartilage at the bottom of the acetabulum begins to ossify at puberty. The ilium begins to ossify at the end of the second month; the ischium at the end of the third; and the pubes at the end of the fourth. The rami of the pubes and ischium unite about the 8th year. The acetabulum is all bony about the 17th year. All the epiphyses unite to the main bone about the 25th year.

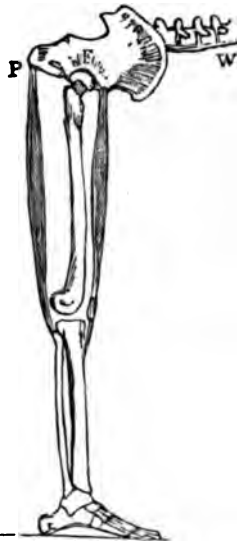THE PELVIS IN GENERAL.

Nomenclature.—The pelvis is named from its resemblance to a basin ($\pi\acute{\epsilon}\lambda\upsilon\chi\acute{\iota}$). The French call it 'le bassin'; and in old English works it is often spoken of as 'the basin.' When accoucheurs speak of the *true* pelvis, they mean all below the brim. All above the brim they call the *false* pelvis. By the brim is understood the 'linea ilio-pectinea.' Again, they speak of the upper opening or 'inlet,' and the lower opening or 'outlet' of the pelvis.'

Pelvis a Lever of the First Order.

—The pelvis forms a great arch of bone which supports the trunk, and transmits the weight of it to the lower limbs. It contains and protects the pelvic viscera, and some of the abdominal. It acts as a lever of the first order in balancing the trunk on the head of the thigh-bone, as when we stand upon one leg. But the most obvious action of the pelvis as a lever of the first order, is when we raise the body from the stooping to the erect attitude. In this action the fulcrum F, as seen in fig. 29, is at the hip-joint; the weight W

FIG. 29.



THE PELVIS A LEVER OF THE FIRST ORDER.

is the trunk of the body; and the power is fixed to the tuberosity of the ischium, P. The power in this case is the contraction of the hamstring muscles. This is a very good example of a muscle answering a double purpose. The hamstring muscle, represented in the figure, is the biceps. When its fixed point is below, i.e. at the fibula, the muscle can raise the body from the stooping position. When its fixed point is at the pelvis, it serves to bend the knee. In the latter case, however, the muscle acts upon a lever of the third order.

Under the head of pelvis in general come—1. Its mechanism as an arch; 2. Its obliquity with regard to the spine; 3. Its axis; 4. The diameters of the inlet and outlet; 5. The difference between the male and the female pelvis.

Pelvic Arch: its Strength.—Its mechanism as an arch is best shown by sawing off the wings of the ilia, as in Plate XXXII. Such a section shows the following points:—The sacrum forms the broad keystone of the arch, and supports the weight of the spine. Now the sacrum being set very obliquely, the weight tends to thrust it downwards and backwards. This tendency is resisted by the sacrum being doubly wedged, that is, wedged from above downwards, and from before backwards: thus, unless the ilia give way, which they never do, the sacrum cannot be dislocated *backwards*. But this is not all: a reciprocal irregularity, or slight ‘dovetailing,’ between the articular surfaces of the sacrum and ilium, and in all cases a ‘bite’ in front formed by the edge of the ilium, prevent dislocation of the sacrum *forwards*.

Observe, in the next place, that the inclination of the arch is such that the weight is transmitted in a perpendicular plane to the heads of the thigh-bones. Again, the thickest and strongest part of the arch is precisely in the line of pressure. Lastly, there are three ‘buffers’ which break shocks; one at the pubic symphysis, the other two at the sacro-iliac symphyses.

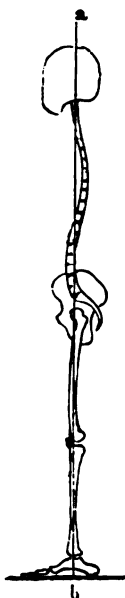
Secondary Arches.—From the main arch, two secondary arches proceed, one on either side: these are the ‘sitting arches,’ and the summit of each is at the tuberosity of the ischium.

The following is a good instance of the enormous weight the pelvic arch will bear without injury, provided the weight be

applied *along the arch*. A waggon wheel passed over a man's pelvis from side to side, immediately over the symphysis pubis. The man stated that the waggon with the load in it weighed 5 tons 7 cwt. There was no injury beyond an ecchymosis of the scrotum and the upper part of the thighs. After three weeks, the man left the Hospital well, with the exception of a slight lameness.

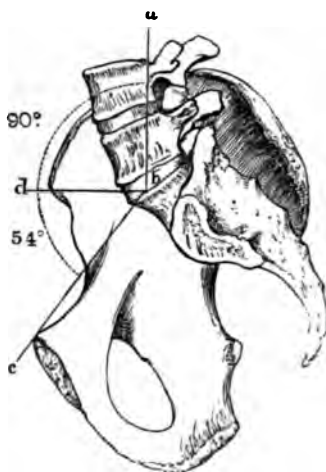
Obliquity of the Pelvis.—In the erect attitude the line of

FIG. 30.



LINE OF GRAVITY OF THE BODY.

FIG. 31.



ANGLE OF INCLINATION OF THE PELVIS, 144°.

gravity of the spine falls perpendicularly on the sacrum, as shown in the line *a b*, fig. 30. With this perpendicular, the inclination of the pelvis forms an angle (*a b c*, fig. 31) of 144° in the male, and 140° in the female. Now this angle is such, that the line of gravity falls through the acetabulum, and consequently the weight is transmitted directly on to the heads of the thigh-bones. For all practical purposes, one may ascertain the proper obliquity of the pelvis by holding it so that the 'notch' shall be the lowest

part of the acetabulum (p. 153). The end of the coccyx will then be about half an inch higher than the lower part of the symphysis pubis.

Axes of the Pelvis.—The *axis of the brim* of the pelvis, that is, a line passing at right angles through the centre of its plane, if prolonged, would pass from the coccyx to the umbilicus. The *axis of the outlet* would fall on the promontory of the sacrum. The *axis of the cavity* would form a curve nearly corresponding with the curve of the sacrum. In all operations about the pelvis, it is of great importance to bear in mind its different axes. As a useful practical rule, we may say, that the axis of the pelvis corresponds with a line drawn from the anus to the umbilicus.

Diameters of the Pelvis.—The next point is the diameters of the pelvis; and it is interesting because it concerns parturition. The inlet or brim of the pelvis is somewhat heart-shaped. Its diameters vary more or less in different cases: in the recent state, with all the soft parts undisturbed, the following are about the average:—

	Inches
Antero-posterior or conjugate	4
Oblique (from sacro-iliac symphysis to acetabulum)	4 $\frac{5}{8}$
Transverse	4 $\frac{6}{8}$

Thus the longest diameter of the *brim* is the transverse. In this direction the long diameter of the head of the child enters the pelvis.

The shape of the *outlet*, in the recent state, is like a lozenge, since the two ischiatic notches are blocked up by the sacro-ischiatic ligaments. Its diameters are as follows:—

	Inches
Transverse (from one tuber ischii to the other)	4
Antero-posterior (from symphysis to coccyx)	4 $\frac{1}{2}$
And, with the coccyx pushed back, the antero-posterior diameter will be	5 $\frac{1}{2}$

The longest diameter of the outlet, therefore, is from before backwards

Now the head of the child enters the pelvis in the *transverse* diameter, but descends in the *oblique*, till it presses upon the spines of the ischia. Here its further progress is arrested by the spines. As the uterus goes on contracting, the slope of the ischium on each side compels the head to turn, so that the face comes to lie in the hollow of the sacrum. Consequently, the long axis of the head is brought into the long axis of the outlet, and is thus easily expelled.

Male and Female Pelvis.—The female pelvis differs very little from that of the male till puberty, at which period the brim has a heart-shaped form in both sexes. After puberty the female pelvis begins to assume its sexual characters, which are the following:—

1. The sacrum is wider and less curved; ⁷⁹ the promontory less projecting; and the coccyx more movable than in the male.

2. The cavity is shallower, and all its horizontal diameters broader, than in the male.

3. The spines of the ilia, the acetabula, and the tuberosities of the ischia, are wider apart than in the male.

4. The symphysis pubis is not so deep: the pubic arch has a much wider span⁸⁰ and its branches are more shelving than in the male, facilitating parturition. To use an architectural expression, the pubic arch in the female resembles a 'Norman' arch; in the male, an 'early English'; the sub-pubic angle being about 61° in males and 80° in females.

Comparative Osteology.—The ilium attains its greatest size in the elephant and mastodon. Observe the very narrow opening in the pelvis of the kangaroo (Marsupialia, *Macropus major*, Nos. 1724, 1725). This extreme narrowness necessitates the birth of the young when they are only about an inch and a quarter long. They are then almost shapeless, and are next placed in a pouch on the abdomen of the mother, with the nipple firmly fixed in their mouths until they are as far developed as the young of other animals at birth. It will thus be seen that the mammæ of the kangaroo open into the pouch. The young are attached to a long nipple, and milk is at first forced into their mouths by the contraction of a muscle spread over the mammary gland. On the

pubes are seen two small bones which do not exist in man. They are called the 'marsupial bones,' and are ossifications or chondrifications of the internal pillars of the external abdominal rings.

In the extinct Mastodon and Megatherium the great sciatic notch is converted into a foramen apparently by the ossification of the sacro-sciatic ligament.

In the Hippopotamus the transverse ligament of the acetabulum is completely ossified, and the notch becomes a bony tunnel.

In cetacea the pelvis is only represented by a small flat bone on each side of the anus, suspended in the soft parts; and there is never more than a trace of hind-limb bones. The manatee (No. 2647A) has no pelvis.

In birds the acetabulum is perforated, the ischiatic notch is converted into a complete foramen, and there is no symphysis pubis, excepting in the ostrich.

The bones forming the os innominatum remain distinct throughout life in some of the lower animals. In No. 1011 (*Testudo elephantapos*) these bones will be seen to be fairly distinct. They articulate, but do not coalesce perfectly as in man.


In Ruminants, Pachydermata, and Solidungula, the pelvis is large and gives attachment to huge glutei muscles. This accords with the extensive development of the great trochanter of the femur, to which these muscles are attached.

Although in snakes generally, there is no sternum, upper limb, or sacrum, nor any appearance of hind legs, yet, in a few instances, viz. *typhlops*, *python regius*, and *tortrix*, there are rudiments of hind limbs in the skeleton.

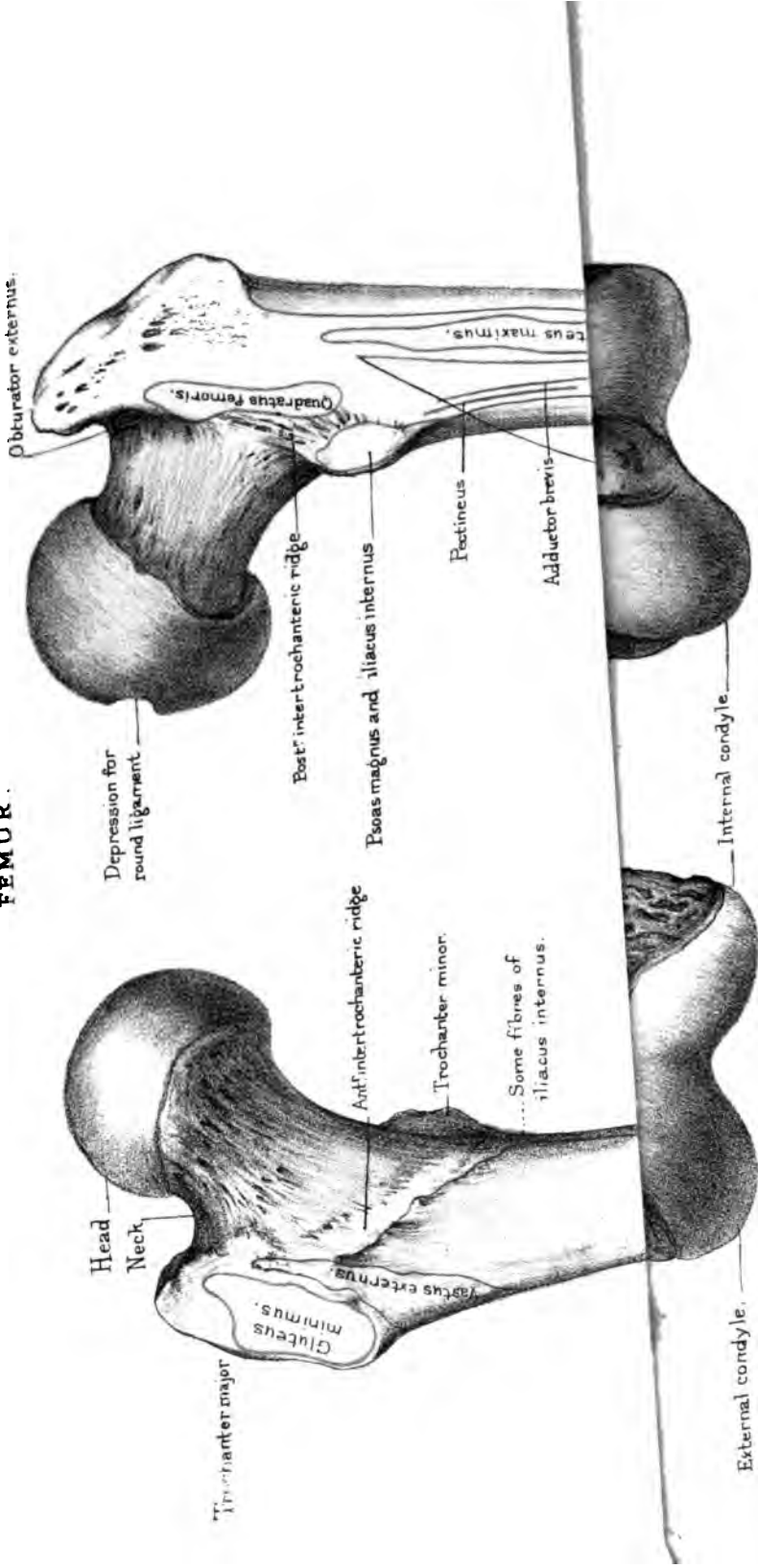
THE FEMUR.

(PLATES XXXIII., XXXIV.)

Length and Direction.—The thigh-bone is the longest and strongest of all the bones. Its great length, in comparison with the other bones of the leg, is characteristic of the human skeleton.



FEMUR.



Anterior surface.

Posterior surface.

Drawn on Stone by T. Godart

Printed by West, Newman & Co.

In consequence of this comparative length, and of the shortness of the arms, the ends of the fingers in the white man do not reach lower than the middle of the thigh-bone. In the chimpanzee the fingers reach down to the knee; in the ourang, down to the ankle.

The direction of the thigh-bone is not quite perpendicular, but slants, so that the knees are nearer together than the hips; by this means the knee-joint is brought nearer the line of gravity of the body. This obliquity is necessarily greater in women, on account of the greater breadth of the pelvis, and accounts for their peculiar gait.

We have to examine the head, the neck, the trochanters for the attachment of muscles, the shaft, and the condyles.

Head.—The head forms rather more than half a sphere, smooth and convex on every part, except at a point a little *behind and below* its centre, where there is a depression for the attachment of the ‘ligamentum teres.’ It forms a perfect ball-and-socket joint with the acetabulum. When crusted with cartilage the ball fits so accurately into its socket, that it is retained in it by atmospheric pressure alone. It has been ascertained by experiment that this pressure is about 26 pounds; that is, more than equal to sustain the weight of the entire limb with all its soft parts. More than this, in walking, the legs swing like pendulums, so that we require very little muscular force to advance one leg before the other.⁸¹ The limb hangs freely in its socket, and the muscles do not expend any of their power in keeping it there. Boerhaave might well say, ‘in mirabili articulatione femoris Creatorem adoramus.’

Neck: its Direction.—The general direction of the ‘neck’ is upwards, inwards, and a little forwards from the shaft. As a result of this direction of the neck of the thigh-bone, the lower extremity naturally turns a little outwards. Everything in the bones of the lower limb and the insertion of its muscles, conforms to this object. It is this which gives elasticity, freedom, and grace to the motion of the body: we owe this to nature, and not, as some suppose, to the dancing-master.

In the adult the neck is set on to the shaft at a very open angle, about 125°. But the angle varies at different ages, in

harmony with the requirements of the age. In children the neck of the thigh-bone is so oblique that it forms almost a gentle curve from the axis of the shaft, as seen in fig. 32. Therefore the trochanters do not project nearly so much as in the adult, fig. 33. This is one reason why it is sometimes difficult to determine the precise nature of accidents about the hip in children. As age advances, the neck, in some instances, drops to nearly a right angle with the shaft, as shown in fig. 34 :

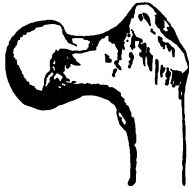FIG. 32.



FIG. 33.



FIG. 34.

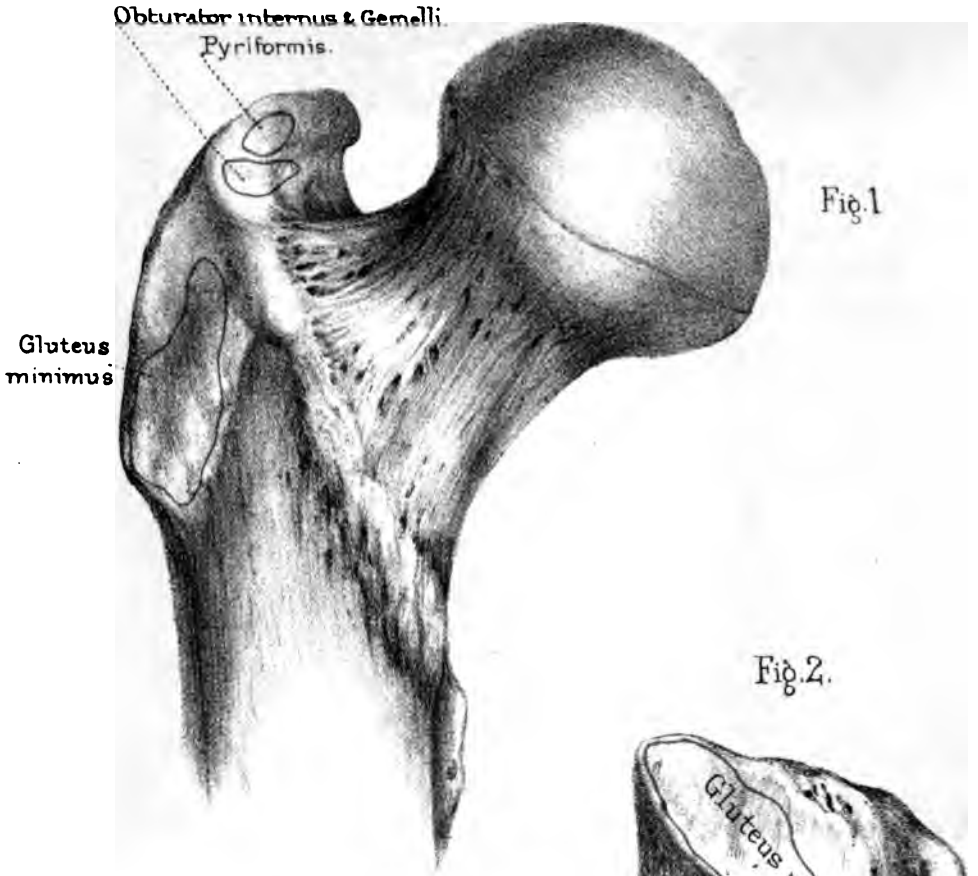


COMPARATIVE OBLIQUITY OF THE NECK OF THE THIGH-BONE IN THE CHILD, THE ADULT, AND THE AGED. (FROM MUSEUM OF ST. BARTHOLOMEW'S HOSPITAL.)

besides which its compact walls become thinner, and its cancellous tissue becomes expanded. No wonder, then, the neck of the femur is so liable to break in old persons. Observe how much broader the neck is in its vertical diameter, and how much thicker the lower wall is than the upper, in order to resist vertical pressure. (Plate I.) The part where the neck springs from the shaft is called the 'base' of the neck. In falls on the trochanter the neck is sometimes broken at the base, and driven into the shaft between the trochanters, forming what is called an 'impacted' fracture of the neck. The symptoms of such a fracture are, more or less shortening of the limb, diminished projection of the trochanter major, and no crepitus.

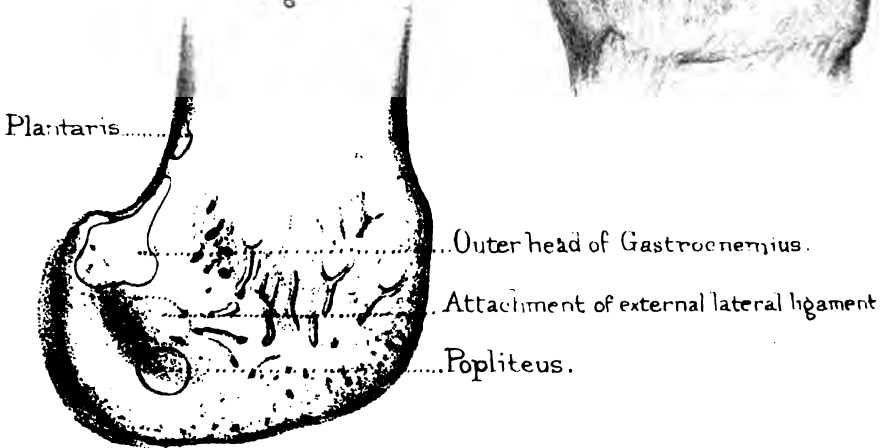
Neck, Oblique.—Since the great length and obliquity of the neck of the femur are peculiar to man, let us consider what advantage his skeleton gains by it.—1. It widens the base of support for the trunk; 2. It disengages the shaft from the hip-joint, and thus increases the range of motion. What animal can separate its legs so widely as man? 3. Greater space is made for the adductor muscles, which balance the pelvis on the inside of the thigh; 4. The great trochanter being removed to a distance from the hip-joint, gives greater leverage to the powerful gluteal





Surface over which
plays the tendon of the
Gluteus maximus

Fig. 3.



muscles which balance the pelvis on the outside; 5. The weight of the trunk, instead of falling vertically on the shaft of the femur, is transmitted to it by an arch.

Trochanters, Major and Minor.—The trochanters ‘major’ and ‘minor’ are outstanding processes which give great leverage to the muscles rotating the thigh (*τροχάω*, *verto*). Observe, they project behind the axis of rotation (which is the centre of the head of the bone), an arrangement which further conduces to the outward rotation of the lower limb as the natural position. The relation of the trochanter major to the other bony prominences of the pelvis deserves especial attention, because it is a great landmark in determining the nature of injuries about the hip. The top of the great trochanter in the adult is about three-quarters of an inch lower than the top of the head of the bone, and nearly on a level with the spine of the pubes.⁸²

Examine first the muscles inserted into the trochanter major. Suppose the trochanter to be square, which it is nearly if seen sideways. (Plate XXXIV.) Into the front part is inserted the ‘gluteus minimus,’ into the upper part is inserted the ‘pyriformis’; also in front of the pyriformis, and extending backwards beneath it, is the insertion of the common tendon of the ‘obturator internus’ and ‘gemelli’ (just above and anterior to the digital fossa, Plate XXXIV. fig. 1); into the back part, upon an eminence on the ‘posterior inter-trochanteric ridge’ called the ‘linea quadrati,’ is inserted the ‘quadratus femoris’; the lower part (base of the trochanter) gives origin to the strong tendon of the ‘vastus externus.’ Draw a diagonal from behind forwards across the square (there is a faint trace of it in nature), and you find that the upper triangle gives insertion to the ‘gluteus medius,’ while the lower triangle remains smooth for the play of the tendon of the ‘gluteus maximus,’ a large ‘bursa’ being interposed. A smaller bursa occupies the front of the upper triangle, in connection with the tendon of the ‘gluteus medius.’ (Plate XXXIV. fig. 2.)

Digital Fossa.—Behind the neck of the femur, and beneath the projecting angle of the trochanter major, is a deep excavation, called the ‘digital fossa.’ (Plate XXXIII.) The ‘obturator

externus' is inserted here; and this insertion is at the bottom of the fossa.

Trochanter Minor.—The trochanter minor projects from the inner and *back* part of the shaft, just below the base of the neck. Its posterior part gives insertion to the tendon of the 'psoas magnus'; the fibres of the 'iliacus' mostly join this tendon, but a few are inserted into the lower border of the lesser trochanter towards the *linea aspera*. Observe that the trochanter minor is directed backwards and that the muscles inserted into it turn the thigh outwards at the same time that they raise it. These are the muscles which, in fracture of the upper third of the shaft, it is often difficult to prevent from tilting up the upper fragment.

Inter-trochanteric Ridges.—Two oblique ridges extend from one trochanter to the other, the one in front of, the other behind the base of the neck of the femur. The anterior 'inter-trochanteric ridge' gives attachment to the powerful ligament (ilio-femoral) which covers the front of the capsule of the hip-joint, limits the extension of the thigh, and is of great utility in the erect position, since it prevents the pelvis and trunk from falling backwards. The posterior 'inter-trochanteric ridge' mainly supports the great trochanter. There is an eminence on its margin, extending downwards, behind the great trochanter called the '*linea quadrati*,' the insertion of the '*quadratus femoris*' already alluded to.

Shaft and Linea Aspera.—The shaft of the femur is slightly arched with the convexity forwards, by which a double advantage is gained: first, it is rendered more springy than if it were straight; secondly, more room is gained for the flexor muscles behind, and more power for the extensors in front of the shaft. The shaft is smooth and cylindrical all round, except behind, where there is a rough longitudinal ridge termed the '*linea aspera*.' This ridge serves as a buttress to the shaft, as well as for an attachment of muscles. The *linea aspera* is most prominent about the middle third of the shaft; here it appears at first sight a single ridge; but look carefully and you will find traces of two borders, termed its external and internal

'lips.' About the lower third of the shaft these lips diverge from each other, and may be traced to the 'tuberosities' of the condyles. The triangular interval between their bifurcation is called the popliteal surface of the femur, and upon it the popliteal artery rests in its passage through the ham. Turning to the upper end of the *linea aspera*,⁸³ notice that here also its two lips branch off: one runs to the root of the lesser trochanter, the other to the root of the greater.

What has been said of the *linea aspera*, and the upper and lower divergence of its two lips, will help us towards understanding the muscles attached to it. Take the *outer* lip first. The '*vastus externus*' arises from it three-quarters of the way down. Along the upper third is a very rough surface for the insertion of the *gluteus maximus*. This part may very properly be called the '*gluteal* ridge.' Lastly, there is the origin of the short head of the *biceps*, beginning just below the insertion of the *gluteus maximus*, and extending nearly down to the external condyle.

The *inner* lip of the *linea aspera* gives origin nearly all the way down to the '*vastus internus*.' Into its upper part is inserted the '*pectineus*,' then comes the insertion of the '*adductor longus*,' and behind both is that of the '*adductor brevis*.' Lastly, the insertion of the '*adductor magnus*' extends all along the line from the base of the trochanter major to the tuberosity of the inner condyle, including the *adductor tubercle*, which is a sharp projection of bone, giving a firm hold to the tendon. The little interval purposely left in the drawing (Plate XXXIII.) is intended to mark where the tendon gives passage to the popliteal artery.

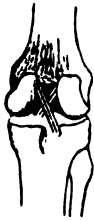Canals for Medullary Arteries.—Along the course of the *linea aspera* are the orifices of the two canals which convey nutrient blood-vessels to the marrow.

The front and outer surfaces of the shaft give origin to the '*crureus*' and to the little muscular slips below, which constitute the '*sub-crureus*.' The inner surface gives origin to part of the '*vastus internus*' (the other and stronger part arising from the *linea aspera*). The origin of these muscles does not occupy the whole of the shaft. Along the lower part, but more especially on the inner side, no muscular fibres arise: here the bone is simply

covered by the fibres of the 'vasti' on each side. This accounts for the great extent to which an inflamed knee-joint may swell beneath the vasti, there being no resistance to the distension of the synovial membrane in this direction.

Condyles and Inter-condyloid Notch.—The lower part of the femur gradually expands to form the condyles for the knee-joint (*κόνδυλος*, a knuckle). The inner condyle projects much more, and is full half an inch lower than the outer, when the bone is perpendicular; but when the bone slants, as it naturally does, both condyles are on the same level. This must needs be, as the plane of the knee-joint is horizontal in adaptation to the erect posture. The condyles are separated behind by a deep notch, the 'inter-condyloid,' for the lodgment of the two 'crucial' ligaments,

FIG. 35.

CRUCIAL LIGAMENTS
OF THE KNEE.

which prevent the knee from being extended beyond the straight line: for the requirements of this joint do not admit of any bony prominence to limit extension, such as we find in the elbow. These ligaments (shown in fig. 35) are attached to the rough surfaces of the condyles facing each other; the anterior crucial to the external condyle, the posterior crucial to the internal. The marks left by these ligaments can be clearly made out on the bone. Notice especially that the mark on the external condyle is placed posteriorly, that on the internal, anteriorly.

Trochlea for Patella.—The articular surfaces of the condyles unite in front to form the pulley (femoral trochlea) over which the 'patella' plays. The larger share of the pulley is formed by the external condyle, and it mounts not only higher, but projects more than the inner, preventing the tendency of the patella to be dislocated outwards. In an antero-posterior section, each articular surface would present something like the long half of an ellipse (as seen in fig. 36). The two woodcuts (35 and 36) show very well the attachments and

FIG. 36.



the direction of the crucial ligaments, *a b, a c*. Being attached

to the condyles behind the centre, they necessarily limit extension beyond the straight line. But they do more; by crossing like braces they prevent lateral displacement of the tibia. In the erect attitude, the flatter part of the ellipse rests on the shallow excavation of the tibia, and all the ligaments are on the stretch; but when the knee is bent, the more convex part of the ellipse rests on the tibia, and admits of a certain amount of rotation, all the ligaments being loose.

Tuberosities.—To the ‘tuberosities’ (external and internal) of the condyles are attached the lateral ligaments of the joint. These tuberosities are situated nearer to the back than to the front part of the condyle. The result of this is, that the ligaments are fixed behind the centre of motion, so that they become stretched when the joint is extended. This arrangement increases the strength of the knee.

There is an impression behind the internal condyle denoting the origin of the inner head of the ‘gastrocnemius’; and another, behind the external condyle, where the outer head of this muscle and the ‘plantaris’ arise. On the outer surface of the external condyle, immediately below the outer tuberosity, is a depression for the origin of the ‘popliteus.’ (Plate XXXIV. fig. 3.)

Ossification.—The femur is ossified from three primary centres (one for the shaft and neck, and one for each articular end), and two secondary centres, one for each trochanter. (See Plate IV.) The centre for the shaft appears about the seventh week of foetal life. The centre of the lower epiphysis does not appear until within the last fifteen days of the full term of gestation. Hence the existence of this centre enables us to pronounce with something like certainty as to the age of a foetus.⁸⁴ It is the only epiphysis in which ossification commences before birth. As this is the first of all the epiphyses to ossify, so, in accordance with the general law, it remains the longest a separate piece. The epiphysis at the upper end of the femur includes only the head of the bone, and begins to ossify about one year after birth. The great trochanter begins to ossify about the third or fourth year; the lesser about the fourteenth. All the pieces have united about the age of twenty-one.

Right or Left?—This bone will be in the same position as the corresponding one in the student's body if he hold the rounded head upwards, and turn it inwards for articulation with the acetabulum; while the *linea aspera* is behind.

Comparative Osteology.—In the horse, the rhinoceros, and the tapir (*Perissodactyla*) the gluteal ridge is so largely developed that it has received the name of a 'third trochanter.' The lower end of the femur in most mammals presents three separate articular surfaces, viz. the patellar articulation and two condyles. In man these three are blended into one, although there can be seen a trace of the separation along the lower border of the surface for the patella. The actual separation in man does exist in the fœtus, but becomes obliterated, the three articulations merging into one. The ligamenta alaria and the ligamentum mucosum are the only remains of the originally separate synovial membranes of the knee-joint.

In Elephants (*Proboscidea*) when standing, the bones of the leg and thigh are vertical, as in man.

If you examine the femurs of birds you will find they have but one trochanter, viz. that corresponding to our trochanter major.

In two or three serpents, e.g. *Python Tigris* (No. 602), *Python Regius* (No. 629), there are rudimentary hind limbs ending in hook-like claws sheathed in horn. These claws are put in action by certain muscles, and, serving as antagonists to the tail, give it greater prehensile power.

The ventral fins of fish correspond to the hind limbs of other animals.

THE PATELLA.

(PLATE XXXV.)

Shape and Use.—The patella is the largest and best example of a 'sesamoid' bone. It is developed in the extensor tendon of the knee, where it protects the knee-joint, and increases the power of the extensor muscles by enabling them to act at a greater

angle. It is a principle in mechanics that the efficiency of a force which acts upon a lever is greatest when its direction is at right angles to the lever, and that the force decreases as the obliquity of its direction is increased. In shape, the patella is triangular, with rounded angles, the apex pointing downwards.

Its Two Surfaces.—Its anterior surface is convex, and marked by longitudinal streaks, indicative of the insertion of the fibres of the extensor tendon.

Its posterior surface is smooth, and crusted in the recent state with cartilage, in order to play upon the trochlea of the femur. It is divided by a vertical ridge adapted to the groove in the femur, and on each side of the ridge are the articular ‘facets’ corresponding to the condyles of the femur.

Ossification.—The patella is developed from a single centre, which appears about the second year. It is not fully ossified until the age of fourteen or fifteen.

The patella, thus serving a mechanical purpose in the substance of the extensor tendon, is liable to be broken by a sudden and violent action of the extensor muscles, as in making a strong effort to regain the balance of the body in danger of falling backwards. In this position—that is, when the knee is *half-bent*—the upper part of the patella is not supported by its trochlea: there is a hollow under it, and here the patella snaps transversely, like a stick broken across the knee. The broken ends separate widely, and therefore in these transverse fractures reunion takes place by ligamentous substance, not by bone.

But even when the knee is *extended*, violent muscular contraction is able to snap the patella. Desault speaks of both patellæ being broken by convulsions in a patient after he had been cut for the stone. Opera dancers sometimes break the patella in practising the step called the ‘entrechat.’

Right or Left?—One has but to feel one’s own knee to find that the patella articulates much more extensively with the outer condyle of the femur than with the inner. The larger facet of the articular surface is therefore external; the apex, for the attachment of the ligamentum patellæ, points downwards.

THE TIBIA.

(PLATE XXXV.)

Situation and Direction.—The tibia is the larger of the two bones of the leg, and is placed on the inner side. It entirely supports the condyles of the femur, and transmits the weight of the body to the foot. Its direction is not oblique like the femur, but vertical; so that in well-formed legs the two tibiae should be parallel. Let us examine in succession the upper end, the shaft, and the lower end.

Head.—The upper end is called the ‘head’ of the tibia. It is very broad in the transverse direction for the support of the condyles of the femur: this great breadth is another peculiarity of the human skeleton. The two articular surfaces for the condyles are very shallow in the dry bone, but slightly deepened in the recent state by discs of fibro-cartilage (termed the ‘semilunar cartilages’). These cartilages convert the shallow articular surfaces of the tibia into *variable* sockets; that is, sockets which adapt themselves to the varying forms of the condyles in flexion and extension of the knee. The outer articular surface is round; the inner is oval, with the long diameter from before backwards, in adaptation to the internal condyle. Between the articular surfaces is a projection termed the ‘spine,’ which is generally topped by two little ‘tubercles.’ In front of the spine is the depression in which the anterior crucial ligament is attached, and behind the spine is another much larger, in which the posterior crucial ligament is attached. These depressions serve also for the attachments of the semilunar cartilages.

Tuberosities, External and Internal.—The lateral masses which support the articular surfaces are called the ‘tuberosities’ of the tibia. The *external* tuberosity has at its back part a small articular surface for the head of the fibula: this articular surface is on a kind of bony ledge, and its direction is oblique. The *internal* tuberosity is much larger, and projects more than the external. It has a groove behind for the insertion of the ‘*semi-membranosus*.’ About one inch and a half below the head of the

TIBIA.

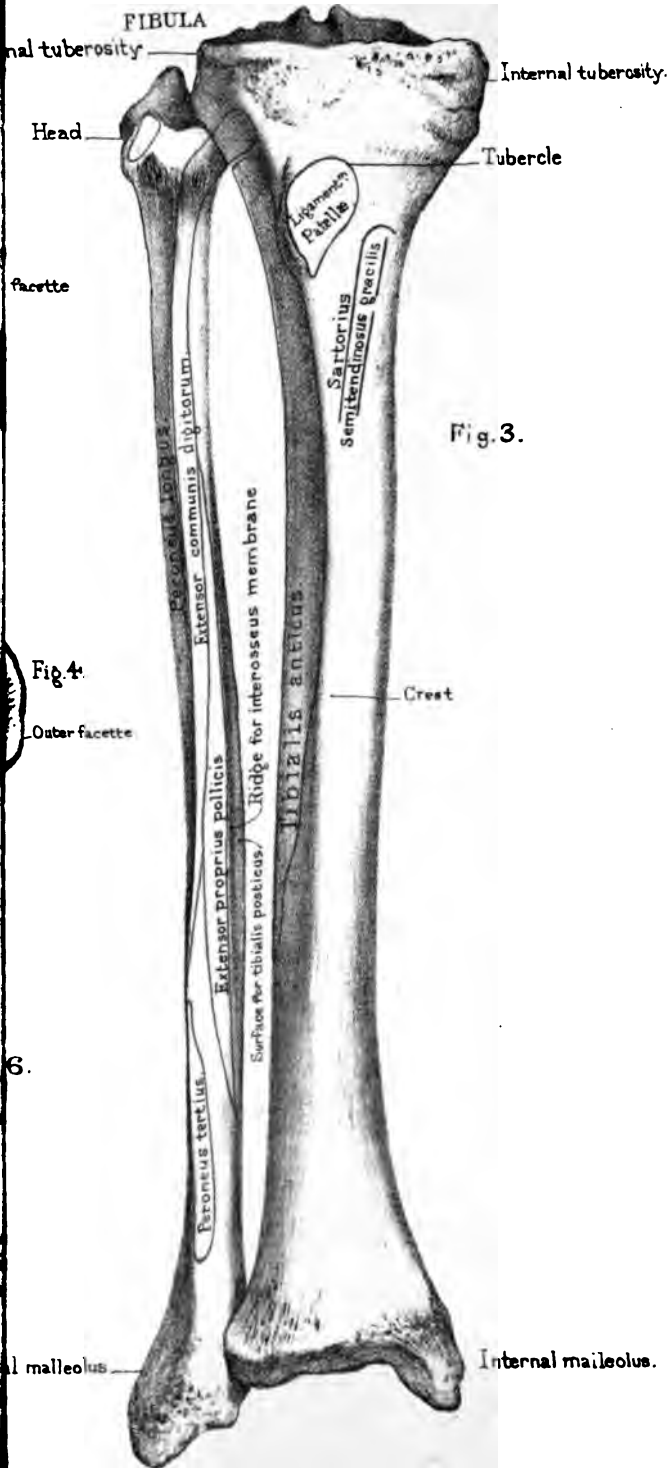


Fig. 3.

Fig. 4.

Anterior view.

Groove for Tibialis posterior Flexor longus

1

tibia, and in front of it, is the 'tubercle' for the insertion of the common extensor tendon of the leg (*ligamentum patellæ*). This insertion takes place into the lower part of the tubercle, which is rough; the upper part is smooth, to allow the easy play of the tendon (a bursa being interposed between the tendon and the bone).

Shaft.—The shaft of the tibia is triangular on section. It is a little twisted outwards, determining the obliquity of the foot; consequently the inner malleolus advances a little more than the outer. This disposition corresponds with the obliquity of the neck of the femur, the position of its trochanters, and the oblique direction of the muscles; the result of all being to give a natural inclination *outwards* to the lower extremity. The narrowest part of the shaft is about the lower third. This is the part most frequently broken.

The *internal* surface is subcutaneous. Notice on it, below the internal tuberosity, the insertions of the 'sartorius,' the 'gracilis,' and the 'semitendinosus.' Behind these is a rough surface for the attachment of the internal lateral ligament of the knee.

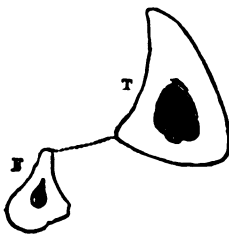
The *external* surface is slightly hollowed along its upper half for the origin and lodgment of the 'tibialis anticus': its lower part is turned forwards, presenting a smooth surface for the play of the tendons which run over the front of the ankle-joint.

The *posterior* surface presents along its upper third a rough line ('soleal ridge') slanting from the outer towards the inner side. It marks part of the tibial origin of the 'soleus'; the remainder of this origin runs down the inner edge of the shaft to the extent of about three inches. This origin is important, since it concerns the operation of tying the posterior tibial artery. Above the 'oblique line' is a triangular surface, indicating the insertion of the 'popliteus.' The surface of the bone below the ridge is occupied, internally, by the origin of the 'flexor longus digitorum'; externally, by part of the origin of the 'tibialis posticus.' Just below the line is the canal for the medullary artery. It is the largest of all the like canals in the long bones, runs very obliquely from above downwards, and when divided in amputations sometimes occasions troublesome hæmorrhage. A

nerve has often been traced through this canal with the artery into the medullary cavity.

Edges.—With regard to the edges of the tibia, the *anterior*, called the ‘crest,’ or ‘shin,’ is very sharp, and readily felt beneath the skin, but only along the upper two-thirds of the shaft: along the lower third the front of the bone is flattened, for the passage of the extensor tendons and the anterior tibial vessels and nerve. The *external* edge looks towards the fibula, and gives attachment

Fig. 37.

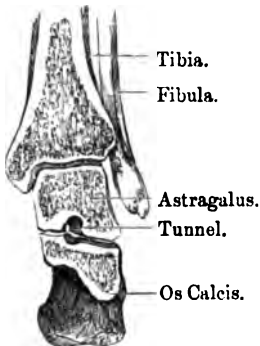


SECTION THROUGH THE TIBIA T, AND FIBULA F, TO SHOW THE THICKNESS OF THEIR WALLS.

to the interosseous membrane (represented by the dotted line in fig. 37) which connects the two bones. The *internal* edge runs from the hinder part of the head of the tibia down to the inner malleolus. It gives attachment to the deep fascia covering the muscles of the back of the leg, beneath those of the calf.

If the direction of the force in running, leaping, or walking be considered, it will be seen that the chief strain on the tibia is at the crest or anterior border—the shin. This, therefore, is by far the strongest and densest part of the bone.

Fig. 38.



SECTION TO SHOW THAT THE PLANE OF THE ANKLE-JOINT IS HORIZONTAL.

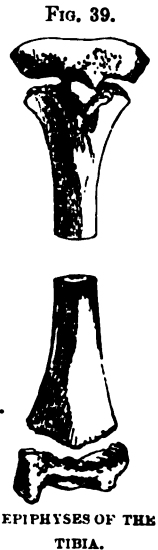
Lower End.—The lower end of the tibia is expanded transversely to form a hinge-joint with the astragalus. Its articular surface is concave from before backwards; but the transverse plane of the joint is horizontal (as seen in fig. 38), like that of the knee, for the better support of the weight of the body. The joint is secured on the inner side by the projection termed the ‘malleolus internus.’ The outer side of this projection is smooth and crusted with cartilage, and articulates with the lateral surface of the astragalus; the inner is subcutaneous. At its apex there is a deep notch for the attachment of the internal lateral ligament of the ankle; and behind it is a longitudinal groove, which transmits

the tendons of the 'tibialis posticus' and the 'flexor longus digitorum.' External to this groove, there is, in some bones, a slight depression for the tendon of the flexor longus pollicis.

Lastly, on the outer surface of the lower end is the rough excavation for the reception of the fibula. There is no sensible movement between the bones, but just enough to give a slight amount of elasticity. The security of the ankle requires that they be firmly riveted together by a strong interosseous ligament; and their contiguous surfaces are found to be rough, marking the attachment of such a ligament.

The ankle joint is such a perfect hinge that when the foot is at right angles to the tibia, as in standing, no lateral movement whatever is permitted; but when the foot is extended, a very slight lateral movement can take place between the tibia and the astragalus, owing to the astragalus being narrower behind than in front.

Ossification.—The tibia is ossified from three centres: one for the shaft, and one for each end. The centre for the shaft appears at the seventh week of fetal life. The one for the upper end, which (see fig. 39) includes the tubercle, appears just before or just after birth, nearly as early as the lower epiphysis of the femur. The centre of the lower end appears about the second year. The epiphyses do not unite with the shaft till the age of twenty or upwards.



Right or Left?—This bone will be in the same position as the corresponding one in the student's body if he hold the crest forwards, the head, or large end, upwards, and the articulation for the fibula outwards.

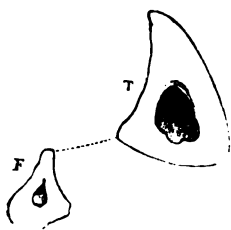
Comparative Osteology.—The tubercle of the tibia is very largely developed in the rhinoceros, but in the elephant there is no trace of it. The high and expanded crest in the pig, camel, and tapir are remarkable. In the higher quadrumana, as the gorilla, chimpanzee, and ourang outan, the tubercle and crest are flattened. (For all these specimens see the Separate Series.)

THE FIBULA.

(PLATE XXXV.)

Relations of Tibia to Fibula.—The ‘fibula’ (a clasp) is the outer of the two bones of the leg. Though quite as long as the tibia, it is a slender bone, and does not sustain any of the weight of the body. The upper end is placed on a lower level than the knee joint, and forms no part of it; but the lower end projects considerably below the tibia, and constitutes the outer ankle. The bone not only secures the ankle externally, but gives additional extent of origin to the powerful muscles of progression. Look well at the relative position of the two bones of the leg in an articulated skeleton. The fibula articulates with the outer and back part of the head of the tibia, and the shaft of the fibula arches *backwards*, while that of the tibia arches *forwards*: the result of this is, that the fibula lies very much in the background, except at its lower part, where it advances to form the malleolus externus. A knowledge of this relative bearing of the two bones is important in the adjustment of fractures, but more especially in the per-

FIG. 40.



formance of flap-amputations; and for this reason: that the knife, introduced from the tibial side, is apt, unless properly directed, to pass *between* the two bones, instead of behind them: and this is the more likely, since the plane of the posterior surface of the tibia slants considerably in front of the fibula. The relative position of the two bones, as well as their relative thickness, is shown by a transverse section (fig. 40). The dotted line represents the interosseous membrane.

Head.—The upper end of the fibula is called its ‘head,’ and can be felt plainly beneath the skin. On its inner side is the small oval surface which articulates with the tibia. Its outer side is very prominent, and rises behind into a short projection termed the ‘styloid process.’ This little process is significant,

because it probably tallies with the olecranon. It forms a little lever for the insertion of the biceps (one of the hamstring muscles). Besides this, the outer part of the 'head' gives attachment to the external lateral ligament of the knee joint.

Shaft.—The fibula must be learned when articulated with the tibia. Immediately below the head, the shaft is rounder and thinner than elsewhere. The lower three-fourths of the shaft is triangular. Its three surfaces are placed so that one (internal) looks towards the tibia; another looks outwards; the third looks backwards.

Ridge for Interosseous Membrane.—The inner or tibial surface is divided into two unequal parts by a longitudinal ridge which gives attachment to the interosseous membrane separating the muscles on the front from those on the back of the leg. Now the grooved surface behind the ridge in question gives origin to part of the 'tibialis posticus'; that in front of it gives origin to the 'extensor communis digitorum' (which arises also from the head of the fibula and the tibia), to the 'extensor proprius pollicis,' and to the 'peroneus tertius.' Thus, four muscles arise from the *inner* side of the shaft; of these, three are situated in front of the interosseous membrane, and one behind it.

The *outer* surface of the shaft gives origin to the 'peroneus longus' above and the 'peroneus brevis' below. Towards the lower end of the bone this surface inclines backwards, and the tendons of these two muscles play along the groove behind the external malleolus.

The *posterior* surface gives origin to two muscles only; namely, along its upper third to the 'soleus,' and along its lower two-thirds to the 'flexor longus pollicis.' Here is the canal for the medullary vessels.

The anterior border of the shaft is the sharpest, like that of the tibia. Trace it down the bone, and you find that it bifurcates about three inches from the lower end, and encloses a triangular surface, which is subcutaneous. Here we feel for fractures of the lower part of the fibula.

Lower End. Malleolus Externus.—The lower end of the fibula descends below the tibia and forms the 'malleolus externus'

which secures the ankle joint on the outer side. It is not only longer than the inner 'malleolus,' but projects more, giving more power to the tendons of the 'peronei,' which play in a groove behind it. On its inner side is the smooth, slightly convex, triangular surface which articulates with the side of the astragalus; and just above this is the rough surface which fits into the groove of the tibia, and gives attachment to the interosseous membrane which rivets the two bones together. The malleolus gives attachment to the three separate bands of the external lateral ligament of the ankle; the middle band is attached to the apex; the anterior to the front edge; the posterior and strongest to a surface above and on the inner side of the apex.

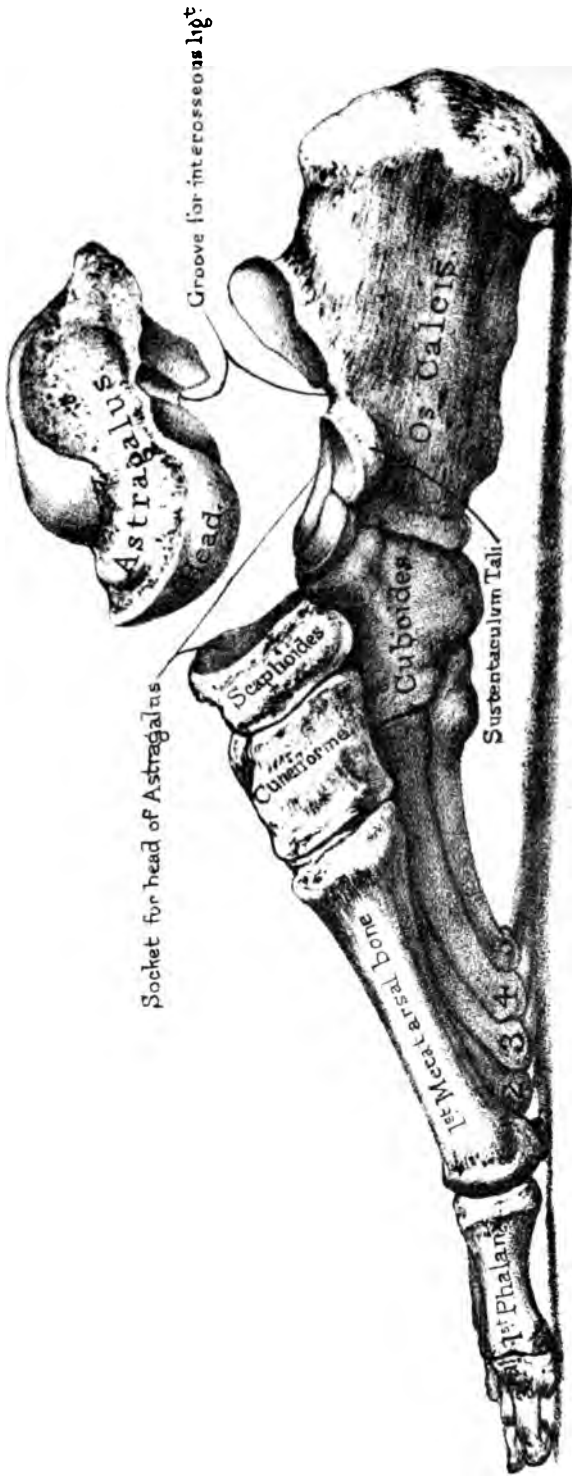
The tibia and fibula are so fixed together at the ankle, that there is no sensible motion between them; only just enough to give a little elasticity. The office of guarding the ankle is performed so well by the fibula, that lateral dislocation rarely takes place unless the fibula be broken. Fractures of the fibula generally occur about $2\frac{1}{2}$ inches from the lower end, and most frequently happen in consequence of a violent outward twist of the foot, as in slipping off the curb-stone. The outer surface of the os calcis comes to press against the end of the fibula; the result of which is, that the shaft of the bone gives way at the weakest part—that is, just above the ankle. The same accident may happen from a violent twist of the foot *inwards*; but in this case it is the astragalus which, by its pressure outwards, causes the fibula to break. This kind of fracture—accompanied, as it usually is, with fracture of the tip of the internal malleolus—is one of the most frequent injuries about the ankle received into a London hospital. Such an accident is commonly called 'Pott's fracture,' after the celebrated surgeon who first described it.

Ossification.—The fibula has three centres of ossification; one for the shaft, and one for each end. The centre for the shaft appears about the seventh week of foetal life. The lower end begins to ossify about the second year; the upper about the third or fourth. It is interesting to note that the lower end, the early solidity of which is so necessary, is the first to unite to the shaft, and is thus contrary to the rule laid down on page 24.

Right or Left?—This bone will be in the same position as the corresponding one in the student's body, if he hold the subcutaneous triangular surface downwards and outwards, bearing in mind that the apex of the triangle runs to the front ridge of the bone, and therefore must be placed forwards.

Comparative Osteology.—It is interesting to notice the gradual disappearance of the fibula in reviewing the vertebrata. In the horse it is reduced to a mere splint at the upper part of the tibia.

In the *Ornithorynchus* (No. 1699) there will be seen a broad flat process, projecting high upwards at the back of the fibula, which gives origin to enormous extensor and flexor muscles, which work the paddle-like foot (see *Phys. Ser. Mus. Roy. Coll. Surg.*, No. 255 C). A similar process exists on the fibula of the *Echidna* (No. 1704 C). The fibula of the *Armadillo* (No. 2335) attains a great size, and is anchylosed above and below to the tibia and enters into the formation of the knee joint.



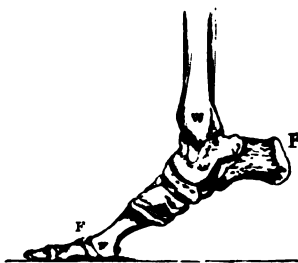
thus breaking shocks and increasing elasticity; and yet their mutual connection is so well secured, that dislocation of any one bone is extremely rare.

Tarso-Metatarsal Articulations.—The second row of tarsal bones consists of four: namely, the three cuneiform and the cuboid. These articulate with the metatarsal bones as follows:—The internal cuneiform with two, those of the great and second toes; the middle cuneiform with one, that of the second toe; the external cuneiform with three, those of the middle, the second, and fourth toes; and the cuboid with two, those of the fourth and fifth toes. See how this exactly corresponds with the articulations of the second row of carpal bones with the metacarpals. Starting from the great toe, or thumb side, these bones articulate with 2, 1, 3, and 2 metatarsal and metacarpal bones respectively.

It is wonderful what habit and necessity will make the foot accomplish. Those who coop it in tight boots, can hardly credit that persons carve, write, and even paint with the toes. ‘*Pes altera manus*’ is not so far from the truth. A French artist, Ducornet, born without arms, used to paint with his toes pictures worthy of a place in the French Exhibition.

The Foot a Lever of the Second Order.—The foot is a lever of the second order for raising the body. The weight is at the ankle joint W (fig. 41); the fulcrum F is at the toes; and the power (which is the contraction of the muscles of the calf) is at the heel P. All the conditions are those of a lever of the second order. The power and the weight act in opposite directions on the same side of the fulcrum.⁸⁵

FIG. 41.



THE ASTRAGALUS.

(PLATE XXXVI.)

The Key-stone: its Six Aspects.—The astragalus (*ἀστράγαλος*, talus, the knuckle-bone, with which the ancients used to

play at dice), is the key-stone of the arch of the foot, and supports the whole weight of the body, which, in the erect position, falls perpendicularly upon it from the tibia. It is so much concerned in the mechanism of the spring of the foot, that the Germans call it the 'spring bone.' To examine it thoroughly study its six aspects.

Superior Aspect.—Its superior surface, broad and *horizontal* in the transverse direction, the best adapted for the erect posture, presents a pulley-like convexity in the antero-posterior direction, which articulates with the tibia, and admits of the flexion and extension of the ankle. In front of this is the rough surface or 'neck,' for the attachment of ligaments. This pulley-like surface is at least one-fifth of an inch broader in front than behind. This prevents dislocation of the astragalus backwards, which would otherwise be a more frequent occurrence, considering the direction of the force in walking, running, or leaping. In consequence of this greater narrowness of the astragalus behind, the ankle joint admits of a very slight lateral movement when the foot is extended. But there can be no lateral movement at the ankle when the foot is at right angles to the tibia, i.e. when we stand upon it.

Lateral Aspects.—Each lateral aspect presents an articular surface adapted to the corresponding malleolus. The outer is much the larger, slightly concave from above downwards, and triangular with the apex below. The inner is comparatively small, rounded in front and pointed behind; it occupies very little of the bone, so that a large, rough excavation is left below, for the attachment of the enormously strong internal lateral ligament upon which the security of the ankle so much depends.

Posterior Aspect.—Its posterior aspect is narrow, and presents a groove running obliquely downwards and inwards for the tendon of the flexor longus pollicis, and a projection on the outer side of it for the attachment of the posterior division of the external lateral ligament of the ankle.

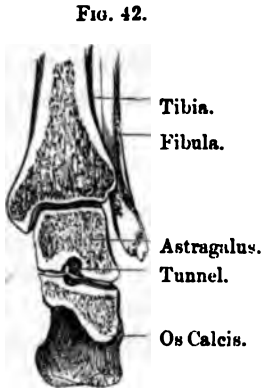
Anterior Aspect.—The anterior aspect presents a large convex 'head,' which is received into a socket, formed, in front, by the scaphoid; below, by the 'sustentaculum tali' (part of the os

calcis); also by a strong and slightly elastic ligament which fills up the gap left, on the inner side and below, between these bones in the skeleton. (Plate XXXVIII.) Sometimes the under surface of the 'head' has two separate 'facets' to articulate with the os calcis. These are distinctly marked in children; and they become united in adults, owing perhaps to the pressure to which they are subjected by the practice of wearing high heels.⁸⁶ It is this ligament (calcaneo-scapoid) which mainly supports the arch of the foot, and gives it its spring. If this ligament yield more than it should do, as is sometimes the case in weakly persons, or in opera-dancers, from excessive straining, or in bakers, from carrying heavy weights, down goes the arch—the foot becomes flat, and the astragalus may sink low enough to touch the ground.

Inferior Aspect.—The inferior aspect rests on the os calcis by two articular surfaces, one behind the other, and separated by a deep groove directed from the inner side obliquely outwards and forwards. Of these surfaces, the posterior is by far the larger, and placed a little more external than the anterior. The posterior is concave, the anterior flat, and both of them slant a little downwards and forwards. The consequence of this is, that when the foot sustains the weight of the body, the astragalus slides a little forwards on the os calcis, and presses with its head firmly against the scaphoid bone and the calcaneo-scapoid ligament underneath, which, being somewhat elastic, yields a little, so that the foot becomes longer. But this is not all. When we step forward, while the foot is raised, the bones (os calcis and scaphoid) roll easily below the astragalus, so that the toes may be directed to suit the inequalities of the ground: but, the foot once planted, the body rests perpendicularly on it, the astragalus sinks into its socket, presses the os calcis backwards and the metatarsal bones forwards, and thus we have a steady base of support.

Tunnel of the Tarsus.—The groove just alluded to, between the articular surfaces of the astragalus, corresponds with another between those of the os calcis. When the bones are together, the grooves form a complete tunnel (*canalis tarsi*) beneath the astragalus, wide on the outside, but narrow on the inside of

the foot (fig. 42). This tunnel is occupied in the recent state by fat and by the strong interosseous ligament which connects



SECTION TO SHOW THE TUNNEL
OF THE TARSUS.

the two bones: its direction is obliquely from before backwards, and permits the free *lateral* movements of the foot, which take place, not at the ankle joint proper (a simple hinge), but between the astragalus and the bones with which it articulates *below*. The astragalus cannot be displaced from the os calcis without rupture of the interosseous ligament.

Connections.—The astragalus articulates with four bones—namely, the tibia, the fibula, the os calcis, and the scaphoid.

Ossification.—It is ossified from a single centre, which appears about the seventh month of foetal life.

Right or Left?—This bone will be in the same position as the corresponding one in the student's body if he hold the groove for the interosseous ligament downwards, the rounded head forwards and on the inner side, for articulation with the hollow of the scaphoid.

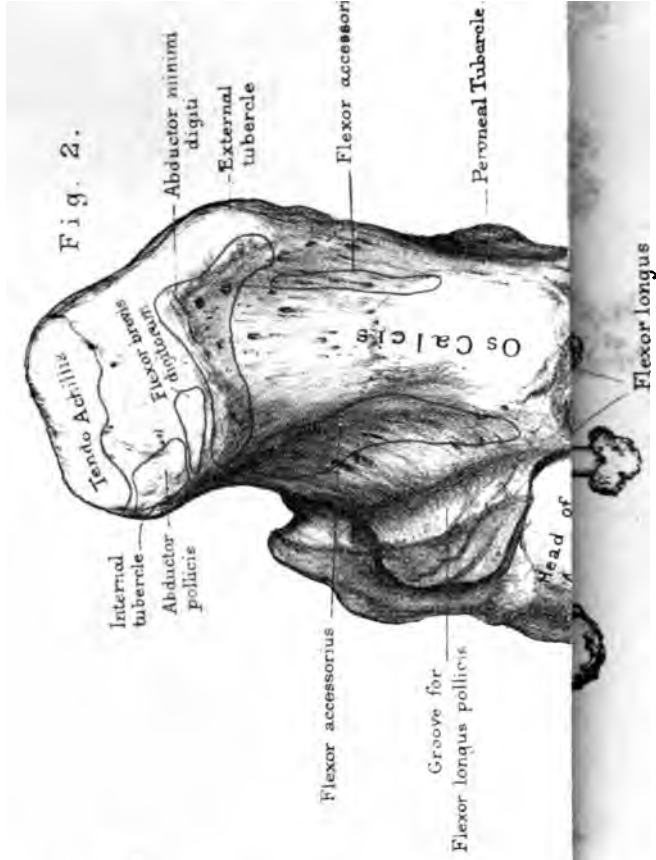
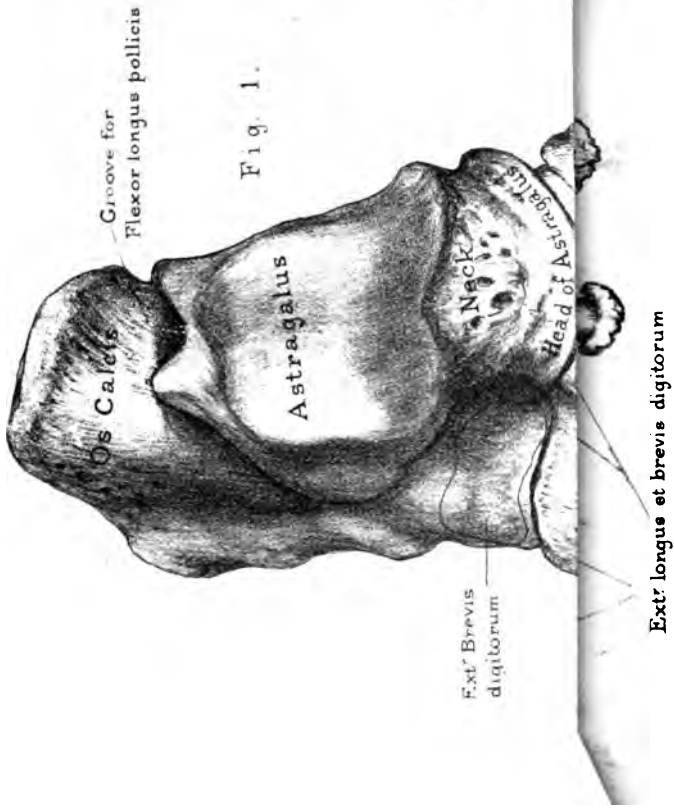
OS CALCIS, OR CALCANEUM.

(PLATES XXXVI, XXXVII.)

Use.—The os calcis, or 'calcaneum,' is the longest and strongest of the tarsal bones. It transmits the weight of the body to the ground, and forms a powerful lever for the muscles of the calf. The nearly horizontal direction of the heel is peculiar to the skeleton of man, in adaptation to his erect position. The oblique projection in the hind limb of a horse, called the 'hock,' is the os calcis.

There is a prevalent opinion that the negro has a longer heel than the white man; but an examination of a series of calcanea in both races proves this to be an error. Professor Flower, in his





Drawn on Stone by I. Godart

From nature by L. Holden.

Printed by West Newman & Co.

Lectures on the 'Comparative Anatomy of Man,' states that the *apparent* lengthening in the negro is due to the smallness of his calf and the slenderness of the tendo-Achillis immediately above the heel.

There are six different aspects on the os calcis.

Superior Aspect.—Its superior aspect presents the two surfaces which support the astragalus. Of these, the posterior is convex and larger than the anterior, which is concave, long and narrow, and is situated on the top of the 'sustentaculum tali' (presently to be described). The plane of both these surfaces is horizontal *transversely*, the better to support the weight; but, like those of the astragalus, they slope a little, so that the weight is transmitted, obliquely downwards and forwards upon the arch of the foot. Observe the groove between the articular surfaces for the attachment of the interosseous ligament: this groove makes, with the astragalus, a complete tunnel shown in fig. 42.

If a perpendicular section be made through the os calcis, it shows that the compact wall is thickest at the articular surfaces for the astragalus; and that, from these, the principal septa of the cancelli radiate towards the back and under part of the bone; that is, precisely in the line of pressure.

Anterior Aspect.—The anterior end presents a concave vertical surface, which articulates with the cuboid bone. The edge of this surface projects a little, superiorly; and the projection deserves notice, chiefly because it is in the way in the performance of 'Chopart's' operation, which consists in the removal of all the bones of the foot, except the os calcis and astragalus. In some instances it supports a third articular facet for the astragalus (see p. 187). The rough tubercle, on the dorsal surface of the anterior end, gives origin to the 'extensor brevis digitorum.'

Posterior Aspect.—The posterior end, or 'great tuberosity,' forms the heel. The lower rough part indicates the insertion of the 'tendo-Achillis'; while the smooth part above indicates the position of the bursa between the tendon and the bone.

External Aspect.—The external surface is broad, flat, and nearly subcutaneous. Rather in front of the middle is a tubercle (peroneal tubercle) which serves to keep the peroneal tendons in

place, that of the 'peroneus brevis' being above, that of the 'peroneus longus' below the tubercle. Behind this tubercle is, generally, another, much smaller, for the attachment of the external lateral ligament of the ankle.

Internal Aspect.—The internal surface presents a concavity for the safe transmission of the plantar vessels and nerves. At its upper part is the process termed the '*sustentaculum tali*,' which helps to support the head of the astragalus, shelters the plantar vessels and nerves, and gives attachment to the calcaneo-scapoid ligament and to some fibres of the internal lateral ligament of the ankle. There is a deep groove along the under surface of this process for the tendon of the 'flexor longus pollicis.'

Inferior Aspect.—The inferior or plantar surface presents at its back part two tubercles, of unequal size, the internal being much the larger. They are the only parts of the os calcis which touch the ground. They serve for the origin of muscles, and for the attachment of the strong plantar fascia which protects the sole of the foot. There is also another tubercle forwards for the attachment of the calcaneo-cuboid ligament. Thus, there are three exceedingly strong ligaments attached to the os calcis for the preservation of the arch of the foot—1, the plantar fascia (which acts as a ligament); 2, the calcaneo-scapoid ligament beneath the head of the astragalus; and 3, the calcaneo-cuboid.

The muscles arising from the os calcis are:—'Abductor pollicis,' 'abductor digiti minimi,' 'flexor brevis digitorum,' 'flexor accessorius' (two heads), and 'extensor brevis digitorum.' The 'tendo-Achillis' is the only insertion; unless we include that of the little 'plantaris,' on the inner side of the tendo-Achillis, and a few fibres from the tibialis posticus into the '*sustentaculum tali*.'

Connections.—The os calcis articulates with two bones, the astragalus and cuboid.

Ossification.—The os calcis has two centres of ossification: one for the great mass of the bone, which appears about the seventh month of foetal life; and another for the great tuberosity which is an epiphysis and appears about the tenth year. The

epiphysis unites to the bone about the sixteenth year. It represents, according to some anatomists, the pisiform bone of the wrist.

Right or Left?—This bone will be in the same position as the corresponding one in the student's body if he hold the cubical heel backwards, the articulation for the astragalus upwards, and the *sustentaculum tali* inwards.

THE SCAPHOID BONE.

Situation.—The scaphoid bone, so named from its boat-like form, is situated on the inner side of the tarsus. It presents, *posteriorly*, a concave oval surface (the narrow end being placed internally), which forms part of the socket for the head of the astragalus. *Anteriorly*, it has three articular facets for the three cuneiform bones. These facets are not all on the same plane or of the same shape: the inner is the largest, and articulates with the inner cuneiform: the middle and the outer facets are triangular with the apices below, to fit the middle and outer cuneiform. *Externally*, it has sometimes a small facet which articulates with the cuboid bone. *Internally*, it has a very prominent *tubercle*, which projects and can be readily felt on the inner side of the foot. It gives insertion to the tendon of the 'tibialis posticus,' which turns the foot inwards. This tubercle is the best guide to the joint behind it, in the performance of Chopart's operation. The lower part of the scaphoid is very rough for the attachment of the calcaneo-scaphoid ligament.

Connections.—The scaphoid articulates with the three cuneiform bones in front, the astragalus behind, and sometimes with the cuboid.

Ossification.—It has a single centre, which appears about the fourth year.

Right or Left?—This bone will be in the same position as the corresponding one in the student's body if he hold the concave surface for the head of the astragalus backwards, the tubercle downwards and on the inner side.

THE CUBOID BONE.

Situation.—The cuboid bone is situated on the outer side of the tarsus, and is wedged in between the os calcis and the fourth and fifth metatarsal bones. The *base* of the wedge is turned towards the cuneiform bones, so that the pressure in the arch of the foot is properly distributed. Suppose, for a moment, the base were turned the other way, would not the lateral thrust from the external cuneiform bone force the cuboid out of the arch, and the falling of the arch be the consequence?

Surfaces.—Its *posterior* surface is slightly concave from above downwards, and convex from side to side, to articulate with a corresponding surface on the os calcis. Observe that the plane of this joint is the same as that between the scaphoid and astragalus. Hence partial amputation of the foot (Chopart's operation) here is easy. But it cannot be done at one stroke of the knife, because the inner corner of the cuboid projects a little beneath the os calcis, which tends to prevent it being dislocated upwards.

Its *anterior* surface has two smooth facets, the inner nearly square, the outer triangular, which support the fourth and fifth metatarsal bones.

Its *internal* surface articulates with the third or outer cuneiform, by a flat oval surface, and, generally, with the scaphoid.

Its *inferior* surface is traversed by a deep groove which runs obliquely inwards and forwards and lodges the tendon of the 'peroneus longus.' The prominent ridge behind the groove, and the rest of its under surface, give attachment to the calcaneo-cuboid ligament. Observe near the posterior part of this ridge a small smooth facet (crusted in the recent state with cartilage), which articulates with the sesamoid bone in the tendon that plays in the groove.

Connections.—The cuboid articulates with four bones—the os calcis, the outer cuneiform, and the fourth and fifth metatarsals—and sometimes with a fifth, namely the scaphoid.

The cuboid gives origin to parts of two muscles in the sole—the 'adductor pollicis,' and the 'flexor brevis pollicis.' Remember that the adductor pollicis arises, not immediately from the bone,

but from the fibrous sheath which bridges over the groove for the peroneus longus.

Ossification.—The single nucleus of the cuboid bone appears at birth.

Right or Left?—This bone will be in the same position as the corresponding one in the student's body if he hold the groove for the peroneus longus downwards, the narrow non-articular edge outwards, and the large concavo-convex surface for articulation with the os calcis backwards.

THE CUNEIFORM BONES.

Position.—The cuneiform or wedge bones are placed at the front part of the tarsus, and are named the 'internal,' 'middle,' and 'external,' according to their position. Behind, they articulate with the scaphoid; in front, with the three inner toes, respectively. The bases of the middle and external are towards the dorsum of the foot; but the base of the internal is turned towards the sole, in order to form one of the buttresses of the transverse arch of the foot.

Internal Cuneiform.—The internal cuneiform is the largest, and supports the metatarsal bone of the great toe. Its anterior articular surface is convex, and kidney-shaped, with the long diameter vertical. Inferiorly, the thick base projects into the sole considerably below the other cuneiform bones, giving broad insertion to the tendons of the two muscles which turn the sole of the foot inwards, namely, the 'tibialis anticus' and 'posticus.' Externally, it is slightly concave, and articulates along its upper and posterior margins with the second cuneiform and the second metatarsal bones: internally, it is convex, and has a little smooth surface over which the tendon of the 'tibialis anticus' plays. Posteriorly, it articulates with the scaphoid by a concave surface, wider below than above.

Thus it articulates with four bones—namely, the scaphoid, the middle cuneiform, and the two inner metatarsals.

Right or Left?—This bone will be in the same position as the corresponding one in the student's body if he hold the sharp edge upwards, the rough non-articular surface inwards, and the smaller concave articular surface backwards to articulate with the scaphoid.

Middle Cuneiform.—The second or middle cuneiform bone is not only the smallest of the three, but does not project so much as the others; consequently the second metatarsal bone, which it supports by a triangular surface, is more deeply set in the tarsus than the other metatarsals. This is a point to be remembered in removing the metatarsal bones (Hey's operation). Posteriorly, it articulates with the scaphoid by a triangular surface with the apex below. It has on each side an articular facet for the adjoining wedge bones. The external facet, slightly concave, runs vertically along its posterior half in correspondence with the external cuneiform. The internal facet, slightly convex, skirts its superior and posterior borders; thus presenting a horizontal and a vertical portion, in exact correspondence with the marginal surface of the internal cuneiform. It is one of the peculiarities of these wedge bones of the foot, that intervals are left between their sides, for the attachment of the interosseous ligaments which fasten the bones together.

Connections.—The middle cuneiform articulates with four bones—the scaphoid, the outer and inner cuneiform, and the second metatarsal.

Right or Left?—This bone will be in the same position as the corresponding one in the student's body if he hold the apex of this wedge-shaped bone downwards, the narrowest side of the base forwards, and the concave side (with the vertical articular surface only) outwards.

External Cuneiform.—The third or external cuneiform bone articulates, externally, with the cuboid by a flat oval facet, and with the inner corner of the fourth metatarsal bone; internally, with the middle cuneiform and the second metatarsal; posteriorly, with the scaphoid; anteriorly, it supports the third (its proper) metatarsal on a triangular surface; thus it articulates with six bones. Notice, especially, the extent to which it juts forwards between the second and fourth metatarsal bones, so that it helps to support three metatarsals just as the os magnum of the wrist supports three metacarpals.

The flexor brevis pollicis partly arises from the under surface of the external cuneiform; and some of the fibres of the tendon of the tibialis posticus are inserted into it.

Right or Left?—This bone will be in the same position as the corresponding one in the student's body if he hold the rough non-articular surface towards the dorsum of the foot, its sharpened end backwards, fitting in between the scaphoid and the cuboid; and the round flat surface for articulation with the cuboid on its outer side.

Articulations of Tarsal Bones.—Look once more at the bones, and remember that the astragalus articulates with four bones; the os calcis with two; the scaphoid with four (sometimes five); the internal cuneiform with four; the middle cuneiform with four; the external cuneiform with six; the cuboid with four (sometimes five, the fifth being the scaphoid).

Ossification of Tarsal Bones.—Each bone of the tarsus has one centre of ossification, except the os calcis, which has two. The os calcis begins to ossify about the sixth month of fœtal life; the astragalus about the seventh month; the cuboid about birth; the external cuneiform about the first year after birth; the middle and internal cuneiform and scaphoid about the third or fourth year.

The second centre (or epiphysis) of the os calcis is at the back part of it. It appears about the tenth year, and joins the rest of the bone about puberty.

THE METATARSUS.

General Description.—The five metatarsal bones are named the first, second, third, fourth, and fifth, counting from the inner side. The first is the shortest and by far the strongest, and supports the great toe. The second is the longest; and from this the third, fourth, and fifth gradually decrease in length. All are slightly arched from before backwards; in addition to this, the three outer incline a little sideways towards the great toe. The spaces between them are termed the 'interosseous spaces,' and gradually decrease in size towards the outer side. As the metatarsal bones are 'long' bones, we speak of their shafts and their articular ends; the upper end of each being termed the 'base,' and the lower or rounded end the 'head' of the bone.

Like the corresponding bones in the hand, the shafts of the metatarsal bones are more or less triangular on transverse section,

being flat on the dorsal surface; and they gradually taper from their proximal ends.

Bases or Upper Ends.—Their *bases* articulate with the second row of the tarsus, and, laterally, with each other; that of the first excepted. The line of the tarso-metatarsal articulations would be a tolerably even curve, but for the second metatarsal, which is jammed into a recess between the cuneiform bones. Thus the second metatarsal is firmly locked in like the second metacarpal. The bases of the outer four slope outwards and backwards.

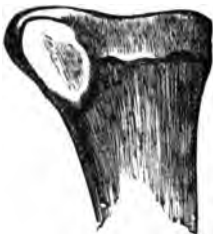Heads or Lower Ends.—Their *heads*, which are much smaller than those of the metacarpal bones, are convex, and fit into the cups of the first phalanges; they are grooved above for the attachment of ligaments.

The convexity of the head of each metatarsal extends downwards towards the sole of the foot—that is, in the direction of flexion—and terminates below in two points called the ‘condyles.’ On each side there is a tubercle for the attachment of the lateral ligament. The external condyle is always the larger and more prominent, and a well-marked ridge connects it with the shaft. Hence, when a metatarsal bone is held with the head forward, and the dorsum of the shaft upward, the more prominent condyle will be on the outer side.

First Metatarsal.—The excessive strength and size of the first metatarsal bone which supports the great toe, are peculiar to man. It is the chief support upon which the body is raised by the great muscles of the calf. Its base presents a kidney-shaped surface, which articulates exclusively with the internal cuneiform bone; and there is an impression on the outer side of its plantar aspect, indicating the insertion of the ‘peroneus longus’ (fig. 43). Its head is remarkably broad, and supports the ball of the great toe. It has on its under surface two grooves (separated by a ridge) for the play of the two sesamoid bones.

FIG. 43.

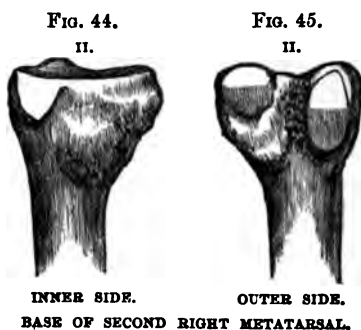
1.



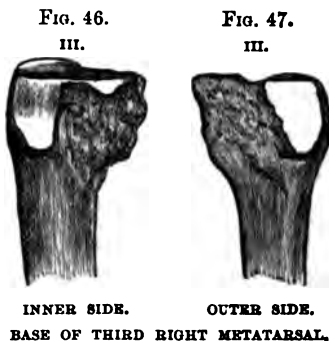
BASE OF FIRST RIGHT METATARSAL. OUTER SIDE

Right or Left?—This bone will be in the same position as the corresponding one in the student's body if he hold it with the base backwards, the concavity of the kidney-shaped surface outwards, and the surface for the insertion of the peroneus longus downwards.

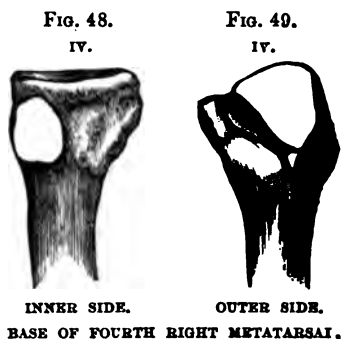
Second Metatarsal.—The second metatarsal bone, the longest of all, may be known by its triangular surface at the base for the middle cuneiform bone, a small lateral facet for the inner cuneiform, and four lateral facets on its outer side; namely, two⁸⁷ for the outer cuneiform, and two for the third metatarsal bone. The right may be readily distinguished from the left by attention to these points.



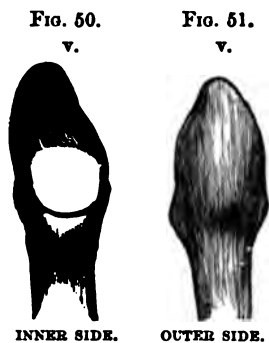
Third Metatarsal.—The third metatarsal bone may be known by its having two articular facets on the inner side of the base, and one on the outer side.



Fourth Metatarsal.—The fourth metatarsal bone may be known by its square tarsal surface for the cuboid, and a single facet on each side (figs. 48, 49). The inner facet is, as a rule, divided by a slight ridge into an anterior and a posterior part; the posterior being for the outer cuneiform. But the fourth metatarsal does not always touch the outer cuneiform. This variation is seen in several specimens in the stores of the Museum of the Royal College of Surgeons.



Fifth Metatarsal.—The fifth metatarsal bone can at once be recognised by the great projection on the outer side of



INNER SIDE.

OUTER SIDE.

BASE OF FIFTH RIGHT METATARSAL.

its base. This projection gives attachment to the outer division of the plantar fascia, and to the tendon of the peroneus brevis. The peroneus tertius is inserted on the dorsal aspect of the base. The surface of articulation with the cuboid slants outwards and backwards. There is a round lateral facet for the fourth metatarsal.

Agreement between Metatarsals and Metacarpals.—It may be well to

remind the reader that there is a remarkable agreement in the majority of cases in the number of bones with which corresponding metatarsals and metacarpals articulate at their bases. Thus, the base of the first, in each case, articulates with one bone—that of the second with four—that of the third with three—that of the fourth with four—and that of the fifth with two.

Ossification.—Each metatarsal bone has two centres of ossification—one for the shaft and base, the other for the head; excepting the metatarsal bone of the great toe, which is ossified like a phalanx, that is the epiphysis is at the base, and thus it resembles the metacarpal bone of the thumb in its development.

Phalanges of the Toes.—Each toe consists of three phalanges, excepting the great toe, which has only two. The phalanges of the other toes differ from those of the fingers mainly in being shorter. To learn the characters of phalanges the student should refer to those of the hand as being better marked than those of the foot. The last two phalanges of the little toe are generally ankylosed in adults, probably in consequence of being cramped by tight shoes. The great toe is the longest of all, but in the Antique the second is represented as being the longest.

Comparative Osteology.—Like the thumb, the first or great toe has only two phalanges. This is the case throughout the whole mammalian class, provided it supports a nail, a hoof, or

a claw. The hind foot of the horse is the representative of the third toe.

SESAMOID BONES.

There are two sesamoid bones which play in two grooves beneath the head of the first metatarsal bone. They act like little 'patellæ,' and increase the leverage of the muscles which work the great toe (see p. 175). Very exceptionally similar bones are met with in the corresponding joints of other toes.

Comparative Osteology.—There are many sesamoid bones in the foot of the great armadillo (*Prionotus gigas*, No. 2335 B). Examine also the under surface of the foot of the dog (No. 4391 A). There are four sesamoid bones behind the pastern joint of the ox, and two behind that of the horse. The sesamoid bone in the tendon of the flexor longus digitorum, behind the last joint, is called by veterinarians from its shape the 'navicular' bone.

OBSERVATIONS ON THE FOOT AS A WHOLE.

General Observations on the Foot.—The knowledge of the individual bones will be of little practical use, unless the skeleton of the foot be studied as a whole.

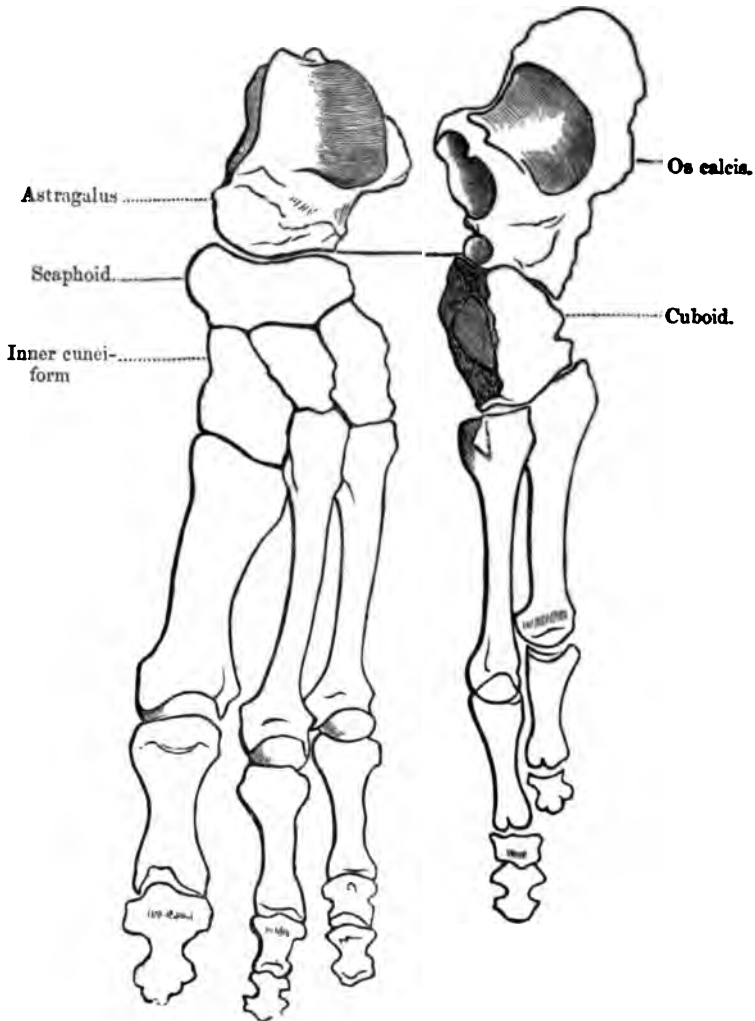
The sketch on page 200,⁸⁸ taken from a preparation, is made to show the sequence of the bones which form the inner and the outer sides of the longitudinal arch of the foot. On the inner side are the astragalus, the scaphoid, and the three cuneiform bones supporting the three inner metatarsals. On the outer side are the os calcis, the cuboid, and the two outer metatarsals. By putting the two sides together, it is easy to study and recollect their relative bearings.

Arches of the Foot.—The foot is a combination of numerous small bones, so adapted and connected as to form strong and, at the same time, elastic arches.

Longitudinal Arch.—The principal arch is in the antero-posterior or long axis of the foot. This 'longitudinal arch' has to bear the weight of the body erect. It is supported, behind, by the tuberosities of the os calcis; and in front, by the distal ends

of the metatarsal bones. Its inner side is much higher than the outer, and is formed by the astragalus, the scaphoid, the three

FIG. 52.



cuneiform and three inner metatarsal bones. This is well seen in fig. 52. The outer side of the arch is much lower than the inner, and is formed by the os calcia, the cuboid, and the two

outer metatarsal bones. It is supported mainly by a strong ligament termed the 'calcaneo-cuboid.'

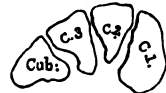Transverse Arch.—Besides the longitudinal arch there is another in the transverse direction. This is most marked over the instep: that is, its greatest convexity is across the cuneiform and the cuboid bones. Its inner side is much thicker than the outer.

Yielding of the Arches.—When we stand, not only does the *longitudinal* arch of the foot yield, but the *transverse* arch yields also. The wedge bones and the metatarsals are connected by interosseous ligaments, which, being slightly elastic, give a little, and thereby increase the transverse breadth of the foot. A transverse section across the instep—that is, through the wedge bones—shows that they are shaped, not like the stones of a bridge, as in fig. 53, but as represented in fig. 54. Their sides are not in apposition all the way down, but gaps are left between them: now these gaps are occupied by elastic ligaments, which permit a certain amount of separation between the bones when the arch is pressed upon.

FIG. 53.



FIG. 54.



TRANSVERSE SECTION TO SHOW THE FORM OF THE CUNEIFORM BONES.

Mechanism of Foot in Walking.—Consider the mechanism of the foot in the act of walking. In standing, the weight of the body is transferred from the astragalus both backwards and forwards; backwards to the heel-bone, forwards to the ends of the metatarsals and toes. The inner side of the arch sinks a little; the outer side touches the ground, or nearly so. Thus the weight is evenly distributed; the head of the astragalus transmitting it to the inner side, the calcaneum to the outer side. The foot then forms a firm basis of support, becoming a little longer, and a little wider at the toes, owing to the widening of the transverse arch and the slight separation of the metatarsals.

When we begin to walk, the heel is first raised; the astragalus is tilted forwards and downwards, but cannot slip off the os calcis by reason of the alternately convex and concave joints between them. The astragalus in this position is almost hooked on to the

calcaneum. It transmits the weight of the body through the scaphoid to the three inner toes, and through the calcaneum and cuboid to the two outer; then the weight is entirely sustained by the heads of the metatarsal bones, especially that of the great toe, which is the last to leave the ground, and propels the body on to the other foot, extended forward to receive it.⁸⁹

Such is the mechanism of the calcaneo-astragaloid joint. It is equally strong and transmits weight with the same security, whether the pressure be vertical, as in the erect position, or oblique, as in the middle of the act of walking, or when we stand on tiptoes.

Our shoes ought to be made so as to permit the natural play of the arches of the foot. It is manifest that the practice of wearing high heels alters the level of the piers of the arches. By thus raising one pier, i.e. the heel bone, we walk on an inclined plane; we alter the bearings of all the other bones; we throw the pressure on the articular surfaces of the heads of the metatarsal bones, and thus give rise to distortion, crooked toes, bunions and corns—local troubles which disincite or prevent us from taking necessary exercise, and set up far more serious constitutional ailments.

Ancient Egyptian and Greek art represents the second toe as longer than the great toe. This was probably copied from the negro, for in our race at the present time the great toe is certainly the longest of all the toes in the vast majority of cases.⁹⁰

Comparative Osteology.—The chief variations in the digits of the vertebrata are of number and connections. In some instances—e.g. seal (No. 3961), also *Platanista Gangetica* (Cetacea, No. 2482 C)—the digits are so bound together in a common sheath that they have little individual movement, though they form an excellent paddle. The number is reduced to four in the boar (Nos. 3248–3253 A), to three in the rhinoceros (No. 2933), to two in the ox (No. 3825 A), and to one in the horse (No. 3133, *Equus Caballus*). The middle digit is the most constant of all the digits in the vertebrata. The bones forming the three joints of this toe answer to those called the ‘great pastern bone,’ the ‘little pastern bone,’ and the ‘coffin bone’ in the horse, while the nail in the toe is represented by the hoof.

An inspection of the separate series of bones in the Osteol. Mus. of the Royal College of Surgeons will show that the horse walks on his third toe (i.e. our middle toe), and the pig and cow on the third and fourth. The kangaroo walks on his fourth and fifth toes, the second and third being greatly diminished in size. Birds have three toes usually developed, viz. the second, third, and fourth; but the ostrich only has two, viz. the third and the fourth. The spur of the cock is the great toe nail.

The elephant (*Proboscidea*, No. 2654) has five toes, and the weight of the body is supported by a palmar and plantar pad under the toes.

The Hyrax *Capensis* (No. 3115 C) will be seen to have four toes in front, and three behind; those in front correspond to the second, third, fourth, and fifth; those behind to the three middle ones. The inner nail on the hind foot is much curved.

In Ungulata there are never more than three full-sized toes on each limb, and they end in hoof-like nails. They are never plantigrade, but unguligrade, or digitigrade.

A very large number of animals, as cats, dogs, tigers, and most carnivora, walk on their toes (digitigrade); but bears may be seen to have five toes of equal length, and to walk on the flat of the foot—that is, they bring the heel to the ground, which makes them bad walkers but good climbers.

Tigers and cats can at will either show or hide their claws. When their claws are hidden, the unguis phalanx with the attached claw is bent backwards and on to the outer side of the second phalanx by a strong elastic ligament.

When these animals wish to scratch or climb they set in action the flexor longus digitorum, which flexes the unguis phalanx and brings down with it the claw. Examine this beautiful arrangement in the digit of a lion, in the comparative anatomy of the soft parts in the College of Surgeons' Museum (No. 287 A).

Bears have not this power; hence their claws are always visible, and rattle on the ground as they walk.

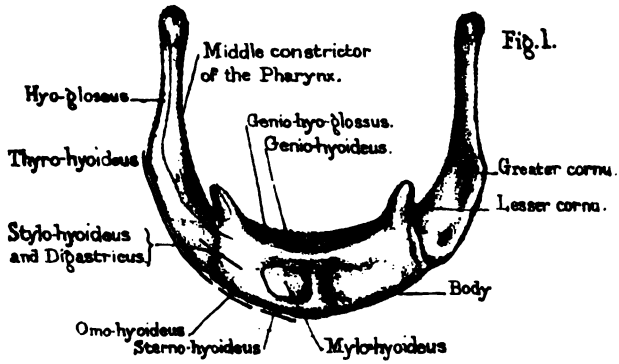
Compare the foot of the tiger with that of the grizzly bear.

INTEROSSEOUS MUSCLES OF THE FOOT.


Plan of Arrangement.—The interosseous muscles in the foot (Plate XXXVII.) are arranged very much like those in the hand. They are seven in number; four on the dorsal surface and three on the plantar. Observe that the *dorsal* arise from the opposite sides of the metatarsal bones, and are inserted into the first phalanges of the second, third, and fourth toes, so that they draw the toes *from* a line corresponding to the axis of the *second* toe. It should be remembered that, in the case of the hand, this line corresponds to the axis of the middle finger.

The *plantar* belong to the three outer toes; each arises from one metatarsal bone, and is inserted into the first phalanx of the same toe on the inner side of its base, so that they draw *towards* the above-mentioned line.

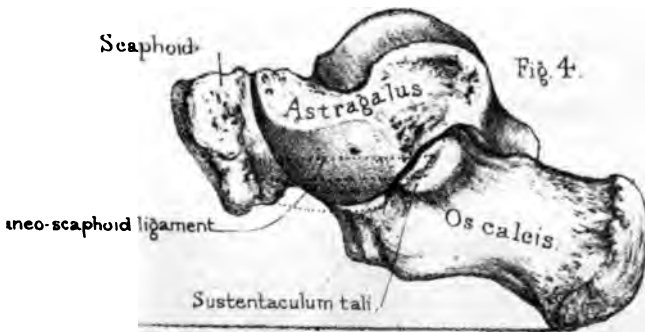
Os-hyoïdes:




Attachment of Thyro-hyoïd lig. Excavation for Thyroid cartilage.
Vertical section of os-hyoïdes.



Arch of the Carpus.





THE THORAX.

(PLATES XXXIX. TO XLII.)

General Description.—The thorax is the framework which contains the heart and lungs. The ribs, with their cartilages, describe a series of arcs, successively increasing in length as far as the seventh, and form, with the spine and sternum, a barrel of a somewhat conical shape, much broader from side to side than from before backwards. The lower aperture or base of the cavity is open in the skeleton, but closed in the recent subject by a thin flat muscle, called the ‘diaphragm,’ which separates the chest from the abdomen, and has openings for the passage of the alimentary canal and the great blood-vessels. This muscular partition is not flat but arched, so that it forms a vaulted floor for the chest. By alternately falling and rising, it increases and diminishes the capacity of the chest. The spaces between the ribs are filled by the intercostal muscles. In each space there are two layers which cross like the letter X: the outer layer runs downwards and forwards: the inner, upwards and forwards.

Such, in outline, is the framework of the chest. Its walls are made up of different structures—bones, cartilages, and muscles, which by their union answer two apparently incompatible purposes. By their solidity and elasticity they protect the important organs contained in the chest; and by alternately dilating and contracting, serve as the mechanical agents of respiration. They enlarge the cavity of the chest in three directions: in *height*, by the descent of the diaphragm; in *width*, by the turning outwards of the ribs; in *depth*, by the raising of the sternum.

THE STERNUM.

(PLATE XXXIX.)

Position.—The sternum (*στέρνον*, the breast) is a long flat bone, situated in front of the chest, and supports the ribs and the clavicles. In the adult male, it is from six to seven inches long: rather less in the female. Observe that its direction is not perpendicular, but that it slants forwards, and thus makes more room for the heart and lungs. It is much broader and thicker at the upper end (manubrium), where it supports the clavicles. The sternum was compared by the ancients to a sword; the broad part was called ‘manubrium,’ the middle part ‘mucro,’ and the cartilage at the end the ‘xiphoid’ or ‘ensiform’ cartilage.

Transverse Lines and Manubrium.—We notice upon the sternum four faintly-marked transverse lines, which are traces of the original division of the bone into five pieces. The most conspicuous of these lines corresponds with the insertion of the second costal cartilage; that is, at the junction of the manubrium with the second piece. This line, easily felt in the living subject, has the second costal cartilage at each end of it. The ‘manubrium’ or ‘presternum’ has a notch on the top (interclavicular notch), on either side of which is an oblong articular surface for the clavicle. In the dry bone, this surface is flat; but in the recent state, the incrusting cartilage makes it somewhat saddle-shaped; that is, concavo-convex. This kind of joint permits the clavicle to rotate nearly as freely as the thumb does on the trapezium. The end of the clavicle is much larger than the surface on which it rotates, yet dislocation of it is exceedingly rare, owing to the great strength of the ligaments. To break the clavicle is much easier than to dislocate it.

Mesosternum and Notches.—Each border of the middle division of the sternum (‘mesosternum’) has six notches in it, which receive the cartilages of six of the true ribs. All the notches, except that for the first rib, are situated where the original pieces of the bone unite. In some instances there is a hole in its lower part.

Ensiform Cartilage.—The ensiform cartilage (or ‘xiphisternum’) at the lower end of the sternum generally remains unossified, even at a great age. Its length and shape vary much in different persons. Sometimes it is bent forwards, or, it may be, backwards, and this especially in workmen who hold tools against the pit of their stomach. Occasionally it is forked at the end. It gives attachment to a narrow aponeurotic band, termed the ‘linea alba,’ which descends along the middle line of the abdomen to the symphysis pubis, and is the fibrous continuation of the sternum.

The anterior surface of the sternum gives origin to the ‘sternomastoid’ and the ‘pectoralis major.’ The posterior surface gives origin to the ‘sterno-hyoid’ and ‘sterno-thyroid’ and to the ‘triangularis sterni.’ The posterior surface of the ensiform cartilage gives origin to the ‘diaphragm.’

Ossification.—Until the middle of foetal life, the sternum is entirely cartilaginous. It is ossified from five centres,⁹¹ not simultaneously, but successively from above downwards, opposite the intercostal spaces. The five bones, thus formed, ultimately coalesce, the lower first, and so on upwards—the reverse of the order in which they were ossified. Thus the fifth unites to the fourth about puberty; the fourth to the third about the age of twenty or twenty-five; the third to the second about thirty-five or forty; the second rarely unites to the first, or, if so, only in advanced age; and even then there is only a thin layer of bone externally; the cartilage in the centre still remains. The first and second bones of the sternum remain ununited on account of a certain amount of motion between them during respiration. In some subjects the line of articulation is very perceptible through the skin, more especially in persons emaciated by disease. It corresponds with the middle of the second costal cartilage.

Comparative Osteology.—Contrast the broad chest of man with that of the ourang outan (No. 5050) and that of the chimpanzee (Nos. 5082–5083 A and B). In the adult gorilla the parts of the sternum, which in us are united, are seen to remain separate.

In the Separate Series, as well as in the two complete skeletons in the Normal Human Osteological Series, examine the sternum of the Bushman and you will see that the manubrium sterni is firmly united to the gladiolus, and there is little or no trace of the original separations between the pieces of which the sternum is composed.

Most flying animals support themselves in the air by the action of their pectoralis major muscle on the upper extremity, and therefore this muscle is large in proportion with the flying capability. The surface of origin in such animals is increased by the development of a great keel down the middle of the sternum, which may be seen in any of the flying birds (*Carinatae*), for instance, in the great bustard (No. 1349), as well as in the extinct flying lizards (*Pterosauria*, No. A 119, Pal. Ser. Mus. Roy. Coll. Surg.). This keel is absent in the non-flying birds, such as the ostrich (No. 1362), the extinct *dinornis* (No. 1588 A, Pal. Ser. Roy. Coll. Mus. Surg.), the *apteryx* (Nos. 1355 and 1355 E), showing that this keel exists for the function of flight and not as a class character of aves.

Among the variations which the sternum undergoes perhaps the most curious is that in the male wild swan and guinea-fowl (see Nos. 1248 B, 1249 A, B, C), where it will be seen to be tunnelled extensively, and to contain a long tortuous trachea as well as the inferior larynx.

The front part of the case of the turtle is formed by the expanded sternum, while the back part is formed by the consolidation of the ribs and expansion of the spines of the dorsal vertebræ (No. 961 A, snapping turtle).

In snakes (*Ophidia*) there is neither a sternum nor a pectoral arch (No. 629), and there is no trace of a fore limb.

There is no sternum either in *ichthyosauria* or *plesiosauria* (Nos. 172 and 222 Palæontological Series, Mus. Roy. Coll. Surg.).

1

2

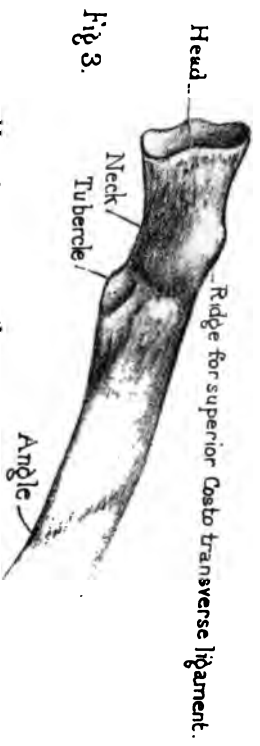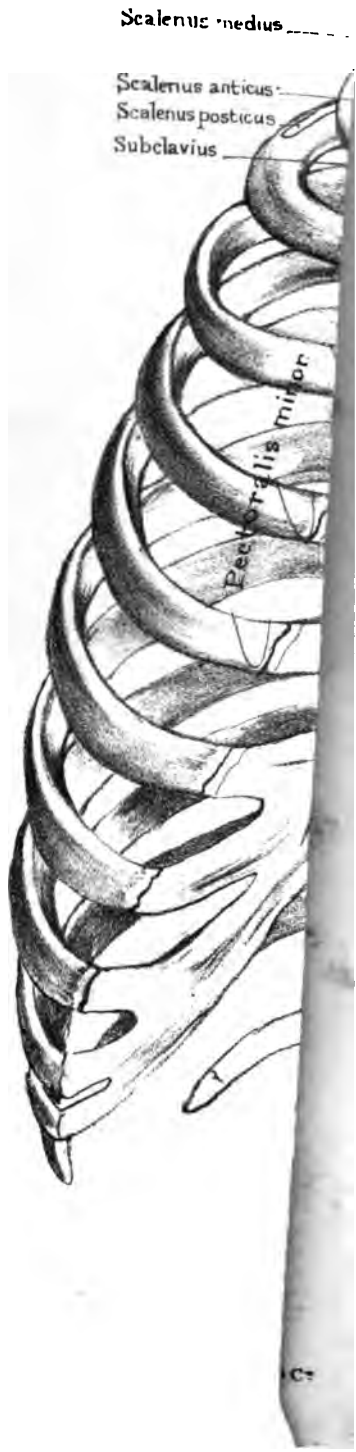3

4

5

6

Sterno-



THE RIBS.

(PLATE XXXIX.)

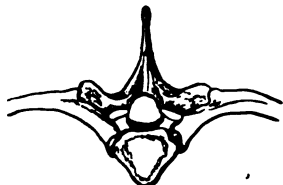Number and Division.—There are twelve ribs on each side; the upper seven, the ‘sternal,’ or ‘true ribs,’ increase in length from the first, and are fixed to the sternum by their cartilages. The lower five, or ‘false ribs,’ decrease in length from above downwards, and their cartilages fall short of the sternum. The cartilages of the eighth, ninth, and tenth ribs are connected to that of the seventh. The eleventh and twelfth are free, and are therefore called ‘floating ribs.’ One sometimes, though rarely, meets with skeletons with thirteen ribs, the thirteenth being a lumbar rib. This is a retrocession. The chimpanzee has thirteen ribs, but the same number of vertebræ as man.

General Characters of a Rib.—As an example of the general characters of a rib, take the fifth or sixth. In the first place, observe that the curve is not uniform. It is more curved towards the vertebral end than elsewhere. Besides which, if laid on a table, the vertebral end will rise. It is plain in the skeleton that the vertebral ends of the ribs are higher than the sternal ends. If both ends had been on the same level, the sternum could not have been raised *forwards* in inspiration.

Vertebral End.—The vertebral end or ‘head’ (Plate XXXIX. fig. 3) has two oblique surfaces (with an intervening ridge, to which the interarticular ligament is attached), which articulate with the sides of the bodies of two contiguous vertebræ. The lower of these two surfaces is always the larger. The head of the rib is the fulcrum upon which the rib moves. It is wedged in between two vertebræ, and is less liable to be dislocated than if supported by one only; and, moreover, it has the benefit of the elasticity of the intervening fibro-cartilage. This, as Paley observes, is ‘the very contrivance employed in the famous iron bridge at Bishop’s Wearmouth.’

Neck.—Next to the head comes the ‘neck’ of the rib. This is smooth in front, where it is covered by pleura, but rough behind,

FIG. 55.



DORSAL VERTEBRA WITH RIBS ATTACHED.

where is attached a ligament (middle costo-transverse) connecting it to the transverse process by which the rib is supported, as seen in the adjoining figure; again, the neck has a ridge along its upper surface to which is attached a second ligament (superior costo-transverse); this connects it to the transverse process *above* it.

Tubercle.—External to the neck is the ‘tubercle.’ It has a little facet which looks *downwards* and articulates with the transverse process supporting the rib; in front and rather above the facet is the rougher part of the tubercle which gives attachment to a third ligament connecting the rib to the transverse process (posterior costo-transverse).

Angle.—External to the tubercle, the rib makes a curve forwards, forming the ‘angle.’ Here there is a prominent line which runs obliquely downwards and forwards, and indicates the attachment of muscles, which form the outer border of the ‘erector spinæ.’ Observe that the distance between the angle and the tubercle increases as we trace the ribs downwards, and makes room for the great muscle of the spine (erector spinæ). It is near the angle that the rib breaks when the chest is compressed, for instance, in a crowd. In this kind of fracture—i.e. by *indirect* violence—the broken ends project outwards, and are therefore less liable to injure the pleura. But in *direct* violence—e.g. a kick by a horse—the rib breaks where it is struck, the broken ends are driven inwards, and consequently are more liable to injure the pleura.

Shaft.—The rest of the rib arching forwards from the angle along the side of the chest is called the ‘shaft.’ It is flattened from above downwards, like a bow. On its inner surface, near the lower border, is a deep groove for the intercostal vessels and nerve. Observe, the groove does not extend the whole length of the rib: it begins about the angle, and is gradually lost before we come to the anterior end. The vessels and nerves are safe

where they lie in the groove; but between the angle of the rib and the spine, and again in front of the chest, they are liable to be injured through the intercostal spaces. In consequence of this groove, the lower edge of the rib is much thinner than the upper, which is thick and rounded. In the groove itself are the orifices of the numerous canals which transmit blood-vessels into the interior of the rib. The ribs are the most vascular bones in the body: hence the rapidity with which they unite after a fracture.

Anterior End.—Respecting the anterior end, remark that it is rough, and a little excavated to receive the costal cartilage.

Right or Left?—A rib will be in the same position as the corresponding one in the student's body if he hold the convex surface outwards, the head backwards, and the groove downwards. In distinguishing right from left ribs it should be borne in mind that the articular facet for the transverse process looks downwards in every case.

Peculiarities of certain Ribs.—The first, second, tenth, eleventh, and twelfth ribs have peculiarities requiring separate notice.

First Rib.—The plane of the first rib is nearly horizontal. It is the shortest, the most curved, the flattest and broadest of all. Its head has a single articular surface which rests on the first dorsal vertebra. It has the largest tubercle, and this is well supported by the strong transverse process of the first dorsal vertebra. There is scarcely a trace of angle. On its upper surface we may see in a well-marked bone two slight transverse grooves about the breadth of a finger; the subclavian artery lies in the posterior groove as it crosses the rib, the vein passes along the anterior. Against this surface the subclavian artery may be effectually compressed. The grooves are separated on the inner border of the rib by a 'tubercle' denoting the insertion of the 'scalenus anticus.' Behind this is the rough surface for the insertion of the 'scalenus medius.' Lastly, there is no groove for the intercostal artery.

It is an interesting fact, that the compact tissue forming the *concave* margin of the first rib is very much thicker than that on the convex side. The first rib is the strongest of all: it has to support the manubrium sterni and the clavicles, and to protect all

the important parts at the base of the neck. The first rib is very rarely fractured, being so well protected by the clavicle; but when it does happen it is a most serious accident, because it is the starting point of all the other ribs in respiration, and because there are so many important vessels and nerves in relation with it.

Second Rib.—The second rib has little or no angle, no twist on its axis, and has, near the middle of its outer surface, a rough eminence for the origin of the second and third digitations of the serratus magnus. It has a short groove for the intercostal artery.

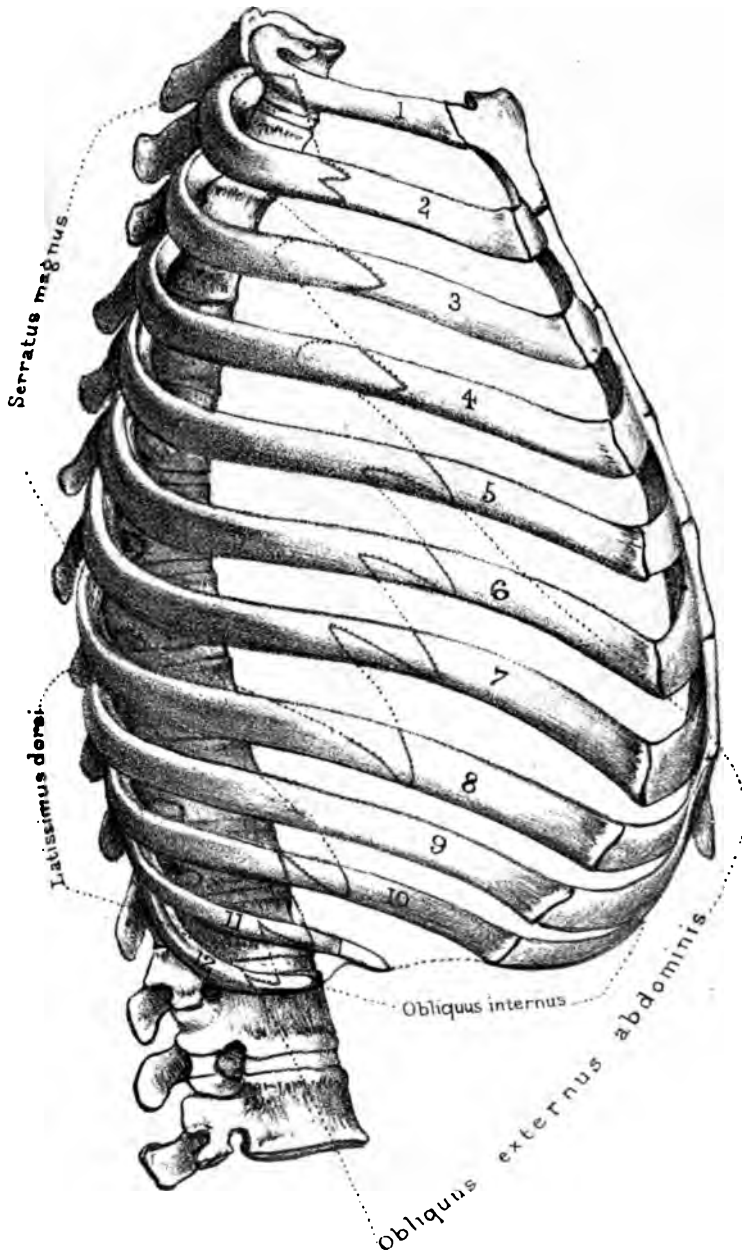
Tenth Rib.—The tenth rib has a single 'facet' on the head, for the tenth dorsal vertebra.

Eleventh and Twelfth Ribs.—The *eleventh* and *twelfth* ribs being shorter and less perfectly developed, are chiefly distinguished by their negative characters. Each articulates with only one vertebra, so that the head has only one facet, does not touch the transverse process, and has no tubercle. Each is tipped with cartilage. The eleventh has a trace of an angle and a groove. In the twelfth, angle and groove are imperceptible.

Ossification.—Ossification in the ribs begins about the seventh week of foetal life. There is one 'primary' centre for the body, an epiphysis for the head, and another for the tubercle. The epiphyses appear from the fifteenth to the eighteenth year, and unite with the rest of the bone about the age of maturity.

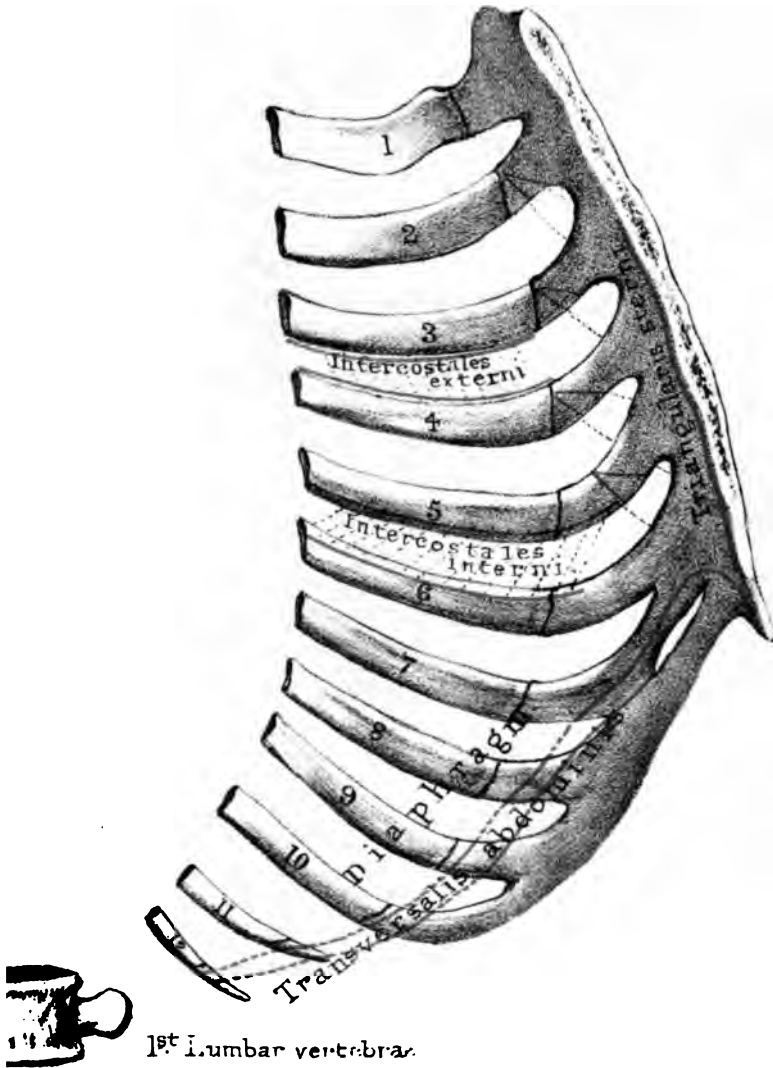
Costal Cartilages.—Respecting the costal cartilages, remember that the first seven are connected with the sternum. The first cartilage is united directly with the manubrium. The others, from the second to the seventh inclusive, are articulated to the sternum with the intervention of synovial membranes which disappear in old age. The cartilages of the eighth, ninth, and tenth ribs are gradually bevelled off, and each joins the costal cartilage immediately above it. Moreover, synovial membranes exist between these last-mentioned ribs. The last two costal cartilages do not join those above, but merely cap the eleventh and twelfth ribs. These numerous little articulations, connected with the cartilages, much facilitate the respiratory movements of the thorax.

The costal cartilages increase in length from above, and allow the requisite play of the ribs in respiration. Their great elasticity



Drawn on stone by E. Godart
From nature by L. Holden
Printed by West, Newman & Co.







answers two purposes. 1. They act as mechanical agents of expiration by depressing the ribs after they have been raised by muscular action. 2. A blow on the sternum is distributed over fourteen elastic arches! One can understand, then, why the chest is able to bear such tremendous blows with impunity; more especially during a full inspiration. During expiration the bones are less able to resist injury, because the muscles are not acting. Notwithstanding these beautiful provisions, the sternum is sometimes broken, especially when the cartilages of the ribs are ossified. Dupuytren mentions the case of a fireman whose sternum was broken by the fall of a piece of timber. The man was carried away, supposed to be dead. Coming up accidentally, Dupuytren replaced the sternum, and the man recovered.

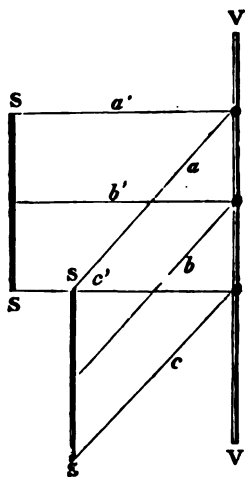
Thorax as a whole.—In addition to what has been said of the thorax at p. 205, attention should be directed to one or two points which might otherwise be overlooked. 1. The great narrowness of the upper opening of the chest. In an adult of average size, it measures about 2 inches from before backwards, and $3\frac{1}{2}$ inches transversely. Yet in this seemingly narrow space there is room for the trachea, the œsophagus, the great blood-vessels and nerves at the root of the neck, besides the apex of each lung, and three muscles on each side. 2. Notice how much the ribs slope in subserviency to the mechanism of respiration. Their sternal and vertebral ends are not in the same horizontal plane; for instance, the sternal end of the third rib is not on a level with the third dorsal vertebra, but, roughly speaking, with the sixth. 3. Notice how much additional space is gained posteriorly (for the lungs) by the backward projection of the ribs. 4. Notice that the lower margin of the thorax is represented by a line sloping from the end of the sternum downwards and backwards to the last rib. 5. Notice that the intercostal spaces are widest where the ribs unite to their cartilages; and narrowest where the ribs join the spine.

Mechanism of Inspiration.—It is proposed to explain now how the chest is enlarged in the transverse and in the antero-posterior direction by the elevation of the ribs.

The spine is fixed, and serves as a fulcrum for the ribs, which are the levers.

At the moment of inspiration, the ribs, which you must remember are oblique, are raised by the intercostal muscles. The centre of motion being at the spine, it is plain that the more nearly the ribs become horizontal, the greater will be the distance between the spine and the sternum.

FIG. 56.

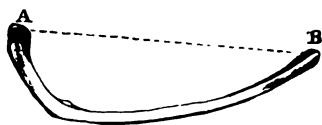


Thus, let the line V V, in fig. 56, represent the spine; the line S S the sternum; a, b, c , three ribs in their oblique position; and a', b', c' , the same ribs elevated. It is obvious that by raising the ribs we increase at the same time the antero-posterior diameter of the chest; or, in other words, we increase the distance between the spine V V and the sternum S S.

The same diagram proves that, when the ribs are raised, the intercostal spaces are widened; that is, a perpendicular let fall between two ribs is longer when the ribs are raised than when they are depressed.

Now, when the ribs rise, they describe a rotatory movement around an imaginary axis, as shown at A B, fig. 57, which unites their vertebral and sternal ends.

FIG. 57.



In consequence of this rotation on its ends, the external surface of the rib, which looks downwards and outwards when at rest, looks directly outwards when raised. Thus the *transverse* diameter of the chest is increased.

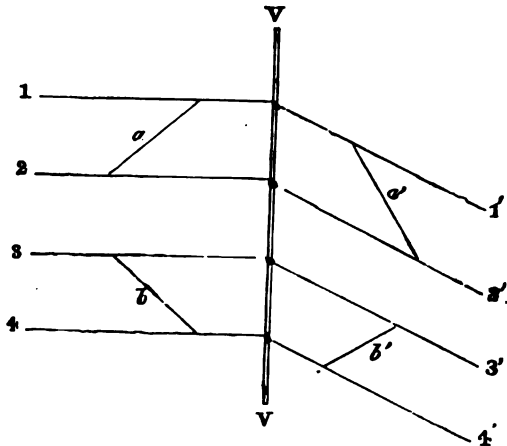
If the ribs were all of the same length, as in fig. 56, the projection of the sternum, caused by their elevation, would be equal all the way down. But since the lower sternal ribs are longer than the upper, it follows that the sternum is projected in inspiration more and more towards its lower end.

The ribs are raised by the external intercostal muscles (which run obliquely downwards and forwards); they are *depressed* by the internal intercostal muscles (which run obliquely upwards and

forwards). These facts are rendered probable (if not absolutely proved) by the following diagram:—

Let V V represent the spine, 1' 2' two ribs in a state of obliquity or rest, and *a'* a fibre of an external intercostal muscle. Now, when the fibre *a'* contracts, it shortens itself: but this shortening cannot take place unless the ribs are at the same time brought more into the horizontal line, as shown at 1, 2;

FIG. 58.



in other words, unless they are raised; therefore the external intercostal muscles are *inspiratory* muscles.

The same kind of demonstration proves that the internal intercostal muscles depress the ribs, and are therefore *expiratory* muscles. For let *b* be a fibre of an internal intercostal muscle extended between the ribs 3 and 4 in a state of elevation, it is easy to see that, when the fibre *b* contracts or shortens itself, it cannot do so without bringing the ribs into a more oblique position, as shown at 3' and 4'. That the fibre *b'* must be shorter than the fibre *b* may be proved by a pair of compasses.

Comparative Osteology.—It is curious that the gorilla and chimpanzee have each 13 pairs of ribs. So that man in his descent from his pretended ancestors must have lost a rib, for he (like the man of the woods, orang utan) has only 12.

In mammalia the number of ribs on each side ranges from 9 in the bottle-nosed whale (*Hyperoodon*, No. 2479), to 24 in the two-toed sloth (No. 2387 A). The horse and tapir have 18 pairs each, and the elephant 19.

The ribs of the manatee (No. 2647 A) are extraordinarily thick, broad, and massive.

In whales some of the posterior ribs are attached only to the transverse processes of the vertebræ. Commonly in mammalia about 6 ribs articulate with the sternum by cartilage or bone, but in whales the number so attached is much smaller, in the whale-bone whale there being only one pair of true ribs.

This freedom of action allows the great play of the respiratory apparatus in cetacea.

Some animals have the costal cartilages ossified, forming sternal ribs, as in the giraffe, crocodile, ox, porpoise, and dolphin; in many there is an intermediate rib, or shaft of bone, set in between the sternal and vertebral ribs (see Nilotic crocodile, No. 717 D, and monotremata, No. 1698).

The ribs are mostly used solely for respiration throughout the animal kingdom. In addition to this the snakes use the tips of them to walk upon, and the flying lizard (*Draco volans*, No. 673) has the 5 posterior ribs so recurvated and elongated as to form the bony skeleton of the membranous sail by which he supports himself in his flight from tree to tree.

The middle part of the ribs in birds (see griffin vulture, No. 1674) presents a long flat process which projects backwards and rests on the rib below. These are called uncinæ processes.

There are no processes in mammalia corresponding to the uncinæ processes in birds. They are, however, seen in alligators (No. 760 A).

Sharks and rays have no ribs. What appear to be ribs in the Porbeagle shark (No. 419 A) are simply the supports of the gills, as may be understood by a reference to the skeleton of the cod-fish (No. 147 A), which has 17 pairs of ribs. The *Alausa tyrannus* (No. 39 A) has not only many ribs, but a good sternum.

Examine the great Nilotic crocodile (No. 717 D), and you will see that an anterior and a posterior bar forming the transverse processes of the cervical vertebræ correspond to the two processes which in the dorsal vertebræ support respectively the head and the tubercle of the rib. In its middle and posterior dorsal regions the end of a transverse process supports both the head and the tubercle of the rib. There will be seen also what are called intermediate ribs, i.e. a piece of bone between the end of the rib and

the costal cartilage or sternal rib. Some of the ribs are furnished with uncinatè processes as in birds; but this is better seen in the alligator (No. 760 A). Seven pairs of false ribs are developed as superficial ossifications of the lineæ transversæ in the abdominal wall (see also No. 711 A).

The extinct flying lizards, Pterosauria (No. 119 A), had splint-like sternal, as well as abdominal, ribs.

In Ophidia (No. 630) the ribs articulate only with the ends of transverse processes.

MUSCLES OF THE BACK.

(PLATES XLII. TO XLVII.)

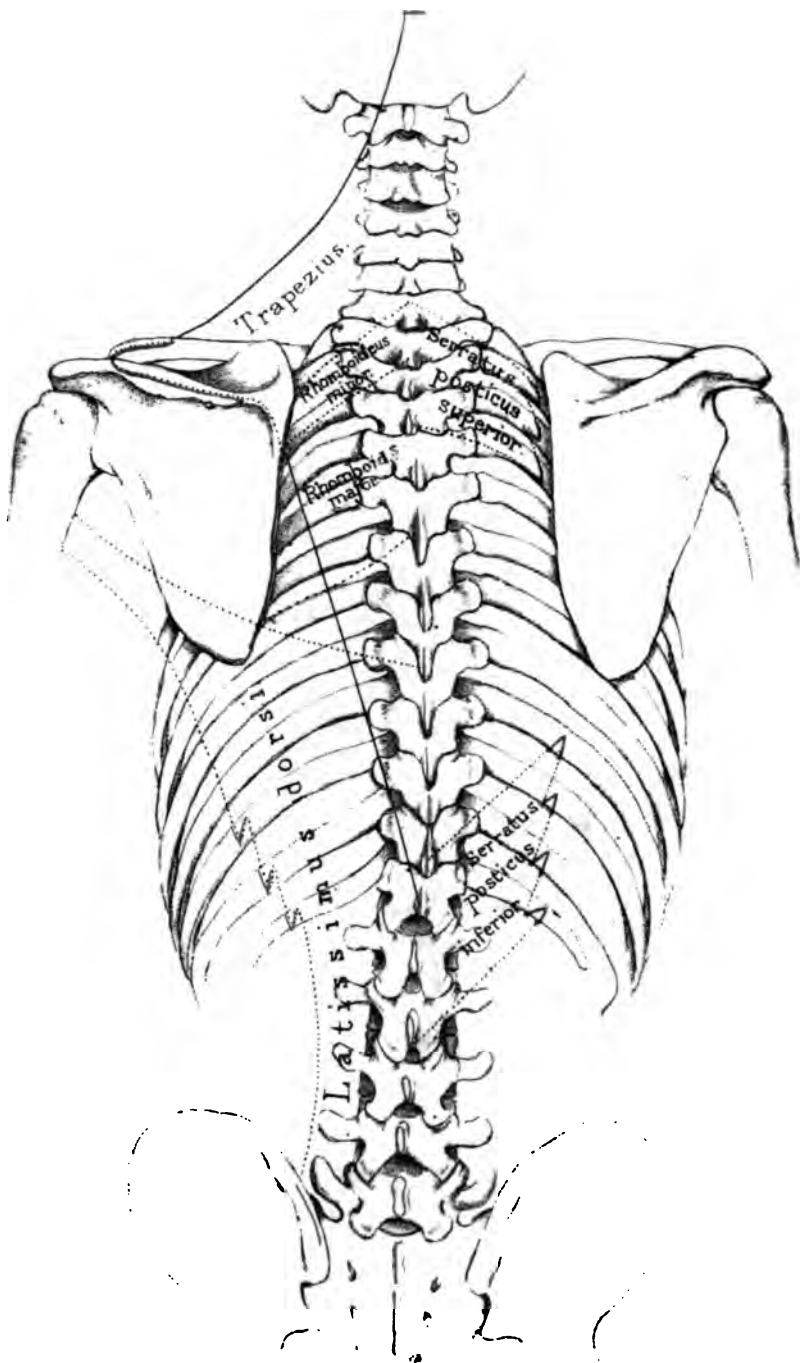
IN the description of the muscles of the back the more superficial muscles, connected with the arm, will be first considered. These removed, the great muscles of the spine, which fill up the vertebral grooves, and keep the body erect, are exposed. Lastly, there is the mass of muscles at the back of the neck attached to the occipital bone.

THE SUPERFICIAL MUSCLES OF THE BACK.

These are shown in Plate XLII. The most superficial is the 'trapezius,' a triangular muscle of which the limits are defined by the continuous dark line. The other wide-spreading superficial muscle is the 'latissimus dorsi.' Under the trapezius we have the 'rhomboidei' and the 'levator anguli scapulæ' shown in Plate XLIV.

Trapezius	{	O. Occiput; ligamentum nuchæ: spines of all the dorsal vertebræ. I. Spine of scapula; acromion, acromial third of clavicle.
Latissimus dorsi	{	O. Crest of the ilium. Spines of all the lumbar, and six lower dorsal vertebræ, and by digitations from the three lower ribs. I. Bottom of bicipital groove of humerus.
Rhomboides (major and minor)	{	O. Spines of last cervical and five upper dorsal vertebræ. I. Posterior border of scapula.
Levator anguli scapulæ	{	O. Transverse processes (posterior tubercles) of four upper cervical vertebræ. I. Upper angle of scapula.

When the preceding muscles are removed, there still remain the 'serratus posticus superior' and 'inferior.' These belong not to the arm, but to the ribs.



Drawn on Stone by T. Godart

an nature by J. Holden.

Printed by West Newman & C





1

2

3

4

5



- Serratus posticus superior . . . { O. Spines of last cervical and three upper dorsal vertebræ.
 { I. Second, third, and fourth ribs.
- Serratus posticus inferior . . . { O. Spines of two last dorsal and two upper lumbar vertebræ.
 { I. Four lower ribs.

Next come the great muscles of the spine concerned in keeping the body erect. These are considered to be complicated; the truth is, they are very simple, provided the plan of their arrangement be borne in mind. An attempt has been made to bring out the plan in Plate XLIII.

The vertebral groove on each side of the spine is occupied by the 'erector-spinae' and its prolongations, and by the 'transverso-spinalis.'

The 'erector-spinae' arises by strong tendons from the crest of the ilium, the back of the sacrum, and the spines of the lumbar vertebræ; and subdivides into two masses of muscle. The outer, termed the 'sacro-lumbalis,' with its prolongations (musculus accessorius and cervicalis ascendens), is attached to the *angles* of the ribs. The inner, termed the longissimus dorsi, with its prolongations (transversalis colli and trachelo-mastoid), is attached to the *transverse processes* of the vertebræ. Subjoined, these muscles are arranged in a natural tabular form. They all run longitudinally.

PLAN OF THE LEFT ERECTOR SPINÆ.

Angles of ribs.	Sacro-lumbalis.	Musculus accessorius.	Cervicalis ascendens.
	I. 6 lower ribs.	O. 6 lower ribs.	O. 6 upper ribs.
		I. 6 upper ribs.	I. 4 lower cervical vertebræ.
Crest of ilium.			
Back of sacrum.			
Spines of lumbar vertebræ.			
	outer mass . . .		
	inner mass . . .		
Transverse processes of vertebræ.	Longissimus dorsi . . .	Transversalis colli . . .	Trachelo-mastoid.
	I. all the lumbar and dorsal vertebræ.	O. 6 or 6 upper dorsal vertebræ.	O. 4 or 5 cervical vertebræ.
		I. 4 or 5 cervical vertebræ.	I. Mastoid process.

The 'intertransversales' pass between the transverse processes of contiguous vertebræ, the 'interspinales' between the spinous processes beginning at the axis. Both these sets are ill developed and mostly tendinous in the dorsal region.

The 'transverso-spinalis' is the mass which fills up the space between the transverse and spinous processes of the vertebræ. It *arises* from transverse, and is *inserted* into spinous processes. Therefore its direction is oblique. It is composed of several bundles. The more superficial pass over many vertebræ; the deeper over one or two; the deepest run from vertebra to vertebra. The 'transverso-spinalis' comprises the 'semi-spinalis-dorsi,' 'semi-spinalis colli,' 'multifidus spinæ,' and 'rotatores spinæ' of systematic authors.

The 'levatoros costarum' arise from the transverse processes, and are inserted into the ribs below them.

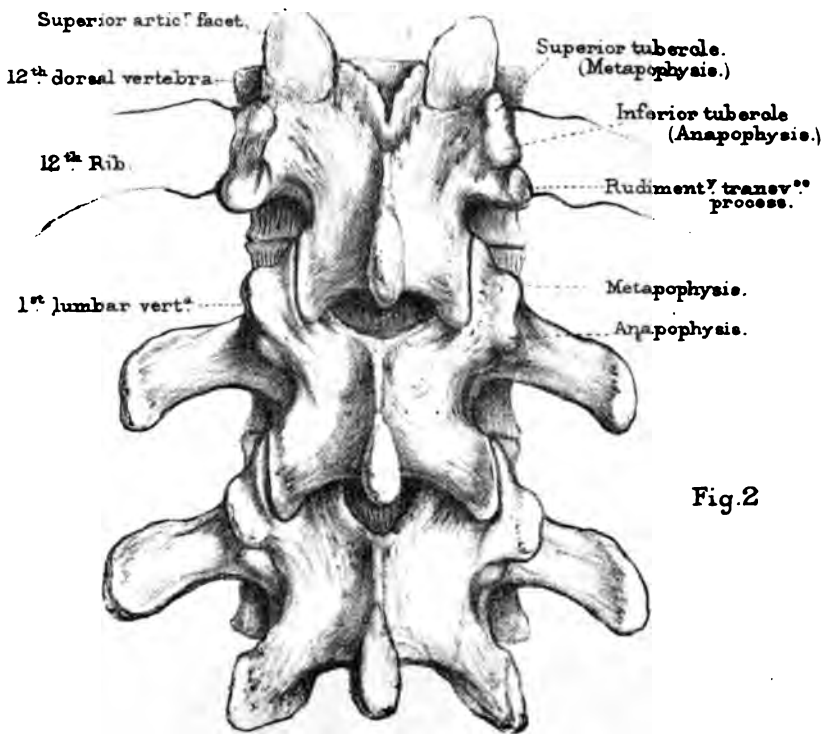
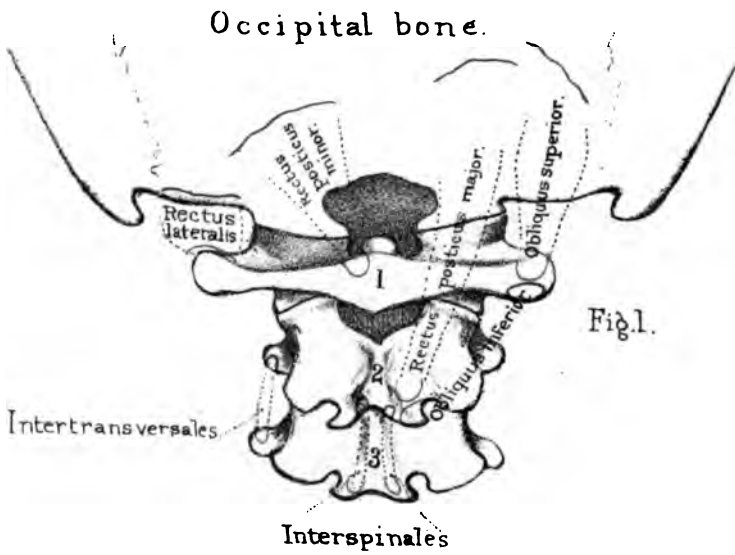
MUSCLES OF THE BACK OF THE NECK.

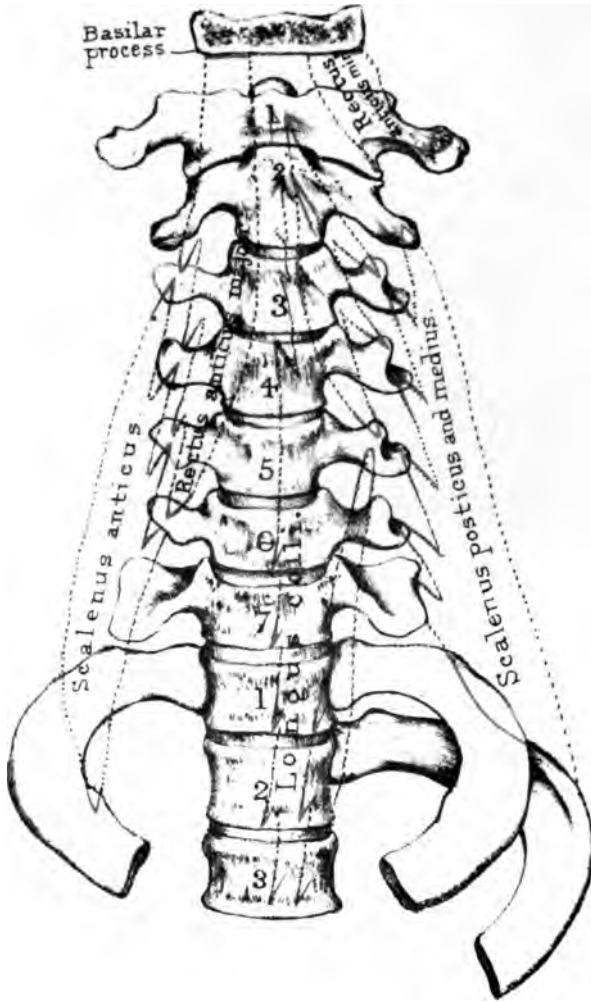
(PLATE XLV.)

A separate group is made of these, because they specially maintain the head erect, and move the first upon the second vertebra. The 'trapezius' being reflected, the 'splenius' is exposed, and beneath that the 'complexus.'


Splenius capitis et colli	{	O. Spines of four cervical and six dorsal vertebræ.
	{	I. Mastoid process and occipital bone; transverse processes of four upper cervical vertebræ.
Complexus	{	O. Transverse processes of six dorsal and articular processes of four cervical vertebræ.
	{	I. Occipital bone.

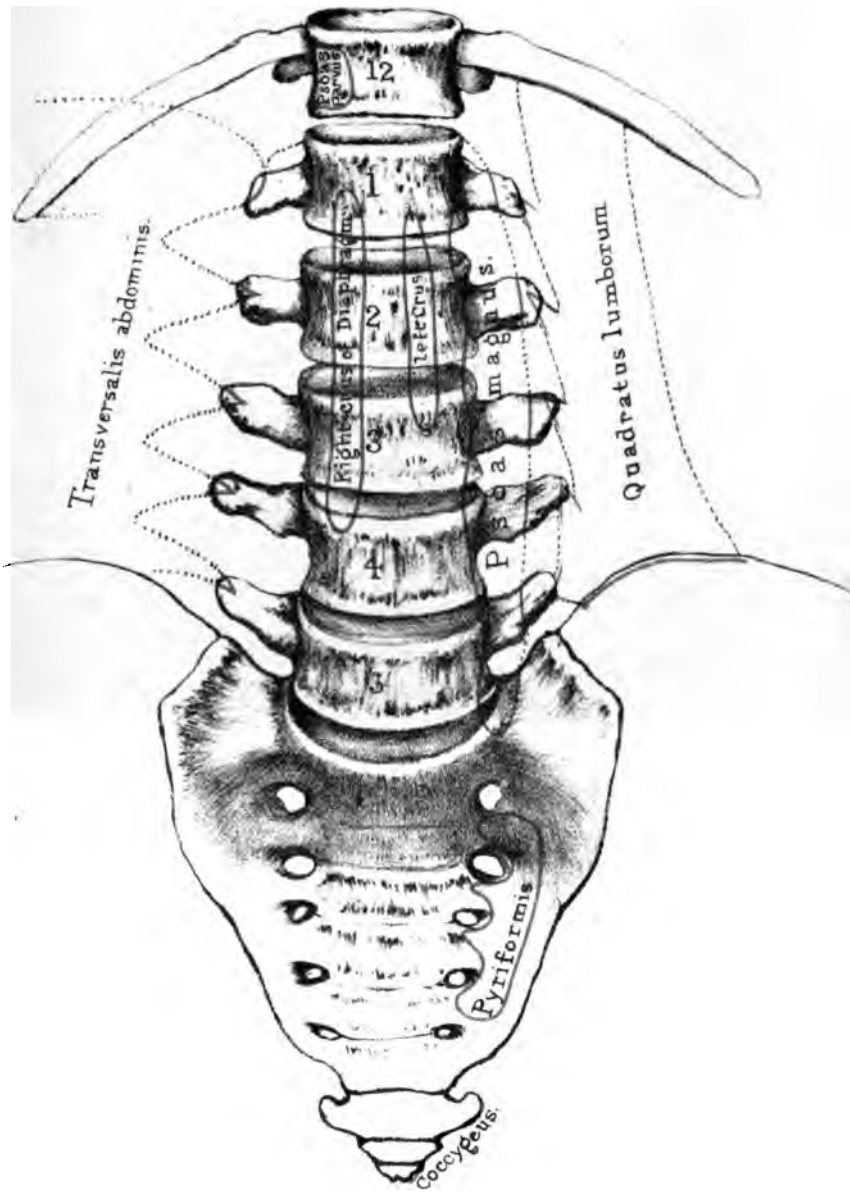
The above muscles being reflected, we expose the muscles of the atlas and axis; namely, the 'rectus capitis posticus major' and 'minor,' 'the obliquus superior' and 'inferior,' and the 'rectus capitis lateralis.'





Drawn and Stenciled by T. Goddard.
From the collection of H. Allen. Printed by West Newman & Co.





Drawn on Stone by T. Godart
Engraving by L. Holden
Printed by West, Newman & Co.

Rectus capitis posticus major .	{	O. Spine of the axis.
	{	I. Occipital bone.
Rectus capitis posticus minor .	{	O. Spine of the atlas.
	{	I. Occipital bone.
Rectus capitis lateralis .	{	O. Transverse process of atlas.
	{	I. Jugular eminence of occipital bone.
Obliquus superior	{	O. Transverse process of atlas.
	{	I. Occipital bone.
Obliquus inferior	{	O. Spine of the axis.
	{	I. Transverse process of atlas.

MUSCLES IN FRONT OF THE SPINE.

(PLATES XLVI. and XLVII.)

There are three pre-vertebral muscles in the cervical region ; namely, the 'rectus capitis anticus major' and 'minor,' and the 'longus colli.' In the lumbar region are the right and left crura of the 'diaphragm,' the 'psoas magnus,' and occasionally a 'psoas parvus.'

Rectus capitis anticus major .	{	O. Transverse processes of third, fourth, fifth, and sixth cervical vertebræ.
	{	I. Basilar process.
Rectus capitis anticus minor .	{	O. Transverse process of atlas.
	{	I. Basilar process.

The 'longus colli' consists of a longitudinal and an oblique portion. The *longitudinal* part *arises* from the bodies of the three upper dorsal and two lower cervical vertebræ, and is inserted into the bodies of the second, third, and fourth cervical vertebræ. The *oblique* part *arises* from the transverse processes of the third, fourth, and fifth cervical vertebræ, and is *inserted* into the tubercle of the atlas. Other oblique fibres arise from the bodies of the three upper dorsal vertebræ, and are inserted into the transverse process of the fifth cervical vertebra.

Diaphragm	{	O. Right crus from four lumbar vertebræ, left from three.
	{	I. Central tendon.
Psoas magnus	{	O. Bodies and transverse processes of all the lumbar vertebræ.
	{	I. Trochanter minor.
Psoas parvus	{	O. Body of last dorsal vertebra.
	{	I. Brim of pelvis.

BONES OF THE UPPER EXTREMITY.

Component Bones.—The bones of the upper extremity consist of the ‘clavicle,’ the ‘scapula,’ the ‘humerus,’ the two bones of the fore-arm, namely, the ‘radius’ and the ‘ulna,’ the bones of the carpus, the metacarpus, and the phalanges of the fingers. The clavicles and scapulæ form the ‘shoulder girdle’ or ‘pectoral arch.’ The length of the arm should be in exact proportion to the height of the individual. If the arms are fully stretched in the same horizontal line, the space from the end of the middle finger of one hand to that of the other is about equal to the length of the body.

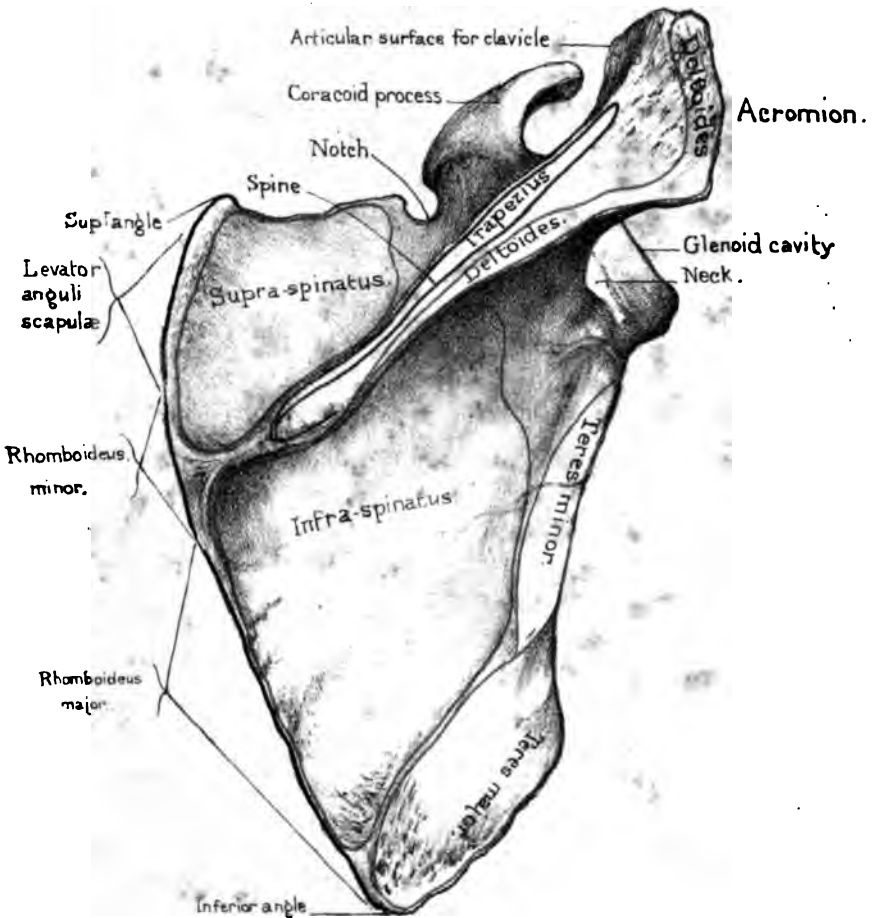
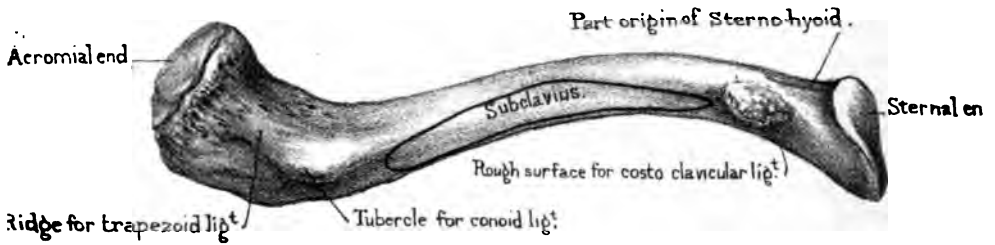
THE CLAVICLE.

(PLATES XLVIII., XLIX.)


Position and Use.—The clavicle, or collar bone, so named from its resemblance to an ancient key, extends nearly horizontally from the upper part of the sternum to the scapula. It keeps the shoulders wide apart, giving the arm a freer range of motion; affords attachment to powerful muscles; and protects the axillary vessels and nerves. By moving the shoulder, you find that the clavicle acts as a prop, the fixed end of the prop being at the sternal joint. Hence, in fractures of the clavicle, the shoulder generally falls a little *forwards*. The patient leans his head towards the injured arm so as to relax the muscles, and supports the elbow in his hand.

Advantage of its Curves.—The shape of the clavicle is like an italic S. It has two curves, arranged so that, viewed from the front, the sternal or inner half is convex, and the acromial or outer half concave. The sternal curve is the larger of the

Under surface of clavicle



Outer surface of Scapula.



two. The great vessels and nerves of the arm pass under it. About the junction of the two curves the bone is most frequently broken. These curves not only make the bone stronger than if it were straight, but better able to resist shocks; since, by virtue of its elasticity, the force is partially broken at each of the curves (p. 6). The strength and degree of curvature vary considerably in different bones. They are usually greater in men than in women, and most marked in those persons who do much manual labour.

Shaft.—The shaft of the clavicle bears the impressions of the muscles attached to it. On its upper surface, at the sternal curve, are the origins of the ‘pectoralis major’ and ‘sterno-cleido-mastoid,’ and on the acromial curve, the origin of the ‘deltoid’ and the insertion of the ‘trapezius.’ On its under surface are—1, a longitudinal groove for the insertion of the ‘subclavius;’ 2, a rough surface near the sternal end for the attachment of the ‘costo-clavicular’ (or rhomboid) ligament; 3, near the acromial end, a tubercle and a ridge for the attachment of the ‘conoid’ and ‘trapezoid’ ligaments (coraco-clavicular): the ridge is about one inch from the scapular end—here fractures of the bone are likely to escape notice, in consequence of the ligaments preventing the separation of the fractured ends; 4, near the middle is a foramen for the nutrient artery of the interior.

Sternal End.—The sternal end of the clavicle is thick, strong, and expanded. It is oblong from before backwards, and articulates, through the medium of an interarticular fibro-cartilage, with the sternum. In the recent state, when crusted with cartilage, the articular surface is slightly convex from above downwards, and concave from before backwards; and, moreover, its circumference projects on all sides considerably beyond the articular surface of the sternum, to which it is so firmly attached by its ligaments that dislocation is very rare, notwithstanding the small size of the articular surface of the sternum. A fracture of the clavicle is ten times more common than a dislocation of its sternal end. Part of the ‘sterno-hyoid’ muscle arises from this extremity of the clavicle a little internal and posterior to the rough surface for the rhomboid ligament. At the point where the clavicle

comes into friction with the cartilage of the first rib, there is often a distinct impression, a sort of improvised articulation blending with the articular surface for the sternum.

Acromial End.—The acromial end is broad and flattened, and presents an oblong surface, which looks forwards and slants a little inwards, to articulate with the inner border of the acromion. The plane of this articulation is such that it is very difficult to keep the clavicle in its proper place after a dislocation.

Like all the long bones, its structure is spongy at the extremities, but very compact in the middle of the shaft, where there is a small medullary cavity. The compact wall is much thicker on the concave side of each of its curves than elsewhere.

Connections.—The clavicle articulates with the acromion process of the scapula, and with the top of the sternum.

Ossification.—The clavicle begins to ossify about the sixth week of fetal life, that is, sooner than any other bone in the body. It has only one centre of ossification for the shaft. The sternal end has an epiphysis which makes its appearance from the eighteenth to the twentieth year, and subsequently coalesces with the shaft.

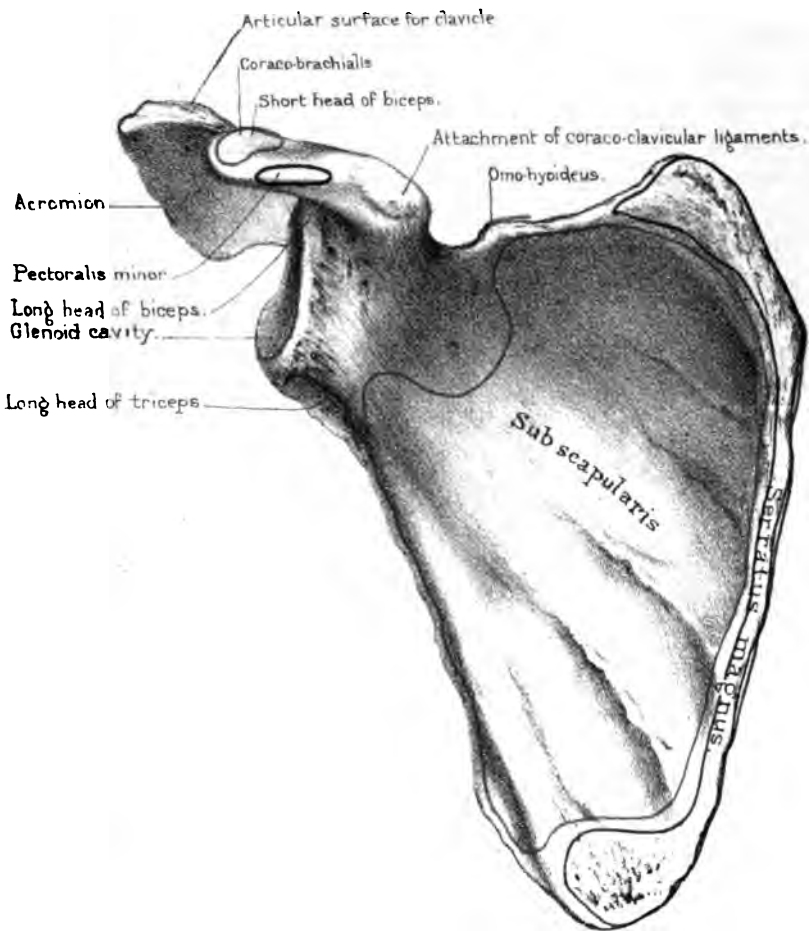

Right or Left?—The bone will be in the same position as the corresponding one in the student's body if he hold the smooth surface upwards; the flat acromial end outwards; and the convex side of the sternal end forwards.

Comparative Osteology.—All Primates have clavicles to which they owe the breadth of their shoulders. In the Carnivora the clavicles do not articulate with any bone, but are simply suspended in the muscles, and are always more or less rudimentary (see *Felis leo*, No. 4475). Bears seldom have clavicles.

There is no clavicle in the elephant (No. 2654), or *Hyrax capensis* (No. 3115 C). The three sub-orders of Ungulata have no clavicles, i.e. Pachydermata, Ruminantia, Solidungula, as the horse and ox. The same is true of all Cetacea, Sirenia and Crocodilia.

The majority of birds have clavicles the strength of which bears a direct relation to the powers of flight. They are early ankylosed together in the middle line, and form a single bone called the furculum or merrythought. The chief action of this

Upper surface of clavicle.



Inner surface of Scapula.

elastic arch of bone would appear to be to counteract the great pectoral muscles which tend to press the humeri inwards during the downward stroke of the wing. The apteryx and some parrots have no clavicles.

THE SCAPULA.

(PLATES XLVIII., XLIX.)

Position and Use.—The scapula, or shoulder-blade, is placed at the back of the chest. When the arm hangs loosely by the side, the scapula ought to extend from the first rib to about the lower edge of the seventh, and the lower angle should be a little further from the spine than the upper. The inferior angle of the scapula is a good guide to the seventh rib. During life this angle is held down by the upper border of the ‘latissimus dorsi,’ and sometimes gives origin to some of its fibres. In emaciated persons the yielding of this muscle allows the lower end of the scapula to project very perceptibly.

The scapula acts as a movable fulcrum in the motions of the arm, and gives extensive attachment to the muscles which effect the movement. It is a flat triangular bone, and so thin in places as to be translucent. We have to examine its two surfaces, its three borders and angles, and its outstanding processes.

Outer Surface.—The ‘outersurface’ of the scapula (‘*dorsum scapulæ*’) is slightly convex, and divided into two unequal parts by a very prominent ridge of bone, termed the ‘spine.’ The part above the spine is called the supra-spinous fossa, and gives origin to the ‘supra-spinatus’ muscle; that below the spine is called the infra-spinous fossa, and gives origin to the ‘infra-spinatus.’ Near the axillary border are distinct impressions, indicating the origins of the ‘teres major’ and ‘minor’ muscles. It is generally marked by the impressions of the ‘*arteria dorsalis scapulæ*.’

Spine and Acromion.—The ‘spine’ of the scapula commences at the posterior border of the bone by a smooth triangular surface over which the tendon of the trapezius plays. From this the spine

can be plainly felt in the living subject as it rises into a high crest, which runs towards the neck of the scapula, where it stands out from the rest of the bone, and suddenly altering its direction at a right angle, projects forwards so as to form a lofty arch overhanging the 'glenoid cavity.' This arch is termed the 'acromion' (*ἄκρον ὀμῶς*). It protects the shoulder joint and gives great leverage to the powerful 'deltoid' which raises the arm. It is not only a defence, but prevents luxation upwards: without this the head of the humerus would not remain a moment in its socket. It is this process which gives breadth to the shoulder. On the inner border of the acromion is the surface which articulates with the clavicle; this surface slants from above inwards, so that the clavicle, once dislocated, is with difficulty kept in its place. The end of the acromion gives attachment to the coraco-acromial ligament, which bridges over the gap left in the bone between it and the coracoid process, and thus completes the arch for the shoulder. Through this coraco-acromial ligament we pass the point of the knife, in excising the head of the humerus, and thus reach the shoulder-joint in a moment. Reverting to the spine, we observe that it has thick rough borders; above, for the insertion of the 'trapezius,' and below, for the origin of the 'deltoid.'

Inner Surface.—The 'inner surface' of the scapula is concave, and called the 'subscapular fossa.' It gives origin to the 'subscapularis,' and presents three or four slanting ridges for the attachment of the tendinous septa by which this muscle is intersected. The hollows between these ridges were mistaken, even by the great anatomist Vesalius, for the impressions of the ribs. On this surface also observe the insertion of the 'serratus magnus,' chiefly into the rough surfaces on the superior and inferior angles, but also into a very narrow tract along the posterior border.

Glenoid Cavity.—The 'anterior angle' of the scapula is the strongest part of the bone, and here is the 'glenoid cavity' for the articulation of the head of the humerus. This cavity is very shallow, of an oval form, with the larger end downwards, and the long diameter vertical; it looks directly outwards and a trifle forwards, giving the arm an extensive range of motion. Its margins are rather prominent and rough, for the attachment of a

collar of fibro-cartilage, which slightly deepens the socket. From the upper part of the margin arises the 'long head of the biceps.' Just below the cavity is the origin of the 'long head of the triceps.' Immediately behind the cavity is a slight constriction termed the 'neck' of the scapula. The neck is most plainly seen behind, where it forms with the spine a deep groove (great scapular groove), leading from the supra-spinous to the infra-spinous fossa.

When we speak of fracture of the neck of the scapula, we mean fracture behind the coracoid process. This kind of fracture is very rare. It happens to old persons from falling on the shoulder. The shock is received by the head of the humerus, and is thence transmitted to the glenoid cavity. The chief symptom of such an accident is slight lengthening of the arm and dropping of the shoulder. Whoever sees for the first time a fracture of the neck of the scapula will probably mistake it for a dislocation of the head of the humerus into the axilla. There is in each case the same lengthening of the arm, prominence of the acromion, and flatness of the deltoid; in each case the head of the humerus can be felt in the axilla: but there is *this* important distinction, that in the case of fracture, the normal appearance of the joint can be restored by simply pushing upwards the arm at the elbow, by which means the head of the humerus, with the glenoid cavity, is at once raised to its proper position.

Coracoid Process.—From the upper part of the neck of the scapula, just behind the upper margin of the glenoid cavity, stands off a projection termed the 'coracoid process,' from its fancied resemblance to the beak of a raven (*κόραξ*). Arising from a very broad base, it takes first a direction inwards, but soon curves forwards towards the acromion, like a half-bent finger, and overhangs the glenoid cavity on the inner side. Its apex is about one inch and a half from the point of the acromion, and on a lower plane. It is necessary to be familiar with the direction of these points of bone, and their accurate bearing to the glenoid cavity and to each other, since they serve as landmarks in determining the nature of obscure injuries about the shoulder. Into the front part of the coracoid process is inserted the tendon of

the 'pectoralis minor,' and from the 'apex' arises the common tendon of the 'caraco-brachialis,' and the 'short head of the biceps.' At the upper part of its root is a rough surface for the attachment of the 'coraco-clavicular' ('conoid' and 'trapezoid') ligaments which bind down the clavicle; and the border next to the acromion gives attachment to the 'coraco-acromial ligament,' which extends across the interval between these points of bone, and completes the arch for the shoulder-joint.

Three Borders.—The 'superior border' of the scapula presents, near the root of the coracoid process, a small notch, which, in the recent state, is bridged over by a ligament. It gives passage to the supra-scapular nerve. Behind the notch is the origin of the 'omohyoid' muscle. The 'posterior border' is always the longest in man, and is therefore called the base of the scapula: in the lower animals it is generally the shortest. It gives insertion to the 'levator anguli scapulæ,' the 'rhomboideus major' and 'minor' muscles, and, as before mentioned, to the 'serratus magnus.' The 'inferior or axillary border' is by far the thickest and strongest, and supports the glenoid cavity. The deep groove along it gives origin to some of the fibres of the 'sub-scapularis' muscle.

Connections.—The scapula is connected by its acromial process to the clavicle which serves to keep well apart the shoulders. In its glenoid cavity it receives the head of the humerus. The 'blade' moves freely on the ribs, to which it is connected by muscles only. The sliding movement of the scapula on the chest can be properly understood only on the living subject. It can move not only upwards and downwards, as in shrugging the shoulders—backwards and forwards, as in throwing back the shoulders, or in reaching forwards as in boxing—but it has a rotatory movement round a movable centre. This rotation is seen while the arm is being raised from the horizontal to the vertical position, and is effected by the co-operation of the trapezius with the serratus magnus. The glenoid cavity is thus made to look upwards; the inferior angle slides forwards, and is well held under the latissimus dorsi.

Ossification.—The scapula has seven centres of ossification. The 'primary' centre, which appears a little behind the glenoid

cavity about the seventh week of foetal life, forms all parts of the bone, except the coracoid process, the acromion, the inferior angle, and the base: these are cartilaginous at birth. There are two centres of ossification for the coracoid process. The chief centre, representing the true coracoid bone, appears soon after birth, and about the fifteenth year unites to the rest of the bone. The second centre is an epiphysis for the tip. About puberty, the other secondary centres appear; namely, two for the acromion (one near the summit, the other near the base); one for the inferior angle; and, lastly, one for the border of the base. They all unite to the scapula about the twenty-second year.⁹² In a practical point of view it is well to remember that the acromion is not invariably united to the spine by bone. In some rare cases it remains permanently distinct, and is united to the spine only by ligament, and may be mistaken for a fracture.

Right or Left?—The bone will be in the same position as the corresponding one in the student's body, if he hold the spine backwards, the acromion upwards, and the glenoid cavity outwards, to receive the head of the humerus which is directed inwards.

Comparative Osteology.—The scapula is present in all mammalia.

In ruminants the coracoid and acromion are absent.

The elephant, rhinoceros, pig, and tapir have a very large process at the lower part of the spine, to which in man is attached a portion of the trapezius.

The supra-scapular notch is converted into a foramen by ossification of the ligament in the two-toed sloth (No. 2387 F).

The coracoid process is a remarkable bone in birds. In them it is of great strength and solidity, and extends from the sternum to the scapula, where it helps to form the glenoid cavity. It forms a buttress on each side, which supports the shoulder during the downward stroke of the wing. This process never articulates with the sternum in any mammal excepting in the *ornithorynchus* and the *echidna*.

On the top of the sternum of the *echidna* (No. 1708) there is a T-shaped bone called the episternum. On each of its lateral

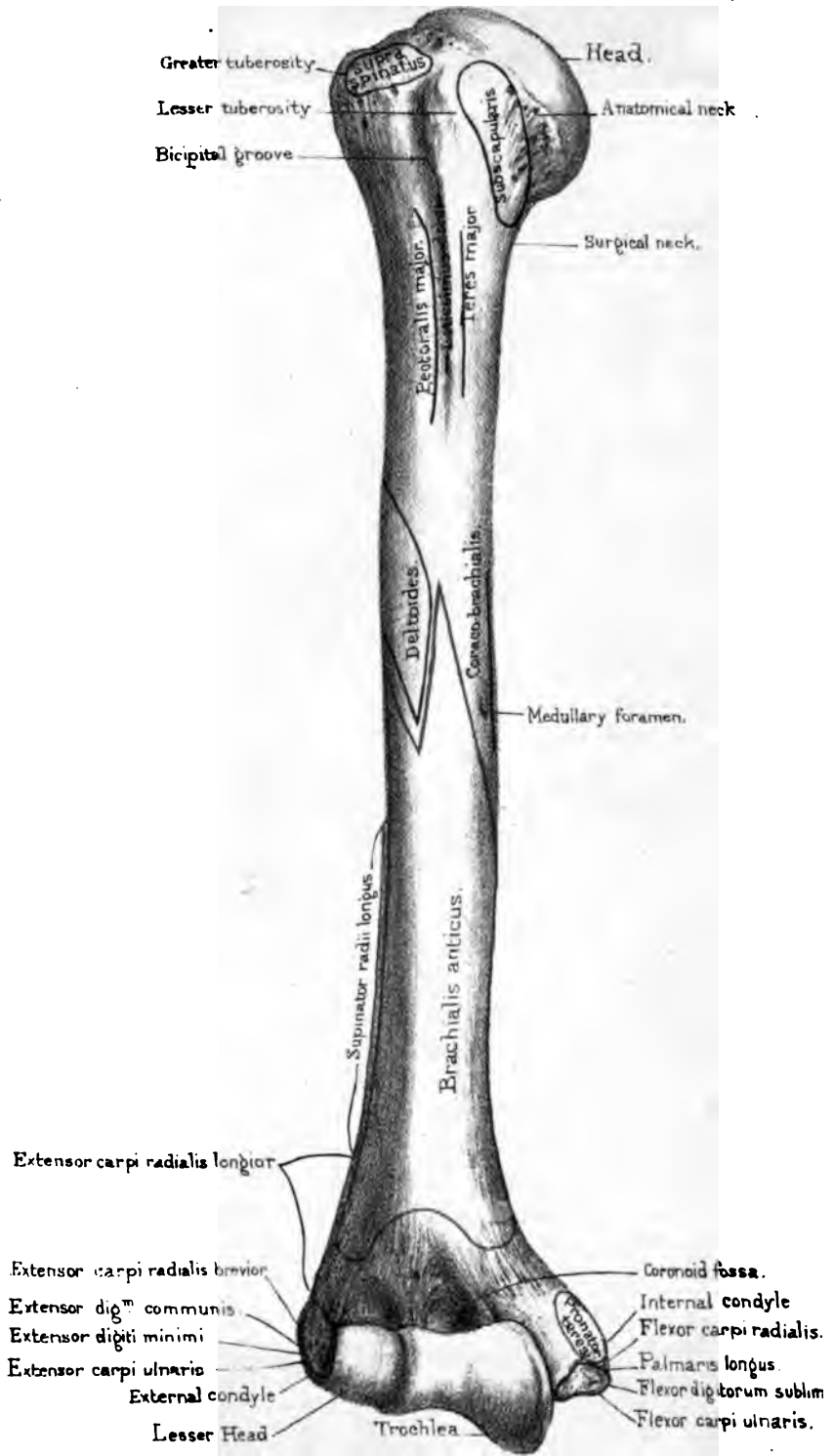
branches lies a thin plate of bone, which is the clavicle in this animal. Extending forward from the glenoid cavity towards the top of the sternum is a block of bone which corresponds to our coracoid process, and on the top of this is a second piece of bone called the epicoracoid. The coracoid being, as we may say, in two pieces is not surprising, seeing that in us the coracoid has two centres of ossification which now and then remain separate. This coracoid will be seen to enter into the formation of the glenoid cavity.

THE HUMERUS.

(PLATES L., LI.)

The humerus is the longest and strongest of the bones of the upper extremity. It is a lever of the third order, the fulcrum being at the shoulder-joint, and the power at the insertions of the several muscles which move the bone. It articulates with the scapula above, and the radius and ulna below. Like all the long bones, it has a body or shaft, and articular ends.

Head and Neck.—At the upper end is the smooth eminence termed the ‘head.’ It forms about one-third of a sphere, and articulates with the glenoid cavity of the scapula. The head of the humerus is much larger than the socket in which it plays. This arrangement, together with the shallowness and direction (p. 226) of the socket, explains the great range of motion which the shoulder-joint enjoys. It is the freest of all the joints, and resembles what mechanics call a ‘universal’ joint: there is no part of the body which cannot be touched by one hand or the other. The head springs from the shaft by a slightly constricted base, called the ‘*anatomical neck*,’ to which the capsular ligament of the joint is attached. Although this is so short and thick as hardly to deserve the name of neck, yet it serves the important purpose of removing the head a little away from the axis of the shaft. In consequence of this, the axis of the head and neck forms an obtuse angle with that of the shaft. When the arm hangs quietly by the side, with the thumb in front, the precise direction of the axis of



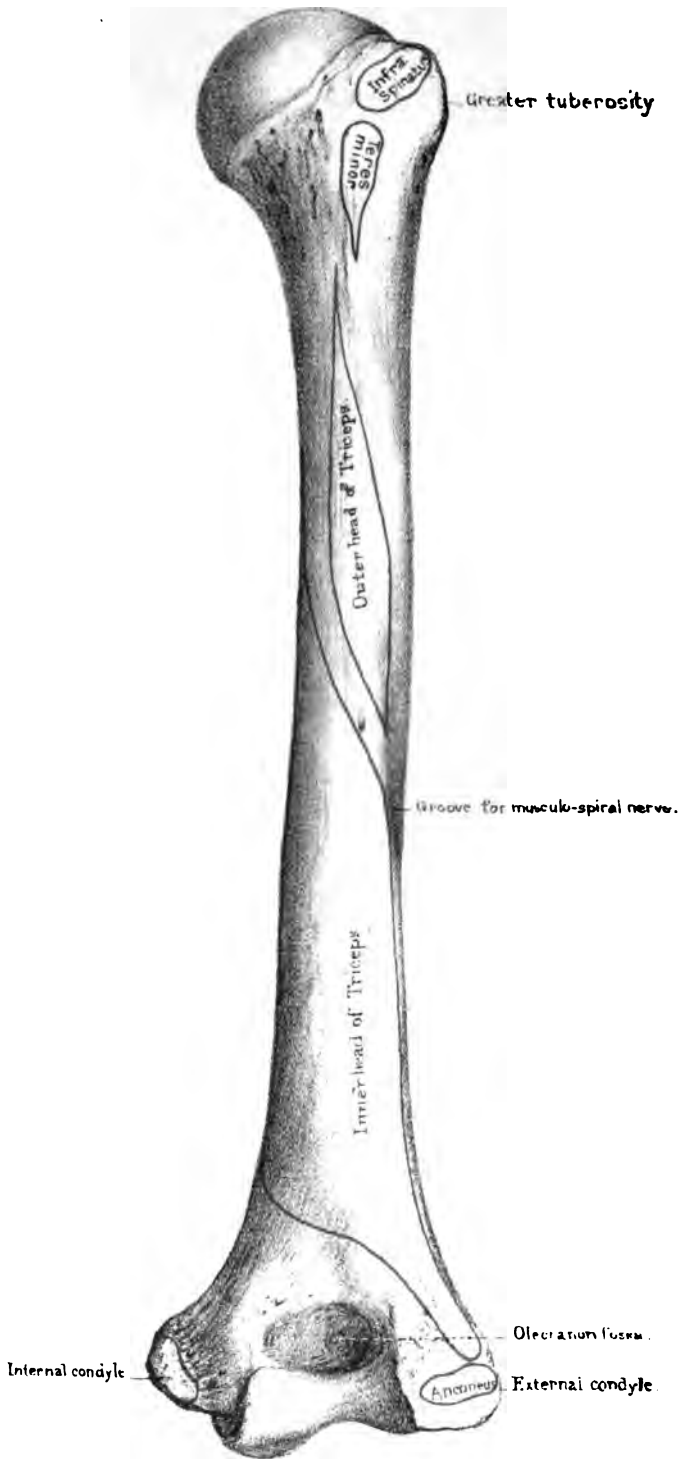
Humerus. anterior view.

Drawn on Stone by I. Godart

From nature by L. Holden

Printed by West Newman & Co





Humerus. posterior view.

Drawn on Stone by T. Godart
From nature by L. Holden

Printed by West, Newman, & Co.

the head and neck of the humerus is upwards, inwards, and a little backwards from the shaft—a direction which facilitates rotation inwards. In the axis of the neck of the femur, where rotation outwards is more required than rotation inwards, this direction is reversed.

Raise the arm of the skeleton to a right angle, and you observe that much of the lower part of the head of the humerus is out of the socket. This is one of the reasons why the humerus is so liable to be dislocated when the arm is extended; the head of the bone in this position being chiefly supported, below, by the fibrous capsule of the joint. Again, when the arm is raised to a right angle, there is another point worthy of notice: that the humerus *alone* cannot be raised higher, for the reason that the articular surface of the head of the bone does not admit of elevation beyond a right angle. When we do raise the arm beyond a right angle, the additional elevation is accomplished by the movement of the scapula upon the chest, an effect chiefly due to the action of the trapezius and serratus magnus muscles.

Tuberosities.—At the root of the neck, or rather at the top of the shaft, are two projections, termed the ‘tuberosities,’ which give greater leverage to the muscles moving the bone. They are separated by a perpendicular groove which runs about three inches down the shaft, and is called the ‘bicipital groove,’ because the tendon of the long head of the biceps plays in it. In the recent state this groove is bridged over, and made into a complete canal, by an aponeurosis. Of these tuberosities the ‘*greater*’ is the more external; in a thin person it can be plainly felt immediately below the acromion. It is useful to know this in determining the nature of injuries about the shoulder. It has three impressions indicating the insertions of muscles, namely—one above and somewhat to the front for the ‘supra-spinatus,’ a second immediately behind the first for the ‘infra-spinatus,’ and a third below the second and quite at the back of the bone for the ‘teres minor.’ The insertion of this last muscle extends beyond the third impression nearly half an inch down the shaft. The ‘*lesser* tuberosity’ is the more internal, and gives insertion to the subscapularis. Lastly, the tuberosities are supported by broad pedicles which run down the shaft,

and form, respectively, the outer and inner margins of the bicipital groove.

Shaft: Bicipital Groove: Surgical Neck.—The first thing to be observed in the shaft is, that its lower part is twisted inwards, and that it is slightly curved forwards. This twist and curve make the axis of motion at the elbow such, that the fore-arm naturally bends towards the front of the body. Immediately below the tuberosities is the ‘*surgical neck*’ of the humerus; so called, in contradistinction to the anatomical neck already described. Fracture of the surgical neck is common; of the anatomical neck rare. On the front of the shaft is the bicipital groove, up which the long head of the biceps runs, to be attached to the top of the glenoid cavity, so that it acts like a strap and keeps down the head of the bone. Up this groove, too, a little artery (a branch of the anterior circumflex) creeps to supply the joint. Into the outer margin of the groove is inserted the tendon of the ‘*pectoralis major*’; into the inner margin the tendon of the ‘*teres major*’; and into the bottom of it the tendon of the ‘*latissimus dorsi*.’ These muscles play an important part in causing displacement in fracture when it occurs through the surgical neck. There is often a double displacement: *i.e.* the upper fragment is drawn outwards by the muscles inserted into the tuberosities, and the lower fragment is drawn upwards and inwards by the muscles which go from the trunk to the arm.

The middle of the shaft is marked by ridges and impressions denoting the attachment of the muscles. Along its anterior aspect runs a very prominent elevation (the ‘*anterior border*’ of some anatomists), continuous with the external border of the bicipital groove.

Deltoid Ridge.—About the middle of the outer aspect there is a rough impression (*deltoid ridge*) for the insertion of the ‘*deltoid*’ which raises the arm. Near this, on the inner aspect, is a smooth surface for the insertion of the ‘*coraco-brachialis*.’ Against this surface the brachial artery can be effectually compressed. The surface looks forwards and inwards, and as the artery runs along it, the surgeon must remember this obliquity and apply compression in the proper direction—outwards and

backwards—or the artery will slip off the bone. Here also is generally situated the foramen for the nutrient artery of the marrow, which runs from above downwards. Below the deltoid ridge the shaft begins to be twisted, and becomes gradually flattened and expanded for the formation of the articular end. It is generally below the insertion of the deltoid that ununited fractures of the humerus are met with, partly on account of the injury to the nutrient artery of the medulla, and partly on account of the action of the deltoid in causing a displacement of the upper fragment over the lower.

Condylloid Ridges.—The lower half of the shaft presents two ridges, one on each side, called respectively the ‘internal’ and ‘external condyloid ridges,’ because they lead to the ‘condyles’ or points of bone which project on each side of the elbow. The *external* ridge begins just behind the insertion of the deltoid, and is the more prominent of the two; its upper two-thirds gives origin to the ‘supinator radii longus,’ and its lower third to the ‘extensor carpi radialis longior.’ It is called the *supinator* ridge, and is generally best developed in animals which possess great power in the fore-legs and paws for fighting or burrowing. It is rather feebly marked in man, considering the mobility and strength of his fore-arm. The ‘supinator longus’ is not so much a supinator, as a powerful assistant to the biceps and brachialis anticus in flexing the elbow. The *internal* ridge serves for the attachment of the ‘internal intermuscular septum.’ The front surface of this part of the shaft gives origin to the ‘brachialis anticus,’ which begins by two little tongues, one on each side of the insertion of the deltoid.

The back part of the shaft is occupied by the origins of the outer and inner ‘heads of the triceps,’ which are separated by a groove directed in a spiral manner downwards and outwards for the passage of the musculo-spiral nerve and superior profunda artery. The origin of the outer head is narrow, and lies external to and above the groove, extending as high as the insertion of the teres minor. The origin of the inner head is below the groove, reaching as high as the lower limit of the teres major and covering all the lower part of the shaft, even to the external condyle.

Lower End.—The lower end of the humerus curves slightly forwards, and presents a pulley-like surface, suited to the flexion and extension, as well as the rotatory movement of the fore-arm. On the outer side, we observe the ‘lesser head’ (*capitellum*), which corresponds with the shallow cavity at the end of the radius. The chief point about this head is, that it projects directly forwards, so that when the fore-arm is bent there is a smooth surface ready for the rotation of the radius. On the inner side is the ‘trochlea’ or pulley for the ulna. This admits of flexion and extension only. The direction of this pulley is oblique; that is, it slants from behind forwards, and from without inwards, so that the fore-arm, in the act of bending, comes naturally in front of the chest. Observe that the inner border of the trochlea descends much lower than the outer, thus protecting the ulna from dislocation inwards. Above the trochlea there is a deep cavity in front (*coronoid fossa*) which receives the coronoid process of the ulna in flexion; and a similar one behind (*olecranon fossa*) receiving the ‘olecranon,’ or the point of the elbow, in extension of the fore-arm. External to the coronoid fossa, immediately above the lesser head, is a shallow depression for the head of the radius in extreme flexion. Between the ‘olecranon and coronoid fossæ’ the bone is translucent, as is well seen in fig. 59, which exhibits a section through the joint. In consequence of this thinness, a transverse fracture through the

humerus in this situation is not uncommon. From the displacement produced so close to the elbow joint this accident is very liable to be mistaken for a dislocation of the radius and ulna backwards. However, the bearing of the condyles with respect to the olecranon enables us in most cases to determine the diagnosis. If the olecranon be higher than the condyles, there is dislocation of the elbow; if not higher, the ulna is in its proper place.

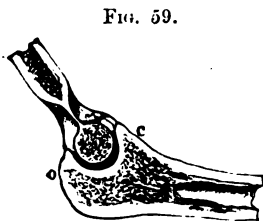

FIG. 59.

SECTION TO SHOW THE TROCHLEA OF THE HUMERUS.

- o. Olecranon.
- c. Coronoid process.

Condyles.—The internal condyle projects more than the external, and gives origin to the powerful pronator and flexors of the hand and fingers, namely, to the ‘pronator radii teres,’ ‘flexor

carpi radialis,' 'palmaris longus,' 'flexor sublimis digitorum,' and 'flexor carpi ulnaris.' The internal lateral ligament of the elbow is also attached to it. The *external* condyle gives origin, in front, to the common tendon of the extensor muscles; namely, the 'extensor carpi radialis brevis,' 'extensor digitorum communis,' 'extensor minimi digiti,' and 'extensor carpi ulnaris': behind, it gives origin to the 'anconeus.' Lastly, the external lateral ligament of the elbow is attached to it.

Connections.—The head of the humerus articulates with the glenoid cavity of the scapula at the shoulder. At the lower end on its outer side is a round convex surface which articulates with the cup on the top of the radius; while the trochlea is adapted to the form of the sigmoid cavity of the ulna.

Ossification.—The humerus has seven centres of ossification. There is one for the shaft, which appears about the seventh week of foetal life when the foetus is about an inch long. About the second year after birth the centre of the head appears; and about the third year, the centre of the tuberosities. About the end of the fifth year, the centres for the head and tuberosities have coalesced, and form a large epiphysis on the top of the shaft. It is necessary to remember that this epiphysis includes the tuberosities (see fig. 60). On the inner side, the line of junction runs close to the cartilage on the head of the bone: therefore, in the event of separation, the shoulder-joint would certainly be implicated.

About the beginning of the third year, ossification of the lower end commences by a fourth centre in the lesser head. About the fifth year, a fifth centre appears in the internal condyle. About the twelfth year, a sixth centre appears in the great sweep of the trochlea; and, lastly, about the fourteenth year, the seventh centre appears in the external condyle, and uniting with the others forms a large epiphysis at the lower end of the shaft. The lower epiphysis unites to the shaft at puberty, while the upper remains separate until maturity. Therefore there may be a separation of the upper epiphysis from the

FIG. 60.



EPIPHYSIS OF THE HEAD OF THE HUMERUS, SHOWING THAT IT INCLUDES TUBEROSITIES.

shaft by violence as late as about the twenty-first year, but of the lower end not later than about the sixteenth year. (See Nor. Hum. Ost. No. 54.)

It is interesting to remark, that the epiphysis of the upper end, though the first to ossify, yet remains separate from the shaft about three or four years longer than that of the lower end. This is in accordance with the rule, that, of the epiphyses of a long bone, those towards which the nutrient artery of the marrow runs are always the first to unite with the shaft. Remember, that the nutrient arteries of the marrow of the bones of the upper extremity run *towards* the elbow. In the bones of the lower extremity, they run *from* the knee.

Right or Left?—The bone will be in the same position as the corresponding one in the student's body, if he hold the rounded head upwards and turned inwards towards the glenoid cavity, the bicipital groove being in front.

Comparative Osteology.—In man the legs are longer than the arms, and grow faster than the rest of the body after birth. In apes and monkeys the converse of this is true, and, after birth, the arms grow faster than the rest of the body. In most giants the great proportion of the height is due to the length of the lower extremity. It is curious that the right humerus of the gorilla (No. 5178) is of the same length as that of the Irish giant O'Brien (Hum. Ost. Ser. No. 223), who stood about eight feet, while the height of the gorilla is only four feet four inches. The left humerus of O'Brien is 20 mm. shorter than the right, and there exists a similar difference in the two humeri of the gorilla. It may be well to mention that the corresponding bones of opposite sides commonly differ a little in length, without giving rise to any obvious deformity.

The olecranon and coronoid fossæ occasionally communicate by a small hole in man. This seems to be pretty constantly the case in the Bushman, gorilla, tapir and dogs. (See separate series, Mus. Roy. Coll. Surg., as well as in the articulated skeletons.)

Above the inner condyle in many carnivora is a foramen (supra-condyloid) which transmits the median nerve and the brachial artery. (See separate series, Mus. Roy. Coll. Surg.: tiger,

lion, and leopard.) A trace of this foramen occurs now and then in man by the ossification of a part of the fibrous band which passes over the median nerve and from which the pronator teres arises.⁹³

The deltoid ridge is especially prominent in the Carnivora (see that of the seal). It is extensive in the rhinoceros, the tapir, and the horse, which have heavy limbs to raise.

The tuberosities are very large in the heavy-limbed rhinoceros and the heavy-boned dugong.

Notice how extensive the supinator ridge is in the aye aye and the beaver.

In moles the clavicle articulates with the humerus (No. 2400 C).

There is no complete articulation between the humerus and fore-arm in Cetacea, nor between their carpus, fore-arm or digits; the upper extremity forming a flipper which has free movement only at the shoulder joint. (See the Cachalot Whale.)

In flying birds, notice the large foramen, at which the air enters the cavity in the bone immediately below the head, and feel the great lightness of their bones. The humerus of the adjutant (No. 1306) is a mere shell. A bone of this bird, thirteen inches long, weighed only half an ounce, while a corresponding one seventeen inches long of an ostrich, weighed half a pound, that is, it was sixteen times as heavy.

In snakes there is no trace of fore-limb, and consequently no humerus (No. 629).

Near the end of the humerus of the turtle there is a line which may appear to denote an epiphysis, but it simply marks the limit to which the cartilaginous cap extended in the recent bone (see No. 1016). These animals have no epiphyses.

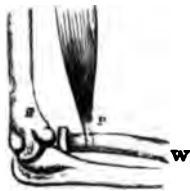THE RADIUS.

(PLATES LII., LIII.)

The radius is the external of the two bones of the fore-arm, and is so called from its resemblance to the spoke of a wheel. In learning this bone, keep in mind that both its ends rotate upon the ulna, and admit of the pronation and supination of the hand.

Axis of Rotation.—In a well-articulated skeleton the axis of rotation of the radius is represented by an imaginary line drawn from the centre of the head of the radius to the centre of the circle of which the sigmoid cavity at the lower end is a segment; in other words, to the centre of the lower end of the ulna. The lower end of the radius is much larger than the upper, and is the chief support of the hand: now since the radius receives all shocks from the hand,

FIG. 61.



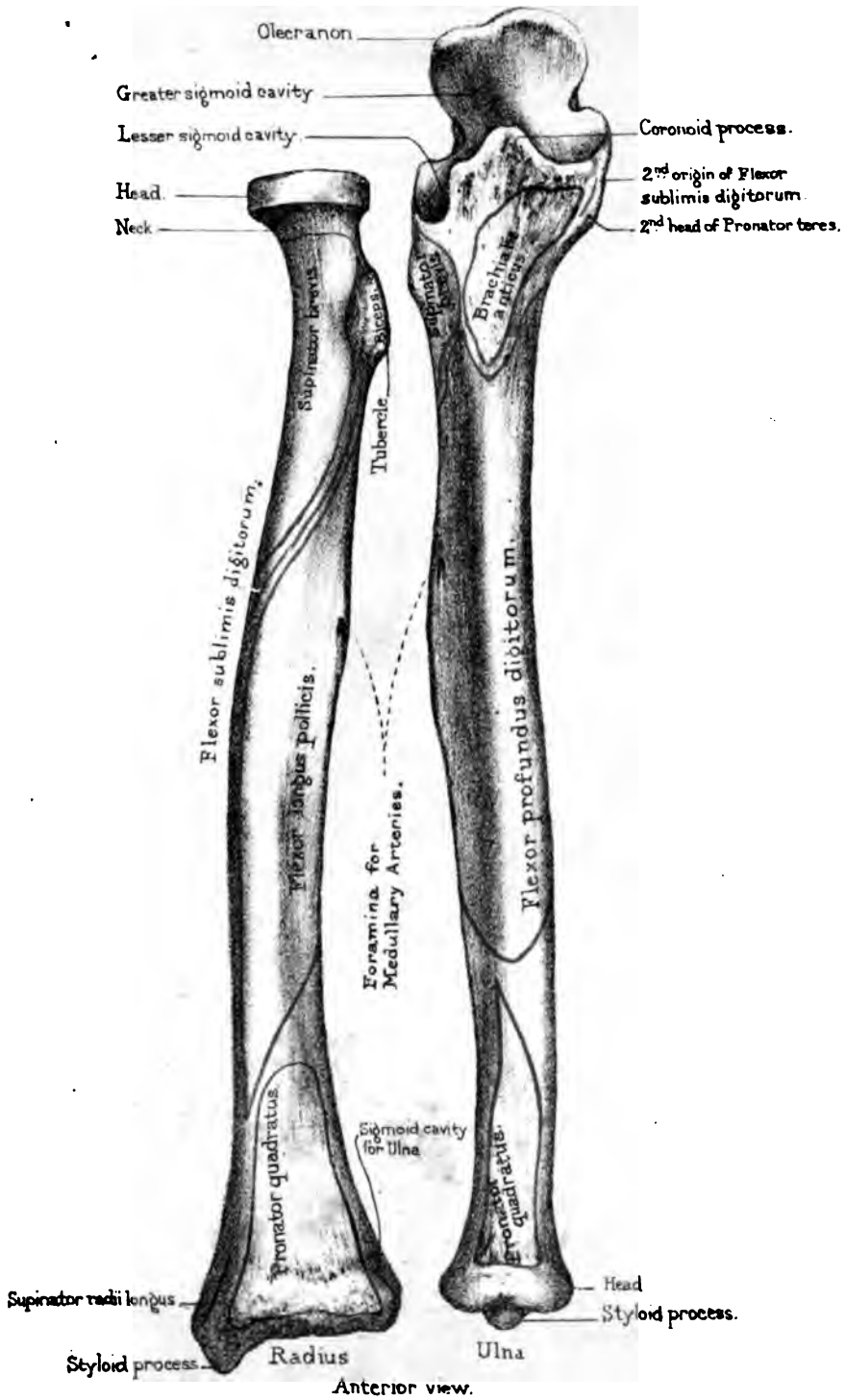
BONES OF THE FORE-ARM
LEVERS OF THE THIRD
ORDER.

it is more liable to be broken than the ulna.

Like the humerus, the radius and ulna are both levers of the third order, as seen in fig. 61. The fulcrum *F* is at the elbow-joint—the weight to be raised is the fore-arm *W*—the power *P* is the insertion of the biceps. The biceps acts to the greatest advantage when the arm is bent to a right angle, because the power acts at a right angle to the lever.

Head, Neck, and Tubercle.—The upper end of the radius is called the ‘head’: it has a shallow circular cup, which articulates (when the fore-arm is bent) with the lesser head of the humerus, and in the recent state is held in its place by the strong ‘orbicular’ ligament which encircles it. Observe that the head has a smooth circular border, which rotates in the lesser sigmoid cavity of the ulna. This rotation of the radius can be distinctly felt in one’s own person below the external condyle of the humerus; a fact of great value in determining the existence of fracture or dislocation. Below the head, is the constricted part termed the ‘neck’; and below this, is the ‘tubercle’ which gives insertion to the tendon of the ‘biceps.’ This tubercle projects on the inner side of the bone, so that the biceps can *supinate*, as well as *bend*, the fore-arm. The posterior half of the tubercle is rough for the insertion of the tendon; the anterior half is smooth, and is the seat of a bursa which facilitates the play of the tendon.

Shaft.—The outer side of the shaft is thick and rounded; and from this side its front and back surfaces gradually converge to a sharp edge, which faces the ulna (see fig. 62), and gives attachment to the interosseous membrane represented by the dotted

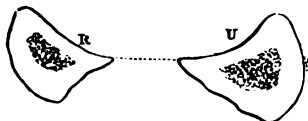


Drawn on Stone by I. Godart.
 From nature by L. Holden
 Printed by West, Newman, & Co.



line. The shaft is slightly arched outwards, by which arrangement it increases the breadth of the fore-arm, and gives more power to the 'pronator teres.'⁹⁴ The bones are furthest apart when the hand is placed vertically with the thumb upwards: hence, fractures of the fore-arm are put up with the hand vertical, that there may be less risk of the opposite bones uniting.

FIG. 62.



On the front surface of the shaft there is a blunt ridge leading from the tubercle obliquely towards the outer side of the bone. It gives origin to part of the 'flexor sublimis digitorum.' Above this ridge is the insertion of the 'supinator brevis,' and below it is a slightly excavated surface for the origin of the 'flexor longus pollicis.' Below this is the insertion of the 'pronator quadratus.' On the outer and *back* part of the middle of the shaft is a rough surface for the insertion of the 'pronator teres.' This insertion being at the outer and *back* part of the shaft, gives the muscle-greater power of pronation. In amputation of the fore-arm it is desirable to saw through the bones below the insertion of this muscle, that the stump may have the benefit of a pronator.

The posterior surface of the shaft is marked by the origin of the extensor muscles of the thumb; namely, the 'extensor ossis metacarpi pollicis,' and the 'extensor primi internodii pollicis.'

Lower End.—The lower end of the radius expands into a surface slightly cupped transversely, as well as from before backwards, which articulates with the 'scaphoid' and 'semilunar' bones of the carpus. In the recent state, if not in the dry bone, this surface is divided by a slight ridge: the part for the 'scaphoid' is triangular, while that for the 'semilunar' bone is square. On its inner side is the concave articular surface ('semilunar' or 'sigmoid' cavity), which rotates upon the lower end of the ulna. On its outer side is the conical projection, termed the 'styloid' process, of which the apex gives attachment to the external lateral ligament of the wrist; while the base gives insertion to the tendon of the 'supinator radii longus.' In front, the lower end has a rough and elevated margin for the attachment of the

powerful anterior ligament of the carpus: and behind there are four grooves for the passage of the extensors of the wrist and fingers. (Plate LVI.) Beginning from the outer side, we observe: 1, a groove for the 'extensor ossis metacarpi pollicis,' and the 'extensor primi internodii pollicis'; 2, a groove for the 'extensores carpi radiales, longior' and 'brevior'; 3, a very distinct and slanting groove for the 'extensor secundi internodii pollicis'; 4, a groove for the 'extensor indicis' and the 'extensor communis digitorum.' In the recent state these grooves are made complete canals by the 'posterior annular ligament.'

The lower end of the radius is composed of cancellous tissue covered by a thin layer of compact bone, as shown in the adjoining fig. 63. In falls, therefore, upon the

FIG. 63.

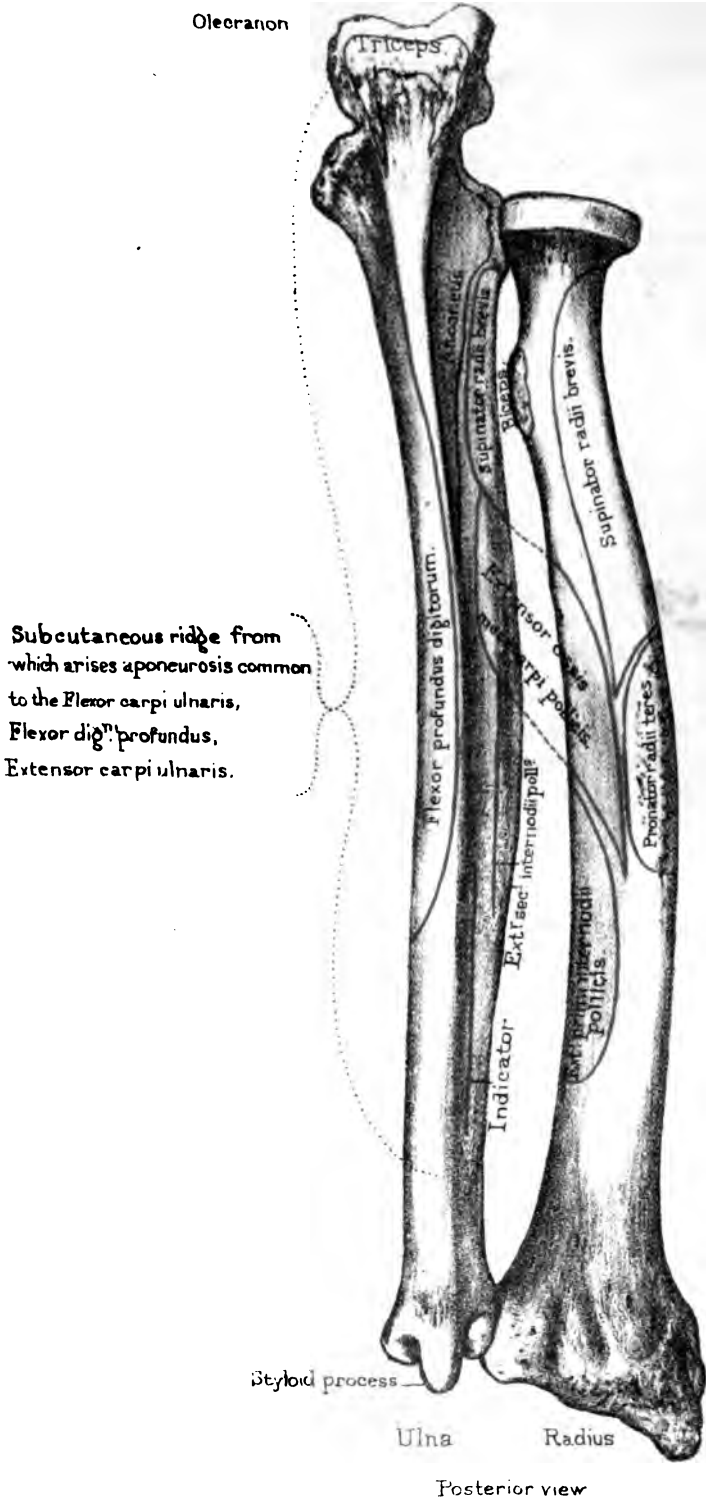


SECTION THROUGH THE LOWER END OF THE RADIUS, TO SHOW THE THINNESS OF ITS COMPACT WALL.

palm of the hand, the lower end of this bone, which receives the full force of the shock, is very liable to be broken transversely about half an inch or an inch above the wrist joint. This fracture of the radius is commonly called Colles's fracture, after the Irish surgeon who first accurately described it. The lower fragment, with the hand, is thrown backwards so as to make an unnatural swelling on the back of the fore-arm: the upper fragment protrudes on the palmar aspect of the fore-arm just above the wrist. Now a fracture with such displacement is liable to be mistaken for a dislocation of the wrist. The two injuries may be distinguished as follows:—If the styloid process be in the same line with the shaft of the radius, the injury is probably a dislocation of the wrist backwards: if it be not in the same line, there is probably a fracture of the lower end of the radius, which is by far the more frequent accident of the two.

Connections.—The radius articulates above with the humerus, and rotates in the lesser sigmoid cavity of the ulna. Below, it articulates with the scaphoid and semilunar bones of the wrist, and rotates upon the head of the ulna.

Ossification.—The radius has three centres of ossification: one for the shaft, and one for each end. The upper end begins to ossify at the fifth year, and is united at the seventeenth. The



Subcutaneous ridge from which arises aponeurosis common to the Flexor carpi ulnaris, Flexor dig^m profundus, Extensor carpi ulnaris.

lower end begins about the second year, and is not united till the age of eighteen or twenty. (Nor. Hum. Ost. No. 54.) This is in accordance with the general law, that epiphyses unite with the shafts in the inverse order of their ossification.

Right or Left?—The bone will be in the same position as the corresponding one in the student's body, if he hold the rounded head upwards, the bicipital tubercle inwards, and the oblique line forwards.

Comparative Osteology.—In ruminants the ulna and radius are immovably united. The ulna is at the back of the radius, and forms a very prominent olecranon, on the top of which may be seen an epiphysis in the fore-limb of the bison.

In the zebra (*Solidungula*) the ulna is represented by an olecranon adhering to the back of the radius, but in the elephant the ulna is very large and the radius is small. (See the Separate Series, Mus. Roy. Coll. Surg.)

In bats and birds the radius is enormously long, forming the principal support of the wing in the former (No. 2616 H).

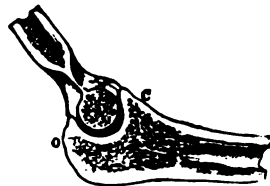
THE ULNA.

(PLATES LII, LIII.)

The ulna, so called because it forms the elbow (*ὠλένη*), is the inner of the two bones of the fore-arm.

Upper End.—Its upper end presents a deep semicircular cavity, with a smooth ridge at the bottom, which accurately fits on the trochlea of the humerus, and forms a perfect hinge-joint admitting of flexion and extension only. (See fig. 64.) This is called the 'greater sigmoid' cavity, in contradistinction to a smaller one, termed the 'lesser sigmoid,' which is placed on its outer side, and forms a socket for the rotation of the head of the radius. In front of the greater sigmoid cavity is a rough projection, termed the 'coronoid process'

FIG. 64.



SECTION THROUGH THE GREATER SIGMOID CAVITY OF THE ULNA.

(*κορώνη*, the top of a curve), the rough surface in front of which gives insertion to the 'brachialis anticus' (a flexor of the fore-arm) and origin to the second head of the 'pronator teres,' and the second head of the 'flexor sublimis digitorum.'⁹⁶ Besides this, it limits the flexion of the fore-arm. When the fore-arm is flexed on the arm as much as possible, the point of the process strikes against the fossa at the lower part of the humerus, and prevents further flexion. In dislocation of the ulna backwards the coronoid process is very liable to be broken: this complication makes reduction more easy, but subsequent retention of the bones in their proper place more difficult. Violent action of the brachialis anticus may break off the coronoid process: but this is very rare. An instance of this happened to a boy about eight years old, in consequence of hanging with one hand from the top of a high wall.⁹⁷ When it is broken, the coronoid process unites by ligament, owing to the separation of the fragments by the brachialis anticus. At the base of the coronoid process, below the insertion of the 'brachialis anticus,' is a rough tubercular elevation for the insertion of the oblique ligament, the other extremity of which is attached to the radius just below the tubercle for the biceps.

Olecranon.—Behind the sigmoid cavity is the 'olecranon' (*ὠλένη*, elbow, and *κρᾶνον*, head). This serves many purposes and plays an important part in the perfection of the hinge of the elbow-joint. It gives leverage to the 'triceps,' which is inserted into it and extends the fore-arm. It forms a convenient knob of bone for the protection of the joint when we lean on the elbow, and it limits the extension of the fore-arm. The surgical interest about it is, that it is sometimes broken by a fall upon the elbow; and the fracture generally takes place just at the slight constriction or notch where the olecranon joins the shaft: so that the joint is involved in the mischief. Fractures of the olecranon, like those of the patella and coronoid process, unite, generally, by ligament, because it is so difficult to keep the fragments in apposition. But if the tendinous expansion from the triceps be not torn, the union may take place by bone.

In almost all injuries about the elbow-joint, however swollen

the parts, one can always feel the olecranon and the internal condyle of the humerus. In determining, therefore, the nature of obscure injuries about this joint, it is useful to know that, when the arm is extended, the tip of the olecranon and the internal condyle are about one inch apart and in the same transverse line. When the arm is bent to a right angle, the olecranon is an inch and a half from the condyle and below it. By this test dislocation of the ulna backwards and fracture through the lower end of the humerus can be distinguished.

Shaft.—The shaft of the ulna is triangular, and tapers gradually from the upper towards the lower end, which inclines a little outwards towards the radius and terminates in the little ‘head’ round which the radius rolls. A transverse section, seen in fig.

65, shows the shape of the radius and ulna about the middle. We observe that their sharp edges are turned towards each other, and that to these is attached the interosseous membrane

(represented by the dotted line) which connects the bones. Together, they form a shallow concavity in front and behind, wherein the muscles of the fore-arm are lodged.



FIG. 65.

The greater part of the front as well as of the inner surface of the shaft is occupied by the origin of the ‘flexor profundus digitorum.’ On the front, too, is the canal for the nutrient artery of the medulla. It runs *towards* the elbow like that in the radius. Lower down is the origin of the ‘pronator quadratus.’ The back part of the shaft is marked by ridges and surfaces for the muscles thus:—near the elbow is the triangular surface for the insertion of the ‘anconeus’; next comes the ridge for the origin of the ‘supinator radii brevis,’ which also arises from the depression just below the lesser sigmoid cavity. Below the supinator brevis arise in succession parts of the ‘extensor ossis metacarpi pollicis,’ of the ‘extensor secundi internodii pollicis,’ and also the ‘indicator.’⁹⁸

Of the three edges of the shaft, the *external* gives attachment to the interosseous membrane; the *anterior* is covered by the origin of the ‘flexor profundus digitorum’; the *posterior* gives

attachment to a strong aponeurosis, which covers the muscles on the inner side of the fore-arm, and affords additional surface for the origin of the 'flexor carpi ulnaris,' the 'flexor profundus digitorum,' and the 'extensor carpi ulnaris.' The posterior edge (or ridge of the ulna, as it is generally called) deserves the more notice, because being subcutaneous it can be traced from the olecranon to the styloid process, and is therefore an important guide in cases of doubtful fracture. Before reaching the elbow the ridge bifurcates, and encloses a triangular space, which is also subcutaneous: here we feel for fractures of the olecranon.

Lower End.—The lower end of the ulna is termed its 'head.' It can be plainly felt at the back of the wrist when the hand is pronated. It has, on one side, a convex surface, forming rather more than half a circle, round which the radius, and with it the hand, rotates to the same extent. It has also another articular surface, lined with a synovial membrane, which looks towards the wrist joint, and corresponds with the interarticular fibro-cartilage interposed between it and the cuneiform bone of the wrist. The ulna does not reach down quite so low as the radius; the fibro-cartilage, however, partly fills up the interval. This difference in the length of the two bones allows more extensive horizontal movement of the wrist towards the ulnar side of the fore-arm.

The *styloid* process projects from the lower end of the *back* part of the ulna, and thus does not interfere with the rotation of the radius; it gives attachment to the internal lateral ligament of the wrist. Between the process and the head there is a groove on the posterior aspect of the bone for the passage of the tendon of the 'extensor carpi ulnaris' (Plate LVI.); and inferiorly, the process is separated from the head by a depression for the attachment of the triangular fibro-cartilage of the wrist.

The styloid processes of the radius and ulna can be readily felt beneath the skin, and are important guides in the determination of injuries of the wrist, whether fracture of the radius or dislocation. The relative position of the styloid processes with regard to the axis of motion at the wrist will settle the question.

Connections.—The ulna articulates, above, with the trochlea of the humerus and with the head of the radius; below, it articu-

lates with the sigmoid notch of the radius, but is prevented from articulating with the cuneiform bone of the wrist, by the intervention of an interarticular fibro-cartilage.

Ossification.—The ulna has three centres of ossification,—one for the shaft and coronoid process, one for the lower end, and a third for the olecranon. The lower end begins to ossify about the fifth year, and unites to the shaft about the twentieth. The top of the olecranon remains cartilaginous until the age of eight, about which time it begins to ossify: it coalesces with the base about puberty. (Nor. Hum. Ost. No. 54.)

Right or Left?—The bone will be in the same position as the corresponding one in the student's body if he hold the greater sigmoid cavity upwards; the lesser sigmoid cavity, which receives the radius, outwards; and the styloid process behind.

Comparative Osteology.—The ulna in many birds will be seen to be very long, like the radius, forming the largest part of the length of the wing, and to be dotted by a line of small tubercles along its outer surface where the wing feathers are attached. See the length of the ulna in the Frigate bird (No. 1188 A) and the prominent feather-tubercles in the Adjutant (No. 1306). Contrast the great length of the ulna and radius in the swift flying birds, as the Frigate (No. 1188 A) and Albatross (No. 1189) with the shortness of those which do not fly, as the Great Auk (No. 1118), the Ostrich (No. 1362), and the Cassowary (No. 1357 A).

BONES OF THE HAND.

(PLATES LIV. LV. LVI.)

THE skeleton of the hand consists of twenty-seven bones. The first eight are the little bones of the carpus; the five succeeding bones constitute the metacarpus: these support the bones of the fingers. Each finger has three bones, termed, in order from the wrist, the first, second, and third or unguis phalanges. The thumb has only two phalanges.

 THE CARPUS.

(PLATE LVI.)

Number and Names.—The carpus consists of eight little bones, arranged in two transverse rows of four bones each, thus forming a broad base for the support of the hand. What is the advantage of so many bones in the wrist? It confers strength and elasticity and permits some motion. The contiguous surfaces are crusted with cartilage and form synovial joints. Suppose there had been a single bone instead of the eight carpal bones, how much more liable it would have been to fracture and dislocation. As it is, dislocation of one or more bones of the carpal range is a rare occurrence; but it does happen sometimes. Sir C. Bell tells us that ‘the boy that played the dragon in a pantomime at Covent Garden, fell upon his hands, owing to the breaking of the wire that suspended him, and he suffered dislocation of some of the carpal bones in both hands.’ The bones of the carpus are named as follow, beginning from the radial side:—

FIRST OR PROXIMAL ROW . ‘SCAPHOID,’ ‘SEMILUNAR,’ ‘CUNEIFORM,’ ‘PISIFORM.’
 SECOND OR DISTAL ROW . ‘TRAPEZIUM,’ ‘TRAPEZOID,’ ‘OS MAGNUM,’ ‘UNCIFORM.’

The student will obtain a better idea of the general shape and arrangement of these bones by examining them, at first, collectively. For this purpose it is very desirable that he should have before him an articulated hand, as well as the separate bones.

Carpal Arch.—The outline of the carpus as a whole is oblong, with the broad diameter in the transverse direction. Its bones are wedged together, and so form an arch with the concavity towards the palm, which gives passage to the flexor tendons of the fingers. Fig. 3 in Plate XXXVIII. shows that the piers of the arch are formed on one side by projections from the scaphoid and trapezium; on the other, by the pisiform and the hook of the unciform. The arch is converted into a complete tunnel by the anterior annular ligament.

Radio-carpal Joint.—To begin with the bones of the first row. Excluding the pisiform, which is only an outstanding 'sesamoid' bone, it will be seen that the scaphoid, semilunar and cuneiform bones form a convex articular surface, which, with the lower end of the bones of the fore-arm, forms the radio-carpal joint. This joint admits not only of the movements of flexion and extension, but also of the horizontal movements of the wrist (abduction and adduction). The upper articular surfaces of the first row of bones are prolonged further down their dorsal than their palmar aspect: hence the free movement of extension at the wrist. The articular surfaces of the scaphoid and semilunar bones fit into the radius; while that of the cuneiform, which is the least extensive of the three, would articulate with the ulna, but for the intervention of the triangular fibro-cartilage attached, in the recent state, to the lower end of the ulna. The bones of the first row articulate with each other by plane surfaces crusted with cartilage, but they are so firmly connected by ligaments that there is very little movement between them.

Intercarpal Joint.—Collectively, the lower ends of the first row form, with the bones of the second row, an important movable joint, which we call the 'intercarpal.' It is very different in form from the first joint (radio-carpal) of the wrist, since its outline is alternately convex and concave. By means of this second joint

we get a great range of flexion and extension at the wrist. If there had been only a single joint for this amount of motion, it would have been comparatively insecure, and very liable to dislocation; whereas dislocation of the wrist happens very rarely indeed. By reference to Plate LVI. it is seen that the lower part of the scaphoid has a *convex* articular surface which corresponds with the trapezium and trapezoid, and also a *concave* one, which, with a concavity in the semilunar and cuneiform bones, forms a deep socket for the reception of the head of the os magnum and the unciform.

Articulations of First Row.—The scaphoid articulates with five bones inclusive of the radius; the semilunar with five inclusive of the radius; the cuneiform with three; and the pisiform with one, namely, the cuneiform.

In consequence of the flexors and extensors of the wrist being inserted below the second row of carpal bones, they necessarily act on the 'intercarpal joint' as well as on the radio-carpal. Thus a greater amount of motion is provided at the wrist than it otherwise could have possessed with safety. If such free motion had been given to one joint, the angle of flexion must have been great and the ligaments looser than would have been consistent with the security of the joint.

Bones of the Second Row.—The trapezium and trapezoid form a shallow socket for part of the scaphoid, while the os magnum and unciform form a convexity, which fits into the deep socket formed by the scaphoid, semilunar, and cuneiform in the first row. Below, the second row articulates with the metacarpal bones, as follows: The trapezium with two, that of the thumb by a concavo-convex surface, and partly with that of the index finger; the trapezoid with one, that of the forefinger; the os magnum with three, that of the middle finger, and besides this with those of the index and ring fingers; and the unciform with two, those of the ring and little fingers. Thus the trapezium supports the metacarpal bone of the thumb; the trapezoid that of the index finger; the os magnum that of the middle finger; and the cuneiform those of the ring and little fingers. The consequence is, that the metacarpal bones present different degrees of mobility,—that of

the thumb being the most movable, those of the fore and middle fingers the least so.

Articulations of Second Row.—Like the bones of the first row, those of the second articulate with each other by plane surfaces firmly connected by ligaments. The trapezium articulates with four bones; the trapezoid with four; the os magnum with seven; the unciform with five.

Distinction of Individual Bones.—Thus far we have examined the bones of the carpus collectively; how are we to distinguish them individually? Whoever remembers what has been already said, will readily recognise the separate bones; and if the rule laid down for the parietal (page 44), which has been applied to the other bones, be also applied to these, there cannot be much difficulty in determining to which hand a given bone belongs.

Scaphoid Bone.—The ‘scaphoid’ bone may be told by its boat-shaped socket (*σκάφη*, a boat), by its long narrow groove on the dorsal aspect between its two convex surfaces, and by its ‘tubercle’ for the attachment of the ligaments of the wrist (anterior annular and external lateral).

Right or Left?—This bone will be in the same position as the corresponding one in the student’s body if he hold the concave surface forward for articulation with the os magnum, the tubercle outwards for articulation with the trapezium and trapezoid, and the groove towards the dorsum.

Semilunar Bone.—The ‘semilunar’ bone may be told by its semilunar shape (whence the name). There is a narrow crescentic surface on its outer side for articulation with a similar surface on the scaphoid, and a broader crescentic surface on its inner side for articulation with a similar surface of the cuneiform.

In the concavity of the bone there are two articular surfaces: the outer, a large one for the head of the os magnum; and the inner, a smaller one for its slight articulation with the unciform.

Right or Left?—The bone will be in the same position as the corresponding one in the student’s body if he hold the concave surface forward for articulation with the os magnum and unciform; the narrower crescentic surface outwards for articulation with the scaphoid, and the small non-articular surface towards the dorsum.

zium and semilunar in the fifth; that of the scaphoid in the eighth; that of the trapezoid in the ninth; that of the pisiform in the twelfth. This is the last bone in the body to ossify.

Comparative Osteology.—In many of the Carnivora, as the seal, walrus, tiger, and dog, the scaphoid and lunar are anchylosed into one mass. In the bat, the scaphoid lunar and cuneiform form only one bone. In the dugong, all the carpal bones are anchylosed into three bones, the distal row being in one piece.

In birds, as in other animals, they are diminished in number according to the disappearance of the digits which each usually supports.

The carpus of the orang-utan, baboon, and several other monkeys contains one more bone than that of man, which seems due to the division of the scaphoid into two parts. (See Separate Series, Mus. Roy. Coll. Surg.)

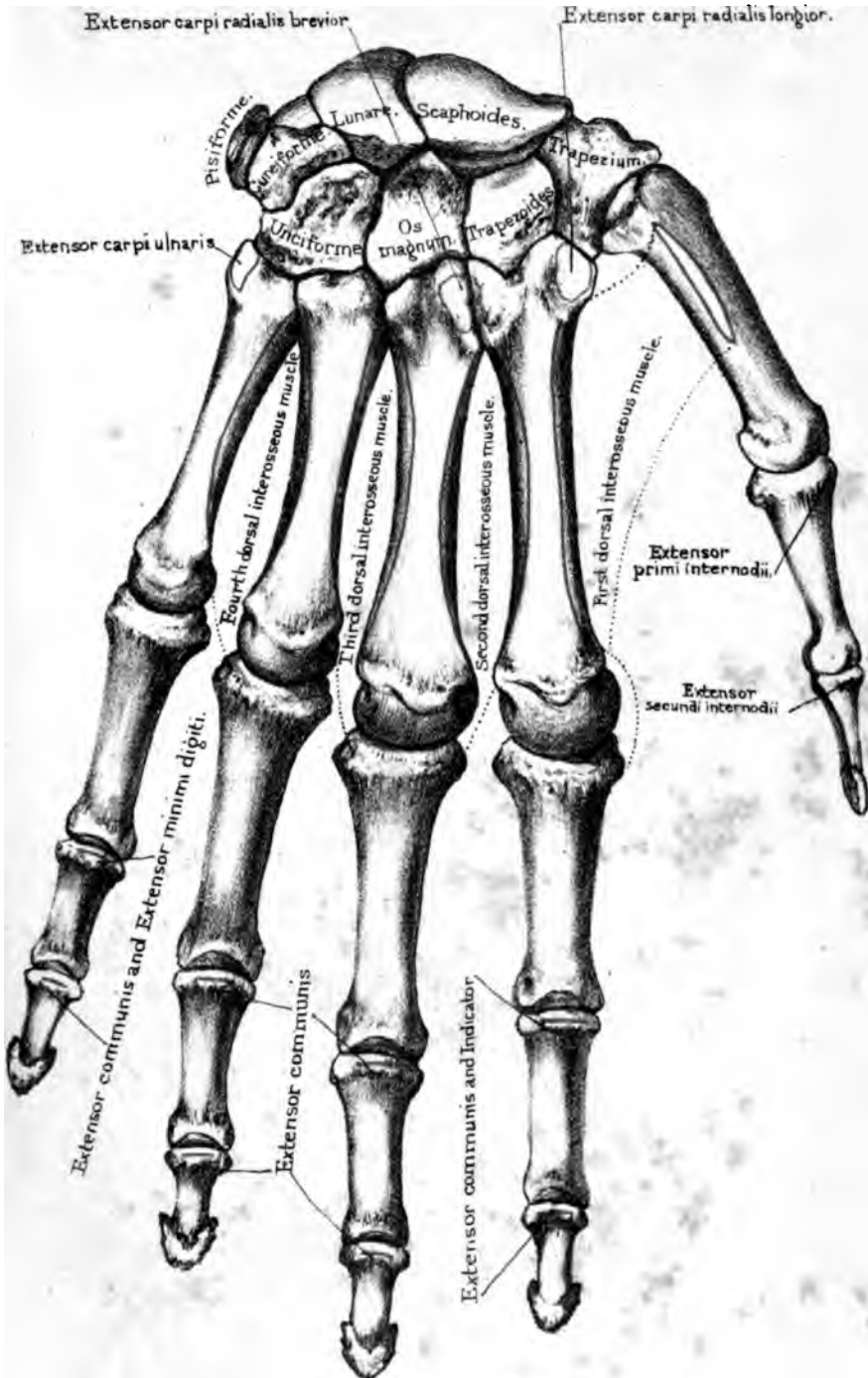
THE METACARPUS.

(PLATES LIV. LV.)

The metacarpus consists of the five bones which support the phalanges of the thumb and fingers. They are described as the first, second, third, fourth and fifth, counting from that of the thumb; and, regarding them as 'long bones,' which they much resemble in their general structure, we speak of their shafts and their two ends; the upper end being termed the 'base,' the lower, the 'head' of the bone.


Shafts.—The 'shafts' are slightly concave towards the palm, forming the hollow of the hand. They are made somewhat triangular on section by the impressions of the 'interosseous' muscles which occupy the 'interosseous spaces.' The apex of the triangle is on the palmar surface, the base on the dorsal surface forming the support of the extensor tendons of the fingers.

Bases.—Their 'bases' articulate not only with the bones of the carpus, but, by 'lateral facets,' with each other: that of the thumb, however, stands out alone, so as to oppose all the others.



Dorsal surface

Drawn on Stone by T. G. Sargent
From nature by L. Holden
Printed by Wood, Jones and Co.



It is one of the great characteristics of the hand of man, that the point of the thumb can touch with perfect ease the tips of all the fingers.

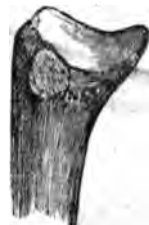Heads.—The lower ends or ‘heads’ are rounded for articulation with the first phalanges of the fingers. The articular surfaces of the heads extend chiefly towards the palm. They allow the fingers not only to be flexed and extended, but to be moved laterally. On each side of their heads are a tubercle and a deep pit for the attachment of the thick and strong lateral ligaments.

The shaft of each metacarpal bone has a canal for the nutrient artery of the medulla. In the second, third, fourth, and fifth metacarpal bones, the direction of this canal is upwards; but in the metacarpal bone of the thumb its direction is downwards.

Metacarpal Bone of the Thumb.—The metacarpal bone of the thumb is distinguished by the characteristic saddle-shaped surface at the base, which articulates with the trapezium. Besides which, its shaft is shorter, broader, and stronger than the others, in accordance with the many and powerful muscles which act upon it. There are no less than nine muscles to work the thumb. Its great mobility in all directions, so essential to the power and perfection of the human hand, depends upon this saddle-shaped joint at its base; and its power of antagonising the fingers is owing to its base being set off on a plane anterior to them. But for a little buttress of bone which projects from the inner and front part of the trapezium, the thumb would fall into the same line as the fingers, and would not possess that power of opposing them which makes the human hand such a wonderful instrument.⁹⁹ On the palmar aspect of its head, observe two smooth surfaces occasioned by the play of the outer and inner sesamoid bones which are connected with the tendons of insertion of the ‘flexor brevis pollicis.’

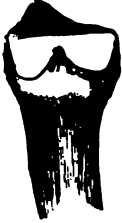Right or Left?—This bone will be in the same position as the corresponding one in the student’s body if he hold the rounded head forward, the flattened surface towards the dorsum, and the process of bone at the base towards the inner side.

FIG. 67.
1.



BASE OF FIRST
RIGHT META-
CARPAL, OUTER
SIDE.

FIG. 68.
II.



BASE OF
SECOND RIGHT
METACARPAL,
INNER SIDE.

Metacarpal of Fore-finger.—The metacarpal bone of the fore-finger is distinguished by its deeply indented surface at the base, which is immovably wedged with three of the carpal bones; also by having a 'lateral facet' on the inner side for the third metacarpal.

Right or Left?—This bone will be in the same position as the corresponding one in the student's body if he hold the rounded head forwards, the flattened surface towards the dorsum, and the facet for the insertion of the extensor carpi radialis longior outwards.

FIG. 69.
III.



INNER SIDE. OUTER SIDE.
BASE OF THE THIRD RIGHT
METACARPAL.

FIG. 70.
III.



Metacarpal of Middle Finger.—The metacarpal bone of the middle finger may be known by its having a smooth square surface at the base for the os magnum, and an angular projection at the corner of it for the insertion of the 'extensor carpi radialis breviar.' It has also 'lateral facets' on each side. Sometimes, as seen in fig.69, the inner facet is divided into two.

Right or Left?—This bone will be in the same position as the corresponding one in the student's body if he hold the rounded head forwards, the flattened surface towards the dorsum, and the pointed process for the insertion of the extensor carpi radialis breviar outwards.

Metacarpal of Ring Finger.—The metacarpal bone of the

FIG. 71.
IV.



INNER SIDE. OUTER SIDE.
BASE OF FOURTH RIGHT
METACARPAL.

FIG. 72.
IV.



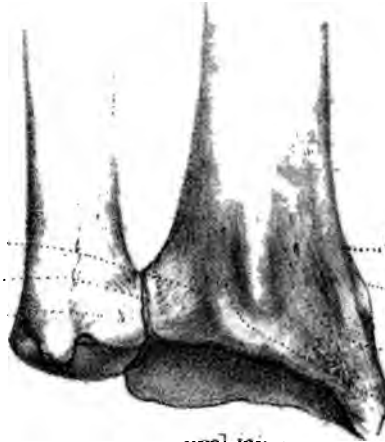ring finger articulates with the unciform and part of the os magnum. It may be distinguished by its smaller size; by the absence of the angular projection at the base, which is flat; and by its having two facets on the outer side and one on the inner (figs. 71, 72).

Right or Left?—The bone will be in the same position as the corresponding one in the student's body if he hold the head forwards, the flattened surface

Ulna. Radius.

Groove for

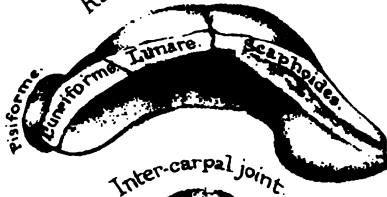
Extensor indicis }
 Ext. comm. digiti }
 Ext. minimi digiti }
 Ext. carpi ulnaris }



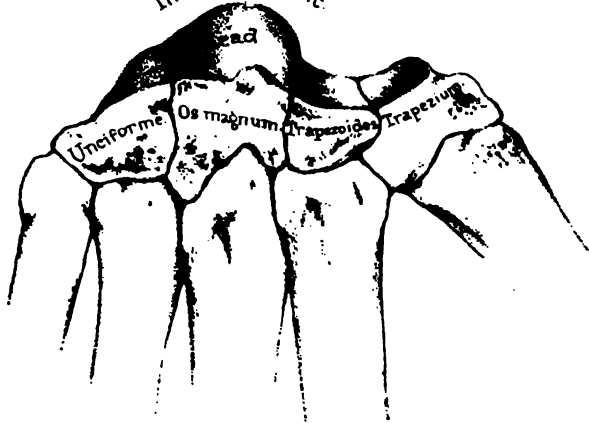Supinator radii longus.

Ext. ossis metacarpi pollicis }
 Ext. primi internodii pollicis }
 Ext. carpi radialis }
 longior et brevior. }
 Ext. secundi internodii pollicis }

Radio-carpal joint



Inter-carpal joint



View of the intercarpal joint.

Drawn on Stone by T. Golar

From nature by L. Holden

Printed by Wm. Newman & Co



towards the dorsum, and the single facet on the side of the base inwards for articulation with the metacarpal bone of the little finger.

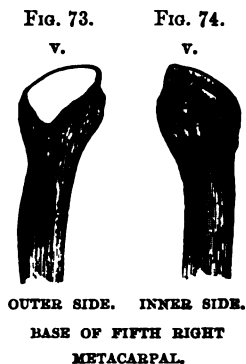
Metacarpal of Little Finger.—The metacarpal bone of the little finger may be recognised by its concavo-convex surface at the base to articulate with the unciform bone, and by its having only one lateral facet, namely, on the outer side (fig. 73). The projection on the inner side of the base is for the 'extensor carpi ulnaris.'

Right or Left?—This bone will be in the same position as the corresponding one in the student's body if he hold the rounded head forwards, the flattened surface towards the dorsum, and the non-articular side of the base inwards.

Ossification.—Each metacarpal bone has a centre of ossification for the shaft and proximal end, which appears about the eighth week of foetal life. Each also has an epiphysis at its distal end, of which the nucleus appears about the fourth year. The metacarpal bone of the thumb, however, has its epiphysis at the proximal end, like the phalanges of the fingers. All unite to the shafts about the twentieth year.¹⁰⁰ (Nor. Hum. Ost. No. 54.)

Comparative Osteology.—In all birds excepting the extinct archæopteryx the metacarpal bones are anchylosed together. (See the Separate Series in the Mus. Roy. Coll. Surg.)

Contrast the short metacarpal bones of the elephant with the enormously long ones of the horse or giraffe.



THE BONES OF THE FINGERS.

(PLATE LIV.)

General Description.—Each finger consists of three bones successively decreasing in size, and termed respectively the first second, and last or unguis ‘phalanges.’ The thumb has only two phalanges. A general description will suffice for all.

The structure of each phalanx is precisely like that of the great long bones, and a longitudinal section through one of them would display the great thickness of the compact wall of the shaft.

Considering the phalanges as ‘long’ bones, we speak of their shafts and their articular ends. The shafts are convex on the dorsal surface, and flat on the palmar; on each side of this flat surface is a ridge for the attachment of the fibrous sheath (theca), which keeps the tendons in their places.

First Phalanges.—The first phalanges are distinguished by their greater length, and by the shape of their metacarpal ends, which do not form strictly hinge-joints, but have concave oval surfaces, with the long diameters transverse, adapted for lateral movement as well as flexion on the heads of the metacarpal bones. In accordance with this lateral movement, we observe, on each side, a tubercle for the insertion of the interosseous muscles which produce it. Their distal ends are divided by a shallow groove into two little condyles with the lateral tubercles and depressions for the lateral ligaments.

Second Phalanges.—The second phalanges are shorter than the first, and are recognised by the shape of their proximal ends, which have two little concave surfaces, with an intervening ridge, and so form a hinge with the little condyles of the first phalanges. The first phalanges have only one articular surface at their proxi-

mal ends, and are thus distinguished from the second. Each has also a tubercle behind, into which is inserted the extensor tendon.

Third Phalanges.—The last or unguial phalanges are the shortest. Their ends expand into a horse-shoe shape, smooth on one surface for the support of the nails, and rough on the other for the support of the pulp of the fingers.

Unequal Length of Fingers.—It has been asked, What are the advantages of the fingers being of unequal length? Close them upon the palm, and then see whether or not they correspond. This difference in the length of the fingers serves a thousand purposes, to which the works of human art and industry bear ample testimony.

Ossification.—Each phalanx has two centres of ossification: one for the shaft and distal end; the other for the proximal end, which remains an epiphysis till about the twentieth year.¹⁰¹ (Nor. Hum. Ost. No. 54.)

Comparative Osteology.—In the separate series in the Mus. Roy. Coll. Surg. it will be seen that the elephant has five digits; the elk four, viz. the 2nd, 3rd, 4th, and 5th; the ox two, the 3rd and 4th; the rhinoceros three, the 2nd, 3rd, and 4th; the tapir four, the 2nd, 3rd, 4th, and 5th; the zebra and horse one, the 3rd.

The flipper of the whale, which corresponds to the front limb, has no nails: some of the digits have more than three phalanges. (See the round-headed whale, No. 2518 B, and the lesser fin-whale.)

Bats (Cheiroptera) have their four ulnar digits very much elongated, forming the framework for the wing. At least three of these digits bear no nails. The hook at the top of the bat's wing is the thumb-nail. (See Sep. Ser. Mus. Roy. Coll. Surg., as well as No. 2416 E and 2416 G to 2416 L.)

In the digitigrade Carnivora, as the tiger and cat, the sharp claws are firmly fixed into the unguial phalanges, and these are under ordinary circumstances bent backwards on to the back and outer side of each corresponding second phalanx by an elastic ligament, and are thus held out of the way as long as the flexor profundus digitorum remains at rest.

When a cat pats you in play she only uses the flexor sublimis

digitorum; but when she claws you in anger she uses her flexor profundus digitorum, which flexes the unguis phalanx and brings down the claw.

That which is commonly called the knee in the horse, is really the wrist. From this joint down to the foot extends the greatly elongated third metacarpal bone.

In birds three fingers can be traced as forming the extremity of the wing. (See Sep. Ser. Mus. Roy. Coll. Surg.)

The phalanges were very numerous in the Ichthyosauria. (Pal. Ser. No. 222, Mus. Roy. Coll. Surg.)

SESAMOID BONES.

(PLATE LIV.)

Position and Use.—These little bones are so called from their resemblance in size and shape to the grain ‘sesamum.’ They are met with in the substance of tendons in the neighbourhood of joints—the ‘patella,’ or ‘knee-pan,’ being the best example. Their use is to increase the leverage of the tendons. The thumb has two of these bones beneath its metacarpal joint, which increase the leverage of the ‘flexor brevis pollicis.’ We rarely find any in the fingers.

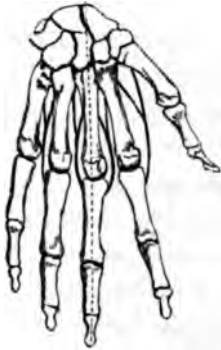Comparative Osteology.—Of all animals, the mole has the most remarkable apparatus of ‘sesamoid’ bones. Its prodigiously strong digging feet are provided with many of them, which increase the leverage of the brachial muscles, and enable the animal almost to swim through the earth.

INTEROSSEOUS MUSCLES.

Number and Arrangement.—There are seven interosseous muscles in the hand: ¹⁰² four on the dorsal aspect, and three on the palmar. The *dorsal* interossei arise by two heads from the opposed sides of the metacarpal bones, and are inserted into the first phalanges of the fingers, so that they separate the fingers from each other; in other words, they draw the fingers *from* a stationary line supposed to pass down the centre of the middle finger, as represented by the dotted line in fig. 75.

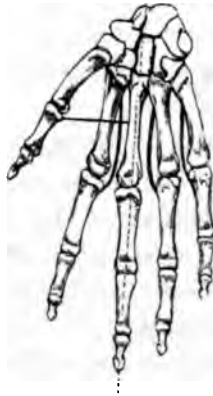The *palmar* interossei arise each from one metacarpal bone, and are inserted into the fingers, so that they bring them

FIG. 75.



FOUR DORSAL INTEROSSEI
DRAWING FROM THE MIDDLE LINE.

FIG. 76.



THREE PALMAR INTEROSSEI
DRAWING TOWARDS THE MIDDLE LINE.

together; in fact, they draw *towards* the stationary line down the centre of the middle finger, as shown in fig. 76.

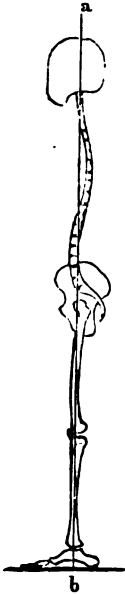GENERAL SURVEY OF THE SKELETON.

A GENERAL survey of the human skeleton shows how admirably it is adapted to the erect attitude.

Adaptation of the Skeleton to the Erect Position.—

1. When a man stands erect, an imaginary vertical plane (*a b*) supposed to fall through the top of the head, would pass through the occipito-atlantoid, lumbo-sacral, sacro-iliac, hip, knee, and ankle-joints; in a word, through all the joints which transmit the weight to the ground. This explains why a man can carry a weight on the top of his head easier than in any other way.

FIG. 77.



Position of Foramen Magnum and Condyles.—

2. The foramen magnum and the condyles of the occiput are nearly horizontal (when the head is held upright), and they are advanced almost to the middle of the base of the skull, and thus the head is nearly balanced on the cups of the atlas. The head has a slight tendency to drop forwards, but this is limited by the ligamentum nuchæ. Contrast the position of the condyles in the human skull with that of the orang-utan, in which the condyles are not only placed nearer to the *back* of the head, but obliquely, making an angle of 40° with the horizon. The lower we go in the scale, the greater is the contrast. In the horse, for instance, the plane of the condyles and foramen magnum is vertical. In this, and all other herbivorous quadrupeds, the weight of the head is sustained by an enormously strong and elastic ligament (ligamentum nuchæ, or *pack-wax*), the strength of which is in proportion to the weight

of the head and its tendency to drop. It extends from the lofty spines (withers) of the anterior dorsal vertebræ to the crest of the occiput.

Direction of the Face.—3. The face is placed perpendicularly under the cranium, so that the planes of the face and forehead are parallel, and this characteristic of the human face is well adapted for the erect attitude. If man went on all fours, he would habitually see and smell nothing but the ground. As it is, the direction of the orbits is horizontal, and therefore gives the greatest range of vision; and the direction of the nose gives the greatest range of smell. We are reminded here of the beautiful lines—

‘Pronaque dum spectent animalia cætera terram,
Os homini sublime dedit, cælumque tueri
Jussit, et erectos ad sidera tollere vultus.’

OVID, *Metam.* I. 84–86.

Breadth of the Thorax.—4. The thorax is much broader in the transverse than in the antero-posterior diameter. This great breadth of the chest is peculiar to man and the highest species of ape; it throws the arms farther apart, and gives them a more extensive range; besides which, it diminishes the tendency there would otherwise be in the trunk to fall forwards. Contrast this with the chest of quadrupeds, compressed laterally, and deep from sternum to spine, so that the fore legs come nearer together, and fall perpendicularly under the trunk.

Curves of the Spine.—5. The vertebral column gradually increases in size towards the base. It is curved, which makes it all the stronger, and better adapted to break and diffuse shocks: and these curves, waving alternately, distribute the weight in the line of gravity. This line passes through all the curves, and falls exactly on the centre of the base. Observe, moreover, the length and size of the spinous processes in the lumbar region for the origin of the ‘erector-spinæ.’

Shape and Inclination of the Pelvis.—6. The weight of the vertebral column is supported on a sacrum broader in proportion than in any other animal. The iliac bones are widely expanded and concave internally; they support the viscera and give powerful leverage to the muscles which balance the trunk. The whole pel-

vis is remarkably broad, and thus the base of support is widened ; and the plane of its arch so inclines as to transmit the weight from the sacrum (or crown of the arch) vertically on to the heads of the thigh bones : lastly, the deepest and strongest part of the socket for the thigh bone is in the line of weight : consequently, the joint is never more secure than in the erect position.

With the broad and capacious pelvis of man, contrast the long and narrow pelvis of animals, which, instead of forming an angle with the spine, is almost in the same line with it.

Lower Limbs.—7. In proportion to the trunk, the lower limbs of man are longer than in any other mammal, the kangaroo not excepted. Their great length prevents their being adapted for locomotion in any but the erect attitude. The femur has a long neck, set on to the shaft at a very open angle, so that the base of support is rendered still wider. The long shaft of the femur inclines inwards, bringing the weight well under the pelvis, which is obviously of great advantage in progression : and when the leg is extended, the femur can be brought into the same line with the tibia ; thus the weight is transmitted vertically on to the horizontal plane of the knee-joint, while the articular surfaces of the bones are expanded and give adequate extent of support.

Contrast our long lower limbs with the short and bowed legs of the gorilla, chimpanzee, and orang-utan. Watch attentively one of these three apes (the highest of the mammalia below man) in the act of walking ; you will find that he supports himself alternately on the right and left knuckles as well as on his feet.

Feet.—8. The foot of man is broader, stronger, and larger in proportion to the size of the body than in any other animal ; so that man can stand on one leg, which no other mammal can do. Its strong component bones form a double arch of exceeding elasticity, which touches the ground at both ends, and receives the superincumbent weight vertically on its ‘ crown.’ The great bulk and backward prolongation of the os calcis at right angles to the tibia support the arch behind, and form a powerful lever for the great muscles of the calf, which raise the body in progression, while the bones of the great toe are proportionately strong, and form the chief support upon which the body may be raised.

Upper Limbs.—9. We see, then, that the whole fabric of the skeleton is so adjusted as to exempt the upper limbs from taking any part in its support. These are kept wide apart by the clavicles, and their component joints admit of the freest range of motion. The twenty-seven bones at the extremity of each constitute those instruments of consummate perfection, the ‘HANDS,’ of which, even if a formal dissertation¹⁰³ had not been written, one might well forbear to speak, since they have such eloquence of their own. ‘*Nam cæteræ partes loquentem adjuvant, hæ, prope est ut dicam, ipsæ loquuntur: his poscimus, pollicemur, vocamus, dimittimus, minamur, supplicamus, abominamur, time-mus; gaudium, tristitiam, dubitationem, confessionem, pœnitentiam, modum, copiam, numerum, -tempus, ostendimus.*’¹⁰⁴

Comparative Osteology.—Some of the vertebrata have bones which do not exist in man as such and are only represented in him by fibrous or cartilaginous tissue. Thus there is the bone of the heart, ‘*os cordis,*’ in the bullock—*bos taurus*--(No. 4), an example of the visceral system of bones or splanchno-skeleton. Another instance is the bony sclerotic of many fishes and some birds. This is well seen in a specimen from the sun-fish (No. 5). There was a ring of bone in the sclerotic of the extinct flying lizards (*Pterosauria*), as well as in that of the *Ichthyosauria*, the life-size models of which animals are seen at the Crystal Palace. In the *Phocidæ*, *Trichechus*, the walrus, and in many dogs, is found the ‘*os penis*’ (Nos. 3906, 3907, 3908, 3909, and 3910, the last showing a fracture which has been repaired). Another is the ‘*interclavicula*’ found in *Reptilia*. It is often, too, present in birds, though it is in them confluent with the clavicles. In many of the *Lacertilia* a partially ossified, or cartilaginous rod runs up from the symphysis of the ischia, and supports the front wall of the cloaca, and is called the ‘*os cloacæ.*’ In all pouched animals (*Marsupialia*), as in the kangaroo (*Macropus major*, *Ost. Ser. Coll. Surg. Mus.* 1724), and in the *Monotremata* (that is, in *Echidna* and *Ornithorhynchus*, *Ost. Ser. Coll. Surg. Mus.* 1698, 1699), are found the marsupial bones: ossifications, or often only chondrifications, of the internal pillars of the external abdominal rings.

OS HYOIDES.

(PLATE XXXVIII.)

Position and Use.—The os hyoides, so called from its likeness to the Greek letter Upsilon, is situated between the larynx and the root of the tongue. It is suspended from the styloid processes of the temporal bones by the stylo-hyoid ligaments, often partly ossified in man, and, generally, distinct bones in animals. When the neck is in its natural position, it can be plainly felt on a level with the lower jaw, and about one inch and a half behind it. It serves to keep open the top of the larynx, and affords attachment to the muscles which move the tongue.

It is divided, for the sake of description, into a 'body' or front part, and a 'greater' and a 'lesser cornu' on each side.

Body.—The 'body' (basi-hyal part) is the thickest and strongest part. Its *upper* surface is marked by the impressions of the muscles attached to it. There are, generally, a transverse and a perpendicular ridge: the latter is in the median line. Often there is a little projection from the middle, which is interesting as a rudiment of the process to which is attached the lingual bone of animals which runs into the substance of the tongue. Its *under* surface is slightly excavated (as seen in Plate XXXVIII. fig. 2), which shows a transverse section through the centre of the body. Into this hollow the thyroid cartilage rises behind the os hyoides in deglutition. The plane of the body is nearly horizontal; the anterior thyro-hyoid ligament is attached to its *posterior* border.

Cornua.—The *greater* cornu ('thyro-hyal' part) projects backwards about one inch and a half, not quite horizontally, but with a slight inclination upwards, and terminates in a blunt end, tipped with cartilage. Until the middle period of life, the great cornu is united to the body by cartilage; but this ossifies in the progress of age.

The *lesser cornu* ('cerato-hyal' part) is not much larger than a barleycorn, and projects backwards at an acute angle from the junction of the body and the greater cornu. It articulates with the body by a little joint, and is freely movable: the stylo-hyoid ligament is attached to the end of it.

The many muscles attached to the hyoid bone are shown in the plate.

The os hyoides is connected to the thyroid cartilage by three ligaments, which contain a large quantity of elastic tissue. These ligaments are:—1. The *anterior thyro-hyoid* (Plate LVII. fig. 1), which extends from the 'pomum Adami' to the upper and back part of the body of the os hyoides. 2. The two *posterior thyro-hyoid*, which extend, one on each side, from the end of the great cornu of the os hyoides to the superior cornu of the thyroid cartilage. The vacant space left in the dried preparation between the hyoid bone and the thyroid cartilage is closed in the recent state by the *thyro-hyoid membrane*.

Ossification.—The bone is ossified from five centres—one for the body, and one for each of its four cornua. The body and greater cornua begin to ossify in the last month of foetal life. The lesser cornua begin to ossify in the first year, and generally in middle age unite to the rest of the bone.

Comparative Osteology.—The posterior surface of the hyoid bone is concave from side to side and from above downwards. This concavity is characteristic of the higher mammalia. In the gorilla it will lodge the tip of the finger, while in the howling monkey, *Mycetes laniger*, it develops into a sac large enough to hold a pigeon's egg.

Notice a remarkable anterior projection from the front of the body of the hyoid bone of the horse, seen also more or less in many other animals and especially in birds. (Sep. Ser. Mus. Roy. Coll. Surg.)

THE LARYNX.

(PLATE LVII.)

Situation and Use.—The larynx is situated at the top of the trachea or windpipe. It answers a double purpose. It guards the opening through which the air passes into the lungs: it is the organ of the voice and of song. Its framework consists of a number of cartilages connected by joints and elastic ligaments in such a way that they can be moved upon each other by appropriate muscles; the result of this motion being to act upon two elastic ligaments termed the ‘vocal cords,’ upon which the voice essentially depends.

Thyroid Cartilage.—The thyroid cartilage (*θυρεός*, a shield) is so named because it shields the delicate apparatus behind it. It consists of two lateral symmetrical plates (*alæ*), united in front at an angle which forms the prominence termed ‘*pomum Adami*.’ This prominence, which is greater in the male than in the female, has a ‘notch,’ at the upper part, as if a portion of the angle had been sliced off to permit the cartilage to rise with greater facility behind the *os hyoides* in deglutition. More than this, there is a bursa of considerable size which diminishes friction between the surfaces. The bursa is practically interesting, because it may enlarge and form a cyst in front of the neck, sometimes as large as a pigeon’s egg.

Outer Surface and Ridge.—Look at the outer surface of the *ala* of the thyroid cartilage (fig. 1). It has an oblique ridge, running downwards and forwards, with tubercles at each end, indicative of the attachments of muscles. The ridge gives origin to the ‘thyro-hyoid’ and insertion to the ‘sterno-thyroid’ muscles. Behind the ridge is the origin of the inferior constrictor of the pharynx, extending down to the side of the cricoid cartilage. The *posterior* border of the *ala* is nearly vertical, and gives inser-

LARYNX.

Fig. 1.

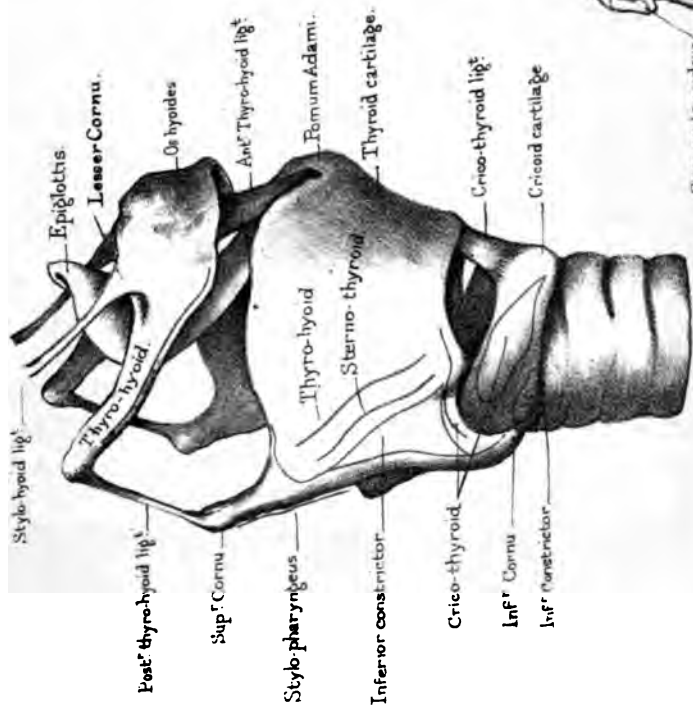


Fig. 2.

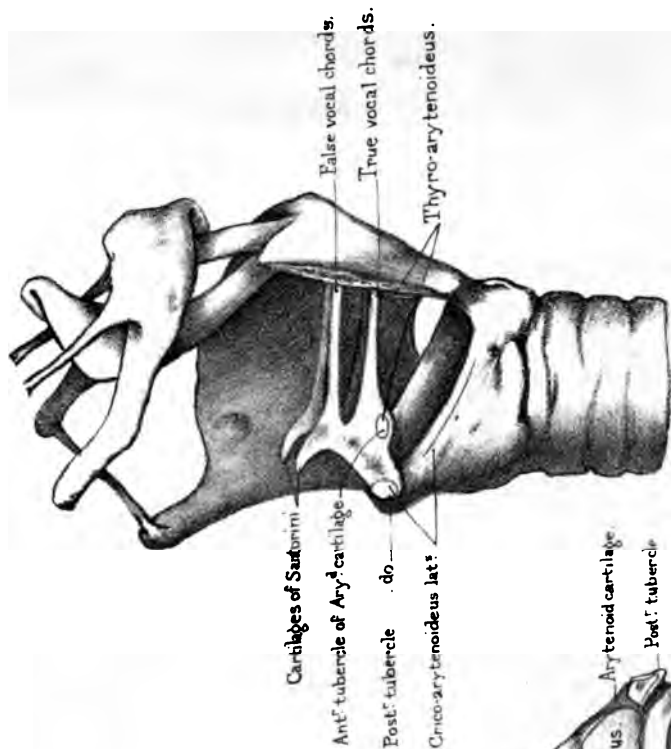
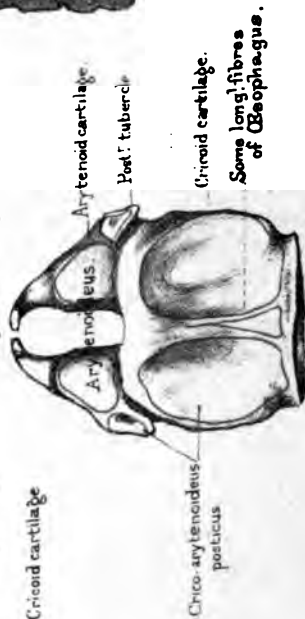


Fig. 3.





tion to the stylo-pharyngeus. The *inferior* border of the ala has generally two curves, and gives insertion to the 'crico-thyroid' muscle. This muscle arises from the side of the cricoid cartilage; consequently, when it acts, it draws the two cartilages together.

Cornua.—The posterior part of each ala has two projections, termed its 'cornua' superior and inferior. The superior cornu gives attachment to the posterior thyro-hyoid ligament. The inferior cornu articulates with the cricoid cartilage. This is a perfect joint, provided with a synovial membrane and ligaments. It is important to remember that the form of the joint admits of only vertical movement of the thyroid cartilage, the axis of motion being a transverse line drawn through both joints. Upon this movement depends the tuning of the vocal cords.

Angle.—So much for the outside of the thyroid cartilage. Now for the parts attached within the angle. To see them properly, one of the alæ should be removed, as in fig. 2. You then observe that the following objects are attached to the angle, beginning at the top: 1, the anterior thyro-hyoid ligament; 2, below this, the apex of the epiglottis; 3, lower down, the false vocal cords; 4, still lower, the true vocal cords; 5, below these, the origin of the 'thyro-arytenoideus'; lastly, at the lower border of the angle, is the attachment of the 'crico-thyroid' ligament.

Cricoid Cartilage.—The cricoid cartilage (Plate LVII.) forms a complete ring (whence its name), a little broader in the antero-posterior diameter than in the transverse. It is situated at the top of the trachea, immediately below the thyroid cartilage. The ring is not of the same depth all round. It is narrow in front, and from this part the upper border of the ring gradually rises, so that, behind, the ring is a full inch in vertical depth, and occupies part of the interval between the alæ of the thyroid. This slope of the cricoid towards the front permits the vertical play of the thyroid. It cannot be too strongly impressed upon a student that he should make his finger familiar, in his own neck, with the projections of the thyroid and the cricoid cartilages, and the slight depression between them, indicating the site of the crico-thyroid membrane. These parts lie, one below the other, in the middle line of the neck, and are the guides in the operation of laryngotomy

and tracheotomy. The operation of laryngotomy consists in dividing the crico-thyroid ligament transversely close to the cricoid cartilage, that the incision may be as distant as possible from the vocal cords.

Passing from the front towards the side of the cricoid cartilage, notice the origin of three muscles, namely—the ‘crico-arytenoideus lateralis’ along the upper edge (fig. 2); the ‘crico-thyroid’ in the middle (fig. 1); and, lower down, a portion of the ‘inferior constrictor of the pharynx.’

At the back part of the cricoid cartilage (fig. 3) there is on either side a broad excavation for the origin of the ‘crico-arytenoideus posticus.’ Generally these muscles are separated by a slight vertical crest which gives attachment to some of the longitudinal fibres of the œsophagus. At the top of the cricoid are the two small oval articular surfaces, one on each side, for the arytenoid cartilages, to be examined presently.

The side of the cricoid articulates with the inferior cornu of the thyroid cartilage by means of a perfect joint, provided with a synovial membrane and ligaments. The structure of this joint permits the two cartilages so to move upon each other that their opposite borders can be approximated by the ‘crico-thyroid’ muscle. It deserves especial attention, because the degree of this approximation regulates the tension of the vocal cords.

Lastly, the lower border of the cricoid is horizontal, and connected to the first ring of the trachea by an elastic membrane.

Arytenoid Cartilages and Cornicula Laryngis.—The arytenoid cartilages, so named from their resemblance to an ancient ewer (*ἀρύταινα*), are situated, one on each side, at the upper part of the cricoid (fig. 3). Each is somewhat pyramidal in form, with the apex above, looking towards its fellow, and slightly curved backwards. The apex of each is surmounted by a nodule of cartilage, termed the ‘cartilage of Santorini’ (‘corniculum laryngis’). The base presents an oval concave surface, which forms a perfect joint, with a corresponding convex surface, on the cricoid cartilage. This joint has a loose synovial membrane and ligaments, so that the arytenoid cartilages admit of being approximated or separated, a freedom of motion which is essential

to the dilatation and contraction of the glottis or chink between the true vocal chords through which the air enters the trachea.

Tubercles of the Arytenoid.—At the base of each arytenoid cartilage (Plate LVII. fig. 2) observe the *anterior* tubercle to which the true vocal cord is attached, and the *posterior* tubercle, which gives insertion to two muscles—namely, the ‘crico-arytenoideus lateralis’ and the ‘crico-arytenoideus posticus’: these muscles are inserted, not into the same side, but into *opposite* sides of the tubercle: the effect of which is that they antagonise each other.

Each arytenoid cartilage has three surfaces—a posterior, an anterior or external, and an internal. The posterior surface is excavated and has attached to it the ‘arytenoideus’ muscle (fig. 3), which crosses from one cartilage to the other, and fills up the gap between them. The anterior surface is also excavated, and occupied by the insertions of the ‘crico-arytenoideus lateralis’ and the ‘thyro-arytenoideus.’ The internal surface is flat, looks towards its fellow of the opposite side, and contributes to form part of the margin of the glottis.

Epiglottis.—The epiglottis is a structure composed of yellow elastic cartilage situated at the base of the tongue, and projecting over the upper part of the larynx like the flap of a valve. In shape it somewhat resembles the leaf of an artichoke. Its apex is attached to the angle of the thyroid cartilage. Its ordinary position is perpendicular, or nearly so, leaving the glottis free for respiration; but during deglutition the larynx is raised, and the tongue is depressed, so that the epiglottis becomes more horizontal, drops like a valve over the top of the larynx, and tends to prevent the entrance of food into it. This falling of the epiglottis is not produced by any special muscle; it is simply mechanical.

Cuneiform Cartilages.—These cartilages are the smallest and least essential of the whole group. They are found in the ‘aryteno-epiglottidean fold,’ a prominent line of mucous membrane running on each side from the edge of the epiglottis to the apex of the arytenoid cartilage. They are thin and narrow, not much larger than pin’s heads and not constant.

Thus there are nine cartilages in all, of which four—namely, the thyroid, cricoid and two arytenoid—are composed of hyaline cartilage

and are prone to ossify in old age. The remaining five are of yellow elastic fibro-cartilage, and have but little tendency to ossify.

Vocal Cords, True and False.—The vocal cords are four elastic ligaments, two on each side, extending horizontally backwards from the angle of the thyroid cartilage to the anterior part of the arytenoid. The two lower, and the most important, are termed the 'true' vocal cords, because, by their vibration, they produce the voice: the two upper cords are called 'false,' because they have little or nothing to do with the voice. The rapidity and accuracy with which the true vocal cords can change their tension, their form, and the width of the slit between them, render the voice the most perfect of musical instruments.

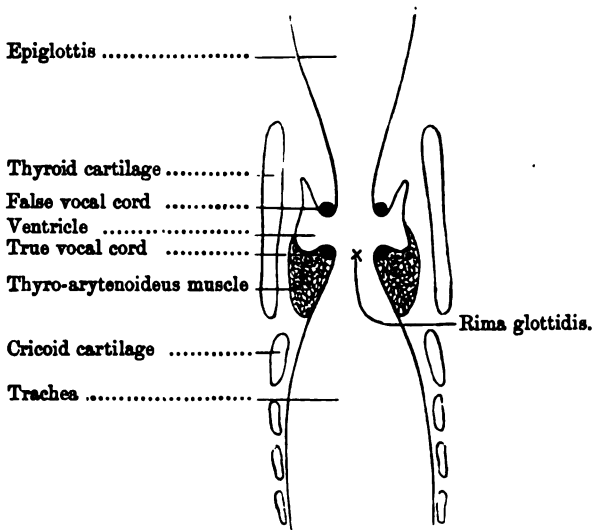
Attachments of Vocal Cords.—The precise attachments of these cords are best seen in the dried larynx, in which all the surrounding soft parts have been removed, as shown in Plate LVII. fig. 2. The true vocal cords are attached in front close together to the angle of the thyroid cartilage, about a quarter of an inch from its lower edge, and they diverge as they pass backwards to be attached to the anterior tubercle of the base of the arytenoid. The false cords also proceed from the angle of the thyroid a little higher than the true, to about the middle of the front part of the arytenoid. In the recent larynx these cords are not free all round, like the strings of a violin; they are only free along the sides which face each other; everywhere else the true cords are in contact with muscle, and the false with fat and areolar tissue.

Length of Vocal Cords.—What is the length of the true vocal cords? During life, their length is continually varying, to a slight degree, with the pitch of the voice; but, in the dead subject, they are about five-eighths of an inch in the adult male. From an examination of several male larynges, the cords are found to differ more or less in length in different individuals, though not more than one-twelfth of an inch. These individual differences in the length of the cords make corresponding variations in the natural tone of the voice: e.g. tenor, barytone, or bass. A deep voice coincides with the longer cords; a shrill voice with the shorter. In the female the cords are about one-fourth shorter than in the male. In boys, too, they are much

shorter than in the adult ; hence the peculiar voice of boys. At puberty the cords lengthen with the development of the larynx, and the voice is said to break.

Ventricles of the Larynx.—In the perfect larynx is a little recess on each side between the true and the false vocal cords, like a little side pocket. These recesses are called ‘the ventricles’ of the larynx, and are best examined by cutting open the larynx. Their shape, depth and situation are represented in the outline of the subjoined fig. 78, taken from a transverse perpendicular section of the larynx. They appear to allow free space for the vibration of the vocal cords and probably strengthen the voice. They are lined by the mucous membrane of the larynx, and the bottom of each is supported by the ‘thyro-arytenoideus’ muscle. The length of the ventricles from before backwards corresponds with the length of the vocal cords. Their greatest vertical depth is towards the front, which is the part represented in the section.

FIG. 78.



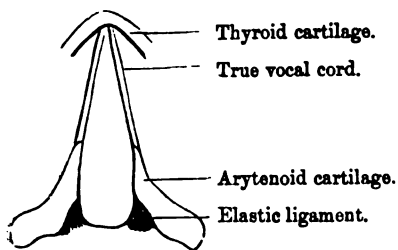
PERPENDICULAR SECTION, SHOWING THE VENTRICLES OF THE LARYNX.

Size of the Ventricles.—The ventricles of the larynx are large enough to lodge a foreign body, such as a pea. A pill forced

down a child's throat against its will has been known to catch in one of the ventricles, and occasion death, after a few struggles, from spasm of the glottis.

Rima Glottidis.—The term 'rima glottidis' or 'glottis' is applied to the interval between the true vocal cords through which

FIG. 79.

SHAPE OF THE GLOTTIS
WHEN AT REST.

the air passes into and out of the trachea. It is about one inch in length. Its boundaries (fig. 79) are formed by the vocal cords and by the arytenoid cartilages. The vocal cords form about the anterior two-thirds, the cartilages about the posterior third of the opening. The glottis admits of

being made wider, or narrower, or may even be completely closed, by the action of muscles which we shall examine presently. In a state of rest it is triangular; the apex being in front at the thyroid cartilage, and the base between the arytenoid, as shown in fig. 79, where the arytenoid are cut through on a level with the vocal cords. When the glottis is dilated in *inspiration* by the 'crico-arytenoidei postici,' it becomes spear-shaped, as seen in fig. 81. During *expiration* the glottis gradually resumes its triangular shape or state of rest; and this return to a state of repose is effected, not by muscle, but by an elastic ligament shown in fig. 81, which draws the arytenoid cartilages towards the mesial line. The glottis, like the chest, is dilated during inspiration by muscular tissue; like the chest, also, it is contracted during expiration by elastic tissue.

Muscles of the Larynx.—There are nine muscles which act specially upon the rima glottidis—four on each side, and one in the middle. The four on each side are the 'crico-thyroidei,' the 'crico-arytenoidei postici,' the 'crico-arytenoidei laterales,' and the 'thyro-arytenoidei.' The single one in the middle is the 'arytenoideus.'

Crico-thyroid Muscles.—The 'crico-thyroid' is a short and strong muscle. It arises from the side of the cricoid cartilage,

and is inserted into the lower border of the thyroid, including the lesser cornu. Its action is to stretch the vocal cords. It does this by depressing the thyroid cartilage, the arytenoid cartilage

FIG. 80.

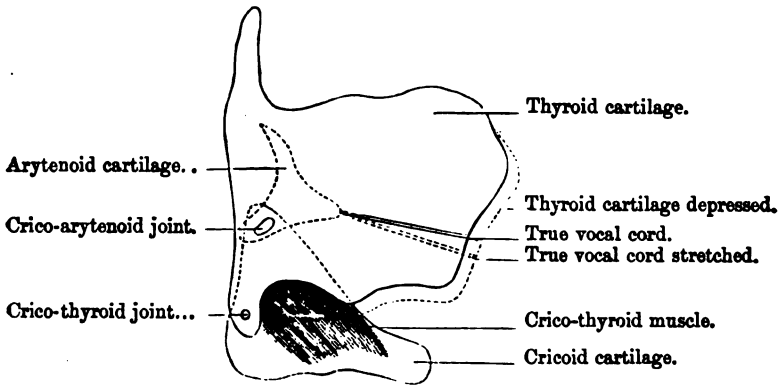
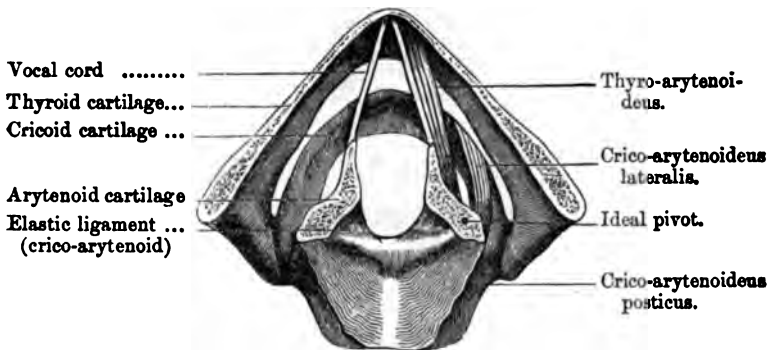


DIAGRAM SHOWING THE ACTION OF THE CRICO-THYROID MUSCLE.

remaining fixed. Under this condition the thyroid cannot be depressed without increasing the distance between the attachments of the vocal cords, as shown by the dotted line in fig. 80. Consequently the 'cricio-thyroid,' when in action, must elongate the vocal cords.

FIG. 81.



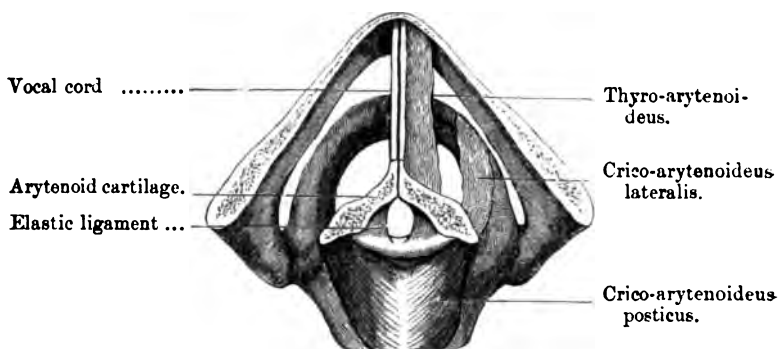
GLOTTIS DILATED. MUSCLES DILATING IT REPRESENTED WAVY.

Cricio-arytenoidei Postici.—Each 'cricio-arytenoideus posticus' arises from the posterior part of the cricoid cartilage, and is

inserted into the posterior tubercle of the arytenoid. The muscle is seen in action (denoted by wavy lines) in fig. 81. Its action is to dilate the glottis. It does this by drawing the *posterior* tubercle of the arytenoid *towards* the mesial line, and therefore the *anterior* tubercle *from* the mesial line. In this movement the arytenoid cartilage rotates upon the cricoid as upon a pivot. Moreover, the arytenoid cartilage is a lever of the first order; the fulcrum or ideal pivot being intermediate between the power at the posterior tubercle and the weight or resistance at the anterior. The muscle in question is a most important one. It is a muscle of inspiration. It dilates the glottis every time we inspire. During expiration, when the glottis is restored to its state of rest, not by muscular action, but by an elastic ligament, the 'crico-arytenoid,' marked in fig. 81, the muscle relaxes, and has time to rest. This alternate contraction and relaxation of the 'crico-arytenoidei postici' is perpetually going on, from the first moment of life till the last.

Crico-arytenoideus Lateralis.—Each 'crico-arytenoideus lateralis' arises from the upper border of the cricoid cartilage, and is inserted into the posterior tubercle of the arytenoid. Its action.

FIG. 82.



GLOTTIS CLOSED. MUSCLES CLOSING IT REPRESENTED WAVY.

is to assist in closing the glottis, as seen in fig. 82. It does this by rotating the arytenoid cartilage in a way directly the reverse of the muscle last examined.

Arytenoideus.—The ‘arytenoideus’ muscle arises from the back of one arytenoid cartilage, and is inserted into the back of the other. (Plate LVII. fig. 3.) It clasps the two cartilages together, and therefore assists very materially in closing the glottis.¹⁰⁵

Thyro-arytenoidei.—Each of these muscles arises from the angle of the thyroid, and is inserted into the front surface of the base of the arytenoid. They relax the vocal cords, since they tend to draw together the cartilages to which they are attached. More than this, they assist in narrowing the glottis. But their special action appears to be that of bringing the lips of the glottis parallel to each other; that of placing them, in fact, in the ‘vocalising’ position. The glottis must be made not only a very narrow chink, but its lips must be brought parallel to each other, before they can be made to vibrate by the stream of the air, in such a manner as to produce voice or song. The motions of the glottis in singing, speaking, breathing, and coughing can be distinctly seen in the laryngoscope.

The following is a tabular arrangement of the action of the muscles of the larynx :

ANTAGONISTS	{ Crico-thyroideistretch the vocal cords } govern the pitch of
	{ Thyro-arytenoidei.....relax the vocal cords } the notes.
ANTAGONISTS	{ Crico-arytenoidei postici.....open the glottis... } govern the opening
	{ Crico-arytenoidei laterales } close the glottis... } of the glottis.
	{ Arytenoideus } }

THE ANATOMY OF THE EAR.

IN describing the anatomy of this intricate and delicate organ, a general outline of its structure will first be given, and afterwards the details of its several parts.

General Idea of the subject.—To obtain a general idea of the organ of hearing, look at the diagram, fig. 1, Plate LVIII. In this is seen the elastic fibro-cartilage termed the ‘pinna’ of the ear, which collects the sonorous undulations of the air, and transmits them down the passage called the ‘meatus auditorius externus.’ This passage, about an inch and a quarter in length, is a little contracted in the middle, where its floor is a little raised. It is closed at the bottom by a fibrous membrane (*membrana tympani*) which is fixed in a groove in the bone, is placed obliquely, and stretched in all respects like the parchment of a drum, except that its outer surface is a little concave.

Tympanum.—On the inner side of the *membrana tympani* is a small chamber in the substance of the temporal bone, termed the ‘tympanum’ or middle ear. This chamber is filled with air, which is admitted through a tube (Eustachian tube) about an inch and a half long, leading from the back part of the nostrils into the front part of the tympanum. Thus there is an equilibrium of air on both sides of the *membrana tympani*. In fact, the Eustachian tube performs the same office for the ear as the hole which is made in the side of a drum for the necessary purpose of opening a communication with the external air. Opposite to the Eustachian tube, that is, at the back part of the tympanum, are the irregular openings of the mastoid cells, which also contain air. All these air cavities are lined by a continuation of the mucous membrane which lines the passages of the nose. This explains the degree of deafness which is often produced by a common

cold, or other disease of the throat; the Eustachian tube being temporarily obstructed by the swelling of its lining membrane.

Ossicula Auditus. Malleus, Incus, and Stapes.—In the tympanum itself we find three little bones (ossicula auditus) known separately by names more descriptive of their shape than their office—‘malleus,’ ‘incus,’ and ‘stapes.’ These bones are connected by perfect joints, so as to form a continuous chain, surrounded by atmospheric air, across the cavity of the tympanum; and the mucous membrane is reflected over them. The handle (*manubrium*) of the malleus at one end of the chain is attached to the ‘*membrana tympani*,’ and the foot-plate of the stapes at the other end closes the ‘*fenestra ovalis*,’ an opening on the inner wall of the tympanum leading to the ‘*vestibule*’ of the internal ear. Both ends of the bony chain are attached to membrane, since the foot-plate of the stapes does not exactly fit into the *fenestra ovalis*; membrane intervening between their edges. Moreover, certain little muscles are attached to the bones, and slacken or tighten the membranes. Besides the *fenestra ovalis*, there is another opening in the inner wall of the tympanum, called the ‘*fenestra rotunda*.’ It leads into the cochlea and is closed by membrane.

Internal Ear.—The internal ear, often called, on account of its intricacy, the ‘*labyrinth*,’ consists of a little chamber termed the ‘*vestibule*,’ the three ‘*semicircular canals*,’ and the ‘*cochlea*.’ All these parts are embedded in the petrous portion of the temporal bone, like passages cut out of a solid rock. Hence the great difficulty of exploring them. Bear in mind their relative position. The ‘*vestibule*’ is in the middle, the canals are behind, and the cochlea is in front.

Vestibule.—The vestibule communicates, behind, with the five openings of the *semicircular canals*; in front, with the cochlea; on the outer side with the tympanum through the *fenestra ovalis* (occupied by the stapes); and on the inner side by minute apertures with the *meatus auditorius internus*, through which the auditory nerve enters the ear. These apertures transmit those branches of the auditory nerve which supply the membranous contents of the vestibule and the *semicircular canals*.

Cochlea.—The cochlea, so named from its resemblance to a

snail's shell, is an exceedingly curious structure. It is placed so that the base of the shell corresponds to the bottom of the meatus auditorius internus, while the apex points forwards and outwards towards the Eustachian tube. It is formed by the spiral convolutions of two gradually tapering tubes, or rather by one tube separated into two compartments by a longitudinal septum (*lamina spiralis*), composed partly of thin bone, but chiefly of membrane. In the diagram the course of the septum is indicated by a dotted outline. This septum is the most important part of the cochlea, because the auditory nerve expands upon it. It runs all through the tube, except at the apex, where it suddenly terminates in a curved hook, and leaves an aperture (*helicotrema*), so that the two portions of the tube communicate. One portion of the tube (*scala vestibuli*) opens into the vestibule; the other portion (*scala tympani*) leads into the tympanum through the 'fenestra rotunda.' This last foramen is open only in the dry bone; in the recent state the fenestra rotunda is closed by the 'membrana tympani secundaria,' which therefore has the air of the tympanum on the one side and the fluid in the cochlea on the other. The central pillar of the cochlea round which the tube makes two and a half turns is called the 'modiolus' or 'axis.'

Semicircular Canals.—The semicircular canals are three in number, and are called, from their position, 'superior,' 'posterior,' and 'external.' They are placed in planes at right angles to each other like the faces of a cube. Each canal forms the greater part of a circle, and opens at each end into the vestibule. There are only five openings, since two of the canals have an opening in common. Each canal has a dilatation at one end termed the 'ampulla;' this makes room for a corresponding dilatation of the membranous canal within it, upon which the auditory nerve expands. The 'ampulla,' therefore, is the most important part of each canal.

Uses of these Excavations.—These curious and elaborate excavations in the petrous bone form receptacles for a fluid in which floats the delicate membrane destined to receive the terminal filaments of the auditory nerve. This membrane is the very essence of the organ of hearing. It is to the ear what the

retina is to the eye. In the vestibule and semicircular canals it forms a continuous, but closed sac, which copies pretty accurately the shape of these cavities, without being in contact with their bony walls. It is bathed within and without by a thin albuminous fluid. That part of the fluid within the membrane is called the 'endolymph'; that without, the 'perilymph,' or 'liquor Cotunnii.' Within the cochlea the membrane is arranged in a different manner. It forms here the greater part of the 'lamina spiralis,' and encloses a third scale or spiral passage, the 'canalis membranacea,' or 'canalis cochleæ,' absent in the macerated labyrinth. Inside this membranous canal is a series of cellular bodies arranged in a very complicated manner, and known as the 'organ of Corti.' The membranous canal is filled with endolymph; the cavities of the scala vestibuli and scala tympani are occupied by perilymph.

The auditory nerve enters the ear through the meatus auditorius internus. At the bottom of this passage are a multitude of small foramina, which transmit the minute subdivisions of the nerve to their respective destinations. Some are distributed upon the sac in the vestibule; some upon the dilatations (ampullæ) of the membranous semicircular canals; others run down the axis of the cochlea, and are distributed to the structures within the canalis membranacea.

Probable Function of these several Parts.—Now for the explanation, usually received, of the function of these several parts. The waves of sound, collected by the cartilage of the ear, pass down the external auditory passage, strike upon the membrana tympani, and cause it to vibrate. These vibrations are carried by the little bones across the tympanum to the membrane, which closes the 'fenestra ovalis,' or opening into the vestibule. This membrane, thus thrown into vibration, communicates motion to the fluid in the labyrinth; the filaments of the auditory nerve receive the impression and transmit the sensation of sound to the brain. The vibrations of the membrana tympani excite corresponding vibrations in the air within the cavity of the tympanum, which again communicates them to the membrane closing the fenestra rotunda, and through this they reach the cochlea. Here

we have a ready explanation of the use of the fenestra rotunda and the membrane closing it : that is, we have, interposed between air and a fluid, a tense membrane, which is the very best medium for transmitting, with increased intensity, vibrations from one to the other.

After the preceding sketch of the anatomy of the ear, proceed now to a more minute examination of its component parts. It is taken for granted that the learner is already familiar with the anatomy of the temporal bone described at page 52.

Meatus Auditorius Externus.—This passage leads to the membrana tympani. Its outer third is formed by a tubular continuation of the cartilage of the ear ; its inner two thirds by the osseous canal in the temporal bone. The cartilaginous part is united by fibrous membrane to the rough margin of the processus auditorius. The cartilage, however, does not itself form a complete tube ; there is a slight deficiency at the upper part, completed by fibrous membrane. There are also one or two vertical fissures in the cartilage. These breaks in the cartilage give greater freedom of motion ; they are interesting practically, as explaining how collections of matter in the parotid gland sometimes make their way into the meatus auditorius.

Length.—The length of the meatus, measured from the middle of its external orifice to the middle of the membrana tympani, is about one inch and two or three lines. The anterior wall is about one-fourth of an inch longer than the posterior, in consequence of the oblique direction of the membrana tympani.

Direction.—The direction of the meatus is inwards and forwards. It describes a slight curve with the concavity downwards. Besides this general curve, the cartilaginous part is slightly curved with the concavity forwards, and the osseous part with the concavity backwards. Altogether, the meatus has such a curious shape that it cannot be well understood without looking at a cast of it. Every surgeon knows how difficult it is to see the whole of the membrane of the tympanum at one view : one can seldom see more than a part of it, however much the ear be dilated and pulled so as to straighten the outer curve. The narrowest part of the meatus is

4
5
6

about the middle. Beyond this point we ought not to introduce the speculum.

Meatus in the Infant.—The preceding description of the external auditory meatus refers to its condition in the adult. In infancy, the meatus is extremely short on account of the non-development of the bony portion, which at this period is a mere ring (see ‘Temporal Bone’). The membrana tympani, too, is almost on the plane of the base of the skull; this is a conspicuous feature in the cranium of a new-born child, where the membrane absolutely lies on the floor of the meatus. It is most important that a surgeon should bear these facts in mind when examining the ears of very young children.

Insects sometimes find their way down the meatus and cause intense pain. An instance is related by Wilde¹⁰⁶ which is worth giving, if only to show how to dislodge them: ‘I remember being out shooting with a friend, who, suddenly exclaiming, “Oh, an earwig!” and throwing aside his gun, fell on the ground, making the most piteous groans, and rolling about in agony. Suspecting that some insect had got into his ear, I procured some water from a ditch, and poured it into the meatus. While watching the result, a little animal, well known among anglers as the hawthorn fly, crept out, and my friend was instantly relieved.’

Membrana Tympani.—The membrana tympani is a thin, semi-transparent, fibrous membrane, of a greyish colour, placed very obliquely at the bottom of the meatus auditorius externus. Its direction is downwards, forwards, and inwards. This obliquity increases the extent of surface; so that every wave of sound, reflected down the meatus, must fall upon it. Its circumference, which is nearly circular, is fixed into a groove in the bone, so fine that it might have been traced with the point of a needle. (Plate LVIII. fig. 2.) This groove, however, does not form a complete circle: it is deficient at the upper part, where the membrana tympani is, more obviously than elsewhere, continuous with the skin lining the meatus.

The membrana tympani is not flat, like the parchment of a drum, but slightly conical, with the apex towards the tympanum. This shape seems given to it by the handle of the malleus,

which draws the membrane a little inwards. The handle of the bone can be seen in the living subject, like a thin white streak, which is not quite vertical, but inclines slightly backwards.

Many times a hole exists in the upper part of the membrane, even in cases where there is no obvious defect of hearing during life. This sufficiently explains why some persons who are not deaf can blow the smoke of tobacco through the ear as well as through the nose.

Structure of the Membrana Tympani.—Thin as it is, the membrana tympani is very strong. It has three strata: an outer stratum of cuticle; a middle, fibrous, on which its strength chiefly depends; and an internal, mucous. (Plate LX. fig. 3.) The middle stratum is composed of fibres radiating and circular, but no longer considered muscular. It is this coat which is fixed into the bony groove, and contains in its very substance the handle of the malleus. The dermal stratum is composed of an extremely thin layer of the true skin, continuous with that lining the meatus auditorius externus. The mucous lining is continuous with the lining of the tympanum. The membrane is well supplied with blood by arteries derived from the stylo-mastoid and the tympanic branch of the internal maxillary.

Tympanum, or Middle Ear.—We need not repeat what has been said already about the tympanum, but pass on to examine what is to be seen on its several aspects, namely: its external aspect, its internal, its anterior and posterior, its superior and its inferior.

External Aspect.—On the outer aspect of the tympanum there is the bottom of the meatus auditorius, closed by the membrana tympani.

Internal Aspect.—On the inner aspect of the tympanum (Plate LVIII. fig. 2) are seen—1. The fenestra ovalis leading to the vestibule: this is open in the dry bone, but closed in the recent state by the base of the stapes which is held to the margins of the fenestra by ligamentous fibres. The fenestra ovalis looks outwards towards the membrana tympani. 2. The fenestra rotunda: this, in the recent state, is also closed by membrane (membrana

tympani secundaria); in the dry bone it leads to the tympanic scale of the cochlea, and also into the vestibule; but the fenestra does not communicate with the vestibule in the perfect state. The fenestra rotunda looks almost directly backwards. 3. The promontory: this is formed by the bulging of the first turn of the cochlea; its surface is marked by grooves for the ramifications of Jacobson's nerve.

Anterior Aspect.—On the anterior aspect of the tympanum, we have—1. The bony canal for the 'tensor tympani' (in the drawing, this canal is cut open). Just before its termination in front of the fenestra ovalis, the canal makes a sudden curve outwards, in order to form a little pulley for the tendon of the muscle within. In most bones this part of the canal is broken, and has the appearance of a little spoon; for this reason, it is called the 'processus cochleariformis.' 2. The Eustachian tube. 3. The orifice of the Glaserian fissure which transmits the 'laxator tympani' and the chorda tympani nerve. In about five specimens out of six, the chorda tympani runs through a little canal, close to, and a little above the Glaserian fissure; but this 'canal of Huguier,' as it has been termed, is of no practical moment, and hardly deserves a new name.

Posterior Aspect.—On the posterior aspect of the tympanum, are—1. The opening into the mastoid cells. 2. The pyramid—a small projection containing a canal, about the size of a bristle, which lodges the 'stapedius muscle.' At the base of the pyramid (but within it) are two minute canals which transmit, the one an artery, the other a nerve, to the stapedius. The pyramid is always supported by a minute bony column, which extends like a flying buttress from its apex to the promontory. 3. The foramen chordæ, or 'iter chordæ posterius.' This minute foramen is a little below the level of the pyramid, and close to the groove for the attachment of the membrana tympani. Introduce a bristle into it, and you find that it leads into the 'aqueductus Fallopii.' It transmits the chorda tympani nerve. This nerve is a branch of the facial (which, remember, is contained in the 'aqueductus Fallopii': see Plate LX. fig. 4). It comes up through the foramen chordæ, runs, not across the tympanum, but


across the membrana tympani, outside the mucous membrane, between the handle of the malleus and the long process of the incus; it leaves the membrane through the Glaserian fissure (or through a distinct canal) and, joining the gustatory, eventually goes to the submaxillary ganglion.

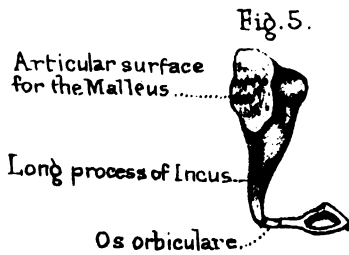
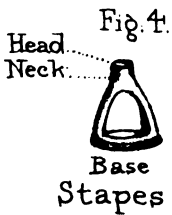
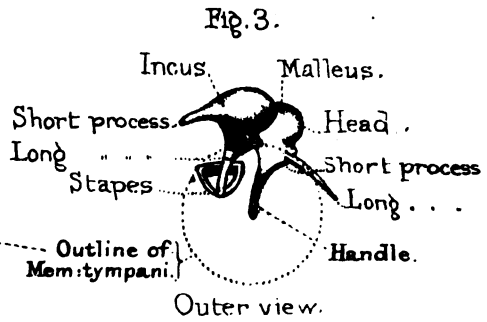
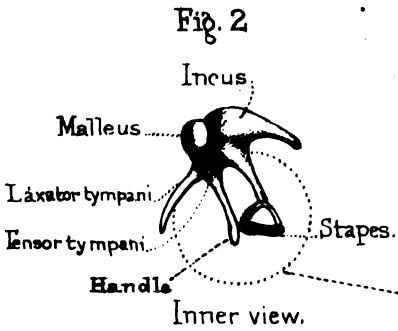
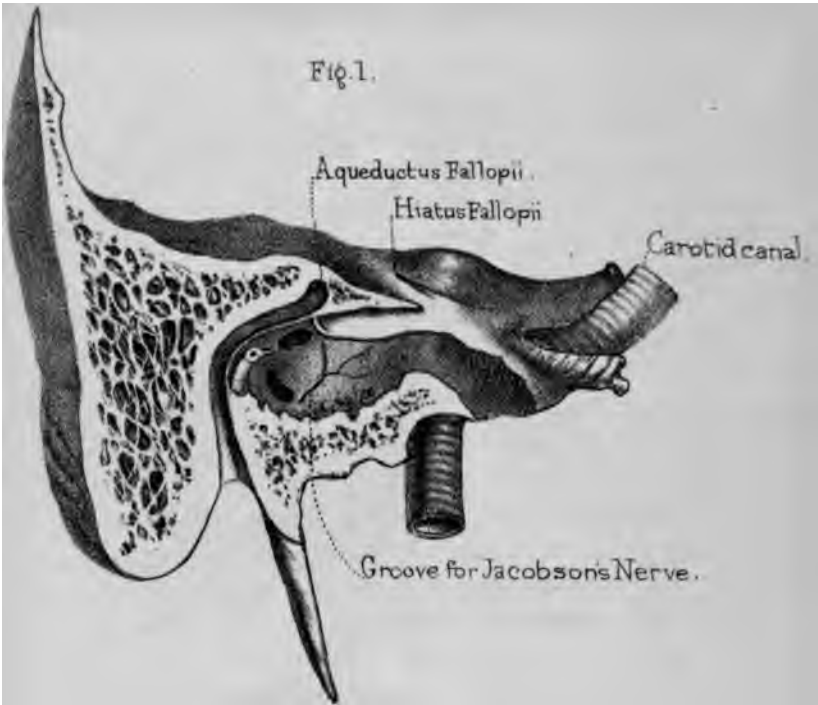
Superior Aspect.—On the superior aspect of the tympanum is a thin plate of bone which separates the cavity of the tympanum from that of the cranium. This is an important relation. For it shows how readily inflammation might spread from the tympanum to the base of the brain.

Inferior Aspect.—The inferior aspect, or floor of the tympanum, is formed by the jugular fossa, which lodges the jugular vein. A little in front of this fossa is the canal for the carotid artery, which is separated from the tympanum only by a thin scale of bone. The vicinity of these great vessels explains the sudden and profuse hæmorrhage which sometimes, though rarely, occurs from the ear when diseased. Professor Porter speaks of blood gushing from the ear with a rapidity such as he never witnessed in a surgical operation.¹⁰⁷ Ulceration had extended into the carotid artery.

In another case of sudden and profuse bleeding from the ear, Mr. Syme tied the carotid artery.¹⁰⁸ The patient died. He however tied the carotid in another similar case in which the patient recovered. Dissection discovered that the blood came from the lateral sinus, near the jugular fossa, the thin bony septum between that fossa and the tympanum having been destroyed by ulceration. Looking at the proximity of these large vessels, there is no wonder that bleeding from the ear, after injury to the head, makes one suspect the existence of a fracture through the tympanum.

In the floor of the tympanum there are a number of minute holes, among which especially note *one*, the upper opening of the canal for Jacobson's nerve. The lower opening of the canal is at the base of the skull, on the little crest of bone which separates the jugular fossa from the carotid canal. The nerve in question is a branch of the glosso-pharyngeal. It enters the tympanum, and ramifies upon the promontory, forming what is called the 'tympanic plexus.' It supplies the mucous membrane of the

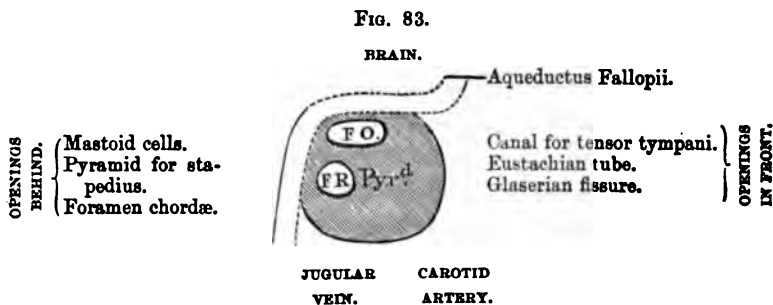




tympanum. Its principal branches are generally indicated by grooves made for their passage on the promontory. In a preparation where there appeared to be neither groove nor nerve, the nerve was subsequently found lodged in a complete bony canal within the promontory.

Aqueductus Fallopii.—The ‘aqueductus Fallopii,’ or canal for the facial nerve, which supplies all the muscles of expression of the face (Plate LIX. fig. 1.), commences at the bottom of the meatus auditorius internus; it runs for a short distance outwards, then turns horizontally backwards along the inner wall of the tympanum, just above the fenestra ovalis, and, lastly, descending behind the tympanum, emerges at the stylo-mastoid foramen. Its course suggests how liable the nerve is to be injured in fracture through the temporal bone, or in disease of the ear. While in this canal the nerve sends off three important branches, all to ganglia. These are shown in Plate LX. fig. 4. The first branch, the greater petrosal, or Vidian, runs down the hiatus Fallopii to the spheno-palatine ganglion; the second, or lesser petrosal, goes to the otic ganglion; the third, or chorda tympani, runs with the gustatory nerve to the submaxillary ganglion. Two less important nerves are also given off from the facial in the aqueductus Fallopii, namely, the external petrosal which communicates with the sympathetic on the middle meningeal artery, and the nerve to the stapedius muscle.

The objects seen on the inner wall of the tympanum may be better understood in the following tabular form:—



Little Bones in the Tympanum.—The three little bones in the tympanum are drawn larger than natural, but in their

proper relative position, Plate LIX. figs. 2, 3, 4, and 5. In fig. 3, you are supposed to be looking at them from the meatus auditorius; in fig. 2, from the inside of the tympanum. The dotted line in each figure is intended to represent the outline of the membrana tympani.

Malleus.—The malleus or hammer presents a head, a neck, and a handle (manubrium). The ‘head’ is the large round part above the membrana tympani. It articulates posteriorly with the incus by means of a concavo-convex joint, crusted with cartilage and provided with a synovial membrane. The ‘neck’ is the narrow portion between the head and the handle. From the front of the neck springs the ‘long process’ or ‘processus gracilis’ which runs down the Glaserian fissure and gives insertion to the ‘laxator tympani.’ In infants this ‘processus gracilis’ may be removed whole, together with the rest of the malleus; but, in the adult, it is adherent to the temporal bone and cannot be extracted entire. The handle or ‘manubrium’ descends nearly perpendicularly from the neck. Near the root of the handle is a little projection called the ‘short process,’ which presses against the upper part of the membrana tympani. The handle itself terminates in a slightly flattened, outwardly curved extremity, a little below the centre of the membrane. On the inner side of the handle, and below the processus gracilis, is inserted the ‘tensor tympani.’

Right or Left?—This bone will be in the same position as the corresponding one in the student’s body, if he hold the articular surface backwards, the handle downwards, and the processus brevis outwards.

Incus.—The incus, or anvil, lies behind the malleus. It has a body, a short, and a long process. The body is convex, placed above and behind the membrana tympani, and has a concavo-convex surface which articulates with the head of the malleus. The ‘short process’ extends horizontally backwards into the mastoid cells, and is fixed there by a ligament. The ‘long process’ descends nearly vertically, parallel to the handle of the malleus, and, like it, is a little convex outwardly. Towards the extremity it suddenly turns up and supports, on a narrow

pedicle, the orbicular process formerly termed 'os orbiculare' (fig. 5).

Right or Left?—This bone will be in the same position as the corresponding one in the student's body, if he hold the short process backwards, the long process downwards and inwards.

Os Orbiculare.—The little 'os orbiculare,' considered by some as a separate bone, is always ankylosed in the adult to the long process of the incus; but it is connected with the stapes by a very distinct joint.

The Stapes.—The stapes, or stirrup, is placed horizontally, with the base in the fenestra ovalis. It has a head, a neck, two 'crura' or branches, and a base or foot-plate. The head articulates by a concave surface with the orbicular process of the incus. The neck gives attachment behind to the 'stapedius.' (Plate LX. fig. 2.) The anterior branch of the stirrup is shorter and less curved than the posterior; both are grooved on their concave sides, and the interval is closed by a membrane. It has been stated that the groove in the crus forms half an Haversian canal, lodging a small vessel.¹⁶⁹ The 'base' is similar in form to the fenestra ovalis, which it nearly fills, and their margins are united by an annular ligament. The lower border of the base is straighter than the upper, and its anterior extremity is the sharpest.

Right or Left?—This bone will be in the same position as the corresponding one in the student's tympanum, if he hold the base inwards, its straighter side downwards, and the shorter limb forwards.

Ossification.—All the bones in the tympanum are ossified and well developed at birth. The ear-bones of a new-born infant and those of the giant O'Brien, seven feet seven inches high, are very nearly the same size. Of the four bones, the stapes is the most essential to hearing. Disease may destroy the others, and still the patient may hear: but when the stapes falls out, the fluid in the vestibule escapes, and inevitable deafness results.

Little Muscles moving the Bones in the Tympanum.—There are two well-marked muscles with distinct tendons attached to the bones in the tympanum, namely, the tensor tympani and

the stapedius. (Plate LX. figs. 1, 2.) The 'laxator tympani' is still described as a muscle by some anatomists, though its muscular structure is doubted by many.

Tensor Tympani.—The 'tensor tympani' is a well-marked muscle. It arises from the apex of the petrous bone, and from the cartilage of the Eustachian tube, and is inserted into the handle of the malleus, just below the processus gracilis. The muscle is lodged in the bony canal running above and parallel with the Eustachian tube; and when its tendon reaches the end of the canal, which forms an elbow, it is reflected at a right angle to reach its insertion. From origin to insertion the muscle is enclosed in a strong fibrous sheath. The tendon slides within the sheath, and has a synovial membrane.

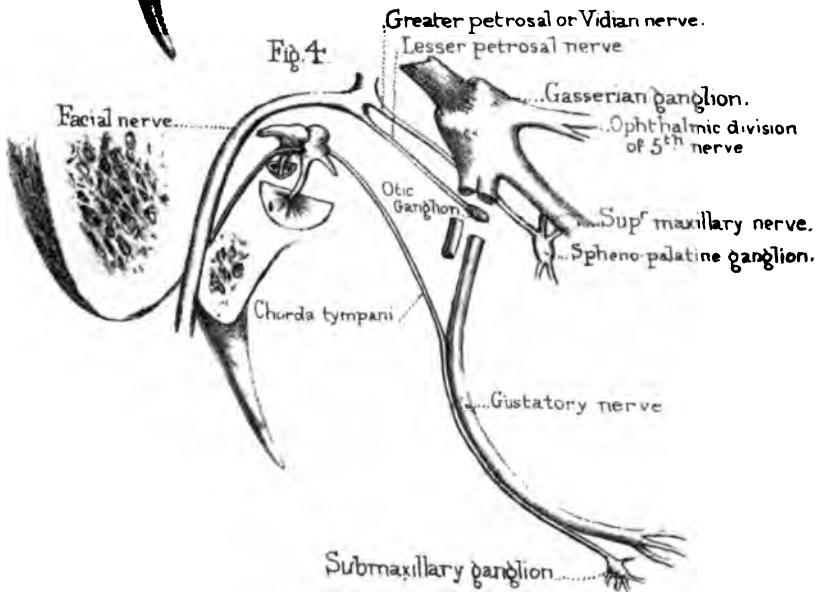
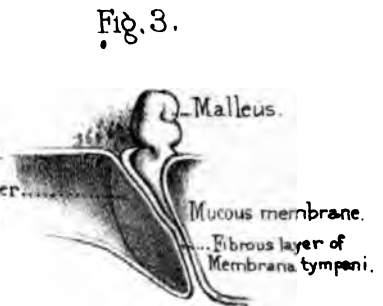
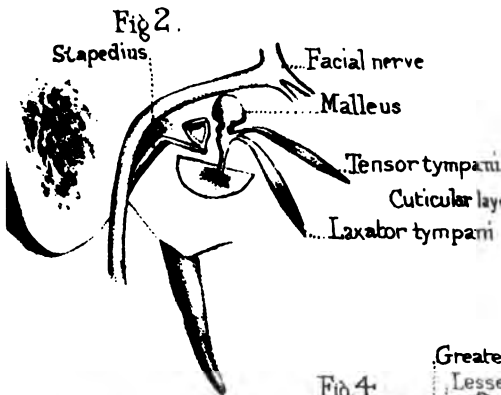
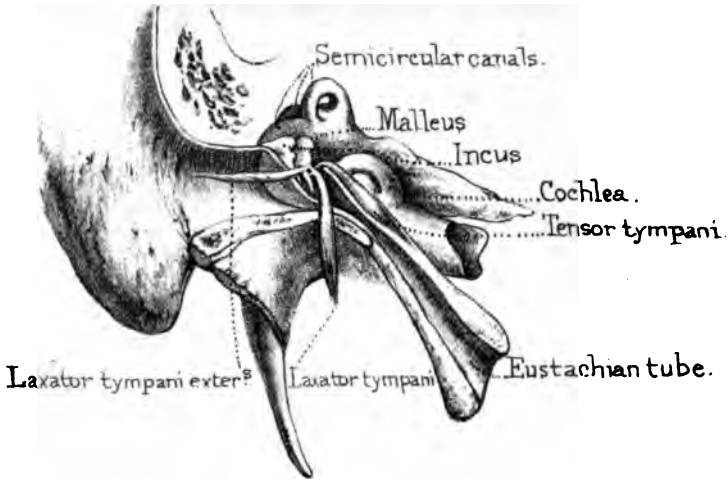
Laxator Tympani.—The 'laxator tympani' arises from the spine of the sphenoid bone, runs up the Glaserian fissure, and is inserted into the processus gracilis of the malleus. Like the last muscle, it is surrounded by a sheath. Whilst there is no doubt whatever about the muscularity of the 'tensor tympani,' many modern anatomists believe the 'laxator tympani' to be a ligament.


Stapedius.—The 'stapedius' arises in the canal of the pyramid. Its little tendon, coming out of the canal at the apex, is reflected outwards, and inserted into the posterior part of the neck of the stapes. Anatomists are not agreed about the precise use of the stapedius. One of its actions would appear to be to tilt the stapes backwards, and thus diminish the pressure upon the fluid in the vestibule.

The internal ear or labyrinth, comprising the vestibule, semi-circular canals, and cochlea, should now be examined. And first of the vestibule, entered through the 'fenestra ovalis.'

Vestibule.—The vestibule is of an ovoid form, measuring about $\frac{1}{3}$ th of an inch in its long diameter, and rather less in its short. Posteriorly it receives the five openings of the semi-circular canals and the opening of the 'aqueductus vestibuli'; anteriorly, and at its lower part, is the opening into the vestibular scale of the cochlea; on its external wall is the 'fenestra ovalis.' In all, then, there are eight openings into the vestibule. The internal wall of the vestibule corresponds with a part of the

Fig. 1.





bottom of the 'meatus auditorius internus.' On this inner wall, as shown in Plate LXI. fig. 3, are two slight depressions separated by a bony ridge. The upper is called the 'fovea hemielliptica,' and lodges the utricle; the lower, or 'fovea hemispherica,' lodges the saccule. The ridge dividing these 'foveæ' is known as the 'crista vestibuli.' The utricle and the saccule, as will be seen, are distinct parts of the membranous labyrinth. The foveæ, as well as the crista vestibuli, are riddled with minute foramina, only visible with a lens, through which the filaments of the auditory nerve enter the vestibule. The vestibule and its eight openings are represented in the annexed diagram, fig. 84.

FIG. 84.

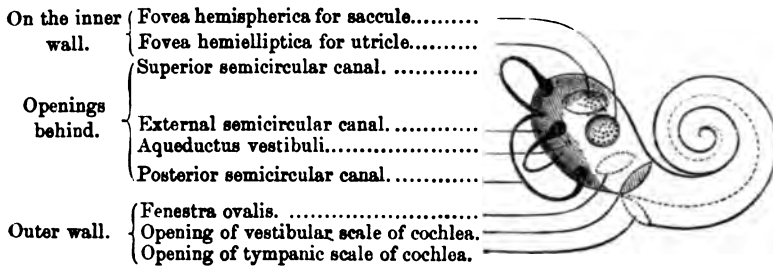


DIAGRAM OF THE RIGHT VESTIBULE, AND THE OPENINGS INTO IT.

Semicircular Canals.—The three semicircular canals are called, according to their position, the 'superior,' the 'posterior' (both vertical), and the 'external' (horizontal). The *superior* canal crosses the petrous bone at right angles, and stands out in relief on its anterior surface. Its 'ampulla' is at the outer orifice. The *posterior* canal is the longest of the three. It runs parallel with the posterior surface of the petrous bone, and makes a little relief just above the aqueductus vestibuli. Its 'ampulla' is at the lower orifice; its upper orifice joins the narrow end of the superior canal. The *external* canal is the smallest of the three; it lies horizontally in the petrous bone behind the superior and external to the posterior canal; its convexity is directed backwards. Its ampulla is at its outer orifice.

Cochlea.—The cochlea is so placed that its base is at the bottom of the meatus auditorius internus, where it receives filaments from the auditory nerve. Its apex is directed forwards

and outwards close to the canal for the tensor tympani. It makes two turns and a half, which run from left to right in the right ear, and from right to left in the left, round the central axis termed the 'modiolus.' Its first turn, bulging into the tympanum, makes the 'promontory.' The outer wall of the coil is composed of a lamella of very hard bone, like the semicircular canals: the inner wall is also formed of compact bone, but the interior of the 'modiolus' is spongy. The last half-turn presents peculiarities, and the best way to examine them is to remove the 'cupola' or rounded apex of the cochlea, as seen in Plate LXI. fig. 4. The last turn forms a kind of half-funnel (infundibulum). Into the apex of this funnel, which is continuous with the modiolus,

FIG. 85.



there opens a canal which runs through the centre of the modiolus. Round the free border of the half-funnel projects the hook-like termination (hamulus) of the lamina spiralis. All this is seen only in the dry bone. In the recent state there would be simply the aperture of communication (helicotrema), between the two scales of the cochlea.

The tympanic scale runs on that side of the lamina spiralis which looks towards the base of the cochlea. Near the beginning of that scale is the minute termination of the aqueductus cochleæ. (Plate LXI. fig. 3.)

Bony Lamina Spiralis.—The bony lamina spiralis, the only portion of the most essential part of the cochlea which can be seen in the dry bone, is shown in fig. 85. It commences at the lower part of the vestibule immediately above the fenestra rotunda. (Plate LXI. fig. 3.) From this, which is its broadest part, it

Fig. 1.

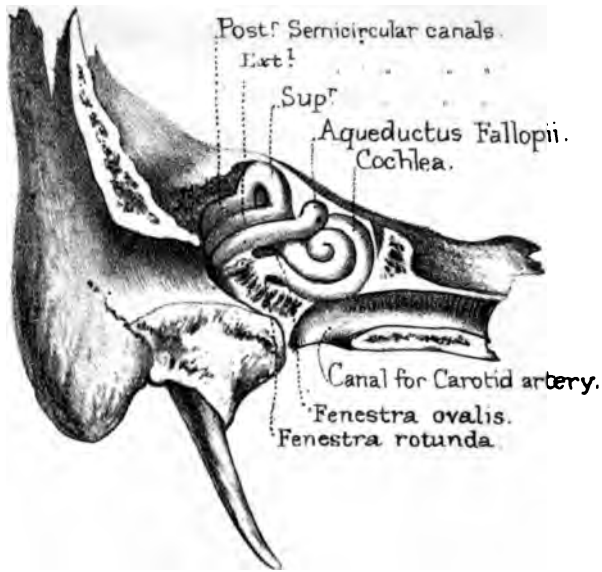
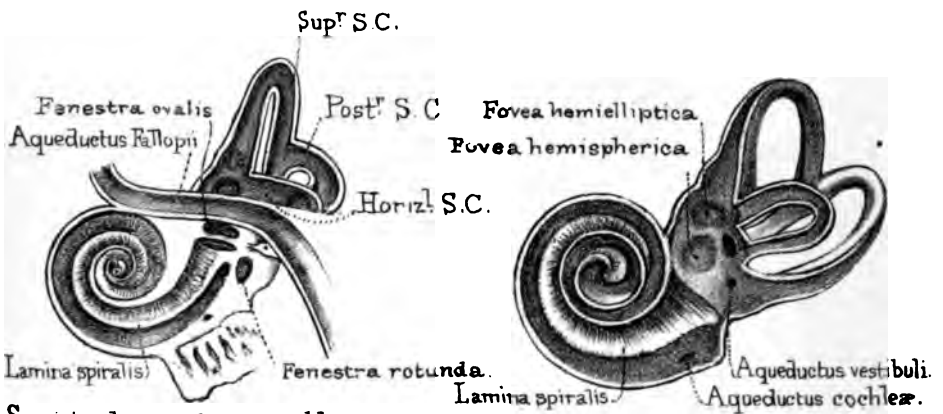


Fig. 2.

Fig. 3.



Semicircular canals and Cochlea cut open.

Vestibule opened to shew its inner wall.

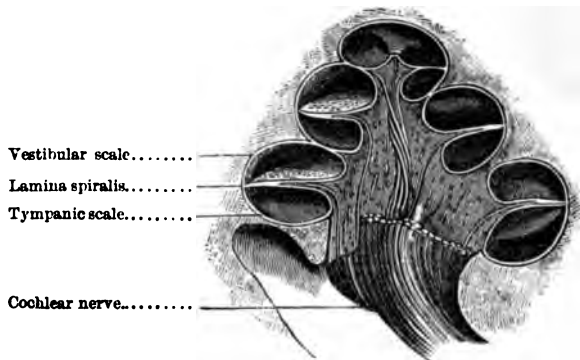
Fig. 4.





gradually diminishes in breadth as it winds round the axis into the apex of the cochlea, never reaching more than half across the tube, and it finally terminates as a little hook (hamulus) in the funnel of the last coil. On the concave side of this hook is situated (in the recent state) the helicotrema or aperture of communication between the two scales. Examined with a lens, both surfaces of the lamina spiralis will be seen to be furrowed by canals which give passage to the nerves before they reach the membranous part of the septum. It is composed of two very delicate and brittle plates which separate from each other at the axis. In the tympanic scale are seen the orifices of the canals just alluded to; they are separated by little columns of bone which give rise to a fluted appearance, shown in fig. 85. These columns themselves are made up of bundles of little tubes, enclosing the filaments of the auditory nerve.

FIG. 86.

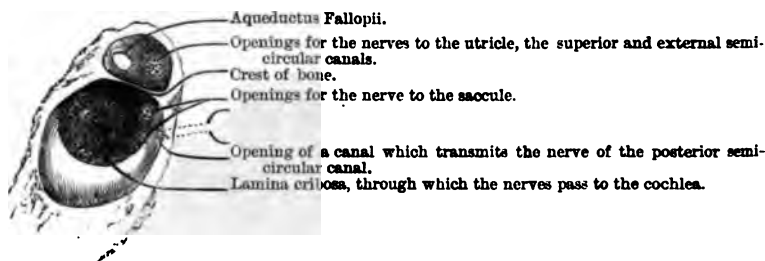


Modiolus.—The axis (modiolus) of the cochlea is conical. The base is at the bottom of the meatus internus; the apex does not extend beyond the second turn of the cochlea, and joins the funnel formed by the last coil. The axis is composed of brittle and porous bone, and its interior is traversed by numerous canals which transmit the cochlear nerves to the lamina spiralis, fig. 86. One canal (*canalis centralis modioli*), larger than the rest, runs through the centre of the axis, and opens on its summit—that is, at the apex of the funnel. It transmits a nerve to the last half turn of the lamina spiralis.

The Meatus Internus.—The meatus auditorius internus is situated on the posterior surface of the petrous bone. Its direction is nearly horizontally outwards; its length, about three-eighths of an inch. Its diameter varies a little in different bones, but is always larger than that of the nerves which it transmits.

The interval between the nerves and their bony canal is occupied by the cerebro-spinal fluid. In fractures through the base of the skull, involving the meatus, this fluid sometimes oozes out through the external ear. Whenever you observe this after an injury to the head, the case must be regarded as very grave. In thirteen cases of injury to the head admitted into St. Bartholomew's Hospital, blood or watery fluid flowed from the ear.

FIG. 87.



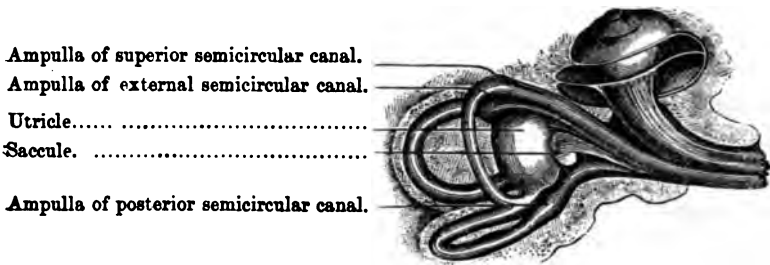
FORAMINA AT THE BOTTOM OF THE RIGHT MEATUS AUDITORIUS INTERNUS.

Of these thirteen, six died, and in all six the corresponding petrous bone was found fractured. In the seven cases that recovered, five had bleeding from the ear, and two only had a discharge of fluid. So that, although a watery discharge be a very unfavourable symptom, it is not necessarily a fatal one.

By cutting away the greater part of the meatus, as in fig. 87, the bottom of it is found to be divided by a crest of bone into two compartments of unequal size, an upper and a lower. In the upper and smaller one, there are two openings, of which the anterior is the aqueductus Fallopii (transmitting the facial nerve); the posterior, when examined with a lens, presents a number of minute foramina which transmit the divisions of the vestibular nerves which supply the utricle, the superior and the external semicircular canals.

In the lower and larger depression, we observe the base of the axis of the cochlea, termed 'lamina cribrosa,' because it has a double row of foramina arranged spirally, as shown in the figure. Now take any one of these foramina, which appear scarcely larger than the point of a pin, magnify it with a lens, and you find that it becomes a fossa pierced by holes varying in number from three to seven. So fine are the canals which transmit the filaments of the cochlear nerve! In the centre of the lamina is the orifice of the central canal of the axis, which is the largest of all. Behind the lamina are two (sometimes three) openings leading to minute perforations which transmit the nerve to the 'sacculé.' Lastly, on the posterior wall of the meatus is the orifice of a very constant

FIG. 88.



MEMBRANOUS LABYRINTH AND NERVES OF THE LEFT EAR.

canal (represented by the dotted outline) which gives passage to the vestibular nerve of the posterior semicircular canal.

Membranous Labyrinth.—The membranous labyrinth comprises the two little bladders, termed the 'utricle' and the 'sacculé,' in the vestibule, and the membranous semircircular canals together with part of the cochlea. It floats in the perilymph, and contains the endolymph. It is partly represented in fig. 88.

Utricle.—The utricle occupies the upper half of the vestibule. It is very difficult to make a good display of it. The best way to examine it, is to remove very carefully the roof of the vestibule and that of the superior semicircular canal, and then to put the preparation into water. All the membranous semicircular canals open into it. It floats free in the perilymph except at its fossa,

the 'fovea hemielliptica,' where it is retained against the sieve-like plate of bone through which the utricular nerves enter. The utricle sends a slender canal down the aqueductus vestibuli, which ends in a blind extremity outside that aqueduct at the back of the petrous part of the temporal bone. This canal is joined, close to its origin, by another from the saccule. Thus the utricle and saccule do communicate, though indirectly.

Saccule.—The saccule is smaller than the utricle and situated below it, close to its appropriate fossa, the 'fovea hemispherica.' It is attached to this fossa by the saccular nerve in the same way as the utricle is attached by nerve filaments to the fovea hemielliptica. The saccule is connected with the membranous canal of the cochlea by a small duct, the 'canalis uniens.' The utricle communicates with the saccule in the indirect manner just described. Hence the different parts of the membranous labyrinth communicate throughout, like the same parts in the bony labyrinth.

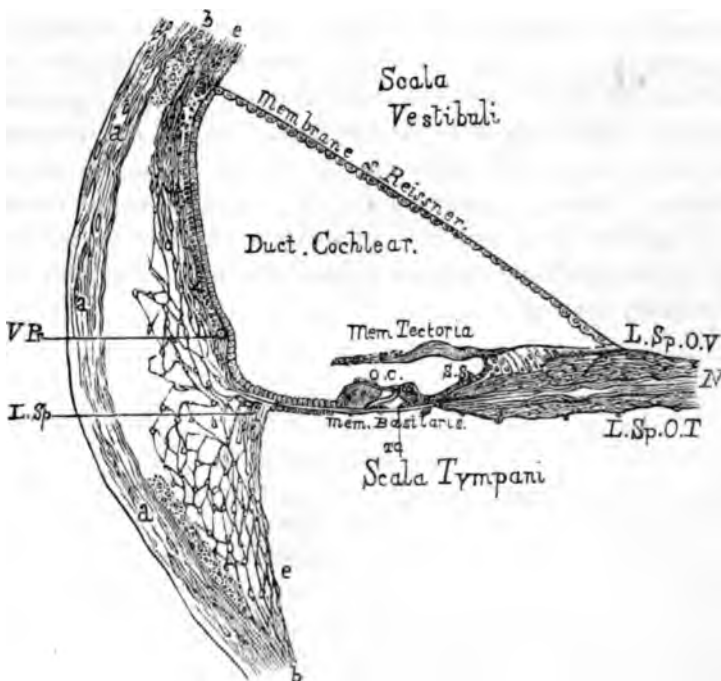
Otoliths.—On the inner wall of the utricle and saccule, at the spot where the nerves spread out upon them, is a small mass of crystals of carbonate of lime. The two masses are the 'otoconia' or 'otoliths,' and are homologues of the large white 'ear-stones' seen in the cod and whiting, and found in most of the osseous fishes.¹¹⁰

Membranous Semicircular Canals.—The membranous semicircular canals, except at their ampullæ, fill only about one-third the space of the bony canals; the remainder is occupied by the perilymph. The nerve destined to each membranous ampulla spreads out only on that surface of the ampulla which is towards the convexity of the rest of the canal. The nerve does not advance beyond the ampulla, but ramifies on a crescent-shaped septum (septum transversum) which projects into the interior.

Membranous Cochlea.—The membranous cochlea forms a third scale, the 'scala media' or 'canalis' or 'ductus cochlearis' (fig. 89), separating the scala vestibuli from the scala tympani. Its floor is attached to the margin of the bony lamina spiralis (L. Sp. O. V., L. Sp. O. T.) and reaches across to the outer wall of the cochlea, to which it is attached by a process of periosteum,

the 'ligamentum spirale' (L. Sp.). This floor is named 'membrana basilaris,' or 'membranous lamina spiralis.' The roof is a very delicate membranous lamina, the 'membrane of Reissner'; it is turned towards the vestibular scale. Hence the 'scala media' is bounded by the 'membrana basilaris,' 'the membrane of Reissner'; and the segment of the outer wall of the cochlea

FIG. 89.



VERTICAL SECTION OF THE FIRST TURN OF THE COCHLEA, SHOWING THE MEMBRANOUS COCHLEA AND THE POSITION OF THE ORGAN OF CORTI. AFTER WALDEYER AND QUAIN.

included between the outer attachments of these two membranes. This 'canalis cochlearis' communicates at one end with the saccule by the 'canalis uniens,' so that the endolymph is continuous in both those cavities; at the other end, towards the apex of the cochlea, it terminates in a blind extremity fixed to the wall of the cupola, partly bounding the helicotrema.

Organ of Corti.—In this ‘canalis cochlearis,’ resting on the ‘membrana basilaris,’ are two rows of cells (fig. 89 O.C.), an outer and an inner, leaning towards each other, so that there is a tunnel (T.C.) formed between them. They are covered, but only partially, by a membrane (membrana tectoria) attached to the edge of the bony lamina spiralis. Their singular characters and very complicated appendages are subjects too minute to be described here.¹¹¹

Probable Use of the Organ of Corti.—This organ is arranged on the principle of the chords or notes of a musical instrument, so that different sets of certain fine appendages to its cells may vibrate in accordance with different kinds of vibrations transmitted from without to the labyrinth. As they communicate with nerves, these differences can thus make an impression on the brain. Hence, by means of the organ of Corti, we can distinguish musical notes and the refinements of tone in delicate sounds, the remaining portions of the labyrinth being sufficient for ordinary hearing.

N O T E S.

1. Dr. Stark, 'Edin. Med. and Surg. Jour.,' April 1845; Nélaton, 'Eléments de Pathologie,' vol. i. p. 636.
2. Berzelius's 'Analysis of Bone.'
3. Dr. Bostock's 'Analysis of Rickety Bones.'
4. Liebig's 'Letters on Chemistry,' p. 522.
5. Gregory's 'Mechanics,' vol. i. c. 5.
6. Bishop 'On Deformities,' 1852, p. 14.
7. 'Outlines of Osteology,' p. 368. T. Ward.
8. 'Lectures on Surgical Pathology.' Sir J. Paget, F.R.S.
9. Curling, 'Medico-Chir. Trans.' vol. xx.
10. Cruikshank, 'Anatomy of the Absorbent Vessels,' 1790, p. 198.
11. Budge, 'Archiv f. Microsc. Anatomie,' bd. 13.
12. Dr. Clopton Havers, an English physician of the seventeenth century, was the first to describe these canals.
13. From a preparation in the museum at St. Bartholomew's Hospital.
14. Discovered by Mr. Queckett.
15. 'Philosoph. Trans.,' 1853. Messrs. Tomes and De Morgan.
16. First described by Domenico Gagliardi, Professor of Medicine at Rome in the seventeenth century. *Anatomie Ossium novis inventis illustrata.* Romæ, 1689, in 8vo.
17. Mr. Queckett.
18. Mr. Bransby Cooper.
19. See 'Catalogue of Histological Series,' Mus. Roy. Coll. Surg., vol. i. plate viii. fig. 11.
20. 'Philosoph. Trans.' for 1736, vol. xxxix.
21. Stanley, 'Diseases of the Bones,' p. 108.
22. 'Callus' is the term applied by the old surgeons to the materials by which fractures are repaired.
23. The term 'sinus' is used very vaguely in anatomy. It means, generally,

the hollow of anything. Thus the air-cavities in the bones of the head are termed 'sinuses.' When used in reference to the brain, a 'sinus' means a channel formed by the fibrous membrane (*dura mater*) of the brain, for the return of its venous blood.

24. In some skulls there are no 'posterior condyloid foramina.' In fifty skulls which I have examined I find them more frequently present than absent. Either the right or the left foramen may be absent.

25. 'Histoire de l'Académie des Sciences,' 1708, 1733.

26. Blumenbach.

27. Hyrtl, 'Topog. Anatomie.'

28. Professor Owen.

29. On this subject see an excellent work by Amman, 'De Loquellâ,' written in 1700.

30. Guthrie, 'Commentaries on Surgery,' 6th edition, p. 374.

31. Dr. Leach and others, who have examined the immense collection of crania in the Catacombs at Paris, have remarked that the number of adult skulls in which the frontal suture remained unobliterated was about one in eleven.

32. 'Aural Surgery,' p. 179. Mr. Wilde.

33. Fallopius was a distinguished Italian anatomist, born 1523, died 1563.

34. Arnold's nerve is the auricular branch of the pneumogastric; Jacobson's nerve is the tympanic branch of the glosso-pharyngeal.

35. This name was given to it by Galen, who thought that it secreted the 'pituita,' or mucus, and that this passed down into the throat through the small foramina which are often found at the bottom of the fossa ('De usu partium,' lib. ix. cap. 1). Its functions are not even yet understood; it is generally classed as a 'ductless' or 'vascular gland,' along with the spleen and thyroid body.

36. Vidus Vidius was a professor at Paris, and physician to François I.

37. In some skulls, in which the malar bone does not enter into the composition of the sphenomaxillary fissure, the sphenoid meets the superior maxillary bone. In such exceptional skulls the sphenoid would be connected with seven bones of the face.

38. The cornua sphenoidalia begin to ossify about the time of birth, and do not unite to the body of the bone till the age of puberty. The internal pterygoid plates are developed from membrane, and begin to ossify about the fourth month. For full information on the development of the sphenoid bone, see Meckel's 'Archiv,' B. 1, and Quain's 'Anatomy,' 8th edition.

39. The 'unciform process' is almost always broken in taking the skull to pieces; but it is evident enough in a good section of the nasal cavities.

40. Blandin ('Anat. Topog.' p. 44) relates a case in which a tumour, originating in the antrum, made its way into the zygomatic fossa, and caused a swelling in the temple.

41. Sometimes there are two openings, separated by the thin plate (unciform process) which descends from the ethmoid bone.

42. Nathaniel Highmore was an English anatomist, born 1613, died 1684, who wrote much about the diseases of the antrum. He did not discover the antrum, for it was known to Galen as the 'sinus maxillaris.'

43. 'Commentaries,' p. 528. Guthrie.

44. 'Anatomie Chirurgicale.' Mr. Jarjavay.

45. See a curious case by Catlin, 'Trans. Odontolog. Soc.' vol. ii. 1857.

46. Drake's 'System of Anatomy,' 8vo. 1707.

47. 'The Teeth a test of Age,' in a pamphlet by Edwin Saunders, 1837.

48. 'Dental Anatomy,' p. 179. Tomes, 1876.

49. These 'incisor' foramina are sometimes called the foramina of 'Scarpa.'

50. These lateral foramina are sometimes called the foramina of 'Stenson.' The description in the text concerning the anterior palatine canals applies to twenty out of forty skulls examined. Their disposition, in other cases, is very apt to vary, both as to number and size. It was Scarpa ('Annot. Anatom.' lib. ii. p. 75) who first pointed out the varieties in these canals. In many instances one of the canals is absent; or, if present, not pervious throughout. For a more complete explanation of this question, see Quain's 'Anatomy.'

51. This part, in man, was first pointed out by the poet Goethe.

52. For the most recent investigations concerning the 'Formation and Early Growth of the Bones of the Human Face,' see a very interesting and elaborate paper by Mr. G. W. Callender in the 'Philosoph. Trans.' for 1869.

53. From an examination of many skulls, I find that the malar bone is excluded from the sphenomaxillary fissure more frequently than is generally supposed. This exclusion is effected in one of two ways; either by the immediate junction of the superior maxillary and sphenoid bones, or by the interposition of a little 'Wormian' bone just at the angle of the fissure.

54. Jarjavay, 'Anatomie Chir.' t. ii. p. 61.

55. For a lucid and elaborate account of the development of the jaws and the teeth see 'Manual of Dental Anatomy,' by C. S. Tomes, M.A. 1876.

56. Skilful as he was, Hippocrates once mistook a natural suture of the skull for a fracture, and was afterwards so ingenuous as to leave his mistake on record. On this, Celsus observes: 'A suturis se deceptum esse Hippocrates memoriæ prodidit, more scilicet magnorum virorum, et fiduciam magnarum rerum habentium. Nam levia ingenia, quia nihil habent, nihil sibi detrahunt: magno ingenio, multaquæ nihilominus habituro, convenit etiam simplex veri erroris confessio; præcipuèquæ in eo ministerio quod utilitatis causâ posteris traditur ne quæ decipiantur eadem ratione, quæ quis antè deceptus est.' (Liber viii. cap. iv.)

57. Broca, 'Ostéologie du Crane,' 1875.

58. The old anatomists call this the 'additamentum suturæ lambdoidalæ.' This old name as well as others mentioned in the text e.g. 'coronal,' 'sagittal,'

and 'lambdoid,' are gradually falling into disuse, and giving place to more appropriate terms, derived from the bones connected, as 'inter-parietal,' 'fronto-parietal,' etc.

59. So called after Olaus Wormius, a physician of Copenhagen, to whom the first description of these 'complementary' bones has been assigned,—but erroneously: they were known to Eustachius and Paracelsus.

60. 'Prognathous' signifies 'with prominent jaws.'

61. These bodies are developed from the 'arachnoid' or serous membrane investing the brain, beneath the 'dura mater,' which they perforate, and thus come to press immediately on the bony vault of the skull. *Vide* Quain's 'Anatomy,' vol. ii. p. 576, 8th edition.

62. 'Thalia,' xii.

63. Except in cases where the sphenoid and superior maxillary come into contact, and exclude the malar. (See note, 37.)

64. 'Euterpe,' chap. 86, 87, 88.

65. Guthrie, 'Commentaries,' Lecture xviii.

66. See Erichsen, 'Science and Art of Surgery.'

67. Craniology is nothing new. An Italian poet in the age of Dante writes:—

Nel Capo son tre celle,
Et io dirò di quelle,
Davanti è lo intelletto
E la forza d' apprendere;
In *mezzo* è la ragione
E la discrezione,
Che scerne buono e male.
Indietro stà con gloria
La valente memoria, etc. etc.

68. Froiep ('Charakteristik des Kopfes,' Berlin, 1845) gives tables showing the relative size of the cranium and face in infancy, childhood, and adult age. They go to prove that the *base* of the skull, and the face, as contrasted with the capacity of the cranium, increase from infancy to old age.

69. Cuvier, 'Recherches sur les ossemens fossiles,' 1822, vol. ii. p. 231.

70. 'Traité des Malad. Chir.' t. iv. c. iv.

71. See a case of this kind, with a drawing, in 'Med.-Chir. Trans.' vol. xxxi., by Sir James Paget.

72. 'Natural Theology.' Paley.

73. The inferior tubercles are alluded to by Monro, 'Anatomy of the Human Bones,' 1726; also by Soemmering, 'De Corp. Human. Fabrica,' 8vo. 1794. The superior as well as the inferior tubercles are developed as little epiphyses with distinct centres of ossification, and unite to the rest of the vertebræ about the twenty-fifth year.

74. Rollin and Magendie make it sixteen times stronger.

75. It is not easy to say why this was called the 'sacred bone' (*ἱερόν ὀστέον*). The reason generally assigned is, that it was the part used in sacrifices. The following is another:—It appears the Jewish Rabbis entertained a notion that this part of the skeleton, which they call the 'luz,' would resist decay, and become the germ from which the body would be raised. Hence Butler has it—

'The learned Rabbins of the Jews,
Write there's a bone, which they call "Luz,"
I' the rump of man, of such a virtue
No force in nature can do hurt to :
Therefore at the last great day
All th' other members shall, they say,
Spring out of this, as from a seed
All sorts of vegetals proceed ;
From whence the learned sons of art
" *Os sacrum* " justly call that part.'

HUDIBRAS, part iii. cant. ii.

76. It is not uncommon to meet with six sacral vertebræ. Sometimes there are but four. The first sacral may be detached from the lower sacral vertebræ. Again, the last lumbar may be ankylosed to the sacrum by its body, or to the ilium by one or both of its transverse processes. This last condition is frequent among the higher monkeys.

77. Dr. Ramsbotham's 'Principles and Practice of Obstetric Medicine and Surgery,' 5th edition, p. 9.

78. The ridge between the origin of the gluteus medius and the iliac origin of the gluteus maximus is called the 'superior curved line' by some anatomists ; then, our 'superior' is their 'middle.' Authors differ about the names of these 'lines,' but agree about their existence.

79. Some authors state the reverse. But Albinus ('De Sceleto') says truly : 'Sacrum feminis latius, per longitudinem rectius, infra non æque incurvatum in priora.'

80. In his lectures 'On the Comparative Anatomy of Man,' 1877, Professor Flower gives 61° as the mean subpubic angle in men, 80° in women.

81. The brothers Weber, 'Mechanik der mensch. Gehwerk.,' Gott. 1836.

82. See 'Medical and Surgical Landmarks,' by the Author, 3rd edition, 1881.

83. These 'lineæ asperæ' are nothing more than partial ossifications of the tendons inserted there. A very rough 'linea aspera' is a character of age. It puts one in mind of the 'bone tendons' which one sees in the regular anatomy of birds.

84. Concerning the bearing of Osteogeny on forensic medicine, see 'Médecine légale,' by M. Orfila.

85. There is, however, room for two opinions on the question ; some calling the foot a lever of the first order.

86. Camper.

87. These facets are sometimes joined so as to form a vertical linear surface, but generally the upper are separated from the lower by a gap for the interosseous ligament.

88. We are indebted for this outline to Mr. Kestley, late Assistant-Demonstrator of Anatomy at St. Bartholomew's Hospital.

89. For further practical remarks on this subject, see 'Anatomy and Surgery of the Human Foot,' by J. Hancock, 1873.

90. Professor Flower, F.R.S., 'Fashion in Deformity,' p. 67; also Professor Marshall, F.R.S., 'Anatomy for Artists,' p. 45.

91. Exceptions to this rule are frequent. There may be two, three, or more centres for the first bone; and, instead of a single centre, any of the other pieces may have two, placed side by side. The sternum is formed in cartilage along the line where the 'ventral laminae' of early embryonic life unite. Partial failure of this union accounts for the longitudinal cleft occasionally seen in the body of the human sternum; and the appearance of symmetrical points of ossification is explained in the same manner.

92. The nucleus at the margin of the glenoid cavity is not to be regarded as an epiphysis, but only an occasionally present scale, like those sometimes found on the coracoid and having no morphological bearing, and scarcely worthy of notice. Professor Humphry, F.R.S.

93. On the supra-condyloid foramen read Hyrtl, 'Topogr. Anat.' vol. ii. p. 283; also Gruber, 'Canalis supra Condylloideus humeri,' Mem. de l'Acad. Imp. de St. Pétersbourg, 1859, p. 57; and Professor Struthers, 'Edin. Med. Jour.' 1848.

94. The radius of the skeleton of the gorilla in the Museum of the College of Surgeons is extremely arched. The power of his arms is enormous.

95. So called from its fancied resemblance to the letter Sigma, which the Greeks originally used in the form of the English C.

96. Very often the coronoid process gives origin to a second head of the flexor longus pollicis.

97. Mr. Liston, 'Practical Surgery.'

98. It is not uncommon to find that some of the fibres of the 'extensor primi internodii pollicis' arise from the ulna.

99. Mr. Lockwood, Demonstrator of Anatomy at St. Bartholomew's Hospital.

100. To the rule stated there are certainly exceptions. I have seen preparations clearly showing separate epiphyses at the bases of the metacarpal bones of the fore and middle fingers. I have also seen a separate epiphysis at the head of the metacarpal bone of the thumb. Whether these additional epiphyses be normal or exceptional, they always unite the first to the shaft, in accordance with the direction of the artery of the marrow, which in the metacarpal of the thumb runs towards the head, in those of the fingers towards the base.

101. The centre of ossification in the shaft of every long bone appears in its middle, excepting in the case of the unguis phalanges, which commence to ossify at their distal ends.

102. If we considered the adductor pollicis as a palmar interosseous muscle, there would be four palmar and four dorsal, all supplied by the ulnar nerve.

103. 'The Hand, its Mechanism and Vital Endowments, as evincing Design. London, 1834, by Sir Charles Bell, F.R.S.

104. Quintilian.

105. Certain muscular fibres in the aryteno-epiglottidean folds of mucous membrane assist the 'arytenoideus' and the 'crico-arytenoidei laterales' in closing the glottis. All these little muscles together form, as Henle has shown, a 'sphincter' of the glottis, a highly developed and complicated homologue of the single and simple sphincter muscle which embraces the entrance of the larynx in reptiles.

106. Wilde, 'Aural Surgery,' p. 178.

107. Graves's 'Clinical Medicine,' vol. i.

108. 'Edinburgh Monthly Journal,' No. III.; 'Edinb. Med. and Surg. Journal,' No. CXV. p. 319.

109. 'Beiträge zur Anatomie des Steigbügels,' Archiv für Ohrenheilkunde, vol. v. Eysell.

110. For details concerning the minute structure of the vestibule and the connection of the otoliths with certain hair-like bodies belonging to the nerve-filaments, see Dr. Urban Pritchard's paper on 'The Termination of the Nerves in the Vestibule and Semicircular Canals of Mammals.'—'Quarterly Journal of Microscopic Science,' October 1870.

111. Corti's original paper in Siebold and Kölliker's 'Zeitsch. f. Wissensch. Zoologie,' vol. iii.



INDEX.

ACE		COS	
	PAGE		PAGE
A CETABULUM	159	Canal, anterior dental.....	77
Acromion.....	225	anterior palatine	82, 110
Air cells in bone	7	carotid.....	60, 284
Alveolar process	79	infra-orbital	77
Ampullæ	278	of Huguier	54, 283
Analysis of bones.....	3	posterior palatine.....	77, 91
Anatomical neck of humerus	230	pterygo-palatine	110
Animal matter of bone	3	malar	85
Anterior clinoid process	67	semicircular	278, 289
Antlers	52	" membranous	294
Antrum of Highmore	76	vertebral	143
Aquæductus cochleæ	58	Vidian	69
Fallopîi.....	285	Canaliculi of bone	14
vestibuli	58	Canalis centralis modioli.....	291
Arch, carpal	247	Cancellous tissue.....	9
of foot	184	Canine fossa.....	77
Arches of foot	199	Carotid canal	284
Articular arteries.....	10	Carpal arch	247
Arytenoid cartilages	268	Carpus	246
Astragalus	185	Cartilages, costal.....	212
Atlas.....	131	Cavity, sigmoid, of radius	239
Axis	133	" of ulna	241
B ASILAR process	37, 113	Cells, ethmoidal	71
Bicipital groove of humerus ...	232	frontal	46
Blood supply of bones.....	10	mastoid.....	55
Bones, air cells in	7	maxillary	78
classification of	6	palatine.....	91
composition of	2	sphenoidal.....	65
elasticity of	5	Clavicle.....	222
hollow shaft of.....	7	curves of	222
microscopic structure of	13	Coccyx	150
naked-eye structure of.....	6	Cochlea	277, 289
nomenclature of	6	membranous.....	294
properties of.....	5	Condylod ridge of humerus, external	233
strength of	5	" " " internal	233
uses of	2	Coracoid process	227
C ALCANEUM	188	Cords, vocal	270
Callus	35	Cornua sphenoidalia	64
Callus provisional	36	Coronoid fossa	234
Canals, accessory palatine	91	process of lower jaw	98
		" ulna.....	241
		Corti, organ of	279, 296
		Costal cartilages	212

CRA		HUG	
	PAGE		PAGE
Cranial fosse	107	Foramen mentale.....	99
Cribriform plate	71	obturatum.....	158
Cricoid cartilago	267	occipital.....	114
Crista galli	71	opticum.....	67
vestibuli	289	ovale.....	158
Cuboid bone	192	parietal.....	104
Cuneiform bone of carpus	260	rotundum.....	68
bones of tarsus.....	193	spheno-palatine.....	91
cartilages of larynx.....	269	spinousum.....	68
Cupola	290	stylo-mastoid.....	59
Cuvier on fossil bones	127	supra-orbital.....	48
		Vesalii.....	68
D ENTAL foramen	98	Fossa, canine	77
Digital fossa	169	coronoid.....	234
Diploe	11, 99	digastric.....	55
Diploic veins	11	digital.....	169
Ductus cochlearis.....	294	iliac.....	153
		jugular.....	60
E AR, anatomy of	276	mental.....	96
Earthy matter of bones	3	olecranon.....	234
Endosteum	12	pituitary.....	64
Ensiform cartilage	207	pterygoid.....	68
Epiglottis	269	scaphoid.....	68
Epipteric bone	62	spheno-maxillary.....	115
Ethmoid bone	71	temporal.....	104
Ethmoidal foramen, anterior	73	zygomatic.....	114
" " posterior.....	73	Fossæ, nasal.....	107
notch.....	50	of skull.....	118
Eustachian tube.....	57, 276	Fovea hemielliptica.....	289
		hemispherica.....	289
F ACE, bones of	76	Fractures, repair of.....	35
Facial angle.....	124	Frontal bone.....	46
Falx cerebri	71	sinus.....	46
Femur	166		
Fenestra ovalis.....	277, 282	G LASERIAN fissure	283
rotunda.....	277, 282	Glenoid cavity.....	54, 226
Fibula	180	Glenoid fissure.....	54
First rib	211	Glottis.....	272
Fissura Glaseri.....	54	Groove, bicipital, of humerus.....	232
Fissure, Glaserian.....	283	optic.....	63
sphenoidal.....	67, 117	Growth in length of bones	33
spheno-maxillary.....	117	Gumboil	81
Floating ribs	209		
Fontanelles	44	H AMULAR process.....	69
Foot, arches of.....	184	Hamulus of cochlea.....	290
as a whole.....	199	Hamulus of lachrymal bone.....	89
bones of.....	184	Hand, bones of.....	246
lever of second order.....	185	Haversian canals.....	13, 16, 33
mechanism in walking.....	201	interspaces.....	15
Foramen cæcum	48	lamellæ.....	14
chordæ.....	283	system.....	15
condyloid, anterior.....	114	Helicotrema.....	290
" " posterior.....	114	Herodotus on Egyptian embalming	118
ethmoidal, anterior.....	73	Hiatus Fallopii.....	57
" " posterior.....	73	Highmore, antrum of.....	76
infra-orbital.....	77	Hollow shaft of bone.....	7
magnum.....	37	Horns.....	52
		Huguier, canal of.....	283

HUM		OST	
	PAGE		PAGE
Humerus	230	Median crest of palate bone	90
Hunter's experiments with shots ...	34	Medullary artery	11
Hyoid bone	264	membrane	12
I NCUS	277, 286	Membrana tympani	276, 281
Inferior maxillary bone	96	Metacarpus	252
Inferior spongy bone	93	Metatarsus	195
turbinate bone	93	Microscopic structure of bone	13
Infra-orbital canal	77	Milk dentition	79
foramen	77	Modiolus	291
Infundibulum	46, 74	Muscles in front of the spine	221
Iliac fossa	153	of back	218
Ilium	153	" superficial	218
Innominate bone	152	of the back of the neck	220
Insertion of muscles	38	Myeloid cells	10
Inspiration, mechanism of	213	N ASAL bone	87
Intervertebral fibro-cartilage	141	Nasal duct	81
Iscium	157	Nasal fossæ	118
J AW, buttresses of upper	123	process of sup. maxillary bone	81
Jaw, joint of	100	slit	72
Jaw-bone, lower	96	spine, anterior	82
" upper	76	" posterior	90
Jugular foramen	113	suture	87
fossæ	60	Neck of humerus, anatomical	230
L ABYRINTH membranous	293	" surgical	232
Lachrymal bone	88	Necrosis	34
Lachrymal fossa	50	Nerves in bone	12
groove	51, 89	Neuralgia of bone	13
process	94	Nose, meatus of	119
sac	81	posterior openings of	110
Lacunæ of bone	14	septum of	120
Lamina cribrosa cochleæ	293	Notch of acetabulum	159
spiralis osseæ	278, 290	intercondyloid	172
Larynx	266	ischiatric, greater	155
Layers of bone	8	" lesser	155
Levers, bones act as	2	sigmoid	241
Linea aspera	170	Notches in sternum	206
Lower extremity, bones of	152	Nutrient artery of bone	11
Lymphatics of bone	13	O CCIPITAL bone	37
M ADDER, experiments with	33	Olecranon	242
Malar bone	85	Olecranon fossa	234
Malar canals	85	Optic foramen	67
Malleolus externus	181	groove	63
internus	178	Orbital wings of sphenoid	66
Malleus	277, 286	Orbits	115
Manubrium	206	Organ of Corti	296
Marrow, artery of	11	Origin of muscles	38
red	10	Os calcis	188
yellow	10	Os hyoides	264
Mastoid process	55	Os innominatum	152
Maxillary sinus	78	Os magnum	251
Meatus auditorius externus	56, 280	Os orbiculare	287
internus	57, 292	Os planum	73
of nose	73, 119	Os unguis	89
		Ossa triquetra	103
		Ossification	33
		Osteoblasts	35

OST	PAGE	SPO	PAGE
Osteology, interest of	1	Ridge, deltoid	232
Otoliths.....	294	gluteal	171
PACCHIONIAN bodies	43, 104	Ridges, intertrochanteric	170
Palate bone	90	condyloid of humerus	333
Parietal bone	42	Rima glottidis	272
Paroccipital process.....	41	Rostrum of sphenoid	64
Patella	174	SABRE cuts	34
Pelvis, arch of	162	Saccule	294
axes of	164	Sacro-iliac symphysis	148, 154
brim of the	153	Sacrum	146
diameters of	164	Santorini, cartilages of	268
lever of first order	161	Scala tympani	278
obliquity of	163	vestibuli	278
sexual differences of	165	Scaphoid bone of carpus.....	249
Periosteum	12	" of tarsus	191
bloodvessels of.....	12	fossa	68
value of.....	34	Scapula	225
Perivascular lymphatics	13	spine of.....	225
Phalanges of fingers	256	Sella Turcica	63, 67
of toes	198	Semicircular canals	278, 289
Phosphate of lime	4	" membranous ...	294
Pisiform bone	250	Semilunar bone	249
Pituitary fossa	64	Septum of nose.....	120
Pre-maxillary bones	83	Sesamoid bones of hand	258
suture	83	" of foot	199
Process, acromion	225	Sigmoid cavity of radius.....	239
alveolar	79	Sinus, frontal	46
basilar	113	inferior petrosal	108
clinoid	64	lateral	109
coracoid	227	superior petrosal	109
coronoid, of lower jaw.....	98	Skeleton, general survey of.....	260
" of ulna	241	Skull as a whole	102
hamular	69	base of	107
lachrymal	94	bones of	37
malar.....	83	buttresses of.....	122
mastoid.....	55	-cap	103
nasal	81	general observations on	121
palatine.....	82	lever of first order	121
post glenoid	54	locking of bones of	121
pterygoid	68, 111	power of resisting shocks	123
sphenoidal.....	92	sexual differences.....	124
styloid	50	tables of.....	121
" , of radius	239	Sphenoid bone	63
" , of ulna	244	lesser wings of.....	66
unciform	74	rostrum of.....	64
vaginal	66	Sphenoidal fissure	117
Promontory of tympanum	283	process	92
Pterygoid process.....	68	Spheno-maxillary fossa	115
Pterygo-palatine canal.....	66	fissure	117
Pubes	156	Spheno-palatine foramen.....	91
Pyramid	283	Spine.....	128
RADIUS	237	curves of	140
Radius, rotation of	238	ethmoidal	63
Repair of fractures	35	extent of motion of	140
Ribs, general characters of.....	209	of pubes	157
Rickety bones	4	of scapula	225
		Spines of ilium, anterior and posterior	154
		Spongy bones	73

SQU	PAGE	ZYG	PAGE
Squamosal bone	53	Tuberosities of femur	173
Stapes	277, 287	of humerus, greater	231
Stature of individual	33	" lesser	231
Sternum	206	of tibia	176
Styloid process of radius.....	239	Tuberosity of ischium	158
" of ulna	244	Tunnel of tarsus	187
Superciliary ridge	46	Turbinated bones.....	73
Superior maxillary bone.....	76	bone, sphenoidal	64
Surgical neck of humerus	232	Tympanum	276
Suture, basilar	64		
coronal	50	U LNA	241
zygomatic	61	Unciform bone	251
Sutures of skull	102	Unciform process.....	74
Symphysis of lower jaw	96	Upper extremity, bones of	222
pubis	156	Utricle	293
sacro-iliac	148, 154		
T ABLES of skull	121	V AGINAL processes	66
Tarsus, bones of	184	Ventricles of larynx	271
Tarsus, tunnel of.....	187	Vertebra, constituent parts of.....	128
Teeth.....	79	Vertebrae, cervical	130
fangs of.....	80	coccygeal	150
milk	79	dorsal	135
of lower jaw.....	97	lumbar	136
of upper jaw.....	80	sacral.....	146
permanent.....	80	Vertebral canal.....	143
sockets of	80	column	128, 139
Temporal bone.....	52	" shape of	141
" mastoid portion of ...	55	" strength of	139
" petrous portion of ...	55	groove	142
" squamous portion of..	53	Vestibule	277, 288
Tendo oculi.....	82	Vidian canal.....	69
Thorax as a whole	213	Vocal cords	270
general description of	205	Vomer	94
Thyroid cartilage.....	266		
Tibia.....	178	W ALKING, mechanism of foot in	201
Toes, relative length of	202	Wormian bones	103
Torcular Herophili	41		
Trapezium.....	250	Z YGOMA	53
Trochanters, major and minor	169	Zygomatic fossa	114
Tubercle of radius	238		
Tubercles of dorsal and lumbar ver- tebrae.....	137		



BY THE SAME AUTHOR

MANUAL OF THE DISSECTION OF THE HUMAN BODY. By LUTHER HOLDEN, President of the Royal College of Surgeons of England; Member of the Court of Examiners; Senior Surgeon to St. Bartholomew's and the Foundling Hospitals; assisted by JOHN LANGTON, F.R.C.S., Assistant Surgeon and Lecturer on Anatomy at St. Bartholomew's Hospital. Illustrated with numerous Wood Engravings. *Fourth Edition.* 8vo. 16s. 1879.

LANDMARKS, MEDICAL AND SURGICAL. By LUTHER HOLDEN, Ex-President, Member of Council, and Member of the Court of Examiners of the Royal College of Surgeons, England; Consulting Surgeon to St. Bartholomew's and the Foundling Hospitals; assisted by JAMES SHUTER, M.A., M.B. Camb., F.R.C.S., Assistant Surgeon to the Royal Free Hospital; late Demonstrator of Physiology, and Assistant Demonstrator of Anatomy at St. Bartholomew's Hospital. *Third Edition.* 8vo. 3s. 6d. 1880.

THE HUNTERIAN ORATION delivered at the Royal College of Surgeons of England, on the 14th February, 1881. 8vo. 2s.

J. & A. CHURCHILL, New Burlington Street.



Catalogue B]

*London, New Burlington Street
January, 1882*

SELECTION

FROM

J. & A. CHURCHILL'S GENERAL CATALOGUE

COMPRISING

ALL RECENT WORKS PUBLISHED BY THEM

ON THE

ART AND SCIENCE OF MEDICINE



N.B—As far as possible, this List is arranged in the order in which medical study is usually pursued.



A SELECTION

FROM

J. & A. CHURCHILL'S GENERAL CATALOGUE,

COMPRISING

ALL RECENT WORKS PUBLISHED BY THEM ON THE
ART AND SCIENCE OF MEDICINE.

N.B.—*J. & A. Churchill's Descriptive List of Works on Chemistry, Materia Medica, Pharmacy, Botany, Photography, Zoology, the Microscope, and other Branches of Science, can be had on application.*

Practical Anatomy:

A Manual of Dissections. By CHRISTOPHER HEATH, Surgeon to University College Hospital. Fifth Edition. Crown 8vo, with 24 Coloured Plates and 269 Engravings, 15s.

Wilson's Anatomist's Vade-Mecum. Tenth Edition. By GEORGE BUCHANAN, Professor of Clinical Surgery in the University of Glasgow; and HENRY E. CLARK, M.R.C.S., Lecturer on Anatomy at the Glasgow Royal Infirmary School of Medicine. Crown 8vo, with 450 Engravings (including 26 Coloured Plates), 18s.

Braune's Atlas of Topographical Anatomy, after Plane Sections of Frozen Bodies. Translated by EDWARD BELLAMY, Surgeon to, and Lecturer on Anatomy, &c., at, Charing Cross Hospital. Large Imp. 8vo, with 34 Photolithographic Plates and 46 Woodcuts, 40s.

An Atlas of Human Anatomy.

By RICKMAN J. GODLEE, M.S., F.R.C.S., Assistant Surgeon and Senior Demonstrator of Anatomy, University College Hospital. With 48 Imp. 4to Plates (112 figures), and a volume of Explanatory Text, 8vo, £4 14s. 6d.

Anatomy of the Joints of Man.

By HENRY MORRIS, Surgeon to, and Lecturer on Anatomy and Practical Surgery at, the Middlesex Hospital. 8vo, with 44 Lithographic Plates (several being coloured) and 13 Wood Engravings, 16s.

Surgical Anatomy:

A Series of Dissections, illustrating the Principal Regions of the Human Body. By JOSEPH MACLISE. Second Edition. 52 folio Plates and Text. Cloth, £3 12s.

Medical Anatomy.

By FRANCIS SIBSON, M.D., F.R.C.P., F.R.S. Imp. folio, with 21 Coloured Plates, cloth, 42s., half-morocco, 50s.

Manual of the Dissection of the Human Body. By LUTHER HOLDEN, Consulting Surgeon to St. Bartholomew's and the Foundling Hospitals. Fourth Edition. 8vo, with 170 Engravings, 16s.

By the same Author.

Human Osteology:

Sixth Edition. 8vo, with 61 Lithographic Plates and 89 Engravings. 16s.

Also.

Landmarks, Medical and Surgical. Third Edition. 8vo, 3s. 6d.

The Student's Guide to Surgical

Anatomy: An Introduction to Operative Surgery. By EDWARD BELLAMY, F.R.C.S. and Member of the Board of Examiners. Fcap. 8vo, with 76 Engravings, 7s.

The Student's Guide to Human

Osteology. By WILLIAM WARWICK WAGSTAFFE, Assistant Surgeon to St. Thomas's Hospital. Fcap. 8vo, with 23 Plates and 66 Engravings, 10s. 6d.

The Anatomical Remembrancer; or, Complete Pocket Anatomist. Eighth Edition. 32mo, 3s. 6d.

Diagrams of the Nerves of the Human Body, exhibiting their Origin, Divisions, and Connections, with their Distribution to the Various Regions of the Cutaneous Surface, and to all the Muscles. By WILLIAM H. FLOWER, F.R.C.S., F.R.S., Hunterian Professor of Comparative Anatomy to the Royal College of Surgeons. Third Edition, with 6 Plates. Royal 4to, 12s.

Atlas of Pathological Anatomy. By Dr. LANCEKEAUX. Translated by W. S. GREENFIELD, M.D., Professor of Pathology in the University of Edinburgh. Imp. 8vo, with 70 Coloured Plates, £5 5s.

A Manual of Pathological Anatomy. By C. HANDFIELD JONES, M.B., F.R.S.; and EDWARD H. SIEVEKING, M.D., F.R.C.P. Edited (with considerable enlargement) by J. F. PAYNE, M.D., F.R.C.P., Lecturer on General Pathology at St. Thomas's Hospital. Second Edition. Crown 8vo, with 195 Engravings, 16s.

Lectures on Pathological Anatomy. By SAMUEL WILKS, M.D., F.R.S., Physician to Guy's Hospital; and WALTER MOXON, M.D., Physician to Guy's Hospital. Second Edition. 8vo, with Plates, 18s.

Post-Mortem Examinations:
A Description and Explanation of the Method of performing them, with especial reference to Medico-Legal Practice. By Prof. VIRCHOW. Translated by Dr. T. P. SMITH. Second Edition. Fcap. 8vo, with 4 Plates, 3s. 6d.

Principles of Human Physiology. By W. B. CARPENTER, C.B., M.D., F.R.S. Ninth Edition. By HENRY POWER, M.B., F.R.C.S. 8vo, with 3 Steel Plates and 377 Wood Engravings, 31s. 6d.

A Treatise on Human Physiology. By JOHN C. DALTON, M.D., Professor in the College of Physicians and Surgeons, New York. Sixth Edition. Royal 8vo, with 316 Engravings, 20s.

Text-Book of Physiology.
By J. FULTON, M.D., Professor of Physiology, &c., in Trinity Medical College, Toronto. Second Edition. 8vo, with 152 Engravings, 15s.

Practical Histology.
By WILLIAM RUTHERFORD, M.D., F.R.S. Third Edition. Crown 8vo, with Engravings. (*In the Press.*)

Sanderson's Handbook for the Physiological Laboratory. By E. KLEIN, M.D., F.R.S.; J. BURDON-SANDERSON, M.D., F.R.S.; MICHAEL FOSTER, M.D., F.R.S.; and T. LAUDER BRUNTON, M.D., F.R.S. 8vo, with 123 Plates, 24s.

Histology and Histo-Chemistry of Man. By HEINRICH FREY, Professor of Medicine in Zurich. Translated by ARTHUR E. J. BARKER, Assistant-Surgeon to University College Hospital. 8vo, with 608 Engravings, 21s.

The Marriage of Near Kin,
Considered with respect to the Laws of Nations, Results of Experience, and the Teachings of Biology. By ALFRED H. HUTH. 8vo, 14s.

Medical Jurisprudence:
Its Principles and Practice. By ALFRED S. TAYLOR, M.D., F.R.C.P., F.R.S. Second Edition. 2 vols. 8vo, with 189 Engravings, £1 11s. 6d.

By the same Author.

A Manual of Medical Jurisprudence. Tenth Edition. Crown 8vo, with 55 Engravings, 14s.

Also.

Poisons,
In Relation to Medical Jurisprudence and Medicine. Third Edition. Crown 8vo, with 104 Engravings, 16s.

Lectures on Medical Jurisprudence. By FRANCIS OGSTON, M.D., Professor in the University of Aberdeen. Edited by FRANCIS OGSTON, JUN., M.D. 8vo, with 12 Copper Plates, 18s.

A Handy-Book of Forensic Medicine and Toxicology. By W. BATHURST WOODMAN, M.D., F.R.C.P., and C. MEYMOTT TIDY, M.D., F.C.S. 8vo, with 8 Lithographic Plates and 116 Engravings, 31s. 6d.

Microscopical Examination of Drinking Water. By JOHN D. MACDONALD, M.D., F.R.S., Assistant Professor in the Army Medical School. 8vo, with 24 Plates, 7s. 6d.

Sanitary Examinations
Of Water, Air, and Food. A Vademecum for the Medical Officer of Health. By CORNELIUS B. FOX, M.D., F.R.C.P. Crown 8vo, with 94 Engravings, 12s. 6d.

Sanitary Assurance:
A Lecture at the London Institution. By Prof. F. DE CHAUMONT, F.R.S. With Short Addresses by J. E. ERICHSEN, F.R.S., Sir J. FAYRER, K.C.S.I., and R. BRUDENELL CARTER, F.R.C.S., &c. Royal 8vo, 1s.

A Manual of Practical Hygiene.

By E. A. PARKES, M.D., F.R.S. Fifth Edition. By F. DE CHAUMONT, M.D., F.R.S., Professor of Military Hygiene in the Army Medical School. 8vo, with 9 Plates and 112 Engravings, 18s.

Dangers to Health:

A Pictorial Guide to Domestic Sanitary Defects. By T. PRIDGIN TEALE, M.A., Surgeon to the Leeds General Infirmary. Third Edition. 8vo, with 70 Lithograph Plates (mostly coloured). 10s.

A Handbook of Hygiene and Sanitary Science.

By GEO. WILSON, M.A., M.D., Medical Officer of Health for Mid-Warwickshire. Fourth Edition. Post 8vo, with Engravings, 10s. 6d.

Also.

Healthy Life and Healthy Dwellings:

A Guide to Personal and Domestic Hygiene. Fcap. 8vo, 5s.

Contributions to Military and State Medicine.

By JOHN MARTIN, L.R.C.S.E., Surgeon Army Medical Department. 8vo, 10s. 6d.

Pay Hospitals and Paying Wards throughout the World.

By HENRY C. BURDETT, late Secretary to the Seamen's Hospital Society. 8vo, 7s.

By the same Author.

Cottage Hospitals — General,

Fever, and Convalescent: Their Progress, Management, and Work. Second Edition, with many Plans and Illustrations. Crown 8vo, 14s.

Dress: Its Sanitary Aspect.

A Paper read before the Brighton Social Union, Jan. 30, 1880. By BERNARD ROTH, F.R.C.S. 8vo, with 8 Plates, 2s.

Manual of Anthropometry:

A Guide to the Measurement of the Human Body, containing an Anthropometrical Chart and Register, a Systematic Table of Measurements, &c. By CHARLES ROBERTS, F.R.C.S. 8vo, with numerous Illustrations and Tables, 6s. 6d.

Madness:

In its Medical, Legal, and Social Aspects. Lectures by EDGAR SHEPPARD, M.D., M.R.C.P., Professor of Psychological Medicine in King's College. 8vo, 6s. 6d.

Idiocy and Imbecility.

By WILLIAM W. IRELAND, M.D., Medical Superintendent of the Scottish National Institution for the Education of Imbecile Children at Larbert, Stirlingshire. 8vo, with Engravings, 14s.

A Manual of Psychological

Medicine: With an Appendix of Cases. By JOHN C. BUCKNILL, M.D., F.R.S., and D. HACK TUKE, M.D., F.R.C.P. Fourth Edition. 8vo, with 12 Plates (30 Figures) and Engravings, 25s.

The Student's Guide to the Practice of Midwifery.

By D. LLOYD ROBERTS, M.D., F.R.C.P., Physician to St. Mary's Hospital, Manchester. Second Edition. Fcap. 8vo, with 111 Engravings, 7s.

Handbook of Midwifery for Mid-

wives: from the Official Handbook for Prussian Midwives. By J. E. BURTON, L.R.C.P. Lond., Senior Assistant Medical Officer, Ladies' Charity, &c., Liverpool. With Engravings. Fcap. 8vo, 6s.

Lectures on Obstetric Opera-

tions: Including the Treatment of Hæmorrhage, and forming a Guide to the Management of Difficult Labour. By ROBERT BARNES, M.D., F.R.C.P., Obstetric Physician to St. George's Hospital. Third Edition. 8vo, with 124 Engravings, 18s.

By the same Author.

A Clinical History of Medical

and Surgical Diseases of Women. Second Edition. 8vo, with 181 Engravings, 28s.

West on the Diseases of

Women. Fourth Edition, revised and in part re-written by the Author, with numerous Additions by J. MATTHEWS DUNCAN, M.D., Obstetric Physician to St. Bartholomew's Hospital. 8vo, 16s.

Observations on the Cæsarean

Section, Craniotomy, and on other Obstetric Operations, with Cases. By THOMAS RADFORD, M.D., late Honorary Consulting Physician, St. Mary's Hospital, Manchester. Second Edition, with Plates. 8vo, 10s.

Clinical Lectures on Diseases

of Women: Delivered in St. Bartholomew's Hospital, by J. MATTHEWS DUNCAN, M.D., F.R.S.E. 8vo, 8s.

By the same Author.

Papers on the Female Perineum, &c.

8vo, 6s.

The Principles and Practice of

Gynæcology. By THOMAS ADDIS EMMET, M.D., Surgeon to the Woman's Hospital, New York. Second Edition. Royal 8vo, with 133 Engravings, 24s.

The Student's Guide to the Diseases of Women. By ALFRED L. GALABIN, M.D., F.R.C.P., Assistant Obstetric Physician to Guy's Hospital. Second Edition. Fcap. 8vo, with 70 Engravings, 7s. 6d.

Notes on the Diseases of Women. Specially designed for Students preparing for Examination. By J. J. REYNOLDS, M.R.C.S. Fcap. 8vo, 2s. 6d.

By the same Author.

Notes on Midwifery: Specially designed to assist the Student in preparing for Examination. Fcap. 8vo, 4s.

Practical Gynæcology:

A Handbook of the Diseases of Women. By HEYWOOD SMITH, M.D. Oxon., Physician to the Hospital for Women and to the British Lying-in Hospital. Second Edition. Crown 8vo, with Engravings. (*In the Press.*)

By the same Author.

Dysmenorrhea, its Pathology and Treatment. Crown 8vo, with Engravings, 4s. 6d.

Obstetric Aphorisms:

For the Use of Students commencing Midwifery Practice. By JOSEPH G. SWAYNE, M.D. Seventh Edition. Fcap. 8vo, with Engravings, 3s. 6d.

Obstetric Medicine and Surgery: Their Principles and Practice. By F. H. RAMSBOTHAM, M.D., F.R.C.P. Fifth Edition. 8vo, with 120 Plates, 22s.

A Complete Handbook of Obstetric Surgery. Giving Short Rules of Practice in every Emergency. By CHARLES CLAY, late Senior Surgeon to St. Mary's Hospital, Manchester. Third Edition. Fcap. 8vo, with 91 Engravings, 6s. 6d.

Schroeder's Manual of Midwifery, including the Pathology of Pregnancy and the Puerperal State. Translated by CHARLES H. CARTER, B.A., M.D. 8vo, with Engravings, 12s. 6d.

Influence of Posture on Women in Gynecic and Obstetric Practice. By J. H. AVELING, M.D., Physician to the Chelsea Hospital for Women. 8vo, 6s.

A Handbook of Uterine Therapeutics, and of Diseases of Women. By E. J. TILT, M.D., M.R.C.P. Fourth Edition. Post 8vo, 10s.

By the same Author.

The Change of Life

In Health and Disease: a Practical Treatise on the Nervous and other Affections incidental to Women at the Decline of Life. Third Edition. 8vo, 10s. 6d.

Ovarian and Uterine Tumours:

Their Diagnosis and Surgical Treatment. By T. SPENCER WELLS, F.R.C.S., Consulting Surgeon to the Samaritan Hospital. 8vo, with Engravings. (*Nearly ready.*)

Rupture of the Female Perineum: Its Treatment, immediate and remote. By GEORGE G. BANTOCK, M.D., Surgeon to the Samaritan Hospital. 8vo, with 2 Plates, 3s. 6d.

Chronic Disease of the Heart: Its Bearings upon Pregnancy, Parturition, and Childbed. By ANGUS MACDONALD, M.D., F.R.S.E., Physician to the Edinburgh Royal Infirmary. 8vo, with Engravings, 8s. 6d.

The Female Pelvic Organs,

Their Surgery, Surgical Pathology, and Surgical Anatomy, in a Series of Coloured Plates taken from Nature: with Commentaries, Notes, and Cases. By HENRY SAVAGE, Consulting Officer of the Samaritan Free Hospital. Fifth Edition. 4to. (*In the Press.*)

Lectures on Diseases of the Nervous System, especially in Women. By S. WEIR MITCHELL, M.D., Physician to the Philadelphia Infirmary for Diseases of the Nervous System. With 5 Plates. Post 8vo, 8s.

A Treatise on the Diseases of Children. For Practitioners and Students. By WILLIAM H. DAY, M.D., Physician to the Samaritan Hospital for Women and Children. Crown 8vo, 12s. 6d.

The Wasting Diseases of Children. By EUSTACE SMITH, M.D., Physician to the King of the Belgians, Physician to the East London Hospital for Children. Third Edition. Post 8vo, 8s. 6d.

By the same Author.

Clinical Studies of Disease in Children. Second Edition. Post 8vo. (*In the Press.*)

Infant Feeding and its Influence on Life; or, the Causes and Prevention of Infant Mortality. By C. H. F. ROUTH, M.D., Senior Physician to the Samaritan Hospital. Third Edition. Fcap. 8vo, 7s. 6d.

A Practical Manual of the Diseases of Children. With a Formula. By EDWARD ELLIS, M.D. Fourth Edition. Crown 8vo, 10s.

By the same Author.

A Manual of what every Mother should know. Fcap. 8vo, 1s. 6d.

Lectures on Nursing.

By W. R. SMITH, M.B., Physician to the Cheltenham Dispensary. Third Edition. Post 8vo, with Engravings. (*In the Press.*)

Manual for Hospital Nurses and others engaged in Attending on the Sick. By EDWARD J. DOMVILLE, Surgeon to the Exeter Lying-in Charity. Fourth Edition. Crown 8vo, 2s. 6d.

The Nurse's Companion :

A Manual of General and Monthly Nursing. By CHARLES J. CULLINGWORTH, Surgeon to St. Mary's Hospital, Manchester. Second Edition. Fcap. 8vo. *(In the Press.)*

Handbook for Nurses for the Sick. By ZEPHERINA P. VEITCH. Second Edition. Crown 8vo, 3s. 6d.

Notes on Fever Nursing.

By J. W. ALLAN, M.B., Superintendent and Physician, City of Glasgow Fever Hospital. Crown 8vo, with Engravings, 2s. 6d.

Medicinal Plants :

Being descriptions, with original figures, of the Principal Plants employed in Medicine, and an account of their Properties and Uses. By Professor BENTLEY and Dr. H. TRIMEN. In 4 volumes, large 8vo, with 306 Coloured Plates, bound in Half Morocco, Gilt Edges. £11 11s.

Royle's Manual of Materia Medica and Therapeutics. Sixth Edition, by JOHN HARLEY, M.D., Physician to St. Thomas's Hospital. Crown 8vo, with 139 Engravings, 15s.

Manual of Practical Therapeutics. By E. J. WARING, C.B., M.D., F.R.C.P. Lond. Third Edition. Fcap. 8vo, 12s. 6d.

The Student's Guide to Materia Medica. By JOHN C. THOROWGOOD, M.D., F.R.C.P. Fcap. 8vo, 6s. 6d.

Materia Medica and Therapeutics : Vegetable Kingdom. By CHARLES D. F. PHILLIPS, M.D., late Lecturer on Materia Medica and Therapeutics to Westminster Hospital. 8vo, 15s.

Bazaar Medicines of India,

And Common Medical Plants : With Full Index of Diseases, indicating their Treatment by these and other Agents procurable throughout India, &c. By E. J. WARING, C.B., M.D., F.R.C.P. Third Edition. Fcap. 8vo, 5s.

Indian Notes.

The Voyage out; Travelling in India; Upper India; Stations; The Hills; Mineral Waters; Herbs and Simples. By F. R. HOGG, M.D., Surgeon-Major. Crown 8vo, 5s.

The National Dispensatory :

Containing the Natural History, Chemistry, Pharmacy, Actions and Uses of Medicines, including those recognized in the Pharmacopœias of the United States and Great Britain and Germany, with numerous references to the French Codex. By ALFRED STILLÉ, M.D., LL.D., and JOHN M. MAISCH, Ph.D. Second Edition. 8vo, with 239 Engravings, 34s.

Binz's Elements of Therapeutics : A Clinical Guide to the Action of Drugs. Translated by E. I. SPARKS, M.B., F.R.C.P. Crown 8vo, 8s. 6d.

A Companion to the British Pharmacopœia. By PETER SQUIRE, F.L.S., assisted by his sons, P. W. and A. H. SQUIRE. Thirteenth Edition. 8vo. *(In the Press.)*

By the same Author.

The Pharmacopœias of the London Hospitals, arranged in Groups for Easy Reference and Comparison. Fourth Edition. 18mo, 6s.

A New System of Medicine ;

Entitled Recognisant Medicine, or the State of the Sick. By B. BOSE, M.D., Indian Medical Service. 8vo, 10s. 6d.

By the same Author.

Principles of Rational Therapeutics. Commenced as an Inquiry into the Relative Value of Quinine and Arsenic in Ague. Crown 8vo, 4s. 6d.

Diseases of Tropical Climates, And their Treatment : with Hints for the Preservation of Health in the Tropics. By JAMES A. HORTON, M.D., Surgeon-Major. Second Edition. Post 8vo, 12s. 6d.

Tropical Dysentery and Chronic Diarrhœa—Liver Abscess—Malarial Cachexia—Insolation—with other forms of Tropical Diseases, &c. By Sir JOSEPH FAYRE, K.C.S.I., M.D., 8vo., 15s.

By the same Author.

Clinical and Pathological Observations in India. 8vo, with Engravings, 20s.

Endemic Diseases of Tropical Climates, with their Treatment. By JOHN SULLIVAN, M.D. Post 8vo, 6s.

Family Medicine for India :

By WILLIAM J. MOORE, M.D., Honorary Surgeon to the Viceroy of India. Published under the Authority of the Government of India. Third Edition. Post 8vo, with 66 Engravings, 12s.

By the same Author.

Health Resorts for Tropical Invalids, in India, at Home, and Abroad. Post 8vo, 5s.

The Elements of Indian Hygiene.

Intended to guide the Public in acquiring some knowledge in the all-important subject of the Preservation of Health and Prevention of Sickness. By JOHN C. LUCAS, F.R.C.S., H.M.'s Indian Medical Service. Crown 8vo, with Map of India, &c., 5s.

The Student's Guide to the

Practice of Medicine. By MATTHEW CHARTERIS, M.D., Professor of Materia Medica in the University of Glasgow. Third Edition. Fcap. 8vo, with Engravings on Copper and Wood, 7s.

Hooper's Physicians' Vade-

Mecum. A Manual of the Principles and Practice of Physic. Tenth Edition. By W. A. GUY, F.R.C.P., F.R.S., and J. HARLEY, M.D., F.R.C.P. With 118 Engravings. Fcap. 8vo, 12s. 6d.

Clinical Studies :

Illustrated by Cases observed in Hospital and Private Practice. By Sir J. ROSE CORMACK, M.D., F.R.S.E., Physician to the Hertford British Hospital of Paris. Two vols. Post 8vo, 20s.

Clinical Medicine :

Lectures and Essays. By BALTHAZAR FOSTER, M.D., F.R.C.P. Lond., Professor of Medicine in Queen's College, Birmingham. 8vo, 10s. 6d.

Clinical Lectures and Cases,

with Commentaries. By HENRY THOMPSON, M.D., F.R.C.P., Consulting Physician to Middlesex Hospital. With Temperature Charts. 8vo, 7s. 6d.

Clinical Medicine :

A Systematic Treatise on the Diagnosis and Treatment of Disease. By AUSTIN FLINT, M.D., Professor of Medicine in the Bellevue Hospital Medical College. 8vo, 20s.

By the same Author.

Phthisis :

In a series of Clinical Studies. 8vo, 16s.

Transfusion of Human Blood :

With Table of 50 cases. By Dr. ROUSSEL, of Geneva. With a Preface by Sir JAMES PAGET, Bart. Crown 8vo, 2s. 6d.

The Spectroscope in Medicine.

By CHARLES A. MACMUNN, B.A., M.D. 8vo, with 3 Chromo-lithographic Plates of Physiological and Pathological Spectra, and 13 Engravings, 9s.

The Microscope in Medicine.

By LIONEL S. BEALE, M.B., F.R.S., Physician to King's College Hospital. Fourth Edition. 8vo, with 86 Plates, 21s.

Also.

On Slight Ailments :

Their Nature and Treatment. 8vo, 5s.

A Manual of Medical Diagnosis.

By A. W. BARCLAY, M.D., F.R.C.P., Physician to St. George's Hospital. Third Edition. Fcap. 8vo, 10s. 6d.

The Student's Guide to Medical

Diagnosis. By SAMUEL FENWICK, M.D., F.R.C.P., Physician to the London Hospital. Fifth Edition. Fcap. 8vo, with 111 Engravings, 7s.

By the same Author.

The Student's Outlines of Medi-

cal Treatment. Second Edition. Fcap. 8vo, 7s.

Also.

On Chronic Atrophy of the

Stomach, and on the Nervous Affections of the Digestive Organs. 8vo, 8s.

The Student's Guide to Medical

Case-Taking. By FRANCIS WARNER, M.D., Assistant Physician to the London Hospital. Fcap. 8vo, 5s.

Asthma :

Its Pathology and Treatment. By J. B. BERKART, M.D., Assistant-Physician to the City of London Hospital for Diseases of the Chest. 8vo, 7s. 6d.

Notes on Asthma :

Its Forms and Treatment. By JOHN C. THOROWGOOD, M.D., Physician to the Hospital for Diseases of the Chest, Victoria Park. Third Edition. Crown 8vo, 4s. 6d.

Observations on the Result of

Treatment of nearly One Hundred Cases of Asthma. By T. L. PRIDHAM, M.R.C.S. Third Edition. 8vo, 2s. 6d.

Diseases of the Chest :

Contributions to their Clinical History, Pathology, and Treatment. By A. T. HOUGHTON WATERS, M.D., Physician to the Liverpool Royal Infirmary. Second Edition. 8vo, with Plates, 15s.

Winter Cough :

(Catarrh, Bronchitis, Emphysema, Asthma). By HORACE DOBELL, M.D., Consulting Physician of the Royal Hospital for Diseases of the Chest. Third Edition. 8vo, with Coloured Plates, 10s. 6d.

By the same Author.

Loss of Weight, Blood-Spit-

ting, and Lung Disease. Second Edition, to which is added Part VI., "On the Functions and Diseases of the Liver." 8vo, with Chromo-lithograph, 10s. 6d.

Also.

The Mont Dore Cure, and the

Proper Way to Use it. 8vo, 7s. 6d.

Relapse of Typhoid Fever, especially with reference to the Temperature. By J. PEARSON IRVINE, M.D., F.R.C.P., late Assistant Physician to Charing Cross Hospital. 8vo, with Engravings, 6s.

Croonian Lectures on Some Points in the Pathology and Treatment of Typhoid Fever. By WILLIAM CAYLEY, M.D., F.R.C.P., Physician to the Middlesex and the London Fever Hospitals. Crown 8vo, 4s. 6d.

Manual of the Physical Diagnosis of Diseases of the Heart, including the use of the Sphygmograph and Cardiograph. By ARTHUR E. SANSOM, M.D., F.R.C.P., Assistant-Physician to the London Hospital. Third Edition. Fcap. 8vo, with 48 Engravings, 7s. 6d.

By the same Author.

The Antiseptic System in Medicine and Surgery: A Treatise on Carbolic Acid and its Compounds, etc. With 9 Plates (42 Figures), 8vo, 10s. 6d.

On Diseases of the Heart.

By THOS. B. PEACOCK, M.D., F.R.C.P. (1) Malformations. 8vo, 10s. (2) Causes and Effects of Valvular Disease. 8vo, 5s. (3) Prognosis in Valvular Disease. 8vo, 3s. 6d.

Medical Ophthalmoscopy:

A Manual and Atlas. By WILLIAM R. GOWERS, M.D., F.R.C.P., Assistant Professor of Clinical Medicine in University College, and Senior Assistant-Physician to the Hospital. Second Edition, with Coloured Autotype and Lithographic Plates and Woodcuts. 8vo., 18s.

By the same Author.

Epilepsy, and other Chronic Convulsive Diseases: Their Causes, Symptoms, and Treatment. 8vo, 10s. 6d.

Also.

Pseudo-Hypertrophic Muscular Paralysis: A Clinical Lecture. 8vo, with Engravings and Plate, 3s. 6d.

Also.

The Diagnosis of Diseases of the Spinal Cord. Second Edition. 8vo, with Coloured Plate and Engravings, 4s. 6d.

The Sympathetic System of Nerves: Their Physiology and Pathology. By Professor EULENBURG and Dr. P. GUTTMANN. Translated by A. NAPIER, M.D., F.F.P.S. 8vo, 5s. 6d.

Studies on Functional Nervous Disorders. By C. HANDFIELD JONES, M.B., F.R.S., Physician to St. Mary's Hospital. Second Edition. 8vo, 18s.

Diseases of the Stomach:

The Varieties of Dyspepsia, their Diagnosis and Treatment. By S. O. HABERSHON, M.D., F.R.C.P., late Senior Physician to Guy's Hospital. Third Edition. Crown 8vo, 5s.

By the same Author.

Pathology of the Pneumo-gastric Nerve, being the Lumleian Lectures for 1876. Post 8vo, 3s. 6d.

Also.

Diseases of the Abdomen,

Comprising those of the Stomach and other parts of the Alimentary Canal, (Esophagus, Cæcum, Intestines, and Peritoneum. Third Edition. 8vo, with 5 Plates, 21s.

Gout, Rheumatism,

And the Allied Affections; with a Chapter on Longevity and the Causes Antagonistic to it. By PETER HOOD, M.D. Second Edition. Crown 8vo, 10s. 6d.

Notes on Rheumatism.

By JULIUS POLLOCK, M.D., F.R.C.P., Senior Physician to the Charing Cross Hospital. Second Edition. Fcap. 8vo, with Engravings, 3s. 6d.

A Treatise on the Diseases of the Nervous System. By JAMES ROSS, M.D., Assistant-Physician to the Manchester Royal Infirmary. Two vols., 8vo, with Lithographs, Photographs, and 280 Wood Engravings. 42s.

Lectures on Diseases of the Nervous System. By SAMUEL WILKS, M.D., F.R.S., Physician to, and Lecturer on Medicine at, Guy's Hospital. Second Edition. 8vo.

(In the Press.)

Nervous Diseases:

Their Description and Treatment. By ALLEN MCLANE HAMILTON, M.D., Physician at the Epileptic and Paralytic Hospital, Blackwell's Island, New York. Second Edition. Royal 8vo, with Illustrations. *(Just ready.)*

Headaches:

Their Nature, Causes, and Treatment. By WILLIAM H. DAY, M.D., Physician to the Samaritan Hospital for Women and Children. Third Edition. Crown 8vo, with Engravings, 6s. 6d.

Fits:

Diagnosis and Immediate Treatment of Cases of Insensibility and Convulsions. By JOHN H. WATERS, M.D., K.C., St.G.C., Surgeon to the C Division of Metropolitan Police. Crown 8vo, bound in leather, 4s.

On Megrim, Sick Headache and some Allied Disorders: a Contribution to the Pathology of Nerve Storms. By E. LIVEING, M.D., F.R.C.P. 8vo, 15s.

Nutrition in Health and Disease: A Contribution to Hygiene and to Clinical Medicine. By HENRY BENNET, M.D. Third (Library) Edition. 8vo, 7s. Cheap Edition. Fcap. 8vo, 2s. 6d.

Food and Dietetics, Physiologically and Therapeutically Considered. By F. W. PAVY, M.D., F.R.S., Physician to Guy's Hospital. Second Edition. 8vo, 15s.

By the same Author.

Croonian Lectures on Certain Points connected with Diabetes. 8vo, 4s. 6d.

Imperfect Digestion: Its Causes and Treatment. By A. LEARED, M.D., Sixth Edition. Fcap. 8vo, 4s. 6d.

Indigestion: What it is; what it leads to; and a New Method of Treating it. By JOHN B. GILL, M.D., formerly Surgeon to the Dover Hospital, &c. Second Edition. Fcap. 8vo, 4s. 6d.

The Climate of the Undercliff, Isle of Wight, as deduced from forty years' consecutive Meteorological Observations. By J. L. WHITEHEAD, M.D. Royal 8vo, 5s.

The Riviera: Sketches of the Health-Resorts of the North Mediterranean Coast of France and Italy, from Hyères to Spezia; with Chapters on the General Meteorology of the District, its Medical Aspect and Value, &c. By EDWARD I. SPARKS, M.B., F.R.C.P. Crown 8vo, 8s. 6d.

Winter and Spring On the Shores of the Mediterranean. By HENRY BENNET, M.D. Fifth Edition. Post 8vo, with numerous Plates, Maps, and Engravings, 12s. 6d.

By the same Author.

Treatment of Pulmonary Consumption by Hygiene, Climate, and Medicine. Third Edition. 8vo, 7s. 6d.

The Ocean as a Health-Resort: A Practical Handbook of the Sea, for the use of Tourists and Health-Seekers. By WILLIAM S. WILSON, L.R.C.P., Second Edition, with Chart of Ocean Routes, &c. Crown 8vo, 7s. 6d.

Davos Platz, and the Effects of High Altitude on Phthisis. By ALFRED WISE, M.D. Fcap. 8vo, 2s. 6d.

Principal Health-Resorts Of Europe and Africa, and their Use in the Treatment of Chronic Diseases. By THOMAS MORE MADDEN, M.D., M.R.I.A. 8vo, 10s.

Handbook of Medical and Surgical Electricity. By HERBERT TIBBITS, M.D., F.R.C.P.E., Senior Physician to the West London Hospital for Paralysis and Epilepsy. Second Edition. 8vo, with 95 Engravings, 9s.

By the same Author.

A Map of Ziemssen's Motor Points of the Human Body: A Guide to Localised Electrification. Mounted on Rollers, 35 x 21. With 20 Illustrations, 5s.

Lectures on the Clinical Uses of Electricity. By J. RUSSELL REYNOLDS, M.D., F.R.S., Physician to University College Hospital. Second Edition. Post 8vo, 3s. 6d.

A System of Practical Surgery. By Sir WILLIAM FERGUSSON, Bart., F.R.S. Fifth Edition. 8vo, with 463 Engravings, 21s.

Surgical Emergencies: Together with the Emergencies Attendant on Parturition and the Treatment of Poisoning. By PAUL SWAIN, F.R.C.S., Surgeon to the Royal Albert Hospital, Devonport. Third Edition. Crown 8vo, with 117 Engravings, 5s.

A Course of Operative Surgery. By CHRISTOPHER HEATH, Surgeon to University College Hospital. With 20 Plates drawn from Nature by M. LÉVEILLÉ, and coloured by hand under his direction. Large 8vo, 40s.

By the same Author.

The Student's Guide to Surgical Diagnosis. Fcap. 8vo, 6s. 6d.

Also.

Manual of Minor Surgery and Bandaging. For the use of House Surgeons, Dressers, and Junior Practitioners. Sixth Edition. Fcap. 8vo, with 115 Engravings, 5s. 6d.

Also.

Injuries and Diseases of the Jaws. Second Edition. 8vo, with 164 Engravings, 12s.

Outlines of Surgery and Surgical Pathology. By F. LE GROS CLARK, F.R.S., assisted by W. W. WAGSTAFFE, F.R.C.S. Second Edition. 8vo, 10s. 6d.

The Practice of Surgery :

A Manual. By THOMAS BRYANT, Surgeon to Guy's Hospital. Third Edition. Two vols. Crown 8vo, with 672 Engravings (many being coloured), 28s.

The Surgeon's Vade-Mecum :

A Manual of Modern Surgery. By ROBERT DRUITT, F.R.C.S. Eleventh Edition. Fcap. 8vo, with 369 Engravings, 14s.

Illustrations of Clinical Surgery.

By JONATHAN HUTCHINSON, Senior Surgeon to the London Hospital. In occasional fasciculi. I. to XIV., 6s. 6d. each. Fasciculi I. to X. bound, with Appendix and Index, £3 10s.

The Principles and Practice of Surgery.

By WILLIAM PIRRIE, F.R.S.E., Professor of Surgery in the University of Aberdeen. Third Edition. 8vo, with 490 Engravings, 28s.

Surgical Enquiries :

Including the Hastings Essay on Shock, the Treatment of Inflammations, and numerous Clinical Lectures. By FURNEAUX JORDAN, F.R.C.S., Professor of Surgery, Queen's College, Birmingham. Second Edition, with numerous Plates. Royal 8vo, 12s. 6d.

Treatment of Wounds :

Clinical Lectures. By SAMPSON GAMGEE, F.R.S.E., Surgeon to the Queen's Hospital, Birmingham. Crown 8vo, with Engravings, 5s.

By the same Author.

Fractures of the Limbs,

And their Treatment. 8vo, with Plates, 10s. 6d.

On Dislocations and Fractures.

By JOSEPH MACLISE, F.R.C.S. Uniform with "Surgical Anatomy." 36 folio Plates and Text. Cloth, £2 10s.

Lectures on Diseases of Bones and Joints.

By CHARLES MACNAMARA, F.R.C.S., Surgeon to, and Lecturer on Surgery at, Westminster Hospital. Crown 8vo, with Engravings, 10s. 6d.

Clubfoot :

Its Causes, Pathology, and Treatment. By WM. ADAMS, F.R.C.S., Surgeon to the Great Northern Hospital. Second Edition. 8vo, with 106 Engravings and 6 Lithographic Plates, 15s.

By the same Author.

On Contraction of the Fingers,

and its Treatment by Subcutaneous Operation ; and on Obliteration of Depressed Cicatrices, by the same Method. 8vo, with 30 Engravings, 4s. 6d.

Orthopædic Surgery,

And Diseases of the Joints. By L. A. SAYRE, M.D., Professor of Orthopædic Surgery in Bellevue Hospital Medical College. 8vo, with 274 Engravings, 20s.

Osteotomy :

With an Enquiry into the Etiology and Pathology of Knock-knee, Bow-leg, and other Osseous Deformities of the Lower Limbs. By WILLIAM MACEWEN, M.D., Surgeon and Lecturer on Clinical Surgery to the Glasgow Royal Infirmary. 8vo, with 51 Engravings, 7s. 6d.

Lectures on Orthopædic Surgery.

By BERNARD E. BRODHURST, F.R.C.S., Surgeon to the Royal Orthopædic Hospital. Second Edition. 8vo, with Engravings, 12s. 6d.

By the same Author.

On Anchylosis, and the Treatment for the Removal of Deformity and the Restoration of Mobility in Various Joints.

Fourth Edition. 8vo, with Engravings, 5s.

Orthopraxy :

The Mechanical Treatment of Deformities, Debilities, and Deficiencies of the Human Frame. By H. HEATHER BIGG, Assoc. Inst. C.E. Third Edition. 8vo, with 319 Engravings, 15s.

The Orthopragms of the Spine :

An Essay on the Curative Mechanisms applicable to Spinal Curvature, etc. By ROBERT HEATHER BIGG, Assoc. Inst. C.E. 8vo, with Engravings, 5s.

A Manual of the Principles and Practice of Ophthalmic Medicine and Surgery.

By T. WHARTON JONES, F.R.C.S., F.R.S. Third Edition. Fcap. 8vo, with 9 Coloured Plates and 173 Engravings, 12s. 6d.

A Manual of Diseases of the Eye.

By C. MACNAMARA, F.R.C.S., Surgeon to Westminster Hospital. Third Edition. Fcap. 8vo, with Coloured Plates and Engravings, 12s. 6d.

On Diseases and Injuries of the Eye :

A Course of Systematic and Clinical Lectures to Students and Medical Practitioners. By J. R. WOLFE, M.D., F.R.C.S.E., Senior Surgeon to the Glasgow Ophthalmic Institution ; Lecturer on Ophthalmic Medicine and Surgery in Anderson's College. With 10 Coloured Plates and 157 Wood Engravings. 8vo, £1 1s.

Hints on Ophthalmic Out-Patient

Practice. By CHARLES HIGGINS, Ophthalmic Assistant-Surgeon to, and Lecturer on Ophthalmology at, Guy's Hospital. Second Edition. Fcap. 8vo, 3s.

Liebreich's Atlas of Ophthalmoscopy :

Composed of 12 Chromolithographic Plates (containing 59 Figures). The Text translated by H. ROSBOROUGH SWANZY, M.B. Second Edition. 4to, 30s.

- The Student's Guide to Diseases of the Eye.** By EDWARD NETTLESHIP, F.R.C.S., Ophthalmic Surgeon to St. Thomas's Hospital. Second Edition. Fcap. 8vo, with Engravings, (*In the Press.*)
- Glaucoma :**
Its Causes, Symptoms, Pathology, and Treatment. By PRIESTLEY SMITH, M.R.C.S., Ophthalmic Surgeon to the Queen's Hospital, Birmingham. 8vo, with Lithographic Plates, 10s. 6d.
- A Manual of Ophthalmoscopy** for the use of Students. By DR. DAGUENET. Translated by C. S. JEAFFRESON, Surgeon to the Newcastle-on-Tyne Eye Infirmary. With Engravings. Fcap. 8vo, 5s.
- Essays in Ophthalmology.**
By GEORGE E. WALKER, F.R.C.S., Surgeon to St. Paul's Eye and Ear Hospital, &c., Liverpool. Post 8vo, 6s.
- Hare-Lip and Cleft Palate.**
By FRANCIS MASON, F.R.C.S., Surgeon to, and Lecturer on Practical Surgery at, St. Thomas's Hospital. 8vo, with 66 Engravings, 6s.
By the same Author.
- The Surgery of the Face.**
8vo, with 100 Engravings, 7s. 6d.
- A Practical Treatise on Aural Surgery.** By H. MACNAUGHTON JONES, M.D., Professor of the Queen's University in Ireland, Surgeon to the Cork Ophthalmic and Aural Hospital. Second Edition. Crown 8vo, with 63 Engravings, 8s. 6d.
By the same Author.
- Atlas of Diseases of the Membrana Tympani.** In Coloured Plates, containing 62 Figures, with Text. Crown 4to, 21s.
- Diseases and Injuries of the Ear.** By WILLIAM B. DALBY, F.R.C.S., Aural Surgeon to, and Lecturer on Surgery at, St. George's Hospital. Second Edition. Fcap. 8vo, with Engravings, 6s. 6d.
- Throat Diseases,**
And the Use of the Laryngoscope: A Handbook for Practitioners and Senior Students. By W. DOUGLAS HEMMING, F.R.C.S.E. With Engravings. Fcap. 8vo, 2s. 6d.
- Lectures on Syphilis of the Larynx** (Lesions of the Secondary and Intermediate Stages). By W. MACNEILL WHISTLER, M.D., Physician to the Hospital for Diseases of the Throat and Chest. Post 8vo, 4s.
- Diseases of the Throat and Nose.** A Manual. By MORELL MACKENZIE, M.D. Lond., Senior Physician to the Hospital for Diseases of the Throat and Chest. Vol. I. Diseases of the Pharynx, Larynx, and Trachea. Post 8vo, with 112 Engravings, 12s. 6d.
By the same Author.
- Diphtheria :**
Its Nature and Treatment, Varieties, and Local Expressions. 8vo, 5s.
- The Ear :**
Its Anatomy, Physiology, and Diseases. By CHARLES H. BURNETT, A.M., M.D., Aural Surgeon to the Presbyterian Hospital, Philadelphia. 8vo, with 87 Engravings, 18s.
- A Treatise on Vocal Physiology and Hygiene,** with especial reference to the Cultivation and Preservation of the Voice. By GORDON HOLMES, L.R.C.P. Edin., Physician to the Municipal Throat and Ear Infirmary. Second Edition. With Engravings. Crown 8vo, 6s. 6d.
By the same Author.
- A Guide to the Use of the Laryngoscope in General Practice.** Crown 8vo, with 15 Engravings, 2s. 6d.
- Ear and Throat Diseases.**
Essays by LLEWELLYN THOMAS, M.D., Surgeon to the Central London Throat and Ear Hospital. Post 8vo, 2s. 6d.
- Sore Throat :**
Its Nature, Varieties, and Treatment. By PROSSER JAMES, M.D., Physician to the Hospital for Diseases of the Throat. Fourth Edition. Post 8vo, with Coloured Plates and Engravings, 6s. 6d.
- A System of Dental Surgery.**
By JOHN TOMES, F.R.S., and CHARLES S. TOMES, M.A., F.R.S. Second Edition. Fcap. 8vo, with 268 Engravings, 14s.
- Dental Anatomy, Human and Comparative: a Manual.** By CHARLES S. TOMES, M.A., F.R.S. Second Edition. Crown 8vo, with many Engravings.
(Just ready.)
- A Practical Treatise on Operative Dentistry.** By JONATHAN TAFT, D.D.S., Professor in the Ohio College of Dental Surgery. Third Edition. With 134 Engravings. 8vo, 18s.
- Dental Materia Medica and Therapeutics.** By JAMES STOCKEN, L.D.S.R.C.S., late Lecturer to the National Dental Hospital. Third Edition. Fcap. 8vo.
(In the Press.)

The Student's Guide to Dental Anatomy and Surgery. By HENRY SEWILL, M.R.C.S., L.D.S. Fcap. 8vo, with 77 Engravings, 5s. 6d.

A Manual of Dental Mechanics. By OAKLEY COLES, L.D.S.R.C.S., Second Edition. Crown 8vo, with 140 Engravings, 7s. 6d.

By the same Author.

Deformities of the Mouth.

Third Edition, 8vo, with 83 Wood Engravings and 96 Drawings on Stone, 12s. 6d.

Mechanical Dentistry in Gold and Vulcanite. By F. H. BALKWILL, L.D.S.R.C.S. 8vo, with 2 Lithographic Plates and 57 Engravings, 10s.

Lectures on Dermatology:

Delivered at the Royal College of Surgeons, by Sir ERASMUS WILSON, F.R.S. 1870, 6s.; 1871-73, 10s. 6d.; 1874-75, 10s. 6d.; 1876-78, 10s. 6d.

Eczema:

By MCCALL ANDERSON, M.D., Professor of Clinical Medicine in the University of Glasgow. Third Edition. 8vo, with Engravings, 7s. 6d.

Eczema and its Management:

A practical Treatise based on the Study of 2,500 Cases of the Disease. By L. DUNCAN BULKLEY, M.D., Physician for Skin and Venereal Diseases at the New York Hospital. 8vo, 12s. 6d.

Psoriasis, or Lepra.

By GEORGE GASKOIN, M.R.C.S., Surgeon to the British Hospital for Diseases of the Skin. 8vo, 5s.

On Certain Rare Diseases of the Skin:

being Vol. 1 of "Lectures on Clinical Surgery." By JONATHAN HUTCHINSON, Senior Surgeon to the London Hospital, and to the Hospital for Diseases of the Skin. 8vo, 10s. 6d.

Leprosy in British Guiana:

An Account of West Indian Leprosy. By JOHN D. HILLIS, F.R.C.S., M.R.I.A., Medical Superintendent of the Leper Asylum, British Guiana. Imp. 8vo, with 22 Lithographic Coloured Plates and Wood Engravings. £1 11s. 6d.

Photographic Illustrations of Skin Diseases. Sixty Cases from Life.

By GEORGE H. FOX, M.D. 4to, £5 5s.

Cancer Life:

Its Causes, Progress, and Treatment. A General and Historical Treatise. By R. MITCHELL, M.R.C.S. 8vo, 7s. 6d.

On Cancer:

Its Allies, and other Tumours, with special reference to their Medical and Surgical Treatment. By F. ALBERT PURCELL, M.D., Surgeon to the Cancer Hospital, Brompton. 8vo, with 21 Engravings, 10s. 6d.

Atlas of Skin Diseases:

By TILBURY FOX, M.D., F.R.C.P. With 72 Coloured Plates. Royal 4to, half morocco, £6 6s

Certain Forms of Cancer,

With a New and Successful Mode of treating it. By A. MARSDEN, Senior Surgeon to the Cancer Hospital. Second Edition. 8vo, with Coloured Plates, 8s. 6d.

Diseases of the Urinary Organs:

Clinical Lectures. By Sir HENRY THOMPSON, F.R.C.S., Emeritus Professor of Clinical Surgery in University College. Fifth Edition. 8vo, with 2 Plates and 71 Engravings, 10s. 6d.

By the same Author.

Diseases of the Prostate:

Their Pathology and Treatment. Fourth Edition. 8vo, with numerous Plates, 10s.

Also.

Practical Lithotomy and Lithotrity; or, an Inquiry into the best Modes of Removing Stone from the Bladder. Third Edition. 8vo, with 87 Engravings, 10s.

Also.

The Preventive Treatment of Calculous Disease, and the Use of Solvent Remedies. Second Edition. Fcap. 8vo, 2s. 6d.

Diseases of the Testis, Spermatic Cord, and Scrotum. By THOMAS B. CURLING, F.R.S., Consulting Surgeon to the London Hospital. Fourth Edition. 8vo, with Engravings, 16s.

Fistula, Hæmorrhoids, Painful Ulcer, Stricture, Prolapsus, and other Diseases of the Rectum: Their Diagnosis and Treatment. By WILLIAM ALLINGHAM, Surgeon to St. Mark's Hospital for Fistula. Fourth Edition. 8vo, with Engravings, 10s. 6d.

Cancer of the Rectum:

Its Pathology, Diagnosis, and Treatment. By W. HARRISON CRIPPS, F.R.C.S., Surgeon to the Great Northern Hospital, &c. Crown 8vo, with Lithographic Plates, 6s.

Hydrocele:

Its several Varieties and their Treatment. By SAMUEL OSBORN, late Surgical Registrar to St. Thomas's Hospital. Fcap. 8vo, with Engravings, 3s.

By the same Author.

Diseases of the Testis.

Fcap. 8vo, with Engravings. 3s. 6d.

Parasites:

A Treatise on the Entozoa of Man and Animals, including some Account of the Ectozoa. By T. SPENCER COBBOLD, M.D., F.R.S. 8vo, with 85 Engravings, 15s.

The Surgery of the Rectum.

By HENRY SMITH, Professor of Surgery in King's College, Surgeon to the Hospital. Fourth Edition. Fcap. 8vo, 5s.

Lectures on the Surgical Disorders of the Urinary Organs. By REGINALD HARRISON, F.R.C.S., Surgeon to the Liverpool Royal Infirmary. Second Edition, with 48 Engravings. 8vo, 12s. 6d.

By the same Author.

The Prevention of Stricture and of Prostatic Obstruction. 8vo, with Engravings, 2s. 6d.

Lithotomy and Extraction of Stone. By W. POULETT HARRIS, M.D., Surgeon-Major H.M. Bengal Medical Service. 8vo, with Engravings, 10s. 6d.

Diseases of the Bladder,

Prostate Gland, and Urethra, with a practical view of Urinary Diseases, Deposits, and Calculi. By F. J. GANT, Senior Surgeon to the Royal Free Hospital. Fourth Edition. Crown 8vo, 10s. 6d.

Renal and Urinary Diseases:

Clinical Reports. By WILLIAM CARTER, M.B., Physician to the Liverpool Southern Hospital. Crown 8vo, 7s. 6d.

Syphilitic Nervous Affections:

Their Clinical Aspects. By THOMAS BUZZARD, M.D., F.R.C.P. Physician to the National Hospital for Paralysis and Epilepsy. Second Edition. Post 8vo.

(In the Press.)

Pathology of the Urine,

Including a Complete Guide to its Analysis. By J. L. W. THUDICHUM, M.D., F.R.C.P. Second Edition, rewritten and enlarged. 8vo, with Engravings, 15s.

Genito-Urinary Organs, including Syphilis:

a Practical Treatise on their Surgical Diseases, designed as a Manual for Students and Practitioners. By W. H. VAN BUREN, M.D., and E. L. KEYES, M.D. Royal 8vo, with 140 Engravings, 21s.

Lectures on Syphilis.

By HENRY LEE, Consulting Surgeon to St. George's Hospital. 8vo, 10s.

Harveian Lectures on Syphilis.

By JAMES R. LANE, F.R.C.S., Surgeon to St. Mary's Hospital. Second Edition. Fcap. 8vo, 3s. 6d.

Photographic Illustrations of

Cutaneous Syphilis. Seventy Cases from Life. By GEORGE H. FOX, M.D. 4to, £5 5s.

Urinary and Reproductive Organs:

their Functional Diseases. By D. CAMPBELL BLACK, M.D. Second Edition. 8vo, 10s.

A Treatise on Syphilis.

By WALTER J. COULSON, Surgeon to the Lock Hospital and to St. Peter's Hospital for Stone. 8vo, 10s.

By the same Author.

Stone in the Bladder:

Its Prevention, early Symptoms, and Treatment by Lithotrixy. 8vo, 6s.

Also.

Coulson on Diseases of the Bladder and Prostate Gland.

Sixth Edition. 8vo, 16s.

The Reproductive Organs

In Childhood, Youth, Adult Age, and Advanced Life, considered in their Physiological, Social, and Moral Relations. By WILLIAM ACTON, M.R.C.S. Sixth Edition. 8vo, 12s.

Student's Primer on the Urine.

By J. TRAVIS WHITTAKER, M.D., Clinical Demonstrator at the Royal Infirmary, Glasgow. With 16 Plates etched on Copper. Post 8vo, 4s. 6d.

A Manual of the Laws affecting

Medical Men. By ROBERT G. GLENN, LL.B., Barrister-at-Law. 8vo, 14s.

The Medical Adviser in Life

Assurance. By EDWARD H. SIEVING, M.D., F.R.C.P., Physician to St. Mary's and Lock Hospitals, &c. Crown 8vo, 6s.

A Dictionary of Medical Science:

Containing a concise Explanation of the various Subjects and Terms of Medicine, &c.; Notices of Climate and Mineral Waters; Formulæ for Official, Empirical, and Dietetic Preparations; with the Accentuation and Etymology of the Terms, and the French and other Synonyms. By ROBLEY DUNGLISON, M.D., LL.D. New Edition. Royal 8vo, 28s.

A Medical Vocabulary:

Being an Explanation of all Terms and Phrases used in the various Departments of Medical Science and Practice, giving their Derivation, Meaning, Application, and Pronunciation. By ROBERT G. MAYNE, M.D., LL.D. Fifth Edition. Fcap. 8vo, 10s. 6d.

Abridged Medical Account

Books. The "Expedite" Method. By JAMES MACNAB, L.R.C.S.E. *Index Ledger.* Royal 4to. For four years, 21s. *Visiting List.* Cloth, 2s. 6d.; Leather, 3s. 6d.

Medical Education

And Practice in all parts of the World. By HERBERT JUNIUS HARDWICKE, M.D., M.R.C.P. 8vo, 10s.

INDEX.

- Acton's Reproductive Organs, 14
 Adams (W.) on Clubfoot, 11
 — Contraction of the Fingers, 11
 Allan on Fever Nursing, 7
 Allingham on Diseases of the Rectum, 13
 Anatomical Remembrancer, 4
 Anderson (McC.) on Eczema, 13
 Aveling's Influence of Posture on Women, 6
 Balkwill's Mechanical Dentistry, 13
 Bantock on Rupture of the Female Perineum, 6
 Barclay's Medical Diagnosis, 8
 Barnes on Obstetric Operations, 5
 — on Diseases of Women, 5
 Beale's Microscope in Medicine, 8
 — Slight Ailments, 8
 Bellamy's Surgical Anatomy, 3
 Bennet (J. H.) on the Mediterranean, 10
 — on Pulmonary Consumption, 10
 — on Nutrition, 10
 Bentley and Trimen's Medicinal Plants, 7
 Berkart on Asthma, 8
 Bigg (H. H.) on Orthopraxy, 11
 Biggs (R. H.) on the Orthopragms of Spine, 11
 Binz's Elements of Therapeutics, 7
 Black on the Urinary Organs, 14
 Bose's Rational Therapeutics, 7
 — Recognisant Medicine, 7
 Braune's Topographical Anatomy, 3
 Brodhurst's Anchylosis, 11
 — Orthopædic Surgery, 11
 Bryant's Practice of Surgery, 11
 Bucknill and Tuke's Psychological Medicine, 5
 Bulkeley on Eczema, 13
 Burdett's Cottage Hospitals, 5
 — Pay Hospitals, 5
 Burnett on the Ear, 12
 Burton's Midwifery for Midwives, 5
 Burrows's Syphilitic Nervous Affections, 14
 Carpenter's Human Physiology, 4
 Carter (W.) on Renal Diseases, 14
 Cayley's Typhoid Fever, 9
 Charteris' Practice of Medicine, 8
 Clark's Outlines of Surgery, 10
 Clay's Obstetric Surgery, 6
 Cobbold on Parasites, 13
 Coles' Dental Mechanics, 13
 — Deformities of the Mouth, 13
 Cormack's Clinical Studies, 8
 Coulson on Stone in the Bladder, 14
 — on Syphilis, 14
 — on Diseases of the Bladder, 14
 Crippes' Cancer of the Rectum, 13
 Cullingworth's Nurse's Companion, 7
 Curling's Diseases of the Testis, 13
 Daguene's Manual of Ophthalmoscopy, 12
 Dalby's Diseases and Injuries of the Ear, 12
 Dalton's Human Physiology, 4
 Day on Diseases of Children, 6
 — on Headaches, 9
 De Chaumont's Sanitary Assurance, 4
 Dobell's Lectures on Winter Cough, 8
 — Loss of Weight, &c., 8
 — Mont Dore Cure, 8
 Domville's Manual for Nurses, 7
 Druitt's Surgeon's Vade-Mecum, 11
 Duncan on the Female Perineum, 5
 — on Diseases of Women, 5
 Dunglison's Medical Dictionary, 14
 Ellis's Manual for Mothers, 6
 — of the Diseases of Children, 6
 Emmet's Gynecology, 5
 Eulenburg and Guttman's System of Nerves, 9
 Fayer's Observations in India, 7
 — Tropical Dysentery and Diarrhoea, 7
 Fenwick's Chronic Atrophy of the Stomach, 8
 — Medical Diagnosis, 8
 — Outlines of Medical Treatment, 8
 Fergusson's Practical Surgery, 10
 Flint on Phthisis, 8
 — on Clinical Medicine, 8
 Flower's Diagrams of the Nerves, 4
 Foster's Clinical Medicine, 8
 Fox's (C. B.) Examinations of Water, Air, and Food, 4
 Fox's (G. H.) Photographs of Cutaneous Syphilis, 14
 — Skin Diseases, 13
 Fox's (T.) Atlas of Skin Diseases, 13
 Frey's Histology and Histo-Chemistry, 4
 Fulton's Text-Book of Physiology, 4
 Galabin's Diseases of Women, 6
 Gangee's Fractures of the Limbs, 11
 — Treatment of Wounds, 11
 Gant's Diseases of the Bladder, 14
 Gaskoin on Psoriasis or Lepra, 13
 Gill on Indigestion, 10
 Glenn's Laws affecting Medical Men, 14
 Godlee's Atlas of Human Anatomy, 3
 Gowers' Diseases of the Spinal Cord, 9
 — Epilepsy, 9
 — Medical Ophthalmoscopy, 9
 — Pseudo-Hypertrophic Muscular Paralysis, 9
 Habershon's Diseases of the Abdomen, 9
 — Stomach, 9
 — Pneumogastric Nerve, 9
 Hamilton's Nervous Diseases, 9
 Hardwicke's Medical Education, 14
 Harris on Lithotomy, 14
 Harrison's Surgical Disorders of the Urinary Organs, 14
 — Prevention of Stricture, 14
 Heath's Injuries and Diseases of the Jaws, 10
 — Minor Surgery and Bandaging, 10
 — Operative Surgery, 10
 — Practical Anatomy, 3
 — Surgical Diagnosis, 10
 Hemming on the Laryngoscope, 12
 Higgins' Ophthalmic Out-patient Practice, 11
 Hillis' Leprosy in British Guiana, 13
 Hogg's Indian Notes, 7
 Holden's Dissections, 3
 — Human Osteology, 3
 — Landmarks, 3
 Holmes' (G.) Guide to Use of Laryngoscope, 12
 — Vocal Physiology and Hygiene, 12
 Hood on Gout, Rheumatism, &c., 9
 Hooper's Physicians' Vade-Mecum, 8
 Horton's Tropical Diseases, 7
 Hutchinson's Clinical Surgery, 11
 — Rare Diseases of the Skin, 13
 Huth's Marriage of Near Kin, 4
 Ireland's Idiocy and Imbecility, 5
 Irvine's Relapse of Typhoid Fever, 9
 James on Sore Throat, 12
 Jones' (C. H.) Functional Nervous Disorders, 9
 Jones (C. H.) and Sieveking's Pathological Anatomy, 4
 Jones' (H. McN.) Aural Surgery, 12
 — Atlas of Diseases of Membrana Tympani, 12
 Jones' (T. W.) Ophthalmic Medicine and Surgery, 11
 Jordan's Surgical Enquiries, 11
 Lancereaux's Atlas of Pathological Anatomy, 4
 Lane's Lectures on Syphilis, 14
 Lee (H.) on Syphilis, 14
 Leared on Imperfect Digestion, 10
 Liebreich's Atlas of Ophthalmoscopy, 11
 Liveing's Megrim, Sick Headache, &c., 10
 Lucas's Indian Hygiene, 8
 Macdonald's (A.) Chronic Disease of the Heart, 6
 Macdonald's (J. D.) Examination of Water, 4
 Macewen's Osteotomy: Knock-knee, Bow-leg, &c., 11
 Mackenzie on Diphtheria, 12
 — on Diseases of the Throat and Nose, 12
 MacLise's Dislocations and Fractures, 11
 — Surgical Anatomy, 3
 MacMunn's Spectroscope in Medicine, 8
 Macnab's Medical Account Books, 14
 Macnamara's Diseases of Bones and Joints, 11
 — the Eye, 11
 Madden's Principal Health-Resorts, 10
 Marsden on Cancer, 13
 Martin's Military and State Medicine, 5
 Mason on Hare-Lip and Cleft Palate, 12
 — on Surgery of the Face, 12
 Mayne's Medical Vocabulary, 14
 Mitchell (R.) on Cancer Life, 13
 Mitchell's (S. Weir) Nervous System in Women, 6
 Moore's Family Medicine for India, 7

[Continued on the next page.]

INDEX—continued.

- Moore's Health Resorts for Tropical Invalids, 7
 Morris' (H.) Anatomy of the Joints, 3
 Nettleship's Diseases of the Eye, 12
 Ogston's Medical Jurisprudence, 4
 Osborn on Diseases of the Testis, 13
 — on Hydrocele, 13
 Parkes' Practical Hygiene, 5
 Pavy on Diabetes, 10
 — on Food and Dietetics, 10
 Peacock's Diseases of the Heart, 9
 Phillips' Materia Medica, 7
 Pirrie's Principles and Practice of Surgery, 11
 Pollock on Rheumatism, 9
 Pridham on Asthma, 8
 Purcell on Cancer, 12
 Radford's Cæsarean Section, 5
 Ransbotham's Obstetrics, 6
 Reynolds' (J. J.) Diseases of Women, 6
 — Notes on Midwifery, 6
 Reynolds' (J. R.) Clinical Electricity, 10
 Roberts' (C.) Manual of Anthropometry, 5
 Roberts' (D. Lloyd) Practice of Midwifery, 5
 Ross's Diseases of the Nervous System, 9
 Roth on Dress: Its Sanitary Aspect, 5
 Rousssel's Transfusion of Blood, 8
 Routh's Infant Feeding, 6
 Royle and Harley's Materia Medica, 7
 Rutherford's Practical Histology, 4
 Sanderson's Physiological Handbook, 4
 Sansom's Diseases of the Heart, 9
 — Antiseptic System, 9
 Savage on the Female Pelvic Organs, 6
 Sayre's Orthopædic Surgery, 11
 Schroeder's Manual of Midwifery, 6
 Sewill's Dental Anatomy, 13
 Sheppard on Madness, 5
 Sibson's Medical Anatomy, 3
 Sieveking's Life Assurance, 14
 Smith's (E.) Wasting Diseases of Children, 6
 — Clinical Studies, 6
 Smith's (Henry) Surgery of the Rectum, 14
 Smith's (Heywood) Dysmenorrhœa, 6
 — Gynæcology, 6
 Smith (Priestley) on Glaucoma, 12
 Smith (W. R.) on Nursing, 6
 Sparks on the Riviera, 10
 Squire's Companion to the Pharmacopœia, 7
 — Pharmacopœias of London Hospitals, 7
 Stillé and Maisch's National Dispensatory, 7
 Stocken's Dental Materia Medica, 12
 Sullivan's Tropical Diseases, 7
 Swain's Surgical Emergencies, 10
 Swayne's Obstetric Aphorisms, 6
 Taft's Operative Dentistry, 12
 Taylor's Medical Jurisprudence, 4
 — Poisons in relation to Medical Jurisprudence, 4
 Teale's Dangers to Health, 5
 Thomas on Ear and Throat Diseases, 12
 Thompson's (Sir H.) Calculous Disease, 13
 — Diseases of the Urinary Organs, 13
 — Diseases of the Prostate, 13
 — Lithotomy and Lithotripsy, 13
 Thompson's (Dr. H.) Clinical Lectures, 8
 Thorogood on Asthma, 8
 — on Materia Medica, 7
 Thudichum's Pathology of the Urine, 14
 Tibbits' Medical and Surgical Electricity, 10
 — Map of Motor Points, 10
 Tilt's Change of Life, 6
 — Uterine Therapeutics, 6
 Tomes' (C. S.) Dental Anatomy, 12
 — (J. & C. S.) Dental Surgery, 12
 Van Buren on the Genito-Urinary Organs, 14
 Veitch's Handbook for Nurses, 7
 Virchow's Post-mortem Examinations, 4
 Wagstaffe's Human Osteology, 3
 Walker's Ophthalmology, 12
 Waring's Indian Bazaar Medicines, 7
 — Practical Therapeutics, 7
 Warner's Guide to Medical Case-Taking, 8
 Waters' (A. T. H.) Diseases of the Chest, 8
 Waters (J. H.) on Fits, 9
 Wells (Spencer) on Ovarian and Uterine Tumours, 6
 West and Duncan's Diseases of Women, 5
 Whistler's Syphilis of the Larynx, 12
 Whitehead's (J. L.) Climate of the Undercliff, 10
 Whittaker's Primer on the Urine, 14
 Wilks' Diseases of the Nervous System, 9
 Wilks and Moxon's Pathological Anatomy, 4
 Wilson's (Sir E.) Anatomist's Vade-Mecum, 3
 — Lectures on Dermatology, 13
 Wilson's (G.) Handbook of Hygiene, 5
 — Healthy Life and Dwellings, 5
 Wilson's (W. S.) Ocean as a Health-Resort, 10
 Wise's Davos Platz, 10
 Wolfe's Diseases and Injuries of the Eye, 11
 Woodman and Tidy's Forensic Medicine, 4

The following CATALOGUES issued by J. & A. CHURCHILL will be forwarded post free on application:—

A. *J. & A. Churchill's General List of more than 600 works on Anatomy, Physiology, Hygiene, Midwifery, Materia Medica, Medicine, Surgery, Chemistry, Botany, &c., &c., with a complete Index to their Subjects, for easy reference.* N.B.—*This List includes B, C, & D.*

B. *Selection from J. & A. Churchill's General List, comprising all recent Works published by them on the Art and Science of Medicine.*

C. *J. & A. Churchill's Catalogue of Text Books specially arranged for Students.*

D. *A selected and descriptive List of J. & A. Churchill's Works on Chemistry, Materia Medica, Pharmacy, Botany, Photography, Zoology, the Microscope, and other branches of Science.*

E. *The Half-yearly List of New Works and New Editions published by J. & A. Churchill during the previous six months, together with Particulars of the Periodicals issued from their House.*

[Sent in January and July of each year to every Medical Practitioner in the United Kingdom whose name and address can be ascertained. A large number are also sent to the United States of America, Continental Europe, India, and the Colonies.]

AMERICA.—*J. & A. Churchill being in constant communication with various publishing houses in Boston, New York, and Philadelphia, are able, notwithstanding the absence of international copyright, to conduct negotiations favourable to English Authors.*

LONDON: NEW BURLINGTON STREET.

1

The first part of the document discusses the general state of the country and the progress of the war. It mentions the various battles and the movements of the armies. The second part is a detailed account of the events of the day, including the names of the officers and soldiers who were involved. The third part is a list of the names of the officers and soldiers who were killed in action. The fourth part is a list of the names of the officers and soldiers who were wounded. The fifth part is a list of the names of the officers and soldiers who were captured. The sixth part is a list of the names of the officers and soldiers who were taken prisoner. The seventh part is a list of the names of the officers and soldiers who were taken prisoner. The eighth part is a list of the names of the officers and soldiers who were taken prisoner. The ninth part is a list of the names of the officers and soldiers who were taken prisoner. The tenth part is a list of the names of the officers and soldiers who were taken prisoner.