

UNIVERSITY OF TORONTO



3 1761 00831502 0

Digitized by the Internet Archive  
in 2008 with funding from  
Microsoft Corporation











8872

THE NEW SYDENHAM  
SOCIETY.

INSTITUTED MDCCCLVIII.

VOLUME CII.



*New Sydenham Society Publications*  
Vol. 102  
LECTURES

ON

THE LOCALISATION OF  
CEREBRAL AND SPINAL DISEASES.

DELIVERED AT

THE FACULTY OF MEDICINE OF PARIS

BY

J. M. CHARCOT,

PROFESSOR TO THE FACULTY OF MEDICINE OF PARIS; PHYSICIAN TO LA SALPÊTRIÈRE; MEMBER OF THE ACADEMY OF MEDICINE, AND OF THE CLINICAL SOCIETY OF LONDON  
PRESIDENT OF THE ANATOMICAL SOCIETY, AND EX-VICE-PRESIDENT OF THE BIOLOGICAL SOCIETY OF PARIS, ETC.

TRANSLATED AND EDITED BY

WALTER BAUGH HADDEN, M.D. LOND.,

MEMBER OF THE ROYAL COLLEGE OF PHYSICIANS OF ENGLAND; DEMONSTRATOR OF MORBID ANATOMY AND MEDICAL REGISTRAR TO ST. THOMAS'S HOSPITAL; PHYSICIAN TO ST. GEORGE'S AND ST. JAMES'S DISPENSARY; CORRESPONDING MEMBER OF THE ANATOMICAL SOCIETY OF PARIS.

*70104*  
*7/6/06*

LONDON:  
THE NEW SYDENHAM SOCIETY.

—  
1883.

RC  
346  
C423

## AUTHOR'S INTRODUCTION

TO

## THE TRANSLATION.

---

Le but qu'on s'est proposé d'atteindre dans cette série de leçons a été de constituer un chapitre d'introduction à l'histoire clinique des affections cérébrales et spinales chez l'homme. C'est, en effet, principalement sur le principe des localisations qu'est fondé ce qu'on a appelé le *diagnostic régional* des maladies des centres nerveux, cet idéal vers lequel doivent tendre les efforts du clinicien.

Sans méconnaître aucunement l'importance que présentent nécessairement dans les études de ce genre, les documents relevant de l'expérimentation sur les animaux, on a dû s'attacher surtout dans ces leçons, aux données fournies par l'observation clinique appuyée sur l'examen méthodique et minutieux des lésions organiques ; car si les premiers ont mis souvent sur la voie des localisations, les dernières permettent seules, puisqu'il s'agit ici de l'homme, de juger en dernier ressort et de *fournir la preuve*.

Personne n'ignore que sur la question des localisations cérébrales, le désarroi est pour le moment, dans le camp des expérimentateurs ; les uns niant formellement ce que les autres affirment avec non moins d'autorité. A ces débats cependant le pathologiste peut assister, non pas certes avec indifférence,

mais tout au moins avec calme, attendant avec patience que l'accord se fasse.

Cela tient à ce que les moyens de recherche qui lui appartiennent en propre et qui constituent à proprement parler la méthode *anatomo-clinique*, l'ont mis désormais sur ces questions en possession d'un certain nombre de faits fondamentaux, relatifs à l'homme et contre lesquels les données fournies par la vivisection ne sauraient jamais complètement prévaloir.

Ainsi, pour ne citer que quelques exemples, nous savons, de science certaine, que chez l'homme la lésion destructive du faisceau pyramidal, dans son trajet capsulaire en arrière du genou, produit l'hémiplégie permanente vulgaire ; que les lésions de l'extrémité postérieure de la capsule interne produisent la syndrôme hémianesthésie cérébrale. Pour ce qui est maintenant de l'écorce des hémisphères, on ne discute plus guère aujourd'hui sur le rôle pathologique de la circonvolution de Broca ; on sait que la destruction des circonvolutions de la zone dite motrice, produit, si elle est générale, l'hémiplégie complète, ou, au contraire, seulement une monoplégie. Si la lésion se circonscrit dans tel ou tel département secondaire, aux lésions irritatives de ces mêmes régions se rattachent les phénomènes de *l'épilepsie Jacksonienne*, &c.

Sans aucun doute ces faits de localisation ne fournissent pas, quant à présent, les éléments d'une doctrine arrêtée concernant le rôle physiologique des diverses régions cérébrales. Mais tels qu'ils sont ils représentent, si je ne me trompe, autant de données empiriques servant de points de repère pour diriger le clinicien et lui permettre de s'orienter dans la difficile recherche du diagnostic.

Monsieur le Docteur W. B. Hadden m'a fait l'honneur de suivre pendant plusieurs mois ma clinique, à la Salpêtrière, et il a été ainsi mis à même de reconnaître l'esprit qui dirige



mon enseignement. Je ne saurais trop le remercier de la peine qu'il a prise de présenter à nos confrères anglais, sous la forme d'une traduction à la fois élégante et fidèle, mes *leçons sur les localisations dans les maladies du cerveau et de la moelle épinière*.

J. M. CHARCOT.

PARIS; le 1 novembre, 1882.



## TRANSLATOR'S PREFACE.

---

No higher testimony can be afforded to Professor Charcot's clinical accuracy and analytical insight into disease than the fact that the New Sydenham Society have determined to publish the translation of another work by this well-known French physician.

The subject dealt with in these pages is as yet only imperfectly understood. Perhaps some of the hypotheses put forward in this work will eventually be found untenable. Still their wonderful suggestiveness will probably open up lines of inquiry which may lead to truth. M. Charcot tries to show that clinical investigation and pathological anatomy are capable of assisting greatly in the elucidation of cerebral and spinal function. Furthermore, he points out that modern anatomy, physiology, and experiment are often out of harmony with pathological facts, and require modification in consequence.

It was thought advisable, almost essential, that the views of other observers relative to some great questions in neurology, should occasionally receive notice in this work. The translator trusts that the determination has been exercised judiciously, and that no superfluous matter has been introduced.

It must be mentioned that these lectures were edited and partly annotated by MM. Bourneville and Brissaud, whose labours in this department of medicine lend additional value to this work.

Our warmest thanks are due to Dr. Horrocks, who read and criticised the first part of this translation when in manuscript,

and to Dr. Gowers, from whose teaching we have learned much and to whose kindness we are indebted for many valuable suggestions.

I. M. Charcot's views as to the causation of hemiopia and crossed amblyopia are in accordance with many clinical facts. Nevertheless, some researches of Professors Ferrier and Gerald Yeo, which were communicated to the Physiological Section of the British Medical Association in 1880,<sup>1</sup> must be taken into careful consideration.

The following is a summary of the results of their experiments on the monkey :

(1) Neither destruction nor the removal of one or both occipital lobes caused any apparent disorder of vision.

(2) Complete destruction of one angular gyrus caused loss of vision in the opposite eye, lasting a few hours only.

(3) The restoration of sight is not dependent on the integrity of the other angular gyrus alone, because when this is subsequently destroyed, vision is either not markedly impaired, or if so, the effect is very transient.

(4) Simultaneous destruction of both angular gyri causes total blindness, lasting not more than three days.

(5) Destruction of one occipital lobe and one angular gyrus entails loss of sight in both eyes towards the side opposite the lesion. It is doubtful whether the hemiopia is quite symmetrical. The visual disorder is temporary, the animal partially recovering in a week.

(6) If in an animal, which had recovered sight after destruction of the left angular gyrus, the right angular gyrus and occipital lobe were destroyed, the result was temporary left hemiopia.

(7) If in an animal in which the occipital lobes had been removed without symptoms, the left angular gyrus was destroyed, the result was transient loss of vision in the right eye.

<sup>1</sup> See abstract in 'Brain,' vol. iii, p. 419.

(8) Destruction of both angular gyri and both occipital lobes causes total and permanent blindness.

It follows from these experiments that the monkey continues to see without its occipital lobes, and that it can regain sight when the angular gyri are completely destroyed. It is evident also that one occipital lobe or one angular gyrus suffices for vision with both eyes. Cases are on record in which one angular gyrus and one or both occipital lobes have been destroyed by disease, without any disturbance of vision during life. Complete destruction of both angular gyri and occipital lobes in man has never been observed, so the results of experiment have not been confirmed.

From his experiments Ferrier concludes that "there is a two-fold relation between the eyes and cortical visual centres; one mainly crossed—the central portion of the retina bilaterally represented—by the angular gyrus; the other bilateral—the corresponding side of both retinae being represented—by the occipital lobe, not alone, but in conjunction with the angular gyrus." ("Cerebral Amblyopia and Hemiopia," 'Brain,' vol. iii.)

The crossed amblyopia, which results from lesion of the angular gyrus, is in harmony with the disturbance of vision occurring in cerebral hemianæsthesia.

It is probable that the fibres which pass to the cortex in the posterior third of the internal capsule enter into special connection with the angular gyrus, and represent the opposite eye as regards those functions affected in hemianæsthesia.

Ferrier believes that hemiopia may result from lesion affecting the occipital lobe and angular gyrus, apart from any implication of the optic tract or corpora geniculata. This conclusion is proved both by experiment and by clinical observation.

In the case of experimental lesions the disturbance of vision is apparently but transient, whereas amblyopia and hemiopia in man persist for a long time, and often remain permanent. This apparent discrepancy has not been explained, but it is possible that the visual defect is really more durable in the

monkey than it seems to be. The question arises whether it is possible to distinguish between hemiopia due to pressure on the optic tract, and that dependent on cortical or sub-cortical lesions in the occipito-angular region. Cerebral symptoms such as hemiplegia, hemianæsthesia, aphasia, &c., are not decisive in favour of either the one or the other. Ferrier gives the following points of difference between them :

(1) In hemiopia from pressure on the optic tract, the defect of vision is absolutely unilateral, because each optic tract supplies precisely the corresponding half of both retinae.

(2) The hemiopia is probably cerebral when central vision is retained for some degrees on all sides of the point of fixation.

This is due to the fact that each angular gyrus has a bilateral relation with the centre of the retina, so that although there may be complete destruction of one visual centre it is still possible for both eyes to possess central vision through the sound angular gyrus.

Hemiopia, therefore, may be present towards the side opposite the lesion with retention of central vision in both eyes.

(3) Rapid atrophy of the optic discs would be rather in favour of hemiopia from pressure on the optic tract than of cerebral hemiopia.

II. In addition to the various tracts of spinal degeneration mentioned in the opening lecture of Part II, we have called attention to another focus situated in front of the pyramidal tracts.<sup>1</sup>

The case was said to be one of locomotor ataxy, but unfortunately no further clinical history could be obtained.

In the highest cervical region, and about the lower half of the medulla oblongata there were two symmetrical areas of degeneration. Microscopically the parts did not present the ordinary connective tissue change, but the degeneration was granular and in the centre showed a confused mass of *débris*.

<sup>1</sup> See 'Brit. Med. Journal,' April 15th, 1882; also 'Transactions of the Path. Soc. of London,' 1882.

At the periphery however, there were numerous swollen axis-cylinders and amyloid bodies.

The grey matter and posterior columns were unaffected, although the patient was said to have suffered from locomotor ataxy.

The degenerative areae were quite visible to the naked eye on stained specimens. Dr. Gowers has described and figured a similar degenerative tract in a spinal cord, the lower end of which had been crushed.

The columns of Goll were densely sclerosed, but in addition there was "a symmetrical area of slight ascending degeneration in the anterior part of the lateral columns, in front of the pyramidal tracts." Dr. Gowers gives reasons for believing that the tract of fibres involved is concerned with the transmission of sensory impressions. The degeneration could not be traced higher than the cervical region, whereas in our own case the alteration was found in the highest cervical and lower region of the medulla. It must be mentioned, however, that only this small part was available for microscopical examination.

In the sections made by Dr. Gowers the degeneration extended to the periphery of the cord, whereas the affected areae in our case were separated from the periphery by healthy tissue.

In short, it is probable (as Dr. Gowers thinks) that the area of degeneration in this latter instance involved only part of the tract.

III. Recent researches into the nature of the so-called tendon-reflexes have led to conclusions at variance with the generally accepted views.

In the present work M. Charcot strongly insists on the essentially reflex character of these phenomena. But reasons have been adduced by several competent observers, which tend to prove that the muscular contractions are excited locally.

Tschirjew<sup>1</sup> has found that the interval between percussion of the patellar tendon and the contraction of the quadriceps is

<sup>1</sup> 'Arch. für Psych.,' 1878, Heft iii.

·033 of a second—a period much too short for a reflex action. This calculation closely agrees with the measurements obtained by Burckhardt, Brissaud, Gowers and Waller.

The last-named observer had pointed out the important fact that the interval between stimulation and contraction is the same, whether the tendon or the muscle itself be percussed.<sup>1</sup> The obvious conclusion is that in both cases the muscular contraction is excited locally.

But if the tendon phenomena are not directly dependent on reflex action, it is nevertheless undeniable that there is a reflex influence concerned in their production.

This is amply proved by experiment, which shows that the knee-phenomenon is absent after division of the nerves to the muscles, after section of the anterior or posterior roots of the spinal nerves, or after destruction of the special spinal centre.

Moreover, the modifications which the tendon phenomena undergo by lesions affecting the various parts of the nervous system certainly tend to the same conclusion. Gowers<sup>2</sup> points out that an essential condition for the production of the tendon-reflex is passive tension. He observes also that tension acts both on the tendon and on the muscle, and that contraction may sometimes be provoked by stimuli which act on the muscle but not on the tendon.

When these phenomena are exaggerated, if the foot be placed at a right angle to the leg so as to make the calf-muscles tense, and if the muscles in the front of the leg be percussed the gastrocnemius contracts just as though the tendon were struck. He terms this the "front-tap contraction."

In the case of the tendo Achillis Gowers has demonstrated that percussion of the tendon excites contraction only when it at the same time increases the tension of the tendon and hence of the muscle also.

<sup>1</sup> 'Brain,' vol. iii, p. 179.

<sup>2</sup> 'The Diagnosis of Diseases of the Spinal Cord,' 2nd ed., 1881, p. 24, *et seq.*



When all the nerves to the patellar tendon are divided the knee-phenomenon may still be called forth in the usual way (Tschirjew). This clearly proves that the muscular contraction is not excited by irritation of the nerves in the tendon, "but that," as Gowers remarks, "the stimulus originates in the muscle, the tendon being only, so to speak, an instrument by which that stimulation is produced." He believes that tension excites reflexly a condition of extreme irritability to local stimulation—an opinion which is confirmed by some experiments of Tschirjew.<sup>1</sup>

Gowers proposes to call the so-called tendon-reflexes the "tendon-muscular phenomena" or "myotatic contractions." (τατικος, extended). For the patellar-tendon reflex he suggests the name of "knee-jerk" which, involving no theory as to its nature, might well be universally adopted.

Dr. Horrocks has recently brought forward arguments in favour of the "tonic theory" of the tendon-reflexes.<sup>2</sup>

Under ordinary conditions all the muscles are in a state of slight contraction which is usually termed that of *tone*. It is an undoubted fact that the tendon-reflexes are abolished or diminished when tone is absent or deficient, and, on the other hand, that these phenomena are exaggerated when tone is in excess.

The experiments performed by Dr. Horrocks showed (1) that a pull on a tendon causes muscular contraction when the reflex loop is intact, (2) that no contraction ensues when the tendon is pulled upon, the reflex loop being destroyed.

It must be admitted, as Dr. Horrocks allows, that his experiments are equally in favour of the reflex nature of the tendon-muscular phenomena. The arguments against this last hypothesis, as stated above, are considered by Dr. Horrocks to be quite conclusive.

The diagnostic significance of the tendon-muscular phenomena

<sup>1</sup> 'Reichert und Du Bois Reymond's Archiv,' 1879.

<sup>2</sup> "Reflex Action in Diagnosis," 'Guy's Hospital Reports,' 1881.

is not yet fully made out. Berger finds that the knee-jerk is absent in healthy persons in one per cent. Westphal asserts that it is universally present, and Horrocks,<sup>1</sup> out of two hundred cases, found it wanting only in those who were very fat and whose ligamentum patellæ was very short. The absence of the knee-jerk should not be too readily assumed. In doubtful cases the patient ought to sit on the edge of a table with the limbs bare and hanging loosely down.

Our experience coincides with that of Dr. Horrocks that the phenomenon is occasionally obtained in this way only.

Is the knee-jerk ever absent in apparently normal individuals when full precautions are taken to overcome the difficulties to which we have alluded?

We are disposed to answer the question in the affirmative.

Such cases are known to many careful observers. We venture to suggest that at least in some instances of this kind the absence of the knee-jerk is dependent on organic change in the cord, as yet unrevealed by symptoms.

This opinion is borne out by a case which came under our attention a few months ago. The patient, a man about forty years of age, was suffering from mixed symptoms of ataxy and disseminated sclerosis with absence of the knee-phenomena.

Some twenty years before the patient declared that both himself and his companions were surprised to find that his knee-jerk was entirely wanting on one side, and but slightly marked on the other. At that time he had absolutely no indications of spinal disease.

The presence of ankle-clonus is usually considered to be related to a structural change in the lateral columns.

Dr. Hughlings Jackson, however, has occasionally found it present immediately after epileptiform attacks. In such cases he believes that the lateral columns have become temporarily exhausted.

Is ankle-clonus, in cases of permanent rigidity, always

<sup>1</sup> Op. cit.

dependent on actual degeneration of the pyramidal-tract system?

M. Charcot is of opinion that contracture may exist without sclerosis, and, in support of this view, calls attention to the fact that rigidity sometimes supervenes suddenly in hysterical subjects.

We have lately seen a case of right hemiplegia in an adult male, in which rigidity occurred in four days after the attack.

Well marked ankle-clonus could be obtained on the paralysed side. There was no suspicion of a previous hemiplegic attack. The condition still exists and seems likely to be permanent.

Briefly then, it may be said, with a fair amount of probability, that coarse lesion in the lateral columns is not the only condition giving rise to over-action of the motor cells in the anterior cornua.

The question cannot of course be definitely solved in the absence of post-mortem evidence.

The front-tap contraction described by Gowers is not unfrequently obtainable in healthy subjects, and not only so, but it commonly exists on one side alone in young and apparently healthy persons.<sup>1</sup>

We have found the presence of the front-tap contraction on one side, and slight but undoubted ankle-clonus on the opposite side in a boy, aged eleven, who was seemingly quite healthy.

<sup>1</sup> Out of fifty-one schoolboys who presented no sign of organic nerve-disorder, we obtained the front-tap contraction on one side only in six cases. The knee-jerk and all the other tendon-muscular phenomena, including the contraction of the gastrocnemius from percussion of the tendo Achillis, were quite absent in one boy said not to be a "good runner." In another young subject the knee-jerk was wanting on one side, but well marked on the opposite side. The knee-jerk was present, to a variable degree however, in all the other boys.



# CONTENTS.

---

## PART FIRST.—CEREBRAL LOCALISATIONS.

---

### LECTURE I.

#### LOCALISATION IN CEREBRAL DISEASES.

	PAGE
SUMMARY.—Introduction. Apparent barrenness of this study. Principles of cerebral localisation. The encephalon in its morphological aspect. Necessity of an exact nomenclature. Topography of the convolutions. Importance of comparative anatomy. Convolutions of the monkey's brain: frontal, parietal, and sphenoidal lobes. Psychomotor centres. Differences in the composition of the cortical layer in the various regions of the encephalon . . . .	3

### LECTURE II.

#### STRUCTURE OF THE CEREBRAL CORTEX.

SUMMARY.—General structural characters of the cerebral cortex.	
Ganglionic nerve-cells; pyramidal cells. Opinions regarding the nerve-cells in the anterior grey cornua of the spinal cord (motor cells). Dimensions, form, body, nucleus, nucleolus, protoplasm, fibrils and granulations; nerve-network; prolongations of the protoplasm; nerve-prolongation.	
Comparison of the motor nerve-cells in the cord with the pyramidal cells.	
Pyramidal cells; dimensions; small variety; large variety, or giant-cells. Constitution of these cells: configuration, body nucleus,	

nucleolus; cell-prolongations; pyramidal prolongation; prolongations resembling those of the protoplasm; basal prolongation.	
Globular cell-elements; elongated cells.	
Medullary tubes; neuroglia.	
Mutual relations of these elements; type of five layers.	
Important results obtained by examining the structure of the cortex, convolution by convolution. Division of the cortex into two regions from a structural point of view. Investigations of Betz.	17

### LECTURE III.

#### ACCOUNT OF THE NORMAL STRUCTURE OF THE CORTEX (continued).

SUMMARY.—Description of a section of the cerebellar cortex. The cellular nerve-elements are arranged according to the type of stratification in five layers. Regions in which this type exists. Department of the pyramidal or giant-cells. Relation between these cells and the psychomotor centres.	
Description of the internal surface of the cerebral hemispheres. Paracentral lobule. Ascending convolutions. Clinical and experimental facts bearing on the development of the pyramidal giant-cells. Structure of the cortex in the posterior regions of the encephalon . . . . .	28

### LECTURE IV.

#### PARALLEL BETWEEN SPINAL AND CEREBRAL LESIONS.

SUMMARY.—Indispensable conditions for the study of cerebral localisation in human diseases.	
Necessity for good clinical observation and careful autopsy.	
Natural history of encephalic lesions.	
Parallel between the great divisions of the cerebro-spinal axis.	
Systematisation of lesions in the spinal cord. Spinal localisation.	
The cerebrum is placed under a different pathological law from the other parts of the neuro-axis; rarity of localisation. Variety of lesions.	
Frequency of vascular lesions in cerebral affections.	
Necessity for the study of the vascular distribution. External distribution of the cerebral arteries . . . . .	37

## LECTURES V AND VI.

## ARTERIAL CIRCULATION OF THE CEREBRUM.

	PAGE
SUMMARY.—Works of Duret and Heubner. Principle arteries of the cerebrum. Cortical arterial system; nutrient vessels. Central arterial or central ganglionic system.	
Branches of the Sylvian artery; arteries of the central grey nuclei; cortical ramifications and arborisations; the nutrient arteries of the cerebral pulp are—(a) long or medullary, and (b) short or cortical.	
Effects of obstruction of these various arteries. Superficial ramolissement, yellow softening. Opinions of Heubner and of Duret on the communication between the vascular areae. Cohnheim's terminal arteries.	
Relative autonomy of the vascular areae of the cerebrum.	
Localisation of cortical lesions.	
Branches of the Sylvian: external and inferior frontal; arteries of the ascending frontal and parietal convolutions; artery of the gyrus angularis.	
Anterior and posterior cerebrals and their branches . . . .	46

## LECTURE VII.

## CIRCULATION IN THE CENTRAL MASSES.

(GREY NUCLEI AND INTERNAL CAPSULE.)

SUMMARY.—Arterial circulation in the central grey nuclei. Intra-encephalic hæmorrhage. Anatomico-pathological differences between the peripheral and central parts of the cerebrum. Comparative rarity of cerebral hæmorrhage in the peripheral, and its frequency in the central, parts.	
Origin of the arteries of the central system. Characteristics of the terminal arteries. Independence of the cortical and central arterial systems. Analogy between the arteries of the pons, medulla, and central ganglia. Their mode of origin explains the predominance of arterial ruptures in these parts. The branches forming this system arise from the anterior and posterior cerebrals and from the Sylvian.	
Arrangement of the grey nuclei: their form and connections. Description of the internal capsule: its constituent parts (direct and indirect peduncular fibres; radiating fibres) . . . .	65

## LECTURES VIII AND IX.

## CENTRAL ARTERIES. LESIONS LIMITED TO THE GREY NUCLEI.

PAGE

**SUMMARY.**—Origin of the arterial system of the central ganglionic masses. Unequal share of the large cerebral arteries in the constitution of this system. Description of the arteries to the corpus striatum.—(a) Internal; (b) external (to lenticular nucleus and optic thalamus). Terminal arteries. Effects of obstruction of the central arteries proceeding from the Sylvian. Softening of the corpus striatum and optic thalamus. Regional diagnosis of intracerebral hæmorrhage.

Lesions limited to the grey nuclei without implication of the internal capsule.

Central and cortical cerebral hemiplegia. Lesions of the internal capsule. Symptoms vary according to the seat of the lesion in the internal capsule.

Additional anatomical considerations. Direct peduncular fibres proceeding to the cortical substance of the occipital lobe. Their importance as regards sensibility exemplified: (1) by lesions of the posterior lenticulo-optic region of the internal capsule (cerebral hemianæsthesia); (2) by experiment . . . . .

76

## LECTURE X.

CEREBRAL HEMIANÆSTHESIA (*continued*). CROSSED AMBLYOPIA. LATERAL HEMIOPIA.

**SUMMARY.**—Description of the characteristic features of cerebral hemianæsthesia. Points of resemblance to hysterical hemianæsthesia. The anæsthesia affects the different varieties of general sensibility and the special senses.

Hysterical amblyopia. Ophthalmoscopic examination.

Functional exploration: diminution of visual acuity; general and concentric contraction of the visual field, &c.

Crossed amblyopia with hemianæsthesia of cerebral origin: identical symptoms.

Lesions of the cerebral hemispheres causing hemianæsthesia give rise also to crossed amblyopia and not to lateral hemiopia.

Hemiopia. Hypothesis of semi-decussation.

Unilateral homonymous hemiopia. Varieties of hemiopia . . . . .

98



## LECTURE XI.

## ORIGIN OF THE CEREBRAL PARTS OF THE OPTIC NERVES.

**SUMMARY.**—Relation between crossed amblyopia and hemianæsthesia resulting from lesion of the internal capsule. Cerebral origin of the optic nerves.

PAGE

Corona radiata of Reil. Cortico-optic radiating fasciculi; anterior fibres (anterior root of the optic thalamus); middle fibres (lateral expansion); posterior fibres (cerebral expansion of the optic nerves). Anatomical relations between the cerebral expansion of the optic nerves and the centripetal fibres of the corona radiata (hemianæsthesia). Optic tracts. Origin of the external root (optic thalamus, corpus geniculatum externum, anterior corpora quadrigemina). Origin of the internal root (corpus geniculatum internum, posterior corpora quadrigemina). Connection between the masses of grey matter and the encephalic cortex: cortico-optic radiating fasciculi.

Effects of lesions of the anterior corpora quadrigemina.

Cases of lateral hemiopia of supposed intra-cerebral origin . . . 109

## LECTURE XII.

## SECONDARY DEGENERATION.

**SUMMARY.**—Anterior or lenticulo-striate region of the central masses (anterior two thirds of the internal capsule, caudate and lenticular nuclei). Influence of lesions of these parts over the production of motor hemiplegia. Experimental facts. Agreement between them and facts in human pathology.

Difference between lesions of the caudate nucleus and those of the anterior part of the internal capsule.

Lesions causing secondary degeneration or descending sclerosis: importance of the seat and extent of these lesions.

Characteristics of descending sclerosis. Extent: appearance of the lesion in the crus cerebri, pons, anterior pyramid, and lateral column of the cord.

Analogies and differences between secondary lateral sclerosis of cerebral origin and primary fasciculated sclerosis of the lateral columns.

Symptoms pertaining to secondary sclerosis: motor impotence; permanent contracture. Muscular atrophy produced by extension of the lateral sclerosis to the grey cornua. Descending sclerosis

	PAGE
secondary to a cortical lesion. Pathological facts in favour of the existence of direct peduncular fibres. Cortical lesions causing secondary degeneration correspond in position to the so-called psychomotor centres . . . . .	124

## [ PART SECOND.—SPINAL LOCALISATIONS.

### LECTURE I.

#### INTRODUCTION. TOPOGRAPHY OF THE SPINAL CORD. SYSTEM AFFECTIONS.

**SUMMARY.**—Introduction. Progress of the pathological anatomy of the nervous system. Many nervous diseases are still inaccessible to pathological anatomy. Short historical account of locomotor ataxy and disseminated sclerosis, which were for a long time looked upon as neuroses. The study of lesions, with the aid of experiment, furnishes the basis for a physiological interpretation of the morbid phenomena.

Constitution of the spinal cord. System lesions; pyramidal tract (direct and crossed fasciculi): columns of Goll and of Burdach. This division of the various parts of the cord obtains from the period of its development. Researches of Pierret and Flechsig.

Elementary affections. Cerebral and bulbar localisations . . . . . 147

### LECTURE II.

#### THE PYRAMIDAL TRACTS AND THEIR DEVELOPMENT.

**SUMMARY.**—System affections of the spinal cord correspond to normal anatomical topography, as illustrated by pathological anatomy, clinical medicine, and developmental anatomy.

Researches of Parrot, Schlossberger, and Weisbach. Incomplete development of the cerebrum in the newly-born child. Predominance of reflex acts. Observations of Soltmann and Tarchanoff on the cerebrum of recently born animals endowed with voluntary motion. At birth the human cerebrum is almost an indifferent organ.

Crossed pyramidal tracts. Direct pyramidal tracts (columns of Türk). Their course in the various regions of the spinal cord and in the medulla oblongata.	
Decussation of the pyramids. Different types of decussation. Importance of a thorough acquaintance with these types in interpreting pathological facts . . . . .	158

## LECTURE III.

## THE PYRAMIDAL TRACT IN THE CRUS CEREBRI, INTERNAL CAPSULE, AND CENTRUM OVALE.

**SUMMARY.**—Continuation of the pyramidal tract above the medulla oblongata. Course in the pons and crus cerebri. Its extent in the lower layer of the peduncle. Flechsig's opinions. Relatively early development of the pyramidal tract in the peduncle.

Division of the internal capsule, on horizontal sections, into three regions: anterior and posterior segments and knee of the capsule. Localisation of the pyramidal tract in the posterior segment of the internal capsule. The pyramidal tract in the centrum ovale. Parrot's chromological observations. Formation of the Rolandic loop. Of all the cortical parts of the hemisphere the so-called motor regions are developed first . . . . . 167

## LECTURE IV.

## SECONDARY DEGENERATIONS. DEGENERATION OF THE PYRAMIDAL TRACT IN THE PEDUNCLE, PONS, MEDULLA OBLONGATA, AND SPINAL CORD. EXCEPTIONAL DEGENERATION OF THE INTERNAL FASCICULUS OF THE CRUS CEREBRI. DIVISION OF THE LOWER LAYER OF THE CRUS INTO THREE REGIONS.

**SUMMARY.**—Introduction to the study of secondary degenerations.

Degenerations of cerebral origin are descending; those of spinal origin are both descending and ascending.

Degenerations of peripheral origin. The question of localisation governs the situation. The nature of the lesion matters little, provided that it is destructive. Secondary lesion of the crus divides the lower layer into three regions. Degeneration in the pons, medulla, and spinal cord.

Localisation of the degenerative lesion in the opto-striate region.

Flechsig's researches. The pyramidal tract, properly called, is not the only part capable of descending degeneration. In the internal capsule it occupies at least the anterior two thirds of the posterior segment. The posterior fasciculus (Meynert's sensitive fibres) never degenerates. . . . . 178

LECTURE V.

SECONDARY DEGENERATIONS (*continued*). LIMITS OF THE PYRAMIDAL TRACT IN THE CEREBRAL HEMISPHERE.

SUMMARY.—In the study of secondary degenerations of cerebral origin, the seat of the lesion is the capital point. Importance of a thorough knowledge of the cerebral convolutions. Motor convolutions. Vicq d'Azyr (1785), Rolando (1829), Leuret (1839). Histological examination of the convolutions. Giant-cells of Betz and Mierzejewsky. Previous description of Luys.  
 Histological analysis and comparative anatomy of the convolutions. Hitzig, Ferrier, Betz, and Bevan Lewis.  
 Diagrammatic view of the pyramidal tract in the cerebral hemisphere. Rolandic region. Focal lesions in this region give rise to secondary degenerations, whether from alteration of the fibres of the centrum ovale or as a consequence of cortical destructive lesions . . . . . 190

LECTURE VI.

SECONDARY DEGENERATION OF CEREBRAL ORIGIN (*concluded*). CONSECUTIVE AMYOTROPHY.

SUMMARY.—The degenerative lesions of the pyramidal tract enable us to definitely fix its anatomical relations. The termination of its fibres in the spinal cord has given rise to several hypotheses. The ending of the pyramidal fibre is an anterior cell, which generally arrests the process of descending degeneration. Sometimes the cell itself is attacked. Trophic disorders consequent on extension of degeneration to the anterior cornua.  
 There is therefore another relation besides that of contiguity between the pyramidal tract and the grey matter of the spinal cord. Muscular atrophy in hemiplegic patients. Observations of Charcot, Vulpian, Hallopeau, Leyden, Pitres, and Brissaud. Is extension effected through the connective tissue or through the nerve-fibres themselves? . . . . . 198

## LECTURE VII.

## SECONDARY DEGENERATION OF SPINAL ORIGIN. ASCENDING DEGENERATION OF THE CEREBELLAR TRACT. DESCENDING DEGENERATION OF THE PYRAMIDAL TRACT.

	PAGE
SUMMARY.—Frequency of secondary degenerations of spinal origin. The commonest case is that of compression of the cord in Pott's disease. Caseo-tubercular pachymeningitis. Total transverse lesion. This lesion must be destructive in order to be followed by degeneration. Classification of degenerations consecutive to total transverse lesion. Descending degeneration. Ascending degeneration involves the lateral and posterior columns. Flechsig's cerebellar tract. Degeneration in the case of a partial transverse lesion takes place only when the white fasciculi are destroyed. Spinal hemiparaplegia with crossed anæsthesia.	
Unilateral lesion of the spinal cord, with subsequent degenerative change of both lateral columns, is of very exceptional occurrence. Anatomical inferences from Müller's observations. Double decussation of certain of the pyramidal-tract fibres . . . . .	205

## LECTURE VIII.

## ASCENDING DEGENERATION OF SPINAL ORIGIN. COLUMNS OF GOLL AND OF BURDACH. SPINAL DEGENERATION OF PERIPHERAL ORIGIN.

SUMMARY.—Secondary degeneration of the posterior columns. These columns are each divisible into two distinct anatomical systems, the autonomy of which is based on considerations relative to development, and to structural and pathological anatomy.	
Development of the posterior columns. Labours of Pierret and of Kölliker. The columns of Goll and of Burdach appear independently one of another. Further division of the two systems by Sappey's intermediate posterior fissures. Structure of the columns of Goll. Their nuclei on the floor of the fourth ventricle. Structure of the columns of Burdach.	
System lesions may be found separately either in the column of Goll or of Burdach. Lesions of the columns of Goll do not give rise to symptoms of locomotor ataxy. Compression of the spinal cord causing complete degeneration of the columns of Goll, and partial degeneration of the columns of Burdach. Degeneration of peripheral origin. There are as yet but three or four observations. Probable theory of this degeneration . . . . .	213

## LECTURE IX.

## SECONDARY DEGENERATIONS OF SPINAL AND CEREBRAL ORIGIN IN RELATION TO WALLER'S LAWS. EXPERIMENTS OF SCHIEFFERDECKER, FRANCK, AND PITRES.

PAGE

SUMMARY.—The *rationale* of secondary spinal degenerations is identical with that of the Wallerian changes. Waller's laws.

Descending and ascending degenerations. Fasciculi which degenerate downwards are comparable to the centrifugal nerves from the anterior roots. Fasciculi degenerating upwards resemble the posterior roots.

Experiments of Westphal, Vulpian, and Schiefferdecker. Initial period of degenerations. Experimental degenerations are in every respect identical with pathological degenerations in man. The pyramidal tract in the dog is not a compact bundle. The degenerated fibres are diffused through the antero-lateral column.

Experiments of Franck and Pitres. Degeneration in the internal capsule consequent on removal of the sigmoid gyrus.

Special exception in disseminated sclerosis. Histological desideratum 222

## LECTURE X.

## DETERMINATION OF THE COURSE OF THE WHITE FASCICULI IN THE SPINAL CORD BY THE STUDY OF SECONDARY DEGENERATIONS. EXPERIMENTAL ANALYSIS OF THE FUNCTIONS OF THE PYRAMIDAL TRACTS.

SUMMARY.—All the white fasciculi of the cord are capable of system degeneration. Diagram of the fasciculi: (a) with long fibres; (b) with short fibres.

Intrinsic fasciculi of the posterior columns: columns of Burdach and of Goll.

Extrinsic fasciculi: direct cerebellar tracts.

Antero-lateral columns: intrinsic fasciculi; extrinsic fasciculi (pyramidal tracts).

Results of experiment. Can the antero-lateral columns be stimulated? The irritability of the pyramidal tract in man is manifest throughout its entire cerebro-spinal course.

Experiments of Vulpian and Schiff. Spinal hemisections. Woroschiloff's vivisections. Influence of the pyramidal tract on the reflex activity of the spinal cord. The pyramidal tracts are the conductors of voluntary impulses . . . . . 230

## LECTURE XI.

GENERAL SEMEIOLOGY OF SECONDARY DEGENERATIONS OF  
THE PYRAMIDAL TRACT.

	PAGE
SUMMARY.—Description of the secondary spinal affection. Condition of patient the day following an apoplectic seizure. The prognosis, which may be made at the outset, is based on the anatomical diagnosis of the seat of lesion.	
Exact determination of the vascular area at the expense of which the cerebral hæmorrhage is produced. The lesion may be circumscribed or may tend to increase. The integrity of the pyramidal tract is the condition <i>sine quâ non</i> for recovery.	
Precursory symptoms of secondary contracture.	
Provoked spinal epilepsy or ankle-clonus. Statistics. Extension of spinal epilepsy to the healthy side. Wrist-phenomenon. Tendon-reflexes . . . . .	241

## LECTURE XII.

LATE HEMIPLEGIC CONTRACTURE AND ITS CLINICAL  
VARIETIES.

SUMMARY.—Foot-phenomenon or ankle-clonus. Its presence in spasmodic paralysis, including hemiplegic contracture. It is sometimes obtainable on the non-paralysed side in hemiplegia. Its reflex nature. The knee-phenomenon, unlike ankle-clonus, exists normally. At birth it is well marked, but diminishes in intensity at the end of a few weeks. It is pathologically significant only when completely absent or when highly exaggerated. Method of provoking the knee-phenomenon. It is inhibited by irritation of certain distant parts. Its reflex nature is confirmed by the experiments of Fürbinger, Schultze, and Tschirjew. Reflexes of upper extremity are usually but little evident in the normal state. They become very manifest when contracture exists or tends to exist in hemiplegia. Graphic analysis of the reflexes. Associated movements or synkinneses are interesting from a theoretical point of view. Effects of strychnia on paralysed parts. It exaggerates the reflexes and hastens contracture. Fourquier's works. Contracture and the tendon-reflexes are allied phenomena . . . . .	250
---	-----

## LECTURE XIII.

LATE HEMIPLEGIC CONTRACTURE AND ITS CLINICAL VARIETIES (*continued*).

	PAGE
SUMMARY.—Various agents exaggerating contracture:—strychnia; traumatism, &c. Contracture is always imminent in hysterical patients and may occur under the influence of the above-named causes.	
Time of its appearance in hemiplegic patients. Its access is gradual. The attitudes and deformities produced are always identical. Explanation of these attitudes. Theory of the action of antagonistic muscles.	
Gaillard's experiments. Muscular tone . . . . .	261

## LECTURE XIV.

## SPASMODIC INFANTILE HEMIPLEGIA. ASSOCIATED MOVEMENTS. INDEPENDENCE OF THE DIASTALTIC ARCS FOR THE TENDON AND CUTANEOUS REFLEXES.

SUMMARY.—Spasmodic infantile hemiplegia has the same characters as apoplectic hemiplegia. Its anatomical causes. Atrophy of limbs, thorax, and pelvis.

Intermissions in hemiplegic contracture.

Influence of voluntary movement on the intensity of contracture.

Synkineses. Part played by associated movements in the varying degrees of contracture. Prognosis of contracture.

Physiological explanation of this phenomenon.

Subsequent to the cerebral lesion it is necessary to distinguish two periods in the development of the secondary spinal lesion.

Exaltation of the reflexes does not result only from suppression of the moderating cerebral influence. Lesion of the anterior cornua in permanent hemiplegia is of an irritative nature. Its action is the same as that of strychnia. Exaggeration of muscular tone.

Independence of the reflex diastaltic arcs. Locomotor ataxy, hysterical hemianæsthesia, hemiplegia of encephalic origin. The hypothesis of a dynamic irritative lesion is a better explanation than other theories relating to the spasmodic symptoms in descending sclerosis . . . . .



## LECTURE XV.

## PHYSIOLOGICAL FUNCTION OF THE PYRAMIDAL TRACT IN PERMANENT CONTRACTURE. HEMIPLEGIA. MYELITIS FROM COMPRESSION. SPASMODIC TABES DORSALIS.

	PAGE
SUMMARY.—Relations between the peripheral extremities of the pyramidal-tract fibres and the cells of the anterior cornua. Lesions of these cells are of an irritative nature. Clinical phenomena; reflex acts. Theories bearing on the pathogeny of contracture.	
Theory of encephalitis. Theory of irritation of nerve-tubes, interspersed with those of the pyramidal tract.	
The immediate cause of contracture is in the grey matter itself.	
Proofs furnished by spinal pathology proper. Transverse myelitis.	
Spasmodic paraplegia. Spasmodic tabes dorsalis . . . . .	283

## LECTURE XVI.

## TRANSVERSE MYELITIS AND SPASMODIC TABES DORSALIS.

SUMMARY.—Transverse myelitis and hemisections of the spinal cord.	
Paralysis of both lower extremities in the case of unilateral spinal lesion. Anatomical hypothesis relative to this phenomenon.	
Opinions of Kölliker, Gerlach, Krause, Schiff, Vulpian, and Schiefferdecker.	
Permanent contracture and spasmodic gait in transverse myelitis.	
Ollivier's description is applicable to the tetanoid paraplegia of Séguin (Erb's spasmodic gait). Chronic forms of transverse myelitis.	
Spasmodic tabes dorsalis. Erb's theory. Its localisation in the cord has not yet been revealed by pathological anatomy. Diagnosis from disseminated sclerosis. Spasmodic tabes in the adult and in the child. Infantile spasmodic paralysis.	
Etiology, pathogeny, and nosographical autonomy of spasmodic tabes.	
Opposite opinions and observations . . . . .	293

## LECTURE XVII.

## SPINAL AMYOTROPHIES AND LOCALISATIONS IN THE GREY MATTER OF THE SPINAL CORD.

SUMMARY.—The study of system spinal lesions should precede that of non-system lesions. Physiological function of the grey matter. Transmission of sensitive impressions and motor impulses.

	PAGE
System lesions of the grey matter are limited to the region of the anterior cornua, and are nearly all of an irritative or inflammatory nature. Systematised anterior poliomyelitis are acute, subacute, or chronic. Fundamental characters of these affections. Motor and trophic disorders. The functions of the bladder and rectum are intact. Abolition of the reflexes.	
Definition of the group of systematised poliomyelites. Protopathic and deuteropathic amyotrophies. Acute forms: infantile spinal paralysis, adult spinal paralysis. Subacute form: Duchenne's subacute anterior general spinal paralysis. Chronic form: progressive muscular atrophy of Duchenne and Aran. Non-systematised poliomyelites. Central myelitis, ependymar sclerosis, disseminated sclerosis, amyotrophic lateral sclerosis. Neuro-muscular system in general . . . . .	397

## APPENDIX.

AMYOTROPHIC LATERAL SCLEROSIS. AUTONOMY AND SPASMODIC CHARACTER OF THIS AFFECTION . . . . .	317
INDEX . . . . .	337

PART FIRST.



## LECTURE I.

### LOCALISATION IN CEREBRAL DISEASES.

SUMMARY.—*Introduction. Apparent barrenness of this study. Principles of cerebral localisation. The encephalon in its morphological aspect. Necessity of an exact nomenclature. Topography of the convolutions. Importance of comparative anatomy. Convolutions of the monkey's brain: frontal, parietal, and sphenoidal lobes. Psychomotor centres. Differences in the composition of the cortical layer in the various regions of the encephalon.*

#### I.

GENTLEMEN,—We shall devote the first part of this year's course to the pathological study of the encephalon. In an audience composed of physicians this is a subject the importance of which no one can overlook. Yet if I mistake not, it has obtained among some, doubtless by reason of its apparently unattractive aspect, rather a bad reputation. I hope to succeed at a later stage in proving to you, gentlemen, that such a censure is unjust, and I am convinced that by the aid of an oft tried method, by the aid too of a little patience and forbearance—and, I promise you, they will not be wanting on my part—we shall accomplish without much difficulty and fatigue the task we are about to undertake.

In order not to enter the domain, which we are to traverse together, abruptly and without preparation, I would to-day, by way of introduction, lay before you some observations relative to general facts, the application of which we shall constantly find in the subsequent lectures. As I am no believer in the efficacy of generalities deprived of their material substratum, especially in the subject of pathological anatomy, I shall cite a

certain number of instances, which, if I may be permitted the expression, we shall use as a *point d'appui*. I shall take these instances from one of the most important chapters in the pathology of the encephalon, that which treats of the *localisation of cerebral diseases*. Various considerations urge me to this choice. In the first place, this is one of those subjects in which the happy influence of pathological attainments on clinical matters is pre-eminently striking. Indeed, on the principle of cerebral localisation is founded what might be called the *regional diagnosis* of encephalic affections—that ideal towards which, in this special branch of pathology, all the efforts of the clinical investigator should tend. On the other hand, this question of cerebral localisation has just entered on a new phase and is attracting general attention abroad as well as in France. Although we would not sacrifice more than is absolutely necessary, still, we cannot withdraw from the fascination, which recent investigations and newly discovered facts are constantly exerting.

I will add, finally, that at the last *concours d'agrégation* in medicine, this interesting subject was elaborated with great ability in the thesis of my friend and old pupil, Dr. Lépine, an *agrégé* of this faculty. I am fortunate, I confess, in being able to utilise the careful observations, in which this work abounds, and in profiting by the invaluable information which the author has accumulated in it.

In these preliminary lectures, it is evident that only a general outline can be given. All the principles laid before you must be subsequently resumed, submitted to a more thorough investigation and, as it were, sifted even to their smallest details.

## II.

It is unnecessary at present, I think, to enter into a lengthy explanation of the meaning of *localisation*, in reference to cerebral physiology and pathology. The term has long since passed into common parlance and we all understand its signification.

I shall simply remind you that the principle of cerebral localisation depends on the following proposition: The en-

cephalon does not represent a single, homogeneous organ, but rather an association, or, if you like, a confederation, made up of a certain number of different organs. To each of these there are attached physiologically distinct properties, functions, and faculties. Further, the physiological functions of each of these parts being known, it is possible to deduce the pathological conditions, which are but more or less pronounced modifications of the normal state, without the intervention of new laws.

We must now inquire into the foundations on which this proposition depends. To attain this object, appeal should be made in turn to the data furnished by normal anatomy, experimental physiology, and finally clinical observations as based on the methodical and careful examination of organic lesions. I cannot too strongly insist that proofs of the last kind should figure constantly among the most important and decisive. For, although the two first may often suggest localisation, the latter only will enable us to judge in the last resort and *furnish the proof*, so far as man, the special object of our investigations, is concerned.

First of all, in accordance with our programme, the time has come to consider the encephalon in its morphological aspect.

We are not about to enter, you are aware, into a formal description. I purpose simply to point out some general features, with which, for our object, you must be acquainted. With a view to simplifying a very complex situation, I shall limit myself to the cerebrum, that is to say, to the mass of nervous substance, composed of two hemispheres and situated at the upper extremity of what we know by the name of *crura cerebri*.

The two hemispheres, as you are aware, are symmetrical or nearly so, and identical in their structure, so that, anatomically speaking, what we say of one applies strictly to the other. Each is covered and as it were enveloped by a layer of grey matter. The central part is composed of a mass of white substance, out of which the ventricular cavities are hollowed, and in which the central ganglionic nuclei, namely, the *optici thalami* and *corpora striata*, appear to lie embedded. A transverse section made at the level of the corpora mammillaria is admirably adapted for displaying the most striking points in the reciprocal disposition of the central parts (Fig. 1). Im-

mediately above the pons, you observe the inferior surface of the crus cerebri, the *foot* or lower layer of which is mainly derived, as we shall see, from the anterior pyramids of the

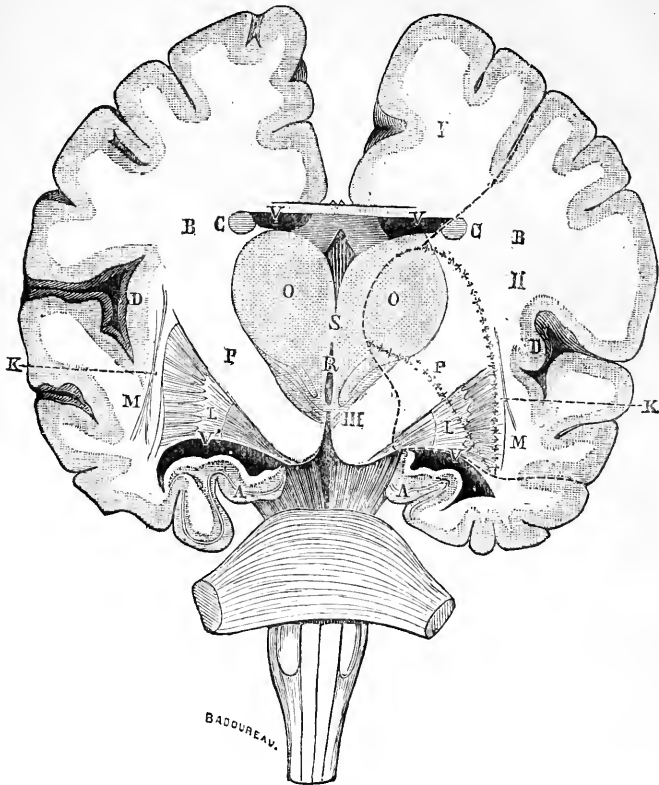


FIG 1.—Transverse vertical section of the cerebrum made behind the corpora mammillaria and in front of the crura cerebri. s, grey commissure; o, o, optic thalami; v, lateral ventricle; v', its sphenoidal cornu; P, P, internal capsule or foot of the peduncular expansion; L, L, lenticular nucleus; K, external capsule; M, M, claustrum (*avant-mur*); R, third ventricle; A, cornu ammonis.

medulla oblongata. Higher up, you will notice at the lower and middle part of the section, two large white tracts (P, P), which diverge towards the cortical region of the hemispheres. They are included between two masses of grey substance,



one of which is internal and superior (o), the other inferior and external (L). These two white bands are the cerebral prolongations of the crura. These latter which, at first, are irregularly quadrilateral, become, on entering the hemispheres, flattened from above downwards and spread out from behind forwards. After passing the narrow interganglionic area, they expand and radiate in all directions; in front, towards the frontal extremity; in the centre, towards the parietal regions; behind, towards the occipital extremity. The flattened out, interganglionic part of the crura cerebri is described in Burdach's nomenclature under the name of *internal capsule*. The fan-like arrangement has been called by Reid the *corona radiata*, the *foot* of which is the point where the crura emerge above the cerebral ganglia. The arrangement of the crura in the hemispheres may be characterised by saying that *they spread out like a fan*.

Let us now indicate briefly, subject to resuming the matter at a later stage, the respective positions of the cerebral ganglia in relation to this fan-like arrangement.

When the lateral ventricles have been opened by the ordinary method, you remember seeing on their floor two projecting masses of grey substance. The one, anterior and external, in the form of a comma or Prince Rupert's drop, of which the large extremity or *head* is in front, and the small end or *tail* behind and to the outside, we shall call the *caudate nucleus* of the corpus striatum; the other, internal and posterior, of an oval shape, is the optic thalamus, which is separated from its fellow on the opposite side by the cavity of the third ventricle. These two grey intra-ventricular masses, the caudate nucleus of the corpus striatum and the optic thalamus, are situated above and to the inner side of the peduncular fan, below which is found a third nucleus of a larger size than the two others, and, having almost the shape of a plano-convex lens, hence derives the name of *lenticular nucleus* (Burdach).<sup>1</sup>

Since it extends the same length from before backwards as the two others, it is invariably found to accompany them in transverse sections (frontal of the Germans, perpendicular to the great inter-hemispherical fissure).

<sup>1</sup> In our nomenclature it is called the *extra-ventricular* nucleus of the corpus striatum.

The study of these sections, when made methodically and progressively from before backwards, through certain fixed points at the base of the hemispheres, is of indispensable service to the anatomist, to whom it indicates the relations of the nuclei both to one another and to the crus; and to the clinical student who has to ascertain precisely the position of the affected parts.

I shall point out to you the appearance of these frontal sections, so far as the requirements of our description demand. To-day, it will be sufficient for you to know one of the most posterior, that made immediately in front of the crura cerebri. You observe here (P, P) the flattened out part of the crura, the internal capsule.

To the inner side lies the section of the optic thalamus (o), and the tail of the corpus striatum (c). External to the internal capsule, you notice the lenticular nucleus of the corpus striatum (L), with its three segments. These grey nuclei are, perhaps, so many centres endowed with distinct properties and functions; nevertheless, do not forget that the fact has not hitherto been incontestably verified. Still more external you see, successively, the external capsule (κ), the claustrum (*avant-mur*)<sup>1</sup> (M), a small, white, nameless band, and, finally, the grey layer of the island of Reil (D).

I do not intend on the present occasion to enter into any structural details. I simply wish, gentlemen, to insist on these terms, minute as they may appear, and, if I have struggled long to introduce them into the French nomenclature, it is because I consider them of the greatest utility, when it is desirable at an autopsy to determine the exact localisation of lesions. Who will venture to affirm that such or such a region, having no place in our nomenclature, has not a physiological importance of the first order? In what terms, too, are we to

<sup>1</sup> This thin strip of grey matter has received various synonyms. In English text-books it is known under the names of *Clastrum* (Burdach), *Nucleus tænieformis* (Arnold) and *Rampart*. By the Germans it is called the *Vormauer*, and by the French *rempart*, *noyau rubané* and *avant-mur*. A few nerve cells, most of which are stained with yellow pigment, are contained in it. The cells resemble in their fusiform shape and bipolar processes those of the posterior vesicular columns of the spinal cord.—(*Translator.*)

describe this region, in the notes of an autopsy, if it is unnamed?

The designations, which I have just given, provide so many landmarks, and are therefore of incontestable utility. Can a good strategical chart ever be too complete? In this manner, by stating with precision the part affected by a hæmorrhagic lesion, the external or internal capsule, the nuclei of grey matter, the foot of the corona radiata, &c., you will succeed in establishing, when occasion requires, symptomatic differences in connection with differences relative to prognosis. An instance, borrowed from the history of cerebral hæmorrhage, will at once prove to you that this is by no means a superfluous study. If a hæmorrhagic lesion has involved the external capsule only, the patient, notwithstanding the extent of the lesion, will in all probability recover without any persistence of the hemiplegia and without weakness; if, on the other hand, it affects the internal capsule, should the patient survive, paralysis with permanent contracture<sup>1</sup> invariably remains. The importance of an exact and minute acquaintance with the configuration of the circumscribed areas of the brain and of an appropriate nomenclature, is especially evident when we consider those folds mapped out on the surface of the hemispheres, which are generally known under the name of *convolutions*. It was thought for a long time that the convolutions were disposed, so to speak, at random, thus defying all description. It was reserved for two French observers, Leuret and Gratiolet, to point out that there exists, on the contrary, a regular plan, which may be followed from the lower mammals, through the ape, to man.

It is necessary, moreover, to distinguish among the convolutions, *fundamental folds*, so called, because their disposition and relations are absolutely *fixed*, and *secondary or accessory folds*, which differ from the others in being *variable*.

You will readily understand that it would be quite impossible to make any progress in the history of the most important cerebral localisations without a good topography of the convolutions. Let us take an instance. In what terms are we to

<sup>1</sup> By the term *contracture*, is meant the more or less permanent rigidity which sometimes supervenes in paralysis. In short, contracture is pathological muscular contraction.—(Translator.)

speak of the lesions producing aphasia, if we cannot describe with accuracy the seat and configuration of the third frontal convolution? Again, how are we to recognise in man the so-called psychomotor regions, which were discovered in animals through the researches of Fritsch, Hitzig, and Ferrier, if we are unacquainted with the arrangement of the folds and furrows on the grey matter of the parietal and posterior parts of the frontal lobe? How many observations calculated to shed light on these interesting questions of localisation have remained valueless, because, through insufficient knowledge of the morbid parts, an exact description could not be given!

Therefore, with a view to obviating, as far as possible this blank in the anatomical descriptions of the cerebrum under normal conditions, it has long been my custom to represent on diagrams drawn after nature the seat of encephalic lesions. In the absence of these precautions, it is impossible to obtain notions exempt from criticism. After all, this subject is far from presenting the difficulties which we are at first inclined to suppose. Although hitherto the fullest information has not made its way into classical works, it is found abundantly elsewhere. Without mentioning the standard works of Leuret and Gratiolet, of Bischoff, Arnold, Turner, &c., which it is unnecessary to consult on every occasion, I recommend for your use the small manual by Ecker.<sup>1</sup> In it you will find, with synonyms, a nomenclature reduced to very simple terms, and a collection of good topographical plates.

At my advice, these plates were utilised by M. H. Duret in his important memoir on the circulation of the encephalon.

Finally, we have in France an excellent work on this subject. It is a thesis, written by M. Gromier at the suggestion of M. Broca, and entitled: '*Étude sur les circonvolutions chez l'homme et chez le singe,*' (1874).

Comparative anatomy, on its part, is of great assistance in the study of the convolutions. Between the ape and man, for example, there is a striking resemblance<sup>2</sup> so far as the funda-

<sup>1</sup> '*Die Hirnwindungen des Menschen nach eigenen Untersuchungen insbesondere über die Entwicklung derselben beim Fötus und mit Rücksicht auf das Bedürfniss der Ärzte.*' Brunswick, 1869. There is an English translation of this work.

<sup>2</sup> In reference to this subject, read in the last edition of Darwin's work,

mental folds and fissures are concerned. Such an arrangement which, in man, appears almost unintelligible, is readily explicable on account of its greater simplicity, when we examine the monkey's brain. For this reason I would endeavour, before speaking to you of the convolutions of the human cerebrum, to give a very brief account of those described in the ape.

This study will afford you the more interest since experiment has already demonstrated on some of the convolutions in the monkey the reality of the so-called psychomotor points, into the existence of which it is necessary to inquire on the corresponding areas in the human cerebrum, placing our reliance no longer on experiment, but on clinical facts and pathological anatomy. This is the representation of a monkey's brain as seen laterally (Fig. 2), after a figure taken from M. Gromier's work. It refers to the baboon (*Pithecus inuus*), an ape of rather a low rank in other respects. For the moment, I shall occupy myself with the description of the external aspect of the hemisphere, the internal and inferior surfaces having for the subject, which is engaging our attention, only a minor importance.

We notice, in the first place, two long fissures, of which one is the fissure of Rolando (*s r*), the other the fissure of Sylvius (*s s'*). These two primary sulci converge to one point, and mark out the limits of the external surface of the frontal lobe. We see, next, more posteriorly another fissure, *the external perpendicular or parieto-occipital (s p e)*, which in the ape clearly divides the occipital from the temporal and parietal lobes. In man this separation is much less evident in consequence of the presence of what are called the annectant convolutions, which fill in this groove more or less completely.

The parietal and sphenoidal lobes in the ape are differentiated less distinctly, so that in order to establish the demarcation it is necessary to prolong the fissure of Sylvius by an imaginary line passing through a convolution known by the name of the *pli courbe (p c)* or *gyrus angularis*.

The external surface of the cerebral hemisphere is divided

“The Descent of Man” (London, 1874), an interesting note by Professor Huxley: “Note on the Resemblances and Differences in the Structure and the Development of the Brain in Man and Apes” (p. 199).

then into four lobes: the frontal, parietal, sphenoidal and occipital.

Each of these, in its turn, is subdivided by fissures or sulci of the second order into secondary lobes, which are termed gyri or convolutions.

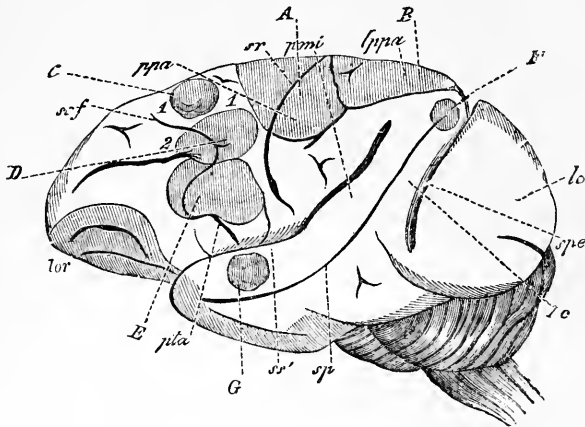


FIG. 2.—External surface of the brain of the baboon (*Pithecus innuus*). After Broca and Gromier.

Fissures: *s r*, fissure of Rolando; *s e f*, transverse frontal fissure; *s s'*, fissure of Sylvius; *s p e*, external perpendicular fissure (external parieto-occipital); *s p*, parallel fissure.

Convolution: *p t a*, ascending frontal; 1, 2, 3, first, second and third frontal; the number 3, which is wanting, should be below the dotted line extending from *D* to the number 2; *p p a*, ascending parietal; *l p a*, superior parietal lobule; *p m i*, inferior marginal convolution; *p c*, angular gyrus (*pli courbe*); *l o*, occipital lobe; *l o r*, orbital lobe.

Situation of the centres for voluntary movements on the monkey's brain, after Ferrier. *A*, centres for the voluntary movements of the anterior extremity; *B*, centres for the posterior extremity; *C*, movements of rotation of the head and neck; *D*, movements of the muscles of the face; *E*, movements of the tongue, jaws, &c.; *F*, certain movements of the eye, vision; *G*, centre in connection with the movements of the ears and with hearing.

*Frontal lobe.*—The *præcentral sulcus* or *transverse frontal fissure* (*s e f*) limits anteriorly, on the frontal lobe, a convolution parallel to the fissure of Sylvius. This is the *ascending frontal convolution*, and, with a view to lending more interest to this

rather uninteresting account, I will ask you to notice that the upper portion of this convolution is, according to Ferrier, the seat of the motor centres for the superior extremity of the opposite side (A).

Sulci, perpendicular in direction to the preceding one, divide the remainder of the frontal lobe into three strata or convolutions :—(1) The posterior extremity of the first constitutes, so Ferrier maintains, a centre (c), stimulation of which causes movements of the head. (2) According to the same author, the posterior part of the second is the centre (D) for the facial movements. (3) Lastly, in the third convolution in the monkey, there is situated a centre (E) presiding over the movements of the lips and tongue.

Here, in the third convolution or, as the English call it, *Broca's convolution*, we find in man the seat of the faculty of articulate language. As I do not wish to appear less French than the English, I am pleased to take the present opportunity of recognising the signal service which my eminent colleague has rendered to the cause of cerebral localisation.

*Parietal lobe.*—The study of this lobe, which in man is so difficult, is, on the contrary, very easy in the monkey. The interparietal fissure divides it into two secondary lobules :—(1) The *superior parietal lobule* (*l p p a*), which, according to Ferrier, is the centre (B) for the movements of the lower extremity. (2) The *inferior parietal* or lobule of the gyrus angularis, so called because of its connection with the lobule (*p c*) of the same name. Lastly a sulcus, better marked in the superior apes, separates the ascending parietal convolution from these lobules. In this lobule, extending as far as the superior extremity of the ascending frontal convolution, the centre (A) for the upper limb is situated.

*Sphenoidal lobe.*—The relations of this lobe are readily intelligible. On the convex aspect of the hemisphere, it is bounded by the lower border of this surface and by the fissure of Sylvius. The parallel fissure, so named because it pursues the same direction as the fissure of Sylvius, divides the lobe into two parts. In the upper portion we find the marginal convolution. At the extremity of the parallel fissure is the gyrus angularis, destruction of which, according to Ferrier, produces temporary blindness of the opposite eye.

*Occipital lobe.*—A transverse sulcus divides this lobe into two parts; but at present we have nothing particularly to say with respect to it.

After this brief account of the cerebral convolutions in the monkey, the study of the corresponding convolutions in man becomes more simple. The description I am about to give, with the assistance of a figure copied from a plate in Foville's beautifully illustrated work, will at once confirm the truth of my assertion (Fig. 3).

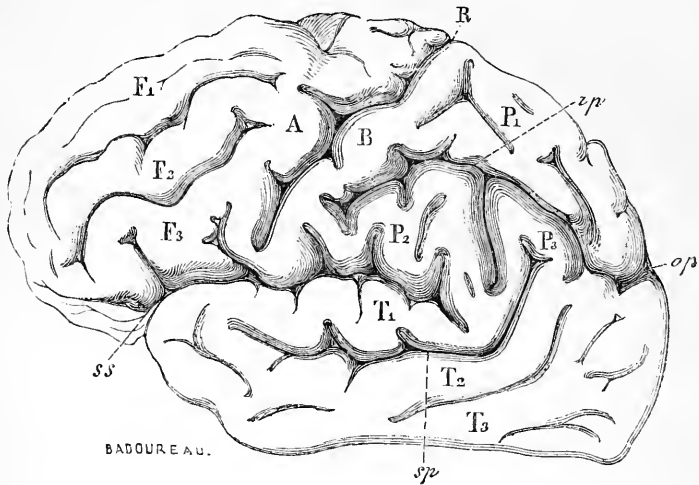


FIG. 3.—Convex surface of one hemisphere of the human cerebrum (semi-diagrammatic view of the parietal lobe).

Fissures: *r*, fissure of Rolando; *s s*, fissure of Sylvius; *s p*, parallel fissure; *o p*, external parieto-occipital fissure; *i p*, interparietal fissure.

Convolution and lobules: *A*, ascending frontal convolution (anterior parietal or anterior central); *F*<sub>1</sub>, *F*<sub>2</sub>, *F*<sub>3</sub>, first, second and third frontal convolutions; *B*, ascending parietal convolution (posterior parietal or posterior central); *P*<sub>1</sub>, superior parietal lobule; *P*<sub>2</sub>, inferior parietal lobule (lobule of the angular gyrus); *P*<sub>3</sub>, angular gyrus; *T*<sub>1</sub>, *T*<sub>2</sub>, *T*<sub>3</sub>, first, second and third temporal convolutions.

You will observe that the fissures of Sylvius and of Rolando (*s s* and *r*) constitute the inferior and posterior boundaries of the frontal lobe, on the surface of which you will see the ascending



or anterior parietal convolution (A) and the first, second and third frontal convolutions ( $F_1, F_2, F_3$ ).

In man, as I remarked just now, the parieto-occipital fissure (*o p*) separates the occipital from the parietal and sphenoidal lobes in a very ill-defined manner, in consequence of the existence of the annectant convolutions.

You will at once recognise the parietal convolution (B) behind the fissure of Rolando and between it and the interparietal fissure (*i p*). Above and behind the latter, you will find in succession the lobule of the parietal convolution or superior parietal lobule ( $P_1$ ), the lobule of the gyrus angularis ( $P_2$ ), and lastly, the angular gyrus itself ( $P_3$ ).

As to the sphenoidal or temporal lobe, it presents in man, as in the ape, a fissure extending to the angular gyrus. This is the parallel fissure, between which and the fissure of Sylvius we see the first temporal convolution ( $T_1$ ); below and behind are the two other temporal convolutions ( $T_2, T_3$ ).

Hence, gentlemen, you have around the parietal lobes and the fissures of Sylvius and Rolando a certain number of fixed points which will serve to guide you at an autopsy.

### III.

Thus, gentlemen, there are mapped out on the surface of the encephalon certain departments, the fixity of which cannot be misconceived. Do these various areas, which correspond to the *fundamental convolutions*, represent so many distinct functional centres? This is a question which we are not in a position to answer, from the mere consideration of external architectural arrangements.

At the present moment I should like to inquire with you if the microscopical examination of the structure of the grey matter, when compared in the various regions marked out by descriptive anatomy, is not capable of supplying very important information to the subject which we have under consideration.

For a long time naked-eye examination has shown that there are differences in the composition of the cortex, corresponding to the various regions of the encephalon. For example, let us consider from this point of view the lower portion of the occi-

pital lobe. The grey matter belonging to the parts of this lobe, which surround the posterior cornu of the lateral ventricles, has not the nearly uniform appearance peculiar to it in other regions of the cerebrum, as for instance in the anterior lobes. Vicq d'Azyr, indeed, had already pointed out that the grey matter of the convolutions in this part of the occipital lobe is very distinctly divided into two secondary layers which are separated by a white band, now called *Vicq d'Azyr's ribbon*.

The convolutions of the cornu ammonis and island of Reil are also different in their naked-eye appearance from the cortex of the convolutions in other regions of the hemispheres.

In order to thoroughly appreciate the value of these facts, it seems to me absolutely necessary to enter into some minute details.

## LECTURE II.

### STRUCTURE OF THE CEREBRAL CORTEX.

SUMMARY.—*General structural characters of the cerebral cortex.*

*Ganglionic nerve-cells; pyramidal cells. Opinions regarding the nerve-cells in the anterior grey cornua of the spinal cord (motor cells). Dimensions, form, body, nucleus, nucleolus, protoplasm, fibrils, and granulations; nerve-network; prolongations of the protoplasm; nerve-prolongation.*

*Comparison of the motor nerve-cells in the cord with the pyramidal cells.*

*Pyramidal cells: dimensions; small variety; large variety or giant-cells. Constitution of these cells: configuration, body nucleus, nucleolus; cell-prolongations; pyramidal prolongation; prolongations resembling those of the protoplasm; basal prolongation.*

*Globular cell-elements; elongated cells.*

*Medullary tubes; neuroglia.*

*Mutual relations of these elements; type of five layers.*

*Important results obtained by examining the structure of the cortex, convolution by convolution. Division of the cortex into two regions from a structural point of view. Investigations of Betz.*

GENTLEMEN,—The structure of the cerebral cortex, in whatever region of the hemispheres it may be studied, presents some general features which we must consider before noticing the distinctive characters. It may be said that all parts of the cortex are composed of the same essential elements. Each of these constituent elements may doubtless present, according to the region under observation, important deviations from the

normal type ; but, in the *regional study* of the structure of the grey matter, we must also take into careful consideration the variations in the mode of arrangement of these elements.

After examining them separately, we shall inquire how they are disposed so as to constitute the cortex. Our description will naturally begin with those elements which incontestably play the most important part. I refer to the ganglionic nerve-cells which undoubtedly constitute the characteristic element of the region, and which are usually described under the name of *pyramidal cells*.

The best method for thoroughly ascertaining the morphological properties of these elements is not, perhaps, to investigate them exclusively in themselves. Accordingly, I thought it preferable to have recourse to the comparative method, relying on the common adage : "Light comes from contrast."

Allow me, then, gentlemen, by way of introduction, to recall to your minds the principal features in the constitution of one of the cellular nerve-elements, the study of which is best understood at the present time. I allude to the *nerve-cells in the anterior cornua of the grey matter of the spinal cord, also called motor cells*. The abbreviated description, which I am about to give you of these nerve-cells, will supply us, if I may use the expression, with a standard. I shall have to notice in the following comparison, more than one difference, but I shall have also to mention in a special manner more than one remarkable analogy.

The motor-cells are *cells* without distinct membrane, the diameter of which is variable, not exceeding however  $\cdot 050$  mm. Nevertheless, M. Gerlach asserts that it may reach  $\cdot 120$  mm. Their form is more or less globular, rarely elongated. Their body is made up of a protoplasm, which appears granular when we are observing the non-living cell ; but in serum or after the action of osmic acid on a fresh cell, the body seems to be composed of a transparent protoplasm, in the centre of which, as Schultze has shown, numerous fibrils exist.

These fibres undergo granular resolution from post-mortem changes. There are in the cell an oval nucleus and a bright nucleolus. Finally, I must notice also the habitual presence in the protoplasm, even under physiological conditions, of brown pigmentary granulations.

But one of the most important peculiarities of these cells is that they are armed with numerous processes which, at the point of emergence from the cell, display a voluminous stem, diminishing in proportion as it undergoes progressive dichotomous division. The last of these ramifications are so slender that it is difficult to follow them very far. M. Gerlach, by means of preparations in chloride of gold, asserts that these ramifications terminate in a kind of anastomotic plexus, which he describes under the name of *nerve-network*. These prolongations are composed, moreover, like the cellular body itself, of a granular protoplasm and of long parallel filaments, which can be followed as far as the body of the cell. They are called the *prolongations of the protoplasm*, in order to distinguish them from another kind of prolongation, of which I am now going to speak to you.

Deiters, a German histologist, discovered some years ago an important fact, confirmed since that time by all anatomists. It consists in this, that the majority of the motor nerve-cells, perhaps all, in addition to the processes which we have described, possess a single prolongation for each cell, which is distinguished from the others by special characters. This process bears the name of *nerve-prolongation*, and you will perceive in a moment the meaning of this term. It is disengaged from the body of the cell or from one of its largest prolongations under the form of a very slender filament, which gradually becomes more and more voluminous. This process never ramifies and it colours less deeply with carmine than the prolongations of the protoplasm. Lastly, if we succeed in following it far enough, we see it covered, like an ordinary nerve, with a cylinder of myeline; so that there are grounds for considering it at its origin as an axis-cylinder, and, at a certain distance, as a complete nerve.

The connection between the nerve-cells and the medullary tubes, by means of this prolongation, is therefore beyond all doubt.

Such, gentlemen, are the main characters of the spinal motor nerve-cells, with which we must now compare the *cortical pyramidal cells* (Fig. 4). These latter have very variable dimensions. Some of them, which are the most numerous, are relatively very small. These, which might be termed the

pyramidal cells of the small variety, have an average diameter of  $\cdot 010$  mm. at the base. The cells of the large variety, which are less numerous than the preceding, usually occupy the lowest part of the layer of pyramidal cells. They may attain a diameter of  $\cdot 022$  mm. (Koschewnikoff).

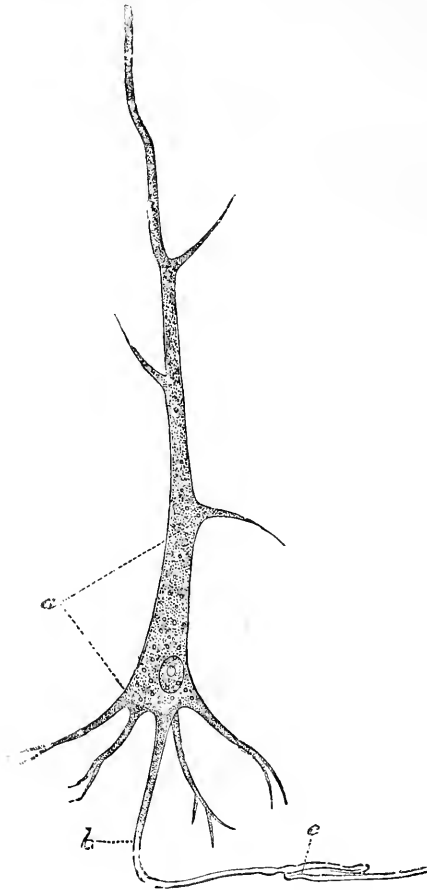


FIG. 4.

Lastly, there are the pyramidal giant-cells (Riesenzellen) which have been carefully studied by Betz (of Kiew) and Mierzejewski. They are met with in special and well-deter-

mined regions of the cortex. The diameter of these giant-cells usually ranges from  $\cdot 040$  mm. to  $\cdot 050$  mm., or, in other words, it is equal to that of the cells in the anterior cornua of the cord. Notwithstanding these differences in size, the constitution of the pyramidal cells appears to be in the main always the same.

Consequently, we shall study it for the sake of convenience in the cells of the large variety or even in the giant-cells.

The term, pyramidal cells, may up to a certain point be taken literally. Their shape, in fact, approaches that of a more or less elongated pyramid. The body of the cell, in which Schultze affirms he has recognised the fibrillar structure, corresponds to the description previously given. The nucleus, according to many authors, is angular and reproduces, as it were, the general form of the cell. The nucleolus calls for no special account.

The cell-prolongations present some interesting peculiarities. There is one that might be termed the *pyramidal prolongation*, because it undergoes progressive attenuation and thus continues, so to speak, the body of the cell. In its course it gives off some lateral prolongations, and occasionally divides in a fork-like manner at its extremity, which is invariably directed towards the surface of the convolution. It follows, therefore, that the cell is so placed that the base lies parallel to the inner or medullary side of the cortical zone. Other prolongations of the same nature proceed both from the angles and the base.

The former ramify in the same manner as the protoplasmic prolongations of the spinal motor cells. Do these prolongations become resolved in the cortex into a nerve-network, as is the case, according to M. Gerlach, with the spinal cells? Some authors affirm that this is so. But, gentlemen, there undoubtedly exists in the pyramidal cells of the large kind and in the giant-cells—perhaps also in the small cells—a special prolongation, analogous to the cylindrical process of the spinal motor cells. In both cases alike, this is a filament which is slender at its origin, but which afterwards becomes slightly thickened. In successful preparations, it is possible, at a certain distance from the cell, to see this prolongation become ensheathed in a cylinder of myelinc. M. Kos-

chewnikoff<sup>1</sup> has incontestably verified this fact by separating the cells in the anterior cerebral lobes in a subject who had succumbed to an encephalitis.

Since the publication of his investigations, the truth of this description has been frequently confirmed.

This *basal prolongation* (Fig. 4*b*), to employ the expression used by Meynert, is always directed towards the medullary substance of the convolutions. All these details go to prove that it is impossible to mistake the analogies, which approximate, on the one hand, the pyramidal cells of the cortex—at least the large and giant-cells—and on the other hand, the motor cells of the anterior cornua. These analogies previously suspected on other grounds by M. Luys,<sup>2</sup> we must take into consideration at a later stage.

The pyramidal cells are not the only cellular elements to be found in the cortex. In addition, we see small cellular bodies, of a globular, rarely pyramidal form, measuring  $\cdot 008$  to  $\cdot 010$  mm. (Meynert)<sup>3</sup> and sometimes provided with small processes. They may be sparsely distributed in all directions or may, in certain regions, form a fairly dense layer.

Among the nerve-elements of the cortical zone, Meynert also includes the elongated cells, generally fusiform and ramified, which in certain parts form a fifth layer. Most frequently, these cells have their long axes directed parallel to the fibres of the *association system*, which is constituted by the medullary fibres uniting one convolution to its neighbours (*fibræ arcuatæ*). They appear to form part of this system.

These then, gentlemen, are the cellular nerve-elements or such as are so reputed, which enter into the structure of the cortex. In relation with them there are others of which we

<sup>1</sup> A. Koschewnikoff, "Axencylinderfortsätze der Nervenzellen im kleinen Hirn des Kalbes," 'Schultze's Archiv,' p. 332, 1869. "Axencylinderfortsätze der Nervenzellen aus der Grosshirnrinde," idem, 1869, p. 375. Betz, 'Centralblatt,' 1874, p. 579. Mierzejewski, "Études sur les lésions cérébrales dans la paralysie générale," 'Archives de physiologie,' p. 194, 1875. J. Batty Tuke, "Morisonian Lectures." 'Edinb. Med. Journ,' p. 394, May, 1874.

<sup>2</sup> J. Luys, 'Recherches sur le système nerveux,' &c., p. 162, and following. Paris, 1865.

<sup>3</sup> Meynert, 'Stricker's Handb.,' vol. ii, and English translation vol ii, p. 381, and following.



must make mention:—the *medullary tubes* and the *neuroglia*. These last, which penetrate the grey matter in the form of fasciculi, shall not detain us at present; to this subject we shall return shortly. As regards the neuroglia, otherwise known under the name of *ependyma* (Rokitansky), it serves the part of a connecting substance. I am not going to give a detailed account of the structural peculiarities relative to the neuroglia of the grey matter. I shall simply remind you that of late several authors have considered it as composed of a distinct variety of connective cells, the body of which is made up of a very small amount of protoplasm and furnished with non-ramifying prolongations (*spider-cells* of Boll and Golgi).

These prolongations, inextricably blended together and cemented by a certain quantity of interposed gelatinous matter, would appear to compose the entire mass of the neuroglia. We shall have to discuss this explanation at a subsequent stage. Without denying the existence, under normal conditions, of branching cells in certain regions (cells of Deiters), I shall merely remark that, in all probability, the grey matter in this respect is constructed on the same model as the white substance. In other words the neuroglia here should correspond to the type of ordinary connective tissue:—connective fasciculi and flat cells (Ranvier); only, in the neuroglia the fibrillar elements would be more loosely arranged than elsewhere. At present, I must pass over the consideration of the vessels, which will shortly receive special attention on our part.

Enough, I think, has been said concerning the individual history of the various elements which compose the grey matter. It is now necessary to inquire into the mode of arrangement of these elements and into the differences which may be noticed, either in this respect or in relation to the constitution of the elements themselves, in each of the regions marked off on the surface of the hemispheres by the primary sulci.

The mode of arrangement, which may be considered as representing the commonest and most general type, is that in which we distinguish, in thin microscopical sections, five superimposed layers.

In the anterior lobes it is found nearly everywhere. The elements are distributed in the following manner:

(1.) The *first layer*, the nearest to the meninges, is almost exclusively composed of connective tissue, the nerve-elements being very scanty. Nevertheless, Kölliker and Arndt<sup>1</sup> describe, near the surface under the pia mater, a layer of parallel and very delicate nerve-tubes. Here also the nerve-cells are very scanty (Fig. 5, 1). To the naked eye, this layer presents the appearance of a small white zone. This defect in colour seems to be in relation both with the poverty of this layer in nerve-elements and with the small number of capillary vessels which it contains.

Indeed, the arterioles which penetrate the cortical layer supply numerous capillaries only to the deeper parts. This structural peculiarity is very well shown in a plate of Henle's,<sup>2</sup> and in a figure in M. Duret's memoir.<sup>3</sup>

(2.) The *second layer* (Fig. 5, 2) is distinguished by an agglomeration of pyramidal nerve-cells of the small variety, numerous and closely packed, and which communicate to it a very manifest grey colour.

(3.) The *third layer* (Fig. 5, 3) is to a large extent composed of pyramidal cells, some of average dimensions, others voluminous. The latter, which are separated by wider intervals than the former, are situated in preference at the lowest part of this layer, and may even penetrate the stratum below. In addition to the cells, we also find in this third layer fasciculi of medullary fibres which sink down perpendicularly to the surface of the cortex, and form species of columns in the interval between the groups of pyramidal cells.

This arrangement has been accurately described by M. Luys<sup>4</sup> and by Henle<sup>5</sup>. It is in the lowest zone of this layer that the giant-cells exist in certain regions. It might be inferred that the paucity of cells and the presence of medullary fibres would confer a white colour on this layer, but this is not the case. The fact is that in consequence, doubtless, of the presence of

<sup>1</sup> R. Arndt, "Studien über die Architektonik der Grosshirnrinde des Menschen," 'Arch. für Mikroskop. Anatomie,' 3rd Bd., 1867, p. 441, Taf. xxiii, fig. 1 a and fig. 2.

<sup>2</sup> J. Henle, 'Handb. der Nervenlehre,' p. 274, fig. 201. Braunschweig, 1871.

<sup>3</sup> 'Archives de Physiologie,' t. vi, pl. vi, figs. 2 and 3.

<sup>4</sup> 'Atlas,' &c., pl. xx, fig. 4.

<sup>5</sup> Loc. cit., fig. 198, p. 281.




FIG. 5.—This figure is copied from M. Meynert's work ("Vom Gehirn der Säugethiere," Stricker's Handbuch, t. II, p. 704). The numbers 1, 2, 3, 4, 5, designate the order of the cortical layers; *m*, medullary substance.

pigment in the cells and of the abundance of capillary vessels, this region of the cortex presents to the eye a yellowish tinge.

(4.) Next come the *fourth layer* (Fig. 5, 4) in which we see globular granulations or cells of an ill-defined nature, and the *fifth*, where we find the fusiform cells of which we spoke a few moments ago (Fig. 5, 5).

This summary investigation will enable us to appreciate the interest afforded by the examination of the structure of the grey cortical matter, when made *convolution by convolution*.

Moreover it has long been known that certain regions of the cortex differ, as regards structure, in a very remarkable manner. But the most recent and most valuable researches on this subject are those accomplished by Betz, the results of which were published in the 'Centralblatt' of last year.<sup>1</sup> Betz made it his purpose to study the textural modifications presented by the grey matter, convolution by convolution. From this standpoint, we must distinguish, according to him, on the surface of the hemispheres two fundamental regions, which are as nearly as possible bounded by the fissure of Rolando.

*In front* of this fissure, the cortex is characterised by the predominance of the large pyramidal cells over the globular cells. The orbital region is comprised within this circumscribed area.

*Behind*, the region includes all the sphenoidal and occipital lobes and the median part as far as the anterior border of the quadrilateral lobe. The granular layers preponderate here over the large cells, which are relatively rare. In each of these regions, moreover, there is a special department, which calls for notice. In the first place, let us consider that of the posterior region.

(1.) The nerve-elements here, which are well developed, are cells of considerable size. Before the discovery of the giant-cells they were, according to Meynert, the largest to be found in the hemispherical cortex. They are sometimes  $\cdot 030$  mm. in diameter; but the prolongations of the protoplasm are few in number, and the basal prolongation, which is directed horizontally, sometimes forms a communication between two cells. The area, in which this arrangement is observed, includes:—(a)

<sup>1</sup> P. Betz, in Kiew, "Anatomischer Nachweis zweier Gehirncentra," 'Centralblatt,' 1874, Nos. 37 and 38.

the *cuneus*; (*b*) the posterior half of the lingual and fusiform lobules; (*c*) all the occipital lobe; (*d*) the two first sphenoidal and the annectant convolutions. According to Betz, this region is concerned with the functions of sensibility. It is now a long time since, on other grounds of an anatomical nature to which we shall return, that the posterior parts of the cerebrum were marked out as being the seat of the *sensorium*.

(2.) The department in the anterior lobe deserving of special mention, might be called, you will see for what reason, *the department of the pyramidal giant-cells or motor cells par excellence*.

It includes the entire length of the anterior frontal convolution, the superior extremity of the anterior parietal convolution, and, lastly, a region presently to be noticed under the name of *paracentral lobule*, which is situated on the internal surface of the hemispheres at the extremity of the ascending frontal and parietal convolutions.

It is here that the giant-cells are almost exclusively found. Their distribution is not uniform, for they are more numerous than elsewhere at the superior extremities of the two median convolutions and especially in the paracentral lobule. They are disposed in groups or islets, and are found, in the parts just indicated, in monkeys of every kind, from the inferior apes to the chimpanzee. Finally, in the dog, Betz has observed these same cells in the parts described by Fritsch and Hitzig as motor centres or, in other words, in the regions situated around the crucial sulcus. What increases the interest of this fact is that, in the dog, the pyramidal giant-cells exist only in the so-called psychomotor regions.

It has doubtless not escaped your notice, gentlemen, that this distribution of the large nerve-cells in the monkey is almost exclusively confined to the convolutions, in which Ferrier's experiments have shown the existence of motor points or, in other words, of central convolutions. The interesting results furnished by histological investigation, when combined with experimental and pathological facts, cannot fail to throw some light on the history of cerebral localisation.

### LECTURE III.

#### ACCOUNT OF THE NORMAL STRUCTURE OF THE CORTEX (*continued*).

SUMMARY.—*Description of a section of the cerebellar cortex. The cellular nerve-elements are arranged according to the type of stratification in five layers. Regions in which this type exists. Department of the pyramidal or giant-cells. Relation between these cells and the psychomotor centres.*

*Description of the internal surface of the cerebral hemispheres. Paracentral lobule. Ascending convolutions. Clinical and experimental facts bearing on the development of the pyramidal giant-cells. Structure of the cortex in the posterior regions of the encephalon.*

GENTLEMEN,—Before entering more closely upon the question which, in these preliminary lectures, has been our real object, namely, as you remember, the theory of localisation in cerebral diseases, I must complete the considerations which I was induced to lay before you in the last lecture with respect to the normal structure of the cortex, as studied comparatively in the various regions of the cerebral hemispheres.

A. First of all I must consider this structure in its common, that is to say, in its most generally distributed type. We might, with Meynert, designate it under the name of *type of stratification in five layers of the cellular nerve-elements or such as are so reputed*. I shall recall to your minds very briefly the most characteristic features of this structure. To that end I must again invite your attention to Fig. 5, which represents a section of the third frontal convolution, made at the lowest part of the separating fissure.

With a view to establishing a contrast, I think it will be of

advantage to give a description, borrowed like the preceding from Meynert, of a section of the cerebellar cortex.

Here you will notice successively :—(1) A thick layer, poor in cellular elements, which receives the protoplasmic prolongations of the nerve-cells situated in the subjacent stratum ; (2) lower down, a layer in which, according to Meynert, there are found fusiform cells, and medullary fibres parallel to the limiting line ; (3) below, the cells of Purkinje occupying the upper part of a well-marked granular layer ; still lower, the medullary substance.<sup>1</sup>

If, now, you glance at the figure representing the five layers of the cerebral cortex, you will see that the grey cortical matter is not constituted exactly on the same plan in the various circumscribed aræ of the encephalon. I shall presently call your attention to some well-pronounced and striking points of difference, according to the region of the hemispheres under examination ; but I must, first of all, return to the type of five layers.

B. The mode of arrangement thus designated is found in all the regions of the hemisphere situated in front of the fissure of Rolando and for a short distance behind it, in a part of the parietal lobes ; the line of demarcation towards the occipital lobe, however, is ill-defined.

We shall see presently that this type appears to undergo very remarkable modifications in the posterior parts of the encephalon, including :—(1) All the sphenoidal lobe, (2) the occipital lobe, and (3) lastly, those parts of the cortex on the internal surface, which are circumscribed by the posterior extremity of the lobe and by a fissure forming the posterior boundary of a perfectly distinct region, which we shall presently describe under the name of lobus quadratus.

(a) But for the sake of greater perspicuity it is necessary, I think, to return to a point which I have already noticed. I allude to the fact that there exists in those regions of the hemisphere where the type of five layers constantly prevails, a distinct department, the cortex of which is distinguished as regards structure, by an interesting peculiarity. I refer to the constant presence in this region of pyramidal cells, which are, comparatively speaking, of enormous dimensions, and on this

<sup>1</sup> See also Henle, 'Nervenlehre,' &c., fig. 162, 163 A, 163 B.

account have been called *giant-cells*. These cells, whilst preserving the pyramidal form peculiar to the cellular-nerve elements of the region, are, as you know, distinguished not only by their size but also by the distinctness of the nerve-prolongation and the development of the protoplasmic prolongations. These latter characteristics justify us in comparing them with the motor nerve-cells in the anterior cornua of the spinal cord. The regions in which this important peculiarity exists are, strictly speaking, the central regions of the external surface of the hemisphere, namely, the *ascending frontal* and *parietal convolutions*, especially at their upper part; and a small lobule situated on the internal surface of the hemisphere which, having remained nameless hitherto, Betz has proposed to call the *para-central lobule* (Fig. 6, LP). I must remind you that the existence of these large cells in the cortex, and their localisation in the regions just indicated, were first recognised by Betz and Mierzejewski. The results obtained by these authors have been recently confirmed by J. Batty Tuke in his Edinburgh lectures.<sup>1</sup> I also have had the opportunity of corroborating their accuracy. I have endeavoured to show you that the regions which are distinguished by this structural peculiarity are identical with those in which, according to Ferrier's experiments on the monkey, the psychomotor centres for the extremities are situated.<sup>2</sup> Did not this coincidence, gentlemen, merit your attention?

Allow me also to revert to the fact that the points in the dog, which are supposed to be excito-motor in accordance with the experiments of Ferrier and with the previous researches of Hitzig, are distinguished, according to Betz, by the presence of the pyramidal giant-cells, which are found in no other part of the cortex in these animals.

I consider myself justified, from the responsibility of my position, in insisting upon these truths and in establishing, as clearly as possible, all these details in your minds.

(b) These facts evidently confer a special interest on those regions of the hemisphere, in which this anatomical peculiarity is observed. In order to be in a position to describe them with

<sup>1</sup> Edinburgh Med. Journ., Nov., 1874, p. 394.

<sup>2</sup> 'West Riding Asylum Medical Reports,' vol. iv, p. 49 and 50. 'Proceedings of the Royal Society,' No. 151, 1874. 'British Medical Journal,' Dec. 19th, 1874.



accuracy in post-mortem records, it is therefore, I think, of immense advantage to possess a thorough *topographical* acquaintance with these regions. Consequently I shall, with your permission, treat this subject somewhat in detail. Moreover, we shall have a convenient opportunity of describing the configuration of the median aspect of the hemispheres, a region which, in my opinion, has hitherto remained rather too much in the shade.

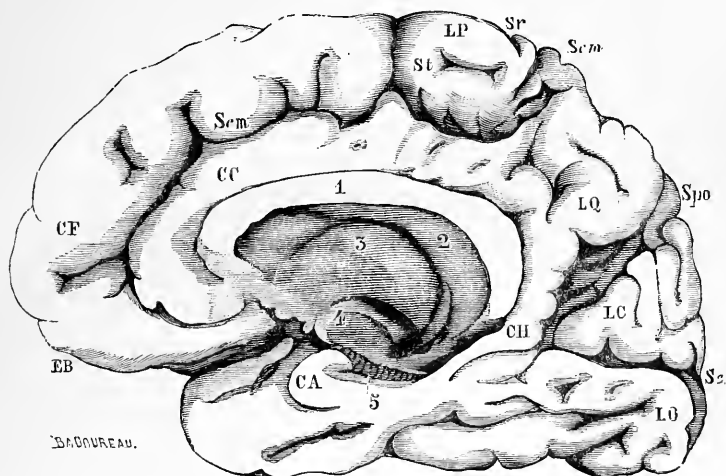


FIG 6.—Internal surface of the cerebral hemisphere, drawn from nature. *Sem*, calloso-marginal fissure; *Spo*, parieto-occipital fissure; *Sc*, calcarine fissure; *St*, transverse fissure of the paracentral lobule; *Sr*, upper extremity of the fissure of Rolando. *LP*, paracentral lobule; *LQ*, lobus quadratus or præcuneus; *LC*, cuneiform lobule or cuneus; *LO*, occipital lobe; *CH*, convolution of the hippocampus; *CA*, convolution of the cornu ammonis; *CC*, convolution of the corpus callosum; *CF*, internal aspect of the first frontal convolution: 1, corpus callosum; 2, cavity of the lateral ventricle; 3, optic thalamus; 4, anterior and external part of the crus cerebri; 5, fascia dentata. (For the topography of the median aspect of the cerebrum, consult pl. viii in Foville's 'Atlas,' and fig. 4 in Ecker's work).

We are already acquainted with the disposition of the ascending convolutions from their origin to the upper border of the hemisphere, so that we can now concentrate our attention on the arrangements observed on the internal surface of the hemisphere. In this section (Fig. 6), which has divided the

corpus callosum from before backwards, you first of all notice in the centre the cut surface of this large commissure (Fig. 6, 1); below are the septum lucidum, the internal aspect of the optic thalamus (Fig. 6, 3), and lastly, the divided surface of the crus cerebri (Fig. 6, 4).

In order to have an accurate idea of the position of the parts, let us take a fixed point on the external surface with which we are now familiarly acquainted, and let us follow the course of the fissure of Rolando as far as its most internal extremity (*Sr*). This fissure sometimes terminates a little below the inter-hemispherical cleft, but at other times is prolonged up to it, causing a kind of notch (*Sr*) on the superior border of the hemisphere. The paracentral lobe (*LP*) is situated immediately below this point. It is bounded as follows: behind by an oblique fissure, which is really the continuation backwards of the calloso-marginal (this fissure when prolonged limits posteriorly the ascending parietal convolution); below, by the horizontal portion of the calloso-marginal fissure (*Scm*), which separates it from the convolution of the corpus callosum (*gyrus fornicatus*); in front by a sulcus, which is usually of little depth, but occasionally, when prolonged over the external surface of the hemisphere, marks off, anteriorly, the internal part of the ascending frontal convolution, and thus forms the boundary of the paracentral lobule.

Accordingly we have under observation a small lobule, of quadrilateral form, the greatest diameter of which is from before backwards. As a rule, a sulcus of inconsiderable depth (*St*), situated at an equal distance from the superior and inferior borders, courses through it lengthwise. In short, taking into account both its structure and relations, we may say that the paracentral lobe represents the two ascending convolutions reversed on the median surface of the hemisphere.

This point being established, the considerations we have yet to propound concerning the topography of the internal surface of the hemispheres are not difficult to present:—(1) in front of the paracentral lobule you will recognise the median surface of the first frontal convolution (*CF*); (2) below, and separated from the preceding by the calloso-marginal fissure is the convolution of the corpus callosum (*CC*) (*gyrus fornicatus*); (3) this convolution is continuous behind with a perfectly circumscribed lobule called the *lobus quadratus* (*LQ*) (*avant-coin*,

*Vorzwickel, præcuneus*). It belongs, properly speaking, to the parietal lobe, and is, as it were, the internal or median surface of the superior parietal lobule. Behind, the *parieto-occipital fissure* which at this point is well marked because it is not interrupted as on the external surface by the annectant convolutions, distinctly separates the lobus quadratus from the occipital lobe; (4) immediately behind the lobus quadratus, in the domain of the occipital lobe, there is seen a triangular lobule, the apex of which is below and in front, the base behind and above, and which is bounded posteriorly by a deep sulcus, the *calcarine fissure*.

This small lobule (L c) is called the *cuneus* (*coin, Zwickel*); (5) below the triangle you observe the promiscuous arrangement between the occipital and sphenoidal lobes previously pointed out on the external surface. For the sake of convenience we distinguish especially two convolutions, running in an antero-posterior direction. These are:—(a) the lateral occipito-sphenoidal or *fusiform lobule*; (b) the median occipito-sphenoidal or *lingual lobule*; (6) I shall confine myself to merely mentioning *the lobule of the hippocampus* which lies more anteriorly in the centre of the sphenoidal lobe, and the *crotchet* which forms part of the system of the cornu ammonis.

In the course of these lectures we shall doubtless have the opportunity of utilising the topographical data we have just acquired, but I hasten to conclude this description which at the present time constitutes, in some respects, a digression.

c. I return, gentlemen, to the paracentral lobule and ascending convolutions. The latter have already obtained a history in experimental pathology and, at a later stage, I shall have occasion to show you that they also possess a history in human pathology.

I am not aware that the paracentral lobule which exists in the monkey as in man, at any rate in the higher apes, has ever been the object of physiological investigation.

(a) An appropriate opportunity now occurs, of which I must avail myself, of noticing a fact in human pathology which of its kind is still unique and which henceforth lends considerable interest to this lobule. The case I am about to relate was published by a careful observer, M. Sander.<sup>1</sup>

<sup>1</sup> 'Centralblatt,' 1875

A child, who died at the age of fifteen, had been seized during its third year with infantile spinal paralysis. The disease had caused more or less atrophy of all the limbs, especially on the left side. The autopsy revealed in the cord all the lesions described by French authors. A minute examination of the cerebrum showed that the two ascending convolutions on the external surface were much shorter than in the normal state. They left the island of Reil slightly exposed and, moreover, were destitute of folds. The paracentral lobule was quite rudimentary, and in this respect contrasted with all the other convolutions which had acquired perfect development. Finally, the lesions were more pronounced in the right than in the left hemisphere, which is in accordance with the circumstance that the spinal lesions were more marked on the left than on the right side.

The author expresses the opinion that, in this case, the limbs having been completely paralysed at an early date, consequent on a profound spinal lesion, the psychomotor centres were affected with inertia at a period when they were still in course of evolution and, accordingly, underwent arrest of development. This explanation, I confess, appears to me deserving of consideration. It is a matter of regret, however, that the idea did not occur of investigating the condition of the nerve-cells in the psychomotor centres.

A case, observed by M. Luys, in some respects resembles the preceding. In a case of old amputation, my colleague at La Salpêtrière noticed atrophy of the cerebral convolutions on the side opposite to the amputated limb. Unfortunately, the seat of the atrophy, at least to my mind, was not precisely indicated.

(b) Hence, I am led to speak to you of another fact, still in reference to the department of the encephalon, which is now engaging our attention. This fact is as follows:—According to the observations of Betz, the pyramidal giant-cells in very young children exist but in small quantity; it is only at a later period that their number increases, and this increase takes place, in all probability, under the influence of functional activity. This fact should be compared, on the one hand, with Sander's case, and, on the other hand, with an observation of an experimental nature, recently published by M. Soltmann.<sup>1</sup>

<sup>1</sup> "Reizbarkeit der Grosshirnrinde," 'Centralblatt,' 1875, No. 14.

This author (and, I believe, Professor Rouget, of Montpellier, has also made a similar observation) remarked that in newly-born puppies stimulation of the regions corresponding to the seat of the psychomotor points produced no muscular movement in the corresponding limbs, although shortly after birth, about the ninth or tenth day, these points became excitable.

These observations, few as they are, are worthy of consideration, since they would seem to indicate that the psychomotor centres are not pre-established, if I may use the expression, so much in an anatomical as in a physiological point of view. They undergo development with age, under the influence, doubtless, of functional activity. In support of this view I shall make some concluding remarks relative to the special subject now under our consideration.

The regions in which the large cells are found belong to the type of five layers, and their only definite and anatomical characteristic is the actual presence of these giant-cells. Now, these latter have no essentially morphological points of difference from the pyramidal cells of the large variety, which possess, according to the results of Koschewnikoff's researches, in addition to the prolongations of the protoplasm, the nerve-prolongations peculiar to motor cells. It seems a natural question to ask whether these cells and even those of the small variety, which represent them in miniature, would not be capable in certain conditions, under the influence, for example, of abnormal functional irritation, of acquiring development and thus giving rise to supplementary motor centres which might replace the primitive centres destroyed by some lesion.

We could thus explain, for instance, how voluntary movements are reproduced in a limb notwithstanding the destruction of a motor centre. Recovery in the case of aphasia, which has several times been observed, in spite of the persistence of the lesion in the third frontal convolution, is a typical instance of this phenomenon.

D. To finish the account of the structure of the cerebral cortex, I have only to make some very brief observations with reference to the peculiarities of this structure in the posterior regions of the encephalon. The parts in which these peculiarities are found include, as I have already said, the entire occipital lobe, the sphenoidal lobe, and the posterior and median

regions of the hemisphere as far as the posterior border of the lobus quadratus.

The general characteristic feature of the cortex in these parts is that the pyramidal nerve-cells are few in number and of inconsiderable size, whereas, on the other hand, the granular bodies are notably in excess. The large nerve-cells are, indeed, present, but they are comparatively thinly scattered or *solitary*, to use Meynert's expression.

Betz states that they have no distinct nerve-prolongation and that even the protoplasmic processes are ill-developed. The cerebral regions, in which this arrangement is met with, correspond, according to many authors, to the *common sensorium*.

If this explanation be correct, it follows that the cells, of which we have just spoken, are sensory cells. This hypothesis receives further confirmation from certain anatomical and pathological facts which I shall have to consider more in detail at a later stage.

## LECTURE IV.

### PARALLEL BETWEEN SPINAL AND CEREBRAL LESIONS.

SUMMARY.—*Indispensable conditions for the study of cerebral localisation in human diseases.*

*Necessity for good clinical observation and careful autopsy.*

*Natural history of encephalic lesions.*

*Parallel between the great divisions of the cerebro-spinal axis.*

*Systematisation of lesions in the spinal cord. Spinal localisation.*

*The cerebrum is placed under a different pathological law from the other parts of the neuro-axis; rarity of localisation. Variety of lesions.*

*Frequency of vascular lesions in cerebral affections.*

*Necessity for the study of the vascular distribution.*

*External distribution of the cerebral arteries.*

GENTLEMEN,—I hope I have succeeded in making you thoroughly understand, in the preceding lectures, that without the preliminary acquisition of sound and precise knowledge in normal anatomy, it would have been useless for us to enter the domain which we propose to travel over together.

The subordination of pathological to normal anatomy is, in truth, especially manifest in all questions relative to cerebral pathology. You will, in a moment, recognise this once again.

### I.

Allow me, in inaugurating to-day's meeting, to recall to your minds the conditions which are indispensable for the preliminary study of the problems relating to the *cerebral localisation of human diseases*. These essential conditions are the following :

—(1) Good clinical observation made, as much as possible, in accordance with the facts of experimental physiology; (2) an exact, that is to say anatomically speaking, a perfectly explicit autopsy.

The topographical inquiries to which we have already devoted attention have greatly facilitated our progress, for by their means we are in a position to determine, better perhaps than has hitherto been done, the extent and configuration of lesions seen post mortem. But, gentlemen, we must indeed confess that in the special subject under our consideration the most exact and minute anatomical observations cannot always be utilised. Here, as elsewhere, it is important to make a judicious selection, and in this respect there will be more than one difficulty which we shall have to surmount.

In order that you may have an accurate knowledge of the condition of affairs, it is essential, I think, to take a preliminary and general survey of what I should like to call the *natural history of encephalic lesions*.

1. What are the changes likely to affect the encephalon (the cerebrum in particular)? It is evident that we are now referring only to the most usual and commonest forms, and to partial or focal lesions, as they are also called, which alone can be utilised in such a subject.

2. What are the general anatomical conditions which preside over, either the development, or, the mode of distribution of these lesions? For, gentlemen, in this order of things nothing happens by chance, even in the encephalon. In order to attain our end, I propose to have recourse once more to the comparative method, which is an agent of great power in the natural sciences. From the standpoint of pathological anatomy, I shall draw a kind of parallel between the main divisions of the cerebro-spinal axis or, in other words, of the *neuro-axis* (if you will kindly consent to the use of this term, which has been adopted in M. Piorry's nomenclature), viz. (a) the spinal cord, (b) the medulla oblongata, (c) the cerebrum proper.

a. A great fact may be said to govern the pathological physiology of the spinal cord; it is the widely-distributed existence in this domain of the so-called *system* lesions. By this expression, which I borrow from M. Vulpian, we mean to designate lesions which are circumscribed systematically—the term is



perfectly appropriate—without trespassing on certain well-defined regions in this complex organ. As an illustration of this I must ask you to glance at Fig. 21, which will remind you of our previous studies.

You have not forgotten that there are lesions confined to the anterior grey cornua (Fig. 7 D, D.). These are of the acute kind, infantile paralysis; of the chronic variety, the different forms of progressive spinal amyotrophy. There are others limited to the lateral columns, which are characterised by paresis of the extremities with tendency to contracture.

You are aware that the columns of Goll may be affected separately, and that lesion of the posterior root-zone (Fig. 7, B, B) is the only anatomical *substratum* required for tabetic symptoms.<sup>1</sup> Under the regulating influence of experiments on animals, and the control exercised by clinical observation, pathological anatomy has succeeded in decomposing in man that complex organ which we call the spinal cord into a certain number of compartments, departments, and secondary organs. There correspond to the system lesions of these various organs as many groups of symptoms having a recognised clinical existence, and thus constituting in spinal pathology a certain number of *elementary affections*. In decomposing the hybrid and complex forms the analysis which is based on a knowledge of these elementary affections is of great assistance.

There is no doubt that the study of these system lesions has powerfully contributed in extricating the question of spinal localisation from the chaos in which it had long remained plunged.

B. System lesions are also met with in the medulla oblongata,

<sup>1</sup> Gowers ('The Diagnosis of Diseases of the Spinal Cord, 2nd edition, p. 9—11) justly insists on the inadvisability of associating, in scientific works, the various parts of the cord with the names of certain individuals. He proposes that we should abandon, for instance, the terms "columns of Goll," and "columns of Burdach," in favour, respectively, of postero-median and postero-external columns. M. Charcot calls the latter posterior root-zone (*zone radriculaire postérieure*). Most of the posterior nerve-roots, it must be remembered, before reaching the grey matter pass through the outer part of the postero-external columns, but in the lumbar regions they penetrate farther into these columns than elsewhere. This anatomical fact is of great practical importance in reference to locomotor ataxy.—(Translator.)

the pons Varolii, and even in the crura cerebri. I will cite, as examples, secondary spinal degenerations consequent on encephalic lesions, primary and symmetrical sclerosis of the lateral columns, bulbar paralysis from lesions confined to the nuclei of origin of nerves, &c.

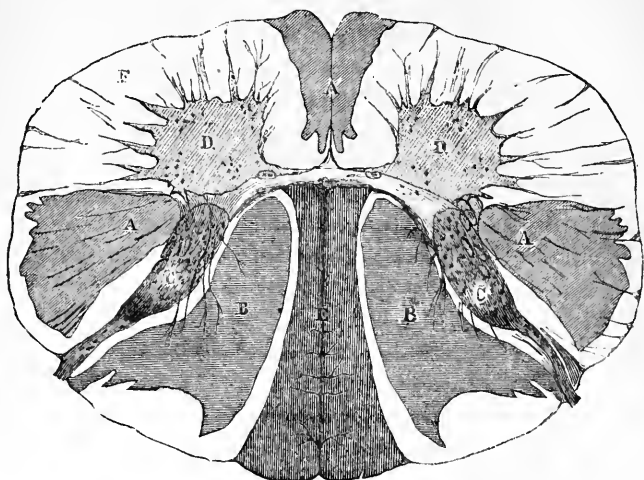


FIG. 7.—A, A, lateral columns; A', columns of Türk; B, B, posterior root-zones; C, C, posterior cornua; D, D, anterior cornua; F, anterior root-zone; E, columns of Goll.

But this mode of pathological alteration apparently ceases to exist higher up and, so far as the present time is concerned, we may assert that system lesions in the brain are absent. So in the cerebrum, we are as yet unacquainted, strictly speaking, with lesions systematically limited to the optic thalami, to the different nuclei of the corpus striatum, and to the various circumscribed areas of the cortex. Not indeed that limited anatomical localisations, adapted to research, cannot take place in the encephalon, but they are comparatively rare and, in a manner, accidental.

What is the material explanation of this singular fact? It is that the encephalon is placed, if I may thus express myself, *under a different pathological law* from the other parts of the neuro-axis.

Indeed, we may assert in a general fashion that, in the

encephalon and more particularly in the cerebrum, the vascular system (arteries, veins, capillaries) governs the situation.

In reference to this subject I must recall to your minds the importance of vascular ruptures giving rise to circumscribed intra-encephalic hæmorrhage, and the predominant rôle of vascular obstruction from thrombosis and emboli, the effect of which is to determine ischæmia, and afterwards partial cerebral softening. I have just enumerated, gentlemen, the anatomical causes of the commonest organic affections of the encephalon.

c. If now we return to the spinal cord and medulla oblongata, we have to notice a remarkable contrast with the encephalon. Hæmorrhage from vascular rupture dependent on an alteration well known under the name of *miliary aneurysms*, softening secondary to arterial obstruction, whether it be due to thrombosis or to embolism, are almost unknown accidents in the spinal cord. The medulla forms, so to speak, the transition between the spinal cord and the encephalon; for, on the one hand, we observe there system lesions similar to those seen in the cord; and, on the other hand, a certain number of hæmorrhages, ischæmias, and softenings, produced by vascular lesions. These last affections are still more marked in the pons, the pathology of which, in this respect, is more closely assimilated to that of the encephalon. Here hæmorrhage from rupture of miliary aneurysms and softening from vascular obliteration are common accidents.

d. These considerations, gentlemen, tend to show that the explanation of the commonest *anatomical localisations* in the encephalon is to be sought for especially in the mode of distribution of the vessels. For, the vessel primarily affected being known, we may hence infer, as M. Lépine has justly remarked, the configuration and limits of the involved area. We are, therefore, compelled to return once more to the domain of normal anatomy in order to acquire some general views relative to the vascularisation of the encephalon. This subject, gentlemen, I do not hesitate to say, is well worthy of your attention, the more so because all the questions bearing upon it have been carefully submitted to fresh investigations, from which our own country has by no means remained aloof.

## II.

For the moment it will suffice to consider the arterial system, although lesions of the venous system may also have a marked influence over the development of encephalic alterations. Our immediate aim is to show, by a few examples, how far a thorough acquaintance with the normal conditions of the cerebral circulation is essential to the good understanding of a considerable number of the anatomical lesions, of which this part of the nervous centres may be the seat. You remember how the large arterial trunks, the two internal carotids and the two vertebals, contribute to the formation of the arterial circulation at the base of the encephalon.<sup>1</sup>

The internal carotids, at their exit from the cavernous sinuses, are directed perpendicularly to the base of the brain, and divide immediately into two branches: the one, which is anterior, is the *anterior cerebral*; the other, which is inclined laterally, bears the name of *Sylvian* or *middle cerebral artery* (fig. 8, s). A transverse anastomotic branch (*anterior communicating*) unites the two anterior cerebrals near their origin, and connects together in a more or less complete manner the circulation of the internal carotids. This vascular arrangement constitutes a special system which we may term the *anterior* or *carotid system*.

The vertebals (v, v), directed obliquely from behind forwards, converge towards the middle line and unite in a single trunk, the *basilar* (B), which divides near the anterior border of the

<sup>1</sup> We know that cerebral softenings and hæmorrhages are much more frequent on the left than on the right side. M. Duret, in his memoir, believes he has discovered the explanation of this fact in the anatomical arrangement which the common carotid and the vertebral of the left side present at their origin. The right carotid springs from the innominate trunk, *which is inclined towards the arch of the aorta*, whereas the *left* carotid ascends nearly perpendicularly and its axis is directly continuous with that of the vertical or ascending portion of the aorta. It therefore follows that a clot thrown into the aorta by a contraction of the heart, enters the left carotid in a direct manner. The right vertebral springs from the subclavian after it has described its curve and when it is horizontal; the left vertebral, on the contrary, takes origin from the summit of the curve of the subclavian.

pons into two branches called the *posterior cerebrals* (CP). In this manner there is constituted a second arterial system, the posterior or *vertebral system*.

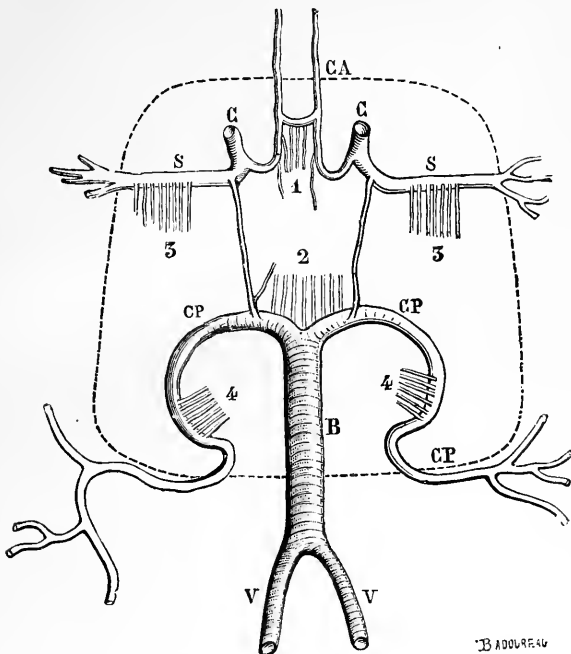


FIG. 8.—Diagram of the arterial circulation at the base of the encephalon. c, c, internal carotids; c, A, anterior cerebral; s, s, Sylvian arteries; v, v, vertebrals; B, basilar; CP, CP, posterior cerebrals; 1, 2, 3, 3, 4, 4, groups of nutrient arteries. The dotted line shows the limits of the ganglionic circle.

The carotid and vertebral systems, which are united by two anastomotic branches, very variable in size and arrangement (*posterior communicating*),<sup>1</sup> form at the base of the encephalon

<sup>1</sup> M. Duret has called attention to the frequent variations and anomalies of the circle of Willis and its communicating branches. The latter are frequently filiform, and quite insufficient to re-establish the circulation in case of arterial obliteration. Certain anomalies explain, also, cases in which softening of one entire hemisphere has occurred in consequence of a clot obstructing the internal carotid near its bifurcation.

a vascular circle, usually described by anatomists under the name of hexagon or *polygon of Willis*.<sup>1</sup>

At the anterior angles of this polygon, the two anterior cerebrals are seen; the two Sylvians, which are directed outwards, spring from the antero-lateral angles; and lastly, the posterior angles are formed by the posterior cerebrals.

From the circle of Willis and from the first two centimètres of these various arterial trunks spring the nutrient arteries of the central ganglia, the corpora striata and optic thalami.

These nutrient vessels form six principal groups:

The first, *antero-median group* (1), has its origin in the anterior communicating and commencement of the anterior cerebrals. The arterioles composing it supply the anterior part of the head of the caudate nucleus.

The second, *postero-median group* (2), comes from the posterior half of the posterior communicating and from the origin of the posterior cerebrals. It supplies the internal surfaces of the optic thalami and the walls of the third ventricle.

The third and fourth, *right and left antero-lateral groups* (3, 3), which are made up of a much larger number of arterioles springing from the Sylvian, form the vascular supply of the corpora striata and anterior part of the optic thalamus.

The fifth and sixth, *postero-lateral groups* (4, 4), are furnished by the posterior cerebrals after they have turned round the crura cerebri; they supply a large part of the optic thalami.

A circular line drawn at a distance of two centimètres from the circle of Willis, and completely surrounding it, would limit the region of origin of the ganglionic arteries. A *ganglionic circle* is thus described, within which the circle of Willis is included (see Fig. 8).

The cortical regions or, in other words, the cerebral convolutions, are nourished by the large arteries which, as we have seen, form the angles and sides of the polygon of Willis. The anterior cerebral turns round the corpus callosum; it is distributed over part of the inferior surface of the anterior or frontal lobe (*gyrus rectus and supra-orbital convolutions*), and over a considerable portion of the internal surface of the hemi-

<sup>1</sup> In English text-books this vascular arrangement is always called the *circle of Willis*.—(Translator.)

sphere. (*First and second frontal convolutions; præcentral lobule; lobus quadratus or præcuneus.*)

The posterior cerebral, which springs from the basilar, turns round the corresponding crus cerebri and divides into three branches, which go to the lower surface of the brain and to the occipital lobe (*gyrus uncinatus; hippocampal convolution; second, third, and fourth temporal convolutions; cuneus; lingual lobule*).

The Sylvian artery is distributed to that part of the frontal lobe which is not supplied by the anterior cerebral, and to all the parietal lobe. At a later stage, it will be necessary for us to consider in detail the distribution of each of these four branches, and to describe exactly their vascular areae.

Such is the general distribution of the arteries proceeding to the internal, external, and inferior surfaces of the cerebrum. In order to ascertain how the internal distribution of these vascular areae is effected, we must have recourse to sections.

Thus, on viewing a section made in the domain of the Sylvian artery, the circulation of the grey nuclei appears to be blended with that of the cortex and subjacent white nuclei. This, however, is an error which we shall explain in the next lecture.

## LECTURES V AND VI.

### ARTERIAL CIRCULATION OF THE CEREBRUM.

SUMMARY.—*Works of Duret and Heubner. Principal arteries of the cerebrum. Cortical arterial system; nutrient vessels. Central arterial or central ganglionic system.*

*Branches of the Sylvian artery; arteries of the central grey nuclei; cortical ramifications and arborisations; the nutrient arteries of the cerebral pulp are (a) long or medullary, and (b) short or cortical.*

*Effects of obstruction of these various arteries. Superficial ramollissement, yellow softening. Opinions of Heubner and of Duret on the communication between the vascular area. Cohnheim's terminal arteries.*

*Relative autonomy of the vascular area of the cerebrum.*

*Localisation of cortical lesions.*

*Branches of the Sylvian: external and inferior frontal; arteries of the ascending frontal and parietal convolutions; artery of the gyrus angularis.*

*Anterior and posterior cerebrals and their branches.*

GENTLEMEN,—I propose to-day to resume and investigate more thoroughly the subject which I merely roughly sketched at our last meeting. If I succeeded in proving that the arterial system governs, so to speak, the situation in the domain of cerebral pathology, I ought at the same time to have convinced you of the necessity for preliminary investigations with regard to the relations which exist, under physiological conditions, between this system and the various component parts of the cerebrum.

How, indeed, are we to understand the causation of the localisation of those foci of hæmorrhage or softening, which constitute one of the principal features in the pathological anatomy of the cerebrum, if we are not perfectly acquainted



with the mode of distribution of the arterial vessels, degeneration of which is the starting-point and primary condition of these various lesions?

The present question, moreover, cannot be solved by the mere contemplation of facts in normal anatomy.

As I have already pointed out and shall, I think, show still more satisfactorily to-day, the application is immediate and *sui generis*.

I am the more willing to linger on this point in the anatomy of the cerebral circulation, because, in the most justly esteemed works, you will only find on this subject information which is vague and quite inadequate for the purpose of our studies.

All our precise knowledge on this matter is of recent date and is the result of investigations which have been called forth by the requirements of pathological anatomy and physiology.

I shall borrow largely from the important work of our compatriot M. Duret, a work which was based on researches made in the laboratory of La Salpêtrière.

I must not, however, leave you ignorant of the fact that M. Duret encountered a rival in the path in which he entered. This rival, Dr. Heubner, is a German physician, and a professor at the University of Leipzig. Both these authors who pursued their researches simultaneously, but unwittingly, arrived, at least in essential point, at identical results.

Assuredly that is a guarantee for the accuracy of the descriptions they have lately given us.

But, in a recent work which treats of syphilitic degeneration of the cerebral arteries,<sup>1</sup> Heubner puts forward the claim of having been the initiator. This is an insupportable pretension. M. Duret's first researches relative to the circulation in the medulla oblongata and pons were communicated to the Société de Biologie at the meeting of December 7th, 1872. By a remarkable coincidence, that same day (December 7th) a summary of Dr. Heubner's investigations on the cerebral circulation was published at Berlin in the 'Centralblatt.' A month afterwards, in January, 1873, M. Duret published an account in the 'Progrès Médical'<sup>2</sup> concerning that part of his researches which has reference to the cerebral circulation.

<sup>1</sup> 'Die luetische Erkrankung der Hirnarterien,' p. 188. Leipzig, 1874.

<sup>2</sup> January 18th and 25th, February 1st, November 8th and 15th, 1873.

M. Duret's investigations are not then two years later than those of Heubner, as the latter insinuates, but are absolutely contemporaneous. Of this fact Professor Heubner might have easily convinced himself, since he was acquainted with M. Duret's last memoir, published in the 'Archives de Physiologie' (1874), in which the history of this question is described in detail.<sup>1</sup>

In opposition to that mania for annexation, I thought it of importance to introduce this chronological account, in order to thoroughly establish the large share which belongs to our fellow-countryman.

## I.

But I must return to the special object of our studies. You know how the three trunks, which arise from the circle of Willis, enter into the formation of the arterial circulation of each cerebral hemisphere. These vessels are: (1) the anterior cerebral; (2) the middle cerebral or Sylvian (both being branches of the internal carotid); (3) the posterior cerebral, which arises from the point where the two vertebrals converge to form the trunk of the basilar.

A. Each of these arteries presides over a special region in each hemisphere. I have already described to you, very briefly it is true, the general topography and limits of these large vascular areae. These areae must be examined not only on the surface of the hemispheres, but also, by means of sections, in the interior of the cerebrum. First of all, we have to fix our attention on the surface of the brain, including the external, superior, internal, and inferior aspects; and, in the second place, on frontal sections, which will show the pre-eminent importance of the Sylvian area.

We shall see presently that these territories or provinces may be divided into a certain number of secondary departments,

<sup>1</sup> M. Duret's researches exhibit considerable pathological interest, for they were especially made with the object of seeking an explanation for the appearance of lesions discovered *post-mortem*. With the assistance of more than two hundred observations, entrusted to him by M. Charcot, he was enabled to make a classification of cerebral hæmorrhages and softenings from an anatomical point of view.

corresponding to the distribution of as many secondary arteries springing from the principal trunks.

b. We must dwell no longer on this preliminary survey, but enter at once into detail. Each of the three principal arteries gives origin to two very different systems of secondary vessels. The first of these may be called the *cortical arterial system*. The vessels composing it ramify in the substance of the pia mater and there divide according to a special plan, before furnishing the small vessels which enter the cerebral pulp, and which are, strictly speaking, the *nutrient vessels* of the cortex and subjacent medullary matter.

The second is termed the *central arterial or central ganglionic system*. The vessels entering into its formation arise from each of the three main arteries, close to their origin, and at once pass downwards, as arterioles, into the substance of the ganglionic masses. *These two systems, although having a common origin, are perfectly independent one of the other, and communicate at no point at the periphery of their domain.*

c. We have to consider these two systems in each of the large vascular arææ and, in the course of our investigations, we shall have to notice features, some of which are common and some special. In the first place, we shall examine the Sylvian, which is the most important and the most complicated of the three cerebral arteries. The description of the two others will then be found much more simple.

## II.

The Sylvian artery penetrates the fissure of Sylvius, the edges of which must be separated in order to thoroughly expose the vessel. But it has already furnished from its upper border, in a region called the *anterior perforated space*, a series of parallel arteries which penetrate into each of the orifices in this perforated space, which is formed by the white substance. These are the arteries of the central grey nuclei or, more particularly, the arteries of the corpus striatum. Excluding for the moment the system of the grey nuclei, we shall consider only the cortical system.

On the floor of the fissure of Sylvius, the island of Reil is

seen, on a level with which the Sylvian artery divides into four branches, each deserving a special name.

These branches follow the sulci separating the convolutions of the island, to which they supply vessels. Subsequently, they make a bend from within outwards and ascend to the surface of the hemisphere, where they are distributed, as we said just now, to certain of the fundamental convolutions, forming so many small secondary arææ corresponding to each of these convolutions (Fig. 9).

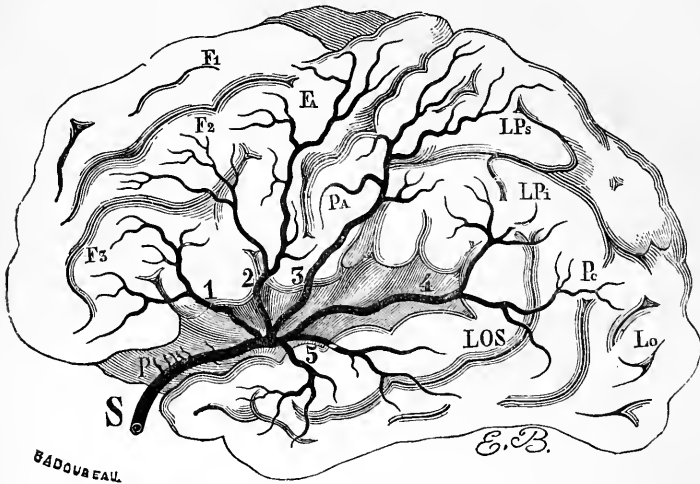


FIG. 9.—Distribution of the Sylvian artery. (Semi-diagrammatic view). S, trunk of the Sylvian entering the fissure of Sylvius, with its branches radiating between the convolutions of the island of Reil; P, perforating branches proceeding to the central grey nuclei; 1, artery of Broca's convolution or external and inferior frontal; 2, ascending frontal artery; 3, ascending parietal artery; 4 and 5, parieto-sphenoidal and sphenoidal arteries. F<sub>1</sub>, F<sub>2</sub>, F<sub>3</sub>, first, second and third frontal convolutions; PA, ascending parietal convolution; LPs, superior parietal lobule; LPA, inferior parietal lobule; Pc, gyrus angularis; Lo, occipital lobe.

We shall dwell no longer at present on this description, but proceed to examine more thoroughly the method, according to which, the cortical arteries divide and ramify in the substance of the pia mater before entering the cerebral pulp. I must

ask you to notice that the branches springing from the Sylvian immediately divide into vessels of the third order, to the number of two or three for each secondary trunk. These tertiary ramifications constitute a kind of vascular framework, on which is grafted the system of *arborisations*. This is a peculiar and very original system of small vessels, proceeding not only from the extremities of the ramifications, but also from their trunks. Contrary to the assertions of most authors, M

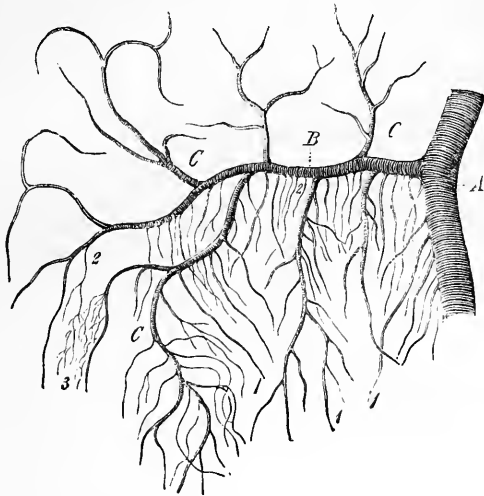


FIG 10.—A, principal artery; B, primary arborisation; c, c, secondary arborisations. 1, 1, 1, medullary arteries; 2, 2, cortical arteries; 3, network of cortical arteries in the cerebral pulp.

This figure is copied from M. Duret's publication in the 'Archives de physiologie,' 1874, p. 312.

Duret affirms that these arborisations do not anastomose, although the ramifications sometimes communicate with those of adjacent areas (Fig. 10).

The ramifications and arborisations are situated in the plane of the pia mater. Towards the internal surface of this membrane they give origin to the *nutrient arteries* which penetrate the encephalic pulp perpendicularly. All these nutrient vessels, according to M. Robin's nomenclature, must already be looked upon as capillaries. This characteristic distinguishes

them from the vessels of the central ganglia, which sink down into the white substance at the base of the brain (anterior perforated space), whilst they still have the dimensions and structure of arteries. We must pass on to consider more closely, by means of sections adapted to microscopical examination, the peculiarities of these nutrient arteries. In sections of an entire convolution made perpendicularly to the surface, we notice first of all, at the periphery, the grey matter which appears under the form of a festoon, having a thickness of two or three millimètres; and internally the medullary substance, which is composed of radiating and commissural fibres connecting one convolution to its neighbour. What is the arrangement of the arteries in such sections? Two kinds of nutrient vessels are at once distinguishable, as indeed several authors, and in particular Todd and Bowman, long ago observed. Of these arteries some are *long*, others *short*.

1. The *long*, or, as they are otherwise called, the *medullary* arteries, spring from the ramifications, or may even form the termination of the arborisations. On a section of a convolution twelve or fifteen of them may be seen: three or four on the free surface; the others distributed over the two sides or in the separating sulcus. The arteries on the summit are vertical, one of them occupying, as a rule, the median part of the convolution. The arteries on the sloping sides are oblique; those situated on the floor of the sulci are, once more, vertical. These arteries penetrate the centrum ovale to a depth of three or four centimètres, and continue their progress without intercommunicating otherwise than by fine capillaries, and thus constitute so many small independent systems. Finally, we must remark that at their termination they approach the extremity of the central arterial system, but *no communication between the two systems* takes place. As a result of this arrangement there is on the confines of the two domains a kind of neutral zone, where nutrition proceeds less actively. This neutral ground is the very frequent seat of certain lacunar softenings in old people.

2. The *short* or *cortical nutrient arteries* have the same origin as the long; but they are more slender and shorter, as though their course had been interrupted. Some proceed as far as the medullary limit of the cortex; others extend less far

and terminate in the substance of the cortex. These short arteries give origin to capillary vessels which, in conjunction with those emanating from the long, form the meshes of a network.

In the convolutions this network possesses the following characters (Fig. 11):—(1) The first layer (*a*) has a thickness

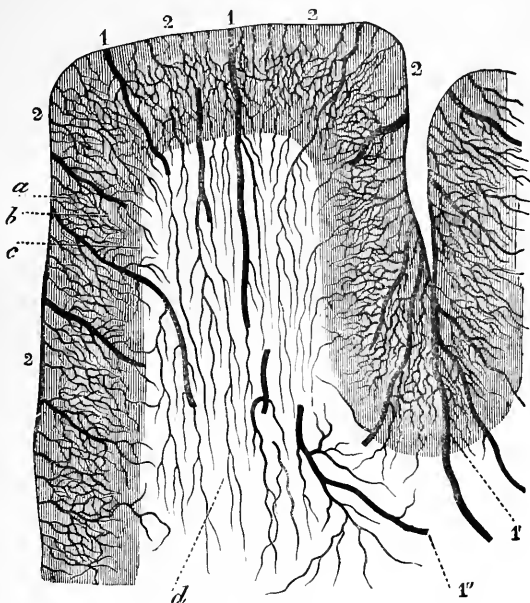


FIG. 11.—1, 1, medullary arteries; 1', group of medullary arteries in the sulcus between two adjacent convolutions; 1'', arteries situated among Gratiolet's commissural fibres; 2, 2, 2, cortical arteries.

*a*, capillary network with fairly wide meshes, situated beneath the pia mata; *b*, network with more compact, polygonal meshes, situated in the cortex; *c*, transitional network with wider meshes; *d*, capillary network in the white matter.

of half a millimètre, and contains but few vessels; (2) the second layer (*b*) corresponds to the two zones of nerve-cells; its vascular network is very compact, and is made up of extremely fine polygonal meshes; (3) towards the limit of the layer (*c*) the meshes become larger; (4) lastly, in the medullary matter (*d*) the meshes are still wider and lengthened out vertically.

It follows from the preceding account that, as regards the arterial distribution, the cortex and subjacent white matter are liable to be affected together, seeing that their vessels in both cases are derived from the arteries which course through the pia mater.

If these latter become obstructed at any point the grey and white matter suffer simultaneously and in corresponding parts, and are likely to undergo that form of mortification which we call *ischæmic cerebral softening*. The reciprocal disposition of the parts is such that I am in a position to lay before you the plan on which superficial softening takes place. You recollect the general distribution of the nutrient vessels which converge towards the central parts. The cortex and underlying white matter may be divided into a certain number of *wedge-shaped* vascular departments, the base of which is turned towards the encephalon, and the truncated apex towards the central parts. This, indeed, is the form assumed by most of the so-called *superficial softenings*. It at once suggests the appearance of splenic and renal infarcts.

If the softening be old, that is to say if it dates from a period of several weeks previously, the grey matter appears depressed in consequence of the destruction which its elements have undergone, and of the concomitant falling in of the subjacent white matter.

The superficial part of the focal lesion forms a patch of what is called yellow softening (*plaque jaune*). The yellow staining is confined to the grey matter, the softened subjacent white substance being merely whitish or sometimes slightly tinged with yellow.

A. We have supposed in this case that obliteration of a branch of the second or third order has taken place. Obstruction of the trunk of the Sylvian itself might have the effect of causing necrosis of the entire cortex and subjacent white stratum.

The central parts would be quite unaffected if the obstruction were situated above the origin of the arteries of the corpus striatum.

B. You must not think, gentlemen, that all obstructions of this kind would necessarily and inevitably produce effects so disastrous. There are instances, rare it is true, in which



obstruction involving either a branch of the Sylvian artery or the trunk of this vessel—I take here the Sylvian as an example, but what I am about to say might apply equally as well to the anterior or posterior cerebral—there are, I repeat, cases in which such an occurrence may even remain without appreciable result or give rise only to transitory effects. If this be true, gentlemen, it is referable to the fact that the three large vascular areas, into which the cerebral cortex is divided, are not, strictly speaking, isolated and autonomous. They may, and in fact do, communicate in the ordinary manner. But, are these communications free and constant, or, on the contrary, are they accidental, indirect, and often impracticable paths?

On the solution of this problem writers are not yet agreed.

Heubner maintains that the communications in question are very free, and that they take place through the medium of vessels which are not less than a millimètre in diameter. He bases this assertion upon the results of injections, which have constantly shown him that the material propelled into any one of the departments, either through the principal trunk or through the ramifications, always penetrates rapidly into the other areas.

He appeals also to pathological cases in which obstruction of one of the vessels of the cortical system, or of its branches, has not revealed itself during life by any evident symptom, and in which, death having supervened, the cerebral pulp has not presented at the autopsy, in the parts corresponding to the obstruction, any trace of softening.

In the first place, as far as the pathological facts cited by Dr. Heubner are concerned, we must confess that they undoubtedly exist. Nevertheless, judging from the very numerous observations which I have been able to collect, they are extremely rare.

On the other hand, it is certain that, in the domain of normal anatomy, things are far, very far, from being always such as Heubner has seen them. M. Duret's observations on this subject have been frequently repeated, and the result has almost always been the same.

The following is a brief account of one of his experiments:

A ligature is placed on each of the three principal arteries

at the base of the encephalon on both sides, immediately beyond their origin in the circle of Willis. An injection is then driven into the Sylvian artery. This at once fills the Sylvian area, and, in most cases, exceeds its limits. The material injected invades the adjacent parts, penetrating them by degrees. This invasion proceeds from the periphery towards the centre of the regions encroached upon. It is effected through the medium of vessels of small calibre, which belong to the system of ramifications, and consequently have a diameter of only a fourth or fifth of a millimètre, contrary to the opinion of Heubner, who maintains that, under such circumstances, the arterioles have a diameter of one millimètre. The number of anastomoses between one area and another is, moreover, very variable. There are cases in which we can inject separately one of the three large areas, the anastomoses being insufficient to allow the injection to penetrate the adjacent parts. The communication which takes place in the peripheral zone of a vascular area explains why obstruction of a main trunk is often followed by softening confined to the central region, the peripheral parts remaining unaffected.

Such are M. Duret's conclusions. In my opinion, they are more in harmony with pathological facts than Professor Heubner's. I must add that Cohnheim, who has also made some experiments on partial injections of the cerebral arteries, has arrived at conclusions similar to those of M. Duret. He remarks that if the arteries of the encephalon are not absolutely *final* or *terminal*—we shall explain what Cohnheim means by this expression—they approach that type very closely. Under the appropriate name of terminal or final arteries (*Endarterien*), Cohnheim<sup>1</sup> aptly describes those arteries or arterioles which, in their course, from their origin to the capillaries, neither supply nor receive any anastomotic branch. An example of terminal arteries, convenient for investigation, is furnished by the tongue of the frog which is transparent, and on which it is easy to follow, *de visu*, all the effects of obstruction under the microscope. You see on these diagrammatic drawings the various consequences of obliteration of a terminal artery. These results are of inevitable occurrence.

If, on the contrary, we take the case of an artery with anas-

<sup>1</sup> "Untersuchungen über die embolischen Prozesse." Berlin, 1872.

tomoses, the blood-current is, as a rule, readily re-established by means of communications below the affected point. But the latter may be obstructed in their turn, and the consequence is that a vessel which, under normal conditions, is not a terminal artery, becomes so accidentally.

The encephalic circulation furnishes a large number of examples of terminal arteries. Thus, without including the ramifications which exist in the pia mater, we may mention the nutrient arteries. Moreover, we shall see that the arterial system of the central ganglia is constituted strictly on this plan.

The same type is found in all other circulatory systems in which occur, either pathologically or experimentally, those lesions consequent on vascular obstruction, which are generally termed infarcts. Such are the spleen, kidney, lung and retina. The viscera, as Professor Cohnheim has remarked, in which, as a rule, infarcts do not occur, do not exhibit this mode of arterial distribution.

I must conclude this digression which, in my opinion, has not been inopportune, and return to the relative autonomy of the vascular arææ of the cerebrum. But this autonomy does not belong exclusively to the large arææ; it is found also in the secondary departments into which the former are divided and which correspond to the arterial ramifications of the second or third order. Between these secondary regions, as in the case of the large arææ, communications may be possible, but are frequently very difficult. As a result of this arrangement, obstruction of one of these secondary branches may have and often has, the effect of causing necrosis of a very limited region of the cortex. This is a point of capital importance in the study of cerebral localisation.

It may happen that the lesion, thus circumscribed, corresponds precisely to one of the convolutions or to a group of convolutions, endowed with special properties, and so manifests its presence during life by special phenomena.

This limited localisation of cortical lesions, consequent on the obliteration of arterial branches of the second or third order, is especially interesting to study, as you will readily understand, in the domain of the Sylvian.

It is, indeed, in this large region, that experiment has placed

the well known motor centres, and it is here too that clinical investigation, with the assistance of pathological anatomy, has localised the seat of the faculty of articulate language. Consequently, we must have a thorough knowledge of each of the principal arteries emanating from the Sylvian, and examine more closely their mode of distribution in the primary convolutions of the region. The Sylvian artery divides into four principal branches, or at least gives origin to four principal branches, the distribution of which has been carefully studied by Duret and Heubner (see Figs. 9 and 12).

The *first* is described by M. Duret under the name of *external and inferior frontal*. This is, properly speaking, the artery of the third frontal convolution (Broca's convolution). For my own part, I have several times seen obstruction of this arterial trunk alone cause softening strictly limited to the region of the third convolution and, more precisely, to its posterior part.

In support of this, the following is a conclusive case. It relates to a woman, named Farn—, who was under observation in my wards at La Salpêtrière. She had been seized with aphasia, but there existed no trace of paralysis either of movement or of sensibility. In this case the aphasia was the sole symptom, and atrophy of the third frontal convolution was also the only corresponding lesion revealed by the autopsy (Figs. 13 and 14). This, gentlemen, is incontestably a beautiful example of cerebral localisation.<sup>1</sup>

The *second* branch of the Sylvian is the *anterior parietal artery* of Duret; I should prefer to call it the *artery of the ascending frontal convolution* (Fig. 9, 2, and Fig. 12, 11).

The *third* is the *posterior parietal artery*, which in my opinion would be better named the *artery of the ascending parietal convolution* (Fig. 9, 3, and Fig. 12, 111).

The *fourth* branch goes to the gyrus angularis and to the first sphenoidal convolution (Fig. 9, 4, 5, and Fig. 12, 1v).

The two convolutions to which the second and third branches of the Sylvian proceed, according to Ferrier's experiments on the monkey, are the seat of the motor centres for the extremities. From the arterial distribution, you see that these two convolutions may be affected separately. I am not aware

<sup>1</sup> We published a full description of this patient in numbers 20 and 21 of the 'Progrès Médical' (1874).

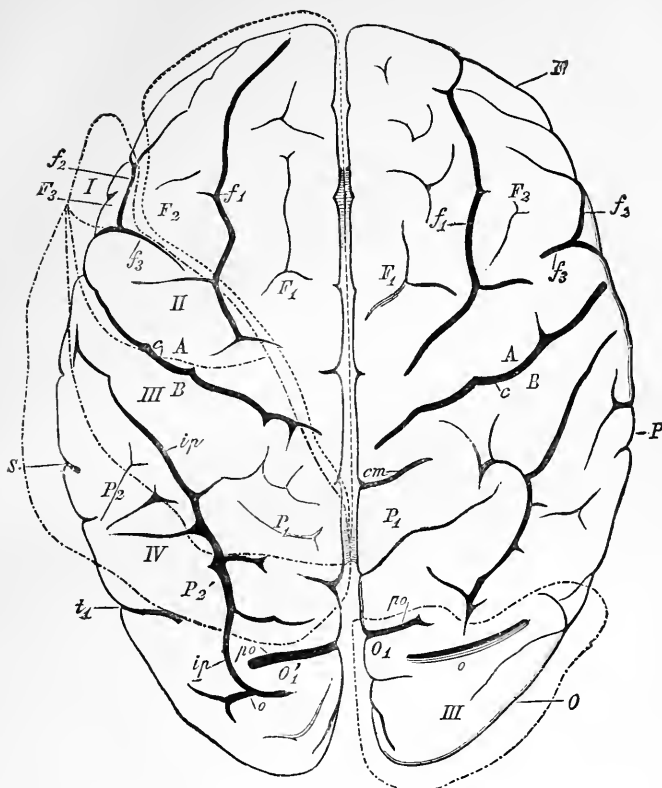


FIG. 12.—Vascular areas of the upper surface of the cerebrum. F, frontal lobe; P, parietal lobe; O, occipital lobe; s, end of the horizontal ramus of the fissure of Sylvius;  $c_1$ , central sulcus (fissure of Rolando); A, anterior central (ascending frontal) convolution; B, posterior central (ascending parietal) convolution;  $F_1$ ,  $F_2$ ,  $F_3$ , superior, middle and inferior frontal convolutions;  $f_1$ ,  $f_2$ , superior and inferior frontal sulci;  $f_3$ , vertical or transverse frontal fissure (sulcus præcentralis);  $P_1$ , superior temporal lobule;  $P_2$ , inferior temporal lobule or gyrus supra-marginalis;  $P_2'$ , gyrus angularis;  $ip$ , inter-parietal fissure;  $cm$ , calloso-marginal fissure;  $po$ ,  $po$ , parieto-occipital fissures;  $t_1$ , superior temporal fissure;  $o_1$ , first occipital convolution;  $o$ , transverse occipital sulcus.

*Arteries.*—The line (-----) marks the limits of the distribution of the anterior cerebral; the line (—) on the left side of the figure limits the distribution of the Sylvian artery; I, external and inferior frontal artery; II, anterior parietal artery; III, posterior parietal artery; IV, parieto-sphenoidal artery.

The line (—) on the right side of the figure limits the distribution of the posterior cerebral. (This figure and Figs. 16 and 17 are copied from M. Duret's work, which was published in the 'Archives de physiologie,' 1874).

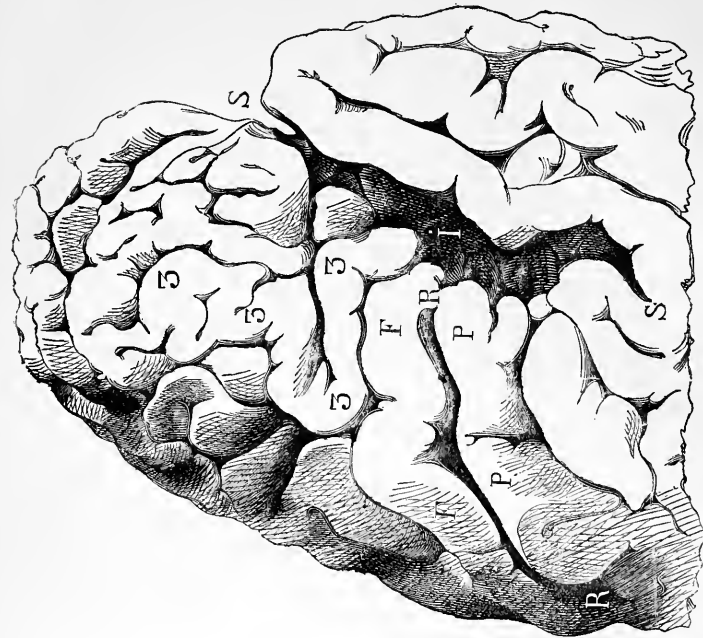


FIG. 13.—3, Broca's convolutions on the left side, atrophied in its posterior part.

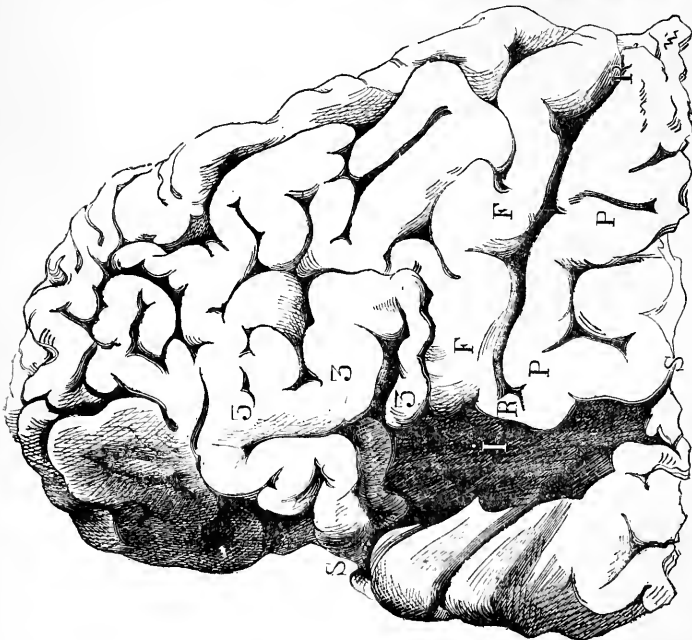

FIG. 14.—3, third convolution on the right side, of normal size.

F, F, ascending frontal convolution; R, R, fissure of Rolando; P, P, ascending parietal convolution; s, s, fissure of Sylvius; I, I, island of Reil.

whether the complete destruction of these two central convolutions has ever been realised; but in the following case the destruction affected the whole of the ascending parietal convolution which in the monkey is the seat, according to Ferrier, of the motor centre for the upper extremity and, in part, for the lower extremity. In this instance the convolution in question was replaced by a depressed patch of yellow softening. The ascending frontal convolution, although partially spared, was manifestly atrophied. Moreover, although the optic thalamus and corpus striatum were in this case quite unaffected—their integrity is mentioned in a very explicit manner in the observation—complete and permanent hemiplegia existed in the upper and lower limbs of the opposite side (Fig. 15). This result,

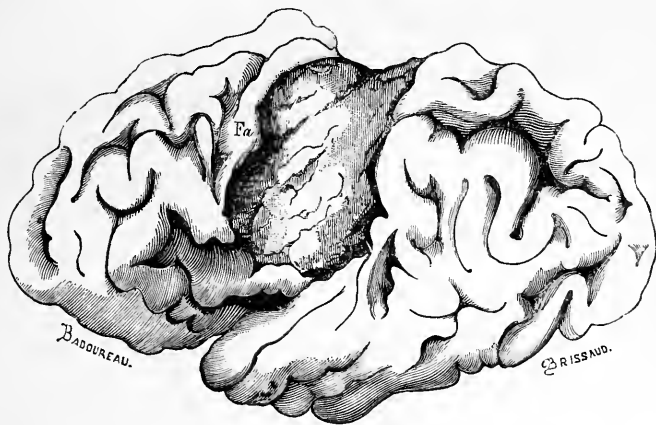


FIG. 15.—Fa, ascending frontal convolution. An extensive area of cortical softening has destroyed the ascending parietal convolution, a large portion of the ascending frontal convolution and the greater part of the island of Reil. The central masses were unaffected.

gentlemen, contrasts singularly with what has been recorded in two other observations relative to extensive lesions occupying other parts of the cerebral cortex. Thus, in a case of yellow softening limited to the lobus quadratus, there was no sign of corresponding paralysis. In another instance also there was a patch of yellow softening involving to a large extent the inferior aspect of the sphenoidal lobe which, as you are aware, is sup-

plied by the posterior cerebral artery. In this case, again, not the least trace of hemiplegia existed during life.

These examples, which I could easily multiply, will be sufficient, I think, to convince you that some day it will be possible in man, and very probably in a not very distant future, to arrive at a decided judgment, based on incontestable evidence, with

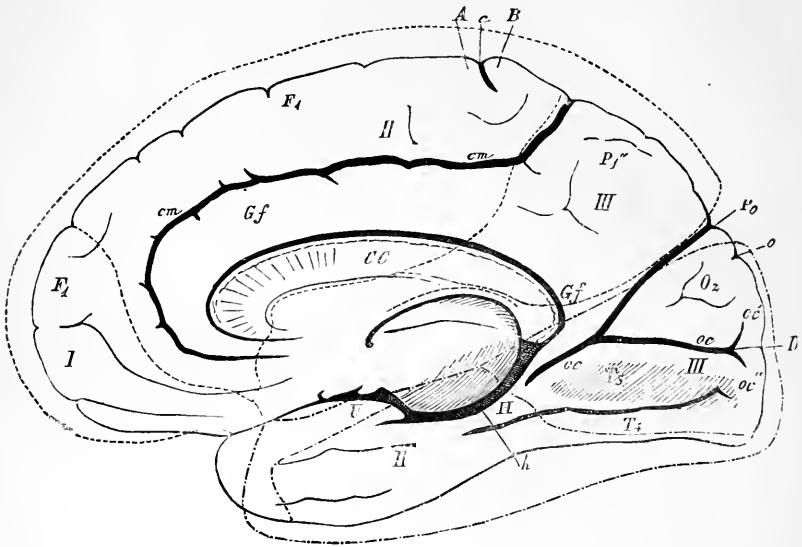


FIG. 16.—Vascular arææ of the internal surface of the cerebrum.

c c, section of the corpus callosum; G f, gyrus fornicatus; H, gyrus hippocampi; h, sulcus hippocampi; U, uncinæ gyrus; cm, calloso-marginal fissure; F<sub>1</sub>, median aspect of the first frontal convolution; c, end of sulcus centralis (fissure of Rolando); A, anterior central (ascending frontal) convolution; B, posterior central (ascending parietal) convolution; P<sub>1</sub>'', præcuneus (*avant-coin*, *Vorzwinkel*); o z, cuneus (*coin*, *Zwikel*); P o, parieto-occipital fissure; o, transverse occipital sulcus; o c, calcarine fissure; o c', its superior branch; o c'', its inferior branch; D, gyrus descendens; T<sub>1</sub>, lateral occipito-temporal convolution (fusiform lobule); T<sub>2</sub>, middle occipito-temporal convolution (lingual lobule).

*Arteries.*—The regions marked off by the line (-----) represent the area of distribution of the anterior cerebral artery. I, anterior and internal frontal arteries; II, middle and internal frontal arteries; III, posterior and internal frontal arteries. The regions marked off by the line (—) represent the area of distribution of the posterior cerebral artery; II, posterior temporal artery; III, occipital artery.



reference to the doctrine of localisation, at least so far as the superficial parts of the cerebrum are concerned.

After the details into which I have entered on the subject of

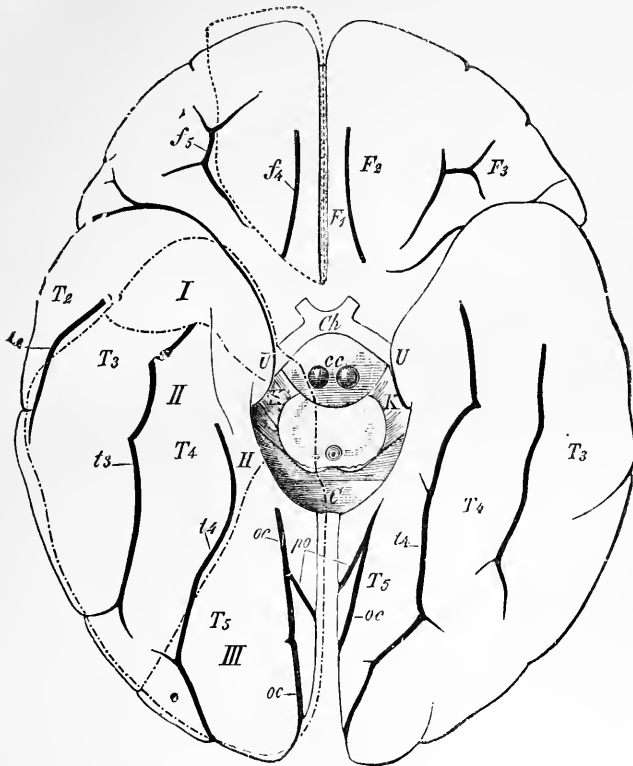


FIG. 17.—Vascular areas of the inferior surface of the cerebrum. F<sub>1</sub>, gyrus rectus (straight gyrus); F<sub>2</sub>, middle frontal convolution; F<sub>3</sub>, inferior frontal convolution; f<sub>4</sub>, olfactory sulcus; f<sub>5</sub>, orbital sulcus; T<sub>2</sub>, second or middle temporal convolution; T<sub>3</sub>, third or inferior temporal convolution; T<sub>4</sub>, middle occipito-temporal convolution (lingual lobule); t<sub>4</sub>, inferior occipito-temporal sulcus; t<sub>3</sub>, inferior temporal fissure; t<sub>5</sub>, middle temporal fissure; po, parieto-occipital fissure; oc, calcarine fissure; II, gyrus hippocampi; U, uncinata gyrus; Ch, chiasma; cc, corpora albicantia; KK, crura cerebri; G, knee of corpus callosum.

*Arteries.*—The line (-----) limits the distribution of the anterior cerebral (inferior and internal frontal arteries). The line (————) shows the distribution of the posterior cerebral. I, anterior temporal artery; II, posterior temporal artery; III, occipital artery.

the Sylvian artery, I think it advisable to give but a brief account of the subdivision into secondary departments of the large cortical vascular area of the anterior and posterior cerebrals.

### III.

The *anterior cerebral* is much less frequently the seat of grave alterations than the Sylvian. This peculiarity is, doubtless, partly referable to its direction in relation to the internal carotid (Figs. 12, 16, and 17).

This artery furnishes three principal branches: the first supplies the two inferior frontal convolutions; the second, of greater importance, is distributed less frequently than the Sylvian, but much more commonly than the posterior cerebral, to the convolution of the corpus callosum (Fig. 16), to the corpus callosum itself (c c), to the first frontal convolution F (inner and outer surfaces), to the paracentral lobule and, over the convex surface of the frontal lobe, to the first and second frontal convolutions (Fig. 17), and lastly to the upper extremity of the ascending frontal convolution. The third branch of the anterior cerebral proceeds to the lobus quadratus, which may be affected independently, an instance of which I have just given.

### IV.

The *posterior cerebral* (Figs. 12, 16, and 17) is the frequent seat of alterations from embolism or thrombosis. Moreover, ischæmic softening of the posterior lobes is much more common than that of the anterior lobes. The area of this vessel is divided into three secondary departments corresponding to three arteries of the second order: the first of these arteries proceeds to the convolution of the crochet; the second to the lower part of the sphenoidal lobe, including the inferior sphenoidal convolution and the fusiform lobule; the third goes to the lingual lobule, to the cuneus, and to the occipital lobe proper.

## LECTURE VII.

### CIRCULATION IN THE CENTRAL MASSES (GREY NUCLEI AND INTERNAL CAPSULE).

**SUMMARY.**—*Arterial circulation in the central grey nuclei. Intra-encephalic hæmorrhage. Anatomico-pathological differences between the peripheral and central parts of the cerebrum. Comparative rarity of cerebral hæmorrhage in the peripheral and its frequency in the central parts.*

*Origin of the arteries of the central system. Characteristics of the terminal arteries. Independence of the cortical and central arterial systems. Analogy between the arteries of the pons, medulla, and central ganglia. Their mode of origin explains the predominance of arterial ruptures in these parts. The branches forming this system arise from the anterior and posterior cerebrals and from the Sylvian.*

*Arrangement of the grey nuclei: their form and connections. Description of the internal capsule: its constituent parts (direct and indirect peduncular fibres; radiating fibres).*

GENTLEMEN,—At our last meeting I concluded the description of the medical anatomy of the cortical arterial system. To-day, I propose to call your attention to the arterial circulation of the *central grey nuclei*. Under this term, as you are aware, we include the optic thalami, the corpora striata, and what might be called their annexes.

This, gentlemen, is a study which must engage our earnest attention; for the phenomena which take place in these nuclei, in consequence of vascular lesions, are by no means inferior as regards their clinical importance to those supervening in the superficial parts of the hemisphere, as a result of alterations in the cortical arterial system. In the central regions of the cerebrum, which we are about to consider, we shall again

notice the ischæmic changes pointed out in connection with the superficial parts of the encephalon; but, in addition, we shall recognise the frequent occurrence of lesions which are, on the contrary, but rarely seen at the periphery. I refer to ordinary intra-encephalic hæmorrhage, which is one of the commonest anatomical causes of apoplexy.

In this respect there is a very interesting antithesis to be observed between the peripheral and central parts of the cerebrum. In the former, intra-encephalic hæmorrhage is comparatively rare, whilst in the latter it is common. This is a fact to which the old statistics of Andral and Durand-Fardel bear striking testimony, and which recent statistics only tend to confirm. Thus, out of 119 cases collected by Andral and Durand-Fardel, the primary seat of the hæmorrhage was the optic thalamus and corpus striatum in 102 instances, the lesion taking origin only seventeen times either in the centre of the anterior or posterior lobes or at the periphery of the encephalon. On the contrary, ischæmic softening of the cerebrum, as Durand-Fardel justly remarks, predominates in the peripheral parts. The observations I have made at Salpêtrière fully corroborate these facts. We shall have to consider, presently, some of the conditions calculated to explain this remarkable opposition; for the moment it will be sufficient to bear in mind the following point, viz. that just as the attention we have bestowed on the *cortical arterial system* was a necessary introduction to the chapter dealing with ischæmic softening of the encephalon, so the details, into which we are about to enter to-day, are the essential preliminaries to the not less interesting subject of intra-encephalic hæmorrhage.

## I.

You have not forgotten, gentlemen, that the arterioles which constitute the central system arise from each of the three large arterial trunks of the cerebrum, in the immediate vicinity of their origin in the circle of Willis. In general, the arteries which form this system are, as regards their calibre, vessels of some importance. Indeed, according to M. Duret, the arterioles of the corpus striatum vary in diameter from half a millimètre

to a millimètre and a half. Their mode of origin reminds one of those young shoots which we see in the forests, sprouting forth at the base of the trees. This simile, which I borrow from Dr. Heubner, is, in addition to its picturesque character, fairly accurate; but we must not pursue it too far, for the arteries of the central system, at their origin, are directed perpendicularly to the main trunk. This perpendicular direction recalls to our minds what we have seen in regard to the nutrient arteries of the cerebral cortex. Moreover, we must not forget that there is a difference between the cortical nutrient vessels and the arteries of the central grey nuclei; the former, indeed, are properly speaking capillaries—at least, according to M. Robin's definition—whilst the latter, on the other hand, are vessels of considerable calibre.

Another characteristic of the arteries of the central nuclei is that they are pre-eminently terminal arteries, in Cohnheim's acceptation of this term. Although a discussion might be raised, as we have seen, on the subject of the autonomy of the cortical vascular area, this is not the case as regards the central arteries. The latter are quite independent one of another; on this point authors are perfectly agreed. Accordingly, as Heubner remarks, we may, by means of Pravaz's syringe, in which the point of the trocar is blunted, inject one by one each of the small vessels supplying the various parts of the corpus striatum or optic thalamus.

In spite of all possible precautions, we can never succeed in injecting the entire optic thalamus or corpus striatum, but only small departments of each of these bodies. If the injection be driven too strongly, ruptures are produced, but the vascular area does not, on that account, extend beyond the limits assigned to it.

M. Duret's numerous experiments lead to the same conclusion. It is necessary to add that, under no circumstances *can the injection be made to enter the domain of the cortical arteries* through the central vessels. I must remind you that the converse is equally true, viz. that an injection, driven into any artery whatever of the cortical system, does not spread to the domain of the central arteries.

It will not perhaps be devoid of interest to notice the analogies which exist, as regards the mode of origin of the nutrient

arteries, between the basilar parts of the encephalon, the pons, and even the medulla oblongata. In the case of the pons the resemblance is striking. The median arteries spring at a right angle from the voluminous stem of the basilar artery, and extend parallel one to another, but without anastomosing, to the posterior parts, thus exhibiting the type of terminal arteries.

In the medulla, the same arrangement exists, but it undergoes a special modification. The median arteries of the medulla do not arise directly from the main trunks of the vertebrals, but take their origin from the spinal arteries.

It is possible then, if I mistake not, to find in this mode of origin and distribution of the bulbar arteries and those of the central ganglia, a mechanical explanation for the predominance of arterial ruptures in these parts. Recollect that at the surface of the cerebrum, where, as I have told you, hæmorrhages are comparatively rare, the arteries only enter the cerebral substance after making a long course in the pia mater and after being transformed into very slender vessels which, strictly speaking, are capillaries; recollect, I repeat, these peculiarities, and you will much more readily understand the differences which I am about to point out to you with respect to the central arteries.

(1) The distance from the heart to the large basal ganglia is very short. The arteries supplying these ganglia arise directly from the arteries of the circle of Willis, that is to say, from arteries of the third order, proceeding from the heart. This circumstance evidently predisposes to arterial ruptures. It is, indeed, compensated to a certain extent by the mode of origin of the vessels, which takes place at a right angle, and also by the great difference in their calibre.

(2) In comparison with the cortical arteries, the central vessels are voluminous; I allude especially to the arteries of the corpus striatum, which have a diameter of half a millimètre to a millimètre and a half.

(3) I must add that the absence of anastomoses is another unfavorable condition, for in case of increased pressure in a vessel, relief is impossible in consequence of the well-established absence of collateral branches. The three large arterial trunks of the cerebrum, as I mentioned at the outset, all take part in the vascularisation of the central regions, but their share is

very unequal. The anterior cerebral, for instance, sends only a few vessels to the head of the corpus striatum, and, moreover, the existence of these branches is not constant. The posterior cerebral has a much more extensive and important domain. It supplies the optic thalami to a large extent, the superior layers of the crura cerebri, and the corpora quadrigemina. But it is the same here as in the case of the cortical arteries, the Sylvian arteries incontestably play the preponderant part.

These vessels supply all the branches proceeding to the caudate nucleus (with the exception of the small area vascularised by the inconstant twigs of the anterior cerebral), and to the various segments of the lenticular nucleus.

Consequently, as a type of our description we shall take the branches of the Sylvian artery, Afterwards, it will be easy to complete the account of the central nutrient system by a few words relating to those branches of this system, which arise from the anterior and posterior cerebrals.

## II.

But, before entering into a detailed description of these vessels, it is absolutely necessary, gentlemen, to consider more closely than we have hitherto done the parts to which they are distributed.

In the preceding account, we limited ourselves to naming these parts, and indicating, briefly, the most general features of their configuration.

That rapid survey has now become inadequate for our purpose, so we must enter into such details as may be necessary to acquire a more profound anatomical knowledge. The parts in question—and I need not insist on this point—are extremely interesting from the standpoint of the theory of cerebral localisation; they are the optic thalamus, the caudate and lenticular nuclei, and lastly, the internal capsule. Such are the various parts, the union of which forms what might be called the *central*, in opposition to the *cortical system*.

Remember that the crus cerebri, which is rounded as it approaches the optic thalamus, becomes flattened after it has passed it from within outwards, and at the same time widens

out like a fan from before backwards. Upon this fan, to continue the comparison, the nuclei of grey matter are arranged as follows: internally and posteriorly is the optic thalamus; more internally, but above and in front, is the caudate nucleus; outside the fan, below the optic thalamus and caudate nucleus, is situated the lenticular nucleus, which extends anteriorly nearly as far as the head of the corpus striatum, and posteriorly as far, or nearly so, as the hinder extremity of the optic thalamus.

I shall only make a passing allusion to the form and principal connections of the grey nuclei which I have just enumerated:

(1) The optic thalamus has the appearance of a flattened ovoid. Of its two surfaces, the upper is turned towards the lateral ventricle, and the lower, which is also internal, towards the third ventricle. It is difficult to separate it by dissection, in consequence of its very numerous and intimate connections with contiguous parts.

(2) The caudate nucleus has the form of a comma or pyramid, the large extremity of which is directed anteriorly and internally, and the tail superiorly and externally. The upper surface forms a prominence in the ventricle; the imaginary inner surface is, in great part, adapted to the superior extremity of the internal capsule. This nucleus is very readily detached by dissection; in order to isolate it, it is necessary, however, to rupture the numerous fibres which it receives from the internal capsule.

(3) The lenticular nucleus, although entirely concealed at its periphery, may be isolated, as we shall see, from the neighbouring parts without much trouble. Its general configuration is that of an ovoid with an anterior and a posterior extremity. Two parts may be distinguished in its composition. (a) The anterior third, which is rounded and formed by a uniform mass of grey substance, blends at its most anterior extremity with the intra-ventricular nucleus of the corpus striatum; (b) the second portion, which corresponds to the posterior two thirds of the lenticular nucleus, is flattened from above downwards, so as to present an angle turned inwards towards the internal capsule. The internal and superior surface is intimately connected to the internal capsule, the inferior being parallel to the base of the cerebrum. The external surface is in relation with the external capsule, and



through it with the claustrum and island of Reil. The latter conceals it indirectly in its whole extent.

An interesting preparation may be made by carefully removing in succession the grey matter of the convolutions of the island of Reil, the claustrum, and the external capsule ; we then come down upon the external surface of the lenticular nucleus. The separation between the external capsule and the outer surface of the lenticular nucleus may be effected, in hardened specimens, with the greatest facility. As a matter of fact, there are no medullary fibres—and you will see that there are no vessels—connecting the external capsule to the third segment of the lenticular nucleus. We may say, in accordance with the relations just pointed out, that the central grey masses (optic thalamus, caudate and lenticular nuclei) are, as M. Foville has remarked, appended like cotyledons to the internal capsule which is the prolongation of the *crura cerebri*.

Towards the ventricles, the optic thalamus and caudate nucleus are free, the lenticular nucleus also being unattached, at least virtually, in the direction of the island of Reil.

These nuclei of grey matter, therefore, form a system distinct from the other parts of the cerebrum, both by their connections and by their mode of vascularisation. You will readily understand the relations of the central parts by the examination of vertical sections. For the moment, I shall not insist on the structural details respecting the different nuclei ; to this I shall return when a suitable opportunity presents itself. But it is, in my opinion, indispensable at the present time to enter somewhat into detail with regard to the constitution of the internal capsule.

The internal capsule is, at least in part, the prolongation, not of all the *crus cerebri*, but only of the foot, *crusta*, or lower layer. The tegmentum or upper layer, which is separated from the foot by the *locus niger*, enters into special connection with the *corpora quadrigemina* and optic thalamus, but takes no direct share in the formation of the internal capsule. It was formerly thought that the internal capsule was a complete and immediate emanation from the foot of the *corona radiata*. This error was removed by Luys and Kölliker.

These authors, indeed, have shown that the fibres proceeding

from the foot are arrested in their course in order to enter the various nuclei. Nevertheless, I believe that they have gone too far in asserting that the internal capsule is entirely formed : (1) from fibres of the corona radiata ending in the ganglia ; (2) from fibres which, proceeding from the ganglia, spread out into the corona radiata.

Relying upon very minute anatomical observations, Meynert, Henle, and Broadbent have expressed the opinion that there exists a third order of fibres, which are directly continuous, on the one hand, with the corona radiata, and hence with the cortex, and, on the other hand, with the foot of the crus.

The reality of the existence of these fasciculi is based, as we shall see, on a considerable number of pathological proofs. I must mention, among others, some cases of descending degeneration observed by M. Vulpian and by myself. In the instances to which I allude, yellow softening had destroyed a large portion of the median convolutions, without concomitant alteration of the corpus striatum, and had given rise to a descending degeneration which could be followed through the pons as far as the lowest regions of the spinal cord. We are indebted to Gudden for a series of experiments which I shall have to quote at a later stage, the results of which lead to the same conclusion.

Henle<sup>1</sup> perhaps goes too far when he writes in his work on the 'Nervous System' that the internal capsule is especially composed of fibres proceeding directly from the foot.

Still, there are numerous and important facts of a pathological and experimental nature which might be invoked in favour of these fibres. To this subject we shall have an opportunity of returning. These facts have even justified us in asserting—the proof we shall see subsequently—that among these direct fibres, some (anterior) are centrifugal and in relation to the movements of the extremities, whilst others (posterior) are connected with the transmission of sensitive impressions (Fig 18).

To sum up, the internal capsule, according to modern researches is constituted as follows :<sup>2</sup>

<sup>1</sup> Henle, 'Nervenlehre,' p. 261.

<sup>2</sup> Huguenin, 'Allg. Patholog. der Krankh. des Nervensystems.' Zurich, 1873, p. 94, fig. 70 ; p. 85, fig. 63 ; p. 119, fig. 82 ; p. 127.

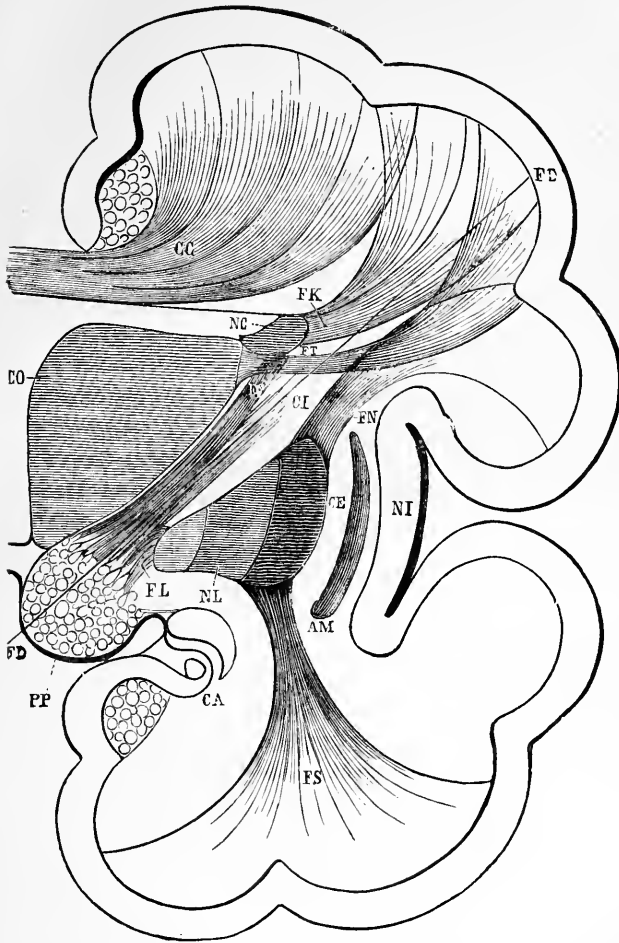


FIG. 18.—(Diagram after Huguenin) NC, caudate nucleus; CO, optic thalamus; NL, lenticular nucleus with its three segments; AM, claustrum; CE, external capsule; CI, internal capsule; PP, foot of the crus cerebri; CA, cornu ammonis; NI, island of Reil; FL, peduncular fibres proceeding to the lenticular nucleus; FC, peduncular fibres going to the caudate nucleus; FS, fibres of the lenticular nucleus passing to the sphenoidal lobe; FN, fibres of the lenticular nucleus going to the periphery; FK, fibres of the caudate nucleus going to the periphery; FT, fibres of the optic thalamus going to the periphery; FD, direct fibres.

(1.) By the *direct peduncular fibres* which pass through the capsule without being arrested in the ganglia.

(2.) By the *indirect peduncular fibres*. Of these, some proceed to the corpora striata, which they penetrated from the inferior surface; others enter the first segments of the lenticular nuclei, where they are very numerous, but become less and less so in the second and third segments. To this unequal distribution is due the difference in colour of the three segments composing the lenticular nucleus.

We are not concerned with the peduncular fibres proceeding from the foot of the corona radiata to the optic thalamus, since the latter does not receive from the crus cerebri any fibres except those of the tegmentum.

In addition to the fibres proceeding from the foot of the crus to the central grey nuclei, there are others, which, taking origin in the grey nuclei, contribute to the formation of the corona radiata and direct their course towards the cortical layer.

These latter bear the name of *radiating fibres* (*Stabkranz-bündel*). It is necessary to distinguish:—(1) The radiating fibres of the corpora striata; (2) those of the optic thalamus; (3) those arising from the lenticular nucleus, which proceed mainly from the upper border of the second and third segments (Fig. 19).

It follows from this account that four kinds of fibres enter into the composition of the corona radiata and connect the internal capsule to the cortex.

These are:—(1) the radiating fibres of the optic thalamus; (2) those of the corpus striatum; (3) those of the lenticular nucleus; these various fibres connect the central grey nuclei to the cortex; (4) the direct fibres which proceed from the foot of the crus to the cortex without being arrested in the central grey nuclei.

In thin sections suitably hardened and examined under a low magnifying power, it is possible to distinguish these various modes of arrangement in the internal capsule itself and even in the foot of the corona radiata.

This investigation, it is true, is not free from difficulty, but, at a somewhat higher level, all the fibres decussate in the most diverse directions, either with one another or with the com-

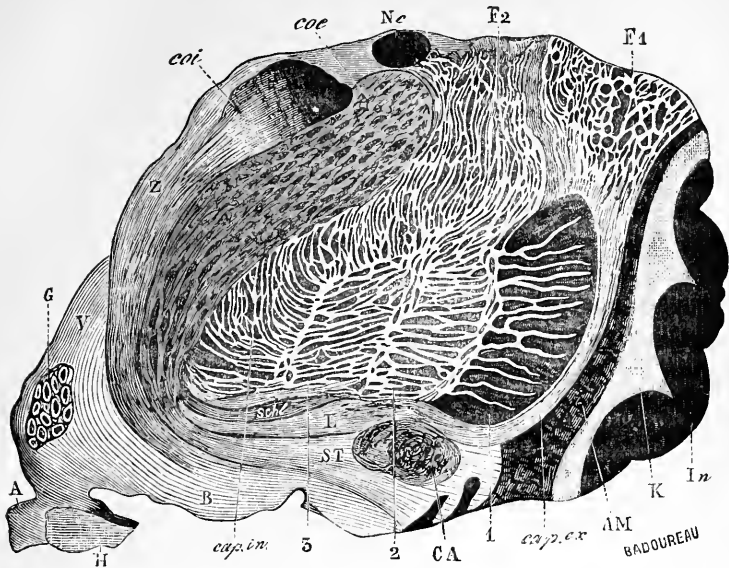


FIG. 19.—(After Meynert) 1, 2, 3, lenticular nucleus; B, basilar portion of the caudate nucleus; *m*, island of Reil; *k*, white matter lying between the island of Reil and claustrum; A M, claustrum; *Cap. ex.*, external capsule; *Cap. in.*, internal capsule; CA, anterior commissure; H, optic nerve and ganglion; A, commissure in the central cavity of the mass of grey matter; G, descending pillar of the fornix; *v*, grey matter of the third ventricle; *coi* and *coe*, internal and external parts of the optic thalamus; *Nc*, caudate nucleus; *F*<sub>1</sub>, fibres proceeding from the tapetum; *F*<sub>2</sub>, fibres proceeding from the two inner segments of the lenticular nucleus; *st*, *L*, *Schl.* and *Z*, the four layers of unnamed substance.

missural fibres, in such a way as to give origin to an inextricable network, which is called the central white matter.

We shall presently refer in detail to the interest which is attached to the arrangement we have just considered.

## LECTURES VIII AND IX.

### CENTRAL ARTERIES. LESIONS LIMITED TO THE GREY NUCLEI.

**SUMMARY.**—*Origin of the arterial system of the central ganglionic masses. Unequal share of the large cerebral arteries in the constitution of this system. Description of the arteries to the corpus striatum: (a) internal; (b) external (to lenticular nucleus and optic thalamus). Terminal arteries. Effects of obstruction of the central arteries proceeding from the Sylvian. Softening of the corpus striatum and optic thalamus. Regional diagnosis of intra-encephalic hæmorrhage.*

*Lesions limited to the grey nuclei without implication of the internal capsule. Central and cortical cerebral hemiplegia. Lesions of the internal capsule. Symptoms vary according to the seat of the lesion in the internal capsule.*

*Additional anatomical considerations. Direct peduncular fibres proceeding to the cortical substance of the occipital lobe. Their importance as regards sensibility exemplified: (1) by lesions of the posterior lenticulo-optic region of the internal capsule (cerebral hemianæsthesia); (2) by experiment.*

#### I.

GENTLEMEN,—You have not forgotten that the three large cerebral arteries take part in the formation of the *arterial system of the central ganglionic masses*, but that they participate in it to an unequal extent.

(a) Thus, the predominant share belongs to the Sylvian artery, which supplies: (1) the greater part of the caudate nucleus; (2) all the lenticular nucleus; (3) a portion of the optic thalamus; (4) the whole extent of the internal capsule.

(b) The anterior cerebral, on the other hand, has a very unassuming position in this system. It furnishes twigs to the head of the caudate nucleus only, and even this distribution is not constant.

(c) As to the posterior cerebral, its sphere is more important and somewhat peculiar.

This artery, the distribution of which is very extensive, seeing that it sends branches to the choroid plexus, to the walls of the ventricles, &c., supplies, as far as the central masses are concerned, the following regions:—(1) the posterior and external part of the optic thalamus; (2) the corpora quadrigemina; (3) the upper layer of the crus cerebri.

The figures I place before you (Figs. 20 and 21), on which the vascular areas are marked off by dotted lines, will enable you to comprehend all these details more readily.

The description of the *striate arteries*, only, necessitates some particulars. Afterwards I shall be in a position to give you an abstract account of the opinions, with which you must be conversant, relative to the central arteries arising from the anterior and posterior cerebrals.

The striate arteries, which spring from the upper border of the Sylvian, enter the orifices of the anterior perforated space, where they soon disappear from view.

But a very simple preparation enables us to follow them in the first part of their intra-cerebral course. I invite your attention to the arrangement, which I am about to describe, because it is indispensable to the knowledge of important facts bearing on the theory of common cerebral hæmorrhage. This preparation consists in removing, successively, the grey matter of the island of Reil, the subjacent white substance, the claustrum, and lastly, the external capsule. In this manner, the external surface of the lenticular nucleus is exposed in its whole extent. If the preparation be made carefully, in a well-injected brain—and the dissection is easily performed, since the lenticular nucleus, at least in its frontal part, is, so to speak, naturally detached from the external capsule—we can follow the principal striate arteries in the first part of their course. By means of this preparation they are seen to be arranged like a fan on the surface of the grey nucleus. But at a comparatively short distance from their origin they pass downwards

into the substance of the third segment, where they are concealed from view.

We must now, gentlemen, follow the further distribution of the striate arteries by means of transverse sections.

The first section, made behind the chiasma (Fig. 20), merely shows us the caudate and lenticular nuclei, the optic thalamus lying more posterior. On the cut surface we recognise in their deeper tract, the arteries we have just mentioned.

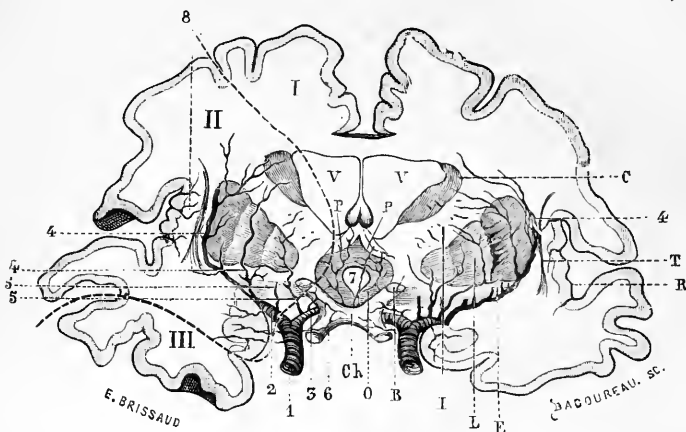


FIG. 20.—(From Duret) Transverse section of the cerebral hemispheres made one centimètre behind the optic chiasma. Arteries of the corpus striatum. *ch*, optic chiasma; *B*, section of optic tract; *L*, lenticular nucleus; *I*, internal capsule or foot of Reil's corona radiata; *c*, caudate or intra-ventricular nucleus of the corpus striatum; *E*, external capsule; *T*, nucleus tæniæformis or claustrum; *R*, convolutions of the island of Reil; *v, v*, section of the lateral ventricles; *P, P*, pillars of the fornix; *o*, grey substance of third ventricle continuous posteriorly with the optic thalamus. *Vascular areae*.—*I*, anterior cerebral artery; *II*, Sylvian artery; *III*, posterior cerebral artery. *1*, internal carotid artery; *2*, Sylvian artery; *3*, anterior cerebral artery; *4, 4*, external arteries of the corpus striatum (lenticulo-striate arteries); *5, 5*, internal arteries of the corpus striatum (lenticular arteries). The opto-striate arteries are not represented.

Moreover, we find on the external surface of the lenticular nucleus other arterioles of smaller size, which might be termed *internal*. After they are detached from the trunk of the Sylvian, they ascend nearly vertically to the first two segments



of the lenticular nucleus and to the contiguous parts of the internal capsule. Greater interest is attached to the external striate arteries, which, in the first part of their course, creep along the outer surface of the lenticular nucleus. They may be divided into two groups, the first, which is anterior, is composed of the *lenticulo-striate arteries*; the second is posterior, the arteries constituting it being the *lenticulo-optic*.

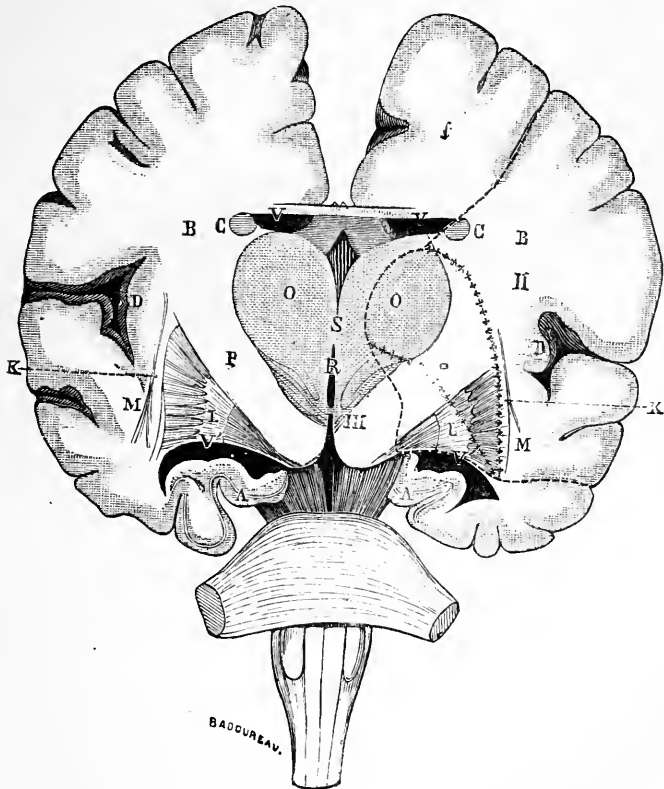


FIG. 21.—Vertical and transverse section of the brain made behind the corpora albicantia and in front of the crura cerebri. s, grey commissure; o, o, optic thalami; v, lateral ventricle; v', its posterior or sphenoidal cornu; p, p, internal capsule or foot of the peduncular expansion; l, l, lenticular nucleus; k, external capsule; m, m, claustrum; r, third ventricle; a, cornu ammonis.

*Vascular areas.*—I, anterior cerebral artery; II, Sylvian artery; III, posterior cerebral artery.

One artery in the anterior group is of special importance from its size and from the pre-eminent part which it plays in intra-encephalic hæmorrhage. We should in a manner be justified in styling it the *artery of cerebral hæmorrhage.*]

After penetrating the third segment, it gains the substance of the caudate nucleus by crossing the upper part of the internal capsule.

It then continues its direction from behind forwards, and extends as far as the most anterior part of this nucleus.

The distribution of this striate artery, as in the case of the other lenticulo-striate vessels, should be examined on sections made in front of the one which has hitherto been employed in our demonstration.

The lenticulo-optic arteries are arranged on the same plan; but, after crossing the most posterior part of the internal capsule, they approach the anterior and exterior portion of the optic thalamus, to which they are distributed.

I must remind you, gentlemen, that the vessels in question are terminal arteries, and that if injections be forced too strongly, there result small extravasations at different points in their course, thus simulating, both in situation and appearance, the hæmorrhagic foci produced under pathological conditions.

We have no special remark to make respecting the trunk or branches of the anterior cerebral, except that the latter have no constant existence. They may, however, give rise to hæmorrhages of very limited extent, but of unquestionable danger from the fact that the extravasation frequently bursts into the ventricles.

As to the posterior cerebral, in some respects it calls for more careful attention. Nevertheless, I shall only consider now the arteries which it sends to the optic thalamus. These vessels are of two kinds:—(1) The *internal posterior optic artery*, a branch of the posterior cerebral near its origin from the trunk of the basilar, supplies the inner aspect of the optic thalamus. In its subsequent course, it sometimes occasions hæmorrhages which, although of small size, are serious, because they are often followed by extravasation into the ventricles. (2) The *external posterior optic artery* arises from the posterior cerebral after it has turned round the *crus cerebri*, within which it

ascends obliquely before entering the posterior portion of the optic thalamus.

Ruptures of this vessel give rise to hæmorrhages which frequently involve the substance of the crus cerebri. It is worthy of your careful attention, for, as we shall see at a later stage, lesions in its area produce a train of symptoms which are quite characteristic.

## II.

In the course of our inquiries, we have just acquired facts of the highest degree of interest as regards the theory of pathological cerebral localisations. These facts we are now about to examine more in detail, commencing with those which bear on the central ganglionic masses.

A.—(a) The entire system of central arteries springing from the Sylvian may be obstructed in consequence of thrombosis or embolism of the principal arterial trunk. Softening then attacks the mass of grey nuclei in its entirety, or nearly so, the regions corresponding to the distribution of the anterior cerebral and posterior optic arteries being alone unaffected.

This is a very comprehensive localisation, and one usually of extreme gravity. Clinically, it embraces, if we may so express ourselves, the whole pathology of the ganglionic centres.

The symptom which corresponds to complete softening of the *opto-striate bodies*, as the association of the central masses is sometimes designated, is no other than common cerebral hemiplegia, together with cerebral hemianæsthesia.

(b)—We can, however, decompose this complex whole by analysis. We must not presume, indeed, that we are in a position at the present time to diagnose, from special symptoms, destruction of the optic thalamus, of the caudate or lenticular nucleus, and *à fortiori* of its various segments.

But it is possible, nevertheless, as a result of the mode of arterial distribution which we have described, that there may supervene an anatomical localisation of such a nature as to be capable of revealing its presence by characteristic symptoms, and admitting consequently of a regional diagnosis.

This condition is realised when softening attacks the entire

or nearly the entire extent, either of the area supplied by the lenticulo-striate or of that supplied by the lenticulo-optic arteries. We shall see, indeed, that the symptoms in the two cases are different, indications of cerebral hemianæsthesia being present in the latter instance, but absent in the former.

B.—What has just been said with regard to ischæmic softening is applicable to intra-encephalic hæmorrhage, which, as you are aware, is a frequent and predominant accident in these regions. The striate arteries, indeed, are very liable to that special form of arterial sclerosis which induces miliary aneurysms. It is a common occurrence to extract from a recent hæmorrhagic lesion a striate or optic artery, the prolongations of which exhibit minute aneurysms.<sup>1</sup>

Most frequently, contrary to the generally accepted opinion, extravasation of blood in such a case, as M. Gendrin had long truly recognised,<sup>2</sup> takes place in the first instance not into the substance of the corpus striatum, but outside it and, more precisely, in contact with the external surface of the lenticular nucleus, between this surface and the external capsule, which becomes, as it were, detached.

In this manner, flattened-out focal lesions are produced, which in transverse sections have the appearance of straight, linear lacunæ, nearly vertical in direction and parallel to the grey nucleus of the claustrum (Fig. 22).

When the sanguineous effusion is abundant, the hæmorrhagic focus increases, especially in a transverse direction, and by reason of the greater resistance of the cranial walls towards the island of Reil, the central masses are, so to speak, enucleated and pushed back *en bloc* towards the ventricular cavity (Fig. 22).

The cases I have just mentioned are very common, but it may happen also that an extravasation proceeding from the extremities of the terminal arteries may take place in the very substance, either of the corpora striata or of the optic thalami.

Be that as it may, the only localisations of this kind accessible to clinical medicine are, in this case as well as in that of

<sup>1</sup> See Plate v, in the 'Archives de physiologie,' 1868.

<sup>2</sup> A. N. Gendrin, 'Traité philosophique de médecine pratique,' vol 1, 1838. See p. 443, Nos. 785, 796; p. 465, Nos. 808, 809, 810, and p. 478, No. 83c.

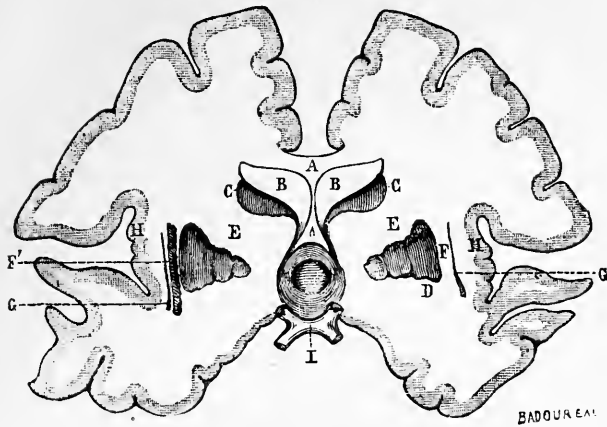


FIG. 22.—Extra-lenticular hæmorrhagic focus. (The section is made behind the chiasma) ; no hemianæsthesia.

A, corpus callosum ; B, B', lateral ventricles ; C, C', caudate nuclei ; D, D', lenticular nucleus ; E, E', anterior or lenticulo-striate region of internal capsule ; F, F', external capsule ; F', hæmorrhagic focus destroying the external capsule ; G, G', claustrum ; H, H', island of Reil ; I, optic chiasma.

softening, those which correspond to the invasion of the lenticulo-striate or lenticulo-optic area.

We must recollect that, so far as hæmorrhage is concerned, difficulties occur in the interpretation of symptoms, which do not exist, at least to the same degree, in softening. If not specially informed we should be liable to refer symptoms, which depend simply on the occurrence of proximity, to the effects of destruction of a part. I allude to the compression, however slight in extent it may be, which an effusion of blood in the early stages never fails to exert, within a certain distance, on surrounding parts. To this point, however, I shall return in a moment.

### III.

In short, the definitely established facts, which relate to the regional diagnosis of the various parts entering into the composition of the central ganglionic masses of the cerebrum, may be reduced to a very small number of propositions.

1. First of all, with respect to lesions limited to each of the central grey nuclei *without implication of the internal capsule*, we are not in a position at the present time, as I have told you, to recognise them by special clinical characters.

(a) Hence it is that during life it is impossible to distinguish a lesion limited to the lenticular nucleus from one confined to the caudate nucleus. Lesions of the optic thalamus—although on this point it is necessary perhaps to speak with some reserve—are, as a rule, clinically confounded with those affecting the two parts of the corpus striatum.

The symptoms which accompany these limited lesions of the central grey nuclei are those of common cerebral hemiplegia. This form of cerebral hemiplegia may be termed *central*, in order to distinguish it from the motor paralysis, which sometimes results from lesion of certain superficial regions and which, in contradistinction, I shall call *cortical cerebral hemiplegia*.

(b) In the majority of cases, paralysis dependent on lesions of the central grey nuclei affects motion only; nevertheless, under special circumstances, which will presently claim our attention, sensory disorders, manifesting their presence by the characteristic symptoms of cerebral hemianæsthesia, are occasionally superadded.

(c) Hemiplegia consequent on alterations thus circumscribed in the grey nuclei is, however, generally transitory, ill-defined, non-persistent, and hence comparatively mild. It is evident that in making this statement I discard all complications capable of seriously modifying the circumstances of the case such, for example, as the extravasation of a hæmorrhagic focus, even of small size, into the cavity of a ventricle. In such a case, symptoms of grave import, viz. early contracture and epileptiform convulsions, would almost necessarily supervene, and death more or less rapid is the all but inevitable consequence of a complication of this nature.

The comparative mildness of lesions limited to the substance of the grey nuclei is doubtless referable in part to the fact, that these nuclei are scarcely ever affected in their entirety. Thus, for example, the caudate nucleus—and this circumstance is explicable by the mode of distribution of the vessels supplying it—never undergoes complete destruction, at least separately,

that is to say, without participation of the internal capsule or of the other grey nuclei.

On the other hand, the transitory nature of the paralysis resulting from these partial lesions of the central ganglionic masses may indicate, as we shall see, a kind of functional substitution which, in case of necessity, may become established either between the various parts of the caudate nucleus, or between the caudate nucleus and the different segments of the lenticular nucleus.

2. Lesions of the internal capsule, on the contrary, when absolutely limited to this white tract, and in no way involving the substance of the grey nuclei, these lesions, I repeat, usually give rise to common cerebral hemiplegia in a well-marked and more or less persistent form.

Hence these lesions, even when of very inconsiderable size, and especially if situated very low down towards the *crus cerebri*, occasion motor paralysis, almost necessarily accompanied by slow contracture, which is a symptom of grave import, because it usually indicates that the paralysis will resist all therapeutic means.

3. This is a convenient opportunity, moreover, to point out an important distinction. As indeed we have already observed, symptoms present remarkable variations according to the situation occupied by the lesion in the internal capsule. If it involves any part of the *anterior two thirds of the capsule*, that region of this white tract, which separates the anterior extremity of the lenticular nucleus from the head of the caudate nucleus, and which appertains, as you are aware, to the domain of the lenticulo-striate artery, there will be motor paralysis only; no permanent disturbance of sensation will be associated with it.

If, on the contrary, the lesion invades the domain of the lenticulo-optic arteries and involves the *posterior third of the internal capsule*, the part which passes between the posterior extremity of the lenticular nucleus and the optic thalamus, *cerebral hemianæsthesia* will inevitably occur. Most frequently the lesion being situated, as it were, on mixed ground, the sensory disorders are accompanied by more or less pronounced hemiplegia. But it may happen that cerebral hemianæsthesia is the unique symptom, at least, as regards being a permanent

phenomenon, as, for example, in the case where the most distant and posterior parts of the internal capsule are alone affected in a definite manner (Fig. 23). In the preceding

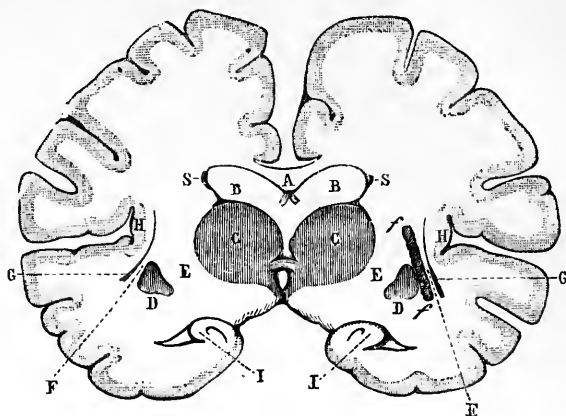


FIG. 23.—Extra-lenticular hæmorrhagic focus on a level with the posterior part of the optic thalamus; cerebral hemianæsthesia. A, corpus callosum and posterior pillars of the fornix; B, B, cavity of the lateral ventricles; C, C, optic thalami; D, D, lenticular nuclei; E, E, posterior or lenticulo-optic region of the internal capsule; F, external capsule; G, G, claustrum; H, H, island of Reil; I, I, cornu ammonis and posterior cornu of lateral ventricle; f, f, extra-lenticular hæmorrhagic focus involving the internal capsule; s, s, posterior extremity of the caudate nucleus.

account, I have intentionally made exclusive reference to the lesions of the internal capsule, which are purely *destructive* or, in other words, to those which, either by laceration, or by necrosis, occasion in this tract an irreparable loss of substance. It is necessary to draw a distinction between this case and that in which the internal capsule is involved not directly, but only, as it were, at a distance, in consequence of the proximity of a lesion limited to the adjacent grey nuclei. Thus, distension of one of these nuclei in a case of interstitial hæmorrhage might have the effect of causing compression of the nerve-fibres composing the internal capsule, and of suspending secondarily the functions of these fasciculi. But since, under such circumstances, the nerve-fibres of the capsule are merely compressed



and not destroyed, the paralytic phenomena resulting from this compression—except, indeed, in the case of tumour—will be merely transitory. The combination to which I have just called your attention is frequently met with in the clinical history of intra-cerebral hæmorrhage; it occasions, as you perceive, rather a complex condition of affairs, and one which may render the interpretation of symptoms difficult. Hence it is that, if not previously informed of these difficulties, we should be inclined—and the mistake has been often made—to ascribe symptoms which are simply the consequence of compression exerted on the internal capsule by an adjacent lesion, to destruction of one of the grey nuclei, optic thalami, or corpora striata.

Allow me—the subject is worth the trouble—to treat this matter somewhat in detail. Let us take the case of a hæmorrhagic focus recently formed in the usual position. Extravasation of blood will be found outside the lenticular nucleus in the imaginary space to which reference has several times already been made; in addition, the third segment of the lenticular nucleus, otherwise called the *putamen*, in most cases undergoes partial laceration. I have told you how, under such circumstances, the external wall of the lesion, which is composed of the convolutions of the island of Reil, the claustrum, and external capsule, resists the pressure of the extravasated blood, whilst the grey nuclei are displaced as a whole towards the ventricular cavities. It is clear that the elements of the internal capsule will necessarily be more or less strongly compressed in consequence of an alteration of this nature (Fig. 24).

As regards the symptoms which result, two conditions may present themselves. Sometimes the sanguineous effusion remains limited to the parts of the lenticular nucleus which correspond to the half or anterior two thirds of this body, that is to say, to the domain of the lenticulo-striate artery. Consequently the *anterior part of the internal capsule* alone will undergo direct compression. The effect produced will be simply motor hemiplegia of the opposite side of the body (Fig. 22). Sometimes the lesion, extending gradually from before backwards, affects the most posterior parts of the lenticular nucleus; pressure being then exerted on the *posterior part of the internal capsule*, symptoms of cerebral hemianæsthesia will be super-

added to those of hemiplegia. The two figures, 24 and 25, will at once enable you to recognise the precise seat, with the mode of formation and extension, of the various focal lesions dependent on hæmorrhage into the central parts (see also Fig. 23).

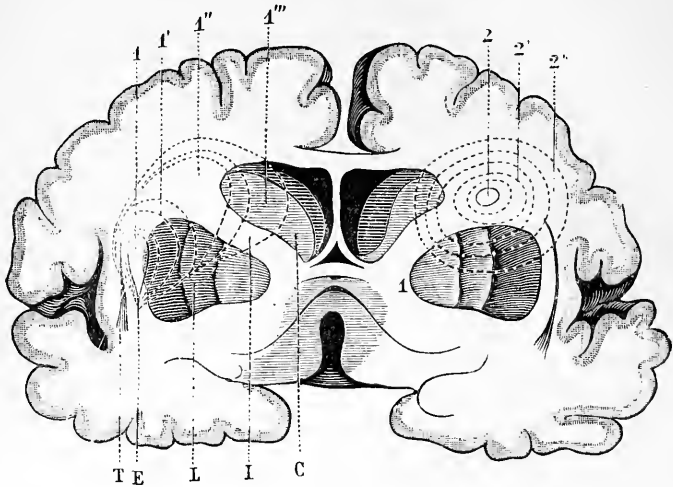


FIG. 24.—This figure shows the seat, the mode of formation, and extension of hæmorrhages corresponding to the anterior part of the internal capsule (hemiplegia). Rupture of the lenticulo-striate artery. c, caudate nucleus of the corpus striatum; i, internal capsule; e, external capsule; t, claustrum; 1, primary focus in the anterior part of the external capsule (hemiplegia); 1', 1'', 1''', progressive extension of the primary lesion (compression or destruction of the internal capsule); 2, primary focal lesion in the internal capsule (hemiplegia); 2', 2'', 2''', progressive extension of this lesion (destruction of the external capsule, displacement or destruction of the caudate nucleus).

Such are the facts. A word now concerning their explanation. When you have recognised during life the above-mentioned symptoms, viz. hemiplegia with hemianæsthesia, and the post-mortem existence of a lesion affecting the lenticular nucleus, is it justifiable to conclude from the concurrence of these two orders of facts that the lenticular nucleus controls at once the sensation and voluntary motion of the opposite side of the body?

This inference would be by no means permissible, for, if the patient survive, the effusion becomes reabsorbed and is represented only by an ochreous linear cicatrix. Notwithstanding the destruction of part of the lenticular nucleus, the hemi-

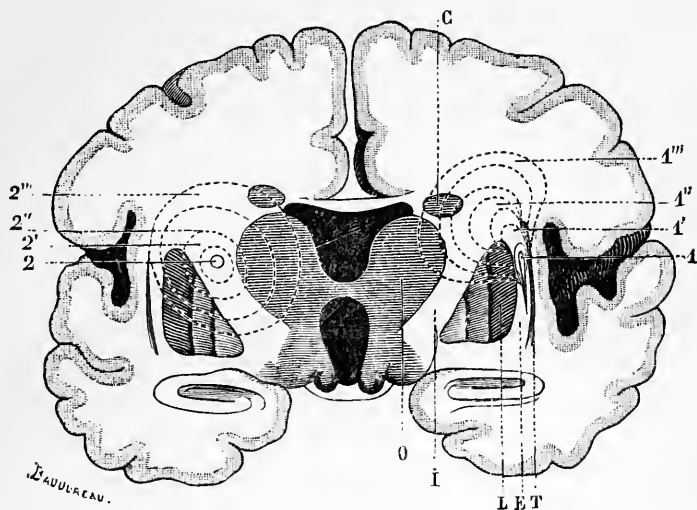


FIG. 25.—This figure shows the seat, the mode of formation, and extension of hæmorrhages corresponding to the posterior part of the internal capsule (hemianæsthesia). Rupture of the lenticulo-optic artery. *o*, optic thalamus; *i*, internal capsule; *L*, lenticular nucleus; *E*, external capsule; *T*, claustrum; *C*, caudate nucleus. *1*, primary focus in the posterior part of the external capsule (hemianæsthesia); *1'*, *1''*, *1'''*, progressive extension of the primary lesion (compression or destruction of the internal capsule); *2*, primary focal lesion in the internal capsule (hemianæsthesia); *2'*, *2''*, *2'''*, progressive extension of this lesion (destruction of the external capsule, displacement or destruction of the optic thalamus).

anæsthesia and even the motor paralysis would doubtless disappear, under the circumstances mentioned, without leaving any traces. What has just been said, gentlemen, with reference to the subject of hæmorrhage into the lenticular nucleus, is equally applicable to hæmorrhage taking place in the substance of the posterior part of the optic thalamus. These hæmorrhages originate in consequence of rupture of the antero-external or lenticulo-optic artery.

As a rule they manifest their presence clinically by more or less pronounced hemiplegia, and nearly always, in addition, by more or less complete hemianæsthesia, provided that the lesion attains sufficient dimensions. Must we draw the direct conclusion—as so many writers have asserted and even now repeat—that the optic thalamus is the seat of the *sensorium commune*? Unquestionably not. It would be easy to quote numerous cases in which lesion of the posterior region of the optic thalamus, caused by extravasation of blood, after producing disorders of common and special sensation in the early stages of the disease, that is to say, when indications of compression are present, ceases to be accompanied by these symptoms in the subsequent stages, or in other words when, after the reabsorption of the effusion, pressure on the posterior or lenticulo-optic region of the internal capsule no longer exists.

It would be superfluous, I think, to dwell on this matter at greater length. I believe I have given sufficient prominence to the fact that, in the regional diagnosis relative to the various parts of the central masses of the cerebrum, it is the participation or non-participation of the two regions of the internal capsule, which controls the situation.

#### IV.

The propositions I have just stated, gentlemen, exhibit a practical interest which none of you will overlook. But they have been hitherto laid before you, as it were, in the form of a postulate. It is now necessary to establish them by actual demonstration or, in other terms, to give you the proofs which serve as their basis in the domain of human pathology. We should endeavour also to discover the theory of the facts in question, that is to say, to investigate as far as possible their anatomical and physiological principles.

To accomplish this purpose we are compelled once more to return to the normal anatomy of the cerebrum, in order to complete in certain respects the facts previously acquired. It shall be one of our last incursions into this domain.

The predominant part appertaining to lesions of the two main departments of the internal capsule, in the pathology of the

central masses, has been fully demonstrated to you in the preceding account. Hence the justification of the detailed description into which we entered regarding the anatomical constitution of this large tract. We must now proceed further, and inquire into the anatomical peculiarities presented by the anterior or lenticulo-striate region of the capsule, in opposition to the posterior or lenticulo-optic region, lesion of which alone determines the appearance of cerebral hemianæsthesia. We shall begin with this last point.

A. Recent anatomical researches, conducted by Meynert, have furnished some important facts bearing on this subject. They were described in detail in a work by one of his pupils, Professor Huguenin, of Zurich.<sup>1</sup> They are based on dissections and, in part also, on the examination of thin and transparent hardened sections.

The brain being placed on its base, the lateral ventricles are opened so as to expose the upper aspect of the central masses which are contiguous to the various parts of the isthmus. Afterwards, by careful dissection, the following parts are removed in succession: (1) the tegmentum or upper layer of the crus, (2) the corpora quadrigemina, (3) the entire optic thalamus.

When this is done, we have under observation the lower layer of the crus (*pes, crusta*), and higher up, in the region of the internal capsule, the fasciculus of peduncular fibres proceeding to the caudate nucleus. The fibres likewise belonging to the internal capsule, which go to the lenticular nucleus, occupy a plane situated below and outside the preceding fasciculus.

On carefully examining the most internal and posterior part of the fan formed by the system of nerve-fibres, which have been exposed in the preparation, we distinguish a fasciculus, detached as it were from the rest, which, without penetrating the substance of the grey nuclei, makes a turn backwards just as it reaches the lower border of the lenticular nucleus (Fig. 26).

This is, as you perceive, a direct fasciculus, seeing that its component fibres penetrate the corona radiata without passing through the central grey masses; it is, moreover, as is evident from the description, a separate fasciculus. What is the destination of these nerve-fibres? In man, it is almost impos-

<sup>1</sup> 'Allgem. Path. der Krankh.,' &c., p. 119, fig. 82. Zurich, 1873.

sible to say, but in certain apes, according to Meynert, it is easy to follow their course into the white matter of the occipital lobe, immediately external to the posterior cornu of the lateral ventricle. They terminate in the grey cortical matter of this lobe.

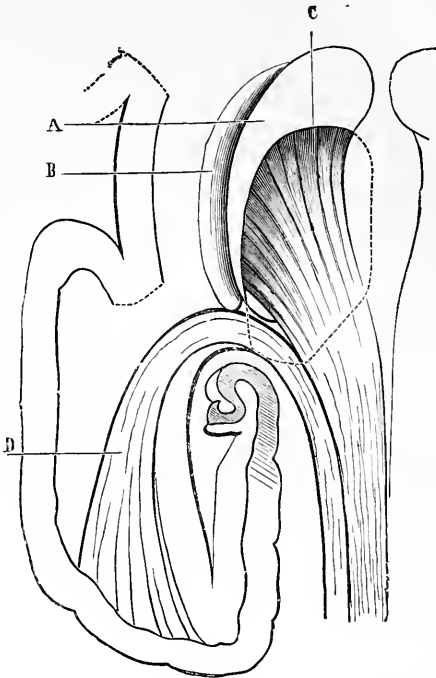


FIG. 26.—(Copied from Huguenin's work, loc. cit., fig. 82, p. 119). A, corpus striatum; B, lenticular nucleus; C, peduncular fibres proceeding to the corpus striatum; D, fasciculus of direct peduncular fibres proceeding to the cortical substance of the occipital lobe.

B. Is there any reason of an anatomical nature tending to prove that the fasciculus in question is really made up of centripetal fibres, the function of which is to transmit sensitive impressions to the surface of the posterior regions of the cerebrum?

Meynert thinks that this is the case, and bases his conclusion on the fact observed by himself, that these fibres may be followed, by the comparative examination of thin sections, from

below up to the pons and through the crus cerebri, in which they occupy the most external part of the foot or lower layer.

In the pons they are situated in the posterior part of the pyramidal tract, and maintain almost the same position in the anterior pyramid as far as the level of the decussation. When they have reached this point—contrary to what takes place in the case of the innermost fasciculi of the pyramid which pass into the lateral columns of the cord—they proceed, after decussating, to enter into relation with the posterior spinal fasciculi. I cannot guarantee the perfectly authenticity of this last portion of the course assigned by Meynert to the fibres which compose the most posterior part of the internal capsule.

Such, at the present time, is the quota furnished by normal anatomy, in its endeavour independently to throw light on the question which is engaging our attention. Interesting as they are, these facts, without the assistance of those supplied by pathological anatomy and experiment, would be quite insufficient for the solution of the problem, and once more I reassert that physiology and pathology cannot be inferred from the mere observation of purely anatomical facts.

c. The time, therefore, has come to invoke proofs of a clinical and pathological order. There is, to-day, abundant evidence on this point. It will be sufficient for me to call attention to the observations of Ludwig Türck, the pioneer in the path which we are traversing,<sup>1</sup> to those of his countryman Rosenthal,<sup>2</sup> to those collected by myself at the hospital of La Salpêtrière, and finally to those amassed by M. Veyssièrè and M. Rendu, the former in his inaugural thesis,<sup>3</sup> the latter in his professorial thesis.<sup>4</sup>

It is perfectly evident on associating and comparing these observations: (1) that lesions affecting the posterior or lenticulo-optic region of the internal capsule are necessarily followed by that form of hemianæsthesia, which I term cerebral, and in which the senses presided over by the cerebral nerves

<sup>1</sup> L. Türck, see Charcot, 'Leçons sur les maladies du système nerveux,' t. i, 2e édit., p. 315.

<sup>2</sup> Rosenthal, 'Klinik der Nervenkrankheiten,' 2te Aufl. Stuttgart, 1875.

<sup>3</sup> R. Veyssièrè, 'Recherches cliniques et expérimentales sur l'hémi-anesthésie de cause cérébrale.' Thèse de Paris, 1874.

<sup>4</sup> H. Rendu, 'Des anesthésies spontanées.' Thèse d'agrégation. Paris, 1875, p. 27 et 95.

proper, the optic and olfactory, are involved in such a manner as to reproduce accurately the special features of hysterical hemianæsthesia; (2) that, on the other hand, anæsthesia is absent in all cases in which, this region being respected, lesions only involve the part of the internal capsule comprised between the lenticular nucleus and the head of the caudate nucleus. These facts, furnished by pathological anatomy and clinical observation, are undoubtedly of capital importance in themselves and independently of all adventitious aid, but when combined with the data of pure anatomy they are of much greater value.

This is not all. Experiment has also supplied its contingent of facts, which lead exactly to the same conclusion.

Experiment may be said to have undergone an amendment at the suggestion of pathological facts. Previously indeed, it had conduced to the belief that the centre of sensory impressions was to be found neither in the cerebrum proper nor in the optic thalami, but at a lower level, in the pons or perhaps in the crura cerebri.

Against this assertion pathology protested by showing that a lesion situated higher than this point, in certain regions of the cerebrum itself, constantly gives rise to complete hemianæsthesia. The recent experimental researches conducted in France by MM. Duret and Veyssière in M. Vulpian's laboratory, have furnished results in harmony with the teaching of pathology. An ingenious instrument, consisting of a trochar from which a spring-stylet escapes at the required moment, is introduced through the cranial walls into the central masses to a depth and in a direction determined beforehand in accordance with previous experiments.

In this manner, one may succeed with a little practice in producing a lesion separately of the two parts of the internal capsule.

If, in the experiments thus performed, the lesion involves the posterior region of the capsule, hemianæsthesia on the opposite side of the body is the inevitable result; most frequently there is associated with it a certain degree of motor paralysis.

On the other hand, the latter symptom is present alone, without the accompaniment of anæsthesia, whenever the lesion



respects the posterior third of the capsule and involves only some point in its anterior two thirds (Figs. 27 and 28). Such, in short, are the principal results of these experiments. Everything tends, as you see from what precedes, to demonstrate in the posterior part of the internal capsule the existence of fasciculi of centripetal nerve-fibres, the function of which is to convey towards the centre the sensory impressions proceeding from the opposite side of the body.

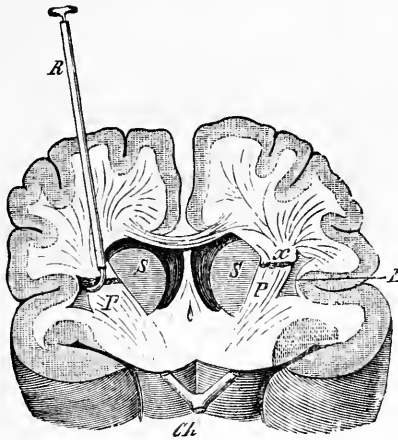


FIG. 27.—Transverse section of a dog's cerebrum, made five millimètres in front of the optic chiasma. *s*, *s*, caudate nuclei; *L*, lenticular nucleus; *P*, *P*, peduncular expansion (internal capsule). *ch*, optic chiasma; *x*, section of internal capsule (anterior or lenticulo-striate region) causing hemiplegia on the opposite side of the body, without anæsthesia; *R*, Veyssière's spring-stylet dividing the internal capsule.

After emanating from the foot of the central peduncle, these fibres on leaving the capsule proceed directly, without communicating with the central grey nuclei, to enter into the formation of the corona radiata. Near their origin, that is to say, at the lower part of the capsule, these fasciculi, being compressed into a narrow space, are liable to be affected simultaneously and in large numbers, by a very inconsiderable lesion, and hence ensues well marked anæsthesia.

We can understand, on the other hand, that higher up, at

the level of the foot of the corona radiata, a lesion of the same extent, in consequence of the divergence of the fibres, will produce effects much less pronounced. In reality this is what takes place. There are, however, several instances of well marked hemianæsthesia, in connection with very limited lesions of the foot of the corona radiata.

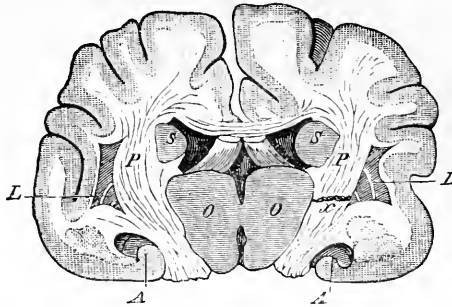


FIG. 28.—Transverse section of the dog's cerebrum at the level of the corpora albicantia.

O, O, optic thalami; S, S, caudate nuclei; L, L, lenticular nuclei; P, P, posterior or lenticulo-optic region of internal capsule; A, A, cornua ammonis; x, section of posterior or lenticulo-optic part of capsule causing hemianæsthesia.

(Both this figure and the preceding are copied from the memoir of MM. Carville and Duret, which was published in the 'Archives de physiologie normale et pathologique,' 1875, pp. 468 and 471).

It would now be desirable to determine whether extensive lesions of the occipital lobes, and especially of their cortical matter, also give rise to crossed hemianæsthesia.

Unfortunately the observations which might be quoted in this respect are not sufficiently explicit, so the question must remain in suspense, until more adequate information is forthcoming.<sup>1</sup>

Be that as it may, we are henceforth justified in believing that the component fasciculi of the posterior part of the internal

<sup>1</sup> In the cases of superficial softening of the occipital lobe, which I have collected, it is quite as often a question of hyperæsthesia, of painful sensations of every kind in the limbs on the opposite side, of hallucinations of sight, &c., as of hemianæsthesia or amblyopia.

capsule and their direct emanations must not be looked upon as a centre for impressions of common and special sensation.

These fasciculi merely represent a centre of passage or cross-way, where the centripetal fibres in question are grouped together, before diverging towards the superficial parts of the cerebrum.

## LECTURE X.

### CEREBRAL HEMIANÆSTHESIA (*continued*). CROSSED AMBLYOPIA. LATERAL HEMIOPIA.

SUMMARY.—*Description of the characteristic features of cerebral hemianæsthesia. Points of resemblance to hysterical hemianæsthesia.*

*The anæsthesia affects the different varieties of general sensibility and the special senses.*

*Hysterical amblyopia. Ophthalmoscopic examination.*

*Functional exploration: diminution of visual acuity; general and concentric contraction of the visual field, &c.*

*Crossed amblyopia with hemianæsthesia of cerebral origin: identical symptoms.*

*Lesions of the cerebral hemispheres causing hemianæsthesia give rise also to crossed amblyopia and not to lateral hemiopia.*

*Hemiopia. Hypothesis of semi-decussation.*

*Unilateral homonymous hemiopia. Varieties of hemiopia.*

GENTLEMEN.—At our last meeting I endeavoured to prove that a particular form of hemianæsthesia is a necessary consequence of lesions involving, either by destruction or compression, the posterior region of the internal capsule or its continuation in the corona radiata; I must now add, or by suspension, postponing the explanation of this term until a later stage. I based this proposition not only on facts in pathological anatomy and clinical medicine, but also on those supplied by experiment.

In addition I mentioned some data in normal anatomy, which certainly in some respects require confirmation, but which, such as they are, already enable us to discern the mechanism concerned in the production of the hemianæsthesia in question.

There are, however, a certain number of special features

relative to this combination of symptoms and to its anatomical and physiological interpretation, which I have purposely kept in the background, so as not to complicate the situation. To this subject I propose now to return.

## I.

Allow me in the first place to recapitulate in a few words the clinical characters of that variety of hemianæsthesia, which I have proposed to term *cerebral hemianæsthesia*, in order to distinguish it from all the other forms of diminution or partial suppression of sensation, not originating in a lesion of the cerebrum proper.

It is only of late years that cerebral hemianæsthesia from gross organic lesion—*coarse disease*, as Hughlings Jackson calls it with characteristically English freedom—has become the object of careful investigation. The features which it presents are the exact counterpart, as you are aware, of those exhibited in hysterical hemianæsthesia. The latter being better understood at the present time shall serve as our prototype.

In hysteria, as you know, we are concerned with *unilateral* anæsthesia. Complete anæsthesia only appears in comparatively exceptional cases. An antero-posterior plane passing through the median line of the body, fixes the limit of insensibility, which on the trunk, however, passes a little beyond the sternum in front, and the crest of the spinous processes behind. Nevertheless, this is a detail of secondary importance. The head, limbs, and trunk on one side of the body are therefore involved at the same time. Certainly, there may be degrees in the functional lesion, still it frequently affects all the varieties of common sensation; thus sensibility to touch, to pain and to temperature are often simultaneously diminished or suppressed.

The insensibility extends to the deep parts and involves the muscles which may be stimulated by electricity without the patient being conscious of it. Neither are the mucous membranes respected.

Let us add lastly—and this is the point to which I am desirous of calling attention to-day—that the hemianæsthesia does not affect common sensibility only; it involves also the

special senses on the same side of the body as the cutaneous anæsthesia. This sensorial hemianæsthesia affects not only the nerves which have their centre in the medulla, such as the nerves of taste and hearing, but also those of smell and of sight, the origin of which is in the brain proper.

Such, gentlemen, is hemianæsthesia as it most commonly occurs in hysterical patients.

If with this we now compare cerebral hemianæsthesia of organic origin, we shall find that a perfect resemblance can be established even in the smallest details. This similarity has already been carefully noted by myself as regards common sensibility,<sup>1</sup> and by M. Magnan as far as the disorders of hearing, smell, and taste are concerned.<sup>2</sup> I see nothing to add to what has been said on this subject.

Attention has recently been more particularly called to the phenomena which relate to vision. In my wards at La Salpêtrière, M. Landolt has been engaged in some investigations on this subject, the results of which must be briefly mentioned.

It will not, in my opinion, be devoid of interest to enter into some details in order to show you that even with respect to visual disorders—and this, as you will presently perceive, is a proposition of great importance—the symptoms in patients affected with circumscribed cerebral lesions are absolutely identical with those in hysterical subjects. It might indeed be said that unilateral amblyopia in hysterical patients, apart from its proverbial variability, differs in no essential feature from crossed cerebral amblyopia dependent on organic causes.

First of all let us consider the case of hysterical amblyopia.

## II.

(1) More or less pronounced diminution or, what is much more uncommon, even absolute loss of the visual faculty in the eye on the same side as the hemianæsthesia, is an important and well-ascertained fact.

(2) A more minute examination shows us the following

<sup>1</sup> Charcot, 'Leçons sur les maladies du système nerveux,' 1re éd., 1872.

<sup>2</sup> Magnan, "De l'hémianesthésie de la sensibilité générale et des sens dans l'alcoolisme chronique." 'Gaz. hebdom.,' 1873, p. 729 et 746.

peculiarities: no alteration visible by the ophthalmoscope exists in the fundus of the eye. The papilla and retina are in a perfectly normal condition. A comparative examination of the fundus on both sides reveals no appreciable difference in the vascularity of the parts.

Although the ophthalmoscope discloses no appreciable change in hysterical amblyopia, this is not the case with respect to the functional exploration, or examination of subjective phenomena. The following information is acquired by this method of proceeding.

(3) The visual acuity, when tested in the ordinary manner, is frequently found to be reduced by a half or even more.

(4) There is *concentric and general contraction of the visual field*.

(5) Lastly, careful analysis has enabled us to recognise certain peculiarities which deserve to arrest our attention for a moment; I refer to *concentric and general contraction of the visual field for colours*.

Several authors, including M. Galezowski, had previously noticed the frequent existence of achromatopsia and dyschromatopsia in hysterical patients. It is to this point that the observations made by M. Landolt in my practice especially relate.

I must remind you that, in the normal state, all parts of the visual field are by no means equally endowed with colour-perception. There are some colours for which the visual field is physiologically more extensive than for others, and these differences in the extent of the field are invariably present in all subjects, according to the same law for each colour.

Thus, the visual field is most extensive for blue; then come yellow, orange, red, and green; lastly, violet is perceived only by the most central parts of the retina. Now, gentlemen, in the pathological state which we are considering, these normal characteristics become exaggerated in various degrees.

In fact, the different circles corresponding, in the exploration, to the visual limits for each colour, become concentrically contracted in a more or less pronounced manner, according to the known law under normal conditions.

You may, therefore, readily forecast the numerous combinations, which are likely to be produced in the cases of hysteria, in which this kind of amblyopia has reached a high degree.

The circle for violet becomes contracted to nothing ; then, as the disease progresses, green, red, and orange follow in turn, yellow and blue persisting until the last. Observation shows that these are the two colours, perception of which is preserved for the longest time in hysterical patients. Lastly, in the most advanced stages no colours can be detected, tinted objects then presenting to the patient an appearance like sepia as seen in a water-colour.

Such, gentlemen, is the series of phenomena which we have over and over again observed in hysterical amblyopia.

These features with all their various shades of difference were found to be of constant occurrence in several cases of crossed amblyopia, accompanied by hemianæsthesia and dependent on circumscribed cerebral lesion, which we have recently investigated from this standpoint. There was the same diminution of the visual acuity, the same concentric and general contraction of the visual field for colours, the same absence of pathognomonic lesions in the fundus of the eye when examined by the ophthalmoscope, &c.<sup>1</sup>

Upon this last characteristic I wish particularly to insist, because it enables us to draw a clear distinction between the functional disorders in question and other visual troubles which also depend on intra-cranial organic lesion. I allude now to those changes in the fundus of the eye, easily recognisable by the ophthalmoscope, which are commonly known by the name of *choked disc* or *neuro-retinitis*, and which so frequently occur in consequence of encephalic tumours, *whatever may be their nature or seat*,<sup>2</sup> and as a result of various lesions acting in a more or less direct manner upon the optic tracts.

<sup>1</sup> The recent researches conducted by M. Landolt in my wards have shown that the contraction of the visual field for colours, in ovarian hysteria with hemianæsthesia, is invariably experienced in both eyes at once ; but it is incomparably more pronounced in the eye corresponding to the side affected with anæsthesia. This same peculiarity is observed in all the cases of cerebral hemianæsthesia originating in an organic lesion, which have been examined with respect to this point. Consequently, the term *crossed amblyopia* employed in these lectures must not be accepted absolutely in a literal sense, seeing that the obnubilation of sight involves both eyes, though to an unequal extent.

<sup>2</sup> On this subject consult the interesting work of Dr. Annuske, "Die Neuritis Optica bei Tumor Cerebri," in 'Archiv für Ophthalmologie,' 19 Bd., Abth. iii, 1873, p. 165.



In asking you to accept, gentlemen, the fact that crossed amblyopia is a consequence of those circumscribed cerebral lesions which occasion hemianæsthesia, I have advanced a truth of the greatest importance as regards cerebral localisation. But you must not fail to remember that this fact is in direct opposition to the generally accepted ideas. Indeed, if we are to believe the theory proposed in 1860 by Alb. von Graefe,<sup>1</sup> and which appears to prevail universally even now, as is evident from an interesting work recently published by Schoen,<sup>2</sup> absolutely unilateral lesions of the cerebrum do not cause crossed amblyopia, but a visual disorder of a different nature, viz. *lateral homonymous hemiopia*.

In other words, a circumscribed cerebral lesion on the left side would, according to the theory in question, give rise to suppression or obscuration of the right half of the visual field, and inversely for the case of a lesion of the right hemisphere.

I think it my duty to protest against this theory, which is, to say the least, too dogmatic. I shall place in opposition to it the following proposition: *Lesions of the cerebral hemispheres producing hemianæsthesia likewise determine crossed amblyopia, and not lateral hemiopia.*

I am not in a position, bear in mind, to peremptorily assert that lateral hemiopia can never result from a circumscribed cerebral lesion; but I am inclined to believe that in cases of this kind—if indeed they exist—it is really a question of pressure-effects, that is, of more or less direct implication of the optic tracts. I do not think there exists at the present time a single observation clearly proving that lateral hemiopia, apart from these conditions, originates in consequence of a lesion of the posterior part of the internal capsule or of the foot of the corona radiata, whereas a certain number of facts are extant in which such a lesion has occasioned crossed amblyopia presenting all the features we have just assigned to it.

### III.

A few details with respect to hemiopia and the alleged anatomical cause of its development must now be placed before

<sup>1</sup> A. von Graefe, 'Gazette hebdomadaire,' 1860, p. 708. See also 'Vorträge aus der V. Graefe'schen Klinik Monatsbl. f. Augenhkde.,' May, 1865.

<sup>2</sup> Schoen, 'Archiv der Heilkunde,' 1875, 1e Heft.

you. You are aware that the existence of this singular phenomenon, which has so often come under clinical observation, long since gave rise to an anatomical hypothesis, according to which the optic nerves in man undergo at the chiasma not a complete interchange of fibres, but what is termed semi-decussation. This hypothesis is very old. It is generally attributed to Wollaston, but the truth is that Newton had previously formulated it in 1704, in his Treatise on Optics.

In 1723 Vater had also adopted it with a view to explaining three cases of hemiopia, which he had observed.<sup>1</sup>

I shall now recall to your minds the constitution of this theory. Among the nerve-tubes entering into the formation of the optic tracts and nerves it is necessary, as has been said, to draw a distinction between those which decussate and those which do not decussate in the chiasma.

These last (*vide* Fig. 29, *a'*, *b'*), that is to say, the nerve-tubes which do not decussate, occupy the external parts of the tract, chiasma, optic nerve and retina; whilst the decussating fasciculi (*b' a'*) occupy the inner sides of all these parts. As a result of this arrangement, the non-decussated fibres of the left tract, for example, proceed to the left half of the retina of the left eye, whilst the decussated fibres of the same tract would go to the left half of the right eye. The distribution of the fibres of the right optic tract is effected, of course, on the same principle, but inversely.

In other words, the fasciculi composing the left optic tract go to the left half (GG) of each retina, and inversely for the nerve-fasciculi proceeding from the optic tract on the right side (DD).

It must not be forgotten that this arrangement of the optic nerve-fibres is, anatomically considered, quite hypothetical. Although several authors, among others, Hannover,<sup>2</sup> Longet, Cruveilhier, Henle,<sup>3</sup> and still more recently, Gudden,<sup>4</sup> are persuaded that they can support it on anatomical grounds, there

<sup>1</sup> Knapp, 'Archiv. of Scientific Medicine,' New York, 1872.

<sup>2</sup> Hannover, "Das Auge," 'Beiträge zur Anatomie, Physiologie und Pathologie dieses Organs.' Leipzig, 1872.

<sup>3</sup> Henle, 'Nervenlehre. Ueber die Kreuzung im Chiasma Nervorum Opticorum.'

<sup>4</sup> Gudden 'Archiv für Ophthalmologie,' 1874, t. 20, 2e Abth.

are others, such as Biesiadecki,<sup>1</sup> E. Mandelstamm,<sup>2</sup> and Michel,<sup>3</sup> who, in opposition, appeal to arguments of the same nature, and endeavour to show that the fibres of the optic nerves undergo complete decussation at the chiasma, even in man.

In short, we must confess that the question, at the present time is far from being settled. I repeat, therefore, that the semi-decussation is to be looked upon simply as a theory which, however, explains the facts observed in clinical medicine, and is certainly superior to the hypotheses which some have endeavoured to substitute for it.

On glancing at the diagram placed before you, you will see that this theory may be applied to the explanation of the varieties of hemiopia (Fig. 29).

Let us consider, in the first place, *unilateral homonymous hemiopia*, which, according to some writers, can only occur as a direct consequence of an intra-cerebral focal lesion. In harmony with our theory, it is evident that a lesion situated at the point  $\kappa$ , so as to interrupt the course of the fibres of the left optic tract ( $b b'$ ), both those which decussate in the chiasma ( $b'$ ) and those which do not decussate there ( $b$ ), will affect the left half of each retina ( $g, g$ ), or in other words, will cause either diminution or complete suppression of the entire visual field on the right side (right lateral hemiopia).

Left lateral hemiopia, on the other hand, would supervene in consequence of a lesion involving in the same manner the optic tract on the right side.

So speaks the theory, and as a matter of fact there are numerous instances proving that lateral hemiopia is really the result of a lesion exerted on one of the optic tracts.<sup>4</sup>

The effect will be the same, whatever the situation occupied by the lesion in the tract, from its origin in the corpora genicu-

<sup>1</sup> Biesiadecki, "Ueber das Chiasma Nervorum Opticorum des Menschen und der Thiere," 'Wiener Sitzungsber. d. math. naturwiss. Classe,' Bd. 42, Jahrg., 1861, p. 86.

<sup>2</sup> E. Mandelstamm, "Ueber Sehnervenkreuzung und Hemiopie," 'Archiv für Ophthalmologie,' t. 16, 1873, p. 39.

<sup>3</sup> Michel, "Ueber den Bau des Chiasma Nervorum Opticorum." Same journal, p. 59, Taf. i, fig. 4. See also Bastian, 'The Lancet,' 1874, July 25th, p. 112.

<sup>4</sup> Among others, see the case of E. Muller in the 'Archiv für Ophthalmologie,' viii, Bd. i, S. 160.

lata to its termination in the chiasma. Lateral hemiopia will ensue, moreover, not only from a lesion confined to the tract itself, but also as a secondary phenomenon, consequent on lesions—hæmorrhage or tumours—originating in the parts which are in more or less immediate relation with this tract, as, for example, the lower layer of the crus cerebri (*pes*) or even the pulvinar.<sup>1</sup>

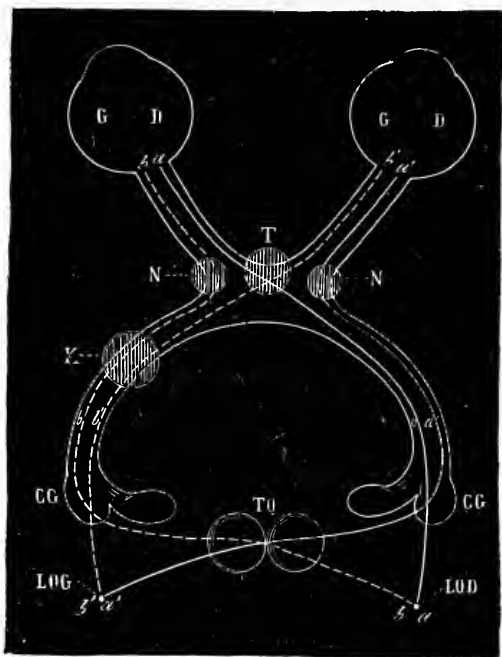


FIG. 29.—Diagram explaining the phenomena of lateral hemiopia and crossed amblyopia. T, semi-decussation in the chiasma; T Q, decussation behind the corpora geniculata; CG, corpora geniculata; a', b, fibres which do not decussate in the chiasma; b', a, fibres decussating in the chiasma; b', a', fibres proceeding from the right eye meeting at a point, LOG, in the left hemisphere; LOD, right hemisphere. K, lesion of the left optic tract causing right lateral hemiopia. LOG, a lesion at this point would produce right crossed amblyopia; T, lesion causing temporal hemiopia; N, N, lesion causing nasal hemiopia.

<sup>1</sup> The pulvinar or *posterior tubercle* of the optic thalamus is the posterior and internal part of the upper surface of this nucleus. It lies beneath the fornix—(*Translator*).

The other varieties of hemiopia are not more difficult of interpretation. A lesion, a tumour for instance, situated at  $\tau$ , that is on the median part of the chiasma, so as to involve only the decussating optic fibres ( $a, b'$ ), would paralyse the left half ( $g$ ) of the retina of the right eye, as well as the right half ( $d$ ) of the retina of the left eye, and give rise consequently to what is termed temporal hemiopia.

In a case of this kind, Saemisch was able to foretell, during the life of the patient, that such was the seat of the lesion, and the autopsy fully justified his anticipations.<sup>1</sup> On the other hand, the so-called *nasal* hemiopia, which is characterised by suppression of the median part of the visual field, would be produced if the course of the direct fibres ( $a', b$ ) were alone interrupted, at the level of the chiasma for example, in consequence of lesions symmetrically occupying on each side the points  $n, n$ . This combination, we apprehend, must occur very rarely. Nevertheless, some instances of it are on record; among others, one which has been carefully described by Knapp.<sup>2</sup>

In this case, pressure was exerted on the above-mentioned points by the anterior cerebral and posterior communicating arteries, which were increased in volume and indurated by atheromatous degeneration.

I shall dwell no further on those forms of hemiopia, which are of no direct interest to us at present, but return to lateral hemiopia. It appears to be a well-established fact that this kind of visual disorder is the necessary result of lesion of one of the optic tracts. Is it likewise, as is generally asserted, the necessary consequence of a lesion involving the optic nerve-fibres beyond the corpora geniculata, in their deep, intra-cerebral course ( $LOG, LOD$ )?

In my opinion, clinical medicine and pathological anatomy contradict this assertion, which has, to say the least, been made in too dogmatic a manner. I can only repeat here what I said just now on this subject; I do not believe that there exists at present a single observation proving satisfactorily that lateral hemiopia has originated in consequence of an intra-cerebral lesion, *without there being any implication of the optic tracts*, whereas facts are on record in which a lesion of the posterior

<sup>1</sup> See also Müller, in E. Meissner's 'Jahresbericht,' 1861, S. 458.

<sup>2</sup> 'Archives of Scientific and Practical Medicine,' 1873, p. 293.

part of the internal capsule or the foot of the corona radiata has given rise, simultaneously with hemianæsthesia, to crossed amblyopia, a visual disorder very different from hemiopia. That being so, how are we to explain diagrammatically this effect of a cerebral lesion, whilst admitting the indisputable fact of hemiopia resulting from lesion of the optic tracts ?

To attain this object, it will be sufficient to make a slight modification in the ordinary diagram of the semi-decussation.

It is usually supposed that the nerve-fibres proceeding from the right and left eyes, and forming the optic tracts on each side, continue their course beyond the corpora geniculata, without further change, to the deep parts of the hemisphere of the corresponding side, and this view is in accordance with the prevailing idea that a lesion of the optic nerve-fibres, in their intra-cerebral course, is equivalent to a lesion of the optic tract, and consequently produces hemiopia.

I propose to submit, on the other hand, that only those fibres of the tract which have decussated in the chiasma ( $a, b'$ ) pursue their course in the deeper parts without further decussation ; whilst the direct fasciculi, before penetrating the substance of the hemisphere (LOG, LOD), undergo complete decussation beyond the corpora geniculata at an indeterminate point of the middle line, probably in the corpora quadrigemina ( $\tau q$ ).

It follows from this arrangement that the fasciculi ( $b', a'$ ) when united, for instance, at a point in the left hemisphere (LOG), represent the sum of the fibres proceeding from the retina of the right eye, and that the fasciculi ( $b, a$ ), represent the sum of the fibres coming from the left eye. The course of the optic fibres, therefore, as far as their deep tract is concerned, is in a manner restored to the type of complete decussation, and it is conceivable that in an arrangement thus constituted, whereas a lesion of the optic tract occasions lateral hemiopia, a lesion situated deeply in the substance of the hemisphere would, on the other hand, produce crossed amblyopia. I give you this hypothesis for what it is worth ; it is not based, at present, on any anatomical grounds, but, nevertheless, if I am not mistaken, it supplies a ready means of presenting in a very simple form the rather complex facts revealed by clinical observation.

## LECTURE XI.

### ORIGIN OF THE CEREBRAL PARTS OF THE OPTIC NERVES.

**SUMMARY.**—*Relation between crossed amblyopia and hemianæsthesia resulting from lesion of the internal capsule. Cerebral origin of the optic nerves.*

*Corona radiata of Reil. Cortico-optic radiating fasciculi. Anterior fibres (anterior root of the optic thalamus); middle fibres (lateral expansion); posterior fibres (cerebral expansion of the optic nerves). Anatomical relations between the cerebral expansion of the optic nerves and the centripetal fibres of the corona radiata (hemianæsthesia). Optic tracts; origin of the external root (optic thalamus, corpus geniculatum externum, anterior corpora quadrigemina); origin of the internal root (corpus geniculatum internum, posterior corpora quadrigemina). Connection between the masses of grey matter and the encephalic cortex: cortico-optic radiating fasciculi. Effects of lesions of the anterior corpora quadrigemina. Cases of lateral hemiopia of supposed intra-cerebral origin.*

GENTLEMEN,—I hope I have succeeded in clearly demonstrating the existence of *crossed amblyopia*, as a symptom of lesions occupying the posterior part of the internal capsule or the corresponding emanations from the foot of the corona radiata.

At the same time, I endeavoured to prove that Von Graefe's statement to the effect that homonymous hemiopia, and not crossed amblyopia, was the only functional disorder of vision likely to result from lesion of one cerebral hemisphere,—I endeavoured, I say, to show that this proposition is, at any rate, far too dogmatic, and that the arguments on which it rests should undergo complete revision.

To-day, I would inquire with you if normal anatomy can inform us why the sensorial disorder in question, that is to say, crossed amblyopia, is a frequent if not an habitual accompaniment of hemianæsthesia resulting from lesion of the internal capsule.

You have not forgotten that this hemianæsthesia of common sensibility depends on the existence of a fasciculus of *direct* centripetal fibres, the course of which is not arrested in the grey nuclei of the central masses, and which, on leaving the internal capsule, forms the most posterior part of the foot of the corona radiata.

Does there exist some connection, some more or less immediate relation, between this sensitive fasciculus and the sensorial fibres, which are intended to place the visual apparatus in communication with the cerebral cortex? In approaching this question we must, at the outset, study the origin of the deep or cerebral parts of the optic nerves. We are about to broach a difficult subject, which is still obscure in more than one point, I must not, however, neglect to indicate its principal headings, were it only in order to point out the path in which future researches should be directed, and in which pathological anatomy is very probably destined to play the predominant part.

In accordance with the general plan, the cerebral nerves have to encounter, before penetrating the cerebrum itself, one or several masses of grey matter, which are conveniently termed the *nuclei of origin*.

They are expansions which have originated in these nuclei and which, in an indirect manner, place these nerves in relation with the cortex of the cerebral hemispheres. *A priori*, nothing conduces to the belief that the optic nerves escape this law. Indeed they do not escape it, but their disposition is very complicated and, moreover, not well understood in certain details.

## I.

In the first place I shall dwell a moment on some points relative to the constitution of a part of Reil's corona radiata.<sup>1</sup>

<sup>1</sup> The various peduncular and other fasciculi forming the corona radiata (*convergent fibres* of Luys, Meynert's *first projection system*) make up, to a



In the diagram placed before you, which I borrow from Huguenin (*loc. cit.*, pl. 69, p. 93), the superior parts of the large extent, the central white mass called the centrum ovale, which the hemispherical cortex envelops and encloses, to use Foville's comparison, like a purse. They do not represent the whole of this mass. The latter also contains fasciculi which, although quite unconnected with the preceding, intermingle with them. These last bundles constitute what Meynert calls the *association system*. The fasciculi which compose this system, may be resolved, in a general manner, into two kinds. Some are collected into commissures uniting, one to another, homologous parts of the cerebral hemispheres. Such, for example, are the corpus callosum and the anterior commissure. Others are composed of fibres having, as a rule, an antero-posterior direction, which bring into relation different parts of the same hemisphere.

The accompanying figure (Fig. 30), borrowed from Meynert (*loc. cit.*,

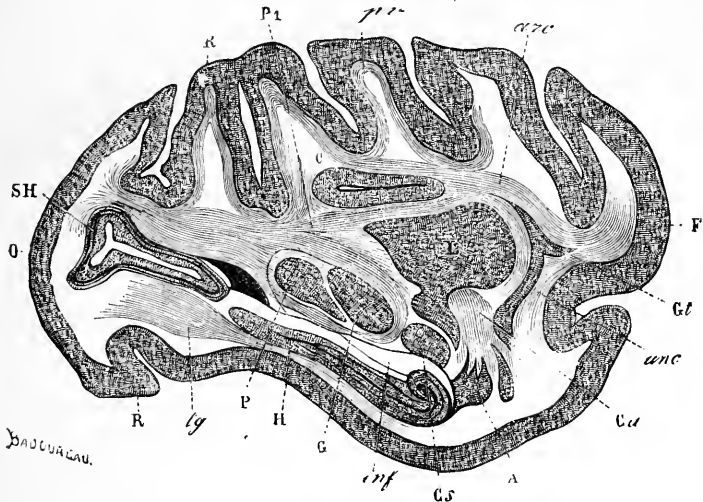


FIG. 30.—After Meynert (Stricker's 'Handbuch,' t. ii, p. 703, Fig. 233). Antero-posterior section of the brain of the *Cercopithecus cinomolgus*. F, frontal extremity; o, occipital extremity; H, cornu ammonis; RR, cortical matter; SH, sulcus hippocampi; L, third segment of lenticular nucleus; gt, claustrum; cs, tail of the corpus striatum; P, pulvinar; G, corpus geniculatum externum. pv, fibræ propriæ connecting two convolutions; arc, fasciculus arcuatus; unc, fasciculus uncinatus; lg, inferior longitudinal fasciculus; ca, anterior commissure; inf, posterior cornu of lateral ventricle.

fig. 233), and representing an anterior section of a monkey's cerebrum (*Cercopithecus cinomolgus*), shows well the direction of the principal fasciculi of

hemispheres, including the corpus callosum, have been removed, and the ventricular cavities laid open. You will notice particularly the lower part or posterior cornu of the ventricle (*f*) which plays an important part here in topography (Fig. 32).

The caudate nucleus has been detached, its outlines being represented by a dotted line; the radiating structure, that is to say, the arrangement of cortico-striate radiating fasciculi, has likewise been removed (Fig. 31, *FK*). In this manner the system of cortico-optic radiating fasciculi has been exposed (*FT*, Fig. 31, *hh*, *ii*, *kk*, Fig. 32). It is possible now to distinguish in these last bundles, three groups of fibres: (1) Those which are anterior (*hh*, Fig. 32) are called the anterior root of the optic thalamus (*Vordere Stiel*); they are directed towards the frontal regions; (2) others are middle or lateral (*ii*, Fig. 32). (lateral expansions); (3) lastly, those which are posterior are described by Gratiolet,<sup>1</sup> who was the first to study them thoroughly, under the name of optic cerebral expansions or expansions of the optic nerves (*kk*, Fig. 32), (*Sehstrahlungen*). The fasciculi of this last group, which are the special object of our inquiry, are only separated from the cavity of the posterior cornu by the ependyma and the *tapetum*, which is a special expansion of the *splenium* of the corpus callosum. In this same region, but at a lower level, are distributed the cerebral expansions of the fasciculus of centripetal fibres, lesion of which determines hemianæsthesia of cerebral origin. There is, therefore, by proximity or contiguity, a relation between these fasciculi and the optic expansions, and this relation would be well adapted to explain anatomically the frequent co-existence of hemianæsthesia and crossed amblyopia, if it were thoroughly established that the bundles known by this name of optic

this antero-posterior association system. We see at *pv*, the fasciculi of fibres, admirably described by Gratiolet as *fibræ propriæ*, which bring into relation neighbouring convolutions; at *arc*, the *fasciculus arcuatus*, the fibres of which extend above the corpus callosum from the occipital to the frontal lobe; at *lg*, the inferior longitudinal fasciculus uniting the occipital to the extremity of the sphenoidal lobe; finally at *unc*, the *fasciculus uncinatus*, the direction of which is nearly vertical, and which establishes a relation between the frontal and sphenoidal lobes.

<sup>1</sup> See Gratiolet.—'Anat. comparée,' t. ii, p. 181, and following.—Luys, loc. cit., p. 173.

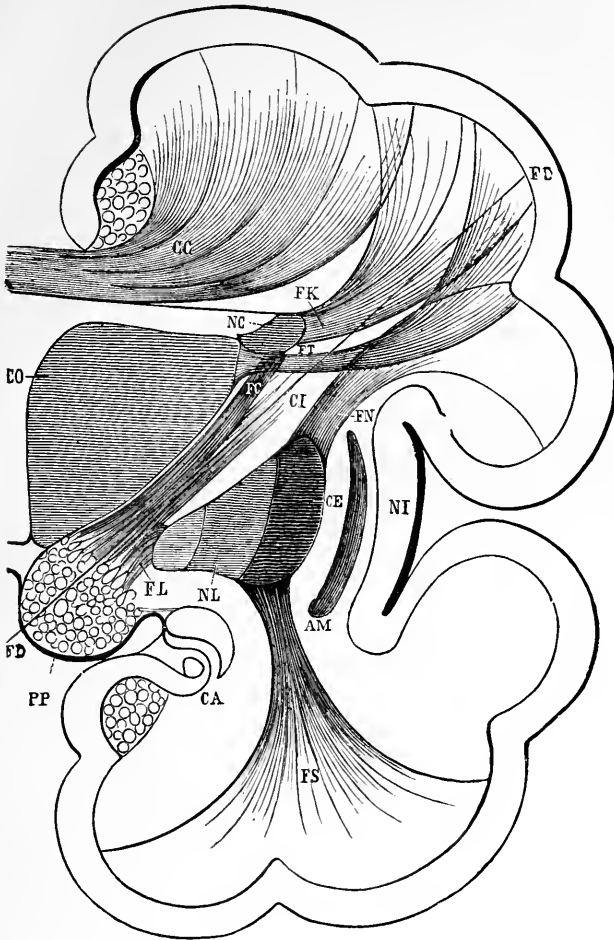


FIG. 31.—(Diagram after Huguenin). NC, caudate nucleus; CO, optic thalamus; NL, lenticular nucleus with its three segments; AM, claustrum; CE, external capsule; CI, internal capsule; PP, foot of the peduncle; CA, cornu ammonis; NI, island of Reil; FL, fibres proceeding from the peduncle to the lenticular nucleus; FC, peduncular fibres proceeding to the caudate nucleus; FS, fibres passing from the lenticular nucleus to the sphenoidal lobe; FN, fibres from the lenticular nucleus going to the periphery; FK, fibres from the caudate nucleus going to the periphery; FT, fibres from the optic thalamus going to the periphery; FD, direct fibres.

expansions are really a more or less direct prolongation of the optic nerves.

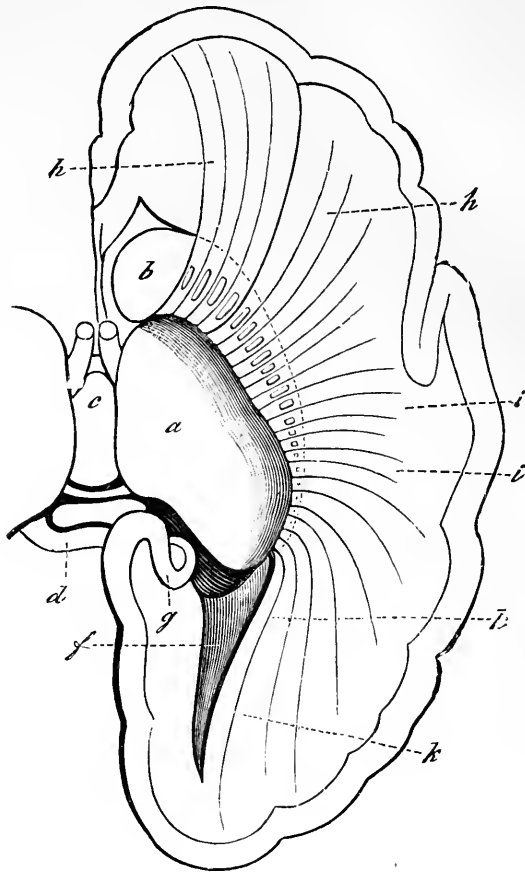


FIG. 32.—Radiations of the optic thalamus (diagram copied from Huguenin's work, p. 93, fig. 69). *a*, optic thalamus; *b*, corpus striatum; *c*, fornix; *d*, corpora quadrigemina; *f*, posterior cornu of lateral ventricle; *g*, cornu ammonis; *h*, *h*, anterior root of optic thalamus; *i*, *i*, lateral radiations; *k*, *k*, Gratiolet's optic radiations.

## II.

In order to examine this last point, it is necessary to make a *détour*, with a view to ascertaining what is known with regard to those nuclei of grey matter where the optic nerves take their first origin at the base of the encephalon, as it were outside the cerebrum proper. Some preliminary observations concerning the external disposition of the parts we have to consider appear to me to demand attention at the present time.

When the entire isthmus is detached from the encephalon, the adjacent optic thalami being left undisturbed, and if the preparation thus obtained be examined on its posterior surface we notice the following: (1) in front, the optic thalami on each side are seen to be separated by the third ventricle; (2) behind, the anterior and posterior corpora quadrigemina; (3) to the outside, the anterior brachia in relation by their internal extremity with the anterior corpora quadrigemina, and the posterior brachia in relation with the posterior corpora quadrigemina. We see, moreover, in the same region on raising the posterior extremity of the optic thalamus, or pulvinar, to the inside, the corpus geniculatum internum, and, to the outside, a grey mass rather more voluminous, which is the corpus geniculatum externum. Behind and above these parts appear the band of Reil, the processus cerebelli ad testes, the crura cerebri, the restiform bodies, and the middle cerebellar peduncles. The corpora geniculata interna and externa are admittedly the two first nuclei of grey matter with which the optic nerves enter into relation in their course towards the encephalon. We know that these nerves, behind the chiasma, take the name of *optic tracts*, and that these latter, in the part corresponding to the posterior two thirds, are divided into two bands, which we may consider as roots, one being internal and the other external.

The external is, at the same time, the most voluminous and the most important. It supplies several fasciculi which enter into relation with the various grey nuclei.

(1) We must notice in the first place a fasciculus which is arrested in the external corpus geniculatum. This last consists

of some rather large masses of grey matter enclosing branching and fusiform cells of pretty considerable size, which you will find well represented in Henle's work (fig. 177, p. 249).

(2) A second fasciculus, situated internal to the preceding, penetrates the lower stratum of the thalamus, about twelve millimètres in front of the extremity of the pulvinar. In a transverse section, such as is figured in Meynert's work (fig. 249, II R), the fasciculus in question is situated between the external corpus geniculatum and the foot of the crus.

The existence of this fasciculus, which is affirmed by Gratiolet, has also been clearly recognised by Meynert, Henle and Huguenin.

(3) A third fasciculus which, according to Gratiolet, is the most evident and the best known of the roots of the optic nerve, turns around the external corpus geniculatum and enters the anterior corpus quadrigeminum of the corresponding side.<sup>1</sup>

The description given by Gratiolet and confirmed by Vulpian and Huguenin<sup>2</sup> is perfectly accurate as far as the majority of mammiferous animals are concerned.<sup>3</sup> As regards the monkey and man, there is not the same degree of certainty. In them, the existence of this fasciculus, which is, however, indisputable, can only be shown anatomically by very careful dissection.<sup>4</sup>

From what precedes you see that the external root of the optic nerves takes origin in three nuclei of grey matter, viz.: (1) the optic thalamus; (2) the external corpus geniculatum; (3) the anterior corpora quadrigemina (nates). These are certainly the principal sources of the optic nerves in man, and in a large number of animals they are probably the only sources. At any rate this appears to have been proved by Gudden's<sup>5</sup>

<sup>1</sup> Gratiolet, loc. cit., p. 180.

<sup>2</sup> Huguenin, 'Westphal's Archiv,' v. Bd., 1 Heft, 2 Heft, 1875.

<sup>3</sup> For the brains of the rabbit and dog, see the plates in Gudden's work, 'Arch. f. Ophth.,' xx, 1875; for the cat's brain, Forel's plates, "Beiträge zur Kenntniss der Thalamus opticus." Sitz. 'Bericht der K. Akad.,' lxvi Bd., 1872, t. ii, fig. 10.

<sup>4</sup> A fourth fasciculus, situated external to the one which is arrested in the outer corpus geniculatum, is distributed over the thalamus and takes part in the formation of the *stratum zonale*. This fasciculus, which was first pointed out by Arnold and Gratiolet, has been described and figured by Meynert, p. 436.

<sup>5</sup> Gudden, 'Archiv für Ophthalmol.,' xx.

interesting experiments, which consisted in extirpating the eye-balls of very young rabbits.

When, at the end of a few months, the animals thus treated were killed, it was found that secondary atrophy affected, as regards the central parts, the anterior corpora quadrigemina, the optic thalami, and lastly the external corpus geniculatum; on the other hand, the posterior corpora quadrigemina and the internal corpus geniculatum did not participate in the atrophy.

Although of less importance than the external, the internal root of the optic nerves must nevertheless not be overlooked, especially in the case of man.

You are aware that it enters into evident connection with the internal corpus geniculatum. This last contains only some rudimentary nerve-cells (Henle), and consequently cannot be looked upon as a centre in the same sense as the external corpus geniculatum. The nerve-fasciculi of the internal root ultimately proceed to the anterior corpora quadrigemina, either after passing through the corpus geniculatum or by a direct course.

Huguenin ('Archiv für Psychiatrie,' 1875, v Bd., fasc. 2, p. 344) has recently asserted that the internal root of the optic nerves, at any rate in man, is in relation anatomically with the posterior corpora quadrigemina, either directly or through the medium of the internal corpus geniculatum. The posterior corpora quadrigemina would seem, therefore, not to be excluded from the system of the optic nerves in man, as they appear to be in animals. This is not inconsistent with what has been observed in certain cases of grey tabetic induration of the optic nerves. Indeed, quite lately, in the case of an ataxic woman, who had been blind about fifteen years, grey induration of the optic nerves could be followed beyond the chiasma to the optic tracts, as far as the corpora geniculata. The corpora quadrigemina, both anterior (nates) and posterior (testes), had almost preserved the white tint of the normal condition, but they had both undergone a most manifest reduction in size (case of the woman named Magdaliat).<sup>1</sup> I have observed several cases in every way similar to the preceding.

We must now inquire how these various masses of grey

<sup>1</sup> The anterior and posterior brachia, also, were in this case remarkably atrophied; they presented a dull white colour, slightly tinged with yellow.

matter, which have just been enumerated, enter into relation with the cerebral cortex. The connection is established, as I have already remarked, by a system of fibres constituting the most posterior part of the radiations of the optic thalamus (cortico-optic radiating fasciculi), and which are sometimes termed *Gratiolet's optic radiations*.

You can follow the somewhat complex anatomical details, relative to this matter on the accompanying figure, copied from Huguenin's work, and which refers to the ape (*Cercocebus cinomolgus*) (fig. 33). You see, on this plate, how the bundles of fibres or radiations, springing from the external and internal corpora geniculata, *Ge* and *Gi*, from the pulvinar, *Th*, from the anterior corpora quadrigemina, *Qu*—these last through the medium of the anterior brachia, *Bs*—become associated, after a recurrent course, with the fasciculus, *Om*, which is no other than the collection of direct peduncular centripetal fibres we have already described (Lectures VIII and IX, Fig. 26), and which controls common sensation on the entire opposite side of the body.

There are, doubtless, mixed with this aggregate of fasciculi fibres proceeding from the olfactory tract through the medium of the anterior commissure, the extremities of which, as we know from the descriptions of Burdach and Gratiolet, are directed backwards into the substance of the occipital and sphenoidal lobes.

Clinical facts conduce to the supposition that there are also associated here decussated nerve-fibres in relation with the auditory and gustatory nerves. If this disposition, which at present is quite hypothetical, be verified anatomically, we shall understand why crossed obnubilation of smell, taste, and hearing, as in the case of amblyopia, invariably forms an integral part of cerebral hemianæsthesia<sup>1</sup>.

The region of the encephalon to which I have called your attention, and which corresponds to the most posterior part of the foot of the corona radiata, may therefore be considered, in accordance with the preceding observations, as a cross-way where all the sensitive and sensory tracks are gathered into a very

<sup>1</sup> Theoretically, cerebral hemianæsthesia would be distinguished from that dependent on a lesion of the pons or crus cerebri, by the non-participation, in these last cases, of vision and smell.



circumscribed space in the substance of the encephalon. It is a cross-way, not a centre. The cerebral centre proper must be sought for in the prolongation of the medullary fibres into the cortex of the occipital and sphenoidal lobes.

We shall have to revert to this point when we come to consider localisations in the cortical system.

### III.

In the anatomical account just given, you will have remarked that the optic nerve-fasciculi, after their decussation in the chiasma, again approach the median line at the corpora quadrigemina only. Does the supplementary decussation which, according to the hypothesis I have proposed, would reduce the optic nerves to the condition of other nerves, take place at this point? This is a question which at the present time seems exceedingly difficult to decide by the aid of anatomy alone.

The existence of numerous decussating fasciculi at the median line between the corpora quadrigemina has certainly been verified anatomically. But we cannot determine if these decussated fibres are really in connection with the optic nerves, and, especially, if they are the prolongations of the optic fibres which have not decussated in the chiasma. Experiment, and particularly pathological anatomy, will, in all probability, take the first step in the solution of this debated question.

The experiments of Flourens on mammals and birds have already shown that removal of the optic tubercles is followed by crossed amblyopia or amaurosis. But the animals in question are those in which the ocular axes are directed outwards and in which, doubtless, the decussation in the chiasma is complete. In man, the data for the solution of this problem are still wanting. Lesions of the corpora quadrigemina are not uncommon in man, but they are usually symmetrical, and, consequently, since they cause bilateral blindness, cannot decide this point. The question, indeed, is still asked, if lesion of the anterior corpora quadrigemina will produce lateral hemiopia, as in the case of lesion of the optic tracts, or if, on the contrary, the result will be crossed amblyopia, which should take place according to my hypothesis. In favour of the latter I can quote but one

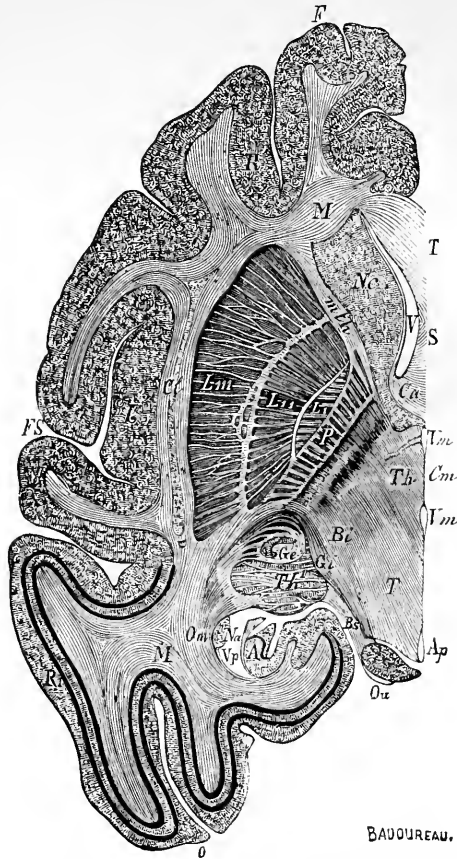


FIG. 33.—This figure is copied from Meynert's work (Stricker's 'Handbuch,' t. ii, p. 721, fig. 243). It represents a longitudinal and horizontal section of the left half of the brain of the *Cercopithecus cinomolgus*.

F, frontal extremity ; O, occipital region ; FS, fissure of Sylvius ; I, island of Reil ; Cl, claustrum ; T, corpus callosum ; S, septum lucidum ; Ca, anterior commissure ; A, cornu ammonis ; V, anterior cornu of lateral ventricle ; Vp, posterior cornu ; Vm, Vm, third ventricle ; Cm, middle commissure ; Ap, aqueduct of Sylvius ; L1, L11, L111, segments of the lenticular nucleus ; Nc, head, and Na, tail of caudate nucleus.

Th, part of optic thalamus situated in front of the corpora geniculata ; Th', pulvinar of optic thalamus.

Qu, corpora quadrigemina ; Gi, internal corpus geniculatum ; Ge, external corpus geniculatum ; P, foot of the cerebral peduncle.

Om, medullary fasciculi proceeding from the occipital lobe to the pulvinar, to the brachia of the anterior and posterior corpora quadrigemina, Bs and Bt, to both corpora geniculata, and to the foot of the cerebral peduncle.

observation, which was published by Dr. Bastian, and in which a unilateral lesion of the anterior corpora quadrigemina had caused crossed amblyopia.

But, at the present time this case remains unique, and, moreover, it cannot be considered decisive, since the details given are too insufficient.<sup>1</sup>

#### IV.

It remains for me to inquire whether crossed amblyopia is the only kind of functional disorder of vision which can result from a lesion of the cerebrum proper, or whether, on the other hand, hemiopia also, as some authors assert, may not supervene in consequence of certain pathological localisations in the hemisphere.

This is a point which at present, I think, we are not in a position to decide.

In the absence of autopsies to the contrary, I am inclined, however, to the opinion that in the majority of the cases of hemiopia, which have been ascribed to cerebral lesion, this either did not occupy the deep regions of the hemisphere or it extended to the basilar parts in such a way as to involve more or less directly one or other of the optic tracts.

In order to prove that lesions in the substance of the cerebrum produce hemiopia—under such circumstances the question is always one of lateral hemiopia—the case especially quoted is that in which visual disorder occurs suddenly, in consequence of an apoplectic attack, the extremities on one side of the body being at the same time affected with motor hemiplegia and sometimes also with anæsthesia. Nothing in clinical medicine is better established than the existence of facts of this nature, several instances of which have been recently quoted in Schoen's interesting work.<sup>2</sup> But the account of the autopsy has hitherto been always defective, and it may be asked if the lesion described in these cases did really occupy the deep parts or, on the contrary, the base of the encephalon.

It seems to be an indisputable fact, as you have not forgotten,

<sup>1</sup> H. C. Bastian, 'The Lancet,' July 25th, 1874.

<sup>2</sup> 'Archiv der Heilkunde,' p. 19, 1875.

that destruction or compression of one of the optic tracts is followed by lateral hemiopia, and, on the other hand, that the anatomical relations existing between the tracts and certain parts of the isthmus, as for example, the *crura cerebri*, is a matter of common knowledge.

This being so, it cannot be denied that a lesion suitably localised, in one of the *crura cerebri*, for instance, is likely to cause at the same time lateral hemiopia, motor hemiplegia, and perhaps also hemianæsthesia. A lesion, such as a hæmorrhagic focus suddenly occurring in the substance of the posterior part of the optic thalami, might also, it is conceivable, be followed by the same effects. It is evident that these various combinations depend simply upon the effects of pressure. Be that as it may, it is important to remember that, among the published cases of lateral hemiopia of supposed intra-cerebral origin, a certain number of them are not amenable to the explanation which I have just suggested. Such, among others, are the cases in which right lateral hemiopia arises in common with aphasia, and sometimes also with various modifications of sensibility or movement in the limbs on the right side of the body.<sup>1</sup> These facts do not constitute a homogeneous group. In the first category we are concerned with a particular form of megrim,<sup>2</sup> that is to say, of symptoms essentially transitory, occurring in paroxysms and characterised especially by the co-existence of scintillating scotoma, of more or less pronounced hemiopia, and sometimes also of a certain degree of aphasia and of numbness in the face and limbs on the right side of the body.

Cephalalgia, nausea, and vomiting usually terminate the scene. It is evident that we cannot invoke here the intervention of a coarse and permanent material change. It is not the same in cases belonging to the second category, in which aphasia, hemiplegia, and hemiopia exist as permanent phenomena.<sup>3</sup>

<sup>1</sup> Several cases of this kind have been described lately by Bernhardt, 'Berliner Klin. Wochenschrift,' 32, 1872, and 'Centralblatt,' 1872, 39; and by Schoen, loc. cit. See also Hughlings Jackson, "A case of Hemiopia with Hemianæsthesia and Hemiplegia," 'The Lancet,' Aug. 29, 1874, p. 306.

<sup>2</sup> On this form of megrim see the works of Tissot, Labarraque, Piorry, and Latham ('On Nervous or Sick Headache,' Cambridge, 1873); and especially Dr. Liveing's recent work 'On Megrim, Sick Headache, and some Allied Disorders,' London, 1873.

<sup>3</sup> It is conceivable, indeed, that a large tumour might occasion all the

In the present state of affairs, I do not see how these different cases, which have been brought to light by clinical observation, can be explained anatomically on the hypothesis of a unique lesion. But I can only point out these difficulties, the solution of which is reserved for the future.

symptoms noticed in connection with cases of the second category. This happened in a case recently published by Hirschberg in 'Virchow's Archiv' (t. lxv, 1 Heft, p. 116.) The patient, who was the subject of this observation, presented in addition to very characteristic right lateral hemiopia, aphasia and right hemiplegia. At the autopsy, there was found in the substance of the left frontal lobe a tumour, the size of an apple, which was described as a vascular glioma. The optic tract on the *left side was much flattened*. I must ask you to notice that the views expressed in the present lecture are corroborated by this observation, since the hemiopia, there described, might be referred to the pressure exerted on the optic tract.

## LECTURE XII.

### SECONDARY DEGENERATIONS.

**SUMMARY.**—*Anterior or lenticulo-striate region of the central masses (anterior two thirds of the internal capsule, caudate and lenticular nuclei). Influence of lesions of these parts over the production of motor hemiplegia. Experimental facts. Agreement between them and facts in human pathology. Difference between lesions of the caudate nucleus and those of the anterior part of the internal capsule.*

*Lesions causing secondary degeneration or descending sclerosis: importance of the seat and extent of these lesions. Characteristics of descending sclerosis. Extent: appearance of the lesion in the crus cerebri, pons, anterior pyramid, and lateral column of the cord.*

*Analogies and differences between secondary lateral sclerosis of cerebral origin, and primary fasciculated sclerosis of the lateral columns.*

*Symptoms pertaining to secondary sclerosis: motor impotence, permanent contracture. Muscular atrophy produced by extension of the lateral sclerosis to the grey cornua. Descending sclerosis secondary to a cortical lesion. Pathological facts in favour of the existence of direct peduncular fibres. Cortical lesions causing secondary degeneration correspond in position to the so-called psychomotor centres.*

**GENTLEMEN,**—We must now direct our attention once more to the anterior region of the central masses, in order to study more closely from the standpoint of pathological anatomy and physiology, the effects of lesions produced there. You have not forgotten that this region, which might be called the *lenticulo-striate*, in opposition to the posterior or *lenticulo-optic*

region, includes :—(1) The anterior two thirds of that white tract which we term the internal capsule ; (2) internal to this, the large extremity or head of the caudate nucleus ; (3) externally, towards the island of Reil, nearly the anterior two thirds of the lenticular nucleus.

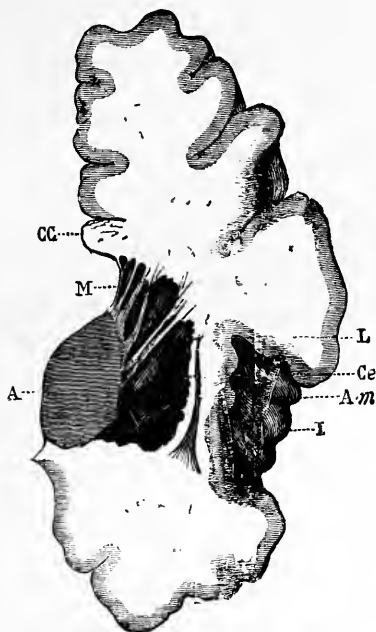


FIG 34.—A, optic thalamus ; Am, claustrum ; cc, corpus callosum ; ce, external capsule ; I, island of Reil ; L, patch of old softening affecting the middle part of the caudate nucleus and internal capsule. The lesion, which consists of a kind of large hollow, is only separated from the lateral ventricle by the ependyma M, which has resisted further extension.

Observation has repeatedly shown, as I have already remarked in the course of these lectures (Lectures VIII and IX, pp. 85—87), that common motor hemiplegia without the accompaniment of disorders of sensibility is the inevitable consequence of all lesions, however small, which have their seat in the various parts just enumerated, on condition, however, that the lesions in question cause destruction or sudden compression

of the nerve-elements of the circumscribed area involved, and not merely simple displacement gradually effected, as is so often seen in the case of tumours.

I called attention, moreover, to the necessity of establishing an important distinction in this respect. Hence it is that even extensive and profound lesions which remain limited to the sphere of the grey nuclei (caudate or lenticular nucleus) determine, as a general rule, symptoms relatively but little marked and of short duration, whilst comparatively slight lesions involving the white tract (internal capsule) give rise to motor hemiplegia, which is not only very pronounced but also of long duration, often, indeed, incurable (Fig. 34).

I would inquire with you the reason of these differences. In the first place, I shall consider the relative intensity of the paralytic symptoms in the case of lesions of the internal capsule in comparison with their mildness in the case of lesions limited to the grey nuclei. Afterwards I shall notice the transitory character of the hemiplegia in cases of the last kind, in opposition to the permanence which this symptom almost necessarily presents when the lesion involves the internal capsule.

## I.

In reference to the first point, I shall once more recall to your minds some peculiarities in the anatomical constitution of the internal capsule. You have not forgotten that this tract contains (1) *direct peduncular* fibres, which arise beneath the cortex and penetrate the lower layer of the crus cerebri without entering into relation with the lenticular or caudate nucleus; (2) *indirect peduncular* fibres which, on the contrary, take origin in the lenticular or caudate nucleus and have no connection with the cortex. For the moment we shall disregard the fasciculi of fibres extending from the cortical matter to the central grey nuclei. We shall assume that the various peduncular fibres, both direct and indirect, pass in a centrifugal direction, and that they transmit to the periphery the motor influence developed either in the cerebral cortex or in the lenticular and caudate nuclei.



According to this hypothesis, it is easy to understand that a slight lesion affecting the internal capsule, particularly its most inferior part near the foot of the cerebral peduncle, where all the fibres are packed into a narrow space, will have the effect of suspending at the same time the influence of the cortex and of the two grey nuclei. Whereas, on the contrary, a lesion limited to the lenticular nucleus will allow the action of the caudate nucleus and of the cortex to continue.

We can readily imagine the effects of the various combinations which are likely to occur in this system: lesion of the caudate nucleus, of certain regions of the cortex, of both grey nuclei at once, with or without participation of the peduncular fibres of the internal capsule.

I do not attach to this theoretical consideration more importance than it deserves. I must mention, however, that it is fairly well adapted to the facts revealed in man by clinical observation; moreover, it is not opposed, as you will see, by experiments made on animals.

It has long been known<sup>1</sup> that the motor disorders which are produced in the majority of animals by methodical destruction of the various parts of the encephalon, particularly of the cerebrum, as a rule, differ considerably from those observed in man, in consequence of lesions occasioned in the corresponding parts by disease.

In the interpretation of these experimental facts and in their application to human pathology, it is necessary to take into consideration, among other circumstances, the more or less inferior species of the animal and its more or less advanced age. Thus, the removal of an entire cerebral hemisphere in a pigeon, and *à fortiori* in a reptile, does not produce any motor disorder comparable to hemiplegia. It is almost the same in the case of the rabbit. A barely perceptible weakness of the extremities on one side of the body is, in this animal, the only consequence of such a lesion; standing and jumping are still possible when the entire cerebrum has been destroyed, provided, however, that the pons remains intact.<sup>2</sup>

In the dog the results are very notably different. If I may

<sup>1</sup> On this subject, see Longet, 'Traité de physiologie,' t. iii, p. 431, and Vulpian, 'Leçons sur la physiologie générale,' &c., p. 676.

<sup>2</sup> Vulpian, Longet.

rely on the recent experiments performed by MM. Carville and Duret in M. Vulpian's laboratory, the symptoms which, in this animal, succeed to the methodical removal of the various parts of the cerebrum appear to resemble very closely those observable in man, in cases of circumscribed lesions of the cerebral hemispheres. It is, at any rate, very probable that the similarity would be still more complete and manifest if the experiment were made on the monkey.

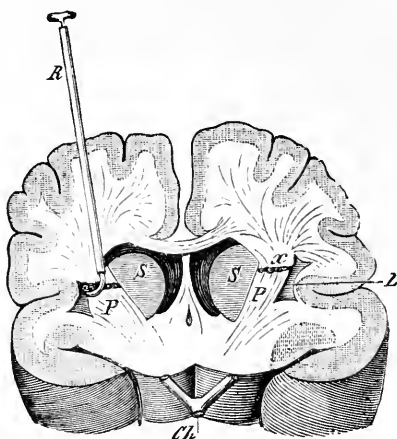


FIG 35.—Transverse section of a dog's cerebrum, five millimètres in front of the optic chiasma. *s*, *s*, caudate nuclei; *L*, lenticular nucleus; *P*, *P*, peduncular expansion (internal capsule); *ch*, optic chiasma. *x*, section of the internal capsule (anterior or lenticulo-striate region), causing hemiplegia on the opposite side of the body without anæsthesia. *Q*, Veyssière's spring-styilet dividing the internal capsule.

The following is a brief account of the principal results obtained by the experiments of MM. Carville and Duret:—1. In the dog removal of the grey matter in the so-called motor regions of the cerebral cortex determines temporary paresis of the extremities on the opposite side of the body. 2. Extirpation of the caudate nucleus gives rise to similar but more marked paresis; it has not as yet been possible to effect the separate removal of the lenticular nucleus in consequence of its topographical position.<sup>1</sup> 3. If the lesion, on the other hand,

<sup>1</sup> It is difficult to arrive at any conclusion from Nothnagel's experiments,

involves the lower part of the internal capsule, there is produced in the fore and hinder extremities on the opposite side of the body not merely simple paresis, but well-marked motor paralysis, similar to the hemiplegia occurring in man as a result of lesion of these same parts (Fig. 35).

When held suspended by the skin of the back the animal thus operated on can still rest on its sound limbs, but the affected extremities are flabby, inert, and capable only of purely reflex movements.

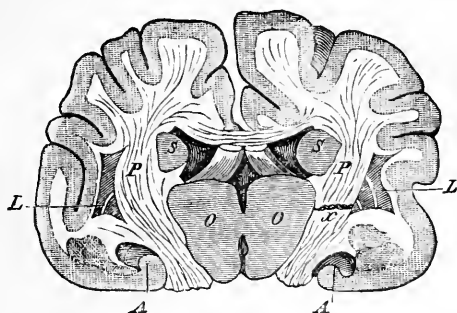


FIG. 36.—(Both this figure and the preceding are copied from the memoir of MM. Carville and Duret, which was published in the 'Archives de physiologie normale et pathologique,' 1875, pp. 468 and 471.) Transverse section of a dog's cerebrum at the level of the corpora albicantia. o, o, optic thalami; s, s, caudate nuclei; L, L, lenticular nuclei; P, P, posterior or lenticulo-optic region of internal capsule; A, A, cornua ammonis. z, section of the posterior or lenticulo-optic part of the capsule causing hemianæsthesia.

In short, gentlemen, you see from these interesting inquiries, which ought to be both repeated and extended, that the contradiction long observed between animals and man with regard to the influence of the various parts of one cerebral hemisphere over the movement of the extremities on the opposite side of the body—this contradiction, I say—seems no longer to exist when, for the sake of comparison, we have recourse to species which are relatively highly placed in the animal scale (Fig. 36).

This, perhaps, is a suitable opportunity to remind you that which were made by means of caustic injections. These would almost necessarily have the effect of causing irritative phenomena, which must certainly complicate the situation.

in the dog also, as these same experiments of MM. Carville and Duret and those of M. Veyssière demonstrate, lesions of the posterior part of the internal capsule produce, as in man, crossed hemianæsthesia.

## II.

The facts just mentioned may be utilised, if I mistake not, to explain why hemiplegia resulting from destructive lesions limited to the substance of the grey nuclei is usually transitory, whereas that consequent on lesions involving the substance of the internal capsule is, on the contrary, of long duration and often, indeed, absolutely incurable.

According to the hypothesis suggested, it is readily conceivable that the lenticular and caudate nuclei, and the so-called motor regions of the cortex, may be mutually supplementary in their functions so long as the conducting fasciculi which form the capsule preserve their integrity and continue to maintain the relation between one or other of the grey centres in question and the peripheral parts, whilst this can no longer take place when the continuity of these fasciculi has been decidedly interrupted.

I must add that, according to all probability, a supplementary relation may be established not only between the various grey nuclei, but even between the different parts of the same nucleus. It has been shown, at any rate as far as the caudate nucleus of the corpus striatum is concerned, that partial destructive lesions affecting the most diverse regions of the nucleus are uniformly indicated by hemiplegia which, although transitory, is more or less pronounced and *total*, that is to say, involving at once both the face and extremities. In this respect there is no difference to be noticed between the head, tail, and middle part of the caudate nucleus. Accordingly it appears, as Dr. Hughlings Jackson has justly remarked, that each particle of the corpus striatum is a miniature representation of the entire corpus striatum. Experiment, moreover, yields results in conformity with those furnished by clinical observation, in showing that stimulation of parts of the caudate nucleus, however made, always produces combined movements on the opposite side of

the body, and never dissociated movements, localised, for example, to an extremity or to part of an extremity.<sup>1</sup>

In the case of a destructive lesion of the internal capsule slow regeneration of the nerve-elements, on the other hand, might allow gradual re-establishment of function. But this work of restitution, if it does really occur sometimes, must certainly only take place under very exceptional circumstances. It has, indeed, been placed beyond all doubt by observations which are now very numerous, that focal lesions destroying, to a certain extent, the motor fibres of the internal capsule are almost necessarily followed by a fasciculated lesion which, commencing immediately below the focal lesion, may be followed on the corresponding side into the foot of the peduncle, the pons, anterior pyramid to the level of the decussation, and below this into the spinal cord on the opposite side, throughout the entire length of the lateral column as far as the lumbar enlargement.

### III.

This is now, I think, an opportune time to enter into a few details with regard to the pathological anatomy and physiology of this *secondary degeneration*, or *descending sclerosis*, as it may also be called. It is undoubtedly one of the main causes of persistence of motor impotence in the cases under our consideration. In my opinion, we must likewise ascribe to it, for the most part, the *permanent* or so-called *late contracture*,<sup>2</sup> which in these same cases sooner or later attacks the paralysed limbs, and usually plays the predominant part in the prognosis of cerebral hæmorrhage.

1. Let us fix our attention, first of all, on the fact which really controls this question: circumscribed cerebral lesions, considered in relation to the position which they occupy, are not all equally calculated to determine the production of

<sup>1</sup> Experiments of Ferrier, Carville, and Duret.

<sup>2</sup> It is well known that we are indebted to Dr. Todd for establishing the distinction between *early* and *late contracture* of the extremities in apoplectic patients. The first shows itself from the commencement, and is almost invariably transitory; the other is scarcely apparent from the fifteenth to the thirtieth day after the attack, is always situated in the extremities of the side opposite to the lesion, and most frequently becomes permanently established there.

secondary sclerosis. Accordingly, some of these lesions are never followed by descending sclerosis, whilst others inevitably excite them. To the second group belong destructive lesions, however small, which involve, according to L. Türck's important observation, the fasciculi of the internal capsule in their course between the lenticular and caudate nucleus, that is to say, in the anterior two thirds of the capsule. On the other hand, lesions which remain limited to the substance of the central grey masses, viz. the caudate and lenticular nuclei and the optic thalamus, do not give rise to secondary sclerosis. This remarkable fact was clearly demonstrated by L. Türck in 1851.<sup>1</sup> M. Vulpian and myself have confirmed its perfect accuracy by the investigations which we made in common on this subject at La Salpêtrière from 1861 to 1866.<sup>2</sup> M. Bouchard's important labours have likewise corroborated it.<sup>3</sup> After L. Türck, we also observed a number of other facts of no less interest, of which the following is a summary.

2. Circumscribed lesions situated outside the central masses, in the centrum ovale of Vieussens, if only they attain certain dimensions, also produce descending sclerosis, provided that they are not too far removed from the foot of the corona radiata.

3. Lesions of the cortical grey matter of the hemispheres, when very superficial (those, for example, accompanying meningitis are invariably of such a nature), do not cause descending sclerosis.

4. On the other hand, cortical lesions extensive both superficially and in depth, or, in other words, involving at the same time the grey matter and the underlying medullary substance, as seen in cases of ischæmic softening resulting, for instance, from obstruction of a large branch of the Sylvian artery (see Fig 37), these lesions, I say, *even when there is no participation of the central masses*, determine under certain conditions secondary sclerosis as pronounced as that which is dependent on lesion of the anterior parts of the internal capsule.

<sup>1</sup> L. Türck, 'Ueber Secundare Erkrankung einzelner Rückenmarkstränge und ihrer forsetzungen zum Gehirne.'—Sitzungber. der mathnatur, Class, d. k. a. k., 1851.—Idem xi, Bd. 1853.

<sup>2</sup> A. Vulpian, 'Physiologie du système nerveux,' Paris, 1866.

<sup>3</sup> Ch. Bouchard, "Des dégénéralions secondaires de la moelle épinière," 'Archiv. gén. de médecine,' 1866.

One of these conditions, which is relative to the seat of the cortical lesion, is of capital importance and demands altogether special notice. It follows, as you will see, from my observations, that extensive superficial ramollissement (yellow softening), when situated either in the occipital or in the posterior parts of the temporal or even in the sphenoidal lobe, or, lastly, in the anterior regions of the frontal lobe, is not followed by consecutive fasciculated sclerosis; whereas, on the contrary, it

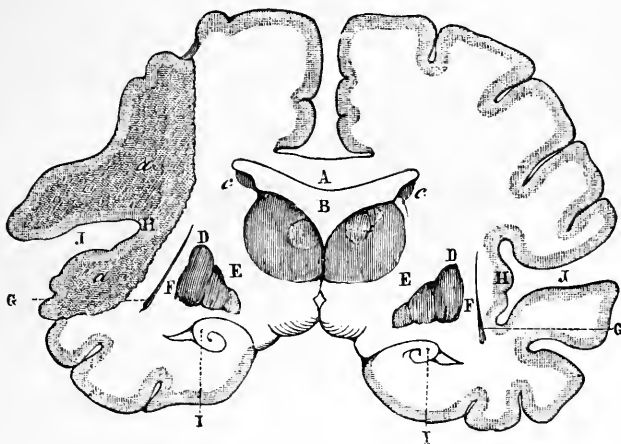


FIG. 37.—Ischaemic softening of cortex without participation of the central masses. H, circumscribed area of softening; J, fissure of Sylvius; E, internal capsule; D, lenticular nucleus; F, external capsule; G, claustrum. There was well marked descending lesion in this case.

is the rule for this to supervene when the lesion involves the two ascending convolutions (ascending frontal and parietal) and the contiguous parts of the frontal and parietal lobes (Fig. 38).

At a subsequent stage I shall reconsider in a special manner this important point, to which, for the present, I merely call your attention.

5. In short, the seat and extent of the lesion appear to be the two primary conditions; the nature of the change has no marked influence. The necessary seat and extent being present, provided that the lesion is destructive, that is to say,

capable of interrupting the course of the medullary fibres, descending sclerosis must follow. Circumscribed lesions from hæmorrhage and softening, simple or syphilitic encephalitis, occupy in this respect nearly the same rank. This is not the case with certain tumours which, during a long period of their development, only displace and separate the medullary fibres without interrupting their continuity. This is the reason

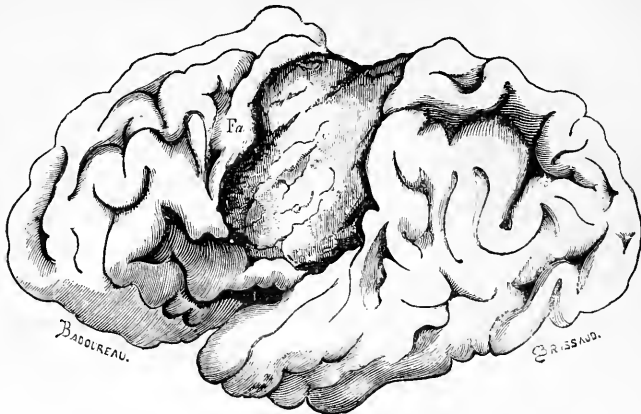


FIG. 38.—Large circumscribed area of cortical softening destroying the ascending parietal, a considerable portion of the ascending frontal, and most of the convolutions of the island of Reil. The central masses were intact.

why tumours may be found, even in the regions of the cortex mentioned above, as being the places of selection, without the accompaniment of secondary fasciculated sclerosis.

#### IV.

With regard to the anatomy of fasciculated sclerosis, I must return for details to the important memoir published by M. Bouchard. I shall simply remind you now of some facts to which our present inquiries lend a special interest :

(1) In the first place, I must recall to your recollection that sclerosis secondary to circumscribed lesion of one cerebral hemisphere always occupies one half of the system of the lateral columns. It is more or less pronounced and extensive



according to the breadth of the column, but it always invades its entire length as far as the lower end of the lumbar enlargement, and is never interrupted in its course. It is invariably *descending*, in the sense that it begins at the level of the affected part and extends only below this point. It cannot be followed upwards towards the cortex. Atrophy of one or several convolutions, or even of an entire hemisphere, which is observed when a central focal lesion becomes developed in very young subjects, must not be looked upon as due to secondary sclerosis. In this case we are concerned with an arrest of development comparable to the atrophy which, under the same circumstances, is presented by the extremities on the side of the body attacked with hemiplegia (infantile spasmodic hemiplegia).

(2) Macroscopic examination alone in cases which are somewhat old and fairly well pronounced, enables us to recognise some of the most striking features of the change. Let us suppose the case of an ochreous focal lesion interrupting in the left hemisphere the course of the fibres of the internal capsule in its middle third. Under such circumstances the foot of the crus cerebri on the left side will appear narrower and more flattened out than that on the opposite side. Furthermore there will be observed a greyish band situated in the middle part of the crus,<sup>1</sup> which, in an antero-posterior section, will be found not to extend beyond the grey matter of Soemmering. The grey tint disappears at the level of the pons, but below this it is again seen in the medulla, where it occupies the entire anterior pyramid on the side corresponding to the cerebral lesion. The affected pyramid, moreover, is narrow and flattened; below, the indentations of the bulbar decussation stand out more distinctly than in the normal condition in consequence of the contrast which exists between the healthy and diseased sides. Below the decussation the sclerotic change must be looked for in the half of the cord opposite to the affected hemisphere, and more explicitly in the lateral column.

The degenerated region appears under the form of a triangular space of a grey colour, situated immediately outside and in front of the corresponding posterior grey cornu. Its size

<sup>1</sup> The position occupied by this band varies according to the seat of the central lesion; the more anteriorly the lesion of the capsule is situated, the more it approaches the internal border of the foot of the peduncle.

progressively diminishes in proportion as the sections of the cord are made lower and lower.

(3) The microscopical examination of suitably hardened and prepared sections greatly assists in the further elucidation of these facts.

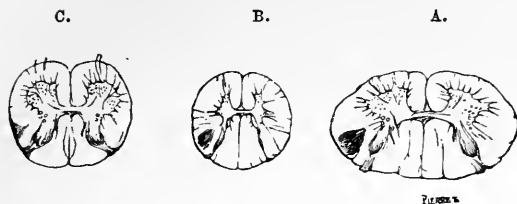
In the first place, it furnishes the means of determining the topography of the lesion with more accuracy and of demonstrating its "precise and systematised limitation to the area of the lateral columns. The other white columns and the grey cornua remain quite unaffected. At the same time, it may be noticed that the nerve-roots, both anterior and posterior, as well as the meninges, present no trace of degeneration.

Lastly, microscopical examination shows also the nature of the morbid process, and displays the characteristics of a grey induration or sclerosis which differs in no essential point from that observed in the case of primary fasciculated sclerosis.<sup>1</sup>

(4) It is now time to notice the analogies which exist, from a pathological point of view, between secondary fasciculated sclerosis of cerebral origin and that primary and symmetrical fasciculated sclerosis of the lateral columns which I described last year in connection with spinal amyotrophies.

These analogies are considerable, seeing that in both cases an identical change, that of grey induration, is found localised in the same system. But there are also differences which call for notice; thus, in primary sclerosis, the fasciculated lesion is necessarily double, that is to say, it occupies the system of the lateral columns on both sides at once, and not on one side only, as is invariably the case in secondary sclerosis, when the circumscribed lesion which was its starting-point is unilateral. I must add that it is always much more extensive in the transverse direction, and that there is therefore reason to believe that, in addition to the cerebro-spinal or pyramidal fibres alone affected in secondary sclerosis, it invades the system of spinal fibres peculiar to the lateral column. (Compare Figs. 39, 40, and 41, and Figs. 42, 43, and 44.)

<sup>1</sup> The extension, in certain cases, of the lesion beyond its usual limits, the invasion, for example, of the anterior grey cornua, which we shall take into consideration later on, is incontestably one of the most decisive arguments that can be brought forward to establish the irritative nature of the morbid process.



FIGS. 39, 40, 41.—Transverse sections of the spinal cord in a patient who was affected with secondary degeneration (lateral fasciculated sclerosis consecutive to cerebral lesion), the result of cerebral softening, which had destroyed the opto-striate bodies and the internal capsule in the right hemisphere.

A, cervical region; B, dorsal region; C, lumbar region. The descending sclerosis is seen to occupy in the cervical enlargement the cervical part of the lateral column, and to become superficial in the lumbar region.

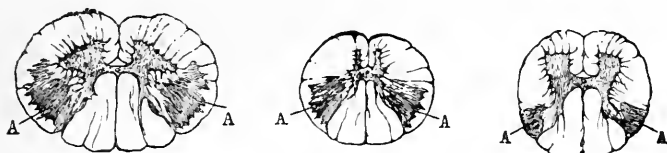


FIG. 42.

FIG. 43.

FIG. 44.

FIG. 42.—Transverse section of the spinal cord through the middle part of the cervical enlargement.

FIG. 43.—Transverse section through the middle of the dorsal region.

FIG. 44.—Transverse section through the middle of the lumbar enlargement.

Lastly, primary sclerosis has a great tendency to encroach on the adjacent spinal regions, either the white fasciculi, or, especially, the anterior grey cornua; secondary sclerosis, as a rule, has no such tendency.<sup>1</sup> In this respect there are, however,

<sup>1</sup> The following are some more precise details relative to the anatomical differences which exist between secondary lateral sclerosis and primary amyotrophic lateral sclerosis. It is found by the examination of hardened transverse sections that, whenever secondary sclerosis in the medulla has involved nearly all the fibres of the anterior pyramid, the lesion in the lateral column of the cord only occupies a comparatively limited region. On a transverse section made at the cervical enlargement, this latter has the form of a triangle, with very distinctly defined margins, the summit of which is directed inwards towards the angle separating the anterior from the posterior grey cornua, and the base of which, somewhat rounded off, never reaches the

a number of exceptions which are, as you will presently see, particularly interesting from the point of view with which we are for the moment concerned.

The facts, which we have gradually acquired in the preceding account, enable us to justify the inaugural proposition of the present chapter. We have just shown that from an anatomical standpoint there exists considerable analogy between the primary and secondary forms of lateral fasciculated sclerosis. This resemblance may be followed in the domain of clinical observation. We know, indeed, that motor impotence, contracture of the extremities, transitory at first and then permanent, with spontaneous or provoked trepidation, &c., constitute a symptomatic whole, indicating during life the existence of fasciculated spinal sclerosis which is primary or, in other words, quite independent of any cerebral lesion.

Now, all the symptoms are reproduced with their essential characteristics in cases of sclerosis secondary to a cerebral lesion, and constitute the special clinical features of ordinary permanent hemiplegia. We may, therefore, assert that between the lesion

cortical zone of the cord, and furthermore does not involve the antero-external border of the posterior cornu (Fig. 39).

In the dorsal region, the sclerotic part gradually diminishes in diameter, and tends to assume an oval form (Fig. 40). Finally, in the lumbar enlargement (Fig. 41), it is again, as in the cervical region, a triangular space, but its base has become quite superficial and lies beneath the pia mater.

In primary lateral sclerosis, the sclerotic zone generally occupies the same region as in the preceding case, but its limits are much more extensive. Thus, in front, the lesion tends to invade the domain of the anterior root-zones and, internally, comes into contact with that fasciculus of nerve-fibres, probably sensitive, which constitutes the deep part of the lateral columns (see Figs. 42, 43, 44). We must add that the limits of the sclerosed part here are diffused and ill-defined. In some cases, they are found to be blended internally with the grey matter. We know that the latter is usually invaded by the sclerotic change in the case of amyotrophic lateral sclerosis, whereas this is quite an exceptional circumstance in secondary sclerosis of cerebral origin. From the consideration of what precedes, there are grounds for thinking that secondary sclerosis affects only a part of the nerve-fibres which form the lateral columns, viz. the cerebro-spinal fibres; whilst, in primary sclerosis, there is invasion of the entire lateral system, including, not only the cerebro-spinal and pyramidal fibres, but also those which, having their origin and termination in the cord, are strictly speaking, spinal.

*lateral sclerosis* and the phenomenon *permanent contracture* there exists a relation, of which in truth the physiological explanation has hitherto completely escaped us, but the reality of which is nevertheless based on a large number of observations.<sup>1</sup>

In my opinion, neither the retraction of the cerebral cicatrix, as Dr. Todd suggests, nor an encephalitis supervening in the neighbourhood of the lesion, as even at the present time many authors maintain, are calculated to explain the appearance of the so-called late contracture in hemiplegic patients. On the contrary, it is necessary to appeal to the existence of a chronic myelitis occurring in the lateral column in consequence of the cerebral lesion. Whilst abstaining from entering into a formal discussion on this subject, I must once more refer you to M. Bouchard's work, which has been already quoted. You will find collected there all the facts which may be invoked in favour of the opinion which I hold.

Originating as a result of a circumscribed cerebral lesion, the secondary sclerosis assumes at a certain period, as you see, an existence, as it were independent and autonomous; it manifests its presence by special symptoms. By reason of this autonomy, it may happen that the lesion extends beyond the limits usually assigned to it in the lateral columns and invades the neighbouring regions of the cord, the grey cornua, for instance. In such a case it is conceivable that important modifications might supervene in the symptoms. Hence it is that the muscles of the paralysed extremities in permanent hemiplegia, which ordinarily preserve their normal texture for a very long period, and merely waste with time, in certain cases undergo more or less rapid degenerative atrophy, whilst simultaneously the rigidity caused by contracture again gives place to flaccidity. In several examples of this kind, M. Pierret and myself have noticed, in addition to the classical lateral sclerosis, lesion of the anterior grey cornu on the same side, leading to destruction of the large nerve-cells in this region. In the same manner, invasion of the posterior grey cornua might explain the appearance of localised patches of anæsthesia in common hemiplegia. Lastly, extension of the irritative process, either to the lateral

<sup>1</sup> Permanent contracture of the extremities, as is evident in the case of hysteria, may occur without the coexistence of lateral sclerosis; but, when this lesion is present, permanent contracture is one of its constant symptoms.

column of the corresponding side in its whole extent, or even to the lateral column of the opposite side, will doubtless account for the fact that, contrary to ordinary observation, contracture sometimes greatly predominates, at a certain period, in the lower extremity, or even extends occasionally to the lower extremity of the opposite side.<sup>1</sup>

## V.

I have spoken hitherto of fasciculated sclerosis of cerebral origin only in so far as it depends on lesion of the central parts. I would now direct attention for a moment to that which is produced in consequence of a lesion of the cortical system. Considered as a spinal or bulbar affection, lateral sclerosis, in this last case, differs in no way from that which occurs in the first. The special conditions of development alone constitute the difference and demand some fresh details.

You have not forgotten that we were induced to admit, in virtue of a very probable hypothesis, the existence of *direct peduncular fibres* or, in other words, of fibres which, after leaving the foot of the crus, cross the internal capsule without entering the central grey nuclei, and consequently are only arrested in the grey cortical matter. In addition to the arguments already put forward, some experimental facts may also be cited in favour of the existence of such fibres, even in animals rather low in the scale, as, for example, in the rabbit.

Thus, in the previously quoted experiments of Gudden,<sup>2</sup> which were made, as you are aware, on very young animals, we find that eight months after the removal of the anterior parts of one hemisphere, the central masses, optic thalamus and corpus striatum remaining intact, we find, I repeat, after this mutilation that the internal capsule on the corresponding side becomes atrophied in a remarkable manner.

It is evident that this atrophy would not take place if the internal capsule, as some anatomists maintain, was exclusively composed of *indirect peduncular fibres*, that is to say, of those ending in the substance of the central grey nuclei.

<sup>1</sup> On this subject, see Bastian, 'Paralysis from Brain Diseases, &c.,' p. 141. London, 1875.

<sup>2</sup> 'Archiv f. Psychiatrie,' Bd. ii, 1870, pl. viii.

MM. Carville and Duret<sup>1</sup> accidentally discovered in a dog a lesion which had destroyed the white matter of the entire frontal part of one lobe, without directly affecting either the central grey nuclei or the internal capsule. In this case there was well-marked atrophy of the foot of the crus, of the pons, and of the bulbar pyramid on the side corresponding to the cerebral lesion. In man, the existence of these direct peduncular fibres seems also to be confirmed by the like production of these secondary degenerations which, as we have remarked, become developed in consequence of extensive and profound lesions of the grey cortical matter. Are these direct peduncular fibres, after spreading out in the corona radiata, distributed indifferently towards all the regions of the hemisphere; or, on the contrary, do they proceed to special departments of the cortex? The facts which I have collected with the object of investigating this question support the second hypothesis. These observations, which have been made in my wards at La Salpêtrière during the course of the last fifteen years, have reference to cases of old ischæmic softening.<sup>2</sup>

In these cases the lesion presented itself under the form of yellow softening (*plaques jaunes*), more or less extensive in area, involving to a variable depth the subjacent white matter and occupying the most diverse regions of the surface of the hemisphere. It is expressly mentioned in all the observations that the softening had not affected the central masses:—optic thalami, caudate and lenticular nuclei, and internal capsule. My observations may be divided into two groups.

The first includes the cases in which permanent hemiplegia had not existed during life, and in which secondary degeneration was found at the autopsy to be absent.

In all, the convolutions supplied by the Sylvian artery and particularly the ascending frontal and parietal, remained intact. The yellow softening was situated in one of the following regions, viz. some part of the sphenoidal lobes, the lobulus quadratus, the cuneus, one or both occipital lobes in their

<sup>1</sup> 'Archives de physiologie,' 1875.

<sup>2</sup> The majority of these observations are accompanied by drawings made from nature; it is evident that these enable us to give the precise seat and extent of the lesion and, consequently, serve to compensate for the unfortunately very common insufficiency of our descriptions.

entirety, some part of the anterior two thirds of the frontal lobes.

In all the cases of the second group there had been, on the other hand, permanent hemiplegia and well-marked secondary sclerosis. The feature common to these cases is that the lesion invariably involved, to a greater or less extent, one or other of the ascending frontal and parietal convolutions, principally in their upper half, and often both at the same time. In addition, the regions nearest to the frontal and parietal convolutions were very frequently involved.

The figure to which I call your attention shows a beautiful example of this kind (Fig. 45). You perceive from what

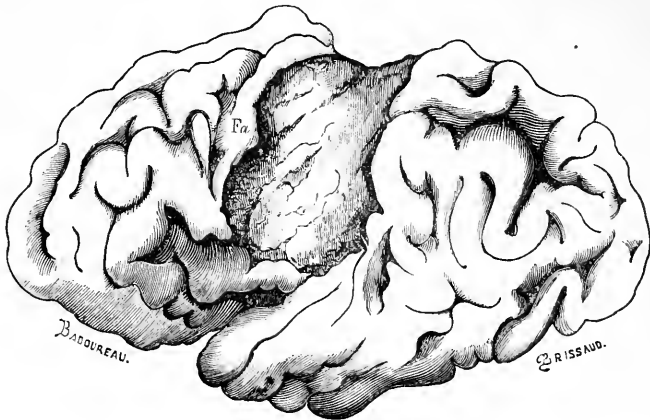


FIG. 45.—*Fa*, large circumscribed area of cortical softening destroying the ascending parietal, a considerable portion of the ascending frontal, and most of the convolutions of the island of Reil. The central masses were intact.

precedes, as I had anticipated, that the production of secondary sclerosis, in consequence of destructive lesions of the hemispherical cortex, appears to be subordinated to the seat occupied by these lesions. I must ask you to notice, in conclusion, that these departments of the cortical system, lesion of which exclusively determines the development of secondary degeneration, correspond to those found by experiment on the monkey to accord with the so-called psychomotor centres. These also



are the regions in which the grey cortical matter contains the largest pyramidal cells.

The important fact, gentlemen, which I have just brought prominently before you, should be utilised in the investigation of localisations in the cortical system of the cerebral hemispheres ; this arduous task we shall undertake in our subsequent lectures.



## PART SECOND.

### SPINAL LOCALISATIONS.

(ANATOMY AND PHYSIOLOGY OF THE PYRAMIDAL  
TRACTS.)



## LECTURE I.

### INTRODUCTION. TOPOGRAPHY OF THE SPINAL CORD. SYSTEM AFFECTIONS.

**SUMMARY.**—*Introduction.* Progress of the pathological anatomy of the nervous system. Many nervous diseases are still inaccessible to pathological anatomy. Short historical account of locomotor ataxy and disseminated sclerosis, which were for a long time looked upon as neuroses. The study of lesions, with the aid of experiment, furnishes the basis for a physiological interpretation of the morbid phenomena.

*Constitution of the spinal cord.* System lesions;—pyramidal tract (direct and crossed fasciculi): columns of Goll and of Burdach. This division of the various parts of the cord obtains from the period of its development. Researches of Pierret and Flechsig.

*Elementary affections.* Cerebral and bulbar localisations.

GENTLEMEN,—In conformity with the programme which have laid down, I must treat, during this year's course, of the pathological anatomy of the nervous system.

In these lectures which now date from seven years ago, I have already on several occasions had the opportunity of entering into some details on various points relative to this great subject. Seven years ago, for instance, in connection with some general considerations on Inflammation, I gave a pathological sketch of *spinal sclerosis*. The year afterwards, when discussing Degeneration and Atrophy, I endeavoured to show the striking influence, at that time but little understood, which affections of certain parts of the nerve-centres exercise over the development of various trophic disorders and of *muscular atrophy* in particular.

Lastly, in a series of lectures four years ago, I tried to prove

that the anatomo-clinical method enables us to establish on a solid basis the doctrine of cerebral localisation in man. But in short, gentlemen, these various subjects were always broached quite incidentally, and simply as elements to be employed in the solution of more general questions. Moreover, in spite of the interest attached to them they are really only episodes in the pathological history of the nervous system. It occurred to me that at the present time it would be advantageous to examine separately the facts which compose this history, and subsequently to consider them as a whole. The time, moreover, seems favorable to undertake this study.

Unlimited material, bearing on these questions, which was distributed in various publications, has been laboriously collected in the course of late years. At a certain period, there was experienced in every country the necessity for a classification, with a view to introducing these facts into general knowledge. Accordingly there have appeared lately, both abroad and in France, several large monographs and even formal treatises specially devoted to the pathology of the nervous system. In these works recent observations invariably hold an honorable place in relation to those of older date, or often, indeed, occupy the foremost rank.

A glance at these books will enable you, gentlemen, to recognise the indications of undoubted progress, and to observe that a large share in the accomplishment of this advance is due to pathological research, which has been turned to greater advantage by the use of improved methods of modern histology. To-day, gentlemen, I would dwell a moment on this point, because it particularly concerns us by reason of the special nature of our subject. The account about to be given will not be a formal history, but merely an introduction or summary, in which the leading points of some of the principal results obtained will be considered. In our progress we shall probably succeed in disengaging the dominant idea which seems to have inspired these works.

## I.

In the first place, since misconception on such a subject is very detrimental, it is necessary to recognise the actual exist-

ence, notwithstanding all efforts, of a considerable number of pathological conditions evidently situated in the nervous system, which leave no material or appreciable trace on the cadaver, or at the most only display trifling and inconstant lesions, incapable of explaining in every case the main facts of the morbid drama. Such, for example, are tetanus and hydrophobia. The old group of neuroses, although considerably curtailed in several points, still exists well-nigh inaccessible to the pathologist. True epilepsy, paralysis agitans, the most inveterate forms of hysteria, and, lastly, chorea, sphinx-like still defy the most minute anatomy.

At the outset, then, we are constrained to confess that, in the domain of neuro-pathology, pathological anatomy is only directly applicable to a certain number of morbid states.

## II.

But let us take matters as they stand, and consider only the pathological conditions in which the constant existence of a material lesion has been well and duly noticed. The field, thus limited, will still be of considerable extent. It has been often said that the progress of pathological anatomy and that of pathology proceed *pari passú*. This is doubtless a general truth, but it is especially applicable as far as diseases of the nervous system are concerned. A few examples will suffice to prove that the discovery of a constant lesion in diseases of this kind is a result of great moment.

The description given by Duchenne (of Boulogne) of the symptoms of the affection which he has called locomotor ataxy, is incontestably one of the most realistic and striking accounts extant. It is a veritable masterpiece. How much hesitation, moreover, prevailed in the minds of practitioners until the time when the lesion first described by Cruveilhier was, by the researches of MM. Bourdon and Luys, referred to the clinical type! Some authors, indeed, still thought that the affection, in its origin, might be a neurosis. All doubt was dispelled when it was discovered that the spinal lesion is perfectly organised and easily recognisable in the early stages of the complaint, although as yet it may only reveal its presence clinically

by a few fugitive and scarcely appreciable symptoms. Ophthalmoscopic examination, which in a manner corresponds to an anatomical investigation made during life, in demonstrating the existence of grey induration of the optic nerve often many years before the development of other tabetic symptoms, affords corroborative evidence in the same direction. The lesion then is always present in some degree. It is not wanting in those exceptional or abnormal varieties which are so multiform, and so different from the normal type. Its constant presence has enabled us to confidently connect these forms, the number of which seems to increase every day, with the regular type, which was alone indicated in Duchenne's classical description. The development of our knowledge relative to the disease known by the name of *disseminated sclerosis* or *multilocular induration* of the nerve-centres furnishes considerations of the same nature.

The disease in its classical type was but imperfectly understood until it was referred to the cerebro-spinal lesion. The regular form is rare, the abnormal varieties, on the contrary, are frequent and numerous. It was only possible to ally them to the type from which they differ clinically, because pathological anatomy served as the connecting link. In the examples, to which I have just called your attention, the intervention of pathological anatomy—and this is what I have been anxious to place in relief—presents a purely practical bearing.

The main point in question, as you will have remarked, is to supply nosology, for the purpose of resolving complex varieties, with more pronounced, more decisive, and, if I may use the expression, more material indications than the symptoms themselves. No speculative idea intervenes, and we scarcely attempt to understand the nature of the bonds which unite the lesions to the external symptoms. Without disparaging, gentlemen, the results obtained in this direction, it is certain that at the present time the study of lesions may be adapted, without any loss to its practical importance, to another point of view, and lay claim to higher and in some respects more scientific aims.

In other words, it may, with the assistance of experimental data, furnish the basis of a rational or, what is synonymous, of a physiological interpretation of the morbid phenomena.



## III.

This I should like now to illustrate to you by a few significant examples, selected from the results recently introduced into the pathology of the nerve-centres: cerebrum, medulla oblongata, and spinal cord. By reason of its comparatively less complex constitution I shall begin with the last-named.

A. The anatomy of the spinal cord, as seen under a low magnifying power, exhibits in the normal state, as you are aware, a relatively simple constitution. A transverse section of the lower cervical region shows an *axis* of grey matter surrounded by the white substance.<sup>1</sup>

In the grey matter you notice:—(1) The anterior cornua with the so-called *motor cells* and the origin of the anterior roots; (2) then the posterior cornua to which the posterior roots proceed. Lastly, you see that the cornua are connected one to the other by a commissure.

In the *medullary substance*, which is formed by a number of nerve-tubes having nearly everywhere a longitudinal direction, two regions are to be distinguished:—(1) The antero-lateral columns, limited by the anterior fissure and the posterior lateral fissure; (2) the posterior columns, limited by the commissure and the posterior cornua. We can scarcely take into consideration the space marked off by the intermediate posterior fissures.

B. As regards the analysis of the functions of the various white fasciculi and the different parts of the grey matter, the experimental method has not materially modified the facts of descriptive anatomy. It has demonstrated the peculiar properties of the antero-lateral columns taken as a whole,<sup>2</sup> of the posterior columns, of the two great regions of grey matter, and beyond that it has not gone much farther.

C. The methodical investigation of pathological lesions, as you are about to see, has shown that the constitution of the cord is really more complicated. A great fact, gentlemen, governs the

<sup>1</sup> The white matter of the spinal cord is often called the *manteau* by French writers (literally *cloak*), in opposition to the central grey matter. —(Translator.)

<sup>2</sup> See, however, Woroschiloff's work, 'Sächs. Academ.,' etc. Leipzig, 1875.

anatomy of the spinal cord. It is the widely distributed existence in this domain of the *so-called system lesions*.

By this expression, which is borrowed from M. Vulpian's works, we mean to designate lesions which are strictly limited to certain well-determined parts of the organ, without involving neighbouring regions.

I place before you a kind of topographical plan, showing the various regions liable to be affected by the system lesions, with which we are as yet acquainted (Fig. 46). The posterior columns, which are considered in physiology as forming a whole,

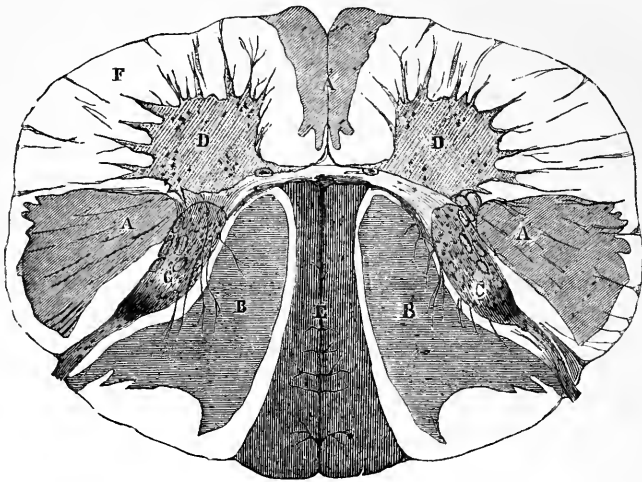


FIG. 46.—A, A, lateral columns; A', columns of Türk; B, B, posterior root-zones; C, C, posterior cornua; D, D, anterior cornua; F, anterior root-zone; E, columns of Goll.

are, on the contrary, clearly divided by pathological anatomy into two very distinct parts. Thus, the parts adjacent to the posterior fissure, viz. the columns of Goll, may be affected separately. Sometimes lesions involve the region of the posterior columns which lies nearest to the posterior cornua, that is to say the *radicular* (Pierret) or *cuneiform* (Burdach) fasciculi.

The antero-lateral columns may be subdivided in the same way. Thus, as a consequence of cervical lesions in a certain position, a well-defined lesion makes its appearance in the anterior part of the antero-lateral columns, close to the median

fissure. The lesion affects a bundle of fibres (scarcely, if at all, evident in the normal state) which extends from the medulla to the dorsal region. This is the column of Türck, or *direct pyramidal tract*, lesion of which is always accompanied by one of the same nature situated in the posterior part of the lateral column on the opposite side in a certain fixed region, the precise limits of which we shall have to examine. This space

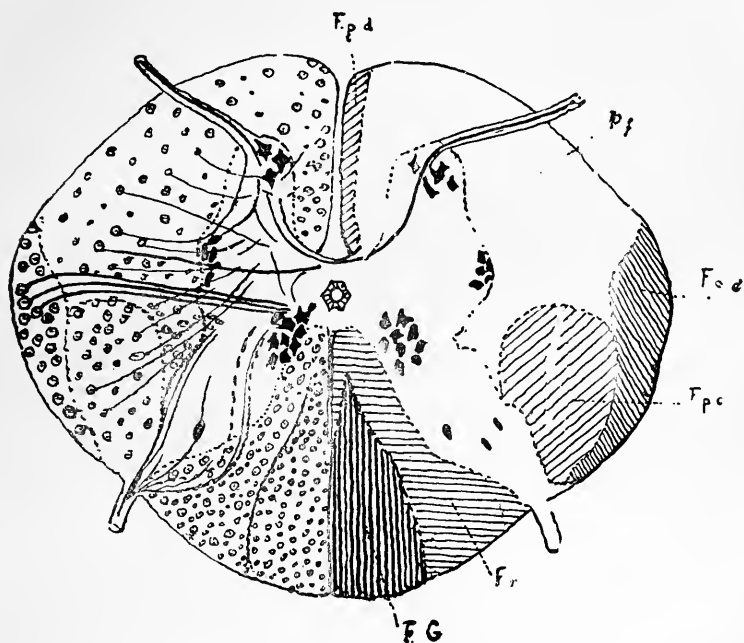


FIG. 47.—(After Flechsig). *Fpd*, direct pyramidal tract; *pf*, fundamental part of lateral column; *Fcd*, direct cerebellar tract; *Fpc*, crossed pyramidal tract; *Fr*, posterior root-zone; *FG*, column of Goll.

corresponds to the *crossed pyramidal tract*. Between the base of the triangle, representing the section of the crossed pyramidal tract and the pia mater, there exists on each side a space which, in such a case as the present, remains intact, at any rate in the cervical region. This space corresponds to the transverse section of the *direct cerebellar tract* (Flechsig). This latter is also liable to be affected systematically.

We are as yet unacquainted with any instances of lesions

involving the region which surrounds the anterior cornua, and which alone maintains its normal condition, when the antero-lateral columns have undergone morbid change. This region has received the names of *anterior root-zone* (Pierret) and *fundamental region of the lateral columns* (Flechsigs).

We must add that, so far as the grey matter is concerned, there is quite a series of lesions, acute, chronic, and subacute, which are characterised by being systematically localised in the anterior grey cornua, where they necessarily involve the structure of the large motor nerve-cells.

You see, then, that the old posterior columns are decomposed by pathological anatomy into two secondary fasciculi, and that the old lateral columns are divided into three secondary tracts.

(D) But do these fasciculi, which may be affected separately in disease by a kind of selection, correspond to so many regions or distinct anatomical systems which are at the same time endowed with special functions? This seems to be now placed beyond all doubt, on the one hand, by the developmental anatomy of the spinal cord, and on the other hand, by the study of the symptoms which clinically reveal these system lesions.

(a.) Let us now take into consideration the first point. The question is not one of early development corresponding to the embryonic period, but of the development of the cord in the mature foetus or rather the newly-born child. According to the very important investigations of Flechsigs and Pierret, to which now I shall merely allude since they are to be the object of a special account, all parts of the cord are not definitely constituted when the child is born.

Thus, on the plate by Flechsigs which I pass round and which has reference to the cord of the recently-born child, you will notice the following peculiarities:—All the parts stained black have undergone development, the axis cylinder being surrounded by its myeline-sheath. The undeveloped parts, by reason of the mode of preparation, remain, on the contrary, quite clear, because, although the axis-cylinder exists, the myeline-sheath is still wanting.<sup>1</sup> What, then, are the parts which have remained clear?

By a coincidence which cannot be fortuitous, they are in

<sup>1</sup> Action of osmic acid.

fact the same crossed and direct pyramidal tracts in the antero-lateral columns, which are sometimes separately affected by disease.

According to Flechsig's researches, as we shall see at a later stage, these fasciculi are in direct relation with the motor regions of the cortex. But again, these identical regions in animals which, like man, only possess automatic life at birth, are not yet developed. It therefore follows that the pyramidal tracts may be considered as a kind of commissure connecting the parts of the cerebrum which preside over voluntary motor determinations, with the parts of the cord which control automatic life.

This topographical plan (Fig. 47) represents with sufficient accuracy Flechsig's researches on this interesting subject of the successive development of the spinal fasciculi. You can satisfy yourselves that it coincides in every respect with the plan which we have employed to indicate the seat of spinal lesions (Fig. 46).

It will then be apparent to you that the spinal fasciculi which are affected by system lesions and consequently endowed with *pathological autonomy*, are identical with those, the independent existence of which has also been demonstrated by the study of development.

(b.) From the preceding considerations it has become more than probable that these same fasciculi are also endowed with *functional autonomy*. In order to solve this question, appeal must be made to clinical facts. Observations are made during the patient's life, and, after death, anatomical investigation is pursued conformably to prescribed methods.

Be good enough to notice that in this case, which we presume to have reference to system, that is to say to clearly defined lesions, we are placed under those ideal conditions at which the experimenter aims in his attempt to reproduce lesion of the parts supposed to possess the special functions he is endeavouring to analyse. We may indeed assert that, in this particular case of the spinal cord, the well-nigh insurmountable difficulties encountered by the experimenter undergo natural solution by system lesions. It is impossible for the most skilful operator to remove the entire length of a spinal fasciculus; it is, moreover, an operation which the animal would not survive. Again, it is scarcely possible to single out the anterior

cornua in the substance of the cord, with a view to destroying the masses of microscopical nerve-cells contained in them.

All these distinctly circumscribed alterations are occasionally produced by disease.

I must add that system spinal lesions are most commonly developed in a chronic manner, and that their symptomatology is not as a rule complicated by those secondary effects on adjacent parts, which are almost necessarily occasioned by traumatic experiments, and which make a physiological analysis of the morbid phenomena so difficult under such circumstances. But these phenomena which we are endeavouring to analyse—and this, gentlemen, leads us directly to pathology,—really constitute the symptomatology peculiar to each of the lesions under investigation. Subsequently, I shall have to show you that this symptomatology differs widely, according as the lesion involves the pyramidal tracts, the cuneiform fasciculi, the anterior grey cornua, and also according to the kind of lesion affecting the fasciculi.

For the moment, I shall merely call attention to the fact which I consider of primary importance in spinal pathology; it is that the system diseases we have just alluded to must be considered as so many *elementary affections*, the accurate knowledge of which must be applied to the elucidation of more complex, non-system affections or, in other words, to those whose anatomical distribution in the cord is diffuse and irregular. Analysis directed conformably to these principles has not yet furnished all that was anticipated. Nevertheless, I believe I am not mistaken when I assert that it has played an important part in the progress recently accomplished in the pathology of the spinal cord.

I find myself obliged to postpone until the time when I shall treat these matters in detail, some considerations which I was desirous of submitting to you to-day, concerning *localisations in the medulla oblongata and cerebral hemispheres*.

Time presses and I must conclude. If I have succeeded in placing the inquiries relative to the morbid anatomy of the nerve-centres in their true light, you cannot have failed to recognise the great tendency which runs through them. They all appear, as it were, governed by what might be termed the

*spirit of localisation*, which, in short, is but the offspring of the spirit of analysis.

The idea of localisation is certainly no novelty<sup>o</sup> in pathological anatomy. It is, indeed, as old as that science itself, although Bichat was really the first to clearly formulate it and, at the same time, demonstrate its scientific importance; but it had never, perhaps, been prosecuted in a methodical and logical manner before his time.

Briefly, what is meant by the term to *localise*? In pathological anatomy, to localise is to determine in the organs and tissues, the seat, extent, and configuration of material or palpable changes; in pathological physiology, it is to establish the connection between the functional disorders noticed during life and the lesions revealed post-mortem, by utilising the facts derived from clinical observation and experiment.

In the course of our studies both these topics will very frequently present themselves and will be the object of equal attention on our part. For, gentlemen, I repeat, we must become acquainted not only with contemplative pathological anatomy, by studying the lesion in itself and for itself, but also with pathological anatomy as applied to nosology and clinical medicine or, in a word, as adapted to the solution of all pathological problems within its province.

## LECTURE II.

### THE PYRAMIDAL TRACTS AND THEIR DEVELOPMENT.

**SUMMARY.**—*System affections of the spinal cord correspond to normal anatomical topography, as illustrated by pathological anatomy, clinical medicine and developmental anatomy.*

*Researches of Parrot, Schlossberger, and Weisbach. Incomplete development of the cerebrum in the newly-born child. Pre-dominance of reflex acts. Observations of Soltmann and Tarchanoff on the cerebrum of recently-born animals endowed with voluntary motion. At birth the human cerebrum is almost an indifferent organ.*

*Crossed pyramidal tracts. Direct pyramidal tracts (columns of Türck). Their course in the various regions of the spinal cord and in the medulla oblongata.*

*Decussation of the pyramids. Different types of decussation. Importance of a thorough acquaintance with these types in interpreting pathological facts.*

GENTLEMEN,—I venture to hope that a primary fact has been evolved from the account which I presented to you at our last meeting. I refer to the existence, in the domain of spinal pathology, of a certain number of diseases having this remarkable feature, that the lesion on which they depend is located in, and if I may be allowed the expression, quartered upon certain well-defined regions of the cord; that these diseases, in a manner, constitute so many elementary affections, an accurate knowledge of which must supply invaluable data for the elucidation of affections which are more complex or, as regards anatomy, non-systematised. These elementary or system affections, however you may term them, ought logically to engage our attention first. But before considering this subject, gentlemen, I wish to show you that certain information derived



from normal anatomy enables us to recognise as so many parts, anatomically and physiologically distinct, those identical regions which are also marked off by pathological anatomy and clinical observation. This I have already demonstrated to you by means of a diagram. To-day, I shall resume and treat this matter more fully, so that you may obtain more detailed information with respect to the subject which is now especially under our consideration.

You are aware that this information is to be sought for, not in the anatomy of the adult which in this respect gives us very insufficient data, but rather in developmental anatomy.

I must likewise remind you that, for the purpose we have in view, it is not necessary to revert to early or embryonic development, but that it is sufficient to consider the anatomical condition of the various parts of the neuro-axis as it exists in the newly-born child.

## I.

A. It has long been observed, gentlemen, that whilst the spinal cord and medulla oblongata of recently-born children are already in an advanced stage of development, this is far from being the case as regards the cerebrum proper.

Bichat remarked that the brain of the young child bears but little resemblance to that of the adult, except in its external configuration; and it is now a matter of common knowledge that its main structural details are barely outlined at this time. According to M. Parrot's description, which has now become classical, the cerebrum at this period of life is a soft organ, of a uniformly grey colour, the grey and white matter being intermingled. When a fragment of this nerve-pulp is crushed and rubbed between the hands, the sensation imparted is that of a gelatinous or pasty mass. Histological examination and chemical analysis have yielded results which, in great measure, explain these macroscopical appearances.

The connective tissue, or, as it is otherwise called, the neuroglia, predominates everywhere; the reticulum is homogeneous and less distinctly fibrillated than in the adult. The cellular elements are present in large numbers, and their protoplasmic substance (as MM. Parrot and Jastrowitz have shown)

contains, even physiologically, a certain amount of granular fat. On the other hand, the nerve-tubes are almost universally absent, or, at any rate, barely represented in outline. They may be seen scattered here and there, under the form of axis-cylinders not yet enveloped in their myeline-sheaths. The chemical constitution corresponds to this anatomical condition. The analyses of Schlossberger and Weisbach have shown, for example, that the proportion of water in the centrum ovale is represented by 92.59; in the cerebellum and pons Varolii by 85.77; and in the spinal cord by 84.38.

The proportion of water, then, is precisely in the inverse ratio to the histological development.

To sum up, therefore, the structure of the cerebrum in the newly-born child is still, as it were, in a rudimentary condition, whereas the medulla oblongata and spinal cord already present the characteristic features of the adult state.

B. A glance at the physiology of the young infant leads to considerations of the same kind. Virchow, reviving an opinion

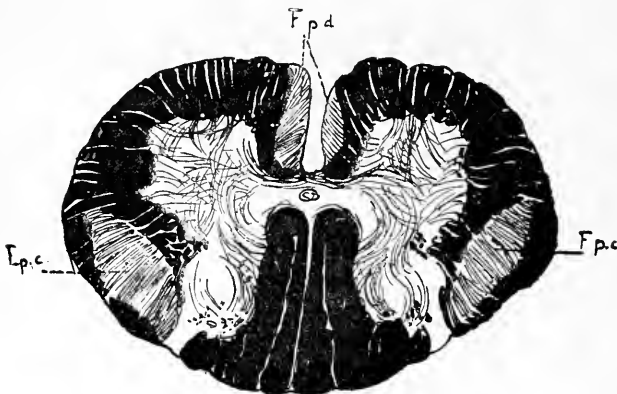


FIG. 48.—Cervical region. *Fpd*, direct pyramidal tract; *fpc*, crossed pyramidal tract.

previously stated by Billard, remarked that the life of the nervous system in the newly-born child is, in a manner, exclusively concentrated in the medulla oblongata and spinal cord.

It is almost certain that voluntary determinations are at that

time absent, and that such acts as are accomplished, however complicated they may appear, suction, for example, are purely instinctive, and, in a word, of a *reflex* nature.

Soltmann's recent experiments, which have been confirmed by MM. Rouget and Tarchanoff, tend in the same direction.

In adult animals, contrary to the teaching of the physiology of ten years ago, electrical stimulation of the so-called psychomotor regions determines movements of the extremities or other parts of the body on the opposite side; and destruction of these same regions produces a more or less pronounced condition of paresis in those same parts, which had previously been made to move under the influence of irritation.

Now, gentlemen, the result of Soltmann's experiments is that these excitable parts of the cerebral cortex have as yet no existence in the young of animals which are born blind, and which, as in man, are deprived of voluntary determinations. Such are the rabbit and the dog. Whereas, on the contrary, these excitable regions or motor centres, according

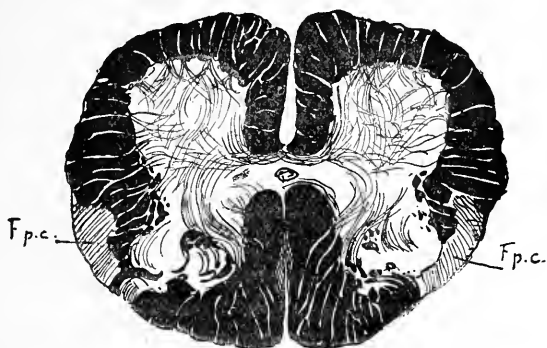

FIG. 49.—Lumbar region. *Fp.c.*, crossed pyramidal tract.

to Tarchanoff's observations, are already in existence in animals which are born with open eyes and which are endowed with voluntary movement.

According to these same researches, the cerebrum of these animals presents also a histological development and a chemical constitution, which differ little from the condition of the adult state.

It may not be devoid of interest to observe incidentally that these facts of an anatomical and physiological order have their counterpart in the pathology of the newly-born child. It is, for instance, well known to all authors, who have made a particular study of the pathology of this period of life, that even the gravest cerebral lesions do not reveal their presence by any special symptom; as a matter of fact, they remain latent and cannot be diagnosed. This is the opinion of Professor Parrot, and it is based on cerebral lesions discovered after death; such are circumscribed and diffused white and red cerebral softenings, intra-encephalic hæmorrhage, meningitis, &c.

You see, gentlemen, that the cerebrum at this age has, as yet, no existence; it is, from the triple point of view, anatomical, functional, and pathological, an indifferent organ.

## II.

The preceding considerations have, at least, served to mark a contrast. It is, indeed, a matter of common knowledge that the spinal cord of the newly-born infant is in a much more advanced stage of development than the brain, so that in some respects it approaches that of the adult state. The same is true of the medulla oblongata. Nevertheless—and this point it is necessary to make prominent—the organisation of both these parts of the neuro-axis is still very imperfect.

To convince yourselves of this, cast a glance at the figures to which I have already called your attention, and recall to mind the ready method used to demonstrate the differences existing between the developed and non-developed parts.

The osmic acid, as I told you, is fixed by the myeline of the developed nerve-elements. Now, on this section of the spinal cord you perceive that four very well-defined fasciculi are respected by this reagent, which is equivalent to saying that these fasciculi are still undeveloped. They are: (1) the two so-called *direct pyramidal tracts*; (2) the two *crossed pyramidal tracts*.

These strands, indeed, correspond to the regions occupied by lesion in one of the most interesting forms of those system affections which we propose to study in detail. It suffices to

call your attention to the interest attached to the anatomical investigation of these fasciculi.

They do not belong exclusively to the spinal cord, but their course and principal anatomical relations may be followed in the medulla oblongata, crura cerebri, and interior of the hemisphere. We shall be guided in our description by the researches commenced in Paris by M. Pierret, and especially by those of Flechsig. Lastly, we shall utilise M. Parrot's investigations, which were based on about a hundred observations, the results of which are to be communicated to the Société de Biologie to-morrow.

(1) Let us then examine, gentlemen, the course pursued by these four pyramidal tracts. I shall begin, with your permission, with the crossed fasciculi (Figs. 48 and 49).

Immediately below the decussation of the pyramids they occupy a position from which they do not depart, so that they may be followed to the lower part of the spinal cord as far as the second or third sacral pair. They are situated throughout this large extent in the posterior half of the lateral column, where they are represented by a compact fasciculus of triangular form in contact posteriorly with the substantia gelatinosa, whilst internally a small space separates the summit of this triangle from the formatio reticularis. The base of the triangle, which is directed outwards, is separated from the pia mater by a zone of nerve-matter, forming a kind of mantle, which is composed of the direct cerebellar fasciculi.

But this disposition is found only in the upper half of the cord; below the dorsal region the cerebellar tracts become less marked, and, in the lumbar region, where no trace of them is left, the crossed pyramidal tracts are in contact with the pia mater. On transverse sections the diameter of these triangular fasciculi is seen to diminish regularly from above downwards, as though their component fibres had been used up on the way, but it is especially at the cervical and lumbar enlargements that this diminution in diameter becomes most appreciable.

(2) As regards the anterior or direct pyramidal tracts, also called the columns of Türck, they are situated on the inner aspect of the anterior columns, and present an ellipsoidal form to the large antero-posterior axis. As a rule, they may be followed as far as the middle of the dorsal region, but to this

arrangement there are numerous exceptions. Sometimes they do not go beyond the cervical region, sometimes, on the other hand, they descend down to the lumbar region.

These four tracts are composed of fibres parallel in direction, and when developed they contain nerve-tubes of all sizes. How are they disposed at their extremities? Since their diameter diminishes in proportion as they descend lower into the cord we are justified in concluding that their component nerve-fibres are successively arrested in their course. The anterior grey cornua are naturally indicated as being the point towards which these fibres converge. But do they penetrate the anterior roots? No, for the anterior roots and nerve-cells are fully developed when the pyramidal tracts are not so. Neither do they pass, at least for the most part, into the commissures, which have likewise attained their development. Therefore they are arrested in the anterior grey matter, where they probably enter into relation with the large motor cells.

### III.

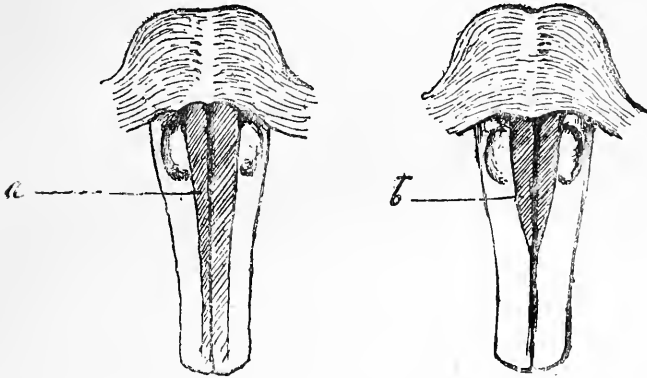
We must now try, gentlemen, to follow the course of the pyramidal tracts above the cord. In the first place, it is very easy to see that the spinal pyramidal fasciculi are simply an emanation or prolongation of the bulbar pyramids. On a transverse section of the medulla through the middle of the olivary bodies, we immediately recognise the position and relations of the pyramids, and we observe that certain parts of the medulla have already reached an advanced stage of development. Such are the nuclei of the hypoglossal with its intra-bulbar filaments and the whole extent of the antero-lateral fasciculi. Now, each of these pyramids gives origin to two spinal bundles, one direct, the other crossed. The direct fasciculus descends in the interior of the corresponding anterior column; the other, or crossed fasciculus, decussates with its fellow on the opposite side, and proceeds to the posterior part of the antero-lateral column, where it has the relations we have already indicated.

In this manner is effected what is generally designated the decussation of the pyramids, all the peculiarities of which are

described at length in classical works. But it is not so well known that this decussation of the pyramids is subject to very numerous variations, at least to judge from Flechsig's observations, which embrace some sixty cases.

The varieties in question may, however, according to Flechsig, be reduced to three types.

The *first* type is the most common (75 p.c.). It consists in symmetrical semi-decussation, each pyramid supplying a direct and crossed bundle. In the great majority of cases, the direct



FIGS. 50 and 51 (after Flechsig).—*a*, predominance of the direct pyramidal tract. *b*, type of total decussation. The direct pyramidal tract is absent.

is much less important than the crossed fasciculus, and is represented by from 3 to 9 p.c. of the pyramidal fibres, whereas the crossed fasciculus contains from 91 to 97 p.c. of these fibres. But there is a very interesting modification of this type, which is mentioned by Flechsig, and which has also been observed by M. Pierret. On merely reversing the proportions I have just given, the direct fasciculus is then represented by about 90 p.c. of the total number of fibres, whilst the crossed fasciculus contains only 10 p.c. The number of decussated fibres in such a case is, therefore, so insignificant that they need scarcely be taken into consideration.

You will perceive, gentlemen, the great interest of cases of this nature, from the standpoint of direct cerebral paralysis. By this we mean, as you are aware, paralysis which, contrary

to rule, takes place on the same side as the lesion. The existence of this paralysis is incontestable, but is certainly less frequent than has latterly been maintained.

The two hundred cases which have been put forward might, even in the absence of certain theories, be considerably reduced if subjected to criticism. Nevertheless, some carefully recorded observations are not open to doubt; such are those of Brown-Séguard, Callender, Hughlings Jackson, Reynaud, and some others.

To explain these cases, Longet's theory, which assumes that under such circumstances decussation is absent, is generally invoked; but this was a pure hypothesis on his part. Indeed, anatomists have always considered the decussation of the pyramids as an absolutely constant occurrence. For example, M. Serres asserted that he had examined eleven hundred subjects without discovering a single exception to the rule. This opinion, gentlemen, as Flechsig's researches prove, seems to us much too absolute. In many cases, if the decussation is not positively absent, it may, as I have said, be represented only by such a limited number of fibres that we may disregard it entirely; the direct then far outbalances the crossed fasciculi, a circumstance quite sufficient to explain direct paralysis.

The *second* type was noticed eleven times in a hundred cases. The decussation is total or, in other words, the direct fasciculi are completely absent.

The *third* type is more frequent than the preceding, since it is present in the proportion of 14 p.c. It might appropriately be termed the asymmetrical type. In such a case there are only three bundles; one of the pyramids divides into two fasciculi, the direct and the crossed; the second pyramid, on the contrary, undergoes complete decussation.

Lastly, gentlemen, it remains for me to point out the remarkable compensatory relation which exists between the two tracts proceeding from the same pyramid, as regards the cases to which I have just alluded.

The more voluminous the one the more slender is the other, and inversely. It is evident that asymmetry in the cord will result from asymmetry in the decussation. This fact it is imperative to bear in mind, since we are liable at first to ascribe it, in certain cases, to a pathological condition.



### LECTURE III.

#### THE PYRAMIDAL TRACT IN THE CRUS CEREBRI, INTERNAL CAPSULE, AND CENTRUM OVALE.

**SUMMARY.**—*Continuation of the pyramidal tract above the medulla oblongata. Course in the pons and crus cerebri. Its extent in the lower layer of the peduncle. Flechsig's opinions. Relatively early development of the pyramidal tract in the peduncle.*

*Division of the internal capsule, on horizontal sections, into three regions: anterior and posterior segments and knee of the capsule. Localisation of the pyramidal tract in the posterior segment of the internal capsule. The pyramidal tract in the centrum ovale. Parrot's chromological observations. Formation of the Rolandic loop. Of all the cortical parts of the hemisphere the so-called motor regions are developed first.*

GENTLEMEN,—In the last lecture, basing our remarks mainly on Flechsig's researches, as verified by our own observations, we succeeded in exhibiting the topography of the pyramidal tracts in the various regions of the spinal cord, and in indicating the relations which they hold with respect to the other constituent parts of this exceedingly complex organ. Afterwards we ascended beyond the decussation and found that these pyramidal columns were united in the medulla into two very distinct fasciculi, which you have been accustomed in descriptive anatomy to know by the name of *anterior pyramids*. To-day, gentlemen, we must ascend still higher and determine, as far as possible, the course of the pyramidal tracts in the other parts of the isthmus, that is to say, in the pons, crura cerebri, and lastly, in the cerebrum proper, where, as you will see, they appear to take their origin.

(1) In the pons, the nerve-elements which had previously formed the bulbar pyramids no longer have the aspect of com-

tract fasciculi; they become dissociated and intermingle with the special fibres of the pons, where they contribute to the formation of a network, within which it is, to say the least, very difficult to distinguish them.

This is not the case in the crura cerebri, where we shall see them to some extent restored to the condition of well-defined fasciculi.

(2) You are all acquainted, gentlemen, with those two columns which unite the pons to the cerebral hemispheres, and which are called the crura cerebri. I shall assume that a section has been made perpendicularly to the direction of the fibres which are so distinctly visible on the lower aspect of these columns, a

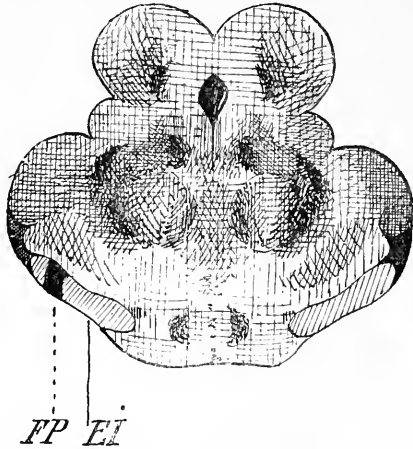


FIG. 52.—Diagrammatic section of the peduncles in the newly-born child (after Flechsig). *EI*, lower layer; *FP*, pyramidal tract.

little above the pons, or, indeed, at the level of origin of the common motor oculi nerves. Let us observe, in the first place, the peculiarities which a section of this kind presents to our consideration in the newly-born child.

The crus cerebri is divided by authors into two parts:<sup>1</sup> (1)

<sup>1</sup> In the preceding figure it may be observed that the pyramidal-tract region only occupies about a fourth part of the lower layer (the third quarter proceeding from within outwards). Such, at least, is the extent assigned to

the lower layer, which is also called the *foot* (*pes crusta*); (2) the upper layer or *tegmentum*, otherwise termed the *calotte* (*Haube* of the Germans). Above these parts, there is seen

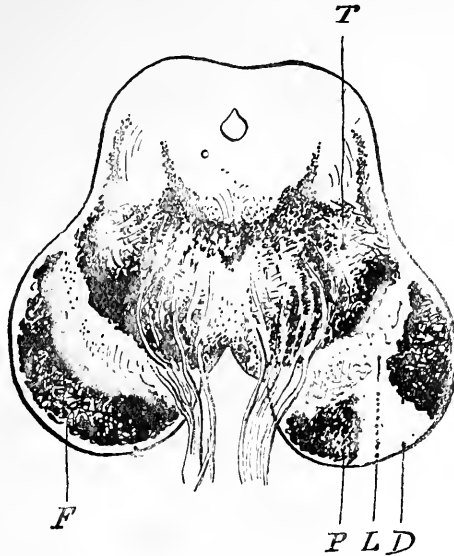


FIG. 53.—Horizontal section of the peduncular region in a case of secondary degeneration. *T*, upper layer; *F*, lower layer on healthy side; *L*, locus niger; *P*, internal fasciculus of lower layer on diseased side; *D*, secondary degeneration occupying about the middle two fourths of the lower layer.

on the section in question the cut vertical surface of the anterior corpora quadrigemina. Lastly, towards the median part, you recognise the opening of the aqueduct of Sylvius, around

it by Flechsig. I must remark that a certain number of examinations of the peduncular region in the newly-born child lead me to think that this region is more extensive than Flechsig gives us to understand. As regards secondary degenerations in the intra-peduncular pyramidal tract, I am in a position to assert that they possess dimensions very much greater than Flechsig's researches would lead us to suppose. A considerable number of anatomical observations, which have been made lately under my superintendence at La Salpêtrière, do not allow the slightest doubt in this respect. The result of these observations is that the pyramidal tract occupies at least the *two middle fourths* of the lower layer.

which is developed a mass of grey matter representing the anterior cornua of the cord. Here, groups of cells are disposed, from which the roots of the common motor oculi nerves are derived. In front of this point we observe the prolongations

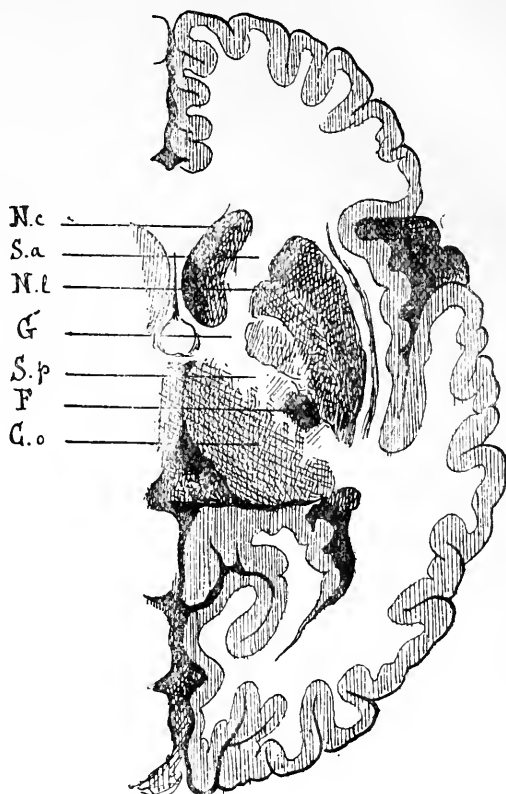


FIG. 54.—Horizontal section of the right hemisphere parallel to the fissure of Sylvius. *Nc*, caudate nucleus; *Sa*, anterior segment of the internal capsule; *Nl*, lenticular nucleus; *G*, knee of the capsule; *Sp*, posterior segment of the internal capsule; *Co*, optic thalamus; *F*, circumscribed lesion in the posterior segment of the capsule occupying part of the intra-hemispherical course of the pyramidal tract.

of the spinal anterior fasciculi (fundamental part of the anterolateral columns); these fibres intermingle with those of the *processus e cerebello ad testes*.

On section the processes have the appearance of red nuclei (Rothe Kerne of Stilling). These various parts, which constitute the tegmentum strictly speaking, are already developed in the newly-born child, and you know that on ascending towards the encephalon we shall see them converge to the optic thalamus, where they disappear. Therefore they take no part in the formation of the peduncular expansion.

I have dwelt on this general description with the object of determining more accurately the topography of the region which we have to investigate.

We are now in a position to apply the data which we have acquired. On the other hand, it behoves us to lend careful attention to the lower layer or *foot* of the peduncle. In the adult, this part is distinctly separated from the tegmentum by a transverse band of grey matter, which is no other than the *locus niger* of Soemmering. The nerve-cells of this region, at the period of life with which we are concerned, are as yet unimpregnated with pigmentary matter.

Be that as it may, the region of the *foot* is to be found below this band; and it is here that we must look for the traces of the pyramidal tracts.

A section of the lower layer of the crus may be divided into three segments of nearly equal dimensions (internal, external, and middle segments).

In the two first, the nerve-tubes which are not yet covered with their medullary sheaths, appear on section as clear spaces. This is not the case with the middle segment, which has the form of an *opaque*, rhomboidal space, owing to the fact that the nerve-tubes have attained their complete development. Now, this space of opaque matter really represents, according to Flechsig, the rearranged prolongations of the pyramidal tracts (see description Fig. 53).

Hence, you see that whereas in the cord and medulla oblongata of the newly-born child the pyramidal tracts are distinguished from neighbouring parts by reason of the rudimentary state to which they owe their clear colour, the contrary is the case in the peduncles.

The nerve-fibres which form the pyramidal tracts in the lower layer are already covered with myeline, and consequently

they bear the stamp of advanced development. It is this circumstance which places them in contrast with adjacent parts.

This fact, gentlemen, is unquestionably significant, since it seems to indicate that the development of the pyramidal tracts proceeds from the cerebrum proper. Flechsig, who did not fail to notice it, was led from his observations to put forward the hypothesis that the nerve-fibres of the future pyramids take origin in the cortical grey matter or rather in its ganglionic cells, where they make their first appearance in the form of buds. These latter, whilst undergoing progressive development, descend little by little into the crura, and after passing through the pons and medulla, reach the spinal cord, finally extending to its lower extremity. To Flechsig of course I leave the responsibility of his own hypothesis. I shall now merely give the data upon which it rests, since I have not yet had the opportunity of verifying *de visu* this last part of his researches.

(3) According to Flechsig, as you are already aware, the pyramidal tract may be followed beyond the foot into the substance of the hemisphere. We can at once recognise its presence in the middle of the opto-striate ganglionic masses, in the region called the *internal capsule*, which is in short, at least to a considerable extent, no other than the expansion of the fasciculi which form the lower layer of the crura. With regard to the internal capsule, a few topographical indications will not be superfluous. If a horizontal section of one of the cerebral hemispheres be made through a line parallel to and a little above Henle's *posterior lateral fissure*, the lower segment of the hemisphere which we have under observation offers for special consideration the following peculiarities.

Posterior and internal, near the median line, is the optic thalamus, in front of which lies the head of the caudate nucleus; to the outside is the lenticular nucleus, the inner margins of which form by their union a kind of wedge projecting into the angle made by the caudate nucleus and optic thalamus.

But the internal ganglionic masses (optic thalamus and caudate nucleus) are separated from the external mass (lenticular nucleus) by a large, white, angular tract, which is no other

than the internal capsule, that is to say, to a certain extent the peduncular expansion.

You perceive, gentlemen, from the topographical disposition of this tract, that it is composed of two very distinct parts: (1) an anterior part, included between the internal and anterior surface of the lenticular nucleus and the head of the caudate nucleus; (2) a posterior part, intermediate between the external surface of the optic thalamus and the postero-internal border of the lenticular nucleus. These two parts unite at an obtuse angle, which we might call, with Flechsig, the "knee of the internal capsule."

Now, gentlemen, according to Flechsig, it is in the posterior part of the capsule that we must look for the origin of the intra-hemispherical course of the pyramidal tract.

At the period of life which we are considering this tract may be recognised in the posterior segment as an elliptical space, marked off from the neighbouring parts by its opacity. Since, then, it is made up of nerve-fibres which have already attained their development, it holds no relation of continuity with the adjacent ganglionic masses.

If, in thought, you divide this posterior part of the internal capsule into three regions of equal extent, it will be found that the pyramidal tract occupies precisely the middle region.

But this is not all. The pyramidal tract may be followed, farther still than the internal capsule, into the centrum ovale, and even to the grey cortical matter.

(4) To examine the pyramidal fibres in this last part of their tract, we must turn our attention to a frontal section. When this is made a little behind the fissure of Rolando and parallel to its direction, it bisects the ascending parietal convolution. According to the topographical system of M. Pitres, this is the parietal section proper.

We see the posterior segment of the internal capsule directed obliquely upwards and outwards; the lenticular nucleus is placed side by side with its external margin, and the optic thalamus, which is divided through the centre and surmounted by the section of the tail of the corpus striatum, bounds it on the inner side.

This then, according to Flechsig, is the region through which

the pyramidal tract passes. When the fibres reach the centrum ovale they begin to separate and spread out in all directions, so that it becomes impossible to follow them. Nevertheless, a portion of the tract remains coherent and continues its course towards the upper extremity of the central convolution.

After leaving the capsular region, the fibres incline outwards to turn around the ventricular walls; subsequently, they bend slightly inwards, and, thenceforward, pursue their vertical course to the parts which we have just mentioned. In short, gentlemen, that portion of the cortex in which the terminal

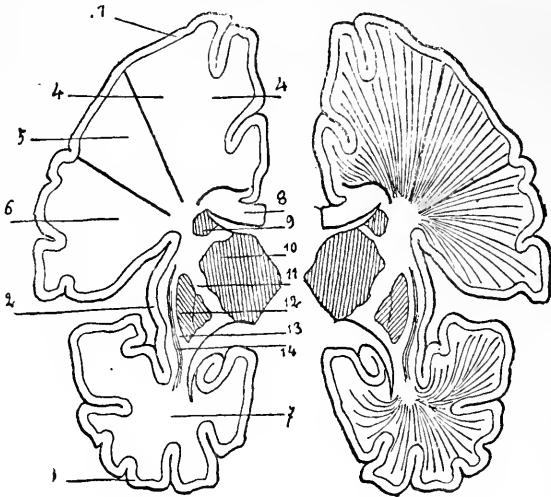


FIG. 55.—Parietal section of the hemisphere (Pitres). 8, corpus callosum; 9, tail of the caudate nucleus; 10, optic thalamus; 11, internal capsule (posterior segment); 12, lenticular nucleus; 13, external capsule; 14, claustrum.

extremities of the pyramidal tract disappear, appertains, as you see, to what is called the motor zone (paracentral lobule, upper extremity of the ascending frontal and parietal convolutions.)

Such are the results of Flechsig's researches concerning the intra-encephalic course of the pyramidal tract.

His conclusions seem to require confirmation in more than one point, and the author himself does not appear to accord



them absolute confidence. But it is essential to keep in mind the general bearing of the course which we have studied progressively in the various regions of the neuro-axis. The hypothesis to which the author in question seems to incline, from the aggregate of facts observed by him, is that the pyramidal fibres take origin in the cortical matter of the motor zone; having become developed first in that part, they descend from thence, as we remarked just now, by a process of budding, to form the pyramidal tracts in the capsule, then in the crus, pons, medulla oblongata, and subsequently, as age advances, in the lowest parts of the neuro-axis.

(5) This, gentlemen, is a suitable opportunity to avail ourselves of Professor Parrot's investigations, to which I alluded in the preceding lecture. These researches, which have been communicated quite recently to the Société de Biologie, do not precisely coincide with the subject treated by Flechsig, but they nevertheless have some bearing on it, and may contribute to its elucidation. Although, in a general manner, they confirm the conclusions arrived at by Flechsig, they tend, however, to modify them in one important point. I refer to the intra-encephalic tract with respect to which the German writer formulated the hypothesis of which I have just spoken.

Parrot's researches were based on the autopsies of ninety-six children under the age of one year. The brain was examined by means of methodical sections, the object being to discover by the naked eye the differences in colour corresponding to the various regions of the cerebral mass, according to the ages of the children.

There is no doubt that *chromological* facts, as Parrot calls them, may furnish information relative to the development of the different portions of the hemispheres. The grey transparent parts may be looked upon as the foetal or embryonic regions, whilst the white are the developed or adult regions.

In short, the white tint corresponds to the perfect structure of the nerve tubes—the axis-cylinder covered with its myelinsheath. Now, from our present standpoint, the following seems to me especially worthy of notice in M. Parrot's interesting researches.

This figure (Fig. 56), which he has very kindly placed at my disposal, represents a vertical section of one hemisphere. It is

made in an antero-posterior direction, parallel to the median plane and about one centimètre and a half from the intra-hemispherical fissure. It has reference to a child seventeen days old. You see that at this period the anterior and posterior regions have a very dark grey colour, which signifies that they are still in a foetal condition. It is only at the end of a month that the substance of the occipital lobe begins to grow white; and it is not until four months afterwards, that is to say,

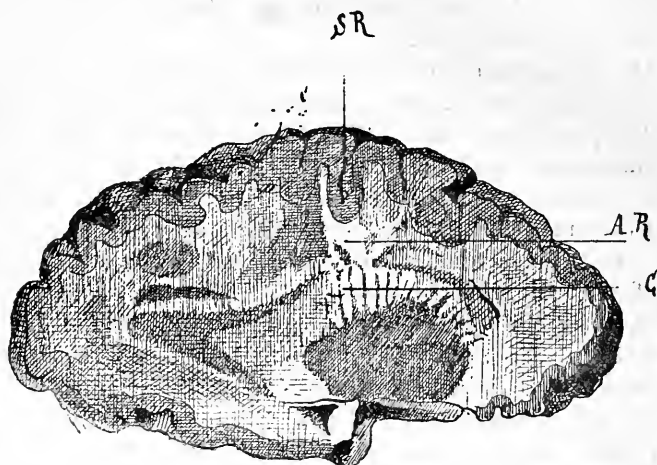


FIG. 56.—Antero-posterior vertical section, a little external to the internal aspect of the hemisphere. The parts are seen to be variously tinted, some being white, others grey.

*AR* represents the Rolandic loop, subjacent to the fissure of Rolando, *SR*.

*C*, internal capsule emerging from the central grey mass.

towards the fifth month, that the anterior regions commence to undergo development, which, moreover, is not completed until about the ninth month.

But already at the seventeenth day, as you see, the median or sub-Rolandic part of the cerebrum is marked by the presence of nerve-fibres ensheathed in myeline. The fasciculi of the centrum ovale, at this point appear as two white tracts, which seemingly are tending to meet one another.

The one which is developed first, judging from the examina-

tion of the cerebrum of younger children, rests on the central ganglionic masses, where it appears to have its centre of formation, and advances in the direction of the fissure of Rolando. The other forms a kind of white loop circumscribing the depression of the fissure of Rolando below the cortex (M. Parrot calls it the *Rolandic loop*); it is situated in front of the preceding fasciculus.

You will at once perceive that these white tracts exactly correspond in their anatomical relations with the description given by Flechsig of the intra-hemispherical course of the pyramidal tracts; only—and in this the opinion hazarded by Flechsig conflicts with the results obtained by M. Parrot—there exist for this part of the pyramidal tract two centres of formation: the one situated in some point of the central nuclei is the first in age; the other has its starting-point in the grey matter of the Rolandic convolutions, otherwise called the motor zones.

In short, I repeat that there is but this one point of disagreement between the two observers. We may, however, infer from Flechsig's researches, that of all parts of the hemispherical cortex the so-called motor regions are developed earliest, and that they are the first to enter into relation with the bulbo-spinal system through the medium of the pyramidal tracts.

We have now finished, gentlemen, the considerations which I was desirous of laying before you concerning the anatomy of the pyramidal tracts, as based on details supplied by the study of the development of the nerve-centres.

This preliminary account, which has been perhaps somewhat long, was indispensable before attempting to investigate those system lesions of the pyramidal tracts, known by the name of secondary degenerations. These lesions are not merely interesting from the standpoint of pure pathological anatomy, but allied to them are a number of clinical facts which make them deserving of the careful attention of physicians.

## LECTURE IV.

SECONDARY DEGENERATIONS. DEGENERATION OF THE PYRAMIDAL TRACT IN THE PEDUNCLE, PONS, MEDULLA OBLONGATA, AND SPINAL CORD. EXCEPTIONAL DEGENERATION OF THE INTERNAL FASCICULUS OF THE CRUS CEREBRI. DIVISION OF THE LOWER LAYER OF THE CRUS INTO THREE REGIONS.

SUMMARY.—*Introduction to the study of secondary degenerations.*

*Degenerations of cerebral origin are descending ; those of spinal origin are both descending and ascending.*

*Degenerations of peripheral origin. The question of localisation governs the situation. The nature of the lesion matters little, provided that it is destructive. Secondary lesion of the crus divides the lower layer into three regions. Degeneration in the pons, medulla, and spinal cord.*

*Localisation of the degenerative lesion in the opto-striate region.*

*Flechsig's researches. The pyramidal tract properly called is not the only part capable of descending degeneration. In the internal capsule it occupies at least the anterior two thirds of the posterior segment. The posterior fasciculus (Meynert's sensitive fibres) never degenerates.*

GENTLEMEN,—After the preliminaries which have hitherto occupied our attention, we are now in a position to enter the domain of pathological anatomy. I propose to discuss the system lesions of the spinal cord.

I shall begin the study of the various forms composing this class by examining the alterations which are generally known by the name of *secondary degenerations*.

## I.

The lesions in question are called secondary because they take place consecutively to another lesion, which is most frequently circumscribed, and primarily developed in the different parts of the neuro-axis—the cerebrum proper, the medulla, spinal cord, or even in the peripheral nerves. A consecutive lesion, when once originated, may acquire individuality or actual autonomy, and occasionally there is connected with it a clinical history which is superadded to that of the original disease and sometimes even overshadows it.

The secondary lesions which are most interesting from this point of view are those affecting the pyramidal-tract system.

I must mention, gentlemen, in the first place, that all system lesions of the pyramidal tracts are not secondary. There are lesions in this region (and on this point I shall have to dwell at a later stage) which become developed as primary or proto-pathic affections, that is to say, they are independent of the influence of a primordial lesion.

I need not insist too strongly, gentlemen, on the fact that the history of secondary spinal degenerations is thoroughly deserving of the attention of the physician. Although, indeed, these lesions were for a long time considered an object of purely scientific curiosity, and as calculated merely to interest the physiologist or anatomist, we can assert that this is no longer the case at the present time.

Recent works have satisfactorily demonstrated that these affections hold, in every respect, an important place in the pathology of the nervous centres.<sup>1</sup>

## II.

Since secondary degenerations of the spinal cord form rather a complex whole, we must in the first place determine their divisions.

<sup>1</sup> It would be useless to revert once again to the history of this question. We shall simply remark that next to the works of L. Türck, Charcot, and Vulpian, the most interesting details relative to secondary degenerations are to be found in M. Bouchard's classical memoir. He was the first to use the processes of hardening and staining in the investigation of medullary lesions, and the first also who sought to establish the symptomatology of degenerative lesions (B.).

(1) In the first group are included *secondary degenerations of cerebral origin*, that is to say, those proceeding from focal lesion occupying certain parts of the encephalon. Accordingly, lesions of this class may result (*a*) either from primary lesion of the cerebrum proper (*b*) or from lesions situated in various parts of the isthmus (crura, pons, and medulla oblongata). Degenerations which have such an origin are commonly termed *descending*, because indeed they seem to descend from their starting-point in the encephalon towards the peripheral parts.

(2) In the second group we must place *secondary degenerations of spinal origin*, that is to say, those which are consecutive to the formation of a circumscribed lesion in some part of the spinal cord. We shall see why these consecutive lesions may be called in some cases descending, and in other cases ascending.

(3) The third category comprehends a small number of very curious cases which have not yet, however, been observed in practical medicine. The degeneration, which is of peripheral origin, is situated in the posterior column of the spinal cord. The known instances are but five or six in number. In every case they refer to the nerves of the horse's tail, or, more explicitly, to the posterior roots which must be looked upon as the starting-point of this special lesion.

### III.

We shall consider, at the outset, degenerations of the first group—those having an encephalic origin. Moreover, in order to limit our initial field of study we shall only investigate at the present time those secondary fasciculated lesions which are engendered by a focal lesion situated in the cerebrum proper. Before entering into details let us indicate the most general characters of the group.

(1) It must be clearly understood that the original lesion exists in the cerebrum strictly speaking. But it does not involve indiscriminately any part of the hemisphere. In other words, there are regions of great extent in the hemispheres, where focal lesions are powerless to provoke secondary degenerations; and, on the contrary, there are other regions where such changes inevitably determine secondary descending lesions.

You perceive, gentlemen, that the question of *localisation* controls, as it were, the situation.

(2) As to the *nature* of the original lesion, nothing is more variable. Intra- or extra-encephalic tumours, focal lesions due to hæmorrhage or softening, and all possible changes have the same effect, provided however—and this is an indispensable condition—that the lesion be *destructive*, in other words, that it produces, in its place of selection, a true loss of substance

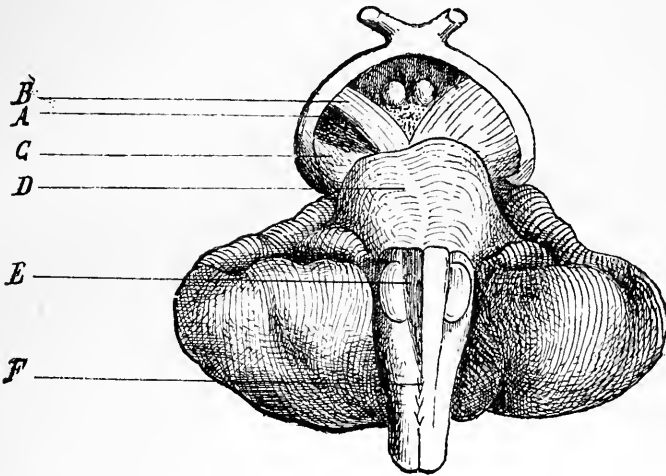


FIG. 57.—A, degeneration in the crus cerebri (pyramidal tract); B, internal peduncular fasciculus degenerating under occasional, but exceptional, circumstances; C, external fasciculus (? centripetal), never degenerating; D, pons Varolii (it is asymmetrical, being atrophied on the side of the lesion); E, greyish, atrophied, and degenerated pyramid, decussating with its fellow at F.

at the expense of the nerve-elements. Accordingly, old focal lesions from hæmorrhage or softening figure much more commonly among the causes of secondary degenerations than the majority of tumours, which merely press upon or push aside the nerve-elements without destroying them.

(3) With the exception of a particular case, which will be mentioned in due time and place, degenerations of this class possess the general character of affecting the pyramidal-tract system, to which they are strictly limited.

If the primordial lesion occupies one only of the two hemi-

spheres, the degeneration is propagated to the crossed pyramidal tract on the opposite side; if, on the other hand, a lesion exists in each of the two hemispheres, both halves of the pyramidal system may be simultaneously invaded.

The lesion in question, gentlemen, I repeat it advisedly, is pre-eminently systematised. The adjacent fasciculi always remain intact, and (except under special circumstances, to which we shall return) the grey matter and the roots of the peripheral nerves are likewise unaffected.

(4) I postpone the question relative to the nature of the degeneration from an anatomical point of view. Is it the result of a purely passive process, as some authors maintain, or, on the contrary, is it, as others assert, of an irritative nature? Or indeed may the two opinions be combined, in the sense that, whilst in the first period the process is passive, in the second it becomes active?

These are doubtless interesting questions, but I repeat that we shall not take them into consideration until a later stage.

For the moment, I shall merely discuss the topography of secondary degenerations, and you will see, as I told you just now, that these lesions are systematised in the domain of the pyramidal tracts.

#### IV.

Let us consider the secondary lesion just as it is emerging from the substance of the hemisphere. It appears first in the crus cerebri; we next see it in the pons, then in the medulla, and, lastly, in the various regions of the spinal cord. In the first place, gentlemen, bear in mind that when the lesion is very pronounced and very old, it is, to use a popular expression, as clear as noonday.

On the same side as the cerebral lesion you will notice that the lower layer of the crus, the pons, and the corresponding pyramid have undergone a true atrophic change, which lends to these parts a grey tint (Fig. 57). On the side opposite to the lesion, below the decussation of the pyramids, you will also observe the asymmetry of the spinal cord consequent on atrophy of the antero-lateral column. This is the aspect under which the lesion was recognised by old authors. But recollect,



gentlemen, that in the great majority of cases the change is not so far advanced, and that the intervention of the microscope is indispensable.

(1) It is interesting to remark that in the *crus cerebri* the degenerated part is greyish and has the form of a triangular space, situated in the middle part of the lower layer. The base of the triangle is towards the encephalon, whilst the apex looks towards the pons. Accordingly, the surface of the foot of the peduncle is in this manner divided into three regions: (a) the middle region, represented by the degenerated pyramidal tract; (b) the external region, which (so far as I can judge from the numerous observations I have made on the subject) never by any chance becomes the seat of degeneration, a very remarkable circumstance to which we shall have occasion to return; (c) lastly, an internal region, which is only under exceptional and very special conditions invaded by the degenerated pyramidal tract, which we shall have also to consider later.

It may, however, take on degeneration separately, without the participation of the middle fasciculus.

By making thin sections of the peduncular region, we may readily ascertain that the degenerated median fasciculus exactly corresponds to the pyramidal tract, which we were enabled to recognise in the crus by means of developmental anatomy.

Under a low magnifying power we see that the lesion occurs, in a vertical section, under the form of a quadrilateral space occupying the middle part of the foot and extending from the grey matter of Soemmering, which forms its upper limit and corresponds to the smallest side of the parallelogram, as far as the surface of the foot which represents the largest side.

The nerve-fibres in the area of the parallelogram being to a large extent destroyed or replaced by connective tissue, there appears in sections stained with carmine a well-marked red tint, which contrasts with the comparatively pale aspect of the neighbouring parts, and hence enables us to determine the exact topography of the lesion.

(2) In the pons, the pyramidal tract is dissociated and extremely difficult to recognise in the midst of the transverse fibres peculiar to the part. Nevertheless, the secondarily degenerated fasciculi may still be distinguished fairly easily, especially

on comparison with the healthy side, in the lower or bulbar regions of the pons, where these fasciculi begin to collect and once more form into groups preparatory to constituting the pyramidal tract a little lower down.

(3) Throughout the entire extent of the medulla oblongata the lesion is found with the utmost ease, as you may judge by examining a section made perpendicular to the main axis of the medulla and passing midway through the olivary bodies. The bulbar lesion is strictly confined to the pyramidal tract on the side of the primary encephalic lesion.

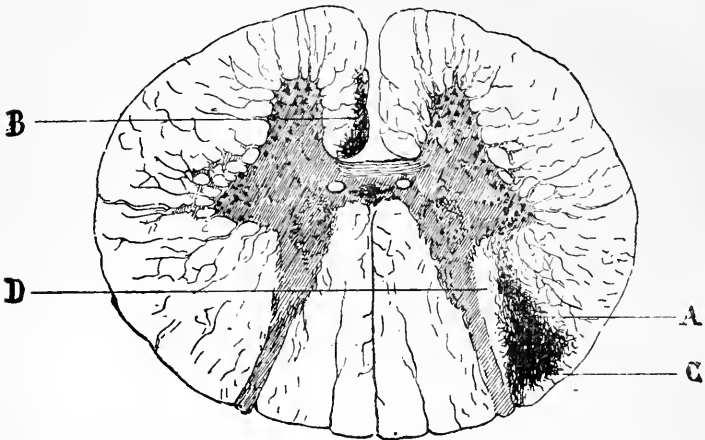


FIG. 58.—Transverse section of the cord in the cervical region. A, degeneration of the pyramidal tract in a case of lesion of the cerebral motor centres; B, degeneration of the direct tract; c, area of white matter corresponding to the cerebellar tract; D, region intermediate between the posterior cornu and the pyramidal tract (this region is never affected in descending degeneration).

(4) If now we examine a series of transverse sections made in the various regions of the cord, we at once recognise the anterior column on the side corresponding to the cerebral lesion, and, on the side opposite to the lesion, the crossed pyramidal tract (Fig. 58).

You know, gentlemen, that these last fasciculi may be followed separately as far as the lower end of the lumbar region, and that their relations, in the various spinal regions, undergo modifications conformably to the indications supplied

to us by developmental anatomy. The demonstration, which I wished to present to you, is therefore complete, and the descending degenerative lesion, in the case under consideration, is, as I had predicted, absolutely limited to the pyramidal-tract system.

## V.

After determining the topography of the so-called secondary degenerations we must now stop to consider one of the most important points in their history.

What is the character common to all circumscribed destructive lesions, which, when developed in the substance of the hemisphere, give rise after a certain time to descending degenerations? On the other hand, what is the nature of lesions of the same kind which do not produce degenerations?

I must repeat that it is pre-eminently a question of situation or, in other words of *localisation*, and this is precisely what it behoves me to prove.

At our last meeting I pointed out to you that the cerebral hemisphere may, broadly speaking, be looked upon as composed of two parts, which are to a certain extent anatomically, functionally, and pathologically distinct. On the one hand, there are the central ganglionic masses; and, on the other hand, what is sometimes called the *manteau*, namely the semi-oval white substance and the layer of grey matter which envelops it.

(1) Let us consider first the central grey masses. A very superficial analysis of the region exhibits (on a transverse section, for example) the white tract which we call the internal capsule, running in an antero-posterior direction. External to this tract is the lenticular nucleus, and internal to it are the optic thalamus and caudate nucleus.

It is by no means an unusual occurrence, gentlemen, to see circumscribed destructive lesions strictly localised to one or other of these nuclei. This is more especially common as regards the lenticular nucleus, and particularly its external part. You are aware that this is the most usual seat of those ochreous foci which are the last vestiges of intra-encephalic hæmorrhage. Focal lesions of more or less considerable size,

limited to the optic thalamus or to the head of the lenticular nucleus, are by no means rare. But, gentlemen, Ludwig Türck, who was the first to study these changes methodically, clearly proved that secondary degenerations never occur when the lesion remains limited to a grey nucleus, and does not extend to the internal capsule so as to cause any material degeneration of its fibres.

Lesion of the internal capsule is, therefore, so far as focal lesions of the central masses are concerned, the necessary condition for the production of secondary degeneration.

(2) But, gentlemen, all destructive lesions of the capsule do not give rise to these degenerations. It is true that some, provided that they have a certain size, which we may estimate at the minimum at half a centimètre in diameter, inevitably determine them; but there are others of much greater extent which never produce them. What is the reason of these differences? Everything, as you will see, depends solely on the seat which the lesion occupies in the white tract.

The problem, then, consists in defining the limits of the capsular regions where destructive lesion is followed by degeneration, in opposition to those parts where the same lesion does not occasion identical results.

Four years ago I formulated the following proposition with respect to this subject:—Secondary degenerations take place when the lesion involves the anterior two thirds of the internal capsule; they never occur when the lesion invades the posterior third of the capsule.<sup>1</sup>

This statement has been criticised by Flechsig, who has devoted careful attention to the matter. In consequence of this criticism, the revision of facts which I was obliged to make forced me to acknowledge that in many respects his objections were well founded. Accordingly, I had to correct my formula, and in a moment I shall state in what the modification I propose consists.

You remember that the topographical inquiries which we made led us to recognise the existence in the internal capsule of two segments, one anterior, the other posterior, these two segments being united one to the other on a level with the region which Flechsig proposes to call the *knee* of the capsule.

<sup>1</sup> See p. 85.

Now, gentlemen, I have found that lesions limited to the anterior segment cause secondary degeneration, but that this degeneration does not affect the *pyramidal tract proper*; it reveals its presence to the naked eye by a grey band occupying the internal segment of the foot of the peduncle, and does not involve the middle segment.

There exists, then, according to all probability, within the fasciculus of pyramidal fibres, which intercross at the level of the bulbar decussation, a bundle of centrifugal fibres proceeding from the anterior segment of the internal capsule.

It is very probable, also, that these fibres are arrested below at some point in the pons, for when this fasciculus is degenerated it is impossible to detect it in the corresponding pyramid; à *fortiori* it does not pass down into the spinal cord. If I failed to recognise the separate existence of this fasciculus, it was because the capsular lesions which I had examined did not involve only the anterior segment, but also the middle segment or knee of the capsule; and in this case the lesion of the capsule being complex it extended downwards into the medulla and spinal cord.<sup>1</sup> The region of the capsule with which we are at present concerned, and the limits of which we are desirous of determining as far as possible, is to be sought for in the posterior or lenticulo-optic segment of the capsule.

If you divide this segment from before backwards into three nearly equal parts (we do not lay claim to mathematical precision in such a case) the region of the capsule corresponding to the anterior two thirds is precisely that in which, according to the observations made by Flechsig, and more recently by myself, a destructive lesion, even of small size, cannot exist without being followed by descending degeneration of the corresponding pyramidal tract. We might call it the *pyramidal region of the capsule*, since the nerve-fibres which traverse it seem to be a direct continuation of the pyramidal tracts.

As regards the last third of the posterior segment of the capsule, I must notice briefly (for to this point I shall have to return) that this region seems to contain only centripetal fibres, which do not appear capable under any circumstances of undergoing descending degeneration.

<sup>1</sup> See 'Progrès Médical,' September, 1879. "Faits pour servir à l'histoire des dégénéralions pédonculaires."

Circumscribed lesions produced in this part always betray their presence clinically by a number of symptoms, which are now well known under the name of cerebral hemianæsthesia.<sup>1</sup> I must remind you that this affection is characterised as follows:—(1) Loss or simple diminution of the general sensibility of the entire opposite half of the body; (2) the special senses in the same side, including sight and smell, are simultaneously affected. In accordance with these anatomo-clinical facts, which are now based on a considerable number of careful observations, the region in question might be considered a kind of crossway, where the conductors of general and special sensibility proceeding from the opposite half of the body are packed together into a narrow space.

This circumstance should be compared with the fact that the external segment in the foot of the crus—at least according to my observations, which are, moreover, fairly numerous—is never affected with secondary degeneration.

Now, the fibres of this external segment were looked upon by Meynert, who was influenced by purely anatomical considerations, as the centripetal prolongations of the sensitive spinal fibres, and as serving to connect them to the posterior regions of the hemisphere. The fibres of the external segment of the foot would appear, then, to ascend directly to the posterior third of the posterior segment of the capsule. This is, doubtless, only an hypothesis, but it is one which is fairly probable, and worthy to be taken into consideration in subsequent inquiries.

Accordingly, the three regions of the capsule are represented in the foot of the crus by the three fasciculi in question:—(1) Internally, a fasciculus which rarely degenerates, and which corresponds to all the anterior segment of the capsule; (2) the median or pyramidal fasciculus, degeneration of which is so common, corresponding to the anterior two thirds of the posterior segment of the capsule; (3) the external fasciculus, which never degenerates, made up of centripetal fibres which go to form the posterior third of the posterior segment of the capsule. I do not mean you, gentlemen, to take this as a definite conclusion, but only as an approximate result which may serve to guide you in future researches.

<sup>1</sup> See p. 91.

Be that as it may, one fact, if I mistake not, has been clearly evolved from the preceding discussion; it is that, so far as the central grey masses are concerned, destructive lesions involving primarily or secondarily the anterior two thirds of the posterior segment of the capsule are alone capable of determining descending degeneration of the pyramidal tracts. Now, this is precisely that region of the capsule the limits of which we had to fix, and so the first part of our demonstration is at an end.

#### TRANSLATOR'S NOTE TO CHAPTER IV.

According to Brissaud ('Recherches anatomo-pathologiques et physiologiques sur la contracture permanente des hémiplegiques,' p. 38), there are four fasciculi in the crus cerebri having the following functions:

(1) A posterior fasciculus (Charcot's *external* fasciculus), which conveys sensitive impressions, and which corresponds to the posterior third of the posterior segment of the capsule.

(2) A middle fasciculus, which innervates the muscles of the extremities and trunk, and which corresponds to the anterior two thirds of the posterior segment.

(3) A small bundle of fibres, which Brissaud calls the "geniculate fasciculus" (*le faisceau géniculé*), because of its connection with the knee (*genou*) of the capsule. It contains motor fibres, and is distributed to the nuclei in the medulla oblongata, giving movement to the face, tongue, and probably the soft palate, in short to all parts of the head and face which are under the control of the will. This fasciculus corresponds to the knee of the capsule.

(4) An internal fasciculus ending in the medulla, degeneration of which seems to coincide usually with intellectual disorder only. It corresponds to all the anterior segment of the internal capsule.

## LECTURE V.

### SECONDARY DEGENERATIONS (*continued*). LIMITS OF THE PYRAMIDAL TRACT IN THE CEREBRAL HEMISPHERE.

SUMMARY.—*In the study of secondary degenerations of cerebral origin, the seat of the lesion is the capital point. Importance of a thorough knowledge of the cerebral convolutions. Motor convolutions. Vicq d'Azyr (1785), Rolando (1829), Leuret (1839). Histological examination of the convolutions. Giant cells of Betz and Mierzejewsky. Previous description of Luys. Histological analysis and comparative anatomy of the convolutions. Hitzig, Ferrier, Betz, and Bevan Lewis. Diagrammatic view of the pyramidal tract in the cerebral hemisphere. Rolandic region. Focal lesions in this region give rise to secondary degenerations, whether from alteration of the fibres of the centrum ovale or as a consequence of cortical destructive lesions.*

GENTLEMEN,—We must now consider the cerebral cortex, for circumscribed lesions here also give rise to secondary degeneration. It has long been known—Türck was already aware of the fact—that the so-called *peripheral* focal lesions, in opposition to those termed *central*, because they occupy the opto-striate region, also cause under certain circumstances secondary degenerations similar to those produced in consequence of lesions of the internal capsule.

But what are the circumstances under which degeneration results from lesions situated in the cortex?

It is only of late, gentlemen, that attention has been called to the fact that the fundamental condition here is still relative to the *seat* of the lesion.

The extent of the primary lesion, the nature even of the



change constituting it, provided, however, that it is destructive, are really only accessory conditions. You see, therefore, that the question now before us is to determine topographically the region which circumscribed lesions must involve in order that descending degeneration of the pyramidal tracts shall result.

## I.

To accomplish satisfactorily the purpose we have in view, a slight digression seems to me indispensable. Moreover, gentlemen, in following the bye-path in which I am going to lead you, we shall notice in our progress several facts in cerebral topography which we have many times had occasion to utilise in the course of the investigations we have undertaken.<sup>1</sup>

When examining the surface of the cerebral hemispheres in man, and when seeking for fixed points by which to discover our whereabouts in that labyrinth which has long been called the cerebral convolutions, we are necessarily struck by the remarkable disposition presented by the two large median convolutions, first figured and described by Vicq d'Azyr in his great treatise on 'Anatomy and Physiology' (1785, pl. iii). "*They are,*" he said, "*obliquely directed from above downwards, more extended in length, and less sinuous than in the other regions of the cerebrum.*"

These two convolutions were described with greater detail by Rolando in 1829 in the work entitled 'De la structure des hémisphères du cerveau.' He refers to them under the name of *processus entéroïdes verticaux*. These two convolutions, gentlemen, really constitute one of the fundamental morphological characters on the surface of the human cerebrum, and are to be seen also in the majority of apes. You are aware that the anterior is now called the ascending frontal convolution, and the posterior the ascending parietal convolution. They are separated one from the other by a sulcus, which, since the time of Leuret (1839), has been termed the fissure of Rolando. On the external surface of the hemisphere they extend from the fissure of Sylvius to the inter-hemispherical cleft; and we know, on the other hand, that they are, as it were,

<sup>1</sup> See pp. 15, 16.

prolonged on the inner aspect of the hemisphere so as to constitute there the so-called *paracentral* or *oval* lobule, at the level of which the two convolutions become blended.

But, gentlemen, this region of the cortex to which I am inviting your attention is distinguished from all others, not only by its altogether special configuration, but also by some structural details which are deserving of notice.

You are not unaware that histological examination has demonstrated the existence in the hemispherical cortex of ganglionic nerve-cells which, by reason of the form under which they occur, are generally called the *pyramidal cells* of the cortex. They are very variable in size, some of them being, comparatively speaking, very small. These latter are the most numerous (pyramidal cells of the small variety). There are others more voluminous occupying the middle part of the grey matter. Lastly, there are the so-called pyramidal giant cells, which were carefully described by Betz and Mierzejewsky. They sometimes attain a diameter of  $\cdot 040$  to  $\cdot 050$  mm., that is to say, a diameter equal to that of the large ganglionic or motor cells in the anterior grey cornua of the spinal cord.<sup>1</sup>

But it is not merely as regards size that it is possible to establish a comparison between the cells in the anterior cornua of the cord and the large pyramidal cells. There exist, indeed, very manifest structural analogies between these two kinds of elements.

Thus, besides the ramifying and subdividing protoplasmic processes, there is also found in the large pyramidal cells, and particularly in the giant cells, a very characteristic disposition, consisting in a special non-divided process, identical with the cylindrical prolongation described by Deiters in the spinal ganglionic cells.

In one case, as in the other, the filament is slender at its origin, but becomes gradually thicker in its course in proportion as it recedes from the cellular protoplasm. By careful dissection it is possible to see that this prolongation becomes enveloped, at a certain distance from the cell, in a cylinder of myeline.

All these facts clearly show the impossibility of mistaking

<sup>1</sup> See p. 21.

the analogies which, notwithstanding differences in form and seat, approximate on the one hand the large pyramidal cells of the cortex and, on the other hand, the motor-cells of the anterior cornua. These analogies had, however, been previously suggested by M. Luys. I shall have the opportunity shortly of again bringing this matter under your notice. Now, gentlemen, the largest of these pyramidal cells, and especially the giant-cells, are not distributed indifferently in all the regions of the cortex; they tend, on the contrary, to be limited to a well-defined area on the surface of the cerebrum, and this circumscribed area is precisely that, the configuration and limits of which we just now pointed out.

It is, indeed, within the grey matter of the ascending frontal and parietal convolutions, principally at their upper half, as well as in the paracentral lobule, that the pyramidal cells of the large variety and the giant-cells exclusively are to be found. They are arranged here in groups, islets, or *nests* as Betz calls them. Hence the region of the median convolutions might be termed the department of the pyramidal giant-cells.

It is very remarkable that this peculiarity in structure does not appertain to man only. Betz has shown that it is to be found also in the monkey. In this case, too, the largest pyramidal cells are observed in the median convolutions and in the paracentral lobule. The same author has likewise pointed out that these cells are met with in the dog in the regions which have been known since the labours of Hitzig and Ferrier by the name of motor centres, that is to say, in the grey matter of the convolutions lying around the crucial sulcus. The observations of Betz have been quite recently confirmed by Bevan Lewis, not only concerning man and the monkey, but also in the case of the cat and the sheep ('Brain,' 1878). This leads me to remark, gentlemen, that the central, median, or, if you will so term them, the Rolandic convolutions, are those in which experiment as regards the monkey and clinical observation as regards man have enabled us to localise the so-called psychomotor or, more simply, motor regions.

I take the present opportunity of reminding you incidentally that the denomination, motor centres, does not imply in my mind any absolutely fixed physiological idea, but that by it I merely wish to designate, in opposition to other areas, those

regions of the cerebral cortex, lesion of which occasions motor disorders in certain well-defined parts on the opposite side of the body.

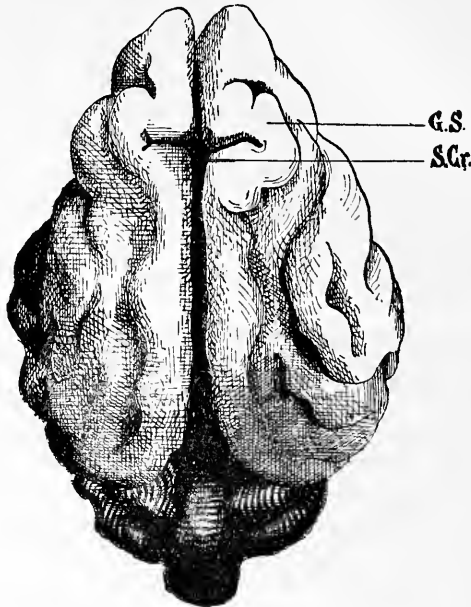


FIG. 59.—Upper aspect of the dog's brain. S.Cr., crucial sulcus; G.S., sigmoid gyrus (region containing the large pyramidal cells).

Our digression is now at an end<sup>1</sup>. You may have thought, gentlemen, that the considerations just placed before you are foreign to our subject-matter, which is, in brief, the pathogenic history of secondary degeneration of cerebral origin. This, however, is not the case. In reality, that part of the cortex, the principal morphological, histological, and physiological characters of which I have tried to make prominent, belongs to the region, the limits of which it was our purpose to determine.

If you remove from the deep layer of this grey zone the nerve-fibres directed towards that portion of the internal capsule which we previously called the *pyramidal* part, you will

<sup>1</sup> For further details, see Lecture III, Part First.

obtain a diagrammatic view not very different from the concrete reality.

Geometrically the region may be described as follows: it is a four-sided pyramid, the truncated apex of which looks downwards (this is the pyramidal region of the internal capsule). The base of the pyramid, which is no other than the cortex of the median or ascending convolutions, is convex and looks upwards and outwards. The anterior surface is represented by a frontal section passing from side to side through the posterior extremity of the base of the three frontal convolutions, and through the anterior extremity of the optic thalamus. This nearly corresponds to the pre-Rolandic or pedunculo-frontal section of Pitres.

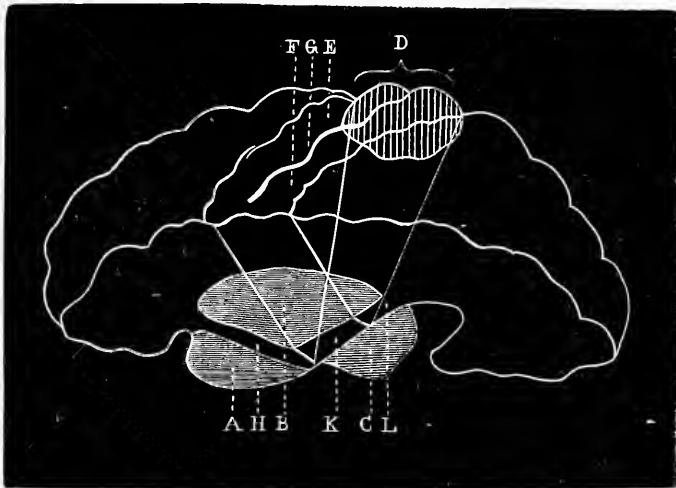


FIG. 60.—A, horizontal section of the caudate nucleus; B, of the lenticular nucleus; C, of the optic thalamus; D, paracentral lobule; E, ascending frontal, and F, ascending parietal convolution; G, fissure of Rolando; H, anterior segment of the capsule; K, pyramidal region in the posterior segment of the internal capsule; L, sensitive portion of the capsule corresponding to the posterior third of the posterior segment.

The post-Rolandic or pedunculo-parietal section passing from side to side through the base of the parietal convolutions and through the imaginary line which separates the anterior two-

thirds of the posterior segment of the capsule from its posterior third, represents the posterior surface of the pyramid in question.

It is easy to understand, without it being necessary to enter into more details, how the other two surfaces, the internal and external, may be obtained.

This geometrical representation is, no doubt, somewhat rough. Nevertheless, this region of the hemisphere, which might be called the *Rolandic*, and which represents within the cerebrum as it were a small brain apart, endowed with special physiological properties, is almost included within these limits. It is in the cortex of this cerebral segment, also, that the starting-point of secondary degenerations must be looked for. Indeed, as regards the so-called peripheral focal lesions, that is to say, those situated external to the opto-striate masses, they only determine the production of secondary degeneration of the pyramidal tract when they involve the central or Rolandic region of the hemisphere. Circumscribed destructive lesions outside this region, whatever may be their size, do not cause descending degeneration of the pyramidal tract.

## II.

Such in a few words, gentlemen, is the formula expressing the state of our present knowledge relative to the question which is engaging our attention. I shall not enter into details as to the facts on which this statement is based, but refer you to the works of Pitres, Issartier and Flechsig, where all information bearing on this subject is contained.

I shall restrict myself simply to the following remarks. It is not yet proved that destructive lesions limited to the grey cortical matter of the Rolandic region are productive of secondary degenerations. Nevertheless, some facts taken from the pathological anatomy of general paralysis,<sup>1</sup> tend to show that this is really the case. Lesions even of small size (1 to 2 c.c.) involving both the grey matter and the underlying white substance, such as yellow softening or superficial foci of cerebral hæmorrhage, especially when they affect the upper two-thirds

<sup>1</sup> Déjerine's case, quoted by Issartier.

of the ascending convolutions and the paracental lobule, give rise to well-marked secondary degeneration of the pyramidal tracts.

Circumscribed lesions involving the centrum ovale in the Rolandic region, without participation of the cortex, determine secondary degeneration of the pyramidal tract, as in the case of superficial lesions.<sup>1</sup>

In order to complete the special history of secondary degeneration of encephalic origin, there remains but one word to be said concerning lesions limited to certain parts of the isthmus.

You will find recorded in M. Bouchard's monograph most of the known cases of secondary degeneration consecutive to lesions localised in the pons and medulla. A comparison of these cases shows that the necessary condition for the production of secondary degeneration, under such circumstances, is that the focal lesion should involve the course of the pyramidal tracts. When this is so, a lesion even of very limited extent situated in the medulla, at the level of the decussation for instance, will certainly give rise to descending degeneration of both pyramidal tracts.

This combination actually occurred in an interesting observation published by Hertz.<sup>2</sup>

A focus of softening the size of a lentil was situated at the site of the decussation of the pyramids. The result was symmetrical secondary degeneration of the pyramidal tracts throughout the whole length of the spinal cord.

<sup>1</sup> Flechsig's 2nd Memoir. Four cases quoted from Türck.

<sup>2</sup> 'Deutsch. Arch.,' 393, 1874.

## LECTURE VI.

### SECONDARY DEGENERATION OF CEREBRAL ORIGIN (*concluded*). CONSECUTIVE AMYOTROPHY.

**SUMMARY.**—*The degenerative lesions of the pyramidal tract enable us to definitely fix its anatomical relations. The termination of its fibres in the spinal cord has given rise to several hypotheses. The ending of the pyramidal fibre is an anterior cell, which generally arrests the process of descending degeneration. Sometimes the cell itself is attacked. Trophic disorders consequent on extension to degeneration of the anterior cornua.*

*There is therefore another relation besides that of contiguity between the pyramidal tract and the grey matter of the spinal cord. Muscular atrophy in hemiplegic patients. Observations of Charcot, Vulpian, Hallopeau, Leyden, Pitres and Brissaud. Is extension effected through the connective tissue or through the nerve-fibres themselves?*

**GENTLEMEN,**—I should have completed the special history of secondary degenerations of encephalic origin, were I not compelled before proceeding farther to call your attention to a few details which were not alluded to in the preceding account. The anatomy of the pyramidal tracts, as derived from the study of their development and of the descending degenerations to which they are liable, has enabled us to assert, as you are aware, that their component nerve-fibres take origin in the cortex of the Rolandic convolutions; moreover, that they proceed from this point and pass down into the cord without exhibiting any relation except that of contiguity with the different parts of the encephalon and medulla oblongata which they traverse. Now we may presume, although the fact has not been proved, that in the cortex these nerve-fibres are in



more or less direct relation with the large pyramidal cells of this region.

But below, where and how do these fibres end in the spinal cord?

We have seen that in the cord the pyramidal tract progressively diminishes in size as it descends towards the filum terminale. This fact is a sufficient proof that the constituent nerve-fibres are gradually used up in the descending course of this fasciculus through the various spinal regions.

On the other hand, certain observations in normal anatomy show that in the different strata of the cord there are fibres directed from behind forwards and from without inwards, which seem to establish a connection between the pyramidal tracts and the anterior grey cornua.

As regards the mode of termination of these nerve-fibres which appear to be a direct emanation of the component fibres of the pyramidal tract, several hypotheses present themselves; either the pyramidal fibres pass directly into the anterior roots; or they end in the grey cornua without proceeding farther; or, lastly, it is possible that some of them are prolonged into the commissure and reach the opposite side of the cord.

Against the first hypothesis, the following facts may be submitted. According to Flechsig's assertions which we can confirm, the anatomy of the cord in the newly-born child shows that whereas the development of the pyramidal tracts is as yet scarcely outlined, that of the cells in the anterior cornua and of the anterior roots is already in a very advanced state. There is, therefore, no *continuity* between the fibres of the pyramidal tracts and the fibres of the anterior roots. This fact has, in a manner, its counterpart in the history of descending degenerations. Although lesion of one of the pyramidal tracts may be most pronounced, the anterior roots emanating from the grey cornu on the corresponding side, as a rule, present no structural modification and no appreciable diminution in size.

The grey matter of the anterior cornu, adjacent to the degenerated pyramidal tract, likewise displays no trace of alteration under ordinary circumstances. The large nerve cells also are perfectly intact, and the cornu itself presents no diminution of volume. But, gentlemen, this does not prove

that no connection exists between the terminal extremities of the pyramidal fibres and the multipolar motor cells. It is, indeed, very probable, as most writers maintain, that the connection does exist.

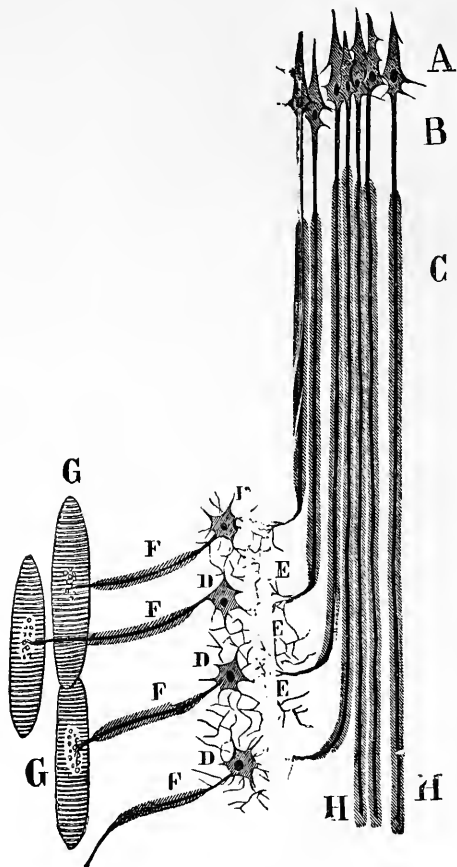


FIG. 61.—Diagram showing the entire pyramidal-tract system from the cells in the cerebral cortex to the end-plates in the muscular fibres. A, motor giant-cells of the convolutions; B, axis-cylinders; C, axis-cylinders covered with myeline, forming the pyramidal tract in the lateral column of the cord; D, D, D, cells in the anterior cornua of the cord; E, E, E, reticulum of grey matter where the nerve-fibres of the lateral column undergo successive diminution; F, F, F, anterior roots represented diagrammatically as axis-cylinders proceeding from the anterior cells, and ending in the muscular fibres, G, G.

The second hypothesis, which I formulated just now, would appear, therefore, conformable to truth; nevertheless we must confess that the anatomical disposition by which this relation is established, has hitherto remained undiscovered. Be this as it may, the motor nerve-cell must be looked upon, in the case of descending degeneration, as the element opposing the degenerative process in the grey matter, and preventing its extension to the nerve-tubes of the anterior roots which, as physiology shows, are certainly in indirect relation with the pyramidal-tract fibres. This hypothesis, as you are about to see, is supported by certain pathological facts appertaining to the history of descending degenerations—facts to which I ask permission to call your attention for a moment.

It has long been remarked that, as a rule, the muscles of the extremities on the paralysed side in patients affected with permanent hemiplegia of cerebral origin, present no other atrophic changes than those resulting very slowly from the functional inertia to which these muscles are condemned.

But in this respect there are numerous exceptions, and it may happen that, contrary to rule, the muscles of the extremities affected with hemiplegia undergo, at a certain period, more or less rapid atrophy, and at the same time present more or less profound modifications in their electrical reactions. I am inclined to think that this anomaly is referable to some anatomico-pathological peculiarity, and, in one case indeed, I made the following observation.<sup>1</sup>

The case in question was that of a woman who was suffering from left hemiplegia dependent on a hæmorrhagic lesion in the right hemisphere. The extremities of the paralysed side, which had become contracted at a very early period, began to diminish in size two months after the attack.

The muscular atrophy was uniformly distributed over all parts of the paralysed limbs, and was accompanied by very notable diminution of the electrical contractility. The muscular wasting made very rapid progress and the patient succumbed. We discovered, in hardened sections of the spinal cord, that in addition to fasciculated sclerosis, there existed in the anterior cornu of the corresponding side a change,

<sup>1</sup> See 'Leçons sur les maladies du système nerveux,' t. i, p. 55, and t. ii, p. 245.

the most striking feature of which was atrophy, even to complete disappearance of a certain number of motor cells.

M. Hallopeau observed some cases of the same kind in M. Vulpian's practice. Leyden has likewise seen at least one instance, although I believe that he has not noticed the relation between the degeneration of the nerve-cells and the muscular atrophy.

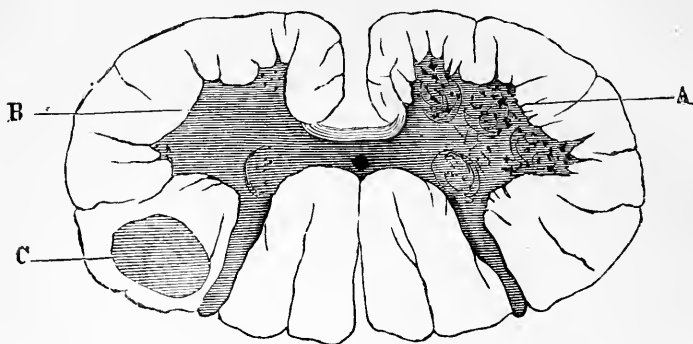


FIG. 62.—(After Pitres.) Section of the spinal cord between the seventh and ninth nerve-roots. A, anterior cornu on the right side containing the normal number of perfectly healthy motor cells; B, left anterior cornu (the motor cells have disappeared, except at the most external and at the antero-internal part); c, sclerosis of the pyramidal tract in the lateral column.

M. Pitres<sup>1</sup> has recently entered into some very important pathological details in reference to a case, observed in my practice four years ago, similar to those which are now engaging our attention.

In the case alluded to, there was an ochreous focus, the remnant of an old cerebral hæmorrhage. The lesion, which was the size of a large almond, had completely separated the middle third of the internal capsule on the right side. The muscular atrophy, which had attracted attention during life, affected the left upper extremity almost in its entirety. On the other hand, the muscles of the paralysed lower limb exhibited no notable atrophy.

Guided by former cases, I believed myself justified in foretelling that this unusual muscular atrophy, supervening in the

<sup>1</sup> 'Arch. de physiologie normale et pathologique,' 1876, p. 664.

course of cerebral hemiplegia with secondary contracture, would find its explanation in partial destruction of the cells in the left anterior cornu, at the level of the cervico-brachial region.

The microscopical examination, which was made with the greatest care by M. Pitres, fully confirmed my anticipations.

There was descending sclerosis on the left side throughout the whole length of the cord; but, in addition, at a limited point of the cervico-brachial enlargement, between the seventh and ninth pairs and for a length of 2 to 3 centimètres, we noticed in the anterior cornu complete disappearance of most of the cell masses which are seen normally in this region (posterior and antero-external groups).

The anterior roots, moreover, in the corresponding regions of the cervico-brachial enlargement, were much greyer than those on the right side. Since cases of this kind form a fairly homogeneous group, it is evident that this is not a question of fortuitous coincidence.

These facts demonstrate that the terminal extremities of the pyramidal fibres, as we remarked just now, are in some kind of relation with the nerve-cells of the anterior cornua.

When there is secondary degeneration of the lateral column, the cell, by reason of its autonomy, generally resists invasion of the morbid process, and, if we may use the expression, protects the corresponding anterior root.

But in certain exceptional cases which are perhaps not so uncommon as is usually believed, under the influence of unknown conditions the cell itself is affected with atrophy, and consecutively the corresponding roots undergo degenerative disintegration.

The final consequence of this invasion of the system of centrifugal nerves is atrophy and degeneration of the muscles to which the diseased roots proceed, according to a mechanism we shall have to study in detail on an early occasion.<sup>1</sup>

As regards the theory, it is important to remark that in the

<sup>1</sup> Since this lecture was delivered (April 21st, 1879), some additional cases of muscular atrophy consecutive to secondary degeneration of encephalic origin, have been observed in M. Charcot's practice. A full account of these observations has been recently published in the 'Revue mensuelle de médecine et de chirurgie,' August, 1879.

case of M. Pitres, as in those which preceded it, the descending degeneration of the pyramidal tract presented no anomaly in its arrangement in the vicinity of the altered cornu. The degenerated part was, as usual, separated from the grey matter by a white tract; in other words, direct extension of the lesion in the lateral column to the corresponding anterior cornu was nowhere to be found.

This observation, therefore, gives support to the idea that extension is effected not through the agency of the connective tissue, but rather through the course of the nerve-fibres which proceed from the pyramidal tract to reach the anterior cornua of grey matter. Anatomy proves that this relation is established by means of small bundles of nerve-fibres which become detached at various points from the pyramidal tract.

In cases of descending degeneration where these fibres have undergone change, a careful examination might enable us to distinguish them in the midst of the healthy fibres in the region of the reticular processes. This investigation, which is, however, very difficult, has not yet been made.

We have just entered into details, gentlemen, which may probably appear to you exceedingly minute. But you will assuredly have no reason to regret them, for we have now acquired a truth of the first importance, which we shall have to utilise shortly for the physiological interpretation of amyotrophies dependent on spinal causes.

## LECTURE VII.

### SECONDARY DEGENERATION OF SPINAL ORIGIN. ASCENDING DEGENERATION OF THE CEREBELLAR TRACT. DESCENDING DEGENERATION OF THE PYRAMIDAL TRACT.

SUMMARY.—*Frequency of secondary degenerations of spinal origin. The commonest case is that of compression of the cord in Pott's disease. Caseo-tubercular pachymeningitis. Total transverse lesion. This lesion must be destructive in order to be followed by degeneration. Classification of degenerations consecutive to total transverse lesion. Descending degeneration. Ascending degeneration involves the lateral and posterior columns. Flechsig's cerebellar tract. Degeneration in the case of a partial transverse lesion takes place only when the white fasciculi are destroyed. Spinal hemiparaplegia with crossed anæsthesia.*

*Unilateral lesion of the spinal cord with subsequent degenerative change of both lateral columns is of very exceptional occurrence. Anatomical inferences from Müller's observations. Double decussation of certain of the pyramidal-tract fibres.*

GENTLEMEN,—We have hitherto been exclusively concerned with the pyramidal tract, which has been considered only from the standpoint of normal and pathological anatomy. Its symptomatology, which is not inferior in interest, equally demands our attention. But, in the first place, I believe it will be advantageous to give you a general account of secondary degenerations of spinal origin, still bearing in mind that our principal object is the pyramidal tract, the history of which is to be the special purpose of our studies this year. This course, which is apparently somewhat circuitous, will nevertheless bring us back to the symptoms, and you will then be in a

better position to appreciate their value in the semeiology of spinal affections.

We shall therefore consider, gentlemen, those system lesions of which I have already spoken to you—those fasciculated lesions, both ascending and descending, which are produced in certain regions of the cord in consequence of the formation of a *circumscribed destructive lesion*.

These secondary degenerations of spinal origin are very common, for, by reason of the relatively limited dimensions of the cord, it is scarcely possible for a destructive lesion to take place in it without secondary degenerations to some extent, or under some form or other, being the consequence.

## I.

Let us first consider a focal lesion which is the cause of all these changes. We shall take a very simple and, at the same time, a very common case. The instance I refer to is that of slow compression of the spinal cord, such as is so commonly observed in Pott's disease.

Since Michaud's researches, the ordinary mechanism of this kind of compression is perfectly intelligible.<sup>1</sup> The compressing agent in a case of this nature is the thickened dura mater. On the outer surface, in contact with the caseo-tubercular deposits, which are derived from the bodies of the vertebra and which have led to destruction of the posterior vertebral ligament, an inflammation also of a caseo-tubercular nature is produced (*external caseo-tubercular pachymeningitis*).

As a result of this thickening of the dura mater the cord becomes displaced and, in consequence, compressed to a degree which varies according to the vertical extent of the caseous neo-formation, generally for a length of two or three centimètres. It is sometimes pushed from before backwards at this point only, at other times it is embraced on all sides and, as it were, strangled.<sup>2</sup>

But this is not a question of a purely mechanical phenomenon.

<sup>1</sup> 'Sur la méningite et la myélite dans le mal vertébral,' 1871.

<sup>2</sup> See 'Leçons sur les maladies du système nerveux faites à la Salpêtrière,' t. ii, p. 84.



Indeed, there is soon established in the organ at the seat of compression a reaction of an inflammatory nature; in other words, partial myelitis is the almost inevitable consequence of spinal compression. Be this as it may, there is developed at this point a destructive lesion involving indifferently the grey matter and all the white fasciculi, both anterior and posterior, of the affected region. This may be called a *total transverse lesion*.

It is well known that the same change occurs, apart from Pott's disease, with identical characteristics and effects as far as secondary degeneration is concerned, whatever may be the cause of compression. Hence cancerous and sarcomatous tumours and psammomata, arising primarily outside the spinal cord, are liable as they increase to cause transverse myelitis by compression, with all its consequences.

Moreover, gentlemen, compression, strictly speaking, is not a necessary condition. Intra-spinal tumours, such as gliomata, syphilomata, and solitary tubercles, syphilitic, traumatic, or other kinds of myelitis, will have the same result as myelitis from compression, provided that destruction of the nerve elements as an essential condition be fulfilled.

So, from the moment the total transverse lesion becomes destructive, whatever be the starting-point of the process, the result is always the same. The only variations are relative to the seat. Hence degenerations present certain peculiarities according as the initial lesion occupies such or such a region of the spinal cord. It is the same in cases where the transverse lesion is partial, that is to say, when it involves only a part of the transverse extent of the organ. But, as you will understand, the general law presiding over the development of secondary degenerations of spinal origin is not thereby sensibly modified.

## II.

For the sake of greater simplicity, we shall notice, first of all, the case of a total transverse lesion which we shall presume to be situated in the upper dorsal region.

You are aware that we must take into consideration the

descending degeneration or that situated below the lesion, and the ascending degeneration which is situated above.

(1) *Descending secondary degenerations.*

(a) Immediately below the lesion, for an extent of one or two centimètres at the most, the entire area of the antero-lateral columns is degenerated; the posterior columns alone remain intact.

(b) Lower down we observe that the degenerative lesion in the antero-lateral columns is represented by two sclerotic bands, which are no other than the columns of Türck.

In the lateral portion proper of the antero-lateral columns, the degeneration only occupies the two crossed pyramidal tracts. But the columns of Türck rapidly disappear, except under anomalous conditions, so that the pyramidal tracts alone preserve the characters of descending degeneration. In this case, as in degenerations of cerebral origin without complications, the grey matter and anterior roots remain unaffected.

(2) *Ascending degeneration* affects two parts:—(a) the lateral columns; (b) the posterior columns.

(a) The lesion in the antero-lateral columns has nothing in common with the descending lesion. The pyramidal tracts in this instance are absolutely intact. They are incapable of degeneration upwards just as the posterior columns are insusceptible of degeneration downwards. On section the lesion has the form of a thin band commencing on a level with the posterior extremity of the corresponding posterior grey cornu and extending in front nearly as far as a transverse line drawn through the anterior extremity of the anterior cornua, and sometimes even beyond.

This band, which is very narrow, is in contact everywhere by its external border with the pia mater. The lesion, which was not unknown to Türck, may be followed to the highest regions of the cord. It is discoverable in the restiform bodies, and even at the level of the cerebellum. The fasciculus which undergoes this ascending degeneration does not seem to be equally developed in all subjects. Its component fibres appear to take origin in the upper regions of the dorsal cord. Consequently, degeneration does not take place when the focal lesion is situated in the lower parts of the dorsal region or below. The fasciculus in question, which Flechsig describes under the

name of *direct cerebellar tract*, undergoes perceptible increase of thickness from below upwards. Flechsig suggests that its fibres arise from Clarke's vesicular column, but its anatomical connections are at present very obscure. I have nothing more to tell you about this fasciculus, except that the ascending lesion does not reveal itself by any special symptom.

(b) Ascending lesion of the posterior columns presents greater interest.

A. Immediately above the primary lesion, for an extent of two or three centimètres at the most, the entire posterior column is degenerated.

B. But, higher up, the lesion seems to taper off and soon occupies only the median part which corresponds in the upper regions of the spinal cord (cervico-brachial enlargement) to the columns of Goll (see Fig. 63, Gc). The degeneration,

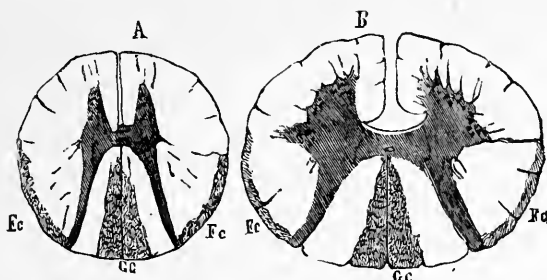


FIG. 63.—A, section of the spinal cord in upper dorsal region; B, cervical region; Fc, cerebellar tract degenerated above the spinal lesion; Gc, column of Goll.

moreover, like the fasciculus itself, may be followed upwards to the posterior bulbar pyramids as far as the level of the fourth ventricle, whilst degeneration of the rest of the posterior column does not ascend above the primary lesion to a distance exceeding two or three nerve-roots. However, gentlemen, at a later stage I shall enter into some details relative to this degeneration of the posterior columns, which we have now met with for the first time, and which we shall have to study much more fully when we discuss locomotor ataxy.

## III.

It now remains for me to notice briefly some modifications which the type just described presents when the lesion, instead of being *total* transverse, is *partial* transverse.

A. (1) In the first place it is necessary to point out that degenerations, ascending as well as descending, only take place when the destructive lesion affects the white fasciculi. Accordingly, even profound changes in the spinal cord, when they are limited to the grey matter, as we see either in an acute form in infantile paralysis, or in a chronic form in protopathic spinal amyotrophy, are never followed by descending degeneration, apart from accidental extension to the white fasciculi.

(2) In the case of the white fasciculi, on the other hand, the consecutive lesion is, so to speak, obligatory. If the primary lesion is in the domain of the antero-lateral column, and if it respects the pyramidal tract, the degeneration will be of small extent, for the change in such a case involves only the very short commissural fibres.

We shall see presently what happens when a focal lesion affects merely the fibres of the posterior columns.

B. We must now consider for a moment a combination which is rather frequently met with in practice, viz. a transverse unilateral lesion of the spinal cord. It is rare for the lesion to be mathematically unilateral, that is to say, not extending a little beyond the antero-posterior axis; but, in place of confining our attention to generalities, let us take a concrete example. The case in question was one of syphilitic lesion of the cord, which revealed its presence by symptoms of spinal hemiparaplegia (paralysis and hyperæsthesia on one side, absence of paralysis, but anæsthesia, on the other side).<sup>1</sup> The autopsy showed that the destructive lesion involved the entire left antero-lateral column and the whole of both posterior columns. Above this lesion, which was distinctly circumscribed to the regions we have just indicated, secondary degeneration of both columns of Goll was observed, and below, in the area of the antero-lateral column, the triangle-shaped degeneration of the left pyramidal tract was noticed.

<sup>1</sup> See 'Leçons sur les maladies du système nerveux,' t. ii, p. 119.

Remember, then, that so far as the pyramidal tract is concerned, this is the general state of affairs. But there is an exception to the rule, which it will not be without profit to consider, because it will perhaps account for some symptoms, the explanation of which would be otherwise somewhat difficult. I have occasionally seen both lateral columns affected in consequence of a unilateral lesion. It is true the degeneration was not symmetrical and equal, that on the side primarily affected being more developed than the other. This disposition was realised in a most remarkable manner in a case of traumatic section of the spinal cord, observed by W. Müller.

A man, aged twenty-one, received a stab at the level of the fourth dorsal vertebra. The entire right antero-lateral column and the posterior columns were divided at this point (see Fig. 64).

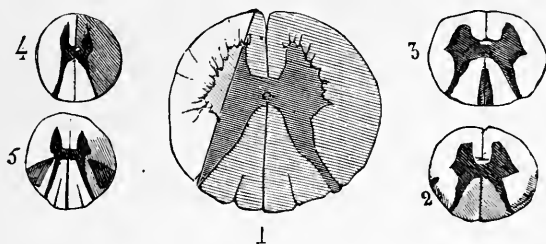


FIG. 64.—1, transverse section of the spinal cord at the level of the 4th dorsal vertebra; the entire right half of the cord and both posterior columns are destroyed. 2, section of the cord at the level of the 3rd dorsal vertebra (sclerosis of both posterior columns and both cerebellar tracts). 3, at a higher level the degeneration affects only the columns of Goll. 4, cord at the level of the 6th dorsal vertebra (degeneration of all the antero-lateral column). 5, lower down, at the level of the 7th or 8th dorsal vertebra, the degeneration of the right lateral column is accompanied by degeneration of the left pyramidal tract.

The patient presented the following symptoms:—on the left side, anæsthesia with preservation of motion, on the right side, hyperæsthesia and paralysis of the lower extremity. Death took place at the end of forty-three days, and at the autopsy it was noticed that the descending degeneration involved, not only the right antero-lateral column in its entirety, but also the left pyramidal tract.

Facts of the same nature have come under my own notice, and M. Hallopeau has made similar observations in certain cases of secondary degeneration of cerebral origin. The extension to the opposite side of a change primarily unilateral may be explained, gentlemen, by the hypothesis I proposed at our last meeting with reference to the mode of termination in the grey matter of the fibres of the pyramidal tract. I said that the majority of these fibres are arrested in the anterior cornua, where they enter into relation with the motor-cells. But it is possible that some of them pass into the anterior commissure, especially in the dorsal region, and gain the lateral column of the opposite side, in order to descend with it into the lumbar region. These fibres, then, would appear to possess a double decussation, one in the anterior bulbar pyramid, and the other in various points scattered throughout the entire length of the dorsal region.

I call your attention to this peculiarity because we can thus explain the more or less complete paraplegia which occasionally ensues in cases of unilateral spinal lesion or of circumscribed cerebral lesion.

## LECTURE VIII.

### ASCENDING DEGENERATION OF SPINAL ORIGIN. COLUMNS OF GOLL AND OF BURDACH. SPINAL DEGENERATION OF PERIPHERAL ORIGIN.

**SUMMARY.**—*Secondary degeneration of the posterior columns. These columns are each divisible into two distinct anatomical systems, the autonomy of which is based on considerations relative to development and to structural and pathological anatomy.*

*Development of the posterior columns. Labours of Pierret and of Kölliker. The columns of Goll and of Burdach appear independently one of another. Further division of the two systems by Sappey's intermediate posterior fissures. Structure of the columns of Goll. Their nuclei on the floor of the fourth ventricle. Structure of the columns of Burdach.*

*System lesions may be found separately either in the column of Goll or of Burdach. Lesions of the columns of Goll do not give rise to symptoms of locomotor ataxy. Compression of the spinal cord causing complete degeneration of the columns of Goll and partial degeneration of the columns of Burdach. Degeneration of peripheral origin. There are as yet but three or four observations. Probable theory of this degeneration.*

GENTLEMEN,—As I intimated to you at our last meeting, we are going to-day to return to certain important facts relative to ascending degenerations of spinal origin; I refer especially to lesion of the posterior columns. But first of all you must become acquainted with some peculiarities in the normal anatomy of these fasciculi.

At the outset it is necessary to recognise the fact that, throughout the entire length of the spinal cord, the posterior columns described in anatomy do not constitute one and the

same system. On the contrary, they are decomposable into two secondary fasciculi representing, as it were, two systems or organs which are perfectly distinct anatomically, and which have separate functions both under normal and pathological conditions.

Now the anatomy of the two constituent systems of the posterior columns is based on considerations derived: (1) from developmental anatomy; (2) from structural anatomy; (3) and lastly, from pathological anatomy.

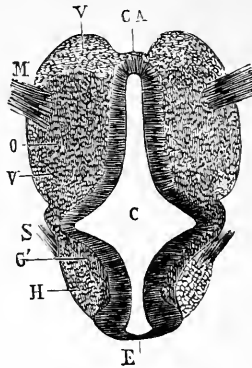


FIG. 65.—Transverse section of the cervical cord of a human embryo of six weeks (from Kölliker),  $\frac{20}{1}$ . c, central canal; E, its epithelial lining; o, anterior grey matter with a dark nucleus, from which the anterior root emanates; G', posterior grey matter; v, anterior column; H, posterior column; CA, anterior commissure; M, anterior root; S, posterior root; v, posterior part of anterior column (or lateral column); E, thin portion of nerve-substance closing in the central canal behind.

We shall review in succession the three orders of facts on which the distinction in question is based.

I hasten to remind you that the details about to follow will be, to a large extent, merely an outline of some very important investigations published by M. Pierret in the 'Archives de physiologie' in 1872 and 1873, that is during the time when he honoured me by working under my direction.



## I.

A. In the first place, a word on the development of the posterior columns.

(a) In the human embryo of six weeks, the posterior columns as yet are represented only by two small bands which cap, as it were, the posterior cornua.<sup>1</sup>

These are the rudiments of the columns of Burdach; the median fasciculi or columns of Goll are not yet developed.

(b) It is only towards the eighth week that the latter begin to appear under the form of two buds which seem to emanate from the columns of Burdach.

About the tenth week they are always quite distinct and are visible throughout the entire length of the cord.

(c) In progress of development the columns of Goll become amalgamated, in certain regions, with the columns of Burdach, without, however, losing their identity.

But, in the cervical region, they remain distinct, even from

<sup>1</sup> For the sake of comparison, we reproduce here the semi-diagrammatic figures published in M. Charcot's lectures on symmetrical sclerosis of the lateral columns (from preparations by M. Pierret).—B.

FIG. 66.

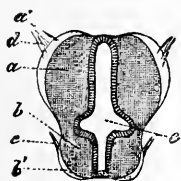


FIG. 67.

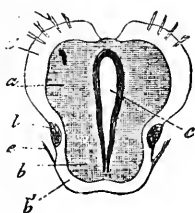


FIG. 68.

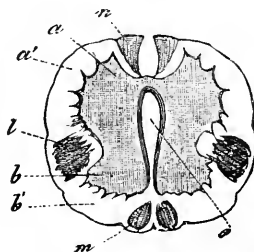


FIG. 66.—Section of the cord in a human embryo of one month. *a*, anterior cornua; *b*, posterior cornua; *c*, central canal; *d*, anterior roots; *e*, posterior roots; *a'*, anterior root-zone; *b'*, posterior root-zone.

FIG. 67.—Section of the cord in a human embryo of six weeks. *a*, *b*, *c*, &c., as in preceding figure; *l*, lateral column.

FIG. 68.—Section of the cord in a human embryo of two months. *a*, *b*, *c*, &c., as in preceding figures; *l*, lateral column; *m*, columns of Goll; *n*, fasciculi of Türk or direct pyramidal tract.

the standpoint of macroscopical anatomy, that is to say, they are limited on each side at this level, by the *intermediate posterior fissures* (Sappey).

So much then for developmental anatomy.

FIG. 69.

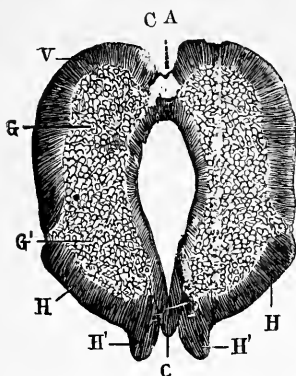


FIG. 70.

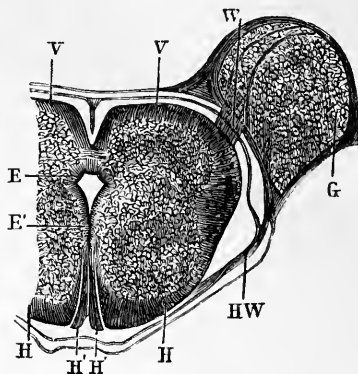


FIG. 69.—Transverse section of the cord of an embryo of eight weeks (from Kölliker),  $\frac{20}{1}$ . H' H', projecting part of the posterior columns H H, which subsequently forms the columns of Goll; CA, anterior commissure; V, anterior column; G, anterior grey matter; G', posterior grey matter; H, posterior column. Between the two projections, H' H', of the posterior columns, C represents the epithelium of the central canal.

FIG. 70.—Transverse section of the cervical cord of an embryo of from nine to ten weeks (from Kölliker),  $\frac{25}{1}$ . E, epithelium of central canal; E', closure of the canal at its posterior part; V V, anterior columns; H H, posterior columns; H' H', columns of Goll; w, anterior root; HW, posterior root; G, ganglion of posterior root.

B. Structural anatomy, as studied under normal conditions in the adult, by means of sections of hardened pieces made in various directions, shows the following:

(a) The columns of Goll are composed of long, parallel fibres forming large commissures which connect distant parts of the central grey matter. Above, this system of commissural fibres ends in a ganglionic mass which is to be found on the floor of the fourth ventricle and which is called the *nuclei of the columns of Goll*. Observe, moreover, that these columns have no con-

nection with the intra-spinal prolongations of the posterior roots.

(*b*) This is not the case with the columns of Burdach which, on the other hand, are traversed by a portion of the fibres emanating from the posterior roots. Some of these root-fibres, as soon as they reach the cord, at once enter the grey matter of the posterior cornua; others proceed only to the grey matter in the region of the *cervix cornu posterioris*, after a much longer course, and when they have traversed the columns of Burdach, where they describe a curve with the convexity outwards.

(*c*) But the group of root-fibres proceeding from the posterior roots is far from constituting in itself the whole of the columns of Burdach. The great bulk of these columns is made up, on the contrary, of vertical or arciform fibres which are much shorter than those in the columns of Goll, and which interlace in very various directions.

Such is the special constitution of the two fasciculi of the posterior columns, as shown by the direct study of the arrangement of their nerve-fibres.

*c.* You have just seen, gentlemen, that developmental and structural anatomy agree in demonstrating the mutual independence of these two fasciculi.

The following is a new proof which, this time, is supplied to us by pathological anatomy :

(*a*) In certain cases, the column of Goll in its whole extent becomes affected separately and systematically, without the columns of Burdach being in any way involved. This was demonstrated by M. Pierret in a case which occurred in my practice. The same fact has been since noted by other observers, who have invariably described the fasciculus as clearly defined throughout the entire length of the cord. In the lumbar region, it appears in transverse sections under the form of two small nodules circumscribed on all sides by the fibres of the columns of Burdach. Both fasciculi in this region possess, indeed, great importance, chiefly by reason of the large number of posterior root-fibres which they receive. In the dorsal region, on the contrary, the median fasciculi surpass the columns of Burdach in size. Lastly, in the cervical region the columns of Burdach once more assume considerable dimensions; but

the columns of Goll are not, on that account, less voluminous. It is indeed of great importance to observe that this is the region where they are most distinctly marked off from neighbouring parts, in consequence of the very great depth of the intermediate posterior fissures. I wish also to remind you incidentally that the symptoms observed in cases of system lesions affecting only the columns of Goll, are not those of progressive locomotor ataxy.

(b) The remarks just made with reference to the columns of Goll are equally applicable to the columns of Burdach. The latter are also liable to undergo separate or autonomous degeneration, without any participation of the columns of Goll. Thus, in a patient who presented all the symptoms of locomotor ataxy, both in the upper and lower extremities, the columns of Burdach alone were involved throughout the entire length of the cord. The columns of Goll were absolutely intact. The same fact has been since noticed in several other observations.

FIG. 71.

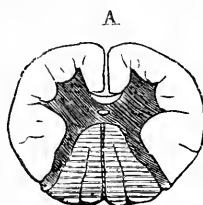


FIG. 72.

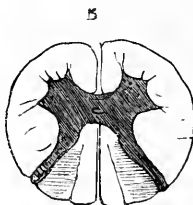


FIG. 73

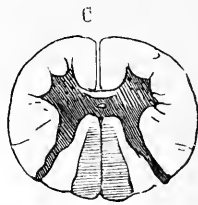


FIG. 71.—A, sclerosis of the whole of the posterior columns (columns of Goll and root-zones). Ordinary locomotor ataxy.

FIG. 72.—B, sclerosis of both posterior root-zones (columns of Goll are unaffected). Locomotor ataxy.

FIG. 73.—C, sclerosis limited to the columns of Goll. Ascending degeneration.

(c) We are now in a position, gentlemen, to understand the peculiar disposition which a lesion of the posterior columns presents when it results from pressure exercised by a tumour, if we bear in mind that this compression would have the effect of destroying, at some point in their course, the fibres of the columns of Goll and of Burdach.

The lesion, when affecting the short commissural fibres of

the columns of Burdach, causes upward degeneration of limited extent in these columns, and we shall see presently the reason why this degeneration is ascending. Lastly, the same lesion involving the long commissural fibres of the columns of Goll likewise determines ascending degeneration of these columns, which may be followed throughout the entire extent of the spinal cord as far as the floor of the fourth ventricle.

(*d*) If now, instead of a case of compression, we imagine one of partial transverse myelitis limited to the posterior column, the result will be absolutely identical as soon as the continuity of the fibres has been interrupted.

On this point, I will ask you to remark, gentlemen, that the most usual disposition of the lesions in locomotor ataxy agrees, with the exception of a few modifications, with what has just been said on the subject of ascending degeneration.

The essential lesion originally affects the radicular fasciculi throughout the entire length of the dorso-lumbar region; but, since this is pre-eminently an inflammatory process, the lesion does not remain limited to its focus of origin. It gradually extends in all directions, in part following the course of the nerve-fibres, in part the connective tissue, and so gains, on one side, the posterior cornua, and on the other the columns of Goll. The consequence of this extension is that the fibres of the columns of Goll, being affected in the lower part of their course, degenerate from below upwards, in the same manner as in the case of direct compression. The lesion thus produced may be followed, as we have just said, as far as the floor of the fourth ventricle.

Such, gentlemen, is the common lesion of locomotor ataxy, that met with ninety-nine times in a hundred patients who succumb to this disease.

## II.

We must interpret the secondary degenerations constituting the third group which now remains for consideration, according to the principle stated with reference to common locomotor ataxy.

Side by side with secondary degenerations of cerebral and

spinal origin, the descriptive account of which is now at an end, we must place, as I told you, the group of secondary degenerations of peripheral origin.

At the present time, this group is made up of three or four observations only, but it is probable that some day it will assume some importance. I shall therefore limit myself to quoting as examples, the observations of Cornil, which are the earliest in date, and that of Th. Simon.<sup>1</sup>

In all the cases hitherto noticed, the lesion was situated external to the spinal cord on the roots of the horse's tail, above the ganglion; it consisted of a sarcomatous or myxomatous tumour, which united and compressed the nerve-fasciculi.

There is no doubt, gentlemen, that the spinal lesion, in the observations to which I allude, was dependent not on lesion of the anterior roots, but of the posterior roots.

The consecutive degeneration had the following characteristics: (1) it occupied the posterior columns exclusively; (2) in the lumbar region, the posterior column was invaded *in its whole transverse extent*; (3) but above this region, the column of Goll alone was affected, and that throughout *its entire length*, that is to say, as far as the floor of the fourth ventricle.

You see that, as regards topography, this is a fairly exact reproduction of the lesions in ordinary ataxy.

Now, the following should be the state of affairs, at least theoretically and according to the principles we previously formulated. Conformably to Waller's law, the posterior roots degenerate above the lesion upwards towards the cord, and the degeneration of these fibres may be followed in their intraspinal course, that is to say, in the substance of the columns of Burdach. As soon as the lesion assumes an inflammatory character, it extends to the short commissural fibres of the column and by degrees reaches in the lumbar region the column of Goll which, according to rule, undergoes ascending degeneration in its whole extent.

If this matter is in harmony with theory, we ought to find at the autopsy, in a recent case of secondary degeneration of this kind, a lesion limited to the columns of Burdach and not yet involving the columns of Goll.

The future will show if this is really the case.

<sup>1</sup> 'Arch. f. Psych. v. Westphal.,' v Bd., 1874, p. 114.

## TRANSLATOR'S NOTE TO CHAPTER VIII.

IN a paper read before the Medico-Chirurgical Society of Edinburgh on March 2nd, 1881, Dr. Grainger Stewart describes certain changes in the spinal cord, which he believes to be secondary to disease of the peripheral nerves.<sup>1</sup>

The affection has usually an acute onset, and is attended by some amount of fever. Sensory disorders, such as pain or, more commonly, numbness and tingling, are the first to appear. Sensation is retarded and blunted, contact is painful, and localisation of impressions imperfect. Both hands and feet are usually affected simultaneously. Paresis affecting the distal parts speedily ensues, spreading up the limb from one group of muscles to another. Voluntary motion is either absent or diminished. The power of flexing and extending the toes and fingers may be absolutely lost within even a week of the commencement of the disease. Later on the arms and legs may become quite paralysed. Trophic changes, such as rapid muscular atrophy and blueness, congestion or glossiness of the skin, sometimes œdema, are apt to make their appearance. Bladder and rectal troubles are rare. The knee-jerk disappears early, but ankle clonus may be present, even after the patellar-tendon reflex is lost. The skin reflexes are usually absent or diminished. Sometimes, however, they are exaggerated, when a strong stimulus is applied. There is no disturbance of the intellectual functions. The morbid process may not reach its highest development for weeks or months, but sooner or later recovery generally takes place.

Dr. Grainger Stewart gives the chief clinical features of the disease in the following words:—"The co-existence of symptoms referable to the sensory, the motor, and the trophic functions of the nerves, the localisation of the symptoms in the feet and hands, the intensity being greatest at the most distal points, and the affection corresponding to certain districts of the extremities, and not to the distribution-areas of particular nerves." An opportunity of ascertaining the pathological nature of the disease was afforded by the death of one of the patients from acute pneumonia. The median, ulnar, and tibial nerves showed very marked changes, whereas the cords of the brachial plexus and the great sciatic nerve appeared normal. The alteration seemed to consist in swelling of the axis cylinder, with subsequent fatty degeneration. In part of the cervical enlargement, and to a less extent in the lumbar enlargement, both columns of Goll were affected, together with the most superficial and posterior part of the lateral columns, including part of Flechsig's cerebellar tracts. The grey matter and nerve-roots were not involved. It is curious to note that the spinal degeneration was evidently not propagated by direct extension of the morbid process from the nerves.

<sup>1</sup> "On Paralysis of Hands and Feet from Disease of Nerves."

## LECTURE IX.

### SECONDARY DEGENERATIONS OF SPINAL AND CEREBRAL ORIGIN IN RELATION TO WALLER'S LAWS. EXPERIMENTS OF SCHIEFFERDECKER, FRANCK AND PITRES.

SUMMARY.—*The rationale of secondary spinal degenerations is identical with that of the Wallerian changes. Waller's laws.*

*Descending and ascending degenerations. Fasciculi which degenerate downwards are comparable to the centrifugal nerves from the anterior roots. Fasciculi degenerating upwards resemble the posterior roots.*

*Experiments of Westphal, Vulpian, and Schiefferdecker. Initial period of degenerations. Experimental degenerations are in every respect identical with pathological degenerations in man. The pyramidal tract in the dog is not a compact bundle. The degenerated fibres are diffused through the antero-lateral column.*

*Experiments of Franck and Pitres. Degeneration in the internal capsule consequent on removal of the sigmoid gyrus.*

*Special exception in disseminated sclerosis. Histological desideratum.*

GENTLEMEN,—The study of secondary degenerations, which we hope to complete to-day, has hitherto been almost exclusively descriptive. We have, indeed, nearly always noticed and described, but, as a rule have explained nothing. Although, for example, we know that degeneration of certain fasciculi of the cord constantly takes place in an ascending direction, whereas degeneration of other fasciculi invariably occurs in the inverse direction, we are absolutely ignorant why this is so and on what principle the law is based.

Ought we to remain content with these ideas which, in a manner, are merely empirical? Or, on the other hand, should



we rather attempt the construction of a pathogenic theory of secondary degenerations?

This is the point which we shall now proceed to inquire into.

## I.

All authors agree to-day, gentlemen, in allowing with M. Bouchard that the *paradigm* of secondary spinal degenerations is to be sought for in the domain of the peripheral nerves. This question has reference to a series of facts which were discovered from 1849 to 1858 by Waller, the English physiologist.

On these facts there is based what is called the *Wallerian Law*. I shall be brief on this subject, which appertains, however, both to physiology and to pathology, since I shall take the opportunity of returning to it shortly.

Moreover, you will find in Claude Bernard's lectures on the Physiology of the Nervous System all that relates to this question, which for the moment I shall merely recall to your remembrance.<sup>1</sup>

Waller's theory is founded on the general fact that when a nerve is divided so as to separate it from its centre, it degenerates in a definite direction. Hence, if a mixed spinal nerve be cut below the union of the two roots, the peripheral end invariably degenerates throughout its entire length; and this degeneration attacks the centripetal as well as the centrifugal fibres which compose it.

The cause of the maintenance of vitality in the nerve-fibres or, in other words, their trophic centres, should, therefore, be looked for in the direction of the neuro-axis. But where are they actually situated? In order to discover them, it is necessary to make methodical sections, both of the anterior and of the posterior roots, at various points in their course.

(1) Section of the anterior roots, wherever made, is always followed by degeneration of the peripheral end, the central part remaining intact. Therefore the trophic centre of these roots and of the nerve-tubes proceeding from them is in the spinal cord, "probably," said Waller, "in the grey matter."

<sup>1</sup> Cl. Bernard, 'Leçons sur la physiologie et la pathologie du système nerveux,' t. i, p. 237.

Thanks to recent researches in pathological anatomy, we can say to-day, with much greater precision, that it is in the anterior cornua, and still more definitely, in the so-called motor cells.

(2) Does this apply to the posterior roots? Decidedly not. We come now to the most original and most unexpected part of Waller's discovery. When a section is made in the course of the posterior root, the part which degenerates is not the periphery of the root, that is to say, the portion next to the ganglion, but the central part or that connected to the cord. The degeneration may be followed throughout the entire extent of the intra-spinal course of the radicular fasciculi as far as the grey matter, so that the trophic centre for the sensitive nerves must be sought for in the inter-vertebral ganglion. This is true, for on extirpation of the ganglion degeneration attacks the entire root and also all the centripetal fibres of the mixed nerve.

You will readily understand, gentlemen, without it being necessary to insist further on this point, the application which can be made of these facts to secondary spinal degenerations. The fibres of the fasciculi which degenerate downwards, below the point of lesion, are comparable to the centrifugal nerves proceeding from the anterior roots. Of this number are:—(1) the *pyramidal tracts* made up of fibres, of which the trophic centre would be in the pyramidal cells of the cortex in the Rolandic region; (2) the *short fibres of the lateral columns*, which arise from above downwards at various points of the central grey axis. The fasciculi which degenerate upwards are, on the contrary, analogous to the posterior roots, the trophic centre of which is peripheral.

In this class are:—(1) the *direct cerebellar tracts*, the trophic centre of which is in the cord itself, whereas their terminal centre is in the cerebellum; (2) the *columns of Goll*, of which the trophic centre occupies the grey matter in the lower regions of the cord and the terminal centres correspond to the grey matter in the medulla oblongata. Lastly, the same interpretation applies to the short commissural fibres of the *columns of Burdach*, which likewise undergo ascending degeneration.

## II.

The analogy which we have just drawn between the results of Waller's experiments and the facts of pathological anatomy relative to secondary degenerations, plausible as it may appear, would be still more legitimate if these degenerations of the nerve-fasciculi could be faithfully reproduced by experiment, as in the case of divided nerves.

Now, gentlemen, recent works tend to show that this can really be effected. Secondary fasciculated degenerations, both of cerebral and of spinal origin, may be reproduced experimentally in animals.

In the first place, let us consider secondary degenerations of spinal origin. The early attempts made by Vulpian and Westphal did not yield decisive results. As you will see, this depends on circumstances which cannot be foreseen at the outset. The spinal cord of the dog, which is the subject of most experiments of this kind, although made on the model of the human cord, is nevertheless distinguished from it by some anatomical peculiarities, the main features of which I am about to impress on you, by relating the labours of the last author who has written on experimental secondary degenerations.

I refer to Schiefferdecker's researches, which were published in Virchow's 'Archives' for 1876. The author had at his disposal about a hundred dogs which had been employed in the experiments of Goltz and Frensburg. The material was quite exceptional, not only by reason of the number, but also of the peculiarities of the subjects. These animals, indeed, in which the cord had been cut across at the level of the twelfth dorsal vertebra, contrary to what generally takes place after such a mutilation, had by careful attention been preserved for several weeks and even months.

After death, by examining hardened sections, the ascending and descending degenerations were systematically investigated.

The following, in a few words, were the principal results obtained :

In the first place, degeneration was a constant fact, exactly as in the case of divided spinal nerves. The appearance of the first traces of the morbid process could be fixed, as to date, with a fair

amount of accuracy. In the first week even, indications were often already visible; but, after a fortnight, the result was absolutely unmistakable. At the end of four or five weeks, the highest degree of degeneration was reached. With reference to this point, I will ask you to observe that, in man, the earliest signs of secondary degeneration can be recognised only after an interval of one or two months. But we must remember, gentlemen, that, from the force of circumstances, observations on man are much less numerous than they were in the case of the animals studied by Schiefferdecker.

As regards the distribution of the degeneration, both ascending and descending, it is, according to Schiefferdecker, nearly the same as in man; there are, however, in the dog, a few peculiarities which, with your permission, I shall briefly indicate.

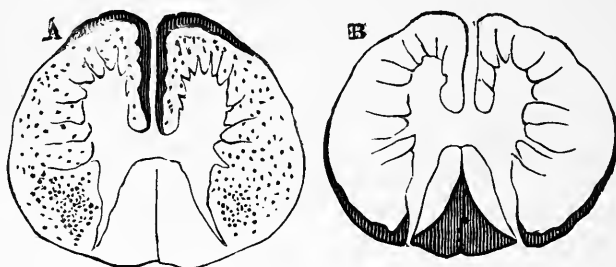


FIG. 74.—A, section of cord below the lesion; B, section of cord above the lesion. At A the descending sclerosis is seen to be diffused in the antero-lateral column, except at the anterior part, where the degeneration is accurately circumscribed to the fasciculi of Türk. B shows degeneration of the columns of Goll and direct cerebellar tracts.

(1) In the case of ascending degeneration, the lesions are perfectly identical with those seen in man under similar circumstances, viz. ascending degeneration of the columns of Goll and of the postero-lateral parts of the lateral columns, corresponding to the direct cerebellar tracts.

(2) But the descending degeneration, when compared with that seen in man, exhibits some peculiarities. It may be said, indeed, that the pyramidal fibres do not usually form, as in man, compact bundles. The fibres of the direct pyramidal tracts are, however, exceptional. Throughout the rest of the antero-lateral

columns fibres capable of degeneration are distributed in small numbers. Nevertheless, they become collected so as to form a group somewhat more compact, in the *pyramidal region* of the lateral column; and at this point the fibres undergo degeneration in a long course, whereas, elsewhere, they degenerate only in a short course. Briefly, *mutatis mutandis*, these secondary degenerations of spinal origin, whether ascending or descending, are absolutely comparable to those occurring in man.

### III.

What has just been said of secondary degenerations of spinal origin may be applied to secondary degenerations of cerebral origin, which can likewise be artificially produced in the dog. First of all, it is necessary to recall to your minds what we have already stated as regards the motor convolutions of this animal. What are the parts homologous to the Rolandic regions in man? This, gentlemen, is a point on which comparative anatomy does not, at present, seem to be definitely decided. Be this as it may, experiment has shown, on the surface of the dog's cerebrum, excitable motor regions which functionally have the same signification as the Rolandic convolutions. These motor regions in the dog are, as it were, grouped around the crucial sulcus and, for the most part, occupy a convolution described under the name of *sigmoid gyrus*.

You are aware, gentlemen, that the lesions, which have hitherto been made with the purpose of determining secondary degenerations in the dog, have affected little else but the cortex and subjacent white matter. But it is extremely probable that the result would be identical if the lesions involved the corresponding regions of the internal capsule. In short, when the sigmoid gyrus is removed from the hemisphere, secondary degeneration takes place in the dog just as in the case of a lesion affecting a part of the motor regions in man. In this respect, I shall content myself with quoting a few experimental observations. (1) Gudden's observation, in which a lesion of the internal capsule in a young dog was accompanied by degeneration in the medulla and spinal cord; (2) an

observation of M. Vulpian, who noticed, five months after removal of the sigmoid gyrus, atrophy with secondary degeneration of the corresponding pyramid; (3) lastly, the observations of MM. Franck and Pitres,<sup>1</sup> who make mention of absolutely identical results.

In addition, gentlemen, it is by no means uncommon to see certain lesions become developed spontaneously in the sigmoid region of the dog, and, under such circumstances, the existence of secondary degeneration has been several times remarked.

In M. Issartier's recent thesis you will find some cases of this nature, which have been referred to by MM. Déjerine, Carville, and Duret.

MM. Franck and Pitres, to whom we owe such important researches bearing on all the questions we are now discussing, have proceeded still farther. They tried to study the progress of the morbid process by means of experiment. It is now a matter of scientific truth that there exists in the hemisphere below the sigmoid gyrus, the excitable part of the cortex, a triangular, tongue-shaped process of white matter, which connects the cortical grey substance to the internal capsule, and which, as in the case of the cortical region, whence it is derived, responds to experimental stimuli, whilst all other parts of the hemisphere are deficient in this property.

Now, gentlemen, the apparent result of the experiments of MM. Albertoni and Michieli is that this white fasciculus loses its irritability four days after removal of the sigmoid gyrus. Thus separated from the cortical trophic centre, its fibres become deprived of their physiological properties, exactly as in the case of a peripheral nerve. MM. Franck and Pitres have corroborated these results. Even before the lesion is appreciable, it certainly is already in existence, since it reveals its presence by loss of the peculiar endowments of nerve-elements.

Consequently, gentlemen, as you perceive, everything admirably concurs in supporting the theory which I have asked you to accept. Nevertheless, I must not conceal from you the fact that there is a black cloud on the horizon. I refer to a well-known exception which, at least up to the present time, seems to<sup>2</sup> contradict the law. Lesions in disseminated sclerosis, even when very extensive, do not produce secondary degenerations

<sup>1</sup> See Issartier's 'Inaugural Thesis,' 1878.

I have previously put forward the hypothesis that this is referable to the prolonged persistence of the axis-cylinders in the patches of multilocular sclerosis. But I did not guarantee the absolute truth of my explanation, which, however, is based on the observation of an actual fact.

It may be that some secondary degenerations, for want of an adequate examination, pass undetected. Whatever may be the hypothesis, I believe that it will be necessary to revise in this respect the pathological anatomy of disseminated sclerosis. To this point, however, I shall for the present merely allude, since we shall doubtless have the opportunity of returning to it subsequently.<sup>1</sup>

<sup>1</sup> In a recent communication to the Société de Biologie, MM. Franck and Pitres have shown that degeneration of the pyramidal tract in the dog may assume the same anatomical characters as in man. It would seem, therefore, that the fibres of the pyramidal tract are collected, up to a certain point, into a fairly compact group. The following, however, are the conclusions from the researches of MM. Franck and Pitres :

“In the dog a cortical lesion situated in the motor zone may be followed by secondary degeneration of the spinal cord.”

“This degeneration, *which is anatomically identical with that occurring in man under the same circumstances*, differs from it as regards symptomatology in the fact that it is not accompanied by muscular contracture.”—‘*Progrès Médical*,’ 1880, p. 147.

See also Tripier’s “De l’anesthésie produite par les lésions des circonvolutions cérébrales,” ‘*Revue mensuelle de médecine et de chirurgie*,’ January 10th, 1880.

## LECTURE X.

### DETERMINATION OF THE COURSE OF THE WHITE FASCICULI IN THE SPINAL CORD BY THE STUDY OF SECONDARY DEGENERATIONS. EXPERIMENTAL ANALYSIS OF THE FUNCTIONS OF THE PYRAMIDAL TRACTS.

**SUMMARY.**—*All the white fasciculi of the cord are capable of system degeneration. Diagram of the fasciculi: (a) with long fibres; (b) with short fibres.*

*Intrinsic fasciculi of the posterior columns: columns of Burdach and of Goll.*

*Extrinsic fasciculi: direct cerebellar tracts.*

*Antero-lateral columns: intrinsic fasciculi; extrinsic fasciculi (pyramidal tracts).*

*Results of experiment. Can the antero-lateral columns be stimulated? The irritability of the pyramidal tract in man is manifest throughout its entire cerebro-spinal course.*

*Experiments of Vulpian and Schiff. Spinal hemisections. Woroschiloff's vivisections. Influence of the pyramidal tract on the reflex activity of the spinal cord. The pyramidal tracts are the conductors of voluntary impulses.*

GENTLEMEN,—You have doubtless not forgotten the proposition which I stated at the very beginning of our investigations on secondary degenerations. These lesions, I told you, are interesting not only from the standpoint of pure pathological anatomy, but are the causes during life of special functional disorders superadded to the symptomatology of the primary lesions which have given origin to them, and that sometimes the secondary even obscure the primary symptoms. On these grounds they are worthy of the careful attention of clinical observers. The moment has arrived for justifying our assertion and for exhibiting the practical side of the delicate and compli-



cated studies which we have hitherto pursued. It is, then, the clinical aspect of secondary degenerations which we are now about to consider. But, before approaching this subject, there are still two points to which, as a preliminary, I would call your attention for an instant.

In order to grasp the nature and origin of the functional disorders allied to the descending degenerative lesions of the various spinal fasciculi, we ought doubtless to make special appeal to the pathological data which we have so carefully collected on all points relating to these lesions.

But this would not suffice to conduct our enterprise to a satisfactory conclusion.

(1) We must, indeed, be decided on some points relative to the structure of the spinal cord, the arrangement of the nerve-fibres and the cellular elements, their mutual relations, &c. It is true that in our progress we collected a certain number of facts having special reference to this subject; but now it is, I think, important to consider the question not partially, but as a whole.

(2) On the other hand, we must use the data supplied by experiments with reference to the physiology of the spinal fasciculi.

It is true that, so far as man is concerned, the anatomo-clinical method is alone capable of leading us to a final decision as to the physiology of the various parts of the nervous system; it is equally true that experiments on animals furnish data of great importance, by indicating the path in which anatomo-clinical investigations should be directed.

I shall, therefore, begin at once with the first point. It has often been said that morbid anatomy sometimes throws light on normal anatomy, and that it may then even decide questions which the latter would be incapable of resolving by itself. The pathological anatomy of secondary degenerations partly justifies this statement. As regards the arrangement of the constituent elements of the spinal cord, it does, indeed, supply information which is certainly not inferior in worth to the facts of pure anatomy; sometimes it is even of much greater value.

I wish to lay before you briefly the following general ideas concerning the structural anatomy of the spinal cord.

## I.

You have been enabled to infer from what has preceded that the white fasciculi which enter into the formation of the spinal cord undergo secondary degeneration when their constituent fibres are interrupted in their course. Now, in this respect, we must make a two-fold division.

A. Some of these fasciculi are composed of long fibres, that is to say, of fibres passing lengthwise and uninterrupted through the neuro-axis. These latter are the seat of what we may call *long-course* secondary degenerations.

Of this nature are: (*a*) the pyramidal tracts (descending degeneration); (*b*) columns of Goll (ascending degeneration); (*c*) direct cerebellar tracts (ascending degeneration).

B. Other fasciculi are made up of short fibres. In this class are: (*a*) the antero-lateral columns, or rather, what is left of them after abstracting the pyramidal tracts and the direct cerebellar tracts. They undergo degeneration from above downwards. (*b*) The special fibres of the columns of Burdach, which degenerate from below upwards. In both cases the degeneration is *short-course*.

If, now we are provided with these data, we consider the constitution of the entire cord, we may construct the following scheme, which, moreover, does not materially differ from that described by M. Bouchard in the work to which I have already several times referred you.

The spinal cord may be looked upon as essentially made up of a grey axis, around which all the other parts are grouped. The fundamental parts of this axis, that is to say, the ganglionic cellular elements, are *kinesodic* or motor, and *æsthesodic* or those concerned with the transmission of sensitive impressions.

These two kinds of elements are, moreover, mutually connected in a thousand ways, through the agency, it is thought, of a nerve-reticulum. Be this as it may, the grey axis gives origin in front to the anterior roots which are in direct relation with the cells of the anterior cornua through the medium of the processes of Deiters. The posterior roots, on the other hand, are in relation with the *æsthesodic* cells.

But the cord, complicated as it thus appears in its structure, is still far from complete.

The point in question is to determine the relation of the grey axis to the various bundles of white fibres which surround it.

We must now consider successively the antero-lateral and posterior columns, beginning with the latter. Of the component fasciculi of the posterior columns some may be termed *intrinsic*, others *extrinsic* (I employ the nomenclature proposed by M. Bouchard). The intrinsic are divided into two groups: (1) in the columns of Burdach the intrinsic fibres are short commis-

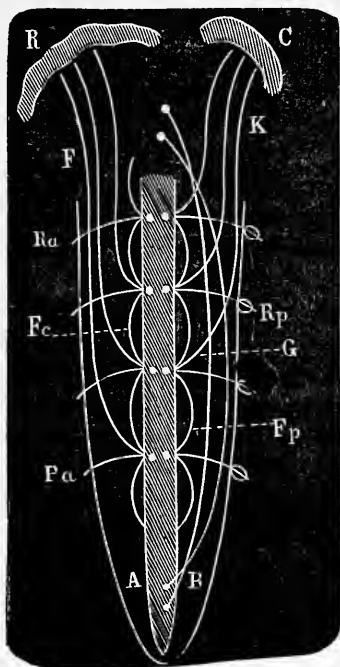


FIG 75.—A, anterior fasciculi; B, posterior fasciculi; R, Rolandic convolutions; C, cerebellum; Ra, anterior roots; Rp, posterior roots; F, pyramidal tract; Fc, centrifugal intrinsic fibres (anterior columns); K, centripetal extrinsic fibres (direct cerebellar tract); Fp, centripetal intrinsic fibres (column of Burdach); G, posterior long fibres (column of Goll).

ures bringing into communication the æsthesodic cells, throughout the entire length of the cord. Each fibre has its trophic centre below and, as you are aware, degenerates in an ascending

direction; (2) in the columns of Goll, on the contrary, there are long commissural fibres, likewise degenerating from below upwards, the trophic centre of which is consequently situated at a lower level than the terminal centre.

These intrinsic fibres of the posterior spinal system have only indirect and, as yet, ill-defined relations with the encephalon.

As regards the extrinsic elements, they are represented by the direct cerebellar tracts which, at their lower extremity, enter the grey matter where they have their trophic centres, and above, the grey substance of the cerebellum, which is thus placed in relation with the spinal cord proper.

In the antero-lateral columns we have also to consider the intrinsic and extrinsic parts. The first are represented by the short commissural fibres, which probably bring into relation the motor cells of different strata. The trophic centre of these fibres is above the terminal centre, since they degenerate from above downwards.

As to the extrinsic fibres of these fasciculi, they are no other than the direct and crossed pyramidal tracts; and, so far as their direction, origin, and termination are concerned, pathological anatomy and experiment have been of the greatest service. There does not appear now to be any doubt that these fasciculi are, as it were, a bridge or true commissure for establishing direct relations between certain regions of the cerebrum and the kinesodic cells in the various parts of the grey axis. The origin of the fibres which constitute these fasciculi is in the cortex of the convolutions, probably in the pyramidal cells of the grey matter, where they have their trophic centre.

These fibres, having traversed the encephalon, reach the medulla oblongata, and finally the spinal cord, without entering into any relations, except those of contiguity, with the parts through which they pass. They become gradually used up in their descending course through the various regions of the cord, where they enter into connection with the motor cells, through the medium of an anatomical arrangement, which as yet is but little understood.

## II.

As regards anatomy, enough has been said. Let us consider now the physiological side of the question, and the principal results which experiment has supplied as to the function of the white fasciculi. We shall begin with the antero-lateral columns.

Ideally, physiology ought to throw light on the special function of each of the secondary fasciculi which developmental and pathological anatomy have taught us to differentiate in this part of the cord. Unfortunately, experiment has not, as a rule, taken these distinctions into account. Nevertheless, I shall have occasion to bring under your notice some attempts recently made in this direction, and which have reference to the special function of the pyramidal tracts in the transmission of voluntary determinations.

(1) With respect to degenerations occurring in the antero-lateral columns when the course of these fibres is interrupted, we have already seen that these fibres obey the same laws as the centrifugal peripheral nerves. Now, may the antero-lateral columns be also compared with the motor nerves in their other properties? Decidedly not. For we know that section of the centrifugal nerves is followed by muscular atrophy, whereas interruption of the antero-lateral fibres does not entail the same result.

The anterior roots are not simple prolongations of the nerve-tubes of these fasciculi, but are separated from them by the ganglionic cells, their true trophic centres. Identity therefore does not exist, but only some analogy.

Are the antero-lateral columns excitable like nerves? In other words, is irritation of their nerve-fibres by mechanical, chemical, or electrical agents followed by muscular contraction, as happens in the case of nerves?

It is now, gentlemen, a well-established fact, owing to the researches of M. Vulpian and more recently of Fick and Engelken, that the antero-lateral columns, like nerves, are themselves excitable. But the effects of stimulation are much less marked as regards the generalisation and intensity of the con-

tractions. It is remarkable also that voluntary or physiological stimulation in this case far surpasses artificial irritation. The cells of the anterior cornua are, without doubt, the obstacle impeding the extension of the irritation to the anterior roots. But it is especially interesting to inquire if the pyramidal columns are *more or less excitable* than the anterior fasciculi. Experiment encounters very serious difficulties in these researches.

Authors agree in allowing that in the dog irritability is most marked in the anterior fasciculi. It is possible, indeed, that this may be so in the dog, in which according to Schiefferdecker's observations, the columns of Türck, appertaining as they do to the pyramidal tract system, and consequently made up of long fibres, would be of considerable importance in this respect.

Is this, however, the case in man, in whom, on the contrary, the columns of Türck are of little consequence, the anterior fasciculi, properly speaking, being composed of short commissural fibres, that is to say, of fibres forming a fasciculus, the course of which is constantly interrupted by ganglionic cells? That this is so is open to doubt. Moreover, we know that the prolongation of the pyramidal tract in the cerebral hemisphere may be stimulated, and we are aware that this prolongation assumes the form of a tongue-like process of nerve-substance, which underlies the Rolandic convolutions and is endowed with very manifest irritability. It may, therefore, be granted that in man the same excitability must exist throughout the entire extent of the prolongation of these fasciculi in the spinal cord.

(2) A. To-day it is a pretty generally admitted fact in experimental physiology that the transmission of voluntary motor stimuli takes place exclusively through the white antero-lateral fasciculi. This, at any rate, is what M. Vulpian's experiments, contrary to those of Schiff on this subject, seem to have peremptorily established. In the frog, and *à fortiori* in mammals, section of the lateral columns in the dorsal region—the posterior columns and grey matter being kept intact—causes decided abolition of voluntary movements of the hinder parts, not only on the day of experiment but also subsequently.

On the other hand, section of the posterior columns and of

the grey matter allows voluntary movements to persist in the hinder limbs.

B. It is of great importance, also, to consider the result of spinal hemisections. Schiff's experiments, which were repeated by M. Vulpian and other observers, have modified, in this respect, the old ideas dating from the time of Galen. Absolutely direct transmission was then entertained, but we know now (in the case of animals) that it is partly direct and partly crossed. When you divide the lateral half of the cord in the guinea-pig, for example, there is at first well-marked paralysis on the corresponding side and slight paresis also on the other side. But, if the animal survive, the paralysis soon diminishes on the side of the hemisection, although still persisting to a certain extent. This has reference to the existence of commissures uniting the antero-lateral fibres on one side to the corresponding parts on the other side. But on making a hemisection of the side which was at first respected, the paraplegia becomes complete in both extremities. Voluntary motor stimuli therefore necessarily pass through the antero-lateral columns and through them alone. *Indifferent conduction* by such or such elements of the spinal cord, as in the case of sensibility, does not exist here.

Hence, whereas transmission of sensitive impressions is still possible when the cord has undergone, at different levels, two hemisections in contrary directions, there is in the same case absolute and complete motor paralysis.

### III.

But do the antero-lateral columns as a whole really transmit the mandates of the will, or is this more particularly the function of the pyramidal tracts? Experiment has nearly always recoiled before this analysis. "A vivisection dividing separately and completely the anterior or lateral fasciculi," says Vulpian, "is scarcely conceivable."<sup>1</sup> To be convinced of this it is only necessary to examine the configuration of a transverse section of the spinal cord. Nevertheless, gentlemen, Woroschiloff, availing himself of the improved instruments in daily

<sup>1</sup> 'Dict. encl. des sc. méd.,' Art. "Moelle."

use at Ludwig's laboratory, was able to make of the rabbit's cord sections of great diversity, both as to the seat and extent of the affected parts. In this way he succeeded in producing combinations by which he was enabled to infer the function of the pyramidal tracts in the transmission of voluntary stimuli. By these means he confirmed the results previously obtained on the same subject by Miescher, Nawrocki, and Dittman.

The object of Woroschiloff's experiments was to discover the influence of the various spinal fasciculi on the execution of some voluntary movements which are easy of analysis (leaping, running, walking, &c.). The extent and configuration of the lesions were studied by Herr Woroschiloff with the greatest care, on the hardened sections which he has reproduced photographically in the work in question.<sup>1</sup> With your permission I shall relate a few of the results to which these researches have led. To us they are particularly interesting, since our great object, as you know, is to determine the special function of the pyramidal tract.

(1) Section of the posterior columns in no way affects voluntary movements (Fig. 76).<sup>2</sup>

(2) It is very remarkable that all the anterior half of the cord may be divided, without the occurrence of any modification in the execution of voluntary movements. It is plain, therefore, that the posterior half suffices for this transmission, and that there are no long fibres, *directly cerebral*, in the anterior fasciculi (Fig. 77).

(3) The grey matter may be cut through in its whole extent, the antero-lateral columns persisting, without any modification in voluntary movements being produced (Fig. 78).

(4) If, on the contrary, the antero-lateral columns be divided on both sides, the grey matter being intact, the posterior extremities are completely paralysed. This means that the grey matter does not suffice for the transmission of voluntary stimuli (Fig. 79).

(5) In the case of section of the posterior and lateral columns, the animal only uses its anterior extremities, the hinder parts being completely paralysed (Fig. 80).

<sup>1</sup> 'Bericht d. Gesellsch. d. Wissensch. zu Leipzig,' 1874.

<sup>2</sup> In the figures the shaded part indicates the extent of the medullary section.



(6) Lastly, if the section be total, one lateral column alone being respected, the lower extremity on the divided side is completely paralysed. On the other hand, the extremity on the side where the lateral column is spared is still subservient to the will; when it is extended the animal draws it back (Fig. 81).

FIG. 76.

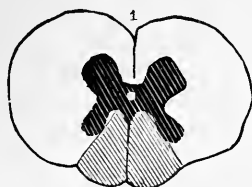


FIG. 77.

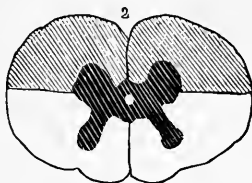


FIG. 78.

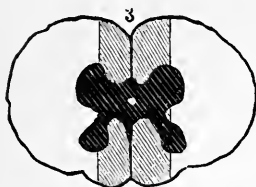


FIG. 79.

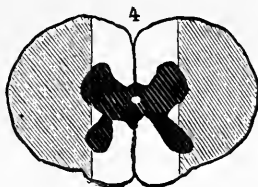


FIG. 80.

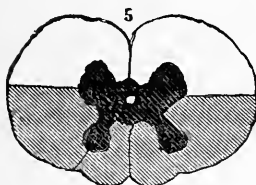
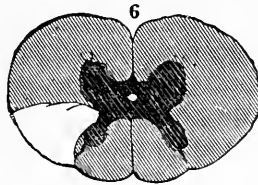


FIG. 81.



Transmission of voluntary stimuli takes place, therefore, through the pyramidal tracts. But it is possible that this is not the function exclusively of the pyramidal tracts; it represents, doubtless, the readiest and most usual path. When, however, this course is interrupted, there are probably others which may obey, at least in certain cases, the mandates proceeding from the cerebrum. To this point we shall have to return.

## IV.

In order to complete these physiological preliminaries, it only remains for me to say a few words on the influence exercised by the pyramidal tracts over the reflex spinal activity. Our inquiries relative to development have already shown us that the pyramidal tracts are to be looked upon as large commissures, serving to establish functional relations between the cerebrum and spinal cord. The latter has a separate existence so long as these fasciculi are as yet undeveloped, and up to this period the movements of the newly-born child are entirely of a reflex nature. Reflex movements, on the other hand, are relegated to a secondary position when the development of the pyramidal tracts is accomplished, voluntary movements henceforward predominating.

The controlling influence of the cerebrum over reflex acts is, moreover, placed in its true light when we consider what takes place after section of the cord. But it is easily shown that this influence is especially exerted through the antero-lateral fasciculi. Indeed, the section may be such that sensibility is preserved, and furthermore, one side of the cord only may be affected. The antero-lateral columns are, therefore, the conductors of voluntary stimuli.

Nevertheless, experimental physiology has not yet decided whether this influence is exerted through the anterior fasciculi or the pyramidal tracts. Yet we shall see that pathological facts settle the question which physiological experiment leaves undecided.

Such are the preliminary ideas which I have considered it my duty to lay before you, relative to the function of the various spinal fasciculi, as revealed by experimental researches. We can now consider with advantage the clinical aspect of secondary degenerations.

## LECTURE XI.

### GENERAL SEMEIOLOGY OF SECONDARY DEGENERATIONS OF THE PYRAMIDAL TRACT.

**SUMMARY.**—*Description of the secondary spinal affection. Condition of patient the day following an apoplectic seizure. The prognosis, which may be made at the outset, is based on the anatomical diagnosis of the seat of lesion.*

*Exact determination of the vascular area at the expense of which the cerebral hæmorrhage is produced. The lesion may be circumscribed or may tend to increase. The integrity of the pyramidal tract is the condition sine quâ non for recovery.*

*Precursory symptoms of secondary contracture.*

*Provoked spinal epilepsy or ankle-clonus. Statistics. Extension of spinal epilepsy to the healthy side. Wrist-phenomenon. Tendon-reflexes.*

GENTLEMEN,—To-day I purpose to consider the clinical aspect of secondary degenerations. In other words, I shall endeavour to lay before you a number of functional disorders which are dependent on these lesions and which serve to reveal their existence during life. Afterwards we shall try to arrive at the physiological interpretation of these symptoms, by utilising the facts of an experimental nature which I briefly stated to you in the last lecture.

#### I.

You are doubtless not unaware, gentlemen, that the question I am about to approach has been treated in a very brilliant way by Professor Bouchard, in the work of which I have

already many times availed myself. The symptomatology of secondary degenerations is incontestably one of the most original features of this book.

On several occasions, in this course of lectures, I sketched an outline of the symptoms allied to secondary degenerations, for the most part in complete harmony with the account given by M. Bouchard. Once again the case will be the same; nevertheless, since 1866, some new facts have been introduced into this interesting subject, and these I shall have to bring under your notice. In addition I shall take the opportunity of proposing some modifications with respect to the physiological interpretation of the phenomena.

The divisions of this subject, which must be established for the requirements of demonstration, are made on natural principles. We shall review in succession consecutive degenerations of cerebral origin and those depending on spinal lesions.

## II.

In order to understand thoroughly the practical interest of the inquiry which we are about to undertake, it is advisable to consider the condition of a patient suddenly attacked with hemiplegia, in consequence of the formation in the cerebrum of a circumscribed hæmorrhagic lesion or patch of softening.

For the sake of greater precision, let us confine our attention to the case of intra-encephalic hæmorrhage; and let us suppose that the instance in question is one of some severity. Our remarks, with the exception of a few modifications of secondary importance, may be readily applied subsequently to the case of apoplectiform softening.

I shall assume, moreover, that the patient has surmounted the first difficulties of the situation, and that the comatose phenomena and intellectual torpor of the apoplectic attack have already passed away. All symptoms of grave import, such as fever, the so-called *early* contracture, the erythema of the buttocks, if indeed they have existed, have now disappeared. In a word, we have reached the twelfth or fifteenth day after the attack, and it appears certain that, apart from any accidental complication, the patient will survive.

But, gentlemen, there is a very important question which will present itself to the physician's mind, and which, moreover, will certainly be addressed to him by interested persons or by the patient himself. At this period there still exists motor paralysis on one side of the body, absolutely complete or nearly so.

The upper extremity is quite flaccid and falls back heavily on the bed when it is let loose after being raised. The patient, moreover, is incapable of executing the slightest movement with the various parts of this extremity. The case is the same as regards the lower limb, although perhaps to a less extent. Lastly, the lower facial regions on the corresponding side are also affected. Accordingly, on the healthy side the labial commissure is raised, the lips at the same time being slightly apart; whereas, on the paralysed side, the commissure is drooping and the lips seem thinner. For the moment, it is unnecessary to enter into further details.

Now, the question to be decided is the following: the patient will live and, doubtless, recover to a great extent the use of his intellectual faculties; but will he regain power some day or other over his paralysed limbs? Will he be able to use his hand and arm, or even leave his bed, stand, or walk? Or, inversely, will he ever afterwards be condemned to a motor impotence, depriving him of the regular use of his extremities? In short, will he pass the rest of his life as an invalid, confined to his room and forced to appeal to the assistance of others, in order to accomplish the most essential acts of common life?

Such, gentlemen, is the problem which presents itself under the special conditions we have laid down. In a case like this, the well informed physician, whilst endeavouring to find, by the examination of the patient, indications which may serve to furnish the solution of this very difficult question, will not fail to recall to mind, it may be even instinctively, the pathological and physiological knowledge calculated to enlighten him. If I may so express myself, he will think anatomically and physiologically as well as clinically.

He will rest satisfied with empirical facts only in the absence of something better, and will strive, if possible, to penetrate the reason of things. We cannot, I think, do better than follow out this course. Let us describe, therefore, the condition of the

affected parts in the patient under our observation, and upon whose future we are called upon to pronounce.

### III.

This will lead us to a digression, but I have no doubt that after traversing the bye-path through which I am about to guide you, the task we have in hand will be made the easier.

You have not forgotten that in the instance we have selected the question is one of intra-encephalic hæmorrhage in its most common form. Where is the lesion situated? What parts has it compressed only? What parts has it destroyed? Ninety-five times in a hundred, perhaps, the state of affairs will be such as we are about to describe.

Let us recall some of the anatomical peculiarities which the region of the central masses offers to our consideration, for it is here that effusion takes place in the great majority of cases.

Let us once more examine the horizontal section which I have already several times brought under your notice. This time I shall particularly call your attention to the relations of the lenticular nucleus. Internally, it is bounded by the internal capsule; externally, by another white tract, the external capsule, which separates it from the claustrum (*avant-mur*) and from the region of the island of Reil.

Now, gentlemen, it may be readily shown in specimens which have been thoroughly hardened in alcohol that the external surface of the lenticular nucleus, especially in its anterior third, is only very loosely united to the external capsule. In fact, there are no intimate anatomical connections between this white band and the outer aspect of the grey nucleus. At this point there exists a kind of potential ventricle; and if, as Gendrin long since observed, the formation of sanguineous effusion in ordinary cases takes place first in this region, the reason is not difficult to understand. Moreover, to this same region belong the nutrient arteries, degeneration of which makes ready the way, as it were, for intra-encephalic hæmorrhage.

If, guided by M. Duret's important labours, you study the arrangement of the nutrient arteries of the central masses in a

brain which has been previously injected, your attention will be especially called to the following points.

The most important of the arterioles proceed from the trunk of the Sylvian, from which they arise perpendicularly, to penetrate the nerve-matter of the anterior perforated space.

We see here a number of small apertures, each of which gives passage to one of these arterioles. Notice particularly that, contrary to what holds good with respect to the cortical vessels which go to supply the grey matter and underlying white substance, the vessels penetrating the substance of the central masses are not, as regards their structure and calibre, capillaries, but true arteries.

The arrangement which the lenticulo-striate vessels present, as soon as they have entered the substance of the central masses, may be readily demonstrated by a very simple dissection. The cortex of the convolutions of the island of Reil, the subjacent white matter, the claustrum, and lastly, the external capsule are removed in succession. In this way, the convex surface of the third segment of the lenticular nucleus is laid bare, and the lenticular arterioles are seen to be distributed fan-like over this surface. The largest of these vessels are those lying most anterior. They are all directed from before backwards and from below upwards, and enter the substance of the nucleus towards its upper extremity, where they are lost to sight.

In order to display the further course of these vessels and their ramifications in the substance of the grey nuclei, it is now necessary to make transverse sections through these nuclei. The examination of one of these special sections will suffice for the purpose we have in view. The section in question is taken a little in front of the chiasma. Here is seen one of the largest striate arteries, which is of the greatest importance by reason of its fundamental rôle in the cerebral hemisphere. After penetrating the interior of the third segment, it crosses the upper part of the internal capsule, and reaches the caudate nucleus. The other arterioles are disposed almost exactly after the same plan. They are *terminal* arteries, or, in other words, they neither communicate one with another, nor with the cortical arteries. An injection propelled with a moderate amount of force readily causes their rupture and produces

minute extravasations similar to those seen in cerebral hæmorrhage.

Lastly, gentlemen, they are particularly liable to that variety of degeneration which leads to the formation of miliary aneurysms, the preparatory lesion of ordinary intra-encephalic hæmorrhage.

It is very common in patients who have been formerly attacked with apoplexy from cerebral hæmorrhage, to extract from the apertures of the perforated space a considerable number of arterioles presenting miliary aneurysms.

When hæmorrhage takes place from the arteries thus degenerated—and this is of very frequent occurrence—the blood is effused into the potential ventricle, of which we spoke just now, between the lenticular nucleus and the external capsule which is found to be separated. In this way are formed those flattened-out foci which, after the effused blood is absorbed, appear as linear ochreous cicatrices bounding the external aspect of the lenticular nucleus.

When the hæmorrhagic lesion in question is still recent, even though the effusion be inconsiderable, it will necessarily displace the grey nuclei towards the ventricles, in consequence of the greater resistance offered by the walls of the cranium towards the island of Reil.

You see, then, that if matters remain thus, no important part will be destroyed; the internal capsule, in particular, will be only compressed indirectly. In a case like this, notwithstanding the intensity which the early symptoms may present, the patient, if he has resisted the effects of shock, will recover, that is to say, he will regain sooner or later nearly perfect movement.

But, on the other hand, the lesion may increase and extend in the direction of the arterioles; it may pass through the internal capsule, and lastly, penetrate the ventricular cavities. If such an accident occurs, the case is one of great gravity. Most usually the patient succumbs, and thereby the question is solved.

Even though extravasation into the ventricles does not take place, if the fibres of the capsule are merely torn, however slightly, the rent may involve the pyramidal-tract fibres, the case is nevertheless very serious; not so far as the patient's life is concerned, which is by no means endangered from this circum



stance, but as regards the return of movement in the extremities affected with hemiplegia. The integrity of these movements is, then, without doubt definitely compromised.

In fact, gentlemen, a destructive lesion of this kind necessarily involves the development of a descending spinal lesion, which in its turn, as we are about to show, inevitably entails more or less complete persistence of motor impotence in the paralysed limbs.

Accordingly, you see that the question of a few millimètres more or less in the extent of the lesion in a certain direction is not an unimportant matter. So long as the pyramidal-tract fibres are spared, whatever be the size of the lesion, the mischief is reparable. This is no longer the case if the fibres of this tract are not only compressed, but have undergone destruction at some part of their course. Such is a brief account of the condition of affairs.

#### IV.

Enough has been said with respect to pathological anatomy. The question now presents itself to us in the following terms. Is it possible to discover by certain clinical characters in patients who have been suffering from hemiplegia for fourteen or fifteen days that the pyramidal tract has undergone destruction at some point of its course, or, in other words, does secondary degeneration reveal its presence by characteristic symptoms?

The answer, gentlemen, may be made in the affirmative. It is certain that the existence of secondary degeneration, under the conditions we have laid down, may be usually recognised. The great revealing symptom in this respect is that collection of phenomena, which is commonly known by the name of *late contracture in hemiplegic patients*. It behoves us, then, to give our careful attention to this remarkable symptom. But it does not exist as a constant phenomenon and in anything like a decisive manner, until about the second or third month after the attack. Is it necessary to wait until this period is reached before declaring our opinion? Do there exist in the symptomatology of hemiplegia any indications which are of earlier date

and yet capable of revealing the presence of consecutive spinal lesion?

In reality, gentlemen, late contracture in incurable hemiplegia is preceded by certain phenomena which, if they do not absolutely enable us to affirm the existence of degeneration, at any rate make its presence very probable. Only, the appearance of these phenomena must be called forth by the observer. They are signs of which we must be informed in order to make them evident, since their presence is only manifest when certain methods are practised. To-day, I shall simply remind you that one of them, which has been introduced for the longest time in neuro-pathological semeiology, is known in France under the name of provoked trepidation, or provoked spinal epilepsy. German writers call it the foot-phenomenon (*Fussphänomen*) or ankle-clonus. But the discovery of this sign belongs to French clinical observers. Since 1863, as our observations of this date testify, it has been practised daily in the wards of La Salpêtrière by M. Vulpian, by myself, and by our pupils. Since then, we have never ceased to study this phenomenon in its relations with the different affections of the nerve-centres and to inquire into its significance. Thus, I pointed out a long time ago that it is habitually absent in the motor inability connected with locomotor ataxy, infantile spinal paralysis, and in other conditions of the same kind, whereas it is never wanting in paralysis of cerebral or spinal origin, in which contracture exists or tends to become established.<sup>1</sup>

The phenomenon may be described as follows. The paralysed lower limb of a hemiplegic patient is supported by placing one hand beneath the ham so that the patient's leg may hang loose and swing; if now, with the other hand, the point of the foot is suddenly raised, a series of shakes is at once provoked, which collectively constitute a kind of rhythmical movement or oscillatory trembling more or less regular and persistent. Spinal trepidation presents the more interest from the fact that, as a rule, no trace of it exists in the normal state. Thus Herr Berger,<sup>2</sup> who has made some observations on the matter, only discovered it three times in fourteen hundred apparently healthy subjects (mostly soldiers).

<sup>1</sup> Dubois, 'These de Paris,' 1868.

<sup>2</sup> 'Arch. d. Heilk.,' 1879, No. 4.

I must, however, repeat emphatically that, in the domain of pathology, this is not a constant phenomenon, since in certain spinal affections it is absent, whilst in others the rule is for it to be present. Briefly, it is one of the characteristic features of the group of spasmodic paralyses; and to this category belongs central hemiplegia with secondary degeneration of the pyramidal tract.

When late contracture has taken place, this phenomenon is nearly constant, but it frequently precedes the contracture by several weeks. In a patient, now an inmate in the infirmary of La Salpêtrière, it began to manifest its presence a week after the attack, and a fortnight later rigidity of the lower limb first made its appearance.

In another patient, it did not appear until a month after the attack, and the muscular rigidity began to be evident in the course of the second month.

M. Déjerine has recently pointed out that this symptom is occasionally present in both lower limbs, and we shall see that this is sometimes the case with contracture.

In hemiplegic patients possessing some slight power of movement, this same trepidation which, in certain cases extends to the entire limb, may also manifest itself in consequence of a voluntary movement. The phenomenon in question is reflex, as I purpose to demonstrate at greater length on a subsequent occasion. For the time being, it will be sufficient to call your attention to the fact that its intensity is increased by the use of strychnia, and, on the contrary, at any rate according to O. Berger, diminished by opium.

An analogous phenomenon is occasionally produced when the hand of a hemiplegic patient is suddenly lifted up by the tips of the fingers. Moreover, these patients, on raising the paralysed arm, often experience a trembling similar to that which occurs in the lower limb under like circumstances. But the *wrist-phenomenon*, provoked or spontaneous, is much more uncommon than the corresponding effect which we call the *foot-phenomenon*.

These two signs, as we shall show, belong to the same category as those recently introduced into the semeiotics of spinal affections by Westphal, and afterwards by Erb, under the collective term of *tendon-reflexes*.

## LECTURE XII.

### LATE HEMIPLEGIC CONTRACTURE AND ITS CLINICAL VARIETIES.

SUMMARY.—*Foot-phenomenon or ankle-clonus. Its presence in spasmodic paralysis, including hemiplegic contracture. It is sometimes obtainable on the non-paralysed side in hemiplegia. Its reflex nature. The knee-phenomenon, unlike ankle-clonus, exists normally. At birth it is well marked, but diminishes in intensity at the end of a few weeks. It is pathologically significant only when completely absent or when highly exaggerated. Method of provoking the knee-phenomenon. It is inhibited by irritation of certain distant parts. Its reflex nature is confirmed by the experiments of Fürbinger, Schultze, and Tschirjew. Reflexes of upper extremity are usually but little evident in the normal state. They become very manifest when contracture exists or tends to exist in hemiplegia. Graphic analysis of the reflexes. Associated movements or synkineses are interesting from a theoretical point of view. Effects of strychnia on paralysed parts. It exaggerates the reflexes and hastens contracture. Fourquier's works. Contracture and the tendon-reflexes are allied phenomena.*

#### I.

GENTLEMEN,—At the conclusion of the last lecture I told you that slow contracture in permanent hemiplegia of cerebral origin is preceded by certain phenomena, which, if they do not always enable us to affirm the existence of degeneration, nevertheless make it very probable.

I remarked that these phenomena are not present in themselves, but that their appearance has to be called forth by the observer. In other words, these signs must be made evident by means of certain manipulations, which are, however, extremely simple.

Apart from the case we are now considering, we shall, in the course of our studies on organic cerebral and spinal affections, frequently encounter these same phenomena with all the characteristic features which I am trying to make prominent; but, in truth, they will be nearly always associated with circumstances of comparatively much greater complexity. This is why we must take the opportunity which presents itself to-day of observing these phenomena under conditions most favorable to physiological analysis. I have already spoken to you of the phenomenon which has been known longest in neuro-pathological semeiotics. At the present time, as you are aware, it is described in France under the names of *provoked trepidation* or *provoked spinal epilepsy*, and in Germany, under the names of *foot-phenomenon* or *ankle-clonus*. In the domain of pathology, it is by no means a constant phenomenon. As a rule, it is absolutely wanting or diminished in certain spinal affections, such as locomotor ataxy, the acute and chronic anterior poliomyelites (infantile paralysis, progressive muscular atrophy, and all other affections of the same nature); whereas, in others, it is habitually present. It is, in short, one of the characteristics of the clinical group of spasmodic paralyses, and to this group belongs cerebral hemiplegia with degeneration of the pyramidal tract.

When slow contracture is once established, spinal trepidation, which always precedes it by several weeks, is a constant symptom, apart from exceptional circumstances.

In a patient, now an inmate of the infirmary at La Salpêtrière, who was attacked a few months ago with hemiplegia, provoked trepidation manifested its presence a week after the attack; and a fortnight subsequently, that is to say, at the end of about three weeks, contracture began to make its appearance. In another patient, the foot-phenomenon did not become appreciable until a month after the attack, and contracture was not established until about the end of the second month.

In addition, M. Déjerine, as I have already told you, has recently made an interesting and very true remark to the effect

that the lower extremity, on the non-paralysed side, sometimes becomes the seat of provoked trepidation.

It is indeed by no means uncommon, in a case like this, for permanent contracture to attack this extremity, so that the hemiplegia becomes complicated with paraplegia and rigidity, which thereby presents an almost invincible obstacle to the upright posture and to walking. Consequently, the patient is confined to bed for the rest of his days.

Lastly, in hemiplegic patients who still possess some power of movement this trembling of the foot, which sometimes extends to all parts of the limb, may manifest its presence in consequence of a voluntary movement.

Provoked or spontaneous, the trembling in question, as I shall have to show, is a phenomenon of reflex nature.

For the moment it will be sufficient to observe that its intensity augments under the influence of strychnine, and that it diminishes, on the other hand, by the use of bromide of potassium in large doses, and, according to Berger, of opium also. This last assertion seems to be much less satisfactorily proved than the preceding.

It is important to notice, gentlemen, that, contrary to what holds good for provoked trepidation of the foot, the knee-phenomenon appertains to the normal state.

It exists to a certain extent in every healthy subject, with very few exceptions. Thus, according to Berger's statistics which I alluded to in the preceding lecture, the patellar reflex is absent in only one per cent.<sup>1</sup> Eulenburg<sup>2</sup> has made the interesting observation that it is very well marked in the child from the day of birth, and that it gradually diminishes at the end of a few weeks.

This last fact, if it be confirmed, is likely to prove of great significance, since it seems to point to the phenomenon being of a spinal reflex character. We must not forget, indeed, that the pyramidal tracts in the newly-born child are as yet incompletely developed, and that, consequently, the moderating influence, which the cerebrum exerts over spinal reflex acts, cannot be exercised through this path at that period of life.

Be this as it may, it is very evident from what precedes that

<sup>1</sup> 'Centralblatt f. d. Nervenkr.,' 1879.

<sup>2</sup> *Ibid.*, 1878.

the knee-phenomenon only acquires pathological significance under the following circumstances: (1) either when it is completely absent, as is constantly the case in locomotor ataxy and in the anterior poliomyelites; (2) or when it is markedly exaggerated, as in spasmodic paralysis. In hemiplegic patients threatened with contracture, exaggeration of the knee-phenomenon very generally precedes the appearance of the foot-phenomenon; and even although it may be but slightly marked, its presence is not devoid of significance, when we consider the diminished intensity of the same symptom on the non-paralysed side.

## II.

Ankle-clonus and wrist-clonus belong, as we shall have no difficulty in showing, to the same category as those which are now about to be taken into consideration, and which have been recently introduced into the semeiotics of cerebro-spinal affections first by Westphal and subsequently by Erb.<sup>1</sup>

These new phenomena are collectively described under the generic term of tendon-reflexes. Of all these, the one which has been most studied, which is most readily provoked, and which, at the same time presents the greatest practical interest, is known by the names of *patellar-tendon reflex* or *knee-phenomenon*.

It is made evident in the following way :

The limb which we wish to test is supported, as in the preceding case, by the left hand of the observer placed under the ham. With the ulnar edge of the right hand a smart tap is made over the centre of the tendon. It is better still to use Skoda's percussion hammer.

A simple fillip bestowed on the above-mentioned point would, in case of necessity, yield the same result, at any rate, under certain pathological conditions. Almost immediately after the shock, the patient's leg becomes straight, rises more or less suddenly, describing a trajectory of variable extent according to circumstances, and then at once falls back. Sometimes, however, the first movement is followed by two or three successive oscillations. The phenomenon has then acquired its highest degree of intensity.

<sup>1</sup> 'Arch. f. Psych.,' t. v, 1875.

## III.

As its name indicates, the knee-phenomenon is certainly of reflex nature. Some clinical observations have already enabled us to surmise that this is the case. Thus, Erb noticed<sup>1</sup> that on percussing the ligamentum patellæ in order to provoke the knee-phenomenon, there is sometimes produced simultaneously a movement of adduction of the opposite thigh. In a case of paraplegia from spinal compression—and this also is Erb's observation—the knee-phenomenon was absent so long as the paralysis lasted; but it reappeared when the patient had regained the use of his limbs. This tends to prove that the existence of the phenomenon is subordinated to the integrity of certain medullary regions.

We must also add that, according to Nothnagel's observations, which have been confirmed by Erb,<sup>2</sup> excessive irritation of certain parts more or less distant from the place where the knee-phenomenon is produced, is sometimes sufficient to prevent its appearance. Thus, pinching the skin of the abdomen or intense faradisation of the opposite limb, suffices to hinder the contraction of the quadriceps. You perceive that this is an inhibitory phenomenon, analogous to those occasionally produced in animals, in whom the various conditions of spinal reflex activity are being studied.

But the reflex nature of the *tendon-phenomenon*, if any doubt in this respect can still exist, has been now demonstrated by experiment.

Fürbinger and Schultze<sup>3</sup> discovered that the tendon-reflexes and the knee-reflex in particular, exist under normal conditions in animals, the rabbit for example, as well as in man, and that they are no longer produced when the spinal cord is destroyed. Tschirjew has quite recently repeated these experiments, and has succeeded in determining the conditions of this phenomenon with great precision.<sup>4</sup>

The region of the cord, the integrity of which is necessary

<sup>1</sup> 'Ziemssen's Handbuch.'

<sup>2</sup> 'Arch. f. Psych.,' vi, 1876.

<sup>3</sup> 'Centralbl. f. d. Nerwenkrankh.,' 1875.

<sup>4</sup> 'Arch. f. Psych.,' viii, 1878.



for the production of the knee-phenomenon in the rabbit, is exactly comprised between the fifth and sixth lumbar vertebræ. When this region of the cord is destroyed, the phenomenon no longer takes place. On the other hand, sections made above or below that level have not this effect.

Now, in the above-mentioned region take origin the roots of the sixth lumbar pair, which supply, as Krause points out in his treatise on the 'Anatomy of the Rabbit,' the largest part of the crural nerve. If, therefore, the anterior and posterior roots of the sixth pairs be divided, the reflex action ceases to exist on both sides.

It is wanting on one side only when the anterior or posterior root of that side is cut through. We see, then, that the reflex nature of the phenomenon is a well-established fact, and that the effect in question is undoubtedly of a spinal reflex order. We must add that the researches of Sachs have shown that, in the substance of the tendon of the quadriceps, and particularly at the junction of the tendinous and muscular parts, there are nerves which are undoubtedly centripetal. These nerves, which become stretched when the tendon is struck, convey a stimulus to the lumbar part of the cord.

This stimulus, which is transmitted to the grey matter through the sensory root of the sixth pair, is reflected on the quadriceps muscle through the corresponding motor root, which is one of the principal origins of the crural nerve. I must add that, according to Berger's observations, the use of strychnia, which calls forth the foot-phenomenon under pathological conditions, increases the intensity of the knee-phenomenon under the same circumstances.

There are other tendon-reflexes of various parts of the upper extremity, in every way comparable to that just described. Only, so far as I am in a position to judge from some observations I have made, they are very slightly marked in the normal state.

On the other hand, in hemiplegic patients under the special conditions we are studying, they become very manifest and consequently acquire considerable interest. Thus, under these conditions, that is to say, when there exists a certain tendency to contracture in the upper extremity, or when this contracture is already established, percussion of the tendon of the biceps

causes sudden flexion of the forearm upon the arm ; percussion of the tendon of the triceps provokes an inverse movement ; and in the same way we can readily succeed in producing flexion of the fingers, flexion and pronation of the hand, by striking at the lower end of the forearm the tendons of the various muscles which execute these movements.

#### IV.

The study of these symptoms, gentlemen, would now be at an end, had I not been desirous of bringing under your notice the valuable indications which may be obtained, from the standpoint of clinical interpretation, by the graphic analysis of these reflex muscular contractions, which undergo such important modifications in the pathological state.

Tschirjew had previously applied the graphic method to the investigation of the phenomena to which I am calling your attention, and had determined the duration of the time of this reflex in healthy subjects. M. Brissaud, with the assistance of M. François Franck, has recently repeated these experiments under my direction, and the results obtained by him, particularly in hemiplegic patients, deserve special mention here by reason of the information which we can derive from them.

Moreover, a glance at the two tracings (Figs. 82 and 83)

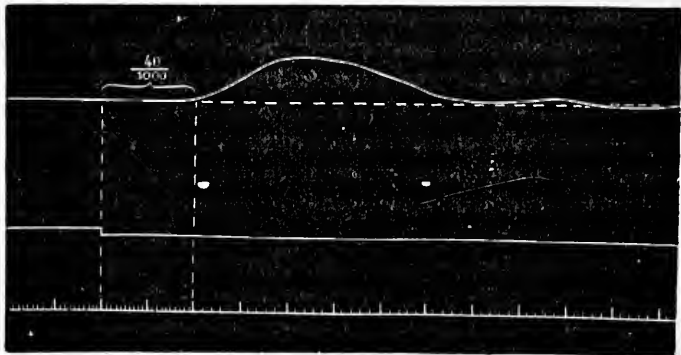


FIG. 82.—Knee-phenomenon on healthy side. The time of the reflex is  $\frac{40}{1000}$ th of a second. The wave of contraction has the normal form.

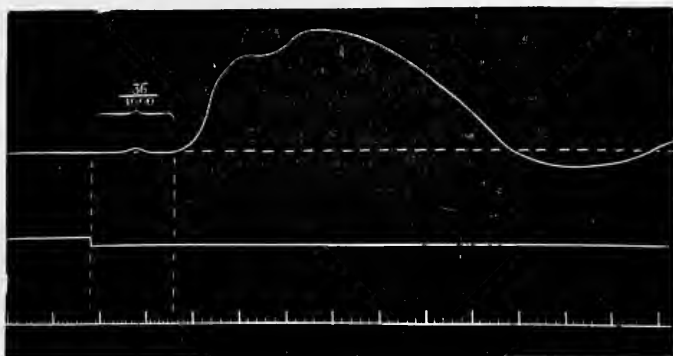


FIG. 83.—Knee-phenomenon on contracted side. The time of the reflex is  $\frac{36}{1000}$ th of a second. The muscular curve is much higher, the contraction more sudden and of different form (dicrotism).

will at once make you appreciate the difference which exists between the reflex contraction of the quadriceps on the hemiplegic side, and that of the corresponding muscle on the healthy side.<sup>1</sup>

All the characteristics of these tracings go to prove the exaggeration of the reflex power of the spinal centre in the half of the cord corresponding to the paralysed limbs. In fact, whereas on the side which remains healthy, the reflex act takes place after a lapse of time equal to  $\frac{40}{1000}$  of a second, it is produced in the quadriceps on the paralysed side at the end of  $\frac{36}{1000}$  of a second only. Moreover, the amplitude of the contraction is much greater on the diseased than it is on the healthy side; that is to say, that on the one hand the contraction of the quadriceps is more considerable and, on the other hand, that it lasts longer.

Lastly, the form of the muscular contraction in question is notably different, in the sense that it nearly always seems to

<sup>1</sup> The first line of these tracings represents the gradations of shortening of the muscle during contraction. The second line, bent towards the left, indicates the precise moment at which the hammer strikes the tendon. The third graduated line shows the duration of the reflex in  $\frac{1}{500}$ th part of a second. We must deduct from the time of the reflex the time which is lost in transmitting the muscular change to the registering cylinder along the caoutchouc tubes of the apparatus. Taking this correction into account, the time of the reflex is no more than  $\frac{36}{1000}$ th of a second on the healthy side and  $\frac{32}{1000}$ th on the contracted side.

be repeated (dicrotism or polycrotism). Sometimes indeed, after a series of oscillations of greater and greater height, the muscle instead of returning to its previous condition, remains for some time more contracted than it was at the moment when the tendon was struck (Fig. 84); so that we then have under observation a continuous tracing of the contracture.

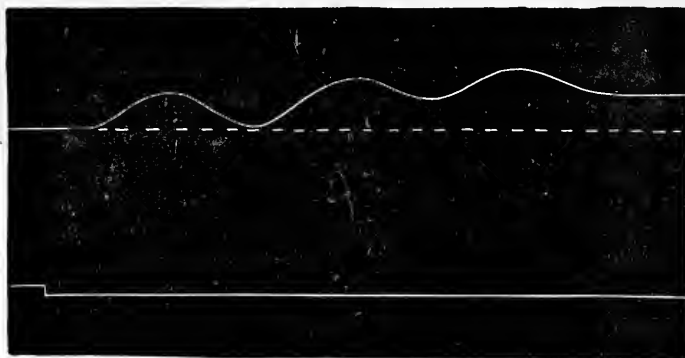


FIG. 84.—Exaggeration of contracture of the quadriceps after percussion of the ligamentum patellæ.

## V.

Such, gentlemen, are the phenomena which it is especially important to observe in the premonitory phase of the period of late contracture in hemiplegic patients.

We shall encounter them I repeat, with all their characteristics, in a large number of organic cerebro-spinal affections in addition to the one that has especially engaged our attention to-day.

But I was anxious, seeing that the opportunity presented itself, to acquaint you once for all with their main details. I now return to the premonitory period of contracture. This period may be indicated by some other signs, more uncommon than the preceding and of less practical interest, but it is nevertheless expedient to call your attention to them, because they are of a nature calculated to throw some light on the question of theory, which is still exciting much controversy.

A. I shall speak, in the first place, of the phenomena known as *associated movements* or *synkineses*, as M. Vulpian calls them.

In 1834, Marshall Hall called attention to a certain number of facts of this kind, several of which, however, had been noticed before him. We are aware that, under the influence of yawning or sneezing, there is sometimes produced in hemiplegic persons an automatic movement of the upper extremity, although this limb is completely paralysed and the patient absolutely incapable of moving it voluntarily. But M. Onimus remarked for the first time in 1872 that, under circumstances analogous to those we are considering, closure of the hand on the non-paralysed side or the individual movement of any one of the fingers occasions the production of similar movements in the hand or fingers on the paralysed side. These movements, which are provoked by *association*, are, I repeat, quite involuntary; and, as a rule, the patients are able to prevent their production only by a great effort of the will. Westphal has likewise pointed out some curious facts which he had observed in several patients affected with infantile hemiplegia. But I can only make a passing allusion to these cases, for they are not of very common occurrence and are interesting only from a theoretical standpoint.

B. Equally curious from the same point of view, but very important to consider as regards their practical bearing, are the effects produced on the paralysed limbs of hemiplegic patients affected with contracture, by the use of certain drugs and, in particular, of *nux vomica* or *strychnia*. We have already seen that the use of this therapeutic agent brings the tendon-reflexes into prominence throughout the entire body.

We shall now see that it precipitates, as it were, events and determines the appearance of contracture.

You are doubtless not unacquainted with the works of Professor Fouquier of this Faculty on "*l'usage de la noix vomique dans le traitement de la paralysie*," which is the title of the second memoir published on this subject by the author in 1820. The first<sup>1</sup> appeared in 1811. The perusal of this work is very interesting from the fact that we find in it the origin of all the knowledge which we now possess on the subject we have in hand. It comprises fifteen or sixteen observations, some of

<sup>1</sup> This second work is published in vol. v of the 'Memoirs' of the old Société de la Faculté de médecine; it was reprinted in vol. ii of the 'Bibl. de therap.,' p. 141, published by Bayle in 1830.

which relate to paraplegia from compression or myelitis, others to common hemiplegia of cerebral origin.

Guided by Magendie's experiments, Fouquier endeavoured to produce an artificial tetanus in paralytic patients, believing that he had found therein a curative means. Among the remarks made by the author on the observations to which he calls attention, I shall quote the following :

"Curiously enough," says Fouquier, "nux vomica may occasion contraction of paralysed muscles without affecting healthy parts. When taken in a suitable dose, it acts only on the diseased parts. These latter seem to experience the effect of the drug the more acutely, in proportion as they are the more completely deprived of movement.

"It would be impossible for us," he adds, "to refer these facts to the laws of physiology."

At the time when this work was published these facts were, without doubt, justly considered to be incompatible with the data of pathological physiology. But now that the action of strychnia on the nerve-centres has been studied experimentally, the interpretation of the phenomenon in question has become very simple.

Fouquier also remarks that as regards the contraction induced in the paralysed limbs by the use of nux vomica, the thoracic extremities are in a state of flexion, the abdominal extremities in extension. We shall presently appreciate the interest of this remark.

But the last point to which I am especially desirous of calling your attention is the following :

"Paralytic patients," says Fouquier—"and I refer to hemiplegia as well as paraplegia—"often experience after the administration of nux vomica, considerable rigidity of the extremities even when the use of the drug has been a long time in abeyance."

You see, therefore, that permanent contracture is determined by strychnia, the same drug which, as we found just now, brings the tendon-reflexes into relief. This circumstance tends to prove that the tendon-reflexes and contracture are allied phenomena. I shall take the opportunity at an early period of reverting to this point.

## LECTURE XIII.

### LATE HEMIPLEGIC CONTRACTURE AND ITS CLINICAL VARIETIES (*continued*).

SUMMARY.—*Various agents exaggerating contracture:—strychnia; traumatism, &c. Contracture is always imminent in hysterical patients and may occur under the influence of the above-named causes.*

*Time of its appearance in hemiplegic patients. Its access is gradual. The attitudes and deformities produced are always identical. Explanation of these attitudes. Theory of the action of antagonistic muscles.*

*Gaillard's experiments. Muscular tone.*

GENTLEMEN,—At the conclusion of the last lecture I called attention to the various causes which, in permanent hemiplegia of cerebral origin, are likely to augment the intensity of the phenomena known as tendon-reflexes. When speaking of the action of strychnia, I pointed out to you that the agent, in these same cases, also hastens the appearance of late contracture, when this latter is imminent, and everything, in a word, is prepared for its production.

This fact deserves to be placed in a strong light, because it appears to indicate that late contracture and the exaltation of the tendon-reflexes are allied phenomena and that they are referable to a common condition.

I will now ask you to notice that there are other causes, which apparently have no analogy with the therapeutic use of strychnia or any other drugs, that are nevertheless liable to bring about the premature appearance of contracture in hemiplegic patients, or to render it more intense when it is already established.

## I.

(1) It has long been known in electrotherapy, that untimely and ill-regulated faradisation of paralysed limbs in patients of this class tends to provoke or exaggerate permanent contracture; but it is not so well known that traumatic influences affecting the paralysed limbs may be quoted among causes of this kind.

As an example calculated to place the reality of this fact in relief, I will mention the following case which was recently observed at La Salpêtrière by my colleague M. Terrier, who at once understood its theoretical interest and consequently investigated it with great care.<sup>1</sup>

The case is that of a woman, now fifty-two years of age, who was suddenly attacked with hemiplegia six years ago, probably in consequence of softening.

The hemiplegia had to a certain extent persisted since that time, but it revealed its presence only by slight rigidity of the right upper extremity, the lower limb being almost entirely intact. She walked fairly well and even made comparatively long journeys. On the twenty-ninth of last March she fell over a bench, and her legs being flexed she sustained a slight contusion on the front part of the leg which, on the following day, became a little swollen and ecchymotic.

But the interesting point is that the day after the accident the right lower extremity—that is, the one on the paralysed side—became rigid throughout. It could be lifted up in one piece, the foot had assumed the attitude of equino-varus, and in short, the case was one of true contracture, as characteristic as could be. In addition, the contracture had considerably increased in the upper extremity where previously it was barely evident, and the limb being fixed in a state of flexion made any movement, spontaneous or provoked, extremely painful. At the present time, six weeks after the injury, the contracture of the extremities has improved, but still persists to a marked extent, and the foot-phenomenon as well as the patellar reflex are much exaggerated in the lower limb.

<sup>1</sup> See 'Revue mensuelle de Médecine et de Chirurgie,' 1879, No. 12.



(2) Cases of this kind are doubtless not very uncommon ; I myself, have observed two or three. In connection with this subject, it may, perhaps, not be devoid of interest to make a comparison, from the special standpoint we have at present under consideration, between permanent hemiplegia resulting from organic cerebral lesion, and the hemiplegia dependent on no appreciable change, as sometimes occurs in hysterical patients. It is well known that in these subjects, particularly when they are hemianæsthetic, the extremities of the side on which the insensibility is situated are frequently affected with more or less pronounced paresis which is liable to become aggravated even to the point of completely flaccid paralysis.

I have found that the tendon-reflexes are, as a rule, manifestly exaggerated in the limbs thus paralysed, and that it is often possible in the case of the lower extremity to provoke epileptoid trembling. Now, under such circumstances, it has several times happened that I have occasioned the onset of more or less intense and permanent contracture in the paretic limbs, by the application to these extremities of feeble galvanic currents or even by the simple application of the magnet. This result enables us perhaps to explain why contracture very often becomes developed, apparently from the beginning, in some nervous subjects, as a consequence of an ordinary injury. I have recently called attention to these singular facts with which Brodie was previously acquainted. Thus, as a result of a fall on the wrist or of moderate pressure exerted on the back of the foot, I have seen in certain subjects the well-nigh immediate development, in the corresponding limb, of contracture which has subsequently continued as a permanent condition for several weeks and even months. The appearance of contracture thus produced is often the first indication of the hysterical diathesis. But, on regarding the matter more closely, it is almost invariably found that, on the side where the contracture has occurred, there exist more or less distinct anæsthesia, ovarian tenderness, and a certain amount of paresis, symptoms comparatively unimportant but which, as we have reason to believe, have preceded the onset of contracture. The ground being, as it were, already prepared, traumatism has simply played the part of an exciting agent.

For the time being, I shall limit myself to pointing out this

relationship between hysterical and hemiplegic contracture, as I shall doubtless have a subsequent opportunity of turning it to account.

## II.

A. It is now time to return to the description of hemiplegic contracture, of which as yet I have given you but a brief sketch.

Under ordinary circumstances, that is to say, when it supervenes spontaneously, it does not become established until about the middle of the second month, sometimes later, rarely sooner. It is, for instance, of exceptional occurrence for it to appear twenty days only after the attack, as M. Vulpian saw it in one of his patients.

Be this as it may, it does not set in suddenly, but it is of gradual onset. It is rare, however, for patients to give us accurate information in this respect. But if it has happened to you to be in attendance during this period of transition, you will find that prior to its becoming definitely installed, contracture at first makes its appearance from time to time, as a temporary condition.

One day you will discover it, the next day it has disappeared and afterwards it again reappears. Finally it becomes permanent.

In the immense majority of cases, it first seizes on the upper extremity. It is then found that the fingers are more or less strongly flexed on the palm of the hand, the elbow placed in semi-flexion, and the forearm in pronation. The contracture may involve all the paralysed parts in succession and even the face, although this is comparatively of rare occurrence. It has the effect, moreover, of bringing about deformities of the extremities, which are almost always identical. I intend presently to give you a brief description of these deformities, for it is not devoid of interest to remark that they do not occur indiscriminately, but obey a law.

Nevertheless, it is especially important to carefully consider the contracture itself and to determine accurately the special features which it presents in hemiplegic patients, since we shall discover the same phenomenon with all the peculiarities we are

about to describe in a large number of spinal affections, in addition to the one that is now engaging our attention.

You will see, gentlemen, that this is a strange and, as it were, paradoxical phenomenon, very difficult to explain in every case on the facts of modern physiology.

Be good enough to observe that these immobile limbs, when placed in a certain position, henceforth remain almost fixed and are in such a condition that the observer desirous of moving them, experiences more or less pronounced and sometimes almost invincible resistance, in whatever direction the attempt is made.

For instance, to speak only of the elbow, it is, as we have said, in semi-flexion. But it is as difficult to increase the flexion of this joint as it is to determine its extension. The resistance is well-nigh equal in both directions, and hence the conviction is forced on us that the antagonistic muscles are contracted nearly to the same degree.

These faulty attitudes represent, therefore, the resultant of the opposite action of antagonistic muscles.

When the biceps is stretched like a cord, the triceps is likewise hard and rigid, and although we may succeed for a moment in overcoming the resistance, either in one direction or another, the extremity when left to itself will almost immediately resume its original position.

B. (1) This fact amply proves that the phenomenon in question is quite different from that causing deformities peculiar to certain kinds of paralysis, and which are sometimes described under the name of *paralytic contracture* or *contracture by adaptation* (Dally).

The deviations which occur in infantile spinal paralysis, at any rate in its early stages, and when the case is as yet uncomplicated with various conditions liable to supervene in the later periods, present the most characteristic type of these so-called paralytic contractures. Let us presume that the case is one of atrophic paralysis of the muscles which normally cause dorsal flexion of the foot. The muscular tone which is constant, and the early attempts of the patient which are intermittent, will fall exclusively on the *gastrocnemii*, the activity of which is shown by plantar flexion; and the predominant action of these muscles will result at length in the attitude of talipes

equino-varus. But it is always easy, when the case is not too old, to re-establish momentarily the normal position, without resistance on the part of the paralysed muscles which are deprived altogether both of tonicity and voluntary movement.

(2) Similarly, it would be easy to distinguish between the permanent contracture of hemiplegic patients and the so-called *myopathic* contracture, which depends on lesion of the muscular tissue itself, as for example, the cirrhosis occurring in certain forms of facial paralysis. In late contracture, on the contrary, at least when it is not very old, it has been frequently shown by post-mortem examination that there is no degeneration of the muscular tissue; and when this does take place, generally after the lapse of a considerable period, it consists in simple wasting. Moreover, during life, faradic stimulation shows that the irritability of these contracted muscles is normal, sometimes even slightly exalted.

In short, gentlemen, hemiplegic contracture is not passive rigidity, but, on the contrary, corresponds to a condition of muscular activity. There is no doubt that it is a phenomenon comparable to normal contraction; only, the contraction is permanent.

This persistence of the muscular activity really constitutes the paradoxical characteristic to which I alluded just now. Day and night, for months and years, these muscles remain rigid, sometimes in such an attitude as could only be maintained, in the healthy state, for a few moments.

According to the experiments of Gaillard (of Poitiers), it is impossible under ordinary circumstance to hold the arms in the horizontal position for more than nineteen minutes. The most vigorous subject cannot keep himself erect for more than thirty minutes on the point of his toes, by the contraction of the calf-muscles.

On the other hand, the contracture in question maintains the lower extremities indefinitely in forced and sometimes almost violent attitudes.

This feature of permanent contracture appears none the less singular, when we consider the intensity of the chemical phenomena of nutrition, which is proceeding in a muscle during the act of contraction.

(3) There is, however, a normal phenomenon which, without

pushing the analogy too far, may perhaps be compared with permanent hemiplegic contracture. I refer to tonicity or *muscular tone*.

You are not unaware, gentlemen, that certain muscles, the sphincters for example, are manifestly in a state of permanent contraction, and that the case is the same, to a less degree however, with all the muscles of animal life.

The latter, in the so-called condition of repose, are, I repeat, in a state of active and incessant contraction, which only disappears when the corresponding motor nerve has been divided. Tonic muscular contraction, as Claude Bernard has shown, is also accompanied by a chemical modification in the blood which has passed through the muscle.

Thus, the quantity of oxygen contained in the arterial blood entering a muscle being represented by 7.31, the quantity contained in the venous blood leaving a muscle in contraction is represented only by 4.28.

When the motor nerve is cut and the muscular tonicity hence abolished, the quantity of oxygen in the venous blood then becomes nearly equal to that in the arterial blood. But it is no more than 5 in a muscle in a condition of repose or, in other words, in a state of simple tonicity, the nerve being intact. This shows that the consumption of oxygen during tonicity is about a third of the total quantity contained in the blood of the afferent vessels.

I must remind you that in order to explain this apparently paradoxical fact of permanent or indefinite muscular rigidity, M. Onimus has suggested that the contractions affect the various muscular fasciculi in succession, and not simultaneously, in such a way that some are in a condition of repose whilst others are in contraction.

This hypothesis of M. Onimus has been supported, moreover, by some experiments which MM. Boudet and Brissaud have recently made on the muscular bruit in my wards at La Salpêtrière. With the aid of a microphonic auscultatory apparatus endowed with extreme delicacy, the analysis of muscular bruits in the normal and pathological state has been extended as far as possible.

In a few words, the following are the results which this new method of investigation has furnished to the special object of

our consideration. Whilst a muscle in a state of normal contraction gives forth a rumbling, sonorous, regular sound (*bruit rotatoire*), constant in the number of its vibrations, the contracted muscle emits a dull, irregular, and jerky sound, with interruptions and renewals; in other words, its characteristic is intermittency. It seems then to be proved that in this case the muscular fibres enter into activity one after another, thus supplementing each other incessantly.

I must add that, according to the dictates of physiology, the slight but permanent contraction of muscles, which we call muscular tone, depends on an equally permanent stimulus exerted by the spinal centre. "The spinal cord," says M. Vulpian, "acts unceasingly on all the muscles, where it produces through the motor nerves, the muscular tone . . . . This continuous action of the cord is doubtless called forth by the centripetal excito-motor stimuli proceeding from the muscles themselves or from the integuments." In this phenomenon, therefore, the reflex power of the cord is in action.

Now, it is easy to give a certain number of facts tending to prove that permanent muscular contraction, in the case of contracture, recognises an analogous origin, that is to say, it also proceeds from permanent spinal action, exalted by certain pathological conditions.

Thus, the phenomena which precede and accompany the development of contracture are referable, as you may have anticipated, to exaggeration of the spinal activity. The use of strychnia, which calls into prominence the tendon-reflexes, similarly hastens the appearance of contracture or exaggerates it when already established; and inversely, agents which lower the reflex spinal activity likewise diminish the intensity of this contracture. It is in this way that bromide of potassium acts, when administered in large doses.

I shall dwell no longer on these physiological considerations, which we shall resume later, but return to the descriptive side of the subject.

### III.

A. The contracture is called permanent; nevertheless, gentlemen, as a matter of fact it undergoes natural improvement in

the majority of patients, under such conditions as sleep and rest in bed, but it never completely disappears. On the other hand, as Hitzig rightly observes, its intensity is renewed or exaggerated on emotion or when the patient rises up or tries to execute a movement. We shall see how it is proposed to explain this phenomenon which has been referred by Hitzig to the category of associated movements.

B. One word more concerning the attitudes of the extremities in old hemiplegia.

It is a remarkable fact that these positions as a rule correspond to a fundamental type. In the upper extremities flexion predominates, whereas in the lower extremities, it is extension. Fouquier long ago pointed out that the same phenomenon is evident when temporary contracture is caused in hemiplegic patients by the use of strychnia. I must ask you to notice that it is the same in the case of partial epilepsy.

(1) In the first place let us consider the upper extremity. As we have said, the type of flexion is observed here: thus M. Bouchard noted this position in twenty-six cases out of thirty.

The shoulder is sometimes lowered, sometimes raised; but the arm in every case is pressed against the thoracic wall by the contraction of the pectoral muscle. We have just seen also that the elbow is generally semi-flexed, that the forearm is in pronation and that the hands are closed.

All variations of the type are reducible to the following: (*a*) The elbow being flexed, the forearm, instead of being in pronation, is in supination. This is the type of flexion with supination. (*b*) The elbow in place of being flexed is in a state of extension; the forearm is more or less straight. This type, which is rather uncommon, presents several varieties: (*c*) sometimes the forearm is in pronation, (*d*) sometimes in supination. I do not think that there exist other attitudes for the upper extremity than those which I have just named. The open hand is of rare occurrence.

(2) As regards the lower extremity, it is the rule, as I have told you, for it to be in rigid extension. The foot then takes the attitude of equino-varus. All things being equal, moreover, contracture here is usually less marked than in the upper limb. Even a fairly marked degree of extension of the lower extremity does not prevent walking.

The development of contracture in the flexor groups of the lower extremity, which is very disastrous, is fortunately a rare event. The thigh is then flexed on the pelvis, the leg on the thigh, the heel is in contact with the buttock, and as this same condition sometimes extends to the opposite limb, it is clear that walking is henceforth rendered permanently impossible (Fig. 85).

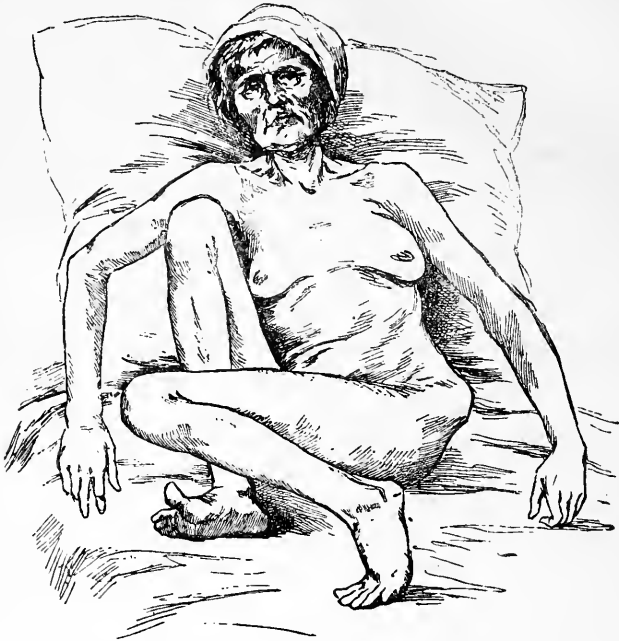

Fig. 85.—(Copied from Brissaud's thesis.) Old hemiplegia. Both lower limbs are contracted in flexion.

(3) Lastly, it is not uncommon for contracture to take place in the lower facial muscles on the paralysed side. This contracture at first only occurs temporarily, when the patient laughs or cries; then, after the lapse of time, it becomes permanent. The labial commissure is much raised, the nasolabial furrow becomes deepened, and the eye sometimes appears smaller than that on the healthy side. From contrast, the sound side then seems to be paralysed, and at first glance one might think that alternate paralysis existed.



(4) I have spoken to you of late hemiplegic contracture as a peculiar muscular condition which, when once constituted, continues permanently for the whole of life, or at least for many years. This is undoubtedly correct, but it often happens that the muscles in the long run undergo emaciation. Muscular spasm henceforward ceases to exist, and contracture, properly speaking, is no longer present. Nevertheless, the attitudes which have been so long maintained, are still liable to persist, for the ligamentous parts being shortened, the articular surfaces adapt themselves to their new position, and voluntary movements, if they should again make their appearance, necessarily remain ever afterwards restricted.

Is this termination, gentlemen, the only one possible? Does contracture ever disappear before the period at which muscular atrophy and ligamentous retraction supervene?

Some authors think so. At all events, it is quite certain that remarkable improvement occasionally occurs in contracture and that voluntary movements thereby may once more be performed. These are the so-called cases of recovery—recovery, it is true, to a very limited extent. Unfortunately they are rare.

I have observed several instances in which, doubtless some modification having taken place in the morbid parts, the result has been not only the disappearance of contracture, but also to a certain extent, the return of motor power.

Does the lesion persist in the spinal cord, and, in such a case, is there supplementary function? In what way, moreover, is this exerted? Or, indeed, has something analogous to repair of the nerve-elements taken place within the indurated pyramidal tract? This is incontestably a question of great interest, but still very obscure. I shall say a word or two about it when treating of permanent contracture of spinal origin, in which this same phenomenon occurs.

## LECTURE XIV.

SPASMODIC INFANTILE HEMIPLEGIA. ASSOCIATED MOVEMENTS. INDEPENDENCE OF THE DIASTALTIC ARCS FOR THE TENDON AND CUTANEOUS REFLEXES.

**SUMMARY.**—*Spasmodic infantile hemiplegia has the same characters as apoplectic hemiplegia. Its anatomical causes. Atrophy of limbs, thorax and pelvis.*

*Intermissions in hemiplegic contracture.*

*Influence of voluntary movement on the intensity of contracture. Synkineses. Part played by associated movements in the varying degrees of contracture. Prognosis of contracture.*

*Physiological explanation of this phenomenon.*

*Subsequent to the cerebral lesion it is necessary to distinguish two periods in the development of the secondary spinal lesion.*

*Exaltation of the reflexes does not result only from suppression of the moderating cerebral influence. Lesion of the anterior cornua in permanent hemiplegia is of an irritative nature. Its action is the same as that of strychnia. Exaggeration of muscular tone. Independence of the reflex diastaltic arcs. Locomotor ataxy, hysterical hemianæsthesia, hemiplegia of encephalic origin. The hypothesis of a dynamic irritative lesion is a better explanation than other theories relating to the spasmodic symptoms in descending sclerosis.*

### I.

**GENTLEMEN,**—At the end of the last lecture, when giving you an abbreviated description of the various attitudes assumed by the paralysed extremities in hemiplegic patients suffering from permanent contracture, I asked you to notice that the apparently rather numerous varieties which these attitudes present may be

reduced to a few constant types : type of flexion with pronation for the upper extremity, type of extension with equino-varus for the lower extremity. Such is the rule and such is the nature of the deformities observed in ordinary cases. Other attitudes which you may possibly meet with are anomalies.

(1) The law we have just stated with reference to permanent hemiplegia in adults holds good in the durable hemiplegia of young children. You are doubtless not unaware that in children, from one to seven years of age, for example, focal lesions of various kinds,—when involving the pyramidal tract in its intra-cerebral course—are followed by more or less pronounced hemiplegia, which persists to a certain degree for the whole of life. The lesion causing hemiplegia is, as my former *interne*, M. Cotard, has shown, of very variable nature.<sup>1</sup>

Sometimes the case is one of partial ramollissement, having the form of yellow softening or of circumscribed cellular inflammation ; sometimes the cerebral lesion is consecutive to meningeal hæmorrhage ; sometimes—and this last case is certainly the most frequent—it consists in partial or generalised sclerosis of one cerebral hemisphere.

The lesions in question are usually cortical, that is to say, they occupy the cortex and subjacent white matter, and not the central masses. Moreover, the affected cerebral hemisphere presents, as a whole, more or less marked atrophy, whence the name of *partial cerebral atrophy* by which the cases I am now bringing under your notice are generally known.

Secondary descending degeneration occurs with all the characteristics with which we are acquainted in the adult, and it is under such circumstances as these that we observe the most beautiful examples of atrophy of the crura cerebri, pons, and anterior bulbar pyramid on the side corresponding to the lesion.<sup>2</sup>

Clinically, cases of this kind are sometimes described under the name of *spasmodic infantile hemiplegia* (Heine).

Permanent contracture, in fact, shows itself in a very pronounced way in this affection. The deformities, moreover,

<sup>1</sup> ' Sur l'atrophie partielle du cerveau,' 1868.

<sup>2</sup> See an observation published by M. Bourneville in ' Progrès Médical,' No. 16, April, 1879.

conform, as I previously stated, to the type described with respect to hemiplegia in the adult. Thus, for the upper extremity, the type of flexion with pronation is here again the rule, and for the lower extremity, it is extension and equinovarus. Only, in the history of spasmodic infantile hemiplegia, a very interesting peculiarity must be noticed, viz. the almost constant existence of shortening of the paralysed limbs. The bones are shorter and less voluminous than on the healthy side; and the arrest of development does not always affect the extremities only. Sometimes the trunk is incompletely developed on the paralysed side, the thoracic wall is narrowed, and the pelvis contracted and oblique.

Atrophic paralysis resulting from a lesion of the grey matter, when appearing in infancy, consequently entails shortening from arrested development of the limb in which the muscular lesion is situated, the extremities at this time only fulfilling their function in part; whereas the shortening naturally cannot exist when the same lesion becomes developed in adult life.

(2) In the somewhat detailed description which I have given of permanent contracture in hemiplegic patients, there are a few points which I neglected to bring before you and to which I now ask permission to call your attention for a moment. One of them is particularly deserving of notice, since some writers have accorded it great importance from a theoretical standpoint. I have described slow hemiplegic contracture as being a *permanent* phenomenon, in the literal acceptance of the word.

Day and night, as I told you, during sleeping and waking, the limbs are rigid and contracted. As a rule this is really so, at least in well-marked cases.

Nevertheless, it is certain that rest in bed and sleep have the effect of rendering the limbs temporarily more flexible; but as soon as the patient rises, or if he attempts to make a movement either with the paralysed or healthy limb, so soon does the contracture reappear in all its intensity.

This increase or return of rigidity under the influence of voluntary movements is brought into special prominence when, as Seguin and Hitzig recommend, the patient is made to raise a weight with the left hand, the contracture being on the right side. The heavier the weight, the more exaggerated does

the contracture become on the right side. These cases are justly considered as belonging to the category of those *synkineses* or associated movements of which I have already briefly spoken.

Hitzig, however, professes to explain the phenomena to which I am calling your attention in the following manner :

In the normal state, the voluntary stimuli proceeding from the grey hemispherical matter are conveyed to the cord by nerve-fibres which are in relation with groups of cells having special connections one with another; and these cellular groups execute the movement which has been willed. Moreover, there are elementary groups for elementary movements, and associated groups for harmonious and more complicated movements. These groups are distributed on each side of the cord, some presiding over the movements of the right side, others over those of the left side.

Nevertheless, relations are established between homologous groups, from one side to the other, through the medium of the reticulum of grey matter. Normally, these connections do not hinder the movement willed from preserving its independence and individuality; but under certain pathological conditions, when the ganglionic elements are hyper-excitable, the slightest discharge occurring on one side and producing a voluntary movement may be communicated to the other side, and there provoke, according to the circumstances of the case, either a movement similar to a voluntary movement or a spasmodic movement identical with contracture, which persists for some time after the discharge.

In certain cases relations of the same nature may become established between cellular groups at a considerable distance one from another, and it is conceivable that, in these instances, the voluntary movements executed by the extremities of the sound side may react on the morbid side.

The facts brought forward by Hitzig, in the interesting memoir to which I have already called your attention and to which I shall once more return, are correct; but the part which he attributes to them in the case of contracture is, in my opinion, exaggerated.

We must consider as exceptional those cases in which the contracted hemiplegic extremities present complete relaxation under the influence of rest. Hitzig has suggested a mecha-

nism calculated to explain why contracture becomes aggravated under the influence of voluntary movements, but he has not informed us why this contracture, as happens in the majority of cases, becomes permanently established.

(3) In the last place, it is necessary to inquire into the eventual history of contracture. Often, very often, when once constituted it persists for the whole of life. Still, a considerable number of cases might be quoted in which, in the course of time, it diminishes or even ceases to exist. As a rule the unfortunate invalids are not much benefited; although, indeed, the spasmodic condition has disappeared, the muscles have undergone more or less profound textural modifications and exhibit extreme emaciation.

The ligamentous parts, moreover, have adapted themselves to the position produced by a long-assumed attitude, and, in short, notwithstanding the possible return of some voluntary movement, deformity continues.

## II.

In conclusion, gentlemen, I now propose to inquire with you into the physiological explanation of the phenomena which we have hitherto considered in their descriptive aspect. In a word, the point is to discover through what bond are the symptoms connected with the lesions.

An attempt of this kind is always one of difficulty and, in this particular case, the questions which will present themselves to our minds cannot at present, owing to insufficient data, be definitely solved. Consequently, you would do well to look upon most of the explanations, which I am about to lay before you, as eminently provisional and likely to undergo modifications some day or other.

(1) I must remind you that, according to most writers, the consecutive lesion of the lateral columns is originally a purely passive process. It is in the second period only, corresponding to the second or third month, that there appear in the degenerated pyramidal tract evident marks of an irritative process, situated in the connective tissue and justifying the term *sclerosis*.

(a) In the first period, the nerve-tubes being separated from their trophic centres, which are also their centres of functional stimulation, the situation is almost equivalent, in well-marked cases, to section of the pyramidal tract. This early period which corresponds to the first four or five weeks is already indicated, as you know, by exaltation of the cutaneous and tendon-reflexes.

Here, we may justifiably invoke the suppression of the moderating cerebral influence which, in the case of experimental section of the lateral columns, serves to explain the exaggeration of the reflex properties in the parts of the cord situated below the section.

But this condition evidently does not account for contracture which, as you are aware, has no existence in the newly-born child, in whom the pyramidal tracts are as yet undeveloped. We must therefore seek another explanation.

(b) Moreover, contracture only manifests its presence at the period when the pyramidal tract has become the seat of an irritative lesion. First of all, I must remind you of the anatomical connections which are established between the extremities of the nerve-fibres of the pyramidal tract and the motor cells of the corresponding cornu. These connections are such that, in certain cases, lesion of the nerve-tubes is propagated to the ganglionic cells, which undergo atrophy, and to the surrounding connective tissue. In this way there is produced a kind of *anterior poliomyelitis*, in consequence of which muscular atrophy supervenes in the paralysed limbs.

(2) But these cases, as you are aware, although far from being uncommon, nevertheless do not constitute the rule. Ordinarily, matters do not proceed to such lengths. We most assume—and this is the first concession I ask of you—that under the influence of the irritation of which the nerve-tubes in progress of destruction are the seat, the cellular elements (ganglionic cells) become affected in their turn. Now, this lesion when communicated to the motor cells is purely dynamic and corresponds to no appreciable anatomical modification. With your sanction I shall call it *irritation*. It is analogous to that produced by strychnia, but more durable.

Under the influence of this change, the properties of the ganglionic elements are not only undiminished, but are even

exalted. The irritation is thus propagated by radiation through the nerve-reticulum over a considerable distance, as far as the other ganglionic elements of the same region, and particularly to the æsthesodic cells.

Exaggeration of the reflex power, in all its varieties, in the corresponding parts of the grey axis is the natural consequence of this hyper-excitability of the ganglionic elements, and supplies us with the key to certain phenomena, such as the exaltation of the cutaneous and tendon-reflexes. Without forcing matters, it may even be taken for granted that the irritative lesion in question likewise provokes exaltation of that variety of reflex activity which, in the normal state, maintains the permanent muscular contraction, known in physiology under the name of *tone*.

### III.

It will not be without advantage to remind you, gentlemen—for it is a fact of great practical interest—that the two modes of spinal reflex activity in question are probably represented in the grey matter by two distinct *diastaltic systems*. Clinical observation, in fact, demonstrates that although these two modes of reflex activity are often affected simultaneously, they are, nevertheless, frequently affected separately. The following are a few examples tending to prove that this is really the case.

(1) In locomotor ataxy, the cutaneous reflexes most frequently persist and sometimes are even manifestly exalted. The tendon-reflexes, however, disappear very early, as is also the case with the muscular tone. Consequently, the muscles are flabby and this diminution in tone undoubtedly in a great measure contributes to confer on the gait and on the movements of the extremities (which however preserve considerable force for a long time), their jerky, abrupt, and irregular character. The condition of affairs in such a case may be represented by the following diagram (see Fig. 86). The diastaltic arc of the cutaneous reflexes is not involved; the diastaltic arc of the tendon-reflexes and of tone is, on the contrary, profoundly affected from the very beginning. This is one of the great characteristics of the disease.



A few days ago, I made a careful observation of a very remarkable instance of this independence of the reflex arcs.

A provincial apothecary, M. X—, came to consult me for some of the cephalic symptoms of tabes (megrin, vertigo, etc.), which had troubled him for many years.

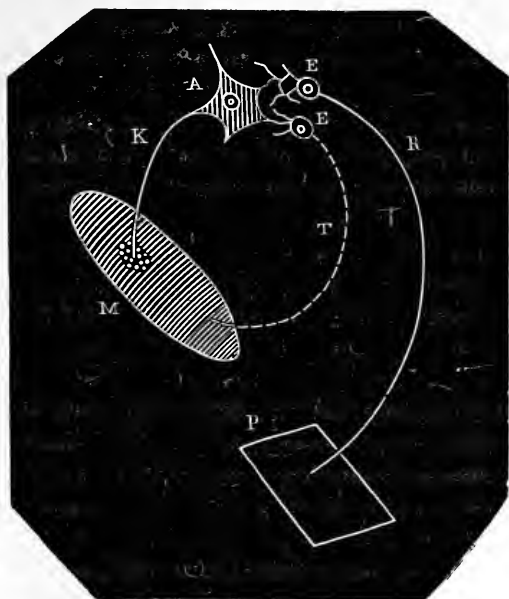


FIG. 86.—Tendon and cutaneous diastaltic arcs in locomotor ataxy. A, spinal motor cell; E E, æsthesodic cells; M, muscle; P, skin; R, posterior or centripetal segment of the cutaneous diastaltic arc; PAM, cutaneous diastaltic arc (unaffected in ataxy); K, anterior root or motor nerve; T, posterior or centripetal segment of the tendon diastaltic arc; MAM, muscular or tendon diastaltic arc (affected in ataxy).

Notwithstanding, motor inco-ordination appeared only about eight or nine months ago. The tendon-reflexes, of course, were abolished in the lower limbs and it was absolutely impossible to excite the least reaction of the quadriceps, however intense the percussion of the patellar tendon. But on the anterior surface of the thigh there was a patch of hyperæsthesia, irritation of which caused violent reflex contraction of the flexor muscles of the leg. Thus, when the patient struck the hyper-

æsthetic region fairly hard with the palm of the hand, the leg was drawn convulsively backwards, but not until the end of two or three seconds. The reflex nature of this contraction was very evident, seeing that all voluntary effort was powerless to prevent it. This then was an ataxic patient in whom the tendon diastaltic arc was interrupted, whilst the conducting tracks for cutaneous impressions were manifestly intact.

(2) I can name at least one disease in which the tendon-reflexes are exalted, whereas the cutaneous reflexes are abolished. I refer to hysterical hemianæsthesia and hemiparesis. The tendon-reflexes on the side corresponding to the hemianæsthesia are very pronounced, but cutaneous sensibility

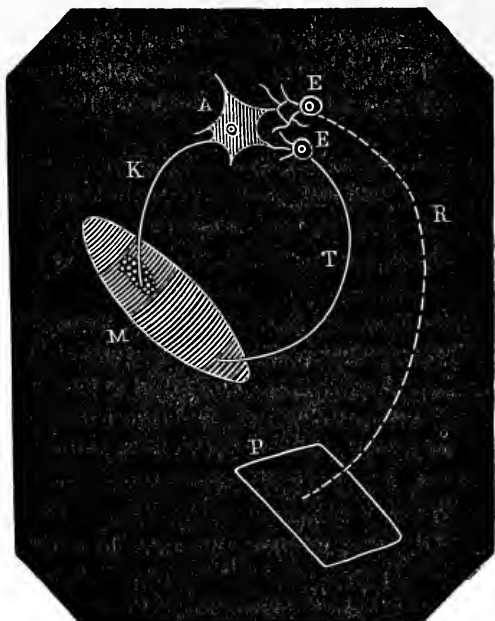


FIG 87.—Tendon and cutaneous diastaltic arcs in hysteria. A, spinal motor cell; E E, æsthesodic cells; M, muscle; P, skin; R, posterior or centripetal segment of the cutaneous diastaltic arc; K, anterior root or motor nerve; PAM, cutaneous diastaltic arc (affected in hysterical hemianæsthesia and hemiparesis); T, posterior or centripetal segment of the tendon diastaltic arc; MAM, muscular or tendon diastaltic arc (preserved, or even exaggerated, in hysteria).

is absent. All stimuli, even the most violent, are without result and are followed by no reflex movement (see Fig. 87).

(3) On the other hand, in the case of permanent hemiplegia, dependent on organic focal lesion, which we shall consider in particular, both diastaltic systems are affected, though unequally. The cutaneous reflexes are only moderately exalted; the tendon-reflexes and especially tone, which is an allied phenomenon, are excessively exaggerated.

#### IV.

Be this as it may, gentlemen, having assumed the hypothesis of irritation of the ganglionic elements of the central grey matter, in contact with the extremities of the nerve-fibres of the pyramidal tract, we are able to explain the various phenomena to which we called attention in the course of our descriptive account.

(1) Strychnia acts especially on the paralysed extremities, and its action, although extending to the entire cord, shows itself, all things being equal, more intense in the parts of the grey axis which are already in a state of irritation.

(2) The irritative influence of injuries, involving the affected limbs, is transmitted to the central axis either through the cutaneous or the muscular centripetal nerves.

(3) Lastly, in the category of associated movements, we are in a position to explain, without difficulty, the aggravation of contracture under the influence of voluntary movements performed by the healthy extremity. It is sufficient here to take for granted that the irritation extends from the non-paralysed side by a kind of diffusion to the ganglionic elements of the grey matter. This same diffusion of the irritation may also explain the cases of hemiplegia to which M. Déjerine has called attention, and in which trepidation or even contracture occurs on the healthy side.

The intensity of this hypothetical irritation of the ganglionic elements, whence the reflex hyperexcitability is derived, appears however to vary according to the circumstances of the case and according to the individual, as well as the extent of

the region to which it is propagated. This shows that permanent contracture dependent on secondary sclerosis of the pyramidal tract is, in a manner, a contingent and not a necessary, pathognomonic symptom. As a rule, it is present; but it may indeed happen that it is absent, although lateral sclerosis exists, and inversely it may manifest itself when lateral sclerosis does not exist.<sup>1</sup> In other words, *permanent contracture is not* (if we may so express ourselves) *a function of sclerosis of the pyramidal tract.*

It is of the greatest importance that this fact should be impressed on the mind in order to clearly explain a considerable number of cases in spinal pathology. On an early occasion, moreover, we shall take the opportunity of utilising it.

It remains for me, gentlemen, to show that the theory I have just stated, imperfect as it may be, is nevertheless superior to those which have been proposed for the solution of this debated question.

The theory of encephalitis has had its day. As a matter of fact, there is no encephalitis in the case of circumscribed cerebral hæmorrhage, unless it is intended to give this name to the process of connective-tissue overgrowth which takes place on the confines of the sanguineous effusion.

But hæmorrhagic foci only produce contracture when localised in such a way as to destroy the continuity of the pyramidal tract; moreover, we shall see that primary sclerosis of the pyramidal tracts give rise to contracture, although there exists no encephalic lesion.

It has been suggested also that contracture results from the irritation of the unaltered medullary tubes within the sclerosed parts. These tubes being extremely few and sometimes even completely absent, although contracture exists, I am at a loss to understand how irritation of these tubes could cause contracture. Once more then, we must ascribe it to some affection of the ganglionic elements of the grey matter.

<sup>1</sup> In the case of hysterical contracture, for instance.

## LECTURE XV.

### PHYSIOLOGICAL FUNCTION OF THE PYRAMIDAL TRACT IN PERMANENT CONTRACTURE. HEMIPLEGIA. MYELITIS FROM COMPRESSION. SPASMODIC TABES DORSALIS.

SUMMARY.—*Relations between the peripheral extremities of the pyramidal-tract fibres and the cells of the anterior cornua. Lesions of these cells are of an irritative nature. Clinical phenomena; reflex acts. Theories bearing on the pathogeny of contracture.*

*Theory of encephalitis. Theory of irritation of nerve-tubes, interspersed with those of the pyramidal tract.*

*The immediate cause of contracture is in the grey matter itself.*

*Proofs furnished by spinal pathology proper. Transverse myelitis.*

*Spasmodic paraplegia. Spasmodic tabes dorsalis.*

GENTLEMEN,—From certain signs which could not escape a professor who has long grappled with the difficulties of teaching, I thought I had discovered that the theory proposed to explain physiologically the permanent contracture of hemiplegic patients had not been grasped in all its details by some of my hearers.

Consequently, I ask your permission to add a few more words to my description.

I am far from attaching an exaggerated importance to this theory, all the imperfections of which I am the first to recognise. I lay stress upon it, because I believe it to be undoubtedly superior to all those which have been previously suggested for the solution of this debated question; and especially because it seems to me to facilitate the interpretation of facts which the physician is certain to meet with every day in the practice of cerebro-spinal diseases.

## I.

(1) At the outset I reminded you of the probably very direct anatomical relations, which appear to exist between the terminal extremities of the pyramidal-tract fibres and the motor cells of the anterior cornua, throughout the entire length of the spinal cord; and I proposed to take for granted that the irritative lesion, of which these nerve-tubes in progress of destruction are the seat, reacts on the ganglionic elements. The lesion, thus communicated to the motor cells, is purely dynamic and accompanied by no material change, appreciable by our methods of investigation. It is comparable to the modification produced in these same elements by strychnia poisoning, but with the difference, however, that the lesion of strychnia poisoning is an essentially transitory phenomenon, whereas that, the existence of which I have assumed, is eminently durable, as durable as the permanent contracture itself.

There is reason to believe that this irritative condition, when once established, does not remain localised to the motor ganglionic elements. It extends by diffusion to the other ganglionic elements of the region, and with them it has more or less direct anatomical connections through the medium of what has been called, since Gerlach's time, the *nerve-reticulum*.

Hence it is that the æsthesodic cells, which are supposed to be the principal termination of the centripetal nerve-tubes, are similarly affected in their turn. Now the motor or kinesodic and the sensitive or æsthesodic cells constitute the central part of the various diastaltic systems through which reflex acts are accomplished; and in consequence of this hypothetical lesion, the properties of the various parts of this system must be exalted.

If this be so, the slightest stimuli proceeding from the periphery and reacting on the central parts of the diastaltic arcs should result in reflex phenomena more than ordinarily energetic. In this manner, the permanent stimuli, which under normal conditions emanate from the muscles or their aponeuroses through the centripetal muscular nerves, produce that phenomenon of incessant reflex activity known by the name of *tone*, the physiological expression of which is slight but permanent

muscular contraction. These same stimuli, in the pathological state, result in equally permanent, but very intense contraction, representing, as it were, the muscular tone carried to its extreme limit.

Such, in short, is the cause of permanent contracture in hemiplegic patients.

(2) I shall inform you later on why I was induced to call your attention to the fact (based as it was on clinical experience) that the various modes of spinal reflex activity, which are differentiated by pathological analysis, appear to be represented in the grey matter of the spinal cord by as many distinct diastaltic systems. Observations show, indeed, that although the various modes of reflex activity may sometimes be affected simultaneously and to the same degree, they may also be involved separately. Recall the special cases of which I have made mention—locomotor ataxy and hysteria.

On the other hand, in hemiplegia, which we have specially considered, the two systems appear to be affected to a nearly equal extent. Moreover, the result of some observations made by Rossenbach<sup>1</sup> is, that in the early stages subsequent to the attack, after the period at which all the reflexes may be temporarily in abeyance, the tendon-reflexes appear much sooner than the cutaneous reflexes. Some of them in this respect are especially remarkable, that of the cremaster for instance, which is brought about by the application of a cold object to the thigh of the corresponding side,<sup>2</sup> or the reflex produced by stimulation of the skin of the abdomen on the paralysed side (*Bauchreflexe* of Rossenbach).

Investigation pursued in the direction I have just indicated would probably furnish interesting facts bearing on the diagnosis and prognosis of a considerable number of cerebro-spinal diseases.

(3) In the last place, I must again refer to the few examples which I quoted in order to prove that the clinical phenomena, mentioned in the course of our descriptive account of permanent contracture, find a ready interpretation on the proposed hypothesis.

(a) All the ganglionic elements of the spinal grey matter are

<sup>1</sup> 'Arch. f. Psych.,' vi Bd., S. 845.

<sup>2</sup> Jastrowitz, 'Berlin. klin. Wochensch.,' 1875.

without doubt simultaneously affected by the introduction of strychnia into the circulation. But the most irritable are naturally the first to react. The influence of traumatic causes on the development of contracture is explicable very nearly in the same way.

(b) If it be assumed that the ganglionic irritation is propagated from one grey cornu to the other, by means of the commissures, it is conceivable that the voluntary movements which cause discharge in the grey matter of the left cornu, for example, will react on the right cornu and there determine either an homologous involuntary movement, or an aggravation of the contracture. We can understand also why exaltation of the reflexes and even permanent contracture are liable, at a certain period, to show themselves on the sound side.

## II.

This, gentlemen, is where we left off, but it still remains for me to prove that our theory is superior to all those which have been suggested.

(1) The old hypothesis of an encephalitis developed around the lesion cannot be upheld. There is no other encephalitis around apoplectic foci than the process of connective-tissue hyperplasia which ends in the formation of what are called cicatrices. On the other hand, focal lesions never occasion permanent contracture except when, by reason of their localisation, they are situated so as to interrupt the course of the pyramidal-tract fibres. Under these circumstances secondary degeneration comes into action.

Moreover, we can quote at least one instance of a lesion involving the pyramidal-tract system primarily, apart from the intervention of any focal cerebral lesion or of encephalitis.

The affection in question is one which I have already several times studied with you and from which to-day I merely wish to abstract an episode. I have proposed to call that disease in which both pyramidal-tract systems are affected in the cord and medulla oblongata, *amyotrophic lateral sclerosis*. Now the lesion cannot usually be followed beyond the *crura cerebri*. It



seems, therefore, to become developed from below upwards.<sup>1</sup> The degeneration reacts on the grey matter of the anterior cornua of the cord and on the analogous grey parts of the medulla oblongata. It is propagated in two ways. In certain regions, there is destructive lesion of the cellular elements. The consequence, then, is atrophy of the muscles supplied by the nerves proceeding from the affected regions of the grey matter.

In other parts there is simply a functional irritative lesion of the ganglionic elements.

The result is that, in these parts, besides more or less marked paralysis there is remarkable exaggeration of the tendon-reflexes, and at a certain period, indeed, considerable contracture of the extremities sometimes supervenes. The contracture and, in its absence, the exaggeration of the muscle and tendon-reflexes, according to my own observation, clinically distinguish this form of spinal muscular atrophy from that in which the cellular elements are destroyed without participation of the white fasciculi.

I shall dwell no longer on this point; it is sufficient to observe that the theory proposed finds here signal confirmation.

(2) Another pathogenic explanation of permanent contracture is the following: it is supposed to be the result of irritation of nerve-tubes which, although not belonging to the pyramidal tract, nevertheless intermingle with its fibres. These nerve-tubes, not being separated from their trophic centres, do not undergo degeneration, but simply remain in a state of irritation within the sclerosed parts. I must remind you that tubes of this kind in the midst of the pyramidal tract are few, and that sometimes not a single healthy tube is to be found within the sclerosed parts. Further, on the assumption that these tubes appertain to the system of the short commissural fibres, they could only take part in the production of contracture through participation of the grey matter.

<sup>1</sup> Some recently observed facts nevertheless show the possibility of intra-encephalic lesions of the pyramidal tract. See Charcot's "Conférence de la Salpêtrière," in 'Progrès Médical,' 1880, No. 3.

## III.

Be good enough, gentlemen, to remark that, according to the theory suggested and which I shall take as granted, the immediate cause of contracture is in the grey matter and not in the lateral column itself. The lesion in question, therefore, is consecutive, deuteropathic and contingent. Its degree is liable to variation according to the individual and according to age, and even its existence is not an absolutely necessary fact. This is an important consideration, for it proves that although permanent contracture is connected with primary or secondary pyramidal sclerosis by rather close relations, it is not however, an essential or pathognomonic symptom. Thus, although sclerosis and contracture as a rule occur simultaneously, we may see sclerosis without contracture, and contracture without sclerosis, as for example in the case of hysteria. It is conceivable, indeed, that the ganglionic irritation which provokes contracture may become established primarily, or in consequence of lesion other than that of the pyramidal tracts. The fact does not appear to me to have been demonstrated, but I consider it as very possible. In short, gentlemen, I repeat advisedly that the situation of affairs may be summed up in a word—permanent contracture is not a function of the pyramidal tract.

## IV.

It is not less certain that whenever, in spinal pathology, sclerosis of the pyramidal tracts exists to any extent, permanent contracture figures among the usual symptoms.

(1) Let us take the case of secondary descending degenerations of spinal origin and presume that it is a question of Pott's disease with compression of the spinal cord. We shall consider the motor disorders exclusively, and assume, what indeed is not uncommon, that they open the scene. Here the onset is not abrupt, unexpected, and well-defined as in apoplexy. The paralytic phenomena most frequently develop slowly and progressively. Be this as it may, at a certain period some paretic weakness comes on, and then, after the lapse of time,

true paralysis, evidently the result of interruption of the conductors of motor stimuli in the antero-lateral columns, and more particularly in the pyramidal tracts.

Notice carefully, gentlemen, the fact that the paralysis in question is not the same as paralysis with contracture. But at the end of a few days or weeks the scene changes. (*a.*) Tremblings and cramps accompanied by temporary rigidity are experienced, similar to the corresponding phenomena observed in hemiplegic patients. (*b.*) Moreover, the tendon reflexes (knee-phenomenon, &c.) are certainly much more pronounced in the early periods than in the case of unilateral encephalic lesion. (*c.*) It is the same with the other varieties of reflex activity. Indeed, it is in the case of spinal compression that the reflex movements are the most intense, being sometimes comparable to those observed in frogs under the influence of strychnia. The acts of urination and defæcation, the introduction of a catheter, occasion violent tremblings or involuntary convulsive movements of the paralysed limbs. (*d.*) Lastly, sooner or later contracture appears, it being very rarely completely absent, except in the case of a particular localisation, as when the pressure is exerted on the lowest part of the lumbar enlargement. As a rule contracture in extension takes place; but, nevertheless, it is not uncommon to see the lower extremities forcibly flexed on the pelvis. This attitude, indeed, seems to be more common in myelitis from compression than in spontaneous transverse myelitis. It is equally interesting to notice that all these phenomena involve one limb only when the compression is unilateral, and that this extremity naturally corresponds to the side on which the lesion is situated. But, in general, the spasmodic symptoms, such as epileptoid trepidation and contracture, are much less marked than in the case of a total transverse lesion.

(2) What is the course of this contracture? Sometimes the patients grow weak, bedsores form, hectic fever comes on, and simultaneously reflex power and contracture disappear. Sometimes, on the contrary, progressive improvement justifies us in hoping for a more favorable issue, and in a certain number of cases absolutely complete recovery has been observed. The spasmodic state passes away, voluntary movements are once more performed, but the extremities still preserve some rigidity,

due to shortening of tendons, a condition which may be remedied by surgery. Of this favorable mode of termination M. Bouchard has related five cases. I myself have observed six or seven such instances.

As regards the determination of the anatomical conditions of these almost un hoped for recoveries, microscopical examinations are not yet sufficiently numerous to enable us to say anything very precise in this respect. Nevertheless, in a case which was observed in my wards and investigated by Michaud, everything led to the belief that actual regeneration had occurred. With reference to this matter I must not forget to mention that the results of experiment are by no means favorable to the idea of regeneration. To speak only of the most recent experiments, I must remind you that Eichorst and Naunyn thinking they had noticed this regeneration in dogs, Schiefferdecker tried to verify their observation in the dogs experimented on by Goltz. Some of these animals, which were numerous, had survived the operation ten, twelve, and even fifteen months. But even under these conditions, which were as favorable as possible, Schiefferdecker could not discover any trace of regeneration in the lower segment of the cord. The fibrillar cicatricial tissue when treated with osmic acid was found to contain no nerve-tubes.

(3) With few modifications, primary transverse myelitis is the counterpart of myelitis from compression, the history of which I have given you. Here again the accompanying *spasmodic paraplegia* is to be referred, in accordance with the preceding conditions, to descending secondary sclerosis. But clinically spasmodic paraplegia occurs fairly often under a form which for a very long time did not receive the attention it deserved. In this affection the patient is not obliged to keep his bed, as in the majority of the cases previously alluded to. From the very beginning of his complaint he is frequently able to walk without support, and even to make fairly long journeys. The gait, however, is quite characteristic. Ollivier of Angers has given an accurate account of it in his description of chronic myelitis; and still more recently Erb, who carefully investigated it, has described it under the name of spasmodic gait (*spasticher Gang*). To the same condition Dr. Seguin has given the term *tetanoid paraplegia*. Even

when the patient is lying down the rigidity of the extremities is very perceptible, and when seated it is still more marked. The legs are then extended on the thighs, and the feet remain suspended in the air, it being impossible for the patient to put them to the ground. Lastly, on attempting to walk "the trunk is straightened and thrown backwards as if to counter-balance the weight of the lower extremities which are agitated by involuntary trembling before being again applied to the ground." The foot is seized with trembling every time it is carried forwards, and this trembling extends temporarily to the whole body.

There is no doubt that this kind of paraplegia is most frequently dependent on ordinary spinal lesions—compression, myelitis, &c. Besides the rigidity of the extremities there are, however, other symptoms, either concomitant or preceding, which admit of no ambiguity in this respect. But in other cases the disease dates from infancy or develops slowly and progressively, all symptoms being absent except the muscular rigidity, which sometimes tends to reach the upper extremities from the lower limbs, to which it usually remains limited.

Erb has suggested that these cases are referable to a special pathological variety which he proposes to distinguish by the name of *spasmodic paraplegia*. He even considers it very probable that the affection in question depends on primary sclerosis of the lateral columns. I also share Erb's opinion concerning the special nature of a large number of those cases which clinically assume the form of spasmodic paraplegia. I have proposed to bring them together into one special nosographical group under the name of *spasmodic tabes dorsalis*,<sup>1</sup> which would thus be a distinct disease. Spasmodic paraplegia would then represent a symptom common to several affections, and among others to spasmodic tabes.

But I was the first to point out that spasmodic tabes dorsalis, considered as a distinct nosographical variety, could have no real and definite existence so long as pathological anatomy did not speak in favour of its autonomy. If this be really a distinct affection, post-mortem examination will reveal a lesion equally special, perhaps primary sclerosis of the pyra-

<sup>1</sup> On this subject see the thesis of M. Bétons, 'Étude sur le tabes spasmodique.'

midal tracts as Erb surmises. If, on the contrary, autopsies show that it is a question sometimes of myelitis from compression, sometimes of syphilitic, transverse, or other forms of myelitis, it is clear that its clinical autonomy is only apparent.

The question, therefore, is as yet undecided. I shall merely remark that the first results of pathological investigation are not favorable to the idea that spasmodic tabes dorsalis is a morbid entity. In fact, some cases which I had referred to this nosographical group had to be separated from it after post-mortem examination, and ascribed to an affection which has long been known as likely to give rise to symptoms of spasmodic paraplegia. I refer to disseminated sclerosis. But this point is worthy of detailed investigation, and this our time to-day does not allow us to undertake.

## LECTURE XVI.

### TRANSVERSE MYELITIS AND SPASMODIC TABES DORSALIS.

*SUMMARY.*—*Transverse myelites and hemisections of the spinal cord. Paralysis of both lower extremities in the case of unilateral spinal lesion. Anatomical hypothesis relative to this phenomenon.*

*Opinions of Kölliker, Gerlach, Krause, Schiff, Vulpian, and Schiefferdecker.*

*Permanent contracture and spasmodic gait in transverse myelitis. Ollivier's description is applicable to the tetanoid paraplegia of Seguin (Erb's spasmodic gait). Chronic forms of transverse myelitis.*

*Spasmodic tabes dorsalis. Erb's theory. Its localisation in the cord has not yet been revealed by pathological anatomy. Diagnosis from disseminated sclerosis. Spasmodic tabes in the adult and in the child. Infantile spasmodic paralysis.*

*Etiology, pathogeny, and nosographical autonomy of spasmodic tabes.*

*Opposite opinions and observations.*

GENTLEMEN,—To-day I propose to continue and conclude the examination of those organic spinal affections in which permanent contracture of the paralysed limbs is an habitual and characteristic symptom of the disease. You are not unaware that my aim is to prove that the regular and almost constant existence of a lesion in the pyramidal tracts, either primary or secondary, is a feature common to all the diseases in question. In the course of this account, which, at first sight, seems to be concerned principally with a question of pure theory, we have already met with, and we shall again meet with facts of considerable practical importance—facts the

application of which we shall frequently find in the clinical study of cerebro-spinal diseases.

## I.

(1) Our attention was particularly directed to transverse myelitis, and we considered the cases in which the lesion occupies, at a certain point, the entire thickness of the spinal cord. I must say a few words relative to those instances in which the transverse lesion is localised to a part only of the breadth of the cord, so as to reproduce in a manner the lesion described in experimental pathology under the name of *unilateral section*. This variety of circumscribed spinal localisation is observed, as I have remarked, fairly often in practice. In myelitis, either syphilitic, spontaneous, traumatic, or from compression, it is by no means uncommon for the lesions to be unilaterally circumscribed. In this category of cases there are two examples, selected among many others, which I must recall to your mind for purposes of demonstration: (1) the case of a traumatic lesion, consisting, for instance, of a stab passing transversely through one half of the spinal cord; (2) the very common case of spontaneous syphilitic myelitis. Here the lesion involves one of the columns of grey matter, together with the posterior and antero-lateral columns; but the essential point, to which I am anxious to call attention, is the secondary descending lesion of the lateral column, which, as we know, is due to interruption of the course of the pyramidal-tract fibres.

(2) I have already had the opportunity of pointing out to you, gentlemen, a fact which has been noticed in several cases, viz. that descending sclerosis is not always limited to the corresponding side, but that it occasionally extends to the opposite side, as in Müller's case, the principal details of which I have given you. In order to explain this apparently singular fact I put forth the hypothesis that some fibres of each pyramidal tract, which have intercrossed at the lower part of the medulla oblongata, undergo a second decussation in the cord, at least in some individuals. On my hypothesis it is necessary to concede that these doubly-decussated fibres are not



interrupted in their course by the presence of a ganglionic cell, and that those proceeding from the pyramidal tract on the right side go to form part of the pyramidal tract on the left side.

This theory is principally based at the present time upon the pathological fact in question ; it will therefore not be devoid of interest to inquire if some facts in normal anatomy may not be quoted in its favour.

A considerable number of writers, amongst whom are Kölliker, Gerlach and Krause, describe in the anterior commissure a decussation in which fibres of various origin take part. But all agree in recognising that there are fibres proceeding from one grey cornu which cross the median line and go to form part of the anterior column on the opposite side. In these accounts there is no allusion to fibres bringing the pyramidal tract of one side into direct communication with the opposite pyramidal tract.

Nevertheless, by means of preparations in chloride of gold Schiefferdecker, who has studied the subject with great care, asserts that he has discovered nerve-fibres which, coming from the right lateral column, proceed directly to the anterior commissure, and that when they have arrived in front of the central canal they may be followed for some distance on the other side of the median line. Do these fibres enter the anterior columns or are they arrested in the grey matter ? Or, on the contrary, do they pass into the opposite lateral column ? Although this is not proved it is not impossible. I doubt whether normal anatomy, if reduced to its own resources, is capable of deciding the question.

It is not improbable that we may succeed in following the course of degenerated fasciculi in pathological cases ; and if the supposed disposition really exists, it will explain not only the well-established fact of descending sclerosis of both pyramidal tracts in the case of unilateral lesion, but also the fact previously discovered in experimental physiology, that a unilateral transverse lesion produces motor paralysis of the opposite extremity as well as of that corresponding to the section. With reference to this subject I must remind you that the experiments of Schiff and Vulpian have had the effect of modifying the traditional teaching, handed down from the

time of Galen. It was thought that the transmission of voluntary stimuli through the white fasciculi was exclusively direct. We now know that although it is chiefly direct, it is, nevertheless, partly crossed. In other words, section of one lateral half of the spinal cord, in a guinea-pig for example, causes paralysis of both sides, the paralysis being undoubtedly much more marked on the side of the lesion than it is on the opposite side.

(3) The condition of affairs is almost the same in man, at least in a certain number of individuals. The paralysis on the side of the lesion is never so complete as might be supposed if the transmission of voluntary stimuli were direct. On the other hand, it is rare for the extremity on the side opposite to the lesion not to present also some degree of paralysis. This hypothetical disposition, therefore, has some advantages, seeing that, however profound the unilateral lesion may be, locomotion is still possible in consequence of the paralysis being, as it were, distributed on both sides. Moreover, during the subsequent course of events, the cutaneous, tendon, and other reflexes, the rigidity and contracture will make their appearance under such circumstances, just as though the case was one of total transverse myelitis. But it is very uncommon for these phenomena to be well marked; and, also, all things being equal, they are always much more pronounced on the side corresponding to the lesion.

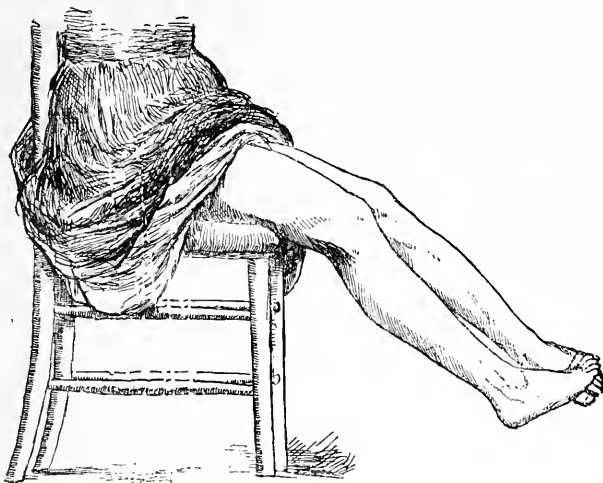
## II.

After this digression I return to total transverse myelitis. As you are aware we paused to consider the various modes of termination which paralysis of this nature may present when permanent contracture has already become established.

I asked you to notice that side by side with cases of complete cure instances of imperfect recovery are to be observed. Owing to diminution in the muscular rigidity, movement reappears in the lower limbs; but this rigidity still persists to a certain extent, and although the patient may be able to leave his bed and walk, he proceeds only by slow and laborious steps. Remember also the condition of affairs under which our supposed patient is placed.

As I told you in the preceding lecture, when he is in bed the rigidity is considerably diminished, but still exists to a certain degree. The tendon-reflexes, moreover, are much more pronounced than in the normal state, and spinal trepidation supervenes on attempting the slightest voluntary movement. When he sits down on a slightly raised seat the legs tend to remain horizontal. In any case the feet do not touch the ground. Lastly, when the patient stands up and holds himself erect both extremities become stiff, applied one against the other, and at the same time agitated by epileptoid trepidation. At first he is as it were fixed to the ground, and succeeds not without difficulty in disengaging his feet before beginning to walk.

FIG. 88.



It will now be of advantage, gentlemen, to lay before you the remarkably accurate description given by Ollivier (of Angers):

“Each foot is removed from the ground with difficulty, and in the effort which the patient then makes to raise it completely and bring it forward the body is straightened and thrown backwards, as though to counterbalance the weight of the lower extremity, which, before being again applied to the ground, is seized with involuntary trembling.

“During these movements of progression the point of the foot is sometimes depressed, and drags more or less along the ground before being raised. Sometimes it is lifted up suddenly, the foot at the same time being thrown outwards. I have seen patients who could only walk, although leaning on a stick, by throwing the trunk and head backwards in such a way that their attitude had some resemblance to that caused by tetanus.”

All this, gentlemen, is true, although perhaps a little exaggerated, as a description of a type must necessarily be. There is, however, a variation in this type. The patient, in such a case, generally uses two crutches or sticks, and walks literally on the point of his toes, in consequence of the exaggerated contraction of the gastrocnemii. His body is bent forwards and forms an inclined plane, so that he is every moment in danger of falling on his face to the ground. This variety, which is described by Erb, is more common than Ollivier's type. It is very remarkable to notice that this very vivid description by Ollivier, which, moreover, does not apply to exceptional cases, remained, as it were, a dead letter until lately. It did not even attract attention at the time when Duchenne described so accurately the characteristic gait of ataxic patients, so that it was quite a revelation when Seguin, of New York, in 1873, and afterwards in 1874 Erb, of Heidelberg, once more called attention to the peculiar gait which certain paralytic patients present, and which they proposed to designate, the former by the name of *tetanoid paraplegia*, the latter by the term *spasmodic gait* (*spastischer Gang*).

You perceive, gentlemen, that notwithstanding the interest attached to this spasmodic gait we cannot recognise it as being characteristic of a particular disease, contrary to what holds good for the gait of ataxic patients, which is really pathognomonic. It is a symptom common to several spinal diseases, and in order to arrive at a nosographical diagnosis we must necessarily appeal to the concomitant symptoms.

## III.

We have hitherto considered cases of transverse myelitis of acute or subacute onset, in which the symptoms rapidly attain their highest degree and then retrograde.

But we must not overlook the fact that there are cases in which the affection from the very beginning assumes the character of a primary chronic disease. Here, also, the lesion is transverse, but incomplete, and its evolution is gradual. The patient, for example, has never been confined to bed; he is a paralytic in whom the paretic symptoms have perchance passed undetected for a more or less considerable time. But the gait has the spasmodic character from the outset, and however slow the course of the disease may be, we should expect, as a rule, to see the paraplegia accompanied by other symptoms, essential to the nosographical determination of the nature of the affection.

## IV.

Nevertheless, gentlemen, it is not uncommon clinically to meet with a certain number of cases in which symptoms of spasmodic paralysis, primarily developed as in the preceding case, occur unaccompanied, from the origin to the termination of the disease, by any other symptoms, such as impairment of sensibility, functional disorders of the bladder and rectum, pseudoneuralgic pains and cephalic disorders. The affection is especially characterised also by its slow evolution, and by a marked tendency to progressive invasion of the upper extremities.

To some physicians, of whom I am one, this spasmodic paraplegia seems to be a special variety, so that we are led to think that these are not common cases of transverse myelitis (compressive, syphilitic, or otherwise) accidentally deprived of their usual features, and occurring under an abnormal form. But it is believed that the affection in question is peculiar, autonomous, and probably dependent on a specially localised lesion.

Erb was the first to put forward this opinion in 1875. I soon followed him, as my lectures in 1876 testify. This alleged special affection was designated by Erb *spasmodic spinal paralysis*. From the fact that it was a question of a particular morbid condition I proposed the name of *spasmodic tabes dorsalis*, since the term "spasmodic paralysis" represents only a symptom common to several spinal diseases. The description given by Erb differs, however, in no essential feature from that which I subsequently traced. I disagreed on one point only with Erb, who practically asserts that the lesion on which the symptoms depend is now known to be no other than symmetrical sclerosis of the lateral columns. As regards myself, whilst believing the localisation suggested by him to be very probable, I determined to reserve my opinion.

I observed that all cases of symmetrical sclerosis without participation of the anterior grey cornua were of old date. "It would be necessary," I remarked, "to revive partly effaced remembrances. We must, therefore, before expressing an opinion on this matter, await the modifying influence of new observations."

Up to the present time, gentlemen, as I shall show shortly, pathological investigation has not yet furnished any proof, and hence the solution of the problem remains in suspense. Meanwhile the clinical description deserves to exist alone.

## V.

But before approaching this subject I would, in conformance with what I promised you in the last lecture, say a few words about a cerebro-spinal disease which is now fairly well made out anatomically and clinically, and which in some of its abnormal forms may reveal itself almost exclusively by spasmodic paraplegia, so that under this guise the affection in question might be, and indeed has been, confounded with that which I have called spasmodic tabes dorsalis. I refer to disseminated sclerosis. I shall merely remind you that the sclerotic patches, which are disposed irregularly in the various parts of the neuro-axis, generally predominate in the cord, where in preference they occupy the antero-lateral columns.

It is necessary to call attention here to an important point on which I have already briefly spoken. These sclerotic patches, when once developed, remain separate in the spinal fasciculi without giving rise to secondary degeneration. This is a startling exception to the Wallerian law. It is of little moment, however, since for the time being it suffices for us to consider the affection exclusively in its clinical aspect.

In the first place it should be noticed, as might be anticipated from the multiplicity of the lesions and the variability of their seat, that the symptoms of the disease in question are themselves both various and numerous: cephalic disorders, such as nystagmus, amaurosis, difficulty of speech, intellectual disturbance and vertigo; spinal disorders, amongst which we must mention as being most constant and important a peculiar trembling of the upper extremities, occasionally replaced by contracture, spasmodic paraplegia, &c. I pass over the muscular atrophy which is observed in those cases where the grey matter is affected, and the tabetic symptoms when lesions of the posterior columns exist. Such, in short, are the signs which, when they are all combined, enable us to readily diagnose this disease. But it is possible for this collection of symptoms to be decomposed, and for a considerable number of them to be absent. So, in one form, only cephalic disorders, vertigo, nystagmus, &c., are observed. In another, on the contrary, there may exist almost no symptoms except those of spasmodic paraplegia. I say *almost no symptoms* because on viewing the matter more closely we may discern the present or past existence of some of those concomitant phenomena which are so numerous in typical cases. Accordingly, in presence of a spasmodic paraplegia, it is necessary to recall to mind the series of symptoms which may be found in combination in a complete case of multilocular sclerosis. It is very exceptional for two or three of them not to appear in association with spasmodic paraplegia at some period of the disease, if this latter depends on disseminated sclerosis; and it is especially in accordance with this principle that the diagnosis must be made.

## VI.

I shall now, gentlemen, briefly trace the outline of the morbid condition which Erb and myself believe ourselves justified, until further information is forthcoming, in considering a special disease—*spasmodic tabes dorsalis*.

(1) The clinical description may be sketched in a few words. The disease becomes developed in subjects from thirty to fifty years of age, particularly in men, and in the absence of any appreciable exciting cause. There is never any disorder of sensibility. The affection comes on slowly and progressively, showing itself first of all by simple heaviness of the legs, and then by true paresis accompanied by rigidity. Finally, the gait takes on the spasmodic character, and the patient is often obliged to keep his bed, but sometimes not until the lapse of many years. It is self-evident that the tendon-reflexes are much exaggerated, whilst the cutaneous reflexes preserve their normal characters.

(2) The disease, as it occurs in early life, deserves special mention (Erb, Seeligmüller, Stromeyer). The rigidity often begins to appear shortly after birth, and is unaccompanied by cerebral symptoms. The nurse notices that the limbs are rigid, and that it has become more difficult to dress the child. Occasionally even the body itself is rigid. When the age for walking is reached it is observed that the upright posture and progression are impossible. When the child is three or four years old it begins, though with difficulty, to stand erect by supporting itself against the furniture. The manner in which children of this age, when supported under the arms, advance in their peculiar fashion is very characteristic. The hips are slightly flexed, the knees are adducted, and adhere so forcibly one to the other that the legs and feet become entangled and overlap.

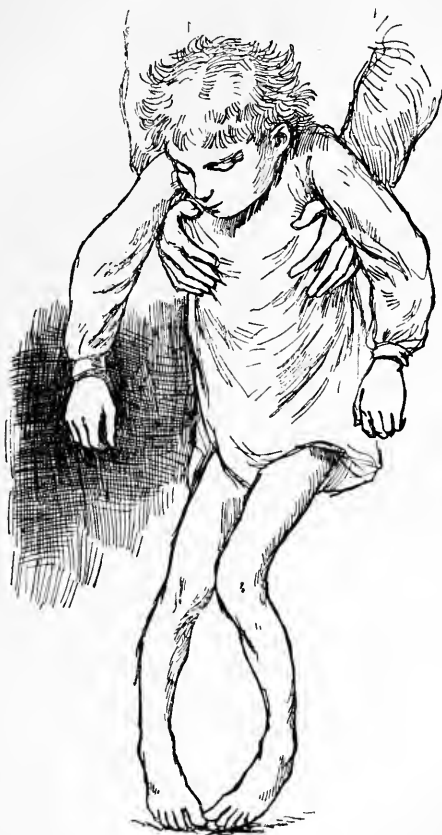Lastly, the plantar flexion of the two feet, which rest upon the toes, causes an inclination of the body forwards, thus placing a further obstacle to walking.

The tendon-reflexes, moreover, are exalted. There is no muscular atrophy and the muscles preserve their normal irritability. There is, therefore, a very decided contrast in



every respect between this affection and infantile spinal paralysis, and hence we see that in addition to this latter disease there exists an infantile *spasmodic* paralysis, perfectly distinct and clearly separable from it. The upper extremities are also affected; the forearm becomes stiffened in a state of semi-

FIG. 89.



flexion and pronation, the fingers being bent on the palm of the hand. Cephalic symptoms, I must repeat, are never observed, and the vertebral column presents no abnormality. The pathogeny of the affection is consequently extremely vague. Seeligmüller mentions premature labour at the seventh

or eighth month and consanguinity. But these are pretexts rather than reasons. In short, autopsies are wanting. We cannot, however, refrain from observing that at the time when the disease begins the lateral column is in full progress of development, and that this condition, under certain influences, may not be unfavorable to the production of an inflammatory lesion.

(3) A lesion of the same nature in the adult, likewise limited to the system of the lateral columns, would account for all the phenomena. But, once again, the hypothesis at the present time has received no verification. There is, therefore, an interesting problem to be solved in pathological anatomy, and I cannot too strongly recommend you to give it your earnest attention, if you should happen to meet with a case of this kind.

(4) I have just said that spasmodic tabes has as yet only a clinical existence, and that although, as I believe, it is really a morbid variety, its anatomical substratum is nevertheless quite undiscovered.

Notwithstanding, a certain number of writers have lately endeavoured to prove that the disease in question is merely an artificial nosographical construction, and that the lesions of some myelitis—spontaneous, compressive, syphilitic or otherwise—may give rise to these collective symptoms, which could no longer, therefore, be looked upon as constituting a special affection.

In support of this theory some observations have been published in which the authors believed they had discovered the characters assigned by Erb and myself, to what I call spasmodic tabes dorsalis, but in which there had been found at the post-mortem examinations the most variable spinal lesions.

I have examined these observations with great care, but I do not think that any one of them really possesses the significance which has been given them.

Clinically, these are cases of ordinary syphilitic myelitis from compression, abnormal in some respects, but always exhibiting more or less pronounced disorders of sensibility, and of the functions of the bladder and rectum, which are so characteristic of this form of myelitis. The various lesions discovered on post-mortem examination presented, however, this common and

essential feature: the changes in question had given rise to lateral sclerosis. This merely shows—what moreover was a matter of common knowledge—that spasmodic gait, or, if you prefer it, spasmodic paralysis may manifest its presence in the most various forms of myelitis. But the gait is not everything in this morbid variety; it is only one element of the disease.

This proves also that the diagnosis is difficult and that before coming to a decision we must consider the matter more in detail. I was mistaken at least once, as I have no hesitation in openly confessing, in a case which was sent to my clinic as an example of spasmodic tabes. The autopsy showed that this was not so, but that it was a case of disseminated sclerosis.

On reading over the notes again, we found that the patient had suffered from vertigo and had experienced tremors of the extremities, significant symptoms, which should have led to an accurate diagnosis. Since that time, I have during life referred to their true origin cases which might have been looked upon as spasmodic tabes; and on these occasions my diagnosis has been verified at the autopsy.

Accordingly, matters remain as they were before the publication of the adverse observations to which I have just alluded. In short, although in the absence of adequate anatomical examinations, the autonomous nosographical existence of spasmodic tabes dorsalis has not yet been placed on a solid basis, we may assert, on the other hand, that, in spite of criticism, it has not as yet been seriously compromised. This question, however, cannot fail to be solved very shortly.

You see, then, gentlemen, from the preceding account, that permanent contracture is a symptom common to those organic spinal affections—and they are many—in which there is lesion of the lateral columns. It is necessary, however, not to forget that permanent contracture is by no means a certain indication of an organic lesion of the spinal cord, for there exist a number of cases in which the lateral columns are affected, perhaps functionally, but undoubtedly apart from any material lesion. The case of hysteria, to which I have often alluded, is one of the most typical examples of this kind.

## TRANSLATOR'S NOTE TO LECTURE XVI.

The existence of Charcot's spasmodic tabes dorsalis (Erb's spastic spinal paralysis) has recently been verified by an observation of Dr. Dreschfeld, of Manchester.

Microscopical examination showed :

- (1) Slight increase of the neuroglia in the anterior bulbar pyramids.
- (2) Sclerosis of the direct and crossed pyramidal tracts in the cervical region.
- (3) The same lesion, with atrophy of some of the motor cells in the anterior cornua, in the dorsal region.
- (4) Sclerosis of the lateral tracts and atrophy of the ganglionic cells in the anterior cornua in the lumbar region.

Dr. Dreschfeld considers the lesion of the motor cells secondary to sclerosis of the pyramidal tracts, seeing that the grey matter was unaffected in those parts of the cord where the sclerosis was in a less advanced stage. Professor Erb, who examined the microscopical preparations, believes that the existence of primary lateral sclerosis is now fully established (*vide* 'Transactions of the International Medical Congress,' London, 1881).

It is very possible that some cases of supposed spasmodic tabes dorsalis in children (infantile spasmodic paralysis) are dependent on a primary cerebral lesion. In an observation published by the translator the condition of the lower extremities corresponded accurately to the description given in the preceding lecture. In addition, however, there were fits, beginning in the right hand, and a certain amount of intellectual deficiency. The right upper extremity was much atrophied, but there was nevertheless some rigidity and the tendon-phenomena were exaggerated. The left arm was quite normal. All the circumstances of the case pointed to a lesion in the left cerebral hemisphere, followed by descending degeneration of both pyramidal tracts. It must be mentioned that the fits began when the patient was in his first year, and that he did not walk until his third year. As M. Charcot suggests, it is not improbable that the pyramidal tracts are more apt to take on degenerative changes at this period of life than subsequently.<sup>2</sup>

Briefly, then, although spasmodic tabes dorsalis may arise primarily in children, it is quite possible that some cases are secondary not only to a spinal but even to a cerebral lesion. Hence, unless great care is taken the primary symptoms are likely to be overlooked, and the existing condition looked upon as a distinct prothopathic affection.

<sup>1</sup> "A Contribution to the Pathological Anatomy of Primary Lateral Sclerosis (Sclerosis of the Pyramidal Tracts)," 'Journal of Anatomy and Physiology,' vol. xv.

<sup>2</sup> "An Anomalous Case of Infantile Hemiplegia," 'Brit. Med. Journ.,' February 18th, 1882.

## LECTURE XVII.

### SPINAL AMYOTROPHIES AND LOCALISATIONS IN THE GREY MATTER OF THE SPINAL CORD.

**SUMMARY.**—*The study of system spinal lesions should precede that of non-system lesions. Physiological function of the grey matter. Transmission of sensitive impressions and motor impulses.*

*System lesions of the grey matter are limited to the region of the anterior cornua, and are nearly all of an irritative or inflammatory nature. Systematised anterior poliomyelites are acute, subacute, or chronic. Fundamental characters of these affections. Motor and trophic disorders. The functions of the bladder and rectum are intact. Abolition of the reflexes.*

*Definition of the group of systematised poliomyelites. Proto-pathic and deuteropathic amyotrophies. Acute forms: infantile spinal paralysis, adult spinal paralysis. Subacute form: Duchenne's subacute anterior general spinal paralysis. Chronic form: progressive muscular atrophy of Duchenne and Aran. Non-systematised poliomyelites: central myelitis, ependymar sclerosis, disseminated sclerosis, amyotrophic lateral sclerosis. Neuro-muscular system in general.*

GENTLEMEN,—You have doubtless not lost sight of that table, or rather topographical plan, which I placed before you at the opening lecture of this year's course, and which since then I have many times taken the opportunity of bringing under your observation.

You have not forgotten that it is intended to give a general view of the various regions of the spinal cord, in which are located by a kind of selection those spinal changes which we now call system lesions. The term *system lesions*, which I have adopted from M. Vulpian's nomenclature, is, as I have already

frequently remarked, perfectly appropriate. In fact, the departments or regions which may be separately affected by disease, without involvement of adjacent regions, represent so many systems anatomically and functionally distinct. They are, as it were, so many organs, each having its own special physiological function. Consequently, it follows logically that disease of each of these organs should, under pathological conditions, reveal its presence by a characteristic symptomatology. So that the symptoms being known, the clinical observer is in a position to ascertain the lesion and to determine its seat.

We are naturally inclined, from the preceding considerations, to look upon system diseases in the domain of the spinal cord as so many elementary affections, the thorough knowledge of which should be applied to the elucidation of more complex, non-system affections, or, in other words, of those which are widely and irregularly distributed throughout the cord; that is to say, the study of spinal system lesions should, if we wish to be methodical, necessarily precede that of non-system lesions.

I venture to hope, gentlemen, that the details into which we entered in reference to lesions of the pyramidal-tract system have partly justified the statements I have several times expressed before you. They have at least enabled you, if I mistake not, to understand the significance of that symptom known as spasmodic paralysis, which, as you have seen, plays such a predominant part in spinal pathology.

## I.

To-day, gentlemen, I would direct your attention to a region which we have several times already encountered incidentally in the course of our studies, but which has not yet been the object of methodical investigation on our part. I mean the spinal grey axis or, as it is still more briefly termed, the grey matter.

It is unnecessary to remind you that, although occupying a comparatively limited space in the cord, the grey matter is nevertheless, from a physiological point of view, the most important part of the spinal axis. It is sufficient to remark that

it is essentially the centre of passage for the transmission of sensitive impressions and of voluntary or reflex motor impulses. Accordingly, if this path happen to become interrupted, the accomplishment of all these functions would thereby be rendered impossible.

But in addition, it seems now to be indisputably demonstrated that all parts of the grey matter are not indifferently concerned with the execution of these various functions. In this limited space there are, indeed, physiological reasons for establishing several perfectly distinct regions. Thus, from this point of view, the central grey matter must be distinguished from the cornua or columns of grey matter. The first alone, with the posterior cornua to some extent, takes part in the transmission of sensitive impressions, whereas the anterior cornua appeared to be exclusively intended for the transmission of motor impulses and have no connection with sensibility.

## II.

These results, which are based on experiment, have found confirmation in the domain of pathology. Disease, in fact, produces changes affecting separately certain departments of the grey matter, better than even the most expert physiologist.

A. But, gentlemen, there is a fact of capital importance in the history of these system lesions of the grey matter. Those changes alone have a right to this name which are now known to be limited to a certain defined region—that of the anterior cornua. The affections in question have therefore, as you see, a special anatomical character, not only from the fact that they are situated in the anterior cornua, but also because they depend on a lesion which is, in the strict acceptation of the word, systematised, that is to say, absolutely limited to the region, and unaccompanied by any alteration of the adjacent parts, except under accidental conditions.

The lesions which observe this rigorous localisation are nearly always of an irritative or inflammatory nature. It has lately been proposed to distinguish them by a term which tends to indicate at once the nature of the process and the kind of localisation. They have been called *systematised anterior polio-*

*myelites*; systematised, because the anterior grey matter may be affected incidentally and secondarily in cases of spinal affections of another order. We must add also acute or chronic, according as the affection proceeds in one or other of these two modes. In consequence of this localisation, and by reason also of the physiological individuality of the involved region, affections of this group, as might be anticipated, are accompanied clinically by a certain number of common features, calculated to distinguish them from all spinal affections situated elsewhere in the cord.

B. The following, in a few words, are the fundamental characters of the group :

(1) The muscles are attacked by motor impotence. The paralysis is more or less complete, but—and this is the essential point—the muscles of the affected parts are also the seat of more or less profound trophic lesions, which reveal their presence by special electrical reactions. This fact at once distinguishes these paralyzes from those depending on lesion of the white fasciculi and especially of the lateral columns, cases in which the nutrition of muscles is in no way affected.

(2) The muscles of animal life only are involved, those of the bladder and rectum remaining intact. The characteristic to which I am now calling your attention, gentlemen, is so singular that you should carefully bear it in mind ; at the present time it is not easy to give its physiological explanation.

(3) In these affections there is no modification of sensibility otherwise than accidental and transitory. This feature distinguishes system affections from those which are widely distributed in the grey matter. Besides disorders of sensibility, there is a marked tendency in these latter to cutaneous trophic disturbances, bedsores, &c. This tendency is never seen in the case of system lesions.

(4) In the majority of cases, especially in the acute or sub-acute forms, the various reflexes are either diminished or completely abolished. You may have anticipated that neither spinal epilepsy nor contracture appertain to affections of this group, but, in consequence of the frequently irregular distribution of the trophic muscular lesions, you will meet with deviations or paralytic deformities in cases such as these.



## III.

A. In short, the systematised anterior poliomyelites form a fairly natural nosographical group. The leading and, so to speak, unique, exclusive symptom is, as you know, the trophic muscular lesion. Accordingly, these alterations are sometimes described under the name of *spinal amyotrophies*. But it is advisable to add the qualification *protopathic*, which indicates that the fundamental fact is lesion of the spinal region on which this muscular lesion depends. On the other hand, the term *deuteropathic spinal amyotrophies* is applied to the various affections of the spinal cord, in which the lesion of the anterior cornua is only secondary and accidental, and in which the trophic muscular change is, in consequence, clinically intermingled with other symptoms.

B. The group of systematised anterior poliomyelites includes some affections which are constantly met with in practice and which should therefore command the special interest of the physician.

I think it necessary, then, to bring them under your notice in a concise and orderly manner. Systematised anterior spinal lesions, as I have said, are developed sometimes in an acute, sometimes in a chronic manner. In this last group I shall only include those varieties with regard to which modern pathological anatomy has come to a definite conclusion.

(1) The first class is made up of the group of *acute protopathic spinal amyotrophies*.

(a) The variety, *infantile spinal paralysis*, is the disease which excited the earnest attention of Duchenne and Heine. It is the model disease for the pathological study of this group. The lesions, indeed, are perfectly circumscribed; its symptomatology also is very limited and very precise, and all or almost all the details included in it are now capable of ready interpretation by the light of pathological facts.

(b) *Adult spinal paralysis* is the same disease referred to the pathology of the adult. For a long time the comparison was made solely on the basis of a very characteristic symptomatology; but anatomical evidence has now pronounced definitely in favour of this relationship. At present, the same does not

hold good with the second group, of which I shall merely make mention.

(2) *Subacute anterior poliomyelitis* corresponds to the affection described by Duchenne under the name of *subacute anterior general spinal paralysis*. This is, however, in more than one point, a subject for future research, for, I repeat, pathological observations have not yet furnished definite results.

(3) Lastly, *chronic systematised anterior poliomyelitis* is represented by that form of amyotrophy, of which Aran and Duchenne have traced the clinical description and to which they have given the name of *progressive muscular atrophy*. In this affection Cruveilhier discovered a lesion of the anterior spinal roots. Modern investigations have shown that the alteration, mentioned and described by Cruveilhier, is connected with an irritative and system lesion of the anterior grey cornua. The disease in question is sometimes described also under the name of *protopathic progressive spinal amyotrophy*.

#### IV.

Such, gentlemen, are the main varieties of the group of amyotrophies related to the anterior poliomyelites. On the other hand, were it only for the sake of fixing a standard of comparison and exhibiting a contrast, it is advisable to refer for a moment to various spinal affections in which lesion of the anterior cornua undoubtedly exists, but does not constitute the main and unique pathological fact. Here, the original lesion is outside the grey matter, or at any rate, external to the region of the anterior cornua, which are only affected consecutively by extension. Trophic changes, however, take place in consequence of participation of the anterior cornua.

It is plain, therefore, that this symptom is superadded to those of the primary disease, and, in such a case, the clinical observer must be prepared to encounter a complex symptomatic whole. For, as a matter of fact, it is not necessary that the acute or chronic spinal lesion should invade the anterior cornua at a definite period, and give rise there to the lesion of the ganglionic elements on which the spinal amyotrophy depends.

I shall pause no longer on these general and necessarily

somewhat vague remarks, but appeal, with your permission, to a certain number of concrete instances.

(1) (a) Among diffused and non-system spinal lesions of the acute variety, we may quote the central myelites or diffuse poliomyelites. Here, the trophic muscular lesion, analogous to that in infantile paralysis, is of frequent occurrence. But it takes place concomitantly with disorders of sensibility, more or less profound interference with the functions of the bladder and rectum, the formation of bedsores, &c., and if the patient survives and the white fasciculi participate in the morbid anatomical process, we see the development of permanent contracture, together with all the other signs of spasmodic paralysis.

(b) Of the chronic variety, I must mention to you perpendymar sclerosis, hypertrophic spinal meningitis, and disseminated sclerosis, all of which, under certain circumstances, may take on the appearance of progressive amyotrophy. There are indeed some non-inflammatory lesions which may have the same result: such are hydromyelia, intraspinal tumours (gliomas, sarcomas, &c.).

(2) Among system lesions, we must mention posterior sclerosis, which, in many cases, extends to the grey matter. But the morbid variety to which, at the present moment, I especially desire to call your attention is amyotrophic lateral sclerosis.

This affection, as I have told you, has two pathological elements: lesion of the lateral columns and lesion of the anterior cornua. The latter is not accidental, but forms an integral part of the disease, although everything tends to the belief that it is developed secondarily. This, therefore, is a system lesion with *combined elements*, as it is termed in Germany. This, too, is the affection which I thought it necessary, several times already, to bring before you in detail, because it shows that the laws of localisation, formulated with respect to the spinal grey matter, hold good in the medulla oblongata. You know that the nuclei of origin of the hypoglossal and facial, which are the representatives of the anterior cornua, are frequently the exclusive seat of pathological lesions; so that there are protopathic, as well as deuteropathic bulbar amyotrophies.

## V.

This general survey will enable you, gentlemen, to understand the subject more thoroughly, since you have considered it from the standpoint both of pathological anatomy and physiology. In other words, when investigating this matter, you must pay particular attention to those alterations in the grey substance, on which the amyotrophic symptoms depend. But here, as elsewhere, pathological investigation, in order to be profitable, necessarily demands a thorough acquaintance with the normal conditions.

Although I do not desire to enter exhaustively into all the details comprised in such a subject, I must particularly bring under your notice some points relative to the anatomy and physiology of the regions you will have to study. In this preparatory inquiry you must not only consider the grey matter itself, but also the motor nerves derived from it and the striated muscles to which the latter convey movement.

In fact, gentlemen, the various parts just mentioned are mutually dependent and constitute anatomically and physiologically one system. The motor nerve-cell, with its multiple processes, may be really looked upon as a small independent organ, which forms the bond connecting several systems one to another, but which belongs exclusively to none of them.

Nevertheless, it is important to remark that, of all these processes of the anterior spinal cell, the most important and characteristic, from a morphological and physiological standpoint, is that which brings the cellular organ into direct continuity with the motor nerves; so that the motor nerve-tube, the essential part of which is the axis-cylinder, is simply a prolongation from the substance of the motor cell. It is now known, indeed, that this prolongation of the ganglionic element enters by its peripheral extremity into immediate relation with the muscular element.

Before 1840 it was thought, in accordance with the researches of Valentin and Burdach, that the peripheral extremities of the muscular nerves terminated in the form of loops, in the interval between the primitive fasciculi. Doyère made an important discovery when he showed that in tardigrades the motor

nerve ends by a single filament in an elevation situated on the primitive fasciculus and which is now called the *eminence* or *hillock* of Doyère.

It is well known also that in 1862 Rouget proceeded farther and showed that beneath the sarcolemma and in the very substance of the primitive fasciculus, Doyère's elevation is composed of a mass of granular matter in which the nerve-tube ends as an axis-cylinder.

The researches of Krause, Kühne, and subsequently of Ranvier, have confirmed the general truth of these facts which they have supplemented by a large number of important details.

But the great point discovered by Rouget is that there really exists a direct connection between the centrifugal nerve and the muscular substance.

You see, therefore, gentlemen, that, on the one hand, between the ganglionic element and the axis-cylinder, which is in fact a prolongation of that element, there is a relation of immediate continuity, just as there is, on the other hand, between the terminal extremity of this prolongation and the substance of the muscular element.

There is then, as I declared, anatomically speaking, an intimate and mutual dependence between the motor cell, the motor nerve, and the muscular fibre. In fact, we may look upon them as three consecutive elements of the same system, and even assert, without exaggeration, that the spinal cell, through its axile prolongation, directly enters the substance of the muscular cell.

But it behoves us, gentlemen, to bear in mind that one of the elements in this association is in the ascendant, the others being subordinate. The integrity of the muscles, as of the nerves, depends on that of the ganglionic elements. It has, indeed, been shown that lesion of the latter necessarily reacts on the muscle through the nerve, and that lesion of the nerve reacts on the muscle, which consequently occupies the last place in the association; but it has by no means been proved, on the other hand, at any rate up to the present time, that lesion of the muscles or motor nerves can influence the ganglionic element and alter its nutrition.

Such, gentlemen, are the considerations I wished to bring

before you with reference to that association of elements which might be termed the *neuro-muscular system*, the preliminary study of which is indispensable to him who wishes to investigate with profit the pathological topography of the various regions of the grey matter.

## APPENDIX.

### AMYOTROPHIC LATERAL SCLEROSIS. AUTONOMY AND SPASMODIC CHARACTER OF THIS AFFECTION.

SINCE the lectures on the history of contracture which M. Charcot has been delivering lately at La Salpêtrière, a typical case of amyotrophic lateral sclerosis has been analysed in detail. This affection, the first description of which barely dates from five or six years ago, has recently been subjected to numerous criticisms, especially with reference to the spasmodic nature and nosographical autonomy which M. Charcot has attributed to it. With the view of once more demonstrating the essentially spasmodic nature of this disease, at least in its early period, M. Charcot, at the commencement of this year's clinical lectures, thought it advisable to give a somewhat ideal example of amyotrophic lateral sclerosis, and to discuss its fundamental characters. It may be said, in a general manner, that certain paralyses reveal their presence mainly by rigidity or spasmodic contracture of the muscular masses; whereas others are marked by the absence of this symptom or even by the opposite state—flaccidity of the limbs. This dichotomous division, summary as it may be, suffices to show the practical interest attached to the interpretation of contracture. For some years, moreover, observers have recognised the importance of various phenomena known by the generic name of tendon-reflexes, and the minute examination to which they have been subjected may throw great light upon the pathological conditions favouring the appearance of contracture. These reflexes, when not exceeding a certain limit, appertain to the normal state. But

when they are manifestly exalted they constitute a morbid symptom of undoubted importance, both in a purely clinical aspect as well as from the standpoint of physiological theory.

Now, according to the present state of our physiological knowledge, the permanent spasmodic contracture of muscles is justly considered a strange, inexplicable, and almost paradoxical phenomenon. Nevertheless, the numerous researches recently conducted in France and abroad tend to prove that exaltation of the tendon-reflexes and contracture are allied and, so to speak, equivalent facts, or, at least, that they belong to the same series; that the physiological explanation applicable to one applies equally to the other, so that permanent spasmodic contracture is thereby deprived of its paradoxical character.

But the following case, to which M. Charcot calls attention, is of great value to the line of argument which he purposes to work out.

The case is that of a woman who is now forty-seven years of age. She is confined to her bed, and seems to be absolutely inert and incapable of movement. Her intelligence, however, is perfect, and although she can no longer make herself understood her condition explains itself. It is at once evident that this woman is paralysed in all her limbs, that the head even is no longer retained in its normal position, but that it inclines sometimes to the right, sometimes to the left, and that the patient is incapable voluntarily of holding it straight. It would, then, be naturally imagined that this unfortunate being is affected with completely flaccid paralysis. Yet in reality this is far from being the case. A more minute examination is requisite in order to explain the relative condition of the various parts of the body.

As regards the lower limbs, we find that they have assumed a somewhat peculiar attitude, the feet are extended, the knees in close contact one with another, and both legs appear rigid, nevertheless, they may be flexed without experiencing any very great resistance. This resistance, however, is more considerable than under ordinary conditions. To satisfy oneself of this it is only necessary to make passive flexion in this patient and afterwards in a healthy individual. It is then evident that rigidity is really present, or, in other words, that the flaccidity of the extremity is replaced by what is called *flexibilitas cerea*.



On striking the patellar tendon with Skoda's hammer the leg at once gives a jerk forwards, and occasionally, indeed, is affected for some time by the rapid movements of spinal epilepsy. Lastly, both limbs are emaciated, but not atrophied, and what is seen in one is also observable in the other.

As to sensibility, it is everywhere intact; the patient in this respect presents no morbid change, and we can assert that, apart from exceptional circumstances, she never will exhibit any.

As regards the functions of the bladder and rectum, there is nothing abnormal to be noticed; so that if we simply take into consideration the condition of the lower limbs and exclude the morbid characters which will be mentioned presently we shall merely see in this patient the symptoms of spasmodic paraplegia.

But the upper extremities also exhibit very peculiar characters, their attitude at first sight being most remarkable. They are semiflexed upon the chest and supinated, the hands are turned forwards, the fingers shrivelled. In addition, these extremities are extremely emaciated and apparently flaccid, so that if we pay exclusive attention to them it might be thought that we were dealing with a case of progressive muscular atrophy. This, however, is not the case; but here again it is a question of spasmodic paralysis. If, indeed, what remains of the muscular masses of the arm and forearm be carefully examined we can distinguish at certain points a cutaneous quivering, corresponding to transitory and spontaneous fibrillar contractions; in addition, forced flexion of these extremities produces the same sense of resistance as in the lower limbs; lastly, percussion of the tendon of the triceps gives rise to a manifestly exaggerated reflex.

If, now, instead of exciting the reflex action of this muscle, the anterior surface of the forearm be tapped lightly at the various points corresponding to the flexor tendons of the fingers, the flexion of the wrist becomes more marked under the influence of each of these shocks. This is a most important feature because the tendon-reflex of the flexors of the digits is usually but slightly pronounced, or even absent, in the normal state. We must likewise notice the fact that both upper extremities are affected symmetrically, the difference, if any,

being very inconsiderable, and that sensibility everywhere is preserved intact.

Now, if we analyse the details presented by the attitude of the head and the expression of the face the following is what we observe. The neck is powerless to support the head, the chin rests against the sternum, and if the patient be inclined slightly backwards the head is carried in the same direction by its weight, the anterior muscles being absolutely incapable of restoring it to its proper position. As regards the face, it exhibits a physiognomy which may be described in one word: labio-glosso-laryngeal palsy.

But the labio-glosso-laryngeal paralysis in this case is slightly different from that described by Duchenne, in which the characteristic mask-like expression often enables us to recognise the nature of this disease at first glance.

The numerous wrinkles, the deeply-grooved furrows, particularly the naso-labial and frontal, the lengthened commissures, the eyes widely opened as though the lids were difficult to close, give a truly specific impress to the countenance which, by its lachrymose aspect, may be readily differentiated from the inert mask-like *facies* in Duchenne's paralysis.

In protopathic labio-glosso-laryngeal paralysis, moreover, nothing further is noticeable. Our patient is now unable to articulate a single word, but she makes a nasal, monotonous sound, which is constantly interrupted by a movement of difficult deglutition. She can, however, slightly protrude between the imperfectly-opened dental arches her wrinkled, small, and trembling tongue. But she is unable either to whistle, inflate the cheeks, or even swallow without choking at each attempt, and from her partly closed mouth the saliva is continually dribbling away.

The minute examination of all these symptoms is certainly most interesting and instructive. We see a mixture of certain muscular paralyses, apparently flaccid, with a number of perfectly typical spasmodic phenomena; and herein lies the difficulty of the problem.

Now, the history of the patient in question enables us to understand the conditions of this curious combination of apparently incompatible phenomena.

Two years and a half ago the woman D— experienced the

first symptoms of the affection which is now approaching its last stage. At the outset she suffered from sharp pains in the loins and thighs. She then began to feel weakness of the legs and difficulty in walking, "as though there were a bullet at each foot." Three months later there appeared paralysis of the upper extremities, characterised by motor impotence, fibrillar contractions, and rigidity. About the sixth month difficulty of speech began to be manifest. All these symptoms gradually increased, and after ten months of suffering the woman D— became absolutely powerless. At that time (March, 1878) she was under the care of Dr. Huchard in the wards of the Hospital Laënnec, and we may say that the affection had then reached its stationary period.

The disease was at that time so very characteristic that Dr. Huchard at once made the diagnosis of amyotrophic lateral sclerosis. But it is of the greatest importance to observe, as regards the state of the patient in this phase of the disease, that all the spasmodic symptoms were most carefully recorded in Dr. Huchard's notes: continuous tremor of the extremities, fibrillar tremblings, contracture of the flexors, spinal trepidation so intense that the slightest contact produced it, and which sometimes persisted for more than a minute after the stimulus, rigidity of the loins and neck. In short there was a kind of generalised tetanus associated with very characteristic progressive muscular atrophy.

It was not until the end of eighteen months that the woman was admitted under M. Charcot at La Salpêtrière, and then, for the first time, some difficulty in swallowing and transitory attacks of dyspnoea were noticed (April, 1879). Up to this date, which may be looked upon as the apogee of the spasmodic period, all the symptoms of reflex hyperexcitability had continued to increase; but from that time, and in proportion as the complication of muscular atrophy became well pronounced, they underwent gradual diminution, first in the upper and then in the lower extremities. Accordingly at the present moment, M. Charcot's patient exhibits only the remnants of the spasmodic symptoms with which she had been previously affected to such an extreme degree.

This case in all its details realises as fully as possible the type which M. Charcot, in 1874, pointed out as being the clinical

manifestation of a bulbar lesion, accompanied by symmetrical sclerosis of the lateral columns, together with a degenerative change in the anterior grey cornua.<sup>1</sup>

But cases of this nature are not fortuitous and accidental. Uncomplicated examples of this morbid variety become more evident in proportion as we analyse with greater care the numerous cases of spinal affections which were formerly described under the collective term of chronic myelitis.

The opportunity was afforded of comparing with the patient just mentioned a man who was affected with absolutely identical symptoms, and whom Dr. de Lorne was good enough to send to La Salpêtrière so that M. Charcot might be able to exhibit the striking resemblance between the two cases. The affection, here, is of much more recent date. The man in question is thirty-five years of age and has been ailing for one year only. In January, 1879, he experienced weakness of the left arm, which lasted but two months. In March there supervened in the course of a few days paresis of the left leg and then of the right upper and lower extremities, considerable difficulty of pronunciation (especially of certain letters, *g* and *l*, for example), and rapid wasting of the left arm and hand. M. Charcot remarked that we might almost be justified, even at this period, in affirming the existence of amyotrophic lateral sclerosis. Other symptoms of the disease gradually supervened, and this is now the condition presented by M. de Lorne's patient.

Both arms are paralysed, there is the characteristic claw-like attitude of each hand (*main en griffe*), and the thenar and hypothenar eminences have disappeared. The upper extremities hang from each side of the body, apparently inert and flaccid; still, considerable resistance is experienced on attempting to bend them, as well as extend them when flexed. The legs are not paralysed to the same degree, but are so very feeble that the patient is constantly falling. This paresis is evidently of a spasmodic nature. In fact, the patient does not bend the knees during progression, and as he says himself, "he walks as though his legs were made of wood." Progression is rendered still more difficult by the spontaneous spinal trepidation, which impedes his movements at every step and gives him a very pecu-

<sup>1</sup> This woman died on May 31st, 1880. The autopsy confirmed the diagnosis; the necroscopical details will be published.

liar hopping gait. Lastly, the reflexes, and particularly the tendon reflexes, are considerably exaggerated in all the limbs. The patellar tendon reflex, especially, is much more pronounced than in the normal state, and is very frequently followed by prolonged trembling. Ankle-clonus (the trepidation produced by straightening the point of the foot) exists also to a very high degree. As to the labio-glosso-laryngeal palsy, although it is as yet only in an early stage, no symptoms are wanting.

We have the characteristic aspect of double facial paralysis, nasal voice, thick monotonous speech, inability to whistle, distressing difficulty in the first two stages of deglutition, &c.

Such are the two cases, almost absolutely identical, upon which M. Charcot relies as the basis of the succeeding discussion. In the first place it is incontestible that both these patients are affected with the same disease, the only difference being that in the second the progress of the malady is more rapid in consequence of the relatively premature appearance of the bulbar symptoms, which followed the first indications of the atrophic paralysis of the extremities at a very short interval. But, apart from this slight difference, both cases display remarkable similarity and, so far as prognosis is concerned, the final result will be the same—that is to say, early death.

This, then, is a well-pronounced autonomous disease, and in typical cases, like the preceding, the diagnosis is quite evident. In both subjects the lesion will be found to correspond with the anatomical term, amyotrophic lateral sclerosis, and we may say in advance, as though the verification were already made, that this alteration does exist. Moreover, the diagnosis in cases of this kind has been made during life with the greatest precision by several observers (Rigal, Huchard, Seguin, Nixon, Piek and Kahler). In the affection in question there are no really characteristic and pathognomonic symptoms, but it must not be forgotten that a comparatively very limited number of elementary phenomena, by combining into diverse groups, may constitute those numerous and varied forms of disease which we find clinically in the nervous centres. The arrangement and association of the symptoms make the only difference, as is the case with the twenty-six letters of the alphabet which, when variously disposed, suffice for all those ingenious and multiform productions of our literature.

It is, moreover, by this arrangement and grouping of the few symptoms which, according to M. Charcot's description, constitute one of the main elements in the determination of the affection in question, that the clinical observers just named were enabled to affirm during the course of the disease a diagnosis which was subsequently verified in every point by post-mortem examination.

Notwithstanding the remarkable agreement in the now numerous cases which have been ascribed to amyotrophic lateral sclerosis, the acceptance of this nosographical variety has not been made clear to many neuro-pathologists, and among others to Professor Leyden, who has frequently expressed his opinion on this subject in various German periodicals, and also in a systematic treatise on diseases of the spinal cord, which has just been translated into French.

The reputation of Professor Leyden justifies the details into which M. Charcot has believed it incumbent on him to enter, in order to refute the criticisms of the Berlin school.

The arguments put forward by Leyden in support of the theory which places in the same group, among others, amyotrophic lateral sclerosis and the muscular atrophy described by Duchenne and Aran, may be summed up under the following heads :

(1) In amyotrophic lateral sclerosis the paralysis is *atonic*, and there are no spasmodic symptoms.

(2) Muscular atrophy is the dominant symptom ; and there is no question of an atrophic *paralysis*, seeing that the period of initial paralysis is absent.

(3) There exists but one form of bulbar paralysis—that described by Duchenne.

(4) Lastly, the lesions of amyotrophic lateral sclerosis are not specific ; the alterations in the white matter of the cord affect the anterior as well as the lateral columns (pyramidal tracts).

If the statements advanced by Leyden were in accordance with truth, it is evident that the autonomy of amyotrophic lateral sclerosis would be compromised. But in order to nullify the indispensable conditions of its autonomy he must, in fact, deny the constancy and even the existence, as a whole, of the essential features upon which M. Charcot's description is based.

Besides, the clinical and anatomical signs which confer such a specific aspect on amyotrophic lateral sclerosis are identical with those, of which the Berlin professor has availed himself in order to formally call in question their worth.

M. Charcot has profited by the presence of the two patients just considered in order to demonstrate once again the accuracy of the facts contested by Professor Leyden.

As regards the spasmodic nature of the disease, the two preceding examples are as conclusive as possible.

The woman D—, in particular who, at the present moment, seems to be affected with a generalised atonic paralysis, experienced for eighteen months a host of permanent spasmodic symptoms, such as limited or extensive contracture of the muscles, subsultus, spinal trepidation, &c.; and even now, in spite of the extreme atrophy of the upper extremities, we can still obtain an exaggerated tendon reflex of the flexors of the fingers by percussing the anterior surface of the forearm at certain points. But the first description of amyotrophic lateral sclerosis does not date so far back that we cannot take cognisance of all the cases. Statistics, therefore, will furnish the solution of the question in dispute.

Now, on making an abstract of the observations hitherto published we obtain the following results. Without including Leyden's cases which we shall consider later, eleven instances have been described together with very minute details of the post-mortem examination. These cases, therefore, are unexceptionable, and in all of them special mention was made of contracture. M. Charcot himself has had five autopsies,<sup>1</sup> and once only<sup>2</sup> (the case of the woman P—) does contracture not figure among the symptoms recorded in the observation; but exaggeration of the tendon reflexes was observed in this instance and this phenomenon, as we now know, is of the same nature as contracture itself.

As to the six other observations in which autopsies were made, they likewise are explicit as regards contracture (Seguin, Worms, Hun, Kussmaul, Rigal, Pick and Kahler). In Worms' case particularly, special mention is made of forced flexion of

<sup>1</sup> Gombault—"Étude sur la sclérose latérale amyotrophique," Observations i, ii, iii, iv.

<sup>2</sup> This case will be published subsequently.

the forearms with convulsive trembling of the lower extremities. The cases of Rigal and of Pick and Kahler were so very characteristic that the diagnosis, which was fully confirmed by the autopsies, was made at a very early period.

We shall now give a brief account of both these observations, for each of them is a faithful reproduction of the type described by M. Charcot.

*Observation I* (Pick and Kahler).<sup>1</sup>—Catherine Mally, æt. 64, a charwoman, began to experience tremors in the left and then in the right arm, in May, 1877. Shortly afterwards both arms became weak and the forearm contracted in the position of slight semi-flexion. The patient, however, was still able to do her work.

In September, the weakness of the arms was well-marked, and they had already undergone evident emaciation. First the left and then the right leg gradually became paretic, and the patient was obliged to keep her bed. She then observed that her pronunciation was not so good as formerly.

In October, the affection made rapid progress. The woman's articulation became so indistinct that her husband had some difficulty in understanding her.

She entered the hospital in October, 1878, when her condition was as follows. (Edema of the lower extremities, pulse 90, respiration 18. Her arms were applied to the epigastrium, the hands contracted in flexion and pronation, and the phalanges flexed. The upper extremities were much emaciated, the forearms being markedly atrophied. The legs were stiff, perfectly paralysed, but free from atrophy strictly speaking. The rigidity was especially marked in the adductor muscles of the thighs. The head was immovable, the movements of the eyeballs unimpaired, but the face, especially on the right side, was devoid of expression. The neck still possessed some amount of lateral movement, but the head was flail-like, sometimes falling backwards, sometimes dropping forwards on to the chest. As a rule it inclined slightly to the right. At the beginning of January, some difficulty in swallowing appeared for the first time. The voice was nasal and the speech unintelligible. The mouth which was widely opened allowed the

<sup>1</sup> 'Beitrag zur Pathologie und Pathologischen Anatomie der Central Nerven Systems,' Leipzig, 1879.



escape of the saliva. The tongue, which was flabby, furrowed, and honey-combed, was affected with fibrillar tremors. The reflexes were exaggerated everywhere, and there was spinal trepidation.

Feb. 1st.—Deglutition has become impossible.

11th.—Difficulty in breathing in more marked; bronchitic râles.

14th.—Respiration laboured.

15th.—Death.

*Observation II* (Rigal)<sup>1</sup>.—X—, æt. 35, a labourer, was attacked with weakness and rigidity of the left upper extremity, about January 1876. The right upper extremity gradually became affected in the same way and, very shortly, marked wasting of the hands supervened.

In April, that is to say, about four months after the onset of the affection, the lower limbs became weak and the patient was troubled with cramps and startings.

In May 1876, he was admitted into the Hôtel-Dieu under the care of M. Rigal. The following is a brief account of his condition at that time. The arms were applied over the front of the chest, the forearms semiflexed. The fingers were claw-like (*en griffe*), and in the hand a piece of wood had to be placed to prevent the nails becoming imbedded in the skin. On attempting to overcome the resistance of the contracture, an exaggerated degree of flexion with some amount of tremulousness was occasioned. Nevertheless, slight voluntary movement was still possible.

The lower limbs were paralysed and contracted, but the patient could still walk, although progression always increased the rigidity of the legs.

The trunk, face and neck were also rigid. The head was inclined slightly forwards, the buccal orifice enlarged, and the commissures lengthened.

There was inability to whistle, but the tongue was unaffected and there was no difficulty in deglutition. The eyes were widely opened, and the eye-lids closed with difficulty.

In November 1876, eleven months after the onset of the

<sup>1</sup> This case will be commented on in an article which MM. Gombault and Debove intend to publish in the forthcoming number of the 'Archives de Physiologie.'

affection, the contracture had diminished in the upper extremities, but the lower limbs were still in a permanent spasmodic condition. The trunk and head also remained rigid. Speech and deglutition were embarrassed; the various symptoms of bulbar paralysis became rapidly worse and the patient died in January 1877, nearly thirteen months after the first symptom of paresis.

In the two preceding observations, as in all those in which microscopical information was forthcoming, the diagnosis was completely confirmed. But since cases of this kind are not yet very common, it is assuredly permissible to quote in support of our argument observations without autopsies, in which the clinical picture is so similar that the diagnosis could not be doubted for a moment. Such, for example, is the case with the two patients shown by M. Charcot at the beginning of his lecture. The following two cases, given in abstract, are strictly conformable to the type, especially as regards the spasmodic symptoms of the first period. Observation III is the epitome of a case recently published by Dr. Nixon.<sup>1</sup> Observation IV has reference to a provincial patient of whom M. Charcot has lost sight, but in whom the affection was sufficiently advanced to make doubt impossible.

*Observation III* (Nixon).—The patient, who was a carter, æt. 35, was seized, in February, 1878, with slight pain in the left arm and with weakness and rigidity of the same limb. The month following, the right arm became involved in its turn, and from that time the patient observed that both arms were emaciating and also affected with frequent muscular tremors.

In April, weakness of the lower extremities supervened and from time to time progression was embarrassed by spinal trepidation.

As the disease increased the lower limbs became "as rigid as sticks," and the patient used to try to bend them with his hands.

At the period when the extremities grew stiff, the physiognomy began to change, deglutition became difficult and the patient observed that he could no longer spit . . . and so on. The affection continued to develop until the ninth month

<sup>1</sup> 'Dublin Journal of Medical Science,' 1879.

when his condition, in a few words, was as follows. The lower lip was pendulous and he was unable to eject things from the mouth. The tongue still moved, but it was small, tremulous, wrinkled, and atrophied. Articulate speech was much embarrassed.

The upper extremities, especially at the thenar and hypothenar eminences, were extremely atrophied, but there was no rigidity to be noticed.

As regards the lower extremities, they were quite free from atrophy; the patient could still walk, although the gait was spasmodic and accompanied by spinal trepidation.

*Observation IV* (Charcot).—Mme. M—, of Cambrai, æt. 54, of no occupation, experienced for the first time in November, 1877, rigidity and feeling of weight in the right hand.

In May, 1878, that is after an interval of six months, the left arm became affected in the same manner, and the weakness of the right hand became more and more marked. In September, some numbness of the left leg, which was soon followed by considerable weakness, made its appearance. The month following, the right leg was invaded in its turn. At the same time, the articulation became thick, the speech assumed a curiously scanning character, and the voice began to be nasal. In January, 1879, the paralytic symptoms became well pronounced, but the patient still suffered from spinal trepidation, especially on walking.

She came to consult M. Charcot at La Salpêtrière in April, 1879. There was the characteristic facies: transverse wrinkles on the forehead, contracture of the lower part of the face, elevation of the commissures and slight paralysis of the labial muscles (the patient said that the saliva dribbled all night long and that even in the day she was frequently obliged to wipe the right commissure). She looked sideways and was unable to turn her head in consequence of the rigidity of the neck. She spoke monotonously, as though she were reciting. She had occasional attacks of dyspnoea. The hands hung down and were wasted, shrivelled, and powerless; the palmar surface was directed forwards. The gait was laboured; the knees were in close apposition and the trembling was a source of constant trouble, so that she was continually making false steps. The

tendon-reflexes were exaggerated. On striking the patellar tendon, the leg became rigid, and some time elapsed before it was possible to bend it with ease. The diagnosis was amyotrophic lateral sclerosis of seven months' standing. The patient has been lost sight of.

It is beyond dispute that the two cases, the history of which has just been briefly related, apart from the duration of their clinical development, are in every respect similar to the state of the other patients exhibited by M. Charcot. We may, indeed, assert that when the disease has reached such an advanced stage, there is no difficulty in diagnosis. But the main interest of both these cases, from the position M. Charcot has taken up, consists in the multiplicity and generalisation of the spasmodic symptoms, which are apparent on the most superficial observation. This feature, however, was well marked, simply because the muscular atrophy had not progressed rapidly.

Be this as it may, the patients in Observations III and IV, are undoubtedly affected with amyotrophic lateral sclerosis, like the two patients whose cases we considered at the outset. Although the autopsies have not yet been made, the existence of the lesion is as certain as though it were actually present to our gaze. Now, since these four cases are peremptory on the subject of spasmodic manifestations (contracture, &c.), there remains out of a total of fifteen published observations but one case in which no mention was made of contracture in decided terms, although exaggeration of the tendon-reflexes was alluded to; so this case, unique as it is, is not altogether an exception. The conclusion drawn from statistics, therefore, is far from invalidating the spasmodic character of the affection. But, it is asked, are there not contradictory cases? Have not instances been quoted in which no contracture was observed?

If we again appeal to statistics the following, in a few words, are the results obtained.

(1) The alleged contradictory cases do not exceed five, or six at the most. At the outset, then, there is a disadvantage in number in relation to the observations of the fifteen positive cases.

(2) In one of these contradictory cases (Shaw's of Brooklyn), it is maintained that no contracture was noticeable.

But did it exist at one time and disappear subsequently?

What, too, was the condition of the tendon-reflexes. There is no reference to these points.

(3) In another case of the same nature (Pick's), although there was no contracture, the patient was liable to involuntary shakings. Now these tremblings, like exaggeration of the tendon-reflexes, are phenomena of similar or identical origin, and closely allied to contracture. As to the reflexes, in this observation as in the preceding there was no allusion to them.

(4) There remain, then, only Leyden's four or five contradictory cases.

Now, as regards the tendon-reflexes, Leyden does not think that absence of the reflexes was unremarked in any of his observations. In this respect, however, Observation II in his memoir is exceptional, for he says, "the tendon-reflexes of the knee are distinctly present."<sup>1</sup> Contracture never existed; at the most a certain amount of rigidity determined by the *habitual position of the limbs* might be granted, this rigidity being perceptible in the knees, shoulders, and elbows.

Seeing that articular rigidity, pure and simple, in the case of flaccid paralysis, appears to be a very improbable occurrence, is it not much more natural to look upon this rigidity as a feeble degree of contracture, as the state characteristic of morbid yet still active muscular tissue, and which, in a word, is sufficient to maintain that amount of adhesion between the articular surfaces, which gives rise to the peculiar sensation of resistance called *flexibilitas cerea*. This, however, is not Leyden's opinion. He enumerates other signs of contracture, such as flexion of the fingers with inability to extend them and provoked trembling.<sup>2</sup>

This phenomenon is common in the state of permanent contracture and has long been noticed in the contracture of hemiplegic patients. Professor Leyden likewise calls attention to the trembling which accompanies the movements of progression and on which M. Charcot has laid such great stress as being a cause of considerable embarrassment in walking. Now, in one of Leyden's patients, the gait was not merely difficult, but

<sup>1</sup> "Sehnenreflexe am Knie sind deutlich vorhanden," 'Arch. f. Psych.', 1878, viii Bd., 3 Heft, p. 675.

<sup>2</sup> "Die Finger können nicht gestreckt werden, und beim versuch der Bewegung, tritt ein eigenthümliches leichtes Littern ein," loc. cit.

had become for this very reason impossible: "The patient can scarcely stand upright and is obliged to sit down again immediately, because his legs begin to tremble."<sup>1</sup>

Such are the cases of which Professor Leyden has availed himself in the attempt to prove that amyotrophic lateral sclerosis has none of the characteristics of a spasmodic disease.

The conclusion which we drew in anticipation from the preceding observations, now obtains much greater force. But Leyden's cases are not, on that account, less valuable. They may, indeed, be utilised with profit, as clinical examples of spasmodic paralysis, in which the collective symptoms peculiar to contracture have undergone modification, at a certain period, on the appearance of muscular atrophy.

The more or less premature occurrence of this additional semeiological element gives rise to some degree of confusion in the collective phenomena which, by their grouping, constitute the state of contracture. But, although one of these phenomena may disappear, another which is intimately allied and as it were homologous sometimes persists still longer. For this reason the characteristics of contracture, which are undoubtedly very various, require to be sought for carefully under all their forms. Although in the case of Pick and Kahler, which is quoted by Leyden, contracture properly speaking was not observed, the spasmodic character of the affection might have been discovered, by carefully analysing the condition of the tendon-reflexes, of which no mention was made.

Leyden's second objection may be summed up as follows: in the amyotrophic lateral sclerosis, as described by M. Charcot, it is simply a question of *primary* progressive muscular atrophy; the muscular atrophy is the leading symptom; and, strictly speaking, there is no *atrophic paralysis*, seeing that there is no previous stage of simple paralysis.

M. Charcot criticised this assertion and refuted it by the observations of Professor Leyden himself. Indeed, when we consider the lower extremities only in which the atrophy is late and consequently exceptional (death generally supervening beforehand), it is incontestable that these extremities are, at an early stage, affected with simple paralysis. Such is the case with the patient quoted in Professor Leyden's Observation I.<sup>2</sup> "As to

<sup>1</sup> Loc. cit.

<sup>2</sup> Loc. cit., p. 670.

the lower limbs, the muscular masses are not exactly atrophied, but flaccid, and their force is extraordinarily diminished." Similarly, in Observation II of the same work: "The lower limbs are evidently weakened, but there is no notable atrophy;" and a little farther: "the legs are not strikingly atrophied, but the muscles are flabby and their force very remarkably lessened; the patient can scarcely hold himself erect."<sup>1</sup>

Westphal has made an absolutely identical remark. He calls attention to the well-marked loss of power of the lower limbs, with preservation of the tendon-reflexes: "The lower extremities, he says, "are flaccid; the patient is unable to walk upright without assistance."<sup>2</sup> So far as the lower extremities are concerned, therefore, no doubt is possible: the atrophy is preceded by a more or less prolonged period of paralysis. When the atrophy does not supervene too suddenly, this paralysis may show itself even in the upper extremities as a symptom characteristic of the disease in an early stage.

In this respect, Observations II, III, and IV, are very conclusive.

As to the identity in nature of Duchenne's labio-glossolaryngeal paralysis and the bulbar symptom of amyotrophic lateral sclerosis, Leyden's supposition is disproved by some recent cases which we shall merely enumerate. Without including the published observations of M.M. Charcot, Joffroy and Duchenne, Eisenlohr, &c., M. Charcot calls attention to the cases of MM. Sabourin and Pitres, Déjérine, Duval, and Raymond, as proving that it is no longer permissible to confound the two diseases under the same heading, at any rate from an anatomical point of view.

Leyden's last objection is the following: the lesion has no anatomically specific characters; it does not involve exclusively the lateral columns (pyramidal tracts), but affects also the anterior columns; the lesion must be followed above the pons Varolii in order to justify us in inferring the systematised nature of the affection.

As to the coexistence of an alteration in the anterior column, M. Charcot long ago pointed out that when present it is, in a manner, fortuitous, and that there are cases, as Flechsig has remarked, in which it is absent. In the second place, this alte-

<sup>1</sup> Loc. cit., p. 675.

<sup>2</sup> Loc. cit., p. 338.

ration is always of slight importance in relation to the sclerosis of the lateral column.

To be convinced of this it is sufficient to glance at the very accurate figures which Leyden has appended to his memoir.<sup>1</sup> It is at once evident that the morbid staining of the anterior column is very pale and diffuse, whereas the lateral column is vividly coloured with carmine. The simple explanation of this is, that the degeneration, primarily localised to the pyramidal tract, has determined, in its neighbourhood, by contiguity and not by continuity, a comparatively slight inflammatory reaction.

Moreover, the extension of the system lesion to the adjacent parts has not escaped the attention of French pathologists, who have unreservedly adopted M. Charcot's opinion.

In the work previously quoted, MM. Debove and Gombault have pointed out and described the same thing, but without attributing to it greater importance than it deserves:—"The intra-spinal roots are not healthy, and it is probable that their degeneration in front of the anterior cornua has given rise to that slight alteration in the part of the anterior column, which is described in the observation under the name of *radiating zone*."

If, on the other hand, passing from the spinal cord to the medulla oblongata, we take into consideration the great distance separating the anterior pyramids from the motor nuclei, we are forced to acknowledge that the sclerosis of the pyramidal tract has very intimate relations with the degenerative alteration of the grey matter.

Lastly, the desideratum which is still wanting in the anatomical description of amyotrophic sclerosis, namely, the pedunculo-cerebral prolongation of the lateral sclerosis, has just been supplied by Pick and Kahler in the observation, the clinical part of which has already been given in abstract.

These writers discovered "numerous granular bodies in the outer part of the middle third of the lower layer of the crura cerebri. After hardening in chromic acid, the sections showed that these points were patches of sclerosis. The sulci included between the frontal and occipital convolutions were hard and slender, the præcentral and central fissures being very wide and deep."

<sup>1</sup> Loc. cit., Taf. xii, fig. 2, A. T.



In a woman examined post mortem by M. Charcot, granular bodies also existed in the foot of the crus cerebri (Pick).

We see, then, that everything goes to confirm the clinical and pathological autonomy of amyotrophic lateral sclerosis; and in proportion as the number of cases increases, the nosographical unity of this affection will appear still more evident.<sup>1</sup>

Amyotrophic lateral sclerosis will then be in the same position as disseminated sclerosis or locomotor ataxy. No one disputes the autonomy of these two spinal diseases; nevertheless the abnormal and irregular forms differ remarkably from the type described by Duchenne. We may, however, assert that these very forms, as soon as they were referred to their true explanation, mainly contributed to the synthetical conception of ataxy and multi-focal sclerosis. But this synthesis would probably not have been realised even now for locomotor ataxy, if Duchenne had not so ably represented the characters of a type or standard with which the numerous varieties of the species might be compared.

The history of amyotrophic lateral sclerosis at the present moment is, therefore, at the same crisis as was locomotor ataxy in Duchenne's time. The fundamental type must first be realised, and such was the object M. Charcot had in view in his previous works and in the account which we have just analysed.

#### TRANSLATOR'S NOTE TO APPENDIX.

We have frequently seen the woman D—, whose case is described at pp. 320, 321, in the Appendix, and can testify to the accuracy of the description there given. We had the opportunity also of seeing the post-mortem examination, and we remember that even with the naked eye distinct changes were visible in the lateral columns.

M. Ballet, M. Charcot's late *interne*, has kindly sent us further particulars, of which the following is the translation:

"Three hours after death rigor mortis was very evident in the right lower extremity, less pronounced in the left lower extremity. The rigidity, which was less marked in the upper limbs, was rather more marked on the

<sup>1</sup> Since these lines were written the series of authentic cases of amyotrophic lateral sclerosis has been increased by some recent facts, and did we not fear repetition we should give an abstract of them here, as we did for the observations of Nixon, Rigal, Pick and Kahler. Among others consult the very complete observation of Adamkiewicz an, in 'Progrès Médical,' 1880 ("Separatabdruck' aus den Charité Annalen," v Jahrgg).

right than on the left side. Sixteen hours after death the upper extremities were flaccid, but the lower limbs, especially the right, were still stiff.

"*Autopsy.*—All the organs healthy except the cerebro-spinal system.

"A. *Brain.*—No change in the condition of the convolutions; paracentral lobule, ascending frontal, and ascending parietal convolutions have their normal size and aspect on both sides. On section nothing abnormal was noticeable; the internal capsule apparently unaffected.

"B. *Medulla oblongata.*—Anterior pyramids slender, atrophied, and greyish.

"C. *Spinal cord.*—On transverse sections the following was seen with the naked eye, but more distinctly with a lens:—The greyish tint characteristic of sclerotic tissue is very marked in the lateral columns; the fasciculi of Türk, which belong to the same system, are also greyish, but the alteration is much more pronounced on the right than on the left side. Although the anterior horns are apparently more slender than usual, naked-eye examination does not allow one to describe the lesion with any precision.

"D. *Spinal roots.*—The anterior roots are more slender than in the normal state, and their reddish tint contrasts with the white colour of the posterior roots.

"E. *Muscles.*—On dissection marked atrophy of various muscles is visible. In the right upper extremity the biceps is reduced to a slender cord of a yellowish tint. The brachialis anticus, coraco-brachialis, and triceps are much atrophied. The muscles of the forearm, which are barely one third their normal size, have also a yellowish tint. The thenar and hypothenar eminences present similar features. The interossei may almost be said not to exist.

"*Microscopical examination.*—The anterior roots and nerves proceeding from them were found degenerated, with proliferation of nuclei and segmentation of the myelin. The majority of the muscular fibres had undergone simple atrophy, others granular degeneration.

"Transverse sections of the spinal cord, previously hardened, showed marked atrophy of the cells of the anterior cornua, sclerosis of the pyramidal-tract system (crossed and direct fibres) throughout the entire cord, the lesion being more pronounced on the right side."

The examination of the medulla oblongata has not yet been made, but M. Ballet expresses the opinion that no doubt lesions of the grey matter will be found, and that the disorders of speech, deglutition, and respiration, which were so evident in this case, will be thereby explained.

# INDEX.

---

## A.

- ABDOMINAL REFLEXES, 285  
 AMBLYOPIA, hysterical, 100  
   — in hemiplegia, 102  
   — relations between, and crossed hemianæsthesia, 109  
 AMYOTROPHIES (spinal), 311  
   — classification of, 311  
   — deuteropathic, 311  
   — progressive protopathic (*see* ATROPHY, progressive muscular)  
 ANKLE-CLONUS, 248, 251  
 ANTERIOR CORNUA, lesions of, 277 (*see* POLIOMYELITIS)  
   — continuation of, in medulla oblongata, 313  
   — irritative lesions of, 277  
 APHASIA, 10  
   — in megrim, 122  
 APOPLEXY, 66, 242 (*see* CEREBRAL HÆMORRHAGE)  
   — prognosis of, 243  
 ARTIFICIAL TETANUS, 260  
 ASSOCIATED movements, 258, 275, 281  
   — Hitzig's theory of, 275  
 ASSOCIATION System, 22  
 ATROPHY, cerebral, 273  
   — muscular, in amyotrophic lateral sclerosis, 321, 322  
   — — in hemiplegia, 202, 203  
   — — progressive, 251, 312  
 ATTITUDE of extremities (in contracture), 264, 269  
   — — varieties and types of, 269, 270  
 AVANT-COIN (*see* LOBUS QUADRATUS and PRÆCUNEUS)  
 AVANT-MUR, 8, 244 (*see* CLAUSTRUM)  
 AXIS, central grey, 308

## B.

- BAND of Reil, 115  
 BRUIT, muscular, 267, 268

## C.

- CELLS, æsthesodic, 232  
   — anterior motor, 18, 199, 200  
   — ganglionic or pyramidal, 18  
   — — analogy between, and spinal motor cells, 18, 19  
   — — structure and prolongations of, 18, 19  
   — giant, 20, 21, 27, 30, 35, 192, 193  
   — kinesodic, 232  
   — spider, 23  
 CENTRES, motor, 11, 35  
   — — development of, 176  
   — trophic, 224  
 CENTRUM OVALE, 174  
 CEREBRAL ARTERIES, 41  
   — — anatomy of central or ganglionic, 68, 76, 80  
   — — anatomy of cortical, 58, 64  
   — — anterior, 42, 64  
   — — at base, 42  
   — — branches of Sylvian, 50, 51  
   — — central or ganglionic, 49  
   — — communicating, 42, 43  
   — — cortical, 49  
   — — division of, into systems, 43  
   — — independence of cortical and central systems of, 49  
   — — lenticulo-optic, 79  
   — — lenticulo-striate, 79  
   — — long and short, 52, 53  
   — — nutrient, 51, 244  
   — — posterior, 43, 64  
   — — researches of Duret and Heubner on, 47, 48  
   — — striate, 77  
   — — Sylvian, 42, 44  
   — — terminal, 56, 245  
   — ATROPHY (*see* ATROPHY)  
   — HÆMORRHAGE, 66  
   — — artery of, 80  
   — — hemiplegia dependent on, 242

- CEREBRAL HÆMORRHAGE, rarity of, in peripheral parts, 66  
 — — seat, mode of formation, and extension of, 88  
 — — INFARCTS, 54, 57  
 — — LOBES, 11 *et seq.*  
 — — PEDUNCLES, 5  
 — — atrophy of, 273  
 — — division of, into three regions, 171  
 — — relations of, with internal capsule, 126  
 — — system degeneration in, 183  
 — — SOFTENING (ischæmic), 54  
 — — frequency of, in peripheral parts, 66  
 — — localised foci of, 196
- CHOKED DISC, 102
- CHROMOLOGICAL facts, 175
- CLAUSTRUM, 8, 244
- COLUMNS, antero-lateral, 152, 184  
 — — of Burdach, 152  
 — — development of, 215  
 — — structure of, 217  
 — — of Goll, 152  
 — — degeneration of, 217  
 — — development of, 215  
 — — nuclei of, 216
- CONTRACTURE, early, 84, 242  
 — — permanent, 85  
 — — exceptional recovery from, 271  
 — — in amyotrophic lateral sclerosis, 318  
 — — in hysteria, 263  
 — — in multilocular sclerosis, 292  
 — — in spasmodic tabes dorsalis, 297, 304  
 — — influence of strychnia on, 259  
 — — influence of traumatism on, 262  
 — — myopathic, 265  
 — — physiological rôle of, 281  
 — — position of extremities in, 264  
 — — premonitory indications of, 247  
 — — relations of, with secondary degeneration, 131  
 — — semeiological value of, 304
- CONTROLLING influence of cerebrum, 240
- CONVOLUTIONS, 9  
 — — ascending, 33  
 — — description of, 11, *et seq.*  
 — — fundamental, 15  
 — — in man, 14  
 — — in the monkey, 11  
 — — structure of, 192
- CONVULSIONS, epileptiform, 84
- CORONA RADIATA, 7  
 — — constitution of, 110  
 — — posterior fibres of, 112
- CORONA RADIATA, relations of, with internal capsule, 74
- CORPORA QUADRIGEMINA, 115  
 — — lesions of, 119  
 — — relation of, with roots of optic nerves, 117
- CORPUS CALLOSUM, 32  
 — — convolution of, 32  
 — — STRIATUM, 5  
 — — arterial supply of, 77  
 — — relations of, with internal capsule, 74
- CORTEX, cerebellar, 29  
 — — cerebral, 10, 24
- CROSSED PYRAMIDAL TRACTS, 153, 155, 163, 164, 184  
 — — (*see also* DEGENERATION and PYRAMIDAL TRACTS)  
 — — intrinsic and extrinsic fibres of, 233  
 — — long and short fibres of, 232
- CRUCIAL SULCUS, 27, 193, 227
- CRURA CEREBRI (*see* CEREBRAL PEDUNCLES)
- CRUSTA, 6  
 — — constitution of, 71  
 — — direct and indirect peduncular fibres of, 140  
 — — lesions of, 127  
 — — position of pyramidal tract in, 168, 169  
 — — relations of, with internal capsule, 71
- CUNEUS, 33
- D.
- DECUSSATION of the pyramids, 164  
 — — varieties and types of, 165, 166  
 — — of the pyramidal fibres in the cord, 212
- DEFORMITIES of paralysed limbs, 264
- DEGENERATION, secondary, 131  
 — — causes of, 132, 179  
 — — descending and ascending, 208  
 — — experimental, 225, 231  
 — — general semeiology of, 241  
 — — of cerebral origin, 180, 190  
 — — of columns of Burdach, 218  
 — — of columns of Goll, 217  
 — — of peripheral origin, 180, 220  
 — — of spinal origin, 180, 205
- DEVELOPMENT of spinal cord, 154
- DIASTALTIC ARCS, 278  
 — — independence of, 280
- DIRECT PYRAMIDAL TRACTS, 153, 162, 164, 234 (*see* PYRAMIDAL TRACTS)

## E.

- ELECTROTHERAPY, 262  
 ELEMENTARY AFFECTIONS, 39, 156, 158  
 EMINENCE of Doyère, 315  
 ENCEPHALITIS, 286  
 EPILEPSY, provoked spinal (*see* PROVOKED SPINAL EPILEPSY)  
 ERYTHEMA of buttocks, 242  
 EXTERNAL CAPSULE, 8, 71, 82, 246

## F.

- FASCICULI, spinal, 151 (*see also* COLUMNS and PYRAMIDAL TRACTS)  
 — — autonomy of, 154  
 — — development of, 215  
 FILUM TERMINALE, 199  
 FISSURES of the brain, 12, *et seq.*  
 FISSURE of Rolando, 14  
 — of Sylvius, 14  
 FLEXIBILITAS CEREAE, 318

## G.

- GYRUS ANGULARIS, 13  
 — fornicatus, 32  
 — sigmoid, 227

## H.

- HEMIANÆSTHESIA, 81  
 — cerebral, 85  
 — characteristics of, 99  
 — dependent on lesion of posterior part of internal capsule, 85, 91  
 — experimental, 94, 130  
 — from lesion of pons or medulla oblongata, 118, *note*  
 — hysterical, 100, 263  
 — relation between, and crossed amblyopia, 110  
 — sensorial, 100  
 HEMIOPIA, 103  
 — causes of, 122  
 — unilateral homonymous, 105, 107  
 — varieties of, 107  
 HEMIPARAPLEGIA of spinal origin, 210  
 HEMIPLEGIA, 81  
 — from hæmorrhage, 242  
 — in hysteria, 263  
 — infantile spasmodic, 135, 273  
 — late contracture in, 247, *et seq.*  
 — trophic disorders in, 201

- HEMISECTIONS of the spinal cord, 237, 294  
 HEMISPHERES of the brain, 5  
 HYSTERIA (*see* AMBLYOPIA, CONTRACTURE, HEMIANÆSTHESIA, HEMIPLEGIA, and PARESIS)  
 HÆMORRHAGE (*see* CEREBRAL HÆMORRHAGE and MENINGEAL HÆMORRHAGE)

## I.

- INDIFFERENT CONDUCTION, 237  
 INTERMEDIATE POSTERIOR FISSURES, 218  
 INTERNAL CAPSULE, 6, 7  
 — constitution of, 74  
 — course of pyramidal tract in, 172  
 — destructive lesions of, 246, 247  
 — influence of lesions of, on the development of secondary degeneration, 126  
 — knee of, 173, 186  
 — lesions of, 85  
 — localisations in, 186  
 — regions of, 91, 188  
 — relations of, with the foot of the peduncle, 71  
 — symptoms of lesions of, 85, 89  
 IRRITABILITY of the pyramidal fibres, 235  
 IRRITATION and irritative lesions, 276, 277, 284, 288  
 ISLAND OF REIL, 8, 244

## K.

- KINESODIC cells, 232 (*see* CELLS)  
 KNEE of the internal capsule, 173  
 KNEE-PHENOMENON, 253 (*see* TENDON-REFLEXES)

## L.

- LAYERS of the crus cerebri (*see* TEGMENTUM and CRUSTA)  
 LESIONS (*see* SYSTEM LESIONS)  
 LOBES (*see* CEREBRAL LOBES)  
 LOBUS QUADRATUS, 32 (*see also* AVANTCOIN and PRÆCUNEUS)  
 LOCALISATION, 4, 38  
 — influence of, over the development of secondary degenerations, 181  
 — of cerebral affections, 181  
 — of system lesions, 40, 152  
 — spinal, 156

LOCOMOTOR ATAXY, 149, 219

— reflexes in, 251

LOCUS NIGER, 71, 171

### M.

MEDULLA OBLONGATA, circulation of, 68

— development of, 162

— system lesions of, 39

MÉGRIM, 122

MENINGEAL HÆMORRHAGE, 273

MENINGITIS, hypertrophic spinal, 313

MILIARY ANEURYSMS, 41

— importance of, in cerebral hæmorrhage, 82, 246

MYELITIS, primary, 288, 290

— secondary, 291

— total transverse, 296

MYOPATHIC CONTRACTURE (*see* CONTRACTURE)

### N.

NATES, 117 (*see* CORPORA QUADRIGEMINA)

NATURAL HISTORY of encephalic lesions, 38

NERVE-NETWORK, 19, 284

NERVE-PROLONGATION, 19

NERVE-ROOTS, section of, 223

NERVE-TUBES, 24, 160, 287

NERVES, structure of, 314

— optic (*see* OPTIC NERVES)

NEURO-MUSCULAR SYSTEM, 315

NEURO-RETINITIS, 102

NEWLY-BORN CHILD, brain of, 159

— absence of contracture in, 277

NUCLEI, central grey, 5

— circulation of, 64

— lesions of, 84

NUCLEUS CAUDATUS, 7

— circulation of, 65

— relations of, with corona radiata, 112

NUCLEUS LENTICULARIS, 7

— hæmorrhage in, 89

— relations of, 70

### O.

OPTIC NERVES, 117

— radiations, 118

— thalamus, 5, 70

— tracts, 104

— — external and internal roots of, 115, 117

### P.

PACHYMENINGITIS, caseo-tubercular, 206

PARACENTRAL LOBULE, 27, 30, 33

— lesions of, 34

PARALYSIS, adult spinal, 311

— infantile spinal, 34, 251, 311

PARAPLEGIA, spasmodic or tetanoid, 290, 298

— — in myelitis, 299

PARESIS in hysteria, 263

PATELLAR TENDON-REFLEX, 252 (*see* TENDON-REFLEXES)

PEDUNCULAR EXPANSION, 171

POLIOMYELITIS, anterior, 277, 309

— — acute and sub-acute, 311

— — chronic, 312

— — clinical characters of, 310, *et seq.*

— — diffuse, 313

POTT'S DISEASE, 288

PRÆCUNEUS, 33 (*see* AVANT-COIN and LOBUS QUADRATUS)

PROCESSUS E CEREBELLO AD TESTES, 170

PROVOKED SPINAL EPILEPSY, 248, 251

PULVINAR, 115

PUTAMEN, 87

PYRAMIDAL TRACTS, 162 (*see* DEGENERATION)

— autonomy of, 155

— cerebral origin of, 177

— course of, 163

— degeneration of, 182

— development of, 154, 199

— diagram of, 195

— function of, 235

— in the crura cerebri, 168, 171

— in the dog, 226

— in the internal capsule, 172

— in the pons, 167

— irritability of, 235

— system lesions of, 152

— termination of, 199, 212

— transmission of voluntary impulses by, 237

— trophic centres of, 224

PYRAMIDS (anterior) of medulla oblongata, 167

— — atrophy of, 273 (*see* DECUSSATION)

### R.

REFLEX ACTS in the child, 161

RIGIDITY of limbs, 291

— — in spasmodic tabes dorsalis, 302

ROLANDIC LOOP, 177

— ZONE, 173, 193

ROLANDIC ZONE in the dog, 227  
 ROOT-ZONES, 154

## S.

SCINTILLATING SCOTOMA, 122  
 SCLEROSIS, amyotrophic lateral, 40,  
 286, 313, 317, *et seq.*  
 — descending (*see* DEGENERATION)  
 — disseminated, 150  
 — — absence of secondary degenera-  
 tion in, 228  
 — — contracture in, 292  
 — — spasmodic paralysis in, 300  
 — peri-ependymar, 313  
 — system fasciculated, 133  
 — — anatomy of, 134  
 — — primary and secondary, 135,  
 136  
 SEMI-DECUSSATION of optic nerves, 104  
 SENSORIUM COMMUNE, 36, 90  
 SPASMODIC PARAPLEGIA (*see* PARA-  
 PLEGIA)  
 SPASMODIC TABES DORSALIS, 291  
 — diagnosis of, 300  
 — theories of, 299  
 SPINAL TOPOGRAPHY, 147, 155  
 — TREPIDATION, 248, 251, 252  
 SPLENIUM, 112  
 STRYCHNIA, influence of, on contrac-  
 ture, 252  
 — Fouquier's therapeutical experi-  
 ments with, 259  
 — Vulpian's experiments with, 268,  
 281  
 SUPPLEMENTARY FUNCTION, 85, 130  
 SYNKINESES (*see* ASSOCIATED MOVE-  
 MENTS)

SYPHILITIC MYELITIS, 292, 294  
 SYSTEM LESIONS, 38, 39, 158, 308

## T.

TAPETUM, 112  
 TEGMENTUM, 71, 169  
 TENDON-REFLEXES, 249, *et seq.*  
 — graphic analysis of, 256  
 — in amyotrophic lateral sclerosis,  
 287  
 — in spasmodic paraplegia, 297  
 TESTES (*see* CORPORA QUADRIGEMINA)  
 TONICITY or Tone, 267, 284  
 TRANSVERSE SECTIONS, 7, 173, 195  
 — of medulla oblongata, 164  
 TRACMATISM, influence of, on perma-  
 nent contracture, 262, 281,  
 286  
 TROPHIC DISORDERS, 201

## V.

VASCULAR AREÆ, 54  
 VICQ D'AZYR'S RIBBON, 16  
 VISUAL FIELD, 101 (*see* AMBLYOPIA)  
 VOLUNTARY STIMULI, transmission of,  
 238, 296

## W

WALLER'S LAWS, 223  
 WRIST-PHENOMENON, 240

## Y.

YELLOW SOFTENING, 54, 141, 273

















RC Charcot, Jean Martin  
346 Lectures on the localisa-  
C423 tion of cerebral and spinal  
diseases

Bi 564

PLEASE DO NOT REMOVE  
CARDS OR SLIPS FROM THIS POCKET

---

UNIVERSITY OF TORONTO LIBRARY

---

