

1967

P. Simons



bla  
agi



ATTSURGE LADDERY OF MEDICINE.

322 North Craig St.

PITTSBURGH, PA.



THE  
GULSTONIAN LECTURES FOR 1878



THE LOCALISATION  
OF  
CEREBRAL DISEASE

BEING THE

*GULSTONIAN LECTURES OF THE ROYAL COLLEGE  
OF PHYSICIANS FOR 1878*

BY

DAVID FERRIER, M.D., F.R.S.

FELLOW OF THE ROYAL COLLEGE OF PHYSICIANS; PROFESSOR OF FORENSIC MEDICINE,  
KING'S COLLEGE; ASSISTANT PHYSICIAN TO KING'S COLLEGE HOSPITAL;  
PHYSICIAN TO THE HOSPITAL FOR EPILEPSY AND PARALYSIS, ETC.  
AUTHOR OF 'THE FUNCTIONS OF THE BRAIN'

LONDON  
SMITH, ELDER, & CO., 15 WATERLOO PLACE  
1878

[All rights reserved]

PITTSBURGH ACADEMY OF MEDICINE  
322 North Craig St. P. A. 11110  
PITTSBURGH, PA.

*new*

1959  
F 7168



PITTSBURGH ACADEMY OF MEDICINE

222 North Craig St.

PITTSBURGH, PA.

TO

M. CHARCOT

IN RECOGNITION OF HIS PRE-EMINENT SERVICES

IN THE

LOCALISATION OF CEREBRAL DISEASE





## PREFATORY NOTE.



THESE Lectures are intended to serve as the complement from a clinical and pathological standpoint of the author's work on 'The Functions of the Brain.' They retain the form in which they were delivered as the Gullstonian Lectures of the College of Physicians, but have been revised and supplemented by numerous additional facts and illustrations.

16 Upper Berkeley Street, London, W.  
*October 1878.*



# CONTENTS.

## LECTURE I.

	PAGE
Localisation of Cerebral Disease—Question stated—Difficulties to be encountered—Methods of Research—Dual aspect of Brain Function—the Brain in Man and Lower Animals—Cross and Direct Paralysis—Brown-Séquard's views—Views of Saucerotte, Bouillaud, &c.—Views of Hughlings Jackson—Experiments of Fritsch and Hitzig, &c.—Objections considered—Experiments of Franck and Pitres—Comparative Pathology of Brain Lesions—Clinical Evidence—The Frontal Lobes—Lesions of the Frontal Lobes—American Crow-bar case, &c.—Clinical and Experimental facts compared . . . . .	1

## LECTURE II.

The Motor Area—Lesions of the Motor Area—Facts of Experiment—Brown-Séquard on Cerebral Paralysis, &c.—Destructive Lesions of the Motor Regions—General—Hemiplegia—Regions of the Centrum Ovale—Divisions of the Centrum Ovale—Partial Lesions of the Motor Area—Hemiplegia—Partial Lesions and Monoplegia—Unilateral Oculo-Motor Monoplegia—Crural Monoplegia—Amputation of Limbs and Local Cerebral Atrophy discussed—Brachio-Crural Monoplegia—Brachial Monoplegia—Brachio-Facial Monoplegia—Facial Monoplegia—Aphasia: Oro-lingual Hemiparesis—Diagnosis of Cortical Paralysis . . . . .	39
---	----

## LECTURE III.

Irritative Lesions of the Motor Area—Jacksonian Epilepsy—Crural Monospasm or Protospasm—Brachial Monospasm or Protospasm—Facial Monospasm or Protospasm—Lesions of the Sensory Area—Sensory Centres and Tracts—Cerebral Hemianæsthesia—Semi-decussation of the Optic Tracts—Lesions of the Occipital Lobes—Goltz on Cortical Lesions—Sensory Centres in the Monkey—Latent Cerebral Lesions—Affections of sight—Affections of Hearing—Affections of Smell and Taste—Affections of Touch—Conclusion . . . . .	100
---	-----



THE  
LOCALISATION  
OF  
CEREBRAL DISEASE.



LECTURE I.

MR. PRESIDENT AND GENTLEMEN,—In these lectures I propose to discuss a question which is at present attracting considerable attention in the world of physiology and medicine, viz., whether different regions of the cerebral hemispheres have different functions, and whether, therefore, the symptoms of cerebral disease vary with the locality of the lesion.

Assuredly, if the problem before us had been an easy one, it would have been definitively solved long ere now, when we consider the frequency of cerebral diseases and the large amount of attention they have received, not only from physicians and physiologists, but from all who interest themselves in the relations between body and mind. But, notwithstanding all the laborious researches and speculations which have been directed towards the elucidation of this subject, we do not seem even yet to have arrived at any general agreement, except on a very few propositions, some of these even now contested: a position contrasting strongly and unfavourably with the state of our knowledge respecting almost every other organ and function in the body.

It is not very difficult to discover many causes of this obscurity and confusion. Two of these only I will mention as being specially worthy of note.

1. It may be asserted without fear of contradiction that, as regards the nervous system more particularly, morbid anatomy is far from being co-extensive with pathology. We know, and are every day confronted with the fact, that the most widely abnormal deviations from healthy functional activity of the nerve-centres may be manifested, which leave no trace discoverable by ordinary dissection, or even by any of our most advanced methods of investigation. For the sake of mental satisfaction, we are constrained to speculate on the intimate molecular changes in the nerve-tissues which lie at the root of neuralgia, convulsions, and various other forms of functional nervous disorder; but they are at present matters only of speculation, and lie beyond the sphere of verification.

2. The organisation and conditions of activity of the brain are such that we are naturally inclined to believe that interference at any one point must necessarily tend to general functional disturbance. The loosening of a pin in a chronometer, it has been said, will derange the whole timekeeping mechanism; but we should not on that account ascribe timekeeping functions to the one part exclusively. So, in all cases of cerebral disease, there is a continual source of doubt as to whether the effects are the direct consequences of the lesion, or merely the expression of general functional derangement.

And, when we examine the actual facts and records of cerebral disease, we find, in apparently similar conditions, so much diversity, that it seems almost impossible, from a clinical point of view, to separate accidental from essential; to distinguish between direct and indirect consequences; or to determine whether phenomena are related by causation or are mere cases of juxtaposition or co-existence. Nor do the facts of experimental physiology seem so consistent with themselves, or with the undoubted facts of clinical research, as to inspire us with unhesitating confidence as to their accuracy, or as to their applicability to human pathology.

It is not to be wondered at, therefore, that many should still doubt, and reserve their opinion on this question of the localisation of cerebral function and cerebral disease.

Before proceeding to consider the facts bearing on this question, I think it advisable, in view of certain arguments

which have been advanced by a distinguished Fellow of this College,<sup>1</sup> to state some of the principles which must guide our researches and determine our conclusions. There can be no doubt that the inductive method of agreement, on which we have mainly to rely in eliminating cause and effect in clinical medicine, is one which does not always succeed in distinguishing between causation and co-existence, and is liable to be frustrated by plurality of causes. Though, therefore, we should have much positive evidence in favour of the localisation of a certain function in a certain region of the cerebral hemispheres, one clear case in which destruction of this region had caused no cessation or disorder of that function would be sufficient to overturn our conclusion.

But, on the other hand, we are not called upon, in the present state of pathology, to show organic alteration in the parts in which we localise certain functions in all cases in which these functions are deranged. When such organic change has been demonstrated in the case of disordered function everywhere else in the body, it may fairly be demanded in the case of the nerve-centres; but we are at present far from having reached that point. We do not always discover organic disease in the heart when the circulation ceases, but we do not on that account doubt that stoppage of the heart was the proximate cause of this effect.

The doctrine of cerebral localisation does not assume, as Brown-Séguard would seem to imply,<sup>2</sup> that the symptoms observed in connection with a cerebral lesion are necessarily the result of derangement of function in the part immediately affected. Every one admits direct and indirect results in cerebral disease. We have no right even to assume any causal relation at all, direct or indirect, between the phenomena, unless the lesion in question is constantly, or more frequently than chance would account for, associated with the same symptoms.

We should think it in the highest degree absurd if anyone

<sup>1</sup> Dr. Brown-Séguard, 'Lectures on the Physiological Pathology of the Brain,' delivered at the Royal College of Physicians of London, July 1876. *Lancet*, 1876 and 1877.

<sup>2</sup> This I take to be the meaning of Dr. Brown-Séguard's so frequently emphasising the statement that 'paralysis can appear otherwise than as an effect of loss of function of the part diseased.'

were to describe a case of sudden death, in which the only discoverable morbid appearance was a boil on the neck, as a case of sudden death 'seemingly caused' by a boil on the neck; and for the obvious reason that such a lesion is not usually followed by a fatal result. So, if we have abundant evidence to show that a certain part of the brain may be diseased without causing any motor paralysis whatever, it would be no less absurd to describe a case of facial paralysis, in which some lesion of this region was the only discoverable anatomical change, as a case of facial paralysis 'seemingly caused' by this lesion. Causation must not be invoked where the facts do not warrant anything beyond co-existence or fortuitous collocation.

It is, however, undoubtedly true that, if we admit, as we must do, that function may be disordered without discoverable organic change in the organ in which we localise this function, our difficulties as regards diagnosis are greatly multiplied. In medicine, thanks greatly to the aid of experimental physiology, the transition from cause to effect is comparatively easy; but from effect to cause, from symptoms to disease, taxes all our skill, and too often baffles all our efforts. We may have doubts as to our diagnosis of the nature and locality of a cerebral lesion, though we may have none as to the localisation of function. The two things are quite distinct; and we must not make our imperfections in the one a measure of the other, or imagine that the facts are equally confused with our notions respecting them.

In estimating the value of evidence, we regard as incredible any statement which is opposed to sound inductions. Our inductions having been once established, we attach comparatively little importance to individual instances which harmonise with them; for, not being necessary to establish our generalisation, they derive a dignity mainly from the fact that they are examples of a general law. But a statement which contradicts our uniform experience we are bound to regard with suspicion and refuse to accept, unless it can successfully stand a stringent cross-examination and satisfy all the requirements of scientific evidence. The slightest doubt is absolute failure. If, however, any clear and in every way satisfactory evidence be forthcoming opposed to our generally accepted beliefs or traditions, we are,



nevertheless, bound to accept it, and be prepared to convert what we have been accustomed to regard as absolute rules into approximate generalisations, or abandon them altogether if they are clearly shown to be untenable.

Even though the new hypothesis which may be set up in place of our old one may not be more satisfactory, yet the value of the facts will remain, and we must modify our views in accordance with them.

In discussing the localisation of brain-function, it is essential to bear in mind that the functions and diseases of the brain manifest themselves under two aspects—the psychological and the physiological: phenomena which appeal to two distinct methods of investigation—the subjective and the objective. There is no doubt that the state of our knowledge respecting the conditions affecting the one is vastly in advance of that of the other.

That the brain is the organ of the mind, no one doubts; and that, when mental aberrations, of whatever nature, are manifested, the brain is diseased organically or functionally, we take as an axiom. That the brain is also necessary to sensory perception and voluntary motion, is also universally admitted; and that the physiological and psychological are but different aspects of the same anatomical substrata, is the conclusion to which all modern research tends. Nevertheless, it appears, as far as our present methods of investigation have gone, that diseases of the brain do not affect these functions equally. Diseases which produce very obvious affections of motility and sensibility cause no obvious mental disorder; and diseases capable of producing the most profound mental disturbances do not necessarily affect the powers of motion and sensation. Beyond the great fact that the brain is the organ which is directly or indirectly diseased in insanity, we are yet in the most profound state of ignorance regarding the intimate pathology of this condition. *Post-mortem* examination reveals morbid conditions as to vascularity, or various forms of degeneration, in the vessels, nerve-cells, neuroglia, &c.; but, with the exception, perhaps, of general paralysis of the insane, we have yet to find out whether there are any morbid appearances

specially characteristic of special forms of mental derangement, or whether there is a definite relation between the locality of the lesion and the symptoms observed. We cannot even be sure whether many of the changes discovered are the cause or the result of the disease, or whether the two are the conjoint results of a common cause.

It is no disparagement of the many valuable researches which have been made into the pathology of insanity, to say that we are only beginning to learn its rudiments. Until the various morbid appearances discoverable in the brains of the insane are translatable into their subjective signification, the morbid anatomy and pathology of insanity run in parallel lines, which never meet. A concrete or incorporate mental pathology distinct from mere speculation will only be furnished when we can give the subjective equivalents of morbid appearances, or, conversely, the anatomical substrata of subjective states. It will not, I think, be denied that we are yet a long way from having reached this desirable consummation of our researches.

From the fact that large tracts of the brain-cortex may be disorganised without causing any very evident mental disturbance, and from the further fact that any *one* part of the brain may be so destroyed with a like negative result, the conclusion has been drawn by Flourens and others, that there is no localisation or differentiation of function, but that each part of the encephalon is a micrencephalon, capable of itself of performing all the functions pertaining to the whole. Supposing the conclusions at all justifiable *quâ* mind, it would be altogether unwarrantable to extend this, as has been done frequently, to physiological function.

If we look at this matter a little more closely, we shall find that not merely extensive lesions in one hemisphere may be latent as regards mental symptoms, but even a whole hemisphere may be disorganised with a like negative result. If, however, *both* sides of the brain be disorganised, the annihilation of mind is complete. The logical deduction from these facts therefore is, not that there is no special localisation of function, but that, as far as the fundamental powers of mind are concerned—sensation, emotion, volition, and intellect—one hemisphere is sufficient.

To show that there is no localisation of mental function, it is necessary to demonstrate that the *same* parts may be destroyed in *both* hemispheres without producing mental disturbance. But has this ever been shown? I cannot find the faintest approach to evidence which would justify such a conclusion. That mental symptoms or mental deficiencies have not been recorded in cases of bilateral cerebral lesions, is a negative statement of very little value. Unless a man becomes so demented as to neglect the ordinary wants of nature, or so furious, maniacal, or irrational as to require restraint, there are few engaged in the practice of medicine who think of inquiring narrowly into a patient's mental state; and, even if more attention were directed towards this subject, are we in possession of any means of accurately gauging the mental condition of an individual, so as to be certain that it has altogether escaped damage notwithstanding the presence of a cerebral lesion? I see little to justify and much to contradict such an assumption. A man may not be incapacitated for the ordinary duties of life; but that his mental powers are altogether unscathed even by an unilateral lesion, I venture to question.

And, if it is difficult to test the mental condition in a human being, how much more difficult must it be in the case of the lower animals? And yet, from the way in which some have treated this question, one would be led to believe that nothing was more simple. Flourens' conclusions are, I think, answerable for many erroneous notions which have long dominated cerebral physiology and pathology. One great fallacy has been the assumption that the results of experiments on frogs, pigeons, and other animals low in the scale, are at once capable of application to man without qualification; an assumption which vitiates the conclusions of numerous physiologists of the present day. The very fact that there exist such patent differences between the effects of destruction of the cerebral hemispheres in different orders of animals ought, one would think, to inspire caution in the application to man of results obtained only by experiments on the brains of animals low down in the scale. Physiology should take a more comprehensive view, and in particular not neglect the facts of clinical medicine and human pathology. To do so in the case of the

functions of the brain would, indeed, be the play of *Hamlet* with the Prince of Denmark left out.

These remarks are, I think, specially applicable to a statement made by Schiff at the International Medical Congress at Geneva, to the effect that, as regards cerebral localisation, there was a great difference of opinion between physiologists and physicians; the former being opposed to it; the latter, with an implied sneer at the *practischer Arzt*, being its only supporters.<sup>1</sup> While it is to be hoped that all physicians are physiologists, it is not the less desirable that physiologists should take the facts of clinical medicine and pathology into their calculations and generalisations. Frog and pigeon physiology has too often been the bane of clinical medicine, and tended to bring discredit on a method of investigation which, used properly, we must regard as the sheet-anchor of accurate biological and therapeutical research.

It has been taught since the time of Aretæus, and accepted almost as an axiom by physiologists and physicians, that, when paralysis results from lesion of the cerebral hemispheres, it occurs on the side opposite the lesion. This law has recently<sup>2</sup> been contested by Brown-Séguard, and I would make a few remarks on this point.

Brown-Séguard disputes the validity of the law of cross action of the cerebral hemispheres, on the authority of two hundred cases of paralysis occurring with disease on the same side of the brain. Accepting for the time the accuracy of every one of these cases, what conclusion do they justify? If we compare the relative frequency of cross and direct paralysis, it would be a very low estimate to say that, for every case of direct paralysis, we might cite nine hundred and ninety-nine cases of cross paralysis. Are we, then, on the strength of one contradictory instance, to say that the nine hundred and ninety-nine cases carry no weight? This is what Brown-Séguard would seem to imply; but the logical deduction appears to me to be that, if

<sup>1</sup> 'Les physiologistes qui se sont le plus occupés du cerveau, Brown-Séguard, Goltz, Hermann, sont opposés aux localisations cérébrales. Les médecins, au contraire, en sont enthousiastes.'—*Le Progrès Médical*, September 22, 1877.

<sup>2</sup> *Lancet*, January 1876.

it had been asserted that the paralysis *invariably* occurred on the side opposite the lesion, then the law is shown, by this one exception, not to be an universal law, but a law admitting of exceptions; an approximate generalisation, instead of an absolute rule; but an approximate generalisation, the validity of which, in any particular instance, would have nine hundred and ninety-nine chances to one in its favour. Certainly the conversion of an absolute rule into an approximate generalisation lowers its practical value; for approximate generalisations are applicable only to numbers and not to individual instances. Hence, in a given case, in which it might be of extreme importance to ascertain whether it was in accordance with the rule or an exception, we might be liable to error, if we had no other means of determining this.

But what would be the practical effect of this, say as regards surgical treatment? Supposing it were a question of trephining (a question which may arise more frequently at no distant date), according to the calculus of probabilities, there would be nine hundred and ninety-nine chances to one in favour of the rule in any given case. Even on this low estimate, would it be a very hazardous thing to operate, granting the advisability of the operation? I question much if there are many surgical operations undertaken for the relief of internal disease which have better chances of being successful. In medical practice, as in life generally, we have to act on probabilities more than on certainties; and if the measure of our belief be our readiness to act, I think few would refuse to perform an operation with nine hundred and ninety-nine chances to one in favour of its being successful, so far at least as exposure of the disease is concerned.

The practical depreciation of the rule would, therefore, be almost infinitesimal; and, if the new (Broca's, Lombard's) observations on cerebral thermometry are correct, this may be even further reduced. But what of the theoretical aspect of the question?

In man, the cross action of the cerebrum, in reference to voluntary motion, is true, with the exception of two hundred cases collected from the remotest antiquity down to the present date. Cerebral paralysis is seen every day; and if cases of direct paralysis were occurring at the present time, we should



be certain to hear of them. In the lower animals, every physiologist who has seen paralysis produced by cerebral lesion, has seen it on the opposite side, with the single exception, I believe, of Brown-Séguard.

Such being the experience of physicians and physiologists, it is surely more natural to suspect sources of fallacy, or to conclude that there is something very abnormal, than attempt to overthrow a law which has such a preponderance of evidence in its favour. That direct paralysis may occur I am prepared to admit, not only on the evidence of recorded facts, but on anatomical grounds. To overthrow the absoluteness of the rule of the cross action of the cerebral hemispheres, one well authenticated case, in which the paralysis occurred on the same side, is sufficient. But we require clear evidence, not merely of the existence of a lesion in the hemisphere of the same side (for, as we shall see, lesions of a very extensive nature may exist in certain regions without causing paralysis), but of the existence of a lesion in what we recognise as a motor region. A solution of continuity of the fibres of the internal capsule, or a complete separation of the corpus striatum from its hemispherical connections, we should look upon as a necessary cause of paralysis, and we should look for it on the opposite side.

If such a lesion can be shown to have existed with paralysis on the same side, I should regard that as a satisfactory proof of direct paralysis. And such seems to have been established by Morgagni. In a case which he had carefully observed and examined *post-mortem*, he was astonished to find paralysis apparently on the same side as the lesion; but, distrusting his recollection and the accuracy of his records, he asked of his students on which side the paralysis had existed. 'All in general and each one in particular answered without hesitation that it was the right side [the side of the disease, which was separation of the corpus striatum from the cortex]; and for this reason,' said he, 'it is clear to me that *sometimes* the paralysis occurs on the same side as the lesion.'<sup>1</sup>

I do not here intend to enter on the question whether some apparent cases of direct paralysis may not be capable of expla-

<sup>1</sup> Quoted from Bayle, *Maladies du Cerveau*, p. 321.

nation in accordance with the usual rule;<sup>1</sup> but, admitting the possibility of direct paralysis, I would offer a few observations on its mode of causation. In this relation, the recent researches of Pierret and of Flechsig have an important bearing. Flechsig, in his elaborate work, *Die Leitungsbahnen im Gehirn und Rückenmark*, 1876, has given the results of his investigations on the course and relations of the several tracts of the brain and spinal cord, with special reference to their respective periods of development in the human fœtus, and to the direction and lines of the secondary degeneration which occurs in consequence of cerebral and spinal lesions, according to the researches of Waller and Türck. This is a method which must be regarded as infinitely superior to mere anatomical or histological investigation of the healthy and completely developed cord.

Flechsig states that the pyramids or pyramidal strands are an adjunct to the fundamental spinal tracts, and are developed always at a later period than the others. Their development coincides with that of the cerebral hemispheres, and they are absent in cases of non-development of the hemispheres. Their connections can be traced above into the cortical regions bounding the fissure of Rolando, and below with the postero-lateral, and partly with the internal aspect of the anterior columns of the spinal cord. These pyramidal strands are subject to very considerable variations, in respect to their decussation at the anterior inferior part of the medulla oblongata, and as to the relative proportion of fibres which proceed down the postero-lateral and antero-internal columns respectively. As a rule, the most of the fibres of the pyramid descend in the postero-lateral column of the end on the opposite side; the rest on the antero-internal of the same side. But occasionally the rule is reversed, and in one case there was no decussation at all.<sup>2</sup>

<sup>1</sup> This question has been ably discussed by Dr. E. H. Dickinson, 'On the Phenomena of so-called Direct Paralysis.'—*Liverpool and Manchester Medical and Surgical Reports*, 1878.

<sup>2</sup> 'The question is, can we look upon any fixed percentage of the relative proportion of the pyramidal strands as the normal? It is evident from the table that the variations are not mere casual exceptions, but that variability is rather the rule. We have two extremes between which there are a number of intermediate grades. The extremes are those in which the pyramids either pass entirely into

A similar case has recently been described by Pierret.<sup>1</sup>

The strands which are subject to this variation are those which, as we shall see, degenerate in consequence of lesion of the motor centres, and the evidence is of the most satisfactory kind that they are the paths of *voluntary motor* impulses. This being so, we must regard paralysis on the same side as the cerebral lesion as a possible occurrence. How often it has actually happened is another question, which, however, I shall not here attempt to answer.

Various attempts have been made at different times to establish constant relations between lesions of certain cerebral regions and certain symptoms, bodily or mental. Thus Saucerotte, Delaye, Foville, and Pinel-Grandchamp, considered that the grey matter of the hemispheres was specially related to mental functions, and that the medullary fibres and basal ganglia were specially concerned in locomotion. They further adduced cases to prove that disease of the corpus striatum and

the lateral columns, and therefore the anterior columns are reduced to 0, or the latter contain 90 per cent. of the pyramidal strands and the former are reduced to a minimum. The commonest modification is that there are four pyramidal tracts. Yet this can scarcely be regarded as the rule as there are so many modifications. If we take the cases in which neither of the anterior columns (*Vorderstrangbahnen*) at the cervical enlargement sinks below 3 per cent., or rises above 9 per cent., as approximately equivalent, we might regard this as the normal' (*Op. cit.*, p. 272). As the anterior columns contain the direct or non-decussating fibres, and the lateral columns those which decussate at the *decussatio pyramidum*, we have the following principal types:—

' 1. Total decussation (*i.e.*, cases in which the anterior tracts are absent).

' 2. Semi-decussation of one pyramid, with total decussation of the other; (*a*) semi-decussation of the right; (*b*) semi-decussation of the left.

' 3. Semi-decussation of both pyramids. (*a*) There may be less than 50 per cent. of one or both pyramidal fibres which do not decussate; (*b*) there may be more than 50 per cent. which do not decussate. The distribution is symmetrical or unsymmetrical,' p. 270. Flechsig remarks in a note that the decussation of the pyramids may entirely fail, a condition which may be regarded as the second extreme. A case in which this occurred is described at p. 111 (No. 33, Plate xvii. 2.)

<sup>1</sup> *Bull. Soc. de Biologie*, Jan. 8, 1876. *Le Progrès Méd.*, Jan. 22, 1876. This was the case of a child in which almost the whole of the pyramidal strands were contained in the anterior columns as far as the middle dorsal region. In this case, in consequence of the almost complete absence of decussation, M. Pierret remarked, that had paralysis occurred as the result of a cerebral hæmorrhage, it would have shown itself in the arm of the same side, while the opposite leg would have been but slightly affected.



adjoining medullary fibres and anterior parts of the brain generally, caused paralysis limited to the leg; and that similar lesions of the optic thalamus and posterior parts of the brain, caused paralysis limited to the arm; and that, when the arm and leg were both affected, the lesion existed in the basal ganglia, more in the corpus striatum if the leg were specially affected, and more in the optic thalamus if the paralysis was greater in the arm. Influenced by the imaginary localisation of the sensory tracts in the posterior columns, and by Bell's demonstration of the respective functions of the anterior and posterior roots of the spinal nerves, they regarded the cerebellum, to which they traced the posterior columns, as the seat of sensation. This opinion was supported by Lapeyronie, Petit-Namur, and others. Bouillaud, from his experiments on animals, and from the facts of clinical research, arrived at the conclusion that lesions of the anterior lobes more particularly caused loss of speech, and in a certain measure gave his adhesion to the doctrines of Saucerotte, &c., respecting the centres of movement of the arm and leg, though he admitted that these were not altogether satisfactory. But he arrived at one other important conclusion which is worthy of special mention. 'Even,' said he, 'though we should admit that certain errors had been made as to the localisation of the seat of the lesions causing paralysis, yet it remains an established fact that there exist in the cerebrum several motor centres. The plurality of motor centres is, in fact, proved by the occurrence of limited paralysis, corresponding to a local alteration in the brain; for it is evident, that if this organ did not contain different centres or conductors of motor impulses, it would be impossible to conceive how a limited lesion could produce a limited paralysis, leaving all other movements intact.

'I am well aware that the preceding propositions appear at variance with the results of experiments on animals. It is certain that after the ablation of the cerebral hemispheres, an animal may walk, run, move its jaws, eyes, eyelids, &c.; and it is not less certain that an alteration of the cerebral hemisphere in man gives rise to a paralysis more or less complete of voluntary motion on the opposite side of the body. Can we refute the one set of facts by the other? No, certainly not. For

facts equally positive are not susceptible of refutation. A time will come when new light will dispel the apparent contradiction which exists between them.'<sup>1</sup>

Profound and philosophical remarks which to-day are amply justified!

The investigations of succeeding years provided many cases so absolutely at variance with the localisation of the motor centres of the arm and leg that Andral, who also admitted that there must be distinct motor centres, 'since each limb may be separately convulsed or paralysed,' earnestly deprecated premature and hasty generalisations as being highly prejudicial to 'la belle doctrine' of the localisation of cerebral functions.<sup>2</sup>

The doctrine of cerebral localisation has in recent years assumed quite a new aspect, and differs so much from older speculations in the kind of evidence on which it rests, as to be essentially a new growth. Hughlings-Jackson made the first decided steps in this direction.

Hughlings-Jackson has repeatedly directed the attention of the profession to the study of convulsions of cerebral origin, and adduced many cases and arguments to show that they are dependent on irritation or *discharging lesions* of certain convolutions near, and functionally related to, the corpus striatum. As regards the exact localisation of these motor convolutions, he did not, however, underestimate the difficulties and uncertainties necessarily attaching to the rude experiments of disease. 'The damage by disease is often coarse, ill-defined, and widespread.'<sup>3</sup> But to Hughlings-Jackson belongs the credit of having first indicated the motor functions of certain regions of the cortex, and given a rational explanation of the phenomena of unilateral cerebral convulsions. For though, as Charcot shows, Bravais, in 1827,<sup>4</sup> described with great accuracy the phenomena of hemiplegic epilepsy, he did not see their true significance or pathology, in which, after all, the discovery lay, and in the light of which the value of his observations mainly consists.

<sup>1</sup> Bouillaud, *Traité de l'Encéphalite*, p. 279.

<sup>2</sup> Andral, *Clinique Médicale*, tome v, p. 569.

<sup>3</sup> *Clinical and Physiological Researches on the Nervous System*, p. 6.

<sup>4</sup> *Recherches sur les Symptômes et le Traitement de l'Epilepsie Hémiplegique*.

Similar facts have also been noticed and commented on by Bright and Wilks. Indeed, Bright had formed very clear notions as to the pathology of unilateral convulsions, so far at least as their primary causation was concerned, and their relation to lesions of the opposite cerebral hemisphere. 'My reason, then, for supposing that the epileptic attacks in this case depended rather on a local affection than on a more general state of cerebral circulation or excitement, was *the degree of consciousness which was observed to be retained during the fits*; for although we meet with great variety in this respect, yet in two cases which have occurred to me, the fact of the patient generally remaining conscious has been a remarkable feature, while in each the injury on which the fits depended was of a local rather than a constitutional or a general character.'<sup>1</sup>

Wilks, agreeing with these observations, remarks: 'For in these cases, the causes being definite and local, an irritation is set up in the corresponding ganglia beneath, and thus the occurrence of convulsions without loss of consciousness is explained.'<sup>2</sup>

Hughlings-Jackson, however, instead of accounting for the phenomena by transmission of some influence to distant motor regions, regarded certain convulsions as themselves motor, and capable of motor discharge by irritation. But certainly, except in the facts so explained, no other evidence could be adduced in support of the direct excitability of the grey matter of the cortex; for the facts of experimental physiology, taking them at their value, were opposed to the doctrine, inasmuch as it had been apparently conclusively demonstrated that none of the usual stimuli of nerves and nerve-centres, electricity included, were capable of exciting movements when applied directly to the surface of the brain.

This dogma was refuted in 1870 by the important experiments of Fritsch and Hitzig, who showed that, though electricity might be applied to some portions of the cortex without producing movements, there were others excitation of which invariably produced movements of the opposite side; and that certain movements could uniformly be caused by

<sup>1</sup> *Guy's Hospital Reports*, Series i. vol. i. p. 39.

<sup>2</sup> *Ibid.* 1866, p. 79.

excitation of certain definite regions. These facts have now been extended and verified by many experimenters on many animals, and even on man himself.

In discussing the signification of these facts, I wish to restrict my observations to those movements which result from excitation of a certain region of the brain—the region which we term motor—in order to avoid discussion at this stage of certain other movements which I regard as the indications of sensation.

Now, it is not unreasonable to suppose that, on applying irritation to that which is the centre of centres—to which, in fact, all the rest of the body must be considered as peripheral—irritation of the grey matter, even though the irritation might not be confined to it, at least entered as one factor into the causation of the resulting phenomena. Every conceivable hypothesis has, however, been invented to degrade the grey matter of the hemispheres, and to exclude it absolutely from all share in the results; and every attempt has been made to discover somewhere else some organ or organs possessed of all those varied and complex forms of activity which we see excited by our stimulation.

One of the latest of these hypotheses is, that the movements which result from the application of electrical stimulation to the cortex are due to the irritation of delicate vaso-motor nerves, which penetrate the brain-substance and descend with the vessels from the pia mater.

The functions ascribed to the brain-cells are these: ‘ Besides their power of receiving, transforming, and conveying impressions, it is not unphilosophical to imagine that, having been impressed by a certain irritation, in a certain way, for producing a certain effect, their dynamic state, through nutrition, is shaped into a definite channel for the circumstance; hence the ability of a certain group of cells to produce a definite effect, always constant, under definite stimulation of whatever nature ’<sup>1</sup>

As my main object, however, is to discuss cerebral localisation from a pathological point of view, I will not enter at length into the purely physiological side of the question, which

<sup>1</sup> Dupuy, *Physiology of the Brain*. New York, 1877, p. 13.

I have elsewhere discussed<sup>1</sup> (*Functions of the Brain*). I would, however, call your attention to some recent researches which seem to me to have effectually disposed of the main objections to the view that the phenomena are the result of excitation of the functional activity of the grey matter of the hemispheres.

One objection is founded on the impossibility of localising the action of the electric current to the parts immediately in relation with the electrodes; and it is argued that the effects are in reality due to mere physical conduction to some underlying region or regions, which, however, those who employ this argument either will not or cannot exactly specify.

Similar objections were made to Duchenne's theory of localised muscular electrification, and yet we know as a fact that we can by this method throw individual muscles into contraction with the greatest precision and certainty, notwithstanding the extrapolar conduction which pertains to all animal tissues. And it is the great characteristic of the reactions which ensue on the application of the electrodes to the cortex, that the results are uniform, definite, and predictable, when the electrodes are on one region, while there is a sudden transition to another movement equally definite, equally constant, and equally predictable when the electrodes are shifted to a region in immediate proximity to the former. This is a remarkable fact, no longer disputed, which no mere physical conduction can account for, unless we admit a differentiation of numerous distinct physical paths, which is but another aspect of localisation after all.

On the conduction theory, it would be natural to expect that the nearer we go to the underlying ganglia and tracts, the more readily the effects should be called forth if it were a question of mere resistance of currents. But we find that electrification of the island of Reil, which is nearest the basal ganglia, is absolutely negative; while electrification of the more distant postero-parietal lobule by the same stimulus produces an immediate and definite movement. Conduction would seem to be put out of

<sup>1</sup> For an able review of the whole question see 'The Localisation of the Functions of the Brain,' by Dr. Dodds, *Journal of Anat. and Phys.*, Jan.-April, and July, 1878.



court by such facts. And we find, as Carville and Duret<sup>1</sup> have shown, that the intervention of a fluid cyst between the cortex and the basal ganglia is quite sufficient to interpose a fatal obstacle to the propagation of functional stimulation, though not of electrical currents; just as a ligature round a nerve will stop neurility but not electricity.

But the fact on which most reliance is placed as proof of mere physical conduction is that, after removal of the grey matter of the cortex (stimulation of which is the supposed cause of the movements), the application of the electrodes to the cut medullary fasciculi produces exactly the same movement as before.

What, it is triumphantly asked, could more conclusively dispose of the view that the cortex is concerned in the results, seeing it may be removed without prejudice to them? Apparently, those who argue in this manner forget that there is such a thing as a plurality of causes or conditions. By parity of reasoning, we might disprove in succession the motor functions of the corpus striatum, crus cerebri, spinal cord, and motor nerves, inasmuch as we can produce all the effects attributed to their activity by direct stimulation of the muscles themselves. But we do not say, when we faradise the distal end of a divided motor nerve, that the resulting muscular contraction is due to electrical conduction to the muscle, and not to neurility or excitation of the functional activity of the nerve. And it is surely not unreasonable to suppose that, after removal of the cortex, the results following application of the electrodes to the medullary fibres are due to the functional excitation of these fibres; and that our electrical stimulation is merely an artificial substitute for that which normally proceeds from the grey matter of the cortex. It is on this point that we have new experiments which, in my opinion, settle the question definitively.

MM. Franck and Pitres<sup>2</sup> have shown that a distinct interval elapses between the excitation and the movement: an interval which, after deducting the latent periods of nervous and muscular stimulation, and the rate of transmission of neural impulse in the cord and nerves, leaves a residue of nine-two-hundredths

<sup>1</sup> *Archiv. de Physiologie*, 1875.

<sup>2</sup> *Soc. de Biologie*, December 23, 1877.

of a second of *retardation in the grey matter*. If, however, the grey matter be removed, and the stimulus applied to the medullary fibres, the period of retardation diminishes to six-two-hundredths of a second. This proves, in accordance with the laws of stimulation of nerve-centres, that the grey matter intervenes, not as a conductor, but as a centre. It has likewise been proved by the experiments of Putnam,<sup>1</sup> Carville, and Duret,<sup>2</sup> &c., and verified by Franck and Pitres, that, in order to excite movements after removal of the cortex, a stronger stimulation is necessary than that required for the cortex itself. This, on the physical conduction theory, would be, the less the resistance, the less the effect: a proposition manifestly absurd. It is, however, the property of the nerve-centres to reinforce an excitation; and such is the case with the cortical grey matter. Still more important, perhaps, than these results, is the fact that certain modifications occur in the excitability of the medullary fibres after removal of the cortex, which conclusively demonstrate that we have to deal with neurility, and not with mere electrical conductivity, as Mr. Lewes<sup>3</sup> supposes.

We know from Waller's researches that, when a motor nerve is divided, the excitability gradually diminishes and ultimately disappears: phenomena which proceed *pari passu* with progressive degeneration of the nerve from the centre towards the periphery. In a similar manner, it has been found by Albertoni and Michieli,<sup>4</sup> confirmed by Dupuy,<sup>5</sup> and by MM. Franck and Pitres, that, after a certain period, excitation of the medullary fibres no longer gives rise to the movements which can be caused by stimulation immediately after removal of the grey matter of the cortex. In dogs, as a rule, as Franck and Pitres have shown, the excitability totally disappears about the fourth day; and this coincides with the period at which, in consequence of the degeneration described, the motor nerves of the dog lose their excitability. By such facts, the only plausible arguments in favour of mere physical conduction of the electri

<sup>1</sup> *Boston Med. and Surg. Journal*, 1874.

<sup>2</sup> *Archiv de Physiologie*, 1875.

<sup>3</sup> Review of 'The Functions of the Brain,' in *Nature*, November 1876.

<sup>4</sup> *Sui Centri Cerebrali di Movimento. Lo Sperimentale*, February 1876.

<sup>5</sup> *Physiology of the Brain*, p. 9.

cal currents are shown to be absolutely without foundation; and, all other evidence apart, the direct relation of the cortical grey matter to movements is established beyond all doubt.

I have purposely excluded until now the consideration of the effects of localised destruction of the cortex. These, as I hope to be able to show you, are, in the case of man at least, clear and decisive in the same direction. But, it must be admitted, there is a considerable want of unanimity among the conclusions which physiologists have considered themselves entitled to draw from their several experiments. Many of these differences seem to me in a great measure due to narrowness of view, and to the entire disregard of the facts relating to man himself.

We should think it a very misleading research if a pharmacologist were to set himself to determine the mode of action of a drug on the human economy by experiment on an animal, before he had first ascertained whether the animal on which he proposed to experiment exhibited symptoms of being similarly affected by the drug as man himself. Before his researches could be allowed to have any bearing on therapeutics, this would have to be established; for we know that drugs may act differently on different animals. It is even more necessary, in regard to the physiology of the brain, that a similar caution should be exercised. Anatomical homologies must not be pushed too far in support of identity of function.

A frog deprived of its cerebral hemispheres still remains capable of a number of the most complicated and adaptive reactions, so little differing from those normally manifested by this animal that, except for the defect of spontaneity, they might be regarded as identical. But no one will say that the symptoms presented by the brainless frog at all resemble the clinical picture of a case of disorganisation of the cerebral lobes in man. The same may be said of pigeons, the favourite subjects of Flourens' experiments, and the origin of many misleading conclusions in human physiology and pathology. Nor are the phenomena in the case of the much-experimented-on rabbit at all comparable to those observed in cerebral disease in man. We might be led, from the effects of ablation of the cerebral hemispheres in this animal, to regard the cerebral



hemispheres as having special functional relation to the upper extremities, as these are more particularly paralysed ; and this conclusion has a germ of truth in it, when looked at in the proper light, but is a grave error if applied without qualification to human physiology.

The destruction of the cerebral hemispheres in the dog approaches more nearly in its results to the universal powerlessness caused by a similar lesion in man, but not so complete or enduring. The destruction of the cortex only, however, though at first producing a greater or less degree of paralysis of the opposite limbs, does not render the animal quite powerless ; and within a few days or weeks the motor powers are regained to such an extent that, except on hurried movements, a superficial observer might come to the conclusion that the animal had not suffered by the lesion.

Some, who do not extend their view beyond dogs, at once jump to the conclusion that facts like these justify them in asserting that not only in dogs, but in man also, the cortex of the brain has no real relation to motility ; and that the phenomena which ensue from cortical lesions are merely transitory disturbances of the functions of other parts. Others, if they do admit any direct relation between the two, assume, from the apparent recovery, that there is no exclusive localisation of function, and formulate a law of functional substitution of one part by another to explain the difficulties, chiefly of their own creation.

When, however, we ascend higher, and come to experiments on animals which in conformation, habits (and shall we say kinship ?) most closely approach man, and to the experiments of disease on man himself, we meet with results little in harmony with the conclusions drawn by some from their researches on the lower animals. In monkeys, destruction of those regions, excitation of which gives rise to definite movements of the limbs, causes paralysis of voluntary motion complete and enduring, and restricted to those very movements the centres of which are specially destroyed. It will be my endeavour to show you that what is true of the monkey is strictly true also of man.

Taking these facts as established—the proofs of which will be given subsequently—may we not, instead of trying to con-

tradict one set of facts by the other, find some generalisation which will admit of all these apparently discordant results being harmonised with each other and with the great law of evolution? This, I think, can be arrived at, if we recognise the fact towards which all these experiments on different animals point; viz., that the same movements have a plurality of causes, and are represented, though with different significations, in different centres, higher and lower. Those which involve conscious discrimination, and which we term volitional in the strict sense of the term, are those alone which are necessarily paralysed by destruction of the cortex; while those which are variously described as automatic, instinctive, or responsive, including all the motor adjustments concerned in equilibration, locomotor co-ordination, and instinctive emotional expression, are more or less completely and independently organised in the centres situated below the cortex. Though there is a general solidarity of the whole cerebro-spinal system, yet there exist in different animals great differences in the degree of organisation of such movements in the lower ganglia, and in their relative independence of the higher centres. This is greatest in the frog and pigeon, and lowest in the monkey and man. Hence the marked differences which we observe in different animals in the results of destruction of the cerebral hemispheres.

If we clearly distinguish, therefore, between the different *kinds* of movement and their respective centres, and regard paralysis of truly volitional movements, or those involving conscious discrimination, as the only essential feature of cortical lesions, we shall be in harmony with the results of comparative experimental physiology, and shall not need a hypothesis of functional substitution, which cannot, I think, be maintained consistently by those who accept the doctrine of specific localisation.

In accordance with this generalisation, I ventured to predict<sup>1</sup> that, even in the case of animals whose motor powers did not seem permanently to suffer from destructive lesions of the cortical motor centres, those movements must be paralysed which involved conscious discrimination, and were not automatically organised. This has been amply verified by Goltz's

<sup>1</sup> *Functions of the Brain*, p. 215.

experiments on dogs.<sup>1</sup> Goltz found that, though a dog's paw is not permanently paralysed as an organ of locomotion by destruction of the cortex, *yet it remains permanently paralysed for all those actions in which it is employed as a hand.*

The conclusion, therefore, which I would provisionally draw from the results of experimental physiology, and proceed to justify by a consideration of the facts of human pathology, is, that there are certain regions in the cortex to which definite functions can be assigned; and that the phenomena of cortical lesions will vary according to their seat, and also according to their character—viz., whether irritative or destructive, two classes into which they may all be theoretically reduced. And, as the experiments of physiology necessitate the strictest topographical accuracy in the position and limits of individual centres, it is of vital importance that the same accuracy should be observed in respect to the situation of lesions in the human brain. For this reason we are, however unwillingly, obliged to discard most of the older records of cerebral disease, unless where supplemented by drawings, or by description of the position of the lesion with reference to certain fixed points; for, although we can now read these cases in the light which laws otherwise arrived at throw upon them, they cannot be used to establish these laws. In the older records, we, as a rule, meet with nothing more exact in the topography of a lesion than that it was situated 'on the convexity' of one or other hemisphere, or in the anterior, middle, or posterior lobe—terms which admit of considerable looseness of interpretation. Anatomically, the frontal lobe was generally considered as marked off from the middle lobe by the *antero-parietal* (Huxley) or *pre-central sulcus* (Ecker), Fig. 1, f<sub>3</sub>; but we find Bouillaud extending the frontal lobe so as to include as much as the half of the hemisphere: an extension of this lobe which may serve to explain his theory as to the seat of the faculty of speech. In the question of localisation of cerebral function, we must follow Bacon's dictum: '*Frustra magnum expectatur augmentum in scientiis ex superinductione et insitione novorum super vetera, sed instauratio facienda est ab imis fundamentis.*'

<sup>1</sup> Pfüger's *Archiv für Physiologie*, Band xiii., Heft i., 1876.

It is in the observations of the last few years, in which only the necessity of strict accuracy in cerebral topography has been duly recognised, that we must look for our chief material, and of this the largest share has been contributed by Charcot and the French school of pathology. As to the kind of evidence on which we must base our conclusions, I cannot do better than quote and emphasise the injunction given by Charcot and Pitres in their recent valuable papers on the localisation of cerebral disease.<sup>1</sup> 'It is necessary rigidly to exclude as valueless in this relation all observations in which the topography of the lesion is not indicated with rigorous exactitude; and, among those which, in a topographical point of view, leave nothing to be desired, it is necessary to make a selection and reject the majority of the cases of multiple lesions, and all those in which the lesion was diffuse. It is necessary also to accept with extreme caution cases of tumour compressing without destroying the cerebral convolutions; for the effects of pressure may be felt at a distance from the seat of lesion, and complicate the results. In making these eliminations, in our opinion absolutely indispensable, the number of ancient observations really available is extremely small; and it is by the aid of new observations, made with all the requisite precautions, that we must approach the study of cerebral localisation.' The lesions which are of special value are cases of wounds, laceration, or loss of substance, with various forms of chronic degeneration, such as atrophy, necrosis, &c., and the results of hæmorrhage, inflammation, and the like, which, though at first complex, subside into local lesions, such as softenings, cysts, and abscesses; or, in general, all lesions which exclude diffuse meningo-encephalitis, mechanical compression, or general cerebral disturbance.

From the standpoint of regional diagnosis, the exact nature of the lesion is unimportant, except in so far as it is likely to cause irritation or destruction of the cerebral substance. The diagnosis of the nature of the lesion will depend on other characters, such as its mode of onset, general symptoms, and the various recognised features by which we are enabled, with more or less accuracy, to arrive at it. To discuss these, however, would be foreign to the subject more immediately in hand.

<sup>1</sup> *Revue Mensuelle*, 1877, No. 1, p. 6.

I would likewise remark at the outset that, notwithstanding the large and daily increasing body of evidence from the pathological side, for the present at least, physiological experiment is considerably in advance of pathology as regards precision and exactitude ; and that, but for the aid of physiological experiment, pathology would not even yet have succeeded in arriving at much beyond general indications as to localisation. For my part, I should consider it hasty and not to the advantage of 'la belle doctrine' of cerebral localisation to make pathological evidence carry more than it can legitimately bear at present, or to found on it measures of treatment, not well considered, the only effect of which will be to excite prejudice and retard its acceptance.

#### LESIONS OF THE FRONTAL LOBES.

I will first direct your attention to lesions of the frontal lobes. The frontal lobe includes the *superior*, *middle*, and *inferior frontal* convolutions, and the *ascending frontal* or *præ-central* convolution, together with the *orbital* and internal aspect of the corresponding region (see figs. 1 and 2, with description).

Though anatomically all this region may be included in the frontal lobe, it is necessary for physiological and pathological purposes to subdivide it, and to term that part which, in its relation to the skull, is roughly bounded by the coronal suture, the *præ-frontal lobe* or antero-frontal region (fig. 3).

In the monkey, electrical irritation of this region causes no motor reaction : and destruction of these lobes causes no paralysis of motion or sensation. If the positive results, which will be alluded to subsequently, are not altogether definite, the negative results are clear and decided.

There are multitudes of cases on record in which these regions have been the seat of extensive disease on one or both sides with a like negative result as regards sensation or motion ; and recovery has taken place after the most frightful lacerations and loss of substance. One of the most remarkable of these is that known as the 'American Crowbar Case ;' and as this case, in addition to its importance otherwise, has lately been



appealed to by Dr. Dupuy,<sup>1</sup> as showing that lesions of the so-called motor region may occur without paralysis, I have thought

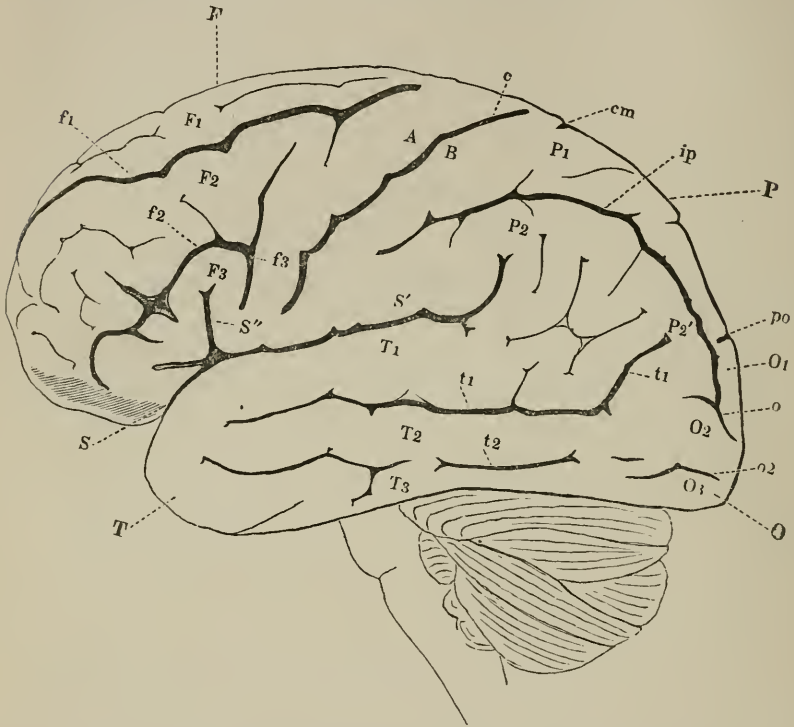


FIG. 1.—Lateral View of the Human Brain.—F. Frontal Lobe. P. Parietal Lobe. O. Occipital Lobe. T. Temporo-sphenoidal Lobe. S. Fissure of Sylvius. S'. Horizontal. S''. Ascending Ramus of the same. c. Sulcus Centralis, or Fissure of Rolando. A. Anterior Central Convolution, or Ascending Frontal. B. Posterior Central Convolution, or Ascending Parietal. F., Superior; F<sub>2</sub>, Middle; F<sub>3</sub>, Inferior Frontal Convulsions. f<sub>1</sub>, Superior; f<sub>2</sub>, Inferior Frontal Sulcus; f<sub>3</sub>, Sulcus Præ-centralis. P<sub>1</sub>, Superior Parietal Lobule, or Postero-Parietal Lobule. P<sub>2</sub>, Inferior Parietal Lobule—viz., P<sub>2</sub>, Gyrus Supramarginalis. P<sub>2</sub>', Gyrus Angularis. p. Sulcus Intraparietalis. c.m. Termination of the Calloso-Marginal Fissure. O<sub>1</sub>, First, O<sub>2</sub>, Second, O<sub>3</sub>, Third Occipital Convulsions. p.o. Parieto-Occipital Fissure. o<sub>1</sub>, Sulcus Occipitalis Transversus. o<sub>2</sub>, Sulcus Occipitalis Longitudinalis Inferior. T<sub>1</sub>, First, T<sub>2</sub>, Second, T<sub>3</sub>, Third Temporo-Sphenoidal Convulsions. t<sub>1</sub>, First, t<sub>2</sub>, Second Temporo-Sphenoidal Fissures.

it necessary to obtain exact particulars in reference to it. And I am enabled, by the kindness of my friend Professor Bowditch of Harvard, to place before you photographic delineations<sup>2</sup> of the skull in this case, which was at one time regarded incredu-

<sup>1</sup> *Med. Times and Gazette*, 1877.

<sup>2</sup> These are not reproduced, but the accompanying woodcuts (figs. 4, 5, and 6), kindly lent me by Dr. Harlow, illustrate the same points.

lously as a mere 'Yankee invention.' The skull is preserved in the Medical Museum of Harvard University. There is no doubt

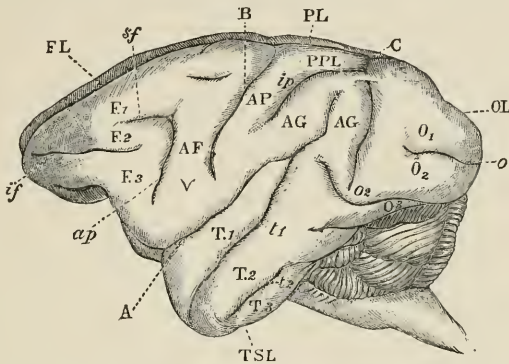


FIG. 2.—Lateral View of the Monkey's Brain.—A. The Fissure of Sylvius. B. The Fissure of Rolando. C. The Parieto-Occipital Fissure. F.L. Frontal Lobe. O.L. Occipital Lobe. T.S.L. Temporo-Sphenoidal Lobe. F<sub>1</sub>, F<sub>2</sub>, F<sub>3</sub>, Superior, Middle, and Inferior Frontal Convulsions. s.f. Supero-Frontal Sulcus. i.f. Infero-Frontal Sulcus. a.p. Antero-Parietal or Præ-central Sulcus. A.F. Ascending Frontal; A.P. Ascending Parietal Convulsions; P.P.L. Postero-Parietal Lobule. A.G. Angular Gyrus. i.p. Intraparietal Sulcus. T<sub>1</sub>, T<sub>2</sub>, T<sub>3</sub>, Superior, Middle, and Inferior Temporo-Sphenoidal Convulsions. t<sub>1</sub>, t<sub>2</sub>, Superior and Inferior Temporo-Sphenoidal Sulci. o<sub>1</sub>, o<sub>2</sub>, o<sub>3</sub>, Superior, Middle, and Inferior Occipital Convulsions. o<sub>1</sub>, o<sub>2</sub>, First and Second Occipital Fissures.

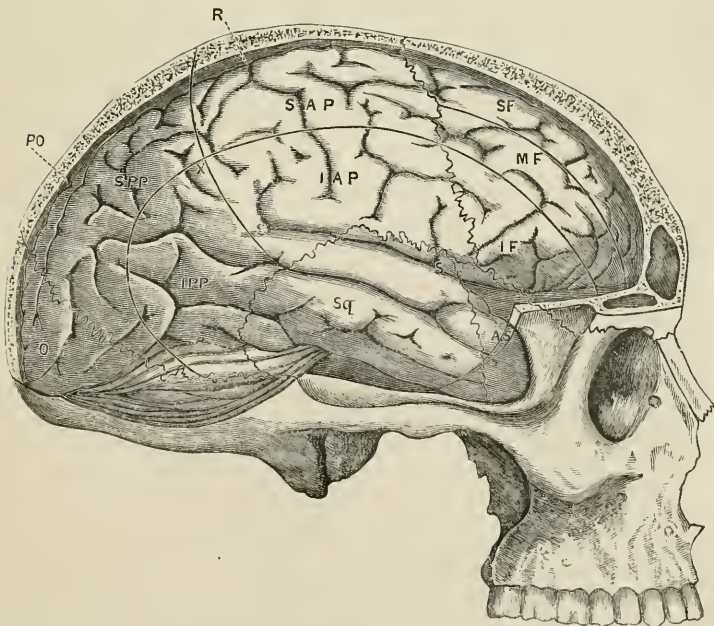


FIG. 3.—Relations of Skull and Brain (Turner).

about its authenticity. An account of the case was published by Dr. Bigelow,<sup>1</sup> and another and later, after the man's death, by Dr. Harlow,<sup>2</sup> under whose care he came immediately after the accident, and through whose interest in the man till death we owe the preservation of this unique specimen. (See figs. 4, 5, 6.)

The subject of the lesion was a young man, Phineas P. Gage, aged twenty-five. While he was engaged tamping a blasting charge in a rock with a pointed iron bar, 3 feet 7 inches in length,  $1\frac{1}{4}$  inches in diameter, and weighing  $13\frac{1}{4}$  lbs., the charge suddenly exploded. The iron bar, propelled with its pointed end first, entered at the left angle of the patient's jaw, and passed clean through the top of his head, near the sagittal suture in the frontal region, and was picked up at some distance covered with 'blood and brains.' The patient was for the moment stunned, but, within an hour after the accident, he was able to walk up a long flight of stairs and give the surgeon an intelligible account of the injury he had sustained. His life was naturally for a long time despaired of; but he ultimately recovered, and lived twelve and a half years afterwards. Unfortunately, he died (of

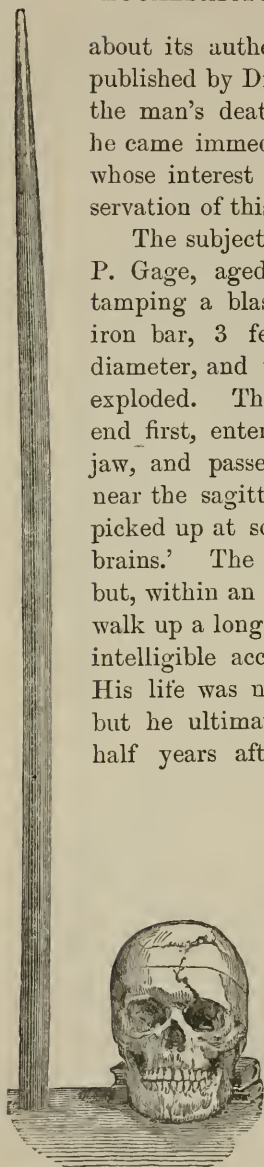


FIG. 4.

FIG. 5.

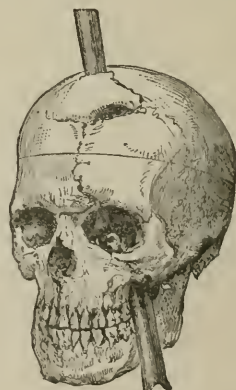


FIG. 6.

FIGS. 4, 5, 6 (Harlow).—Illustrations of Dr. Harlow's Case of the Passage of an Iron Bar through the Head.

<sup>1</sup> *American Journal for Medical Sciences*, July 1850.

<sup>2</sup> 'Recovery from the Passage of an Iron Bar through the Head.' Read before the Massachusetts Medical Society, June 3, 1868; Boston, 1869.



epileptic convulsions) at a distance from medical supervision, and no *post-mortem* examination of the brain was made; but, through the exertions of Dr. Harlow, the skull was exhumed and preserved. Upon this the exact seat of the lesion can be determined. The line of union of the cicatrices of entrance and exit, however, allowed a pretty accurate estimation of the track of the bar during life, and Dr. Bigelow did so with considerable accuracy. Dr. Bigelow, who examined the man two years after the accident, thus describes the appearances presented: 'A linear cicatrix of an inch in length occupies the left ramus of the jaw near its angle . . . The eyelid of this side is shut, and the patient unable to open it; the eye considerably more prominent than the other. [Vision lost (Harlow).] . . . Upon the head, and covered by the hair, is a large unequal depression and elevation . . . A piece of the cranium of about the size of the palm of the hand, its posterior border lying near the coronal suture, its anterior edge low on the forehead, was raised upon the latter as a hinge, to allow the egress of the bar; still remains raised and prominent.'

From his examination of the skull itself, Dr. Harlow thus describes the track of the bar. 'The missile entered, as previously stated, immediately anterior and external to the angle of the inferior maxillary bone, proceeding obliquely upwards in the line of its axis, passed under the junction of the superior maxillary and malar bones, comminuting the posterior wall of the antrum, entered the base of the skull at a point the centre of which is an inch and a quarter to the left of the median line, in the junction of the lesser wing of the sphenoid with the orbital process of the frontal bone—comminuting and removing the entire lesser wing with one half of the greater wing of the sphenoid bone—also fracturing and carrying away a large portion of the orbital process of the frontal bone, leaving an opening in the base of the cranium, after the natural effects at repair by the deposit of new bone, of one inch in its lateral, by two inches in its antero-posterior, diameters.' (*Op. cit.*, p. 17.) Dr. Harlow does not describe the further track of the bar through the frontal bone, but you will clearly see, from the figures, that the whole lesion is situated anterior to the coronal suture. If, now, you will compare the track of the bar through the skull

and brain with the diagram before you (fig. 3) showing the relations between the skull and the brain, you will, I think, have no doubt in convincing yourselves that the whole track is included within that region of the brain which I have described as the præ-frontal region, and that, therefore, the absence of paralysis in this case is quite in harmony with the results of experimental physiology. The only other region which the bar could have injured is the tip of the temporo-sphenoidal lobe and the outer root of the olfactory bulb. Respecting the condition as to smell, nothing is, however, said, by either Bigelow or Harlow. This case is generally quoted as one in which the man suffered no damage bodily or mental. But hear what Dr. Harlow says as to his mental condition. 'His contractors, who regarded him as the most efficient and capable foreman in their employ previous to his injury, considered the change in his mind so marked that they could not give him his place again. The equilibrium or balance, so to speak, between his intellectual faculties and animal propensities seems to have been destroyed. He is fitful, irreverent, indulging at times in the grossest profanity (which was not previously his custom), manifesting but little deference for his fellows, impatient of restraint or advice when it conflicts with his desires, at times pertinaciously obstinate, yet capricious and vacillating, devising many plans of future operation, which are no sooner arranged than they are abandoned in turn for others appearing more feasible. A child in his intellectual capacity and manifestations, he has the animal passions of a strong man. Previous to his injury, though untrained in the schools, he possessed a well-balanced mind, and was looked upon by those who knew him as a shrewd, smart business man, very energetic and persistent in executing all his plans of operation. In this regard, his mind was radically changed, so decidedly, that his friends and acquaintances said he was "no longer Gage."' (*Op. cit.*, p. 13.)

After these facts, I do not think it can be said with justice that the man suffered no damage either bodily or mentally, or that the 'American Crowbar Case' is in opposition to the experimental facts which I have adduced as to the effect of lesions of the frontal lobes.

A similar case of wound of the frontal lobe, also without motor or sensory paralysis, is related by Bouillaud.<sup>1</sup> The wound was caused by a bullet which traversed the upper lip and right nostril, and, passing through the roof of the orbit, emerged at the upper part of the frontal bone, near the sagittal suture.

Trousseau gives a frequently quoted case of an officer who, in a duel, received a bullet, which passed through the head in the middle of the frontal lobes. The man could speak freely, and showed no signs of paralysis of any kind. Death occurred from encephalitis.<sup>2</sup>

An interesting case of wound of the frontal lobe has been recorded by Congreve Selwyn.<sup>3</sup> A boy, aged 4, while at dinner, accidentally fell on a cheese-knife, four inches and a half long in the blade, which penetrated the orbit above the right eye to the depth of three inches and a quarter. After removal of the knife, some brain-matter escaped, and more was discharged on the eighth day. The accident occurred in September 1821. At the date of writing (1838), the only symptoms observable were blindness of the right eye, dilated pupil, and ptosis. 'As regards the present state of his mind, all the senses are perfect, excepting the vision of the injured eye. The memory is very defective. He is incapable of applying to any pursuit requiring mental activity. His disposition is irritable, especially after indulging in liquor, or after any unusual stimulus. He has occasional pain on the injured side of the forehead, and has once had typhus fever since. His bodily health is now good, and he has the free use of the superior and inferior extremities.'<sup>4</sup>

But cases of injury of one or other frontal lobe, without sensory or motor affection, are very numerous. Many are given by M. Pitres, in his recent work,<sup>5</sup> to which reference may be made for citations; viz., a case, by Morgagni, of perfora-

<sup>1</sup> *Traité de l'Encéphalite*, p. 331.

<sup>2</sup> Peter, 'De l'Aphasie.' *Gaz. Hebd.*, 1864, p. 433.

<sup>3</sup> *Lancet*, February 28, 1838.

<sup>4</sup> *Ibid.*, p. 16.

<sup>5</sup> *Lésions du Centre Ovale*. Paris, 1877.

tion of the right anterior lobe by a pointed iron; a case, by Morrin, of recovery from a bullet-wound of the left frontal lobe; a case, by Padeau, of recovery after a bayonet-wound of the same region; a case, by Tavignot, of fracture of the frontal bone, and death, without affection of sensation or motion, in which the right anterior lobe was disorganised; a case of wound of the left frontal lobe by the ferrule of an umbrella which penetrated the orbit, related in the *Dublin Journal of Medicine*, 1851; a case of a bullet-wound above one of the orbits, the bullet lodging and causing no symptoms; recorded by Quesnay.

Sir Joseph Fayrer has given me the particulars of two cases of injury of the frontal lobes, which have come under his observation. The first was that of a young soldier who, at the battle of Rangoon in 1853, was struck by a bullet near the left frontal eminence. The bullet passed transversely with a direction downwards, and, as was found after death, lodged in the right orbit. The patient exhibited no paralysis, and retained his senses and intelligence till fatal encephalitis set in. The second case was that of a girl, aged 4, who suffered fracture of the frontal bone, and laceration of the corresponding cerebral region. There was no paralysis, and the girl recovered after an attack of encephalitis. After the lapse of a year she exhibited no symptoms, her 'intellect being apparently unaffected.'

A case has been recently reported by Marot<sup>1</sup> of fracture of the frontal bone, followed by pyæmia and death, in which were found effusion into, and laceration of, the first frontal convolution, on the right side. No cerebral symptoms were observed.

The same observer brought another similar case before the Société Anatomique.<sup>2</sup> In this, there was depressed fracture of the frontal bone and laceration of the frontal region. There was no affection of sensation or motion. Death occurred a month afterwards. The laceration occupied the middle frontal convolution of the right side, at the junction of the anterior with the posterior two-thirds. The superior frontal

<sup>1</sup> *Prog. Méd.*, February 26, 1876.

<sup>2</sup> Meeting of February 11, 1876; *Le Progrès Méd.*, June 3, 1876, p. 437.

was injured at the same level. There was loss of substance, and an irregular cavity filled with detritus and blood replacing it. There was also slight extravasation over the left frontal lobe. In the discussion which followed, M. Renault quoted a similar case, also without symptoms; and M. Petit two like instances.

I might multiply instances all demonstrating the same fact, that sudden and extensive lacerations may be made in the præ-frontal region, and large portions of the brain-substance may be lost, without causing impairment either of sensation or of motion; and, indeed, without very evident disturbance of any kind, bodily or mental, especially if the lesion be unilateral. And if it be true that sudden lesions may be thus latent, *à fortiori*, it might be expected that the slowly progressive lesions of disease would be free from objective symptoms; for it is frequently said that the absence of symptoms may be accounted for by the compensation and functional substitution of other centres: a hypothesis which the negative character of sudden lesions renders altogether inadmissible.

Of cases of softening or abscess, &c., in these regions many are on record. Charcot and Pitres,<sup>1</sup> and Pitres in his before-mentioned memoir,<sup>2</sup> have collected numerous cases in which one or both frontal lobes have been the seat of disease without any objective symptoms. Time will not permit me to describe these cases in detail, and I will content myself with merely giving the headings, viz.: a case of hæmorrhage into the substance of the second right frontal convolution; a case, by Andral, of softening of the orbital lobule of the left hemisphere; a case, by Bergeron, of abscess of the left frontal lobe following a blow; a case, by Hertz, of abscess of the left frontal lobe; a case, by Reed, of fracture of the frontal bone followed by abscess occupying the whole of the right frontal lobe; a case, by Begbie, of abscess of the whole of the left anterior lobe in connection with an abscess of the ethmoid; a case, by Cholmeley, of abscess of the anterior part of the left hemisphere; a case, by

<sup>1</sup> *Revue Mensuelle*, 1877.

<sup>2</sup> *Lésions du Centre Ovale*.



Evans, of abscess of the left frontal lobe following a blow; a case, by Prescott Hewett, of abscess of the left anterior lobe; and a similar case by Bouilly. To these, quoted by Charcot and Pitres, may be added a recent case, reported by Lepine,<sup>1</sup> of abscess of the right frontal lobe, connected with disease of the nasal fossæ.

In all these cases, there was an entire absence of sensory or motor paralysis; and in many, there was nothing recorded or nothing calling for special attention as regards the mental condition. In some of them, however, and in one or two others to be referred to, the psychological condition seems to have attracted notice. Lepine says of his patient with abscess of the right frontal lobe: 'He was in a state of hebetude. He seemed to comprehend what was said, but could scarcely be got to utter a word. He would sit down when he was told to do so, and when taken up could walk a few steps with assistance.'

A very interesting case is reported by Baraduc,<sup>2</sup> in which there was atrophy of the frontal convolutions in both hemispheres. The patient was an inmate of the Hospice de Ménages for six years. His muscular powers and sensation were unimpaired. He was, however, in a state of complete dementia, marching about restlessly the whole day, picking up what came in his way, mute, and quite oblivious of all the wants of nature, and requiring to be tended like a child. The lesion in this case was purely cortical, atrophic, and dependent on partial obliteration of the arterial supply. The lesion occupied the two anterior lobes, that is to say, the first, second, and third frontal convolutions, and also the internal aspect of the frontal lobes. The ascending frontal, ascending parietal, and paracentral convolutions were intact. The rest of the brain was normal, except in the region of the inferior parietal lobule of the right hemisphere (supramarginal and angular gyrus).

Another case, presenting several interesting features, has been put on record by Dr. Davidson.<sup>3</sup> A labourer received a

<sup>1</sup> *Revue Mensuelle*, November 1877, p. 862.

<sup>2</sup> *Soc. Anat.*, March 1876; *Le Progrès Méd.*, August 19, 1876, p. 598.

<sup>3</sup> *Lancet*, March 19, 1877, p. 342.

severe blow on the head with an iron hook, which smashed and carried away a considerable portion of the frontal bone, exposing and injuring the brain as far back as the coronal suture. The injured portion of the brain, as determined *post-mortem*, included, on the right side, the greater part of the superior and middle frontal convolutions; and on the left side, a piece of bone was found firmly adherent to the superior frontal convolution at its middle part, this part being disintegrated to the depth of an inch or so. With the exception of a spasmodic extension of the right arm occasionally, the only symptoms of the cerebral lesion in this case were of a psychical nature. Though the man seemed to understand what was said to him and did what he was told, 'every action he performed left the impression on the mind of the observer that it was purely automatic' or machine-like.

Marked mental deficiency has been frequently noted in connection with arrested development, or atrophy, of the frontal lobes, without any objective symptoms as regards motility or sensibility. One good instance of this has been described and figured by Cruveilhier. This was a case of a girl aged 15, who had remained in a complete state of idiocy from birth. The præ-frontal regions or anterior two-thirds of the frontal lobes in this case were completely wanting. But, indeed, the frequent association of idiocy with such defect of the frontal lobes is a generally recognised fact.

Whatever opinion we may form as to the positive indications of disease of the præ-frontal lobes, I think it is abundantly manifest, from the cases I have cited from among many, that, in the total absence of affections of motility or sensibility, whether in connection with sudden or slowly progressive lesions of these regions, we cannot attach objective motor or sensory functions to them. With such evidence before us, to say nothing of the facts of experimental physiology, we cannot regard cases in which, with lesions in the præ-frontal lobes, sensation or motion has been affected, as other than cases of co-existence or multiple lesions, whether organic or functional. Between lesions of the præ-frontal lobes and such symptoms, we have no grounds for assuming even indirect causal relationship, unless they can

be shown to be of very frequent, if not constant, occurrence. Such relationship we all admit in the case of tumours, which, as we know, influence regions at a distance from the actual seat of disease; or in the case of diseases spreading backwards, such as encephalitis or meningitis. This latter is well illustrated by a case recently<sup>1</sup> recorded by Mr. Treves.

This was a case of fracture of the frontal region and laceration of the brain by a fragment of rock during blasting.

At first there were no motor or sensory disturbances, establishing the fact, as Treves says, 'that bilateral destruction of the antero-frontal region causes neither motor nor sensory disturbances.' As encephalitis advanced, convulsive phenomena and paralysis limited to the left arm set in, and the patient died on the seventh day after the accident. After death the anterior two-thirds of the right frontal convolutions were found destroyed, and behind this there was a zone of softening and congestion. On the left side about one-fourth or one-sixth of the frontal convolutions were destroyed. The motor symptoms in this case are clearly attributable to the progressive invasion of the motor centres by the inflammatory action.

It is chiefly on the indirect or accessory symptoms that we at present rely for our diagnosis of lesions in the frontal regions. We may obtain indications from the history of some traumatic lesion, or from the proximity of some such affection as disease of the nasal fossæ; or we may have uncertain signs of pain localised in the frontal region; or there may be disturbances of the sense of smell. But, in the absence of all these—and they may be absent—the question is: whether there are any symptoms directly indicating disease of the præ-frontal lobes? Even if we have to admit that such symptoms cannot be definitely specified, yet it will not have been in vain if experimental physiology has succeeded in bringing into prominence certain facts to which attention should be more particularly paid in future.

Touching the effects of removal of the præ-frontal lobes in monkeys, I may be allowed to quote from myself: 'Removal

<sup>1</sup> *Lancet*, March 9 and 16, 1878.



or destruction by the cautery of the antero-frontal lobes is not followed by any definite physiological results. The animals retain their appetites and instincts, and are capable of exhibiting emotional feeling. The sensory faculties, sight, hearing, touch, taste, and smell, remain unimpaired. The powers of voluntary motion are retained in their integrity, and there is little to indicate the presence of such an extensive lesion, or a removal of so large a part of the brain. And yet, notwithstanding this apparent absence of physiological symptoms, I could perceive a very decided alteration in the animals' character and behaviour, though it is difficult to state in precise terms the nature of the change. The animals operated on were selected on account of their intelligent character. After the operation, though they might seem to one who had not compared their present with their past fairly up to the average of monkey intelligence, they had undergone a considerable psychological alteration. Instead of, as before, being actively interested in their surroundings, and curiously prying into all that came within the field of their observation, they remained apathetic or dull, or dozed off to sleep, responding only to the sensations or impressions of the moment, or varying their listlessness with restless and purposeless wanderings to and fro. While not actually deprived of intelligence, they had lost to all appearance the faculty of attentive and intelligent observation.<sup>1</sup>

I have elsewhere attempted some explanation of the faculty of attention—the basis of the higher intellectual operations—and its relation to the anatomical substrata of the præ-frontal lobes; but I will not enter further on these speculations at present. I would, however, call your attention to the psychical characters in some of the cases of disease and injury of the frontal lobes to which I have referred (*e.g.*, the 'American Crowbar case,' Baraduc's, Selwyn's, Lepine's, Davidson's), as, in many respects, similar to those seen in monkeys after removal of the præ-frontal lobes. I may also adduce the observation of Dr. Crichton Browne on General Paralysis of the Insane,<sup>2</sup>

<sup>1</sup> *Functions of the Brain*, p. 230.

<sup>2</sup> *West Riding Reports*, vol. vi. p. 170.

tending to show that the earlier symptoms, *inter alia* 'general restlessness and unsteadiness of mind, with impairment of attention, alternating with apathy and drowsiness' (page 223), coincide with the morbid changes occurring at this stage, more particularly in the frontal regions.

## LECTURE II.

## A.—LESIONS OF THE MOTOR REGIONS.

THE motor area, as determined by experiments on monkeys, includes the bases of the three frontal convolutions, with those bounding the fissure of Rolando; viz., the *ascending frontal*, or *anterior central* (Ecker); the *ascending parietal* or *posterior central* (Ecker), with its superior continuation, termed the *postero-parietal* or *superior parietal* (Ecker) lobule; together with the internal aspect of the same, which by our French brethren is generally called the *paracentral* lobule. (See fig. 1.) The homologous regions of the brain of the monkey and man are sufficiently evident as not to require my taking up valuable time with any detailed anatomical description. In this region are situated certain definable areas stimulation of which by the electric current gives rise to certain definite movements on the opposite side—viz., of the leg and hand, facial, oral, and lingual muscles; and destruction of which causes paralysis of all those movements (*exc. exc.*) if the entire region be destroyed; limited or dissociated paralysis, if individual areas only be destroyed—the paralysis in this case being confined to those movements which are excited by irritation of the same. This region is supplied by the middle cerebral or Sylvian artery by four or five branches, each of which nourishes a special area. The artery may be occluded in its main trunk or in its individual branches; and the arrangement is such, according to the researches of Duret and Heubner, that the arteries of the basal ganglia may still remain pervious though the cortical arteries are occluded by emboli. Hence it is that softening limited to the cortical grey matter and subjacent medulla may and does frequently occur, while the basal ganglia remain absolutely intact.

The lesions which invade this region we may divide into *destructive* and *irritative*, in accordance with their main symptomatic characters. But a complete practical separation is not always possible, inasmuch as lesions which result ultimately in total disintegration and paralysis are not unfrequently associated at times with irritative or convulsive phenomena limited or more or less generalised: a combination which may be likened to that in *anæsthesia dolorosa*.

We have now a very considerable body of evidence to show that destructive lesions of this region invariably cause paralysis of voluntary motion; and that there is a differentiation in this part of the cortex of distinct centres, corresponding in situation to those experimentally established in the brain of the monkey, destructive lesions of which cause limited or dissociated paralysis of their respective movements or muscular combinations. It is not maintained, however, that in all cases of purely cortical paralysis anatomical lesions are demonstrable in these centres; but I am unable, after much investigation, to find any satisfactory evidence of the occurrence of a destructive lesion here *not* associated with motor paralysis. I have met with occasional statements or hypotheses as to what may or must have been, but no proof of such a lesion having actually existed without paralysis.

Truly, Samt<sup>1</sup> has recorded a case in which a cyst was found on the cortex in the motor zone without motor disorder; but, as Charcot and Pitres remark,<sup>2</sup> the actual destruction of the grey matter was not proved, since we know that tumours may press aside, without destroying, the tissue on which they rest. Let the subject, however, be investigated anew, with all the most modern methods, and with the utmost possible scrutiny. When a clear case of destructive lesion of the cortex in this region without motor paralysis is forthcoming, it will be time to cast aside the immense body of positive experimental and clinical evidence which we possess in favour of the thesis enunciated.

The experimental evidence in the case of monkeys is of the following nature. The brain is exposed. The application of

<sup>1</sup> *Archiv für Psychiatrie*, 1874.

<sup>2</sup> *Revue Mensuelle*, 1877.

that which is universally recognised as an excitant of nerves and nerve-centres to a certain spot is followed by a definite movement. All other conditions remaining the same, this spot is destroyed by the cautery (universally recognised as a destroyer of animal tissues), and immediately we see paralysis of the muscles formerly thrown into action by the electrical stimulus. I am describing no hypothetical experiment, but one I have actually performed and frequently varied. If motor function is ascribed to a nerve because on irritation the muscle contracts, and on section the muscle is paralysed, I cannot see why motor function should not be predicated of the cortical centre, seeing that the phenomena are essentially the same.<sup>1</sup>

Brown-Séquad, however, holds that, in all cases of paralysis from cortical lesion, there is some intermediate link or *tertium quid* intervening between the antecedent and the consequent: a kind of inhibitory influence exerted by the lesion on some centre or centres which are credited with the functions which are lost. It would, I think, be easy by parity of reasoning—and I say it with all due respect to the distinguished author of this theory—to make a complete *reductio ad absurdum* of the whole of experimental physiology. We should never be entitled to infer direct relationship between organ and function, but be condemned to a perpetual search after some

<sup>1</sup> In the *Archives de Physiologie*, March-April 1877, Brown-Séquad thus summarises his views:—

Prop. 1.—All the symptoms of organic disease of the brain, when the lesion exists in any part outside the cells whence in the last instance the fibres spring which go to form the cranial nerves, even though they constitute two distinct groups (characterised, the one by cessation, the other by manifestation of an activity), are the effects of an influence exercised on the parts more or less distant by an irritation starting from the seat of lesion or its neighbourhood.

Prop. 2.—The mechanism of the production of the symptoms characterised essentially by a cessation of activity (such as paralysis, anæsthesia, amaurosis, aphasia, loss of consciousness), is identical with that of the arrest of the heart by irritation of the vagus, and consists in this, that an irritation proceeding from the point injured in the brain, propagates itself to the cells whose functions are made to disappear, and thus produces a more or less complete arrest of their activity.

Prop. 3.—The mechanism of the production of the phenomena which consist in a manifestation of activity (such as delirium, epileptiform convulsions, chorea, tremors, vomiting, hiccup, rotation, &c.) is essentially the same as when due to peripheral irritation whether of the skin, mucous membranes, or any part of a centripetal nerve.

*tertium quid*, which, like an *ignis fatuus*, would for ever elude our grasp.

It is generally considered that explanation is satisfied when we assimilate one fact to another familiar fact or set of facts; and, if we call a nerve motor because motion ceases when it is cut, so, it seems to me, we may call a part of the brain motor if a similar result invariably follow on its destruction.

I. *Destructive Lesions of the Motor Area.*—I will first direct your attention to destructive lesions of the motor area, and under this head consider (1) general and (2) partial lesions.

1. *General or Extensive Lesions.*—The type of general disorganisation of the cortical area in the monkey is paralysis of voluntary motion without affection of sensation on the oppo-

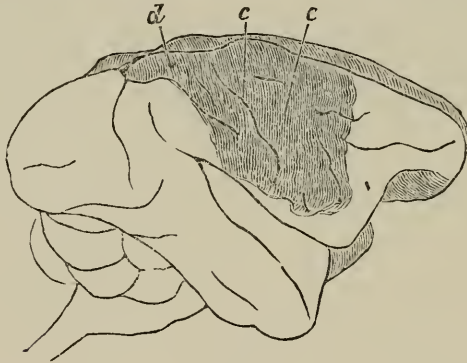


FIG. 7.

site side of the body, and possessing all those features which characterise ordinary cerebral paralysis (*hémiplegie centrale vulgaire*, Charcot); viz., hemiplegia which, though at first absolute, gradually subsides into a condition in which there is complete paralysis of all the most volitional movements, while associated, alternating, or bilateral movements are more or less spared. Hence the hand is more paralysed than the arm, the arm more than the leg, and the lower facial movements more than the upper; while the muscles of the trunk are scarcely, if at all, affected.

In fig. 7<sup>1</sup> is a representation of the extent of a lesion of the

<sup>1</sup> For details of this and the next two cases, *vide Phil. Transactions*, 1875, vol. ii.



brain of the monkey causing complete hemiplegia of the opposite side. This was a case of encephalitis resulting from irri-

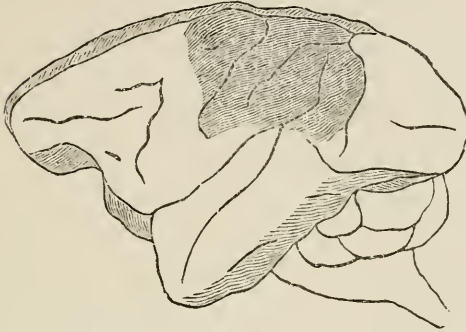


FIG. 8.

tation and exposure, in which the phenomena in the early inflammatory stage were localised spasms on the opposite side, which gradually became general, followed by complete paralysis

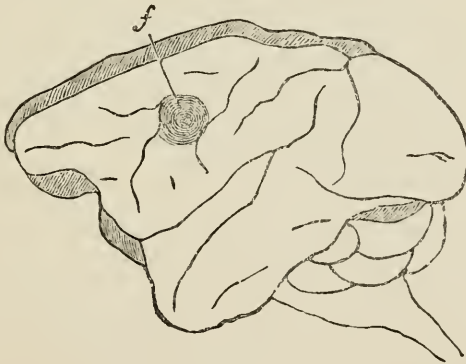


FIG. 9.

and flaccidity, without loss of sensation, when softening was complete.

Fig. 8 is a representation of a lesion causing<sup>1</sup> paralysis of the arm and leg of the opposite side; and fig. 9 (*f*) represents

<sup>1</sup> Also temporary blindness of opposite eye, which will be explained below in connection with lesions of the angular gyrus.



a lesion in a region stimulation of which caused supination and flexion of the forearm. The result was paralysis of voluntary motion limited to this movement.

These will suffice to indicate the difference between general and partial lesions of the cortex under circumstances free from all complication. The lesions of disease, however, are, as a rule, rarely so simple. I have already indicated the forms of disease which can scarcely be admitted as relevant in relation to the question of localisation, and I would further add that considerable caution requires to be exercised in reference to traumatic lesions. These are most valuable in a negative point of view, as, for instance, in the case of the frontal lobes; but, when accompanied by positive symptoms, it is necessary that lesions of the base of the brain, which, as Duret shows, may result from concussion and are apt to complicate the symptomatology of the local injury, should be shown to be absent.

Apart from traumatic lesions, the cases of cortical disease which I proceed to quote clearly establish the fact that lesions in that part of the *human* brain which corresponds to the area termed motor in the brain of the monkey produce paralysis of voluntary motion on the opposite side of the body: a hemiplegia like that resulting from destructive lesion of the corpus striatum, or more particularly of the anterior part of the internal capsule (*hémiplégie centrale vulgaire*). This paralysis is frequently associated with rigidity or convulsive spasms in the paralysed parts, particularly in the early stage; and, if destruction of the cortical substance be complete, the paralysis is of permanent duration, and sooner or later is followed by late rigidity and secondary sclerosis of the motor tracts. This degeneration is traceable in the medullary fibres, crus cerebri, pons, and pyramid of the medulla oblongata on the side of the lesion; and thence mainly on the opposite side of the spinal cord in the posterior part of the lateral column (*faisceaux encéph. externes ou croisés*, Bouchard; *faisceaux latéraux*, Charcot; *Pyramiden Seitenstrangbahnen*, Flechsig); while a corresponding band of secondary degeneration frequently exists on the internal aspect of the anterior column of the same side as the lesion (*faisceaux encéph. directes ou internes*, Bouchard; *faisceaux de Türck*, Charcot; *Pyramiden Vorderstrangbah-*



lobule, and the corresponding internal aspect of this region, or *paracentral lobule*. (See figs. 10 and 11.)

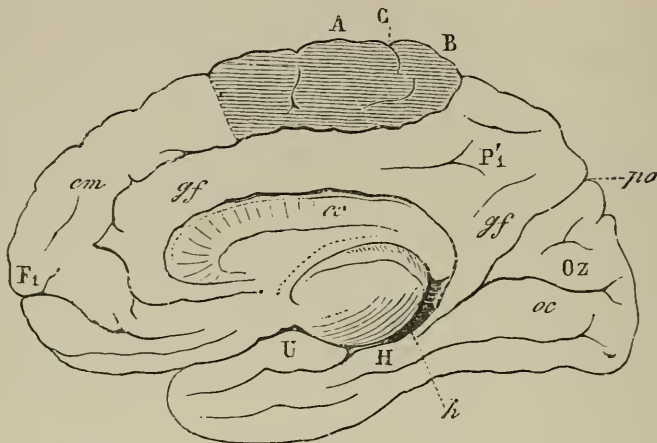


FIG. 11.

Lepine<sup>1</sup> has recorded a case of right hemiplegia, without affection of sensation, of six years' duration, caused by yellow softening of the *ascending parietal* convolution in its whole extent, with partial affection of the *ascending frontal*, posterior digitations of the island of Reil, and anterior part of the *superior and inferior parietal lobule* of the left hemisphere. The ganglia were intact. Secondary degeneration was traced in the left side of the pons Varolii and left pyramid.<sup>2</sup> (Fig. 12.)

In a case communicated by M. Brun to MM. Charcot and Pitres,<sup>3</sup> left hemiplegia without aphasia had existed for four years, with late rigidity of the arm, and in a slighter degree of the leg. Yellow softening (*plaque jaune*) was found in the lower two-thirds of the *ascending frontal*, lower half of the *ascending parietal*, the posterior three-fourths of the *second and third frontal*, and the whole of the convolutions of the

<sup>1</sup> *Localisations dans les Maladies Cérébrales*. Thèse d'Agrégation, 1875.

<sup>2</sup> A misprint occurs in the account given of this case, which has been copied by MM. Charcot and Pitres (*Op. cit.*, p. 123), the atrophy being described as being on the *right* of the pons instead of the left. This is corrected by M. Lepine's own hand in the copy which I possess.

<sup>3</sup> *Op. cit.*, p. 121.

island of Reil in the right hemisphere. (Fig. 13.) The ganglia were intact. No examination, however, was made in reference to secondary sclerosis in this case.

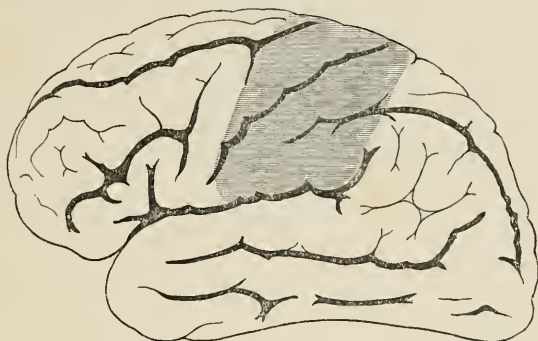


FIG. 12.

Another case is given by the same authors<sup>1</sup> of right hemiplegia, with aphasia, of one year's duration, and accompanied by

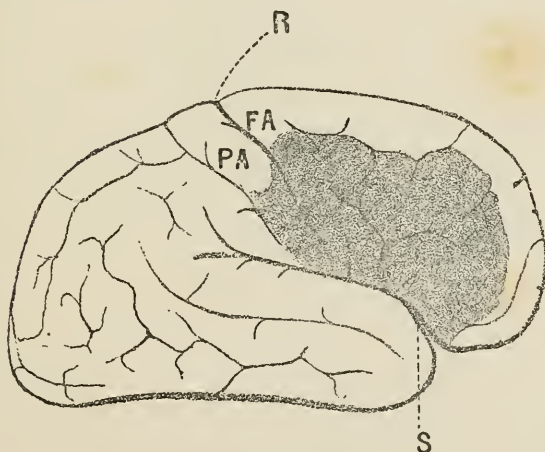


FIG. 13.

late rigidity of both limbs, more particularly of the arm. A patch of yellow softening was found involving the whole of the *ascending frontal* and base of the *third frontal* convolution, the whole of the *ascending parietal*, together with the inferior parietal lobule and two posterior digitations of the island of Reil in the left hemisphere. The ganglia were normal. Se-

<sup>1</sup> *Localisations dans les Maladies Cérébrales*, p. 121, et seq.

condary degeneration was evident in the crus, pons, and pyramid on the same side ; but the cord was not examined. (Fig. 14.)

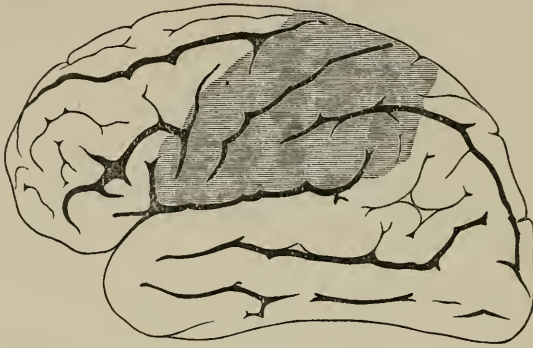


FIG. 14.

Trousseau quotes a case which occurred in the *clinique* of M. Charcot,<sup>1</sup> in which secondary degeneration was traced in the crus, pons, and pyramid of the same side as the lesion, and in

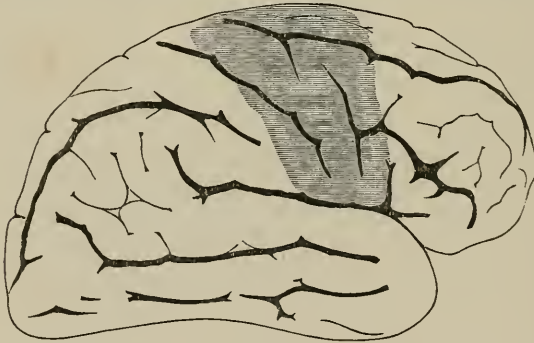

FIG. 15.

the opposite side of the spinal cord ; the lesion being, softening of the *ascending frontal*, the *three frontal convolutions*, and of the island of Reil in the right hemisphere. The case was one of left hemiplegia of three months' duration ; death occurring from pneumonia. (Fig. 15.)

These cases, out of many on record,<sup>2</sup> are sufficient to show

<sup>1</sup> Charcot and Pitres, *Op. cit.*, p. 123.

<sup>2</sup> The reader is referred to the works, among others, of Cotard (*Atrophie Partielle du Cerveau*, 1868; and Landouzy (*Convulsions et Paralysies liées aux Meningo-Encéphalites Fronto-Pariétales*, 1876) for many similar cases.



that, from purely cortical lesions, permanent paralysis may result; that, in consequence of such lesions, secondary degeneration takes place in the motor tracts, with its accompaniment late rigidity.

In the cases I have quoted, there has been more or less complete hemiplegia. In some of these, the lesion has invaded the whole of the motor area, and it only; in others, the lesion of the motor area, though extensive, has not been anatomically co-extensive with this area; and in most there has also been affection of parts not considered as belonging to the motor area. Clinical cases in which a lesion should be extensive enough to involve the whole motor area, and it alone, must naturally be considered as quite exceptional. But it is not at all difficult, by a process of exclusion, to eliminate those regions, a lesion of which does not cause paralysis or secondary degeneration; and it may be stated provisionally (of which proofs will be adduced subsequently) that it is only in cases of lesion of the motor area, as above defined, that secondary degeneration occurs, and only in these that paralysis is invariably the result.

I will return to the fact of complete hemiplegia, with comparatively restricted lesions of the motor area.

But before doing so, I would call your attention to the researches of M. Pitres, who in his recent work,<sup>1</sup> has collected a large body of evidence to show that what is true of the lesions of the cortical substance holds also in respect to lesions in corresponding parts of the centrum ovale; a term which he extends to the whole of the medullary substance intervening between the cortex and the basal ganglia. In all future observations and pathological records, it would be advisable to follow M. Pitres' system of nomenclature of the divisions of the centrum ovale. A vertical section of the hemisphere at right angles to the long axis in the præ-frontal region gives the *præ-frontal section* (fig. 16).

The next section, carried two *centimètres* in advance of the fissure of Rolando, passes through the bases of the three frontal convolutions and forms the *pediculo-frontal section*, divided into a *superior*, *middle*, and *inferior pediculo-frontal*

<sup>1</sup> *Lésions du Centre Ovale*. Paris, 1877.

*fasciculus*, corresponding with the respective frontal convolutions (fig. 17).

The next section is the *frontal*, formed by dividing the

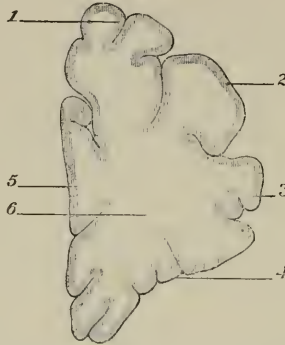


FIG. 16 (after Pitres).—Præ-frontal Section. 1, 2, 3, First, second, and third frontal convolutions. 4, Orbital convolutions. 5, Convolution on the internal aspect of the frontal lobe. 6, Præ-frontal fasciculi of the centrum ovale.

hemisphere parallel to the fissure of Rolando through the ascending frontal convolution. Here also there are three divisions—

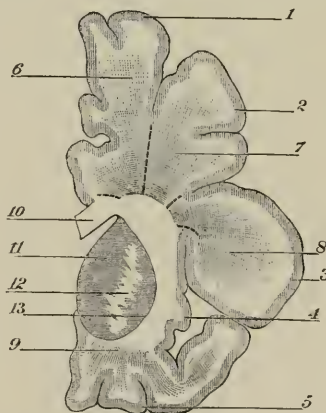


FIG. 17 (after Pitres).—Pediculo-Frontal Section. 1, 2, 3, First, second, and third frontal convolutions. 4, Anterior extremity of the insular lobe. 5, Posterior extremity of the orbital convolutions. 6, Superior pediculo-frontal fasciculus. 7, Middle pediculo-frontal fasciculus. 8, Inferior pediculo-frontal fasciculus. 9, Orbital fasciculus. 10, Corpus callosum. 11, Caudate nucleus. 12, Internal capsule. 13, Lenticular nucleus.

the *superior, middle, and inferior frontal fasciculi*. (In this section, the sphenoidal region is partly shown) (fig. 18).



Next is the *parietal section*, carried in a similar manner through the ascending parietal convolution. Three

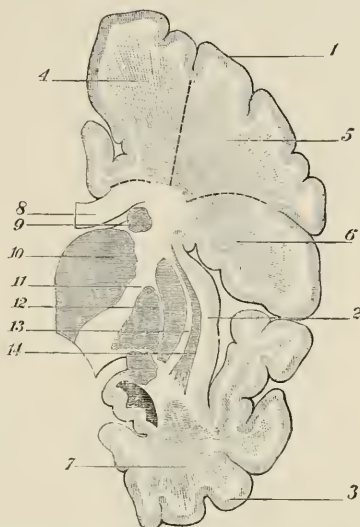


FIG. 18 (after Pitres).—Frontal Section. 1, Ascending frontal convolution. 2, Insular lobule; 3, Sphenoidal lobe. 4, 5, 6, Superior, middle, and inferior frontal fasciculus. 7, Sphenoidal fasciculus. 8, Corpus callosum. 9, Caudate nucleus. 10, Optic thalamus. 11, Internal capsule. 12, Lenticular nucleus. 13, External capsule. 14, Claustrum (Vornauer).

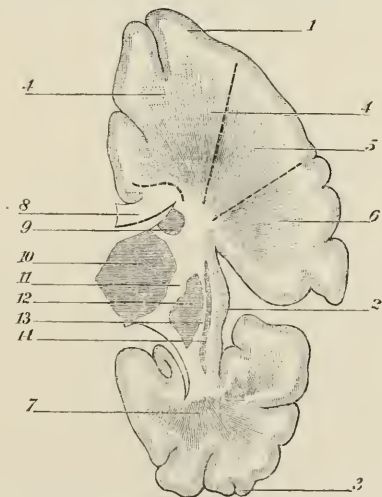


FIG. 19 (after Pitres).—Parietal Section. 1, Ascending parietal convolution. 2, Insular lobe. 3, Sphenoidal lobe. 4, Superior parietal fasciculus. 5, Middle parietal fasciculus. 6, Inferior parietal fasciculus. 7, Sphenoidal fasciculus. 8, 9, 10, 11, 12, 13, 14, as in the preceding figure.

segments are also seen here; viz., the *superior, middle, and inferior parietal fasciculi* (fig. 19).

Next is the *pediculo-parietal section*, made by dividing the hemisphere three *centimètres* (1.18 inches) posterior to the fissure of Rolando, and cutting the superior and inferior parietal lobules. Here we distinguish a corresponding *superior and inferior pediculo-parietal fasciculus*. Below is the *sphenoidal fasciculus* (fig. 20).

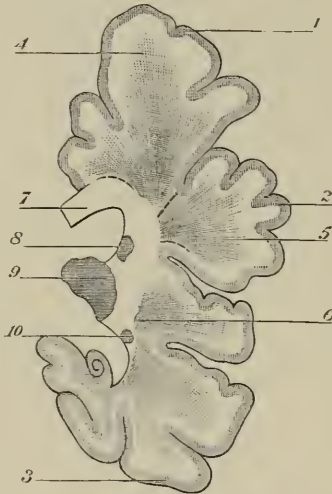


FIG. 20 (after Pitres).—Pediculo-Parietal Section. 1, Superior parietal lobule. 2, Inferior parietal lobule. 3, Sphenoidal lobe. 4, Superior pediculo-parietal fasciculus. 5, Inferior pediculo-parietal fasciculus. 6, Sphenoidal fasciculus. 7, Corpus callosum. 8 and 10, Caudate nucleus. 9, Optic thalamus.

Section of the occipital lobe gives the *occipital section*, in which no separate fasciculi are differentiated (fig. 21).

Now, it is only in certain of the medullary fasciculi so marked out, that lesions cause paralysis of motion and degeneration of the motor tracts. These regions are included in the pediculo-frontal, frontal, and parietal sections, or, generally, in the *fronto-parietal area*. Lesions here have exactly the same effect as lesions of the corresponding cortical region, according as they are destructive or irritative, or according as they are limited or general. And M. Pitres has brought forward evidence of a very satisfactory kind to show (p. 100 *et seq.*)

that the early rigidity and muscular spasms, which so frequently accompany hemiplegia with effusion into the lateral ventricles,

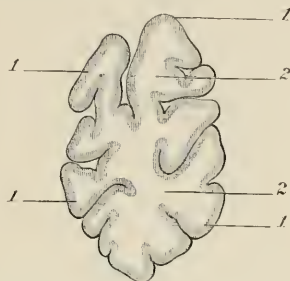


FIG. 21 (after Pitres).—Occipital Section. 1, Occipital convolutions. 2, Occipital fasciculi of the centrum ovale.

are essentially due to irritation of the fronto-parietal fasciculi of the centrum ovale.

As to the occurrence of hemiplegia with recent hæmorrhage into the fronto-parietal region of the centrum ovale, without direct affection of the cortex or basal ganglia, I might quote many cases; but, though the explanation is, through other facts, rendered simple enough, they may be objected to as evidence of paralysis from direct lesion of this area. For it might be said, and not without reason, that the paralysis was due to indirect affection, by pressure, &c., of the motor ganglia and tracts.

It will be better, therefore, to restrict ourselves to cases in which this element of suddenness or of pressure is entirely absent, *i.e.*, cases in which there was mere softening or solution of continuity of the medullary fibres.

Hodgson<sup>1</sup> has related a case of right hemiplegia with aphasia, followed several months after the seizure by late rigidity of the right arm. Death occurred from chronic bronchitis more than a year after the attack. In the centrum ovale of the left hemisphere, was a cavity nearly empty, one inch and a quarter long, situated external to the lateral ventricle and between its anterior horn and the island of Reil. The rest of the brain, except the part immediately around the cavity (which was yellowish), was normal.

<sup>1</sup> *Lancet*, 1866, vol. i. p. 397.

A similar case of right hemiplegia, but without aphasia, was recently brought before the Société Anatomique<sup>1</sup> by Landouzy. In this case, there was late rigidity with atrophy of the paralysed limbs. Sensation was unaffected. A slough formed on the sacrum, and death resulted six months after the attack. The lesion was a lacuna or cicatrix resulting from a hæmorrhagic effusion, situated in the centrum ovale, and extending from the base of the first frontal to the postero-parietal lobule. The form was irregularly triangular, the widest part situated posteriorly. Secondary degeneration was visible in the left crus and right side of the spinal cord, but the exact extent of the degeneration had not been minutely examined at the time

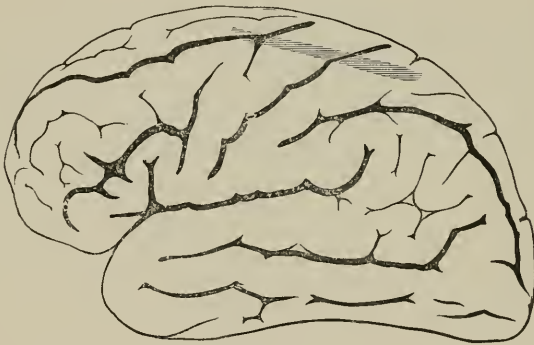


FIG. 22.

the record was made. The position of the lesion is indicated on the accompanying figure (fig. 22).

Dr. Ringrose Atkins has recorded a case<sup>1</sup> ('Brit. Med. Journal,' May 11, 1878,) of right hemiplegia due to embolism, in which, in addition to a patch of softening at the lower extremity of the ascending parietal convolution of the left hemisphere (fig. 23) there was a focus of softening in the centrum ovale, circular in outline and with a diameter of two inches, extending from a point two inches and a quarter behind the apex of the left frontal lobe, to a point three inches and a

<sup>1</sup> October 1877. *Progrès Médical*, December 29, 1877.

quarter anterior to the apex of the occipital lobe. This softening was continuous with that of the grey matter above mentioned. The ganglia were normal. To this softening of the centrum ovale in the fronto-parietal region, Atkins justly

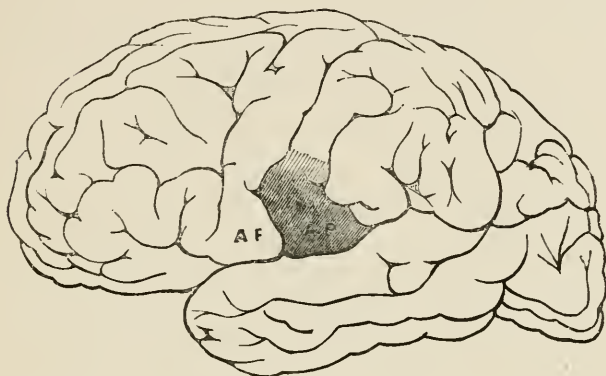


FIG. 23.

ascribes the greater extent of the paralysis than could be accounted for by the partial lesion of the cortex. Other similar cases will be found recorded in M. Pitres' above-mentioned work.

2. *Partial Lesions of the Motor Area.*—*a. With Hemiplegia.*  
 It would seem that, in order to cause more or less complete hemiplegia of the opposite side, it is not absolutely necessary that the anatomical lesions should be co-extensive with the whole motor area. I have already given one or two instances in which the lesion, though extensive, did not involve the whole of this region; to these I add one or two instances of hemiplegia in which the lesion was still more limited anatomically than in those already mentioned. But the area of anatomically demonstrated lesion is not necessarily co-extensive with the area of functional disturbance; and it is this element of uncertainty which, as I have before indicated, renders conclusions as to exact localisation, from a purely clinical point of view, always more or less doubtful.

There is, of course, no difficulty in accounting for complete hemiplegia in connection with very limited lesions of a *sudden* character in the motor area, such as hæmorrhagic extravasations or traumatic lesions. In time, however, the paralytic symptoms disappear, with the exception of those attributable to the part immediately destroyed or injured. But there are on record a few cases in which, though the lesions were of a chronic nature

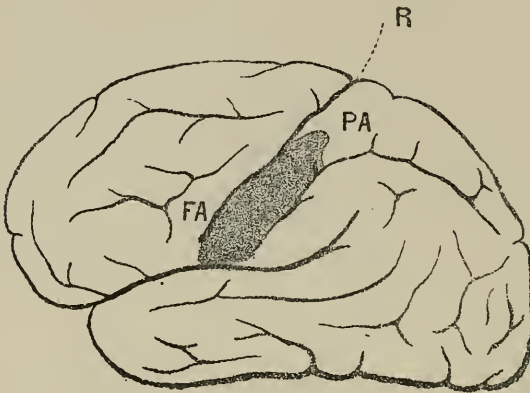


FIG. 24.

and apparently anatomically circumscribed, a more extensive paralysis has existed than can be accounted for by the amount of cortex visibly destroyed.

MM. Charcot and Pitres<sup>1</sup> gave a case of right hemiplegia, without aphasia, but with facial paresis and late rigidity of the limbs. The lesion was situated in the lower two-thirds of the ascending parietal convolution of the left hemisphere (fig. 24). Secondary sclerosis existed in the motor tracts.

In another,<sup>2</sup> of right hemiplegia, without aphasia, and rigidity of the limbs (the paralysis alternating with unilateral convulsions), the chief lesion occupied the left paracentral lobule (fig. 25), which was softened and atrophied. The lesion also involved the anterior third of the quadrilateral lobule and the upper extremity of the ascending frontal convolutions. In

<sup>1</sup> *Revue Mensuelle*, 1877, p. 191.

<sup>2</sup> *Op. cit.*, 1877, p. 193.



this case there were also other indications of degeneration in different parts of the hemispheres. Secondary degeneration of the motor tracts existed.

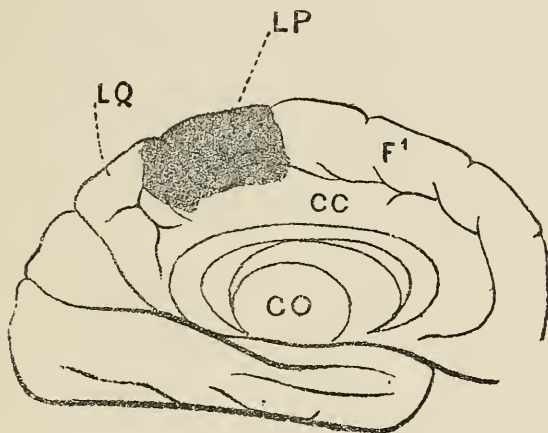


Fig. 5.

A similar case has been also reported by Pitres.<sup>1</sup>

The first of these cases is the most difficult to account for, if the lesion were actually confined to the region indicated. This, however, I venture to doubt. The other two are more in accordance with the usual results of lesion situated at the upper extremity of the fissure of Rolando.

*b. Partial Lesions and Monoplegia.*—I will now proceed to lay before you some of the more carefully recorded clinical cases of limited lesions of the cortex with correspondingly limited paralysis or monoplegia of the movements governed by these parts respectively; and I hope to be able to show you that the situation of the various motor centres in the human brain closely corresponds with the position I have assigned to them on grounds of experiment and anatomical homology. But I would repeat that the observations on record are not yet sufficiently numerous to establish by themselves, apart from the precise facts of physiological experiment, the exact situation

<sup>1</sup> *Le Progrès Médical*, September 19, 1876.

and limits of these centres. With these facts, however, the case is altogether altered.

*Unilateral Oculo-motor Monoplegia.*—At the base of the first frontal, and extending partly into the second frontal convolution in the brain of the monkey, there is an area ([12] figs.

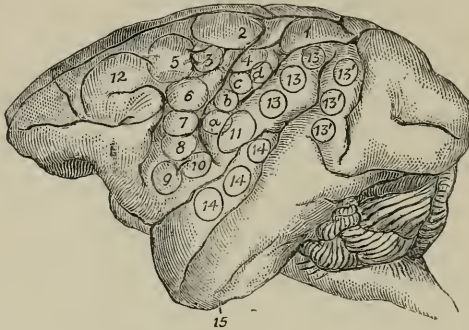


FIG. 26.

26 and 27) irritation of which causes *elevation of the eyelids, dilatation of the pupils, conjugate deviation of the eyes and turning of the head to the opposite side.* I have placed these various reactions in the order in which they occur with slight and longer continued stimulation respectively. In the faintest form of stimulation, elevation of the eyelids is the only effect observable. Whether individual centres, incapable of sharp demarcation from each other for each of the movements indicated, exist here, has not been determined experimentally.

There are, however, clinical facts which seem to require the existence of a distinct centre for the levator palpebræ superioris, inasmuch as paralysis may occur, limited to this muscle without affecting the other muscles supplied by the third nerve; an occurrence difficult to explain by peripheral affection of this nerve. Some such cases have been observed in connection with disease of the cortex, and attempts have been made, but not, I think, successful or in accordance with experimental lesions, to localise this centre in the angular gyrus.<sup>1</sup> If a distinct voli-

<sup>1</sup> Landouzy, 'Blépharoptose Cérébrale.' *Archiv. Gén. de Méd.*, August 1877. Landouzy has brought together the cases which have been reported (by

tional centre for the levator palpebræ superioris exists in the

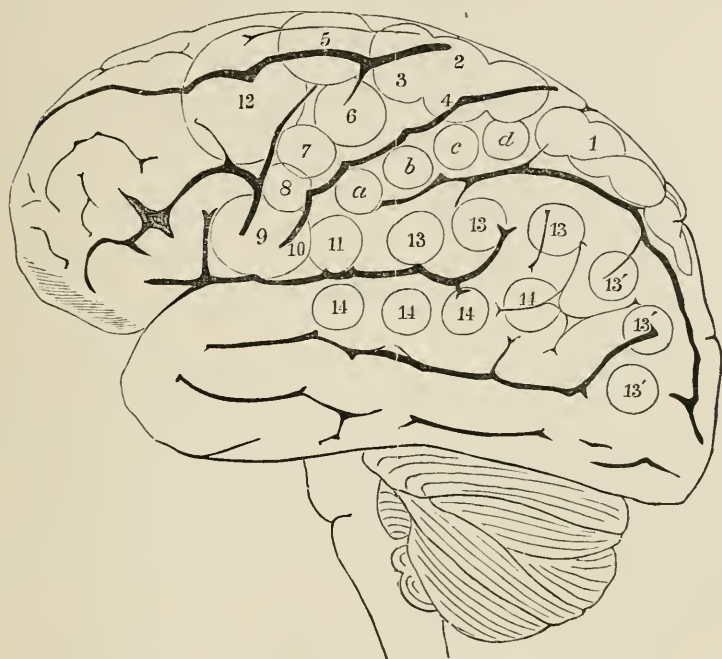


FIG. 27.

human brain, I think it must be sought for in the region now under consideration ([12] fig. 27.)

Grasset, Rendu, &c.) of isolated paralysis of the Levator palpebræ superioris associated with cortical lesions situated 'pour la plupart' towards the posterior part of the parietal lobe. It would appear further that the lesions occur in the pli courbe when ptosis alone manifests itself, and in the lobule of the pli courbe when the ptosis is associated with paralysis of the face and limbs (p. 14). But in opposition to these conclusions we have cases on record of lesion of the pli courbe and its lobule without any such results. Charcot and Pitres (*Revue Mensuelle, &c.* 1877, p. 456) have reported a case of the kind, and Saint (*Archiv für Psychiatrie*, 1874, p. 209) has reported another, in which the angular gyrus and supramarginal lobule were the seat of lesion on both sides, likewise without paralysis. Several other similar cases are on record; Gallopain (*Bull. Soc. Anat. Séance*, November 23, 1877) relates a case of an epileptic in whom the pli courbe and supramarginal gyrus were deficient on the right side without ocular symptoms; and Chavanis (*Comptes Rendus de la Soc. des Sciences Méd. de Lyon*, 1877) gives a case of old hæmorrhage into the lobule of the pli courbe, in which, though there was hemiplegia of the opposite side, no ocular symptoms were observable.

It is obvious, therefore, that as ptosis does not necessarily accompany lesion

There are, however, difficulties in the way, for lesions of this region are not uncommon, whereas insolated affection of the levator palpebræ is a comparatively rare occurrence, or at least has not been so obvious as to call for remark. This absence of paresis or paralysis therefore requires explanation. It seems to me not improbable that the intimate bilateral association of the oculo-motor nuclei may account for this, and that the escape of the levator palpebræ from paralysis in cases of unilateral lesion is simply a higher degree of that which is seen in the orbicularis oculi in facial paralysis of cerebral origin.

The question, however, is one which deserves further investigation.

In the case, however, of the bilateral and antagonistic movements of the head and eyes, it would be natural to look for lateral distortion should the centre in one hemisphere be suddenly removed; and the distortion would be towards the side of lesion, owing to the unantagonised action of the centre which remains. This affords a sufficiently satisfactory explanation of the conjugate deviation of the head and eyes observed in the early stages of hemiplegia, whether of cortical or ganglionic origin.

But, apart from conjugate deviation of the eyes in connec-

of the pli courbe, no causal relationship can be considered as established between the two, any more than between such lesions and general hemiplegia of the opposite side, as in the case reported by Chavanis.

As to the evidence from experimental physiology, I regard it as being opposed to the localisation of a motor centre for the levator palpebræ superioris in the angular gyrus. My experiments are frequently adduced in support of this view, but, as I consider, erroneously. It is true, that on stimulation of a neighbouring region—the superior temporo-sphenoidal convolution—along with other phenomena, marked elevation of the eyelids occurs; but, as I have indicated, these reactions are to be taken only as reflex or associated indications of sensory stimulation. Destruction of the angular gyrus in the monkey causes no motor paralysis whatever, whether of pupils, eyelids, &c. Hence I see no good grounds for regarding this region as a motor one.

In regard to unilateral ptosis there is one source of fallacy which may be overlooked. I have observed that in a large majority of persons one eyelid (generally the left) droops over the cornea more than the other, a condition which is greatly intensified by prostration and fatigue, so as in some cases to result in almost complete ptosis. In one case of this kind, well known to me, the drooping of the left eyelid, not obvious in health, occurred to such an extent during a prostrating illness, as to lead another physician to suspect lesion of the third nerve. With returning strength the ptosis disappeared.

tion with hemiplegia, there are some cases on record in which conjugate deviation of the eyes has occurred alone, constituting what may be regarded either as unilateral oculo-motor monoplegia or monospasm. It seems impossible to account for the phenomena which have been observed otherwise than on the hypothesis of an irritative lesion on the opposite side, or destructive lesion on the same side, either in the cortex or subjacent medullary fasciculi, in a region where these movements are specially differentiated. Such is the conclusion to which Hughlings-Jackson<sup>1</sup> and Priestley Smith<sup>2</sup> have been led by a consideration of the facts, and with them I am in entire agreement. Owing to recovery having taken place in all but one of the recorded instances, the direct evidence is as yet comparatively scanty, as far as regards the localisation of the centre in question.

Priestley Smith<sup>3</sup> reports a case in which, after an attack of pain in the head, giddiness and vomiting lasting several days, the eyes became persistently turned to the right, with complete inability on the part of the patient to turn his eyes to the left. All the other movements of the eyeballs could be carried out as usual, and though the patient could not follow an object moved to the left, yet his eyes retained their power of convergence on an object moved up to within five inches of the face. It was also noticeable in this case that the right side of the forehead was marked with wrinkles, and that the left eyelids were more open than on the right; and also that there was frequent winking of the right eyelids, and synchronous but imperfect action of the eyelids on the left. Gradually the right eye recovered its power of mobility to the left, while the outward motion of the left eye still continued very imperfect and caused double vision. There was no other indication of affection of motion.

At first Priestley Smith was inclined to regard the symptoms as due to tonic spasm from irritation of the oculo-motor centre in the left hemisphere, but the subsequent history of the patient

<sup>1</sup> 'Ophthalmology in relation to General Medicine.' *Lancet*, May 1877.

<sup>2</sup> 'Bilateral Deviations of the Eyes.' *Birmingham. Med. Rev.*, 1875. *Ophthalmic Hosp. Reports*, vols. viii. and ix.

<sup>3</sup> *Ophthalmic Hosp. Reports*, vol. ix. part 1, 'Bilateral Deviations of the Eyes.'



showed that they were more probably due to destructive lesion of the right hemisphere. For three months after the first appearance of the symptoms, the patient became affected with left hemiplegia, and complained of severe headache and vomiting. A fortnight later the right side became paretic. There was no loss of consciousness at any time. There were no new symptoms in respect to the eyes. After a few weeks the right side regained its power, the arm first, and then the leg. Later the left side gradually improved, the arm recovering before the leg.

The symptoms in this case point to a cortical lesion, probably meningo-encephalitis, commencing in the right hemisphere, and ultimately extending to the left. The manner in which the paralytic symptoms advanced, coincident with progressive extension of the disease, and also the order in which the different movements recovered, are thoroughly in harmony with the characters of cortical lesions. It is to be concluded that the disease first affected the right oculo-motor centre, and partially the facial centre, leading to paralysis of the lateral movements to the left, and hence distortion to the right by the action of the centre in the left hemisphere. The imperfect closure of the left eye indicated some slight affection of the facial centre and partial facial paralysis.

The same author gives particulars of a second case in which, after some pain in the head, and vomiting, continuing for eight weeks before admission into the Birmingham General Hospital, the symptoms noticeable were deviation of the eyes to the right, facial paralysis on the left, and some degree of paralysis in the left limbs. After some weeks the patient could move his right eye to the left, while the left eye could not be moved outwards. The left eyelids winked less perfectly than the right.

In this case also we have symptoms indicating lesion mainly of an oculo-motor and facial centre in the right hemisphere, for the affection of the limbs was comparatively slight. The case is, therefore, not an ordinary example of conjugate deviation of the eyes with hemiplegia, but is to be looked upon as an instance of dissociated paralysis, due to limited lesion, with partial disturbance of the other motor centres. In a third case, which Priestley Smith saw with Dr. Sawyer, there had



been, according to the patient's account, severe pain in the right side of the head and face, followed by 'squinting of both eyes' to the right, twelve months before admission into the hospital. There was no definite history of loss of power in the limbs.

At the time of admission there was an appearance of paralysis of the left external rectus. But as both eyes had at first been turned to the right, the symptoms are explicable, as in the two preceding cases, by the recovery of the right eye, while the outward movement of the left eye remained paralysed.

In its pathology the case resembles the other two which have been described.

Dr. Carroll, of Staten Island, New York, has furnished me with the particulars of a case which recently came under his observation.

The patient, a child aged five months, fell a distance of about six feet, and was stunned for a few minutes. Dr. Wilson, who saw the child soon after the injury, stated that there was no affection of the limbs; and the only phenomenon which struck him was a conjugate deviation of the eyes and rotation of the head to the right, with, at first, dilatation of the pupils. During the first two days after the accident, any sudden movement caused intensification of the symptoms. No other symptom occurred, and the child's general health did not appear to suffer. Dr. Carroll found the head 'rotated to the right, and its range of motion never extending to the left of the mesial line; the eyes, when at rest, were turned to the right, but could be voluntarily moved almost to the middle line; pupils perhaps a little dilated, but responsive to light; upper lids elevated.' There was a swelling in the right parietal region, and a linear fracture could be detected in the parietal bone, about midway between the squamous and sagittal sutures, and intersecting a vertical line drawn upwards from the auditory meatus. Dr. Carroll also noted that pressure at the seat of injury caused a distinct increase of the deviation: which he is inclined to regard as due to irritation, and therefore of the character of monospasm. The difficulty would then arise as to the spasm occurring from lesion on the same side as the deviation. But it seems to me the symptoms can be more satisfactorily

accounted for by unantagonised action of the left centre, from (hæmorrhagic) lesion of the right. The position of the fracture was such as might easily coincide with injury of centre ([12] fig. 27); and the fact that the eyes could be voluntarily moved up to the middle line shows that the distortion was not of an active nature, and easily overcome by the action of the right centre.

The following case, related by Chouppe,<sup>1</sup> which is quoted by Landouzy,<sup>2</sup> bears more nearly on the question of the situation of the oculo-motor centre in man. This was a case of a lad, aged 19, who showed symptoms of tubercular meningitis, in which, in addition to pain, vomiting, etc., the most remarkable symptom was a rotation of the head and eyes to the right. This could be overcome with moderate effort, but the head and eyes returned to their position when left to themselves. No other paralysis or contracture existed elsewhere. After death, a patch of disease, free from granulations and quite superficial, of the size of a franc piece, was found on the 'superior part of the middle frontal convolution' in the left hemisphere. Other lesions were found in the superior and lateral part of the sphenoidal lobe of the right hemisphere, but, as will be subsequently shown, these cannot be regarded as much complicating the case. There was no other cerebral lesion. The exact situation of the lesion in the left hemisphere is not indicated more precisely than in the words quoted; but they may, I think, be taken in support of the theory that these special symptoms were due to irritative lesion of that which corresponds with the oculo-motor centre in the brain of the monkey.

*Crural Monoplegia.*—As there seems to be some misapprehension abroad in reference to the centres of movement of the hinder extremity, let me first call your attention to the facts of experiment. Irritation of the *postero-parietal* or *superior parietal lobule*—area 1—(fig. 26) causes flexion of the foot in the ankle, occasionally combined with flexion of the thigh on the pelvis, and extension forward of the leg as in the act of walking.

On the other hand, in my experiments on monkeys, stimulation of area 2 (fig. 26), a region which includes the upper

<sup>1</sup> *Bulletin de la Soc Anat.*, 1871, p. 380.

<sup>2</sup> *Op. cit.*, p. 160.

extremity of the ascending frontal, as well as part of the ascending parietal, gave rise to more complex movements, the result of which was to bring the foot towards the middle line of the trunk, as if the animal were to scratch its abdomen or lay hold of something in this position. The area 3, near it, gave rise to movements of the tail. Below it (4), certain movements of the arm—viz., adduction and retraction—were excited.

It is a question by no means easy to answer *à priori*, how far the movements of the human leg can be compared with those of the leg-arm and foot-hand of the monkey; or what is the representative in man of the centre for the tail which, in the New World monkeys, plays the part of a hand. We must, therefore, be cautious in drawing conclusions as to the exact position of the arm and leg centres in man from considerations merely of anatomical homology. And there is reason for exact and careful analysis of the movements which are affected, or more particularly affected, in any given case of crural monoplegia of cortical origin, for on this may depend the exact regional diagnosis.

Clinical evidence in favour of a distinct centre or centres for the leg, clearly differentiated from those of the arm, is not as yet very extensive. We have many cases on record in which the leg and arm have been paralysed together—brachio-crural monoplegia—an association easily accounted for by the close relation of the leg and arm centres to each other. Still, there are some cases in which the leg *only* has been paralysed; and in others, in which leg and arm have been ultimately conjointly affected, the paralysis has shown itself *first* in the leg. This latter fact has an important bearing on the question of a distinct leg-centre, and its exact situation. A few cases are on record of paralysis occurring in one or both legs from injury to the vertex in the parietal region; but we cannot exercise too much caution in the inferences we draw as to the seat of lesion in such cases. The researches of Duret<sup>1</sup> have shown that local and general spinal paralysees may result from bulbar and spinal lesions owing to sudden displacement of the cerebro-spinal fluid in consequence of blows on the head. A case in which, from the symptoms, this was evidently the mode of causation, is

<sup>1</sup> *Traumatismes Cérébraux*. Thèse, 1878.

related by Guthrie.<sup>1</sup> A soldier at Waterloo was struck by a shot which caused depressed fracture of both parietal bones. On his recovering consciousness, he was found paralysed in both legs, and benumbed from the loins downwards. He recovered on being trephined ten days afterwards. It cannot be doubted that the paralysis in this case was spinal paraplegia, and easily accounted for in the manner demonstrated by Duret.

In some other cases, however, the symptoms may be ascribed to local cerebral lesion; and the fact of the paralysis being crossed would support this view. Hitzig<sup>2</sup> quotes from Löffler the following among others. A Danish corporal was struck by a shot at the *superior and posterior extremity of the left parietal bone*, close to the sagittal suture (overlying the postero-parietal lobule, see fig. 3). The right leg was immediately paralysed. The right arm became affected on the seventh day. On trephining, recovery took place—the arm first, and then the leg. This may fairly be taken as a cortical lesion, as the subsequent affection of the arm is in accordance with extension of softening to neighbouring centres; a feature so characteristic of cortical lesions. Another case of fracture of the ‘summit of the right parietal bone’ by a shot was followed by paralysis of the left leg.

As instances of disease of the cortex with crural monoplegia without traumatic lesion the following two (though they are not altogether precise) may be taken, quoted from Landouzy.<sup>3</sup> One is reported by Becquerel, of paralysis limited to the left leg. The lesion in this case is described as being situated ‘at the upper part of the right hemisphere,’ consisting of granulations and adhesions (p. 211). Slight affections of the pia mater and subjacent cortex were, however, also observed in the left hemisphere. The second is recorded by Rendu. This was a case of paralysis of the right leg followed by paresis of the right arm, which gradually increased. In the *parietal convolutions* of the left hemisphere, *close to the longitudinal fissure*, was a zone of exudation and interstitial hæmorrhages, affecting both the cortex and medullary substance to a considerable depth, but not

<sup>1</sup> Quoted by Wilks, *Guy's Hospital Reports*, 1866, p. 51.

<sup>2</sup> *Untersuchungen über das Gehirn*, 1874.

<sup>3</sup> *Op. cit.*, pp. 211–212.

extending to the basal ganglia. In the parietal convolution (exact position not stated) was found a caseous nodule of the size of a nut. It is, however, to be noted that the cerebral membranes generally in both hemispheres indicated signs of tubercular inflammation. Hence, the case is not quite free from complication.

I would here mention a case which, though one of tumour, has a considerable value in reference to the question before us. The particulars were communicated to me by Dr. Haddon of Manchester,<sup>1</sup> and the question arose during life as to the exact locality of the tumour and the advisability of trephining. Though our diagnosis proved absolutely correct, the operation, for other reasons, was not performed. The patient began first to have tingling in the left leg, followed by paresis of this limb, gradually increasing, and continuing restricted to the left leg for five months. Then the left arm became weak. After occasional attacks of rigidity and twitching, the arm and leg became both completely paralysed. Shortly before death, signs of weakness showed themselves also in the right leg. After death, a tumour, three inches in diameter, was found growing from the dura mater, and pressing perpendicularly downwards on the region included in the *upper extremity* of the *ascending frontal, ascending parietal, and postero-parietal* convolutions (figs. 28 and 29). The tumour had grown downwards as far as the floor of the lateral ventricle, compressing the brain-substance in its course. It also impinged on the other hemisphere. The point of origin of this tumour, and the mode of growth, warrant the conclusion that the paresis of the left leg, which was the first, and for a long time the only motor symptom, was due to the affection of the cortex in the region where experiments in the monkey would lead us to localise the leg-centres.

Gougenheim<sup>2</sup> has recorded a case of a man aged 45 who was seized with paralysis of the left leg, without affection of sensation. A few days after, the paralysis increased, and the left arm became similarly affected. Coma came on and death.

<sup>1</sup> The case has been published in *Brain*, Part ii. 1878.

<sup>2</sup> *Soc. Mec. des Hôpitaux. Séance*, February 22, 1878. *Le Prog. Méd.*, March 16, 1878.



Diagnosis was made of a lesion of the upper extremity of the ascending frontal. The necropsy revealed a lesion, tuberculo-

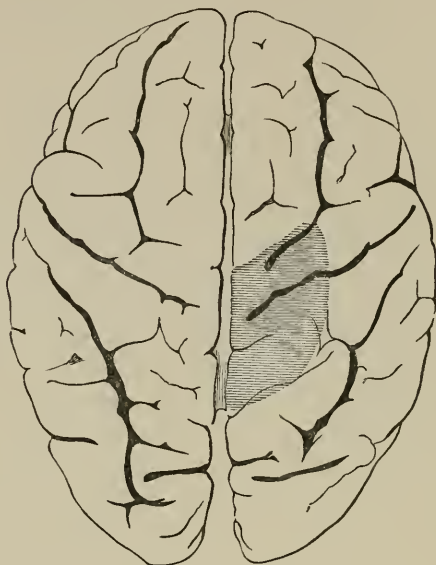

FIG. 28.

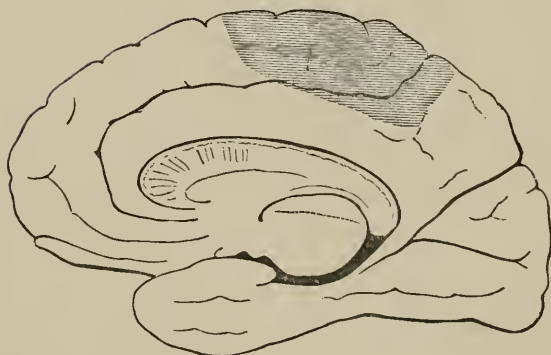


FIG. 29.

meningeal, of the ascending frontal, but especially involving the paracentral lobule.



Two cases are reported by Bourneville, which, though not uncomplicated cases of crural monoplegia, yet deserve to be taken in consideration with the others. They might also be referred to as instances of partial hemiplegic epilepsy. The first of these<sup>1</sup> is quoted by Charcot and Pitres. This was the case of a girl, aged 18, who had been affected with infantile hemiplegia of the left side at the age of four. She was subject to epileptic attacks, beginning in the left leg, which was paralysed. There was no facial paralysis. After death, a patch of degeneration was found in the right hemisphere, occupying the

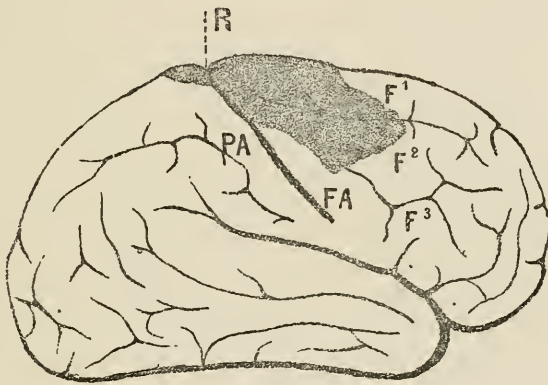


FIG. 30.

*upper half of the ascending frontal, the bases of the first and second frontal, the anterior part of the postero-parietal lobule, and the whole of the internal aspect of these regions (fig. 30).* Secondary degeneration of the motor tracts of the spinal cord existed. The second case was a similar one of infantile hemiplegia, followed by partial epilepsy; the spasms being limited to the right leg at first, but gradually invading the right arm and the right side of the face. The position of the lesion, diagnosed during life, was the *upper extremity of the ascending frontal and parietal convulsions, and the internal surface corresponding, or paracentral lobule.* This region was the seat of softening. No other lesion existed. In this case also, secon-

<sup>1</sup> *Gazette Médicale de Paris*, December 1876.

dary degeneration was found in the right half of the spinal cord, in the postero-lateral column.

These cases, I think, suffice to prove that the lesions which have been described in connection with crural monoplegia have been in a region which very closely agrees with the position of the centres for the movements of the leg in monkeys. In the absence of other facts serving to determine the exact position and extent of the leg-centre, M. Bourdon<sup>1</sup> has endeavoured to arrive at this by another method. The method he adopts is to examine the brain in cases of amputation or arrested development of the lower extremity, with the expectation of finding atrophy of the corresponding centre in accordance with Luys' views. Whether these expectations are altogether justifiable may be questioned. For my own part I should on theoretical grounds regard this as highly improbable, except in cases of congenital deficiency. Mere absence of a limb after it has been for a long time in full functional activity, would not, I think, induce perceptible atrophy in the *cortical* motor centres. For mere objective or actual movement is not the only function of these centres. Being also the organic registers of the memory of their corresponding movements, and the basis of motor ideation, it is, I think, possible that their nutrition may be maintained notwithstanding the cessation of their activity in the innervation of actual or objective movement.

But, theoretical considerations apart, the practical difficulties in the way of a satisfactory solution of this problem are very great, and I do not think that, up to the present at least, they have been disposed of successfully. An important communication on this subject was recently presented to the Société de Biologie (January 5, 1878), by M. Féré, well known for his valuable researches in cerebral topography. M. Féré argues that neither the method of ascertaining the existence of atrophy, by comparing the relative size of homologous convolutions in each hemisphere, nor that founded on the advance or recession of the fissure of Rolando, round which the motor centres are grouped, is reliable; inasmuch as in the perfectly normal brain

<sup>1</sup> *Recherches Cliniques sur les Centres Moteurs des Membres.* Paris, 1877.

there are great variations and asymmetry in the convolutions and fissures in the two hemispheres, and there is no absolutely constant relation between the position of the fissure of Rolando and a given cranial region, or in its position in the one hemisphere as compared with the other. Hence the necessity of receiving all statements with regard to atrophy with extreme caution if not with complete distrust.

With these considerations, let us consider the results of M. Bourdon's analysis of cases of amputation. In one of amputation of the thigh, thirty-five years before death, atrophy was said to exist at the upper extremity of the ascending frontal, at its junction with first frontal convolution of the opposite hemisphere. In a second, of amputation of the thigh, fifty-two years before death, atrophy was said to exist in exactly the same situation. In a third, of amputation of the thigh, twenty-one years before death, a linear depression was found interrupting the continuity of the second frontal convolution in the opposite hemisphere.

To these cases, which M. Bourdon quotes from M. Luys, a fourth is added, observed by M. Landouzy. This was a case of arrested development of the right leg at the age of eighteen months, death occurring at the age of forty-five. The left hemisphere was smaller than the right, and the fissures of Rolando were unsymmetrical. The left ascending parietal convolution appeared somewhat smaller than the same convolution in the right hemisphere. There was also asymmetry of the pons and medulla, the left being the smaller.

None of these cases appear to have been investigated microscopically. If we regard them as satisfactory, which I think we are scarcely entitled to do, we do not find any more exact correspondence as regards the situation of the leg-centre, than in the cases of lesion already mentioned. I have recently had an opportunity of examining with Mr. Barrow the brain of a patient who died in King's College Hospital, having had his right leg amputated at the middle third of the thigh twenty-eight years before death. A careful comparison of the two sides of the brain showed that there was a considerable degree of asymmetry of the hemispheres, and the left fissure of Rolando

abutted on the longitudinal fissure posterior to the right. But both sides of the brain as a whole and the several lobes of the brain were equally well nourished and plump, and there was not the slightest appearance which could be construed into atrophy of any one part on one side as compared with the other. The man before death showed symptoms of paraplegia, which was found to be due to pressure by an abscess on the lumbar region of the cord. Sections of the lumbar region indicated atrophy of the right side of the cord, corresponding to the limb amputated. But beyond this, where atrophy might reasonably be expected, no other indication of atrophic degeneration could be detected. On these grounds I do not place much confidence on Luys' method, or on Bourdon's attempt to determine the position of the leg-centre by its aid. I think, however, that, though the exact limits of the leg-centres are not defined, the clinical evidence points to a position closely in harmony with that defined in the brain of the monkey; and that the conclusion formed by M. Lucas Championnière is well justified, viz., that, to expose the leg-centre, it is necessary to apply the crown of the trephine over the upper extremity of the fissure of Rolando.

*Brachio-Crural Monoplegia.*<sup>1</sup>—Paralysis of the leg occurs more frequently in association with paralysis of the arm than singly as the result of cortical lesions. I have already mentioned several cases of this kind, to which the following may be added.

MM. Charcot and Pitres<sup>2</sup> give a case of paralysis with rigidity of the left limbs of three years' duration, sensibility being unimpaired. A patch of softening  $5 \times 2.5$  centimètres was found at the upper extremity of the fissure of Rolando, on the convex surface of the right hemisphere (fig. 31).

M. Moutard-Martin<sup>3</sup> reports a case of fracture of the skull and injury of the brain, causing paralysis of motion of the right arm and leg, for which trephining was practised without success. The cerebral lesion occupied the *upper extremity of the ascending frontal, ascending parietal, and anterior two-thirds*

<sup>1</sup> I use the term monoplegia here to indicate paralysis of a distinct group of movements, and not as meaning paralysis of a muscle or a limb.

<sup>2</sup> *Rev. Mens.* 1877, p. 185.

<sup>3</sup> *Bulletin de la Société Anatomique*, December 8, 1866.

of the *postero-parietal lobule*, and slightly the inner aspect of this region, or *paracentral lobule* (fig. 32).

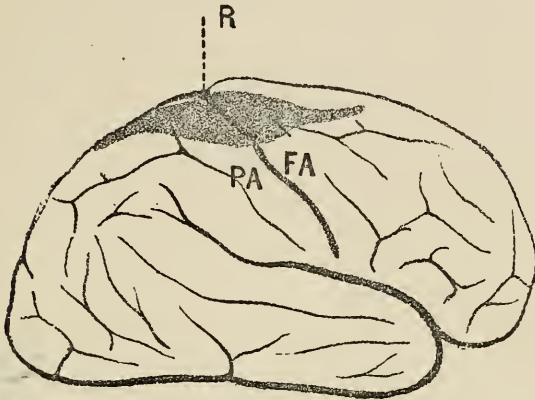


FIG. 31.

M. Pitres<sup>1</sup> gives a similar case in which the lesion affected, not the cortex, but the medullary fasciculi of the superior frontal and parietal region (fig. 33, 4). For other cases reported

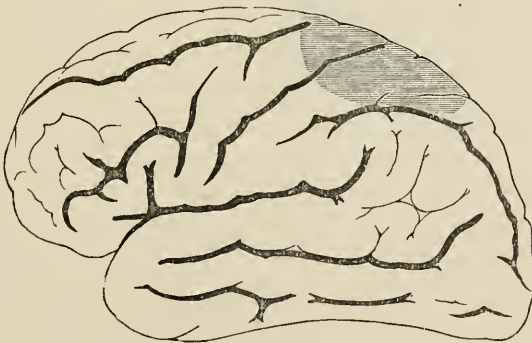


FIG. 32.

by Laveran, Faisans, Dreyfus, Langlet, &c., see Grasset, 'Localisations dans les Maladies Cérébrales,' p. 117.

*Brachial Monoplegia.*—The centres for the movements of

<sup>1</sup> *Lésions du Centre Ovale*, p. 85.



the arm and hand occupy a considerable space, as might be expected from their importance as organs of intelligence. Area [5] (figs. 26 and 27) is the centre for the forward extension of the arm and hand; area [4], for the adduction and retraction; area [6], for the supination and flexion; while the various letters (*a, b, c, d*) placed in the ascending parietal convolution indicate the position of centres for the movements of the wrist and fingers. With these latter, retraction of the angle of the mouth is apt to be associated, owing to the proximity of the facial and oral centres (7, 8, 9, 10, 11, fig. 26): a proximity which serves to explain, among other things, the retraction of the angle of the mouth so commonly seen associated with powerful action of the hand. Hence also the fact that brachial monoplegia occurs less often than brachio-facial paralysis.

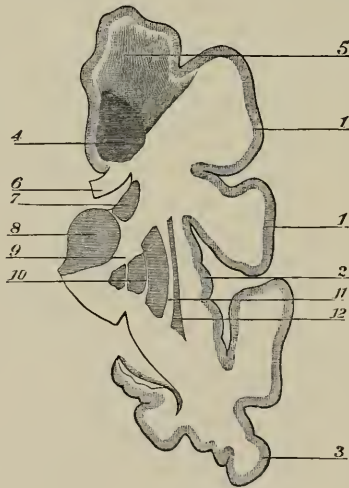


FIG. 33.

It is obviously highly important, in any given case of brachial monoplegia of cortical origin, to determine, if possible, which of the movements of the upper extremity are particularly affected. This has not been done with any great degree of accuracy in many of the recorded cases.

M. Maurice Raynaud<sup>1</sup> reports a case of paralysis limited to

<sup>1</sup> *Bulletin de la Société Anatomique*, July 1876.



the left arm, and more particularly to the extensor muscles, though the flexors were also paretic. There was no diminution in sensation, or alteration in electro-motor contractility. The lesion was situated in the *ascending parietal convolution* of the right hemisphere, in the position of a line drawn back from the second frontal. It was an area of softening surrounding a tubercle the size of a millet-seed, and of about a *centimètre* in diameter; the softening affecting the adjacent medullary fibres more than the cortex. A smaller area of softening of the size of a pea was situated near this, but within the fissure of Rolando. The whole lesion could be covered with the pulp of the finger (fig. 34).

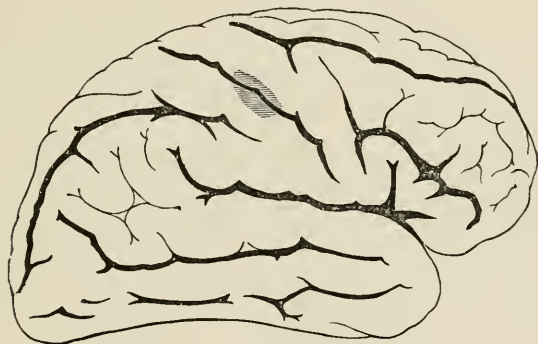


FIG. 34.

M. Sabourin<sup>1</sup> records a case of sudden partial right hemiplegia without loss of consciousness, which soon disappeared, leaving paralysis of the right hand and arm, which continued till death seven days afterwards. A focus of red softening was found in the left hemisphere of the size of a two-franc piece, the centre of which, in which the softening was greatest, corresponded with the *junction of the ascending parietal convolution and supramarginal lobule*. The softening extended halfway up the ascending parietal convolution, somewhat concealed within the fissure. The ganglia were intact (fig. 35).

M. Boyer<sup>2</sup> has recorded a case of sudden paralysis of the left arm and leg. After four or five days, the leg regained its power,

<sup>1</sup> *Le Prog. Méd.*, 1877, p. 391.

<sup>2</sup> *Bull. Soc. Anat.*, May 4, 1877.

while the left arm remained permanently paralysed. The affection happened in 1872. In 1877, the condition was rigidity of the left arm and atrophy of the muscles of the forearm. Sensation was unimpaired. The patient died of broncho-pneumonia.

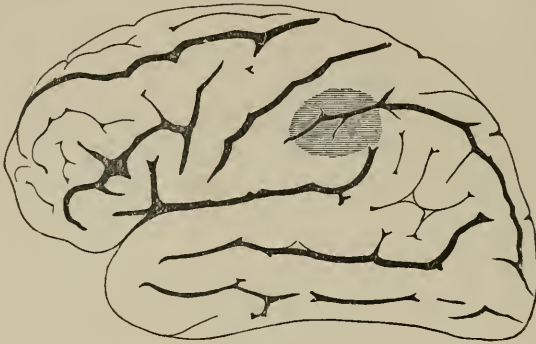


FIG. 35.

The left hemisphere was normal. In the right hemisphere, a patch of atrophy, caused by an old yellow softening, existed in the ascending parietal and ascending frontal convolutions ;

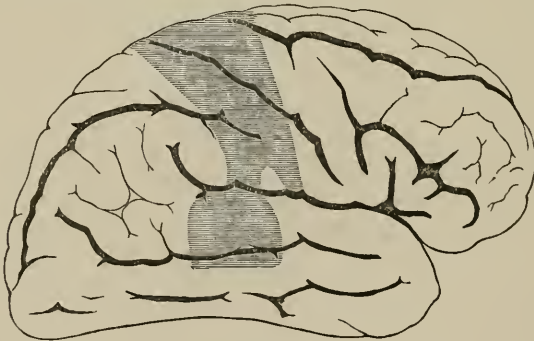


FIG. 36.

and an extension of the same existed in the temporo-sphenoidal region. The position of the lesion is indicated from a drawing sent me by M. Boyer in fig. 36.

Ringrose Atkins<sup>1</sup> has recorded a case of paralysis of the right

<sup>1</sup> *Brit. Med. Journal*, May 11, 1878.

hand and arm in a general paralytic, which came on a few days before death. The membranes were adherent and the cortex was softened in a region including 'a small portion of the middle of the ascending frontal, the middle third of the ascending parietal convolution, extending further below than above the anterior edge of the gyrus supramarginalis, and a little piece of the gyrus angularis where it grows with the gyrus supramarginalis adjoining the ascending parietal,' as illustrated in the accompanying figure (fig. 37). A peculiar feature in this case, which will be referred to subsequently, was the presence of visual hallucinations.

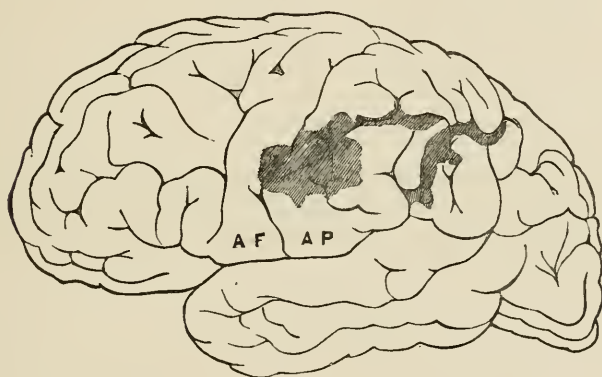


FIG. 37.

M. Bourdon<sup>1</sup> has collected several other cases, from which I quote the following.

A case related by M. Pierret,<sup>2</sup> of an apoplectic attack with early rigidity of the left arm and retraction of the right angle of the mouth, followed by partial paralysis of the left arm. Death occurred twelve days afterwards, from sudden coma and epileptiform convulsions. In the right hemisphere, at the *junction of the middle frontal with the ascending frontal convolution*, a focus of red softening of the size of a franc-piece existed (fig. 38). A similar focus existed in this case in the median occipital of the same hemisphere.

<sup>1</sup> *Centres Moteurs des Membres.*

<sup>2</sup> *Bull. Soc. Anat.*, 1874, p. 196.

Another case, observed by Darolles, is given, of cerebral affection (symptoms of congestion) resolving itself ultimately into paralysis of the right arm. A hæmorrhagic extravasation

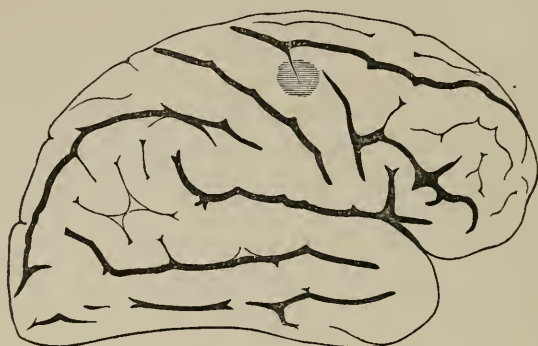

FIG. 38.

was found in the left hemisphere, embedded in the cortical substance, three millimètres in extent, at the upper part of the ascending frontal convolution (fig. 39). A patch of softening

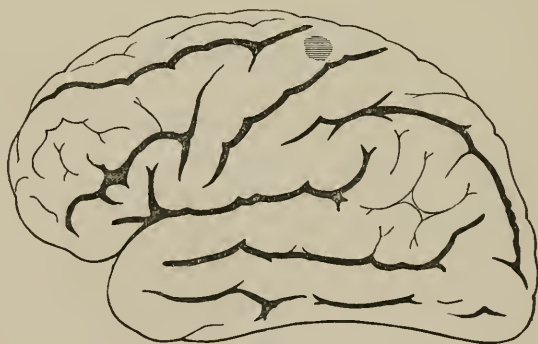


FIG. 39.

also existed in the median occipital lobe of the right hemisphere in this case.

M. Bourdon also relates an interesting case of double brachial monoplegia communicated to him by M. Vermeil. This was the result of a cranial injury. The arms only were paralysed

as to motion, sensation being unimpaired. Death occurred two days after the accident. There was no depression of the skull at any part. On the surface of the brain were two small superficial hæmorrhagic extravasations of about fifteen *millimètres* in diameter. The one of these was situated towards the upper part of the ascending frontal in the left hemisphere (fig. 40, 1). The other, in the right hemisphere, was situated at the junction of the ascending parietal with the inferior parietal lobule (fig. 40, 2).

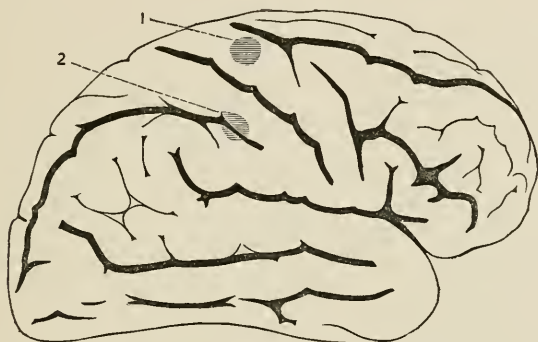


FIG. 40.

Several other cases of brachial monoplegia in connection with cortical disease are on record, but in some which have been adduced in support of distinct localisation, the character of the lesion was such as to necessitate their exclusion on the principles above laid down. Among these must be reckoned a case of a right brachial monoplegia reported by M. Raymond, and another of a similar nature related by Demongeot de Confevron, as the lesions in both cases were of a tuberculo-meningeal nature (quoted by M. Bourdon).

I will refer only to one other case of brachial monoplegia, and chiefly because it seems to be opposed to the localisation of the arm and leg centres as above maintained.

The case is related by M. Cotard.<sup>1</sup> A woman, who died at the age of seventy-one, had been seized with convulsions, fol-

<sup>1</sup> *Atrophie partielle du Cerveau*, p. 21.

lowed by paralysis of the left arm, about the age of two years. The left arm continued paralysed and rigid. She walked with difficulty; but this was apparently due to fracture of the neck of the left femur a few years before. Formerly no difficulty was noted in this respect. The right hemisphere was smaller than the left. 'Behind the upper extremity of the fissure of Rolando, there was a longitudinal depression of the cortex, which extended parallel with the longitudinal fissure as far as the occipital lobule, five *centimètres* in length by one *centimètre* in breadth.' It is not clear in this case what extent of the ascending parietal convolution was involved, or how much of the postero-parietal lobule, as it is only said that the linear depression was parallel to the longitudinal fissure. M. Charcot, in whose *clinique* the case occurred, is unable to give me further particulars as to the exact seat of the lesion.

The apparent difficulty in this case is to account for the non-affected of the leg—granting that it was not affected—withstanding the existence of a lesion in the region in which we localise the motor centres of the leg.

With this should be compared the case reported by Boyer, cited above, in which, though the leg was at one time paralysed, recovery took place, notwithstanding the existence of a partial lesion, as in Cotard's case, in the leg-centres.

It would appear, therefore, that the leg may recover its mobility notwithstanding partial lesion of its cortical centres, and this is quite in harmony with other facts relating to cerebral paralysis.

As a further illustration of the same fact I would quote a case reported by Ringrose Atkins,<sup>1</sup> in which there was a superficial erosion of the cortex on the postero-parietal lobule of the left hemisphere without motor disturbance. The position of this superficial lesion is indicated in the accompanying figure (fig. 41).

In a private communication to me in reference to M. Cotard's case, M. Charcot expresses his opinion that the effects of cortical lesions in infancy are not altogether the same as similar lesions in adults, owing to the fact that the functions

<sup>1</sup> *Brit. Med. Journal*, May 4, 1878.



of the cortical centres are not distinctly defined and differentiated for some time after birth. This is a point worthy of careful investigation clinically. In regard to the lower animals Soltmann<sup>1</sup> has shown that at birth there is no distinct functional differentiation of motor centres in the cortex. This does not occur for some days, and judging from analogy, the distinct functional differentiation of the various cortical centres in the human brain must be relatively much more tardy.

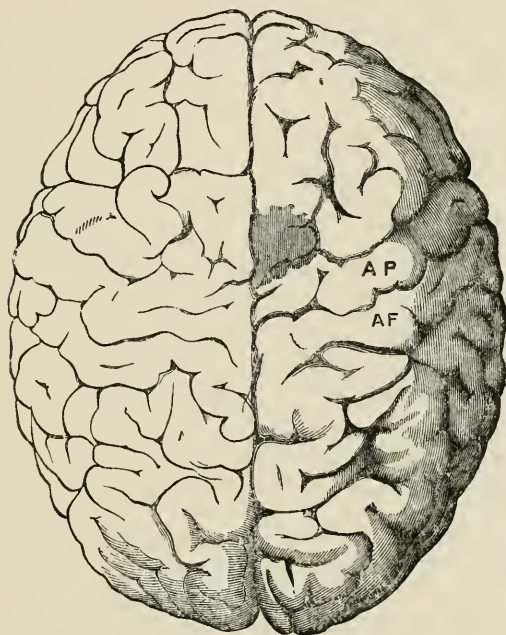


FIG. 41.

With the exception of Cotard's case, which may justly be excluded, the seven cases I have cited of limited lesions with brachial monoplegia are entirely in harmony with experimental localisation; for, though the lesions recorded did not occupy the same position in all, yet they were all in regions included within the area in which these centres are situated, viz., the

<sup>1</sup> *Jahr. für Kinderheilk.* Bd. ix.

*ascending parietal and upper part of the ascending frontal convolutions.*

In those in which it was noted that the hand in particular was affected, the lesion invaded the *ascending parietal* convolution, in harmony with the facts of experimental localisation. In others, no differentiation was made, or was possible. It would have been most interesting if this had been done in Vermeil's case of double brachial monoplegia, as the lesions occupied centres for different movements of the upper extremity.

Atrophy has been stated to occur in the opposite hemisphere in consequence of long-standing amputation of the upper extremity. The following two cases have been cited by M. Bourdon :—<sup>1</sup>

A case reported by Chuquet<sup>2</sup> of amputation of the right arm six years before death. In the left hemisphere, there was atrophy of the upper third of the ascending parietal convolution and corresponding part of the internal surface of the hemisphere. The length of the atrophied part was two *centimètres*.

M. Boyer<sup>3</sup> examined the brain of a man who died at the Bicêtre, having had his left arm amputated thirty years previously. The ascending convolutions of the opposite hemisphere were atrophied at their superior extremity, and the ascending frontal was throughout very slender and flattish.

Dr. Gowers has kindly given me the particulars, accompanied by a photograph of the brain, of a case of congenital absence of the left hand.<sup>4</sup> The middle part of the *ascending parietal convolution* in the right hemisphere is, as clearly shown in the photograph, much smaller than the corresponding convolution in the left. Microscopical examination revealed no difference between the two. The cortical layers had the same appearance, and there seemed no difference as regards the number and form of the cells.

With respect to the atrophy said to exist in the cases reported by Chuquet and Boyer, the observations already made

<sup>1</sup> *Centres Moteurs des Membres*, p. 21.

<sup>2</sup> *Bull. Soc. Anat.*, November 1876.

<sup>3</sup> *Ibid.*, April 1877.

<sup>4</sup> Notes of the case have been published in *Brain*, Part III., 1878.

in reference to atrophy following amputation of the lower extremity may be repeated. Recently—'Soc. de Biologie, Séance Jan. 19, 1878.'—M. Charcot exhibited a photograph of the brain of a woman who had had her left arm amputated at the shoulder joint thirty-eight years before death. There was no cerebral atrophy, but in the cervical region of the cord there was atrophy and sclerosis in the lateral column. Dr. Gowers' case, however, stands on a different footing, inasmuch as the absence of the limb was congenital. The position of the atrophy in this case is in complete harmony with that which we have assigned to the manual centres in the human brain. A case similar to Gowers' was brought before the Société de Chirurgie (Séance, May 15, 1878) by M. Marc Séé.<sup>1</sup> Atrophy of the right arm existed owing to paralysis dating from infancy, and the left ascending parietal convolution was smaller than the right. MM. Bourdon and Luys looked upon this as due to atrophy, but M. Charcot doubted whether the asymmetry were greater than in perfectly normal individuals.

*Brachio-facial Monoplegia.*—The combination of brachial with facial paralysis is a much more frequent occurrence than brachial or facial paralysis singly in connection with cortical disease; and very commonly, and for obvious reasons, it is associated with aphasia when the disease is in the left hemisphere. This, however, is not always the case; and I have recently seen two cases of right brachio-facial monoplegia without aphasic symptoms. Many such occur, but recover and are lost sight of. Post-mortem examination has, however, been made in several.

Dieulafoy<sup>2</sup> has recorded the case of a woman, aged 60, who was suddenly seized with paralysis of motion in the right arm and right lower facial region. Sensibility was unimpaired. Death occurred the day after from coma. The necropsy revealed a hæmorrhagic extravasation, the size of a nut, surrounded by a zone of softening in the medullary fibres of the ascending frontal convolution of the left hemisphere, posterior to the third frontal convolution (fig. 42).

<sup>1</sup> *Bull. Soc. de Chirurgie*, tome iv., 1878, p. 334.

<sup>2</sup> *Bull. Soc. Anat.*, 1868, p. 139.

Troisier<sup>1</sup> gives a case of a man, who died of phthisis, who had been suddenly seized with paralysis in the right arm, at first showing itself in the muscles supplied by the musculo-spiral, and followed by complete paralysis of the limb, with the addition of right facial paralysis; sensation was intact. In the left hemisphere, a patch of hyperæmia with yellow granulations and adhesions, of seven to eight square *centimètres* in extent, was found posterior to the third frontal convolution. The lesion was not very definite in this case, and it was further complicated by the simultaneous occurrence of granulations in the membranes behind the posterior parietal convolution. The lesion, however, invaded the same region as in the former, and in the following case:—

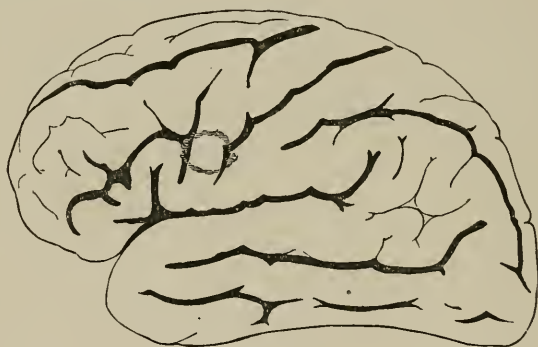

FIG. 42.

M. Hippolyte Martin<sup>2</sup> has recorded a case of left facial paralysis, with paresis of the left arm, more particularly shown in the first three fingers. There was no aphasia. The affection had come on suddenly, without loss of consciousness or other paralysis, five or six months previously. The necropsy revealed a patch of yellow softening in the lower fifth of the ascending parietal convolution of the right hemisphere. The softening extended up the fissure of Rolando to a level with the extremity of the second frontal convolution (fig. 43). The softening penetrated about one *centimètre* from the surface. The basal ganglia and the rest of the brain were normal.

<sup>1</sup> *Bull. Soc. Anat.*, 1872, p. 262.

<sup>2</sup> *Revue Mensuelle*, No. iii., p. 136.

Cruveilhier<sup>1</sup> gives a case, illustrated by a figure, of paralysis suddenly occurring on the right side of the face and tongue (aphasia), with paralysis and rigidity of the right arm. The lesion in this case was a patch of red softening of about  $2 \times 4$  centimètres in extent, situated at the lower third of the fissure of Rolando, and affecting also very specially the ascending parietal convolution, corresponding to fig. 43.

A case reported by Anton Frey<sup>2</sup> is referred to by M. Pitres,<sup>3</sup> as showing that brachio-facial monoplegia may occur from lesions limited to the medullary fibres of the middle pediculo-frontal and frontal section. The symptoms were paresis of the left arm and left side of the face, without affection of sensation. Death occurred from gangrenous erysipelas of the face.

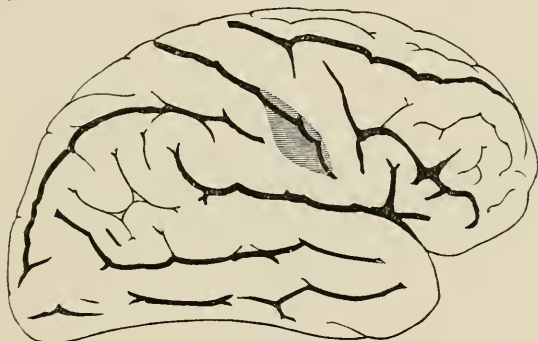

FIG. 43.

In the right hemisphere, a small focus of hæmorrhage formed by the juxtaposition of three minute extravasations, each of the size of a mustard-seed, was found in the medullary fibres at the junction of the middle frontal with the ascending frontal convolution (fig. 44).

Other similar instances might be quoted in connection with lesions in the medullary fasciculi. For these reference may be made to M. Pitres' work, and for other cases of brachio-facial monoplegia in connection with cortical lesions the reader is referred to the works of Landouzy and Grasset, above

<sup>1</sup> *Atlas*, liv. xx., plate 4.

<sup>2</sup> *Archiv für Psychiatrie*, 1875, p. 327.

<sup>3</sup> *Lésions du Centre Ovale*, p. 76, plate-ii., fig. 3.



mentioned, as also to a recent memoir by Dr. Maragliano, 'Le Localizzazioni Motrici nella Corteccia Cerebrale,' 1878. I have selected only those in which the lesion was of such a nature as fairly to exclude objections on the score of pressure, diffuse inflammatory, or obvious indirect action.

A comparison of the position of the lesions, in these various cases, with the position assigned to the manual and facial (areas 7, 8, 11, fig. 27) centres will show a very close correspondence. The lesions causing brachio-facial paralysis are all towards the middle or lower third of the ascending convolutions, where experiments on monkeys establish the position of the facial and manual centres.

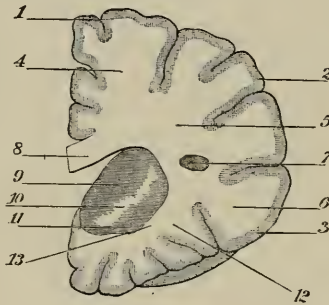


FIG. 44.

*Facial Monoplegia.*—Facial paralysis of the cerebral type, *i.e.*, paralysis limited almost exclusively to the lower facial region—is not a very common occurrence by itself in connection with cortical disease. Usually, it is complicated with brachial paralysis or with aphasia; with the latter more especially when the lesion is in the left hemisphere. This is naturally to be expected from the proximity of the facial centres ([7] [8], [11], fig. 27) to those of the arm and hand already indicated and to the oro-lingual centres ([9] [10], fig. 27).

Brown-Séguard<sup>1</sup> has collected a number of cases of facial paralysis, 'seemingly caused' by lesions in various parts of the brain, such as the frontal, occipital, and temporo-sphenoidal lobes; but as there is far from being a constant relation between

<sup>1</sup> *Lancet*, April 1877.



such lesions and motor paralysis of any kind, as will appear subsequently, and as there seems to have been no attempt at differentiation between peripheral and central facial paralysis, the facts have little or no bearing on the question of localisation.

The cases on record in which paralysis limited to the face uncomplicated by aphasia, or paralysis of the hand or arm, has been found in connection with cortical disease have been due to lesion of the right hemisphere; but in none can the lesion be said to have been circumscribed. Charcot and Pitres<sup>1</sup> give a

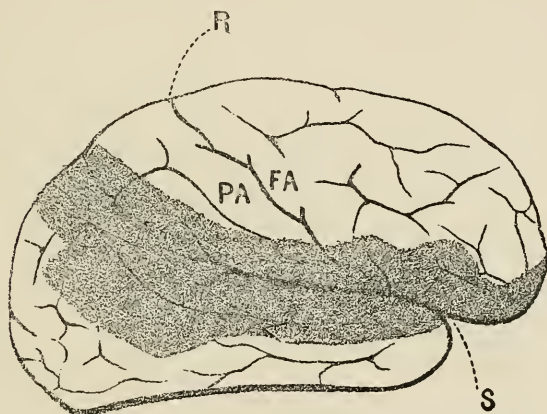


FIG. 45.

case, with a figure (fig. 45), of a lesion, extensive in one sense, but limited as regards the motor area of the brain involved. This was a case of apoplexy with facial paralysis and early rigidity of the limbs on the left side. The rigidity of the limbs disappeared, but the facial paralysis persisted till death. An extensive area of softening was found in the right hemisphere, invading the third frontal, the lower extremities of the ascending convolutions, and a large extent of the parietal, temporo-sphenoidal, and insular lobes.

Hitzig<sup>2</sup> relates the case of a French soldier, who, two months after a bullet-wound on the right side of the head,

<sup>1</sup> *Revue Mensuelle*, 1877, p. 181.

<sup>2</sup> *Archiv für Psychiatrie*, 1872, p. 231.

began to be affected with clonic spasms in the left side of the face. These were followed by transient, but complete, paralysis of the left side of the face and left side of the tongue. Clonic spasms occurred also in the left hand. After death, an abscess was found corresponding to the seat of the injury, situated in the *ascending frontal convolution, between the præ-central fissure and the fissure of Rolando* (fig. 46). It should, however, be noted that there were indications of meningeal inflammation over the whole surface of the right hemisphere, though there was no cerebral softening except in the neighbourhood of the abscess. A similar case is reported by Wernher.<sup>1</sup>

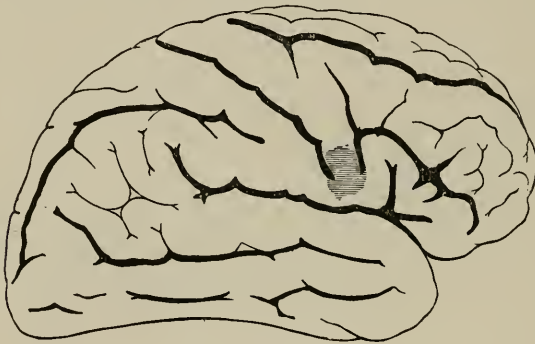

FIG. 46.

Had the lesions been in the left instead of the right hemisphere, we should in all probability have had the symptoms of aphasia superadded, as in the following case—to select one from a host—related by Hervey.<sup>2</sup> This was a case of right facial paralysis with aphasia. A focus of softening was found anterior to the fissure of Rolando, at the junction of the third frontal with the ascending frontal convolution of the left hemisphere (fig. 47).

Dr. Gowers<sup>3</sup> has reported a case of left hemiplegia, which gradually recovered, with the exception of very marked paralysis of the inferior facial muscles. Under the influence of

<sup>1</sup> *Archiv für Path. Anat. und Physiologie*, Bd. lvi. p. 289.

<sup>2</sup> *Bull. Soc. Anat.*, 1874, p. 29.

<sup>3</sup> *Path. Transactions*, 1876, p. 35.

emotion, however, the muscles acted equally well on both sides. (This is a good illustration of what has been stated to be the essential character of cortical paralysis, p. 22.) The lesion was hæmorrhagic extravasation in and beneath the upper half of the præ-central sulcus, which had pressed upon the convolutions bounding it—viz., the posterior extremity of the middle and superior frontal, and corresponding part of the ascending frontal of the right hemisphere.

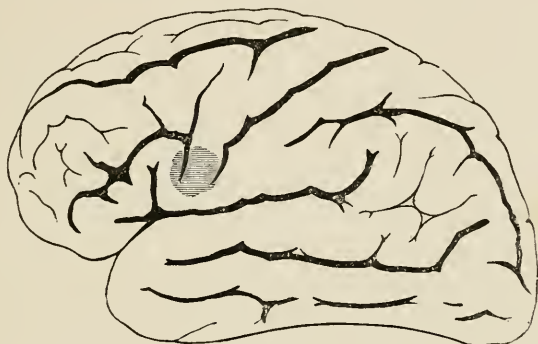


FIG. 47.

*Aphasia.—Oro-lingual Hemiparesis.*—Lastly, we come to the consideration of the effects of destructive lesions of the motor centres, which I have termed the oro-lingual centres (fig. 27. [9, 10]). These centres, as I have shown experimentally in monkeys and other animals, have a more or less bilateral action. Hence, unlike the effects of destructive lesion of the limb centres, destructive lesions of these centres in the one hemisphere do not cause paralysis, but only, if anything, slight unilateral weakness or hemiparesis of the oro-lingual movements. As is well known, lesions of this region in the left hemisphere are generally associated with aphasia or speechlessness. The symptoms of lesion here have both an objective and subjective aspect. The former is oro-lingual hemiparesis, the latter is the remarkable psychological affection—aphasia. I have elsewhere<sup>1</sup> endeavoured to explain the relation between the physiological and psychological functions of the motor centres of articulation,

<sup>1</sup> *Functions of the Brain*, § 99.

and will not enter further into this subject at this time. Nor do I think it necessary, in the present state of clinical medicine and pathology, to take up time with an enumeration of cases of aphasia associated with lesions in this region, generally termed Broca's region or convolution. I would only make a few observations in reference to certain objections which have been urged by the opponents of localisation of a speech centre, or of localisation of function in the cortex generally.

The occurrence of aphasia in the immense majority of instances in connection with disease of the left hemisphere and with disease in a region which, as you will see by reference to the diagrams, corresponds with the oro-lingual centres in the monkey ([9, 10], fig. 26), is a fact which can no longer be disputed. It is also a fact that, in the great majority of instances, aphasia is associated with a greater or less degree of right hemiplegia or monoplegia, of which the most frequent is facial or brachio-facial paralysis.

It is necessary that those who dispute the validity of inferences as to causal relationship between the lesions indicated and aphasia should clearly understand what is contended for by those who consider this relationship established. Aphasia, in the strictly limited sense of the term, or Broca's aphasia, does not mean speechlessness from paralysis of articulation, nor speechlessness from general cerebral disturbance, such as emotional shock, &c., but the inability to express thoughts in articulate speech, or to think in words, and all that this implies.

Nor does it mean, in the sense in which it is to be understood in connection with lesions of Broca's region, such disorders of speech as depend on want of comprehension of the meaning of spoken or written symbols ('Cæcitas et surditas verbalis.'—Kussmaul).

It is not contended that there is an absolute restriction of the speech centre to the left hemisphere. This, though the rule, is not an absolute rule, but only an approximate generalisation, and therefore exceptions may be admitted without invalidating the localisation of the speech centre in one side or the other, which is what is really maintained. Hence, to overturn the localisation of a speech centre, it is not enough to bring forward

a case of lesion of the left speech centre without aphasia. This is admitted by all; and it is a very significant fact, that in several at least of the cases of aphasia with disease of the right speech centre, the patients have been left-handed.

It is incumbent upon the opponents of the doctrine of localisation to bring forward a case in which, with bilateral lesion of this centre, no aphasia occurred. But, I need scarcely say, no such evidence exists.

The effect of a bilateral lesion would be, according to the results of experimental physiology, both aphasia and anarthria, or paralysis of articulation.

A striking, and perhaps unique, instance of this has been put on record by Dr. Barlow.<sup>1</sup> A boy aged 10, the subject of aortic disease, of which he ultimately died, was seized with right hemiplegia, chiefly brachio-facial, and aphasia. Of this he had apparently recovered at the end of a month. Three months after, he was seized with left brachio-facial monoplegia. This time there was not only aphasia, but paralysis of all voluntary movements of the mouth and tongue. Reflex deglutition, however, was unimpaired. There was no affection of sensation in the paralysed parts, either in the skin or mucous membranes of the palate, &c., and the muscles reacted normally to the faradic current. 'To sum up the cerebral condition,' says Dr. Barlow, 'there appeared to be loss of voluntary motor power over the muscles concerned in deglutition and articulation.' This lasted till death, while the arms improved somewhat in power. Intelligence was fair, and comprehension good. On post-mortem examination, a lesion was found in each hemisphere, and in exactly corresponding situations. The region involved by the lesion—which was yellow softening—was 'the lower end of the ascending frontal and the hinder end of the middle and inferior frontal convolutions' (fig. 48).

This case, in all its features, whether we look at it as an experiment of disease, approaching to the conditions of an exact and precise experimental lesion, or to the care with which it was observed and differentiated from peripheral or bulbar paralysis, is a most satisfactory and conclusive demonstration of the harmony between human pathology and experimental physiology.

<sup>1</sup> *Erit. Med. Journal*, July 28, 1877, p. 103.

Some ingenious—if we cannot call them successful—attempts have been made to overthrow the causal relationship between lesions in Broca's region in the left hemisphere and aphasia, and to make it a relationship merely of coexistence.

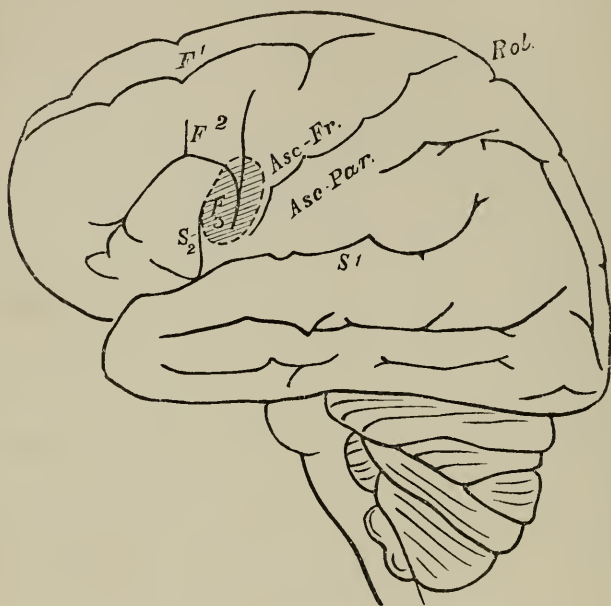

FIG. 48.

As embolism or thrombosis of the left middle cerebral artery, or one of its branches, is perhaps the most frequent cause of aphasia, it has been suggested by Jaccoud and others, that the greater frequency of aphasia with left cerebral lesion might be accounted for by the greater frequency of embolism in the left middle cerebral artery than in the right. That this is so appears to be an indisputable fact, and perhaps to be accounted for by the physical conditions of the blood-supply. Meissner<sup>1</sup> found in 38 cases of embolism, 26 in the left and 12 in the right; and Bertin found 31 cases of embolism of the left to 7 of the right middle cerebral. Aphasia, however, does not always depend on embolic softening; and if we take the rela-

<sup>1</sup> For these various statistics I am indebted to Kussmaul, 'Die Störungen der Sprache,' *Ziemssen's Handbook*, vol. xii. Anhang, 1877.



tive frequency of softening due to any cause, in the right and left hemisphere respectively, we find, according to Andral's statistics, that the right hemisphere is more liable than the left. Thus out of 169 cases, 73 were in the right, 63 in the left, and 33 in both hemispheres. And in reference to diseases of the hemispheres generally, Charcot and Vulpian found the relative proportions in the two hemispheres very nearly equal. They found 58 cases of left hemiplegia with disease of the right hemisphere, to 52 cases of right hemiplegia with disease of the left. As regards the relative frequency of aphasia with right and left hemiplegia respectively, Seguin found, from an analysis of 266 cases of hemiplegia with aphasia, 243 with right hemiplegia, and 17 with left hemiplegia; *i.e.*, a proportion of 14·3:1. Now, if we take Bertin's statistics as to the relative proportion of embolism of the left and right middle cerebral as 4·4:1, and Seguin's association of aphasia with lesion of the left hemisphere as 14·3:1, we have, in favour of the association of aphasia with lesion of the left hemisphere, a preponderance of 10:1, which cannot be accounted for by mere fortuitous collocation; and even if the arguments founded on the relative frequency of disease in the left and right hemisphere respectively, had not been thus shown to be without foundation, they would be at once disposed of by cases of aphasia resulting from traumatic lesions of the left hemisphere. Several interesting cases of this kind are on record.

Sydney Jones<sup>1</sup> gives a case of aphasia resulting from fracture of the left side of the skull by the kick of a horse. After death, an abscess of the size of a nut was found in the medullary substance of the third left frontal convolution.

Simon<sup>2</sup> gives a case of a healthy man who fell from horseback, and who was found by a physician who came up to be aphasic, and without any signs of paralysis. Death occurred from meningitis. A small wound with depressed fracture of the left side of the skull was found; and corresponding to this was a cerebral softening—surrounded by meningeal inflammation—of the third left frontal (in which a spiculum of bone was imbedded), the second frontal, and the island of Reil.

<sup>1</sup> *Lancet*, 1873, vol. ii., p. 449.

<sup>2</sup> *Berliner Klinische Wochenschrift*, 1871.

A similar case of aphasia from fracture of the left side of the skull, in which recovery took place on trephining, has been recorded by MM. Proust and Terillon.<sup>1</sup>

Mr. Mac Cormac<sup>2</sup> has recorded a case of aphasia with right brachio-facial paralysis caused by a traumatic lesion of the left hemisphere, which also recovered.

That gross anatomical lesions have not always been discovered in Broca's region in cases of aphasia may be true, but this, from the considerations advanced above, is a fact of no value against the localisation of the speech centre here. Perhaps they might have been discovered more frequently if careful search had been made, for on more than one occasion they have been found, when supposed absent, in the subjacent medullary fibres. Of instances of this kind several have been collected by M. Pitres.<sup>3</sup> In one case observed by himself, of right hemiplegia and aphasia, no lesion was found in the cortex in Broca's region, but on section a zone of softening was found in the centrum ovale, affecting the inferior pediculo-frontal fasciculus (fig. 49).

The clinical evidence alone is amply sufficient to establish the relation between aphasia and lesion of Broca's region as an empirical generalisation; but when we take into consideration also the facts of experimental physiology and the light they throw on the motor substrata of mind, the connection between lesion of Broca's region and aphasia is no longer merely an empirical generalisation, but a derivative law, which in my opinion is established on as firm grounds as any other fact in scientific medicine.

*Diagnosis of Cortical Paralysis.*—Apart from considerations as to the diathetic indications, mode of onset, &c., of the affection, there are no features which clearly enable us to distinguish between hemiplegia depending on general destruction of the motor area of the cortex, and hemiplegia due to destructive lesions of the corpus striatum, more particularly those involving the anterior two-thirds of the internal capsule. There is the same relative affection of the different movements; those being most paralysed which are most volitional, at least after

<sup>1</sup> *Acad. de Médecine*, November 1876.

<sup>2</sup> *Brain*, Part ii., 1877, p. 256.

<sup>3</sup> *Lésions du Centre Ovale*, Obs. xxxviii., plate 2, fig 2.

the first rude shock of the disease has subsided. The facial paralysis is seen especially in the lower facial region, or in those movements which are most independent; while the frontal and the orbicular muscles of the eye are but slightly affected. The movements of the leg are less paralysed than those of the arm, and the proximal movements of the arm less than those of the hand. Sensation is not affected, if the lesion be strictly limited to the cortex, or to the anterior two-thirds of the internal capsule; and in neither case is the nutrition or electric contractility of the paralysed muscles directly impaired. The same tendency exists to the development, sooner or later, of descending sclerosis of the motor tracts of the crus, pons,

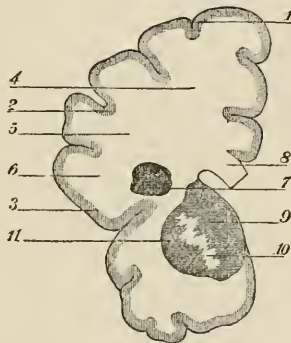


FIG. 49.

medulla, and spinal cord, and the appearance of late rigidity or contracture of the paralysed limbs. This late rigidity seems, according to the views of Charcot, Bouchard, Bastian, &c., to be essentially dependent on the degenerative process, and has its analogue in lateral sclerosis of protopathic origin. Hughlings Jackson, however, looks on late rigidity as a species of tonic distortion, caused by the cessation of the cerebral influence, and the consequent unantagonised action of the cerebellar centres; for, says he, 'there is unimpeded cerebellar influx, and hence rigidity of the muscles which in health the cerebrum chiefly innervates.'<sup>1</sup> But if this were so, we should expect the antagonism or cerebellar influx to show itself at the beginning

<sup>1</sup> *Med. Examiner*, April 5, 1877.

of the paralysis; for distortion, consequent on the cessation of an antagonist, is always most marked at the commencement, whereas, in the rigidity of hemiplegia, it is usually weeks or months before it sets in. And if it were cerebellar influx, I should further look for the rigidity in the extensor muscles of the trunk and legs, owing to the more especial relation of the cerebellum to these movements as indicated by experiment; whereas the very contrary holds, as the rigidity is most marked, and, in a large majority of cases, is confined to the arm and flexors more especially. The rigidity, in fact, seems to affect those muscles most which are most paralysed by destructive lesions of the hemispheres. If it be objected—and this seems to be the main objection—that the remittent or intermittent character of the late rigidity, in its early stages, militates against the idea of its being dependent on a permanent organic lesion, we can find analogous phenomena. The neuralgic pains which are associated with progressive sclerosis of the posterior columns of the spinal cord are not constant, but remit, intermit, or vary under different conditions, which modify the nutrition and activity of the nerve-centres. So we may account for variations in the state of contracture, depending as we may regard it on irritation induced by the chronic myelitis of the motor tracts. It is possible also that in some cases reflex contracture may be superadded, by the irritation extending to sensory tracts. Duret<sup>1</sup> is inclined to attribute late rigidity exclusively to reflex irritation; but it is not the recognised character of reflex spasm to be tonic or continuous, but rather clonic and intermittent. And if irritation of the sensory tracts existed to such an extent as to keep up such constant and marked contraction, we should certainly observe more clear indications of sensory disturbance than are discernible in old standing hemiplegia with rigidity.

It is true, as Charcot<sup>2</sup> has pointed out, that in protopathic lateral sclerosis, joined with amyotrophy, there are sensory disturbances such as spontaneous pains, formication, &c., and also very marked pain on pressure or traction on the muscles, but in this disease the sclerosis does not remain limited to the lateral columns, but extends into the grey matter.

<sup>1</sup> *Brain*, 1877, Part i. 'On the Rôle of the Dura Mater in Cerebral Traumatism.

<sup>2</sup> *Leçons sur les Maladies du Système Nerveux*, 3me partie, p. 233.

Sclerosis depending on cerebral lesion, however, remains, as a rule, confined to the pyramidal strands, though in some cases it extends transversely into the grey matter, and gives rise to trophic and other disturbances.<sup>1</sup>

As regards the temperature of the paralysed limbs, in central and cortical disease respectively, there is some difference of opinion as to the relations of the cortex to the vascular system. It is, however, generally stated<sup>2</sup> that there is less difference in temperature between the two sides when the paralysis depends on cortical than on central disease, and subsides more rapidly. It is certainly less marked than in paralysis due to mesencephalic lesions. Experiments have been made on animals, with a view to determine the question; but the results do not seem quite in harmony with each other. Eulenburg and Landois state that vaso-motor paralysis occurs in dogs, in consequence of destruction of the cortical motor centres in this animal, and in this they are supported by Hitzig. Vulpian, however, contests these facts. And it would appear, from a preliminary communication by Küssner,<sup>3</sup> that, in rabbits at least, no vaso-motor paralysis occurs from cortical lesions. These discrepancies appear to me to be more apparent than real, and that the same law holds good in reference to vaso-motor paralysis, which is observable in reference to the degree of motor paralysis following cortical lesions in different animals, and in respect to different movements in the same animal. Motor paralysis from cortical lesions varies with the degree of independent organisation of the movements in the centres situated beneath the cortex. Hence the comparative escape and rapid recovery of certain movements as compared with others. That this holds also in respect to vaso-motor affections appears established by the observations of Lépine.<sup>4</sup> Lépine has shown that the vaso-motor paralysis, and therefore the difference of temperature in hemiplegia, is more marked in the arm than in the leg, just as the motor paralysis is greater in the one than in the other. That vaso-motor should accompany motor paralysis from cortical lesions

<sup>1</sup> Bastian, *Paralysis from Brain-Disease*, p. 173.

<sup>2</sup> *Op. cit.*, p. 243.

<sup>3</sup> *Centrallblatt für die Medicin. Wissenschaften*, November 10, 1877.

<sup>4</sup> *La Localisation dans les Maladies Cérébrales*, p. 85.



is, I think, what might be expected, from what we know of the physiology of motor and its correlated vaso-motor innervation; and that such vaso-motor paralysis should subside more rapidly in cases of cortical lesion would, I think, be in harmony with the comparative escape of movements independently organised in lower centres. To the coincident vaso-motor disturbances, I would ascribe the subjective sensations of numbness, tingling, and the like, which so frequently usher in paralysis or spasm in connection with lesions of the motor centres, rather than look upon them as projected central sensory irritation.

Hemiplegia, complete from the first and permanent, is not, however, the most common type of paralysis depending on lesion of the cortex or subjacent medullary fibres. More frequently, paralysis of cortical origin is fractional or dissociated, or is a succession of dissociated paralyzes or monoplegiæ. In cortical affections, we frequently find a hemiplegia, at first complete, resolving itself into a monoplegia; or a monoplegia becoming a hemiplegia by progressive advance of the disease to other motor centres. This latter is a significant indication of cortical disease. Paralysis of voluntary motion of the arm and leg; of the arm and face, or this combined with aphasia, if the lesion be in the left hemisphere; or paralysis of the inferior facial region: of the arm alone; or of certain movements of the hand and arm; or of the leg alone; without affection of sensation, and without qualitative or quantitative changes in electrical contractility, or direct impairment of nutrition, may be looked upon as depending on lesions of the cortex or subjacent medullary fibres.

Monoplegia is very often associated with monospasm or early rigidity of the paralysed limb, or of the muscles governed by the centres surrounding the lesion. Sometimes the paralysed limb may remain motionless while convulsions occur in the others.

Cortical paralysis is frequently erratic and transitory, more especially in connection with superficial or meningo-encephalitis; appearing and then vanishing, first on one side and then on the other. According as the lesion is superficial or invading the whole depth of the cortex and subjacent medulla, we get transitory paralysis, or a paralysis which re-



mains permanent, and is followed by descending sclerosis and late rigidity.

Whereas early rigidity is of frequent occurrence in cortical disease, it is rare in central cerebral disease; and then particularly, it would seem, when the medullary fasciculi of the fronto-parietal region are irritated—a condition generally found in connection with hæmorrhagic effusions into the lateral ventricles. Consciousness is less frequently lost in cases of sudden cortical lesion than when similar disease occurs in the central ganglia. This is to be accounted for by the special tendency in the latter case to sudden displacement of the cerebro-spinal fluid, and, through this, general disturbance of the cerebral circulation, in the manner indicated by Duret.

As an accessory element in the diagnosis of cortical lesions, may be taken the fact, noticed by Callender<sup>1</sup> and others, that cortical lesions are more frequently accompanied by localised pain in the head; and I have frequently observed that, even when pain is not spontaneously complained of, it may be brought out by percussion over the seat of lesion.

While we cannot be quite certain of the position or extent of a cortical lesion causing a sudden and complete hemiplegia, we may take a monoplegia of the leg, or of the arm and leg, as an indication of lesion of the upper extremity of the ascending convolutions close to the longitudinal fissure; brachial monoplegia, as a sign of lesion of the upper part of the ascending frontal convolution, or, if the paralysis affect the hand more particularly, of the ascending parietal convolution; brachio-facial monoplegia as indicating lesion of the mid-fronto-parietal region; while facial and lingual monoplegia, or this combined with aphasia, indicates lesion of the lower part of the ascending frontal convolution, where the third frontal unites with it.

<sup>1</sup> *Barth. Hosp. Reports*, 1869.

## LECTURE III.

II. *Irritative Lesions of the Motor Area.*—Hitherto I have directed your attention more particularly to destructive lesions of the motor area indicated by paralysis of voluntary motion, general or partial, theoretically separating them from irritative lesions indicated by unilateral convulsions or monospasms. Practically, however, they cannot be separated from each other by a hard and fast line; for many cases of limited destructive lesions are associated with unilateral convulsions or monospasms, and I have already referred to instances of this association. There are numerous cases, however, in which the predominant, and sometimes the only, feature has been a convulsive affection limited to a limb or combined in the way in which monoplegiæ are combined, or which, commencing in a constant or definite way, becomes generalised into an unilateral convulsion with or without loss of consciousness, or occasionally passes into bilateral convulsions. It is the great merit of Hughlings Jackson to have first clearly indicated the pathology of these affections.

I have already alluded to some of the observations and generalisations which had been made by Bravais, Bright, Wilks, &c.; and I ought to mention here the very close approximation to regional localisation of the lesions most commonly associated with convulsive affections of the opposite side at which Mr. Callender<sup>1</sup> arrived. Callender found that convulsions occurred more particularly with superficial lesions of the cortex in the neighbourhood of the middle meningeal artery; an approximation amply borne out by subsequent clinical and experimental research.

From the mere occurrence of an unilateral convulsion with

<sup>1</sup> *St. Bartholomew's Hospital Reports*, 1867; *Medico-Chirurgical Trans.*, 1871.

loss of consciousness, or of an epileptic attack in which the convulsions are exhibited mainly on one side, we can form no opinion as to the nature or seat of the lesion. We may suppose, and with reason, that the opposite cerebral hemisphere is more particularly at fault; but there need be no discoverable lesion; and, should a lesion exist, it need not be in any definite position. This is in accordance both with clinical facts and also with those of experiment, for I have found that long continued irritation applied to any part of the hemisphere other than the motor area may result in an attack of unilateral convulsions. If, however, the convulsion be of the character of a monospasm, or if, tending to become generalised, it begin invariably in the same way and do not cause loss of consciousness, and if it be followed by paresis or paralysis more or less permanent, we may diagnose an irritative lesion of the motor area of the opposite hemisphere.

The seat of the lesion may be approximately determined by the rules as to the localisation of destructive lesions, but only approximately, as the diagnosis of the seat of an irritative lesion is naturally more uncertain than that of a destructive lesion, owing to the difficulty of determining the extent of the zone or the special point in this zone in which vital irritation concentrates itself. Yet many cases are on record in which the phenomena of irritation have been such as to allow exact regional diagnosis in accordance with the principles of localisation of distinct centres.

Irritative lesions vary in their morbid anatomy. They are all such as tend to induce irritability and hyperæmia of the cortical grey matter or subjacent medullary tracts; a condition which I have invariably observed in my own experiments. Magnan<sup>1</sup> has found the same condition of hyperæmia of the cortex in the epileptic convulsions induced by the introduction of absinthe into the system; and MM. Pitres and Franck<sup>2</sup> have shown that, in the partial or unilateral epileptiform attacks to which dogs are liable after injury to the cortex, the grey matter surrounding the cicatrix is so hyperæmic, tumefied, and irritable,

<sup>1</sup> *Recherches sur les Centres Nerveux*, 1876, p. 101.

<sup>2</sup> *Le Prog. Méd.*, January 5, 1878.

that even mechanical stimulation, which normally has no effect, is sufficient to cause motor discharge.

The irritative lesion may, therefore, be an acute inflammation, or a condition of irritability set up by some chronic morbid product. Most frequently the lesion is some form of meningo-encephalitis; and of these syphilitic disease is by far the most common, so that now syphilitic epilepsy is sometimes spoken of as synonymous with 'Jacksonian epilepsy.' Tubercular affections, tumours or cysts situated superficially, cicatrices of old wounds, spicula of bone, &c., are all capable of producing irritation.

Hughlings Jackson is of opinion that the lesion causes the centres to become charged to a state of high tension, so that, under certain vital conditions, they discharge themselves in a sudden and explosive manner, and become exhausted for the time being; hence the temporary epileptic hemi- or monoplegia. This would account for the occurrence of intermittent effects with a constant lesion; for, according to the law of discharge formulated by G. H. Lewes,<sup>1</sup> stimulations which fall short of actual discharge of a nerve-centre increase the tension; hence, after a certain accumulation of stimuli, sudden discharge is readily induced.

Frequently the disease, which begins as an irritative lesion, tends to invade and destroy the region on which it grows, and leads to permanent paralysis with secondary degeneration; irritative phenomena being liable to occur so long as the vitality of the grey matter and subjacent medullary fibres has not been absolutely annihilated.

'Jacksonian epilepsy,' in the early stages at least, has frequently a character of a monospasm, which may be brachial, facial, or crural, or these combined, as in the manner of monoplegiæ. When the monospasm tends to become generalised into unilateral convulsion, the spasms seem to march usually in a certain definite order. In facial monospasm, the arm next becomes affected, and then the leg. If it commence in the hand, it goes up the arm, then to the face, and next attacks the leg. If it begin in the leg, it next invades the arm, and then the face. This order is very rarely inverted. Usually, when the

<sup>1</sup> *Physical Basis of Mind*, p. 290.

convulsions have become unilateral, consciousness is lost, if not before. When the convulsion becomes bilateral, as is sometimes the case, Hughlings Jackson thinks that the spasms march in the reverse order; *e.g.*, if it have passed to the leg from the face, it ascends the opposite leg, and so to the arm and face. I have not confirmed this in experiments on animals, for I have frequently seen the same order followed on the other side as on that on which the spasms began. It would be in accordance with the bilateral association of motor nuclei (which Dr. Broadbent has applied so successfully to the explanation of the comparative escape of bilaterally associated movements in cerebral disease), that bilaterally associated movements should have most tendency to be discharged together. This fact has been well brought out by MM. Franck and Pitres, for they have shown that bilateral convulsions may still occur from excessive irritation of one hemisphere even when the motor centres of the other have been extirpated.

And many clinical cases might be cited which do not support the views of Hughlings Jackson as to the march of bilateral spasms.<sup>1</sup> It is not, however, my intention to discuss at length the pathology and symptomatology of irritative lesions: subjects which are well known to the profession in this country through the writings of Hughlings Jackson, and abroad more particularly through the writings of M. Charcot. I will content myself with calling attention to one or two of the more accurately recorded cases of circumscribed lesions with irritative symptoms, in order to show how closely the situation of irritative lesions (notwithstanding all the elements of uncertainty pertaining to them, as compared with destructive lesions) may be determined from the symptoms manifested; and, as I have already intimated, I allude only to those in which irritation or spasm was the predominant or only symptom, and only to those verified by *post-mortem* examination, though I might justifiably cite others of the same kind, depending particularly on syphilis, which recover.

1. *Crural Monospasm or Protospasm.*—Of spasms limited

<sup>1</sup> See Gowers's 'Cases of Convulsion from Organic Brain-Disease' (*Brit. Med. Journal*, September 26, 1874); 'Case of Intracranial Tumour,' by Bramwell (*Brit. Med. Journal*, September 1, 1877).



to the leg, or invariably commencing in the leg, there are not many cases on record free from complication with paralysis, or in which the lesion remained circumscribed till death. I have already quoted two cases by Bourneville, in which crural monospasm complicated with paralysis was the chief symptom.

A case is recorded by Broca<sup>1</sup> of crural monospasm caused by injury to the left side of the skull which was cured by trephining; but the exact position of the lesion I do not find recorded.

MM. Charcot and Pitres<sup>2</sup> quote a case from Griesinger of spasm of the leg frequently recurring, and also invading the arm, followed in the interval by paralysis of the leg and arm. The lesion, however, was not strictly limited in this case. A hydatid cyst 4 centimètres × 4·3 centimètres was found on the surface of the opposite hemisphere, in such a position that its anterior border corresponded with a line drawn perpendicularly upwards from the external auditory meatus, *i.e.*, about the upper extremity of the fissure of Rolando. There were also several small cysts on the frontal and parietal surface of the hemisphere. If the spasm can be ascribed exclusively to the large cyst, then its position agrees with the motor centres of the leg (fig. 27, [1] [2]).

Hughlings Jackson<sup>3</sup> has described a case in which fits began almost invariably in the right leg, and were frequently limited to it. The leg began to become weak, and more so after each fit, the paresis deepening ultimately into a permanent paralysis. In the last stages, signs of general affection of the left hemisphere—aphasia, &c.—manifested themselves. A tumour was found at the upper posterior part of the left frontal lobe, about two inches in diameter, bounded posteriorly by the fissure of Rolando, and extending forward into the posterior part of the first and second frontal convolutions.

Another case is given by Hughlings Jackson<sup>4</sup> of convulsions beginning in the left great toe, often confined exclusively to the left leg, and followed ultimately by paresis of the left foot. This patient also had paralysis of the right third nerve. After

<sup>1</sup> Soc. de Chirurgie, meeting of December 16, 1866.

<sup>2</sup> *Revue Mensuelle*, 1877, p. 369.

<sup>3</sup> *Medical Times and Gazette*, September 4, 1875.

<sup>4</sup> *Ibid.*, September 18, 1876.



death, a syphilitic lesion was found 'at the upper part of the posterior ascending or ascending parietal convolution, extending over part of the upper end of the ascending frontal and over several of the adjacent convolutions of the parietal lobule' of the right hemisphere. On the right third nerve, a tumour of the size of a pea was found. This case is in exact correspondence with the situation which I have assigned to the motor centres of the foot and leg (fig. 27, [1] [2]).

2. *Brachial Monospasm or Protospasm.*—Of spasms limited to, or beginning in, the arm or hand, depending on localised cortical lesion, there are several cases on record. As a rule, the fits begin in the fingers, and more especially in the thumb and index finger—in the most volitional movements of the upper extremity, according to Hughlings Jackson—but this is not necessarily or invariably so. In the upper extremity, it must be remembered, there are several combinations of movements which have each a representative in the cortical motor area. These centres being all situated close to each other, and all liable to be discharged by one irritative lesion, it is nevertheless possible that each may be the primary origin of the discharge, and so the mode in which the monospasm commences may vary accordingly. Hence the necessity of making minute investigation of the march of the spasm in any particular case.

Hughlings Jackson has recorded several cases of brachial monospasm. I will only mention those in which the lesion of the cortex was single and circumscribed. A man had frequent convulsions limited to the right arm, which subsequently became partially paralysed. A nodule was found situated at the hinder extremity of the first frontal convolution of the left hemisphere. In this case, there was also a tumour in each lobe of the cerebellum, but there were no cerebellar symptoms. The march of the spasm was not recorded.<sup>1</sup>

In a second case of convulsions, nearly always limited to the right arm, and followed by temporary paralysis of that arm after each fit, the lesion, which was diagnosed by Hughlings Jackson during life, was a nodule, situated at the 'posterior extremity of the first frontal convolution where it joins the

<sup>1</sup> *Medical Mirror*, September 1, 1869.

ascending frontal.' In this case, it was noted that the spasms always began in the shoulder and went *down* the arm, contrary to the usual order.<sup>1</sup> This is an important case, as showing that the spasm began in muscles which, as the experiments on monkeys indicate, relate to the movement of the arm as a whole, and not to those of the fingers or wrist (fig. 26, [3] [4] [5]).

In a third case,<sup>2</sup> convulsions invariably began in the left thumb. After death, a tumour of the size of a hazel-nut was found under the grey matter at the posterior extremity of the third frontal convolution of the right hemisphere. Some granulations existed in the bed from which it was enucleated, or in the grey matter near it.

In a fourth case, the spasms began in the right hand, and occasionally in the right cheek. Before death, left hemiplegia came on, which, however, soon passed off. Disease was found in both cerebral hemispheres, probably syphilitic. In the left hemisphere, *i.e.*, the side opposite the spasms, adhesion was found between the dura mater and the brain in a region including 'the lower part of the ascending frontal and ascending parietal convolutions, to a trifling extent to the hinder part of the third frontal, and several of the convolutions of the upper wall of the fissure of Sylvius behind the ascending parietal.' In the right hemisphere—the side opposite the paralysis—'on the surface, behind the fissure of Rolando, was a mass about the size of a chestnut. The dura mater was firmly adherent to it. There was very little softening about it.'<sup>3</sup>

In a fifth,<sup>4</sup> temporary right hemiplegia came on after an unilateral convulsion in which the patient did not lose consciousness. Convulsions occurred from time to time, beginning in the little finger of the right hand, occasionally in the right cheek, and followed always by slow and hesitating speech. After death, a syphilitic tumour of considerable size—as large as three small walnuts—was found growing into the cortex about the junction of the frontal and parietal lobes, surrounded by an area of softening in the posterior part of the frontals, ascending frontal and ascending parietal, and partly of the

<sup>1</sup> *Medical Times and Gazette*, June 5, 1875.    <sup>2</sup> *Ibid.*, November 30, 1872.

<sup>3</sup> *Ibid.*, December 28, 1872.

<sup>4</sup> *Ibid.*, March 1, 1873.

island of Reil. The sphenoidal lobe was also softened. This case, though of interest, is rather a complex one, and should, perhaps, scarcely be quoted as a limited lesion.

Dr. Dreschfeld<sup>1</sup> has recorded a very interesting case of brachial monospasm depending on syphilitic disease, the nature and position of which he accurately diagnosed during life. The patient suffered from repeated attacks of convulsion limited to the left arm, of which the phenomena were 'sudden clenching of the fist, flexing of the wrist, and pronation of the forearm of the left side, the left angle of the mouth being at the same time strongly drawn downwards. This sudden tonic spasm lasted for several seconds, and was then followed by a few clonic spasms of the same extremity and a slight tremor of the arm ;

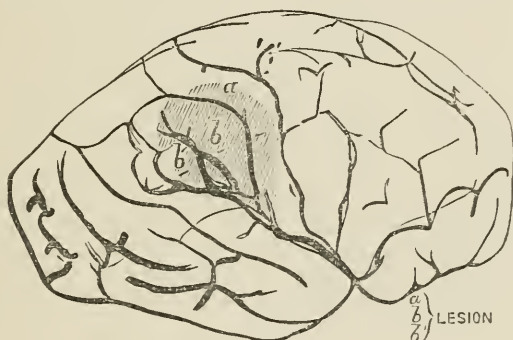

FIG. 50.

the patient at the same time was very agitated and looked very pale, but remained perfectly conscious. He stated that these paroxysms had always had the same character, varying only in degree.' Death occurred from phthisis two years after the first onset of the disease. On *post-mortem* examination, the dura mater was found adherent to the brain on the right side, over a space including the greater part of the ascending parietal convolution and the supramarginal lobule (fig. 50, *a* and *b*).

To these cases in which irritative symptoms chiefly predominated, I may add one or two others, which may be considered as belonging equally to irritative and destructive lesions. The cases are cited in full by MM. Charcot and Pitres.<sup>2</sup>

<sup>1</sup> *Lancet*, February 24, 1877.

<sup>2</sup> *Revue Mensuelle*, 1877, p. 365.

A case is recorded by Lépine, of left hemiplegia, followed by convulsions, limited chiefly to the left arm. A small hæmorrhage of the size of a nut was found at the 'posterior extremity of the first frontal convolution of the right hemisphere.' In another, by the same observer, of left hemiplegia, convulsions occurred, either limited to the left arm, or invariably commencing there. A yellow patch was found at the base of the first and second convolutions of the right hemisphere.

A third case is given by Mahot,<sup>1</sup> of monoplegia and monospasm of the right arm. A glioma of the size of a pigeon's egg was found on the middle third of the ascending frontal convolution of the left hemisphere.

In a fourth, recorded by Henrot,<sup>2</sup> convulsions began in the fingers of the left hand, and were repeated at intervals, followed by left hemiparesis. A mass of tubercle was found embedded in the grey matter of the ascending frontal convolution of the right hemisphere, about the middle third. In this case, however, there was also a small tubercular mass on the right side of the pons.

It will be seen from these cases that the situation of the lesion causing brachial monospasm is not a single definite spot; yet it is in correspondence with the position of the various centres concerned in the movement of the arm and hand. As has been already said, there are several centres, each for a distinct movement. In four of these cases, in which the spasms were said simply to be in the arm, and in one of them in which it was noted that the spasms began in the proximal movements of the arm, the lesion was situated at the *hinder extremity of the first frontal convolution*, a position which, as will be seen by reference to the figures (figs. 26, 27, [5]), corresponds with the localisation of the centres of such movements in this region.

In some cases, there was no exact description of the march of the spasm; but in those in which it was more especially noted that the spasms began in the fingers or hand, the lesion was either in, or in close proximity to, the *ascending parietal*

<sup>1</sup> Soc. Anat., December 15, 1876.

<sup>2</sup> *Un. Méd. et Scientif. du Nord-Est*, 1877, p. 94.

*convolution*, in which, in the monkey, these movements are especially centralised (fig. 26, *a b c d*). Of these Dreschfeld's case is the most striking, both as regards the precise character of the movements and the limited extent of the lesion, so precise as to have allowed of exact diagnosis, which was verified to the letter *post-mortem*.

3. *Facial Monospasm or Protospasm*.—Though partial epileptiform convulsions beginning in the face are not uncommon, and not frequently alternate with convulsions beginning in the hand, yet there are very few cases on record of facial monospasm, uncomplicated with brachial monospasm or other convulsive or paralytic symptoms, in which the position of the lesion has been verified by *post-mortem* examination.

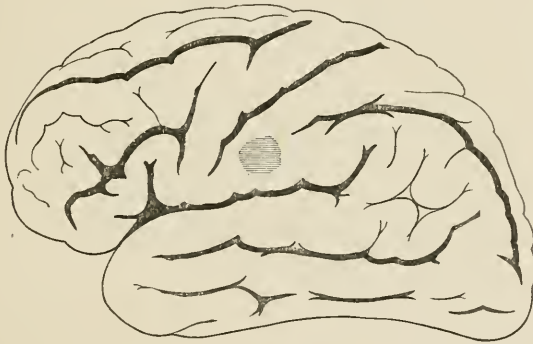

FIG. 51.

The cases of Hitzig and Wernher, already quoted, in which lingual and facial monoplegia and facial monospasm alternated, are about the best examples of this on record. The lesion—the principal, at least—in these cases was the same in position, viz., the lower extremity of the ascending frontal.

A very interesting case, illustrating another fact of experimental localisation, has been recorded by Dr. Bramwell.<sup>1</sup> A woman, who had received a cranial injury some years previously, began to have right-sided convulsions, and numbness in the

<sup>1</sup> *Brit. Med. Journal*, August 28, 1875.



thumb and forefinger, followed by paralysis of the right arm and leg. She remained subject to frequently repeated convulsions, which always began in the right platysma, and frequently were almost entirely confined to this muscle. On *post-mortem* examination, a spiculum of bone was found projecting from the inner table of the skull, and causing a very limited lesion of the inferior margin of the ascending parietal convolution (fig. 51). A reference to the figure of the brain of the monkey (fig. 26, [11]) will show that at the lower extremity of this convolution, and just posterior to the oral and lingual centres, there is an area marked off, irritation of which specially causes action of this muscle. Bramwell's case receives its explanation from this fact, and in Dreschfeld's case, in which spasm of the platysma was also a special feature, the lesion affected this point. Pathology and physiological experiment are here again in harmony.

#### B.—LESIONS OF THE SENSORY REGIONS.

I would now call your attention to the subject of lesions of the sensory regions of the cerebral hemispheres.

That the cerebral hemispheres are the seat of sensation or—in order to avoid disputes as to the meaning of sensation—of sensory perception, is abundantly evident both from the results of experimental physiology and from the facts of clinical medicine. And that the regions of the brain we have already considered, viz., the fronto-parietal regions, may be disorganised without causing loss of sensory perception, I consider to be demonstrated both by the facts of experiments on monkeys, and by the clinical evidence which I have laid before you. Some statements which have been made to the contrary, based on experiments on dogs and rabbits, are, as I hope to be able to show you, susceptible of a totally different interpretation, and one in harmony with the facts relating to monkeys and man.

It is clear, therefore, that if the centres of sensory perception are localised in the hemispheres—and this, I think, no one will dispute—they are to be sought for in those regions yet remaining to be considered, viz., the occipital and parieto-



temporal lobes. That this is so, we should be led to believe from anatomical as well as from other considerations. For, though from the intricate nature of the subject and imperfect methods, I do not place much reliance on mere anatomical investigation as a means of determining the exact course and destination and various connections of the cerebro-spinal tracts, yet, so far as main features are concerned, it furnishes us with bases for other lines of research. It has been established, I think, beyond doubt, that the posterior strands of the crus, and their connections with the brain and the cord, are more especially the paths of centripetal or sensory impressions. The researches of Meynert and others would seem to show that these tracts are connected with those parts of the cortex which we

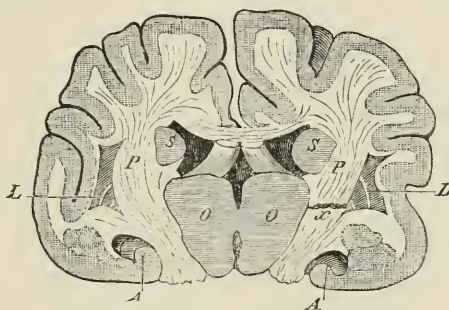


FIG. 52.

are now considering. Beyond these general indications, however, I am very sceptical as to the results of anatomical localisation. But in addition to general anatomical indications, we have experimental and pathological evidence as to the exact position of the paths which convey sensory impressions to the cortex.

The experimental evidence has been furnished by the researches of Veyssière,<sup>1</sup> which have been repeated and verified by Carville and Duret, Raymond, and others. These experiments show that when section is made of the posterior part of the internal capsule, that part of the 'projection system' which lies between the optic thalamus and lenticular nucleus of the corpus striatum (fig. 52 [x]), there ensues a condition of

<sup>1</sup> *Sur l'Hémianesthésie de Cause Cérébrale*, 1874.

hemianæsthesia of the opposite side of the body, frequently associated, temporarily however, with some degree of motor paralysis; whereas when the anterior part (two-thirds) of the internal capsule (fig. 53 [x])—that part lying between the caudate and lenticular nuclei of the corpus striatum—is divided, motor paralysis, unaccompanied by sensory paralysis, or if so, functional and fleeting, is the constant result.

The facts of human pathology are no less precise. Motor hemiplegia is invariably the result of destructive lesion of the anterior two-thirds of the internal capsule, which may be

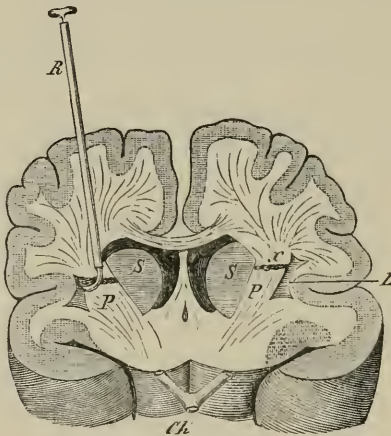


FIG. 53.

accompanied temporarily by hemianæsthesia, if the lesion be such as to cause pressure, or functional disturbance of the posterior third. And we have now a tolerably large body of evidence to show that destructive lesions limited to the posterior third of the internal capsule cause hemianæsthesia on the opposite side of the body.

The first observations relative to this localisation were made by Türck<sup>1</sup> in 1859, and since then, Charcot, Magnan, Bourneville, Rendu, Raymond, Pierret, Decaudin, Pitres, Boyer, &c., by their observations and researches, have established the pathology and symptomatology of this affection in a manner which leaves little to be desired.

<sup>1</sup> *Sitzber. der kais. Acad. der Wissensch.*, Bd. xxxv., 1859.

Since the publication of Türk's four cases, in 1859, of the association of hemianæsthesia with lesion of the posterior part of the internal capsule, there have been recorded at least twenty others, all establishing the same fact.<sup>1</sup>

The symptoms of cerebral hemianæsthesia, which correspond with those of that strange and, as regards its therapeutics, mysterious affection termed hysterical hemianæsthesia, are such as to clearly differentiate it from anæsthesia of spinal or mesencephalic origin. The special diagnostic feature is, that all the forms of sensibility, general or special, are impaired or abolished; the organs of sense whose nerves take origin above the medulla oblongata being equally affected with those which arise here. Whereas in mesencephalic anæsthesia, in addition to the usual association of alternate paralysis, sight and smell remain unaffected.<sup>2</sup>

In cerebral hemianæsthesia, tactile sensation is affected unilaterally up to the middle line of the face and trunk; there being more or less complete insensibility to touch, pain, temperature, and also abolition of muscular sensibility, with complete retention of electro-motor contractility. The conjunctival, nasal, buccal, cutaneo-mucous membranes are also anæsthetic. The viscera, however, remain sensitive, and deep pressure, as on the ovary, &c., is felt as before. In hysterical hemianæsthesia, there is usually hyperæsthesia in the ovarian region, and frequently also the condition termed by Charcot hystero-epilepsy. Taste, smell, and hearing are deficient, or almost entirely abolished in a similar manner on the one side. As regards vision, the symptoms are especially noteworthy. The eye on the anæsthetic side is rarely rendered completely blind. There is rather a condition of amblyopia or diminution of the acuteness of sight, and a very remarkable contraction of the field of vision, more especially as regards the perception of colour. Landolt has found that the field of colour-perception becomes contracted in a manner corresponding to the relative extent of the colour-field in the normal state. Normally the

<sup>1</sup> For references, &c., see Grasset, *Localisations dans les Maladies Cérébrales*. Montpellier, 1878.

<sup>2</sup> See Couty, 'De l'Hémianesthésie Mésocéphalique, *Gaz. Hebdomadaire*, 1877, p. 30 *et seq.*

blue field is the largest, next the yellow, orange, red, green, and last in order the violet, which is perceived only by the most central parts of the retina. In cerebral hemianæsthesia the sensibility for violet first disappears, then for the green, and later for the orange. Sensibility for yellow and blue may still persist; but in the higher degrees of anæsthesia, all colours merge into an uniform sepia tint. Landolt<sup>1</sup> has lately pointed out another important fact, viz., that the affection of vision is not altogether unilateral, but that the eye on the side of lesion participates, though to a less extent, in the anæsthesia.

It is further noteworthy that in this form of amblyopia, ophthalmoscopic examination reveals no organic lesion or degeneration of the optic nerve or retina, in the first instance at least; any atrophic changes which may show themselves subsequently being the consequence and not the cause of the blindness.

It is clear from these facts that the representation in each hemisphere, only of the corresponding parts of both retinae, is untenable. If this were the case, we should have, as the result of a cortical or subcortical lesion, a hemiopia of both eyes; whereas we have not a hemiopia, but an amblyopia, which, though to some extent bilateral, is most marked on the side opposite the lesion.

Yet we know that hemiopia is not an uncommon symptom in connection with intracranial disease, and is often associated with hemiplegia; but from the facts mentioned, we may conclude that in such cases the lesion must be situated or act below the cerebral cortex.

The scheme of the optic tracts and their relations, given by Charcot, enables us to give a satisfactory explanation of these facts (fig. 54). This scheme, apparently in opposition to anatomical facts according to Biesiadecki, Mandelstamm, and Michel, has received conclusive confirmation by the researches of Baumgarten<sup>2</sup> and Gowers<sup>3</sup> as to the effects of lesion of the eye and optic tract, and the degeneration which ensues in consequence. Each optic tract contains two sets of fibres; the outer, passing to the eye on the same side; the inner, decussating with their fellows

<sup>1</sup> *La France Médicale*, February 3, 1877.

<sup>2</sup> *Centralblatt für die Med. Wissensch.*, August 3, 1878.

<sup>3</sup> *Ibid.*

of the opposite side in the chiasma and passing to the corresponding part of the opposite eye. The fibres which do not decussate in the chiasma undergo decussation in the corpora quadrigemina, and pass on with the fibres which have done so to the opposite hemisphere, so that each hemisphere is brought into relation with the whole of the opposite eye. This scheme does not represent the bilateral relation of each hemisphere to both eyes, which is indicated by Landolt's researches; but we can account for this by the bilateral association in the lower ganglia. It is easy to see that a lesion of the one optic tract (κ, fig. 54) will cause bilateral hemiopia, as in a case reported

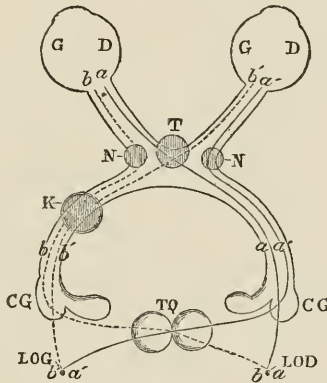


FIG. 54.

by Gowers;<sup>1</sup> and that a lesion in the region of the corpora geniculata (CG), or posterior part of the optic thalamus, will have a similar effect, as in a case reported by Hughlings Jackson.<sup>2</sup> We may also have cross amblyopia and bilateral hemiopia, as in a case reported by Gowers,<sup>3</sup> but as there was no necropsy, the position of the lesion was not verified. I hope to be able to show you that these clinical observations are in harmony with the results of my experiments on monkeys.

It is evident that the lesion which causes hemianæsthesia, being in the medullary fasciculi, produces this effect, not by

<sup>1</sup> *Centralblatt*, August 3, 1878.

<sup>2</sup> 'A Physician's Notes on Ophthalmology.'—*Lond. Hosp. Reports*, vol. viii., part ii., 1875.

<sup>3</sup> *Med. Chir. Trans.*, vol. lix., case 7.



destroying the centres of sensory perception, but by causing solution of continuity of the paths of centripetal impressions; and the question is, whether the sensory fibres, like the motor fibres of the internal capsule, are distributed to localisable areas in the cortex. On this point, experimental physiology is, I think, in some respects at least definite enough; though it must be admitted that the same cannot as yet be said of clinical medicine and pathology. To these let us now turn.

*Lesions of the Occipital Lobes.*—I will first call your attention to the occipital lobes, and compare the results of experimental investigation with the facts of disease of these regions. In reference to experimental investigation, we must rely mainly, if not exclusively, on experiments on monkeys; as in other animals these lobes are not specially differentiated and developed. I have found, as the result of numerous experiments, that electrical irritation may be applied to the occipital lobes without producing any objectively discoverable reaction. Neither does destruction or complete removal of these lobes singly, or on both sides, cause any appreciable sensory or motor disturbance. Animals so mutilated continue to see, hear, touch, taste, and smell, and retain all their powers of voluntary motion. The results of destruction, like those of irritation, are, therefore, mainly negative, and do not succeed in throwing very clear light on the functions of these regions. In one or two instances, I should mention that there seemed to be some affection of vision; but in these cases, I found that the lesion had extended beyond the occipital lobes, into the angular gyri; while in those in which the lesion did not extend beyond the occipital lobes, no such symptoms occurred. As a rule, the animals rapidly succumbed, with one exception; and I also observed that, contrary to the usual effects of destructive lesion of other parts of the hemispheres, the animals refused to eat: an occurrence which, from my numerous and close observations of the effects of destruction of every other part of the brain, I regard as in some way causally related to this lesion.

I admit that this inference is considerably weakened by the fact that, in one of the animals in which I had removed both occipital lobes, the appetite for food returned after five days' abstinence. I have, however, attempted, whether successfully



or not, to explain this, and propounded the hypothesis that the occipital lobes are specially related to the visceral sensibilities, and are the anatomical substrata of the correlated feelings which form a large portion of our personality and subjectivity. Whether the hypothesis is well founded or not, I leave to further investigation; but one thing is, in my opinion, clearly established by these experiments, viz., that lesions of the occipital lobes, whether unilateral or bilateral, cannot be regarded as the direct cause either of motor or special sensory affections; and, therefore, I cannot accept the anatomical representations of Meynert, Huguenin, and others, which would place the central terminations of the optic tracts in the occipital lobes. They are not, I think, in harmony either with physiological experiment, or, as far as I can discover, with the facts of human pathology. It is true that Hermann Munk has recently asserted that lesions of the occipital lobes cause hemiopia if unilateral, and total blindness if bilateral, but his statements will not bear examination.<sup>1</sup>

Though many speculations exist, to some of which I shall refer, as to the symptoms dependent on lesions of the occipital lobes, it does not as yet appear, as the following cases will show, that there are any symptoms, attaching to disease of these lobes, so definite and constant as to establish any direct causal relationship between them, or indicate the functions which these regions subserve. Lesions of the occipital lobes are, as a rule, *latent*.

M. Vauttier<sup>2</sup> records a case of yellow softening of the right occipital lobe, and, to a larger extent, of the internal aspect of the left (quadrilateral lobule). No affection of motion or sensation existed; and, with the exception of considerable hebetude, there were no other symptoms of cerebral affection.

Pitres<sup>3</sup> relates a case, in which, in consequence of a fall on the head, an abscess, the size of a billiard-ball, formed in the postero-inferior aspect of the brain. There was no paralysis of

<sup>1</sup> *Verhand. der Physiolog. Gesellsch. zu Berlin*, Nos. 9 and 10, 1878; Review in *Brain*, part ii., 1878.

<sup>2</sup> *Essai sur le Ramollissement Cérébral Latent*, 1868.

<sup>3</sup> *Lésions du Centre Ovale*.

motion or sensation, and mental obtuseness was the only indication of cerebral lesion.

Sir W. Gull<sup>1</sup> has recorded a case of abscess of the left posterior lobe, also without any objective symptoms.

A similar case, in which the abscess was situated in the right occipital lobe, is recorded by Rodocalat.<sup>2</sup>

Other cases, cited by M. Pitres in his before-mentioned work,<sup>3</sup> are reported by Bleyne,<sup>4</sup> Hébread,<sup>5</sup> Martinet,<sup>6</sup> Merriman,<sup>7</sup> Ogle,<sup>8</sup> Parrot,<sup>9</sup> and Baillarger.<sup>10</sup>

It may be said, in reference to these cases, that the lesions being unilateral, and of slow growth, the absence of symptoms may be explained by functional compensation by the same or the opposite hemisphere. There are, however, some cases on record of traumatic lesions of the occipital lobes, also negative as regards objective symptoms.

Marcé<sup>11</sup> records a case of contusion, with effusion into the meninges, and softening of the cortex in the right occipital lobe, without any symptom as regards sensation or motion.

In addition to Vauttier's case already mentioned, a very important case of bilateral lesion of the occipital lobes has been put on record by Sestié.<sup>12</sup> In Sestié's case, there was an abscess in each occipital lobe, without any objective symptoms; although the patient's memory was somewhat defective, there was nothing very remarkable in his mental condition.

Leger<sup>13</sup> relates a case of tumour invading both occipital lobes, in which, beyond general mental obtuseness and headache, there were no objective symptoms. Sight was not impaired in this case, notwithstanding the existence of a cerebral tumour, and in this region. Except, therefore, as regards the fact of latency of lesions of the occipital lobes, these cases do not give us much positive material for generalisation.

<sup>1</sup> *Guy's Hospital Reports*, 1857.

<sup>2</sup> *Bull. Soc. Anat.*, 1870, p. 289.

<sup>3</sup> *Ibid.*, p. 134.

<sup>4</sup> *Thèse Doct.*, Paris, 1809, No. 51, p. 11.

<sup>5</sup> *Annuaire Méd. Chir. des Hôpitaux*, 1819, p. 586.

<sup>6</sup> *Revue Méd.*, 1824, T. iii. p. 20.

<sup>7</sup> *Lancet*, 1846, part i. p. 389.

<sup>8</sup> *Brit. and For. Med. Chir. Rev.*, 1864 and 1865, Case 32.

<sup>9</sup> *Bull. de la Soc. Méd. des Hôpitaux*, 1868, p. 56.

<sup>10</sup> *Gazette des Hôpitaux*, January 1861.

<sup>11</sup> *Bull. Soc. Anat.*, 1854, p. 295.

<sup>12</sup> *Ibid.*, 1833.

<sup>13</sup> *Ibid.*, November 1876.

Joffroy<sup>1</sup> attempts to establish a relation between lesions of the occipital lobes and the occurrence of acute sloughing of the sacrum; and thinks that the occipital lobes may be trophic centres. He quotes three cases in support of this hypothesis. One, a case of general paralysis, in which, though the cerebral lesions were not confined to the occipital lobes, yet the sacral sloughing was greater on the side opposite the lobe most affected. In the other two, there was only slight unilateral lesion: in the one case, a small focus of hæmorrhage; in the other, of softening, with sloughing on the opposite side of the sacrum.

But, in reference to this hypothesis, it needs only to be remarked that sacral sloughing occurs in connection with hemiplegia where no affection of the occipital lobes has been detected; and lesions of the occipital lobes are not even commonly associated with such results. Cases have occurred, and been carefully examined, in reference to this point since the publication of M. Joffroy's views, without confirming them. One such case is reported by Sazic,<sup>2</sup> and another by Dreyfus-Brisac.<sup>3</sup> These may be taken in conjunction with the other cases mentioned; for it is not likely that such a prominent affection would have been overlooked had it actually existed.

In connection with softening of the occipital lobes, M. Charcot has occasionally noted, in addition to headache, &c., cutaneous formication and similar subjective sensation, but no true anæsthesia.

Hughlings Jackson and Bastian are of opinion that disease of the posterior lobes is more frequently associated with mental derangement than disease of the anterior lobes or other parts of the brain. Hughlings Jackson goes somewhat further, and thinks that such derangements, particularly 'defective perception,' are more commonly seen when the right side is affected, and that irritative lesions here give rise to coloured vision and other subjective ocular spectra. We can only look upon these as hypotheses deserving consideration and further investigation.

Even on my own hypothesis as to the relation between the

<sup>1</sup> *Soc. de Biologie*, Séance December 4, 1875.

<sup>2</sup> *Bull. Soc. Anat.* December 15, 1876.

<sup>3</sup> *Ibid.*, March 23, 1877.

occipital lobes and the organic sensations, I should regard it as highly probable that lesions of the occipital lobes should cause profound mental disturbances. For, if our feelings are our chief motors, it might readily be allowed that lesions of the anatomical substrata of such an important element of our feelings and emotions should lead to mental derangement.

But, speculation apart, I think we must admit that up to the present the facts do not yet enable us to generalise with certainty as to the positive effects of lesions of the occipital lobes. It is clear, however, from the negative effects of extirpation or disease that we cannot place in the occipital lobes the central terminations of the fibres of the internal capsule which convey impressions of special sense to the cortex.

*Lesions of the Parieto-Temporal Region.*—There remains, therefore, a region, situated between the motor area and the occipital lobes, in which it is natural to look for a cortical distribution of these tracts. This region includes the supramarginal lobule and angular gyrus or inferior parietal lobe, the convolutions of the temporo-sphenoidal lobe on its external and internal aspect, viz., the superior, middle, and inferior temporo-sphenoidal convolutions, the occipito-temporal convolutions (lingual lobule, fusiform lobule), the uncinate gyrus, and hippocampus major or cornu Ammonis (fig. 1). We may call the whole of this the *parieto-temporal* region. It has, I think, been shown conclusively that experimental lesions of the cortex in this region in the lower animals—a region in which I claim to have demonstrated the existence of individually differentiated centres of special sense—are capable of producing impairment or paralysis of sensation on the opposite side of the body.

This has been shown more particularly as regards vision (which seems specially to have been investigated), by the experiments of McKendrick on pigeons, and by those of Hitzig, Goltz, &c., on dogs. Without precisely defining the regions, lesion of which causes sensory disturbances, we may take it as firmly established that unilateral lesions of the cortex are capable of causing such effects in the lower animals. And here it will be convenient to consider the views advanced by Goltz, with respect to the effects of cortical lesions.<sup>1</sup>

<sup>1</sup> Pfüger's *Archiv für Physiologic*. Band xiii., Heft i., 1876,

According to Goltz, it is not so much the position as the extent of the injury on which the phenomena of cortical lesions depend. These he finds to be a conjunction of motor paralysis or paresis, tactile anæsthesia, and blindness or impairment of vision on the opposite side. I need scarcely say, from what I have already brought before you, that if that is the type of cortical lesions in the dog, then we must look upon canine and human pathology as having no resemblance to each other. But it requires very little examination of Goltz's facts to discover that his views are equally at variance with the facts themselves, as with those of clinical medicine and pathology. Instead of laying bare a distinct region in the brain, and accurately limiting his destructive lesion to the part the functions of which he is desirous to investigate, he merely trephines a hole or holes in the temporal region and destroys the cerebral substance by squirting it out with a strong stream of water. This method he adopts in order to avoid risk of hæmorrhage or subsequent meningitis; and therefore, to keep the animal alive as long as possible. While we may credit it with securing the latter object more or less, it is clearly impossible to say what extent of brain-substance may thus be rendered functionless; and that it produces profound derangement of the whole cerebro-spinal system, is evident from the frequently fatal consequences resulting from this procedure. The extent of grey matter destroyed or rendered functionless, Goltz himself admits, it is impossible to estimate, and he nowhere attempts it in the record he has given of his experiments.

These are fatal objections to Goltz's experiments, as bearing on the question of cerebral localisation. The explanation of his results is, I think, easily afforded by the facts to which I will presently call your attention, as well as by the above-mentioned experiments of Veyssière as to the effect of lesion of the posterior part of the internal capsule. These latter, however, Goltz seems to have altogether ignored, as he makes no allusion to them.

The situation usually chosen by Goltz for his trephine openings and syringing operations is such as to, almost without fail, ensure damage of the sensory fibres of the internal capsule; and he has, in a rude way, practically produced the same results



as Veyssière obtained by careful limitation of his experimental lesion.

While Goltz's description of the phenomena themselves resulting from this procedure may be accepted without question, his theory that the effects of cortical lesions depend more on their extent than on their position, must, I think, be unhesitatingly rejected.

I will now give you a brief *résumé* of the results of my experiments on the brain of monkeys, full details of which I have published elsewhere.<sup>1</sup> On these facts I take my stand, and hold that they establish the differentiation and localisation of special sensory centres in the cortex.

*Angular Gyrus* (fig. 26 [13] [13']).—Electrical irritation of the angular gyrus in the monkey causes movements of the eyeballs, pupils, and head, which are to be taken as reflex or associated signs of subjective visual sensation, for the reason that destruction of this region causes no motor paralysis whatever, whether of eyelids, ocular muscles, or pupils. But unilateral destruction has the effect of causing temporary blindness of the opposite eye, while bilateral destruction causes total and permanent blindness in both eyes. Hence it appears that each hemisphere is in relation with both eyes, and the destruction of this centre in one hemisphere is not necessarily followed by complete or permanent blindness. This conclusion is confirmed by Goltz's experiments on dogs, and is in harmony with the researches of Landolt in regard to the affection of both eyes in cerebral hemianæsthesia depending on lesion of the posterior third of the internal capsule.

*Superior Temporo-sphenoidal Convolution* (fig. 26 [14]).—Electrical irritation of this region causes twitching of the opposite ear and other reflex indications of excitation of subjective auditory sensation. Destruction causes no motor paralysis whatever; but, though it is certain that hearing is at least impaired on the opposite side, the difficulty of ascertaining the conditions of auditory perception in animals, when only one ear is affected, is such as to render it impossible to speak definitely as to the extent and duration of the affection of

<sup>1</sup> *Philosophical Trans.*, vol. ii., 1875; *Functions of the Brain*, chap. ix.



hearing ; whereas, when these centres are destroyed bilaterally, there seems to be total loss of the sense of hearing ; meaning by that, auditory discrimination as contra-distinguished from mere auditory reaction.

*Subicular Region.*—Irritation of the lower extremity of the temporo-sphenoidal lobe, or region of the subiculum cornu Ammonis, causes movements of the nostril and head indicative of excitation of subjective olfactory sensation. Destruction causes no motor paralysis, but is followed by loss of smell on the same side ; and, when the lesions invade not merely the subiculum but the neighbouring regions on one side, taste also is affected on the opposite side of the tongue. Bilateral lesions cause complete loss both of taste and smell.

*Hippocampal Region.*—On account of the concealed position of this region, it is impossible to cause localised irritation free from all complication ; nor is it possible to destroy it, without injuring other parts of the hemisphere. I found, however, that only in cases in which this region was involved along with others, there occurred impairment or abolition of tactile sensation on the opposite side ; and when the region of the hippocampus and uncinate gyrus was ploughed up in such a manner as to avoid the internal capsule and the medullary fibres of the other cortical regions (with the exception of part of the occipital lobe), tactile sensation was abolished on the opposite side, sight and hearing remained unimpaired. A condition resembling motor paralysis was also induced ; but in reality, a functional paralysis depending on the abolition of tactile and muscular sensation, such as occurs from division of sensory nerves.

Such being the indications furnished by experiments on monkeys, we may now proceed to consider the effects of disease of the corresponding regions in the human brain. The facts I am about to quote seem to point to a remarkable and apparently irreconcilable discrepancy between human pathology and experimental physiology. Cases are on record in which lesion or some form of degeneration has been found in one or other of all these so-called sensory areas, and in which no affection of sensation has been observed. Lesions here are usually said to be latent.

First, as to the cases:—

MM. Charcot and Pitres<sup>1</sup> report a case, latent as regards symptoms, in which there was found a yellow softening of the cortex of the right hemisphere, occupying the posterior half of the island of Reil, the posterior two-thirds of the inferior parietal lobule, comprising the angular gyrus, and the upper or posterior half of the second and third temporo-sphenoidal convolutions (fig. 55). There was no secondary degeneration of the spinal cord.

M. Pitres<sup>2</sup> records a case of extensive hæmorrhage into the medullary substance of the left temporo-sphenoidal lobe, in

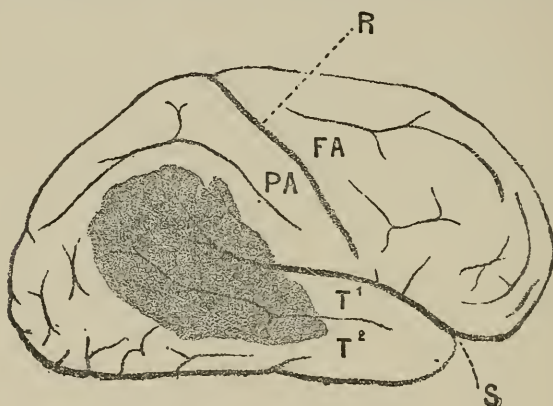


FIG. 55.

which, though consciousness was deeply affected, there was no real paralysis and no lateral distortion or conjugate deviation of the eyes. He quotes a case reported by Thibault,<sup>3</sup> also latent as regards sensory or motor symptoms, in which, in addition to a layer of extravasation on the posterior three-quarters of the left hemisphere, there was found, in the sphenoidal lobe, a large extravasation extending from its anterior extremity to within three *centimètres* of the posterior extremity of the hemisphere.

Sabourin<sup>4</sup> has recorded a case of extensive lesion of the

<sup>1</sup> *Revue Mensuelle*, No. 1, p. 10.

<sup>2</sup> *Lésions du Centre Ovale*, p. 54.

<sup>3</sup> *Bulletin de la Société Anatomique*, 1844, p. 93.

<sup>4</sup> *Ibid*, October 21, 1876.

sphenoidal and occipital convolutions in which there was no paralysis.

MM. Charcot and Pitres<sup>1</sup> also give a case in which the chief symptoms were a state of dementia and very marked itching of the chest and abdomen without apparent cause. After death a yellow softening was found in the left hemisphere, occupying the first and second occipito-temporal convolutions, commencing about one *centimètre* behind the anterior extremity of the temporo-sphenoidal lobe, and extending backwards to within about three *centimètres* from the tip of the occipital lobe (fig. 56).

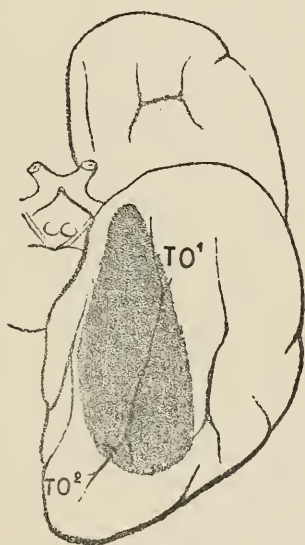


FIG. 56.

M. Sabourin communicated to MM. Charcot and Pitres a case exactly similar to the above, and another in which a yellow softening existed in the *cuneus* and posterior two-thirds of the quadrilateral lobule of the left hemisphere, likewise latent as regards symptoms.

A case is reported by Humbert of abscess in the anterior and inferior part of the right temporo-sphenoidal lobe, result-

<sup>1</sup> *Bulletin de la Société Anatomique*, October 21, 1876, p. ii.

<sup>2</sup> *Ibid.*, 1870, p. 367.

ing from suppuration of the ear, in which there were no special symptoms indicative of such a grave cerebral lesion.

Of similar affections of this part of the brain in connection with otitis, and with nothing but the general symptoms of cerebral abscess, I might quote a multitude. References are given by Pitres to cases of this kind related by Ormerod,<sup>1</sup> Sir W. Gull,<sup>2</sup> Blondeau,<sup>3</sup> Haslewood,<sup>4</sup> Homolle,<sup>5</sup> and Renaut.<sup>6</sup>

Of lesions specially confined to the hippocampus, I have not been able to find any on record, except those in respect to degeneration or sclerosis of the hippocampus in chronic epileptics. Bouchut,<sup>7</sup> in twelve out of forty-three cases which he examined, noted the existence of sclerosis in one or both hippocampi, but he did not attach any special importance to this; as induration of the brain in chronic epilepsy he looked upon as a general affection, of which this was only a local manifestation. This condition of the hippocampus has been observed also by Casauvielh, Foville, Lelut, Delasiauve, Bourneville, in epileptics. In 1868, Meynert<sup>8</sup> called special attention to this degeneration of the hippocampus in epileptics, giving nineteen cases in which one or other hippocampus was indurated or atrophied. Meynert, without looking upon this as *the* cause of epilepsy, thought that there was some special relation between this degeneration and the lesion on which epilepsy depended. In a recent paper, Hemkes<sup>9</sup> states that he has seen atrophy of the hippocampus in only six out of thirty-four cases of chronic epilepsy. Beyond the fact of the existence of such degeneration in epileptics, we have no record of the exact symptoms in the cases in which it was found. Meynert<sup>10</sup> believed that the optic tracts had special relations with this region; and he gives four cases of disease situated in or near the hippocampus and fusiform lobule, in which disorders of vision were observed. The cases, however, are altogether deficient as regards ophthal-

<sup>1</sup> *Lancet*, 1847, vol. i. p. 29.

<sup>2</sup> *Guy's Hosp. Reports*, 1875, Case 2.

<sup>3</sup> *Bull. Soc. Anat.*, 1858, p. 271.

<sup>4</sup> *Lancet*, 1872, vol. ii., p. 218.

<sup>5</sup> *Bull. Soc. Anat.*, 1874, p. 873.

<sup>6</sup> *Ibid.*, 1874, p. 642.

<sup>7</sup> 'Sur l'Epilepsie,' *Annales Médico-Psycholog.*, 1853, t. v., p. 209. Quoted by Lépine, *op. cit.*, p. 130.

<sup>8</sup> *Vierteljahrsch. für Psychiatrie*, p. 381.

<sup>9</sup> *Allgemeine Zeitsch. für Psychiatrie*, Band xxxiv., Heft vi.

<sup>10</sup> *Op. cit.* p. 400.

moscopic appearances, on which it would be necessary to have some information before coming to a conclusion as to whether the disorders of vision were the direct or indirect results of the cerebral disease.

I have quoted a number of cases of unilateral lesion of the sensory regions, mostly of a chronic form, in which no special symptoms were noted. It may be said that the absence of symptoms in all these cases may be accounted for by functional compensation by the same or the opposite hemisphere. Yet there are on record cases of traumatic lesion, also apparently latent, which would militate against this idea, supposing them in every respect carefully investigated.

M. Herpin<sup>1</sup> has recorded a case of fracture of the skull and injury of the brain in the region of the squamous portion of the temporal and greater wing of the sphenoid. The man did not lose consciousness, and, from the time of the accident till death, four days afterwards, nothing was observable, either as regards motility or sensibility. After death, a contusion of the third degree was found in the inferior aspect of the temporo-sphenoidal lobe (which side not stated), extending five *centimètres* in an antero-posterior direction, three *centimètres* in breadth, and affecting more particularly the middle and external (inferior) temporo-sphenoidal convolutions; a situation corresponding exactly to the cranial injury. A clot, of the size of a bean, existed at the anterior extremity of the lesion. A case in some respects similar has been put on record by Alcock.<sup>2</sup> This was a case of cranial injury, followed by restlessness and sleeplessness; and only on the third day after the accident did the patient seem to hear when spoken to. He gradually got worse, and died on the thirty-third day after the accident, without being affected by paralysis. Wilfulness and obstinacy were his most prominent mental symptoms. On the right hemisphere, there was a patch of ecchymosis, of the size of a florin, in the pia mater, over the upper extremity of the superior temporo-sphenoidal convolution, but the brain-substance underneath was not injured. On the left side, 'the portion of brain corresponding to the lower part of the

<sup>1</sup> *Bulletin de la Société Anatomique*, May 1875.

<sup>2</sup> *Lancet*, March 10, 1877.



squamous portion of the temporal bone was soft and pulpy, being easily washed away by a stream of water, leaving a cavity with ragged walls, the area of which equalled that of half-a-crown, and about a quarter of an inch in depth. The ventricles contained an excess of serum.' The only indication as regards sensory affection in this case was the apparent want of auditory perception at first; but whether this was a part merely of the general dazed condition of the man, or the result of affection of the auditory centres, it is impossible to say definitely, though the position of the lesions might be taken in favour of the latter.

I have not been able to find any cases of bilateral lesions of the hemispheres in corresponding parts of the sensory area without such profound mental disturbance as to render the determination of the existence or absence of sensory impairment a matter of impossibility.

But if we confine our attention to the cases of unilateral lesion of the sensory area which I have mentioned, and compare the negative results as regards sensation, whether with chronic or sudden lesions of the sensory regions in man, with the affections of sensation, carefully observed and verified by many physiologists, which result from similar cortical lesions in the lower animals, we cannot but be struck by the discrepancies which exist. To account for these, we must adopt one or other of two suppositions: either, taking the facts as equally well established, that the parallel which has hitherto been shown to exist between the brain of man and that of the monkey and the lower animals now suddenly ceases to hold, and that, in respect to sensory localisation, the brain of man is constituted on a totally different type from that of the lower animals; or, if this be regarded as improbable, that the latency which is said to characterise lesions of the sensory area in man is a latency not so much of actual symptoms as of observation.

M. Pitres<sup>1</sup> is of opinion that the sensory fibres which are gathered together in the posterior third of the internal capsule, instead of distributing themselves like the motor fibres to

<sup>1</sup> *Lésions du Centre Ovale*, p. 53.



individually differentiated areas in the cortex, spread themselves indifferently over the whole occipito-sphenoidal region. But this does not remove the difficulty; for we should then expect that extensive lesions of this region should cause general impairment of all the sensory powers of the opposite side together; a hypothesis which the clinical records no more support than that of special localisation. And it would seem strange if there should be a distinct differentiation of centres of motion, and a general *confusion* in the centres of organs so highly specialised as the organs of sense. This is a supposition which I cannot entertain, and for which I see no substantial grounds. That the organs of sense may be more bilaterally represented in each hemisphere in man than in the lower animals, is not impossible. That bilateral representation does exist to a large extent, and particularly as regards sight and hearing, is in accordance with the facts of experiment, and is sufficient to account for the absence of any very obvious impairment of these faculties in cases of unilateral lesion of a slowly progressive character. But that there is no impairment at all of sensory perception or discrimination in *sudden* unilateral lesions, or even in *chronic* lesions, is a fact which I do not admit as proved; and I adopt the alternative supposition, that the latency has been in observation rather than in symptoms.

This may seem a sweeping charge, and a very summary method of disposing of difficulties; but I cannot help expressing the frequent disappointment I have experienced in reading through multitudes of cases of cerebral lesion, which might have served to throw light on this subject, and finding no indication of any attempt having been made to investigate the conditions of special sense. Considering the perfunctory manner in which this is so commonly carried out, if investigation be made at all, and the frequent omissions in this respect which are to be found in the records of even our most accurate and competent clinical observers, I cannot take mere absence of remark as proof of negation of symptoms, unless there be clear evidence that the various points had been fully and fairly investigated, and the negation of symptoms positively established. For the clinical facts are not all of the same negative

order as those I have brought before you, and many of them are, in my opinion, capable of satisfactory explanation only on the views I have advanced.

*Affections of Sight.*—Let us take first the question of affections of sight directly dependent on cerebral lesion. Here, of course, we must eliminate all those cases in which impairment or abolition of vision is caused by changes in the optic nerve and retina, secondary to intracranial disease wherever situated. Hence most of the records of cerebral disease, before the invention of the ophthalmoscope, and, I may add, very many since, are for the most part worthless in this relation. But the following case, which is recorded by Abercrombie,<sup>1</sup> and which I give in his own words, has a special value. ‘The effect of superficial inflammation of the brain or its membranes is well illustrated by another case related by Dr. Anderson, in which the disease took place under his own eye. A boy suffered from an injury of the head, the depression of a considerable portion of the *right parietal bone*, the depressed portion being forced through the dura mater and driven inwards upon the brain. *He had paralysis of the left side, and the left eye was insensible.* The depressed portion being removed, the paralysis was greatly diminished, and the eye recovered a considerable degree of vision. On the third day after the operation, the wound in the dura mater was inflamed, with considerable tumefaction; and immediately the left leg and arm became paralysed, the paralysis being accompanied by convulsion: and *the left eye also became again insensible.* He had frequent convulsion of these parts for several days, the right side not being in the least affected, when, suppuration having taken place, all the symptoms subsided’ (p. 121–2). Now, though recovery took place, and therefore the case is incomplete in an anatomical point of view, it is clearly a case of cortical lesion, and possesses all the typical features of such; and that the affection of the opposite eye, which proceeded *pari passu* with the motor symptoms, had a similar cause—viz., lesion of the cortex—is, I think, unquestionable. Though the exact extent and position of the depressed fracture is not stated, yet, as it was in the parietal region, we may conclude that the lesion involved not only the

<sup>1</sup> *Diseases of the Brain and Spinal Cord*, second edition, 1829.

cortical *motor* area, but also the *visual* centre, which is in close proximity to it under the parietal eminence (fig. 3). This case, in my opinion, distinctly confirms the sensory localisation which I have arrived at by experiment, or at least is explicable only in this way.

The same author also quotes another case related by John Bell, in which, from injury to the head, extravasation of blood occurred on the surface of the brain, for which the patient was repeatedly trephined. Local inflammatory attacks with suppuration occurred from time to time on the left hemisphere after the trephining. These local attacks, when they occurred towards the anterior part, were accompanied by double vision; but, 'when they were towards the posterior part, they were not double vision, but in a state of vision in which, a candle was seen with a halo round it' (p. 122).

I mention this case chiefly because it harmonises with the observations of Hughlings Jackson, already referred to, in respect to the frequent association of optical illusions, coloured vision, &c., with disease of the posterior lobes. These spectra are the counterpart of the motor discharges caused by irritative lesions of the motor centres. That they should occur more particularly with lesions situated towards the posterior aspect of the hemispheres is quite in accordance with the localisation of the visual centre in the angular gyrus. These sensory discharges in connection with epilepsy of cortical origin, whether in the domain of sight, hearing, smell, taste, or tactile sensation, are without doubt to be looked upon as indications of irritative lesion of the sensory centres, though we have not yet sufficient material to enable us, from a purely clinical point of view, to connect any particular form of sensory discharge with a specially localisable lesion, unless we regard it as established in respect to optical illusions. These were a prominent symptom in a case of lesion of the angular gyrus and neighbourhood which I commented on in the West Riding Reports, vol. iv., 'Pathological Illustrations,' case 2. Atkins also noticed the same in his patient above referred to, p. 77. Not unfrequently the sensory centres are discharged together, as in a general unilateral convulsion, and there is no clear discrimination of one form of sensation from another. This was well exemplified

and graphically described to me by a highly intelligent patient, who told me that his epileptic attacks (*petit mal*) were ushered in by a 'horrible smell of green thunder,' or by some equally strange compound of smells, colours, and sounds, inextricably intermingled.

Reverting to the impairment of sight in connection with destructive lesions, it has been remarked by Dr. Bastian that not unfrequently, in cases of thrombosis of the posterior cerebral artery, vision is impaired on the side of motor paralysis.<sup>1</sup> This he attributes to affection of the opposite optic tract, or to the opposite side of the corpora quadrigemina. But, as lesion of the optic tract would seem to be associated rather with bilateral hemiopia than with unilateral amblyopia, and as lesion of the corpora quadrigemina is generally accompanied by more complex symptoms than mere motor hemiplegia, it seems to me that the impairment of vision may be attributed to sudden interference with the visual centre.

Fürstner<sup>2</sup> has reported unilateral affections of sight with a greater or less degree of motor paralysis in several cases of general paralysis, in which though the lesions were, as is usual, more or less diffuse, yet the occipital regions or their neighbourhood seemed specially involved. The cases cannot be employed to establish distinct localisation, but they are important inasmuch as in all the impairment of vision was unilateral, and bilateral hemiopia was clearly disproved. There were no ophthalmoscopic appearances to account for the blindness. Another point observed in reference to these visual disturbances in general paralytics was that they remitted or totally disappeared.

*Affections of Hearing.*—Apart from the evidence of auditory discharges and subjective auditory spectra of various kinds in connection with epilepsy and other cerebral affections, I cannot find any altogether satisfactory evidence of impairment or abolition of hearing in connection with destructive lesions of the cortex. Hughlings Jackson repeatedly emphasises the statement that he has never met with deafness as the result of disease of the cerebral hemispheres directly.

But, though we may admit, in accordance with the results

<sup>1</sup> *Paralysis from Brain-Disease*, p. 113.

<sup>2</sup> *Archiv für Psychiatrie*, Band viii., 1877, p. 162.

of experimental physiology, that unilateral destruction of the centres of hearing and sight need not cause actual insensibility to optical or auditory stimuli of a complete or enduring character, there are certain facts which tend to show that unilateral lesions of these centres may produce what we may call *subjective* deafness and blindness, or abolition of visual or auditory perception and discrimination. Such conditions are not unfrequently classed with aphasia, and may occur with it; but they may occur *without* true aphasia or speechlessness. They have been termed by Kussmaul 'word-blindness' and 'word-deafness' (*cacitas et surditas verbalis*). These two conditions may occur

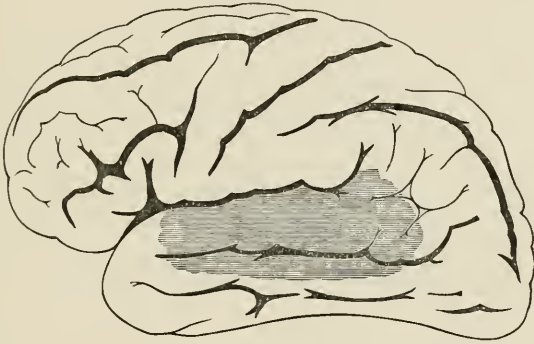


FIG. 57.

separately or in association. In the one case, though a man may be able to speak and write, he cannot translate written symbols into ideas, though he may understand articulate sounds; in the other, he may be able to read, though he cannot understand spoken words, or he may be unable to do either. In neither case is there actual insensibility of the eye or ear. In a case of word-deafness of this kind reported by Wernicke,<sup>1</sup> there was, besides a general atrophy of the convolutions, a thrombotic softening of the *first and a large portion of the second temporo-sphenoidal convolution of the left hemisphere* (fig. 57). The auditory centre was thus destroyed. A very interesting

<sup>1</sup> *Der Aphatische Symptomen Comp'lex*, 1874, Case 11.



case of subjective or word-blindness has been recorded by Dr. Broadbent.<sup>1</sup> The essential points are thus summed up by him. 'After an acute cerebral attack, absolute inability to read printed or written words (except own name), while the patient wrote correctly from dictation, and composed and wrote letters with a little prompting. Inability to recall the name of the most familiar object presented to his sight, while he conversed intelligently, employing an extensive and varied vocabulary, making few mistakes, but occasionally forgetting names of streets, persons and objects.' The primary lesions on which the softening and subsequent fatal hæmorrhage appeared to depend were two old clots. The first, the size and shape of an almond, was loosely imbedded in the inframarginal gyrus or superior temporo-sphenoidal convolution, about opposite the junction of the upper third with the lower two-thirds of the descending cornu. The other, which Broadbent regards as the more important and the cause of the softening which led to the fatal hæmorrhage, was a clot the size of a bean, surrounded by softening, situated at the upper extremity of the fissure of Sylvius externally, and at the junction of the descending cornu with the body of the ventricle internally (fig. 58). This, it will be seen by reference to fig. 26, is in the region of the angular gyrus and supra-marginal lobule, the homologue of the visual centre in the monkey. These cases I take to be in harmony with the views I have elsewhere expressed, that the sensory centres are also the substrata of corresponding sensory memory and sensory ideation. In the one of these cases (Wernicke's) in which the *auditory* centre was the seat of lesion, there was paralysis of auditory ideation; in the other (Broadbent's), in which the *visual* centre was the seat of disease, there was paralysis of visual ideation, more particularly in connection with articulate symbols or their visible equivalents.

The paralysis of visual and auditory ideation in special reference to words in these cases is accounted for by the fact that in both the disease was situated in the visual and auditory centres of the left hemisphere, between which and the speech-

<sup>1</sup> 'Cerebral Mechanism of Thought and Speech.'—*Med. Chir. Trans.*, lv., 1872.



centre we may reasonably suppose there exists a more intimate organic or functional connection than between this and the sensory centres of the right hemisphere. But, as regards sensory discrimination and sensory ideation in general, there is no reason to suppose that the right hemisphere is subordinate to the left, as is the rule with respect to volitional action; for, with equally acute sensibility on both sides, we find that, for delicate sensory discrimination, some invariably use one eye or one ear in preference to the other, and therefore the opposite cerebral hemisphere. Thus the same individual will use his *right* eye for microscopic work, and his *left* ear for auscultation; which we may take to mean that his left visual

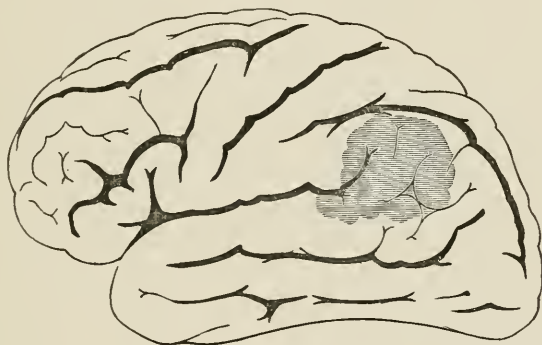


FIG. 58.

and right auditory centres are more especially cultivated and developed.

Hence we may conclude that unilateral lesions of the sensory centres will vary considerably in respect to their effects on sensory ideation, according as the lesion is on the side of the more or less developed centre. It is not impossible, therefore, that what Hughlings Jackson terms 'defective perception' may be more common with lesions of the sensory regions of the right hemisphere, if these be more commonly cultivated and developed.

Before passing from this subject, I would refer to an interest-

ing case related by Dr. Banks<sup>1</sup> of Dublin, in which, though unfortunately no *post-mortem* examination could be made, there are certain facts bearing on the question as to whether actual deafness may occur from cerebral disease. In this case, after a sudden cerebral seizure, but without coma or paralysis, the patient was found to be incapable of understanding either speech or writing, though he could both speak and write. He was found to be completely deaf, taking no notice of what was said to him, or even of the loudest noises; and, indeed, he used to allude to his deafness himself. One day, he said he could neither hear nor read; 'only a little could read the words, but not take in the meaning.' This patient died ultimately of coma and right hemiplegia; but no *post-mortem* examination was allowed. Unless we suppose, in this case, that the patient had a separate lesion in both auditory nerves or both ears, occurring simultaneously with his cerebral lesion, we may take it as a case of deafness depending directly on cerebral disease; but whether the lesion was unilateral or bilateral, the absence of a *post-mortem* examination unfortunately renders it impossible to decide.

*Affections of Smell and Taste.*—Affections of smell and of taste, we have seen, occur with affections of the other senses in cerebral hemianæsthesia; but affections of smell alone, or of taste and smell combined, may occur without other sensory impairment in connection with certain forms of cerebral lesion. As regards smell, there seems to be some discrepancy between my localisation of the olfactory centre and the facts of cerebral hemianæsthesia. I find that destruction of the subicular region causes loss of smell on the *same* side; while in hemianæsthesia the impairment of smell on the side *opposite* the cerebral lesion. I have endeavoured to account for this by the fact, discovered by Magendie, that abolition of the *common* sensibility of the nostril by section of the sensory branches of the fifth nerve causes loss of smell; and, as in hemianæsthesia the sensibility of the mucous membrane of the nostril is lost, so we may consider this to be a sufficient cause of the unilateral anosmia. I see no reason to doubt the validity of this explanation; but I would supplement it by another consideration.

<sup>1</sup> *Dublin Quarterly Journal*, February 1865, vol. xxxix., p. 62.

Though the outer root of the olfactory tract can be directly traced to the subiculum of the same side, it is not unlikely that the inner root passes on to the opposite hemisphere with the other sensory tracts; and hence each hemisphere may maintain a bilateral relation with the organ of smell. If this were so, then the partial impairment of smell, which would result from lesion of the special sensory paths of the opposite hemisphere, would be rendered more complete by the simultaneous abolition of common sensation in the nostril. I cannot give anatomical evidence of this arrangement, for the inner root of the olfactory tract has not been traced by Meynert beyond the nucleus caudatus; but that it ends here is, I think, more than improbable.

Unilateral anosmia has been observed in many cases of cerebral lesion, and on the same side as the lesion, but, without a necropsy, it is of course difficult to decide whether this was due to direct lesion of the olfactory tract, or of its centre. Several such cases have been reported in connection with aphasia, the anosmia being on the left side.<sup>1</sup>

A good many cases are now on record of loss of smell, or combined loss of smell and taste, as the result of blows on the head, more particularly of the vertex or occiput.<sup>2</sup>

As regards the anosmia, the mode of causation suggested by Ogle,<sup>3</sup> viz., injury by counterstroke to the olfactory nerves, bulbs, or tracts, seems in every way satisfactory. To the loss of smell, Ogle further ascribes such affections of taste as may be combined with it, viz., the impairment or abolition of the perception of flavours, which are a compound of smell and taste. And, indeed, in many of the so-called cases of loss of taste and smell, taste proper does not appear to have been affected. Hence they may be accounted for in the manner indicated by Ogle. But even when there is absolute loss of smell, we find cases in which taste is but little interfered with. A patient of mine who had suffered from complete anosmia for six years,

<sup>1</sup> Ogle, *Med. Chir. Trans.*, 1870; Fletcher and Ransome, *Brit. Med. Journal*, April 1864; Hughlings Jackson, *Lond. Hosp. Reports*, vol. i., 1864, Cases 2, 5, 15, 22.

<sup>2</sup> See 'Collected Cases' by Knight, *Boston Med. and Surg. Journal*, September 13, 1877.

<sup>3</sup> *Medico-Chirurgical Transactions*, 1870.

dating from a fall on the head which had rendered him temporarily unconscious, made no complaint as regarded his power of taste, as he could distinguish all the ordinary articles of food from each other, and could clearly perceive the flavour of onions. Yet, though there was no obstruction of the nasal passages, anteriorly or posteriorly, he could recognise no smell in assafœtida or musk; acetic acid, he said, caused some sensation about two-thirds up the nostril, but no real odour. I have no doubt that in this case there had been rupture of the olfactory nerves or tracts; but the mere loss of smell is incapable of accounting for the symptoms in another case which I have seen. This patient had lost both smell and taste in consequence of a fall on his head into the street six years before. I was not aware until lately that my colleague Dr. Burney Yeo had already brought the particulars of the same case before the Clinical Society,<sup>1</sup> and, therefore, the subsequent history of the patient will be all the more interesting. This man had not merely total loss of smell, but also total loss of taste proper, such as for bitter, sweet, salt, sour, &c. One day, in fact, when suffering from pain in the stomach, he swallowed a glass of what he took to be brandy, and was not aware it was vinegar until the aggravation of his pain made him ask his wife what was in the bottle. While under Dr. Yeo's care, and taking iodide of potassium, he recovered taste to some extent, but he did not, as he told me, recover smell, though he once or twice had something like a subjective sensation of camphor or burnt wood. When he left off the iodide, he became as bad as before. This was in 1872. In 1875, when he came under my care for another affection, he had absolute loss of taste and smell, and had given up all thoughts of recovery, and had tried to accommodate himself to circumstances. Again, on the administration of iodide of potassium, taste returned to some extent, but there was no improvement as regards smell, with the exception of an occasional subjective sensation; and a relapse again occurred on leaving off the medicine. I lost sight of him till the end of 1876, and found him in his original condition. In January, 1877, I began to treat him with the constant current (ten cells

<sup>1</sup> *Brit. Med. Journal*, May 25, 1872.

gradually increasing) directed transversely through the head in the zygomatic fossæ, varied occasionally by the application of one pole here, and the other on the bridge of the nose. After one or two applications, while he felt somewhat giddy, various subjective smells were experienced during the passage of the current, which he described as 'gassy,' 'rank,' &c. At the end of a week of daily treatment with the current, he began to smell strong odours; subjective sensations also occurring at intervals, and taste became more acute. He gradually and steadily improved, and, after a few weeks' treatment, the power of smell returned, so that he could recognise such things as assa-fœtida, musk, coffee, tobacco. He could readily distinguish between one smell and another, but continued to have some difficulty as to identification of the substance. There has been no relapse, and now (Feb. 28th, 1878), at the end of a year, he continues to enjoy perfect taste, and his powers of smell, which were never very acute, he thinks are as good as ever.

I will not attempt to decide what was the exact *modus operandi* of the galvanic current, whether it acted by stimulation of the olfactory nerve direct, or by stimulation of the cerebral centres of taste and smell; but, as a therapeutic experiment, it may be regarded as worthy of repetition in similar cases. But as regards the pathology of this case I think it is evident that both smell and taste were abolished independently of each other, and that we cannot account for the loss of taste by the loss of smell; nor can we say that the olfactory nerves were ruptured. It is also in the highest degree improbable that the loss of taste and smell could have resulted from simultaneous affection of the various nerves concerned in these functions; situated as they are so widely apart from each other, and bound up more or less with others not conjointly affected. But it might well happen that such a blow on the vertex as this man received would cause such injury to the subicular regions, by what is usually termed counterstroke, or by what Duret terms the *cône de soulèvement*, as to cause impairment or temporary abolition of the functional activity of the cerebral centres of taste and smell, which, as experiments on monkeys indicate, are here localised. Hence I would take this, and similar instances in which smell and taste proper are



abolished by cranial injuries, as clinical corroboration of physiological experiment.

*Affections of Tactile Sensibility.*—In respect to tactile sensation, though this form of sensibility is more frequently affected than any of the others by cerebral disease, it is extremely difficult, from a clinical standpoint only, to localise the centres of tactile sensation. Motor paralysis and tactile anæsthesia are frequently associated with each other. But that the cerebral centres of motion and tactile sensation are distinct from each other is evident from the fact that we may have the most complete motor paralysis without impairment of tactile sensation, as is the case with cortical lesions. And though motion is more or less impaired by the abolition of tactile sensation (by which motion is mainly guided), yet we have many instances in which the power of voluntary motion is retained notwithstanding the complete annihilation of tactile sensation, cutaneous or deep. There is, therefore, no organic fusion of the motor and tactile centres with each other, seeing that each may be affected independently of the other, and the two do not vary quantitatively with each other when they are conjointly affected.

The facts of cerebral disease in general, and of cerebral hemianæsthesia in particular, would seem to show that in respect to tactile sensation there is less bilateral representation in each hemisphere than as regards the other forms of sensibility. For in cerebral hemianæsthesia, tactile sensation is always most deeply affected, and may still remain greatly impaired after all the other forms of sensory impairment have disappeared. Hence, in the slighter forms of affection of the posterior third of the internal capsule, tactile sensation only may be impaired. Hence, also, with motor paralysis due to lesion of the anterior division of the internal capsule, we frequently get partial or temporary impairment of tactile sensation, owing to pressure on, or slight organic or functional derangement of the posterior or sensory fibres.

If, therefore, tactile sensibility be more unilaterally represented in each hemisphere—and this would appear probable from the remarkable power we possess of localising the seat of tactile impressions on any part of the body—we should naturally



expect to find that lesions of the cortical centres of tactile sensation should be accompanied by symptoms of impairment or abolition of this sense. These centres, as I have already indicated, are situated in the hippocampal region. Lesions of this region are not, however, common; and I have not been able to find any cases of localised lesion of the hippocampus, except those I have already alluded to in connection with chronic epilepsy and insanity. But, as we have no record of the facts relating to the condition of tactile sensation in these cases, I must leave this question to be settled by future clinical investigation.

There are, however, some facts which would seem to indicate that lesions in the neighbourhood of the hippocampus do cause affection of tactile sensation, though doubt may be entertained as to whether the phenomena are dependent on direct affection of the hippocampus, or affection of the posterior part of the internal capsule, directly or indirectly.

Mr. Jonathan Hutchinson<sup>1</sup> concludes, from his observations on cranial injuries, that contusion of the sphenoidal lobe more particularly, causes, along with partial motor paralysis, paralysis of tactile sensation on the opposite side of the body. As I have said, these effects may be attributed to injury of the sensory fibres of the internal capsule; but contusion of the sphenoidal lobe might also be interpreted as injury of the hippocampal region; and if the impairment of sensation in the cases described by Hutchinson were to be proved absolutely restricted to *tactile* sensation, we should have good grounds for considering the phenomena dependent on lesion of the cortical centres here situated. The definitive settlement, however, of these various points must be left to future research.

I have now brought under your notice a considerable number of facts, both positive and negative, in reference to the localisation of special sensory regions in the human brain; and though the positive clinical evidence is as yet comparatively scanty, and leaves much to be desired, I entertain the hope and belief that it will not long remain so. And I trust that those who rely more on the evidence of human pathology and the phenomena of disease than on the facts of experiment, even on

<sup>1</sup> *Medical Times and Gazette*, 1875, p. 165.

the most human of the lower animals, and do not, therefore, share my own very decided convictions as to the localisation of special sensory regions, will take the facts I have adduced into careful consideration, and, when opportunities occur, investigate the conditions as to sensation in cerebral disease with rigorous care and exactitude. For only thus are we likely to arrive at a solution of the doubts and difficulties which still surround this important question.

# WORKS PUBLISHED BY SMITH, ELDER, & CO.

---

Demy 8vo. with numerous Illustrations, 15s.

## THE FUNCTIONS OF THE BRAIN.

By DAVID FERRIER, M.D., F.R.S.

Assistant Physician to King's College Hospital; Professor of Forensic Medicine, King's College.

'This is in many respects an important work, full of experimental facts and theoretical suggestions, clearly and forcibly written. . . . It will long remain a storehouse to which all students must go for material.'—G. H. LEWES, in *Nature*.

'The turbid chaos of facts in which the laws of the functions of the encephalon have so long lain dissolved seems at last to be clearing itself up by depositing something like an orderly precipitate of doctrine. Dr. Ferrier's work may be regarded as the first successful attempt to collect and exhibit this doctrine in its full generality—in other words, we may regard it as marking the end of an old era, and the beginning of a new one in cerebral physiology.'—BOSTON MEDICAL AND SURGICAL JOURNAL.

'We welcome this work as a very important and valuable contribution to an obscure and difficult department of physiological inquiry. It is indeed, as the Germans phrase it, an "epoch-making" or "path-breaking" treatise.'

LANCET.

'It is a book deserving of the most careful and attentive study.'—LONDON MEDICAL RECORD.

'The work must be studied by all who claim to be well informed in their profession. Though the subject is one of great intricacy, the author has dealt with it in such a manner that it is competent for any highly educated non-medical reader to be gradually led on to the most profound questions in cerebral physiology.'

MEDICAL EXAMINER.

---

Post 8vo. 4s. 6d.

## ON THE CONVOLUTIONS OF THE HUMAN BRAIN.

By DR. ALEXANDER ECKER,

Professor of Anatomy and Comparative Anatomy in the University of Freiburg, Baden.

Translated, by permission of the Author, by JOHN C. GALTON, M.A. Oxon.  
M.R.C.S., F.L.S.

---

With Illustrations, 8vo. 12s. 6d.

## THE PATHOLOGICAL ANATOMY OF THE NERVOUS CENTRES.

By EDWARD LONG FOX, M.D., F.R.C.S., F.R.C.P.

Physician to the Bristol Royal Infirmary; late Lecturer on the Principles and Practice of Medicine and of Pathological Anatomy at the Bristol Medical School.

---

London: SMITH, ELDER, & CO., 15 Waterloo Place.



270-1  
qua







