

MBL/WHOI



0 0301 0018409 9



DAVISON'S
MAMMALIAN ANATOMY
WITH SPECIAL REFERENCE TO
THE CAT

STROMSTEN

MAMMALIAN ANATOMY

WITH SPECIAL REFERENCE TO

THE CAT

BY

ALVIN DAVISON, PH. D.

EX-FELLOW OF PRINCETON UNIVERSITY; PROFESSOR OF BIOLOGY
IN LAFAYETTE COLLEGE

FOURTH EDITION. REVISED BY

FRANK A. STROMSTEN, D. SC. (Princeton)

ASSOCIATE PROFESSOR OF ANIMAL BIOLOGY
STATE UNIVERSITY OF IOWA

WITH 123 ILLUSTRATIONS, MOST OF WHICH
WERE MADE BY W. H. REESE, A. M., FROM
THE AUTHOR'S DISSECTIONS

“Study nature, not books.”

—*Agassiz*.

PHILADELPHIA
P. BLAKISTON'S SON & CO.
1012 WALNUT STREET

COPYRIGHT, 1923, BY P. BLAKISTON'S SON & CO.
REPRINTED, WITH CORRECTIONS, 1927

PRINTED IN U. S. A.
BY THE MAPLE PRESS COMPANY, YORK, PA.



PREFACE TO THE FOURTH EDITION

In the present edition certain additions have been made and the sections on the muscular and vascular systems rewritten and considerably enlarged. In the section on the muscles Reighard and Jennings has been followed rather closely, but the entire group of muscles with exception of a very few belonging to the reproductive organs and the ear have been worked over in class and by private dissections during the progress of revision. In addition to Reighard and Jennings, reference has also been frequently made to Hyman's "Laboratory Manual for Comparative Vertebrate Anatomy;" Wilder and Gage's "Anatomical Technology;" William's edition of Straus-Durchein's plates; Kingsley's "Comparative Anatomy;" Bensley's "Anatomy of the Rabbit;" Cunningham's "Human Anatomy;" Wilder's "Mammalian Anatomy;" Jayne's "Mammalian Anatomy; The Skeleton of the Cat;" Eycleshymer's "Anatomical Names;" and numerous journals.

A number of new drawings have been made for this edition, five of which depict the muscles of the hind limbs—these, with those already in the book, show more muscles than the average student is likely to dissect. Other new pictures illustrate the development of the vascular system. These have been redrawn for the most part from the original papers to which credit is given. The conventional figures of Boas showing the phylogeny of the aortic arches are from Kingsley's Comparative Anatomy. Huntington and McClure's colored figures showing the development of the postcava have been so well reproduced in black and white by Miss Hyman that they have been borrowed and the figure showing the composite diagram of embryonic veins of the cat has been redrawn to correspond with Hyman's figures. The figure showing the adult venous system has been

drawn from photographs taken from actual dissections by the writer. One specimen had a persistent jugular lymph sac and this has been added to the figure to show its position and venous tap. Certain other variations are shown also. The writer will be glad to receive communications regarding variations in any of the systems as well as criticisms and suggestions. The aim has been to make the text as concise as possible and to keep to the present convenient size of the book as nearly as possible. The index has been very much enlarged to make it more useful.

FRANK A. STROMSTEN.

CONTENTS

	PAGE
INTRODUCTION	I
The Biological Sciences	I
Phylogeny and Classification of Vertebrates	2
Preparation and Preservation of Material	9
GENERAL STRUCTURE OF A VERTEBRATE.	17
The Skin and Its Appendages	25
THE SKELETON.	28
General Terms Used in Description of Bones.	28
Tabulation of Bones.	29
Structure of Bone.	31
Bones of the Head	33
Vertebral Column.	53
Sternum.	61
Ribs	61
Thoracic Limb	63
Pelvic Limb	74
THE JOINTS	83
THE MUSCLES	87
ORGANS AND DIGESTION.	127
Alimentary Canal.	127
Viscera	134
Accessory Glands of Digestion	143
Peritoneum	145
THE VASCULAR SYSTEM	150
Heart.	150
Arteries of Trunk.	154
Arteries of Neck and Head.	157
Arteries of Thoracic Limb	160
Arteries of Pelvic Limb	162
Venous System.	165
Development of Vascular System.	171
Development of Heart.	172
Development of Aortic Arches	174
Development of Venous System	177
Lymphatic System	182
Development of Lymphatic System	187
Ductless Glands	188
RESPIRATORY SYSTEM.	191

	PAGE
EXCRETORY AND REPRODUCTIVE SYSTEMS	198
Glands of the Skin	198
Urinary Organs.	198
Female Organs of Reproduction	200
Male Organs of Reproduction	203
NERVOUS SYSTEM.	209
Brain	209
External Features.	210
Internal Structure	214
Spinal Cord	225
Peripheral Nerves.	231
Cranial Nerves.	231
Spinal Nerves	233
Sympathetic System	240
Organs of Sense.	244
Cutaneous.	244
Olfactory	245
Gustatory	245
Visual.	246
Auditory.	249
GLOSSARY	256
INDEX.	266

LIST OF ILLUSTRATIONS

FIG.	PAGE
1. Injecting Syringe.....	10
2. Diagrammatic View of Operation for Injection.....	11
3. Method of Making Incision in the Carotid Artery for Injection.....	11
4. Method of Inserting the Cannula into a Vessel.....	12
5. Palmar Aspect of Cat's Paw with Cannula Inserted.....	12
6. Squamous Epithelial Cells.....	17
7. Stratified Epithelium.....	17
8. Involuntary Muscle.....	18
9. Heart Muscle.....	20
10. Cartilage.....	21
11. Fibers of Voluntary Muscle.....	22
12. Fibers of Connective Tissue.....	23
13. Longitudinal Section of the Humerus of a Kitten.....	30
14. Longitudinal Section of the Femur.....	30
15. Cross-section of Bone.....	32
16. Diagram of the Bones of the Mammalian Skull Viewed Laterally.....	39
17. Dorsal Aspect of the Cat's Skull.....	40
18. Ventral Aspect of the Skull with the Left Auditory Bulla Removed...	44
19. Cut Surface of a Sagittally Bisected Skull.....	47
20. Medial or Inner Aspect of the Mandible.....	50
21. Ventral Aspect of Larynx, Hyoid Bones, and Tongue.....	51
22. Lateral Aspect of the Skeleton.....	54
23. Plan of a Vertebra.....	56
24. Dorsocaudal Aspect of Atlas.....	56
25. Lateral Aspect of the Epistropheus.....	57
26. Latero-caudal Aspect of a Thoracic Vertebra.....	57
27. Caudal Aspect of Fourth Lumbar Vertebra.....	59
28. Dorsal Aspect of the Sacrum.....	59
29. Ventral Aspect of the Bones of the Thorax.....	60
30. Caudal Aspect of Sixth Rib.....	62
31. Lateral Aspect of the Scapula.....	64
32. Caudal Aspect of the Clavicle.....	64
33. Cranial Aspect of the Humerus.....	65
34. Lateral Aspect of the Ulna.....	66
35. Medial Aspect of the Radius.....	67
36. Genealogy of the Horse.....	68-69
37A. Dorsal Aspect of Cat's Manus.....	70
37B. Generalized Type of Carpus.....	70
38. Lateral Aspect of Forelimb of Equus.....	71
39. Lateral Aspect of Coxal Bone.....	75
40. Ventral Aspect of Innominate Bones.....	75

FIG.	PAGE
41. Caudal Aspect of Femur.....	77
42. Cranial Aspect of Tibia.....	77
43. Medial Aspect of Fibula.....	79
44. Dorsal Aspect of Hind-foot.....	80
45. Diagram of a Diarthrodial Joint.....	83
46. Lateral Aspect of Dissected Knee-joint.....	84
47. Caudal Aspect of Knee-joint.....	85
48. Ventral Aspect of Trunk and Neck Muscles.....	91
49. Medial or Inner Aspect of Hind Limb.....	99
50. Lateral View of Hind Limb.....	100
51. Lateral aspect of Upper Part of Hind Limb.....	101
52. Muscles of Dorsal Side of Hind Foot.....	106
53. Muscles of Sole of Foot.....	106
54. Lateral Aspect of the Muscles of the Cat.....	116
55. Lateral Aspect of the Muscles of the Thoracic Limb.....	118
56. Medial Aspect of the Muscles of Thoracic Limb.....	120
57. Ventral Aspect of the Muscles of Trunk and Thigh.....	123
58. Lateral Aspect of the Muscles of the Leg.....	123
59. Caudal Aspect of the Muscles of Crus and Foot.....	125
60. Diagram of a Gland.....	125
61. Diagram of the Chief Organs of the Cat.....	127
62. Dorsal Aspect of the Tongue and Larynx.....	128
63. Longitudinal Section of the Canine Tooth.....	130
64. Lateral Aspect of the Permanent Dentition.....	131
65. Viscera of the Human Body.....	135
66. Ventral Aspect of the Alimentary Canal.....	137
67. Transverse Section of the Cat.....	138
68. Cross-section of the Cardiac End of the Stomach.....	138
69. Gastric Glands.....	139
70. Cross-section of the Small Intestine.....	140
71A. Villi and Glands of Intestine.....	140
71B. Lacteals and Portal System of Dog.....	141
72. Salivary Glands.....	143
73. Diagram of the Stomach of a Ruminant.....	147
74. Photograph of the Human Heart.....	151
75. Heart Viewed Ventrally.....	151
76. Heart Viewed Ventrally with Caudal Third Cut Off.....	152
77. Heart Viewed Dorsally.....	152
78. Chief Arteries of the Trunk.....	155
79. Ventral Aspect of the Arteries of the Head and Neck.....	158
80. Arteries of the Forelimb.....	161
81. Arteries of the Leg.....	163
82. Cross-section of Artery and Vein.....	166
83. Vein with Valves.....	167
84. Chief Arteries of Cat.....	169
85A. Arterial System of a Rabbit.....	170

FIG.	PAGE
85B. Arterial System of a Man.....	170
86A, B, C. Development of Heart.....	172-173
87. Development of Aortic Arches.....	175
88. Modifications of Aortic Arches in Vertebrates.....	176
89. Development of Venous System.....	178
90. Composite Diagram of Embryonic Veins.....	180
91. Ventral Aspect of Chief Lymphatic Vessels of the Cat.....	185
92. Photograph of the Lymphatic Capillaries and Vessels of Cat's Ear....	186
93. Diagrammatic Transverse Section of the Chest.....	192
94. Photograph of a Lung Corrosion of a Puma.....	193
95. Diagrammatic View of the Lung.....	195
96. Photograph of Human Heart and Lungs.....	196
97. Ventral Aspect of Female Urogenital System.....	199
98. Median Longitudinal Section of a Kidney.....	200
99. Diagram of Structure of Kidney.....	200
100. Section of Ovary.....	202
101. Ventral Aspect of Male Reproductive Organs.....	204
102. Spermatozoa.....	205
103. Dorsal Aspect of the Brain.....	211
104. Ventral Aspect of the Brain.....	213
105. Diagram of the Ventricles.....	215
106. Sagittal Section of the Brain.....	216
107. Dorsal Aspect of the Brain with the Cerebellum and Portion of Cere- brum Removed.....	218
108. Cross-section of the Brain Caudad of the Optic Chiasm.....	220
109. Cross-section of the Brain through Anterior Commissure.....	222
110. Photomicrograph of Cross-section of Human Spinal Cord.....	226
111. Diagrammatic Section of Spinal Cord.....	227
112. Nerve-cell.....	228
113. Diagram of the Relation of Cells and Fibers in the Spinal Cord.....	229
114. Ventral Aspect of the Branchial Plexus.....	234
115. Ventral Aspect of the Nerves of the Pelvic Limb.....	238
116. Cranial Half of Sympathetic System.....	241
117. Caudal Half of Sympathetic System.....	242
118. Pacinian Corpuscle.....	245
119. Longitudinal Section of the Eye.....	247
120. Diagram of the Mammalian Ear.....	250
121. Section of the Cochlea of the Calf.....	251
122. Photograph of Human Brain.....	253
123. Brain of the Rabbit.....	254



ELEMENTS OF MAMMALIAN ANATOMY

INTRODUCTION

Since this book is designed for the use not only of students who have pursued the study of biology for some time, but also for those making their first actual acquaintance with the subject, it may be well to call attention to the fact that any animal or plant may be considered from several different standpoints. A general study of structure and of the relations of the various systems and organs is known as *Anatomy*. *Histology* concerns itself with the cell and cell aggregates or tissues composing the organs. These two sciences are included in *Morphology*, a term which by many is made to include also *Embryology* or *Ontogeny*, treating of the development of an organism from the egg, or its vegetable homologue, to the period of assuming adult characteristics. Since ontogeny deals not only with the growth of structure but also the process of growth, it may likewise be included under *Physiology*, a science which has for its province the investigation of the functions of the organs and systems. A special field of physiology having for its consideration the operations, especially the conscious operations of the nervous system, constitutes the science of *Psychology*.

The same species of animals are not found in all parts of the world. The lion and tiger are found wild only in the old world, while the opossum is confined to the new world. Again, many species of animals whose fossil remains indicate their existence on earth several millions of years ago, have at present no living

representatives. A consideration of this geographical and stratigraphical location of organisms forms the science of *Distribution*. The science of *Phylogeny* seeks to discover the geological ancestral history of an organism.

A casual glance shows at once striking similarities and differences between the common cat, the lion, and the tiger. All have retractile claws, the same number and kind of teeth, and the same number of toes. On the other hand, the resemblances between these cat-like animals and the dogs are less marked, while the differences are more striking. The cats and dogs resemble each other more closely than either does a horse. Horses, dogs, and cats have numerous characters in common which are not present in birds. The recognition of such resemblances and differences furnishes a basis of classification, the treatment of which forms the science of *Taxonomy*.

THE PHYLOGENY AND CLASSIFICATION OF VERTEBRATES

Vertebrates have existed upon the earth for a very long time, so long, indeed, that the time and manner of their origin is very uncertain. From what great group of invertebrates they were derived can only be surmised from embryological and morphological data. The evidence from paleontology is very incomplete and unsatisfactory. Within the class of vertebrates, however, the geological history is more certain. As a matter of fact, the detail in which the phylogeny of such groups as the horse, the camel, and the elephant can be reconstructed from their fossil remains is indeed marvelous.

Geologic time has been conveniently divided into eras, periods, epochs, ages, etc. The following table has been inserted for reference in connection with the geological history of the vertebrate types. Certain dates have been assigned to the several eras more as a reminder that the mind must think in terms of millions of years than that they are even approximately correct.

Era	Time	Period	Age	Animal life
CENOZOIC	8,000,000 years.	Quarter-nary.	Holocene. Pleistocene.	Age of Man. Recent Mammals. Ice Age.
		Tertiary.	Pliocene. Miocene. Oligocene. Eocene.	Modern Mammals. Equus. Earlier modern Mammals. Protophippus. Beginning modern Mammals. Mesohippus. Ancestors of modern Mammals. Hyracotherium.
MESOZOIC	80,000,000 years.		Cretaceous. Jurassic. Triassic.	Reptiles dominant, birds and mammals. Reptiles preëminent. Reptiles abundant, Mammals first appear.
PALEOZOIC	130,000,000 years.		Permian. Carboniferous. Devonian. Silurian. Ordovician. Cambrian.	Reptiles appear. Amphibians dominant. Age of Fishes. Selachians and Ostracoderms. Ostracoderms. Invertebrates.
			Proterozoic.	
			Archeozoic.	

1. *The Invertebrate Stage*

I. Invertebrata.—Animals with no skeletal axis and without a central nervous system entirely dorsal of the alimentary canal. Their earliest appearance in geologic time is not known.

2. *The Protochordal Stage*

II. Protochordata.—Small marine forms having, during part of their life at least, a rudimentary skeletal axis and other features marking them as a connecting link between the

invertebrates and vertebrates. They must have been present in the Cambrian and Precambrian seas several hundred million years ago. They are represented in modern times by the worm-like *Balanoglossus*, the Tunicates and Branchiostoma (*Amphioxus*).

III. Vertebrata.—Forms with a skeletal axis and dorsal nerve-cord whose anterior end is dilated into a brain.

3. *The Cyclostome Stage*

(A) **Cyclostomata.**—Fish-like forms having a circular mouth, no jaws present, no paired appendages, skeleton poorly developed. They make their appearance in the early Ordovician. The modern representatives are the lampreys and hagfishes.

4. *The Selachian Stage*

(B) **Gnathostomata.**—True jaws, well-developed skeleton, and usually with paired appendages. Include all vertebrates above the cyclostomes.

α *Ichthyopsida* (Anamnia): Fish-like forms that breathe, at least while young, by gills; paired appendages, no amnion or allantois.

1. *Pisces* (*Fish*).—Breathe by gills; median and paired fins, except where the latter are lost by degeneration.

(a) *Selachii.*—True jaws present for the first time; gill slits reduced in number; body covered with plate-like (placoid) scales; notochord strengthened by blocks of cartilage; general organ systems foreshadowing those of the higher types. A knowledge of the anatomy of selachians is fundamental to a proper understanding of the embryology and morphology of vertebrates in general. Sharks swarmed the Silurian seas. The modern representative of the selachians are the sharks, rays and torpedoes.

5. *The Ganoid Stage*

- (b) *Ganoidei*.—An ancient group of armored fishes in which the skeleton becomes partly ossified; air-bladder with a persistent open duct present hydrostatic in function and foreshadowing the lungs. Abundant in Devonian and Carboniferous times. Modern representatives are the sturgeon and pike.
- (c) *Teleostei*.—True bony-fishes; an offshoot from the main line of evolution devonian to modern times.
- (d) *Dipnoi*.—Lung or mud-fishes; isolated survivors of a very ancient group of Devonian fishes.

6. *The Amphibian Stage*

- 2. *Amphibia*.—Legs instead of fins; lungs replacing gills in adult. Mud tracks attributed to amphibians have been found in the Devonian and early carboniferous times but abundant fossils are first found in the latter Carboniferous times. The earlier forms were called *stegocephalians* on account of a curious bony protection for the skull. One branch which reached its highest development in the Permian has been thought by some palaeontologists to be the ancestor of mammals. Many forms reached considerable size. The modern representatives are frogs, toads and salamanders.

β Amniota: Amnion and allantois present; gills never functional; fins never present.

7. *The Reptilian Stage*

- 3. *Reptilia*.—Whole body covered with scales or plates; poikilothermic, *i.e.* body temperature more or less changeable with surroundings. Although fossil reptiles have not been found until toward the close of the Paleozoic during the early part of the Per-

mian, they doubtless began to differentiate from the stegocephalian amphibians much earlier. Their development was so rapid in the Mesozoic times that they dominated the earth, the sea and the sky. They reached enormous proportions. One of the terrestrial forms, a *dinosaur*, measured over 90 feet in length; with head erect could reach to a height of 30 feet, although its normal height was but 15 feet. The sea forms, or *ichthyosaures*, were also of large size. They were fish-like in shape and were frequently provided with long slender jaws armored with sharp conical teeth. There were also flying reptiles, *Pterosaures*, with a wing-spread of over 20 feet. Of the twenty-five or more Mesozoic orders, but a few of the more insignificant types remain to-day; such as snakes, turtles, lizards, crocodiles and alligators.

4. *Aves* (*Birds*).—"Warm-blooded" animals with feathers: An offshoot of the reptiles.

8. *The Mammalian Stage*

5. *Mammalia*.—Vertebrates suckling their young; hairs never entirely absent; diaphragm complete; heart four-chambered; aorta curved to the left; red blood-cells, when fully formed, without a nucleus and round, except in the camel where they are elliptical. The advent of mammals occurs during the triassic. They are probably related to the reptiles through the theromorphs. The mammals of the early Cenozoic were small and insignificant. However, they soon become the dominant type of animal, so that the Cenozoic becomes known as the age of mammals. The secret of their success is their four-chambered heart and their protective covering of hair.

- (A) **Prototheria**.—Very primitive, egg-laying (oviparous) mammals. Represented in modern times by the duck-bill (*Ornithorhynchus*) and spiny ant-eater (*Echidna*) of Australia. Upper Triassic to modern times.
- (B) **Eutheria**.—Viviparous mammals with anus and urogenital openings distinct.
- α *Didelphia* (*Marsupialia*): Pouched mammals. Typically carrying the young in a pouch; placenta rudimentary or primitive. Jurassic to modern. The modern representatives are the opossums and kangaroos.
 β *Monodelphia* (*Placentalia*): Young nourished before birth by a placenta; never carried in pouch.
- (A) **Unguiculata**.—Clawed placental mammals. Mesozoic to modern. Adapted to terrestrial, fossorial, arboreal, aquatic, cursorial, and volant life.
1. *Insectivora*.—(Moles, shrews, and hedgehogs.) Eocene to modern.
 2. *Chiroptera*.—(Bats). Miocene to modern.
 3. *Carnivora*.—Eocene to modern. Modern forms under two suborders:
 - (a) *Fissipedia*.—Dogs, raccoons, bears, weasels and the cats, hyenas, etc.
 - (b) *Pinnipedia*.—Seals, walruses, etc.
 4. *Rodentia*.—Rabbits, squirrels, beavers, rats, mice, and porcupines. Oligocene to modern.
 5. *Edentata*.—Sloths, ant-eaters, and armadillos. Miocene to modern.
- (B) **Primates**.—Fingers terminating in “nails” as distinguished from mammals with claws (unguiculates) or hoofs (ungulates). Eocene to modern. Adapted to arboreal and ambulatory life. Lemuroids, lemurs, monkeys, apes and man. Probably arose from shrew-like insectivores.
- (C) **Ungulata**.—Hoofed mammals. Eocene to modern. The Condylarthra and other primitive and

extinct forms are omitted from this list. The modern orders are as follows:

6. *Artiodactyla*.—Even-toed ungulates (pigs, camels, deer, sheep and oxen).
7. *Perissodactyla*.—Odd-toed ungulates (tapirs, horses, and rhinoceroses).
8. *Proboscidea*.—Mastodons and elephants.
9. *Sirenia*.—Aquatic modifications of the Ungulata (sea cows and dugongs).
10. *Hydracoidea*.—(Conies). Rock and tree-living ungulates. Oligocene to present. Syria and Africa.

(D) **Cetacea**.—Whales and Dolphins. Eocene to present.

A glance at the above outline shows that the *class* Mammalia is divided into two *subclasses*, Prototheria and Eutheria; the latter of which include the Didelphia and the Monodelphia. The Monodelphia, or placental mammals, includes four *cohorts*; mammals with claws, mammals with nails, mammals with hoofs, and aquatic mammals. The Cat belongs to the unguiculates and to the order Carnivora, or flesh-eaters. There are two suborders of modern carnivores, the Fissipedia, or terrestrial forms, and the Pinnipedia, or aquatic forms. There are eight families in the suborder Fissipedia, of which the Canidæ (dogs), Ursidæ (bears), and Felidæ (cats) are the most frequently seen in America. The family Felidæ is represented by only two living genera, *Cynaelurus* and *Felis*. The genus *Felis* includes several species, of which *Felis leo* (the lion), *Felis tigris* (the tiger), and *Felis domestica* (the cat) are the most familiar. Of the last species, there are several varieties, such as Maltese, Angora, and Manx cats.

Linnaeus, born in Sweden, 1707, invented the system of *binomial nomenclature* in accordance with which the scientific name of every plant and animal is composed of two parts, the generic and specific. Thus the house cat is designated *Felis*

domestica; the lion, *Felis leo*; the dog, *Canis familiaris*; the wolf, *Canis lupus*; the pig, *Sus scrofa*; the red deer, *Cervus elephas*; the elephant, *Elephas Africanus*; the orang-outang, *Simia satyrus*; and man *Homo sapiens*.

METHODS OF PRESERVING MATERIAL

Alcohol has been widely used as a preservative, but owing to the fact that it is expensive and quickly evaporates from the specimen exposed to the air, thereby rendering the parts dry and brittle, its use has been largely supplanted by formalin. Formalin, CH_2O , is often sold under the names of formose, formol, formine, formalosa, and formaldehyd. It can be purchased for about thirty cents a pound. For preserving any animal or plant, the concentrated 40% formaldehyd is diluted with water in the proportion of ninety-five parts of the latter to five parts of the former. It is evident, therefore, that one pound of formaldehyd will make about ten liters of preserving fluid.

The specimens may be kept a year or two without changing the formalin in ordinary stone jars with covers, but for permanent preservation the glass jar with the ground-glass cover should be used.

Preparation of Vascular System.—To render the vessels plainly visible and distinguish the arteries from the veins, it is advisable to inject the former with a yellow or red mass and the latter with a blue mass. These fluid masses should be of such a character as to harden in a short time after injection, so that they will not run out when the vessels are cut during dissection.

A syringe of hard rubber, having a capacity of about two ounces, serves very well for injection. A cannula of correct size may be had by asking the druggist for the filling cannula of the Parke Davis serum syringe. The end to be inserted into the blood-vessel should be ground off obliquely and smoothly on a whetstone. The connection between the cannula and nozzle is formed by stiff rubber tubing which should be securely tied to the cannula (Fig. 1).

The injecting mass is prepared by thoroughly mixing 100 c.c. of water, 20 c.c. of glycerin, 20 c.c. of concentrated formalin, and 85 gm. of common laundry starch. One-half should be

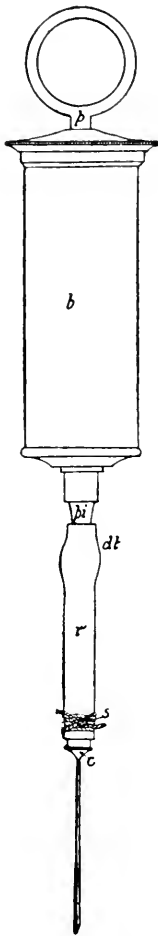


FIG. 1.—INJECTING
SYRINGE. $\times \frac{1}{6}$.

p, Plunger handle;
b, barrel; *pi*, nozzle;
c, cannula; *r*, rubber
tube; *dt*, point of detachment; *s*, string.

other colored blue by dissolving in it a gram or two of soluble Berlin blue. These liquid masses, after being passed through a fine wire strainer or a coarse piece of cheese-cloth stretched across a funnel, may be preserved for any length of time in covered jars.

The animal may be anesthetized by placing it in a tight box and administering illuminating gas, ether or chloroform. If only the arteries are to be infected, the cat may remain in the box until dead; but if the veins are also to be injected, it is preferable to use illuminating gas for the anæsthetic and then remove the animal to the tray as soon as it is unconscious, and reflect a portion of skin, exposing the external jugular veins (Fig. 2). With the curved forceps thrust beneath the vein a cord may be pulled through and tied in a loose knot. One-half inch from the latter a second cord should be tied around the vein loosely. An oblique cut (Fig. 3) with the point of the scissors directed caudad is then made in the veins between the cords. The incision should extend about half-way through the vessel. Absorbing the blood

with absorbent cotton as it runs from the vessel will prevent clogging. If too much ether has not been used, the blood will continue running fifteen minutes. When it has nearly ceased flowing the carotid artery must be found by making a slit in the muscle alongside of the trachea

just medial of the jugular, as indicated by the line *d* (Fig. 2). Having cut through the muscle, two white cords are seen along either side of the trachea. The medial one may be red, as it is the carotid artery. The lateral one, lying in the same sheath with the preceding, is the vagus or tenth cranial nerve. Separate the artery from the nerve and tie two cords loosely around the vessel as in the case of the jugular. Lift up the artery with the index finger (Fig. 3), and make an oblique incision with the scissors. The cannula with the connecting tube attached should then be inserted caudad in the oblique cut of the artery (Fig. 4), and the string *s* drawn tight so as to hold the cannula in place. The string *st* should then be tightened to

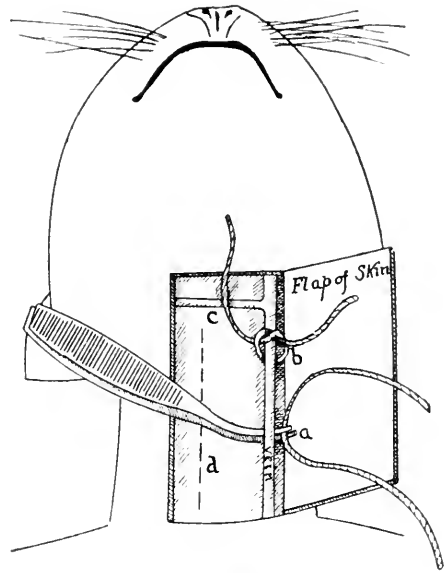


FIG. 2.—DIAGRAMMATIC VIEW OF OPERATION FOR INJECTION.

d, Broken line showing course of the carotid artery beneath; *b*, string loosely tied; *c*, transverse vein uniting external jugulars; *a*, points of curved forceps containing string.

prevent the injection mass from running out where the cannula is inserted. After stirring the red mass, filling the syringe, and slipping the nozzle into the connecting tube the operator should press slowly but continuously on the plunger until that portion of the carotid craniad of the string *st* is well distended. In a large cat this will not occur until the syringe is nearly or quite empty. When the vessels are full, the cannula is withdrawn while the string *s* is tightened. The syringe is washed out, after which the blue mass is well stirred

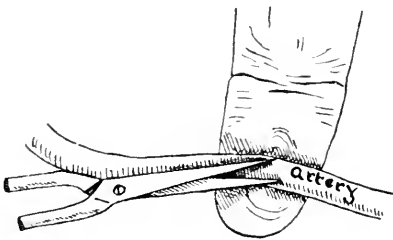


FIG. 3.—METHOD OF MAKING INCISION IN THE CAROTID ARTERY FOR INJECTION.

and injected caudad into the external jugular in the same manner as described for the arteries.

By making a slit about three inches long in the abdominal wall, a fold of the intestine may be pulled out so that its lumen can be filled with about 200 c.c. of 15% formalin. The same amount should be injected into the lungs by inserting the cannula caudad into the ventral wall of the trachea. If the cat is not to be used at once, it may be preserved indefinitely in a jar of five per cent. formalin.

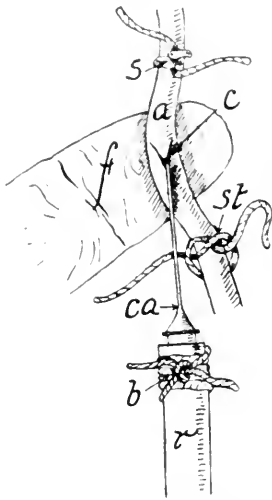


FIG. 4.—METHOD OF INSERTING THE CANNULA INTO A VESSEL.

The **portal system** is not injected through the jugular vein. The portal trunk just caudad of where it enters the liver may be found by cutting a piece from the abdominal wall on the right ventral aspect just caudad of the last rib. After two loose knots are tied around this trunk as directed for the jugular, the cut is made and the cannula inserted into the portal system of a large specimen. This should not be injected until the other systems have been filled.

The **lymphatic system** must likewise be injected for demonstration. While the cat is being anesthetized, dilute India ink, or 5 gm. of soluble Berlin blue are dissolved in 100 gm. of water, and the solution warmed to about the temperature of the body. As soon as the cat is unconscious the syringe should be warmed by filling it with hot water, and the point of the cannula pushed obliquely proximad under the thick skin on the palm (Fig. 5) of the paw. The syringe after being half filled with India ink or Berlin blue solution is attached to the cannula and the plunger

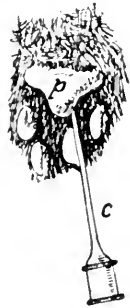

FIG. 5.—PALMAR ASPECT OF CAT'S PAW WITH CANNULA INSERTED.

pushed in very slowly so that one-fourth of the amount in the syringe is forced out in ten minutes. While the injection is being made the limb should be gently massaged by pinching and rubbing from the foot toward the body. This facilitates the flow of the liquid in the lymph-vessels. In this manner the lymphatics of each limb are filled. The author has been able to fill the left thoracic duct by continuing the injection for about twenty minutes in the palm of the left paw. The lymphatics of the head and neck may be injected in a similar manner by inserting the cannula beneath the skin on the tip of the ear, the top of the tongue, the tip of the nose, and the lips.

In order to inject the lacteals the abdominal cavity must be opened, and the cannula inserted very obliquely into the wall of the small intestine so that its point is between the mucous and muscular coats. The half-filled syringe being attached, very gentle pressure should then be exerted on the plunger, until the injecting solution appears in the lacteals. To inject all the lacteals it is necessary to insert the cannula into the wall of the intestine at a dozen different places. To fill the thoracic duct, injection may be made into the large lymphatic gland lying at the point where the covering blood-vessels of the mesentery meet. The best solution for injecting the thoracic duct is made by dissolving 7 gm. of gelatin in a warm Berlin blue solution (4 gm. of Berlin blue to 100 c.c. water). This should be filtered through a single layer of absorbent cotton and then injected, while still quite warm. In all cases injections to fill the lymphatics must be warm and must be pushed in very slowly. These lymphatic injections are best preserved by injecting the trachea and intestine with 95% alcohol and immersing the cat in a jar of 70% alcohol. Professor Gage makes a beautiful demonstration of the lymphatic system by feeding—a cat that has been starved 18 to 24 hours some butter colored—with Sudan III. After three or four hours the cat is killed and dissected. The lymphatics stand out in red.

Preparation of a Mammal for Dissection of the Muscles, Peripheral Nerves and Viscera.—The simplest method is to anesthetize the animal as before described and then remove the skin, taking great care to avoid cutting away the superficial muscles. The cannula should be pushed through into the trachea and 100 c.c. of 15% formalin injected to fill the lungs. An equal amount of formalin should be injected into the stomach through a glass tube pushed down the esophagus. The same quantity of formalin should be injected at two or three different places into the intestines by making a median incision into the abdominal wall and pulling out a loop of the intestine into which the cannula may be thrust. The specimen is then to be immersed in a jar of 5% formalin. A better method is to inject into the carotid artery 200 c.c. of glycerinated formalin (water 140 c.c., glycerin 30 c.c., formalin 30 c.c.), and half that amount into the intestine and trachea. The specimen may then be preserved in 5% formalin.

Preparation of the Central Nervous System.—The animal may be killed either with chloroform or ether. About 200 c.c. of formal-bichromate (170 c.c. of 5% potassium bichromate and 30 c.c. of formalin) are then injected slowly craniad into the carotid artery (Figs. 2, 3, and 4). After skinning, the eyes should be cut out and the flesh removed from the head and dorsal side of the vertebral column. On a line connecting the caudal borders of the orbits, cut through the skull to the brain with the bone cutters and remove piece by piece the roof of the skull. Next cut away the lateral walls down to the base of the brain. Care must be exercised in laying bare the cerebellum, and cutting loose the *tentorium cerebelli*, the plate of bone separating the cerebrum from the cerebellum. The spinal cord is next laid bare dorsally, beginning with the atlas, by cutting through the pedicles of the neural arches on either side. With a sharp knife or a pair of scissors the spinal nerves may then be cut and the cord lifted from behind forward out of its bed, until the brain is reached. The latter must be carefully

raised while the nerves at its base are cut, and the dura mater loosened.

The brain is firm enough to dissect as soon as removed, but it is better to further harden it and differentiate the white and gray matter by placing it in weak formal-bichromate (5% formalin, 500 c.c. + 5% potassium bichromate, 500 c.c.) one week in the dark. Light causes a precipitate. At the end of one week the specimen should be placed in 1000 c.c. of 5% formalin for another week, after which it is ready for dissection. In case brains of calves or sheep are used a hammer and bone chisel are necessary for opening the skull. The head should first be nailed to the tray. As soon as the brain is removed it should be placed in a large pan of water and the dura mater carefully cut away, the clotted blood washed off and a syringe-ful of strong formal-bichromate injected into the third ventricle by pushing the cannula about an inch through the infundibulum (Fig. 103). The brain of a sheep or calf will be very soft when removed, as it cannot be hardened previously by injecting the hardening fluid into the arteries. Therefore it is necessary to lay the specimen on absorbent cotton in the jar of formal-bichromate, which must be exchanged for fresh fluid on the second and third days. At least two weeks are required for hardening the brain of a sheep or calf, after which it is placed in 5% formalin for a week or more to wash out the bichromate before dissection. Brains are best preserved permanently in 85% alcohol. The brain of the cat or sheep may be satisfactorily prepared for dissection by placing it immediately upon removal from the skull into a 5% solution of formaldehyd, where it may remain until needed.

Preparation of the Osseous System.—A mounted skeleton of the cat may be purchased for about eight dollars. It is far more satisfactory, however, to use the disarticulated bones for study. These are easily prepared in the following manner: As soon as the animal is dead, the skin and the greater part of the flesh should be cut away and the internal organs removed.

The bones with much flesh remaining on them are then put into 7000 c.c. of water containing 150 grams of "Gold Dust," or powdered soap. This may then be boiled from two to four hours but better results are given by using the low flame and keeping the solution at a temperature between 75 and 90 degrees centigrade from 3 to 6 hours. As soon as the flesh falls freely off the bones they should be brushed clean in a pan of water and the brain broken to pieces with a bent wire thrust into the foramen magnum. The contents of the skull may then be washed out under the tap. This treatment renders the bones perfectly clean, white and free from grease.

By heating the bones from one to two hours only and not allowing the temperature to rise above 85 degrees, the flesh may be brushed from the limbs without removing the ligaments holding the bones together. When dry, the bones are held firmly in their natural relations. In treating the skeletons of kittens or those of smaller animals such as mice, birds and frogs, only one half the amount of gold dust should be used and a temperature between 70 and 80 degrees maintained.

GENERAL STRUCTURE

The study of any vertebrate reveals the presence of numerous *organs*, each of which is for the performance of a particular function. Thus the heart is the organ for the propulsion of the blood, the kidney for the elimination of the nitrogenous waste. Several organs combined for a common purpose constitute a *system*. The heart, with the various vessels for conveying the blood, forms the circulatory system. The following eight systems are found in all Mammalia: Osseous or bony, muscular, digestive, respiratory, vascular, excretory, reproductive, and nervous.

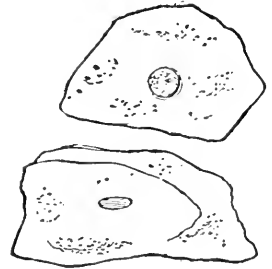

FIG. 6.—DETACHED SQUAMOUS CELLS FROM THE MOUTH. (Lewis and Stöhr.)




FIG. 7.—STRATIFIED EPITHELIUM FROM THE ESOPHAGUS OF A CHILD. (Lewis and Stöhr.)

The relative locations of the various systems are represented diagrammatically in Fig. 61. The organs have the same arrangement throughout all the orders of mammals. Moreover, the minute structure of the same organ is so similar in the different species that in many cases even the microscope will not enable one to tell from which of several kinds of mammals the organ has been taken.

Organs are made up of simpler elements, the tissues. *Tissues* are formed of cells and intercellular substance, sometimes the one and sometimes the other is more in evidence.

The cell has been called the structural unit of the body. Typically, it is a mass of living matter, *protoplasm*, containing a central denser body, the *nucleus*. The nuclear substance is very

complex and is separated from the rest of the cell by a *nuclear membrane* which performs an important function in general cell activity. The nucleus contains a highly organized substance, the *chromatin*, which is important in reproduction and metabolism and is supposed to be the bearer of hereditary characters. During cell-division the chromatin material may be collected in definite masses or rods, *chromosomes*, the number and appearance of which are constant for the species. The animal cell has no definite cell wall but the peripheral layer of protoplasm is so modified as to act like a semipermeable membrane which plays an important rôle in cellular activity.




FIG. 8.—INVOLUNTARY
MUSCLE-CELLS. $\times 250$.
n, Nucleus of a cell.

Cells vary in size, shape, structure and arrangement according to function or pressure. Cells differentiated to perform a certain definite function are grouped together with a certain amount of intercellular substance to form a tissue.

There are four primary tissues: *epithelial*, *connective*, *muscular*, and *nervous*.

Epithelial tissues line all the inner and outer surfaces of the body. They are distinguished by the importance of the cells and the small amount of intercellular substance, *cement*. They serve for protection, secretion, excretion, and reaction to stimuli. They may be simple, that is made of a single row of cells as in the intestine, or *complex* or *stratified*, made up of several layers as in the skin. Epithelial cells form the parenchyma of all secreting glands.

Connective tissues are distinguished by the large amount of intercellular substance. They form the supporting elements of the body. *Ordinary connective tissues* are recognized by the character of their fibers or their cells. Those recognized by their fibers are *white fibrous* or tendon, *yellow elastic*, *reticular*, and *areolar*. The areolar is the commonest kind and is found everywhere, as just beneath the skin, between muscle

bundles and elsewhere loosely joining structures together. Reticular tissue forms binding tissue of many glands. These recognized by their cells are *fat* or *adipose tissue*, *pigmented tissue*, and *lymphatic* or *adenoid tissue*.

Skeletal connective tissues form the more rigid supporting tissues of the body. They are of two kinds: *cartilage* and *bone*. There are three kinds of cartilage, distinguished by the character of the intercellular substance or *matrix*.

Hyaline cartilage is characterized by its homogeneous matrix in which the cells are imbedded singly or in groups of two or more. It is the most abundant and is commonly known as gristle. It forms the articular cartilage of long bones, the costal cartilage of ribs, and the cartilages of the respiratory system. The entire embryonic skeleton with exception of a few bones of the skull was at first hyaline cartilage. *White fibro cartilage* and *yellow elastic cartilage* are recognized by the presence of white or yellow fibers as the name indicates and have a much more limited distribution.

Bone is a much more compact firm tissue than cartilage and is limited to the skeleton. The superficial layers of flat bones and of the epiphysis and the main portion of the diaphysis or shaft of long bones are composed of *compact bone* while the middle layer of long flat bones and the larger portion of the epiphysis of long bones is *spongy* or *cancellous bone* (Fig. 14). In the epiphysis the plates of cancellous bone are arranged in curved lines such as to give the greatest strength to the bone (Fig. 14).

Muscular tissues are of three types: *striated*, *unstriated* or *smooth* and *cardiac*. The voluntary striated are the skeletal muscles of the body. They are composed of long cylindrical fibers or cells having a number of nuclei located peripherally just beneath the cell membrane, or *sarcolemma*. The unit of structure is the myofibril or sarcofile which is cross-striated and gives the characteristic appearance to this type of muscle. The number of myofibrillæ in each cell or muscle fiber may be very great. The involuntary or smooth muscle cell has no

sarcolemma, the nucleus is central, and the shape is spindle-like or the cells may be joined together to form a syncytium (Fig. 8). The cardiac muscle is composed of broad branching fibers of cells united into a syncytium. The nucleus is central and the fibrils striated. A sarcolemma has been described surrounding the cardiac fibers (Fig. 9).

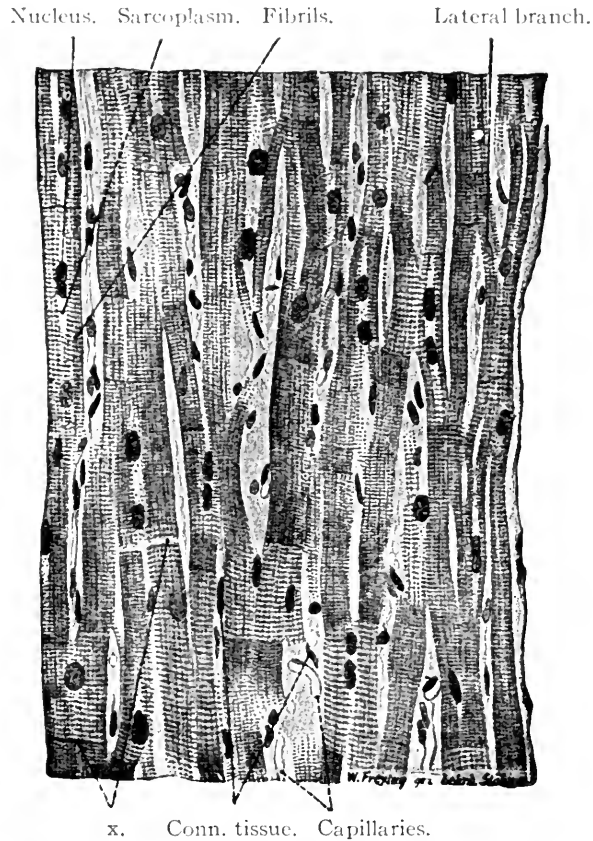


FIG. 9.—LONGITUDINAL SECTION OF A PAPILLARY MUSCLE FROM THE HUMAN HEART. $\times 240$. (Lewis and Stöhr.)

The transverse lines (x) are partly light (where the fiber has broken) and partly dark (*intercalated discs*).

Nervous tissues are made up of two kinds of elements: *nerve cells* and *nerve fibers*. Nerve cells vary much in size and shape, but typically comprise cell body, a fiber-process or axone, and a series of branching processes, the dendrites. The nerve cell with all its processes is known as a neurone (Fig. 112). The nerve fiber has as its axis or core the axone, which in most cases

is enclosed in certain membranes or coats. Certain fibers of the sympathetic nervous system are surrounded by a delicate homogeneous membrane, the neurolemma, and are known as *nonmedullated* fibers. The fibers of the central nervous system are generally distinguished by an intermediate layer of myelin

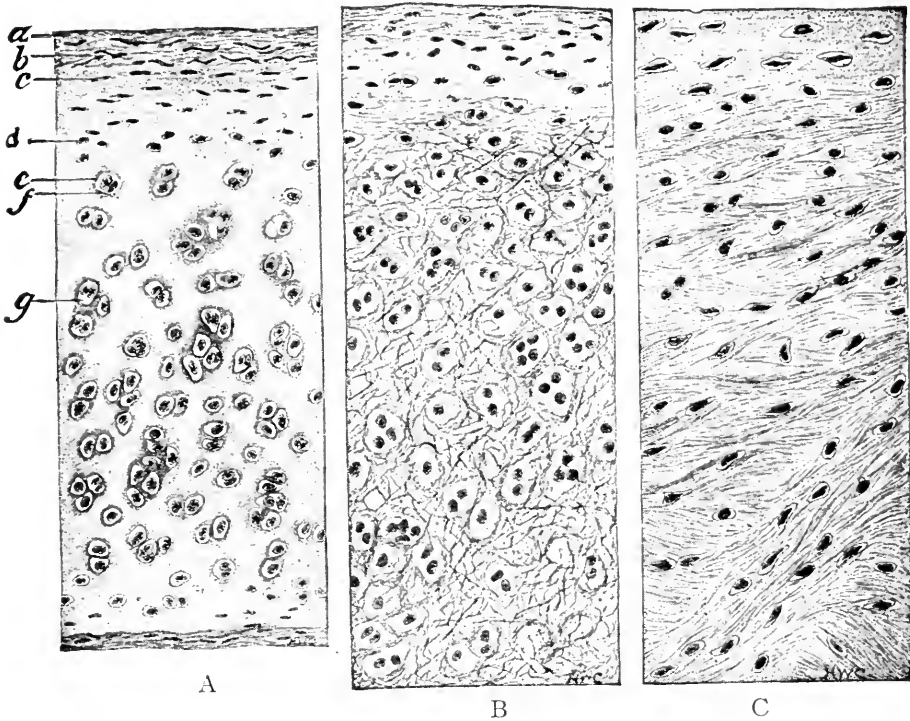


FIG. 10.—THE THREE TYPES OF CARTILAGE: A, HYALINE; B, ELASTIC; C, FIBROUS. (Radasch.)

a, b, Outer and inner layers of perichondrium; *c*, young cartilage cells; *d*, older cartilage cells; *e, f*, capsule surrounded by deeply staining matrix; *g*, lacuna.

between the axis cylinder and the neurolemma and are known as *medullated fibers*. The myelin sheath is more or less interrupted at regular intervals by the so-called *nodes of Ranvier*. Nerves are bundles of nerve fibers arranged in a parallel fashion and enveloped in a connective-tissue sheath or epineurium. Nerves carrying impressions to the central nervous system are known as afferent or sensory nerves; those carrying impulses peripherally are the efferent or motor nerves.

The different relative arrangements of these anatomic elements together with their morphology, permit one to know from what organ any particular section of tissue under consideration has been taken.

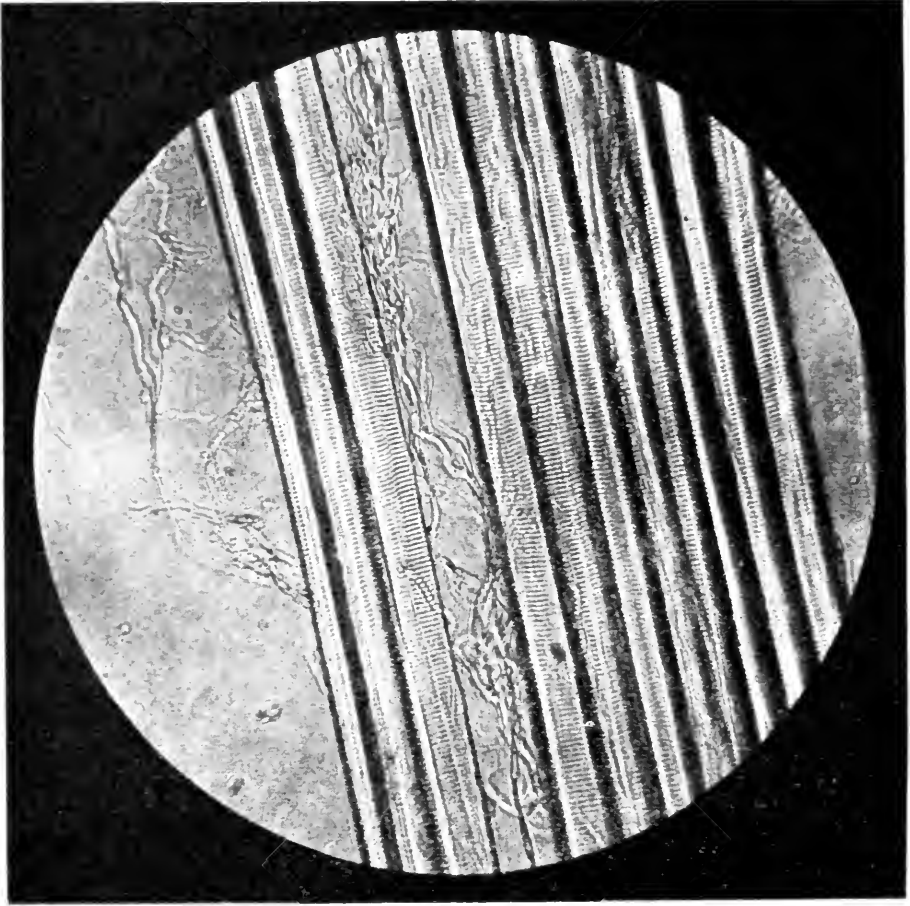


FIG. II.—PHOTOMICROGRAPH OF FIBERS OF VOLUNTARY MUSCLE. $\times 100$.
Note the finer threads of connective tissue.

These ultimate units of structure are still further resolved into parts by the chemist, who has shown that they are composed largely of carbon, hydrogen, oxygen, and nitrogen. Since there can be no energy developed in the body without the breaking down of the complex organic compounds stored up by the cells or else by the destruction of the cells themselves, it is plain that they must have their losses replaced in

order to continue their existence. Therefore a method of preparing the food for the use of the cells, and a way of transporting it to each of them are necessary.

The former is accomplished by the *digestive system*, which, through the agency of the salivary, gastric, pancreatic, and other glands, transforms the food into a special liquid state capable of being absorbed by the millions of minute finger-like villi of the small intestine (Fig. 71a). Thence it is transferred by the lacteal vessels and veins to the heart, whence it is con-



FIG. 12.—SUBCUTANEOUS TISSUE FROM A CAT. (Lewis and Stöhr.)

The fiber *a* has been treated with dilute acetic acid; the other fibers have been teased apart and examined, unstained, in water. *a*, *c*, White fibers; *b*, fat cell; *d*, connective tissue cell; *e*, elastic fibers.

veyed by the arteries to their capillary distribution in the neighborhood of every cell in the body.

The waste material resulting from the cell activity is of two kinds, gaseous and liquid. These waste products diffuse through the capillary walls into the blood or are carried through the lymphatics to the veins. *Carbon dioxid* is carried to the heart and thence by the pulmonary arteries to the lungs, where it passes into the terminal branches of the trachea, and finally by expiration reaches the exterior. The liquid excretion is transported by means of the lymphatics, veins and arteries to the kidneys, where it diffuses through the walls of the capillaries into the minute tubules opening into the ureters leading to the

bladder. It must be remembered that the material known as *feces* passed out of the alimentary canal through the anus is not an excretion of the cells of the body, but largely that portion of the food not transformed into a condition permitting it to be absorbed by the villi.

In addition to these systems necessary for the maintenance of life, the cat requires a means for supporting the body and moving about, furnished by the osseous and muscular systems. The osseous system serves not only for support and locomotion, but also for the protection of the delicate vital organs. The skull and spinal column contain the brain and spinal cord, while the heart and lungs are well shielded by the dorsal vertebræ, the ribs, and sternum. Likewise the muscles ward off serious injuries from the blood-vessels, as they cover to a considerable depth nearly all large arteries, and also aid by their contraction in moving the lymph through the numerous lymphatic vessels extending from the extremities to the jugular veins.

These systems previously described are capable of performing their functions only when supplied with nerves through which impulses can be transmitted from the brain and spinal cord.

The only system which is not absolutely necessary to the life of the cat is the reproductive; but this is required for the continuance of the species. It is not, however, functional during the entire life, but as a rule only from the end of the first to the tenth year.

LABORATORY STUDIES AND SUGGESTIONS

1. What advantages are derived from the study of mammalian anatomy?
2. Define morphology and state a fact from that science.
3. What two sciences does biology include?
4. What five sciences are included in zoology?
5. Make a physiologic statement concerning the heart.
6. State five facts belonging to the science of distribution.
7. What is taxonomy?
8. Name five classes of vertebrates.
9. By examining specimens discover what external feature distinguishes a reptile from an amphibian.

10. Do all mammals have hair?
11. What habit is common to no other vertebrates except mammals?
12. Give two points of difference between the two subclasses of Mammalia.
13. Name the orders of Eutheria and give an example of each.
14. Which orders derive their names from the habits of the animals?
15. Which orders derive their names from anatomic features?
16. Which orders are aquatic?
17. What is the ultimate syllable of all family names?
18. Explain what is meant by binomial nomenclature.
19. Name three families of Carnivora.
20. Examine specimens and determine where in the teeth of Canidæ differ from those of Felidæ.
21. What two rank names constitute the scientific name of an animal?
22. Give the scientific name of five Carnivora, two Ungulata, and two Primates.
23. Define organ, system, tissue, and cell.
24. Name two organs belonging to each system.
25. How do the elements of the four kinds of tissue differ?

THE SKIN AND ITS APPENDAGES

The skin invests the body completely and is continuous with the lining of the digestive and urogenital canals. It varies in thickness in different regions, being very thin on the lips, ears, and eyelids, and exceedingly thick on the pads of the feet and on the ventral neck region, where, in contest with an enemy, it is most likely to be seized. A fibrous connective tissue binds the skin to the subjacent structures. In some places the union is very firm, as on the distal parts of the limbs and the head, while in other regions it is loose, as on the lateral aspect of the trunk.

The skin consists of an external layer, the *epidermis*, and beneath this, the *dermis* or true skin, designated the *corium*. The epidermis is composed of numerous strata of epithelial cells. Those on or near the surface are much flattened while the deeper ones are more or less cubical. As the superficial layer desquamates in minute fragments, forming what is commonly called dandruff, it is replaced by cells developed from the deeper layers.

At the orifices of the internal passages, such as the digestive and genital tracts, the epithelium changes to a soft delicate nature, and is then known throughout these passages as mucous membrane.

The *corium* or *dermis* is a form of fibrous connective tissue whose deepest portion forms the white fluffy areolar substance cut in removing the skin. In many regions just below the true skin is a layer of adipose tissue, which when examined under the microscope is seen to be composed of numerous globular fat-cells supported by fibrous areolar tissue. The seven pads on the forepaw and the five on the hind one consist of greatly thickened epidermis, the corium, and masses of fibrous connective tissue enveloping many fat-cells.

The *sebaceous* or *oil glands* lie in the corium, and by means of a duct open into the hair follicle near the surface. The *sudoriferous* or *sweat glands*, composed of coiled tubes, are present in the subcutaneous tissue, from whence a duct extends to the surface. Although there are no blood-vessels in the epidermis, numerous nerve terminations are present in the deeper portions. The true skin is richly supplied with both nerves and blood-vessels.

The claws produced by a special modification of the epidermis are among the most important appendages of the skin. Five of these are present on each forefoot, while only four occur on the hind one. At the root of each claw, the dermis forms a crescentic fold over it, and beneath is a number of papillæ richly supplied with blood-vessels. This entire structure forms the *matrix* of the claw, which is set around the terminal part of the distal phalanx of each digit. Claws, or some similar structures, such as nails or hoofs, are present in all mammals except the Cetacea.

Another important appendage of the skin is the hair, which covers the entire body except the tip of the nose and the pads of the feet. Its length and color vary with the variety of the cat. The Mombus cat of Africa has short stiff hair, while

the Angora or Persian cat is remarkable for the length and delicacy of its soft fur. The hair, like the nails, is an extreme modification of the epidermis. Each hair grows from a papilla at the bottom of a small sac, the *follicle*, which is a depression in the corium. The central part of the hair is the pith, and the external portion, formed of thin overlapping scales, the cuticle. The coloring-matter lies in the cortex, and may be disposed in such an irregular manner that one-half of a hair is white, and the other half yellow.

The large hairs on either side of the nose are known as *vibrissæ*. Their roots are provided with delicate nerve-endings of touch, so that the animal may find its way with ease through dark narrow passages. There are a few long hairs above the eyes, forming the eyebrows, but no eyelashes are present.

Most of the hairs are inserted obliquely into the skin, but when angered the cat can erect them by the contraction of a small muscle passing from the skin to the hair-bulb.

On some mammals the hairy covering is partial and limited to particular regions; in others, as the hippopotamus and the Sirenia, it is very scanty, but scattered over the whole surface; while in the Cetacea it is reduced to a few small bristles about the mouth.

Some kinds of hair, as those of the mane and tail of the horse, are shed and renewed annually. Most mammals have a long hairy coat in winter which gives place in spring to a short coat. The Arctic fox, hare, ermine, and numerous other animals of the colder regions undergo a complete change of color in the two seasons, being white in winter and brown or gray in summer. By this protective coloration they escape many of their enemies.

THE SKELETON

The number of bones in the skeleton of the cat varies with its age, since two or more bones separate in the young may form one mass in the old animal. The three portions of the innominate bone which are distinct (Fig. 39) in the young, become fused in the adult. In very old age many sutures of the skull become partially or wholly obliterated. In the young adult cat the number of bones, exclusive of the teeth, ear bones, chevron bones, and sesamoid bones, is about 233. The sacrum is reckoned as one bone, though composed of three coalesced vertebræ. The structure and embryology of the teeth show that they belong to a different category from the bones. The *ossicula auditus*, or ear bones, are the malleus, incus, and stapes of the middle ear. The *chevron bones* are eight in number, attached to the ventral side of the vertebræ of the tail. The *sesamoid bones* number about forty, of which the patella, or knee-cap, is the largest. They are formed in the tendons where there is much pressure or friction, as upon the volar surface of the metacarpus. The outline on page 29 gives the classification, names, and number of the different bones of the skeleton.

GENERAL TERMS USED IN DESCRIPTION OF BONES

In reference to shape the bones are spoken of as long, short, flat, and irregular. *Long bones* are those having a *shaft* or *diaphysis* in which is a cavity filled with marrow, and two enlarged extremities or *epiphyses* (Fig. 13): femur, fibula, metacarpals, and phalanges. *Short bones* are those not elongated and with no medullary cavity: tarsus and carpus. *Flat bones* are plate-like, with a layer of cancellous tissue between two layers of compact tissue: parietal, scapula, and innominate. *Irregular bones* are those which have an exceedingly irregular

AXIAL SKELETON	Head	Skull	Cranium	Frontal.....	2	
				Ethmoid.....	1	
				Temporal.....	2	
				Parietal.....	2	
				Interparietal.....	1	
				Occipital.....	1	
				Sphenoid.....	1	
			Face	Premaxillary.....	2	
				Maxillary.....	2	
				Palatine.....	2	
				Vomer.....	1	
				Maxilloturbinal.....	2	
				Nasal.....	2	
	Trunk	Hyoid bones	Lachrymal.....	2		
			Malar or Jugal.....	2		
			Mandible.....	1		
			Tympanohyal.....	2		
			Stylohyal.....	2		
			Epihyal.....	2		
			Ceratohyal.....	2		
			Basihyal.....	1		
			Thyrohyal.....	2		
			Vertebral column	Cervical vertebræ.....	7	
				Thoracic vertebræ.....	13	
				Lumbar vertebræ.....	7	
				Sacral vertebræ.....	1	
Caudal.....	21					
		Thorax	Ribs.....	26		
			Sternum.....	1		
		Shoulder girdle	Scapula.....	2		
			Clavicle.....	2		
		Arm	Humerus.....	2		
		Forearm	Ulna.....	2		
			Radius.....	2		
		Thoracic limb	Hand	Carpus	Scapholunar.....	2
					Triquetral.....	2
					Pisiform.....	2
					Greater multangular.....	2
					Lesser multangular.....	2
					Capitate.....	2
Hamate.....	2					
Metacarpus.....	10					
Phalanges	Proximal.....			10		
	Middle.....			10		
Distal.....	8					
	Pelvic limb			Pelvic girdle	Innominate.....	2
					Femur.....	2
		Leg	Patella.....	2		
			Tibia.....	2		
			Fibula.....	2		
			Talus.....	2		
		Foot	Tarsus	Calcaneum.....	2	
				Scaphoid.....	2	
				Internal cuneiform.....	2	
				Middle cuneiform.....	2	
				External cuneiform.....	2	
				Cuboid.....	2	
				Metatarsus.....	10	
Phalanges	Proximal.....		8			
	Middle.....	8				
Distal.....	8					

shape: ethmoid and vertebræ. The *aspect* of a bone is the portion seen when viewed from a given direction. The *border* of a bone is the margin, edge, or ridge at the juncture of two surfaces. *Proximal* is used to designate the portion of a

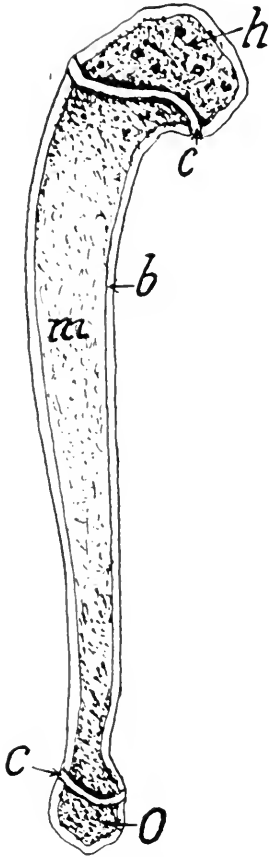


FIG. 13.—LONGITUDINAL SECTION OF THE HUMERUS OF A KITTEN.

h, Epiphysis for head; *c*, cartilage; *b*, bone; *m*, medullary substance; *o*, epiphysis for olecranon process.

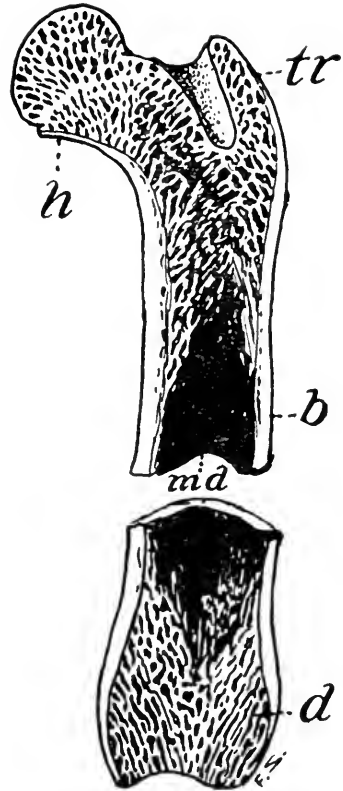


FIG. 14.—LONGITUDINAL SECTION OF THE FEMUR.

md, Medullary cavity; *d* and *h*, cancellous tissue; *tr*, cancellous tissue of trochanter process; *b*, compact bony tissue.

structure nearer the axis or spinal column, in distinction to *distal*, which signifies the part farther removed from the axis. *Cranial* indicates the part of an organ nearer to the plane passing just beyond the head and perpendicular to the spinal axis, while *caudal* is applied to the other part of the organ nearer to the perpendicular plane at the end of the extended tail.

Sagittal refers to the plane bisecting the animal in a vertical and longitudinal direction. *Medial* and *lateral* are adjectives, the former meaning nearer to the sagittal plane and the latter more remote on either side of that plane. *Proximal*, *distad*, *craniad*, *caudad*, *mediad* and *laterad* are adverbs indicating direction in accordance with the adjectives to which they are related.

A *process* is projection or elevation.

A *tuberosity* is a rough obtuse process.

A *tubercle* is a small and usually more or less pointed process.

A *condyle* is a rounded and somewhat elongated smooth articular process. The distal end of the femur presents a pair of condyles (Fig. 41).

A *fossa* is an irregular depressed area (Fig. 31).

A *foramen* is an aperture for the passage of vessels or nerves.

The *shaft* is the body or middle portion of an elongate bone.

The *head* is a spheroidal prominence at one end of an elongated bone (Fig. 41).

The *epiphysis* is a small process of bone ossified from a separated center. In the young animal it is attached to the main bone by cartilage, but in the adult becomes a part of the main bone (Fig. 13). The femur has four epiphyses, one for the head, one for the distal extremity, and one for each trochanter process (Fig. 41). With the exception of the phalanges, metacarpals, and metatarsals, all of the long bones have an epiphyses at each extremity. In the human, these epiphyses do not unite with the shaft before the sixteenth year. *Diploë* is the spongy layer of bone between the compact surface layer of the flat bones (Fig. 19).

The *articulation* of a bone has reference to its contact with other bones by means of joints.

STRUCTURE OF BONE

Every bone is completely covered except on its articulating surfaces with a tough membrane, the *periosteum*, which serves

for the attachment of muscles, and the renewal of bony tissue in case of injury. The long bones contain a cavity, the *medullary cavity*, filled with marrow (Fig. 13). This cavity is lined with *endosteum*, a membrane similar to the periosteum.

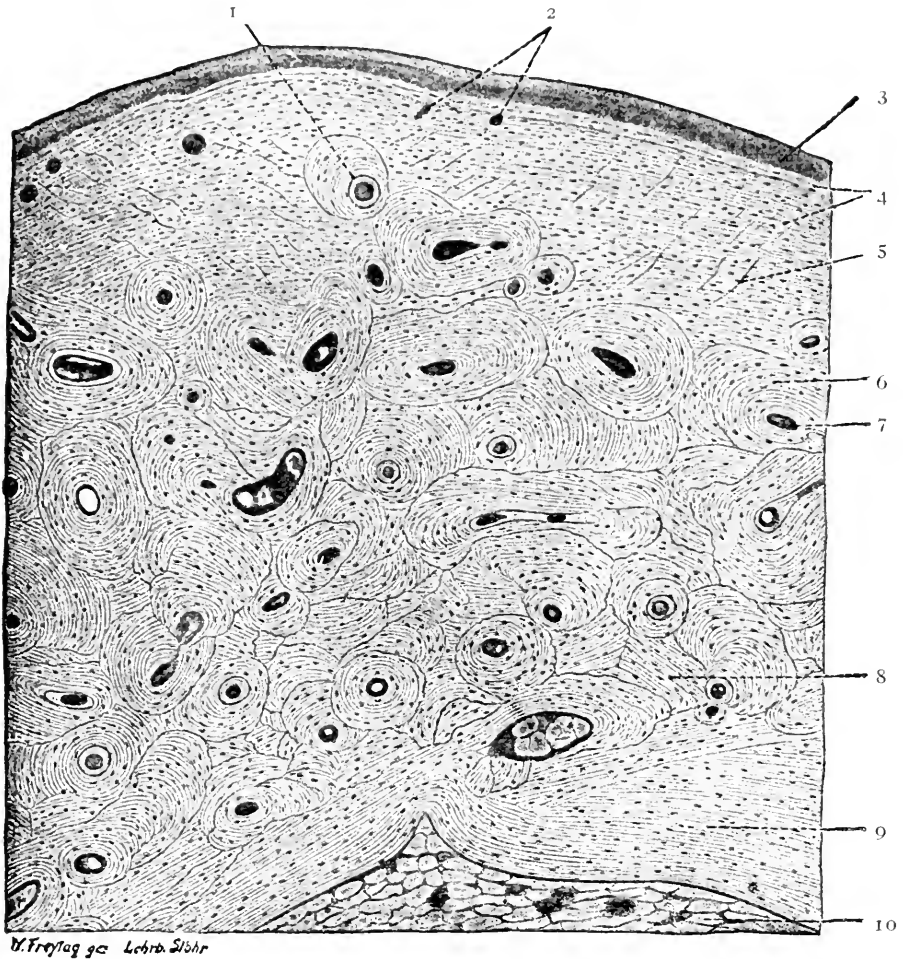


FIG. 15.—PART OF A CROSS-SECTION OF A DECALCIFIED PHALANX FROM AN ADULT.

1, Resorption line; 2, Volkmann's canals; 3, periosteum; 4, periosteal lamellae; 5, perforating fibers; 6, Haversian lamellae; 7, Haversian canal; 8, interstitial lamellae; 9, endosteal lamellae; 10, marrow. (Lewis and Stöhr.)

The shaft of the long bone is composed mainly of compact bony tissue through which extend longitudinally intercommunicating microscopic channels, *Haversian canals*, for the conveyance of blood-vessels, nerves and lymphatics.

The *lacunæ*, or spaces for the bone cells during life, are arranged concentrically about the Haversian canals. The *canaliculi*, or processes of the *lacunæ*, communicate with one another. At the extremities of the bones the place of the medullary canal is taken up by *cancellous tissue* (Fig. 14, *d*), the *compact tissue* being very thin. The flat bones have no medullary canal, but the diploë or cancellous tissue lying between the outer compact tissue has its spaces filled with a *red marrow* of the same nature as that in the cancellous tissue of the long bones, wherein the red blood-corpuscles are formed. The large medullary cavity or canal is filled with *yellow* or *fatty marrow*.

THE BONES OF THE HEAD

The Skull As a Whole.—The skull is the expanded cranial portion of the axial skeleton. It encloses the brain and affords protection and support for the organs of taste, smell, sight, and hearing. In the adult state, it is a very complex structure. It differs from the rest of the skeleton in that, save for the mandible and hyoidean apparatus, its several parts are so tightly joined together by immovable joints (*synarthrosis*) that it can be separated only with great difficulty. Some of the bones are so completely fused together that the individual parts can no longer be recognized. A skull in which the bones have been separated is known as a *disarticulated skull*. A skull may be disarticulated by filling it with dried beans and soaking in water for some time.

When the skull of a cat is examined with respect to its morphological structure it appears to be formed of three, or including the olfactory capsule, four rings or segments. Each of these rings is made up of a series of bones which enclose the space occupied by the central nervous system. Older anatomists believed that they saw in these relations evidence for a theory that the skull was formed by the fusion of four modified vertebræ, each corresponding to one of these rings. This

theory is no longer held, being contrary to well-established facts of comparative anatomy and embryology. Nevertheless a study of the make-up of these rings will be a convenient way of introducing the names and locations of the bones of the skull.

The most posterior or caudal of these rings may be called the *occipital segment*. It consists of four bones completely fused together to form a single bone. These are the *basioccipital*, the two *exoccipitals*, and the *supraoccipital*. Each of these take part in forming the border of the foramen magnum, although the exoccipitals have the greatest share.

Immediately anterior to the occipital ring is the *parietal segment*. It is formed of five bones: the *basisphenoid*, two *alisphenoids*, and two *parietals*. The occipital and parietal segments are separated ventrolaterally by a hiatus into which is wedged the auditory capsule.

The most anterior of the rings which form the wall of the brain case proper is the *frontal segment*. It, too, consists of five bones: the *presphenoid*, two *orbitosphenoids*, and two *frontals*. Like the occipital segment it is also separated ventrolaterally from the parietal by an open space which in this case is the *orbital fissure*, an exit for several nerves from the brain.

In addition to the three segments mentioned above, there are three *sense capsules*.

The *olfactory capsule* forms the most anterior of the cranial segments and may be called the *olfactory segment*. It consists of two tubular cavities open at each end. Each of these cavities is partially divided into an upper *olfactory chamber*, closed behind by the cribriform plate; and a lower *nasal chamber*, terminating in the *choanae*.

The inner wall of each cavity is formed mainly by the *mesethmoid* and *vomer*. The outer wall is formed mainly by the *pterygoid*, the *palatine*, the *maxilla*, the *premaxilla*, the *lacrimal*, and a portion of the *frontal*. The roof is formed by the *nasal process* or the *frontal* and the *nasal*. The horizontal

plates of the *palatine*, *maxilla*, and *premaxilla* form the floor of the nasal cavity and as well, the *hard palate* or roof of the mouth. The interior of the nasal cavity is occupied by the *ethmoid*. A portion of the ethmoid sometimes forms part of the inner wall of the orbit back of the lachrymal bone and is known as the *os planum*.

The *auditory capsule* is enclosed in the temporal bone. The temporal bone is formed by the fusion of the *squamous*, *petrous*, and *tympanic* bones, which form, respectively, the squamous, petrous, and tympanic portions of the bone.

The *optic capsule* is the largest and most conspicuous of the sense capsules. With exception of the *malar* all bones connected with it have already been noted.

It is thus seen that each of the three posterior cranial rings is related to an important sense organ. The olfactory organ is anterior to the frontal segment, the organ of sight lies between the frontal and parietal, and the organ of hearing, between the parietal and occipital segments.

These anatomical relations kept in mind will serve to orient the several features of the complex bony skeleton of the head. We shall now examine the skull from its several aspects.

As seen from the *dorsal aspect* (Fig. 17) the general outline of the skull is oval. It presents a median somewhat pear-shaped portion and the lateral expanded *zygomatic arches*. The surface is smooth and unevenly convex in both directions. The anterior half is flattened and triangular in shape. The posterior half is very convex and circular. The antero-posterior midline is marked by the *sagittal suture*, which divides the surface into two symmetrical halves. The sagittal suture is crossed transversely midway back by the *fronto-parietal* or *coronal suture*. The postero-lateral angles of the anterior moiety is projected outward and downward as the *fronto-postorbital processes*. These approach similar projections from below and form the posterior bony rim of the orbits. The orbit of the cat is not entirely closed behind, differing in that respect from

the condition found in the sheep, horse, and ox. On the other hand, the orbit is less widely open in the cat than in the dog and rabbit.

The posterior or caudal boundary of the dorsal surface is sharply elevated into the *lambdoidal crest*. The edge of the lambdoidal crest becomes broadened at its central point into a triangular or diamond-shaped area, the *external occipital protuberance*, which is continued forward on the interparietal bone as the *sagittal crest*.

Viewed from the *posterior aspect* the general outline of the skull, neglecting the zygomatic arches, is dome-shaped. The posterior or *nuchal surface*, is somewhat triangular in shape and is placed at right angles to the axial line of the cervical vertebræ. The surface is roughened below the lambdoidal crest for the attachment of several important muscles of the head and neck. The lower portion is perforated by a large opening, the *foramen magnum occipitale*, for the exit of the central nervous system. On either side of the foramen magnum there is a smooth cylindrical projection, the *occipital condyle*, for articulation with the atlas of the vertebral column. Laterad and separated from the condyle by the deep *jugular fossa* is the *jugular process*. Still laterad from this and separated by a V-shaped notch is the *mastoid process* of the temporal bone. The two processes cover most of the caudal and caudo-lateral portions of the tympanic bulla. They also furnish attachment for the *digastric* (depressor mandibulæ), *styloglossus*, and *stylomastoid* muscles. The *dorsal alanto-occipital* membrane is attached to the dorsal border of the foramen magnum, between the condyles. The *ventral alanto-occipital membrane* is attached to the ventral border of the foramen magnum. These together with the *articular capsules* form the *capsular ligament* between the occipital bone and the vertebral column.

Viewed from the *ventral aspect* (Fig. 18) the skull presents a somewhat oval outline. Its surface is flattened and is divided

by the orbits into an anterior triangular portion and a posterior quadrilateral portion, joined medially by a trough-like isthmus and laterally by the zygomatic arches. The anterior surface or *hard palate* forms the floor of the nasal chamber and lies on a lower level than the basicranium. The *basicranium*, or posterior portion, comprises the basioccipital, basisphenoid, and presphenoid bones. On each side of the basioccipital a large, rounded *tympanic bulla* projects boldly below the general level of the surface. The presphenoid is likewise flanked by two downward projections, the *lateral laminae* of the *pterygoids*, which are terminated ventro-caudally by the *hamular processes*. These laminae form the walls of a deep *median fossa* which, in life, is covered by soft palate and constitutes the nasopharynx.

A number of foramina and depressions may be seen on the ventral surface. The *foramen magnum occipitale* has already been noted. The *condyloid canal* perforates the lateral margin of the foramen magnum near the upper extremity of the condyle. The *hypoglossal foramen* opens into the inner caudo-medial margin of the *jugal foramen* located at the caudomedial angle of the tympanic bulla. The *stylomastoid foramen* and the *pit* for the *tympano-hyal* at the caudolateral border of the bulla. Craniad of these is the large *external acoustic meatus*. In front of the bulla are the slit-like *petrotympanic fissure*, the *canal of Hugier*, and the opening of the *tuba auditiva* or Eustachian tube. On the lower surface of the zygomatic process of the temporal bone is the *mandibular fossa* for the articulation of the lower jaw. Mediad from this is the clearly defined *foramen ovale* and in front of this on the margin of the orbit is the somewhat smaller *foramen rotundum*. Above these is a shallow groove, the *lateral pterygoid fossa*. Mediad of this is a shorter, shallower groove, the *scaphoid fossa*, which passes diagonally inward to within the lateral lamina of the pterygoid. Caudally the scaphoid fossa passes into the auditory tube. Just within and anterior to the scaphoid fossa is

a small slit-like opening of the *pterygoid* (Vidian) *canal* for the passage of a branch of the trigeminal nerve. The *posterior palatine foramina* are small and are found about one-fourth the distance forward from the caudal border of the hard palate. The *anterior palatine foramina* or *foramina incisiva* are seen just back of the incisor teeth.

Viewed from the *lateral aspect* the skull, after the mandible has been removed, is elongate with the ventral margin in its general trend straight, but made emarginate by the presence of several projections. The dorsal margin is somewhat flattened in the middle but strongly curved at either end. The surface is convex in both directions and is deeply impressed by the orbital cavity and temporal fossa. The projections forming the orbital rim and the zygomatic arches are prominent features of the lateral view. The inner wall of the orbit present a number of foramina. These are, beginning with the most posterior: *foramen ovale*, *foramen rotundum*, the *orbital fissure*, the *optic foramen* for the optic nerve, and the *sphenopalatine foramen*. A slight depression limited dorsally by a slightly curved elevated line joins the orbital fissure with the sphenopalatine foramen. It makes the origin of the external pterygoid muscle. Immediately in front of and slightly below the sphenopalatine foramen is the much smaller *posterior palatine foramen*. The *infraorbital foramen* pierces the maxillary at the junction of the malar with the nasal process at the lower anterior margin of the orbit. Above this is the *nasolachrymal groove* and *canal*. The center of the orbital wall is perforated by the *ethmoidal foramen*. A portion of the ethmoid is sometimes visible in the orbit as an irregular area, the *os planum*, behind the lachrymal bone.

Viewed from the *frontal aspect* the outline is nearly circular when the mandible is present and somewhat greater than a semicircle with it removed. The most striking feature from this point of view are the four large openings in the bone framework of the face: the *orbits*, the *nasal aperture*, and the *oral*

aperture. The orbits appear almost circular in shape in this view while the nasal aperture is median and heart-shaped.

Bones of the Disarticulated Skull.—The skull is usually considered in two parts, the *cranium* and the *face*. The former is composed of nine bones which will be described in order.

The **frontal bones** (Figs. 16 and 17) are two in number, lying between the orbits, and articulating with one another

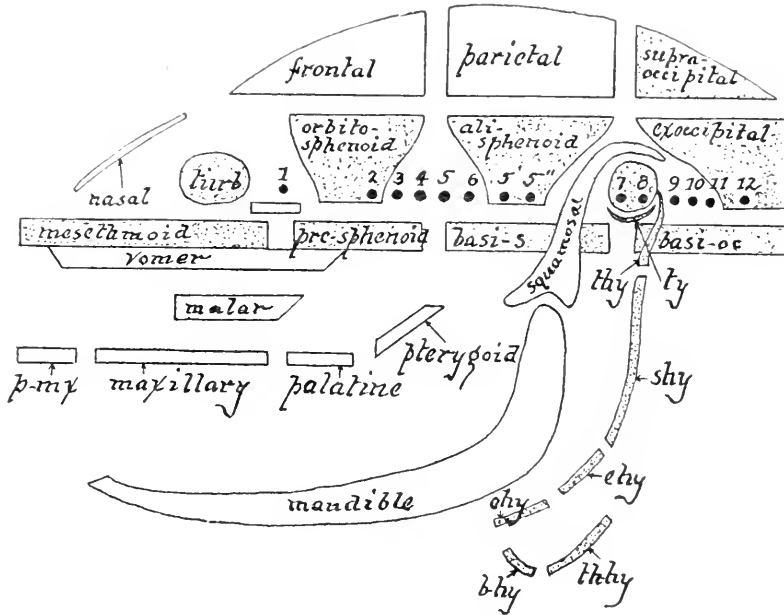


FIG. 16.—DIAGRAM OF THE BONES OF THE MAMMALIAN SKULL VIEWED
LATERALLY.

1, 2, 3, etc., indicate the places of exit of the twelve cranial nerves. *pmx*, Premaxillary; *ty*, tympanic, 7 and 8 are on periotic; *thy*, tympanophyal; *shy*, stylohyal; *ehy*, epihyal; *chy*, ceratohyal; *bhy*, basihyal; *thhy*, thyrohyal. The cartilage bones are shaded. (From Flower, after Huxley.)

in the median line. They form the roof of the cranial part of the brain cavity and the caudal portion of the roof of the nasal chamber. A lateral projection (*po*, Fig. 17) is known as the *postorbital process*. Within the frontal bone is a cavity, the *frontal sinus* (Fig. 19), which contains air and is lined with mucous membrane. It communicates with the nasal cavity. The lateral descending portion of the bone, articulating with

the palatine and orbitosphenoid, is the *orbital plate* of the frontal.

In the majority of the Mammalia the frontal is a paired bone, but in man the two portions become anchylosed during the fifth or sixth year. The horns of ruminants are out-

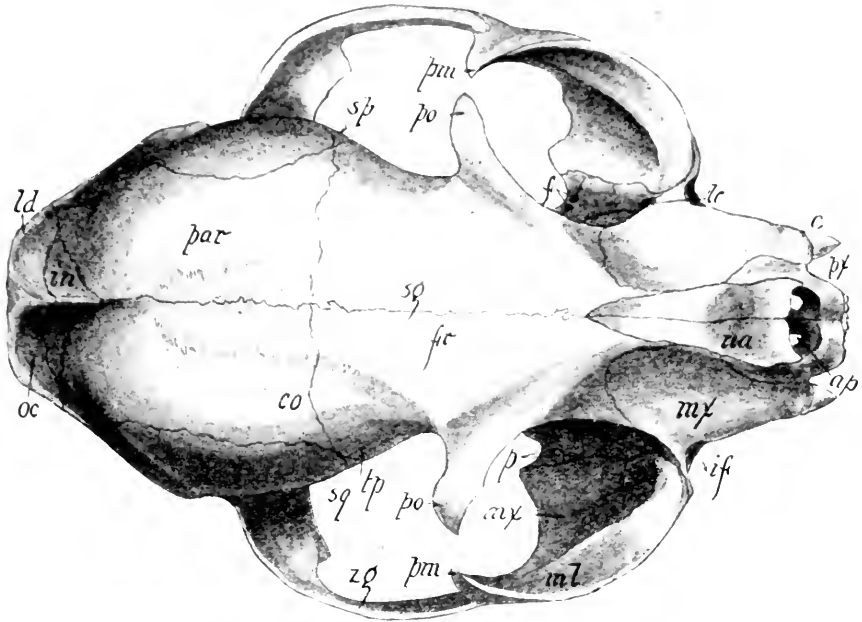


FIG. 17.—DORSAL ASPECT OF THE CAT'S SKULL.

ap, Anterior palatine foramen; *c*, canine tooth; *co*, coronal suture; *f*, foramina in palatine bone, the lateral one is the posterior palatine and the medial one is the sphenopalatine; *fr*, frontal; *if*, infraorbital foramen; *in*, interparietal; *lc*, lachrymal canal at the medial border of the lachrymal bone; *ld*, lambdoidal crest; *ml*, malar; *mx*, maxillary; *na*, nasal; *oc*, occipital; *p*, vertical plate of the palatine; *po*, postorbital process of the frontal; *pm*, postorbital process of the malar; *par*, parietal; *px*, premaxillary; *sq*, squamosal part of the temporal; *sg*, sagittal suture; *sp*, alisphenoid part of the sphenoid; *tp*, temporal fossa; *zg*, zygomatic process of the squamosal.

growths of these bones. Among the Cervidæ (deer) horns are usually developed only on the male, and are shed every year. In the Bovidæ (cattle) the horns are permanent when present.

The **ethmoid** (Fig. 19) is a single bone lying ventral to the frontals and nasals. It separates the cranial cavity from the nasal cavity and projects into the latter in the form of two thin scroll-like plates of bone and a median vertical plate. In order to see the relations of this bone, three skulls must be

used, one of which should be bisected sagittally, a second should have the roof of the cranial and nasal cavities removed, and the third should be cut transversely on a line joining the middle of the orbits. The ethmoid is usually visible externally as a small rhomboid plate on the medial wall of the orbit between the frontal, lachrymal, and palatine bones. It consists of four parts: the paired *ethmoturbinals* or *lateral ethmoids* (Fig. 19), the *mesethmoid*, and the *cribriform plate*. The ethmoturbinals are in the form of scroll-like laminae which project forward from the transverse cribriform plate into the nasal cavities. The portion which appears externally in the medial wall of the orbit is the *os planum*. In the recent state, the surfaces of these bones within the nasal cavity are covered with a mucous membrane over which the first pair of cranial nerves (olfactory) are distributed. The delicacy of the sense of smell is proportional to the development of the ethmoturbinals. In most orders of animals five scrolls are present, but in *Echidna* there are six and in some Ungulates there are eight, while in adult Primates there are only from one to three more, however, being present in the embryo.

The *mesethmoid* is the perpendicular plate of bone which, prolonged craniad by cartilage, separates the nasal cavity into two portions. Caudad it is united to the cribriform plate, dorsally it articulates with the median descending plates of the frontals and the nasals, and ventrally it articulates with the vomer and presphenoid. The *cribriform plate* is the caudal portion of the ethmoid (Fig. 19), which extending transversely between the frontals, separates the cranial cavity from the nasal cavity. It is pierced by many pinhole foramina for the exit of the olfactory nerve. In *Ornithorhynchus* (duck-bill of Australia) there is a single large foramen in the cribriform plate, as is also the case in birds.

The **temporal** is a paired bone lying at the base and side of the skull. It contains the organs of hearing. It consists of four parts: the *squamous* or expanded portion (Fig. 17),

to which the *zygomatic process* is attached; the *mastoid* (Fig. 18), which is the part caudad of the squamosal and dorsal to the bulla; the *tympanic*, which forms the *auditory*, or *tympanic bulla*; and the *petrous* (Figs. 18 and 19), which contains the internal ear. The squamous portion overlaps the parietal dorsally in a scale-like manner and is limited ventrally by a clearly defined projecting ridge extending above the external auditory meatus as the dorsal border of the *zygoma*.

The *zygomatic process* extends craniad to join the zygomatic process of the malar, the two together forming the *zygomatic arch*, or *zygoma*, to which the masseter muscle is attached. Ventral of the root of the zygomatic process is the *mandibular fossa* for the articulation of the condyle of the mandible. Immediately caudad of this cavity is the *postmandibular process*. The *mastoid portion* of the bone is somewhat triangular in shape, about two centimeters long, and lies caudad of the external meatus.

The *tympanic portion* appears on the base of the skull as the *tympanic bulla*. Its cavity is divided into two unequal chambers by a bony septum rising from the floor and reaching almost to the roof. The cranial or true tympanic chamber, sometimes called the *middle ear*, is the smaller, and has on its lateral wall a horseshoe-shaped prominence known as the *tympanic ring*, to which the tympanic membrane of the drum of the ear is attached. There are four apertures in the walls, of the cranial tympanic chamber: The *meatus acusticus externus* or the external *acoustic canal*; the *auditory* or *Eustachian tube*, leading from the cranial dorsal angle of the chamber to the pharynx; the *fenestra vestibuli* and the *fenestra cochleæ*, opening into the internal ear. The caudal or medial chamber of the bulla is larger than the cranial, but has no special features worthy of consideration.

The *petrous portion* of the temporal bones is not visible on the external surface of the skull, but may be seen by looking into the external acoustic meatus. It forms the medial wall

of the tympanic cavity. The foramen seen in its dorsal part is the fenestra vestibuli. In a sagittally dissected skull the petrous (Fig. 18) may be recognized by the internal acoustic meatus entering it. By removing the bulla, a large portion of the petrous bone may be seen from its ventral aspect. A central prominence, the *promontory*, contains the fenestra cochleæ opening into the base of the cochlea. The apex of the promontory, mediad of the fenestra cochleæ forms the wall of the first whorl of the cochlea. Dorsal to the fenestra cochleæ is the fenestra vestibuli, opening into the vestibule of the internal ear. In the recent state this opening is closed by a membrane in which is imbedded the foot of the stapes. The *cochlea* in the interior of the bone may be displayed by cutting away the bony rim of the fenestra cochleæ and then chipping off a crust of bone in a line from this foramen to the juncture of the basioccipital and basisphenoid bones.

The petrous bone, viewed dorsally in a bisected skull, appears in the floor of the brain cavity ventrad of the tentorium, the plate of bone partly separating the cerebrum from the cerebellum. Its surface is pierced by the *internal acoustic meatus*, which gives passage to the acoustic nerve. Close examination reveals a division of the canal into two parts, a ventral for the eighth nerve and a dorsal, the *canalis facialis*, for the facial nerve. This canal twists through the petrous laterad, and thence between the petrous, squamosal, and mastoid to the stylomastoid foramen (Fig. 18, *sf*).

The **parietal bone** is paired and joins its fellow in the median line, forming the caudal half of the sagittal suture. Its point of greatest convexity is the parietal eminence. Its cerebral or internal surface presents slight arborescent grooves which in the recent state sheltered the meningeal artery of the brain. The plate of bone projecting obliquely craniad from the caudal border of the parietal is the *tentorium*, an ossification of the dura mater separating the cerebrum from the cerebellum.

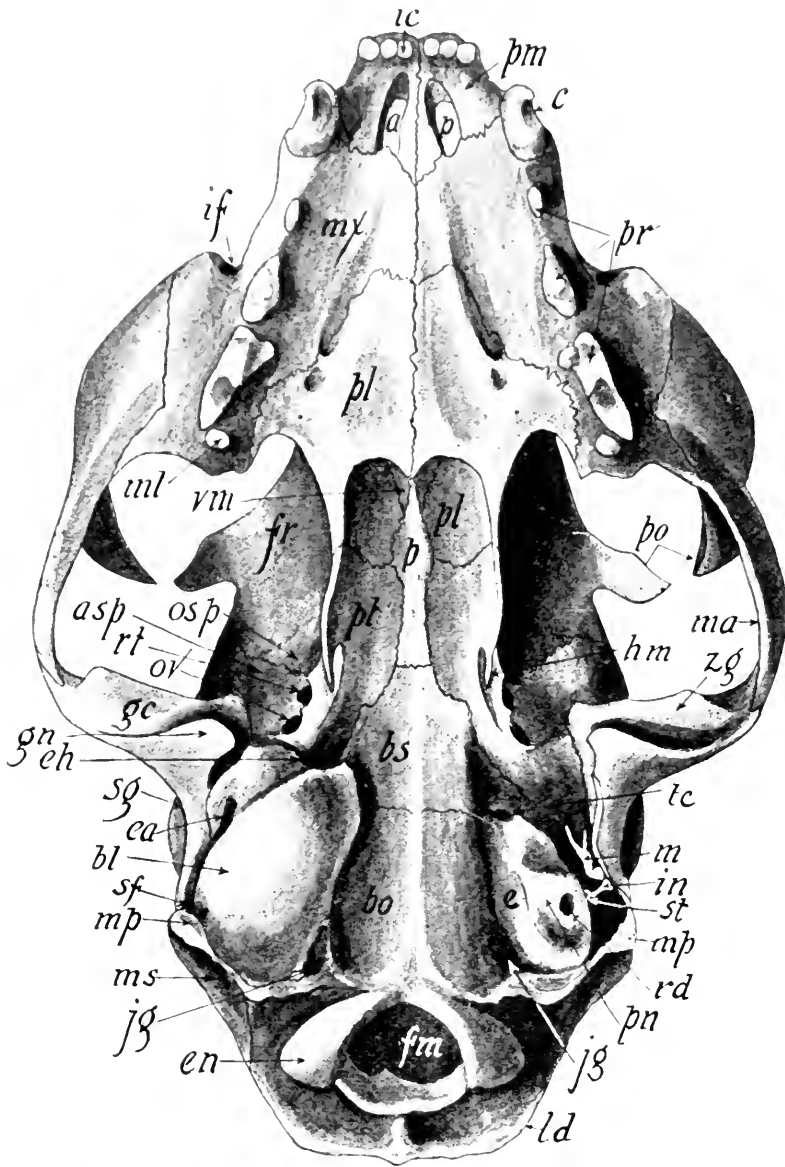


FIG. 18.—VENTRAL ASPECT OF THE SKULL WITH THE LEFT AUDITORY BULLA REMOVED.

asp, Alisphenoid; *ap*, anterior palatine foramina; *bs*, basisphenoid; *bl*, auditory bulla; *bo*, basioccipital; *c*, canine tooth; *e*, petrous portion of the temporal; *en*, occipital condyle; *ea*, external acoustic meatus; *eh*, opening of the Eustachian tube; *fr*, frontal; *fm*, foramen magnum; *gc*, mandibular fossa; *gn*, postmandibular process; *hm*, hamular process of the pterygoid; *ic*, incisor tooth; *if*, infraorbital foramen; *in*, incus; *jg*, jugular foramen; *ld*, lambdoidal ridge; *mx*, maxilla; *ml*, molar tooth; *mp*, mastoid process; *ms*, mastoid portion of the temporal; *ma*, malar; *m*, malleus; *osp*, orbitosphenoid; *ov*, foramen ovale; *p*, presphenoid; *pl*, palatine; *pt*, pterygoid; *pn*, promontory of the petrous; *po*, postorbital process; *pr*, premolar teeth; *pm*, premaxillary; *rd*, fenestra cochleae; *rt*, foramen rotundum; *st*, stapes; *sg*, squamosal; *sf*, stylomastoid foramen; *tc*, carotid foramen, or foramen lacerum medius; *vm*, vomer, forming the septum between the posterior nares; *zg*, zygomatic process of squamosal.

The **interparietal** is a triangular bone situated at the junction of the two parietals and occipital bones. Its sutures are usually obliterated quite early.

The **occipital** (Figs. 17, 18, and 19) is a single bone surrounding the foramen magnum and articulating with the interparietal, parietals, temporals, and sphenoid. In the young kitten it is composed of four parts: the *supraoccipital*, lying dorsal to the foramen magnum, the two *exoccipitals*, lying laterad of it, and a *basioccipital*, bounding it ventrally. The crescentic elevation on the supraoccipital near its parietal margin is the *lambdoidal ridge*, to which several muscles are attached.

The *exoccipitals* bound the cerebellum laterally and support the *occipital condyles*, which articulate with the atlas or first vertebra. Immediately caudad of the bulla is the *jugular process*. There are two foramina, one of which, the *hypoglossal canal*, opens ventrally with the jugular foramen adjacent to the bulla, while the other, the *condyloid canal*, opens more dorsally at the side of condyle. The former transmits the twelfth (hypoglossal) cranial nerve, supplying the larynx, hyoid bone, and tongue. The *jugular foramen*, or foramen lacerum posterius, is at the juncture of the bulla, exoccipital, and basioccipital. The internal jugular vein and the ninth, tenth and eleventh nerves pass through it. The *basioccipital* portion of this bone lies entirely on the ventral aspect of the skull. It articulates craniad with the basisphenoid by a suture which is generally obliterated in cats three or four years old.

The **sphenoid** one lies in the center of the base of the skull. It is composed of eight parts, corresponding to eight distinct bones in the lower vertebrates: the *basisphenoid*, articulating caudad with the basioccipital; two *alisphenoids*, extending dorsad from the basisphenoid and articulating caudad with the temporals (Figs. 18 and 19) two *pterygoids*, projecting ventrally from the basisphenoid and terminating in sharp processes; a *presphenoid* in the mid-ventral line craniad of the basisphenoid;

two *orbitosphenoids*, extending dorso-laterally from the presphenoid and articulating cranially with the frontals. In an old cat, the sutures between these eight parts become more or less obliterated. The basisphenoid together with the alisphenoids is sometimes called the *posterior sphenoid* in distinction to the *anterior sphenoid*, composed of the presphenoid and orbitosphenoids.

TABLE OF THE FORAMINA OF THE SKULL

Foramina	Bones surrounding the foramina	Structures traversing the foramina
Infraorbital.	Superior maxillary.	Infraorbital nerve of the superior maxillary division of the fifth.
Anterior palatine.	Maxillary and premaxillary.	Nasopalatine branch of the fifth cranial nerve and nasal artery.
Sphenopalatine.	Palatine.	Sphenopalatine nerve.
Posterior palatine.	Palatine.	Palatine nerve and artery.
Olfactory foramina.	Ethmoid.	Olfactory nerve.
Optic.	Orbitosphenoid.	Optic nerve and meningeal artery.
Lacerum anterius, or sphenoidal sinus.	Alisphenoid and orbitosphenoid.	Third, fourth, and sixth cranial nerves and first division of fifth cranial nerve.
Rotundum.	Alisphenoid.	Second division of fifth cranial nerve.
Ovale.	Alisphenoid.	Third division of fifth cranial nerve.
Lacerum medium.	Petrous and basisphenoid.	Internal carotid artery.
Internal acoustic meatus.	Petrous.	Eighth cranial nerve.
Canalis facialis.	Petrous, mastoid, and tympanic.	Seventh cranial nerve.
Stylomastoid.	Tympanic and mastoid.	Seventh cranial nerve.
Jugular or posterior lacerated.	Occipital and temporal.	Ninth, tenth, and eleventh cranial nerves and jugular vein.
Hypoglossal canal.	Exoccipital.	Twelfth cranial nerve.

The *basisphenoid* presents on its dorsal or cerebral surface the sella turcica, or *hypophyseal fossa*, which lodges the hypophysis

of the brain (Fig. 104). The posterior boundary of this fossa is the *clinoid plate*, and its lateral projections are the posterior *clinoid processes*. On each side of the basisphenoid there extends dorsally in a narrow strip to the parietal the *alisphenoid*,

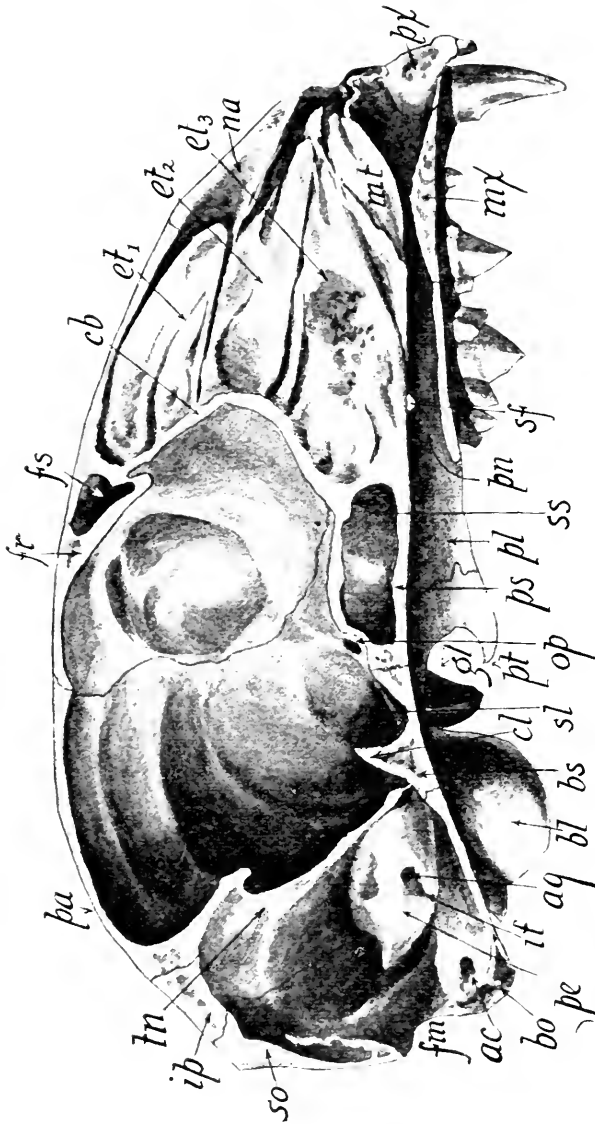


FIG. 19.—CUT SURFACE OF A SAGITTALLY BISECTED SKULL. It was cut slightly to the left side of the median plane so that the mesethmoid and vomer remained in the other half.
ac, Hypoglossal canal; *aq*, canalis facialis; *bo*, occipital condyle; *bl*, tympanic bulla; *bs*, basisphenoid; *cb*, cut edge of cribriform plate of ethmoid; *cl*, posterior clinoid process; *et₁*, *et₂*, *et₃*, scrolls of ethmoturbinal or lateral ethmoid; *fr*, frontal bone; *fm*, foramen magnum; *fs*, frontal sinus; *gl*, postmandibular process; *it*, internal acoustic meatus; *ip*, interparietal; *mi*, maxillo-turbinal; *mx*, maxillary; *na*, nasal; *op*, optic foramen; *pa*, parietal; *pl*, palatine; *pn*, posterior nares in the palatine; *ps*, presphenoid; *px*, premaxillary; *pe*, petrous; *pt*, pterygoid; *so*, supraoccipital; *sf*, sphenopalatine foramen; *ss*, sphenoidal sinus; *sl*, sella turcica; *tn*, tentorium.

at the base of which, craniad of the tympanic bulla, are three foramina in a line. The most cranial and largest one is the *sphenoidal sinus* or *anterior lacerated foramen*, which transmits the third, fourth, and sixth cranial nerves supplying the eyeball

muscles, and the first branch of the fifth nerve. This foramen is between the alisphenoid and the orbitosphenoid. The other two foramina, *rotundum* and *ovale*, transmit the second and third divisions of the fifth nerve.

The *pterygoid* portion of the sphenoid is a paired bone (Figs. 18 and 19) lying on either side of the cranial half of the basisphenoid and the caudal half of the presphenoid. In the adult cat the sutures are sometimes obliterated so that this bone appears as a caudal continuation of the palatine. The two pterygoid bones or plates form the descending walls, and, together with the median portion of the sphenoid, the roof of the median pterygoid fossa, whose cranial continuation is the *posterior nares*. From the ventral posterior angle of each projects the *hamular process*, dorsal of which is seen the small external pterygoid process. Between the bases of the hamular and the external pterygoid processes is the small *external pterygoid fossa*.

The *presphenoid bone* is the narrow median bone extending from the basisphenoid to the vomer. It contains within it two large sinuses into which project the ventral scrolls of the ethmoturbinal bones. The orbitosphenoids enter into the formation of the medial walls of the orbits and are perforated at their bases by the *optic foramina*, through which pass the optic nerves.

BONES OF THE FACE

There are seven paired bones in the face and two single ones, making in all sixteen (Figs. 17 and 18).

The **premaxillary**, with its fellow, extends ventrad and laterad of the anterior nares. These bones bear the six incisor teeth. The *anterior palatine* or incisor foramina connect the oral cavity with that of the anterior nares. In life, these foramina transmit the naso-palatine nerves. In the Primates, the premaxillary is ankylosed to the maxillary although it arises from a separate center of ossification.

The **maxillary** is a paired bone which meets its fellow in the median line in the roof of the mouth. All its articulations are visible externally except those with the maxillo-turbinal, ethmoid, and vomer. Five teeth, a canine, three premolars, and a molar, are present in this bone of the adult cat. The molar is wanting to the young. The several portions of the bone are as follows: the *palatine plate*, appearing in the roof of the mouth; the *nasal process*, extending dorso-caudad to the frontal; the *process*, extending ventrad to the orbit to articulate with the malar bone; and the *orbital plate*, which is the roof of the malar process, forming a partial floor to the orbital cavity. The large foramen leading from the orbital cavity through the orbital plate is the *infraorbital foramen* for the passage of the infraorbital branch of the superior maxillary branch of the fifth nerve.

The **palatine bone** with its fellow helps to form the roof of the oral cavity and the floor of the nasal cavity. It is composed of two plates: one, vertical, forming the lateral walls of the posterior nares and the cranial part of the walls of the median pterygoid fossa, and a portion of the nasal wall of the orbital cavity; the other, horizontal, forming part of the roof of the mouth. The vertical plate is pierced by two foramina the *posterior palatine* and the *sphenopalatine*, each of which transmits a palatine nerve and artery (Fig. 17).

The **vomer** is a single narrow bone which in the nasal cavity articulates dorsally with the mesethmoid and ventrally with the palatines and the palatine plates of the maxillary, in the median line. This bone, with the mesethmoid and its cartilage, forms the nasal septum, dividing the nasal cavity into two chambers. It is best demonstrated by removing the palatines, when it may be seen extending craniad from its bifurcated articulation with the presphenoid to its articulation with the premaxillaries. The caudal portion of the bone is expanded horizontally and articulates with the ventral ethmoturbinals. Its dorsal margin is bifurcated for articulation with the mesethmoid.

The **maxilloturbinal** is a paired bone occupying the anterior portion of the nasal cavity (Fig. 19). It is composed of a few scrolls which, when the nasal bone is removed may be seen attached to the maxillary. It consists of a horizontal longitudinal plate, whose lateral border is fixed to the maxillary while the medial border bifurcates into a dorsal curved plate and a ventral scroll. The space between the maxilloturbinal and cranial portion of the lateral ethmoid is the middle nasal meatus. The maxilloturbinal bone in man receives the name of the inferior turbinate, in distinction to the middle and superior turbinated bones, constituting the lateral ethmoid.

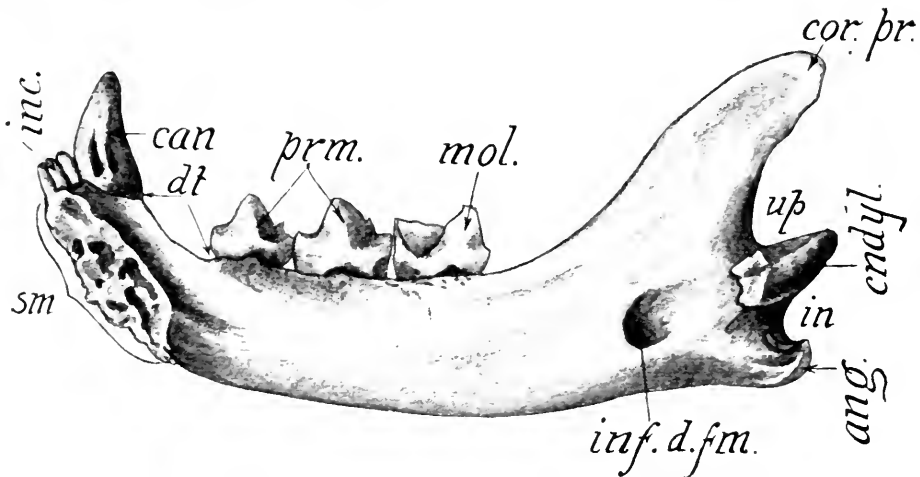


FIG. 20.—MEDIAL OR INNER ASPECT OF THE MANDIBLE.

ang, Angle; *cndyl*, condyle; *cor. pr.*, coronoid process; *can*, canine tooth; *inc.*, incisor teeth; *inf. d. fm.*, inferior dental or mandibular foramen; *in*, inferior notch; *mol.*, molar tooth; *prm.*, premolar teeth; *dt*, diastema; *sm*, surface of symphysis; *up*, superior notch.

The **nasal bone**, joining with its fellow in the median line, forms a large part of the roof of the nasal chamber. It articulates with the premaxillary, maxillary, and frontal on the surface, and the ethmoid within the nasal chamber.

The **lachrymal bones** are two in number and lie on the cranial part of the nasal walls of the orbits. Each articulates with the maxillary, frontal, os planum of the ethmoid, and the malar. The bone has about half of the area of the finger-nail. The *naso-lachrymal canal* is bounded by the lachrymal and the

maxilla. This canal, beginning in a vertical groove, the naso-lachrymal groove, carries the duct permitting the tears to pass from the eye into the nasal chamber (Fig. 16).

The **malar bone** is paired. It forms the cheek as well as the lateral and cranial border of the orbit. The arch largely formed by this bone is the *zygoma*. The process projecting dorsad toward the postorbital process of the frontal bone is the *postorbital process* of the malar. The masseter muscle originates on the border of the malar.

The **mandible** or inferior maxillary is the single bone forming the lower jaw (Figs. 20 and 22). It is made up of two halves which are united by an immovable articulation or *symphysis* at the chin. Each half consists of a *horizontal* and an *ascending ramus*. On its alveolar border the horizontal ramus bears three incisor teeth, a canine, two premolars and a molar tooth. In the caudal part of the medial surface of this ramus is the *mandibular foramen*, which transmits the inferior-alveolar nerve and artery traversing the mandibular canal extending within the bone to the *mental foramen* on the lateral surface near the base of the canine tooth. The space on the dorsal border between the canine and the first premolar tooth is called the *diastema*.

The ascending ramus or portion of the bone caudad of the inferior tooth is marked by six features: (1) the *fossa* on the outer or lateral surface which gives insertion to the masseter

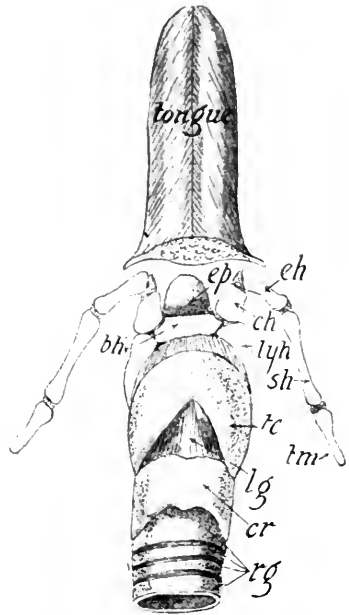


FIG. 21.—VENTRAL ASPECT OF LARYNX, HYOID BONES, AND TONGUE.

The tongue has been cut transversely near its middle and its muscles fixing it to the hyoid have been removed.

bh, Basihyal; ch, ceratohyal; cr, cricoid cartilage of the larynx; eh, epihyal; ep, epiglottis; lg, cricothyroid ligament; lyh, thyrohyal; rg, rings of cartilage of the trachea; tc, thyroid cartilage of the larynx; tm, tympanohyal; sh, stylohyal.

muscle; (2) the *angle* which is the caudoventral termination of the bone; (3) the *inferior notch* immediately dorsal of the angle; (4) the condyle for the articulation with the glenoid cavity of the temporal; (5) the *superior notch* dorsal of the condyle; (6) the *coronoid process*, which is the dorsal termination of the ascending ramus and gives insertion to the temporal muscle.

THE HYOID BONES OR HYOID APPARATUS

The **hyoid bones** consist of two jointed rods, one on either side (Figs. 21 and 22), hanging from the temporal bone, and supporting the larynx. Each rod is composed of six parts: the *epihyal*; the *ceratohyal*; the *tympanohyal*; the *basihyal*; and the *thyrohyal*. The dorsal end of the thyrohyal is prolonged by a piece of cartilage, the *chondrohyal*.

The hyoid apparatus varies greatly among mammals. In man it consists of a single bone composed of the body or basihyal, two small cornua representing the ceratohyals, and two large cornua representing the thyrohyals. The bone is suspended from the skull by ligaments corresponding to the bony chain in the cat.

LABORATORY STUDIES AND SUGGESTIONS

1. How many more bones are present in the cat than in man?
2. In what two parts of the skeleton does the number of bones in the cat exceed those in man?
3. What is a sesamoid bone?
4. Find on a specimen a sesamoid bone and describe it.
5. Draw a lateral aspect of the skull and label all parts.
6. What are the paired bones of the cranium?
7. Name the single bones of the face.
8. Draw the caudal aspect of the skull and label all parts.
9. Which bones of the skull derive their names from their location?
10. Which bones of the skull are pierced by more than two foramina?
11. Write a description of the orbital cavity.
12. Which foramina of the skull derive their names from their shape or size?
13. Which foramina derive their names from their location?
14. Which foramina transmit important blood-vessels?
15. Draw figures representing relative shapes and sizes of all foramina of the skull.

16. What bones enter into the formation of the brain cavity?
17. Write about 200 words describing the nasal cavity.
18. Draw a ventro-lateral aspect of the tympanic bulla and label all features.
19. Write a description of the tympanic bulla and name some mammals in which it is absent.
20. Which bones of the skull are composed of more parts in the young than in the adult?
21. Name the principal sutures of the skull.
22. Name the parts of the sphenoid bone in the order of size.
23. Name the bones of the skull visible from the dorsal aspect.
24. Name the bones of the skull visible from the cranial aspect.
25. What bone of the cranium paired in the cat is single in man?
26. What bone present in face of the cat is wanting as a separate element in man?
27. Draw lateral aspect of mandible and label all features.
28. Name the bones bearing the teeth.
29. Name the elements of hyoid apparatus in order.
30. Draw a section of the frontal bone showing diploë.
31. Describe the difference between the relative locations of the cranial and facial portions of the skull in cat and man.
32. Name five membrane bones and five cartilage bones.

VERTEBRÆ

The vertebral column is composed of the following five groups of vertebræ; seven cervical, thirteen thoracic, seven lumbar, three sacral, and caudal varying from four to twenty-six. The following six features are common to all of the vertebræ in the first four groups except the atlas: (1) the *body* of the vertebra (Fig. 23), which forms the floor of the neural canal and articulates with the adjacent vertebra by means of interposed discs of cartilage; (2) the *transverse processes*, which project laterad from the body or from the walls of the neural canal; (3) a *spinous process*, which projects dorsad from the roof of the neural canal; (4) the *vertebral arch*, composed of a *pedicle* on either side, forming the ventrolateral walls of the vertebral canal, and the *laminae*, extending dorsad from the pedicles to complete the dorsal wall of the neural canal; (5) the *intervertebral notch*, which, with the notch of the succeeding vertebra, forms the *intervertebral foramen* for the exit of a spinal nerve; (6) the *articular processes*, two of which project

craniad and two caudad from each vertebra. The former are called the anterior articular processes and the latter posterior articular processes.

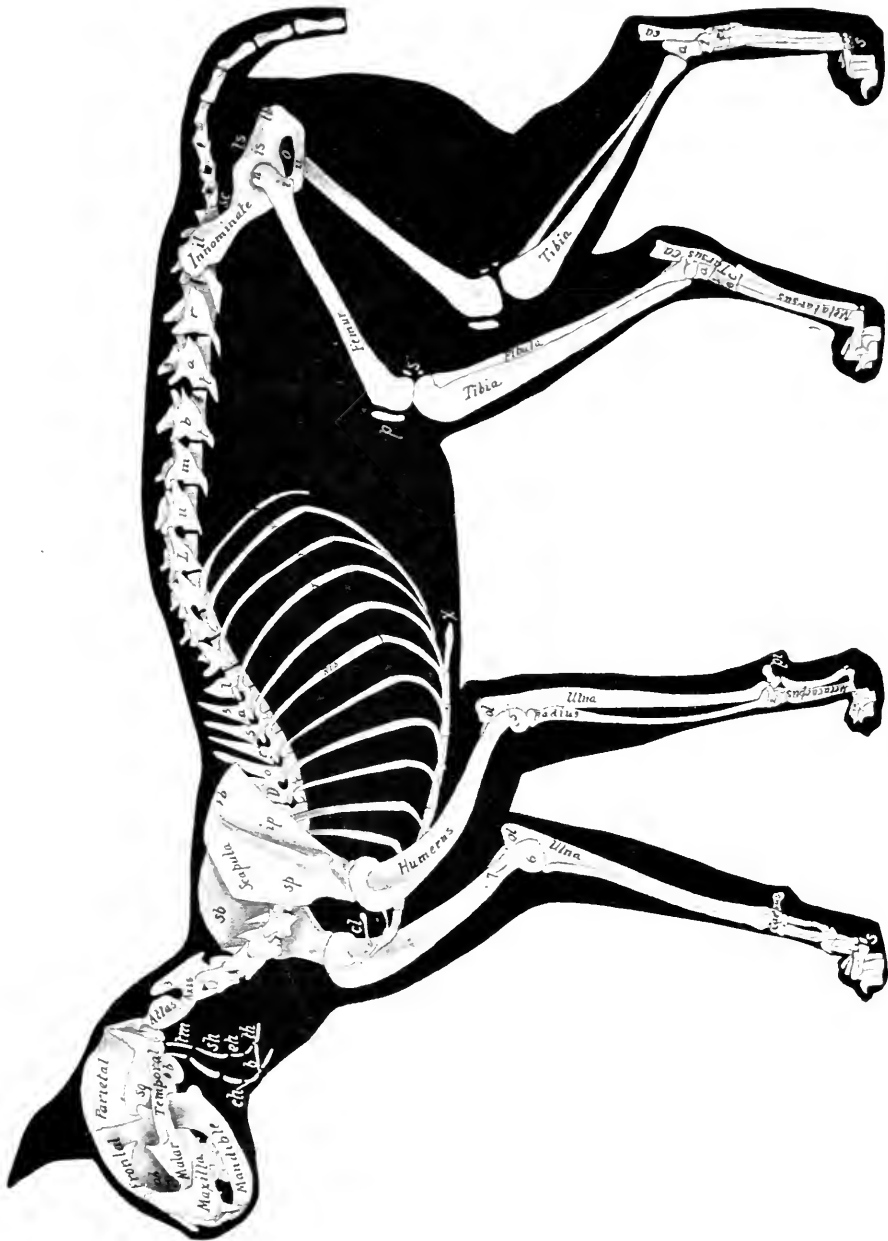


FIG. 22.

The first cervical vertebra, or **atlas**, is characterized by its large horizontally expanded transverse ear-shaped processes,

FIG. 22.—LATERAL ASPECT OF THE SKELETON OF THE CAT. The left chain of hyoid bones is pulled slightly cephalad so as to show the right chain.

a, Talus; *b*, basihyoid; *c*, cuboid; *ca*, calcaneum; *cl*, clavicle; *ch*, ceratohyal; *e*, external cuneiform; *eh*, epihyal; *i*, lesser trochanter process; *is*, ischium; *il*, ilium; *ip*, infrapineous fossa; *l*, internal cuneiform; *ls*, lesser sciatic notch; *n*, greater trochanter; *ob*, orbital cavity; *o*, obturator foramen; *ol*, olecranon process; *pi*, pisiform; *p*, patella; *r*, middle cuneiform; *s*, sesamoid bones; *sq*, squamosal; *sh*, stylohyal; *sb*, subscapular fossa; *sp*, supraspinous fossa; *sc*, great sciatic notch of the ilium; *tm*, tympanohyal; *th*, thyrohyal; *tb*, tuberosity of the ischium; *t*, transverse processes; *u*, pubis; *v*, the floating ribs; *vb*, vertebral border of the scapula; *x*, xiphoid or ensiform cartilage of the sternum; *1*, navicular; *2*, scapholunar; *3*, spinous process; *4*, body of the fourth lumbar vertebra; *5*, outer condyle of the humerus; *6*, inner condyle of the humerus; *7*, supracondylar foramen.

the absence of a spinous process, and its rudimentary body. Its true body in the embryo becomes united to the axis as the

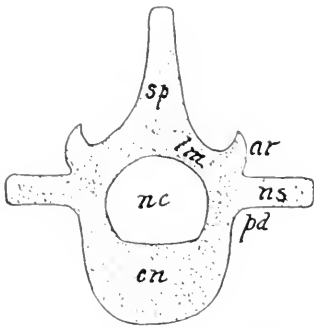


FIG. 23.—PLAN OF A VERTEBRA.

sp, Spinous process; *ar*, articular process; *ns*, transverse process; *nc*, vertebral canal; *pd*, pedicle; *lm*, lamina; *cn*, centrum or body.

odontoid process. The cranial margin of the vertebral arch is prolonged at each side into a process or articulation with the occipital condyles (Fig. 18) of the skull. The root of this articular process is pierced by a foramen giving passage to the first spinal nerve and the vertebral artery and vein (Fig. 24, *fr*). From the lateral opening of this foramen (*fr*) a groove is continued ventrad to the middle of the transverse process, where it leads into the *transverse foramen* common to the first cervical vertebrae. The vertebral artery

and vein course through this canal (Fig. 24).

The **epistropheus** (**axis**), or second vertebra, is characterized by its dens or *odontoid process*, which projects within the atlas, and also by its elongated spinous process which projects both craniad and caudad. The transverse process projects caudad from the body, which is flattened dorsoventrally. This process is pierced at its base by the transverse foramen.

The remaining five cervicals are very similar to one another. The seventh has no transverse foramen. The spinous processes grow successively longer from the third to the seventh (Fig. 22). The transverse processes of the fourth and fifth are bifurcated, the dorsal branch being called the *transverse element* and the ventral one the *costal element*, since it is really the rudiment

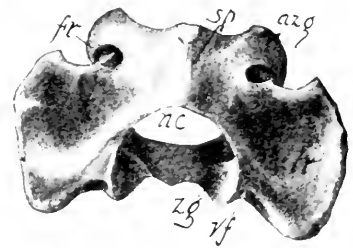


FIG. 24.—DORSOCAUDAL ASPECT OF ATLAS.

tr, Transverse process; *nc*, neural canal; *sp*, spinous process; *fr*, aperture of the transverse foramen which enters the atlas at *vf*; *azg*, anterior articular process; *zg*, posterior articular process.

of a rib. The transverse process of the fifth ends in three branches. The following features are common to all thirteen

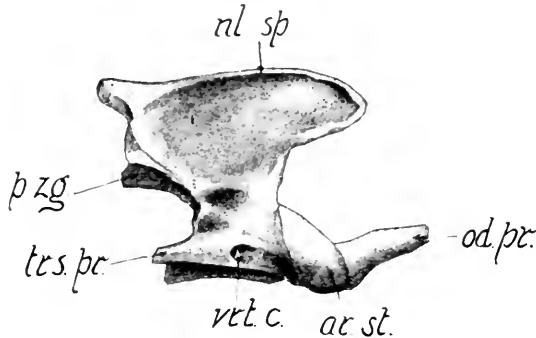


FIG. 25.—LATERAL ASPECT OF THE EPISTROPHEUS.

ar. st., Anterior articular process; *od. pr.*, odontoid process; *nl. sp.*, neural spine or spinous process; *p. zg.*, posterior articular process; *trs. pr.*, transverse process; *vtl. c.*, transverse foramen.

thoracic vertebræ: a *spinous process*, projecting from the dorsum of the neural arch; two *cranial articular processes*, facing dorsad or dorsolaterad; two *caudal articular processes*, facing ventrad or ventromediad; a *body* whose transverse diameter is greater than the vertical diameter; and *transverse processes*. There are two half facets on each side of the body of every thoracic vertebra except the first, eleventh, twelfth, and thirteenth. The head of a rib thus articulates with two vertebræ (Fig. 29). The body of the first vertebra bears on each side a whole facet and a half facet. The eleventh, twelfth, and thirteenth bear a whole facet on each side of the body.

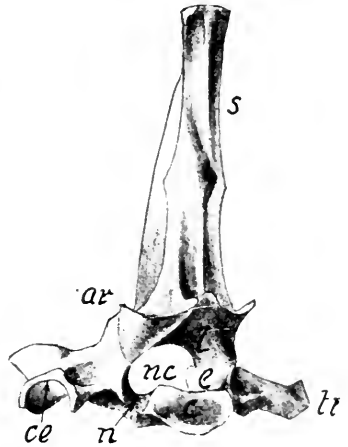


FIG. 26.—LATEROCAUDAL ASPECT OF THE SECOND THORACIC VERTEBRA.

tr., Transverse process; *ce*, neural canal; *ar*, face for tubercle of rib; *ar*, posterior articular process; *s*, spinous process; *c*, centrum; *n*, intervertebral notch; *e*, pedicle; *l*, lamina.

The transverse processes of the first eleven bear facets for the articulation with the tubercles (Fig. 26) of the ribs. The

last three thoracic vertebræ are characterized by *mammillary processes* springing from the dorsolateral portion of the roots of the anterior processes.

The following features are common to all of the *lumbar vertebræ*: a *spinous process* projecting dorsocraniad (Fig. 27); a *transverse process* projecting ventrocraniad on either side from the body; *anterior articular processes* and *posterior articular processes*. A mammillary process is present on the root of the anterior articular process of the first five bones, and an accessory process occurs on the caudal margin of the wall of the neural arch of all except the last vertebra. The transverse processes increase in length and curvature caudally. The spinous processes increase in length in the same order, and the neural canal likewise enlarges caudally.

The **sacrum** is a single bone (Fig. 28) formed by the union of three sacral vertebræ. The limit of each element is marked by the dorsal and ventral intervertebral foramina which furnish passage for the dorsal and ventral branches of the spinal nerves. The two tubercles on either side of each of the three median spinous processes are the result of the fusion of the articular processes. The cranial portion of the bone presents on its lateral aspect the *auricular surfaces* for articulation with the ilium. This expansion appears to be a modified transverse process. Prominent transverse processes also project from the caudal angles.

The **caudal vertebræ** vary greatly in number. According to Mivart, there are only four in the Manx cat; and according to Jayne, there may be as many as twenty-six in some varieties of the common cat. The transverse processes and articular processes become less prominent from the third vertebra to the eighth or ninth, where they are present only as slight ridges. The spinous process is present in the first three, but dwindles to a ridge in the fourth. The first six or seven elements possess a neural arch which more distally loses its roof, making the neural canal a mere groove. The groove becomes fainter dis-

tally and finally disappears entirely. The *chevron* bones are the paired ossicles projecting ventrad from the cranial ends of the bodies of the vertebræ, from the second or third to the thirteenth vertebra. In the sixth, seventh, and eighth vertebræ the chevron bones unite ventrally in the middle line, forming an arch. The last ten caudal vertebræ are scarcely more than cylinders of bone representing the bodies of the vertebræ.

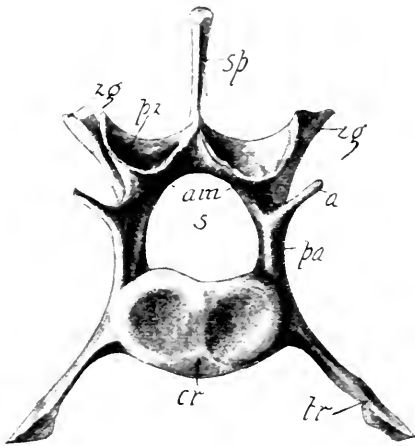


FIG. 27.—CAUDAL ASPECT OF FOURTH LUMBAR VERTEBRA.

a, Accessory process; *cr*, centrum or body; *pa*, pedicle; *tr*, transverse process; *s*, neural canal; *sp*, spinous process; *zg*, the mammillary process of the anterior articular process; *am*, lamina; *pz*, articular process.

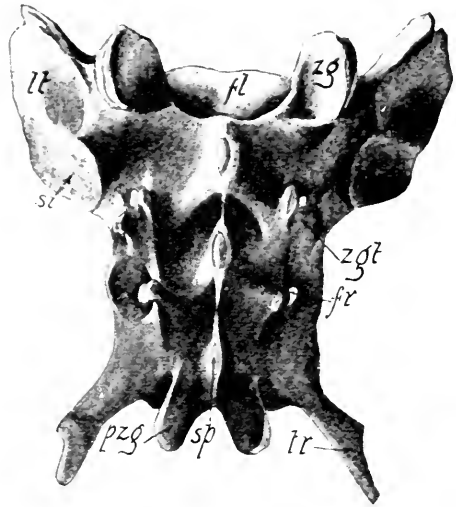


FIG. 28.—DORSAL ASPECT OF THE SACRUM.

fl, Floor of the neural canal; *fr*, dorsal aperture of the intervertebral foramen; *ll*, lateral mass; *pzg*, posterior articular process; *sp*, spinous process; *si*, auricular surface for articulation with the ilium; *zgt*, tubercle formed by fusion of the articular processes; *zg*, anterior articular processes.

The number of vertebræ in the different species of mammals varies widely. As a rule, there are seven elements in the cervical region. The sea cow (*Manatus*) has only six cervical vertebræ, while the three-toed sloth has nine. The number of thoracico-lumbar varies from sixteen in the organ to thirty-six in the cetacean *Delphinus*. The elements composing the sacrum likewise vary from one in the ape, *Cercopithecus*, to

nine in some of the Edentata. The human sacrum is composed of from four to six vertebræ. The same is true of the gorilla,

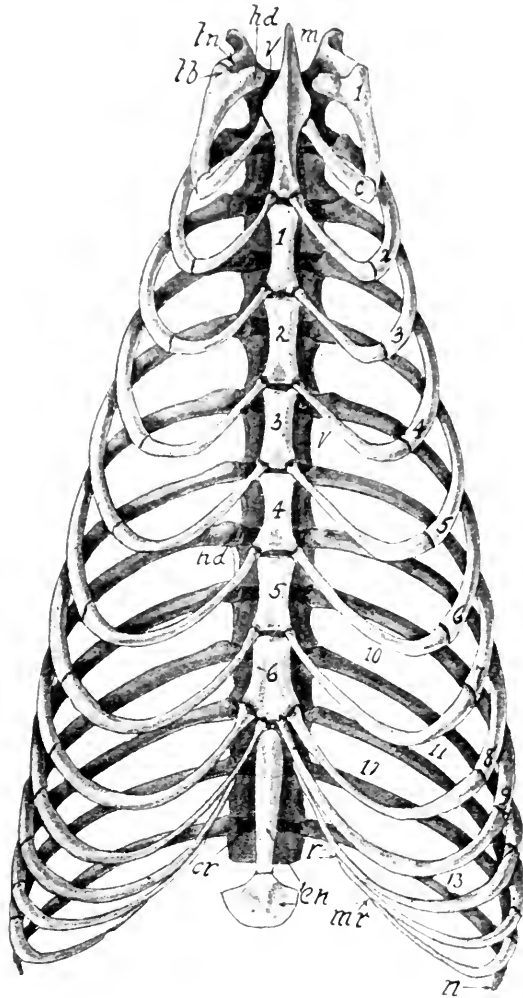


FIG. 29.—VENTRAL ASPECT OF THE BONES OF THE THORAX. The numbers on the vertebral or bony portions of the ribs indicate the names of the ribs. The numbers of the last four ribs are placed just cranial of them.

c, Cartilaginous part of the first rib; *cr*, cartilaginous disc between the bodies of the vertebræ; *en*, xiphoid process; *hd*, heads or capitula of ribs; *m*, manubrium; *mr*, attachment of twelfth to the eleventh rib; *n*, free termination of thirteenth rib; *r*, attachment of the eleventh to the tenth rib; *tb*, tubercle of first rib; *ln*, transverse process of first thoracic vertebra; *v*, body of vertebra.

chimpanzee, and orang. The caudal vertebræ vary greatly in number in the different forms. In the adult human there are present only four or five vertebræ, which form a single

bone, the coccyx, while in the embryo eight segments make up the caudal region. Ossification takes place, however, in only five or six segments.

THE STERNUM

The sternum of the cat is composed of eight pieces, called *sternebræ*, which lie in the median line on the ventral side of the chest (Fig. 22). The sternum serves for the attachment of the cartilaginous portions of nine pairs of ribs. The first sternebra (Fig. 29), which ends cranial in a laterally compressed pointed process is the **manubrium**. The six succeeding sternebræ form the body or **corpus sterni**; the caudal piece is called the **xiphoid process**. It is terminated by a flat piece of cartilage. The cartilaginous portion of the first rib articulates with manubrium near its middle. The ribs from the second to the seventh inclusive are attached at the junctions of the sternebræ. The eighth and ninth ribs are attached near together on the caudal end of the seventh sternebra.

RIBS

There are thirteen pairs of ribs in the cat. The nine cranial are called *true ribs* because they articulate dorsally with the spinal column and ventrally with the sternum. The other four (Fig. 29) are *false ribs*, three of which articulate ventrally with other ribs, while the fourth has no ventral articulation, and is therefore called a *floating rib*. Each rib is composed of two parts, the *vertebral* or bony portion and the *sternal* or cartilaginous portion.

The following description of the sixth will serve to give a correct idea in general of the anatomy of a rib. Its vertebral portion (Fig. 30) presents four features: a head or *capitulum*, which articulates with the bodies of the fifth and sixth thoracic vertebræ; a *tubercle*, which articulates with the transverse process of the sixth thoracic vertebra; a *neck*, which is the con-

stricted portion between the capitulum and tubercle; and the *shaft*, including the portion of the rib between the tubercle and its articulation with the sternal or cartilaginous portion. The bend in the shaft beyond the tubercle is the *angle*. The sternal portion of the rib, consisting of cartilage, is sometimes called the costal rib. In the sixth rib the costal portion is about half as long as the vertebral portion.

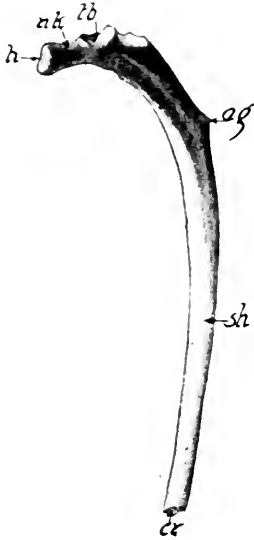


FIG. 30.—CAUDAL ASPECT OF SIXTH RIB.

ag, Angle; *cr*, pit for articulation with cartilaginous portion; *h*, capitulum; *nk*, neck; *sh*, shaft; *tb*, tubercle with facet for articulation with transverse process.

Certain ribs present marked features varying from the sixth. The first rib is stout and flat and has no distinct angle. The articular surface of its head is not divided into two facets, as is the case in all the others except the three caudal ones. The lengths of the ribs increase from the first to the ninth. The last three ribs have no necks and no tubercles for articulation with the transverse processes of the vertebræ.

The number of ribs varies from nine pairs in the cetacean *Hyperoödon* to twenty-four in the two-toed sloth (*Choloepus*). In most fishes and snakes, ribs are present throughout both the trunk and tail regions, but with the assumption of life on land, and the development of limbs, the vertebrates have suffered a degeneration of the ribs in all parts except the middle portion of the trunk. In the embryo, however, anlage (beginning) of ribs occurs in all regions of the trunk, but they early coalesce with the vertebræ except in the thorax.

LABORATORY STUDIES AND SUGGESTIONS

1. Draw caudal aspect of third thoracic vertebra and label all features.
2. Describe the differences between the first and last thoracic vertebræ.
3. What feature common to all thoracic vertebræ not present on any of the other vertebræ?

4. Draw the caudal aspect of the fourth cervical vertebra.
5. What feature common to all cervical vertebræ except seventh but not present in any other vertebræ?
6. Draw cranial aspect of atlas and label all features.
7. Compare the third and seventh cervical vertebræ.
8. What two features serve to distinguish the lumbar from all other vertebræ?
9. Draw the cranial aspect of the second lumbar vertebra and label all features.
10. Wherein does the seventh lumbar vertebra differ from the first?
11. How do you distinguish the caudal from the cranial aspect of any vertebra?
12. Draw ventral aspect of sacrum and label all features.
13. Give the two features distinguishing the caudal vertebræ from all others.
14. Note the size and direction of the spinous process throughout the column.
15. Describe the variation in number of the different groups of vertebræ in other mammals.
16. Draw lateral aspect of sternum and label all features.
17. Describe the attachment of ribs to sternum.
18. What features common to all the ribs?
19. Name ribs having a tubercle.
20. Draw first rib and label all features.
21. Draw cranial aspect of ninth rib and label all features.
22. How do you distinguish a false rib from a true rib?
23. What features make the caudal aspect of a rib?
24. Make a drawing showing the articulation of a rib with the spinal column and label all parts.
25. How do ribs vary as to number in mammals?

THE THORACIC LIMB

The thoracic or fore-limb of the cat is composed of a scapula, clavicle, humerus, ulna, radius, seven carpals, five metacarpals, and fourteen phalanges (Fig. 22). The scapula and clavicle form the shoulder girdle.

The **scapula**, commonly called the shoulder-blade (Fig. 31), is not articulated with the bones of the trunk, but is held in position by the serratus magnus, levator anguli scapulæ, and other less important muscles. It articulates with the head of the humerus by the glenoid cavity. It presents three well-marked borders: the *cranial* or *anterior*, the *vertebral*, and the *axillary* adjacent to the vertebræ on the side near the axilla or armpit.

The outer surface of this bone is divided by a strong spine into two nearly equal fossæ, the cranial of which is the *supraspinous*, and the caudal one the *infraspinous, fossa*. From the lower part of the spine project the *acromion* and *metacromion proc-*

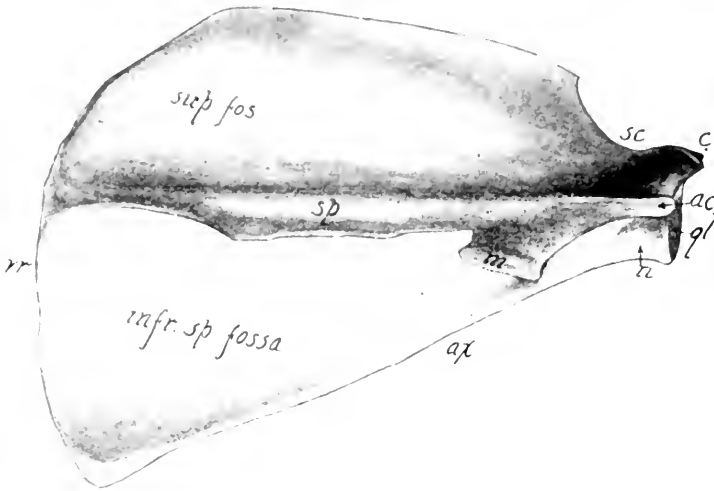


FIG. 31.—LATERAL OR OUTER ASPECT OF THE SCAPULA.

ac, Acromion process; *ax*, axillary border; *c*, coracoid process; *gl*, glenoid cavity; *m*, metacromion process; *sc*, scapular notch; *sp*, spine; *sup. fos*, supraspinous fossa; *vr*, vertebral border; *n*, neck.

esses. The *subscapular fossa* occupies the entire inner or medial surface.

A slight constriction between the base of the spine and the margin of the glenoid cavity is termed the neck. From the cranial side of the latter the *coracoid process* curves mediad.



FIG. 32.—CAUDAL ASPECT OF LEFT CLAVICLE.

b, Medial end; *a*, lateral end.

The **clavicle** is a slender curved bone, about one inch long, imbedded in the muscle

between the manubrium and the coracoid process (Fig. 22). It does not articulate with any bone, but is held in place by the cephalohumeral and cleidomastoid muscles (Fig. 49).

The shoulder girdle varies somewhat among the Mammalia. The clavicle is never fully developed in any of the Carnivora. Primates, Chiroptera, Edentata, and Monotremata are the

only orders in which all the species possess clavicles. A third element of the shoulder girdle, known as the coracoid, is a fully developed bone only in the Monotremata, where it articulates at one end with the scapula, forming part of the glenoid cavity, and at the other end with the presternum. In the other mammals the coracoid is represented by the coracoid process of the scapula, which ossifies from a separate center. In many of the lower vertebrates a distinct coracoid is present.

The **humerus** is the bone of the arm or brachium. It articulates proximally with the glenoid cavity of the scapula (Fig. 22) and distally with the ulna and radius. It consists of three parts, the proximal extremity bearing the *head*, the middle portion or *shaft*, and the *distal extremity* (Fig. 33). The *greater* and *lesser tuberosities* separated by the bicipital groove lodging the tendon of the biceps muscle, are the two processes on the proximal extremity. The former is the larger and more craniad and serves for the insertion of the supraspinatus muscle (Fig. 55). The distal extremity is marked by two important projections, the *external* and *internal condyles*. Extending proximad from the external condyle is the supinator ridge. Proximad of the internal condyle is the supracondyloid foramen transmitting the *median* nerve and branchial artery (Figs. 78 and 100). The *olecranon* fossa is the deep cavity on the caudal aspect of the bone, opposite the coronoid fossa. The



FIG. 33.—CRANIAL ASPECT OF RIGHT HUMERUS.

bl, Bicipital groove; *cr*, supracondyloid ridge; *cp*, capitulum for articulation with the radius; *dr*, deltoid ridge; *et*, external condyle; *gt*, greater tuberosity; *it*, internal condyle; *lt*, lesser tuberosity; *sp*, supracondyloid foramen or entepicondylar foramen; *sr*, supinator ridge; *tr*, trochlea for articulation with ulna.

articular surface of the distal extremity consists of the *capitulum* for articulation with the head of the radius, and the *trochlea* for articulation with the semilunar notch of the ulna. On

the cranial side of the proximal third of the bone is the rough *deltoid ridge* for the insertion of the deltoid muscle which arises from the shoulder girdle.

The **ulna** is the longest bone of the *fore-arm* or *antebrachium*, and is caudad of the radius. It articulates in the *semilunar notch* with the trochlea of the humerus and in the *radial notch* with the head of the radius. The distal articulation is with the radius, triquetral and pisiform (Fig. 22). The *olecranon* process forms the proximal termination of the bone and serves for the insertion of the triceps muscle. Distad of the semilunar notch is a projection known as the *coronoid process*. The *styloid process* forms a small projection on the distal extremity of the bone.



FIG. 34.—LATERAL OR OUTER ASPECT OF THE RIGHT ULNA.

ar, Articular facet for radius; *cr*, coronoid process; *gs*, semilunar notch; *ls*, radial notch; *on*, olecranon process; *st*, styloid process.

The **radius** is the preaxial or cranial bone of the antebrachium. It articulates proximally with the capitulum of the humerus and the radial notch of the ulna, and distally with the scapholunar and ulna. It bears but two processes, the *tubercle* and the *styloid process*. The *tubercle* (Fig. 35) is a slight knot near the proximal end in the ulnar side. Proximal from the tubercle is the neck which supports the head bearing a concave crown for articulation with the capitulum of the humerus. The *styloid process* projects from the distal end parallel with the process of the same name on the ulna.

The bones of the antebrachium in many mammals are more or less coalesced. In the Chiroptera and many of the Ungulates the radius is enlarged at the expense of the ulna, whose proximal third only remains. The primitive Ungulates of the lower tertiary period possessed a complete ulna as well as radius. The phylogeny of the horse's limb illustrates the gradual development of the antebrachium of the Equidæ (Fig. 36). Fossil remains reveal the fact that mammals existed as early as the *triassic* period, when the sedimentary rock forming the triassic strata was laid down. This probably occurred 80,000,000 years ago.

According to paleontological investigations, the Ungulata probably arose from the *Condylarthra*, a group of small five-toed mammals of the lower Eocene, best represented by the typical genus *Phenacodus*. In this genus and its successor, *Hyracotherium*, the ulna and radius are well developed and distinct. *Orohippus*, the descendant of *Hyracotherium*, also shows a distinct radius and ulna, but in the later forms of the horse line the ulna gradually diminishes in size and becomes more and more coalesced with the radius, until in *Equus* scarcely more than the proximal third remains (Fig. 38).

Carpus.—The carpus consists of seven bones arranged in two rows (Fig. 37). Beginning on the pollex (thumb) side, the scapholunar, triquetral, and pisiform compose the proximal row, and the greater multangular, lesser multangular, capitate, and hamate form the distal row. The *scapholunar*, easily dis-



FIG. 35.—MEDIAL OR INNER ASPECT OF RIGHT RADIUS.

fc, Articular surface for capitulum of humerus; *hd*, head—the point of the arrow is on the articulating surface for the radial notch; *nk*, neck; *sc*, articular surface for scapholunar; *st*, styloid process; *tb*, tubercle; *ul*, facet for ulna.

tinguished because of its large size, articulates with the radius, triquetral, hamate, capitate, lesser and greater multangular. The *triquetral* articulates with the ulna, hamate form, pisiform, and scapholunar. The *pisiform* is next to the scapholunar in

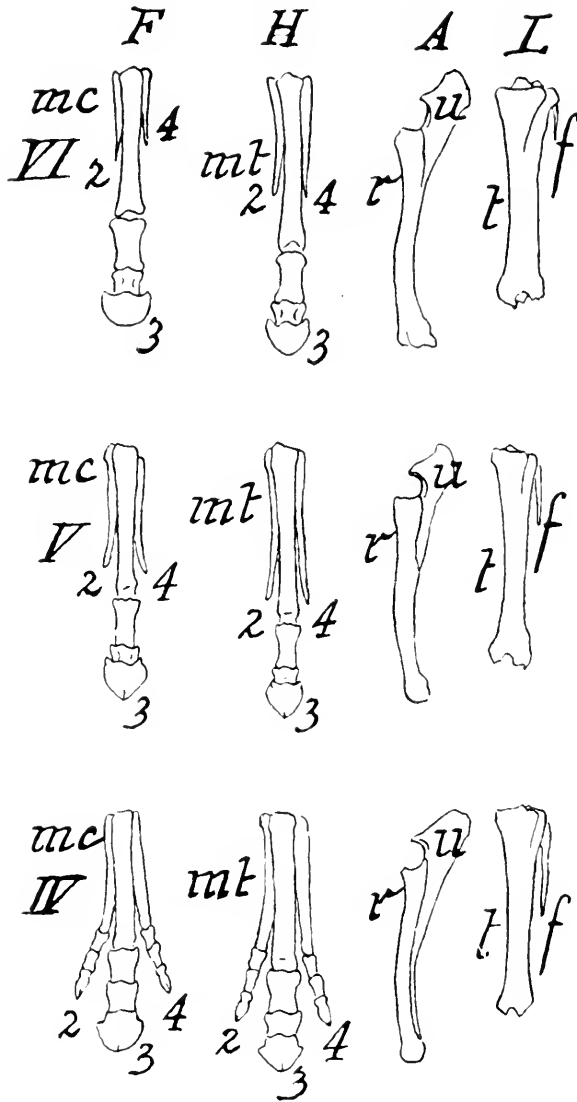


FIG. 36.—(See next page for explanation.)

size. It projects prominently laterad from the triquetral and articulates with the ulna and triquetral. The *greater multangular* is crescentic in shape and articulates with the scapholunar, lesser multangular and first and second metacarpals. The

lesser multangular is distinguished by its flatness. It articulates with the scapholunar, capitate second metacarpal, and greater multangular. This bone is not visible on the palmar surface

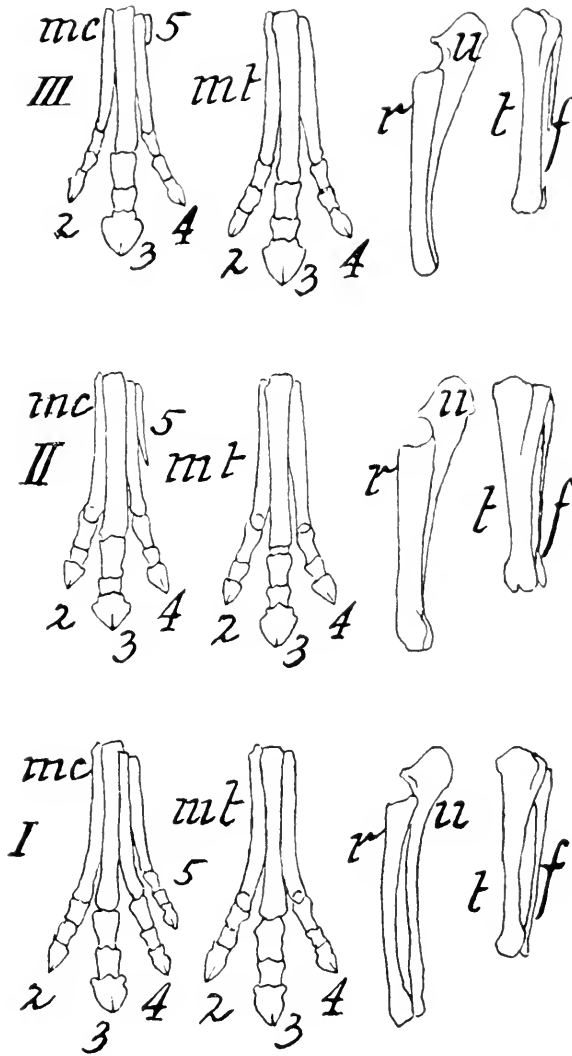


FIG. 36.—GENEALOGY OF THE HORSE.

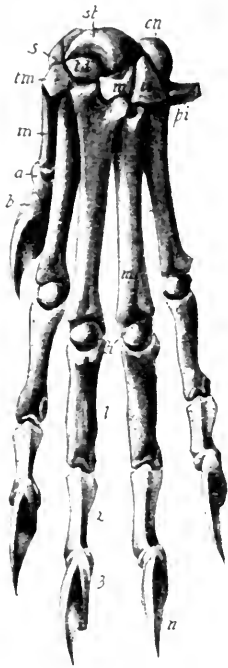
F, Forefoot; H, hindfoot; A, forearm; L, leg; I, Orohippus; II, Mesohippus; III, Miohippus; IV, Protohippus; V, Pliohippus; VI, Equus; 2, 3, 4 and 5 are the second, third, fourth, and fifth digits respectively; mc, metacarpus; mt, metatarsus; p, phalanges; u, ulna; r, radius; t, tibia; f, fibula.—(After Marsh.)

of the wrist. In the cat the lesser multangular is larger than the greater multangular. The *capitate* articulates with the

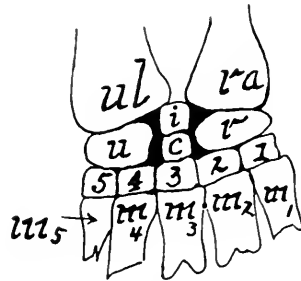
scapholunar; lesser multangular, hamate and second, third, and fourth metacarpals. The *hamate* can be recognized by its wedge shape. It articulates with the scapholunar, triquetral, capitate and fourth and fifth metacarpals. Each carpal bone

develops from a single center except the scapholunar, which develops from two centers.

The typical arrangement of the vertebrate carpus is shown in figure 37, B. The pisiform does not belong to the cartilaginous skeleton, but is a sesamoid bone. In all mammals



A.



B.

FIG. 37.

A, Dorsal aspect of left manus of cat; *a*, first phalanx of the pollex; *b*, second or terminal phalanx; *cn*, triquetral; *h*, head of fourth metacarpal; *m*, capitate; *mt*, metacarpal 4; *u*, claw; *pi*, pisiform; *s*, sesamoid bone; *st*, scapholunar; *ul*, lesser multangular; *tm*, greater multangular; *u*, hamate; 1, 2, and 3, first, second, and third phalanges of the middle digit.

B, Generalized type of carpus as found in lower vertebrates: *c*, Centrale; *i*, intermedium or lunare; *r*, radiale or scaphoid; *ra*, radius; *m*, metacarpals; *u*, ulnare or cuneiform; *ul*, ulna; 1, carpalia 1, or trapezium; 2, carpalia 2, or trapezoid; 3, carpalia 3, or magnum; 4, and 5, carpalia 4 and 5, or unciform.

possessing five digits, the anlage of three bones in the proximal row, five bones in the distal row, and a central element occurs in the embryo, but through fusion of elements a less number is present in most adults. Thus, in the cat the radiale and intermedium and centrale unite to form the scapholunar. In all forms carpalia 4 and 5 coalesce to form the hamate.

Metacarpus.—There are five metacarpal bones forming the middle region of the forefoot. They are named, beginning on

the pollex side, *first, second, third, fourth, and fifth metacarpals* respectively. Each bone consists of a proximal extremity or base, a middle portion of shaft, and a distal extremity or head (Fig. 37). These bones are curved so as to be slightly convex on the dorsal aspect.

The number of metacarpals in mammals varies from one in *Equus* to five which are present in most orders. Nearly all the species of every order, except the *Edentata* and *Ungulata*, possess five metacarpals. In the pig and hippopotamus there are four metacarpals, in the rhinoceros three, and in the camel, deer, sheep, and cow two. In the last three forms the metacarpals present are the third and fourth, which in the adult are coalesced into a single bone known as the *cannon-bone*. Remnants of the second and fifth metacarpals are present in the deer, sheep, and cow, as the small caudo-lateral hoofs indicate. The functional metacarpal present in the horse is the third. The reduction of metacarpals in the ancestral forms of the horse is shown in figure 36, and will be referred to again in the description of the phalanges.

Phalanges.—The cat has five toes or digits on the forefoot, called *pollex, index, medius, annulus, and minimus*. Each digit, except the pollex, consists of three phalanges (Fig. 37).

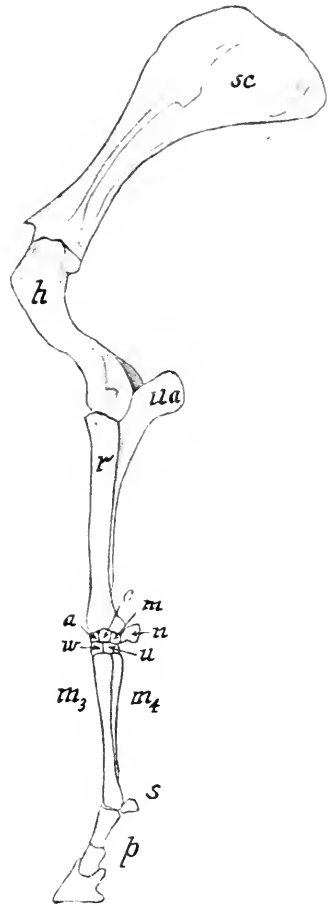


FIG. 38.—LATERAL ASPECT OF LEFT FORELIMB OF EQUUS.

h, Humerus; *m*₃, third metacarpal; *m*₄, fourth metacarpal; *p*, phalanges; *r*, radius; *s*, sesamoid; *sc*, scapula; *ua*, ulna; *a*, navicular; *c*, lunate; *m*, triquetral; *n*, pisiform; *w*, capitate; *u*, hamate.

The pollex or thumb has only two phalanges. The row of phalanges articulating with the metacarpals is called the *proximal*, the terminal row the *distal*, and the remaining row the *middle phalanges*. Two small sesamoid bones are attached on the volar side of the junction of each proximal phalanx with the metacarpal. Each distal phalanx has its proximal end produced caudal on the palmar aspect so that its articular surface faces dorsal. The distal phalanges terminate in claws which are retractile.

The number of digits in the forefoot of Mammalia varies from one to five. Nearly all the species of every order except the Edentata and Ungulata possess five digits (pentadactyl). The tapir has four functional digits (tetradactyl). The cow, deer, sheep, and pig also have four digits, but only two are functional (didactyl), the second and the fifth being atrophied and terminating in the small caudo-lateral hoofs which do not touch the ground. The rhinoceros has three functional digits (tridactyl), and the Equidæ possess only one digit (monodactyl) (Fig. 38), the third, though the atrophied remnants of the second and fourth metacarpals are present as *splint* bones which do not support phalanges.

As before stated, the Ungulates are undoubtedly descendants of a five-toed ancestor of Eocene times. The evolution of the horse's limb and the reduction in the number of digits are shown in figure 36. Fossil remains of the ancestors of the horse have been found in western United States, Europe, and South America. Orohippus lived in the region of Wyoming, Montana, and Idaho probably more than 5,000,000 years ago, when that country was more or less marshy, and it was necessary that the mammals should possess a spreading foot which would not permit them to sink too deep into the mud. As the ground became firmer and preying Carnivora more numerous, the foot of the horse became adapted to rapid flight over solid ground. Thus, through the process of evolution the third digit was enlarged at the expense of the other digits. Confir-

mation of this ancestral history of the horse is found by an examination of the early embryonic stages. According to Ewart, a horse embryo 35 cm. long possess quite well-developed second and fourth metacarpals terminating with phalangeal structures. The ulna and radius of an embryo 50 mm. long are strikingly similar to these same bones in *Meshippus*. In a still younger embryo the ulna is complete and correspondingly as large as in *Orohippus*.

As to the method of walking, mammals are spoken of as *plantigrade*, *digitigrade*, *unguligrade*, and *rectigrade*. The first mode of progression is exemplified by the bear, which places its metacarpals and phalanges flat on the ground in walking. The cat is *digitigrade*, walking on its toes. The horse and cow are *unguligrade*, as they walk upon the hoof. The elephant is *rectigrade*, the entire weight resting on a large pad, and the foot immobile. In some cases, as in the *Cetacea*, the forefoot is adapted for swimming instead of walking, and the number of phalanges to each digit is more than three.

LABORATORY STUDIES AND SUGGESTIONS

1. What bones compose the shoulder girdle?
2. How is the thoracic limb attached to the trunk?
3. What does the condition of the clavicle in the cat indicate as to its past history?
4. Draw the medial aspect of the scapula and label all parts.
5. What is the significance of the coracoid process?
6. Which processes of the scapula derive their names from their location and which from their shape?
7. How do you distinguish the right from the left scapula?
8. Draw the caudal aspect of the humerus and label all features.
9. Describe what is seen in looking directly at the distal articulating surfaces of the humerus.
10. How do you distinguish the right from the left humerus?
11. What features of the humerus derive their names from their shape?
12. Draw the medial or inner aspect of the ulna and label all features.
13. What features of the ulna derive their names from their form?
14. How do you distinguish the right from the left ulna?
15. Describe the articulations of the radius.
16. Draw lateral aspect of radius and label all features.

17. Describe the condition of the bones of forearm in the horse and its ancestors.
18. In a five-month fetus of the horse the ulna is distinct from radius and complete, while in the mature animal but little more than the distal third remains, and is ankylosed to the radius. Explain significance of this fact.
19. Draw ventral aspect of carpus and label all parts.
20. Wherein is the chief difference between carpus of cat and man?
21. Draw the lateral aspect of the third metacarpal and label all features.
22. How do you distinguish the distal from the proximal end of the metacarpals?
23. Describe the variation in the number of metacarpals in mammals.
24. Describe the usual arrangement of the phalanges in mammals having five digits.
25. How do you distinguish a phalanx from a metacarpal?
26. Give the number of functional digits in forelimb of dog, pig, cow, sheep, horse, and rabbit.
27. Name some mammals with atrophied digits.
28. What is the significance of these?
29. In the evolution of the perissodactyls (odd-toed ungulates) describe the order in which the digits are lost.
30. In the Bovidae and Cervidae which two digits are functional?

THE PELVIC LIMB

The pelvic or hind-limb of the cat is composed of the innominate bone, femur, patella, tibia, fibula, seven tarsals, five metatarsals, and twelve phalanges.

The **coxal** or **hip bone** is composed of four parts, the *ilium*, *ischium*, *pubis* (Figs. 22 and 39), and the small *acetabular* or *cotyloid bone*. The *ilium* is the dorsal portion, extending down to and occupying about one-third of the acetabulum. The *ischium* includes the caudal portion of the bone, extending ventral and forming two-thirds of the boundary of the obturator foramen. The *pubis* is the ventral portion, possessing two rami, one projecting laterad to unite with the ilium, cotyloid, and ischium, and the other projecting caudad along the mid-ventral line, joining its fellow and the ischium. In young kittens the junction of these parts is plainly visible, but in adult specimens it is wholly obliterated. In old specimens the ischium and pubis become more or less ankylosed with their fellows in the mid-ventral line. The cranial and dorsal border of the ilium is the *crest* (Fig. 40). The rough crescentic area on the medial

aspect is the *auricular surface* for articulation with the sacrum. The cranial rounded angle of the crest is the *anterior superior spine*. The *anterior inferior spine* is the small prominence craniad from the ventral termination of the auricular surface.

The *ischium* presents a *spine* on its dorsal border near the acetabulum. Between this spine and the posterior inferior

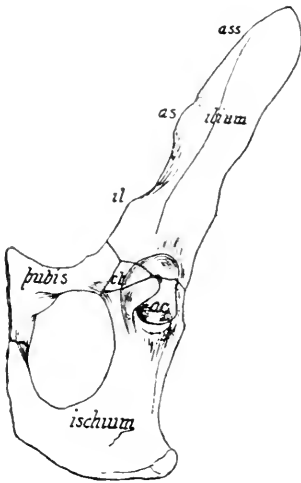


FIG. 39.—VENTRO-LATERAL ASPECT OF LEFT COXAL BONE OF A KITTEN.

ct, Cotyloid bone; *ac*, acetabulum; *il*, ilio-pectineal eminence; *as*, anterior inferior spine. (*Modified after Jayne.*)

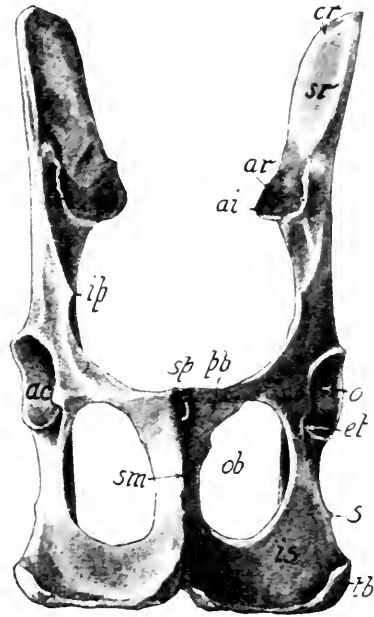


FIG. 40.—VENTRAL ASPECT OF THE COXAL BONES.

ac, Acetabulum; *ai*, posterior inferior spine; *ar*, auricular surface; *cr*, crest; *ct*, cotyloid notch; *ip*, iliopectineal eminence; *is*, body of ischium; *ob*, obturator foramen; *pb*, body of pubis; *s*, spine; *sm*, symphysis pubis; *sp*, spine of pubis; *sr*, surface of ilium for attachment of spinal muscles; *tb*, tuberosity of the ischium.

spine of the ilium, is a shallow concavity termed the *greater sciatic notch* in distinction to the *lesser sciatic notch* between the spine of the ischium and the tuberosity. The *acetabulum* or *cotyloid* cavity forms the cup for the articulation of the femur. The interruption in its ventral border is the cotyloid notch, at whose base there is a depression for the attachment of the

ligamentum teres holding the femur in place. The junction of the pubis with its fellow is known as the symphysis. The cranial portion of the bone lying on either side of this is called the *body*, the caudal part taking the name of *ramus*. The latter forms part of the boundary of the *obturator foramen* and meets the ramus of the ischium. This foramen gives passage to the obturator nerve and vessels.

In the Sirenia, which have no pelvic limbs, the innominate bones are rudimentary. In the Cetacea these bones are also rudimentary, which fact indicates that the ancestors of these forms possessed functional hind-limbs.

The **femur**, or thigh-bone, may be recognized by its spherical head with a pit for the attachment of the *ligamentum teres* which aids in holding the head in the acetabulum.

The *greater trochanter* projects from the proximal end of the bone to a level with the head. On this process are inserted the *pyriformis*, *gluteus medius*, and *gluteus minimus* muscles, all of which originate on the innominate bone. The *lesser trochanter* is the small projection on the caudal aspect of the proximal portion of the bone (Fig. 41). The *intertrochanteric ridge* or posterior intertrochanteric line extends between the two trochanters, and lying between this line and the neck is the *digital fossa*. The external and internal condyles are the articular processes on the distal end of the bone. The blunt projections at their roots are the *external* and *internal tuberosities*. The *intercondyloid notch* forms the depression on the caudal aspect between the condyles. On the cranial aspect is the trochlear surface for articulation with the patella. Two small sesamoid bones, the *fabellæ*, are present on the caudal aspect of the condyles, but they are usually removed in preparing the skeleton. The *linca aspera* is the slightly roughened line beginning on the caudal side, distal to the middle and extending proximally a short distance, where it bifurcates.

The form of the femur varies but little among mammals having functional posterior limbs. No living Sirenia have any

trace of a femur, but a vestigial femur is present in *Halitherium*, a fossil form. The hind-limbs are wanting among the Cetacea, but in a few forms nodules of bone or cartilage may represent

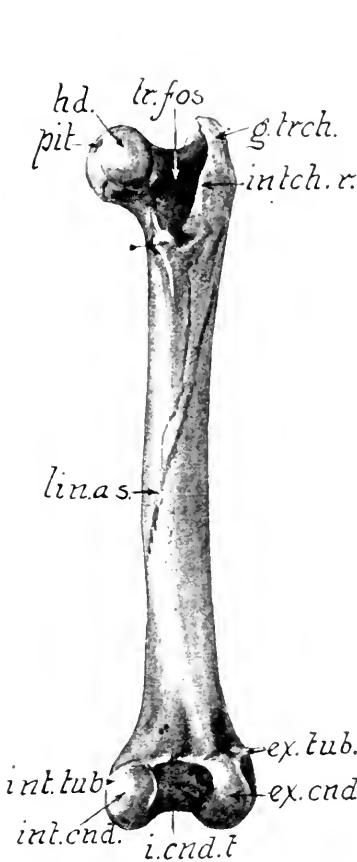


FIG. 41.—CAUDAL ASPECT OF FEMUR.

ex. tub., External tuberosity; *int. tub.*, internal tuberosity; *ex. cnd.*, external condyle; *int. cnd.*, internal condyle; *i. cnd. t.*, intercondylar notch or fossa; *intch. r.*, intertrochanteric ridge; *g. trch.*, greater trochanter; *hd.*, head; *lin. as.*, linea aspera; *pit.*, pit for the ligamentum teres; *tr. fos.*, trochanteric fossa or digital fossa.




FIG. 42.—ANTERIOR OR CRANIAL ASPECT OF RIGHT TIBIA.

al., Articular surface for the ankle bone; *cr.*, crest; *et.*, external tuberosity; *fc.*, facet for articulation with the fibula; *im.*, internal malleolus; *it.*, internal tuberosity; *lg.*, ligament of the patella cut off; *tb.*, tubercle.

the femur. In most Perissodactyla and Rodentia, and in some Insectivora and a few fossil Carnivora, a third trochanter is present.

The **patella**, or knee-cap (Fig. 22), is a sesamoid bone developed in the tendon of the quadriceps extensor muscle (Fig. 58). It is somewhat the shape of an almond and about half its size. It articulates with the trochlea of the femur.

The **tibia** is the larger bone of the crus. It presents two enlarged extremities and a shaft whose cross-section is triangular. It articulates with the femur and fibula proximally and the fibula and talus distally (Fig. 22). This is the longest bone in the cat's skeleton. Between the concave condyles on the proximal end is a notch giving attachment to the crucial ligament of the knee-joint (Figs. 42, 47).

The prominences of the lateral and medial aspects of the proximal extremity are the *external* and *internal tuberosities* respectively. Beneath the former is the facet for articulation with the fibula (Fig. 42). The tubercle, a prominence on the cranial side of this extremity, is for the insertion of the *ligamentum patellæ*, which is really the termination of the tendon of the quadriceps extensor muscle (Fig. 58). On the caudal aspect between the condyles is the popliteal notch. The sharp cranial border of the bone forms the crest. On the distal extremity is a process, the *internal malleolus*, bearing two grooves, the more caudal of which shelters the tendon of the flexor longus digitorum muscles while the other is for the tibialis posticus (Fig. 58). A facet is present on the lateral aspect of this extremity for articulation with the fibula.

The **fibula** in proportion to its length is the slenderest bone in the skeleton. It is the outer or lateral bone of the crus, and articulates proximally with the tibia and distally with the tibia and talus (Fig. 22). The proximal extremity is the head, upon which is a circular facet for articulation with the tibia. The sharp edge along the cranial aspect of the shaft furnishes attachment to the interosseous membrane uniting the two bones of the crus. The medial aspect of the distal extremity shows a prominent facet for articulation with the talus. Immediately proximal to this is the articular surface for the tibia.

From the lateral aspect projects the *external malleolus*, on the caudal side of which is a groove for the peroneus brevis muscle, and on the cranial side is a slight depression for the peroneus longus (Fig. 58).

In many of the Mammalia the two bones of the crus are more or less united. In most of the Chiroptera and Ungulata the fibula is rudimentary. The middle portion of the fibula is absent in the horse and its distal portion is fused with the tibia (Fig. 36). The ancestor of the Equidæ in Eocene times had a well-developed fibula, but in the evolution of the horse this bone has gradually diminished in size, as shown in the figure.

The **tarsus** is composed of seven bones in two rows. The proximal row contains the os calcis, talus, and navicular or scaphoid; the distal row the cuboid, and three cuneiform bones. The *os calcis*, or *calcaneum*, is the largest bone of the tarsus, being twice as long as broad (Fig. 44). Its caudal end presents a groove for the tendon of the plantaris muscle. The *peroneal tubercle* is on the outer side of the distal extremity. The *sustentaculum tali*, a shelf-like process projecting from near the middle of the inner side, supports a facet for the tendon of the flexor longus digitorum muscle (Fig. 59).

The *talus* lies on the inner or medial side of the calcaneum and articulates with the tibia, fibula, calcaneum, and scaphoid. The bone is composed of a body, neck, and head. The *body* is proximal and bears a trochlear surface for articulation with the tibia.



FIG. 43.—INNER OR MEDIAL ASPECT OF RIGHT FIBULA.

a, Facet for tibia; *ar*, facet for talus; *ex*, external malleolus; *h*, head; *s*, shaft; *t*, articular surface for tibia; *gr*, groove for peroneus longus muscle.

The *head* bears a convex surface for articulation with the navicular. The *neck* is the constricted portion between the body and the head.

The *scaphoid* lies on the medial side of the foot and articulates with the remaining six bones of the tarsus. It may be recognized by its deep concave surface for articulation with the talus, and also by the tuberosity, a process on its medial plantar angle (Fig. 44).

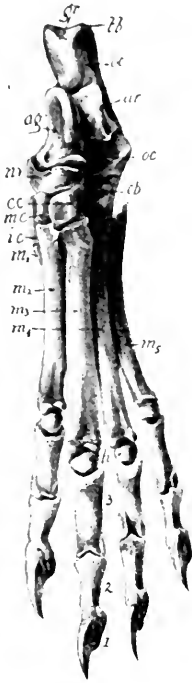


FIG. 44.—DORSAL ASPECT OF LEFT HIND-FOOT.

ag, Talus; *ar*, articular surface of the tibia; *cb*, cuboid; *ec*, external cuneiform; *gr*, groove for the tendon of the plantaris; *h*, head of the fourth metatarsal; *ic*, internal cuneiform; *mc*, middle cuneiform; *m₁*, hallux or first metatarsal; *m₂*, *m₃*, *m₄*, and *m₅*, second, third, fourth, and fifth metatarsals; *nv*, navicular or scaphoid; *oc*, os calcis, or calcaneum; 3, proximal row of phalanges; 2, middle row of phalanges; 1, distal row of phalanges.

The *internal cuneiform* is next to the smallest bone of the tarsus. It articulates with the navicular, middle cuneiform, and first and second metatarsals. The *middle cuneiform* is a wedge-shaped bone and the smallest element of the tarsus. It articulates with the other two cuneiforms, the scaphoid and second metatarsal. The *external cuneiform* may be recognized by a strong hook-like process on its plantar surface. It articulates with the scaphoid, middle cuneiform, cuboid, and second and third metatarsals.

The *cuboid* is the lateral bone of the distal row. It may be recognized by the deep groove on its plantar surface which shelters the tendon of the peroneus longus muscle.

The typical arrangement of the tarsal elements in vertebrates is similar to that of the carpus. Three bones, a *tibiale*, *intermedium*, and *fibulare*, compose the proximal row, while five *tarsalia* form the distal row. The *centrale* occupies the center of the tarsal region. In the

adult mammal, fusion of some of these elements occurs, so that not more than seven distinct bones are present in any form. The talus contains the tibiale and intermedium, while the fourth and fifth tarsalia form the cuboid.

The **metatarsus** consists of five bones, the first of which is rudimentary, while the other four are longer than the metacarpus, which they resemble (Fig. 44). The first metatarsal is smaller than any bone of the tarsus. It articulates with the internal cuneiform and is also in contact with second metatarsal. The four long metatarsals have a slight dorsal convexity, each one consisting of a *base* or enlarged proximal part, a *shaft* or middle portion, and a *head* or distal rounded articular process. On the plantar surface of the head of each metatarsal is a median spine, on each side of which is a concavity for a sesamoid bone. These sesamoid bones are frequently lost in cleaning the skeleton.

The number of functional metatarsals in mammals varies from one to five. Usually the number of metacarpals and metatarsals is the same, but in the tapir there are four metacarpals and but three metatarsals. All Monotremata, Carnivora, and Primates have five metatarsals, but in the cats, dogs, and hyenas the first metatarsal is vestigial. In early geological times all mammals possessed five metatarsals, the number of which in many cases has gradually diminished owing to environment, as is shown in the phylogeny of the horse (Fig. 36).

The Equidæ possess but one functional metatarsal and two rudimentary ones, although *Orohippus*, the ancestor of the horse, had three functional metatarsals.

The **phalanges** of the cat's foot are twelve in number. Each metatarsal except the first supports three phalanges. The proximal phalanges are the stoutest, and the distal the smallest. Each distal phalanx bears a claw.

In all five-toed animals, such as Primates, there are fourteen phalanges, each digit being composed of three, except the hallux, which has two.

LABORATORY STUDIES AND SUGGESTIONS

1. Describe the articulations of the innominate bone.
2. How do you distinguish the cranial from the caudal aspect of the os innominatum?
3. Which processes derive their names from their location?
4. Draw the lateral aspect of the os coxae and label all features.
5. Name the four parts of the bone in order of size.
6. What two orders of mammals have no pelvic limbs?
7. Describe what is seen in viewing the femur from the cranial aspect.
8. Name the processes of the femur.
9. Draw the distal aspect of the femur.
10. How do you distinguish the right from the left femur?
11. Describe the patella.
12. Draw the caudal aspect of the tibia and label all features.
13. How do you distinguish the right from the left tibia?
14. Describe the articulations of the fibula.
15. What features distinguish the proximal from the distal extremities of the fibula?
16. Write 100 words describing the crus in other mammals than the cat.
17. Draw the ventral aspect of the tarsus and label all parts.
18. Which of the tarsals support metatarsals?
19. Name the tarsals in order of size.
20. Draw the lateral aspect of the third metatarsal.
21. How do you distinguish a metatarsal from a metacarpal?
22. How do you distinguish the proximal from the distal end of a metatarsal?
23. Describe the condition of the metatarsals in various mammals.
24. In most mammals how many phalanges to each digit?
25. What artiodactyls have you seen with only two functional digits on the posterior limbs?

THE JOINTS

The study of the articulation of the bones and the ligaments holding them in place is known as syndesmology. There are three general classes of articulations: **Synarthroses**, or immovable joints; **amphiarthroses**, or joints with slight motion; and **diarthroses**, or joints freely movable. A synarthrodal joint is exemplified in the sutures between the bones of the skull. The two surfaces of bone are separated by fibrous membrane only. An amphiarthrodal articulation occurs between the bodies of the vertebræ and also in the union of the sacrum with the ilium. In the articulation of the vertebræ the contiguous surfaces of the bone are faced by flattened discs of fibrocartilage (Fig. 22).

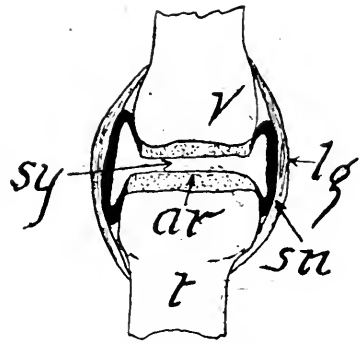


FIG. 45.—DIAGRAM OF A DIARTHRODAL JOINT.

ar, Articular cartilage; *lg*, ligament; *sn*, synovial membrane; *sy*, synovial fluid in synovial cavity; *t*, tibia; *v*, femur.

The diarthrodal articulation is exemplified in all joints allowing free motion. Such joints are composed of the following parts: the ends of two bones having their contiguous surfaces covered with cartilage; a synovial membrane forming a short tube whose ends are closed by the cartilaginous articulating surfaces; and several ligaments varying in number from two or three to a dozen (Fig. 45). There are four kinds of the diarthrosis: the *arthrodia*, or *gliding joint*, which occurs between the bones of the carpus; the *enarthrosis*, or *ball-and-socket joint*, such as at the hip or shoulder; the *ginglymus*, or *hinge joint*, exemplified at the elbow and knee; and the *rotatoria*, or *pivot joint*, formed by the articulation of the axis and atlas.

As the knee-joint can be readily dissected and the parts well displayed, it is here described somewhat in detail. The

leg should be detached at the hip-joint and the muscles largely removed, taking care in the immediate neighborhood of the knee that the ligaments are not cut. There are eight ligaments to this joint. These may be classified into those

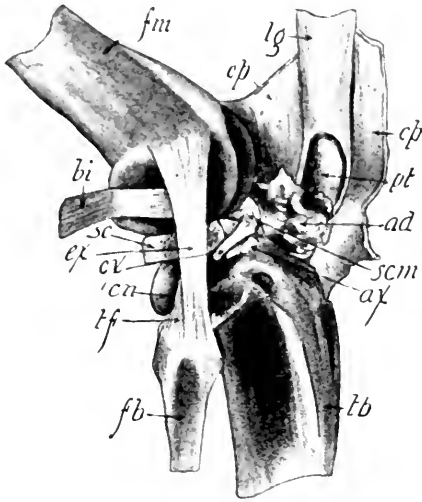


FIG. 46.—LATERAL ASPECT OF DIS-
SECTED KNEE-JOINT.

ad, Adipose tissue; *ax*, antero-internal ligament of the meniscus; *cp*, capsular ligament cut and reflected mediad; *bi*, tendon of the popliteus muscle pulled proximad to display *sc*; *cn*, caudal projection of condyle of tibia; *cx*, antero-external ligament of the meniscus; *ex*, external lateral ligament; *fb*, fibula; *fm*, femur; *lg*, ligament of the quadriceps femoris muscle; *pt*, patella; *sc*, external or lateral meniscus; *scm*, medial or internal meniscus, *tf*, tibio-fibular ligament; *tb*, tibia.

connected with the patella: the capsular ligaments; the collateral ligaments; the crucial ligaments; and the meniscal ligaments (Fig. 46).

(1) The *ligamentum patellæ*, or anterior ligament, extending from the patella to the anterior tubercle on the tibia, is the strongest ligament of the knee-joint, and is really a continuation of the tendon of the quadriceps femoris muscle. (2) The *capsular ligament*, which entirely surrounds the joint except in the places occupied by the anterior and lateral ligaments, consists of two parts, a *cranial* and a *caudal portion*. The former is seen on either side of the anterior ligament, extending from the femur to the tibia as a thick membrane, and more laterally

being attached to the menisci. The caudal part extends from the fabellæ and the femur to the tibia and menisci. (3) The *collateral ligaments* pass directly from the epicondyles of the femur to the tibia or fibula. (a) The *ligamentum collaterale fibulare* or *external lateral ligament* proceeds from the external tuberosity of the femur to the head of the fibula. (b) The *ligamentum collaterale tibiale* or *internal lateral ligament*, much shorter than the external one, extends from the internal tuber-

osity of the femur to the internal tuberosity of the tibia. The anterior and capsular ligaments must be cut in order to see the (4) *crucial ligaments*, which are short, and cross each other in the region of the intercondylar notch. The *posterior crucial* extends from the caudal margin of the head of the tibia to the mediocranial angle of the intercondyloid notch of the femur. The *anterior crucial* extends from the summit of the tibia to the caudolateral angle of the intercondyloid notch. (5) The *ligamenta capituli fibulæ*. These are very short, extending from the head of the fibula to the outer tuberosity of the tibia. In addition to these ligaments, there are (6) the *ligaments of the menisci*, four bands uniting the menisci to the bones. The *menisci* or *semilunar cartilages* are two biconcave cartilaginous plates, about one millimeter thick, interposed between the condyles of the femur and tibia.

The **synovial membrane** is a very thin transparent sheet lying within the capsular sheath of the joint. It secretes the white glairy synovia for lubricating the joint. The synovial fluid and membrane may be demonstrated by cutting open a fresh joint obtained from the butcher-shop (Fig. 45).

All other freely movable joints are similar in structure to the knee-joint, but have no menisci and fewer ligaments. The shoulder-joint has only two or three ligaments, the most important of which is the capsular. The elbow-joint has

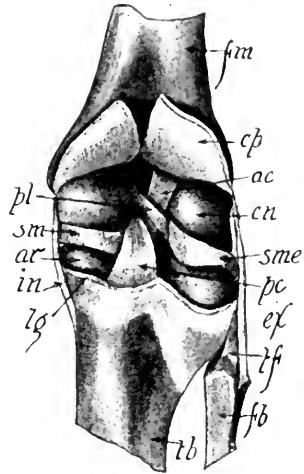


FIG. 47.—CAUDAL ASPECT OF KNEE-JOINT WITH CAPSULAR LIGAMENT CUT.

ac, Anterior crucial ligament; ar, articular surface of condyle of tibia; cn, condyle of femur; cp, capsular ligament cut along the line lg and reflected proximad; ex, external lateral ligament; fb, fibula; fm, femur; in, internal lateral ligament; lg, cut edge of capsular ligament; pc, posterior crucial ligament; pl, posterior external ligament of the meniscus; sm, medial or internal meniscus; sme, lateral or internal meniscus; tf, ligaments of the head of the fibula; tb, tibia.

four ligaments and the hip-joint only two. In the ankle-joint there are eight ligaments in addition to the capsular.

These ligaments which bind the joints consist of white fibrous connective tissue which under the microscope is seen to be composed of parallel and interlacing fibers. They are very tough and have but little elasticity, so that the joints are seldom dislocated.

LABORATORY STUDIES AND SUGGESTIONS

1. Give three examples of each of the three general classes of joints.
2. Explain difference in anatomy of the three classes of joints.
3. Without aid of the microscope can you detect any differences between a ligament and a tendon?
4. By removing the capsular ligament describe the ligaments that can be displayed on the lateral and caudal aspects of the knee-joint.
5. After bringing to view by dissection as many ligaments as possible on inner aspect of knee-joint, draw and label all parts.
6. Draw the menisci.
7. By careful dissection note the ligaments present in the hip-joint.
8. How many ligaments can you find in the shoulder-joint?
9. In what joints is synovia present?
10. Cut a very thin slice of articular cartilage about a millimeter square, mount in dilute acetic acid, and make drawing as seen under the microscope.

THE MUSCLES

The study of the muscular system is known as myology. The muscles are of two kinds: **voluntary**, which are under the control of the will; and **involuntary**, which cannot be controlled by the will. All muscles moving the bones are voluntary and are supplied with branches of the cerebrospinal nerves. Examples of involuntary muscles are found in the walls of the alimentary canal, the ureter, bronchial tubes, and blood-vessels. These are supplied with nerves from the sympathetic nervous system (Fig. 116). The structure of a voluntary muscle may be seen by teasing a small piece on a slide in a drop of water, covering with a cover-glass, and examining with the compound microscope. It is composed of striated fibers from one to fifteen centimeters in length, while involuntary muscle is composed of cells more or less spindle-shaped and non-striated, except in the heart (Figs. 8 and 11).

There are over five hundred voluntary muscles in the cat, each of which is usually attached at either end to the periosteum of a bone. The point of attachment on the unmoved bone is known as the *origin* of the muscle. The insertion of a muscle is its attachment to the bone which it moves. In the case of the biceps, its origin is on the scapula and its insertion on the radius. Usually a muscle originates and terminates in a white glistening cord called a *tendon*, composed for the most part of white fibrous tissue.

Each muscle-fiber is surrounded by a transparent elastic sheath, the *sarcolemma*. A number of fibers bound together by a loose connective tissue, and the whole enveloped by an extension of the same, is a *fasciculus*. The tissue connecting the fibers is the *endomysium*, while that enveloping the fasciculus is the *perimysium*. A number of fasciculi bound together in a sheath, the *epimysium*, constitutes the entire muscle. The

epimysium is merely a deflected portion of the sheath enveloping the fasciculus. It is visible to the naked eye as a thin shining sheath beneath the tougher *fascia* which covers the muscles and binds them together. According to function, muscles are spoken of as *flexors*, *extensors*, *adductors*, *abductors*, *rotators*, *elevators*, *depressors* and *sphincters*. A *flexor muscle* is one which by its contraction bends a limb or any portion of it. An *extensor muscle* is the antagonist of a flexor and serves to bring the two long bones into line. An *abductor muscle* is the one inserted on a long bone, which it draws laterad from the axis of the limb or the sagittal plane of the body. An *adductor muscle* is the antagonist of an abductor. The pectoral muscles are adductors of the forelimb. A *rotator muscle* is one which produces more or less of a rotatory motion in the bone upon which it is inserted. A rotator muscle is exemplified in the obturators, which arise on the innominate bone and are inserted in the digital fossa of the femur. An *elevator muscle* is represented by the temporal, extending from the temporal bone to the mandible, which it elevates. A depressor muscle is the antagonist of an elevator. The digastric is a depressor of the mandible. A *sphincter muscle* is one surrounding an orifice which it closes by contraction. The orbicularis oris in the lips is an example.

Muscles are named according to their function, shape, or part to which they are attached. Thus the sternomastoid muscle arises on the sternum and is inserted on the mastoid process of the skull. The latissimus dorsi is so named because it is a very broad muscle (Fig. 48) and occupies the dorsal part of the cat's body. The extensor communis digitorum muscle signifies by its name that it is the common extensor of the digits.

DISSECTION OF THE MUSCLES

Since the other systems are of more importance from the standpoint of comparative anatomy and physiology than the muscular, only the more important muscles will be described. Great care should be exercised in removing the skin of the

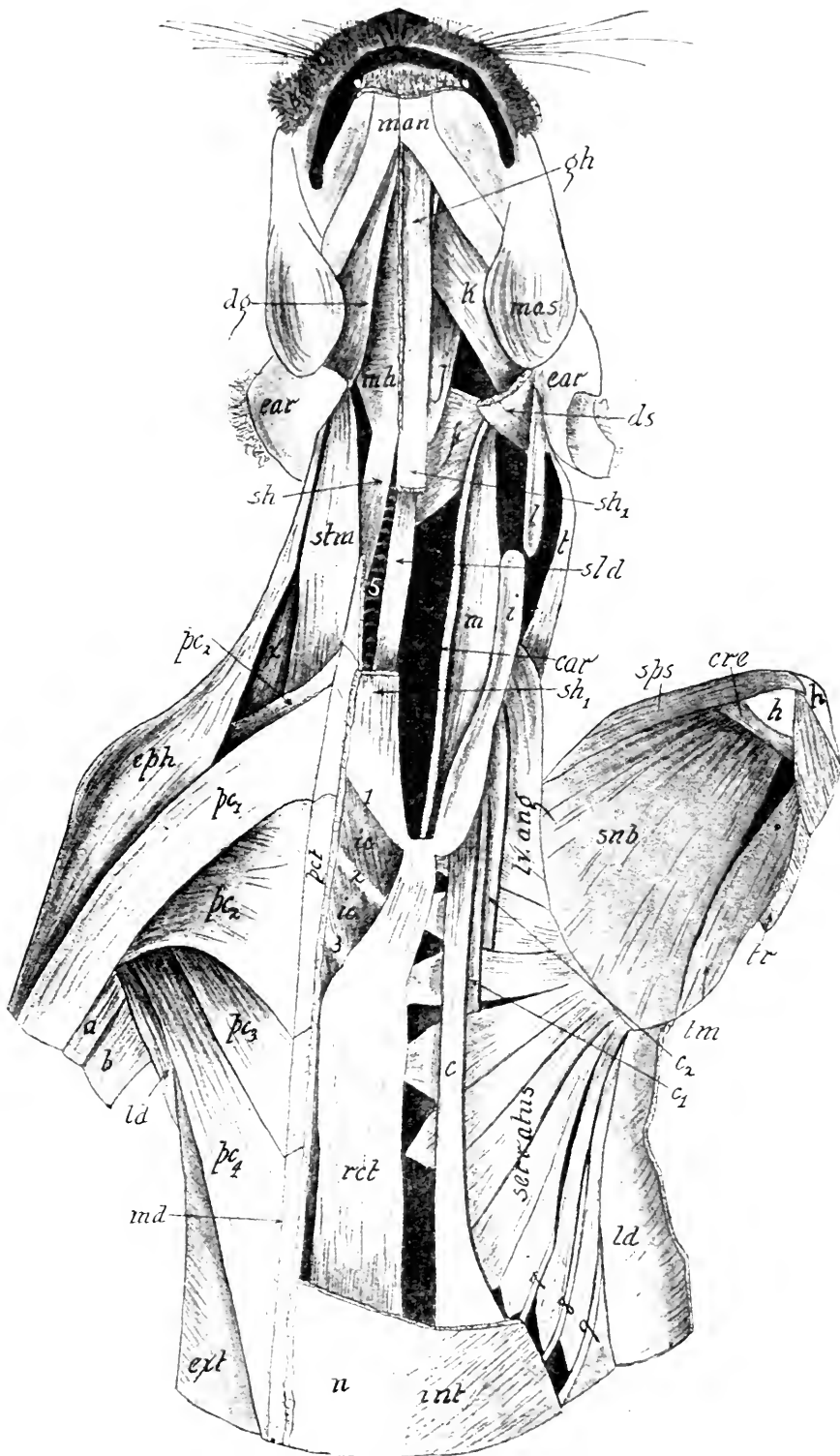
cat, in order that such superficial muscles as the platysma myoides on the neck and side of the face, and occipitofrontalis, may not be cut away. The skin is attached to the underlying muscles by the *superficial fascia*, a fibrous areolar tissue, which contains the subcutaneous fat more or less abundant in all specimens. The *deep fascia* is the fibrous and membranous layer of dense tissue lying close against the muscles and dipping down between them. The stronger parts of this fascia are called *aponuroses*.

Directions for Dissection.—Dissection does not mean the cutting up, but the intelligent separation of one organ from another and the removing of known portions to study the deeper structures more carefully. The muscles should not be cut loose from their origin or insertion, but merely separated from each other by cutting the deep fascia in the longitudinal direction of the muscle. If it is necessary to remove a muscle for displaying those beneath, it should be cut transversely in the middle and the two parts reflected. No portion of a muscle or other tissue should be removed without knowing what it is and noticing carefully its relation to the surrounding parts. The specimen under dissection should be securely nailed to the tray so that the muscles are made tense. When the parts become dry, they should be thoroughly wet with water. If the formalin in which the specimen has been preserved is irritating to the mucous membrane of the dissector, a half liter of 5% ammonium hydrate should be poured over the specimen.

In the following tables most of the important muscles of the cat are arranged according to their location and ease in dissection. Perhaps no class will have time to dissect out all of the muscles here described. In most cases only those of the forelimb with such others as the instructor may assign will be all that the student will have time to study carefully. The more ambitious in the class may wish to work out the posterior limb and compare with the anterior. This is to be encouraged. The origins and insertions are given only in a very general way,

FIG. 48.—VENTRAL ASPECT OF THE CRANIAL HALF OF THE CAT. The superficial muscles have been removed from the left side and the scapula reflected laterad to display the serratus and adjacent muscles.

a, Triceps; *b*, triceps; *car*, carotid artery; *c*, *c*₁, and *c*₂, scalene muscles; *cph*, cephalohumeral; *cre*, coracobrachialis; *dg*, digastric; *ds*, cut end of the digastric; *ext*, external oblique; *f*, inferior constrictor; *gh*, geniohyoid; *h*, humerus; *i*, scalene; *ic*, triangularis sterni; *int*, internal oblique; *j*, hyoglossus; *k*, styloglossus; *l*, rectus lateralis; *ld*, latissimus dorsi reflected lateral and much of the reflected portion cut off; *lv*, levator scapulæ; *m*, longus colli; *man*, mandible; *mas*, masseter; *mh*, mylohyoid; *md*, median ventral line; *n*, facial aponeurosis of the external oblique; *pc*₁, *pc*₂, *pc*₃, and *pc*₄, first, second, third and fourth parts of the pectoralis muscle; *pct*, portion of the pectoral muscle of the left side; *rct*, left rectus abdominalis; *sh*, sternohyoid; *sh*₁, sternohyoid of the left side with its middle portion removed; *std*, sternothyroid; *stm*, sternomastoid; *st*, portion of left sternomastoid; *sub*, subscapularis; *sps*, suprascapularis; *t*, occipitoscapularis; *tm*, teres major; *tr*, triceps; *x*, cleidomastoid; 1, 2, 3, 7, 8, and 9, ribs; 5, trachea.



thus leaving to the student the pleasure of working out the details. In general, the arrangement and descriptions follow Reighard and Jennings very closely, however, in nearly every case they have been verified by special dissections and in class work. The student will be interested in finding many minor variations which will add zest to the work. He should also note carefully the muscles which together effect a certain motion, such as the flexion of the forearm or the extension of the digits.

DESCRIPTION OF MUSCLES

The skin muscles are usually removed with the skin and are rather difficult to study.

(1) **Cutaneous maximus** has its origin from the outer surface of the latissimus dorsi; the bicipital arch in the axilla; the linea alba and from the thorax; and is inserted onto the skin. It covers almost the whole side and moves the skin.

(2) **Platisma**: from the middorsal line from occiput to first thoracic vertebra, and from side of neck; to the skin and muscles of face and neck. A thin muscle covering side of face and neck and sometimes described as two muscles, the portion dorsal to insertion in skin is known as the supercervicocutaneous and the portion ventral to the insertion as the cervicofacial muscle.

MUSCLES OF THE SHOULDER REGION

These muscles of the forelimb (3-45) will usually be dissected in a short course. The more difficult muscles of the hand may be omitted except for students who have developed a careful technique. Drawings should be made during the progress of dissection. The exact determination of origin and insertion should be deferred until later in any case where it would injure undissected parts.

(3) **Spinotrapezius** (Fig. 54) (Trapezius inferior); neural spines of thoracic vertebræ to spine of scapula and adjacent fascia; draws scapula upward and backward.

(4) **Acromiotrapezius** (Fig. 54) (Trapezius superior); neural spines of cervical vertebræ to spine of scapula; holds scapulæ together.

(5) **Clavotrapezius** (Fig. 54); occipital bone and fascia of middorsal line of neck to clavicle; pulls scapula upward and forward. This muscle continues to the humerus as the clavo-brachial. Both together are frequently described as one muscle, the *cephalohumeral* or *cephalobrachial*.

(6) **Occipitoscapularis** (Fig. 48, *t*) (Levator scapulæ dorsalis or Rhomboideus capitis); lambdoidal ridge to scapula; draws scapula forward and rotates it.

(7) **Rhomboideus** (Fig. 54) (Rhomboideus major and minor of man); spines of adjacent cervical and thoracic vertebræ to scapula; draws scapulæ dorsomedial.

(8) **Levator scapulæ ventralis** (Fig. 54) (Levator claviculæ); atlas and basioccipital to metacromion and infraspinal fossa; pulls scapula cranial.

(9) **Cleidomastoideus** (Fig. 48) (clavicular portion of sternocleidomastoid of man); mastoid process to clavicle; turns head and depresses snout.

(10) **Latissimus dorsi**; (Fig. 54); neural spines from fourth thoracic to sixth lumbar vertebræ to shaft of humerus; draws arm dorsocaudal.

(11) **Serratus anterior** (Fig. 48) (Serratus magnus); first nine or ten ribs to scapula; depressor of scapula.

(12) **Levator scapulæ** (Fig. 48); last five cervical vertebræ to scapula; draws scapula cranioventrad. Continuation forward of serratus anterior and scarcely separable from it.

BREAST MUSCLES

(13) **Pectoantibrachialis** (Fig. 48); lateral surface of manubrium to superficial fascia of forearm near elbow; aids pectoralis group and is the most superficial of this group.

(14) **Pectoralis major** (Fig. 48) (Ectopectoralis); two layers, the superficial from manubrium and raphe anterior to it, the

deep layer from the ventral surface of manubrium and sternum; both layers insert onto shaft of humerus.

(15) **Pectoralis minor** (Fig. 48) (Entopectoralis); sternum to shaft of humerus.

(16) **Xiphohumeralis** (Fig. 48); Xiphoid process of sternum to humerus. The pectoralis group of muscles draws the arm mediad.

MUSCLES ON THE OUTER SURFACE OF THE SCAPULA

(17) **Spinodeltoideus** (Fig. 54); scapular spine to deltoid ridge on humerus; flexor and rotator of humerus.

(18) **Acromiodeltoideus** (Fig. 54); acromion and metacromion to humerus and on spinodeltoideus; flexor and rotator of humerus.

(19) **Clavobrachialis** (Fig. 54); clavicle and raphe adjacent, to ulna; continuation of clavotrapezius; flexor of antibrachium.

(20) **Supraspinatus** (Fig. 55); supraspinatus fossa to greater tuberosity of humerus; extensor of humerus.

(21) **Infraspinatus** (Fig. 55); infraspinatus fossa to greater tuberosity of humerus; rotator of humerus.

(22) **Teres minor**; glenoid border of scapula to proximal end of humerus; rotator of humerus. Best studied after removal of teres major, later.

MUSCLES ON THE INNER SURFACE OF SCAPULA

(23) **Subscapularis** (Fig. 48); subscapular fossa to lesser tuberosity of humerus; pulls humerus mediad.

(24) **Teres major** (Fig. 56); glenoid border of scapula and fascia with latissimus dorsi on humerus; rotator and flexor of humerus.

(25) **Coracobrachialis** (Fig. 56); coracoid process to proximal end of humerus; adductor of humerus.

MUSCLES OF THE UPPER ARM (BRACHIUM)

(26) **Epitrochlearis** (extensor antibrachii longus); latissimus dorsi to olecranon process of ulna; extensor of arm and supinator of hand.

(27) **Biceps brachii** (Fig. 57); bicipital tubercle of scapula to proximal end of radius; flexor of arm and supinator of hand.

(28) **Brachialis** (Fig. 55); lateral surface of humerus to proximal end of ulna; flexor of forearm.

(29) **Triceps brachii** (Figs. 54, 55); divisible into three main portions:

(a) *Caput laterale* (Fig. 54) (*Anconeus lateralis* or *ectotriceps*); proximal end of humerus to olecranon process of ulna.

(b) *Caput longum* (Fig. 54) (*Anconeus longus* or *mediatriceps*); glenoid border of scapula to olecranon process of ulna.

(c) *Caput mediale* (Fig. 55) (*entotriceps*); consists of three parts:

(x) Long portion (*Anconeus posterior*); shaft of humerus to ulna.

(y) Intermediate portion (*Anconeus internus*); humerus to olecranon.

(z) Short portion; supracondyloid bar to olecranon.

Triceps forms strong extensor of forearm; short portion alone acts as supinator of hand.

(30) **Anconeus**; distal portion of humerus to proximal end of ulna; tensor of capsule of joint.

MUSCLES OF THE FOREARM (ANTIBRACHIUM) SUPINATORS AND EXTENSORS

Note that the muscles of the forearm are covered by a tough antibrachial fascia which is made up of a superficial and a deep layer. At the wrist the fascia becomes thickened to form, on the ventral side, the transverse ligament, holding the flexor tendons in place. On the fingers it forms tendinous sheaths (vaginal ligaments) for the flexor muscles and ring-like annular ligaments for the flexor tendons.

(31) **Brachioradialis** (Fig. 56) (*supinator longus*); from the middle fifth of the humerus to the styloid process of the radius; supinator of hand.

(32) **Extensor carpi radialis longus** (Fig. 56); lateral supracondyloid ridge of humerus to second metacarpal; extensor of hand.

(33) **Extensor carpi radialis brevis** (Fig. 56); lateral supracondyloid ridge of humerus to third metacarpal; extensor of hand.

(34) **Extensor digitorum communis** (Fig. 56); lateral supracondyloid ridge of humerus to phalanges of second, third, fourth and fifth digits; extensor of four ulnar digits.

(35) **Extensor digitorum lateralis** (Fig. 55) (extensor digiti quinti proprius of man); lateral supracondyloid ridge to dorsal aspect of three or four lateral digits; extensor of three or four ulnar digits.

(36) **Extensor carpi ulnaris** (Fig. 55); lateral condyle of humerus to lateral aspect of fifth metacarpal; extensor of fifth digit; largest extensor of the forearm.

(37) **Extensor indicis** (*proprius*) (Fig. 54) (includes ex. pollicis longus); shaft of ulna to base of second phalanx of second digit; extensor of second digit.

(38) **Supinator** (ligaments of elbow joint to ventral surface of radius).

(39) **Extensor brevis pollicis** (Fig. 54) (ex. ossis metacarpi pollicis; includes abductor longus pollicis of man); shaft of ulna to base of first metacarpal; extensor and abductor of thumb.

FLEXORS AND PRONATORS OF FOREARM

(40) **Pronator teres** (Fig. 56); internal condyle of humerus to cranial aspect of middle third of radius. Much of this muscle is covered by those next described.

(41) **Flexor carpi radialis** (Fig. 56); internal condyle of humerus to palmar aspect of proximal end of second and third metacarpals; slender muscle flexing the hand.

(42) **Palmaris longus** (Fig. 56); internal epicondyle of humerus to palmar fascia; flexor of first phalanx of each digit.

(43) **Flexor carpi ulnaris**; (Fig. 54) by two heads, one from the medial epicondyle of humerus, the other from the medial aspect of the olecranon to pisiform bone. The two heads are separated by the ulnar nerve, but unite before reaching the middle of the ulna. Flexor of hand.

(44) **Flexor sublimis digitorum** (or *perforatus*) (Fig. 56); by two heads, one from the palmaris longus near the wrist, the other from the flexor profundus digitorum; coalesce near origin then sends tendons which are perforated by the flexor profundus digitorum near their insertion onto the bases of the second row of phalanges; flexor of the second phalanx of the four ulnar digits.

(45) **Flexor profundus digitorum** (or *perforans*); (Fig. 56) five heads which join at the wrist; first head from proximal end of ulna; second head from medial epicondyle of humerus; third and fourth heads from medial epicondyle; fifth head from ventral surface of shaft of radius; the common tendon of the wrist divides into five tendons, four of which perforate the tendons of the sublimis at the bases of the first phalanges; to be inserted in the base of the terminal phalanx of each digit. Flexor of all digits.

(46) **Pronator quadratus** (Fig. 56); ventral surface of ulna and adjacent interosseus membrane to ventral surface of radius; pronator of hand.

MUSCLES OF HAND

For a more complete description the student is referred to Reighard and Jennings.

(47) **Lumbricales**; four small muscles in palm of hand from the tendon of the flexor profundus to the radial side of the base of first phalanx of the four ulnar digits; bends digits mediad.

(48) **Abductor pollicis brevis** (includes opponens pollicis of man); transverse ligament on radial side of wrist to base of phalanx of thumb; abducts thumb.

(49) **Flexor brevis pollicis**; capitate (os magum) and scapulo-lunar bones to the first phalanx of thumb; flexor of thumb.

(50) **Adductor pollicis**; ventral surface of capitate to base of first phalanx of thumb.

(51) **Interossei**; small stout muscles between the metacarpals; ventral of lateral surfaces of metacarpals to lateral surfaces of first phalanges of the four ulnar digits. The second interosseus is frequently called the *flexor brevis digiti secundi* (indicis). Sometimes a second portion of the second interosseus is called also the *abductor digiti secundi*.

(52) **Adductor digiti secundi**; ventral surface of capitate bone to base of first phalanx of second digit.

(53) **Abductor digiti quinti**; pisiform bone to first phalanx of fifth digit.

(54) **Flexor brevis digiti quinti**; ventral surface of fifth metacarpal to first phalanx of fifth digit. It is an interosseus of the fifth.

(55) **Opponens (adductor) digiti quinti**; ventral surface of capitate bone to radial surface of fifth metacarpal and base of first phalanx.

MUSCLES OF THE POSTERIOR LIMB

If time permits it is advisable to dissect at least part of the muscles of the hind limb and to compare where possible with the muscles of the forelimb. It is well to note that the posterior limb is much more closely fastened to the body than the forelimb which makes it extremely difficult if not impossible to compare the muscles of the shoulder and thigh. The student will, however, be interested in comparing the forearm with the shank.

LATERAL SURFACE OF HIP AND THIGH

Note the tough fascia lata covering the muscles of the thigh; carefully dissect it away so as not to injure any of the underlying muscles.

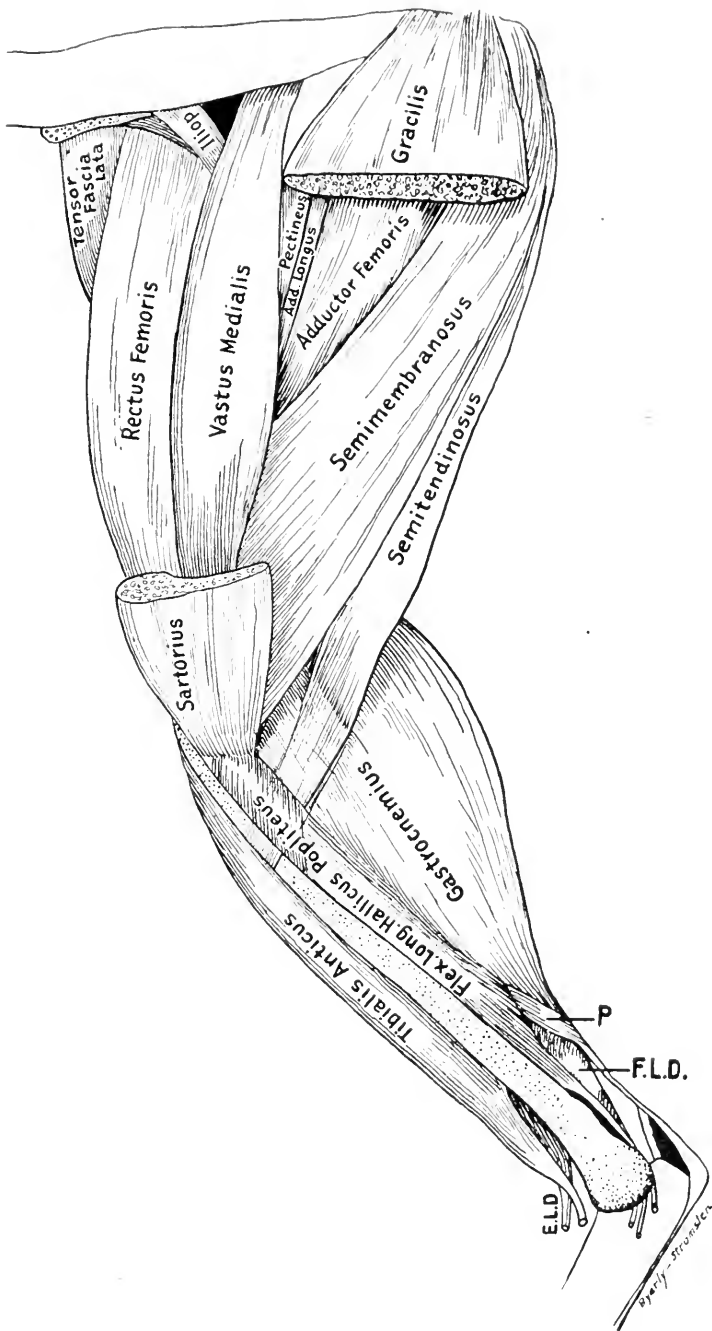


FIG. 49.—MEDIAL OR INNER ASPECT OF THE HIND LIMB. (Drawn from dissections made by Mr. Byerly).

Sartorius and gracilis muscles have been removed. *Iliop.*, iliopsoas; *P.*, plantaris; *F.L.D.*, flexor longus digitorum.; *E.L.D.*, tendon of extensor longus digitorum.

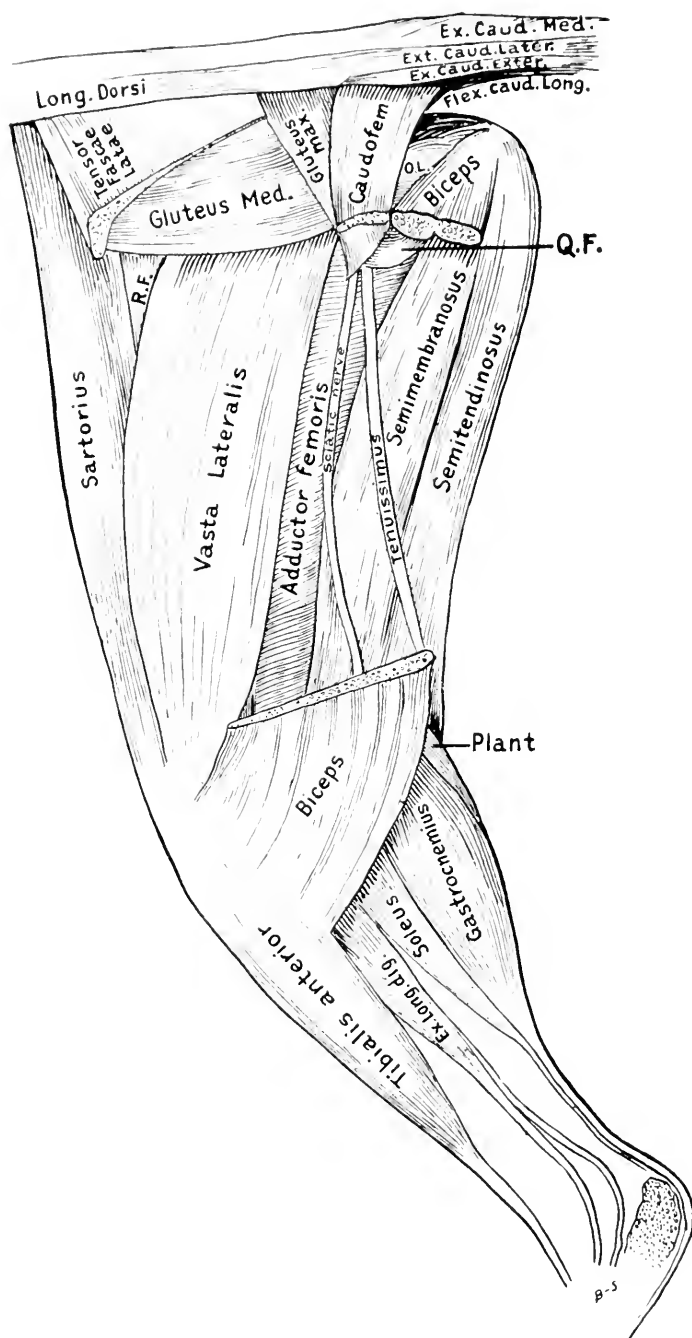


FIG. 50.—LATERAL VIEW OF HIND LIMB AFTER BICEPS, TENSOR FASCIA LATA, AND CAUDOFEMORALIS HAVE BEEN REMOVED. (From dissections made by Mr. Byerly.)

Q.F., quadratus femoris; R.F., rectus femoris; o.l. obturator internus; Plant. plantaris near origin.

(56) **Tensor fasciælatæ** (Fig. 54); ventral border of ilium to fascia lata.

(57) **Biceps femoris** (Fig. 54); tuberosity of ischium by aponeurosis to the cranial aspect of the tibia and on the patella; abductor of thigh and flexor of shank; broad muscle on lateral aspect of thigh.

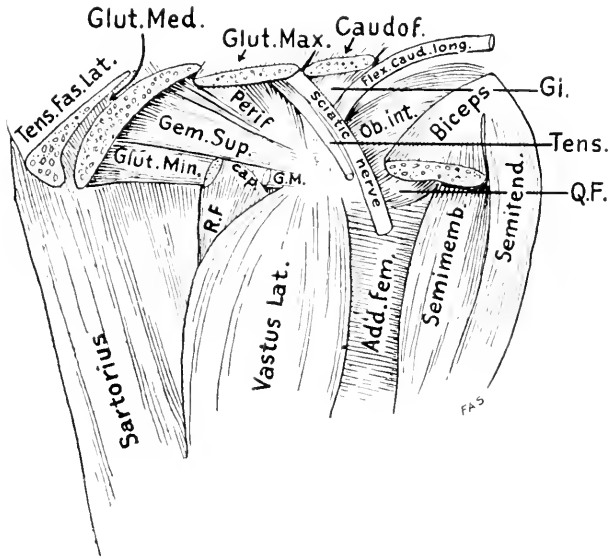


FIG. 51.—LATERAL ASPECT OF UPPER PART OF HIND LIMB AFTER TENSOR FASCIA, GLUTEUS MEDIUS, GLUTEUS MAXIMUS, CAUDOFEMORALIS, BICEPS, TENIUSSIMUS, AND THE GREAT SCIATIC NERVE HAVE BEEN SEVERED AND REMOVED.

Ob. int., obturator internus; *Q.F.*, quadratus femoris; *Gi*, gemellus internus; *Add. fem.*, adductor femoris; *Tens.*, tenuissimus; *Perif.*, pyriformis; *Glut. Min.*, gluteus minimus with piece removed to show capsularis beneath. *G.M.*, insertion end of gluteus minimus; *Gem. Sup.*, gemellus superior; *Cap.*, capsularis; *R.F.*, rectus femoris.

(58) **Tenuissimus** (abductor cruris); transverse process of second caudal vertebra, becomes continuous with biceps femoris.

(59) **Caudofemoralis** (*parameralis*) (Fig. 50); transverse processes of second and third caudal vertebrae to lateral border of patella; abductor of thigh and flexor of shank.

(60) **Gluteus maximus** (Fig. 50), fascia and transverse processes of last sacral and first caudal vertebrae to fascia lata and greater trochanter of femur; abductor of thigh.

(61) **Sartorius** (Fig. 51); crest and ventral border of ilium to ligament of petalla and adjacent crest of the tibia; abductor and rotator of thigh and extensor of shank.

(62) **Gluteus medius**; ilium and fascia at root of tail to greater trochanter of femur; abductor of thigh (Fig. 50).

(63) **Pyriformis**; last two sacral and first caudal vertebræ to greater tuberosity of femur; abductor of thigh (Fig. 51).

(64) **Gemellus superior**; dorsal border of ilium and ischium to greater trochanter of femur; rotator and abductor of thigh.

(65) **Gluteus minimus**; ventral half of ilium to greater trochanter of femur; rotator of thigh (Fig. 51).

(66) **Obturator internus**; ischium to trochanteric fossa of femur; abductor of thigh (Fig. 51).

(67) **Gemellus inferior**; lateral surface of ischium to inner surface of the tendon of obturator internus and to capsule of joint; abductor of thigh (Fig. 51).

(68) **Gracilis** (Fig. 57); ventral aspect of ischiopubal symphysis to shaft of tibia; adductor of thigh.

(69) **Semitendinosus** (Fig. 50); ischial tuberosity to the crest of the tibia; flexor of shank; subcylindrical muscle of the inner hamstring group.

(70) **Semimembranosus** (Figs. 49, 50); ischium to medial epicondyle of femur and proximal end of tibia; extensor of thigh; largest of inner hamstring group.

(71) **Adductor femoris** (*magnus et brevis*) (Figs. 49, 50); ischiopubal symphysis to shaft of femur; extensor of thigh.

(72) **Quadratus femoris**; ischial tuberosity to great trochanter and adjacent surface of lesser trochanter of femur; extensor and rotator of thigh (Fig. 51).

(73) **Obturator externus**; obturator foramen and adjacent parts of pubis and ischium to trochanteric fossa of femur; rotator and flexor of thigh (Fig. 50).

(74) **Adductor longus** (Fig. 49); cranial border of pubis to middle of femur.

(75) **Pectineus** (Fig. 49); cranial border of pubis to shaft of femur; adductor of thigh.

(76) **Iliopsoas** (Fig. 49); corresponds to human psoas and iliacus; psoas portion arises by ten vertebral heads, the iliacus portion from the ventral border of ilium; both parts converge to insert in apex of lesser trochanter of femur; rotator and flexor of thigh.

(77) **Capsularis** (*gluteus quartus, epimeralis*); ilium to dorsal surface of femur; rotator of thigh (Fig. 51).

(78) **Quadriceps femoris**; consists of four muscles and may be compared with triceps brachii of forelimb.

(a) *Rectus femoris* (Figs. 57, 58); ilium near acetabulum to outer, proximal surface of patella.

(b) *Vastus lateralis* (Figs. 50, 51); great trochanter and surface of femur to outer, lateral surface of patella.

(c) *Vastus medialis* (Fig. 49) (*crural*); shaft of femur to outer, medial surface of patella.

(d) *Vastus intermedius*; dorsal surface of femur to capsule of joint. Entire group acts as extensor of shank; the intermedius alone acts as tensor of capsule.

MUSCLES OF SHANK OR LOWER LEG

(79) **Gastrocnemius** (Figs. 49, 50) arises by two heads; *caput laterale* has four origins: (a) superficial fascia; (b) lateral sesamoid bone of femur; (c) tendon of plantaris; (d) aponeurosis covering plantaris; *caput mediale* from medial sesamoid bone of femur and surface of femur; both heads unite in a tendon which forms part of the *tendon of Achilles* and inserts onto the proximal end of the calcaneus; extensor of foot.

(80) **Plantaris** (Figs. 50, 58), lateral border of patella and lateral sesamoid bone to the plantar aponeurosis which gives origin to the flexor brevis digitorum; flexor of digits. Its tendon passes down through a sheath formed by the gastrocnemius and soleus and over the insertion of the tendon of Achilles (*tendo calcaneus*).

(81) **Flexor brevis digitorum** (Fig. 52) (*pedis perforatus*); continuation of tendon of plantaris to base of second phalanges; each tendon is split at the proximal phalanx to transmit a tendon of the flexor longus digitorum; flexor of second phalanges of digits.

(82) **Soleus** (Figs. 50, 59); lateral surface of head and ventral surface of fibula to tuberosity of os calcis; helps to form the tendon of Achilles (tendo calcaneus) and the sheath for the tendon of the plantaris; extensor of foot.

(83) **Popliteus** (Fig. 49); lateral epicondyle of femur to proximal end of ventral surface of tibia; rotator of thigh.

It will be necessary to remove the deep crural fascia from the ventral surface of the shank in order to study the following three muscles.

(84) **Flexor longus hallucis** (Fig. 59); from crural fascia, ventral surface of tibia, medial surface and head of fibula to bases of the terminal phalanges; the four tendons perforate the four tendons of the flexor brevis; flexor of phalanges.

(85) **Flexor longus digitorum** (Fig. 59); mediocaudal surface of middle third of tibia and head of fibula to join with tendon of flexor hallucis longus.

(86) **Tibialis posterior**; from caudal aspect of proximal third of tibia and head of fibula to plantar surface of internal cuneiform; extensor of foot.

MUSCLES OF DORSAL AND LATERAL SURFACES OF SHANK

(87) **Peroneus longus** (Fig. 52); head and shaft of fibula to bases of fifth and first metatarsals and slender branches to other metatarsals; flexor of foot.

(88) **Peroneus brevis** (Fig. 53); lateral surface of distal half of fibula to base of fifth metatarsal; extensor of foot.

(89) **Peroneus tertius** (Fig. 53); lateral surface of proximal half of fibula to lateral border of extensor tendon of fifth digit; extensor and abductor of fifth digit, and flexor of foot.

(90) **Extensor digitorum longus** (Fig. 50); lateral epicondyle of femur with four tendons to dorsal aspect of digits; extensor of phalanges.

(91) **Tibialis anterior** (Fig. 50); lateral surface of tibia, and shaft and head of fibula to outer surface of first metatarsal; flexor of foot.

MUSCLES OF FOOT

(92) **Extensor brevis digitorum** (Fig. 52); calcaneal ligament and three metatarsals to proximal phalanges with tendon of extensor longus.

(93) **Quadratus plantæ** (plantar head of *flexor longus digitorum*); lateral surface of calcaneus and cuboid to outer surface of flexor longus digitorum; holds flexor digitorum tendon in place (Fig. 53).

(94) **Lubricales**; six muscles from flexor longus digitorum to medial side of first phalanges of outer three digits; moves these digits mediad (Fig. 53).

(95) **Interossei**; the interosseus muscle of the second digit has five parts, three of which act as abductors of the second digit and are known as *abductor longus*, *brevis*, and *intermedius digiti secundi*, respectively; the fourth is an adductor, *adductor longus digiti secundi*; and the fifth is the *adductor medius digiti secundi*; the interossei of the third and fourth digits are alike and divide into two parts forming *middle* and *long abductors* and *abductors digiti tertii and quarti*.

There are five short muscles connected with the fifth digit: (Fig. 53).

(96) **Abductor medius digiti quinti**; calcaneus and metatarsal to first phalanx.

(97) **Adductor medius digiti quinti**; cuboid to first phalanx.

(98) **Opponens digiti quinti**; ligament of peroneal canal to fifth metatarsal.

(99) **Abductor digiti quinti brevis**; ligament of peroneal canal to lateral sesamoid.

(100) **Adductor digiti quinti longus**; lig. of peroneal canal to tendon of extensor.

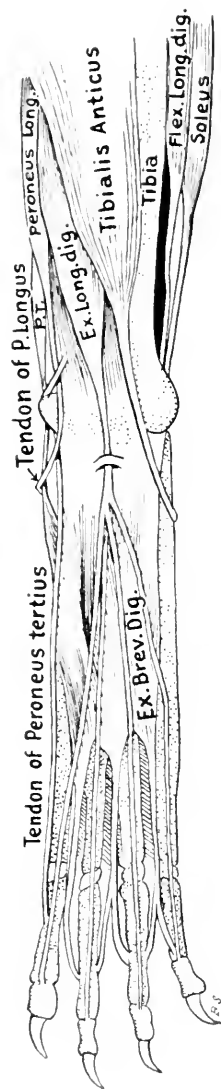


FIG. 52.—MUSCLES OF DORSAL SIDE OF RIGHT HIND FOOT. (From dissections made by Mr. Byerly.)
P.T., peroneus tertius.

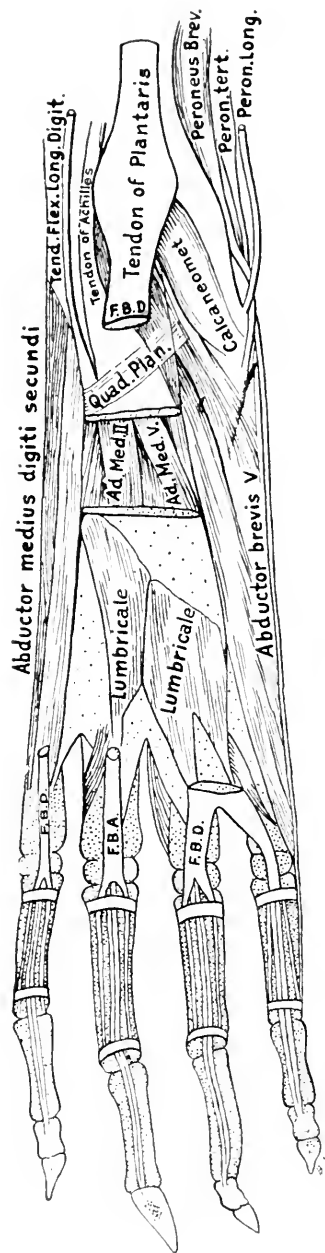


FIG. 53.—MUSCLES OF SOLE OF RIGHT HIND FOOT. (From dissections made by Mr. Byerly.)
F.B.D., flexor brevis digitorum; Ad. Med. V., adductor medius digiti; quinti Ad. Med. II., adductor medius digiti secundi; Quad. Plan., quadratus plantaris.

MUSCLES OF TARSUS

(101) **Calcaneometatarsalis** (part of *adductor digiti quinti*); calcaneus to metatarsal, cuboid.

(102) **Scaphocuneiformis**; scaphoid to cuneiform.

The student may now pass by the following muscles to those of the body wall, omitting (102-175).

SUPERFICIAL MUSCLES OF HEAD AND FACE

(The following muscles will not usually be dissected.)

(104) *Intermedius scutulorum*, between scutiform cartilages; draws ears dorsomedial.

(105) *Corrugator supercilii medialis*, midline of head to upper eyelid; raises eyelid.

(106) *Orbicularis oculi*, frontal processes of maxillary, upper and lower parts joined by tendon-fibers at outer angle of eye; closes eye.

(107) *Corrugator supercilii lateralis*, ear to caudolateral border of eye; pulls angle of eye caudad and ear forward.

(108) *Frontoauricularis* (Fig. 54) (if present), upper eyelid to auricular cartilage.

(109) *Levator auris longus*, (Fig. 54), atlas and sagittal crest to scutiform cartilage and to auricle. Pulls ear dorsocaudad. (part of *auricularis posterior* of man).

(110) *Auricularis superior* (Fig. 54) (*Attollens auris*), sagittal crest to auricular cartilage. Pulls ear dorsad.

(111) *Abductor auris longus* (part of *auricularis posterior* of man) sagittal crest to eminentia conchae. Pulls ear caudad.

(112) *Abductor auris brevis*, lambdoidal crest to concha. Pulls concha caudad.

(113) *Epicranii* (*occipitofrontalis*) Occipital portion from sagittal crest, joins levator auris longus to form a tendinous sheath, the galea aponeurotica, which covers skull between ears and eyes and gives origin to the frontalis portion to be inserted into the integument near the tip of the nose. It moves the skin of nose and head.

(114) *Zygomaticus* (major), angle of mouth to scutiform cartilage of ear; pulls angle of mouth dorsocaudad and ear ventrocraniad.

(115) *Submentalis*, ventral midline to be inserted with zygomaticus; draws ear ventrad.

(116) *Depressor conchæ*, ventral surface of neck to summit of antitragus; draws ear ventrad.

(117) *Frontoscutularis*, frontal bone to scutiform cartilage; draws ear craniad.

(118) *Adductor auris inferior* (part of auricularis anterior of man), between zygomatic process of frontal bone and frontal process of malar; draws ear craniodorsad.

(119) *Tragicus lateralis*, mandible to tragus; pulls ear ventrad.

(120) *Rotator auris* (scutuloauricularis inferior) scutiform cartilage to eminentia conchæ; rotates ear mediad and caudad.

(121) *Adductor auris superior* (part of auricularis anterior of man), scutiform cartilage to spina helicis draws auricle craniad.

(122) *Adductor auris medius* (part of auricularis anterior of man), scutiform cartilage to tragus; draws concha dorso-craniad.

(123) *Transversus auriculæ*, concha to auricular cartilage; enlarges opening of ear.

(124) *Auricularis externus*, eminentia concha to auricular cartilage; flexes auricular cartilage.

(125) *Helicis*, median surface of concha to auricular cartilage; pulls cranial margin of concha proximad.

(126) *Mandibuloauricularis* (maxilloauriculare) mandible to auricular cartilage. (Described in Anatomischer Anzeiger No. 56 page 57.)

(127) *Antitragus*, antitragus to tragus; constrictor of auditory opening.

(128) *Tragicus medialis*, tragus to concha; Flexes concha.

(129) *Conchæus externus*, bridges a shallow gap in concha; constricts concha.

(130) *Tensor tympani*, small fossa in petrous bone to malleus.

(131) *Stapedius*, lateral surface of petrous bone to head of stapes.

(132) *Orbicularis oris*, concentric subcutaneous fibres around the mouth.

(133) *Zygomaticus minor* (malaris) if present—ventral side of eye to angle of mouth.

(134) *Quadratus labii superioris*, may be distinguished in two parts:

(134 a) *Levator labii superioris alaeque nasi*, on side of nose, and

(134 b) *Levator labii superioris proprius* (or caput angulare) or larger portion. Erects whiskers and raises upper lip.

(135) *Caninus* (levator anguli oris); retracts whiskers and raises upper lip.

(136) *Buccinator*, beneath caninus; raises upper lip.

(137) *Myrtiformis* (nasalis of man in part); dilator of nares and elevator of upper lip.

(138) *Moustachier* (incisivi of man) in upper lip; carries lip cranial.

(139) *Quadratus labii inferiores*, in lower lip, not constant, depresses lip.

(140) *Transversus menti*, usually not present, from cranial portion of alveolar border of mandible to join in midline with corresponding fibres from opposite side.

DEEP MUSCLES OF HEAD AND NECK

(145) *Sternomastoid* (sternal portion of sternocleidomastoid of man), cranial end of manubrium to lambdoidal ridge; turns head and depresses snout.

(146) *Sternohyoid*, first costal cartilage to body of hyoid; draws hyoid backward.

(147) *Sternothyreoid*, first costal cartilage to thyreoid cartilage; draws larynx backward.

(148) *Stylohyoid*, stylohyal bone to body of hyoid; elevates hyoid.

(149) *Digastric*, jugular process of occipital to external coronoid fossa; depressor of lower jaw.

(150) *Mylohyoid*, mandible to median raphe from symphysis to hyoid; elevates floor of mouth.

(151) *Geniohyoid* mandible near symphysis to body of hyoid; draws hyoid forward.

(152) *Jugulohyoid*, jugular process to stylohyoid; draws hyoid backward.

(153) *Ceratohyoid* cranial horn of hyoid to caudal horn; brings horns of hyoid together to bring body of hyoid forward.

(154) *Masseter*, divided into three layers;

(a) Superficial layer, malar bone to lateral margin of ventral border of mandible.

(b) Middle layer, ventral border of malar bone to ventral border of external coronoid fossa.

(c) Deep layer, ventral border of zygoma to external coronoid fossa. Elevator of jaw.

(155) *Temporalis* divided into two layers.

(a) Superficial layer, zygomatic process and temporal fascia to outer surface of coronoid process.

(b) *Deep layer*, temporal fossa to inner surface of coronoid process. Elevator of lower jaw.

(156) *Pterygoideus externus* (sphenomeniscus of Prentiss), external pterygoid fossa to medial surface of mandible. Elevator of lower jaw.

(157) *Pterygoideus internus*, internal pterygoid fossa to mandible; elevator of jaw.

MUSCLES OF TONGUE

(158) *Styloglossus*, mastoid process and adjacent parts to tip of tongue; retracts and raises tongue.

(159) *Genioglossus*, symphysis of lower jaw to dorsal part of tongue; draws root of tongue forward and tip backward.

(160) *Hyloglossus*, body of hyoid bone to integument of tongue; retracts and depresses tongue.

MUSCLES OF PHARYNX

(161) *Tensor veli palatini*, sphenoid to aponeurosis of roof of mouth.

(162) *Levator veli palatini*, sphenoid to velum palatum.

(163) *Glossopharyngeus*, fibres from genioglossus and styloglossus to the medial dorsal raphe of pharynx; constrictor of pharynx.

(164) *Constrictor pharyngis inferior*, lateral surfaces of thyroid and cricoid cartilages to median dorsal raphe of pharynx.

(165) *Constrictor pharyngis medius*, horns of hyoid to median dorsal raphe of pharynx.

(166) *Stylopharyngeus*, mastoid process of temporal to middle and superior constrictors. Constrictor.

(167) *Constrictor pharyngis superior* (pterygopharyngeus). Hamular process to dorsal raphe of pharynx.

MUSCLES OF LARYNX

(168) *Thyreohyoideus*, caudal border of thyroid cartilage to caudal horn of hyoid. Elevator of larynx.

(169) *Cricothyreoideus*, cricoid cartilage to thyroid cartilage.

(170) *Cricoarytenoideus*, cricoid cartilage to arytenoid cartilage.

(171) *Arytenoideus transversus*, between caudal ends of arytenoid cartilages.

(172) *Glossoepiglotticus*, median septum of tongue to dorsal surface of epiglottic cartilage. Draws epiglottis forward.

(173) *Hyoepliglotticus*, cranial surface of hyoid to epiglottic cartilage.

(174) *Thyreothyroarytenoideus*, thyroid cartilage to arytenoid cartilage; closes glottis.

(175) *Cricoarytenoideus lateralis*, cranial border of cricoid to laterocaudal angle of arytenoid cartilage. Closes glottis.

MUSCLES OF THE BODY WALL

(176) **Scalenus**, divisible into several parts which may be described as separate muscles.

(a) *Scalenus medius*, sixth to ninth ribs to join rest of muscle near first rib.

(b) *Scalenus posterior*, third or fourth rib, joins rest of muscle as (a).

(c) *Scalenus anterior*, second and third ribs, joins either portions of muscle near first rib and the entire muscle is inserted into the transverse processes of all cervical vertebræ. Flexes neck and draws ribs forward.

(177) **Transversus costarum** (*sternocostalis externus*), sternum to first rib; draws sternum forward.

(178) **Seratus posterior superior**, first nine ribs to dorsal medial raphe from the atlas to the tenth thoracic vertebra; draws ribs forward.

(179) **Serratus posterior inferior**, last four or five ribs to lumbar spinous processes; draws ribs forward.

(180) **External oblique**, last nine or ten ribs and lumbodorsal aponeurosis to the median ventral raphe and linea alba from the seventh costal cartilage to the pubic tubercle; constrictor of abdomen.

(181) **Internal oblique**, lumbar aponeurosis from fourth to seventh lumbar vertebræ, aponeurosis from ventral half of iliac crest, and the three crural arches to the ventral midline; compressor of abdomen.

(182) **Transverse abdominal**, false and floating ribs, transverse processes of lumbar vertebræ, ilium, and crural arches to linea alba; constrictor.

(183) **Rectus abdominis**, tubercle of pubis to first and second costal cartilages and sternum; retracts ribs and sternum and compresses abdomen.

(184) **External intercostals**, between ribs in intercostal spaces; protractors.

(185) **Internal intercostals**, between ribs; retractors of the ribs.

(186) **Transverse thoracic** (*triangularis sterni*; *sternocostalis internus*), sternum to cartilages of ribs and fascia covering internal intercostals;

DEEP MUSCLES IN NECK VENTRAL TO VERTEBRAL COLUMN

(187) **Longus capitis** (*rectus capitis anterior major*) second to sixth cervical vertebræ to basioccipital and basisphenoid; depresses snout.

(188) **Longus coli**, a number of separate bundles of which the thoracic group arise from the first six thoracic vertebræ and are inserted into the costal process of the sixth cervical vertebra; and the cervical group arises from the cervical vertebræ and are inserted further forward in the midline of the centra; bends the neck.

(189) **Rectus capitis anterior minor**, atlas to basioccipital; depresses snout.

(190) **Obliquus capitis superior**, atlas to mastoid process; turns head laterally.

(191) **Rectus capitis lateralis**, atlas to external surface of jugular process; flexes head laterally.

MUSCLES OF THE VERTEBRAL COLUMN (BODY REGION)

(192) **Longissimus dorsi**, median division connects spinous process of vertebræ with accessory and mamillary processes of other vertebræ in lumbar and thoracic regions; the lateral division arises from the ilium and lumbodorsal fascia and are inserted into the transverse processes of the lumbar, thoracic and cervical vertebræ. In the thoracic region the spinalis dorsi separates off. The cervical portion is sometimes distinguished as the *longissimus cervicis*; and the cranial portion as the *longissimus capitis*. Extensor of vertebral column.

(193) **Extensor caudæ lateralis**, sacral and caudal vertebræ to dorsal surface of caudal vertebræ; raises tail.

(194) **Iliocostalis**, from the longissimus dorsi and ribs to ventrolateral surface of ribs; draws ribs together.

(195) **Splenius**, cervical ligament and fascia of deep muscles to lambdoidal ridge; lateral flexor of head; both acting together elevates head.

(196) **Longissimus capitis** (*trachelomastoideus*), last four cervical vertebræ to mastoid process; lateral flexor of head.

(197) **Spinalis dorsi**, tenth to thirteenth thoracic vertebræ to first nine or ten thoracic vertebræ and cervical forward to second; extensor of vertebral column.

(198) **Biventer cervicis** (medial portion of *semispinalis cervicis* et capitis), aponeurotic arches of last cervical and first three thoracic vertebræ to lambdoidal crest; raises snout.

(199) **Complexus** (lateral portion of *semispinalis cervicis* et capitis), closely associated with biventer cervicis; raises head.

(200) **Longus atlantis**, a portion of longissimus dorsi from third cervical vertebræ to wing of atlas; extends neck and draws head laterad.

(201) **Multifidus spinæ**, from transverse processes to spinous processes craniad; extends back when both sides act; turns vertebral column laterad when one side acts alone.

(202) **Extensor caudæ medialis**, caudal extension of multifidus spinæ; raises tail.

(203) **Semispinalis cervicis**, cervical portion of multifidus; extends neck.

(204) **Interspinales**, between spinous processes.

(205) **Intertransversarii**, between transverse processes of vertebræ.

(207) **Rectus capitis posterior major**, crest of axis (epistropheus) to lambdoidal crest; raises snout.

(208) **Obliquus superior**, lateral border of transverse process of axis to mastoid process; flexes head laterally.

(209) **Obliquus capitis inferior**, lateral surface of spine of axis to transverse process of atlas; rotates head.

(210) **Rectus capitis posterior medius**, cranial end of axial spine to occipital bone; raises snout.

(211) **Rectus capitis posterior minor**, dorsal arch of atlas to occipital bone; raises snout.

(212) **Levator costarum**, transverse processes of thoracic vertebræ to angle of rib caudad of origin; continuous with external intercostals; pulls ribs dorsocraniad.

MUSCLES VENTRAL TO VERTEBRAL COLUMN

(213) **Diaphragm**, muscle fibres run radially from wall to central (semilunar) tendon; the vertebral portion of the muscular part arises from the second to fourth lumbar vertebræ, while the sternocostal part arises from the xiphoid process and the last five ribs.

(214) **Psoas minor**, last one or two thoracic and first three of four lumbar vertebræ to the iliopectineal line craniad of acetabulum; flexes back.

(215) **Quadratus lumborum**, last two thoracic vertebræ and last rib to anterior inferior spine of ilium, rests on ventral surface of transverse processes of lumbar vertebræ; bends vertebral column sideways.

(216) **Iliocaudalis**, ventral half of medial surface of ilium of caudal vertebra. Flexor of tail.

(217) **Levator ani** (*pubiicaudalis*) symphysis of pelvis to third, fourth and fifth caudal vertebræ. Frequently continuous with iliocaudalis. Flexor of tail and compresses rectum.

(218) **Abductor caudæ internus** (*Coccygeus*) spine of ischium to second, third and fourth caudal vertebræ. Flexor of tail.

(219) **Flexor caudæ longus**, last lumbar vertebra, sacrum and caudal vertebræ to ventral surface of tail; flexor of tail.

(220) **Flexor caudæ brevis**, first seven or eight caudal vertebræ to ventral surface of caudal vertebræ as far back as the tenth; flexor of tail.

(221) **Abductor caudæ externus** (*coccigis*) dorsal border of ilium and dorsal surface of sacrum to caudal vertebræ back to eight or ninth. Bends tail sideways.

FIG. 54.—LATERAL ASPECT OF THE MUSCLES OF THE CAT.

a, Levator auris longus; *ad*, adductor magnus; *a₁*, flexor profundus digitorum; *b* and *c*, attolens auris; *bf*, biceps femoris; *ch*, cephalo-humeral; *cl*, cut surface of biceps femoris; *dl₁*, spinodeltoid; *dl₂*, acromiodeltoid; *dg*, digastric; *di*, flexor longus digitorum; *ec*, extensor communis digitorum; *ed*, extensor indicis; *em*, extensor digitorum lateralis; *ei*, external intercostal; *ed*, extensor longus digitorum; *er*, extensor carpi radialis longior; *ex. ob*, external oblique with a rectangular piece cut out; *erb*, extensor carpi radialis brevior; *eo*, extensor brevis pollicis; *eu*, extensor carpi ulnaris; *f*, stylohyoid; *fer*, flexor carpi radialis; *feu*, flexor carpi ulnaris; *fu*, second head of flexor carpi ulnaris; *fi*, fibula; *fa*, flexor longus hallucis; *gas*, external head of gastrocnemius; *gi*, internal head of gastrocnemius; *gm₁*, and *gm₂*, gluteus maximus; *inob*, internal oblique with a portion cut out to show *tr*; *h*, cleidomastoid; *l*, levator scapulae ventralis; *lat*, latissimus dorsi with a piece cut out; *ms*, masseter; *mtr*, acromiotrapezius; *n*, vastus lateralis revealed by cutting a rectangular piece out of the fascia lata; *o*, fronto-auricular; *ol*, olecranon process of ulna; *p*, peroneus longus; *pl*, plantaris; *plr*, spinotrapezius; *pm*, palmaris longus; *pc*, pectoralis; *pt*, pronator teres; *r*, rib; *ra*, radius; *rm*, rhomboides; *s*, sartorius; *s_{pa}*, serratus posterior superior; *ser*, serratus magnus; *sd*, sternomastoid; *sp*, serratus posterior inferior; *sb*, semimembranosus; *so*, soleus; *st*, supinator longus; *t*, peroneus tertius; *tr*, transversalis exposed by cutting away the external oblique and internal oblique; *tb*, tibia; *tib*, tibialis anterior; *tri*, ecto-triceps; *t₂*, medi-triceps; *tm*, temporalis *trif*, tensor fascia latae; *u*, vertebral border of the scapula.

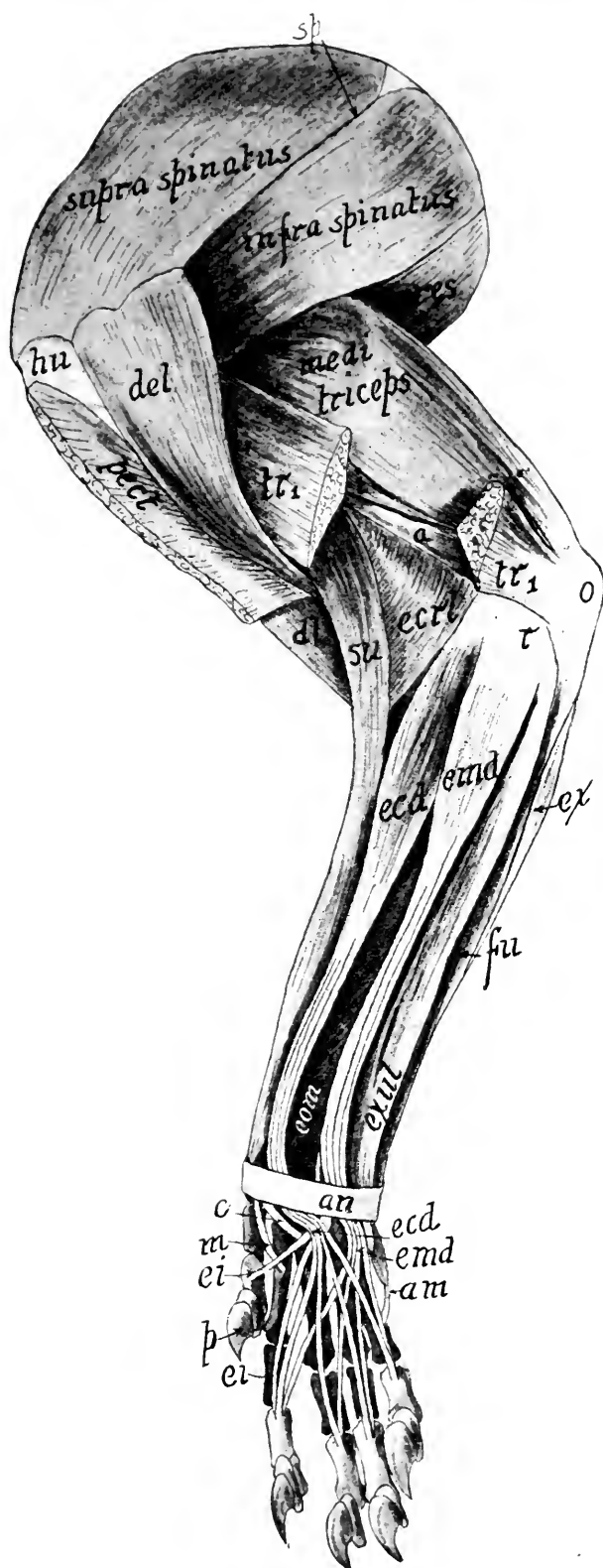


FIG. 55.

FIG. 55.

FIG. 55.—LATERAL OR OUTER ASPECT OF MUSCLES OF THE PECTORAL LIMB.

a, Cranial part of the ento-triceps; *an*, annular ligament; *am*, abductor digiti quinti; *c*, extensor carpi radialis brevis; *del*, acromiodeltoid; *dl*, biceps; *ecd*, extensor communis digitorum; *ecrl*, extensor carpi radialis longus, whose tendon is marked *m*; *emd*, extensor digitorum lateralis; *ei*, extensor indicis; *exul*, extensor carpi ulnaris; *eom*, extensor brevis pollicis; *ex*, ulnar head of the flexor carpi ulnaris; *fu*, flexor profundus digitorum; *hu*, humerus; *i*, caudal part of the ento-triceps; *o*, olecranon process of the ulna; *p*, claw of first digit; *pect*, portion of the pectoralis; *r*, region of the head of the radius; *sp*, spine of the scapula; *su*, supinator longus; *tr*₁, ecto-triceps (caput laterale of triceps brachii) with its middle portion cut out.

FIG. 56.—MEDIAL OR INNER ASPECT OF THE MUSCLES OF THE FORELIMB.

a, Supracondyloid ridge of humerus; *ab*, abductor pollicis; *b*, humerus; *c*, humeral head of the flexor carpi ulnaris; *cp*, ento-triceps; *d*, insertion of a tendon of flexor sublimis digitorum; *e*, ulnar head of flexor carpi ulnaris; *ec*₁, extensor carpi radialis longus; *ec*₂, extensor carpi radialis brevis; *f*, portion of the flexor sublimis digitorum arising from the flexor profundus digitorum; *fs*, the portion of the flexor sublimis arising from the palmaris longus; *pp*, common tendon of the flexor profundus digitorum; *flx*, flexor profundus digitorum; *g*, radial part of flexor sublimis; tendon to second digit; *h*, flexor profundus digitorum; *i*, styloid process of radius; *k*, pronator quadratus; *l*, flexor carpi radialis; *o*, short part of the ento-triceps; *ol*, olecranon process; *ol*, tendinous loops; *pect*, pectoralis cut off; *pl*, origin of the palmaris longus which is reflected caudad; *pt*, pronator teres; *r*, ento-triceps; *ro*, coracobrachialis; *s*, split in the tendon of the flexor sublimis revealed by cutting away the tendinous loop; *ss*, supraspinatus; *sl*, supinator longus; *tm*, teres major; *th*, the head of the humerus; *x*, a tendon of the flexor profundus digitorum whose portion between the two letters is cut out to display the insertion of *d*. ("Ecto-triceps" in figure should be "medi-triceps.")

FIG. 57.—VENTRAL ASPECT OF MUSCLES OF CAUDAL PORTION OF TRUNK AND THIGH.

a, Transversalis abdominis becoming aponeurotic; *adct*, adductor femoris magnus; *c*, pectineus; *ex. ob*, external oblique, whose aponeurosis on the left side is removed; *f*, aponeurosis of external oblique; *grc*, gracilis with its middle part cut out on the left side; *m*, median ventral line; *ps*, iliopsoas; *p*, penis; *rcf*, rectus femoris; *rct*, rectus abdominis; *sar*, sartorius with its middle part cut out on the left side; *smb*, semimembranosus; *smt*, semitendinosus; *spmc*, spermatic cord; *t*, aponeurosis; *trs*, internal oblique with a rectangular piece cut out to show the rectus and transversalis; *tv*, tensor fasciae latae; *ts*, testicle; *vi*, vastus medialis; *x*, external abdominal ring.

FIG. 58.—LATERAL ASPECT OF THE MUSCLES OF THE LEG WITH THE GLUTEI, TENSOR VAGINÆ FEMORIS, SEMITENDINOSUS, AND BICEPS FEMORIS REMOVED.

a, Portion of semimembranosus; *ab*, adductor femoris magnus; *b*, peroneus tertius; *cl*, cut surface of the vastus lateralis; *d*, peroneus brevis; *eld*, extensor longus digitorum; *gas*, gastrocnemius; *l*, tendinous loop; *lp*, annular ligament; *lt*, external lateral ligament of the knee-joint; *lg*, tendon of the extensor longus digitorum; *o*, tendinous arch of the peroneus longus; *oc*, os calcis; *pl*, peroneus longus; *rct*, rectus femoris; *t*, ligamentum patellæ; *tr*, greater trochanter; *ts*, soleus; *tg*, tendon of gastrocnemius; *tpl*, tendon of the plantaris; *tb*, tibialis anterior; *vex*, vastus lateralis with a piece cut out.

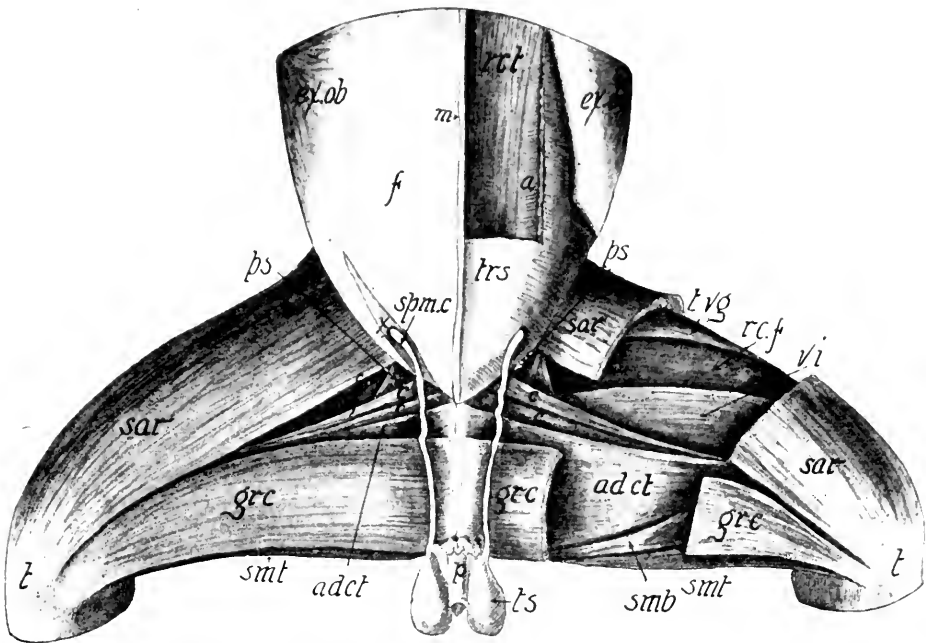


FIG. 57.

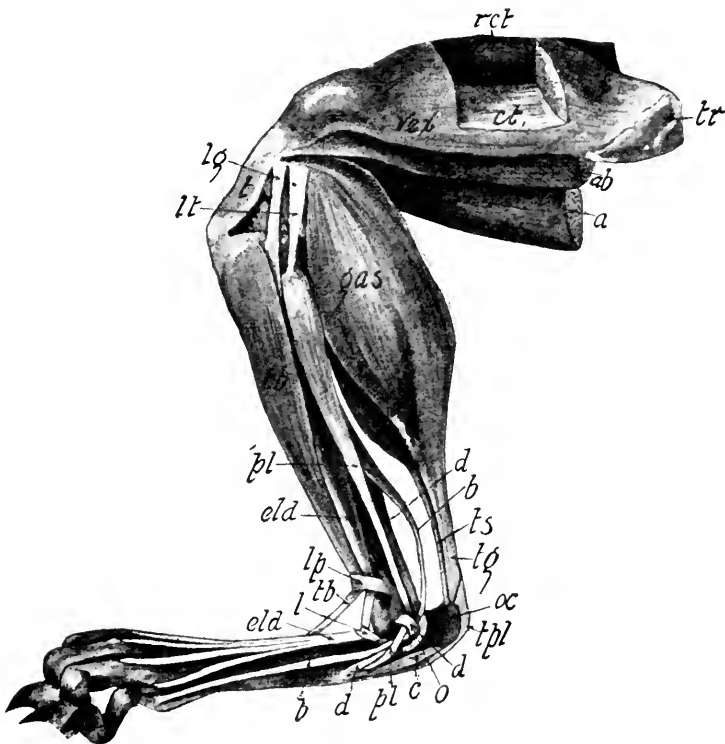


FIG. 58.

(222) **Extensor caudæ lateralis**, sacral and caudal vertebræ to dorsal surface of tail. Raises tail.

(223) **Extensor caudæ medialis**, sacral and first caudal vertebræ to dorsal surface of tail; raises tail.

(224) **Sphincter ani externus** with (225) **Sphincter ani internus** form the constrictors of the anal pouch.

(226) **Ischiocavernosus**, ramus of ischium to outer surface of crus penis. In female the insertion is at base of clitoris.

(227) **Transversus perinei**, medial surface of ischium to join sphincter internus.

(228) **Caudorcetalis**, ventral surface of sixth and seventh caudal vertebræ to spread over sides of rectum.

(229) **Caudoanalis**, ventral surface of second and third caudal vertebræ to unite with sphincter ani internus; draws anus craniodorsad.

MUSCLES OF UROGENITAL SYSTEM PECULIAR TO MALE

(230) **Levator scroti**, sphincter ani internus to scrotum.

(231) **Rectocavernosus** (*retractor penis*) sphincter ani internus to corpus cavernosum.

(232) **Caudocavernosus**, first two caudal vertebræ to corpus cavernosum.

(233) **Bulbocavernosus** (*accelerator urinæ*)

(234) **Compressor urethrae membranaceæ.**

MUSCLES PECULIAR TO FEMALE

(235) **Levator vulvæ** (*constrictor cunni*) homologous with levator scroti of male.

(236) **Constrictor vestibuli** (*rectovaginalis*) sphincter internus to urogenital sinus.

(237) **Caudovaginalis**, first two caudal vertebræ to base of clitoris.

(238) **Urethralis** symphysis of ischium to sides of vagina and urogenital sinus.

The muscles in the different orders of mammals have the same general arrangement. Over four hundred muscles occurring in the cat are found in man and have approximately the same relative location and function, and the same nerve-supply. The size and the shape of the muscles may vary somewhat in accordance with the habits of the animal. The pectoralis in the cat consists of five parts, while in man there are only two parts. The biceps is a simple muscle in the cat, but in man it has two well defined heads. The muscles for moving the ear, which are well developed in the horse, cow, and cat, are exceedingly rudimentary in man. The Cetacea and Sirenia possess fewer muscles than the other orders of mammals, as they have no hind-limbs. These few remarks serve to show that a familiarity with the muscles of any one mammal guarantees a general knowledge of the muscular system of all mammals.

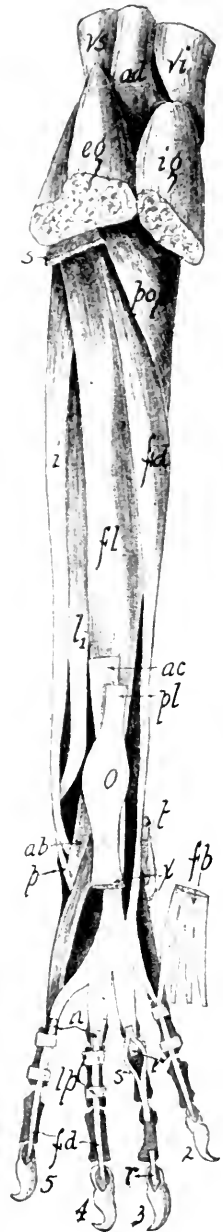


FIG. 59.—CAUDAL ASPECT OF THE MUSCLES OF THE CRUS AND FOOT WITH THE GASTROCNEMIUS, SOLEUS, AND PLANTARIS REMOVED.

ad, Adductor; *ac*, tendon of Achilles; *eg*, external head of gastrocnemius; *fb*, flexor brevis digitorum cut at *x* and turned aside; *fd*, flexor longus digitorum; *fl*, flexor longus hallucis; *i*, peroneus longus; *l*, peroneus brevis; *lp*, tendinous loop through which pass the tendons of the flexor brevis digitorum and the flexor longus digitorum; *n*, cut tendons of *fb*; *o*, plantaris over the tuberosity of the os calcis; *p*, tendon of the peroneus brevis; *pl*, tendon of the plantaris, whose proximal portion is cut away; *r*, tendon of the flexor longus digitorum cut off as it passes through the slit in the flexor brevis digitorum; *s*, tendon of the flexor brevis digitorum split for the transmission of the tendon of the flexor longus digitorum; *so*, soleus; *t*, tendon of the flexor longus hallucis; *x*, plantaris giving origin to the flexor brevis digitorum.

LABORATORY STUDIES AND SUGGESTIONS

1. Describe the two kinds of muscles.
2. Draw a diagrammatic cross-section of the palmaris longus muscle representing the relation of the fibers, fasciculi, sarcolemma, endomysium, and epimysium.
3. Describe an example of each class of muscles as to function.
4. Which muscles of the head and neck region derive their names from their function?
5. Describe the chief muscles moving the mandible.
6. Describe the muscles lying ventral to the trachea.
7. Name three important muscles attaching the thoracic limb to the trunk.
8. Draw the caudal aspect of the triceps muscle.
9. What muscles flex the forearm on the arm?
10. Name the chief extensors and flexors of the digits.
11. On what process of the humerus do several of the flexors of the manus arise?
12. On what process of the humerus do most of the extensors of the manus arise?
13. Draw the outline of the ventral aspect of the flexor profundus digitorum as it would appear detached from limb and with origins slightly separated.
14. Draw cranial aspect of the radius and mark the areas to which the muscles are attached and the names of the same.
15. What muscles flex the manus on the forearm?
16. Describe the muscles extending the manus on the forearm.
17. What muscles in the forearm region derive their names from their function and location?
18. Describe the large adductor of the thoracic limb.
19. Describe the muscles serving to move the humerus in four directions.
20. Describe the location and the use of the tendinous loops in the manus.
21. What muscles form the ventral and lateral walls of the abdomen?
22. Describe from your dissection four muscles causing the movement of the ribs.
23. After removing the biceps femoris and sartorius, and dissecting the muscles on the lateral aspect of the thigh, draw the muscles visible on the lateral aspect, and label.
24. Name the muscles flexing the crus on the thigh.
25. Describe from your dissection the muscles extending the crus on the thigh.
26. Describe the muscles forming the calf of the leg.
27. What muscles are the opponents of the adductor magnus?
28. Draw the plantar aspect of pes showing the superficial muscles, and label all the features.
29. Describe three muscles moving the digits.
30. Show by drawing the location of the muscles flexing the pes on the tibia and label all the features.

ORGANS OF DIGESTION

A young lean cat which has had no food for twenty-four hours is the best subject for the demonstration of the digestive system. Directions for preparing the specimen are given in the chapter on technique.

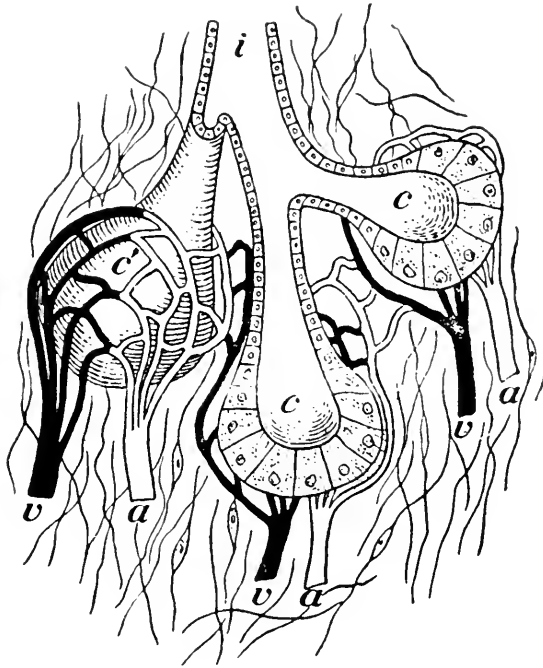


FIG. 60.—DIAGRAM OF A GLAND.

a, artery; *v'*, vein; *c*, part of gland covered with capillaries; *c*, an acinus like *c'*, cut open; *i*, duct.

The digestive system (Figs. 61 and 62) consists of the alimentary canal and the accessory glands of digestion. The canal is made up of the *mouth*, *pharynx*, *esophagus*, *stomach*, *small intestine*, and *large intestine*. Its entire length is about five times that of the cat from the tip of the nose to the root of the tail. The accessory glands consist of five pairs of *salivary glands*, the *liver*, and the *pancreas*. A *gland* is a tiny

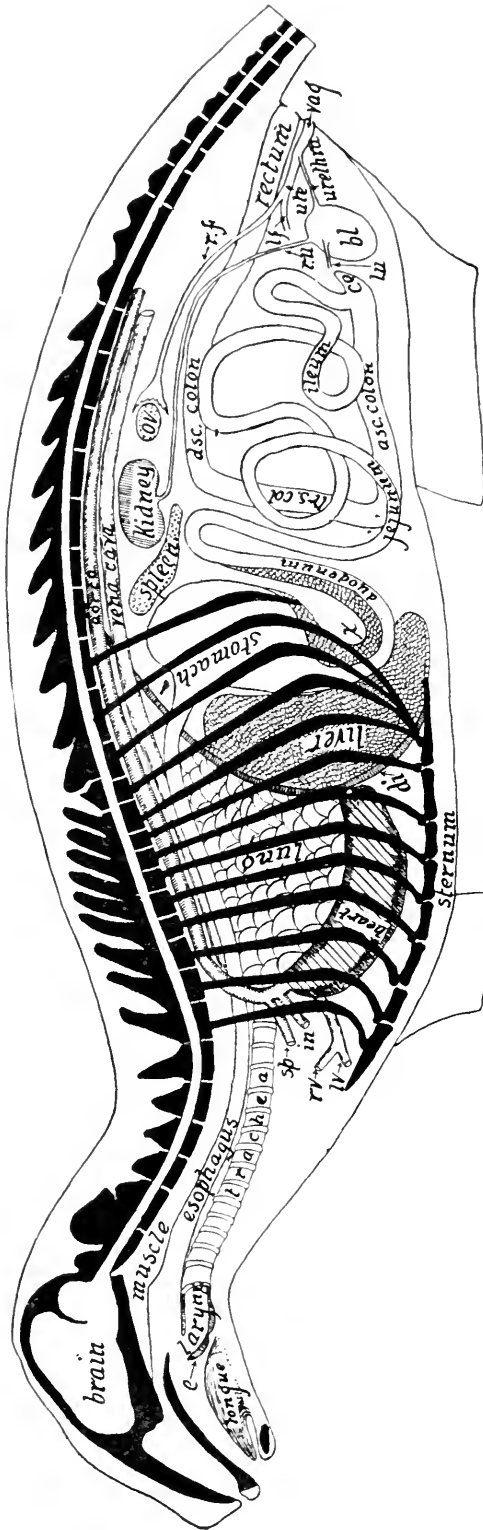


FIG. 61.—DIAGRAM OF THE LOCATION OF THE CHIEF ORGANS OF THE CAT.

bl, Bladder; *ce*, cecum; *di*, diaphragm; *e*, epiglottis; *in*, innominate artery; *lf*, left horn of the uterus; *lu*, left ureter; *lv*, left innominate vein of the precava; *ov*, ovary; *ra*, right ureter; *rv*, right innominate vein of the precava; *rf*, right horn of the uterus; *sp*, left subclavian artery; *ut*, body of the uterus; *vag.*, vagina; *x*, pancreas.

tube or collection of branching tubes which remove certain materials from the blood and manufacture them into a fluid useful to the body.

THE MOUTH

The mouth is bounded cranially by the lips, laterally by the cheeks, and dorsally by the palate, where the mucous membrane lies in seven or eight transverse ridges or rugæ, and caudally depends from the palatine bones forming the *velum palati*. To display the anatomy of the mouth, one should remove the right half of the mandible. From either side of the *velum palati* two folds of membrane diverge as they extend to the floor of the mouth at the root of the tongue. The cranial fold is the *anterior pillar* and the caudal one is the *posterior pillar* of the fauces (Fig. 62). The caudal portion of the mouth between these folds is known as the *fauces*. It opens into the pharynx. On either side of the tongue between the two pillars is a crescentic depression holding a *tonsil*. In man, the tonsils sometimes become inflamed and enlarged, giving rise to a disease called tonsillitis. The tonsil is a compound lymphatic gland whose function is unknown.

Folds of mucous membrane called *frena* bind the lips to the gums which are composed of dense fibrous tissue investing the alveolar margins of the jaw-bones. The mucous lining of the mouth contains many simple mucous glands invisible to the naked eye. Those of the lips are called labial, of the cheeks, buccal, and of the palate, palatine glands.

The **tongue** lying in the floor of the mouth is a muscular mass composed of the geniohyoglossus, lingualis longitudinalis superior and inferior, styloglossus, and hyoglossus muscles. Caudally it is attached to the hyoid bone. Its investment of mucous membrane is formed into a fold beneath it, called the *frenulum linguæ*. The dorsal surface of the tongue displays four kinds of papillæ (Fig. 62): The *vallate*, numbering from six to eight arranged in a V shape near the root; the *flat*,

very numerous at the root; the *conical*, most numerous and thickly set over the entire dorsal aspect; and the *fungiform*, which are blunt and located more thickly on the sides and near the tip of the tongue (Fig. 62).

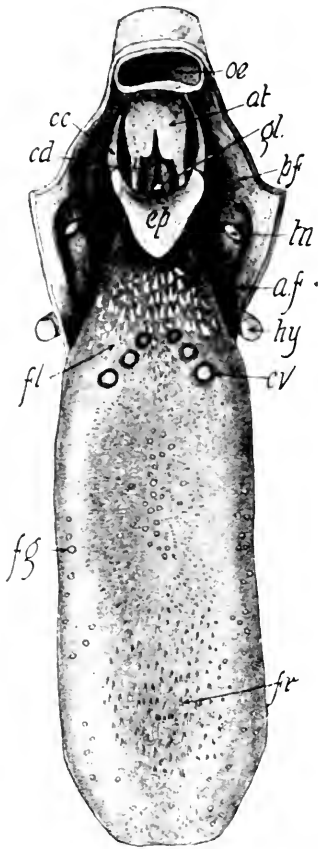


FIG. 62.—DORSAL ASPECT OF THE TONGUE AND LARYNX.

at, Arytenoid cartilage; *af*, anterior pillar of the fauces; *cc*, erico-epiglottic ligament; *cd*, true vocal cords; *cv*, vallate papilla; *ep*, epiglottis; *fl*, flat papilla; *fg*, fungiform papilla; *fr*, filiform papilla; *gl*, glottis; *hy*, epiphyseal bone cut off; *i*, false vocal cord; *a*, lumen of the esophagus, which is cut off just as it opens into the pharynx; *pf*, posterior pillar of the fauces; *tn*, tonsil.

The Teeth.—During the first year the cat develops twenty-six teeth, known as the deciduous or temporary set, as they are later replaced by a permanent set. The three parts of a tooth are the crown, neck, and fang (Fig. 64). The crown may be divided into several portions called cusps. A tooth split longitudinally presents the following four features (Fig. 63): The *enamel*, a hard glistening substance covering the entire crown of the tooth down to the neck; the *cement*, a bony substance investing the fang; the *dentine*, forming the interior hard portion of the tooth; and the *pulp cavity*, containing in the recent state the nerve- and blood-vessels. The enamel consists mostly of the phosphate of lime. It is the covering which when broken permits the tooth to decay.

In an adult cat there are in each half of the upper jaw three incisors, one canine, three premolars, and one molar (Fig. 64).

In each half of the lower jaw there are three incisors, one canine, two premolars, and one molar. The permanent dentition of the cat is therefore expressed by the formula $i \frac{3}{3}$, $c \frac{1}{1}$, $pm \frac{3}{2}$, $m \frac{1}{1}$.

The upper incisor teeth are small and undivided both as to root and crown. They are scarcely one-third as long as the canine and are planted in the alveoli or sockets of the pre-maxillary. The remaining teeth of this jaw are in the maxilla. The canine or eye tooth is the longest and likewise is undivided as to root and crown. The next three teeth are known as the premolars. They vary much in size. The anterior one is the smallest, being about the size of the incisors. Its crown is usually simple, although occasionally there is seen a small posterior cusp, called triticone, in distinction to the main cusp or protocone. The root is usually composed of only one fang. The second premolar is much larger than the first. Its crown presents a large median cusp, or protocone; a very small cusp, triticone, on the posterior side of the protocone half-way between its base and apex; and a basal cusp, the talon, on the posterior side of the base of the tooth. The prominent ridge encircling the tooth at its base is the *cingulum*. The root is composed of two fangs.

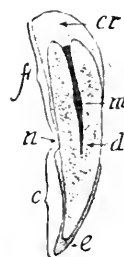

FIG. 63.—LONGITUDINAL SECTION OF THE CANINE TOOTH.
c, crown; cr, cement; d, dentine; e, enamel; f, fang; m, pulp-cavity; n, neck.

The third premolar or *carnassial tooth* is fully twice as large as the second premolar. Its protocone is the large central cusp, posterior to which is the large triticone. At the median anterior angle is the deuterocone. The small projection at the lateral anterior angle is the protostyle. The root of the tooth usually consists of three fangs. The posterior tooth in the maxilla is called the molar, since it is the only one not preceded by a milk tooth. It is very small and its crown presents a grinding surface instead of a cutting one. Its root consists of two fangs.

Each half of the mandible holds three incisors, one canine, two premolars, and one molar. The incisors and canine are so similar to the upper ones that they need no further description. The first premolar presents a principal cusp or protoconid, a lower small cusp or metaconid, and a projection, on

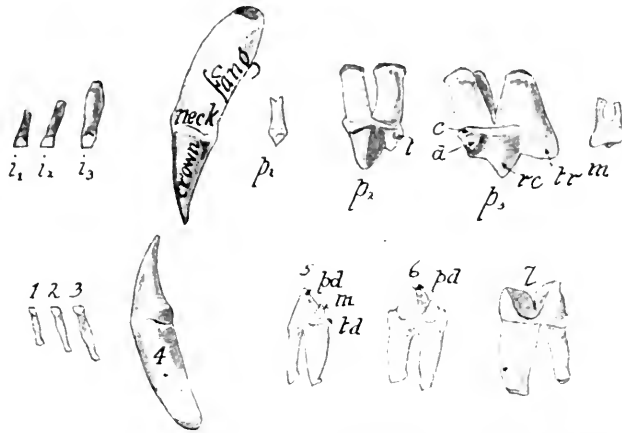


FIG. 64.—LATERAL ASPECT OF THE PERMANENT DENTITION OF THE CAT.

i_1 , i_2 , i_3 , First, second, and third incisors of the upper jaw; c , canine; p_1 , p_2 , and p_3 , first, second, and third premolars; m , molar; 1, 2, 3, the incisors of the lower jaw; 4, canine; 5 and 6, first and second premolars; 7, molar; c , cingulum; d , deutocone; m , metaconid; m , molar; pl , protoconid; rc , protocone; td , talonid; t , talon; tr , triticone.

the posterior side of the base, known as the talonid. A cingulum or encircling ridge is also present at the base of the tooth. The root consists of two fangs.

The second premolar is very similar to the first except that it is larger and presents an anterior basal cusp in addition to the others. The lower molar, sometimes called the *sectorial*, because it shears against the upper sectorial or carnassial premolar, presents two nearly equal cusps, the protoconid and the paraconid. The root consists of two fangs, the anterior of which is the larger.

The *deciduous* or *milk teeth* begin to appear above the gums when the kitten is two weeks old. The incisors and the canine appear first, then second and third molars. The first upper molars do not appear till the kitten is about six weeks old. According to Jayne, the deciduous dentition is complete at

the end of the second month. At the end of the fourth month the milk incisors are being displaced by the permanent teeth. The formula for the temporary set is di $\frac{3}{3}$, dc $\frac{1}{1}$, dm $\frac{3}{2}$.

Teeth are present in nearly all adult mammals. The whale-bone whales, the duck-bill, and some of the ant-eaters have no teeth in the adult state, but teeth are present during their embryonic life. The Echidna shows no evidence of teeth at any time. Most mammals have two distinct sets of teeth, known as the *milk* or *deciduous set*, and the *permanent set*. In the Marsupialia, the milk dentition is in a degenerate condition. The milk teeth are present, but none become sufficiently developed to appear above the gums, except the last premolar, and in some cases the canine and the incisors. The sloths have only one set of teeth and are therefore *Monophydont*. Mammals having both a milk and a permanent set are termed *Diphydont*.

In the majority of mammals the teeth are divided according to form and function into four groups: incisors, canines, premolars, and molars. Such a dentition is known as Heterodont, in distinction to the Homodont dentition, in which all the teeth have the same form, as is the case in the dolphins. In mammals with a heterodont dentition the number of teeth in the different genera varies considerably, as seen by the following formula:

Pig.....	i $\frac{3}{3}$, c $\frac{1}{1}$, p $\frac{4}{4}$, m $\frac{3}{3}$ = 44
Dog.....	i $\frac{3}{3}$, c $\frac{1}{1}$, p $\frac{4}{4}$, m $\frac{2}{3}$ = 42
Cat.....	i $\frac{3}{3}$, c $\frac{1}{1}$, p $\frac{3}{2}$, m $\frac{1}{1}$ = 30
Porcupine.....	i $\frac{1}{1}$, c $\frac{0}{0}$, p $\frac{1}{1}$, m $\frac{3}{3}$ = 20
Sheep.....	i $\frac{0}{3}$, c $\frac{0}{1}$, p $\frac{3}{0}$, m $\frac{3}{3}$ = 32
Horse.....	i $\frac{3}{3}$, c $\frac{1}{1}$, p $\frac{4}{4}$, m $\frac{3}{3}$ = 44
Opossum.....	i $\frac{5}{4}$, c $\frac{1}{1}$, p $\frac{3}{3}$, m $\frac{4}{4}$ = 50
Man.....	i $\frac{2}{2}$, c $\frac{1}{1}$, p $\frac{2}{2}$, m $\frac{3}{3}$ = 32

The elephant presents a very specialized dentition. It has no canines nor any lower incisors. The single pair of upper incisors is developed into long tusks, much prized for ivory. They continue to grow through out the entire life of the animal.

Six molars are present on each side, only one or two of which are functional at once. The posterior ones move forward to take the place of the anterior as these become worn out. The tusks of the walrus are its canines greatly developed. None of the typical modern Ruminants have upper incisors in the adult state, though they are present in the embryo. Paleontology has demonstrated that the ancestors of the Ruminants had well-developed upper incisors in the later Eocene times. The occurrence of the rudimentary upper incisors in the embryo furnishes evidence of a full dentition in the ancestors of the ruminants, since the individual embryological history is somewhat of a recapitulation of the ancestral history of the race.

THE PHARYNX

The pharynx is that portion of the alimentary canal between the mouth and the esophagus. The structure is well shown by making a sagittal section through the head and neck. This is best done with a saw, after the specimen is frozen by placing it out-of-doors during one or two days of cold winter weather.

There are seven openings into the pharynx: The two *posterior nares* (Fig. 19), opening anteriorly from the roof; auditory or *Eustachian tube* on each side; the *esophagus*; and the *larynx*, leading into the trachea. The mucous membrane lining the pharynx contains many simple microscopic mucous glands.

VISCERA

The body cavity known as the *celom* must be opened before the rest of the alimentary canal can be displayed. The entire ventral wall of the thoracic and abdominal cavities should be cut away with the bone forceps and scalpel. The body cavity is divided into two parts by the diaphragm (Fig. 61). The cranial portion, the *thoracic cavity*, contains the esophagus, heart, blood-vessels, thoracic duct, trachea, and lungs. In the young cat there is present also the thymus gland, stretching

craniad several centimeters from the base of the heart. The transparent membrane lining this cavity and investing the lungs is the *pleura*.

The caudal part of the celom is the abdominal cavity containing the abdominal viscera, which are here briefly described.

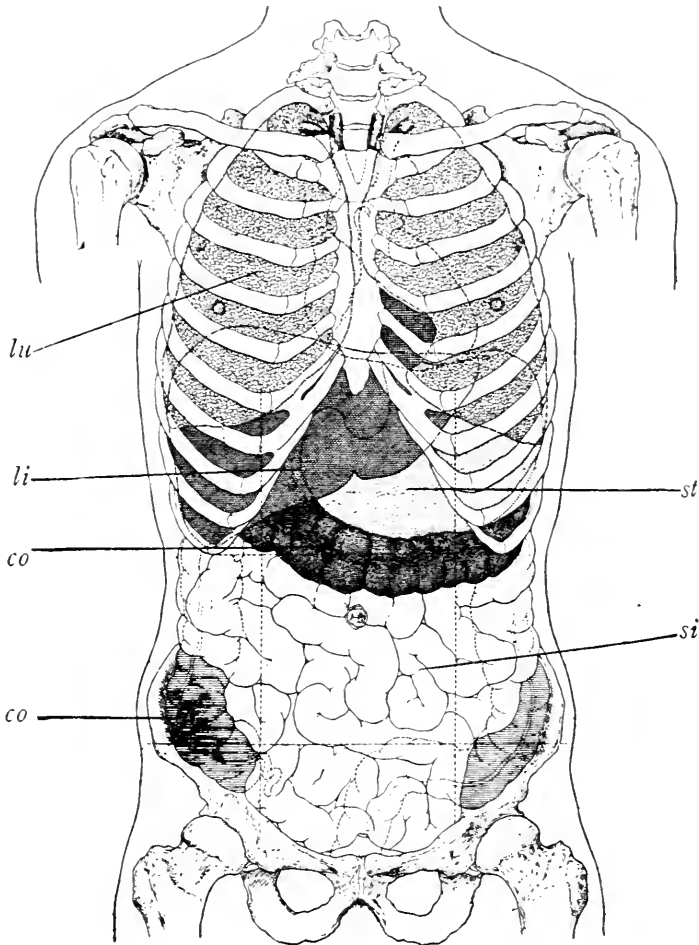


FIG. 65.—VISCERA OF THE HUMAN BODY. (Deaver.)
co, Colon; li, liver; lu, lung; si, small intestine; st, stomach.

The *liver*, a large brownish-red organ, is adjacent to the diaphragm on the right side, while the stomach (Fig. 61) lies close to the diaphragm on the left. The *spleen* is the dark red, flat, elongated organ caudad of the stomach on the left side. The sheet of thin transparent tissue more or less laden with

fat, depending from the stomach and covering the intestines like an apron, is the *greater omentum*. It is a portion of the peritoneum which lines the abdominal cavity and invests most of the organs therein. The *pancreas* is a pinkish elongate body, bent at a right angle near its middle, so that one portion lies in the bend of the duodenum and the other dorsal to the stomach. The *kidneys* may be recognized by their well-known shape and dorsal location in the cranial lumbar region. The *ovaries* are small pinkish bodies lying near the kidneys, adjacent to the dorsal abdominal wall. The *uterus* is easily known by its two horns extending caudad from the ovaries to their junction at the body of the uterus. The *bladder*, if full of urine, is at once recognized; and if empty, appears as a small hard pear-shaped mass ventrad to the rectum (Fig. 61).

ESOPHAGUS

The esophagus or gullet is that portion of the alimentary canal leading from the pharynx to the stomach. In the thoracic cavity it lies dorsal to the heart (Fig. 61) by the side of the aorta. Immediately caudad of the diaphragm it opens into the cardiac end of the stomach (Fig. 66).

STOMACH

The stomach is that dilated portion of the canal lying immediately caudad of the diaphragm on the left side. The esophageal end of the stomach is known as the *cardiac portion*, and the intestinal end is the *pyloric portion* (Fig. 66). Here a circular fold of mucous membrane embraced by a sphincter muscle serves as a valve to open and close the *pylorus* or gateway to the intestine. The dorsal surface of the stomach is its lesser curvature and the ventral convex surface is its greater curvature. The structure of the walls of the stomach is described below.

INTESTINE

The intestine is that much contorted portion of the canal leading from the stomach to the external aperture or anus. The first portion, the small intestine (Fig. 66), is about three

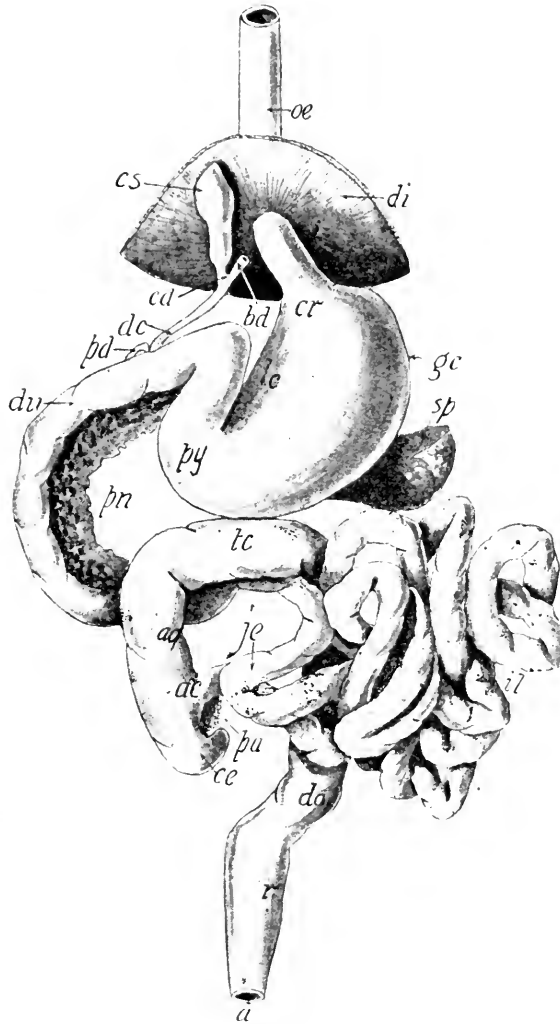


FIG. 66.—VENTRAL ASPECT OF THE ALIMENTARY CANAL WITH THE ILEUM PULLED TO ONE SIDE.

ac, Small intestine opening into the large intestine; *a*, anus; *ao*, ascending colon; *bd*, hepatic duct; *ce*, cecum; *cd*, cystic duct; *cs*, bile-cyst or gall-bladder; *cr*, cardiac portion of the stomach; *di*, diaphragm; *du*, duodenum; *do*, caudal part of the descending colon; *dc*, common bile duct; *gc*, greater curvature of the stomach; *il*, ileum; *je*, jejunum; *lc*, lesser curvature of the stomach; *œ*, esophagus; *pn*, pancreas; *py*, pyloric portion; *pa*, mesenteric gland; *pd*, pancreatic duct; *r*, rectum; *sp*, spleen; *tc*, transverse colon.

feet long in a large cat, and is less in diameter and much more convoluted than the second portion, or large intestine.

The **small intestine** consists of three parts: the *duodenum*, the *jejunum*, and the *ileum*. The *duodenum* is the first twelve or fifteen centimeters. A duct from the liver and the gall-bladder and two ducts from the pancreas, empty into it. The

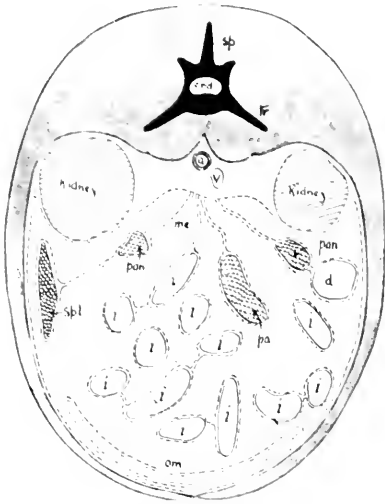


FIG. 67.—TRANSVERSE SECTION OF THE CAT.

i, Sections of the intestine; *d*, duodenum; *a*, aorta; *pan*, pancreas; *pa*, pancreas Aselli; *spl*, spleen; *sp*, spinous process of the lumbar vertebra; *tr*, transverse process; *v*, post-cava or inferior vena cava; *om*, greater omentum; the broken line is the peritoneum.

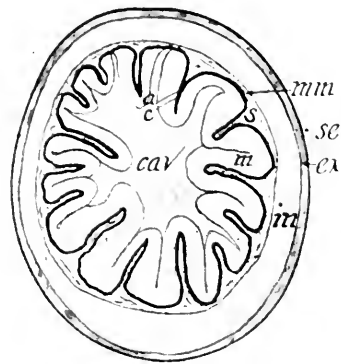


FIG. 68.—CROSS-SECTION OF THE CARDIAC END OF THE STOMACH. X3.

cav, Cavity of the stomach; *ex*, external muscular coat; *m*, internal muscular coat; *mm*, muscularis mucosae; *s*, submucous or areolar coat; *se*, serous or peritoneal coat.

former is the *common bile duct* and the latter are the *pancreatic ducts*. The *jejunum* is the portion of the small intestine next to the duodenum. It is about twenty five centimeters long. No special mark indicates its limits. It is so called because that portion of the canal in man is frequently empty after death. The *ileum* constitutes more than two-thirds of the small intestine, is much convoluted, and extends from the jejunum to the large intestine on the right side of the abdominal cavity, near the iliac bone. The intestine is supported by the folds of the peritoneum known as the *mesenteries*.

The **large intestine** consists of the *cecum*, *colon*, and *rectum*. The *cecum* is the blind conical projection at the beginning of the large intestine. It is only one or two centimeters long. There is no vermiform appendix in the cat. The ileum opens into the large intestine at the junction of the cecum and colon. An annular fold of mucous membrane, strengthened by a sphincter muscle, forms the *ileocecal valve*, which retains the food in the small intestine until the nutriment is absorbed (Fig. 66).

The colon, extending from the cecum to the rectum, is composed of the *ascending*, *transverse*, and *descending parts*. The ascending colon lies on the right side, the transverse extends crosswise, connecting the ascending with the descending, which lies on the left side. The descending colon terminates in the rectum, which is five or six centimeters long.

The **wall of the alimentary canal** is composed of three chief coats—*mucous*, *areolar*, and *muscular*. These coats may be seen by cutting transversely, with a sharp scalpel, a portion of the stomach hardened in formalin. The mucous coat (Fig. 68) lines the lumen and contains four typical structures: (a) an inner epithelial layer, (b) a tunica propria supporting (c) the secreting glands, and (d) muscular layer—the *muscularis mucosæ*—separating the mucous from the submucous coat. The glands of the mucosa vary much in the different portions of the canal. The mucous coat of the esophagus of the cat is free from glands, for the greater part, at least. In some animals

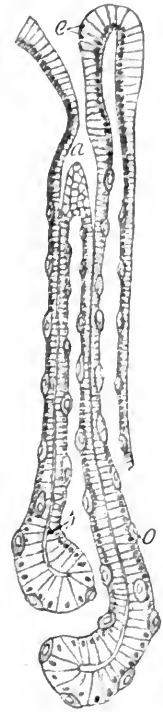


FIG. 69.—A CROSS-SECTION OF THE MUCOUS COAT OF THE STOMACH BETWEEN THE LINES *a* AND *c* IN FIG. 61 SHOWS A GASTRIC GLAND. $\times 250$. Diagrammatic.

a, Mouth of gastric gland; *c*, columnar epithelial cells on the food surface of the stomach; *l*, lumen of a gland; *o*, oxyntic or acid cell.

like the dog, opossum, etc., esophageal glands are present in the submucous coat. The function of these glands when present is not exactly known (Goetsch Am. Jour. Anat., 1910). The mucous coat of the stomach contains the *gastric*

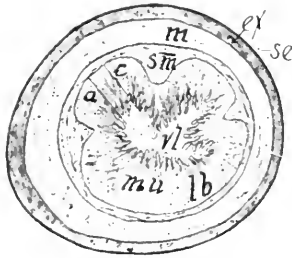


FIG. 70.—CROSS-SECTION OF THE SMALL INTESTINE. $\times 5$.

ex, Longitudinal muscular coat; *m*, circular muscular coat; *mu*, mucous coat; *lb*, glands of Lieberkühn; *se*, serous or peritoneal coat; *sm*, submucous or areolar coat.

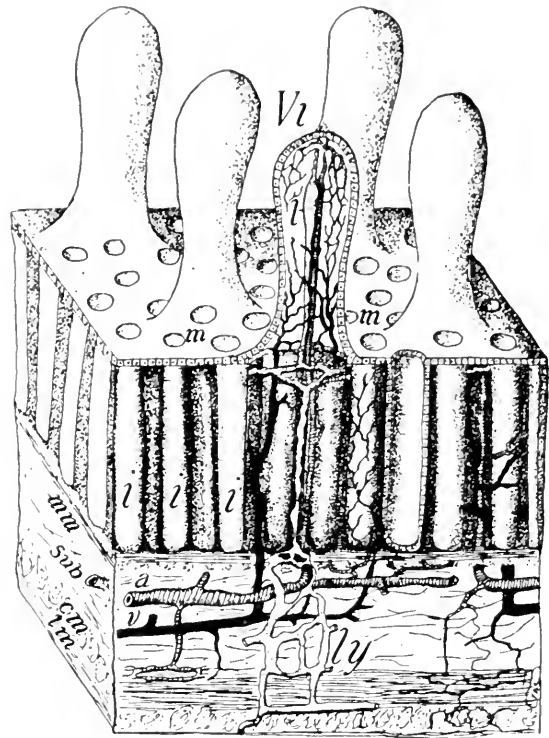


FIG. 71a.—DIAGRAM OF A SMALL CUBE CUT FROM THE WALL OF THE JEJUNUM.

a, Artery; *v*, vein; *ly*, lymphatic; *i*, lacteal; *vi*, villi; *m*, mouth of intestinal gland; *i*, intestinal gland of Lieberkühn; *mm*, muscularis mucosæ; *sub*, submucosa; *cm*, circular muscular coat; *lm*, longitudinal muscular coat.

glands, which yield pepsin and hydrochloric acid, the chief agents of the gastric digestive fluid (Fig. 69). The glands in the cardiac end of the stomach differ from those in the pyloric end in containing numerous *parietal* or *acid cells* which probably secrete the hydrochloric acid for digestion.

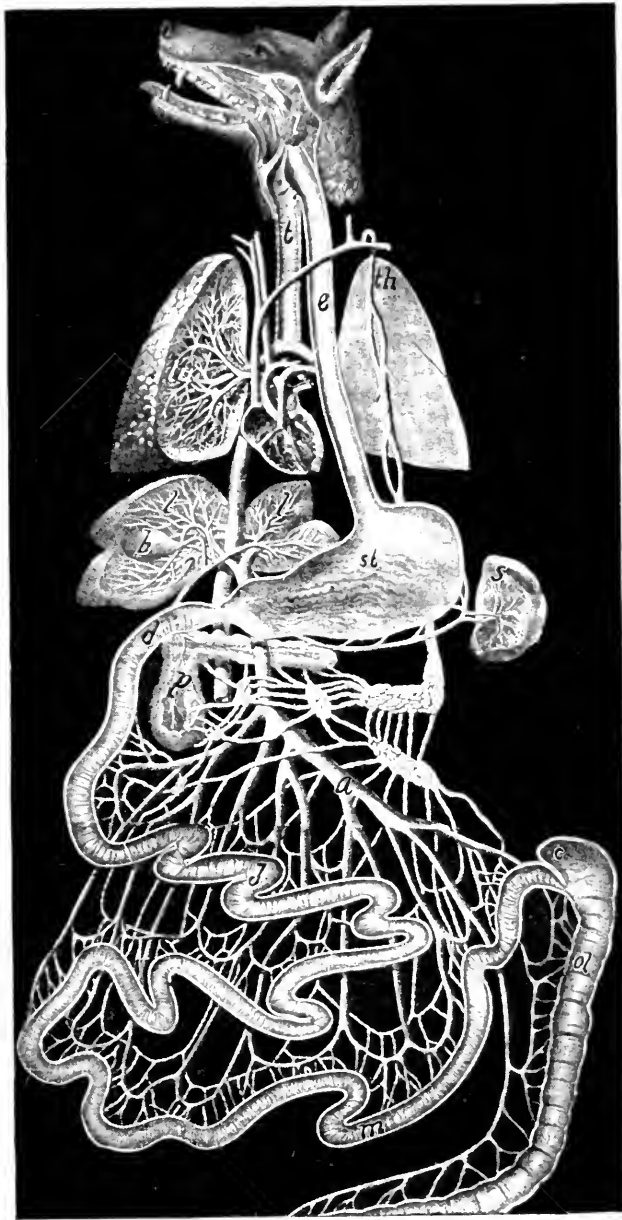

FIG. 71b.—LACTEALS AND PORTAL SYSTEM OF DOG.

a, Inferior mesenteric vein; *b*, gall-bladder; *c*, cecum; *d*, duodenum; *e*, esophagus; *i*, parotid gland; *j*, jejunum; *l*, branches of portal vein in liver; *lu*, branches of trachea and pulmonary artery in the lung; *m*, ilium; *ol*, colon; *p*, pancreas; *s*, spleen; *st*, stomach; *th*, thoracic duct into which empty the white tubes, the lacteals.

The *mucous coat* of the small intestine contains tube-like glands, the intestinal glands of Lieberkühn, whose secretion acts on the sugars, assists the pancreatic juice in the digestion of proteins, and contains a hormone which plays an important rôle in the control of pancreatic secretion. In the duodenum and jejunum the mucous membrane is thrown into numerous transverse folds, *valvuli conniventes*, which increase the surface for absorption. The *villi* are minute finger-like processes (Fig. 70), barely apparent to the naked eye, projecting into the lumen for the purpose of absorbing the nutriment from the chyle. They consist of a covering of columnar epithelial cells (Fig. 71a), within which ends a chyle vessel or *lacteal* surrounded by small blood-vessels held in place by connective tissue. The fatty portions of the food are carried by the lacteals (Fig. 71b) to the left thoracic duct, and thence to the jugular vein, while other portions of the food are taken up by the capillaries of the portal system, which begin in the villi (Fig. 71a). The mucous membrane of the large intestine likewise contains tube-like glands similar to the intestinal glands, but no villi.

The *submucous* or *areolar coat* is adjacent to the mucous coat of the intestine. It contains blood and lymphatic vessels, nerve fibers and plexuses supplying the mucous coat. In certain regions of the digestive tube, as the duodenum and in some mammals the esophagus, it also contains secreting glands whose ducts penetrate the mucous coat and open upon the epithelial surface. Next to the submucous coat is the *muscular coat*, composed of two layers, one of circular fibers, the other of longitudinal fibers. An additional layer of oblique fibers is present in the cardiac end of the stomach, which aid in giving that organ the peculiar churning or peristaltic motion necessary for chymification of the food. A fourth coat or serous covering surrounds the muscular coat of the stomach and intestines. It is merely a reflected portion of the peritoneum which lines the entire abdominal cavity.

THE ACCESSORY GLANDS OF DIGESTION

The **salivary glands** are five in number on each side of the head. They secrete the saliva, of which certain elements have the power of changing starch into sugar.

The **parotid gland** is the largest of the salivary group and lies just ventrad to the base of the external ear (Fig. 72) beneath the skin. It is flat and about two centimeters in diameter. Its secretion is poured into the mouth through the parotid duct, (*ductus parotideus stemonis*), which may be seen extending from the cranial margin of the gland over the masseter muscle, to near the angle of the mouth, where it perforates the buccinator muscle, and opens within the mouth on the cheek, opposite the prominent cusp of the last premolar. The duct and gland may be injected with Berlin blue by inserting the cannula into the orifice of the duct (Fig. 72).

The **submaxillary gland** is near the angle of the mandible and ventrad to the parotid. The submaxillary duct extends from its anterior surface, between the digastric and masseter muscles, to its orifice on the floor of the mouth, opposite the last tooth of the mandible.

The **sublingual gland** is quite small, elongated, and lies craniad of the submaxillary. Its duct extends parallel with that of the submaxillary and opens within the mouth upon the same papilla beneath the tongue. The *molar gland* is very small and lies near the angle of the mouth ventrad of the parotid. Its several ducts, which are not easily demonstrated, pass through the cheek to open within the mouth. The *zygomatic* or *infraorbital gland* lies on the lateral part of the orbit

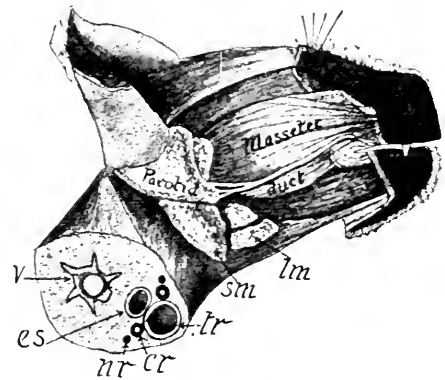


FIG. 72.—LATERAL ASPECT OF THE HEAD WITH THE SKIN REMOVED.

cr, Carotid artery; es, esophagus; lm, lymphatic gland; sm, submaxillary gland; tr, trachea; v, cervical vertebra.

on the ventro-lateral surface of the eye-ball. It may be seen by cutting away the zygomatic arch and the masseter muscle. From near the ventral angle of the gland a duct leads to the roof of the mouth posterior to the molar tooth.

The **liver** (*hepar*) is the largest gland in the body and is situated immediately caudad of the diaphragm (Fig. 56), and in contact with the right lateral and cranial surfaces of the stomach. It is strongly convex on its cranial aspect while its opposite surface presents a deep concavity occupied by the stomach. Several deep incisions named *fissures* divide the liver into five parts called *lobes*. The *falciform* or *suspensory ligament* which is a fold of peritoneum joins the liver to the diaphragm and extends into the large median fissure known as the *umbilical notch* because during fetal life it shelters the vein leading through the umbilical cord to receive nourishment from the mother.

On the right side of the body from the umbilical notch is the large *right median lobe* enfolding the gall bladder. On the other side of the notch is a small *left median lobe* and a much larger *left lateral lobe*. The *right lateral lobe* is dorsal of the right median lobe, and is divided into two parts by a deep cleft. A fifth lobe known as the *Spigelian* or *caudate lobe* is a small triangular portion of the liver connected to the base of the right lateral lobe and lying between the neck of the gall bladder and the end of the stomach joining the esophagus.

The *bile* secreted by the liver passes through the several ducts from the various lobes, to the main *hepatic duct*, which may be seen by cutting away the liver from the right side of the gall-cyst, and carefully picking off the peritoneum ensheathing the vessels between the Spigelian lobe and the *cystic duct*. The latter is somewhat convoluted in its course from the deeply imbedded end of the cyst, to a point on the duodenum about three centimeters from the pylorus. The main hepatic duct joins the cystic duct (Fig. 66) near its middle. The common duct thus formed is known as the common bile duct. When the

bile is secreted faster than it is permitted to enter the intestine, it passes backward from the common bile duct into the cyst.

The bile aids in the absorption of the fats by the villi, and renders the chyme alkaline. The formation of red blood-corpuscles takes place in the liver of the embryo, while in the adult, the liver destroys these corpuscles. The chief function of this organ, however, is the formation of glycogen from the sugars and starches eaten and the gradual transformation of this glycogen into sugar as demanded for the nutrition of the body. Diabetes mellitus is caused by a diseased liver or pancreas which permits sugar to accumulate in the blood.

The **pancreas** (Fig. 66) is an elongated gland bent at a right angle near its middle. The body of it lies dorsal to the pyloric portion of the stomach, and the head lies close along the concavity of the duodenum. It has two ducts, one of which enters the duodenum in common with the common bile duct, while the other enters about three centimeters further caudad. The pancreatic juice acts on the starches, proteids, and fats. A pancreatic bladder is sometimes found in the cat, although it has not been described for any other vertebrate. It probably has its origin as an accessory pancreas in which the terminal lobe has become dilated to form the bladder while the proximal portion atrophies, leaving only the duct (Boyden). Another theory is that the pancreatic bladder is split off from the gall bladder primordium. "Neither of the two theories as to the cause of pancreatic bladders will explain all known cases. Both theories must therefore be retained" (Bremer '23).

THE PERITONEUM

The peritoneum (Fig. 67) is the serous sac lining the abdominal cavity and investing most of the organs therein contained. The four portions of the peritoneum are known as the *omenta*, the *mesenteries*, *parietes*, and *ligaments*.

The **omenta** are three in number, the largest of which is the *great* or *gastrocolic omentum*, stretching caudad from the

dorsal abdominal wall and the greater curvature of the stomach, so as to cover the intestine like an apron. It is composed of four layers of peritoneum forming a closed sac, and bearing more or less fat. Two layers form the ventral wall of the sac attached to the stomach, and two layers are also present in the dorsal wall of the sac which invests the pancreas.

The *lesser omentum*, or *gastrohepatic omentum*, extends caudad from the liver to the pyloric part of the stomach and duodenum. Its two folds extend from the two sides of the portal fissure, ensheathing the portal vein, hepatic artery, and cystic duct. The *gastrosplenic ligament* stretches from the cardiac region of the stomach to the spleen, which it embraces, and then proceeds to the diaphragm.

The **mesenteries** are the two layers of peritoneum suspending the intestine from the dorsal abdominal wall. There are four mesenteries: the true mesentery, suspending the jejunum and ileum; the mesoduodenum, suspending the duodenum; the mesocolon, suspending the colon; and the mesorectum, suspending the rectum.

The **parietes** or parietal peritoneum is that portion lining the walls of the abdominal cavity. It is a closed sac in the male, but in the female the uterine tubes open into it.

The **ligaments** are the layers of the peritoneum suspending other organs than parts of the alimentary canal. The *suspensory* or *falciform ligament* extends from the caudal surface of the diaphragm and the abdominal wall, to the surface of the liver, which its line of attachment divides into halves. The *round ligament* is the thickened free caudal border of the suspensory ligament. It is the remains of a vein which in fetal life joined the offspring to the mother. A third ligament connects the dorsal border of the liver with the diaphragm. The *broad ligaments* of the uterus are the folds of peritoneum which embrace the uterus, the uterine tubes, and the ovaries. The *ovarian ligaments* are short cords extending from the ends of the uterine cornua to the ovaries. The round ligaments of the

uterus pass from the sides of the uterus to the brim of the pelvis.

The peritoneum is called a *serous membrane* because of the colorless serum secreted by it. Other serous membranes are the pericardium of the heart, the pleura lining the thoracic cavity and investing the lungs, and the synovial membranes of the joints. Serous membranes invest only such cavities as are not exposed to the air. All other cavities are lined by mucous membrane. A serous membrane consists of a layer of fibrous connective tissue covered by plate-like endothelial cells.

REMARKS ON THE MAMMALIAN DIGESTIVE SYSTEM

The digestive system of mammals varies somewhat among the different groups. In carnivorous animals, as a rule, the alimentary canal is much shorter than in herbivorous. In the wildcat the canal is four times the length of the body, while the canal of the sheep is twenty times as long as the

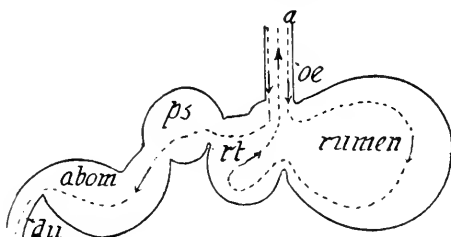


FIG. 73.—DIAGRAM OF THE STOMACH OF A RUMINANT.

a, Dotted line showing the direction of the food in the process of digestion; *abom*, abomasum; *du*, duodenum; *oe*, esophagus; *ps*, psalterium; *rt*, reticulum.

body. In man it is about nine times as long as the distance from the crown of the head to the coccyx. In Ruminants, such as the cow and the sheep, the stomach is very large and divided into four chambers—the *rumen* or *paunch*, *reticulum*, *psalterium* or *manyplies*, and *abomasum* (Fig. 73). The rumen and reticulum serve as mere storage cavities, from which the food returns to the mouth for thorough mastication, and then passes direct, by means of a groove in the esophagus, into the psalterium, and finally on to the abomasum. The latter is the true stomach, and is provided with gastric glands. In

the camels the rumen and reticulum have connected with them pouch-like diverticula for the storage of water. The constricted openings of the pouches into the rumen or reticulum may be entirely closed by sphincter muscles.

In man and the higher apes there is present an attenuated extension of the cecum known as the *vermiform appendix*. In the fetus of man it is proportionally longer than in the adult. In the herbivorous mammals, such as the cow and rabbit, the cecum is greatly enlarged, so as to play an important part in digestion. In a few forms, such as the sloths, some Cetacea, and a few Carnivora, the cecum is absent.

The lowest mammals, the Monotremata, resemble birds and reptiles in possessing a *cloaca* into which open the rectum and the urinary and genital ducts. The cloaca opens externally through the anus. Salivary and thyreoid glands, pancreas, and the liver are present in all mammals, but the gall-cyst is absent in Cetacea, the Perissodactyla, Hyracoidea, and a few Rodentia. The liver is usually relatively larger in fat-eating animals.

LABORATORY STUDIES AND SUGGESTIONS

1. Describe the fauces.
2. Describe in detail every feature visible on the dorsal surface of the tongue.
3. Give the number of fangs in each tooth of the permanent set.
4. Give the number of each kind of teeth in the two sets.
5. Draw two aspects of the sectorial tooth.
6. How thick is the enamel of the teeth?
7. Name some mammals which do not have enamel on the teeth.
8. Name some toothless mammals.
9. Name some mammals having only one set of teeth.
10. Give the dental formulæ for three ungulates.
11. In what animals are some of the teeth greatly enlarged?
12. Do any ruminants have upper incisors?
13. Name the important features of the pharynx.
14. Name every organ in the abdominal cavity, telling with what other organs it is in contact.
15. Describe as much of the peritoneum as you can see in your specimen.
16. Draw the alimentary canal in its natural position, showing all ducts leading into it, and label all parts.

17. How much longer is the small intestine than the large one?
18. On what does the length of the canal in different mammals largely depend?
19. Make a section of a portion of the wall of the stomach and draw what is seen, labelling all parts.
20. Make a section of the small intestine, draw what can be seen by naked eye or simple microscope.
21. About how many villi to each square millimeter?
22. Describe the two channels through which the food passes from the intestines to the heart.
23. Make a somewhat diagrammatic drawing representing that part of the venous system conveying the food from the intestines to the heart.
24. What is the size of the cecum in other mammals than the cat?
25. Give the location, size, and form of the salivary glands.
26. Name the lobes of the liver in order of their size.
27. How is the liver held in place?
28. Draw the pancreas, showing ducts leading to the intestine.
29. Draw the complex stomach characteristic of many ruminants.
30. What is the cloaca and in what mammals is it present?



THE VASCULAR SYSTEM

The vascular system is composed of the central forcing muscular organ, the heart; a system of vessels, the arteries, carrying the blood from the ventricles to the lungs and all parts of the body; a system of vessels, the veins, returning the blood to the atria; and numerous microscopic vessels, the capillaries, connecting the termination of the arteries with the origin of the veins.

THE HEART

The location of the heart in the cat may be seen by removing the ventral thoracic wall, but for the study of the parts, the heart of an ox or a sheep will be found more satisfactory. The heart of the cat lies between the lungs (Fig. 86) in the thoracic cavity a little to the left of the median line. The caudal end is the apex, and the cranial end is the base. The entire organ is invested in a fibro-membranous sac the pericardium, which when cut permits the pericardial fluid to run out. The walls of this pericardial sac comprises two layers, the visceral layer or epicardium, which closely invests the heart and a perietal layer, or the pericardium proper, which forms a loose sac. All the blood-vessels originate from the dorsocranial aspect of the heart.

It is composed of a right and left half, each of which consists of an **atrium** or auricle and a **ventricle**. The separation between the two halves is apparent on the ventral surface. The atria receive the blood from the veins and pass it to the ventricles, which disperse it through the arteries. There is no aperture between the atria or the ventricles. The atrio-ventricular opening between the right atrium and the right ventricle is guarded by the *tricuspid valve* which prevents the blood from returning into the atrium when the *systole* or contraction pushes the blood into the pulmonary artery. The

left atrioventricular opening is guarded by the *bicuspid* or *mitral* valve. These valves may be displayed by cutting away the caudal half of the ventral wall of the ventricles, when the

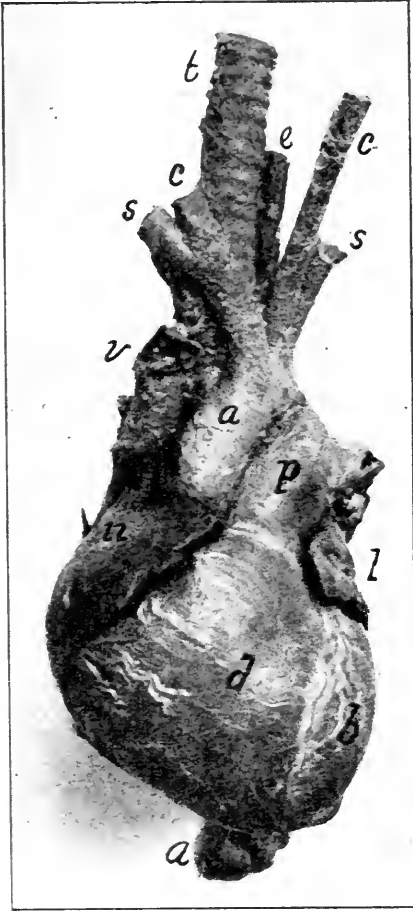


FIG. 74.—PHOTOGRAPH OF THE VENTRAL ASPECT OF THE HUMAN HEART INJECTED.

a, Aorta; b, left ventricle; c, carotid arteries; d, right ventricle; e, esophagus; l, left atrium; n, right atrium; s, subclavian artery; t, trachea; v, superior vena cava. $\frac{1}{3}$ natural size.

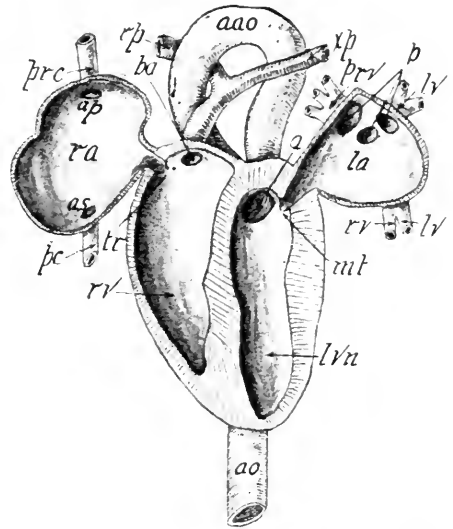


FIG. 75.—HEART VIEWED VENTRALLY, WITH VENTRAL HALF OF THE ATRIA AND VENTRICLES CUT AWAY AND THE ATRIA DRAWN LATERAD. Partly diagrammatic.

a, Orifice of the aorta; ao, aorta; aao, arch of the aorta; ap, orifice of the precava; as, orifice of the post-cava; lv, left pulmonary veins; lvn, left ventricle; mt, mitral or bicuspid valve; la, left atrium; p, orifice of the pulmonary veins; pc, inferior vena cava; prc, superior vena cava; ba, orifice of the pulmonary artery; prv, right pulmonary veins; rv, right ventricle and one of the right pulmonary veins; ra, right atrium; rp, right pulmonary artery; tr, tricuspid valve; xp, left pulmonary artery.

chordæ tendineæ, delicate tendinous cords, will be seen extending from the margins of the translucent membranous valves to the trabeculæ carneæ or muscular projections on the walls

of the ventricles. The walls of the atria are thin in comparison with the walls of the left ventricle, which are twice as thick as the walls of the right ventricle (Fig. 76).

The walls of the heart are made up chiefly of a peculiar type of striped muscle—cardiac muscle forming the *myocardium*. In

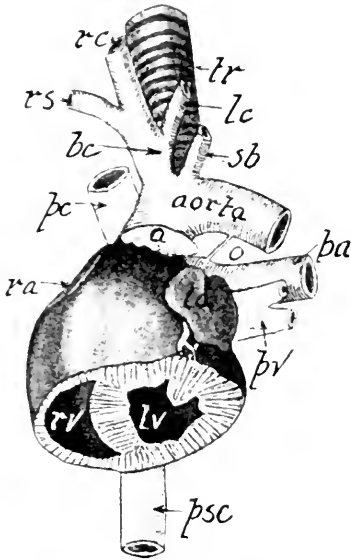


FIG. 76.—VENTRAL ASPECT OF THE HEART WITH ITS CAUDAL THIRD CUT OFF TRANSVERSELY.

a, Adipose tissue; bc, innominate artery; la, left atrium; lv, left ventricle; lc, left carotid artery; o, ductus arteriosus; pv, pulmonary vein; pa, pulmonary artery; pc, superior vena cava; psc, inferior vena cava; ra, right atrium; rc, right carotid artery; rs, right subclavian artery; rv, right ventricle; sb, left subclavian artery; tr, trachea.

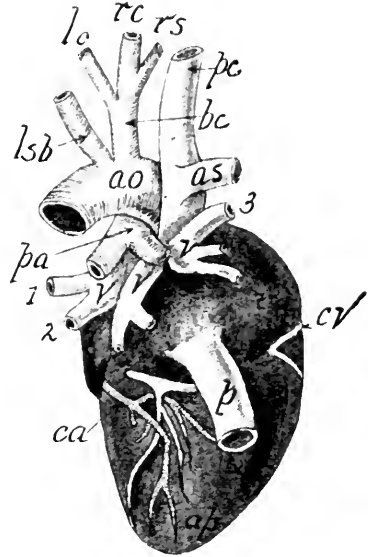


FIG. 77.—DORSAL ASPECT OF THE HEART OF THE CAT.

ao, Aorta; ap, apex; as, azygos vein; bc, innominate artery; ca, coronary artery; cv, coronary vein; l, left atrium; lc, left carotid artery; lsb, left subclavian artery; p, inferior vena cava; pc, superior vena cava; pa, pulmonary artery dividing into its right and left branches; ra, right atrium; rc, right carotid; rs, right subclavian; v, pulmonary veins.

addition to the cardiac muscle there are certain other fibers known as *Purkinji fibers* which form a network just below the endocardium. In 1893 W. His Jr. discovered a bundle of muscle fibres arising in the posterior wall of the right atrium which extends down into the ventricular septum and connects the atrial and ventricular musculature. This has since been known as the atrioventricular bundle of His. In 1906 Tawara

demonstrated that the *Purkinji fibers* were parts of the bundle of His and in 1908 Retzer proposed the name sinoventricular system for the entire apparatus and suggested that it is neuromuscular in nature. Miss Lydia Dewitt in 1909 succeeded in making a very complete reconstruction of the entire system in man, dog, sheep, calf and cat. The system is of interest because it seems to have to do with the coördination of atrial and ventricular rhythm and because of its relations to certain peculiar pathological conditions, such as Stokes-Adams disease. Whether it may originate rhythmic impulses in the heart is still a problem for investigation.

The atria are very small when not injected, and may by the beginner be cut away with the pericardium and surrounding adipose tissue. The right atrium receives three veins, the *superior vena cava*, *inferior vena cava* and *coronary sinus*, all of which enter its dorsal aspect. The slit-like opening of the coronary sinus is guarded by the semilunar *valve of Thebesius*, *valvula sinus coronarii* (Thebesii). The portion of the atrium into which the above veins open is the *sinus venosus*. At the dorsal part of the septum which divides this atrium from the adjoining one is an oval depression, the *fossa ovalis*, where, in an embryo, the two atria communicated. The left atrium is in contact with the right dorsally, and receives three *pulmonary veins* (Fig. 77).

The right ventricle is smaller than the left. It makes a half spiral turn about the left and terminates at its cranial end into the pulmonary artery. The portion between the atrioventricular opening and the pulmonary artery is known as the *conus arteriosus*. Between it and the pulmonary artery are three pocket-like semilunar valves which prevent the return of the blood. Between each valve and the wall of the artery is a pulmonary sinus, or *sinus of valsalva*. The left ventricle gives origin to only one important vessel, the aorta, which arches dorsally around the left atrium, and at the apex of the arch gives off two branches, the *innominate*, and the left *subclavian*.

Three semilunar valves also guard the mouth of the aorta, each of which partly conceals an aortic sinus, sinus aortæ [Valsalvæ]. The arteries of the heart may easily be distinguished from the veins by the fact that the walls of the former are much thicker.

THE ARTERIES OF THE TRUNK

The blood-vessels form two systems of circulation; the one known as the *pulmonary circulation* includes the arteries carrying blood from the right ventricle to the lungs, and the veins returning the blood from the lungs to the left atrium; the other, known as the *systemic circulation*, includes the arteries conveying the blood from the left ventricle to all parts of the body, and the veins returning the blood to the right atrium.

The pulmonary artery (A. pulmonalis) is united with the aorta by a ligament, ligamentum arteriosum or ligamentum Botalli, which represents the remnant of an embryonic connection between the two vessels, ductus Botalli (Fig. 88c). The ligament is sometimes obliterated in the adult.

The main artery of the systemic circulation is the *aorta*, which, beginning in the left ventricle, arches dorsal to the heart and extends along the spinal column to the tail. That portion in the thoracic cavity is termed the *thoracic aorta*, while that portion in the abdominal cavity is the *abdominal aorta*. Three semilunar valves guard the mouth of the aorta at its opening from the ventricle, in order that the blood may not be forced back into the heart by the contraction of the muscular coat of the arteries.

The branches of the thoracic aorta are as follows: the right and left coronary, arising from the aortic sinus are distributed to the walls of the heart. From the arch of the aorta arise two branches; first, the innominate (A. anonyma), giving rise to a small mediastinal artery and the left and right carotids supplying blood to the head and neck. The anonymous artery then continues as the right subclavian to supply the

arm and hand. Second, the left subclavian, which supplies the left arm, brain, and sternum.

There may be considerable variation in the order and arrangement of these branches as may be seen by consulting Figs. 78 and 84. The innominate artery has sometimes been called the brachiocephalic. Ten pairs of *intercostal* arteries supply the intercostal spaces, muscles of the back, and the spinal cord. Two *bronchial* arteries go to the lung tissue. Two to four *esophageal* arteries are distributed to the esophagus. Two or three pairs of *lumbar* arteries pierce the muscles of the back.

The *abdominal aorta* gives off the following branches: the celiac axis, the superior mesenteric, the adrenolumbalis, a pair of renal, a pair of genital, an inferior mesenteric, a pair of iliolumbar, seven or eight pairs of lumbar, a pair of external iliacs, a pair of internal iliacs, (hypogastric), and a caudal artery (Fig. 78).

The *celiac axis* is a large branch arising just caudad to the diaphragm and gives off the *hepatic* branch to the liver, pancreas, and duodenum, the *gastric* (gastrica sinistra) to the stomach, and

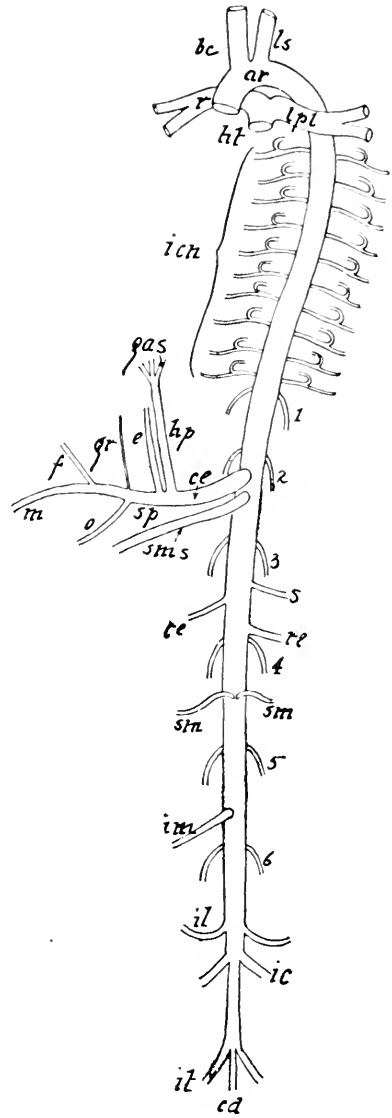


FIG. 78.—CHIEF ARTERIES OF THE TRUNK, VENTRAL ASPECT.

ar, Arch of the aorta; bc, innominate; ce, celiac axis; cd, caudal; e, gastric; f, gastric; gr, gastric; gas, gastroduodenalis; hp, hepatic; ht, location of heart; icn, intercostals; ic, external iliac; it, internal iliac; il, iliolumbar; im, inferior mesenteric; ls, left subclavian; lpl, left pulmonary; m, splenic; o, splenic; r, right pulmonary; re, renal; sp, splenic trunk; sms, superior mesenteric; sm, spermatic or ovarian; s, adrenolumbalis; 1, 2, 3, 4, 5, and 6, lumbar arteries.

is continued as the *splenic*, supplying the pancreas and the spleen. The *phrenic* artery, supplying the diaphragm, sometimes arises from the celiac axis, but usually from the adrenolumbalis.

One or two small branches (*As ventriculi dorsales*) may arise from the celiac near its division, but frequently they are given off by the left gastric artery.

The hepatic branch of the celiac axis gives off the gastroduodenalis just before entering the liver. Within the liver the hepatic breaks up into branches for the several lobes and a cystic branch to the gall bladder. The gastroduodenalis soon divides into three branches: the pyloric (*A. pylorica*) to the pylorus and the lesser curvature of the stomach. Its terminal branches anastomose with the left gastric. (*b*) The pancreaticoduodenalis superior, to the duodenum and pancreas. Its terminal branches anastomose with those of the pancreaticoduodenalis inferior. (*c*) The gastroepiploica dextra, to the greater curvature of the stomach and anastomosing with the terminal branches of the splenic artery (*A. lienalis*). The gastrica sinistra supplies the lesser curvature of the stomach and anastomosis with the pyloric artery.

The *superior mesenteric* is about the same size as the celiac axis, and arises within one centimeter caudad. It sends branches to the pancreas and both intestines. The *adrenolumbalis* is a small branch on the left dividing into the adrenal, phrenic, and muscular. The superior mesenteric gives off four large branches and breaks up into about sixteen smaller ones. (*a*) Pancreaticoduodenalis inferior, to the pancreas and duodenum, anastomosing with the gastroduodenalis superior. (*b*) Colica media to the colon. It divides into two branches, one anastomosing with the colica dextra and the other with the inferior mesenteric. (*c*) Colica dextra, to the colon and anastomosing with the colica media and the ileocolica. (*d*) Ileocolica, supplies the cecum and ileocecal valve and anastomoses with the colica dextra and branches of the superior mesenteric. The

sixteen or more smaller branches supply the small intestine. The renal arteries supply the kidneys and sometimes the adrenal bodies. Occasionally the spermatic artery may arise from the renal and in rare instances the phrenic artery has a similar origin. The genital arteries are small, and arise from one to two centimeters caudad of the renal arteries. They pass obliquely caudad to the ovaries in the female, and more directly caudad to the testes in the male. The ovarian arteries are larger than the spermatic. The *inferior mesenteric* is almost as large as the superior mesenteric. It is distributed to the large intestine. Its two large branches are, the *colica sinistra*, and the *superior hemorrhoidal*. The *iliolumbar* arteries are small branches supplying the muscles of the iliac region.

Four of five pairs of *lumbar arteries* are given off from the dorsal side of the aorta at regular intervals between the diaphragm and the origin of the external iliac arteries. They supply the muscles of the back and spinal cord. The *external iliac* arteries are the largest branches of the abdominal aorta and carry blood to the hind-limbs. The *internal iliac* arteries arise more than a centimeter caudad to the external iliacs and furnish blood to the pelvic viscera and the muscles of the innominate region. The *caudal* (sacralis media) artery is the continuation of the aorta beyond the origin of the internal iliacs. It extends into the tail (Figs. 78 and 84).

ARTERIES OF THE HEAD AND NECK

From the arch of the aorta arise the *innominate* and left *subclavian*, which supply the sternum, neck, head, and anterior extremities with blood. The innominate gives off the left *carotid* and then divided into the right carotid and right subclavian (Fig. 79). Sometimes the two carotids arise as a single trunk from the innominate, which is then continued as the right subclavian. In this case the common trunk of the carotid usually bifurcates within one or two centimeters of its origin,

forming the right common carotid and the left common carotid, lying on the respective sides of the trachea beneath the sternomastoid and the sternohyoid muscles. The vagus or tenth

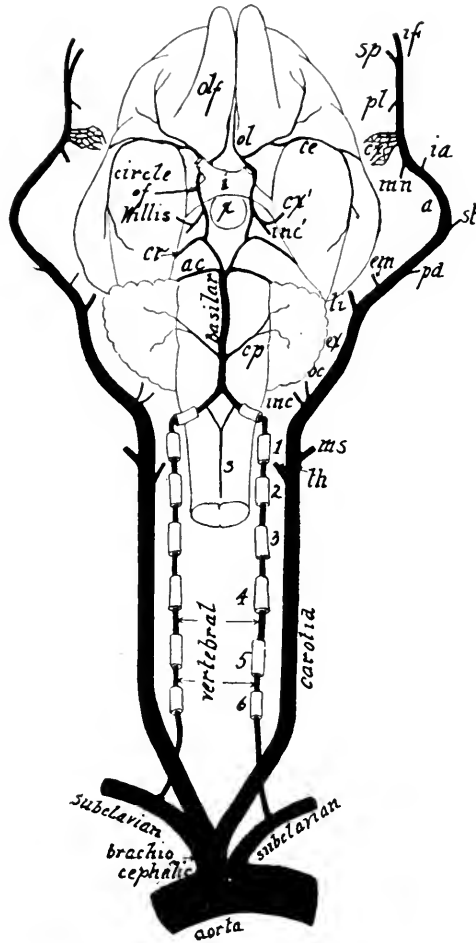


FIG. 79.—VENTRAL ASPECT OF THE ARTERIES OF THE HEAD AND NECK.

The carotids with their branches have been drawn laterad.

a, Internal maxillary; *ac*, anterior cerebellar; *ce*, median cerebral; *cr*, posterior cerebral; *cp*, posterior cerebellar; *cx*, carotid plexus, many of whose branches reunite in one; *cx'*, which is cut off; *ex*, external carotid; *em*, external maxillary; *inc*, origin of internal carotid; *inc'*, union of internal carotid with circle of Willis; *ia*, inferior alveolar; *iv*, infraorbital; *i*, optic chiasma; *li*, lingual; *mm*, middle meningeal; *ms*, muscular; *oc*, occipital; *ol*, anterior cerebral; *pl*, palatine; *pa*, posterior auricular; *s*, anterior spinal; *th*, thyreoid; *x*, hypophysis; 1, 2, 3, 4, 5, and 6, transverse foramina in cervical vertebrae.

cranial nerve and the sympathetic trunk lie in the same sheath with the carotid (Fig. 72).

Each *carotid artery* in the neck region gives off the following branches: an *inferior thyroid* to the trachea and oesophagus, a *superior thyroid* to the thyroid cartilage and gland, and a *muscular* to the muscles of the neck. At the base of the skull, about the middle of the bulla of the temporal bone, a slight enlargement of the vessels is seen, from which arises the very small *internal carotid*, leading through the foramen lacerum medius to the base of the brain, where it joins the *circle of Willis*. The continuation of the common carotid is now known as the *external carotid*. This, after giving off a *lingual* branch to the tongue, an *external maxillary* branch to the lower jaw, a *post-auricular* branch, and a superficial *temporal* branch, turns to pass along the medial aspect of the mandible, where it is named the *internal maxillary*, whose main branches are the *inferior alveolar*, the *middle meningeal** supplying the dura mater, several branches to form the *carotid plexus*, a *palatine*, *sphenopalatine*, and *infraorbital*. The latter is the direct continuation of the internal maxillary. It supplies the upper teeth, lower eyelid, parts of the nose, and upper lip. An *ophthalmic* branch, supplying structures in the orbit, may arise from the carotid plexus or the internal maxillary. The branches of the *external maxillary* artery are the *submental* to the symphysis of the lower jaw, and the *superior* and *inferior labial* arteries.

The *vertebral artery* is the first branch given off by either subclavian. It proceeds dorsad and craniad to the sixth cervical vertebra, whence it extends through the transverse foramina of the cervical vertebræ (vertebrarterial canal) and foramen magnum, to a junction with its fellow in the median line on the ventral aspect of the medulla oblongata. The union of the two vertebral arteries forms the *basilar* artery, which, after giving off several branches to the medulla and cerebellum, divides craniad of the pons Varolii, forming the *circle of Willis* around the infundibulum and the optic chiasma at the base of the brain. The circle of Willis receives the

* The middle meningeal may arise variously, frequently it arises from the intracranial portion of the carotid plexus, Fig. 79 (Norris).

internal carotid and gives off several arteries to the cerebrum. In man the internal carotid is much larger proportionately than in the cat (Fig. 74). The branches of the basilar artery are the *posterior inferior cerebellar*, *anterior cerebellar* and *posterior cerebral* arteries.

THE ARTERIES OF THE THORACIC LIMB

There is more or less variation in the branching of the arteries in the limbs. No two cats are found exactly alike as to their arteries or veins. The same is true of all other mammals.

The *subclavian artery*, which on the right side springs from, or is merely a continuation of, the innominate and on the left side arises from the arch of the aorta, supplies the forelimbs with blood (Figs. 79 and 80). When the subclavian reaches the armpit, it is called the *axillary artery*, and its continuation along the humerus is the *brachial artery*. A continuation of the same artery along the radius is the *radial artery*, furnishing a large part of the blood to the fingers.

Four branches arise from the subclavian: (1) the vertebral artery, extending to the brain through the transverse foramina of the cervical vertebræ (2) the internal mammary, arising from the ventral side of the subclavian opposite the origin of the vertebral, and extending along the visceral surface of the sternum and sometimes supplying the pericardium of the heart; (3) the costocervical axis, arising near the vertebral artery, it gives off the superior intercostal artery supplying the first and second intercostal spaces and some deep muscles of the neck, and the transversa colli to the serratus anterior and continues as the deep cervical (*cervicales profunda*) to supply the deep muscles of the neck; and (4) the thyreoid axis, extending craniad giving off the ascending cervical to some muscles of the neck, and the transverse scapular to the lateral aspect of the scapula (Fig. 80).

The axillary artery gives origin to three branches: (1) the anterior thoracic, supplying the pectoral muscles; (2) the long thoracic, distributed chiefly to the latissimus dorsi; and (3) the

subscapular, which is almost as large as the continuation of the axillary, now called the brachial from this point on. The subscapular, about a centimeter from its origin gives off the thoracodorsalis to the teres major, latissimus dorsi, and epitrochlearis muscles; and the posterior circumflex which winds around the neck of the humerus to its distribution in the triceps and deltoid muscles. The subscapular may also give origin to the anterior circumflex and deep branchial arteries, although these usually arise from the brachial.

The brachial artery, in addition to several muscular branches, gives origin to the anterior circumflex, superior profunda, the nutrient, and anastomotica magna. The *anterior circumflex* supplies the biceps and head of the humerus. The *superior profunda* is distributed to the muscles on the caudal aspect of the humerus. The *nutrient artery* enters the nutrient foramen of the humerus. The *anastomotica magna* or *superior ulnar collateral* artery is the small branch supplying the convexity of the elbow. The *superior collateral radial* artery rises at about the same point

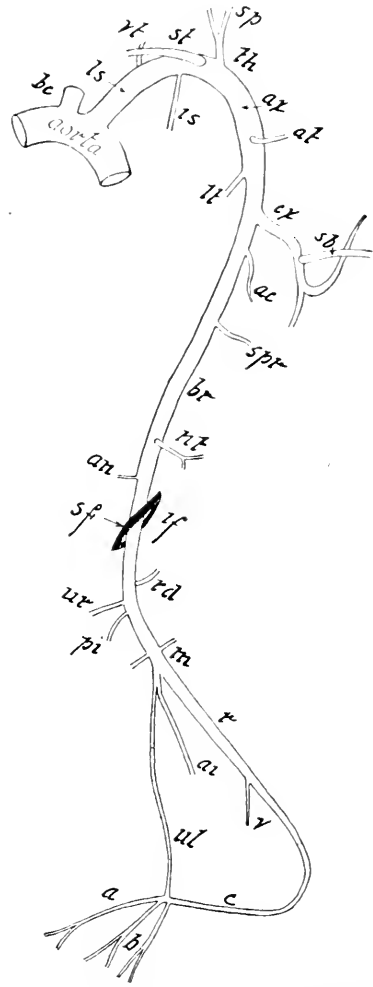


FIG. 80.—ARTERIES OF THE FORELIMB; VENTRAL ASPECT.

a, Digital artery; *an*, anastomotica magna; *ac*, anterior circumflex; *ai*, anterior interosseous; *ax*, axillary; *at*, anterior thoracic; *b*, digital artery; *bc*, innominate; *br*, brachial; *c*, dorsal branch of the radial where it passes between the second and third metacarpals to the palmar side; *cx*, circumflex; *is*, superior intercostal; *ls*, left subclavian; *lt*, long thoracic; *m*, branch to extensor muscles; *nt*, nutrient; *pi*, posterior interosseous; *r*, radial; *rd*, radial recurrent; *sf*, supracondyloid foramen of the humerus; *spr*, superior profunda; *sb*, subscapularis; *sp*, supra-scapularis; *st*, sternal; *th*, thyreoid axis; *ul*, ulnar; *ur*, ulnar recurrent; *vt*, vertebral.

in company with the median vein of the elbow (v. mediana cubita). It passes to the ventroradial border of the forearm and accompanies the cephalic vein and superficial nerve to the wrist where it turns onto the dorsal side of the hand, giving rise to the *dorsal digital* arteries of the hand (Aa. digitales dorsales manus). The brachial artery after passing through the supracondyloid foreman takes the name of radial.

The *radial artery*, which lies deep beneath the flexor muscles on the caudal aspect of the proximal half of the radius (Fig. 80), becomes superficial along its distal half, where the vessel is covered by skin and fascia only. In the region of the wrist, it curves dorsad and then pierces between the second and third metacarpals to the palmar side, where it sends branches to each of the digits, and forms the palmar arch by anastomosing with the ulnar artery beneath the flexor muscles. In addition to a few small branches, the radial gives off the following: the *radial recurrens*, supplying the concavity of the elbow; the *ulnar recurrens*, supplying the convexity of the elbow; the *posterior interosseous*, passing caudad between the radius and the ulna to the extensor muscles; the *anterior interosseous*, passing along the cranial side of the interosseous membrane; the *ulnar*, extending beneath the flexor muscles, which it supplies, to the palm, where it anastomoses with the radial to form the palmar arch; and the *volar* branch, supplying the superficial palmar region. The ulnar and anterior interosseous frequently arise from the same trunk, as shown in the figure. The ulnar artery in the cat is so small that it is frequently not filled by the starch injection, but in man it is larger than the radial.

THE ARTERIES OF THE HIND-LIMB

As in the forelimb, the branching of the arteries in the hindlimb varies considerably in different specimens. The main artery of the leg lies on the ventral or medial aspect of the femur,

passing obliquely to the caudal side of the knee-joint, where it divides into two branches (Fig. 81), one extending along the cranial, the other along the caudal aspect of the crus. The cat, or at least the caudal half of a cat, should be fastened to the dissecting tray on its back, the abdominal wall removed, and the viscera pushed laterad to demonstrate the origin of the artery of this limb. As in the forelimb, the main artery in different portions of the leg takes the name of the corresponding region.

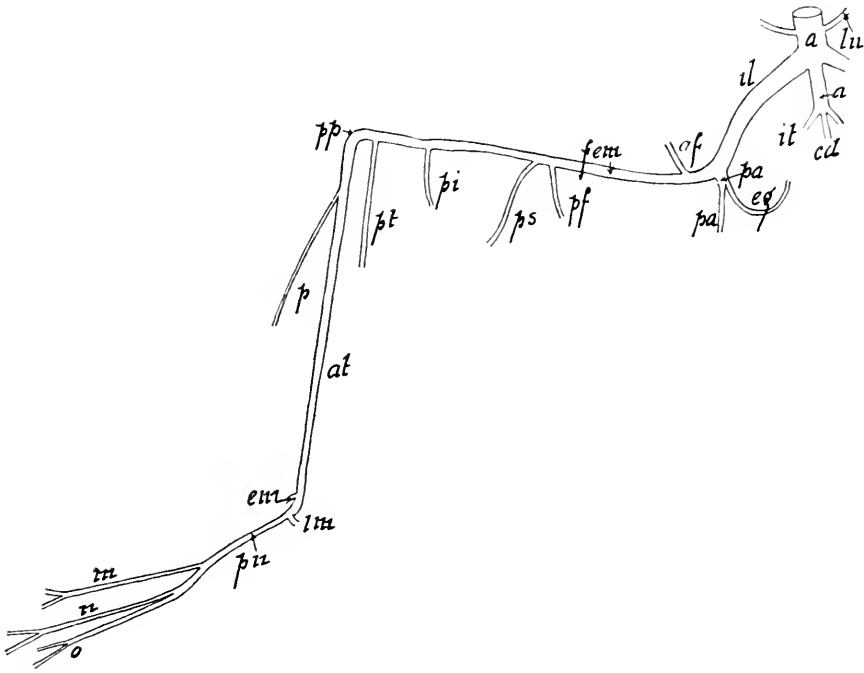


FIG. 81.—ARTERIES OF THE RIGHT LEG. VENTRAL ASPECT.

a, Aorta; *at*, anterior tibial; *af*, anterior femoral; *cd*, caudal; *eg*, epigastric; *em*, external malleolar; *fem*, femoral; *im*, internal malleolar; *il*, external iliac; *it*, internal iliac; *lu*, iliolumbar; *m*, digital; *n*, digital; *o*, digital; *p*, peroneal; *pa*, profunda; *pf*, posterior superior femoral; *pi*, posterior inferior femoral; *pn*, plantar; *pp*, popliteal; *pt*, posterior tibial; *ps*, saphenous.

The *external iliac* is the largest artery arising from the aorta in the lumbar region. It gives off but one important branch, the deep artery of the thigh (*A. profunda femoris*), which, extending caudad soon gives off three branches a large *inferior epigastric* artery to the abdominal wall, a branch to the

bladder then a smaller branch to the external genital organs, and numerous branches to the muscles on the caudal aspect of the femur. The branches of the *hypogastric* (internal iliac) are the umbilical to the bladder, the *superior gluteal* to the pelvic wall, the *middle hemorrhoidal* to the rectum and the *inferior gluteal*.

The *femoral artery*, which is a continuation of the external iliac, extends along the medial aspect of the femur. In the proximal half of its course it is quite superficial, and lies in a triangular space known as Scarpa's triangle and in Hunter's canal, but the distal portion is covered by the gracilis, sartorius, and semimembranosus muscles. It furnishes four important branches: the circumflexa femoris lateralis supplying mainly the quadriceps extensor muscle; the muscular branches supplying the adductor and hamstring muscles; *genu suprema* to the knee, the *saphenous*, accompanying the saphenous nerve and vein to the foot, where it branches and anastomoses with the plantar artery; and the sural artery supplying mainly the gastrocnemius group of muscles (Fig. 49).

The *popliteal artery* is the continuation of the femoral artery in the popliteal region on the caudal aspect of the knee-joint. One or two articular branches are given off here to the joint, in addition to the *posterior tibial*, which supplies the deep muscles of the crus.

The *anterior tibial artery* is the continuation of the popliteal on the lateral cranial aspect of the tibia, adjacent to the bone. By separating the tibialis anticus and extensor longus digitorum muscles, this artery is well displayed. Near the knee-joint a small branch, the *peroneal*, is given off, and passes to the dorsal aspect of the foot, where it anastomoses with the dorsal branch of the saphenous, forming a superficial arch sending branches to the digits. The peroneal is so small that it is frequently not injected. In the tarsal region two branches, an *external* or *lateral anterior malleolar* and an *internal* or *medial anterior malleolar*, are given off. A centimeter or two distal to the latter branch, the main artery passes between the second and third

metatarsals to the deep plantar region, where it receives an anastomosing branch from the saphenous forming the *plantar arch*, and sends off branches to the digits. (*Aa digitales plantares*.)

THE VENOUS SYSTEM

The veins are the vessels returning the blood to the heart. As a rule, veins carry only impure blood, but the pulmonary veins returning blood from the lungs to the left atrium carry pure blood. After death the veins can readily be distinguished from the arteries by the fact that they have much thinner walls than the arteries and are usually full of blood, while the arteries are empty (Fig. 82). This is due to the fact that the thick muscular coat of the arteries, by its contraction tends to drive the blood into the veins, whose muscular coat is very thin. The three coats composing the walls of the veins are the epithelial, or *tunica intima*; the middle or *muscular*; and the *tunica adventitia*, or outer elastic coat of fibro-areolar tissue. The veins of the central nervous system and its membranes have no muscular coat. While the only valves in the arteries are found at their origin from the heart, the veins of the limbs, neck, and the head possess numerous valves. These *valves* are formed by semilunar folds of the epithelial coat, strengthened by fibrous tissue (Fig. 83).

The main deep veins of the limbs accompany the arteries and take the same names as the arteries. A superficial set of veins is present also in the limbs. The large superficial vein on the lateral aspect of the forelimb is the *cephalic*. The superficial vein extending along the medial aspect of the hind-limb is the *saphenous*.

The Veins of the Trunk, Head, and Neck.—There are two chief venous trunks: the *precava*, or *superior vena cava*, and the *postcava*, or *inferior vena cava*. Both vessels open into the dorsal aspect of the right auricle or atrium. The veins received by the inferior vena cava are thirteen in number. The *phrenic*

veins collect the blood from the diaphragm and empty into the vena cava immediately caudad of the diaphragm. The several *hepatic* veins collect the blood from the liver, which must be partly dissected away to see their entrance into the vena cava.

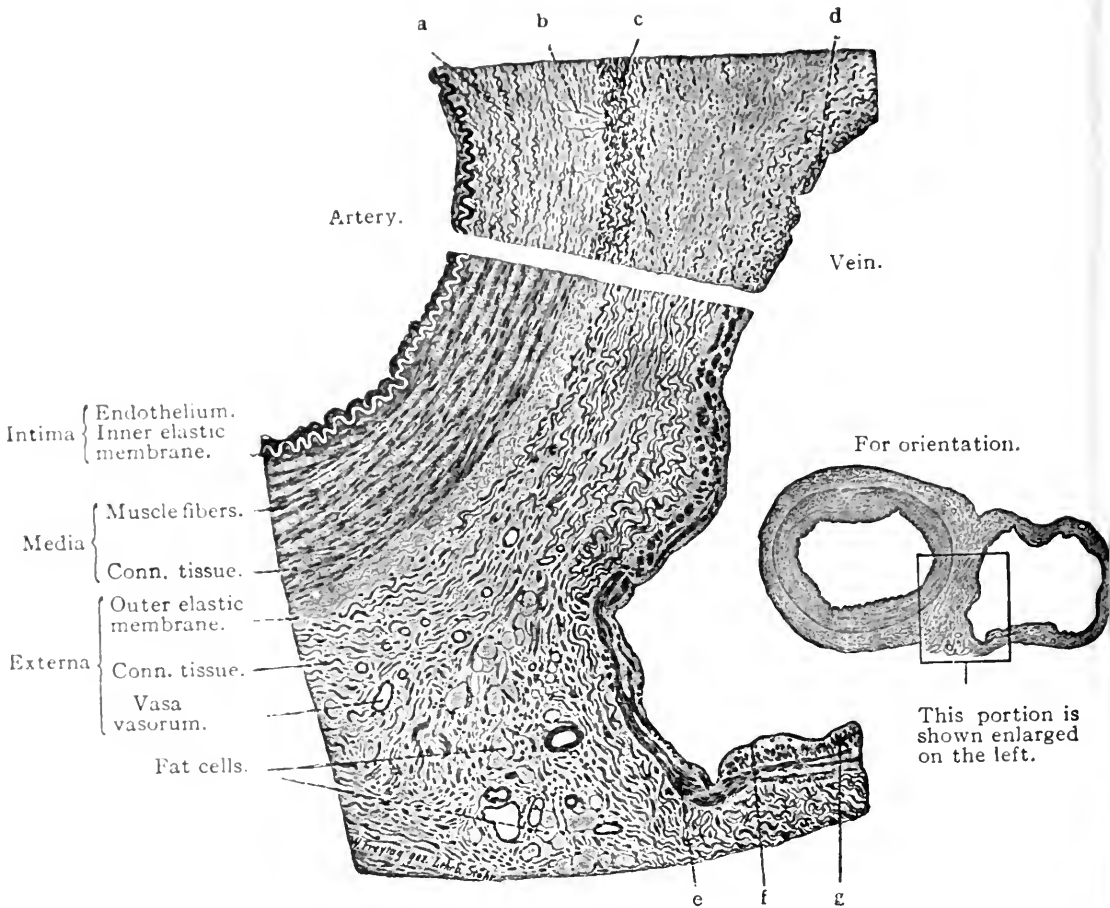


FIG. 82.—A SECTION THROUGH A HUMAN ULNAR ARTERY AND VEIN, SHOWING THE WALL OF THE ARTERY ON THE LEFT AND OF THE VEIN ON THE RIGHT. THE UPPER PART OF THE FIGURE (a-d) IS FROM A SECTION OF THE SAME VESSELS STAINED WITH RESORCIN-FUCHSIN, AN ELASTIC TISSUE STAIN. $\times 550$.

a, Circular, and b, radial elastic fibers of the media of the artery; c, external elastic membrane; d, elastic fibers in the media of the vein; e, circular, and g, longitudinal muscle fibers of the media; f, endothelium. (Lewis and Stöhr.)

The two *adrenolumbar veins* return the blood from the suprarenal bodies and body walls, *lumbar veins* to muscles of dorsal wall and two *renal veins* carry the blood from the kidneys. The left *ovarian* or *spermatic vein* is a tributary to the left renal, but

the *right ovarian* empties directly into the vena cava. A pair of small *iliolumbar* veins collecting blood from the lumbar muscles empty into the vena cava a centimeter or more craniad to the large common iliacs. The union of the *common iliac veins* collecting the blood from the hind-limbs and the pelvic region, and the caudal vein, forms the beginning of the inferior vena cava. The common iliac is formed by the union of the external and internal iliac veins in the pelvis. The former is much the larger of the two.

The **portal system** begins with the veins collecting the blood from the intestines, pancreas, spleen, and stomach, and terminates where the hepatic veins enter the vena cava. The *inferior mesenteric* vein collects the blood from the large intestine; the *superior mesenteric*, from the small intestines; the *gastro-splenic*, from the spleen, stomach, and pancreas; the *coronary*, from the lesser curvature of the stomach; the *gastro-epiploica*, from the greater curvature of the stomach; and the *pancreatoduodenalis*, from the pancreas and duodenum. The last three may empty directly into the portal vein or into one of the three branches first named. Within the liver the blood is carried to the hepatic lobules through the *interlobular branches* of the portal vein, from which it is distributed to the *intralobular sinusoids*. It is then collected by the *central vein* of the lobule and conveyed through the *hepatic veins* to the *postcava* through which it reaches the heart.

The *superior vena cava* (precava) extends from the union of the innominate veins to the right atrium. Three important veins empty into the superior vena cava: the *azygos*, collecting blood from the intercostal spaces; the *sternal*, lying on the visceral surface of the sternum; and the *right vertebral*, which, with its fellow, collects the blood from the deep muscles and

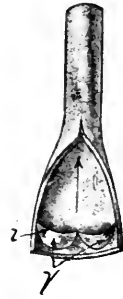

FIG. 83.—VEIN CUT OPEN. ARROW SHOWS THE DIRECTION OF THE BLOOD. *v*, Semilunar valves; *i*, free edge of the valve.

spinal cord in the region of the atlas, and after making a strong anastomosis with the internal jugular vein, descends in company with the vertebral artery through the transverse foramina canal of the first, six cervical vertebrae. The *left vertebral vein* is a tributary of the left innominate (Fig. 84).

The *innominate vein* is formed by the union of the subclavian and the external jugular. Sometimes the vertebral vein joins also in the union instead of emptying into the superior vena cava. The *subclavian vein* returns the blood from the arm and accompanies the subclavian artery. The *external jugular veins* are large vessels lying on either side of the neck beneath the platysma myoids muscle. When the skin is removed, the veins are plainly seen through this very thin muscle. The external jugular is formed ventral to the angle of the mandible by the union of the *anterior and posterior facial veins*. The anterior facial are united by a large transverse vein. The two tributaries of the external jugular are the *transverse scapular vein* and the *internal jugular*. The former receives the cephalic vein, a superficial vein on the lateral aspect of the arm, and the latter is the small vein returning from the brain.

A system of tube-like spaces, called *sinuses*, whose walls are formed by the dura mater lined with epithelium, takes the place of the large venous trunks within the cranial cavity. These sinuses are usually not filled by a starch injection, but may be filled by a gelatin mass. They cannot be dissected by the beginner. The *superior longitudinal sinus* extends in the median line beneath the roof of the skull, from the ethmoid region to the tentorium cerebelli, where it bifurcates to form the *lateral sinuses*, which proceed laterad and ventrad in the substance of the tentorium. The *lateral sinus* emerges from the tentorium just caudad to the petrosal bone, where it follows the groove to the jugular foramen. This groove may be seen in a bisected or unroofed skull.

The *superior petrosal sinus* lies in the angle formed by the junction of the tentorium and the petrosal bone, and unites

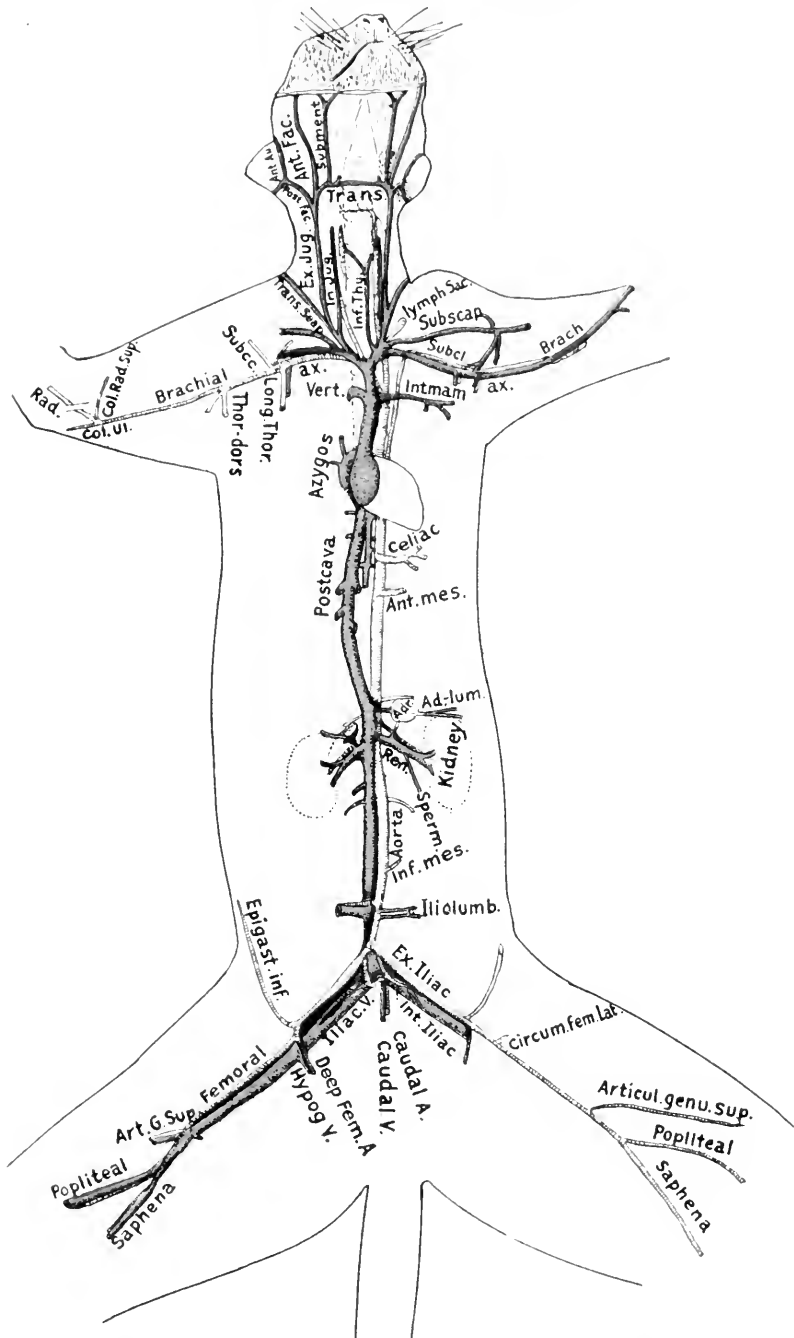


FIG. 84.—CHIEF ARTERIES AND VEINS OF THE CAT.

Ad. lum., adrenolumbar; *Ant. au.*, anterior auricular; *Ant. Fac.*, anterior facial; *Ant. mes.*, anterior mesenteric; *Art. G. Sup.*, articularis genu supra (vein); *Articul. genu. sup.*, articularis genu supra (artery); *Ax.*, axillary artery and vein; *Brach.*, brachial vein; *Circum. fem. lat.*, circumflexa femoris lateralis (artery); *Col. Rad. Sup.*, collateralis radialis superior artery; *Col. ul.*, collateralis ulnaris artery; *Epigast. inf.*, epigastrica inferior; *Ex. iliac.*, external iliac artery; *Ex. Jug.*, external jugular vein; *Hypog. V.*, hypogastric vein; *Int. iliac.*, internal iliac; *Int. Jug.*, internal jugular; *Int. mam.*, internal mammary; *Inf. mes.*, inferior mesenteric; *Inf. Thy.*, inferior thyroid; *Long. Thor.*, long thoracic; *Pos. Fac.*, posterior facial; *Ren.*, renal; *Subcl.*, subclavian; *Subment.*, submentalis vein; *Subscap.*, subscapular vein; *Trans.*, transverse vein; *Trans. Scap.*, transverse scapular vein; *Thor.-dors.*, thoracodorsalis artery; *Vert.*, vertebral vein.

with the lateral sinus just before it reaches the jugular foramen. The *inferior petrosal sinus*, collecting blood from the base of the brain, lies in the groove ventral to the petrosal bone, and unites with the lateral sinus at the jugular foramen. The union of these sinuses at this foramen forms the *internal jugular vein*,

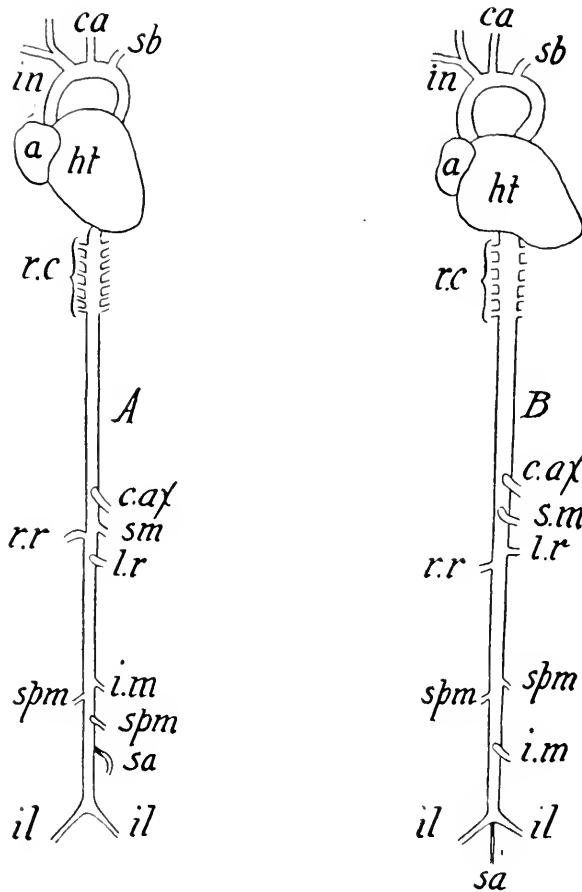


FIG. 85.—A, VENTRAL VIEW OF HEART AND MAIN ARTERIES IN THE TRUNK OF THE RABBIT. B, ARTERIES OF MAN.

a, Right atrium; *ca*, left carotid; *c. ax*, celiac axis; *i. n*, innominate; *il*, common iliac; *i. m*, inferior mesenteric; *l. r*, left renal; *r. r*, right renal; *r. c*, right intercostals; *sm*, superior mesenteric; *spm*, spermatic; *sa*, sacral; *sb*, left subclavian.

which extends deep beneath the muscles of the neck with the carotid artery. It joins the external jugular opposite the shoulder-joint. At the base of the skull the internal jugular gives off a large transverse anastomosing vein to the vertebral,

so that the blood from the vein may return partly by the latter vessel.

The *pulmonary veins* convey the pure blood from the lungs to the left atrium. There are three main trunks from each lung. These six veins are arranged in pairs (Fig. 77), constituting a left pair from the left lung; a median pair, composed of one branch from the right and one from the left lung; and a right pair from the right lung. Each pair forms a common trunk before entering the atrium. In order to demonstrate these veins one must remove the heart and lungs from an injected cat, and carefully dissect away the fatty and connective tissues enveloping the vessels.

The peripheral connection between the arteries and veins is by means of *capillaries*, which are microscopic vessels with an extremely thin wall composed of a single layer of epithelial cells. These capillaries are so abundant everywhere in the flesh that a needle cannot be inserted without penetrating some. They form a kind of mesh or network, so that every cell may be supplied with oxygen and food and discharge its waste matter. All the blood carried to any portion of the body by the arteries is not returned by the veins, as a considerable amount of the plasma and some of the white corpuscles escape through the thin capillary walls and are returned to the circulation by a system of vessels called lymphatics (Fig. 91).

DEVELOPMENT OF THE VASCULAR SYSTEM

In the cat as in all other vertebrates the vascular system has its origin in the mesenchyme. Small spaces or clefts appear among the mesenchymal cells, enlarge and fuse together to form a network or plexus of channels. Following certain laws of hydrodynamics the blood stream comes to flow along the most direct line of least resistance. The channels thus formed are usually oriented with respect to the longitudinal axis of the body. Those carrying blood toward the central organ of circulation develop into the venous system, while those carrying the blood stream peripherally form the arterial system.

DEVELOPMENT OF THE HEART

The development of the heart in the cat has been carefully worked out for the earlier stages by Schulte ('16) and in the

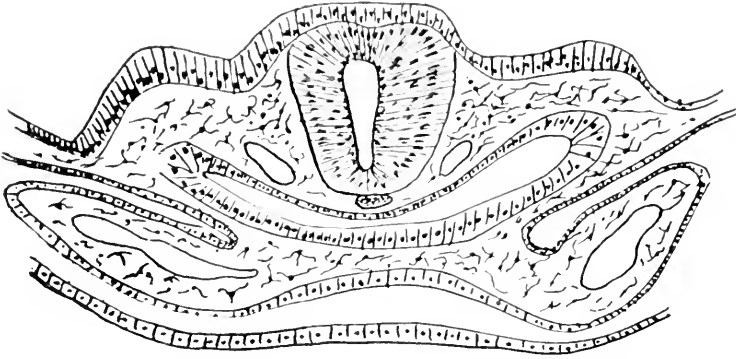


FIG. 86a.—CAT EMBRYO OF NINE SOMITES. (Modified after Schulte, *Am. Jour. Anat.*, Vol. 20, p. 51.)

a, lateral hearts; b, digestive tract; c, nervous system.

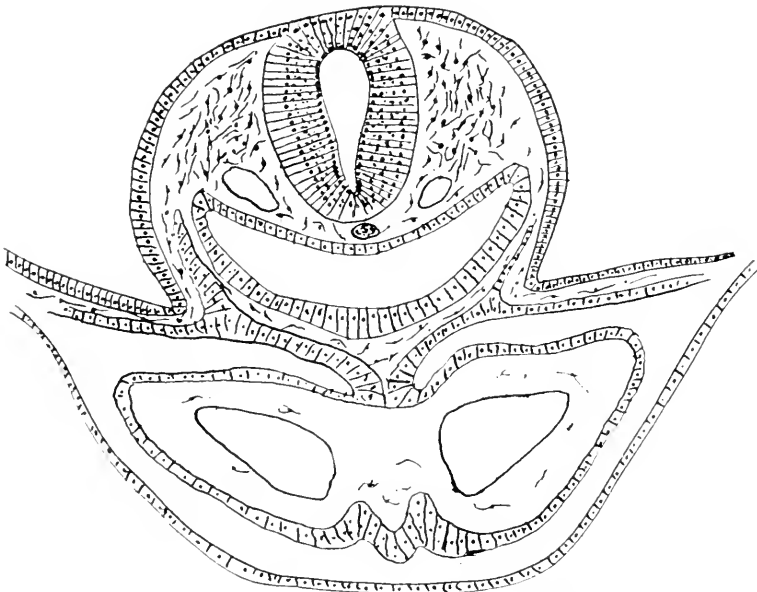


FIG. 86b.—CAT EMBRYO OF TWELVE SOMITES. (Modified after Schulte.)

a, lateral hearts about to fuse; b, endothelial layer; c, myocardium.

pig by Miss Sabin ('17). According to Schulte the heart develops by an approximation, fusing and looping of certain lateral primordia lying in the dorsal wall of the open intestine

in a cat embryo of about nine pairs of mesodermic somites (Fig. 86a). These "lateral hearts" are the continuation forward of the omphalomesenteric veins after they have reached the intraembryonic region. Widely divergent at their caudal ends they converge cranially so as to lie close together for a short distance. The primordia consists essentially of two parts, an inner endothelial layer which eventually becomes the endocardial lining of the adult heart, and a heavier outer part, the myo-epicardial mantle, which forms the muscular walls of the adult organ. In an embryo of about twelve pairs of somites (Fig. 86b) the two lateral moities fuse in the midline of the body to

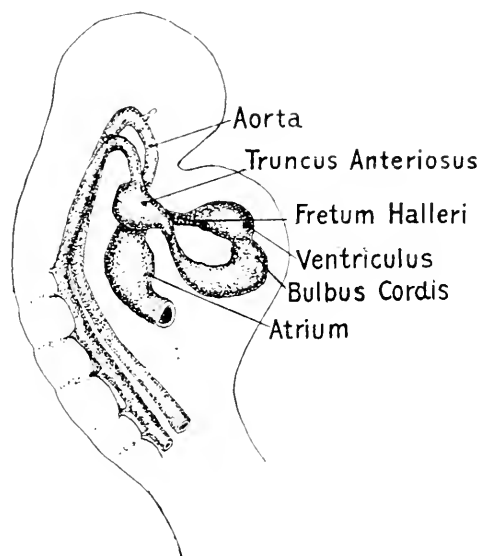


FIG. 86c.—PIG EMBRYO OF TWENTY SOMITES. (After Sabin, *Contributions to Embryology*, Carnegie Institution of Washington, 226, plate 5.)

form a simple tube-like heart resembling in many respects the condition found in the earlier fishes. The primitive heart in its further development then bends on itself and twists so as to bring the caudal or venous end forward and dorsal to the cranial or arterial end. This is well shown in Fig. 86c after Miss Sabin's figure of a pig embryo of about twenty somites. Eventually by a fusion of parts and certain other changes the

venous portion is transformed into the atrial or auricular portion of the adult heart and the arterial into the ventricular portion. It is interesting to note that the heart in its embryonic development passes through a stage in which there is a single circulation, resembling the condition found in lower gill-breathing aquatic vertebrates where only impure blood is found in the heart. Also that an arterial arrangement is set up as though for a gill-breathing animal. It is only later when the true lungs are developed that the heart becomes four chambered and a double circulation characteristic of higher vertebrates is established. In connection with this change in the structure of the heart there are certain transformations in the arrangement of the arterial system changing it from the gill-breathing type to that of the lung-breathing, a change that will be better understood when compared with the phylogeny of the aortic arches shown in Fig. 83.

DEVELOPMENT OF THE AORTIC ARCHES

The aortæ and aortic arches are developed from an arterial plexus in the region cranial and dorsal to the developing heart. The aortæ are developed from a plexus in the area vasculosa along the lateral edge of the myotomes. This capillary plexus appears to be developed *in situ* by the fusion of intercellular mesenchymal spaces or clefts. According to Coulter ('09) only the first aortic arch is complete in a cat embryo of 3 mm., although there are indications of the second and third arches (Fig. 87*a*). These are completed at the time an embryo has reached the length of 4.5 mm. and the fourth arch has begun to be formed (Fig. 87*b*). In a 5 mm. embryo the first arch begins to degenerate, while the fourth is completed and the sixth is begun (Fig. 87*c*). It is doubtful whether the fifth arch is ever completed in the cat although rudiments of it can be seen at a stage slightly older than five millimeters (Fig. 87*d*). Before the six millimeter stage is reached the sixth arch is usually completed and gives origin to the pulmonary arteries

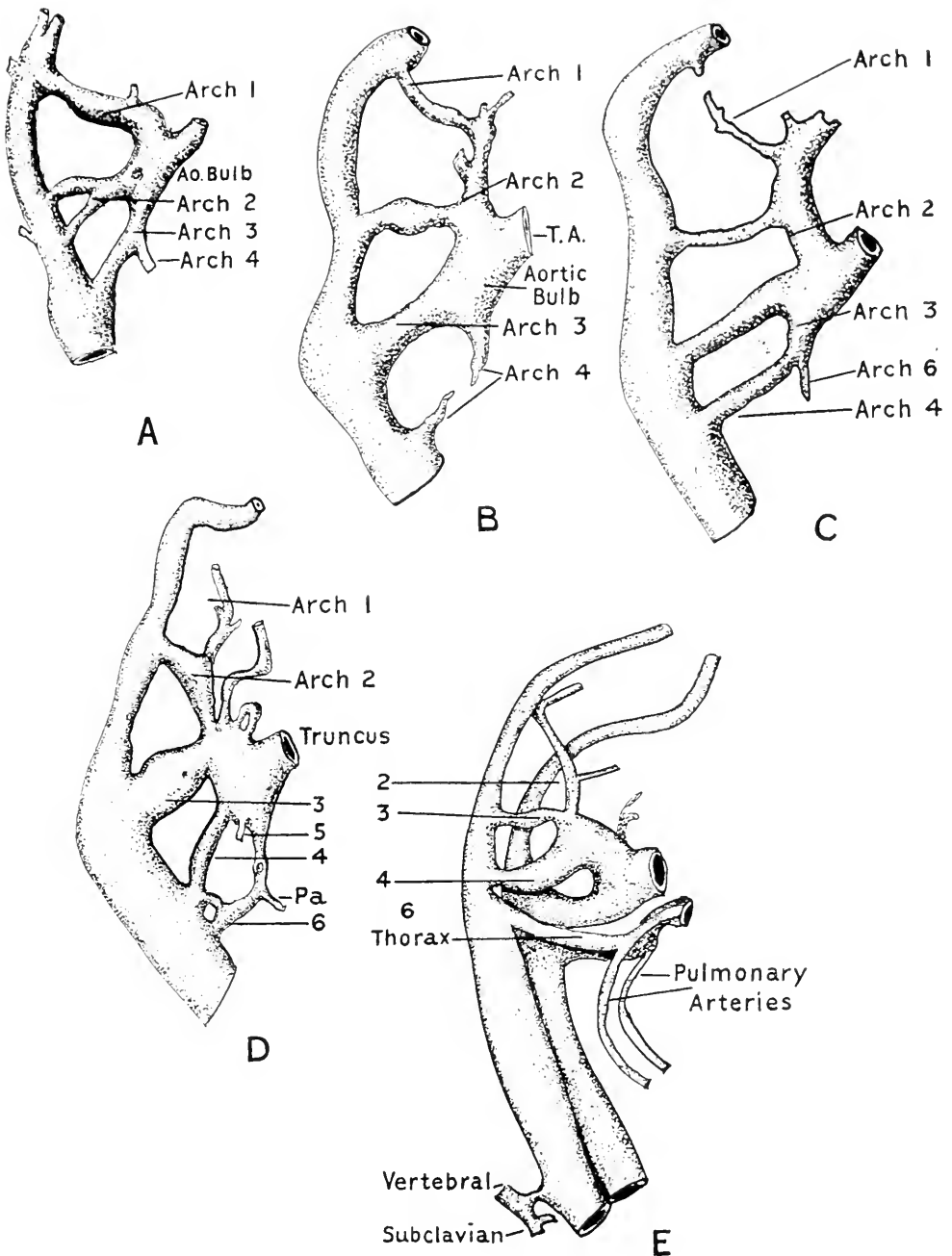


FIG. 87.—DIAGRAMS OF RECONSTRUCTIONS OF AORTIC ARCHES IN CAT EMBRYOS.
(After Coulter, *Anatom. Record*, Vol. 3, p. 580.)

A. aortic arches of a Cat embryo of 4.5 mm. B. aortic arches of a Cat embryo of 5 mm. C. aortic arches of a Cat embryo of 5 mm. D. aortic arches of a Cat embryo of 5 mm. E. aortic arches of a Cat embryo of 10 mm.

(Fig. 87*c*). It is interesting to compare the embryonic history of the aortic arches with the arrangement found in different

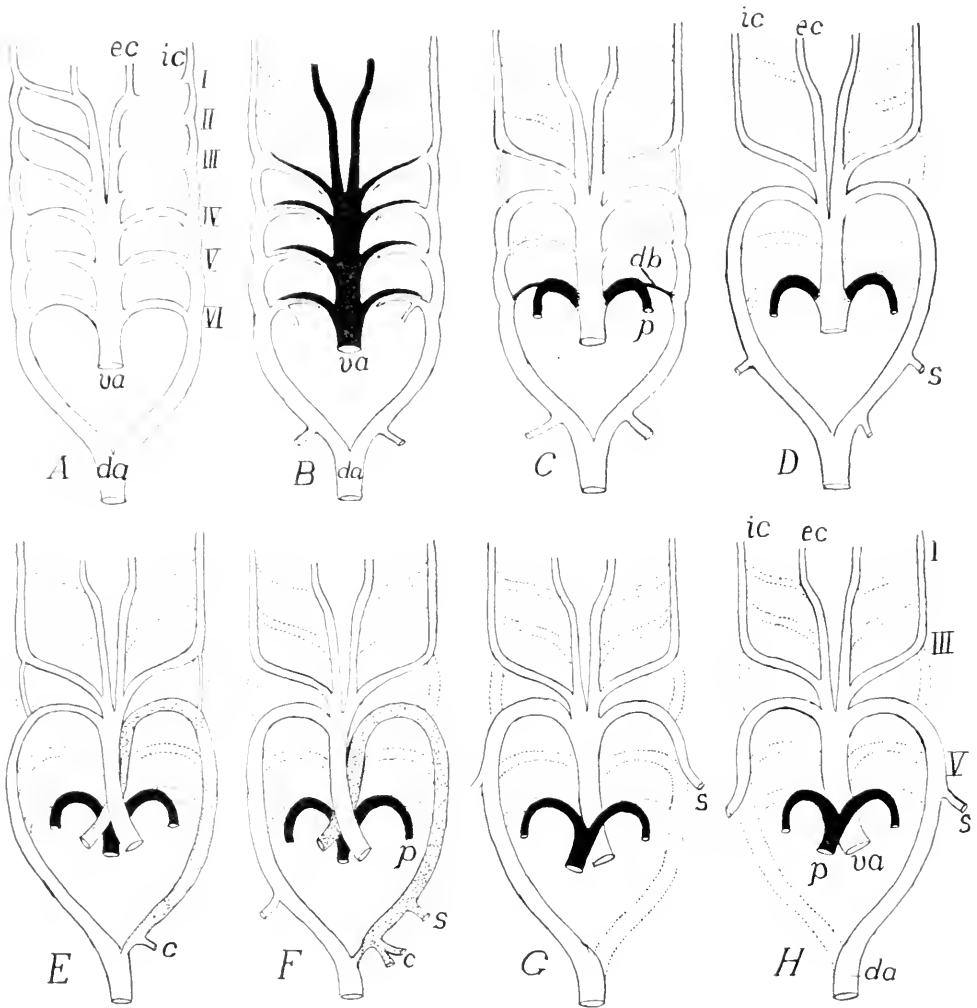


FIG. 88.—MODIFICATIONS OF THE AORTIC ARCHES IN DIFFERENT VERTEBRATES.
(From Kingsley's *Comparative Anatomy of Vertebrates*, after Boas.)

A. Primitive scheme; B. Dipnoian; C. Urodele; D. Frog; E. Snake; F. Lizard; G. Bird; H. Mammal; *c*, celiac artery; *da*, dorsal aorta; *db*, Ductus Botallii; *ec*, *ic*, external and internal carotids; *p*, pulmonary artery; *s*, subclavian; *va*, ventral aorta. Vessels carrying venous blood back; those with mixed blood shaded; those which disappear, dotted outlines.

vertebrates. The schematic diagrams in figure 88 A-H shows the arrangement in fishes (A, B), amphibians (C, D), reptiles (E, F), birds (G) and mammals (H).

DEVELOPMENT OF THE VENOUS SYSTEM

The primary veins of the mammalian embryo are four pairs to which there is early added a fifth pair. These are the precardinals, the postcardinals, the subcardinals, the umbilicals, and later the supracardinals. These primary vessels may be regarded as forming the fundamental ground plan common to all vertebrates. The precardinals and postcardinals join in the heart region to form a duct of Cuvier on each side which open into the sinus venosus. The ducts of Cuvier also receive the umbilicals. The subcardinals open into the postcardinals some distance caudad of the duct of Cuvier. The subcardinals and supracardinals play an important rôle in the formation of the postcava. From these five pairs of veins are developed the larger venous trunks of the adult.

A short outline of the history of the development of the postcava will serve to illustrate the complexity of vascular ontogeny and of the interesting transformations taking place during the embryological development of an animal. The account is based upon the work done by Huntington and McClure on the development of the postcava in the cat.

After the four primary systems have been differentiated from the general plexus system the first important step is the formation of an anastomosis between the subcardinals in the neighborhood of the origin of the omphalomesenteric artery from the aorta, the intersubcardinal anastomosis. (Fig. 89, B.) At about the same level and time there is also formed on each side a subcardino-postcardinal anastomosis. During this stage of development there is a rearrangement of the channels and sinusoids of the liver so as to furnish a more direct route for the blood stream through this organ to the heart so that most of the blood from the posterior regions of the body passes through the liver rather than through the duct of Cuvier. There is thus established in the liver a broad channel which is later to form the hepatic segment of the postcava. However, in order to accomplish this there has been formed in the caval

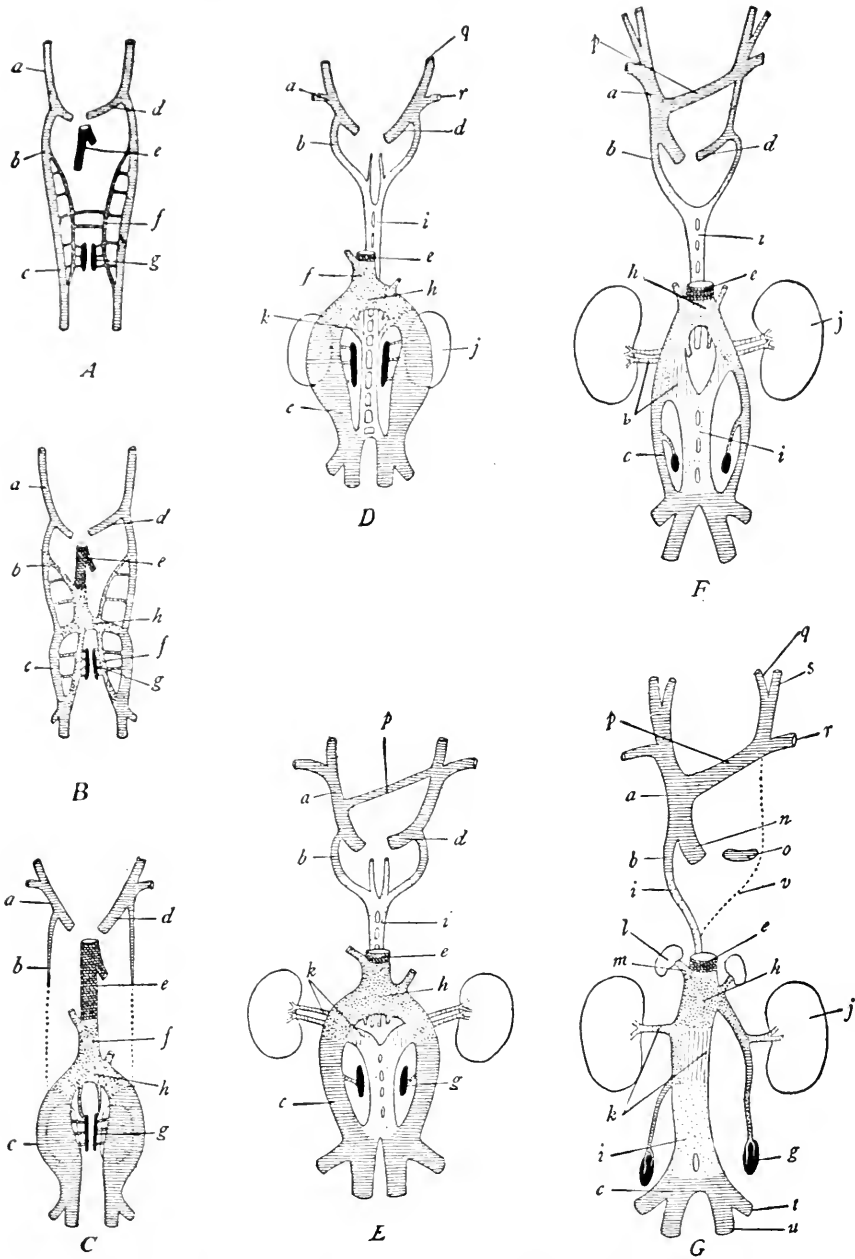


FIG. 89.—DIAGRAMS SHOWING THE DEVELOPMENT OF THE POSTCAVA IN THE CAT. (From Hyman's *Laboratory Manual of Vertebrate Anatomy*, after Huntington and McClure.)

Crosshatching, cardinal system of veins and their derivatives; close stippling, subcardinal system of veins and their derivatives; cross, vertical, and oblique hatching combined, hepatic veins; open stippling, supracardinal system of veins and their derivatives; vertical hatching, the renal collar.

Figs. A-G inclusive, showing various stages of development of the veins in the cat. a, precardinal; b, postcardinal; (thoracic division); c, postcardinal (lum-

mesentery a hepatico-subcardinal anastomosis (Fig. 89B). The result of this diversion of the blood stream through the liver results in the dwindling of the postcardinals cranial of this point. The growth of the pelvic regions of the embryo due to the developing limbs is accompanied by an increase in the size of the posterior part of the postcardinals (Fig. 89C). There now appears a new pair of vessels in the prevertebral regions, the supracardinal veins, which are destined to play a very important part in the formation of the postcava. They make connections with the postcardinals in the caudal regions and also cranially (Fig. 89D). In the pig according to Sabin, the supracardinal are more directly related to the duct of Cuvier than to the postcardinals in that region. An anastomosis is also made with the subcardinals at about the level of the intersubcardinal anastomosis, the subcardino-supracardinal anastomosis. In the same region there is also an intersupracardinal anastomosis. The aorta is thus entirely surrounded by a venous ring, known as the renal collar. The renal collar, therefore, "is formed by the pars subcardinalis of the postcava, the intersubcardinal anastomosis, the right and left subcardino-postcardinal anastomoses, the right and left supracardinals, and the anastomoses between the supracardinals dorsal to the aorta at this point, at which level the renal veins enter the collar." (Fig. 89E.) Further development results in the complete degeneration of the anterior segment of the postcardinal except such part as may enter into the formation of the azygos and such other changes as may be seen by consulting the diagrams in figure 89.

"The embryonic veins which typically enter into the formation of the adult postcava are the right supracardinal

bar division); *d*, duct of Cuvier; *e*, pars hepatica of postcava (hepatic communis and ductus venosus Arantii); *f*, subcardinal; *g*, gonad; *h*, pars subcardinalis of postcava (intersubcardinal anastomosis); *i*, supracardinal; *j*, kidney; *k*, renal collar (subcardino-supracardinal anastomosis); *l*, adrenal gland; *m*, vein to adrenal; *n*, precava; *o* coronary sinus; *p*, left innominate; *q*, internal jugular; *r*, subclavian; *s*, external jugular; *t*, external iliac; *u*, internal iliac.

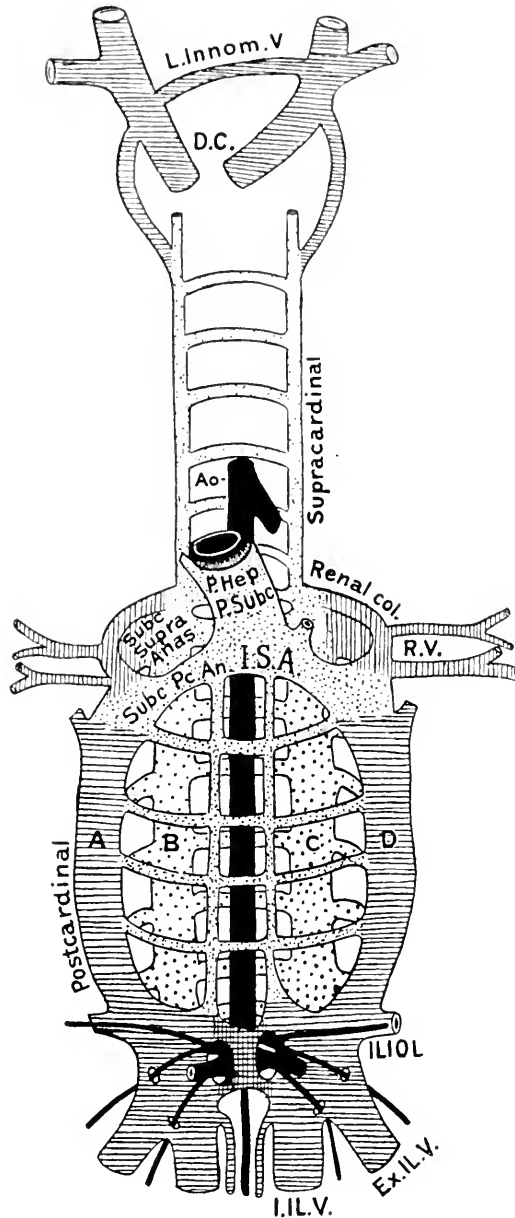


FIG. 90.—COMPOSITE DIAGRAM OF THE EMBRYONIC VEINS OF THE CAT. (After Huntington and McClure, *Anat. Record*, Vol. xx.)

L. Innom. V., left innominate vein; *D. C.*, duct of Cuvier; *Ao.*, aorta; *P. Hep.*, pars hepatica; *P. subc.*, pars subcardinalis of postcava; *I.S.A.*, intersubcardinal anastomosis; *Subc. supra.*, subcardino-supracardinal anastomosis; *Subc. pc. an.*, subcardino-postcardinal anastomosis; *R.V.*, renal vein; *A.*, right postcardinal; *B.*, right supracardinal; *C.*, left supracardinal; *D.*, left postcardinal; *Iliol.*, iliolumbar; *Ex. il. v.*, external iliac vein; *I. il. v.*, internal iliac vein.

(Fig. 90), the right subcardino-supracardinal anastomosis (subc.-supra. anas.), the right subcardino-postcardinal anastomosis (subc.-pc.-an.) the intersub-cardinal anastomosis (I. S. A.), the pars subcardinalis (P. Sub) and the pars hepatica (P. Hep.).”

Figure 90 is also introduced to aid the student interpret some of the variations in the venous system likely to be found in the cat. Huntington and McClure list some seventeen types of variation which may be explained. (Anatomical Record, Vol. 20, page 14.) There may be double postcava, persistence of right postcardinal, or subcardinal, or in some animals and in man of the renal collar. Students are advised to look for and make records of such variations as they may find in their dissection. They will find great pleasure in trying to interpret them embryologically.

LABORATORY STUDIES AND SUGGESTIONS

1. What holds the heart in place?
2. Draw the ventral aspect of the heart with the pericardium removed and label all features.
3. When the heart is detached from the body, how do you distinguish the dorsal from the ventral aspect?
4. How many veins open into each atrium?
5. What arteries lead from each ventricle?
6. After dissecting write a detailed description of the valves of the heart.
7. Describe the difference in the appearance of the walls of the aorta and vena cava.
8. From your dissection write a description of the features seen in each cavity of the heart.
9. Name the branches of the thoracic aorta in order.
10. Name the branches of the abdominal aorta and tell what organs each supplies.
11. Draw the celiac axis and its branches throughout their course and label all parts.
12. Show by a drawing the relations of the aorta and venæ cavæ throughout.
13. Make a diagrammatic cross-section of the neck, showing location of arteries and veins.
14. Describe the three routes by which blood may reach the brain and the two routes by which it may be returned to the heart.
15. Name the arteries arising from the arch of the aorta.
16. Draw the inner or medial aspect of your dissection of the arteries of the thoracic limb and label all parts.

17. Draw cross-section of arm at middle of humerus to show location of main artery and vein.
18. Draw cross-section of the middle region of the forearm to show location of chief arteries.
19. Draw outline of the bones of the manus and show relation of arteries to the bones as seen from palmar aspect.
20. Draw outline of femur and show course of main artery in relation to the bone as seen from medial aspect.
21. Draw outline of bones of the pes and show relations of the arteries to the bones as seen from the plantar aspect.
22. At what points in its course is the chief artery of the pelvic limb most superficial?
23. Describe the difference in structure of a vein and an artery.
24. What veins open into each atrium of the heart?
25. Name the veins returning the blood from each organ of the abdominal cavity.
26. Draw the portal system and label all vessels.
27. Describe the veins returning the blood from the head.
28. Describe the chief blood sinuses in the skull.
29. Where are the valves found in the blood-vessels?
30. If the brachial vein were cut, how could the blood from the manus reach the heart?

THE LYMPHATIC SYSTEM

The lymphatics constitute that part of the vascular system which collects the colorless fluid called lymph from the tissues, and the chyle from the small intestine, and conveys them to the external jugular veins. The portions of the lymphatic system originating in the villi of the small intestine and conveying the chyle to the left thoracic duct are known as the *lacteals* (Fig. 71, *b*).

The lymphatic system consists of four parts: (1) the *lymphatic spaces* between the skin and muscles in all parts of the body, the spaces between the muscles adjacent to the bones, and internal spaces such as those enclosed by the peritoneum and pleura; (2) minute *thin-walled vessels* draining the spaces just described and leading to larger vessels which empty into the tracheal trunks or thoracic duct; (3) the *glands*, which vary in size from a mustard-seed to two centimeters in diam-

eter, and are located chiefly on the side of the neck, in the axillary region, at the bifurcation of the trachea; in the inguinal region, lumbar region, and mesentery; (4) the two *tracheal trunks* and *thoracic duct* (Fig. 91).

One of the largest of the lymphatic spaces is the *greater cavity* of the *peritoneum*. The *cavity* or the *lesser peritoneum*, a large lymphatic space, may be shown by separating the layers of the great omentum carefully. The *cavity* of the *pleura* within the chest is also a large lymphatic space. Numerous small lymph spaces are present in all parts of the body. The beginnings of lymphatic capillaries draining these spaces are invisible to the naked eye, but their union into larger vessels may be demonstrated satisfactorily in a cat just killed, by pulling forward the tongue, and injecting very slowly beneath the skin, on its ventral aspect five or ten centimeters of a two per cent. solution of Berlin blue in warm water. A very good demonstration of the thoracic duct may be had by feeding the cat a half pint of milk about two hours before killing, or by using Gage's method described on page 13.

The lymph glands (Fig. 91) of the cat are not nearly so numerous as in man. The largest lymph glands is the *mesenteric lymph gland* in the mesentery. It is considerably flattened and about two centimeters long. It is formed by the grouping of several smaller glands and was formerly known as the *pancreas Aselli*. A few other very small lymphatic glands are also present in the mesentery. The two largest lymph glands of the head are just beneath the skin cranial of the submaxillary gland. On the side of the neck beneath the cephalohumeral muscle are three large lymph glands at the cranial border of the scapula. A small *axillary gland* lies on the caudal side of the axillary vein beneath the scapula. A single *popliteal gland* is in the popliteal space, an *inguinal gland* lies on each side of the penis, two or three *iliac glands* are near the origin of the femoral artery, and a few small *lumbar glands* lie in the lumbar region of the abdominal cavity.

All parts of the body have communication with the lymphatic vessels, which for the most part are so small as to be invisible unless injected, when they are easily recognized by their beaded appearance caused by the numerous valves within them. There are two systems of vessels in the head and extremities—the *superficial* and the deep. The former accompany mainly the superficial veins, and the latter follow the deep veins. On the outer aspect of the thoracic limb just beneath the skin two vessels are present, which flow into the cervical glands. They carry the lymph from the ball of the foot and the skin of the foot and forearm. One or two deep lymph-vessels are found accompanying the brachial vein and artery, which convey the lymph from the bones and muscles of the arm to the axillary gland.

In the pelvic limb two or three superficial vessels are present transmitting the lymph from the foot of the popliteal gland, whence two vessels proceed to the deep lymphatic system. The lymph from the bones and muscles of the leg reaches the iliac glands through two or three deep vessels lying near the femoral vein and artery. The inguinal glands receive most of the lymph from the skin of the leg.

The lymph from the superficial parts of the head flows largely into the submaxillary lymph glands, while that from the brain, tongue, esophagus, and larynx empties into the laryngeal glands.

The lymph of the right forelimb, right side of the neck and head, and right side of the thoracic wall is received by the right tracheal trunk. The left tracheal trunk receives the lymph from the left side of the head, neck and thoracic wall, and the left forelimb. The thoracic duct receives the lymph from the lungs, heart, all the abdominal viscera, and muscles, and the hind-limbs. With but few exceptions, all the main-lymphatic vessels pass through lymphatic glands before reaching one of the three main trunks. In fact, the vessels bringing the lymph to the glands may be said to terminate there.

They are called *afferent lymphatics*. The lymph moves free through the tissue of the gland, and on the opposite side is taken up by the *efferent lymphatics*.

The *right and left tracheal trunks* lie on their respective sides of the trachea and empty into the external jugular vein in the common jugular and jugulo-subclavian districts together with the right lymphatic and thoracic ducts. The openings are guarded by valves which prevent the blood from entering the lymphatic trunk.

The *thoracic duct* (Fig. 91) is the largest vessel of the lymphatic system, but is usually invisible unless injected. It extends from the region of the kidneys on the dorsal aspect of the body cavity, along the left side of the spinal column, to

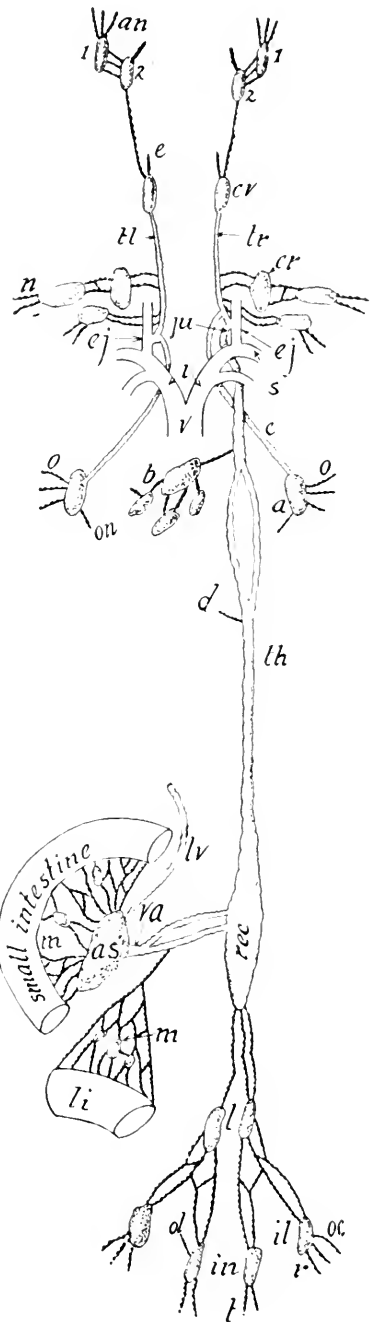


FIG. 91.—VENTRAL ASPECT OF CHIEF LYMPHATIC VESSELS OF THE CAT.

a, Axillary gland; *as*, pancreas Aselli; *an*, superficial lymphatics from the head; *b*, bronchial glands receiving lymph from lungs; *c*, lymphatic trunk; *cr*, cervical glands; *cv*, laryngeal glands; *d*, vessel from diaphragm; *ej*, external jugular vein; *in*, inguinal glands; *il*, iliac glands; *ju*, junction of thoracic duct with tracheal trunk; *l*, lumbar glands; *li*, large intestine; *lv*, lymph-vessel from liver; *m*, lacteal vessel and glands of mesentery; *n*, superficial lymphatics from limb; *o*, deep lymph-vessels from limb; *on*, lymphatics from thoracic wall; *ol*, vessel from abdominal wall; *oc*, vessels from limb; *rec*, receptaculum chyli; *s*, subclavian vein; *t*, lymphatics from skin of leg; *tr*, *tl*, tracheal trunks; *va*, lymph trunk from pancreas Aselli to thoracic duct; *v*, superior vena cava; 1 and 2, submaxillary lymph glands.

its openings into the external jugular vein near the common jugular and jugulo-subclavian junctions. The caudal end of the thoracic duct is expanded, forming the *receptaculum chyli*. Numerous valves are present in the duct, and give to it a moniliform or beaded appearance. It receives all the lymph

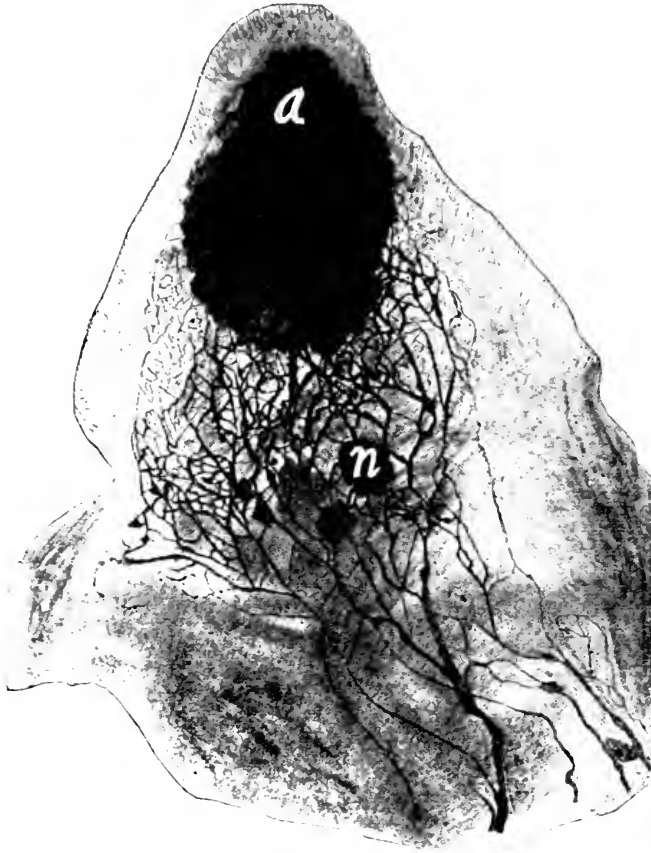


FIG. 92.—PHOTOGRAPH OF LYMPHATIC CAPILLARIES INJECTED WITH BERLIN BLUE. They lie immediately beneath the skin on the outer aspect of the ear.

a, Point of injection; the black area is Berlin blue lying in the connective-tissue spaces from which the capillaries arise; *n*, injection escaped from ruptured vessel.

from the left abdominal wall, both pelvic extremities, a large part of the thoracic wall, and the thoracic and abdominal viscera.

There is considerable variation in the number and position of the lymphatico-venous connections in mammals. Usually,

as in the cat, there are two openings in both the right and left external jugular veins. However, the jugulo-subclavian tap may be absent on one or both sides. Jugular lymph sacs connecting the lymphatic and venous systems in the jugulo-subclavian region have been described by Huntington and McClure as usually present, more or less well-defined, in adult cats. This interesting survival of an embryonic structure has also been found in man and other mammals. In amphibians and reptiles, lymph sacs and pulsating lymph hearts are normal adult structures. In addition to the cervical communications other venous taps may occur in the trunk region, as has been shown by Silvester for monkeys and Job for rats. Lumbar "taps" have also been found in cats. The significance of these venous taps has been worked out by McClure and Silvester, and more recently, in the rat, by Job.

DEVELOPMENT OF THE LYMPHATIC SYSTEM

The lymphatic system like the bloodvascular system is developed in the mesenchyme by the enlargement and fusion of intercellular spaces. According to Huntington and McClure (*Anat. Record*, IX, 571) "the development of the thoracic ducts and the mesenteric lymphatics in the cat is correlated with the degeneration of certain venous channels, many of which are tributaries of the azygos division of the supracardinal veins. A series of independent lymph spaces arise discontinuously in the mesenchyme external to the intimal lining of these degenerating vessels and, as these lymph spaces gradually become concrescent to form continuous channels, the latter following a line of least resistance, utilize the static line vacated by these degenerating veins. This extraintimal replacement accounts for the sinistral drainage plan finally assumed by the thoracic duct system in the embryo of the cat." Not all of the lymph channels are related to degenerating veins in this way. As a matter of fact, perhaps the usual method of development is by the concrescence of mesenchymal spaces independent of venous

channels, as is found to be the case in lower vertebrates. The theory that the lymphatic system is budded off directly from the venous system is held by some investigators, however, the theory outlined above seems best to agree with the results of investigations in fishes (Allen, McClure), amphibians (Kampmeier) reptiles (Stromsten, Huntington) and birds (Miller). The development of the lymphatic system is a very difficult problem and much depends upon the kind of technique and its interpretation. In the adult system as with the bloodvascular system there are many variations, such as place and number of lymphatico-venous taps, the persistence of lymph sacs (Fig. 84) or lymph plexuses etc. There are many problems relating to the development, morphology and function of the lymphatic system yet to be solved.

DUCTLESS GLANDS

The *spleen*, *thyreoid gland*, *thymus gland*, and *suprarenal* (adrenal) *bodies* are ductless glands whose functions are imperfectly known. The largest of these is the **spleen**, which is of a deep red color in a fresh specimen, and lies in the abdominal cavity on the left side caudad to the stomach (Fig. 61). It is about five centimeters long, two centimeters wide, and less than a centimeter thick. It is composed of lymphoid tissue of two forms, supported by connective-tissue trabeculae which are merely prolongations of the enveloping capsule. The two forms of tissue can be seen by cutting the organ transversely. The dense lymphoid tissue appears as white spots less than the size of a pin-head. They are the *splenic nodules*. The intervening looser lymphoid tissue forms the greater part of the spleen, and is known as the *splenic pulp*. The splenic artery, a branch of the celiac axis, enters the spleen at its *hilus* and divides into capillaries which terminate in irregular spaces, thus permitting the blood to flow freely through the splenic pulp, whence it is taken up by the capillaries of the splenic vein leading to the portal vein. In embryonic life the spleen

forms blood-corpuscles, but in post-natal life it seems to destroy blood-corpuscles. An animal from which the spleen has been removed may live many years in good health.

The **thyreoid gland** is composed of two parts lying on the lateral aspects of the trachea, just caudad to the larynx. Each part is less than two centimeters long. The two parts are sometimes connected by a small isthmus extending ventrally across the trachea, as in man. An enlargement of this gland in man is called *goiter*. An animal can live only a short time after the removal of the thyreoid unless it is fed thyreoids or an extract of thyreoid gland. The function of the gland is to supply iodine compounds and certain internal secretions to the system.

The **thymus gland** is a median structure varying in size according to age. In a cat about one-third grown it is very large, extending craniad from the heart along the ventral aspect of the trachea three or four centimeters. As the cat grows older, it gradually dwindles, and is entirely absent in aged specimens. Its function is unknown. It persists throughout life in the lower vertebrates.

The **suprarenal bodies** are small, somewhat bean-shaped organs lying craniad of the kidneys. An animal from which they have been removed can live but a short time. They give to the blood an internal secretion very essential to life. A hormone known as adrenalin is one of the products, "probably having to do with maintaining the proper tonus of the muscle of the heart and blood-vessels thus underlying blood-pressure." They are sometimes spoken of as suprarenal capsules or adrenal bodies.

The above-named ductless glands occur in all mammals in the same relative locations. The anatomy of the lymphatic system is also similar throughout the various orders of mammals. In some animals, especially man, the lymphatic glands are more numerous than in the cat. The tracheal trunks are also wanting in man and a right thoracic duct about two centi-

meters long is usually present. A failure of the lymphatics to do their work results in dropsy.

LABORATORY STUDIES AND SUGGESTIONS

1. Which of the four parts of the lymphatic system are visible in your specimen?
2. Describe size and number of lymphatic glands in the mesentery.
3. Describe the location of lymph glands present in any other portion of your specimen.
4. How do you distinguish a lymph gland from other glands?
5. What causes the lymph to flow in one direction only?
6. What is meant by afferent and efferent lymphatics?
7. Which kind of blood-corpuscles are found within the lymph-vessels?
8. From what regions does the thoracic duct receive the lymph?
9. What glands receive the lymph from the thoracic limb?
10. What glands receive the lymph from the pelvic limb?
11. Describe location of spleen, thyreoid and thymus glands, and suprarenal capsules by naming the organs with which they are in contact.
12. Draw a cross-section of the spleen and label all features visible.
13. Draw a cross-section of the suprarenal body and label parts.
14. Tell what you know of the functions of the ductless glands.
15. What is a gland?

THE RESPIRATORY SYSTEM

Respiration is the process whereby the tissues are supplied with oxygen and relieved of their carbon dioxid. In mammals, the special organs of respiration are the lungs, wherein the carbon dioxid is received from the blood, while at the same time the oxygen of the air passes through the thin-walled capillaries to the red blood-corpuscles capable of conveying it to the cells throughout the body. Each cell is composed largely of carbon, hydrogen, oxygen, and nitrogen, and any activity on the part of the cell is the result of the chemical union of some of its elements, whereby several waste products are formed, one of which is the gas, CO_2 (carbon dioxid). This gas is a poison and therefore must be eliminated. It passes through the thin walls of the capillaries adjacent to every cell, and is transferred through the veins to the heart and thence to the lungs. Here the pulmonary artery divides up into capillaries ramifying over the air sacs (Fig. 95), thus permitting the carbon dioxid to escape into the air sacs. Other waste products resulting from chemical activity within the cells are carried away by the kidneys and sweat glands.

The **respiratory system** consists of the *nasal passages*, *pharynx*, *larynx*, *trachea*, and *lungs*. The air taken in at the *anterior nares* is warmed in passing over the mucous membrane of the turbinated bones, after which it goes on through the *posterior nares* (Fig. 18) to the pharynx, and thence into the larynx.

The **larynx** is the cartilaginous expansion of the cranial end of the trachea, at the base of the tongue. The basihyal bone is attached to the cranial ventral margin of the larynx and on each side is a thyreohyal bone (Fig. 21). Dorsal to the larynx is the esophagus. By removing carefully the muscles and

fibrous tissue from the cartilage the larynx is seen to be composed of five pieces: the epiglottis, thyroid cartilage, two arytenoid cartilages, and the cricoid cartilage (Fig. 21). The *epiglottis* is the small triangular cartilage that closes the glottis when food passes into the esophagus (Fig. 62). The *thyroid cartilage* constitutes the largest part of the larynx. In man it forms the prominence known as Adam's apple. Dorsally the

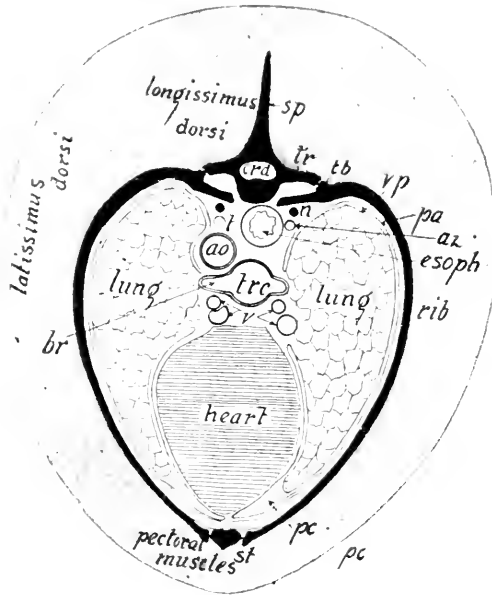


FIG. 93.—DIAGRAMMATIC TRANSVERSE SECTION OF THE CHEST.

ao, Aorta; br, bronchus; crd, spinal cord; esoph, esophagus; hd, head of rib; pa, parietal pleura; pc, cavity of the pleura; sp, spinous process; st, sternum; tb, tubercle of rib; tr, transverse process; vp, visceral pleura; t, thoracic duct; n, sympathetic nerve cord; az, azygos vein; trc, trachea; v, pulmonary veins.

two halves of the thyroid cartilage are separated, each projecting cranial into a process known as a *cornu*. The *arytenoid* cartilages are the two small paired pieces caudad to the thyroid, on the dorsal side. The *cricoid* cartilage forms a complete ring at the caudal end of the larynx (Fig. 21).

There are a number of ligaments connecting the various parts of the larynx, the most important of which are the *vocal cords*. These are of two kinds—true and false. They are best demonstrated by dividing the larynx, sagittally. The superior or *false vocal cords* are the two superior thyreo-ary-



FIG. 94.—PHOTOGRAPH OF A LUNG CORROSION OF A PUMA IN MORPHOLOGIC MUSEUM OF PRINCETON UNIVERSITY. The specimen was prepared by Mr. Sylvester. The trachea with all its ramifications was injected with white paraffin, and the pulmonary artery with red paraffin, after which the lung substance was eaten away with acid.

tr, Trachea; *br*, bronchus; *b*, bronchial tube; *c*, bronchiole. The pulmonary artery and its branches are much darker than the air tubes.

enoid ligaments passing from the arytenoid to the thyroid cartilage, at the base of the epiglottis. The cat is said to use these cords in purring. The inferior or *true vocal cords* are the inferior thyreo-arytenoid ligaments, consisting, as in man, of a fold of mucous membrane on either side, just caudad to the false vocal cords (Fig. 62). The depression on either side between the true and false vocal cords is the *ventricle*. By means of the muscles attached to the arytenoid and thyroid cartilages, the tenseness of the vocal cord is regulated, and the various pitches of voice produced.

The **trachea**, or windpipe, is the tube leading from the larynx to the lungs (Fig. 61). Its walls are prevented from collapsing by the presence of about forty-five cartilaginous rings which are incomplete dorsally. Before passing into the lungs the trachea bifurcates into a right and a left *bronchus*. The trachea and bronchi are lined by *ciliated columnar epithelium*. The cilia project freely into the lumen from the columnar walls, and are always waving in such a manner as to carry the secreted mucus lodged thereon toward the mouth, thereby preventing the lungs from becoming clogged with foreign material. Ciliated cells with the cilia in action may be easily demonstrated by scraping very lightly a little mucus from the posterior part of the roof of the frog's mouth, and mounting the same in a drop of saliva on a glass slip, which is then to be examined with a microscope magnifying about 300 diameters. The diaphragm of the microscope should be arranged so as to admit but little light.

The **lungs** together with the heart fill up the greater part of the thoracic cavity. In a cat recently killed the lungs may be expanded by tying a piece of glass tubing on the trachea and blowing into it strongly for a few seconds. Each lung is completely invested by a sac of delicate transparent serous membrane called *pleura* (Fig. 93). Each sac is reflected at the root of the lung, where the blood-vessels and bronchus enter, so as to form a parietal layer lining its half of the thoracic cavity.

The median space between the two sacs is called the *mediastinum*. The anterior or ventral mediastinum contains blood-vessels and the thymus gland. The dorsal or posterior mediastinum lodges the trachea, esophagus and aorta and the heart occupies the middle mediastinum.

Each lung is divided by deep clefts into several lobes. The left lung is composed of two large lobes and a small one. The

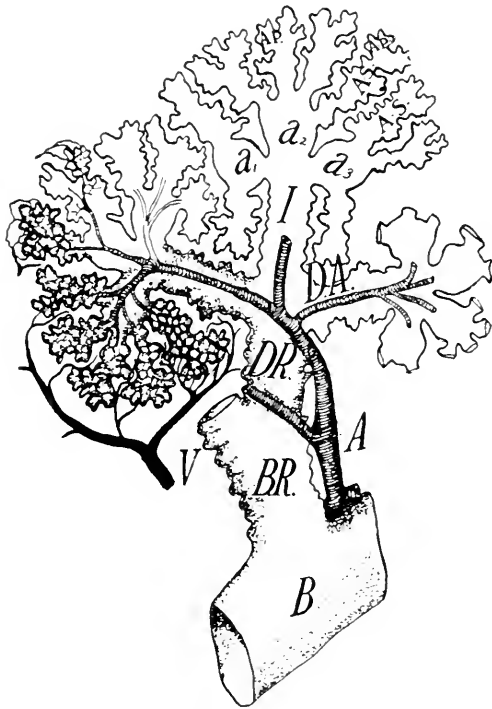


FIG. 95.—DIAGRAM SHOWING STRUCTURE OF THE LUNG ON THE CAT. (Modified after Miller.)

A, Artery; B, bronchiolus; B.R, respiratory bronchiole; D.A, alveolar duct; a, atria; A.S, alveolar sac; A.P, pulmonary alveolus; V, vein.

right lung consists of four unequal lobes. The cranial end of the lung is the apex and the caudal end, resting against the diaphragm, is the base. The bronchi, as they are continued into the lungs, subdivide into smaller tubes, whose later subdivisions are the bronchioles. The latter, dividing like the branches of a tree, finally terminate in blind pouches known as *infundibula* or *alveoli*, the wall of which are thickly beset with microscopic

sac-like evaginations named *air sacs* (Figs. 94 and 95). The walls of these air sacs are very thin, somewhat like the peritoneum. Over them course numerous thin-walled capillaries, so that the carbon dioxide of the blood passes out into the air as

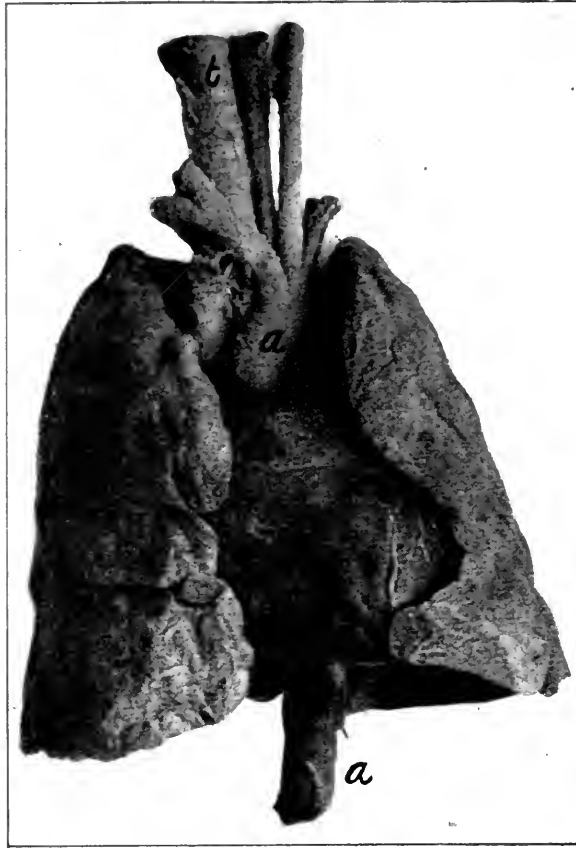

FIG. 96.—PHOTOGRAPH OF HUMAN HEART AND LUNGS FROM VENTRAL ASPECT.
a, Aorta; *t*, trachea.

the oxygen passes into the blood. Expiration is the process of forcing the air out of the lungs which have been filled by an inspiration chiefly effected by depressing the diaphragm and elevating the ribs. The two processes together are spoken of as a respiration.

LABORATORY STUDIES AND SUGGESTIONS

1. Of what four elements are the soft parts of the body largely composed?
2. What waste gas is formed in every part of the body exercised?
3. Through what three channels do waste materials pass from the blood?
4. Describe the manner in which the oxygen of the air reaches the blood?
5. Write a description of the pharynx.
6. Bisect the larynx in the sagittal plane, make a drawing of the cut aspect, and label all features.
7. How many cartilaginous rings in the trachea and what is their use?
8. Describe as much of the pleura as can be seen in your specimen.
9. Do the right and left bronchi have the same number of main branches?
10. Why do the air cells seldom become clogged?
11. What muscles are largely used in respiration?
12. Describe the hyoid bone as seen from your dissection.
13. What part of this bone can you feel beneath your mandible?
14. How does the carbon dioxid given off by the cells in the foot reach the lungs?
15. What causes the air to enter the lungs?
16. Inflate the lungs of a freshly killed animal by forcing air from your lungs into a glass tube tied into its trachea.
17. After retaining a full inspiration of air as long as possible, expire it through a glass tube into the bottom of a two-liter bottle and insert into the bottle a lighted splinter.
18. Describe the pulmonary circulation.

THE EXCRETORY AND REPRODUCTIVE SYSTEMS

As explained in the last section, a portion of the waste products produced by the activity of the cells of the body is passed off through the lungs, but some other outlet must be provided for the excretions that are not in the form of gases. These liquid excretions, containing various salts and urea, pass off through the kidneys and the glands of the skin.

The latter are of two kinds, *sudoriferous* or sweat glands, and *sebaceous* or oil glands, with ducts opening into the hair follicles near the surface. The sweat glands lie deeper than the sebaceous glands. The former are subcutaneous and consist of a more or less coiled tube with a straight duct opening on the surface. They are most abundant on the tip of the nose and the balls of the feet. The sebaceous glands are very numerous all over the body. Both are of microscopic size.

A still more important part of the excretory system is the urinary system, consisting of the *kidneys*, two *ureters* leading from the kidneys to the bladder, the *bladder*, and the *urethra*.

The student should note that the **kidney** is not enveloped by the peritoneum, like the other abdominal organs, but lies dorsad to it and is encased by a fibrous covering known as the capsule. The *hilus* is that portion of the concave surface where the renal artery and vein and ureter enter. A median longitudinal section of the kidney will show that the ureter within the kidney enlarges, forming the *pelvis*, into which projects the *renal papilla* (Fig. 98). This is better demonstrated in a transverse section.

The substance of the kidney is composed of an outer *cortical layer*, about a half centimeter thick, and an inner *medullary substance* adjacent to the pelvis, and projecting into the latter

in the form of a papilla. In the cortical substance are hundreds of *renal corpuscles*, each composed of a ball of capillaries (Fig. 99) enveloped by the invaginated enlarged extremity of a tubule which carries away the urine by a tortuous course to the papilla (Fig. 99). In the renal corpuscles the water and other mineral substances of the urine are extracted from the blood by means of the epithelial cells forming the inner wall of the *capsule of Bowman*. These urinary products pass through the *proximal convoluted tubule* and the *loop of Henle* to the *distal convoluted tubule*, where they are mingled with the urea extracted from the blood by the columnar epithelial cells of the tubule. From this point the excretions flow into the *collecting tube* which empties into the pelvis at the papilla. In a prepared microscopic section of the kidney, these renal corpuscles and renal tubules may be seen with a microscope magnifying about 200 diameters.

The **ureter** is a small tube leading from the pelvis of each kidney along the dorsal aspect of the abdominal cavity to the dorsal and caudal end of the bladder.

The **bladder** is the sac for retaining the urine. It lies ventrad to the rectum, a little to the right of the median line, being held in place by the *ligamentum suspensorium*, a fold of the perito-

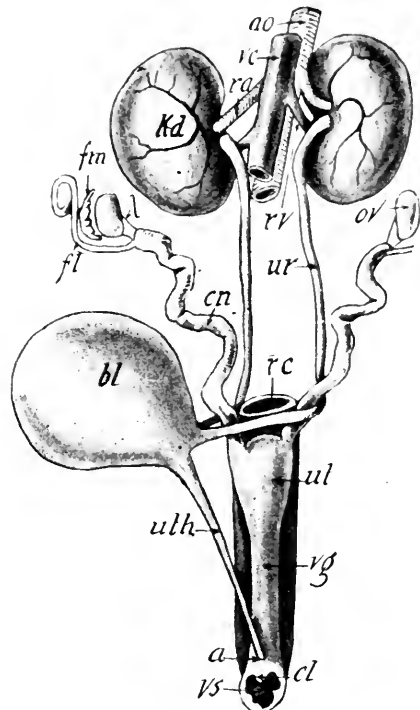


FIG. 97.—VENTRAL ASPECT OF FEMALE URINO-GENITAL SYSTEM WITH THE BLADDER PULLED TO ONE SIDE.

a, Entrance of the urethra into the vestibule; *ao*, aorta; *bl*, bladder; *cl*, clitoris; *cn*, cornu or horn of the uterus; *ft*, Fallopian tube, the left one is cut off; *fm*, fimbriated extremity of the Fallopian tube; *kd*, kidney; *l*, ovarian ligament; *ov*, ovary; *ra*, renal artery; *rv*, renal vein; *rc*, rectum; *ur*, ureter; *ul*, body of the uterus; *uth*, urethra; *vc*, vena cava; *vg*, vagina; *vs*, vestibule.

neum attached to the mid-ventral line. It is also attached by lateral ligaments. On its dorsocaudal aspect near where the ureters empty, the *urethra* originates and passes along the ventral surface of the vagina to the vestibule, within which it opens (Fig. 97). In the male it passes directly from the bladder along the ventral surface of the rectum to the root of the penis at the pubic symphysis, and thence on through the corpus spongiosum to

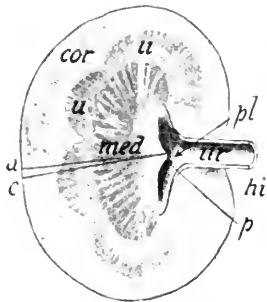


FIG. 98.—MEDIAN LONGITUDINAL SECTION OF A KIDNEY.

cor, Cortical substance; *hi*, hilus; *med*, medullary portion; *p*, papilla; *pl*, pelvis; *u*, pyramids; *ur*, ureter.

the point of the penis. The ureter, bladder, and urethra consist largely of muscular tissue, the lining being formed by mucous membrane.

THE FEMALE REPRODUCTIVE SYSTEM

The female reproductive organs are the two *ovaries*, a pair of *uterine tubes*, a *uterus*, and a *vagina*. To demonstrate these, the entire ventral abdominal wall must be removed and the pubic symphysis severed with the bone-cutters. The *ovaries* are the small yellowish oval bodies about one centimeter long lying just caudad of

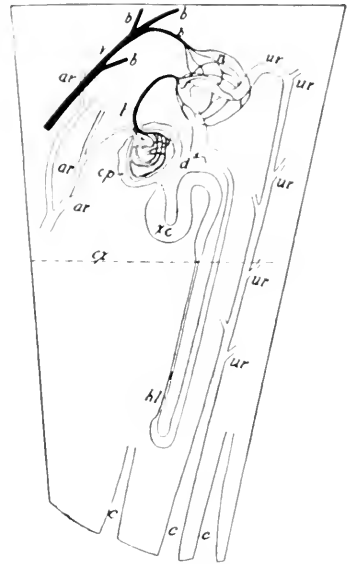


FIG. 99.—DIAGRAM OF THE STRUCTURE OF THE KIDNEY BETWEEN THE LINES *a* AND *c* IN FIG. 98.

ar, Arteries leading to the renal corpuscles, only one capsule being shown; *b*, veins leading from the capillary network about a convoluted tubule as at *n*; *cx*, line marking the boundary between the cortical and medullary portions of the kidney; *cp*, capsule of Bowman enveloping the bunch of capillaries; *d*, distal convoluted tubule; *hl*, Henle's loop; *n*, capillary network about the tubule; *t*, the bunch of capillaries of Malpighian tuft; *ur*, portions of renal tubules emptying into the collecting tubule *c*; *xc*, proximal convoluted tubule.

the kidneys, against the dorsal abdominal wall. From the vicinity of each extends a tube caudad to join its fellows in the median line ventrad to the rectum (Figs. 61 and 97). The cranial portions of these are the *uterine* tubes, and the larger caudal portions are the *cornua* of the uterus. The junction of the cornua in the median line forms the *body of the uterus*.

The **uterine tube** is smaller in diameter than the cornu of the uterus, generally more or less contorted, and terminates by a fimbriated expansion or mouth opening freely into the abdominal cavity.

The uterine tubes and uterus are suspended by the **broad ligament**, or ligamentum latum, which is a fold of the peritoneum attached to the dorsal abdominal wall. The **round ligament**, or ligamentum rotundum, also aids in keeping the uterus in place. This appears as a thickening of the broad ligament when the latter is looked through toward the light. The round ligament extends from about the middle of the horn or cornu of the uterus ventrad of Poupart's ligament, and through the muscles of the abdominal wall beneath the skin of the inguinal region, where it gradually loses itself. It is exceedingly delicate and thread-like. During pregnancy a portion of the uterine wall becomes very vascular and undergoes other important changes. It unites with the chorion of the fetus to form the *placenta*. The blood-vessels of both parts of the placenta, maternal and fetal, interlace but do not directly communicate with each other. It is through the placental blood-vessels that the fetus receives its nourishment and oxygen.

The **vagina** extends from the uterus to the vestibule, opening on the surface ventrad to the anus. The small papilla just caudad of the orifice of the urethra on the ventral surface of the vestibule is the *clitoris*, the homologue of a part of the penis in the male. The prominent circular fold of mucous membrane craniad of the orifice of the urethra represents the *hymen*, which marks the separation between the vagina and vestibule. This structure may be shown by making a

median longitudinal section through the vagina. *Bartholin's vestibular glands* lie on the lateral aspect of the vestibule, into which their ducts open. Each one is about the size of a small pea. The vagina, uterus, and uterine tubes are lined with mucous membrane in which are many glands. The mucous lining is surrounded by a muscular coat especially thick in the uterus.

The **ovaries** are the organs producing the female germ cells or ova which when fertilized are known as the eggs (Figs. 61 and 97). One lies caudad of the kidney on each side and is invested by peritoneum, which should be carefully dissected

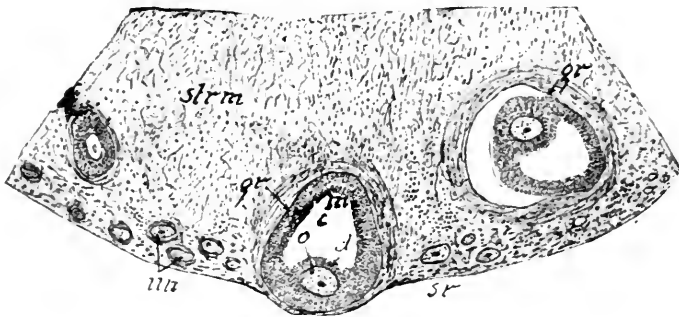


FIG. 100.—SECTION OF OVARY. X 40.

sr, Surface of the ovary; gr, Graafian follicle with mature ovum; o, ovum; c, cavity of the follicle; un, undeveloped ova; strm, stroma or connective elements of the ovary; m, membrana granulosa; d, discus proligerus (cumulus oöphorus).

away. A microscopically prepared section of the adult ovary magnified about 100 diameters will reveal a number of ova in a more or less mature state. Usually a peripheral ring of very young ova is present, more mature ones are near the center, while one or two quite ripe ova are very near the circumference. As the ova develop, a follicle or sac known as the *vesicular follicle* (Graafian follicle) is formed about them. This is lined with several layers of epithelial cells forming the *stratum granulosum*. At one side of the follicle the stratum granulosum thickens and envelops the *ovum*, forming the cumulus oöphorus. The cavity of the follicle is filled with liquor folliculi. When the ovum becomes almost mature, the walls of the follicle have grown peripherad, so as to cause a pin-head protuberance on the surface of the ovary clearly visible to the naked eye. In a

fresh specimen this protuberance may be picked open and the ovum expelled on a slide for examination with the microscope. The ovum is scarcely visible to the unaided eye. The human ovum is still smaller.

The ova of all mammals, except the duck-bill and spiny ant-eater, are very small. When the ovum becomes mature, the protruding wall of the follicle bursts, permitting its contents to be received by the expanded end of the uterine tube, whence it passes to the uterus. If the male element, the spermatozoon, enters the ovum, the latter is soon enveloped by a growth of mucous membrane and retained in the uterus for development. Ripe ova occur near the close of the first year of the cat's life and new ones probably continue to mature during the next ten years. The discharge of the ova from the ovary is accompanied by a constitutional disturbance, during which an extra amount of blood is sent to the sexual organs, and the sexual appetite becomes very marked. In the human species this disturbance occurs about every twenty-eight days. Mature ova occur in the human ovary between the thirteenth and forty-eighth years.

The **mammary glands** of the adult female cat reach their full development when it gives birth to young. They may be seen by carefully removing the skin from the ventral aspect of the body, when they will appear somewhat like a thin layer of adipose tissue extending from near the axilla to the pubic symphysis. There are four teats or nipples on each side. In some mammals the nipples are less numerous and confined either to the thoracic or inguinal region. In the elephant, Chiroptera, and Primates there are but two nipples, and they are thoracic. In most Ungulates the nipples are inguinal.

THE MALE REPRODUCTIVE SYSTEM

The organs of generation in the male consist of the *testes*, the *ducts* leading from the *testes* to the urethra, the *prostate gland*, *bulbo-urethral glands* (Cowper's gland), and the *penis*.

The **testes** are two in number, contained in a pouch of integument called the **scrotum**,

which hangs beneath the anus. Internally the scrotum is divided into two chambers. By dissecting away the adipose tissue covering the spermatic cord in the inguinal region (Fig. 57) it may be seen that the cord and the testes are enveloped by a tough sheath. This is composed of *cremasteric fascia* derived from the aponeurosis of the external oblique muscle, and of the *tunica vaginalis*.

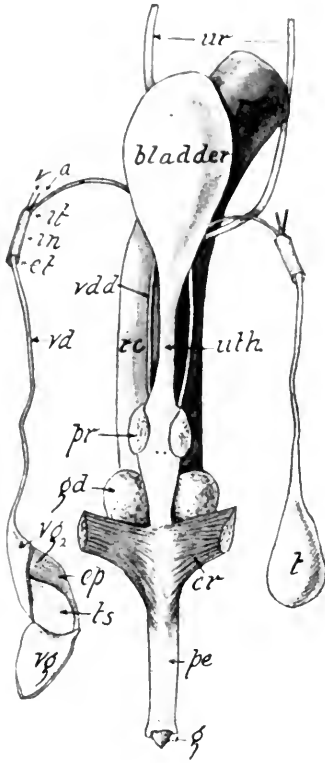


FIG. 101.—VENTRAL ASPECT OF THE MALE REPRODUCTIVE ORGANS.

cr, One of the crura of the penis; *cp*, epididymis revealed by cutting and reflecting; *vg*, a piece of the tunica vaginalis and albuginea; *ct*, external abdominal ring; *it*, internal abdominal ring; *in*, inguinal canal; *g*, glans penis; *gd*, Cowper's bulbo-urethral glands; *pe*, penis; *pr*, prostate gland; *rc*, rectum; *t*, testis from which the tough sheath composed of the levator scroti muscle and cremaster fascia has been removed, leaving it enveloped by the tunica vaginalis; *ts*, testicle from which a portion of the tunica vaginalis and albuginea has been reflected; *uth*, urethra; *ur*, ureters; *vd*, spermatic cord; *vdd*, vas deferens within the abdominal cavity; *vg*, tunica albuginea reflected; *vg₂*, tunica albuginea; *v*, spermatic vein.

During the fetal life the testes lie in the abdominal cavity, and when they descend into the scrotum about the time of birth, a double layer of peritoneum is pushed down before them through the inguinal canal, forming a diverticulum whose blind end lies within the scrotum, while the constricted portion forms a channel for the vas deferens, spermatic nerve, and vessels. These three structures form the *spermatic cord* (Fig. 57). The fascia propria (tunica vaginalis communis) is inseparably united with the adjacent parietal layer of the peri-

toneum. The visceral layer of peritoneum is quite delicate and transparent and lies close to the testis. Within the tunica vaginalis, is the tunica albuginea, closely investing the testicle and adjacent to the epididymis, penetrating the substance of the gland, forming a septum known as the *mediastinum testis* or *corpus Highmori* (Fig. 101).

The **testis** is about $1\frac{1}{2}$ centimeters long by 1 centimeter thick. On its dorsal surface lies the *epididymis*, an elongated body composed of an enlarged extremity, the *globus major*, and an attenuated portion, the *globus minor*. The main portion of a testicle is composed of many minute coiled tubules, *tubuli seminiferi*, which unite into a few tubules near the surface of the testis beneath the *globus major*, into which they extend. These tubules are the *ductuli efferentes testis*. The epididymis is composed of a single greatly convoluted tubule of which the *ductus deferens* is a continuation. The latter proceeds craniad to the external abdominal ring, which it enters to traverse the inguinal canal into the abdominal cavity. It then curves caudad and enters the urethra on its dorsal aspect in the region of the prostate gland.

The **inguinal canal** begins with the *external abdominal ring*, which is an opening in the tendon of the external oblique muscle, and ends with the *internal abdominal ring*, which is an opening in the fascia of the transversalis muscle (Fig. 56). By accident, a fold of the small intestine in man sometimes descends through the inguinal canal, which condition is known as *hernia* or *rupture*.

The **penis** is a cylindrical pointed body about three centimeters long when in repose. It is composed of two kinds of tissues arranged in three bundles. The *corpus spongiosum* is the median ventral bundle, extending throughout the length

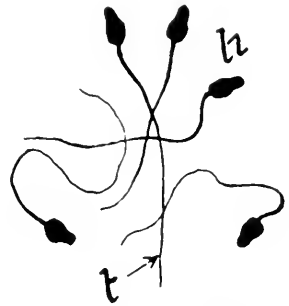


FIG. 102.—SPERMA OR MALE GERM CELLS. $\times 500$.
h, Head; t, tail.

of the organ, and at the end forms the *glans* or head. The two dorsal lateral bundles are the *corpora cavernosa*. They form the greater part of the penis proximad of the glans, and by diverging somewhat before their attachment on either side to the pubis and ischium form the *crura*. The penis is suspended from the wall of the abdomen by a fold of integument inserted at the base of the glans, and forming the *prepuce*. The latter is a free projection of skin covering the glans. In the midst of the penis is a small bone. The penis is the organ of copulation, and is composed of a spongy mass of elastic and muscular fibers richly supplied with highly distensible blood-vessels which when filled render the organ erect.

The **prostate gland** surrounds the urethra dorsally and laterally about two or three centimeters from the bladder. This gland secretes a milky fluid which is poured into the urethra through many ducts, during copulation, and serves as a medium for the spermatozoa (Fig. 101).

Cowper's bulbo-urethral glands are two in number, about the size of a pea, and lie in the angles formed by the urethra and the crura of the corpora cavernosa. These glands secrete an alkaline viscid fluid of unknown function, "but which may be to neutralize any acidity of the urethra which might inhibit the activity of the spermatozoa" (McMurrich). One duct from each gland opens into the urethra.

REMARKS ON THE MAMMALIAN UROGENITAL SYSTEM

The urogenital system is subject to some variations in the different orders of Mammalia. In the *Ornithodelphia*, the mammary glands are devoid of teats and the oviducts corresponding to the Fallopian tubes and horns of the uterus do not unite in the median line to form the body of the uterus, but unite with the urethra, forming the urogenital canal. The latter opens into an enlarged terminal portion of the rectum, called the *cloaca*. The ureters also open directly into the cloaca, so that there is but one external opening for the genital

and excretory products. In the above features the Monotremes resemble the Amphibia and reptiles. All mammals are viviparous except the Monotremata, which are oviparous, laying eggs as large as those of the robin. The *Ornithorhynchus* incubates its eggs in an underground nest, while the *Echidna* carries her single egg in a temporary abdominal pouch.

The *Marsupialia* bring forth their young in a very immature condition. They are then carried for several months in an abdominal integumentary pouch, the *marsupium*, within which are the nipples. In the Monotremata, Cetacea, Sirenia, and elephant the testes do not descend into a scrotum, but are retained in the primitive location within the abdomen. In Primates and some Edentates, the uterus is merely a pear-shaped body without any cornua, the uterine tubes leading directly into the body of the uterus.

In the ox, bears, seals, and cetaceans the kidneys are distinctly lobulated. Internal evidence of lobulation is presented in most mammals by the renal papillæ. In the embryo, the kidneys of all mammals are lobulated.

LABORATORY STUDIES AND SUGGESTIONS

1. What other waste products besides CO_2 result from the chemical action in the tissues of the body?
2. Write a description of all parts of the urinary system visible in your dissection.
3. Bisect a kidney longitudinally in the horizontal plane, draw the cut surface, and label all features.
4. Explain the parts of a renal tubule.
5. Wherein does the male urinary system differ from the female?
6. Make a drawing of the uterine tubes and uterus and label all parts.
7. Describe location, size, external appearance, etc., of the ovary as seen in your specimen.
8. How are the female reproductive organs held in place?
9. Can you distinguish externally the termination of the uterus and the beginning of the vagina?
10. Are there any eggs protruding from the ovary or any cavities from which eggs have been recently discharged?
11. Describe a Graafian (vesicular) follicle.
12. What must be added to the ovum to produce another animal?

13. Name the parts of the male reproductive system present in your specimen and locate them.
14. Describe the course of the spermium from the testis to the exterior.
15. Do all mammals nourish their young in the same manner?
16. What mammals incubate their eggs externally?

THE NERVOUS SYSTEM

The nervous elements of the cat form three systems, known as the *central*, *peripheral*, and *sympathetic*. The central nervous system includes the brain and spinal cord. The peripheral system includes the twelve pairs of nerves emanating from the brain and the forty pairs of nerves emanating from the spinal cord to supply the extremities and trunk. The sympathetic system is composed of two ganglionated nerve cords extending throughout the trunk within the body cavity, one on either side of the vertebral column, and their various branches to all the viscera, blood-vessels, etc., of the body (Figs. 105 and 106).

THE BRAIN

The central nervous system is known as the *cerebro-spinal axis*. It is composed of the brain and spinal cord. The brain lies within the cranial cavity and is protected by three membranes called the *meninges*. These may be demonstrated by cutting away the roof of the skull with the bone forceps. The *dura mater* is the tough fibrous membrane lining the interior of the skull. It dips down between the two halves of the cerebrum, forming the *falx cerebri*. Between the cerebrum and cerebellum in the cat it is ossified, thus forming the bony shelf or tentorium cerebelli (Fig. 19). The second membrane of the brain is the *arachnoid*. Between the *dura mater* and the *arachnoid* is the subdural space, containing a fluid having the nature of the aqueous humor. The *arachnoid* is a very delicate membrane which does not dip down into the clefts between the folds of the brain, as is the case with the *pia mater*, but passes across these depressions, where it may be easily demonstrated (Fig. 109).

The subarachnoidal space lies between the *arachnoid* and *pia mater*. The *pia mater* is the delicate vascular membrane follow-

ing so closely the folds and clefts of the brain that it becomes apparent only when lifted carefully by the forceps.

In order to study the brain satisfactorily each student should have a specimen hardened according to directions on page 14, and also should be permitted to examine a series of sections cut transversely about a centimeter thick. The brain of a calf or sheep serves the learner's purpose better than that of a cat, as the parts are larger, and they are also easier to procure. An additional advantage is also found in the fact that there is some difference between the brains of the cat and calf, and the student must therefore rely more on his own observations.

External Features.—The brain is composed of five parts: the *medulla oblongata*, or *myelencephalon*; the pons Varolii and cerebellum, forming the *metencephalon*; the corpora quadrigemina and crura cerebri, composing the *mesencephalon*; the *diencephalon*, including the optic thalami and other parts bounding the third ventricle; and the *telencephalon*, or cerebral hemispheres. The medulla oblongata, sometimes called the bulb or *stem* of the brain, is the expansion of the spinal cord as it passes through the foramen magnum. The *pons Varolii* is the bridge of transverse fibers seen on the ventral aspect of the brain just craniad of the medulla (Fig. 104). The *cerebellum* or little brain lies on the dorsal side of the medulla and is partly covered by the caudal part of the cerebrum. The *mesencephalon* is not visible externally on the dorsal aspect, but may be seen immediately craniad of the cerebellum by cutting away the cerebrum (Fig. 107). The *diencephalon* is visible externally only on the ventral aspect of the uncut brain, where it forms the floor of the third ventricle. It may be viewed as a whole if the dorsal half of the cerebrum including the corpus callosum is cut away. The *telencephalon* or *end brain* is composed of the two large hemispheres partially surrounding the diencephalon and mesencephalon.

The brain is composed of two kinds of matter, white and gray. The former is constructed for the most part of fibers, while the

latter is formed largely of cells. The outer or cortical portion of the cerebrum and cerebellum is a layer of gray matter less than a half centimeter thick, and is disposed in folds called *gyri* or *convolutions* with intervening slit-like depressions termed *sulci*, the most important of which are called *fissures*.

The four different portions of the cerebrum are known as *frontal*, *parietal*, *occipital*, and *temporal* lobes, which occupy the respective regions of the cranial cavity. The frontal and parietal lobes are separated by the *crucial fissure*, extending transversely between them. The *olfactory lobe* (usually torn off in removing the brain from the skull) projects from the cranial portion of the frontal lobe. The parietal lobe is marked by three gyri, named according to location gyrus marginalis, gyrus, suprasylvius, and gyrus ectosylvius (Figs. 103 and 104). The caudal portions of the gyri marginalis and suprasylvius constitute a portion of the occipital lobe. These two gyri are separated by the lateral sulcus. The suprasylvian sulcus extends between the gyrus suprasylvius and the gyrus ectosylvius. The splenial

sulcus (Fig. 106) separates the gyrus marginalis from the gyrus fornicatus on the medial aspect of the parietal and occipital lobes. There are no definite sulci or fissures separating the parietal, occipital, and temporal lobes. The *postrhinal fissure*, extending caudad from the fissure of Sylvius, divides the temporal lobe into two portions on the ventral aspect.

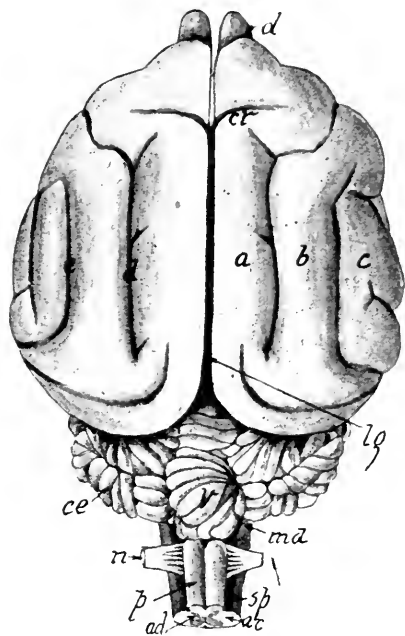


FIG. 103.—DORSAL ASPECT OF THE BRAIN.

a, Gyrus marginalis; *ac*, white matter of the cord; *ad*, gray matter of the cord; *b*, gyrus suprasylvius; *c*, gyrus ectosylvius; *cr*, crucial fissure; *ce*, lateral lobe of cerebellum; *d*, lateral sulcus; *e*, suprasylvian sulcus; *lg*, great longitudinal fissure; *md*, medulla oblongata; *n*, first spinal nerve; *ol*, olfactory lobe; *p*, posterior pyramids; *sp*, spinal cord; *v*, vermis of cerebellum.

The ventral surface (Fig. 104) of the brain also presents important features which should be noted by the student before investigating the internal structure. The *anterior pyramids*, two indistinctly differentiated bundles of fibers, occupy the middle of the ventral region of the medulla, and craniad of the pons help form the peduncles of the cerebrum. Laterad of each pyramid is the olivary projection. A broad band of transverse fibers appearing just caudad of the pons Varolii and lateral of the anterior pyramids is the *corpus trapezoideum*.

The *pons Varolii* is itself composed of a band of transverse fibers which on either side forms the middle peduncle of the cerebellum. The fibers originate either in cells of the medulla or those of the cerebellum.

The *crura cerebri*, or *peduncles of the cerebrum*, the ventral portions of which are continued as the anterior pyramids (Fig. 104), are seen just craniad of the pons. Their fibers unite the cerebrum to the rest of the brain and the spinal cord. In the space between the crura and the optic chiasm is a prominent projection, the terminal nodular portion of which is the *pituitary body* or *hypophysis*. It occupies the hypophyseal fossa of the skull and is usually torn off in removing the brain. Caudad of the hypophysis are two small rounded white bodies, the *corpora mamillaria*. The *tuber cinereum*, a slightly elevated mass of gray matter behind the optic chiasm, bears on its surface the funnel-shaped stalk, the *infundibulum*, to which the hypophysis is attached. If the two latter parts are removed, there is seen a small elongated aperture through the tuber cinereum into the third ventricle (Figs. 104 and 106).

The *optic commissure*, or *optic chiasm*, is the commissure formed by the crossing of the optic nerves just craniad of the tuber cinereum. The prolongation of the optic nerves dorsad from the optic commissure forms the *optic tracts*, partly covered by the temporal lobes. On either side of the median fissure just craniad of the optic chiasm is a somewhat triangular area known as the *anterior perforated space* because of the numerous vessels that enter the brain in this region. Laterally this space

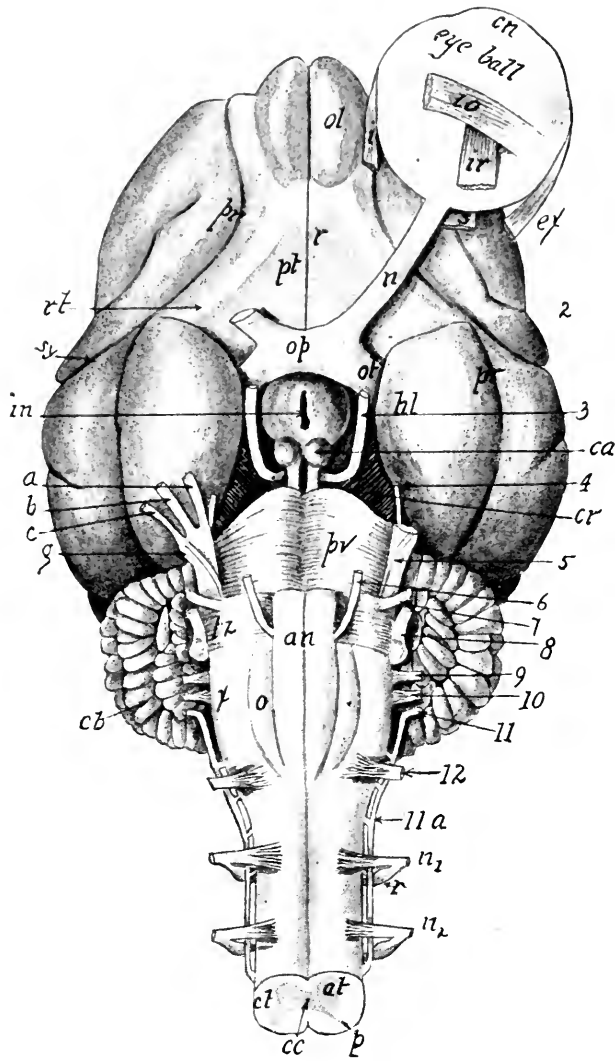


FIG. 104.—VENTRAL ASPECT OF THE BRAIN.

2, 3, 4, 5, 6, 7, 8, 9, 10, 11, 12, The cranial nerves; *a*, ophthalmic branch of the trigeminal nerve; *an*, anterior pyramids; *al*, anterior horn of gray matter; *b*, superior maxillary branch of the trigeminal nerve; *11a*, eleventh cranial nerve with roots from the spinal cord; *c*, mandibular branch of the trigeminal nerve; *ca*, corpus mamillare; *cb*, cerebellum; *cc*, canalis centralis; *cn*, cornea; *cl*, cut surface of spinal cord; *ex*, external rectus muscle; *cr*, peduncle of the cerebrum; *g*, Gasserian ganglion of the trigeminal nerve; *hl*, pyriform lobe; *in*, opening into the tuber cinereum revealed by removal of the infundibulum and hypophysis; *i*, internal rectus; *io*, inferior oblique; *ir*, inferior rectus; *n₁* and *n₂*, first and second spinal nerves; *ol*, olfactory lobe; *op*, optic commissure; *ot*, optic tract; *p*, posterior horn of gray matter; *pt*, anterior perforated space; *pv*, pons Varolii; *r*, medial or inner root of olfactory nerve; *rt*, lateral root of olfactory nerve; *pr*, postrhinal fissure; *sy*, Sylvian fissure; *s*, superior rectus muscle; *tz*, corpus trapezoideum; *x*, external arciform fibers.

is bounded by the lateral olfactory tract or lateral root of the olfactory nerve, which presents the appearance of a band of white fibers extending from the olfactory lobe into the temporal lobe. The medial or inner root of the olfactory nerve is seen adjacent to the median ventral line craniad of the anterior perforated space. The olfactory lobes project from the cranial ventral portion of the cerebrum and give origin to the first pair of cranial nerves.

Internal Structure.—The *canalis centralis*, a small canal extending throughout the center of the spinal cord, enlarges in the region of the brain, forming four cavities or *ventricles* communicating with each other by narrow channels. The brain is therefore to be considered as a hollow structure. The *first* and *second* ventricles, also known as *lateral ventricles*, occupy the cerebral hemispheres (Fig. 105). The *third* and *fourth* ventricles lie in the median line, and are therefore well seen in a sagittal section of the brain (Fig. 106).

The Ventricles of the Brain.—The *fourth ventricle* is visible on the dorsal aspect of the medulla oblongata (Fig. 106). It is about three centimeters long by one centimeter wide, and lies ventral to the cerebellum. This ventricle is merely an expansion of the *canalis centralis* of the spinal cord. Its roof is very thin and consists of two portions, one of which, the *superior medullary velum*, sometimes called the *valve of Vieussens*, covers the cranial half of the ventricle; the other portion is the *inferior medullary velum*, lying over the caudal half. The latter velum is composed of a fold of pia mater tucked in between the cerebellum and medulla, in addition to a layer of epithelial cells on the ventricular aspect of the pia mater. Some nervous matter in addition to the pia mater and epithelium forms the superior velum. Two longitudinal vascular fringes hanging from the roof of the ventricle on either side of the mid-line, form the *choroid plexus*, which is merely a network of blood-vessels carried by a reflected portion of the pia mater. The choroid plexus appears to be the main source of the cerebrospinal fluid.

Craniad the fourth ventricle is continued as a small canal, the *iter*, or *aqueduct* of *cerebrum*, which lies ventrad to the corpora quadrigemina and opens into the *third ventricle* (Fig. 106). The latter is a narrow, vertical, cleft-like space between the optic thalami. The two thalami are united by the *soft* or *middle commissure*, better designated as the *massa intermedia*, extending through the ventricle. Unless this ventricle has been injected with a starch mass through the infundibulum before the brain was hardened, its cavity will not exceed a millimeter in width. The roof is formed much in the same manner as that of the fourth ventricle, by a reflection of the pia mater lined with epithelium (Figs. 106 and 108). A sagittal section of the brain placed in a pan of water will show the fold of pia mater called *velum interpositum* extending craniad from the pineal gland. Two folds of the pia mater hanging on either side from near the median line form the *choroid plexus* as in the fourth ventricle. The body of the fornix lies dorsad of the membranous roof of the ventricle. In the floor lie the corpora mamillaria, the infundibulum, the tuber cinereum, and the optic commissure. Craniad the third ventricle communicates with the lateral ventricles by slit-like apertures, the interventricular *foramina of Monroe*, passing laterad and ventrad of the anterior pillars of the fornix (Figs. 106 and 107).

The *lateral ventricles* are found in the cerebral hemispheres ventrad to the corpus callosum. They are the largest ventricles of the brain. In order to view them satisfactorily, the entire dorsal portion of the brain down to the corpus callosum must be cut away, and a hole cut through the corpus callosum.




FIG. 105.—DIAGRAM OF VENTRICLES OF THE BRAIN VIEWED DORSALLY.

ah, Anterior horn of the right lateral ventricle; as, aqueduct of cerebrum; cc, canalis centralis of the spinal cord; 3 and 4, third and fourth ventricles; m, foramen of Monroe; mi, middle horn or cornu of the ventricle.

A number of cross-sections of the cerebral hemispheres should also be studied.

Each ventricle is composed of a body from which projects an anterior cornu and a middle or descending cornu. The former extends into the frontal lobe and thence into the olfactory lobe, and the latter descends into the temporal lobe. The

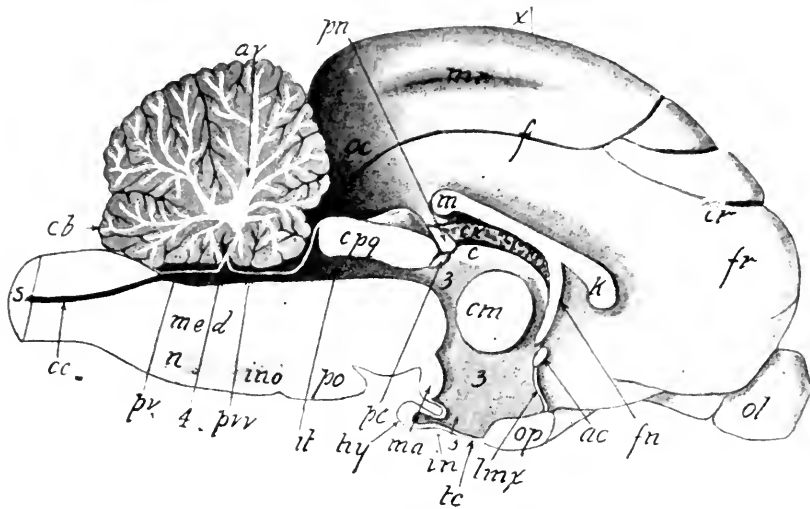


FIG. 106.—SAGITTAL SECTION OF THE BRAIN.

ac, Anterior commissure; *av*, arbor vitæ; *c*, habena; *cc*, canalis centralis; *cb*, cerebellum; *cm*, middle commissure or massa intermedia; *cr*, sulcus crucialis; *cpq*, corpus quadrigemina; *cx*, choroid plexus of third ventricle—the dark line dorsad of *cx* is the velum interpositum; *f*, sulcus splenialis; *fr*, frontal lobe of cerebrum; *fn*, anterior pillars of the fornix; *in*, infundibulum; *it*, iter, or aqueduct of cerebrum; *k*, genu of corpus callosum; *lma*, lamina terminalis; *m*, splenium; *ma*, corpus mamillare; *mr*, sulcus marginalis; *med*, medulla; *op*, optic chiasm; *oc*, occipital lobe; *ol*, olfactory lobe; *pn*, pineal gland; *po*, pons Varolii; *pc*, posterior commissure; *pv*, inferior medullary velum; *pvr*, superior medullary velum or valve of Vieussens; 3 and 4, third and fourth ventricles.

roof of the body of the lateral ventricle is formed by the corpus callosum (Figs. 106, 107 and 108) and the medial wall by the septum pellucidum, a mass of gray matter lying between the fornix and the corpus callosum. A fringe of pia mater projects through the interventricular foramen of Monro into the lateral ventricle, where it forms the choroid plexus. The lateral ventricles are lined with the epithelial layer common to the other ventricles.

These cavities within the central nervous system result from the manner in which the brain and cord are formed. In the embryonic life of most vertebrates the nervous system appears as a trough of matter extending dorsally throughout the length of the body. The sides of this trough grow dorso-mediad, thus forming a roof and thereby converting the trough into a canal which in the spinal cord becomes the *canalis centralis*, and in the brain the ventricles. This continuous cavity of the central nervous system contains a fluid having the nature of the aqueous humor of the eye.

The Commissures of the Brain.—The paired portions of the brain are united across the median line by bands of fibers known as commissures, two of which are visible on the ventral surface of the brain, and the others may be seen in a sagittal section (Fig. 106).

The *pons Varolii* is the commissure on the ventral aspect of the medulla. Its fibers pass into the cerebellum on either side, forming the middle peduncle or *crus cerebelli ad pontem*. The *optic commissure* or optic chiasm is formed by the crossing of the optic nerves, craniad of the tuber cinereum. Some of the fibers originating in the cells of the retina of one eye pass by this commissure directly to the cells in the retina of the other eye, while a second set passes from the eye to the optic tract on the opposite side of the brain, and still a third set, originating in one corpus quadrigeminum, passes by the optic commissure direct to the opposite corpus quadrigeminum (Fig. 106).

The *corpus callosum* is the largest commissure of the brain. It joins the two cerebral hemispheres, and forms the roof of the lateral ventricles. This broad plate of fibers (Figs. 106, 107, 108, 109), which may be seen at the bottom of the great longitudinal fissure by pressing the hemispheres slightly apart, is about one millimeter thick and three centimeters wide. Laterally the fibers radiate in all directions to the gray matter of the cortex. The ventral bend of the median cranial portion of the callosum is the *genu* or knee. The caudal border is the *splenium*.

The *fornix* lies ventral to the callosum (Figs. 106 and 108) and consists of a median plate of fibers, the *body*, two *posterior columns* or *crura*, and two *anterior columns*. The median plate or *body* of the fornix sends some fibers into the ventral surface

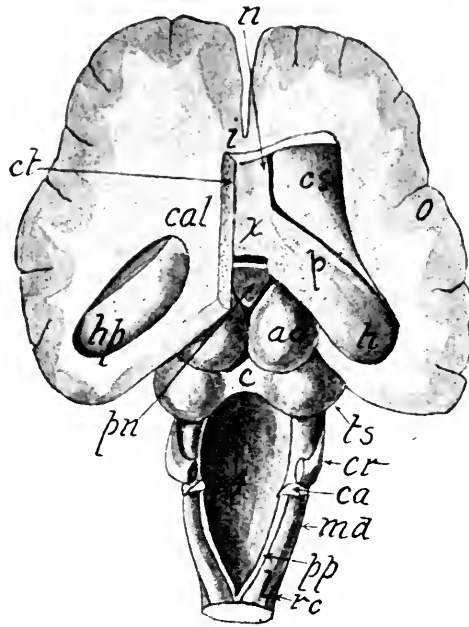


FIG. 107.—DORSAL ASPECT OF THE BRAIN WITH THE CEREBELLUM AND THE DORSAL THIRD OF THE CEREBRUM REMOVED AND MOST OF THE CORPUS CALLOSUM CUT AWAY FROM THE RIGHT HALF.

ac, Right anterior corpus quadrigeminum; *c*, commissure of the quadrigemina; *ca*, the united superior and inferior peduncles of the cerebellum; *cr*, the middle peduncle of the cerebellum; *cs*, corpus striatum; *ct*, edge of corpus callosum cut slightly to the left of the median line; *cal*, dorsal surface of the callosum into which a hole has been cut; *hp*, hippocampus in the median cornu of the lateral ventricle; *h*, hippocampus near where it is joined by the fibers of the crus of the fornix; *i*, uncut portion of the callosum; *md*, medulla oblongata; *n*, columns of the fornix; *o*, gray cortex of the cerebrum; *p*, crus of the fornix; *pn*, pineal body, cranial to which is the heavy white line, the commissure of the habenæ or tæniæ thalami; *pp*, funiculus gracilis; *rc*, funiculus cuneatus lateralis of Rolando; *l*, funiculus cuneatus; *ts*, posterior corpora quadrigemina; *x*, body of the fornix.

of the callosum. From the cranial border of the body near the median line the two anterior columns descend in a curve, forming the cranial boundary of the third ventricle as far ventrad as the anterior commissure. Here the two columns diverge slightly from the median line, but continue their descent, curving caudad to their termination in the corpora

mamillaria. The posterior columns, or crura, descend from the caudal border of the body, curving laterad into the median cornu of the lateral ventricle, and gradually unite with the hippocampus. The *hippocampus* is a thickened projecting fold of the wall of the median cornu of the lateral ventricle (Fig. 107). The free lateral margin of the crus of the fornix is the *fimbria*, or *tænia hippocampi*. Adjacent to the median line in either hemisphere, a thick lamina of matter, the *septum pellucidum*, stretches from the cranial part of the fornix dorsad to the callosum. The very narrow cavity formed by the adherence of the margins of the septum of one hemisphere to those of the septum in the other hemisphere is sometimes called the fifth ventricle, or cavity of septum pellucidum. Between each column of the fornix and the optic thalamus is a cleft, the *interventricular foramen* leading from the third ventricle, laterad of the septum pellucidum, into the lateral ventricle.

The three remaining commissures are known according to their location as the *anterior*, *middle*, and *posterior*. The anterior commissure (Figs. 106 and 109) perforates the corpora striata, extending across the median line immediately craniad of the columns of the fornix. It is about two millimeters in diameter. The middle commissure, or massa intermedia, lies between the thalami. It is sometimes called the soft or gray commissure. It is nearly one centimeter in diameter and passes through the third ventricle (Fig. 106). The posterior commissure is a cord of fibers about a millimeter in diameter connecting the caudal portions of the thalami.

The Basal Ganglia.—A semi-independent group of nerve cells forming a definite mass is known as a ganglion. In the ventral portion of the brain lie three pairs of large ganglia, called *corpora quadrigemina*, *thalami*, and *corpora striata*. To study them, the entire dorsal surface of the brain down to and including the corpus callosum should be removed.

The *corpora quadrigemina* (Fig. 107) forming the dorsal part of the mesencephalon lie craniad of the medulla, and consist of an anterior pair and a posterior pair. The former are known as the *superior colliculi* and the latter as *inferior colliculi*. The anterior pair lie nearer to the midline than the posterior pair, which are slightly separated by a depression occupied by the middle portion of the central lobe of the cerebellum. The posterior pair are united by a white commissure. The posterior commissure of the brain unites the cranial portions of

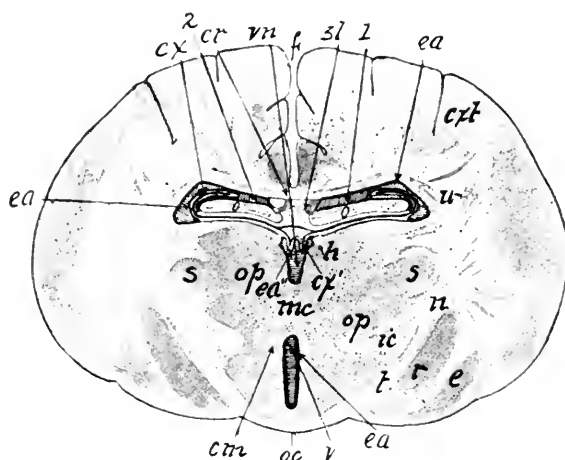


FIG. 108.—CROSS-SECTION OF THE BRAIN IN THE PLANE x IN FIG. 105.

The plane is just caudad of the optic chiasm.

1 and 2, First and second or lateral ventricles; *cr*, corpus callosum; *cm*, columns of fornix; *cx*, choroid plexus of lateral ventricle; *cx'*, choroid plexus of third ventricle; *cxt*, gray cortex; *ea*, ependyma lining the ventricles; *f*, median longitudinal fissure; *h*, tænia thalami; *mc*, middle commissure, or massa intermedia; *n*, fibers of the optic tract as they enter the lateral geniculate body *s*; *o*, fornix; *r*, caudal portion of nucleus lenticularis; *op*, thalamus; *oc*, optic tract as it leaves the chiasm; *sl*, septum pellucidum; *vn*, part of third ventricle dorsad to the commissure; *v*, third ventricle; *l*, fibers of optic tract.

the anterior pair (Fig. 106). Its cut end may be seen ventrad to the base of the pineal gland.

Laterally each of the corpora quadrigemina is prolonged into two white bands, the *anterior and posterior brachia*. The latter are about a half centimeter long, and pass forward beneath a pisiform ganglion, the *corpus geniculatum internum* or *mediale*. The anterior brachia pass from the cranial end of the posterior pair laterad beneath the caudal projections of the thalami, where they join the optic tracts.

Homologues of the corpora quadrigemina exist in all vertebrates. In these bodies originate partly the optic nerves, and therefore their size is in proportion to the animal's power of sight. In the mole, which has little use for eyes, the anterior pair is rudimentary.

The *thalami* forming the sides of the diencephalon or tween brain are the largest pair of basal ganglia, and lie craniad of the corpora quadrigemina and form the lateral walls of the third ventricle, across which they meet, forming the massa intermedia; or middle commissure.

On the dorsal aspect of each thalamus, near the median line, is a longitudinal band of white fibers called the *tænia thalami*, which at its caudal limit is united to its fellow by the commissure habenæ. The thalamus is composed largely of gray matter, but there are two important bundles of fibers, known as the *optic tract* and *internal capsule* (Fig. 108), appearing on its lateral surface. The optic tract, of which the optic nerve is a continuation, arises by two roots, the larger of which comes from the cells forming the *lateral geniculate body*, which is the lateral and caudal projection of the thalamus. The internal capsule, well shown in a transverse section, is composed of the fibers forming a communication between the cells of the cortex and those in the lower brain centers and spinal cord.

The *pineal gland*, or *pineal body* (Fig. 106), is a conical projection about a half centimeter long, from the caudal part of the dorsal surface of the thalamus. It is a vestigial structure which in some of the lower vertebrates in early geological time functioned as a third eye. In *Hatteria*, a New Zealand lizard about a foot long, the eye is present, projecting slightly through a foramen in the parietal bone. Traces of this third eye with a lens have also been noticed in the embryo of the viper and some of the lizards.

The *corpora striata* lie deep in the telencephalon. They are the most anterior of the basal ganglia and are somewhat pear-shaped, the larger ends being craniad and nearer the median

line than the caudal portions, which curve laterad around the optic thalami (Fig. 107). They form a part of the floor of the lateral ventricles, and are pierced by the anterior commissure (Fig. 109), a small cord of white fibers.

The corpus striatum consists of both white and gray matter. The latter, composed of cells, is disposed in two chief nuclei or masses, known as the *nucleus caudatus*, lying anterior and nearer the median line than the *nucleus lenticularis*, which is more lateral

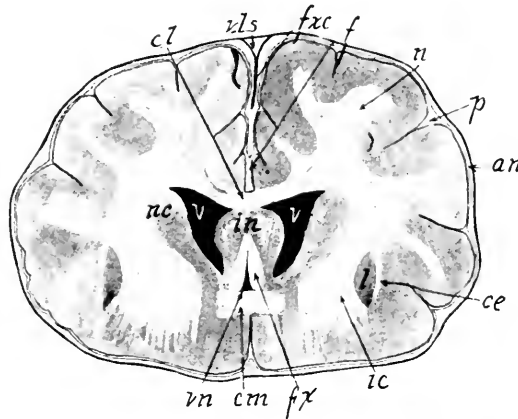


FIG. 109.—CROSS-SECTION OF THE BRAIN THROUGH THE ANTERIOR COMMISSURE.

an, Arachnoid; *ce*, external capsule; *cl*, corpus callosum; *cm*, anterior commissure; *fxc*, falx cerebri; *f*, great longitudinal fissure; *fx*, columns of the fornix; *ic*, internal capsule; *n*, radiating fibers of callosum; *in*, septum pellucidum; *nc*, nucleus caudatus of corpus striatum; *l*, nucleus lenticularis; *p*, pia mater; *vls*, superior longitudinal sinus; *vn*, third ventricle; *v*, lateral ventricle.

and caudal (Fig. 109). The center of the nucleus lenticularis is laterad of the optic thalamus and dorsad of the crus cerebri. A thin layer of white matter, the *lamina semicircularis*, separates the optic thalamus from the nucleus caudatus. A few fibers from the cerebral peduncles form the lamina semicircularis, whose edge may be seen in the floor of the lateral ventricle on the lateral boundary of the nucleus caudatus. A group of fibers, known as the *internal capsule*, separates the thalamus from the nucleus lenticularis, laterad of which is the *external capsule*, a group of fibers probably descending from the cells of the cerebral cortex. The two nuclei of the corpus striatum are connected by fibers, and other fibers connect these nuclei with the cortex of the cerebrum and the optic thalamus.

The Medulla Oblongata.—The medulla oblongata, or myelencephalon, is the stem of the true brain and extends from the point of origin of the first spinal nerve to the pons Varolii. The cerebellum must be removed in order to study carefully the features of the medulla, and as it is cut away the student should notice just ventrad to it the very thin roof of the fourth ventricle. Its caudal portion, composed of a reflection of the pia mater lined with epithelium, takes the name of *inferior medullary velum*, and the cranial part, formed of pia and a thin layer of nervous matter, is called the *anterior medullary velum* (Fig. 106).

The *fourth ventricle* (Figs. 106 and 107) is an enlargement of the canalis centralis of the cord. Two bands of fibers called *clavæ*, the three peduncles or crura of the cerebellum, and the posterior corpora quadrigemina form its lateral boundaries. Its cavity is shallow and pointed at either extremity. The floor, called *fossa rhomboidea*, is formed by the continuation of the gray matter of the spinal cord. Where the ventricle is widest a tract of fibers, the *stria medullaris*, arises from the midline and proceeds laterad to help form the auditory nerve.

Laterad of the clava a larger band of fibers, the *funiculus cuneatus*, runs parallel with a more lateral lying bundle, the *funiculus cuneatus lateralis*, or *funiculus of Rolando*. The band of fibers on either side uniting the cerebellum to the medulla oblongata is the *restiform body*, or *inferior peduncle* of the cerebellum. On the ventral aspect of the medulla may be seen the *anterior pyramids*, composed of a band of fibers lying on either side of the median line and apparently emerging from the pons. They form a section of the crossed pyramidal or motor tract connecting the brain with the cord. The olivary eminence lies just laterad of the pyramid. The fact that seven posterior cranial nerves originate from the medulla shows the importance of this part of the brain. The destruction of the respiratory centers, or *vital knot*, lying ventrad to the caudal end of the fourth ventricle causes instant death.

The Cerebellum, or Little Brain.—The cerebellum, which in the cat lies caudad of the cerebrum and dorsad of the medulla, resembles the cerebrum in being composed of an outer layer of gray matter or cells and an inner mass of white matter made up of fibers. While within the cerebrum there are several important ganglia or masses of gray matter, in the cerebellum only one chief mass of gray matter, the *corpus dentatum*, is present in each hemisphere.

The outer layer of gray matter, known as the *cortex*, is folded into numerous convolutions, between which are deep sulci (Fig. 106). The central core of white matter forms an arborescence known as the *arbor vite*.

The cerebellum (Fig. 103) is seen to consist externally of two lateral portions, the *cerebellar hemispheres*, a median *vermiform process* and three pairs of *peduncles* or *crura* which are bands of fibers uniting it with other parts of the brain and cord (Fig. 107). The separation between the hemispheres and vermis or vermiform process is most marked on the cranial aspect.

The *peduncles* are named, according to their location, *superior*, *middle*, and *inferior*. The middle peduncle, or brachium pontis, is a dorsal prolongation of the fibers of the pons Varolii (Fig. 104). In order to display the other peduncles a portion of the cerebellum must be cut or picked away with the forceps. The superior one, known also as the *brachium conjunctivum*, extends as a cord of fibers along the cranial half of the fourth ventricle and then beneath the corpus quadrigeminum. The inferior peduncle, or *restiform body*, forms part of the boundary of the caudal half of the fourth ventricle and enters the cerebellum between the other two peduncles. It is composed of fibers from the spinal cord and medulla.

LABORATORY STUDIES AND SUGGESTIONS

1. Describe the meninges of the central nervous system.
2. Which of the five parts of the brain are exposed dorsally?
3. Draw the lateral aspect of the brain and label all features.
4. Draw the ventral aspect of the brain and label all features.
5. Draw the dorsal aspect of the brain after the dorsal portion, including corpus callosum and fornix, has been removed.

6. Describe the differences existing between the gyri and sulci of your specimen and the one described in the text.
7. Write a description of the ventricles, giving dimensions and boundaries.
8. Describe the attachment of the pineal body.
9. Which of the cranial nerves derive their name from their function?
10. Name the foramina giving passage to one or more of the cranial nerves.
11. From which of the five parts of the brain do most of the cranial nerves originate?
12. Describe the choroid plexus.
13. What is the internal capsule?
14. Draw a cross-section of the brain made by cutting through the optic commissure and label all parts.
15. Draw a cross-section of the brain made by cutting through the middle commissure and label all parts.
16. Draw a cross-section of the brain made by cutting through the corpora quadrigemina and label all parts.
17. Write a description of the corpus callosum.
18. Which is the smallest commissure of the brain?
19. Explain the difference in structure between the white and gray matter.
20. Describe the cerebellum.

THE SPINAL CORD

The spinal cord extends from the foramen magnum through the vertebral canal. It is more or less cylindrical throughout and has a diameter of about one centimeter except in the lumbosacral region, where it grows gradually smaller until it is only one or two millimeters in diameter. In order to study the cord, one should have a mounted transverse microscopic section, and an entire cord *in situ* with the dorsal wall of the vertebral canal removed, so that the exit of the spinal nerves may be seen.

The **membranes** (Fig. 110) which envelop the spinal cord are the same as those that envelop the brain. The *dura mater* is the external tough coat; the *pia mater*, the internal delicate vascular coat sending a process deep into the anterior fissure on the ventral side; and the *arachnoid*, the very thin membrane between the two preceding. The arachnoid lies close against the dura mater, but is separated from the pia mater by the subarachnoid space, which is filled with a serous fluid called the cerebrospinal fluid. It is apparently the same as that in

the ventricles of the brain and the aqueous humor of the eye. It seems to be supplied for the most part by the choroid plexus of the ventricles although other sources have been suggested.

The cord presents two enlargements, the *cervical*, whence issue the nerves of the forelimbs, and the *lumbar*, giving origin

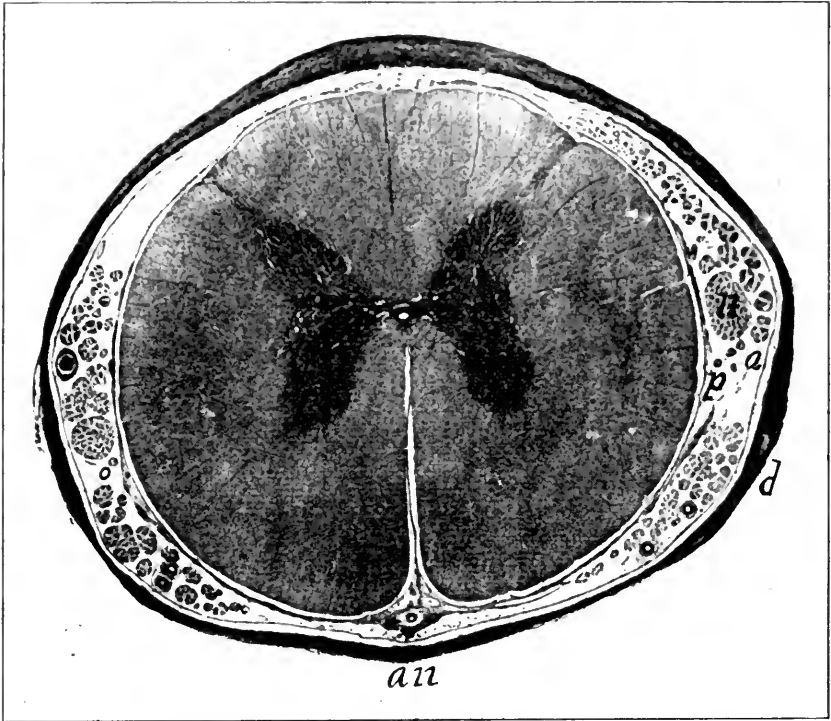


FIG. 110.—PHOTOMICROGRAPH OF CROSS-SECTION OF HUMAN SPINAL CORD.

a, Arachnoid membrane; *an*, ventral side in which appears the deep anterior fissure; *d*, dura mater; *n*, one of several nerve bundles; the tiny white spot in the center of the dark gray matter is the canalis centralis; *p*, pia mater. $\times 5$.

to the nerves of the posterior limbs. Two deep fissures, the *ventral (anterior) median* and the *dorsal (posterior) median*, penetrate about one-third through the cord, incompletely dividing it into halves longitudinally. The pia mater is prolonged into the ventral fissure, but not into the dorsal fissure. Slightly laterad of the ventral median fissure issue the **ventral roots** of the spinal nerves, and at about the same distance from the dorsal median fissure are the **dorsal roots** of the spinal nerves. These two roots unite about one centimeter from their origin

(Fig. 104). On the dorsal or sensory root is a small ganglion located very near the junction of the two roots. The common spinal nerve, formed by the union of the two roots, almost immediately divides into four branches, one of which, the dorsal, supplies the muscles and skin along the vertebral column; a second, the ventral branch, supplies the limbs or intercostal spaces; while the other two branches, *rami communicantes*, join the adjacent ganglion of the sympathetic cord (Fig. 118).

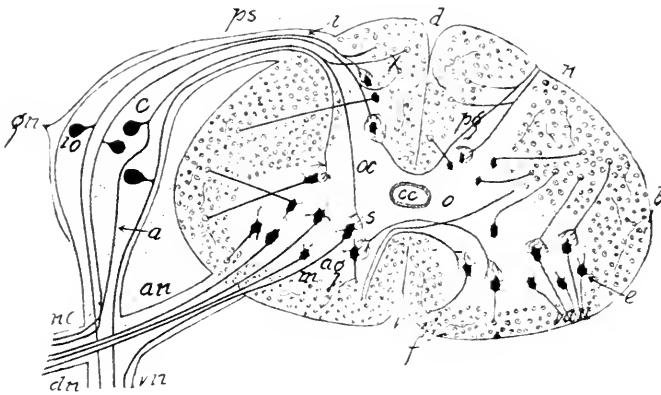


FIG. 111.—DIAGRAMMATIC CROSS-SECTION OF THE SPINAL CORD. The cells and fibers are represented too few and too large in proportion to the size of the cord.

ag, Ventral horn or column of gray matter; a, nerve process of the cell; c, an, ventral root; cc, central canal; c, one of the cells forming the ganglion on the dorsal root; d, dorsal median sulcus; e, cell giving off an axone into the ventral root; dn, dorsal branch; f, cut-off fibers; gn, ganglion of dorsal root; i, axone of the cell io; nc, junction of dorsal and ventral roots; ps, dorsal root of nerve; pg, dorsal column of gray matter; s, terminal arborization of part of fiber from c; v, ventral median fissure; vn, ventral branch of nerve; van, axones of ventral column cells; x, the part of the dorsal root fiber extending craniad in the cord.

Each of the four branches contains both motor and sensory fibers, or, in other words, fibers from both roots.

The exit and entrance of the nerve roots divide the white matter of the lateral half into three columns named, according to their location, the *ventral column*, the *lateral column*, and the *dorsal column*. The first is ventral to the ventral nerve roots, the last is dorsal to the dorsal nerve roots, while the lateral column is between the roots.

The elements of the spinal cord, like those of the brain, are of two kinds—the cells composing the gray matter and the fibers composing the white matter. While in the brain the gray matter is largely on the surface, forming the cortex, in the cord it occupies the central region. A canal, the *canalis centralis*, about one-half a millimeter in diameter, extends throughout the cord, opening into the fourth ventricle of the

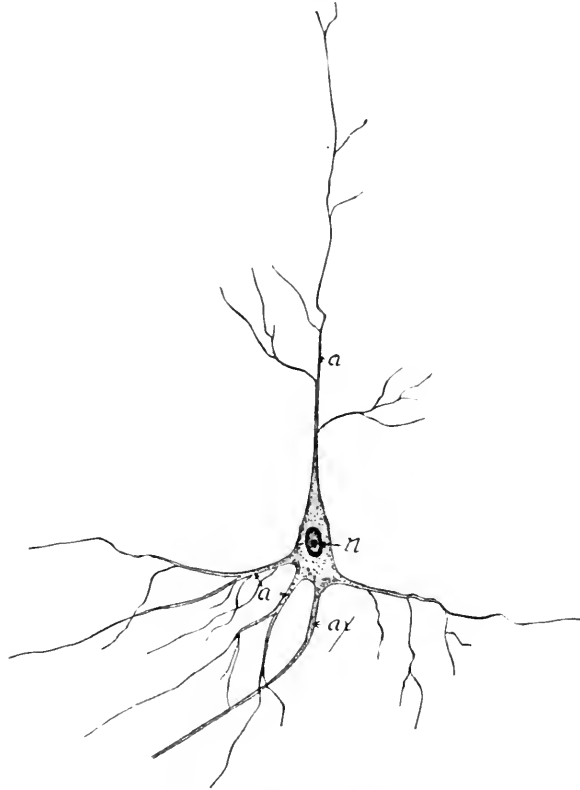


FIG. 112.—CELL FROM THE CENTRAL NERVOUS SYSTEM. $\times 100$.
a, Dendrites or protoplasmic processes; ax, axone; n, nucleus of the cell body.

brain. A cross-section of the cord shows the gray matter arranged in the shape of a letter **H**. The ventral columns of gray matter are the *ventral horns*, and the posterior columns, the *dorsal horns* (Fig. 111).

Many of the fibers extend in a longitudinal direction throughout the cord, but the roots of the spinal nerves upon entering the cord run transversely a longer or shorter distance, and in many cases cross to the opposite side. Numerous experiments

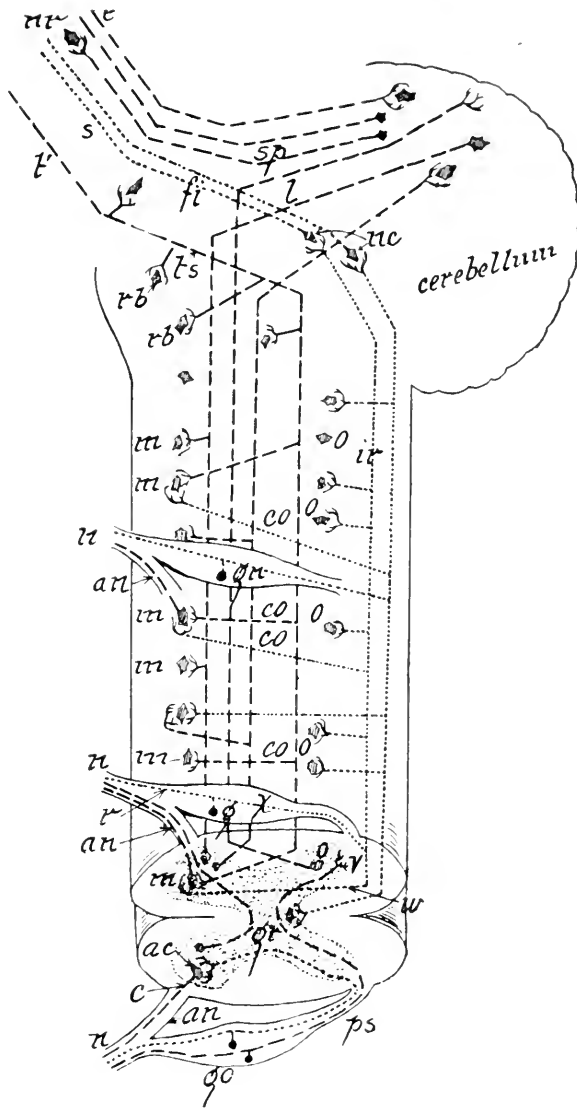


FIG. 113.—DIAGRAM SHOWING THE RELATION OF SOME OF THE CELLS AND FIBERS OF THE SPINAL CORD. Lateral aspect of the cord.

a, Ventral median fissure; *ac*, cells of the ventral horn; *an*, ventral root of spinal nerve; *c*, axone; *co*, collateral fibers; *e*, fibers connecting higher brain centers with cerebellum; *fi*, sensory fibers of fillet to the brain; *g*, *gn*, *go*, ganglion of dorsal root; *gr*, gray matter; *ir*, fibers of the dorsal sensory tract; *l*, fibers to cerebellum; *m*, cell in the ventral horn or column of gray matter; *n*, spinal nerves; *o*, cells in the dorsal horn or column of gray matter; *nc*, nucleus gracilis and nucleus cuneatus; *nr*, nucleus ruber; *r*, a fiber of posterior root; *rb*, ganglion cells of medulla; *s*, tract of fillet to the brain; *sp*, fibers of superior peduncle of the cerebellum; *t'*, fiber of crossed pyramidal tract; *ts*, point of decussation; *v*, division of fiber *x* into its cranial and caudal extensions; *w*, a collateral of the longitudinal fiber *ir*.

show that the ventral root fibers are, for the most part, the axones of the cells in the ventral horn (Fig. 113).

Each dorsal root fiber after passing into the cord separates into two parts one of which extends craniad, the other caudad (Fig. 113). Both give off branches at right angles, called collaterals, which terminate in arborizations about the cells of the cord.

Each nerve cell with all its processes is called a *neurone*. It presents two kinds of processes, *protoplasmic processes* or *dendrites* and an *axis-cylinder process* or *axone* (Fig. 112). The dendrites, except in the ganglia outside of the central nervous system, are usually several in number and comparatively short, while there is but one axone from each cell, which may be more than a foot in length. A number of axones (nerve fibers), each of which is surrounded by a sheath, the neurilemma, constitutes a nerve bundle or *nerve*. Every axone or nerve fiber originates in a cell, but terminates freely either within the central nervous system or in some other part of the body (Figs. 112, 113). Within the central nervous system a fiber usually ends in an arborescence which may be contiguous but not continuous with the dendrites of another cell. The nerve processes have the power of conducting impulses whether derived from the cell itself or an external stimulus. The dendrites conduct impulses toward the cell, while the axone conducts them from the cell.

The sensory fiber *r* (Fig. 113), leads from the dermis of the cat's paw. A pin-prick in the paw causes an impulse to be transmitted along the fiber to the cell *g*, and thence by its axone, *x*, to the point *v* within the cord where the fiber splits. From the point *v* the impulse will proceed both through the ascending portion of the fiber, *ir*, and the collateral, *w*. By the latter route it will stimulate the cell *m*, whose axone terminates in the foreleg muscles, which are thereby made to contract and pull the paw away from the irritating object. This process may take place without consciousness, and is then

known as *reflex action*. If, however, the impulse travels along the fiber *ir*, and thence through the fiber *s* to the brain, whence an impulse descends through the fiber *l'*, *ls*, the process is known as voluntary reaction.

LABORATORY STUDIES AND SUGGESTIONS

1. Describe the membranes of the cord.
2. What difference is there in the size of the nerve roots in the various regions of the cord?
3. Draw a cross-section of the cord showing all features visible to the naked eye.
4. How does the arrangement of the gray matter of the cord and brain differ?
5. Describe the processes of nerve cells.
6. In what portions of the body are nerve cells found?
7. Procure a piece of spinal cord from the butcher-shop. Smear a bit of the gray matter on a glass slip, dry, then stain in hematoxylin, wash, and after drying mount in balsam. Draw and describe nerve cells thus found.

THE PERIPHERAL NERVES

All portions of the head, trunk, and limbs of the cat are supplied with nerve fibers which are in communication with the central nervous system by means of fifty-two pairs of nerve bundles, forming what are known in the brain region as the *cranial nerves* and in the region of the cord as the *spinal nerves*.

The Cranial Nerves.—There are twelve pairs of cranial nerves, all of which pass through foramina in the base of the skull, and all except one, the tenth or vagus, are distributed to structures of the head and neck. They are divided according to function into *motor* and *sensory*. Some of the nerves communicate with the brain by more than one root, and in such cases the same nerve may have sensory fibers in one root and motor fibers in another. For example, the trigeminal nerve transmits a stimulus causing the muscles of mastication to contract and also supplies the teeth and other portions of the fore-parts of the head with sensory fibers (Fig. 104).

The *olfactory* (I), *optic* (II), and *acoustic* (VIII) are the only cranial nerves wholly sensory. The *oculomotor* (III), *troch-*

CRANIAL NERVES

	Superficial origin	Exit from skull	Distribution
1. Olfactory	Olfactory bulb.	Foramina of ethmoid.	Schneiderian membrane.
2. Optic.	Optic chiasm.	Optic foramen.	Retina.
3. Oculomotor.	Cerebral peduncle craniad of the pons.	Foramen lacerum anterius, or sphenoidal fissure.	Inferior oblique and all recti muscles of the eye except the external.
4. Trochlear.	Anterior medullary velum.	Same as preceding.	Superior oblique.
5. Trigeminal.	Caudal region of pons Varolii.	{ F o r a m e n lacerum anterius—first or ophthalmic division. Foramen rotundum—second or maxillary division. Foramen ovale—third or mandibular division.	Eye-ball and integument in region of orbit and nose. Integument of nose and maxillary region and maxillary teeth, lachrymal gland and palate. Integument and muscles of mandibular region, mandibular teeth, tongue, and submaxillary gland.
6. Abducens.	Trapezium laterad of the pyramid.	Foramen lacerum anterius.	External rectus of the eyeball.
7. Facial.	Latero-cranial portion of trapezium.	Canalis facialis (Fallopian) and styloid mastoid foramen.	Muscles of head and face, parotid and submaxillary glands.
8. Acoustic.	Immediately caudad of the preceding.	Meatus auditorius internus.	Internal ear.
9. Glossopharyngeal.	Immediately caudad of the preceding.	Foramen lacerum posterius, or jugular foramen.	Tongue, tonsils, palate, pharynx.
10. Vagus or pneumogastric.	Immediately caudad of the preceding.	Foramen lacerum posterius, or jugular foramen.	Pharynx, larynx, trachea, esophagus, heart, lungs, stomach, and thyroid gland.
11. Accessory.	By several roots in cord and medulla from sixth cervical nerve to point near the vagus.	Foramen lacerum posterius, or jugular foramen.	Muscles of neck and shoulders.
12. Hypoglossus.	Latero-caudal portion of olivary prominence.	Hypoglossal canal.	Hyoid muscles, tongue muscles.

learis (IV), and *abducens* (VI) are wholly motor. The *trigeminal* (V), *facial* (VII), *glossopharyngeal* (IX), *Vagus* (X), *accessorius* (XI) (mainly motor), and *hypoglossus* (XII) contain both motor and sensory fibers.

The dissection of the cranial nerves is very difficult. A head, containing a brain hardened by a formalin injection, should be placed in 500 c.c. of 5 per cent. nitric acid, which will decalcify the bone in about a week. After washing out the acid by soaking the specimen in running water twenty-four hours, the dissector may with much care follow the nerves peripherad from their origin at the base of the brain. The vagus nerve must, of course, be traced in an entire specimen, where it may be easily followed in the neck region along with the carotid artery, whence it passes to the lungs and stomach (Fig. 72).

Some of the sensory nerve roots bear ganglia, the largest of which is the *semilunar* (*Gasserian*) *ganglia*, more than a half centimeter in diameter, forming a knot on the sensory root of the trigeminal, within the cranial cavity (Fig. 104).

The Spinal Nerves.—There are forty pairs of nerves connected with the spinal cord. They issue from the vertebral canal through the intervertebral foramina. Each nerve is connected to the cord by a *ventral* and *dorsal* root (Figs. 104 and 113). The former is also known as the *motor root*, since its fibers are almost entirely motor, while the latter is the *sensory root*, as it is composed of fibers transmitting impulses to the central nervous system. A ganglion about the size of a pinhead is located on the dorsal root immediately proximad of its junction with the ventral root, within the intervertebral foramen. This anatomy can be displayed by cutting away the dorsal muscles on either side of the column, and then, with the bone-cutters, severing the laminae of several of the arches of the vertebrae, so that the roof may be removed from the vertebral canal (Fig. 23).

Immediately beyond the intervertebral foramen each nerve gives off a dorsal branch to the muscles of the back, and a small connecting twig to the sympathetic system. The main nerve

is then spoken of as the ventral branch. These main nerves or ventral branches, in various regions of the trunk, anastomose

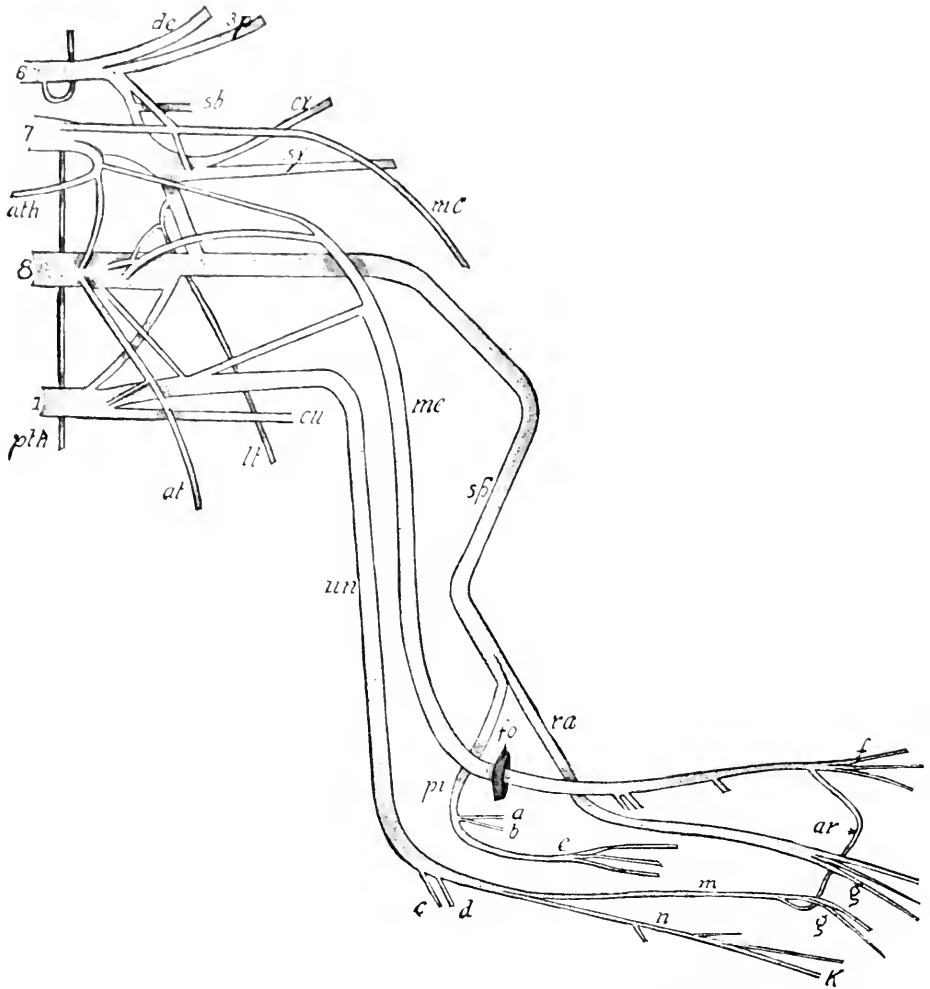


FIG. 114.—VENTRAL ASPECT OF THE BRACHIAL PLEXUS AND CHIEF NERVES OF THE ARM.

6, 7, 8 and 1, Sixth, seventh, and eighth cervical and first dorsal nerves; *at*, *ath*, anterior thoracic nerves; *a* and *b*, to muscles of the forearm; *c* and *d*, to the joint; *cx*, circumflex nerve; *cu*, internal cutaneous; *de*, to the deltoid; *g*, to the digits; *f*, to the digits; *fo*, supracondyloid foramen; *lt*, long thoracic; *mc*, musculo-cutaneous; *me*, median nerve; *pi*, posterior interosseous; *pth*, posterior thoracic; *sp*, musculospiral; *sp*, to suprascapular region; *sb*, to subscapular region; *sx*, subscapular; *ra*, radial; *un*, ulnar nerve.

with each other, forming *plexuses*. In the region of the neck, where is formed the *cervical plexus*; in the region of the shoulder the *brachial plexus*; in the region of the loins, the *lumbar plexus*;

and in the region of the sacrum, the *sacral plexus* (Figs. 114 and 115).

There are eight *cervical nerves*, the first of which does not make its exit through the intervertebral foramen, as do all the other spinal nerves, but traverses a foramen in the atlas. The first five cervical nerves, the three posterior cranial nerves, and branches from the sympathetic trunk, form the **cervical plexus**. These five cervical nerves supply mainly the structures of the neck.

There are thirteen pairs of *thoracic nerves*. The ventral branches of the sixth, seventh, and eighth cervical nerves and the first thoracic nerve form the **brachial plexus**. This may be displayed by removing the cephalo-humeral muscle and cutting through the pectoral muscles about two centimeters from their origin (Fig. 48). The manner in which the nerves anastomose varies somewhat, but the following will be found approximately correct:

The *sixth cervical nerve* gives off a small branch to the rhomboideus and levator scapulæ muscles of the shoulder, and then divides into two nearly equal branches, one of which supplies the muscles on the lateral aspect of the scapula, and the other joins with the seventh cervical nerve. Small branches from the fifth and sixth cervical nerves unite to form the phrenic nerve supplying the diaphragm.

The *seventh cervical nerve* gives off three small branches at about the same point, one of which is the posterior thoracic supplying the serratus magnus muscle, a second helps to form the musculocutaneous, and the third forms part of the median and anterior thoracic. The main portion of the seventh cervical unites with the eighth and first thoracic, to form the *musculospiral* (radial) *nerve*. The circumflex (axillaris) and subscapular branches supplying the deltoid and subscapular muscles are also derived from the seventh.

The *eighth cervical nerve*, after giving off a small branch to the pectoral muscle, a small twig to the median nerve, and a large

branch to the first thoracic nerve, is continued as the main part of the musculospiral nerve.

The *first thoracic nerve* gives first a large branch to the musculospiral nerve, a second small branch to the anterior thoracic, and a third branch forming the internal cutaneous nerve supplying the skin of the arm and forearm on the caudal aspect. The main portion of the first thoracic nerve then continues as the main part of the ulnar nerve.

The nerves of the forelimb are five in number (Fig. 114): the external cutaneous or musculo-cutaneous, the internal cutaneous, the musculospiral, the median, and the ulnar. The *external cutaneous* arises from the sixth and seventh cervical nerves and passes distad along the caudal aspect to the biceps to the cranial aspect of the forearm, where it becomes subcutaneous. It supplies the biceps and coracoid muscles and the skin of the forearm. The *internal cutaneous* arises from the first thoracic and passes along the ventral side of the arm, becoming subcutaneous just proximad of the elbow, where it is distributed to the skin of the arm and forearm on the caudal and ventral aspects.

The *musculospiral* (radialis) arises from the seventh and eighth cervical and first thoracic nerves. It is the largest component of the brachial plexus. It winds obliquely around the humerus to the cranial aspect, where it divides into two branches, the radial and the posterior interosseous. The superficial *radial nerve* is the smaller and becomes subcutaneous near the elbow, and passes along the radial region. The *posterior* (dorsal) *interosseous* proceeds along the dorsal aspect of the forearm to the wrist, where it divides into branches supplying the digits.

The *median nerve* arises from the seventh and eighth cervical and first thoracic. It follows the course of the brachial artery, passing through the supracondylar forearm to the elbow, where it passes beneath the pronator teres to the carpal region, and supplies the first, second, and third digits. It also supplies the pronator teres and flexor muscles of the forearm.

The *ulnar nerve* (Fig. 114) is derived from the eighth cervical and first thoracic. It courses with the brachial artery to the middle of the humerus, where it turns caudad to pass between the olecranon process and internal condyle of the humerus. It is here subcutaneous and furnishes the sensation experienced when one strikes what is popularly called his "funny bone," but what is really the ulnar nerve. It then passes down the ulnar side of the forearm, supplying some of the flexor muscles, and finally divides to supply the fourth and fifth digits. The ventral branches of the remaining thoracic nerves encircle the body, supplying the muscles and skin of those regions.

The **lumbar plexus** (Fig. 115) is composed of the anastomosing of the ventral branches of the four caudal lumbar nerves. As in the cervical and thoracic nerves, the lumbar nerves divide into dorsal and ventral branches immediately without the intervertebral foramen. The former supply the muscles and skin of the back. In order to display the lumbar nerves, the entire ventral and lateral abdominal wall should be cut away and the specimen securely nailed to the tray on its back. The adipose tissue and muscles lying on either side of the bodies of the lumbar vertebræ must be carefully picked away until the roots of the nerves are apparent. They may then be easily followed distad.

The first three lumbar nerves of the cat are represented in man by the ilio-hypogastric and ilio-inguinal. The first nerve supplies the rectus muscle and skin of the abdomen. This nerve and the two next described are scarcely as large in diameter as an ordinary pin. The ventral branch of the second lumbar nerve divides into two branches, and supplies the skin of the caudal part of the abdomen, and structures in the inguinal region. The ventral branch of the third lumbar nerve supplies the inguinal region and is also distributed to the transverse and rectus muscles. The fourth lumbar nerve divides into two parts, one of which is the *genito-crural* (genitofemoral) *nerve*, supplying the skin and other structures of the ventral abdominal wall and thigh, the other branch together with part of the fifth

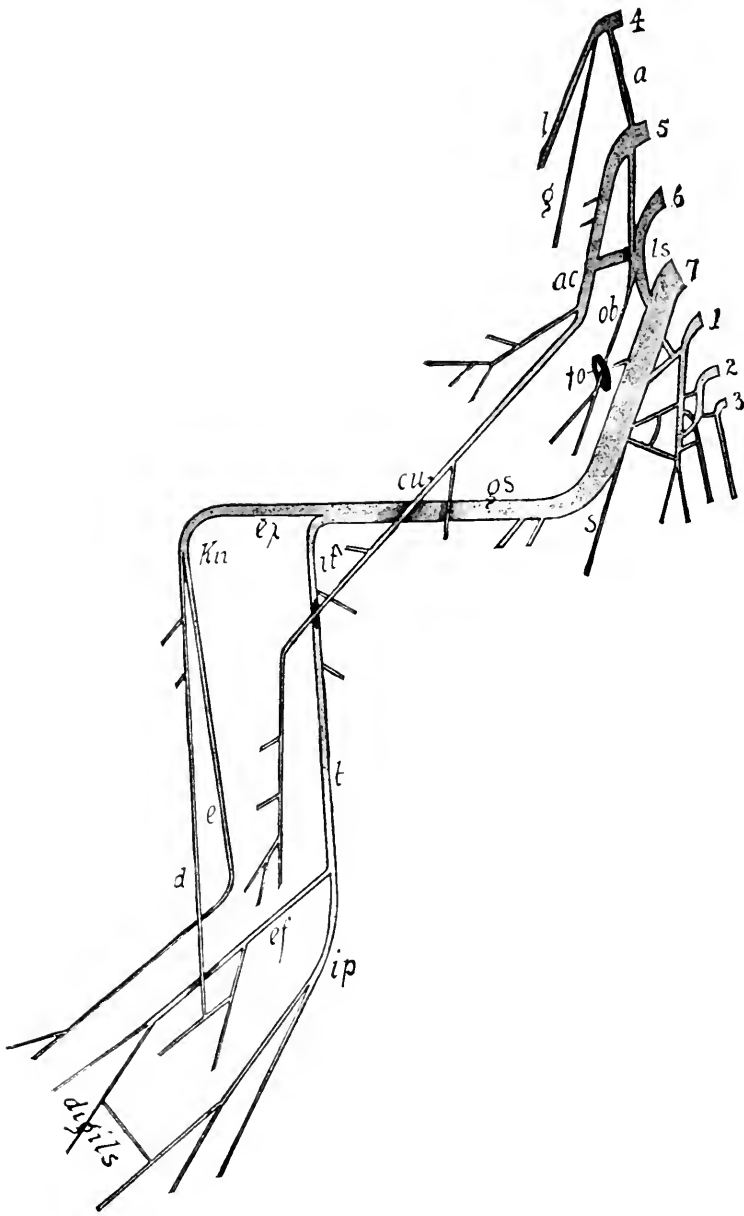


FIG. 115.—VENTRAL ASPECT OF THE NERVES OF HIND-LIMB.

4, 5, 6, 7, 1, 2, and 3, Fourth, fifth, sixth, and seventh lumbar, and first, second, and third sacral nerves; *a*, branch from the fourth to the fifth; *ac*, anterior crural; *cu*, saphenous; *d*, anterior tibial; *e*, peroneal or musculocutaneous; *ex*, external popliteal or peroneal; *ef*, external plantar; *fo*, obturator foramen; *gs*, greater sciatic; *g*, genito-crural; *il*, internal popliteal; *ip*, internal plantar; *kn*, knee; *l*, external cutaneous; *ls*, lumbosacral cord; *t*, posterior tibial; *s*, small sciatic.

nerve forms the *external cutaneous*, supplying the lateral surface of the thigh region.

The *anterior crural* nerve is composed mainly of branches of the fifth and sixth lumbar. It receives a small branch from the fourth. It supplies the psoas muscles, which it pierces, and then divides into several branches, one of which is the *saphenous*, passing subcutaneously along the medial aspect of the leg. The other nerves supply the muscles of the thigh on the cranial and medial aspect. The *obturator nerve* is composed of branches from the sixth and seventh lumbar. It is smaller than the preceding, and passes through the obturator foramen to supply the obturator, adductor, gracilis and pectineus muscles.

The **sacral plexus** is formed of the three sacral nerves with branches from the sixth and seventh lumbar nerves.

The great *sciatic nerve* is composed mainly of the ventral branches of the seventh lumbar and first sacral nerves. It usually receives accessions from the other sacral nerves and the sixth lumbar. The great sciatic is the largest peripheral nerve in the body. It passes caudad from its origin around the greater sciatic notch and thence along the caudal aspect of the thigh to the popliteal space, where it divides into the *internal* and *external popliteal nerves*. The former continues down the caudal side of the tibia as the *posterior tibial nerve* to the internal malleolus, where it divides into *internal* and *external plantar nerves*, which supply the digits. The external popliteal or peroneal nerve extends to the outer cranial aspect of the leg, where it divides into the *musculocutaneous* and *anterior tibial nerves*. The former extends between the extensor longus digitorum and peronei muscles to its ramification on the dorsum of the foot. It supplies the skin along its course and the peronei muscles. The anterior tibial nerve passes down on the cranial aspect of the tibia beneath the extensor longus digitorum muscle to the tarsal region, where it anastomoses with a branch of the external cutaneous, and supplies the skin, tibialis anticus, and the extensor muscles.

The *lesser sciatic nerve* comes chiefly from the second and third sacral nerves. It supplies the region of the anus and the biceps muscle.

Other nerves given off from the sacral plexus are the *glutei* and *pudic* nerves supplying the buttock muscles and external genital organs.

THE SYMPATHETIC NERVOUS SYSTEM

The sympathetic nervous system is composed chiefly of a pair of nerve-cords extending from the base of the skull to the root of the tail, a number of ganglia and branches supplying the thoracic and abdominal viscera, and numerous minute fibers supplying the muscular walls of the blood-vessels in all parts of the body. The sympathetic system supplies all non-striated or involuntary muscles in any part of the body. The two branches connecting each spinal nerve with a sympathetic nerve-cord are called *rami communicantes*.

In order to demonstrate this system successfully, one should use a lean injected specimen. After the cat has been securely nailed on its back to the tray, the entire ventral half of the thoracic and abdominal walls should be removed. By pushing the heart and lungs to the left side a white cord about one millimeter in diameter may be seen lying near the median dorsal line (Fig. 116). The left cord may be found in a similar manner and both followed craniad and caudad, noting their numerous branches in accordance with the following description.

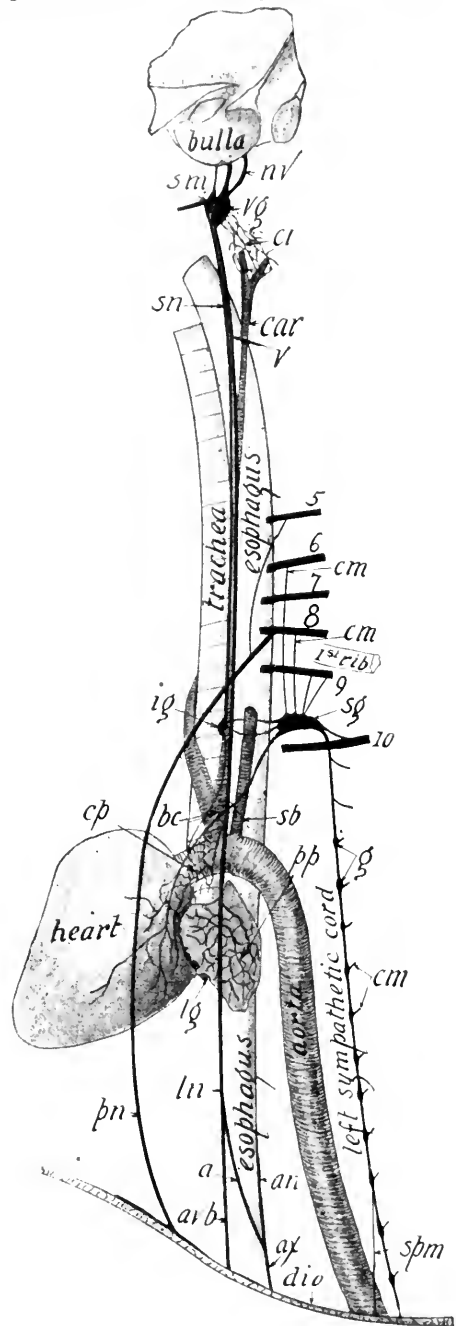
The **sympathetic nerve-cord** begins in the *superior cervical ganglion* lying near the angle of the mandible, beneath the sub-maxillary and lymphatic glands. This ganglion is about the shape of a grain of wheat, but not more than half so large, and is adjacent to the small *vagus* ganglion on the dorsal side of the carotid artery. The ganglia are masses of large nerve cells and occur at regular intervals on the sympathetic cords in the body cavity, and are present also on some of the branches of the cords (Fig. 117). On the cords there are three pairs of *cervical ganglia*,

thirteen pairs of *thoracic ganglia*, seven pairs of *lumbar ganglia*, and one or two pairs of *sacral ganglia*, in addition to two median unpaired *sacral ganglia*.

In the cervical region the sympathetic and vagus, or tenth cranial nerve, are bound in a common sheath lying along the lateral aspect of the carotid artery. One or two centimeters craniad of the first rib is the thyroid or *middle cervical ganglion*, whence the nerve proceeds in two cords, enclosing the subclavian artery, to the large *inferior cervical ganglion* just caudad of the first rib. From the cervical portions of the sympathetic cord are given off numerous delicate branches, forming the carotid plexus on the carotid artery, and uniting

FIG. 116.—CHIEF PART OF LEFT HALF OF SYMPATHETIC SYSTEM CRANIAD OF THE DIAPHRAGM. Semidiagrammatic.

5, 6, 7, 8, 9, and 10, Fifth, sixth, seventh and eighth cervical nerves, and first and second thoracic spinal nerves: *a*, the dorsal branch of the left vagus; *ln*, dorsal branch of the right vagus; *an*, common dorsal vagus formed by *a* and *ln*; *avb*, ventral vagus; *bc*, cardiac branch of *sg*; *cr*, carotid plexus; *car*, carotid artery; *cm*, rami communicantes; *cp*, cardiac plexus; *dia*, diaphragm; *g*, ganglia in the thoracic cavity; *ig*, middle cervical ganglion; *lg*, portion of left lung; *ln*, left vagus nerve; *nv*, cranial nerve; *pn*, phrenic nerve; *pp*, pulmonary plexus; *sn*, sympathetic cord; *sm*, superior cervical ganglion; *sb*, left subclavian artery; *sg*, stellate ganglion or inferior cervical; *spm*, splanchnic major nerve; *vg*, vagus ganglion; *v*, vagus nerve.



with the eight posterior cranial nerves and the first spinal nerve. From the inferior cervical ganglion a branch goes to the vagus nerve, several branches to the brachial

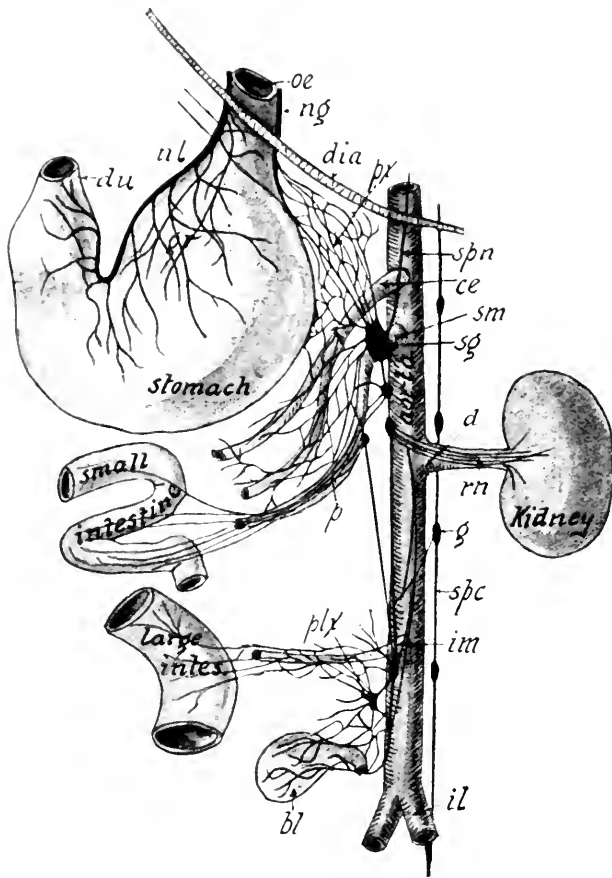


FIG. 117.—CHIEF PART OF LEFT HALF OF SYMPATHETIC SYSTEM CAUDAD OF THE DIAPHRAGM. Semidiagrammatic.

bl, Bladder; *ce*, celiac axis; *du*, duodenum cut off; *dia*, diaphragm; *gr*, anterior gastric plexus; *g*, ganglion; *im*, inferior mesenteric artery; *il*, external iliac artery; *ng*, dorsal branch of vagus (Fig. 106, *ax*); *nl*, ventral branch of vagus; *oe*, esophagus cut off; *p*, superior mesenteric plexus; *plx*, inferior mesenteric plexus; *px*, branches to dorsal gastric plexus; *rn*, renal plexus; *sm*, superior mesenteric artery; *spn*, splanchnic major or greater splanchnic nerve from the sympathetic cord; *sg*, semilunar ganglion; *spc*, sympathetic cord of left side.

plexus, and a branch to the heart, forming the *cardiac plexus*, while the main sympathetic cord continues along the dorsal thoracic wall. A ganglion occurs opposite each vertebral body, from which it gives off a branch to the corresponding spinal nerve. The *great splanchnic* arises from the main cord

just craniad of the diaphragm and extends to a group of ganglia in the region of the trunk of the celiac axis (Figs. 116 and 117). These ganglia and anastomosing branches constitute the *solar* or *epigastric plexus*, lying dorsad of the stomach, to which it sends numerous branches. This plexus also receives the lesser splanchnic nerve coming from the sympathetic cord just craniad of the diaphragm, and branches from the tenth cranial nerve.

The largest ganglion of the solar plexus is the celiac or *semi-lunar*. The solar and its allied plexuses send nerves to the diaphragm, suprarenal bodies, many of the blood-vessels of the abdominal cavity, stomach, kidneys, ureters, testes or ovaries, uterus, liver, gall-bladder, spleen, pancreas, and intestines.

The *hypogastric plexus* is the third great sympathetic plexus. It lies on the ventral aspect of the two caudal lumbar vertebrae and is formed by branches from the solar plexus and a few twigs from the sympathetic cords. It supplies the blood-vessels of the pelvic region and all the organs of the pelvis. The sympathetic cords in the lumbar region lie near together and the communicating branches between them and the spinal nerves are longer than in the thoracic region. In the sacral region there are no rami communicantes, and the ganglia are irregularly arranged. A median ganglion in the sacral region is known as the ganglion impar. There may be two median ganglia. The sympathetic cords terminate in the tail.

LABORATORY STUDIES AND SUGGESTIONS

1. Name the foramina of the skull giving passage to one or more cranial nerves.
2. From a study of one or more specimens and the description in the book make a diagrammatic drawing of each cranial nerve.
3. Which cranial nerves have their roots in the medulla?
4. Name the cranial nerves which are wholly motor.
5. Which of the cranial nerves do not supply structures of the head?
6. Of what are ganglia composed?
7. Make a drawing of your dissection showing the connection between the spinal and sympathetic nerves.

8. Which spinal nerves form the several plexuses?
9. Make a drawing showing wherein the brachial plexus in your specimen differs from that described in the text.
10. Write a description of your dissection of the nerves of the thoracic limb.
11. Mention in what way the lumbar plexus differs from the description in the book.
12. Draw the great sciatic nerve and its branches as seen from the caudal aspect.
13. What nerves supply the digits?
14. Describe the chief plexuses of the sympathetic system.
15. How do stimuli from the viscera reach the brain?
16. What portion of the body is not supplied with nerves from the sympathetic system?

THE ORGANS OF SENSE

The organs of sense are the specialized peripheral terminations of the sensory nerves, and are so constructed as to be capable of receiving only a certain kind of stimulus. The stimuli for the eye are ether vibrations; those for the ear are vibrations of the air. The stimulation of the sensory nerves produces sensations in the cells of the cerebral cortex to which they lead.

The external stimuli giving rise to the internal sensations of seeing, hearing, smelling, and tasting are transmitted by only four pairs of cranial nerves, while the stimuli of cutaneous sensations are transmitted by three pairs of cranial nerves and all the spinal nerves.

Cutaneous Sense Organs.—The cutaneous sense organs are composed of the endings of the sensory nerves in all parts of the skin and the mucous membrane of the mouth, nose, arms, vagina, and urethra. One kind of sense organs, those of pain, are present in every organ of the body. The sense organ of pain is probably an unmodified free nerve-ending.

While all portions of the skin and perhaps other parts of the body are supplied with organs capable of receiving stimuli giving rise to tactile sensation, the soles of the feet and the skin at the base of the vibrissæ are specially sensitive regions.

The nerves terminate in a kind of wreath formation about the base of the vibrissæ.

All of these sense organs are invisible to the naked eye except the Pacinian corpuscles. If the mesentery is held up and looked through toward the light, the Pacinian corpuscles or sensory nerve terminations appear as translucent oval bulbs about two millimeters long. If a piece of the mesentery containing a corpuscle is pinned tense on a piece of cork and then cut out and placed ten minutes in 3% acetic acid, the termination of the nerve within the corpuscle may be seen with a microscope magnifying thirty diameters. All the spinal sensory nerve fibers enter the cord by the dorsal root (Figs. 104 and 111).

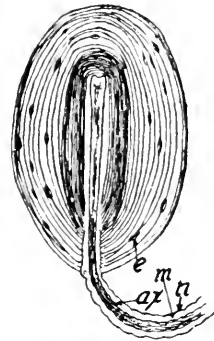


FIG. 118.—PACINIAN CORPUSCLE FROM THE MESENTERY. $\times 20$.

ax, Axis-cylinder; *n*, neurilemma; *m*, the myelin sheath; *e*, epithelial cell.

The Olfactory Organ.—The organ of smell lies in that part of the mucous membrane lining the caudal part of the nasal cavity and the basal third of the ethmoturbinal bones (Fig. 19). That part of the mucous membrane containing the olfactory cells is known as the *Schneiderian membrane*. In a fresh specimen it is of a grayish color while the other mucous membrane is red. The first pair of cranial nerves convey the olfactory impulse to the brain. They pass through the foramina in the cribriform plate of the ethmoid bone, to the olfactory bulbs, from each of which two roots extend to the base of the cerebrum (Fig. 104).

The Gustatory Organ.—The organ of taste is located chiefly in the mucous membrane on the dorsum of the tongue, the soft palate, the pillars of the fauces, epiglottis, and part of the cheek. On the dorsum of the tongue are seen four kinds of papillæ—the *vallate*, the *fungiform*, the *filiform*, and *flat*. The vallate papillæ are from eight to twelve in number, forming two sides of a triangle on the caudal portion of the dorsum of

the tongue. The fungiform are blunt papillæ scattered sparsely in the midst of the numerous filiform or pointed papillæ (Fig. 62). The special organs of taste, known as *taste-buds*, are very numerous in the fungiform and vallate papillæ of most mammals, but in the cat they are few and not well differentiated. These taste-buds occur in many parts of the mucous membrane of the mouth cavity, each being supplied with a branch of the glossopharyngeal nerve.

The Visual Organ.—The special organ of sight is the eye, which occupies the orbital cavity of the skull. The ball of the eye is protected above and below by extensions of skin called the eyelids or palpebræ, which are lined with mucous membrane, a transparent layer of which, known as the *conjunctiva*, extends over the front of the eyeball between the two lids. The dorsal lid is raised by the levator palpebræ muscle, which has its origin in the occipitofrontalis muscle. A sphincter muscle, the orbicularis oculi (palpebrarum), lies on the margin of the lids, and by its contraction closes the eye.

The point on either side where the two eyelids meet is termed the *canthus* or angle. At the medial or inner canthus are two minute apertures, the *puncta lachrymalia*, leading into two short canals which unite to form the *nasal duct*. The lachrymal canal, which forms the channel for this duct, is clearly visible in the lachrymal bone of the dried skull. At the medial canthus there is a prominent fold of mucous membrane, the *membrana nictitans*, or *plica semilunaris*, which is a rudimentary structure in the cat, but is found well developed in birds which have the power of sweeping it rapidly across the eyeball, thereby removing dust.

On the inner surface of each lid are the large sebaceous *tarsal glands*. The *lachrymal gland* lies in the dorso-lateral region of the orbit, and its ducts open on the ventral surface of the upper lid, whence the tears flow over the conjunctiva ventrad to the puncta lachrymalia. The *Harderian gland* is

the very small mucus-secreting gland at the medial canthus. It is usually vestigial or absent in man and other primates.

The muscles controlling the movements of the eyeball are seven in number: four are recti muscles, two are oblique, and one is a retractor. The recti muscles (Fig. 104) originate on the bone around the optic foramen, and are inserted on the sclerotic coat, caudad of the equatorial ring. The *external rectus* is inserted on the lateral aspect; the *internal rectus*, on the medial aspect; the *superior rectus*, on the dorsal aspect; and the *inferior rectus* on the ventral aspect. The superior

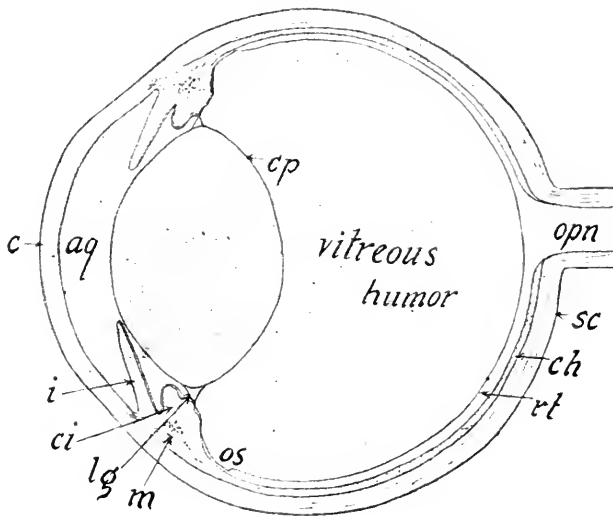


FIG. 119.—LONGITUDINAL SECTION OF THE EYE.

aq, Aqueous humor; *c*, cornea; *cp*, capsule of the lens; *ch*, choroid; *ci*, ciliary process; *i*, iris; *lg*, ligament of lens; *m*, ciliary muscle; *opn*, optic nerve; *rt*, retina; *sc*, sclerotic coat; *os*, ora serrata.

oblique muscle arises from the sphenoid bone medial of the optic foramen, extends along the medial wall of the orbital cavity to its dorso-medial margin, where it passes through a tendinous loop fastened to the frontal bone and then turns laterad to its insertion in the sclerotic beneath the superior rectus. The *inferior oblique* arises from the lachrymal bone and is inserted on the sclerotic between the external and inferior recti muscles. The above muscles may be demonstrated

by cutting away the lateral and dorsal walls of the orbital cavity. The *retractor oculi* originates on the boundary of the optic foramen and divides into four heads which are inserted into the sclerotic around the entrance of the optic nerve. This muscle is partly hidden by the recti muscles.

The eyeball is composed of three membranes and three humors. The outer coat, the *sclerotic*, consists of the opaque portion forming the caudal two-thirds, and the transparent portion, or *cornea*, forming the remainder (Fig. 119). The optic nerve pierces the sclerotic a little mediad of the longitudinal axis of the eye. The surface of the cornea is more strongly curved than that of the opaque portion of the sclerotic, and contains no blood-vessels. The *second* or *middle* coat of the eye is formed by the *choroid membrane* and its extension, the *iris*. This coat is incomplete, as there is an aperture, the *pupil*, through the iris for the admission of light. The choroid appears as a jet-black membrane, less than half as thick as the sclerotic, lying closely appressed to the latter. The choroid is lined internally by dark pigment cells, except in the caudal area around the optic nerve, which has a metallic luster. This portion is called the *tapetum*. It causes the shining appearance of the cat's eyes in the dark. The choroid is a vascular membrane, being supplied by the ophthalmic artery, a branch of the internal carotid.

The *iris* is attached by its peripheral margin to the sclerotic and choroid coats, and hangs free in the aqueous humor. It gives color to the eye. In the cat it is yellowish, while in man it is frequently blue or black. The iris is merely a curtain to regulate the amount of light admitted to the retina. There is a sphincter muscle lying in it, which by contraction renders the pupil very small. There is probably no dilating muscle of the iris present in the cat. The short, thickened, radial projecting folds of the choroid are the *ciliary processes*, which contain numerous blood-vessels, and in some mammals a gland. The ciliary muscle arises from the sclerotic coat near its junc-

tion with the cornea, and is inserted into the cranial part of the choroid coat.

The inner membrane of the eye is the *retina*, which is of a light gray color in a fresh specimen and seems quite free from the choroid. It is thickest in the caudal two-thirds of the cavity of the eyeball (Fig. 119). At the base of the ciliary bodies it seems to end with a free margin, called the *ora serrata*. In reality it becomes very thin here and is prolonged over the ciliary bodies and covers the caudal aspect of the iris. The blind spot is the point of entrance of the optic nerve, laterad of which is the yellow spot, or *macula lutea*, containing the *fovea centralis*, or acute point of vision. This is the point on which the rays of light are focused when the cat sees distinctly.

The refracting media of the eye are the *aqueous humor*, the *crystalline lens*, and the *vitreous body*. The aqueous humor is a watery fluid occupying the cavity between the cornea and crystalline lens. It always escapes as soon as the cornea is punctured. The aqueous humor appears to be supplied by the ciliary processes. The vitreous body is of a jelly-like consistency, filling the part of the eyeball caudad of the lens. It is perfectly transparent and is surrounded by a delicate capsule, the *hyaloid membrane*.

The *crystalline lens* is a transparent biconvex tissue having a vertical diameter of about one centimeter and a shorter diameter through its optical axis. It is enclosed in a transparent elastic capsule, some of whose fibers are continued peripherad as the *suspensory ligament* which is inserted in the choroid coat (Fig. 119).

The Auditory Organ.—The organ of hearing is composed of three parts—the external ear, middle ear, and internal ear. The first consists of the pinna and the auditorius meatus externus. The auricle is the projecting portion of the ear capable of being moved by muscles, and is composed of integument strengthened by fibrocartilage. The *auditorius meatus externus* extends from the base of the auricle to the tympanic membrane

(Fig. 120). Its outer or lateral third is formed by cartilage, and the remainder by the tympanic portion of the temporal bone (Fig. 18). The meatus is lined with mucous membrane in which are numerous sebaceous and oleaginous glands. The latter secrete the wax of the ear.

The *middle ear*, or *tympanum*, is an irregular cavity about one centimeter in diameter contained in the lateral chamber of the bulla (Fig. 120). It is separated from the external auditory meatus by the delicate translucent membrane, the *membrana tympani*. The petrous bone containing the internal

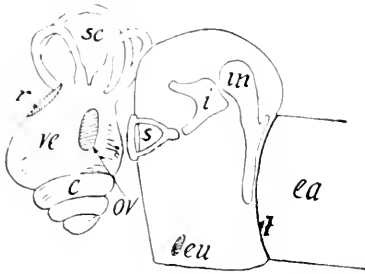


FIG. 120.—DIAGRAM OF THE MAMMALIAN EAR.

The internal ear is represented removed about a centimeter from the middle ear and slightly rotated to the left. The base of the stapes, *s*, in nature, covers the fenestra vestibuli, *ov*; *c*, basal whorl of the cochlea; *ea*, external auditory meatus; *eu*, opening of the Eustachian or auditory tube; *i*, incus; *in*, malleus; *sc*, semi-circular canals; *ve*, vestibule; *t*, tympanum.

ear forms part of the inner or medial wall. In the petrous bone are two foramina which may be seen in a dry skull by looking through the external auditory meatus. The more dorsal foramen is the *fenestra vestibuli*, which in the recent state is closed by a membrane to which the foot of the stapes is attached. The ventral one is the *fenestra cochleæ*, also closed by a membrane in the recent state. In the dry skull the fenestra vestibuli opens into the first or basal whorl of the cochlea, and the fenestra cochleæ opens into the vestibule of the internal ear.

The auditory tube (Fig. 19), whose opening may be seen craniad of the tympanic bulla, connects the middle ear with the posterior nares and thus admits air to the tympanic cavity.

To demonstrate further the anatomy of the middle ear, one should clean the flesh from a fresh or preserved head and carefully cut away the ventral walls of both chambers of the tympanic bulla (Fig. 18).

In the middle ear are three bones, the *malleus*, *incus*, and *stapes*, commonly called hammer, anvil, and stirrup. They form a crooked chain across the cavity. The long process of the malleus is fastened throughout nearly its whole length to the inner surface of the *membrana tympani*, and its enlarged extremity articulates with the body of the *incus*. The latter has two legs, to one of which the *stapes* is attached. The base of the *stapes* is inserted in the membrane closing the *fenestra vestibuli* (Figs. 118 and 120).

The *internal ear*, or *labyrinth*, consists of three parts—the *vestibule*, *cochlea*, and *semicircular canals* (Figs. 119 and 120). All of these parts are of membrane and lie in cavities of corresponding shape within the *petrous bone*. A lymphoid, *periotic*

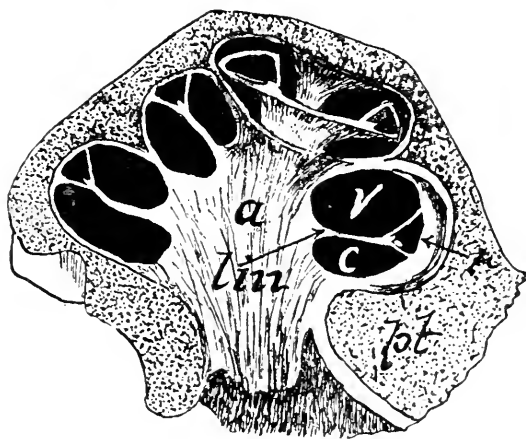


FIG. 121.—SECTION OF THE COCHLEA OF THE CALF. $\times 10$. (From Ellenberger, after Kölliker.)

a, Modiolus; *c*, scala tympani; *v*, scala vestibuli; *lm*, lamina spiralis; *pt*, portion of the *petrous bone*; *r*, scala media, or *ductus cochlearis*.

fluid, the *perilymph*, floats the delicate membranous internal ear within its bony cavity, while within the membrane is a similar fluid, the *endolymph*. The *vestibule* is a small sac adjacent to the tympanum, and may be seen by looking through the *fenestra vestibuli*. From the dorso-caudal aspect of the vestibule, arch three *semicircular canals* at nearly right angles to one another. The external semicircular canal is in a horizontal plane and surrounds a small fossa almost caudad of the

fenestra vestibuli. The superior semicircular canal lies in a transverse plane caudad to the preceding. The posterior semicircular canal lies in a vertical longitudinal plane, immediately laterad from the jugular foramen.

The *cochlea* is a coiled canal lying within the coiled cavity, the bony cochlea, extending craniad from the vestibule. If both chambers of the tympanic bulla are removed and a bristle thrust into the fenestra cochleæ (Fig. 18), it will enter the basal whorl of the bony cochlea. A line drawn from the lateral margin of the foramen vestibuli to the medial margin of the fenestra cochleæ passes through the apex and middle of the base of the cochlea, which may be rendered visible by carefully clipping off with the bone-forceps the ventral portion of the petrous bone along the line indicated. This coiled canal, the cochlea, is divided into two channels by a shelf of bone, the *lamina spiralis*, projecting from the central axis or *modiolus* of the coil (Fig. 121). The bony lamina extends but partly across the canal, the remaining distance being bridged by membrane. The cranial channel, or the one nearer the apex of the cochlea, is called the *scala vestibuli*. The other is the *scala tympani*.

The semicircular canals probably have nothing to do with hearing, as they are well developed in fishes, some of which do not hear at all. They may aid in helping the cat to maintain its equilibrium. The auditory nerve, however, is distributed to the vestibule and semicircular canals as well as to the cochlea upon the lamina spiralis, where the *organ of Corti*, the essential organ of hearing, is located.

REMARKS ON THE MAMMALIAN NERVOUS SYSTEM

So far as known, the relation of the sympathetic to the peripheral and central nervous systems is the same in all mammals. The number of spinal nerves varies with the number of vertebræ. The distribution of these nerves, however, is approximately the same in all forms with five digits. In those having a less number of digits the nerve branch corresponding to the lacking

digit or digits is wanting. The arrangement of the columns or tracts of fibers in the spinal cord is very similar in all the orders. The anterior or direct pyramidal tract, however, is partially or wholly absent in most orders below the Primates. It is best developed in man, although in a number of cases it has been found entirely wanting in the human. The number of the cranial nerves is always twelve and their distribution is very similar in all forms investigated.

The structure of the brain in the Ornithodelphia and Didelphia differs considerably from that of the Monodelphia. In the two former subclasses the corpus callosum and fornix are very

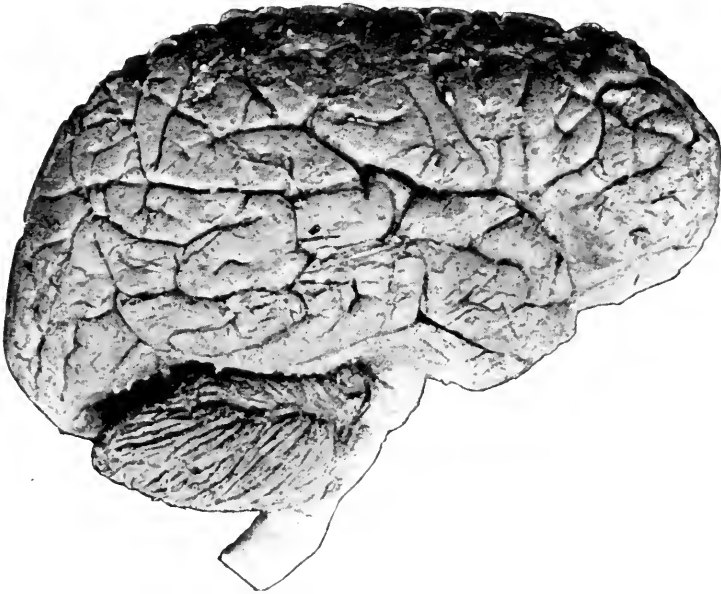


FIG. 122.—PHOTOGRAPH OF THE HUMAN BRAIN FROM THE LATERAL ASPECT.
Two-fifths natural size.

rudimentary, but the anterior commissure piercing the corpora striata is unusually large. The fibers, which in the Monodelphia arise from the cells of the hippocampus, and extend craniad to form the fornix, cross transversely to the opposite hippocampus in the two lower subclasses.

In all higher mammals the cerebrum is greatly convoluted, but in the lower ones the convolutions are few or almost absent,

as in *Ornithorhynchus*. The above-mentioned features show that the ornithodelphian brain presents a striking similarity to the brains of reptiles and birds. The brains of Rodentia possess but few convolutions, while the brain of man is the most highly convoluted.

The size of the brain varies widely. As a rule, the larger the brain in proportion to the size of the animal, the greater is its intelligence. However, in man there appears to be but slight connection between size of brain and intelligence, as an individual with a small brain may be much more capable mentally than one with a large brain. Mental power in man seems to depend upon the development of the cells and fibers of the brain.

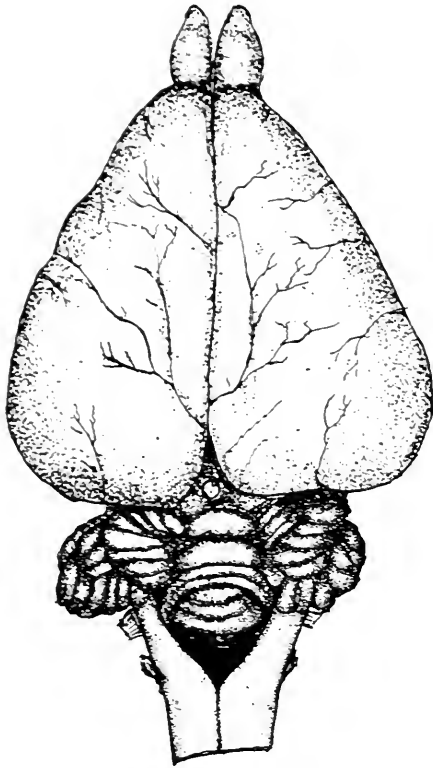


FIG. 123.—BRAIN OF THE RABBIT
FROM DORSAL ASPECT.

The average weight of a male human brain is about three pounds; of a female, about two and two-thirds pounds. The human brain is $\frac{1}{44}$ the weight of the body; the ape's, $\frac{1}{29}$; the rat's, $\frac{1}{82}$; the sheep's, $\frac{1}{351}$;

and the elephant's, $\frac{1}{500}$. The brain of man is larger than that of any other mammal except the whale and elephant. The brain of a large whale weighs over four pounds, while that of a large elephant will weigh about ten pounds.

LABORATORY STUDIES AND SUGGESTIONS

1. How many nerves transmit the stimuli received by the organs of special sense?
2. Where are the sense organs of pain located?

3. How many sense organs are visible in the mesentery of your specimen?
4. Through which nerve roots would the stimuli received by the cutaneous sense organs pass into the cord?
5. Describe the nerves transmitting the stimuli from the olfactory organ.
6. Describe the gland secreting the tears and how they reach the nasal cavity.
7. By cutting away the lateral and dorsal walls of the orbit dissect the muscles of the eyeball and make a drawing of them, labelling all parts.
8. What nerves control the movements of the eyeball?
9. Procure the eyes of any mammal from the butcher-shop or slaughter-house; bisect one in the meridional and the other in the equatorial direction. Make a drawing of the features seen and label.
10. Remove the crystalline lens from a fresh eye, describe its size, shape, structure, length of focus, and power of magnification.
11. Describe the path of a stimulus from the retina to the area of sight in the brain.
12. Name every feature visible in the eyes you have dissected.
13. What nerve supplies the auditory organ?
14. Describe the middle ear.
15. In what part of the temporal bone is the internal ear located?
16. By looking into the auditorius meatus of the dried skull two openings are seen. Into which portions of the internal ear do these lead?
17. Write a description of the internal ear.
18. Mention some important points of difference in the nervous system of various mammals.
19. What relation, if any, between intellectual ability and brain development?



GLOSSARY

- Ab du' cens** (*ab*, from; *ducens*, leading): the sixth cranial nerve.
- Ab duc' tor** (*ab*, from; *duco*, I lead): a muscle drawing a part outward.
- Ac e tab' u lum** (small cup): cavity of the innominate bone for articulation with the femur.
- A cro' mi on** (summit of shoulder): name of certain parts at the shoulder.
- Ad**: a Latin prefix of words; signifying to, toward or at.
- Ad duc' tor** (*ad*, to; *duco*, I draw): a muscle drawing a part inward.
- Af' fer ent** (*ad*, to; *fero*, I carry): the name of a nerve carrying an impulse to the brain or cord, and also applied to a vessel conveying fluid to the organ in which a physiologic process is to occur.
- An æs thet' ic** (want of feeling): any drug which when used externally or internally causes loss of feeling.
- Al i sphe' noid** (*ala*, wing; *sphen*, wedge; *oid*, like): the wing-like part of the sphenoid bone.
- Al ve' o lar** (*alveolus*, small hollow): relating to the sockets of the teeth.
- Al ve' o lus**: the socket of a tooth.
- Am' bu la tory**: slow-moving, walking.
- Am phi ar thro' sis** (*amphi*, around; *arthron*, a joint): a joint in which there is limited movement in every direction.
- Am phib' i ans** (*amphi*, both; *bios*, like): a class of vertebrates including frogs which spend part of the life in water and part on land.
- A nas to mo' sis**: the intercommunication of vessels.
- An chy lo' sis** (stiff joint): a firm union of the bones forming a joint.
- An' nu lar** (*annulus*, a ring): a name given to the encircling ligaments at the wrist and ankle.
- Ap o neu ro' sis** (*apo*, from; *neuron*, a tendon): a membranous expansion of a tendon.
- A rach' noid** (like a spider's web): the delicate middle membrane enveloping the brain and spinal cord.
- Ar bo re' al**: tree-climbing.
- A re' o lar** (open space): relating to connective tissue loosely woven.
- Ar ti dac' ty la** (even-fingered): those ungulates having an even number of digits on each foot.
- A ryt' e noid** (*arytaina*, pitcher; *oid*, like): the name of a pair of cartilages of the larynx.
- Au ric' u lar** (*auricula*, outer ear): relating to the ear.
- Au' dit o ry** (*audire*, to hear): pertaining to the act or the organs of hearing.
- Ax il' la** (*axilla*, armpit).
- Ax' il la ry**: a name given to several structures in the region of the armpit.
- Ax' one**: the process which carries the impulse away from a nerve cell.

- Bi' ceps** (*bis*, twice; *caput*, head): a term applied to muscles having two origins.
- Brach** (*brachium*, arm).
- Brach' i al**: a name given to several structures in the upper arm region.
- Bra c' hy ceph' aly**: short-headed.
- Bron chi**: plural of bronchus.
- Bron' chus** (*bronchos*, windpipe): one of the two tubes into which the trachea divides.
- Buc' cal** (*bucca*, cheek): pertaining to the cheek.
- Ce' cum** (blind): first part of large intestine.
- Cal ca' ne um** (*calcaneum*, the heel): the os calcis or heel-bone.
- Cal lo' sum** (*callosus*, thick-skinned): the largest commissure of the brain.
- Can a lic' u li**: the small canals opening into the lacunæ of bone.
- Can' nu la** (*canna*, a tube): a small tube.
- Ca pit' u lum** (*capitulum*, a small head): the enlarged terminal portion of an organ.
- Car' di ac** (*kardia*, the heart): pertaining to the heart.
- Ca rot' id**: the chief artery lying on either side of the windpipe.
- Car pal** (*karpos*, wrist): pertaining to the wrist.
- Cau' dad**: toward the tail.
- Cau' dal** (*cauda*, tail): relating to the tail.
- Cen' trum**: the body of a vertebra.
- Ceph' a lic** (*kephala*, head): relating to the head.
- Cer a to hy' al**: a part of the hyoid apparatus.
- Cer' vic al** (*cervix*, neck): a name applied to structures in the region of the neck.
- Cer' vi dæ**: the name of the deer family.
- Chev' ron bones**: the bones on the underside of some of the caudal vertebræ.
- Chi' asm** (*ki' azm*, mark crosswise): the optic commissure.
- Chi rop' te ra** (*cheir*, hand; *pteron*, wing): an order of mammals including the bats.
- Cho an' æ**: the posterior nares.
- Cho' roid**: the middle lining of the eyeball.
- Cir cum val' late** (*circumvallere*, to surround with a wall): see vallate.
- Clit' or is**: a small erectile organ occupying the same relative position in the female as the penis occupies in the male.
- Coc' cyx** (*kokkux*, the cuckoo, resembling the bill): the several united vertebræ forming the tail in man.
- Coch' le a** (*kok' le ah*) (*kochlos*, a conch-shell): the coiled canal of the internal ear.
- Ce' il ac** (*se' le ak*) (*koilia*, belly): a name applied to a large artery and a nerve plexus in the abdomen.
- Ce' lom** (*se' lum*): the body cavity.
- Con' dyle** (*kondulos*, a knuckle): a paired rounded eminence of a bone for articulation.
- Cor' nu** (a horn): a name given certain structures resembling a horn.
- Cor' nu a**: the plural of cornu.
- Cor' o noid** (*corona*, crown; *oid*, like).
- Cor' por a** (*corpus*, body): plural of corpus. Corpora quadrigemina.

- Cor' pus**: a name given to the main portion of an organ. Corpus callosum.
- Cos' ta** (*costa*, rib).
- Cos' tal**: pertaining to the ribs.
- Cot' yl oid** (*kotula*, a cup; *oid*, like): relating to the articular cavity in the innominate bone.
- Cra' ni ad**: toward the plane in front of the cranium and perpendicular to the spinal axis.
- Cra' ni al**: pertaining to the cranium.
- Cra' ni um**: those bones of the skull encasing the brain.
- Cru' ra**: plural of crus.
- Crus** (*crus*, a leg): the part of the leg between the knee and ankle. It is also applied to structures resembling the leg.
- Cu' boid** (like a cube): one of the tarsal bones.
- Cu ne a' tus** (*kuncus*, a wedge): a fiber tract in the spinal cord.
- Cu ne' i form** (wedge-shaped): bones of the ankle and wrist.
- Cur so' ri al**: fitted for running.
- Cu ta' ne ous** (*cutis*, the skin): relating to the skin.
- De cus sa' tion** (*decussatus*, crossed): an oblique crossing of the nerves.
- Dem i fac' et** (*dem*i, half; *facette*, little face): the articular surface on the body of a vertebra for the articulation of half the head of a rib.
- Den' drites** (*dendron*, a tree): the processes of a nerve cell which transmit the impulse toward the cell-body.
- Di aph' y sis** (*dia*, between; *phuein*, to grow): the shaft of a long bone.
- Di a ste' ma** (*diascema*, a distance): a space between any two consecutive teeth.
- Di ar thro' sis** (*dia*, throughout; *arthrosis*, articulation): a form of articulation giving much freedom of motion.
- Di dac' tyl**: two digits as in deer, ox, etc.
- Di del' phi a** (*dis*, twice; *delphus*, uterus): an order of mammals including the kangaroos and opossums in which a paired uterus is present.
- Di en ceph' a lon** (*dia*, between; *encephalos*, the brain): the tween brain formed largely by the thalami.
- Di gas' tric** (*dis*, double; *gaster*, belly): the muscle depressing the lower jaw.
- Dig' it** (*digitus*, a finger): the name of a finger or toe.
- Dig' iti grade**: where foot rests only on the rows of phalanges, as in dog and cat.
- Dig it or' um**: of digits.
- Diph' y o dont** (*diphyes*, twofold; *odous*, tooth): mammals having two sets of teeth.
- Dis' tad**: away from the axis of the body.
- Dis' tal**: the part farther from the axis of the body.
- Do li cho ceph' aly**: long-headed.
- Dor' sad** (*dorsum*, the back): toward the line passing from head to tail along the tips of the spinous processes.
- Du o de' num** (*duodeni*, twelve each): first part of the small intestine; in man it is twelve finger-breadths.
- Du ra ma' ter** (*durus*, hard; *mater*, mother): the outer membrane of the brain and cord.

- E den ta' ta** (*e*, without; *dens*, a tooth): an order of mammals some of which have no teeth.
- Ef' fer ent** (*effereus*, carrying from): the opposite of afferent.
- Em' bry o**: the undeveloped young.
- En ceph' a lon** (*en*, in; *kephala*, the head): the brain.
- En do mys' i um** (*endon*, within; *mys*, muscle): the extension of the perimysium between the muscular fibers.
- En' si form** (*ensis*, sword; *forma*, form): the cartilaginous process at the caudal end of the sternum. Xiphoid process.
- Ep i did' y mis** (*epi*, upon; *didymos*, the testes): the contorted tubule forming the small body lying against the testis.
- Ep i mys' i um** (*epi*, upon; *mys*, muscle): the delicate membrane enveloping muscle.
- E piph' y ses** (*epi*, upon; *phyo*, to grow): a process of bone attached for a time to another bone by cartilage, but later becoming firmly united to it.
- Ep i the' li um**: the outer layer of the skin and all mucous surface.
- Eth' moid** (*ethmos*, a sieve; *oid*, like): the bone at the root of the nose.
- Eu sta' chi an** (*u sta' ke an*) (named after the anatomist Eustachio, 1500-1570). Sometimes applied to auditory tube.
- Eu the' ria** (*eus*, good; *therion*, beast): a subclass including all mammals above the marsupials.
- Fa bel' læ**: sesamoid bones in tendon of gastrocnemius muscle.
- Fac' et** (*facette*, a little face): a small plane surface usually on a bone for articulation.
- Fal lo' pi an tube**: the canal conducting the eggs from the ovary to the uterus. Uterine tube.
- Fal lo' pi us**: a noted Italian anatomist (1523-1562).
- Fas' ci a** (*fash' e ah*): the membranous fibrous covering of muscles.
- Fas cic' u lus** (*fascis*, a bundle): a little bundle of fibers forming part of a nerve or muscle.
- Fau' ces** (*faw' sez*): that part of the throat surrounded by the palate, tonsils and uvula.
- Fe nes' tra** (*a window*).
- Fil' i form** (*filum*, thread; *forma*, form): name of papillæ on tongue.
- Fo ra' men** (*forare*, to pierce): a passage or opening, usually in bone, for the transmission of nerves or vessels.
- Fo ram' i na**: the plural of foramen.
- For mal' de hyde**: an excellent disinfectant.
- For' mal in**: a 40 per cent. solution of formaldehyde in water.
- For' nix** (an arch): the projecting bundle of fibers from the gyrus hippocampus, beneath the corpus callosum.
- Fos' sa** (*a ditch*): a depression or furrow.
- Fos so' ri al**: digging or burrowing.
- Fu nic' u lus** (*funis*, a cord): applied to various cord-like structures.

Gas' tric (*gaster*, stomach): relating to the stomach.

Gas troc ne' mi us (*gaster*, stomach; *knema*, leg): large muscle in the calf of the leg.

Gen' e ra: plural of genus.

Ge nic u la' tum (*geniculare*, to bend the knee): a name applied to certain bodies in the brain.

Gen' us: a species or collection of species marked by one or more common characteristics distinguishing them from other groups.

Ging' ly mus (*ginglymos*, a hinge): a kind of joint having free motion in two directions.

Glen' oid (*glena*, a cavity; *oid*, like): pertaining to a shallow cavity.

Glis' sant: gliding as in flying squirrel.

Glos' sa: the tongue.

Glu' te al: pertaining to the buttocks.

Glu' te us (*gloutos*, buttock): one of several muscles, *gluteus maximus*, etc.

Gly' co gen (*glukos*, sweet): animal starch.

Grac' i lis (slender): the name of a muscle in the leg.

Gy' ri: plural of gyrus.

Gy' rus (*gyros*, a circle): a convolution of the brain.

Hal' lu cis (from *hallux*, the great toe).

He pat' ic (*hepar*, liver): pertaining to the liver.

Het' er o dont (*heteros*, other; *odous*, tooth): having teeth of more than one kind.

Ho moi o ther' mal: preserving a uniform temperature, as in warm-blooded animals.

Hom' o dont (*homos*, the same; *odous*, tooth): having teeth all of one form.

Hy' oid: the name of the bone at the root of the tongue.

Hy' po: under.

Hy po gas' tric: under the stomach.

Hy po glos' sus: under the tongue.

In' fra: below.

In fra or' bit al: under the orbit.

Il' e um (*cilo*, twist): the last part of the small intestine.

Il' i ac (*ilia*, the flanks): pertaining to the region of the ilium or hip bone.

In' guin al (*in' gwin al*): pertaining to the groin or ventral region where the pelvic limb joins the body.

In' ter: a Latin prefix meaning between.

In ter cos' tal: between the ribs.

In ter os' se ous: between the bones.

In ter ver' te bral: between the vertebræ.

Is' chi um (*is' ki um*): the middle part of the innominate bone.

Je jun' um (*jcjunus*, empty): the two-fifths of the small intestine extending between the duodenum and ileum.

Ju' gal (*ujgum*, a yoke): the malar bone.

Ju' gu lar (jugulum, throat); the name of the large veins in the neck.

Lac' er um (*laccros*, torn): name of foramina in the skull.

Lach' ry mal (*lachryma*, a tear): pertaining to the lachrymal apparatus.

Lac' te als (*lac*, milk): the lymphatics of the small intestine which take up the chyle and carry it to the thoracic duct.

Lamb doi' dal (after a Greek letter): pertaining to the suture between the parietal and occipital bones.

Lam' i na (a plate or scale): a term designating a thin layer of tissue.

Lar' ynx: the cartilaginous tube at the cranial end of the trachea.

Lat' er ad (*latus*, side; *ad*, to): toward one side.

Lat' er al: pertaining to the side.

La tis' si mus (broadest): a name applied to certain muscles.

Le va' tor (a lifter): a name given to muscles which raise parts.

Lin' gual (*lingua*, tongue): pertaining to the tongue.

Lum' bar (*lumbus*, the loin): relating to the region of the loins which is the lower part of the back.

Lym phat ics (*lymph*a, water): the absorbent system.

Mag' num (great).

Ma' lar (*mala*, cheek).

Mal le' o lus (*malleus*, hammer): a process of bone.

Mal pigh' i: an Italian anatomist (1628-1694).

Mam ma' li a (*mamma*, breast): the highest class of vertebrates.

Ma nu' bri um (a handle): the cranial piece of the breastbone.

Ma' nus (hand): the hand.

Mar su pi a' li a (*marsupos*, a pouch): a subclass of mammals having a pouch beneath the belly in which they carry the young.

Ma' ter (mother): one of two membranes covering the brain.

Mas' toid (*mastos*, breast; *oid*, like): the process of bone behind the ear.

Me a' tus (passage): a channel or canal.

Me' di ad (*medius*, middle): toward the middle.

Me' di al: pertaining to the middle.

Me di as ti' num (standing in the middle): the space between the lungs, including the heart and other organs.

Me dul' la (*medulla*, marrow): the inner portion of an organ; the marrow of bone; a portion of the brain (medulla oblongata).

Men in ge' al (*meninx*, membrane): pertaining to the membranes of the brain or cord.

Men' tal (*mentum*, chin): pertaining to structures about the chin.

Mes ati ceph' aly: medium-headed, as in taper.

Mes en ter' ic (*mesos*, middle; *enteron*, intestine): pertaining to the mesentery.

Mes' en ter y: a fold of the peritoneum joining parts of the intestine to the dorsal part of the abdominal cavity.

Met' a (beyond).

Mes en ceph' a lon (*mesos*, middle; *encephalon*, brain): the mid-brain, consisting of the corpora quadrigemina and crura cerebri.

Met en ceph' a lon: the pons Varolii and cerebellum.

Mo di' o lus: the central pillar or axis of the cochlea.

Mo no dac' tyl: one-toed, as in horse.

Mon' o phy dont (*monos*, single; *phyo*, grow; *odous*, tooth): having only one set of teeth during life.

Mon o tre' ma ta (*monos*, single; *tremos*, hole): the lowest subclass of mammals. The intestinal and urinary products are voided through one opening as in birds; duck bill and spiny ant eater.

Mor phol' o gy (*morpha*, form; *logos*, discourse): that part of biology dealing specially with form and structure.

My el en ceph' a lon (*myelos*, marrow; *encephalon*, brain): the medulla oblongata.

Mo' tor (*movere*, to move): a name given nerves stimulating muscles.

Na ta tor' i al: amphibious, aquatic, swimming.

Neu' ral (*neuron*, nerve): pertaining to a nerve.

Neu' rone: a nerve cell with all its processes.

Nu' clei: plural of nucleus.

Nu' cle us (*nux*, a nut): the essential part of every cell; also applied to a definite bunch of nerve cells.

Ob' tu ra tor: the name of the large foramen in the coxal bone or of structures near to it.

Oc cip' i tal (*ob*, against; *caput*, the head): relating to structures in the region of the back part of the head.

Oc' u lar (*oculus*, the eye): pertaining to the eye.

O don' toid (*odous*, tooth; *oid*, like): relating to the tooth-like process of the axis. Dens.

Oid: a common suffix derived from Greek *eidos* and signifying like.

Olec' ran on (*olea*, elbow; *kranion*, head): process of the ulna.

O men' tum: a fold of the peritoneum connecting the abdominal viscera.

Ol fac' to ry (*olfacere*, to smell): pertaining to the nose.

Oph thal' mic (*ophthalmos*, eye): pertaining to the eye.

Op tic (*optikos*, to see): relating to the eye.

O' ra: mouth.

Or' bit al (*orbis*, circle): pertaining to the cavity for the eye.

Or' gan: any part having a definite function.

Or nith o del' phi a (*ornis*, bird; *delphus*, womb): the oviparous mammals.

Os: bone.

O' va: plural of ovum.

O va' le: oval.

O vip' a rous (*ovum*, egg; *parere*, to bring forth): those animals which deposit eggs instead of bringing forth living young.

O' Vum: egg.

Pa ri' e tal (*paries*, a wall).

Par ot' id (*para*, near; *ous*, ear): the name of a salivary gland.

Pec' to ral (*pectus*, breast): pertaining to structures in the region of the breast.

Ped' i cles (*pediculus*, a little foot): the foot of the neural arch.

Pe' dun cles (*pedunculus*, a little foot): bands of fibers uniting certain parts of the brain.

Pel' vic: relating to the cavity between the innominate bones.

Pent a dac' tyl: five-toed, as in phenacodus, etc.

Per i mys' i um (*peri*, around; *mus*, a muscle): the tissue which envelops the primary bundles of muscle fibers.

Per is so dac' ty la (*perissos*, odd; *ductyl*, finger): those ungulates having an odd number of digits.

Pe riph' e ral: pertaining to the outside.

Per i to ne' um (*peri*, around; *teinein*, to stretch): the serous membrane lining the abdominal cavity and surrounding most of the organs within it.

Per o ne' al (*perone*, a pin): relating to the fibula.

Pe' des: plural of pes.

Pes: foot.

Pha lan' ges: plural of phalanx.

Phal' anx: one of the bones of the fingers or toes.

Phar' ynx (throat): the cavity back of the mouth.

Phren' ic (*phren*, diaphragm): pertaining to the diaphragm.

Phy log' e ny (*phyla*, tribe; *genas*, producing): that science treating of the evolution of a group.

Pi' a ma' ter (soft mother): the delicate membrane next to the brain and cord.

Plan' ti grade: where entire sole of foot or hand rests on ground, as in the hind-foot of the bear.

Pneu mo gas' tric (*pneuma*, air; *gaster*, stomach): the vagus nerve.

Poi kil o ther' mous: bodily temperature varying with surrounding medium, as in cold-blooded animals.

Pons: bridge. Pons Varolii.

Pop lit' e al (*poples*, knee): pertaining to the caudal region of the knee-joint.

Post: a common prefix meaning after or behind.

Pri ma' tes (*primus*, first): the highest order of mammals, including man and the monkeys.

Pro fun' da (*profundus*, deep); a term given to a part deep-seated.

Pro to chor da' ta (*protos*, first; *chorda*, cord): those forms between the invertebrates and vertebrates. Seasquirts.

Pro to the' ri a (*protos*, first; *therion*, beast): the oviparous mammals.

Prox' i mad: toward the central axis of the body.

Prox' i mal: that part nearest to the central axis of the body.

Pter' y goid (*pteron*, wing; *oid*, like): part of the sphenoid bone.

Pul' mo na ry (*pulmo*, lung): pertaining to the lung.

Py lor' us (*pyloros*, gate-keeper): the opening of the stomach into the duodenum.

Quad' ri ceps (*quadri*, four; *caput*, head).

Quad ri gem' i na: plural of quadrigeminum.

Quad ri gem' i num (*quadri*, four; *geminus*, twin born): part of the brain.

Ra' mi: plural of ramus.

Ra' mus: the branch of an organ.

Rec' ti grade: where weight of foot rests on large pad; as in elephant.

Rec' tus: straight.

Rhin' al: pertaining to the nose.

Ro lan' do: an anatomist.

Ro tun' dum: round.

Ru' mi nant (*ruminare*, to chew the cud): any of the ungulates which chew the cud.

Sa' crum (*sacer*, sacred): the part of the backbone between the coxal bones.

Sag' it tal (*sagitta*, an arrow): a name given to a vertical longitudinal plane of the body.

Sal ta tor' i al: leaping.

Scaph' oid (*skapha*, a boat): a bone in the wrist and also the ankle.

Sci at' ic (*si at' ic*): relating to structures in the region of the ischium.

Scle rot' ic (*skleros*, hard): relating to the outer coat of the eye.

Se ba' ce ous (*sebum*, suet or fat): the name of glands in the skin.

Sec to' ri al (*secare*, to cut): the carnassial or last premolar tooth in many of the carnivora.

Sem i lu' nar (*semi*, half; *luna*, moon).

Semi plan' ti grade: where half the sole rests upon the ground; fore-foot of bear.

Ses' a moid (*sesamon*, a grain; *oid*, like): the name of small bones developed in tendons.

Sig' moid: shaped like the Greek letter sigma.

Si' nus (*sinus*, a hollow): a cavity or channel.

So' le us (flat): a muscle of the calf of the leg.

Sper mat' ic (*sperma*, seed): pertaining to the reproductive fluid called semen.

Sper ma to zo' a (*sperma*, seed; *zoa*, animals): plural of spermatozoön.

Sper ma to zo' ön: the male reproductive cell developed in the testis.

Sphen' oid: (*sphen*, wedge; *oid*, like): as the sphenoid bone.

Sphinc' ter (to squeeze): the name of a muscle surrounding and capable of closing an orifice.

Splan' ch' nic: pertaining to the viscera.

Sub: a common prefix denoting under or beneath.

Sty' loid (*stylos*, a pillar).

Sudoriferous (*sudor*, sweat).

Sudoriparous (*sudor*, sweat; *parere*, to produce): secreting sweat.

Su' pra: a' prefix denoting above.

Sul' ci: plural of sulcus.

Sul' cus (*sulcus*, a furrow): a cleft or furrow in the brain.

Syl' vi us: a noted anatomist.

Sym' phy sis (*sym*, together; *phyo*, grow): the junction of bones usually in the median line of the body.

Syn ar thro' sis (*syn*, together; *arthron*, a joint): a form of articulation in which the bones are immovably united.

Sys' tem: a collection of organs for one general purpose.

Tel en ceph' a lon (*telos*, end; *encephalon*, brain): the cerebral hemispheres and corpora striata; the end brain.

Te' res: round.

Tet ra dac' tyl: four-toed, as in hippopotamus and dog.

Thal' a mus (*thalamos*, bed): the thalami form the chief part of the tween brain.

Thy' reoid (*thyrcos*, a shield; *oid*, like): the name of structures in the region of the thyreoid cartilage.

Tib' i al (*tibia*, shin): pertaining to the tibia or shin bone.

Tri dac' tyl: three-toed, as in rhinoceros and early horse.

Tri' ceps (*tres*, three; *caput*, head): a large muscle on the back of the arm.

Tri cus' pid: having three points or cusps. Tricuspid valve of the heart.

Tri gem' i nal: the fifth cranial nerve, so called because of its three divisions.

Tro chan' ter: the name of two processes on the femur.

Troch' le ar (*trochilia*, a pulley).

Tur' bin al: one of the turbinated or lateral ethmoid bones.

Tym' pan um (*tympanum*, a drum): the middle ear.

Um bil' i cus (navel): the depressed cicatrix in the center of the abdomen marking the hole giving passage to the vessels formerly connecting the young with the mother.

Un' ci form (*uncus*, a hook; *forma*, form): a bone of the carpus.

Un gu la' ta (*ungula*, a hoof): an order of mammals characterized by hoofs.

Un' gu li grade: where the foot rests only on the end of the phalanx, horse, deer.

U re' ter: the tube from the kidney to the bladder.

U re' thra: the tube from the bladder to the exterior.

U' ter us: the womb or cavity in which the young are developed.

Val' late: large papillæ at the base of the tongue.

Ven' trad (*venter*, stomach): toward a plane passing along the underside.

Ver' te bra (*vertere*, to turn); a bone of the spinal column.

Ver' te bræ: plural of vertebra.

Ves tig' i al: rudimentary; existing only as a trace.

Vis' ce ra: the organs within the body cavity.

Vo' lant: flying, as the bat.

Whar' ton: an English anatomist (1610-1673); name of the duct from the sublingual gland.

Wil' lis: an anatomist (1621-1666).

Wir' sung: an anatomist (———1643); name of a duct from the pancreas.

Xiph' oid: same as ensiform.

Zy go' ma (*zygoma*, cheek-bone): the arch formed by a process of the temporal bone and the malar.

INDEX

- Abdominal aorta, 154, 155
- Abducens nerve, 232
- Acetabular (cotyloid) bone, 74
 - notch, 75
- Acetabulum, 75
- Achilles, tendon of, 103
- Acoustic meatus, external, 42, 44
 - internal, 43, 46
- Acromion process, 64
- Air sacs, 191, 196
- Alimentary canal, 127
 - walls of, 139
- Alisphenoid bone, 44, 45, 47
- Allantois, 5
- Alveolar ducts, 195
 - sacs, 195
- Alveoli (lungs), 195
- Amnion, 5
- Amniota, 5
- Amphiarthroses, 83
- Amphibia, 5
- Amphioxus, 4
- Anamnia, 4
- Anatomy, 1
- Anesthetizing, 10
- Aorta, 153, 154
 - abdominal, 154, 155
 - arch, 154, 155
 - thoracic, 154
- Appendix vermiformis, 139
- Aqueductus cerebri, 215
- Aqueous humor, 247, 248
- Arachnoid, 209, 225
- Arbor vitae, 216, 224
- Arch, aortic, 154, 155
 - development of, 174
 - zygomatic, 35, 42
- Arm, arteries, 160
 - articulation, 83
 - bones, 63
- Arm, muscles, 94
 - nerves, 234, 236
 - veins, 168
- Arteries, 154
 - development, 174
 - head and neck, 157
 - hind limb, 162
 - names, adrenolumbar, 156
 - alveolar, inferior, 158
 - anonymous, 154
 - anastomotica magna, 161
 - articularis genu suprema, 164
 - auricularis posterior, 158, 159
 - axillaris, 160
 - basillaris (basilar), 158, 159
 - brachialis (brachial), 160, 161
 - bronchiales (bronchial), 155
 - carotis communis (c o m m o n carotid), 157, 158, 159
 - externa, 158, 159
 - interna, 158, 159
 - caudalis (sacralis media), 157
 - celiac, 155
 - cerebellar, anterior, 158, 160
 - inferior posterior, 160
 - cerebral, anterior, 160
 - medial, 158
 - posterior, 158, 160
 - circumflex, femoral, lateral, 164, 169
 - humeral, anterior, 161
 - posterior, 161
 - colica dextra (right colic), 156
 - media (middle colic), 156
 - sinistra (left colic), 157
 - collateral radialis superior (superior radial lateral), 161
 - ulnaris superior, 161
 - coronaria (coronary), 154
 - costocervical axis, 160

- Arteries, digitales dorsales (dorsal digital), 162
 plantaris (plantar digital), 165
 epigastrica inferior, 163
 esophageal, 155
 femoralis (femoral), 163, 164
 gastrica sinistra (left gastric), 155
 gastroduodenalis (g a s t r o - duodenal), 156
 gastroepiploica dextra (right gastro-epiploic), 156
 genital (spermatic, ovarian), 155, 157
 genu suprema, 164
 glutea inferior (inferior gluteal), 164
 superior (superior gluteal), 164
 hemorrhoidalis media (medial hemorrhoidal), 164
 hepatic, 156
 hypogastric, (internal iliac), 155, 164
 ileocolic, 156
 iliaca externa (external iliac), 157, 169
 interna (internal iliac, hypogastric), 155, 157, 169
 iliolumbalis (iliolumbar), 155, 157, 169
 infraorbital, 158, 159
 innominate (anonymous), 154, 155, 157, 169
 intercostal, 155
 interosseae (anterior, posterior), 162
 lienalis (splenic), 156
 lingual, 158, 159
 lumbales (lumbar), 155
 lumboabdominalis (adrenolumbalis), 156
 malleolaris anterior lateralis (external malleolar), 164
 anterior medialis (internal malleolar), 164
- Arteries, mamma interna (internal mammary, sternal), 160
 maxillaris externa (external maxillary, facial), 158, 159
 interna (internal maxillary), 159
 meningea media (middle meningeal), 159
 mesenterica inferior (inferior mesenteric), 155
 superior (superior mesenteric), 155
 occipital, 158
 oesophageac (esophageal), 159
 ophthalmic, 159
 ovarian, 155
 palatina descendens (descending palatine), 158
 pancreaticoduodenalis inferior (inferior pancreaticoduodenal), 156
 superior (superior pancreaticoduodenal), 156
 peroneal, 164
 phrenic, 156
 plantar arch, 165
 popliteal, 164
 profunda brachii (superior profunda), 161
 profunda femoris (d e e p femoral), 163
 pulmonary, 154
 pyloric, 156
 radialis (radial), 160
 recurrens (radial recurrent), 162
 renal, 157
 sacralis media (caudal), 157
 saphenal, 164
 spermatic, 157
 sphenopalatine, 159
 spinalis anterior, 158
 splenic (lienalis), 156
 subclavian, 160
 submental, 169
 subscapular, 160, 169

- Arteries, superior profunda (profunda femoris), 161, 169
 suprascapular, 161, 169
 temporalis superficialis (superficial temporal), 159
 thoracica anterior (anterior thoracic), 160
 longa (long thoracic), 160, 169
 thoracodorsalis (dorsal thoracic), 160, 169
 thyreoid axis, 160
 thyreoides ima (lowest thyreoid), 159, 169
 inferior, 159, 169
 superior, 159
 tibialis anterior, 164
 posterior, 164
 transversa colli (transverse artery of the neck), 160
 transversa scapulae, 160
 ulnaris (ulnar), 162
 recurrens, 162
 collateralis superior, 161
 umbilical, 147
 vertebral, 159, 160, 169
 volar, 162
 thoracic limb, 160
 trunk, 154
- Articulations, 83
 amphiarthrodal, 83
 atlanto-occipital, 36
 diarthrodal, 83
- Artiodactyla, 8
- Arytenoid cartilage, 197
- Atlanto-occipital articulation, 36
 membrane, 36
- Atlas, 54
- Atrium (heart), 150; (lung), 195
- Auditory bulla, 37, 38
 meatus, external (meatus acusticus externus), 42
 internal (meatus acusticus internus), 43
 nerve (acoustic), 232
 organ, 249
- Auricle (ear), 249; (heart, atrium), 150, 151, 153
- Axis (epistropheus), 56
- Back bone, 53
- Balanoglossus, 4
- Basioccipital bone, 44, 45
- Basisphenoid bone, 44, 45
- Bicipital groove, 65
 tubercle, 95
- Bicuspid valve, 151
- Bile, 144
 cyst, 144, 148
 duct, 138, 144
- Bladder, 199
- Blind spot, 249
- Bloodvessels, 150
 injection of, 9
- Body cavity, 134
- Bones, structure of, 19
 ear, 250
 head, 32
 method of cleaning, 15
 number of, 28
 pelvic limb, 74
 table of, 29
 thoracic limb, 63
- Brachial plexus, 234
- Brachium conjunctivum, 218
 pontis, 218
- Brain, 219
 arteries of, 158
 basal ganglia of, 229
 commissures of, 217
 external features, 210
 extraction of, 14
 human, 253
 internal structure of, 214
 mammalian, 253
 parts of, 210
 rabbit's, 254
 ventricles of, 214
 weight of (in mammals), 254
- Branchiostoma, 4
- Bronchial tubes, 193, 195

- Bulbourethral glands, 213
 Bulla, auditory, 42
 tympenic, 37, 42, 44, 47
 Calcaneous bone, 29, 79
 Callosal sulcus, 189
 Cambrian, 3
 Canal, alimentary, 134
 anterior palatine, 49
 condyloid (posterior condyloid), 45
 facial (aqueduct of Fallopius), 46
 Hunter's, 164
 hypoglossal (anterior condyloid),
 45, 46
 lachrymal, 50
 nasolachrymal, 50
 of Huguier, 37
 posterior palatine, 49
 pterygoid, 38
 semicircular, 250, 251
 Vidian (pterygoid), 38
 Canine teeth, 130, 131, 132
 Canthus, 246
 Capillaries, 171
 Capitae (os magnum), 29, 69
 Capsular ligament, 84
 Capsule, external, 222
 internal, 221, 222
 of lens, 259
 Carboniferous, 3
 Cardiac plexus, 241
 Carnivora, 7
 Carotid plexus (arterial), 159; (nerv-
 ous), 241
 Carpus, 67
 Cartilages, 19
 costal, 62
 kinds of, 19
 of larynx, 51
 Caudate nucleus, 222
 Cecum, 122, 139, 147
 Celiac artery, 155
 ganglion, 243
 Celom, 134
 Centrum, 53, 56
 Ceratohyal, 51
 Cerebellar, arteries, 160
 hemispheres, 224
 Cerebellum, 210, 223
 Cerebral, aqueduct (iter, aqueduct of
 Sylvius), 215
 arteries, 160
 fissures (sulci), 211
 gyri (convolutions), 211
 hemispheres, 211, 214
 peduncles, 212
 veins, 168
 Cerebrum, 210, 211
 Cerebrospinal fluid, 225
 Cervical ganglia, 240
 lymph glands, 183
 nerves, 234, 235
 plexus, 234, 235
 vertebræ, 54
 Cetacea, 8
 Chambers of eye, 249
 Chevron bones, 59
 Chiasma, optic, 213
 Chiroptera, 7
 Choanæ, 34
 Chondrohyal, 52
 Chordæ tendinæ, 151
 Choroid plexus, 214
 Ciliary, body, 248
 folds, 248
 Circle of Willis, 158, 159
 Circumflex nerve, 207
 Circumvallate papillæ, 230
 Classification, 2
 Clavicle, 64
 Clinoid plate, 46
 process, 47
 Clitoris, 201
 Cloaca, 148, 207
 Coats of eye, 247
 testis, 205
 Coccyx, 61
 Cochlea, 252
 Collateral ligaments, 84
 radial artery, 161
 ulnar artery, 161
 Colon, 139

- Commissure habenæ, 221
 Condyle, occipital, 34, 36
 of femur, 77
 of tibia, 77
 Condylloid canal, 45
 Conjunctiva, 219, 246
 Connective tissues, 18
 Coracoid border, 64
 process, 64
 Cord, spinal, 225
 Corium, 26
 Cornea, 247, 248
 Coronoid process, 50
 Corpora, mammillaria, 213, 216, 218
 quadrigemina, 219
 striata, 219, 221
 Corpus callosum, 217
 cavernosa, 206
 dentatum, 224
 spongiosum, 206
 Corti, organ of, 252
 Costal cartilage, 62
 Costocervical axis, 160
 Cowper's glands, 203
 Cranial cavity, 47
 Cranium, 39
 Cretaceous, 3
 Cribriform plate, 47
 Cricoid cartilage, 192
 Crucial ligaments, 85
 Crura, cerebelli, 218
 of penis, 206
 Crus, 78, 79
 Crystalline lens, 249
 Cuboid, 29
 Cuneiform bones, 29, 80
 Cutaneous sense organs, 244
 Cuvier, duct of, 177, 179
 Cyclostomes, 4
 Cystic duct, 144

 Deltoid ridge, 65
 Dermis, 25
 Devonian, 3
 Diaphragm, 115
 Diastema, 50, 51

 Didelphia, 8
 care of young, 8, 207
 Diencephalon, 210
 Digestive system, 127, 147
 Digit, 71, 73, 81
 Digital fossa, 76
 Digitigrade, 73
 Dinosaur, 6
 Dipnoi, 5
 Dissection, preparation for, 13
 Duct of Cuvier, 177, 179
 Ductus Botalli (ductus arteriosus),
 154, 176
 Dura mater, 209

 Ear, 249
 bones containing, 42
 ossicles of, 250
 Ectocuneiform (external cuneiform),
 29, 80
 Edentata, 7
 Elbow-joint, 83
 Embryology, 1
 circulatory system, 150
 Eminence, iliopectineal, 75
 Entocuneiform (internal cuneiform),
 29, 80
 Eocene, 3
 Epicondyles, 65
 Epidermis, 25
 Epididymis, 205
 Epiglottic cartilage, 192
 Epiglottis, 192
 Epihyal, 51
 Epistropheus (axis), 56
 Epithelium, 18
 Epitrochlea (medial epicondyle, in-
 ternal condyle), 65
 Ethmoid, 40
 Ethmoturbinals, 41
 Eustachian tube (tuba auditivii), 42,
 134
 Eutheria, 7
 Excretory system, 198
 Exoccipital bones, 45
 External occipital crest, 36

- External occipital protuberance, 36
 Eye, 246
 muscles of, 247
 nerves of, 232, 233
 structure of, 248
 Eyeball, 247
 Eyelids, 246

 Face muscles, 107
 Facet, articular, 57, 62
 auricular, 74
 costal, 57, 62
 transverse costal, 57, 62
 tubercular (transverse costal), 57, 62
 Facial bones, 48
 canal, 46
 nerve, 233
 vein, 168, 169
 Fallopian (uterine) tube, 200, 201
 False ribs, 61
 vocal cords, 192
 Families, 8
 Fascia, antibrachial, 92
 cremasteric, 204
 deep crural, 104
 endothoracica, 135
 intercolumnar (cremasteric), 204
 lata, 98
 lumbodorsal, 113
 of back, 113
 of thigh, 98
 propria, 205
 Fauces, 129
 Feces, 24
 Female genital organs, 200
 Femur, 76
 Fenestra cochleæ (rotunda), 42, 250
 ovalis (vestibuli), 42, 250
 rotunda (cochleæ), 42, 250
 vestibuli (ovalis), 42, 250
 Fibrocartilage, 19
 intervertebral, 53
 Fibula, 78
 Filliform papillæ, 130
 Finger, bones of, 70
 Finger, muscles of, 97
 Fissipedia, 7
 Fissura cerebri lateralis, 211
 Fissure of Sylvius, 211
 orbital, 47
 Fissures of cerebrum, 211
 spinal cord, 226
 Floating ribs, 61
 Follicles, Graafian, 202
 Foot, bones of, 67, 79
 muscles of, 105
 of horse, 72, 81
 Foramen, anterior palatine, 46
 atlantal, 56
 carotid, 44
 ethmoidal, 41
 hypoglossal, 46
 incisivum, 38
 infraorbital, 38, 49
 interventricular (of Monroe), 229
 jugular, 45, 46
 lacerum, anterius (sphenoidal sinus), 46
 medium, 46
 magnum, 47
 mandibular, 51
 mental, 51
 obturator, 75
 of Monroe (interventricular), 215, 229
 optic, 46
 ovale, 46
 (heart), 153
 rotundum, 37, 46
 sacral, 75
 sphenopalatine, 46, 49
 stylomastoid, 44
 supracondyloid, 65
 transversum, 57
 vertebral, 53
 Foramina of skull, 46
 Forearm, bones of, 63
 bloodvessels of, 160
 muscles of, 95
 nerves of, 234
 Formaldehyde, 9

- Formalin, 9
 Formula for teeth, 133
 Fornix, 216, 218
 Fossa coronoid, 65
 digital, 77
 external pterygoid, 37, 48
 glenoid, 63, 65
 hypophyseal (sella turcica), 46
 infraspinatus, 64
 intercondyloid, 65
 internal pterygoid, 37
 jugular, 36
 lateral pterygoid, 37
 mandibular, 37, 42
 masseteric, 51
 median, 37
 olecranon, 65
 orbital, 40
 ovalis, 153
 radial, 66
 rhomboidea, 223
 scaphoid, 37
 subscapular, 64
 supraspinous, 64
 temporal, 40
 trochanteric, 77
 Fovea centralis, 249
 Frenulum linguæ, 129
 Fretum Halleri, 173
 Frontal bone, 39
 plate, 39
 sinus, 39
 Fundus of stomach, 136
 Fungiform papillae, 130
 Funiculus cuneatus, 223
 lateralis, 223
 of Rolando, 223
 Funny bone, 237

 Gall bladder, 137, 144
 Ganglia, celiac, 243
 semilunar, 242, 243
 sympathetic, 240
 thoracic, 241
 Ganglion, stellate, 241
 vagus, 241

 Ganoids, 5
 Gastric plexus, 242
 Gastroduodenal ligament, 145
 Gastrohepatic ligament, 145
 Gastrolenal ligament, 146
 omentum, 146
 Gastrosplenic omentum, 146
 Genera, 8
 Geniculate body, lateral, 221
 Genital organs, 198
 Geological time, 3
 Ginglymus (hinge-joint) 83
 Gland, adrenal, 188, 189
 Bartholin's, 205
 bulbourethral, 203, 206
 Cowper's, (bulbo-urethral), 203,
 206
 digestive, 147, 160, 162
 ductless, 188
 infraorbital, 143
 lacrimal, 246
 mammary, 203
 molar, 143
 oleaginous, 250
 parotid, 143
 prostate, 203
 sublingual, 143
 submaxillary, 143
 thymus, 188, 189
 thyreoid, 188, 189
 Glands, Harderian, 246
 inguinal (lymph), 183, 184
 lymphatic, 183
 Meibomian, 246
 of mouth, 143
 of stomach, 140
 salivary, 143
 sudiparous, 26
 tarsal, 246
 Glans penis, 206
 Glenoid angle, 63
 border, 63
 fossa, 63
 Glottis, 192
 Gnathostomata, 4
 Graafian follicles, 202

- Great omentum, 145
 - scapular notch, 64
 - sciatic nerve, 239
 - notch, 75
 - sigmoid cavity, 66
 - trochanter, 76
 - tuberosity, 65
- Gustatory organ, 245
- Gyri of cerebellum, 224
 - of cerebrum, 211
- Gyrus ectosylvius, 211
 - fornicatus, 211
 - marginalis, 211
 - suprasylvius, 211
- Hair, 26
- Hamate bone (unciform or hooked bone), 70
- Hamular (hook) process (hamulus pterygoideus), 37
- Hand, bones of, 67
 - muscles of, 97
- Harderian glands, 246
- Hatteria (sphenodon), 221
- Head, bones of, 33
 - muscles of, 107
- Heart, 150
 - development of, 172
 - human, 151
- Hemispheres of cerebellum, 224
 - of cerebrum, 210
- Hepatic artery, 155
 - duct, 144
 - plexus, 242
 - veins, 167
- Hind brain, 219
- Hip-joint, 74
- Hippocampus, 218, 219
- Histology, 1
- Holocene, 3
- Horns, 40
 - of uterus, 174
- Horse, evolution , 67
 - limbs of, 67, 68, 69, 71, 72
- Hugier, canal of, 37
- Humerus, 65
- Humor, aqueous of eye, 247, 249
- Humor, vitreous (body) of eye, 247, 249
- Hunter's canal, 164
- Hyaloid membrane, 249
- Hymen, 201
- Hyoid bone, 52
- Hypogastric plexus, 243
- Hypoglossal canal, 46
 - foramen, 37
 - nerve, 232, 233
- Hypophysis, 212
- Ichthyopsida, 4
- Ichthyosaur, 6
- Ileocolic valve, 139
- Ileum, 138
- Iliac glands, 183
- Iliopectineal eminence, 75
 - fossa, 75
 - line, 75
- Ilium, 74
- Incisor teeth, 131
- Inferior cervical ganglion, 241
 - maxillary bone, 51
 - vena cava (postcava). 165
- Infraorbital foramen, 38
 - gland, 143
- Infraspinous fossa, 64
- Infundibulum, 212
- Inguinal canal, 205
 - glands, 183
 - ligament (Poupart's), 201
- Injection method, 9
- Innominate artery, 154
 - (coxal) bone, 74, 75
 - vein, 168
- Insectivora, 7
- Integument, 25
 - muscles of, 92
- Intercondyloid fossa, 76
- Intermediate cuneiform bone 29, 80
- Internal capsule, 222
 - ear, 251
- Interparietal bone, 43
- Intertrochanteric line, 77
- Interventricular foramen (of Monroe), 216
- Intervertebral foramen, 53

- Intestinal glands, 140
- Intestine, large, 139
 - small, 138
- Invertebrata, 3
- Involuntary muscles, 18, 19
- Iris, 211
- Ischiadicus nerve, 239
- Ischium, 74
- Jaw, lower, 51
 - upper, 48
- Jejunum, 125
- Joints, kinds of, 83
 - ligaments of, 84
 - structure of, 83
- Jugular foramen, 37
 - ganglion, 186
 - notch, 36
 - process, 36
 - veins, 168, 169
- Jurassic, 3
- Labyrinth, 251
- Lachrymal bones, 50
 - canal, 50
 - gland, 246
 - groove, 51
- Lacteals, 141, 182
- Lambdoidal ridge, 36
- Lamina semicircularis, 222
 - spiralis, 252
- Large intestine, 139
- Larynx, 191
 - cartilages of, 192
 - muscles of, 111
- Lateral cuneiform (ectocuneiform)
 - bone, 80
 - ventricles of brain, 215
- Leg, arteries of, 162
 - bones of, 74
 - ligaments of, 84
 - muscles of, 98
 - veins of, 165, 169
- Lens, crystalline, 249
- Lenticulate nucleus, 222
- Lesser curvature of stomach, 136
 - omentum, 145
 - palatine artery, 159
 - sciatic notch, 75
 - trochanter, 76
 - tuberosity of humerus, 65
- Ligament, (s), (tum), 83, 146
 - annular, 95
 - Botalli, 154, 176
 - broad, 146, 210
 - capsular, 36, 84
 - collateral, 84
 - crucial, 85
 - duodenohepatic, 133
 - falciform, 146
 - flava, 85
 - gastroduodenal, 146
 - gastrohepatic, 146
 - gastrosplenic (gastrosplenic), 146
 - iliosacral, 85
 - inguinal (Poupart's), 201
 - of bladder, 199
 - of hip-joint, 76
 - of liver, 145
 - of malleoli, 84
 - of minisci, 85
 - of ovary, 201
 - of patella, 78, 84
 - of skull, 36
 - of thoracic limb, 95
 - of uterus, 201
 - pelvic limbs, 84
 - Poupart's, 201
 - pulmonary, 195
 - round, 145, 201
 - suspensory, (eye), 249
 - suspensorium, 199
 - teres, 76
- Linea aspera, 76
- Liver, 144
- Lumbar aponeurosis, 112
 - nerves, 237
 - plexus, 237, 238
 - vertebrae, 58
- Lumbodorsal fascia, 112
- Lumbosacral plexus, 238

- Lungs, 194
- Lymph, 182
- Lymphatic duct, 182, 185
 - development of, 187
 - glands, 182, 183
 - injection of, 13
 - system, 182
- Macula lutea, 240
- Magnum os, 29
- Malar bone, 29, 51
- Male genital organs, 203
- Malleoli, ligaments of, 78
- Malleolus, lateral, 78
 - medius, 78
- Malleus, 250
- Mammals, 6
- Mammary glands, 203
- Mammillary bodies, 212
- Manatus, 59
- Mandible, 51
- Mandibular fossa, 37, 42
 - foramen, 51
- Manubrium, 61
- Manus (hand) bones of, 70
 - muscles of, 97
- Marginal gyrus, 216
 - sulcus, 216
- Marsupialia, 7, 217
- Massa intermedia, 221
- Mastoid process, 36
- Maxillary bone, 48
 - external (artery), 158, 159
 - internal (artery), 159
- Maxilloturbinal, 49
- Meatus, external acoustic, 37
 - inferior, 43
 - internal acoustic, 43
- Medial cuneiform bone, 80
- Mediastinum, 168
- Medulla oblongata, 196
- Meibomian glands, 246
- Membrana nictans, 246
 - tympani, 240
- Membrane, anterior atlanto-occipital, 36
- Membrane, interosseus, 78
 - mucous, 139
 - posterior atlanto-occipital, 36
- Membranes, of brain, 209
 - of spinal cord, 225
- Meninges, 219
- Menisci, 85
 - ligaments of, 85
- Mesencephalon, 210
- Mesenteric ganglion, inferior, 242
 - superior, 242
 - glands, 182
 - plexus, 242
- Mesentery, 146
- Mesethmoid, 41
- Mesocolon, 145
- Mesocuneiform, 80
- Mesogastrum, 145
- Mesorectum, 145
- Metacarpals, 70
- Metacarpus, 70
- Metacromion, 64
- Metatarsals, 81
- Metatarsus, 81
- Metencephalon, 223
- Midbrain, 219
- Middle ear, 250
- Miocene, 3
- Mitral valve, 151
- Modiolus, 251, 252
- Molar gland, 143
 - teeth, 131
- Mole, 221
- Monodelphia, 8
- Monotremata, 7, 207
- Monroe, interventricular foramen of, 215
- Morphology, 1
- Mouth, 129
 - glands of, 143
- Mucous membrane, 129, 136, 139
- Multangular, greater (trapezium), 68
 - lesser (trapezoid), 69
- Muscles, 87
 - of abdomen, 112
 - of chest, 93

Muscles, dissection of, 88

of fore limb, 84, 95, 96

of hand, 97

of head and neck, 109

of hind limb, 98

of hip, 98

kinds of, 19

of scapula, 94

of shoulder region, 92

structure, 19

of thigh, 98

of trunk, 112

abductor auris brevis, 107, (112)

longus, 107, (111)

brevis pollicis, 97 (48)

caudae (coccygis) externus, 115,
(221)

internus, 115, (218)

cruris, 101, (58)

digiti quinti, 98 (53)

brevis, 105, (99)

digiti secundi, 98, (51)

medius digiti quinti, 105, (96)

accelerator urinae, 124, (233)

acromiodeltoideus, 94, (18)

acromiotrapezius, 93, (4)

adductor auris inferior, 108, (118)

digiti quinti longus, 105, (100)

femoris, 102, (71)

quinti (opponens), 98, (55)

secundi, 98, (52)

longus, 102, (74)

medius, 108, (122)

digiti quinti, 105, (97)

pollicis, 98, (50)

superior, 108, (121)

anconeus, 95, (30)

internus, 95, (29y)

lateralis, 95 (29a)

longus, 95, (29b)

posterior, 95, (29k)

antitragicus, 108, (127)

arytenoideus, 111, (171)

attollens auris 107, (110)

auricularis externus, 108, (124)

superior, 107, (110)

Muscles, biceps brachii, 95, (27)

femoris, 101, (57)

biventer cervicis, 114, (198)

brachialis, 95, (28)

brachioradialis, 95, (31)

buccinator, 109, (136)

bulbocavernosus, 124, (233)

calcaneometatarsalis, 107, (101)

caninus, 109, (135)

capsularis, 103, (77)

caudoanalis, 124, (229)

caudocavernosus, 124, (232)

caudofemoralis, 101, (59)

caudorectalis, 124, (228)

caudovaginalis, 124, (237)

cephalobrachialis, 93, (5)

cephalohumeralis, 93, (5)

ceratohyoideus, 110, (135)

cervicofacialis, 92, (2)

clavobrachialis, 94, (19)

clavotrapezius, 93, (5)

cleidomastoideus, 93, (9)

coccygeus, 115, (218)

complexus, 114, (199)

compressor urethrae mem-

branaceae, 124, (234)

concheus externus, 108, (129)

constrictor cunni, 124, (235)

pharyngeus inferior, 111, (164)

superior, 111, (167)

coracobrachialis, 94, (25)

corrugator supercillii lateralis, 107,

(107)

medialis, 107, (105)

cricoarytenoideus lateralis, 111,

(175)

posterior, 111, (170)

cricothyreoideus, 111, (169)

cruralis, 103, (78c)

cutaneous maximus, 92, (1)

deltoideus, 94, (18)

depressor conchae, 108, (116)

diaphragm, 115, (213)

digastric, 110, (149)

ectopectoralis, 93, (14)

entopectoralis, 94, (15)

- Muscles, epicranii, 107, (113)
 epimeralis, 103, (77)
 epitrochlearis, 94, (26)
 extensor antibrachii longus, 94, (26)
 brevis digitorum, 105, (92)
 pollicis, 96, (39)
 carpi radialis brevis, 96, (33)
 longus, 96, (32)
 carpi ulnaris, 96, (36)
 caudae lateralis, 114, (193)
 medialis, 114, (202)
 communis digitorum, 96, (34)
 digiti quinti proprius, 96, (35)
 digitorum lateralis, 96, (35)
 longus, 105, (90)
 indicis proprius, 96, (37)
 ossis metacarpi pollicis, 96, (38)
 flexor brevis digiti quinti, 98, (54)
 secundi, 98, (51)
 brevis digitorum, 104, (81)
 pollicis, 98, (49)
 carpi radialis, 96, (41)
 ulnaris, 97, (43)
 caudae brevis, 115, (220)
 longus, 115, (219)
 longus digitorum, 104, (85)
 hallucis, 104, (84)
 perforans, 97, (45)
 perforatus, 97, (44)
 profundus digitorum, 97, (45)
 sublimis digitorum, 97, (44)
 frontoauricularis, 107, (108)
 frontoscutularis, 108, (117)
 gastrocnemius, 103, (79)
 gemellus inferior, 102, (67)
 superior, 102, (64)
 genioglossus, 110, (159)
 geniohyoideus, 110, (151)
 glossoepiglottis, 111, (172)
 glossopharyngeus, 111, (163)
 gluteus maximus, 101, (60)
 medius, 101, (62)
 minimus, 102, (65)
 quartus, 103, (77)
 gracilis, 102, (68)
- Muscles, helices, 108, (125)
 hyoepiglottus, 111, (173)
 hyoglossus, 110, (160)
 iliocaudalis, 115, (216)
 iliocostalis, 114, (194)
 iliopsoas, 103, (76)
 incisivi, 109, (138)
 infraspinatus, 94, (21)
 intercostales externi, 112, (184)
 interni, 113, (185)
 intermedius scutellorum, 107, (104)
 interossei, 98, (51), 105, (95)
 interspinalis, 114, (204)
 intertransversarii, 114, (205)
 ischiocavernosus, 124, (226)
 jugulohyoideus, 110, (152)
 latissimus dorsi, 93, (10)
 levator anguli oris, (caninus), 109, (135)
 ani, 115, (217)
 auris longus, 107, (109)
 claviculae, 93, (8)
 labii superioris alaeque nasi, 109, (134)
 proprius, 109, (134b)
 palpebrarum, 246
 scapulae, 93, (12)
 dorsalis, 93, (6)
 ventralis, 93, (8)
 scroti, 124, (230)
 veli palatini, 111, (162)
 vulvae, 113, (235)
 levatores costarum, 115, (212)
 longissimus capitis, 113, 114, (196)
 cervicis, 113, (192)
 dorsi, 113, (192)
 longus atlantis, 114, (200)
 capitis, 113, (187)
 colli, 113, (188)
 lumbricales, 97, (47), 105, (94)
 mandibuloauricularis, 108, (126)
 masseter, 110, (154)
 maxilloauricularis, 108, (126)
 moustachier, 109, (138)

- Muscles, multifidus spinae, 114, (201)
 myohyoideus, 110, (150)
 myrtiformis, 109, (137)
 nasalis, 111, (173)
 obliquus abdominis externus, 112, (180)
 internus, 112, (181)
 capitis inferior, 114, (209)
 superior, 113, (190)
 superior, 115, (208)
 obturator externus, 102, (73)
 internus, 102, (66)
 occipitofrontalis, 107, (113)
 occipitoscapularis, 93, (6)
 opponens digiti quinti (hand), 98, (55),
 (foot), 105, (98)
 orbicularis oculi, 107, (106), 246
 oris, 109, (132)
 palpebrarum, 246
 palmaris longus, 96, (42)
 parameralis, 101, (59)
 pectineus, 103, (75)
 pectoantibrachialis, 93, (13)
 pectoralis major, 93, (14)
 minor, 94, (15)
 pedis perforatus, 104, (81)
 peroneus brevis, 104, (88)
 longus, 104, (87)
 tertius, 104, (89)
 plantaris, 103, (80)
 platysma, 92, (2)
 popliteus, 104, (83)
 pronator quadratus, 97, (46)
 teres, 96, (40)
 psoas minor, 115, (214)
 pterygoideus externus, 110, (157)
 internus, 110, (158)
 pterygopharyngeus, 111, (167)
 pubiicaudalis, 115, (217)
 pyriformis, 102, (63)
 quadratus femoris, 102, (72)
 labii inferioris, 109, (139)
 superioris, 109, (134)
 lumborum, 115, (215)
 plantae, 105, (93)
- Muscles, quadriceps femoris, 103, (78)
 recti (eye), 247
 rectocavernosus, 124, (231)
 rectus abdominis, 112, (183)
 capitis anterior major, 113, (187)
 minor, 113, (189)
 capitis lateralis, 114, (191)
 posterior major, 114, (207)
 medius, 115, (210)
 minor, 115, (211)
 femoris, 103, (78a)
 inferior, 247
 lateralis, 247
 medialis, 247
 superior, 247
 retractor oculi, 247
 penis, 124, (231)
 rhomboideus, 93, (7)
 capitis, 93, (6)
 rotator auris, 108, (120)
 sartorius, 102, (61)
 scalenus, 112, (176)
 anterior, 112, (176a)
 medius, 112, (176a)
 posterior, 112, (176b)
 scaphocuneiformis, 107, (102)
 scutuloauricularis inferior, 108, (120)
 semimembranous, 102, (70)
 semispinalis capitis, 114, (199)
 cervicis, 114, (203)
 semitendinosus, 102, (69)
 serratus anterior, 93, (11)
 magnus, 93, (11)
 posterior inferior, 112, (179)
 superior, 112, (178)
 soleus, 104, (82)
 sphincter ani externus, 124, (224)
 internus, 124, (225)
 spinalis dorsi, 114, (197)
 spinodeltoideus, 94, (17)
 spinotrapezius, 92, (3)
 splenius, 114, (195)
 stapedius, 109, (131)
 sternocleidomastoideus, 93, (9)
 sternocostalis externus, 112, (177)

- Muscles, sternocostalis internus, 113, (186)
 sternohyoideus, 109, (146)
 sternomastoideus, 109, (145)
 sternothyreoideus, 109, (147)
 styloglossus, 110, (159)
 stylohyoideus, 110, (148)
 stylopharyngeus, 111, (166)
 submental, 108, (115)
 subscapularis, 94, (23)
 supercervicocutaneus, 92, (2)
 supinator, 96, (38)
 longus, 95, (31)
 supraspinatus, 94, (20)
 temporalis, 110, (155)
 tensor fasciae latae, 101, (56)
 tympani, 109, (130)
 veli palatini, 111, (161)
 tenuissimus, 101, (58)
 teres major, 94, (24)
 minor, 94, (22)
 thyreoarytenoideus, 111, (174)
 thyreohyoideus, 111, (168)
 tibialis anterior, 105, (91)
 posterior, 104, (86)
 trachelomastoideus, 114, (106)
 tragicus lateralis, 108, (119)
 medialis, 108, (128)
 transversus abdominis, 112, (182)
 auriculæ, 108, (123)
 costarum, 112, (177)
 menti, 109, (140)
 pereni, 124, (227)
 thoracis, 113, (186)
 trapezius, 92, (3)
 triangularis sterni, 113, (186)
 triceps brachii, 95, (29)
 surae (gastrocnemius and soleus), 103
 urethralis, 124, (238)
 vastus intermedius, 103, (78d)
 lateralis, 103, (78b)
 medialis, 103, (78c)
 xihumeralis, 94, (16)
 zygomaticus major, 108, (114)
 minor, 108, (133)
- Myelencephalon, 210

 Nares, 47, 48, 191
 Nasal bone, 50
 process, 49
 Nasolachrymal canal, 50
 duct, 50
 groove, 50
 Navicular (scaphoid), 80
 Naviculare pedis os (scaphoid bone), 80
 Nerve cell, 228
 fibre, 228
 Nerves, arm, 234, 235
 cranial, 232, 233
 leg, 237
 motor, 231
 peripheral, 231
 plexuses, 234
 sensory, 231
 spinal, 233
 sympathetic, 240
 Nervous system, 14, 219
 Nervus abducens, 232, 233
 accessorius, 232, 233
 acusticus, 232, 233
 anterior crural, 239
 auditory (acoustic), 232, 233
 axillaris, 235
 circumflexus, 235
 cutaneous, external, 239
 internal, 236
 femoralis lateralis, 238
 medialis, 238
 posterior, 238
 genitocrural, 237
 genitofemoralis, 238
 glossopharyngeus, 232, 233
 glutei, 240
 hypoglossus, 232, 233
 iliohypogastric, 238
 iliolingualis, 238
 ischadicus, 239
 median, 235
 musculocutaneus, 235
 musculospiral, 235, 236
 obturator, 239
 oculomotorius, 232, 233

- Nervus olfactorius, 232, 233
 opticus, 232, 233
 patheticus (trochlear), 232, 233
 peroneus profundus, 238
 superficialis, 238
 plantaris, internus, 238
 lateralis, 238
 medialis, 238
 pneumogastric (vagus), 232, 233
 pudic, 240
 radialis, 236
 superficialis, 236
 saphenus, 239
 splanchnic, great, 242
 subscapularis, 235
 thoracicus anterior, 236
 longus, 236
 posterior, 236
 tibialis, 238, 239
 trigeminis, 232, 233
 trochlearis, 232, 233
 ulnaris, 237
 vagus (pneumogastric), 232, 233
 Neurone, 232
 Nictitating membrane, 246
 Nomenclature, 8
 Notch, jugular, 45
 inferior mandibular, 52
 superior mandibular, 52
 Nucleus, caudate, 222
 lenticular, 222
 Number of bones, 28, 29
 Obturator foramen, 75, 76
 Occipital bone, 45
 condyle, 36
 crest, 45
 Odontoid process (dens), 56
 Oleaginous gland, 250
 Olecranon, 65
 fossa, 65
 process, 66
 Olfactory bulb, 245
 lobe, 211
 organ, 245
 tract, 214
 Oligocene, 3
 Omenta (um), 132
 gastrocolic, 147
 gastrohepatic, 147
 greater, 132, 147
 lesser, 136, 147
 Optic chiasma, 212, 213
 commissure, 212
 foramen, 38
 nerve, 232, 233
 tract, 212, 213
 Ora serrata, 249
 Orbicularis palpebrarum, 246
 Orbital cavity, 38
 fissure, 38
 fossa, 38
 gland, 143
 gyrus, 211
 plate, 40, 49
 process, 40
 Orbitosphenoid, 45
 Orders, 8
 Ordovician, 3
 Organ of corti, 252
 Organs, 17
 of body, 128
 Ornithodelphia, 7
 Os planum, 41
 Ova of animals, 203
 Ovary, 202
 Pacinian corpuscle, 245
 Pads of feet, 12, 26
 Pain, sense organs of, 244
 Palate, hard, 37
 Palate, soft, 37
 Palatine bone, 49
 foramen, 38
 Pancreas, 145
 of Aselli, 183
 Pancreatic bladders, 145
 ducts, 145
 Papillae of tongue, 129, 130
 Parietal bone, 43
 eminence, 43
 Parotid duct, 143

- Parotid gland, 143
 Patella, 77
 Patellar ligament, 85
 Pathetic (trochlear) nerve, 232, 233
 Peduncles of cerebellum, 224
 of cerebrum, 212
 Pelvic arch, 75
 bones, 75
 Penis, 205
 Pericardium, 150
 Peripheral nervous system, 231
 Perissodactyla, 8
 Peritoneal cavity, 194
 Peritoneum, 145
 Permian, 3
 Petrotympanic fissure, 37
 Phalanges, 71, 81
 Pharynx, 133
 Phylogeny, 2
 of horse, 67, 68, 69, 72
 Physiology, 1
 Pia mater, 209
 Pillars of fornix, 218
 of fauces, 129
 Pineal body, 221
 Pinna, 249
 Pinnipedia, 7
 Pisiform, bone, 29, 68
 ganglion, 220
 Pituitary body (hypophysis), 212
 Plantigrade, 73
 Pleistocene, 3
 Pleura, 194
 Plexus, anterior gastric, 241
 aortic, 241
 brachial, 234
 cardiac, 242
 carotid, 241
 celiac, 242
 cervical, 234
 hepatic, 242
 inferior mesenteric, 242
 lumbar, 237
 lumbosacral, 237
 posterior gastric, 241
 Plexus, pulmonary, 241
 renal, 242
 sacral, 239
 solar, 242
 splenic, 242
 superior mesenteric, 242
 suprarenal, 242
 Plica semilunaris, 246
 Pliocene, 3
 Poikilothermic, 5
 Pons varolii, 224
 Portal system, 12, 167
 Postglenoid process, 44
 Postorbital process, 42
 Poupert's ligament, 201
 Premaxillary bone, 48
 Premolar teeth, 118
 Preparation of bones, 15
 Prepuce, 179
 Preservation of material, 8, 233
 Presphenoid bone, 37, 48
 Primates, 7
 Proboscidea, 8
 Process, acromion, 64
 alveolar, 131
 angular, 50
 anterior clinoid, 46
 articular, 53
 ciliary, 248
 clinoid, anterior, 46
 condyloid, 50
 corocoid, 64
 coronoid, 52
 frontal, 51
 hamular, 48
 jugular, 45
 malar, 49
 mammillary, 58
 mastoid, 44
 nasal, 49
 odontoid, 56, 57
 orbital, 44
 palatine, 44
 posterior clinoid, 47
 postglenoid, 44

- Process, postmandibular, 42
 - postorbital, 39, 51
 - pterygoid, 48
 - spinous, 53, 57
 - styliform, 66
 - transverse, 53, 57, 58
 - xiphoid, 61
 - zygomatic, 42
- Promontory, 43
- Prosencephalon, 210
- Prostate gland, 206
- Proterozoic, 3
- Protocordata, 3
- Prototheria, 7
- Protuberance, external occipital, 36
- Pterosaur, 6
- Pterygoid bone, 45, 48
 - canal, 38
 - fossa, 37
 - process, 48
- Pubis, 74
- Pulmonary ligament, 195
 - plexus, 241
- Puncta lachrymalia, 246
- Pupil, 248
- Psychology, 1
- Pyramids, anterior, 223

- Quadrigemina, corpora, 219

- Radial fossa, 66
 - notch, 66
- Radius, 66
- Rami communicantes, 227
- Ramus of ischium, 75
 - of mandible, 51
 - of pubis, 75
- Receptaculum chyli, 185, 186
- Rectigrade, 73
- Rectum, 139
- Reflex action, 231
- Reproductive system, 200, 203
- Reptiles, 5
- Respiratory system, 191
- Restiform body, 223, 224
- Retina, 248

- Rhinencephalon, 213
- Ribs, 61
- Ridge, deltoid, 66
 - lambdoidal, 45
 - pectoral, 65, 66
 - supracondylar, 65
- Rodentia, 7
- Rotatoria (pivot joint), 83
- Ruminant, 134
 - stomach of, 147

- Sacral canal, 71
 - foramina, 71
 - plexus, 212
 - vertebra, 58
- Sacrum, 58
- Sagittal crest, 36
- Salivary glands, 142
- Santorini, duct of, 145
- Scala tympani, 241
 - vestibuli, 241
- Scaphoid bone, 80
- Scapholunar bone, 67
- Scapula, 63
- Scarpa's triangle, 164
- Schneiderian membrane, 245
- Sciatic nerve, 239
 - notch, 75
- Sclera, 248
- Sclerotic, 248
- Scrotum, 204
- Scutiform cartilage, 108
- Sea cow, vertebrae of, 59
- Sebaceous glands, 142
- Selachian, 4
- Sella turcica, 46
- Semicircular canals, 251
- Semilunar cartilages, 85
 - ganglion, 242, 243
 - notch, 66
 - tendon, 115
 - valve, 154
- Sense organs, 244
- Serous membrane, 146
- Sesamoid bones, 28, 72, 81
- Shoulder girdle, 63

- Sight, organs of, 246
- Sigmoid cavity, 66
- Silurian, 3
- Sinus, frontal, 39
 - inferior petrosal, 170
 - lateral, 168
 - sphenoidal, 47
 - superior longitudinal, 168
 - petrosal, 168
- Sirenia, 8
- Skeleton, 28
 - preparation of, 15
- Skin, 25
 - sense-organs of, 244
- Skull, 33
- Smell, organ of, 245
- Soft palate, 120
- Solar plexus, 243
- Species, 8
- Spermia, 205
- Sphenoid bone, 45
- Sphenopalatine foramen, 38
- Spigelian lobe of liver, 144
- Spinal column, 53
 - cord, 225
 - ganglia, 227
 - nerves, 206, 233
- Spine, of ischium, 75
 - of scapula, 64
 - of tibia, 78
- Spinous process, 53, 56, 67
- Splanchnic nerves, 242
- Spleen, 198
- Splenic plexus, 242
- Squamous portion of temporal bone, 42
- Stapes, 240
- Stenon's duct, (ductus parotideus stenonis), 143
- Sternum, 61
- Stria medullaris, 223
- Stomach, 136, 140
- Stylohyal, 51
- Styloid process, 67
- Stylomastoid foramen, 37
- Sublingual gland, 143
- Submaxillary gland, 143
- Sulci of cerebellum, 211
 - of cerebrum, 224
- Supracondyloid foramen, 65
 - ridge, 65
- Supraoccipital bone, 43
- Suprarenal (adrenal) gland, 188, 189
- Sutures of skull, 35
- Sweat glands, 26
- Sympathetic nervous system, 240
- Synarthroses, 83
- Synovial membrane, 85
- Systems, 17
- Taenia thalami, 221
- Tail bones, 58
- Talus (astragalus), 20, 79
- Tapetum, 248
- Tarsal glands, 246
- Tarsus, 29, 79
- Taste, organs of, 245
- Taxonomy, 2
- Teeth, 130
 - mammalian, 133
 - milk, 133
 - permanent, 133
- Telencephalon, 210
- Teleosts, 5
- Temporal bone, 41
 - fossa, 38
- Tendo calcaneus (Achilles), 103
- Tendon of Achilles, 103
- Tentorium, 43
- Testes, 204
- Thalamus, 221
- Thebesius, valve of, 153
- Theromorph, 6
- Thigh, bones of, 74
 - muscles of, 98
- Thoracic, aorta, 154
 - cavity, 132
 - duct, 182, 185
 - ganglia, 241
 - vertebrae, 57
- Thymus gland, 189
- Thyreohyal, 52
- Thyreoid cartilage, 52

- Thyroid gland, 189
 Tibia, 78
 Tissues, 17, 18, 19, 20
 Tongue, 129
 Tonsils, 129
 Tooth formula, 133
 structure of, 130
 Trabeculae carnae, 151
 Trachea, 194
 Tragus, 108
 Trapezium (large multangular), 29, 68
 Trapezoid (small multangular), 29, 69
 Triangle, Scarpa's, 164
 Triassic, 3
 Tricuspid valve, 150
 Triquetral (cuneiform) bone, 29, 68
 Trochanter, great, 76
 lesser, 76
 Trochanteric fossa, 76
 Trochlea tali, 79
 humeri, 65
 True ribs, 61
 Truncus arteriosus, 173
 Tuba auditiva (Eustachian tube), 37
 Tuber cinereum, 212, 213
 Tubercle, peroneal, 79
 pubic, 75
 of radius, 66
 of ribs, 62
 Tuberosity, great, 65
 lesser, 65
 of ischium, 75
 of scapula, 64
 tibia, 78
 Tunica albuginea, 205
 dartos, 104
 fibrosa, 198
 vaginalis communis, 204
 proprius, 204
 Turbinates, 49
 Tympanic bone, 35
 bullae, 37, 42
 cavity, 42
 membrane, 240
 Tympanohyal, 37
 Ulna, 66
 Unciform (hamate) bone, 29, 70
 Unguiculate, 7
 Ungulate, 7
 evolution of, 67, 72
 Unguligrade, 73
 Ureter, 199
 Urethra, 200
 Urogenital organs, 198
 of mammals, 206
 Uterine tubes, 201
 Uterus, 201
 Vagina, 201
 Vagus nerve, 212, 213
 Valsalva, sinuses of, 154
 Valve of Vieussens, 214
 Valves of heart, 150
 of veins, 165
 Vas deferens, 205
 Vasa efferentia testis, 205
 Vascular system, 150
 injection of, 9
 Vater, ampulla of (opening of pancreatic and bile ducts), 145
 Veins, 165
 development of, 177
 of lungs, 171
 of trunk, head and neck, 165
 Velum medullare superior, 214
 inferior, 214
 medullaris inferior, 223
 Vena adrenolumbales, 166, 169
 anonyma (innominate), 168
 auricularis anterior, 169
 posterior, 169
 axillaris, 169
 azygos, 167, 169
 brachialis, 169
 cardinalis, 179
 cava, 165
 cava anterior (precava), 165, 167, 169
 cephalica, 165, 169
 coronaria ventriculi, 165
 facialis anterior, 168, 169

- Vena Cava, facialis posterior, 168, 169
 gastroepiploica, 167
 gastrolienalis (gastrosplenic), 167
 hepatica, 167
 hypogastrica, 169
 iliaca communis, 167, 196
 externa, 167, 169
 interna, 167, 169
 iliolumbalis, 167, 169
 innominata, 168
 jugularis externa, 168, 169
 interna, 168, 169
 lumbales, 166
 mamma interna (sternal), 167, 169
 mesenterica inferior, 167
 superior, 167
 ovarian, 167
 pancreaticoduodenalis, 167
 posterior, (postcava), 165, 169, 179
 phrenica, 165
 poplitea, 169
 portae, 167
 postcardinal, 177
 postcava, 165
 precordial, 177
 precava, 165
 pulmonales, 171
 renalis, 166, 169
 sacralis media (caudal), 167, 169
 saphena magna, 169
 subcardinal, 177
 subclavia, 168, 169
 submental, 169
 supracardinal, 177
 thyroideus inferior, 169
 transversa scapulae, 169
 umbilicalis, 177
 vertebralis, 167, 168, 169
 Ventricles of brain, 214
 of heart, 152, 153
 Vermiform appendix, 139, 147
 Vermiform process, 224
 Vermis, 224
 Vertebrae, 53
 caudal, 58
 cervical, 54
 lumbar, 58
 number in mammals, 53, 59
 of Orang, 59
 of sea cow, 59
 plan of, 53
 thoracic, 53
 Vertebral arch, 53
 canal, 54
 column, 53
 foramen, 54
 Vertebralarterial canal, 54
 Vertebrata, 4
 Vestibule of ear, 241
 Vibrissae, 27
 Vidian canal, 38
 Villi, 142
 Viscera, 134
 Vital knot, 223
 Vitreous body, 247, 249
 humor, 247, 249
 Vocal cords, false, 192
 true, 192
 Vomer, 49
 Wharton's duct (submaxillary), 143
 White matter of brain, 222
 Willis, circle of, 158, 159
 Winslow, foramen of, 145
 Wirsung, duct of (larger pancreatic duct), 145
 Wrist bones, 67
 Xiphoid (ensiform) process, 61
 Zygoma, 42
 Zygomatic arch, 35
 bones, 42
 process, 42

