



This is a digital copy of a book that was preserved for generations on library shelves before it was carefully scanned by Google as part of a project to make the world's books discoverable online.

It has survived long enough for the copyright to expire and the book to enter the public domain. A public domain book is one that was never subject to copyright or whose legal copyright term has expired. Whether a book is in the public domain may vary country to country. Public domain books are our gateways to the past, representing a wealth of history, culture and knowledge that's often difficult to discover.

Marks, notations and other marginalia present in the original volume will appear in this file - a reminder of this book's long journey from the publisher to a library and finally to you.

Usage guidelines


Google is proud to partner with libraries to digitize public domain materials and make them widely accessible. Public domain books belong to the public and we are merely their custodians. Nevertheless, this work is expensive, so in order to keep providing this resource, we have taken steps to prevent abuse by commercial parties, including placing technical restrictions on automated querying.

We also ask that you:

- + *Make non-commercial use of the files* We designed Google Book Search for use by individuals, and we request that you use these files for personal, non-commercial purposes.
- + *Refrain from automated querying* Do not send automated queries of any sort to Google's system: If you are conducting research on machine translation, optical character recognition or other areas where access to a large amount of text is helpful, please contact us. We encourage the use of public domain materials for these purposes and may be able to help.
- + *Maintain attribution* The Google "watermark" you see on each file is essential for informing people about this project and helping them find additional materials through Google Book Search. Please do not remove it.
- + *Keep it legal* Whatever your use, remember that you are responsible for ensuring that what you are doing is legal. Do not assume that just because we believe a book is in the public domain for users in the United States, that the work is also in the public domain for users in other countries. Whether a book is still in copyright varies from country to country, and we can't offer guidance on whether any specific use of any specific book is allowed. Please do not assume that a book's appearance in Google Book Search means it can be used in any manner anywhere in the world. Copyright infringement liability can be quite severe.

About Google Book Search

Google's mission is to organize the world's information and to make it universally accessible and useful. Google Book Search helps readers discover the world's books while helping authors and publishers reach new audiences. You can search through the full text of this book on the web at <http://books.google.com/>



MANUAL OF GYNECOLOGY.

MANUAL
OF
GYNECOLOGY

BY

D. BERRY HART, M.D., F.R.C.P.E.,
LECTURER ON MIDWIFERY AND DISEASES OF WOMEN, SCHOOL OF MEDICINE, EDINBURGH;
LATE ASSISTANT TO THE PROFESSOR OF MIDWIFERY, UNIVERSITY OF EDINBURGH;
LATE PRESIDENT OF THE ROYAL MEDICAL SOCIETY, ETC.:

AND

A. H. FREELAND BARBOUR, M.B., F.R.C.P.E.,
ASSISTANT TO THE PROFESSOR OF MIDWIFERY, UNIVERSITY OF EDINBURGH;
LATE PRESIDENT OF THE ROYAL MEDICAL SOCIETY.

WITH NINE LITHOGRAPHS AND FOUR HUNDRED WOODCUTS.

SECOND EDITION.

EDINBURGH: W. & A. K. JOHNSTON.

1883.

160. e. 286.

PRINTED BY
FRANK MURRAY, 9 AND 11 YOUNG STREET,
EDINBURGH.

TO

OUR FRIEND AND TEACHER,

ALEXANDER RUSSELL SIMPSON,

M.D., F.R.S.E.,

PROFESSOR OF MIDWIFERY AND DISEASES OF WOMEN AND CHILDREN
IN THE UNIVERSITY OF EDINBURGH.

PREFACE TO SECOND EDITION.

IN the Appendix, a description of Weir Mitchell's Treatment of Chronic Cases, and Hysteria and Hystero-Epilepsy, have been substituted for Syphilis and Chlorosis.

The whole text has been carefully revised and brought up to date.

D. BERRY HART.

A. H. FREELAND BARBOUR.

EDINBURGH, *July*, 1883.

PREFACE TO FIRST EDITION.

IN writing this Manual we have tried to keep before our eyes the great principle that the Anatomy, Physiology and Pathology of the Pelvic Organs form the foundation of good Clinical work. As students we felt the want of a text book based on this principle and embodying the most recent views from the various literatures instead of giving those of one school. This want we have endeavoured to supply.

Our thanks are due to Professor SIMPSON for his kind advice in matters of difficulty: and specially to Mr. J. A. MELVILLE, for the literary revision of the text and the preparation of the copious Table of Contents and Indices.

Messrs. W. & A. K. JOHNSTON have executed the lithographs with their well-known accuracy and finish: and to Mr. JAMES BAYNE we are indebted for the care and fidelity with which he has drawn on the wood the majority of the engravings. We have in all cases acknowledged the source of every illustration not specially prepared for this work.

D. B. HART.

A. H. F. BARBOUR.

EDINBURGH, *July*, 1882.

TABLE OF CONTENTS.

PART I.

ANATOMY, PHYSIOLOGY, AND METHODS OF EXAMINATION OF THE FEMALE PELVIC ORGANS.

SECTION I. ANATOMY AND PHYSIOLOGY OF THE FEMALE PELVIC ORGANS.

	PAGE
CHAP. I. General Anatomy of External Genitals and Contents of Pelvis	2
External Genitals as observed Clinically	3
The Pelvic Floor and Organs resting on it, considered as a whole	7
The Pelvis considered in detail	8
The Pelvic Floor dissected from below	8
The Pelvic Floor dissected from above	12
The Uterus and its Annexa	13
Fallopian Tubes	21
Ovaries	23
Vagina	26
Bladder	29
Rectum	35
Perineal Body	38
Peritoneum	38
Connective Tissue of Pelvis	41
CHAP. II. The Position of the Uterus and its Annexa, and the Relation of the Superjacent Viscera	47
The Normal Form and Position of the Uterus	49
The Local Divisions of the Pelvic-floor Peritoneum as viewed through the Pelvic Brim, and the position of the Uterine Annexa	52
The Physiological Changes in the position of the Uterus	53
The Relation of the Small Intestine to the Pelvic Floor and to the Uterus with its Annexa	55

	PAGE
CHAP. III. Structural Anatomy of the Female Pelvic Floor . . .	56
Pubic Segment	57
Sacral Segment	57
Pelvic-Floor Projection	61
CHAP. IV. Blood-vessels of the Pelvis	65
Arterial Supply	65
to Uterus, Ovaries, etc.	65
to Perineal Region	66
Venous Supply	66
Lymphatics of the Pelvis	68
Lymphatic Glands	68
Lymphatic Vessels	68
of External Genitals	69
of Vagina and Cervix Uteri	69
of Uterus	69
Nerves of the Pelvis	70
Spinal	70
Sympathetic	71
Development of Pelvic Organs	71
CHAP. V. Physics of the Abdomen and Pelvis, with special refer- ence to the Semiprone and Genupectoral Postures . . .	73
The effect of Intra-abdominal Pressure on the Female Pelvic Floor	73
Results brought about by change of Posture, especially by the Genupectoral Posture	74
The effect on Uterine position of Digital Pressure in the Vaginal Fornices	79
CHAP. VI. Menstruation and Ovulation	81
Preliminary Considerations	81
General Phenomena	82
Local Phenomena	82
Ovulation	82
Corpus Luteum	83
Source of Discharge	84
Changes in the Uterine Mucous Membrane	84
SECTION II. PHYSICAL EXAMINATION OF THE FEMALE PELVIC ORGANS.	
CHAP. VII. External Abdominal Examination	90
Inspection of External Genitals	93
Vaginal Examination	94
Bimanual or Abdomino-Vaginal Examination	96
Other Methods of Abdominal Examination	100
CHAP. VIII. Examination per Rectum	101
Simple Rectal	101
Abdomino-Rectal and Abdomino-Recto-Vaginal	102
Simon's Method of passing the Hand into the Rectum	103

CONTENTS.

xiii

		PAGE
CHAP. IX.	The Volsella	104
	Description of Instrument	104
	Methods of Use	105
	Mechanism of Displacement it causes	105
	Uses in Diagnosis	105
	in Treatment	106
	Contra-indications	107
CHAP. X.	Vaginal Specula	108
	Spatular Speculum—the Sims	108
	Tubular Speculum—the Fergusonson	111
	Bivalve Speculum—the Neugebauer	112
	—the Cusco	114
	Uses and comparative value of the various Specula	114
CHAP. XI.	The Uterine Sound	115
	Nature	115
	Preliminaries to its use ; when not to use it	116
	Method of use	117
	Employment of the Sound for Diagnosis	121
	" " Treatment	122
	Dangers attending its use	122
	Sound combined with Bimanual	123
	Relation of Sound to Bimanual and Rectal Examination	124
CHAP. XII.	Means of Dilating the Cervical Canal	125
	Tents	125
	Material	125
	Purposes for which used	126
	Preliminaries to and method of use	127
	Dangers in use and contra-indications	130
	Hard rubber dilators—Tait's, Hanks'	130
CHAP. XIII.	The Curette	132
	Varieties	132
	Cases in which useful	133
	Method of use	133
	Cautions and dangers	134
	Relation of Posture to Examination and Treatment	134
CHAP. XIV.	Instruments	135
	Knives	135
	Scissors	135
	Needles	136
	Sutures	137
	Antiseptics	137
	Vaginal Syringes and Douches	138
	Cautery	140
	Anæsthetics	142
	Action of Chloroform	143
	Uses of Chloroform	143
	Method of Administration	143
	Dangers	145

PART II.

DISEASES OF THE FEMALE PELVIC ORGANS.

SECTION III. THE PERITONEUM AND CONNECTIVE TISSUE.

	PAGE
CHAP. XV. Pelvic Peritonitis	151
Pathological Anatomy and Varieties	151
Etiology	152
Symptoms and Physical Signs	154
Differential Diagnosis	155
Course and Results	155
Prognosis	155
Treatment	155
Prophylactic	156
General	156
Local	158
Pelvic Cellulitis	159
Pathological Anatomy and Varieties	159
Etiology	160
Symptoms	161
Physical Signs	161
Differential Diagnosis between Pelvic Peritonitis and Cellulitis	162
Course and Results	163
Prognosis	164
Treatment	164
CHAP. XVI. Pelvic Hæmatocele	165
Nature	165
Pathological Anatomy	166
Etiology: Sources of Hæmorrhage and Varieties	168
Symptoms	170
Physical Signs	170
Diagnosis and Differential Diagnosis	172
Course and Results	172
Prognosis	172
Treatment	172
At onset of Hæmorrhage	172
After Suppuration has occurred	173

SECTION IV. AFFECTIONS OF THE FALLOPIAN TUBES AND OVARIES.

CHAP. XVII. Fallopian Tube	176
Abnormalities	177
Stricture of the Tubes	177
Patent Condition of the Tubes	178
Inflammatory Condition of the Tubes—Catarrhal Salpingitis	178

CONTENTS.

		XV
		PAGE
CHAP. XVII.	Fallopian Tube—<i>continued.</i>	
	Hydrops Tube	179
	Pyosalpinx	180
	Hæmatosalpinx	180
	New Formations	180
	Parovarium	180
	Round Ligament	180
	Hydrocele	180
	Broad Ligament	181
	Tubo-Ovarian Cysts	181
CHAP. XVIII.	Malformations of Ovary	182
	Ovaritis and Periovaritis	183
	Pathological Anatomy	183
	Etiology	183
	Symptoms and Physical Signs	184
	Differential Diagnosis	184
	Progress and Results	184
	Treatment	184
	Periovaritis	185
	Displacements of the Ovary—Hernia	185
	Etiology	185
	Diagnosis and Differential Diagnosis	185
	Treatment	186
	Prolapsus	186
	Pathological Anatomy	186
	Etiology	186
	Symptoms	187
	Physical Signs	187
	Treatment	187
CHAP. XIX.	Batley's Operation	189
	History of Operation	189
	Nomenclature	189
	Nature and Aims of Operation	190
	Indications for Operation	190
	Method of performing the Operation	191
	Vaginal Method	191
	Abdominal Section	192
	General Conclusions	194
	Removal of Uterine Appendages (Tait's Operation)	195
	Removal of Uterine Appendages	195
CHAP. XX.	Pathology of Ovarian Tumours	197
	Mode of Origin of Ovarian Cysts	197
	Varieties of Ovarian Tumour	201
	Naked-eye Anatomy	202
	Microscopic Anatomy	202
	Nature of Ovarian Fluid	202
	of Parovarian Fluid	203
	Solid Ovarian Tumours	204
	Malignant	204
	Non-Malignant	204

	PAGE
CHAP. XXI.	Diagnosis of Ovarian Tumours 206
	When Small and Pelvic in position 206
	Lateral to Uterus 206
	Posterior to Uterus 207
	When Large and chiefly Abdominal in position 208
	Symptoms 208
	Physical Signs 208
	Differential Diagnosis 210
	Diagnosis of Adhesions 212
	Co-existence of Pregnancy and Ovarian Tumour 212
CHAP. XXII.	Operative Treatment of Ovarian Tumours 213
	Ovariotomy 214
	Vaginal method 214
	Abdominal method 215
	Requisites 215
	Preliminaries 217
	The Incision 217
	Evacuation of Cyst 218
	Drawing out of the Cyst from Abdomen 219
	Separation at the Pedicle 219
	Treatment of Adhesions and Bleeding 221
	Toilette of the Peritoneum 222
	Closure of Wound 222
	Drainage 222
	Dressing of Wound 222
	After-Treatment: Treatment of Complications 222
	Relation of Listerism to Ovariotomy 223
	Ovariotomy by Enucleation 224
	Ovariotomy when Pregnancy is present 224
	Contra-indications to Ovariotomy 224
	Course and result of Ovarian Tumours when left alone 224
	Adhesions 225
	Torsion of Pedicle 225
	SECTION V. AFFECTIONS OF THE UTERUS.
CHAP. XXIII.	Malformations of the Uterus 229
	Pathology 230
	Etiology and Classification 234
	Symptoms 235
	Diagnosis 236
	Prognosis 239
	Treatment 239
CHAP. XXIV.	Atresia of the Cervix Uteri 240
	Etiology and Pathology 240
	Stenosis of the Cervix 241
	Pathology 241
	Etiology 241
	Symptoms 242
	Diagnosis 243
	Prognosis 243
	Treatment 243
	Dilatation 244
	Division 244

CONTENTS.

xvii

	PAGE
CHAP. XXV. Atrophy of the Cervix and Uterus	249
Superinvolution of the Uterus	250
Pathology	250
Etiology	250
Symptoms	250
Diagnosis	252
Prognosis	252
Treatment	252
CHAP. XXVI. Hypertrophy of the Cervix—Vaginal portion	254
Pathology	254
Etiology	255
Symptoms	255
Diagnosis	255
Treatment—Amputation	256
With Scissors or Knife	256
With Ecraseur or Cautery	261
Hypertrophy of the Cervix—Supra-vaginal portion	261
Treatment	263
CHAP. XXVII. Laceration of the Cervix	266
Pathology	267
Etiology	269
Symptoms	269
Diagnosis	270
Treatment	271
Emmet's Operation	272
CHAP. XXVIII. Chronic Cervical Catarrh	277
Pathology	277
Etiology	282
Symptoms	283
Physical Signs	283
Diagnosis and Differential Diagnosis	284
Prognosis	285
Treatment	285
CHAP. XXIX. Endometritis	289
Pathology	289
Etiology	293
Symptoms of acute Endometritis	294
of Chronic Endometritis	294
Physical Signs of Acute Endometritis	295
of Chronic Endometritis	296
Diagnosis, Differential Diagnosis	296
Prognosis	297
Treatment of Acute Endometritis	297
of Chronic Endometritis	298
CHAP. XXX. Acute Metritis	303
Pathology	303
Etiology	303
Symptoms	304
Physical Signs	304
Progress and Termination	304

	PAGE
CHAP. XXX. Acute Metritis— <i>continued</i> .	
Diagnosis	305
Prognosis	305
Treatment	305
Chronic Metritis	305
Pathology	306
Etiology	308
Symptoms	309
Physical Signs, Diagnosis	310
Differential Diagnosis	311
Treatment	311
CHAP. XXXI. Displacements of the Uterus	314
Anteflexion	318
Pathology	318
Etiology	321
Symptoms	322
Diagnosis	324
Differential Diagnosis	325
Prognosis	326
Treatment	326
Anteversio	331
Pathology	331
Etiology	331
Symptoms	331
Diagnosis	332
Treatment	332
Retroversio	335
Pathology and Etiology	335
Symptoms	336
Diagnosis	336
Treatment	337
Retroflexion = Retroversion + Retroflexion	337
Pathology	337
Etiology	340
Symptoms	341
Diagnosis	342
Differential Diagnosis	344
Prognosis	345
Treatment	346
Replacement by Bimanual	347
with the Sound	347
by Genupectoral Posture	349
Retaining the replaced Uterus by Pessaries	350
CHAP. XXXII. Inversion of the Uterus	358
Pathology	358
Etiology and Frequency	362
Symptoms	363
Diagnosis	364
Differential Diagnosis	366
Course and results of Chronic Inversion	368
Prognosis	368
Treatment	368
Reposition	369
Amputation	374

CONTENTS.

xix

		PAGE
CHAP. XXXIII.	Fibroid Tumours of the Uterus	376
	Pathology	376
	Situation	376
	Structure	377
	Mode of Growth, Varieties	379
	Changes in the Uterus	383
	Degenerative Changes	384
	Fibroid Tumours of the Cervix	386
	Etiology	386
CHAP. XXXIV.	Fibroid Tumours of the Uterus—(continued)	388
	Symptoms	388
	Menorrhagia, Irregular Hæmorrhages	388
	Painful Menstruation	389
	Sensations due to size and weight of Tumour	390
	Pressure Symptoms	390
	Progress and Results	391
	Physical Signs : Differential Diagnosis	392
	Of small Fibroid Tumours	392
	Of large Fibroid Tumours	394
	Prognosis	397
CHAP. XXXV.	Fibroid Tumours of the Uterus—(continued)	398
	Medical Treatment	398
	Surgical Treatment	400
	Removal through the Vagina	400
	Removal through Abdominal Walls by Laparotomy	403
CHAP. XXXVI.	Fibro-Cystic Tumour of the Uterus	413
	Pathology	413
	Symptoms	415
	Diagnosis ; Differential Diagnosis	415
	Treatment	415
CHAP. XXXVII.	Polypi of the Uterus	416
	Varieties	416
	Symptoms	421
	Diagnosis	422
	Differential Diagnosis	424
	Prognosis	426
	Treatment	426
CHAP. XXXVIII.	Carcinoma Uteri (of Cervix)	429
	Pathology	429
	Classification	429
	Origin	431
	Position	431
	Progress	432
	Extension to neighbouring Organs	433
	Etiology	436
	General predisposing Causes	436
	Local predisposing Causes	438

	PAGE
CHAP. XXXIX. Carcinoma Uteri (of Cervix)—(continued)	440
Symptoms	440
Local Symptoms	440
Hæmorrhage	440
Offensive discharge	441
Pain	441
General Symptoms	442
Diagnosis	443
Differential Diagnosis	444
Prognosis	446
Causes of Death	447
CHAP. XL. Carcinoma Uteri (of Cervix)—(continued)	450
Treatment of Symptoms	451
Hæmorrhage	451
Offensive discharge	451
Pain	452
Treatment of the Disease	453
Application of Caustics	454
Scraping out of diseased tissue	455
Amputation of the Cervix	455
Ecraseur or Galvano-cautery	456
Knife and Scissors, with Ligature or Caustics	460
Excision of the whole Uterus	463
By Abdominal Excision (Freund's method)	464
Through the Vagina	466
CHAP. XLI. Carcinoma of the Body of the Uterus	468
Pathology and Etiology	468
Symptoms and Diagnosis	469
Treatment	470
CHAP. XLII. Sarcoma Uteri	471
Pathology	471
Etiology and Frequency	475
Symptoms	475
Diagnosis	476
Prognosis	478
Treatment	478
SECTION VI. AFFECTIONS OF THE VAGINA.	
CHAP. XLIII. Atresia Vaginæ	480
Pathology	480
Atresia Hymenalis	480
Atresia Vaginalis	481
Etiology	483
Symptoms	484
Diagnosis	484
Prognosis	486
Treatment	487
Operation for Imperforate Hymen	488
for Atresia Vaginæ	488
for Atresia of the Cervix	490
Atresia of one-half of a Septate Uterus and Vagina	491

CONTENTS.

xxi

		PAGE
CHAP. XLIV.	Vaginitis	493
	Nature and Varieties	493
	Pathology	493
	Etiology	495
	Symptoms	496
	Diagnosis	496
	Treatment	497
	Vaginismus	498
	Etiology	498
	Symptoms and Diagnosis	498
	Treatment	499
	Sims' Operation	500
	Tumours of the Vagina	500
	Cysts	501
	Fibroid Tumours	502
	Carcinoma	502
	Sarcoma	503
SECTION VII. AFFECTIONS OF THE VULVA AND PELVIC FLOOR.		
CHAP. XLV.	The Vulva: Malformations	506
	Hermaphroditism	507
	True	508
	False	508
	Inflammation of the Vulva	510
	Pruritus Vulvæ	510
	Eruptions on the Vulva	512
	Tumours of the Vulva	512
CHAP. XLVI.	Rupture of the Perineum	517
	Nomenclature	517
	Pathology and Varieties	517
	Etiology	518
	Treatment	520
	Prophylactic	520
	Operative—immediate	521
	deferred	521
CHAP. XLVII.	Displacements of the Pelvic Floor: Prolapsus Uteri	528
	Structural and Anatomical Considerations	527
	Symptoms and Physical Signs	527
	Mechanism	528
	Summary of Displacement in Prolapsus	529
	Diagnosis and Differential Diagnosis	530
	Etiology	530
	Nature	530
	Treatment, by Pessaries	532
	by Operation	534
	Repair of Perineum	534
	Repair of Perineum and Paring of Posterior Vaginal Wall	535
	Making Raw Surface on Anterior Vaginal Wall	537
	Making Raw Surface on both Walls, etc.	538
	Vaginal Enterocele	538
	Treatment	539

SECTION VIII. DISTURBANCES OF MENSTRUAL FUNCTION.		PAGE
CHAP. XLVIII.	Amenorrhœa	542
	Local Causes	542
	Constitutional Causes	542
	Menorrhagia	544
	Dysmenorrhœa	545
	Varieties	546
	Treatment	548
SECTION IX. DISTURBANCES OF REPRODUCTIVE FUNCTION.		
CHAP. XLIX.	Sterility	550
	Abortion	551
	Retroflexion of the Gravid Uterus	553
CHAP. L.	Extra-uterine Gestation	555
	Pathology	555
	Etiology	558
	Symptoms and Diagnosis	559
	Progress and Termination	561
	Treatment	561
	Case of	562
SECTION X. AFFECTIONS OF BLADDER AND RECTUM.		
CHAP. LI.	The Bladder	568
	Anatomy and Physiology	568
	Exploration by Catheter and Sound	570
	Finger and Speculum	571
	Catheterisation of Ureter	574
CHAP. LII.	Affections of the Urethra	575
	Neoplasms; Urethral Caruncle	575
	Urethritis	577
	Dilatation and Stricture	577
	Diseases of the Bladder	577
	Displacements	577
	Cystocele	578
	Neoplasms	578
	Cystitis	578
	Calculi and other Foreign Bodies	581
	Functional Diseases	582
CHAP. LIII.	Vesico-vaginal Fistula	585
	Pathological Anatomy and Varieties	585
	Etiology	588
	Symptoms	589
	Diagnosis	589
	Prognosis	590
	Treatment	590
	Operation for Vesico-vaginal Fistula	593
	Obliteration by Cauterisation	603
	Closure of the Vagina: Kolpokleisis	604

CONTENTS.

xxiii

	PAGE
CHAP. LIV. The Rectum	607
Physiology	607
Examination	609
Diseases	609
Displacements of	610
Fissure of the anus	610
Piles	612
Recto-vaginal fistula	613
Coccygodynia	614

APPENDIX.

The Systematic Treatment of Nerve Prostration	615
Seclusion	616
Absolute Rest in Bed	616
Systematic extra Feeding	616
Use of Massage and Electricity	617
Hysteria and Hystero-epilepsy	617
Hysteria	618
Hystero-epilepsy	619
Etiology of Uterine Disease	621
Case-Taking	622
Physical Examination	623
Sources of Gynecological Literature	627
Index of Authors	631
Index of Subjects	633

CLASSIFIED LIST OF ILLUSTRATIONS.

To facilitate study, we have grouped the Illustrations under the following heads :

Anatomy—naked eye. Sectional anatomy. Anatomy—microscopic. Pathology—naked eye. Pathology—microscopic.	Charts of etiology. Gynecological examination. Instruments. Operations.
--	--

ANATOMY—NAKED EYE.

PLATE I. Surface view of abdomen and thorax	facing p. 57
„ III. Distribution of ovarian, uterine and vaginal arteries	„ 65
„ VIII. Erosion and laceration of cervix	„ 284

Fig.	Page	Fig.	Page
1 External genitals	3	36 The rectum inflated, showing sphincters	36
2 External genitals in section	5	48 Diagram of coronal section of pelvis	48
3 Hymen of virgin with vertical slit	6	49 Transverse section of pelvis in line of pyriform muscle	48
4 Hymen of virgin with oval opening	6	50 Schultze's diagram of position of uterus	49
5 Crescentic Hymen	6	53 Contents of female pelvis viewed through pelvic brim	52
6 Outlet of bony pelvis	7	54 Uterus seen through brim, with bladder distended	53
7 Dissection of perineal region	9	55 Diagram of position of uterus, according to distension of bladder	54
8 Diagram of perineal muscles	9	57 Lines of cleavage in pelvic floor	59
9 Muscles of clitoris and bulb	10	59, 61 Diagram of pelvic floor projection	62, 63
10 Oblique coronal section through external genitals	11	62 Venous supply of uterus and vagina	67
11 Transverse section of pelvis	12	63 Diagram of intra-abdominal pressure	74
12 Levator ani and coccygeus	13	64 Outline of figure in genupectoral posture	75
13 Virgin uterus, from front and in section	14	68, 69 Diagram of uterus before and after menstruation	84
14 Multiparous uterus from front and in section	14	154 Nulliparous os uteri	246
15 Diagram of divisions of cervix	16	155 Multiparous os uteri	247
16, 17, 18 Sections of uterus at various levels	17	319 Sacral segment of the pelvic floor	518
22 Fallopian tube, ovary and parovarium	22	348 Front view of pelvis and tumour	563
25 Vagina on vertical section	26	350 Bladder in systole	569
26 Anterior vaginal wall and multiparous cervix	27	360 Normal relations of the cervix, the ureters, and the urethra	587
27 Diagram of vertical mesial section of pelvis	28	395 Direction of rectum and of anus in relation to intra-abdominal pressure	608
28 Horizontal section of pelvic floor at pelvic outlet	29		
31 Urethral glands of Skene	31		
33 Course of the ureters	33		

SECTIONAL ANATOMY.

PLATE II. Coronal section of female cadaver—frozen	facing p. 56
„ IX. Vertical mesial section of pelvis with extra-uterine gestation—frozen	„ 563

CLASSIFIED LIST OF ILLUSTRATIONS.

xxv

Fig.	Page	Fig.	Page
34		45	
Vertical mesial section, showing Y-shape of bladder—frozen	34	Lateral sagittal section—spirit hardened	43
35		46	
Vertical section of pelvis, with bladder contracted—frozen	35	Transverse section at level of hip-joints—frozen	44
38		47	
Vertical mesial section showing peritoneum—frozen	40, 41	Coronal section of pelvis—frozen	45
39		51	
Vertical mesial section, with bladder contracted, showing peritoneum—frozen	40, 41	Vertical mesial section with bladder distended	50
40		52	
Vertical mesial section, with uterus drawn back, showing peritoneum—spirit hardened	40, 41	Vertical mesial section with bladder contracted—frozen	51
41		56	
Vertical mesial section with peritoneum dipping abnormally deep—frozen	40, 41	Vertical mesial section, during parturition—frozen	58
42		65	
Vertical mesial section, at end of pregnancy—frozen	40, 41	Vertical mesial section of pelvis in genupectoral posture—frozen	78
43		274	
Vertical mesial section, during parturition—frozen	40, 41	Vertical mesial section of pelvis from a case of carcinoma uteri—spirit hardened	434
44		275	
Vertical mesial section, with bladder distended—frozen	40, 41	Vertical mesial section of pelvis from a case of carcinoma uteri et vaginae—spirit hardened	435

ANATOMY—MICROSCOPIC.

PLATE VII. Section of Ovary and Wolffian body of a fetal lamb	facing p. 204
„ „ Connective tissue sprouting up and surrounding the germ epithelium	„ „

Fig.	Page	Fig.	Page
19		30	
Course of glands of mucous membrane of uterus	19	Transverse section of urethra	31
20		32	
Vertical section through mucous membrane of uterus	19	Epithelial cells from vesical mucous membrane	32
21		37	
Vertical section through mucous membrane of cervix	20	Perpendicular section through end of rectum	37
23		70	
Section of ovary of cat	23	Mucous membrane of menstruating uterus	85
24		348a	
Section of human ovary	24	Microscopic section of upper part of wall of gestation sac	564
29			
Section of posterior wall of bladder and anterior of vagina	29		

PATHOLOGY—NAKED EYE.

PLATE IX. (with fig. 348) Extra-uterine gestation	facing p. 563
---	---------------

Fig.	Page	Fig.	Page
101		142	
Cervical canal dilated by a poly-pus	128	Uterus septus	233
119		143	
Uterus retroverted and fixed with adhesions	159	Infantile uterus	233
120		144	
Retro-uterine hæmatocele, with pouch of Douglas obliterated	167	Primary atrophy of uterus	234
121		145	
Retro-uterine hæmatocele, with pouch of Douglas not previously obliterated	167	Fætation in detached horn of uterus	237
122		146	
Ante- and retro-uterine blood effusion	169	Uterus septus, puerperal	238
123		147	
Free blood in pouch of Douglas	170	Conical vaginal portion	241
124		148	
Hydrops Tube	178	Stenosis of os with dilated cervical canal	242
137, 138		149	
Rudimentary uterus	230, 231	Normal and pinhole os in speculum	243
139		158	
Uterus bipartitus	231	Uterus and ovaries from a case of superinvolution	251
140		160, 161	
Uterus unicornis	232	Hypertrophied vaginal portion of cervix	255, 256
141		169	
Uterus bicornis	232	Hypertrophy of intermediate portion of cervix	263

Fig.	Page	Fig.	Page
170 Hypertrophy of supra-vaginal portion of cervix	263	270 Carcinomatous nodule	432
171 Prolapsus uteri with cervical elongation	264	273 Carcinoma of cervix uteri producing fistula	434
173 Single laceration of cervix	267	274 Vertical mesial section of pelvis in carcinoma uteri	434
174 Multiple or stellate laceration of cervix	268	275 Vertical mesial section of pelvis in carcinoma vaginae et uteri	435
194 Diagrammatic scheme of flexions	316	278 Cauliflower excrescence growing from cervix uteri	443
195 Diagrammatic scheme of versions	316	280 Carcinoma of the cervix leading to occlusion of os uteri	448
196 Antelexion with stenosis at os externum	319	281 Mode of the spreading of carcinoma	453
197 Diagram to show antelexion produced by cicatrization of utero-sacral ligaments	320	286 Cervix uteri amputated for cauliflower excrescence of posterior lip	459
198 Myoma of anterior wall	325	291 Carcinoma of the body of the uterus	469
206 Uterus retroverted and bound back by peritonic adhesions	335	292 Sarcoma uteri with tumours in the vagina	472
207 Extreme retroflexion of uterus	338	294 Section of sarcoma uteri, showing fibroid nodules	473
208 Congenital retroflexion	339	295 Sarcoma uteri invading Fallopian tubes	474
221 Inversion of uterus	359	298 Atresia vaginae, seen from behind	481
222 Inversion of uterus + inversion of vagina, caused by a small sub-mucous fibroid	361	299 Case of double atresia	482
223 Inversion of uterus	362	300 Atresia hymenalis	485
236 Section of a large fibroid tumour, fibres round several centres	377	301 Atresia vaginae—lower third	485
237 Section of a fibroid tumour showing wavy bundles of fibrous tissue	378	302 Atresia of cervix at os externum	486
238 Section of a fibroid tumour showing spaces between bundles of fibrous tissue	378	303 Atresia of cervix at os internum	486
239 Pediculated sub-peritoneal fibroid tumour	379	306 Atresia in a septate uterus	491
240 Uterus with elongated cavity due to presence of several fibroids	380	311 to 315 Normal development of external organs of generation	506
241 Interstitial fibroid tumour	381	316, 317 Spurious herniaphroditism	508
242 Submucous fibroid tumour projecting into uterine cavity	382	318 Abscess of the Bartholinian gland	513
243 Pediculated submucous fibroid in process of extrusion	383	320 Central rupture of the perineum	519
244 Cervical polypus having apparently two pedicles	385	326 Hernial nature of prolapsus uteri	531
246 Uterus containing large fibroid tumour	389	340 Posterior vaginal interocele	539
247 Case of two-and-a-half months' pregnancy associated with two large fibroids	394	341 Dysmennorrhœal membrane as seen under water	547
260 Large three-lobed fibroid from the fundus	414	342 Dysmennorrhœal membrane laid open	548
261 Fibrous polypus laid open to show its identity in structure with a fibroid tumour	417	343 Retroflexion of the gravid uterus producing distension of the bladder	554
262 Intra-uterine submucous fibroid becoming vaginal	418	344 Gestation in detached left horn	556
263 Submucous fibroid which has come to lie wholly in the vagina	419	345 Interstitial gestation	557
264 Group of mucous polypi growing in the cervix uteri	420	346 Fallopian-tube gestation	558
266 Pediculated submucous fibroid	423	347 Section of a uterus in a tubo-abdominal pregnancy of seven months' duration	559
267 Submucous fibroid which simulated inversion	425	349 Extra-uterine pregnancy of seven months' duration	565
		355 Caruncle at urethral orifice	576
		356a Large stone extracted by vaginal lithotomy	582
		357 Chief varieties of urinary fistula	586
		358, 359 Deep and superficial vesico-vaginal fistula	586
		361 Relation of peritoneum to a fistula	588
		396 Rectocele	610

PATHOLOGY—MICROSCOPIC.

PLATES VI. { Foulis cells, from ascitic fluid in malignant tumour } facing p. 200
 and VII. { of ovary } „ p. 204
 PLATE VIII. Section of cervix with simple erosion „ p. 284

Fig.	Page	Fig.	Page
126 Cellular bodies—the source of ovarian cysts	198	193 Section of uterine tissue in chronic metritis	307
127 Diseased blood-vessels in ovary	199	265 Section of a mucous polypus of the cervix	420
128 Epithelial tubes—the source of ovarian cysts	200	271 Section of a portion of cervix uteri with carcinomatous nodule	432
129 Papillæ of ovarian cyst wall	201	272 Section of a flat canceroid of the cervix	433
130 Colloid degeneration of ovarian stroma	202	279 Scraping from carcinoma of the cervix	444
131 Cells from ovarian fluid	203	293 Section of mucous membrane in sarcoma	473
179 Papillary form of erosion	278	296 Scraping from a fibroid tumour	477
180 Follicular form of erosion	279	297 Scraping from a spindle-celled sarcoma	477
181 True ulceration of the cervix	280	307 Granular vaginitis—acute form	494
186 Hypertrophied glands in endometritis	290	308 Granular vaginitis—chronic form	494
187 Mucous membrane in endometritis fungosa	291	309 Colpitis emphysematosa	494
188 Dilated blood-vessels in endometritis	291	310 Section of vaginal cyst	501
189 Granulation from endometritis composed of embryonic tissue	292		

CHARTS OF ETIOLOGY.

Fig.	Page	Fig.	Page
245 Influence of age on development of fibroid tumour	387	277 Influence of age on development of carcinoma	439
276 Influence of sex on development of carcinoma	437		

GYNECOLOGICAL EXAMINATION.

PLATE IV. Female cadaver in semiprone posture facing p. 109
 „ V. Female cadaver in semiprone posture, with Sims' speculum passed and uterus drawn down with volsella „ p. 110

Fig.	Page	Fig.	Page
66 Anteversion produced by digital pressure	79	97 Sound combined with Bimanual	123
67 Retroversion produced by digital pressure	80	102 Introduction of tangle tents	129
71, 72 Right hand in Bimanual	97	132 Area of dullness in ovarian tumour and ascites	209
73 Left hand in Bimanual	98	198 Diagnosis between fibroid and antelexion	325
74 Displacement in pelvic floor and abdominal wall in Bimanual	100	209 Diagnosis of retroflexion by Bimanual	343
75 Right hand in abdomino-recto-vaginal examination	102	225, 226, 227 Diagnosis of inversion and polypus in vagina	365
78 Uterus drawn down by volsella	107	228, 229 Diagnosis of partial inversion and intra-uterine polypus	367
84 Method of holding Sims' speculum	110	230 Uterine polypus + Inversion	367
92 First stage of passing sound	117	248 Sound used to detect pediculated submucous fibroid	395
93 Second stage of passing sound, in retroverted uterus	118	300, 303 Diagnosis of various forms of atresia	485, 486
94 Proper contrasted with improper method of turning the sound	119	354 Catheterisation of ureters	574
95 Second stage of passing sound with uterus to the front	119	398-400 Diagrams for case-taking	624, 625
96 Sound arrested in antelexion	120		

INSTRUMENTS.

Fig.	Page	Fig.	Page
58 Hand holding pessary	61	205 Thomas' anteversion pessary	384
60 Callipers for measuring pelvic floor projection	62	213 Hodge pessary	351
76 A. R. Simpson's volsella	105	214 Albert Smith pessary	351
77 Hart's volsella	106	215 Side view of Albert Smith pessary	351
79 Sims' tenaculum	107	218 Hodge pessary <i>in situ, ad naturam</i>	354
80, 81 Sims' speculum	109	219 Position and support of pessary illustrated	355
82 Bozeman's speculum	109	220 Position and action of pessary in vagina	356
83 Batten's speculum	109	249 A. R. Simpson's nail-curette for fibroids	402
85 Ferguson's speculum	111	250 Thomas' spoon-saw	402
86, 87 Neugebauer's speculum	112	251 Sims' enucleator	402
88 Barnes' crescent speculum	113	252 Sir J. Y. Simpson's volsella for intra-uterine fibroids	404
89 Cusco's speculum	113	255 Thomas' clamp for pedicle of fibroids	408
90 Sir J. Y. Simpson's sound	115	256 Péan's curved needle for ligaturing pedicle of fibroids	408
91 A. R. Simpson's sound	116	257 Cintrat's serre-noeud	409
98 Laminaria tents before and after expansion	126	258 Kaltenbach's needle for elastic ligature	410
99 Tupelo tents before and after expansion	127	268 Forceps with catch for mucous polypi	427
100 Tupelo tent expanded	127	269 Sir J. Y. Simpson's polyptome	428
103 Tait's dilators	130	282 Simon's sharp spoon	455
104 Hank's dilators	131	283 Chain ecraseur	456
106 Recamier's curette	132	304 Perforated glass plug used after operation for atresia vaginae	489
106 Simon's spoon	133	305 Breisky's instruments for operating in atresia with retention	490
107 Thomas' curette, modified by A. R. Simpson	133	309a Henderson's vaginal spatulae	496
108 Sims' curette	133	327 Greenhalgh's pessary with transverse bars	532
109 Bozeman's scissors	135	328 Ring pessary with diaphragm	532
110 Kuchenmeister's scissors	136	329 Simple ring pessary	532
111 Hart's scissors	136	330 Ring pessary <i>in situ</i>	533
112 Emmet's needles	137	331 Pessary for prolapsus	533
113 Needle-holder	137	332 Zwanck's pessary	533
114 Higginson's syringe	138	351, 352 Simon's urethral specula	572
115 Vaginal douche	139	353 Skene's urethral specula	573
116 Paquelin's cautery	140	356 Skene - Goodman self-retaining catheter	580
117 Cones for cautery	141	365, 366, 367 Knives for operating on fistulae	594
118 Chloroform drop-cork	144	368 Sponge-holder	594
125 Mundé's pessary for prolapsed ovary	187	369, 370 Startin's tubular needle and method of use	595
133 Spencer Wells' trocar	218	373, 374 Bozeman's fork and method of use	597
134 Ordinary trocar	218	378 Bozeman's suture adjuster	599
135 Nélaton's forceps	218	379, 380 Coghill's wire-twister and method of use	599
136 Spencer Wells' clamp	219		
150 Schultze's dilator	244		
151 Marion Sims' dilator	245		
152 Sir J. Y. Simpson's metrotome	245		
157 Glass plug for cervical canal	248		
159 Galvanic intra-uterine stem	252		
168 Rake for removing sutures	261		
199 Intra-uterine stem pessary made of copper	327		
200 Greenhalgh's intra-uterine stem	328		
202 Graily Hewitt's cradle-pessary	333		
203 Gehrung's anteversion pessary	333		
204 Gehrung's anteversion pessary as placed by Mundé	334		

OPERATIONS.

Fig.	Page	Fig.	Page
153 Incision made by metrotome	246	164 A. R. Simpson's method of amputating the cervix	259
156 Bilateral division of cervix with Kuchenmeister's scissors	247	165, 166 Introduction of sutures in amputation of cervix	260
162 Sims' method of passing the sutures after amputation of cervix	257	167 Hegar's method of passing the sutures	260
163 Marckwald's method of splitting and stitching the cervix in amputation	258	172 Amputation of hypertrophied cervix in prolapsus uteri	265

CLASSIFIED LIST OF ILLUSTRATIONS.

xxix

Fig.		Page	Fig.		Page
175	Emmet's operation — denuded surface	273	288	Sims' method of removing carcinomatous cervix	462
176	Denuded surface as made by Emmet	274	289, 290	Freund's extirpation of the uterus	464
177	Emmet's operation—introduction of sutures	275	321-323	A. R. Simpson's operation for complete rupture of the perineum	523, 524
178	Emmet's operation — tying of sutures	275	324	Position of sutures in above, as seen in section	524
182	Forceps dressed with cotton wadding for applications to cervical canal	286	325	Hildebrandt's method of passing sutures in repair of perineum	525
183	Barnes' speculum for introducing vaginal tampons	286	329	Introduction of ring pessary	532
184, 185	Schroeder's excision of cervical mucous membrane	287	333-336	Operation for repair of perineum	534, 535, 536
190	Sound dressed with wadding for intra-uterine applications	299	337	Various forms of raw surface made on posterior vaginal wall in operation for prolapsus	536
191	Curetting of uterus	300	338	Raw surface as made by Martin	537
192	Sir J. Y. Simpson's porte-caustique	301	339	Raw surface on anterior vaginal wall as made by Sims	537
201	Sims' division of cervix, lines of incision	329	358	Closure of superficial vesico-vaginal fistula	586
210	Reposition of retroflexed uterus by finger in rectum	346	359	Closure of deep vesico-vaginal fistula	586
211	Reposition of retroverted uterus with the sound	348	361	Relations of peritoneum to extensive fistula	588
212	Reposition of uterus with volsella, and finger in rectum	350	362	Simon's method of paring edges of fistula	591
216	Introduction of pessary	352	363	Silk sutures passed to close fistula	592
217	Pessary carried on by finger	353	364	American and German methods of paring edges of fistula contrasted	592
224	Drawing down of inverted uterus with tape-noose and lines of incision for Barnes' operation	365	371	Knife transfixing edges of a fistula	596
231	Reposition of inverted uterus with the hand	370	372	Fistula closed with sutures	596
232	Reposition of inverted uterus with White's reposer	371	373, 374	Fork used to prevent sutures from cutting	597
233	Reposition of inverted uterus with finger in bladder and rectum	372	375	Counter-pressure made with blunt hook	597
234	Emmet's method of retaining partially replaced uterus with sutures	372	376, 380	Method of twisting sutures	598, 599
235	Cup with stem for gradual reduction of inversion	373	377	Mode of tying wire sutures	598
253	Schroeder's amputation of uterus at level of os internum	407	381, 382	Bozeman's method of fixing sutures with plates and shot	599
254	Ligature of uterine stump treated intra-peritoneally	407	383, 392	Removal of sutures	599, 603
259	Extra-peritoneal treatment, with elastic ligature, of pedicle of fibroids	411	384, 385	Closure of a four-cornered fistula	600
284	Wire ecraseur used to amputate cervix	457	386	Anterior lip of cervix used to close fistula	600
285	Chain ecraseur applied to cervix in amputation	458	387	Cervix split and stitched in closure of a fistula	601
287	Schroeder's supra-vaginal amputation of cervix	461	388	Obliteration of cervical canal for vesico-uterine fistula	602
			389	Operation for atresia urethræ in fistula	602
			390, 391	Sims' stationary catheter	602
			393, 394	Simon's operation for closure of vagina: kolpokleisis	605, 606
			397	Division of base of an anal fissure	611

PART I.

ANATOMY, PHYSIOLOGY, AND METHODS OF EXAMINATION OF THE FEMALE PELVIC ORGANS.

Section I. Anatomy and Physiology of the Female Pelvic Organs.

„ II. Physical Examination of the Female Pelvic Organs.



SECTION I.

ANATOMY AND PHYSIOLOGY OF THE FEMALE PELVIC ORGANS.

IN order to give a comprehensive idea of the Anatomy and Physiology of the Female Pelvic Organs, it will be advisable to consider them in the following manner:—

CHAPTER I. (1.) The External Genitals as observed clinically. (2.) The Pelvic Floor and Organs resting on it considered as a whole. (3.) The Pelvis considered in detail as follows:—Pelvic Floor dissected from below; Uterus, Fallopian Tubes, and Ovaries; Vagina; Bladder; Rectum and Perineal Body; Peritoneum and Connective Tissue.

CHAPTER II. The position of the Uterus and its Annexa, and the relation of the superjacent Viscera.

CHAPTER III. The Structural Anatomy of the Pelvic Floor; Pelvic Floor Projection.

CHAPTER IV. The Blood-vessels, Lymphatics, and Nerves of the Pelvis. Development of Pelvic Organs.

CHAPTER V. Physics of the Abdomen and Pelvis, with special reference to the Semiprone and Genupectoral Postures.

CHAPTER VI. Ovulation and Menstruation.

CHAPTER I.

LITERATURE.

- EXTERNAL GENITALS.** *Budin*—Recherches sur l'hymen et l'orifice vaginal: Paris 1881. *Matthews Duncan*—Papers on the Female Perineum: Churchill, London, 1880. *F. P. Foster*—A Contribution to the Topographical Anatomy of the Uterus and its Surroundings: Am. J. of Obst., Vol. XIII., p. 30. *Garrigues*—The Obstetric Treatment of the Perineum: Am. J. of Obst., Vol. XIII., p. 231. *Henle*—Handbuch der Eingeweidelehre des Menschen: Braunschweig, 1866. *Klein*—The External Genitals of the Male and Female, by E. Klein: Stricker's Manual of Human and Comparative Histology, Vol. II. (Sydenham Soc. Tr., 1872). *Klein and Smith*—Atlas of Histology: Smith, Elder, & Co., London, 1880.
- MUSCLES OF PELVIC FLOOR.** *Cunningham*—The Dissector's Guide; Abdomen: Mac-lachlan & Stewart, Edinburgh, 1880. *Henle*—op. cit. *Luschka*—Die Musculatur am Boden des weiblichen Beckens: Wien, 1861. *Savage*—Female Pelvic Organs, 2d Edition: London, 1870. *Turner*—An Introduction to Human Anatomy: A. & C. Black.
- UTERUS, AND ANNEXA; VAGINA.** *Barnes*—The Diseases of Women; London, 1878. *Breisky*—Die Krankheiten der Vagina: Billroth's Handbuch, Stuttgart, 1879. *Cruveilhier*—Traité d'Anatomie Descriptive: Paris, 1871. *Engelmann*—The Mucous Membrane of the Uterus: Am. J. of Obst., Vol. VIII., p. 30. *Farre*—The Uterus and its Appendages: Todd's Cyclopædia, Vol. V. *Hart*—Structural Anatomy of Female Pelvic Floor: Mac-lachlan & Stewart, 1880. *Henle*—op. cit. *Hennig*—Der Katarrh der inneren weiblichen Geschlechtstheile: Leipzig, 1862. *Mundt*—Prolapse of the Ovaries: American Gynecological Transactions, Vol. IV., 1879. *Rainey*—On the Structure and Use of the Ligamentum Rotundum Uteri: Lond. Phil. Tr., 1880, p. 515. *Ruge and Veit*—Zur Pathologie der Vaginal Portion: Stuttgart, 1878. *Sappey*—Traité d'Anatomie Descriptive: Paris, 1873. *Schroeder*—Handbuch der Krankheiten der weiblichen Geschlechtsorgane: Leipzig, 1879. *Taylor*—American Journal of Medical Science, Vol. LXXX., p. 126. *Turner*—op. cit.
- BLADDER.** *H. J. Garrigues*—Remarks on Gastro-Elytrotomy: Am. Gynecol. Tr., Vol. III., p. 212. *Skene*—Diseases of the Bladder and Urethra: New York, 1870. The Anatomy and Pathology of Two Important Glands in the Female Urethra: Am. J. of Obst., Vol. XIII. *Winckel*—Die Krankheiten der weiblichen Harnröhre und Blase: Billroth's Handbuch, Stuttgart, 1877.
- RECTUM.** *Braune*—Topographisch-anatomischer Atlas, Zweite Auflage: Leipzig, Veit and Co., 1872. *Chadwick*—The Function of the Anal Sphincters so-called: Am. Gyn. Tr., Vol. II., p. 43. *Pirogoff*—Anatome Topographica, sectionibus per corpus humanum congelatum: Petropoli, 1859. *Ruedinger*—Topographisch-Chirurgische Anatomie des Menschen: Vierte Abtheilung.
- PERINEAL BODY.** *Hart, Henle, Savage*, op. cit. *Ranney*—The Female Perineum: New York Medical Journal, Vol. XXXVI., Nos. 1 and 2. *T. G. Thomas*—The Female Perineum; its Anatomy, Physiology, and Pathology: Am. J. of Obst., Vol. XIII., p. 312.
- PERITONEUM AND CELLULAR TISSUE.** *Bandl*—Die Krankheiten der Tuben, der Ligamente, und des Beckenperitonäums: Stuttgart, 1879. *Barnes*—St. George's Hospital Reports, Vol. VII., p. 57. *Freund*—Anatomische Lehrmittel zur Gynäkologie: Beiträge zur Geburtshülfe und Gynäkologie. Herausgegeben von der Gesellschaft für Geburtshülfe in Berlin. IV. Band, 1 Heft. S. 58. *Gutrin*—Sur la Structure des Ligaments larges: Comptes Rendus, 1879, 1364. *Le Bec*—Contribution à l'étude des ligaments larges (au point de vue de l'anatomie et de la pathologie): Gaz. Hebd.,

15 Avril 1881. *De Sittly*—Gynecologie : Paris, 1880. *Spiegelberg*—Remarks upon Exudations in the Neighbourhood of the Female Genital Canals : German Clinical Lectures (New Syd. Soc. Tr.), p. 169. *Brawne, Cunningham, Hart, Pirogoff*, op. cit.

(I.) EXTERNAL GENITALS AS OBSERVED CLINICALLY.

UNDER the term external genitals are comprised the structures known as Labia Majora, Fourchette, Labia Minora, Clitoris with its prepuce, Vestibule, and Fossa Navicularis. For clinical convenience the urethral

External
Genitals.

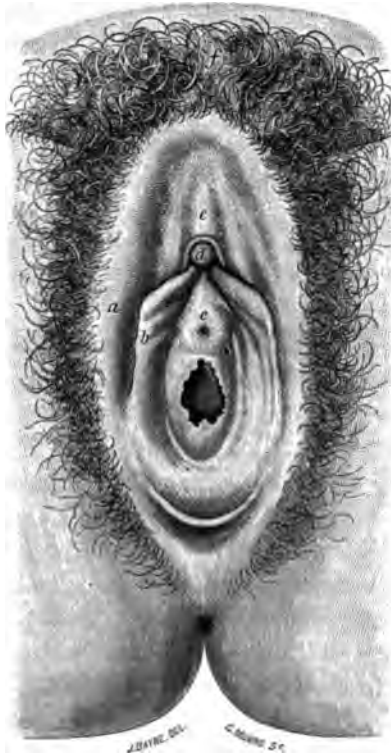

FIG. 1.

EXTERNAL GENITALS OF VIRGIN, with Diaphragmatic Hymen. The Labia Majora and Minora are drawn apart, and the prepuce drawn back. The cadaver is in the lithotomy posture (modified from *Sappey*).

a Labium majus; b Labium minus; c Præputium clitoridis; d Glans clitoridis; e Vestibule just above urethral orifice; f Mons Veneris. (†)

orifice and hymen also are described with these; although the urethral orifice belongs to the urinary system, and the hymen separates anatomically the external genitals (vulva) from the vagina.

The *Labia Majora* (fig. 1. a) are two thick folds of hair-clad skin, *Labia Majora*.

extending from the symphysis pubis backwards between the thighs, and meeting each other posteriorly in the middle line about 2.7 cm. (1 inch) in front of the anus. Each labium has an outer and inner surface, and consists of a thick fold of skin enclosing a quantity of fat, blood-vessels, and dartos. Superiorly, where they are best developed, they form by their junction—*anterior commissure*—the structure known as the *mons veneris* (*vide* Plate I.); while posteriorly they are a mere fold of skin known as the *Fourchette* or *posterior commissure*. The fat and connective tissue are therefore almost entirely wanting at the *fourchette*, which is not a distinct structure but is simply the posterior junction of the thinned-out *labia majora*. Both *labia* are, in the adult, covered with *crisp hair* which is most abundant over the *mons veneris* and outer surface but very much less on the inner.

Labia
Minora.

The *Labia Minora* (fig. 1, *b*) are two small oblique folds of skin, one on the inner surface of each *labium majus*. Posteriorly they blend insensibly with the *labium majus* at about its middle, while anteriorly they converge and each divides into two small branches—an upper and a lower. The upper branches meet to form the *prepuce* of the *clitoris* (fig. 1, *c*), while the lower in a similar way form its *suspensory ligament*. As a rule the *labia minora* do not, in the adult, project beyond the *labia majora*. *Sebaceous glands* are present on both *labia*.

Clitoris.

The *Clitoris*, covered by its *prepuce*, lies in the middle line and at the apex of the smooth piece of mucous membrane known as the *vestibule*. Only that part analogous to the *glans penis* is seen (fig. 1, *d*). The *clitoris* proper consists of two *crura* which arise from the *rami* of the *ischium* and *pubis* and unite superiorly to form the body of the *clitoris*, which lies beneath the mucous membrane. The *glans clitoridis* is not directly continuous with the body, but joins it through the *pars intermedia* of the *bulb* (*vide post*, p. 10).

Vestibule.

The *Vestibule* (fig. 1, *e*) is a triangular smooth mucous surface bounded superiorly by the *clitoris*, laterally by the *labia minora*, and inferiorly by the upper margin of the *vaginal orifice*. In the middle line, at its base, the dimple of the *urethral orifice* can be distinctly felt 2-2.5 cm. (1 inch) in front of *fourchette*. Small depressions and mucous glands open on its surface.

Vaginal
Orifice.

The *Vaginal Orifice* lies in the middle line between the base of the *vestibule* and the *fossa navicularis*. Its orifice is guarded by the *hymen*, a thin fold of mucous membrane enclosing some connective tissue, blood-vessels, and nerves (!) The *hymen* may be *crescentic* in shape,

attached to the posterior margin of the vaginal orifice and with free edge towards the base of the vestibule (figs. 2 and 5); or diaphragmatic, attached all round the vaginal orifice but with a small hole (figs. 1 and 4) or vertical slit (fig. 3) in it. Sometimes it is not so perforated, constituting a pathological condition.

Fossa Navicularis.—Normally, the inner aspect of the fourchette is ^{Fossa} in contact with the outer and lower surface of the hymen. When the ^{Navicularis.} fourchette is pulled down by the finger, a boat-shaped cavity is made—the fossa navicularis. Its posterior boundary is, therefore, the inner aspect of the fourchette; its anterior is the posterior aspect of the hymen. These two are in contact unless artificially separated (fig. 2).

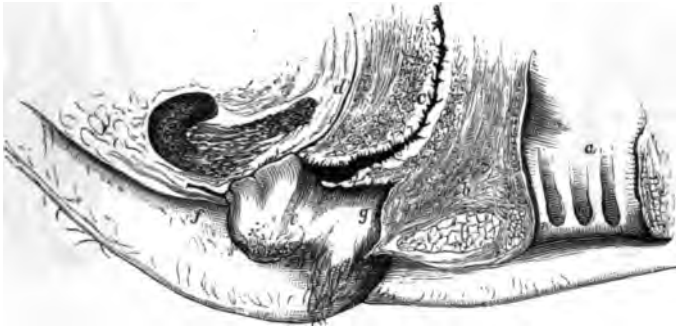

FIG. 2.

VERTICAL MESIAL SECTION OF EXTERNAL GENITALS (*Henle*).

a Anus; *b* Perineal body; *c* Vagina; *d* Urethra; *e* Labium Minus; *f* Prepuce of Clitoris; *g* Fossa Navicularis, with Hymen in front and Fourchette behind. (†)

From behind forwards, in the female ano-vulvar region there lie in the middle line the following structures:—

- (1.) Anus.
- (2.) Skin over base of Perineal Body.
- (3.) Fourchette.
- (4.) Fossa Navicularis.
- (5.) Vaginal orifice, with Hymen or its remains.
- (6.) Urethral orifice.
- (7.) Vestibule.
- (8.) Clitoris with its prepuce.

Laterally we have the labia majora and minora.

The following points should be carefully noted. In the nude erect female only the mons veneris is seen, and the labia majora and minora lie in a plane nearly parallel to the horizon. The well-developed labia

majora have their inner surfaces always in contact, and are only slightly separated by the widest divergence of the knees. The labia minora are always in contact, and require to be artificially separated in order to see their inner surfaces. The fossa navicularis only exists when artificially opened up. Therefore, to see the external genitals fully, the labia must be separated and the prepuce drawn back.

A line running as follows separates mucous membrane from skin. Starting from the base of the inner aspect of the right labium minus, it passes *down* beside the base of the outer aspect of the hymen, *up* along the base of the inner aspect of the left labium minus, *in* beneath the prepuce of the clitoris, and *down* to where it first started from.

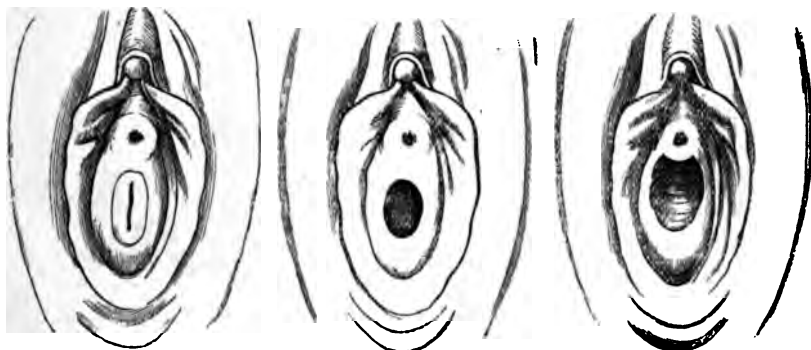


FIG. 3.

HYMEN of VIRGIN, with Vertical Slit. (†)

FIG. 4.

HYMEN with oval opening. (†)

FIG. 5.

CRESCENTIC HYMEN. (‡)

The vulvar slit is sagittal, and lies in the middle line between the labia majora and minora.

Hymen. The vaginal orifice is transverse, only exists when artificially made, and is anatomically defined by the hymen which separates the external genitals from the internal genitals. The sharp line between skin and mucous membrane can be distinctly seen on the living woman. The labia minora are skin, thin and fine, and not mucous membrane as often alleged.

The following measurements by Foster are useful for reference:—

	Tip of Coccyx to Anus.	Anus to Fourchette.
Average distance in nulliparae, . . .	4.5 cm.	2.7 cm.
" " multiparae, . . .	4.7 cm.	2.5 cm.
Meatus urinarius, 2—2.5 cm. from fourchette, in nulliparae; 2—3.1 cm., in women who have borne children.		

The virginal vaginal orifice should have the appearances shown at figs. 1, 3, 4, and 5, and the free edge of the hymen should be intact.

In a healthy woman who has experienced complete coitus, the hymen is torn or often only stretched. It admits two fingers without pain. In a woman who has borne full-time children, the vaginal orifice is always torn, although the fourchette and all behind it may be intact. The *carunculæ myrtiformes* are probably the remains of the hymen. In addition, the passage of the child's head may cause tears of the posterior vaginal wall, perineal body, or even anterior wall of rectum.

(2.) THE PELVIC FLOOR AND ORGANS RESTING ON IT
CONSIDERED AS A WHOLE.

The outlet of the bony female pelvis is filled in by what is generally described as the 'soft parts.' This term, however, should not be

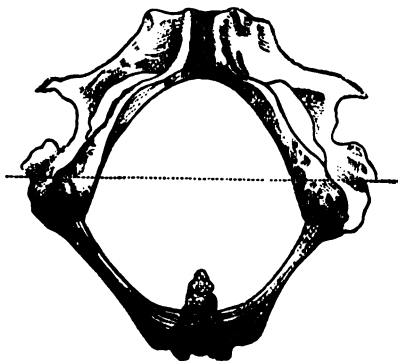


FIG. 6.
BONY PELVIC OUTLET, with transverse line showing Rectal and Urethral Triangles
(D. J. Cunningham). (4)

employed, as it is misleading, especially in scientific obstetrics. It is better named the pelvic floor or pelvic diaphragm.

The pelvic floor is a thick fleshy elastic layer, dovetailed all round to the bony pelvic outlet (fig. 6). It may be considered as an ^{Pelvic} Floor. irregularly-edged segment of a hollow sphere, with an outer *skin* aspect and an inner *peritoneal* one. On the outer *skin* aspect lie the external genitals already described. On the inner *peritoneal* surface we have the organ known as the uterus, and its appendages the Fallopian tubes and ovaries. The vagina runs, in the erect female, at an angle of about 60° to the horizon from the vaginal orifice upwards to the mouth of the womb, as a transverse slit in the pelvic diaphragm. In front of the vagina lies the bladder, while behind it the rectum is placed; these

structures, along with muscles, connective tissue, blood-vessels, nerves, and lymphatics, making up the pelvic diaphragm.

Figure 1 shows, accordingly, the pelvic floor seen from its convex, skin aspect; fig. 53 gives it and the organs resting on it as viewed from its concave, peritoneal side; while fig. 34 displays it as seen in sagittal mesial section.

(3.) THE PELVIS CONSIDERED IN DETAIL.

PELVIC FLOOR DISSECTED FROM BELOW.

If a female cadaver be placed in the Lithotomy posture and a transverse line drawn just in front of the ischial tuberosities, the perineal region will be divided into a posterior rectal triangle and an anterior urethral one (fig. 6). The former contains the anus, the latter the external genitals.

The fascia of the pelvic floor and its relations demand a few words here.

- (1.) *The superficial fascia.*
- (2.) *The deep layer of the superficial fascia.*
- (3.) *The triangular ligament in two layers.*

(1.) *The superficial fascia* lies beneath the skin, and is simply the continuation over the pelvic floor of the general superficial fascia of the body.

(2.) *The deep layer of the superficial fascia* has the following attachments:—Laterally and above, it is joined to the pubic arch; while posteriorly it passes round the transverse perineal muscles to join the base of the anterior layer of the triangular ligament. If air be injected beneath this deep layer, its passage is limited by the attachments given, and a sac is made—the pudendal sac. Into this sac an inguinal hernia may push its way, and in it the round ligaments of the uterus end.

(3.) *The triangular ligament* consists of two layers of fascia, filling in the pubic arch. They are termed anterior and posterior. The following table may be omitted at present, until the whole anatomy is mastered.

<i>Between skin and superficial fascia.</i>	{	Suppl. hæmorrhoidal vessels and nerves. Suppl. perineal artery and nerve.
<i>Between deep layer of supfl. fascia and anterior layer of triangular ligament.</i>	{	Transversus perinei. Bulbo-cavernosus. Erector clitoridis. Transverse perineal blood-vessels and nerves. Venous plexuses. Bulbs of vagina. Pudendal sacs. Dorsal artery and vein of clitoria.
<i>Between the layers of the triangular ligament.</i> (v. also p. 11.)	{	Compressor urethrae. Vagina—in part. Urethra—in part. Pudic vessels and nerves.

By suitable incisions the skin and superficial fascia can be removed ischiorectal around the anus, and the ischiorectal fossa defined. This is a small pyramidal cavity on each side of the rectum, bounded externally by the Fossa.

obturator internus muscle, internally by the levator ani. Its apex is formed by the junction of these muscles, while its base is partially closed in by the transversus perinei and the edge of the gluteus maximus muscle (fig. 7). If the skin and superficial fascia be now removed from the urethral triangle, the following muscles, etc., will be exposed (fig. 7).

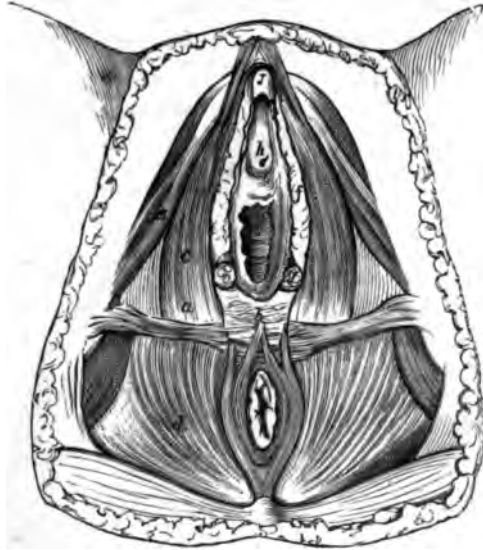


FIG. 7.

DISSECTION OF PERINEAL REGION (*Sarage*).

a is just above Transversus Perinei; *b* Base of Perineal body; *c* Bulbo-cavernosus; *d* lies on Levator Ani and in Ischio-rectal Fossa; *e* Erector Clitoridis; *f* Bulb of Vagina; *g* Bartholinian Gland; *A* Vestibule; *i* Glans Clitoridis. (*h*)

Perineal muscles.—On each side of the vaginal orifice three muscles lie, viz., the bulbocavernosus (fig. 8, *b c*), erector clitoridis or ischiocavernosus (fig. 8, *e c*), and transversus perinei (fig. 8, *t p*).

The *Bulbocavernosi* consist of two muscular slips, one on each side of the vaginal orifice, which spring behind from the perineal body and pass round the vaginal orifice, partially covering the bulb and the vagina (fig. 7, *c*). The anterior end of each slip splits into three portions which end as follows:—

One passes to the under surface of the corpus cavernosum of the clitoris, a second goes to the posterior surface of the bulb, and a third blends

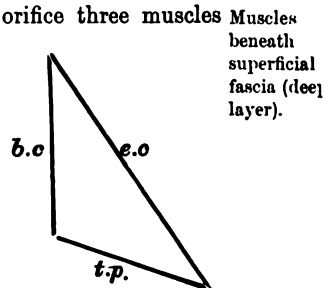


FIG. 8.

with the mucous membrane between the clitoris and urethral orifice (*Henle, v. fig. 9*).

The *Erector Clitoridis* arises from the inside of the ischial tuberosity and becomes inserted into back and sides of the crus clitoridis (*fig. 9, e*).

The *Transversus Perinei* arises from the ramus of the ischium, and passes to the perineal body. It is difficult to define practically in dissection (*fig. 7, a*).

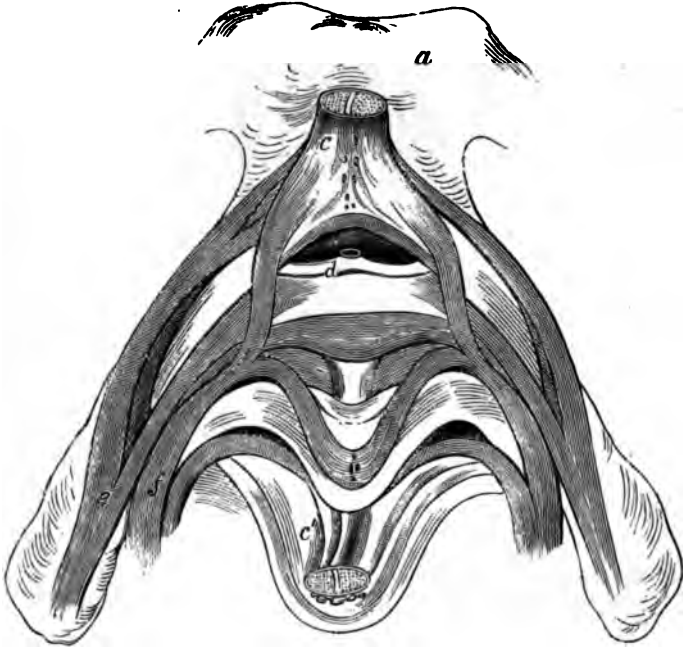

FIG. 9.

a Symphysis Pubis, showing muscles in connection with Clitoris and Bulb. The Clitoris, c, c', is cut across near its point, and thrown down with the vestibular mucous membrane (*Henle*).
 e Erector Clitoridis; f Bulbo-cavernosus with its three insertions; d Venous branch to Dorsal Vein of Clitoris. (†)

Now that these muscles are defined, we are in a position to localise more important structures.

Bulbi
Vaginae.

The *Bulbi Vaginae* (corpora cavernosa urethrae) are small masses of erectile tissue about the size of a bean, lying one on each side of the vaginal orifice and partly under cover of the bulbo-cavernosus muscle. Each rests on the triangular ligament, and has internally the mucous membrane of the vagina; while, as already said, they are partly covered by the bulbo-cavernosus muscle. Anteriorly each blends with

its fellow, and this *pars intermedia* becomes continuous with the clitoris (fig. 7, *f*).

The *Bartholinian Glands* lie one on each side of the vaginal orifice, close to the posterior end of the bulb, and in front of the posterior layer of the triangular ligament (figs. 7, *g*, and 10, *e*). Each has a long duct opening at the sides of the hymen. Ranney asserts that these glands lie behind the posterior layer of the triangular ligament.

Between the lower one-third of the posterior wall of the vagina and the anterior wall of the rectum, is an angular interspace (fig. 2, *b*) filled up by the structure known as the perineal body. This will be more fully described afterwards. At the present stage of the dissection only

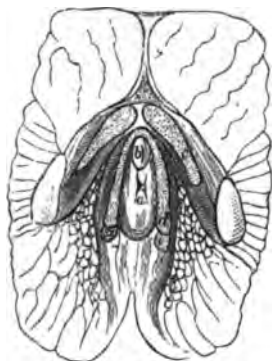


FIG 10.

OBLIQUE SECTION, parallel to the Anterior Pelvic Wall and through the External Genitals (*Henle*).
a Vagina; *b* Urethra; *c* Corpus Caverosum Clitoridis, covered by its Erector; *d* Bulbus Vaginae covered by Bulbo-caverosus Muscle; *e* Bartholinian Gland.

its base is seen, with the following muscles taking origin from or having an insertion into it,—sphincter ani, transversus perinei, bulbo-cavernosus, levator ani (fig. 7).

Between the layers of the triangular ligament lie the urethra, a portion of the vagina, compressor urethrae, dorsal vein of the clitoris, internal pudic vessels and nerves, the artery to bulb, dorsal nerve of clitoris, and Bartholinian glands (*Cunningham*).

The dissection of the urethral triangle has now been considered until the bladder has been exposed as it lies behind the pubis, from which it is separated by a considerable amount of loose fatty tissue. In order to complete the consideration, we have now to take up the muscles not yet described, viz., the levator ani and coccygeus.

THE PELVIC FLOOR DISSECTED FROM ABOVE.

The pelvic floor must now be looked at from its internal concave or peritoneal aspect. If the peritoneum and connective tissue beneath it, with the nerves and blood-vessels, be removed on one side of the pelvis, say the right, the two muscles known as the coccygeus and levator ani will be exposed. These spring from the middle of the inner side of the

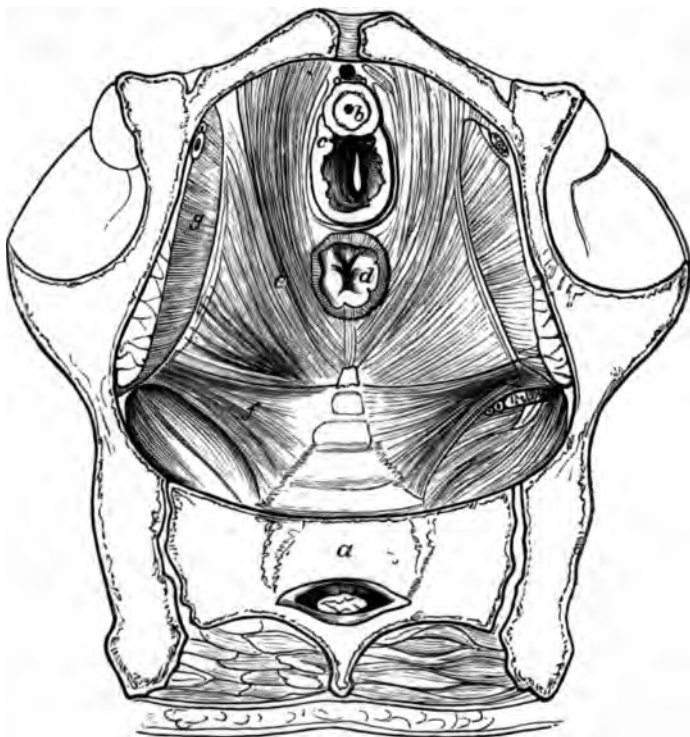


FIG. 11.

DISSECTION OF PELVIS from above (*Savage*). (†)
a Sacrum ; *b* Urethra ; *c* Vagina ; *d* Rectum ; *e* Levator Ani ; *f* Coccygeus ; *g* Obturator internus.

true pelvis and, blending partly directly and partly indirectly with one another, form what may be termed the diaphragmatic muscles of the pelvic floor. If looked at through the pelvic brim, they are seen to form on both sides a concave arrangement analogous to the thoracic diaphragm (fig. 11).

Coccygeus. The *Coccygeus* springs from the spine of the ischium and is inserted

into the side of the lower part of the sacrum, and side and front of coccyx. There are two coccygei, one on each side (figs. 11 and 12).

The *Levator Ani* has an extensive origin. It springs in front from the back of the pubis, from the pelvic fascia (white line) and the spine of the ischium. From this the muscle sweeps downwards and inwards to become attached in the middle line from before backwards as follows,—to the vagina, the rectum, its fellow of the opposite side, and finally to the tip of the coccyx (fig. 12).

Luschka's monograph may be consulted for a more minute account.

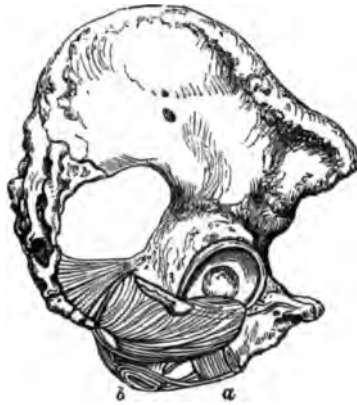

FIG. 12.

LEVATOR ANI and COCCYGEUS seen from without, after removal of part of hip bone and clearing out of Ischio-rectal Fossa (*Luschka*).
 a Fibres of Levator Ani on Vagina; b Anus, with Sphincter. (3)

We have now to take up the consideration of the generative organs. It is difficult to describe these without alluding to structures not fully considered until further on. The student may, therefore, not entirely grasp some of the points until the whole anatomy of the organs has been mastered.

THE UTERUS AND ITS ANNEXA.

The *Uterus* is a triangular body, with a truncated apex downwards, placed between the bladder and rectum, and with the appearance seen at figs. 13 *A* and 14 *B*. In describing it we take up its external appearance, its nature on section, and its structure and relations.

On external examination we find the parts known as the body (fig. 13, *A, c*), and neck (fig. 13, *A, a, b*). Keeping in mind the description
 Corpus Uteri.

of a triangle, we see the neck occupying the apex and the uterine orifices

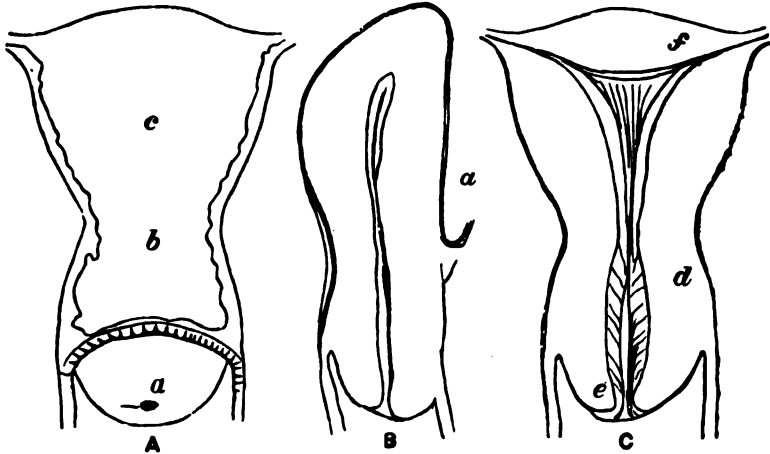


FIG. 13.

- A. VIRGIN UTERUS (front view) (*Sappey*). The Appendages and Vagina are cut away.
 a Cervix (vaginal portion); b Isthmus; c Body; a b Cervix proper.
- B. The SAME in vertical mesial section.
 a is anterior surface, and lies just above where peritoneum passes on to bladder.
- C. The SAME with cavity exposed by coronal section.
 e Os Externum; d Os Internum; f Uterine Opening of Fallopian Tube. (†)

of the Fallopian tubes at the two other angles. Between the Fallopian

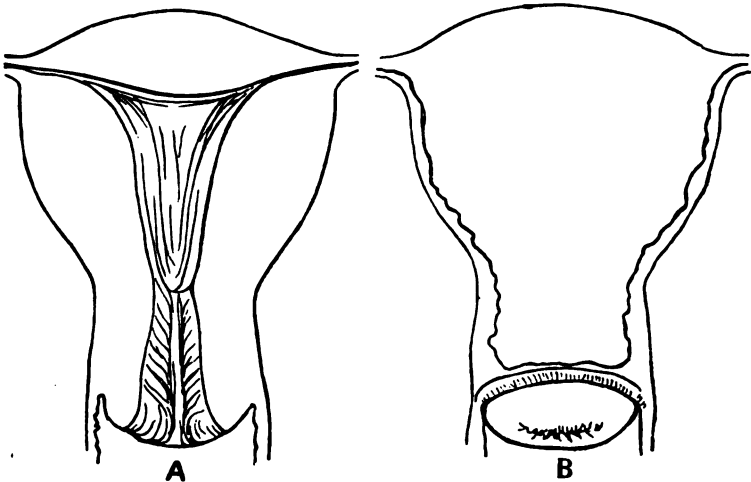


FIG. 14.

- A MULTIPAROUS UTERUS in coronal section to show cavity.
 B MULTIPAROUS UTERUS from front (*Sappey*). (†)

tubes lies the fundus uteri. The anterior surface of the uterus is almost straight; the posterior is convex at its upper part, as is well seen in fig. 13, *B*. Where the body passes into the cervix there is a slight depression noticed on the posterior surface. This corresponds to the isthmus.

On making a vertical mesial section, we observe that the uterus is a ^{Cavity of} hollow organ possessing a cavity with the anterior and posterior walls ^{Uterus.} in apposition (fig. 13, *B*). In order to see the cavity it is advisable to look at the uterus in coronal section, *i.e.*, a section which, passing through the cavity, divides the uterus into an anterior and posterior half, as shown in fig. 13, *C*, fig. 14, *A*. This latter section enables us more fully to understand the division of the uterus into body proper and cervix, and the division of the uterine cavity into cavity of the body proper and cervical cavity.

Cavity of Body.—This is a triangular slit in the uterus with the apex downwards, and with anterior and posterior walls. At each angle there is an opening, *viz.*, at the lower angle we have the *os internum* opening into the cervical canal (fig. 13, *C*, *d*), and at the upper angle the uterine openings of the Fallopian tubes (fig. 13, *C*, *f*). The lining of the cavity is known as its mucous membrane.

Cavity of the Cervical Canal.—This is spindle-shaped or conical (fig. 13, *B*, *C*), and has two openings, *viz.*, *os internum* above and *os externum* below. The former opens into the uterine cavity, the latter into the vagina.

The Cervix is divided into two portions, the vaginal and the supra- ^{Cervix} vaginal portion. The vaginal portion is within the vagina, and appears ^{Uteri.} as a conical mass of the size and shape seen at fig. 13, *A*, *a*. The *os externum* is in virgins a mere dimple, and feels to the examining finger like the tip of the nose. In women who have borne children it is transverse (fig. 14, *B*), and in most cases has its lips fissured more or less deeply, and the mucous membrane of the cervical canal partially everted. The supra-vaginal portion is continuous with the body through the isthmus.

The length of the whole unimpregnated uterus is, speaking generally, about 3 inches; the length of the cavity of cervix and body about 2½ inches.

Measurements with the sound on the living female are a little in excess of those obtained in sections on cadavera, owing probably to the sound elongating the uterus somewhat.

ANATOMY OF PELVIS.

	Virgin.	Nulliparae.	Multiparae.
Length of uterus	2.35 in.	2.50 in.	2.70 in.
Width	1.50 "	1.55 "	1.70 "
Thickness	0.85 "	0.90 "	1.00 "
			<i>Sappey.</i>
Vertical diameter of cavity	1.80 "		2.44 in.
Transverse " " " " " " " "	0.60 "		1.24 "
	(" On Cadavera.")		<i>Richt.</i>
Length of entire organ in young women			5-6 cm.
Do. body of uterus			3-3.5 "
Do. cervix			2-3 "
Do. vaginal portion of cervix55-.6 "
			<i>Hennig.</i>
			<i>Sappey.</i>

Capacity of uterus in nulliparae = 2.3 c. cm. ; in multiparae 3.5 c. cm.

Divisions
of cervix
uteri.

Various authors divide the cervix uteri more minutely as follows.
They consider it as made up of—

- a. an infravaginal portion ;
- b. an intermediate portion ;
- c. a supravaginal portion. (Fig. 15. *Schroeder.*)

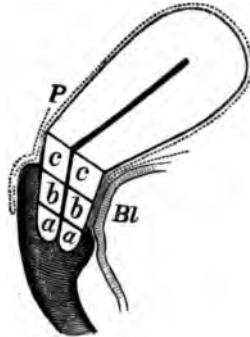


FIG. 15.

DIAGRAM of UTERUS to show divisions of Cervix. (*Schroeder.*)

a Infravaginal portion; b Intermediate portion; c Supravaginal portion; Bl Bladder; P Peritoneum.
The Dotted line shows peritoneum.

Dr. I. E. Taylor of New York speaks of—

1. The firm and true muscular element belonging to the body of the uterus solely, clearly, and distinctly ;
2. The fibro-serous element, or isthmus, existing between where the true muscular structure terminates, and the cervix uteri begins ;
3. The glandular structure—the cervix proper.

These two views are of importance in relation to the causation of the changes in the size of the uterus in prolapsus uteri.

Transverse sections of the uterus at different levels are of different

shapes (figs. 16, 17, and 18). A consideration of what has been already said will make this clear.

Recently the question of the boundary between the canal of the cervix

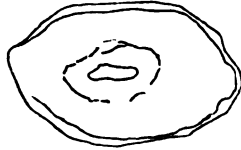

FIG. 16.

DIAGRAM of SECTION of UTERUS through centre of Cervical Canal (*Farre*). (†)

and uterus proper has been raised afresh by Bandl and others in reference to pregnancy and parturition. Its discussion here would, however, bring

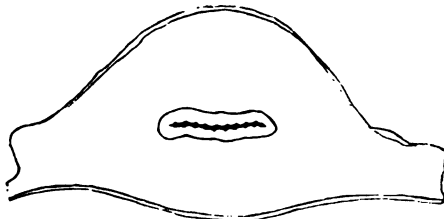


FIG. 17.

TRANSVERSE SECTION through centre of Cavity (*Farre*). (†)

in too much extraneous matter, and is therefore omitted, more especially as the whole question is still *sub lite*.

Structure of the Uterus.—If the uterus be viewed in vertical mesial Structure of Uterus.

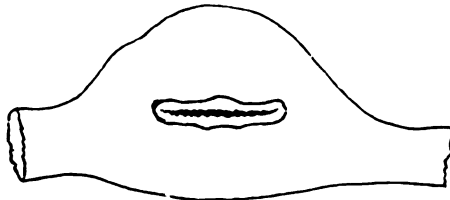


FIG. 18.

TRANSVERSE SECTION of UTERUS above Fallopian Tubes (*Farre*). (†)

section, it will be seen to be made up of three distinct elements, viz., peritoneum, unstriped muscular fibre, and mucous membrane (fig. 13, *B*). The peritoneum covers, partially, its external surface; the mucous mem-

brane lines the cavity of the body and cervix ; while the muscular fibre, by far the largest constituent, forms the tissue lying between these.

Peritoneum of Uterus. *The Peritoneum of the Uterus* clothes its posterior surface (except the infra-vaginal and middle portions of the cervix), but only dips down on the front surface as far as the isthmus, at which level it is reflected on to the bladder (fig. 13, *B, a*). At the sides of the uterus the peritoneum on the anterior and posterior surfaces runs out to the wall of the pelvis, thus forming the important structures known as the broad ligaments.

Ligaments of Uterus. *The Ligaments of the uterus* are—
 Broad ligaments ;
 Round ligaments ;
 Utero-sacral and Utero-vesical.

The broad ligaments are described under the peritoneum. (See p. 40.)

Round Ligaments. *The round ligaments* are two in number. According to Rainey, each springs by three fasciculi of tendinous fibres—the inner from the tendons of the internal oblique and transversalis, the middle from the superior column of the external abdominal ring near its upper part, and the outer fasciculus from just above Gimbernat's ligament. These unite into a rounded cord which crosses in front of the deep epigastric artery and passes between the layers of the broad ligament backwards, downwards, and inwards to the anterior and superior part of the uterus. Striped and unstriped muscle, blood-vessels, etc., are found in each.

Utero-sacral Ligaments. *The utero-sacral ligaments* are peritoneal folds, two in number, enclosing connective tissue and unstriped muscular fibre, passing from the lower, lateral part of the body of the uterus outwards and backwards towards the second sacral vertebra. They are known as the folds of Douglas, and form part of the upper, lateral boundaries of the pouch of Douglas. They are of the highest importance practically. The peritoneum, as it passes between uterus and bladder, constitutes the utero-vesical ligaments.

Musculature of Uterus. *The Musculature of the Unimpregnated Uterus* is of little importance in Gynecology, and needs only a passing notice. Three coats are described:—a thin subperitoneal coat passing into the round ligaments, broad ligaments, utero-sacral and utero-vesical ligaments ; a middle coat ; and an inner concentric and very abundant layer which surrounds the Fallopian tubes, *os externum*, and *os internum*. The student should not forget that the arrangement of the muscular fibres is of the highest importance in practical obstetrics.

Mucous Membrane of Uterus. *The Mucous Membrane* of the cavity of the body of the uterus is a

thin reddish-gray layer, about 1 mm. (.04 inch) thick in the unimpregnated but fully developed organ. It is set on the inner aspect of the




FIG. 19.
 DIAGRAM OF COURSE OF GLANDS OF MUCOUS MEMBRANE OF UTERUS (Engelmann). (4f)

muscular layer of the uterus without the intervention of any sub-mucous layer, is made up of ciliated columnar epithelium on a basis of connective

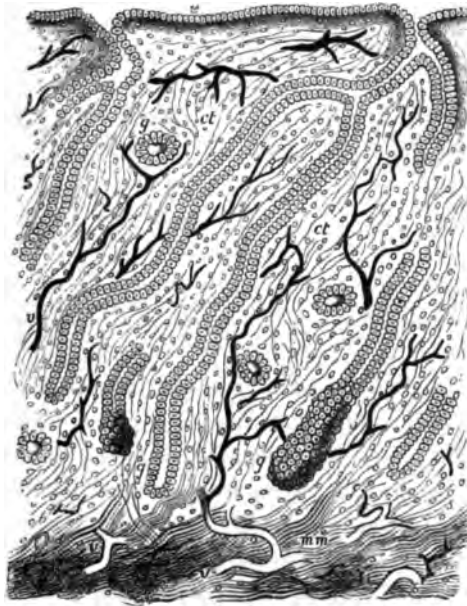

FIG. 20.
 VERTICAL SECTION, through the MUCOUS MEMBRANE of the HUMAN UTERUS (Turner).
 e Columnar Epithelium, the Cilia are not represented; gg Utricular Glands; ct, ct Interglandular
 Connective Tissue; vv Blood-vessels; mm Muscularis Mucosae. (4f)

tissue, and has numerous glands—the utricular glands. On section and microscopic examination, the glands, lined by the ciliated epithelium,

lying on a thin *membrana propria*, can be seen coursing down obliquely from the free surface and ending at the muscular fibre. Fig. 19 shows them perpendicular, but this is less correct, as Turner's diagram indicates (fig. 20). The glands usually bifurcate at their lower ends, and two may have a common mouth. The innermost layer of muscular fibre sends up prolongations between them—*muscularis mucosae*.

The connective tissue in which the glands are embedded consists of delicate round and spindle-shaped cells, the former being more abundant near the surface, the latter deeper. Fibrillated bundles of connective

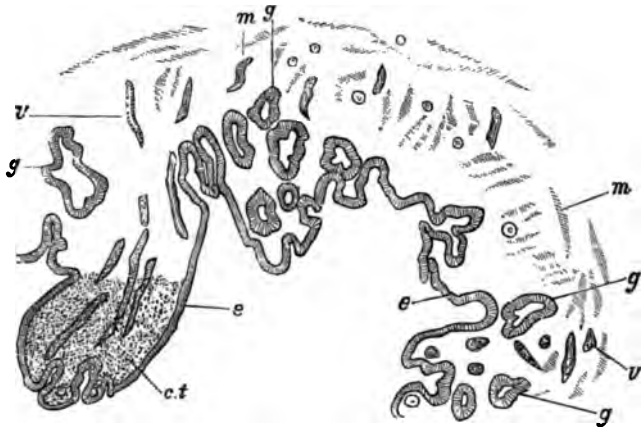


FIG. 21.

MUCOUS MEMBRANE OF CERVIX in Microscopical Section (*de Sinéty*).

e Ciliated Columnar Epithelium, Cilia not shown; *g* Glands; *m* Muscular Fibre; *v* Blood-vessels; *c.f.* Connective Tissue shown only at one part of figure. (49)

tissue lie also between the cells and pass out between the muscular fibre of the uterine wall (fig. 20). According to Leopold, the connective tissue is in the form of a plexus of fine bundles, covered with endothelial plates each with a nucleus. The spaces between these bundles form lymph sinuses.

Mucous Membrane of Cervix.

The *mucous membrane* lining the cervix is different in arrangement and structure from that lining the cavity of the uterus. It is thrown into numerous folds, presenting to the naked eye the appearance known as the *arbor vitæ*, which consists of a longitudinal mesial ridge on the anterior and posterior walls, from both sides of which secondary ridges branch off obliquely. It is lined throughout with a single layer of epithelium (fig. 21), which is ciliated on the elevated portion of the ridges, but is columnar in the depressed portions (*de Sinéty*).

The glands are of the racemose type, and consist of elongated repeatedly-branching ducts, which extend deeply into the connective tissue, and are somewhat dilated at their extremities (*Ruge* and *Veit*). They are lined by columnar epithelium, resting on a *membrana propria*, and open on the ridges and furrows of the mucous membrane.

There is a sharp line of demarcation between this single layer of epithelium (columnar and ciliated) which lines the cervical canal and the epithelial covering of the external surface of the vaginal portion, and this line of demarcation corresponds in the adult to the *os externum*. Beyond the *os externum*, the epithelial covering has all the characters of skin; it consists of vascular papillae covered with many layers of squamous epithelium. The vascular papillae are not easily recognised without the help of reagents (*Ruge* and *Veit*). The epithelial cells are like those found in the skin, and dovetail into one another by denticulate edges (*de Sinéty*).

It is a disputed question whether glands are present on the vaginal aspect of the normal cervix. *De Sinéty* says he has never met with them except in the neighbourhood of the *os externum*, and their occurrence there he attributes to an eversion of the mucous membrane of the canal. *Ruge* and *Veit* also consider the existence of glands as a pathological condition, which is, however, easily induced.

The normal histology of the cervix uteri has an important bearing on the pathology of the so-called ulcerations and on laceration of the cervix and ectropium.

FALLOPIAN TUBES.

The *Fallopian tubes* are two tubes, one on each side of the uterus, Fallopian Tubes. running sinuously from its upper angles out towards the side of the pelvis (figs. 22 and 53). They lie enclosed in the upper free margin of the broad ligaments, and vary in length from 10 to 16 cm. (4 to 6 inches). They are not of equal length, the right being frequently longer than the left.

After leaving the superior angle of the uterus, the course of the tube is straight for about $2\frac{1}{2}$ centimetres (1 inch). It then curves outwards and forwards, and finally backwards and inwards, so that the whole tube has roughly the shape of a shepherd's crook (fig. 22). Three parts come up for consideration—the isthmus, the ampulla, and the pavilion or fimbriated end.

The *isthmus* is the straight narrow part of the tube (fig. 22, *b*), which Isthmus.

at its internal end opens into the uterine cavity, and has a lumen barely admitting a bristle. On transverse section the diameter of the whole thickness is about 2 to 3 mm.

Ampulla. The *ampulla* is the curved and thick part of the tube (fig. 22, *c*), having an average diameter of about 6-8 mm., with a lumen admitting the ordinary uterine sound.

Fimbriae. The free *fimbriated end* of the Fallopian tube (pavilion) is expanded and funnel-shaped; and it is provided with primary and secondary fimbriae surrounding the opening of the tube to which they converge. One special fimbria runs to the ovary (fig. 22).

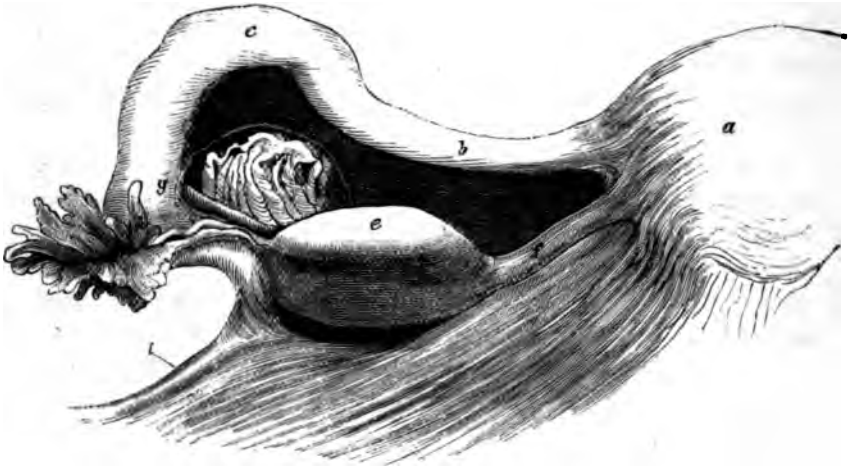


FIG. 22.

VIEW from behind of the LATERAL ANGLE of the UTERUS, with part of the Left Broad Ligament, Fallopian Tube, Ovary, and Parovarium (*Henle*).

a Uterus; *b* Isthmus of Fallopian Tube; *c* Ampulla; *g* has Parovarium to the right, and Fimbriated end of Fallopian Tube and Ovarian Fimbria just below it; *e* Ovary; *f* Ovarian Ligament; *i* Infundibulo-pelvic Ligament. (†)

Structure of Fallopian Tube.

On section the Fallopian tube is seen to be made up of three layers from without inwards, viz., peritoneal, longitudinal and circular unstripped muscular fibres (the latter being inner), and mucous membrane lined with ciliated columnar epithelium. Connective tissue and elastic fibres lie between the peritoneal and muscular layers. No glands exist in the mucous membrane which is much folded in a longitudinal direction, especially in the ampulla.

It is remarkable that the ciliated epithelium lining the Fallopian tube and pavilion should be continuous with the squamous epithelium of the peritoneum; and that, further, there is direct continuity between the

vagina, uterus, Fallopian tubes, and peritoneum,—so that the peritoneal sac in the female is not closed as in the male.

Parovarium or Organ of Rosenmüller.—If the broad ligament be held between the light and the observer's eye, this rudimentary structure will be seen enclosed in its folds in the space between the ovary and ampulla (fig. 22, *d*). It consists of closed tubules lined with ciliated epithelium, which converge towards the ovary, and are united by a longitudinal tube [*v.* under Development]. Their pathological degeneration produces the cystic tumours known as parovarian.

OVARIES.

The ovaries, two in number, lie one on each side of the uterus, projecting markedly through the posterior layer of the broad ligament.

Form, Size, and Relations.—The ovary is a small oval-shaped body about



FIG. 23.

SECTION OF CAT'S OVARY (*Schrön*). The free border of the ovary is, in the fig., above; the base of attachment—hilum—below. The division into Cortical and Medullary Layers is indicated. Note smallest Graafian Follicles at surface, and larger ones not so superficial. A Corpus Luteum lies to the left of the hilum. (†)

the size of an almond, the weight of which varies from 60 to 135 grains. According to Farre its measurements are as follow :—

	Longitudinal Diameter.	Transverse Diameter.	Perpendicular Diameter.
Greatest . . .	2 in.	1½ in.	½ in.
Smallest . . .	1 in.	½ in.	¼ in.
Average . . .	1½ in.	¾ in.	⅓ in.

The ovary has an anterior and posterior border, and an upper and lower surface. The posterior border is convex and free, the anterior flattened and attached to the broad ligament. It should be noted that

this anterior border is called the hilum, and that the blood-vessels and nerves enter there.

The position of the ovary will be discussed afterwards (p. 53), but at present it is sufficient to consider it as lying behind the broad ligament with its posterior border looking backwards, and its outer end farther back than its uterine one.

Ligaments
of Ovary.

Ligaments of the Ovary.—In addition to the attachment which the broad ligament gives to the ovary, two important ligaments are described—the ovarian ligament and the infundibulo-pelvic ligament.

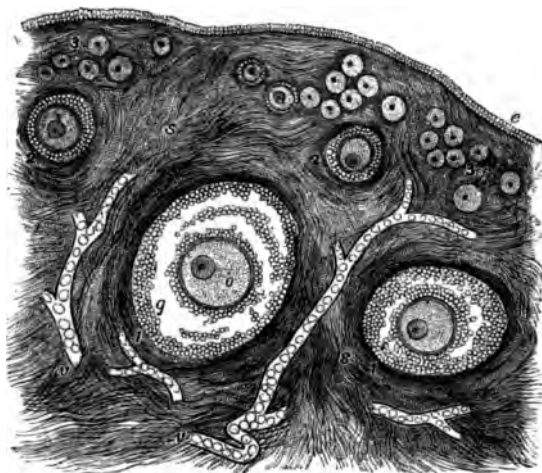

FIG. 24.

SECTION through the CORTICAL part of the OVARY (Turner).

e Germ Epithelium; st Ovarian Stroma; 1, 1, large-sized Ovarian Follicles; 2, 2, middle-sized; and 3, 3, smaller-sized Graafian Follicles; o Ovum within Graafian Follicles; v, v, Blood-vessels in the Stroma; g Cells of Membrana Granulosa.

Ovarian
Ligament.

The *Ovarian Ligament* (fig. 22, *f*) is about 3 cm. ($1\frac{1}{8}$ inch) long, and extends from the inner end of the ovary to the corresponding upper angle of the uterus, just below the uterine origin of the Fallopian tube. It is a longitudinal fold of the peritoneum into which the unstriped muscular fibre of the uterus is prolonged.

Infundi-
bulo-
Pelvic
Ligament.

The *Infundibulo-Pelvic ligament* (fig. 22, *i*) is about 2 cm. long, and runs from the outer end of the Fallopian tube to the side wall of the pelvis. It is simply that part of the upper margin of the broad ligament unoccupied by Fallopian tube.

Ovarian
Fimbria.

The *Ovarian Fimbria* (fig. 22, *i*) prevents the separation of the ovary and infundibulum tubæ. Thus the ovary is kept in position by its

attachment to the broad ligament, by the ovarian and by the infundibulo-pelvic ligaments. Its own specific gravity has also a share, *i.e.*, the ovary floats at a certain level.

Structure of the Ovary.—The ovary is covered by epithelium differing from the squamous epithelium of the peritoneum in being made up of columnar nucleated cells with a dull lustre. It is continuous, however, with the peritoneal epithelium, the line of contact being marked by a whitish and elevated line. The epithelium covering the ovary is known as the germ-epithelium. This distinctive term is of importance in connection with the development of the ova, and will be more particularly alluded to afterwards. A tunica albuginea made up of condensed connective tissue has been described as lying below the germ-epithelium.

On section and microscopical examination, the ovary is found to consist of connective tissue with the structures known as the Graafian follicles embedded in it, along with blood-vessels, nerves, lymphatics, and some unstripped muscular fibre. These are enclosed in the epithelial covering already described. The connective tissue is divided into a cortical and medullary layer; the former lying beneath the peritoneum, the latter being at and near the hilum (fig. 23). The medullary layer is very vascular, and has some unstripped muscular fibre round the branches of the ovarian artery (fig. 24).

The Graafian follicles are scattered through the whole substance of the ovary. The following points should be carefully noted:—

a. The younger and smaller Graafian follicles lie in the cortical layer. Their size is generally about $\frac{1}{100}$ th in., and they exist in immense numbers. According to careful estimates, the ovary of a female infant may contain 40,000 to 70,000 such follicles.

b. The larger follicles are much fewer in number and lie deeper in the ovary. Size $\frac{1}{30}$ th to $\frac{1}{100}$ th in.

c. There are also still larger follicles nearer the surface than the latter. These have advanced from the deeper layer (*vide* under Menstruation).

Structure of a Graafian Follicle.—This consists of

1. A Tunica fibrosa and Membrana propria;
2. The Membrana granulosa, a layer of nucleated columnar epithelial cells forming the discus proligerus at one part;
3. Fluid—the liquor folliculi.

The ovum (size $\frac{1}{100}$ to $\frac{1}{130}$ in diameter) lies in the discus proligerus; it has the following structure.

1. External envelope—zona pellucida, a homogeneous membrane,
2. Yolk protoplasm,
3. Germinal vesicle ($\frac{1}{700}$ th in. diameter),
4. Germinal spot $\frac{1}{3000}$ th in. diameter.

THE VAGINA.

Vagina—
Position.

The vagina is a mucous slit in the pelvic floor, extending from the hymen to the cervix uteri, and lying between the urethra and bladder in front and the rectum behind. In the upright posture it makes an angle of about 60° with the horizon, *i.e.*, it is nearly parallel to the pelvic brim.

Vaginal
Walls.

The vagina has two walls, an anterior and posterior, which are continuous at their sides. The anterior vaginal wall is triangular in shape,

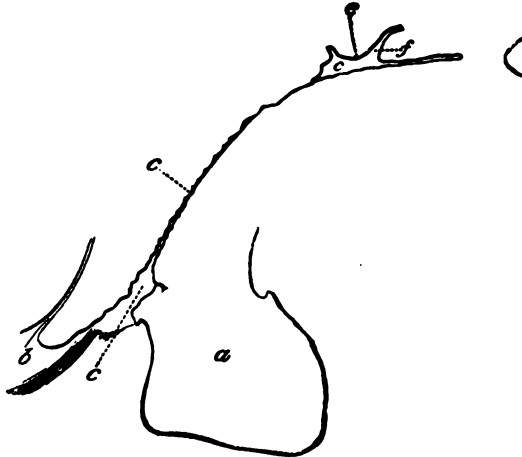


FIG. 25.

LIFE-SIZE DRAWING OF VAGINA in vertical section (*Hart*).

a Perineum; b Urethra; c Vagina; e Anterior Lip of Cervix; f Os Uteri. The axis is not normal in its upper part, as the Uterus was drawn back. (†)

the base being above. Its lower limit is marked out by the hymen. At its upper end it is reflected down to a very small extent on the anterior lip of the cervix uteri, the anterior fornix being thus formed (fig. 25.) It is closely incorporated with the urethra, but between it and the posterior aspect of the bladder there is loose connective tissue. Its length is about 5 cm., *i.e.*, 2–2½ inches.

Vaginal
Mucous
Membrane.

The mucous membrane of the wall is arranged in folds roughly transverse. At its lower end is a vertical mesial single or double thickening of the mucous membrane, about 2 cm. long, known as the anterior

vaginal column (fig. 26, *b*). This begins near the urethral orifice, or about $1\frac{1}{2}$ cm. above it. According to Budin, the columns are prolonged on the hymen.

The posterior vaginal wall is triangular in shape, and extends from the vaginal orifice upwards to the cervix uteri, upon which it is reflected, thus forming the posterior fornix vaginae, which is deeper than the anterior one. Its length is about $7\frac{1}{2}$ cm. (3 inches), *i.e.*, about $2\frac{1}{2}$ cm.

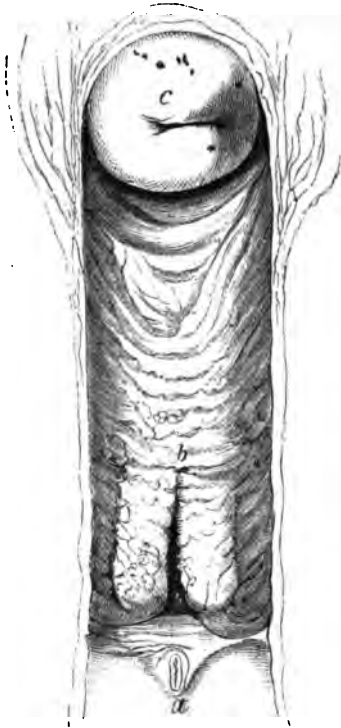


FIG. 26.

ANTERIOR VAGINAL WALL AND MULTIPAROUS CERVIX, looked at from behind (*Hensle*).
a Urethral Orifice; *b* Anterior Vaginal Column; *c* Cervix Uteri. (†)

(nearly an inch) longer than the anterior. It is also transversely rugous, and has a posterior column analogous to the anterior, but smaller.

While the direction of the anterior vaginal wall is almost straight, that of the posterior vaginal wall is sigmoid (fig. 27). The curve varies, however, according to the position of the uterus and the fulness or emptiness of the adjacent bladder and rectum.

When the bladder and rectum are empty, we find the direction of the

vagina parallel to the pelvic brim. When the bladder is distended, the vagina is, chiefly at its upper part, driven nearer the sacrum; while, if the rectum be distended, the vaginal axis may be almost perpendicular.

Structure
of Vagina.

Structure of Vagina.—The vaginal wall, on section and microscopical examination, is found to consist of mucous membrane, made up of epithelium (the superficial layer being squamous and nucleated, the deeper layer cylindrical and with elongated nuclei); of connective tissue, elastic tissue, and some unstriped muscular fibre. The superficial layer of the connective tissue forms papillæ, into which blood-vessels project. The

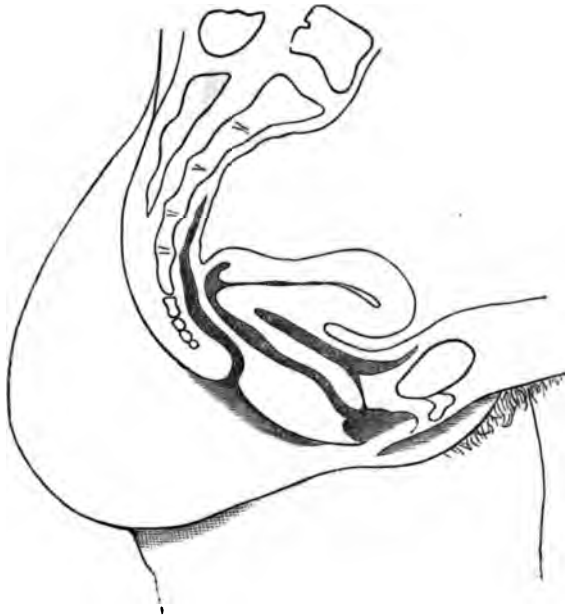

FIG. 27.

DIAGRAM OF VERTICAL MESIAL SECTION OF FEMALE PELVIS, showing Sigmoid curve of posterior Vaginal Wall (Schultze). (2)

epithelium is therefore ridged. External to this lie two layers of unstriped muscular fibre; the inner longitudinal, the outer circular (*Henle*). Breisky alleges the inner to be circular. There are no glands in the vagina, but gland-like crypts and lymph follicles exist (*Löwenstein*) (fig. 29). The whole is surrounded by loose connective tissue, containing the outer venous plexus of the vagina (fig. 29).

As already said, the vagina is a mere slit in the pelvic floor, although it is often erroneously described as a tube or cavity. On vertical section, as fig. 25 shows, it appears as a mere linear slit; while on transverse

section it is H-shaped, or crescentic (figs. 28 and 46). Of course the vagina is eminently dilatible and its walls separable, as will be more fully considered under the structural anatomy of the pelvic floor, but

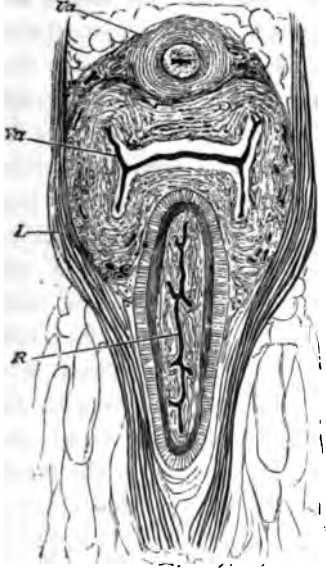


FIG. 28.

HORIZONTAL SECTION OF THE PELVIC FLOOR AT THE PELVIC OUTLET (*Henle*).

Ua Urethra; Va Vagina; R Rectum;
L Levator Ani.

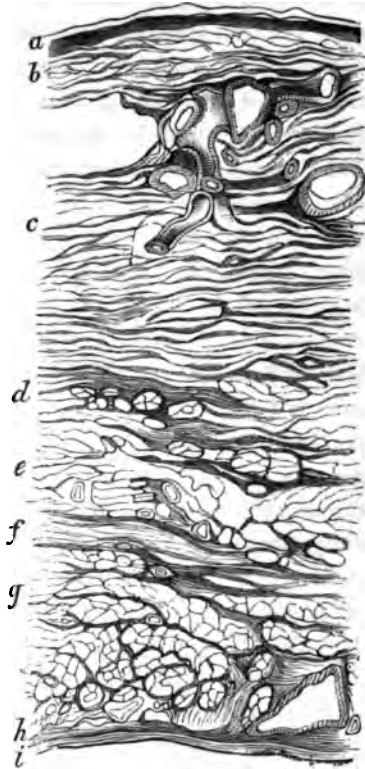


FIG. 29.

HORIZONTAL SECTION OF THE POSTERIOR WALL OF BLADDER AND THE ANTERIOR WALL OF THE VAGINA (*Henle*). (1f)

a Epithelium of the Bladder; b Mucosa; c Layer of circular fibres; d Layer of longitudinal fibres; e Loose Tissue; f Layer of circular fibres; g Layer of longitudinal fibres; h Mucosa; i Epithelium of Vagina.

this dilatation or separation is the result of posture with manipulation, or of Parturition. Whatever posture a woman may assume, the vagina on section is slit-like unless in certain exceptional instances.

THE BLADDER.

Position.—The empty female bladder lies behind the pubis and in front of the vagina. We here consider the urethra and bladder.

Urethra—
position.

The urethra is a straight slit (some describe it as sigmoid) about $1\frac{3}{8}$ inches long, with thick walls closely incorporated with the anterior vaginal wall behind. It runs parallel to the plane of the pelvic brim. Its lower opening is known as the meatus urinarius, the position of which has been already considered in the section on the External Genitals; its upper opening is at the neck of the bladder. On section and microscopical examination, its mucous membrane is found covered with squamous epithelium in its lower part; while higher up it is like that of the bladder, and is very rich in elastic fibres. There is a double layer of *unstriped* muscular fibre, the longitudinal layer being internal and the circular outside; and, according to Uffelmann, a circular (inner) and longitudinal layer of *striped* muscle, which stretches from the neck of the bladder to within $1\frac{1}{2}$ cm. of the meatus urinarius. Luschka also describes a special sphincter of the vaginal and urethral orifices. It should be further noted that the mucous membrane is folded longitudinally, and contains mucous glands lined with cylindrical epithelium, papillae, and lacunae, and also villous tufts near the meatus; and that there is a submucous layer between the mucous membrane and unstriped muscle, containing many veins. Recently Skene, of New York, has described two tubules in the female urethra. They lie on each side, "near the floor of the female urethra, and extend up from the meatus urinarius for about $\frac{3}{4}$ inch (figs. 30 and 31). They lie beneath the mucous membrane, and in the muscular walls of the urethra." We have in section of the female urethra:—

Microscopic
Structure.

Skene's
Tubules.

Mucous membrane;
Submucous layer;
Muscular layer, longitudinal and circular, unstriped;
do. do. striped (*Uffelmann*).

External to these there is the anterior vaginal wall behind, and loose tissue in front.

According to Henle, the closed urethral slit is on section transverse near the bladder, sagittal at the meatus, and star-shaped between these two points.

Bladder—
openings.

In the bladder proper we have three openings, the internal orifice of the urethra and the orifices of the two ureters. The latter lie one on each side, about $1\frac{1}{2}$ inches from the internal orifice. These openings give us the landmarks for the division of the bladder into neck, base, and body. All above the lines joining the ureteric openings and the centre of the symphysis is the body; all below is the base, and that portion between

the ureteric openings and the internal orifice is the trigone. Just above

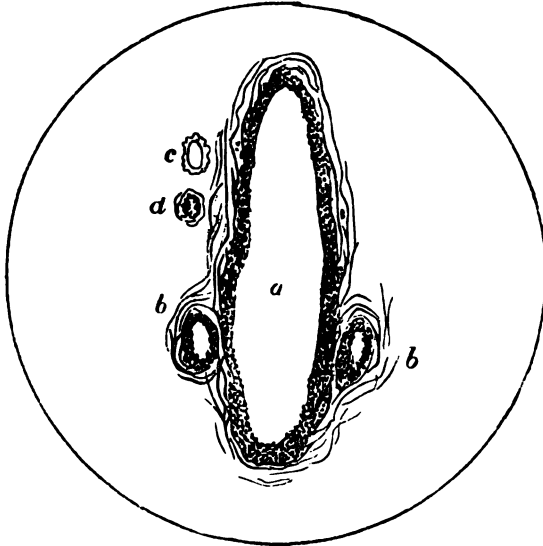


FIG. 30.

TRANSVERSE SECTION of URETHRA much enlarged (*Skene*).
a Urethra; *b b* Glands described by Skene; *c* Vein; *d* Artery.

the ureters is the *bas fond*. (*Skene*.)

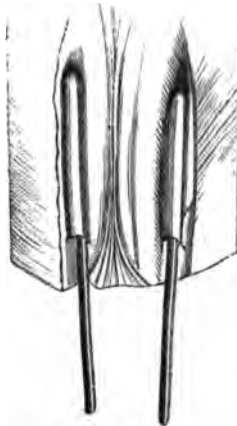


FIG. 31.

URETHRA LAID OPEN from above, showing glands with probes passed in (*Skene*).

The wall of the bladder is made up of three layers, viz., a mucous, a muscular, and a peritoneal. Structure of Bladder.

The mucous membrane consists of connective tissue lined by several layers of transitional or multiform epithelium (fig. 32). It is arranged in folds, except over the trigone and openings. The folds or rugæ are due to the laxity of the submucous coat.

The muscular coat of the bladder is of the unstriped variety, and has a complicated arrangement. There are external longitudinal fibres, circular fibres within these, and an internal longitudinal layer on which rests the submucous coat. It is disputed whether there is a sphincter at the neck of the bladder. Probably there is not; but the puckering of the mucous membrane at the neck is alleged to have a valve-like function.

The peritoneal covering of the bladder will be considered subsequently.

Ureters.

The relation of the ureters to the bladder is of importance. Garrigues




FIG. 32.

EPITHELIAL CELLS from the MUCOUS MEMBRANE of the BLADDER. Those in the upper row are the superficial squamous cells; those in the lower row are the peculiar cells of the middle stratum (Turner).

has recently investigated this subject, owing to its importance in Gastro-Elytrotomy.

In this obstetric operation, employed in cases where craniotomy or the Cæsarian section is the alternative, the operator cuts through the abdominal walls with the same incision as that for ligature of the external iliac artery. The peritoneum is pushed aside and the vagina partly cut and partly torn by an oblique incision. The child is then extracted. In some of the cases the bladder or ureter has been torn into.

According to him, "The ureter does not lie in the broad ligaments, it does not keep the same direction on reaching the wall of the bladder, and it does *not* lie close up to the wall of the cervix, all of which is taught by anatomical authorities. After having crossed the iliac vessels the ureters diverge, running downward, backward, and a little outward on the wall of the pelvis, behind the broad ligaments to a point near the *spina ischi*. Then they bend downward, forward, and considerably inward, so as to converge toward the bladder. They pass beneath the base of the broad ligament, lying in the abundant cellular tissue found in this locality. They cross the cervix at some distance from behind, at an acute angle, so

as to come in front of and below it. They lie outside and above the anterior part of the side wall of the vagina, on a spot as large as the tip of the finger. On reaching the wall of the bladder they turn rather sharply inward and go less downward until they open with a small slit into the interior of the bladder at the outer angle of the *trigonum vesicæ*. But on dissecting the bladder from the uterus and vagina, their substance is seen to continue running as a solid ridge between the two apertures, and forming the base of the trigone (*Jurie's* interureteric ligament)." (See fig. 33.)

Shape of empty Bladder and changes in its position.—The empty Shape and Position of Bladder.

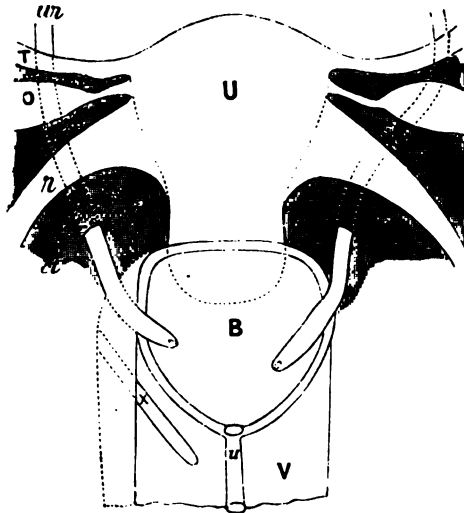


FIG. 33.

RELATIONS OF URETERS (*Garrigues*).

U Uterus; ur Ureter; B Bladder; u Urethra; V Vagina; T Fallopian tube; O Ovary; b Broad ligament; r Round ligament; ct Connective tissue; z Incision of Vagina in Gastro-Elytrotomy. (f)

female bladder lies completely behind the pubis, and has its fundus covered by peritoneum. When empty and viewed in mesial section it may present one of two shapes. In the large majority of specimens figured, it forms with the urethra a Y-shape on sagittal mesial section. The oblique legs of the Y may be about equal in size, or the posterior may be shorter (figs. 34, 40.) This form is so common that it has been accepted hitherto by all authors as the normal one. In certain cases, however, but not in so many as the former, the empty bladder cavity forms with the urethra a continuous tube on vertical mesial section (fig. 35). In such cases, it is oval in shape, corrugated, and

firm to the touch. This latter shape is the one always found in the lower animals, such as the rabbit and dog, and is the only one seen in the human fœtus. If, therefore, the pelvic floor be viewed on its peritoneal aspect, the fundus of the empty bladder will be found to be very often large and concave, while in some cases it is small and

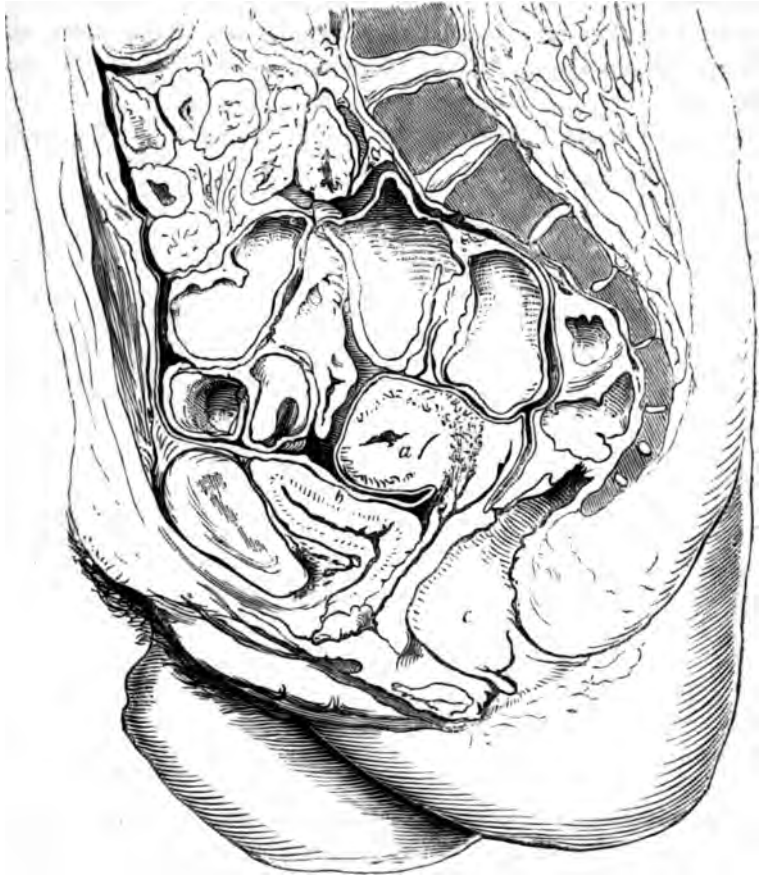


FIG. 34.

VERTICAL MESIAL SECTION OF FEMALE PELVIS, showing Y-shape of Bladder (*Fürst*). (½)

convex. In the former case, the inner surface of the upper segment of the bladder, large in area, is in contact with the surface of the lower segment; in the latter, the anterior and posterior inner walls, small in area, touch one another.

It is probable that when the bladder has the Y-shape on section, it is

relaxed and empty (fig. 34); and when the oval shape (fig. 35), it has been caught in systole. The bladder contracts to expel the urine and then relaxes. Between the acts of urination the bladder is therefore only a flaccid sac. Some additional facts as to the position and distention of the bladder are best considered further on, under the structural anatomy of the pelvic floor. We may here state, however, that (1) when empty, in the non-parturient female, it is behind the pubis (fig. 32); (2) it is

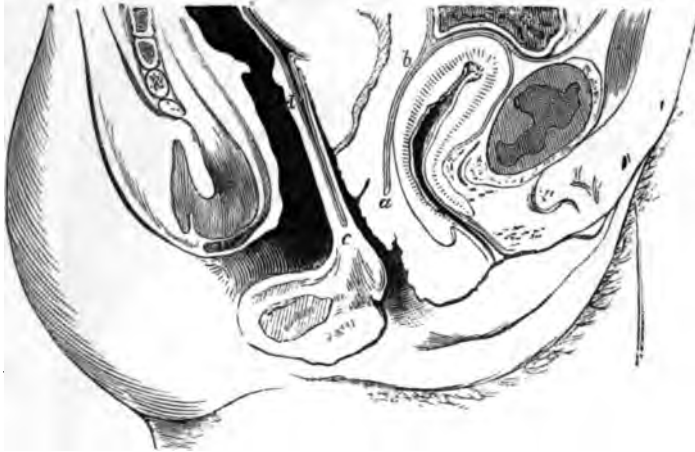

FIG. 35.

VERTICAL MESIAL SECTION OF FEMALE PELVIC FLOOR, showing contracted bladder in a suicide (*Braune*). (†) The peritoneum descends in front of the uterus to *b* and behind it to *d*; *b a* and *d c* are loose extra-peritoneal tissue.

drawn above the pubis in the parturient female; (3) it is tilted above the pubis in retroversion of the gravid uterus.

RECTUM.

The *Rectum* extends from the left sacroiliac synchondrosis, where the sigmoid flexure of the colon terminates, to the anus. It curves downwards, backwards, and inwards, to about the third sacral vertebra. This is known as the first part of the rectum; it is completely covered by peritoneum, which forms the mesorectum. The peritoneum is reflected from the rectum on to the upper part of the vaginal wall, about 3 inches above the vaginal orifice. Thereafter, the rectum lies in relation anteriorly to the posterior vaginal wall to which it is loosely attached until about $1\frac{1}{2}$ inches from the anus.

The rectum is made up of peritoneal investment; unstriped muscular

Micro-
scopic
Structure
of Rectum.

fibre in two layers, longitudinal and circular, the former being the outer ; a submucous coat ; and a mucous lining with its muscularis mucosae, columnar epithelium, no villi, but with Lieberkuhnian follicles closely set together. At the upper limit of the anus, the circular fibres are very well marked, and constitute the sphincter ani internus (fig. 37).

Certain oblique folds in the rectum—consisting of mucous, submucous, and circular unstripped muscular coats—are of special interest. One



FIG. 36.

RECTUM INFLATED (Chadwick).

a b Sphincter tertius ; c Ampulla of Rectum.

exists $1\frac{1}{2}$ inches from the anus, another is near the sacral promontory, and one is intermediate (*Turner*). The lowest (the valve of Houston or sphincter ani tertius of *Hyrtl*) has been described by *Chadwick* of Boston, as being not an entire circular fold, but made up of two semi-circular constrictions, one on the anterior wall, and one on the posterior an inch higher up (fig. 36).

Anus.

The *Anus* is that part of the rectum at its external orifice. It is about an inch long, and has its long axis directed backwards and cutting the axis of the vagina at about a right angle. The rectum, therefore, when in contact with the posterior vaginal wall closely follows its direction, but at a little above the anus turns sharply backwards. There is thus

left between it and the last $1\frac{1}{2}$ inch of the posterior vaginal wall, an angular inter-space to be filled up by the structure known as the perineal body.

Fig. 37, from Ruedinger, shows the arrangement of the voluntary and



FIG. 37.

PERPENDICULAR SECTION through the end of the RECTUM enlarged (*Ruedinger*).

- 1 Mucous Membrane of the Rectum; 2 boundary between Mucous Membrane and skin of buttock; 3 Fat; 4 Levator Ani; 5 Sphincter Ani externus; 6 Fibres of Longitudinal Layer separating external Sphincter into parts; 7 Sphincter Ani internus; 8 Longitudinal Fibres of muscular coat, which radiate outwards at 9; 9 Longitudinal Fibres of Muscularis mucosae which radiate outwards at 12; 10, 11, 12, 13, 14 Slips of muscular fibre passing into tissue beyond.

involuntary muscle of the anus. The division of the external sphincter into two parts, and the separation of the lower division (5) into compartments by fibres from the longitudinal unstriped layer (9), are noteworthy.

Similarly the internal sphincter (7) is divided into compartments by fibres from the muscularis mucosae (13). Near the anal orifice the mucous membrane has certain perpendicular folds in it known as the Columnae Morgagni, with depressions between these—the Sinus Morgagni (fig. 2).

PERINEAL BODY.

Perineal
body.

The posterior vaginal wall is in contact with the anterior rectal wall, for about $1\frac{1}{2}$ inches above the apex of the perineal body, there being only loose tissue between. The anus has its long axis directed backwards, while the vaginal axis runs forwards; we thus get a pyramidal space filled up by the structure known as the Perineal body (*Henle* and *Savage*).

The Perineal body is made up of muscular insertions and origins (striped and unstriped), and fibrous and elastic tissue. Its base is covered by the skin lying between the anus and vagina; its anterior side is behind the posterior vaginal wall; its posterior side lies in front of the anterior rectal wall and anus; while laterally, it is bounded by fat. The voluntary muscles passing into it are the Sphincter-ani, Transversus perinei, Bulbo-cavernosus, and Levator-ani (fig. 7).

This Perineal body measures about $1\frac{1}{2}$ inches (4 cm.) vertically, the same transversely, and $\frac{3}{4}$ in. antero-posteriorly. If a straight line be made to join the tip of the coccyx and the subpubic ligament, it will just clear the apex of this structure.

Its functions are important, but have been both exaggerated and underrated. It gives a fixed point for many muscles, prevents pouching of the rectum forwards, and strengthens that part of the pelvic floor which has no posterior bony support.

Its special significance, however, will be considered further on.

At present, the nomenclature in regard to the "Perineal region" is exceedingly vague; as the term Perineum is used in varying senses by accoucheurs, especially in regard to the tears caused by Parturition. It is better to be precise, and speak of tears of the hymen, fourchette, and perineal body, instead of saying "perineal tears." The surface between the anal and vaginal orifices is not the perineum, but the "skin over the base of the perineal body" and "the fourchette."

PERITONEUM.

Pelvic
Periton-
eum.

This is the thin serous covering of the concave surface of the pelvic floor, uterus, and its appendages, etc. A knowledge of its disposition is

of the highest importance to the gynecologist. This is best considered as follows:—

1. *The Pelvic Peritoneum followed in a Vertical Mesial Section and from before backwards.*—The Peritoneum of the anterior abdominal wall is reflected, at a point a little above the symphysis pubis, on to the fundus of the empty bladder (figs. 38 and 39). It passes downwards over the posterior surface of the bladder, from which it crosses on to the anterior surface of the uterus at a point about the level of the os internum. From this it passes up over the anterior surface of the uterus. Thus there is formed a vesico-uterine pouch, containing no small intestine either when the bladder is in systole or in diastole (figs. 38 and 39.) When the bladder has the Y-shape pathologically produced [*vide postea*], the peritoneum passes directly backwards across the fundus of the bladder and on to the anterior surface of the uterus at or below the level of the os internum (fig. 40). There is thus produced a utero-abdominal pouch (fig. 40).

Vesico-uterine Pouch.

The peritoneum covers the whole of the anterior surface of the uterus above the os internum, passes over the fundus and down the posterior surface, which it covers almost completely. From this it descends still deeper, on to the posterior aspect of the posterior vaginal wall for about one inch (fig. 38). The amount of its dip varies, however. In one section by Pirogoff (fig. 41) the peritoneum runs down on the posterior vaginal wall till within about an inch from the vaginal orifice. This extent of posterior peritoneal duplicature is, of course, abnormal. The depth of the peritoneal pouch behind the uterus is greater on the left side than on the right. That its depth varies is quite evident on section, as in some sections it ends at the level of the posterior fornix (fig. 39), while in others it is seen passing as deeply as has been already described (figs. 38, 41). This descent of the peritoneum behind the uterus is of the highest importance practically, and forms the well-known pouch of Douglas. This pouch is best defined as follows:—Its upper lateral boundaries are the utero-sacral ligaments; its anterior boundary is the uppermost inch of the posterior vaginal wall and posterior aspect of the supra-vaginal portion of cervix; its posterior boundary is the sacrum and rectum, covered by peritoneum. It is the lowest part of the peritoneal cavity, and from its relation to the posterior vaginal wall can be explored through the posterior vaginal fornix. It is partially filled by intestine when the uterus lies to the front, which becomes displaced when the uterus is retroverted or retroflexed.

Pouch of Douglas.

Broad
Ligaments.

2. *The Disposition of the Pelvic Peritoneum at the sides of the Uterus.*

The Broad Ligaments.—At the sides of the uterus, the peritoneum clothing its anterior and posterior surfaces, passes outwards and somewhat backwards to the sides of the pelvis in front of the sacro-iliac synchondrosis. In this way we get two laminae of peritoneum nearly in apposition, which become more separated at their junction with the pelvic floor and sides of the pelvis. These are the broad ligaments of the uterus.

Just within their upper free margin, the Fallopian tubes are placed. That part of the free margin not occupied by the Fallopian tube forms the infundibulo-pelvic ligament of the ovary (figs. 22 and 53). Projecting through the posterior lamina of the broad ligament is the ovary, covered by its germ-epithelium. The ovarian ligament and parovarium have already been described under the ovary and Fallopian tube.

Between the layers of the broad ligament lie connective tissue, unstriped muscle, blood-vessels, and lymphatics. According to M. Guérin, the broad ligaments enclose a small space shut off from the rest of the cellular tissue of the pelvis, and he denies that as yet there is proof of any special diagnosable inflammatory affection of the broad ligaments. Guérin alleges that, by inflation, it can be demonstrated that the broad ligaments are thus shut off—a fact denied by other observers.

The position of the broad ligaments varies according to that of the uterus. When the uterus is normal in position, *i.e.*, lying to the front, their posterior surfaces look upwards and somewhat backwards, and they run outwards and backwards as already described. Displacement of the uterus backwards causes their coincident displacement, and in pregnancy they are drawn up and lie almost vertically. Pathologically, they cicatrize after inflammatory attacks, causing unilateral deviations of the uterus.

Peritoneum
on side
walls of
Pelvis.

3. *The Pelvic Peritoneum on the side walls of the Pelvis.*—The pelvic peritoneum clothes the side walls of the pelvis. It dips down least at the side of the bladder, and most at the utero-sacral ligaments.

Although the pelvic peritoneum has been described in three sections, it must of course be kept in mind that it is a continuous membrane, with no breaks in its continuity.

Some special facts about the peritoneum should now be noted.

Relation to
Bladder
and
Rectum.

1. *As to the Bladder.*—When the bladder is distended, the peritoneum is stripped off the lower part of the anterior abdominal wall to an extent varying with the distention (fig. 44). During parturition, the peritoneum is drawn off the bladder (fig. 43) (*Hart*).

2. *As to the Rectum.*—Its upper part is completely invested by peri-

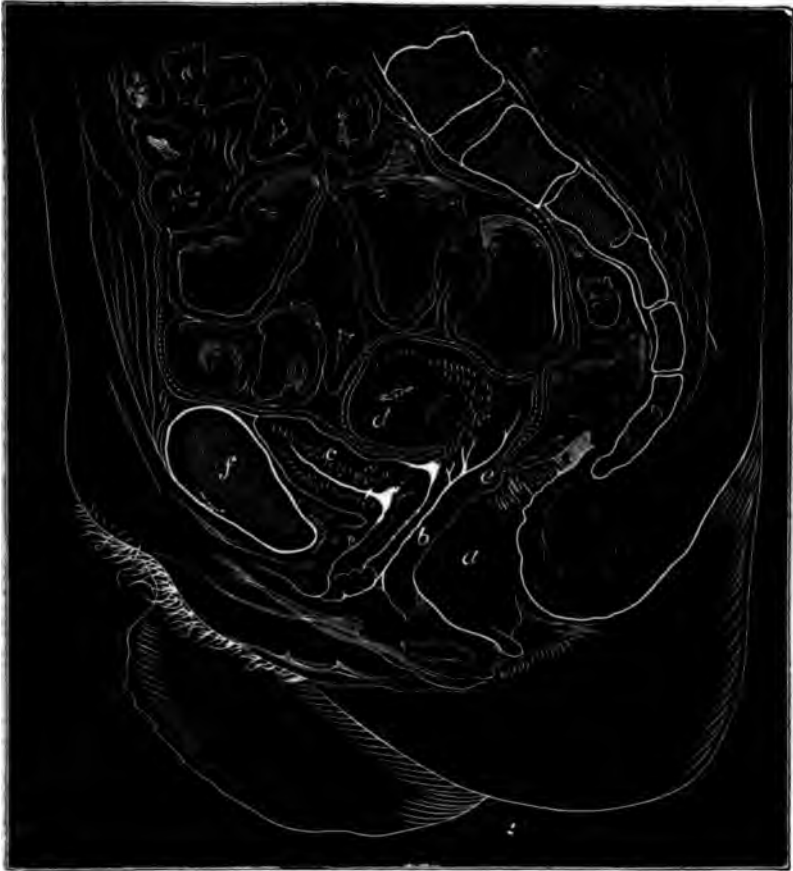

FIG. 38.

FROZEN SECTION showing Peritoneum (*Fürst*). The dotted line indicates Peritoneum in this and figs. 36-44. a Anus; b Vagina; c Bladder; d Uterus; e below pouch of Douglas; f Symphysis Pubis (1).



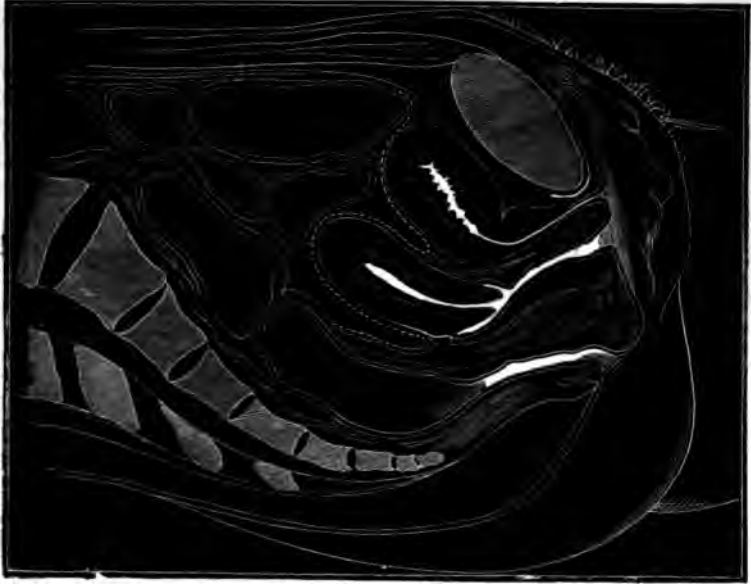


FIG. 39.
FROZEN SECTION SHOWING PERITONEUM IN CONTRACTED BLADDER (HEITZMANN).

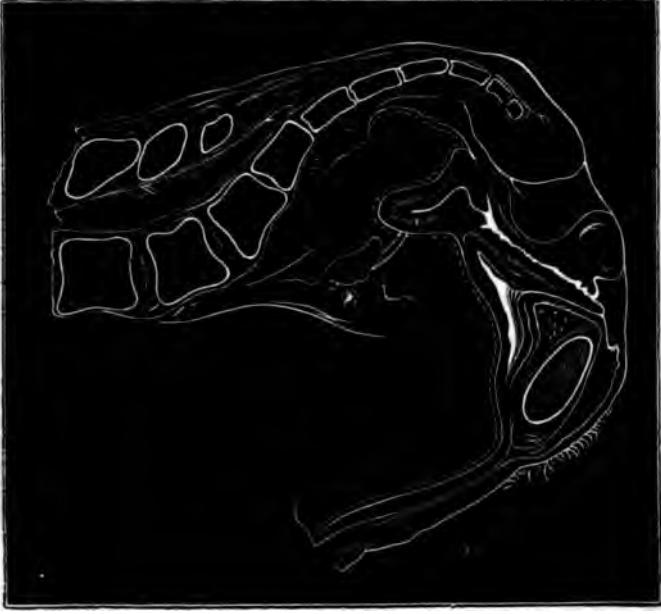


FIG. 40.
SECTION (SPRIET-WAARDEN) SHOWING PERITONEUM WHEN UTERUS IS DRAWN BACK BY UTERO-VAGINAL CELLULITIS (HARR).

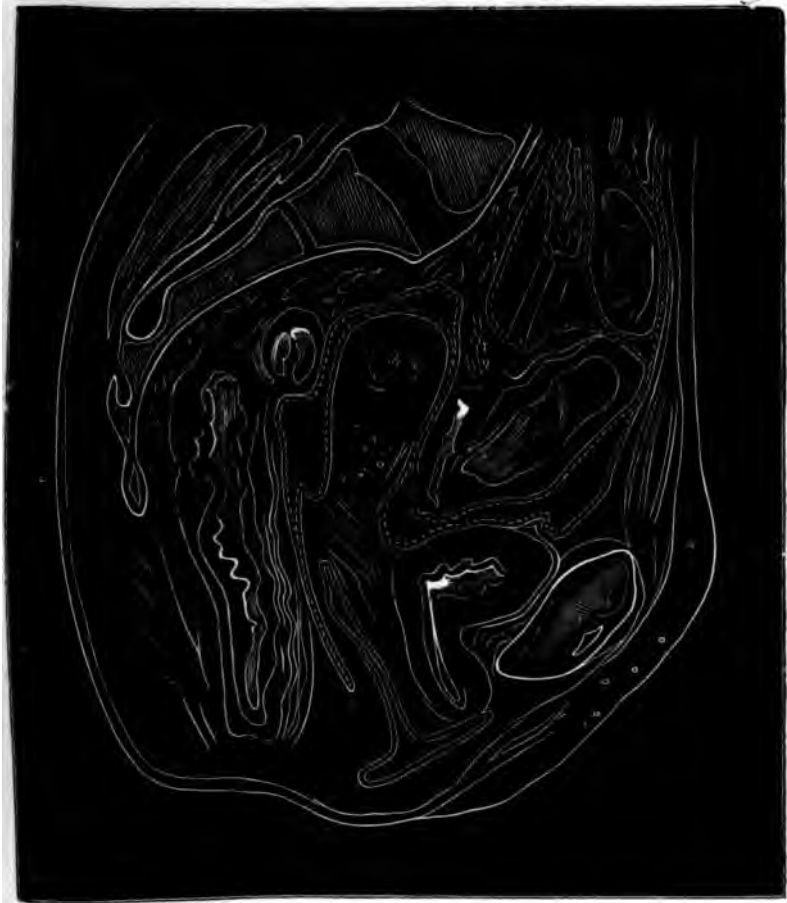

FIG. 41.

PERITONEUM DIPPING ABNORMALLY DEEP between Rectum and Vagina (*Pirogoff*).



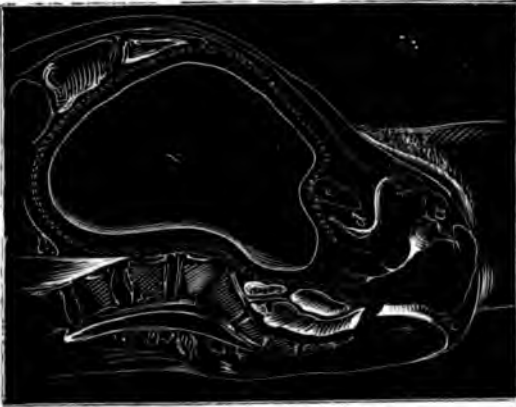

FIG. 42.
RELATION OF PERITONEUM TO BLADDER AT END OF
PREGNANCY (*Brune*). (Frozen.)
a Vaginal Entrance; b Uterus; c Anus; d Bladder;
e Symphysis.

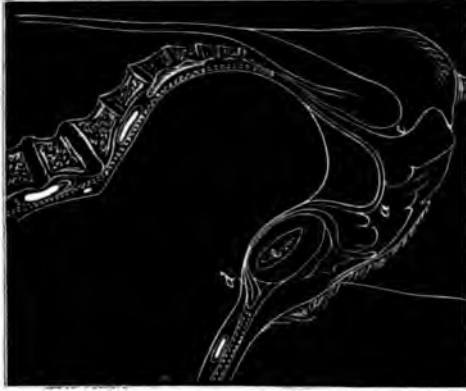

FIG. 43.
RELATION OF PERITONEUM TO BLADDER DURING
PARTURITION (*Brune*).
a Vagina; d Bladder; c Anus; e Symphysis.

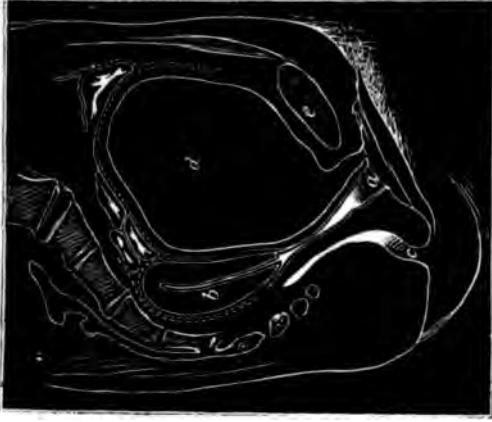


FIG. 44.
RELATION OF BLADDER AND PERITONEUM WHEN
BLADDER DISTENDED (*Hrooff*).
a Vagina; b Uterus; c Anus; d Bladder; e Symphysis

toneum; the second part is only partially covered, *i.e.*, the peritoneum gradually leaves the rectum, quitting first the posterior surface, then the sides, and finally passing from the anterior surface on to the posterior vaginal wall, as already described.

Over the bladder and anterior abdominal wall the peritoneum is easily separable. According to Spiegelberg, above the os internum uteri posteriorly it is closely blended with the uterus, below this quite loosely.

Practical Points.—In no operative procedure involving the anterior vaginal wall can the peritoneal cavity be opened into. In the upper third or so of the posterior vaginal wall the peritoneum may be opened into. This has indeed been done by the most skilful operators, but the risks attending it are not so considerable as usually alleged, especially when drainage is employed. When the fingers are passed into the posterior fornix vaginae, only about $\frac{1}{2}$ inch of tissue intervenes between them and the peritoneum. The possibility of there being a deep dip of the peritoneum, as shown at fig. 41, should not be forgotten in operations on the posterior vaginal wall.

CONNECTIVE TISSUE OF PELVIS.

By this we understand (I.) the Fascia described so elaborately by the human anatomist as the Pelvic Fascia; and (II.) the loose Connective Tissue padding the interstices between the muscles, lying round the cervix uteri, and spreading out beneath the pelvic peritoneum.

I. The *Pelvic Fascia* of the anatomist is carefully described in the ordinary systematic and dissecting-room manuals, to which the student is therefore referred.

II. The *loose connective tissue* found lying subperitoneally, surrounding the cervix uteri, and spreading out between the layers of the broad ligament, is of the highest importance pathologically, as in it and in the pelvic peritoneum occur those inflammatory exudations so common in women. Of late years our knowledge of the disposition of this tissue has been rendered much more accurate, and accordingly our discrimination of pelvic inflammatory attacks made much more precise.

The distribution and relations of the pelvic connective tissue may be studied in various ways. The most valuable information is obtained by considering sections of frozen or spirit-hardened pelvis. This gives the precise position of the tissue, its amount, and distribution. The sections are made in various directions: antero-posteriorly, in the middle line (sagittal mesial); antero-posteriorly, at the junction of the broad liga-

Peritoneum
in relation
to opera-
tions.

Pelvic
Fascia.

Pelvic Con-
nective
Tissue.

Methods of
studying
it.

ments and uterus (lateral sagittal); horizontally, at various levels; and finally, coronally, *i.e.*, parallel to the coronal suture, and dividing the pelvis into anterior and posterior portions. Another valuable method of investigation is to inject air beneath the peritoneum, between the layers of the broad ligament, and at other points. By this we learn the varying attachments of the pelvic peritoneum to the subjacent tissue, and the lines of cleavage, as it were, of the pelvic connective tissue along which pus will burrow.

Instead of air we may inject plaster of Paris or water; plaster of Paris will be found the most useful. We therefore consider—

a. Results obtained by section.

b. Results obtained by the injection of water, air, plaster of Paris.

a. *Results obtained by Section.*

Pelvic Con-
nective
Tissue—as
seen in
Vertical
Mesial
Section.

1. *Vertical Mesial Section.*—This shows a large amount of loose tissue lying between the posterior aspect of the symphysis pubis and the angle formed by the urethra and anterior wall of bladder—the retro-pubic fat deposit (*Hart*). It is a matter of some importance to note its shape when the bladder is empty and the female in the dorsal posture. It is then distinctly triangular. Between the sacrum and rectum, between the posterior wall of the bladder and the uterus, and between the supra-vaginal portion of the cervix and posterior vaginal wall, connective tissue in comparatively small amount is distributed (figs. 34, 39). Note specially that loose tissue separates the posterior vaginal wall from the anterior rectal wall as far as the apex of the perineal body where they are closely blended (fig. 35); that the urethra and anterior vaginal wall have no such loose tissue intervening, *i.e.*, are closely united; while, as already stated, the anterior vaginal wall and posterior aspect of bladder are separated by tissue.

Pelvic Con-
nective
Tissue—as
seen in
Lateral
Sagittal
Section.

2. *Lateral Sagittal Section.*—By this section a specially valuable view is obtained. Fig 45 shows an accurate drawing of such a section, just at the junction of the uterus and broad ligaments. It should be noted that the amount of retro-pubic tissue is less than in the sagittal mesial one; that at the junction of the broad ligaments with the uterus there is a large amount of tissue with large blood-vessels; and specially that the finger placed in the lateral fornix vaginae touches the base of the broad ligament there. This fact is valuable as to diagnosis. On section, the boundaries of the space between the broad ligaments are seen; superiorly the cut section of the Fallopian tube, anteriorly and pos-

teriorly the peritoneum, and inferiorly the vaginal fornix. The assertion by Guérin and Le Bec as to the insignificance of the tissue here is not borne out.

Sections made nearer the side pelvic wall display specially the lessening tissue between the layers of the broad ligaments and show sections of the ovary.

3. *Horizontal Sections* give results confirming those above stated. It

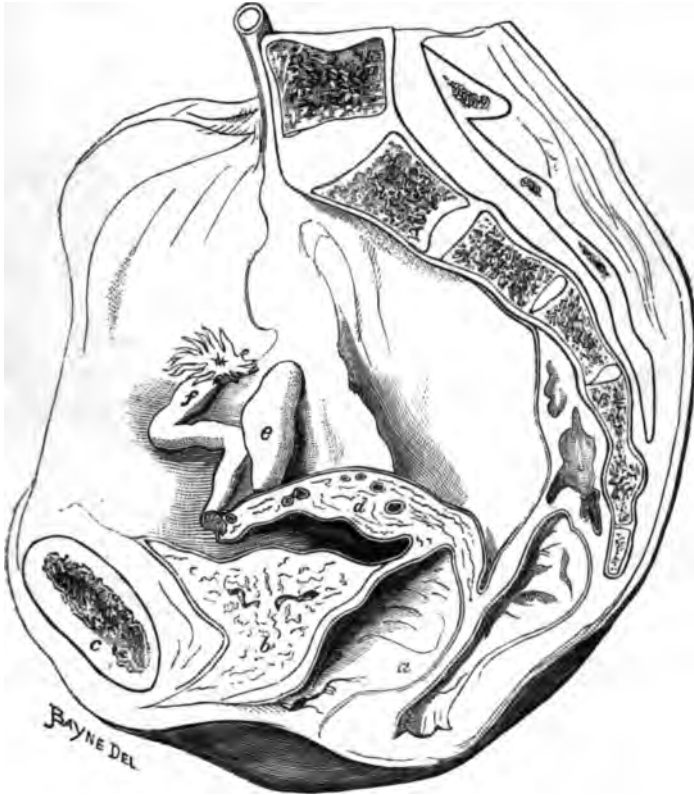


FIG. 45.

SAGITTAL MESIAL SECTION OF PELVIS cutting at Junction of Broad Ligament and Uterus. *a* Vagina with its walls separated; *b* Bladder; *c* Symphysis; *d* Broad ligament; *e* Ovary; *f* Fallopian Tube. In the specimen this Uterus was laterally displaced.

is unfortunate that no good sections are as yet published. Pirogoff gives several, but these are not clearly defined in their connective tissue relations. Freund has published an admirable description of his preparations, but it is to be regretted that he has not figured them. The most valuable sections are those at the level of the supra-vaginal portion of the Pelvic Connective Tissue—as seen in Horizontal Section.

cervix, which show the tissue lying here all round it. At fig. 46 we show a section from Ruedinger, where the retropubic fat and ischiorectal cavities are well shown.

Parametric Tissue.

This is the best place to draw special attention to what Virchow first termed the parametric tissue. By this term he meant the loose fatless tissue (2 cm. thick), with abundant blood-vessels and lymphatics, surrounding "the lower portion of the uterus and the upper portion of the vagina" (*Spiegelberg*). This is the parametric tissue proper. Some

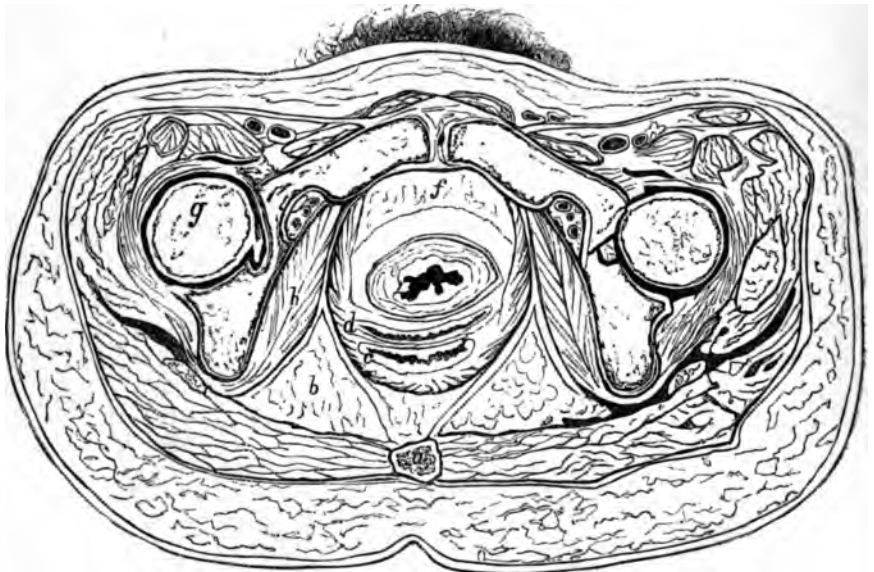


FIG. 46.

TRANSVERSE SECTION OF FEMALE PELVIS AT PLANE OF HIP-JOINTS (*Ruedinger*).

a Coccyx; b Ischiorectal fossa; c Rectum; d Vagina; e Bladder; f Retropubic fat; g Hip-joint.

extend the meaning of the term parametric tissue so as to include all the connective tissue in the pelvis.

Pelvic
Connective
Tissue—in
Coronal
Section.

4. *Coronal Section*.—There has been published no frozen coronal section of the pelvis alone. Fig. 47 and Plate II show Ruedinger's coronal section of a female cadaver, but this displays little of the pelvic relations. This section will, however, be considered afterwards.

A useful diagram of a coronal section of the pelvis is given by Luschka. It shows well the relations of the cavity of the pelvis to the subperitoneal connective tissue and the ischiorectal fossa (fig. 48). These Luschka terms—

- (1.) Cavum pelvis peritoneale (fig. 48, a).
- (2.) „ „ subperitoneale (do., b),
- (3.) „ „ subcutaneum (do., c).

According to him, the ischiorectal fossa communicates with the subperitoneal connective tissue by means of minute apertures.

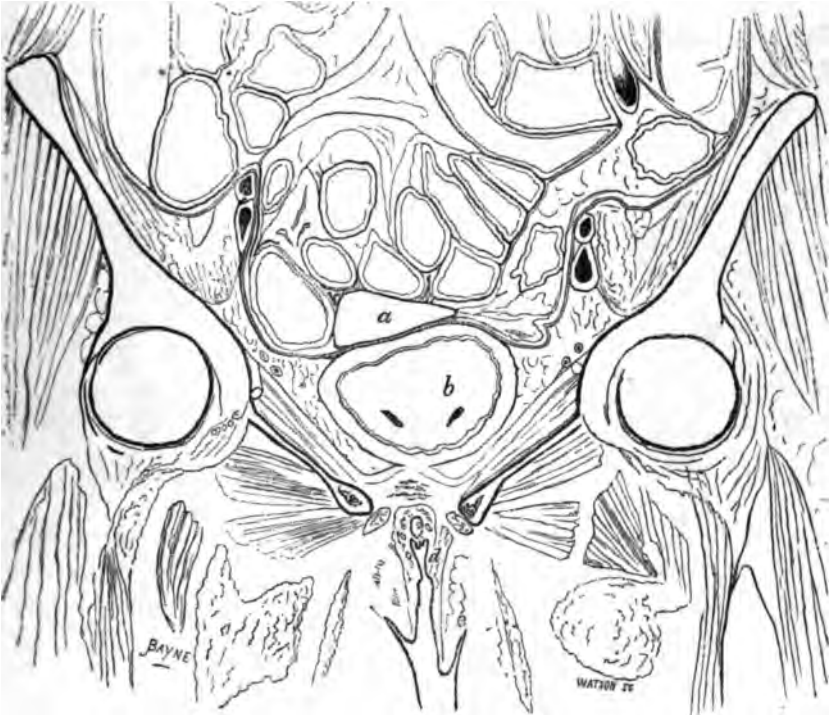


FIG. 47.

CORONAL FROZEN SECTION OF PELVIS (Ruedinger).
a Fundus uteri; b Bladder; d Labium minus; e Labium majus.

b. Results obtained by injections of water, air, or plaster of Paris.

The best summary of these results is given by Bandl, to whom on this point we are indebted for much valuable information.

König in his researches employed the bodies of women who had died a short time after labour from non-puerperal diseases, and injected air or water. The following briefly are his results:—(1.) Water injected between the layers of the broad ligament, high up in front of the ovary, passed first into the tissue lying at the highest part of the side wall of the true pelvis. It then passed into the tissue of the iliac fossa, lifting

Connective
Tissue in-
vestigated
by inject-
ions.

up the peritoneum, and followed the course of the psoas, passing only slightly into the hollow of the iliac bone. Lastly, it separated the peritoneum from the anterior abdominal wall for some little distance above Poupart's ligament, and from the true pelvis below it.

(2.) On injection beneath the base of the broad ligament to the side and in front of the isthmus, the deep lateral tissue became filled first ;

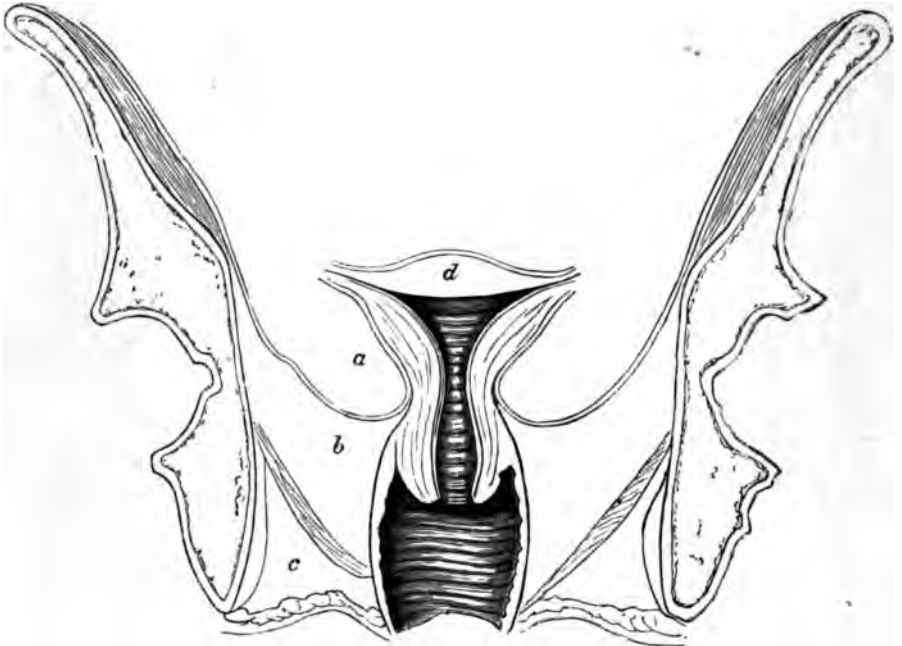


FIG. 48.

DIAGRAM OF CORONAL SECTION OF PELVIS (*Luschka*).

a Peritoneal cavity ; b Subperitoneal cavity ; c Ischioanal fossa ; d Uterus.

then the peritoneum became lifted up from the anterior part of the cervix uteri. The separation passed thence first to the tissue near the bladder, and ultimately the fluid passed along the round ligament to the inguinal ring. There it separated the peritoneum along the line of Poupart's ligament, and passed into the iliac fossa.

(3.) An injection at the posterior part of the base of the broad ligament filled the corresponding tissue round Douglas' pouch, and then passed on as described at (1).

Schlesinger has followed out these results in more elaborate researches, which space prevents us quoting.

The significance of these investigations will be referred to under Pelvic Peritonitis and Pelvic Cellulitis.

CHAPTER II.

THE POSITION OF THE UTERUS AND ITS ANNEXA, AND THE RELATION OF THE SUPERJACENT VISCERA.

LITERATURE.

Braune—Topograph. Anatom. Atlas, Zweite Auflage : Leipzig, Veit & Co., 1872. *Claudius*—On the Position of the Uterus : Med. Times and Gazette, 1865, p. 5. *Credé*—Beiträge zur Bestimmung der normalen Lage der gesunden Gebärmutter : Archiv. f. Gynäkologie, Bd. I., S. 84. *Foster*—A Contribution to the Topographical Anatomy of the Uterus and its surroundings : Am. J. of Obst. XIII., p. 30. *Hasse*—Beobachtungen über die Lage der Eingeweide im weiblichen Beckeneingange : Archiv. f. Gynäk. Band, viij., S. 402. *Pirogoff*—(Anatome Topograph. : Petropoli, 1859.) *Sappey*—Traite d'Anatomie Descriptive : Paris, 1873. *Schroeder*—Handbuch der Krankheiten der weiblichen Geschlechtsorgane : Leipzig, 1879. *Schultze*—Zur Kenntniss von der Lage der Eingeweide im weiblichen Becken : Archiv. für Gynäk., Bd. IX., S. 262. An admirable account of the subject will be found in Dr. Van de Warker's articles on a study of the Normal Movements of the Unimpregnated Uterus : N. Y. Medical Journal, XXI., p. 337 ; and on the Normal Position and Movements of the Unimpregnated Uterus : Am. J. of Obst., Vol. XI., p. 314. The literature is also well given there and in Foster's paper.

THE amount of literature, chiefly French and German, on this subject is much too extensive even to be mentioned here. This is partly due to the inherent difficulty of accurate clinical observations, to the erroneous opinions advanced by many eminent anatomists, and to arbitrary demands as to the normal uterine position made by gynecologists with strong opinions on anteversion.

Thus, in the well-known works of Braune, Luschka, Cruveilhier, and Henle, the uterus is figured from actual sections as normal with the fundus in the hollow of the sacrum, *i.e.*, retroposed. Claudius of Marburg, also an anatomist, is uncompromising on this point. He states, indeed, that the uterus is normal only when, with its broad ligaments, its posterior surface touches the sacrum as closely as the lungs do the ribs (fig. 49). Now, almost all gynecologists agree, from clinical observation, that the body of the uterus lies over on the bladder, with the os uteri looking more or less back. This divergence of opinion is extraordinary ; and it leads to this interesting practical observation, that what the anatomist considers a uterus normal in position, the gynecologist believes to be abnormal. That is, the retroverted uterus—considered

Difference
in opinions
as to posi-
tion of
Uterus.

normal in cadavera by the anatomist—is, when found in the living woman, replaced by the gynecologist so that it lies with its body over the bladder.

There can be no doubt that the uterus lies normally to the front, with its anterior surface resting on the bladder. Great refinement is exercised, quite unnecessarily, by many gynecologists in settling what they believe to be the exact angle which the long axis of the uterus should make with the horizon, when a woman is in the erect posture; and this refinement

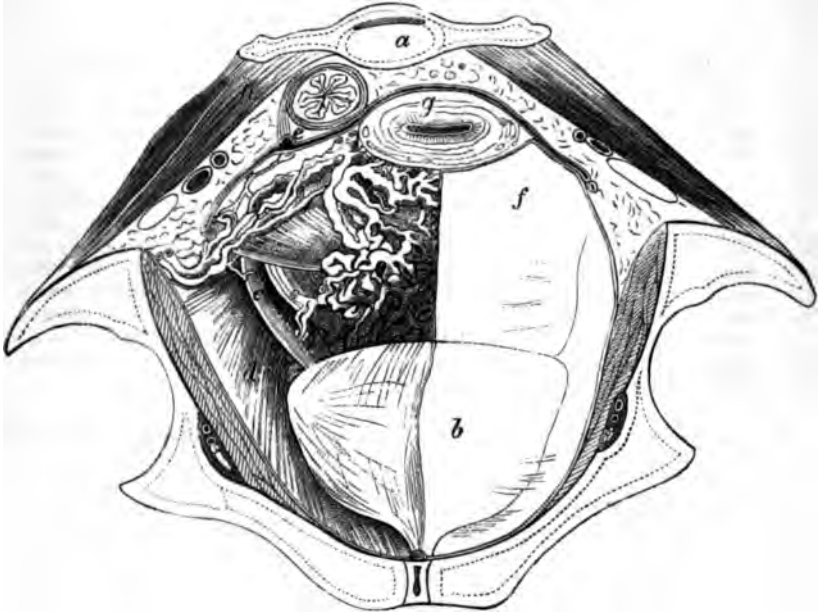


FIG. 49.

TRANSVERSE SECTION OF PELVIS in line of PYRIFORM MUSCLES (*Luschka*). The Peritoneum has been removed on the right side. *a* 3d Sacra Vertebra; *b* Bladder; *c* Ureter; *d* Levator Ani; *e* Rectum; *f* Anterior Layer of Broad Ligament; *g* Uterus; *h* Pyriform Muscle. Note that here the uterus is retroverted, and the pouch of Douglas without intestine.

has been greatly stimulated by the mechanical treatment of what is known by many as anteversion of the uterus.

In treating of this vexed question, we shall consider—

1. The normal form and position of the uterus.
2. The local divisions of the pelvic floor peritoneum as viewed through the pelvic brim, and the position of the uterus and its annexa.
3. The physiological changes in the position of the uterus.
4. The relation of the small intestine to the pelvic floor and to the uterus and its annexa.

THE NORMAL FORM AND POSITION OF THE UTERUS.

The question of the form of the uterus we consider only in the limited Normal aspect of the angular relation of the long axis of the uterus to the long form of axis of the cervix. These are not in the same straight line, but, when Uterus. the bladder and rectum are empty, lie at an obtuse angle of varying value. This angle is much less in multiparous women (fig. 27), and more marked in nulliparæ (fig. 50). The position of the uterus, with empty

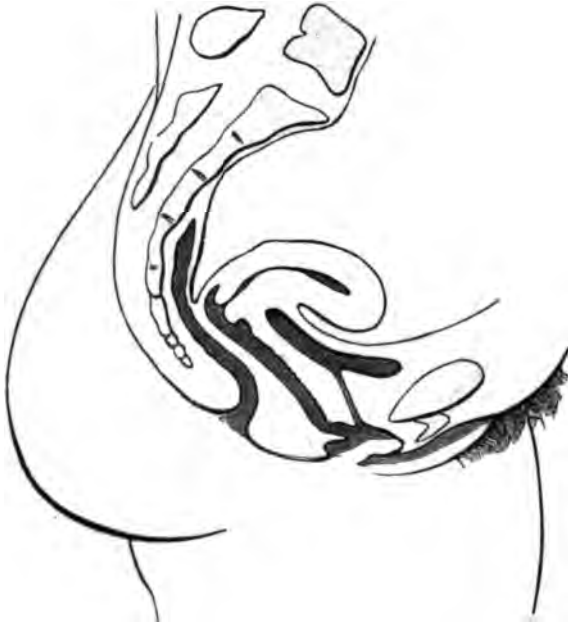

FIG. 50.

DIAGRAM to show Normal Form and Position of VIRGIN UTERUS (Schultze).

bladder and rectum, is such that it lies with its anterior surface touching Normal the posterior aspect of the bladder, no intestine intervening; the os position of externum uteri looks downwards and backwards; and the uterus is Uterus. slightly twisted as a whole on its long axis, so that the uterine end of the right Fallopian tube is nearer the symphysis than that of the left. We have expressly said with bladder and rectum empty. According to Schultze, the long axis of the uterus is nearly parallel to the horizon. This is probably exaggerated, as Schultze's researches were conducted in a way that certainly anteverted the uterus unduly (figs. 27 and 50).

Many authors figure the uterus nearly vertical to the horizon, for this purpose distending the bladder until the uterus is elevated to what they consider the proper angle (fig. 51). It is needless to say how absurd this is. Kohlrausch's diagram, so often quoted in support of this allegation,

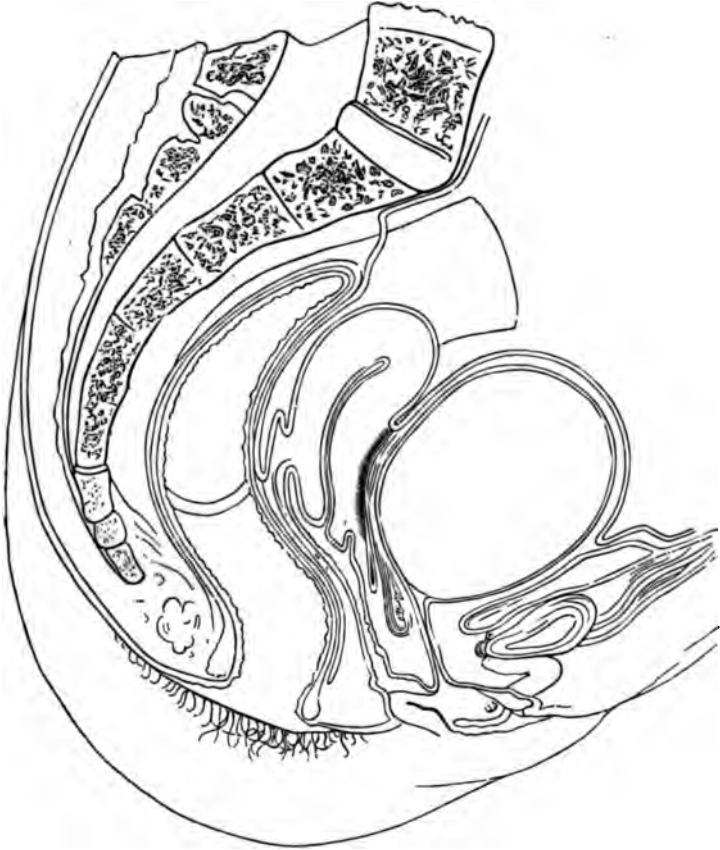


FIG. 51.

SECTION OF PELVIS, showing Uterus driven back by distended Bladder, and Peritoneum disturbed (Kohlrausch). This is not a normal condition of parts by any means.

really shows, if it show anything, the position of the uterus when the bladder is well distended. The student should note this point, as Kohlrausch's section is the favourite diagram of those who treat as pathological what is really a normal uterus. Fig. 52, from Pirogoff, shows a frozen section supporting Schultze's contention.

It is important to know how results as to the uterine position have been obtained. The chief methods are as follows:—

(1.) *By frozen, spirit-hardened, or chromic acid sections.*—Results obtained in this way are not specially valuable, as there is some *post mortem* change in the uterine position not yet thoroughly understood.

Methods of investigating position of Uterus.

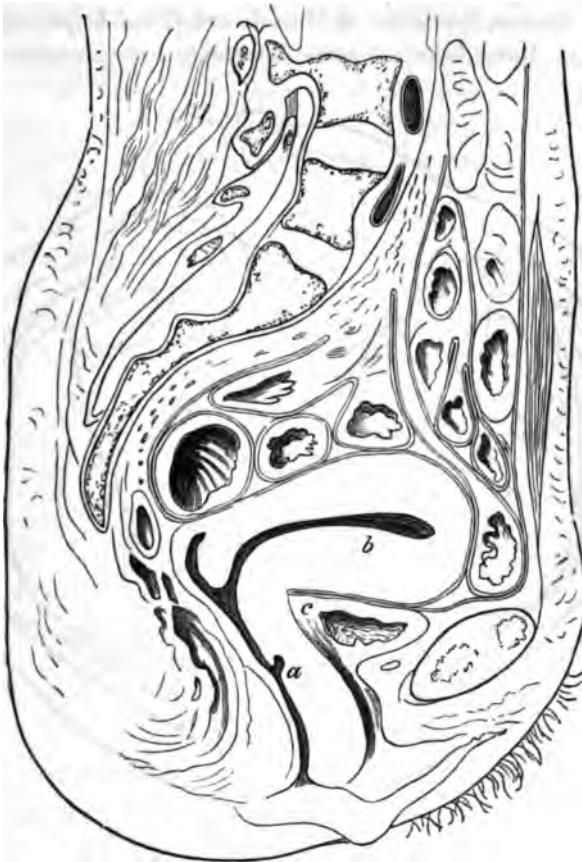


FIG. 52.

SECTION OF FEMALE CADAVER (*Pirogoff*).

a Vagina ; b Uterus ; c Bladder.

Note Bladder in diastole, Uterus parallel to horizon, and shallow dip of Douglas' Pouch.

(2.) *By the bimanual examination of the Pelvic Contents.*—This is probably the best method, although it exaggerates the normal anteversion of the uterus in a way that will be readily understood when the chapter on the Bimanual has been studied.

(3.) *By the use of the sound,* or by a more elaborate means described by *Schultze*. Space does not permit of a full description of the latter, but a good account of it is given in *Foster's* paper.

THE LOCAL DIVISIONS OF THE PELVIC FLOOR PERITONEUM AS VIEWED THROUGH THE PELVIC BRIM, AND THE POSITION OF THE UTERINE ANNEXA.

For valuable papers and sections on this subject, we are indebted to Haase of Breslau, Ruedinger of Munich, and His of Leipzig (fig. 53 and plate II.). Haase froze not quite thoroughly a female cadaver in the

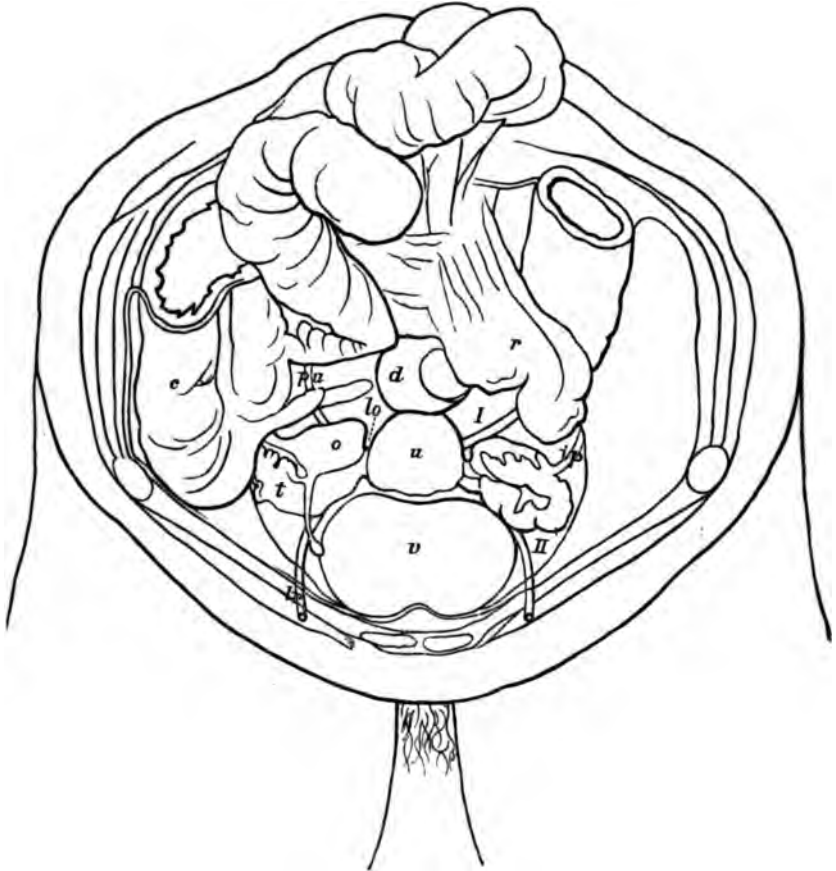


FIG. 53.

FEMALE PELVIS and CONTENTS viewed through the Pelvic Brim (*Haase*).
 v Bladder; II. Paravesical Pouch; u Uterus; o Ovary; t Fallopian Tube; d Pouch of Douglas;
 I Lateral Pouch of Douglas; t p Infundibulo-pelvic Ligament; l r Round Ligament; p u
 Position of Ureter; l o Ovarian Ligament; r Rectum; c Colon.

upright posture, cut through the abdomen transversely, and then lifted out the softened viscera until the pelvic contents were exposed undisturbed. The bladder was moderately distended.

Fig. 53 shows Hasse's drawing. The fundus of the uterus lying on the bladder is well seen. In front of the broad ligament—of which the infundibulo-pelvic ligament is the only portion visible in fig. 53—we have, on each side, the paravesical pouch of the peritoneum. Behind it, lies the lateral pouch of Douglas; while just behind the uterus and bounded on each side by the utero-sacral ligament is the pouch of Douglas proper. The Fallopian tubes lie in the true pelvis, in the paravesical pouch. Each broad ligament sweeps outwards and backwards to near the sacro-iliac synchondrosis of its own side. The position of the ureter is well indicated.

Pelvic Contents as seen through the Brim.

According to Hasse the long axis of both ovaries runs outwards and

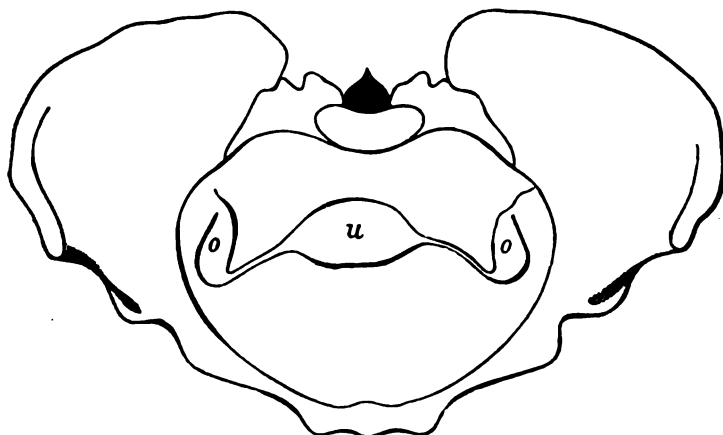


FIG. 54.

POSITION OF FUNDUS UTERI and lie of OVARIES. Bladder distended (Schultze).

forwards, forming with the transverse axis of the uterus an angle open to the front. Part of each ovary (the half) projects above the plane of the pelvic brim. Schultze figures the ovaries as having their long axes almost antero-posterior (fig. 54), and His in his cases found the long axes vertical.

Direction of Ovaries.

THE PHYSIOLOGICAL CHANGES IN THE POSITION OF THE UTERUS.

The mobility of the uterus is one of its most characteristic features. With every movement of respiration, in singing, walking, and in all violent movements, the uterine position is changed. Dr. Van de Warker has studied, in a valuable paper, the influences bringing about these changes in position; this may be consulted for details of his method of investigation and results obtained.

Effect of
Bladder
on position
of Uterus.

Of the greatest importance is the effect of the distended bladder on the uterine position. As the bladder fills, the uterus becomes retroposed to an extent shown at figs. 51, 54, and 55. The intestines are forced out of the upper part of Douglas' pouch, and the height of the peritoneal reflection from the anterior abdominal wall is considerably increased. All these points are well illustrated by fig. 44 from Pirogoff. As the

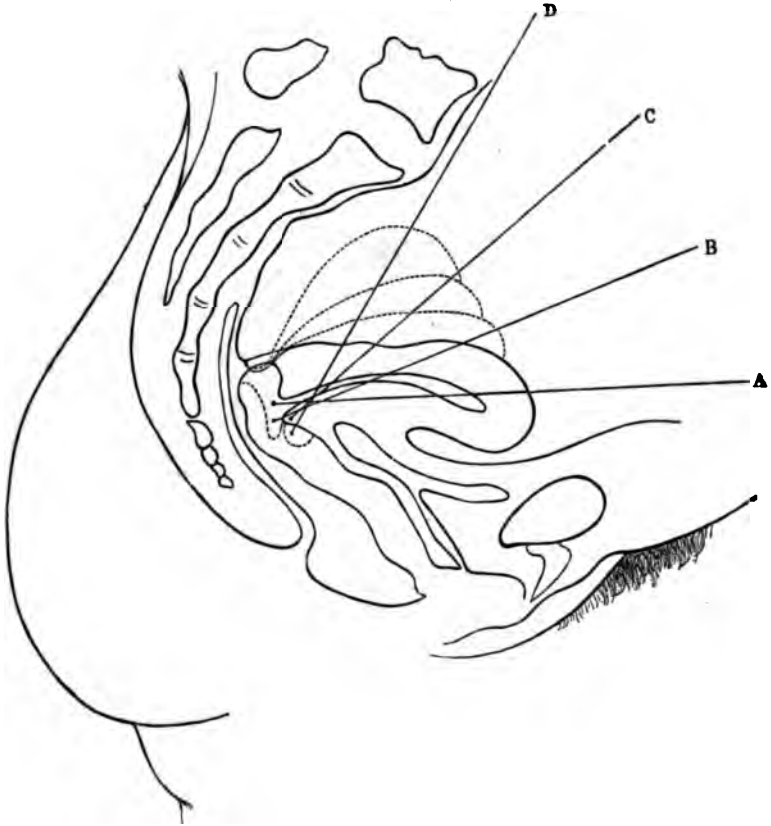


FIG. 55.

POSITION OF UTERUS. A with bladder and rectum empty; B, C, D according to distention of bladder (Van de Warker).

urine is evacuated, the uterus passes forward to its normal anteverted condition and the intestines pass back into Douglas' pouch. Probably, undue distention of the bladder leads to permanent retroversion in some cases, especially if the uterus be gravid. Rectal distention displaces the uterus forwards and to the right side.

THE RELATION OF THE SMALL INTESTINE TO THE PELVIC FLOOR
AND TO THE UTERUS WITH ITS ANNEXA.

The small intestine lies resting on the uterus, ovaries, Fallopian tubes, and broad ligaments. There is no small intestine in the vesico-uterine pouch. *When the bladder is empty and the unimpregnated uterus to the front, there is small intestine in Douglas' pouch except at its very lowest part.* The pouch of Douglas becomes emptied of intestine as the bladder distends, and has no intestine in it when the uterus is retroverted. Many authors assert that there is never small intestine in Douglas' pouch. This opinion is undoubtedly wrong, as any one can satisfy himself by studying sections. Often Douglas' pouch contains serum, and this displaces the intestine. Figures 35, 39, 44 bear out these opinions; fig. 47 and plate II. should be carefully studied as illustrating the position of the superjacent intestines. The paravesical pouch probably contains intestine when the uterus lies to the front, and certainly contains it when the uterus is pathologically retroverted. Occasionally the omentum may interpose between the small intestine and the pelvic viscera.

Relation
of small
Intestines
to Uterus.

To sum up briefly:—

- a. The uterus and bladder behave practically as one organ *quâ* position (*i.e.*, they move together), when the uterus is to the front.
- b. The exact angle which the uterus makes with the horizon cannot be fixed, and knowledge on this point is not necessary.
- c. The uterus lies normally to the front, but has a range of mobility indicated in fig. 55. The posterior lip of the cervix is 1.5 to 3 cm. above the tip of the coccyx. By digital pressure the uterus can be elevated about 4 cm. (1½ in.)

Summary
as to
position
of Uterus.

CHAPTER III.

THE STRUCTURAL ANATOMY OF THE FEMALE PELVIC FLOOR: THE PELVIC-FLOOR PROJECTION.

LITERATURE.

STRUCTURAL ANATOMY. *Hart*—The Structural Anatomy of the Female Pelvic Floor: Edinburgh, 1881.

PELVIC-FLOOR PROJECTION. *Foster*—(Am. J. of Obst. XIII., p. 30.) *Schroeder*—Noch ein Wort über die normale Lage und die Lageveränderungen der Gebärmutter: Arch. f. Gynäk., Bd. IX., S. 68. *Schultze*—Zur Kenntniss von der Lage der Eingeweide im weiblichen Becken: Archiv. f. Gyn., Bd. IX., S. 262. *Simpson and Hart*—The Relation of the Abdominal and Pelvic Organs in the Female: W. and A. K. Johnston, Edinburgh and London, 1881.


THE STRUCTURAL ANATOMY OF THE FEMALE PELVIC FLOOR.

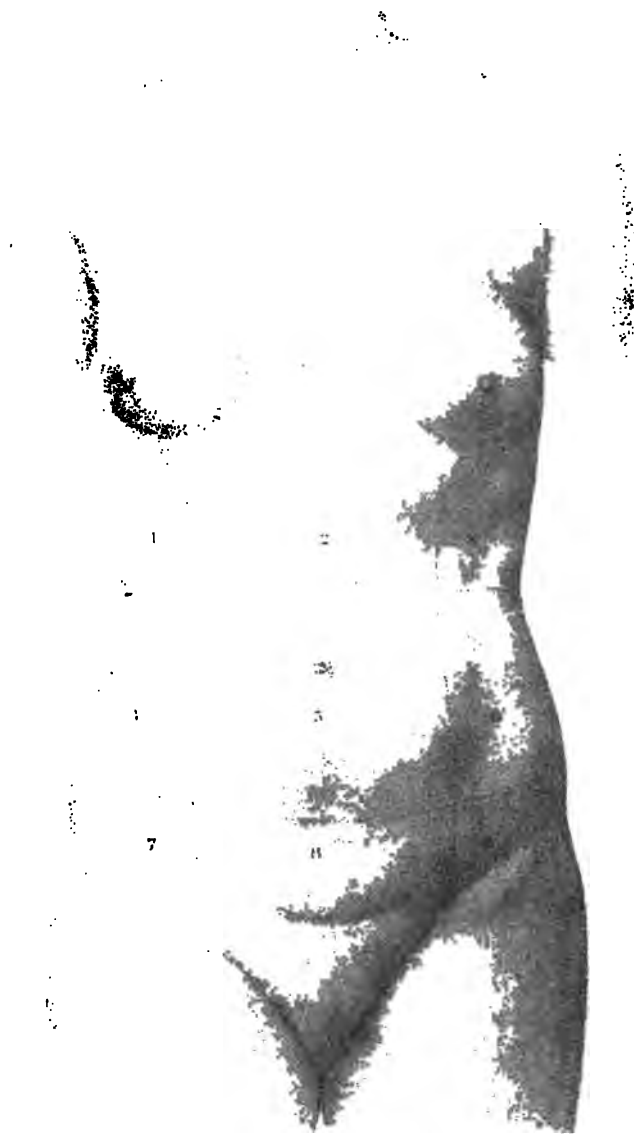Structure of Pelvic Floor with regard to function.

HITHERTO we have regarded the pelvic floor in detail as made up of bladder, vaginal walls, rectum, connective tissue, and peritoneum. In this chapter we purpose considering it in its structural aspect. In its formation, the following functions have been provided for. As compared with the floor of the male pelvis, the female pelvic floor differs in having in it the cleft known as the vagina. Then further, women have to undergo parturition in which the child is born through the vagina, which is then greatly distended. At the same time a woman has resting on her pelvic floor the same abdominal viscera as the male, and her pelvic floor is also subjected to the same strain from intra-abdominal pressure. Thus we have to explain how the female pelvic floor has been constructed so as to allow of parturition and yet remain strong enough to resist ordinary intra-abdominal pressure. The question is a *structural* or architectural one. We study it in this present chapter just as we would study the structure of a box or chair.

Its appearance in Sagittal Mesial Section.

In order to understand this question, we must look at the pelvic floor in sagittal mesial section as at fig. 40. In this view we see the pelvic floor or diaphragm stretching from symphysis pubis to sacrum. The anus is to be imagined closed as in life. The first thing to note is the vagina, which is seen as a cleft running upwards in the pelvic floor from hymen to cervix uteri. Its walls are in close apposition (*vide* figs.





ANTERIOR VIEW OF ABDOMEN AND THORAX. THE SECTION IS SHOWN AT 7.

- | | | |
|-------------------------|-------------------------|-------------------|
| 1. Right Pleural Cavity | 2. Esophagus | 3. Left Diaphragm |
| 4. Right Lung | 5. Liver | 6. Left Lung |
| 7. <i>Ab. Wall</i> | 8. H. <i>Ab. Cavity</i> | 9. Left Intestine |

Diagram of the human body, showing the position of the organs.

(RUBINER)

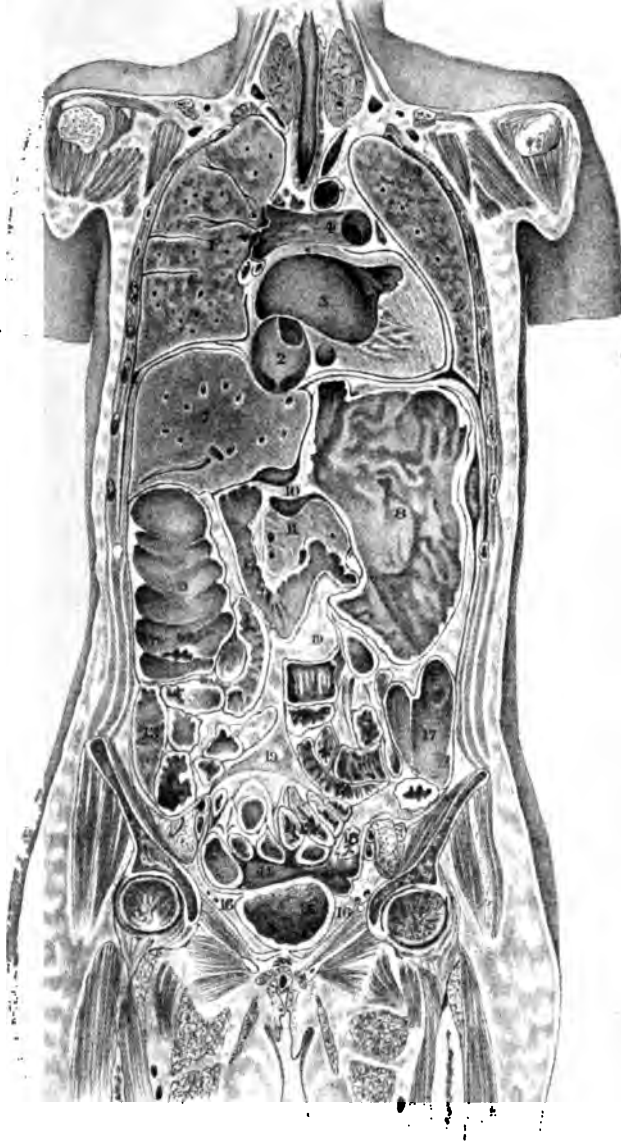


PLATE II. -CORONAL SECTION OF FROZEN FEMALE CADAVER
(RUEDINGER).

passim). They are often erroneously represented apart; in order, as it were, to let the student *see* the vagina. This is wrong, however. It is no more necessary to figure the vaginal walls always apart, than it would be always to sketch a man with his mouth open to render it visible. The first idea one gets on looking at such a section is that, owing to the apposition of the vaginal walls, the pelvic floor in the woman is unbroken; and that the vaginal cleft, the introduction of which does weaken the floor somewhat, cuts the floor not perpendicularly to the horizon but obliquely at an angle of about 60°.

The pelvic floor, as seen in this section, is made up of two segments which are known as the *pubic* and *sacral* segments. It is of importance to define these exactly.

The *Pubic Segment* is made up of loose tissue, viz., bladder, urethra, anterior vaginal wall, and bladder-peritoneum. It is attached in front to the symphysis pubis. This attachment is a loose one; the bladder and urethra, meeting one another at right angles, are separated from the pubis by the pyramidal deposit of loose fat already described as the retropubic fat deposit. Note specially that the retropubic fat deposit as seen in this section—that of a woman in the dorsal or the erect posture—is triangular; and that the peritoneum passes from the anterior abdominal wall on to the fundus of the bladder, just a little above the top of the symphysis.

The *Sacral Segment* is attached to the coccyx and sacrum; it consists of rectum, perineum, and strong tendinous and muscular tissue. The inferior portion of this segment, the perineum, lies about 1½ inches from the symphysis.

So far we have described the mesial attachments of the segments. The pubic segment, however, is also attached on each side to the anterior bony pelvic wall, while the sacral segment is attached in a like manner to the posterior bony pelvic wall. Finally, these two segments blend with one another on the right and left sides of the vagina.

The two segments are thus *anatomically* contrasted:—

The pubic segment is made up of loose tissue, and is loosely attached to the pubic symphysis; the sacral segment is made up of dense tissue and is firmly dovetailed into the sacrum and coccyx.

The Seg-
ments
contrasted.

They are further contrasted *functionally*:—

The pubic segment is drawn up during labour; the sacral segment is driven down.

The proof for this functional contrast is too elaborate to be given

here, and will be found in detail in Dr. Hart's atlas. It may be briefly explained, however, that during labour the pubic and sacral segments act like two folding doors. Uterine action pulls up the pubic segment, and drives the child down against the sacral one. This action is analogous

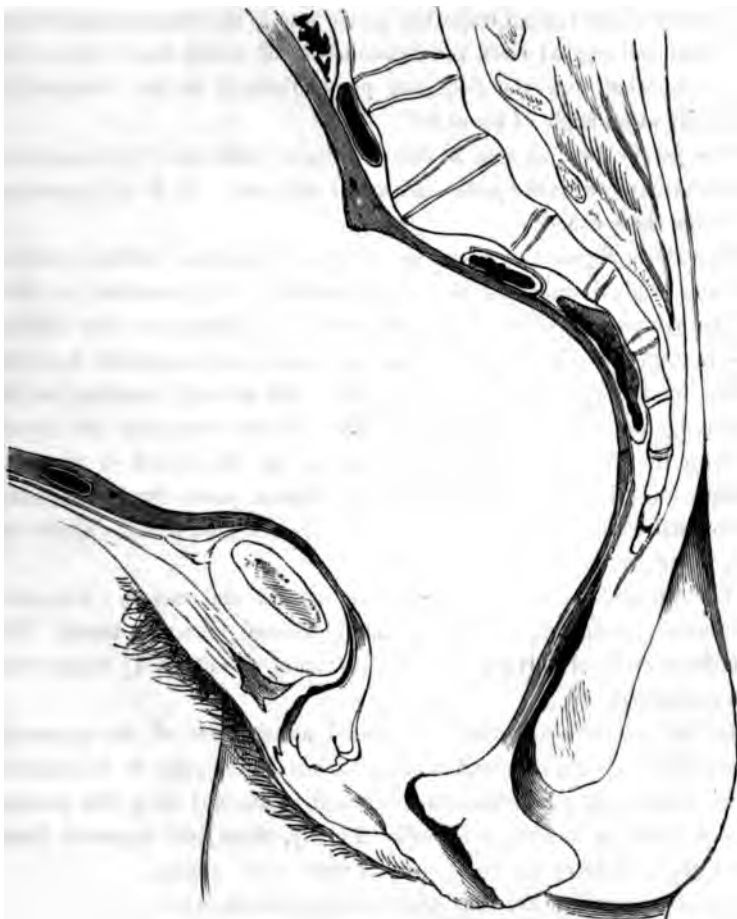

FIG. 56.

PELVIC FLOOR differentiated in parturition (*Braune*). The Pubic Segment is drawn up and the Sacral one driven down. Note position of bladder and its peritoneum: for lettered description, see fig. 43.

to the way one passes out through two folding doors, where he pulls the one door towards him and pushes the other from him.

As the result of this elevation of the pubic segment, the bladder is drawn above the pubis and its peritoneum stripped off (fig. 56).

In addition to the retropubic fat deposit, it should be noted that—

- a. The posterior wall of the bladder is *loosely* attached to the anterior vaginal wall ;
- b. The urethra and anterior vaginal wall are *closely* blended ;
- c. The posterior vaginal wall and anterior rectal wall are *loosely* connected, as far down as the apex of the perineal body (fig. 35).

There are three lines of cleavage in the pelvic floor (fig. 57).

1. **Physiological**, between the vaginal walls ; all in front of this line is drawn upwards in parturition.
2. **Pathological**, between the posterior vaginal and anterior rectal walls ; all in front of this is displaced downwards in prolapsus uteri.
3. **Bimanual**, between the anterior and posterior rectal walls ; all in front of this is displaced on bimanual recto-vaginal examination.

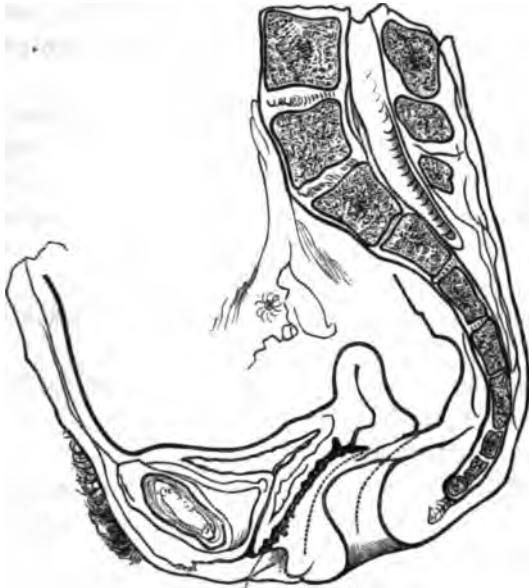


FIG. 57.

Lines of cleavage indicated by dotted lines. From before backwards they are—1. Physiological
2. Pathological ; 3. Bimanual (*Hart*).

From the structural arrangement of the pelvic floor, the following changes result, as will be shown more fully afterwards :—

1. There is a definite opening up of the pelvic floor during parturition and when a woman assumes the genupectoral posture with the vaginal orifice opened up ;
2. There are produced definite displacements of the pelvic floor

when the various specular means of exploring it are employed and under excessive intra-abdominal pressure or hypertrophic growths of the cervix.

The nomenclature employed should be noted. It is better to speak of the pubic segment being separated from the sacral one than of the vaginal walls being apart. The vaginal walls are not special structures, from this point of view. The anterior vaginal wall is the posterior boundary of the pubic segment; the posterior vaginal wall is the anterior boundary of the sacral segment. Thus they are analogous to the *edges* of two folding doors. We shall refer to this again under prolapsus uteri and examination with the Sims speculum.

The support of the Uterus.

The question of the support of the uterus is still disputed. The broad and round ligaments have nothing to do with its support; they are only useful as giving fixed points for the contracting uterine muscle during parturition. The utero-sacral ligaments, however, probably help in supporting the uterus.

Many allege most erroneously that the vagina supports the uterus, as if the vagina were a special structure. *The chief support is the compact unbroken pelvic floor*, on which the uterus rests just as one sits on a chair. It is the whole pelvic floor that supports the uterus and viscera, not the perineum alone. The perineum is only a small though strong part of the sacral segment.

Displacement of the Pubic Segment.

The various components of the pubic segment are definitely displaced in its movements. Thus the retro pubic fat is—

1. Behind the pubis in the nonparturient female (fig. 52);
2. Above it in the parturient female (fig. 56);
3. Below it in prolapsus uteri;
4. Below it in the extra pelvic-floor projection of pregnancy;
5. Partially above the symphysis in the genupectoral posture (fig. 65).

The peritoneum is—

1. Reflected on to the top of the empty bladder in the nonparturient female;
2. Stripped off the bladder during parturition;
3. Reflected on to fundus of empty bladder, at a higher level above symphysis, in the genupectoral posture.

Thus the peritoneum over the bladder is movable; the peritoneum over the sacral segment is fixed.

It will now be seen that the structural problem stated at the beginning of the chapter is solved thus. The sacral segment, strengthened at its

tip by the perineal body, is the supporting one; it supports the pubic segment, just as the hand at fig. 58 holds the pessary. The anterior margin of the sacral segment stops short of the pubis by about $1\frac{1}{2}$ inches, and this interspace is filled up by the pubic segment. Intra-abdominal pressure presses the pubic segment against the oblique sacral one, which closes the pelvic outlet, therefore, like a valve; excessive intra-abdominal pressure displaces, in prolapsus uteri, a definite part of the pelvic floor, viz., all in front of the anterior rectal wall.

A further development of this will be found in the chapter on Prolapsus uteri.

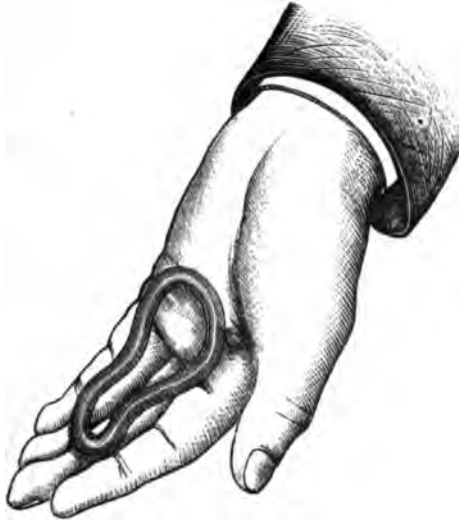

FIG. 58.
Hand holding Pessary.

PELVIC-FLOOR PROJECTION.

By this is understood the amount of projection of the pelvic floor, in sagittal mesial section, beyond the straight line joining the tip of the coccyx and the subpubic ligament—conjugate of outlet (fig. 59). Definition of Pelvic-Floor Projection.

Definite results have not as yet been obtained, but this is one special reason why attention should be directed to it.

Schroeder measured the conjugate at the outlet with callipers; and then passed a measuring line from the coccyx to the apex of the pubic arch, the tape following the curve of the pelvic floor. The subjoined table gives some of his results.

	Distance from tip of coccyx to lower border of symphysis.	
	By Tape Measure.	By Callipers.
Average of the pregnant woman	c.m. 13.35	9.15
„ „ gynecological patients	„ 12.6	8.27
„ „ nulliparæ	„ 13.2	8.75

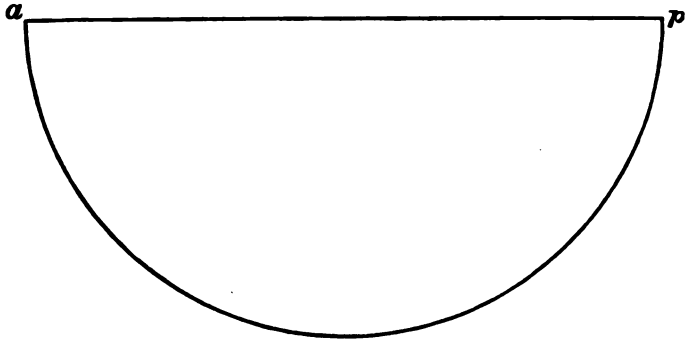


FIG. 59.

DIAGRAM to show what is meant by PELVIC-FLOOR PROJECTION. $a-p$ =conjugate of outlet. A perpendicular bisecting $a-p$ and cutting the arc gives the greatest pelvic-floor projection (*F. P. Foster*).

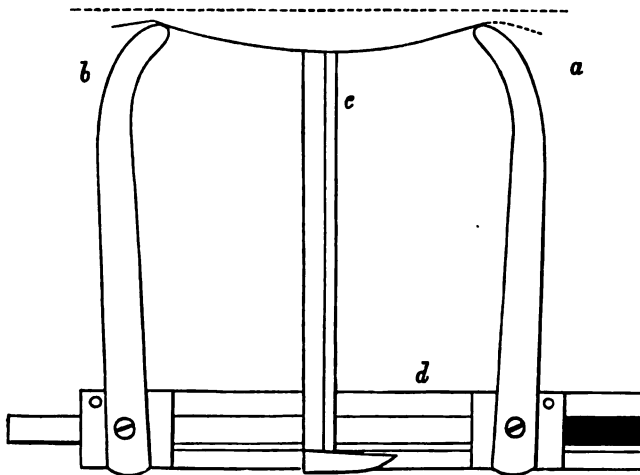


FIG. 60.

CALLIPERS for measuring PELVIC-FLOOR PROJECTION (*Foster*).

Schroeder's deduction is that the average projection of the pelvic

floor beyond the plane of the pelvic outlet is 4.1 cm. There is no doubt that this is an excessive average.

F. P. Foster of New York has written ably on this subject, and made a large series of observations. Fig 60 shows the callipers he employed. An end of each limb (*a* and *b*) is placed on the tip of the coccyx and lower border of the symphysis pubis. The horizontal bar between these limbs is graduated in c.m., and the limb (*a*) glides along it in a groove. A movable upright (*c*), also graduated, ^{Mode of measuring Pelvic-Floor Pro-}jection.

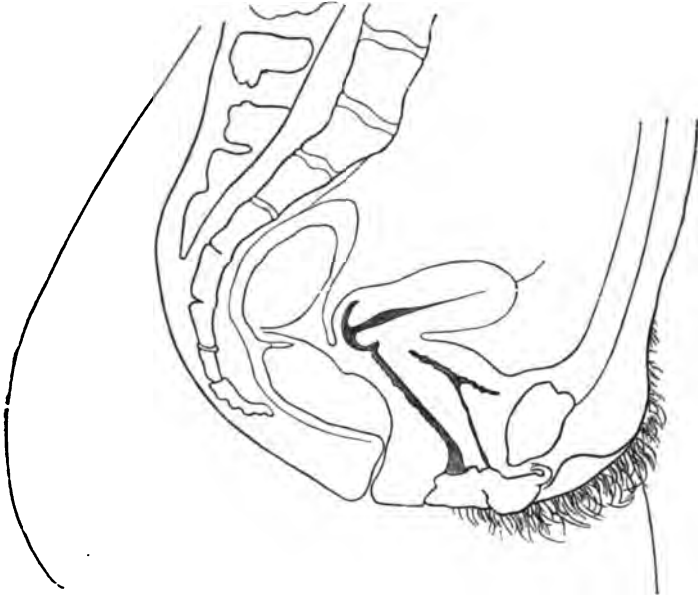


FIG. 61.

DIAGRAM OF PELVIC-FLOOR PROJECTION and position of uterus, modified from Foster.

has its upper point placed against the most projecting part of the pelvic floor. If now the whole apparatus be removed and laid flat on a sheet of paper, the conjugate and amount of projection can be read off at once. Greater accuracy is ensured by noting, before removing the apparatus, the point on the transverse bar at which the upright (*c*) stands as well as the reading which it gives.

Foster's average (2.5 cm.) of the pelvic-floor projection is less than Schroeder's. He placed his patient semiprone, however; a position in which the pelvic-floor projection is slightly diminished. Fig. 61 shows

Foster's diagram of pelvic-floor projection. The uterus has been more anteverted than in Foster's original drawing.

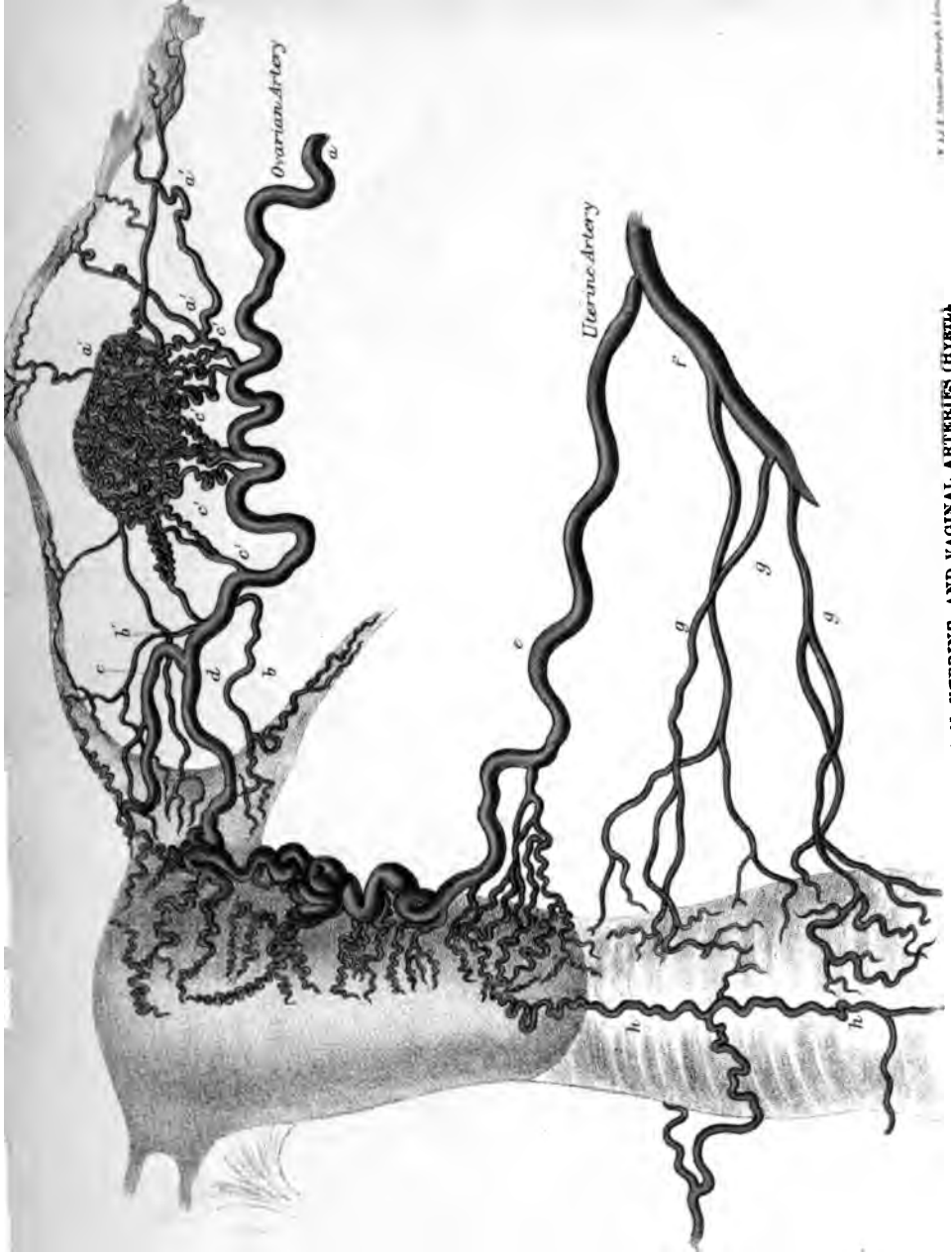Measurements made on frozen sections must be used with caution. Schroeder has justified his average by such measurements, but has taken no account of the existence of pregnancy in some of the cases.

We might tentatively advance the following statements:—

Summary
as to Pelvic-
Floor Pro-
jection.

- (1.) The pelvic-floor projection is over-estimated by Schroeder ;
- (2.) Foster's and Schultze's average is nearer the mark ;
- (3.) The retropubic fat gives a rough index of the position of the pubic segment. (Figs. 41, 42, 50) ;
- (4.) The pelvic-floor projection is increased by advanced and even by early pregnancy (Braune's Plates).

The whole enquiry needs further investigation in order to settle also other points, among which we may mention the relation of the vagina to the pelvic outlet and the varying amount of pelvic-floor projection in different postures.



The first part of the document discusses the importance of maintaining accurate records of all transactions. It emphasizes that proper record-keeping is essential for ensuring the integrity and reliability of financial data. This section also outlines the various methods and tools used to collect and analyze financial information, highlighting the need for consistency and transparency in the reporting process.

The second part of the document focuses on the challenges and opportunities associated with digital transformation in the financial sector. It explores how emerging technologies, such as artificial intelligence and blockchain, are reshaping traditional business models and creating new avenues for growth. The text also addresses the risks of cyber threats and the importance of robust security measures to protect sensitive financial data.

The third part of the document examines the role of regulatory bodies in maintaining market stability and protecting investors. It discusses the impact of recent regulatory changes and the need for ongoing collaboration between industry stakeholders and regulators to address emerging risks and ensure a level playing field for all participants in the market.

The fourth part of the document provides a detailed analysis of the current economic environment and its implications for the financial industry. It discusses the effects of inflation, interest rate changes, and global economic uncertainty on market performance and investor behavior. The text also offers insights into the strategies that financial institutions can adopt to navigate these challenges and capitalize on emerging opportunities.

In conclusion, the document underscores the need for continuous innovation, collaboration, and risk management in the financial industry. It calls for a proactive approach to addressing the challenges of the future and a commitment to upholding the highest standards of ethical conduct and transparency.



CHAPTER IV.

THE BLOOD-VESSELS, LYMPHATICS, AND NERVES OF THE PELVIS: DEVELOPMENT OF PELVIC ORGANS.

LITERATURE.

- BLOOD-VESSELS.** *Hyrtl*—Die Corrosions-anatomie und ihre Ergebnisse, W. Braumüller: Wien, 1873. *Hentle*—Handbuch der Eingeweidelehre des Menschen: Braunschweig, 1866. *Klein and Smith's Atlas.* *Luschka*—Die Musculatur am Boden des weiblichen Beckens: Wien, 1861. *Quain*—Anatomy, 8th Ed.: London, 1882. *Sappey*—Traité d'Anatomie Descriptive: Paris, 1873. *Savage*—Female Pelvic Organs, 5th Ed.: London, 1882.
- LYMPHATICS.** *Bourguery and Jacob*—Traité Complet de l'Anatomie de l'Homme: Paris, 1839. *Championnière*—Lymphatiques Utérines et Lymphangite Utérine: Bull. de la Soc. Med. des Hôpitaux de Paris, Vol. VII. *Curnow*—The Lymphatic System and its Diseases, Lancet, 1879. *Klein*—The Anatomy of the Lymphatic System: London, 1873. *Le Bec*—Contributions à l'Etude des Ligaments larges, etc.: Gaz. Heb., 15 Avril 1881. *G. Leopold*—Die Lymphgefäße des normalen nicht schwangeren Uterus: Archiv. für Gynäk., Bd. VI., S. 1. *W. T. Lusk*—Puerperal Fever: International Congress Tr., Philad., 1877. *Sappey, Savage*—Op. cit. Curnow's article is one of the best.
- NERVES.** *T. Snow Beck*—The Nerves of the Uterus: Phil. Tr., 1846. *Flower*—Diagrams of the Nerves of the Human Body: J. and A. Churchill, London, 1872. *Frankenhäuser*—Die Nerven der Gebärmutter und ihre Endigung in den glatten Muskelfasern: Jena, 1867. *R. Lee*—The Anatomy of the Nerves of the Uterus: London, Baillière, 1841. *Tiedemann*—Tabulæ Nervorum Uteri: Heidelberg, 1822.
- DEVELOPMENT OF THE PELVIC ORGANS.** *Fowlis*—The Development of the Ova, and the Structure of the Ovary in Man and the other Mammalia: Tr. R. S., Edin., Vol. XXVII. *Klein and Smith, Quain*—Op. cit. *Turner*—Introduction to Human Anatomy: Edin., 1882.

BLOOD-VESSELS.

Preliminary Remarks:—The blood supply to the pelvic organs and perineum is derived from the ovarian arteries (which are branches of the abdominal aorta), and from the uterine, vaginal, and internal pudic arteries (which are all branches of the anterior division of the internal iliac).

We consider the arterial supply of the uterus, ovary, Fallopian tubes, vagina, bladder, and rectum; that of the perineal region; and lastly, the venous distribution.

ARTERIAL SUPPLY.

(1.) *Arterial supply to uterus, ovary, etc.*—The *Ovarian artery* of each side (corresponding to the spermatic of the male) is a branch of the abdominal aorta. Its relations when in the abdomen do not concern

Arterial supply of Uterus and Ovary.

us here. In the pelvis it passes between the layers of the broad ligament, running tortuously towards the upper angle of the uterus. Near this it divides into two branches. The upper supplies the fundus uteri; the lower anastomoses at the side of the uterus with the uterine artery (Plate III. *c, d*).

The Ovarian Artery gives off—

Branches to the ampulla of the Fallopian tube (Plate III. *a' a'*),

Branches to the isthmus (*b'*),

Numerous branches to the ovary (*c' c' c'*),

Branch to the round ligament (*b*).

The *Uterine Artery* (Plate III. *e*) springs from the anterior division of the internal iliac, and passes downwards and inwards towards the cervix uteri. It then passes upwards between the layers of the broad ligament by the side of the uterus, in an exceedingly tortuous manner well shown in Plate III., to anastomose with the lower branch of the ovarian. Branches pass from it into the substance of the uterus: these are the curling arteries of the uterus. The *Vaginal arteries* (*g g g*) usually spring immediately from the anterior division of the internal iliac artery, but sometimes arise from the uterine or middle hæmorrhoidal. A special branch of the uterine artery to the cervix joins with its fellow at the isthmus to form the circular artery, and with those of the vagina to form the azygos artery of the vagina (*h h*). The vaginal arteries of one side anastomose freely with those of the other. Plate III., from Hyrtl, illustrates beautifully the free anastomosis of branches of the aorta with the ovarian, uterine, and vaginal arteries. It should be noted that, in operation for removal of the uterus, ligature of the broad ligament controls all hæmorrhage.

From the same anterior division of the internal iliac proceeds the blood supply to the bladder and rectum.

Arterial
supply of
Perineum.

Arterial supply to the perineal region.—This comes from the internal pudic. The superficial perineal branch supplies the labia; the artery to the bulb supplies the bulbos vaginæ; the terminal branches go to the clitoris.

VENOUS SUPPLY.

Veins of
Pelvis.

The venous supply of the pelvis is very abundant, and exists in the form of numerous plexuses freely communicating with one another. The veins are unprovided with valves; hæmorrhage from a wound is therefore often exceedingly profuse, especially during pregnancy when the whole pelvic vascular system is hypertrophied.

BLOOD-VESSELS AND LYMPHATICS OF PELVIS. 67

The following is a summary of the main facts as to the venous supply of the female pelvis.

The *Vesical plexus* lies external to the muscular coat of the bladder. The *Hæmorrhoidal plexus* lies below the mucous membrane of the lower part of the rectum.

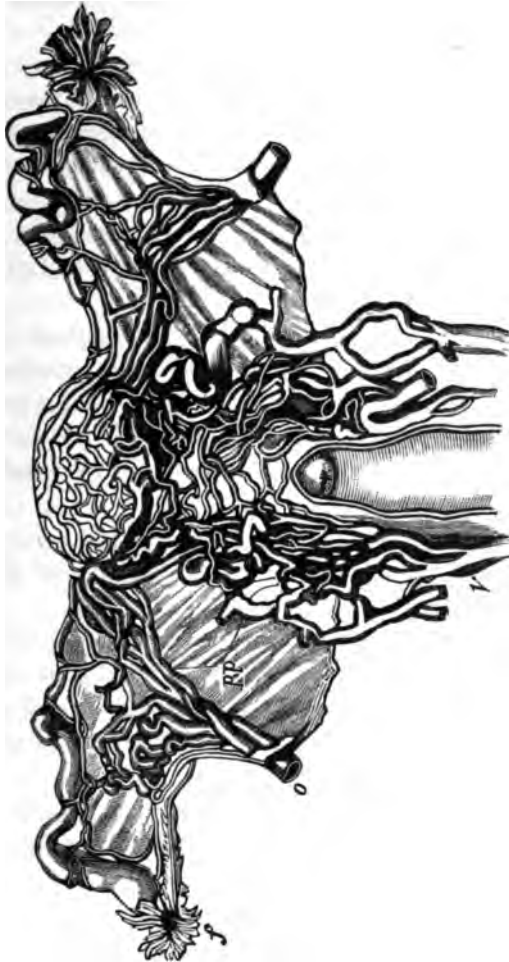


FIG. 62.
UTERUS AND VAGINA WITH THEIR VENOUS SUPPLY, SEEN FROM BEHIND—(Luscka). / Fallopian tube; pp
parametrial plexus.

The veins of the *labia* correspond in distribution to the arteries, and those from the outermost parts drain into the pudic which opens into the common iliac vein. Large veins from the labia minora open into the *pars intermedia* of the bulb.

The veins from the *glans* and *corpora clitoridis* pass into the dorsal vein of the clitoris, which communicates with the vesical plexus.

The veins of the *bulb* pass into the vaginal plexus.

The *Vaginal plexuses*—one outside the muscular coat and one in the submucous tissue—are most abundant at the lower part of the vagina, communicate with the hæmorrhoidal and vesical plexuses, and open into the internal iliac vein.

The *Uterine plexus* is very abundant, as is well shown in one of Hyrtl's plates; it ultimately opens into the ovarian veins (fig. 62), which pass, on the right side to the inferior vena cava, on the left to the left renal vein. The veins are small, lie in the outer muscular coat, and run longitudinally; in the middle layer of that coat they open into large sinuses (surrounded by circular unstriped muscle) with which the capillary vessels communicate. This is an arrangement like that in the corpus spongiosum of the penis (*Klein*).

The *Ovarian plexus*, otherwise known as the pampiniform plexus, lies between the folds of the broad ligament and communicates with the uterine plexus (fig. 62). Some apply this term to all the veins in the broad ligament. The ovarian plexus opens into the inferior vena cava. Just at the hilus of the ovary lies the collection of veins known as the bulb of the ovary.

Beneath the peritoneum and between the layers of the broad ligaments are vast venous plexuses. Knowledge on this point is of the highest importance in relation to pelvic hæmatocæle.

The vesical, hæmorrhoidal, and vaginal plexuses, with the pudic veins, open into the internal iliac vein which joins the inferior vena cava.

From the hæmorrhoidal plexus, the superior hæmorrhoidal vein passes into the portal system; and thus we get a communication between the pelvic and portal venous systems.

In the vaginal mucous membrane, clitoris and uterus, we have erectile tissue, *i.e.*, veins in connective tissue with unstriped muscular fibre.

LYMPHATICS.

Under this we take up—

- a. The Lymphatic Glands;
- b. The Lymphatic Vessels.

Lymphatic Glands. a. *The Lymphatic Glands*.—These are (1.) the *inguinal glands*, which lie parallel to and just below Poupart's ligament; and (2.) the *pelvic glands*. These latter consist of the following:—

- (a) A gland at the isthmus uteri (*Championnière*);
- (b) Hypogastric glands, which lie subperitoneally in the space between the external and internal iliac vessels;
- (c) Sacral, on the lateral aspect of the anterior surface of the sacrum and in the mesorectum; and
- (d) A gland or collection of small glands at the obturator foramen—the obturator gland of Guérin.

These all pour into the lumbar glands, which lie in front of the lumbar vertebrae and discharge into the thoracic duct.

b. The Lymphatic Vessels. (1.) *Of External Genitals.*—Numerous Lymphatic Vessels of External Genitals, vessels form a network on the internal aspect of the labia majora, over the labia minora, and round the vaginal and urethral orifices, vestibule, and clitoris; all of these open into the inguinal glands. From this arrangement, the enlargement of the inguinal glands in syphilis and vulvar cancer is intelligible. The lymphatics of the lower fourth of the vagina also open into these glands.

(2.) *Of Vagina (upper three-fourths) and Cervix Uteri.*—These lymphatics Of Vagina, open into the hypogastric glands.

So far we have followed Sappey's description. Le Bec, however, asserts that the lymphatics of the vagina pour into a series of trunks at the level of the isthmus uteri, and that those of the cervix join them; and that the conjoined lymphatics then pass below the base of the broad ligament to the obturator gland, from which vessels communicate with others from the thigh and even from the epigastrium.

The relation between lymphatics and glands is as follows:—

- (a) Those of the external genitals pass into the inguinal glands;
- (b) The lymphatics of the bladder, vagina, and cervix pass to the hypogastric glands (*Sappey*). According to Le Bec, they pass to the obturator gland.

(3.) *Of Uterus.*—The lymphatics of the body of the uterus pass Of Uterus, through the broad ligaments; and, along with those from the ovary and Fallopian tube, enter the lumbar glands. If Le Bec be right, the lymphatics from the cervix pass below the broad ligament and those from the uterus along the upper part of the same. Some of the uterine lymphatics pass along the round ligament to the groin.

Leopold, who has investigated the lymphatics in the unimpregnated uterus, considers "the mucous membrane of the uterus as a lymphatic surface which contains no special lymphatic vessels, but consists of lymph sinuses covered with endothelium" (cf. p. 20).

“The lymph passes from the lymphatic spaces of the mucous membrane, through the mucous membrane hollows, into the lymph spaces and vessels of the muscular coat, surrounds here all the bundles up to the serous covering, and flows into the larger vessels which enter the broad ligament in the neighbourhood of the blood-vessels” (*loc. cit.*, S. 31).

These are matters not of mere anatomical detail, but of the very highest pathological and practical importance. The richness of blood and lymphatic supply to the vagina, cervix, and uterus explains the extraordinary rapidity with which septic matter spreads through the body, and the extreme danger which may attend even an insignificant lesion of the internal genital organs, when septic matter is present and is absorbed. We may remark here that septic matter will of course follow the lymphatic routes already laid down, and that bacteria can penetrate the walls of blood-vessels and pass into the general circulation. It should not be forgotten, however, that the bacteria passing along the lymphatic vessels may penetrate them, pass into the peritoneal cavity, and thence spread through the diaphragm to set up the pleurisy and pericarditis so common in septicæmia (*Lusk*). Thorough comprehension of lymphatic distribution and knowledge of the evil effects of septic matter are of the first importance to the student.

The lymphatics of *the Rectum* lie in two layers (mucous and muscular), and open into the glands of the mesorectum or into the sacral glands.

The stomata of the peritoneum of the pelvis communicate with lymph capillaries lying in the subendothelial tissue.

Relation
between
Glands
and Lym-
phatics.

The *Inguinal Glands* (parallel to Poupart's ligament) receive the lymphatics of the vulva, lower $\frac{1}{4}$ th of vagina, and urethra.

The *Hypogastric or Internal Iliac* receive those of the bladder, upper $\frac{2}{3}$ ths of vagina and neck of uterus.

The *Sacral Glands* receive those from the rectum.

The *Lumbar Glands* receive the lymphatics from the pelvic glands, body of the uterus, Fallopian tubes, and ovaries.

NERVES.

Pelvic
Nerves.

These are (a) Spinal ; (b) Sympathetic.

(a) *Spinal*. The following is the nervous supply of the pelvic muscles :—

Levator and Sphincter ani are supplied by inferior hæmorrhoidal branch of pudic, 4th and 5th sacral, and coccygeal nerves ;

Coccygeus, by 4th and 5th sacral and coccygeal nerves ;

Muscles of Perineum and Clitoris, by the branches of pudic nerve.

(b) *Sympathetic*. The hypogastric plexus lies between the common iliac arteries; it gives off branches which, reinforced by branches from the lumbar and sacral ganglia and sacral nerves, form the *inferior hypogastric plexuses*—one on each side of the vagina. From these, filaments proceed to the vagina, uterus, Fallopian tube, and ovary.

The terminations of the nerves in the muscular layers of the uterus have been studied by Frankenhäuser, who figures them passing to the nuclei of the unstriated muscle. Those entering the mucous membrane are said to end in ganglia. Numerous end bulbs have been found in the clitoris and vagina.

DEVELOPMENT OF PELVIC ORGANS.

The following is a very brief summary:—

The *Wolffian bodies* appear in the fœtus about the third and fourth ^{Develop-} week. They fulfil the function of kidneys until the second month, and ^{ment.} then wither.

The *Fallopian tubes*, *uterus*, and *vagina* are derived from the Ducts of Müller. These appear on the anterior aspect of the Wolffian bodies. Their lower portions coalesce to form the uterus and vagina; while, above, they remain separate, as the Fallopian tubes.

The *ovary* first appears as a thickening on the Wolffian bodies. It is made up of interstitial tissue projecting from them and covered by epithelium—the germ epithelium. According to Foulis, the ova are developed from the latter; the cells of the *membrana granulosa* are formed from the connective tissue corpuscles of the interstitial tissue. Waldeyer believes that the ova and the cells of the *membrana granulosa* both originate from the germ epithelium; and in this Balfour agrees with him (*vide* Chap. XX.)

The *parovarium* arises as a small distinct structure at the summit of each Wolffian body. It persists in the female (fig. 22). In the male it forms the epididymis.

The *clitoris* develops from a small eminence at the front of the urogenital sinus.

Up to the second month of foetal life the genital, urinary, and intestinal ducts open into the cloaca; which then becomes divided by a transverse partition into a posterior anal, and anterior urogenital sinus. The *vestibule* in the adult female is simply the lower part of the latter sinus.

The *labia minora* result from the non-coalescence of folds analogous

to those which, by their coalescence, form in the male the corpus spongiosum urethræ.

The *labia majora* are two folds which remain separate in the female, but coalesce in the male to form the scrotum.

The *two bulbi vaginae* are homologous to the corpus spongiosum urethræ.

For fuller details, see *Turner and Quain*.

CHAPTER V.

PHYSICS OF THE ABDOMEN AND PELVIS, WITH SPECIAL REFERENCE TO THE SEMIPRONE AND GENUPECTORAL POSTURES.

LITERATURE.

W. Braune—Die Oberschenkelvene des Menschen in anatomischer und klinischer Beziehung : Leipzig, Veit and Co., 1871. *J. M. Duncan*—On the Retentive Power of the Abdomen : Researches in Obstetrics, p. 409. *Hart*—The Structural Anatomy of the Female Pelvic Floor. *Simpson and Hart*—The Relations of the Abdominal and Pelvic Organs in the Female. *Schatz*—Beiträge zur physiologischen Geburtskunde : Archiv. für Gynäk., Bd. IV., S. 191. Einfluss der Lehre vom intraabdominalen Drucke auf die Gynäkologie : Archiv. für Gynäk., Bd. V., S. 227. *Van de Warker*—A Study of the Normal Movements of the Unimpregnated Uterus : N. Y. Med. Jour., Vol. XXI., p. 337.

In this chapter it is proposed to give a brief sketch of a subject of the highest importance but still in its infancy. The *resumé* must be restricted, from want of space, to certain practical points ; we consider here the following :—

1. *The effect of intra-abdominal pressure on the female pelvic floor ;*
2. *The results brought about by change of posture, especially by the genupectoral posture ;*
3. *The effect on uterine position of digital pressure in the vaginal fornices.*

THE EFFECT OF INTRA-ABDOMINAL PRESSURE ON THE FEMALE PELVIC FLOOR.

We suppose the woman to be in the upright posture. For simplicity, the pelvic floor is considered as being under fluid pressure. Fig. 63 shows the effect of this on the pelvic-floor segments. Fluid pressure acts at right angles to the limiting surface, which in this case is the pelvic peritoneum. Thus, if the perpendiculars be counted, starting from the symphysis, it can readily be seen that the first three will press the pubic segment against the symphysis ; that the fourth and fifth will do this also, but will further have a resultant tending to drive the pubic past the sacral segment ; that the sixth and seventh will, directly, tend to do this ; and that the others will drive it partly past the sacral segment, and partly against it. From want of rigidity in the pubic segment,

Effect of
intra-ab-
dominal
pressure.

this driving down tendency is partly lost. Thus the effect of ordinary intra-abdominal pressure is to press the pubic against the sacral segment. Extra intra-abdominal pressure displaces downwards a definite portion of the pelvic floor, viz., all lying in front of the anterior rectal wall.

There is in the pelvic floor a definite line of cleavage at which it yields, which line runs between the anterior rectal and posterior vaginal walls (see p. 59). This definite downward displacement causes the lesion known as prolapsus uteri.

From this we see that the female pelvic floor is not equally strong

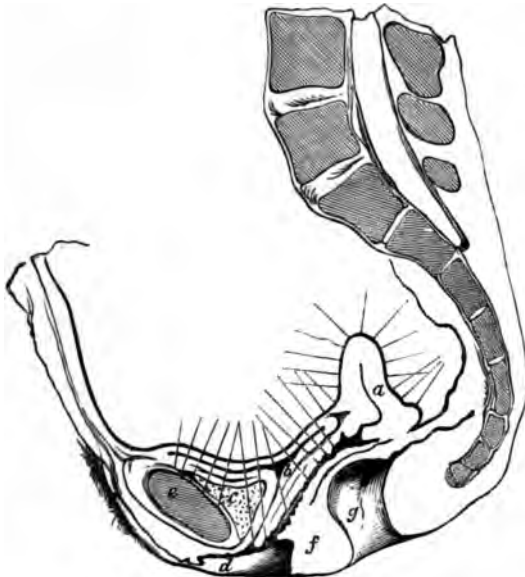


FIG. 63.

DIAGRAM to illustrate effect of intra-abdominal pressure on the segments of the pelvic floor (*Hart*).

a Uterus pathologically anteverted; *b* Bladder; *c* Retropubic fat; *d* Labium majus;
e Symphysis; *f* Perineal body; *g* Rectum.

throughout. It would be, were the sacral segment prolonged and attached to the symphysis pubis. But then parturition would have been an impossibility. It has been constructed not only *quâ* intra-abdominal pressure, but also *quâ* parturition and the vesical and rectal functions.

THE RESULTS BROUGHT ABOUT BY CHANGE OF POSTURE, ESPECIALLY
 BY THE GENUPECTORAL POSTURE.

The abdominal walls, along with the viscera bounded by them, are

often spoken of as the abdominal cavity with its contained viscera. We must, however, keep in mind that this cavity is always perfectly full. There is never any vacuum in it. The viscera are always in apposition, with only a little fluid as a film separating them. The abdominal walls are yielding, and any tendency to a vacuum is counteracted by atmospheric pressure on the walls. The vertical height of the abdomen is too small to admit of a Torricellian vacuum; and therefore it is no more wonderful that we have no vacuum in the abdominal cavity, than that there is no vacuum in an ordinary test-tube filled with water and with its open end immersed. There would be a vacuum if the test-tube were above 33 feet long; and so would there be in a race of giants, the vertical

Effect of
change of
Posture.




FIG. 64.

OUTLINE OF FEMALE FIGURE IN GENUPECTORAL POSTURE. The dotted line indicates the contour when the vaginal orifice is unopened; the continuous line, the change in contour after air is admitted into the vagina (*Simpson and Hart*).

height of whose abdominal cavity was such that the column of contained viscera could not be counterpoised by the atmospheric pressure. In no posture a woman can assume is there ever a vacuum in the abdominal cavity. However high the pelvis be, though the woman stand on her head, the small intestines still touch the uterus as they do in fig. 47 and Plate II. The abdominal walls and viscera enclosed by them behave, therefore, like a plastic viscous fluid—like so much thick gum or treacle.

When a woman is in the *upright posture*, the viscera bulge above the symphysis pubis, more or less, according to her development. Plate I. shows this bulging in a well-formed nude female; the bulging is excessive if the woman is fat. Just below the sternum, the antero-posterior diameter of the abdomen is lessened. The pelvic floor is convex as seen from without, *i.e.*, the pelvic-floor projection is well marked. Atmospheric pressure is acting equally all over the abdominal and pelvic surfaces; but the pelvic floor, bearing the weight of the

viscera, bulges more than the other boundaries of the abdomen. A fluid contained in a bag suspended from a fixed point is pyriform, with the bulb nearer the earth. This shape is due to the weight of the fluid.

If a woman be made to assume the *posture* known as the *genupectoral* (better *genufacial*), the bulge of the viscera is at the sternum. The following points should be noted in regard to this posture (fig. 64).

1. The antero-posterior diameter of the abdominal cavity is increased at the sternum.
2. It is diminished above the pubis and in the iliac fossæ.
3. The pelvic-floor projection is diminished.
4. The pubic and sacral segments are still in contact, and the abdominal viscera always in contact with the uterus and one another.

Let us now contrast these postures.

Upright posture (Plate I.)

Genupectoral posture (fig. 64).

Upright
and Genu-
pectoral
Postures
contrasted.

- | | |
|---|---|
| 1. Greatest antero-posterior (<i>a-p</i>) diameter of abdomen just above pubis. | 1. Greatest antero-posterior diameter at sternum. |
| 2. Least <i>a-p</i> diameter at sternum. | 2. Least <i>a-p</i> diameter below pubis. |
| 3. Pelvic-floor projection at its maximum. | 3. Pelvic-floor projection diminished. |
| 4. Pelvic-floor segments in contact. | 4. Pelvic-floor segments in contact. |

In the latter posture, on inspection of the genitals the labia can be seen to be furrowed, and the skin over the ischio-rectal fossa slightly hollowed. If now the labia majora and minora be separated and the fourchette lifted up, no further change as yet takes place: but when the hymen is opened up, air passes into the vagina (often with a distinct hiss), and the vaginal walls become separated, enclosing a somewhat large cavity. The bulge at the sternum is now slightly increased, while that above the pubis is diminished (see fig. 64). *It is only when the anatomical entrance of the vagina (the hymeneal orifice) is opened up, that the vagina distends with air.*

It has been shown by Drs. A. R. Simpson and D. Berry Hart, that the segments of the pelvic floor separate from each other when a woman assumes the genupectoral posture and the hymeneal orifice is opened. The pubic segment passes down with the viscera; the sacral segment remains behind, recoiling slightly upwards. *Thus functionally, the pubic segment is visceral, the sacral one is vertebral.*

They have shown further that there is quite a definite displacement of the pubic segment constituents, viz. :—

- a. The empty bladder is partly above the pubis ;
- b. The peritoneum passes from abdominal wall to symphysis, at a point $1\frac{1}{2}$ inches above the latter ;
- c. The retropubic fat is partly above and partly below the top of the symphysis. We may now once more contrast these postures.

<i>Upright posture</i> (Plate I.)	<i>Genupectoral posture</i> (with vagina distended by air) (fig. 65).	
1. Pubic and sacral segments in apposition and vagina a slit.	1. Pubic and sacral segments separated and vaginal walls bounding a cavity.	Result of distention of Vagina with Air.
2. Retropubic fat behind pubis.	2. Retropubic fat partly above pubis.	
3. Empty bladder behind pubis.	3. Empty bladder partly above pubis.	
4. Peritoneum passes from anterior abdominal wall to fundus of empty bladder, immediately above symphysis.	4. Peritoneum passes from anterior abdominal wall to fundus of empty bladder, $1\frac{1}{2}$ inches above symphysis.	
5. Urethra and bladder meet at a right angle.	5. Urethra and bladder almost in same line.	

The reason why the pubic segment passes downwards when the vaginal orifice is opened is, that atmospheric pressure now acts on the vaginal aspect of the pubic segment (with its weak mesial attachment to the pubis) and drives it further down. As the result of this posture, changes take place in the length and direction of the vaginal walls and in the position of the uterus. These are briefly :—

- 1. *Vagina*.—(a.) Both walls elongate.
 - (b.) The anterior follows the direction of the posterior aspect of the symphysis ; the posterior, the curve of the sacrum.
- 2. *Uterus*. — (a.) The normally placed uterus passes nearer the sacrum and nearer the thoracic diaphragm.
 - (b.) The retroverted uterus, fixed or unfixed, becomes more retroverted.
 - (c.) The retroverted unfixed uterus does not become replaced so as to lie anteverted.

The results given have been obtained as follows :—

a. By observation on living patients, aided by silhouettes of the outlines of the nude body in the upright and genupectoral postures ;

b. By study of frozen sections of the female pelvis, and especially by study of a frozen section of a cadaver placed in the genupectoral posture.

For further details on this subject Simpson and Hart's atlas may be consulted.

An important practical result follows from these observations. *The*

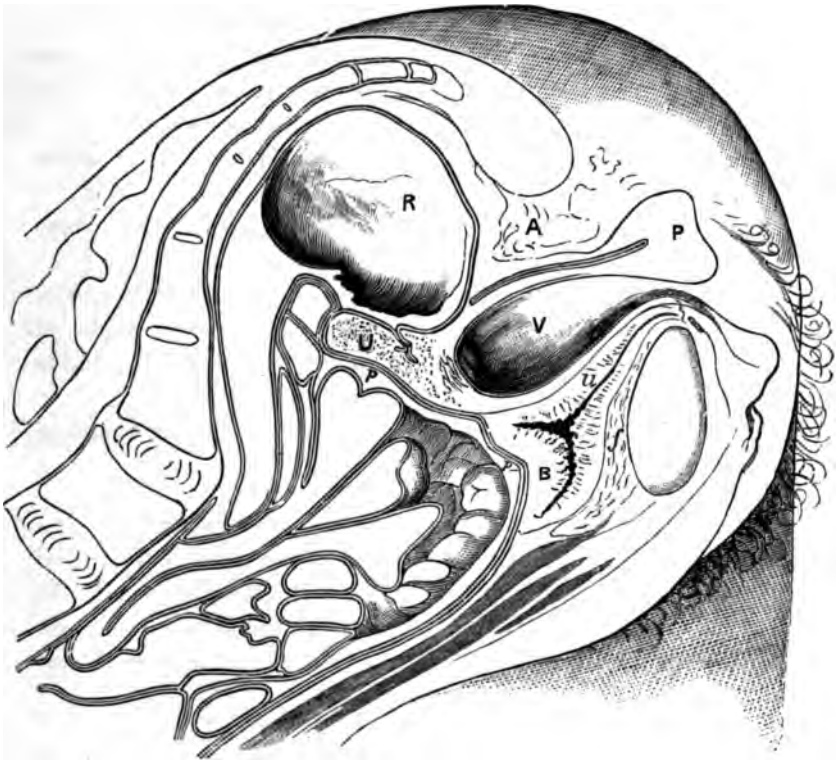


FIG. 65.

PELVIS IN FROZEN SECTION OF CADAVER IN GENUPECTORAL POSTURE. *A* anus ; *P* perineum ; *R* rectum ; *V* vagina ; *u* urethra ; *B* bladder ; *S* symphysis ; *f* retropubic fat ; *U* retroverted uterus ; *pp* peritoneum. Between the small intestine and peritoneum is fatty omentum (*Simpson and Hart*).

vagina dilates, or, more properly, the segments of the pelvic floor separate exposing their free margins—the vaginal walls—when a patient assumes the genupectoral posture and the hymeneal orifice is opened so as to admit air. If a patient be so placed opposite a good light, and the sacral segment be drawn up, a complete view of the vaginal walls and cervix

is obtained. The same results can be got by placing the patient in the posture known as the *semiprone*. On this last fact is based the use of the vaginal speculum known as Sims' Duckbill speculum (*v.* Chap. X.).

THE EFFECT ON UTERINE POSITION OF DIGITAL PRESSURE IN THE VAGINAL FORNICES.

This is a subject of great practical importance.

If, when a patient is lying on her left side, the index finger of the examiner's right hand is passed into the vagina as far as the posterior fornix, and pressure made there in the direction of the antero-posterior axis of the fornix, the following results may be noted :—

Effect of Digital Pressure in the Fornices.

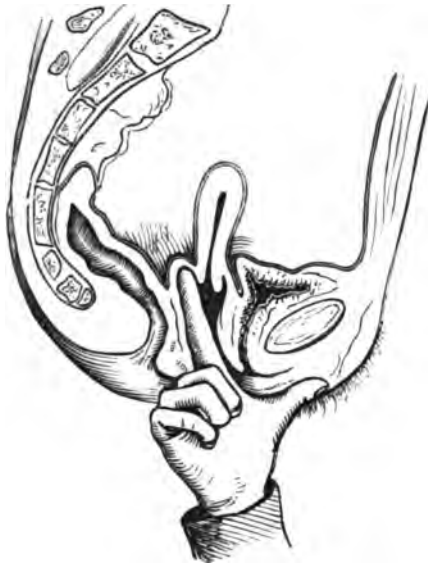

FIG. 66.

ANTEVERSION BEING PRODUCED BY DIGITAL PRESSURE IN POSTERIOR FORNIX.

(1.) The posterior vaginal wall is elongated, the cervix drawn back, and the uterus, if anteverted, becomes more so (fig. 66).

(2.) If the uterus is retroflexed, the flexion is not remedied. Should the fundus be fixed, the retroflexion is increased as the cervix is drawn back while the fundus remains.

Similarly, if pressure be made in the anterior fornix :—

(1.) The uterus becomes elevated and slightly rotated backwards, because the cervix is pulled forwards (fig. 67).

(2.) If the uterus is anteflexed, the flexion is not diminished.

By pressure in these fornices, therefore, we only act on the cervix, unless the uterus is very much retroverted or anteverted. The body of the uterus is acted on only indirectly, through its union with the cervix.

Consequently, no vaginal pessary can undo the flexion of a retroflexed or anteflexed uterus.

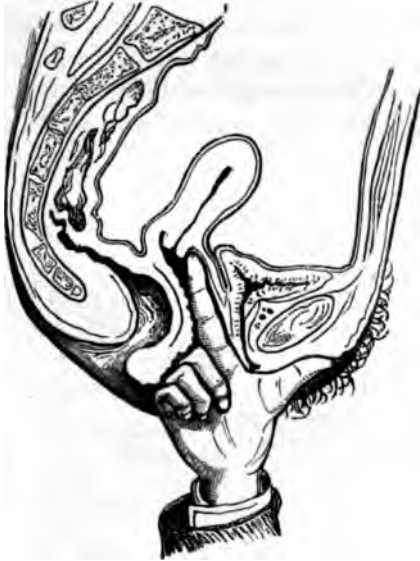

FIG. 67.

RETROVERSION OF UTERUS PRODUCED BY DIGITAL PRESSURE IN ANTERIOR FORNIX.

CHAPTER VI.

MENSTRUATION AND OVULATION.

LITERATURE.

Beigel—Die Krankheiten des weiblichen Geschlechtes: F. Enke, Stuttgart, 1875. *Dalton*—Report on the Corpus Luteum: Am. Gyn. Tr., Vol. II., p. 11. Physiology, 6th edition, J. and A. Churchill, 1876. *Engelmann*—The Mucous Membrane of the Uterus, with especial reference to the Development and Structure of the Decidua: Am. J. of Obst., Vol. VIII., p. 30. *Frey's Histology*—Barker's Tr., 1874. *Kinkead*—Med. Press, September 14, 1881. *Kundrat*—Untersuchungen über die Uterusschleimhaut: Strickers Jahrbuch, 1873. (Kundrat and Engelmann were co-workers.) *Leopold*—Studien über die Uterusschleimhaut während Menstruation, Schwangerschaft und Wochenbett: Archiv. für Gynäk., Bd. XI., S. 1091. *Loewenhardt*—Die Berechnung und die Dauer der Schwangerschaft: Archiv. für Gynäk., Bd. III., S. 456. *Mörcke*—Die Uterusschleimhaut in den verschiedenen Altersperioden und zur Zeit der Menstruation: Ztschr. für Geburtshilfe und Gynäk., VII. Band, 1 Heft, 1881. *Underhill*—Note on the Uterine Mucous Membrane of a Woman who died immediately after Menstruation: Ed. Med. J., 1875. *Simpson, A. Russell*—Emmenologia; Contributions to Obstetrics and Gynecology: Edinburgh, A. and C. Black. *Lawson Tait*—Br. Med. Journ., June 4, 1881. *Williams*—On the Structure of the Mucous Membrane of the Uterus, and its periodical changes: London Obst. Jour., Vol. II., p. 681.

THE subject of Menstruation is not as yet well known, and on many points eminent and trustworthy observers are at variance. So far as our present knowledge goes, the following is a brief *resumé*.

PRELIMINARY CONSIDERATIONS.

Definition.—A periodical flow of blood from the uterine cavity, with shedding of the superficial layers of its mucous membrane, accompanying the discharge of an ovum from the ovary, occurring in properly developed women between the ages of 14 and 44, and interrupted by uterogestation and lactation. Prelim-
naries.

Period of its Onset.—Menstruation begins, in this country, usually at the age of 13 to 15 (puberty). It may be delayed to 16, 17, or 20; but this is unusual. Its onset is earlier in warm countries, later in cold ones; earlier in delicately nurtured girls.

Period of its Cessation.—With the interruptions of pregnancy and lactation, it continues in healthy women until the age of 44 to 50. The period of its final cessation is known as the menopause. As a general rule the menopause is early when menstruation has begun early, and *vice versa*.

GENERAL PHENOMENA OF MENSTRUATION.

General
Pheno-
mena.

Changes at Puberty.—At this period of life, when the girl becomes the woman, we find certain well marked general changes occurring. The bust and mons veneris develop and the whole contour of the body becomes more rounded and attractive; hair appears on the genitals. The romping carriage of the girl becomes subdued, and greater shyness characterises her conduct to the opposite sex.

Phenomena premonitory to each menstrual flow.—There is usually a feeling of weight in the pelvis and increase of sexual inclination. Many women, however, have very little uneasiness during the whole flow; while others are always considerably distressed,—this distress being still outside the boundary of actual disease.

Periodicity and duration of Discharge.—When once established it recurs with great regularity every 28 days (in - 71 p. c.), 30 days (in - 14 p. c.), 21 days in - 12 p. c.), or 27 days in + 1 p. c.). We speak therefore of the 21 day *type* and so on. It lasts for a number of days, varying from 2 to 8. If below 2 or above 8 it is abnormal; but of course other points besides mere duration must be taken into account.

LOCAL PHENOMENA.

Local
Pheno-
mena.

Three periods are distinguished: 1. Invasion; 2. Persistence; 3. Decline.

1. *Invasion.*—Discharge pale.

2. *Persistence.*—Discharge bright red, non-coagulable from its admixture with mucus. It consists microscopically of epithelium from vaginal, cervical, and uterine cavities; mucous globules; compound granular corpuscles, and red and white blood-corpuscles.

3. *Decline.*—Discharge lessens in amount and becomes lighter in colour. The total *quantity* varies from 2 to 8 ounces.

Thus far we have related facts fairly well ascertained and not much disputed. We now enter on more debateable ground, in considering—

I. Ovulation;

II. The Corpus luteum;

III. Source of discharge, and changes in the uterine mucous membrane.

Ovulation.

I. *Ovulation.*—So far as our present knowledge goes, ovulation forms the starting point of the process of menstruation. We have already considered the structure and development of the ovary, and now describe

The changes in the Ovary at each Menstrual Period.—A graafian follicle enlarges and moves nearer the surface. Probably this produces, through

a nervous mechanism, a hyperæmia of the whole pelvic contents,—peritoneum, connective tissue, uterus, ovaries, Fallopian tubes, and vagina. It is alleged, as yet on insufficient grounds, that the fimbriated end of the Fallopian tube grasps the ovary, and that the ovum from the ruptured graafian follicle passes into it and along the tube to the uterine cavity. Professor Kinkead of Galway has recently advanced another explanation. He points out that, between the fimbriated end of the Fallopian tube and the ovary, we have the ovarian fimbria (fig. 22) forming a groove which is converted into a tube by the surrounding viscera; and that we have capillary action towards the uterus. This will lead the ovum into the Fallopian tube. However it may reach the Fallopian tube and uterus, its further development depends on its fertilization or non-fertilization. In the latter case it passes off unnoticed in the menstrual discharge; in the former it develops into the foetus.

II. *The Corpus luteum.*—After the rupture of the graafian follicle, we get its cavity filled up by the structure known as the corpus luteum. This is formed by proliferation of the cells of the membrana granulosa, by the sprouting of new capillaries with migratory cells into the hypertrophied convoluted epithelium. The central portion degenerates into gelatinous tissue, the cortical into fatty tissue (*Klein and Smith*).

The corpus luteum thus consists of a vascular framework, with a yellow pigmentary and cellular substance. It varies according as pregnancy does or does not follow its formation. The difference is well given in Dalton's table, which we subjoin.

	CORPUS LUTEUM OF MENSTRUATION.	CORPUS LUTEUM OF PREGNANCY.
End of 3 weeks.	12 by 13 mm. in diameter; central clot reddish, convoluted wall pale.	
One month.	Smaller; convoluted wall bright yellow; clot still reddish.	Larger; convoluted wall bright yellow; clot still reddish.
Two months.	Insignificant cicatrix.	12 by 22 millimetres in diameter; convoluted wall bright yellow; clot perfectly decolorized.
Four months.	Absent or unnoticeable.	18 by 22 millimetres in diameter; clot pale and fibrinous; convoluted wall dull yellow.
Six months.	Absent.	Still as large as at the end of the second month; clot fibrinous; convoluted wall paler.
Nine months.	Absent.	10 by 13 millimetres in diameter; central clot converted into a radiating cicatrix; external wall tolerably thick and convoluted, but without any bright yellow colour.

Source of Discharge.

III. *Source of Discharge and Changes in the Uterine Mucous Membrane.*—All observers are agreed that the mucous membrane of the uterine cavity is the source of the discharge, *i.e.*, that it comes from the area limited by the uterine ends of the Fallopian tube and the os internum.

Now begins the divergence.

Williams' view.

(1.) Williams holds that "uterine contraction drives the blood from the muscular wall into the mucous membrane; the vessels of this membrane, having undergone fatty degeneration, give way, and extravasation of blood results. This extravasation takes place always near the surface,

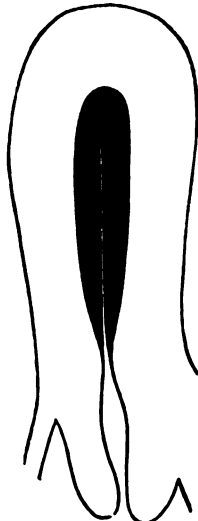


FIG. 68.

DIAGRAM OF UTERUS just before MENSTRUATION. The shaded portion represents the MUCOUS MEMBRANE (*J. Williams*).

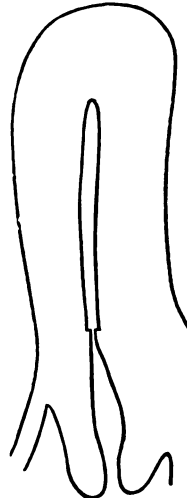

FIG. 69.

DIAGRAM OF UTERUS when MENSTRUATION has just ceased, showing the cavity of the body deprived of MUCOUS MEMBRANE (*J. Williams*).

for in that situation the degenerative change has most advanced. The rush of blood into the vessels of the mucous membrane expels the contents of the glands, together with the greater part of their lining epithelium. . . . When hæmorrhage has taken place into the membrane, it undergoes rapid disintegration, and becomes entirely removed." The new mucous membrane "is produced by proliferation of the elements of the muscular wall of the organ, the muscular fibres producing the fusiform cells, the connective tissue, the round cells, and the groups of round cells in the meshes formed by the muscular bundles, the glandular epithelium."

Entire removal of the mucous membrane and its regeneration from the muscular coat, are the essentials of Williams' views.

(2.) Kundrat and Engelmann describe the change at the menstrual period as follows:—

Mucous membrane becomes swollen and pulpy, and measures in thickness 3–6 mm. The thickness is most marked at the fundus and central

Kundrat
and Engel-
mann's
views.

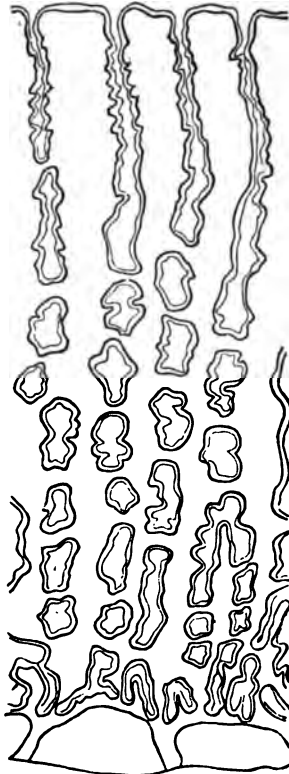


FIG. 70.

MUCOUS MEMBRANE OF MENSTRUATING UTERUS (A^o Kundrat and Engelmann).

portions of the anterior and posterior surfaces. The surface is puffy and injected; glands are distinctly seen on section as fine spirals.

Microscopically, this increase in thickness is seen to be due to a proliferation of the round cells of the stroma, an enlargement of all the cell elements in the superficial layers, and an increase of the intercellular substance. This superficial layer has grown far above the original gland openings, causing the funnel-shaped depressions or small pits seen on

surface view. The glands are increased in thickness and length. The vessels are enlarged and gorged with blood. Fig. 70 shows the mucous membrane of the menstruating uterus magnified 40 times; it should be compared with the mucous membrane of the non-menstruating uterus at fig. 19, also magnified 40 times.

The increase of the thickness of the mucous membrane begins as the time of menstruation approaches, is most marked during the period itself, and gradually decreases after the cessation of the catamenial flow.

Fatty degeneration takes place in the cells of the interglandular tissue, blood-vessels, and glandular and surface epithelium.

They hold that "the hæmorrhage is always confined to the surface of the lining membrane, and is due to the fattily degenerated tissue being unable to resist the blood pressure;" and *they therefore maintain, what is most probably the case, that only the superficial layer of the mucous membrane is shed at a menstrual period.*

Leopold's
view.

(3.) Leopold denies the existence of any fatty degeneration of the superficial layers of the mucous membrane. He believes that an extravasation of red and white blood corpuscles from the superficial capillaries takes place especially towards the superficial layer, undermining the uppermost layer of cells; and that, finally, the copious supply of blood reaching these capillaries from the numerous arteries causes rupture and bleeding. The mucous membrane is regenerated by an upward growth of the glandular epithelium.

Möricke's
view.

Williams, Kundrat, Engelmann, and Leopold examined uteri from *post-mortem* cases. Recently Möricke has curetted the uteri of living women at various stages of menstruation, and microscopically examined what he removed. He asserts that "during menstruation the mucous membrane disappears neither partially nor fully." This shows how widely microscopists vary. Williams says all the mucous membrane is removed; Kundrat, Engelmann, and Leopold say only the superficial layers are removed; and Möricke says none is removed.

We have deemed it best to lay these views before the student. The subject is difficult to investigate, and one on which the authors are not qualified to give an opinion. They incline, however, to the views of Kundrat, Engelmann, and Leopold. The chief difficulty in regard to Williams' view is the regeneration of the new mucous membrane from the muscular coat.

Finally, it should be noted that almost all observers consider *ovulation* and *menstruation* as occurring together. Beigel's view, that ovulation

occurs at any time, and that menstruation is a mere evidence of sexual excitement, has found no supporters.

A dispute still exists as to which ovum is fertilized when pregnancy occurs—the ovum of the bleeding period, or that of the first period missed. Many observers believe in Loewenhardt's theory, viz., that the ovum fertilized is that of the first period missed.

Lately the dominant influence of the ovary in menstruation has been questioned by some, notably by Lawson Tait. The operation known as Battey's operation, where both ovaries are removed, does not always cause a cessation of menstruation. Tait asserts that menstruation will always cease if the Fallopian tubes are also excised; and therefore believes that they play an important part in menstruation, hitherto unsuspected.

Leopold's monograph is illustrated by many valuable lithographs, and the same may be said in regard to Dalton's work on the Corpus Luteum.

SECTION II.

PHYSICAL EXAMINATION OF THE FEMALE PELVIC ORGANS.

IN this section we have to take up the physical examination of the female pelvic organs—that is, exploration by the hands and instruments of the gynecologist. This will be considered in the following manner:—

CHAPTER VII. Abdominal Examination; Vaginal Examination: the Bimanual Examination, with its various modifications.

CHAPTER VIII. Examination per Rectum.

CHAPTER IX. The Volsella.

CHAPTER X. Vaginal Specula.

CHAPTER XI. The Uterine Sound.

CHAPTER XII. Sponge Tents and other Uterine Dilators.

CHAPTER XIII. The Curette.

CHAPTER XIV. Knives, Scissors, Needles, Sutures, Antiseptics, Douches and Syringes, Anæsthetics.

CHAPTER VII.

ABDOMINAL EXAMINATION: VAGINAL EXAMINATION: THE BIMANUAL EXAMINATION, WITH ITS VARIOUS MODIFICATIONS.

In a female patient whose symptoms point to a pelvic cause, it is necessary to investigate the case by what is commonly known as a vaginal examination. A mere vaginal examination, however, gives very little information. The proper method is first to make an external abdominal examination and then the vaginal examination, the latter being only a stage of the more complete method of investigation known as the bimanual. Special cautions as to cases unsuitable for pelvic exploration are given under the head of vaginal examination. We consider the examination in the following order:—

- I. External abdominal examination.
- II. Inspection of external genitals (only when necessary).
- III. Vaginal examination.
- IV. The bimanual or abdomino-vaginal examination.

EXTERNAL ABDOMINAL EXAMINATION.

External
Abdomi-
nal Exami-
nation.

The patient should lie on her back, with her knees drawn up, and her head supported on a pillow. The bowels and bladder should be empty. The abdominal surface should be bared and exposed from the epigastrium downwards; no part of the mons veneris should be uncovered. The most delicate method of accomplishing this is as follows. A sheet or blanket should be thrown over the recumbent patient; beneath this she should raise up her dress as far as the pit of the stomach; the examiner then places his one hand on the sheet, a little above the mons veneris, and turns it down over it with his other hand. The abdominal surface is examined in four ways, viz., inspection, palpation, percussion, auscultation.

Inspection.

A. *Inspection*.—The form, colour, equality or inequality of bulge of the abdominal surface should be noted; the presence or absence of the *linea nigra*, *lineæ albicantes* (fresh and old), pigmentary deposits, fat streaks, and skin eruptions. The *linea nigra* has no significance. The

lineæ albicantes indicate that the patient's abdominal cavity is or has been distended beyond the normal. They are not specially significant of pregnancy. Fresh lineæ albicantes are glistening and pearly; old ones have a dull white or scarred appearance.

B. *Palpation* should be performed with both hands. For this purpose the hands, well warmed, are laid flat on the abdominal surface, and the whole area manipulated between them. One hand alone is of no use. By this method the abdominal contents are compressed and driven between the hands. The feeling given normally is that of manipulating a plastic fluid. Tapping with one index finger so as to give a fluctuating impulse to the other hand is of great value. Circumscribed nodules or tumours, fluid collections, thickening of the skin, should be noted and mapped out on the scheme given in the chapter on case-taking.

For the more exact localisation of the normal and abnormal abdominal contents, anatomists divide the anterior abdominal surface into definite regions. The lower transverse line is drawn at the level of the anterior superior iliac spines; the upper one, between the most prominent parts of the ninth costal cartilages. A vertical line joining the cartilage of the eighth rib with the middle of Poupart's ligament on each side, completes the division into nine areas, which are named in order as follows (*vide* Plate I).

- | | | |
|-------------------------|-----------------|------------------------|
| 1. Right Hypochondriac. | 2. Epigastric. | 3. Left Hypochondriac. |
| 4. „ Lumbar. | 5. Umbilical. | 6. „ Lumbar. |
| 7. „ Iliac. | 8. Hypogastric. | 9. „ Iliac. |

In these regions the following structures are found:—

Epigastric Region.—Right part of stomach; pancreas; liver.

Right Hypochondriac.—Right lobe of liver; gall bladder; part of duodenum; hepatic flexure of colon; part of right kidney, and its suprarenal capsule.

Left Hypochondriac.—Cardiac end of stomach; spleen and narrow extremity of the pancreas; the splenic flexure of the colon; the upper part of the left kidney, with the left suprarenal capsule; sometimes also a part of the left lobe of the liver.

Umbilical.—Part of the omentum and mesentery; the transverse part of the colon; lower part of the duodenum, with some convolutions of the jejunum and ileum.

Right Lumbar.—The ascending colon; lower half of the kidney; and part of the duodenum and jejunum.

Left Lumbar.—The descending colon; lower part of the left kidney, with part of the jejunum.

Hypogastric.—The convolutions of the ileum; the bladder in children, and, if distended, in adults also; the uterus when in the gravid state.

Right Iliac.—The cæcum, with the appendix vermiformis, and the termination of the ileum.

Left Iliac.—The sigmoid flexure of the colon. (*Quain.*)

Ruedinger's Section. Plate II. shows a valuable coronal section, published by Ruedinger; it should be carefully studied. The numbers refer to the following structures.

1. Right lung. 2. Right auricle; to its left is the larger coronary vein. 4. Right branch of pulmonary artery. The shorter left branch is seen at the left. 7. Liver. Note the impression on its under and right side from the right flexure of the colon. 8. Stomach. Note how its long axis is vertical, and that the main bulk of the stomach is to the left of the middle line. 9. Ascending colon. 9*. Opening of small intestine. 10. Small piece of junction between stomach and duodenum. 11. Pancreas. 12. Duodenum. 13-13. Small intestine. 14. Fundus uteri. 15. Bladder, with ureteric openings. 16. Connective tissue. 17. Descending colon. 18. Sigmoid flexure. 19. Mesentery.

In palpating the normal abdomen, the sensation given is one of impulse communicated generally through a plastic fluid. When free fluid is in the abdominal cavity, the impulse is more distinct. When the fluid is encysted, the impulse and tense feeling are localised.

When any large body is felt in the abdominal cavity, the first point to be determined is whether the body is pelvic or abdominal. This is easily done by attempting to press the hand downwards just above the symphysis pubis. If the tumour is pelvic, and rising up into the abdomen, the hand cannot be so pressed; and conversely.

In all tumours, the existence or non-existence of intermittent contractions should be carefully noted. Their presence indicates a uterine tumour—pregnancy or soft fibroid.

The following general points should be kept in mind. The bladder is only in the hypogastric region when distended or displaced upwards; if empty, it is behind the pubis and in the true pelvis; a distended bladder may be as large as a six months' pregnancy. Ovarian tumours are more or less lateral; uterine tumours generally central, although the pregnant uterus has usually a right lateral obliquity. In advanced pregnancy, the

parts of the foetus can be distinctly palpated. Finally, it should be kept in mind that in all cases of cystic tumours the catheter should be passed into the bladder, for an obvious reason.

CASE.—Mrs. A. was sent for consultation as to removal of internal tumour. On examination, a cystic tumour was felt mesially in the abdomen, and reaching up to umbilicus. Vaginal and bimanual examination were exceedingly painful. A catheter passed into the bladder evacuated a large amount of urine. The uterus was now found to be retroverted and gravid $3\frac{1}{2}$ months, and the cystic tumour had disappeared.

C. *Percussion* is to be performed in the usual way. To perform this thoroughly, the patient should be percussed (a) when on her back; (b) when on her left side; (c) when on her right side; (d) when sitting up. Changes in the percussion note on the patient changing her posture should be carefully noted, as they are of great value (*vide* under Ovarian Tumours and Ascites).

D. *Auscultation* is of great value, and is performed with the ordinary stethoscope. The foetal heart, uterine souffle, and friction may be heard by it. The importance of auscultation is evident. Foetal heart-sounds indicate pregnancy; the point of greatest intensity of the heart-sounds indicate the lie of the child. Uterine souffle and no heart-sounds (after $4\frac{1}{2}$ months) indicate either pregnancy and child dead, or fibroid tumour. Ovarian cysts have no souffle.

Before finishing abdominal examination, the patient should be made to raise her shoulders by grasping the examiner's hands. When there is no encysted abdominal tumour, the recti can be seen to flatten the abdominal contour; if, however, a solid or cystic tumour be present, the contour is unaltered. An exception should be made in the case of thin-walled cysts with fluid of a low specific gravity, where the recti do flatten the contour, as in the former case.

INSPECTION OF EXTERNAL GENITALS.

This should not be made a routine practice. As a general rule, inspection of the genitals should only be made when there is local tenderness, where syphilis or gonorrhœa is suspected, or where it is said by the patient that something comes down at the vaginal orifice. Soft chancres, hard chancres (almost never seen in females), mucous patches, condylomata; urethral caruncles; irritable spots causing vaginismus; labial abscess; parturition tears of perineum and labia; prolapsed pelvic organs; external or internal piles, may be found.

PALPATION OF INGUINAL REGION.

Palpation
of Groin.

Glandular and other enlargements in the inguinal region may be the following :—

- (1.) Glands enlarged from gonorrhœa. There are usually one or two—large, painful, and often suppurating.
- (2.) Glands enlarged from syphilis. These are multiple, hard, small, painless, and never suppurate in an uncomplicated case.
- (3.) Glands enlarged from vulvar malignant disease, or malignant disease of vagina (lowest $\frac{1}{4}$) or urethra.
- (4.) Femoral or inguinal hernia.
- (5.) Thrombosis of femoral vein.

VAGINAL EXAMINATION.

Vaginal
Examina-
tion.

Preliminaries.—Vaginal examination should not be made on girls below or little beyond the age of puberty, unless the symptoms are urgent, *e.g.*, mechanical retention of menstrual fluid from atresia. In the case of unmarried women it should not be performed unless specially necessary. In both classes of patients the value of a rectal examination should be kept in mind. The vaginal examination should be made on married women whose symptoms point to a pelvic cause. Finally, no woman should be examined vaginally when menstruating normally, unless under exceptional circumstances.

Special cases require consideration, *viz.*, that of a mistress who requests a medical man to examine her servant, who is suspected of pregnancy, or of a young woman, who, owing to a malicious report, requests examination as to her condition and a certificate that she is not pregnant.

In the first case, it is better for the medical man not to examine the patient, as he may be liable for an action for assault.

In the second case, the medical man should advise the patient against being examined. This latter case is, of course, quite different from that of an unmarried woman who requests examination to settle whether she is pregnant or not, and who has, of course, run the risk of impregnation. In this instance the medical man investigates the case as usual.

After settling these preliminaries, and having obtained the patient's consent to "examine" (a term understood by all women as meaning a vaginal examination), the next point is to determine the position the woman is to occupy while the examination is being made.

Position of
Patient.

In this country it is customary to place the woman on her left side for the vaginal examination, and to turn her on her back for the performance of the Bimanual. The patient, therefore, lies on a convenient couch, with her knees well drawn up and her clothes loose. The examiner carefully oils or soaps the index and middle finger of his right hand.

With his left hand he clears away the clothes from the hips so as to make a passage for the examining fingers, which he passes onwards till he reaches the cleft between the buttocks. He next passes them forwards over the anus, skin over base of perineum and fourchette, until the pulp of the finger rests at the vaginal orifice. In multiparous women, the lax vaginal orifice is easily felt. When in doubt, the student should pass his fingers cautiously on until he touches the vestibule, which is always smooth. Passing his fingers back, he will then reach the vaginal orifice at the base of the vestibule.

The student must be careful not to pass his finger into the rectum by mistake. He should remember that the vaginal axis passes backwards, the anal axis forwards; that no force is required to pass his finger into the vagina of a woman whose hymen has been ruptured, whereas some force is necessary to overcome the resistance of the sphincter ani. The clitoris, lying at the apex of the vestibule, should never be touched digitally.

The two fingers being now at the vaginal orifice, should be carried backwards into the vagina until its upper limits are felt. While doing so the student should note—

1. *State of Vaginal Orifice*; patulous or narrow, presence or absence of painful spots, presence or absence of spasm. What to note.

2. *Walls*; presence or absence of rugæ; moisture, heat, secretion, tumours attached to them; fistulæ, foreign bodies, such as pessaries, glycerine plug, oakum plug; shape of walls, length of walls.

3. *Cervix*; direction, size, shape, and consistence. Note especially if thickened, expanded, and fixed; drawn to one or other side; or if mobile and not fixed; or if split and with cicatrices radiating from it to vaginal roof.

4. *Os*; size, shape, consistence of lips. Thus, it may be a dimple, as in nulliparæ; transverse, as in parous women (figs. 13 and 14); or the cervix may be split on one or both sides, and thus no *os externum* is present, but the cervical canal is more or less exposed (Plate VIII.) Bodies projecting through it should be noted. They may be polypi, fragments of abortion, cancerous masses, stem pessaries.

5. *Posterior fornix* is concave when felt from below. It has normally a feeling like that of the inside of the angle of the mouth. Note if any lump can be felt through it, projecting down from Douglas' pouch, rendering the fornix convex. A body or a feeling of resistance felt through the posterior fornix may be the following:—

Tumours in Douglas' Pouch felt through posterior fornix.

- (1.) Fæces ;
- (2.) Acute or chronic inflammatory deposit, cicatrization of utero-sacral ligaments ;
- (3.) Retroverted fundus uteri (non-gravid or gravid) ;
- (4.) Blood effusion ;
- (5.) Fibroid attached to posterior wall of uterus ;
- (6.) Ovary inflamed or cystic ;
- (7.) Ascitic fluid ;
- (8.) Extra-uterine foetation or hydatid (rare).

6. *Anterior fornix.*—Note if there is any body felt through it. If so, it is most probably the fundus uteri, normal or enlarged from pregnancy or fibroid. There may be also inflammatory or blood effusion, or a tender ovary, but these are rare here.

7. *Lateral fornices.*—Note cicatrices, prolapsed or cystic ovary, lateriflexed uterus, inflammatory or blood effusion in broad ligament, dilatation of Fallopian tubes, fibroids placed laterally.

The vaginal examination has now been completed. The student should keep in mind that he really learns very little from a vaginal examination, just as he can learn very little as to the size and relation of any object by touching it with the fingers on a but limited area. Vaginal examination is thus only the preliminary to the bimanual or abdomino-vaginal.

BIMANUAL OR ABDOMINO-VAGINAL EXAMINATION.

Bimanual. This method of examination is the all important one in gynecology, and is the one which the student and practitioner will find most valuable, so that its practice should precede all other methods of internal investigation. As the practitioner's experience increases, he will find that he relies more upon this, and becomes less dependent on other means of examination.

Method of performing Bimanual. Position of Patient.—The patient must now be made to lie on her back. The head and shoulders should be supported and the knees drawn up.

Arrangement of Examiner's hands.—The *internal* hand (the right) is placed as follows:—Two fingers (index and middle) are in the vagina, the thumb rests in the fold between a labium majus and the thigh, and the other fingers lie in the cleft of the nates (fig. 71). The whole hand is then rotated backwards so as to bring its long axis as nearly as possible into the axis of the brim, and is then pushed up towards the brim of

the pelvis. Thus the pubic segment, uterus with annexa, and posterior vaginal wall are lifted up towards the brim. The middle finger is placed

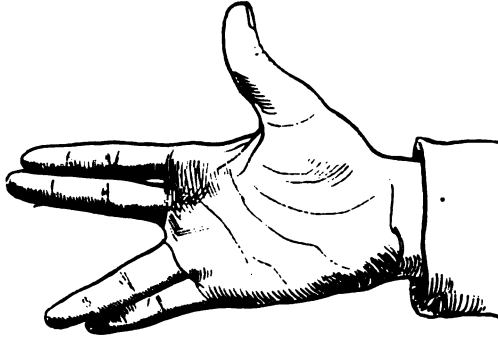


FIG. 71.
RIGHT HAND AS IN BIMANUAL EXAMINATION.

over the os and the index one in the anterior fornix, so that the uterus as it is pushed up becomes more anteverted. The right hand while

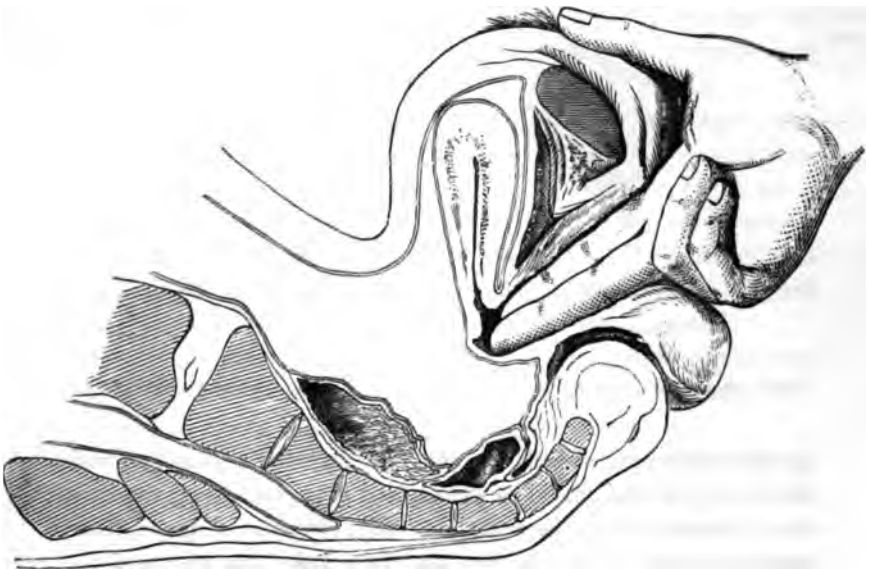


FIG. 72.
BIMANUAL EXAMINATION. The upper hand is not shown (*Hart*).

examining, therefore, has the appearance at fig. 71. The little and ring fingers may be doubled up as in fig. 72. The external hand (the left) is

98 *PHYSICAL EXAMINATION OF PELVIC ORGANS.*

Position of Hands in Bimanual. placed on the abdominal wall just above the pubis, with its long axis running obliquely between the iliac crests, its ulnar edge near the promontory and much deeper than the radial one. It is now steadily depressed until the abdominal wall below it is markedly cupped (figs. 72 and 73) and moulded over the uterus and appendages, which have been elevated by the inner hand. In this way the two hands estimate the size and relations of the pelvic contents, just as one would estimate the

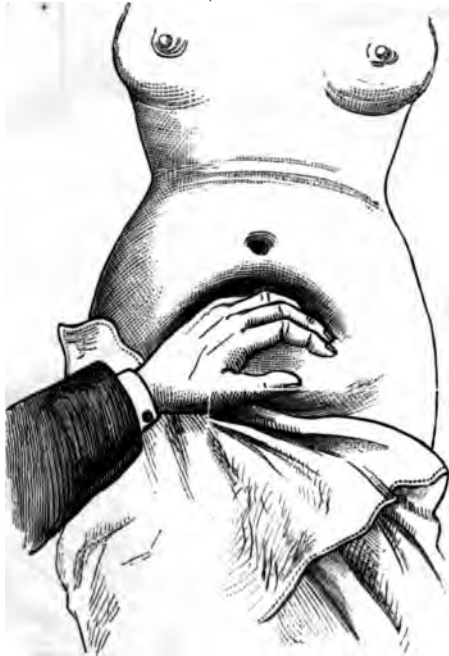

FIG. 73.

ANTERIOR ABDOMINAL SURFACE OF FEMALE, with upper hand placed for Bimanual (*ad naturam*).

size of a watch covered with a cloth. The student should note specially that the upper hand should be steadily and not spasmodically depressed; that he should always keep the ulnar edge of this hand deeper, that is, nearer the sacrum, so that he may not retrovert the uterus; and that he should palpate all the abdominal areas along the pelvic brim so as not to miss anything. *His first object in the bimanual examination is to determine where the uterus is, as this greatly simplifies the recognition of abnormal products in the pelvis. He then bimanually explores the*

fornices, moving the internal fingers appropriately and noting what he feels. At first his diagnosis should be simply physical, *e.g.*, "uterus felt to front and a large firm lump behind it;" or, "uterus felt retroverted and a small moveable tumour on its left side."

It is of importance that the student should know what a "normal bimanual" is. The following is a description of the condition found in a nulliparous married woman, on vaginal and bimanual examination. Normal condition on Bimanual.

"Ostium vaginæ patulous, and admits two fingers; vaginal walls moist, rugous, with no abnormalities. Vaginal portion of cervix normal in size (fig. 13); os uteri felt like a dimple, looking downwards and backwards. No bodies are felt through the lateral and posterior fornices, which are concave on their vaginal aspects, and have the feeling, on pressure, of the angle of one's mouth. In the anterior fornix a body is felt, which on bimanual examination is discovered to be the uterus lying to the front and not enlarged. The fundus and cervix meet at a very large angle. Bimanual exploration of the fornices reveals nothing distinctly palpable.¹ The patient complains of no pain during the whole examination, and has no symptoms referable to the pelvis."

Cases where the Bimanual is difficult.—The student will soon find that the Bimanual can be performed in certain cases with great facility and accuracy, while in other women it is exceedingly unsatisfactory. Difficult Bimanual.

The best case for a Bimanual is a woman a fortnight or three weeks after delivery. The reasons for this are evident. A puerperal woman has had the ostium vaginæ and vaginal walls relaxed by the child's head; the pubic segment has been drawn up and its attachments slackened; the abdominal walls have had their elasticity diminished by the full time uterus, and the uterus itself is not involuted to its normal size. In such a case there are evidently all the requisites for a good bimanual.

Difficult bimanual cases are found in stout nulliparous women, and in cases of pelvic inflammation. In such, the rectal examination, with or without the use of the volsella, is indicated.

Students at first find their Bimanual unsatisfactory. By perseverance, however, they will obtain by means of it an accuracy in diagnosis which is astonishing. It is not only the best means of investigation, but one from which no possible harm can arise. In no cases is it contra-indicated except those of advanced cancer or of acute inflammation.

We have described the simple abdomino-vaginal examination. It will be readily understood that we may have others, as follows:— Varieties of Bimanual.

¹ One practised in the Bimanual can feel the normal ovaries.

100 *PHYSICAL EXAMINATION OF PELVIC ORGANS.*

- (1.) Recto-abdominal (finger in rectum and left hand above);
- (2.) Recto-vagino-abdominal (middle finger in rectum, index finger in vagina, and left hand above);
- (3.) Vesico-vagino-abdominal (middle finger in vagina, index in bladder, and hand above).

Of these the third is very rarely practised.

Anatomy
of Bi-
manual.

Note that in the Bimanual the pubic segment with uterus and its

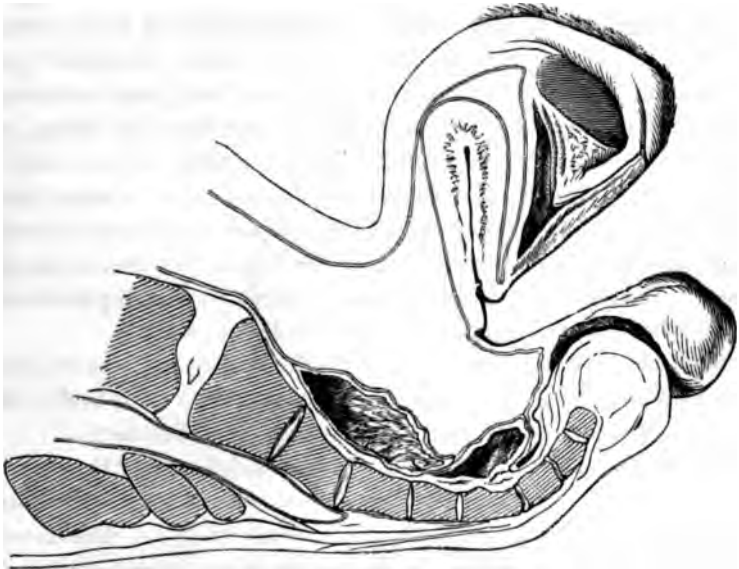


FIG. 74.

DISPLACEMENT OF PELVIC FLOOR SEGMENTS AND ABDOMINAL WALL IN BIMANUAL (Hart).

annexa are elevated, the sacral segment shortened, and the abdominal walls depressed (fig. 74).

Cleansing
after
Bimanual.

After the Bimanual or other examination is finished, the examiner should scrupulously cleanse his hands. There are no better nor cheaper substances for this than turpentine and ordinary soap, as Dr. Foulis of Edinburgh has shown. The odour is by no means disagreeable, and if found objectionable can be easily covered by vinegar, which in itself is a good cleanser. In examining cancerous cases, where the odour is exceedingly penetrating and persistent, it is a good plan to dip the fingers in turpentine prior to the examination.

CHAPTER VIII.

EXAMINATION PER RECTUM.

LITERATURE.

Hegar—Die operative Gynäkologie, zweite Auflage: Stuttgart, 1881. *Munds*—Minor Gynecology: Wood & Co., New York, 1881. Consult *Hegar* for additional references.

THE results obtained by a vaginal examination are limited by the fact that the reflection of the vaginal walls to form the fornices, prevents the finger being pushed up to a sufficient distance. This defect is compensated for by the downward pressure of the upper hand in the Bimanual; but in those other cases where the abdominal walls are unyielding and the pubic segment stiff, due pelvic exploration by an abdomino-vaginal examination alone is impossible. In such cases, rectal exploration and the abdomino-rectal or abdomino-recto-vaginal examination are invaluable. They give better information than the more commonly practised abdomino-vaginal.

Rectal Examination.

The usual methods are—

Methods.

- (1.) Simple rectal : abdomino-rectal : abdomino-recto-vaginal.
- (2.) Passage of the *whole* hand into the rectum (*Simon's method*).

SIMPLE RECTAL : ABDOMINO-RECTAL : ABDOMINO-RECTO-VAGINAL

Preliminaries.—The patient should be told that it is necessary to examine the bowel. If the rectum is loaded the examination should be deferred till next day, and the patient instructed to use a purgative at night and an enema in the morning.

Preliminaries.

The following points should be especially noted. The examiner should thoroughly soap the fingers and nails. A vaginal examination may be made first; and then, the index finger being kept in the vagina, the middle one is passed into the rectum (fig. 75). If the patient is virginal, and it is wished to avoid a vaginal examination, then the index finger alone is passed into the rectum. When the finger or fingers are withdrawn from the rectum the hands should be at once cleansed; there can be nothing more hurtful to a patient's feelings than the passing of the uncleaned fingers from the rectum into the vagina. The patient lies first on her left side and then on her back.

Manner of Performance.

**Anatomy
of Rectal
Examina-
tion.**

The finger passed into the rectum goes forwards ; when passed into the vagina, the direction is backwards. After overcoming the resistance of the strong external sphincter it enters the rectal ampulla (fig. 36), which is often expanded by flatus. Passing the finger onwards and to the left side, a confused mass of tissue is felt in which we may detect the opening betwixt the segments of the sphincter tertius.

**What to
Note.**

As we pass the finger inwards we note piles (internal and external), fissures, polypi, ulcers, stricture (specific and malignant).

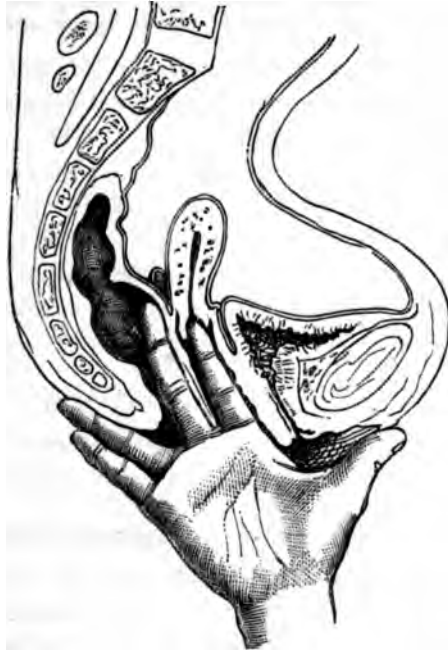

FIG. 75.

ABDOMINO-RECTO-VAGINAL EXAMINATION. Upper hand not shown. Note prolapsed ovary.

We next turn the pulp of the examining finger so that it lies on the anterior rectal wall. Through this can be felt the cervix. Note that the whole cervix is felt, which is much larger than the vaginal portion felt on vaginal examination. Be sure not to mistake it for the body of the uterus. If the uterus lies to the front its forward direction can be noted ; if to the back, then the body will be felt on passing the finger further up. Pushing the finger well upwards and passing it first to the right and then to the left, we feel the ovaries (more distinctly when enlarged) as small oval tender bodies (fig. 75).

Fig. 40 shows a common condition of the uterus which is frequently mistaken for and treated as a retroversion. We allude to the uterus anteflexed and drawn back by pelvic cellulitis of the utero-sacral ligaments. As the patients are usually sterile and have therefore somewhat unyielding abdominal walls which cause a difficult bimanual, and as a lump is felt in the posterior fornix, the diagnosis of retroversion is often made. The rectal examination, however, clears up the case, as the finger feels the knee of the flexion and the fundus going forward from it.

Diagnosis
of Ante-
flexion.

The *upper hand* is used during the rectal examination just as in the Bimanual, *i.e.*, the examination is abdomino-recto-vaginal or abdomino-rectal. The simple rectal (with the finger in the rectum unaided by the other hand) does not give much information as to the condition of the uterus.

Where, from rigidity of the abdominal walls, it is difficult to press down or fix the uterus with the external hand, this may be done with the volsella in the vagina. The use of the volsella enables us to draw the uterus better within reach of the finger in the rectum. This examination per rectum aided by the volsella will be considered in the next chapter.

Of all manual examinations of the pelvis, the abdomino-rectal or abdomino-vagino-rectal is the most thorough. In retroversions, prolapsed ovaries, and pathological anteflexion, it is of special value. A patient may object to it and refuse to allow it; and, of course, the practitioner must keep this in mind.

Value of
Rectal
Examina-
tion.

SIMON'S METHOD OF PASSING THE HAND INTO THE RECTUM.

This consists in passing the whole hand through the sphincter ani into the rectum, and even up to the transverse colon. The patient is deeply narcotised; the hand is passed cautiously through by inserting first two fingers and the others successively until the entire hand is passed; incision of the sphincter ani may be necessary. Sometimes an incurable incontinence of *fæces* has resulted.

Simon's
Method.

The unanimous opinion of gynecologists is that this severe method of examination is unnecessary. Careful bimanual examination, aided when necessary by anæsthetics, gives equally good results.

For specialists it is of use to know that valuable results in minute precise rectal examination can be got by first injecting air into the rectum. The whole rectum up to the sigmoid flexure can be dilated, the sphincters made out and the bony pelvic wall carefully explored. It is necessary to add, however, that this is an adjunct to the rectal method of examination of use only in certain very rare instances.

CHAPTER IX.

THE VOLSSELLA.

LITERATURE.

Goodell—Some Practical Hints for the Treatment and the Prevention of the Diseases of Women: Medical and Surgical Reporter, January 1874. *Hegar*—Zur gynäkologischen Diagnostik: Die combinirte Untersuchung, Volkmann's Sammlung, No. 105. *Simpson, A. R.*—The Use of the Volsella in Gynecology: Contributions to Obstetrics and Gynecology, p. 183.

Volsella. We have already seen that one of the most striking anatomical features and properties of the uterus is the considerable range of its mobility in almost every direction. It can be pushed upwards from its normal position $1\frac{1}{2}$ or 2 inches, and is displaceable forwards or laterally in a very marked degree. If laid hold of with the instrument known as a volsella, it can be drawn downwards (by a force not exceeding five or six pounds) until the os externum lies close to the vaginal orifice. This procedure facilitates, in suitable cases, diagnosis and treatment of gynecology so much that it is well worthy of the allotment of a special chapter to its discussion. We take up—

1. Description of instrument;
2. Method of use;
3. Mechanism of the displacement it causes;
4. Uses;
5. Contra-indications.

Description of Volsella.

1. *Description of Volsella.*—At fig. 76 is seen the useful volsella employed by Professor Simpson. As it is generally the anterior lip of the cervix that is laid hold of, the slight pelvic curve given to the blades is unnecessary, since the volsella lies along the straight anterior vaginal wall. Fig. 77 shows Hart's volsella, where this straightness of the blades *quâ* the vagina is secured, and the handle and fingers of the gynecologist are kept away from the vaginal orifice by the bend on the handle. Every volsella should have a catch on it. Sometimes it is useful to have an instrument whose blades pass over one another, so as to separate, for instance, the lips of a split cervix: such is Hanks' instrument.



FIG. 76.

PROFESSOR A. R. SIMPSON'S VOLSELLA with catch.

this purpose the anterior and posterior lips are laid hold of, and when

2. *Method of Use.* (a.) *Without previous passage of Speculum.*—The patient is placed in the ordinary left lateral posture. Two fingers of the right hand are passed into the vagina, and the anterior lip of the cervix touched. The volsella, held in the left hand, is guided along between the index and middle exploring fingers; the anterior lip of the cervix is seized and drawn down. Rectal examination is now made. (b.) *With the Speculum.*—For this see Chapter X.

Method of Use.

3. *Mechanism of displacement it causes.*—The uterus is drawn down so as to lie behind the symphysis pubis. If drawn down fully, as it may be in exceptional cases, it has its long axis in the vagina and the os externum, near the vaginal orifice.

Mechanism of Displacement caused.

The vaginal walls are inverted, *i.e.*, when the os externum is at the vaginal orifice, we have a deep pouch behind and in front of the uterus.

The relations of the bladder and rectum are given in fig. 78.

4. *Uses.* (a) *In diagnosis.*—(1.) The cervix, which may seem "ulcerated," as it is commonly called, is easily demonstrated by the volsella to be singly or doubly lacerated. For

Use in Diagnosis.

brought together the ulceration is seen to be due to laceration with eversion.

(2.) Abdominal tumours can be shown to be connected with the uterus or not as the case may be. If the patient be placed in the dorsal posture and the tumour be laid hold of by an assistant, then when the uterus is drawn down, the tumour can be felt to descend, if fixed to it.

(3.) To the examination *per rectum* the volsella is a valuable addition. If one finger be placed in the rectum, and the cervix laid hold of with a volsella and drawn down, the mobility of the uterus can be estimated; the whole posterior uterine surface may be palpated for small fibroids. The ovaries are made more accessible, and the uterus, especially if small, can have its length estimated by the rectal finger.

This method of examination of the uterus by rectum and volsella, judiciously conducted, is of the very greatest value.

It is evident that it will also help one as to the diagnosis of displacements of the uterus; but its value in this respect is somewhat lessened by the displacement its use causes. Thus it makes a retroversion less retroverted; an anteflexion less anteflexed; an anteversion less anteverted.

Use in
Treatment.

(b) *In treatment.*—In this the volsella is one of the most useful instruments the gynecologist possesses. Thus it helps greatly in the examination of the aborting uterus; in replacement of the gravid or non-gravid retroverted uterus; in insertion of sponge and tangle tents, or stem pessaries. In operations such as Emmet's for repair of the cervix, Sims' division of the cervix, amputation of vaginal portion of cervix, excision of the uterus through the vagina for cancer, it is indispensable.

Details of its uses in these cases will be given under the special descriptions of the operations; and it will also be shown in the Chapter on




FIG. 77.
DR. HART'S VOLSELLA.

Specula, that by using the volsella the speculum may be dispensed with in certain cases.

5. *Contra-indications.*—It should not be used in acute peritonitic or cellulitic attacks, in distended Fallopian tubes, in hæmatocele or in advanced cancerous disease. No pain should be caused by its use provided that only the vaginal aspect of the cervix is laid hold of.

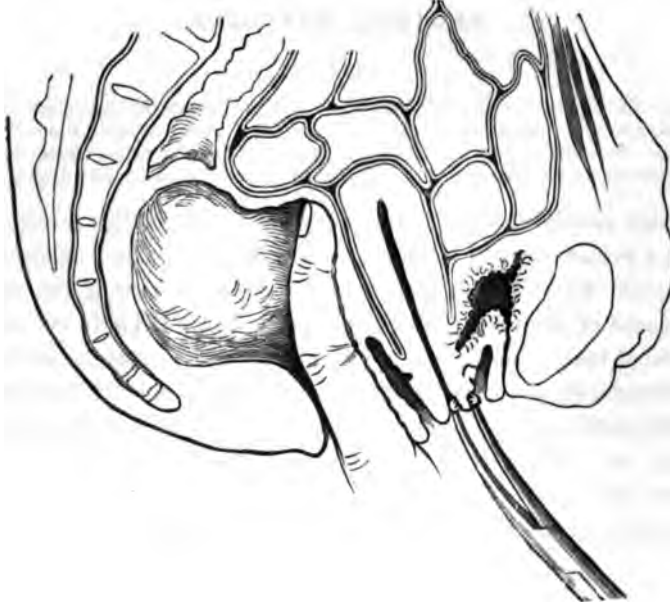


FIG. 78.

MECHANISM OF DISPLACEMENT OF PELVIC-FLOOR SEGMENTS when Volsella is used.

The amount of traction to be made will vary with the necessities of the case. In many instances only a mere steadying action is requisite; in others the cervix has to be drawn half-way down the vagina. In special

Amount of
Traction
to be used.




Fig. 79.

SIMS' TENACULUM.

cases the cervix is drawn down to the vaginal orifice or beyond it, as in amputation of the cervix or excision of the uterus. For simply steadying the cervix, Sims' tenaculum is of great service (fig. 79).

CHAPTER X.

VAGINAL SPECULA.

LITERATURE.

Barnes—Diseases of Women: London, 1878. *Goodell*—Lessons in Gynecology: Philadelphia, 1890. *Hart*—Structural Anatomy: Edin., 1890. *Munds*—Minor Gynecology: Wood & Co., New York. *Sims, J. Marion*—Clinical Notes on Uterine Surgery: Hardwicke & Co., London, 1866. *Thomas*—Diseases of Women: Philadelphia, 1861.

Vaginal
Specula.

WE have already seen that the segments of the pelvic floor are separable when a woman assumes certain postures; that the sacral segment can be hooked up, and that by this means we get a view of the vaginal boundaries of these segments and of the os uteri. This is the natural method of opening up the pelvic floor; or the natural specular method.

Gynecologists had used various instruments for enabling them to look into the vagina: but all of these proved unsatisfactory until Marion Sims, noting the natural postural dilatation of the vagina, introduced his famous duckbill speculum.

Varieties.

We take up the consideration of four typical specula, viz. :—

1. The duckbill or Sims speculum,
2. The tubular or Fergusson speculum,
3. The Neugebauer and its modifications,
4. The bivalve ofCUSCO.

We note under each its nature, the method of employing it, and the theory of its action and uses.

Sims'
Speculum.

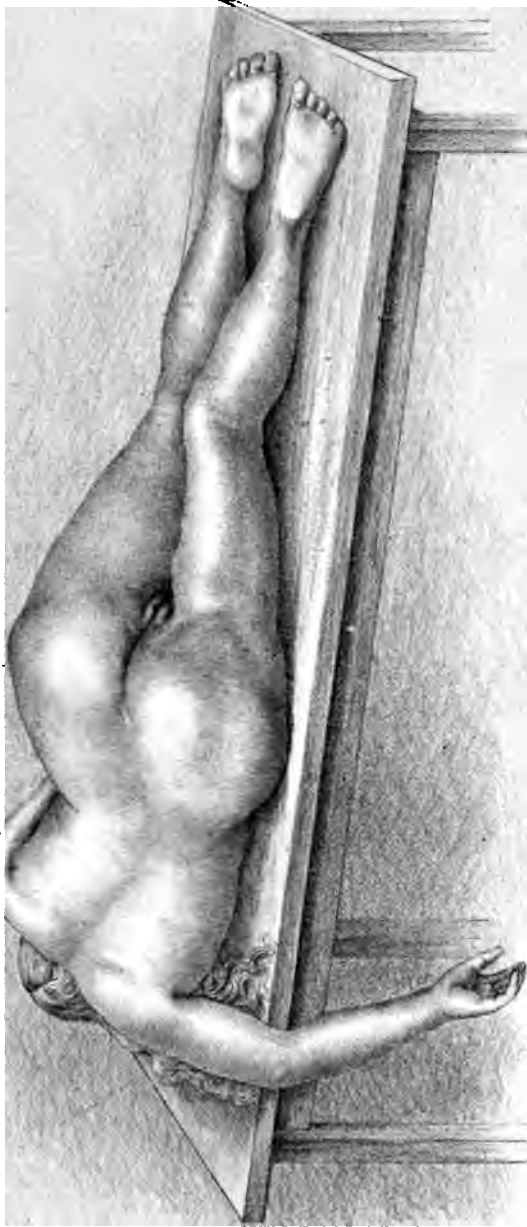
1. The SIMS or DUCKBILL SPECULUM is shown at figs. 80, 81, and Plate V.

Nature.

Its Nature.—Each instrument in reality consists of *two specula*, which are of different size and connected by a handle; usually, however, we speak of these specula as the *blades* of the *speculum*. The real Sims speculum is light, has each blade slightly concave on its anterior aspect, and has the blades at *right* angles to the intermediate handle.

Modifica-
tions.

Modifications of Sims' speculum are numerous. Indeed, it seems difficult for gynecologists to resist modifying an instrument, and rare to *Bozeman's*. find them improving it. The most widely known modification is *Boze-*



W. G. C. No. 107. Anatomical Institute.

PLATE IV — FEMALE CADAVER IN SEMI-PRONE POSTURE (DRAWN FROM NATURE).


Pat. 1,111,111

Highly resistant to corrosion and
suitable for use in the presence of acids

Pat. 1,111,111




Pat. 1,111,111



Pat. 1,111,111

Pat. 1,111,111



Pat. 1,111,111

Pat. 1,111,111

man's; it is heavier than Sims', has the blades meeting the handle at an acute angle, and the blades more concave on the anterior aspect. (Figs. 81 and 82.)

One curious fact about almost all specula is, that they are too long.




Fig. 80.
SIMS' SPECULUM.

Sims' blade is 4 inches long, though the posterior vaginal wall measures only $3\frac{1}{2}$ inches. Thus, as we wish to expose only the anterior vaginal wall and cervix uteri, a 3-inch length of blade is sufficient.



Fig. 81.
SIMS' SPECULUM.



Fig. 82.
SIMS' SPECULUM modified by BOZEMAN.

A modification of Sims' speculum, by Dr. Battey of Georgia, is worthy Battey's of note. It has one short blade which meets the handle at a more acute angle. (Fig. 83.)

The method of employing Sims' speculum.—Under this it is important Method of Use.

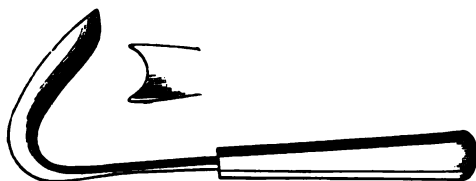


Fig. 83.
BATTEY'S SPECULUM.

to note—(a) How to place the patient, (b) How to pass the speculum, and (c) How to hold it when passed.

(a.) *How to place the patient.*—The patient must be placed in the Position of Sims or semiprone posture. This is briefly as follows. The patient Patient.

lies almost on the breast: *the lower left arm is over the edge of the couch next the gynecologist: the hips are close to the edge: the knees are well drawn up; and the upper or right knee touches the couch with its inner aspect.* The posterior aspect of the sacrum is therefore oblique to the horizon. (Plate IV.)

As the result of this posture—a modified genupectoral one—the vaginal walls separate when air is admitted; the pubic segment passing down with the viscera, the sacral one remaining behind.

Passage of Speculum.

(b.) *How to pass the Speculum.*—Choose the blade which is of the proper size to pass the vaginal orifice; warm it, and oil it with the fingers on its convex aspect only. The concave surface must be dry to reflect light, and therefore the speculum should never be oiled by dipping it. Hold it by the other blade in the left hand, as shown at fig. 84.





FIG. 84.

One method of holding the SIMS SPECULUM.

Then pass the index and middle fingers of the right hand into the vagina to separate the labia; carry in the speculum between them; push it onwards, following the curve of the posterior vaginal wall, until the beak of the instrument lies in the posterior fornix. Now draw the instrument back as a whole, in a direction at right angles to the posterior vaginal wall; then turn the beak forwards, so as to bring the cervix more into view. Finally, tilt the blade, so that the beak lies on a lower level than the proximal end of the blade: this keeps up the upper labium.

How it is held.

(c.) *How to hold the Speculum when passed.*—Plate V. shows the speculum passed, and a convenient way of holding it. When passed, the cervix may be drawn down with a volsella (also shown in Plate V). Various attempts have been made to add to the Sims speculum a means of rendering it self-sustaining; the majority of these are by no means successful, and therefore we need not describe what is seldom used. The knowledge of a simple method of effecting this in Battey's speculum is of use. This has a piece of indiarubber, with a hook at the end attached to

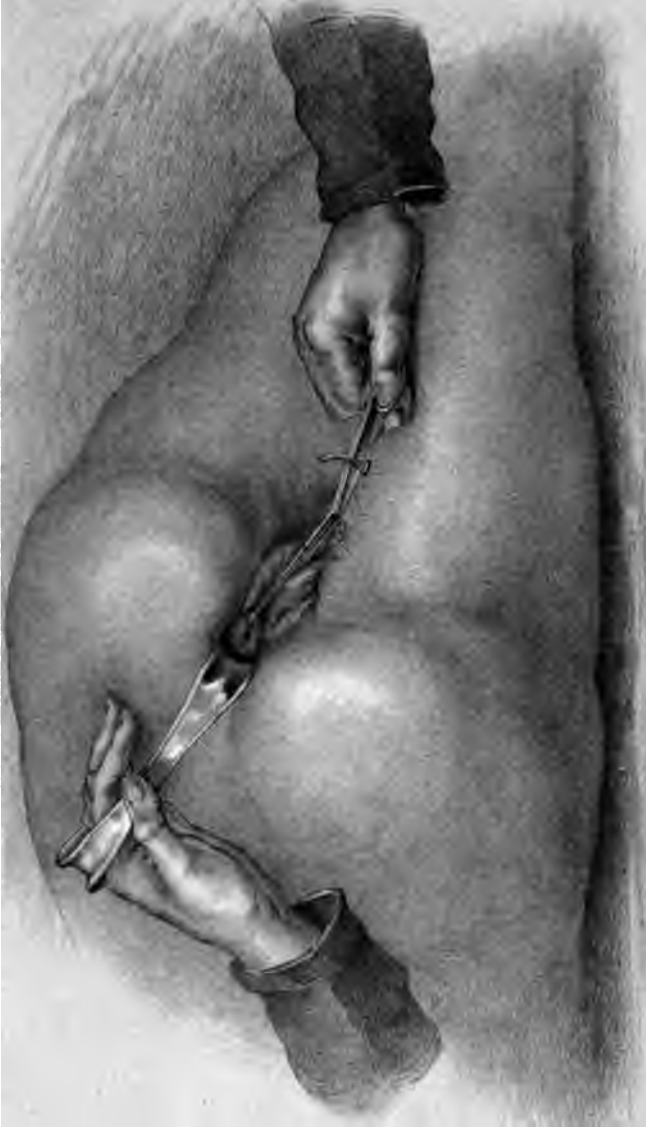

The first part of the paper
 discusses the general theory
 of the subject. It is
 divided into two main
 sections. The first section
 deals with the general
 theory of the subject, and
 the second section deals
 with the special theory.
 The first section is
 divided into two main
 parts. The first part
 deals with the general
 theory of the subject, and
 the second part deals
 with the special theory.
 The second section is
 divided into two main
 parts. The first part
 deals with the general
 theory of the subject, and
 the second part deals
 with the special theory.

Passag
specu

How i
held.

PLATE V



W. & A. G. & Co., Edinburgh & London

PLATE V -- FEMALE CADAVER IN SEMI-PRONE POSTURE, WITH SIMS' SPECULUM PASSED, AND UTERUS DRAWN DOWN WITH A VOLSELLA.

the handle, which can be fastened in the pillow, sheet, or patient's dress : the cervix is drawn down with a volsella held in the one hand, leaving the other free for minor manipulation.

Theory of action and uses of the Sims Speculum.—The Sims speculum is based on the effects consequent on the genupectoral posture. When the patient is semiprone and the vaginal orifice opened, the segments of the pelvic floor separate ; and then the Sims speculum is a simple means of hooking the sacral segment well back.

The Sims speculum is, on the whole, by far the most useful speculum. It is difficult to manipulate at first, but amply repays practice. Its dis-



FIG. 85.
FERGUSSON SPECULUM.

covery has been one of the greatest strides in gynecology. In vaginal and cervical operative surgery, it is the only speculum that can be used.

2. THE FERGUSSON SPECULUM is seen at fig. 85. It is made in three suitable sizes ; and may be described as a glass tube, with a proximal trumpet and a distal bevelled end. It is made of glass, silvered on the outside and coated with caoutchouc. The bevelling of the distal end makes a shorter anterior side and a longer posterior one. The maker's name is usually placed at the trumpet end, at the foot of the anterior side, and serves to indicate that side when the speculum is in the vagina.

Mode of employment of the Fergusson Speculum.—The patient lies in the left lateral position with hips raised. Warm the speculum, and oil it on the outside. Take it by the trumpet end with the right hand and

pass it into the vaginal orifice previously opened up by index and middle fingers of the left; now push it in, short side to the front, until arrested. By looking along it, the practitioner can note if the cervix is in view. It is generally not so, but may be snared by the following manoeuvres; carry the trumpet end well back towards the perineum, and then depress the distal end first to the left and then to the right, finally turning it round if these fail. In multiparæ with lax vaginae it is easy to pass the Fergusson; but it is more difficult in nulliparæ.

Uses. The Fergusson is a favourite speculum with many. It is useless in




FIG. 86.
NEUGEBAUER'S SPECULUM when passed.




FIG. 87.
Cross section showing relation of blades; the upper is posterior.

vaginal and cervical surgery, but with it applications to the cervix can be made very well and easily. When used for making applications to the endometrium, it is advisable to pull the cervix well down with a volsella after the speculum is passed, and to use a straight sound covered with cotton wool.

Neugebauer.

3. The NEUGEBAUER is like a Sims speculum divided transversely at the middle of the handle (fig. 86). It is also made in suitable sizes.

How used.

Mode of employment.—Warm and oil *two* blades. Introduce one blade (the broader one) with its convexity touching the posterior vaginal wall. Then introduce the other with its convexity touching the anterior vaginal

wall and so that its edges fit within the edges of the posterior vaginal wall blade (fig. 87). The beak of the posterior blade is thus in the




FIG. 88.
BARNES' CRESCENT SPECULUM.

posterior fornix ; that of the anterior blade in the anterior fornix. From their contact a leverage is obtained on approximating the handles, by



FIG. 89.
CUSCO'S SPECULUM.

which traction is made on the fornices, and the cervical canal more or less everted.

Barnes' Crescent Speculum.

Fig. 88 shows a useful modification of this by Barnes, known as the Crescent speculum.

The Neugebauer and Crescent specula are useful in making cervical and endometric applications, and are better specula than the Fergusson.

Cusco Speculum.

4. The CUSCO or BIVALVE SPECULUM is shown at fig. 89. It is composed of two blades jointed on to one another at their bases. The blades are opened to the desired distance by pressure on the thumb-piece and kept open by a screw. It is introduced with its blades right and left, and then turned so that they lie anterior and posterior, that with the screw being posterior. It is then pushed onwards, and the blades opened and fixed by the screw.

Care should be taken not to catch any of the perineal hairs in the screw; and, in withdrawing it, not to pinch up the vaginal walls.

The Cusco speculum is self-retaining and useful in cervical and endometric applications.

If the patient be placed in the genupectoral or semiprone posture, the posterior vaginal wall hooked back with the fingers and the cervix drawn down with a volsella, a useful view can be obtained without the aid of any speculum.

USES AND COMPARATIVE VALUE OF THE VARIOUS SPECULA.

The Sims is undoubtedly the best and most scientific speculum we possess. When properly used and aided by the volsella or tenaculum, it leaves nothing to be desired. For operative cases its use is imperative; and it is the only speculum which does not distort the split cervix. It is objected by some—on insufficient grounds—that it is difficult to manipulate, requires a skilled assistant, and exposes the patient unduly.

The Fergusson is easily passed, involves only slight exposure, and is good in very minor gynecology. It gives only a limited view of the vaginal walls. The student should note that it brings the flaps of a split cervix together and somewhat conceals the lesion.

The Neugebauer, on the other hand, opens up the cervical split, and may do this so effectually as to give the impression that there is none. The Fergusson and Cusco are *self-retaining*.

CHAPTER XI.

THE UTERINE SOUND.

LITERATURE.

Simpson, Sir J. Y.—Memoir on the Uterine Sound, Selected Obst. Works: A. & C. Black, Edinburgh, 1871. See *Mundé's* Minor Gynecology and *Thomas* as to *Huguiet & Lair*.
Simpson, A. R.—The Uterine Sound: Ed. Med. Journal, 1882.

In considering this important gynecological instrument, we take up— Uterine Sound.

1. Its nature ;
2. Preliminaries to its use ; when not to use it ;
3. Method of use ; difficult cases ;
4. Employment for diagnosis and treatment ;
5. Dangers attending its use ;
6. Relation to bimanual and rectal examination.

NATURE.

The sound of Sir James Simpson is not only the classical instrument, Nature. but, taken all in all, is probably the best. We describe it, therefore, as a type of the instrument, and then consider its modifications.



FIG. 90.
SIR J. Y. SIMPSON'S SOUND.

Simpson's sound is a rod of flexible metal 12 inches long, specially graduated, and provided with a suitable handle (fig. 90). It is made of copper, nickel-plated ; this is sufficiently pliable to be moulded, and yet sufficiently stiff to retain any special shape given to it. Instrument-makers often make this sound too unyielding. It should be always pliable enough to be bent with two fingers.

The handle has the shape shown at fig. 90. Note that it is roughened on the same side as that towards which the point of the instrument lies. Consequently, when the sound is in the uterus, we can tell the direction of the point by noting this roughness on the handle.

The graduation is important. $2\frac{1}{2}$ inches from the point is a rounded

knob: this is the length of the fully-developed unimpregnated uterine cavity. Other markings are 3 inches, $4\frac{1}{2}$ inches, $5\frac{1}{2}$ inches, and so on up to $8\frac{1}{2}$ inches. The notch, $1\frac{1}{2}$ inches from the point, is of little use, and weakens the instrument.

The modifications of this instrument are numerous. The changes are chiefly in its flexibility, lightness, and in the use of another material.

Prof. A. R. Simpson has modified the instrument by making it shorter, abolishing the $1\frac{1}{2}$ inch notch, and squaring the handle (fig. 91): this gives a very handy and useful instrument. Sims, Emmett, and Thomas have each a special sound. Thomas' is made of hard rubber or whalebone, and he claims that it is specially useful in the case of sub-mucous fibroids. Other modifications are by Matthews Duncan, Protheroe Smith, Aveling, Jennison, Hanks, etc.



FIG. 91.

A. R. SIMPSON'S SOUND.

PRELIMINARIES TO ITS USE.

Prelimi-
naries to
Use.

No instrument should have the preliminaries to its use more carefully considered. The rash and careless use of the sound may do immense mischief to the patient. Note, then, *when not to use it*.

- (1.) The sound is not to be passed during an ordinary menstrual period.
- (2.) It is not to be passed in an acute inflammatory attack of uterus, ovaries, pelvic peritoneum, or connective tissue.
- (3.) It is not to be passed in cases of cancer of the cervix or body of the uterus.
- (4.) It is not to be passed if the patient has missed a menstrual period. This is a safe rule, but admits of limitation, as we shall see afterwards.

Before using it—

- (1.) Ascertain that the patient has not missed a period.
- (2.) Do the bimanual carefully. If in doubt, use the rectal examination, aided by the volsella.
- (3.) Place the patient in the left lateral posture.
- (4.) Give the sound the curve you find the uterus to have.

METHOD OF USE.

After the preliminaries mentioned above, take the sound in the hand Method and oil its first 3 inches with carbolic oil 1-20. Pass the index finger of of Use.

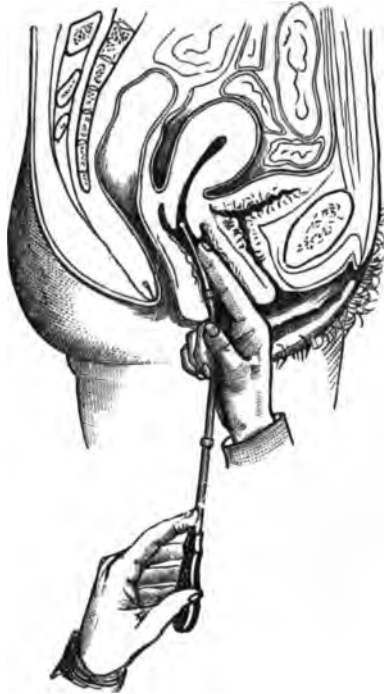


FIG. 92.
FIRST STAGE OF PASSING THE SOUND.

the right hand into the vagina and touch the anterior lip of the cervix, *i.e.*, in front of the os. Guide the sound along the vaginal finger and make the point enter the os uteri (fig. 92). Pass it in for an inch or so, to fix it.

If the uterus be retroverted then carry the handle towards the symphy-

When
Uterus Re-
troverted.

118 *PHYSICAL EXAMINATION OF PELVIC ORGANS.*

sis, when the point of the instrument will glide into the uterine cavity until arrested by the fundus (fig. 93). No force is needed. If force seems necessary, the instrument should be withdrawn, and a more careful Bimanual performed.

When
Uterus to
front.

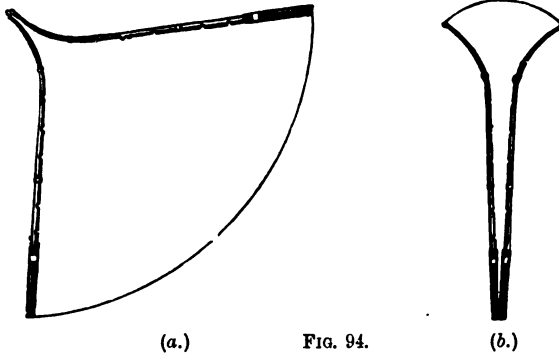
If the uterus lie to the front, the procedure is different. Pass the sound

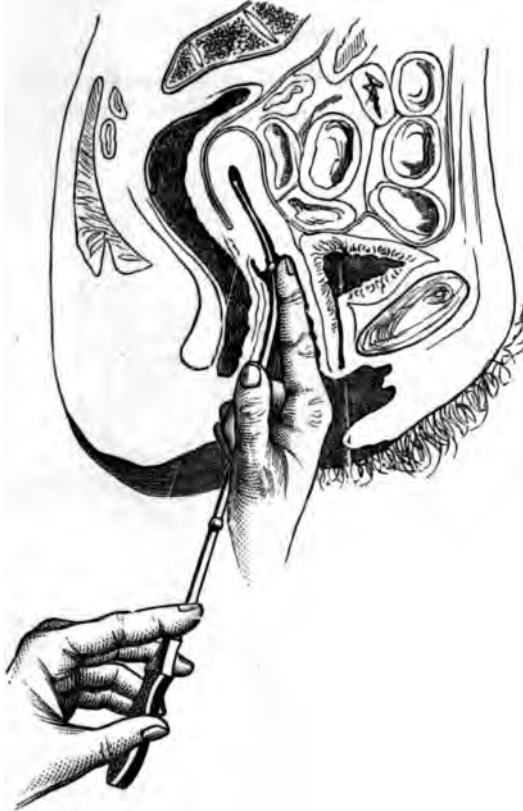

FIG. 93.
SECOND STAGE OF PASSING THE SOUND when UTERUS is Retroverted.

as already described until it has entered the cervix for an inch or so (fig. 92). Note now that the point of the sound looks back, whereas the fundus lies to the front. Clearly, we must make the point look to the front. This is done by turning the handle so that its roughened surface looks to the front. To do this we do not twist round the handle on its long axis, but make it sweep round the arc of a wide semi-circle as in

fig. 94. The point, during this manœuvre, remains fixed or nearly so.



(a.) Proper method of TURNING THE SOUND, contrasted with improper method (b.)

Now carry the handle back to the perineum when the point glides into the cavity (fig. 95).

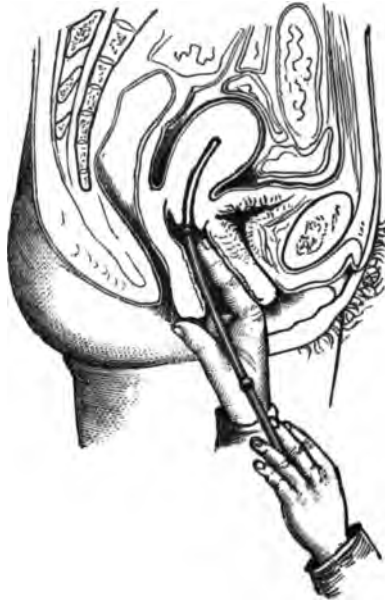


FIG. 95.
SECOND STAGE OF PASSING THE SOUND when UTERUS is to the Front.

Another way of passing the sound, when the uterus lies *to the front*, is as follows. Place the patient well across the bed. Do bimanual and curve sound appropriately. Take the sound in the right hand. Pass

two fingers of the left hand, palmar surface forward, into the vagina, and touch the posterior lip of the cervix. Carry the sound, point looking forwards, into the vagina; make it enter the os, and then carry the handle towards the perineum, when the point will glide on. This method

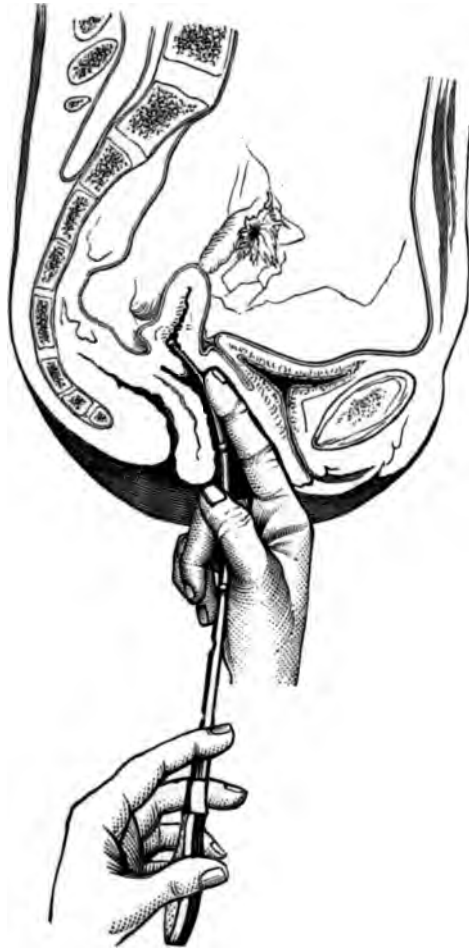


FIG. 96.
SOUND ARRESTED (before Rotation) in a case of Anteflexion.

avoids the sweeping round of the handle, and is useful if the uterus is very much anteverted.

The sound may be passed after the uterus is drawn down with a volsella, or after the Sims speculum has been introduced.

Difficult Cases.—These are chiefly found in markedly anteflexed uteri. The sound passes in so far (fig. 96), but when turned has its point looking too directly upwards. In such cases first draw the cervix down with a volsella, now pass the sound, and should it still stop at the flexion make pressure with a finger in the anterior fornix to push up the fundus. Then get an assistant to carry the handle of the sound towards the perineum. Difficult Cases for Sound.

When the uterine cavity is tortuous as in submucous fibroids a gum elastic bougie—No. 10—may be used to ascertain the length of the uterine cavity. Thomas', Jennison's, or Emmet's sound is specially useful here.

EMPLOYMENT OF THE SOUND FOR DIAGNOSIS AND TREATMENT.

(A) DIAGNOSIS.

(1.) *Length of uterine cavity.* This varies in different pathological conditions. Thus the cavity is Use of Sound in Diagnosis.

(a) lessened in superinvolution of uterus,
Atrophic uteri;

N.B.—The sound easily perforates the thinner wall of the super-involute uterus. This does no harm. It may also pass along the Fallopian tube.

(b) increased in Subinvolution of uterus,
Hypertrophy of uterus,
Cervical hypertrophy,
Endometritis,
Submucous fibroids,
Interstitial fibroids,
Small uterine polypi,
Prolapsus uteri.

(2.) *Direction of uterine axis;* whether retroverted, anteverted, lateri-verted.

(3.) *Relation of axis of uterine body to that of cervix,* whether we have anteflexion or retroflexion.

(4.) *Stenosis and atresia at os internum and os externum; tenderness of fundus,* as in endometritis.

(5.) *Mobility of uterus.* This should be ascertained in the following way. Pass the sound as already described. Make the patient turn on her back, and then place two fingers in the vagina palmar surface upwards and touching the posterior lip of the cervix. The sound lies on the palm of the hand, is steadied with the thumb, and can be used to

move the uterus gently about as desired. When the uterus is not easily defined by the upper hand in the Bimanual, the sound, passed and used as just indicated, enables the upper hand to map it out better. Prof. A. R. Simpson's sound is specially useful for this manœuvre, as the shortness of the stem and the form of the handle allow the latter to lie flat on the palm.

(6.) *Rough condition of endometrium*; often associated with bleeding when sound is passed.

(7.) *Differential diagnosis between uterine polypi projecting into vagina, and inverted uterus, etc.*—When we have a polypus to deal with, the sound passes in through the cervix for more than the usual distance because the uterine cavity is enlarged. In inversion it passes for only a short distance into the cervix, and is then stopped by its reflexion. Sometimes, however, the neck of the polypus is adherent all round to the cervical canal thus simulating inversion: and in some very rare cases the mucous membrane of the uterus becomes separated and expelled from the uterine cavity, simulating inversion of the whole uterus owing to the separation stopping at the os internum. It is evident that in these last two cases the Bimanual clears up the diagnosis, the upper hand feeling the body of the uterus in its normal position in both of them. The sound is only confirmatory of the Bimanual.

(B) TREATMENT.

Use of
Sound in
Treatment.

(1.) *Rectification of undue angular relation between the uterine body and cervix* (anteflexion, retroflexion): *dilatation of uterine canal as a whole, or of stricture at os internum.*

(2.) *Replacing of retroverted unfixed uterus.*

(3.) *Application of acids to endometrium on the sound covered with cotton wool.*

DANGERS ATTENDING ITS USE.

Dangers of
Sound.

The great dangers to the patient from the passage of the uterine sound are abortion, and abrasion of the mucous membrane with absorption of septic matter and resulting pelvic cellulitis or peritonitis.

The former untoward result must be very carefully guarded against. One valuable caution is never to omit the question as to the menstruation, and to ask if it was the usual amount. Some women have a slight discharge of blood at the first period after they conceive, some even menstruate during the whole period of uterogestation. The best safe-

guard is the careful performance of the Bimanual. This soon teaches the practitioner to know whether he has an unimpregnated uterus between his hands, or one at the second or third months of gestation. Special care should be taken when the uterus is retroverted: it may be also gravid; and the pregnancy may, by causing pressure, have induced the patient to consult a medical man. As the Bimanual is often difficult, an unwary use of the sound may make the diagnosis disagreeably evident.

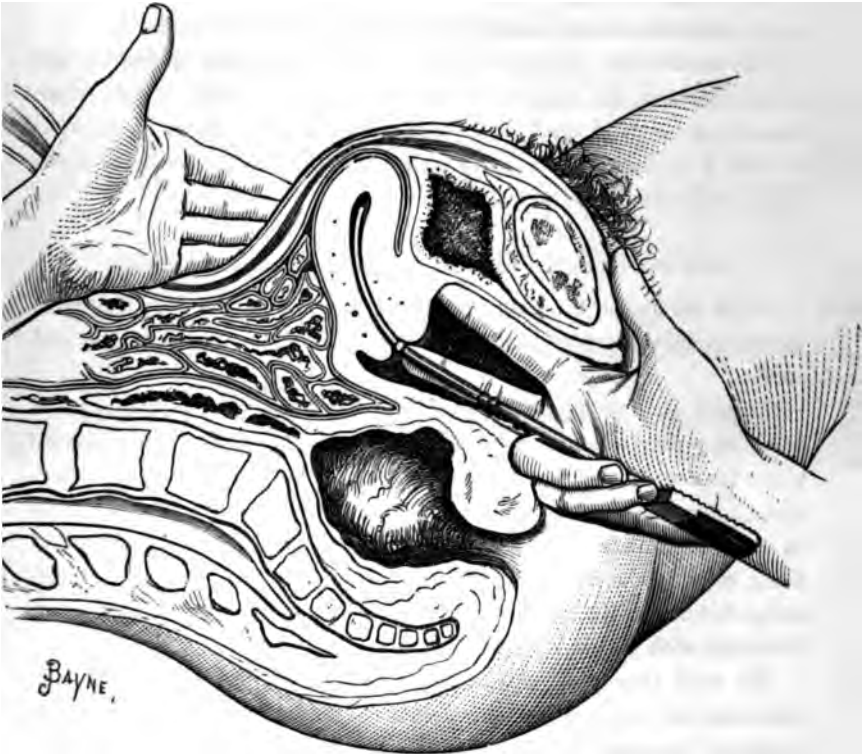


FIG. 97.

SOUND combined with BIMANUAL Examination.

The means to avoid setting up any inflammatory disturbance are—to perform the Bimanual carefully, to curve and oil the sound properly, and to pass it gently.

SOUND COMBINED WITH BIMANUAL.

The importance of this method of examination has been recently pointed out by Professor A. R. Simpson. For its performance the short Use of Sound in Bimanual.

sound with the square handle (fig. 91) is necessary. It is of such a length that, when the middle finger is at the knob, the flat surface of the handle rests on the ball of the little finger, against which it is steadied by the flexed little and ring fingers.

The sound is introduced into the uterus in the ordinary way. The fingers are passed into the vagina as for a vaginal examination, and the sound grasped as in fig. 97. The thumb rests on the symphysis pubis. While the middle finger steadies the sound, the index is in the anterior fornix, and the external hand placed as in the ordinary bimanual.

This method is specially useful (*a*) when the uterus is flaccid; the sound stiffens it, and enables the external hand to define it: (*b*) when, from the presence of small fibroids or pelvic deposits, there is doubt as to what is the fundus uteri; the sound, felt by the external hand in the uterus, indicates the fundus.

RELATION OF SOUND TO BIMANUAL AND RECTAL EXAMINATION.

Relation of
Sound to
Bimanual
and Rectal
Examina-
tion.

Before Sir James Simpson introduced the use of the sound, gynecological examination was confined to the exploration of the vagina and cervix.

Simpson gave an immense impulse to Gynecology, by placing in the hands of gynecologists an instrument which explored the uterine cavity above the cervix, and thus enabling them to obtain a perfection of diagnosis before undreamt of; thus gynecological examination was made up of a vaginal examination, and then a passage of the sound, due attention being given to the non-existence of pregnancy. J. Y. Simpson recommended, further, the elevation of the uterus with the sound, and its definition with the upper hand.

The next step in Gynecology was the use of the two hands—the bimanual and rectal examinations—which in the last twenty years has developed immensely. Consequently, the use of the sound has become more limited. The teaching in this chapter has been based on a recognition of this fact, inasmuch as the use of the sound is recommended only after the bimanual, rectal, and volsellar examinations have been carefully employed.

CHAPTER XII.

THE SPONGE TENT AND OTHER UTERINE DILATORS.

LITERATURE.

Simpson, J. P.—Selected Obst. Works, Vol. I., Edinr. 1871. *Sims, J. M.*—Uterine Surgery, London, 1867. *Landau*: Ueber Erweiterungsmittel der Gebärmutter: Volkmann's Sammlung, No. 187. *Mundé*—Minor Gynecology, New York, 1881.

HITHERTO we have considered only the means which have placed the Uterine Dilators. vagina and cervix within range of digital examination. In this section we take up the methods by which we get digital examinations of the uterine cavity—methods of the highest practical value, which, like the sound, we owe to the genius of Sir James Simpson.

We therefore consider—

- I. *Means of slowly dilating the Cervical Canal by Sponge Tents, Tangle Tents, Tupelo Tents;*
- II. *Means of slowly dilating the Cervical Canal by graduated hard rubber Dilators—Tait's, Hanks' ;*
- III. *Means of dilating the Cervical Canal by incision and screw Dilators ;* this last will be described under Treatment of Stenosis of the Cervix (*v.* Chap. XXIV.)

Under each we take up—

1. Material or instrument,
2. Purposes for which used,
3. Preliminaries to and method of use,
4. Dangers and contra-indications to use.

DILATATION BY SPONGE, TANGLE, AND TUPELO TENTS.

1. *Material.*—The sponge tent is a cone of good, unbroken, thoroughly Spongedried sponge, impregnated with some antiseptic, and then firmly compressed into small transverse bulk, its original length being preserved. material. When thus prepared and placed under conditions where it can absorb moisture, it swells up, and in thus expanding dilates any dilatable structure which may grasp it.

Good sponge tents of various sizes may be had from all chemists. In order to prevent the antiseptic from volatilizing, the sponge tents are

covered with grease. They are provided with a tape at the base to aid their extraction from the cervix after use.

Tents are also made from the ordinary sea-tangle (*laminaria digitata*) (fig. 98), and from tupelo wood (*nyssa aquatilis*). It is alleged that the tupelo expands more rapidly than either tangle or sponge. Fig. 99 shows its power in this respect. Tangle tents may be had hollow; this facilitates the imbibition of moisture but weakens their expanding powers.

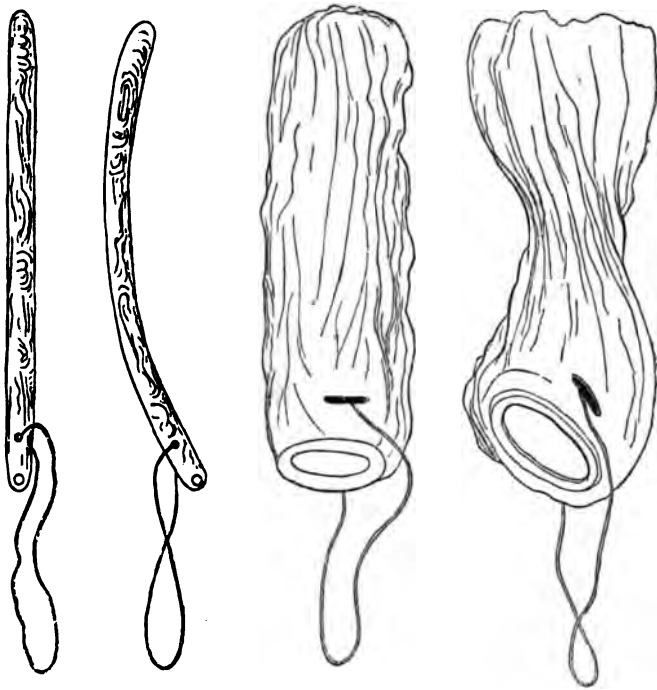


FIG. 98

Shows on the left a straight and a curved laminaria tent, and on the right these tents after expansion. Note how one has been gripped by the os internum (*Mundé*).

Uses of
Tents.

2. *Purposes for which used.*—Sponge tents are used as follows.

(1.) To restrain hæmorrhage in cases of abortion, and at the same time dilate the cervix for further interference.

(2.) To dilate the cervix and uterine cavity, and enable the practitioner to ascertain and remove the cause of pathological uterine hæmorrhage, whether due to endometritis, sarcomata, polypi, or incomplete abortion.

(3.) To correct pathological flexions of the uterus, to dilate a stenosed cervix.

Tangle and tupelo tents have the same scope as the sponge tent. These do not, however, expand so well and thoroughly. Their special advantages are due to their smaller size, and the fact that several may be

Scope of Tangle and Tupelo Tents.




FIG. 99.

DIAGRAM to show relations between size of Tupelo Tent, before and after expansion. The dotted outside line indicates the size of the tent after expansion (Mundé).

passed into the same cervix. They are specially useful, therefore, in cases of narrow cervix and flexions. Tupelo tents are highly praised by Landau and Mundé, but are still on trial.



FIG. 100.

EXPANDED TUPELO TENT with constriction at os internum (Mundé).

3. *Preliminaries to and Method of use.*—Tents should not be passed Preliminaries and Mode of Use. during an ordinary menstrual period, although they often require to be used when pathological bleeding is going on. They should always be

passed at the patient's own house; and she should be kept strictly in bed during their use, and for some time after. Before their use, the vagina should be thoroughly washed out with warm carbolic lotion (1-40). Schultze, in passing tangle tents for flexions, first ascertains the uterine curve with the sound; if blood follows its use, he postpones the introduction of the tent for forty-eight hours, in the meantime applying pure carbolic acid to the endometrium. Before using the sponge tent it is advisable to remove most of the grease covering it.

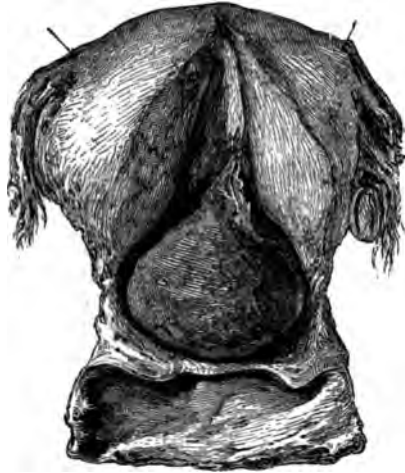

FIG. 101.

SPONGE TENT POLYPUS OF SIR JAMES SIMPSON (†).

Drawing of the uterus which contained a polypus—obtained from a patient of Sir James Simpson's, who died from the hæmorrhage it caused. It was this preparation which suggested to him the sponge tent.

Sponge tents may be passed in various ways.

How
passed.

(1.) The patient is placed in the genufacial, or better, in the semiprone posture. Sims' speculum is passed, the anterior lip of the cervix laid hold of with a volsella and drawn down. The sponge or tangle tent, held in forceps, can then be passed into the cervix (fig. 102).

(2.) The tent is fixed on the spike of an appropriate instrument, and is then passed just as the uterine sound; *i.e.*, with the patient placed in the left lateral position, the index and middle fingers carried into the vagina and placed on the anterior lip of the cervix. The tent, fixed on the spike, is passed along these fingers and its point made to enter the cervix. The handle is then rotated and carried to the perineum.

(3.) The patient is placed on her left side and athwart the bed. Pass the volsella, draw the anterior lip of the cervix down. The volsella is not always needed. Place the tent between the index and middle fingers of the left hand with the thumb at its base, carry these fingers into the vagina with their dorsum on the posterior vaginal wall, make the point of the tent enter the cervix and push it on with the thumb.

Another way is to use the volsella as above described, but to fasten it to the bed. Then pass Sims' speculum holding it with the left hand, so that the tent held in the right hand can be passed into the cervix just as one would thread a darning-needle.

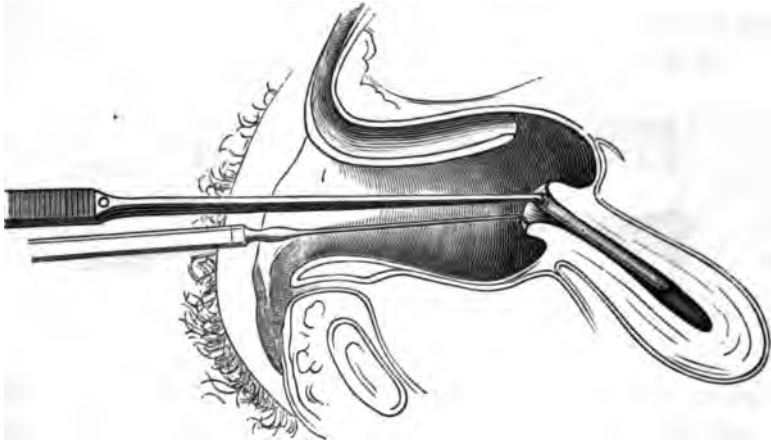


FIG. 102.

SIMS' DIAGRAM ILLUSTRATING PASSAGE OF TANGLE TENT. Patient is semiprone, Sims' Speculum passed, and cervix steadied with Tenaculum. The tent is passed with forceps.

Tangle and Tupelo Tents.—The same instructions as for sponge tents hold good. Tangle tents, however, when used to correct flexions must first be moulded as follows:—Ascertain the curve of the uterus by bimanual and sound, select a suitable tent and dip it for a few seconds in boiling water, then mould it to uterine curve and pass it as already explained. Moulding
of Tangle
and Tupelo
Tents.

Tents require to be left in the cervix for a period varying from 12 to 15 hours, and the vagina should be frequently douched with carbolic lotion during this time. At the end of this period the tent requires to be removed. During the removal no great force should be used. Sometimes the removal is difficult owing to constriction by the os internum or irregularities in the mucous membrane.

The cervix is generally now sufficiently dilated to admit of digital examination of the endometrium. If not, another tent should be employed.

Dangers
and
Contra-
indica-
tions.

4. *Dangers of Sponge and Tangle Tents and contra-indications.*—The practitioner must keep prominently before him that the use of a tent may prove by no means a harmless measure. Cases of death from septicæmia after the careful and proper use of *one* tent have occurred. The patient runs a risk proportionate to the number used; and, therefore, it is not advisable to use more than two consecutively unless under special circumstances. They are not to be used if acute or sub-acute pelvic inflammation, ovaritis (acute or chronic), carcinoma cervicis, or pelvic hæmatocele be present.

The reason why sponge tents may prove dangerous is only too ap-

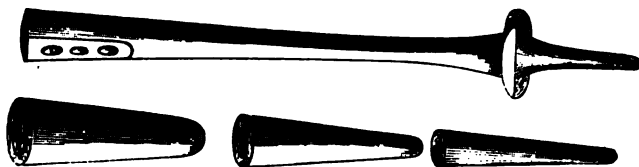


FIG. 103.
TAIT'S DILATORS.

parent. The uterine mucous membrane is a lymphatic surface absorbing most rapidly. We cannot insert sponge tents with Listerian precautions; and in addition we have the expanding pressure of the tent forcing septic matter into the mucous membrane. Thus it is quite evident that the consecutive use of two or more sponge tents is dangerous.

To sum up briefly, tents are highly useful in necessary cases—no means at the disposal of the gynecologist gives him in proper cases such valuable help; but he should not forget the risks occasionally arising from their use—risks which should make him cautious but not timid.

Hard
Rubber
Dilators—
Tait's,
Hanks'.

DILATATION BY GRADUATED HARD RUBBER DILATORS—TAIT'S, HANKS'.

Tait's dilators consist of graduated vulcanite cones (fig. 103) which can be screwed into a suitable handle. The proximal end of the handle is perforated for elastic bands which, passing in front and behind, are attached to a suitable belt round the patient's waist. Thus the elasticity of the indiarubber causes the cone gradually to pass up into the cervix,

dilating it as it goes. By this apparatus, Tait claims to avoid septic infection and to dilate rapidly.

The obvious objection to this apparatus is the amount of watching it entails and the absence of the pelvic curve on the handle.




FIG. 104.
HANKS' DILATOR (t).

In cases, chiefly of abortion where the os is dilatable, Hanks' dilators seem serviceable. They have the oval shape seen at fig. 104, are graduated in size and screw into the sigmoid handle. They can be used manually to dilate the cervix until the fingers can be passed through.

CHAPTER XIII.

THE CURETTE.

LITERATURE.

Mundé—The Dull Wire Curette in Gynecological Practice: Ed. Med. Jour., XXIII., p. 819. *Noeggerath*—Am. J. of Obst., IV., p. 3. *Recamier*—Memoire sur les Productions Fibreuses et les Fongosités Intra-uterines: Univ. Med., 1850. *Sims, J. Marion*—Clinical Notes on Uterine Surgery: London. *Simon*—Die Auslöfflung breitbasiger weicher sarkomatöser und carcinomatöser Geschwülste aus Körperhöhlen: Beiträge zur Geburtshilfe von der Gesellschaft in Berlin, 1872. *Thomas*—Diseases of Women, 1882.

Curette. **THE** curette is an instrument, provided with a cutting or with a dull edge, which can be introduced into the uterine cavity previously dilated by tents (although this is not always necessary) for the purpose of scraping off or removing abnormal endometric granulations, sarcoma of the mucous membrane, carcinoma of the cervix, or the remains of an incomplete abortion. This instrument has had a somewhat chequered career. Originally introduced by Recamier, whose instrument was stiff and sharp, it did good work in some cases, but fell into disrepute, undoubtedly deserved, after the record of certain instances where its use had caused perforation of the uterus. Marion Sims and Simon recommend a

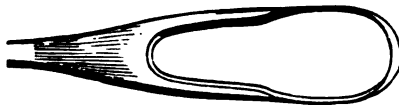

FIG 105.

LOOP OF RECAMIER'S CURETTE. (†)

modified instrument which, owing to its stiff unyielding nature, has found little favour with the profession. Thomas then introduced his flexible dull wire curette, which, popularised by Mundé in an able article, has taken its place in the gynecologist's armamentarium as a useful instrument, to whose employment there is attached no more risk than attends most intra-uterine manipulations.

There are four varieties of curette—(1.) Recamier's (fig. 105); (2.) Simon's (fig. 106); (3.) Thomas' (fig. 107); (4.) Sims' (fig. 108).

Thomas' instrument is 9 inches long, and has a handle $3\frac{1}{2}$ inches long. The metal portion ($5\frac{1}{2}$ " long) is made of soft copper wire, $\frac{1}{8}$ inch thick near the handle, and $\frac{1}{16}$ inch thick half an inch from the end, where it forms a loop (fig. 107) flattened on the scraping edge. Prof. A. R. Simpson, of Edinburgh, has modified it usefully by adding a knob $2\frac{1}{2}$ inches from the point. This enables one to use it with more precision.

Cases in which the Curette is useful.—Recamier's is useful in the same class of cases as Thomas'. Simon's is specially good in carcinomatous cervix, but not in endometric conditions. Thomas' is good in hyper-

Uses of
Curette.



FIG. 106.
SIMON'S SPOON. (i)

Simon's
Spoon.




FIG. 107.
THOMAS' DULL WIRE CURETTE, with knob added by A. R. Simpson. (j)

Thomas'
Curette.

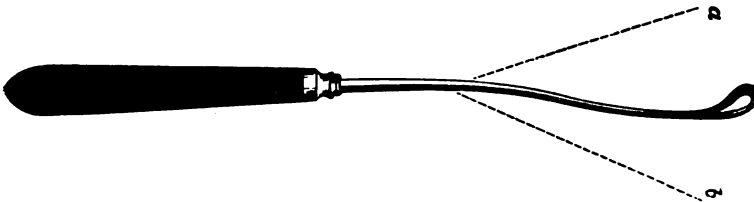


FIG. 108.
SIMS' CURETTE, with Flexible Shank.
a and b, extent of flexibility.

Sims'
Curette.

plastic endometritis, sarcoma of the mucous membrane, and, above all, in incomplete abortion.

It is evident, from what has been said, that the curette aids immensely in intra-uterine diagnosis. By it portions of abnormal intra-uterine tissue can be removed and submitted to microscopic investigation.

How to use Thomas' Curette.—Place the patient semiprone, pass Sims' How to employ Thomas' Curette.
speculum and draw down cervix slightly with volsella. Then pass in the curette, curved if needed (no previous dilatation with tent being required), and gently pass it over the mucous membrane, pressing against

it while the loop is being brought down. Do this systematically over the whole anterior and posterior uterine surface, remembering its shape (fig. 14, A).

Curetting may be done single-handed when the volsella and Battey's speculum are used, as described at p. 108; or in some cases Fergusson's speculum may be employed, and the cervix then drawn well down with the volsella.

After the curetting is finished, apply pure carbolic acid to the endometrium as given under endometritis.

Cautions
and
Dangers.

Cautions and dangers.—The same precautions should be used as given under sponge tents. The dangers have proved in the authors' hands slight, a minor attack of pelvic peritonitis being the worst.

RELATION OF POSTURE TO EXAMINATION AND TREATMENT.

We have already mentioned several postures as being the proper ones for certain manipulations; and we here sum up briefly what it is of use to know in regard to these.

The *side-lateral*, where the patient lies on her side in the ordinary way, is convenient for vaginal examination; passage of Fergusson's, Neugebauer's, or Cusco's speculum; passage of the sound and catheter.

The *dorsal posture* is imperative for abdominal examination and the bimanual.

The *semiprone* is the best posture for passage of Sims' speculum; vesico-vaginal fistula operation.

The *lithotomy posture* is specially valuable for operations on the perineum, vaginal walls, cervix and uterus.

The *genupectoral posture* is useful for replacement of the retroverted uterus.

CHAPTER XIV.

KNIVES; SOISSORS; NEEDLES; SUTURES; ANTISEPTICS; DOUCHES AND SYRINGES; CAUTERY; ANÆSTHETICS.

KNIVES.

For perineal operation, the surgeon's ordinary straight bistoury is sufficient. For vaginal and cervical surgery, long-handled knives with the blade straight or at an angle to the shaft are required (*v.* under operation for vesico-vaginal fistula). Knives.

SCISSORS.

These are of the greatest use to the gynecologist and supersede the use of the knife in many instances. Straight, sharp-pointed scissors are valuable in repair of the perineum. Curved scissors are necessary for fistula cases (fig. 109), Bozeman's being specially good. They are right Scissors.

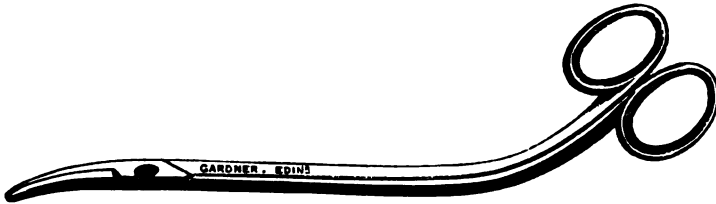


FIG. 109.

SIMPLE CURVED SCISSORS.

and left, but no woodcut gives a proper idea of their curves. For cervical operations, stout and sharp scissors are necessary. It is very important to remember that the vaginal portion of the cervix is exceedingly tough, and that the ordinary scissors in dividing it slip down or even turn obliquely, leaving the tissue uncut. Kuchenmeister's scissors have this tendency obviated by one of the blades being hooked (fig. 110). Even these scissors sometimes prove unsatisfactory, as the finger-and-thumb grip they give is not powerful enough. Fig. 111 shows a pair of cervical scissors devised by Hart, where the handles are like those of bone forceps,

and are provided with a ratchet. They can, therefore, be grasped in the palm of the hand while being used, and cut even the densest cervix with great precision. Scissors are highly useful in perineal, vaginal, and cervical operations.



FIG. 110.
KUCHENMEISTER'S SCISSORS.

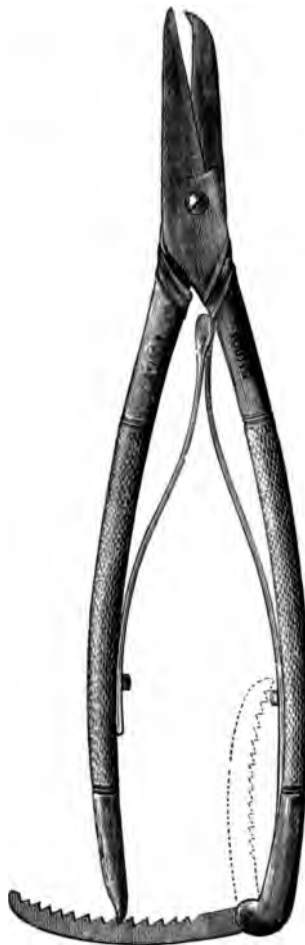

FIG. 111.
HART'S CERVICAL SCISSORS.

NEEDLES.

Needles. We need only note that for cervical and fistula operations strong and short needles with only a slight curve (or perfectly straight) are needed.

The cervical tissue is so dense that markedly curved slight needles snap. Needle-Holders.




FIG. 112.
FORMS OF NEEDLES (Emmet).

They are passed with a needle-holder, of which fig. 113 shows a simple form. Curved or tubular needles set on handles are also useful.

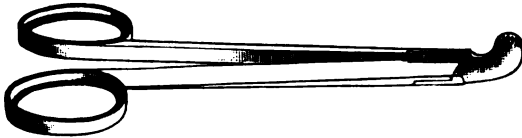


FIG. 113.
NEEDLE-HOLDER.

SUTURES.

These may be silver wire, carbolized silk, catgut, silk-worm gut, or horse-hair. For fistulæ, deep stitches, and cervical laceration, *silver wire* is best. For perineal operations, for superficial stitching, as also for stitching the ovariotomy incision, *silk-worm gut* is good. *Catgut* is valuable in the rectal stitches of complete rupture of the sphincter ani. *Carbolized silk* (thin and fine) is best for the ovariotomy pedicle. Simon also used silk in his fistulæ cases. *Horse hair* is useful for superficial skin stitches.

ANTISEPTIOS.

This naturally divides itself into two sections: viz., Listerism, as con-
ducted in peritoneal operations; and the modified form of antiseptics ^{Anti-septics.}
carried out in vaginal and cervical surgery. Details on the first of these will be given most conveniently in speaking of ovariotomy. We may remark, however, that at present the question of the propriety of the spray in peritoneal operations is still under discussion. Listerism is directed against the atmospheric surrounding of wounds, and is not in any sense a direct treatment of wounds. In peritoneal operations there is the peculiarity that the peritoneum is an absorbing sac which readily takes up carbolic acid in the form of the finely divided spray. Many eminent ovariotomists allege, therefore, that the spray at present considered necessary for Listerism is hurtful in all peritoneal

operations; and that it causes, for the reason already given, high temperatures and kidney complications. This has not been absolutely proved, but is worthy of the careful attention of all operators. Even if sustained, it does not invalidate the high claims of Listerism on general surgery.

Anti-
septic
Douche.

During perineal, vaginal, and cervical operations the use of the *douche* is invaluable. For this purpose a large douche apparatus filled with carbolic lotion, 1-40, with long indiarubber tube and small narrow nozzle is employed. It is placed somewhat above the level of the part to be operated on, and under the charge of an assistant plays a small jet on the surface. Apart from its valuable antiseptic action, it clears away blood from the cut surfaces, enables the operator to pare the fistular edges very exactly, and altogether is a most valuable help. It can be suitably




FIG. 114.
HIGGINSON'S SYRINGE.

warmed; and the excess of fluid flows into any receptacle, such as a foot-bath or large tray on which the legs of the table are placed. Instead of carbolic lotion, boracic or thymol lotion can be substituted.

VAGINAL SYRINGES AND DOUCHES.

For the purpose of applying antiseptic and astringent lotions to the vagina and split cervix, for hot-water injections, and for merely cleansing purposes, the vaginal syringe and douche are employed.

Vaginal
Syringe.

Vaginal Syringes.—Fig. 114 shows the well-known Higginson syringe. Valuable as this is, it is difficult for ordinary patients to manage single-handed. For them we should therefore recommend the

Vaginal
Douche.

Vaginal Douche.—A convenient form of this is shown at fig. 115. It can be hung up after being filled, and by the gravitation thus afforded a gentle flow is obtained. The overflow from the vagina is received into any suitable receptacle on which the patient sits.

For patients in bed its use is equally easy. The nurse or attendant should be instructed to make the patient lie on her back, the hips being

well raised with a pillow. The pillow itself should be covered with a waterproof or folded blanket. An ordinary basin is then slipped below the hips to receive the overflow.

Instead of the douche, a simple tube working by siphon action may be employed.

The great advantage of the douche is its simplicity. Half of the women who buy a Higginson do not know how to use it, and find it troublesome even when they do know.



FIG. 115.
VAGINAL DOUCHE.

The material for injection is varied. Hot water, as hot as the patient **Medicated Injections.** can bear it, is invaluable in inflammatory conditions.

Hot carbolic lotion (equal parts of boiling water and 1-20 lotion) is admirable in abortion cases, for cleansing purposes.

In leucorrhœal conditions; injections of alum (3j to 0j), sulphate of copper (3ss to 0j), sulphate of zinc (3ss to 0j) are good. The general formula for these is—

R. Aluminis
 vel
 Cupri Sulphatis.
 vel
 Zinci Sulphatis 3j.

Fiat pulv ; mitte tales xij.
Sig. To be used as directed.

The patient is told to dissolve one powder, or half of one, in a pint of water, to place this in the douche and use it as already explained.

It is a good plan to make the patient first douche with hot water and

then finally, in the dorsal posture, to finish up with the special lotion. After it is finished the dorsal posture should be maintained for ten minutes, and the last of the injection expelled by sitting up.

CAUTERY.

The ordinary cautery may be employed in the treatment of the pedicle in ovariectomy. Details on this are postponed till that is considered.

Fig. 116 shows the well-known Paquelin's cautery. In this very elegant and useful instrument the vapour of benzoline is pumped through a slender, hollow cone of platinum, the latter being previously heated in a gas flame or spirit lamp. It speedily becomes red or white hot by the combustion of the vapour, and can then be used.

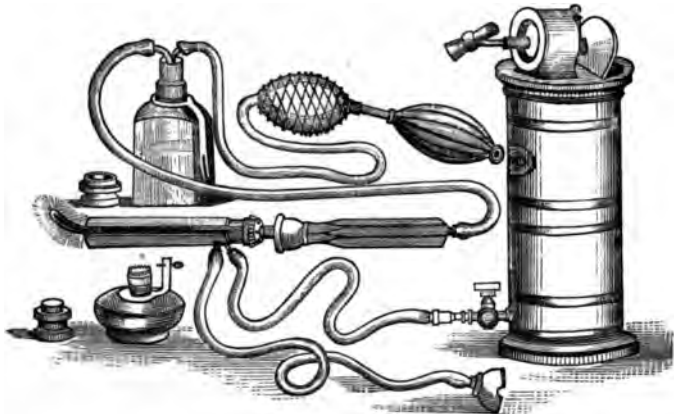


FIG. 116.

PAQUELIN'S CAUTERY AND WILSON'S ANTITHERMIC SHIELD. The shield is seen covering the rod. The water apparatus is to the right. A spirit lamp is also figured (*Mundé*).

Use.

Note as to its use—(1) To be careful with the benzoline as it is exceedingly inflammable; (2) To heat the platinum cone first (in outermost zone of the flame) before pumping in the benzoline. If the vapour is pumped in before the platinum is hot enough to ignite it, the cone is cooled by its cold stream.

The cautery should be used at a dull heat. When white hot it causes bleeding, because it thoroughly burns the tissues, and thus leaves no char to act as a hæmostatic.

When used to cauterize the cervix, care should be taken that the hot metal rod does not touch the vaginal walls. It requires considerable care to avoid this. Various plans have been tried. Thus the rod may

be covered except at its terminal two inches with a wooden case which Wilson's Antithermic Shield must not touch the metal. More recently Dr. Wilson of Baltimore has




FIG. 117.

VARIOUS FORMS OF PAQUELIN'S CONES. *A* rectangular; *B* curved; *C* straight.

devised an antithermic shield through which a stream of cold water is sent by an appropriate apparatus (fig. 116). Fig. 117 shows some of the various rods of Paquelin's cautery; and fig. 116 the same covered with Wilson's antithermic shield.

ANÆSTHETICS.

LITERATURE.—*Brunton, T. L.*—Remarks on One of the Causes of Death during the Extraction of Teeth under Chloroform, *Br. Med. J.*, II., 1875, p. 395. *Chiens*—Chloroform, *London Practitioner*, January 1877. *Hart, D. B.*—On Death from Insufficient Administration of Chloroform, *Ed. Med. J.*, 1879. *Lister*—Chloroform in *Holmes' System of Surgery*, Vol. V.—Report of *Br. Med. Asso. Committee*, *Br. Med. J.*, Vol. I., 1879.

Anæsthetics.

THE chief anæsthetics are chloroform and ether. Other agents or mixtures have been tried, viz., ethidene; mixtures of alcohol, ether, and chloroform; nitrous oxide; bichloride of Methylene: the results have not been satisfactory with these. In the *British Medical Report* on the action of anæsthetics, ethidene is strongly recommended. Chloroform and ether, however, still remain our most trustworthy agents.

Action of Chloroform.

Action of Chloroform.—Chloroform when administered to a patient has a perfectly definite effect on the nervous system. Sensation is first abolished, and then reflex action. This is all the effect wished for in any case. If, however, the chloroform be pushed further, the respiratory centre becomes paralysed so that breathing ceases, and finally the heart stops from paralysis of its ganglia. In almost all cases this is the *sequence in the susceptibility* to chloroform of those parts of the nervous system regulating sensation, reflex action, respiration, and the circulation. Rarely have we the heart affected before the respiratory centre. When first administered, it causes a transient rise in the blood pressure, and then a gradual irregular fall. The more recent investigators on this point (see the *British Medical Report*) found that in dogs chloroform reduced the blood pressure more rapidly and to a greater extent than ethidene, and that ether did not cause any appreciable depression. As the blood pressure is the resultant of the force and frequency of the heart's action and the state of dilatation of the small blood-vessels, it is evident that chloroform when administered to dogs slowed the heart and weakened the vasomotor centre more than ethidene or ether. It should be kept in mind, however, that dogs are very susceptible to the action of chloroform and easily killed by it.

Death not always due to overdose.

It is wrong to suppose that in every chloroform death the fatal result is caused by an over-dose of chloroform, or by the action of the chloroform on a fatty heart. This is a very common view, but an exceedingly erroneous one.

The one great object of anæsthesia is to prevent the patient's feeling pain. This is one of its most gratifying results, but is not by any means *the* great object in operative cases. One of the most essential aims of

its administration is to prevent the reflex transmission of powerful nervous impulses from the part operated on to the heart, or their direct transmission to the respiratory or vasomotor centres. If chloroform be administered to a limited extent so that sensation alone is abolished, and if any large nervous trunk like the Fifth, or large nervous area like the Splanchnic, be irritated, then we may have reflex inhibition of the heart, or paralysis of the vasomotor and respiratory centres; in man, death may result. There are good clinical reports that this reflex inhibition of the heart has caused its stoppage in man. It is sometimes urged against this that no amount of stimulation of the lower end of the cut vagus in a rabbit can permanently stop its heart; in man, however, the conditions are not the same as in the rabbit. Goltz, quoted by Lauder Brunton, gives some most interesting facts in this connection. A frog was decapitated, its heart exposed, and the animal hung with its legs downwards. On tapping the intestines pretty hard, the heart stopped through reflex inhibition of the vagus but soon resumed again. It contracted vigorously but had no blood in it to propel. The irritation of the splanchnics had not only inhibited the heart but so lowered the tone of the vasomotor centre that the veins of the abdominal cavity were widely dilated; and thus the blood, when the animal was vertical, did not reach the opening of the inferior vena cava into the right auricle. When the frog was laid on its back, however, the blood flowed at once to the heart.

This then gives us the proper view of the administration of chloroform in all cases where cutting operations or operations involving large nervous trunks are being performed.

The chloroform must be pushed until sensation and reflex action are abolished, and this state is to be kept up during the operation.

Uses.—Chloroform is used in all cutting operations except in very slight ones; in cases where the straining of the patient prevents the manipulation necessary for accurate diagnosis and treatment; in cases of phantom tumours; and also, when necessary, in cases where vaginal examination of virgins is requisite. Uses.

In division of the cervix, curetting of the endometrium, and application of caustics to the endometrium, it is unnecessary unless the patient is unusually sensitive.

Method of administration.—The patient should have no food for three or four hours prior to the operation. Just before the administration of chloroform is begun, half a glass of wine or brandy may be given. Method of Administration.

The patient should lie on her back with all fastenings unloosed, and

Drop Cork. should not sit up. A towel or napkin folded square is taken and chloroform poured on it. Fig. 118 shows a convenient and economic drop cork which can be fitted into any bottle. The amount does not matter. We judge of the state of the patient not by the amount poured on the cloth but by the effect on the patient. If reflex action be not abolished, even though a quart has been used, the patient has not had enough; while, if respiration be affected after a few whiffs, she has had too much.

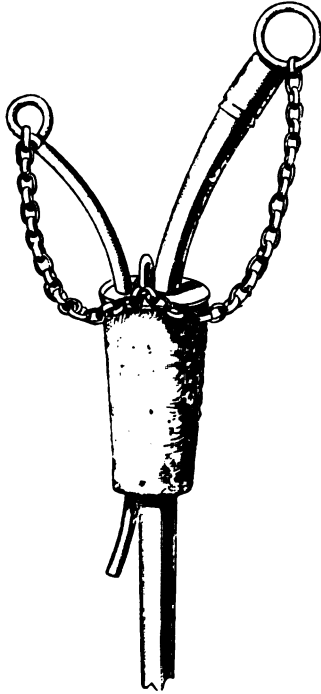


FIG. 118.
CHLOROFORM DROP CORK.

The face of the patient should look to the side, and the chin should be kept well away from the sternum. The administrator should keep the chin forward with his right hand. This is, in addition, valuable, as he can always feel the puff of the breath on the palm.

The cloth is to be held not too closely over the face, and the patient directed to take long breaths.

The administrator has to keep two points before him. He is to watch the breathing most narrowly, and to ascertain when reflex action is abolished.

He can watch the breathing well by feeling the puff of the breath constantly on his hand. The abolition of reflex action is generally tested by touching the conjunctiva; when the patient is not fully under, the orbicularis contracts. This is not a perfect test, but the best we have.

When reflex action is abolished, no more chloroform is to be given; should it show signs of returning, fresh chloroform is put on the cloth.

DANGERS.

These may be the following:—

(1.) *Asphyxia*;

Dangers.

(2.) *Reflex inhibition of Heart or respiratory or vasomotor centres.*

(1.) *Asphyxia*.—This may arise early from fainting, muscular relaxation allowing the tongue to fall back on the pharynx; or from closure of the glottis, owing to paralysis of its intrinsic muscles. The marked extension of the head already insisted on prevents the former from happening. If it arise, the tongue is to be pulled well forward with a pair of forceps. Foulis recommends that the tongue be pressed forward by a spatula or spoon applied at its root.

When asphyxia arises from paralysis of the respiratory centre owing to an overdose of chloroform, the treatment is immediate stoppage of the administration of the chloroform and artificial respiration by *Sylvester's* or *Howard's method* for hours if necessary. The head should be kept hanging over the edge of the table, so as to send blood to the respiratory centre; or the patient may be inverted (Nelatonized).

(2.) *Reflex inhibition of the Heart or respiratory or vasomotor centres.*— Reflex Inhibition. This can only happen when there has not been given sufficient chloroform to abolish reflex action. It is by no means an uncommon thing, therefore, for the patient to die because sufficient chloroform has not been administered; sensation alone has been abolished when the operation is begun. The usual account is that "the patient gave a start when the first incision was made, and died." In some cases this has happened after only a teaspoonful had been poured on the cloth. Yet this is often called "a death from chloroform."

Contra-indications.—Every patient on whom an operation is to be performed may have chloroform; if the operation is indicated, so is chloroform. If the patient has a weak heart, then chloroform is imperative for any major operation; it must be given till reflex action is abolished, as reflex inhibition of the heart is specially dangerous here. Contra-indications

Occasionally, chloroform causes severe vomiting after the operation. Vomiting.

146 *PHYSICAL EXAMINATION OF PELVIC ORGANS.*

For this reason Keith always uses ether instead. Vomiting during the operation is dangerous only when any solid vomit regurgitates back into the trachea ; tracheotomy may then be necessary.

Sickness. Sickness after the operation is treated by the sucking of ice and the application of a mustard leaf to the pit of the stomach.

PART II.

DISEASES OF THE FEMALE PELVIC ORGANS.

WE classify the diseases of the female pelvic organs according to the structure which is affected, and devote one section to each group of affections as follows :—

- Section III. The Peritoneum and Connective Tissue ;
- „ IV. The Fallopian Tubes and Ovaries ;
- „ V. The Uterus ;
- „ VI. The Vagina ;
- „ VII. The Vulva and the Pelvic Floor.

Further, we shall consider under special sections disturbances of the following functions :—

- Section VIII. The Menstrual function ;
- „ IX. The Reproductive function.

Finally, we shall devote one section to affections of the neighbouring organs :—

- Section X. The Bladder and the Rectum.

Hystero-epilepsy and Weir Mitchell's treatment of Chronic Cases will be considered in the Appendix, in which also a Chapter will be given to Case-taking and to Gynecological Literature.

SECTION III.

AFFECTIONS OF PERITONEUM AND CONNECTIVE TISSUE.

CHAPTER XV. Pelvic Peritonitis and Pelvic Cellulitis.

.. XVI. Pelvic Hæmatocele.

CHAPTER XV.

PELVIC PERITONITIS AND PELVIC CELLULITIS.

LITERATURE.

Bandl—Die Krankheiten der Tuben, etc.: Billroth's Handbuch, Stuttgart. *Barnes*—Diseases of Women: London, 1878. *Bernutz and Goupil*—Clinical Memoirs of the Diseases of Women, Vol. II.: New Sydenham Society, Meadow's translation, 1866. *Churchill*—On Inflammation and Abscess of the Uterine Appendages: Dub. J. of Med. Sc., 1843. *Doherty*—On Chronic Inflammation of the Uterine Appendages after Childbirth: Dub. J. of Med. Sc., 1843. *Duncan, J. Matthews*—A Practical Treatise on Perimetritis and Parametritis: Edinburgh, A. & C. Black, 1869. *Freund*—Anatomische Lehrmittel, etc.: Gesellschaft f. Geburtshülfe, Berlin, Band iv. Hft. 1. *Lusk*—Puerperal Fever: Internat. Cong. Trans., 1877. *Mundt, P. F.*—The Diagnosis and Treatment of Obscure Pelvic Abscess in Women, with remarks on the differential Diagnosis between Pelvic Peritonitis and Pelvic Cellulitis: Archives of Medicine (E. C. Seguin, Ed.), Vol. IV., No. 3. *MacDonald, Angus*—Three Cases of Parametritis, with observations on its Diagnosis and Treatment: Ed. Med. J., 1880, p. 1060. *Noeggerath*—Latent Gonorrhœa especially with regard to its influence on Fertility in Women: Am. Gyn. Tr., Vol. I. *Olshausen*—On Puerperal Parametritis and Perimetritis: New Syd. Soc. Transl., 1876. *Priestley, W. O.*—Pelvic Cellulitis and Pelvic Peritonitis: Reynold's System of Medicine, Vol. V. *Schroeder*—Krankheiten der weiblich. Geschlechtsorgane, Leipzig, 1879. *Schultze, B. S.*—Ueber die pathologische Anteflexion der Gebärmutter und die Parametritis Posterior: Hirschwald, Berlin, 1876. *De Sinsky*—Gynecologie: Paris, 1879. *Simpson, Sir J. Y.*—On Pelvic Cellulitis and Pelvic Peritonitis, Clinical Lectures on the Diseases of Women (edited by Simpson, A. R.): Edinburgh, A. & C. Black, 1872. *Simpson, A. R.*—Quarterly Report of the Royal Maternity and Simpson Memorial Hospital: Ed. Med. Journal, Vol. XXVI., p. 1059. *Spiegelberg*—Remarks upon Exudations in the neighbourhood of the Female Genital Organs: Second Series of German Clinical Lectures, Translated by New Sydenham Society, 1877. *Tait, Lawson*—On the Treatment of Pelvic Suppuration by Abdominal Section and Drainage: Tr. of Med. Chi. Soc., Lond., 1880, p. 307. *Winckel*—Die Pathologie der weiblichen Sexual-organe: Leipzig, 1881. This gives photo-lithographs of great value. *Ziegler*—A Text-book of Pathological Anatomy and Pathogenesis, Macalister's translation: London, Macmillan and Co., 1883.

Pelvic Peritonitis. In considering the subjects of pelvic peritonitis and pelvic cellulitis it will be convenient to take up some preliminary matter and then to consider separately each condition under the following heads:—

<p>Nature.</p> <p>Pathological anatomy and varieties.</p> <p>Etiology.</p> <p>Symptoms.</p> <p>Physical signs.</p>		<p>Diagnosis: Differential diagnosis.</p> <p>Course and results.</p> <p>Prognosis.</p> <p>Treatment.</p>
--	--	--

Preliminary considerations.—The subjects of pelvic peritonitis and pelvic cellulitis are by no means thoroughly worked out. The literature is extensive, but not so valuable as medical literature often is. This arises from various causes, among which the most important is the change in the theories as to the anatomical site of pelvic inflammatory conditions. Nonat and Simpson contended that pelvic peritonitis and pelvic cellulitis were distinct affections, and considered the latter as being of frequent occurrence. Then Bernutz and Goupil turned the tide for some time by their able work, where they classed almost all pelvic inflammatory affections as peritonitic. They, however, greatly underrated the amount of connective tissue surrounding the cervix, just as Guérin has more recently written in the same strain as to the connective tissue of the broad ligaments; and Le Bec, too, has endeavoured to support the opinions of the latter by his observations on the lymphatic distribution of the broad ligament.

There is now little doubt that Bernutz and Goupil pushed their views too far; so that in America, Germany, and Britain, gynecologists now consider pelvic inflammation as either peritonitic or cellutic. Clinical, anatomical, and pathological facts are each day putting this view on a firmer basis. The fact, however, that these diseases are not rapidly fatal, and that generally we get *post mortems* only of advanced or resolved cases, along with the admitted difficulty of exact clinical differentiation, renders our knowledge at present much less complete and exact than could be wished.

Finally, we must note that both diseases are always combined. Thus in a marked pelvic peritonitis there is always some pelvic cellulitis, and in a marked pelvic cellulitis always some pelvic peritonitis. This is quite analogous to what is found in pleurisy and pneumonia.

PELVIC PERITONITIS.

SYNONYMS.—Perimetritis: Pelveo-peritonitis.

NATURE.—An acute or chronic inflammatory condition affecting chiefly the pelvic peritoneum.

PATHOLOGICAL ANATOMY AND VARIETIES.

In the early stages, the peritoneum is injected and the epithelial cells dull in lustre. Soon, in marked cases, fibrinous or serous fluid is poured out: the former stiffens the peritoneum and often causes extensive adhesions between uterus and rectum, Fallopian tubes and ovary; the latter

Patho-
logical
Anatomy.

either remains free in the cavity, or becomes encysted by the false membranes already alluded to, often making Douglas' pouch to bulge down.

Varieties. In bad cases, pus is formed. We may therefore speak of simple pelvic peritonitis, adhesive pelvic peritonitis, and serous or purulent pelvic peritonitis. These, however, are mere varieties.

ETIOLOGY.

Etiology. The causes of pelvic peritonitis are numerous. They are chiefly the following.

1. The previous existence of a pelvic cellulitis; pelvic hæmatocele; ovaritis; ovarian tumour; fibroid tumour; tubercle, and carcinoma.
2. Childbirth and abortion.
3. Gonorrhœa.
4. Latent gonorrhœa in the male.
5. Menstruation.
6. Venereal excess.
7. Instrumental examination by the sound: stem pessaries; sponge tents; tangle tents.

1. *The previous existence of a pelvic cellulitis; ovaritis; ovarian tumour; fibroid tumour; tubercle; and carcinoma.*

We have already noted that marked pelvic cellulitis is always associated with some pelvic peritonitis. The pelvic peritoneum and cellular tissue are adjacent and intimately connected with one another in their vascular, nervous, and especially in their lymphatic supply. We have already seen how the stomata of the peritoneum communicate with subendothelial lymphatics. In the same way we can understand a pelvic peritonitis arising secondarily from ovaritis.

Ovarian tumours often set up pelvic peritonitis after being tapped as well as from their mere mechanical pressure—a fact of the highest importance as regards the operation of ovariectomy. Small fibroids, tubercle, and cancer do the same, and thus give rise to considerable difficulty in diagnosis. Dr. Foulis of Edinburgh has thrown much light on malignant peritonitis, by showing that in the ascitic fluid we find very characteristic cell clusters. This will again be referred to under ovarian tumour.

2. *Childbirth and abortion.*—When an inflammatory lesion follows these, it is generally cellulosic and, as we shall afterwards see, septic. Pelvic peritonitis often enough follows, and is then probably likewise septic. According to Lusk, who quotes Steurer's as yet unpublished

researches, "bacteria pass along the lymphatics . . . and perforating those beneath the peritoneum set up pyaemic peritonitis." At the same time, the peritonitis may result from simple bruising.

3. *Gonorrhœa* is one great cause of peritonitis. It may result from actual spread of the gonorrhœal virus ; or be sympathetic, like orchitis, in the male. In the former case the purulent infection probably passes along the Fallopian tubes and out at the fimbriated end, setting up a severe peritonitis. In puerperal women, gonorrhœa is by no means innocent, therefore, as the following case by Prof. A. R. Simpson shows :—

"J. C., primipara, prostitute, æt. 18, admitted to the hospital and was delivered of a male child. On the afternoon following severe peritonitis set in, which proved fatal in ten days. On *post mortem* the abdomen contained 3 viii. of yellow pus. Surface of intestines covered with recent fibrinous lymph becoming purulent. Mucous membrane of bladder much congested and in certain areas rough and granular. . . . On squeezing the Fallopian tubes a large quantity of pus was expelled, and the tubes appeared to be much distended with it. Mucous membrane much congested." (Report by Dr. D. J. Hamilton.)

4. *Latent Gonorrhœa in the Male*.—By this term Noeggerath of New York, who first directed attention to the subject, means a gonorrhœa in the male apparently cured, which some time after—even two years—infects a healthy vagina, causing discharge and pelvic peritonic disturbance. This subject comes up under *Gonorrhœa*. The authors have seen some cases bearing out Noeggerath's views.

5. *Menstruation*.—It can be readily understood how the pelvic congestion of menstruation may in certain cases cause peritonitis. There may be some blood effused which sets it up.

6. *Venereal excess* in prostitutes and newly married women may, for evident reasons, have peritonitis as its sequel.

7. *Instrumental manipulation*.—This is alluded to under the various instruments and needs mere mention here.

We append Bernutz's analysis of the causes of pelvic peritonitis in ninety-nine cases. Bernutz's
Analysis.

43	occurred in	puerperae.
28	,,	after gonorrhœa.
20	,,	during menstruation.
8	traumatic	{
		3 due to venereal excess.
		2 ,, syphilitic diseases of cervix.
		2 ,, introduction of the uterine sound.
		1 ,, use of vaginal douche.

SYMPTOMS AND PHYSICAL SIGNS.

A. Acute Peritonitis.

Symptoms. *Symptoms* :—Increased, full, and bounding pulse ; increased temperature ; rigor ; shooting pains very severe.

Physical Signs. *Physical Signs* :—On palpation of lower part of abdomen the patient complains of pain ; and the abdominal muscles, apart from the patient's volition, resist pressure. She lies usually on her back, and with both legs drawn up.

On vaginal examination the vagina feels hot and tender, and pulsating vessels may be felt in the fornices.

After exudation is present, we may feel one or other of the following conditions.

1. A flat hard non-bulging condition of the fornices round the cervix, which is not displaced to one or other side but is immobile. The usual simile, and a very good one, is that it feels as if plaster of Paris had been poured into the pelvis.

2. An indistinct fulness high up in the pelvis. This is from free serous exudation.

3. A bulging tumour behind the uterus displacing it to the front ; or a tense fluid laterally, apparently in the site of the broad ligament (fig. 45). The former is due to encysted serous effusion in the pouch of Douglas, the latter to encysted serous fluid behind the broad ligament displacing it forwards. As a general rule these effusions are high in the pelvis and symmetrical. Sometimes the bulging retro-uterine tumour feels nodulated after a time ; this is from extension of the inflammatory condition into the subjacent connective tissue.

Note that the Bimanual is often impossible owing to the rigid condition of the fornices and abdominal muscles. The bimanual estimation of effusion is often wrong owing to the fact that we feel the rigid peritoneal membrane through the fornices, and from the rigidity of the abdominal wall draw the conclusion that there is effusion between these. Careful examination under chloroform is of the highest value in such instances.

B. Chronic Peritonitis.

Symptoms. *Symptoms* :—These are chiefly backache, sideache, leucorrhœa, increased menstruation and sterility. Pain is the most marked symptom, and is felt most on vaginal examination or coitus.

Physical Signs. *Physical Signs* :—On vaginal examination obscure thickening is felt in the fornices. The uterus, if displaced, is often markedly anteverted from

cicatrization of the peritoneum in the pouch of Douglas. Very frequently it is retroverted and bound down by adhesions, which may, however, allow of a certain range of mobility.

The chronic form may occur as a sequel to the acute; most frequently it develops slowly of itself.

DIFFERENTIAL DIAGNOSIS.

This will be considered under Cellulitis.

Differential
Diagnosis.

COURSE AND RESULTS.

Very often the inflammatory condition clears up. The adhesive form leaves its mark in the shape of pathological anteversions, and retroversions bound down (fig. 119). The Fallopian tubes may have their ovum-conducting power so interfered with that an incurable sterility results. When they are not injured to this extent, conception may occur; and the adhesions may ultimately yield to the stretching brought to bear on them by the developing uterus. They may, however, resist this and cause abortion.

Course and
Results.

Occasionally, pelvic peritonitis becomes general and is then rapidly fatal.

Serous exudations may become absorbed; pus may dry up, but oftener perforates into the bladder, bowel, or roof of vagina.

PROGNOSIS.

Each case must be judged on its own merits. We give, therefore, only general hints. Prognosis.

As to life.—Pelvic peritonitis is not usually fatal. If it becomes general and is septic or gonorrhoeal in its origin, then the prognosis is very grave. A high and rapid pulse of long continuance, with a temperature not in the same ratio, also makes prognosis grave.

As to sterility.—This is difficult to give, and often time alone settles the point. The mechanical closure by pressure of the Fallopian tube—a condition not diagnosable—and ovaritis rendering ovulation impossible, are conditions often produced and are both incurable. Prognosis as to conception should always be cautious, and never absolute when the peritonitis has been extensive.

TREATMENT.

A. Acute pelvic peritonitis.—*a. Prophylactic.*

Treatment

b. General.—(1.) Diet. (2.) Septicity. (3.) Pain. (4.) Pulse and Temperature.

c. Local.

Prophy-
lactic
treatment.

a. Prophylactic.—This is of the very highest importance. The practitioner should always attend most scrupulously to antiseptic cleanliness in all vaginal, cervical, and uterine operations. Cautions on these points are given under the head of the respective operations and need not be here repeated.

During their menstrual periods young patients should avoid all undue fatigue, late hours, violent exercise, alternate exposure to heat and cold when insufficiently clad.

General
treatment.

Gonorrhœa should be thoroughly treated, especially during pregnancy.

b. General.—Under this we attend to diet, and employ remedies intended to combat the septic condition when present, to alleviate pain, and to bring down pulse and temperature.

Diet.

(1.) *Diet.*—In the early stages of inflammation, this should be chiefly milk iced or mixed with lime water, potash water or lemonade. Among the better classes, apollinaris or seltzer water can be used. Seltzer water helps to combat the constipating tendency of milk diet.

Stimulants.

When the patient's strength is reduced and the pulse flagging, nutritious stimulating food must be frequently given. Milk should be still continued; but beeftea or strong soups every two or three hours must be added. Stimulants are requisite at this stage, viz., brandy, champagne, gin, or whisky. Care must be taken to give these in their stimulating doses, *e.g.*, for brandy, a table-spoonful every two or three hours.

Regulation
of Bowels.

The regulation of the bowels is not requisite in the early stages; but in the later periods must be looked after. Gentle aperients such as compound liquorice powder, colocynth and hyoscyamus pills, castor oil, etc., can be used; and occasional enemata are of service. Enemata should not, however, be used exclusively, as this may lead to the formation of troublesome scybala.

Tonics.

When suppuration is tedious, it should be seen that no bed sores form; and iron and quinine should be administered.

R. Ferri et Quiniæ Citratis gr. lxxx.
 Aquæ ℥ij.
Sig. Teaspoonful thrice daily.

or

R. Ferri et Ammoniæ Citratis gr. lxxx.
 Aquæ ℥ij.
Sig. Teaspoonful thrice daily.

The bitterness is best masked by dilution with water and not with orange or other syrups which derange the stomach.

(2.) *To combat any septic condition.*—We know no specific medicine for this purpose. A favourite one is the muriate of iron of the Ed. Phar. Treatment
against
Sepsis.

R. Tincturæ Ferri Muriatis (Ed. Phar.) ℥ij.
Sig. Thirty drops thrice daily in a glass of water. Water should be drunk freely after the dose is given, and the mouth thoroughly rinsed with bicarbonate of soda and water.

Quinine may be used for the same purpose.

R. Quiniæ Sulphatis gr. xxiv.
Acidi Sulphurici diluti ℥ij.
Aquam ad ℥vj.
Sig. Tablespoonful thrice daily in water.

(3.) *To alleviate pain.*—Nothing is so good for this as the hypodermic injection of morphia deep into the deltoid. Treatment
of Pain.

R. Morphiæ Bimeconatis gr. viij.
Spiritus Vini Rectificati miij.
Aquæ ℥j.
Sig. For Hypodermic injection. Fifteen minims contain $\frac{1}{4}$ grain of Morphia.

The bimeconate is a good preparation and causes less sickness than other forms; as one drachm of this preparation contains one grain of morphia, and as the hypodermic syringe holds only 30 min., it is impossible to give an overdose to an adult.

When doses larger than half-a-grain are needed, the hypodermic solution of the acetate of morphia (B. P.) may be employed. Twelve minims contain 1 grain, and therefore 3 minims is the first dose for an adult.

It is a good plan for the practitioner to keep the ordinary 8 gr. to ℥i. solution, and to prescribe the stronger solution only for any patient requiring it; in this way he avoids carrying two solutions of different strength by which mistakes might arise. The *stronger* solution is prescribed as follows:—

R. Injectionis Morphiæ Hypodermicæ (B. P.) ℥ij.
Sig. For Hypodermic injection. Three minims contain $\frac{1}{4}$ grain Acetate of Morphia.

Chlorodyne (25 min.); Battley's solution (liquor opii sedativus, 15 min.) or Laudanum (tinctura opii, 25 min.) may be used. More useful than these are morphia suppositories.

R. Morphiæ Hydrochloratis gr. $\frac{1}{2}$
Fiat Suppositor. Mitte tales vj.
Sig. As directed.

It is a good plan to quiet the pain rapidly with the hypodermic injec-

tion; and to keep up the good effect by suppository, in $\frac{1}{2}$ grain doses every six hours, beginning 6 to 8 hours afterwards. See that the patient or attendant understands that the suppositories are to be passed into the empty bowel.

Treatment
of high
Pulse and
Tempera-
ture.

(4.) *To bring down pulse and temperature.*—In early stages, tincture of aconite is invaluable.

R. Tincturæ Aconiti

ʒij.

Sig. Six drops are to be put in a wine glass containing six teaspoonfuls of water. Give a teaspoonful every quarter of an hour.

Drop doses of aconite are of great value. They should be given every quarter of an hour until the pulse is reduced and sweating brought on.

If this fail and the temperature keep high, quinine in 15 grain doses should be tried. The salicylate of quinine is a good preparation and is given just as quinine is. When the stomach is irritable the quinine, in 20 grain doses, suspended in an ounce of mucilage, may be given per rectum.

Sometimes the ice-cap is useful.

After the fever has subsided and suppuration is threatened, the strength must be kept up by tonics (such as quinine and iron) and by nutritious food with a judicious amount of stimulant, claret for example.

Local
Treatment.

c. Local Treatment.—In the early stages of sthenic nonseptic cases, 8-10 leeches may be applied over the iliac regions.

Ice is not generally used as a local application in this country, and has its disadvantages.

Of greater use are large hot linseed poultices. They should be made very hot, a layer of flannel intervening between them and the skin, and should be covered with a layer or two of cotton. Such a poultice will be effective for 2 or 3 hours. Blisters and turpentine stupes are good, but soon render the skin so sore that after-treatment by poultices is difficult.

The hot vaginal douche (as directed at page 139), with carbolic acid added in septic cases, should on no account be omitted.

Encysted serous collections should, as a general rule, be left to be absorbed. When troublesome from pressure, they may be tapped by Matthieu's aspirator. A clear serous fluid, often coagulable, is then drawn off, so like urine that the almost involuntary first thought is that the operator has tapped the bladder by mistake.

Pus does not form so often in pelvic peritonitis. It may perforate into the rectum or through the posterior fornix. The treatment of suppuration will be best considered under pelvic cellulitis.

B. Treatment of chronic pelvic peritonitis.—When adhesions are extensive, the case is better left alone. When the uterus is retroverted, it may ultimately be replaced by bimanual manipulation. Massage is good in such cases, but its employment will be considered afterwards when we speak of Weir Mitchell's method of treatment by rest and food.

Treatment when Chronic.

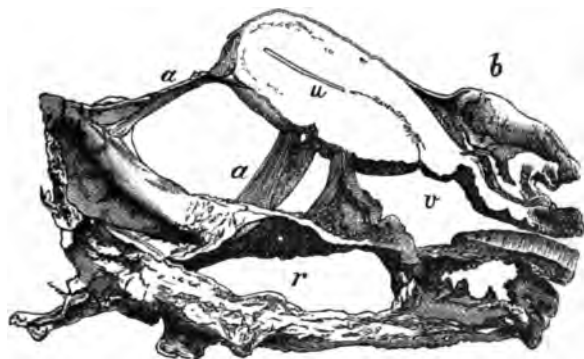


FIG. 119.

UTERUS retroverted and bound back by peritonic adhesions (*Winckel*). *a a* adhesions; *b* bladder; *v* vagina; *u* uterus; *r* rectum. (4)

PELVIC CELLULITIS.

SYNONYM.—Parametritis: *Parametritis proper* is a term applied sometimes to inflammation limited to the cellular tissue round the cervix and upper part of vagina, Virchow's parametric tissue.

Pelvic Cellulitis.

NATURE.—An acute or chronic inflammatory affection, usually septic, affecting the cellular tissue of the pelvis.

PATHOLOGICAL ANATOMY AND VARIETIES.

It is the rare exception to examine a female pelvis without finding some traces of a previous cellulitis or peritonitis. Thus split cervix, so common in women who have borne children, is almost always associated with some cellulitis at the base of the broad ligaments. The uterus is rarely central, but is often drawn to the one side by the cicatrisation of some previous lateral cellulitic inflammation of the broad ligament; the traction may even be so great that it lies at right angles to its proper axis.

Pathological Anatomy and Varieties.

We have seen that the utero-sacral ligaments are peritoneal folds containing connective tissue and unstriped muscular fibre. Inflammatory attacks in one or both of these folds (combined pelvic peritonitis and pelvic cellulitis) are very common. Schultze calls this "parametritis posterior,"

but utero-sacral cellulitis is a more accurate term. The cicatrisation of these ligaments after such inflammation, causing traction just above the isthmus, brings about the most common cause of dysmenorrhœa and sterility—pathological ante flexion of the uterus (*v.* Ante flexion of the Uterus). It is evident that in this way, too, we get the uterus ante flexed and drawn to one side, or ante flexed and drawn back (fig. 40).

Sometimes pelvic abscesses are found in localities to be afterwards alluded to. Often the uterus and ovaries are in an atrophic condition owing to compression of the vessels and nerves by the cellulitic attack; this quite agrees with the clinical fact that many women with bad pathological ante flexion do not suffer much at their periods, because the withered condition of the organs produces scanty menstruation. Freund has written on a peculiar condition under the term "*Parametritis chronica atrophicans*;" he asserts that we have a chronic inflammatory condition, ultimately causing atrophy by compression of blood-vessels: perhaps this may be a final stage of cellulitis. According to some, we can have no cellulitis in the broad ligaments and no formation of pus—abscess of the broad ligaments. Clinical, anatomical, and pathological evidence is in favour of the occurrence of both. At the same time, it is almost impossible clinically to distinguish abscess of the broad ligament from an encysted serous pelvic peritonitis behind it, pushing it forwards.

ETIOLOGY.

Etiology. In *parous women* the great cause of pelvic cellulitis is septic matter absorbed by the lymphatics from the torn perineum, vagina, or cervix. This passes along the abundant lymphatics and blood-vessels in the cellular tissue beneath and in the broad ligaments, causing inflammation of the glands and proliferation of the connective tissue in which these are embedded. Thus we find childbirth, premature labour, and abortion, often followed by cellulitic attacks for obvious reasons. In parturition we have the cervix, for instance, torn vertically at one side; and septic matter deposited there often speedily spreads along the lymphatic stream. Steurer, who investigated an epidemic of puerperal fever at Strassburg, found such cases with diphtheritic patches about the vulva; and from these traced bacteria into the connective tissue spaces where their presence gave rise to cellulitis; from the spaces they entered the lymphatics causing lymphangitis.

Klebs, who terms the bacteria found in a wound "*microsporion septicum*," traced their penetration with or without the aid of wandering

white-blood corpuscles, from serous membranes into the connective tissue, and noted their penetration through the eroded wall of a vein.

Recklinghausen found the lymphatics of the skin, at the edge of an erysipelatous patch, filled with bacteria.

Still more recently, Koch has investigated the relation of bacteria and micrococci to traumatic infective diseases in his recent monograph translated by Watson Cheyne. It is well worth perusal.

The practical result of all this is that, in gynecological operations and abortion, all wounds must be kept strictly clean; and that Listerism, when possible, should be carried out (*v.* Ovariotomy and Treatment of Pelvic Abscess). The student will, as he proceeds, see endless applications of these results.

In *nulliparæ*, cellulitis may arise from the same causes as are given under pelvic peritonitis, *e.g.*, exposure to cold during menstruation.

Pelvic peritonitis, in a minor degree, is always associated with cellulitis for reasons already given. So far as we have considered the etiology of pelvic inflammatory affections, we have associated them with some virus, most frequently septic. We do not believe that mere traumatic injury, apart from septicity and tension, can cause any inflammatory attack.

SYMPTOMS.

The patient has a rigor or chill. Pain is felt over the lower part of Symptoms the abdomen, but it is not so intense as in peritonitis. The pulse and temperature are raised. Often after exudation has taken place, the patient has one thigh alone drawn up.

PHYSICAL SIGNS.

There is pain on palpation of the abdomen; and after exudation has Physical taken place, we feel a fulness at one side of the uterus or in the iliac Signs. fossa.

Bimanual examination, always difficult, reveals at first nothing but increased heat and tenderness. After exudation has occurred, it is found in the following positions:—

- (1.) As a bulging at the side of the uterus, depressing the lateral fornix and pushing the uterus usually to the other side;
- (2.) in the upper portion of the broad ligament, and therefore not bulging downwards;
- (3.) in the iliac fossa;

- (4.) very rarely, behind the uterus ;
- (5.) almost never, between uterus and bladder.

We have seen pus pointing in the inguinal region on one side, and with no dipping down into the pelvis or immediate connection with the side of the uterus. When pus is present in large amount, the fluctuation can be felt bimanually. When it forms in the centre of a large inflammatory exudation, an obscure boggy feeling may or may not be made out. Aspiration helps here very much.

Explana-
tion of
Course of
Exuda-
tions.

The course of these exudations, inflammatory and purulent, is explained in two ways.

(a.) By the course of the lymphatics, which run, as we have seen, from the uterus outwards beneath and between the layers of the broad ligament to the glands in the lumbar region.

(b.) By the lines of cleavage in the cellular tissue of the pelvis. The student should refer back to König's researches (page 45). Based on these, and on clinical work, König holds that—

- (1.) An exudation in the broad ligament, near the tube and ovary, passes first along the psoas and iliacus and then sinks into the true pelvis ;
- (2.) exudations which begin primarily in the deeper cellular tissue on the antero-lateral aspect of the cervix, pass first on to the cellular tissue of the true pelvis at the side of the uterus and bladder ; and then pass with the round ligament to Poupart's ligament beneath the inguinal canal ; thence they pass outwards and backwards into the iliac fossa ;
- (3.) abscesses, developing from the posterior aspect of the broad ligaments, fill first the postero-lateral part of the pelvis and then pass as in (1).

DIFFERENCES AND DIFFERENTIAL DIAGNOSIS BETWEEN ACUTE PELVIC
PERITONITIS AND CELLULITIS.

Differences
and Differ-
ential
Diagnosis.

Differences.

Pelvic Peritonitis.

Pelvic Cellulitis.

- | | |
|---|--|
| (1.) Inflammatory affection of pelvic peritoneum chiefly. | (1.) Inflammatory affection of pelvic cellular tissue chiefly. |
| (2.) Usually general, round the uterus. | (2.) Usually lateral. |
| (3.) Not always septic. | (3.) Usually septic. |

Differential Diagnosis.

Pelvic Peritonitis.

- (1.) Pain very severe.
- (2.) Patient's legs drawn up on both sides.
- (3.) Firm flat effusion not bulging into fornices, and round the uterus. Symmetrical bulging of serous effusion behind uterus. Cervix (vaginal portion) is normal length.
- (4.) Does not spread along round ligament or into iliac fossa, but may affect all peritoneum.
- (5.) Uterus displaced to front, or unaltered in position.
- (6.) Vomiting more frequent.

Pelvic Cellulitis.

- (1.) Pain not so severe.
- (2.) Usually, only one leg drawn up.
- (3.) Firm effusion, bulging usually into fornix of one side. Thus cervix (vaginal portion) apparently shortened on one side.
- (4.) Exudation or pus spreads in definite directions, and is usually localised.
- (5.) Uterus usually displaced to one side.
- (6.) Vomiting less frequent.

It is often very difficult to differentiate these; and therefore in some cases the diagnosis must be pelvic inflammation, probably cellulitic or peritonitic, as the case may be.

COURSE AND RESULTS.

Very often the attack passes off and leaves no trace. The septic poison is too small in amount to do harm; or it sets up some inflammatory exudation, which mechanically arrests progress, and then becomes absorbed. The vitality or health of the tissues and the strength of the poison have also their share in determining its progress. Exudation may take place and may be absorbed almost completely, may suppurate slowly, and only to a limited extent, or may form a large abscess. This abscess may open into the bowel or bladder, or pass below Poupart's ligament, or upwards beneath the kidney. Rarely does it appear in the perineum, or pass through the sciatic notch to the buttock. In one case where the last occurred, the patient complained of a very deep-seated pain just over the notch.

It is valuable to note how rarely the abscess perforates into the peritoneal cavity. The peritoneal surfaces of the abdominal contents are in contact; and as the inflammatory attack spreads, it sets up a peritonitis, glueing the adjacent surfaces together. When pus does enter the peritoneum, it sets up a rapidly fatal peritonitis.

PROGNOSIS.

Prognosis. This depends on the extent of the inflammatory attack, and its effect on the patient's health. Its septic origin usually causes anxiety; but it does not spread so rapidly as peritonitis. Resolution of inflammatory deposits is slow. Pathological antelexion gives rise to troublesome dysmenorrhœa and sterility. Prognosis should always be guarded as to complete recovery.

TREATMENT.

Treatment. The general and the local treatment are exactly the same as in pelvic peritonitis. The occurring of suppuration is indicated by rigors, and should be hastened by the hot douche and poultices. We may have only part or parts of the exudation suppurating, so that in a cellulitic swelling we may have inflammatory exudation containing separate abscess cavities. In these, tapping with Matthieu's aspirator is very good, and may be often repeated. Care should be taken that the aspiratory needle has been purified in carbolic lotion (1-20), and prior to introduction dipped in carbolic oil (1-20).

Treatment of Pelvic Abscess. When pus is present in large quantity, the treatment varies according to the part at which it points.

(1.) If it point above or below Poupart's ligament, in the buttock, or behind the kidney, it is to be opened under Listerism, and a drainage tube inserted. Results by this method are admirable.

(2.) If it bulge in the vaginal roof, it should be opened as follows:— Pass Sims' speculum, and open into the cavity with Paquelin's cautery at a dull heat; make the opening big enough to admit two good-sized drainage tubes. Daily irrigate the cavity with weak carbolic lotion (1-100) or boracic lotion (1-30). If the discharge is profuse it may be received into pads of salicylic cotton wool placed over the vulva; oakum or marine lint may be used among poor people.

The drainage tubes should be double, and with a small piece at the end at right angles which prevents their slipping out. They should not be perforated, as this prevents the washing out. If only straight tubes can be had, a small piece of ivory can be stitched to the upper end.

The practitioner will very often find the remains of cellulitis as an indistinct thickening in the fornices. For these, blisters in the iliac regions, the glycerine plug, and hot douche, are useful (*v.* under Chronic Ovaritis).

CHAPTER XVI.

PELVIC HÆMATOCELE.

LITERATURE.

Aitken, Lauchlan—Case of Pelvic Hæmatocele: Ed. Med. J., 1862, p. 104. *Bandl*—Die Krankheiten der Tuben, etc., Billroth's Handbuch: Stuttgart, 1879. *Bernutz and Goupil*—Clinical Memoirs of the Diseases of Women, Vol. II., New Syd. Soc., Meadows' Tr., 1866. *Barnes*—Diseases of Women: London, 1878, p. 590. *Bourdon*—Tumeurs fluctuants du petit bassin: Rev. Med., 1841. *Credé*—Monatsschrift f. Geburtskunde, Bd. IX., S. 1. *Duncan, Matthews*—Uterine Hæmatocele: Ed. M. J., 1862, p. 418: Diseases of Women, Churchill, Lond., 1883. *Fritsch*—Die Retro-uterine Hæmatocele: Volkmann's Sammlung, No. 56. *Kuhn*—Ueber Blutergüsse in die breiten Mutterbänder und in das den Uterus umgebenden Gewebe: Zurich, 1874. *Martin*—Das extraperitoneale peri-uterine Hæmatom: Stuttgart, Enke, 1882. *M'Clintock*—Diseases of Women: 1853. *Macdonald, Angus*—Uterine Hæmatocele, Ed. Med. J., Jan. 1883. *Nélaton*—Gaz. des Hôpitaux, 1851 and 1852. *Pelletan*—Clinique Chirurgicale: Paris, 1810. *Priestley, W. O.*—Pelvic Hæmatocele: Reynolds' System of Med., Vol. V., p. 783. *Simpson, J. F.*—Periuterine or Pelvic Hæmatocele, Collected Works, Vol. III., p. 121: A. & C. Black, Edinburgh. *Schroeder*—Handbuch der Krankheiten, etc.: Leipzig, 1878, S. 453. Kritische Untersuchungen über die Diagnose der Hæmatocele Retro-uterina: Arch. f. Gyn., Bd. V. *Tyll*—Pathology and Treatment of Sanguineous Tumours, Lond. 1853. *Voisin*—De l'hématocèle Rétro-utérine: Thèse, Paris, 1858. The literature is well given in Bandl's work and Priestley's article.

SYNONYMS—Retro-uterine Hæmatocele: Uterine Hæmatocele.

THIS subject will be considered under the same heads as the preceding.

Preliminary Considerations.—The abundant venous supply of the Preliminary pelvic organs, the congestion induced by menstruation, and the hæmorrhages accompanying the monthly rupture of the Graafian follicle, render women peculiarly liable to hæmorrhages into the pelvic cavity. Yet it is astonishing that it is only since 1850 that this subject has really attracted gynecologists' attention. It was in that year that Nélaton gave the subject due prominence; although Voisin (1810), Recamier, Bourdon (1841), Ollivier, and Bernutz had all recorded cases—under such titles as "Bloodgush from an aneurism of the ovary," "Blood cysts of the pelvic cavity." Nélaton had diagnosed his case as an abscess, and opened it with a bistoury; the blood and blood clots escaping from the incision showed its real nature unmistakably. Since that time pelvic hæmatocele has taken its place in gynecology as a serious and important symptom.

NATURE.—An effusion of blood into the pelvic peritoneum, enclosed

either by anatomical structures or previously existing inflammatory adhesions.

Many will consider this definition unsatisfactory; it must be taken, however, in connection with the following remarks. Pelvic hæmatocele is not a disease. It is only a symptom of some previously existing pathological condition of the pelvic organs, just as hæmoptysis is not a disease but usually a symptom of some lung condition. We have limited the term hæmatocele to hæmorrhages into the peritoneal cavity.

It is disputed whether the inflammation encysting and limiting the hæmorrhage is antecedent or consequent to it. The former view has much more evidence in its favour, although some cases support the latter. This, however, belongs more especially to pathological anatomy.

It may be urged that we have limited the term pelvic hæmatocele to hæmorrhages enclosed by anatomical relations or inflammatory adhesions. We do this, however, for the following reason. The hæmorrhage gives no physical sign until enclosed, and is no more palpable to the finger examining through the fornices than the intestines or ascitic fluid are. Fluid blood in the pelvis can usually only be diagnosed by abdominal incision or *post-mortem*.

PATHOLOGICAL ANATOMY.

Patho-
logical
Anatomy.

Post-mortem cases are rare, but enough have been recorded to give us some idea of its pathology.

In almost all the cases, the blood is found enclosed by pelvic inflammatory adhesions, apparently antecedent. Dr. Lauchlan Aitken has recorded a case which, during life, presented the usual physical signs of retro-uterine hæmatocele, viz., a retro-uterine tumour bulging into the posterior fornix vaginæ and displacing the uterus markedly forward; and in which, on *post-mortem*, clotted blood, not enclosed by adhesions, was found behind the uterus.

Usually, however, the tumour when retro-uterine has, as its boundaries, the uterus and broad ligaments in front and the sacral peritoneum behind; while, above, it is roofed in, as it were, by adherent intestine or by the retroverted and adherent uterus. The uterus is markedly driven forward by the effusion.

Sometimes the blood is found effused between the layers of the broad ligament, which limits it unless the effusion is so great as to perforate a lamella and escape into the peritoneum. Occasionally the blood is below the peritoneum and dissects it up as it escapes from the vessels; or it is found in the cellular tissue of the pelvis (Hæmatoma).

It is of the highest pathological importance to note that in a very large proportion of the cases diseased ovaries have been found ; changes

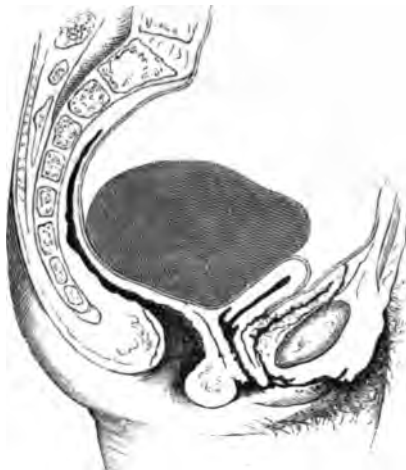

FIG. 120.

RETRO-UTERINE HÆMATOCELE. Pouch of Douglas previously obliterated by inflammation.

in the Fallopian tubes (dilatation and filling with blood or pus) being less common.

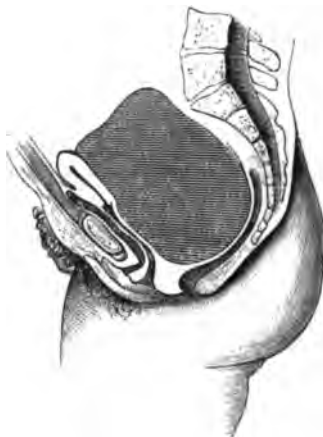


FIG. 121.

RETRO-UTERINE HÆMATOCELE. Pouch of Douglas not previously obliterated (*Schroeder*).

The effused blood undergoes changes in course of time, so that blood crystals, granular corpuscles, and oil drops are found as traces of the

previous blood effusion. When the patient dies soon after the hæmorrhage, the blood is merely clotted. In most cases of recovery it becomes entirely absorbed.

ETIOLOGY : SOURCES OF HÆMORRHAGE AND VARIETIES.

Etiology. The table quoted below shows that pelvic hæmatocele is most common in women between the ages of 25 and 35; that is, women in their period of full menstrual and sexual vigour. Out of 43 cases, the ages, according to Schroeder, were as follows:—

In	3 cases, or	7·0 p. c.,	the ages were	.	.	22-25
„	14	„	32·5	„	„	25-30
„	13	„	30·2	„	„	30-35
„	9	„	20·9	„	„	35-40
„	3	„	7·0	„	„	40-43
„	1	„	2·2	„	„	53

It is also most common in multiparæ, and occurs in about 4 or 5 per cent. (*Olshausen*), or 7 per cent. (*Schroeder*), of female diseases.

The following are the chief causes of hæmorrhage and its anatomical sources:—

**Sources of
Hæmorrhage.**

1. *Predisposing causes.* Profuse menstruation; violent exercise during menstruation, such as dancing; violent coitus during menstruation; varicose conditions of the subperitoneal veins; purpura; scorbutus; hæmophila.

2. *Anatomical sources.* (a.) *Pelvic Peritoneum.*—There may be rupture of veins of the pampiniform plexus, or of the veins below the uterine peritoneum. In the former case, we may get the blood pouring directly into the peritoneum; or first passing between the layers of the broad ligament, and either remaining enclosed there or rupturing into the peritoneum. The hæmorrhage, according to Virchow, may arise from vessels developed in the false membranes of pelvic peritonitis. Credé of Leipzig quotes a case where he tapped a tumour and first got serum, then blood-stained serum, and finally blood. In two days, a fresh tapping first gave putrid blood and then fresh blood in abundance.

(b.) *Connective tissue.*—Rupture of veins occurs here also.

(c.) *Uterus.*—We may have regurgitation in menorrhagia from the uterus along the dilated Fallopian tubes. Rupture of interstitial extra-uterine pregnancy is another cause of hæmorrhage.

(d.) *Fallopian tube.*—Blood may come from its hyperæmic mucous

membrane and pass into the peritoneum. More usually it arises from rupture of an extra-uterine pregnancy there.

(e.) *Ovary*.—Here it results from rupture of congested vessels, of the Graafian follicles, or of extra-uterine pregnancy in Graafian follicles.

Of all these causes, rupture of veins below the peritoneum, and rupture of Fallopian tube and ovarian pregnancies are the most common. The student will now clearly see the *symptomatic nature* of hæmatocele.

Varieties.—We have adopted “pelvic hæmatocele” as a convenient general term. When the blood effusion is retro-uterine and intra-peritoneal, then “retro-uterine hæmatocele” is the term usually employed.

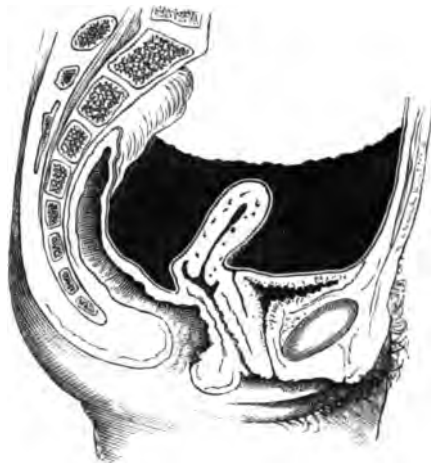

FIG. 122.

COPIOUS BLOOD-EFFUSION, ANTE AND RETRO UTERINE.

In cases where the blood effusion is copious, it may flow up to the anterior fornix, “ante-uterine hæmatocele.” When beneath the peritoneum—extra-peritoneal—and extensive, it may be termed “peri-uterine.” An effusion into the connective tissue is conveniently termed *hæmatoma*.

All these may be classed under two heads, viz.:—

1. Intra-peritoneal, *i.e.*, blood effusion into the pelvic peritoneum; the most common class.
2. Extra-peritoneal, *i.e.*, blood effusion beneath the peritoneum, between the layers of the broad ligament or deep in the connective tissue.

Classifica-
tion.

SYMPTOMS.

Symptoms. The chief symptoms are menorrhagia, sudden onset, sudden bloodlessness, pain. The pulse may become feeble from anæmia, and the temperature is not above normal. Menorrhagia is not always present, and the bloodlessness may not be very well marked; sometimes patients have a sudden faint feeling. In cases of copious effusion from rupture of an extra-uterine pregnancy, the symptoms are often like those of irritant poisoning, viz., sudden onset, prostration, vomiting. The marked anæmia, however, points to some internal hæmorrhage; inquiry

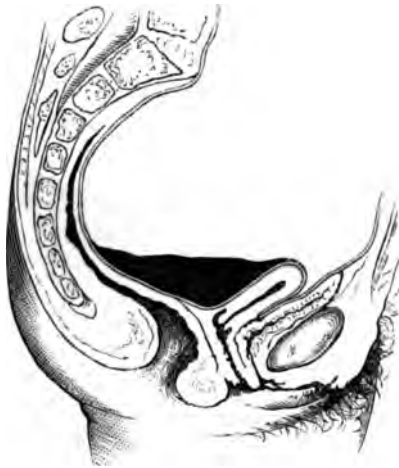

FIG. 123.

FREE BLOOD NOT CAUSING POUCH OF DOUGLAS TO BULGE DOWN.

should then be made as to menstruation, and this always followed by bimanual examination.

In retro-uterine hæmatocele, we find frequent painful micturition and difficulty in evacuation of the bowels. There is sometimes retention of urine.

PHYSICAL SIGNS.

Physical Signs. These are sometimes negative; oftener characteristic, especially in retro-uterine hæmatocele.

Blood effused into the pelvic peritoneum, and neither coagulated nor enclosed by adhesion, is not palpable to examination, and does not cause the pouch of Douglas to bulge downwards more than ascitic fluid does (fig. 123). It will be pressed out of the pouch of Douglas as the

bladder distends, and return into it when it empties. It is often said that the effused blood naturally gravitates into the pouch of Douglas. The question as to how effused liquid blood behaves when free in the peritoneal cavity is, however, not well known yet. The relative behaviour of blood and intestine must vary according to whether or not the intestine is distended with gas. It has not been conclusively shown that fluid blood will gravitate into the pouch of Douglas so as to bulge it down, unless adhesions limiting its spread above, are present.

When, however, blood is poured out near the pouch of Douglas and below adhesions, we get the following characteristic state. On abdominal palpation, a tumour may be felt. On vaginal examination a firm convex bulging tumour is felt, varying in size from a billiard ball to a child's head, and sometimes filling up a large part of the pelvic cavity; the os uteri is pressed close behind the symphysis, looks downward, and is often almost inaccessible (fig. 121). A good plan to get at it is to turn the index finger palmar surface to the symphysis, and push it well up. *On bimanual examination, the fundus uteri is felt unusually distinct, below the abdominal walls, behind the symphysis, and generally to one or other side.* This settles the point that the retro-uterine tumour is not the uterus. The sound confirms the Bimanual as to the position of the uterus, but is not as a rule necessary.

Physical
Signs in
Retro-
uterine
Hæmato-
cele.

When the effusion is into the broad ligament the exact diagnosis is more difficult. Such cases are usually found on post-mortem or operation. During life, reliance must be placed on symptoms, viz., sudden occurrence, and absence of inflammation at the first. The physical signs in large peri-uterine effusions are that the bulging is round the uterus, and that it is not confined to the pouch of Douglas. *Hæmatoma* is difficult to diagnose, and is probably often mistaken for a cellulitic deposit.

When the blood effusion is large, the patient may sink before any very definite physical signs are found. We have taken the view that pelvic peritonitis is usually antecedent to the hæmatocele. At the same time we always have a resulting peritonitis coming on in a day or two, this being indicated by increased pulse and temperature and by tenderness on pressure.

All that has been given here is only how to diagnose the *symptom* of the occurrence of hæmorrhage. The diagnosis of the condition causing the hæmorrhage is, unless in the case of extra-uterine pregnancy, as yet beyond our clinical knowledge.

DIAGNOSIS AND DIFFERENTIAL DIAGNOSIS.

Diagnosis and Differential Diagnosis. Pelvic hæmatocele requires to be diagnosed from—
Pelvic peritonitis followed by enclosed serous effusion in pouch of Douglas,
Pelvic cellulitis,
Fibroid on posterior wall of uterus,
Ovarian cyst behind uterus,
Extra-uterine pregnancy,
Retention of blood in horn of maldeveloped uterus,
Retroversion of non-gravid or gravid uterus.

Of these we consider at present only pelvic peritonitis and pelvic cellulitis.

In these two purely inflammatory affections we have the inflammatory symptoms from the first, without a history of sudden onset or of menorrhagia. Further, the difference in etiology of hæmatocele and peritonitis will help us. The history is of the greatest service.

COURSE AND RESULTS.

Course and Results. In many cases ($\frac{1}{3}$ according to Voisin) the blood effused becomes entirely absorbed, in a time varying from 2 to 10 months.

The tumour, with partially clotted or purulent contents, may burst into the rectum, vagina, or peritoneal cavity: in the last case, fatal peritonitis follows.

When the blood effusion is very large, death may be rapid.

PROGNOSIS.

Prognosis as to Life. *As to Life.*—This is, as a rule, settled soon. The most fatal cases are extra-uterine pregnancies, and rupture of varicose vein into the peritoneum with no peritonitic adhesions to limit the blood effusion. After peritonitis is set up, the prognosis is much as in pelvic peritonitis.

TREATMENT.

(1.) *At onset of hæmorrhage.*

(2.) *When suppuration occurs.*

Treatment. (1.) *At onset of hæmorrhage.*—The treatment here is expectant. The patient is to be put at complete rest, with ice-bags to the abdomen. Ergotine should be injected into the buttock. The ice-bag is to be kept on for several days, as this will limit the subsequent peritonitis. If the

patient is collapsed, then stimulants and hypodermic injections of sulphuric ether or whisky must be freely used, and a large mustard poultice over the abdomen is often serviceable, both as a blood derivative and in allaying vomiting. In most cases, the source of the bleeding is unknown; the present state of knowledge does not enable us to lay down any rule as to the opening of the abdominal cavity and the attempt to ascertain and secure the bleeding source. In Fallopian tube pregnancies which have burst, the abdomen has been incised and the tube ligatured on either side of the rupture; but no case of cure has been reported, so far as we know. The plan of incising the retro-uterine tumour and clearing out clots is wrong; it simply leads to more bleeding from rupture of adhesions. When absorption is going on, the treatment is just as in pelvic peritonitis.

(2.) *After suppuration has occurred.*—The tumour is to be opened and drained, as recommended at p. 164 for suppurating pelvic cellulitis.

Recently, Mr. Lawson Tait has recommended that some pelvic abscesses be opened by abdominal section, as we often get very tedious cases when they perforate into the bowel. The following was the treatment in one of six cases in which he performed it:—"I determined to open it from above. . . . I found a large cavity containing about two pints of fœtid pus with decomposing blood clots. This I carefully cleansed out, and after having united the edges of the opening into the cyst carefully to the abdominal wound, I fixed in one of Kœberlé's drainage tubes five inches long. . . . The patient went home cured on the thirtieth day."

Tait's cases were chiefly suppurating hæmatoceles (Tr. of Lond. Med. Chir. Soc., vol. 62).

SECTION IV.

AFFECTIONS OF THE FALLOPIAN TUBES AND OVARIES.

- CHAPTER XVII. Fallopian Tube : Parovarium : Round Ligament : Broad
Ligament : Tubo-ovarian Cysts.**
- „ **XVIII. Malformations of Ovary : Ovaritis and Periovaritis :
Displacements of Ovary—Hernia, Prolapsus.**
- „ **XIX. Battey's Operation : Tait's Operation.**
- „ **XX. Pathology of Ovarian Tumours.**
- „ **XXI. Diagnosis of Ovarian Tumours.**
- „ **XXII. Operative Treatment of Ovarian Tumours.**

CHAPTER XVII.

FALLOPIAN TUBE: PAROVARIIUM: ROUND LIGAMENT: BROAD LIGAMENT: TUBO-OVARIAN CYSTS.

LITERATURE.

Bandl—Die Krankheiten der Tuben, etc., Billroth's Handbuch: Stuttgart. *Barnes*—Diseases of Women: London, 1878, p. 376. *Hennig*—Krankheiten der Eileiter und die Tubarschwangerschaft: Stuttgart, 1876. *Duncan*—Diseases of Women: Lond., 1882. *Klob*—Pathologische Anatomie der weiblichen Sexualorgane: Wien, 1864. *Næggerath*—The Vesico-vaginal and Vesico-rectal Touch: Am. J. of Obst., VIII., p. 123. *Simpson, J. Y.*—Diseases of Women (Edit. A. R. Simpson), p. 539. *Schroeder*—Handbuch der Krankheiten, etc.: Leipzig, 1878, S. 329. *Tait*—Menstrual Fluid retained in the Left Fallopian Tube simulating Ovarian Tumour: Br. Med. J., 1878, p. 677. *Thomas*—Diseases of Women: Philadelphia, 1880, p. 760. *Williams*—Ovarian Tumours: Reynold's System of Medicine, Vol. V. *Wells, T. S.*—Diseases of Ovarian and Uterine Tumours: London, 1882. For other literature see Bandl, whose work and that of Hennig we mainly follow.

FALLOPIAN TUBE.

Fallopian
Tube.

Preliminary Considerations.—The anatomical relations of the Fallopian tubes have been already considered (p. 21). Functionally, they act as ducts along which the spermatozoids pass to fertilise the ovum; and along which the ovum, fertilised or non-fertilised as the case may be, is carried to the uterine cavity. So far as we know this is all their physiological function, unless we hold with Tait that they play some important though as yet undefined part in menstruation. Pathologically, the Fallopian tubes are important from the occurrence of extra-uterine pregnancy in them and their occasional dilatation with pus or blood. From the fact that they open on the one hand into the uterus, and on the other hand into the peritoneum, very serious results may follow from fluid accumulations in them, from spreading gonorrhœa, or from injections into the uterus. It is interesting to note that Leopold found bloody serum in the Fallopian tubes of a girl who had died suddenly on the first day of menstruation.

Palpation
of Tubes.

Can the normal Fallopian tubes be palpated in the Bimanual? The student will probably have already noted that, in considering the Bimanual (p. 96), we did not name the Fallopian tubes as structures whose form and limits he was expected to define. In a very favourable case, the conjoined manipulation may define them at their uterine origin—

more especially if the rectal examination be made and the uterus be well drawn down with the volsella. Næggerath has pointed out that they may be defined in those cases where the finger is passed along the urethra to explore the interior of the bladder, an operative procedure to be described afterwards. Practically the Fallopian tubes, unless much dilated, are not palpable on ordinary examination. It must not be forgotten that many cases have now been recorded by Tait and Thomas, especially the former, where, on abdominal section, the Fallopian tubes were found dilated with pus to the size of coils of small intestine, but where during life the most careful Bimanual had failed altogether to detect their presence.

Catheterisation of the tubes.—In certain undoubted cases the uterine sound has been passed along the Fallopian tube, while in others the supposed sounding of the tube has been really the perforation of the uterine wall. It is impracticable to sound the normal Fallopian tubes to any effect; and the procedure, or rather the attempt, is by no means devoid of danger. Catheterisation of Tube.

We now take up their pathological conditions under the heads of—

- Abnormalities,
- Stricture and Occlusion,
- Patent condition of the Tubes,
- Inflammatory conditions of the Tubes,
- Hydrops Tubæ,
- Pyosalpinx and Hæmatosalpinx,
- New Formations,
- Extra-uterine Fœtation (to be considered under Section IX.)

ABNORMALITIES.

These are of little practical interest. The chief one is an accessory fimbriated end. Abnormalities.

STRICTURE OF THE TUBES.

The tube may have a congenital stricture; or may become closed at the uterine or the fimbriated end or in the middle. When stricture occurs at the uterine end, it is caused by implantation of the placenta there or by endometritis with adhesion. In the middle, small tumours or adhesions may cause strictures—in the latter case usually partial. At the fimbriated end, the occlusion is due to a catarrh of the tubes which has spread to the peritoneum and set up adhesive peritonitis.

178 AFFECTIONS OF FALLOPIAN TUBES AND OVARIES.

These strictures are of importance in relation to sterility and fluid accumulations, but cannot be diagnosed during life.

PATENT CONDITION OF THE TUBES.

Patency. By this is meant undue dilatability. It is of great importance in relation to uterine injections. Even in careful injection of the uterine cavity, post partum or otherwise, fatal results have followed from the fluid's passing along the tube into the peritoneal cavity. "Forcible uterine injections on the cadaver, with the cervix entirely filled up by the syringe, almost always sent fluid along the tubes into the peritoneal cavity. Less forcible injections under like conditions sent the fluid along a less distance (2-3 mm.), and often sent it into the veins; while gentle injections

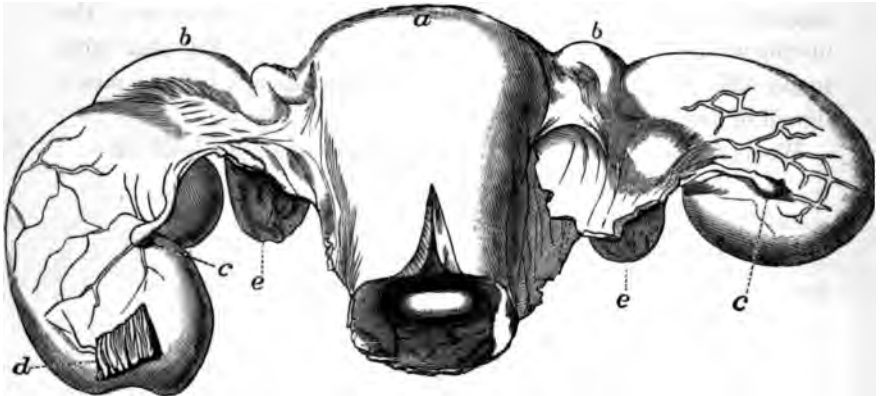


FIG. 124.

HYDROPS TUBÆ: *a* Uterus with Cervix laid open in front; *bb* Fallopian Tubes; *cc* hydrops; *d* part of an inflammatory adhesion; *ee* ovaries (*Hennig*).

with a tube not filling the cervical canal sent fluid neither into the tubes nor veins." Bandl, from whom the above is taken, records a case where death resulted from injection of an aborting uterus with perchloride of iron, although the injection pipe was less in diameter than the cervix. The death may be immediate from shock, or some days after from peritonitis. In uterine injections, no more than 1-4 drops should be used.

INFLAMMATORY CONDITIONS OF THE TUBES, CATARRHAL SALPINGITIS.

Salpingitis. The Fallopian tube has three layers—peritoneal, muscular, and mucous. An inflammatory condition of the peritoneum (perisalpingitis) is simply part of ordinary pelvic peritonitis, is not diagnosable, and is not in itself

of any importance. The same may be said of mesosalpingitis (inflammation of the muscular coat).

Catarrh of the mucous membrane lining the Fallopian tube (catarrhal salpingitis) is not idiopathic, but is secondary to endometritis.

Pathological Anatomy.—In acute catarrh in adults the tube contains neutral or acid mucus in excess, glandular cells, and ciliated epithelium.

Chronic catarrh is more frequent than acute, and occurs in all degrees from a simple hyperæmia to the formation of pus. The tube is often dilated and may communicate with a cavity in the ovary.

TREATMENT.

This will be taken up under the Chapter on Battey's Operation.

HYDROPS TUBÆ.

As the result of stricture of the tube and marked catarrh, we get the tube distended with serum (hydrops tubæ) or pus (pyosalpinx). Hydrops
Tubæ.

Pathological Anatomy.—The whole or only a part of the tube is dilated, according to the locality of the stricture (fig. 124). There may be several strictures and thus several cysts. The tube distends and atrophies, so that the mucous membrane becomes thin and the muscular coat disappears. The fluid is usually serum with cholesterine and occasionally blood.

It is alleged that fluid can accumulate in the tube although the uterine end is open; the fluid, at a certain stage of its accumulation, flows into the uterus (profuent dropsy of the tube).

Physical Signs.—An elongated tortuous tube is found at one side of the uterus and high up in the pelvis. Usually a small piece of the undilated tube can be felt between the sac and the uterus.

The *Differential Diagnosis* must be made from the following:—

- (1.) Inflammatory conditions or blood extravasation in the broad ligament,
- (2.) Fallopian tube pregnancy,
- (3.) Small ovarian cyst,
- (4.) Parovarian cyst,
- (5.) Retention of blood in maldeveloped uterus.

Treatment.—When adhesions are present we should puncture with Matthieu's aspirator through the lateral fornix. When the dilated tubes are free or but partially adherent, they may be removed by abdominal incision, as Lawson Tait has recently done (*v.* Chapter XIX.)

PYOSALPINX.

Pyosalpinx.

This is acute or chronic, and consists in the accumulation of pus in the tubes.

Diagnosis and Treatment is much as in hydrops tubæ. If the tube burst, a fatal peritonitis is set up; adhesions may form, and perforation into the vagina or rectum ensue (*v.* Chapter XIX.)

HÆMATOSALPINX.

Hæmatosalpinx.

This is a rare condition in which the blood from the congested mucous membrane of the tube is detained there and dilates it. It is often associated with retention of menstrual blood in the uterus (*v.* Atresia Vaginæ, Chapter XLIII). *Diagnosis* is difficult; Bandl records one case where he diagnosed the condition as a fibroid, and Lawson Tait one simulating an ovarian cyst. Rokitansky indeed has said, "Die Gynäkologen erkennen leider diesen Zustand zu spät" (Gynecologists diagnose this condition unfortunately too late).

NEW FORMATIONS.

New Formations.

These we merely enumerate. They are connective tissue growths, fibromata, lipomata, primary tuberculosis, carcinomata. In tuberculosis of the Fallopian tube, Steven has found, sparingly distributed, the bacillus tuberculosus recently discovered by Koch in tubercular phthisis of the lungs. (*Glas. Med. J.*, Jan. 1883.)

PAROVARIIUM.

Parovarium.

We have already described the rudimentary structure known as the parovarium. Sometimes one or more, usually one of the tubules becomes distended with fluid. This distention may be very great, and constitutes the tumour known as parovarian; its consideration will be best deferred till we treat of Ovarian Tumours.

ROUND LIGAMENT; HYDROCELE.

LITERATURE. *Goodell*—Lessons in Gynecology: Philadelphia, 1880. *Schroeder*—Krankheiten der weiblichen Geschlechtsorgane: Leipzig, 1878, S. 417. *Thomas*—Diseases of Women: Philadelphia, 1880, p. 136. *Wile*—Hydrocele in the Female: *Am. J. of Obst.*, July 1881, which see for further literature.

Hydrocele.

Nature and Pathological Anatomy.—This is a rare malady, and may exist as encysted fluid round the round ligament (extra-peritoneal), or in the canal of Nuck—a process of peritoneum extending from the internal

inguinal ring into the labium majus. It may be closed at the internal ring, thus forming a cyst; or it may communicate with the peritoneal cavity.

The fluid is serous in its nature; it may be olive green in colour. The authors have seen three cases—one extra-peritoneal, two intra-peritoneal.

Physical Signs (a.) Of encysted hydrocele of the cord.

An oval translucent swelling exists in the inguinal canal. It cannot be returned into the abdominal cavity, has usually existed for some time, is not tender on pressure, and gives rise to no symptoms. It must be differentiated from an ovary in the inguinal canal, and from incarcerated hernia.

Physical Signs when Encysted.

(b.) Of hydrocele in the labium majus.

The labium majus is distended with a fluctuating tumour, dull on percussion and of translucent appearance; usually the contents cannot be returned into the abdominal cavity. Aspiration gives a clear fluid. It is to be diagnosed from hernia in the usual way.

When in Labium Majus.

Treatment.—Aspiration and drainage; or aspiration and injection of a few drops of tincture of iodine. Goodell recommends that when the labial form communicates with the abdominal cavity, the internal ring should first be firmly compressed and the injected fluid then sucked out.

Treatment.

BROAD LIGAMENT.

Hæmatoma and inflammatory conditions of the broad ligament have been already considered. We need only further mention that we may have cysts, fibroids (rare), phleboliths, cancer, and tuberculosis; the last two are only parts of the general peritoneal affection. Ovarian cysts may develop into the Broad Ligament (*v. pp. 203 and 217*).

Broad Ligament.

TUBO-OVARIAN CYSTS.

These result from adhesions between the fimbriated end of the Fallopian tube and the ovary, with degeneration of the corpora lutea of the Graafian follicles thus enclosed. The contents may be poured into the uterus along the tube.

Tubo-Ovarian Cysts.

CHAPTER . XVIII.

MALFORMATIONS OF OVARY: OVARITIS AND PERIOVARITIS: DISPLACEMENTS OF OVARY—HERNIA, PROLAPSUS.

LITERATURE.

Barnes—Diseases of Women, p. 297: Lond. 1878. On Hernia of the Ovary, and Observations on the Physiological Relations of the Ovary: Am. J. of Obst. XVI. p. 1, 1883. *Englisch*—Oesterr. Med. Jahrbuch, 1187, p. 335; or, Sydenham Year Book, 1871-72, p. 293. *Freund*—Die Lage und Entwicklung der Beckenorgane: Breslau, 1863. *Herman*—Prolapse of the Ovaries: Med. Times and Gazette, 22d October 1881. *Klob*—Pathologische Anatomie der weiblichen Sexual Organe: Wien, 1864. *Mundt*—Prolapse of the Ovaries: Am. Gyn. Tr., 1879, p. 164. *Olshausen*—Die Krankheiten der Ovarien: Billroth's Handbuch, Stuttgart. *Schroeder*—Die Krankheiten der weiblichen Geschlechtsorgane: Leipzig, 1878, S. 341. *Schultze*—Zur Kenntniss von der Lage der Eingeweide in weiblichen Becken: Arch. f. Gynäk, Bd. ix. S. 262. *Sarjansky*—Die Entzündung der Eierstöcke: Arch. f. Gyn. Bd. iii. S. 183.

We first take up some preliminary considerations.

Examina-
tion of
Ovaries.

Palpation of Normal Ovaries.—After the student has had practice in the Bimanual, he will probably meet with some favourable case where he is able to feel the normal sized ovary. This is best done as Schultze recommends. To map out the right ovary, use the index and middle fingers of the right hand internally and the left hand externally; for the left ovary, the left hand is used internally, and the right externally. The patient should lie on her back, with the knees drawn up and the legs rotated outwards. This rotation of the knees renders the psoas muscles tense, thus making their inner edges (which Schultze gives as a guide to the position of the ovaries) more easily palpable. Normally, they lie at about the level of the pelvic brim, half way between the Fallopian tube angle of the uterus and the psoas.

Another method of palpating the ovaries is to draw down the uterus with the volsella, and make the examination with the finger per rectum.

MALFORMATIONS OF OVARY.

Malforma-
tions.

Absence of one or both ovaries or rather their very rudimentary development, is generally only part of maldevelopment of the uterus. Occasionally a third ovary is present—a fact worth keeping in mind in relation to Battey's operation (Chap. XIX.)

OVARITIS AND PERIOVARITIS.

SYNONYMS—Oöphoritis : Peri-oöphoritis.

Ovaritis.

NATURE.—An acute or chronic inflammation of the ovary.

PATHOLOGICAL ANATOMY.

Acute ovaritis.—In this we recognise two forms occurring in the two subdivisions of ovarian tissue, the follicular or parenchymatous, and the interstitial. Pathological
Anatomy.

In the *follicular form*, the ovary is not much enlarged ; but we find, on microscopical examination, the peripheral follicles increased in size, their contents turbid or purulent, the cells of the membrana granulosa and contents of ovum in a state of cloudy swelling. The zona pellucida becomes thickened and folded. Usually the surrounding tissue participates, though to a less marked degree, in the inflammatory changes, and in marked cases the Germ Epithelium becomes cloudy and broken down, with fibrinous deposits on its surface.

In the *interstitial form*, the ovary is increased in size and its connective tissue elements are proliferated. Pus may form, and often there are small apoplexies. Slavjansky speaks of the following varieties of the interstitial form, viz., serous, suppurative, hæmorrhagic, and necrotic.

Chronic ovaritis.—As the result of this, we get the destruction of the follicles and a cirrhotic condition of the organ. Occasionally the ovary remains distinctly larger. Whether or not we get a super-involution of the uterus as the result of severe and double ovaritis, is not as yet settled.

ETIOLOGY.

The causes of ovaritis are the following :—

Etiology.

1. Chill at menstrual period ;
2. Gonorrhœa, latent gonorrhœa in the male ;
3. Instrumental exploration of the uterus ;
4. Childbirth and abortion ;
5. Acute febrile diseases ;
6. Pelvic peritonitis.

Gonorrhœa.—The ovaries may be inflamed sympathetically, just as the testicles are in gonorrhœa of the male.

Instrumental exploration.—Sometimes after the passage of the uterine sound, especially in difficult cases, the ovary becomes tender.

184 AFFECTIONS OF FALLOPIAN TUBES AND OVARIES.

Childbirth and abortion.—This is a common cause of ovaritis. Thus, in 27 septic cases at Halle, Olshausen found the ovaries affected in 13. Usually both ovaries are implicated.

Acute febrile diseases.—Cholera, the exanthemata, septicæmia, phosphorus and arsenic poisoning have ovaritis as one of their results.

Pelvic peritonitis.—It will readily be understood that ovaritis often occurs as part of general pelvic peritonitis.

The follicular form usually occurs in febrile diseases and pelvic peritonitis; the interstitial form is generally puerperal.

SYMPTOMS AND PHYSICAL SIGNS.

Symptoms and Signs. *Acute ovaritis.*—A case of simple acute ovaritis is not common. The patient usually complains of pain at the side radiating to the back, and of pain on pressure in the iliac fossæ.

When the Bimanual is made, the ovary or ovaries are more accessible, and are felt as mobile, tender, and somewhat enlarged bodies, often about the size of a walnut; and pressure causes great pain of a sickening character. Owing to adhesions, the mobility may be wanting. The uterus is felt distinct from them.

Chronic ovaritis.—The symptoms and physical signs are just as in the acute form, but much less marked and with a chronic history. Menorrhagia is often present. Sympathetic pain is sometimes felt below the left mamma.

DIFFERENTIAL DIAGNOSIS.

Differential Diagnosis. When the ovary is not fixed, there is nothing else with which it can be confounded.

PROGRESS AND RESULTS.

Progress and Results. We may have resolution of the affection, adhesion, suppuration, and abscess. Sterility is a frequent result of double ovaritis; hysteria is often present.

TREATMENT.

Treatment when Acute. *Acute ovaritis.*—A fly blister should be applied over the appropriate iliac region, and the hot vaginal douche frequently used. Bromide of potassium may be given as follows:—

R. Potassii Bromidi gr. xxx to ʒi.
Fiat pulv: tales xii.
Sig. One powder at night.

Chronic ovaritis.—The hot douche and occasional blisters are best. When
The glycerine plug is of value. Chronic.

A glycerine plug is made as follows: Take a square piece of absorbent Glycerine
cotton wool about the size of the palm of the hand; pour on its centre Plug.
about ʒss . glycerine; turn the corners over and squeeze the whole so as to
saturate it; lastly, tie a piece of thread about 8 inches long round it. Pass
Sims' or Fergusson's speculum, and place the plug in the fornix below
the ovary. It should be left in for 18 to 24 hours, and then withdrawn.

This plug reduces congestion, owing to the affinity of glycerine for
water; has an antiseptic action; and, as we shall afterwards see, forms
an admirable pessary. It sets up a watery discharge, so that the patient
should be told to wear a diaper on account of this.

The following mixture is of use.

R. Potassii Bromidi	ʒij .
Potassii Iodidi	ʒj .
Inf. Gentian. Co.	ʒvi .

Sig. Tablespoonful thrice daily.

PERIOVARITIS.

By this we understand an inflammatory affection of the tissues sur- Peri-
rounding the ovary, which fixes the organ. It is a convenient clinical ovaritis.
term for local peritonitic inflammations in the site of one of the ovaries.
It is higher up than the usual cellulitic deposit. The treatment is the
same as in chronic ovaritis.

DISPLACEMENTS OF THE OVARY—HERNIA.

The term *Hernia* is limited to those cases where the ovaries are Hernia of
present in the inguinal canals, in the obturator foramen (rare), or as the Ovary.
part of an abdominal hernia. Percival Pott's case, where this first con-
dition existed and where he excised both of the displaced organs, is the
classical instance of this displacement. The usual form is where they
are present in the inguinal canal.

ETIOLOGY.

Ovaries in the inguinal canal are usually congenital, having descended Etiology.
along the unobliterated process of peritoneum. In 17 out of 23 cases
Englisch found it to be congenital; and in one-third of these the hernia
was double.

DIAGNOSIS AND DIFFERENTIAL DIAGNOSIS.

An oval tumour of the size of the ovary, tender on pressure, is found Diagnosis.

186 AFFECTIONS OF FALLOPIAN TUBES AND OVARIES.

in the inguinal canal. Its connection with the uterus may be demonstrated by drawing the latter down with a volsella.

It requires to be diagnosed from an ordinary hernia, and from hydrocele of the round ligament.

TREATMENT.

Treatment. A protecting shield may be worn ; and where very troublesome, the ovaries may be cut down upon and removed. Reduction is usually impossible, owing to adhesions.

PROLAPSUS.

Prolapse of Ovary. We have already considered the support of the ovary. Its attachments to the broad ligament, to its own special ovarian ligament, and to the ovarian fimbria of the Fallopian tube, support it directly. The infundibulo-pelvic ligament of the Fallopian tube does so indirectly ; and, in addition, its own specific gravity has an influence in determining its level. The ovary has its position constantly changing. As the bladder fills, it is displaced backwards ; and during pregnancy, it is drawn upwards out of its pelvic position and somewhat enlarged. The ovary is thus an organ liable to displacement, of which the most important is the downward one—known as *prolapse of the ovary*.

PATHOLOGICAL ANATOMY.

Pathological Anatomy. The ovary may lie lower than usual, in the lateral or in the true pouch of Douglas ; the uterus may be in its normal position, but oftener it is retroverted. The ovary is usually enlarged, and often fixed by peritonitic adhesions.

Mundé considers the varieties of prolapsus as—

- (1.) Retro-lateral, in the lateral pouch of Douglas ;
- (2.) Retro-uterine, in the true pouch of Douglas ;
- (3.) Ante-uterine, in the anterior fornix, very rare ;
- (4.) In the infundibulum of an inverted uterus. The authors have seen this last in a case under Professor Simpson's charge.

ETIOLOGY.

Etiology. The conditions present in the puerperium favour displacement of the ovary for two reasons ; the normal ascent of the uterus during pregnancy may stretch the ovarian ligament, and the ovary may not return to its normal size after parturition. Simple congestion of the organ may cause

it to descend ; and it is alleged that sudden jolts may also drive it below its normal site. It is not quite certain whether the congestion is cause or result. Probably it is the cause ; but it is also aggravated by the displacement.

SYMPTOMS.

These are radiating pains, pain on defæcation and coitus, a dragging sensation, reflex nervous symptoms with general irritability.

PHYSICAL SIGNS.

Bimanually, we feel in the true or in the lateral pouch of Douglas a small body or bodies, exquisitely tender and lying distinct from the uterus. By the rectal examination, the ovary is felt with unusual distinctness.

TREATMENT.

Blisters over the iliac region, hot vaginal douche, and bromide of potassium in fifteen grain doses thrice daily. The bowels are to be

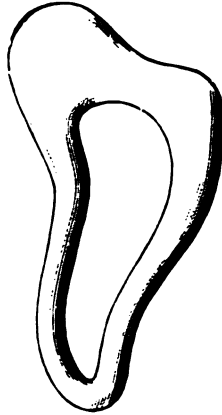

FIG. 125.

MUNDE'S PESSARY FOR PROLAPSED OVARY. The cut away corner lies below the prolapsed ovary.

opened by means of saline purgatives, such as the Friedrichshall water or Carlsbad salts. The following mixture is good :—

R. Magnesiæ Sulphatis	ʒvj.
Quiniæ Sulphatis	gr. xxiv.
Acidi Sulph. dil.	ʒiij.
Tincturæ Capsici	ʒj.
Aquam ad	ʒvj.

Sig. Tablespoonful thrice daily.

This relieves the congestion by unloading the bowels.

Often the prolapsed and non-fixed organ becomes, after a week of this treatment, distinctly higher in position. The glycerine plug is then of the utmost value.

In the chronic stage, when the uterus is retroverted and not fixed, the ring or the Albert Smith pessary is good (*v.* Retroversion of Uterus).

The cases where the tender ovaries are fixed low down by adhesions are exceedingly difficult to treat. When the uterus is retroverted and fixed and the ovaries below it, we get one of the most troublesome cases possible. Palliative treatment by blisters and the hot douche is best; if the case is not amenable to this treatment and the patient's general health is suffering, the propriety of Battey's operation should be considered.

Prolapse of the ovaries and their fixation are contra-indications to treatment indicated otherwise—such as Sims' division of the cervix and Emmet's operation.

In some cases of chronic unilateral prolapse, Mundé has found the pessary shown at fig. 125 of value. It indicates the kind of variation of the form of the instrument required in different cases; as, for example, in double prolapse or prolapsed ovary lying just behind the cervix. (For reflex conditions dependent on ovarian irritation, *see* Chapter on Hystero-Epilepsy.)

CHAPTER XIX.

BATTEY'S OPERATION: TAIT'S OPERATION.

LITERATURE.

The literature on this operation is too extensive to be given in detail in a student's manual. The best summaries of cases are by Engelmann, Hegar, and Simpson. *Batthey*—*Batthey's Operation*: Transactions of International Medical Congress, Lond., 1881. See *Am. J. of Obst.*, October 1881, for discussion. *Engelmann*—*The Difficulties and Dangers of Batthey's Operation*: *Am. Med. Asso. Trans.*, 1878 (date of reprint); also, *Batthey's Operation*, 3 fatal cases: *Am. J. of Obst.*, July 1878. *Hegar*—*Die Castration der Frauen*, *Volkmann's Sammlung*, Nos. 136-138. *Simpson, A. R.*—*History of a Case of Double Oophorectomy, or Batthey's Operation*: *Br. Med. J.*, May 24th, 1879. *Sims, J. Marion*—*Remarks on Batthey's Operation*: *Br. Med. Journal*, 1877. For additional literature see *American Gynec. Trans.*, 1879, 1880, and 1881.

HISTORY OF OPERATION.

THE real history dates from August 17th, 1872, when Dr. Batthey of History. Rome, Georgia, U.S.A., successfully removed the ovaries of a patient who suffered from intolerable dysmenorrhœa. On July 27th of the same year, Hegar of Freiburg removed both ovaries in a case of severe ovarian neuralgia: the patient died, and Hegar did not publish an account of the case. Blundell of London (1823), with that rare medical insight and experimental knowledge which led him to advocate—if not to practise—what recent obstetric science has shown to be the safest mode of performing the Cæsarean Section, had already thrown out the suggestion that the ovaries should be removed in dysmenorrhœa and to arrest hæmorrhage in inverted uterus. To Batthey, however, is due the honour of independently conceiving the idea, and—what was more difficult—of successfully carrying it into execution and impressing the profession with its importance and value in special cases.

NOMENCLATURE.

We have adopted the term *Batthey's Operation*, first proposed by *Nomenclature.* Marion Sims, as a convenient and useful one. Other terms, however, have been proposed. The name "*Normal Ovariectomy*" is a misnomer, inasmuch as the ovaries are not normal. "*Spaying*," a term advocated

190 *AFFECTIONS OF FALLOPIAN TUBES AND OVARIES.*

by Goodell, does not recommend itself by its delicacy. "Die Castration der Frauen," the German name for the operation, is open to a similar objection.

NATURE AND AIMS OF OPERATION.

Nature
and Aims.

Batthey's operation consists in the removal of both ovaries which, although diseased, are not appreciably enlarged. Batthey proposed it for dysmenorrhœa, on the theory that it would bring on the menopause prematurely. This, however, does not occur as an immediate result. More recently, Batthey has declared that he operates to arrest ovulation.

INDICATIONS FOR OPERATION AND ITS RESULTS.

Indica-
tions.

These are not as yet strictly determined; *i.e.*, so far as our present knowledge goes, the operation is indicated in certain conditions, but as yet we do not know whether in all of them it produces the anticipated effect. They are as follows:—

- (1.) Intolerable Dysmenorrhœa;
- (2.) Bleeding from Fibroid Tumours, uncontrollable by other means;
- (3.) Hystero-epilepsy, convulsions and threatened insanity, dependent on ovarian irritation or presence of ovaries with absence of uterus;
- (4.) Hydroperitoneum;
- (5.) Prolapsed and fixed ovaries.

(1.) *Dysmenorrhœa.*—In those cases where the patient has intolerable and prolonged pain every month, wearing her down and rendering habitual recourse to opiates necessary, the operation may be performed. It should not be forgotten that the results in such cases are not so brilliant as was once expected. The menstruation is not at first entirely arrested by the removal of the ovaries; and, as we have always in such cases pelvic peritonitis adding to the patient's misery and untouched by the operation, it is evident that we must not expect too much from it. Lawson Tait believes that the Fallopian tubes must also be removed; but on this point our information is not yet complete.

(2.) *Bleeding from fibroid tumours, uncontrollable by other means.*—It is in this condition, for which Batthey's operation was first advocated by Trenholm and Hegar, that the most brilliant successes have been won. Not only has hæmorrhage been checked, but the tumours themselves have diminished in size and even in some cases disappeared.

(3.) In some cases of *hystero-epilepsy, convulsions, insanity, and dancing mania*, dependent on ovarian irritation, the operation has been performed with but moderate success. Engelmann, Gilmore, A. R. Simpson, and Battey quote some remarkable cases.

(4.) *Hydroperitoneum*.—Granvill Bantock of London has recently recorded a case where removal of both ovaries cured the hydroperitoneum.

(5.) In cases of *ovaries prolapsed or fixed by adhesions*, and giving rise to intolerable pain in coitus or seriously affecting the patient's health, their removal is called for.

At the London International Congress the operation was discussed. According to Battey, the mortality has been 22 per cent. for incomplete operations, and 9½ per cent. for complete; in the other cases, the results as to relief have been—

	No.	Per Cent.
Cured,	68	75
Greatly benefitted,	15	17
Not benefitted,	7	8

Of the incomplete operations—

	No.	Per Cent.
Cured,	3	18
Greatly benefitted,	7	41
Not benefitted,	7	41

METHOD OF PERFORMING THE OPERATION.

The ovaries may be removed (1.) *by the vaginal method*, or (2.) *by Operation. abdominal section*. As the former is the less usual method, we shall describe it but shortly.

(1.) *The vaginal method*. Give chloroform. Place the patient semi-prone or, better, in the lithotomy posture. Pass Battey's speculum, lay hold of cervix uteri with a volsella and draw it down. Wash out the vagina thoroughly with the douche. Vaginal Section.

Now incise the posterior vaginal wall, behind the cervix, in the middle line for about an inch and a half. Open into the peritoneal cavity, pass in the index finger or long polypus forceps, and hook down the nearer ovary; supra-pubic pressure is made by an assistant. Ligature the ovary at the hilus with thin carbolized silk threaded on a fixed needle. The hilus is transfixed mesially with the needle, the double ligature drawn through and cut, one thread is tied round the one-half of the base and

192 *AFFECTIONS OF FALLOPIAN TUBES AND OVARIES.*

the other round the other half ; the ovary is then cut off and the ligature cut short. The other ovary is treated in the same way ; we make certain that there is not a third ovary which would likewise require to be ligatured. Battey passes a temporary ligature round the base of the ovary and then uses the *écraseur*. Lastly, pass in a drainage tube, stitch the wound (Battey leaves it unstitched), and irrigate twice daily with weak carbolic solution (1-100). After-treatment as in ovariectomy (*v.* Chap. XXII.)

This method is good when the ovaries are low down. It is sometimes difficult to make out the ovary, and even impossible to remove it. In one case Battey had to dig out portions with his finger nail ; all was not removed, and the patient conceived some time afterwards.

Abdominal
Section.

(2.) *Abdominal section.* The instruments needed are the following :—

- Spray (?);
- Carbolic lotion ;
- Sponges (a definite number) ;
- Ordinary knives ;
- Probe-pointed bistoury ;
- Spatulæ ;
- Dissecting and dressing forceps ;
- Tenacula, blunt hooks ;
- Péan's artery forceps, a definite number (20) of pairs ;
- Needles on fixed handles ;
- Catgut for bleeding vessels ;
- Long straight needles, threaded two on each suture of silk-worm gut ;
- Needle holder with small needles on horse-hair sutures ;
- Thin carbolised silk for ligaturing ovary ;
- Drainage tubes (glass) ;
- Carbolic gauze, mackintosh, and flannel bandages.

The spray should be placed eight or nine feet from the patient. It is at present an open question whether the spray is required during the operation (*v.* Chapter on Ovariectomy). The instruments to be used are placed in a porcelain tray containing carbolic acid 1-40. The sponges are wrung out in 1-60 solution ; when the peritoneal cavity is opened, the solution (1-60) used for the sponges must be *warm*.

The patient is placed in the dorsal posture and chloroformed ; the skin is shaved clean and washed with turpentine and soap, and then with 1-20 carbolic lotion.

An incision, four inches long and ending a little above the mons

veneris, is made in the middle line. The knife passes in succession through the following structures—skin, fat, linea alba, fascia transversalis, and peritoneum. Bleeding is to be arrested by Péan's forceps left on for a time, or by catgut ligature.

Great care must be taken to recognise the *peritoneum*. It should be lifted up with a tenaculum and an opening cautiously made with a knife or scissors. Remember that the small intestines lie behind and may be easily cut into. This accident, indeed, has occurred to such a distinguished operator as Spencer Wells; when it happens, the aperture should be stitched up with fine catgut. When once an opening has been made through the peritoneum, it can be readily enlarged to the size of the original incision by means of a probe-pointed bistoury guided on the finger.

Caution about Peritoneum.

The fingers are now passed in, the fundus uteri is touched; and then the fingers, carried along the Fallopian tube, will recognise the ovary usually lying behind it. It should be lifted up if possible to the incision, and ligatured with thin carbolised silk as described under the vaginal method; the ligatures are cut short and each side of the pedicle held with Péan's forceps. Marion Sims recommends his uterine repositor as an aid to the elevation of the ovaries. This elevation, however, can be more easily managed by introducing the two fingers or whole hand into the vagina, and elevating all in front of the posterior vaginal wall.

Ligature of Ovaries.

The ovary is then cut away with the knife at a point about half an inch clear of the ligature. The other ovary is treated in the same way. We hold the pedicle for a time in the Péan's forceps, before dropping it back, to see that there is no bleeding. The peritoneal cavity is now to be thoroughly and carefully cleansed with sponges well wrung out of the warm carbolic solution (*vide* Chapter XXII.)

Removal of Ovaries.

The abdominal incision is now closed; to prevent blood from passing down while this is being done, a large flat sponge, also well wrung out, is placed in the peritoneal cavity just below the incision. Silk-worm gut is most suitable for the deep sutures in the abdominal incision. Straight needles are threaded one at each end of the silk-worm gut suture; the needles are passed, first the one and then the other, from the peritoneal aspect towards the skin. All the sutures are passed before any one of them is ligatured, and the ends drawn together to judge if there be sufficient to close the wound. The sponge placed below the incision is now removed before the sutures are tied. *All the sponges and forceps must now be counted.* Superficial stitches of horse hair are passed

Closure of Incision.

Sponges and Forceps counted.

to adapt the edges of the skin between the deep sutures. If the operation has been an uncomplicated one, no drainage is needed.

Difficulties
of Opera-
tion.

The whole operation is by no means an easy one. The skin incision is more difficult than in ovariectomy, for there is always a risk of wounding intestine. In some cases, Hegar has made a lateral incision. Sometimes, especially in cases of fibroids, it is exceedingly difficult to get at the ovaries. Engelmann has more particularly directed attention to this point. In one of his cases he says:—"The ovaries were so deeply imbedded within the folds of the broad ligament, and with them so firmly tied down to the sides and floor of the pelvis that it was impossible to move them. With the greatest difficulty several unsatisfactory ligatures were placed about the left ovary; but it was useless even to attempt to tie the right, so intimately was it blended with the broad ligament, and so immovably adherent to the pelvic walls. . . . I enlarged the incision to two inches above the navel, removed the intestine from the pelvic cavity, and then succeeded in enclosing the entire mass in the ligature, and removing the ovaries complete." Kaltbach in one case ruptured the Fallopian tube dilated with pus; the patient died of septic peritonitis. Freund, Martin, Sims, and Battey have also recorded difficult cases.

GENERAL CONCLUSIONS.

Conclu-
sions.

This operation is as yet on its trial. Gynecologists have not settled the exact indications for it, nor the question as to whether it is always worth the risk.

The mortality is high; up to 1879 it was 37.1 per cent. (A. R. Simpson).

Part of this is, of course, due to the worn-out state of many of the cases operated on and to the extensive adhesions present. Probably the mortality will diminish, although it must be kept in mind that operators have had the benefit of the previous advice and experience of ovariectomists as to its results. We have already seen that its most brilliant successes have been got in fibroids; its success in other cases has been moderate. When many adhesions exist, it is probably better not to attempt it.

Some interesting physiological points have been brought out by it: removal of the ovaries does not bring on the menopause, sexual appetite is not diminished, and no womanly attributes are in any way removed. The outcry that it unsexes a woman is absurd. The ovaries removed were probably useless for procreation; and when their presence is causing *serious* bodily illness, they are better removed.

REMOVAL OF UTERINE APPENDAGES (TAIT'S OPERATION).

LITERATURE. *Bertram*—Laparotomie bei Tumoren des Tuba Fallopii: Berliner Klinische Wochenschrift, Jan. 22, 1883. *Savage*—Diseases of the Fallopian Tubes: Birm. Med. Rev., Jan. 1883. *Tait, Lawson*—The Diagnosis and Treatment of Chronic Inflammation of the Ovary: Br. Med. Jour., July 29, 1882. An Account of 208 consecutive cases of Abdominal Section performed between Nov. 1, 1881, and Dec. 31, 1882: Br. Med. Jour., Feb. 17, 1883. Recent Advances in Abdominal Surgery: Int. Med. Cong. Tr., Lond., Vol. II., p. 228. *Thomas, T. G.*—A Contribution to the Subject of the Removal of the Uterine Appendages (Tait's Operation) for Prolonged Menstrual Troubles with Recurrent Pelvic Inflammations: N. Y. Med. Jour., Jan. 13, 1883.

WE have already noted the difficulty in the diagnosis, by Bimanual examination, of Fallopian tubes dilated with serum or pus. Even when as large as coils of small intestine, their presence escapes the most thorough abdomino-vaginal examination.

To the abdominal section initiated by Battey in certain chronic cases, we owe the discovery of the interesting fact that Hydrosalpinx and Pyosalpinx exist in a hitherto unsuspected number of cases. Battey's operation has certainly not fulfilled the sanguine hopes once entertained of it; but indirectly in the hands of Lawson Tait of Birmingham, it has revealed the interesting facts as to Pyosalpinx and Hydrosalpinx already alluded to.

As the result of abdominal section in many cases, Tait has come to the following interesting and practical conclusions.

Tait's conclusions.

- "1. He assumes that the view formerly held—that laparotomy operations should be postponed until absolute risk to the life of the patient rendered them necessary—should now be abandoned; and that, in the hands of an expert, they are at present so free from danger as to be justifiable even when life is not jeopardized. . . .
- "4. That many cases of abnormal menstruation are justifiably treated, and are relievable in no other way than, by extirpation of the ovaries and tubes.
- "5. That in chronic ovarian disease the tubes are invariably involved, and that in most cases it is the tubes which are chiefly at fault.
- "6. That the mortality in his last thirty-five operations having been only one, even this slight loss of life is susceptible of diminution in the future.
- "7. That many of those cases heretofore regarded as instances of menstrual or recurrent pelvic peritonitis or cellulitis, are really due to tubal dropsy and ovarian disease, an occasional discharge of the purulent accumulation of the former giving rise to slight and passing attacks of these affections.
- "This last statement Mr. Tait does not make in the paper to which I have alluded. I am indebted for it to my friend Dr. Emmet, who, in a recent visit to Europe, obtained it from a personal conversation with that gentleman."

The above summary is given by Thomas in his paper. In a more recent one, Tait gives his results as follows.

Results of the operation.

REMOVAL OF UTERINE APPENDAGES.		
	Cases.	Deaths.
For Myoma	26	2
„ Chronic Ovaritis	12	3
„ Menstrual Epilepsy	1	0
		} 39 Cases, 5 Deaths
		} = mortality of
		} 12.8 per cent.

The best idea of the great innovation which Mr. Tait has introduced in dealing with a class of cases of a nature thoroughly intractable to ordinary treatment, will be given by quoting one of the cases operated on by Thomas, in which the patient had been a confirmed invalid for 6½ years.

“Mrs. R. W., a coloured woman, who was born in North Carolina, thirty years of age, menstruated at fourteen, has been married nine years, and is the mother of one child, eight years old, entered my service in the Women's Hospital with the following history:— Her menstruation was perfectly normal up to the period of weaning her child, eighteen months after delivery. In reference to the year and a half immediately following the birth of her child, no symptom bearing with any prominence upon her case can be elicited. At that time, in the intermenstrual period, she was taken with very sudden symptoms resembling those of cellulitis or peritonitis, accompanied by a slightly bloody discharge from the vagina. This attack confined her to bed for one week, and since its occurrence she has been a confirmed invalid. Her menstrual periods have been painful, scanty, and irregular; she has suffered constantly from neuralgic pains in the pelvis; locomotion has been difficult, and standing so painful that she has been unable to gain a livelihood, or even to attend to her ordinary household occupations. She has had an attack of severe pelvic inflammation, similar to that already described, about once a year, almost invariably about the menstrual period. During the past eighteen months she has been almost constantly a sufferer from pain in both ovarian regions and across the back, headache, leucorrhœa, and, for the last six months, profuse loss of blood at the menstrual periods.

“Upon examining her, I arrived at the conclusion that the case was one of menstrual or recurrent pelvic inflammation, due, as we have heretofore supposed these cases to be, to some unknown influence. As the uterus was large and anteverted, and gave forth too free a menstrual flow, I supposed that endometrial fungosities probably existed, and cautiously scraped the cavity of the body with the wire curette. To my surprise, very few and small fungoid growths were removed. I then endeavoured to give relief to some of the existing symptoms by an anteversion pessary, but this attempt resulted in absolute harm. Upon more careful examination, I now detected enlargement over the site of the ovaries extending from the uterus toward the iliac bones, and strongly suspected that this was one of the cases of coincident ovaritis and tubal dropsy which have been so well described by Mr. Tait; and as by observation I became more and more convinced of the truth of this conclusion, I decided upon an explorative incision, to be followed by Tait's operation, if the diagnosis were found to be correct.

“Upon making an incision in the median line and passing two fingers into one iliac fossa, I drew up an ovary about as large as an English walnut, distended by a multitude of small cysts and a Fallopian tube resembling closely in size an ordinary sausage, and giving to the touch very much the feel of a loop of intestine. Tube, ovary, and ovarian ligament were ligated by an aseptic banjo-string, and removed. The same condition was found to exist on the other side, and the same procedure was adopted. I would remark here that this and all the other operations to be related were performed under the strictest antiseptic measures, with the exception only of the use of the spray during the operation.

“On the thirteenth day after operation the patient was sitting up in bed, and recovered completely without a bad symptom.

“The time of one menstrual period has passed for this patient, but as yet no sanguineous discharge has occurred.

“I here show the ovaries and Fallopian tubes. The latter have greatly diminished in size since removal, but even now equal in circumference an ordinary spermaceti candle.”

The brilliant results obtained by Tait have thus been corroborated by Thomas, Savage, Spanton, and others, and all gynecologists will watch the further progress of this operation with interest (*v.* Chapter on Treatment of Fibroid Tumours).

CHAPTER XX.

PATHOLOGY OF OVARIAN TUMOURS.

LITERATURE.

Bantock—On the Pathology of certain (so-called) Unilocular Ovarian Tumours: Lond. Obst. Jour., Vol. I., p. 124. *Barnes*—Diseases of Women, p. 322, Lond. 1878. *Coe*—Fibromata and Cystofibromata of the Ovary: Am. J. of Obst., XV., 561. *Cullingworth*—Fibroma of both Ovaries: Lond. Ob. Tr., XX., p. 276. *De Sinéty*—(v. Malassez). *Doran*—(v. Harris). *Drysdale*—On the Ovarian Cell found in Ovarian fluid: Trans. Americ. Med. Ass. (1873, date of reprint). *Eichwald*—Colloidartung der Eierstöcke: Wurzburg. Med. Z., B.V. 1864, p. 270. *Foulis*—Cancer of the Ovary: Ed. Med. Jour., 1875, p. 838. The Diagnosis of Malignant Ovarian Tumours, and Malignant Peritonitis: Brit. Med. Jour., 1878, pp. 91 and 658. *Fox, Wilson*—On the Origin, Structure, and Mode of Development of the Cystic Tumours of the Ovary: Med. Chir. Tr., Vol. XLVII., p. 227. *Garrigues*—Diagnosis of Ovarian Cysts by means of the Examination of the Contents: Am. J. of Obst., XV., p. 1. *Gusserow*—Ueber Cysten des breiten Mutterbandes: Archiv. f. Gynäk., Bd. IX., S. 478. *Harris and Doran*—The Ovary in Incipient Cystic Disease: Jour. of Anat. and Physiol., Vol. XV., Pt. IV., July 1881. *Malassez et De Sinéty*—Sur la Structure, l'Origine et le Development des Kystes de l'Ovaire: Archiv. de Physiologie Normale et Pathologique, Vol. V., 1878, p. 343. *Neeggerath*—The Diseases of Blood-vessels of the Ovary in Relation to the Genesis of Ovarian Cysts: Am. Jour. of Obst., Vol. XIII., 1880. *Olshausen*—Die Krankheiten der Ovarien: Billroth's Handbuch: Stuttgart. *Patenko*—Ueber die Entwicklung der Corpora Fibrosa in Ovarien: Virchow's Archiv., Bd. 84, 1881. *Rindfleisch*—Pathological Histology, New Sydenham Society Translation, 1873, p. 171. *Schroeder*—Die Krankheiten der Weiblichen Geschlechtsorgane: Leipzig, 1879. *Slavjansky*—Zur normalen und pathologischen Histologie des Graaf'schen Bläschens des Menschen: Virchow's Archiv., Bd. 51, 1870. *Waldeyer*—Die Eierstockscystome: Archiv. f. Gynäk., Bd. 1, S. 252. *Wells, T. S.*—Ovarian and Uterine Tumours: Churchill, London, 1882. *Williams*—Ovarian Tumours: Reynold's System of Medicine, Vol. V. Olshausen, Schroeder, and Williams give the literature well. *Coe's* and *Cullingworth's* articles give the literature for solid tumours. They should be consulted for full references if necessary.

UNDER this head we take up the following:—

1. *The mode of origin of ovarian cysts;*
2. *Varieties of ovarian tumours, their naked-eye and microscopic anatomy;*
3. *The nature of ovarian fluids and of Parovarian fluid;*
4. *Solid ovarian tumours, malignant tumours and the nature of the ascitic fluid associated with them.*

THE MODE OF ORIGIN OF OVARIAN CYSTS.

Our knowledge of the pathological anatomy of the ovary depends on our information as to its development, its anatomical structure, and the

Origin of
Ovarian
Cysts.

physiological changes it undergoes. On each of these we must make some preliminary remarks.

Develop-
ment of
Ovary.

(1.) As to its *development*.—We have already seen that the actively growing connective tissue of the ovary encloses the germ epithelium; that certain of the germ epithelial cells thus enclosed develop into ova; while the connective tissue itself, according to Foulis, forms the *membrana granulosa* (*v.* plate VII., fig. F.). The germ epithelium thus enclosed gave rise to the idea that the developing ovary was a tubular organ; and to the epithelium thus enclosed (or rather, according to Pflüger, the epithelium *penetrating* into the ovarian stroma) was given the name of Pflüger's ducts.

Pflüger's
Ducts.

A section of a developed ovary shows cellular structures, which (according to Waldeyer) are some of Pflüger's ducts that have not developed as they should have done into Graafian follicles. Waldeyer, therefore, regards *Pflüger's ducts* as seats of origin of ovarian cysts (fig. 126).



FIG. 126.

CELLULAR BODIES alleged by Waldeyer to be enclosed germ epithelium which has not developed into normal Graafian follicles. He believes these to be one source of ovarian tumours (*Næggerath*).

Peculi-
arities in
Ovary.

(2.) *The peculiarities of the anatomical structure* are due to the Graafian follicles and certain cellular structures whose exact nature is as yet debated. Of the 30,000 Graafian follicles contained in each ovary, only an insignificant number develop and rupture at each menstrual period. Many of the rest atrophy, forming the *corpora fibrosa* which are seen on section as fibrous points and contain no vessels; it is alleged that these *corpora fibrosa* may originate also from ripe follicles or from follicles where there has been hæmorrhage.

The vessels around the follicles sometimes degenerate. The cellular structures shown at fig. 127 are, according to *Næggerath*, *diseased blood-vessels*.

Physiology
of Ovary.

(3.) *Its physiology*.—When we consider that at each menstrual period a Graafian follicle distends and then ruptures, we are led to expect what really does sometimes occur, *viz.*, that the follicle may not rupture but merely distend to form a pathological cyst. When pregnancy occurs, the

ruptured follicle has its large corpus luteum filling it; and in this also we may have pathological development.

From these preliminary considerations we see that the alleged sources for the origin of ovarian cysts are the following:—

Sources of
Ovarian
Cysts.

- (a.) Distention and coalescence of Graafian follicles;
- (b.) Degeneration of true corpora lutea;
- (c.) Degeneration of undeveloped Graafian follicles, colloid degeneration of the ovarian stroma;
- (d.) Degeneration of blood-vessels;
- (e.) Pathological development of enclosed germ epithelium, so-called Pfüger's ducts;
- (f.) Certain epithelial tubes running into the ovary;
- (g.) Malignant development of connective tissue of ovary.

The student should clearly note that these are the *theoretical* sources



FIG. 127.

CELLULAR BODIES which Næggerath believes to be diseased blood-vessels and not germ epithelium as Waldeyer asserts (*Næggerath*).

of ovarian cystic development, but that (as we shall presently see) some are disputed.

(a.) *Distention and coalescence of Graafian follicles.*—There can be no doubt that small cysts may so originate. The proof of this is positive, as Rokitansky found ova in cysts about the size of a bean. Wilson Fox has attempted to show, in his well-known paper, that all the varieties of cystic tumours may be formed in this way.

Wilson
Fox's view.

(b.) *Degeneration of true corpora lutea.*—This has been noted in some cases.

(c.) *Degeneration of undeveloped Graafian follicles.*—This is probably an important source. (For details see Harris and Doran's article, and also Slavjansky's and Patenko's papers for normal and abnormal involution.)

(d, e, and f.) *Degeneration of blood-vessels; degeneration of Pfüger's ducts; epithelial tubes running into the ovary.*—Næggerath of New York

Nægger-
ath's view.

first pointed out that *diseased blood-vessels* might form a source of ovarian cysts; and, more recently, Harris and Doran have confirmed his views. According to Nøggerath, we have disease of the intima of the vessel, loss of its endothelium, and percolation of the contents of the vessel into the intima. Migrating cells accumulate in the interstices of the intima and break it up. The large granular nucleated cells found in ovarian cysts are, according to him, these lymph corpuscles. Nøggerath considers

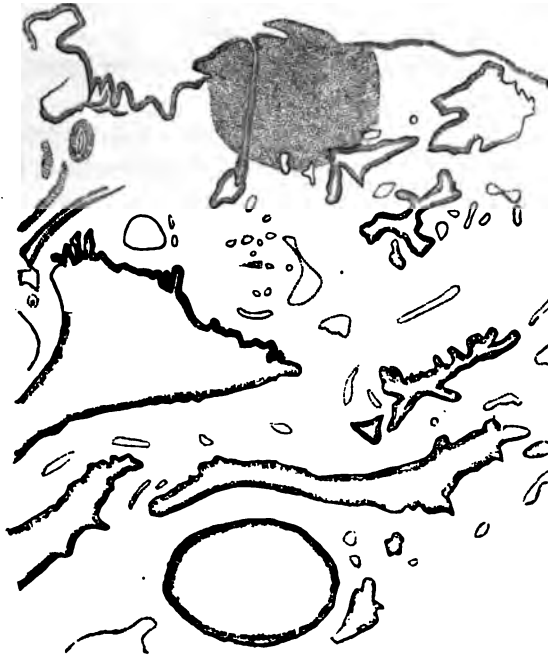

FIG. 128.

SECTION OF OVARY showing an epithelial tube (at the shaded part of the section). Lower down are seen spaces of varying size, and lined with a single layer of epithelium; these cysts are developed from the epithelial tubes. The connective tissue basis is shown only at the shaded part of section (*De Sinéty* 24).

that the cellular structures, which other observers hold to be Pflüger's ducts, are diseased vessels.

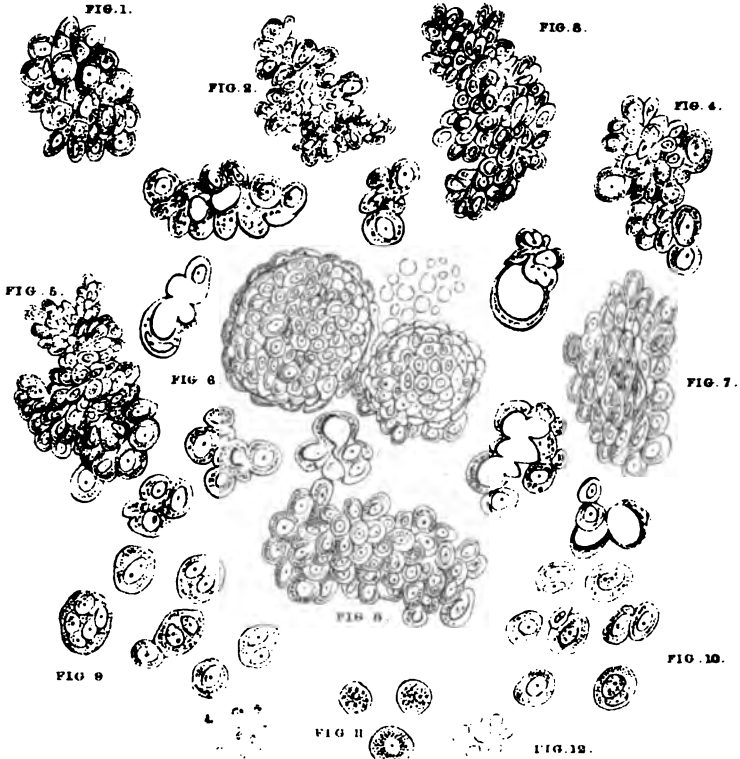
Waldeyer's
view.

Waldeyer considers that ovarian Tumours are developed from the processes of epithelium known as *Pflüger's ducts*; they arise, therefore, from the same source as the Graafian follicles.

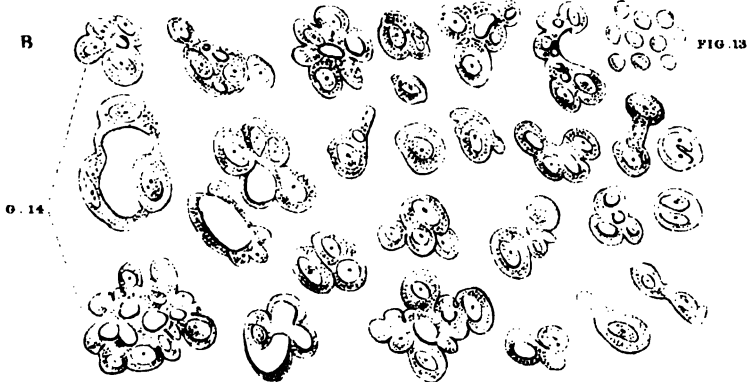De Sinéty
and
Malassez's
views.

De Sinéty and Malassez first described certain *epithelial tubes* from which ovarian tumours develop; these are not true Pflüger's ducts, but differ from them in being hollow and having no ovum. They consider

A



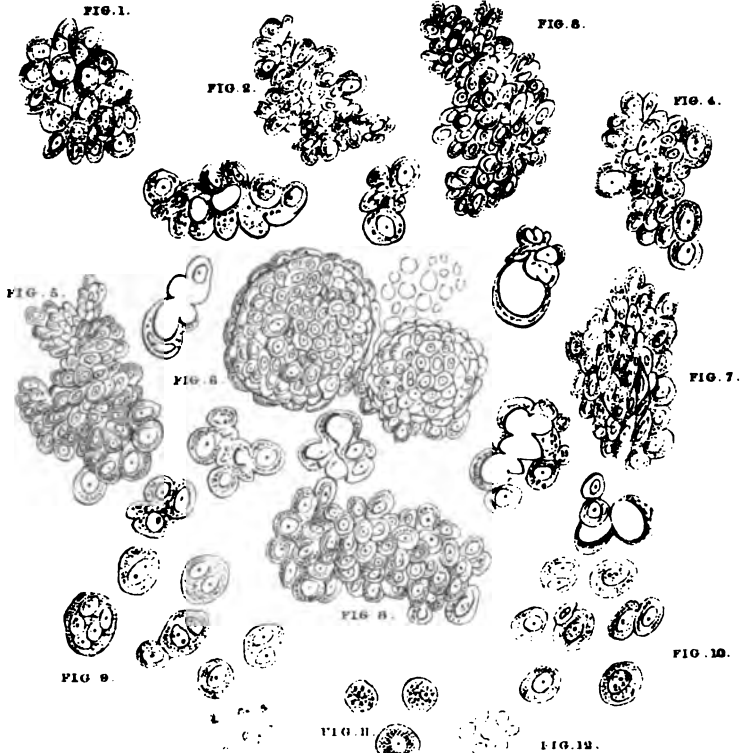
B




1
2
3
4
5
6
7
8
9
10
11
12
13
14
15
16
17
18
19
20
21
22
23
24
25
26
27
28
29
30
31
32
33
34
35
36
37
38
39
40
41
42
43
44
45
46
47
48
49
50
51
52
53
54
55
56
57
58
59
60
61
62
63
64
65
66
67
68
69
70
71
72
73
74
75
76
77
78
79
80
81
82
83
84
85
86
87
88
89
90
91
92
93
94
95
96
97
98
99
100

1
2
3
4
5
6
7
8
9
10
11
12
13
14
15
16
17
18
19
20
21
22
23
24
25
26
27
28
29
30
31
32
33
34
35
36
37
38
39
40
41
42
43
44
45
46
47
48
49
50
51
52
53
54
55
56
57
58
59
60
61
62
63
64
65
66
67
68
69
70
71
72
73
74
75
76
77
78
79
80
81
82
83
84
85
86
87
88
89
90
91
92
93
94
95
96
97
98
99
100

A



B



them as Pflüger's ducts which have taken on a low type of development (fig. 128).

The student will therefore see that the cellular structures found on section of ovaries, although considered by all as a source of origin for ovarian cysts, have their nature disputed. Noeggerath believes them to be diseased blood-vessels; Waldeyer, Spiegelberg, Schroeder, consider them to be Pflüger's ducts; De Sinéty and Malassez hold that they are Pflüger's ducts degraded in development. Variance in opinions.

(y.) *Malignant development of connective tissue of ovary.*—In malignant disease of the ovary ascitic fluid is often formed in which are characteristic cells, first described by Dr. J. Foulis of Edinburgh. Plates VI. and VII. show these. They will be considered under the ascitic fluid associated with malignant tumours. Foulis' developmental work on the ovary has valuable bearings on its pathology. Malignant Ovarian Disease.

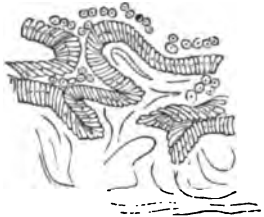


FIG. 129.

SECTION THROUGH CYST WALL, showing papillæ covered with columnar epithelial and sub-epithelial layer of connective tissue (*Rindfleisch's*) z^{y} .

At present more light is needed in ovarian pathology, as can readily be seen from the heterogeneous facts as yet at our disposal.

VARIETIES OF OVARIAN TUMOURS; THEIR NAKED-EYE AND MICROSCOPIC ANATOMY.

- (1.) Hydrops folliculorum :
- (2.) Cystoma ovarii—

Varieties of Ovarian Cysts.

- a.* Cystoma ovarii proliferum glandulare ;
- b.* Cystoma ovarii proliferum papillare :

This is Waldeyer's classification. Rindfleisch speaks of a papillary form, a form caused by colloid degeneration of the ovarian stroma (figs. 129, 130), and a form with cysto-colloid degeneration.

- (3.) Dermoid cysts :
- (4.) Cystoma malignum.

202 AFFECTIONS OF FALLOPIAN TUBES AND OVARIES.

Naked-eye
Anatomy.

Naked-eye anatomy.—We have the cysts and their pedicle. The cysts are always multiple; and the pedicle is usually made up of ovarian ligament, Fallopian tube, and broad ligament. Both cysts and pedicle are covered with peritoneum. On section of the cystoid tumour many cysts are found with papillary projections and inter-communications. The papillæ may coalesce and form retention or daughter cysts. Microscopically we have already noted that in cases of hydrops folliculorum, where the size is that of a bean, the ovum has been found.

Micro-
scopical
Anatomy.

Microscopic anatomy.—The wall of the cysts is made up of stratified connective tissue lined by columnar epithelium. In the *glandular form* (*cystoma ovarii proliferum glandulare*), the *epithelium* grows more outwards and forms occluded follicles in the cyst wall; in these again other follicles may develop. In the *papillary form* (*cystoma ovarii proliferum*

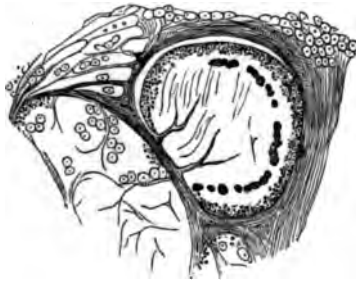

FIG. 130.

COLLOID DEGENERATION OF OVARIAN STROMA (*Rindmetzsch*).

papillare), the *connective tissue* of the cyst wall sprouts out pushing the lining of the cyst before it; these papillæ are covered with the columnar epithelium of the cyst.

Dermoid
Cysts.

Dermoid cysts are due to abnormal inclusion of the epiblast, *i.e.*, are developmental in their origin. They have an outer fibrous coat and an inner one composed of true skin. They may contain hair, teeth, bone, striped muscle, nervous matter, cholesterine, and sebaceous matter.

The *cystoma malignum* is a cystic tumour which has undergone malignant degeneration. It is noteworthy that malignant disease often develops after the removal of an apparently simple tumour.

THE NATURE OF OVARIAN FLUIDS AND OF PAROVARIAN FLUID.

Ovarian
Fluid.

Ovarian fluid varies much in consistence and colour. It is usually viscid, and may be so thick as to be almost gelatinous. Its colour is

yellowish or greenish; and the specific gravity, when of the more fluid consistence, varies from 1010 to 1020. Chemically, the fluid is complex. The chemical composition has been investigated by Eichwald, whose paper may be consulted.

Ovarian fluid does not give a flocculent precipitate as ascitic fluid does.

The corpuscular elements of ovarian fluids are various. There may be oil globules, cholesterine crystals, blood fresh or altered, with large granular cells.

Hughes Bennett of Edinburgh and Drysdale of Philadelphia have described a corpuscle, seen at fig. 131, as characteristic of ovarian fluids. According to Drysdale it "is generally round, delicate, transparent, and contains a number of granules but no nucleus;" its size varies from $\frac{1}{8000}$ of an inch to $\frac{1}{2000}$ of an inch in diameter. Acetic acid added to

Bennett
and
Drysdale's
Corpuscle.



FIG. 131.

SOME CELLULAR ELEMENTS OF OVARIAN FLUID. At the upper right hand corner we have red blood corpuscles. Below these lie the granular ovarian cells, and below them free granular matter. At the upper left hand corner is shown an epithelial cell; below it, a pus cell after addition of acetic acid; and below this, pus cells before addition of acetic acid (*Drysdale*).

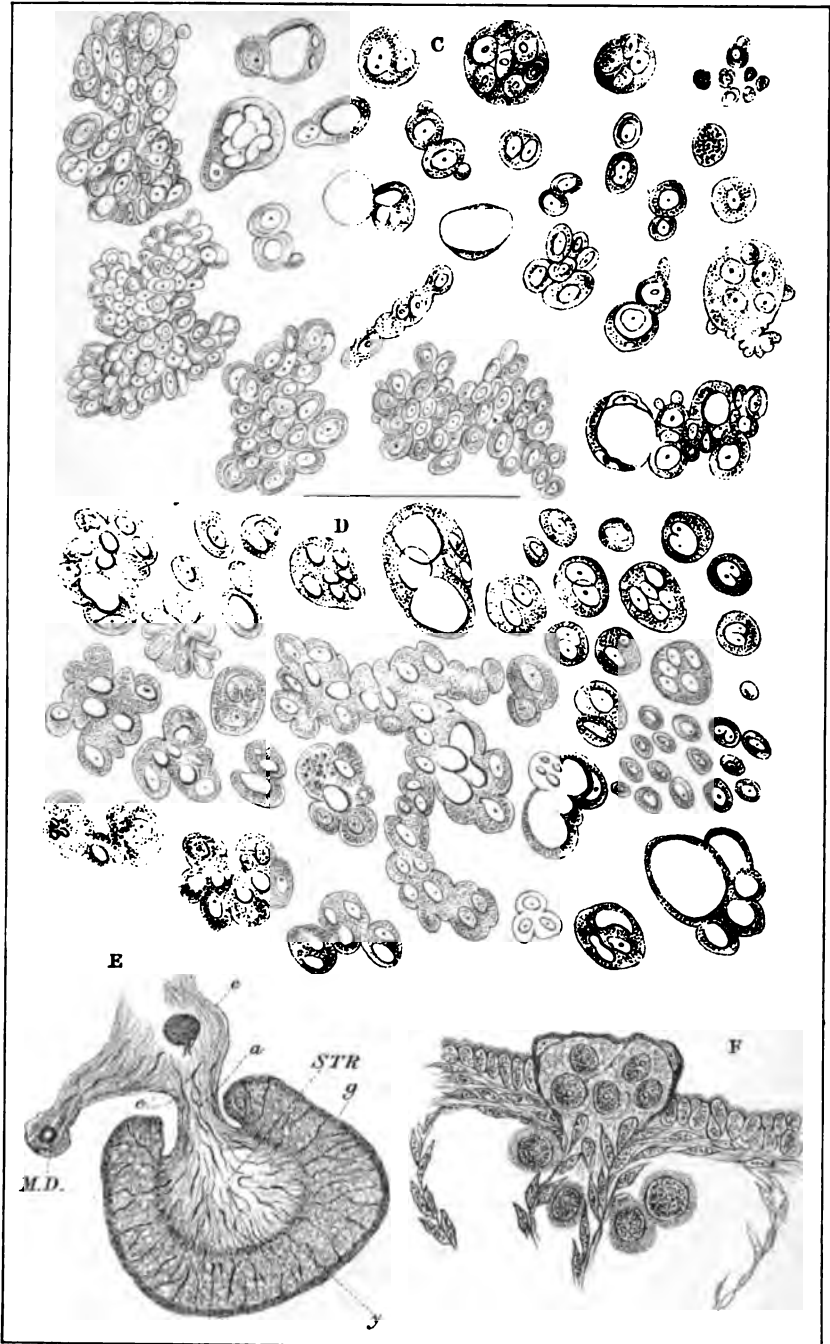
pus makes the cells larger and brings nuclei into view; while it only increases the transparency of the ovarian cell and makes its granules more evident. Recently, Garrigues has investigated the microscopical nature of ovarian fluids in an able research. He believes *Drysdale's* cell and *Bennett's* corpuscle to be the nuclei of epithelial cells fattily degenerated, and that there is no pathognomonic ovarian cells.

Parovarian fluid is often little more than a solution of salt, and is then to the naked eye like clear water; it usually contains no cellular elements. It should be noted that we may have other cysts in the broad ligament which may have developed from germ epithelium there; and it should not be forgotten that ovarian cysts proper may grow into the broad ligament. Thus we have no fluid characteristic of a broad ligament cyst (v. *Garrigues*, *Bantock*, *Gusserow*).

Parovarian
Fluid.

**Solid
Malig
Tum:**

**Fou
rese:**



SOLID OVARIAN TUMOURS ; MALIGNANT TUMOURS AND THE NATURE OF
THE ASCITIC FLUID ASSOCIATED WITH THEM.

Solid and
Malignant
Tumours.

Non-malignant (fibrous¹ and cartilaginous) tumours are rare. A tubercular condition of the ovary is found as part of general tuberculosis.

Foulis'
researches.

Malignant disease of the ovary is a comparatively frequent occurrence. It often complicates cystic degeneration, specially the papillary form of ovarian cyst. It arises also independently, and may occur either in the scirrhous or medullary form. The most important feature is the rapid development of ascites, without the existence of cardiac, hepatic, or renal disease to explain it. Of great importance are the cells in the ascitic fluid associated with malignant ovarian disease. Dr. Foulis of Edinburgh has investigated this subject, and has brought out results of very great value. Through his kindness we have been able to reproduce in plates VI. and VII. the cells he has drawn attention to; and he has kindly furnished us with the following description.

“A. Sprouting cell groups found in ascitic fluid surrounding a large cysto-sarcoma of the ovary.

For a history of this case see *Edin. Med. Jour.*, 1875. p. 838.

In figures 3, 4, 5, 7, great variation in form and size of the cells in each group is seen. The largest cells are generally seen at the margins of the groups.

Fig. 9. Several large polynucleated cells, evidently detached from cell groups.

Fig. 11. Cells undergoing fatty degeneration.

Fig. 12. Blood corpuscles.

“B. Cell groups found in the deposit from ascitic fluid surrounding a large soft malignant tumour of the ovary. In many of the cell-masses, large vacuoles are seen.

“C. Cell groups found in the deposit from ascitic fluid surrounding a large flat or pancake-shaped tumour of the omentum. The tumour was thought to be ovarian. In the fluid in the pleural sacs exactly similar cells and cell groups were seen, and the pleural surface of the diaphragm was studded over with cancerous nodules.

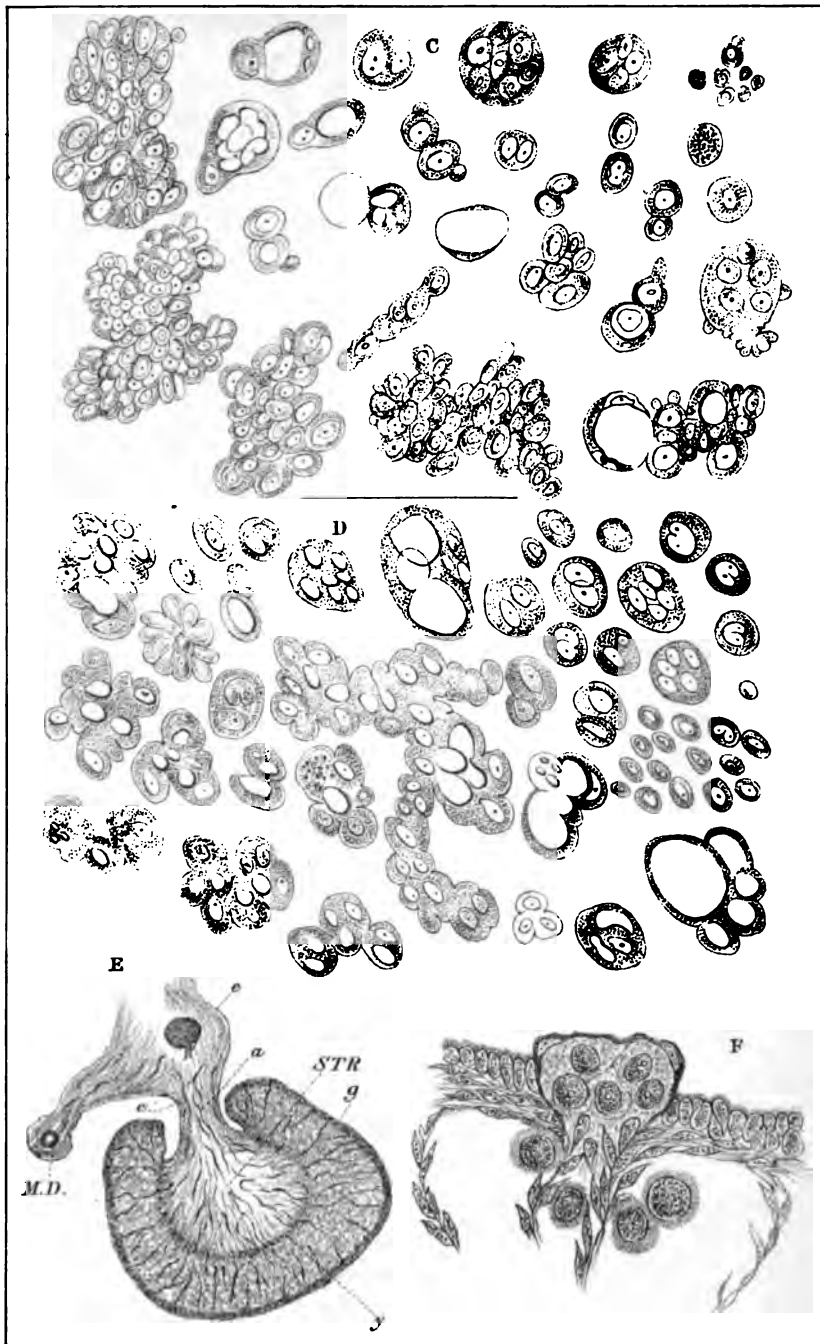
“D. Cell groups found in ascitic fluid in the case of a gentleman, aged seventy, suffering from malignant peritonitis. In the

¹ In *London Obst. Trans.*, Vol. XX., p. 276, is an interesting case (with plate) reported by Cullingworth as fibroma of both ovaries. Each ovary was converted into a solid nodulated tumour—one the size of a fist, the other larger. There was no ascites. The microscopic examination gave suspicion of *commencing sarcoma*. The literature of fibroma ovarii is fully given in this paper.

S
Y
T

I
I





centre a very large cell mass, with numerous vacuoles in the substance of the protoplasm, is seen.

All the cell groups and cells were drawn by the aid of the camera lucida under a power of 350 diameters, with No. 3 ocular."

It is probable that these liberated cells found in ascitic fluid graft themselves on the peritoneum, and pass through the diaphragm into the pleura and pericardium. They behave as we have seen bacteria do (*vide* p. 153).

To illustrate the development of the normal ovary and of the Graafian follicles, we have added the following figures from Foulis' paper on this subject.

Plate VII.—“*E.* Section through ovary and Wolffian body of a foetal lamb.

a stalk of ovary, *STR* stroma, *MD* duct of Müller, *e* epithelium of peritoneum, *g* germ epithelium, *y* deepest part of the parenchymatous zone of the ovary.

“*F.* Connective tissue sprouting out and surrounding the germ epithelium.”

CHAPTER XXI.

DIAGNOSIS OF OVARIAN TUMOURS.

LITERATURE.

Atlee, W. L.—The General and Differential Diagnosis of Ovarian Tumours: Lippincott and Co., Philadelphia, 1873. On Sarcoma of the Ovaries: Am. Gyn. Tr., Vol. II. *Barnes*—Diseases of Women, p. 400: London, 1878. *Brown, J. Baker*—Surgical Diseases of Women: London, 1866. *Duncan, J. Matthews*—Diseases of Women: London, Churchill, 1883. *Hicks, Braxton*—Further Remarks on the Use of Intermittent Contractions of the Pregnant Uterus as a means of Diagnosis: Lond. Inter. Congress Tr., 1882. Also Tr. of Lond. Obst. Soc., Vol. XIII., and Proc. of Royal Soc. of Lond., 1878. *Jastrebov*—On a point in the Diagnosis of Ovarian Tumours: Lond. Inter. Congress Tr., 1882. *Olishausen*—Die Krankheiten der Ovarien: Billroth's Handbuch: Stuttgart, 1877. *Ritchie, C. G.*—Contributions to Ovarian Physiology and Pathology: Churchill, London, 1865. *Schroeder*—Handbuch der Krankheiten der weiblichen Geschlechtsorgane: Leipzig, 1879. *Tait, Lawson*—Diseases of the Ovary: Hastings Prize Essay, Lond., 1874. *Williams, John*—Article, Ovarian Tumours: Reynold's System of Medicine, Vol. V. *Wells, T. Spencer*—Ovarian and Uterine Tumours: London, 1882. Lectures on the Diagnosis and Surgical Treatment of Abdominal Tumours: Br. Med. Jour., 1878.

For convenience we take up the diagnosis and differential diagnosis of ovarian tumours under two heads:—

- A. When small, and pelvic in position ;
- B. When large, and chiefly abdominal in position.

A. WHEN SMALL, AND PELVIC IN POSITION.

They may be either (a.) Lateral to uterus, or (b.) Posterior to uterus.

(a.) Pelvic ovarian tumours lateral to Uterus.

Diagnosis
of Ovarian
Tumours
when
pelvic and
lateral to
Uterus.

1. *Symptoms.*—These are chiefly those of pressure and bearing down, and have no diagnostic value. There is no menorrhagia.

2. *Physical signs.*—Palpation and percussion give evidence of the presence of a tumour only when it projects much above the brim. Auscultation gives negative results. On vaginal examination, the cervix is found displaced to the side opposite to that where the tumour is. Through the fornix a tense, rounded, fluctuating mass is felt projecting downwards. Bimanually the uterus is felt not enlarged, but is displaced to the one side and is distinct from the tumour, which can be mapped out between the hands. Usually the uterus and tumour are not very

movable, owing to the limited space of the pelvic cavity. When the tumour is tapped, ovarian fluid is got.

3. *Differential diagnosis.* When *lateral* to the uterus they require to be differentiated from the following :—

- (1.) Pelvic cellulitis ;
- (2.) Pelvic peritonitis (encysted serous effusions) ;
- (3.) Parovarian cysts ;
- (4.) Hydrosalpinx, Pyosalpinx ;
- (5.) Fallopian tube gestation ;
- (6.) Fibroid and fibro-cystic tumours of uterus ;
- (7.) Blood effusion ;
- (8.) Solid ovarian tumours.

(1.) *Pelvic cellulitis.*—With this we have inflammatory history and probable cause, as abortion or labour, to guide us. When the cellulitis has gone on to suppuration, there will be rigors and other indications of suppuration. Cellulitic deposits, unless when in the broad ligament, are always fixed ; are firm when not purulent, and even when purulent do not give very distinct fluctuation.

(2.) *Pelvic peritonitis.*—This will not cause the fornix to bulge downwards, and the history will help us. Tapping gives serum, and not ovarian fluid. When an ovarian tumour is fixed by peritonic adhesions, it will be almost impossible to diagnose it from encysted pelvic peritonic effusion except by examination of the fluid.

(3.) *Parovarian cysts* are not so rounded and have very distinct fluctuation ; their secretion is usually simple salt and water, and when tapped they do not recur (*v. p. 203*).

(4.) *Hydrosalpinx and pyosalpinx* are high in pelvis, tortuous, elongated from side to side.

(5.) *Fallopian tube gestation* (*v. extra-uterine gestation under Section IX.*)

(6.) *Fibroid and fibro-cystic tumours of uterus* (*v. Section V.*)

(7.) *Blood effusion* in the broad ligaments is difficult to diagnose during life, and is chiefly discovered on operation or post-mortem. The same is true of *Hæmatometra*.

(8.) *Solid ovarian tumours* are rare. When malignant there are often nodules in the fornices and ascitic fluid which shows the cells shown at plates VI. and VII.

b. Pelvic Ovarian Tumours posterior to Uterus.

1. *Symptoms.*—The most striking one is associated with urination ;

Diagnosis
when small
and pos-
terior to
Uterus.

there is either retention or constant desire to micturate. There is no menorrhagia.

2. *Physical signs.*—Palpation, auscultation, and percussion give the same result as when the tumour is lateral. On Bimanual examination, the uterus is felt markedly displaced to the front but is not enlarged: and bulging downwards behind the cervix, the round globular cystic ovary can be grasped. Tapping gives ovarian fluid.

Differential diagnosis.—When *posterior* to the uterus, they require to be differentiated from the following conditions:—

- (1.) Encysted serous peritonitic effusion,
- (2.) Retro-uterine hæmatocele,
- (3.) Fibroid and fibro-cystic tumours of the uterus,
- (4.) Retroverted gravid uterus and extra-uterine foetation,
- (5.) Parovarian cysts.

(1.) *Peritonitic effusion* has an inflammatory history; it is not so rounded nor so well defined above. The fluid is serous.

(2.) *Retro-uterine hæmatocele* has, after the blood has coagulated, a hard feeling and is more expanded transversely. There is a history of sudden onset, menorrhagia, and subsequent inflammatory symptoms.

(3.) *Fibroid and fibro-cystic tumour of the uterus* (v. Section V.)

(4.) *Retroverted gravid uterus and extra-uterine foetation* (v. Section IX.)

(5.) *Parovarian cysts.*—The character of the fluid is our only certain guide.

It should be specially noted that these pelvic ovarian tumours are apt to cause *pelvic inflammation*, and thus render the exact diagnosis, unless aided by tapping, very difficult.

B. DIAGNOSIS OF OVARIAN TUMOURS WHEN LARGE, AND CHIEFLY ABDOMINAL IN POSITION.

Diagnosis when large. 1. *Symptoms.*—These are chiefly due to its bulk. The patient's notice is attracted to the fact that she is getting rapidly stout. Recently Jastrebow has alleged that the sensibility of that part of the groin supplied by the genitocrural nerve is impaired on the same side as that on which the tumour is.

2. *Physical signs.*—When the patient lies on her back and the abdominal surface is bared, the following points can be noted.

On *inspection* the abdomen is seen to be greatly distended. The distention may be uniform, but is often more or less markedly lateral. The distance from the anterior superior spinous process to the umbilicus is

greater on one side than the other. The superficial abdominal veins may be dilated, and lineæ albicantes are sometimes present.

On *palpation*, the distention is felt to be due to an encysted collection of fluid. A mass is felt in the abdominal cavity which is like a sac filled with fluid. Fluctuation is got by placing one hand at a special part and tapping at an opposite point with the fingers of the other hand. However long the tumour be manipulated, *there is never felt any muscular contraction of the cyst wall.*

On *percussion* when the patient lies dorsal, a dull note is obtained over the tumour (fig. 132); but at the flank where the tumour does not bulge,

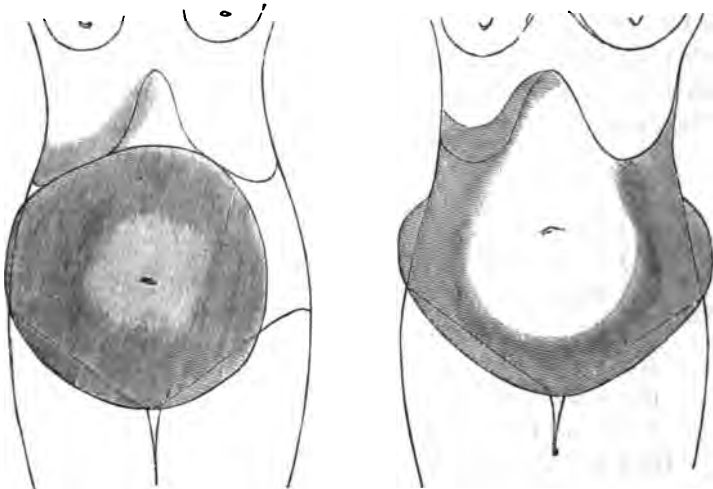


FIG. 132.

The shaded portion shows the dull area; left figure—ovarian tumour, right figure—ascites (*Barnes*).

it is clear and tympanitic, since the intestines are there. When the patient turns on her side, with this flank uppermost, the dullness and tympanitic note do not change in position. This sign shows we have to deal with an *encysted* collection of fluid.

Auscultation gives entirely negative results. No sound is heard unless that of friction over a localised peritonitis.

On *vaginal examination*, the uterus is felt displaced to one or other side, or very much to the front. It is rarely retroverted, and—unless impregnated—is not enlarged. The tumour does not usually bulge down into the fornices, but may be made out bimanually.

In order to ascertain how the pedicle lies, we have to make the

examination *per rectum*. The tumour is drawn upwards in the abdominal cavity by an assistant. We now lay hold of the cervix with a volsella, pass the index finger of the right hand into the rectum, make traction on the cervix till the fundus is brought within reach of the rectal finger. We recognise a tense band passing from one angle of the fundus, and the enlarged ovarian artery may be felt pulsating in it. We now examine for the ovary of the opposite side, to ascertain if it is normal in size. The possibility of both ovaries being cystic (which would produce a pedicle on each side), should not be forgotten, though this is comparatively rare. The examination with the volsella is made easier by placing the patient *in the genupectoral posture*; the weight of the tumour makes it gravitate into the abdomen, and renders the pedicle tense; it is also easier to make the rectal examination in this position.

Differential
Diagnosis.

3. *Differential Diagnosis of Abdominal Ovarian Tumours.*

They must be diagnosed from the following conditions:—

- (1.) Pregnancy and Hydramnios,
- (2.) Fibroma uteri,
- (3.) Ascitic fluid,
- (4.) Fibrocystic tumours of the uterus,
- (5.) Parovarian tumours,
- (6.) Encysted dropsy,
- (7.) Thickened omentum enclosing intestines by adhesions,
- (8.) Omental tumours,
- (9.) Renal tumours,
- (10.) Hydatid of liver,
- (11.) Pseudocystitis,
- (12.) Distended bladder.

In observing a case of abdominal tumour, the practitioner makes first his positive examination systematically; he makes in every case what is called the routine examination, noting what he observes. By this means he may get facts enough to warrant his drawing a distinct conclusion as to its nature. This, however, is not always the case; he has then to use diagnosis *by exclusion*: it must be one of a certain fixed number of things; the possibilities are excluded one by one till a definite diagnosis is reached. When examination is unsatisfactory, it should be repeated under chloroform.

We have stated above that ovarian tumours require to be diagnosed from twelve conditions. On each of these we make some brief remarks.

(1.) *Pregnancy*.—At the period of pregnancy when the uterus is so

enlarged as to be above the pelvic brim, certain conditions are present. These are suppression of menstruation for a given period, and size of the uterus corresponding to this; mammary signs; lineæ albicantes, and pigmentation. On palpation, we feel a tumour without distinct fluctuation and *having intermittent contractions*; the fœtus can be palpated out. The fœtal heart (after the fourth month) and the uterine souffle are heard. The vagina is dark in colour, the mucous secretion increased, and the cervix soft.

We need hardly say that the palpation, the fœtal heart-sounds, bruit and vaginal changes mark out the pregnancy unmistakably. These points may seem too simple to require mention, but cases have been recorded where the pregnant uterus has been tapped for an ovarian cyst.

Hydramnios may simulate an ovarian cyst. The amenorrhœa will help, and especially the occurrence of intermittent contractions as Braxton Hicks has specially pointed out. In one of his recorded cases, the tumour was the size of a seven months' uterus with distinct fluctuation, and there was amenorrhœa for five months. Palpation gave the uterine hardening. Previous to this it had been tapped as a cystic ovarian tumour.

(2.) *Fibroma uteri* (v. Section V.)

(3.) *Ascitic fluid*.—When the patient lies on her back, percussion gives a tympanitic note at the umbilicus and a dull one at the flanks (fig. 132); when on her left side, the note is dull on that side and clear over the right; when on her right, it is dull on that side and tympanitic on the left; when she sits up, the upper limit of the dulness is curved with the convexity downwards.

The reason of this is evident. The intestines float on the fluid at its highest point, and give the tympanitic note accordingly (fig. 132).

(4.) *Fibrocystic tumours of the uterus* are difficult to diagnose. The following points should be noted. Fluctuation is only partial, and the consistence is variable; the rate of growth is slower; and the fluid drawn off coagulates spontaneously (*Atlee*). It is often difficult to separate these from ovarian tumours, and the best operators have sometimes failed to do so (v. Section V.)

(5.) *Parovarian tumours* have very well marked fluctuation, have their characteristic fluid, and when once tapped do not usually refill as they are mere retention cysts.

(6), (7), and (8.) In many cases we can make out that the tumour

212 AFFECTIONS OF FALLOPIAN TUBES AND OVARIES.

does not pass down into the pelvis and is not connected with the uterus. Sometimes the case is obscure, and abdominal incision alone clears matters up.

(9.) *Renal tumours* grow downwards and inwards. When right-sided, the tympanitic colon lies between them and the liver. Their fluid contains urea.

(10.) The connection of the *hydatid* with the liver can be made out.

(11.) In *Pseudocystis* the percussion note is tympanitic, and the swelling disappears under chloroform.

(12.) The *distended bladder* is of course emptied by the catheter.

DIAGNOSIS OF ADHESIONS.

Diagnosis
of Adhe-
sions.

When pelvic, the fixation of the tumour they cause can be felt. Tappings are one great cause of adhesions; they may also arise from mere pressure. Careful inquiry should always be made as to the history of inflammatory attacks. On palpating the tumour, one can often feel friction. On making the patient take a deep breath, it should be noted whether the abdominal walls move over the surface of the tumour. Much less importance is attached now-a-days to the existence of abdominal adhesions. When pelvic, especially if to the bladder or deep in the pouch of Douglas, they are more serious.

CO-EXISTENCE OF PREGNANCY AND OVARIAN TUMOUR.

Co-exist-
ence of
Pregnancy.

It should be kept in mind that pregnancy may co-exist with an ovarian tumour, giving its own special symptoms and physical signs in addition.

CHAPTER XXII.

OPERATIVE TREATMENT OF OVARIAN TUMOURS.

LITERATURE.

- Atlee*—The General and Differential Diagnosis of Ovarian Tumours: Philadelphia, 1873.
Bantock—First Series of Twenty-five Cases of Completed Ovariectomy: Brit. Med. Jour., 1879, p. 766. Early Operative Treatment of Ovarian Cysts: Lond. 1882.
Cheyne, Watson—Antiseptic Surgery: Smith, Elder, & Co., London, 1882. *Hegar and Kallenbach*—Die operative Gynäkologie: Stuttgart, 1881, S. 201. *Lister*—Address on the Treatment of Wounds: Lancet, Nov. 19 and 26, 1881. *Mahomed*—Lancet, 1879. *Miner*—Ovariectomy by Enucleation: Philad. Intern. Cong. Tr., 1877. *Mundé, P. F.*—The Value of Electrolysis in the Treatment of Ovarian Tumours: Am. Gyn. Tr., Vol. II., p. 348. *Semeleder*—Twenty Cases of Ovarian Cysts treated by Electrolysis, Am. Jour. of Obst., XV., 515. *Sims, J. M.*—Thomas Keith and Ovariectomy: Am. Jour. of Obst., April 1880. *Tait, Lawson*—On Axial Rotation of Ovarian Tumours leading to their Strangulation and Gangrene: London Obst. Tr., Vol. XXII., p. 86. The Antiseptic Theory tested in Ovariectomy: Lond. Med. Chir. Tr., Vol. LXIII., p. 161. Recent Advances in Abdominal Surgery: London Intern. Cong. Tr., 1882. *Thornton*—The Silk Ligature as a means of securing the Ovarian Pedicle: Brit. Med. Jour., 1878, p. 125. *Wells, T. S.*—Ovarian and Uterine Tumours: Lond. 1882. Recent Advances in the Surgical Treatment of Intraperitoneal Wounds: London Intern. Cong. Tr., 1882. Additional Cases of Ovariectomy performed during Pregnancy: London Obst. Tr., Vol. XIX., p. 184.

REMOVAL of the ovarian tumour by abdominal or vaginal section—in almost all cases abdominal—is the treatment now practised. Other methods have, however, been employed; a brief *resumé* of these will be useful to the student.

These methods have been tapping, tapping and injection of the cyst with iodine, electrolysis, drainage into the peritoneal cavity or through the vagina.

Tapping is not a method of treatment followed by cure, and should be used only when it is necessary to obtain fluid for diagnosis. It cures parovarian cysts, as these are mere retention cysts. Ovarian cysts are not retention cysts but have a proliferating lining membrane, for which reason tapping does not cure them. An additional reason against tapping is that it is a procedure by no means free from danger, even to life. By oozing of the fluid through the puncture, adhesions are set up; in some cases, septic peritonitis has proved fatal. Tapping, further, is only palliative and must be followed by ovariectomy.

Method of Tapping.—See that the bladder is empty. With the patient lying on her back make an incision through skin and fat for about an inch, and midway between umbilicus and pubis. Then plunge in the trocar seen at fig. 134. To the side-tube a long piece of tubing is attached, which dips under water. While the fluid is flowing, the patient lies on her side. No bandage is necessary. Care should be taken to prevent regurgitation of air, and a suitable dressing should be applied to the wound (*vide* under Ovariectomy).

Tapping and injection of the cyst with iodine is a procedure not now practised, owing to the risks and uncertainty attending it.

Electrolysis was at one time advocated as a means of cure. Its pretensions to this are unfounded, and few now practise it. Its use has been carefully considered by Mundé of New York, and Semeleder, city of Mexico, in the articles cited, which may be consulted for details and information.

Drainage into the peritoneal cavity, or through the vagina.—The former is dangerous, and the latter is only practised in those cases where the cyst is immovably fixed by adhesions.

One fact must be finally noted. Cases of cure of ovarian cysts by tapping, drainage, or electrolysis, are sometimes recorded. These cysts have probably not been ovarian, but cysts of the broad ligament—parovarian. Mere tapping often cures the latter. Electrolysis does the same. Electricity has nothing to do with it, the puncture of the needle is enough.

OVARIOTOMY.

This is performed by vaginal or by abdominal incision. The former is very rarely employed, the latter is the usual method.

VAGINAL METHOD.

Vaginal
Ovari-
ectomy.

This may be practised when the tumour is pelvic and small. Thomas of New York, Goodell of Philadelphia, Gilmore, Hamilton, and others have recorded cases. The following is the plan of procedure.

Chloroform or etherize the patient. Place her semiprone or in the lithotomy posture. Pass the Sims speculum. Incise the posterior vaginal wall behind the cervix, in the middle line. Tap the tumour with an aspirator, and then draw it through the incision with the finger or curved forceps. Ligature the pedicle with thin carbolised silk threaded on a handled needle, and divide it on the side next the tumour.

OPERATIVE TREATMENT OF OVARIAN TUMOURS. 215

Pass a T-shaped drainage tube into the wound which may be stitched round it or left open. Should the temperature rise or the discharge become fœtid, irrigate daily with weak carbolic lotion (1-100).

Encouraging results have been got by this method.

ABDOMINAL METHOD.

These questions are often asked: When is the best time to operate on an ovarian tumour? Should it be removed when small, or should the operator wait until it is of good size? If the latter, how large should it be? Abdominal
Ovari-
otomy.

It is better not to operate by this method when the tumour is small, but to wait until its size is that of a five or six months' pregnancy. A tumour of this size has displaced the small intestine from its usual position behind the anterior abdominal wall, and has stretched and thinned out somewhat the latter. The abdominal incision is therefore more easily made and the intestines are out of harm's reach. Of course it should not be forgotten that, when the medical man is consulted, ovarian tumours have usually become abdominal and large.

Bantock and others have, however, advised its performance whenever it is diagnosed.

Let us suppose, then, that the ovariologist has a patient—who is otherwise healthy—with an ovarian tumour free from adhesions, and that her period has occurred ten days before. How is the operation performed?

If the patient has not been in any way confined to bed, it is probably better to delay the operation till another period has passed, in order to accustom her to an invalid's life. She is kept on light diet, and has no solid food for six hours previous to the administration of chloroform. On the evening prior to the operation, castor oil should be given and an enema used in the morning.

The following are the requisites for operation:—

Chloroform and ether;

Hypodermic syringe;

Spray?;

Carbolic lotion;

Porcelain trays for instruments;

Sponges (a definite number), some small and fixed on sponge-holders;

Waterproof, with oval opening of which the edges are coated with adhesive plaster;

Requisites
for Opera-
tion.

Ordinary knives ;
 Probe-pointed curved bistoury ;
 Scissors, straight and curved ;
 Spatulæ ;
 Dissecting and dressing forceps ;
 Péan's or Wells' artery forceps—a definite number (20) of pairs ;
 Tenacula, blunt hooks ;
 Needles on fixed handles ;
 Aneurism needle ;
 Fine catgut for bleeding vessels ;
 Carbolised silk (Nos. 3 and 4) ;
 Two pairs ovariotomy forceps (Nélaton's or Keith's) ;
 Wells' trocar ;
 Clamp (in reserve) ;
 Cautey, actual or Paquelin's ;
 Cautey-clamp ;
 Long straight needles, threaded two on each suture of silk-worm gut ;
 Needle-holder with small needles on horse-hair sutures ;
 Drainage tubes (glass or ordinary) ;
 Carbolic gauze, protective silk, mackintosh, flannel bandages.

Assistants. The assistants necessary are five or six in number, viz., one for chloroform, one for instruments, one to help the operator, one to look after the spray, and one for the cautey. A trained nurse who can pass the catheter and administer purgative or nutritive enemata, is necessary. The patient is placed on an ordinary table, of convenient height and length, and lies on her back. The table is placed so that the patient's feet are towards the window. The legs and chest are to be warmly covered, and hot-water bottles should be laid at her side and feet. The room should be comfortably warm. The best position for the operator is to stand on the patient's right side, with his back to her feet and to the window. The question of the use of antiseptics in ovariotomy will be discussed afterwards. The instruments are placed near the operator in shallow porcelain trays, and in 1-40 carbolic solution.

Sponges. The sponges should be soft, fine, and thoroughly clean. Seven or eight are sufficient. Some are small and on sponge holders ; one is large and flat. They should be thoroughly wrung out of warm 1-60 solution. *The sponge assistant should know how many sponges he has, and should be sure that he has recovered them all before the abdominal wound is closed. Sponges should never on any account be torn up during an operation.*

OPERATIVE TREATMENT OF OVARIAN TUMOURS. 217

The spray, if used, should be placed eight or ten feet from the wound, **Spray.** and should throw out a finely-divided vapour.

Preliminaries.—The patient, who has had a very light breakfast some Prelimi-
hours previously, should be chloroformed; the skin washed and shaved; ^{naries.}
and the waterproof made to adhere to the skin, so that the incision shall
bisect the portion exposed through the oval opening. This waterproof
keeps the patient dry and comfortable.

The following are the steps of an ordinary operation :—

1. The abdominal incision ;
2. Evacuation of the cyst contents ;
3. Drawing out of the cyst from the abdomen ;
4. Securing of the pedicle ;
5. Treatment of adhesions, and bleeding from them ;
6. The peritoneal toilette ;
7. Closure of the abdominal wound ;
8. Drainage—when necessary ;
9. Dressing of the wound ;
10. After-treatment—complications.

1. *The abdominal incision.*—This is usually four or five inches long, **Incision.**
is made in the middle line, and has its lower limit about an inch above
the symphysis. It passes through—

skin,
fat,
linea alba,
fascia transversalis,
extraperitoneal fat,
peritoneum.

Sometimes the linea alba is missed, and the rectus muscle cut into.
By passing a probe in towards the middle line, the operator gets the
right track and thus avoids bleeding. The extraperitoneal fat is a good
landmark. All bleeding points are carefully attended to before the peri-
toneum is opened. They may be seized with Péan's forceps, which are
left on for a time, or they may be ligatured with catgut. When the
smooth shining peritoneum is reached, it should be hooked up with a
fine tenaculum and cut into. The cyst wall is now exposed.¹

¹ Sometimes the cyst develops between the layers of the broad ligament, lifts up the anterior lamina, and strips the peritoneum off the anterior abdominal wall. When the operator has cut through the abdominal muscles he is puzzled by finding no peritoneum. Puncture and dragging out the collapsed cyst will, however, clear up matters.

218 *AFFECTIONS OF FALLOPIAN TUBES AND OVARIES.*

Evacuation
Methods.

2. *Evacuation of the cyst contents.*—This may be accomplished in various ways. Wells' trocar (fig. 133), with its point projected, is plunged

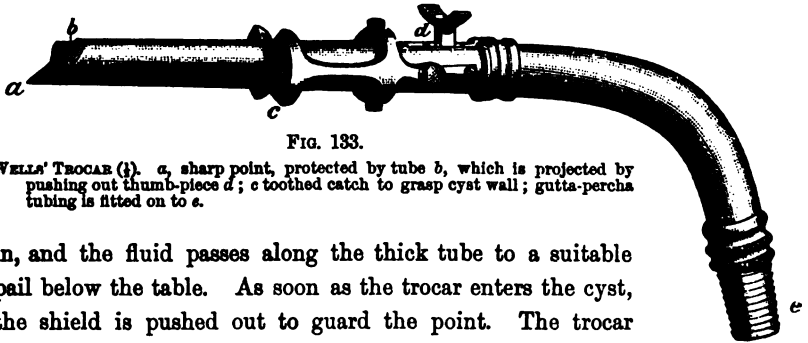


FIG. 133.

WELLS' TROCAR (j). *a*, sharp point, protected by tube *b*, which is projected by pushing out thumb-piece *d*; *c* toothed catch to grasp cyst wall; gutta-percha tubing is fitted on to *e*.

in, and the fluid passes along the thick tube to a suitable pail below the table. As soon as the trocar enters the cyst, the shield is pushed out to guard the point. The trocar has teeth for catching up the cyst wall. Keith uses a large aspirator, so as to empty speedily. Schroeder uses no trocar, but simply cuts in with his knife and squeezes the fluid out. The kneed trocar may be used (fig. 134). When the fluid is very thick it may not flow, and

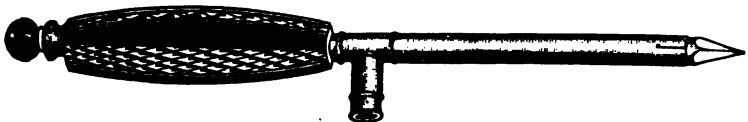

FIG. 134.

TROCAR FOR TAPPING. Tubing is fitted to side-piece.

have to be squeezed or scooped out. Secondary cysts, if large, are also perforated.

While the fluid is being evacuated an assistant keeps up steady pres-

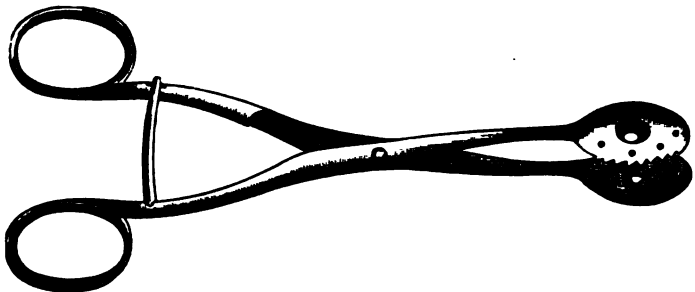


FIG. 135.

NÉLATON'S FORCEPS.

sure on the abdominal walls, in order to prevent the intestines from passing out.

3. *Drawing out of the cyst from the abdomen.*—This is accomplished by seizing the collapsed walls of the tumour with Nélaton's (fig. 135) or Keith's forceps, and steadily pulling it out. The assistant still keeps up pressure. By this means the operator now has the pedicle at the abdominal incision, and the cyst outside.

4. *Securing of the pedicle.*—This is one of the most important steps of the operation. There are three methods which may be used, viz.—

- The clamp,
- The cautery,
- The ligature.

Cyst drawn out.
Cyst separated.
Securing of Pedicle.

Of these, the clamp is now seldom used. Keith and others advocate the cautery; but the ligature and dropping back of the pedicle is the favourite and probably the best method.

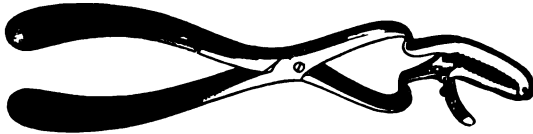

FIG. 136.

WELLS' CLAMP (1), with removable handles. The serrated part with the screw is the clamp proper.

The clamp was introduced by Jonathan Hutchinson, but, as already said, is now yielding to the ligature. The varieties of clamp are numerous. Fig. 136 shows Wells'; it consists of two short arms jointed together and provided with a screw and removable handles. It is used as follows:—

The clamp is held by its handles and made to grasp the pedicle between the cyst and the uterus; the bars of the clamp proper are then approximated, and the screw tightly screwed up. The pedicle is examined to see that it is grasped and equally compressed; if one part is thin, Spencer Wells recommends that the pedicle be first secured with a ligature. The pedicle is treated extra-peritoneally with the clamp, which rests on the skin. The great advantage of the clamp is its security against hæmorrhage. Its evident disadvantages are the following:—it does not suit all cases, as it cannot be used when the pedicle is too large or too short; it may cause ventral hernia; it exercises undue traction on the uterus; but, above all, it may cause a slough deeper down than the skin, and the discharges, passing into the peritoneal cavity, may do great mischief.

By Cautery *The cautery* was introduced, as a means of treating the pedicle, by Baker Brown of London. It gives better results than the clamp.

In order to use the cautery, we need a special cautery-clamp, and either cautery irons or Paquelin's cautery. Keith uses ordinary cautery irons heated in a little charcoal brazier. The *cautery-clamp* has two hinged bars provided with handles; each bar has one surface which is made of ivory—a non-conductor—and is placed next the skin; the other surface is made of metal; one of the bars has on its metal surface a metal upright running the whole length of the bar. The pedicle is seized with the clamp (ivory side next to the skin), and the screw turned to fix it. Then the cyst is cut off, so as to leave about an inch of the pedicle on the metal side. The dull cautery iron, which is hatchet-shaped, is then passed firmly over the surface, in the angle between the horizontal bar and the upright, until the pedicle is seared flush with the clamp. The pedicle is now caught at the under surface of the clamp with two pairs of forceps, and the clamp removed. If all is right, it is dropped into the abdomen after the peritoneal toilette is finished.

By Ligation.

The ligation should be thin carbolised Chinese silk No. 3 or 4. It is used in the following way.

A double silk ligation is threaded on a *blunt* needle. The pedicle is transfixated with this, and the ligation cut. Thus we have two ligatures through the pedicle; one is passed round the one half of the pedicle, the other round the other half. They may be made to interlace first so as to make a figure of eight. Each is tied firmly in a reef knot. The pedicle is then seized with Péan's forceps, one on each side below the ligation; the cyst is clipped off about half an inch on the cyst side of the ligation; as the pedicle is still held up by the forceps it can be carefully examined to see if any bleeding occurs. It should be noted whether the ligation splits the pedicle vertically so as to cause bleeding; if so, the ends of the thread can be made to surround the whole pedicle below this. If there is no bleeding, the ligation is cut short and the pedicle dropped into the pelvis.

The raw end of the pedicle may be stitched with catgut to the broad ligament, so as to prevent its adhering to and constricting intestine (*Thornton*).

By Ligation when pedicle thick.

When the pedicle is thick and fleshy it may require to be tied in three portions as follows:—Pass a double thread so that its shorter half will embrace only *one-third* of the pedicle; withdraw the needle, but keep it still running on the thread, and use it to carry the longer half of the

thread through a second point so as to embrace the *middle third* of the pedicle ; one portion of the longer half thus forms a loop round the middle third, while the other portion embraces the *other third* of the pedicle.

After the pedicle has been secured by one of these methods, the other ovary should be examined, and if cystic removed also.

The distal portion of the pedicle does not slough ; according to Thornton we may have Changes in the five following results : Pedicle.

(1.) Adhesion of the peritoneal surfaces on opposite sides of the ligature, and absorption of ligature.

(2.) Lymph effused over ligature and end of stump, formation of new vessels.

(3.) Adhesion of pedicle raw surface to some neighbouring peritoneal surface and passage of blood-vessels between.

(4.) Hæmorrhage from pampiniform plexus at outer edge.

(5.) No change or sloughing if patient dies soon.

5. *Treatment of adhesions and bleeding.*—The adhesions in certain Treatment of adhe- cases may give a great deal of trouble. They may be at any point of the sions and periphery of the tumour. When close to important viscera—especially bleeding. the bladder, intestine, or liver—they are serious. Their treatment is best considered as follows :—(a.) when short, (b.) when long.

(a.) When they are *short* and connected with the anterior abdominal wall, the cyst is sometimes cut into. The operator then separates the cyst from the wall by passing his finger in between them where the adhesion ceases ; or he may evert the abdominal wall, and strip the cyst off it with dissecting forceps. Spencer Wells recommends in bad cases to evacuate the cyst, and then, by seizing the posterior wall of the cyst with a hand passed into the interior, to evert it and afterwards separate the adhesions. Pressure on the ligature will arrest any bleeding, or the cautery may be applied. If the bleeding is intractable, a good plan is to pinch up the abdominal walls at the bleeding part and pass a long straight needle through this fold, so as to keep the bleeding peritoneal surfaces in apposition.

(b.) When the adhesions are *long*, they may be ligatured at two points close to the cyst and divided between these.

When adhesions to the bladder are present great care must be taken, as, in separating them, the bladder may be torn into. If this happens, the tear should be stitched with fine catgut, and a catheter kept in for some days. (*Vide* under Vesico-vaginal Fistula.) When adhesions are inseparable, the adherent portion of the cyst may be ligatured all round with silk, and then cut beyond the ligatures ; or it may be simply cut all round the adherent portion, and the edges then cauterized.

For reflecting light into the pelvis or other deep parts, an ophthalmoscopic mirror is invaluable.

Peritoneal toilette. *The peritoneal toilette.*—This term is a convenient one used by German operators to indicate the *cleansing of the peritoneum*. It must be laid down as a cardinal principle in abdominal section that no serum or blood is to be left in the abdomen. The peritoneum should be thoroughly dry, and no oozing points are to be left. The importance of the toilette cannot be too strongly insisted on. Keith of Edinburgh, whose success in ovariectomy is unrivalled, takes the greatest care in this matter, and attributes his success to it. Sims indeed says, "But I think now that it matters very little what we do with the pedicle, whether we use the clamp, the cautery, or the ligature, provided we take every care against the exudation of bloody serum into the peritoneal cavity after the closure of the abdominal wound."

Closure Wound. 7. *Closure of the abdominal wound.*—This is done as described in Battey's Operation (p. 192).

Drainage. 8. *Drainage.*—As to drainage, the rule is that none is needed in simple cases; in cases of many adhesions, however, a glass drainage tube should be passed in at the lower angle of the wound and down into the pelvis. This rule may seem to the student to clash with the invaluable principle that every wound from which there will be discharge ought to be drained. In ovariectomy, however, the peritoneum is an absorbent sac, and the discharge, after a simple operation, is absorbed *before it has time to putrefy* (Lister). In complicated cases, this drainage by absorption is insufficient; it becomes also dangerous from the amount of serum thrown out, and the risk of its putrefying. *External drainage* is, in such cases, imperative.

Dressing. 9. *Dressing of the wound.*—This should be as follows: a piece of protective silk over the wound, over this two ply of carbolic gauze wrung out of 1-40 lotion, then an eight-ply dressing of dry gauze with mackintosh, and finally padding of salicylic wool; all is secured by a broad flannel bandage. If the pulse and temperature do not rise, and there is no uneasiness, this may be left untouched—in simple cases—for eight or nine days. If there is discharge the dressing should be changed when it soaks through.

After-treatment and Complications. 10. *After-treatment: treatment of complications.*—Morphia may be given hypodermically, but only when necessary (*vide* p 157). Little food is allowed for the first thirty-six hours. Hot water should be given *ad libitum*, as it helps flatus. At the end of this time milk and beef-tea are added. An enema may be administered on the third or fourth day.

Complications may be—Secondary hæmorrhage ;
 High temperature ;
 Septicæmia.

Secondary hæmorrhage, if from the pedicle or adhesions, must be treated by the reopening of the wound and application of ligatures.

For high temperatures the ice-cap is good. The Americans recommend the more wholesale method of reduction of temperature by Kibbee's ice-cot. Krohne and Seseman of London supply very convenient ice-caps made of block-tin pipe. Quinine in fifteen grain doses should be tried. It is probable that some high temperatures, recorded by ovariologists, have been due to the absorption by the peritoneum of carbolic acid used in Listerism.

In cases of septicæmia with peritonitis where drainage has been employed, the peritoneal cavity should be washed with very weak carbolic lotion whenever there seems to be any tension or accumulation of putrid fluid ; the abdominal incision may require to be reopened for this purpose. The condition should be further treated by iron and stimulants as needed. (*Vide* Treatment of Pelvic Peritonitis.)

THE RELATION OF LISTERISM TO OVARIOTOMY.

The Listerian method of treating wounds is based on the now generally accepted theory that the germ-laden air coming in contact with a wound leads to putrefactive changes which may end in septicæmia. Lister found carbolic acid destructive to the activity of these germs ; and, consequently, Listerism requires that the air in contact with the wound, and all else that touches it, must be purified either with the spray or lotion. Listerism is in no sense a treatment of wounds, but is a *treatment of wound-surroundings*. The application of carbolic lotion to a wound is a necessary evil, as carbolic acid is an irritant and may be absorbed. In the cases treated by the surgeon, Listerism is of the greatest value ; and, with drainage, has worked the most mighty revolution in surgery. In peritoneal operations, however, its good is marred by the fact that the peritoneum absorbs the carbolic lotion, and thus its surface is irritated and often toxic effects ensue. Keith, Tait, and Bantock have therefore abandoned Listerism in abdominal surgery ; but Wells and Thornton still carry it strictly out. It is evident that ovariologists must find some method which, while locally purifying the air, will yet be innocuous to the wound surface.

Practically most ovariologists at present trust to modified Listerism, Modified
Listerism.

and to drainage when necessary. All Listerian precautions should be used except the spray.

OVARIOTOMY BY ENUCLEATION.

Miner's
Enuclea-
tion.

This is a method of ovariectomy introduced by Miner of Buffalo. According to him the pedicle divides into three or four bands containing blood-vessels gradually diminishing in the peritoneal investment of the cyst. The peritoneal covering of the cyst can be slit open, and can be readily separated by the finger. The vessels in the tissue between the peritoneum and cyst are capillary and do not bleed. In this way the tumour is enucleated, and the artificial stalk—*i.e.*, peritoneum and pedicle—of tumour either left or treated by ligature, cautery, or clamp. This method is good when the tumour is irremovable on account of adhesions.

OVARIOTOMY WHEN PREGNANCY IS PRESENT.

Pregnancy
and Ovari-
ectomy.

Although pregnancy co-exists with a large ovarian tumour, ovariectomy should be performed. In the paper of Spencer Wells quoted he gives a table of nine cases where the pregnancy varied from the third to the seventh month, with the following results. Only one mother died: the pregnancy went on to full time in five of the cases; in three the child was expelled prematurely, and in one the child was removed at the same time. The question of the treatment of a labour complicated with an ovarian tumour concerns the obstetrician rather than the gynecologist.

CONTRA-INDICATIONS TO OVARIOTOMY.

Contra-
indications.

These are, universal adhesions and malignant disease. Ordinary ascites, kidney disease or heart disease, are not contra-indications unless far advanced. Prognosis should be careful in these cases. In some fatal cases it has been found on post mortem that the kidneys were small and granular from interstitial inflammation. This may be present while there is no albumen in the urine. There is usually a pulse of high tension and cardiac hypertrophy (*v.* Mahomed's articles.)

COURSE AND RESULTS OF OVARIAN TUMOURS WHEN LEFT ALONE.

Natural
History of
Ovarian
Cysts.

In some rare cases the operator is unable to remove the cyst after he has begun his operation. He may then stitch the cyst edges to the abdominal walls carefully closing it off from the peritoneum. The best results by this method are got in dermoid and parovarian cysts: they are not good in ordinary ovarian cystomata.

Adhesions may be set up as the result of chronic peritonitis arising from pressure or tapping. Occasionally the cyst bursts, and in the case of the ordinary ovarian tumour we may get rapid death. When par-ovarian tumours burst, the fluid is usually unirritating and is absorbed by the peritoneum, the patient thus becoming cured. Matthews Duncan and others have recorded cases of burst ovarian tumour rapidly becoming fatal. Waxy disease of the liver, kidneys, etc., may result in those cases where the tumour suppurates and discharges into the bowel or through the skin.

Torsion of the pedicle to a slight extent is often noticed in ovarian tumours. When the torsion is so great as to cut off the blood supply from the cyst, we get gangrene of the tumour, and in some cases very serious symptoms, viz., peritonitis, vomiting, and severe abdominal pains. Dr. Wiltshire of London was the first to operate for this condition, and recently Lawson Tait has operated successfully in three cases. His paper should be consulted for details. It is interesting to note that the tumours so rotated are usually right-sided, and not necessarily ovarian. The usual explanation of the rotation is that it is caused gradually by the fæcal contents passing down the rectum.

The course and results of ovarian tumours when left alone can fortunately not now be studied. The picture of ovarian disease running its course unchecked, so eloquently described by West, is happily now almost unknown.

“ We have symptoms of the same kind as we see towards the close of every lingering disease, betokening the gradual failure, first of one power, then of another ; the flickering of the taper, which, as all can see, must soon go out. The appetite becomes more and more capricious, and at last no ingenuity of culinary skill can tempt it, while digestion fails even more rapidly, and the wasting body tells but too plainly how the little food nourishes still less and less. The pulse grows feebler, and the strength diminishes every day, and one by one each customary exertion is abandoned. At first the efforts made for the sake of the change which the sick so crave for are given up ; then those for cleanliness ; and lastly, those for comfort—till at length one position is maintained all day long in spite of the cracking of the tender skin, it sufficing for the patient that respiration can go on quietly, and she can suffer undisturbed. Weariness drives away sleep, or sleep brings no refreshing. The mind alone, amid the general decay, remains undisturbed ; but it is not cheered by those illusory hopes which gild, though with a false brightness, the

decline of the consumptive ; for step by step death is felt to be advancing ; the patient watches his approach as keenly as we, often with acuter perception of his nearness. We come to the sick chamber day by day to be idle spectators of a sad ceremony, and leave it humbled by the consciousness of the narrow limits which circumscribe the resources of our art." (Quoted by Spencer Wells.)

At present, ovariectomy is one of the most successful of operations. Most ovariectomists have now a mortality of about 13 to 15 per cent. Keith indeed has had 76 consecutive cases without a death.

SECTION V.

AFFECTIONS OF THE UTERUS.

THERE are three periods during which morbid conditions of the uterus arise.

1. The period of evolution or development—from the ovum up to puberty. During this stage they appear as anomalies in development—before birth or during childhood. They produce no marked symptoms, but a recognition of their existence is important as regards the future history of the patient.

2. The period of physiological activity—from puberty to the menopause. During this stage there occur in the uterus the morbid processes of acute and chronic inflammation, and of new-formation or tumour growth; on account of its mobility, the uterus is also liable to various forms of displacement. These pathological processes give rise to symptoms of themselves, and also from their effect on the normal functions of the uterus—menstruation, conception, and pregnancy. During parturition the cervix uteri is frequently lacerated, and this may be the starting-point of important pathological conditions.

3. The period of senile involution or retrogressive development—from the menopause to death. The term involution is generally used in the restricted sense of the process which occurs after childbirth, but it is the only one which conveniently expresses the retrogressive changes after physiological activity has ceased. During this stage, the most important pathological process is that of malignant new formation.

Accordingly this section of the subject falls into chapters as follows :—

- CHAPTER XXIII. Malformations of the Uterus.
- „ XXIV. Atresia and Stenosis of the Cervix Uteri.
- „ XXV. Atrophy of the Cervix and Uterus ; Superinvolution.
- „ XXVI. Hypertrophy of the Cervix ; Amputation.
- „ XXVII. Laceration of the Cervix.
- „ XXVIII. Chronic Cervical Catarrh.
- „ XXIX. Endometritis.
- „ XXX. Metritis, Acute and Chronic : Subinvolution.
- „ XXXI. Displacements of the Uterus : Ante flexion ; Anteversion ; Retroversion ; Retroflexion.
- „ XXXII. Inversion of the Uterus.
- „ XXXIII. Fibroid Tumour of the Uterus : Pathology and Etiology.
- „ XXXIV. Fibroid Tumour of the Uterus : Symptoms and Diagnosis.
- „ XXXV. Fibroid Tumour of the Uterus : Treatment.
- „ XXXVI. Fibrocystic Tumour of the Uterus.
- „ XXXVII. Polypi of the Uterus.
- „ XXXVIII. Carcinoma Uteri (of Cervix) : Pathology and Etiology.
- „ XXXIX. Carcinoma Uteri (of Cervix) : Symptoms and Diagnosis.
- „ XL. Carcinoma Uteri (of Cervix) : Treatment.
- „ XLI. Carcinoma Uteri (of Body).
- „ XLII. Sarcoma Uteri.

CHAPTER XXIII.

MALFORMATIONS OF THE UTERUS.

LITERATURE.

Barnes—Diseases of Women : London, 1878, p. 462. *Churchill*—Obst. Journal of Great Britain, 1873, p. 256. *Kussmaul*—Von dem Mangel, der Verkümmerng und Verdoppelung der Gebärmutter, etc. : Würzburg, 1859. *Mayerhofer*—Die Entwicklungsfehler der Gebärmutter: Billroth's Handbuch für Frauenkrankheiten, Stuttgart, 1878. *Schroeder*—Krankheiten der weiblichen Geschlechtsorgane: Leipzig, 1878, S. 33. *Simpson, A. R.*—Ed. Med. Jour., 1863, p. 957. *Turner*—Edin. Med. Jour., June 1865 and May 1866. The standard work is that of Kussmaul. The literature is given most fully by Mayerhofer.

WHAT is usually described as "a malformation" is really a non-formation of one part, involving a relative disproportion. Of this we have an illustration in the uterus. The one-horned uterus is not a "malformation," if by this term we mean that the part which is present is maldeveloped; the condition is a result of the nonformation of the other horn and intervening fundus. It is misleading also to speak of a "double uterus;" the condition thus described is really a halved uterus, in which the halves have not united into the whole. The word as used, therefore, means an incomplete result, not a defective process. *Maldevelopment* is a contradiction in terms, there can only be *arrested* developments.

Malformations must be studied in connection with the normal development of the organ. In this way, they become at once intelligible. There are two processes in the progression of an organ to its mature form—*development* and *growth*. There are therefore two causes which together operate in producing malformations—arrested development and arrested growth. The period of development of the uterus, by which we mean formation of parts, extends up to the twentieth week; the period of growth is much longer, and extends to the twentieth year (*Arnold*).

The student should not pass over this section of the subject as of little importance. To the practical man, malformations seem of little value because he has no power of modifying the result. To the

scientific man they are, however, of the greatest interest as furnishing him with permanent impressions of the transient states of development; they are development caught in the act and fixed permanently for after-investigation. In this chapter we recommend the student to read Etiology before Pathology.

PATHOLOGY.

Uterus
absent or
rudi-
mentary.

Complete absence of the uterus is an extremely rare occurrence, and cannot be demonstrated except on post-mortem examination. It has been described only in cases of foetal monstrosities. A *rudimentary condition* sometimes occurs; in this the uterus is represented by a band of muscular fibre and connective tissue on the posterior wall of the bladder (fig. 137), and the peritoneum forms a single pouch between the bladder and the rectum (fig. 138).

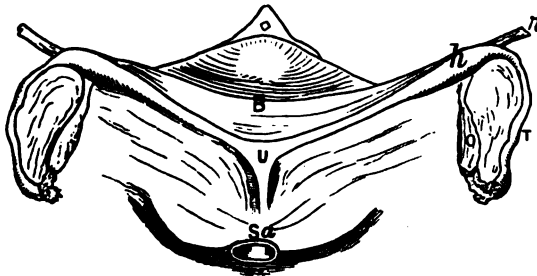


FIG. 137.

RUDIMENTARY UTERUS (*Veit*). *Sa* Sacrum; *U* Solid Rudiment of Uterus; *A* Rudimentary Horn; *B* Bladder; *O* Ovary; *T* Fallopian Tube; *r* Round Ligament.

Uterus
Bipartitus.

In the *uterus bipartitus* (fig. 139), rudimentary horns are present and are solid or hollow. The cervix is represented by a fibrous band which connects the horns with one another and with a rudimentary vagina. The ovaries are sometimes well developed, so that ovulation takes place. The breasts and external genitals may be fully formed.

Uterus
Unicornis.

The uterus unicornis (fig. 140) may exist with or without a rudimentary second horn. The vaginal portion of the cervix is small; the palmæ plicatæ within the cervical canal are most marked towards the non-developed side. The body of the uterus is of disproportionate length and curves towards one side. The fundus, by which we understand the fully-developed horn, is small and tapering; it has only one Fallopian tube and ovary connected with it. On the convex side of the somewhat curved body, is the representative of the other horn which is

either solid or hollow ; it is connected with the developed one by fibrous tissue which may or may not form a pervious canal. Connected with this rudimentary horn are the Fallopian tube and ovary of the same side, which are sometimes perfectly developed. In examining preparations of

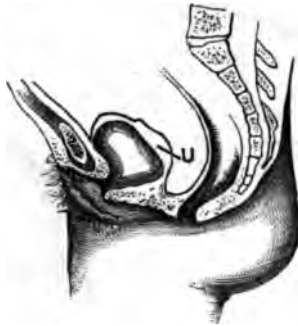

FIG. 138.

The same in its relation to the Pelvic Organs. *U* Rudiment of Uterus on the posterior wall of Bladder. The Peritoneum forms one pouch between Bladder and Rectum (*Schroeder*).

this and other uterine malformations, it is sometimes difficult to determine what is rudimentary horn and what is Fallopian tube. Here development furnishes us with a guide. The insertion of the round ligament indicates the point up to which the ducts of Müller are to be formed first into uterine horn and then into fundus uteri. Accordingly, on examining such preparations we determine the point of attachment of

Round ligament indicates junction of uterine Horn and Tube.

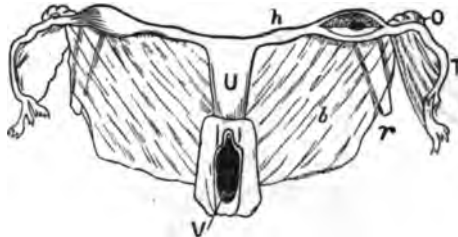


FIG. 139.

UTERUS BIPARTITUS (*Bokitansky*). *V* Vagina ; *U* Uterus ; *h* Rudimentary Horn ; *O* Ovary ; *T* Tube ; *r* Round Ligament ; *b* Broad Ligament.

the round ligament ; all below this is uterine horn, all above it is Fallopian tube. Associated with this malformation we sometimes find absence or rudimentary condition of the kidney of the same side, since the development of the renal is closely connected with that of the generative system.

Uterus
Didelphys.

In the *uterus didelphys* the two halves of the uterus remain separate throughout their course. It is a very rare condition in the living adult female, and has been usually described in foetal monstrosities. The vagina may be absent, single, or double.

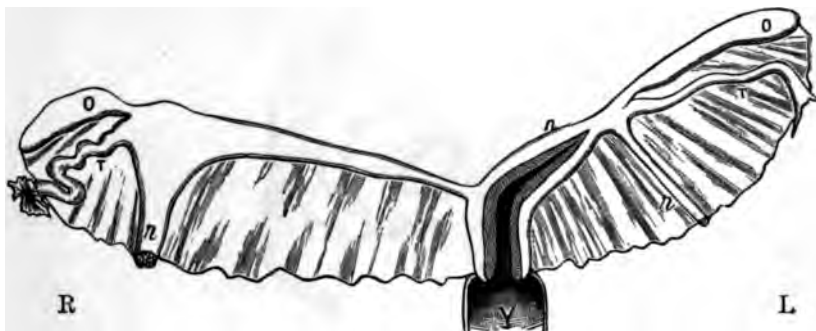

FIG. 140.

UTERUS UNICORNIS (Schroeder). R Right Side; L Left Side. The left horn (h) is well developed and communicates with the Uterine Cavity. The right horn is in the form of an elongated band; its point of connection with the Fallopian tube is indicated by the insertion of the round ligament which is hypertrophied. Other letters as in preceding diagrams.

Uterus
Bicornis.

By *uterus bicornis* we understand that the separation into two horns is distinctly visible *externally*. Of this there are various degrees, from a mere depression at the middle of the fundus to a well-marked bifurcation, which rarely extends lower than the os internum; the further down the




FIG. 141.

UTERUS BICORNIS UNICOLLIS (Schroeder). † Round Ligament.

separation extends, the more obtuse is the angle between the divergent horns. In addition to this external division, the separation is usually carried further down by an internal septum which may extend to the os externum.

In the *uterus septus* (fig. 142) there is no external indication of the

internal division. The uterus is divided by a septum beginning at the Uterus fundus uteri and extending downwards for varying distances, sometimes Septus. as far as the os externum. It is otherwise normal.

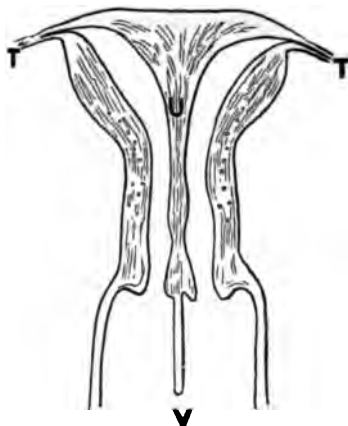


FIG 142.

UTERUS SEPTUM IN VERTICAL TRANSVERSE SECTION (*Kusmaul*). *U* (Uterus) placed on septum which divides Cavity into two lateral portions; *T* Fallopian Tubes; *V* Vagina divided into lateral cavities by prolongation of septum downwards.

The *infantile uterus* (fig. 143) is characterised by shortness of body and Infantile disproportionated length of cervix; in fact the relative lengths of body and Uterus. cervix remain the same as at birth, from which the name "*infantile*" is

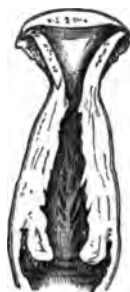

FIG. 143.

INFANTILE UTERUS (*Schroeder*).

derived. The cervix ($1\frac{1}{2}$ inches long) is two or even three times the length of the body ($\frac{1}{2}$ inch to $\frac{3}{4}$ inch). The whole uterus is smaller than the normal. The walls (specially those of the body) are thin and the cavity is small.

Congenital
Atrophy of
Uterus.

The term *congenital atrophy* is applied to cases in which the proportions of body and cervix are of the normal *virgin* type, while the organ as a whole is atrophied (fig. 144). An excess of connective tissue is present in the walls, which makes their consistence firmer. This malformation occurs in scrofulous and chlorotic patients, and is often associated with hysteria and epilepsy.

ETIOLOGY AND CLASSIFICATION.

Five
periods in
develop-
ment of
Uterus.

Malformations differ according to the period at which development and growth are arrested, and the extent to which they are interfered with. There are five periods in development and growth (*Fürst*), which can be

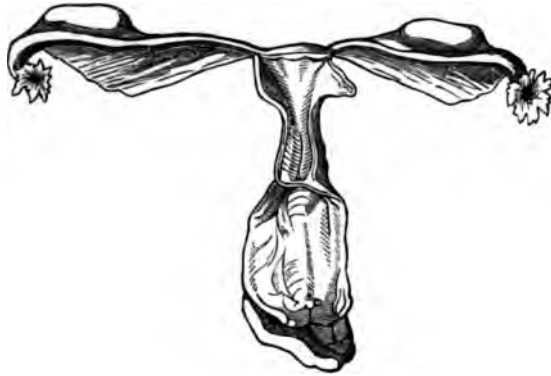


FIG. 144.

PRIMARY ATROPHY OF THE UTERUS (*Virchow*).

easily remembered when we bear in mind the division of the period of intra-uterine life into ten *lunar months*. In the first period, which extends over the *first* and *second* lunar months (from fertilization to the eighth week), the septum between the adjacent ducts of Müller is as yet unbroken. By the end of the second period, which corresponds to the *third* month (*i.e.*, eighth to twelfth week), the septum has entirely disappeared; but the upper portions of the ducts remain distinctly separate, forming the horns of the uterus and the Fallopian tubes. During the third period, *fourth* and *fifth* months, the angle between the uterine horns disappears so that the base of the uterus becomes flat. In the fourth period, *last five months*, the flattened end of the uterus, between the Fallopian tubes, becomes arched through the development of the fundus. The fifth period extends from *birth to puberty*. During this period no

important change takes place till, at puberty, the uterus passes from the infantile to the virgin form. It does not, however, cease to grow till the twentieth year.

We are not yet in a position to refer each malformation in detail to its proper period; but the more perfectly we are able to do this the more satisfactory will our classification be. At present we separate the first four periods from the fifth, and speak of the period of foetal life in contradistinction to the period of childhood. This forms the basis of our classification.

Classifica-
tion of
Malforma-
tions.

1. MALFORMATIONS ARISING DURING FŒTAL LIFE. Of these there are the following:—*complete absence* or *rudimentary condition* of the uterus; the *uterus bipartitus*, produced by a development of only the upper parts of the ducts of Müller into rudimentary horns of the uterus and Fallopian tubes; the *uterus unicornis*, due to the development of only one duct; the *uterus didelphys*, due to the development of the ducts separately, without coalescence; the *uterus bicornis*, in which the ducts coalesce below, and the horns remain un-united by a fundus above; the *uterus septus*, in which the coalescence of the ducts and development of the fundus takes place so that the uterus appears normal externally while internally the septum has persisted.

2. MALFORMATIONS ARISING DURING CHILDHOOD. Of these there are the following:—the *uterus infantilis*, in which the uterus does not undergo the development which should take place at puberty, but remains of the same type as it was at birth; *congenital atrophy* of the uterus, in which it assumes the virgin type but the organ as a whole is atrophied.

SYMPTOMS.

The symptoms of malformation consist in an *impairment of function*, and hence do not appear until puberty.

In the external appearance of the patient there is not necessarily anything to attract attention. The figure, features, temperament, and voice are of the feminine type, even though the uterus is not developed. The mammæ may be fully formed. The developmēt of the external genitals is independent of the development of the internal organs.

Complete absence and rudimentary condition of the uterus may give rise to no local symptoms, except the non-appearance of menstruation. If the ovaries are developed, ovulation with associated monthly disturbance is present and the accumulation of menstrual blood in a rudimentary horn may call for operative measures to form a channel for its escape.

Sometimes
local
symptoms
absent.

Even on entering married life the condition need not necessarily attract attention; if the vagina be not well developed, the urethra becomes dilated so as to take its place.

Cause of
local
symptoms.

In the uterus unicornis, menstruation, conception, and pregnancy may go on undisturbed in the developed horn. It is the *imperfectly developed horn which gives rise to symptoms*—the result of the retention of menstrual blood and of the products of conception. If the mucous membrane of this horn discharge blood periodically and there be no communication with the uterus to allow of escape, the blood collects and produces a distended sac. It is of great interest to note that we may have a fertilized ovum growing in the isolated horn; we have not space here to discuss how this interesting condition is produced (fig. 145). Uterus bicornis and uterus septus produce no symptoms, unless one half of the septate uterus does not open into the cervical canal—in which case hæmatometra occurs at puberty (*v.* Chap. XLIII.) The statement that the patient menstruates regularly throws the practitioner off his guard. He should remember that the menstrual blood *may flow undisturbed from one half of the uterus while it is accumulating in the other*. In both of these forms we have two possible seats for a growing ovum (fig. 146), and thus we can explain some cases of superfœtation; after a fœtus has begun to develop in one half of the uterus, a second ovum becomes fertilized in the other, and reaches maturity at a later period than the first. We may thus also explain some cases in which menstruation occurs during the early months of gestation.

The uterus infantilis and the congenitally small uterus are characterised by the absence of menstruation and the constitutional nervous disturbance which is usually associated with them.

DIAGNOSIS.

Diagnosis
of absence
of Uterus.

Complete absence of the uterus cannot be diagnosed with certainty in the living subject. A rudimentary condition may be present, and yet not be detected on the most careful examination. To examine cases in which this condition is suspected, we first pass a sound into the bladder and then with one or two fingers of the right hand in the rectum palpate the tissues which lie between the sound and the fingers. It is evident that in such a condition as is represented in fig. 138 the rudiment of the uterus may escape observation, or be considered as a thickening of the posterior wall of the bladder. We now remove the sound from the bladder, as it only reaches to a limited height in the pelvis, and with the

left hand on the abdomen make a careful recto-abdominal examination. To do this last satisfactorily, we anæsthetise the patient. If we feel two

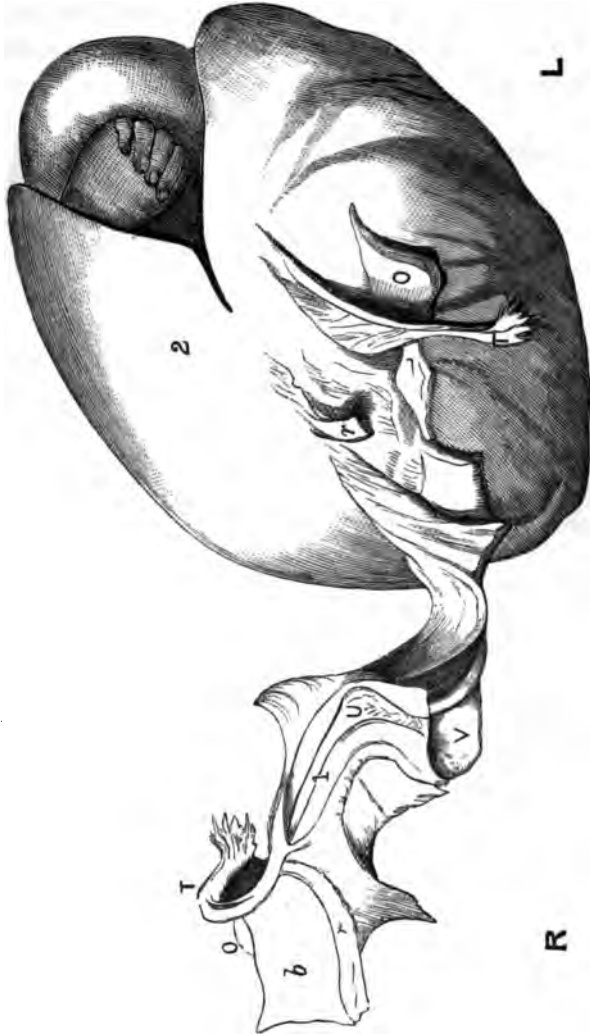

FIG. 145.
ONE-HORNED UTERUS WITH FETATION IN THE DETACHED LEFT HORN (TURNER). The right horn (1) has its ovary (O), Tube (T), and Broad (B) Ligaments in normal relation to it. The gestation sac (2) is on the proximal side of the left round ligament (r) and consists therefore of the left horn; this does not communicate with the Uterine Cavity (U). The left Ovary (O) and Tube (T) are attached near the Round Ligament (r).

bodies laterally without any distinct body between, it is impossible to say whether these are rudimentary horns or ovaries.

The diagnosis of the one-horned uterus is not easy. The points to Diagnosis of Uterus Unicornis, rely on are the following: the fundus turns to one side of the pelvis, is

tapering, and has only one ovary connected with it. The rudimentary horn and the other ovary lie removed from it.

Of Uterus
Didelphys,

The uterus didelphys is extremely rare. A groove on the external surface of the uterus separating it into lateral halves, so that sounds could be passed into the separate cavities without coming in contact, indicates this condition.

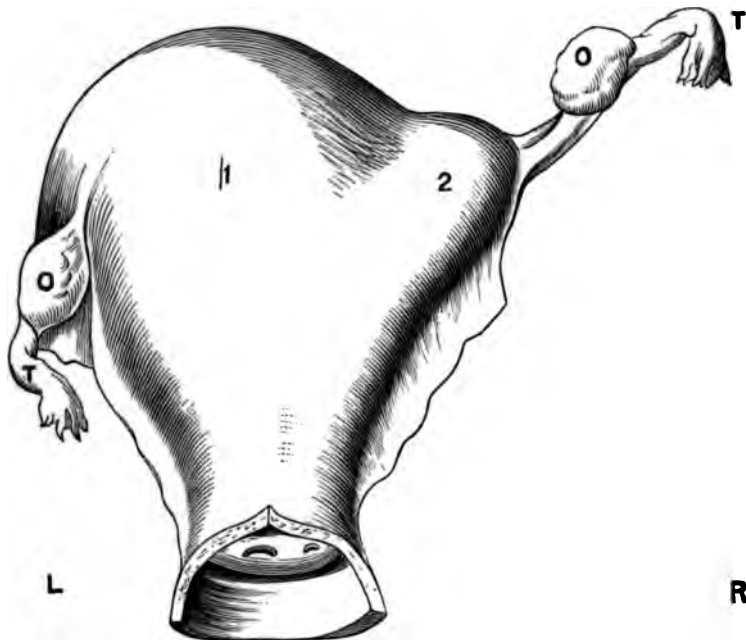


FIG. 146.

UTERUS SEPTUS (posterior view) FROM A WOMAN WHO DIED IN THE PUERPERIUM (*Crucilhier*). The Uterine Cavity is divided by a septum which extends to the os externum. The left half (1) is strongly developed and contained the foetus. The right half (2) was empty.

Of Uterus
Bicornis,

The uterus bicornis is a comparatively frequent condition, and if well marked is easily recognised. Unusual breadth of the fundus, with a slight depression in the centre, points to a minor degree of this deformity.

Of Uterus
Septus,

The uterus septus is easily diagnosed if the septum extend as far as the os externum, so as to be within reach of the examining finger. If the septum does not extend so far, the condition may not be detected as there is no change in the external form to direct attention to the internal malformation. The sound may pass with equal ease into either cavity, or always into the same, and thus furnish no indication. In a case that came under our own observation the patient was examined frequently

during life, bimanually and with the sound, and the uterus pronounced normal. At the post-mortem, the external appearance of the uterus was normal; it was only on cutting into it that it was observed that the cavity was divided into two portions by a septum which extended to the os internum.

The uterus infantilis and the congenitally atrophic uterus are recognised by the smallness of the uterus. This is most distinctly made out with the finger in the rectum, the uterus being at the same time drawn down and fixed with the volsella. The well-developed vaginal portion and the unusual length of the cervix, as felt per rectum, enable us to diagnose the infantile from the congenitally small uterus.

Of Infantile
and con-
genitally
atrophied
Uterus.

PROGNOSIS.

In prognosis we must keep in view the possibility of ovulation with menstrual molimina, the secretion of menstrual blood and its accumulation in a closed cavity, the probability of conception and of gestation in an isolated horn. The most difficult cases are those in which the practitioner has to decide whether marriage is justifiable or not.

Prognosis
of Malfor-
mations.

TREATMENT.

Malformations of the uterus lie beyond the range of treatment, except when they give rise to retention of menstrual blood or of the products of conception. The treatment of these conditions will be considered under Atresia of the Vagina (see Section VI.), and Extra-uterine Gestation (see Section IX.)

Treatment.

CHAPTER XXIV.

ATRESIA AND STENOSIS OF THE CERVIX UTERI.

LITERATURE.

Barnes—Diseases of Women: London, 1878, p. 245. *Greenhalgh*—British Med. Jour., June 1878. *Mackintosh*—Practice of Physic: London, 1836, p. 481. *Schroeder*—Krankheiten der weiblichen Geschlechtsorgane: Leipzig, 1878, S. 64. *Schultze*—Ueber Indication und Methode der Dilatation des Uterus: Wiener med. Blätter, 1879, Nos. 42, 43, 44, 45. *Simpson, Sir J. Y.*—Diseases of Women: Edinburgh, 1872, p. 245. *Sims, Marion*—On the Surgical Treatment of Stenosis of the Cervix Uteri: Am. Gyn. Trans., 1878, p. 54. *Smith, H.*—Obst. Jour., London, Vol. V., p. 256. *Thomas*—Diseases of Women: London, 1880, p. 613.

DEFINITION.—Atresia (*α-τρήσις*, non-perforation) is an occlusion of the canal. Stenosis is a concentric contraction of its lumen.

ATRESIA OF THE CERVIX.

ETIOLOGY AND PATHOLOGY.

Atresia is rare as a *congenital* condition; this is due to the presence of a cap of tissue covering the os uteri. An imperforate condition of the canal throughout its course is seldom, if ever, found.

Causes of
acquired
Atresia of
Cervix.

It is more frequently *acquired*, and results from the following causes:—

Sloughing and cicatrisation after labour;

Cicatrisation after the application of caustics, and after amputation of the cervix;

Adhesion of granulations in cervical catarrh (after menopause), and round the base of tumours.

The practical point for the practitioner to remember is, that atresia may follow the repeated application of caustics and amputation of the cervix. It occurs also as part of the physiological changes which take place after the menopause. Twenty-eight per cent. of women above fifty years of age have atresia of the cervix (*Hennig*).

Results of
Atresia.

Atresia of the cervix is chiefly of importance in regard to the accumulation of menstrual blood or mucus above the obstruction. It is this which produces the Symptoms and calls for Treatment. It will be

better to defer the consideration of these till we treat of *Atresia Vaginæ* (Section VI.)

STENOSIS OF THE CERVIX.

This condition is described in English and American text-books under "Obstructive Dysmenorrhœa." Dysmenorrhœa is however a symptom common to this and many other pathological conditions, each of which is considered under the organ in which it occurs. Stenosis of the *os externum* is a precise pathological condition which requires a definite line of treatment.

PATHOLOGY.

The common seat of the stenosis is at the *os externum*. It is a disputed point whether there is ever stenosis (as we have defined) at the *os* Seat of
Stenosis of
Cervix.

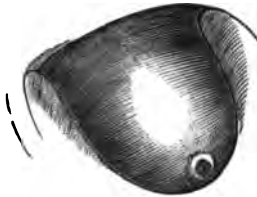


FIG. 147.

CONICAL VAGINAL PORTION (*Barnes*).

internum. Barnes says that when he has found the obstruction at the *os internum* it was almost always due to flexion of the uterus. The obstruction is, in such a case, not a true stenosis; it might be compared to the kink produced on a gutta-percha tube when it is bent. Spasmodic contraction of the muscular fibres surrounding the *os internum*, taking place at the menstrual period, is adduced by some to explain the symptoms of dysmenorrhœa.

In the congenital variety, the cervix is conical in form (fig. 147) and of unusually firm consistence. Sometimes it is hypertrophied, the vaginal portion measuring as much as two inches (*Barnes*). The *os* is small, and appears as a pin-hole on the extremity of the cervix. The contrast between this and the normal *os* is well seen in fig. 149. The cervical canal above the obstruction is often dilated into a spindle-shaped cavity (fig. 148):

ETIOLOGY.

Like atresia, stenosis of the cervix is congenital or acquired. The commonest causes of the acquired form are cicatrisation after labour,

after amputation of the cervix, and after the repeated application of strong caustics; the last is perhaps the most frequent cause. Inflammation of the mucous membrane, resulting in adhesions, also produces it.

SYMPTOMS.

The symptoms primarily produced by the stenosis are *dysmenorrhœa*, *sterility*, *dyspareunia*. In addition, there is in some cases *menorrhagia*. If the condition exist for a time, pelvic peritonitis or ovaritis may complicate the case.

The
mechanical
theory of
Dysmen-
orrhœa.

The cause of the dysmenorrhœa is evident. The menstrual blood is poured into the cavity of the uterus, the contracted condition of the outlet prevents its escape, it coagulates, the coagula excite uterine contractions which are accompanied with pain. Hence the menstrual blood

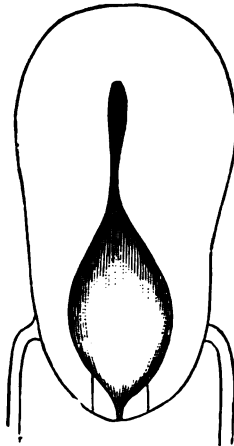


FIG. 148.

STENOSIS of Os EXTERNUM with DILATED CERVICAL CANAL (*Mundé*). The parallel lines beside the os show the extent of the bilateral incision.

is usually discharged as clots. In the first instance, the simple mechanical obstruction is the cause of the dysmenorrhœa. Other pathological conditions, as endometritis and metritis, may be also present; and the monthly congestion of the tissues, thus diseased, will also produce pain. We shall refer to this subject again under Antelexion of the Uterus.

The association of sterility with a conical cervix and pin-hole os has been for a long time recognised. We are not able to explain why a narrow os should lessen the probabilities of fertilisation, yet it is a well observed fact that it does so.

Sterility due to this cause alone is amenable to treatment, and presents the most satisfactory cases which the practitioner has to deal with, as by the operation to be presently described he sometimes removes the great opprobrium of married life.

DIAGNOSIS.

The history of dysmenorrhœa and sterility may have already led us to suspect this condition; but since these symptoms as frequently accompany anteflexion, we have recourse to the physical examination.

The conical cervix projecting markedly into the vagina attracts attention. On feeling for the os uteri, the first impression is that it is absent; more careful examination detects a slight depression.

The speculum shows the appearance represented in fig. 149. The normal os uteri is placed alongside, to be compared with it.




FIG. 149.

NORMAL and PIN-HOLE Os, as seen in the SPECULUM (Schroeder).

The sound is passed with difficulty; sometimes a surgical probe is all that the orifice will admit. After it has passed the os externum, the instrument may enter a dilated cervix (fig. 148).

PROGNOSIS.

This will depend on (1) the existence of stenosis of the os externum uncomplicated by anteflexion, (2) the absence of pelvic peritonitis and ovaritis. If these conditions are fulfilled, the prognosis is favourable as regards the cure of the dysmenorrhœa and probably so as regards the cure of the sterility. As regards the latter, however, we must remember that there are many other causes which may be operative and may escape detection. All that we can say to the patient is, that by operative procedure we can increase the probability of the occurrence of pregnancy.

TREATMENT.

The methods of treatment are—

- A. Dilatation,
- B. Division.

Dilatation of the stenosis is carried out by passing graduated bougies, by sponge or laminaria tents, by forcible dilatation with instruments. Division is effected by the metrotome or by scissors.

A. Dilatation.

Treatment
of Stenosis
by Dilata-
tion,

Dilatation by means of *graduated bougies* was brought into prominent notice by Dr. Mackintosh who employed straight metallic bougies of different degrees of thickness. He passed first a small one not thicker than a probe, and then larger ones till the os was rendered quite patulous.

Sponge and laminaria tents have also been largely used. The objection to them, as well as to the dilatation with graduated bougies, is that the cure is only temporary. With a laminaria tent we may dilate the stenosis so that the finger easily passes it, but in a few days it will have contracted to its original size. The use of tents is also attended with the risks of cellulitis, peritonitis, and even septicæmia (see p. 130).

Forcible dilatation is effected by Schultze of Jena with the dilator represented at fig. 150. He dilates the cervical canal beforehand with

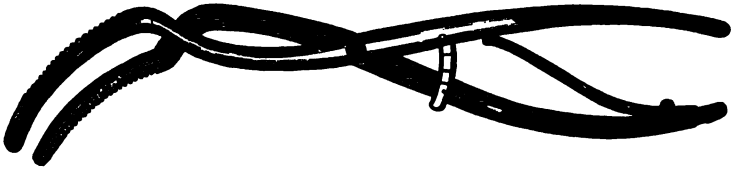


FIG. 150.
SCHULTZE'S DILATOR.

laminaria; he then washes it out with a 2 per cent. solution of carbolic acid, as he attributes many of the serious consequences of forcible dilatation and incision to the absorption of the secretions. The dilator is now introduced, and the blades (which open antero-posteriorly) are forcibly separated. We have had no experience of this method of treating stenosis.

The dilator employed by Marion Sims is seen at fig. 151.

B. Division.

By Divi-
sion.

Division of the cervix with the knife was introduced by Sir James Simpson. The instrument which he devised for this purpose was the *metrotome* represented at fig. 152.

Sir James
Simpson's
Metrotome.

It is a bistoury caché, with a single blade sharp on the outer edge which is unsheathed on compressing the handle. The screw on the handle regulates the extent to which the blade is to be protruded. The instru-

ment was passed in till the point almost reached the os internum; it was turned with the blade to one side, and then withdrawn, the handle being at the same time more and more compressed. The result was a lateral incision in the cervix, superficial at its upper extremity but becoming deeper as it passed downwards till at its base it completely divided the intra-vaginal portion. The instrument was re-introduced and a similar incision made on the opposite side. The extent of this

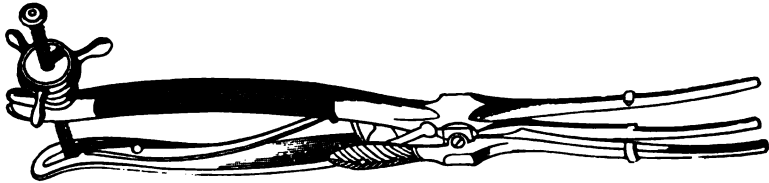


FIG. 151.
MARION SIMS' DILATOR (*Sims*).

bilateral incision is seen in fig. 153. The result of this operation is that the narrow circular os becomes an orifice with gaping lips.

By effecting this change in the form of the os uteri, we not only remove the obstruction to the outflow of the menstrual blood but also favour the entrance of the spermatozoa into the cervical canal. As Sir J. Y. Simpson points out, we make the nulliparous os resemble in form the os of a uterus which has been pregnant; that is, instead of being




FIG. 152.
SIR JAMES SIMPSON'S METROTOME (*Sir J. Y. Simpson*). a shows position of blade when protruded.

circular and small, it is made transverse and gaping (*cf.* figs. 154 and 155). That a patulous condition of the os and cervical canal greatly favours fertilisation is proved by the readiness with which conception follows abortion.

Other forms of metrotome have been introduced by Coghill, Greenhalgh, Savage, and Routh. Those of Greenhalgh and Savage are double-bladed, while that of Routh has the blades curved.

We are indebted to Marion Sims for substituting the *scissors* for the

metrotome. The objections to the latter instrument are that we do not know how deep the incision is being made, nor whether both incisions are being made equally. The practitioner will find the scissors easier to handle than the knife. A pair of ordinary strong scissors will do,

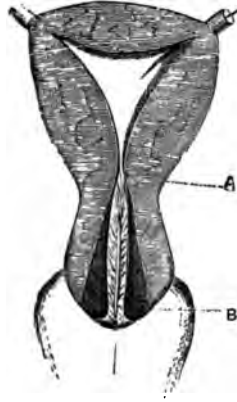


FIG. 153.

INCISION MADE BY METROTOME (*Sir J. Y. Simpson*). The dark-shaded portion B represents extent of incision, A os internum.

provided they are sharp and the cervix be firmly held with the volsella. The scissors of Kuchenmeister (fig. 110) and Hart (fig. 111) have this advantage, that the hook on the external blade prevents the cervix from slipping out as the section is being made.



FIG. 154.

NULLIPAROUS OS UTERI (*Sir J. Y. Simpson*).

Operation
for bi-
lateral
division of
Cervix.

The operation is performed as follows. The patient is placed semiprone. The Sims' speculum is passed and held by an assistant; if Battey's speculum is used, an assistant is not necessary. We recommend that this operation, as indeed all operations on the cervix or vagina, be performed under continual irrigation from a vaginal douche. It is difficult to do this in private practice and without assistants; but, if

always carried out, the possibility of cellulitis and peritonitis is reduced to a minimum. If the irrigation be not employed, the vagina should be thoroughly syringed beforehand with 1 to 40 carbolic acid solution. The anterior lip of the cervix is laid hold of with the volsella; the scissors are introduced, the straight blade being passed within the cervical



FIG. 155.

PAROUS OS UTERI (Sir J. Y. Simpson).

canal; the point or hook of the external blade is carried to about one-third up the cervix (see fig. 156 and fig. 148) and the section made. In many cases, all that is necessary is to divide the ring round the os externum; when this is divided we find the cervical canal dilated above it.



FIG. 156.

SHOWING THE BILATERAL DIVISION OF THE CERVIX, with Kuchenmeister's Scissors (Barnes).

In this respect this operation differs from that of dividing the posterior lip (see under Anteflexion), in which it is essential to make the scissors cut as far as the reflexion of the mucous membrane at the fornix. Should the cervical canal not be patulous, it may be necessary to make the incisions extend deeper—to the base of the vaginal portion. There is generally not much bleeding after the section is completed, but we watch a few minutes to see. If there is none, a vaginal tampon is not required. Should hæmorrhage occur, some perchloride of iron is swabbed

on the cut surface and a vaginal tampon of lint soaked in carbolised oil is applied.

Treatment
after bi-
lateral
division of
Cervix.

More important than the incision is the after-treatment. The patient must be seen on the following day, and every second day for a fortnight, and the finger passed in on each occasion to prevent union of the cut surfaces and dilate the cervical canal. To keep the canal open, Thomas



FIG. 157.

GLASS PLUG TO KEEP THE CERVIX PATULOUS AFTER DIVISION (Thomas).

recommends the use of a glass cervical plug (fig. 157) kept in position by a solid plate of the form of an Albert Smith pessary. This is useful after division of the posterior lip, but we think that it is not necessary after the bilateral incision.

One result of Emmet's work on laceration of the cervix has been to draw the attention of gynecologists to the fact that ectropion of the mucous membrane and secondary cervical catarrh may follow artificial division of the vaginal portion of the cervix. When this operation is necessary, we recommend, therefore, that it be done by three or four shallow notches round the margins of the os externum.

CHAPTER XXV.

ATROPHY OF THE CERVIX AND UTERUS: SUPERINVOLUTION.

WE meet with an atrophic condition of the cervix and uterus under four different conditions:—

Conditions
under
which
Atrophy of
Uterus
occurs.

1. As a congenital condition ;
2. Associated with certain constitutional affections, as phthisis, scrofula, chlorosis ;
3. In the puerperal uterus, as the result of superinvolution ;
4. After the menopause.

Should the student find on vaginal examination that the cervix is small and projecting only slightly into the vagina, and on Bimanual examination that the body of the uterus is found with difficulty and is smaller than it should be, he must next ascertain which of the above-mentioned causes has produced the atrophy.

The history will enable him to form his diagnosis. With the *congenital condition* there is a history of amenorrhœa or scanty menstruation since puberty, of sterility if the patient has entered married life, and of hysteria and other disturbances of the nervous system which usually accompany imperfect development of the uterus. The *constitutional condition*, and especially the state of the blood and of the lungs, in other cases enables him to account for the condition of the uterus. Probably the small uterus found in chlorotic patients is a congenital condition, and not secondary to the constitutional state. If the atrophic condition be the result of *superinvolution*, there is a history of childbirth with non-appearance of menstruation after it. With regard to the *menopause*, the age of the patient is the chief guide ; we must remember the possibility of an early menopause, as early as at the age of thirty-five.

The only atrophic condition which we shall consider here is that occurring in the puerperal uterus as the result of superinvolution. To Sir James Simpson's description of this condition we are chiefly indebted.

SUPERINVOLUTION OF THE UTERUS.

LITERATURE. *Frommel*—Ueber puerperale Atrophie des Uterus: Zeits. f. Geburts. und Gynäk., Bd. vii., H. ii., S. 305. *Jaquet*—Berl. Beiträge zur Geburts. und Gynäk., Bd. ii., S. 3. *Klob*—Patholog. Anatom. der weib. Sexualorgane: Wien, 1864, S. 205. *Simpson, Sir J. Y.*—Med. Times and Gazette, 1861. Diseases of Women: Edin., 1872, p. 547. *A. R. Simpson*—Superinvolution of the Uterus: Edin. Med. Jour., May 1883, in which the literature is fully given.

PATHOLOGY.

The uterus is small. Its external length may be reduced from the normal 3 to $1\frac{3}{4}$ inches. The walls are thin and flaccid, sometimes of a dense and fibrous consistence. The vaginal portion projects only slightly into the vagina, and may be almost flush with the vaginal roof. The os may be relatively patulous, or contracted so as only to admit a probe. The uterine cavity is reduced to $2\frac{1}{4}$, 2, or even $1\frac{1}{2}$ inches in length. The ovaries are atrophied, and sometimes show an increase of fibrous tissue in their structure. The accompanying specimen (fig. 158), described by Sir James Simpson, illustrates these points.

ETIOLOGY.

As to the frequency of this condition, A. R. Simpson found it present in 22 out of 1300 cases, that is in about 1·7 per cent.; *Frommel* estimates its frequency at 1 per cent. The reason why, in certain cases, the process of involution during the puerperium goes on till the uterine cavity is reduced to less than $2\frac{1}{2}$ inches in length is not known. A condition of transitory superinvolution—in which the superinvolved uterus returns to the normal length again—has been observed. *Protracted Lactation* seems the most important cause (*Frommel*). We have seen this in two cases, and *Chiari* has also drawn attention to it. In some instances there is a history of great *loss of blood* at the confinement; A. R. Simpson found this in 10 out of his 22 cases, and in a case of this, reported by *Whitehead*,¹ the atrophic changes had progressed so far that no trace of a uterus was found on the most careful examination. In other instances *pelvic peritonitis* has occurred during the puerperium: this can produce, we know, atrophy of the ovary through binding it down with adhesions; and atrophy of the ovaries may lead to atrophy of the uterus. It is also associated with the *tubercular diathesis* (*Klob*).

SYMPTOMS.

Continued amenorrhœa is the symptom which leads the patient to seek advice. After she has ceased nursing, she expects the flow to return.

¹ British Med. Jour., Oct. 1872.

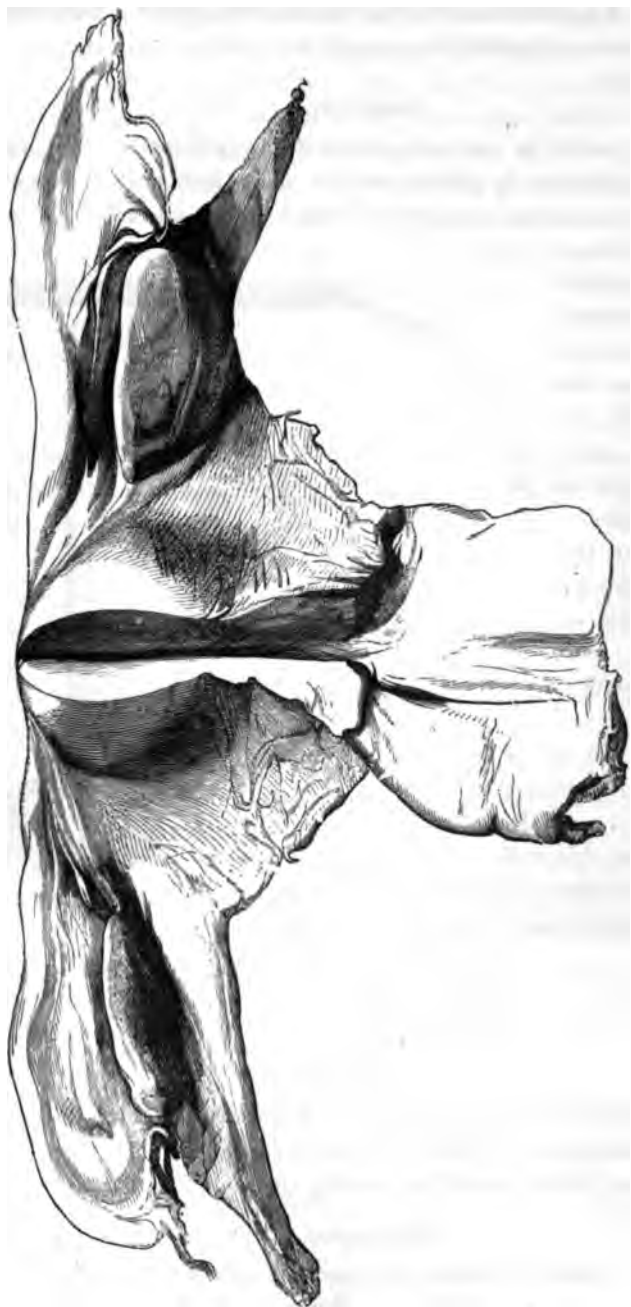


FIG. 158.

PREPARATION OF UTERUS AND OVARIES IN A CASE OF SUPERINVOLUTION *ad naturam*. Weight of parts represented.—one ounce, four drachms, twenty-five grains. Uterine cavity measures $1\frac{1}{4}$ in. Thickness of posterior uterine wall (laid open in figure) $\frac{1}{2}$ in. Tissue of uterus, dense and fibrous. Ovaries atrophied, with increase of fibrous tissue and no appearance of Graafian vesicles. (Sir J. Y. Simpson.)

It does not do so, however, even after months have passed. Pain in the back, weakness, and hysterical symptoms are sometimes present.

DIAGNOSIS.

The small cervix at once suggests what the condition is. We sometimes have difficulty in making out the uterus bimanually; here the examination per rectum, combined with the volsella, is useful. The best idea of the size of the uterus is gained by pressing the ball of the finger in the rectum against the isthmus of the uterus, and then moving the uterus upwards and downwards upon the finger which can thus estimate accurately its size; having done this, we make more traction on the uterus to bring it as far down as possible, and examine the ovaries.

The sound must be used with care, as it easily perforates the thin walls of the uterus. It does not pass into the uterus as far as the $2\frac{1}{2}$ in. knob.

Differential diagnosis must be made from—

- Congenital malformation;
- Congenital atrophy;
- Senile atrophy.

PROGNOSIS.

This should always be guarded. In a few cases, local treatment has been followed by re-establishment of menstruation. As to the possibility of conception, the chances of its occurring are small.

TREATMENT.

From the unsatisfactoriness of treatment, such cases may, as a rule, be left alone. Iron and other constitutional remedies may be tried.




FIG. 159.

GALVANIC INTRA-UTERINE STEM †; a perforation in bulb of Stem for the staff c, used to introduce it; the Stem is of copper from b to d, of zinc from d to the point (Sir J. Y. Simpson).

When local treatment is called for, this consists in stimulating the uterus to hypertrophy by placing a foreign body in its cavity. The galvanic intra-uterine stem pessary of Sir James Simpson is the best instrument for this purpose. The stem is made in its upper half of zinc, in its lower half of copper; the bulb is also of copper. The form of it is seen in fig. 159, which is drawn full-size. The stem should always be shorter than the uterine cavity by a $\frac{1}{4}$ of an inch; otherwise it may perforate the fundus. It is introduced as follows. The cervix is laid hold of with the volsella to draw it towards the vaginal orifice and to steady it. The stem is held with the bulb between the finger and thumb, and passed into the cervix for about an inch. If the vaginal orifice be too narrow to allow of this manipulation, the bulb is fixed on the end of a staff (fig. 159) and thus carried in. Once the stem is within the cervix difficulty is sometimes felt in pressing it onwards. The following manœuvre facilitates this:—Pass the index finger of the right hand well upwards into the rectum till the point of it gets fairly behind the cervix and fixes it; now put the thumb into the vagina, and with it make pressure on the bulb which is thus between the thumb and finger (the recto-vaginal septum of course intervening), and the stem can be satisfactorily pushed home.

Mode of
introducing
intra-
uterine
stem.

A glycerine plug is passed to keep the stem in position at first. The patient should keep at rest for one day after the stem has been introduced, and should be instructed to send at once if pain is felt in the pelvis; we have seen pelvic inflammation follow the introduction of a stem pessary. Should the practitioner not be within call, it is a good plan to tie one piece of string to the bulb and another to the plug, so that the patient can draw them out herself when symptoms of inflammation arise. The pessary can be worn for months without being removed, does not interfere with menstruation, and keeps its position without any plug in the vagina.

CHAPTER XXVI.

HYPERTROPHY OF THE CERVIX: AMPUTATION.

LITERATURE.

Byrne—Amputation and Excision of the Cervix Uteri: Trans. Americ. Gyn. Soc., Boston, II. pp. 57 and 110. *Galabin*—Lond. Obst. Journ., Sept. 1878. *Goodell*—Clinical Notes on the Elongations of the Cervix Uteri: Am. Gyn. Trans., 1880, p. 268. *Hegar und Kaltendach*—Operative Gynäkologie: Stuttgart, 1881, S. 445. *Huguier*—Memoires sur les Allongements Hypertrophiques du Col de l'Uterus, Paris, 1860. *Leblond*—Operative Gynecologie: Paris, 1878. *Marckwald*—Ueber die kegelmantelförmig Excision der Vaginal-Portion, etc.: Archiv. f. Gyn. Bd. viii. S. 48. *Schroeder*—Charité-Annalen, 1878: and Zeitschrift für Geburt, u. Gyn., Bd. iii. S. 419; Bd. vi. Hft. 2, S. 218. *Simon*—Monatsch. f. Geburtskunde, xiii. S. 418. *Sims, Marion*—Uterine Surgery, p. 264.

HYPERTROPHY of the whole uterus occurs in two forms:—

1. Hypertrophy of the muscular tissue—in pregnancy;
2. Hypertrophy of the connective tissue—in subinvolution and chronic metritis, both of which will be considered under Chronic Metritis (chap. XXX.)

Hypertrophy of the cervix alone calls for special notice here.

HYPERTROPHY OF THE CERVIX.

Under this head we consider two conditions:—

- A. Hypertrophy limited to the vaginal portion, which is a distinct *primary* lesion;
- B. Hypertrophy of the supra-vaginal portion which is usually associated with hypertrophy of the body of the uterus, this occurs in prolapsus uteri and is probably *secondary* to that condition.

A. HYPERTROPHY OF THE VAGINAL PORTION.

Hyper-
trophy of
vaginal
portion.

Pathology.—The peculiarity of this condition is that the cervix is normal in every respect except length (fig. 161). The mucous membrane and the subjacent tissue are not thickened, so that the diameter of the cervix is not much increased. As the result of the increase in

length, the conical apex of the cervix comes to lie immediately behind the hymen and may protrude through the vaginal orifice (fig. 160). The os externum is often small.

Etiology.—This condition is a true hypertrophic growth; it is not very common and the cause of it is unknown. As it occurs in the virgin, it is probably congenital. Sometimes it does not attract attention till the patient enters married life, when it produces as a rule sterility because the form of the cervix interferes with conception.

The cervix is frequently *thickened* as the result of chronic inflammation consequent on laceration of the cervix in child-birth; this is not a

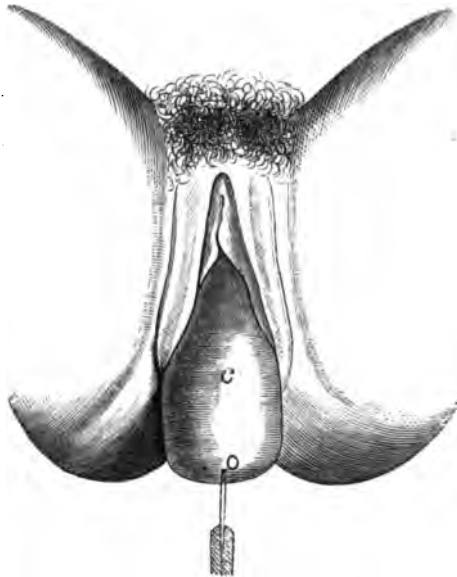


FIG. 160.

HYPERTROPHIED VAGINAL PORTION C PROTRUDING THROUGH THE VULVA. The Sound has passed very far into the small os *o* (*Schroeder*).

true hypertrophic growth, and will be considered under Laceration of the Cervix. (Chap. XXVII.)

Symptoms.—The symptoms are due to the presence of the hypertrophied cervix in the vagina. There is bearing-down as in prolapsus uteri, irritation of the mucous membrane of the vagina and consequent leucorrhœa, discomfort on walking about and on rising suddenly. If the cervix protrude beyond the vulva, ulceration of its mucous membrane and excoriation are produced.

Diagnosis.—This presents no difficulty. The fornices are found in

their normal position on vaginal examination (see fig. 161), the fundus uteri at its normal height in the pelvis on Bimanual examination. These two clinical facts indicate that the low position of the apex of the cervix is not due to a descent of the fundus but to a hypertrophy of the cervix, and that the hypertrophy of the cervix is limited to the portion which projects into the vagina (*cf.* fig. 161 with fig. 169 and fig. 170). The sound will pass five inches or more into the cervical canal; as the patient is usually a nullipara and the abdominal walls therefore firm, it facilitates the Bimanual to do it with the sound in the uterus. The combined recto-vaginal examination shows that the uterus, above the vagina, is of normal length.

Treatment. This consists in amputation of the cervix which is the

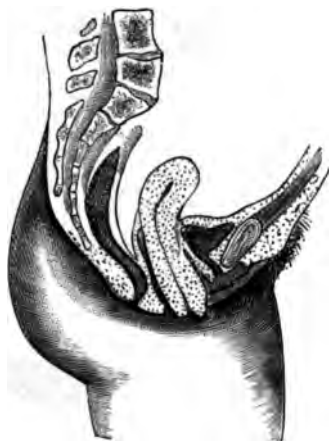

FIG. 161.

HYPERTROPHY OF INTRA-VAGINAL PORTION OF CERVIX. Neither fornix is obliterated (*Schroeder*).
Section of Pelvis seen in fig. 160.

only course open to us, because the hypertrophy will not diminish but rather increase. Amputation is performed by three methods:—

1. Scissors or knife,
2. Ecraseur,
3. Galvano-caustic wire.

The successive improvements in the method of amputation *with the knife* may be thus tabulated; by Marion Sims was made the advance of covering the stump with mucous membrane.

- (1.) *Old method.* Circular amputation; raw surface touched with caustic or cautery; healing by granulation.

- (2.) *Sims' method.* Circular amputation ; vaginal mucous membrane stitched to vaginal mucous membrane ; healing partly by first intention (fig. 162).
- (3.) *Hegar's method.* Circular amputation ; vaginal mucous membrane stitched to mucous membrane lining cervix (fig. 167) ; healing by first intention.
- (4.) *Simon and Marckwald.* Flap amputation by wedge-shaped excision of lips separately (fig. 163) ; vaginal mucous membrane stitched to that lining cervix on each lip (fig. 165) ; healing by first intention.

As there is often considerable hæmorrhage, it is well to place a constricting band on the cervix above the point of section. A common

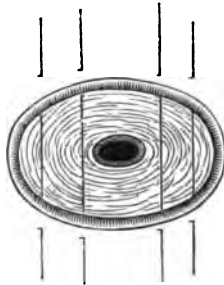


FIG. 162.

SIMS' METHOD OF PASSING THE SUTURES. Vaginal mucous membrane stitched to vaginal (*Sims*).

india-rubber umbrella ring serves admirably to control hæmorrhage in this and in Emmet's operation for lacerated cervix. The ring is warmed beforehand to make it less rigid and slipped over the handle of the volsella which grasps the cervix ; after the operation is completed we notch it with the scissors, and thus gradually slacken it before finally cutting it through.

The best method of performing the amputation is to split the cervix by a transverse incision into an anterior and posterior lip ; then amputate each lip separately making the line of amputation wedge-shaped ; finally bring together the projecting flaps of vaginal and cervical mucous membrane with wire sutures.

The operation. The instruments required are the following :—

- Antiseptic douche,
- Sims' speculum,

R

Amputation of the Cervix for simple Hypertrophy.

Spatulae,
 Volsella,
 India-rubber ring,
 Straight needles fixed on handles,
 Silver wire,
 Bistouries,
 Dissecting forceps,
 Blunt hook,
 Scissors,
 Artery forceps,
 Small curved needles and needle holder.

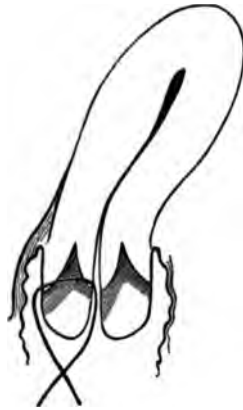

FIG. 163.

MARCKWALD'S METHOD OF SPLITTING THE CERVIX into an anterior and posterior lip and then uniting cervical to vaginal mucous membrane (Schroeder).

A. R.
 Simpson's
 method.

A. R. Simpson operates as follows. The patient is placed in the lithotomy posture. Continued irrigation with a 2 p.c. solution of carbolic is employed. The cervix is drawn down with volsellae; an india-rubber ring is passed over the volsellae on to the cervix and placed so as to constrict the cervix just below the fornices (fig. 164). The cervix is pierced in the middle line from below with a straight needle on a fixed handle. A straight needle passes more easily through the dense tissue of the cervix; if the cervix does not project sufficiently through the vulva to allow of the straight one being used, a curved one is required. When the point of the needle projects as far as the eye, this is threaded with a *long* wire suture and then drawn back (fig. 164, *MN*). A similar thread is carried through on either side of the middle

line so that the cervical canal is pierced with three long sutures, one in the middle of it, and one at each side of it. The cervix is now split horizontally with the knife or scissors so as to divide it into an anterior and posterior lip; this horizontal section is carried as far as the sutures, so that they are exposed at the bottom of the incision. We now hook them up in turn and drag the loop of each down through the wound (fig. 164, *mn*). Each loop is then divided; the three sutures are thus converted into six—three through the base of each lip. A portion of the anterior lip is now excised along the line 1, 2, 3. The sutures are

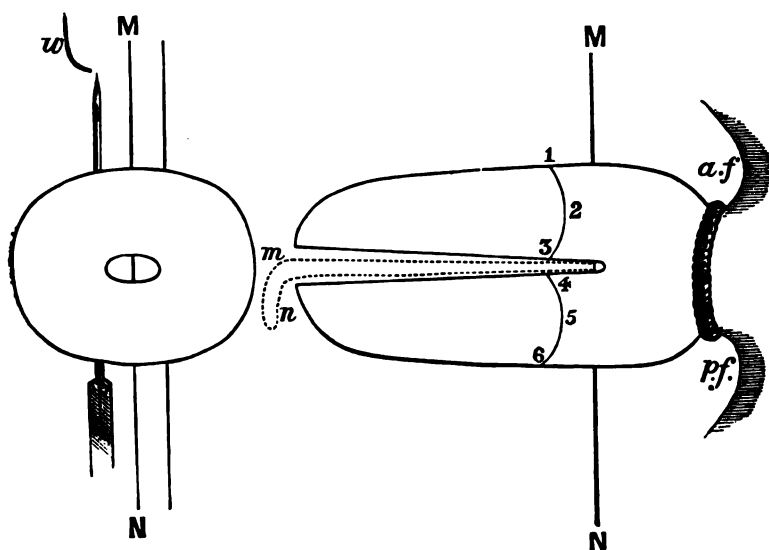


FIG. 164.

DIAGRAM OF AMPUTATION OF CERVIX. To the right is seen the cervix with the ring constricting it, a suture, *MN* in position, the cervix split and the line of amputation marked 1 to 6; *a.f.* anterior and *p.f.* posterior fornix. To the left is seen the cervix in cross-section; two threads are passed and the needle carried through but not yet threaded with the wire *w*.

now used to bring together the margins of this amputation. The posterior lip is next treated in the same way. Additional sutures are put in on each side to close in the side walls of the cervix (fig. 165, *x* and *y*). When the cervix is not unusually thick, these lateral sutures are passed as in fig. 165; but when the cervical walls are thick, it makes a neater stump to bring these sutures also out through the cervical canal and unite vaginal to cervical mucous membrane all round (see fig. 167, *x* and *y*).

The peculiarity of this method of operating is, that the sutures are

introduced before the knife is used. The advantages of this are the following:—it is easier to pass the needle through the dense tissue when the cervix is fixed with the volsella; the sutures serve as a means of traction when the portion grasped by the volsella has been cut away;

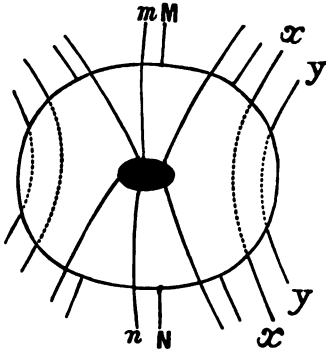


FIG. 165.

THE SUTURE *MN* has been divided and the halves brought down as *Mm*, *Nn*; the lateral ones also. *x*, *x* and *y*, *y* are additional side Sutures.

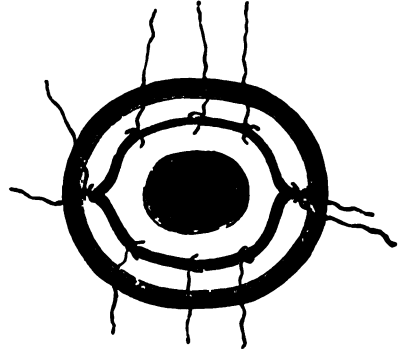


FIG. 166.

APPEARANCE OF STUMP of fig. 165 when Sutures are twisted up.

we can ligature the flaps immediately after the lip has been amputated and thus check hæmorrhage. This refers specially to amputation in prolapsus uteri, where we cannot constrict the cervix with a ring.

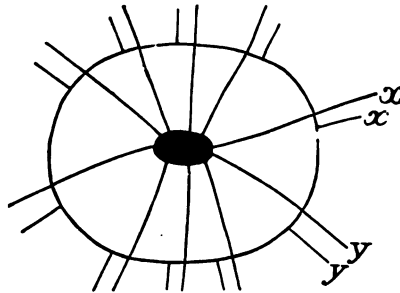


FIG. 167.

MODE OF PASSING SUTURES when stump is very thick.

The appearance of the stump after the sutures have been twisted is seen at fig. 166. Wire sutures are most convenient in all operations on the cervix or vagina, because they are most easily removed. They should be twisted or tied; the ends are left long enough to protrude clear of the vulva; the free ends of the same suture are twisted together to keep

them separate from the others; finally, all the ends are wrapped in a piece of lint to prevent their fretting the labia.

Removal of the Sutures.—The sutures are removed in a week's time. The patient is put in the Sims' position and the Sims' speculum passed. Slight traction is made on a suture, and if the twisted knot is visible, we clip the wire with the wire scissors. Generally we find the knot is embedded in tissue; in which case the rake (fig. 168) is used to hook up the loop. In snipping the loop we place one blade of the scissors under it, and then press the tissue back from the wire so as to divide the loop as far away from the knot as possible.

Mode of removing Sutures.

Amputation with the *Ecraseur* or with the *Galvano-caustic wire* is not such a neat method of operating as with the knife. Further, there is liability to closure of the cervical canal through cicatrisation; this may be prevented by introducing a stem pessary after amputation. The galvano-caustic wire is recommended by Barnes, Thomas, and others;

Amputation with Ecraseur or Galvano-caustic wire.



FIG. 168.

POINT OF RAKE; although finely made, it should be blunt (†).

its use has been followed with remarkably good results in the hands of Byrne of Brooklyn, whose valuable paper on this subject should be consulted.

The method of using the *ecraseur* and galvano-cautery will be described under amputation of the cervix for carcinoma (see Chap. XL.)

With the galvano-caustic wire we must see that the wire does not *slip downwards*, and thus “scalp” instead of amputating the cervix. The fact that the galvano-cautery diminishes hæmorrhage is of no advantage in amputating the hypertrophied cervix. The use of the india-rubber ring makes this a bloodless operation; and the introduction of the sutures in the way described minimizes the danger of hæmorrhage where the ring is not employed.

B. HYPERTROPHY OF THE SUPRA-VAGINAL PORTION.

The existence of hypertrophy limited to the supra-vaginal portion of the cervix and not affecting the body of the uterus cannot be determined by *clinical* examination alone. The obvious reason is that we have no

Hyper-
troph-
y limited to
supra-
vaginal
portion of
Cervix.

means of ascertaining in a case of hypertrophy where the precise upper limit of the cervix lies. The position of the os internum is not indicated by the sound, and the distance to which the utero-vesical pouch of peritoneum descends can only be ascertained on post-mortem examination. We cannot affirm, therefore, that the hypertrophy is limited to the supra-vaginal portion of the cervix and that it does not affect the body of the uterus as well.

In the present state of our knowledge it is impossible to say whether this hypertrophy is primary or secondary. We believe that in the great proportion of cases it is secondary to prolapsus uteri.

By French and by many German gynecologists, however, hypertrophy of the supra-vaginal portion of the cervix is considered a distinct primary lesion. Huguier first drew attention to the increase in the length of the uterine canal in cases described as prolapsus uteri; he affirmed that the fundus uteri always remained in its normal position, and that the os externum came to lie outside the vulva *because* the cervix had increased in length; this hypertrophied condition of the cervix was occasioned by a prolapse of the vaginal walls which made traction on the cervix, and thereby stimulated it to increased growth.

By these gynecologists, three forms of cervical hypertrophy are described according to the portion of the cervix which is hypertrophied. The division of the cervix into three portions—a vaginal, an intermediate, and a supra-vaginal portion—has been already described (see page 16). The vaginal portion is limited superiorly by the insertion of the anterior fornix; the intermediate by that of the posterior fornix; the supra-vaginal by the os internum. Hypertrophy of the vaginal portion is characterised by the *persistence of both* fornices in their normal position; it has been already described (see fig. 161). In hypertrophy of the intermediate portion the posterior fornix remains, while the *anterior is obliterated* (see fig. 169). In hypertrophy of the supra-vaginal portion *both anterior and posterior fornices are obliterated* (see fig. 170).

In the accompanying preparation (fig. 171), described by Barnes, the elongation affects both uterus and cervix—if we take the utero-vesical pouch of peritoneum as indicating the position of the os internum. Winckel figures and describes a similar specimen (Die Pathologie der weiblichen Sexual-Organen, Tafel XIX*a*).

As we have already said, we consider supra-vaginal hypertrophy to be merely one of the consequences of prolapsus uteri, under which its etiology, pathology, and diagnosis will be considered (*v.* Section VII.).

Treatment.—The amputation of the hypertrophied cervix, though a part of the treatment of prolapsus uteri, is most conveniently considered

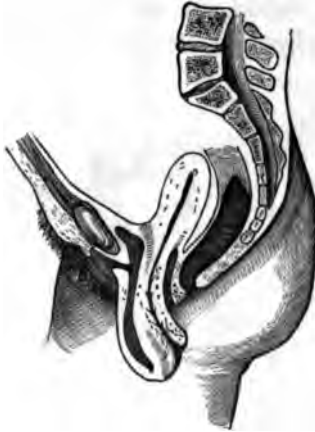

FIG. 169.

HYPERTROPHY OF INTERMEDIATE PORTION OF CERVIX. The anterior fornix is obliterated (*Schroeder*).

here, as it resembles the amputation in simple primary hypertrophy of

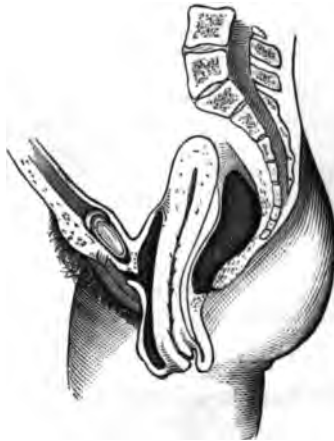

FIG. 170.

HYPERTROPHY OF SUPRA-VAGINAL PORTION OF CERVIX. Both fornices are obliterated (*Schroeder*).

the vaginal portion. In amputating for supra-vaginal hypertrophy, however, the relations of the bladder and peritoneum of the pouch of

Amputation of
Hypertrophied
cervix in
Prolapsus.

Douglas require to be considered. The bladder invariably descends for a varying distance in relation to the front of the hypertrophied cervix. The peritoneum of the pouch of Douglas, inasmuch as it lines the upper part of the posterior vaginal wall, will, when that wall is everted, dip down alongside of the hypertrophied cervix. If the posterior fornix is

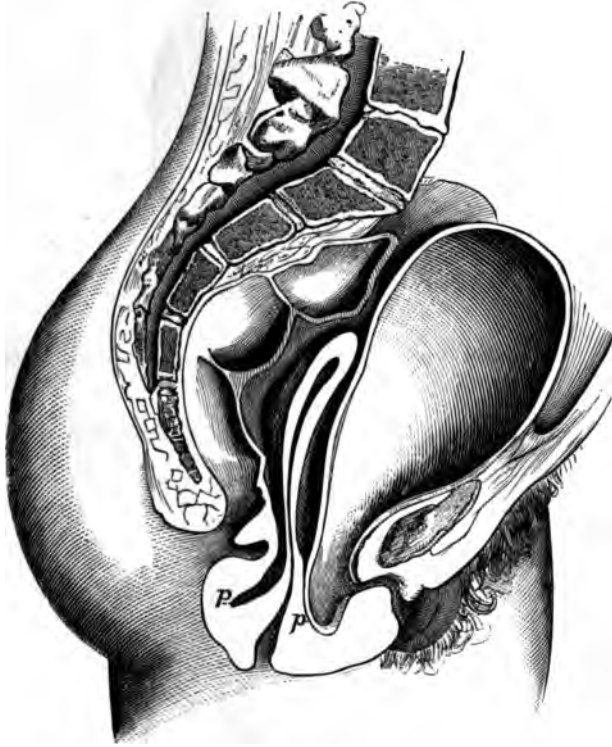


FIG. 171.

PROLAPSUS UTERI WITH CERVICAL ELONGATION (*Barnes*); *p, p*, peritoneum.

not obliterated, the peritoneum will not descend alongside of the protruding cervix.

The relations of the bladder and peritoneum are represented diagrammatically in fig. 172. The line of reflection of the posterior vaginal wall on to the cervix indicates how much is vaginal portion, and by entering the needle below that line we keep clear of the pouch of peritoneum. The sound passed into the bladder will show us how far

down that organ comes, and the needle is brought out an inch below that point.

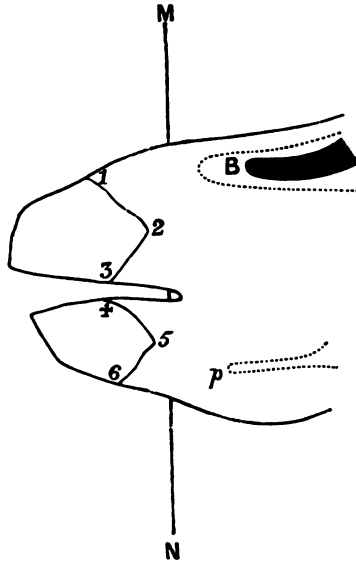


FIG. 172.

AMPUTATION OF HYPERTROPHIED CERVIX IN PROLAPSED UTERI. *B* sound in bladder; *p* peritoneum of pouch of Douglas. The sutures are passed as *MN*, and the cervix split laterally, so as to form an anterior lip, which is amputated along lines 1, 2, 3, and a posterior lip amputated along 4, 5, 6.

The steps of the operation are the same as in the former case. A much smaller portion is excised here.

CHAPTER XXVII.

LAOERATION OF THE CERVIX.

LITERATURE.

Baker—Boston Med. and Surg. Jour., April 1877. *Breisky*—Wiener med. Wochenschrift, 1876, Nos. 49-51: and Prager med. Wochenschrift, 1876, No. 18; 1877, No. 28. *Chase*—Trans. of Med. Soc. of State of New York, 1878. *Desvernine*—Thèse de Paris, 1879. *Dudley*—New York Med. Jour., Jan. 1878. *Emmet*—Surgery of the Cervix: Am. Jour. of Obst., Feb. 1869; *ibid.*, Nov. 1874. American Practitioner: Indianapolis, Jan. 1877. Principles and Practice of Gynecology, p. 488: London, 1880. *Goodell*—Laceration of the Cervix: Philadelphia, 1878. *Hegar*—Operative Gynäkologie, S. 538: Stuttgart, 1881. *Howitz*—Gynäkologische og. Obstetriciske Meddelelser, Bd. I., Heft 3. *Kaltenbach*—Ueber tiefe Scheiden- u. Cervicalrisse bei der Geburt: Zeitschrift f. Geb. u. Gyn., Bd. II., S. 274. *Klein*—Prager med. Wochenschrift, 1878, No. 24. *Lee*—The Proper Limitations of Emmet's Operation: New York Med. Jour., Sept. 1881. *Macdonald, Angus*—The Causes, Results, and Treatment of Laceration of the Cervix: Ed. Med. Jour., July 1882. *Mundt*—Am. Jour. of Obst., Jan. 1879; Death after Trachelorrhaphy, New York Med. Jour., 1883, p. 332. *Nieberding*—Ueber Ectropium und Risse: Würzburg, 1879. *Olshausen*—Zur Pathologie der Cervicalrisse: Centralbl. f. Gyn., 1877, Nr. 13. *Pallen*—St. Louis Med. and Surg. Jour., May 1868; Richmond and Louisville Med. Jour., 1874: British Med. Jour., May 1881. *Rokitansky*—Wiener med. Presse, 1876, Nr. 29. *Roser*—Das Ectropium am Muttermund: Arch. f. Heilk. II. Jahrg., 2 H., 1861. *Ruge u. Veit*—Zur Pathologie der Vaginal Portion. *Simpson, Sir J. Y.*—Edin. Jour. of Med. Science, 1851, p. 162. *Skene*—Proceedings of Med. Soc. of Kings, June 1878. *Spiegelberg*—Ueber Cervicalrisse, ihre Folgen u. ihre operative Beseitigung: Brealauer ärzt. Zeitschrift, 1879, No. 1. *Thomas*—Diseases of Women: London, 1880, p. 352.

Historical. THE recognition of laceration of the cervix as a distinct and important lesion, with the operation introduced for its cure, is one of the many gynecological advances of the last twenty years. For this we are indebted to the genius of Dr. Emmet of New York, who first drew attention to the clinical significance of the lesion and elaborated the operation for its removal. Sir James Simpson had previously drawn attention to its frequent occurrence, and its importance as a diagnostic of parturition. Roser of Marburg had described the pathology of the condition; but its importance as a factor in uterine disease was brought into notice by Emmet's first paper which was published in 1869, seven years after he had instituted the operation for its cure.

As the subject of laceration has only recently received attention and is

at present a *questio vexata* in gynecology, we have given a full bibliography. After the writings of Emmet himself, the student might refer to Roser, Ruge, and Veit for the pathology of the lesion; to Mundé's article for diagnosis; and to the papers by Pallen and Lee for operative treatment.

PATHOLOGY.

The commonest *seat* of the laceration is to the front and left side of the cervix, probably because the long diameter of the child's head is most commonly in the right oblique diameter of the pelvis, and the thicker end of the wedge is to the front. The next in frequency is a double laceration—to the front and left, and to the back and right sides. Less frequently is the laceration at either end of the left oblique diameter.

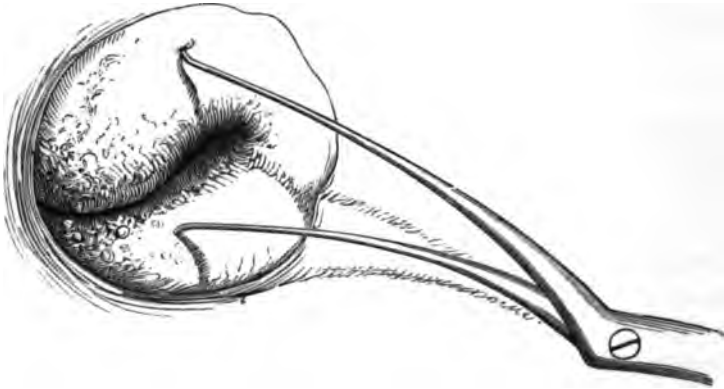


FIG. 173.

SINGLE LACERATION. The flaps are held apart with a double tenaculum (Emmet).

We have found lacerations to the front and right side in cases where the head presented right occipito-antérieur. The *form* of the laceration is various—single (see fig. 173), double (see plate VIII, fig. 2), or multiple (see fig. 174). The *extent* of the laceration varies, from a mere indentation of the ring of the os externum to a gaping fissure separating the lips of the cervix up to the vaginal fornices. Occasionally it extends into the roof of the vagina, and is marked by a cicatricial band drawing the cervix to one side. We have noted this in forceps cases, specially when the forceps had been applied before the os was dilated.

The *result* of the laceration is that the mucous membrane of the cervical canal is exposed, and becomes inflamed (*v.* Cervical Catarrh). Of

this, as yet, no exact explanation has been given. The submucous tissue is also thickened and the whole cervix thus hypertrophied. With these inflammatory changes there is *eversion* of the lips of the cervix. Emmet formerly explained its occurrence on purely mechanical principles—that the weight of the uterus pressed the cervix against the posterior vaginal wall, which flattened or “rolled out” the lips. In his most recent utterances, however, he has abandoned this theory.

This eversion is sometimes counteracted by the formation of cicatricial tissue in the cleft, which leads to approximation of its edges and even to its complete obliteration.

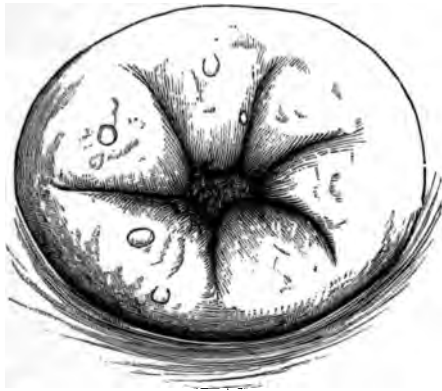


FIG. 174.

MULTIPLE OR STELLATE LACERATION (Emmet).

Patho-
logical
conditions
associated
with lacera-
tion.

Other pathological conditions are often associated with laceration. According to Emmet they are the result of it, though the casual connection is not obvious. Cellulitis is the most important of these; frequently we find, on the same side as the laceration, a localised cellulitis in the shape of a distinct deposit, or a tense condition of the utero-sacral or broad ligament, accompanied with pain on pressure through the fornix. Subinvolution of the uterus is also frequently present; there is a formation of cicatricial tissue, which compresses the blood-vessels and leads to passive congestion and hypertrophy.

Further, we find cylindrical epithelium covering the mucous membrane beyond the limits of the os externum. The cylindrical apparently proliferates more rapidly than the squamous epithelium, and, replacing it, produces the appearance of an Erosion (*v.* Cervical Catarrh, Chap. XXVIII.)

ETIOLOGY.

A laceration of the cervix will be found, according to Emmet's statistics, in 32·8 per cent. of parous women; according to Mundé, in 30 per cent. Though it is obvious that lacerations may be produced and heal again so that all trace of them escapes notice, we cannot affirm that the cervix is lacerated with every first full-time labour. When present, a laceration of the cervix (if we exclude the possibility of the cervix having been divided artificially) *is the most reliable diagnostic of a former parturition.*

Of the condition of the cervical tissues which predispose to laceration we at present know nothing. It is evident that an indurated cervix would, *ceteris paribus*, be more liable to be torn than a flaccid one.

We should have expected that lacerations would be more readily produced in a rapid labour, in which the os had not time to dilate. Emmet and Pallen, however, have found that they are more commonly the result of tedious labours.

Barker and Mundé both draw attention to the fact that they are less common among the wealthy than among the poor. This is probably explained by the better care and longer rest in the puerperium which the former enjoy.

During pregnancy, according to Nieberding, slight fissuring of the cervix with ectropium is produced. He examined the cases admitted to the lying-in hospital at Wurzburg at three periods—during pregnancy, as shortly as possible after delivery, and on dismissal. Only in 26 per cent. of the primiparæ examined (thirty-eight cases) was the appearance of the cervix normal during pregnancy; in all the others more or less ectropium was present. In 50 per cent. there were in addition small fissures, which made the os stellate or irregular in form.

SYMPTOMS.

It is very important to know what symptoms are referable to a lacerated cervix. Those who revel in operative treatment ascribe every pathological condition in the uterus to lacerations, while others altogether deny that they have any pathological significance.

We advance the following considerations in regard to the symptoms.

1. Lacerations of the cervix in themselves produce no symptoms. Hæmorrhage may arise at the time of production, but is not a symptom of the persistence of the laceration.

2. Other pathological conditions arise secondarily as the result of the

laceration, of which the most important is cervical catarrh; cicatricial tissue in the cleft may produce reflex nervous symptoms.

Symptoms
of laceration.

3. Pathological conditions are frequently present along with the laceration, as cellulitis and subinvolution. These have each their own train of symptoms. We are not as yet in a position to say how these are related to lacerations.

We sometimes find a well-marked laceration by chance, as it were, the patient having had no symptoms referable to a pelvic cause.

Frequently she complains of *leucorrhœa* and symptoms common to pelvic or uterine inflammation. *Menstruation* is often irregular, increased in 50 per cent. according to Emmet's statistics; this is in many cases due to subinvolution. *Neuralgia* is sometimes present, which may show itself locally in excessive tenderness to touch at the seat of laceration and has been compared to the sensitiveness present in toothache. In other cases it has taken the form of neuralgic pain in the pelvis generally, or sympathetic neuralgia elsewhere. It may seem a very gratuitous assumption to ascribe neuralgia to this cause; we know, however, that neuralgia is the result of nerve filaments being caught in the cicatrix of a stump; Emmet and others record cases in which persistent neuralgia disappeared on excision of the cicatricial plug in a lacerated cervix.

Cataleptic convulsions were present in an interesting case recorded by Sutton (*Am. Gyn. Trans.*, 1880). The convulsions could be produced at will by pressing the finger into the angle of laceration, though they did not occur on any other manipulation of the cervix. They occurred spontaneously several times during the day. The excision of the cicatricial tissue by Emmet's operation effected a complete cure.

DIAGNOSIS.

This presents, in many cases, no difficulty.

Occasional
difficulty
in recogni-
tion.

The finger feels the indentation or fissuring of the vaginal portion. Sometimes the cervical canal is patulous, and admits the distal phalanx of the finger easily. Difficulty in diagnosis arises when there is much eversion of the mucous membrane of the cervical canal with thickening of the cervical tissue; the fissure is thus obliterated, because the circle of the os is not formed of the os externum but of a higher unfissured portion of the canal. This thickening and the velvety feeling of the everted mucous membrane lead us to suspect the condition.

The *speculum* clears up all uncertainty. We see a bright red irregular patch on one side of or surrounding the os; from its granular appear-

ance, its vascularity, and the fact that it bleeds easily, it resembles an ulcerated surface. For this reason it is often described as "*ulceration*" of the cervix, but it is no more an ulceration than is the inflamed mucous membrane of the conjunctiva. By ulceration we understand a destruction and loss of tissue. The epithelium and subepithelial tissue may be destroyed as an immediate result of injury during labour; but the raw-looking surface, appearing secondary to and also independent of lacerations (*see* Catarrh in Nulliparæ), is not an ulcerated surface and should therefore not be treated as such.

For the appearance presented by the various forms of laceration when seen in the speculum, the student should compare fig. 173 and fig. 174. The difference between the colour of the everted cervical mucous membrane and that of the vagina is represented in plate VIII., figs. 1 and 2. A beautiful series of chromo-lithographs is appended to Mundé's article (*Am. Jour. of Obst., Jan. 1879*), which illustrates the various degrees of laceration. The most complete series is in Nieberding's pamphlet which gives representations of the cervix uteri before and after parturition, both in primiparæ and multiparæ; the colouring, however, is unnatural.

Appear-
ance of
Laceration
in Specu-
lum.

The microscopic changes which produce the appearance simulating ulceration will be described under Cervical Catarrh.

The *tenacula* are a valuable adjunct in examination with the speculum. If we place one in the anterior and one in the posterior lip, and roll these in on one another, the raw-looking surface will in many cases disappear. This easily demonstrated fact had not been recognised till Emmet drew attention to it, and based on it the operation which will be always associated with his name. By thus rolling the lips inwards, we restore the laceration and see the extent of it so as to judge of the possibility of approximating the lips with sutures.

We need not remind the student that he must not be satisfied with finding a laceration of the cervix, however striking it may appear in the speculum. The bimanual examination should be done with all the greater care, to ascertain that there is not also present cellulitis or sub-involution of the uterus.

TREATMENT.

Treatment, to be scientific, must be based on correct pathology. This, we think, is the strongest argument against the old treatment by caustic.

Like every new method in medicine and surgery, the operation has

been performed in numbers of cases where it was not called for. After the practitioner has been in practice he will find cases of chronic metritis (or subinvolution) and cellulitis the most difficult to treat; hence Emmet's operation was hailed in America by the weary and baffled gynecologist as the panacea for which he was waiting. This abuse of the operation in America is one reason why it is so slowly finding acceptance in this country. In Germany it has been taken up by Breisky, Spiegelberg, and others. Schroeder's operation for cervical catarrh is practically a bilateral Emmet's operation combined with excision of the cervical mucous membrane.

Immediate
operation
for Laceration.

The stitching up of the laceration *immediately after parturition* was first performed by Pallen of New York. Having failed to check by the tampon post partum hæmorrhage from a lacerated cervix, he passed Sims' speculum and sewed up the laceration with silver-wire sutures; this checked the hæmorrhage. We have never had occasion to perform the "immediate" operation; injections of very hot water have always sufficed to check hæmorrhage. Considering the liability to septic inflammation in the puerperal condition, we would be very chary about operating unless the hæmorrhage were considerable and not diminished by hot injections.

Emmet's
Operation.

The paring of the edges of an old laceration and uniting of them with sutures, we shall call "Emmet's operation"—a simpler and more suggestive name than "Trachelorrhaphy."

Indica-
tions.

Indications for Emmet's operation.—In the treatment of lacerations as of many other uterine affections, skill may often be shown in knowing to leave the case alone rather than in operating. (See Lee's paper.)

We should not operate :—

1. When laceration, however well marked, has produced no symptoms,
2. Where chronic pelvic peritonitis or cellulitis is present.

As to the circumstances in which an operation is called for, Emmet says, "In every instance where the condition is evident, and where enlargement of the uterus still remains, or where the woman suffers from neuralgia, I consider an operation necessary, notwithstanding the parts may have completely healed." As he ascribes sterility to laceration, he holds this also as an indication for his operation in certain cases. Secondary catarrh may prevent conception, but lacerations are so common in the fertile that we should not consider them a cause of sterility.

We recommend the operation in cases of pronounced eversion of the mucous membrane with cervical catarrh, with or without subinvolution. Subinvolution often disappears after the operation, but we cannot say

that this is due to the closure of the laceration ; involution is stimulated by every operation on the cervix (*v.* Chronic Metritis).

Preliminaries to the Operation.—The patient should use hot-water injections for some weeks previous to the operation, and apply a blister if there be any indication of cellulitis. Emmet lays great stress on this preparatory treatment, and says that we should not operate so long as there is any tenderness on pressure in the fornices. He further recommends, in cases where the cervix is thickened and the mucous follicles enlarged, scarification of the cervix and painting with iodine or tannin and glycerine.

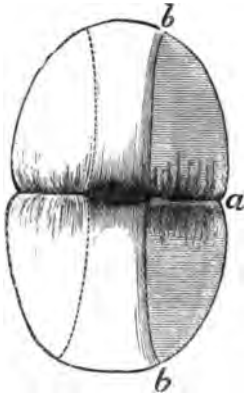


FIG. 175.

OPERATION FOR LACERATED CERVIX ; a b extent of denuded surface.

The Operation. The following instruments are required :—

- Vaginal douche,
- Sims' speculum,
- Volsella,
- Tenacula,
- Rubber ring,
- Bistoury and scissors,
- Dissecting forceps,
- Short needles (fig. 112) straight and curved,
- Needle holder,
- Medium silver wire.

Emmet's
Operation
for lacerated
Cervix.

The patient is placed under chloroform in the lithotomy posture (in the semiprone posture by Emmet, but this does not give the operator so much room) ; the sacral segment is drawn back with the speculum by an

assistant, and the cervix is laid hold of with the volsella and drawn down. Draw the edges of the laceration together with the tenacula to see how much tissue must be pared from the edges of the cleft to allow it to be sewed up, and then proceed to operate. Slip the rubber ring over the volsella on to the cervix and place it so as to constrict the base; this prevents bleeding and thus allows the operator to see that the edges are completely pared, which is essential to union of the raw surfaces. Wash

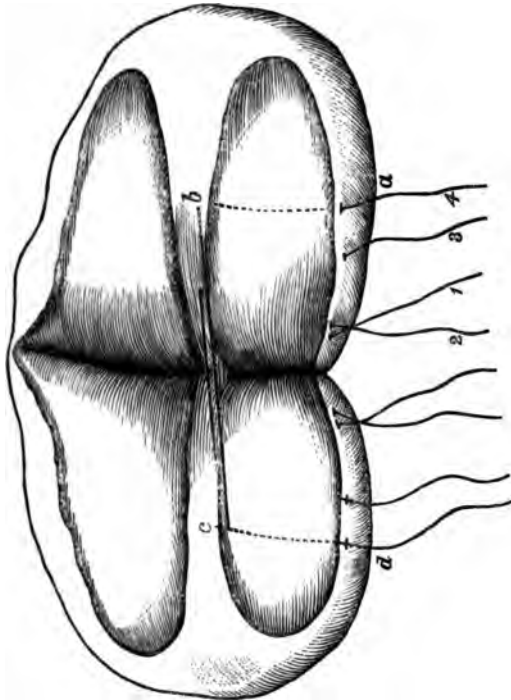


FIG. 176.

EXTENT OF DENUDED SURFACE AND COURSE OF SUTURES ACCORDING TO EMMET (*Emmet*).
The sutures are passed in order 1 2 3 4; the course of suture 4 alone is indicated by letters *a b c d*.

out the vagina with carbolised water. When possible, continual irrigation is kept up during the operation; with this, the india-rubber ring is not required as the stream of water keeps the denuded surface always clean. Now pare the edges of the laceration with the scissors or knife (fig. 175); scissors are preferable, because they cut with greater ease and rapidity. With long-bladed scissors we can remove the tissue from one edge of the laceration with a steady clean cut right into the angle; Emmet lays great stress on the removal of the cicatricial tissue in

the angle but uses the bistoury to do this. When the laceration is bilateral this must be done on both sides. Fig. 176 shows the extent of

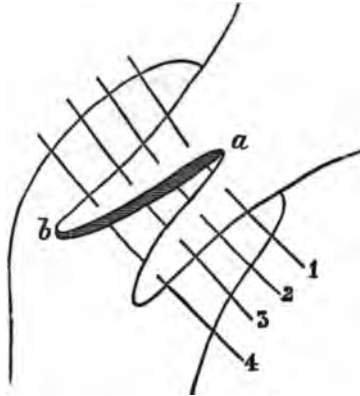


FIG. 177.

MODE OF PASSING SUTURES ; a b denuded surface as in fig. 175. The sutures are passed in order as numbered.

surface denuded by Emmet in a case of bilateral laceration. Great

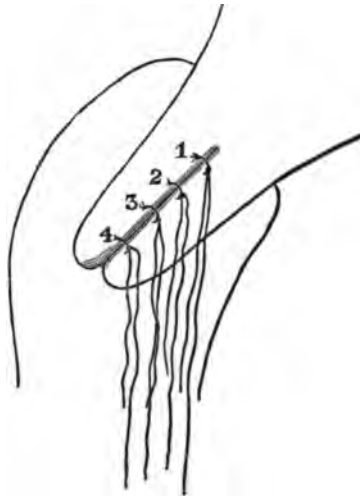


FIG. 178.

APPEARANCE OF CERVIX WHEN SUTURES TWISTED UP. They are left long so as to extend to vaginal orifice and are removed in order as numbered.

care must be taken to leave a broad strip (broader than represented in fig. 176) undenuded in the middle line to form the walls of

the cervical canal. Now introduce the sutures; these are about eight inches long so that both ends protrude from the vagina, and are well adapted to the eye of the needle so as not to obstruct its passage. Emmet recommends the round needle as it makes a smaller hole and is therefore followed by less hæmorrhage; when the tissues are dense, the lance-shaped point perforates more easily. Pass the sutures as in fig. 177, beginning at the upper part of the wound: each is drawn half through but is not twisted up till its fellows are in position, as it is sometimes necessary (when the tissues are thick) to pass the needle first through one lip and then through the other; they are then twisted up; the ends are brought out at the vaginal orifice, tied together, and wrapped round with a piece of wadding (fig. 178).

Emmet cuts the sutures short, but the long ends facilitate their removal. No special regimen is required afterwards, the diet need not be restricted.

Removal of sutures.—The stitches are removed on the seventh or eighth day. To do this we require speculum, wire-scissors, rake, and forceps. The rake is almost indispensable in removing sutures from the cervix or vagina; it is represented and described at fig. 168. The sutures are removed *from above downwards*; if we reverse the order, we may tear the lower portion apart in removing the upper sutures; if the surfaces have not entirely united, the lower sutures should be left in for a few days longer.

The cicatrix does not cause difficulty in subsequent parturition. The cervical catarrh may persist after the operation. Sometimes metritis, cellulitis, or peritonitis has unfortunately followed it. Fatal cases have been recorded by Emmet, Hunter, and Mundé.

CHAPTER XXVIII.

CHRONIC CERVICAL CATARRH.

LITERATURE.

Barnes—Diseases of Women: London, 1878, p. 530. *Bennett, G. H.*—Practical Treatise on Inflammation, Ulceration, and Induration of the Neck of the Uterus: London, 1845. *Clifton, Wing*—Brit. Med. Journ., Mar. 16, 1875. *Duncan, Matthews*—Diseases of Women: Lond., 1883. *Fischel*—Ein Beitrag zur Histologie der Erosionen der Portio Vaginalis Uteri: Archiv. f. Gyn., Bd. XV., Hft. 1. *Hatton*—Dublin Journ. of Med. Soc., 1st June 1875. *Hennig*—Der Katarrh der inneren weiblichen Geschlechtstheile: Leipzig, 1862. *Heywood, Smith*—Obst. Journ. of Great Britain, 1876, p. 604. *Hildebrandt*—Volkmann's Sammlung klin. Vorträge: Leipzig, 1872, No. 32. *Klotz*—Gynäkologische Studien über die pathologischen Veränderungen der Portio Vaginalis Uteri: Wien, 1879. *Ruge and Veit*—Zeitschrift f. Geb. u. Gyn., Bd. II., S. 415. *Schroeder*—Krankheiten der weiblichen Geschlechtsorgane: Leipzig, 1879, S. 122. *Thomas*—Diseases of Women: London, 1880, pp. 275 and 336.

Acute catarrh of the cervix is known to us only as part of a general catarrh affecting both body and cervix, and will be described under Acute Endometritis. *Chronic catarrh* occurs localised in the cervical mucous membrane; it is a very common condition and one of the most troublesome which the practitioner has to treat.

DEFINITION.—A chronic inflammatory process affecting the mucous membrane lining the cervical canal.

SYNONYMS.—Cervical endometritis, Endo-cervicitis.

PATHOLOGY.

The mucous membrane of the cervical canal is inflamed. When the os externum has been lacerated, the lips gape and the mucous membrane is thus everted; on bringing the margins of the laceration together, this eversion will disappear. Further, there are granular patches with irregular outline which extend beyond the limits of the os externum; these have a red appearance similar to the cervical mucous membrane, and therefore are sharply defined from the paler mucous membrane which covers the vaginal portion of the cervix.

This last condition was till late years generally held to be an "ulceration" and is still described, even in recent English works, under that name. The term should, however, be discarded as based on an erroneous

Pathology
of so-called
Ulceration
of the
Cervix.

pathology and suggesting most pernicious treatment. The cause of the error is easily explained ; a raw-looking granular surface was seen with the speculum ; the raw appearance was ascribed to the loss of the epithelium, and this supposition was supported by the microscopic examination of specimens taken from the dead body, in which the epithelium had been macerated and removed ; the granular points were supposed to be the subjacent papillae which had become hypertrophied.

Ruge and
Veit's
investiga-
tions.

Both of these suppositions have been shown to be erroneous by the careful investigations of Ruge and Veit, who examined specimens of the so-called ulcerations cut fresh from the living subject ; they demonstrated (1) that the apparently raw surface is covered with epithelium, (2) that the granular points are new formations and have no connection with the papillae of the mucous membrane.

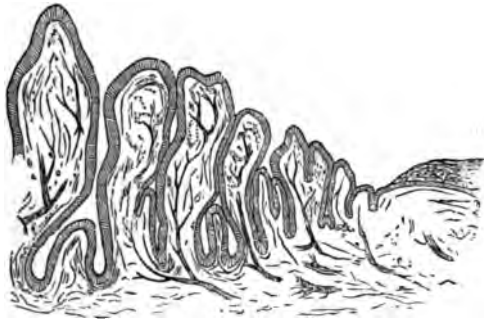


FIG. 179.

PAPILLARY FORM OF EROSION (Schroeder).

The microscopic appearance of the mucous membrane described by them is as follows. The surface is covered with a single layer of epithelium ; the cells are smaller than those which line the normal cervical canal, and being narrow and long have a palisade-like arrangement ; the thin layer of cells allow the subjacent vascular tissue to shine through, hence the *redness* of colour. The surface is further thrown into numerous folds producing glandular recesses and processes ; these processes cause the *granular* appearance of the surface. This condition is well seen in plate VIII, and constitutes the *simple* erosion : fig. 1 shows such an erosion as seen in the speculum : fig. 3 shows a microscopic section of the same, stained with carmine ; the left half of the section corresponds to the deep red portion of fig. 1, the right half to the paler portion outside of this. If the recesses be long and narrow, the surface is split up into

distinct papillae ; this constitutes the *papillary* erosion (see fig. 179). If the ducts of the glandular recesses become obliterated, the secretion will distend the gland below and produce retention-cysts ; these will increase in size, and may come to the surface and burst. Thus there is formed the *follicular* erosion (see fig. 180).

The raw-looking surface is therefore a *newly-formed glandular secreting surface*, resembling in structure the cervical mucous membrane. This addition to the extent of secreting surface increases the leucorrhœal discharge which is the leading symptom.

These observations of Ruge and Veit have been confirmed in their essential points by Fischel and other observers ; Fischel considers the secreting processes, while being new formations, to have the structure of papillae and not to be mere foldings of the mucous membrane.

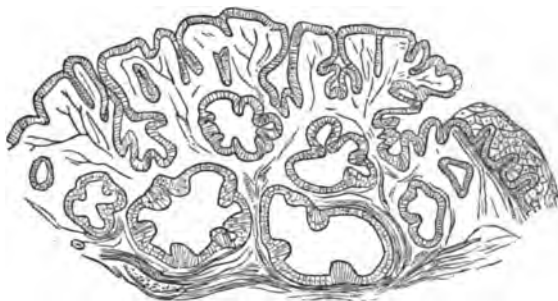


FIG. 180.

FOLLICULAR FORM OF EROSION (Schroeder).

While there is, therefore, no disagreement as to the microscopical appearance of the so-called "ulcerations," the *origin* of this new epithelial structure is disputed. Ruge and Veit hold that this single layer of small cylindrical cells is produced by proliferation of the cells of the *deepest layer of the rete Malpighi*, while those of the superficial layer are shelled off ; the appearance seen in fig. 180 favours this view. It will be observed also that they regard the simple follicular and papillary "ulcerations" as the results of one and the same process, viz., proliferation of epithelial cells. On the other hand, those red patches are generally continuous with the mucous membrane of the cervical canal and resemble it in their microscopic structure ; it is therefore much more probable that they are occasioned by proliferation of the *epithelium which lines the cervical glands*, leading to an extension of the glandular surface beyond the os externum. Fischel holds that there is not only the proliferation

of epithelial cells, but of connective tissue; and that according to the preponderance of the one over the other, the follicular or papillary forms are produced.

Nomenclature of the changes in Cervical Catarrh.

This description of the microscopic changes makes it evident that the process is not one of "ulceration;" and this term should, therefore, be abandoned. The German term Erosion is open to a similar criticism. "Ectropium" or "Eversion of the mucous membrane" describes the condition in its relation to laceration, but does not describe the extension of the secreting surface beyond the os externum; the term is preferable to "ulceration," as, at least, it is not misleading. Thomas describes these conditions under the name of "Granular and Cystic Degeneration of the Cervix Uteri." This term is based on the naked eye *appearance* of the cervix, and conveys no idea as to the pathological change which takes

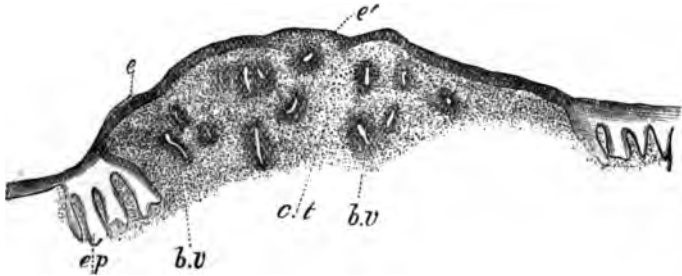


FIG. 181.

TRUE ULCERATION OF THE CERVIX. At the sides of diagram is seen the normal epithelium, which is prolonged in processes, *e. p.* between the connective tissue papillae; *e* is superficial layer of squamous epithelium reduced to a thin layer at *e*; *c. t.* tissue of mucosa infiltrated with small cells; *b. v.* blood-vessels surrounded by small-celled infiltration (*Fischel*).

place. Under granular degeneration, he describes the papillary form; under cystic degeneration, the follicular. As we are not in a position to introduce a term based on pathology, it is preferable to designate it according to its symptom as Cervical Catarrh. The red patches which lie outside the os externum, we shall speak of as "*catarrhal patches*."

Catarrhal Patches.

True Ulceration.

Sometimes a true ulcerated process—destruction of epithelium with inflammation of connective tissue—does occur; such a condition is represented in fig. 181.

Along with those changes in the mucous membrane, chronic inflammatory changes occur in the other tissues of the cervix. There is increased formation of connective tissue, which produces antero-posterior thickening and sometimes elongation. The secretion in the obstructed glands becomes inspissated, and hence the retention cysts are felt as

firm pea-like bodies—ovula Nabothii—in the substance of the cervix or projecting from it; or their contents may suppurate and form small abscesses. As there are no racemose glands on the vaginal portion beyond the limits of the os externum (see Histology of Normal Cervix, p. 20), these ovula Nabothii must be produced from the glands of the mucous membrane of the cervical canal or from the newly-formed glandular tissue. Fritsch draws attention to the fact that the glands of the cervix are enormously hypertrophied during pregnancy, so that the cervix becomes almost a glandular organ; the persistence of this condition after the puerperium, may explain the increased glandular formation which is described above as the chief pathological element in cervical catarrh.

Sometimes we find a single large cyst in the cervix, due to obstruction of the mucous glands. When it is in the substance of the wall, the soft bulging into the cervical canal and the accompanying menorrhagia may lead one to suspect commencing sarcomatous infiltration. Puncturing with a trocar removes a clear or straw-coloured fluid, rich in mucous corpuscles. We have seen a cyst of such a size as to cause serious obstruction to labour in a woman who had had a succession of uncomplicated labours.

The microscopic pathology of the cervix has only of recent years been carefully investigated, and there are many points on which definite information has not as yet been obtained. The following is a brief summary of the pathological changes described, which are best understood by comparison with the microscopic structure of the normal vaginal portion.

NORMAL CONDITION. The vaginal portion is covered on its vaginal surface with many layers of squamous epithelium, resting on papillae of connective tissue; there are no mucous follicles. The cervical canal is lined with a *single layer* of cubical epithelium (ciliated only on the ridges), folded so as to form shallow recesses which do not branch; there are *racemose mucous glands*, which have branching ducts. The substance of the cervix is made up of *connective* tissue.

PATHOLOGICAL CHANGES. These, according to the extent and duration of the process, affect the three elements—epithelium, glands, connective tissue.

The *epithelium* of the cervical canal may be simply exposed (ectropium after laceration), or it may be inflamed. When inflamed, the folding of the mucous membrane is greatly increased so that the surface

Ovula
Nabothii.

Cysts in
the Cervix.

Normal
and Patho-
logical
conditions
of Cervix
contrasted.

has a papillary or granular appearance. Further, this inflamed mucous surface may be found extending beyond its normal limit (the os externum) in the form of red patches (catarrhal patches) which are smooth or granular.

The *glands* hypertrophy, and new glands form as the result of the proliferation of epithelium described above. The openings of the glands are at first restricted to the area covered with a single layer of cubical epithelium, but their branching ends extend below the limiting surface of stratified squamous epithelium. Their ducts become obstructed, and retention cysts form not only on the red patches but also underneath the adjacent apparently normal vaginal mucous membrane. They may remain as little nodules in the mucous membrane, or may come to the surface and burst; in the latter case, the cubical epithelium and papillae on the inner wall of the cystic gland are exposed and, being now on a free surface, proliferate. When the glands are the special seat of the pathological changes, the whole substance of the cervix is converted into a cystic mass.

The *connective tissue* always increases in amount, specially when the process is chronic. This increase constitutes the "areolar hyperplasia" of Thomas.

ETIOLOGY.

Frequency
of Catarrh
in Multi-
paræ.

The most important cause is, undoubtedly, the injury of the cervix produced in *parturition*; hence cervical catarrh is common in parous women. How this injury produces the inflammatory condition is a disputed point. Emmet refers it immediately to the laceration, and holds that the exposure of the mucous membrane to friction against the vaginal walls leads to irritation and inflammation; but we frequently see cases of well-marked lacerations without consequent cervical catarrh. It is admitted by all that the existence of lacerations greatly favours the development of catarrh.

Other less important causes are the *spread of inflammation* from the vagina *upwards* (vaginitis, which may be simple or gonorrhœal), and from the endometrium *downwards*. The latter is favoured by the fact that the discharges from the endometrium necessarily flow over the cervix and irritate it.

Cervical catarrh is the most frequent complication of retroflexion of the uterus. The flexion favours gaping of the lacerated cervix and produces passive congestion of the cervical tissues.

SYMPTOMS.

These are—Leucorrhœa ;

Pain in back and loins, increased on exercise ;

Irregular menstruation ;

Sterility.

Leucorrhœa is the prominent symptom. Under normal conditions the secretion from the mucous membrane of the uterus and cervix is not sufficient to attract attention ; when it is excessive, it is termed leucorrhœa (λευκός; white, ῥίω to flow) or in popular language “whites.” A transient leucorrhœa from the cervix and uterus occurs before and after the menstrual flow ; this is a hyper-secretion due to temporary congestion.

The secretion from the glands of the cervical canal is clear and viscid, resembling unboiled white of egg. It becomes of an opaque white when mucous corpuscles are abundant, yellowish when pus corpuscles are present. Frequently, it is tinged with blood from the blood-vessels of the newly-formed vascular tissue.

Characters
of Cervical
Leucorr-
hœa.

Pain in the back and loins is present, as in all uterine disease. It is aggravated on active exercise, such as walking and riding, or whatever causes friction of the cervix against the vaginal walls.

Menstruation is irregular, and often increased in quantity ; this is probably due to extension of inflammation upwards to the endometrium. We must take care not to mistake leucorrhœa tinged with blood for the regular menstrual flow.

Sterility is often present. In nulliparæ with a small os externum, the plug of mucus in the cervical canal is alleged to be a bar to conception. In multiparæ, we have seen conception take place even though there was a deep laceration and well-marked catarrh ; the presence of catarrh, however, though not an obstacle to conception, greatly diminishes its probability.

PHYSICAL SIGNS.

On *vaginal examination*, the condition of the cervix is found to vary according as the patient is nulliparous or multiparous and the disease of long or short duration. In a nullipara, the cervix feels puffy and large, the margins of the os soft and velvety (when there is eversion with extension of catarrhal area beyond the os externum) ; or the os and cervix are apparently normal but movement causes pain (when the

Condition
of Cervix
in Chronic
Catarrh.

catarrhal area does not extend beyond the os externum). In a multipara, the existence of a laceration must first be determined and the extent of it noted; the margins of the os are soft and velvety, and pea-like nodules (nabothian follicles) are felt on and sometimes round them; polypoidal projections may be present and, more rarely, the cervix is converted into a mass of cysts; the os is usually gaping so that the finger can be passed into the cervical canal, where the mucous membrane has an irregular surface and is often thrown into longitudinal ridges.

Appear-
ance in
Speculum
of Cervix
in Catarrh.

The *speculum* is now employed; its use must always be preceded by a careful examination with the finger to ascertain, when laceration is present, the undisturbed relations of the lips of the cervix. Neither finger nor speculum alone is sufficient, we must employ both, and learn to associate what is felt by the finger (*e.g.*, lacerations, velvety mucous membrane, pea-like follicles) with what is seen with the speculum. The superiority of the Sims speculum for examination is very marked, as it exposes the lips of the cervix without disturbing the relations.

In a nullipara, we see the os apparently normal but with a tenacious plug of mucus projecting through it; or there may be red catarrhal patches such as are represented in plate VIII., fig. 1, which shows very well the contrast between the appearance of these patches and the surrounding mucous membrane; no chromo-lithograph, however, perfectly displays the natural colours.

In a multipara, a laceration is sometimes evident. Oftener it escapes recognition; the os appears to be wide and unfissured, while on both lips there is a red velvety surface (plate VIII., fig. 2); if, now, tenacula be fixed in the gaping lips and these rolled in on one another, the red surfaces will disappear and a bilateral laceration become evident. Sometimes, white cicatricial tissue indicates the situation of the laceration. Though the lips are thus approximated, a red surface is often visible because the catarrhal area has spread beyond the os externum. The obstructed nabothian follicles appear as bluish-red projections from the mucous membrane; occasionally, they form small polypi.

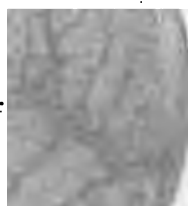DIAGNOSIS AND DIFFERENTIAL DIAGNOSIS.

Diagnosis
of Cervical
from
Vaginal
Leucorrhœa,

The diagnosis between cervical and vaginal catarrh is made clear by using the speculum, for we see in the former case the leucorrhœa coming from the cervix and having the characters above described. Should the discharge not be profuse enough to be seen with the speculum, we may employ the method recommended by Schultze for diagnosing between

100

100

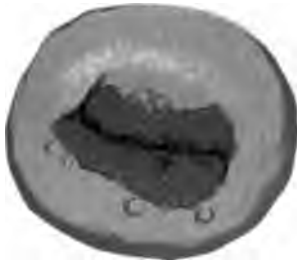

100

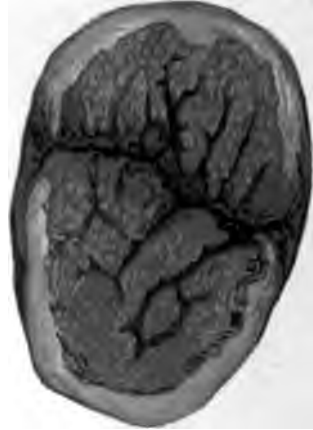Ap
and
Sp
of
in

1911
1912
1913
1914
1915
1916
1917
1918
1919
1920
1921
1922
1923
1924
1925
1926
1927
1928
1929
1930
1931
1932
1933
1934
1935
1936
1937
1938
1939
1940
1941
1942
1943
1944
1945
1946
1947
1948
1949
1950
1951
1952
1953
1954
1955
1956
1957
1958
1959
1960
1961
1962
1963
1964
1965
1966
1967
1968
1969
1970
1971
1972
1973
1974
1975
1976
1977
1978
1979
1980
1981
1982
1983
1984
1985
1986
1987
1988
1989
1990
1991
1992
1993
1994
1995
1996
1997
1998
1999
2000
2001
2002
2003
2004
2005
2006
2007
2008
2009
2010
2011
2012
2013
2014
2015
2016
2017
2018
2019
2020
2021
2022
2023
2024
2025

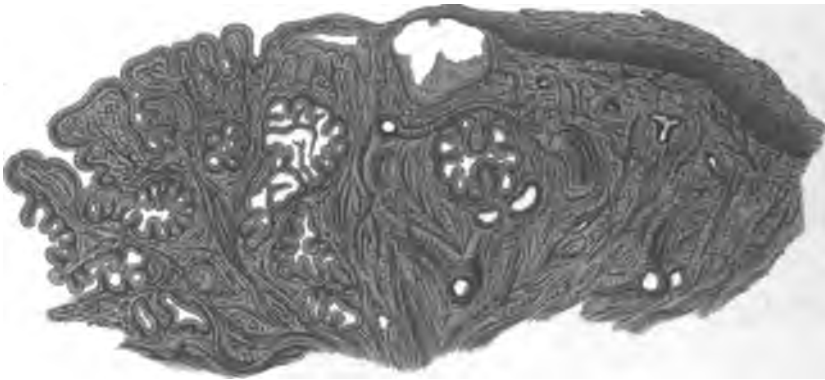1911
1912
1913
1914
1915
1916
1917
1918
1919
1920
1921
1922
1923
1924
1925
1926
1927
1928
1929
1930
1931
1932
1933
1934
1935
1936
1937
1938
1939
1940
1941
1942
1943
1944
1945
1946
1947
1948
1949
1950
1951
1952
1953
1954
1955
1956
1957
1958
1959
1960
1961
1962
1963
1964
1965
1966
1967
1968
1969
1970
1971
1972
1973
1974
1975
1976
1977
1978
1979
1980
1981
1982
1983
1984
1985
1986
1987
1988
1989
1990
1991
1992
1993
1994
1995
1996
1997
1998
1999
2000
2001
2002
2003
2004
2005
2006
2007
2008
2009
2010
2011
2012
2013
2014
2015
2016
2017
2018
2019
2020
2021
2022
2023
2024
2025



1



2



3

uterine and vaginal catarrh. The vagina is douched out in the evening, and a tampon soaked in a solution of tannin is placed against the os externum; in the morning the tampon is removed through the speculum, and we note the quantity and character of the discharge which has accumulated upon it.

The diagnosis between cervical catarrh and endometritis is difficult, and in many cases cannot be made; when cervical catarrh is present, we cannot be positive that there is not some endometritis as well. Increase in the length of the uterine cavity (especially with tenderness or irregularities of the mucous membrane) ascertained by the sound, indicates endometritis. When the cervix is much thickened and indurated, we may suspect the commencement of malignant disease; this will be considered under Carcinoma of the Cervix.

PROGNOSIS.

In this we must consider the constitutional health of the patient, the duration of the symptoms, and the extent to which the tissues are affected. According to Thomas, the prognosis is less favourable when there is considerable secretion of mucus with little apparent "granular degeneration." The practitioner will often find that cases of cervical catarrh have already passed through several hands, and he should therefore be on his guard in offering hopes of speedy cure.

TREATMENT.

In the first place, special attention must be given to the patient's *general health*; if we trust to local treatment alone, we shall often be disappointed. We should recommend change of air and light nourishing food. A certain amount of exercise is valuable; but too much of it, specially of riding, is injurious. Tonics (such as arsenic, quinine, and iron) are useful. Disturbances of the digestive system, which are frequent in chronic cases, must be treated as each case indicates. Complete rest from sexual activity is advisable; this can often be secured by recommending that the patient go away from home for a time.

Cervical catarrh is in some cases only a local manifestation of a constitutional state such as tuberculosis or anæmia.

The *local treatment* varies according as the patient is nulliparous or multiparous. In both cases we must be prepared to carry out a system of treatment which lasts for weeks.

Local
treatment
in Nulli-
paræ.

1. *In nulliparæ* we begin with a course of vaginal injections of hot water. These are used freely, from ten minutes to a quarter of an hour, every night. To the simple water, sulphate of zinc (3j to the pint) sulphate of alumina or sulphate of copper (3ij to the pint) may be added.

If the os be narrow, as it usually is, it is good to notch it bilaterally with the scissors. This acts beneficially by allowing the mucus to escape freely.

When catarrhal patches are present round the os, or when we find that the secretion continues copious in spite of the frequent injections, we



FIG. 182.

FORCEPS DRESSED WITH COTTON WADDING.

must make a local application to the mucous membrane. Of applications the best are iodine (the tincture or the strong liniment) and carbolic acid, the former in milder and the latter in more severe cases. The liquor hydrargyri pernitratæ is recommended by Heywood Smith, and chromic acid is much praised by de Sinéty. In making these applications we proceed as follows. The mucus, which would prevent the action of the medicament on the mucous membrane, is first thoroughly removed by the forceps dressed with cotton wool as represented at fig. 182. A second pair of forceps, covered merely with a film of cotton wadding, is now



FIG. 183.

BARNES' SPECTULUM for introduction of medicated cotton wool into the vagina (*Barnes*).

dipped in the medicament and applied to the surface. Should the canal be narrow, a sound dressed as for endometric applications (see fig. 190) is preferable. Care is taken that there be no free drop of the solution on the cotton wool, which might fall on the vaginal mucous membrane; after the application is made a pledget of cotton wadding with glycerine is placed below the cervix.

Rarely in nulliparæ is the pathological process so extensive as to require operative means for removing cervical tissue.

2. *In multiparæ.* Here the cervical catarrh is usually associated with other conditions—retroflexion, subinvolution, and, especially, marked laceration of the cervix. The first treatment indicated is to diminish the passive congestion of the cervix by hot-water injections and the use of the glycerine plug. The latter is prepared as already described (p. 185), and should be renewed daily. The patient can introduce it herself with Barnes' speculum (fig. 183). A simpler means is to draw the string through a piece of glass tubing, and to keep it taut with the finger on the end of the tube till the plug is carried into the roof of the vagina; then the finger is removed and the tube is slipped out over the string. If the uterus be retroflexed, it should be replaced and kept in position by a pessary. Even where it is not retroverted, a pessary is often useful in

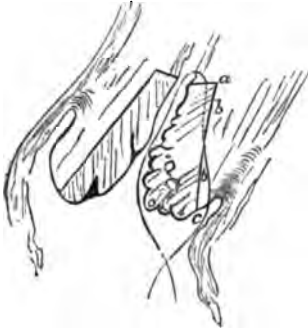

FIG. 184.

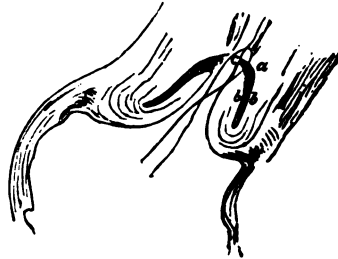

FIG. 185.

SCHROEDER'S EXCISION OF THE CERVICAL MUCCOUS MEMBRANE in cervical catarrh. FIG. 184 LINE OF INCISION IN MUCCOUS MEMBRANE. FIG. 185 MUCCOUS MEMBRANE EXCISED and flap *bc* turned in on *ab*. (Schroeder).

lifting the uterus upwards in the pelvis and diminishing passive congestion. In cases where there is a distinct laceration of the cervix, and especially where the catarrhal patches can be made to disappear by rolling the lips inwards on each other, Emmet's operation is indicated.

Local depletion by scarification or leeches was formerly much employed, but is going out; its effects are only transitory. Scarification is done best through the Fergusson speculum, and with a lancet-shaped bistoury; a number of small punctures are made, from a quarter to half-an-inch in depth. Leeches are applied as follows:—Fergusson's speculum is passed; a pledget of lint, with string attached, is placed in the cervical canal to prevent their crawling upwards into the uterine cavity; a little blood is drawn by superficial scratches and three or four leeches thrown into the speculum, and pushed up towards the cervix with a pledget of cotton

Depletion
by Scarifi-
cation or
Leeches.

wadding. We must watch the speculum lest the leeches slip out; after the speculum and leeches are removed, the vagina is douched with a tepid injection of carbolised water.

Scarification is, however, useful for another object. When there are hard knobby retention cysts producing irritation by the pressure of their contents, the puncturing of these diminishes the chronic inflammation. When these cysts project as small polypi, they are easily snipped off.

In very chronic cases, the only remedy is the destruction of the diseased glandular tissue—just as in tonsilitis we partially excise the tonsils. This has been done by the application of strong nitric acid or the cautery; but the use of the curette or knife is a much more effective and safe method than any process of cauterisation. Thomas recommends the steel curette for the removal of the diseased glands; it is applied “so forcibly as to remove the arbor vitæ and mucous glands from the os internum to the os externum. Sometimes a second operation in two or three weeks after the first has been necessary, and sometimes even a third.”

Schroeder's
Operation
for Cervical
Catarrh.

Schroeder uses the knife, and operates as follows. The cervix is laid hold of with two volsellæ, one on each lip, and drawn downwards. It is divided laterally as far as the fornix with the scissors, so as to form an anterior and a posterior lip which are separate as far as the vaginal roof (fig. 184). A transverse incision (seen in section, at *a*, in fig. 185) is made across the base of the anterior lip, dividing the whole thickness of the cervical mucous membrane. He next pierces the point of the lip at *c*, pushing the knife in the direction *bb* till it reaches the cross incision *a*; he carries the blade outwards first to one side and then to the other, so that all outside of the line *a b c* is cut away. The flap of cervix is now turned in, and stitched as in fig. 185. The advantage claimed for this method of operating is that the degenerated cervical mucous membrane is replaced by vaginal mucous membrane which shows no tendency to degenerate. Schroeder has operated thus more than three hundred and fifty times (two deaths), and with very good results as to the cure of the catarrh.

CHAPTER XXIX.

ENDOMETRITIS.

LITERATURE.

Atthill—On Endometritis: Dublin Jour. of Med. Sc., Jan. 1873. *Barnes*—Diseases of Women: London, 1878, p. 530. *Braun, Carl*—Therapie der Metritis und Endometritis, etc.: Wiener med. Wochenschrift, 1873, Nos. 39-43. *De Sinlty*—Gynecologie, p. 327: Paris, 1879. *Guérin*—De la Métrite aigue: Annales de Gynecolog., Juillet, 1874; and Arch. de Tocologie, July 1877. *Hennig*—Der Katarrh der inneren weiblichen Geschlechtstheile: Leipzig, 1862. *Klob*—Pathologische Anatomie der weiblichen Sexualorgane: Wien, 1864, S. 211. *Olshausen*—Ueber chronische hyperplasirende Endometritis des Corpus Uteri: Archiv. f. Gynäkologie, Band. VIII., Heft 1. *Playfair*—Intra-uterine Medication: Brit. Med. Jour., December 1869; Ibid., March, 1880; Lancet, January and February, 1873. *Récamier*—Union Méd. de Paris, 1850, 1-8 Juin. *Routh*—On "Fundal Endometritis:" Obst. Trans., Vol. XII. Cases of Menorrhagia treated by injections, etc.: Obst. Trans., Vol. II. *Schroeder*—Krankheiten der weiblichen Geschlechtsorgane: Leipzig, 1879, S. 108. *Simpson, Sir J. Y.*—Diseases of Women: Edinburgh, 1873, p. 736. *Smith, Tyler*—Pathology and Treatment of Leucorrhœa: London, 1855. *Thomas*—Diseases of Women, London, 1880, p. 268.

INFLAMMATORY action may affect the peritoneal covering, the muscular substance, or the mucous membrane of the uterus, producing *perimetritis*, *metritis*, or *endometritis*. Usually we find more than one of these conditions present at once, as the inflammatory action is rarely limited to one of these coats. Perimetritis is only a part of pelvic peritonitis, under which head it has already been considered.

We now consider inflammation limited to the mucous membrane of the uterus—endometritis, which may be acute or chronic.

DEFINITION.—Inflammation of the mucous membrane of the uterus.

SYNONYMS.—Uterine catarrh, internal metritis.

PATHOLOGY.

In *acute endometritis* both body and cervix are involved, and usually the underlying muscular coat also. The mucous membrane is swollen and soft, and covered with red-stained mucus or creamy pus. Extravasations of blood are present as red streaks or patches. These changes are not so marked in the cervical mucous membrane as in that of the

body; the vaginal portion has the same appearance as during pregnancy, being soft and swollen and showing round the os red catarrhal patches.

The ciliated epithelium is destroyed, and sometimes casts of the epithelium of the glands are found in the discharge (*Schroeder*). The secretion is at first serous, then purulent.

In *chronic endometritis*, the mucous membrane is hypertrophied and marked with patches of old extravasation.

Micro-
scopic
changes in
Chronic
Endo-
metritis.

The microscopic appearances vary with the structures which are principally affected. Our knowledge upon this subject is principally derived from the examination of the portion of mucous membrane removed by the curette. We can distinguish three pathological types according to the tissue chiefly involved. In the first, the glands are hypertrophied; in the second, the vessels are dilated and enlarged; in the third, an

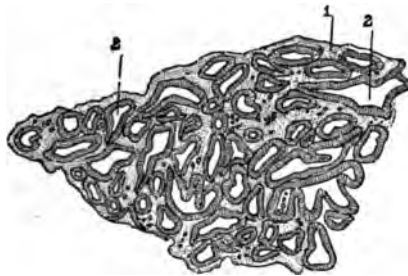


FIG. 186.

CROSS SECTION OF A GRANULATION IN A CASE OF ENDOMETRITIS (4th). 1. Stroma; 2. Dilated glands (*De Sinéty*).

undifferentiated embryonic tissue is produced. We must remember, however, that in no case is one structure alone affected; there is no hard and fast line between the different processes. For the following description we are indebted to the researches of Olshausen, Carl Ruge, and De Sinéty.

Ruge's
investiga-
tions.

According to *Schroeder's* clinical observations, the microscopic investigation of which has been made by Ruge, the most frequent condition is a hypertrophy of the glands. In some cases they are so much hypertrophied that the granulations appear as masses of glandular tissue, as is well shown by the accompanying figure from De Sinéty (186). In such a condition, the chief symptom is leucorrhœa.

Olshausen's
investiga-
tions.

Olshausen has described very carefully the changes of the mucous membrane in cases of the second type, in which the only symptom is hæmorrhage. The mucous membrane is hypertrophied to three or four times its normal thickness. It is elevated through its whole extent in a

soft cushion-like swelling, or in more localised spongy masses; the hypertrophy does not extend beyond the os internum to the cervix and thus resembles in its situation a decidual membrane. The portions removed by the curette are unusually thick; one side presents a smooth rose-

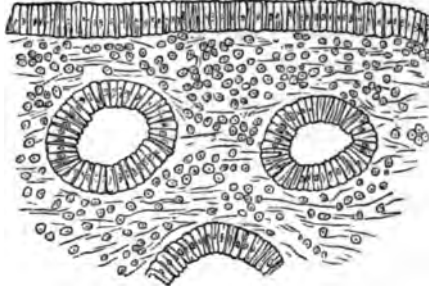


FIG. 187.

VASCULAR TYPE OF ENDOMETRITIS—*Endometritis fungosa (Olshausen)*.

coloured surface which resembles the appearance of the mucous membrane of the intestine, and the other has a deep-red raw-surface. “The microscopic examination of these scrapings,” Olshausen says, “shows that there is great hypertrophy of the mucous membrane with increase of the hæmorrhagic type.”

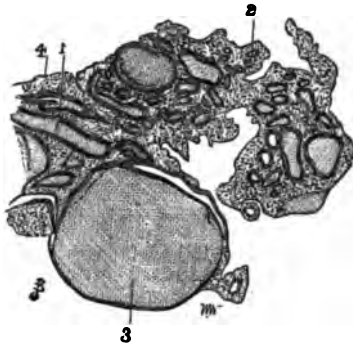


FIG. 188.

CROSS SECTION OF GRANULATION COMPOSED OF DILATED VESSELS IN A CASE OF ENDOMETRITIS (49).
1. Vessels cut longitudinally; 2. Vessels cut transversely; 3. Dilated vessel filled with blood corpuscles; 4. Embryonic tissue (*De Sindy*).

of all its elements—moderate dilatation of the lumina of the glands, enlargement of the blood-vessels, and marked cellular infiltration of the connective tissue” (fig. 187). The characteristics of this type are, that the glands do not become enlarged so as to produce cystic dilatations, and that the blood-vessels are greatly distended; the latter fact explains the

body; the vaginal portion has the same appearance as during pregnancy, being soft and swollen and showing round the os red catarrhal patches.

The ciliated epithelium is destroyed, and sometimes casts of the epithelium of the glands are found in the discharge (*Schroeder*). The secretion is at first serous, then purulent.

In *chronic endometritis*, the mucous membrane is hypertrophied and marked with patches of old extravasation.

Microscopic changes in Chronic Endometritis.

The microscopic appearances vary with the structures which are principally affected. Our knowledge upon this subject is principally derived from the examination of the portion of mucous membrane removed by the curette. We can distinguish three pathological types according to the tissue chiefly involved. In the first, the glands are hypertrophied; in the second, the vessels are dilated and enlarged; in the third, an

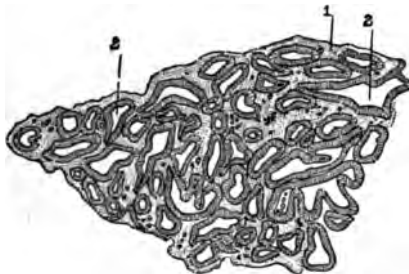


FIG. 186.

CROSS SECTION OF A GRANULATION IN A CASE OF ENDOMETRITIS (47). 1. Stroma; 2. Dilated glands (*De Sinéty*).

undifferentiated embryonic tissue is produced. We must remember, however, that in no case is one structure alone affected; there is no hard and fast line between the different processes. For the following description we are indebted to the researches of Olshausen, Carl Ruge, and De Sinéty.

Ruge's investigations.

According to *Schroeder's* clinical observations, the microscopic investigation of which has been made by Ruge, the most frequent condition is a hypertrophy of the glands. In some cases they are so much hypertrophied that the granulations appear as masses of glandular tissue, as is well shown by the accompanying figure from De Sinéty (186). In such a condition, the chief symptom is leucorrhœa.

Olshausen's investigations.

Olshausen has described very carefully the changes of the mucous membrane in cases of the second type, in which the only symptom is hæmorrhage. The mucous membrane is hypertrophied to three or four times its normal thickness. It is elevated through its whole extent in a

soft cushion-like swelling, or in more localised spongy masses; the hypertrophy does not extend beyond the os internum to the cervix and thus resembles in its situation a decidua membrane. The portions removed by the curette are unusually thick; one side presents a smooth rose-

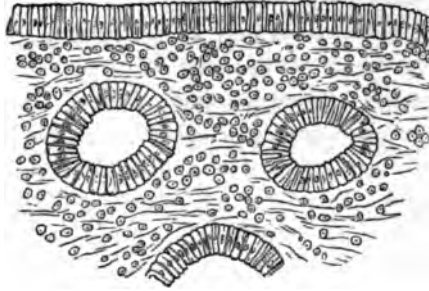


FIG. 187.

VASCULAR TYPE OF ENDOMETRITIS—*Endometritis fungosa* (Olshausen).

coloured surface which resembles the appearance of the mucous membrane of the intestine, and the other has a deep-red raw-surface. “The microscopic examination of these scrapings,” Olshausen says, “shows that there is great hypertrophy of the mucous membrane with increase

Hæmorrhagic type.

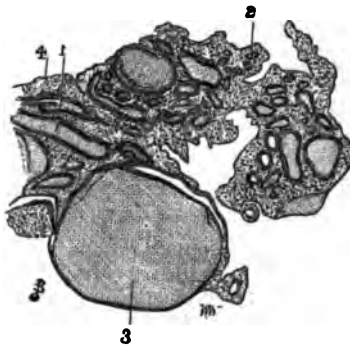


FIG. 188.

CROSS SECTION OF GRANULATION COMPOSED OF DILATED VESSELS IN A CASE OF ENDOMETRITIS (49).
1. Vessels cut longitudinally; 2. Vessels cut transversely; 3. Dilated vessel filled with blood corpuscles; 4. Embryonic tissue (*De Sinéty*).

of all its elements—moderate dilatation of the lumina of the glands, enlargement of the blood-vessels, and marked cellular infiltration of the connective tissue” (fig. 187). The characteristics of this type are, that the glands do not become enlarged so as to produce cystic dilatations, and that the blood-vessels are greatly distended; the latter fact explains the

of the uterus. After full-time labour, the seat of the placenta seems to be in many cases the starting point of the inflammatory process.

In nulliparæ with a narrow os externum causing obstruction to the menstrual flow, we frequently find the uterine cavity increased in length and endometritis present.

Uterine displacements do not necessarily produce endometritis. We sometimes find a retroversion or retroflexion which has produced no symptoms. As a rule chronic inflammation of the endometrium, as well as of the muscular coat, results from passive congestion.

SYMPTOMS.

A. *Of Acute Endometritis.*

These are fever more or less severe according to the inflammation, pain in the back and lower part of the abdomen with the sensation of weight in the pelvis, and in severe cases vesical and rectal tenesmus. The characteristic symptom is the discharge, which is at first clear and watery but after a few days becomes creamy and purulent. The menstrual flow is sometimes suppressed, rarely is it increased.

B. *Of Chronic Endometritis.*

The leading symptoms are the following:—

- Leucorrhœa ;
- Menorrhagia ;
- Dysmenorrhœa ;
- Weakness in the back ;
- Pain in pelvis and loins ;
- Digestive derangements ;
- Nervous derangements ;
- Sterility ;
- Abortion.

Uterine
Leucorrhœa.

Leucorrhœa is the characteristic symptom. The secretion from the body of the uterus is of a watery character, less dense and gelatinous than that from the cervix ; usually, however, there is cervical catarrh as well. The uterine secretion has an alkaline reaction, while vaginal leucorrhœa is acid. Sometimes it is tinged with blood, producing an appearance which Bennet aptly compares to the rust-coloured sputum in pneumonia. This blood-stained leucorrhœa must not be confounded with the menstrual flow. In some cases the discharge is purulent, accumulates in the uterine cavity, and is only discharged at intervals.

Menorrhagia is frequently present. In one class of cases (see Pathology) it is the leading symptom, and is grave from the anæmia which it produces. It shows itself first in increased duration of the menstrual flow, which becomes gradually prolonged over the intermenstrual period till the loss of blood becomes continuous. *Dysmenorrhœa* is frequently present, but is more probably due to complications (e.g., flexions or chronic metritis) than to the condition of the mucous membrane. Membranous dysmenorrhœa (accompanied with exfoliation of the mucous membrane at the menstrual period) might be considered here, as its pathology is most nearly allied to endometritis; from its peculiar symptoms, however, it is better to consider it in the chapter on *Dysmenorrhœa* (Section VIII.)

"*Weakness in the back*" is the common complaint made by the patient. It may amount to actual pain, but more generally it shows itself as feebleness or weariness which incapacitates the patient for her daily work.

Derangements of the digestive and nervous systems invariably follow when the disease has become chronic. There is impaired digestion with loss of appetite and, as the result, general debility. Whether these are due to the drain of the system produced by the leucorrhœa or to the close connection between the nervous centres for the sexual organs and those for the digestive apparatus, we do not know. Derangements of the nervous system show themselves in frontal headache and depression of spirits amounting sometimes to melancholia.

Anæmia, with its characteristic train of symptoms, is the leading symptom in the hæmorrhagic type (*Olshausen*).

Sterility is frequently present, and has been in certain cases the only symptom complained of. The secretion may destroy spermatozoa, may mechanically prevent them from passing upwards, or the villi of the fertilised ovum may be prevented from finding an attachment in the diseased mucous membrane. Again, the ovum is attached for a time but, from the imperfect formation of the uterine portion of the placenta, *abortion* takes place; repeated abortion is characteristic in chronic endometritis. A vicious circle is thus produced: as mentioned under etiology, endometritis frequently follows abortion; abortion, in its turn, frequently follows endometritis.

PHYSICAL SIGNS.

A. *Of Acute Endometritis.*

There is tenderness on pressure over the lower part of the abdomen

due to peritonitis which generally accompanies the acute form. On vaginal examination the cervix is found to be swollen and puffy, the os is dilated and feels velvety from eversion of the mucous membrane, the Bimanual is unsatisfactory from sensitiveness to pressure. The speculum shows the vaginal portion to be congested, with catarrhal patches round the os and the follicles enlarged and sometimes containing pus. The leucorrhœal discharge already described is seen coming from the os uteri. The sound should not be used, as its introduction causes pain and sometimes hæmorrhage.

B. Of Chronic Endometritis.

Tenderness on pressure is not necessarily present, though we frequently find it as the result of complications—peritonitis, cellulitis, ovaritis.

On vaginal examination the vaginal portion of the cervix is normal, or has the characters described under cervical catarrh. The Bimanual shows the uterus to be *enlarged*; it is soft and flabby so that its form cannot easily be made out, or of a firm consistence from chronic metritis.

The sound passes *beyond* the 2½-inch knob to a varying extent, and on withdrawal is frequently tinged with blood. Its introduction may be difficult from irregularities in the mucous membrane, and is sometimes painful. In some cases pain is complained of when the sound touches the fundus of the uterus, which some consider characteristic of endometritis. Routh has described a variety of the disease under the name "Fundal Endometritis," in which this is prominent: on forcible pressure of the sound against the fundus "absolute agony may result, which may producè vomiting, an hysterical faint or fit, sometimes a regular epileptic fit." The sound is most useful in demonstrating *irregularities of the mucous membrane*, and their recognition is of great importance: to detect these, the sound is held lightly between the finger and thumb and moved slowly backwards and forwards over the mucous membrane; a grating or catching sensation is felt when they are present. We must note, however, as Olshausen points out, that the spongy irregularities may escape detection by the sound.

Fundal
Endo-
metritis.

In the speculum we see, issuing from the os, the leucorrhœal discharge with the characteristics given above; usually it is mixed with that from the cervix. The appearances described under cervical catarrh are also frequently present.

DIAGNOSIS; DIFFERENTIAL DIAGNOSIS.

The curette is invaluable in diagnosis, especially when its use is fol-

lowed by *microscopical examination* of the scrapings—the importance of which cannot be overrated.

This throws light on the etiological question, whether the endometritis be due to incomplete emptying of the uterus after *parturition*? In such a case we find among the scrapings large decidual cells or fragments of the villi of the chorion in a state of fatty degeneration. It shows us the *character* of the *inflammatory changes*. Of these De Sinéty describes three forms on which we based our description of three pathological types of endometritis. The microscopic appearance of these (40 diameters) is given at figs. 186 to 189.

It enables us to differentiate endometritis from commencing malignant disease—*carcinoma* and *sarcoma*. In carcinoma we see under the microscope abundance of epithelial cells of irregular form and with many nuclei (*v. fig. 279*). In sarcoma we see under the microscope the typical round or spindle-shaped cells. The hæmorrhagic type of endometritis may readily be mistaken for sarcoma uteri, because “it spreads in a diffuse manner, pre-eminently causes hæmorrhage, produces pain not at all or only late” (*Olshausen*). The microscope, however, settles the diagnosis. Care must be taken not to mistake the small-celled infiltration of the tissue (*fig. 187*) for round-celled sarcoma. The unstriped muscular fibre of the uterus may be present in the scrapings, but could only on hasty examination be mistaken for spindle-celled sarcoma. The latter are characterised by their larger size and oval nuclei (*v. figs. 296 and 297*).

Differential
Diagnosis.

PROGNOSIS.

Endometritis is not a fatal disease in itself, though, when long protracted, it seriously affects the constitution and produces permanent ill-health. In cases of excessive hæmorrhage, the condition becomes grave.

The treatment is often protracted, and the patient should always be warned of this. The occurrence of conception will produce the most favourable conditions; and, if due care be taken to prevent abortion in the early months and in the management of the puerperium, we may hope for a cure.

When endometritis is associated with a strumous, tubercular, or syphilitic diathesis, it may baffle all our efforts.

TREATMENT.

A. Of Acute Endometritis.

Rest in bed, warm fomentations over the abdomen, and the free use of opium if there is much pain, form all the treatment required. Should

the bowels not be moved freely before the attack, castor oil with an enema should be given since the loaded rectum presses injuriously on the inflamed uterus. Should the bowels not be loaded the patient is not to be troubled with purgatives but rather kept under the influence of opium. If there is menorrhagia, ergot is required; when the discharge is free, it is to be given hypodermically. Warm water injections should not be used until the acute stage is passed, the pain and other signs of inflammation have subsided, and the leucorrhœa is abundant.

B. Of Chronic Endometritis.

Prophylactic treatment is of great importance. A patient who is subject to endometritis, should guard against exposure during the menstrual period. When conception takes place, the practitioner should remember the liability to abortion, the importance of seeing that the uterus be thoroughly emptied after parturition, and that the patient take proper care during the puerperium; in the latter period ergot is beneficial.

We begin with hot-water injections, and the administration of ergot; this is given as the liquid extract (twenty drops in water three times a day increased to thirty at the menstrual period) or Ergotin pills—four grains in each.

If the uterine cavity be enlarged so that the sound moves freely within it, if there be roughness of the endometrium, or if there has been a recent miscarriage or confinement, we employ *the curette followed by the application of carbolic acid*. In the last class of cases the cause of the endometritis has been the incomplete separation of the placental villi; if treated while still recent, such cases furnish the most satisfactory instances of an immediate and complete cure.

Curetting
of Uterus.

Curetting should not be performed while active cellulitis or peritonitis is present. The fixing of the uterus by adhesions or cicatrisation does not contra-indicate the operation, though they render it more difficult through preventing the uterus from being drawn down by the volsella; when these are present, undue traction must not be made. The time selected for operation is a week after a menstrual period; when the discharge is continuous, the period is indicated by increase in amount.

Curetting of the Uterus with application of Carbolic Acid. The following instruments are necessary:—

- Sims' or Battey's speculum,
- Three or four sounds dressed with cotton wool,
- Volsella,

Simpson's modification of the dull-wire curette,
 Crystals of carbolic acid liquefied,
 Cotton wadding and glycerine,
 Mackintosh.

Chloroform is not necessary unless the patient be nervous.

The sounds should be covered with a thin layer of cotton wool, extending almost to the knob (fig. 190). The sound is dressed as follows:—A film of cotton wadding is laid on the palm of the left hand, the last two and a half inches of the sound are moistened and pressed firmly on the cotton wadding, the left hand is closed over it, the sound is turned twice or thrice round within the shut hand till the cotton wadding becomes tightly rolled on. The dressing must bite the sound firmly so that it may not come off within the uterine cavity, and must not be too thick to be easily carried in. To remove the cotton wadding afterwards, the dressing is unrolled under water.



FIG. 190.

SOUND DRESSED WITH WADDING FOR THE APPLICATION OF CARBOLIC ACID.

Thomas' dull-wire curette is the most serviceable, because from its small size it can be used without previous dilatation and from its flexibility it can be curved to suit the form of the uterine canal. A. R. Simpson has distinctly improved it by adding a knob at the two and a half inches, which informs the operator how far the curette has passed. The crystals of carbolic acid are kept in stoppered bottles, at the ordinary temperature a portion remains liquid; tincture of iodine, strong nitric acid, or chromic acid may be substituted for it.

The patient is placed semiprone; Sims' speculum is passed and held by an assistant who with the left hand draws back the upper labium (fig. 191)—if there be no assistant, Battey's speculum is used and fixed to the mattress; the vagina is washed out with carbolised water. The anterior lip is laid hold of by the volsella and drawn downwards, the volsella being steadied with the fingers of the left hand the curette is

taken in the right hand, dipped in carbolised oil (1-20), and carried into the uterine cavity (fig. 191). The anterior wall of the uterus is first scraped from the fundus downwards; only slight pressure on the instrument is made, unless it be felt to slip over the irregularities of the mucous membrane without removing them; the detached fragments are brought down to the cervix with a raking motion, and set aside for microscopical examination: the posterior wall is scraped in the same way. A sound, dressed with dry cotton wadding, is passed to clear

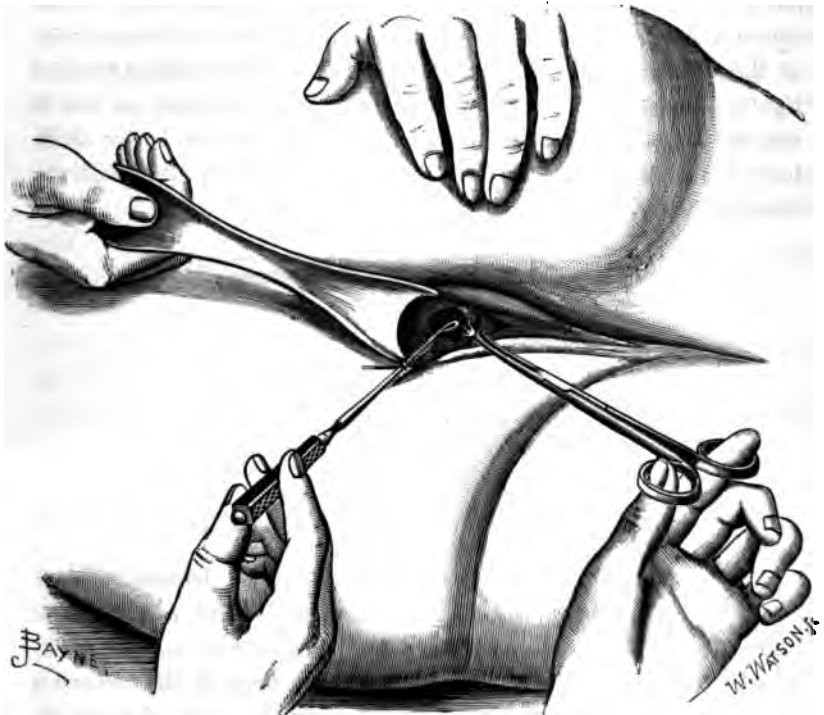

FIG. 191.

UTERUS DRAWN DOWN WITH THE VOLSELLA AND CURETTE IN POSITION. The speculum is held and the labium drawn upwards by an assistant. The operator's hands are crossed (*A. R. Simpson*).

away the blood and mucus; the same process is immediately repeated with a second, and with a third if necessary. A reserve sound, previously dipped in the carbolic acid so as to be ready for use, is carried in immediately after the last of these has been withdrawn; if there is much bleeding or the uterine cavity is large, a second application should be made; our aim is to apply the carbolic acid to the whole of the raw surface, without its being diluted with blood or mucus. The volsella

being withdrawn, a pledget of cotton wadding soaked in glycerine is placed in the upper part of the vagina so as to embrace the cervix; this prevents the carbolic acid from running down into the vagina.

The patient keeps her bed for a week after the operation, the pledget having been removed on the second day. Special care should be taken at the next menstrual period.

Applications without a previous curetting are indicated in cases where there is no history of recent parturition or where no irregularities are detected by the sound. (In endometritis fungosa, which specially requires the curette, no irregularities are detected by the sound—*Olshausen*.) In all other cases the preliminary use of the curette is a distinct advantage, as it removes the fungosities and thus allows the caustic to act more efficiently.

Atthill advocates the use of strong nitric acid, and the preliminary dilatation of the cervix with tents so as to allow a thicker dressing of the

Endo-
metric
Applica-
tions.

Atthill's
Method.




FIG. 192.

PORTE-CAUSTIQUE (Sir J. Y. Simpson).

sound and more abundant application of the acid. He uses an intra-uterine speculum of vulcanite which is passed within the cervix; this prevents the acid from acting on the cervical canal.

The application may be made in a *solid form*, of which the best is nitrate of silver. This is employed as follows: the nitrate of silver is fused in a watch-glass over a spirit flame; a probe with a roughened end is dipped in this and the film allowed to cool, and then dipped again repeatedly till several layers are deposited. Sir James Simpson applied the nitrate of silver in powder on the porte caustique represented at fig. 192. The simplest way is to carry an ordinary quill with a nitrate of silver point into the cavity of the uterus; it may be passed in and withdrawn again, or held there till the point melts off; Credé of Leipsic has got very good results from this mode of treatment. Barnes has devised an ointment positor for introducing ointments or fluids; he applies the iodide of mercury ointment in this way, and also tincture of iodine on a sponge.

The importance of constitutional treatment must not be forgotten. The

bowels should be moved regularly by saline aperients ; the aloes and iron pill is also useful. The preparations of quinine, iron, and strychnine, are valuable in improving the tone of the nervous and digestive systems.

Cold baths and sea-bathing aid greatly in strengthening the constitution. The water of certain mineral springs, such as Ems and Kreuznach, seems to have a special action on the uterine as well as on other mucous membranes. The regular diet and exercise required at these baths have also, no doubt, their beneficial effect.

The diathesis—strumous, tubercular, or syphilitic—should not be forgotten. In them, the treatment must from the first be constitutional.

Intra-uterine Injections.

Intra-uterine injections. Applications to the interior of the uterus are also made in the form of a fluid injected by a syringe. The nozzle of the latter is shaped like a sound, so that it may be passed into the uterine cavity ; the barrel is of glass, and is graduated (like a hypodermic syringe) so that the quantity injected (not more than a few minims) is exactly known. The solutions used are carbolic or chromic acid, tincture of iodine or perchloride of iron, nitrate of silver, and sulphate of iron or copper. The cervix must be well dilated, to allow the fluid to escape readily past the nozzle of the syringe. To facilitate this reflux, syringes have been devised with a double canula. Injection of fluid *into the non-puerperal uterus* is not unattended with risk (*v. p. 178*), and the fact that we have the equally effective and perfectly safe method of intra-uterine medication described above renders it unnecessary. As a means of treating endometritis it is condemned by the general opinion of gynecologists in this country and America ; in France and Germany, however, it is extensively practised. For further details of this method the student may consult the following references: Klemm—"Die Gefahren der Uterininjection," Leipzig, 1863 ; Cohnstein—"Beiträge zur Therapie der chronischen Metritis," Berlin, 1868 ; Leblond—"Manuel de Gynecologie," p. 220, Paris, 1878 ; and Hegar und Kaltenbach—"Operative Gynäkologie," S. 104, Stuttgart, 1881.

CHAPTER XXX.

METRITIS, ACUTE AND CHRONIC: SUBINVOLUTION.

LITERATURE.

Barnes—Diseases of Women, p. 507: Lond. 1878. *Bennet, J. H.*—Practical Treatise on inflammation of the Uterus: London, 1853. *Byford*—Medical and Surgical Treatment of Women: Philadelphia, 1881. *Courty*—Diseases of Women (Dr. Agnes MacLaren's Translation: Lond. 1882). *De Sinéty*—Manuel de Gynecologie, pp. 315 and 351, Paris, 1879. *Gallard*—Traitement de la Métrite Chronique. Bull. gén. de thérapeut, etc., 1879, T. XCVII. 4—12, liv. *Gutrin*—Ann. de Gyn., 1878, Tom. II. p. 9. *Klob*—Pathologische Anatomie der weiblichen Sexualorgane, S. 124: Leipzig, 1878. *Scanzoni*—Die chronische Metritis: Wien, 1868. *Schroader*—Krankheiten der weiblichen Geschlechtsorgane, S. 84: Wien, 1864. *Simpson, Sir J. Y.*—Diseases of Women, p. 535: Edin. 1872. *Thomas*—Diseases of Women, p. 307: Philadelphia, 1880.

DEFINITION.—Inflammation in the muscular coat of the uterus leading, when chronic, to increased formation of connective tissue.

ACUTE METRITIS.

PATHOLOGY.

The uterus is enlarged and may be of the size of a goose's egg; it is thickened, specially antero-posteriorly, and of a doughy consistence. The peritoneal surface is usually covered with lymph.

On section the muscular wall is thickened, but soft and pulpy; the cut surface is of a bright red colour, shows the veins to be engorged, and yields on compression a yellowish-red exudation. The mucous membrane is thickened and vascular, but the cavity of the uterus is not altered in size. Microscopically, the muscular bundles are infiltrated with pus corpuscles.

ETIOLOGY.

Acute metritis is produced by extension of inflammatory action from the mucous or serous lining of the uterus to the intervening muscular tissue. It occurs most commonly as part of the general inflammation produced by absorption of septic matter during the puerperium. It also arises from exposure to cold at a menstrual period—the active congestion

passing readily into acute inflammation, from gonorrhœal infection and immoderate sexual activity.

Frequently it is the result of surgical interference:—careless use of sound, intra-uterine injections, pessaries and sponge-tents; scraping the uterus, the removal of submucous fibroids, operations on the cervix.

SYMPTOMS.

There is fever and general constitutional disturbance varying with the intensity of the inflammation. The onset may be marked with rigors. There is a sensation of fulness, weight, and burning heat in the pelvis; pain in the hypogastric and sacral regions, aggravated on movement of the body or emptying the bladder and rectum; nausea and vomiting, diarrhœa and tenesmus of rectum and bladder.

Menstruation is suppressed in those cases where the metritis is occasioned by exposure to cold at the menstrual period. In other cases, it is diminished in amount; exceptionally, there is menorrhagia.

PHYSICAL SIGNS.

There is tenderness on pressure in the hypogastric region. On vaginal examination, the vaginal walls are hot and dry, the cervix is swollen and movement of it causes pain. The bimanual examination cannot be made on account of the pain and the resistance of the abdominal walls; if the patient be put under chloroform, the uterus will be felt to be enlarged but freely movable unless fixed by old adhesions (fig. 206). The sound should not be used, as it causes hæmorrhage from the vascular mucous membrane.

PROGRESS AND TERMINATION.

The acute symptoms do not last usually more than a week. The fever and pain diminish; there is less heat in the pelvis and vagina, and leucorrhœal discharge becomes free. As complications, there may be catarrh of the bladder, rectum, or vagina.

The acute *usually* passes into the chronic stage to be immediately described; though *sometimes*, under proper treatment and care, there is resolution with absorption of the exudation; rarely does it terminate in abscess formation. Circumscribed abscesses in the uterine walls—recorded by Scanzoni, Reinmann, Bird, Ashford, Schroeder, Macdonald, and others—are sometimes produced and burst into the uterus itself; or adhesions may form and perforation take place into the bladder, vagina, rectum, and intestines, or even through the abdominal walls.

DIAGNOSIS.

The diagnosis that there is acute metritis and *nothing more*, is a refinement to which few would lay claim. But if the symptoms and physical signs are as described above, if the uterus be freely movable and no deposit is felt in the fornices, we may conclude that acute metritis is the prominent lesion. The possibility of abscess-formation should be kept in view. The practitioner may also, though very rarely, see cases where there is acute metritis and endometritis, and nothing else. It is wrong to say that acute metritis is rare. It is often a complication of pelvic peritonitis and cellulitis, with the physical signs masked by these latter diseases.

PROGNOSIS.

The *immediate result* will depend on the extent to which the peritoneum is involved. Even when the attack is not severe, the liability to pass into a chronic intractable condition makes us guarded in giving an opinion as to *complete recovery*.

TREATMENT.

If the metritis is supposed to be due to a septic cause, the first measure indicated is the *removal of that cause*. Thus if it come on during the puerperium, if the lochia are fetid and we suspect that a portion of the placenta has been retained, the uterine cavity should be washed out with an injection of 1 to 40 carbolic solution. Great care must be taken not to introduce air with the injected fluid.

In all cases of metritis, the patient must be kept *at rest*. This is done by keeping her recumbent. The bowels are evacuated by an enema—not by purgatives—followed by a morphia suppository. Pain is relieved by warm fomentations, to which turpentine may be added, applied over the lower part of the abdomen; but if it be severe, the patient should be kept under the influence of opium as already described in the treatment of Pelvic Peritonitis. If the temperature be above 102°, quinine should be given—10 grains every two or three hours—till it falls. The sulpho-carbolate of soda (15 grains) is useful in some cases.

CHRONIC METRITIS.

SYNONYMS.—Chronic parenchymatous inflammation (Scanzoni), Diffuse proliferation of connective tissue (Klob), Infaret (Kiwisch), Areolar hyperplasia (Thomas).

There has been great divergence of opinion among gynecologists as to the term which should be applied to the changes occurring in chronic metritis. Virchow describes the process as a hyperplasia of fibromuscular tissue, and places chronic metritis alongside of fibroid tumours of the uterus. Klob classes it among the new formations, and characterises it as "die diffuse Bindegewebswucherung"—"diffuse proliferation of connective tissue." Thomas calls it "Areolar Hyperplasia," and Noeggerath has suggested the term "diffuse *interstitial* metritis."

From a *pathological point of view* the term "metritis" is incorrect, because there has never been demonstrated a chronic inflammation of the muscular fibre of the uterus. The morbid process described as chronic metritis consists in an *increase of connective tissue* out of proportion to that of the muscular fibre, which remains normal or is but slightly increased in quantity. We are not yet in a position to propose a term resting on a sure pathological basis; to do this would require a complete knowledge of the pathological changes, which has not yet been attained. We prefer to retain the term "chronic metritis."

From a *clinical point of view*, this term is very convenient, including a variety of cases of different origin but presenting the same clinical features on examination.

It may be objected that to apply the term "chronic inflammation to the process" is misleading, as it implies a previous acute stage which is rarely present; the process would be more correctly described as an increased connective-tissue formation dependent on long-continued hyperæmia. But the term chronic inflammation is applied to the process producing similar changes in other organs, as cirrhosis of the liver; chronic metritis produces, in fact, cirrhosis of the uterus.

Subinvolution of Uterus.

We have brought "Subinvolution of the uterus" under this head, though in other English text-books it is treated as a separate lesion. The term subinvolution is *etiological* and simply expresses one mode, the most important one in which the condition to be described is produced. *Apart from the history*, it is not possible to diagnose between a subinvoltuted uterus and one enlarged by chronic metritis alone. Further, the condition of subinvolution is maintained by the process of chronic metritis, that is, by the formation of connective tissue which takes the place of the fattily-degenerated muscular fibre. Finally, the treatment is the same in both cases.

PATHOLOGY.

The condition of the uterus depends on the duration of the disease.

At an early stage (as in cirrhosis of the liver) the organ is enlarged, hyperæmic, and soft ; at a later period it is indurated, anæmic, and hard. The peritoneal surface is of normal colour, or shows here and there patches of extravasated blood. The enlargement is uniform, so that the shape of the uterus is not altered.

On section, the tissue is soft and hyperæmic in the early stage ; firm, cartilaginous, and of a whitish colour (from the compression of the capillaries by the cicatricial tissue) in a later stage. The uterine walls are increased in thickness. The uterine cavity is increased in size.

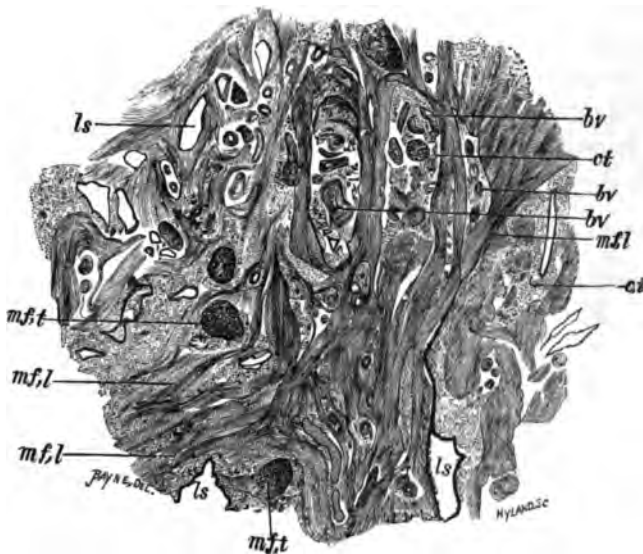


FIG. 193.

SECTION OF THE UTERINE TISSUE IN A CASE OF CHRONIC METRITIS 49. *ct* connective tissue round the blood-vessels *bv*; *ls* dilated lymphatic spaces; *mfl* muscular fibre cut longitudinally; *mft* muscular fibre cut transversely (*De Sinéty*).

“In the first period,” says De Sinéty,¹ “the dominant lesion is the De Sinéty. presence in great number of embryonic elements throughout the whole thickness of the muscular wall. These elements are met with specially round the blood-vessels or form islands of variable dimensions which are more or less apart.” The second period is characterised by two changes; (1) Marked dilatation of the lymphatic spaces, and (2) a localised hyperplasia of the connective tissue round the blood-vessels (fig. 193). The sclerosis, for such it may be called, differs from a similar

change in the kidney or liver in the fact that the formation of connective tissue is localised round the blood-vessels. In the case described by De Sinéty, he says that it was difficult to say whether the muscular tissue was normal or diminished in quantity.

Snow Beck. Snow Beck¹ also describes the presence of "an increased amount of round and oval globules, with amorphous tissue in the uterine walls." The increase in the size of the uterus is due to the presence of the soft tissue rather than to an increase in the muscular fibre.

On the other hand, Finn² gives the following result of his investigation of the pathology of chronic metritis:—The muscular fibres are increased in length and breadth and number, though their disposition is not altered; the amount of connective tissue is relatively diminished. Finn's observations have not been supported by any other investigators.

We may therefore sum up the microscopic changes of the second stage as an increase in the amount of connective tissue with a relative and perhaps absolute diminution in the muscular fibre.

ETIOLOGY.

The causes of chronic metritis may be arranged under two heads:—

- A. Causes which operate through interference with the normal involution of the puerperal uterus;
- B. Causes which operate through the production of repeated or protracted congestion of the uterus.

A. Causes which operate through interference with the normal involution of the uterus.

- (1.) Retention of portions of placenta, membranes, or blood-clot in the uterus;
- (2.) Lacerations of the cervix uteri;
- (3.) Pelvic inflammations, occurring after labour;
- (4.) Rising too soon after delivery;
- (5.) Non-lactation;
- (6.) Repeated miscarriages.

Puerperal Involution. In the process of involution there are two factors, the fatty degeneration of the muscular fibre and the removal of the products of this degeneration. The condition of permanent enlargement or subinvolution is not due to the non-degeneration of muscular fibre, but to the

¹ *Lond. Obst. Trans.*, vol. xiii., p. 239.

² *Centralblatt f. Gyn.*, 1868, S. 564.

substitution of connective tissue for the products of this degeneration. This seems to be the reason why the process of chronic metritis is met with more frequently in those who have borne children ; if there be a tendency to hyperæmia leading to connective tissue formation in the uterus, the most favourable circumstances for such formation occur during the process of involution (*Thomas*).

Any source of irritation in or beside the uterus leads to chronic metritis ; in this way we explain the effect of the *retention of portions of placenta or membranes*. An extensive *laceration of the cervix*, Emmet says, favours subinvolution for a similar reason. Continued *cellulitis or peritonitis* acts in the same way, or through interference with the circulation. If the patient *rise too soon*, the increased weight of the non-involuting uterus leads to passive congestion and formation of connective tissue. Passive congestion will, on the other hand, be diminished by whatever produces uterine contractions ; the physiological stimulus of suckling, excited reflexly through the mammæ, favours involution ; in *non-lactation* this stimulus is absent. *Abortions* are an important cause ; because patients do not take so much care of themselves as after a full-time labour, and the stimulus of lactation is absent. After abortion conception readily takes place before the uterus has returned to its normal size, and this favours a re-occurrence of abortion.

B. *Causes which operate through production of repeated or protracted congestion.*

- (1.) Displacements of the uterus ;
- (2.) Pressure of tumours in or near the uterus ;
- (3.) Causes producing increased flow of blood to the uterus ; as endometritis, too free use of caustics.

SYMPTOMS.

In the great proportion of cases, the patient *dates her suffering from a confinement* ; frequently, there is a history of repeated abortions. The patient finds, on rising after the puerperium, that she does not regain her former strength. There is weakness in the back amounting in more severe cases to pain, a sensation of weight and bearing-down in the pelvis and of want of power in the limbs.

There is *leucorrhœa*, according to the extent to which the mucous membrane is affected.

Menstruation is irregular and often increased in frequency and quantity, though this is more characteristic of endometritis.

Effect on
Reproduc-
tion.

The *reproductive function* is variously affected. Before the structure of the uterus has become permanently altered, pregnancy followed by early *abortion* may repeatedly happen. The cause of the abortion is probably the alteration which is taking place in the structure of the mucous membrane, rendering it unfitted for the development of the placenta; after an abortion, the conditions are peculiarly favourable for a second conception even before the uterus has had time to undergo involution; an excessive development of connective tissue gradually renders the uterus incapable of involution, and thus the condition of subinvolution is perpetuated. Should the pregnancy go on to full time, the presence of an undue proportion of connective tissue in the uterine wall leads in the third stage of labour to atony of the uterus and retention of the placenta; see an interesting case of this reported by Kaschkaroff,¹ who gives the result of his microscopic investigation. After the condition has existed for some time, there is *sterility*. This is due not so much to the changes in the uterus itself, though the *leucorrhoea* may prevent fertilisation, but to the *ovaritis* or *pelvic peritonitis* which is usually superadded; ovulation may be prevented by change in the structure of the ovary or by its being bound down by adhesions; the Fallopian tubes may be obstructed by cicatricial contractions.

The general constitutional derangements are very important, and it is on account of these that the patients usually seek advice. Chronic metritis is the most important of all the diseases of women; the suffering of the patient, in cases of displacement of the uterus, is not due so much directly to the displacement as to the chronic inflammation secondary to it.

PHYSICAL SIGNS, DIAGNOSIS.

The uterus is *equally* enlarged; there is no alteration in its form. The character of the enlargement is best understood by contrasting it with that due to pregnancy. In the second or third month of pregnancy, there is antero-posterior broadening of the uterus; the vaginal finger comes on the anterior wall springing out from the cervix; the abdominal hand feels the rounding out of the fundus, combined with a softness which prevents us from distinctly defining its outline. In chronic metritis the vaginal finger does not feel any bulging of the anterior wall,

¹ *Centralblatt für Gynäkologie*, No. 5, 1879.

and the abdominal hand recognises the fundus to be uniformly thickened ; the outline of the latter may be felt with unusual distinctness through the greater firmness of the uterine tissue.

The enlarged uterus may be in its normal position, and freely movable or fixed by adhesions ; it is often retroflexed.

The sound passes more than the $2\frac{1}{2}$ inches ; it passes *readily*, and is felt to be freely movable in the uterine cavity.

DIFFERENTIAL DIAGNOSIS.

The conditions which are most liable to be confounded with chronic metritis are *early pregnancy* and *small fibroid tumours*.

In a case of early pregnancy, the "having passed a period" will put us on our guard ; some patients, however, menstruate after conception. Discoloration of the vagina points to pregnancy, but is often not marked. The softening of the cervix is a more reliable sign, less reliable should pregnancy occur in a uterus which has undergone changes of chronic metritis. Our only guide is the bimanual examination, which shows us the change in the form and consistence described above. When the abdominal muscles are resistant, the finger can recognise per rectum the bulging and softness of the posterior uterine wall. The interesting question suggests itself in this connection, how soon it is possible to recognise the changes in the uterus peculiar to pregnancy? *How soon can we diagnose pregnancy?* Before auscultation was known the first reliable signs were foetal movements ; the date at which the mother first recognised these varied indefinitely. Auscultation gave us an earlier and more reliable indication in the sounds of the foetal heart ; these cannot be heard before the fourth month. The bimanual examination enables us to detect pregnancy from the eighth to the tenth week. We have under very favourable circumstances diagnosed it at the fifth week, and the subsequent history has confirmed our diagnosis.

Diagnosis
of Early
Pregnancy.

For the differential diagnosis of chronic metritis from small fibroid tumours, we refer the student to the "Diagnosis of Small Fibroid Tumours" (Chap. XXXIV.)

TREATMENT.

Our first object is to diminish the passive congestion of the pelvic organs. The patient should be instructed to lie down for a few hours every day. Sedentary occupations or those that require the patient to stand for a long time in one position should be avoided. While enjoined

ing a certain amount of rest, we must remember that rest becomes injurious when it interferes with nutrition. A certain amount of exercise, especially in the open air, should be as emphatically prescribed as a certain amount of rest.

Passive congestion is also diminished by giving local support to the uterus by a Hodge pessary; where the vagina is roomy, a soft ring pessary sometimes answers better.

The pelvic circulation is stimulated by vaginal injections; hot water will generally be found to be the most valuable; cold water is a more effectual stimulus, but few patients can stand it. The vaginal injection should be employed just before going to bed; the douche is preferable to Higginson's syringe (*v.* page 138). The injection should be continued from ten minutes to a quarter of an hour. It is a decided advantage to have the douche given with the patient in the *dorsal posture*, as Gallard recommends. Occasional warm baths are useful in some cases; when the patient is in the bath, the vaginal douche can be used at the same time with greater freedom and effect. A cold hip-bath every morning is the best stimulus to the circulation. *Medicinal baths* have a peculiarly beneficial effect in chronic metritis. Amongst those the first place has always been held by Kreuznach, the waters of which are specially rich in bromides and iodides. The baths at Kissingen are rich in carbonates, and are of a lower temperature than those of Wiesbaden and Baden-Baden which contain a smaller portion of salts.

Mineral
Waters in
Chronic
Metritis.

Further, the *drinking* of medicinal waters is also beneficial. The mineral springs at Ems and Vichy have, from their action upon the mucous membrane, always had a great reputation for the treatment of chronic uterine inflammation. Where there is much catarrh, they are specially serviceable. In scrofulous and chlorotic individuals, the advantage of waters which are rich in salts of iron is evident. Comparatively few of our patients, however, will be able to enjoy the luxury of a course of treatment at one of these watering-places; but much benefit will be derived from change of air to the sea-side, or to the regular regime and cheerful surroundings of a hydropathic.

Attention to the action of the bowels is all important. Accumulations in the rectum and sigmoid flexure of the colon favour passive congestion, and interfere with the appetite and digestion. The mineral waters—Friedrichshall, Carlsbad and Hunyadi Janos—are the best aperients.

The Carlsbad salts are specially useful in bilious patients; a teaspoonful should be dissolved in a tumblerful of water and drunk in repeated

sips during the morning. Friedrichshall and Hunyadi Janos waters act best mixed with an equal amount of hot water; their dose varies from a wineglassful to a tumblerful. A good substitute for these waters is the tonic and aperient prescription given on page 187.

The iodide and bromide of potassium are given internally, as recommended at page 185.

Great care, and in some cases complete rest, should be enjoined at the menstrual period. As exacerbations usually occur at these times, a great deal is done towards a cure by prophylactic measures in regard to this.

Of local treatment the most important is *counter-irritation* by occasional blistering or repeated application of iodine or of croton oil to the iliac regions. French gynecologists recommend the application of the blistering fluid to the cervix; we have had no experience of this method. Thomas speaks highly of it, and practises it in the following way. A large cylindrical speculum is passed, and the cervix cleansed and dried with a pledget of cotton. The preparation of vesicating collodion, made with acetic acid, is painted in two or three coats over the whole of the vaginal portion; after it has dried, a stream of cold water is applied to wash off any superfluous collodion. In eight or twelve hours there is a free discharge of serum. The patient remains quiet for some days, and uses occasional warm-water injections; a pledget of cotton wadding soaked in glycerine is applied afterwards. Many gynecologists apply iodine to the cervix and roof of the vagina; Scanzoni recommended a solution of 4 grs. of iodide of potassium in 30 mm. of glycerine. The simple tincture of iodine, or a solution of equal parts of iodine and glycerine, may also be applied in this way. *Local depletion* by scarification or leeches, as described under Endometritis, is less frequently employed than formerly.

In speaking of Emmet's operation, we mentioned that it was sometimes followed by diminution in the size of the uterus. Carl Braun¹ has shown that after *amputation of the cervix* for hypertrophy the uterus sometimes undergoes changes which resemble those which occur physiologically in the puerperal uterus. Martin of Berlin strongly recommends the amputation of the posterior lip; in a paper read before the German Scientific Association at Cassell, he gives the results of the operation in 72 cases in all of which the uterus was stimulated to undergo subinvolution.

Weir Mitchell's method of treatment by feeding and massage has given good results in cases of chronic metritis (*v. Special Chapter*).

¹ *Zeitschr. d. Ges. d. Wiener Aerzte*, 1864, s. 43.

CHAPTER XXXI.

DISPLACEMENTS OF THE UTERUS: ANTEFLEXION; ANTEVERSION; RETROVERSION; RETROFLEXION.

LITERATURE.

Barnes—Diseases of Women, p. 679: London, 1878. *Campbell, H. F.*—American Gynecological Transactions, Vol. I., 1876. *Duncan, Mattheos*—Diseases of Women, p. 352: London, 1883. *Emmet*—Gynecological Transactions, 1876. *Fritsch*—Die Lagerveränderungen der Gebärmutter, Billroth's Handbuch: Stuttgart, 1881. *Hart*—The Structural Anatomy of the Female Pelvic Floor. *Herman*—On the Relation of Anteflexion of the Uterus to Dysmenorrhœa: Lond. Obst. Tr., Vol. XXIII., p. 209. *Hewitt Graily*—The Mechanical System of Uterine Pathology: London, 1878. *Mundé*—The Curability of Uterine Displacements: Amer. Jour. of Obst., Oct. 1881. *Routh*—London Obst. Trans., Vol. XV., p. 252. *Ruge*—Zeitschrift für Geburtshülfe und Gynäkologie, 1878, Band II., p. 24. *Schroeder*—Krankheiten der weiblichen Geschlechtsorgane, S. 140, Wien, 1878. *Schultze, B. S.*—Volkmann's Sammlung klin., Vorträge, 50. *Simpson, Sir J. Y.*—Diseases of Women, pp. 253, 245, and 764, Edin. 1872. *Skene*—American Jour. of Obst., Vol. VII., 1874, p. 391. *Thomas*—Diseases of Women, pp. 363, 408, London, 1880. *Van de Warker*—The relation of symptoms to Versions and Flexions of the Uterus: Amer. Gyn. Trans., 1879, p. 334.

Preliminaries.

As the uterus is a movable organ within the pelvis, it is subject to various changes of *position*; as it is composed of muscular tissue, it is liable to alterations of its normal *curvature*. Both of these changes are described in English text-books as "displacements," although, strictly speaking, this term should be applied only to the former.

The normal form, position, and relations of the uterus have been already described (see Chap. II.)

The uterus is constantly exposed to forces producing a temporary displacement. In front there is the *bladder*, the dilatation of which displaces the uterus backwards and somewhat upwards (fig. 44). Behind there is the *rectum*, which normally should have little influence on the position of the uterus; but, owing to inattention to its regular evacuation, it is frequently over-distended and thus acts as a displacing cause operating from above and behind. Above there is the *abdominal pressure*, which is constantly acting on the uterus especially during inspiration. One has only to watch the movements of the anterior vaginal wall during respiration to see that this factor is always operating. Its action is of course increased by whatever increases the

intra-abdominal pressure, that is, by any straining efforts which bring the abdominal muscles into play. Below there is the *pelvic floor*, which has a constant action in supporting the uterus against the abdominal pressure.

We must distinguish between *physiological* and *pathological* displacements. The former is transient, and passes away when the cause has ceased to operate; the latter is persistent, and produces permanent alterations in form, position, and structure. It is difficult to draw the line between those two. The pathological condition is frequently due to simple overstepping of the limits of the physiological. Thus the carrying of the uterus backwards into a retroverted position by the distention of the bladder is physiological, while its remaining permanently in that position is pathological.

Physiological and Pathological Displacements.

It is evident that the uterus can be displaced in at least three ways: *first*, the different parts of it may alter their position relative to one another; *second*, it may rotate round the transverse axis; *third*, the organ may be displaced as a whole. Any great rotation round the vertical axis is prevented by the attachments of the uterus.

1. Alteration in the relative position of body and cervix constitutes *flexion* of the uterus, in which there is a change in the curvature of the long axis, *i.e.*, in the direction of the uterine canal. Definitions.

2. Rotation of the organ round an imaginary transverse axis constitutes *version* of the uterus.

3. Displacement of the organ as a whole, although frequently observed, has not been described in English works by a precise term. We might use the term *position* with the suitable prefix. Thus when the uterus lies "back as a whole" in the pelvis, it might be described as "a retroposition" or as "retroposed" (*Germ.*, retroponirt).

The uterus, in its normal condition, is anteflexed, anteverted, anteposed—placed as far forward as the bladder will allow.

Various deviations from the normal condition may occur.

(a.) There are three possible changes in *flexion*. To understand these, suppose the direction of the cervix to be fixed. The uterine axis may be (pathologically) anteflexed (fig. 194 a), so that the normal curvature is increased; this is sometimes associated with retroposition. The axis may become *straight*, as occurs in so-called anteversion (fig. 194 b). It may also be *retroflexed* (fig. 194 c); this condition occurs rarely by itself, but associated with retroversion it is a common displacement.

(b.) *Version* round a transverse axis is either forwards or backwards.

An increase of the normal *anteversion* (fig. 195 *a*) is not frequent; the condition generally so described is more often the result of straightening of the uterine axis (fig. 194 *b*). *Retroversion* occurs alone (fig. 195 *b*), and is further always present where there is retroflexion (fig. 195 *c*).

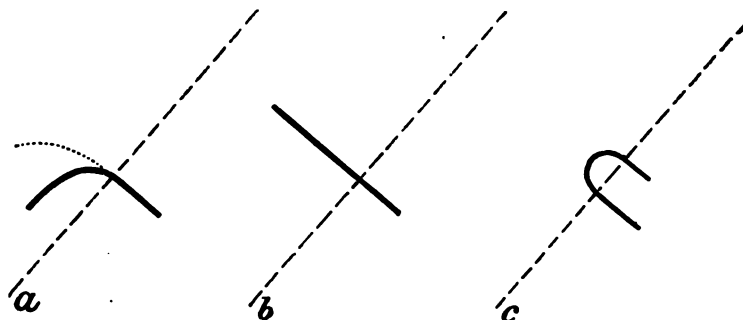


FIG. 194.

DIAGRAMMATIC SCHEME OF FLEXIONS. The broken line represents plane of brim; the dark line the axis of uterus; the dotted line its normal curvature. For letters see text.

The body of the uterus may also be drawn to either side of the pelvis, the cervix being directed to the opposite side. This constitutes *lateri-version*. Normally, the uterus is slightly lateri-verted to the right.

(c.) Change in *position*, or displacement of the organ as a whole, is

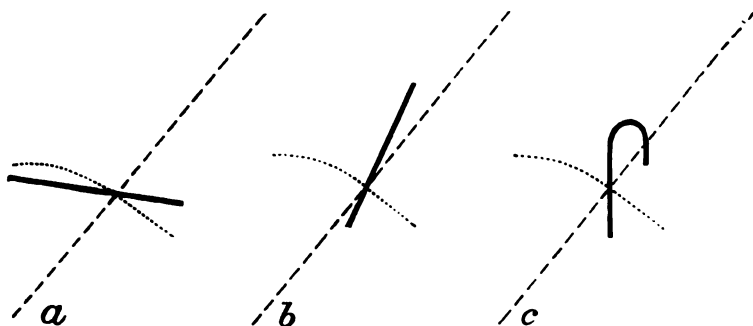


FIG. 195.

DIAGRAMMATIC SCHEME OF VERSIONS.

upwards, downwards, backwards, or to either side. *Upward* displacement occurs in pregnancy or whenever there is a tumour present which lifts the uterus out of the pelvis; it is of little pathological significance. *Downward* displacement occurs in prolapsus uteri, and will be discussed

under that head (Section VII. Affections of the Pelvic Floor). A change in position *backwards* or to *either side* is produced by pressure or by traction; when produced by cicatricial contraction, these are the most important conditions we have to deal with.

We have considered from a theoretical point of view the variations in flexion and version in detail, to enable the student to understand clearly what these terms mean. Too much importance should not be attached to slight variations; the student need only note the following points.

1. The normal curvature may be exaggerated—anteflexion.
2. The uterus may be straightened, the normal angle becoming less pronounced and thus throwing the cervix more backwards—anteversion.
3. The uterus may be directed backwards—retroversion.
4. It may not only be turned backwards but the normal angle may be reversed, the fundus being bent backwards instead of forwards—retroversion + retroflexion.
5. The uterus may be displaced as a whole, usually by cicatricial contraction. This last condition is the most difficult to treat.

The *etiology* of flexions and versions is a subject on which little Etiology. definite is as yet known. This is the more unfortunate as a knowledge of etiology is of first importance in rational treatment. We should recommend the student to enquire carefully into the origin and duration of the symptoms; and on making his physical examination not to be content with ascertaining merely that there is a displacement, but to find out if possible the cause. This will guide him both in prognosis and treatment; it will indicate what cases he may hope to cure, and what cases he should leave alone. A knowledge of etiology enables him to prevent the occurrence of displacements, as, for example, of retroversion in the puerperal condition; and in this case prevention is better than cure.

The *symptoms* of these displacements have given rise to much discussion, some maintaining that they produce no symptoms at all. We sometimes, on examining a patient, find a retroflexion which has not made its presence felt by any symptoms. This is however the exception; as a rule, backward displacements are followed by a train of symptoms. *This apparent contradiction is to be explained by the fact that flexions and versions, in themselves, give rise to no symptoms primarily.* The symptoms arise *secondarily*, and are due (1) to interference with the functions of menstruation, conception, and pregnancy; (2) to chronic metritis and endometritis which is produced by the

displacement; (3) to pelvic cellulitis and peritonitis, which frequently accompany the displacement and are often the cause of it.

Physical
Examina-
tion.

As regards the *physical examination*, it is evident that the position and direction of the cervix is not a guide to the position of the fundus. If we had simply to do with versions, we might compare the uterus to a lever of which the body would be the long and the cervix the short arm; and the direction of the short would indicate the position of the long arm. But the possibility of flexion introduces a joint on the lever, so that the direction of the short is no guide to the direction of the long arm. We cannot from a simple vaginal examination of the cervix infer the position of the fundus, which is the point to be ascertained. A careful bimanual examination, supplemented if necessary by the use of the sound, is essential for a diagnosis.

Treatment.

As regards *treatment* the student should recognise how many lesions are present, and whether they are causes or results; a frequent chain is that a cellulitis produces a displacement which is followed by metritis, endometritis, and ovaritis. In most cases there is more than one pathological condition present, and these must be treated in order. We first *check existing inflammation* by hot-water injections, blistering, rest, and the use of the glycerine plug. Ergot is given when menstruation is increased. When the absence of tenderness on examination has shown that inflammation is checked, we then—but not till then—think of treating the displacement. The time chosen should be between two menstrual periods. In backward displacement, we bring the uterus to its normal position and retain it there. In some cases of ante flexion we dilate or straighten the uterine canal. *The after-treatment requires more attention than the immediate correction of the displacement*, and months of careful watching are necessary. Thus, the keeping of the uterus in its place by a carefully adapted pessary is more important than the replacement; the keeping of the uterine canal open after Sims' operation is more important than the operation itself.

ANTEFLEXION.

PATHOLOGY.

Anteflexion, as has before been stated, is merely an exaggeration of the normal condition. As to its frequency, there is great difference of opinion. The reason of this diversity is that a degree of flexion which would be called pathological by one observer would still be called physiological by

another. The question of symptoms does not help us in deciding this; because, on the one hand, we sometimes find an amount of flexion which is decidedly pathological although the patient does not complain of any special symptoms; on the other hand, symptoms often described as characteristic are due to a different cause. *Anteflexion is more common in nulliparæ* just as retroflexion is more frequent in multiparæ, the reason being that anteflexion is a frequent cause of nulliparity.

The usual *seat of the flexion* is at the upper portion of the cervix, or at its junction with the body. Flexion of the body itself is rare. Sometimes the cervix is bent sharply forwards, so that it lies in the axis

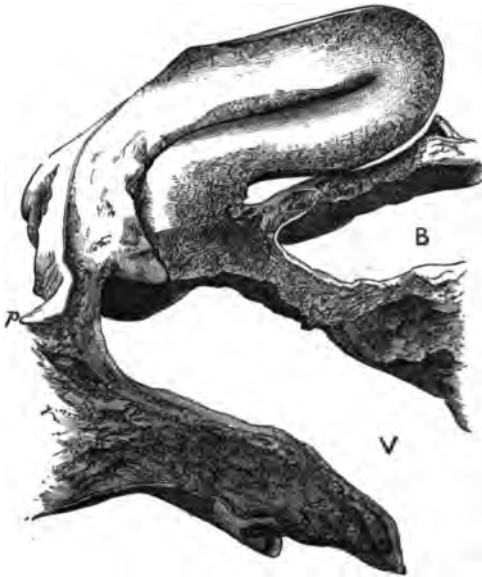


FIG. 196.

ANTEFLEXION WITH STENOSIS AT OS EXTERNUM. *V* vagina, *B* bladder, *p* peritoneum of pouch of Douglas (*Winkel*).

of the vagina and forms a distinct right angle with the body which is approximately in its normal position (see fig. 196). In other cases, the uterus is sharply curved on itself (see figs. 40 and 197). This last condition is sometimes mistaken for retroversion, because the finger feels through the posterior fornix the supra-vaginal portion curving backwards and the position of the fundus is not ascertained till the bimanual examination is made. In such cases the examination with one finger in the rectum is useful, as we can thus get above the point of flexion and feel that the fundus turns forwards.

The vaginal portion is frequently small and the os reduced to a pin hole (congenital cases); sometimes it is high up and difficult to reach, being drawn upwards and backwards by cicatricial bands. As regards the microscopic changes in the tissue, we are still in want of information.

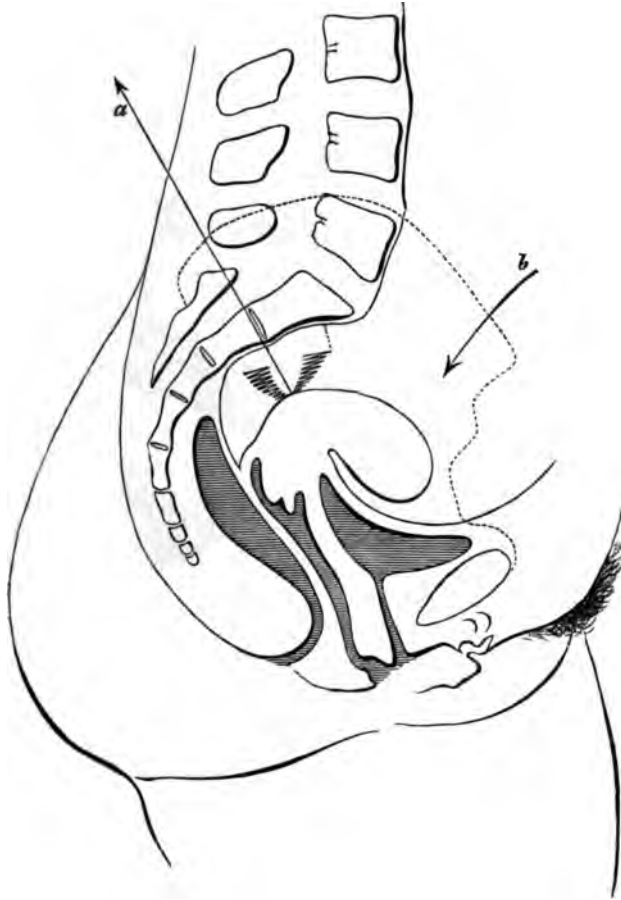


FIG. 197.

DIAGRAM TO SHOW ANTEFLEXION PRODUCED BY CICATRISATION OF UTERO-SACRAL LIGAMENTS (Schultze).

Virchow found no fatty degeneration of muscular fibre at the angle of flexion; the tissue was anæmic at this point but congested elsewhere. According to Rokitansky, the connective tissue framework of the uterus is thinnest at the os internum; hence the liability to flexion at this point.

ETIOLOGY.

Etiologically we distinguish two kinds of antelexion, the congenital and the acquired.

In cases in which the antelexion is *congenital*, the whole uterus is imperfectly developed, the cervix is small and the pin-hole os looks downwards and forwards. Fritsch gives an ingenious explanation of how the flexion is produced in such cases. The uterus of the new-born child has thin walls and is flexible: the intra-abdominal pressure acts on the posterior surface of the fundus and produces antelexion; this action is counteracted by the bladder on which the uterus is, as it were, moulded; when the uterus remains small and thin walled, it does not offer such a large surface to the bladder so as to be raised by it and have its flexion undone. Accordingly, a pathological degree of antelexion is produced. The same writer would also refer some cases to congenital shortening of the utero-sacral ligaments.

As regards *acquired* antelexion, it is undoubtedly often the result of inflammatory changes behind the uterus. In many cases of antelexion, we observe that the cervix is higher than its normal position and far back in the pelvis; and that the attempt to bring it to its normal position produces pain. The cause of this condition was first brought into notice by Schultze,¹ who ascribes it to a cellulitis in the utero-sacral ligaments. This produces cicatricial contraction so that the cervix is drawn upwards and backwards, and the fundus thrown more forwards. Schroeder, however, holds that the retraction of the cervix is produced by adhesions resulting from peritonitis. We draw attention specially to this cause of antelexion, because it can be distinctly made out by careful examination. When it has been made out it is a contra-indication to hasty operative interference, and the prognosis as to cure is unfavourable.

Graily Hewitt refers this, as all other flexions, to the softness of the uterine tissue.

It is alleged that a fibroma, or other tumour increasing the weight of the fundus, will favour antelexion if the fundus be directed forwards. In the commencing enlargement of pregnancy, the fundus droops more forwards or is at least more distinctly felt in the anterior fornix.

Unequal growth of the uterine walls has been given as the cause of congenital flexions, and unequal involution of the walls as the cause of flexions acquired during the puerperium. This is merely an explana-

¹ Loc. cit., S. 414.

tion of how it is produced ; the cause of this unequal growth requires, in turn, an explanation.

SYMPTOMS.

The most important symptoms are—

Dysmenorrhœa,
Sterility.

In addition to these there are sometimes present—

Leucorrhœa,
Menorrhagia.

Frequently there are the ordinary symptoms of pelvic inflammation.

In some cases we find a well-marked anteflexion giving rise to no symptoms which patients complain of, as they are not accustomed to speak of sterility as a symptom ; but dysmenorrhœa is generally present, and is the symptom which leads the patient to seek advice.

Dysmen-
orrhœa.

Dysmenorrhœa. By this we understand that menstruation is accompanied with pain. The form of dysmenorrhœa present in anteflexion is called "uterine," in contradistinction to "ovarian" (see Dysmenorrhœa, Section VIII.) By "uterine dysmenorrhœa," we understand that the pain is not marked until the menstrual flow has appeared and that it continues as long as the discharge continues. The pain is felt in the small of the back and sometimes in the pelvis generally, but is not localised in one ovarian region. In typical cases, the pain resembles labour pains and the menstrual blood is clotted.

Two different explanations of this pain have been given, and these have an important bearing on treatment. For convenience we describe these as the obstruction and the congestion theories.

Mechanical
theory.

1. The *obstruction* or *mechanical theory* is the one most generally accepted, and furnishes the rationale of the operative modes of treatment introduced by Sir J. Y. Simpson and Marion Sims. According to this explanation, the flexion of the uterus produces a narrowing of the uterine canal at the point of flexion. Hence, when the menstrual decidua and blood are shed, they find an obstacle to their free exit. There is consequent retention and coagulation, and the coagula stimulate the uterus to muscular contractions to effect their expulsion. The mechanical resistance to the outflow of blood and the uterine contractions excited to overcome this, are the cause of the pain. The condition is comparable to that in stricture of the male urethra. The blood, like the urine, is secreted but cannot be passed without pain ; there is dilatation with sometimes secondary hypertrophy of the uterus in the former case, as of

the bladder in the latter. It may fairly be objected to this mechanical explanation that the discharge is not always clotted, that in some cases it is very small in quantity, that it is doubtful whether the blood coagulates in the uterus, and that in many cases the pains complained of have not the distinctive character of labour pains. On the other hand, if this theory be not the true one, it is difficult to explain the occasional benefit derived from various modes of treatment based on it to be presently described.

2. The *congestion theory* is clearly stated and advocated by Fritsch.¹ Congestion theory. According to this gynecologist, the dysmenorrhœa is not due directly to the bend on the canal. The pain arises from the resistance which the muscular tissue of the uterus offers to the hyperæmia. In normal cases, this tissue yields to the distending vessels ; but, when the uterus is small or bent on itself, there is an obstruction offered to the flow of blood. The mucous membrane cannot swell up as it does normally. Thus there is undue vascular tension and compression of the nerve endings in the uterus. This last causes the pain.

Whether this explanation harmonises better with the facts it is difficult to say ; but we should suggest a modification of Fritsch's views, which the student might combine with the purely mechanical theory. The flushing of any diseased tissue with blood causes an aggravation of pain, which is increased if the tissue be of a dense structure. The cause of the intense pain in periostitis as the affected limb becomes warm in bed, is thus explained. Now the tissues of the uterus are frequently in a state of chronic inflammation, and there is sometimes increase of connective tissue making it of a less yielding structure ; this occurs in retroflexion complicated with subinvolution. The monthly flushing of the pelvis with blood would, under these circumstances, be accompanied with pain. We must also remember that cellulitis and peritonitis are often present with antelexion ; and increase of pelvic congestion will, of course, produce increase of pain.

Sterility is frequently associated with antelexion ; the patient is not Sterility. so likely to refer to it, as the dysmenorrhœa is the more pressing symptom and that for which she seeks advice. This symptom has been referred to the obstruction in the uterine canal ; as the menstrual blood is prevented from passing downwards, so the spermatozoa are prevented from passing upwards. But it is evident that this mechanical explanation is insufficient, because no mere contraction could prevent the passage of microscopic

spermatozoa ; without doubt sterility is frequently the result of the binding down of the ovaries or the Fallopian tubes by concomitant inflammation. However we explain it, the clinical fact remains that by passing the sound or dividing the cervix we place the patient under more favourable conditions for conception.

Dyspareunia—pain on sexual intercourse—is occasionally an important symptom, though naturally the patient does not refer to it. In such cases we generally find that there is inflammatory action behind the cervix.

Leucorrhœa is generally present, more especially if the uterus be enlarged. It is not so important a symptom as it is in retroflexion.

Menorrhagia is sometimes present, when there is uterine enlargement or endometritis as the result of ante flexion.

PHYSICAL DIAGNOSIS.

On making the vaginal examination the cervix is felt to be high up, and lies in the axis of the vagina with the os looking downwards and forwards. It may be small and conical with a pin-hole os (congenital, *v.* fig. 147); or the anterior lip may be elongated, the end of the cervix being at the same time somewhat flattened against the posterior vaginal wall. The body of the uterus is felt in the anterior fornix continuous with the cervix, with which it forms a distinct angle in which the tip of the finger may be placed. If the flexion be high up or the uterus drawn upwards, the body may not be felt on simple vaginal examination. Even if it be felt, we cannot be certain that it is the body of the uterus till the Bimanual is made as follows. Endeavour to get the body felt in the anterior fornix fairly between the hands ; by examining all round, make sure that what is grasped is the body of the uterus. Now place the index finger under the fundus in front of the angle and the middle finger against the cervix, and making pressure with the external hand, ascertain to what extent the flexion yields. Examine carefully the posterior fornix to see if there are any bands drawing the cervix backwards ; try whether bringing the cervix forcibly forwards causes pain, which would indicate an inflammatory condition in the utero-sacral ligaments or the presence of adhesions in the pouch of Douglas. We can ascertain this even better by passing the middle finger into the rectum, the index finger being in the vagina, and at the same time making the bimanual examination. The finger in the rectum feels a pouch in the anterior rectal wall bounded by a tense band on each side (utero-sacral ligaments), or one or more cord-like adhesions (the result of former peritonitis), or a general resistance to

pressure which produces pain. Any of these conditions indicates that the cause has been inflammation, which has produced cicatrisation behind the cervix.

Though the bimanual examination is in many cases sufficient, it may be supplemented by the use of the sound. This is necessary for differential diagnosis, and its frequent introduction constitutes one form of treatment. Curve the sound to correspond to the angle of flexion. It will be found to pass with comparative ease for about an inch or an inch and a half, and then it is stopped by the angle of flexion. To get it past this, press up the fundus through the anterior fornix with the finger in the vagina or draw down the uterus with the volsella. The sound shows that the length of the uterine cavity is sometimes diminished (congenitally small uterus), sometimes increased (the result of the obstruction to the out-flow of menstrual blood). It may further show tenderness in the uterine cavity (endometritis). The use of the sound is undesirable where there is inflammation behind the uterus and, when the Bimanual places the diagnosis beyond doubt, is unnecessary except for treatment.

DIFFERENTIAL DIAGNOSIS.

The only conditions which, after careful examination, might yet be mistaken for an antelexion are—

- Myoma in the anterior uterine wall,
- Cellulitis between the cervix and the bladder—a very rare condition.

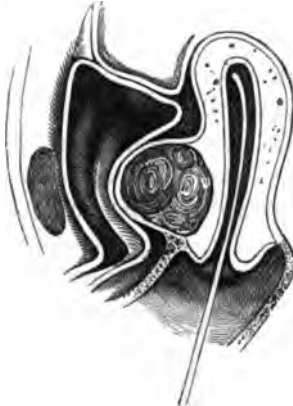

FIG. 198.

SOUND PASSED TO SHOW THAT A MYOMA OF THE ANTERIOR WALL IS NOT AN ANTEFLEXION ; the bladder is to the left (*Leblond*).

A *myoma* is easily diagnosed by the sound. As in antelexion, a body

Diagnosis
from
Myoma,

is felt in the anterior fornix ; and we must ascertain whether this body is the fundus uteri. When the sound is passed into the uterus (fig. 198) in a case of myoma, a finger in the anterior fornix does not feel the sound or feels that a body lies between it and the instrument. Now make the bimanual examination with the sound in the uterus ; the position of the fundus is indicated by the external hand feeling the point of the sound.

from
Cellulitis.

The diagnosis from *cellulitis* is less easy, because through the tenderness it is difficult to ascertain whether the body felt in the anterior fornix is the fundus uteri or a cellulitic deposit. A careful bimanual examination will, if it be a cellulitic deposit, show that the fundus uteri is lying in some other position. When active inflammation is present, the use of the sound is contra-indicated.

PROGNOSIS.

The prognosis should always be guarded in respect of the disappearance of symptoms. The most favourable cases as to a cure are those where the antelexion is congenital, is situated low down, and where there is no pelvic inflammation.

TREATMENT.

Pelvic inflammation, if present, must first be treated. Where the uterus is displaced by cicatricial bands, the stretching of these by massage has been suggested and is worthy of trial. With two fingers of the right hand in the posterior fornix behind the cervix and the external hand pressed deeply into the hollow of the sacrum so as to get behind the fundus uteri, we manipulate the uterus between the hands so as to bring it near the pubis and thus stretch the adhesions behind it. Massage is accompanied with free use of the vaginal douche. This process is repeated at weekly intervals, but is stopped if inflammation ensues.

A considerable number of cases are benefited by operative treatment ; but we must select the cases on definite principles.

Contra-
indications
to opera-
tive treat-
ment.

1. We should not operate if there be active inflammation present, as indicated by tenderness on pressure in the fornices. The presence of an old cellulitic deposit or thickening of the pelvic peritoneum is not a contra-indication.

2. We should not operate if the whole uterus is congenitally small. The introduction of a uterine stem in such cases may stimulate the uterus to increased growth ; if dysmenorrhœa be present, the mere correcting of

the flexion will not probably cure it; the sterility is probably due to some other effect of the arrested development. Such cases should be left alone. Nor should we operate when the menstrual flow is gradually diminishing in quantity.

To understand the *methods of operative treatment*, let us compare them with those of stricture of the male urethra. Here we have three modes of treatment: we may dilate the stricture by passing instruments of gradually increasing size; we may pass an instrument and leave it, thus producing vital dilatation; if both of these means fail, we may divide the stricture with the knife. For the treatment of anteflexion, we have three analogous methods: we pass the uterine sound occasionally, or pass uterine dilators of gradually increasing calibre; we introduce an intra-uterine stem, and leave it in; we divide the constricting portion of the




FIG. 199.

SOLID INTRA-UTERINE STEM MADE OF COPPER.

canal at the os externum, and the knee-shaped bend at the point of flexion.

1. The occasional *introduction of the sound*, say twice-a-week between the menstrual periods, is sometimes followed by distinct relief of the symptoms. It has the advantage of being easily done, is seldom followed by injurious effects if done with ordinary care, and should always be tried in the first instance. Dr. Mackintosh employed sounds (made of steel) of gradually increasing calibre to dilate the canal more effectually. Treatment
by Sound,

2. Where the flexion is not acute or resistant, the *intra-uterine stem* is useful. It serves both to straighten the canal and also to keep it open. The copper intra-uterine stem (see fig. 199) introduced by Sir J. Y. Simpson, or one of similar form made of vulcanite which has the advantage of being lighter, or the hollow gutta-percha one (see fig. 200) recommended by Greenhalgh (which acts like a drainage tube), may be used for this purpose. In employing the rigid intra-uterine stem, we must see that the stem is a quarter of an inch shorter than the uterine canal so that it may not press injuriously upon the fundus. Greenhalgh's by Stems,

stem is carried in on the ordinary uterine sound. For the method of introducing the rigid stem see page 253. The stem can be worn for months; it need not be removed during the menstrual period, but should be taken out when there is suspicion of pregnancy. Conception sometimes takes place with the stem *in situ*. Even the judicious use of stem pessaries is apt to be followed by mischief; they require, therefore, careful watching.

by division
of Cervix.

3. If both of these means of treatment fail, we have recourse to division of the cervix. In some cases, it is evident from the first that

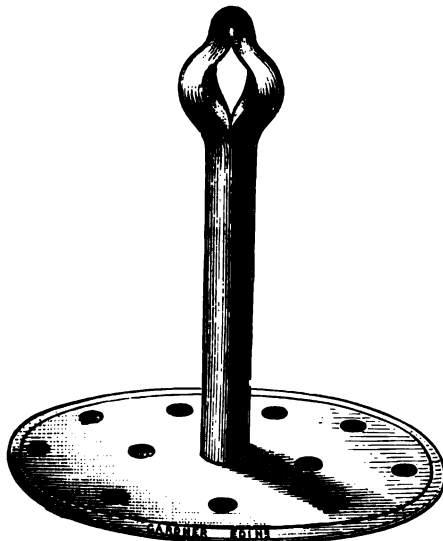


FIG. 200.

GREENHALGH'S INTRA-UTERINE STEM.

this is the proper mode of treatment; it is sometimes followed by brilliant results. There are two distinct modes of procedure, each adapted to a particular class of cases. There is (1) the bilateral division of the cervix introduced by Sir J. Y. Simpson; and (2) the antero-posterior section of the posterior lip with division of the mucous membrane of the anterior wall of the cervix at the seat of flexion, introduced by Marion Sims.¹

Sir J. Y.
Simpson's
method.

(1.) When there is a small pin-hole os and the flexion not pronounced (the symptoms being due to the narrow os externum), or when sterility rather than dysmenorrhœa is the leading symptom, the indication is

¹ For fuller details, see his paper: "On the Surgical Treatment of Stenosis of the Cervix Uteri."—*Am. Gyn. Trans.*, 1878.

for Simpson's operation. This has been already fully described under Stenosis of the Cervix (Chap. XXIV.)

(2.) Marion Sims recommends that his operation be performed in Marion Sims' method. cases where there is well-marked flexion, and the intra-vaginal portion unequally developed, *i.e.*, where the posterior lip is elongated so that the os looks downwards and forwards. The intention of the operation is to correct the flexion of the canal by making the exit at the base of the posterior lip of the cervix instead of at its apex, that is, at the outer end of the dotted line *a* (fig. 201). But as the flexion is too high up to be reached by this incision alone, it is necessary for the more complete straightening of the canal that the tissue of the knee-shaped bend in the

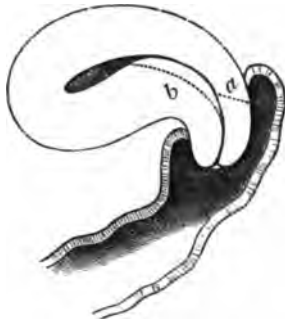

FIG. 201.

SIMS' DIVISION OF CERVIX ; *a* incision in posterior lip, *b* incision at knee of flexion (*Marion Sims*).

anterior wall be partially divided—the incision to be made to the depth of the line *b* (fig. 201).

This operation should not be performed indiscriminately in all cases of uterine dysmenorrhœa, but only after we have ascertained by careful examination that the flexion is sufficient to account for the dysmenorrhœa and that the latter is due to nothing else. The patient should be informed that sometimes the symptoms return afterwards ; this is due to the partial closing up of the incision, which may occur in spite of the greatest precautions. When pelvic inflammation is present, we should not operate. If the cervix is drawn backwards and fixed, we are not likely to have a good result.

The operation is performed as follows. The speculum having been passed, the cervix is drawn downwards with the volsella. Marion Sims divides the posterior lip with his uterotome. A pair of strong scissors does equally well. Kuchenmeister's scissors have the point

of one blade turned in like a hook; this blade is placed externally in making the section, and the pointed hook keeps the scissors from slipping. The scissors in fig. 111 have this peculiarity; and the form of the handles, with their greater length in proportion to that of the blades, gives the hand better purchase and enables the operator to cut steadily through the dense tissue of the cervix. The instrument is passed, with the straight blade in the cervical canal, till the incurved point of the external blade is opposite the line of reflexion of the mucous membrane on the posterior wall of the vaginal portion. The handles are now approximated, the ratchets on them enabling us to do this slowly and steadily. When they are brought together, the instrument is withdrawn. The finger is passed into the cut to see if it is of sufficient depth; if any projecting band of tissue be felt, it is divided with the knife. The mucous membrane of the anterior wall of the cervix at the seat of flexure is now divided as follows:—A curved tenotomy-knife, with a narrow probe-pointed blade, is passed into the canal; the sharp edge is turned forwards, but the back of the knife is pressed against the posterior wall so that the knife does not cut on being passed in; having passed it fairly to the point of flexion, we now withdraw it and at the same time press the blade forwards. We judge as to the extent of this incision from the amount of flexion present (ascertained by previous examination) and from the sensation of the hand in cutting through the tissue.

After-treatment.—The incision must be kept open by the introduction of a glass plug (fig. 157). Unless this be done, the result is only temporary; we speak from experience, having operated in several cases without the introduction of a plug subsequently. The patients in these cases derived great benefit for two or three menstrual periods, but after this the symptoms returned; and it was found, on examination, that the new opening had been obliterated by cicatrisation. The vagina is then douched and packed with lint soaked in carbolised oil.

Treatment
by Pessaries.

The treatment of ante flexion by specially adapted vaginal pessaries is recommended by Thomas and others, but is not a scientific one. It is wrong in principle, because the fundus uteri cannot be propped up by an arm of the pessary projecting through the anterior fornix so as to diminish the angle of flexion. In some cases where the uterus is large and heavy we find that benefit is derived from supporting the uterus as a whole. But this is best effected by an ordinary vaginal pessary (Hodge or Albert Smith), and is not a mode of treatment specially of ante flexion. We shall refer to this again under the treatment of anteversion.

ANTEVERSION.

PATHOLOGY AND ETIOLOGY.

The *pathological change* consists in a straightening of the uterine axis, so that the normal angle of forward curvature is diminished and the cervix passes more directly backwards. The uterus is usually enlarged and its texture is firmer. In this condition it is movable or fixed. If the former, its position varies with the distention of the bladder; if the latter, the fixed uterus will press more or less on the bladder as it distends and thus produce one of the symptoms of anteversion.

According to Fritsch, the fixation of the uterus is never to the pubis; this is because the bladder, lying between the fundus and the symphysis, prevents adhesions from forming. On post-mortem examination of a case in which he had diagnosed anteversion with fixation, he found that the fundus was bound down at its left angle.

ETIOLOGY.

As anteversion is *the form and position taken up by the uterus when it is enlarged through chronic metritis*, the causes which produce anteversion are those which produce chronic metritis—subinvolution, laceration of the cervix, and other causes of pelvic inflammation (*v.* Chronic Metritis). Significance of Anteversion.

This position also occurs physiologically in early pregnancy; probably because the increased weight of the uterus causes it to fall more forwards.

SYMPTOMS.

There are no symptoms characteristic of anteversion, *per se*, but we generally find present, in the first place, the local symptoms of chronic uterine and pelvic inflammation.

Thomas draws attention specially to loss of power in walking—when the version was treated, power was restored; this was probably a reflex phenomenon. Sometimes there are symptoms due to interference with the functions of the bladder and the rectum. Pressure of the fundus (when the uterus is *fixed*) on the bladder produces frequent calls to micturition; pressure of the cervix on the posterior wall of the vagina produces erosion and catarrh, and on the anterior wall of the rectum produces painful defæcation. The last two are very doubtful.

Further, we may have the train of general symptoms which follow

on any long-standing disturbance of the reproductive system, viz., derangements of the digestive and nervous systems. Schroeder draws attention to the fact that discomfort is often produced when the uterus is enlarged but freely movable, and that this is due to the heavy organs becoming displaced on the movements of the patient; further, that it is relieved if the uterus is fixed by a vaginal ring pessary.

DIAGNOSIS.

There is usually no difficulty in diagnosis. The finger in the vagina feels the cervix passing directly backwards, the os looking towards the hollow of the sacrum. The body of the uterus is distinctly felt through the anterior fornix; and on tracing it back to its junction with the cervix, we do not feel the normal forward curvature. The whole organ is usually enlarged and firm in texture. From the distinctness with which the uterus is felt when the bladder is empty, we might infer that only the anterior vaginal wall lay between it and the finger. But, if we make the examination when the bladder is partially distended or if we pass the sound into the empty bladder, we find that the bladder passes backwards almost as far as the cervix uteri. Perhaps the bladder symptoms, which are present in marked cases, might be explained through the traction thus made on the bladder and its abnormal position; these interfere with its dilatation.

Bladder symptoms in Ante-version.

The bimanual examination shows that the body felt in the anterior fornix is the fundus uteri. The student should not however be content with this knowledge, but should examine carefully the size and mobility of the uterus; and, when it is fixed, should ascertain the cause of this.

The introduction of the sound is difficult on account of the high position of the os, and its use is unnecessary except in cases of doubt as to whether the body felt anteriorly is the fundus uteri.

The only case in which there is difficulty in differential diagnosis is when there has been inflammatory deposit in front of and around the cervix, simulating the anteverted fundus. In these cases the combined examination is difficult from existing inflammation. The examination with one finger in the rectum enables us, in such cases, to ascertain that the fundus uteri is at least not lying to the back.

TREATMENT.

From what we have said in regard to the symptoms, it follows that the treatment, in the first instance, is that of endometritis, metritis,

cellulitis, or peritonitis, according to the condition which is present. As regards the supporting of the uterus, great benefit may be derived

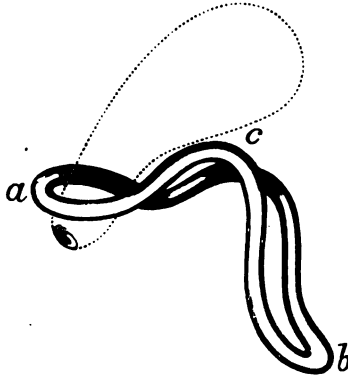


FIG. 202.

GRAILY HEWITT'S CRADLE PESSARY. *a* is in posterior fornix; *b* at vaginal orifice; *c* in anterior fornix (*Barnes*).

from the glycerine plug, which in this case should be well packed into the posterior fornix. The simple vaginal pessary (*Hodge, Albert*




FIG. 203.

GEHRUNG'S ANTEVERSION PESSARY *in situ* (*Gehrung*).

Smith, ring) is useful in supporting the uterus as a whole, and in fixing the cervix.

Ante-
version
Pessaries.

As already said under anteflexion, the fundus cannot be immediately supported through the anterior vaginal wall. Various forms of pessary have been devised, but none can be recommended. There is the Hewitt's "cradle pessary" of Graily Hewitt (fig. 202), made of vulcanite.

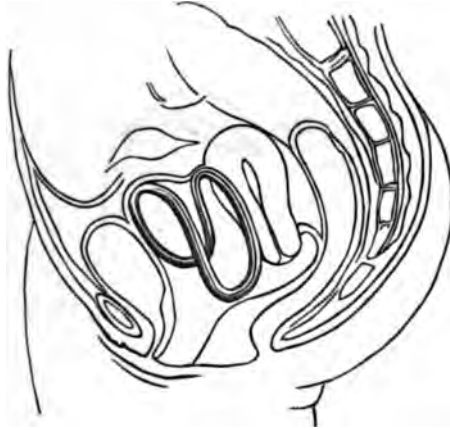

FIG. 204.

GEHRUNG'S ANTEVERSION PESSARY AS PLACED BY MUNDÉ. The Pessary is figured relatively too large (Mundé).

Gehrung's. Mundé strongly recommends Gehrung's anteversion pessary (fig. 203). Its position in the vagina is seen at fig. 204. Thomas has devised several forms of anteversion pessary, of which one is represented at Thomas'. fig. 205. It is simply a Hodge pessary, with a projecting bar which




FIG. 205.

THOMAS' ANTEVERSION PESSARY.

passes into the anterior fornix and tilts the cervix forwards, and thus slightly retroverts the fundus. To facilitate its introduction the bar moves on a hinge so that it may be brought parallel with the pessary as it is passed in, while a concealed india-rubber spring brings it into place when it is within the vagina. The patient requires careful watching

after its introduction, as it is liable to set up pelvic inflammation. Several cases are recorded by Thomas of benefit derived from wearing such a pessary.

We have described anteversion as one of the displacements of the uterus. The student should note, however, that anteversion is in itself not a lesion but one of the "physical signs" of metritis, chronic pelvic peritonitis or pregnancy. It is improbable that the mere anteversion of the uterus causes any distress. The ordinary statement that the uterus when anteverted presses on the bladder, is open to the fatal criticism that the uterus always presses on the bladder; while, so far as mere weight is concerned, there are, in the majority of cases, no special symptoms referable to the anteversion of early pregnancy. Any enthusiastic believer in anteversion pessaries is bound to insert them in all cases of early pregnancy. Probably, in a few years, anteversion will cease to be considered among uterine displacements.

RETROVERSION.

PATHOLOGY AND ETIOLOGY.

Physiological retroversion occurs whenever the bladder is fully Physio-
distended (*v.* fig. 44). This is distinguished from the pathological Retro-
condition by the fact that it is transient, and ceases when the bladder version.
is emptied.

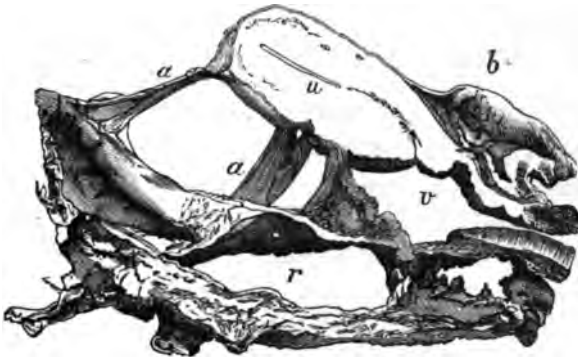


FIG. 206.

UTERUS RETROVERTED AND BOUND BACK BY PERITONIC ADHESIONS (*Winkel*). *a a* adhesions; *b* bladder; *v* vagina; *u* uterus; *r* rectum (*l*).

Pathological retroversion is found under the following conditions.

1. During the first days of the puerperium the uterus lies retroverted, or at least retroposed. The weight of the uterus and the laxity of its version.

Patho-
logical
Retro-

attachments makes it occupy this position when the patient is recumbent.

2. It is produced by the mechanism of prolapsus uteri (*v.* Section VII.) The axis of the uterus changes its direction as the organ descends.

3. It is also of importance as a stage in the production of retroflexion, which is the most frequent and important displacement which calls for treatment. The uterus becomes retroverted, and then acquires a backward flexion.

4. Chronic peritonitis producing obliteration of the pouch of Douglas, or cicatricial bands which drag the uterus backwards, will produce a permanent retroversion—as is beautifully shown in the accompanying preparation from Winckel's Atlas (fig. 206).

The chief causes of retroversion are :—

1. A sudden straining effort, or a violent blow ;
2. Non-return of the uterus to its normal form and position during the puerperium ;
3. Inflammatory action behind the uterus, producing adhesions or cicatricial bands.

SYMPTOMS.

The symptoms of retroversion are the same as those found in retroflexion, to be presently described. When it arises during the puerperium, a late flooding—two to three weeks after labour—is sometimes a prominent symptom ; or there is a daily loss of blood in small quantities whenever the patient rises and goes about (*Fritsch*).

DIAGNOSIS.

On vaginal examination, the cervix is low down in the pelvis and the os looks downwards and forwards. The finger feels the supra-vaginal portion of the cervix through the posterior fornix and may be able to reach the fundus, but the posterior surface is straight—there is no angle of flexion.

Bimanual
in Retro-
version.

On bimanual examination, the hands can meet in the anterior fornix with nothing but the vaginal and abdominal walls between them. It is difficult to make out the body of the uterus ; we may try to do this in two ways. *First*, with one finger in front of the cervix and the other behind it, lift the uterus upwards towards the abdominal walls ; the hand placed on the abdomen will feel the anterior surface of the body of the uterus moving under it. *Second*, tilt the cervix well

forwards with the index finger in the vagina, and thus increase the retroversion; the middle finger will feel the body of the uterus through the posterior fornix.

The rectal examination is of great service here. The sound will pass as in fig. 93.

The differential diagnosis is the same as in retroflexion. The only point requiring special notice here is that we may have a retroversion with an antelexion high up. Cases of antelexion due to cicatrisation of the utero-sacral ligaments are often, from the backward direction of the cervix, diagnosed as a retroversion (*v. p.* 319).

TREATMENT.

This consists in (1) removing existing inflammation; (2) replacement of the uterus, when not fixed by adhesions; (3) retention of it in its normal position by pessaries. These will all be considered under retroflexion.

When adhesions are present, it is better not to interfere; or we may be content by supporting the retroverted uterus with a pessary.

RETROFLEXION.

For convenience this condition is usually called "Retroflexion," to distinguish it from "Retroversion" already described; strictly speaking the condition is **RETROVERSION + RETROFLEXION**.

PATHOLOGY.

The pathological changes in the position and structure of the organs in the pelvis consequent on retroversion + retroflexion, can only be learned from sections made with the organs *in situ*. An exact knowledge of these changes is very desirable, as this displacement, with its accompanying complex train of symptoms, is one of the most important which comes under the notice of the gynecologist.

The following facts are based more on clinical examination than on pathological study. The changes in the various structures will be considered separately and shortly.

The *cervix* is directed downwards and forwards, or directly downwards (*v. fig.* 209). We observe clinically that it is much more easily reached. This is due partly to the alteration in its direction and position (being nearer the symphysis pubis it is more within reach), partly to the sinking

down of the uterus as a whole in the pelvis. The os is patulous, because retroflexion usually implies previous parturition. If deeply fissured, it may form a gaping cleft which readily admits the tip of the finger. There is often ectropium and cervical catarrh. Sometimes there is marked hypertrophy of the posterior lip, so that it is mistaken for the projection of the whole vaginal portion.

The *uterus* is flexed on itself, so that the fundus lies in the pouch of Douglas, the depth to which the fundus descends and the acuteness of the angle of flexion varying in different cases (*v.* figs. 207 and 209). If the condition of the uterine walls offers no resistance to flexion, the intra-abdominal pressure will tend to drive the fundus downwards till equi-

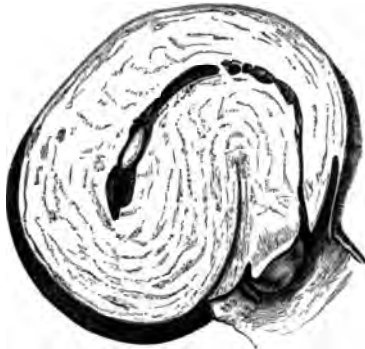

FIG. 207.

EXTREME RETROFLEXION OF UTERUS (*Barnes*).

brium is maintained—that is, till the fundus rests in the bottom of the pouch of Douglas. In retroflexion, there is no counteracting force operating from below similar to that of the distending bladder in ante flexion.

Condition
of Uterus
in Retro-
flexion.

The size of the uterus is increased, and its cavity measures more than two and a half inches. Since the flexion generally occurs while the uterus is still enlarged through subinvolution, it is difficult to say whether this hypertrophy arises as the direct result of the displacement or through its interfering with the process of involution. Whatever the cause of this hypertrophy is, its effect is to interfere with the natural cure of the displacement. The thickness of the uterine walls at the angle of flexion varies in different cases. Sometimes neither wall is atrophied at the point of flexion (fig. 207). Barnes says that according to his clinical experience this is the usual condition. On the

other hand, Fritsch states that he has found marked thinning of the posterior wall at the angle of flexion. It is interesting to note that in a case of *congenital retroflexion* (see fig. 208) described by Ruge it is the *anterior wall* which is atrophied at the angle. The mucous membrane of the uterus is generally in a condition of chronic catarrh.

The microscopic changes consist in a dilated condition of the bloodvessels, with increase of connective tissue—the appearances produced by long continued passive congestion. At the point of flexion, however,

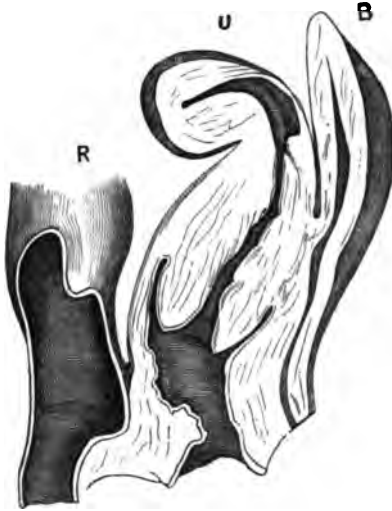

FIG. 208.

CONGENITAL RETROFLEXION (Ruge). Note the thinning of the anterior wall of the uterus.

an opposite condition has been described; the bloodvessels were compressed and the tissues atrophied.

The *ovaries* follow as a rule the displaced fundus, the thin infundibulo-pelvic ligament stretching more readily than the ovarian. The position of the ovaries will, however, depend on the effects of peritonitic adhesions, which may fix them in any position. Sometimes we feel them below the fundus in the pouch of Douglas. They are frequently enlarged and tender on pressure.

The *bladder* is not necessarily altered in position, but has no longer the uterus resting upon it. The utero-vesical pouch is obliterated in cases of well-marked retroflexion. The ureters are often compressed or bent, which leads to dilatation; frequently they are found dilated to the thickness of the finger. Fritsch observed in one case the left ureter

Ovaries in Retroflexion.

Bladder in Retroflexion.

obliterated by a mass of cicatricial tissue, and the corresponding kidney changed into a sac full of white atheromatous debris.

The *rectum* may have the retroflexed fundus pressing against its anterior wall.

The *peritoneum* is altered in its normal relations as follows. The broad ligaments have their surfaces reversed, that is to say, the anterior, which was formerly inferior, is now superior; from their attachments, they offer no obstacle to retroflexion. The utero-vesical pouch is necessarily obliterated. The pouch of Douglas must, on the other hand, be distended by the fundus uteri; this implies a *stretching of the utero-sacral ligaments* associated with the alteration in position of the cervix.

The *pelvic nerves* are occasionally affected, as shown by weakness in the lower limbs. This loss of power must be produced reflexly; from the anatomical relations, the retroflexed fundus cannot compress the motor nerves of the sacral plexus as is sometimes affirmed.

ETIOLOGY.

Retroflexion of the uterus is the commonest pathological condition, next to pelvic inflammation, which we are called on to treat. It is rarely present as a congenital condition, in which respect it contrasts with antelexion. It is frequent in multiparæ (rare in nulliparæ) because the etiology is specially related to the *puerperal condition*. In this condition the uterus is enlarged and heavy, and its walls are soft. The ligaments are lax, and the tissues of the pelvic floor have been recently stretched and have not recovered their tone. Through the distention of the bladder, the uterus is often thrown into a retroverted position.

We sometimes find on examining a patient shortly after her confinement that the uterus is lying back in the pelvis even though the bladder be not distended; we may thus suppose that the *intra-abdominal pressure* (which, when the uterus is in its normal position, is directed upon its posterior surface) comes now to act on the anterior surface, and drives the fundus backwards and downwards. If the uterine tissue is soft enough to allow the fundus to be flexed on the cervix, such a flexion will gradually take place when the patient makes straining efforts. Apart from this, the *dorsal posture* and the common practice of *tight bandaging* after confinement will favour backward displacement of the fundus. If the patient *rise too soon*, while the uterus is still large and heavy and the uterine supports correspondingly lax and weak, the tendency to displacement is increased.

The cause of retroflexion in nulliparæ is obscure.

SYMPTOMS.

The following are the more important local symptoms :—

- Weakness in the back,
- Symptoms of chronic pelvic peritonitis,
- Painful defæcation ;
- Leucorrhœa,
- Dysmenorrhœa,
- Menorrhagia ;
- Sterility,
- Abortion.

In long-standing cases, there may follow the train of general constitutional symptoms consequent on chronic uterine disease.

The symptoms are arranged in three groups :—the first, including those which are more or less continuous ; the second, those which are within the menstrual period, variable or periodic ; the third, those connected with the function of reproduction.

Weakness in the back is the most common complaint. It may amount to actual pain, which is aggravated on muscular exertion and generally at the menstrual periods. The symptoms of *chronic pelvic peritonitis* are usually present ; the feeling of weight and discomfort in the pelvis is sometimes due to the stretching of old adhesions. The importance of pelvic inflammation, fixing the uterus in its abnormal position and preventing its replacement, we shall consider under treatment. *Painful defæcation* with tenesmus is explained by the relation of the loaded rectum to the retroflexed uterus ; irritation from pressure of the fundus against the wall of the rectum may produce straining efforts, but this is very rare.

The *leucorrhœa* is due to chronic inflammation of the mucous membrane. As the result of the displacement, there is passive congestion of all the tissues of the uterus ; this leads in the first instance to a simple hypersecretion of mucus, which gradually passes into chronic inflammation. The mucous secretion is more marked immediately after the increased congestion of the menstrual period ; but, gradually, it spreads itself over the intermenstrual period. *Dysmenorrhœa* is not so frequent a symptom here as in antelexion ; the explanation is, on the mechanical theory, that retroflexion usually occurs in multiparæ where the cervical

canal is patulous. *Menorrhagia* forms one of the more prominent symptoms; it is due partly to the chronic inflammation of the mucous membrane, partly to obstruction to the return of the blood from the uterus.

Affection
of Repro-
ductive
System.

The *reproductive function* is variously and seriously affected. This is brought prominently under our notice, because retroflexion usually occurs in one who has already been pregnant, and presents an obstacle to further conception. Frequently, the patient tells us that she had a child several years ago; that she has suffered from pain in the back, leucorrhœa, and irregular menstruation since that time and has never conceived again. With this history, we commonly find retroflexion of the uterus. The *sterility* may, of course, be due to a variety of causes—the altered position of the cervix, the increased mucous secretion, obstruction of the Fallopian tubes, malposition of the ovaries. We cannot therefore be sure of curing the sterility by replacing the uterus, although we frequently find that the patient *does* conceive shortly after this treatment.

Abortion
in Retro-
flexion.

After conception has taken place, there is the further risk of *abortion*; with a history of repeated abortion, we often find retroflexion. Conception probably often takes place in a retroflexed uterus, which afterwards rights itself so that pregnancy goes on to the full time. Abortion is due to the inability of the uterus thus to right itself, or to the pathological condition of the mucous membrane which prevents the ovum from becoming securely attached. When abortion does not occur and the pregnant uterus does not straighten itself so as to grow upwards into the abdomen, it enlarges without the undoing of the flexion; in this case it will expand more and more into the hollow of the sacrum and become wedged below the promontory. This constitutes Retroflexion of the Gravid Uterus (*v. Disturbances of the Reproductive Function, Section IX.*)

DIAGNOSIS.

On *vaginal* examination the cervix is felt low down in the pelvis, the cause of which has been explained under Pathology. The os looks directly downwards. A firm round body is felt in the posterior fornix, continuous with the cervix uteri but separated from it by a groove more or less distinctly marked according to the amount of flexion. Place the forefinger on the cervix, and the middle finger on this body; on moving the former, the latter moves with it.

Bimanual
in Retro-
flexion.

But a fibroid tumour of the posterior wall would produce similar conditions; therefore, make the *bimanual* examination. First place the

vaginal fingers in the anterior fornix and make pressure with the external hand until the fingers of both hands meet; there is nothing between them except the abdominal and vaginal walls, the fundus is therefore not to the front. Now put the vaginal fingers into the groove behind the cervix, or, better still, lay hold of the cervix with the index finger in front of it and the middle finger in the groove behind (see fig. 209), and lift up the uterus as high in the pelvis as possible; make pressure with the external hand until the cervix lies fairly between the hands; the upper surface of the uterus is felt to curve backwards. In a favourable case (with lax abdominal walls) we can do the bimanual examination

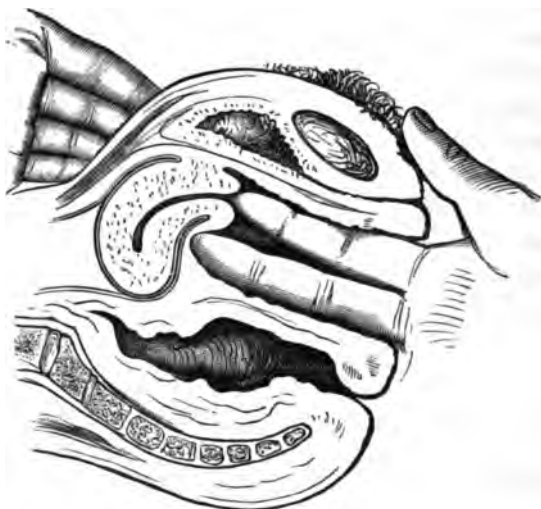

FIG. 209.

DIAGNOSIS OF RETROFLEXION BY BIMANUAL EXAMINATION.

on a still deeper plane, and get both hands to meet behind or at least fairly embrace the retroflexed fundus. Having ascertained that the fundus uteri is retroflexed, we ask ourselves whether it be fixed or movable—*whether it can be replaced or not*. In making our diagnosis we at the same time take a step towards treatment. To ascertain the mobility of the fundus, make steady pressure on it upwards; observe whether it gives way before the finger, and whether, on its yielding, the flexion becomes undone or the uterus simply rotates as a whole; note also whether this manipulation causes pain.

Rectal
examina-
tion in
Retro-
flexion.

The *rectal* examination has this advantage, that the finger passes upwards over the free surface of the fundus without displacing it. It

is indispensable in cases where the rigidity of the abdominal walls prevents our getting the uterus between the hands in the bimanual. The drawing down of the uterus with the volsella is an additional help in such cases, as it enables the finger in the rectum to reach the fundus.

Uterine
sound in
Retro-
flexion.

The *sound* confirms the diagnosis in doubtful cases, and tells us further whether the retroflexed uterus is enlarged. Before using the sound, we must palpate the uterus carefully to ascertain that it is not becoming enlarged with a growing ovum and inquire as to the patient's menstruation. We curve the sound to correspond with the degree of flexion ascertained on bimanual examination. If introduced with the concavity directed backwards, it passes into the uterine cavity without our having to make the rotation (*v. fig. 93*); through the posterior fornix, we feel the end of it in the retroflexed fundus; it usually passes in beyond the two and a half inches. We can also learn from the sound whether the uterus can be replaced or not; but it is better to get the information from the bimanual examination. The sound is of most use in differential diagnosis.

Differential
Diagnosis
of Retro-
flexion,

Differential diagnosis. The following are the conditions arranged in the order of frequency, which might be mistaken for retroflexion:—

Fæces in the rectum;

Pelvic deposit in the pouch of Douglas { Peritonitis,
Hæmatocele,
Carcinoma;

Cellulitis behind the cervix;

Myoma of the posterior wall;

Prolapsed ovary or small ovarian tumour.

from Load-
ed Rectum,

Fæcal matter in the rectum gives rise to difficulty only on superficial examination. We should always decline to give an opinion as to the condition of the pelvic organs when the rectum is loaded. If this be attended to, no mistake in diagnosis will be made under this head.

from
Pelvic
Deposit,

Pelvic deposit in the pouch of Douglas gives rise to more difficulty, because it may closely simulate the condition found in retroflexion—"a body felt through the posterior fornix and moving along with the cervix." Such a deposit will be proved not to be the fundus uteri by our finding the latter in another position. If inflammation is present, it is difficult to make the examination necessary to ascertain this; we may not be justified in using the sound just where it would give us the desired information: such cases present great difficulty in diagnosis, and the true

condition can only be ascertained on repeated examination or after the inflammation has subsided.

Cellulitis behind the cervix is rarely present in such a form as to give rise to a mistake in diagnosis, unless the inflammation renders the necessary examination difficult. Cellulitis,

A *myoma* projecting posteriorly from the lower segment of the uterus resembles, in form and firmness, the retroflexed fundus. On bimanual examination, however, we find that we have between the hands a larger body than the uterus alone. The fundus may also be felt to the front, and distinct from the tumour. To ascertain its position, it is best to make the bimanual examination with the sound in the cavity of the uterus. Fig. 198 shows the information given by the sound, if we suppose that the structure to the left of the figure is the rectum. A fibroid tumour accompanied by inflammation presents great difficulty. Myoma,

If the *ovary* be *prolapsed*, enlarged through inflammation, and adherent to the posterior aspect of the uterus, it simulates (on vaginal examination) the retroflexed fundus. So also does a small *ovarian tumour* lying in the pouch of Douglas, though it is softer and more elastic than the uterus. The bimanual examination, supplemented if necessary by the use of the sound and the drawing down of the uterus with the volsella, enables us to ascertain the exact position of the fundus and its relation to the tumour. from Pro-
lapsed
Ovary.

PROGNOSIS.

The prognosis depends upon the mobility of the uterus, and the possibility of replacing it. It is always less favourable where inflammation is present; though we have seen considerable exudations become after a time absorbed, and the uterus again movable so that it could be replaced. As regards the probability of future conception, our statements should be guarded; though the probabilities are greatly increased if we can replace the uterus.

Whether a permanent cure of the displacement (so that the uterus will keep its normal position after the instrument is removed) is often effected, we have not much definite information. *A priori*, we should not expect that the stretched utero-sacral ligaments would readily become shortened again unless a pregnancy supervene. The curability of the retroflexion depends, according to Mundé, on the *recentness of the displacement*; "recent displacements of any variety are the only cases which offer a fair chance of complete recovery by any of the mechanical means at our disposal." The length of time during which a pessary must be worn so as Possibility
of cure of
Retro-
version.

to effect a cure of recent puerperal retroflexion is, according to Mundé, six months to a year.

TREATMENT.

This consists of two parts:—

1. Replacement of the retroflexed uterus ;
2. Retention of it in its normal position by suitable means.

The first question which suggests itself on discovering a retroflexion is, whether we can replace the uterus ; this has been ascertained at the same time as we made the diagnosis.

The two obstacles to treatment are the presence of existing inflamma-

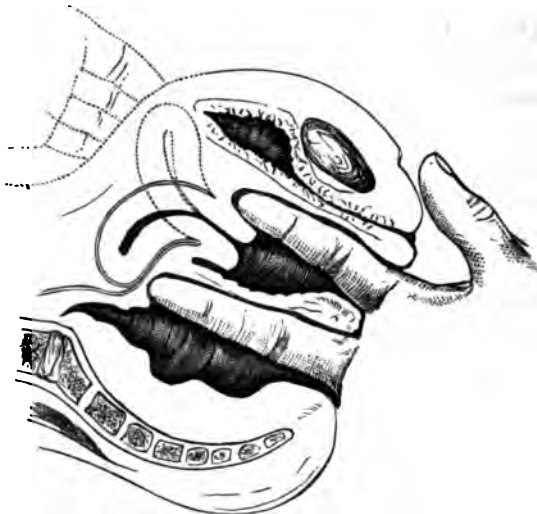

FIG. 210.

REPOSITION OF THE RETROFLEXED UTERUS BY THE FINGER IN THE RECTUM.

tion and the fixation of the uterus in its abnormal position. The former must be treated by blistering, hot-water injections, and the use of the glycerine plug ; these may have to be continued for a month or more, and then we may attempt the reposition. This last may be impossible through the firmness of the flexure or the presence of old adhesions. It must be left to the operator to determine how much force he is justified in employing. Sometimes it is necessary to put the patient under chloroform. In cases where we cannot replace the uterus, benefit may be derived from simply supporting it with a pessary.

Let us suppose that we are treating a case suitable for reposition, after inflammation has subsided.

1. *Methods of Replacing the Retroflexed Uterus.*

These are the three following:—

- (1.) By bimanual vagino-rectal manipulation ;
- (2.) With the sound ;
- (3.) By genupectoral posture, combined with traction on the uterus with the volsella and (if necessary) pressure on the fundus with the finger in the rectum.

(1.) The bimanual manipulation is the safest method, and can be at once proceeded with as soon as we have diagnosed the pathological condition. We thus make the diagnosis, form the prognosis, and begin the treatment at one examination. The replacement is best effected with the index finger in the vagina and the middle finger in the rectum. If with both fingers in the vagina we make pressure through the fornices, we simply push the uterus, as a whole, upwards. With the finger in the rectum, however, we get behind the uterus and push it forwards. Place the patient in the dorsal position ; pass the fingers into the vagina and rectum, as in the accompanying diagram (fig. 210). Make steady gradual pressure on the posterior surface of the fundus with the middle finger. Direct the pressure to one side of the middle line, so as to keep the fundus clear of the promontory of the sacrum. With the index finger placed *in front of the cervix*, push it backwards and thus rotate the fundus forwards. Having by this manœuvre brought the fundus uteri to the front (into the position indicated by the dotted line in the diagram), make with the external hand steady downward pressure so as to get between it and the hollow of the sacrum and thus depress the fundus still more to the front. A glycerine plug is now placed in the vagina to keep the uterus in position. The plugging should be chiefly in the anterior fornix, so as to exert upward pressure on the cervix and thus favour the tilting of the fundus forwards. On the following day, if there be no indication of inflammation, a pessary may be introduced.

(2.) Replacement with the sound has the advantage that it causes less discomfort to the patient ; it is therefore the method generally employed. We may have the sound already in the uterus to make sure of our diagnosis, and (without withdrawing it) we can proceed at once to effect the reposition. In the employment of force we require to be more careful than in the bimanual manipulation, because the sound gives us greater leverage, the pressure is being made on the mucous membrane of the uterus, and there is not the same delicate sense of resistance as when the

Reposition
of Retro-
flexed
Uterus by
Bimanual.

Replace-
ment with
the Sound.

finger is immediately in contact with the uterus. The end of the sound should not be too much curved. If the flexion be pretty acute, so that the sound requires to be well curved to pass easily into the body of the uterus, we should first reduce the acuteness of the flexion by repeatedly passing in the sound more and more straightened. Having by this means partially converted the retroflexion into a retroversion, we proceed to reposition

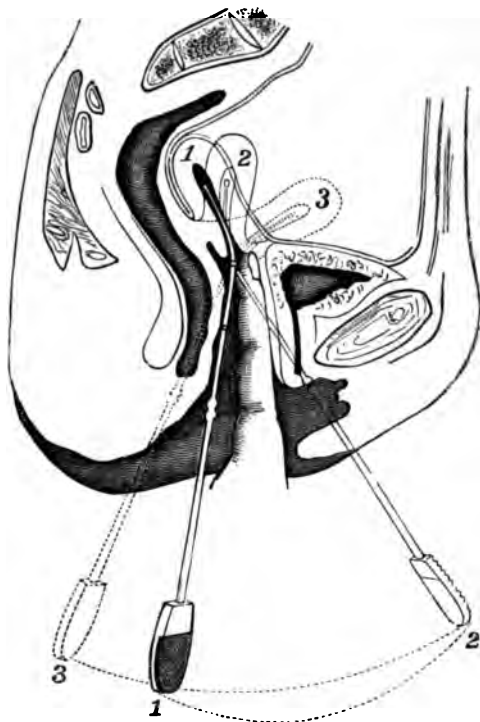


FIG. 211.

REPLACEMENT OF THE UTERUS WITH THE SOUND. 1, 2, 3, the successive positions of the SOUND and of the UTERUS.

as follows. The sound lies as in position 1 in the figure (fig. 211): the direction of the handle is backwards, and the roughened face looks to the back; the intra-uterine portion (1) also has the curve backwards. Now lay hold of the handle loosely, rather allowing it to lie between the fingers than grasping it. Carry the handle upwards towards the patient's right buttock (as she is on her left side) forwards with a wide sweep and downwards again towards the couch, the shaft describing half of a cone. The sound thus comes to lie in position 2 in the figure: the direction

of the handle is forwards, and the roughened face is now to the front; the intra-uterine portion of the sound has also rotated, so that the curve is now forwards, but the uterus as a whole is still to the back (fig. 211, 2, 2). Now carry the handle of the sound gently and slowly backwards, in a straight line towards the perineum. The sound now lies in position 3: the roughened surface is to the front, but the handle is now directed backwards; the fundus uteri is consequently in its normal position (fig. 211, 3). The reason for this manipulation is evident. If we rotated the handle of the sound forcibly round its long axis (bringing it at once from position 1 to 3), the intra-uterine portion would describe a wide curve within the uterine body and probably produce laceration of the mucous membrane. Before withdrawing the sound we make sure by external palpation that the fundus uteri is to the front, as the latter is more easily felt when stiffened by the sound. After withdrawal of the sound the uterus must be kept in position by the glycerine plug or pessary. Frequently we find that the uterus falls back into its abnormal position as soon as the sound is withdrawn; in such cases, the pessary should be slipped in over the handle of the sound and put in position before the latter is withdrawn.

Various forms of uterine repositors have been devised by Sims and others. They might be compared to a sound having the intra-uterine portion jointed to the stem, on which it can be rotated antero-posteriorly by a suitable mechanism. They are not of such practical value as to require further description here. No mechanism can equal the fingers in nicety of action.

(3.) The importance of the genu-pectoral posture in replacing the retroflexed uterus has been brought forward by H. F. Campbell. On placing the patient in this posture, the abdominal contents gravitate downwards and forwards; this displacement withdraws the internal pressure from the pelvic floor, so as to subject it to the atmospheric pressure from without. If the vaginal orifice be now opened, the vaginal cavity becomes distended with air; if the walls are lax, the cavity may be so large that the finger reaches the cervix with difficulty. The position of the uterus changes;¹ but the retroflexed uterus does not become

The Retro-
flexed
Uterus
not re-
placed in
Genu-
pectoral
Posture.

¹ For full account of changes produced by the genu-pectoral posture, the student should consult the Atlas of the "Relations of the Abdominal and Pelvic Organs in the Female:" *Simpson and Hart*, 1881.

ment, we must either push the fundus forwards or draw the cervix backwards. It is best to combine these actions; having laid hold of the cervix with the volsella per vaginam, we draw it downwards while with the index finger of the right hand, per rectum, we press the fundus towards the bladder (see fig. 212). This method of reposition is only used in cases of retroflexion of the gravid uterus.

Having replaced the uterus by one of those methods, we have to retain it in its normal position.

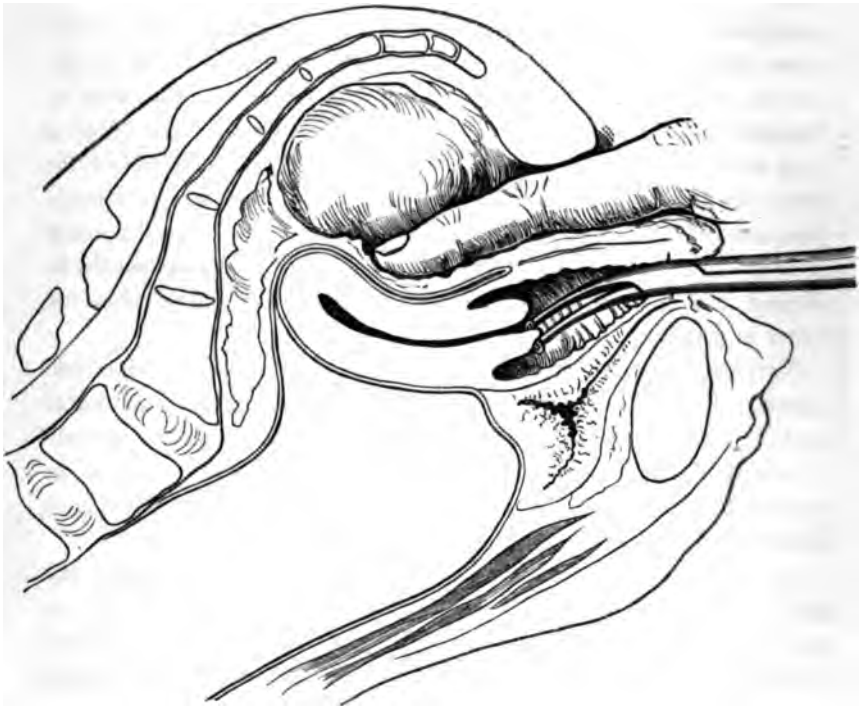


FIG. 212.

REPLACEMENT OF THE UTERUS WITH THE VOLSELLA AND THE FINGER IN THE RECTUM; the patient is in the genupectoral position.

2. *Methods of Retaining the Replaced Uterus.*

The retention of the uterus in its normal position is effected by vaginal pessaries. Of these the best forms are the Hodge or, its modification, the Albert Smith.

Material of
Pessaries.

The *material* of which they are made is vulcanite, which is light and smooth and not affected by vaginal discharges. To bend the vulcanite, the pessary should be placed in hot, almost boiling, water. It is thus

made pliable and can be moulded to the desired form, but becomes firm again on placing it in cold water; this is also effected by oiling the pessary and heating it in a spirit lamp. Pessaries are also made of gutta-percha, which has the advantage of being easily moulded; these cannot,




FIG. 213.
HODGE PESSARY.



FIG. 214.
ALBERT SMITH PESSARY.

however, be worn for a long time, as the gutta-percha is absorbent and, retaining the secretions, sets up irritation. The patient can wear one for a few weeks till we see that it fits comfortably and is effective, and then we can substitute one of a similar form made of vulcanite.

The *form* of the Hodge is an elongated horse-shoe, with a straight Hodge's
Pessary.



FIG. 215.

SIDE VIEW OF ALBERT SMITH PESSARY. The Hodge is similar, but has the lower curve less marked.

transverse bar joining the free ends. Seen from the front (fig. 213), it has a curved upper end which is adapted to the posterior fornix; the lower end consists of a straight bar which serves to keep the sides apart, and lies under cover of the symphysis pubis; the external angles of this

end are rounded to prevent their cutting the vagina; the sides run almost parallel. Seen from the side (fig. 215), it is a mould of the vaginal slit; there is an upper sacral curve, which is long and well-marked; there is a lower pubic one, which is not necessarily present or is only slightly marked. The pessary lies so that the concavity of the sacral curve looks forward, that is to say, the upper end of the pessary (like the posterior fornix vaginae) curves forwards. The Albert Smith (fig. 214) contracts in its lower half to a more or less beak-shaped end;

Albert
Smith's
Pessary.

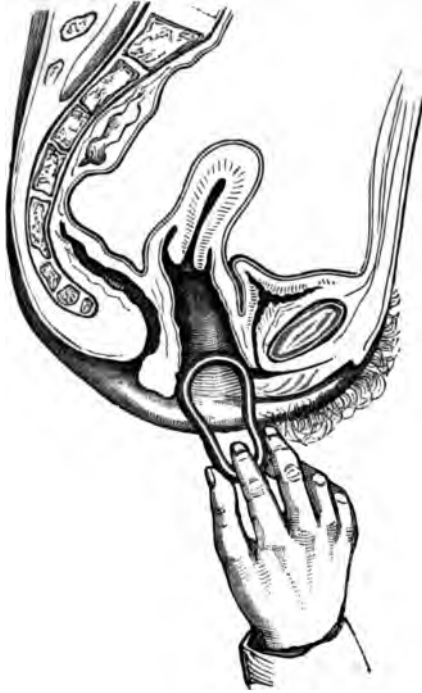

FIG. 216.
INTRODUCTION OF PESSARY, FIRST STAGE.

seen from the side, it has the pubic curve more marked (fig. 215). Scientifically it is the more correct form, because the posterior wall of the vagina is narrower below than it is above. The lower end should not be too much contracted, otherwise it is apt to interfere with married life; also when the vaginal orifice is wide, it favours the expulsion of the instrument. A second modification of the Hodge is recommended by Thomas, in which the upper bar is thicker, the sacral curve more pronounced, and the whole instrument longer.

The *choice of an instrument* suitable to the case must be made. The Choice of Hodge's Pessary. pessary should be narrower and shorter than the posterior vaginal wall, so that it produces no tension when it is in position. The upper bar should be of such a size that it can be passed in easily ; the lower should be narrower than the upper, but not too narrow for the reasons given above. The proof of a good fitting instrument is that the patient does not feel its presence, nor should it interfere with married life.

The *mode of introduction* of the pessary demands special attention. It Introduction of Hodge's Pessary. is important that this apparently simple manœuvre be effected without

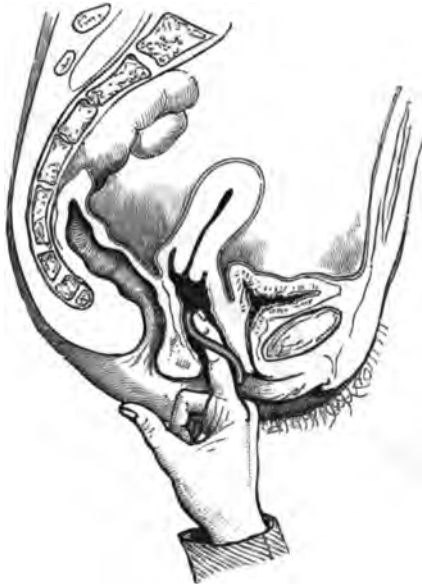

FIG. 217.

SECOND STAGE : PESSARY CARRIED ON BY FINGER.

causing pain to the patient. From the fact that the vulvar orifice is antero-posterior while the cavity of the vagina is transverse, the instrument must be introduced with its plane surface horizontal (the patient is supposed to be on the side) and afterwards rotated so that this comes to be vertical. From the position of the cervix, the instrument is very liable to run into the anterior fornix. When in position the upper end must curve forwards. Having oiled the instrument, grasp it with the lower end (the square end in the case of the Hodge, the narrower end in the case of the Albert Smith) between the finger and thumb of the right

hand. Separate the labia with the first and second fingers of the left hand; when the vaginal orifice is narrow hook back the fourchette with one finger, or get the posterior corner of the end which is being introduced within the vaginal orifice, and press back the perineum with it so that the anterior corner is not pushed against the clitoris or vestibule. Now push the pessary backwards in the axis of the vagina till it is half within the cavity (see fig. 216), and rotate it so that the concavity of the sacral curve looks forwards. Pass the index finger behind the instrument into the vagina, and place the tip of it against the upper bar; carry the pessary onwards, keeping the upper bar well against the

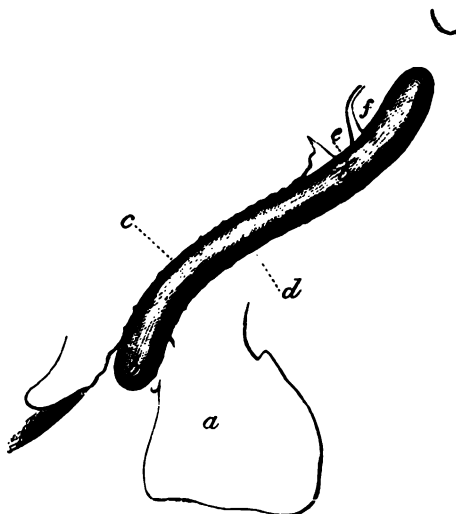


FIG. 218.

PESSARY *in situ* IN THE VAGINA, *ad naturam*. a perineum, bb pessary, c anterior and d posterior vaginal wall, e anterior and f posterior lip of cervix.

posterior vaginal wall to prevent its slipping up in front of the cervix (fig. 217).

How
Hodge's
Pessary
lies when
in situ.

The *position* and *action* of the pessary when *in situ* are as follows. It lies exactly adapted to the vaginal walls (see fig. 218); the upper end being in the posterior fornix behind the cervix, the lower just within the vaginal orifice. It is kept in position through its resting on the oblique anterior face of the sacral segment of the pelvic floor, against which it is compressed by the posterior face of the pubic segment.

The student will readily understand and remember the position of the pessary in the following way. Hold the hand inclined as in fig. 219,

with the palm slightly inflexed. It resembles the posterior vaginal in the following points:—(1) it is broader above than below; (2) it curves forwards above; (3) from its obliquity, it allows the pessary to sit on it. Now place the pessary on it. It will only lie adapted to the hand when the broad end is above and the upper curve is directed forwards.

The Hodge pessary does not act as a lever; that is to say, the intra-abdominal pressure does not act specially on the lower bar and depress it, causing the superior one to rise. The intra-abdominal pressure acts

Action of
Hodge's
Pessary.

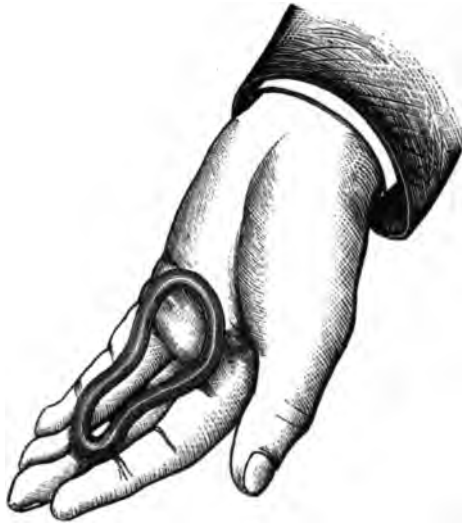

FIG. 219.

HAND HOLDING ALBERT SMITH PESSARY.

nearly equally on both bars, of which fact the student may satisfy himself clinically. Its action is that the *upper bar gives a point d'appui to the posterior fornix*. The posterior vaginal wall runs round the upper bar as on a pulley, and, as it is inserted into the cervix, the latter is thereby drawn upwards and the fundus thrown forwards (fig. 220). The pessary, therefore, has the same action as the utero-sacral ligaments, if we suppose that these keep the cervix backwards. This is only the action in the case of a retroverted uterus which has been replaced. A vaginal pessary, however, gives relief even though we may not be able to replace the uterus. In this case we must suppose that it acts by supporting the

uterus as a whole, thus diminishing tension on the ligaments and passive congestion.¹

Another way of showing how the Hodge pessary acts is as follows. With the patient lying on her left side, pass the index finger into the posterior fornix vaginæ and push it up in a direction parallel to the posterior vaginal wall. This necessarily pulls the cervix back, and thus

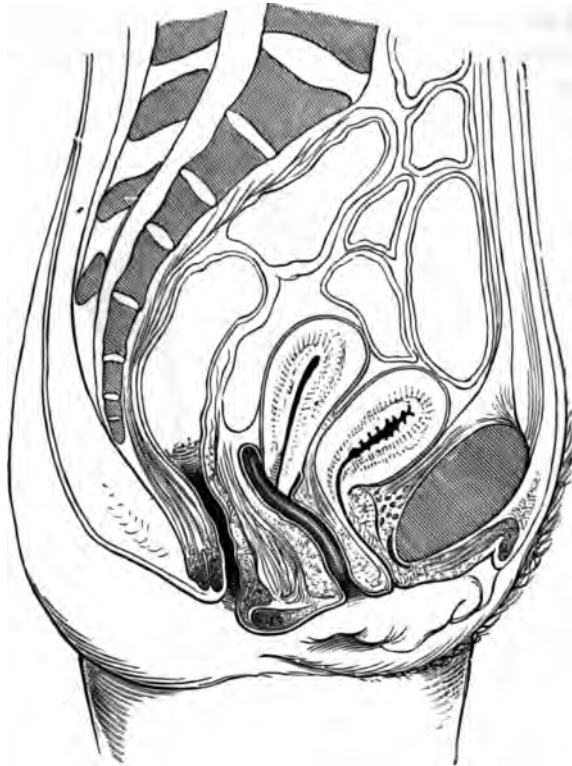


FIG. 220.
POSITION AND ACTION OF PESSARY.

the fundus is kept forward (see fig. 66). In other words, if the cervix be thus kept back by the tension of the finger in the posterior fornix, the uterus cannot become retroverted although the fundus may become retroflexed. Now if a Hodge pessary be passed into position and held by the hand, it will act just as the finger does. It does not require to

¹ See Granvill Bantock on *The Use and Abuse of Pessaries*, London 1878; Hart on *The Structural Anatomy of the Female Pelvic Floor*.

be held, however, as it rests on the oblique sacral segment and is pressed against it by the pubic segment and abdominal viscera. Note that the pressure on the Hodge is at right angles to the posterior vaginal wall; there is no side to side pressure on the instrument, and thus it does not require to extend from side to side of the vaginal walls.

The after-watching of the case is important. The patient should be instructed to return in two days to see that the instrument is in place, and to return at once if it causes pain. After this she should report herself occasionally, say at intervals of a month, when examination is made to ascertain that the uterus keeps its place. If she uses hot-water injections occasionally, it is not necessary to remove the instrument to clean it more frequently than this. After the pessary has been worn for some months, it may be removed to see if the uterus remains in position without it. Sometimes we find that the uterus falls back again into its abnormal position as soon as the instrument is withdrawn; in such a case, it must be introduced again and may have to be worn for years. Should conception occur, the pessary may be worn till the fourth month after which the uterus rises above the brim and there is no longer reason to fear displacement.

In some cases the uterine tissue is flaccid at the angle of flexion, and the body falls to the back or front as if it were jointed to the cervix. Here the Hodge, which acts on the body through the cervix, does no good; the intra-uterine stem, along with a Hodge which has transverse bars, does good in some of these cases. Wynn Williams has devised a good form of pessary on this principle.

From what has been said on the action of the Hodge pessary, it is evident that in the treatment of Retroversion + Retroflexion *the version alone is affected by the pessary.* Whether the flexion is remedied will depend on the state of the uterine walls and the effect of intra-abdominal pressure upon them.

Hodge's
Pessary
only good
in Retro-
version.

CHAPTER XXXII.

INVERSION OF UTERUS.

LITERATURE.

Atkill—Inversion of uterus due to fibroid tumour: Dublin Medical Journal, Feb. 1879. *Barnes*—Diseases of Women: London 1878, p. 721. Med. Chir. Trans., 1869. *Crosse*—An Essay, literary and practical, on Inversio Uteri: Trans. Provincial Med. and Sur. Assoc., London 1845. *Duncan, Matthevs*—On the Production of inverted uterus: Edin. Med. Jour., May 1867. *Emmet*—Principles and Practice of Gynecology: Churchill, London 1880, p. 410. *Fritsch*—Die Lageveränderungen der Gebärmutter: Billroth's Handbuch für Frauenkrankheiten: Stuttgart 1881. *M'Clintock*—Diseases of Women: Dublin 1863, p. 76. *Macdonald*—Two cases of chronic inversion of the uterus: Edin. Obst. Trans., vol. VI., p. 170. *Spiegelberg*—Archiv. f. Gyn., B. IV. S. 350, and V. S. 118. *Thomas*—Diseases of Women, p. 453, Philadelphia 1880. The essay by Crosse gives the fullest anatomical description of inversion, and contains a series of lithographic plates of specimens. The literature up to 1879 is fully given by Fritsch. Other references are given as foot-notes.

PATHOLOGY.

IN inversion the uterus is turned inside out, so as to form a polypoidal projection into the vagina; its peritoneal surface is converted into a cup-shaped hollow; its mucous membrane becomes *everted* so as to lie exposed on all sides in the cervix and vagina.

The mechanism by which this condition is brought about is the following.

1. A portion of the muscular wall of the uterus *having lost its tone*, becomes depressed towards the uterine cavity. In the puerperal condition this is usually that portion of the wall to which the placenta has been attached, and the condition has been described by Rokitansky as "paralysis of the placental seat;" this partial inversion will be frequently found on abdominal palpation in cases of post-partum hæmorrhage (*Fritsch*). In cases of tumour growth, fatty degeneration (*Scanzoni*) or malignant infiltration (*A. R. Simpson*) weakens the wall of the uterus round the base of the polypoidal growth, and thus produces an analogous condition.

2. *Muscular contractions* of the non-depressed portion of the uterus, combined with *intra-abdominal pressure*, carry the depressed portion further into the uterine cavity, until the fundus uteri reaches the os

internum (fig. 229). In the puerperal condition, muscular contractions are present of themselves or are produced by the presence of the placenta; in the case of a polypoidal tumour, they are due to the presence of the foreign body. *Traction from below*, such as the pulling away of the placenta or the tension of the pedicle of a polypus which is being extruded, also produces inversion.

3. The fundus of the uterus, by continuation of the same process, dilates the cervical canal and is "born" into the vagina (fig. 226).

In some cases inversion seems to take place from below upwards with a mechanism similar to that of prolapsus uteri, the lower part of the body of the uterus becomes inverted into the cervical canal (*Taylor*).

Matthews Duncan, whose paper was a valuable contribution towards establishing the correct theory of inversion, distinguishes between active Varieties of Inversion.

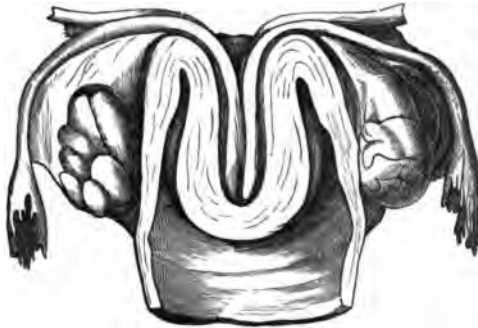

FIG. 221.

INVERSION OF UTERUS (half-size, *Barnes* from *Crosse's* essay.) The fundus lies in the vagina; the cervix is not inverted; the lips are flattened out to a swelling seen below the angle of inversion. The ovaries (seen from behind) are not in the peritoneal cup.

and passive inversion. The active is that described above; the passive is produced by inertia of the whole uterus, in which the organ is driven down entirely by intra-abdominal pressure or by traction from below—and not by uterine contractions.

It is evident that the process may become arrested at any of these stages and persist as a permanent condition. When it has persisted for a few weeks, it constitutes "chronic inversion;" this is found in the following forms. (1.) Inversion of one horn only is a rare occurrence. Slight inversion of the uterine wall, at the base of a polypoidal fibroid, has been more frequently observed. (2.) Partial inversion, when the fundus has descended as far as the os internum, is also found as a chronic condition. (3.) Complete inversion is the condition most frequently met with.

Anatomy
of Inver-
sion.

An exact knowledge of the relation of parts in *complete inversion* is necessary for diagnosis and treatment. This can only be gained by studying the inverted uterus as seen in section (fig. 221). We must study the position of—

The body of the uterus,
The cervix uteri,
The Fallopian tubes and ovaries,
The peritoneum,
The bladder.

The body of the uterus. The inversion extends, in simple uncomplicated cases (see below), as far as the os internum but *no further*. The uterus lies partly in the vagina, partly in the cervical canal. Its neck is embraced by the os externum, which may lie loosely on it (favouring hæmorrhage) or constrict it firmly (favouring gangrene). After involution takes place, it becomes small, rounded and of firm consistence, closely resembling a pediculated fibroid tumour; and it has been amputated by mistake for such. It has a rounded form, is of a softer consistence and deeper red colour than a pediculated fibroid, and has a smooth and slippery surface which bleeds freely when handled. The softness may be so marked that the uterus moulds itself to the vaginal cavity and, becoming flattened against the posterior vaginal wall, takes on a mushroom-like form (*Freund*).

The mucous membrane of the uterus may undergo all the changes of any tumour with a constricted base and exposed surface. It is usually congested and bleeds easily; it may become ulcerated and even gangrenous, or may be hypertrophied with polypoidal formations; it may lose its single layer of cubical epithelium and develop a stratified squamous epithelium. The occurrence of these changes has an important bearing on the necessity of replacing the organ.

The cervix uteri. This is rarely¹ displaced in simple uncomplicated inversion; it forms a broad ring embracing the neck of the tumour. Sometimes the inversion is complicated with prolapsus, or, more properly, the vagina also becomes inverted and the inverted uterus caps the inverted vagina (fig 222). When this occurs, the cervix uteri is also more or less inverted; a part remains just above the os externum, as a depressed ring which also disappears on making traction on the uterus (*Fritsch*).

¹ Crosse figures one preparation in which the cervix as well as the body of the uterus was inverted although there was no prolapsus.

The *Fallopian tubes and ovaries*, with some coils of small intestine, may (at first) lie within the inverted cup, which is lined with *peritoneum*; afterwards, they retract out of it. In long-standing cases, the rim of the peritoneal cup is contracted by the muscular fibre of the cervix so as

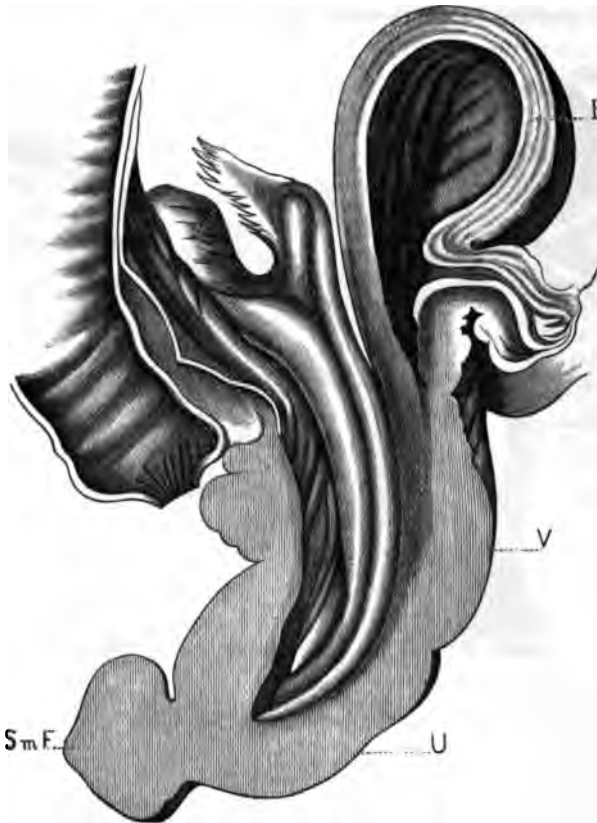

FIG. 222.

INVERSION OF UTERUS + INVERSION OF VAGINA, occasioned by a small sub-mucous fibroid (M'Clintock). Sm F, sub-mucous fibroid. Other letters as before.

scarcely to admit a finger (fig. 223). In a case of six months' standing, in which A. R. Simpson performed Thomas' operation before having recourse to amputation, the contracted ring just admitted the finger; an ovary was caught within it.

Adhesions rarely form between the *peritoneal surfaces*; this is an interesting fact and is of importance in regard to replacement. We might have expected detachment of the peritoneal lining or tearing of

it by the sudden dislocation; the previous stretching of it during pregnancy is perhaps the reason why this has not been noticed. Fritsch says that the lifting up of the fornices by the tumour in the vagina, diminishes the strain on the peritoneum.

The *bladder*, from its relation to the cervix (*v. Chap. III.*), is not altered in position unless there is prolapsus. When the latter occurs,

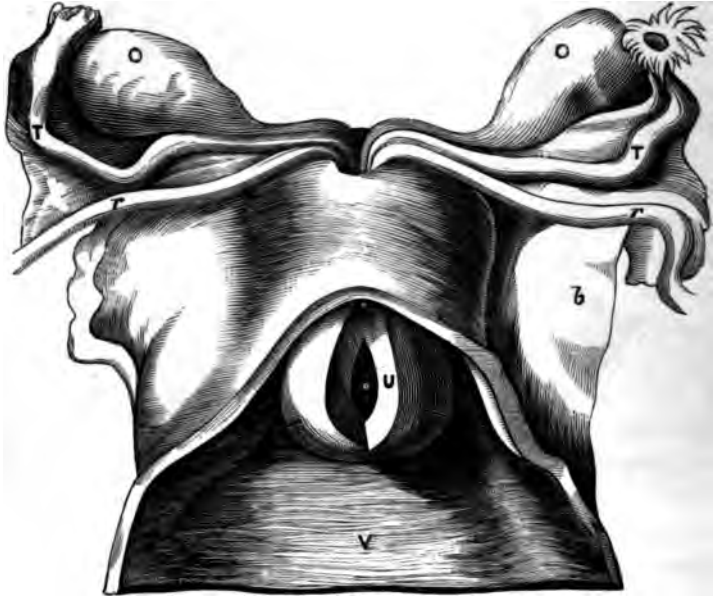


FIG. 223.

INVERSION OF UTERUS (Crosse). The inverted uterus (*U*) lying in the vagina (*V*) is cut open to show the peritoneal sac which does not contain the ovaries (*O*); bristles are passed into uterine orifices of tubes.

there is cystocele (*v. fig. 222*). We may therefore contrast the two types of inversion as follows.

Inversion of uterus—cervix and bladder normal in position;

Inversion of uterus + prolapsus (*i.e.*, inversion of vagina)—cervix inverted and cystocele.

ETIOLOGY AND FREQUENCY.

Inversion arises under two different conditions:

1. In the puerperium—puerperal inversion;
2. Secondary to intra-uterine tumours growing from the fundus.

Inversion has also occurred independent of the puerperal condition and of tumour growth; this is quite exceptional.

1. *Puerperal inversion.* This is by far the most frequent form; out of 400 cases, 350 occurred in the puerperal uterus (*Crosse*). Etiology of Puerperal Inversion,

Its frequency was formerly due to improper management of the third stage of labour. When the uterus was flabby and not contracting and the placenta not coming away, the removal of the latter by traction on the cord drew down the part of the wall to which it was attached and thus inverted the uterus. This accident was favoured by the situation of the placenta over the fundus (*Hennig*). Since the removal of the placenta by compression (which is best done by the *Credé* method—with the thumbs of both hands well down behind the fundus so that the uterus may be firmly compressed antero-posteriorly) has been enforced, this accident has become rarer.

A dilated condition of the uterus (distention by blood clots) or a flaccid condition of the walls favours inversion.

2. *Inversion secondary to uterine tumours* is much rarer. Of 400 cases, only forty (ten per cent.) arose in this way (*Crosse*). It has been observed with pediculated fibromata (fig. 222), and will be referred to again when we treat of them (*v. Chap. XXXVI.*) It is peculiarly frequent in sarcoma (*v. Chap. XLI.*) We know of no case where it has followed on carcinoma uteri; Barnes describes a specimen in which both conditions were present, but does not say which was the primary lesion. of Inversion due to Tumours.

SYMPTOMS.

The symptoms produced by inversion at the time of its occurrence, concern the obstetrician rather than the gynecologist. There is the feeling of something giving way in the pelvis, accompanied with pain, hæmorrhage, and sometimes collapse. With complete inversion, there is retention of urine; it often occurs, or at least becomes so marked as to attract the patient's notice, when she has made a straining effort. The cases where the patient says that it first came down several days after labour, are to be explained by supposing that partial inversion occurred after labour but only the final stage attracted attention.

If the uterus be not replaced at the time, the case becomes one of chronic inversion. The symptoms of chronic inversion are—

- Hæmorrhage,
- Pain in the pelvis of a bearing-down character,
- Anæmia and weakness.

Hæmorrhage is the most dangerous symptom. The menstruation is always profuse, as may be easily understood from the fact that the

mucous membrane is extended in its area and lies exposed in the cervical canal and vagina. There is also inter-menstrual hæmorrhage, which comes on unprovoked or on straining.

The *bearing-down pain* in the pelvis resembles that felt in prolapsus uteri. It varies indefinitely in intensity; sometimes it is very acute, rarely is it so slight that the patient becomes reconciled to her discomfort and is able for work.

The *anæmia* and *weakness* may be so marked as to cause suspicion of malignant disease.

DIAGNOSIS.

Diagnosis
of recent
Inversion,

The diagnosis of *recent inversion* is easy. If the placenta has not yet been expelled, the hands laid on the fundus to expel it by the Credé method find that the rounded fundus is replaced by a cup-shaped hollow. The cervix is sometimes lifted up by the inverted uterus, so as to be "high above the pubes, even near the umbilicus" (*Crosse*). On passing the hand into the vagina to remove the placenta, care is required to recognise what is placenta and what is inverted uterus, and not to increase the inversion in detaching the placenta. If the placenta is already expelled, the hand on the abdomen recognises the same condition; while a large soft body, varying in size according to the extent of the inversion, fills the vagina.

of Chronic
Inversion.

Chronic Inversion. Before the sound and the Bimanual came to the gynecologist's aid in diagnosis, it was impossible to diagnose this condition with certainty. Mistakes were committed by the most eminent surgeons, just because they had not the means of examination which we now possess. Even now-a-days mistakes occur through the *hasty* making of a diagnosis before all the means of examination have been employed. We therefore describe fully the routine examination.

1. Pass the fingers into the vagina; a rounded and firm or flattened and soft tumour, which bleeds easily, is felt in the vaginal cavity. Sweep the fingers round it, and recognise that it is free on all sides except at its upper extremity. Round this extremity is felt the cervix, the lips and fornices being recognised; or the cervix is thinned out to a ring and the fornices obliterated. If the cervical canal be obliterated by adhesions, the finger will not pass farther up; if it be patulous, it will pass for one-and-a-half to two inches and find that the cervical mucous membrane is reflected equally all round on to the neck of the tumour.

2. With one finger in front of the tumour and the other behind it, lift it up towards the abdominal wall which is depressed with the

external hand till the fingers in the vagina are in contact with it. The

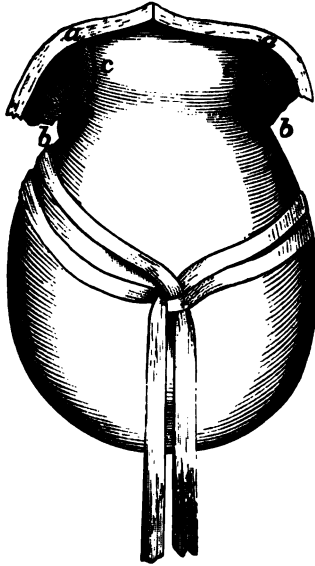


FIG. 224.

INVERTED UTERUS DRAWN DOWN BY TAPE-NOOSE ; *a, c, b.* line of incision in cervix in Barnes' operation (*Barnes*).



FIG. 225.

UTERINE POLYPUS (after *Thomas*). The uterus in its normal position. Sound passes into uterine cavity.

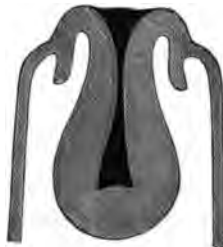

FIG. 226.

INVERSION OF UTERUS (after *Thomas*). A cup-shaped depression is in the place of the uterus. Sound arrested at angle of flexion.



FIG. 227.

UTERINE POLYPUS. Adhesions round pedicle obliterate cervical canal.

external hand feels, in the place of the fundus uteri, a truncated body with a depression in the centre (see fig. 226).

3. Now pass one finger into the rectum, which first comes on the body in the vagina: drag this body downwards with the noose represented at fig. 224, as the volsella causes hæmorrhage; the finger in the rectum, reaching the upper border of the body, can thus feel that it ends abruptly and can pass into the cup-shaped end. Now depress the abdominal walls till they reach the finger in the rectum, or pass a sound into the bladder and direct the point of it backwards till it can be touched by the rectal finger.

4. The sound may be used to probe round the neck of the body where there is not space for the finger to pass upwards. It is most useful, however, in differential diagnosis.

Differential Diagnosis of Inversion from Polypus. DIFFERENTIAL DIAGNOSIS. Inversion must be differentiated from the following conditions:—

1. Polypus in the vagina, simple or with adherent pedicle;
2. Intra-uterine polypus;
3. Uterine polypus with partial inversion;
4. Prolapsus uteri;
5. Inversion and prolapsus.

1. In a uterine polypus which lies in the vagina, the fundus will be found to lie somewhere else than in the vagina; it may be retroverted and thus escape recognition in the bimanual; the rectal examination will then discover it. Having found what we suppose to be the fundus, pass the sound along the side of the pedicle; if it is in the uterus, the sound passes more than $2\frac{1}{2}$ inches; if it passes $2\frac{1}{2}$ inches or less, suspect that partial inversion complicates the polypus.

When there are adhesions round the pedicle obliterating the cervical canal, a careful bimanual will reveal the fundus in its normal position and justify us in breaking down the adhesions with the sound so as to effect a passage into the uterine canal (fig. 227).

2. In a uterine polypus which is still *intra-uterine* the differential diagnosis is more difficult. A case has been recorded in which inversion of one horn of the uterus was diagnosed and amputated as a polypus. A careful examination per rectum under chloroform might detect the cup-shaped depression found in partial inversion; the uterine cavity is always enlarged when a polypus is present (fig. 228 and fig. 229).

3. Having satisfied ourselves that there is a polypus, the possibility of there being *partial inversion* of the uterus at its attachment must be kept in view (fig. 230). A careful rectal examination might reveal a depression on the peritoneal aspect of the uterus. The greater sensitiveness of the

uterine mucous membrane also helps us; thus if we apply the ecraseur without chloroform—which is not necessary—to remove the polypus and the patient has great pain on our tightening up the wire, we may suspect that the loop has embraced the wall of the uterus.



FIG. 228.

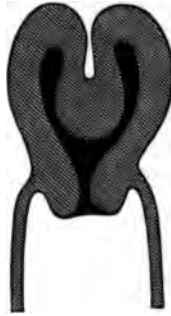

FIG. 229.

POLYPUS STILL INTRA-UTERINE (after Thomas). PARTIAL INVERSION OF UTERUS (after Thomas).

4. *Uncomplicated prolapsus uteri* would only on a very superficial examination be mistaken for inversion. The obliteration of the fornices, the presence of the os externum at the end of the protruded tumour, and that of the uterus within it—as demonstrated by the sound and examina-



FIG. 230.

UTERINE POLYPUS + PARTIAL INVERSION.

tion per rectum—show that it is a case of prolapsus. If, however, the prolapsus be due to a fibroid tumour of the cervix and the os externum be closed by adhesions or distorted in position, diagnosis is more difficult (*v.* Uterine Polypi).

5. *Prolapsus + inversion* is a rare condition. The specimen represented at fig. 222 is quite unique; the apex of the tumour protruding through the vulva consists of a submucous fibroid, the inverted uterus constitutes the next portion, while the base is formed by the inverted vagina.

COURSE AND RESULTS OF CHRONIC INVERSION.

Spontaneous Reversion. *Spontaneous reinversion* and cure has been observed in twelve cases (Thomas). From the rarity of its occurrence, it is to be regarded as a gynecological curiosity rather than a natural termination; the mechanism of its production is not as yet known.

Toleration of the condition is also rare, though cases are reported in which the uterus has become reconciled to its new position and surroundings and the patient has recovered perfect health.

The greater proportion of unrelieved cases end fatally through *anæmia*, hæmorrhage, septicæmia, or peritonitis.

PROGNOSIS.

As to the hope of reduction—of sixty-six cases collected by Macdonald, forty-four were successful.

TREATMENT.

Historical. The reposition of the inverted uterus is one of the gynecological triumphs of the last five and twenty years. Up to 1856 when Tyler Smith effected reposition by gradual compression with an air pessary, the only hope of cure was by amputation with the many risks attendant on that operation. About the same time White of Buffalo (1858) independently succeeded in replacing an inversion by pressure with the hand. After these a number of successful cases are recorded, among which the most noteworthy is one of Noeggerath who replaced an inversion of thirteen years' duration.

Various methods of reduction have been recommended by Tyler Smith, White, Emmet, Courty, Noeggerath, Thomas, Matthews Duncan, Barnes, Braxton Hicks, and Tate. It would take too much space to describe each method in detail; the references will enable the student to consult the original articles.

The treatment of inversion is best considered as follows:—

- A. Reposition (a) with the hand alone or aided by instruments,
(b) by continuous slight elastic pressure;
- B. Amputation.

A. Reposition.

The obstacle to reposition is the resistance of the tissue of the lower segment of the uterus; the principle of treatment is to overcome this by steady pressure.

Suppose that we have a case of inversion, how are we to proceed? The patient is kept perfectly at rest for a few days; injections of very warm water are employed twice or thrice daily; a liberal diet is given, and iron is usually required for anæmia. Ergot is required if there is menorrhagia; should it not be the menstrual period, the best thing to check hæmorrhage is injection of very hot water.

Having thus prepared the patient we proceed to reposition. Are we to employ the more rapid manual method or the slower one with an instrument? If the patient does not object to an operation under chloroform and if we can have assistants to take turns with us in keeping up manual pressure, the former method should certainly be tried first.

(a.) *Reposition with the hand alone or aided by instruments.* For a few days previously, the largest size Barnes bag which the patient can bear is placed in the vagina and distended; this makes space for the operator's hand, and may itself effect the reposition.¹ The patient, under chloroform, is placed in the lithotomy position; pass the right hand into the vagina, and grasp the uterus with the fingers as far into the angle of reflexion as possible (fig. 231). Now press the uterus steadily upwards against the left hand on the abdomen. The fingers may be separated as far as possible so as to open out the cervix.²

Sometimes the process of re-inversion is started by dimpling inwards one horn of the uterus, and then forcing the depressed horn onwards as a wedge to open up the ring of the cervix.³ As the hand cannot keep up steady pressure for any length of time, a cup is set on a curved iron rod with a spiral spring⁴ to make the pressure equal. A curved wooden rod, with a large cup at one end and a small one at the other, has also been used to keep up pressure.⁵ The end of the instrument is pressed

¹ Kroner has collected six cases of inversion (longest of eleven years' standing) replaced by this means; the pressure was applied for periods varying from one to eleven days. *Archiv. f. Gyn.*, B. xiv., S. 270.

² Emmet—Op. cit. p. 424. It is very doubtful whether the constricting cervix has anything to do with preventing reposition, though upward and outward pressure round the neck favours it.

³ Noeggerath—*Am. Med. Times*, 1862, vol. iv., pp. 230, 235.

⁴ White—*Intern. Med. Cong. Trans.*, Philadelphia, 1876. Byrne—*New York Med. Journ.*, Oct. 1878.

⁵ Atthill—Loc. cit. Braxton Hicks—*Brit. Med. Jour.*, Aug. 1872.

against the operator's chest, and the cup is steadied with the hand in the vagina. It is evident that these instruments require a roomier vagina than when the hand alone is used; and if the cup slips unexpectedly it may rupture the fornix. Counter-pressure is made over the abdomen with the hand, or, if the abdominal walls are thin and there is a distinct cup on the peritoneal aspect, with a cone of wood¹ which is used to distend the ring of the cervix; the traction can be taken off the vaginal walls by fixing the cervix with volsellae.² Counter-pressure may be made per rectum in the following way:—Pass index and middle fingers of right



FIG. 231.

REPOSITION OF THE INVERTED UTERUS WITH THE HAND ALONE (after Emmet).

hand into rectum, draw down the uterus with the left hand or the noose (fig. 224) until these fingers get fairly above the cervix so as to press on the margins of the peritoneal depression; grasp uterus now with left hand, turning it so that the fundus is towards the symphysis and the cervix towards the sacrum; finally, make pressure with the index and thumb in the angle of reflexion against the two fingers in the rectum.³ The urethra has also been dilated so as to allow one finger to press on the anterior rim of the depression, while the rectal finger presses on the

¹ Thomas—Op. cit., p. 468.² Schroeder—Op. cit., S. 203. Atthill—Loc. cit.³ Courty—*Maladies de l'utérus*, 1866.

posterior.¹ To weaken the resistance of the cervix, lateral incisions have been made into its substance (*Barnes*, see fig. 224).

This manual pressure is, with the help of assistants, to be kept up from half-an-hour to two hours according to the condition of the patient. If not successful in this time, the patient is kept in bed and under the influence of opium while a Barnes bag is placed in the vagina to maintain the uterus as far as it has been replaced. When the uterus has been so far re-inverted that the fundus is above the level of the os externum, the lips of the latter may be drawn together with wire sutures.²

Emmet.

Abdominal section, so as to allow the operator to get at the constricting rim of the cup from its peritoneal side and dilate it with ex-

Abdominal Section for Inversion.

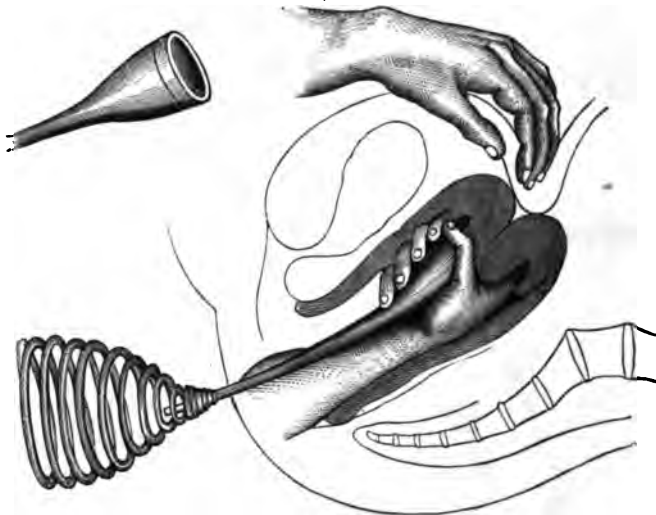


FIG. 232.

WHITE'S REPOSITOR, WITH ELASTIC SPRING PLACED AGAINST THE OPERATOR'S CHEST. While the right steadies cup and uterus, counter-pressure is made with the left hand or better by an assistant (*Thomas*).

panding forceps, has been proposed by *Thomas*. It was successful in the first case; a second proved fatal from peritonitis. *A. R. Simpson* tried it in one case before having recourse to amputation, but could not dilate the ring.

(b.) *Reposition by continuous slight elastic pressure.* If manual reposition has failed, we try the more gradual method; in some cases we employ it from the first. It is effected by the use of an air-bag, or of a wooden cup set on a stem³ with a vaginal (or, better still, a vaginal and

Reposition by Elastic Pressure.

¹ *Tate*—*Cincinnati Lancet and Observer*, March 1878.

² *Emmet*—*Op. cit.*, p. 437.

³ *Lawson Tait*—*Obst. Journ.*, vol. vi., p. 555.

Lawson
Tait.

perineal) curve, so that the pressure is made in the axis of the brim.

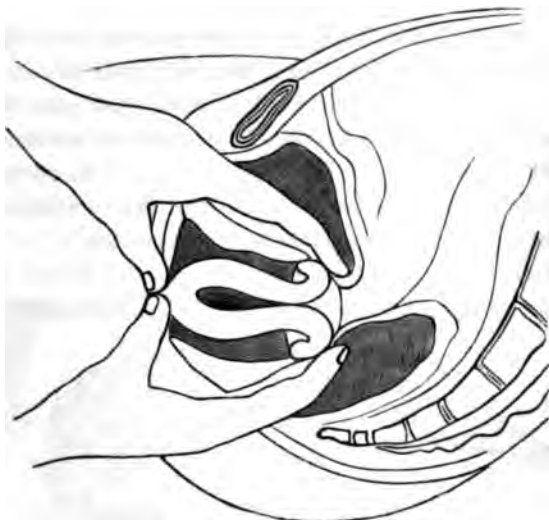

FIG. 233.

TATE'S METHOD OF MAKING COUNTER-PRESSURE WITH FINGERS IN BLADDER AND RECTUM (*Mundé*).

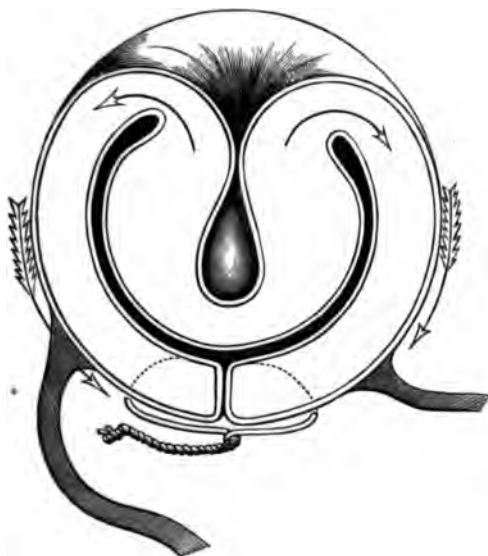


FIG. 234.

EMMET'S METHOD OF RETAINING THE PARTIALLY RE-INVERTED FUNDUS BY CLOSING THE OS EXTERNUM WITH SUTURES; the traction, produced in the direction of the arrows, favours re-inversion (*Emmet*).

Pressure is made by the four elastic bands which pass, two in front and

two behind, to a broad abdominal bandage; by the tightening of the front or the back bands, the direction of pressure is altered.

In this method there are two points which require careful attention. (1.) The elastic pressure must always act in the line of the axis of the inverted uterus, and likewise of the axis of the pelvic brim; the cup is apt to slip off the uterus, and the handle of the instrument to alter its direction. *Pressure in a wrong direction is injurious, and may produce sloughing.* To prevent these accidents we pad, with wadding soaked in carbolized oil, all round the neck of the

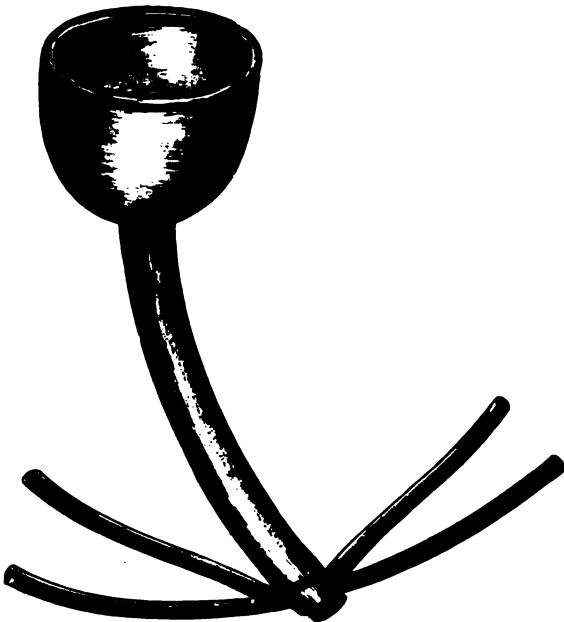


FIG. 235.

CUP WITH STEM AND ELASTIC BANDS which are fixed to an abdominal belt, for gradual reduction of inversion (*Thomas*).

inverted uterus and round the cup of the repositor when *in situ*; we watch the position of the instrument, and remove and re-apply it every day so as to see how it is pressing and whether there is sloughing.

(2.) There must be effective counter-pressure, so as to take the strain off the vaginal walls. This is effected by means of a broad flannel bandage, firmly secured round the loins, under which cotton wool is padded in such a way as to press exactly upon the fundus.

The elastic pressure may be kept up from one to three weeks. Cases of reposition at this period, or even after it, are recorded.

In cases of inversion due to tumour growth, the tumour—if simple—must be removed in the first instance; we then wait to see if the uterus will replace itself, and if it does not we proceed to replace it. If the tumour be malignant, the propriety of amputating the uterus with the tumour must be considered.

B. Amputation.

Amputation of the inverted uterus is justifiable (except in cases of malignant disease) only after all means of reposition have been fairly tried and failed, or when the uterus is extensively ulcerated and gangrenous. The length of duration of the inversion is no argument for amputation; Noeggerath replaced one of thirteen years' standing.

The mortality in amputation is high, 1 in 3 (*Crosse*). The dangers of the operation are—

Hæmorrhage,

Septicæmia,

Peritonitis,

Retraction of the stump into the peritoneal cavity.

We describe the operation as we have seen A. R. Simpson perform it with success.

The following are the instruments required :—

Vaginal douche,

Elastic ligature,

Sims' speculum,

Spatulae,

Volsellae,

Dissecting and artery forceps,

Bistouries,

Scissors,

Long straight fixed needles,

Smaller curved needles and holder,

Silver wire—two thicknesses,

Carbolized silk and catgut.

Place the patient in the lithotomy posture, under chloroform. Keep up irrigation with the douche during the whole operation. Hook back the labia with spatulae, to be held by the assistants who steady the legs; draw down the perineum with Sims' speculum, to be held by another assistant.

Ascertain before making any traction on the uterus where the natural neck of the inverted portion lies, and pass round it an elastic ligature knotted so as to control hæmorrhage. The natural neck is our guide as

Amputa-
tion of
Inverted
Uterus
with the
knife.

to the line of amputation ; if we drag more of the uterus down into the constricting loop, the stump is liable to spring back after the amputation has been performed.

Pass three or four wire sutures through the uterus in an antero-posterior direction, about an inch below the constricting ring, as described under the operation for amputation of the cervix (*v. p. 257*) ; the same figures will show how the sutures are passed in this operation, if we suppose the inner circle (which represents the mucous membrane of the cervical canal in fig. 164) to represent the cross section of the peritoneal pouch. The advantages of passing these sutures before amputating are the following : they are ready *in situ* to control hæmorrhage ; they give us a purchase on the stump when the portion in the bite of the forceps is cut away ; they are more easily passed at this stage.

The uterus is now amputated about half an inch below these sutures. Bleeding points of any size are ligatured with catgut on the end of the stump. The lips are then brought together with the deep sutures already passed. More superficial ones are placed between these to bring the mucous membrane together. The india-rubber constrictor is now notched so as to diminish its pressure, and finally cut through. The ligatures are left long enough to be brought out at the vaginal orifice, and a drainage tube is placed in the cervical canal.

Another method is to constrict the uterus with an elastic cord which is left on for two days ; this diminishes the hæmorrhage on amputation. It is then cut loose, and the galvano-caustic wire or ecraseur applied in the track of the ligature.

Spencer Wells transixed the uterus with needles, placed an elastic ligature above them, and amputated below them with Paquelin's cautery.

The old method of strangulation by ligature, with clipping away of the uterus as it sloughed off, should never be practised.

Re-inversion of the stump is a serious accident, as the raw surface now lies in the peritoneal cavity and may be a source of septicæmia ; further, it is beyond our control should hæmorrhage occur. In two cases of amputation with the galvano-caustic wire, performed by Spiegelberg,¹ this accident occurred : in these cases no bad result followed, because the discharge escaped by the cervical canal ; he attributes this happy result to the fact that the stump-surface of the galvano-caustic wire, being a convex cone, became, on re-inversion, a concave cone opening into the cervical canal.

Re-inversion of the Stump.

¹ *Archiv. f. Gyn.*, Bd. IV., S. 358.

CHAPTER XXXIII.

FIBROID TUMOURS OF THE UTERUS: PATHOLOGY AND ETIOLOGY.

LITERATURE.

Barnes—Diseases of Women, p. 746: London, 1878. *Duncan, Matthews*—Edin. Med. Jour., Jan. and Feb. 1867. *Gusserow*—Die Neubildungen des Uterus: Stuttgart, 1878. *Klob*—Pathologische Anatomie der weiblichen Sexualorgane, S. 149: Leipzig, 1878. *M'Clintock*—Diseases of Women: Dublin, 1863. *Routh*—Fibrous Tumours of the Womb: London, 1864. *Schroeder*—Krankheiten der weiblichen Geschlechtsorgane, S. 206: Wien, 1864. *Simpson, Sir J. Y.*—Diseases of Women, p. 659: Edin. 1872. *Thomas*—Diseases of Women, p. 519: Philadelphia, 1880. *Winckel*—Ueber Myome des Uterus, etc.: Volkmann's Sammlung klin. Vorträge, No. 98, 1876.

SYNONYMS.—Myoma or Fibro-myoma Uteri; Fibrous Tumour; Tumeur fibreuse; Hystérome.

Nomenclature.

As this tumour is composed of both the connective-tissue and muscular elements of the wall of the uterus, it is at once a fibroma and a myoma; the most correct term therefore is *fibro-myoma*. In the majority of cases, however, the fibrous tissue preponderates, so that the tumour resembles a fibroma; the English term fibroid (a term derived from the root of fibroma and $\epsilon\tilde{\iota}\delta\omicron\varsigma$ =like a fibrous tumour) is therefore not inappropriate, and is also more convenient.

PATHOLOGY.

Under this head we shall describe their

- Situation;
- Structure—naked-eye and microscopic;
- Mode of growth, varieties;
- Changes in uterus;
- Degenerative changes.

SITUATION.

They occur much more frequently in the body of the uterus than in the cervix; of seventy-four cases of fibroid tumours recorded by Lee, only four were in the cervix. In the body of the uterus the most common seat is *the posterior wall*; they occur less frequently in the

anterior wall, and very rarely at the sides of the uterus. The soft, truly muscular, form is most commonly situated at the fundus.

STRUCTURE.

They are composed of the same elements as the muscular wall of the Naked-eye Structure of a Fibroid Tumour. uterus, viz., of non-striped muscular fibre and fibrous tissue. These are both present in every case, hence the correct name for these tumours is fibro-myoma. The proportion of these constituents, however, varies; in some rare cases the muscular tissue preponderates, producing a true

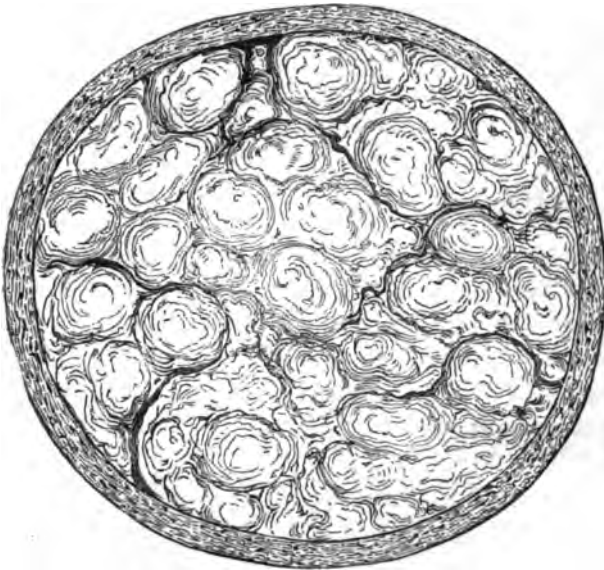


FIG. 236.

SECTION OF A LARGE FIBROID TUMOUR, with the Fibres arranged round several centres
(Sir J. Y. Simpson).

myoma which is not circumscribed and grows rapidly; more usually there is excess of fibrous tissue producing a *fibro-myoma*, which is distinctly marked off from the wall of the uterus and grows slowly. The naked-eye characters of the myoma are those of a pale flesh-coloured tumour having a soft consistence, passing gradually into the surrounding uterine wall, and usually single. The fibro-myoma, by far the most frequent form, is of firm consistence which makes it feel like a foreign body in the softer muscular wall; it is of a pale colour, resembling fibrous tissue; it cuts like cartilage, the cut surface having a glistening satin-like appearance and being often uneven through the firmer fibrous tissue forcing out the

Capsule of
a Fibroid.

softer parts between; the bundles of fibrous tissue have a concentric arrangement round one or more centres (fig. 236). The tumour is surrounded by loose fibrous tissue, which with the immediately adjoining muscular layer constitutes the so-called *capsule*; it has a broad connection at one point with the muscular tissue of the wall, or becoming entirely detached from it lies free in its capsule. This looseness of the tissue round the tumour is important in relation to its removal by the



FIG. 237.

SECTION OF FIBROID TUMOUR, showing wavy bundles of fibrous tissue † (*Gusserow*).

process described as *enucleation*. Few blood-vessels penetrate into the substance of the tumour, although the tissue immediately round it is very vascular and often contains enlarged veins which resemble the venous sinuses of the pregnant uterus (fig. 246); nutrition is apparently effected by transudation from the capsule. In some rare cases, however, these tumours possess a cavernous structure consisting of dilated blood-



FIG. 238.

SECTION OF FIBROID TUMOUR, showing spaces between bundles of fibrous tissue † (*Gusserow*).

vessels. Virchow has described this form as “*Myoma teleangiectodes seu cavernosum* ;” cases are recorded by Leopold and Schroeder.

Micro-
scopic
Structure.

Lymphatic
Spaces.

On microscopic examination, the myomatous form has the appearance of muscular fibre of the uterus. The fibromatous form (common fibroid tumour) has the appearance shown at fig. 237, in which the wavy bundles of fibrous tissue are well seen. Sometimes the bundles of fibrous tissue are separated by spaces (fig. 238), which Klebs considers

to be lymphatic spaces. Nerves have been traced into the substance of these tumours by Lorey ; but, as an interesting case recorded by Freund shows, they are not sensitive :—a sub-mucous fibroid was extruded beyond the vulva ; the lower third, which protruded beyond its capsule of mucous membrane, was not sensitive to the prick of a needle ; the upper two-thirds, from their being still covered by *mucous membrane*, were very sensitive.

MODE OF GROWTH, VARIETIES.

All fibroid tumours are, in the beginning, interstitial or intra-mural. As they increase in size they expand in the substance of the wall or towards one of the free surfaces (peritoneal or mucous), thus becoming

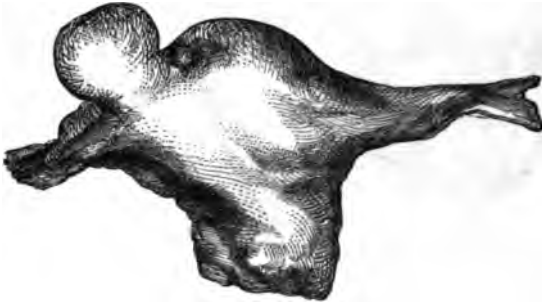

FIG. 239.

PEDICULATED SUBPERITONEAL FIBROID TUMOUR (Sir J. Y. Simpson).

subperitoneal or submucous. Hence three varieties are recognised—*interstitial*, *subperitoneal*, and *submucous*. It is evident that these terms are relative, as it is difficult to say when an interstitial fibroid becomes submucous. Gusserow limits the term “submucous” to *pediculated* submucous, and “subperitoneal” to *pediculated* subperitoneal fibroids. A submucous tumour, however, often gives rise to the clinical signs diagnostic of the submucous variety long before it becomes pediculated. Each variety requires short description. For the sake of convenience, we describe first the fibroid tumours found in the body of the uterus ; the comparatively rare fibroid tumours of the cervix are best noticed separately (p. 385).

A. *The Subperitoneal* grow outwards into the peritoneal cavity. The thickness of the pedicle varies (compare fig. 239 with fig. 240) ; its length determines the mobility of the tumour. When the tumour attains a certain size, one of two things happens. (1.) It may grow

Subperi-
toneal
Fibroids.

up into the abdomen and expanding there draw the uterus forcibly upwards, producing by this traction elongation of the cavity (fig. 240) with thinning of the walls. An interesting case is recorded by *Times*¹ in which the cavity of the body of the uterus was elongated to six inches; the cervical canal extending only one inch inwards from the os externum, ended blindly at a point two inches distant from the beginning

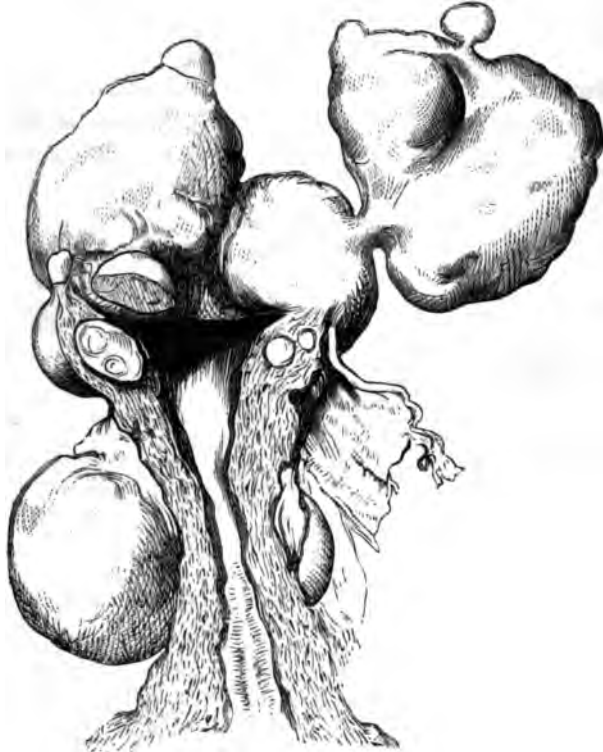


FIG. 240.

UTERUS WITH ELONGATED CAVITY DUE TO THE PRESENCE OF SEVERAL FIBROID TUMOURS
(*Sir J. Y. Simpson*).

Incarceration in Pelvis.

of the cavity of the body; the intervening portion was obliterated so as to form a solid muscular cord. Virchow says that the body may even be torn from the cervix by forcible traction. (2.) The tumour, growing from the first within the pelvis, may through pressure produce the symptoms of incarceration; or, having a long pedicle, may fall down from the abdomen into the pelvis and produce similar symptoms. The

¹ *Lond. Obst. Trans.*, vol. ii., p. 34.

point of origin of the tumour and the length of the pedicle determine whether these symptoms can be relieved by pushing the tumour out of the pelvis. Twisting of the pedicle occurs less frequently in fibroid than in ovarian tumours; when it occurs, it leads to œdema or gangrene. Schroeder¹ mentions a case where, on operating, he found the tumour distended with blood from partial twisting of the pedicle. Gangrene of the tumour, leading to a fatal peritonitis, was observed by Cappie;² the pedicle was twisted round its axis one and a half times. Adhesions form with other organs, as occurs with all abdominal tumours; these may become new sources of nutrition. Sometimes they lead to detach-

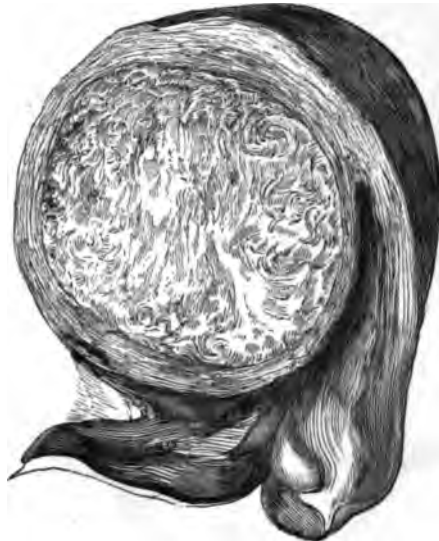


FIG. 241.

INTERSTITIAL FIBROID TUMOUR (Sir J. Y. Simpson).

ment of the tumour from the uterus: the tumour is anchored, as it were, to the abdominal walls; and, when the uterus from pregnancy or other causes becomes displaced, the pedicle gives way. Turner³ reports a case in which a small calcareous fibroid was found free in the pouch of Douglas; a second was attached to the posterior wall of the bladder and to the pelvis; a third was bound down to the bladder and the pelvic wall by adhesions, but still retained its connection with the uterus by a thin pedicle. Adhesions to the intestines have produced symptoms of

¹ *Op. cit.*, S. 218.² *Obstet. Journ.*, ii., p. 303.³ *Edin. Med. Journ.*, 1861, p. 698.

intestinal obstruction.¹ Hernial protrusion of the abdominal walls has been described by Düll:² he reports two cases of this very rare occurrence; in one case, the skin covering the hernial sac became gangrenous, so that the tumour lay exposed.

Interstitial
Fibroids.

B. The Interstitial remain in the substance of the uterine wall, and do not become pediculated. The appearance of such a tumour is well seen at fig. 241. Usually there are many such tumours present (fig. 240); Schultze counted as many as fifty in one uterus, and Thomas describes the uterus of a negress containing thirty-five.

Sub-
mucous
Fibroids.

C. The Submucous are the most important clinically. They lie immediately underneath the uterine mucous membrane, and project into the cavity of the uterus (fig. 242). They are attached along a broad base, or

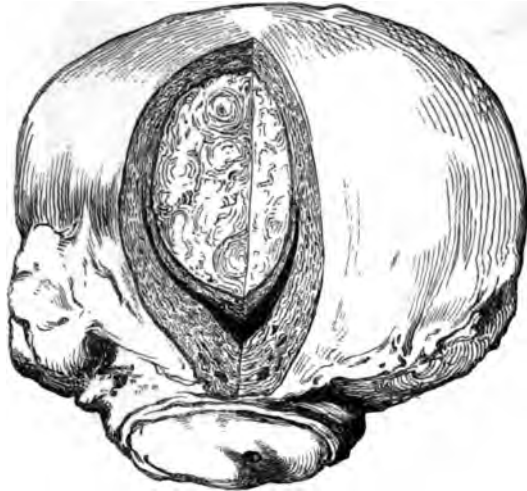

FIG. 242.

SUBMUCOUS FIBROID TUMOUR PROJECTING INTO UTERINE CAVITY (*Sir J. Y. Simpson*).

by a pedicle; when they hang free, they are known as fibrous polypi—the most frequent form of uterine polypi (*v. Chap. XXXVII.*) When a fibroid tumour projects into the uterine cavity, it acts as a foreign body and produces uterine contractions. These lead, in some instances, to *pedunculation* of the tumour and even to its extrusion from the uterine cavity; in such a case, it hangs as a polypus into the vagina. In other rare cases, the capsule ruptures and the liberated tumour is expelled in shreds—*spontaneous enucleation*.

¹ Eade—*Lancet*, Dec. 21, 1872.

² Cited by Schroeder, *op. cit.*, S. 221.

CHANGES IN THE UTERUS.

The muscular wall hypertrophies, more especially when the tumour is submucous or interstitial. A small fibroid lying in the lower segment of the uterus has caused the whole organ to hypertrophy to the size of a ^{Changes} _{in Uterus,}

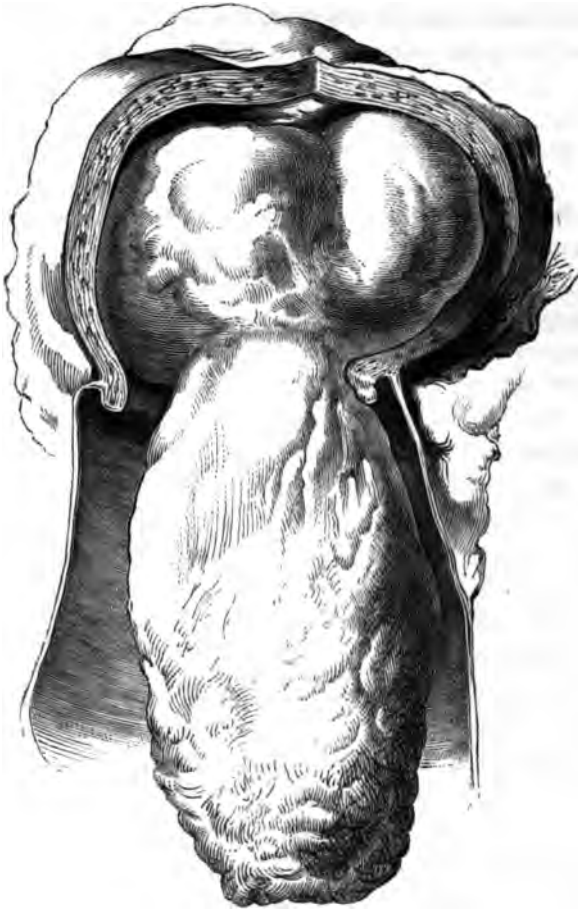


FIG. 243.

PEDICULATED SUBMUCOUS FIBROID IN PROCESS OF EXTRUSION (Sir J. Y. Simpson).

child's head.¹ In submucous fibroid, the *mucous membrane* is also hypertrophied; over the surface of the tumour, it may form adhesions or may ulcerate. The changes in the structure of the uterus generally, thus resemble those of pregnancy and have been described by French writers

¹ Tillaux—*Gaz. des Hôp*, 1867, No. 144.

as "Une grosseuse fibreuse." Changes in the position of the uterus have been already referred to; when subperitoneal fibroids rise up into the abdomen, it is sometimes drawn forcibly upwards by them and may be twisted on itself.¹ At other times the weight of a subperitoneal or interstitial tumour leads to prolapsus uteri. Inversion of the uterus is also occasioned by submucous fibroids when these are situated near the fundus and when their pedicle does not admit of their extrusion as polypi.

DEGENERATIVE CHANGES.

These are the following:—Softening, Induration, Calcification, Suppuration.

Softening. The softening may be due to œdema, to fatty degeneration, or to myxomatous degeneration. The occurrence of the œdema is unquestioned, and many cases of sudden increase in the size of fibroid tumours may be thus explained. From analogy with the changes affecting muscular fibre in the puerperal uterus, we should expect fatty degeneration to occur; there is, however, only a small quantity of muscular tissue present in these tumours. There are only two cases² recorded in which the existence of fatty degeneration has been demonstrated by microscopic examination, although many cases are reported in which this is supposed to have occurred. Myxomatous degeneration, resulting in the formation of spaces containing mucus between the layers of the tumour, sometimes occurs.

Induration. Induration, with atrophy or shrinking of the tumour, occurs in some cases after the menopause. The muscular tissue fattily degenerates and disappears, the fibrous tissue contracts.³

Calcification. When calcification occurs, lime salts (chiefly phosphates) are deposited in the fibrous tissue and produce the so-called womb-stones. This deposit usually commences in the centre of the tumour and extends outwards, more rarely in the external layers so as to form a shell round the tumour. Sometimes it is so extensive that the tumour can be cut with the saw, and the cut surface polished; more usually it is incomplete, and forms a coral-like skeleton. Calcification affects only subperitoneal and interstitial fibroids. Calcification of portions of the tumour is often accompanied with suppuration in others, probably from interference with nutrition.

Suppuration. Suppuration occurs frequently in submucous fibroids, as the result of injury from operative interference or from constriction of its pedicle

¹ As in the case reported by Küster—*Beiträge zur Geb. u. Gyn.* 1872, Bd. i., S. 7. The uterus was twisted two and a half times, so that the broad ligaments formed a spiral.

² Gusserow—*Loc. cit.*, S. 31. The cases are reported by Freund and Martin.

³ Sir J. Y. Simpson—*Obst. Mem.*, p. 115.

during the process of expulsion. It has also been observed as a rare occurrence in subperitoneal fibroids, accompanying calcification or from torsion of the pedicle. In such a case, the tumour either finds its way through the abdominal walls or fatal peritonitis follows.

Whether *carcinomatous* degeneration specially affects fibroid tumours, is a disputed point. We occasionally find carcinomatous degeneration in a uterus where a fibroid tumour is also present (fig. 273) or from which a polypus has on a former occasion been removed. Whether this is merely a coincidence, or whether there is a liability that the non-malignant tumour may become the seat of malignant disease, is not settled. The practical importance of this question is evident.

FIBROID TUMOURS OF THE CERVIX.

The occurrence of fibroid tumours in the cervix is rare ; but, when they are present, they often give rise to difficulty in diagnosis on account of the

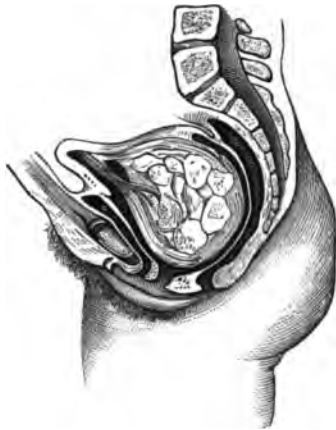

FIG. 244.

CERVICAL POLYPUS springing by a fibrous pedicle from the region of the os internum, and pushing itself under the whole mucous membrane of the cervical canal ; so that its insertion is partly continuous with the tissue of the uterus, partly truly submucous. Between these a cavity has formed, through tearing of the mucous membrane, so that the tumour has apparently two pedicles (*Schroeder*).

distortion which they produce. They spring from either wall, and grow outwards towards the peritoneal cavity or downwards into the cellular tissue beside the vagina. When sub-serous, they easily produce symptoms of incarceration, as, from their low position, they are liable to become wedged in the pelvis. When submucous, they produce elongation of one lip and may form a polypoidal tumour in the vagina (fig. 244) ; the accompanying distortion of the os externum leads to difficulty in diag-

nosis. Cases in which a large tumour bulges through the ostium vaginae have been mistaken for inversion and prolapsus. Sometimes, prolapsus is due to the weight of the tumour and disappears after its removal.¹ The interstitial form is easily mistaken for inversion when the os is converted into a transverse cleft which escapes observation and the unaffected lip is thinned out to a mere band.

ETIOLOGY.

Gusserow, to whose exhaustive article—Die Neubildungen des Uterus—in Billroth's Handbuch we are greatly indebted in this Chapter, says in regard to etiology, "Ueber die Ursachen der Uterusmyome wissen wir so wenig, wie über die Ursachen der meisten pathologischen Neubildungen, nämlich *nichts*" (of the causes of fibroid tumours we know as little as of the causes of most pathological new-formations, that is *nothing*). Virchow and Winckel have both made elaborate attempts to assign a cause to the development of fibroid tumours. The number and variety of causes adduced by these observers only show how far we are from the knowledge of the real cause; with such a variety of causes, the difficulty would not be to explain why they are present in some but why they are not present in every case.

They are without doubt the most frequent new-formation in the uterus. Klob says that they are present in 50 p.c. of women who die over fifty years of age; and Bayle, in 20 p.c. of those who die over thirty-five years; both of these estimates are probably beyond the mark.

Develop-
ment of
Fibroids
according
to age.

Their development is in some way related to the development of the sexual apparatus. Thus, there are no well-authenticated cases of their arising before puberty or after the menopause. The majority of patients are between the ages of thirty and forty when they first seek medical advice, as is evident from the accompanying table based on statistics collected by Gusserow (fig. 245). Schroeder says that of 196 patients, who during three years of his private practice consulted him for fibroid tumours, 104 were between forty and fifty and 62 between thirty and forty.

Sexual activity predisposes to their development as they are almost twice as frequent in married as in unmarried women; of 959 cases collected by Gusserow, 672 were married women. It is important to note this as it was formerly supposed that single life favoured their development. As the presence of a fibroid tumour interferes with conception, we often find sterility present.

¹ Barnes—*Obst. Trans.*, III., p. 211.

TABLE AND DIAGRAM SHOWING FREQUENCY OF FIBROID TUMOURS ACCORDING TO AGE OF PATIENT.

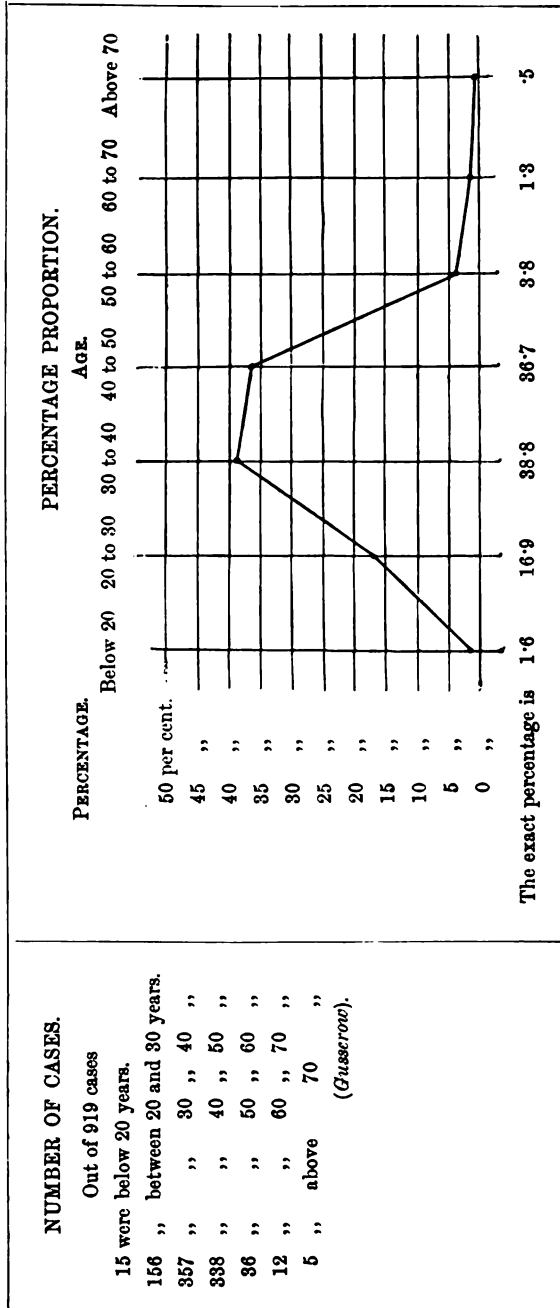


FIG. 245.

CHAPTER XXXIV.

FIBROID TUMOURS OF THE UTERUS: SYMPTOMS; DIAGNOSIS; PROGNOSIS.

LITERATURE—See Literature of Chaps. XXXIII. and XXXV.

LIKE other pathological conditions of the uterus, fibroid tumours sometimes produce no symptoms and their presence is discovered accidentally or on *post-mortem* examination. This absence of symptoms is more likely to occur should the tumour be small, or should there be no sexual activity as in unmarried women. In the latter case, although symptoms appear only when the patient enters married life, the tumour may have been already a long time present. Subperitoneal tumours, even when large, may only produce discomfort from undue abdominal distention.

The symptoms usually present may be tabulated as follows :—

1. Menorrhagia, irregular hæmorrhages ;
2. Painful menstruation ;
3. Pelvic sensations due to size and weight of tumour, peritonitic pain ;
4. Symptoms of pressure on bladder and rectum,
blood-vessels and nerves,
ureters ;
5. Sterility and abortion.

Hæmorrhage in
Fibroids.

1. *Hæmorrhage* is the most characteristic symptom in submucous fibroids, and appears first as a *gradual increase* of the normal menstrual flow; it never begins with a sudden flooding as in carcinoma uteri. In *menorrhagia*, the hæmorrhage comes from the hypertrophied mucous membrane of the uterine cavity generally; it does not come from the mucous membrane covering the surface of the tumour which is frequently thinned and atrophied, nor from the substance of the tumour itself which as we have seen is sparingly vascular. When, however, the submucous fibroid projects as a polypus, passive congestion and hæmorrhage from the mucous membrane covering it may be occasioned by the constriction of

its pedicle. *Irregular hæmorrhages* arise from ulceration of the mucous membrane covering the tumour, or rupture of the dilated veins in its capsule. Fig. 246 shows a case¹ in which, through the rupture of a uterine sinus in the lower part of the tumour, a sudden and fatal hæmorrhage occurred.



FIG. 246.

UTERUS CONTAINING FIBROID TUMOUR, from a case which terminated fatally through hæmorrhage. Note the large venous sinuses in the capsule, one of which ruptured at the point *a* (Matthews Duncan).

hæmorrhage occurred. In subperitoneal fibroids menstruation is not increased, and in certain rare cases is diminished.

2. *Pain accompanies menstruation.* In the submucous variety there is often characteristic uterine *dysmenorrhœa*, in which the pain resembles Pains in Fibroids.

¹ Reported by Matthews Duncan—*Edin. Med. Jour.*, 1867, p. 634. He also refers to a case of Cruveilhier's in which death was occasioned in the same way.

labour pains. The congestion causes the polypus to swell, and this produces uterine contractions (*v.* Uterine Polypi). In interstitial and even in subserous fibroids, there is often pain at the menstrual period which cannot be thus explained. In subserous fibroids with a pedicle containing large vessels, as well as in interstitial, Gusserow ascribes the pain to the distention of the tumour with blood. This pain is of a stretching or dragging nature, and is quite different from the pain of uterine contractions.

3. *Increased weight* of the uterus occasions *sensations* of discomfort, which are described as "fulness or weight in the pelvis," "a sensation of dragging," "bearing-down pain." When the tumour is so large that it fills the pelvis and becomes wedged in it, intense pain is produced; this is either always present, or recurs only at the menstrual periods when the tumour is distended by blood. As in carcinoma uteri, peritonitic pains—indicated by local tenderness and reflex contraction of abdominal muscles—may arise at any time from secondary chronic peritonitis. Neuralgic pain is sometimes present locally (see below), but may be also through the whole body.

Pressure
Symptoms
in Fibroids.

4. Frequency of micturition, due to *pressure on the bladder*, is the most common pressure symptom. *Pressure on the urethra* produces difficulty of micturition and even retention; with some patients, this recurs regularly at the menstrual period. Even very small fibroids, when they are situated in the anterior uterine wall, may press *on the neck of the bladder* and produce symptoms of cystitis. *Pressure on the rectum* by fibroids in the posterior wall, occasions constipation or, more rarely, mucous diarrhoea. Incarcerated fibroids have produced complete obstruction, and led to a fatal result¹ or furnished an indication for colotomy. Intestinal obstruction has also resulted from adhesions between the tumour and the small intestine.² *Pressure on the veins* produces hæmorrhoids and varicose veins in the legs. Interesting cases of neuralgia due to pressure on *pelvic nerves* have been recorded. In these cases the neuralgia entirely disappeared as soon as the tumour was lifted up and supported by a pessary.³ Compression of *the ureters*, with consequent dilatation and hydronephrosis, occurs less frequently in fibroid tumours than in carcinoma. The reason for this is evident; in carcinoma the compression is due to infiltration of the tissue round the ureter, which

¹ Holdhouse—*Lond. Path. Soc. Trans.*, III. 371.

² Eade—*Lancet*, Dec. 21, 1872.

³ Kidd—*Dub. Quart. Journ.*, 1872. Jude Hüe—*Annales de Gyn.*, IV., p. 239.

from the anatomical relation of the ureters to the cervix easily occurs; fibroid tumours in their growth simply press against the ureters, and may push them aside. Several cases of single and double hydronephrosis and of death from uræmia,¹ have been recorded. Bright's disease has developed secondarily.² In fibroid tumours where pressure symptoms are present, we should always examine the urine.

5. *Sterility* is frequent. Of 149 cases of married women collected by Schroeder, 33 per cent. were sterile and the average number of children to each mother was about three. When conception occurs, fibroid tumour may lead to abortion or complicate labour.

PROGRESS AND RESULTS.

A *relative cure* usually takes place at the menopause, when the tumour ceases to grow. In the case of subserous tumours, this may happen even before that time.

Spontaneous disappearance of the tumour has been observed in certain cases, although nothing definite is known as to the means by which it is effected. After sifting the reported cases, Gusserow's conclusion is that there are thirty cases in which this undoubtedly occurred.³ Out of these thirty, thirteen were associated with the puerperium and the rest chiefly with the menopause. We might account for their disappearance during the puerperium by a process analogous to involution. Of the reason of the disappearance at the menopause we know nothing.

Complete cure also results from *spontaneous expulsion*. This occurs in three ways:—

- (1.) By pediculation and extrusion of the tumour as a polypus (*v.* under Uterine Polypi);
- (2.) By enucleation, in which the tumour is shelled *en masse* out of its bed;
- (3.) By the breaking down of its substance and consequent expulsion in fragments.

Enucleation occurs in submucous and also in interstitial tumours. The mucous membrane of the capsule ulcerates, and the tumour is thus exposed; partly through suppuration, partly through uterine contractions, it becomes detached all along the line of its capsule and, being thus liberated, is expelled. This process is comparatively safe for the patient,

¹ Gusserow quotes cases from Jude Hie, Murphy, Hanot—*Neubildungen*, etc., S. 47.

² Hubert—*Bul. de la Soc. anatom.*, 1873, p. 870.

³ He does not refer to a case observed by A. R. Simpson, and probably others have been overlooked.

though there is always the risk of hæmorrhage from the large veins in the capsule (fig. 246). In spontaneous enucleation, suppuration does not occur in the tumour itself but only in its capsule.

Breaking
down of
Fibroids.

The *breaking down* of the substance of the tumour is a much more dangerous process for the patient. As it is a slow one, there is a risk of absorption of septic matter. The commencement of this change is indicated by increase in the size of the tumour, which becomes tense and painful to the touch. There is a purulent foetid discharge from the vagina, and sometimes hæmorrhage. The constitutional symptoms of loss of appetite and hectic fever afterwards develop, and most of such cases end fatally.

Expulsion of the tumour generally takes place per vaginam. As in other tumours we have inflammatory adhesions forming with neighbouring organs, followed by suppuration and perforation by the tumour. Thus calcified fibroids have perforated into the bladder, and have been mistaken for vesical calculi.¹ A fibroid has perforated into the rectum, and has been discharged per anum. In some cases adhesions with the abdominal wall have formed, and the tumour has been thus discharged.

Causes of
Death in
Fibroids.

Considering the frequency of fibroid tumours, it is rare that *death* follows immediately from their presence. A fatal result, however, may follow from (1) suppuration in the tumour producing death from septicæmia, or a septic peritonitis; (2) uræmia, due to compression of the ureters; (3) direct hæmorrhage; (4) acute simple peritonitis.

PHYSICAL SIGNS: DIFFERENTIAL DIAGNOSIS.

The physical signs of fibroid tumours are usually so well marked that diagnosis is easy. In certain cases, however, diagnosis is very difficult; and when inflammation is superadded, certainty is impossible. Physical diagnosis is best considered under two heads: *a.* of small fibroid tumours, up to the size of a walnut or egg; *b.* of larger ones, which rise up as a distinct tumour unto the abdomen.

a. OF SMALL FIBROID TUMOURS.

Diagnosis
of Small
Fibroid
Tumours.

1. Pediculated *submucous* fibroids should be easily recognised. When they are small and not projecting through the os, we have to dilate the cervix to ascertain their presence and attachment; when larger and projecting into the vagina, they may readily be mistaken for inversion of the uterus. On sweeping the finger round the base, we recognise the

¹ M'Clintock—*Dub. Quart. Jour.*, Feb. 1868.

commencement of the cervical canal unless the polypus be adherent at its neck leading to obliteration of the canal (*v.* fig. 227.) Further, the bimanual or rectal examination shows the fundus uteri to be in its normal position.

2. Small *interstitial* fibroids when situated *low down* and causing bulging of one lip of the cervix, give rise to difficulty; owing to the great enlargement of one lip, the os is displaced to the other side and its form altered to that of a mere slit which easily escapes observation. Such cases have been occasionally mistaken, even by the most experienced for inversion. This mistake is prevented by examination per rectum. Further, the sides and base of the tumour must be carefully scrutinised to discover the os; when this is found, the sound will show the position of the uterine cavity.

3. *Interstitial* fibroids placed *high up* in the uterus, or small *subserous* ones with a *broad base* of attachment, often escape detection. To ascertain their presence we proceed as follows. Pass the sound; this defines the course of the uterine canal and position of the fundus. Now make the bimanual examination with the sound, as represented in fig. 97; the finger in the anterior fornix detects the thickening of the anterior wall, produced by a small fibroid. Now steady the sound with the left hand, and pass the forefinger of the right hand into the rectum so as to feel the sound lying in the uterus. Should there be a fibroid in the posterior wall, the finger recognises an unusual thickness of tissue between it and the sound. Carry the sound, firmly grasped by the left hand, towards the symphysis, so as to bring the fundus better within reach of the rectal finger; and, by moving it from side to side, ascertain whether the tumour is intimately connected with the uterus so that it moves along with it. From their being largely composed of fibrous tissue, these tumours are firmer than the uterine wall; the *localised hardness*, therefore, helps us in recognising them.

Small fibroid tumours require to be diagnosed from

Chronic metritis,
Early pregnancy,
Ante- and retro- flexion.

Differential
Diagnosis
of Small
Fibroid
Tumours.

In *chronic metritis* the uterus is not globular but flat, and the enlargement is equable; the uterine canal is patulous; the os is everted, and shows catarrhal patches. We must remember that chronic metritis is occasionally present along with a fibroid tumour.

In *early pregnancy*, the uterus is soft and elastic; the cervix is

generally softened, while in fibroids it remains hard. Pregnancy, however, may occur in a uterus which is already the seat of a fibroid tumour (fig. 247); and in such a case the diagnosis becomes certain only after the uterus is considerably enlarged. The possibility of pregnancy must specially be kept in mind here, as we involuntarily think of using the sound to aid in detecting fibroids.

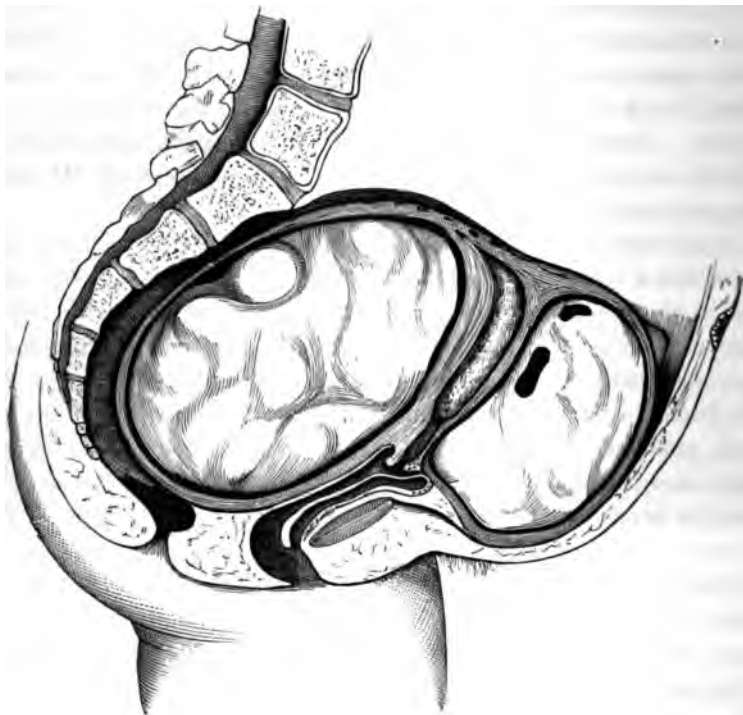


FIG. 247.

CASE OF TWO-AND-A-HALF MONTHS' PREGNANCY ASSOCIATED WITH TWO LARGE FIBROID TUMOURS.—one in the anterior, the other in the posterior wall. The uterus and tumours were removed by Laparotomy (Barnes).

Anteflexion is closely simulated by a fibroid in the anterior wall; a body is felt in the anterior fornix, continuous with it, but separated by a groove. Similarly, a fibroid in the posterior wall has all the characters of the *retroflexed fundus*. Examination by the sound (*v.* fig. 198), and especially by the sound plus the Bimanual, clears up the case.

b. OF LARGE FIBROID TUMOURS.

When the tumour extends into the abdomen, we proceed with the systematic examination as described at page 90.

DIFFERENTIAL DIAGNOSIS OF FIBROID TUMOURS. 395

Palpation. The tumour has a well-defined outline, and a firm solid consistence. It is intimately connected with the uterus; this is best ascertained by laying hold of the cervix with the volsella, when the cervix will be found to move along with the abdominal tumour. Subserous fibroids have a certain range of free movement depending on the length of the pedicle. In soft fibroids, there may be intermittent contractions. *Percussion.* The note is absolutely dull, unless intestines come between the tumour and the abdominal wall. *Auscultation.* The uterine souffle is heard most distinctly at the sides, sometimes all over the tumour. As the uterine souffle simply means enlarged uterine arteries, there is no souffle when these are not enlarged; hence it is absent in subserous fibroids with a small pedicle. *Vaginal examination.* Should the tumour be large and lifting the uterus into the

Diagnosis
of large
Fibroid
Tumours.



FIG. 248.

SOUND USED TO DETECT PEDICULATED SUBMUCOUS FIBROID (*Leblond*).

abdomen, the cervix will be high up; or it may be displaced in various ways, according to the position of the tumour; it has a firm consistence. *Bimanual.* With pediculated subserous fibroids, the uterus is felt distinct from the tumour; with interstitial and submucous, we simply feel a large mass continuous with the cervix. *The Sound.* This should not be used till all possibility of pregnancy has been excluded. In doubtful cases, we wait three or four months till the positive signs indicative of pregnancy should have had time to develop. From the use of the sound we learn (1) the length, (2) the direction of the uterine

cavity. The length of the cavity is always increased in submucous, and generally in interstitial, but not in subserous tumours; it may measure six or eight inches. The direction of the canal is often tortuous in submucous tumours; hence the passage of the sound is difficult, sometimes impossible. We feel that the sound goes so far and then catches on a hard projection. In such cases, a soft (No. 8) bougie is very useful, as its flexibility allows it to pass the obstruction. Usually, the sound passes to only one side of the tumour; sometimes we can sweep it more or less round the tumour, showing that it projects free into the uterine cavity (fig. 248).

Differential
Diagnosis
of large
Fibroid
Tumours.

Large fibroid tumours require to be diagnosed from—

Advanced pregnancy,

Ovarian tumours;

Extra-uterine gestation,

Hæmatocele and inflammatory deposits.

In *advanced pregnancy* the uterus is of softer consistence, and shows ballottement—the indication of a solid within a fluid; further, we can feel the parts of the fœtus. It becomes occasionally harder under the hand, specially if we make the patient change her position; this *variation in consistence* is a most valuable diagnostic, as it is rarely present in fibroid tumours. We hear the uterine souffle and, unless the child be dead, we hear in addition the *fœtal heart*; the possibility of the child's being dead should always be kept in mind. On vaginal examination, there is discoloration of the vaginal walls with free secretion; the cervix is softened. There is usually amenorrhœa corresponding in duration to the size of the uterus.

Ovarian tumours are soft and elastic; small ones may be firm. There is no uterine souffle. They only give rise to difficulty in diagnosis when they have become adherent to the uterus, and move along with it. It is sometimes impossible to diagnose between them and cystic fibroid tumours (*v. Fibro-cystic Tumours*).

Extra-uterine gestation presents great difficulty in diagnosis, but we delay its consideration till the Chapter on that subject (*v. Section IX.*)

In *hæmatocele and inflammatory deposits* we have the history of the attack to guide us. It may be impossible to form a diagnosis on first examination; but after watching the case for a few weeks and noting any change in the deposit in addition to ascertaining its precise situation, we can form a diagnosis. Pelvic peritonitis frequently occurs round a subperitoneal fibroid, or any fibroid producing pressure; and in

such a case it is impossible to diagnose between the tumour and the effusion round it. Many cases reported of gradual absorption of a fibroid tumour under treatment, were probably cases of mistaken inflammatory exudation.

PROGNOSIS.

In forming our prognosis we must take into account (1) the site of the tumour in the uterus, most favourable when subserous; (2) its position in the pelvis, whether low down and likely to become wedged within it; (3) the symptoms already present, of which hæmorrhage is the most important. Though (as already said) they are rarely dangerous to life, they may cause the patient many years of suffering from which she only finds relief at the menopause.

CHAPTER XXXV.

FIBROID TUMOURS OF THE UTERUS: TREATMENT.

LITERATURE.

Atlee—The treatment of the fibroid tumours of the uterus: Internat. Med. Cong. Trans., Sept. 1876. *Bantock*—British Medical Journal, 1882, p. 426. *Duncan, Matthews*—Diseases of Women: London, 1883, p. 289. *Greenhalgh*—On the use of the actual cautery in the enucleation of fibroid tumours of the uterus: London Med. Chirurg. Trans., Vol. LIX. *Hegar u. Kallenbach*—Die operative Gynäkologie: Stuttgart, 1881, S. 416. *Keith, Skene*—Seven cases of removal of large uterine fibroids at vaginal junction (operations by Thos. Keith): Br. Med. Jour., 1863, pp. 10 and 55. *Leblond*—Traité élémentaire de Chirurgie gynécologique: Paris, 1878. *Palmer*—Laparotomy and Laparo-Hysterotomy, their indications for fibroid tumours of the uterus: Americ. Gyn. Trans., 1880, p. 361. *Simpson, A. R.*—The treatment of fibroid tumours of the uterus; Contributions to Obstetrics and Gynecology, Edinburgh, 1880. *Sims, Marion*—On intra-uterine fibroids: New York Medical Journal, April 1874. *Wells, Spencer*—Brit. Med. Journ., May and Dec. 1878. See also references in the text.

THIS is best considered under the heads of medical and surgical treatment.

A. MEDICAL TREATMENT.

Ergot in
Fibroids.

There is no medicine which acts immediately upon fibroid tumours so as to cause disintegration and absorption. We have, however, a very important remedy in *ergot of rye*; the beneficial effects of this have been brought forward by Hildebrandt,¹ and by A. R. Simpson whose paper on the treatment of fibroids may be consulted for illustrative cases. It acts beneficially in two ways—by checking their nutrition through diminishing the amount of blood circulating to them, and by favouring their pedunculation and expulsion; these are both due to its action on the unstriped muscular fibre of the walls of the uterus and coats of the blood-vessels. Success in its use depends, according to Simpson, on securing that the preparation of ergot used be active, that it be properly administered, and that the case be a suitable one. The formula for the preparation which he recommends is—

R	Ergotinæ	ʒii.	
	Aquæ	ʒvi.	
	Chloral-hydratis	ʒss.	M.

¹ *Berlin klin. Wochenschrift*, 1872, No. 25.

Three grains of ergotin are contained in twelve minims of the fluid, which is a good medium dose. Chloral is added to make the solution keep; but even with this it becomes after some weeks unfit for use, and should therefore be made up repeatedly and in small quantities. It is administered with the ordinary hypodermic needle. Care must be taken that the syringe contains no air; this is best secured by holding it with the needle upwards and squirting out some of the liquid. The injection is made in the gluteal region, which is readily done when the patient is lying on her side; and on the right and left sides alternately, so as to diminish the frequency of punctures in the same region. Enter the needle vertically and plunge it rapidly *deep into the muscle*, the point entering to the depth of from an inch to an inch and a half; now empty the syringe, and quickly withdraw the needle. After use, remember to cleanse the needle with water and to replace the wire in it. The patient soon becomes accustomed to the prick of the needle and, if it be entered deeply into the muscle, there is little fear of local suppuration; after three years' experience we have seen this in but one case, and this was probably due to a bad preparation of the solution. For the first few weeks the injections may be made twice a-week, afterwards only once a-week. The treatment is continued for several months until its effect is seen in diminution of the size of the tumour or, at least, of the hæmorrhage from it. The suitable cases are those in which the tumour is intra-mural or submucous; "it must be surrounded by layers of muscular fibre, sufficiently developed to be capable of being excited to contraction."

Adminis-
tration of
Ergotin
subcutane-
ously.

When the patient cannot be seen frequently by a physician, a friend or a nurse should be instructed how to apply the needle. Ergot can also be administered in the form of pill, suppository (4 grs. in each) or liquid extract (30 drops thrice daily). When given by the mouth, however, it does not act so quickly or surely as when given hypodermically.

Bromide of potassium was recommended by Sir J. Y. Simpson, who believed that it had a marked influence in checking the growth and even in reducing the size of fibroid tumours. It is impossible to say whether, in cases where the tumour diminished in size during its administration, this result was due to the bromide. As a prolonged use of the bromide is generally necessary, small doses (ten grains, three times a day) should be administered. Being a nervine sedative, it is useful to give it in cases where the only symptoms are discomfort from the presence of the tumour or neuralgic pain. Should the tumour be in-

Bromide
of Potas-
sium in
Fibroids.

creasing in size, or should there be much hæmorrhage, we must have recourse to ergot.

When the patient can afford it, benefit is undoubtedly derived from a course of treatment of *mineral waters* (such as those of Kreuznach) as recommended for chronic metritis.

The symptoms due to the weight of the tumour may be relieved by *artificial support*. Thus patients with a small fibroid often derive great benefit from wearing a Hodge pessary; the discomfort of a large abdominal tumour is materially lessened by wearing a broad flannel bandage.

When the tumour nearly fills the pelvis and is beginning to press injuriously upon the bladder and rectum, we should, when possible, *push it up out of the pelvis* into the abdomen; this is done before the occurrence of pelvic peritonitis, which may hopelessly bind it within the pelvis. The most favourable case for this manipulation is a subserous fibroid with a distinct pedicle.

B. SURGICAL TREATMENT.

This consists in the removal of the whole tumour or portions of it through the vagina, or through the abdominal walls.

a. REMOVAL THROUGH THE VAGINA.

We have seen that this process takes place *spontaneously*, either by pedunculation and extrusion as a polypus or by enucleation. In *operating*, we simply favour these natural processes. The former will be described under "Treatment of Polypi" (see Chapter XXXVII.)

We favour enucleation of the tumour (1) by dilating or dividing the cervix uteri; (2) by incision of the mucous membrane covering the surface of the fibroid; (3) by stimulating the uterus to contract and expel it spontaneously from its bed, or by laying hold of and forcibly detaching it. These might be considered either as different consecutive operations, or as successive steps in the same operation.¹

The *dilatation of the cervix* is effected by sponge tents or a bilateral incision with the scissors; incision with the thermo-cautery, as suggested by Thomas, reduces the risk of hæmorrhage and septic infection. Sometimes this is all that is required. After the division of the cervix, the hæmorrhage (which is usually the indication of the operation) ceases; if the tumour is in the process of expulsion, this takes place more readily through the dilated cervix. Even diminution of the size has

¹ Matthews Duncan—*Elin. Med. Jour.*, Feb. 1867.

been observed after the operation, though there is no explanation of how this occurs.

Should this operation be insufficient, we proceed next to *incision of the mucous membrane covering the tumour*. The purpose is twofold. (1.) It checks hæmorrhage. We have referred to the existence of venous sinuses in the capsule of the tumour, from which profuse hæmorrhage sometimes occurs (*v. fig. 246*); when these are cut through, they retract and are closed by thrombi. After this operation the hæmorrhages are, for a long period at least, checked. (2.) It favours spontaneous enucleation of the tumour, which comes to protrude through the incised mucous membrane.

The mucous membrane is incised either with the bistoury or with the thermo-cautery as follows. Carry a probe-pointed bistoury, which has the lower half of the blade sheathed, into the uterus through the previously dilated cervix; make one or more incisions, about an inch long and from a quarter to half-an-inch deep, upon the surface of the tumour. The great danger of the operation is the introduction of septic matter; to diminish this risk, Greenhalgh employs the actual cautery with an olive-shaped bulb to incise the mucous membrane and at the same time to destroy the heart of the tumour; he also uses it to burn away, from time to time, portions of the tumour as they protrude through the capsule.

Thermo-cautery in Pediculated Fibroids.

It is evident that the cautery can be used only when we have an interstitial fibroid which has forced itself into one lip of the cervix and projects markedly into the roof of the vagina (*v. fig. 244*); or when a submucous fibroid has dilated the os sufficiently to become accessible to the cautery. The cautery, of which the Paquelin is the most convenient form, reduces the dangers of hæmorrhage and septic infection to a minimum.

The separation of the tumour should be left to the natural efforts, and may extend over a period of months; during this time, to promote uterine contractions, the patient is kept fully under the influence of ergot. Greenhalgh remarks that "spontaneous expulsive efforts shortly followed the use of the cautery."

Should sloughing of the tumour occur during the process of natural enucleation, we interfere to remove the tumour rapidly. Even although there is no sloughing it is sometimes necessary to shell the tumour out of its bed.

The detachment of the tumour from its capsule may be effected by

Nail
curette.

A. R. Simpson's nail curette (fig. 249). It is intended, as its name implies, as a substitute for the finger nail which would be the best instrument were it only strong enough to scrape through the tissues.

Thomas'
Spoon-Saw.

Thomas has devised a similar instrument which has the form of an

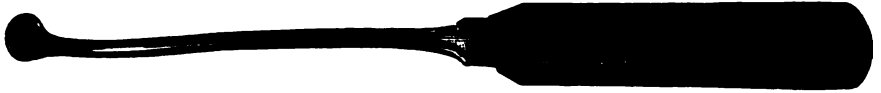

FIG. 249.

A. R. SIMPSON'S NAIL CURETTE, \ddagger (A. R. Simpson).

elongated spoon with a serrated edge (fig. 250); it is worked with a pendulum-like movement of the hand. The advantages claimed for it are that it limits hæmorrhage and, from its concave form, "hugs the




FIG. 250.

THOMAS' SPOON-SAW (Thomas).

tumour" so as not to cut deeply into the uterine wall. Before operating, he measures with a whalebone probe the extent of attachment of the tumour to the wall of the uterus. He has "operated more than twenty




FIG. 251.

SIDE-VIEW (to show curve) AND FACE-VIEW (to show cutting edge) OF MARION SIMS' ENUCLEATOR (Marion Sims).

times with this spoon-saw, and its efficiency becomes more and more apparent with increasing experience."

Marion
Sims'
Enuclea-
tor.

Marion Sims employs the enucleator represented at fig. 251, and operates as follows. The tumour is drawn down to the os uteri; the

capsule is incised with scissors, and detached as far as possible with the fingers; the enucleator is passed in between the tumour and its capsule, and worked round the former so as to free it on all sides; a tumour-hook is now hooked deeply into its substance, with which it is dragged down while the enucleator is used to sever any remaining connections; when necessary, the os is incised to allow it to pass.

When the tumour has been so far enucleated, spontaneously or by the artificial means described, the extraction of it is often difficult on account of its size. When it projects into the vagina we lay hold of it with large volsellae (fig. 252) and make traction while the hand is passed up to the base of the tumour to sever any connection between it and its bed. The fundus uteri is at the same time pressed down and steadied by an assistant. In the case of large tumours, midwifery forceps are used for extraction. To allow a tumour of large size to be extracted, it may be necessary to divide it with scissors or the ecraseur and remove it in portions; we may even require to incise the perineum, if the vaginal orifice be small.

Thus with regard to *enucleation* and removal per vaginam, it is evident that, from the risks of the operation, we should interfere only when the severity of the symptoms justifies a dangerous operation or when nature is unable to complete the process of expulsion. The circumstances most favourable for removal by this means are when the tumour is small and loosely connected with the uterus, or when it has been already "born" into the lax and roomy vagina of a multipara.

b. REMOVAL THROUGH THE ABDOMINAL WALLS BY LAPAROTOMY.

We must remember that, as fibroid tumours do not endanger life in the same way that ovarian tumours do, the operation for their removal, being apparently associated with so much more danger, is only to be had recourse to in extreme cases. Whether the removal of fibroid tumours by laparotomy will in the future take the place that ovariectomy has at last gained for itself, we are not in a position to say. The fact that these tumours threaten the life of the patient only in exceptional cases makes this improbable. In reporting some cases of successful operation to the London Obstetrical Society in April 1880, Knowsley Thornton says that he believes "that the removal of uterine fibroids by laparotomy is not only justifiable, but is an operation with a position in the immediate future in no way second to that now held by ovariectomy."

The merits of the operation cannot be judged from statistics, because

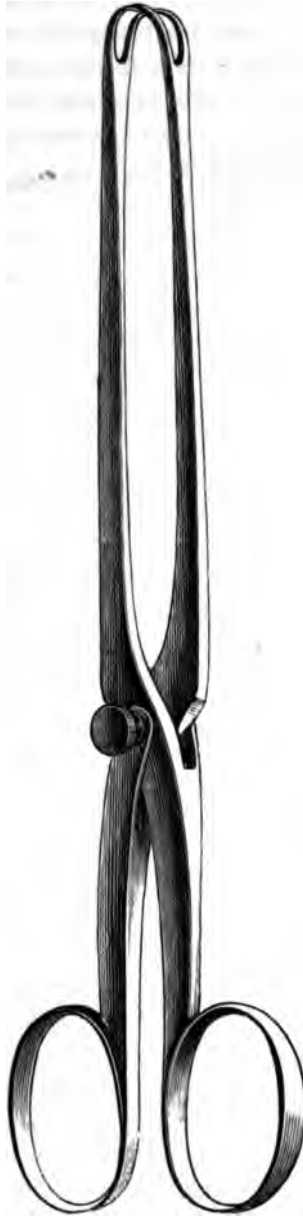

FIG. 252.

SIR JAMES SIMPSON'S VOLSELLA FOR SEIZURE OF UTRA-UTERINE FIBROIDS—TWO-THIRDS SIZE. The blades are separable, and lock like a pair of midwifery forceps; after being locked, the blades are fixed with a screw-pin which serves as a joint (*A. R. Simpson*).

SURGICAL TREATMENT OF FIBROID TUMOURS. 405

each operator has tried a different method. Statistics enable us rather to compare the success of different methods of operating than to decide on the merits of the operation itself.

The following table gives the results of the leading operators.

Péan, ¹	up to Nov. 1879,	had operated 46 times with 30 recoveries.							
Spencer Wells, ²	Dec. 1878,	"	25	"	10	"			Statistics of Lapar- otomy for Fibroids.
Billroth, ³	Mar. 1880,	"	25	"	10	"			
Kœberlé, ⁴	Dec. 1877,	"	19	"	9	"			
Schroeder, ⁵	Dec. 1879,	"	18	"	11	"			
Hegar and Kaltenbach, ⁶	} (new method),	Sep. 1881,	"	12	"	11	"		
Thornton, ⁷		Apr. 1880,	"	10	"	6	"		
Thomas, ⁸	Sep. 1880,	"	7	"	4	"			

From the above table two things are evident: (1) the mortality from the methods taken together has been great (45 per cent.); (2) the results from Hegar's method, to be presently described, are remarkably successful (mortality 8·3 per cent.) The number of cases (twelve) is not great; it remains to be seen whether this method will be equally successful in other hands.

Dr. Keith has recently performed seven cases with no death; and Dr. Granvill Bantock has recorded a series of fourteen, where the pedicle was treated extra-peritoneally, with only one fatal.

Under laparotomy we include (1) the removal of pediculated subserous fibroids in which the uterus is left untouched, and (2) the amputation of a portion of the uterus along with the tumours. The ovaries may or may not be removed at the same time. When a portion of the uterus is cut away, it is necessary, should the operation be during the period of sexual activity, to remove the ovaries; fatal hæmorrhage has occurred when they were left, and even abdominal conception and pregnancy.

The operation may be divided into three stages:—(1) the opening into the abdominal cavity, (2) the diminution of the size of the tumour and its extraction, (3) the treatment of the stump.

1. The opening into the abdominal cavity is made as in ovariectomy, but the incision may in some cases extend from ensiform cartilage to pubis (*v.* Chap. XXII.)

¹ *Académie de Méd.*—Séance, 18 Nov. 1879.

² *Brit. Med. Journ.*, May and Dec. 1878.

³ Cited by Hegar and Kaltenbach—*Operative Gynäkologie*, S. 419.

⁴ Gusserow—*Neubildungen, etc.*, S. 90.

⁵ *Krankheiten der weiblichen Geschlechtsorgane*, S. 244.

⁶ *Die operative Gynäkologie*, S. 420.

⁷ *London Obs. Trans.*, April 1880.

⁸ *Diseases of Women*, 1880, p. 551.

2. The diminution of the size of the tumour is necessary when it is so large that it cannot be projected through the abdominal incision.

When the tumour is cystic, it is diminished by puncturing the cysts before extraction. Péan diminishes the size of solid tumours by "morcellement:" the tumour is transfixcd with a double thread which carries in the wires of two of Cintrat's serre-nœuds (fig. 257); by means of these, two portions are removed with little loss of blood; this process is repeated until the tumour is sufficiently reduced in size to be drawn through the abdominal wound.

3. The treatment of the stump is either by the *intra-peritoneal* or *extra-peritoneal* method.

When it is small and consists only of the pedicle of the tumour, it can be ligatured and *dropped* into the peritoneal cavity as in ovariectomy; when it is large and especially when (from the removal of a portion of the uterus) it consists of a uterine stump, the dangers of hæmorrhage and peritonitis have led most operators to adopt the *extra-peritoneal* method. When a portion of the uterus is cut away along with the tumour, there is not only a greater risk of hæmorrhage from the larger pedicle but there is a track opened for septic infection as the uterine canal communicates through the vagina with the external air.

Intra-peritoneal Treatment of Pedicle in Laparotomy for Fibroids.

Schroeder, however, prefers the *intra-peritoneal* method even when there is a uterine stump. We shall describe his method of amputation of the uterus at the level of the os internum, as we saw him do it in the case of a large submucous fibroid of the anterior wall which endangered the patient's life by hæmorrhage. The abdominal incision was made in the ordinary way. Vascular adhesions passing from the tumour to the pouch of Douglas were ligatured at two points and divided between these. The ovarian arteries—the course of which is seen in plate III.—were ligatured on each side. (These can be recognised by feeling their pulsation with the finger; or by holding the ligament against the light, when their course is easily seen.) A double silk ligature was carried on a needle from behind through the cervix so as to come out at the bottom of the vesico-uterine pouch in front; this was divided and the end of each half carried backwards through the broad ligament of its respective side, just external to the cervix, and knotted to its corresponding end; the cervix was thus tied in two portions, each uterine artery—the position of which is seen in plate III.—being controlled by a ligature (fig. 253). The tumour, with the body of the uterus and the ovaries, was cut away rapidly, with a large knife, above the ligatures. The uterine stump was

cut in a V shape; and first the muscular walls were adapted with coarser, then the peritoneal covering with finer silk sutures (fig. 254). The

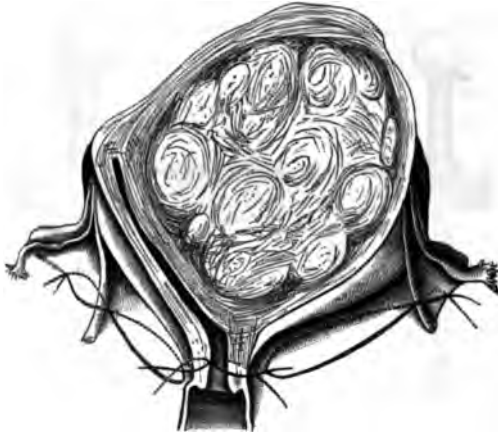

FIG. 253.

POSITION OF LIGATURES IN AMPUTATION OF UTERUS AT LEVEL OF OS INTERNUM. The cervix is ligatured in two portions, so that a ligature controls each uterine artery. Each broad ligament is ligatured in two portions which meet at the round ligament. The outer ligature controls the ovarian artery (*Schroeder*).

patient made a good recovery. Bantock, however, had five cases with the pedicle treated intra-peritoneally, and only one recovery. This contrasts markedly with his success by the extra-peritoneal method (*v. p. 405*).

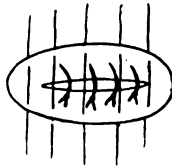


FIG. 254.

LIGATURES OF THE INTRA-PERITONEAL STUMP OF THE CERVIX. The deep ligatures which bring the muscular tissue together are represented as tied. The superficial ones bring only the peritoneal flaps together.

The *extra-peritoneal* method has been carried out by the following means:—

- The ligature or clamp,
- The clamp and cautery,
- The *serre-nœud*,
- The elastic ligature.

Extra-peritoneal Treatment of Pedicle in Laparotomy for Fibroids.

The extra-peritoneal method was, we believe, first attempted by Spencer

Spencer
Wells'
Method.

Wells. Comparing the two methods, he says, "when it has been possible to secure the pedicle and fix it outside the wound in the abdominal wall, the result has been much more satisfactory." Of his 25

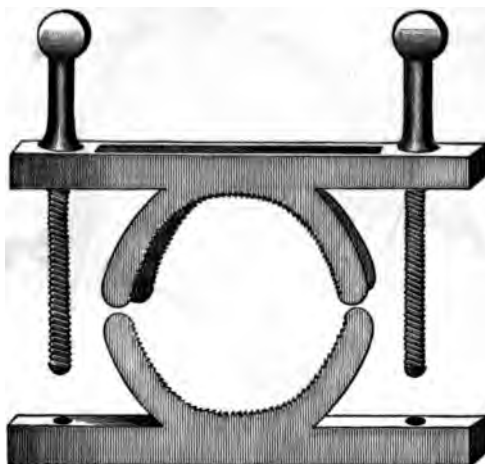


FIG. 255.

THOMAS' CLAMP FOR SECURING THE STUMP EXTRA-PERITONEALLY IN THE EXTIRPATION OF FIBROID TUMOURS; the halves of the clamp are represented as lying apart (Thomas).

cases, setting aside 3 of which the method is not specified, 13 were extra- and 9 intra- peritoneal. In 6 of the 13 cases, the pedicle was retained in the wound by means of a clamp; in the rest by means of the ligature, aided in some cases by use of a pin.




FIG. 256.

PÉAN'S CURVED NEEDLE FOR CARRYING THE WIRES THROUGH THE STUMP OF THE CERVIX (Leblond).

Thomas'
Method.

The searing of the stump with the *actual cautery* without any ligatures, is the modification of the extra-peritoneal method adopted by

Thomas. He uses the *clamp*, represented at fig. 255, to arrest hæmorrhage during the amputation of the uterus and while the pedicle is being seared. It is in two separate portions; the one half is placed below the neck of the tumour or uterus, and the other then adapted to it and screwed down. To prevent retraction of the pedicle, it is before cauterisation transfixd above the clamp with long wire needles. After cauterisation the clamp is loosened, but left *in situ* for fourteen days so as to be screwed up should hæmorrhage occur.

The extra-peritoneal method has met with great success in the hands of Péan of Paris, who has the merit of having elaborated it as a distinct method. He operates as follows. The tumour having, if necessary,

Péan's
Method.

been reduced by "morcellement," it is drawn out of the abdomen and held perpendicularly by an assistant. The operator, having ascertained with a sound the relations of the bladder (which only in rare cases requires to be dissected off), transfixes the cervix with two strong wires at right angles to each other. Below

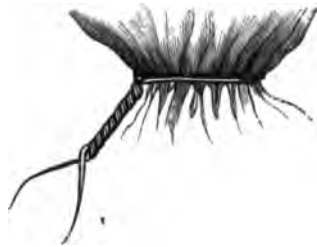


FIG. 257.

CINTRAT'S SERRE-NEUD (*Hegar*). The wire after having been placed round the neck of the uterus or tumour is fixed on the two knobs which travel on the thread of the screw. On turning the handle when the middle piece is held firm at the larger loops, we tighten the noose; when the head piece is held at the smaller loops, we twist the wire. The result is seen to the right hand side (*Leblond*).

these wires, the curved needle represented at fig. 256 is carried through the cervix and drags back a double wire. This wire is divided, and each half is fitted into a *serre-neud* of Cintrat (fig. 257) by means of which it is both tightened and twisted. The tumour and uterus are amputated above the wires. The pedicle is placed in the abdominal wound, and is kept from retracting into the abdomen by means of the

wires and the *serre-nœuds* ; these are left in position so that they may be tightened in case of hæmorrhage.

Keith's
Method.

An account of Mr. Keith's cases will be found in the paper quoted. He operates without the spray, and treats the pedicle usually with the clamp. His results have been remarkably good, although very few of his cases were easy.

Hegar's
Method.

The elastic ligature was introduced by Kleeberg. Its method of employment has been devised and carried out by Hegar of Freiburg, in whose hands (as already said) it has produced good results. Hegar's method consists in "constriction of the uterine stump with elastic ligatures, exact closure of the abdominal cavity by stitching the peritoneum round the stump, and antiseptic treatment of the latter with the cauterium and chloride of zinc." The abdominal incision is always made long enough to allow the tumour to be projected through it without artificial diminution. Temporary sutures are placed along its margins to keep the peritoneum in relation to the skin. Vascular adhesions are ligatured in two places and divided between. The tumour is laid hold of with a dry towel by one assistant and raised out of the



FIG. 258.

NEEDLE FOR CARRYING THROUGH ELASTIC LIGATURE. It consists of a sharp curved point, and a canula split halfway up the side. A loop of the elastic ligature, stretched till it is thin, is drawn with a thread into the canula, which is then screwed into the steel point. (*Hegar and Kallenbach*).

abdomen, while another presses the edges of the abdominal wound behind the advancing tumour ; the greatest care is required to hold the tumour steadily and vertically, as the stretched broad ligaments readily tear—leading to hæmorrhage. The relations of the bladder and the ovaries having been exactly ascertained, the elastic ligature is placed round the cervix below the seat of amputation. This consists of a double ply of india-rubber ligature 5 millimetres thick. While kept at full stretch it is brought round the uterus and firmly knotted. Should this constriction of the whole stump be judged insufficient, it is further ligatured in two portions with the elastic ligature. The needle represented at fig. 258 is used to carry through the stump a double ligature, which is then divided and tied round each half. The tumour and uterus are amputated above these ligatures. The peritoneum is now

carefully adapted round the neck of the stump below the elastic ligatures; the silk suture, which brings only the edges of the peritoneum together in the bottom of the wound just below the pedicle, is looped into the side of the latter (fig. 259, *a*) underneath the ligature (fig. 259, *b*): the margins of the peritoneum above the pedicle are united in a similar way; the next two sutures of the wound bring together only the peritoneum, while those further up bring together all the coats of the

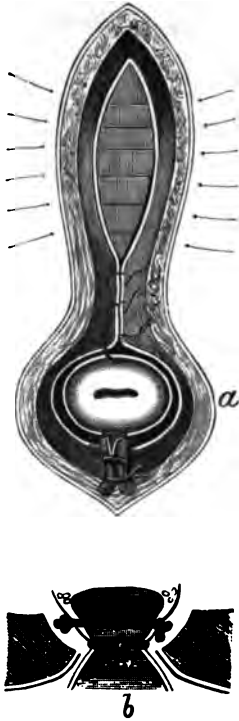


FIG. 259.

TREATMENT OF FIBROID TUMOURS BY ELASTIC LIGATURE (*Hegar and Kaltendach*).

a, Abdominal incision with the stump in its lower angle; only the peritoneum is brought together with the lower sutures, while the upper sutures take in the whole abdominal wall. *b*, Same in section, to show the trough floored by the peritoneum round the stump and the position of the elastic ligatures.

abdominal wall. Thus there is produced a space which surrounds the pedicle and is floored by peritoneum; to keep this space thoroughly dry and aseptic, is the aim of the after treatment. The projecting end of the stump is thoroughly cauterised; the raw surfaces round it are painted with solution (3-10 per cent.) of chloride of zinc, and cotton wadding, which has been soaked in a 2 per cent. solution of the chloride and then

thoroughly dried, is packed round the stump. Finally, the end of the stump alone is touched with 100 per cent. solution. The whole is covered with protective silk and carbolised wool, and the antiseptic dressing laid on so that it can be easily lifted.

The space round the stump is kept thoroughly dry by repeated dressing (three or four times daily, according to amount of discharge) with the chloride of zinc wool; the pedicle is pared away gradually with scissors to diminish its size, to allow the chloride to act more thoroughly, and to prevent pus from burrowing. The elastic ligature is clipped away about the tenth day.

Battey's operation has been frequently performed to check the menorrhagia associated with fibroid tumours and with good result. It is better, however, to remove the uterine appendages and not the ovaries only.

SUMMARY AS TO OPERATIVE TREATMENT OF FIBROID TUMOURS.

We may sum up the question of the treatment of fibroids, so far as it is known at present, as follows:—

(1.) Treat them when polypoid, or submucous and being expelled, as recommended in Chap. XXXVII.

(2.) When subperitoneal, if causing no inconvenience, though large, leave them alone.

(3.) When threatening life from hæmorrhage, and where the patient is not near the menopause, we may operate.

(a.) We may remove the uterine appendages if they are accessible. It should be kept in mind that it is sometimes very difficult, or even impossible to do so.

(b.) Abdominal section and treatment of the pedicle by clamp or *serre-nœud* gives the best results. This presupposes that the neck can be clamped, and consequently cannot be performed when this is very large.

CHAPTER XXXVI.

FIBRO-CYSTIC TUMOUR OF THE UTERUS.

LITERATURE.

Ailee—Ovarian Tumours: Philadelphia, 1878. *De Sindy*—Manuel de Gynecologie, Paris, 1879, p. 413. *Gusserow*—Neubildungen, etc., S. 102. *Heer*—Ueber Fibrocysten des Uterus: Zurich, 1874. *Leopold and Fehling*—Archiv. für Gyn., Bd. VII., S. 531. *Peaslee*—Ovarian Tumours: London, 1873. *Rein*—Archiv. f. Gyn., IX., S. 414. *Schroeder*—Die Krankheiten der weiblichen Geschlechtsorgane, S. 213: Leipzig, 1878. *Spencer Wells*—Ovarian and Uterine Tumours: London, 1883. *Spiegelberg*—Archiv. f. Gyn., VI., S. 348. *Thomas*—Diseases of Women, p. 551: London, 1882.

SYNONYM—Cysto-fibroma.

Attention has been directed only of recent years to this, the rarest form of uterine tumour. Its pathology is now being worked out, and at present we group under this head tumours which may afterwards be shown to be anatomically separable. Since ovariectomy has come to be extensively practised, they have derived their clinical importance from a close resemblance to ovarian tumours.

PATHOLOGY.

The majority of fibro-cystic tumours are simply fibroid tumours which have become softened. The spaces between the bundles of fibrous tissue open out and contain serum; the trabeculae between adjoining spaces give way, which allows these to run together to form larger cavities. Fig. 260 shows this in a *subserous fibroid*, which form most frequently undergoes this change.

The term "cystic" is, it is evident, misleading as applied to this form of tumour. The cavities are not "cysts," that is, they do not possess a special wall.

Kœberlé was the first to suggest that some forms of fibro-cystic tumour might be due to *dilated lymphatics*. Leopold and Fehling have carefully described a case in which the cavities were lined with endothelium. The fluid from these cavities was of a clear yellow colour, and *coagulated* as soon as it was exposed to the air; fibrin was present in it. To this form the name of *Fibromyoma lymphangiectodes* has been given. Lymphatic
origin.

Atlee says this coagulation of the fluid—formation of colourless blood-clot—is diagnostic of the fluid from *all* fibro-cystic tumours, and may be relied on to distinguish them from ovarian. Spiegelberg records a case in which this spontaneous coagulation of the fluid was observed, but the most careful microscopic examination could detect no epithelial lining of the cavities. A transition case has been described by Rein, in which

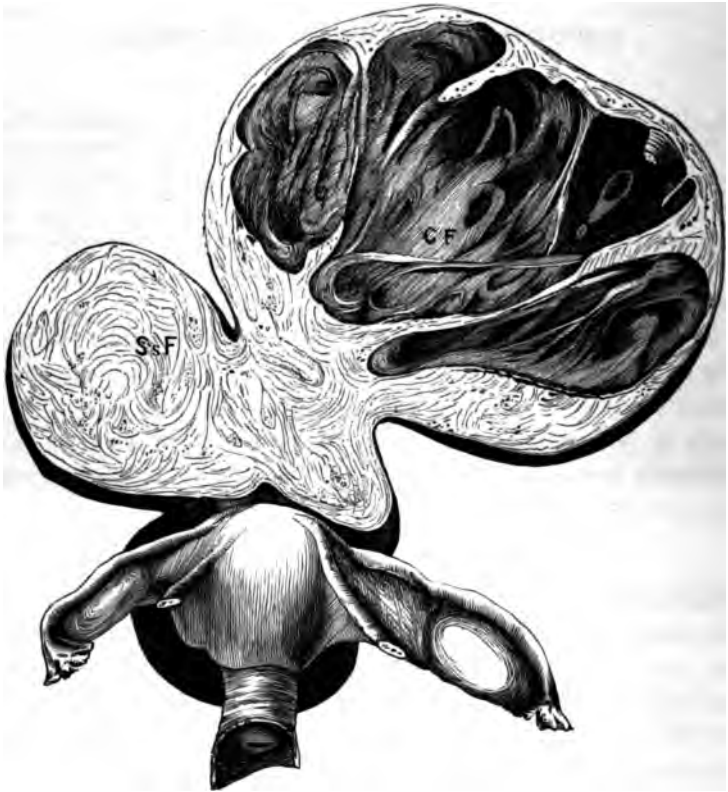

FIG. 260.

LARGE THREE-LOBED FIBROID SPRINGING FROM THE FUNDUS BY A SOMEWHAT THIN PEDICLE, of which C F is cystic, while S & F and the dark shaded mass behind the uterus are subserous. This, along with two smaller fibroids growing from the posterior surface of the uterus was removed by Laparotomy (Schroeder).

the cavities were not themselves lined with endothelium but *communicated* directly with the lymphatic spaces.

Mucoid
degenera-
tion.

Mucoid degeneration of a fibroid tumour has been described by Virchow as Myxomyoma. In this case the interstitial tissue contained fluid rich in mucin and with numerous nucleated round cells.

SYMPTOMS.

These are the same as those of fibroid tumours, except that their increase in size is rapid. As they are usually subserous, menorrhagia is not often present.

DIAGNOSIS ; DIFFERENTIAL DIAGNOSIS.

Their diagnosis is often difficult, as the difference in consistence between the more solid and the fluid parts may escape detection. The most important point to make out is *the relation to the uterus*, and the *displacement* of the latter which is produced. To ascertain its connection with the uterus, we make the examination per rectum : to do this thoroughly, it may be necessary to anaesthetise the patient and to introduce two fingers ; the uterus is at the same time drawn down with the volsella. As to the displacement of the uterus, it is elevated towards the abdomen ; with an ovarian tumour, it is depressed to the front or to the back. The sound is now passed ; if the uterine cavity is increased in size, and more especially if the movement of the tumour by an assistant is immediately communicated to the sound, the tumour is probably uterine.

Differential Diagnosis.—Their diagnosis *from ovarian tumours* is the most important and, at the same time, the most difficult. As in the majority of cases they are merely altered fibroid tumours, their differentiation *from a simple fibroid* is merely a matter of degree of softness. Their diagnosis from ovarian tumours is of importance as regards ovariectomy, though with greater experience in the extirpation of fibroids and a lower mortality, this may come to be of less importance.

TREATMENT.

The treatment consists in removal through the abdominal walls, according to the method described for fibroid tumours (*v. p. 403*).

CHAPTER XXXVII.

POLYPI OF THE UTERUS.

LITERATURE.

Barnes—Diseases of Women, p. 195: London, 1878. *De Sindty*—Manuel pratique de Gynécologie, p. 419: Paris, 1879. *Gusserow*—Die Neubildungen des Uterus, Billroth's Handbuch, S. 160: Stuttgart. *Hegar and Kallenbach*—Die operative Gynäkologie, S. 498: Stuttgart, 1881. *Hicks, Braxton*—Three cases of very large polypi of the uterus, etc.: Obstet. Journ. of Great Brit., Jan. 1879. *Matthews Duncan*—Edin. Med. Journal, July 1871; and Obstet. Journ., 1873, p. 497. *Simpson, Sir J. Y.*—Diseases of Women, p. 704: Edin. 1872. *Thomas*—Diseases of Women: London, 1880, p. 558. *Underhill*—On the Structure of three cervical Polypi, and The Structure of a true mucous Polypus of the Cervix: Edin. Obst. Soc. Trans., vol. IV., pp. 231 and 241.

By the term "Polypus" is understood a pediculated tumour attached to the mucous membrane of the uterus. It includes the following tumours, which are anatomically distinct:—

Varieties
of Polypi.

- (1.) Submucous fibroids, which have become pediculated and are in process of extrusion;
- (2.) Mucous polypi;
- (3.) Pediculated cystic follicles;
- (4.) Placental polypi.

For clinical reasons, it is convenient to use the term polypus in its general sense as implying an external form alone; the symptoms produced by these tumours resemble one another, and their exact nature is sometimes not made out till they are removed. Pathologically, the term should be limited to mucous polypi. It is confusing to speak of a fibroid tumour which has a broad base of attachment as a submucous fibroid, and of one which has a pedicle as a fibrous polypus. The polypoidal projections formed by pediculated ovula Nabothii are only pediculated retention cysts. Placental polypi are not true new-formations.

Fibrous
Polypi.

1. *Pediculated submucous fibroid tumours* form the so-called "fibrous polypi." They spring from the muscular wall of the uterus, usually from the *body* which, as we have seen, is more commonly the seat of fibroid tumours than the cervix. They are of *firm* consistence, of a size

varying from a goose's egg and upwards, and are of a rounded or pyriform shape (fig. 261), sometimes elongated and constricted through the pressure of the uterine walls (fig. 243); the surface is smooth or marked with furrows corresponding to the fasciculi of fibrous tissue.

Sometimes they are of such a size that, although lying in the vagina, they fill the pelvis and press on the bladder and rectum; the uterus is then raised above the pelvic brim (just as it is elevated when the vagina

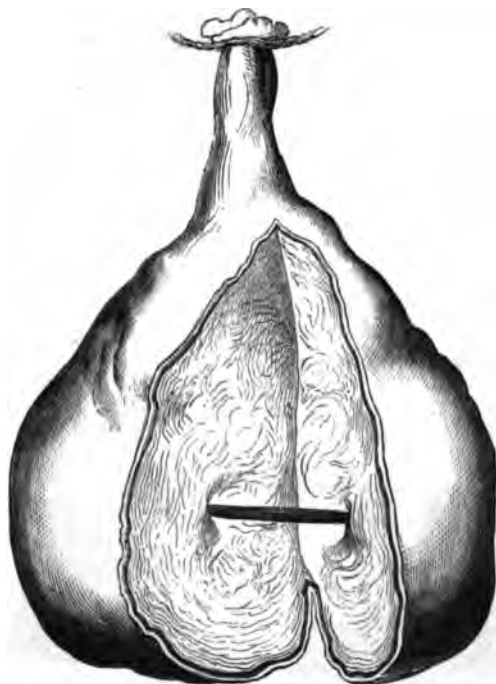


FIG. 261.

FIBROUS POLYPUS LAID OPEN TO SHOW ITS IDENTITY IN STRUCTURE WITH A FIBROID TUMOUR
(*Sir J. Y. Simpson*).

is distended with fluid), and is felt as a smaller body riding on the top of the tumour. Adhesions may form between the surface of the fibroid and the vagina, producing the impression that the tumour springs from the vaginal mucous membrane.¹

The pedicle consists of a narrowing of the calibre of the tumour towards its base of attachment, or of a distinct stalk which may be long enough to allow the fibroid to lie at the vulva. As fibroid tumours are sparingly vascular, the pedicle does not as a rule contain large vessels.

¹ Braxton Hicks—*Loc. cit.*

When a pediculated submucous fibroid lies in the cavity of the uterus, it sets up uterine contractions which lead to its expulsion: there is a stage at which it lies partly within the uterus (fig. 262), partly in the vagina (the portion constricted by the cervix has been mistaken for a pedicle, and only the lower lobe of the hour-glass tumour removed);

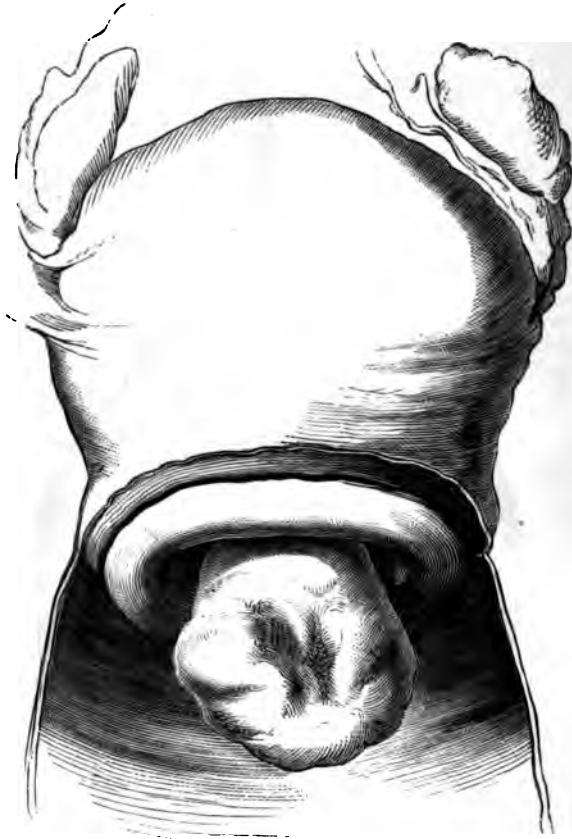

FIG. 262.

INTRA-UTERINE SUBMUCOUS FIBROID WHICH IS BECOMING VAGINAL (*Sir J. Y. Simpson*).

finally, the whole tumour lies in the vagina but still maintains its connection with the uterus through its pedicle (fig. 263). The congestion of the fibroid excites uterine contractions specially at the menstrual period, and thus favours its expulsion. At those times only, we may have the cervical canal temporarily dilated and the polypus projecting through it; after the period, the contractions pass off and the polypus is retracted

into the uterine cavity. This condition is fully described by French writers under the name of "polypes à apparitions intermittentes." Its practical importance is that we should examine sometimes at the menstrual period, when a polypus (not recognisable at other times) may be felt through a dilated cervix.

They have the microscopic structure described at p. 378 (*v. fig. 261*).

2. *Mucous polypi* are developed from the *mucous membrane* of the *Mucous* uterus, most frequently from that of *the cervix*. They are of *soft pulpy Polypi.* consistence, of about the size of an almond—rarely larger—and have a

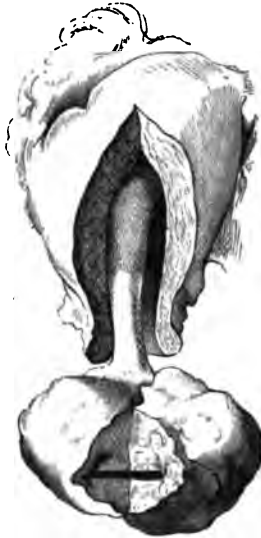

FIG. 263.

SUBMUCOUS FIBROID WHICH HAS COME TO LIE WHOLLY IN THE VAGINA (*Sir J. Y. Simpson*).

flattened form; usually, there are more than one present (*fig. 264*). They are extremely vascular and have the microscopic structure of the mucous membrane from which they are developed.

The typical cervical polypus has the structure seen at *fig. 265*; the student should compare this with the section of the normal mucous membrane given at p. 20. From the fact that the gland-ducts appear as channels on the surface, it was described by Oldham as the "channelled polypus." Sometimes the polypus shows also the stratified epithelium of the vaginal aspect of the cervix, as in a specimen described by Underhill; he supposes that in this case it sprang from the margin of the *os externum*: he describes also a polypus which sprang from the *vaginal aspect*

and showed only the stratified epithelium. These polypi sometimes

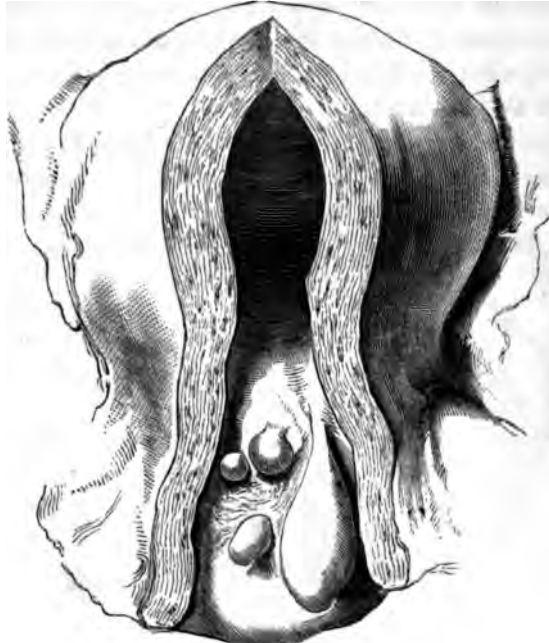

FIG. 264.

GROUP OF MUCOUS POLYPI GROWING IN THE CERVIX UTERI (Sir J. Y. Simpson).

form the starting point of malignant disease; Underhill traced the commencement of sarcomatous formation in one case.

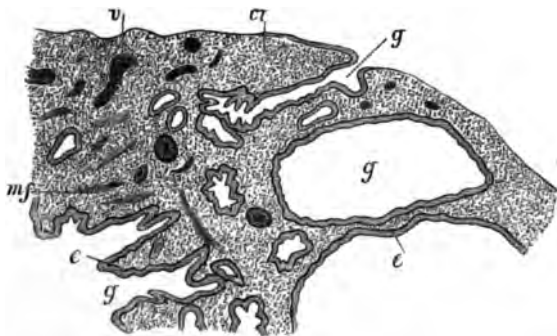


FIG. 265.

SECTION OF A MUCOUS POLYPUS OF THE CERVIX 4^o. *g* dilated glands, *e* epithelium, *mf* muscular fibre, *v* blood-vessel, *ct* connective tissue (De Sinéty).

De Sinéty divides them into two groups according as they spring (1) from the cervix, (2) from the body of the uterus. Each has the

characteristic epithelium (see p. 19) lining the ducts and cysts; the former have the columnar non-ciliated epithelium of the cervix, the latter the ciliated cylindrical epithelium of the body.

3. *Pediculated nabothian follicles* have been already described under cervical catarrh (p. 281.) Pedicu-
lated
Nabothian
Follicles.

In old people we often find the whole mucous membrane of the uterus covered with small polypoidal cysts. We have already referred to this condition as a final stage of chronic endometritis (p. 292).

4. *Placental or fibrinous polypus*. These are produced as the result of incomplete detachment of the placenta; in some cases we can trace placental villi in their structure. On the surface of this irregularity of the mucous membrane, blood coagulates; and thus the fragment of placenta grows larger through being coated with fibrin. This increase in size may go on until the polypus is the size of an egg. This form of polypus is not a new formation and only finds a place here on account of its polypoidal form. Placental
Polypus.

SYMPTOMS.

These are Hæmorrhage,
Leucorrhœa,
Dysmenorrhœal pains,
Sterility,
Irritation and discomfort.

The *hæmorrhage* shows itself first as an increase of the ordinary menstrual flow; afterwards, it comes at irregular intervals. In the case of a submucous fibroid, it comes from the uterine mucous membrane which is hypertrophied. In the mucous polypus, it comes from the tumour itself which is vascular and bleeds easily; when the polypus protrudes through the cervix, there may be hæmorrhage whenever the patient strains or after coitus. It is important to remember that a small polypus has produced a fatal hæmorrhage¹ (*v.* the preparation represented at fig. 101.) In other cases the drain of blood, though not directly fatal, may produce profound anæmia. The cachectic appearance of the patient, thus induced, may be such as to lead us to form a strong prepossession in favour of the existence of malignant disease before we proceed to physical examination. Hæmorrhage.

Hence the importance of ascertaining and removing the cause of the hæmorrhage.

¹ Barnes records the case of a woman of twenty-six years of age in which a polypus the size of a walnut produced a fatal hæmorrhage.

Leucorrhœa.

The *leucorrhœa* is due to the endometritis which is always present. The polypoidal retention cysts are the result of a chronic catarrh of the cervix or uterus. It is disputed whether mucous polypi are the cause or the result of the inflammatory changes; De Sinéty inclines to the latter view. When the polypus comes to lie in the vagina, it produces an irritating vaginal leucorrhœa.

Dysmenorrhœal Pains.

The *dysmenorrhœal pains* are due to the muscular efforts of the uterus to expel the polypus, and are most marked when the polypus has descended to the os internum or lies in the cervical canal.

In rare cases the presence of the foreign body in the uterus has produced the sympathetic phenomena of pregnancy—pigmentation of the breasts and abdomen, and morning sickness.

Sterility.

Sterility is occasioned by the mechanical obstruction of the polypus, either in the cervical canal or at the entrance to the Fallopian tubes. The obstruction in one case was not sufficient to prevent the spermatozoa from passing upwards, but hindered the entrance of the fertilised ovum into the uterine cavity and thus produced Fallopian tube gestation.

A pediculated fibroid may form a serious complication to labour, in preventing the progress of the child's head; such a polypus has been laid hold of with the forceps under the impression that it was the presenting head.

DIAGNOSIS.

1. *When the polypus has dilated the os externum*, it will be recognised by the finger per vaginam. If it be larger than a walnut and of firm consistence, and if the uterine cavity be increased in length, it is a pediculated fibroid tumour. If it be small and of a pulpy consistence, it is a true mucous polypus; mucous polypi do not, as a rule, produce hypertrophy of the uterus.

Having learned that there is a pediculated body in the vagina or cervical canal, carry the finger upwards to ascertain its point of attachment; if this be high up in the uterine cavity the tumour is a pediculated fibroid; if it springs from the cervical mucous membrane, it is probably a mucous polypus.

On bimanual examination, the uterus is found to be enlarged in the case of pediculated fibroids; it is not enlarged with mucous polypi, unless from associated chronic metritis.

The speculum shows that the surface of the true mucous polypus has a bright cherry-red colour, which contrasts with the darker red of the cervical mucous membrane embracing it. The appearance of the fibroid

tumour depends on the condition of the investing mucous membrane which is often ulcerated or sloughing. When the capsule has given way, the fibrous substance of the tumour is seen to be of a paler colour.

2. *When the uterus is enlarged but the os externum not dilated*, the diagnosis is more difficult (fig. 266). If the uterus be markedly enlarged and of firm consistence and (the possibility of pregnancy being excluded) the sound pass for 4 or 5 inches, there is probably a sub-

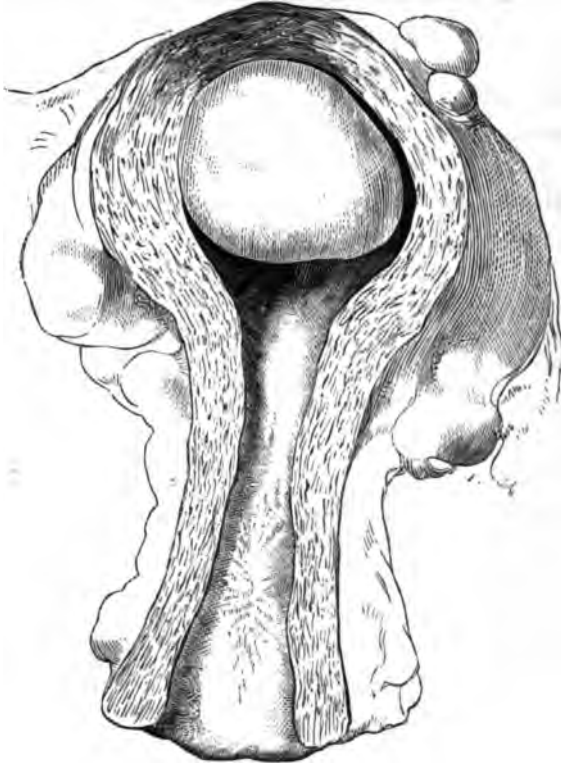

FIG. 266.

PEDICULATED SUBMUCOUS FIBROID, springing from the fundus, which has not dilated the cervical canal (Sir J. Y. Simpson).

mucous fibroid tumour. It is difficult to determine whether it is pediculated or not. We endeavour first to pass the sound round the tumour or upwards on different sides of it. Fig. 248 shows how the sound passes in a case of a pediculated tumour attached to the fundus. The sound must be used with care as its use is not unattended with risk; laceration of the mucous membrane, with the introduction of septic matter, has resulted from too free and repeated exploration in this

way. Dilatation of the cervix and exploration with the finger are sometimes necessary to ascertain whether the fibroid be pediculated, and to what part of the uterus it is attached.

3. *When the uterus is not much enlarged*, the diagnosis is very difficult. The possibility of a fibroid tumour is excluded. A small mucous polypus, however, may exist in the uterine cavity and escape detection with the sound. In such a case, it is only recognised on dilating the cervix and exploring the uterine cavity with the finger.

The *curette* is a valuable aid to diagnosis when the actual exploration of the uterine cavity with the finger is not desirable. By its use we diagnose and treat the case at the same time. Thus irregularity of the uterine surface (which is easily detected by the *curette*) and the character of the scrapings removed, may show that we have to do with pediculated retention cysts or placental polypi.

DIFFERENTIAL DIAGNOSIS.

The characters which distinguish a pediculated fibroid from a mucous polypus are its larger size, firmer consistence, and its springing from the body of the uterus. The uterine cavity is increased in size. We find probably other fibroid tumours interstitial or subserous.

A pediculated fibroid hanging down into the vagina, may readily be mistaken for the inverted fundus uteri; this is most likely to happen when there is much hæmorrhage from the former, and when concomitant pelvic inflammation makes examination difficult. A true diagnosis here is all-important, as removal of the fibroid may save the patient's life; while amputation of the uterus, under the supposition that it was a fibroid, might lead to disastrous consequences. The preparation shown at fig. 267 is interesting in this connection. The case had been sent into hospital as one of inverted uterus. It is evident how the form of the tumour in the vagina and the fact that it bled freely, would in the absence of further examination lead to this mistake.

Given a tumour the size of a pear hanging down through the cervical canal into the vagina, we wish to make sure that it is not the inverted body. First, sweep the finger carefully round the neck and note whether the mucous membrane of the cervical canal is reflected on to the neck of the tumour; sometimes inflammatory adhesions round the neck produce a condition simulating inversion. Now make the Bimanual; if the body in the vagina be a fibroid, the uterus will be in its normal place. The abdomino-vaginal examination is often difficult

on account of the body in the vagina ; therefore pass the finger into the rectum, through the anterior wall of which we can distinctly feel whether the cervix has a truncated end above (inversion) or passes up into the body of the uterus (fibroid) ; the abdomino-rectal makes this more evident. When examination is difficult and the diagnosis doubtful, we should not hesitate to give chloroform and make a thorough examination ; it is well to be prepared to operate at the same time, if necessary.

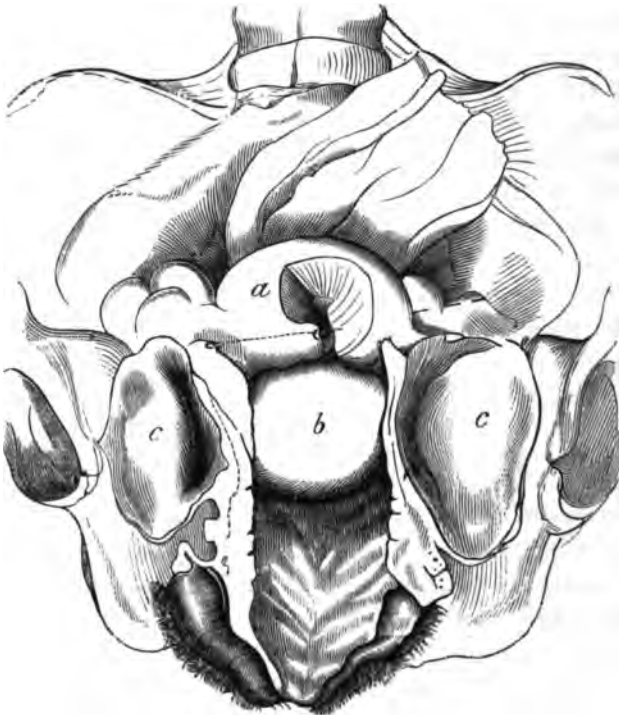

FIG. 267.

a, Uterus with a portion of the anterior wall cut out ; *b*, pediculated fibroid attached to back wall immediately above os internum. The front of the bony pelvis has been removed ; *cc*, halves of divided bladder (*A. R. Simpson*).

Finally use the sound, which is an important test. Sweep the finger carefully round the neck of the tumour and feel for a depression corresponding to the os, into which endeavour to introduce the sound. If it passes for two and a half inches or more and is then arrested, it is probably in the uterine cavity ; make sure of this by pressure with the hand on the abdominal wall, or per rectum.

When the tumour in the vagina fills the pelvis or rides above the

brim, so that the finger cannot reach the pedicle or feel whether the os is present, the diagnosis is very difficult. We rely on careful abdominal palpation to ascertain whether the uterus can be felt resting on the top of the tumour.

We must not forget that we may have both conditions present, *i.e.*, pediculated fibroid + a certain amount of inversion.

PROGNOSIS.

The prognosis as to *danger to life* will depend on the hæmorrhage. Wherever a polypus is present, we should advise its removal.

As to *the operation*, the removal of mucous polypi and smaller fibroids is a safe and easy operation. The fear of hæmorrhage from the pedicle of a fibroid tumour, which led to the treatment by ligature, has been found by experience to have been exaggerated. Where there is a rigid cervix to be dilated before we can remove the tumour, where the tumour is large so that it must be removed in portions, where there is a thick pedicle and consequently a larger raw surface, the operation will be a more serious one and the prognosis given more guardedly.

Should there be pregnancy, the polypus may be removed without interrupting its course. If it be of such a size as to interfere with labour, it should be removed as soon as discovered.

TREATMENT.

Removal
of Polypi.

Whenever it is necessary to dilate the cervix for diagnosis, we should have instruments ready to remove the tumour at the same sitting. The dilatation is effected by laminaria tents, or by Tait's graduated dilators. A good method is to place a laminaria tent in the cervix to start the dilatation; after six or eight hours chloroform the patient, fix the cervix with volsellæ, and introduce the graduated dilators in succession till the cervical canal is wide enough to admit the index finger; remove the polypus by the means to be described; wash out the uterine cavity with 1 to 60 carbolic solution.

Small *polypoidal projections* are removed with the curette, as described under Endometritis, followed by the application of carbolic acid.

Mucous polypi are twisted off with the forceps, shown at fig. 268. It is advantageous to use forceps with a catch, as this keeps a steady hold of the tumour and leaves the operator's fingers free to twist the forceps round.

In removing *fibroids*, we first ascertain the seat of insertion and size of the pedicle. When the tumour is small, we can learn this by the

fingers ; when so large that we cannot get the fingers past the tumour to the pedicle, we probe round its base with the sound or, laying hold of the tumour with forceps, endeavour to rotate it and thus test the thickness of the pedicle.



FIG. 268.

FORCEPS WITH CATCH, FOR REMOVING MUCOUS POLYPI.

The pedicle will yield to torsion with the forceps. This is the simplest method and should always be tried in the first instance ; the forceps shown at fig. 252, or a pair of Nélaton's forceps (fig. 135), are most suitable. If this fail divide the pedicle with curved scissors.

Make traction with the forceps to render the pedicle tense ; too forcible traction might produce inversion. Guarding the uterine wall with the fingers, carry in the curved scissors. In cutting, make the scissors hug the surface of the tumour and thus keep clear of the uterine wall. To divide the pedicle Sir James Simpson introduced the polyptome (fig. 269). Strangulation by ligature, formerly widely practised, is now entirely abandoned ; the sloughing stump was a fruitful source of septicæmia.

When the pedicle is of considerable thickness, it may be divided with the *ecraseur* or with the galvano-caustic wire. The wire *ecraseur* is preferable to the chain *ecraseur*, as it is more easily applied. For the nature and method of use of the *ecraseur*, the student is referred to Treatment of Carcinoma of the Cervix. The galvano-caustic wire has been used

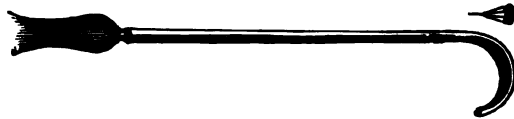


FIG. 269.

SIR J. Y. SIMPSON'S POLYPTOME (*Sir J. Y. Simpson*).

extensively by Byrne¹ of Brooklyn, whose paper on this subject should be consulted.

When the size of the tumour makes the pedicle inaccessible, it must be diminished. This is best effected by Hegar's method : traction is made on the tumour, which is at the same time incised in a spiral manner with scissors ; the tumour is thus (as it were) unwound, till finally the pedicle is reached and divided.

Chloroform is not necessary for the removal of smaller polypi. The section of the pedicle is painless ; if pain be present on tightening the *ecraseur* round the neck of a polypus, the operator should examine carefully again to make sure that the wire is not constricting the inverted fundus. Where the polypus is large and the operation tedious, it is better to have the patient anæsthetised as the operator has then more freedom.

¹ *Electro-cautery in Uterine Surgery* : New York, 1873.

CHAPTER XXXVIII.

CARCINOMA UTERI (OF CERVIX): PATHOLOGY AND ETIOLOGY.

LITERATURE.

Barbour—Cases of Carcinoma of the Female Pelvic Organs: *Edin. Med. Jour.*, July 1880. *Barnes*—Diseases of Women, p. 821: London, 1878. *Gusserow*—Die Neubildungen des Uterus, S. 117: Stuttgart 1878; and Ueber Carcinoma Uteri, *Volkmann's Samml. klin. Vor.*, N. 18. *Ruge and Veit*—Zur Pathologie der Vaginalportion, Erosion und beginnender Krebs: Stuttgart, 1878. *Schroeder*—Die Krankheiten der weiblichen Geschlechtsorgane, S. 264: Leipzig, 1878. *Simpson, Sir J. F.*—Diseases of Women: Edinburgh, 1872, p. 140. *Tanner*—On Cancer of Female Sexual Organs: London, 1863. *Virchow*—Ueber Cancroide und Papillargeschwülste, 1850. The student will find the fullest references to literature in *Gusserow* and in *Ruge*.

By Carcinoma Uteri is usually understood Carcinoma of the Cervix, because in by far the larger proportion of the cases (98 per cent.) this is the seat of the disease. The rarer condition of Carcinoma of the Body will be described separately.

PATHOLOGY.

On no subject in pathology has more been written and a greater variety of opinion expressed than on carcinoma. We have endeavoured to arrange, in the table on the following page, the facts most important for the student to know.

CLASSIFICATION.

There are three varieties of carcinoma usually given in the English text-books. These are medullary (encephaloid) and scirrhus cancer, and epithelioma. Now the distinction between the first two is merely a question of degree; in the former the cellular element, in the latter the fibrous stroma is in excess. When we say that medullary cancer is frequent but scirrhus rare, we only mean that carcinoma runs a rapid course when it occurs in the uterus. The distinction between these two and epithelioma is more marked and is therefore given in the table, but it is very doubtful whether it rests on a pathological basis.

From the above it is evident that we are not yet in a position to make

AFFECTIONS OF UTERUS.

CLASSIFICATION ACCORDING TO CLINICAL FEATURES.	FORMS.	ORIGIN.	POSITION.	PROGRESS.
<p style="text-align: center;">CARCINOMA</p> <p>progresses rapidly; produces metastasis, affects connective tissue rapidly.</p>	<p>{</p> <p style="text-align: center;">flat (flache canceroid)</p> <p>}</p>	<p>{</p> <p>from the cervical epithelium of constricted cervical glands (<i>Krebs</i>);</p> <p>from plugs of the deepest layers of squamous epithelium on the vaginal aspect of cervix (<i>Waldeyer</i>);</p> <p>from connective tissue cells of cervix (<i>Virchow</i>).</p> <p>}</p>	<p>in substance of cervix.</p>	<p>produces thickening, then ulceration;</p>
<p style="text-align: center;">EPITHELIOMA OR CANCROID</p> <p>progresses slowly; does not produce metastasis; spreads by extension.</p>	<p>{</p> <p style="text-align: center;">papillary</p> <p>}</p>	<p>{</p> <p>from the cubical epithelium of cervical canal (<i>Krebs</i>);</p> <p>from plugs of the deepest layers of squamous epithelium on vaginal aspect of cervix (<i>Waldeyer</i>).</p> <p>}</p> <p>{</p> <p>from the deepest layers of squamous epithelium on vaginal aspect of cervix (<i>Krebs and Waldeyer</i>);</p> <p>from connective tissue cells (<i>Kuge and Veit</i>).</p> <p>}</p>	<p>superficial within cervical canal.</p> <p>superficial, outside of cervix.</p>	<p>excavates cervix;</p> <p>spreads downwards into vagina (cauliflower excrescence).</p>

When ulceration and breaking down have been produced, these forms are no longer distinguishable.

a scientific classification. The division according to clinical features into *true carcinoma* and *canceroid* (*καρκίνος* and *εἶδος*, like *cancer*) is convenient: it expresses nothing more than that in some cases progress is more rapid than in others; and that the disease in the one case produces metastatic deposits, in the other remains local.

ORIGIN.

As regards the origin, there are two distinct views. That the disease arises from *connective tissue cells alone*, is the view maintained by Virchow and his followers; while Thiersch and Waldeyer hold that in *all cases* it originates in *epithelial cells*. In the cervix, as possible sources, there are two varieties of epithelium; the squamous on the vaginal aspect, the cubical lining the canal. In the *flat* canceroid of the cervical canal, it arises from the cubical epithelium which lines the latter; in the papillary form, it originates in the cells of the rete Malpighi on its outer aspect (*Klebs*). It will be seen that Waldeyer holds the view that, in all cases, it arises from the latter only.

The most recent investigations into the origin of carcinoma are by Ruge and Veit. According to them carcinoma arises, in the majority of cases, from a transformation of the connective tissue cells; even the papillary form which produces the so-called cauliflower excrescence, although it apparently springs from the epithelium, is developed from the connective tissue cells. The connective tissue stroma becomes vascular and almost like granulation tissue. The young cells, which are apparently produced from the connective tissue corpuscles, take on an epithelial character. These observers never saw plugs of epithelium extending downwards into the connective tissue.

POSITION.

There are apparently three places in the cervix where carcinoma may develop. It may begin as hard *nodules in the substance of the cervix*, underneath the mucous membrane; these increase in size, come to the surface of the mucous membrane (fig. 270) and produce ulceration. More rarely does it commence in the *interior of the cervical canal* and spread along its mucous membrane so as to excavate the canal. In the third place, it may appear *on the vaginal aspect of the cervix* as an irregular papillary tumour, which, extending downwards into the vagina, attains considerable size. It is then known as the cauliflower excrescence. Whether this form of carcinoma is the result of degenera-

tion of simple papillary growths or is malignant from the commencement, it is impossible to say.

PROGRESS.

During the first stage we may distinguish the three forms, but after



FIG. 270.

CARCINOMATOUS NODULE GROWING IN ONE LIP OF THE CERVIX AND PUSHING THE MUCOUS MEMBRANE OUTWARDS. The figure to the right is a section of the cervix made through the line *x* (Schroeder).

ulceration has occurred they pass into one another and are no longer distinguishable.

As regards the further progress, Schroeder distinguishes *three modes of the spreading* of the disease: first, upwards, into the body of the uterus;

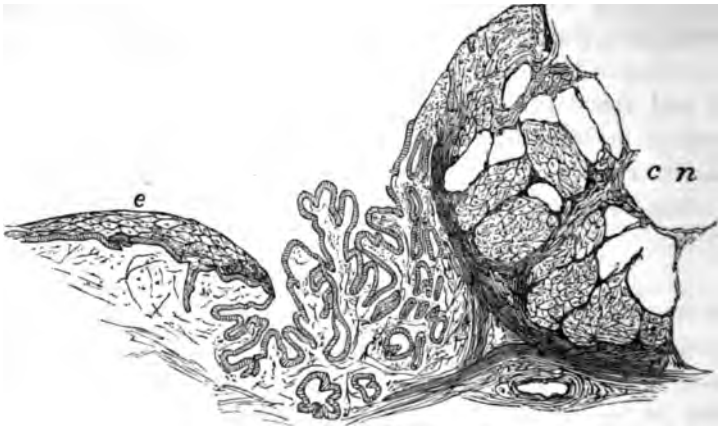


FIG. 271.

MICROSCOPIC SECTION OF A PORTION OF THE CERVIX UTERI SEEN IN FIG 270. *e* squamous epithelium in several layers; *c n* carcinomatous nodule; between these is seen a portion of inflamed mucous membrane covered with a single layer of epithelium (Schroeder).

second, downwards, into the vagina; and, third, into the connective tissue of the pelvis. This last is the most important. It takes place either by a continuous infiltration of the adjacent connective tissue, or

as a chain of nodules running in the direction of the utero-sacral ligaments; these nodules, probably, correspond to lymphatic glands.

EXTENSION TO NEIGHBOURING ORGANS.

In its further progress, the carcinomatous growth invades the surrounding organs. Pushing its way forwards in the cellular tissue between the *bladder* and the uterus, it involves the mucous membrane of the former; it first produces vesical catarrh, then sloughing of the walls, and finally vesico-vaginal fistula. The bladder is affected in a considerable proportion of cases; of 311 cases of carcinoma this occurred in 41 per cent., fistula resulting in 18 per cent. (*Gusserow*). From the

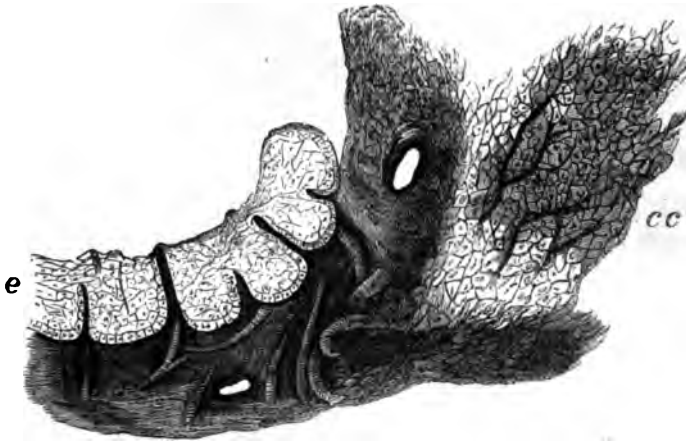

FIG. 272.

SECTION OF A FLAT CANCEROID (EPITHELIOMA) OF THE CERVIX. *e* squamous epithelium; *cc* carcinomatous cells, between these is seen some granulation tissue (*Schroeder*).

position of the ureters, they are frequently involved. The carcinomatous growth may press upon the ureters near their point of entrance into the bladder, or it infiltrates their walls and the consequent thickening produces constriction at the part affected. Dilatation of the ureter above thus results, which produces hydronephrosis and finally atrophy of the kidney. The frequency of this condition will be apparent from the fact that *Blau* found it present in 57 out of 93 post-mortem examinations. More rarely does the carcinomatous infiltration extend backwards into the *rectum* and produce recto-vaginal fistula; of 282 cases the rectum was affected in 18 per cent., fistula resulting in 8.5 per cent. (*Gusserow*). When both bladder and rectum have been opened into, a common cloaca is produced as in fig. 273.

Perforation into the *peritoneal cavity* is rare. The peritoneum is not simply pushed forward, but is taken up into the carcinomatous growth.

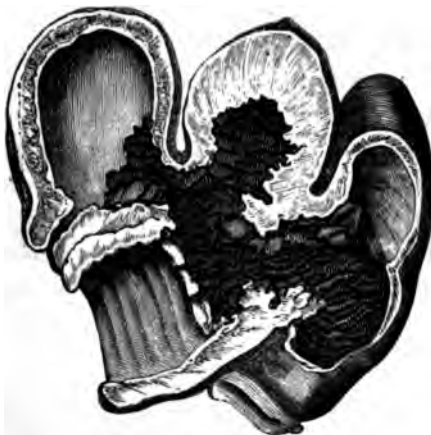

FIG. 273.

CARCINOMA beginning in the CERVIX UTERI, and ending in the production of recto-vesico-vaginal fistula (Farre).

As this process goes on, adhesions are constantly being formed between the walls of the peritoneum in front of the growth so that it does not

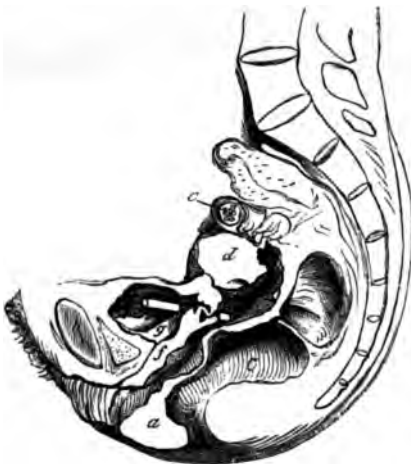

FIG. 274.

VERTICAL MESIAL SECTION OF PELVIS, FROM CASE OF CARCINOMA UTERI. *a*, Perineal body; *b*, Symphysis pubis; *c*, Rectum; *d*, Body of Uterus; *e*, Small fibroid; *f*, Urethro-vaginal septum; *g*, Bladder. A small tube passes between bladder and excavated cervix through a fistula (Barbour).

project free into the cavity beyond. These adhesions further prevent the peritoneal cavity from being opened into when the carcinomatous mass breaks down.

The accompanying sections, made from post-mortem preparations, will serve to illustrate some of the points noted above.

Points to be noted in fig. 274.

1. Seat of disease in the *cervix* ;
2. Complete destruction of the cervix and lower segment of the uterus ;
3. Production of an irregular cavity through the extension of the disease in *three* directions through the cellular tissue—

- (a) Behind the uterus,
- (b) Behind the uterus and the bladder,
- (c) Between the vagina and the bladder ;

4. The pouch of Douglas entirely obliterated and partially replaced by the carcinomatous excavation, the vesico-uterine pouch shortened by adhesions, perforation into the peritoneal cavity at one point ;
5. Bladder small and contracted, carcinomatous fistula ;
6. Rectum intact.

Description
of Pelvis
with
Cancer of
Cervix.

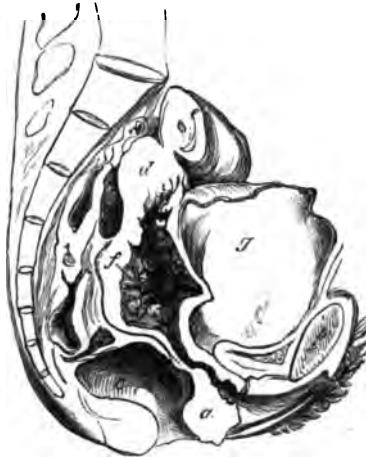

FIG. 275.

VERTICAL MESIAL SECTION OF PELVIS, FROM CASE OF CARCINOMA VAGINÆ ET UTERI. *f*, points to vagina eroded by disease ; *e* is a malignant growth attached to uterus. Other letters as in fig. 274 (*Barbour*).

Points to be noted in fig. 275.

1. Vagina (as well as cervix) affected, the nymphæ had a cartilaginous consistence, inguinal glands enlarged—although not shown in figure ;

2. Extension of the disease along the mucous membrane of the uterus, excavating it though not destroying the walls to the same extent as in fig. 274 ;

3. Partial obliteration of the pouch of Douglas ;

Description
of Pelvis
with
Cancer of
Vagina
and
Uterus.

4. Bladder dilated through pressure on the urethra, its walls apparently not involved ;
5. Rectum intact.

ETIOLOGY.

The female sex is more liable to carcinoma than the male. According to Sir J. Y. Simpson's statistics, the proportion is as $2\frac{1}{2}$ to 1. These statistics are drawn from the Annual Reports of the Registrar-General for England during the years 1847-1861. During that time there were 87,348 fatal cases of carcinoma, of which 61,715 were among women and 25,633 among men. For the year 1860, the deaths from carcinoma among men were .97 per cent. of the total male mortality, among women were 2.2 per cent. The cause of this greater relative frequency is connected with the development of the sexual organs in the female. Up to puberty, the mortality (from carcinoma) of the sexes is the same ; afterwards, the relative proportion of female to male deaths gradually rises till it attains its maximum about the age of 50, after which it falls away again (fig. 276).

The diagram on page 437 is based on the statistics of 91,058 deaths in Great Britain. It brings out three facts : the total number of deaths in each sex increases with age to a certain point ; the increase among women is relatively the greater ; it reaches its maximum at an earlier age with the female sex.

The most frequent seat is in the uterus, where fully one-third of the total cases occur ; the next in frequency is the mamma.

Although the immediate etiology of carcinoma is unknown, there are certain causes general and local which favour its development.

1. The *general predisposing causes* are the following :—

Heredity ;

Age ;

Depreciation of the vital powers.

Race and
Heredity.

The influence of *race* is brought out in Chisholm's statistics, which show that carcinoma is more than twice as frequent among the white population as among the black. As regards *heredity in families*, much less stress is now laid upon this than formerly.

According to Gusserow's statistics, in 1028 cases heredity was only proven in 79, that is in about 7.6 per cent. Schroeder placing the statistics of Sibley and of Barker together shows that heredity has only been proven in 8.2 per cent.; Picot places it at 13 per cent. These figures show that we cannot lay much stress on heredity as a predisposing cause. On the other hand we must remember that these

TABLE AND DIAGRAM OF COMPARATIVE FATALITY OF CARCINOMA IN MALE AND FEMALE, ACCORDING TO AGE.

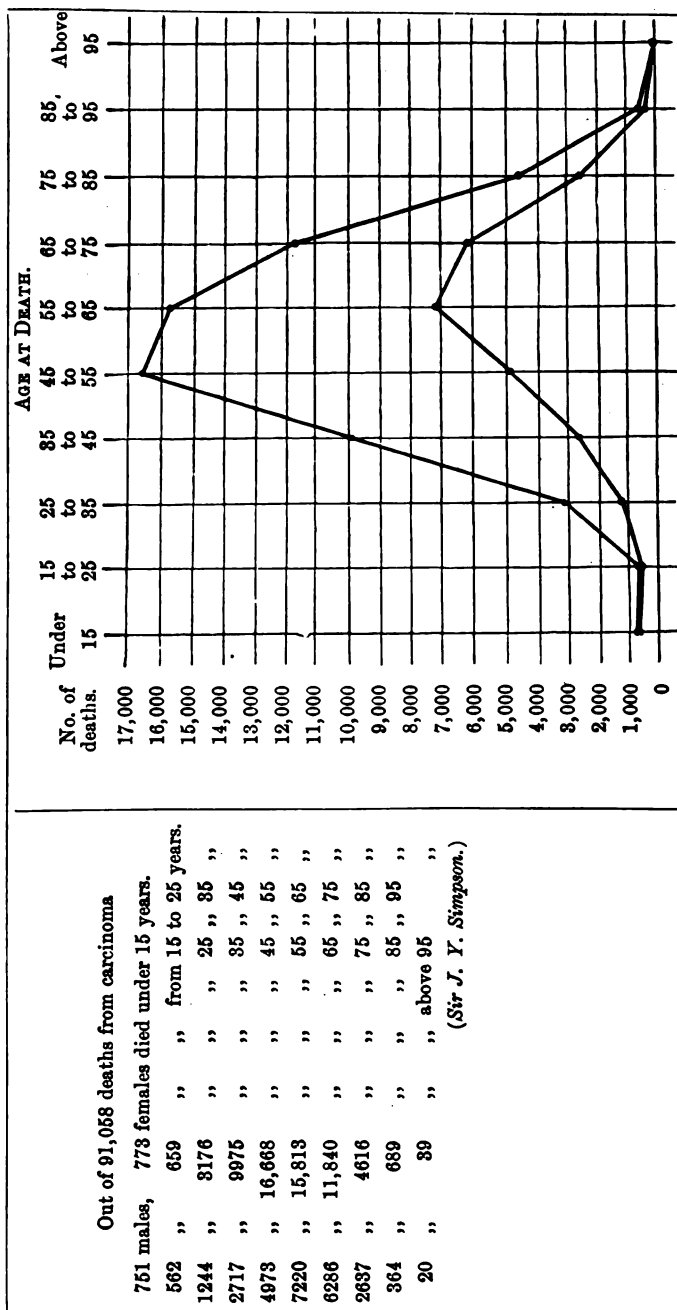


FIG. 276.

In the DIAGRAM, the upper line indicates mortality in female, the lower that in the male.

statistics are drawn principally from hospital reports, from a class of people who know little about the former history of their families.

Age.

Age has undoubtedly a considerable influence upon the frequency of this disease. This is evident from the table given on page 439. Gusserow collected statistics of 2270 cases reported by various authorities. The mortality per cent. for various ages is represented by the curve in the diagram on page 439. From the table it is evident that carcinoma does not occur before puberty. The proportion of cases below 20 (2 in 2270) is so small that it need not be taken into account. The first glance at the diagram would lead one to believe that the increasing frequency of the disease is due to the development of the functional activity of the sexual organs, but a more careful consideration shows that the increase continues and reaches its maximum after the latter has ceased. This table should be compared with that for Fibroid Tumours on page 387.

Whatever tends to *depreciate the vital powers* favours the occurrence of this disease. We meet with it more frequently among the poorer classes, where there is insufficiency of food with privation and hardship. Schroeder contrasts, in this respect, the development of carcinoma with that of myoma. In his polyclinique among the poorer classes, the proportion of carcinoma to myoma was as 100 to 61; in his private practice among the wealthier, it was as 100 to 332.

2. The *local predisposing causes* are the following:—

Erosion of the cervix and protracted catarrh;

Repeated parturition.

Influence
of Split
Cervix.

The relation of *erosion and laceration of the cervix* to the development of carcinoma has been recently pointed out by Ruge and Veit and also by Breisky. We draw attention to this point specially, because the most important differential diagnosis is that between long-standing inflammation and commencing malignant disease. The possibility that the former may pass into the latter should always be kept in view.

Of Re-
peated
Parturi-
tion.

Repeated parturition has an important influence. Carcinoma is much more frequent in multiparæ. Gusserow finds an average of 5.1 children to every case of carcinoma, which is a high average productivity. Whether this is due to the greater functional activity of the uterus or to the production of fissures with their resulting chronic inflammatory changes, is a more difficult question.

TABLE AND DIAGRAM SHOWING FREQUENCY OF CARCINOMA ACCORDING TO AGE OF PATIENT.

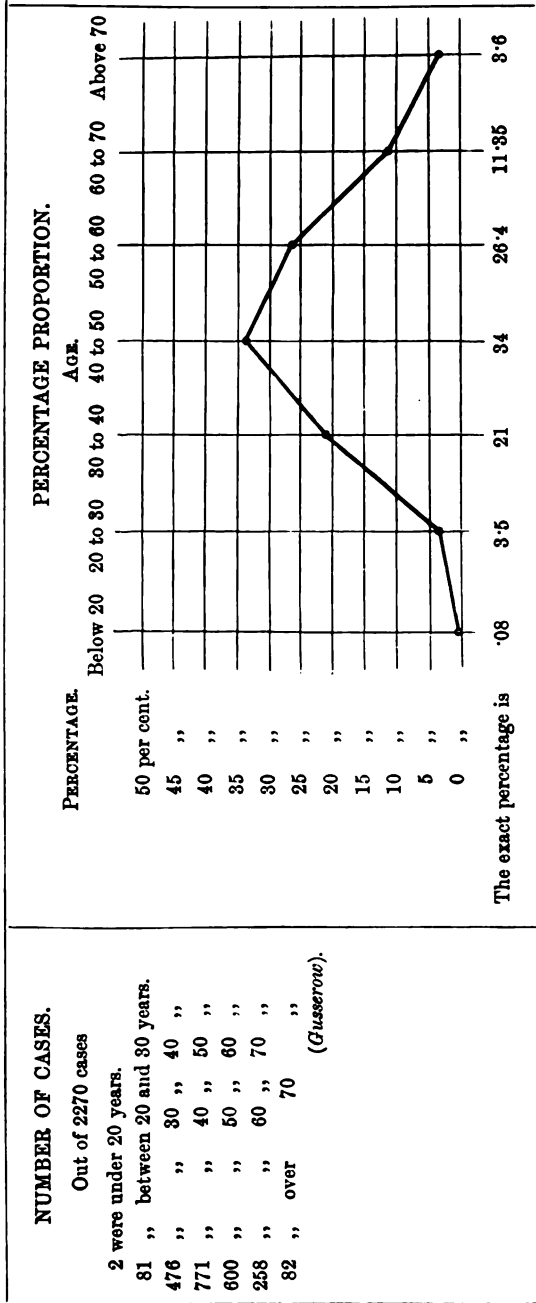


FIG. 277.

CHAPTER XXXIX.

CARCINOMA UTERI (OF OERVIX): SYMPTOMS AND DIAGNOSIS.

LITERATURE.—See Literature of Chapters XXXVIII and XL.

SYMPTOMS.

The *local* symptoms of carcinoma uteri are three :—

Hæmorrhage,
Offensive discharge,
Pain.

There are in addition a considerable number of *general* symptoms, which arise secondarily.

As a rule, however, no symptoms are present in the first stage, that is until ulceration sets in. In exceptional cases, when infiltration of the connective tissue or of the walls of the uterus has taken place at an early period, pain may be an early symptom ; there is no pain so long as the disease is limited to the cervix. This entire absence of symptoms until the disease has already made considerable progress, is the reason of the great difficulty in ascertaining the period of its probable commencement. From the same cause, the patient does not seek relief till the possibility of eradicating the disease is much diminished.

LOCAL SYMPTOMS.

Hæmorrhage.

Hæmorrhage is usually the first symptom noticed by the patient. She observes that menstruation is more profuse than formerly. This, when the disease occurs late in life, she attributes to approach of the menopause. In other cases, profuse hæmorrhage occurs irregularly between and independent of the menstrual periods. Sometimes the hæmorrhage is noticed only after exertion (as straining at stool) or after coitus. Sometimes the patient states that "the menstrual flow never

entirely ceases;" which means that the vaginal discharge is always tinged with blood. The explanation of hæmorrhage in these earlier stages is to be found in the vascularity of the stroma of the new formation. It is rich in delicate vessels which readily rupture. In the later stages, hæmorrhage is not a prominent symptom unless a large vessel be accidentally eaten into. Death from hæmorrhage is rare.

The *discharge* characteristic of carcinoma is not present until ulceration has occurred. In the papillary form of epithelioma¹ (cauliflower excrescence), there is a free discharge before the growth has begun to break down; this is of a watery character, has no odour, and is due simply to the transudation of serum. As soon, however, as ulceration occurs in any of the forms, there is a discharge containing the molecular debris of the breaking down tissue which gives it a characteristic and peculiarly offensive odour. In the rapidly growing forms (medullary) of carcinoma, there is an almost equally rapid molecular death of the newly formed tissue due to fatty degeneration of the epithelial cells. In epithelioma this discharge is less marked, because there is less necrosis of tissue; but in true carcinoma, especially in advanced stages, it is quite characteristic. In fact, a diagnosis may be sometimes made merely from the odour which hangs about the person. At first the discharge is yellowish-white in colour, but afterwards from the decomposition of the fatty cells it becomes of a reddish-brown; if there is hæmorrhage, it will be tinged with blood.

Pain is not such a constant symptom as is usually supposed. Some cases run their whole course without the patient's complaining specially of pain. It is not present so long as the disease is limited to the cervix; hence it is of no use as a diagnostic of carcinoma of the cervix in its early stage, unless the cellular tissue has been at the same time involved. But as soon as the new growth has extended upwards to the body of the uterus or to the cellular tissue of the pelvis, pain is produced through pressure on or actual lesion of the terminations of the nerves. The character of the pain varies. It is "a dull gnawing pain localised in the pelvis or back," or "a sharp pain shooting through to the back or down the thighs to the knees;" this last is caused by simple pressure on the crural and sciatic nerves or, in the later stages, from affection of the cellular tissue

¹ Though, as we have said, we have not at present a truly *pathological* classification of the different forms of carcinoma, it is convenient, *clinically*, to use the terms Epithelioma and true Carcinoma. By them we do not imply anything as to the origin of the disease. By epithelioma we understand those forms which begin more superficially, spread more slowly, and do not tend to involve the connective tissue.

of the nerve sheaths. Occasionally it is felt in the mammæ or other seats of uterine sympathetic pain. The intensity of the pain varies also in different cases; it is marked where there is more formation of new tissue and less ulceration, that is when there is more pressure on the nerve endings. Thus, if there has been much deposit between the uterus and the bladder accompanied with an increase of pain, we find that the pain diminishes when the mass breaks down and a vesico-vaginal fistula is formed. We may distinguish between pain due to the development of carcinoma, and that produced by the chronic peritonitis which accompanies it when the peritoneum becomes affected; the latter produces great sensitiveness of the abdominal walls to pressure, and a board-like rigidity from reflex spasm of the muscles.

GENERAL SYMPTOMS.

In addition to these local symptoms which are immediately due to the carcinomatous infiltration and degeneration, there are more general symptoms which arise secondarily.

Debility. First we mention *loss of flesh* and *general debility*. The patient may continue healthy and well-looking, in the early stages; sometimes, one is surprised to find that the disease is already well advanced in a patient who to outward appearance is in perfect health. But, sooner or later, the drain on the system produces great emaciation. The patient also has a careworn expression, partly from this loss of flesh and partly from the constant pain; from this expression alone, known as the "cancerous facies," the diagnosis may sometimes be made.

Marasmus. The wasting (marasmus) is occasioned not only by the drain of the new growth, but also by *disturbances* of the *digestive system* which arise in the course of the disease. Loss of appetite may amount to disinclination for food, and digestion is interfered with. This is produced at first sympathetically, as in other uterine disorders; but latterly it is due to gastric catarrh, constipation, the condition of the blood (anæmia and uræmia), and the unhealthiness of the atmosphere resulting from the offensive discharges.

Bladder and Bowel Symptoms. There is, further, *painful micturition and defæcation* according to the extent to which the bladder and rectum are involved. The latter is always present, as the rectum, whenever it is distended, presses upon the carcinomatous growth. When fistulæ are produced, the urine and fæces pass per vaginam.

Pruritus vulvæ frequently results from the acrid and irritating dis-

charge, and from the dribbling of the urine from a fistula. The *skin* acquires in the later stages a *dingy straw tint*, which when very marked is suggestive of jaundice. That disease may actually be present when there is secondary carcinoma of the liver, but this is rare. The colour is due to the anæmia, or (according to Barnes) to the absorption of decomposed fæcal matter (copræmia).

DIAGNOSIS.

As the patient does not seek advice till the carcinoma has begun to ulcerate, the physical signs have by that time become well marked and the diagnosis is usually easy.

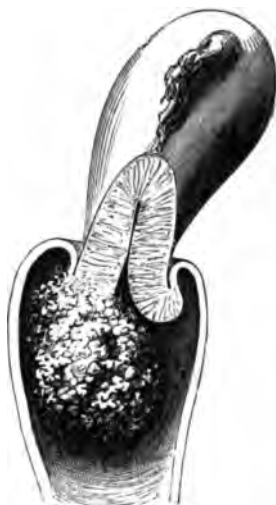

FIG. 278.

CAULIFLOWER EXCRESCENCE GROWING FROM THE CERVIX UTERI (Sir J. Y. Simpson).

On making a *vaginal examination*, the finger feels the enlarged, thickened, irregular, everted lips of the cervix spreading like a mushroom in the vagina (described by Malgaigne as “champignons cancéreux”). Sometimes a distinct tumour is present, the form of which is sufficiently indicated by the term cauliflower excrescence (see fig. 278). In other cases the finger feels an irregular ulcerated surface in the position of the cervix, soft and friable with hard and unyielding margins. The examining finger is stained with blood, and the odour of the discharge cannot fail to be recognised. If there is any doubt as to diagnosis, a fragment should be removed and examined microscopically. The appearance of a fibrous stroma with alveoli which contain irregular cells of an epithelial type with one or more large nuclei, will confirm the diagnosis of carcinoma.

By Vaginal Examination,

By
Speculum,

The *speculum* need not be used for the recognition of carcinoma, except in its early stage or to ascertain more exactly the seat and extent of the growth. If the disease be far advanced and the diagnosis certain, the introduction of it causes unnecessary pain and hæmorrhage.

By Rectal
Examina-
tion.

The *rectal examination* is valuable, and in these cases should always be carefully carried out. It gives us important information in two distinct classes of cases. First, in early carcinoma or in cases where there is a suspicion of commencing carcinoma, the cellular tissue of the pelvis should be carefully examined to ascertain whether any localised deposit or enlarged glands can be felt; this can be done most easily by the rectal examination. If it is desirable to introduce two fingers into the rectum or if the examination causes much pain, the patient should be narcotised. Second,



FIG. 279.

SCRAPING FROM CARCINOMA OF THE CERVIX, STAINED WITH LOGWOOD, $\times 40$; drawn by S. Delépine.

in cases of advanced carcinoma where the vaginal examination is difficult on account of the hæmorrhage and pain which it occasions, a more thorough examination can be made per rectum. The finger can reach higher up than per vaginam, and thus we can ascertain the extent of the carcinomatous deposit and the size and mobility of the uterus. The condition of the rectal mucous membrane itself is observed at the same time, to ascertain whether it is already involved in the disease. In some cases the rectal examination is the only one possible, as in the case of carcinoma vaginæ represented at fig. 275 where the deposit round the ostium vaginæ made the introduction of the finger impossible.

DIFFERENTIAL DIAGNOSIS.

The following are the most important lesions from which carcinoma is to be differentiated :—

- Hypertrophy of the cervix, with induration and occluded follicles ;
- Papillary erosion or ectropium, with cicatricial tissue ;
- Syphilitic ulceration, condylomata on the cervix ;
- Small fibroid in the cervix, sloughing polypi ;
- Retained portions of placenta or membranes ;
- Diphtheritic inflammation of the mucous membrane ;
- Sarcoma of the cervix.

As regards the first two of these, it is evident that carcinoma resembles them only at an early stage. But it is precisely at this stage that a correct diagnosis is all important for treatment. We should also remember (as Ruge and Veit have pointed out) that these conditions may be at once the result of chronic inflammation and the starting-point of malignant disease. The statement of the patient that the symptoms have existed for a long time, should not throw us off our guard. In *all* cases in which a patient *over forty years of age* seeks advice *with symptoms referable to the pelvis, a careful examination should be made.* We may thus accidentally discover carcinoma in an early stage, while still within the possibility of radical treatment. If the carcinomatous infiltration be general it cannot be distinguished, except by microscopical examination, from chronic induration. Spiegelberg proposed two tests: (1) the mobility of the mucous membrane over the indurated tissue below, which is lost when the disease is malignant; (2) when a sponge or laminaria tent is passed into the cervix, the infiltrated parts do not dilate like normal tissue. It is difficult to apply these tests practically: to pronounce on the mobility of the mucous membrane, requires a tactus eruditus such as few can claim; chronic induration, as well as malignant infiltration, prevents dilatation. In such cases we must watch the further progress; and, if there is suspicion of carcinoma, there is no harm in excising a portion of the suspected part and submitting it to *microscopic investigation.* A careful examination per rectum of the pelvic cellular tissue should always be made as mentioned above.

Importance
of Pelvic
Examina-
tion in
Cancer.

A superficial ulcerating epithelioma might be mistaken for a simple erosion, but has *thickened infiltrated edges.* The latter may, however, pass into the former.

Condylomata on the cervix simulate epithelioma, but they disappear under appropriate treatment. Syphilitic ulceration produces sometimes deep excavation, even a rectal fistula. This at the first glance might be taken for carcinoma, but more careful examination and inquiry into the history of the case will remove all doubt.

Small myomata are more sharply defined than a carcinomatous nodule of the same size, because the surrounding tissue is not infiltrated.

When a small submucous fibroid or a cervical polypus has ulcerated, it presents appearances similar to an ulcerating carcinomatous nodule. The former however is firmer and fragments cannot be broken off by the finger-nail, while the latter is friable and breaks down easily.

Carcinoma
in the
Puer-
perium.

The possibility that carcinoma may be first noticed during the puerperium, should always be remembered. There should be no difficulty in diagnosing between carcinoma of the cervix and a retained portion of placenta. If the finger be passed in, it will discover whether the suspected fungus-like mass be simply lying in the cervical canal or be springing from its walls. We have seen several cases of carcinoma in patients who were supposed to be having an abortion. In the case of carcinoma of the fundus, differential diagnosis is more difficult and will be discussed under that head.

Diphtheritic inflammation of the mucous membrane may easily be confounded with ulcerating carcinoma (*Schroeder*). The irregular swelling of the mucous membrane and the offensive discharge tinged with blood, which are present in diphtheritic inflammation, may be suggestive of carcinoma at the time; but this superficial resemblance soon disappears.

Sarcoma of the cervix is a very rare condition. Sarcomatous tumours are softer and grow more rapidly than carcinomatous. A positive diagnosis can only be made after microscopical examination of scrapings taken from the tumour.

PROGNOSIS.

The prognosis in carcinoma is always very grave. The possibility of spontaneous cure is a disputed point. There is one apparently well authenticated case recorded by *Habit*.¹ Another is mentioned by *Barnes*,² in which there is some doubt as to the correctness of diagnosis. The prognosis as to the probable duration of life, will depend on the extent to which the disease has already advanced and the possibility of checking its progress or even extirpating it altogether by operative interference. We are not yet in a position to form an opinion upon the possibility of extirpation, because the operation for this purpose is of but recent date and statistics as to the occurrence of recurrence cannot yet be gathered.

As regards the duration of disease if not interfered with, there is a

¹ *Sydenham Society's Year Book*, 1864, page 401.

² *Barnes, Diseases of Women*: London, 1878.

slight difference of opinion. This may be explained by the variable period in the course of the disease at which the symptoms appear. Sir J. Y. Simpson gives the probable duration of life after the detection of the disease as from 2 to 2½ years; Gusserow and Schroeder give it as from 1 to 1½; while, according to Fordyce Barker, it is as long as 3 years and 8 months. The statistics of H. Arnott, drawn from 57 carefully observed cases, give the duration, after the first symptom (usually a flooding), of true cancer as 53·8 weeks; of epithelioma, 82·7 weeks. We may say therefore to the patient's friends that the disease will run a course of from one to two years. It is better not to tell the patient herself what her trouble is, though its serious nature should not be disguised.

CAUSES OF DEATH.

The causes of death, arranged in the order of importance, are the following:—

- Exhaustion,
- Uræmia,
- Peritonitis,
- Septicæmia,
- Hæmorrhage,
- Venous thrombosis.

Exhaustion, under which we include *marasmus*, is the result partly of the drain on the system and partly of the inability to take food. Exhaustion.

The importance of *uræmia* as a frequent cause of death has only recently been pointed out. According to Seyfert,¹ in the majority of cases death results from it. It is due to compression of the ureters, as already described under Pathology. It may be acute, accompanied by coma and convulsions; more generally it is chronic, and shows itself in the dulness of the patient, occasional headache, and decreasing sensibility to pain—which diminishes suffering as the disease approaches its termination. Uræmia.

Peritonitis is sometimes the cause of death, but not so frequently as one would suppose; the disease is prevented from extending generally to the peritoneum by the adhesions which are formed. When peritonitis occurs, it is localised and chronic; in some cases, however, a general peritonitis is set up which proves fatal. *Perforation* may take place from the sudden giving way of adhesions; the escape of the carcinomatous debris into the peritoneal cavity produces death from shock. Peritonitis.

¹ *Saxinger, Prager med. Vierteljahrsschrift*, Bd. I., S. 103.

or septic peritonitis. The preparation shown at fig. 280 was taken from a patient in whom the immediate cause of death was *rupture of the uterus*. The case is reported and the preparation described by A. R. Simpson (op. cit., p. 276). There was carcinoma of the cervix which had contracted the lumen of the canal; the cavity of the uterus was expanded, the walls being thinned out; at the fundus "was a small

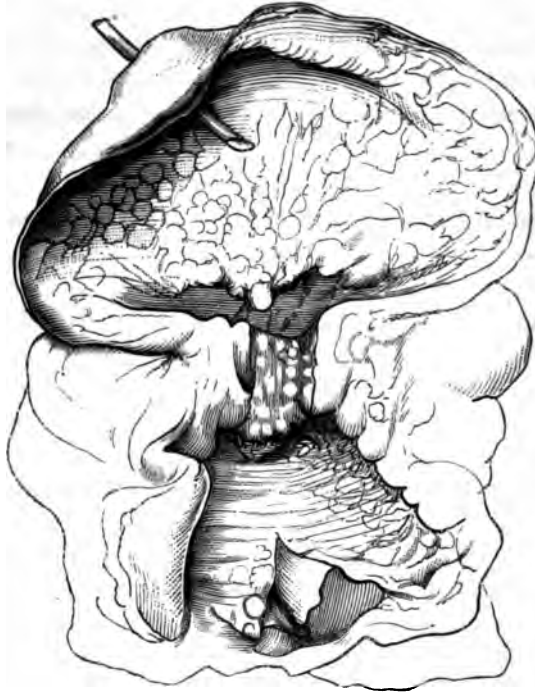


FIG. 280.

CARCINOMA OF THE CERVIX LEADING TO OCCLUSION OF OS UTERI, dilatation of uterus and perforation (A. R. Simpson). Uterus and vagina laid open; a quill is passed through the perforation.

perforation about the size of a pea, with thin edges," through which fluid had escaped and set up peritonitis which rapidly proved fatal.

Septi-
cæmia.

Septicæmia suggests itself as a likely cause of death. We are familiar with it as produced in the puerperal condition: it is explained by the fact that, at that time, there is abundant means for absorption in the numerous lymphatics and the large veins which have been recently lacerated; hence, whenever septic matter is present, there is great risk of septicæmia. Similar conditions exist in carcinoma, during the progress of which the blood-vessels are eroded and their extremities bathed

in putrid matter. Barnes has drawn special attention to this as a source of blood-poisoning; according to Eppinger's¹ observations its occurrence is rare, and this he ascribes to the diminution of the absorptive power of the eroded vessels.

Hæmorrhage is in very rare instances immediately fatal. As already ^{Hæmorrhage.} pointed out, though it is important as an early symptom, it occurs less frequently and is less abundant as the disease advances. If a large vessel be suddenly opened into, a fatal hæmorrhage may follow.

Venous thrombosis, due to mechanical compression of the veins, some- ^{Throm-} times occurs; and a clot may be detached producing embolism in the ^{bosis.} lungs. Fatty degeneration of the heart is, sometimes, also present.

¹ *Prager med. Wochenschrift*, 1876, S. 210.

CHAPTER XL.

CARCINOMA UTERI (OF CERVIX): TREATMENT.

LITERATURE.

Barnes—Diseases of Women, p. 856: London, 1879. *Currier, And. F.*—Removal of the Uterus for Cancer: N. Y. Med. Jour., vol. xxxiv., p. 494. *Freund*—Samm. klin. Vorträge, Nr. 133; and Centralbl. f. Gyn., N. 12, 1878. *Gusserow*—Die Neubildungen, etc., S. 203. *Hegar and Kallenbach*—Die Operative Gynäkologie, S. 301. *Singer*—Zur vaginalen Total extirpation des carcinomatösen Uterus, Archiv. f. Gyn., Bd. XXI., Hft. I. *Schroeder*—Charité Annalen: V. Jahrgang, S. 343, Zeitschrift für Geburtshilfe und Gynäkologie: B. III., S. 419; B. VI., Heft II., S. 218. *Simpson, A. R.*—Carcinoma Uteri; Contributions to Obstetrics and Gynecology, p. 261: Edinburgh, A. & C. Black. Case of Extirpation of the Cancerous Uterus through the Vagina: Edin. Obst. Trans., vol. vii., p. 136. *Simpson, Sir J. Y.*—Diseases of Women, p. 170: Edinburgh, 1872. *Sims, Marion*—The Treatment of Epithelioma of the cervix uteri: American Journ. of Obst., July 1879. *Thomas*—Diseases of Women, p. 591: 1882.

THE treatment of carcinoma ought to be regarded in two aspects: first, as treatment of *the symptoms*; second, as treatment of *the disease*. Again, the treatment of the disease may be either *palliative* or *radical*.

We need not discuss here the vexed question whether carcinoma is a constitutional or a local disease. It cannot be too strongly impressed on the student that, as far as our present experience goes, in attacking the disease itself he must rely upon *surgical* and not on *medical* treatment. Our aim ought to be the removal of the disease and not merely the alleviation of the symptoms. To remove it completely we must recognise it early. Up to the present time successful treatment has been a rare occurrence, because we have failed to recognise carcinoma in its commencing stages. The possibility of treating it successfully in the future will depend on the possibility of our recognising it in its commencement. Not less important than early recognition is complete removal and that without delay. In the uterus, more readily than in the mamma, does the carcinoma get beyond the reach of the operator. In carcinoma mammæ, we can excise not only the breast but also the axillary glands if these should be already implicated. But, in carcinoma uteri, as soon as the pelvic glands are involved the case is hopeless as regards a radical cure.

We shall consider, first, the treatment of the symptoms; because, in

the majority of cases, when the patient comes under our notice, the disease itself has already got beyond our remedies.

TREATMENT OF SYMPTOMS.

These are hæmorrhage, offensive discharge, pain.

HÆMORRHAGE.

In the treatment of hæmorrhage, there are two points to be considered: *first*, the instructions to be given to the patient; and, *second*, the means which we can ourselves employ.

(1.) The patient is instructed to take the liquid extract of ergot in large doses whenever there is much hæmorrhage either during the menstrual period or independent of it. If she is subject to floodings, a friend might be taught how to give the ergotin solution hypodermically. Ice applied to the vagina and injections of cold water check hæmorrhage; a small piece of sponge or tampon of wadding, soaked in perchloride of iron, might be passed into the vagina if cold is not sufficient. The patient is recommended to avoid sexual intercourse, as this favours active congestion and in some cases is the cause of hæmorrhage.

(2.) The means at our own command are the following:—

Simple pressure, effected by complete and thorough plugging of the vagina; The Vaginal Tampon.

The use of styptics, caustics, or the actual cautery;

The removal of diseased tissue by the curette or other means.

The plugging of the vagina should be done whenever we are called in on account of profuse hæmorrhage. The packing is carefully done with pledgets of lint or cotton wadding (with string attached) soaked in carbolic oil; the speculum is introduced carefully and not carried high up.

Of styptics, the best are the perchloride and the permanganate of iron. Sir J. Y. Simpson recommended a saturated solution of the perchloride in glycerine. A pledget soaked in either of these is introduced, and placed so as to be in contact with the bleeding surface; and the rest of the vagina is packed, as above described, with the pledgets steeped in carbolic oil. The perchloride should be used with great caution in cases of advanced ulceration, as we have seen it corrode into the tissue so as to reach the peritoneum and produce peritonitis. The use of caustics, cautery, and curette, will be considered under Operative Treatment.

OFFENSIVE DISCHARGE.

This is best treated by astringent and antiseptic injections. These

should be used frequently, as it is important to keep down the unpleasant odour and make the patient's surroundings as comfortable as possible. If the discharge be plentiful and not very offensive, as in the cauliflower excrescence, the indication is more for the use of astringents like sulphate of alumina and iron (4 grains to the oz). Tannin or sulphate of zinc can also be used, and it is well to change the astringent occasionally. If there is much necrosis of tissue with very offensive discharge, carbolised water (1 to 50) is required.

Acetate of lead (31 to 320) is recommended by Barnes. Solution of bromine (1 of the B.P. solution to 3 of water) is a good disinfectant, but its odour is disagreeable. Condy's fluid is largely used, but it is only deodorant not disinfectant. The skin round the external genitals should in all cases be protected from the acrid discharges, as the irritation is a source of discomfort. A lotion of equal parts of olive oil and glycerine or of olive oil and lime water, applied after each vaginal injection, serves this purpose well.

PAIN.

Use of
Opium.

This can only be effectually relieved by some preparation of opium; it is well to delay the habitual use of this remedy as long as possible, as it interferes with digestion and nutrition. It may be given as a morphia suppository ($\frac{1}{4}$ of a grain in each) per rectum, or as the liquor morphia hydrochloratis by the mouth. We obtain its action most surely and quickly and with the least disturbance of the digestive system by giving it hypodermically. It is desirable to change the narcotic, as even opium gradually loses its effect; the hydrate of chloral, in 20 grain doses, may be used as a substitute. Various local anodynes have been suggested, but are of little use.

General
Treatment.

Attention to the *general condition* of the patient is very important. The three main points are to give a sufficient quantity of nutritious and easily digestible food, to keep the bowels regular, and to have the atmosphere healthy and the surroundings cheerful. Food should be given in small quantities and frequently; milk, eggs and beef-tea should be substituted for more solid food as soon as digestion fails. In the later stages, the bowels should be evacuated by enemata rather than by purgative medicines. The room should be well ventilated by day and night, and the vaginal injections repeated frequently. Gusserow recommends that during the night a piece of waterproof sheeting be tied round the patient's waist to keep away the disagreeable odour.

TREATMENT OF THE DISEASE.

As before stated, our aim here is extirpation. If complete removal be possible, carcinoma will be no longer the incurable disease which haunts the mind of the patient and baffles the skill of the practitioner. The principles of treatment can be best understood by considering the progress of the disease as consisting of three stages: (1) when the disease is present as a germ infiltrating healthy tissue; (2) when the germ has developed into a tissue having the typical carcinomatous structure; (3) when this newly-formed tissue breaks down. The accompanying diagram (fig. 281) illustrates this progress. The three stages are represented by three zones.

Diagram of Spread of Cancer.

The extent of zone 1 is not well defined, for we have no means, unless with the microscope, of ascertaining how far the surrounding

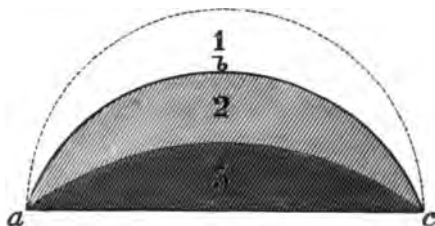


FIG. 281.

DIAGRAM TO ILLUSTRATE THE SPREADING OF CARCINOMA. 1, Healthy tissue infiltrated with germs of Carcinoma; 2, Carcinomatous tissue fully developed; 3, Carcinomatous tissue breaking down.

tissue is infiltrated. The area of zone 2 is more definite; the line *a b c* is well marked, for the carcinomatous tissue when fully formed has characteristics by which it can be recognised from the surrounding healthy tissue by touch or sight. Zone 3 represents the third stage, in which the immediate danger to the patient lies. It is not the *formation* of the carcinomatous tissue which is dangerous, but its *ulceration* with accompanying hæmorrhage and exhausting discharge.

From these facts we deduce the following principles of treatment. *First*, to effect radical cure we must remove zone 1, as well as zones 2 and 3; *i.e.*, we must remove not only the tissue which is evidently carcinomatous, but also all the surrounding tissue which may contain germs of the disease. Sometimes by a chance the operator has done this through keeping well clear of the evidently diseased part, and thus we can explain the few recorded cases of cure. *Second*, we may anticipate the natural process of breaking down, with its accompanying exhausting results and risks of a fatal hæmorrhage, by destroying the newly formed carcinomatous tissue as far as it is recognisable. We shall thus save the patient

from the effects of the disease until zone 1 has passed into the condition of zone 2 and is beginning to break down. Thus we explain the temporary benefit (for a period measurable by months) derived from the partial excision of the new growth. *Third*, the application of caustics alone may effect the destruction of area 2; but we are not so sure that we are removing the *whole* up to line *a b c*, as we are when we are using the knife or other cutting instrument. The latter means is preferable because we can make certain that we have reached this line in all cases where it is attainable by operative means. *Fourth*, the use of the knife and the application of caustic to the raw surface will, where the disease has spread far, be more effectual than the use of the knife alone; the caustic will now without doubt operate on the area of zone 1 and destroy so far the germs of the disease:—

There are four methods of operative treatment:—

1. Application of caustics,
2. Scraping out of diseased tissues,
3. Amputation of the cervix,
4. Excision of the uterus.

APPLICATION OF CAUSTICS.

Caustics in
treating
Cancer.

This should scarcely come under the head of treatment of the disease. All that we can hope for in the application of caustics is merely a superficial destruction of the growth and consequent temporary alleviation of the distressing symptoms. The caustics which we may use are the following. *Strong nitric acid* is applied with a dossil of lint: wash and, to prevent the acid from running, carefully dry the diseased surface before the application; wash again afterwards to remove superfluous acid. An alcoholic *solution of Bromine* (1 to 5) has been recommended by Routh¹ and Wynn Williams:² cotton wadding soaked in it is applied to the diseased part to produce a slough, and the rest of the vagina protected by wadding wet with bicarbonate of soda. Numerous other caustics have been tried.

The results of this method are only temporary. The superficial layers of the growth are destroyed while the hæmorrhage and discharge cease for a time. Cicatricial contraction takes place on the surface, but the hard infiltration can be felt extending beyond. According to Campbell de Morgan,³ the superficial application of caustics acts as an irritant

¹ *British Medical Journal*, February and March 1880.

² *London Obstetrical Transactions*, vol. xii., p. 249.

³ "The origin of Cancer considered with reference to the treatment of the disease," 1872.

producing increased growth of the new formation; so that when they are used they must be applied thoroughly.

SCRAPING OUT OF DISEASED TISSUE.

We have recourse to this means of treatment (1) in cases in which the disease is not of a form suitable for amputation—when it does not form a pediculated mass but is spreading along the mucous membrane of the vagina, (2) in cases which are too far advanced for amputation of the cervix. This method is good and safe in principle, because the carcinomatous tissue is soft and friable compared with the surrounding connective tissue and can be therefore easily scraped away.

The means which we employ are the curette or the sharp spoon. Sir J. Y. Simpson used to scrape out the diseased tissue with the finger-nail or the curette. The sharp spoon introduced by Simon¹ is the most efficient instrument: it should be used with short firm strokes, and the raw surface examined from time to time with the finger to feel whether all the hard nodules have been removed. After the scraping has been

Curette in
treating
Carcinoma.



FIG. 282.
SIMON'S SHARP SPOON.

thoroughly carried out, the surface is burned by the actual cautery and the vagina tamponed to prevent hæmorrhage. The results of this method are more satisfactory than those which follow the application of caustic alone; they depend entirely on the thoroughness with which the scraping has been done.

AMPUTATION OF THE CERVIX.

This operation is called for by two sets of circumstances: (a) when the disease is as yet limited to the cervix and there is a distinct line of demarcation above, so that in operating we can cut through healthy tissues; (b) when it has spread so far that although we cannot operate upon healthy tissue, we are yet justified in removing as far as possible the projecting mass.

The means of amputation are the following:—

Ecraseur, or galvano-cautery;

Knife and scissors, followed by ligature or caustics.

¹ *Berlin. Beitrag. zur Geburt. u. Gyn.*, 1872, Bd. I.

I. ECRASEUR, OR GALVANO-CAUTERY.

Relative advantages. Both of these possess the advantages that they are easy of application and cause less hæmorrhage than the knife,



FIG. 283.

ORDINARY CHAIN ECRASEUR. By compressing the small side handles, the chain is allowed to run out freely. It is drawn in by a pumping motion of the large cross-handle.

although with the latter we can follow more certainly the line of demarcation. The ecraseur has the advantage that it is easily portable, requires no preparation, and is always ready when wanted. On the other

hand, there is danger that the peritoneum of the pouch of Douglas or of the bladder may be lacerated by the chain. The galvano-cautery is inconvenient to carry about and is not always ready when wanted, but has the advantage that we do not need to draw down the uterus to apply it; in all cases of operation upon the cervix for carcinoma, the less traction that is made upon the uterus the safer for the patient. As the ordinary ecraseur (fig. 283) has the chain in a line with the handle, the cervix must be drawn down to the vulva for the working of the instrument. This difficulty is obviated in the curved instrument, and in the wire ecraseur devised by Sir J. Y. Simpson (fig. 284). The galvano-cautery not only amputates but, at the same time, cauterises

Ecraseur
and
Galvano-
cautery
compared.

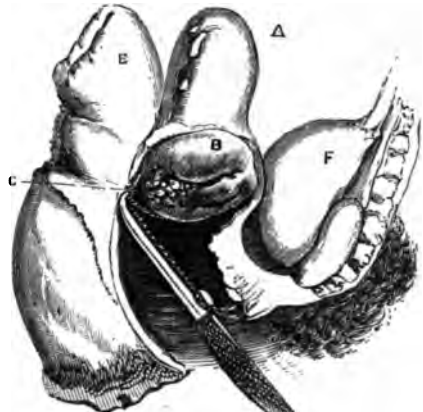


FIG. 284.

WIRE ECRASEUR applied to cervix uteri *B*; the uterus *A* is not dragged down; *E* rectum; *F* bladder; ecraseur relatively too small (Sir J. Y. Simpson).

the stump; this is a questionable advantage as, though it may diminish the probability of hæmorrhage, it prevents us from examining whether all the diseased tissue has been removed.

Mode of employment. Put the patient under chloroform. If the curved ecraseur or the galvano-caustic wire be used, place the patient semi-prone; only one assistant is necessary—to hold the Sims speculum. If the straight ecraseur is used or it is desirable to have the parts well exposed, the lithotomy posture is better; the two assistants who hold the legs can at the same time draw aside the labia with retractors, while a third draws back the posterior vaginal wall and perineum with the Sims speculum. Now lay hold of the cervix or tumour with the volsellæ, if necessary draw it down to the vulvar orifice. Place the wire or chain

Mode of
using
Ecraseur,

round the cervix or the pedicle of the carcinomatous mass (fig. 285), as far above the limits of the disease as possible, so as to cut through healthy tissue, but not above the line of reflexion of the mucous membrane of the posterior fornix upon the vaginal portion lest it should cut into the pouch of Douglas. After the ecraseur has begun to crush the tissues, *work it slowly*—shortening the loop at the rate of one notch in every twenty to thirty seconds.

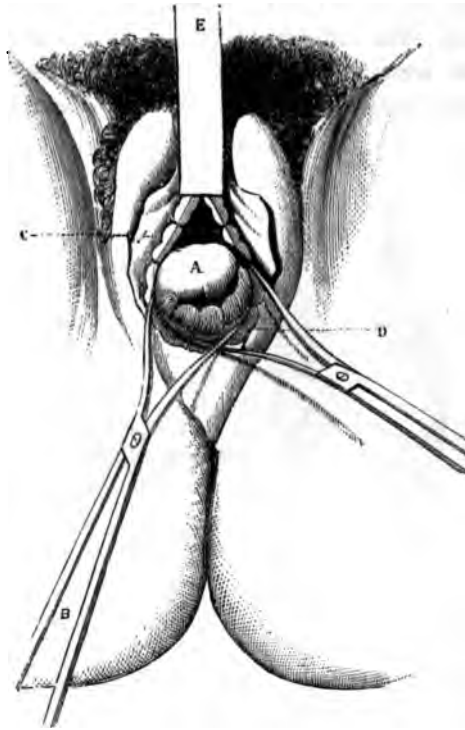


FIG. 285.

STRAIGHT ECRASEUR IN POSITION. *A* cervix drawn down to vulva by Museux's forceps; *C D* chain; *E* stem of ecraseur (*Chassaiguac*).

of using
Galvano-
cautery.

In using the galvano-caustic wire place it in position cold, tighten it up so as to constrict the cervix, and then make the current. To prevent slipping of the wire, Thomas has devised forceps with shoulders, which he uses in place of volsellae. Byrne of Brooklyn, who has had a large experience with the galvano-cautery, has pointed out that if gradual traction be made on the cervix during the action of the wire the result will be a funnel-shaped amputation; by this means more of the cervix

will be removed. *Tighten the wire gradually*, so as to burn through—not cut—the tissue. After amputation, examine the surface of the stump. If there is much hæmorrhage, apply a styptic to the stump directly or on a pledget of cotton wadding, and pack the vagina with carbolised lint or wadding; this packing should not be discarded for a week or ten days, as the great after-danger is hæmorrhage.

The results of this method of amputation, which is recommended by Barnes, Byrne of Brooklyn, A. R. Simpson, Thomas, and others, are so far satisfactory. Cases of complete eradication of the disease are extremely rare, and therefore the one recorded by Sir J. Y. Simpson¹ has a peculiar interest. He removed the cauliflower excrescence seen at fig. 286

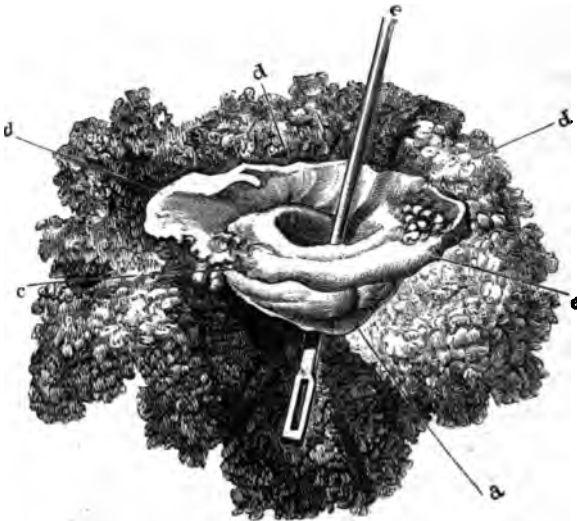


FIG. 286.

CERVIX UTERI AMPUTATED FOR CAULIFLOWER EXCRESCENCE OF THE POSTERIOR LIP. *a* healthy anterior lip, *c c* base of anterior lip, *d d d* portion of healthy mucous membrane removed along with the cervix, *e* rod passed through cervical canal (Sir J. Y. Simpson).

from a patient who was much reduced by the hæmorrhage and discharge. Eighteen years after the operation she was still perfectly healthy, had borne five children, and had had no return of the carcinomatous growth. The diagnosis was confirmed by the microscopical examination of the tumour by Goodsir and Reid who found it to have the structure of an epithelioma. This result is only to be accounted for on the supposition that, by a happy accident, the extent of the disease was so limited that the amputation could be made through healthy tissue. In two other

¹ Simpson—*Diseases of Women*, 1872, p. 180.

cases of amputation for canceroid disease, the life of the patient was prolonged for four years after the operation; death was due in one case to acute diarrhoea, in the other to the reappearance of the disease in the mesenteric glands. Even this result is exceptionally good; more frequently it is only a matter of months till the infiltration, which was not removed on amputation, develops into fully formed carcinomatous tissue.

II. KNIFE AND SCISSORS. The advantage claimed for this method of operating is that it allows the operator to follow the line of demarcation between the diseased and the healthy tissues; if in the course of the amputation he finds the carcinomatous new formation extending higher up than he anticipated, he can remove as much more of the suspected part as may be necessary.

There are disadvantages in stitching up the wound so as to produce union by first intention. We must save enough mucous membrane to close in the wound, which would be cut away were we to leave the wound to granulate; and in this, diseased tissue may be left. Further, in the wound itself, germs of the disease may be present which would be destroyed by the subsequent application of caustic.

As examples of amputation by the knife and closure of the wound by sutures, we shall describe the method adopted by Schroeder of Berlin. According to the extent of tissue to be removed, he performs either (*a*) amputation of the vaginal portion, or (*b*) supra-vaginal excision of the whole cervix.

A. *Amputation of the vaginal portion.* The cervix is divided on both sides with the scissors so that distinct anterior and posterior lips are produced. A wedge-shaped portion is excised out of each of these (fig. 163) and the flaps stitched together. The lateral incisions in the cervix are then closed by sutures.

Schroeder's
mode of
amputating
Cervix.

B. *Supravaginal excision of the whole cervix.* 1. The cervix having been drawn down with the volsellae, the knife is carried through the vaginal mucous membrane of the *anterior fornix* round the base of the anterior lip into the cellular tissues below. The bladder is easily separated from the cervix almost as far as the utero-vesical pouch of peritoneum, and retracts upwards carrying the ureters with it.

2. The cervix is now carried forwards; and the mucous membrane of the *posterior fornix*, which is thus exposed, is incised in a similar way, the ends of this incision being made continuous with those of that made in the anterior fornix. The peritoneum of the pouch of Douglas is liable to injury, but this accident is not of importance. In cases where the

posterior lip must be divided high up, it is better to cut into the pouch and remove the peritoneal covering along with the portion amputated.

3. The clearing of the cervix from the cellular tissue above the *lateral fornices* is more difficult, on account of the firmness of the connective tissue and the presence of large branches of the uterine artery which enter at the sides. The scissors are useful here, and any bleeding points must be ligatured.

4. The cervix being thus made free all round, the knife is carried through its anterior wall at the desired height, *till the cervical canal is opened into*. The anterior vaginal wall is stitched to the anterior wall of the cervix (fig. 287). This prevents retraction of the cervix while the

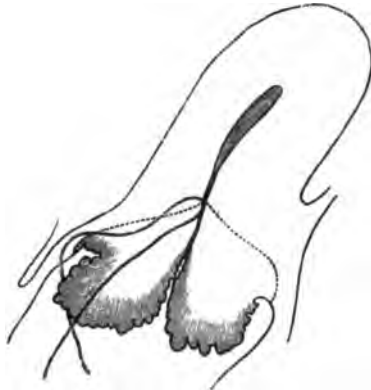

FIG. 287.

LINE OF INCISION AND POSITION OF SUTURES IN THE SUPRA-VAGINAL AMPUTATION OF THE CERVIX (*Schroeder*).

posterior wall is cut through and the amputation thus completed. The posterior vaginal wall is now stitched to the posterior lip of the cervix. The ends of the wound in the lateral fornices are closed with sutures which, if placed deeply, also control hæmorrhage. As the ureters retract, they are not in danger of being caught in the ligatures.

As regards the operation itself, *Schroeder's* results show that it is not a very serious one; of thirty-seven cases, four succumbed to the operation; one from hæmorrhage, one from phlegmon, and two from peritonitis. As regards the cure of the disease, the report is not so favourable. Of nineteen cases of which a definite report is given, thirteen had a recurrence of the disease at varying periods of which the average is four and a half months. In three, no recurrence had been observed within a period of eighteen, nine, and eight months respectively. The report of the condition of the other three, in which there was no recurrence, is

made at too short a period after the operation to justify any deduction from it.

Sims'
Operation
for Cancer.

III. WITH THE KNIFE AND SCISSORS FOLLOWED BY THE APPLICATION OF CAUSTICS. This is the method recommended by Marion Sims for the treatment of epithelioma of the cervix uteri. The steps in the operation are the following.

1. The epitheliomatous mass is broken down and removed with the curette, or cut away with the scissors if it is of a sufficiently firm consistence. It is not merely removed as far as its base (dotted line *a*, fig. 288), but the bed of the tumour is exsected with the knife and scissors

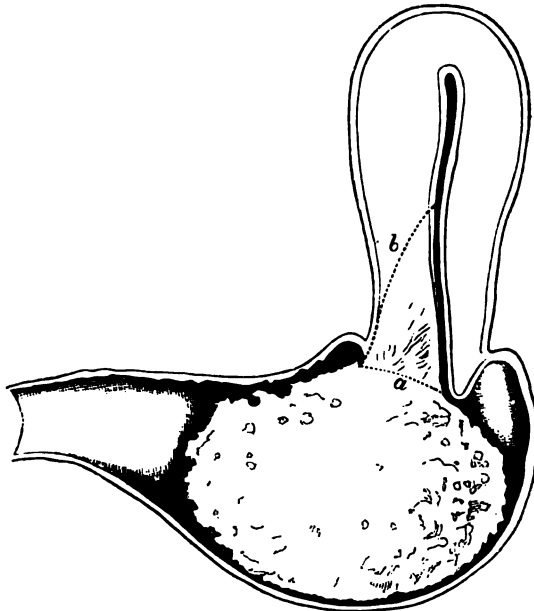


FIG. 288.

EXCISION OF EPITHELIOMA OF THE CERVIX (*Marion Sims*). For letters see text.

or scraped out with the curette as far as diseased tissue is present (dotted line *b*, fig. 288).

2. The cavity thus produced is cleaned out with sponges, and examined with the finger to ascertain that all indurated structure has been removed.

3. The edges of the cavernous opening are trimmed. The parts are sponged quite dry, and the cavity plugged with cotton wool squeezed almost dry out of either of the following styptic solutions; liquor ferri subsulphatis (1 part to 2 of water), or solution of carbolic (1 to 40) saturated with pulverised alum (1 to 12). The upper third of the vagina

is packed with the same material, and the rest with cotton wool soaked in carbolic solution.

4. After an interval of five days, this plug is removed and the caustic introduced. Pledgets of cotton wadding soaked in a strong solution of chloride of zinc (3 v to 3 i) and wrung dry, are packed into the scraped out cavity; the upper part of the vagina is tamponed with wadding soaked in a solution of bicarbonate of soda. Morphia is given hypodermically to relieve the intense pain produced by the action of the chloride.

5. After another interval of five days, the cotton wool containing the caustic is removed. A cup-shaped greyish slough will be found under it and is easily taken away. The granulating surface beneath will cicatrize in a fortnight.

The results of this method of operating are said by Marion Sims to be more satisfactory than those which follow from the use of the knife with healing by the first intention. He mentions one case in which he removed an epithelioma of the anterior lip (represented in fig. 288) the size of a Sicily orange. A year afterwards, the operation had to be repeated to remove a similar tumour from the posterior lip. Five years after this the patient was still in good health, though smaller growths had been removed in the interval.

We are not as yet in a position to decide which of these three methods of amputation is the best. The supra-vaginal amputation of Schroeder and the method of Marion Sims, enable us to remove more diseased tissue than the infra-vaginal amputation does.

EXCISION OF THE WHOLE UTERUS.

To Freund of Strassburg is due the credit of having first thought out and carried into execution a method by which the whole uterus can be removed. This method has increased the possibility of a radical cure of malignant disease of the uterus, though the number of cases suitable for extirpation is more limited than we should have supposed. The uterus alone can be removed by it, not the glands or connective tissue in the pelvis to which the disease in the majority of cases soon spreads. But when the disease has originated in the body of the uterus, or beginning at the cervix has extended upwards into the uterus rather than into the vagina or the connective tissue, the *extirpation of the uterus* holds out the prospect of a radical cure. This may be done

- Freund's
Operation.
- A. By abdominal incision,
 - B. Through the vagina.

A. BY ABDOMINAL INCISION (Freund's method). The following are the steps in the operation. (As a preliminary in the operation referred to in the note,¹ the cervix was stitched to check hæmorrhage from the cavity of the uterus.) The vagina is thoroughly washed with carbolised water, and the most careful antiseptic precautions are observed. The bladder is emptied, and the catheter left in it as a guide to its position.

1. An incision is made in the abdomen in the middle line extending downwards to the symphysis pubis and, unless the abdominal walls are unusually lax, the recti are partially divided on each side at their insertion into the pubes. The peritoneal cavity having been opened into, the intestines are drawn up out of the pelvis; if there is not room for them

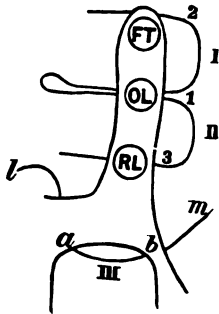


FIG. 289.

VERTICAL SECTION THROUGH BASE OF RIGHT BROAD LIGAMENT TO SHOW THE POSITION OF THE LIGATURES IN FREUND'S EXTIRPATION OF THE UTERUS. The posterior aspect of the broad ligament is to the right. *FT* Fallopian tube; *OL* ovarian ligament; *RL* round ligament. The end *m* of ligature *iii*. has not yet been carried through round ligament. For other letters see text.

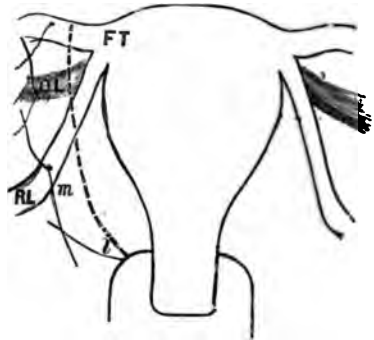


FIG. 290.

UTERUS SEEN FROM THE FRONT. The ligatures shown only on the right side to correspond with figure 289; they are drawn through but not tightened. The dotted line is line of amputation. For letters see fig. 289 and text.

in the upper part of the abdomen, they are brought out and covered with a cloth soaked in warm carbolised water. The uterus is laid hold of with forceps, of which Freund has devised a special form, and drawn upwards out of the pelvis.

2. The broad ligament is ligatured on both sides in three portions as follows. The uterus being drawn over to the opposite side to make the ligament tense, a needle armed with a double silk suture (fig. 289, 1) is passed from behind through the ovarian ligament; the end 2 of this thread is carried through the broad ligament just below its free margin;

¹ In a case in which we saw Freund operate for Sarcoma uteri, the operation lasted 24 hours. The patient made a good recovery.—A. H. B.

thus loop I. is formed, which when tied in front controls the *ovarian artery*. The lower end 3 is passed through the round ligament and thus loop II. is formed, which when tied controls the *pampiniform plexus*.

The same is done upon the opposite side; the threads are not yet cut away, but drawn upwards by assistants.

The ligature III. dips into the fornix vaginæ so as to control the uterine arteries. It is passed from the vagina on a curved needle sheathed in a canula. Guided by the hand in the vagina, the needle is made to pierce the lateral fornix (at *a*); a piece of cork pressed against the point facilitates penetration. The free end *l* of this double thread is laid hold of and held while the needle is withdrawn and, running on the thread, carries it through the lateral fornix (at *b*). The thread is then cut at *m* beyond the eye of the needle, so that the needle still threaded can be used to place a similar ligature in the lateral fornix of the opposite side. The end *m* is carried through the round ligament at the same point as 3, so as to form the ligature III. which controls the *uterine artery*. It is important that it should include but a small portion of the vaginal roof, so as to compress the artery more securely.

3. The uterus is now excised. The knife is carried through the utero-vesical pouch between the cervix and the bladder, of which latter the position is defined by the catheter. The free edge of the divided peritoneum, resting on the bladder, is fixed to the underlying tissue by a fine silk ligature. The peritoneum of the pouch of Douglas is now cut through at a lower level, and the free margin fixed in a similar manner with a fine silk thread. The cellular tissue underneath the peritoneal wound, before and behind the uterus, is separated *with the finger*; then the vaginal mucous membrane is divided in the anterior and posterior fornices with the knife passed in from the vagina. The uterus is thus free before and behind; and, the broad ligaments being cut through with the scissors internal to the three ligatures (fig. 290), the whole organ is removed.

4. The ends of the six ligatures are brought down through the wound in the roof of the vagina. (Formerly, Freund stitched this wound carefully up; the ligatures referred to above as placed through the margin of the peritoneum—before on the bladder and behind in the pouch of Douglas—were used to bring the peritoneal edges of the wound together.) A T-shaped drainage tube, kept in its place by a catgut suture, is laid in the wound. Any bleeding points in the margins of the wound are secured. The abdominal incision is closed; the peritoneum with fine

silk thread, the muscular layer with silver wire, and the skin with fine silk sutures.

The results of this method of extirpation (as given by Hegar and Kalténbach—loc. cit., S. 408) are that, of 89 cases of completed operation, 26 recovered. The mortality of this operation has thus been about 71 per cent.

B. EXTIRPATION FROM THE VAGINA. The following is the method adopted by Schroeder of Berlin.¹

1. The uterus being firmly drawn down to the vulva, the cervix is separated from the bladder as in the supra-vaginal amputation but the peritoneum is not cut into. The mucous membrane of the posterior fornix is incised, and the cervix freed all round.

2. The pouch of Douglas is opened into, and two fingers of the left hand passed in over the fundus uteri into the vesico-uterine pouch. By cutting down through the wound in front of the cervix upon these fingers, the peritoneum is divided anteriorly.

3. The uterus, being thus freed before and behind, is retroflexed on itself so that the fundus is forced through the wound in the posterior fornix. This was done with comparative ease in the case observed; but where the uterus is enlarged or of a firm consistence or where the vagina is small, it can only be done with great difficulty; it is facilitated by laying hold of the fundus with forceps.

4. A needle armed with a double thread, is made to transfix the broad ligament which is ligatured in two portions and an additional ligature is put round the whole. This is done on each side. It is not difficult if the ovaries and Fallopian tubes are not to be removed, as the stumps are sufficiently long for the application of the ligatures; but if they are cut away, the ligatures are apt to slip.

5. The uterus is cut away; and the pedicles examined for bleeding points, which must be secured.

6. Each pedicle is brought into the wound in the roof of the vagina, and kept in position by a suture which is passed through the edge of the wound in the anterior fornix, through the pedicle above the ligatures, and then through the edge of the wound in the posterior fornix. This also brings together the margins of the wound at each side, and the ends of the wound external to them are closed. A T-shaped drainage tube is passed between the stumps into the peritoneal cavity. The

¹ In a case in which we saw Schroeder operate for carcinoma uteri, the operation lasted half-an-hour. The patient made a good recovery.—A. H. B.

vagina is packed with salicylic wool and the end of the drainage tube wrapped round with the same. Should the temperature rise or the discharge become foetid, the pelvic cavity is washed out with carbolised water. The sutures are removed after an interval of from two to three weeks.

In a recent case Professor Simpson modified the above procedure as follows. Steps 1-3 were done as above. He then passed a ligature round each broad ligament, divided the uterus vertically into two halves with scissors, pulled down each half, passed a second double ligature round the broad ligament nearer the uterus than the first, and finally clipped each half of the uterus away.

The results of this operation are as follows. Schroeder has operated in eight cases (one of these was performed by his assistant), and in one only did the patient die; the death resulted from internal hæmorrhage caused by the rupture of a vessel in the broad ligament. The other seven made good recoveries. As regards the extirpation of the disease, sufficient time has not elapsed to ascertain whether or not it will return. The total results are (according to Hegar and Kaltenbach) that, of 29 completed operations, 21 recovered. The mortality has been therefore only 27·6 per cent., which contrasts favourably with that in Extirpation by Abdominal Incision (71 per cent.)

Sänger found that in 133 completed cases there were 89 recoveries: that in 7 cases the average period before return was 4·2 months, and that in 6 cases the average duration of life after this operation was 14·1 months.

CHAPTER XLI.

CARCINOMA OF THE BODY OF THE UTERUS.

LITERATURE.

Breisky and Eppinger—Prager med. Wochenschrift, S. 78, 1877. *Gusserow*—Neubildungen des Uterus, S. 222: Stuttgart, 1878. *Schroeder*—Die Krankheiten der weiblichen Geschlechtsorgane, S. 295. *Simpson, Sir J. Y.*—Selected Obstetrical and Gynecological Memoirs, edited by Dr. Watt Black, p. 769. *Veit*—Zeitschrift für Geburts- und Gyn., Bd. I., S. 467.

PATHOLOGY AND ETIOLOGY.

CARCINOMA affects the body of the uterus much more rarely than the cervix; in only 13 out of 686 cases of uterine cancer, that is in rather less than 2 per cent., was the disease situated in the body of the uterus (*Schroeder*).

Its rarity is apparent from the fact that *Gusserow*, after a careful survey of the whole literature, has collected but 80 cases.

As in the cervix, the disease originates either in the substance of the walls of the uterus or in the mucous membrane. In the former case, it begins as localised nodules which grow rapidly and produce bulging of the mucous membrane or of the peritoneal coat but do not tend to ulcerate. When in the mucous membrane it causes a uniform swelling or, more usually, projects in polypoidal masses (fig. 291).

By *Eppinger* and *Ruge* the disease has been directly traced to the epithelium of the uterine glands; these first hypertrophy, and then their proliferating epithelium passes into carcinomatous epithelial cells. The new-formation ulcerates, so that the wall of the uterus becomes converted into an excavated surface with a hard base. Adhesions rapidly form with neighbouring organs, while secondary deposits may develop in the peritoneal cavity.

As to *Etiology*, what has been said of carcinoma of the cervix applies here with two additional facts. (1.) The age in the majority of cases is between 50 and 60 years, ten years later than in the cases of carcinoma of the cervix (v. fig. 277). Out of 34 cases, 23 occurred during these

years (*Pichot*). (2.) A surprisingly large proportion of the cases are in nulliparæ (*Schroeder*).

SYMPTOMS AND DIAGNOSIS.

Again, as in carcinoma of the cervix, the symptoms are pain, hæmorrhage, and fœtid discharge. 1. Pain, in contrast with carcinoma of the cervix, is always an early symptom. It occurs periodically; "slight and intermittent, perhaps, at first, but soon reaching a high pitch of intensity, at which it continues for an hour or two, and then gradually

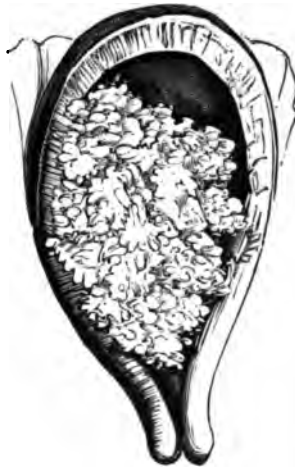

FIG. 291.

CARCINOMA OF THE BODY OF THE UTERUS. The uterine cavity is increased in size but the cervix is undilated (*Sir J. Y. Simpson*).

subsides" (*Sir J. Y. Simpson*). 2. *Hæmorrhage* is also present at an early stage; it takes the form of profuse menorrhagia, because the mucous membrane from which the menstrual flow takes place is diseased. 3. *The Discharge* is usually profuse and becomes after a time fœtid. Sometimes it is watery and not offensive; in rare cases is it altogether absent.

On vaginal examination, the cervix is found to be either normal or dilated. The uterus is enlarged, and may be freely movable or may be fixed by adhesions. The sound shows the cavity to be enlarged and may recognise irregularity of the mucous membrane; its introduction is followed by hæmorrhage. The condition of the mucous membrane is more precisely ascertained by examination *with the finger after dilatation of the cervix with a tent*. In the majority of cases, certainty of diagnosis

is possible only through *microscopic examination* of fragments removed by the curette. Should these show merely hypertrophied glands, we must remember that this is sometimes a transition stage to malignant disease. Typical carcinomatous cells are seen at fig. 279.

The *Differential Diagnosis* must be made from—

Portions of retained placenta,
Sloughing submucous fibroid,
Hæmorrhagic endometritis.

These conditions have been already described. As to the first of these we note that carcinoma sometimes develops during the puerperium. In three cases observed by Chiari, the development of carcinoma was directly connected with the puerperium and ran a rapid course to a fatal termination within six months after the birth of the child.

During the period of sexual activity, differential diagnosis is often extremely difficult; rapid growth and development of peritonitis fixing the uterus, point to malignant disease. After the menopause, the recurrence of hæmorrhage is an important diagnostic. The microscope is, when available, the most reliable guide.

TREATMENT.

As to the treatment of the symptoms, this is the same as in Carcinoma of the Cervix (*v. Chap. XL.*) As to the treatment of the disease, the scraping away of the polypoidal masses with the curette or sharp spoon gives temporary relief from the hæmorrhage and discharge. The only hope of cure lies in extirpation of the uterus. These cases are more favourable for extirpation than cases of carcinoma of the cervix, as there is a better prospect of excising the whole of the affected tissue.

CHAPTER XLII.

SARCOMA UTERI.

LITERATURE.

Clay, J.—On diffuse Sarcoma of the Uterus: *Lancet*, Jan. 1877. *Galabin*—Lond. Obst. Trans., Vol. XX. *Gusserow*—Die Neubildungen des Uterus, S. 142: Stuttgart, 1878. *Jacobash*—Vier Fälle von Uterussarcom: Zeitschrift f. Geburts. u. Gyn., Bd. VII., Hft. I. *Kunert*—Ueber Sarcoma Uteri: Arch. f. Gyn., Bd. VI., S. 29. *Rogivue*—Du Sarcôme de l'utérus: Inaug. dissert., Zürich 1876. *Schroeder*—Die Krankheiten der weiblichen Geschlechtsorgane, S. 301. *Simpson, A. R.*—Contributions to Obstetrics and Gynecology, p. 240. *Thomas*—Diseases of Women, p. 566, London 1880; and Sarcoma of the Uterus, Lond. Obst. Journ., Vol. II., 1875, p. 437. *Virchow*—Die Krankhaften Geschwulste: Bd. II., S. 350. For a full *resumé* of the literature, see *Gusserow* and *A. R. Simpson*.

By sarcoma we understand a *connective tissue* tumour of an embryonic Nature of type (*Cohnheim*). As we trace back carcinoma to the epithelium and true myoma to the muscular fibre, so we trace back sarcoma to the connective tissue. Sarcoma.

For the recognition of sarcomata as of connective-tissue origin and the limitation of the term to malignant tumours of this type, we are indebted to *Virchow*. Formerly they were known in English literature as "recurrent fibroids;" the existence of this form of tumour in the uterus was recognised and fully described by *Hutchinson* (1857).

PATHOLOGY.

Unlike carcinoma, sarcoma rarely occurs in the cervix; in the larger proportion of cases it is in the *body* of the uterus.

It occurs in two forms:—

1. Diffuse sarcoma of the mucous membrane;
2. Circumscribed fibrous sarcoma.

The *diffuse sarcoma of the mucous membrane* arises from the sub-epithelial connective tissue. It appears as a general swelling of the mucous membrane which becomes soft and crumbly, or as irregular foldings or knobby projections into the uterine cavity; sometimes these projections have a polypoidal and apparently circumscribed character. Diffuse Sarcoma.

(fig. 292) so that this form passes insensibly into the fibrous. The masses have a greyish-white brain-like appearance and soft pulpy consistence. The mucous membrane may be broken down but is not deeply excavated as in carcinoma. On microscopic examination the mucous membrane is seen to be infiltrated with masses of closely-set round cells,

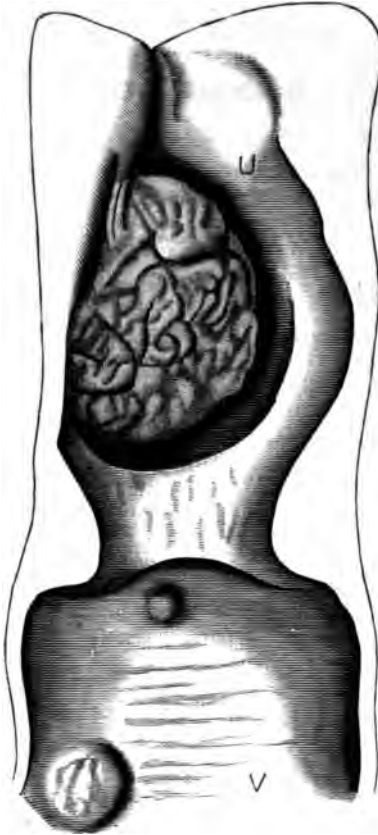


FIG. 292.

SARCOMA UTERI WITH TUMOURS IN THE VAGINA—*from a specimen in the Pathological Institute at Strassburg (Gusserow).*

more rarely spindle-cells. Epithelial-cell proliferation often complicates this form of sarcoma and brings it into close relation to carcinoma. Klebs has proposed to call such forms carcino-sarcomata.

Circum-
scribed
Fibro-
Sarcoma.

The *circumscribed fibro-sarcoma* arises in the muscular coat; like the fibroid it may be submucous, interstitial or sub-peritoneal and is found usually in the body, rarely in the cervix. The tumours are of a firm con-

sistence, and feel like knots in the muscular wall of the uterus or project as polypi into its cavity; they thus resemble small fibroids, but *have no capsule*. Microscopically they consist of a localised sarcomatous—generally round-celled—infiltration (fig. 293).

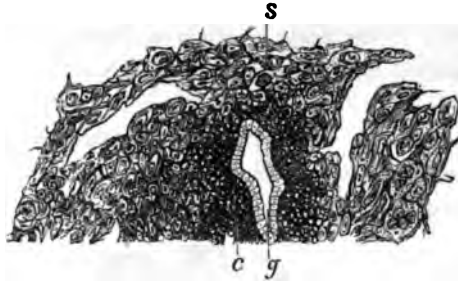


FIG. 293.

MICROSCOPIC SECTION OF THE MUCOUS MEMBRANE OF THE UTERUS IN A CASE OF SARCOMA (Schroeder).
s Sarcomatous tissue; c small celled infiltration; g uterine glands.

In some cases it has been alleged that sarcoma is a *degeneration of a fibroid tumour*, as in the following specimen described by A. R. Simpson. "On section it presented a uniformly smooth surface of pale-pinkish colour, with some islands in it presenting the familiar cotton-ball structure and clear white glistening aspect seen on section of an ordinary fibroid tumour of the uterus, and separated from the softer surrounding

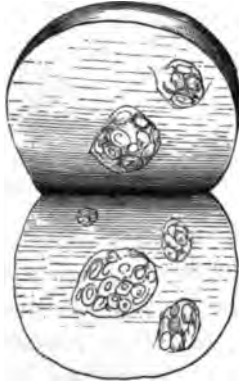


FIG. 294.

SARCOMA UTERI, seen on section, showing fibroid nodules (A. R. Simpson).

tissue by a connective-tissue capsule (fig. 294). The larger part of the tumour was composed of fusiform nucleated cells, with an intercellular matrix having a fibrillated appearance, and running for the most part in small sections in parallel directions." A portion of the tumour, probably

then a fibro-myoma, had been removed five years previous to this; a third portion of the tumour, removed four years subsequent to this, showed only sarcomatous tissue.

Chrobach, Müller and others have traced the development of sarcoma in tumours which were originally undoubted fibroids. There is therefore no doubt that this is one mode of origin of fibro-sarcoma; whether (as Schroeder and Kunert have suggested) this is always the origin, is as yet undecided.

Secondary nodules may form in the vagina (fig. 292) and peritoneal cavity. Sometimes the peritoneum is affected by continuous spreading of the new growth outwards towards the peritoneal covering; here it causes

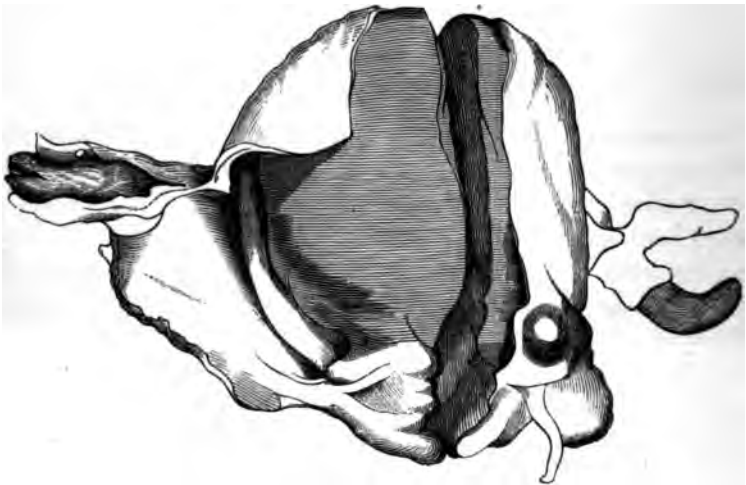


FIG. 295.

SARCOMA UTERI INVADING THE FALLOPIAN TUBES and projecting from their fimbriated ends
(A. R. Simpson).

adhesions, through which the sarcomatous infiltration may extend to other organs (*Gusserow*). A. R. Simpson records a unique case in which the infiltration spread along the mucous membrane of the Fallopian tubes (fig. 295), so that from their fimbriated ends there projected "rounded masses, having the appearance of the thrombus projecting from a small vein into a larger trunk." The uterus was of the size of a four-months' pregnancy.

Co-existence of Inversion of Uterus.

A. R. Simpson draws attention to the frequency of *inversion of the uterus* as the result of sarcoma. We referred to it as a rare complication of pediculated submucous fibroid tumours. In sarcoma, it appears to occur more frequently—in 4 out of 48 cases. He attributes this to

the paralysis of the muscular wall of the uterus through sarcomatous infiltration and to the peculiar dilatibility of the cervix observed in some cases.

Sarcomata may undergo *mucoid degeneration*, resulting in a myxo-sarcoma. Large vascular spaces may form in their substance—as occurs in fibroid tumours; in a case recorded by Jacobash, the bursting of such a vascular tumour into the peritoneal cavity proved suddenly fatal.

Metastatic deposits, though rare, are found more frequently in fibro-sarcoma than in diffuse spreading sarcoma. They have been found in the lymphatic glands, lungs, liver, and vertebræ.

ETIOLOGY AND FREQUENCY.

Of the reason why a source of irritation should lead the connective tissue to produce a sarcomatous new-formation, we know as little as why the same cause produces a carcinomatous new-formation from the epithelium.

As to its frequency, a sufficient number of cases has not yet been collected to form any generalisation. It is, however, so rare that every carefully observed case which has been authenticated by microscopic examination should be placed on record. Up to 1878, Gusserow had collected 63 cases; since that time Jacobash has collected 9 additional cases from German sources, Galabin has reported a case of sarcoma of the cervix, and we have seen two cases since 1879 in Professor Simpson's ward—one in the body of the uterus and the other in the cervix.

Age has the same predisposing influence as in fibroma and carcinoma. Of 62 cases collected by Gusserow—

2	were	under	20,
3	„	between	20 and 30,
14	„	„	30 „ 40,
26	„	„	40 „ 50,
14	„	„	50 „ 60,
2	„	„	60 „ 70,
1	was	above	70.

The number of sterile patients among those affected with sarcoma (25 out of 63) is noteworthy; in this respect it contrasts with carcinoma (*Gusserow*).
Influence of Age.
Frequency.
Metastatic Deposits.
Mucoid Degeneration.
Frequency.
Influence of Age.

SYMPTOMS.

The following symptoms characterise the early stage, in which the patient seeks advice:—

1. Hæmorrhage,
2. Absence of pain,
3. Watery non-offensive discharge,
4. Cachexia.

Hæmorrhage. *Hæmorrhage* appears first as increase of the menstrual flow, or as irregular hæmorrhages after the menopause. As the new-formation *does not ulcerate* rapidly like carcinoma, the increased menstruation is due to hyperæmia of the mucous membrane (*Clay*).

Pain. The *absence of pain* in the early stage is remarked on by *Clay* and *A. R. Simpson*; in this respect it differs from intra-uterine cancer. According to *Gusserow*, on the other hand, pain is frequently present and that of an intense and rending character. This apparent discrepancy of opinion may be explained by the varying progress of the infiltration. In the spreading of carcinoma, we noted that pain was most severe when the disease was extending upwards and compressing the nerve endings in the uterus and connective tissue.

Discharge. The free rice-watery discharge has a slight odour but is not nearly so offensive as in carcinoma; this is due to the fact that there is not the same rapid ulceration and necrosis of tissue. When the disease has progressed further, the discharge becomes equally foetid. The presence in the discharge of *greyish-white shreds*, like particles of brain matter, is diagnostic; under the microscope these are seen to consist of small portions of sarcomatous tissue.

Cachexia. *Cachexia* is of importance as it helps us to distinguish developing sarcoma from a non-malignant polypus; the drain from the latter may make the patient gradually anæmic; but there are not the loss of flesh, the loss of appetite and the rapid failure of strength, which point to malignant disease.

DIAGNOSIS.

If the tumour projects through the os, the diagnosis is not difficult. The age of the patient with the symptoms given above and the existence of a *soft friable* pediculated tumour which springs *from the body* of the uterus, will point to the diagnosis; a portion, detached with the nail, shows the characteristic microscopical structure. When nothing projects through the cervical canal, we try to dilate it with the finger, or, if this fails, with a sponge tent or the rapid method described at p. 426. The finger recognises a soft friable condition of the mucous membrane, or a distinct polypoidal tumour, or a localised thickening in the walls.

The uterus is in some cases distinctly enlarged and may reach half-way to the umbilicus or lie retroverted; in the early stages it is movable, but it soon becomes fixed.

The sound shows the cavity to be enlarged; its use causes hæmorrhage.

The differential diagnosis is here often very difficult, as these conditions are also present in—

Chronic endometritis (hæmorrhagic type),
Small fibroid tumours (interstitial or polypoidal),
Carcinoma.

Curetting the surface, with microscopic examination of the scrapings, will help us in the first case.



FIG. 296.

SCRAPINGS FROM A FIBROID TUMOUR to show the size and form of the muscular fibre, their rod-shaped nuclei—stained, $\frac{1}{40}$; drawn by S. Delépine.




FIG. 297.

SCRAPINGS FROM A SPINDLE-CELLED SARCOMA to show the larger size of the spindle cells and their oval nuclei—stained, $\frac{1}{40}$; drawn by S. Delépine.

The removal of the polypoidal mass, with the finger nail or nail-curette, will enable us to examine its nature; the possibility of both conditions being present, polypoidal fibroid + commencing sarcomatous degeneration, must be remembered. With an interstitial thickening, we can only watch the progress of the case.

In carcinoma of the fundus, there is generally excavation of the uterine wall and the base of the ragged surface is harder than in sarcoma. The examination of scrapings is not always decisive, as the cells found in sarcoma sometimes closely resemble epithelial cells.

In all cases of doubt we must watch for a few months, when the

rapid growth of the tumour or the *development of cachexia* will clear up the case.

PROGNOSIS.

The prognosis is grave. Compared with carcinoma, its development is not so rapid nor are the symptoms of pain and offensive discharge so aggravated in the early stage. In two of the cases recorded by A. R. Simpson the patient survived for four years after the diagnosis of sarcoma was made out, and Gusserow mentions a case where the course was prolonged for ten years.

The temporary relief procured by removal is longer of duration than in carcinoma. No case of radical cure is, as far as we know, recorded; after removal it reappears at periods varying from two to fourteen months (*Clay*). When it returns, the development of the new tumour is more rapid than that of the first growth.

As to the communication of the prognosis to the patient and friends, see under Carcinoma.

TREATMENT.

The tumour should be removed as soon as we suspect malignancy. Even when there is doubt, its removal will clear up the case.

The cervix should be well dilated so as to allow the finger to pass freely into the uterus. Gradual dilatation is preferable; injury of healthy mucous membrane in dilating or curetting should be avoided, as sarcomatous cells have become engrafted on a fresh wound surface.

When circumscribed and polypoidal, remove it with the finger nail or nail curette. After its removal apply carbolic acid thoroughly to its base.

When diffuse, curette the uterus. Continue the scraping till all the loose tissue and irregularities of the mucous membrane are removed. After curetting the surface of the uterus, examine with the finger to ensure that all is removed and apply carbolic acid freely. When the os is widely dilated and the seat of the growth low down, cauterisation with Paquelin's cautery would be even more effectual. *Clay* injected perchloride of iron after curetting, and without any bad result; the application of the caustic on a rod is safer.

Extirpation of the uterus offers the only hope of radical cure (*v. p. 463*).

SECTION VI.

AFFECTIONS OF THE VAGINA.

THESE we shall consider in the following order :—

CHAPTER XLIII. Atresia Vaginæ.

„ XLIV. Inflammations of the Vagina : Vaginismus : New Formations.

CHAPTER XLIII.

ATRESIA VAGINÆ.

LITERATURE.

Barnes—Diseases of Women, p. 219: London, 1818. *Breisky*—Die Krankheiten der Vagina: Stuttgart, 1879. *Delamay*—Étude sur le cloisonnement transversal du Vagin, etc.: Paris, 1877. *Dohrn*—Angeborene Atresia vaginalis: Archiv. für Gynäk., X. 3. *Duncan, J. Mattheus*—Case of so-called Imperforate Hymen: Lond. Obst. Tr., Vol. XXIV. *Emmet*—Principles and Practice of Gynecology, p. 202: London, 1880. Congenital Absence and Accidental Atresia of the Vagina, etc.: Trans. Am. Gyn. Soc., II., p. 437. *Puech, A.*—Des Atresis complexes des voies génitales de la Femme: Ann. de Gynécolog.: Paris, 1875. *Simpson, Sir J. Y.*—Diseases of Women, p. 256: Edin. 1872. *Simpson, A. R.*—Contributions to Obstetrics and Gynecology, p. 195: Edin. 1880. *Thomas*—Diseases of Women: London, 1882, p. 220.

Definition. *ATRESIA* (ἀ-ρρησις, non-perforation) has been already defined as occlusion of the genital tract where the obstruction is complete and leads to accumulation of menstrual blood or mucous secretion. This occurs at three places—the *hymen*, the *vagina*, and the *cervix uteri*. Atresia of the *cervix* has been already described (*v.* Chap. XXIV). Accumulation of blood in one half of a *septate uterus* or *vagina* will be considered by itself at the end of this Chapter.

PATHOLOGY.

1. *ATRESIA HYMENALIS*.—The structure of the normal hymen has been already described (page 6). In atresia hymenalis it forms a continuous membrane, is thicker and of an almost cartilaginous toughness; this explains the rarity of spontaneous cure by rupture of the membrane. This condition is produced by the occurrence of inflammatory adhesion of the folds after their formation, that is after the nineteenth week of foetal life. When the vagina is distended with menstrual blood, the hymen bulges forwards. As the menstrual blood accumulates, the vagina distends so as to form a tense membranous-walled sac nearly filling the pelvis, and with a smaller firmer body (the undilated uterus) rising from its upper surface (*v.* fig. 300). If the tension be not relieved, the cervix next becomes dilated and may rupture. Finally the uterus itself becomes opened out, though this does not occur till late.

During this period accumulations of blood may take place in the Fallopian tubes in the form of diverticula, usually situated towards the fimbriated end (figs. 298 and 299). These are not produced, as we should suppose, by a simple reflux of the blood from the distended uterus into the tubes but by hæmorrhage from the mucous membrane of the tubes themselves (*Schroeder*); the uterine end of the Fallopian tube is sometimes undilated or even entirely closed. Blood may escape gradually from the fimbriated end of the tube, and set up a localised peritonitis



FIG. 298.

ATRESIA VAGINÆ, SEEN FROM BEHIND. Thickness of obstruction (through which a probe is passed) 3-4 mm.; of vaginal wall below atresia 2-3 mm. above it (at x) 6 mm. Dilatation of the body of the uterus is small compared with the common cavity formed by cervix and upper portion of vagina. Left Fallopian tube markedly dilated, with no distinct flexion on it, and changed at its free end into a thin-walled blood sac which had burst. Right tube undilated (*Dreisky*).

matting down the tube and uterus; a hæmatocele is sometimes thus produced.

2. ATRESIA VAGINALIS. The *thickness of the obstruction* varies in different cases, according to the extent of the original obliteration and the thinning produced by the pressure from above. The *dilatation of the vagina* above the obstruction is remarkable; it may form a tumour filling the pelvis, pressing on the bladder and rectum, and raising the uterus above the brim; the walls become *hypertrophied* as is well seen in the

preparation represented in fig. 298, taken from a patient who died on the same day as the operation for atresia was performed.

Seat of
Obstruc-
tion.

The *seat of the obstruction* is most frequently in the *lower third* of the vagina. This condition may be mistaken for imperforate hymen; as the wall of the sac, bulging through the hymeneal orifice, becomes adherent to the hymen which appears as a mere fringe on the bulging membrane. There is not, however, the same distension of the vulvar orifice and

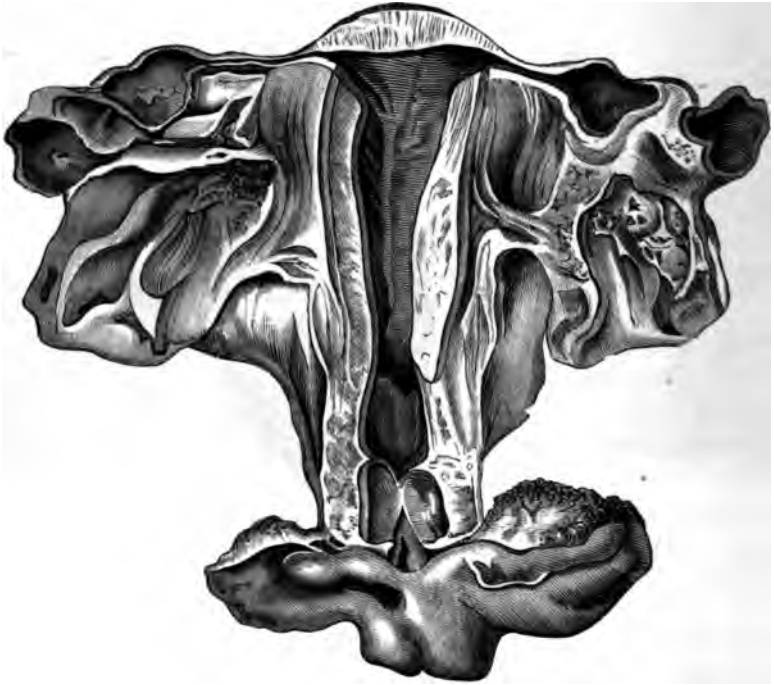

FIG. 299.

CASE OF DOUBLE ATRESIA. The lower affects the hymen and was *acquired*; above this was a cavity one inch long which contained purulent debris: the upper obstruction was one inch thick and was *congenital*; above it is the dilated uterus and cervix. The Fallopian tubes contain blood-sacs with small rents in their walls (*Breisky*, case reported by Steiner).

perineum as in atresia hymenalis. *Atresia of the whole vagina* is usually associated with imperfect development of the uterus (*Breisky*).

Atresia may exist at more than one point in the vagina. The specimen represented in fig. 299 illustrates this. It has this further interest that the lower atresia—at the vaginal orifice—was *acquired*, the result of a fall on a block of wood when the patient was two years old; the upper atresia was *congenital*. The accumulation of menstrual blood in

the upper sac called for operative interference when the patient was seventeen years of age. The lower sac contained purulent matter. On the fifteenth day after the operation, death occurred from septic peritonitis.

The character of the *retained menstrual blood* is peculiar. It is of a brownish chocolate-red colour, of a thick treacle-like consistence, and contains no coagula. Microscopically, it shows shrivelled red blood-corpuses, flat epithelial cells, mucous corpuscles, extravasated blood-pigment, and granular debris. The mucus prevents coagulation; part of the fluid portion is probably reabsorbed, since the quantity removed is less than the sum of what we should expect from the successive periods passed (*Puech*).

ETIOLOGY.

1. Atresia may be *congenital*, due to non-development of a part of the canal or its subsequent closure during fœtal life. Congenital
Atresia.

Atresia hymenalis implies that the hymeneal folds were developed (at the nineteenth week) but afterwards became blended into a continuous membrane.

Atresia of the vagina behind the hymen is, according to Dohrn, due to the fact that (at the eighteenth week of fœtal life) the walls of the genital canal become closely approximated behind the site of the hymen, so that closure of the vagina is especially favoured in that part.

Atresia of the middle or upper third implies the development of the ducts and their coalescence into a vagina, with a subsequent occlusion due perhaps to inflammation (*Breisky*).

Complete absence of the vagina or its representation by a fibrous cord is due to the non-development of the ducts of Müller; *absence of the lower third* is occasioned by the non-extension of the ducts downwards so as to open into the cloaca.

2. Atresia is also *acquired*; that is, it arises during life. The most important causes which produce this condition are the following:— Acquired
Atresia.

Sloughing and subsequent cicatrisation after labour;

Sloughing from impaired vitality in typhus, scarlet-fever, small-pox, and cholera;

Cicatrisation after injuries received in childhood;

Superficial inflammation of the mucous membrane, leading to adhesion of apposed surfaces.

The commonest form of congenital atresia is due to imperforate hymen;

of acquired, is due to cicatrisation of the upper part of the vagina and cervix after labour.

SYMPTOMS.

As congenital atresia is productive of bad results only in so far as it impedes the menstrual flow, symptoms do not arise till puberty. Should menstruation not take place at puberty, the condition may not attract attention till the patient enters married life. Cases are however on record in which the accumulation of mucus has called for operative interference even in childhood.

Symptoms
arise at
Puberty.

At puberty the patient experiences menstrual molimina without the appearance of a discharge. As the vaginal sac distends, pain is felt in the pelvis at first only at the periods and then more continuously. With this there is also constitutional disturbance. The periods of suffering become more protracted, the intervals of relief shorter. When the dilated vagina presses on the bladder and rectum, it causes difficulty in micturition and defæcation. The abdomen swells and this, with the amenorrhœa, causes suspicion of pregnancy which is sometimes the occasion for seeking advice. If the case is left to itself it terminates fatally through rupture of the uterus or cervix (usually the latter) or of a blood sac in the Fallopian tube, or through a simple or septic peritonitis independently of rupture. In some cases, the obstructing membrane has given way by rupturing (in acquired atresia) or sloughing (in the congenital form). But even this is not a favourable termination, as the risks consequent on operative interference are still more likely to ensue when the hymen ruptures of itself.

DIAGNOSIS.

The importance of physical diagnosis will be evident from the following case. "A. B., aet. 16, unmarried, has for twelve months suffered from pain in the pelvis and back, with occasional acute exacerbations accompanied by nausea and vomiting. She has been treated for inflammation; and mercurial ointment had been applied to a swelling which had appeared in the left groin, on the supposition that it was an enlarged gland." Examination per rectum showed a condition similar to that seen at fig. 301; the swelling in the left groin was the elevated uterus.

The practitioner will often ask himself whether a vaginal examination is necessary. On the patient's returning several times and there being nothing in the constitutional state (phthisis, chlorosis) to explain the

amenorrhœa, tell the friends that there is no apparent cause for the non-appearance of menstruation except on the supposition of a mechanical obstruction to its outflow. If there be pain in the pelvis and marked constitutional disturbance, the reasons for demanding an immediate examination will be evident. The conditions found in the various forms of atresia will be easily understood by studying figs. 300 to 303. The external genitals are first examined; a wide urethral orifice may be mistaken at first glance for the vagina, as in *atresia hymenalis* the urethral orifice is more patulous than it is normally (*Oldham*); the hymen is seen bulging forwards at the ostium vaginæ. The finger is passed into the rectum and feels that the anterior wall is made to bulge by a tense elastic sac.

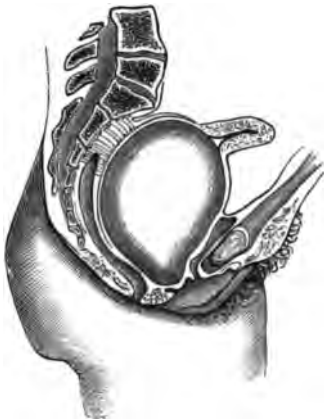

FIG. 300.
ATRESIA HYMENALIS (*Schroeder*).

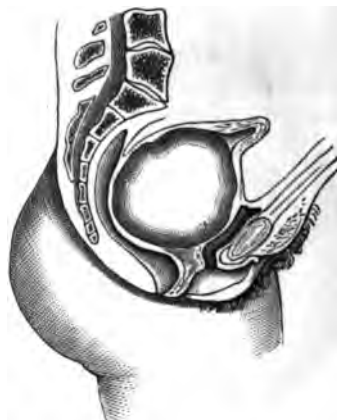

FIG. 301.
ATRESIA VAGINÆ—lower third (*Schroeder*).

On bimanual (recto-abdominal) examination, this sac is felt to be equally distended and to fill the pelvis; it may extend into the abdomen as far as the umbilicus. The feeling of the sac is quite characteristic and is like that of a tense india-rubber ball; on its upper surface, the uterus is felt as a small firmer tumour.

In *atresia vaginæ* the condition is the same, except that the hymen does not bulge and that the sac does not extend so low down.

Atresia of the cervix (figs. 302, 303) might be mistaken for early pregnancy; as the amenorrhœa and the distended uterus are present in both cases. But the condition of the cervix, the form of the uterus, and specially the characteristic tense feeling of the tumour, enable us to distinguish it from a pregnant uterus. Malignant tumours (sarcomata)

Diagnosis
from
Pregnancy.
from
Sarcoma.

have a similar elastic consistence, but with them we should not have amenorrhœa.

It is not in all cases easy to say whether the atresia be congenital or acquired. The existence of other malformations would favour the former view, of cicatrices beside the obstruction the latter. There will also be a greater thickness of tissue felt between the urethra and rectum in the acquired form, corresponding to the obliterated vaginal canal.

Estima-
tion of
extent of
Atresia.

In atresia vaginæ it is important to estimate the distance to which the atresia extends, so that we may know how much tissue we must cut through to reach the sac or the cervix uteri. This is best done by passing the index finger into the rectum till the tip is on the place where

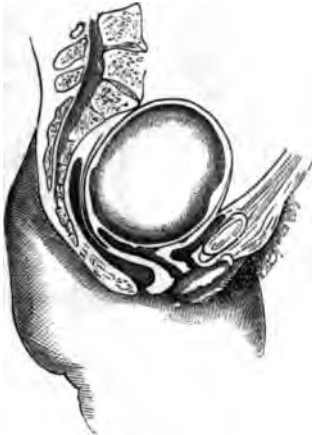

FIG. 302.
ATRESIA OF CERVIX AT OS EXTERNUM
(Schroeder).

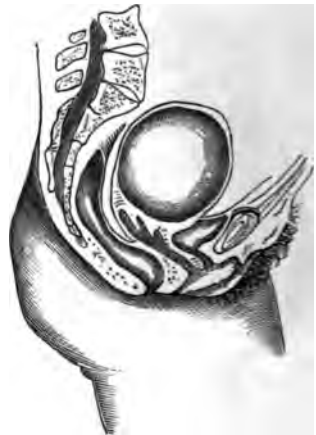

FIG. 303.
ATRESIA OF THE CERVIX AT OS INTERNUM
(Schroeder).

the bulging of the sac begins or where the projection of the cervix is felt; the thumb is at the same time passed into the ostium vaginæ till it reaches the obstructing membrane; the thickness of the latter can thus be estimated.

PROGNOSIS.

If menstrual blood be accumulating, the prognosis is always grave. In atresia of the hymen the prospect of cure by operative treatment is more hopeful than in congenital atresia of the vagina. In acquired atresia of the vagina, if the obstruction be removable, the prognosis is favourable. The unfavourable cases are those in which the vagina is partially or not at all developed; the prognosis as to curability by

operation depends on the thickness of the tissue between the urethra and the rectum, which determines the possibility of opening up a vagina.

When menstrual blood has accumulated, while explaining to the patient's friends the necessity of immediate operative treatment, we should inform them also of the dangers attendant on the operation—the immediate danger of rupture of a blood sac in the Fallopian tube, the more remote of simple or septic peritonitis.

TREATMENT.

The treatment consists in the formation of a channel to allow the menstrual blood to escape; in the case of imperforate hymen this is easily done by incising the membrane, but in atresia vaginæ we have to construct a new vaginal canal. Two dangers associated with this operation must be kept in view. *First*, too rapid collapse of the sac may lead to rupture of the Fallopian tubes or of vascular adhesions round the uterus. This rupture may be brought about in the following way, as has been shown by post-mortem examination. The Fallopian tube has been previously bound down to the side wall of the pelvis by adhesions; when the sac is opened into, the uterus necessarily follows its retreating wall and, if this retreat takes place rapidly, the tube is exposed suddenly to a strain which ruptures it; death results from hæmorrhage or peritonitis. To prevent this accident, the operator should allow the contents of the sac to escape slowly and should on no account apply pressure from above to hasten the process. *Second*, the operation is frequently followed by septicæmia. To prevent this, anti-septics should be used. Listerism cannot be carried out here; but by washing out the sac carefully with carbolised water, preventing the entrance of air, and allowing free drainage when fluid collects, we greatly diminish this risk.

A third danger, which follows some time after the operation, is the contraction of the new canal which, unless specially guarded against, may lead to its obliteration. Emmet expresses this well when he says "the surface of the canal is essentially a cicatricial one, and will consequently contract to a greater or less extent." To diminish the liability to contraction, he recommends that the tissues be torn with the finger nail or broken up with the scissors rather than divided with the knife; the raw surface is made to heal upon a glass plug.

We shall describe shortly the operations for (1) imperforate hymen, (2) atresia of the vagina, (3) atresia of the cervix.

Operation
for Imperforate
Hymen.

1. *Imperforate Hymen.* This operation, though apparently simple, should never be performed in the consulting room but always at the patient's house or in hospital. The time chosen should be between two menstrual periods which are indicated by menstrual molimina. The hymen is punctured with a small trocar which has been rendered thoroughly clean and aseptic beforehand. The fluid is allowed to escape slowly. After it has ceased to flow, the opening in the hymen is enlarged with a knife. This incision is made in the form of a cross, or the membrane is pinched up with forceps and an elliptical portion cut out. A. R. Simpson recommends that the opening in the hymen be made with the cautery, which prevents septic absorption by the wound. We can dispense with the trocar if we take care to make at first only a small opening, which can afterwards be enlarged. A stream of warm carbolised water is now made to flow gently into the cavity; the opening should be large enough to permit the fluid to flow outwards at the same time, so that the sac may be washed out without being subjected to any pressure. A plug of lint soaked in carbolised oil is placed in the hymeneal orifice, and a larger pad over the vulva. The patient keeps her bed for ten days after the operation. If there be a rise of temperature or other indication of septic inflammation, the vagina should be again washed out.

Operation
for Atresia
Vaginae.

2. *Atresia of the Vagina.* The patient is placed in the lithotomy posture, and the labia are retracted by the fingers of the assistants who hold the thighs. The sound is passed into the previously emptied bladder; it is then held by an assistant in such a way that the urethra and bladder are drawn well upwards towards the pubis. The index finger (with, if necessary, the second) of the left hand is introduced into the rectum and the thickness of tissue between the finger and the sound, as well as the position of the distended sac above, carefully ascertained: the finger is kept in the rectum during the operation, both to hook that structure backwards so as to prevent its being cut into and to guide in tearing up the septum. Should the operator wish to have both his hands free to use instruments, an assistant can pass the finger into the rectum. The operator now makes with a knife a transverse incision over the hymen, or through the skin between the anus and the urethra. When the sac is reached, it is punctured and washed out with the same precautions as in the operation for imperforate hymen; it is then carefully and gently packed with strips of lint soaked in carbolised oil. These are taken out on the following day, but a tightly fitting plug is left in the newly

formed portion of the vagina to prevent its contraction ; after three or four days, a perforated glass plug (fig. 304) is passed in to keep the new canal dilated. The plugs are made of various thicknesses, and have a rim at the external end to prevent their being pushed in too far. The plug must not be so long as to press on the roof of the vagina, and should be of such a thickness that, while it can be easily slipped out and in by the wearer, it stretches the new canal ; it is kept in position by tapes which are fastened to the rim and, before and behind, to an abdominal band. A pessary can be employed subsequently ; some instrument may have to be worn constantly for a year or more, and where there is continued tendency to contraction, for a short period daily during many years.

This operation has been performed even when there has been no accumulation of menstrual blood. The indications for operating are thus

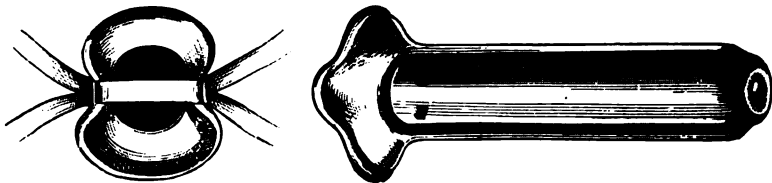


FIG. 304.

PERFORATED GLASS PLUG TO BE USED AFTER OPERATION FOR ATRESIA VAGINÆ. The left hand figure shows the external end of the tube with the tapes attached.

given by Thomas : “ It should be resorted to (*a*) if menstrual blood be imprisoned ; (*b*) if a uterus can be distinctly discovered and the patient be suffering from absence of menstruation ; (*c*) if the necessity for sexual intercourse be imperative.” Cases have been recorded in which the formation of a vaginal canal has led to the establishment of menstruation when it was formerly absent, to the development of the uterus and ovaries where these were rudimentary (?), or to an improvement in the general health of the patient although there was no indication of further development in the rudimentary uterus and ovaries.

More difficulty is experienced in operating where there is no accumulation of menstrual blood and the vagina is entirely absent or represented by a fibrous cord. In such a case, there is not the same necessity for surgical interference unless it be to satisfy the claims of married life. If the uterus and ovaries be well developed and the patient be anxious to have her condition remedied, the operation is justifiable. Here we have

not the distended sac as a guide to the point on which we are to cut down. The cervix, of which the position should be ascertained by a combined recto-abdominal examination, should be fixed as far as possible by an assistant's making firm pressure from above upon the uterus; there is no danger in such pressure if there be no accumulation of menstrual blood. The mode of procedure is the same as that just described.

Operation
for Atresia
Cervicis.

3. *Atresia of the cervix.* Usually the obstruction is so slight that the forcible passage of the sound overcomes it. Should the obstruction resist all efforts to pass the sound we require to use the knife to open the canal. If the uterus be much distended with menstrual blood, it is safer to empty it first with the aspirator-needle passed through one of the fornices; the emptying should be effected slowly and, if the distension be considerable, at more than one sitting; rapid emptying is apt to set up uterine contractions which may produce rupture of a dilated Fallopian




FIG. 305.

BREISKY'S FORCEPS, TUBE, AND NOZZLE FOR OPERATING IN ATRESIA OF THE CERVIX (*Breisky*).

tube. To open up the cervical canal, the following method is adopted by Thomas. The cervix is steadied with a tenaculum. A long exploring needle is passed along the line of the cervical canal into the uterine cavity, the sense of resistance overcome and the escape of a drop of blood indicating that the needle has reached it. A delicate tenotome is placed in the gutter of the needle and pushed upwards for the required distance. This process is repeated so as to divide the cervix on four sides in a radiate manner. The cavity of the uterus is washed out with a syringe, and a glass tube passed into the cervical canal to keep it open.

Breisky's
Instru-
ments.

Breisky has devised the instruments represented in fig. 305, to facilitate the washing out of the uterine sac in cases of extensive atresia of the vaginal canal and cervix with hæmatometra. The septum which separates the urethra and bladder from the rectum is split up so as to form a new vagina, and the cervix is thus exposed. To form the new cervical canal, Breisky employs a knife-edged trocar running in a canula. The canula

is pressed firmly against the cervix, and the knife is run out piercing through the cervix into the dilated uterus above; the canula is then run on the knife into the cavity, and the knife withdrawn. The contents of the sac escape through the canula. The forceps represented at fig. 305 are now passed in with one blade on each side of the canula. They are forcibly opened so as to distend the new canal still further, and they serve to keep it patulous while the canula is withdrawn and the tube represented at fig. 305 inserted in its place. This tube has two channels; into one of these a nozzle (fig. 305) fits and is employed to pass the stream of water into the sac, while the outflow takes place by the other.

4. *Atresia of one half of a septate uterus and vagina.* This form of

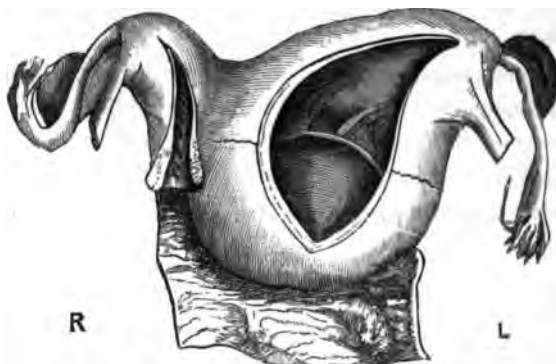


FIG. 306.

SEPTATE UTERUS; the right half is pervious, the left half has been distended with retained menstrual blood (*Schroeder*).

atresia has certain characteristics which distinguish it from the other forms described above.

The chief peculiarity is that it presents the phenomena of free menstruation + those of retained menstruation.

The pathological condition is apparent from fig. 306. Spontaneous rupture of the septum with escape of the retained fluid (in this case through the patulous uterus or vagina) occurs more frequently in this than in other forms of atresia; rupture of the Fallopian tube, with its fatal consequences, is also a more frequent occurrence (*Puech*). The spontaneous rupture of the septum does not usually occur at its lowest point; hence there is liability to accumulation of purulent matter in the pouch below the point of perforation, which is a source of septicæmia.

The symptoms are the same as in the other forms of atresia, but they are masked by the presence of a menstrual flow. This visible menstrea-

tion is often irregular, and profuse leucorrhœa (from the patulous cavity) is frequently present.

Physical examination shows a fluctuating tumour lying beside the uterus and alongside of the patulous vaginal canal. Sometimes it winds in a spiral manner round the latter.

The diagnosis is not difficult if the blind sac extend to the ostium vaginæ and be felt running alongside of the vaginal canal or winding round it. If, however, it be limited to the side of the uterus or only extend partially on to the vagina, it may easily be mistaken for other para-uterine tumours—most frequently for hæmatocele (*Schroeder*). To clear up the diagnosis and also as a step towards treatment, we puncture the sac with the aspiratory-needle. The character of the discharged blood will indicate the diagnosis.

The treatment consists in slowly but thoroughly evacuating the sac, washing out and establishing a permanent opening from it.

A *septate vagina* is sometimes found with a septate uterus (*v. fig. 143*) both halves being pervious so that there are no symptoms. Traces of a septate condition may persist as bands.

CHAPTER XLIV.

VAGINITIS: VAGINISMUS.

LITERATURE OF VAGINITIS.

Barnes—Diseases of Women, p. 865: London, 1878. *Hennig*—Der Katarrh der weiblichen Geschlechtsorgane. *Hildebrandt*—Monat. f. Geb., Bd. XXXII., S. 128. *Macdonald, Angus*—Edin. Med. Journ., June 1873. *Miller, A. G.*—Four and a Half Years' Experience in the Lock Hospital, Edinburgh: Edin. Med. Journ., 1883. *Noeggerath*—Latent Gonorrhœa in the Female Sex: Am. Gyn. Trans., Vol. I., p. 268. *Ruge*—Zeitschrift, f. Geb. u. Gyn., Bd. II., S. 29, and Bd. IV., S. 133. *Schroeder*—Die Krankheiten der weiblichen Geschlechtsorgane, S. 460: Leipzig, 1879. *Thomas*—Diseases of Women, p. 211: London, 1882. *Winckel*—Arch. f. Gyn., Bd. II., S. 406.

VAGINITIS.

SYNONYMS.—Colpitis (Gr. κόλπος, *a fold*); Elythrits (Gr. ἔλυτρον, *a sheath*).

NATURE AND VARIETIES.

Vaginitis is an inflammation of the mucous membrane of the vagina. The structure of this mucous membrane has been already described (*v. p.* 28). From its consisting of connective-tissue papillæ covered with several layers of squamous epithelium, it resembles the structure of the skin rather than that of a mucous membrane; exceedingly few mucous glands are present. Consequently, the inflammatory changes are more allied to those of the skin than to those of a mucous membrane (*Schroeder*).

According to etiology, vaginitis is either *simple* or *gonorrhœal*. Apart from the history, we cannot for certain distinguish between these (*v. Etiology*).

The clinical distinction between *acute* and *chronic* vaginitis is merely a question of degree.

Diphtheritic vaginitis will be referred to by itself.

Senile vaginitis is one of the physiological retrogressive processes occurring after the menopause.

PATHOLOGY.

Vaginitis occurs most frequently in the form of slight elevations of the mucous membrane, which produce a granular surface. These granulations, according to *Ruge*, consist of groups of papillæ infiltrated with Simple
Vaginitis.

small cells; these swell up and push before them the stratified squamous epithelium, the superficial layers of which are shed (fig. 307). When

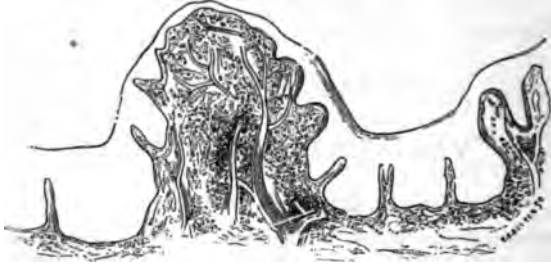

FIG. 307.

GRANULAR VAGINITIS—acute form (Schroeder).

the condition has existed some time, the surface becomes more equal through the thinning of the epithelial covering (fig. 308).

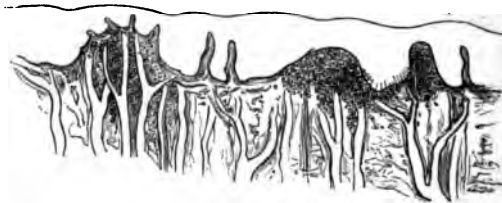


FIG. 308.

GRANULAR VAGINITIS—chronic form (Schroeder).

Emphyse-
matous
Vaginitis.

Associated with vaginitis in pregnancy, there is sometimes an emphysematous condition of the vaginal mucous membrane. Winckel has

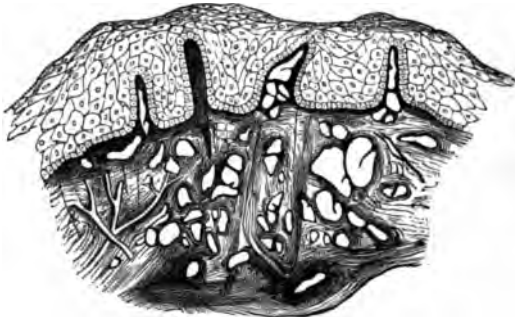


FIG. 309.

COLPITIS EMPHYSEMATOSA (Schroeder).

described cysts containing gas and fluid; according to Ruge, the air is present in spaces among the cellular tissue (fig. 309).

The cicatricial contraction of the vagina observed after the menopause, is due to a senile vaginitis. The epithelium is shed in patches, and the raw surfaces thus produced adhere together (*Hildebrandt*). This process is similar to that which produces occlusion of the cervical canal after the menopause.

Diphtheritic vaginitis occurs either as localised patches or as an affection of the whole vagina. In the latter case, the mucous membrane may be so swollen that the finger scarcely reaches the cervix which also is found to be thickened and covered with the diphtheritic membrane.

ETIOLOGY.

The following are the most important causes :—

Gonorrhœal infection ;

Irritating discharges from the uterus ;

Injurious vaginal injections, badly-fitting pessaries or other causes which injure the vaginal mucous membrane ;

Exanthemata.

Gonorrhœal infection produces the most intractable form of vaginitis, which may extend over months or years. We have not space here to discuss the question whether there is a specific poison in the gonorrhœal discharge.

Irritating discharges from the uterus, as in endometritis, produce a secondary vaginitis which can only be treated by curing the affection. In carcinoma and vesico-vaginal fistulæ, vaginitis arises secondarily.

Among the causes which irritate or injure the vaginal mucous membrane, we mention injections of too hot or too cold water and of substances to produce abortion, badly-fitting pessaries, tampons or pieces of sponge which have been allowed to lie some days in the vagina. Vaginitis may also develop on a patient's entering married life, simply from awkwardness in sexual intercourse ; on being consulted about such cases, we must remember that *a simple vaginitis may produce most of the symptoms of one due to gonorrhœa.*

Diphtheritic inflammation occurs usually in the puerperal condition and that through bad hygiene. It has been observed in *typhus, small-pox, and cholera,* and also in some cases of gonorrhœa. Localised diphtheritic patches are seen in fistulæ, in carcinoma, and round badly fitting pessaries.

SYMPTOMS.

These are the following:—

A burning heat in the vagina ;

Pain in the floor of the pelvis ;

Frequent desire for micturition, with a scalding sensation while water is passing ;

Free muco-purulent leucorrhœa.

These symptoms are present both in simple vaginitis and that due to gonorrhœal discharge. In the latter case, the urinary symptoms are more pronounced ; there is a distinct period from which all the symptoms commenced, their duration is longer, and they resist treatment ; they are often complicated with those of enlarged inguinal glands, endometritis, cystitis, or pelvic peritonitis.

DIAGNOSIS.

On vaginal examination, the finger recognises the discharge which

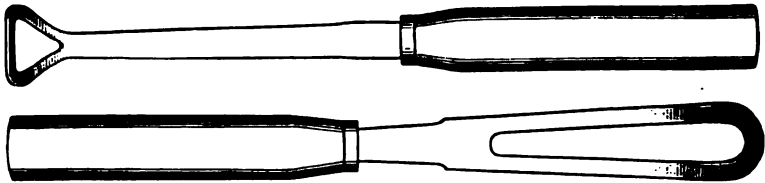


FIG. 309^a.

HENDERSON'S VAGINAL SPATULÆ (A. G. Miller).

escapes on separating the labia, and, in many cases, the rough condition of the mucous membrane.

The speculum shows that the mucous membrane is inflamed and covered with muco-purulent discharge ; the redness is usually in the form of patches but may be diffuse.

The appearance of the cervix must be noted to ascertain that the leucorrhœal discharge does not come from it ; the differentiation of discharge from the uterus and that from the vagina, is made as described on page 284.

Fig. 309^a shows two spatulæ used by Dr. Henderson of Shanghai in examining gonorrhœal and specific cases. They are exceedingly useful in separating the labia ; one blade can be employed as a Sims speculum, and pressure can be made along the anterior vaginal wall over the course of the urethra to ascertain if there is any urethritis.

The *differential diagnosis* between *simple and gonorrhœal vaginitis* is often very difficult. The history of a distinct source of infection is the only certain guide, and the ascertaining of this is a very delicate question. Apart from this, the following conditions point to a gonorrhœal origin: sudden development of vaginitis with urinary symptoms, in a patient who has had previously no marked leucorrhœal discharge; absence of any other cause to explain these; protracted duration of symptoms and resistance to treatment. However convinced the practitioner may be in his own mind that the vaginitis is of a specific nature, the social unhappiness caused by his expressing a decided opinion should deter him from giving it in cases where a cause is not admitted.

Pelvic abscesses discharging through the roof of the vagina have been mistaken for vaginitis (*Thomas*). Such a mistake will not arise when the Bimanual and other methods of examination are employed. We must not be satisfied with finding vaginitis; the whole routine examination of the pelvic organs must be made after the pressing symptoms have been relieved.

TREATMENT.

In *acute cases*, rest in bed is necessary. Hot water injections are given three or four times daily, the douche is much more convenient than the syringe; it leaves the hands free, requires less exposure of the patient, and keeps up a steady stream (*v. p. 139*). The stream should run for a quarter of an hour. A piece of gutta-percha tubing, weighted at one end and with a clip at the other, makes a handy douche; the weighted end is placed in a ewer of water above the level of the bed, the tube is coiled up in the water so as to be filled, the clamp is put on at the other end and the tube withdrawn; the siphon-action is started by the column of water in the tube and continues till the ewer is empty. The bowels are freely moved and then a morphia suppository is given. Complete rest from sexual activity is absolutely necessary.

In chronic cases or after the acute stage has passed off, astringents are added to the injections. The vaginal walls having been first thoroughly dried, a solution of nitrate of silver ($\mathfrak{z}\text{j}$ to $\mathfrak{z}\text{j}$ of water) is applied and a tampon of carbolised cotton soaked in glycerine introduced to keep the walls apart (*Thomas*).

Applications to the vagina are usually made by means of medicated pessaries. The following are those most frequently used¹:—

Medicated
Pessaries.

¹ As made up and supplied by Messrs. Duncan, Flockhart & Co.

Atropine	Sedative	1-20	grain.
Belladonna	do.	2	do. Alo. Ext.
Morphia	do.	$\frac{1}{2}$.	do.
Bismuth, Oxid	Cicatrising & Emollient	15	do.
Borax	do.	15	do.
Zinc, Oxid	do.	15	do.
Tannin	Astringent	10	do.
Alum	do.	15	do.
Acetate of Lead and Opium	do.	5	do. 2 grs. Opium
Gallic Acid	do.	10	do.
Persulphate of Iron	Hæmostatic	5	do.
Sulphate of Zinc (dried)	Caustic	10	do.
Iodide of Lead	Alterative & Resolvent	5	do.
Mercurial	do.	30	do. (<i>Ung. Hydrarg.</i>)
Carbolic Acid	Deodorant	5	do.

Tampons. Lawton's absorbent cotton¹ is the best material for vaginal tampons which are to be soaked in glycerine or other medicaments.

VAGINISMUS.

LITERATURE.—*Duncan, Matthews*—Diseases of Women, p. 142: Lond. 1883. *Hildebrandt*—Archiv. f. Gyn., Bd. III., S. 221. *Scanzoni*—Lehrbuch der Krankheiten der weiblichen Geschlechtsorgane, S. 704: Wien, 1875. *Simpson, Sir. J. F.*—Edin. Med. Journ., Dec. 1861; and Diseases of Women, p. 284: Edin., 1872. *Sims*—Cases of Vaginismus: Americ. Med. Times, 1862, Nos. 22 to 25. *Thomas*—Diseases of Women, p. 203: Lond. 1882. *Tilt*—The Lancet, Aug. 1874.

Nature. By vaginismus, we understand a painful reflex contraction of the muscular fibres surrounding the vaginal orifice—just as laryngismus is applied to the same condition in the larynx. Marion Sims first drew attention to this condition.

ETIOLOGY.

It is found in some patients of a nervous and sensitive temperament without there being any local source of irritation, but this is exceptional.

Usually one of the following conditions is present:—

An irritable spot in the fossa navicularis;

An inflamed hymen which has not been ruptured, or irritable carunculæ myrtiformes;

Fissures in the fourchette or round the vaginal orifice;

Small ulcers within the hymen;

Fissure of the anus;

Urethral caruncle.

SYMPTOMS AND DIAGNOSIS.

Dyspareunia and sterility are the leading symptoms.

¹ Sold in packets (2 oz.— $\frac{1}{2}$ lb.)

By *dyspareunia* (a term introduced by Barnes), we understand painful or difficult sexual intercourse; hence the conditions which produce vaginismus arise on the patient's entering married life. The suffering may be so great that medical advice is at once sought; more frequently, a sense of delicacy prevents this till the condition has existed some time.

In some cases there is a care-worn and anxious expression of countenance, in others a hysterical manner. As the ordinary vaginal examination is painful—the patient involuntarily drawing away as soon as the painful spot is touched—it is best to make inspection of the genitals first. Here we may see any of the conditions mentioned under Pathology. Sometimes no local cause is evident; but on carrying the finger into the vagina the reflex contraction of the muscle is felt.

Hildebrandt has shown that this muscular contraction is sometimes noticed in the upper part of the vagina, and is then due to spasm of the levator ani.

The possibility that the dyspareunia may be due to some local pathological condition at the roof of the vagina (prolapsed ovary or cellulitis) and not at the ostium, should be kept in mind.

The *prognosis* as to cure is good. From the distressing nature of the symptoms and the relief obtained by the means to be described, they prove very satisfactory cases for treatment.

TREATMENT.

First remove any cause of local irritation, as urethral caruncle or irritable carunculæ myrtiformes; in some cases it is necessary to clip away carefully the whole hymen. Divide the base of irritable fissures of the anus with the knife, or touch them with the actual cautery. Iodoform in powder or made into an ointment, is the best local application to allay irritation or favour healing. Its penetrating and disagreeable odour makes many patients object to it. This is diminished by keeping Tonquin beans in the powder, and by adding oil of eucalyptus or citronelle (10 m. to ʒi) to the ointment or pessary.

R. Iodoform.	gr. x.
Olei eucalypti	M. i.
Fiat pessarium.	Mitte tales xii.
<i>Sig.</i> As directed.	

After the cause has been removed, the ostium vaginæ must be dilated. This is best effected by making the patient wear a vaginal dilator night and morning, for an hour at a time; it may be made of wood or of glass, and should have a bulbous end about 1½" long. The conical form is

not good. The pain caused by the introduction passes off after a time. Dilators of gradually increasing size should be used.

If the dilator cannot be worn, we must have recourse to Sims' operation. In some cases, when the vaginismus is evidently due to the narrowness of the ostium and specially when a reflex contraction of the muscle is noted, this operation is done without previous use of the dilators.

Sims'
operation.

Sims' operation for vaginismus. We have already seen (p. 9) that the bulbo-cavernosi muscles embrace the ostium vaginae and form a kind of sphincter for it; their position is seen in fig. 7. To divide the superficial fibres of this muscle is the aim of the operation.

The patient being under chloroform, two fingers of the left hand are passed into the vagina so as to stretch the ostium. With an ordinary scalpel, an incision is made on each side of the fourchette; the incision is about 2 inches long, and extends from $\frac{1}{2}$ an inch above the ostium to the raphe of the perineum. The ostium is now thoroughly and firmly plugged with lint which is kept in place with a T-bandage; thorough plugging is essential as there is often smart hæmorrhage from the incisions. Next day the lint is removed and a glass dilator introduced, which must be worn for one or two hours night and morning during a period of several weeks.

Instead of dividing the sphincter with the knife, it may be forcibly stretched with the fingers till the muscular fibre is ruptured. This is done by passing the thumbs (*Tilt*) or several fingers (*Hegar*) of each hand into the ostium, and then forcibly separating them till we feel the muscular fibre give under the traction. The advantage of this method is that it is bloodless and there is no granulating wound left to heal.

With these local measures, we should always combine constitutional treatment. Exercise, fresh air and change of scene are beneficial. It is self-evident that complete rest to the sexual system must be strictly enjoined during any course of local treatment; this should be maintained for some time afterwards, which may be secured by recommending a few weeks' residence from home. Tonics (such as quinine, iron, and arsenic) are given as the case requires.

TUMOURS OF THE VAGINA.

Under tumours of the vagina we briefly describe the following:—

- Cysts,
- Fibroid tumours,

Carcinoma,
Sarcoma,

Tubercular and syphilitic ulceration do not call for special description.

CYSTS OF THE VAGINA.

LITERATURE. *Breisky*—Die Krankheiten der Vagina, S. 130: Stuttgart, 1879. *De Sinéty*—Manual de Gynécologie, p. 164: Paris, 1879. *Mundt*—Americ. Jour. of Obst., vol. X., p. 673. *Von Preuschen*—Virchow's Archiv., Bd. LXX., S. 3.

Pathology. They are situated most frequently in the anterior vaginal wall, and usually in the lower third but within the ostium. They are generally single, rarely have two or more been found together. They are lined with a single layer of cylindrical epithelium which contrasts with the many layers of squamous epithelium of the vaginal mucous membrane from which they lie separate (fig. 310). We have seen them

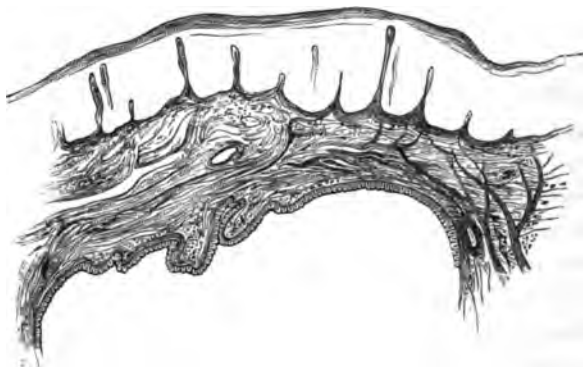


FIG. 310.

SECTION OF VAGINAL CYST (*Schroeder*). The cyst wall which is lined with a single layer of epithelium is separated by some tissue from the mucous membrane which is covered with many layers of squamous epithelium not detailed in the section.

of the size of a hen's egg. Their contents vary from a clear thin fluid to a gelatinous chocolate-coloured inspissated mucus.

Etiology. As there are hardly any mucous glands present in the vaginal mucous membrane, the mode of origin of these cysts is disputed. In some cases they can be traced to crypt-like depressions of the mucous membrane which become shut off (*Von Preuschen*). It has been suggested by Veit that they are due to persistence of the canals of Gärtner, an exceptional occurrence.

Symptoms. These are often nil; and such cysts readily escape observation, so that they may be more frequent than is supposed. When of large size, they produce bearing down pain with leucorrhœa and in some cases dyspareunia.

Diagnosis. Small cysts readily escape detection. When large, their smooth elastic surface and fluctuation make them easily recognised. They must not be confounded with cysts due to obstructed Bartholinian glands, which are situated on the labia minora or at the ostium. Careful examination will easily distinguish them from a pouching of the bladder or rectum.

Treatment. This consists in laying the cyst open and destroying its lining wall, which is best done by the cautery. Schroeder cuts out a portion of the cyst wall, and stitches the margins of the rest to the adjoining vaginal mucous membrane so that the cyst is taken up into the vagina; this does away with the granulating surface and subsequent cicatrization which accompany cauterisation. If the patient is past the menopause and the cyst gives no trouble, there is no occasion to interfere.

FIBROID TUMOURS OF THE VAGINA.

LITERATURE. *Breisky*—Die Krankheiten der Vagina, S. 139. *A. R. Simpson*—Fibroma Vaginae, Contributions to Obstetrics and Gynecology, p. 201: Edinburgh, 1880.

Pathology. Fibroid tumours rarely originate in the vagina; *Breisky* has collected only 37 cases out of their literature. Like fibroid tumours of the uterus, they consist chiefly of fibrous tissue with some unstripped muscular fibre; they are usually situated in the anterior wall, in 17 out of 27 cases (*A. R. Simpson*); they are pediculated (forming so-called fibrous polypi) or sessile.

Symptoms. These are produced only when the tumour is large. In the case described by *A. R. Simpson*, in which the tumour was the size of two fists, it interfered with micturition and the escape of the uterine discharges.

Diagnosis. This is easy, except in the case of large tumours when the pedicle is difficult to reach. The relation of the bladder should always be carefully ascertained by passage of the sound.

Treatment consists in division of the capsule and enucleation of the tumour when it is sessile, or ligature and division of the pedicle when it is pediculated.

CARCINOMA OF THE VAGINA.

LITERATURE. *Breisky*—Die Krankheiten der Vagina, Billroth's Handbuch, S. 151. *Bruckner*—Der primäre Scheidenkrebs und seine Behandlung, Zeitschrift für Geburtshilfe und Gynäk., B. VI., Hft. 1., S. 110. *Goodell*—Boston Gyn. Jour., vol. VI., p. 383. *Küstner*—Archiv. f. Gynäk., Bd. IX., S. 279. *Parry*—Amer. Jour. of Obstet., vol. V., p. 163: and Philad. Med. Jour., Feb. 1873. *Simpson, A. R.*—Contributions to Obstetrics and Gynecology, p. 205: Edinburgh, 1880.

Pathology. Primary carcinoma occurs very rarely in the vagina—in

14 out of 8287 cases (*Beigel*); in the paper cited above, Küstner has collected but 28 cases out of the whole literature. This is the more surprising when we remember how very frequently it affects the cervix. It occurs in two forms, either as a localised broad-based papillary swelling seated most frequently in the posterior wall or as a diffuse infiltration which often constricts the canal in a ring-like manner. The inguinal glands are generally enlarged by carcinomatous infiltration.

Symptoms and Diagnosis. As in carcinoma of the cervix, there is hæmorrhage and fœtid discharge; the pain is slight in the early stage. The diagnosis that there is *primary* carcinoma of the vagina is often doubtful, because it is difficult to ascertain the condition of the cervix and uterus; in the specimen represented at fig. 275, it was supposed to be primary until the post-mortem showed that it was secondary to carcinoma of the cervix. The examination per rectum is useful in these cases.

Treatment. This consists in the removal of as much as possible of the diseased tissue with the cautery, spoon, or knife. Bruckner recommends that, where possible, the wound produced by extirpation of the carcinomatous mass be closed by deeply placed sutures.

SARCOMA VAGINÆ.

LITERATURE. *Breisky*—Die Krankheiten der Vagina: Billroth's Handbuch, S. 150. *Man*—Amer. Jour. of Obst., vol. VIII., p. 541. *Meadows*—Lond. Obst. Trans., vol. X., p. 141. *Simpson, A. R.*—Contributions to Obstetrics and Gynecology, p. 204: Edin. 1880. *Smith*—Amer. Jour. of Obst., vol. III., p. 671. *Spiegelberg*—Arch. f. Gyn., Bd. IV., S. 348.

Sarcoma of the vagina has only recently been described, and is still rarer than sarcoma uteri. As in the uterus, it is either diffuse or in circumscribed nodules (*v. fig. 292*). The symptoms are the same as in sarcoma uteri; and the treatment consists in removal (more easily effected in the circumscribed form), which in a case reported by Spiegelberg effected a permanent cure.



SECTION VII.

AFFECTIONS OF THE VULVA AND PELVIC FLOOR.

CHAPTER XLV. The Vulva: Malformations; Inflammation; Tumours.

„ XLVI. Rupture of the Perineum and its Operative Treatment.

„ XLVII. Displacements of the Pelvic Floor: Prolapsus Uteri;

Enteroccele.

CHAPTER XLV.

THE VULVA: MALFORMATIONS; INFLAMMATION; TUMOURS.

LITERATURE.

- MALFORMATIONS.** *Hildebrandt*—Die Krankheiten der äusseren weiblichen Genitalien: Stuttgart, 1877, S. 2. *Meyer*—Virchow's Archiv., XI., p. 420. *Schroeder*—Die Krankheiten der weiblichen Geschlechtsorgane, S. 497: Leipzig, 1879. *Simpson, Sir J. Y.*—Hermaphroditism: Collected Works, vol. II., p. 407. *Tait, Lawson*—Am. Gyn. Trans., vol. I., p. 318.
- INFLAMMATION.** *Hildebrandt*—Die Krankheiten der äusseren weiblichen Genitalien, Billroth's Handbuch, S. 17 and 64. *Simpson, Sir J. Y.*—Diseases of Women, p. 286. *Thomas*—Diseases of Women, p. 122: London, 1880.
- TUMOURS.** *Hildebrandt*—Op. cit. Chap. VII., where the student will find the literature of the various forms of tumour fully given.

MALFORMATIONS.

Develop-
ment.

THESE are easily understood when we remember the normal development of the external organs of generation. 1. At the sixth week of foetal life, the *genital eminence* appears externally; at this period the rectum, allantois and ducts of Müller communicate with one another but not with the exterior (fig. 311). 2. At the tenth week, a depres-



FIG. 311.

R rectum continuous with *All* allantois (bladder) and *M* duct of Müller (vagina). *x* Depression of skin below genital prominence which grows inwards and forms vulva (*Schroeder*).



FIG. 312.

The depression has extended inwards and, becoming continuous with the rectum and allantois, formed the cloaca *cl* (*Schroeder*).

sion of the skin (known as the *genital cleft*) occurs; this extends inwards till it meets the conjoined allantois and rectum, and thus the cloaca is formed (fig. 312). 3. The tissue between the rectum and the allantois grows downwards, and divides the cloaca into an anterior part (the *uro-genital sinus*, into which the ducts of Müller open) and a posterior part (the anus); thus the *perineum* is formed (figs. 313 and 314). 4. The

uro-genital sinus contracts in its upper portion to form the urethra, while the lower part persists as the vestibule (fig. 315); the ducts of Müller coalesce to form the vagina (v. p. 71).

The parts round the vulva develop, therefore, as follows; the *clitoris* from the genital eminence, the *labia minora* from the margins of the genital cleft, the *vestibule* from the uro-genital sinus.

The following malformations have been described. 1. *Complete Malformations.* *atresia of the vulva* through the non-formation of the depression of the



FIG. 313.

The cloaca is becoming divided into uro-genital sinus *Su* and anus by the downward growth of the perineal septum. The ducts of Müller have united into the vagina *V* (Schroeder).



FIG. 314.

The perineum is completely formed (Schroeder).

skin (fig. 311); the allantois and rectum either communicate as in fig. 311 or have become separated. This condition has only been found in foetal monstrosities. 2. *Persistence of a cloaca* so that the rectum, vagina and urethra have a common orifice (fig. 312); such cases are sometimes spoken of as *atresia of the anus* but are really due to non-formation of the recto-vaginal septum. 3. *Persistence of the uro-genital sinus* into



FIG. 315.

The upper part of the uro-genital sinus has contracted into the urethra; the lower portion persists as the vestibule *Su* (Schroeder).

which the bladder opens directly as the urethra has not formed (fig. 314); in such cases the vulvar orifice is contracted and opens into a long narrow vestibule which, at its farther end, communicates with the bladder and vagina. This condition is sometimes described as *hypospadias*.

HERMAPHRODITISM.

For a detailed description of this condition with illustrative cases, the student should consult Sir J. Y. Simpson's exhaustive article on *Hermaphroditism* (Collected Works, Vol. II., p. 407).

Of *hermaphroditism* ('*Ερμῆς* and '*Ἀφροδίτη*) there are two varieties, true and spurious.

True
Herma-
phroditism.

By *true hermaphroditism*, we understand that from the Wolffian bodies both ovary and testicles have developed so that both forms of gland co-exist in the same individual. This is an extremely rare occurrence; when it has occurred, there is a tendency towards the better development of one form of organ (determining the sex) while the other is rudimentary. According to Hildebrandt (*loc. cit.*, S. 6), only two authentic cases of bilateral hermaphroditism (ovary and testicle present on each side) have been recorded; of unilateral hermaphroditism (ovary and testicle present on one side, the other side having only one form of

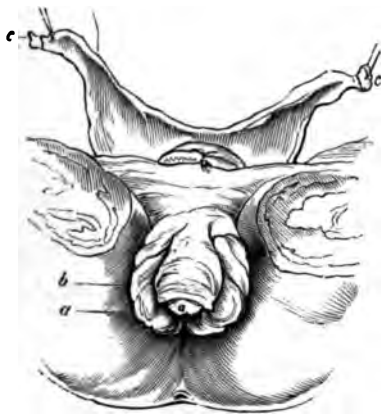


FIG. 316.

SPURIOUS HERMAPHRODITISM (*Sir J. Y. Simpson*).

Pelvis of a female infant in which the external organs simulated those of a male. *c* Uterus and appendages, *b* hypertrophied clitoris with a sulcus, *a* at its extremity, which ended blindly and did not communicate with the urethra.

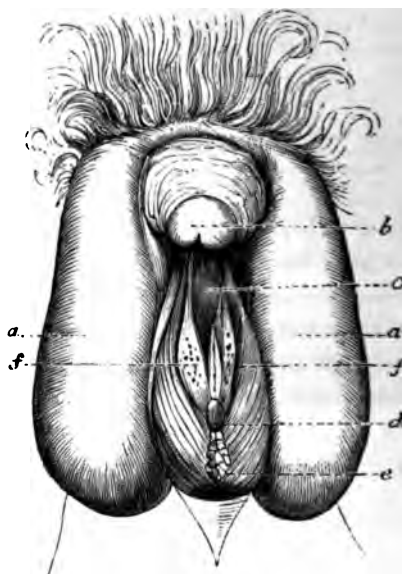


FIG. 317.

Case of hypospadias in the male, making the external organs simulate those of the female. *aa* Lobes of scrotum; *b* imperforate penis, $1\frac{1}{2}$ inches long; *c* perineal fissures $1\frac{1}{2}$ inches deep, lined with mucous membrane, at bottom of which the urethral orifice *d* is seen; *e* the split urethra, with openings *f* of glands beside it—supposed to be orifices of prostatic ducts, of Cowper's glands, and of seminal canals.

False
Herma-
phroditism.

gland), a case has been recorded by Bannon; lateral hermaphroditism (ovary on one side and testicle on the other) has been more frequently met with and cases, confirmed by microscopic examination, have been recorded by Berthold, Barkow, and Meyer.

By *false or pseudo-hermaphroditism*, is understood a malformation of

the external organs so that they simulate those of the opposite sex. This occurs in two forms. 1. The external organs in the female may simulate those of the male. This is due to a hypertrophy of the clitoris and its prepuce, with approximation of the labia majora (simulating a scrotum) and contraction or occlusion of the ostium vaginæ; in very rare cases is the clitoris perforated by the urethral canal. This condition is seen at fig. 316, which represents the pelvis and external organs of an infant christened as a boy; a post-mortem dissection showed that the sex was female.¹

2. The external organs in the male may simulate those of the female; the non-closure of the lower surface of the urethra and perineum, which constitutes hypospadias, produces an appearance resembling the external organs in the female. Numerous cases are on record in which the sex of males has been mistaken, even by medical experts, and the persons have entered married life as belonging to the female sex. The penis may be small and imperforate, the urethra opening at its base; the perineal fissure, lined by mucous membrane, may closely resemble the vagina; and the halves of the scrotum may appear like labia. This condition is seen at fig. 317: the case is reported by Otto;² the person lived in a state of wedlock with three husbands before the true sex was ascertained by medical examination.

Cases of epispadias, in which the urethra (through defect of the upper portion of the penis) is exposed along with a portion of the bladder, would only on hasty examination be mistaken for the external female organs. The exposed vesical mucous membrane with its skin margins resembles the vagina with the labia, but it is situated above the pubis; further, below the penis we find the normal scrotum and testicles. Epispadias mistaken for Herma-phroditism.

Diagnosis. In examining a case, proceed as follows. Palpate the supposed labia carefully to ascertain whether testicles are present in them; the possibility of hernia of the ovaries into the labia and of non-descent of the testicle into the scrotum, must be kept in view. 2. Examine per rectum for traces of uterus or ovaries. 3. After puberty watch for the menstrual molimina or hæmorrhage in the female, and for development of sexual powers in the male. 4. Note secondary sexual characters: development of breasts, appearance of face, tone of voice, and inclination towards one or other sex.

Hermaphroditism, like malformations in general, lies beyond treatment.

¹ Ramsbotham—*Medical Gazette*, XIII., p. 184.

² Sir J. Y. Simpson—*Op. cit.* p. 427.

INFLAMMATION OF THE VULVA (VULVITIS).

Pathology. In the acute stage, the mucous membrane round the ostium vaginæ and urethra is red, swollen and painful. Sometimes the mucous glands are obstructed, and a form of acne develops; the glands of Bartholini may inflame and suppurate, producing an abscess about the size of a pigeon's egg; the sebaceous glands at the roots of the hair on the labia majora are sometimes specially affected, producing the "Folliculite vulvaire" of Huguier. In the chronic stage, there is abundant secretion of creamy purulent matter; when due to gonorrhœa, condylomata form round the vaginal orifice.

Abscess of Bartholini's gland.

Etiology. It is often secondary to vaginitis, and accompanies urinary fistula and carcinoma. Want of cleanliness and protracted exercise, specially in hot weather, produce it and that most readily in patients with much adipose tissue. It is sometimes occasioned by awkward coitus and by masturbation. In children, it is not uncommon; it is important to remember this, as the inflamed appearance of the vulva and the profuse discharge make the parents suspect that the child has been violated and has contracted specific disease. It is caused by irritation of urine, want of cleanliness, and the strumous diathesis; sometimes it takes an epidemic form in the children of a family or district (*Sir J. Y. Simpson*).

The Symptoms and Physical Signs will be apparent from what has been said under Pathology.

Treatment. Strict attention to cleanliness must be enjoined; frequent bathing with warm water and the application of hot linseed poultices will ease pain. In children, the pain in micturition is relieved by its being done while in a warm bath. Sedative lotions such as acetate of lead and opium may be required:—

R	Tinct. opii.	ʒss.	
	Plumbi acetat.	ʒi.	
	Aquam ad	ʒvi.	M.

In chronic cases, frequent washing with 2 per cent. sol. of carbolic or with astringent lotion is necessary. In abscess of the glands, the pus is evacuated through the gland ducts on pressure, or by free incision.

PRURITUS VULVÆ.

Definition. An irritable condition of the external genitals producing excessive itchiness.

Pathology. The irritable region is at the upper convergent angle of

the labia majora at the mons veneris ; it may extend from that over the vestibule and the vaginal orifice, and sometimes over the mons veneris on to the abdomen. The pathological changes in the skin which produce this irritability are not known, because the cases are not seen in an early stage. By the time that the irritation has become so unbearable that advice is sought, the skin is inflamed and excoriated by continued scratching which masks its original condition.

Etiology. Any irritating discharges from the vagina as in carcinoma, and even simple leucorrhœa as from senile vaginitis, may produce it. It occurs in diabetes—due to the irritation of the sugar in the urine (*Friedreich*)—and in affections of the kidney and bladder, just as similar conditions produce irritation of the penis in man. In children, it accompanies vulvitis and has been traced to the passing of the oxyuris vermicularis from the anus to the vulva. It is also caused by whatever produces congestion of the labia—hence its occurrence at the menstrual period and in early pregnancy—and by irritable skin affections as herpes, eczema, and the so-called eczema marginatum which is really parasitic.

Symptoms. The irritation is not continuous but recurs periodically. In some cases, it appears only after taking a long walk or after getting warm in bed ; sometimes it is most marked before the menstrual period. The irritability is slight at first but becomes aggravated by scratching. To obtain this temporary relief, the patient gradually avoids company and this, along with the constant irritation, has led in some cases to nervous depression and melancholia ; sometimes the practice of masturbation is learned at the same time, and the consequent nervous symptoms gravely complicate the case.

Diagnosis. As the most hopeful cases for treatment are those in which a distinct removable cause is found, a thorough examination is necessary : (1) Carefully inspect the external genitals for irritating skin eruptions, and examine scrapings of the affected parts microscopically for parasites ; (2) expose the vagina and cervix thoroughly with the speculum to ascertain whether there is irritating leucorrhœa, the plugging of the vagina with cotton wadding to check discharge from the vagina or cervix will help us to exclude this (*Thomas*) ; (3) test the urine for albumen and sugar ; (4) examine per rectum for any source of irritation there.

Treatment. We must first remove the cause. When parasites are present, the mercurial or sulphur ointment is required ; with vaginal or cervical catarrh, a tampon of wadding and glycerine (with acetate of lead ʒii to ʒi) in the vagina will check the irritating discharge. Attention.

512 AFFECTIONS OF VULVA AND PELVIC FLOOR.

to diet (which should consist largely of vegetables) and to the regular action of the bowels is necessary; when the gouty diathesis (with which pruritus is often associated in old patients) is present, lithia water is useful. It is a safe rule to forbid all stimulants. Frequent vaginal injections or sponging with warm water, followed by the application of boracic ointment or bismuth, will relieve mild cases; in more severe, the patient should have, several times a day, a warm sitz-bath combined with the douche; after this, iodoform is dusted over the vestibule or, if the patient is recumbent, lint soaked in acetate of lead and opium lotion is laid between the separated labia. In some cases, chloroform and almond oil have given relief (*Scanzoni*).

R Chloroformi ℥ii.
Olei amygdalae ℥ii. M.
Sig. Apply externally as directed.

Preparations of mercury give benefit in other cases.

R Hydrargyri perchloridi ℥ss.
Aqua. ℥vi. M.
Sig. Apply externally as directed.

Schroeder has seen very good results from the application of carbolic acid of varying strength—1 to 40 up to 1 to 10. Where milder measures have failed, solid nitrate of silver well rubbed into the irritated parts and followed by cold-water dressing has given relief. In parasitic cases a lotion of equal parts of sulphurous acid and glycerine may be used. To procure rest at night, morphia and chloral may be necessary; Hildebrandt has found tinct. cannabis indicæ (m. 10-20) even more effective than these.

ERUPTIONS ON THE VULVA.

The skin round the vulvar orifice may be affected with any of the eruptions found on other parts of the body. Of these the most important are erysipelas, eczema, prurigo, herpes, acne. These eruptions have the same character as when they occur in other situations and their treatment is the same. Condylomata and mucous patches may be found.

Hebra's plates of Skin Diseases illustrate these conditions very well. See also a recent paper in the *Annales de Dermatologie et Syphilographie* for April 1882, by Gougenheim and Soyer.

TUMOURS OF THE VULVA.

Under these we shall notice briefly—

Cysts of the Bartholinian glands,
Elephantiasis,

Neuromata,
 Fibroma,
 Lipoma,
 Carcinoma.

This is also the most convenient place to refer to

Pudendal hernia,
 Varix, hæmatoma and hæmorrhage.

Cysts of the Bartholinian glands. The Bartholinian or vulvo-vaginal Cysts and Abscesses of Bartholini's glands, which are the analogue of Cowper's glands in the male, are situated at each side of the ostium vaginæ (see fig. 7); their ducts (about 2 c.m. long and wide enough to admit a fine probe) run upwards to about

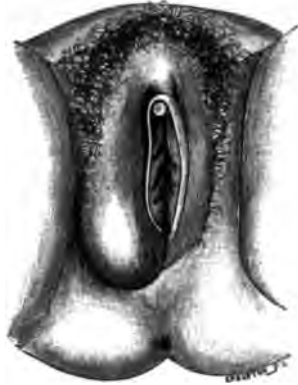

FIG. 318.

ABSCESS OF THE BARTHOLINIAN GLAND (*Hugnier*).

the middle of the ostium vaginæ, where their mouths may be seen in front of the hymen.

A cyst may form by dilatation of the *ducts* or of the *glands* themselves. When due to distension of the duct, it has at first an elongated oval form; when the gland itself is affected, there may be multiple cysts or a lobulated swelling. The contents are thick mucus which is clear or of a brownish tinge. Suppuration may occur and abscess form (*v.* fig. 318).

The symptoms are due to the discomfort of the swelling, which is most felt on walking. The diagnosis is easy, from the position of the swelling and its fluctuating character; when it has developed during the puerperium, we must differentiate it from hæmatoma (which after a time becomes firm from coagulation) and inflammation after injury.

The treatment consists in complete evacuation of the cyst and destruction of its walls. It is not sufficient to open it and allow the fluid to escape; we must cut out a portion of the wall and then plug the cyst with carbolised lint. By far the best instrument is the thermo-cautery: we first puncture the cyst with it; when the fluid has escaped, we pick up the outer cyst wall with forceps and lay it fairly open with the cautery; we then cauterise the inner wall also. A piece of carbolised lint is laid over the wound.

Elephantiasis.

Elephantiasis. This is a common condition in tropical countries, but is comparatively rare in Europe and America although a minor degree of it is occasionally met with.

The pathological changes consist in a dilatation of the lymphatic spaces and ducts, with secondary formation of connective tissue and thickening of the layers of the cutis vera; sometimes the papillæ are specially enlarged, producing swellings which resemble condylomata in form. The labia majora are most frequently affected, next in frequency the clitoris; more rarely are the labia minora hypertrophied (*Mayer*).

Period of Development.

It develops, according to Mayer, most frequently at ages of from 20 to 30 years—that is in the period of sexual activity. It has been traced to direct injury, but the most fruitful cause of minor degrees of hypertrophy is syphilis.

The symptoms are due to the weight and discomfort of the tumour which may reach to the knees.

The treatment of the larger growths is removal with the thermo-cautery.

Neuromata.

Neuromata, or exquisitely sensitive red papules which resemble a urethral caruncle, have been described by Sir J. Y. Simpson (see fig. 355); their occurrence, except at the urethral orifice, is extremely rare.

Fibromata.

Fibromata. These spring from the labia majora, resemble in structure fibroid tumours of the uterus and, like them, are embedded in cellular tissue or hang down by a pedicle.

Lipomata.

Lipomata may arise from the fatty tissue of the mons veneris or labia majora. Emmet¹ describes a case in which the tumour hung down to the patient's knees and was supported in a bag round the waist; Stiegele² removed one which weighed 10 lbs.

Carcinoma.

Carcinoma of the vulva is rare in comparison with its frequency in the uterus. The most frequent form is the cancrioid (*West*). It begins,

¹ Op. cit., p. 601.

² *Zeits. f. Chir. u. Geb.*, Bd. IX., S. 243.

usually on the inner surface of the labia majora, as small round nodules which elevate the skin; they may remain for a long time unnoticed, as their growth is at first slow and painless (*Hildebrandt*). After ulceration they spread more rapidly, and extend forwards and backwards but rarely into the vagina (*Mayer*). The inguinal glands are early involved.

Complete removal before the glands are affected, is the only treatment. As the growth is accessible, there seems a prospect of cure; during the last few years cases are reported by *Schroeder* and others of extirpation without recurrence, but the time elapsed is too short to justify definite conclusions.

Pudental hernia. This corresponds with scrotal hernia in the male. Pudental
Hernia. The round ligaments are the analogues of the spermatic cord, and after emerging from the inguinal canal pass into the substance of the labia majora which correspond to the scrotum; if the process of peritoneum surrounding the round ligaments—known as the canal of *Nuck*—does not become obliterated at birth, it forms a track for the hernia.

Though it be very rare, the possibility of a hernia must be kept in mind on examining a tumour of the labia; the crackling feeling, the impulse communicated on coughing, and disappearance on taxis, indicate hernia. The serious consequences of cutting into such a hernia by mistake for an abscess, are self-evident.

Varix. The plexus of veins which forms the erectile tissue of the Varix. bulbi vaginæ has been already referred to (*v. p. 10 and fig. 7*). A varicose condition of the veins sometimes occurs in pregnancy and with pelvic tumours. In a case described by *Holden*,¹ they formed, when the patient was erect, a tumour of the size of a child's head. When these vessels rupture and the blood is effused into the cellular tissue, a hæmatoma is formed.

Hæmatoma. This condition is also called "Thrombus" and "Hæma- Hæma-
toma. tocele" of the vulva; the former term should be limited to a coagulum within a vein, and the latter to blood effusion into the peritoneal cavity. It arises most frequently during labour, from injury produced by the child's head; the effusion may appear rapidly, as a tumour from the size of a walnut to an orange or larger, or may take place gradually. It has also been known to occur independent of labour or pregnancy, as the result of a blow or violent muscular effort.

The treatment consists in the application of ice to the vulva, and regular evacuation of the bladder and rectum without the patient's being

¹ "Immense Vulvar and Vaginal Varix:" *N. Y. Med. Record*, July 1868.

allowed to strain. With this treatment, the mass may be absorbed. Should inflammation occur, poultices are applied and pus is evacuated with the knife; if this occurs in the puerperal condition, special care is required to keep the wound aseptic by repeated washing with carbolic solution and dressing with carbolised lint.

External
Hæmorrhage.

External hæmorrhage from ruptured veins sometimes occurs. The rupture may be caused by muscular straining, or by a blow or wound of the vulva. The dilated state of the veins makes such an injury serious during pregnancy, and several cases of a fatal result from a blow or kick have been the subject of criminal prosecution (*Sir J. Y. Simpson*). The vascular tissues are forcibly driven against the pubic arch and cut on it. In a case recorded by Hyde,¹ hæmorrhage from a vein ruptured by a fall proved fatal in forty minutes. Those who suffer from varicose veins should lie down for some hours during each day; should a vein rupture, the patient must lie down at once and apply pressure to the bleeding point.

¹ *Lond. Obst. Trans.*, Vol. XI.

CHAPTER XLVI.

RUPTURE OF THE PERINEUM AND ITS OPERATIVE TREATMENT.

LITERATURE.

Bantock, G.—On the Treatment of Rupture of the Female Perineum, Immediate and Remote: London, 1878. *Duncan, Mattheus*—Papers on the Female Perineum: Churchill, London, 1879. *Goodell*—Lessons in Gynecology: Philadelphia, 1880. *Hart, D. B.*—The Structural Anatomy of the Female Pelvic Floor: Edin., 1880. *Hildebrandt*—Die Krankheiten der äusseren weiblichen Genitalien: Stuttgart, 1877. *Schroeder*—Die Krankheiten der weiblichen Geschlechtsorgane, S. 512: Leipzig, 1880. *Simpson, Sir J. F.*—Diseases of Women, p. 644. *Thomas*—Diseases of Women, p. 165: Philadelphia, 1880. See *Duncan* and *Hildebrandt* for literature.

Nomenclature. It will be most convenient to retain the nomenclature Preliminary already used in the Section on Anatomy. The pelvic floor is made up of pubic and sacral segments, as already defined; in labour, each of these behaves characteristically—the pubic segment is drawn up, the sacral one drawn down.

In this chapter we are specially concerned with the sacral segment. During parturition it is driven downwards and backwards by the advancing foetus and is more or less torn at its inferior angle. The term perineum is often vaguely applied; in this Chapter, however, the perineum is defined as *the inferior angle of the sacral segment* (v. p. 57). Fig. 319 shows the perineum. At its lower end, this part of the pelvic floor is made up of the following:—

1. Posterior vaginal wall,
2. Hymen,
3. Fossa Navicularis,
4. Fourchette,
5. Perineal body and skin over its base.

These are mesial structures; latterly, we have the labia majora and minora.

PATHOLOGY AND VARIETIES.

It should be kept in mind that the vaginal orifice is transverse, the vulvar orifice antero-posterior. Pathology
and
Varieties.

When the foetal head is passing through the vaginal orifice, it distends

it all round; while, when passing through the vulvar orifice, it distends the lower half of this only, *i.e.*, it does not stretch so much those parts of the vulva lying above the level of the meatus urinarius.

As the result of normal and abnormal child-birth, we get certain tears of the inferior end of the perineum. In all primiparæ there is at least one laceration of the hymeneal orifice, usually mesially and posteriorly—the “inevitable laceration” of Matthews Duncan. There may be also laceration of the following structures: (*a*) of the vaginal orifice, radiating; (*b*) of vestibule; (*c*) of fourchette; (*d*) of labia minora; (*e*) of perineal body to a varying depth, the most extensive involving the

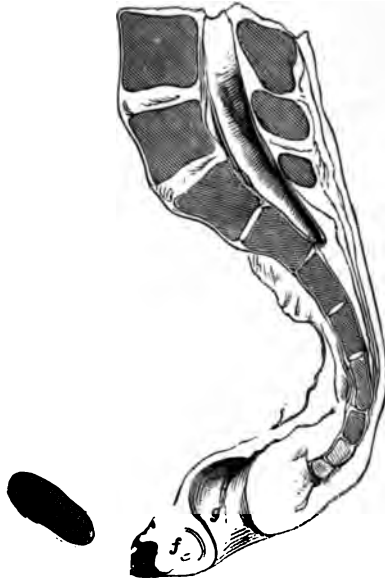

FIG. 319.

THE SACRAL OR SUPPORTING SEGMENT OF THE PELVIC FLOOR (*Hart*). *e* Symphysis pubis; *f* perineum, or inferior angle of sacral segment; *g* anus.

sphincter ani. Further, there is sometimes central rupture of the perineum. In this lesion, the skin over the base of the perineal body alone may be involved or only the vagina may be torn. Rarely is it a lesion of vaginal wall, connective tissue, and skin, with an unruptured band of tissue between it and the fourchette (fig. 320); this, therefore, is a perforation through the inferior angle of the thinned-out sacral segment.

ETIOLOGY.

Etiology. The following causes produce rupture in parturition:—

- (1) Passage of a large head or of an occipito-posterior rotated into sacrum, passage of the shoulders ;
- (2) Narrowness of pubic arch ;
- (3) Straightness of sacrum, as in flat or rickety pelvis ;
- (4) Syphilitic ulceration ;

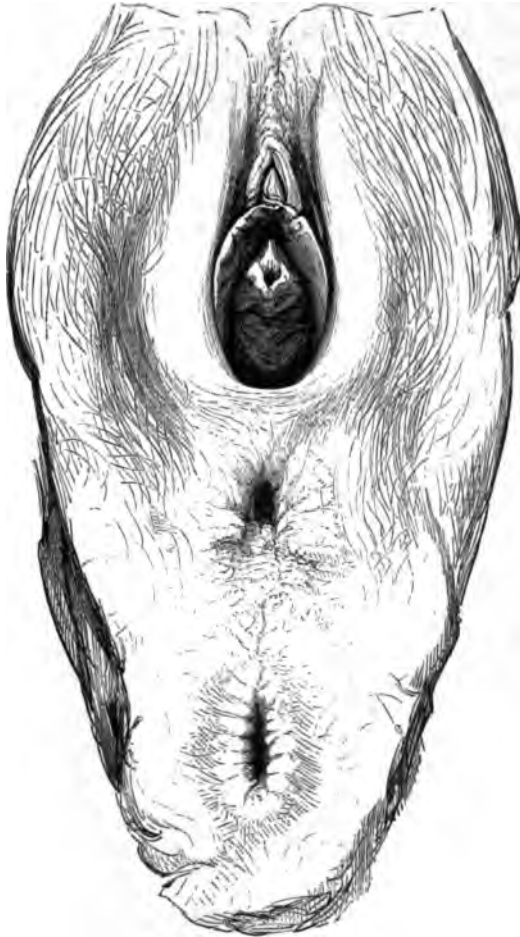

FIG. 320.

CENTRAL RUPTURE OF THE PERINEUM, the child was born not through the Vulva but through the Ruptured Opening (*Sir J. Y. Simpson*).

- (5) Rigidity of parts in elderly primiparæ ;
 - (6) Careless use of forceps ;
 - (7) Too early passage of hand into vagina to bring down arms in turning.
- Comment on these would lead us too much into Obstetrics.

TREATMENT.

Treatment. We take this up under the following heads:—

a. Prophylactic ;

b. Operative, immediate and deferred.

Prophy-
lactic.

a. *Prophylactic.* This properly belongs to midwifery. The obstetrician is too apt to think of the perineum as something that delays the exit of the foetal head, and to forget the gynecological aspect—that it is the supporting segment of the pelvic floor. Extensive tear of this during labour means not only a larger raw surface, for septic absorption, but also is one factor predisposing to prolapsus uteri. The question, therefore, of *support of the perineum* during parturition comes up here for consideration. To understand this we must keep in mind that the foetal head, in passing through the outlet, drives the sacral segment back and glides forward in a direction parallel to the driven-back posterior vaginal wall. The normal curve of the sacrum favours this latter motion.

The perineum may tear (1) from over-distension of the orifice, or (2) from the too forcible driving of the foetal head against it, *i.e.*, at right angles to the perineum. If, therefore, while the head is crowning and rupture threatening, the palm of the hand covered with a napkin be placed on the skin aspect of the perineum, we can by gentle support keep the head flexed, retard its progress somewhat, and elongate the perineum towards the pubic arch.

In addition the practitioner can materially help in preventing an awkward tear by the preliminary free inunction with medicated vaseline of the head, vagina and skin of perineum, and by tucking in the anterior vaginal wall when projecting too much over the occiput.

Goodell passes two fingers into the rectum and restrains the head with the thumb. The perineum should never be forcibly supported, as this damages the vestibule and may cause serious hæmorrhage by driving the vestibular vessels against the pubic arch. As regards the use of forceps, the authors have been struck with the fact that with axis-traction forceps the head can be brought over a rigid perineum with a minimum amount of tear.

Operative. b. *Operative treatment* ; (1) immediate, (2) deferred. No practitioner should leave a labour case until he is satisfied, by actual inspection or digital examination, as to the amount of perineal tear. When the sphincter ani is involved, the operation is on no account to be deferred but must be performed at the conclusion of the third stage. The prac-

titioner should never run the risk of his patient's having incontinence of fæces.

(1.) *Immediate operation.* When the *perineum* is torn to the edge of the anus, it is stitched as follows. Wait until the third stage is completed. The patient lies on the left side with the knees drawn up. Chloroform need not be given unless the patient insists on it. The raw surface is sponged with 1-40 carbolic lotion, and all bleeding arrested (usually by pressure). The tear has probably split the perineal body vertically and mesially, so that there is a triangular raw surface on each side continuous along the posterior side; the skin over the base of the perineal body forms the second side of each triangle, while the third is vaginal. By means of a fully curved needle armed with coloured silk-worm gut, stitches half-an-inch apart are passed as deeply as possible on the skin aspect of the perineal body; the same is done on the vaginal aspect although this is not always necessary. The vaginal stitches are tied first, and then the skin ones. Silver wire may be used in place of silk-worm gut. The patient's knees are kept tied together, and, if necessary, the urine drawn off by catheter for the first few days. Immediate
Operation.

When the *sphincter ani* is torn, the stitches are passed as before. The rectal sutures (catgut) are passed first, then the vaginal, and lastly the skin ones; the rectal ones are probably unnecessary.

The patient's food must be liquid, and the bowels should be kept confined for eight or nine days. Castor oil is then given; the nurse must be instructed to inject oil when the bowels are about to move, and to break up and assist the passage of scybala. Some operators recommend that the bowels be moved every day by small doses of castor oil—a plan not to be recommended.

The stitches are removed on the eighth or ninth day. The silk-worm gut irritates very little; in one case where a perineal stitch was overlooked, it gave no trouble subsequently. It was detected at parturition ten months after and removed, when it was found to be quite unaltered; it had caused no irritation.

(2.) *Deferred operation.* This may be simply to repair the perineal body, or to operate for a rupture through the sphincter. The former will be considered under prolapsus uteri. At present we take up the operation for restoration of the ruptured sphincter ani. Deferred
Operation.

Diagnosis of long-standing rupture of perineum into anus. The patient complains of inability to control the passage of flatus or of fæcal matter when a call to stool happens; she is especially troubled

when diarrhœa is present. Sometimes there is a certain amount of control, when some of the fibres of the upper margin of the sphincter are intact. A patient in the lower classes occasionally treats her unpleasant condition as of little moment; to a woman of any refinement, the condition is a most distressing one.

On inspection, the practitioner notes that the skin surface between the vaginal and anal apertures is gone, so that these apertures are blended. The finger passed into the rectum feels no muscular constriction, and notes that the anterior and posterior rectal walls are in contact. The perineal body appears to be gone, and a V-shaped projection of cicatrised mucous membrane (apex above) is all that remains of it.

If the edges of this V-shaped projection be pared and stitched, the function of the sphincter is restored.

Operation for restoration of function of sphincter ani. The patient's bowels are first freely cleared out by castor-oil and enemata so as to ensure that no scybala remain.

Requisites. The instruments requisite are the following:—

- Straight knife,
- Two pairs of artery forceps,
- Dissecting forceps,
- Catgut ligatures,
- Silkworm gut or silver wire,
- Scissors,
- Operating douche,
- Fully curved needles, large and small,
- Needle-holder.

Methods. The patient is chloroformed and placed opposite a good light in the lithotomy posture. The knees are held by assistants as follows. Each stands facing the light, and places a knee of the patient under the armpit next to it; with the hand of the same arm, he exercises tension on the labium majus as the operator wishes. With his other hand, the assistant controls the patient's foot.

The stages of the operation are—(1) Making raw the mucous edges, (2) Applying the stitches.

The mucous edges may be made raw in two ways: (a) by splitting each edge into its constituents of rectal mucous membrane and vaginal mucous membrane, as introduced by Dr. John Duncan, Edinburgh; (b) by paring each edge with scissors.

The former is preferable and is performed as follows. Our aim in

operating is threefold ; to close the anterior wall of the rectum, to close the posterior wall of the vagina, to construct a new perineal body between.

The incisions, as made by A. R. Simpson, are shown in fig. 321. An A. R. Simpson's Operation. incision is carried from the end of the septum (between the rectum and vagina) outwards on the inner surface of the labium to the point 1 ; a second incision is made from the point *a* parallel to the vulvar outlet, passing through the outer extremity of the first incision to *b* at the end of the torn sphincter. This is done on both sides.

The two triangular flaps thus formed are dissected off as shown at

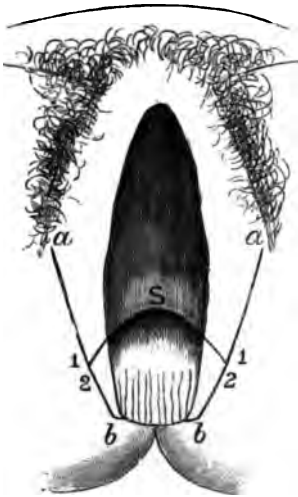


FIG. 321.

LINES OF INCISION IN OPERATION FOR REPAIR OF RUPTURE OF PERINEUM THROUGH SPHINCTER ANI. For letters see text.

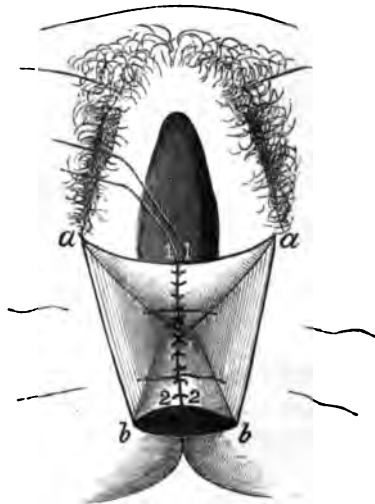


FIG. 322.

PASSING OF SUTURES IN SAME OPERATION. For letters see text.

fig. 322. The flaps *a* 1 *S* are turned forwards to the vagina on each side to meet one another, so that the corners marked 1 in fig. 321 take the position 1 in fig. 322 ; the flaps *b* 2 *S* are turned backwards to the rectum, so that the corners 2 (fig. 321) meet at 2 in fig. 322.

Introduction of stitches. The vaginal flaps are stitched with wire or silk, care being taken to knot the threads *on the vaginal side* of the flaps ; the sutures are left long so as to protrude at the vaginal orifice (fig. 322). The rectal flaps are stitched with catgut, knotted *on the rectal side* of the flaps, and cut short.

We have in this way repaired the vaginal and rectal walls ; the sides of

524 *AFFECTIONS OF VULVA AND PELVIC FLOOR.*

the pyramidal-shaped raw area, thus formed, have to be brought together to construct the perineum. Two deep sutures are passed as in fig. 322; they are of strong wire and are entered at a little distance from the skin




FIG. 323.
RESULT OF SAME OPERATION.

edge. Bleeding, which can be checked by a stream of very hot water, should have ceased before we tighten up these sutures with button-plates (fig. 323). Finally, superficial sutures bring together the skin edges

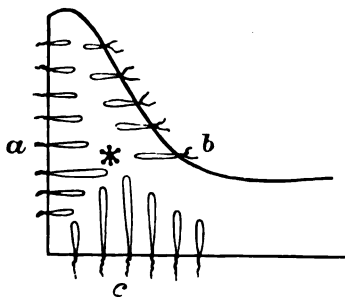


FIG. 324.
POSITION OF SUTURES AS SEEN IN SECTION, a skin of perineum, b vagina, c rectum (*Hildebrandt*).

which form the raphe of the new perineum along the line *l a b*. The result is seen at fig. 323.

Hildebrandt draws attention to the risk of the collecting of discharge

at the centre of the new perineal body indicated by the asterisk in fig. 324. He thinks this is diminished by passing the sutures as in fig. 325; the perineal ones are passed into the skin margin of one side posteriorly,

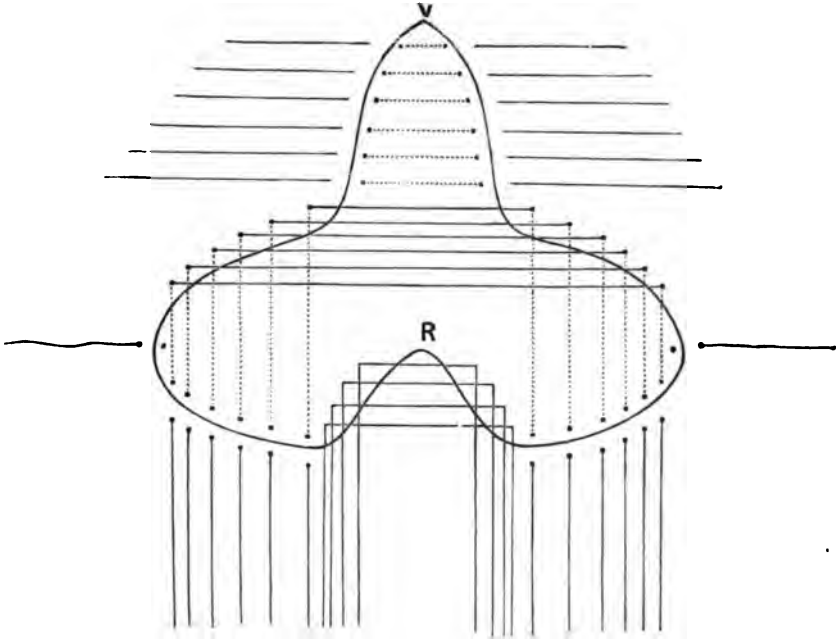


FIG. 325.

TO SHOW DIRECTION OF SUTURES IN OPERATION FOR PROLAPSUS UTERI WITH COMPLETE RUPTURE INTO RECTUM; *V* apex of raw surface in vagina, *R* in rectum (*Hildebrandt*). . .

out through the skin margin anteriorly, entered again through opposite skin margin anteriorly and brought out again on same side posteriorly. The central space is thus constricted in a ring-like manner.

CHAPTER XLVII.

DISPLACEMENTS OF THE PELVIC FLOOR: PROLAPSUS UTERI; VAGINAL ENTEROCELE.

LITERATURE.

Duncan, Matthews—Papers on the Female Perineum: Churchhill, London, 1879. *Esmond*—Principles and Practice of Gynecology, p. 367: Lond. 1879. *Freund, W. A.*—Arch. f. Gyn., Bd. VI., p. 317. *Fritsch*—Die Lageveränderungen der Gebärmutter, Billroth's Handbuch. *Goodell*—Lessons in Gynecology, Lesson VII.: Philadelphia, 1879. *Hart*—The Structural Anatomy of the Female Pelvic Floor: Edinburgh, 1880. *Hegar and Kallenbach*—Operative Gynäkologie, 1881. *Huguiet*—Mémoire sur les Allongements Hypertrophiques du Col de l'Utérus: Paris, 1860. *Legendre*—De la chute de l'Utérus. *Schroeder*—Die Krankheiten der weiblichen Geschlechtsorgane: Leipzig, 1879. *Schultze*—Die Pathologie und Therapie der Lageveränderungen der Gebärmutter: Berlin, 1881. *Schutz and Spiegelberg*—Arch. f. Gynäk., Bd., XIII. *Sims, J. M.*—Uterine Surgery. *Thomas*—Diseases of Women, p. 168: Philadelphia, 1880. *Veit*—Klinische Untersuchungen über den Vorfall der Scheide und der Gebärmutter: Zeits. f. Geb. u. Gyn., Bd. I. *Winckel*—Die Pathologie der weiblichen Sexualorgane: Leipzig, 1880. See Fritsch for additional literature.

PROLAPSUS UTERI.

DEFINITION.

A DOWNWARD displacement of retropubic fat, bladder and urethra, anterior vaginal wall, uterus and posterior vaginal wall.

PRELIMINARIES.

The subject of Prolapsus Uteri is a complex one, and has been in part made so by erroneous terminology.

Thus the well-known term Prolapsus Uteri has biassed many observers as to the nature of this lesion, inasmuch as they have considered some change in the uterus as initiating the prolapsus. This is a natural error, and is perpetuated in most of our text-books by the writers of these considering prolapsus uteri under affections of the uterus. Prolapsus uteri is, however, considered here under Displacements of the Pelvic Floor, as it is really a hernial displacement of the pelvic floor where the retropubic fat, pubic segment (bladder, urethra, and anterior vaginal wall), uterus, and posterior vaginal wall are driven down by intra-abdominal pressure. There is no doubt that changes take place in the length of the

uterus as the result of the downward displacement. This change is, however, a secondary one, as will presently be explained, and does not initiate the lesion.

The student must therefore use the term prolapsus uteri not in its literal sense, but as equivalent to "sacro-pubic hernia," the term suggested by Dr. Hart.

Prolapsus uteri is sometimes applied to hypertrophy of the vaginal portion of the cervix. This is wrong, as this hypertrophy is a growth phenomenon.

STRUCTURAL AND ANATOMICAL CONSIDERATIONS.

We have already considered (Chap. III.) the Structural Anatomy of the Pelvic Floor, and therefore now briefly allude to only one or two points. The sacral segment is the supporting one, the pubic segment the displaceable one. If fig. 35 be looked at, the following points can be noted :—

- (1) There is the pyramidal interspace behind the pubis, filled up with the retropubic fat ;
- (2) There is loose tissue between the anterior rectal and posterior vaginal wall ;
- (3) There is loose tissue between bladder and anterior vaginal wall.

This may be otherwise stated under this generalisation—those organs in the pelvic floor (viz., bladder, urethra and rectum) containing unstriped muscular fibre which enables them to diminish their lumen, are surrounded entirely or partially by loose tissue.

The pelvic floor has been constructed quâ parturition, rectal and vesical functions, and intra-abdominal pressure. From the loose tissue surrounding the bladder and rectum, evidently introduced to allow of their contraction, we get weak lines of cleavage in the pelvic floor at which it separates or becomes dislocated under increased intra-abdominal pressure. Thus strong pressure applied to the pelvic floor will cause it to bulge and displace all in front of the anterior rectal wall.

The student will recall (fig. 15) the division of the cervix into intra-vaginal, intermediate, and supra-vaginal portions.

SYMPTOMS AND PHYSICAL SIGNS.

The discomfort caused by the protrusion and the excoriation of the parts is the prominent symptom. The patient complains of "something coming down in front." Further, there is difficulty in micturition.

The physical signs are distinct. If the prolapsus be *incomplete*, a

Physical Signs.

portion of the anterior vaginal wall has passed out at the vaginal orifice, the os uteri is equally displaced downwards, and the posterior fornix is apparently deeper from the descent of the cervix. The uterus, in addition to being low down, is usually enlarged; it lies with its axis coinciding with that part of the pelvic curve in which it is. If the prolapsus be *complete*, we find the whole anterior vaginal wall outside the vulva, the cervix extruded, and the posterior vaginal wall everted (fig. 171). The student must specially note that this description is based on *clinical* observation.

From the *study of frozen sections*, we further learn that the posterior vaginal and anterior rectal walls are separated by peritoneum driven in between them, and that the uterus with other parts has become hypertrophied through long-standing congestion and the cervix elongated.

MECHANISM OF PROLAPSUS.

The displaced organs can be replaced—posterior vaginal wall first, then uterus, and lastly pubic segment; on the patient's straining, the mechanism of the displacement is repeated and is seen to be perfectly definite and to occur as follows.

hanism
clinical
rva-

We have first the appearance of the anterior vaginal wall, from below upwards, at the orifice. *Pari passu* with its descent, the uterus and posterior vaginal wall have come down; its lowest point tracing out the pelvic curve, while the uterus becomes more and more inclined backwards until at the vaginal orifice it lies in the vaginal axis; the posterior vaginal wall forms a pouch, the depth of half its own length, behind it. Finally, the uterus is driven outside; the os sweeps upwards and forwards, and the posterior vaginal wall is now completely everted—its lowest part appearing last.

ear-
of
apsus
section.

On vertical section, we now find these conditions:—(1) Almost complete extrusion of the anterior or pubic part of the floor, the upper and anterior part of the bladder still behind the symphysis; (2) Complete extrusion of the uterus, which sometimes lies with the fundus below the level of the anus; (3) Rectum in position and only posterior vaginal wall down, the latter has peeled from the rectum downwards as far as the lowest inch-and-a-half (of close connexion) which is elongated (fig. 326).

lana-
of
han-

The *explanation of this mechanism* is as follows. The displacement in prolapsus uteri is caused by intra-abdominal pressure, pushing down that part of the pelvic floor which lies in front of the anterior rectal wall. This part consists of pubic segment, uterus, and posterior vaginal wall.

The posterior angle of the pubic segment is attached to the cervix uteri, and the cervix uteri to the top of the posterior vaginal wall. Thus, when intra-abdominal pressure is excessive, this part when driven down must have the following sequence of protrusion at the vaginal orifice: (a) Anterior vaginal wall from below upwards; (b) Os uteri; (c) Posterior vaginal wall from above downwards.

The uterus, while it is being forced down, has the *direction of its long axis* continually altering. This is often expressed by saying that the uterus becomes more and more retroverted as it is forced down. The real fact is, that, as the pubic segment is forced down, it is stretched—chiefly on its peritoneal aspect. In this way tension is made on the cervix uteri, with the effect of throwing the fundus back and making it rest on the retrojacent structures. As these have (roughly speaking) the pelvic curve, we get the uterus in this way constantly altering its axis-lie.

The *enlargement* is not purely cervical; but affects the whole uterus, the pubic segment, and the posterior vaginal wall. This enlargement is a *consequence* of prolapsus uteri, and not a factor in its production. If we view a prolapsed uterus (with the os at the ostium vaginæ) through the pelvic brim, it can be seen that it lies, as it were, at the bottom of a valley—the sides of the valley being the broad ligaments, the bed of the valley the uterus. The parts of the uterus do not lie on the same horizontal plane, the cervix lies low. It is thus evident that the venous supply of the uterus, having a mechanical disadvantage to its return, will have a tendency to stasis. This may lead to areolar hyperplasia at first, and, so far as our present knowledge goes, partly accounts for the increased size of the uterus in prolapsus. There is further a tensile elongation of the cervix produced which increases the uterine length.

SUMMARY OF DISPLACEMENT IN PROLAPSUS.

I. On clinical observation while a complete prolapsus is being reproduced we note

- (a) The anterior vaginal wall from below upwards passing down and out at the vaginal orifice;
- (b) The cervix uteri appearing at the vaginal orifice;
- (c) The posterior vaginal wall, from above down, coming last.

II. If a frozen section of a cadaver with prolapsus uteri be examined (fig. 326), we note that the pubic segment, uterus and posterior vaginal wall are displaced down and out. Fig. 326 is based on Schutz's drawing of such a frozen section.

III. The combined study of I. and II. shows that

- (a) The bladder and uterus are displaced down, the vagina everted or turned inside out, and the small intestine coincidentally lowered in the pelvis, the displaced parts congested and hypertrophied, and the cervix uteri elongated secondarily.

DIAGNOSIS AND DIFFERENTIAL DIAGNOSIS.

The diagnosis is made by noticing the relations of the parts extruded and by passing the sound if necessary into the bladder and uterus.

The differential diagnosis must be made from the following conditions:—

- (1.) *Hypertrophy of the infra-vaginal portion of the cervix* ;
- (2.) *Hypertrophy of middle portion of cervix.*

For both of these conditions the student is referred back to page 262 (see figs. 161, 169, 170).

- (3.) *Cystocele.* Uterus is in position, and displacement is found to be due to bulging back of posterior wall of bladder.
- (4.) *Rectocele.* The finger, passed through the anus, can be pushed into the pouched rectum.
- (5.) *Inversion and polypus* (v. pp. 366 and 424).

ETIOLOGY.

The factors producing prolapsus uteri are three in number:—(1) *Deficient sacral support* ; (2) *Deficient tone of pubic segment of pelvic floor* ; (3) *Intra-abdominal pressure.*

Deficient sacral support. By this is meant that through parturition the sacral segment has become straightened out or deficient at its lower margin—the perineum. It is wrong to imagine that tear of the perineum is everything in prolapsus uteri ; the perineum may be considerably torn and yet, if the sacral segment is still sufficiently curved and the intra-abdominal pressure not too great, there will be no prolapsus. Tear of the perineum diminishes the sacral support, and deficient sacral support makes the task of intra-abdominal pressure easier. The bearing of the *second* and *third* factors is sufficiently evident. Of all the three, increased intra-abdominal pressure is the most important and is sufficient to cause prolapsus in virgins. The first and second are adjuvant.

A dispute still exists as to the etiology of prolapsus uteri ; some gynecologists assert that the perineal tear has little or nothing to do with it.

NATURE.

The uterus has nothing to do with prolapsus. It is a classical

term, but a misleading one. Prolapsus uteri is really a *hernia*; and is analogous in every point to what we term a surgical hernia (such as femoral hernia). Prolapsus
Uteri a
Hernia.

Thus it has (1) a *sac*, the peritoneum; (2) a definite road to travel along, whose boundaries are—*a.* in front the pubic symphysis, *b.* behind the portion of the sacral segment of the pelvic floor from anterior wall of rectum back to sacrum, *c.* side walls; (3) definite coverings, viz., *a.*

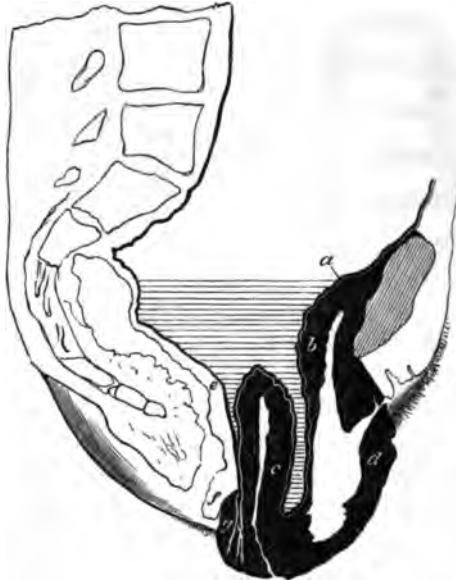


FIG. 326.

TO SHOW THE HERNIAL NATURE OF PROLAPSUS UTERI: *a* peritoneum; *b* bladder; *c* uterus; *d* anterior vaginal wall; *e* anterior rectal wall; *f* perineum; *g* posterior vaginal wall. The dark portions are the coverings of the Hernia (after Schutz).

pubic segment of pelvic floor, *b.* the uterus, *c.* posterior vaginal wall. Like all herniæ, its sac contains small intestine (fig. 326).

Huguier alleged that, by a hypertrophic elongation of the supra-vaginal portion of the cervix, the bladder and posterior vaginal wall were displaced downwards; and that many cases of alleged prolapsus uteri are really due to this. Such cases differed from prolapsus uteri in the fact that the fundus uteri and fundus of bladder are in position. Many gynecologists hold this view of Huguier, most of them modifying it somewhat. Schroeder's Handbock, Goodell's Gynecology, and Hart's Structural Anatomy may be consulted on this moot point. Huguier's
view.

TREATMENT.

A. Treatment by Pessaries,

B. Treatment by Operation.

A. *Treatment by pessaries.* In slight cases, where the anterior vaginal wall protrudes only a little, we may use an Albert Smith or Hodge pessary with or without transverse bars at the lower part. If this fails, a ring pessary with spring inside should be tried; this instrument is useful here, inasmuch as it is shorter vertically than the Albert Smith and




FIG. 327.

GREENHALGH'S PESSARY, with transverse bars.



FIG. 328.

RING PESSARY with diaphragm.

therefore does not project over the lower end of the shortened posterior vaginal wall. The instrument may be made of vulcanite, block tin, or india-rubber. The india-rubber forms are best, and should be provided with a perforated diaphragm.

The pessary is taken in the right hand, and compressed between the finger and thumb as in fig. 329 while it is being passed through the vaginal orifice; the labia are separated with the fingers of the left hand.




FIG. 329.

SIMPLE ELASTIC RING PESSARY, compressed between the fingers for introduction (*De Statty*).

If the ring instrument fail, then one of the so-called anteversion pessaries, such as that shown in fig. 331 may be tried. Fig. 332 shows Zwanck's pessary, a bad form. A thin india-rubber bag distended with air and provided with a stop-cock is good. In very bad cases and in old women where an operation is out of the question, the patient or her friends should be instructed how to pack the vagina with marine lint; the packing, if thorough, may remain *in situ* for a week. Some recom-

mend pessaries which are attached externally to an abdominal belt. When there is much congestion and excoriation, rest in bed with the use

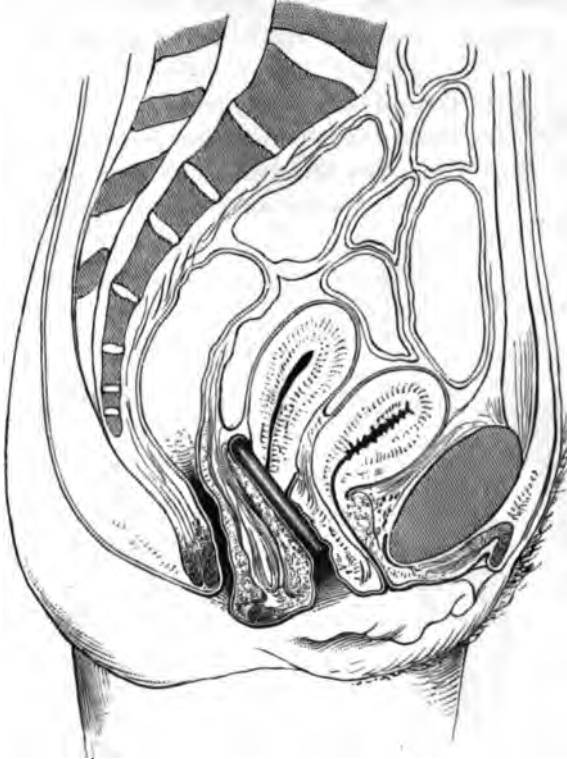


FIG. 330.

RING PESSARY *in situ* (Hart).

of alum injections (3i to Oi) and application of boracic or zinc ointments to the raw surfaces, is indicated.




FIG. 331.

PESSARY FOR PROLAPSUS.

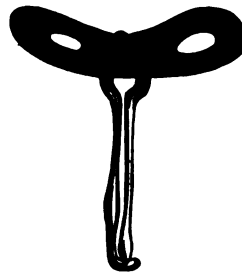


FIG. 332.

ZWANK'S PESSARY FOR PROLAPSUS.

If the patient has good abdominal development, an abdominal belt

534 *AFFECTIONS OF VULVA AND PELVIC FLOOR.*

will be of use ; when applied, it should be fairly tight at the lower edge and slack at the upper one.

B. Treatment by operation. We must first consider the *status quo* in an advanced prolapsus. There are the following primary and secondary lesions.

Condition
of parts in
Prolapsus
Uteri.

- | | | |
|-----------|---|---|
| Primary | { | (1) Perineal body usually torn ; |
| | | (2) Increase of intra-abdominal pressure ; |
| Secondary | { | (3) Congestion of uterus, pubic segment, and posterior vaginal wall ; laxity of everted vagina ; |
| | | (4) Separation of anterior rectal and posterior vaginal walls, with peritoneum clothing their surfaces. |

These secondary lesions, especially the last, are serious and incurable.



FIG. 333.

LINES OF INCISION IN OPERATION FOR REPAIR OF RUPTURED PERINEUM. For letters see text.




FIG. 334.

SUTURES PASSED IN SAME OPERATION.

In order to restore the pelvic floor to its pristine state we should require (1) to repair the perineal body and narrow the vagina ; (2) to restrain increased abdominal pressure ; these are possible : (3) to do away with congestion and areolar hyperplasia is probably beyond our powers, while (4) to bring about adhesion of the anterior rectal and posterior vaginal walls is impossible. *Prolapsus uteri* is therefore a condition with serious and irremediable secondary results.

The varieties of operative treatment practised are as follow :—

1. Repair of Perineum (Perineorrhaphy) ;

2. Repair of Perineum and paring of mucous membrane of posterior vaginal wall (Elytro¹-perineorrhaphy);
3. Making raw the mucous membrane of anterior vaginal wall (Elytrorrhaphy);
4. Making a raw surface on each vaginal wall, and stitching them together.

Along with these the vaginal portion of the cervix may be amputated.

1. *Repair of Perineum.* A mesial incision is made from *b* to *c* along the posterior vaginal wall and ruptured perineum; a lateral one is carried

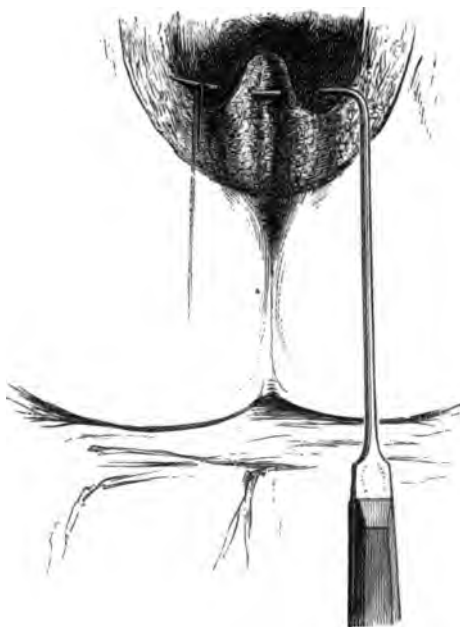

FIG. 335.

NEEDLE CARRYING IN STITCHES FOR REPAIR OF THE PERINEUM (Sir J. Y. Simpson).

forward on each side from the point *b* to *a* along the inner surface of the labium minus. The triangular flaps thus formed are dissected upwards so that their corners *b* (fig. 333) lie as in *b* (fig. 334); they are united with silk or wire sutures knotted on the vaginal side. Two deep sutures are passed as in fig. 334 to close in the sides of the raw area left by the flaps; the skin edges are united by superficial sutures. The result is seen at fig. 336. This operation is of no use in advanced prolapsus uteri.

2. *Repair of Perineum and PARING of mucous membrane of posterior vaginal wall.*

¹ Elytron = vagina : Epision = vulva.

Fig. 337 shows the various forms of raw surface made by different




FIG. 336.
RESULT OF SAME OPERATION.

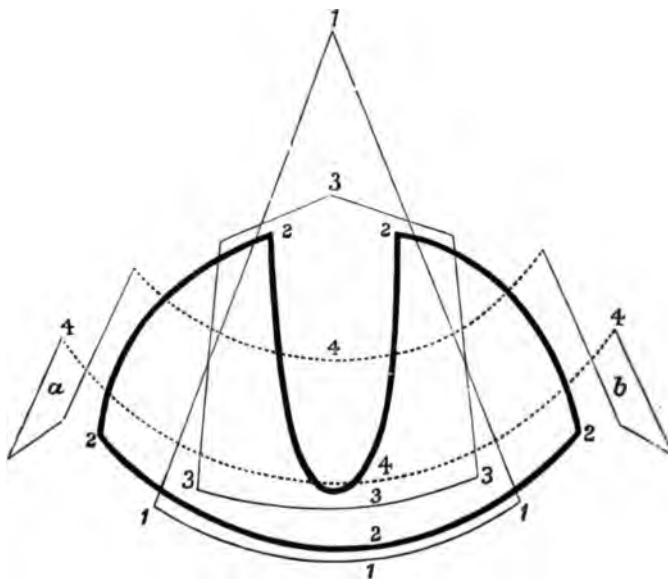


FIG. 337.

TO SHOW VARIOUS FORMS OF RAW SURFACE MADE ON POSTERIOR VAGINAL WALL IN OPERATION FOR PROLAPSED UTERI: 1111, Hegar's; 2222, Bischoff's; 3333, Simon's; 444ab Winckel's (*Winckel*).

gynecologists; the operation is a complicated one, especially the stitching.

4. *Making a raw surface on both vaginal walls, or on both labia majora (Episiotomy) and stitching these surfaces together.* This prevents the eversion of the vaginal walls and hinders the mechanism of descent.

These raw surfaces can be made with knife or scissors. Care should be taken to avoid all excavation of tissue. Just so much tissue is to be removed as will give a rawness.

The result of any of these operations is not perfectly satisfactory. All of them aim at cicatrisation of the vaginal walls, and do nothing towards the amendment of the serious secondary results already described. When union by first intention is secured, there is risk that the cicatrix may stretch and the prolapse recur. There is no radical operation for prolapsus uteri.

When the vaginal portion of the cervix is hypertrophied, it may be amputated at the same time.

Of all the raw surfaces recommended, Hegar's is probably the best and simplest.

If supra-vaginal elongation of the cervix causes a lesion like prolapsus uteri, prolapsus is an irremediable lesion inasmuch as the proper treatment is excision of the cervix up to the level of the os internum. If the student looks at figs. 169 and 170 he will see what this operation involves.

We would therefore sum up as follows. *The displacement of the pelvic floor—where pubic segment, uterus and posterior vaginal wall are driven down with the characteristic mechanism given at page 528, and where the serious secondary lesions of uterine enlargement and separation of the anterior rectal and posterior vaginal walls ensue—is a hernia; there is not sufficient evidence that this precise displacement is a hypertrophic elongation of the supra-vaginal portion of the cervix.*

Whether a gynecologist adopts Huguier's or the hernia theory, he usually operates as if the latter were the true one.

VAGINAL ENTEROCELE.

Of this there are two forms, *anterior* and *posterior*. Excessive intra-abdominal pressure usually displaces all of the pelvic floor that lies in front of the anterior rectal wall. Occasionally, but very rarely, intestine is forced down between the posterior aspect of the bladder and upper part of anterior vaginal wall, or between the anterior rectal and posterior vaginal walls (fig. 340). We thus get a mass bulging into the vagina, but only affecting one wall the uterus and cervix remain in

position. This distinguishes it from prolapsus uteri and cervical elongation; by rectal examination, the posterior form of *enterocele* can be easily distinguished from rectocele.

The *causation* is not well known. In the posterior form, a deep dip of the peritoneum behind the posterior vaginal wall may have existed; but of this there is no evidence.

Treatment. If an ordinary Albert Smith or anteversion pessary fail, an operation may be tried. In the posterior vaginal enterocele, for

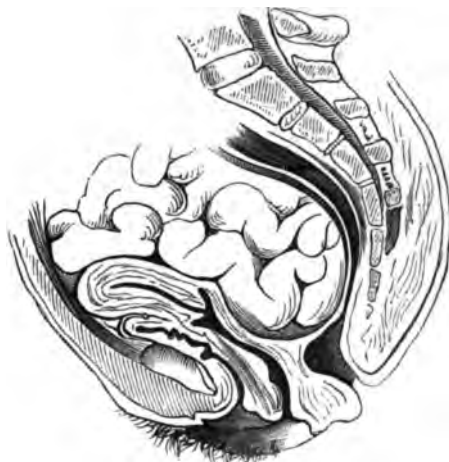

FIG. 340:

POSTERIOR VAGINAL ENTEROCELE (*Dreitsky*).

example, the protrusion should be replaced; a raw surface is then made on the posterior lip of the cervix and a portion of the posterior vaginal wall about its middle; these surfaces are then stitched.

Prolapsus uteri and both forms of vaginal enterocele are therefore essentially the same in nature, viz., hernial. Intra-abdominal pressure usually displaces all in front of the anterior rectal wall; but may also force intestine in front of the anterior vaginal wall, or behind the posterior one.



SECTION VIII.

DISTURBANCES OF THE MENSTRUAL FUNCTION.

CHAPTER XLVIII. Amenorrhœa : Menorrhagia : Dysmenorrhœa.

SECTION IX.

DISTURBANCES OF THE REPRODUCTIVE FUNCTION.

CHAPTER XLIX. Sterility: Abortion : Retroflexion of the Gravid Uterus.

„ L. Extra-uterine Gestation.

CHAPTER XLVIII.

AMENORRHŒA: MENORRHAGIA: DYSMENORRHŒA.

THE three subjects to which this section is devoted are not diseases, but are symptoms of a large number of the more or less well-ascertained pathological conditions already considered. Theoretically, therefore, they should not come up for special consideration; practically, however, it is of use to the practitioner to summarize the conditions causing these symptoms, and to give some special hints as to their treatment.

AMENORRHŒA.

This means cessation of menstruation during the period between Puberty and the Menopause. It is normal to have Amenorrhœa during pregnancy and lactation. Amenorrhœa may be caused by the following *Local conditions* :—

Causes.

Congenital	{	Absence or incomplete development of uterus and annexa, atresia of the genital canal (with or without accumulation of the menstrual blood), state of Cretinism ;
Acquired		
	{	Superinvolution, simple atrophy of uterus, cystic ovarian disease, extensive inflammatory conditions of uterus and ovaries.

Constitutional conditions—such as phthisis, chlorosis, pre-maturity of menopause—also cause amenorrhœa.

The local conditions have already been fully described under the various heads; we give here only a few hints as to the investigation of the causes of this symptom. When the patient complains of *never having menstruated* and there is no constitutional cause for the amenorrhœa, the question of examination should always be entertained; abdominal palpation and rectal examination are employed to ascertain that there is no retention from atresia. To ascertain the condition of the uterus, a vaginal examination may be necessary. *Sudden cessation* of the menstruation in a girl neither phthisical nor chlorotic is usually due to

pregnancy; early sickness, mammary and other signs should be looked for. Nothing is a sure sign of pregnancy except the characteristic increase in the size of the uterus, agreeing with the number of periods passed.

In cases where amenorrhœa is due to chlorosis, Blaud's pills are Treatment indicated. These contain sulphate of iron and carbonate of potash made up as undernoted; as the result of the combination, the carbonate of iron is formed.

R Ferri sulphatis.
 Potassæ carbonatis āā gr. iiss.
 Mucilaginis tragacanthæ q.s.
 Fiat pilula: mitte tales 96.
Sig. Three, thrice daily.

Nine pills must be taken per diem continuously for six to eight weeks, by which time a complete cure usually results.

Before the pills are given, the state of the tongue and bowels should be looked to. If the tongue is foul and the bowels constipated, we may give the following:—

R Magnesiæ sulphatis ̄j.
 Quiniæ sulphatis gr. xxiv.
 Acidi sulphurici dil. ̄ij.
 Tincturæ capsici ̄j.
 Aquam ad ̄vi.
Sig. Tablespoonful twice or thrice daily.

This is taken for a week. The Carlsbad salts or Friedrichshall water may be substituted. This hint as to the preliminary purgation is a good one, and is given by Milner Fothergill; if not attended to, the result will be disappointing as the iron will not be so readily absorbed by the intestinal mucous membranes.

Note. The original composition of Blaud's pills is as follows:—Sulphate of iron, carbonate of potash, of each half-an-ounce; marshmallow root thirty grains; gum tragacanth q.s. to make 120 pills.

The following are the proportions in the pill as made by Messrs. Duncan, Flockhart and Co. of this city: Ferri sulph. siccat. 15, Potass. carb. siccat. 15, Pulv. gum. acaciæ 3, Syrup. simp. 9; Divide in ̄-gr. pil.

Blaud's pill gives a ferrous carbonate and a potash salt, the decomposition taking place after the pill is swallowed.

In Vallet's pill, which is popular on the continent, the decomposition is effected first and the carbonate of iron thus freshly formed is used to make the pill. The quantities taken to make Vallet's pill are as follows:—Protosulphate of iron (in crystals) 10, Carbonate of soda (in crystals) 12, White honey 3, Sugar of milk 3; Divide in 5-gr. pil.

Ringer recommends Permanganate of potash. The following is a good formula:

R Potassæ Permanganatis.
 Kaolin aa gr. ij.
 Vaselini q.s.
 Fiat pilula : mitte tales xxiv.
Sig. One thrice daily.

These pills should not be made with any excipient containing glycerine or with an oxidizable substance.

MENORRHAGIA.

Menorrhagia is the term applied to excessive hæmorrhage at the menstrual periods ; when the hæmorrhage is intermenstrual, it is termed metrorrhagia.

Causes. The causes of menorrhagia are the following :—

Constitutional	Hæmorrhagic diathesis, scorbutic conditions ;			
Local	<table> <tr> <td rowspan="2" style="font-size: 3em; vertical-align: middle;">{</td> <td>Endometritis, metritis, subinvolution, retroversion of uterus, inversion of uterus, submucous and interstitial fibroids, polypi, carcinoma uteri, sarcoma uteri, incomplete abortion.</td> </tr> <tr> <td></td> </tr> </table>	{	Endometritis, metritis, subinvolution, retroversion of uterus, inversion of uterus, submucous and interstitial fibroids, polypi, carcinoma uteri, sarcoma uteri, incomplete abortion.	
{	Endometritis, metritis, subinvolution, retroversion of uterus, inversion of uterus, submucous and interstitial fibroids, polypi, carcinoma uteri, sarcoma uteri, incomplete abortion.			

It should not be forgotten that we may have menorrhagia in cardiac disease, and also in hepatic congestion (*Matthews Duncan, Warner*).

Treatment. The treatment of menorrhagia is the treatment of the condition producing it. In cardiac disease we give digitalis ; and in hepatic disease we may try chloride of ammonium, euonymium or iridin.

R Ammonii chloridi ʒiij.
 Aquae ʒvj.
Sig. Table-spoonful thrice daily.
 R Euonymii
 vel
 Iridin gr. ii.
 Pil. aloes et ferri q.s.
 Fiat pilula : mitte tales xij.
Sig. One at night.

In cases where there is menorrhagia due to a simple congested condition or to a flabby state of the uterine muscle, we may give the following at the menstrual periods :—

R Ergotinae gr. iv.
 Argenti oxidi gr. ¼.
 Mica panis q.s.
 Fiat pilula : mitte tales xij.
Sig. One thrice daily as directed.

Note that it is well not to write “at the menstrual period” on the prescription, but to put “as directed.” When the practitioner is con-

sulted as to menorrhagia in unmarried ladies or young girls, he should first try the ergotin and oxide of silver pill. If this fail and the case be urgent, he should request a local examination. If this be declined, the responsibility rests with the patient.

Ergot may be given also as follows :—

R Ergotæ liquidi extracti ʒij.
Sig. Thirty drops as directed.

or

R Ergotinæ gr. iv.
Fiat suppositorium : mitte tales xij.
Sig. As directed.

Inform the patient that two suppositories are to be passed into the rectum each morning after the bowels move.

In some cases the hypodermic injection is required (*v. p. 399*).

DYSMENORRHŒA.

LITERATURE. *Duncan, Mattheus*—Clinical Lectures, p. 131. *Goodell*—Lessons in Gynecology: Philadelphia, 1879. *Gusserow*—Menstruation and Dysmenorrhœa: Germ. Clin. Lect., New Syd. Soc. Tr., 1877. *Herman, G. E.*—On the Relation between Backward Displacements of the Uterus and Painful Menstruation: Lond. Obst. Trans., 1882. *Solowieff*—Decidua Menstrualis: Archiv. f. Gyn., Bd. II., S. 66. *Schroeder*—Die Krankheiten der weiblichen Geschlechtsorgane: Leipzig, 1879. *Simpson, Sir J. Y.*—Diseases of Women, p. 225: Edin., 1872. *Williams, John*—Pathology and Treatment of Membranous Dysmenorrhœa: Lond. Obst. Tr., 1877.

Dysmenorrhœa may be defined as the occurrence of pain just before, during, or after the menstrual period.

The pain of dysmenorrhœa varies greatly in intensity. It may be so severe as to render the sufferer a miserable invalid, it may interfere with her work more or less, or it may cause only marked uneasiness. It is always advisable in cases of dysmenorrhœa to ascertain how much the pain interferes with the patient's occupation or whether it confines her to bed. Note also when the pain occurs—prior to, during, or after the blood-flow; in the purely spasmodic form, it is during the flow.

In order to treat dysmenorrhœa intelligently, we must endeavour to ascertain its cause and try to make out how this condition brings about the pain. We know nothing at all as to the real cause of dysmenorrhœa. We know that in many instances it is associated with certain pathological conditions, but how these actually cause the pain is as yet disputed.

Some facts as to menstruation help us in understanding dysmenorrhœa. The uterus is an erectile organ (*p. 68*), and as the decidua menstrualis is five or six times thicker than the uterine mucous membrane, it is evident that metritis or pathological antelexion when present will hinder

the erection and expansion of the uterus, and cause intense pain analogous to the chordee of the penis in gonorrhœa.

In normal menstruation, a fluid made up of blood and epithelial debris escapes from the uterus. Probably, it does not drain away by mere capillary action but is expelled by uterine contractions. There is no absolute proof of this, but it is a fair deduction from anatomical facts. If a patient be examined while menstruating, we may feel an arching of the fornices indicative probably of uterine action.

Dysmenorrhœa is usually divided into certain forms. It is to be regretted that this has been done, because there have not been collected pathological facts sufficient to warrant a classification. The forms usually given are the following:—

Forms usually given.

1. Dysmenorrhœa associated with certain diatheses, such as the gouty and rheumatic;
2. Spasmodic dysmenorrhœa;
3. Membranous dysmenorrhœa;
4. Dysmenorrhœa associated with inflammatory conditions of the uterus, ovary, peritoneum or cellular tissue;
5. Ovarian dysmenorrhœa.

The last term is applied to certain cases which were supposed to be specially connected with the ovaries and which could not be classified under the preceding heads. The term is a most unfortunate one. It assumes a cause for dysmenorrhœa which is not, as yet, demonstrated; and, instead of pathological facts or a confession of our ignorance of them, gives us what we have too much of already—erroneous terminology.

Practical varieties.

So far as our present knowledge goes we can speak of three varieties:—

1. Spasmodic dysmenorrhœa;
2. Congestive dysmenorrhœa;
3. Membranous dysmenorrhœa;
4. Dysmenorrhœa associated with maldevelopment of the sexual organs, pyosalpinx, fibroma uteri, rheumatic diathesis, and some other unknown causes.

1 and 2. *Spasmodic and Congestive dysmenorrhœa.* Of these the most frequent cause is pathological ante flexion, *i.e.*, ante flexion of the uterus produced by inflammation in the utero-sacral ligaments with cicatrisation.

The Erection and Expansion of the Uterus hindered.

The pathology, diagnosis and treatment of this affection is given at pp. 318-331. We only remark here that it is a very serious lesion owing to its inflammatory etiology. From the flexion produced we get spasmodic uterine contraction, accompanied with very great pain and expulsion of

clots. Two theories of dysmenorrhœa have been already explained (p. 322). Those who hold the purely mechanical theory seem to forget that fluid blood passes easily through a capillary. Does any one believe that the lumen at the flexion is less than that of a capillary?

Spasmodic contraction of the os internum and constriction of the cervical canal are also advanced as causes.

3. *Membranous dysmenorrhœa*. In this condition the superficial layer of the mucous membrane is cast off as a triangular sac or in shreds of a more or less firm consistence (figs. 341, 342). This may result from the occurrence of hæmorrhage in the deeper layers of the mucous membrane; and then we can understand that, according to the depth, we




FIG. 341.

SKETCH OF A DYSMENORRHŒAL MEMBRANE AS SEEN UNDER WATER (Sir J. Y. Simpson).

have present no part of the glands or only their cœcal extremities (*Solowieff and Gusserow*). Microscopically, there is excess of round cells and fibrillated tissue in the membrane.

Williams of London, who has written ably on this subject, believes that, owing to an excess of fibrous tissue in the walls of the uterus, the mucous membrane is expelled in coherent shreds. This excess of fibrous tissue is due to defective evolution, sub-involution, or metritis. The membrane is, further, never a plastic exudation. *It is of the greatest importance to remember that it is not a product of conception and should not be mistaken for an early abortion.*

no account whatsoever allow alcohol in any form to be given. If the mother has been giving whisky and water or gin and water, at once point out the risk the patient is running. Do not give morphia, or other opiate, unless driven to it; always give it yourself and hypodermically, never by the mouth or rectum, and give no prescription for it.

When the Dysmenorrhœa is urgent, then an examination should be advised; the index finger well oiled can usually pass in without much pain.

If pathological anteflexion is found, note the amount of inflammatory disturbance, the degree of flexion, and the implication or non-implication of the ovaries. Begin by ordering blisters to the iliac regions, bromide of potassium, the glycerine plug, and the hot vaginal douche. See that the bowels are regulated, and soft motions secured by the use of liquorice powder (*Pulv. glycyrrhizæ co.*) and occasional enemata, and that no tight lacing is allowed. Chlorotic patients should be put on *Blaud's pills* and *digitalis*, and change of air, when requisite, ordered. Note the effect of this for some periods; and then, if unrelieved, pass the sound or graduated bougies or use uterine dilator. This course benefits the Dysmenorrhœa, and it is safer than the use of stem pessaries; the dilatation by bougies seems to act like the stretching of the sphincter ani in fissure of the anus. In certain cases, *Sims' operation* is required (*v. p. 329*).

If the Dysmenorrhœa is membranous, treatment is of little service. The following prescriptions may be tried.

- ℞ *Liquoris arsenicalis* ʒij.
Sig. Three drops in water thrice daily after food.
- ℞ *Liquoris arsenici et hydrargyri hydriodatis* ʒij.
Sig. Five drops in water thrice daily after food.

The action may be analogous to that of arsenic in *Psoriasis*.

Treat any endocervicitis or stenosis of cervix present. The prognosis is unfavourable as to cure. The patients are not necessarily sterile.

In the third class of cases, *Battey's operation* has not given the results anticipated. We have not as yet, however, facts warranting any dogmatic utterances. Where the ovaries are developed but not the uterus, with serious menstrual molimina resulting in consequence, *Battey's operation* is undoubtedly indicated. We hope that abdominal section for removal of Fallopian tube ovaries (*Tait's operation*), as now practised by many gynecologists, will lessen the number of otherwise incurable cases.

Where any diathesis (rheumatic or gouty) is supposed to influence the Dysmenorrhœa, *guaiac*, *colchicum* and such specific drugs may be given.

CHAPTER XLIX.

STERILITY: ABORTION: RETROFLEXION OF THE GRAVID UTERUS.

LITERATURE.

- STERILITY.** *Duncan, Matthews*—Fecundity, Fertility, Sterility and Allied Topics: Edinburgh, A. & C. Black, 1866. *Gulstonian Lectures*: Brit. Med. Jour., April and May, 1883. *v. Gränewaldt*—Ueber die Sterilität geschlechtskranker Frauen: Archiv. f. Gyn., Bd. 8, Hft. 3, 1873. *Kehrer*—Archiv. f. Gyn.; Bd. 10, Hft. 3. *Mayrhofer*—Sterilität des Weibes, etc., Billroth's Handbuch, Stuttgart, 1882. *Sims, Marion*—Uterine Surgery. *Simpson, Sir J. Y.*—Selected Obstetric Works, p. 830.
- ABORTION.** *Duncan, Matthews*—Missed Abortion; Diseases of Women, p. 18: London, 1883. *Hegar*—Monats. f. Geburtskunde, Bd. 21, Suppl. S. 1. *Simpson, A. R.*—Contributions to Obstetrics and Gynecology: On the complete Evacuation of the Uterus after Abortion, p. 104. *Whitehead*—On the Causes and Treatment of Abortion and Sterility: London, 1847.
- RETROFLEXION OF THE GRAVID UTERUS.** *Barnes*—Obst. Operations, 2d ed., p. 242: London, 1871. *Chantreuil*—Leçons faites à l'hôpital des Cliniques, p. 1: Paris, 1881. *Schroeder*—Lehrbuch der geburtshilfe, S. 380: Bonn, 1880.

STERILITY.

Definition. By sterility is understood that conception has not taken place, not that it is impossible. So little is known on the physiology of normal conception that our considerations with regard to sterility must be mostly theoretical. We do not know at what time a Graafian follicle ruptures, how long the ovum takes to pass down the Fallopian tube, at what point it is impregnated, what the circumstances are which diminish its vitality and lessen the probability of its impregnation. The rarity of conception, although an ovum capable of fertilisation is discharged at each monthly period during the whole time of sexual activity, shows that a great variety of conditions must be essential. According to Farr, the average number of children to each marriage in Great Britain is 4.2 p.c., which contrasts strikingly with the number of ova matured during married life.

With regard to sterility we should advance the following considerations. *First*, the spermatic fluid must contain spermatozoa, and these must possess vitality high enough to impregnate the ovum; according to Kehrer, one-fourth of the cases of sterility is due to the non-fulfilment of this condition. *Second*, acid solutions at once destroy, while alkaline solutions preserve the vitality of spermatozoa; the secretion of the vagina is there-

fore destructive. *Third*, as the spermatozoa are microscopic structures, mere stenosis of the genital canal cannot mechanically prevent their passage. *Fourth*, pelvic inflammation binding down the ovaries or displacing the Fallopian tubes will produce sterility. *Fifth*, under the causes of sterility we must include not only those which prevent impregnation of the ovum but those which hinder its attachment to the uterus. The fertilised ovum is implanted, as it were, in the uterine mucous membrane by the root-like chorionic villi; pathological changes in either of these structures prevent the ovum from becoming firmly rooted or from receiving the requisite nutriment.

Sterility is found associated with the following conditions already described:—vaginismus, p. 498; hypertrophied cervix, p. 255; conical cervix with pin-hole os, p. 242; cervical catarrh, p. 282; anteflexion, p. 322; retroflexion (more rarely), p. 341; endometritis, p. 294; ovaritis, p. 184; pelvic peritonitis, p. 154. The last three are probably the most important. The treatment of these has been already described. Cases of vaginismus are the most hopeful as regards the cure of the sterility; with retroflexion the replacement of the uterus is sometimes followed by conception, but in these cases the patient is rarely a nullipara.

ABORTION.

Abortion is so important a factor in the causation of uterine disease that its proper management calls for notice in a work on Gynecology. Many cases of endometritis and metritis may be traced back to a mis-managed abortion.

The cause of abortion may be (1) in the fœtus or (2) in the mother. Causes. On the part of *the fœtus*, disease of the chorion and hæmorrhage into the foetal part of the placenta produce death of the fœtus and consequent abortion; these conditions are most frequently due to syphilis. On the part of *the mother*, endometritis and metritis are the most important causes. General debility and fevers (typhus and scarlet) also produce abortion. Patients show a marvellous ingenuity in tracing back miscarriage to a mechanical cause, such as a violent muscular effort; the cause is rarely of this nature, although it is evident that a severe blow or fall might lead to hæmorrhage and separation of the membranes. When the fœtus dies at the second or third month and is not immediately expelled, it is a "missed abortion;" in such a case the fœtus does not usually putrefy but shrivels up and becomes mummified. In a case reported by Matthews Duncan, the fœtus died at the second month but

remained in the uterus for over five months during three of which the amenorrhœa continued.

Sometimes the practitioner is puzzled exceedingly by such cases. Thus a patient may have had a slight bloody discharge at the second month, so that the practitioner cannot definitely say that the case will or will not go on to full time. He should watch the patient and examine the uterus bimanually at the third month. If the uterus has grown, then it is not a missed abortion. When the abortion is "missed," foetid discharge is found, and the patient may develop septicæmic symptoms if the uterus is not cleared out at once.

Treatment
of impending
abortion.

The treatment of *threatened abortion* is to keep the patient recumbent, perfectly quiet, and under opium if necessary; where there is hæmorrhage, ergot (liquid extract) in *ten minim doses* every few hours may check it without expelling the ovum.

Management
of actual
abortion.

In the management of abortion in a patient who is the subject of chronic inflammation of the uterus, two points require special attention. *The patient should lose as little blood as possible*: hence, when abortion is imminent, the case should not be allowed to drag on for days in the hope that the abortion may be staved off—the doubtful life of the fœtus is of little value compared with the health of the mother; and besides there will, probably, soon be a second conception, and the proper management of this abortion will have brought the uterine mucous membrane into a condition more favourable for pregnancy. *The uterus should be completely evacuated*, and as long a period of rest allowed for involution as after a full-time labour.

To secure these ends we proceed as follows. The vagina having been washed out with carbolised water, a large-sized sponge or tupelo tent is passed fairly into the cervix; this is facilitated by drawing down the cervix with a volsella. After twelve or sixteen hours, the os should be sufficiently dilated to admit one or two fingers.

The patient is put under chloroform as this greatly facilitates the bimanual manipulation. A douche of hot carbolised solution (2 p.c.) is prepared, a nozzle the size of a catheter being fixed on to the tube—the sponge-tent, if not already expelled, is withdrawn, and two or three fingers (if possible, the whole hand) are passed into the vagina. One or sometimes two fingers are introduced through the cervical canal into the body of the uterus, and made to sweep round and round the wall so as to detach the decidua on all sides. If there is room at first for only one finger, a second may be slowly introduced so as gradually to stretch

the canal; the uterus is at the same time grasped through the abdominal wall with the left hand, and pushed down upon the fingers of the right hand until they reach the fundus. No portion of the ovum is removed until the whole is felt to be perfectly free within the uterine cavity. To remove the ovum, hook (not pull) it down with the fingers aiding by expression. The two fingers are the best pair of abortion forceps, although various forms of instrument have been devised.

The uterus having been thus completely emptied, the nozzle of the douche is carried up to the fundus and the cavity gently washed out with the hot carbolic solution; this prevents hæmorrhage and septicæmia. Twelve minims of the ergotin solution (3 grs.) are given hypodermically. The patient keeps at rest for a fortnight or three weeks.

RETROFLEXION OF THE GRAVID UTERUS.

This condition belongs properly to obstetrics; it is important, however, to the gynecologist in regard to differential diagnosis, and has been so frequently mentioned in this connection that it requires brief notice here.

When conception occurs in a retroflexed uterus, it may right itself (*v.* The Retroflexed Gravid Uterus may right itself. p. 342); how often it does so we do not know, as we only see those cases in which reposition has not taken place. Compared with the frequency of this displacement in the non-pregnant uterus, Retroflexion of the Gravid Uterus rarely comes under our notice. Among the patients admitted to the Buchanan Ward during two years, we have seen only four cases.

At the fourth month, the retroflexed gravid uterus is of such a size that it fills the pelvis and presses on the bladder and rectum; the relation of the pelvic organs will be evident from fig. 343.

The diagnostic symptoms are *retention of urine and four months' amenorrhæa*; sometimes there is constant dribbling of urine from over-distension, which may mislead the practitioner. Complete retention is often first noticed on the patient's having retained water for a longer period than usual. Catarrh of the bladder, and even exfoliation of its mucous membrane, arises secondarily. Further, there is difficulty in defæcation, and, when the pressure is great, pain in the pelvis. The usual symptoms of pregnancy are also present.

The *physical examination* shows a fluctuating tumour in the abdomen reaching to the umbilicus and usually to the right of the middle line—this disappears on using the catheter; the vagina is elongated and compressed against the pubis; the cervix may be more accessible than

usual, more frequently it is high up and may be above the pelvic brim; the posterior fornix is depressed by an elastic tumour which fills the pelvis, and is found on combined recto-abdominal examination to be the retroflexed uterus. The bladder is lifted upwards into the abdomen (*v. p. 35*).

Reposition may occur spontaneously after the urine has been drawn off and the bowels have been thoroughly emptied by a purge and enema; **Treatment.** the patient is instructed to pass water every hour. After a day or two if reposition has not occurred, or at once if the uterus is found to be firmly wedged and the symptoms are distressing, we replace it in the

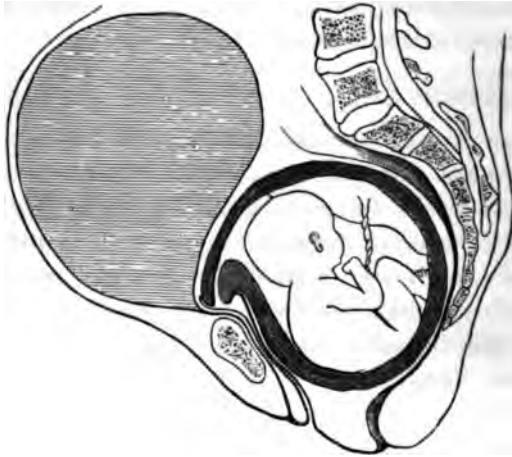

FIG. 343.

RETROFLEXION of the GRAVID UTERUS producing, through compression of the Urethra, distension of the bladder; it also presses on the rectum (*Schroeder*).

following way. The patient is placed in the genu-pectoral posture, and steady pressure is made on the bulging tumour in the posterior fornix by two fingers per rectum; the cervix is at the same time drawn downwards with the volsellae (*v. fig. 212*).

An interesting process of gradual spontaneous reposition occurred in one of the four cases referred to. The portion of the uterus above the brim, as it increased in size, drew the portion wedged in the pelvis upwards into the abdomen.

Sometimes the pregnant uterus expands into the abdomen while a portion remains wedged below the promontory. Such a condition seriously complicates the labour, as in the case reported by W. L. Reid.¹

¹“On a Labour Obstructed from an Unusual Cause:” *Trans. Edin. Obst. Soc.*, Vol. V., Part III., p. 36. This condition is also referred to by Pallen—“A Case of Abdominal Pregnancy Treated by Laparotomy:” *Amer. Jour. of Obst.*, July 1880.

CHAPTER L.

EXTRA-UTERINE GESTATION.

LITERATURE.

Bandl—Die Krankheiten der Tuben, etc.: Stuttgart, 1879, S. 41. *Barnes*—Diseases of Women, p. 339; and Lond. Obst. Trans., XIV., p. 325. *Hecker*—Beitr. zur Lehre von der Schwangerschaft ausserhalb der Gebärmutterhöhle: Monats. f. Geburtskunde, Berlin 1859, Bd. XIII. *Hennig*—Die Krankheiten der Eileiter u. die Tubenschwangerschaft: Stuttgart, 1876. *Parry*—Extra-uterine Pregnancy: Lewis, London, 1876. *Reeve*—A case of Extra-uterine Pregnancy, with successful Application of Electricity: Amer. Gyn. Trans., 1879, p. 313. See discussion on this paper. *Schroeder*—Lehrbuch der Geburtshilfe: Bonn, 1880, S. 401. *Spiegelberg*—Lehrbuch der Geburtshilfe: Lahr, 1878, S. 308. *Thomas*—Diseases of Women, p. 765. The student will find the pathology most fully in Bandl, the diagnosis and statistics of the various modes of treatment in Parry.

THIS comparatively rare condition concerns the gynecologist as much as the obstetrician; the cases come under notice at an early period of pregnancy and, in symptoms and diagnosis, have much in common with purely gynecological cases; the treatment belongs more to operative gynecology than to obstetrics.

PATHOLOGY.

The following is the course of the fertilised ovum in its passage to the uterus: Graafian follicle, fimbriated end of Fallopian tube, canal of Fallopian tube, interstitial (within uterine wall) portion of Fallopian tube, horn of uterus. It may be arrested at any point in this course and, becoming attached, pass through the stages of foetal development just as it does in the uterine cavity.

Of *extra-uterine* gestation, there are therefore the following varieties: ovarian and abdominal, tubo-ovarian, tubal, interstitial, and that which occurs in an isolated horn.

As to the frequency of extra-uterine gestation, Bandl mentions that out of 60,000 gynecological and obstetrical cases (received during seven years at the cliniques of Carl Braun and Späth in Vienna) there were only five cases.

Tubal form most frequent.
Ovarian form disputed.

As to the relative frequency of the various forms, tubal gestation is the most common—about two-thirds of all the recorded cases.

Whether there is an ovarian gestation, by which we understand that the ovum is fertilised in the Graafian follicle and continues to grow there, is a disputed point; Schroeder holds that many cases described as abdominal were really ovarian, that is that the ovum was fertilised while in the ruptured Graafian follicle and developed within it.

After the gestation has gone on for some months, the structures in the

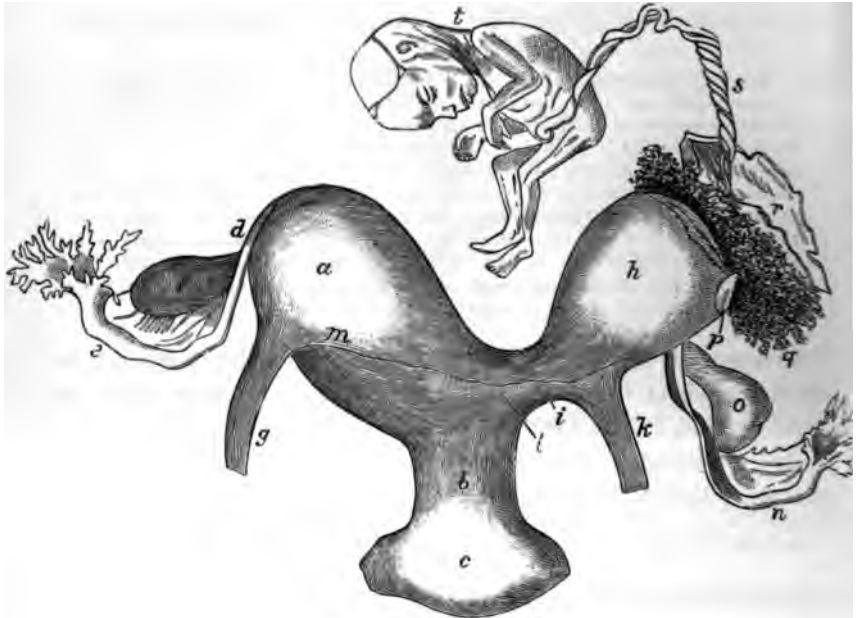


FIG. 344.

GESTATION IN THE DETACHED LEFT-HORN: a Right-horn of uterus; b neck; c vagina; d point of right horn; e right Fallopian tube; f right ovary; g right round-ligament; h detached left horn; i its connection with uterus; k left round-ligament; l muscular fibre springing from the left round-ligament and passing to the right horn; m margin of peritoneum dissected off; n left Fallopian tube; o left ovary with corpus luteum; p seat of rupture with everted margins; q placenta; r membranes; s cord; t fetus (*Kussmaul*, reported by *Heyfelder*).

broad ligament become displaced by the tumour and obscured by adhesions so that it is impossible to say where the ovum began to grow. Cases of abdominal gestation probably begin as tubal or tubo-ovarian.

Occurrence in isolated horn.

Gestation in the isolated horn of a uterus bicornis has been already referred to (*v. p. 236*) and a case of it has been described (*v. fig. 145*); *fig. 344*, taken from *Kussmaul*, represents a case reported by *Heyfelder*.

Interstitial Gestation.

In interstitial gestation, the fertilised ovum has been arrested in the

tube at its uterine end where it passes through the substance of the wall of the uterus; in these cases it was supposed that the ovum was growing interstitially, in the substance of the wall. This form of gestation is seen at fig. 345.

The two structures which call for special notice are (1) the wall of the gestation sac, and (2) the placenta.

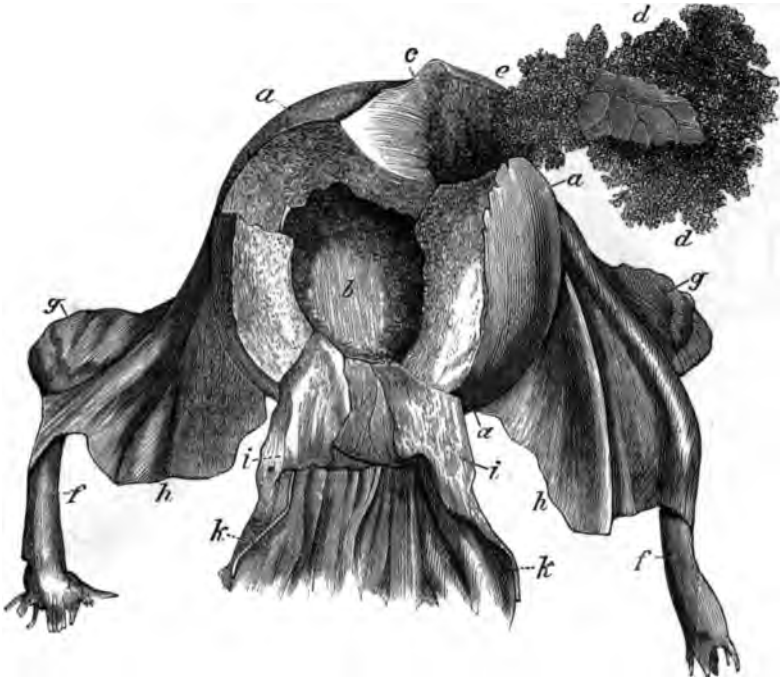


FIG. 345.

INTERSTITIAL GESTATION (*Breschet*): *a* Body of uterus; *b* cavity laid open from the front; *c* embryo sac in wall of uterus; *d* ovum with branching villi; *e* place where the placenta is forming and is still adherent to the wall of the uterus; *f* Fallopian tubes; *g* ovaries; *h* broad ligaments; *i* cervix; *k* vagina.

The *wall* of the sac consists, in a tubal gestation, of the dilated Fallo- Structure
pian tube; this does not develop with the developing foetus (as the uterine of Wall
wall does) and hence, when the latter has grown till about the second of Sac.
or third month, it ruptures from the strain. When the ovum is growing at the fimbriated end or in the abdominal cavity, the wall is formed by adhesions; these yield, and when they rupture new adhesions form outside; hence the sac is capable of increasing in size. Tubo-ovarian and abdominal pregnancies go on for a longer period than tubal—even to full time.

Placenta. The *placenta*. The mucous membrane of the tube hypertrophies and forms a highly vascular areolar tissue; a structure analogous to the decidua serotina is thus formed, in which the chorionic villi are embedded (*Rokitansky*).

Changes in Uterus. The uterus itself undergoes some of the changes of pregnancy. It becomes softer and larger, a decidua forms in its cavity (fig. 346); these changes are most marked in interstitial, less constant in tubal, and still

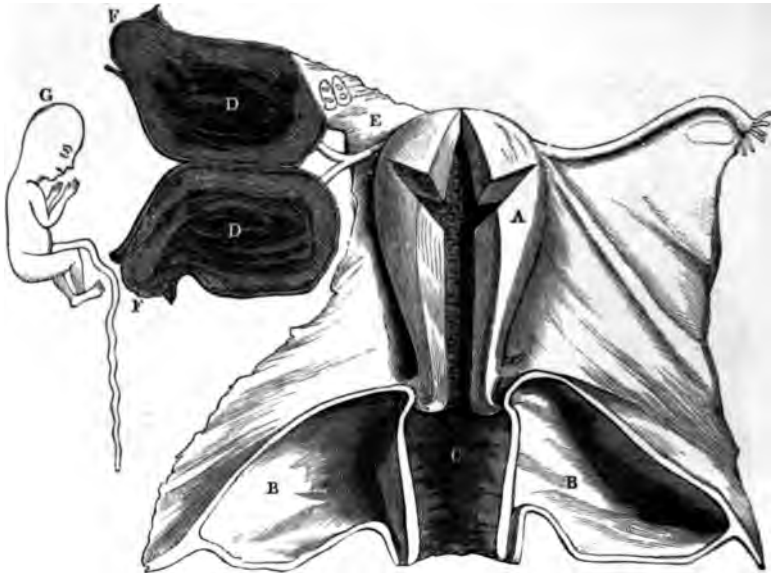

FIG. 346.

FALLOPIAN-TUBE GESTATION WHICH HAS BURST: A, uterus with decidua; B, bladder; C, vagina; D, gestation sac which has ruptured at F; E, posterior layer of broad ligament turned up so as to show ovary with corpora lutea; G, Fœtus (*W. Wilson*).

less so in tubo-ovarian. Fig. 347 shows the size of the uterus in a case of tubo-abdominal gestation of seven months' duration, described by Bandl. The vagina, cervix and mammæ undergo the changes of pregnancy and thus aid in the recognition of the condition.

ETIOLOGY.

The cause must evidently be some mechanical obstruction to the passage of the ovum through the Fallopian tube. Pelvic peritonitis, producing adhesions, will constrict the lumen of the tube (*Hecker*). Bandl explains the relatively greater frequency of extra-uterine gestation in older patients by the fact that catarrh of the tubes (which produces adhesions with obliteration of the lumen) is more frequent in them.

Polypi at the entrance to the tube or in the tube itself have been found as the cause of obstruction.

SYMPTOMS AND DIAGNOSIS.

These, briefly described in the order of their development, are the following.

1. *Those of Pregnancy.* Amenorrhœa, morning sickness, enlargement of the breasts; the patient says that she supposes herself pregnant. As to the amenorrhœa, we must note that it is not continuous; two periods

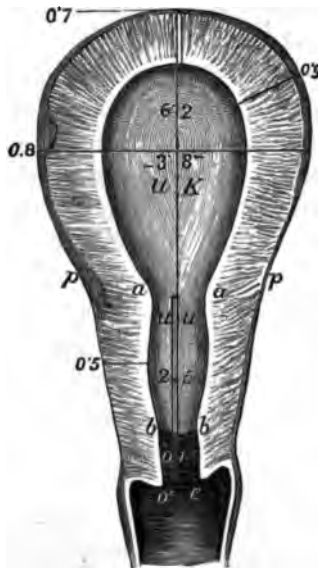


FIG. 347.

SECTION OF A UTERUS IN A TUBO-ABDOMINAL PREGNANCY OF SEVEN MONTHS' DURATION. UK body of uterus; pp fixed point of reflexion of peritoneum; aa os internum of Braune; bb os internum of Muller; uu os externum. The decidua extended as far as bb, from which Bandl concludes that the part of the cervix uu is taken up into the body of the uterus during pregnancy. The numbers indicate the thickness (in cm.) of the walls and the size of the cavity (Bandl).

are passed; and then the menstruation may return, or there may be more frequent hæmorrhages as in the case to be described; with hæmorrhage, portions of decidual membrane may be expelled.

2. *Sudden onset of pain, collapse and internal hæmorrhage.* This means that the gestation sac has ruptured. From the greater frequency of the tubal gestation and the fact that it bursts at an early period—second or third month—with a fatal result, the practitioner often sees the case just at this stage and with these symptoms. He must remember, however, that a hæmatocele due to any other cause will produce the

same symptoms and physical signs; the history of supposed pregnancy is presumptive of this condition, but absolute certainty is only gained on post-mortem examination.

Inflam-
matory
Symptoms.

3. If the case does not thus terminate, there are *occasional attacks of pain in the pelvis and symptoms of inflammation*. This means that the sac has not ruptured, or has done so only partially; the old limiting adhesions are being stretched or torn, and new ones are forming.

Pressure
Symptoms.

4. After the fourth month, *pressure symptoms* often develop; there is difficulty in micturition (amounting to retention), and in the action of the bowels. This is due to the sac's having fallen down behind the uterus into the pouch of Douglas and being of such a size as to fill the pelvis; with this, the uterus will also be displaced. The condition is in many points analogous to retroflexion of the gravid uterus (*Barbour*). Pressure symptoms are not always present; the sac may be fixed by adhesions which prevent its falling into the pouch of Douglas.

Signs as in
advanced
Pregnancy.

5. Finally, the *physical signs of advanced pregnancy* appear; the fetal heart is heard; the parts of the child are felt on palpation. This may be prevented by two causes. (1.) The gestation sac may at any period cease to enlarge; suppuration may lead to discharge of the foetus, or lime salts may be deposited in it producing a lithopædion. (2.) The foetus may die but the sac with the placenta continue to grow and enlarge. It is evident that the diagnosis of this during life is impossible, as the death and shrivelling up of the foetus remove the features which distinguish this from other tumours beside the uterus.

Differential
Diagnosis.

Differential Diagnosis. When the sac ruptures early, differential diagnosis of hæmatocele due to this cause (from that due to any other cause) is impossible without a post-mortem examination. The abdominal pain and vomiting which sometimes accompany rupture of the sac have led to suspicion of *irritant poisoning*, as occurred in the case¹ seen at fig. 346.

When the sac has not ruptured, it must by careful palpation be differentiated from the following conditions:—

1. Normal gravid uterus,
2. Retroflexed gravid uterus,
3. Simple hæmatocele,
4. Ovarian tumour,
5. Fibroid or fibro-cystic tumour,
6. Extensive pelvic inflammation.

¹ See *Trans. Elin. Obst. Soc.*, Vol. V., Part III., p. 169, for the history of this case; for the figure we are indebted to Dr. W. Wilson.

1 and 2. The fact that *the uterus may be felt separate from the tumour* differentiates this from the first two conditions. It is evident, however, that when the gestation sac is close to the uterus, this separation will not be made out. Also when the uterus is stretched upon the wall of the sac (*v. plate IX.*), a condition is produced which simulates retroflexion of the gravid uterus. Contractions are not felt in the sac as in the pregnant uterus. Normal intra-uterine has co-existed with extra-uterine gestation.

3. Gradual increase in size and the symptoms of pregnancy distinguish the unruptured sac from hæmatocele; the latter becomes firmer and is then absorbed.

4. The close resemblance between a small ovarian tumour and a tubal gestation demands, where pregnancy is suspected, careful watching of the development of the tumour and examination for ballottement or the souffle and fœtal heart; in some cases puncturing and drawing off a little fluid aid diagnosis, but this must be done with caution (*v. Treatment*).

5. Fibroid tumours are of a firm unyielding consistence and do not grow so rapidly as a gestation sac would. They are of a large size before they become cystic.

6. Pelvic inflammatory deposit has not the same defined outline. We must remember that an abdominal gestation owes the formation of its sac to inflammatory changes.

PROGRESS AND TERMINATION.

More than four-fifths of the cases end fatally; the mortality is 82·5 Mortality. p.c. (*Kivisch*). In 150 cases of tubal gestation, Hennig found that a fatal result followed in 88 p.c. This occurs most frequently at the second, third or fourth month (*Bandl*).

A favourable result may be due to operative interference, or to the death of the fœtus and its expulsion piecemeal; more rarely does it shrivel up and, becoming calcified, form a lithopædion.

TREATMENT.

Four methods have been adopted: (1) Tapping the sac and drawing off the liquor amnii; (2) Tapping and injecting morphia or other narcotics; (3) Electricity; (4) Removal of the fœtus by abdominal section or through the roof of the vagina. The first three simply aim at destroying the life of the fœtus, leaving it to become mummified or to be discharged by inflammation and suppuration. Tapping should not be

employed unless the nature of the tumour be doubtful, in which case it is necessary for diagnosis; the sudden evacuation of the sac has been followed by contractions, complete rupture and death. Where the diagnosis is certain and the sac situated low down in the pelvis, it may be opened into through the vaginal roof with the thermo-cautery. The fœtus is removed but not the placenta. The advantage of cutting into the sac through the vagina is that it allows us, in the case of hæmorrhage, to plug the sac with salicylic silk. The risk here will be that in opening the sac we cut into the placenta. The seat of the placenta might perhaps be ascertained by a preliminary puncture (*Fränkel*). When the sac is inaccessible from the vagina, laparotomy should be performed; here it is best, if possible, to remove the sac entire as one would an ovarian tumour. If this cannot be done, the fœtus might be removed and the sac stitched to the abdominal walls. In the case of tubal pregnancy, we should operate as soon as the case is diagnosed; in the case of abdominal, we can wait till the full time of pregnancy has been reached.

When the fœtus is dead, are we to operate? The preparation (plate IX.) shows that the placenta may continue to grow and lead to fatal internal hæmorrhage; it also shows that after a time removal may be impossible.


CASE OF EXTRA-UTERINE GESTATION, WITH DEATH OF THE FŒTUS BUT CONTINUED GROWTH OF THE PLACENTA, WHICH LED TO FATAL HÆMORRHAGE.

Barbour's
Case.

History. A. B. æt. 24, IV-para. Five months ago, passed two periods without menstruating, had morning sickness, thought herself pregnant. Three months ago, began to have irregular hæmorrhages thrice a month and in considerable quantity; at same time began to have pain in the back and across the abdomen sometimes so severe that she had to sit down, but was never confined to bed. For the last six weeks has had difficulty in moving the bowels; three weeks ago and on other occasions since, has had retention of urine requiring catheterisation.


Clinical features. After drawing off 3100 of urine with the catheter, a tumour is found impacted in the pelvis. The vagina is compressed against the pubis, the cervix is beyond reach above the brim, the bladder is displaced into the abdomen. The tumour is of the size of a 4½-months pregnant uterus but of a firmer consistence, no uterine contractions are felt in it; auscultation reveals neither uterine souffle nor foetal heart; no uterus can be felt separate from the tumour. Professor Simpson

Haemaphysalis





EXTRA-UTERINE GESTATION.



punctured the cyst with an aspirator-needle through the posterior fornix ; only blood was obtained.

The patient died with symptoms of internal hæmorrhage with increase in size of the pelvic tumour.

Post-mortem examination. The uterus is seen to form part of the anterior wall of a tumour which completely fills the pelvis (fig. 348) ; on each side is the peritoneum of the anterior surface of the broad ligaments ; the round ligaments can be traced as in fig. 348, the right one passing

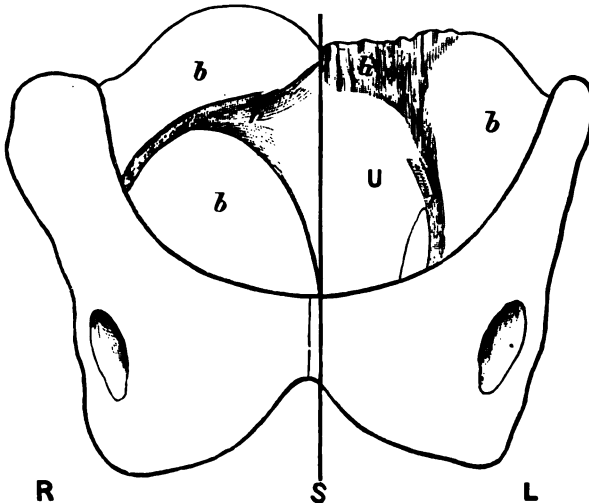


FIG. 348.

FRONT VIEW OF PELVIS AND TUMOUR, SEEN IN SECTION AT PLATE IX. *U* uterus, *b**b* broad ligaments, *rr* round ligaments, *h* adhesions from uterus to omentum which enclosed hæmatocele (*Barbour*).


more directly outwards than the left. The intestines were adherent to its upper surface at the point *h* ; on detaching them, a recent hæmatocele was opened into.

The pelvis was frozen and a section made, with a saw, through the line *S*. An accurate tracing of the frozen section was taken on glass, of which plate IX. is a faithful representation.

Description of Plate IX. The empty bladder extends to 3 inches above the symphysis pubis. The utero-vesical pouch of peritoneum is almost on a level with the pelvic brim. The uterus is divided through its left wall—the cavity not being cut into ; it measures $5\frac{1}{2}$ inches (14·6 cm.) long, the fundus being 5 in. (12·7 cm.) above the symphysis :

Frozen
Section of
a case of
Extra-
uterine
Gestation.

the cervix is drawn up so that the fornices are obliterated. From the upper border of fundus adhesions passed to the omentum, which enclosed a hæmatocele (fig. 348 *h*). The gestation sac lies apparently in the pouch of Douglas, the lower part of which contains recently effused blood. The sac is chiefly occupied by the placenta, into which numerous hæmorrhages have occurred. The cavity of the amnion can be traced down to the lowest part of the sac, but contains little fluid; it is separated from the anterior wall of the sac by blood effusion. The foetus has been divided about the level of the diaphragm, so that the thoracic viscera and ribs are visible; an arm is seen in section below the trunk; the head has collapsed and fallen down to one side of the thorax, so that the flat bones are seen (like a compressed shell) in section. The foetus is about the size of a four-months pregnancy.

FIG. 348^a.

MICROSCOPIC SECTION OF UPPER PART OF WALL OF GESTATION SAC (*Barbier*). *m f, t*, muscular fibre cut transversely; *m f, l*, muscular fibre cut longitudinally; *c t*, connective tissue; *d*, decidual cells; *b c*, blood-clot; *v*, placental villi.

Microscopic examination. *a.* Section cut out of upper part of the sac wall—where it gives attachment to the placenta—is shown at fig. 348^a. This shows the following structures from above downwards: fibrous tissue; layer of muscular fibre cut transversely; fibrous tissue; layer of muscular fibre cut longitudinally, and containing large blood-vessels; fibrous tissue, composed chiefly of proliferating cells; layer of more condensed fibrous tissue with decidual cells; a few villi in patches, separated by masses of blood-clot. Sections made of other portions of the wall showed only fibrous tissue.

The definite disposition of the muscular fibre in the upper portion of

the wall of the sac shows that this part consists of Fallopian tube. To explain its absence in other parts we must suppose that it is either a tubal gestation which has ruptured below into the broad ligament, or a tubo-abdominal which has fallen down into the pouch of Douglas (*Barbour*).

This case presents the following points worthy of note. The patient was young and had had a series of normal pregnancies immediately be-

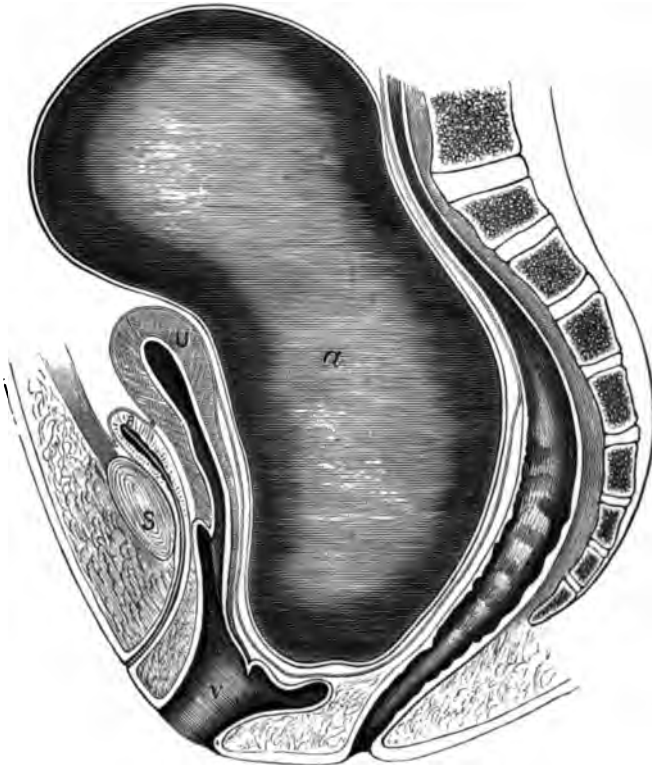

FIG. 349.

DIAGRAMMATIC REPRESENTATION OF AN EXTRA-UTERINE PREGNANCY OF SEVEN MONTHS DURATION (*Bandl*).

B Bladder; *U* uterus (anterior wall measured 12 cm. long; posterior 16 cm.; thickness at side-walls was 2 cm.); anterior lip is at level of middle of symphysis *S*, posterior lip is at level of urethral orifice; *a* gestation sac, which reached to the umbilicus.

fore this one: after two months' amenorrhœa, irregular hæmorrhages occurred from the uterus; there was no history of rupture of the sac; foetal movements had never been felt and the auscultation gave negative results; pressure symptoms appeared at the fourth month as in retro-

flexion of the gravid uterus ; the uterus was taken up, as it were, into the wall of the sac so that the latter simulated an enlarged uterus ; the continued growth of the placenta, after the fœtus had died, led to the fatal hæmorrhage. Removal of the sac by abdominal section was impossible.

Bandl's
Case.

To contrast with this preparation, we have represented at fig. 349 one from Bandl. The pregnancy had gone on for seven months ; fœtal movements and heart sounds were made out. The anatomical relations are given in the figure. The sac was incised through the posterior fornix, and the child extracted by the feet ; the placenta was removed immediately afterwards with profuse hæmorrhage ; the cavity was washed out and a drainage-tube inserted.

SECTION X.

AFFECTIONS OF BLADDER AND RECTUM.

- CHAPTER LI. The Bladder : Anatomy, Physiology, and Methods of Examination.
- „ LII. Affections of the Bladder and Urethra.
- „ LIII. Vesico-Vaginal Fistula.
- „ LIV. The Rectum : Coccygodynia.

APPENDIX.

- Weir-Mitchell's Method of Treating Chronic Cases.
- Hysteria and Hystero-Epilepsy.
- Etiology of Uterine Disease.
- Case-Taking.
- Guide to Gynecological Literature.

INDEX OF AUTHORS AND SUBJECTS.

CHAPTER LI.

THE BLADDER: ANATOMY, PHYSIOLOGY AND METHODS OF EXAMINATION.

LITERATURE.

Chiene—Bladder Drainage: Ed. Med. Jour., 1880. *Croom, J. H.*—On Retention of Urine in the Female: Ed. Med. Jour., April and May 1878. *Hart*—Physics of Rectum and Bladder: Ed. Obst. Trans., 1882. *Noeggerath*—The Vesico-vaginal and Vesico-rectal Touch: Am. J. of Obstetrics, viii., 135. *Ogston*—Ed. Med. Jour., 1878. *Power*—Physiology of Micturition: The Practitioner, 1875. *Skene*—Diseases of the Bladder and Urethra in Women: W. Wood & Co., New York, 1878. *Winckel*—Die Krankheiten der weiblichen Harnröhre und Blase: Billroth's Handbuch, Stuttgart, 1877.

DISEASES of the bladder are of the greatest importance as they are not only very painful but, for a reason to be given shortly, very intractable. In a Manual of the present scope, a full consideration of vesical disease is impossible; we therefore give a mere sketch, and refer the practitioner for details to Skene's or to Winckel's Manual.

ANATOMY AND PHYSIOLOGY.

For the anatomy, the student is referred to pp. 29 to 35. We should here only point out that the female bladder, owing to its greater breadth transversely at the base (*v. fig. 360*), is relatively more capacious than that of the male.

Physiology
of Urina-
tion.

Urination. The mechanism of the storage and expulsion of urine from the bladder is full of interest, both from a theoretical and a practical point of view. The urine trickles along the ureters, a result partly due to blood pressure and partly to the peristaltic action of the ureters themselves. It thus reaches the bladder, at this stage an empty flaccid sac with its upper half fitting into the lower calyx-like portion. Gradually the bladder distends, until at last the activity of the motor centre (whose constant action keeps the urethral muscles contracted) is reflexly inhibited, and the urine is expelled by the muscular contraction of the bladder and intra-abdominal pressure. The bladder is now contracted and, on section, has the shape seen at *fig. 350*—its shape in systole. The bladder then

relaxes, *i.e.*, becomes flaccid or has its diastole, and once more the urine trickles into it (fig. 27).

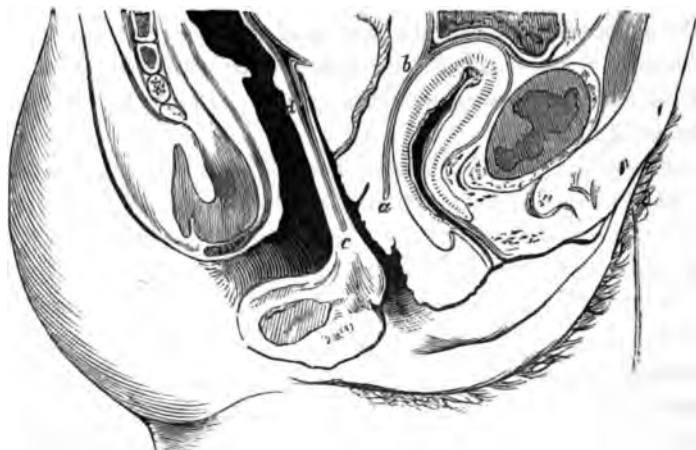

FIG. 350.
BLADDER IN SYSTOLE (*Braune*).

The bladder therefore has, like the heart, its systole and diastole. A knowledge of this is important practically. It explains the intractability of inflammatory conditions of the bladder, since the bladder when inflamed does not get—what every inflamed organ requires—rest.

The average amounts of the several urinary constituents passed in 24 hours, as given by Parkes, are the following.

	1500·000 Grms.	Composition of Urine.
Water	1500·000	
Total solids	72·	
Urea	33·180	
Uric acid	·555	
Hippuric acid	·400	
Kreatinin	·910	
Pigment, etc.	10·00	
Sulphuric acid	2·012	
Phosphoric acid	3·164	
Chlorine	7·00	
Ammonia	·770	
Potassium	2·500	
Sodium	11·090	
Calcium	·260	
Magnesium	·207	

Urine also contains various epithelial scales, a little mucus, nitrogen and carbonic-acid gases.

The reaction is acid, and the specific gravity is 10-20.

METHODS OF EXPLORING THE URETHRA AND BLADDER.

A. *By Catheter and Sound.*

The catheter is passed for the purpose of drawing off the urine, while the sound is usually employed for diagnostic purposes—ascertaining the state of the mucous membrane, the presence of stone or other pathological conditions.

Method of passing the catheter. The instrument to be employed for this purpose is a male gum-elastic catheter, No. 8 or 10. In some special cases, a silver instrument is required. Battey recommends a long rubber catheter as a very useful instrument. The catheter must first be thoroughly washed with carbolic lotion 1-20, and then its end dipped in 1-40 carbolic oil. Cleanliness in the use of the catheter is of the very highest importance, as cystitis and even pyæmia may be caused by putrid urine in old people.

The patient lies on the left side square across the couch, with the hips at the edge and the knees drawn up. The pulp of the index finger of the left hand is passed over the base of the perineal body and onwards until it touches the vestibule. It should then be carried a little backwards until we feel the meatus at the base of the smooth vestibule and in the middle line. The catheter is passed with the right hand; the index of the left hand feels, through the anterior vaginal wall, that it passes into the urethra. After the last drop of urine has been expelled, it is withdrawn and the finger held over its proximal end so as to retain the fluid remaining in the catheter until it can be poured into the receptacle.

The catheter may also be passed with the patient lying on the back; the index of the right hand is carried under the drawn-up right thigh to feel the meatus, and the catheter is passed between the thighs with the left.

Battey's catheter is very convenient, as from its length it reaches to the floor and can be withdrawn without any precaution as to spilling. Further, it is easily cleaned; to do this it is coiled up in a bowl of 1-40 carbolic lotion, and then when one end is brought over the edge it empties by syphon action. The indications for the catheter will be given afterwards; at present we only remark that it should never be passed unless necessary, and that the greatest care should be taken not to introduce septic matter.

B. *Digital and Specular Exploration of the Urethra and Bladder.*

Owing to the large amount of muscular and elastic tissue in the

urethra, it can be stretched to an extent that permits of digital and specular examination of the urethral and vesical lining membrane.

Digital examination. With the patient lying on the left side and under chloroform, the tip of the little finger is placed against the meatus and by a rotary motion passed through it in the direction of the urethral axis. The meatus is the most resistant portion of the urethra; therefore, to aid in its dilatation, some recommend to notch it with radiating nicks. This is unnecessary (*A. R. Simpson*). By steady pressure, the little finger is first pushed in and then the index one substituted. For exploratory purposes, this is sufficient. To complete the examination, the patient should be turned on the back and the Bimanual done as shown at fig. 73. This is aided by the middle finger in the vagina, and is therefore termed the vesico-vaginal Bimanual.

Dilatation
of Urethra
with finger.

The presence of stone or of tumours, the state of the mucous membrane of the bladder, the nature of obscure bodies in front of the uterus can all be thoroughly ascertained; vesico-vaginal fistulæ can be examined, when the vagina has been obliterated; intestino-vesical fistulæ can be detected; calculi, impacted in the vesical portion of the ureters, can be removed; fissures of the neck of the bladder can be stretched; Winckel adds to these that we can open a hæmatometra through the bladder, when its evacuation between the bladder and rectum is impossible—a very rare indication. The Fallopian tubes can also be palpated (*Noeggerath*); and, in one special instance, Croom proved by this method that the sound had perforated the walls of the thin superinvolved uterus and not passed along the Fallopian tube.

Simon's method of specular dilatation of urethra. Simon of Heidelberg drew special attention to the dilatation of the urethra by his specula as a means of treatment. The object is to dilate the urethra sufficiently to allow of the passage of calculi, crushed or uncrushed. By it we also destroy temporarily the sphincteric action of the urethra and thus establish an incontinence of urine; this allows to the inflamed mucous membrane, undisturbed now by the frequent muscular contractions which before were necessary to expel the urine, the rest it needs. The difficulty of Simon's method is the risk of causing, by over-stretching, permanent incontinence of urine—a condition as yet incurable.

with
Specula.

Simon's specula are shown at fig. 351, and the various sizes at fig. 352. The specula are provided with bulbous plugs, to be used while they are being introduced and afterwards withdrawn. Simon estimated the limit of safe dilatability for the female urethra at various ages as

Simon's
Specula.

diameter of $1\frac{3}{8}$ in., but Dunlap has recorded a case where a stone $2\frac{1}{4}$ in. in diameter was safely extracted uncrushed through the urethra without consequent incontinence of urine (*Am. J. of Obst.*, Vol. XIV., p. 855).

The dilators of Simon are graduated, and are passed slowly until the desired limit is reached.

It is doubtful if they can, without risk, be used as Simon recommends.

Specular examination by Skene's specula. Fig. 353 shows Skene's ^{Skene's} specula. Each may be described as a small test tube which fits into a ^{Skene's} specula.



FIG. 353.

SKENE'S URETHRAL SPECULA (Skene).

truncated or fenestrated case of vulcanite. The glass tube projects beyond the outer truncated case; and a small mirror can be carried through the inner tube so as to reflect light.

Skene's directions are to pass the tube (with mirror inside) along the urethra, and to use sun-light or gas-light from a movable bracket. When a large Skene's speculum is used, the urethra should be first dilated with the index finger. When viewed through the speculum, the mucous membrane of the bladder is somewhat pale.

The hard rubber speculum can be used to make applications.

A specially narrow Fergusson's speculum with a hand mirror is also simple and useful (*M. Duncan*).

c. *Catheterisation of the Ureter.*

This is by no means an easy operation, but is useful in certain cases.

By this means we can ascertain the position of the ureter in operating on vesico-vaginal fistula, and prior to excision of the cancerous uterus; and, in proposed excision of the kidney, can ascertain the state of the other kidney by examination of the urine from it.

Catheterisation of Ureter.

Method of Performance. Pass the index finger into the bladder as already described (p. 571); about an inch from the neck of the bladder and at each end of the inter-ureteric ligament, a prominence (in which

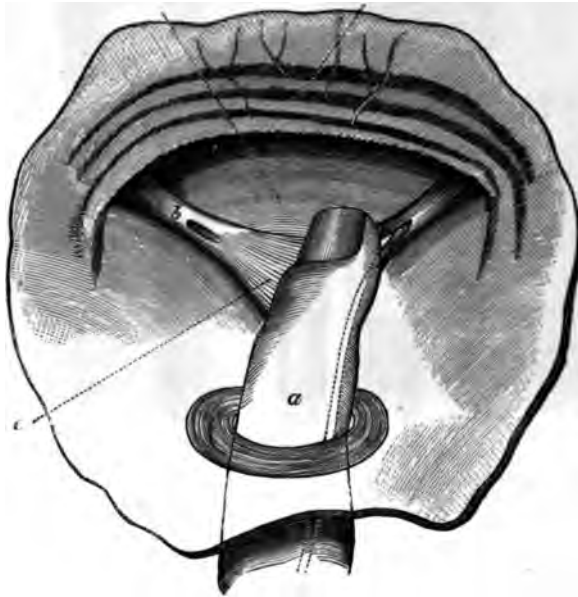


FIG. 354.

FINGER PASSED THROUGH URETHRA INTO BLADDER TO GUIDE HOLLOW PROBE INTO LEFT URETER.
a Internal Sphincter of Urethra, b Orifice of right Ureter, c Inter-ureteric Ligament (*Wunderl.*)

is the vesical opening of the ureter) can be felt with the pulp of the examining finger. A fine hollow probe is guided into this and its point carried to the side (fig. 354). The urine will now trickle out drop by drop. According to Pawlik, the inter-ureteric ligament can be felt through the anterior vaginal wall when the patient is in the genu-pectoral posture. He thus passes the ureteric catheter without dilating the urethra (*Centr. f. Gyn.*, Oct. 15, 1881).

CHAPTER LII.

AFFECTIONS OF THE BLADDER AND URETHRA.

For LITERATURE, *see* CHAPTER LI.

MALFORMATIONS OF THE BLADDER AND URETHRA.

THESE comparatively rare malformations are easily understood on consideration of the development of the organ.

The bladder is the part of the allantois included by the abdominal plates of the embryo (figs. 311 to 315); the upper portion of the posterior wall of the urethra is formed by Müller's ducts, while the lower is formed by an invagination from the genito-urinary sinus. The developmental defects are therefore the following:—

- (1) Total absence of urethra ;
- (2) Defect of external portion of urethra—hypospadias ;
- (3) Defect of internal portion of urethra ;
- (4) Atresia of the urethra (in malformed fœtuses) ;
- (5) Extroversion of the bladder from deficient closure of the embryonic abdominal plates.

We would here only note the rarity of these conditions, and refer the practitioner to Skene or Winckel for details.

DISEASES OF THE URETHRA.

Of these the most important are Displacements, Neoplasms, Urethritis, Dilatation, and Stricture.

Displacements of the urethra will be easily understood by reference to those of the bladder.

NEOPLASMS OF THE URETHRA ; URETHRAL CARUNCLE.

The urethra is liable to be invaded by papillomata, polypi, sarcomata, carcinomata, and vascular growths (angiomata).

Of these last, the most common is the well-known Urethral Caruncle.

Urethral
Caruncle.

Pathology. This is a vascular excrescence varying in size from a pin head to a strawberry; it consists of dilated capillaries in connective tissue, the whole being covered with squamous epithelium. *Physical Signs.* A cherry-red tumour, exquisitely tender and vascular, is seen at the urethral orifice (fig. 355). *Symptoms.* These are pain on micturition or even retention of urine, pain on coitus. *Treatment.* Place the patient under chloroform in the lithotomy posture, and destroy the growth by Paquelin's cautery at a dull heat. If bleeding occurs, do not

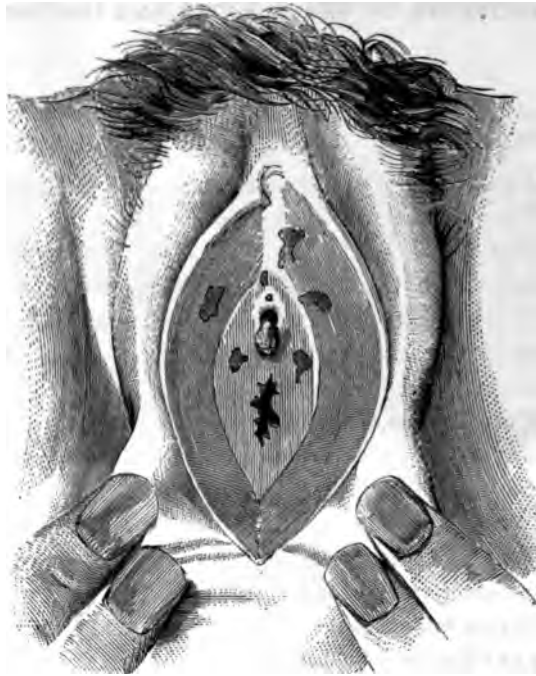

FIG. 355.

CARUNCLE AT URETHRAL ORIFICE (a) AND, IN ADDITION, NEUROMATA IN SURROUNDING MUCOUS MEMBRANE—see page 514 (Sir J. Y. Simpson).

treat it lightly; plug the vagina, bringing the half of the last strips of lint over the urethral orifice and fixing with a perineal band.

As regards the other neoplasms, papillomata are painless, sarcomata very rare and their nature settled microscopically, while carcinomata appear as hard peri-urethral tubercles which break down (*Skene*). In regard to treatment, they may be removed by the curette, or by small loop-snare when high up. We may also have inflammatory changes in Skene's "tubules" (v. p. 31).

URETHRITIS.

Acute urethritis is usually part of a gonorrhœa. When pus is secreted, the urethra can be felt swollen and tender; the pus can be squeezed out of the urethral orifice by pressure from above downwards; on passage of the sound, pain is felt in the urethra although no cystitis be found.

Treatment. Give diluent drinks so as to increase the flow of urine. Copaiba may be given in the form of the well-known Nesbitt's specific:—

R. Liquoris Copaibæ Co. (Nesbitt) ʒ ij.
Sig. Teaspoonful thrice daily.

Iodoform bougies may be passed in, and counter-irritation applied in the shape of the tincture of iodine over the anterior vaginal wall.

DILATATION AND STRICTURE OF THE URETHRA.

The urethra may be unusually *dilated*, a condition rarely met with; in some cases the dilatation has been caused by coitus, as in malformations of the vagina (*v. p.* 236). The dilatation may be local or general. When it is general, the cautery may be used to burn a vertical furrow, the rest of the urethra being guarded by a speculum.

Stricture of the urethra is a rare condition and readily yields to dilatation by bougies or to incision.

DISEASES OF THE BLADDER.

Of the diseases of the bladder we shall here consider Displacements, Neoplasms, Stone in the Bladder, and Cystitis. Vesico-vaginal fistula will be considered in a separate chapter (Chap. LIII).

DISPLACEMENTS OF THE BLADDER.

The female bladder when empty lies between the pubis and usually to one or other side. It is never exactly central.

From its loose attachment to the pubis, it is pre-eminently displace-
able. (1) It is drawn up during labour; and (2) is displaced upwards by retroversion of the gravid uterus, pelvic ovarian or fibroid tumours, and pelvic hæmatocele. (3) It may be adherent to the anterior surface of an abdominal ovarian or fibroid tumour, and may thus be cut into on abdominal section. (4) It is displaced downwards in prolapsus uteri and in cystocele. (5) In utero-sacral cellulitis of the uterus, the bladder is

The
mobility
of the
Bladder.

drawn back and fixed; its systole is thus interfered with, which explains some cases of so-called hysterical retention of urine.

From this mobility it follows that the height of its fundus above the symphysis gives no indication of the amount of urine in the bladder.

CYSTOCELE.

By this we understand a pouching of the posterior wall of the bladder downwards and backwards; the uterus and summit of the bladder are in normal position.

Senile
form of
Prolapsus.

Many a case, regarded as cystocele, is really part of a prolapsus uteri; on the other hand, the so-called "senile prolapsus uteri" is really a cystocele; at the menopause the cicatrisation of the vaginal walls chiefly affects the posterior one, and thus the bladder tends to bulge outwards at the vaginal orifice.

The diagnosis is easily made by the Bimanual and use of the sound. The treatment consists in the use of a ring pessary with diaphragm (fig. 328) or such a one as is seen at fig. 331. Should these fail, the vagina may be packed with oakum or a raw surface (as shown at fig. 339) may be made and stitches applied.

NEOPLASMS OF THE BLADDER.

Pathological anatomy. We may have mucous, fibroid or fibro-mucous polypi. There may also be sarcomatous or carcinomatous disease of the bladder wall, as well as so-called tubercle. The carcinomatous condition is not infrequent, and is termed by some "villous cancer." It is most common at the trigone, and is held by some authorities not to be malignant. The bladder may be secondarily affected in carcinoma uteri (v. p. 433).

Symptoms. These are disturbances of micturition, with bloody and phosphatic urine.

Physical signs. The passage of the index finger into the bladder will show the position, shape, and other characters of the growth.

Treatment. This will vary according to the position, nature, and pediculation or non-pediculation of the growth. Thus it may be twisted off by narrow polypus forceps, snared by a loop of fine catgut, or removed by incision into the posterior wall of the bladder and use of the galvano-cautery or curette (v. *Stone*).

CYSTITIS.

Nature. An acute or chronic inflammatory affection of the mucous membrane of the bladder.

Pathological anatomy. In the acute catarrhal form, we have congestion of the vessels and loss of epithelium ; in the chronic catarrhal form, the congestion is duller and there is marked rugosity of the lining of the bladder. The submucous and even the muscular tissues also become affected. The mucous membrane may be ulcerated and the muscular tissue exposed.

The inflammatory process may extend deeper, to the muscular tissue (interstitial cystitis) or to the peritoneum (pericystitis). Occasionally, though rarely, we may have diphtheritic inflammation.

In advanced cases, the patient is usually septicæmic and there is often hydro-nephrosis. In some cases of prolonged retention the mucous membrane may slough off and be passed per urethram, but may be regenerated. Results of Cystitis.

Etiology. The causes are as follows :—Gonorrhœa ; latent gonorrhœa ; exposure to cold ; injury from coitus ; prolonged parturition ; introduction of septic matter by catheter or bougie ; prolonged retention of urine.

Symptoms. In *acute cystitis* the patient has very frequent and painful micturition. In *chronic cystitis* also, there is frequent micturition but accompanied with less intense pain ; there are, further, shooting pains with secondary phenomena—septic, vascular and nervous.

Physical signs. (a) *Acute cystitis.* The urine has a low specific gravity and acid reaction ; the colour is little altered, and mucus is present in excess. On vaginal examination, pain is not felt when pressure is made on the posterior vaginal wall but is felt severely *when the anterior wall is touched.*

(b) *Chronic cystitis.* The urine has a low specific gravity, is usually alkaline, and is often offensive ; it contains pus, epithelium, phosphates and bacteria ; albumen, derived from the pus, is present. The vaginal examination gives the same results as in acute cystitis. If the finger be passed through the urethra (*v. p. 571*), the roughened condition of the lining membrane is felt ; crystals of phosphate and marked rugosities can also be detected. Characters of Urine in Cystitis.

Prognosis. In both acute and chronic cystitis, the prognosis is not good ; the treatment is difficult, and in bad chronic cases the patient's strength sometimes becomes exhausted and septicæmia may cause death.

Treatment. (a) *Acute cystitis.* Put patient on milk diet, and give Friedrichshall or Carlsbad water freely. Diluent drinks may be taken *ad libitum.* Treatment of Acute Cystitis.

The following prescription is useful.

R Potassæ Bicarbonatis	ʒ iss.
Tincturæ Hyoscyami	ʒ i.
Infusum Buchu	
vel Pareiræ	ʒ vj.
vel Uvæ Urai ad	

Sig. Tablespoonful thrice daily.

In gonorrhœal cystitis, the following may be substituted :

R Liquoris Copaibæ Co. (Nesbitt)	ʒ ij.
----------------------------------	-------

Sig. Teaspoonful thrice daily.

If the pain is very acute give morphia suppositories ($\frac{1}{4}$ grain) at night, omitting the mixture with the hyoscyamus if necessary.

Treatment
of Chronic
Cystitis.

For (b.) *Chronic cystitis*, we recommend the following treatment *seriatim*.

1. Put on milk diet with abundant fluids, and purge freely. Give

R Acidi Nitrici diluti	ʒiij.
Tincturæ Hyoscyami	ʒi.
Infusum Buchu ad	ʒvj.

Sig. Tablespoonful thrice daily.

The hyoscyamus eases the pain ; and the nitric acid corrects the alkaline phosphatic urine, for which also benzoate of ammonia is admirable.

R Ammoniae Benzoatis	ʒiii.
Aquæ	ʒvj.

Sig. Tablespoonful thrice daily.

The benzoate of ammonia is converted into hippuric acid and corrects alkalinity. Nesbitt's specific is also useful.



FIG. 356.

THE SKENE-GOODMAN SELF-RETAINING CATHETER ; AN INDIA-RUBBER BAG CAN BE WORN WITH IT (Skene).

2. If this fail, then wash out bladder as often as possible by means of double catheter, such as Skene's ; use weak boracic lotion, or carbolic lotion ; inject with the douche or Higginson's syringe. Paint anterior vaginal wall with tincture of iodine.

3. A long (winged) india-rubber catheter may be kept in the bladder so as to drain off the urine constantly and give the bladder rest. The patient need not remain in bed if the Skene-Goodman catheter (fig. 356) is used.

4. In obstinate cases, the formation of an artificial vesico-vaginal

fistula may be tried. To do this, chloroform the patient; place her in the lithotomy posture and apply Sims' speculum. Open into the bladder through the anterior vaginal wall, in the middle line, with Paquelin's cautery at a dull heat. This may also be done with the scissors, as follows: pass the finger into the bladder, and then by means of a pair of straight scissors cut it open in the middle line. Preliminary dilatation of the urethra with the finger enables the operator with certainty to avoid cutting into it. The advantage of the cautery is that the wound does not readily unite; when the opening is made with knife or scissors, care is required to prevent its healing. Emmet stitches the vesical and vaginal edges together (button-hole operation).

The urine trickles through the artificial fistula; in this way, the bladder gets complete rest and can be thoroughly washed out.

After some months the fistula is easily closed, as in the operation for vesico-vaginal fistula. Severe cases of cystitis will tax, more than any other disease, the practitioner's patience and knowledge. It is well to keep in mind the reason of this intractability, viz., the inability of the bladder to remain at rest.

As can be seen from what has gone before, the principles of treatment are the following:—(1) to correct abnormalities in the urine; (2) to allay the irritability of the bladder; (3) to lessen the congestion of the bladder by purgatives and counter-irritants, and to render the urine bland and lessen the work of the kidney by milk diet; (4) to allay the irritable condition of the bladder by injection; (5) to give it complete rest by a permanent catheter or, in extreme cases, by an artificial fistula.

CALCULI AND OTHER FOREIGN BODIES IN THE BLADDER.

The female bladder is liable to receive foreign bodies from three sources.

A. Calculi from the kidneys—uric acid, oxalates, phosphates or cystine.

B. Substances from neighbouring organs—pus from pelvic abscess, concretions from the intestines, bones from an extra-uterine foetation, pessaries from the vagina, echinococci and other parasites such as those associated with chyluria.

C. Foreign bodies introduced wilfully into the bladder by patients of depraved taste; these often form nuclei for stones (fig. 356*).

Of these, *calculi* are the most important. Stone is less common in the female than in the male, as small calculi can pass along the dilatable female urethra; occasionally, therefore, the gynecologist has to remove from the urethra small stones impacted there—usually at the meatus

urinarius. The introduction of foreign bodies, which act as nuclei, is more common in the female.

Symptoms. These are severe pain in micturition, especially at the close; alterations in character of urine; blood in urine.

Diagnosis
of Calculi.

Physical signs. The stone, when at all large, can be easily detected bimanually; when any doubt exists, the use of the sound or the passage of the finger into the bladder renders the diagnosis easy.

Treatment. Measure the stone: if it be less than an inch, it may be extracted through the urethra dilated first by the finger or Simon's

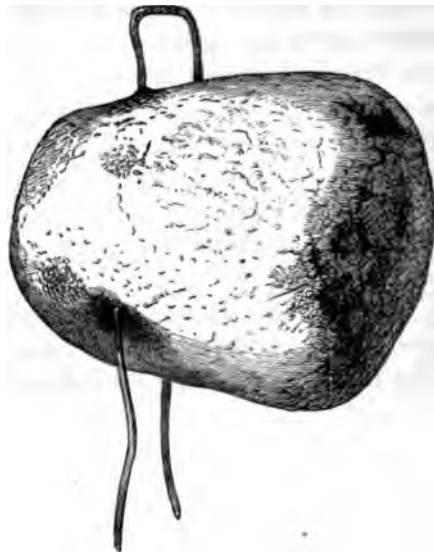


FIG. 356^a.

LARGE STONE WHICH FORMED ROUND A HAIR-PIN AS NUCLEUS, EXTRACTED BY VAGINAL LITHOTOMY
(*Angus Macdonald*).

specula; if greater than an inch, then dilate the urethra and crush; if very large or hard or if it have a nucleus, extract by vaginal incision. This incision may be stitched up after the operation, or kept open when the bladder has been much irritated; it can afterwards be stitched as in vesico-vaginal fistula.

For other foreign bodies, the urethra can be dilated and the substance grasped by polypus forceps or manipulated out. When large, they may be extracted as in the case of large stones.

FUNCTIONAL DISEASES OF BLADDER.

By these we understand derangements of the bladder in regard to

urination. Either these are due to causes as yet unascertained, or the same derangement (*e.g.*, retention) is associated with many lesions.

The chief functional diseases are these—

Irritability,
Incontinence,
Retention.

Functional
affections
of the
Bladder.

In regard to all of them, we may remark that in no case should the diagnosis of a functional disease of the bladder be made until the practitioner is satisfied that there is no organic lesion.

Irritability. In this, frequent micturition associated with disagreeable feeling is present. It may be due to excessive acidity of the urine but is often a nervous affection. When it is due to excessive acidity, give lithia or potash.

R Lithiæ Carbonatis gr. v.
Fiat pulv. mitte tales vj.
Sig. One thrice daily.

Incontinence, or inability to retain urine, is most common in little girls; occasionally we meet with it in adults, as the result of prolonged labour or as a permanent condition from infancy.

In the incontinence of girls, note whether there be any irritability of the genitals (vulvitis) or ascarides. Goltz found that, where section of the spine in the dog above the lumbar enlargement had produced retention of urine, he could make it urinate by sponging the anus with cold water; a reflex impulse passed from the rectum, inhibiting the activity of the motor centre and causing bladder contraction. In a child, ascarides in the rectum will act in the same way when it is asleep.

Treatment. Treat the irritating cause—as vulvitis or ascarides. If no irritating cause be detected, then give belladonna.

R Tincturæ Belladonnæ ʒij.
Sig. Three drops thrice daily.

In strumous cases, give syrup of the iodide of iron or cod liver oil.

R Syrupi Ferri Iodidi ʒij.
Sig. Thirty drops thrice daily.

Retention of Urine. Palpation shows a fluctuating mesial tumour rising into the abdomen; the position of the fundus of the bladder gives no indication of the amount of urine, as it may be tilted up by retroversion of the gravid uterus. Remember that a bladder may be distended so as to be as large as a six or eight months' pregnancy, and that constant dribbling-away of the urine may be a symptom of retention. Examine the pelvis for an organic lesion.

Retention may be due to one of three great classes of causes :—

Hysterical,
Reflex,
Mechanical.

1. *Hysterical.* By this we mean that from perversity or a prurient desire to have the catheter passed, a patient feigns inability to pass urine.

The treatment is to give a hot hip-bath followed by a cold one ; if the catheter is needed, get it passed by a nurse of unsympathetic tendencies.

2. *Reflex* causes are the following :—

- (1) Gonorrhœa ;
- (2) Urethritis ;
- (3) Irritable caruncle ;
- (4) Carcinoma, urethral and vaginal ;
- (5) Perineal and especially vestibular tears after labour, tears of cervix ;
- (6) Ligature of internal piles.

The treatment is hot appliances in (1), (2), (3), and (5) and (6) ; and the catheter in (4). Remove the source of irritation when possible.

3. *Mechanical.* These are pressure of fibroids, retroversion of the gravid uterus ; ovarian or parovarian tumours (pelvic and retro-uterine).

Where the tumour is impacted in the pelvis, a silver male (No. 10) catheter will pass best. The urethra is compressed, the bladder bulging over the symphysis ; accordingly, a rigid instrument whose handle can be carried to the perineum is good.

CHAPTER LIII.

VESICOO-VAGINAL FISTULA.

LITERATURE.

Baker Brown—Surg. Diseases of Women, 3d Ed., p. 133; and *Lancet*, March, 1864. *Bandl*—*Wiener Med. Woch.*, 1875, Nos. 49 to 52; and 1877, Nos. 30 to 32. *Bozeman*—Remarks on Vesico-vaginal Fistula, 1856; *Americ. Journ. of Med. Science*, July 1870; *Obst. Journ. of Great Britain*, June to Aug. 1878. *Byford*—Medical and Surgical Diseases of Women: Philadelphia, 1882. *Emmet*—On Vesico-vaginal Fistula: New York, 1868. *Hegar and Kallenbach*—Die Operative Gynäkologie, S. 582: Stuttgart, 1881. *Simpson, Sir J. Y.*—Diseases of Women, p. 30: Edin. 1872. *Sims, Marion*—On the Treatment of Vesico-vaginal Fistula: *Americ. Jour. of Med. Science*, Jan. 1852. *Silver Sutures in Surgery*: New York, 1858. *Simon*—Ueber die Heilung der Blasenscheidenfisteln; Giessen 1845, and Rostock 1862; *Wiener med. Wochenschrift*, 1876, Nos. 27-32. *Winckel*—Die Krankheiten der weiblichen Harnröhre u. Blase: Stuttgart, 1877, S. 95.

PATHOLOGICAL ANATOMY AND VARIETIES.

THE septum between the urinary and genital tracts may be broken through at various points. According to their situation, we have the following varieties of urinary fistulæ:—

- Urethro-vaginal,
- Vesico-vaginal,
- Vesico-uterine,
- Uretero-vaginal,
- Uretero-uterine.

The situation of these is sufficiently indicated by their names, and will be easily understood by reference to fig. 357.

A urethro-vaginal fistula rarely occurs alone, but is sometimes present along with a vesico-vaginal one. It lies in the middle line and is, naturally, of smaller size.

By far the most frequent are the vesico-vaginal fistula. They may occur at any point of the vesico-vaginal septum, which measures in height (from the internal orifice of the urethra to the vaginal fornix) about 5 cm. and in breadth 4 cm. (*Kallenbach*). Their size varies from a pin-point or slit-like hole to a large oval (fig. 362) or four-cornered (fig. 384) aperture. When recent they are of larger size, but after some months become contracted through the formation of cicatricial

Pathology
of Vesico-
vaginal
Fistula.

tissue. The *margins* of the *fistula* are at first irregular, swollen, and ulcerated; but after a time they become thin and firm, through cicatri-

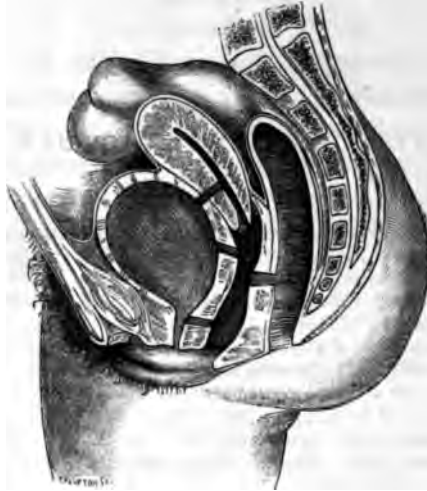


FIG. 357.

TO REPRESENT THE CHIEF VARIETIES OF URINARY FISTULA—URETHRO-VAGINAL, VESICO-VAGINAL, AND VESICO-UTERINE. Those with the ureters are not seen. The seat of a recto-vaginal fistula is indicated (*De Sinéty*).

sation: these changes have an important bearing on treatment. Jobert divided fistulæ in the anterior fornix into *superficial* and *deep*; in the

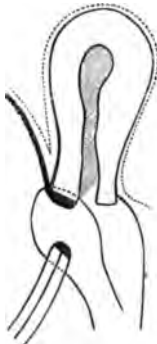


FIG. 358.

SUPERFICIAL VESICO-VAGINAL FISTULA, the Cervix is intact (*Hegar and Kallenbach*).

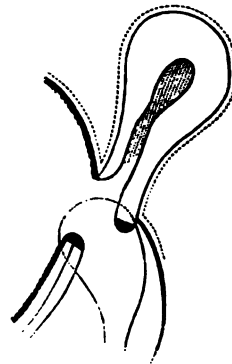


FIG. 359.

DEEP VESICO-VAGINAL FISTULA, the anterior lip of the Cervix is destroyed (*H. and K.*)

former (fig. 358) the anterior lip of the cervix was not implicated, in the latter it was more or less destroyed (fig. 359). In cases of

fistulæ which allow a free flow of urine, the *bladder* becomes permanently contracted and its walls thickened; in large fistulæ, the mucous membrane protrudes through the opening and is easily recognised from its deep red colour. The normal relation of the openings of the *ureters* to that of the *urethra* and to the *cervix uteri* (fig. 360) renders them liable to be involved in an extensive fistula, or even in a small one lying to one side of the middle line. Sometimes we can recognise their openings on the exposed vesical mucous membrane by means of the urine trickling from the orifices; should the urine be bloodstained, it can be distinguished from blood by its acid reaction to test paper. The *urethra*, through disuse, becomes contracted; sometimes complete atresia is present and seriously complicates treatment, and a portion of the

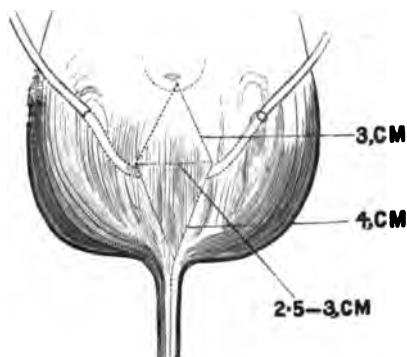


FIG. 360.

THE NORMAL RELATION OF THE CERVIX, THE URETERS, AND THE URETHRA (*H. and K.*) From cervix to orifice of ureter measures 3 cm., from orifice of ureter to that of urethra measures 4 cm., from orifice of one ureter to that of the other measures 2.5 to 3 cm. The ureters run through the bladder wall in an oblique direction downwards and inwards, for from 1.5 to 2 cm.

canal may even be completely destroyed by pressure (*v. fig. 389*). The *vagina* is often contracted by cicatricial tissue originating from injuries received during labour. The margins of the fistula are often drawn apart, and sometimes fixed down to the bone, by these cicatrices; this interferes with their closure. Contraction of the vagina below the fistula sometimes makes it impossible to ascertain the condition of the upper part and whether the uterus communicates with the fistulous tract. The relations of the *peritonæum* to fistula are shown in fig. 361, from which it is evident that only in the repair of very extensive fistulæ would its relations require to be considered. The difficult labour which leads to the production of the fistula is liable to be followed by

puerperal peritonitis or cellulitis; these may disturb the normal relation of the peritoneum.

Vesico-uterine fistulæ are rare. From their position they can be recognised only after dilatation of the cervical canal (*v. fig. 388*), and it is evident that they must be very small.

Uretero-vaginal fistulæ are situated in the fornix vaginae. They are of small size, admitting only the point of the sound, and have either sharp edges or open at the point of a small papilla.

Of uretero-uterine fistula, only nine cases are on record (*Kaltenbach*).

ETIOLOGY.

Malignant disease is the most common cause of fistula (*v. p. 433*); but we place this form aside, as it is beyond treatment and merely indicates a stage in the progress of the malignant growth.

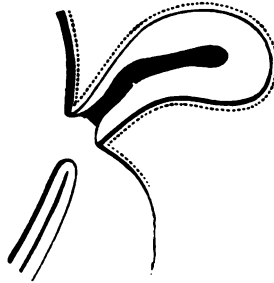

FIG. 361.

RELATIONS OF PERITONEUM, indicated by dotted line, to a fistula which has destroyed the whole of the anterior wall of the cervix and the infra-vaginal part of the posterior wall (*H. and K.*)

Mode of
production
of Fistula
in labour.

The most important cases of fistulæ which we have to consider here, arise through *injury received during labour*. This injury may act *directly*, producing laceration of the septum; more frequently it acts *indirectly*, producing necrosis secondary to pressure or inflammation. The causes which predispose to fistula are a narrow pelvis and pendulous abdomen, a firm or large head (hydrocephalus) and face presentations (*Winckel*). The immediate cause is the compression of the soft parts between the child's head and the bony wall of the pelvis; if this pressure continues for a long enough time, it destroys the vitality of the soft parts which afterwards separate as a slough.

Fistulæ produced by instruments are situated in the lower part of the vagina, and are accompanied with extensive cicatrices and adhesions; those due to pressure of the foetal head are placed in the upper part

(*Winckel*). In craniotomy, the soft parts have been sometimes lacerated by the instruments, or by splinters of fœtal bone. Forceps are often cited as a cause of the injury. It is not however *the use* of the forceps after a prolonged labour which is to blame, but the *not using* of them at an early period—before the parts have been destroyed by pressure.

Fistulæ have followed diphtheritic inflammation in the puerperium, but this is rare. Inflammation and ulceration round badly fitting pessaries have also produced them.

SYMPTOMS.

The leading symptom is the *involuntary flow of urine* from the vaginal orifice. *This will not appear until the slough separates*, that is till about the third or fourth day; its separation may be delayed for three or four weeks, when the necrosis is secondary to puerperal vaginitis (*Byford*). When a direct laceration has been produced, the urine will flow *at once* per vaginam; but even here it may escape notice till the second or third day, as it is masked by the lochial discharge.

The power of retaining varies, in certain cases, with the position of the patient; with a fistula situated high up, the erect posture allows the lower portion of the bladder to be used though the flow is continuous in the recumbent posture. With a urethro-vaginal fistula, there may be perfect continence from a sphincter-like action of the muscular fibre in the wall of the urethra; the patient observes, however, that the urine does not pass by the urethral orifice.

Secondary symptoms are due to a constant wetting of all the surrounding parts with the urine. The urinous *odour* is quite characteristic in urinary fistula; there is *excoriation* round the vulva, the inside of the thigh is red and irritated. *Menstruation* is generally in abeyance, returning after the fistula has been cured. There is usually *sterility*; although cases of conception, often followed by abortion or premature labour, have been recorded. The disagreeable surroundings interfere with the appetite and digestion; there is *constipation*, which Freund has ascribed to increased secretion by the kidneys but which is more probably due to reflex contraction of the muscular fibre of the rectum (*Winckel*). The general health thus becomes seriously impaired so that the patient is willing to submit to any operation which promises relief.

DIAGNOSIS.

The irritated appearance of the external genitals with the characteristic

odour at once indicates that there is fistula, but the diagnosis of its position is often very difficult.

Urethro-vaginal and *vesico-vaginal*. When large, these may be felt by the examining finger; on our passing the sound into the bladder the finger touches it through the fistula. The speculum shows their position and extent, and reveals smaller ones which escape detection with the finger; by stretching the folds of the mucous membrane with tenacula, we may detect a fistula concealed by them.

Diagnosis
of small
Fistulæ.

To recognise *small vesico-vaginal* fistulæ and to differentiate them from the *vesico-uterine* and *ureteric*, proceed as follows:—pass Sims' speculum, carefully wipe away all mucus from the anterior vaginal wall, clear out the cervical canal with a dressed sound and plug it with a pledget of dry cotton wadding; now pass a catheter, and through it distend the bladder slowly with a coloured fluid such as milk or permanganate of potash; as the bladder distends, watch carefully the anterior vaginal wall for any oozing of the fluid. If there is no oozing, the fistula is not vesico-vaginal. If on withdrawing the plug from the cervix it be found stained with fluid, the fistula is *vesico-uterine*. If neither of these forms be present, the urine must come from a *ureteric* fistula; the rarity of this form should lead us to suppose that the fluid may have been temporarily kept from escaping from the bladder by a valvular action of the mucous membrane, and the examination should be repeated after a time. In a case of uretero-uterine fistula, Bérard collected the urine which escaped per vaginam in one vessel and that in the bladder was drawn off per urethram by a catheter into another; the quantities in a given time were found to be equal. His conclusion was that he had obtained the secretions from each kidney separately, so that the fistula was ureteric.

PROGNOSIS.

A *natural cure* will depend on the recentness of the fistula and its size. Small fistulæ, if kept clean, heal of themselves during the puerperium. Large ones require operative treatment; cure by this means depends partly on the size of the fistula, but more on the condition of its margins—whether they contain much cicatricial tissue, and whether they are bound down.

TREATMENT.

There are two essentials for successful operative treatment: (1) complete exposure of the fistula, so that (2) the edges may be thoroughly

pared and carefully adapted with sutures. The great difficulty lies in the inaccessibility of the field of operation, to which the failure of the older operative measures is chiefly to be attributed.

Marion Sims (1849) first rendered successful treatment really possible Historical. by the complete exposure of the fistula with his *speculum*, and by the

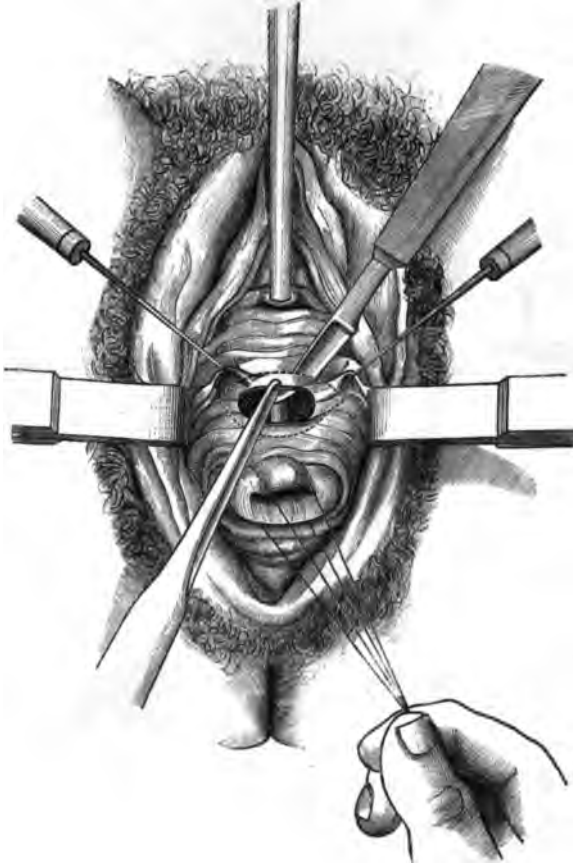

FIG. 362.

METHOD OF PARING THE EDGES OF A FISTULA (*Simon*).

careful adaptation of its margins with *silver-wire sutures*. To Simon of Heidelberg is due the credit of having elaborated the operation, and of having extended its sphere so that almost no form of fistula has in his hands proved incapable of treatment. We may shortly contrast the Sims' and Simon's methods compared. methods of these two leading operators as follows: Sims pares the edges of the fistula in a sloping manner (fig. 364) carefully avoiding the

mucous membrane of the bladder, then adapts the margins of the fistula with silver wire, and drains the urine continuously per urethram through

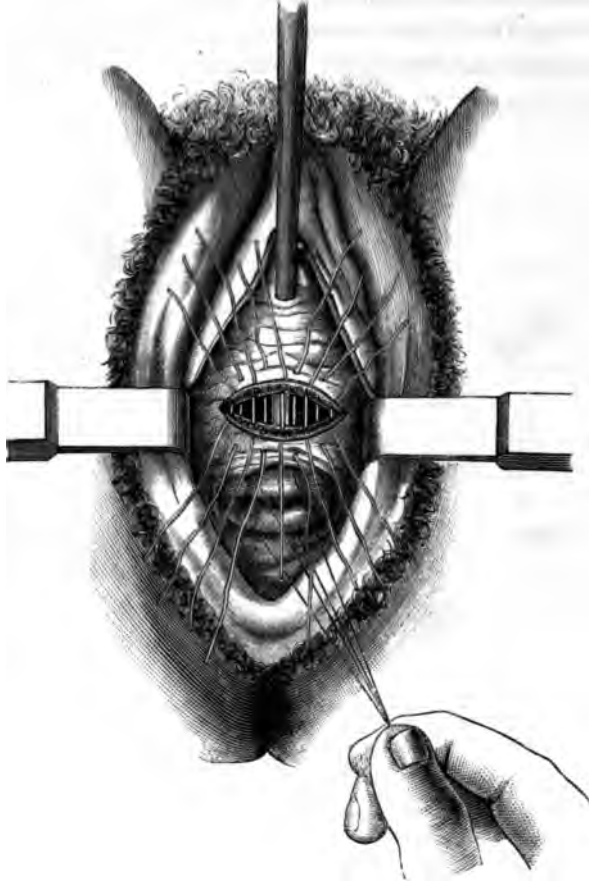


FIG. 363.
SUTURES PASSED IN A CASE OF URINARY FISTULA (*Simon*).




FIG. 364.

THE AMERICAN AND GERMAN METHODS OF PARING THE EDGES OF FISTULA CONTRASTED; Sims' is shown on the right margin of the fistula, Simon's on the left. The mucous membrane of the bladder is above, that of the vagina is below. The edges may be pared first according to Sims' method, and if a raw surface is not thus obtained the tissue can be removed up to the fine line (*Kaltenbach*).

a catheter; Simon pares away the edges vertically not specially avoiding the mucous membrane of the bladder, unites the edges with silk sutures,

and encourages the patient to pass water unaided from the first—drawing it off with the catheter only when necessary. Bozeman, a pupil of Sims, has drawn attention to the advantages of the genu-pectoral posture in operating and to the importance of preparatory treatment by dividing and stretching cicatricial contractions; he fixes the sutures with lateral plates and buttons.

When a fistula has been discovered during the puerperium our first aim is to *aid the natural effort at cure*. A catheter (fig. 390) is placed in the urethra to carry off the urine by the natural passage; the vagina is syringed out frequently with warm water; the edges of the fistula may be kept together, in some cases, by tampons suitably placed in the vagina.

If the fistula does not close by the natural process, we have recourse to operation.

Operation for Vesico-vaginal Fistula.

There is difference of opinion as to the *time for operating*. According to Hegar and Kaltenbach, the best time is six to eight *weeks* after the confinement; “the lochial discharge has ceased, the necrosis of the tissues is defined, the margins of the fistula are vascular and juicy and are at the same time of sufficient firmness to hold the sutures;” the cicatricial tissue which forms round the margins makes the operation more difficult afterwards. Marion Sims delays the operation for a few months.

Under the operation, we shall describe—

1. Preparatory treatment;
2. The operation, which consists of (*a*) the paring of the edges of the fistula and (*b*) their adaptation with sutures;
3. After-treatment.

1. *Preparatory treatment* is only necessary when there are cicatricial bands drawing the margins of the fistula apart or contracting the field of operation. These must be divided and made to heal over a glass plug, or the vagina must be kept distended with air-bags. Frequent vaginal injections are necessary in all cases, to bring the edges into as good condition as is possible.

2. For the operation itself the following instruments are required.

Sims' speculum,
Spatulæ,
Three or four tenacula,
Blunt-hook,
Vaginal douche for permanent irrigation,

Instruments for
Operation.

Hot water to check hæmorrhage,
 Dissecting and artery forceps,
 Small bistouries straight or set at an angle—on long handles,
 Bozeman's scissors,
 Several small sponges and sponge-holders,
 Short curved needles and needle-holder,
 Curved needles on fixed handles,
 Silver wire (catgut in reserve),
 Wire twister.

Good light is essential and as *complete exposure* of the field of operation as is possible; this last will determine the *position* of the patient,



FIG. 365.



FIG. 366.



FIG. 367.

KNIVES FOR PARING A FISTULA. Fig. 365, straight knife; fig. 366, bent knife which is shown laterally at fig. 367 (*Sir J. Y. Simpson*).

according as Sims' or the lithotomy posture allows us to get more readily at the fistula. The drawing down of the cervix with volsellæ or sutures (fig. 362), or the protrusion of the edges of the fistula by a catheter in the bladder, is of use in some cases; where the mucous membrane of the bladder (by prolapsing through the fistula) comes in the way, it can be



FIG. 368.

SPONGE-HOLDER.

kept back by the sound in the bladder or a sponge probang pushed through the fistula (*Sir J. Y. Simpson*).

Chloroform is always an advantage, as it gives the operator more freedom in exposing the parts and prevents the patient from moving; the actual pain of the operation does not demand it.

Three *assistants* are essential—one to give chloroform, a second to hold the speculum, a third for the sponges; six are better, as two are required with the patient in the lithotomy posture and there is one to



FIG. 369.

STARTIN'S TUBULAR NEEDLE FOR VESICO-VAGINAL FISTULA (Sir J. Y. Simpson).

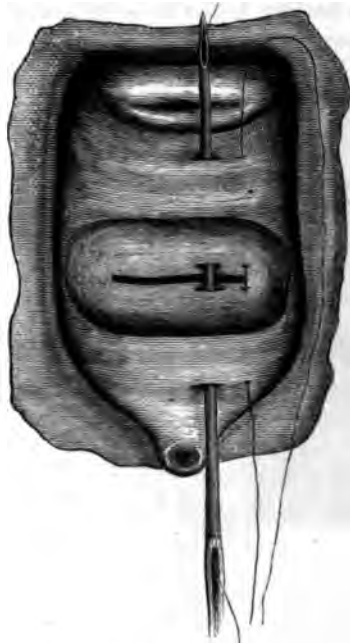


FIG. 370.

PASSAGE OF THE THREAD WITH THE TUBULAR NEEDLE (Sir J. Y. Simpson).

take charge of the instruments. The knives employed are shown at figs. 365-67. The sponges should be very small and fitted on holders of

which a convenient form is shown at fig. 368. Fixed *needles* are required when the tissue is dense. Sir J. Y. Simpson used a tubular needle such as that seen at fig. 369, which is sometimes of service.

Steps of
Operation:
paring
edges.

(a.) *The paring of the edges of the fistula.* To produce union, it is essential to have a *continuous raw surface* all round the margin. To procure this, we hook up with a tenaculum the portion of vaginal mucous membrane to be removed and transfix it with the knife (*v.* fig. 362 and fig. 371). The knife should not pass through the mucous membrane of the bladder, unless there be so much cicatricial tissue that a large piece requires to be cut out; the reason for avoiding the vesical mucous mem-

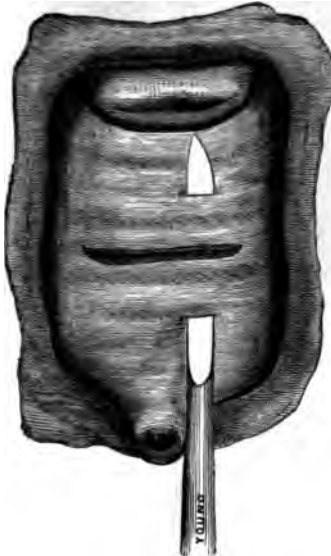


FIG. 371.

TRANSFIXING WITH A KNIFE BOTH EDGES OF THE FISTULA AT ONCE (*Sir J. Y. Simpson*).

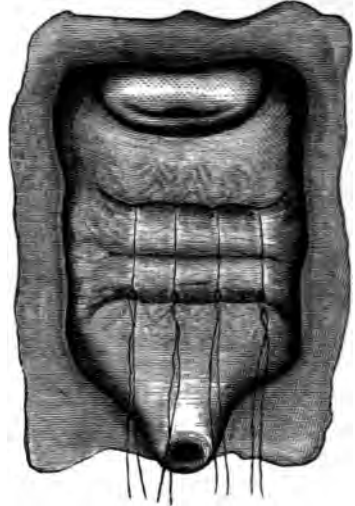


FIG. 372.

FISTULA SHOWN AT FIGS. 370 AND 371 CLOSED WITH SUTURES (*Sir J. Y. Simpson*).

brane is to prevent after-hæmorrhage into the bladder. In small fistulæ, we can remove the tissue in a ring and thus ensure a continuous raw surface; in larger fistulæ, we may have to clip portions away with scissors (*v.* fig. 109).

Another method of making a raw surface is to split up the edges so that the vesical mucous membrane is separated from that of the vagina; the advantage of this method is that no tissue is lost, but the stitching is less accurate.

Hæmorrhage is best checked by hot douche; large bleeding points may require twisting or even ligature.

(b.) *The adaptation of the edges with sutures* must be carefully done. Passages
of Sutures.
The sutures may be passed on an ordinary curved needle, a fixed needle (which is made to transfix both margins of the fistula and then threaded),




FIG. 373.

BOZEMAN'S FORK, used in drawing through the wires to prevent their cutting the Vaginal Mucous Membrane (*Sir J. Y. Simpson*).

or a hollow needle (fig. 370). To prevent the sutures from cutting the vaginal mucous membrane as they are drawn through, the fork or pulley (figs. 373, 374) can be used. The sutures must be pretty close together

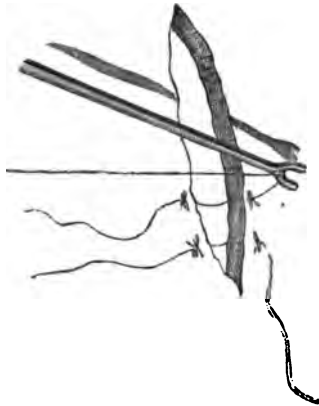


FIG. 374.

METHOD OF USE (*Emmet*).

and should either not pierce the vesical mucous membrane or should take Counter-pressure in only its margin. When the tissues are dense, counter-pressure against the point of the needle may be made with a blunt hook as in fig. 375. in dense
tissue.




FIG. 375.

MODE OF APPLYING COUNTER-PRESSURE TO THE POINT OF THE NEEDLE BY MEANS OF A BLUNT HOOK (*Emmet*).

Sims passes a silk thread first and then uses it to draw through the wire suture.

After all the sutures are passed, they are tied (fig. 377) or twisted

(figs. 376, 380); to bring the wires together we can use Bozeman'

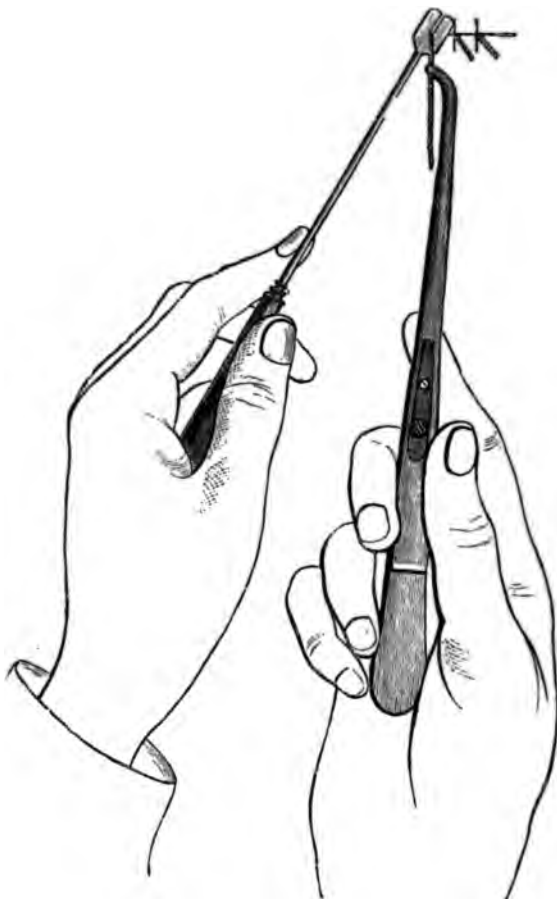

FIG. 376.

SIMS' METHOD OF FIXING AND TWISTING THE SUTURES (*after Sims*).



FIG. 377.

MODE OF TYING SILVER-WIRE SUTURES (*Sir J. Y. Simpson*).

suture-adjuster (fig. 378); the wire twister (devised by Coghill) is very

convenient for twisting the wires close, especially when the fistula is deeply placed and not very accessible (fig. 379). Bozeman uses a ^{Bozeman's} method.



FIG. 378.
BOZEMAN'S SUTURE-ADJUSTER (Sir J. Y. Simpson).



FIG. 379.

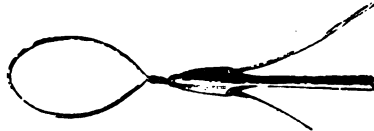


FIG. 380.

COGHILL'S WIRE TWISTER, fig. 379; its point threaded with a wire is shown at fig. 380 (Sir J. Y. Simpson).




FIG. 381.



FIG. 382.

WIRES DRAWN THROUGH BOZEMAN'S PLATE, fig. 381; fixed with shot as in fig. 382 (Sir J. Y. Simpson).

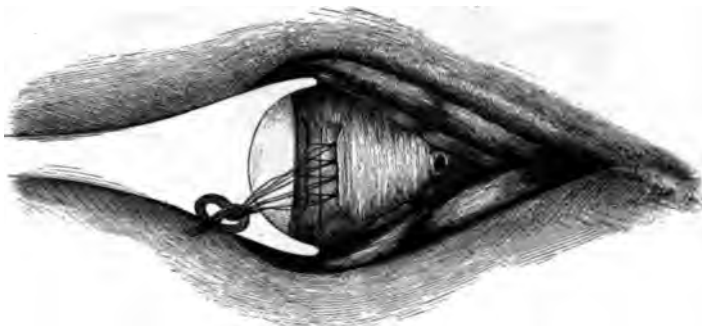


FIG. 383.

SPECULUM PASSED FOR REMOVAL OF SUTURES; the patient is on her side (Sir J. Y. Simpson).

plate to fix the sutures. The fistula seen at fig. 370 is shown, after the sutures have been twisted up, at fig. 372. With a triangular

fistula the closed wound will be Y-shaped, while a quadrilateral fistula will give an I-shaped wound (figs. 384, 385).



FIG. 384.

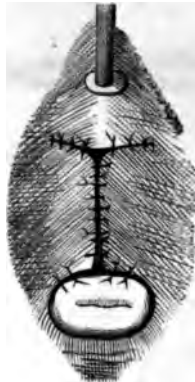

FIG. 385.

FOUR-CORNERED FISTULA, fig. 384, closed by Sutures in fig. 385 (*Hegar and Kalttenbach*).

Fistulae close to Cervix.

In the case of fistulae situated close to the cervix, we make use of the

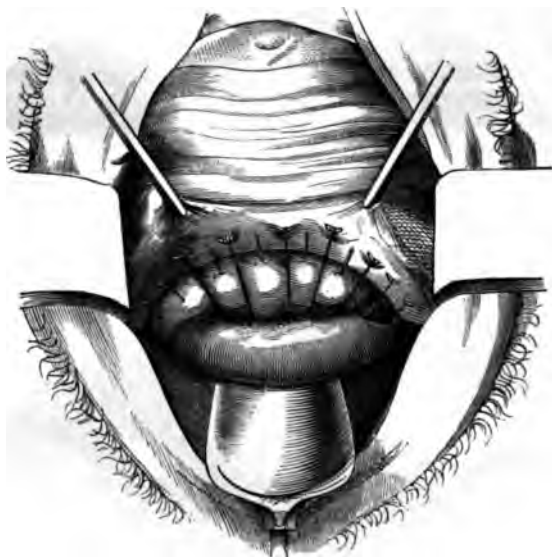


FIG. 386.

SUTURES PASSED THROUGH ANTERIOR LIP OF CERVIX SO AS TO CLOSE IN TRANSVERSELY A FISTULA OF THE ANTERIOR FORNIX (*H. and K.*).

anterior lip to close the fistula; the result is a crescentic wound (fig. 386). Sometimes we have to excise a portion of the cervix to get a

sufficient raw surface (fig. 387). When much of the anterior lip is destroyed, it may be necessary to use the posterior lip to close the fistula (see fig. 359, and compare it with fig. 358); in this case the uterus will communicate with the bladder and the menstrual blood be discharged per urethram. With vesico-uterine fistulæ, two courses are open. If possible, we expose the fistula by splitting the cervix bilaterally and treat it as vesico-vaginal fistula: when this cannot be done, we pare the edges of the os and stitch up the cervical canal; we thus make the uterus open into the bladder (fig. 388).

When there is a *urethral* as well as a vesical fistula, the *former must*

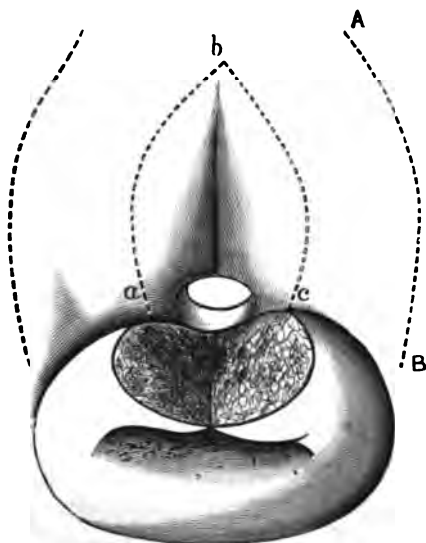


FIG. 387.

ANTERIOR LIP DIVIDED TO CLOSE IN VERTICALLY A FISTULA CLOSE TO IT: *a b c* shows extent of surface, round the oval fistulous opening, to be made raw; the mucous membrane may have to be incised outside the sutures, along the line *A B*, to relieve tension (*Emmet*).

be closed first: when there is *atresia* of the urethra, the free margins of the urethral wall above and below are pared and united by sutures so as to bridge over the atresic portion (fig. 389); the vesical fistula is obliterated by a second operation.

3. *After-treatment.* A stationary catheter is placed in the bladder. After-treatment.
The form in fig. 390 is the one generally used, the urine being made to drip into a long narrow vessel (as a soap-dish) passed between the patient's thighs; two catheters are required, so that they may be changed every day as the salts of the urine readily occlude the tube; the one not in use should be thoroughly washed.

After-dangers of Operations. The after-dangers of the operations are hæmorrhage into the bladder and vesical catarrh. The former is a troublesome complication, as the

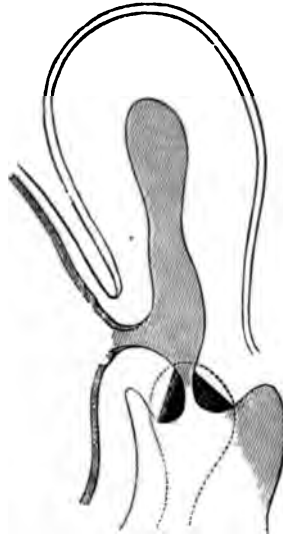

FIG. 388.

VESICO-UTERINE FISTULA. The lips of the cervix are pared, preparatory to stitching up the cervical canal (*H. and K.*)

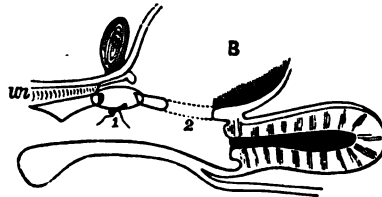


FIG. 389.

VESICAL FISTULA + Atresia of a portion of the urethra *or* just below the symphysis *s.* The latter is first bridged over at 1 and then the vesical fistula closed in at 2 (*Winkel*).



FIG. 390.



FIG. 391.

SIMS' STATIONARY CATHETER : fig. 390, first model; fig. 391, newest model. That in fig. 390 is made of block tin so that it can be bent to any curve; when *in situ*, it must be bent so that the external end has its groove uppermost: that in fig. 391 is of rubber and has tubing attached to it.

blood-clots collect in the bladder; when there is marked hæmorrhage distending the bladder, the fistula must be opened up again. Sometimes

the ureter has been caught in a stitch and compressed; intense pain, shooting from the kidney downwards along the course of the ureter, with vomiting and other symptoms of uræmia followed but passed off on relaxing the sutures.

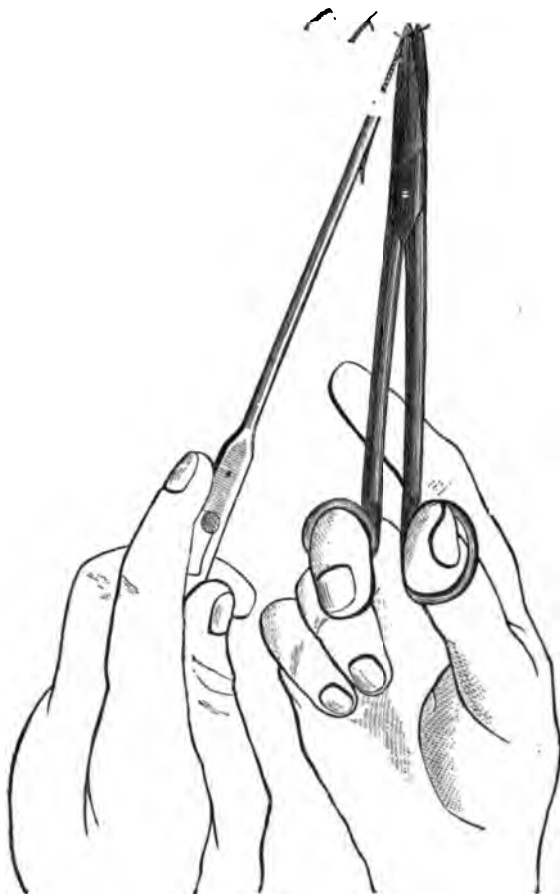


FIG. 392.

METHOD OF REMOVAL OF SUTURES (after Sims).

The sutures are removed on the tenth day. The method of removing Removal of Sutures.
sutures is shown at figs. 383 and 392.

Obliteration of Fistula by Cauterisation.

This treatment is only applicable to very small fistulae. Cauterisation Cauterisation
may be done with nitrate of silver or the red-hot wire. Where the of
Fistula.

fistula is of any size, cauterisation not only fails to close it but converts its margins into cicatricial tissue; this makes its subsequent closure with sutures more difficult. This method of treatment, even in the case of larger fistulæ, has been recently revived and advocated by Bouqué,¹ whose writings may be consulted.

Closure of the Vagina: Kolpopleisis.

Where direct closure of the fistula is impossible, the only means for relieving the patient's discomfort is closure of the vagina below the fistulous opening. The portion of the vagina above this becomes, as it were, an extension of the bladder; the menstrual blood is discharged with the urine.

Vidal de Cassis, who originated this operation, performed it as follows. The inner surfaces of the labia majora were pared and brought together by sutures: the vulva was thus closed in an *antero-posterior* direction. After this operation, there always remained just below the urethral orifice a small cleft through which the urine trickled. Unless complete continence is obtained, such an operation is useless.

Simon's
Kolpok-
leisis.

Kolpopleisis is the name given to the operation introduced by Simon. It consists in obliteration of the vagina *transversely* by making a raw surface on its walls above the level of the ostium vaginæ. It is evident that this operation is justifiable only where closure of a fistula is impossible, either through the binding down of its margins to the bone with cicatricial tissue or through the complete destruction of the urethra. As the closure of the vagina interferes with married life, the nature of the operation should be explained to the patient beforehand and full permission obtained.

The operation is performed as follows. By pinching up the mucous membrane ascertain where it is most lax, so that the vaginal walls can be easily approximated; the point of closure should be as high up as possible. Mark out with the knife the ring of tissue to be excised. Lay hold of its lower margin and dissect it from below upwards; with the finger in the rectum and the sound in the urethra, we can judge of the thickness of tissue to be removed (compare fig. 393 with fig. 394). On each ligature of wire or carbolised silk, two small curved needles are threaded so that *both* ends of the thread may be passed *from above downwards*. The needle must be entered into the vaginal mucous membrane above, carried through the substance of the vaginal wall

¹ "Du Traitement des Fistules uro-gén.; par la réunion secondaire." Paris, 1875.

(without appearing in the wound) and brought out through the vaginal mucous membrane below; it is difficult to prevent these sutures from catching up either bladder or rectum but this should, if possible, be avoided. Care is required in the introduction of the first mesial suture as it is the guide for the others.

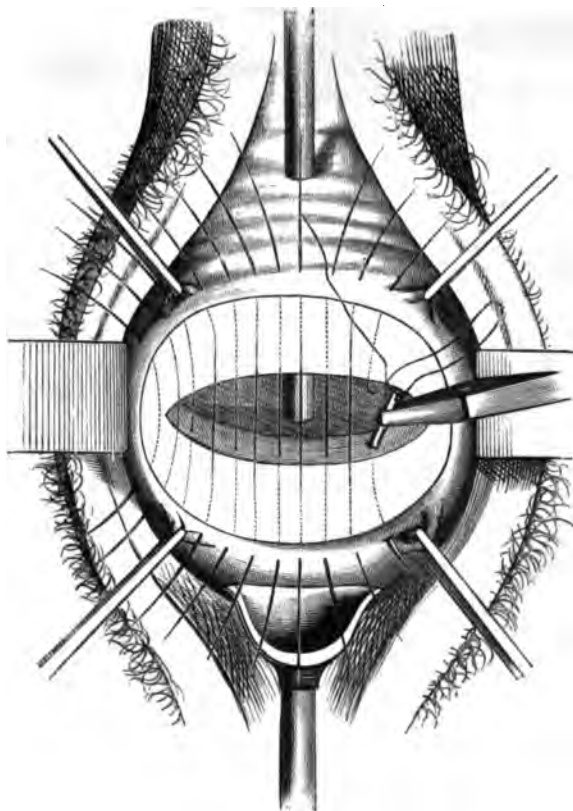


FIG. 393.

SIMON'S OPERATION FOR KOLPOPLEKTHIS. The patient is in the lithotomy posture; the sound has been passed through the urethra and fistula, and is seen in the upper portion of the vagina; the perineum is drawn back with the speculum and the labia majora with spatulae. A band-like piece of tissue has been removed from both the vaginal walls above the ostium; the raw surface is left unshaded in the figure. The vaginal mucous membrane is held tense by four pairs of forceps outside the raw surface, the shaded area within the latter is the upper third of the vagina. An end of the last suture has been passed through one raw surface, the second end is being carried through the other raw surface (*H. and K.*)

The results of this method are satisfactory as regards the production of complete continence. There is no liability to stagnation of urine or formation of concretions (*Hegar and Kaltenbach*). Hæmatometra will not occur unless there has been atresia of the cervix uteri. If men-

struation has been in abeyance, it will probably return after the operation; in a case operated on by A. R. Simpson, the patient had not

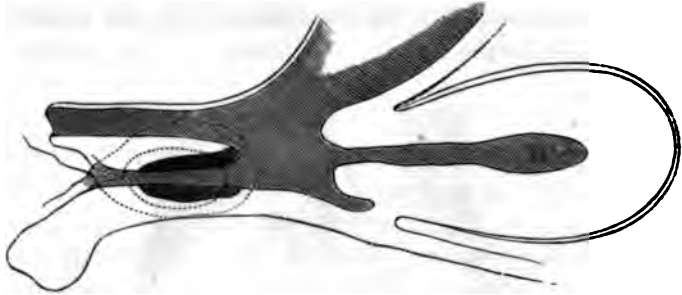

FIG. 394.

SAME OPERATION AS SEEN IN SECTION TO SHOW RELATION OF RAW SURFACES (shaded dark), position of sutures and common receptacle above for urine and menstrual blood. The bladder and urethra are in upper part of figure (*H.* and *K.*)

menstruated for a year, but a few weeks after the operation the menstrual blood appeared in the urine.

CHAPTER LIV.

THE RECTUM: COCCYGDYNIA.

LITERATURE.

Allingham—Diseases of the Rectum: Churchill, 1871. *Chadwick*—On the Functions of the Anal Sphincters: Am. Gyn. Trans., 1877. *Cripps*—Cancer of the Rectum: Churchill, 1880. *Hart*—Physics of the Rectum and Bladder: Edin. Obst. Trans., 1882. *Ruedinger*—Topographisch-chirurgische Anatomie des Menschen, vierte Abtheilung. *Storer*—The Rectum in its relation to Uterine Disease: Am. Jour. of Obst., Vol. I., p. 66. *Syme*—Diseases of the Rectum: Edin., 1859. *Van Buren*—Diseases of the Rectum: H. K. Lewis, 1881.

Not only is the gynecologist frequently consulted about rectal mischief, but as a matter of fact female patients sometimes refer rectal disease to the uterus or vagina; therefore, in investigating gynecological cases, one has occasionally to satisfy himself that the rectum is not the seat of the affection.

Vaginismus may be caused by fissure of the anus, as we have already seen, and pruritus vulvæ by ascarides from the rectum passing into the vagina.

PHYSIOLOGY OF THE RECTUM.

The anatomy of the rectum has been already considered (p. 35). The relations of the axes of rectum, anus, vagina and urethra, to one another and to intra-abdominal pressure are of importance. As we have already seen, the vagina and urethra are parallel to one another and to the plane of the brim.

Relation
of Rectal,
Vaginal
and
Urethral
Axes.

Strictly speaking the surface whose outer boundary is the brim of the bony pelvis is not a plane surface, inasmuch as the various points in the outline of the brim are not on the same level. The vagina is thus, properly speaking, parallel to the internal conjugate of the brim.

The rectum runs, in part of its course, close behind the vagina for $1\frac{1}{2}$ inches and parallel to it; the anal canal turns directly backwards so as to cut the vaginal axis at right angles. Intra-abdominal pressure acts at right angles to the vaginal walls, as can be noted from the fact that in

defæcation the Hodge pessary is not driven out of the vagina. Consideration of fig. 395 will show that the direction of intra-abdominal pressure on the pelvic floor coincides with the long axis of the anus, so that intra-abdominal pressure will act with its full driving force on any body in the anal canal.

**Mechanism
of Defæca-
tion.**

The mechanism of defæcation is probably the following. According to Hilton, in his now classical book on "Rest and Pain," the lower part of the rectum is sensitive but the upper two-thirds are but slightly so;

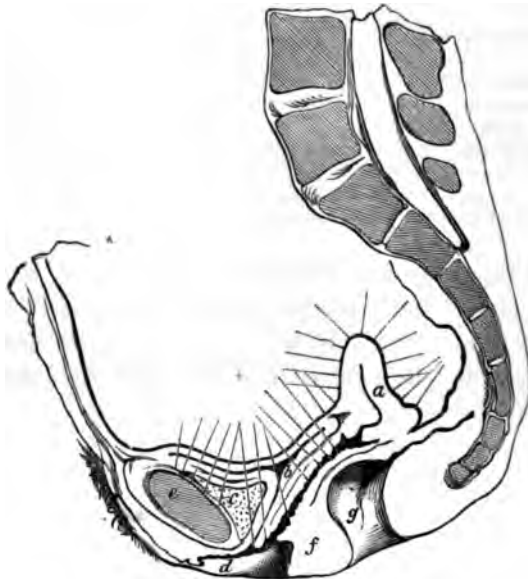


FIG. 395.

TO SHOW DIRECTION OF RECTUM AND OF ANUS IN RELATION TO INTRA-ABDOMINAL PRESSURE.
For letters see fig. 63 (Hart).

the rest of the large intestine and the small intestine are non-sensitive. Hilton limits the sensitive portion to the lowest two inches of the rectum—to the part below the so-called sphincter tertius. When there is accumulation of fæcal matter in this portion, pain and uneasiness produce the desire to expel these contents. There result the following reflex movements:—

- (1) Relaxation of the sphincter ani;
- (2) Peristaltic contraction of the circular unstripped muscle;
- (3) Shortening of the longitudinal muscle with eversion of the mucous membrane. Since the longitudinal fibres have a

fixed point below, their contraction will probably pull the rectum more into the line of the anal axis ;

(4) Contraction of the segments of the sphincter tertius.

In this way the lowest portion of the rectum becomes roofed in above by the sphincter tertius and open below. Intra-abdominal pressure drives this portion downwards ; and the rectal contents, elongated by peristalsis and depressed by intra-abdominal pressure and eversion of the mucous membrane, are finally brought into the relaxed anal canal from which intra-abdominal pressure readily expels them. Ruedinger's diagram (fig. 37) shows well how the Levator ani will reinvert the everted mucous membrane.

Inattention to the proper evacuation of the bowels leads to non-sensitiveness of the mucous membrane and is thus one factor in constipation.

EXAMINATION OF THE RECTUM.

This may be done in three ways :

- (a) By finger (*v. p.* 101),
- (b) By speculum,
- (c) By eversion of the anterior rectal wall through digital pressure in the vagina (*Storer*).

By Speculum. The anal speculum has usually an oval fenestra ; it is passed into the anus in the direction of its long axis, and rotated so that each portion of the anal lining comes opposite the aperture (fig. 397). Specular
Examina-
tion of
Rectum.

Storer's method is as follows. Place the patient on her side ; pass two fingers (or one) half way into the vagina, with the pulps of the fingers on the posterior vaginal wall. Then press these downwards and backwards, and thus evert the rectal mucous membrane through the dilatable sphincter ani which is at the same time pressed open with the fingers of the other hand. This method is most easily employed in multiparæ. Storer's
method.

DISEASES OF THE RECTUM.

Women are especially liable to rectal disease owing to the distension of parts accompanying parturition, as well as from their habitual neglect of the regular evacuation of the bowels. As rectal diseases often simulate those of the vagina, a sketch of the more important of them is necessary in a Manual of Gynecology. We shall therefore consider the following affections :—

- Displacements of the rectum,
- Fissure of the anus,

Piles,
 Recto-vaginal fistula ;
 Functional disturbance of Rectum—Constipation.

Displacements of the Rectum.

These are—Rectocele ;
 Prolapsus Recti (a) of mucous membrane,
 (b) of whole thickness of bowel.

Prolapsus Recti. For *Prolapsus Recti*, which is properly surgical, see Van Buren or Allingham.

Rectocele. *Rectocele* is a protrusion of the lower part of the anterior wall of the rectum covered by the posterior vaginal wall, into the lumen of the

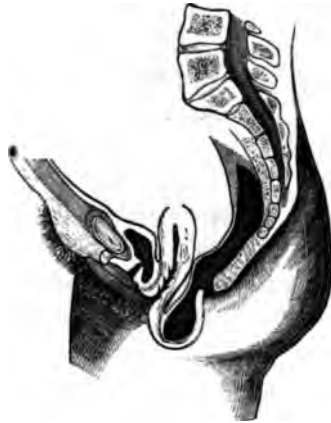

FIG. 396.
 RECTOCELE (Schroeder).

vagina or even through the vaginal orifice. *Etiology.* There are two factors—tear of perineal body and pressure of scybala in rectum. *Diagnosis.* The posterior vaginal wall is seen protruding into the vagina or out at the vaginal orifice. The diagnosis is made by noting the relations of the protruded vaginal wall and by passing the finger through the anus into the pouch (fig. 396). *Treatment.* The patient should wear in the vagina a Hodge or Albert Smith pessary with cross bars ; explain the necessity of a regular daily evacuation of the bowels.

Fissure of the Anus.

Fissure of Anus. This is a crack, or ulceration, of the anal skin or of the mucous membrane covering the internal sphincter. In the edges of the crack

there is usually a nerve filament, and below the crack lies the powerful sphincter ani.

This apparently insignificant lesion gives rise in most cases to an unbearable and even incredible amount of pain, lasting for hours after the bowels have moved. Hilton's explanation of this is so good that we give it entire.

"The reason for this anal ulcer being so very painful is the number of nerves associated with it; and the cause of the continued painful explanation of pain in Fissure.

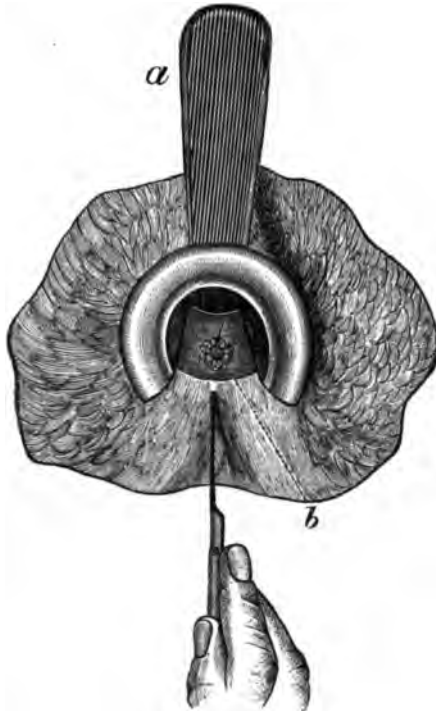


FIG. 397.

ANUS WITH *a* ANAL SPECULUM *in situ*; it is turned so as to expose in the fenestra *a* fissure *b* beneath which a tenotomy knife has been passed (*Hilton*).

contraction which accompanies it lies in the enduring strength of the sphincter muscle. Thus it happens that exposure of those nervous sensory filaments upon the ulcer causes excito-motory or involuntary and spasmodic contraction of the sphincter, through the medium of the spinal marrow. The sphincter muscle contracts towards its own centre, and, as long as the muscle is in a state of contraction, it brings the sensitive

edges of the ulcer into forced contact ; this excites more muscular contraction, and thus, by time and exercise, the muscle becomes hypertrophied, massive, and increased in dimensions."

Symptoms. *Symptoms.* The patient complains not so much of pain while the bowels are being moved as of *an unbearable pain coming on after the evacuation and continuing for some hours.* The pain is described as unendurable, causing the patient to dread and postpone natural motions. There are often iliac pains and vaginismus ; this last symptom is not infrequent.

Physical Signs. *Physical signs.* By speculum or eversion, the crack is seen.

Treatment. *Treatment.* Chloroform the patient, pass a tenotomy knife beneath the base of the ulcer (fig. 397) and cut upwards. This divides the muscular fibre so that the irritated edges can no longer be brought together. The fissure gets rest and heals readily ; a cure is thus effected. Another and very good plan is to chloroform the patient, and introducing the thumbs (with the dorsal surfaces in contact) to stretch the anus by forcibly separating them ; this ruptures the muscular fibre and acts just as the knife does, and is especially good when the fissures are multiple.

The bowels are not to be moved for a day or two ; the patient has then some pain when the motion is passing, but none after it.

Piles.

Hilton has pointed out that at the anus the line of demarcation between skin and mucous membrane is marked out distinctly by "the white line," as he terms it. This line is of great practical importance, as we shall see.

Piles are small tumours at the anus, on either side of this white line. They consist of dilated veins embedded in connective tissue and covered by skin or mucous membrane. We speak of external piles, *i.e.*, those outside of the white line and covered by skin, and internal piles, *i.e.*, those inside of the white line and covered by mucous membrane. Occasionally we have, as a special form of external pile, a dilated vein outside of the white line and usually containing a clot (venous pile).

Symptoms. *Symptoms.* Venous piles cause great pain ; while external piles, unless inflamed, occasion little inconvenience ; from internal piles, there is bleeding when the bowels are moved.

Signs. *Physical signs.* The venous pile is a purplish tumour outside of the white line ; external piles are like tags of skin, or are more or less distended ; internal piles are cherry-red and easily bleed.

Treatment. 1. When venous piles contain a clot, incise and turn out Treatment. clot.

2. For internal piles, employ the following *palliative* treatment. Give sulphur confection when necessary.

R Confectionis Sulphuris ʒij.
Sig. Dessertspoonful at night.

Order gall and opium ointment to be applied.

R Unguenti Gallæ c̄ Opio ʒij.
Sig. As directed.

For any abrasions, order iodoform ointment (p. 499) or Bismuth suppositories.

The *radical* operative treatment belongs more to the surgeon.

Recto-vaginal Fistula.

The situation of such a fistula is shown in fig. 357. It may be due to carcinomatous or syphilitic ulceration, or to injury received during parturition. The last is alone amenable to operative treatment, which is the same as for a vesico-vaginal fistula.

Functional disturbance of Rectum—Constipation.

Women are usually exceedingly careless in the matter of regulation of the bowels; very often, evacuation is practised once a week or even at longer intervals. This is in many respects not their fault but is due to the insufficient water-closet accommodation, to modesty, and to the fact that evacuation is for evident reasons postponed during menstruation.

When consulted for constipation, the medical man should insist on the value of a daily evacuation at a fixed hour; this educates the bowels to demand it regularly. All quack pills should be tabooed as dangerous. The diet should be regulated; bran-bread, porridge and milk, stewed fruit, figs, etc., taken as part of food. The following pill is good.

R Extracti Nucis Vomice
Extracti Belladonnæ āā gr. ʒ
Pilulæ Colocynthis et Hyoscyami „ iij.
Fiat pilula: mitte tales vj.
Sig. One occasionally.

The nux vomica and belladonna strengthen the peristalsis of the bowel: the colocynth and hyoscyamus pill is purgative; aloes and iron pill may be substituted for it.

The purgative mineral waters are very useful. The best are the

Friedrichshall, Hunyadi Janos and Aesculap. The patient should take in the morning a wine-glassful or half-tumblerful with an equal amount of hot water; the taste may be masked by the juice of a lemon with sugar. The Carlsbad salts are good and may be used as already directed (p. 312). Very often an enema of cold water is helpful. The medical man should deprecate the habitual use of purgatives, and insist on natural and daily evacuation.

The aloes and iron pill is good in sluggishness of the lower bowel. Rhubarb is bad as a habitual purgative, owing to its tendency to constipate after purging; the well-known "Gregory's Mixture" should not be used as a habitual purgative, but is good in diarrhoea inasmuch as it first purges and then binds. Fluid magnesia, castor oil, and some of the milder salines (*e.g.*, the easily-taken Seidlitz powder) may be employed. Blue pill should be avoided; Euonymium or Iridin are better hepatic stimulants (*v.* p. 544).

COCYGDYNTIA.

LITERATURE. *Hildebrandt*—Die Krankheiten der äusseren weiblichen Genitalien, S. 127: Stuttgart, 1877. *Nott*—N. O. Medical Journal, May 1844. *Simpson, Sir J. F.*—Diseases of Women, p. 202: Edinburgh, 1872. *Thomas*—Diseases of Women, p. 151: London, 1880.

By this we understand a painful condition in the region of the coccyx induced by sitting, walking, and the various muscular contractions associated with defæcation and coitus. When we consider the anatomy of the coccyx, its muscular attachments (to the levator ani, coccygeus, external sphincter ani, and gluteal muscles), as well as the strain put on it when driven back during parturition, we are not astonished that in some cases there should be inflammatory changes around and in it causing pain in its movement.

Symptoms. *Symptoms.* The chief symptom is pain on sitting, walking, and defæcation.

Signs. *Physical signs.* By digital pressure on the coccyx and examination per rectum, the seat and nature of the pains are made out.

Treatment. *Treatment.* (1) Pass a tenotomy knife beneath the skin on the posterior aspect of the coccyx, and free its lateral and apical muscular attachments; or (2) amputate the coccyx. To do the latter, make a vertical mesial incision over the posterior aspect of the coccyx; seize its tip and pull it well back; then free its muscular attachments with the knife, keeping close to the bone; finally separate it at the sacrococcygeal joint.

APPENDIX.

THE SYSTEMATIC TREATMENT OF NERVE PROSTRATION.

LITERATURE.

Bramwell, Byrom—The Diseases of the Spinal Cord : Edin. 1882. *Gaskell*—Preliminary Notice of Investigations on the Action of the Vasomotor Nerves of Striated Muscle : Proc. Roy. Soc., Lond., 1876-7, p. 430. *Goodell*—Lessons in Gynecology, Lesson XXX : Philadelphia, 1880. *Mitchell, Weir*—Fat and Blood, and how to make them : Londr., 1878. *Playfair, W. S.*—The Systematic Treatment of Nerve Prostration and Hysteria : Lond., 1883.

THE gynecologist will not have long practised his specialty before he finds that he has occasionally to deal with a class of patients who are quite *sui generis*. The condition of such puzzles him at first extremely, inasmuch as he can find no tangible disease but yet is bound to confess that the general condition of health is highly unsatisfactory. Very often these patients have gone the round of all medical and surgical specialists, and have come at last to the gynecologist in the hope that his art may do something to remedy their lamentable state.

The class of patients has the following characteristics :—They are thin, often emaciated, unable for any exertion, suffer from neuralgia, have little or no appetite, and are nursed by some devoted sister or mother or husband. As we have said, there is no local condition to account for their state ; but often there is a history of overwork, in the case of governesses and teachers, or of an improper training. By this latter we mean that a sensitive child of high nervous organisation has had this over-cultivated, her mental energies too constantly on the rack, and has ultimately collapsed under the strain. For this class of patients Dr. Weir Mitchell of Philadelphia introduced a plan of treatment in his well-known book, the results of this method being in suitable cases highly satisfactory.

The main factors in Weir Mitchell's plan are—

- I. Seclusion of the patient, and absolute exclusion of all but the medical attendant and nurse ;

- II. Absolute Rest in Bed ;
- III. A Systematic extra feeding of the Patient ;
- IV. Use of Massage and Electricity.

I. Seclusion of the patient, and absolute exclusion of all but the medical attendant and nurse.

This is imperative, and the treatment should not be gone on with unless this condition is agreed to absolutely. Very often the friends have devoted themselves to every whim and fancy of the patient so assiduously as to impair their own health without improving that of their tyrannous charge.

The nurse should be thoroughly trained and refined, and should implicitly obey all the medical attendant's orders.

II. Absolute rest in bed.

This means muscular and mental rest, and reduces the force and frequency of the heart's action. The nutrition taken is below the amount worked off, and benefit in this way results. This absolute rest is after a while modified, and the patient allowed to sit up for a little until she may at length go about as usual, with the exception of taking a two-hours' sleep during the day.

III. A systematic extra feeding of the patient.

This is one of the essential features of the method. Dr. Mitchell begins with milk diet, about three ounces every two hours, until two quarts are given during the day. At the end of the first week raw beef soup¹ is given, and gradually the diet is increased until the dietary for a day, in one of Mitchell's cases, was as follows:—"Coffee at 7 ; at 8, iron and malt. Breakfast, a chop, bread and butter ; of milk a tumbler and a half ; at 11, soup ; at 2, iron and malt. Dinner, closing with milk, one or two tumblers. The dinner consisted of anything she liked, and with it she took about six ounces of Burgundy or Dry Champagne. At 4, soup. At 7, malt, iron, bread and butter, and usually some fruit, and commonly two glasses of milk. At 9, soup ; and at 10, her aloe pill. At noon, massage occupied an hour. At 4.30 p.m., electricity was used for an hour."

In addition to this diet, iron in the form of Blaud's pills (p. 543) and

¹ Chop 1 lb. of raw beef, and place in a bottle with 1 pint of water with 5 mm. strong hydrochloric acid. Place in ice all night, and in the morning set in a pan of water at 110° Fahr. for 2 hours. Strain thoroughly, and give filtrate in portions daily.

maltine may be added to aid the digestion of starchy food. The maltine should be given in cold milk or at the end of pudding. The evident question now arises, How does the patient digest all this? The digestion of this immense mass of food is rendered possible by the last feature of the treatment, viz. :—

IV. *The use of Massage and Electricity.*

This is most important, and consists in the systematic rubbing of the patient, and the application of Faradic electricity.

The massage is begun a few days after the milk diet, and consists in the systematic kneading of the skin and muscle of the whole body first for half-an-hour, and afterwards for an hour daily. A special massage nurse is necessary for this, and it should be kept up for six or seven weeks. Cocoa-nut oil should be used to render the manipulations easy, and it will also help in fattening the patient.

Electricity is employed for half-an-hour daily in order to cause muscular action, increase the blood-supply to the muscle, and act as a tonic and bracing agent. Dr. Mitchell has found that after the electricity the temperature usually rises about $\frac{4}{5}$ ths of a degree. The current should not be painful, and Ziemssen's diagrams of the points of stimulation should be followed as a guide.

For further details, the literature given should be consulted by the practitioner wishing to carry it out.

The results in some cases are wonderful, and as yet no harm has been shown to arise to the kidneys from the over-feeding. The bowels must of course be regulated, and a daily motion secured. Before beginning this treatment in any case, it should be thoroughly ascertained that there is no organic disease, and no obscure and rare form of disease such as Addison's disease, myxoedema, etc. A consultation with a specialist should always be had in cases of doubt.

The patient for whom it is suitable is one where there has been under-feeding, or improper food, undue mental strain, and consequent loss of flesh and nervous energy.

HYSTERIA AND HYSTERO-EPILEPSY.

LITERATURE. *Bourneville et Regnard*—Iconographie photographique de la Salpêtrière: Paris, 1877. *Bourneville et d'Olier*—Recherches sur l'Épilepsie, l'Hystérie et l'Idiotie: Progrès Médical, 1881. *Charcot*—Diseases of the Nervous System: Sydenham Society's Series, London, 1877. *Fritsch*—Krankheiten der Frauen: Braunschweig, 1881. *Jolly*—Article "Hysteria" in Ziemssen's Cyclopædia of Medicine. *Mills*—Hystero-epilepsy,

American Journal of the Medical Sciences, Oct. 1881. *Richer*—Études cliniques sur l'Hystero-Epilepsie: Paris, 1881.

HYSTERIA.

The frequency of hysteria as a complication of pelvic disease requires that we notice it briefly. We can only indicate the leading points and refer the student to the literature given above. The connection which exists between hystero-epilepsy and the ovary also calls for short reference.

As to the pathological changes present in hysteria, nothing definite is known. In regard to etiology, we note first the influence of heredity; defective moral education by a hysterical mother, and the power of imitation in developing hysteria, confirm this influence. A reduced state of the system is also a very important cause, and the one to which treatment must be specially directed. As to the exciting causes usually given (such as dysmenorrhœa, uterine displacements, ovaritis), these are so common that we cannot regard them as a cause of hysteria. The only ascertained facts are that removal of the ovaries has in some cases cured hysteria, and that pressure in an ovarian region does sometimes inhibit a hystero-epileptic attack.

The symptoms of hysteria are protean. *Sensation* is affected as follows. There may be increased sensitiveness to touch (hyperæsthesia) and to pain (hyperalgesia). Hyperæsthesia of the joints is important as simulating arthritis, from which it is diagnosed by the fact that the pain is around not in the joint and that it is not aggravated on forcing the articular surfaces together. Neuralgia along the spine with tender points simulates disease of the vertebral column. The typical headache (known as the "clavus hystericus" from the localised and intense character of the pain), neuralgia of the muscles generally, localised pain in the breast, in one ovarian region, in the bladder and urethra, and the perversions of the special senses need only be mentioned here. When sensitiveness is impaired, it is usually that to pain which is diminished while that to heat and touch remains; one half of the body may be affected or isolated portions of skin—as the back of the hands and feet. Loss of the muscular sense prevents the patient, if the eyes be closed, from knowing what movements she has made. Anæsthesia of any of the mucous membranes may occur. The special senses are often also impaired.

The *motor* disturbances resulting in convulsions will be referred to under hystero-epilepsy. The paralysis, due to hysteria, is very important

in regard to its diagnosis from that due to a cerebral or spinal lesion. It varies in distribution and may affect one limb only, or the arm and leg of one side, or the arm on one side and the leg on the other. In the face, the levator palpebrae superioris is frequently affected; paralysis of the muscles supplied by the facial and hypoglossal nerves is rare. This last fact is of value in diagnosing between hysteria and hemiplegia; further, gradual onset, presence of anaesthesia and its varying distribution, normal reaction to the electric current, the progress of the case with variations in the degree and extent of the paralysis, warrant us in diagnosing hysteria. The diagnosis of hysterical paraplegia from multiple sclerosis is more difficult. Paralysis may also affect the laryngeal muscles, producing aphonia, and the muscular wall of the oesophagus, stomach, and intestines.

Of the disturbances of the circulatory system, the most important are palpitation with increased force of the apex beat; in some cases, the heart's action fails and there is syncope. Vaso-motor disturbances are seen in the pale skin which does not bleed when pricked, and in the flushings and profuse sweatings which are often present. Salivation and polyuria often occur after a hysterical attack.

In forming a diagnosis, we must be careful to exclude the possibility of organic, cerebral, or spinal disease. A case reported by Dr. Bruce¹ is of interest in this connection; here the patient had symptoms of hysteria, there was no optic neuritis or other indication of cerebral mischief, and yet the post-mortem showed a large tumour in the temporo-sphenoidal lobe.

In treatment, the following points are of importance. Care must be taken in the mental and moral training of the children, when there is a tendency to hysteria.² If the system is below par, Weir Mitchell's method should be tried, and iron given when there is anaemia; cold baths are always beneficial. In grave cases, Battey's or Tait's operation may be contemplated.

HYSTERO-EPILEPSY.

This term is applied to attacks which present at once the features of hysteria and epilepsy; they are also described as Grave Hysteria or Hysteria Major by Charcot. The standard work on this subject is by Richer; the English reader will find a good account of it in the paper by Mills, cited above, in which he gives (with the description of two cases observed by

¹ Brain, part XXII. : 1883.

² Clouston : Puberty and Adolescence medico-psychologically considered : Edin., 1880.

himself) the results of the valuable researches of Charcot, Bourneville and Regnard, and Richer.

Hystero-epilepsy is rare in this country. We have seen one case in which it was present in a modified form. The seizures consisted in regular movements of the lower limbs, so that the patient performed a sort of dance till she sank down exhausted; pressure on the ovary checked the attack.

A typical attack is divided by Richer into four periods: (1) the epileptoid period; (2) the period of contortions and great movements; (3) the period of emotional attitudes; (4) the period of delirium.

For some days before an attack, *prodromic symptoms* occur in the form of the varying symptoms of hysteria given above. Charcot¹ has drawn attention to the occurrence of acute pain or sensitiveness to pressure in one ovarian region as forming the starting-point of the *aura hysterica*; slight pressure in one ovarian region will, in some cases, excite an attack. In other cases, different hyperæsthetic areas have been localised, the touching of which produces an attack. These areas are known as hystero-epileptogenic zones and are analogous to the epileptogenic zones described in epilepsy by Brown Séquard. During the *epileptoid period* there is complete loss of consciousness; further there is (as in true epilepsy), a tonic phase, a clonic phase, and a phase of resolution; it lasts several minutes. It is important to note that there is loss of consciousness in grave hysteria, as the absence of this in ordinary hysterical convulsions is one of the features by which the latter are diagnosed from an epileptic attack. The *contortions* and *great movements* of the second period differ from those of the first period in this that the muscles are quite relaxed apart from the contortions; there is no tetanus. Consciousness is not lost. The whole body may be rolled about, as if the patient were writhing in pain; or more regular movements occur, *e.g.*, the movements of "salutations" in which the patient, lying with the knees bent up, suddenly throws the head and chest forwards so that the forehead strikes the knees and then falls back again. The *emotional attitudes* of the third period are beautifully illustrated by a series of photographs in Bourneville and Regnard's work. Ecstasy, irony, disdain, terror, and other emotions are seen on the face, and the attitude of the body corresponds to the expression. Hallucinations are present, and the patient remembers these afterwards; voluntary motion is unaffected, but general and special sensibility are completely suspended. This period lasts from

¹ *Lectures on Diseases of the Nervous System*: Sydenham Translations, 1877, p. 262.

a few minutes to a quarter of an hour. The fourth period is not sharply marked off from the preceding one. The patient partially recovers consciousness and is influenced by external impressions, but these are largely mixed with hallucinations.

A succession of hystero-epileptic attacks produces the hystero-epileptic status which is diagnosed from the status epilepticus by the important fact (ascertained by Charcot) that there is no rise of temperature during it.

As to prognosis, it is less grave than in true epilepsy.

As to treatment, pressure on the ovaries often checks the attack at once; place the patient on the back and forcibly press the fist into the iliac region. Inhalation of chloroform or nitrite of amyl, and the subcutaneous injection of morphia are also valuable. For the treatment by electricity and metallo-therapy, we refer the practitioner to Richer's work.

ETIOLOGY OF UTERINE DISEASE.

LITERATURE. *Bennet, J. Henry*—A Practical Treatise on Inflammation of the Uterus and its Appendages: London, 1849. *Emmet*—The Principles and Practice of Gynecology: J. & A. Churchill, London, 1880. *Hewitt, Graily*—The Mechanical System of Uterine Pathology: London, Longman, Green & Co. *Jacobi*—The Question of Rest for Women during Menstruation: London, 1878. *Simpson, Sir J. Y.*—Collected Works: Edinburgh, A. & C. Black, 1872. *Thomas, T. G.*—A Practical Treatise on the Diseases of Women: London, Henry Kimpton, 1880.

Diseases of the uterus and its appendages are the same essentially as diseases elsewhere—the uterus has no pathology special to it, more than the stomach or brain. The attempts made (by Bennet, Emmet, Hewitt and others) to found a system of uterine pathology, in which some special lesion (whether an inflamed cervix or an anteflexed uterus) was to play the leading part in disease and to be not only an important lesion itself but the parent of most other pelvic diseases, have been unsuccessful. Those interested in this subject may consult the literature we have given.

Diseases of women are, however, modified by certain anatomical points and functions connected with the pelvic organs; the modifications in the pelvic floor for parturition; the functions of menstruation, sexual intercourse, pregnancy and parturition. It would be of the greatest interest to trace the influence of these functions, when abnormal, in causing disease as well as in helping to perpetuate it; but our space is too limited for this. One familiar instance will render our meaning clear. The student's ordinary dissection-wound of the finger soon makes him aware of the lymphatic and glandular anatomy of his arm; the axillary glands become swollen and tender, and he is feverish and out of sorts for some

days. Soon, however, all this passes off and he becomes quite well. Let us take now such a case as curetting the uterus for endometritis. In some instances, the patient becomes feverish after the operation from absorption of septic matter by the cut surface; a moderate cellulitis in the utero-sacral ligaments results. This diminishes in intensity, but becomes aggravated at the next menstrual period from the increased pelvic congestion. This continues time after time and ultimately dysmenorrhœa develops. Why and how? The cellulitis has affected the utero-sacral ligaments and their cicatrisation has produced pathological ante flexion. The inflammation resulting on the one hand in the student's finger and on the other in the patient's endometrium is precisely the same—the result of septic absorption by the lymphatics. The difference is due, in the case of the latter, to the fact that the inflammation has occurred in a region with a peculiar anatomical structure and with certain functions which modify and perpetuate the lesion.

We might multiply instances illustrating this point but the above one will show our meaning.

The function of menstruation, when disturbed, causes hæmatocele, dysmenorrhœa and other allied affections. Parturition causes laceration of the cervix, subjecting the patient to the risk of septic infection; and, further, tends to cause prolapse of the uterus. With sexual intercourse may be associated vaginismus, ovaritis, gonorrhœa, etc. Almost every disease given in the preceding pages will illustrate our statements here.

Some minor points are worthy of consideration as favouring uterine disease: such are carelessness at the menstrual periods and after abortion, tight-lacing, and neglect of the due evacuation of the bowels and bladder.

The gynecologist can therefore help to limit disease by insisting on the proper hygiene of the bowels and bladder, by advising rest during menstruation and after abortion; and he does this more directly by taking care in all cases to prevent septic infection, to treat abortion thoroughly, and to avoid undue operative interference.

CASE-TAKING.

LITERATURE. *Emmet*—Gynecology, p. 57: London, 1880. *Simpson, A. R.*—Contributions to Obstetrics and Gynecology, Method of Case-Taking in Gynecology, p. 317.

It is of importance to give some hints as to case-taking or the investigation of cases of diseases of the female sexual organs.

In hospitals, some form of case-taking card is usually employed; and we purpose describing the method of case-taking adopted by Professor

Simpson in the Buchanan Ward (for the Diseases of Women) in the Edinburgh Royal Infirmary (see page 626).

Our first object is to learn all we can from the patient herself. This information is considered under six heads and comprised under the term ANAMNESIS, a convenient word, which literally means "a statement of what she recollects."

The questions asked under "Sexual History" need little explanation. In regard to Menstruation as well as abnormal Hæmorrhage, we may note that when either follows Amenorrhœa of some weeks' or months' duration it makes us suspect abortion. Hæmorrhage coming on after the menopause usually indicates cancer, especially if followed by fœtid discharge (v. p. 441); patients may complain of bleeding after coitus (p. 440), which is often an early sign of carcinoma. As to Dysmenorrhœa we should note whether the pain is before, during, or after the flow; we should also enquire as to clots or shreds discharged, and the latter should be examined microscopically. For the various conditions with which Amenorrhœa, Menorrhagia and Dysmenorrhœa are associated, see Index under these heads and Chap. XLVIII.

Intermenstrual discharge. Ascertain its colour; its amount—Whether it requires the use of diapers; and whether it be fœtid, watery, or acrid. Leucorrhœa is present in vaginitis (p. 496), cervical catarrh (p. 282), endometritis (p. 294), and wherever there is secondary catarrh of the uterine mucous membrane as in retroflexion (p. 341) and uterine polypi (p. 422); it is also present in Chlorosis and Phthisis. Fœtid Leucorrhœa is characteristic of Carcinoma, whether affecting the cervix (p. 441) or body of the uterus (p. 469); in Sarcoma, it is not fœtid till the later stages (p. 476). For other references to Leucorrhœa, see Index.

Pareunia. This refers to the absence or presence of pain during coitus (v. p. 499). It is enquired into only in special cases, or when the patient complains of the pain. For conditions producing dyspareunia, see Index.

PHYSICAL EXAMINATION. The *general appearance* and *configuration* should always be noted. The sallow look of the dyspeptic and constipated, yellow appearance of the chlorotic, pinched face of the patient with ovarian cyst, are in some cases helpful in giving the hint as to the line of enquiry. The student should always note anything in the appearance or configuration which may enable him to recognise the diathesis of the patient. It is of importance to ascertain the occurrence of the gouty diathesis in a case of dysmenorrhœa, the tubercular diathesis in chlorosis,

and the strumous in syphilis. The physician will be puzzled by the varied complaints of the patient over some slight pelvic inflammatory con-

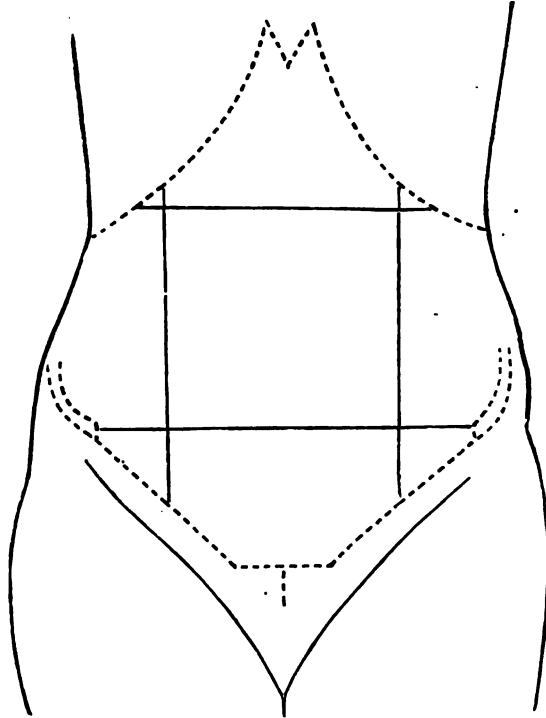


FIG. 398.

OUTLINE DIAGRAM OF ABDOMEN FOR RECORDING POSITION OF TUMOURS RELATIVE TO THE BONY LANDMARKS.

dition, unless he note the thin and anxious face of a patient of nervous temperament. Information gained in this way is valuable, but must be used with discrimination. Thus cancerous patients are often florid enough, while a sallow cachectic-looking woman may have some insignificant lesion.

Mammæ. Note whether virginal, or those of Pregnancy or Lactation.

The *abdomino-vaginal examination* is the ordinary Bimanual. The *abdomino-vesico-vaginal* is a rare form but useful in some cases (p. 571). The *tent* is not used as a mere diagnostic except in the case of tumours in the cavity of the uterus.

Prognosis. A great deal depends on this. Thus we have to tell the patient whether her lesion is serious or slight, whether she will get well soon, or if her trouble is chronic but not dangerous. Unless she is told

that it is chronic, she may ultimately come to the conclusion that its nature has been misunderstood by the physician. Prognosis is often difficult to give and should always be cautious, especially as to sterility.

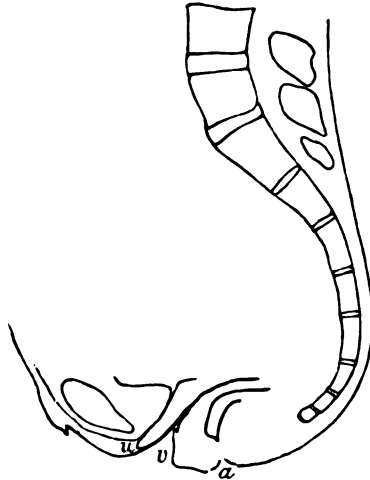


FIG. 399.

OUTLINE DIAGRAM OF PELVIS FOR FILLING IN POSITION OF UTERUS OR TUMOURS (*A. R. Simpson*).

Treatment. In no class of cases has the physician to be so careful not to do harm by his treatment. From the great fact that cellulitis and

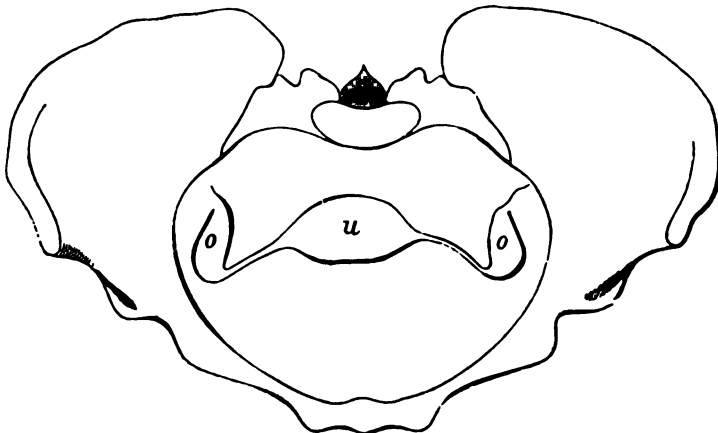


FIG. 400.

OUTLINE DIAGRAM OF PELVIS AS SEEN THROUGH THE BRIM, TO FILL IN POSITION OF TUMOURS RELATIVE TO UTERUS (*Schultze*).

peritonitis cause or accompany many of the diseases of women, we

should first use palliative measures. All operations should be carefully considered, and only undertaken when we feel fairly confident they will benefit and not make the patient worse. The great success of peritoneal operations is now undoubted; but the question as to the actual good resulting from repeated cauterisation of the uterine mucous membrane, division of the cervix, stitching the cervix, etc., is more *sub lite* than is admitted in many text-books. The problem of how to remove cervical cancer without risk to life and with a fair hope of its non-recurrence is at present being worked out. Unfortunately the patient has usually recurrence of the disease.

CASE-TAKING CARD.

ANAMNESIS.

1. NAME; AGE; OCCUPATION; RESIDENCE; MARRIED, SINGLE, OR WIDOW; DATE OF ADMISSION.

2. COMPLAINT AND DURATION OF ILLNESS.

3. GENERAL HISTORY OF—(a) Present attack; (b) Previous Health; (c) Diathesis; (d) Social Condition and Habits; (e) Family Health.

4. SEXUAL HISTORY.

(1) Menstruation—

A. Normal—(a) Date of Commencement; (b) Type; (c) Duration; (d) Quantity; (e) Date of Disappearance.

B. Morbid—(a) Amenorrhœa; (b) Menorrhagia; (c) Dysmenorrhœa.

(2) Intermenstrual Discharge—(a) Character; (b) Quantity.

(3) Pœrnesia.

(4) Pregnancies—(a) Number; (b) Dates of First and Last; (c) Abortions; (d) Character of Labours; (e) Puerperia; (f) Lactations.

5. LOCAL FUNCTIONAL DISTURBANCES—(a) Bladder; (b) Rectum; (c) Pelvic Nerves and Muscles.

6. GENERAL FUNCTIONAL DERANGEMENTS—(a) Nervous System; (b) Respiratory System; (c) Circulatory System; (d) Digestive System; (e) Emunctories.

PHYSICAL EXAMINATION.

1. GENERAL APPEARANCE AND CONFIGURATION.

2. MAMMÆ.

3. ABDOMEN—(a) Inspection; (b) Palpation; (c) Percussion; (d) Auscultation; (e) Mensuration.

4. EXTERNAL PUDENDA.

5. PER VAGINAM—(a) Orifice; (b) Walls and Cavity; (c) Roof; (d) Os and Cervix Uteri.

6. BIMANUAL EXAMINATION (Abdomino-vaginal, Recto-vaginal, Abdomino-rectal, Abdomino-recto-vaginal, Abdomino-vesico-vaginal)—

(1) Uterus—(a) Size; (b) Shape; (c) Consistence; (d) Sensitiveness; (e) Position; (f) Mobility; (g) Relations.

(2) Fallopian Tubes.

(3) Ovaries—(a) Size; (b) Situation; (c) Sensitiveness.

(4) Peritoneum and Cellular Tissue.

(5) Bladder. (6) Rectum. (7) Pelvic Bones.

7. USE OF—(a) Speculum; (b) Volsella; (c) Sound; (d) Curette; (e) Aspiratory Needle; (f) Tent.

8. PHYSICAL CHANGES IN—(a) Nervous, (b) Respiratory, (c) Circulatory, (d) Digestive, (e) Emunctory Organs; (f) Skin; (g) Bones.

DIAGNOSIS.

PROGNOSIS.

TREATMENT.

PROGRESS AND TERMINATION.

SOURCES OF GYNECOLOGICAL LITERATURE.

At the beginning of each subject we have already given a summary of the literature to which we were indebted. The literature given, therefore, represents what we considered important, and what we had in most cases personally studied.

Gynecological Literature is so extensive that a full resumé of it would have occupied several times the space we have allotted to the whole subject. We wish however to point out here the sources, so that any practitioner who wishes to ascertain the best books and monographs on any special subject may know how and where to begin his search.

The sources of Gynecological Literature are threefold :—

- I. Catalogues, Dictionaries ;
- II. The larger Text-books of Gynecology ;
- III. Articles and Abstracts in the various Gynecological *quarterlies*, *monthlies*, and *weeklies*, with *Retrospects* and *Jahrbücher*.

I. CATALOGUES, DICTIONARIES.

- (1.) *Index-Catalogue of the Library of the Surgeon-General's Office, U.S.A.*: Washington Government Printing Office, 1880. In this splendid work, the authors and works are arranged alphabetically; its value cannot be overrated. (*In course of Publication.*)
- (2.) *Nouveau Dictionnaire de Médecine et de Chirurgie pratiques*: Paris, J. B. Bailliére et Fils, 1870.
- (3.) *Dictionnaire Encyclopédique des Sciences Médicales*: Asselin et Cie, Paris.
- (4.) *Real-Encyclopädie der gesammten Heilkunde*: Wien, 1881-83.

II. LARGER MODERN TEXT-BOOKS OF GYNECOLOGY.

ENGLISH.

- Barnes*—The Diseases of Women: London, J. & A. Churchill, 1878.
Byford—Medical and Surgical Treatment of Women: Philadelphia, 1881.
Duncan, Matthews—Diseases of Women: London, Churchill, 1883.
Edis—Diseases of Women: London, Smith, Elder, & Co., 1881.
Emmet—Principles and Practice of Gynecology: London, Churchill, 1880.
Goodell—Lessons in Gynecology: Philadelphia, Brinton, 1879.
Hewitt—The Diseases of Women: London, Longmans, Green, & Co., 1882.
Mundé—Minor Surgical Gynecology: London, Sampson, Low, & Co., 1881.
Simpson, A. R.—Obstetrics and Gynecology: Edinburgh, A. & C. Black, 1880.
Simpson, Sir J. Y.—Diseases of Women (edited by A. R. Simpson): A. & C. Black, 1872.
Sims, J. Marion—Uterine Surgery: London, Hardwicke, 1865.

Tait, Lawson—Diseases of Women: Williams & Norgate, 1877.

The Pathology and Treatment of Diseases of the Ovary: Birmingham, 1883.

Thomas—Treatise on Diseases of Women: London, Kimpton, 1880.

Wells, Sir T. S.—Ovarian and Uterine Tumours: London, 1882.

West (Duncan's Edition)—Diseases of Women: Churchill, 1879.

GERMAN.

Fritsch—Krankheiten der Frauen: Braunschweig, 1881.

Hegar und Kallenbach—Die operative Gynäkologie: Stuttgart, Enke, 1881.

Schroeder—Handbuch der Krankheiten der weiblichen Geschlechtsorgane: Leipzig, Vogel, 1879.

Billroth's Series.

Bandl, Die Krankheiten der Tuben, der Ligamente des Becken-peritonäums und des Beckenzellgewebes;

Billroth, Die Krankheiten der weiblichen Brustdrüsen;

Breisky, Die Krankheiten der Vagina;

Chrobak, Die Untersuchung der weiblichen Genitalien;

Fritsch, Die Lageveränderungen der Gebärmutter;

Gusserow, Die Neubildungen des Uterus;

Hildebrandt, Die Krankheiten der äusseren weiblichen Genitalien;

Mayrhofer, Die Sterilität des Weibes;

Olshausen, Die Krankheiten der Ovarien;

Winckel, Die Krankheiten der weiblichen Harnröhre und Blase.

(All published by Enke at Stuttgart.)

FRENCH.

Bernutz and Goupil—Clinical Memoirs on the Diseases of Women: Sydenham Society Tr., 1866.

Courty—Traité pratique des Maladies de l'utérus: Paris, Asselin, 1866: also Dr. Agnes Maclaren's Translation, London, 1882.

De Sinéty—Manuel pratique de Gynécologie: Paris, Doin, 1879.

Leblond—Traité élémentaire de Chirurgie gynécologique: Paris, 1878.

Tripier—Leçons cliniques sur les Maladies des Femmes: Paris, Doin, 1883.

III. JOURNALS: RETROSPECTS: INDEXES: JAHRBÜCHER.

American Journal of Medical Sciences: New York, H. Lea.

American Journal of Obstetrics: New York, Wm. Wood & Co.

British Medical Journal: London.

Dublin Journal of Medical Science: Dublin, Fannin & Co.

Edinburgh Medical Journal: Edinburgh, Oliver & Boyd.

Glasgow Medical Journal: Glasgow, MacDougal.

Lancet: London.

London Medical Record: Smith, Elder & Co.

SOURCES OF GYNECOLOGICAL LITERATURE. 629

Medical Press and Circular: London.

Medical Times and Gazette: London.

New York Medical Journal and Obstetrical Review: New York, Appleton & Co.

Archiv. für Gynäkologie: Berlin, Hirschwald.

Centralblatt für Gynäkologie: Leipzig, Breitkopf und Härtel.

Zeitschrift für Geburtshülfe und Gynäkologie: Stuttgart, Enke.

Berliner klinische Wochenschrift.

Wiener medizinische Wochenschrift.

Archives de Tocologie et des Maladies des Femmes, etc.: Paris, Delahaye et E. Lecrosnier.

Annales de Gynécologie, Paris.

Annali di Ostetricia, Ginecologia e Pediatria: Milano, Pietro Agnelli.

Braithewaite's Retrospect: London, Simpkin, Marshall & Co.

Index Medicus: a monthly classified Record of the current Medical Literature of the World: New York, F. Leypoldt.

Schmidts's Jahrbücher: Leipzig.

Supplement to Ziemssen's Cyclopædia: Low, Sampson, Low, Marston, Searle, and Rivington.

Révué des Sciences Medicales: Paris, E. Masson.

Neale's Digest: London, Ledger, Smith & Co., 1882.

American Gynecological Transactions (Index at end): Boston, Houghton & Co.

London Obstetrical Transactions: Longmans, Green & Co.

Edinburgh Obstetrical Transactions: Oliver & Boyd.

In looking up literature on any special subject, first consult the literature given at the beginning of each chapter: then look up the necessary volume in Billroth's series. For recent literature the Index Medicus and Neale's Digest are best. The U.S.A. Index Catalogue gives the literature most elaborately. The various Retrospects and Jahrbücher mentioned above give abstracts of the papers, and the French and German Cyclopædias give special exhaustive articles on each subject.



The text in this section is extremely faint and illegible. It appears to be a list or a series of entries, possibly a table of contents or a list of references, but the specific details cannot be discerned due to the low resolution and blurriness of the image.

INDEX OF AUTHORS.

- AITKEN, LAUCHLAN**, 166.
Allingham, 610.
Arnold, 229.
Arnott, H., 447.
Ashford, 304.
Atlee, 414.
Athill, 301, 369.
Aveling, 116.
BALFOUR, 71.
Bandl, 17, 45, 178, 179, 555, 558, 561, 566.
Bannon, 508.
Bantock, Granvill, 191, 223, 356.
Barbour, 560, 564, 565.
Barker, 269, 436, 447.
Barkow, 508.
Barnes, 118, 241, 261, 258, 287, 301, 338, 363, 368, 371, 386, 421, 443, 446, 448, 452, 459, 499.
Batley, 87, 109, 189, 191, 192, 194, 570, 619.
Bayle, 386.
Beck, Snow, 308.
Beigel, 86, 503.
Bennet, Henry, 294, 621.
Bennet, Hughes, 293.
Bernutz, 151, 153, 165.
Berthold, 508.
Billroth, 405.
Bird, 304.
Blau, 433.
Blundell, 189.
Bouque, 604.
Bourdon, 165.
Bourneville, 620.
Bourneville and d'Olier, 617.
Bozeman, 108, 135, 593, 598, 599.
Bramwell, Byrom, 615.
Braun, Carl, 313, 555.
Braune, 47, 64.
Breisky, 28, 282, 438, 482, 483, 490, 502.
Brown, Baker, 220.
Bruckner, 502.
Brumton, Laudier, 143.
Budin, 27.
Byford, 589.
Byrne, 261, 369, 428, 458.
CAMPBELL, H. F., 349, 350.
Cappie, 381.
Chadwick, 36.
Championnière, 69.
Cheyne, Watson, 161.
Chiari, 250, 470.
Chisholm, 436.
Chrobach, 474.
Cintrat, 409.
Claudius, 47.
Clay, 476, 478.
Coghill, 245, 598.
Cohnheim, 471.
Cohnstein, 302.
Courty, 368, 370.
Crede, 168, 301, 364.
Croom, 563.
Crosse, 359, 360, 363, 364, 374.
Cruveilhier, 47, 389.
Cullingworth, 204.
Cunningham, 11.
Cusco, 114.
Charcot, 617, 619, 620, 621.
Clouston, 619.
DALTON, 83, 87.
De Cassis, Vidal, 604.
De Morgan, Campbell, 454.
De Sinety, 20, 21, 200, 286, 290, 292, 297, 307, 420, 422.
Dohrn, 483.
Doran, 199.
Drysdale, 203.
Düll, 382.
Duncan, John, 522.
Duncan, Matthews, 116, 225, 359, 368, 380, 400, 518, 544, 548, 551, 573.
Dunlap, 573.
EADE, 382, 390.
Eichwald, 203.
Emmet, 106, 116, 266, 267, 268, 269, 270, 271, 272, 273, 274, 275, 276, 282, 287, 309, 313, 369, 371, 372, 487, 514, 621, 622.
Engelmann, 85, 86, 191, 194.
Englisch, 185.
Eppinger, 449, 468.
FARR, 550.
Farre, 23.
Fehling, 413.
Fergusson, 111.
Finn, 308.
Fischel, 279.
Foster, 6, 51, 63, 64.
Foulis, 71, 100, 145, 152, 198, 201, 204, 205.
Fox, Wilson, 199.
Frankel, 562.
Frankenhäuser, 71.
Freund, 43, 160, 194, 360, 379, 384, 463.
Friedreich, 511.
Fritsch, 281, 321, 323, 331, 336, 339, 358, 360, 362.
Frommel, 250.
Fürst, 234.
GALABIN, 475.
Gallard, 312.
Garrigues, 32.
Gehring, 334.
Gilmore, 191, 214.
Goltz, 143, 583.
Goodell, 181, 190, 214, 520, 581, 615.
Goodair, 459.
Goupil, 151.
Greenhalgh, 245, 327, 401.
Guérin, 40, 43, 69, 151.
Gusserow, 379, 384, 386, 387, 390, 391, 405, 433, 436, 438, 439, 447, 452, 468, 474, 475, 476, 478, 547.
Gaskell, 615.
HABIT, 446.
Hamilton, 153, 214.
Hanks, 104, 116, 125, 130, 131.
Hanot, 391.
Harris, 200.
Hart, 40, 42, 58, 76, 78, 104, 136, 246, 349, 356, 531.
Haase, 52, 53.
Hecker, 558.
Hegur, 189, 194, 257, 302, 406, 409, 428, 466, 467, 500, 538.
Henderson, 496.
Henle, 10, 27, 30, 38, 47.
Hennig, 16, 240, 363, 561.
Hewitt, Graily, 321, 334, 621.
Heyfelder, 556.
Hicks, Braxton, 211, 368, 369, 417.
Hildebrandt, 398, 495, 499, 506, 512, 515, 524, 614.
Hilton, 608, 611, 612.
Hodge, 350, 351, 352.
Holden, 515.
Holdhouse, 590.
Houston, 36.
Hubert, 391.
Hüe, 390, 391.
Huguler, 202, 510, 531, 538.
Hutchinson, Jonathan, 219, 471.
Hyde, 516.
Hyrzl, 36, 66, 68.
JACUBASH, 475.
Jastrebow, 208.
Jennison, 116.
Jobert, 586.
Jolly, 617.
KALTENBACH, 194, 302, 405, 466, 467, 584, 588.
Kaschkaroff, 310.
Kehrer, 550.
Keith, 146, 218, 219, 222, 223, 226.
Kidd, 390.
Kinkead, 83.
Kiwisch, 305, 561.
Klebs, 160, 378, 430, 431, 472.

- Kloeberg, 410.
 Klemm, 302.
 Klob, 250, 306, 386.
 Koch, 161.
 Koberlé, 173, 405, 413.
 Kohlrausch, 50.
 König, 45, 182.
 Kroner, 369.
 Kuchenmeister, 135, 246, 329.
 Kundrat, 85, 86.
 Kunert, 174.
 Kussmaul, 556.
 Küster, 384.
 Küstner, 503.

 LANDAU, 127.
 Le Bec, 45, 69, 151.
 Leblond, 302.
 Lee, 267, 272, 376.
 Leopold, 69, 86, 87, 378, 413.
 Lister, 137, 138, 222, 223, 487.
 Löwenhardt, 87.
 Lorey, 579.
 Löwenstein, 28.
 Luschka, 13, 30, 44, 47.
 Luak, 72, 152.

 M'CLINTOCK, 392.
 Macdonald, Angus, 304, 368.
 Mackintosh, 244, 327.
 Malasses, 201.
 Malgagne, 443.
 Marckwald, 257.
 Martin, 194, 313, 384, 537.
 Mayer, 614.
 Meyer, 508.
 Mills, 617.
 Miner, 324.
 Mitchell, Weir, 159, 313, 615.
 Mörcke, 86.
 Müller, 474.
 Mundé, 127, 132, 186, 188, 214,
 267, 269, 271, 334, 345.
 Murphy, 391.

 NELATON, 165, 219.
 Neugebauer, 112.
 Nieberding, 269, 271.
 Noeggerath, 153, 177, 197, 198,
 199, 200, 306, 368, 369, 374,
 571.
 Nonat, 151.
 Nott, 614.

 OLDHAM, 419, 485.
 Ollivier, 165.
 Olshausen, 182, 290, 291, 295,
 296, 297, 301.
 Otto, 509.

 PALLEN, 267, 269, 272, 554.
 Paquelin, 140, 141.
 Parkes, 569.
 Patenko, 199.
 Pawlik, 574.
 Pean, 220, 406, 409.

 Pflüger, 198.
 Pichot, 469.
 Picot, 436.
 Pirogoff, 39, 43, 50, 54.
 Pott, Percival, 185.
 Puech, 483, 491.
 Playfair, W. S., 615, 616.

 QUAIN, 72, 92.

 RAINEY, 18.
 Ramsbotham, 508.
 Recamier, 132, 133, 165.
 Recklinghausen, 161.
 Regnard, 620.
 Reid, W. L., 554.
 Rein, 414.
 Reinmann, 304.
 Richet, 16.
 Rindfleisch, 201.
 Rokitsansky, 180, 199, 320, 358,
 558.
 Roer, 266, 267.
 Routh, 245, 293, 296, 454.
 Ruedinger, 37, 44, 52, 62, 609.
 Ruge, 21, 267, 278, 279, 290, 330,
 430, 431, 438, 445, 468, 493,
 494.
 Richer, 618, 620.

 SANGER, 467.
 Sappey, 16, 69.
 Savage, 38, 139, 245.
 Scanzoni, 304, 305, 313, 358, 512.
 Schlesinger, 46.
 Schroeder, 16, 61, 62, 63, 168,
 201, 218, 272, 288, 290, 292,
 304, 321, 332, 370, 378, 382,
 386, 391, 405, 406, 432, 438,
 446, 447, 460, 461, 466, 467,
 468, 469, 474, 481, 485, 492,
 493, 502, 515, 531, 556.
 Schultze, 49, 50, 51, 64, 128,
 159, 182, 244, 254, 321, 382.
 Seyfert, 447.
 Sibley, 436.
 Simon, 101, 103, 130, 133, 137,
 257, 455, 571, 592, 605.
 Simpson, A. R., 76, 78, 104, 110,
 123, 133, 153, 191, 194, 250,
 258, 299, 349, 358, 361, 371,
 374, 391, 398, 402, 448, 459,
 467, 473, 474, 476, 488, 502,
 523, 571, 622.
 Simpson, Sir J. Y., 115, 124,
 125, 151, 244, 245, 250, 253,
 266, 301, 322, 327, 328, 384,
 399, 428, 436, 437, 447, 452,
 455, 457, 459, 469, 507, 509,
 510, 514, 516, 594, 595, 596,
 621.
 Sims, 79, 106, 107, 116, 125, 132,
 133, 180, 193, 194, 222, 244,
 256, 257, 318, 322, 323, 320,
 402, 462, 500, 537, 590.

 Skene, 30, 31, 568, 573, 576.
 Slavjansky, 199, 293.
 Smith, Albert, 350.
 Smith, Heywood, 286.
 Smith, Protheroe, 116.
 Smith, Tyler, 368.
 Solowieff, 547.
 Späth, 555.
 Spiegelberg, 41, 44, 201, 272,
 375, 414, 445, 503.
 Steurer, 152, 160.
 Stiegele, 514.
 Storer, 609.
 Sutton, 270.
 Squard, Brown, 620.

 TAIT, LAWSON, 87, 125, 130, 131,
 173, 178, 179, 190, 195, 196,
 228, 225, 371, 426.
 Tate, 368, 371.
 Taylor, 16, 359.
 Thiersch, 431.
 Thomas, 116, 132, 133, 214, 248,
 261, 285, 288, 305, 309, 313,
 330, 331, 334, 352, 368, 370,
 371, 382, 400, 402, 405, 409,
 458, 489, 490, 497, 511, 621.
 Thornton, 220, 223, 403, 404.
 Tillaux, 383.
 Tilt, 500.
 Times, 380.
 Trenholm, 190.
 Turner, 20, 36, 72, 381.

 UFFELMAN, 30.
 Underhill, 419, 420.

 VAN BUREN, 610.
 Van de Warker, 53.
 Veit, 21, 267, 278, 279, 430, 431,
 438, 445, 501.
 Virchow, 44, 159, 168, 306, 320,
 378, 380, 386, 414, 430, 431,
 471.
 Voisin, 165, 172.
 Von Preuschen, 501.

 WALDEYER, 71, 198, 201, 430,
 431.
 Warner, 544.
 Wells, Spencer, 193, 218, 219,
 221, 223, 224, 226, 375, 405,
 407, 408.
 West, 225, 514.
 White (of Buffalo), 368, 369.
 Whitehead, 250.
 Williams, 84, 85, 86, 357, 454,
 547.
 Wilson (of Baltimore), 141.
 Wilson, W., 560.
 Wiltshire, 225.
 Winckel, 262, 336, 336, 494, 568,
 585, 589.
 ZWANCK, 532.

INDEX OF SUBJECTS.

Note.—As the student will see in the *Table of Contents* the details of each special subject, we give only one reference—in bold figures—to the pages where each subject is specially treated of. Passing references in other parts of the book, are given fully.

Thus, for the "Pathology of Carcinoma Uteri," see "Carcinoma Uteri" in *Table of Contents*; for references to Carcinoma, not contained in the chapter on Carcinoma, see Index.

For instruments figured in text, see *Instruments in Classical List of Illustrations*.

- ABDOMEN**—distension of, in ovarian tumour 208.
- Abdominal contents**, relation to skin 91.
 examination 90.
 pressure, action on uterus 314.
 regions 91.
 section for pelvic abscess 173.
 in hæmatocele 173.
- Abortion 561.**
 and endometritis 293, 294, 295, 297.
 causing pelvic peritonitis 152.
 in retroflexion 341, 342.
 cause of subinvolution 308, 309.
- Abscess**—pelvic 160, 163.
 opened by cautery 164.
 tapping of 164.
 of uterine wall 304.
- Adhesions**—limiting hæmatocele 166.
 diagnosis in Ovarian tumours 212.
 treatment in Ovarian tumours 221.
- Age**—influence on carcinoma 436, 438.
 on fibroid tumours 386, 387.
 in relation to menstruation 81.
- Amenorrhœa 542.**
 due to atresia 484.
 in chlorosis 543.
 physiological 542.
 in superinvolution 249.
- Ampulla of Fallopiian tube 22.**
- Amputation**—of cervix 256.
 " hypertrophied in pro-
 lapsus 263.
 of inverted uterus 374.
- Anæmia in hæmorrhagic endometritis 295.**
- Anæsthetics 142.**
- Anteflexion of uterus 315, 317, 318.**
- Anteflexion and small fibroid tumour 304.**
 pathological 103, 160.
 mistaken for retro-
 version 319, 337.
 passage of sound in 121.
- Anteversión of uterus 317, 331.**
 due to chronic metritis 331.
- Antiseptics in gynecology 137.**
- Antiseptic douche 138.**
- Anti-thermic shield 141.**
- Anus 36.**
 fissure of 610.
 " producing vaginismus 498.
- Areolar hyperplasia**—of cervix 282.
 of uterus 305.
- Arsenic in membranous dysmenorrhœa 549.**
- Ascites and ovarian tumours 209.**
- Ascitic fluid, in malignant ovarian disease, 152,**
 201, 204.
- Asphyxia from chloroform 145.**
- Atresia of cervix uteri 240.**
 senile 292.
 in septate uterus 491.
 of vagina 480, 481.
 dangers of operation for 487.
- Atrophy of cervix and uterus 249.**
 congenital of uterus 234, 235, 236.
- Auscultation 93.**
- BACTERIA, in cellulitis 160.**
 in erysipelas 161.
- Baden-Baden waters in chronic metritis 312.**
- Ballotement, in extra-uterine gestation 561.**
- Barnes' ointment-positor 301.**
 speculum for vaginal tampons 287.
- Bartholinian glands 11.**
 cysts of 513.
 inflammation of 510.
 abscess in 513.
- Battey's operation 87, 189.**
 in dysmenorrhœa 549.
- Benzoate of ammonia in cystitis 580.**
- Bimanual Examination 96.**
 in anteflexion 324.
 in early pregnancy 311.
 in inversion 365.

- Bhnanual, position of hands in** 96.
to replace retroflexed uterus 347.
in retroflexion 344.
in retroversion 336.
with sound 123.
for stone in bladder 582.
in uterine displacements 318.
- Bladder, Anatomy of** 29, 561.
affection of, in carcinoma 433, 435.
in amputation of cervix 264.
attachment to anterior vaginal wall 59.
calculi in 581.
changes in, after fistula 587.
changes in position of 35.
diastole of 35.
dilated, in carcinoma 436.
displacements of 577.
in extra-uterine gestation 563.
in retroflexed gravid uterus 554.
distended, and ovarian tumours 210, 212.
functional diseases of 582.
injuries to in ovariectomy 221.
malformations of 575.
methods of exploring 570.
physiology of 568.
neoplasms of 578.
position 29.
position in inversion of uterus 362.
pressure on, by fibroid tumour 390.
in retroflexion 339.
shape when empty 34.
shape in fetus 34.
structure 31.
astole and diastole of 569.
effect of its distension on the uterus 54, 314, 315, 335.
- Blaud's pills in chlorosis,** 543.
Blistering of the cervix uteri 313.
Blood effusion into pelvis 166.
Blood-vessels of pelvis 65.
Bougies graduated, to dilate cervix 244.
Breisky's instruments for operating in atresia 490.
Bright's disease in fibroid tumour 391.
Broad ligament 40.
affections of 181.
anatomy 18, 40.
blood effusion into 166.
cellular tissue of 42.
position 40.
- Bromide of Potassium in chronic metritis** 313.
in fibroid tumours 399.
in ovariitis 184.
- Bromine solution in carcinoma** 452, 454.
- Bulbocavernosi** 9.
Bulbi vaginæ 10.
- CACHEXIA in carcinoma** 442.
in sarcoma 476.
- Calcification of fibroid tumours** 384.
Calculi in bladder 581.
Cancer (see Carcinoma).
Carbolic acid in cervical catarrh 286.
in endometritis 298.
in pruritus vulvæ 512.
- Carcinoma—of bladder** 578.
of cervix 429, 440, 450.
- Carcinoma—cure by amputation** 459.
commencement in cervix 285.
duration of life in 447.
and endometritis 297.
of Fallopian tubes 180.
in male and female compared 436.
affecting fibroid tumours 385.
combined with sarcoma 472.
diagnosis from sarcoma 477.
spontaneous cure of 446.
of body of uterus 488.
of vagina 502.
secondary 435.
of vulva 514.
- Carlsbad salts** 312.
- Case-taking, method of** 622.
A. R. Simpson's card for 626.
- Cataleptic convulsions and lacerated cervix** 270.
- Catarrh of cervix** 277.
diagnosis from vaginal 284.
of Fallopian tube 178.
of uterus 269.
- Catarrhal patches** 280.
- Catheter—methods of passing** 570.
stationary, for fistula 602.
- Cauliflower excrescence** 431, 441.
- Caustics producing atresia** 240.
in carcinoma 454, 462.
- Cautery in dividing cervix** 400.
in incising capsule of fibroid 401.
in laparotomy for fibroids 406.
in ovariectomy 220.
Paquelin's 140.
in opening vaginal cysts, 502.
- Cellular tissue of pelvis, hæmorrhage into** 169.
(v. Connective tissue).
- Cellulitis, pelvic** 159.
and antelexion 326.
diagnosis from anteversion 332.
producing anteversion 331.
and lacerated cervix 268.
relation to peritonitis 151.
and retroflexion 345.
in utero-sacral ligaments 321.
- Cervical catarrh in lacerated cervix** 270.
with retroflexion 338.
- Cervical mucus, character of** 283.
- Cervical plug, Thomas' 248.**
- Cervical polypus** 419.
- Cervix—amputation of** 256.
in carcinoma 455.
in prolapsus 263.
producing involution 313.
anatomy 15.
atrophy of 249.
atresia of 240, 485.
operation for 490.
senile 292.
dilated above stenosis 241.
dilatation of 244.
division of, in cervical catarrh 286.
antero-posterior division of 329.
bilateral division of 244, 245, 328.
cancer of (see carcinoma).
carcinoma of 429, 440, 450.
catarrh of 277.

- Cervix**—chronic thickening of 255, 280.
 conical 241.
 closure for vesico-uterine fistula 601.
 descent in prolapsus 526.
 dilatation of 126, 400.
 displacement in retroflexed gravid uterus 553.
 examination of 95.
 fibroid tumour of 376, 385.
 glands of 21.
 hypertrophy of 241, 254.
 in prolapsus 529.
 induration of, in carcinoma 445.
 in infantile uterus 233, 239.
 position in inversion 300.
 laceration of 266.
 producing cervical catarrh 282.
 mucous membrane of 20.
 normal structure contrasted with pathological 281.
 position in retroversion + retroflexion 337.
 rupture in atresia 484.
 stenosis of 241.
 in superinvolution 250.
 supra-vaginal amputation of 455, 460.
 vaginal aspect of 21.
- Channelled polypus**, 419.
Chloral in carcinoma 452.
Chloride of zinc in carcinoma 463.
Chloroform—action of 142.
 death from 145.
Chlorosis, amenorrhœa in 542.
 leucorrhœa in 203.
 small uterus in 234, 249.
Cholera and endometritis 293.
Chromic acid—in cervical catarrh 286.
 in endometritis 299.
Chronic metritis and fibroid tumour 393.
Cinrat's serre-noeud, 407 409.
Clamp in ovariectomy 219.
 disadvantages of 219.
 in laparotomy for fibroids, 408, 409.
Cleavage in pelvic floor, lines of 59.
Clitoris—anatomy 4.
 development of 507.
Cloaca 506.
 persistence of 507.
Colpitis 493.
 emphysematosa 494.
Conception in an undeveloped horn 236.
Constipation 613.
 in fistula 539.
Connective tissue of pelvis 41.
 as seen in sections 42.
 studied by injections 45.
 spread of carcinoma in 432, 435.
 relation to cellulitis 160, 162.
Connective tissue of uterus, increase of in metritis 307.
Connective-tissue origin of cancer 431.
Coccygeus 12.
Coccygodynia 614.
Corpus luteum of menstruation and pregnancy 83.
Cradle-pessary of Graily Hewitt 334.
Credé's method of expressing placenta 363.
- Curette** 132, 298.
 nail, A. R. Simpson's 402.
 Recamier's 133.
 Simon's 133.
 Sims' 133.
 Thomas' 133.
 in carcinoma 455.
 in cervical catarrh, 288.
 in endometritis 297, 299.
 in diagnosis of small polypi 424.
 in sarcoma uteri 477.
Cystic fibroid tumours 413.
Cystitis 578.
Cystocele 578.
 in prolapsus 530.
Cysts in the cervix 281.
Cystoma ovarii 201.
Cysto-fibroma 413.
- DECIDUA**, in extra-uterine gestation 558.
Defaecation—mechanism of 608.
 difficult in hæmatocele 170.
 in retroflexed gravid uterus 553.
 painful in carcinoma 442.
 in retroflexion 341.
 want of control, in ruptured perineum 521.
- Dermoid cysts** 202.
Development—intra-uterine periods of 234.
 of pelvic organs 71.
 of uterus, period of 227.
- Diabetes**, pruritus in 511.
Diagnosis—sound in 121.
 voisella in 105.
Diathesis—strumous and tubercular 234, 285, 297.
 syphilitic 297.
- Diet** in carcinoma 452.
 in peritonitis 156.
 Weir Mitchell's system of 913, 615.
- Digestive derangements** in endometritis 295.
Dilatation of cervix 125, 470.
 by rapid method 426.
- Dilators**—Tait's and Hanks' 130.
 various forms of 244, 245.
- Diphtheritic inflammation** and carcinoma 445, 446.
Discharge—fetid, in carcinoma 440, 451.
 in carcinoma of body of uterus 469.
 watery, in sarcoma uteri 476.
- Discus proligerus** 25.
Displacements of pelvic floor 59, 526.
 of uterus 314.
 due to cellulitis 159, 163.
 hæmatocele 160, 171.
 ovarian tumours 206.
 peritonitis 163.
 relation to chronic metritis 309.
 to endometritis 293, 294.
 diagnosed with sound 121.
 etiology 317.
 physiological and pathological 315.
 symptoms of 318.
 produced by voisella 105.
- Douche**, antiseptic 138.
 forms of 138.
Douglas, pouch of 39.

- Drainage of abscess 164.
 after Battey's operation 192.
 in extirpation of uterus 465.
 in ovariectomy 222.
- Drop-cork for chloroform 144.
- Dysmenorrhœa 545.
 in ante flexion 322.
 mechanical and congestion theories of 322, 323.
 relation to Battey's operation 190.
 in cellulitis 164.
 stenosis of cervix 242.
 endometritis 294, 295.
 fibroid tumours 389.
 uterine polypi 421, 422.
 retro flexion 341.
 membranous 547.
 obstructive 242, 322.
 spasmodic 546.
- Dyspareunia in ante flexion 324.
 in peritonitis 154.
 causes 498.
 definition 499.
 in prolapsed ovary 187.
 treatment 499.
- ECRASEUR**—in amputating cervix 261.
 mode of application 456.
 for removal of ovaries 192.
 polypi 428.
 and galvano-cautery, relative advantages 457.
- Ectropium of cervix 280.
- Elastic ligature in amputating uterus 374.
 in laparotomy for fibroids 407, 410.
- Electrolysis in ovarian tumour 213.
- Elythrytis 493.
- Emaciation in carcinoma 442.
- Emmet's operation for lacerated cervix 272.
- Emu, waters of, in endometritis 302.
 in chronic metritis 312.
- Endometritis 289.
 relation to abortion 295.
 in ante flexion 321.
 leading to chronic metritis 309.
 diagnosis by sound 121.
 changes in final stage of 422.
 fundal 293, 296.
 fungosa of Olshausen 291, 297, 301.
 hæmorrhagic type and carcinoma of the body 470.
 and sarcoma 477.
 secondary to stenosis of cervix 242.
 three types of 290.
- Enterocele, vaginal 538.
- Enucleation of fibroid tumours
 spontaneous 378, 382, 391.
 artificial 403.
 of ovarian tumours 224.
- Epispadias 509.
- Epithelial origin of cancer 431.
- Epithelioma of the cervix 429.
- Erector clitoridis 10.
- Ergot and endometritis 293.
 fibroids 398.
 methods of administration in menorrhagia 544.
- Ergotine—hypodermic injection of 399.
 in treatment of fibroids 399.
- Erosion—follicular 279.
 and lacerated cervix 268.
 papillary 279.
 papillary and carcinoma 445.
 simple 278 and Plate VIII.
- Ether 142.
- Ethidene 142.
- Eversion of lips of cervix 268, 271, and Plate VIII.
- Examination of cases 624.
 posture in 134.
- Exanthemata and endometritis 293.
 vaginitis in 495.
 atresia vaginae after 483.
- External genitals—anatomy 3.
 development 71, 506.
 relation in erect posture 6.
 examination of 93.
 lymphatics of 69.
- Extirpation of uterus—through abdominal walls 464.
 through vagina 466.
- Extra-uterine gestation 555.
 and fibroid tumour 396.
 causing hæmatocele 168, 560.
- Exudations in the pelvis 161.
 course of 162.
- Epithelial cells found in carcinoma 443, 444.
- FACIES**, cancerous 442.
- Fallopian Tubes—anatomy 21.
 abnormalities 177.
 blood-sacs in 481.
 catheterisation of 177.
 development of 71.
 distension with pus or blood 180.
 divisions 21.
 functions 176.
 inflammation of 178.
 palpation of 177.
 patulous condition of 178.
 position 21.
 removal by abdominal incision 179, 195.
 affected with sarcoma 474.
 stricture of 177.
 gestation in 555.
 structure 21.
 tumours of 180.
- Fatty degeneration around polypoidal fibroid 358.
 in fibroid tumour 384.
- Fevers causing ovaritis 184.
- Fibroid tumour of uterus 376, 388, 398.
 producing ante flexion 321.
 and ante flexion 325.
 Battey's operation for 190.
 compared with carcinoma 438.
 and chronic metritis 311, 393.
 and extra-uterine gestation 560, 561.
 + inversion 363.
 pediculated submucous 416.
 sloughing and carcinoma 445, 446.
 and retro flexion 345.
 sarcomatous degeneration of 473.
 and sarcoma 477.

- Fibroid tumour, spontaneous expulsion of 418.
 Fibroid tumours of vagina 502.
 tumour of cervix 376, 385.
 Fibromata of vulva 514.
 Fibro-myoma uteri 376.
 Fibrous tumour of uterus (*v.* Fibroid).
 Fimbriated end of Fallopiian tube 22.
 Flexions of uterus 315.
 Flooding, producing superinvolution 250.
 (*v.* Hæmorrhage).
 Fibro-cystic tumours of the uterus 413.
 and ovarian tumours 211.
 Fœtal heart—in diagnosing pregnancy 311, 396.
 Fœtal life—malformations arising in 235.
 Fœtus in detached horn of uterus 236.
 Forceps and lacerated cervix 267.
 used for extracting fibroids 403.
 and fistula 589.
 and ruptured perineum 519, 520.
 Fornices—condition of, in peritonitis and cellulitis 163.
 effect on uterus of digital pressure in 79.
 examination of 95, 96.
 position of, in hypertrophied cervix 262.
 Fossa navicularis—atomy 5, 6.
 irritability producing vaginismus 498.
 Freund's extirpation of uterus 463.
 Friedrichshall water 313.
 GALVANO-CAUSTIC WIRE in removal of polypi 428.
 for amputation of inverted uterus 375.
 in amputating cervix 261.
 compared with ecraseur 456.
 mode of application 458.
 Gastro-elytrotomy 32.
 Gehrung's anteversion pessary 334.
 Genito-crural nerve, affection in ovarian tumour 208.
 Genupectoral posture 73, *et seq.*
 to replace retroflexed gravid uterus 554.
 in replacing retroverted uterus 349.
 Germinal vesicle 26.
 Gestation—abdominal 555, 557.
 in detached horn 236, 556.
 in Fallopiian tube 555, *et seq.*
 interstitial 556.
 in a septate uterus 236.
 Glycerine plug, making of 185.
 Gonorrhœa—causing ovaritis 183.
 cystitis 578.
 peritonitis 155.
 vaginitis 495.
 and endometritis 293.
 latent in the male 153.
 and metritis 304.
 Gonorrhœal vaginitis, diagnosis from simple 497.
 Gouty diathesis and dysmenorrhœa 546.
 Graafian follicles—development 198.
 distension of 199.
 number 25.
 position 25.
 rupture of 83.
 structure 25.
 Greenhalgh's intra-uterine stem 327.
 pessary for prolapsus 532.
 HÆMATOCELE—pelvic 165.
 and rupture of extra-uterine gestation 559, 560, 563.
 and fibroid tumour 396.
 Hæmatoma 169, 171; of vulva 515.
 Hæmatosalpinx 180.
 Hæmorrhage in amputation of cervix 260.
 in carcinoma uteri 440.
 in carcinoma of body of uterus 469.
 causing death in carcinoma 447, 449.
 in carcinoma, treatment of 451.
 in fibroid tumours 388.
 fatal, from fibroid tumours 389, 393.
 internal, in operation for atresia 487.
 intra-peritoneal and extra-peritoneal 169.
 in inversion of uterus 363.
 into the peritoneum of pelvis 165.
 post partum 272.
 in sarcoma uteri 476.
 in uterine polypi 421.
 Heart, action of chloroform on 143.
 Hernia and hydrocele 181.
 Hegar's amputation of cervix 257.
 method for laparotomy for fibroids 410.
 Heredity, influence on carcinoma 436.
 Hermaphroditism 507.
 false 508.
 true 508.
 Hernia of fibroid tumour 382.
 of ovary 185.
 Hiernal nature of prolapsus 526, 531, 538.
 Hewitt's (Graily) cradle-pessary 334.
 Higginson's syringe 133.
 Hodge pessary 350, 351.
 mode of action 355.
 Houston, valve of 36.
 Hunyadi Janos water 312.
 Hydatid of liver and ovarian tumour 210.
 Hydramnios and ovarian tumour 210, 211.
 Hydrargyri pernitratilis liquor in cervical catarrh 286.
 Hydrocele of round ligament 180.
 Hydronephrosis in cystitis 579.
 in carcinoma 433.
 Hymen—atresia of 480.
 development of 483.
 forms of 4, 6.
 imperforate, operation for 488.
 persistent or inflamed, producing vaginismus 498.
 Hypodermic injection of morphia 157.
 Hydro-peritoneum and Battey's operation 190.
 Hydrops folliculorum 201.
 tube 179.
 Hyperplasia areolar of uterus 305.
 of cervix 282.
 Hypertrophy—primary, of cervix 254.
 secondary, of cervix 254, 261.
 Hypospadias 509.
 Hysteria 618.
 —due to ovaritis 184.
 small uterus in 234.

- Hysteria**—in superinvolution 252.
Hystero-Epilepsy and Batten's operation 618.
Hystero-Epilepsy 619.
- Ice-Bags** in hæmatocele 172.
Ice-cap 223.
Ice in peritonitis 157.
Incontinence of urine 575.
India-rubber ring to control hæmorrhage 257.
Infarct of uterus 305.
Inflammation of uterus 289.
 in muscular coat of uterus 303.
 of peritoneum and cellular tissue 150.
 puerperal 303.
Inflammatory deposits and fibroid tumour 396.
Infundibulo-pelvic ligament 24.
Inguinal glands 68, 69.
 affection in carcinoma 435.
Injections—intra-uterine in endometritis 302.
 into uterus and tubes 178.
 dangers of 178.
Interstitial metritis 306.
Inter-ureteric ligament 33.
Intestinal obstruction due to fibroid tumours 390.
Intestines—in pouch of Douglas 55.
 relation to uterus and pelvic floor 55.
Intra-abdominal pressure upon pelvic floor 59, 60, 73.
 in prolapsus 528, 531.
 action on rectum 609.
Intra-uterine galvanic stem 252.
Inversion of uterus 358.
 caused by fibroid tumour 384.
 diagnosed from fibroid tumour 392.
 pediculated fibroid with inflammatory adhesions 424.
 mechanism of 358.
 and prolapsus 530.
 in sarcoma 474.
Inverted uterus—amputation of 374.
 replacement of—Barnes' method 371.
 Courty's method 370.
 Emmet's method 369.
 Lawson Tait's method 371.
 Noeggerath's method 369.
 Tate's method 371.
 Thomas' method 370.
 White's method 369.
Involution and operations on cervix 273.
 senile 227.
 artificially produced by amputation of cervix 313.
Iodide of potassium in ovaritis 185.
 in chronic metritis 313.
Iodine in cervical catarrh 286.
 in endometritis 299.
Iodoform—in vaginismus 499.
 in pruritus vulvæ 512.
Isthmus—of uterus 15.
 of Fallopian tube 21.
- KISSINGEN** waters in chronic metritis 312.
- Knives** 135.
Kolpokleisis 604.
Kreuznach waters in endometritis 302.
 in chronic metritis 312.
 in treatment of fibroids 400.
Kuchenmeister's scissors for dividing the cervix 247.
- LABIA MAJORA**, anatomy 4.
Minora, anatomy 4.
 development 507.
- Labour**—atony of uterus in third stage of, due to chronic metritis 310.
 rapidity of, and lacerated cervix 369.
 complicated by polypus 422.
 protracted, producing fistula 589.
- Laceration of cervix** 286.
 and cellulitis 159.
 and subinvolution 308, 309.
 of perineum 518.
- Lactation**—effect on uterus if protracted 250.
 and subinvolution 308, 309.
- Laminaria** tents 125, 129.
- Laparotomy**, for extra-uterine gestation 562.
 for fibroid tumours 403.
- Lateri-version** of uterus 316.
- Leeches**—application of, to cervix 287.
 in peritonitis 158.
- Leucorrhœa**—as a symptom 623.
 in ante-flexion 322, 324.
 cervical catarrh 279, 283.
 chronic metritis 309.
 endometritis 290, 294.
 hypertrophied cervix 255.
 lacerated cervix 270.
 retroflexion 341.
 uterine polypi 421, 422.
 vaginitis 496.
 vaginal cysts 501.
 producing pruritus 511.
- Levator ani** 13.
- Ligature** in ovariectomy 220.
- Lineæ albicantes** 91.
- Lipomata** of vulva 514.
- Listerism**—in gynecology 137, 161.
 in ovariectomy 223.
- Literature**, Gynecological—Sources of 626.
- Lithia** water in pruritus 512.
 salts of, in irritable bladder 583.
- Lithopædion** 560.
- Locomotion** impaired in uterine inflammation 332.
- Lymph**, coagulable—from fibroid tumour 413.
- Lymphatics**—relation to cellulitis 160, 162.
 of external genitals 69.
 in fibroid tumours 378.
 dilatation of 413.
 relation to septicaemia 70.
 of uterus 69.
 dilatation in metritis 307.
 of vagina 69.
- Lymphatic glands** of pelvis 68.
 in carcinoma 433.
- MALFORMATION** of uterus 229.
 rectal examination in 236.
- Malignant peritonitis** 152, 204.

- Marckwald's amputation of cervix** 257, 258.
- Marriages, average productivity of** 550.
- Massage** 159.
 general, in uterine disease 313, 617.
 in pathological antelexion 326.
- Medullary cancer** 429.
- Membrana granulosa** 25.
- Menopause and Battley's operation** 194.
 changes in cervix after 240.
 in uterus after 249, 292.
 in vagina after 493, 495.
 influence on fibroid tumours 387, 397.
 premature 542.
- Menorrhagia** 544.
 in antelexion 322, 324.
 carcinoma 440.
 lacerated cervix 270.
 stenosis of cervix 242.
 chronic metritis 310.
- Menorrhagia in** endometritis 290, 295.
 fibroid tumour 388.
 hæmatocele 170.
 inversion 363.
 ovaritis 184.
 peritonitis 154.
 uterine polypi 421.
 retroflexion 341.
 retroversion 336.
 treatment by Battley's operation 190.
- Menstruation** 81, *et seq.*
 and Battley's operation 194.
 irregular, in cervical catarrh 283.
 diminished in chronic cellulitis 160.
 in endometritis 295.
 absence in fistula 589, 606.
 during gestation 236.
 relation to hæmatocele 168.
 and metritis 304.
 periodicity and duration 82.
 descent of polypus during 418.
 in an undeveloped horn 236.
 in bicornuous and septate uterus 236.
- Menstrual blood**—composition 82.
 origin 84.
 quantity 82.
 character of retained 483.
- Metritis** 289.
 acute 303.
 chronic 305.
- Metrotome**—various forms 244.
 Sir Jas. Simpson's 245.
- Micrococci in wounds** 161.
- Microscope**—in carcinoma uteri 445.
 endometritis 290.
 sarcoma uteri 477.
- Micturition** 568.
 difficult, in advanced extra-uterine gestation 560.
 in fibroid tumour 390.
 hæmatocele 170.
 prolapsus 527.
 retroflexion of gravid uterus 553.
 frequent 583.
- Micturition frequent in cystitis** 579.
 in fixation of uterus 331.
 vaginitis 496.
 painful, in carcinoma 442.
- Mobility of uterus, ascertained by sound** 121.
- Morcellement in fibroid tumours** 409.
- Morgagni, columns and sinus of** 38.
- Morphia**—methods of administration 157.
 in carcinoma 452.
 caution as to use in dysmenorrhœa 549.
- Mucoid degeneration in fibroid tumour** 414.
 in sarcoma 475.
- Mucous membrane of bladder** 32.
 cervix 20.
 rectum 36.
 urethra 30.
 uterus 18.
- Mucous membrane of vagina** 26, 593.
- Mucous polypi** 416, 419.
- Musculature of bladder** 32.
 rectum 35.
 urethra 30.
 uterus 18.
- Myoma uteri** 376.
- Myxomatous degeneration of fibroids** 384.
- NABOTHII ovula** 281.
- Nabothian follicles** 284.
 pediculated 416, 421.
- Nail-curette, A. R. Simpson's** 402.
- Needles** 136, 190.
- Nélaton's forceps** 218.
- Nervous derangements in endometritis** 294, 295.
 reflex symptoms, and lacerated cervix 270.
 system, action of chloroform on 142.
- Neuralgia from pressure by fibroid tumours** 390.
 in lacerated cervix 270.
- Neuromata of vulva** 514.
- Nitrate of silver in endometritis** 301.
- Nitric acid in endometritis** 299, 301.
 in carcinoma 454.
- OBTURATOR gland** 69.
- Oöphoritis** 183.
- Opiates in dysmenorrhœa** 549.
- Omental tumours and ovarian** 210, 211.
 cells found in fluid from 204.
- Os externum**—contracted, 241, 243, 255, 320.
 examination of 95.
 position 15, 21.
- Os internum and utero-vesical fold of peritoneum** 262.
- Os uteri, form in nulliparæ and multiparæ** 245.
- Ovarian artery**—course 65.
 in removal of fibroids 406.
 extirpation of uterus 465.
 corpuscles 203.
 fimbria 24.
 fluid 203.
 gestation 555, 556.
 ligament 24.
 plexus, of veins 68.
- Ovarian tumours**—cystic 197, 206, 213.
 and extra-uterine gestation 560, 561.
 and fibroids 397.

- Ovarian tumours and fibrocystic** 415.
 malignant 202.
 position of 92.
 causing peritonitis 152.
 solid 204.
- Ovariectomy** 214.
 compared with laparotomy for fibroids 408.
 normal 189.
- Ovaritis** 183.
 and Battey's operation 191.
- Ovaries—Anatomy** 23.
 arterial supply 65.
 degeneration of blood-vessels 199.
 development 71, 205.
 displacements 185.
 epithelial tubes 199.
 examination of 102.
 inflammation 183.
 ligaments 24.
 malformations 182.
 malignant development of connective tissue 201.
 measurements 23.
 changes at menstrual period 82.
 effect on menstruation 87.
 palpation of 182.
 position 23, 53.
 in inversion 361.
 in retroflexion 339.
 prolapsed and retroflexion 345.
 removal by abdominal section 192.
 per vaginam 191.
 structure 25.
 in superinvolution 250.
 tumours of 196.
 in rudimentary uterus 230, 237.
 in uterus unicornis 231.
- Ovulation** 82.
 with rudimentary uterus 230.
- Ovum**—formation of membrana granulosa 25.
 structure 25.
 passage into uterus 83.
- PAIN**—in endometritis 294, 295.
 carcinoma uteri 441.
 carcinoma of body of uterus 469.
 cervical catarrh 283.
 inversion 363, 364.
 retention of menses in atresia 484.
 ovaritis 184.
 acute and chronic peritonitis 154.
 prolapsed ovary 187.
 retroflexion 341.
 sarcoma uteri 476.
- Palpation, method of** 91.
- Pampiniform plexus** 68.
 in extirpation of uterus 465.
- Parametric tissue** 44.
- Parametritis** 159.
 chronica atrophicans 160.
 posterior, of Schultze 159.
- Paravesical pouch of peritoneum** 53.
- Parenchymatous inflammation** 305.
- Parovarium** 23.
 development 71.
- Parovarium distension** 180.
- Parovarian fluids, nature of** 203.
 tumours and ovarian 210, 211.
- Parturition repeated, and carcinoma** 438.
 endometritis 293.
 ovaritis 183, 184.
- Péan's method of laparotomy for fibroids** 409.
 needle for pedicle 408.
- Pedicle**—changes in, after ligature 221.
 treatment in fibroid tumours 406.
 extra- and intra-peritoneal methods compared 408.
- Pedicle of ovarian tumour** 202.
 examination 209.
 torsion 225.
 treatment in ovariectomy 219.
- Pedunculation of fibroid tumours** 382.
- Pelveo-peritonitis** 151.
- Pelvic abscess** 162, 163.
 bursting of 163.
- Pelvic cellulitis** 159.
- Pelvic connective tissue** 41.
- Pelvic floor**—general anatomy 8.
 structural anatomy 56.
 displacements 60, 526.
 preventing downward displacement 315.
 affected by genupectoral posture 74.
 intra-abdominal pressure on 61, 73.
 loose tissue in 527.
 measurements on external surface 6.
 muscles 8.
 opening up of, in genupectoral posture 59.
 in parturition 59.
 relation to parturition 57, 74.
- Pelvic floor projection** 61.
 callipers for measuring 63.
 measurements 62.
 effect of pregnancy on 64.
- Pelvic floor segments** 57.
 contrast between 57.
 as affected by genupectoral posture 77.
 in parturition 57.
- Pelvic glands** 68.
- Pelvic inflammation producing displacement** 317, 318.
 after stem pessary 253.
 and subinvolution 308, 309.
- Pelvic peritonitis** 151.
 producing anteversion 321.
 with anteversion 331.
 producing small uterus 250.
- Pelvis**—blood-vessels of 65.
 coronal sections of 44.
 section in genupectoral posture 78.
 horizontal sections 43.
 lateral sagittal section 42.
 lymphatics 68.
 nervous supply 70.
 venous plexuses 66.
- Perchloride of iron to check hæmorrhage** 451.
 caution as to use 451.
- Percussion, method of** 93.

- Percussion**—ovarian tumour and ascites 210.
- Perforation into peritoneal cavity in carcinoma** 434, 435, 447.
- Perimetritis** 151.
- Perineal body** 38, 111.
structure 38.
measurements 38.
- Perineal muscles** 9.
- Perineum**—arterial supply 65.
development 506.
rupture 517.
central rupture 518.
operative treatment 520, 534.
support in parturition 520.
- Periovaritis** 185.
- Peritoneum**—anatomy of 38.
of bladder 39, 41, 60.
in parturition 60.
of broad ligaments 40.
in carcinoma 434.
amputation of cervix 264.
prolapsed 528.
fistula 587.
inversion 361.
method of opening into 193.
in relation to operations 41.
in parturition 40.
on sides of pelvis 40.
local divisions on pelvic floor 52.
of rectum 40.
in retroflexion 340
of uterus 18, 39.
on posterior vaginal wall 39.
vesico-uterine pouch of 38.
- Peritonitis**—pelvic 150.
and carcinoma 447.
relation to cellulitis 151.
malignant, cells found in fluid from 204.
after uterine injections 178.
producing retroversion, 336.
- Pessary**—intra-uterine 327.
in retroflexion 357.
vaginal—Albert Smith 350, 352.
antefflexion 330.
anteversion 334.
in chronic metritis 312.
effect on position of uterus 80.
in fibroid tumour 400.
Hodge 350, 351, 355.
mode of introduction 353.
medicated, composition of 498.
in pregnancy 357.
(Munde's) for prolapsed ovaries 187.
ring 532.
Zwanck's 532.
- Pflüger's ducts**, a source of ovarian tumours 198.
- Phthisis**—amenorrhœa in 540.
uterus in 249.
- Physics of abdomen and pelvis** 73.
- Piles** 612.
- Placenta**—in extra-uterine gestation 558.
growth after death of the fetus 562.
treatment of 562.
portions retained, and carcinoma 445, 446.
- Placenta**—relation to inversion 358, 359, 363.
- Placental polypi** 416, 421.
- Polypes à apparitions intermittentes** 419.
- Polypi of uterus** 416.
and endometritis 293.
fibrous 416.
producing Fallopian tube gestation 422, 559.
diagnosis from inversion 366.
producing inversion 359, 363.
+inversion, diagnosis of 364.
mucous 416, 419.
mucous and fibrous contrasted 422.
placental 416, 421.
- Polytome**, Sir J. Y. Simpson's 428.
- Porte-caustique** 301.
- Posterior fornix**, effect of pressure on 350.
- Posture**—relation to examination and treatment 134.
of patient in cellulitis and peritonitis 163.
- Pouch of Douglas** 39, 53.
intestines in 55.
- Pregnancy**—advanced, and fibroid tumour 396.
early, diagnosis 311.
from fibroid tumour 394, 396.
characters of uterus 310.
diagnosis from chronic metritis 311.
ovarian tumour 210.
uterus dilated from atresia 485.
fissuring of cervix in 269.
course in an extra-uterine gestation 559.
complicated by large fibroid tumours 394.
+ovarian tumour 212, 224.
hypertrophy of cervical glands in 281.
anteversion of uterus in 331.
sympathetic phenomena of, in uterine polypus 422.
- Prognosis in gynecological cases** 624.
- Presentation of head and lacerated cervix** 267.
- Prolapse of ovary** 186.
- Prolapsus uteri** 74, 528.
due to fibroid 386.
+inversion 368.
mechanism 528.
retroversion in 336.
- Pruritus vulvæ** 510.
in carcinoma 442.
- Pseudocyesis and ovarian tumour** 211, 212.
- Puberty**—changes at 82.
symptoms of atresia at 484.
- Pubic segment**—of pelvic floor 57.
displacements 60.
in bimanual examination 97, 100.
in semiprone posture 110.
- Puerperal inflammation** 303.
inversion, frequency of 363.
- Puerperium**—rapid development of carcinoma in 446, 470.
and endometritis 297.
inversion 358, 363.
peritonitis 152.

- Puerperium and retroflexion** 340.
 retroversion 336.
 subinvolution 309.
- Pulse**—in hæmatocele 170.
 peritonitis 154.
- Pyosalpinx** 180.
- RAKE** for removing sutures 261.
- Rectal examination** 101.
 in atresia 485.
 carcinoma 444.
 hypertrophied cervix 256.
 inversion 366.
 pathological antelexion 324.
 retroflexion 843.
 superinvolution 252.
 uterine malformations 237.
 Simon's method 103.
- Recto-abdominal examination** 100, 101.
- Rectocele** 610.
 and prolapsus 530.
- Recto-vaginal fistula** 613.
- Recto-vagino-abdominal examination** 101.
- Rectum**—anatomy 35.
 diseases of 609.
 examination 609.
 pressure on, by fibroid tumour 390.
 lymphatics of 70.
 physiology 607.
 position 35.
 in retroflexion 340.
 structure 36.
 ulceration in carcinoma 433.
 displacing uterus 314.
 connection with the vagina 85, 59.
- Reflex action and chloroform** 142, 145.
- Reinversion of stump of amputated uterus** 375.
- Renal calculi** 581.
 tumours and ovarian 210, 212.
- Respiratory centre in chloroform** 143.
- Retention of urine** 584.
 producing cystitis 553, 570.
 due to fibroid tumour 390.
 extra-uterine gestation-sac 560.
 retroflexed gravid uterus 553.
- Retroflexion** 315, 317, 318, 337.
 and cervical catarrh 282.
 congenital 339, 340.
 and small fibroid tumour 394.
 relation to retroversion 337.
 of gravid uterus 342, 553.
 and extra-uterine gestation 560.
- Retro-pubic fat deposit** 42, 57.
- Retro-uterine hæmatocele** 165.
- Retroversion** 316, 317, 335, 337.
 passage of sound in 117.
 caused by peritonitis 336.
 action of pessary on 356, 357.
 physiological and pathological 315, 335.
 in prolapsus 529.
- Retroversion + Retroflexion** 317, 337.
- Rheumatic diathesis and dysmenorrhœa** 546.
- Ring pessary** 532.
 with diaphragm 532.
 mode of introduction 532.
- Ring pessary**—position in vagina 533.
- Rosenmüller, organ of** 23.
- Round ligament**—anatomy of 18.
 hydrocele 180.
 a guide to parts of uterus 231.
- SACRAL SEGMENT** of pelvic floor 57.
 rupture of inferior angle 517.
 the supporting one 61, 513, 530.
 supporting pessary 357.
- Salpingitis** 178.
- Sarcoma of ovary, cells found in fluid from** 204.
 of uterus 471.
 and carcinoma 445, 446.
 endometritis 297.
 inversion 363.
 of vagina 503.
- Sarcomatous degeneration in polypus** 420.
- Scarification of cervix** 287.
- Schroeder's operation for cervical catarrh** 272, 288.
- Schultze's dilator** 244.
- Scirrhus cancer** 430.
- Scissors** 135.
 Bozeman's 135.
 for division of cervix 246.
 Hart's 135, 330.
 Kuchenmeister's 135.
- Scrofula, leucorrhœa in** 293.
- Semiprone posture** 79, 109.
- Septic matter causing cellulitis** 160.
- Septicæmia**—after amputation 374.
 after operation for atresia 487.
 in carcinoma 447, 448.
 from suppuration of fibroid tumours 392.
 in inversion of uterus 368.
 relation of lymphatics to 70.
 and metritis 303.
 after ovariotomy 223.
 after tents 130.
- Septic peritonitis** 152, 155.
- Serre-nœud of Cintrat** 406, 409.
 in laparotomy for fibroids 406, 409.
- Serous peritonitis** 154, 159.
- Serum, collection in Fallopian tubes** 179.
- Sexual excess and endometritis** 293.
- Sickness after chloroform** 146.
- Silk-worm gut** 137.
- Silver-wire sutures** 137.
- Simon and Marekwald's amputation of cervix** 257.
- Simon's sharp spoon** 455.
- Simpson's (A. R.) amputation of cervix** 258.
 nail-curette 402.
 sound 116.
 modification of Thomas' curette 133.
- Simpson's (A. R.) volsella** 104.
- Simpson's (Sir J. Y.) division of cervix** 244, 328.
 galvanic intra-uterine stem 252, 327.
 metrotome 244.
 sound 115.
 volsella for fibroids 404.
- Sims' (Marion) division of cervix** 329.

- Sims' (Marion) amputation of cervix 257.
 dilator 245.
 enucleator 402.
 speculum 108, 284.
 operation for vaginismus 500.
- Skene-Goodman catheter 580.
- Smith (Albert) pessary 350, 352.
 mode of action 356.
- Souffle—uterine, in fibroid tumour 395.
 absence of, in ovarian tumour 209.
- Sound—uterine 115.
 combined with Bimanual 123.
 in antelexion 325.
 hypertrophied cervix 256.
 endometritis 296.
 small fibroid tumours 395.
 pediculated submucous fibroid 423.
 inversion 366.
 polypus and inversion 425.
 polypoidal fibroid 396, 423.
 chronic metritis 311.
 retroflexion 344.
 superinvolution 252.
 uterine displacements 318.
 method of dressing 299.
 in replacing retroflexion 344.
 in treating antelexion 327.
- Spray in ovariectomy 223.
- Specula, vaginal—comparative advantages of various forms 114.
 Barnes' crescent 114.
 Battey's 109.
 Bozeman's 108.
 Cusco's 114.
 Fergusson's 111.
 Neugebauer's 112.
 Sims' 108.
- Speculum—anal 609.
 intra-uterine 301.
 urethral and vesical 571, 573.
- Spencer Wells' clamp 219.
 trocar 218.
- Sphincter ani—externus 36.
 internus 36.
 tertius 36.
 operation to restore 522.
- Sponge tents 125.
 in abortion 553.
- Stem—galvanic intra-uterine 253.
 in antelexion 327.
- Sterility 550.
 in antelexion 322, 323.
 cellulitis 160.
 cervical catarrh 283.
 hypertrophied cervix 255.
 stenosis of cervix 242.
 dyspareunia 498.
 endometritis 294, 295.
 stricture of Fallopiian tubes 178.
 fibroid tumour 388, 391.
 fistula 589.
 chronic metritis 310.
 peritonitis 155.
 double ovaritis 184.
 uterine polypi 421, 422.
- Sterility in retroflexion 342.
- Strumous diathesis and endometritis 297.
- Subinvolution 306.
 and lacerated cervix 268.
 with retroflexion 338.
- Superfetation 236.
- Superinvolution 250.
 ascribed to ovaritis 183.
- Supra-vaginal portion of cervix, hypertrophy of 254, 261.
- Supra-vaginal amputation of the cervix 460.
- Suppuration after cellulitis 163.
 hæmatocele 173.
- Sutures 137.
 removal of 261.
- Sympathetic pain in ovaritis 184.
- Syringe, Higginson's 138.
- Syphilitic ulceration and carcinoma 445.
 ulceration of perineum 519.
- Tait's graduated dilators 130, 426.
- Tait's operation for removal of uterine appendages 195.
- Tangle and tupelo tents 125, 129.
- Tapping in cellulitis 164.
 hydrocele 180.
 ovarian tumours 213.
 peritonitis 158.
- Temperature, reduction of 158.
- Tenaculum—Sims' 107.
 in diagnosing lacerated cervix 271.
- Tents 125.
 dangers of 244.
 in stenosis of cervix 244.
- Thomas' anteversion pessary 334.
 cervical plug 248.
 clamp for pedicle of fibroid tumours 408.
 spoon-saw 402.
- Torsion for removal of polypi 427.
- Trachelorrhaphy 272.
- Treatment—operative, in gynecology 625.
 sound in 122.
 specula in 114.
 volsella in 106.
- Triangular ligament 10.
- Trigone of bladder 31, 33.
- Trocars for tapping ovarian cysts 218.
- Tubal gestation 555, 557.
- Tubo-ovarian cysts 181.
 gestation 555
- Tubercular diathesis in superinvolution 250.
- Tumours, pelvic, and chronic metritis 309.
- Type of menstruation 82.
- ULCERATION of Cervix—so-called 271, 277.
 true 280.
- Upright posture 5, 73, 75.
- Uræmia in carcinoma 447.
- Uræmia in fibroid tumour 392.
- Ureter—anatomy of 32, 53.
 catheterisation 574.
 relation to cervix and urethra 587.
 dilatation in carcinoma 493.
 dilatation due to cicatrisation 339.
 compression by fibroid tumours 390.
 relation to gastro-elytrotomy 32.

- Ureter—opening of 30.
- Uretero-uterine fistula 585, 588, 590.
vaginal fistula 585, 588, 590.
- Urethra—*anatomy of* 30.
atresia in fistula 587, 601.
caruncle 575.
development 507.
dilatation 570.
direction 30.
exploration 570.
glands 30.
malformations 575.
neoplasms 575.
pressure on, by fibroid tumour 390.
relation to vaginal wall 59.
- Urethral orifice 4.
- Urethritis 577.
- Urethro-vaginal fistula 585, 590.
+ atresia of urethra 601.
- Urination, physiology of 568.
- Urine—normal composition 569.
character in cystitis 579.
incontinence and retention 583.
in fistula 589.
- Uro-genital sinus 506.
persistence of 507.
- Utero-sacral ligaments—*anatomy of* 18.
cicatricial contraction in 159, 321.
function compared with pessary 355.
stretching of, in retroflexion 340.
- Uterine artery—course 66.
in extirpation of uterus 465.
removal of fibroids 406.
- Uterine cavity—*variations in length of* 121.
contractions—importance in diagnosis 209, 306.
disease—etiology of 621.
mucous membrane in long-standing endometritis 292.
changes in, at menstrual period 84.
plexus of veins 68.
- Uterus—absent, or rudimentary 230, 235, 236.
amputation at os internum 406.
anatomy 13.
antelexion 315, 317, 318.
anteversion 316, 317, 331.
atrophy 249.
arterial supply 65.
bicornis 232, 235, 236, 238.
carcinoma 429, 440, 450, 468.
changes after birth 234.
congenital atrophy 234, 235, 239.
curetting 133, 290.
development 71.
didelphys 232, 235, 238.
dilatation in atresia 480.
dilatation and perforation in carcinoma 448.
displacement 314.
in extra-uterine gestation 561, 563.
large fibrous polypi 417.
hæmatocele 166, 171.
ovarian and uterine tumours 415.
- Uterus—displacement in peritonitis and cellulitis 163.
enlargement of, in endometritis 296.
extirpation of, through abdominal walls 464.
through the vagina 466.
changes in extra-uterine gestation 558.
evacuation after abortion 552.
effect of digital pressure in fornices 79.
fibroid tumour 376, 388, 398.
changes with fibroid tumour 383.
fibro-cystic tumours 413.
changes in, at angle of flexion 320, 339.
glands 19.
hypertrophy 254.
in prolapsus 528, 529.
infantile 233, 235, 239.
inflammation (endometritis, metritis) 289, 303.
inversion 358.
spontaneous reinversion 368.
lateri-version 316.
ligaments 18.
lymphatics 69.
malformations 229.
measurements 16.
mobility 53, 104.
range 54.
changes in a menstrual period 84.
periods at which morbid conditions arise in 227.
mucous membrane 18.
musculature 18.
nervous supply 70.
peritoneum of 18.
polypi 416.
position, means of ascertaining 50.
with distended bladder 50.
normal 49.
physiological changes in 53, 315.
relation to viscera 55.
prolapse 528.
retroflexion 315, 317, 337.
retroflexion of gravid 342, 553.
retroversion 316, 317, 335, 337.
sarcoma 471.
septus 232, 235, 236, 238.
atresia of 491.
shape 13.
form in section 15.
structure 17.
subinvolution 306, 308.
superinvolution 250.
support of 60.
unicornis 230, 235, 236, 237.
- VAGINA—*anatomy of* 26.
arterial supply 66.
atresia 430.
cancer of, primary 502.
secondary 435.
cicatrisation after fistula 587.
after labour 483.
artificial closure for fistula 604.
congenital bands in 492.
cysts 501.

- Vagina — development 507.
dilatation in atresia 480.
direction in upright posture 26.
fibroid tumours 502.
form in section 28.
in genupectoral posture 76.
inflammation of 493.
lymphatics 69.
change after menopause 495.
plugging to check hæmorrhage 451.
sarcoma 503.
structure of 28.
relation of walls 56.
- Vaginal cleft 57.
columns 27.
- Vaginal examination 94.
glands 28.
glass-plugs 489.
- Vaginal orifice—*anatomy* 4.
dilatation of 499.
division of sphincter 500.
fissures around, producing vagin-
ismus 498.
- Vaginal portion of cervix, hypertrophy of 254, 262.
- Vaginal walls—*connection* of 59.
inversion in prolapsus 528.
length 27.
- Vaginismus 498.
- Vaginitis 493.
diphtheritic 493, 495.
gonorrhœal 493, 495, 497.
senile 493, 495.
- Varicose veins, due to fibroid tumours 390.
- Varix of vulva 515.
- Veins, pelvic—*compressed* by fibroid tumours 390.
- Veneral excess, causing peritonitis 153.
- Venous sinuses round fibroid tumours 378, 380.
- Venous thrombosis in carcinoma 447, 449.
- Versions of uterus 315, 316.
- Vesico-uterine fistula 585, 590, 600.
- Vesico-vaginal fistula 433, 435, 585.
artificial, for cystitis 580.
- Vesico-vaginal septum 585.
- Vesico-vaginal-abdominal examination 100.
- Vestibule—*anatomy* 4.
development of 507.
- Vichy waters in chronic metritis 312.
- Volsella—*description* of 104.
examination with 105.
Hart's 106.
A. R. Simpson's 105.
Sir J. Y. Simpson's for fibroids 404.
with speculum 110.
in superinvolution 252.
for introducing tents 129.
in replacing uterus 350.
- Vomiting in hæmatocele 170.
peritonitis and cellulitis 163.
- Vulva—*atresia* of 507.
carcinoma 514.
cysts 503.
elephantiasis 504.
fibromata 514.
hæmatoma 515.
hæmorrhage from varicose veins 515.
inflammation 510.
lipomata 514.
malformations 500.
neuromata 514.
pruritus of 510.
varix 515.
- Vulvitis 510.
of children 510.
- WATER injections into connective tissue 44.
- Weir Mitchell's treatment of chronic uterine
disease 313, 615.
- White's repositor for inversion 371.
- Wiesbaden waters in chronic metritis 312.
- Wire sutures in amputation of cervix 258.
in fistula 591.
- Wolffian bodies 71.
- ZONA pellucida 26.
- Zwanck's pessary for prolapsus 532.



Will be ready immediately.

Atlas of Female Pelvic Anatomy,

BY

D. BERRY HART, M.D., F.R.C.P.E.,

LECTURER ON MIDWIFERY AND DISEASES OF WOMEN, SCHOOL
OF MEDICINE, ETC., EDINBURGH;

CONSISTING OF

*Numerous Imperial Quarto Plates drawn from Nature,
under the direct Superintendence of the Author, and
copious Letterpress explanatory of each Plate. Full
Bound in Cloth.*

EXTRACT FROM PREFACE.

“ . . . In this work the Author's object has been to give an accurate account of the Anatomy of the Female Pelvis, illustrated fully by Drawings from original Specimens or by a reproduction of special Plates from valuable Monographs not usually accessible to the practitioner. . . . The subject is in addition studied from a practical point of view in relation to the various Gynecological and Obstetrical operations. In the chapter on the Physics of the Pelvis many interesting points have been discussed. The section on the Microscopical Anatomy will contain Micro-photographs of special interest. These will be reproduced by a new and valuable process recently acquired by the Publishers, by which a Copper-plate is obtained direct from the photographic negative, and in this way an Engraving, with all the details of the photograph, clearly and permanently given.

W. & A. K. JOHNSTON,

EASTER ROAD, EDINBURGH.

MANUAL OF GYNECOLOGY

(FIRST EDITION.)

OPINIONS OF THE PRESS.

“From this outline it will be observed that the authors aim at completeness and thoroughness, and we think they have in a great measure succeeded in their efforts. The book is undoubtedly a good one, more especially the first part. Indeed, it contains a better statement of the anatomy and physiology of the female pelvic organs than we have seen in any other handbook extant. The well-known reputation Dr. Hart has already gained for accuracy in regard to pelvic anatomy prepared us to expect that this portion of the work would be a masterpiece. . . .

“However, taking it all in all, the work does at once credit to the authors and to the school which has produced them. We feel certain that it will be hailed by the gynecological student as a great boon, since it presents him, within comparatively short compass, with an amount of valuable knowledge of the subject which hitherto he could only attain by wide reading in at least three languages. We regard the work as certain to be widely useful, and cordially recommend it to the attention of all our readers who are interested in scientific gynecology.”—*Edinburgh Medical Journal*, November 1882.

“Nous sommes peu habitués à voir un manuel présenter un pareil luxe de figures, et loin de nous en plaindre, nous en félicitons les auteurs qui ont compris que, pour qu'un ouvrage de gynécologie fût à la portée de tous les praticiens, il fallait que chaque affection, et surtout chaque opération fût décrite dans ses moindres détails et accompagnée de planches en montrant les différentes phases. Tout d'abord on trouve une description très détaillée de l'anatomie et de la physiologie des organes pelviens; l'anatomie descriptive est exposée d'une façon complète, comme du reste dans tous les ouvrages, mais ce qui fait l'originalité de ce chapitre, c'est la façon dont les auteurs ont adapté leur description au but qu'ils poursuivent, c'est-à-dire à l'étude de la gynécologie; c'est ainsi que l'on trouve mentionnés les effets produits par la pression intra-abdominale sur le plancher pelvien, les modifications de rapports déterminés par les changements de posture, surtout par la position genu-pectorale, etc.

“En résumé, on ne peut s'empêcher de reconnaître que c'est un manuel excellent et qui peut rendre de grands services aux praticiens auxquels nous le recommandons tout particulièrement.”—*Annales de Gynécologie*, Janvier 1883.

“It seldom falls to our lot to notice a text-book that seems to us to deserve so much praise and so little criticism as this one. We have had occasion before to commend Dr. Hart's writings, and the work now under consideration, written in conjunction with Mr. Barbour, is quite as meritorious—perhaps more so, regard

being had to the fact that to produce an acceptable text-book is a much more difficult matter than to make a fragmentary contribution, however valuable, to our advance in knowledge. The former taxes a higher faculty than that of observation or that of deduction; it calls for judgment. Taking this duly into consideration, we have little else than praise for our authors. They have given us a text-book of gynecology which, in our opinion, is unexcelled; it is replete with evidence of abundant knowledge, ingenuity in practical application, and rare discrimination in generalising, and its faults are few and for the most part trivial. . . .

“Had the authors written a commonplace book, we should not have thought it worth while to devote so much space to its consideration. The truth is, their work is exceptionally clever, and we should be glad to see it in the hands of every practitioner who undertakes gynecological work. We think it exemplifies a tendency to return to the inflammatory theory of pelvic pathology in a measure—a tendency that has cropped out in more than one quarter of late. To our mind, that doctrine is a far safer guide than the mechanical theory.”—*New York Medical Journal and Obstetrical Review*, November 1882.

“It is unquestionably one of the most original works on gynecology which has been written during the past decade.”—*American Journal of Obstetrics*, April 1883.

“. . . B. H., welcher in Verbindung mit B. das Buch geschrieben, ist wohlbekannt als Verf. einer Anzahl trefflicher Monographien, welche vorwiegend die anatomischen Verhältnisse der Beckenorgane behandeln. Das Buch ist unserer Ansicht nach bei Weitem das vorzüglichste, welches in englischer Sprache über diesen Gegenstand geschrieben wurde. Reiches allgemeines Wissen, ausgebreitete Kenntniss der gesammten, auch fremden und vorzüglich deutschen Litteratur, eingehendes Studium der Anatomie und Physiologie, grosse praktische Erfahrung sind verwerthet, den umfangreichen Stoff gleichmässig zu verarbeiten und zur klaren, schönen Darstellung zu bringen. So ist ein Werk entstanden, welches der altberühmten Schule von Edinburg zur hohen Ehre gereicht und Zeugnis dafür ablegt, dass der Geist eines Sir James Simpson und Matthews Duncan unter den Gynäkologen Schottlands fortlebt. . . .

“Die Ausstellungen, welche wir zu machen hatten, sind nur geringfügiger Natur und beinträchtigen den wirklichen Werth des Buches nicht. Derselbe ist, wir wiederholen es, ein ungewöhnlich hoher. Die Ausstattung des Werkes ist, besonders was Illustrationen betrifft, eine sehr schöne und des Inhaltes würdig.”—ENGELMANN, Kreuznach—*Centralblatt für Gynäkologie*, Feb. 3, 1883.

8vo, cloth, Illustrated, price 15s.

CONTRIBUTIONS TO OBSTETRICS
AND GYNECOLOGY.

By ALEXANDER R. SIMPSON, M.D.,
PROFESSOR OF MIDWIFERY AND THE DISEASES OF WOMEN AND CHILDREN IN THE
UNIVERSITY OF EDINBURGH.

EDINBURGH: ADAM & CHARLES BLACK.

Large Folio, price 25s.

THE RELATIONS OF THE ABDOMINAL AND
PELVIC ORGANS IN THE FEMALE.

ILLUSTRATED BY A FULL-SIZED CHROMO-LITHOGRAPH OF THE
SECTION OF A CADAVER FROZEN IN THE GENUPECTORAL
POSITION, AND BY A SERIES OF WOODCUTS.

By ALEXANDER R. SIMPSON, M.D.,
PROFESSOR OF MIDWIFERY AND THE DISEASES OF WOMEN AND CHILDREN IN THE
UNIVERSITY OF EDINBURGH;

AND

DAVID BERRY HART, M.D., F.R.C.P.E.,
LECTURER ON MIDWIFERY AND DISEASES OF WOMEN, EDINBURGH.

EDINBURGH AND LONDON: W. & A. K. JOHNSTON.

Large Quarto, price 10s. 6d.

THE STRUCTURAL ANATOMY OF THE FEMALE
PELVIC FLOOR.

By DAVID BERRY HART, M.D., F.R.C.P.E.,
LECTURER ON MIDWIFERY AND DISEASES OF WOMEN, EDINBURGH.

EDINBURGH: MACLACHLAN & STEWART.

1

