



This is a digital copy of a book that was preserved for generations on library shelves before it was carefully scanned by Google as part of a project to make the world's books discoverable online.

It has survived long enough for the copyright to expire and the book to enter the public domain. A public domain book is one that was never subject to copyright or whose legal copyright term has expired. Whether a book is in the public domain may vary country to country. Public domain books are our gateways to the past, representing a wealth of history, culture and knowledge that's often difficult to discover.

Marks, notations and other marginalia present in the original volume will appear in this file - a reminder of this book's long journey from the publisher to a library and finally to you.

### **Usage guidelines**

Google is proud to partner with libraries to digitize public domain materials and make them widely accessible. Public domain books belong to the public and we are merely their custodians. Nevertheless, this work is expensive, so in order to keep providing this resource, we have taken steps to prevent abuse by commercial parties, including placing technical restrictions on automated querying.

We also ask that you:

- + *Make non-commercial use of the files* We designed Google Book Search for use by individuals, and we request that you use these files for personal, non-commercial purposes.
- + *Refrain from automated querying* Do not send automated queries of any sort to Google's system: If you are conducting research on machine translation, optical character recognition or other areas where access to a large amount of text is helpful, please contact us. We encourage the use of public domain materials for these purposes and may be able to help.
- + *Maintain attribution* The Google "watermark" you see on each file is essential for informing people about this project and helping them find additional materials through Google Book Search. Please do not remove it.
- + *Keep it legal* Whatever your use, remember that you are responsible for ensuring that what you are doing is legal. Do not assume that just because we believe a book is in the public domain for users in the United States, that the work is also in the public domain for users in other countries. Whether a book is still in copyright varies from country to country, and we can't offer guidance on whether any specific use of any specific book is allowed. Please do not assume that a book's appearance in Google Book Search means it can be used in any manner anywhere in the world. Copyright infringement liability can be quite severe.

### **About Google Book Search**

Google's mission is to organize the world's information and to make it universally accessible and useful. Google Book Search helps readers discover the world's books while helping authors and publishers reach new audiences. You can search through the full text of this book on the web at <http://books.google.com/>

B 3 893 913







2



THE  
SYDENHAM SOCIETY.

INSTITUTED

MDCCLXIII.



LONDON

MDCCLXIV.



MANUAL  
OF  
HUMAN HISTOLOGY.

BY

A. KÖLLIKER,

PROFESSOR OF ANATOMY AND PHYSIOLOGY IN WÜRZBURG.

TRANSLATED AND EDITED

BY

GEORGE BUSK, F.R.S., AND THOMAS HUXLEY, F.R.S.

VOLUME II.

LONDON:  
PRINTED FOR THE SYDENHAM SOCIETY.

MDCCCLIV.



---

**PRINTED BY J. E. ADLARD,**  
BARTHOLOMEW CLOSE.

K-QM551

K7

v. 2

Blair

Lib.

## CONTENTS.

### OF THE DIGESTIVE ORGANS, pp. 1—160.

#### OF THE INTESTINAL CANAL, pp. 1—111.

|                                    | PAGE |
|------------------------------------|------|
| § 128. General structure . . . . . | 1    |

#### OF THE ORAL CAVITY, pp. 2—77.

##### A. *Of the Mucous Membrane of the Oral Cavity*, pp. 2—7.

|  |   |
|--|---|
| § 129. Mucous membrane and submucous tissue . . . . .  | 2 |
| § 130. Epithelium of the cavity of the mouth . . . . . | 4 |

##### B. *Of the Tongue*, pp. 7—24.

|   |    |
|---|----|
| § 131. Muscular structure of the tongue . . . . . | 7  |
| § 132. Mucous membrane of the tongue . . . . .    | 14 |

##### C. *Of the Glands of the Oral Cavity*, pp. 24—39.

###### (1) *Mucous Glands* :—

|  |    |
|--|----|
| § 133. Different kinds of glands . . . . .     | 24 |
| § 134. Their more intimate structure . . . . . | 25 |

###### (2) *Follicular Glands* :—

|   |    |
|---|----|
| § 135. Simple follicles and Tonsils . . . . . | 28 |
|---|----|

###### (3) *Salivary Glands* :—

|                |    |
|----------------|----|
| § 136. . . . . | 34 |
|----------------|----|

##### D. *Of the Teeth*, pp. 39—77.

|   |    |
|---|----|
| § 137. Constituent parts . . . . .                      | 39 |
| § 138. Dentine ( <i>substantia eburnea</i> ) . . . . .  | 40 |
| § 139. Enamel ( <i>substantia vitrea</i> ) . . . . .    | 49 |
| § 140. Cement ( <i>substantia osteoidea</i> ) . . . . . | 54 |

b

MS 405

## CONTENTS.

|  | PAGE |
|--|------|
| § 141. Soft parts of the teeth . . . . .               | 58   |
| § 142. Development of the teeth . . . . .              | 5    |
| § 143. Physiological conditions of the teeth . . . . . | 71   |

## OF THE ORGANS OF DEGLUTITION, pp. 78—81.

1. *The Pharynx.*

|                |    |
|----------------|----|
| § 144. . . . . | 78 |
|----------------|----|

2. *The Œsophagus.*

|                |    |
|----------------|----|
| § 145. . . . . | 79 |
|----------------|----|

## OF THE ALIMENTARY CANAL, pp. 81—111.

|   |     |
|---|-----|
| § 146. General conformation . . . . .                     | 81  |
| § 147. <i>Peritoneum</i> . . . . .                        | 82  |
| § 148. Muscular coat of the alimentary canal . . . . .    | 82  |
| § 149. Mucous membrane of the stomach . . . . .           | 85  |
| § 150. Gastric glands . . . . .                           | 86  |
| § 151. Other particulars of the mucous membrane . . . . . | 89  |
| § 152. Mucous membrane of the small intestine . . . . .   | 91  |
| § 153. Villi of the small intestine . . . . .             | 92  |
| § 154. Glands of the small intestine . . . . .            | 99  |
| § 155. Closed follicles of the small intestine . . . . .  | 101 |
| § 156. Mucous membrane of the large intestine . . . . .   | 106 |
| § 157. Development of the intestinal canal . . . . .      | 108 |

## OF THE LIVER, pp. 111—136.

|  |     |
|--|-----|
| § 158. General structure . . . . .               | 111 |
| § 159. More intimate structure . . . . .         | 111 |
| § 160. Hepatic cells and cell-networks . . . . . | 115 |
| § 161. Excretory ducts of the liver . . . . .    | 121 |
| § 162. Vessels and nerves of the liver . . . . . | 126 |
| § 163. Development of the liver . . . . .        | 132 |

## OF THE PANCREAS, pp. 137, 138.

|                |     |
|----------------|-----|
| § 164. . . . . | 137 |
|----------------|-----|

## OF THE SPLEEN, pp. 138—160.

|   |     |
|---|-----|
| § 165. General structure . . . . .                            | 138 |
| § 166. Coats and trabecular structure of the spleen . . . . . | 139 |
| § 167. Malpighian corpuscles of the spleen . . . . .          | 141 |
| § 168. Red substance of the spleen . . . . .                  | 145 |
| § 169. Vessels and nerves of the spleen . . . . .             | 152 |
| § 170. Physiological remarks . . . . .                        | 158 |

## OF THE RESPIRATORY ORGANS, pp. 160—192.

|  | PAGE |
|--|------|
| § 171. Enumeration of the respiratory organs . . . . . | 160  |

## OF THE LUNGS, pp. 160—180.

|  |     |
|--|-----|
| § 172. General structure . . . . .                       | 160 |
| § 173. <i>Larynx</i> . . . . .                           | 161 |
| § 174. <i>Trachea</i> . . . . .                          | 165 |
| § 175. <i>Lungs</i> . . . . .                            | 167 |
| § 176. Air-vessels and -cells . . . . .                  | 168 |
| § 177. Minute structure of the <i>bronchie</i> . . . . . | 171 |
| § 178. Vessels and nerves of the lungs . . . . .         | 174 |
| § 179. Development of the lungs . . . . .                | 178 |

## OF THE THYROID GLAND, pp. 180—184.

|   |     |
|---|-----|
| § 180. General structure of the thyroid gland . . . . . | 180 |
| § 181. Minute structure . . . . .                       | 180 |

## OF THE THYMUS, pp. 184—192.

|   |     |
|---|-----|
| § 182. General structure of the <i>thymus</i> . . . . . | 184 |
| § 183. Minute structure . . . . .                       | 187 |
| § 184. Development of the <i>thymus</i> . . . . .       | 190 |

## OF THE URINARY ORGANS, pp. 193—221.

|   |     |
|---|-----|
| § 185. Enumeration of the urinary organs . . . . .    | 193 |
| § 186. <i>Kidneys</i> —general structure of . . . . . | 193 |
| § 187. Composition of the renal substance . . . . .   | 193 |
| § 188. <i>Tubuli uriniferi</i> . . . . .              | 196 |
| § 189. Vessels and nerves of the kidneys . . . . .    | 201 |
| § 190. Urinary passages . . . . .                     | 206 |
| § 191. Physiological remarks . . . . .                | 208 |

## OF THE SUPRARENAL GLANDS, pp. 214—221.

|   |     |
|---|-----|
| § 192. General description of the suprarenal glands . . . . . | 214 |
| § 193. Minute structure . . . . .                             | 215 |
| § 194. Vessels and nerves . . . . .                           | 217 |
| § 195. Physiological remarks . . . . .                        | 218 |

## OF THE SEXUAL ORGANS, pp. 221—280.

A. *Male Sexual Organs*, pp. 221—246.

|  |     |
|--|-----|
| § 196. Enumeration of the male sexual organs . . . . . | 221 |
| § 197. <i>Testes</i> . . . . .                         | 221 |

|   | PAGE |
|---|------|
| § 198. <i>Tubuli seminiferi</i> . . . . .   | 224  |
| § 199. Membranes, vessels, and nerves of the <i>testes</i> . . . . .                | 229  |
| § 200. <i>Vasa deferentia, vesiculae seminales</i> , and accessory glands . . . . . | 231  |
| § 201. Organ of copulation . . . . .  | 234  |
| § 202. Physiological remarks . . . . .  | 240  |

B. *Female Sexual Organs*, pp. 246—272.

|   |     |
|---|-----|
| § 203. Enumeration of the female sexual organs . . . . .                        | 246 |
| § 204. Ovary, <i>paraovarium</i> . . . . .                                      | 247 |
| § 205. Detachment and re-formation of the <i>ova</i> . . . . .                  | 250 |
| § 206. Uterus and oviducts . . . . .  | 254 |
| § 207. Changes in the uterus at the menstrual period and in pregnancy . . . . . | 257 |
| § 208. <i>Vagina</i> and external genitals . . . . .                            | 264 |
| § 209. Physiological remarks . . . . .  | 266 |

C. *Of the Lacteal Glands*, pp. 272—280.

|  |     |
|--|-----|
| § 210. Their structure . . . . .       | 272 |
| § 211. Physiological remarks . . . . . | 274 |

OF THE VASCULAR SYSTEM, pp. 281—350.

|                               |     |
|-------------------------------|-----|
| § 212. Its elements . . . . . | 281 |
|-------------------------------|-----|

1.—OF THE HEART, pp. 281—289.

|                |     |
|----------------|-----|
| § 213. . . . . | 281 |
|----------------|-----|

2.—OF THE BLOOD-VESSELS, pp. 289—312.

|   |     |
|---|-----|
| § 214. General structure of the blood-vessels . . . . . | 289 |
| § 215. Arteries . . . . .                               | 294 |
| § 216. Veins . . . . .                                  | 301 |
| § 217. Capillaries . . . . .                            | 308 |

3.—OF THE LYMPHATIC SYSTEM, pp. 312—319.

|                                    |     |
|------------------------------------|-----|
| § 218. Lymphatic vessels . . . . . | 312 |
| § 219. Lymphatic glands . . . . .  | 314 |

4.—OF THE BLOOD AND LYMPH, pp. 320—350.

|  |     |
|--|-----|
| § 220. Different kinds of fluids included in those terms, and their mode of occurrence . . . . . | 320 |
| § 221. General structure of the morphological elements . . . . .                                 | 320 |
| § 222. Of the blood . . . . .  | 324 |
| § 223. Physiological remarks . . . . .   | 339 |

## OF THE HIGHER ORGANS OF SENSE, pp. 351—422.

## I.—OF THE ORGAN OF VISION, pp. 351—402.

|                            | PAGE |
|----------------------------|------|
| § 224. Its parts . . . . . | 351  |

A. *Of the Eye-ball*, pp. 351—391.

|   |     |
|---|-----|
| § 225. Fibrous tunic of the eye . . . . . | 351 |
| § 226. Vascular tunic . . . . .           | 360 |
| § 227. Nervous tunic . . . . .            | 368 |
| § 228. The lens . . . . .                 | 382 |
| § 229. The vitreous humor . . . . .       | 386 |

B. *Accessory Organs*, pp. 391—394.

|  |     |
|--|-----|
| § 230. Eye-lids, <i>conjunctiva</i> , lacrymal apparatus . . . . . | 391 |
| § 231. Physiological remarks . . . . .                             | 395 |

## II.—OF THE ORGAN OF HEARING, pp. 403—415.

|  |     |
|--|-----|
| § 232. . . . .   | 403 |
| § 233. External and middle ear . . . . .               | 403 |
| § 234. The vestibule and semicircular canals . . . . . | 405 |
| § 235. <i>Cochlea</i> . . . . .                        | 407 |

## III.—OF THE OLFATORY ORGAN, pp. 415—422.

|                            |     |
|----------------------------|-----|
| § 236. Its parts . . . . . | 415 |
|----------------------------|-----|

## APPENDIX.

|   |     |
|---|-----|
| § 1. <i>Corpuscula tactilis</i> and Pacinian bodies . . . . . | 423 |
| § 2. Malpighian bodies of the spleen . . . . .                | 425 |
| § 3. <i>Corpora lutea</i> . . . . .                           | 426 |
| § 4. Development of the teeth . . . . .                       | 428 |



# SPECIAL HISTOLOGY.

## OF THE DIGESTIVE ORGANS.

### I.—OF THE INTESTINAL CANAL.

#### § 128.

THE intestinal canal is composed fundamentally of the so-called membranes of the intestine. The innermost of these, the *mucous membrane, membrana mucosa*, corresponds in its structure with the skin, and like it possesses, (1) a non-vascular investment composed of cells—the *epithelium*; (2) the *mucous membrane, more strictly speaking*, composed of connective and elastic tissues; containing vessels, nerves, smooth muscular fibres, and different forms of minute glands, and often presenting peculiar processes (*papillæ, villi*); and (3) an external layer of loose connective tissue, the *submucous cellular tissue*. The second intestinal tunic, the *muscular membrane, tunica muscularis*, is provided, for a certain distance at the commencement and at the termination of the intestine, with striated fibres, but in the remainder of its extent the muscles are everywhere of the smooth kind, and form in general two distinct layers; an external, with longitudinal, and an internal, with transverse fibres; more rarely there are three separate layers. The third membrane, the *serous, tunica serosa*, exists only upon those portions of the intestine which occupy the cavities of the abdomen and pelvis; it is a delicate, transparent membrane, poor in nerves and vessels, and provided with an epithelium; it invests the intestinal canal, and connects it with the walls of the abdominal cavity and with the other viscera.



## OF THE ORAL CAVITY.

## A. OF THE MUCOUS MEMBRANE OF THE ORAL CAVITY.

## § 129.

The commencement of the intestine may be said to have only one tunic, the mucous membrane, which is applied more or less closely to the bones and muscles bounding the oral cavity; and is distinguished by its not inconsiderable thickness, by its red colour, arising from the abundance of its vessels, and by its numerous nerves and papillæ.

The *proper mucous membrane*, although it is continuous with, and gradually passes into, the cutis upon the lips, is more transparent and softer than the *corium*; however, it possesses considerable firmness and is still more extensible. Like the thinnest portions of the cutis, it consists of a single layer, 0.1—0.2''' in thickness, and presents a great number of papillæ, like those of the skin, upon its outer surface; they are in general simple, but occasionally bifurcated (when hypertrophied they may possess even more processes), are conical or filiform, 0.10—0.18''' in length, 0.02—0.04''' in breadth, (extremes, 0.024—0.28''' length, 0.004—0.05''' breadth), and stand, without any very regular distribution, so close together, that their bases are almost in contact and are rarely more than their own breadth apart.

Besides these papillæ, the mucous membrane presents upon its free surface the orifice of the naso-palatine duct, and a great number of glandular apertures, a few of which are situated at the extremities of large papillary elevations.

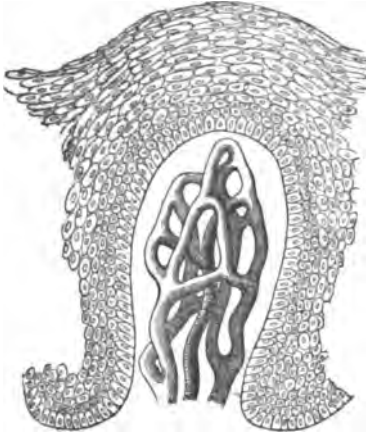
The *submucous cellular tissue* of the mouth varies in its structure. On the floor of the oral cavity, on the anterior surface of the *epiglottis*, and especially upon the *fræna* of the lips, of the tongue, and of the *epiglottis*, it is thin and yielding; and therefore, in these localities, the mucous membrane is very moveable upon the subjacent parts. Where glands occur in the submucous tissue, it is more solid, as in the lips and cheeks; at the root of the tongue, and on the soft palate, it may be said to be firmly fixed, and here, especially in the last-named localities, we find large masses of fat in it. The submucous tissue is very dense, firm and of a whitish colour,

upon the alveolar processes; where, united into one mass with the proper mucous membrane and the periosteum, it forms the *gums*; upon the hard palate, to which the mucous membrane is attached by an immoveable thick fibrous layer, which in some parts contains glands; and finally upon the tongue where the papillæ are situated. In the latter case, there is a very close union between the mucous membrane and the muscular tissue, the processes of many muscular fibres extending into it and terminating especially in a white, very solid, and dense, tendinous layer, which is in immediate contiguity with the upper longitudinal muscular fibres, and has been described as the *fascia linguæ* (Zaglas).

With respect to the *minute structure* of the mucous membrane of the mouth, connective tissue is the predominant constituent of the submucous cellular tissue, while throughout the proper mucous membrane, very numerous elastic elements are everywhere found. In both localities, the former usually presents itself in bundles of 0.002—0.005''' in breadth, not united into a network, but while they cross one another in the most various directions, presenting a certain indistinct lamination. The felted mass of connective fibrils becomes densest towards the epithelium, and finally passes into a more structureless layer, which in my opinion is here, as little as in the *corium*, to be considered a special membrane. In the interior of the *papillæ* also, with the exception of those of the tongue, a fibrous structure is usually very indistinct, the whole more resembling a homogeneous substance, slightly granular. The *elastic* element in the subcutaneous cellular tissue has generally the form of scattered, interstitial, and occasionally, though more rarely, of spirally convoluted, fine fibres; here and there, as in the *frenulum epiglottidis*, they are not only more abundant, but thicker. The latter is invariably the case in the proper mucous membrane, which, even close to the epithelium, contains in the midst of its connective tissue, very close and intimately connected networks of elastic fibrils, or (and this is the general rule) of moderately thick elastic fibres of 0.001—0.0015'''. Spirally convoluted elastic fibres exist here also, though rarely. In addition, the mucous membrane contains common fat-cells, sometimes in groups, sometimes more isolated, and especially in the submucous layer.

The *vessels* of the mucous membrane are very numerous, and present essentially the same arrangement as in the skin. The

Fig. 167.



smaller *papillæ* contain only a single capillary loop, whilst in the larger, either simple or branched, a network of capillaries may be observed (fig. 167); this is especially the case in the gums, the palate, the glandular region of the root of the tongue, the lips, and the lower surface of the tongue. The investigation of the *nerves* presents many difficulties. If caustic alkalis be added, a wide network of the finer and finest

branches is rendered distinct in the outermost layers of the mucous membrane, in which also, divisions of the nervous fibrils may be observed in some localities, particularly upon the anterior surface of the *epiglottis*; on the other hand, it is often impossible to detect so much as a trace of nerves in the *papillæ*. Sometimes, however, even in these, especially in the larger, one or two, often twisted, nerve-fibrils of 0.02'' in diameter, diminishing to 0.0012'' may be detected, without its being possible to make out their ultimate destination; upon the lip the *papillæ* possess axile-corpuscles similar to, but smaller than, those of the hand, though not in all individuals. I found here, also, the nerve-coils described by Gerber (see § 37). Of the origin and relation, in the *t. mucosa* itself, of the abundant *lymphatic vessels* of the oral mucous membrane, nothing is known.

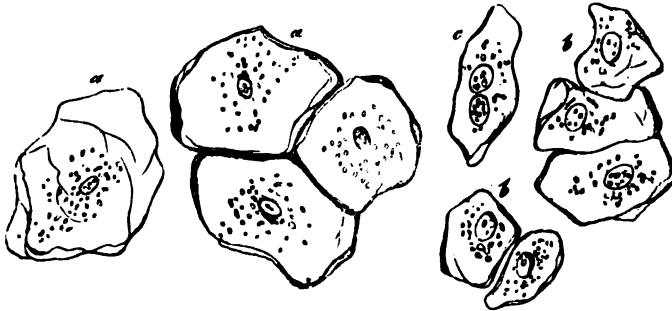
#### § 130.

The *epithelium of the cavity of the mouth* (fig. 167), is a so-called *pavement epithelium*, consisting of many superimposed layers of roundish, polygonal, more or less flattened cells. Taken altogether, this epithelium is a transparent, whitish, pellicle, 0.1—0.2'' thick on the average, very flexible, but possess-

Fig. 167. A simple papilla with manifold vessels and epithelium, from the gum of a child,  $\times 250$ .

ing little elasticity or firmness; it may be detached in considerable flakes by macerating and scraping the mucous membrane, and also by the use of acetic acid. Its elements are, throughout, nucleated cells, whose arrangement and structure strongly recall those of the epidermis; they are not, as in the latter case, distinguishable into two sharply defined laminæ, but constitute one connected layer, more resembling the mucous layer, but representing the horny layer also. The cells are thus disposed, from within outwards: immediately upon the free surface of the mucous membrane, and upon the *papillæ*, rest many layers of small vesicles of 0.004—0.005'' (fig. 167), the deepest of which are, almost without exception, elongated and larger (0.006—0.009''), and disposed perpendicularly. To these succeed many layers of roundish, angular, flattened cells, which gradually increase in size, become flatter from within outwards, and assume a more and more distinctly polygonal form (fig. 168, *b*).

Fig. 168.



On the outer surface, finally, we meet, gradually proceeding from the deeper cells, with a few layers of the so-called *epithelial plates* (fig. 168, *a*), that is, large (0.02—0.036'') bodies with rounded corners, in which the flattening has gone so far that they no longer deserve the title of vesicles.

All these cells possess a delicate membrane, easily demonstrable by alkalis and acetic acid; clear contents, present in greater or smaller quantity, according to the amount of flattening, with frequently a few fatty granules, and invariably a

Fig. 168. Epithelial cells of the oral cavity of Man: *a*, large; *b*, middle-sized; *c*, the same with two nuclei;  $\times$  350.

nucleus. In the smallest cells the nuclei measure from 0·002—0·003<sup>'''</sup>, they are elongated or round, and usually without any distinct nucleolus; in the polygonal cells, there are invariably one or two beautiful, clearly vesicular, usually spherical nuclei, of 0·004—0·005<sup>'''</sup> with clear contents, and 1—2 nucleoli; finally, in the plates, the nuclei have begun to retrograde, are smaller, 0·004—0·006<sup>'''</sup> long, 0·002—0·0015<sup>'''</sup> broad, generally flattened and more homogeneous, without any distinct cavity or *nucleolus*, or containing instead several granules. With respect to its chemical relations, the pavement epithelium of the mouth agrees, so far as we know, in all essential points with the mucous layer of the epidermis, and with the deepest layer of the horny lamina, particularly in the circumstance, that even the plates readily swell up in alkalies; the reader may therefore be referred to § 45.

[The most essential *physiological* characters of the epithelium of the oral cavity are, the continual change to which it is subjected, and its relations as regards *absorption and secretion*. With respect to the former, it may be said that the epithelium undergoes a continual desquamation, which, however, does not here, any more than in the epidermis, appear to be the effect of special vital energies in the mucous membrane, or in the epithelial cells, but rather to result from the manifold mechanical disturbances to which the surface of the oral mucous membrane is subjected during mastication and speaking. On the one hand, these disturbances give rise to a constant detachment of the uppermost plates; and on the other, an uninterrupted regeneration of the lost parts takes place, a process which I am disposed to interpret in this case exactly as I have done in § 46, for the epidermis, and in § 64, for the hairs. As regards the exact mode of that growth of the oral epithelium, which, from what has been said, must perhaps, always be going on in one part or another, we invariably find, upon the surface of the epithelium, during and after very copious desquamation, large, completely flattened cells (which, of course, possess no power of multiplication), never younger and smaller structures, and, therefore, the reparation of any loss cannot take place by the formation of new cells at the surface of the epithelium; on the contrary, everything indicates that the renewal occurs in

the layers of smallest cells, for although no new development of cells can here be directly observed, yet the analogy with other epidermic structures, and the frequent occurrence of two nuclei in the cells of these layers, nay, even of constricted cells (*Bowman*, compare § 46), are striking facts in favour of the multiplication of the cells which already exist (by division) and against their actual new formation.

The *epithelium* of the oral cavity, although thick, is yet readily permeable, differing widely in this respect from the epidermis, which presents similar relations, only in the *stratum Malpighii*. Fluids of the most different description permeate it from without, and once in contact with the mucous membrane, may either be absorbed by its vessels, or perceived by its nerves. Other conditions remaining the same, the activity of the sensitive and absorbent powers will depend upon the thinness of the epithelial layer, particularly of the plates, which must always be least permeable, and upon the abundance and superficiality of the vessels and nerves; and these considerations readily explain why the lips, in which the *papillæ* are very numerous, and nearly reach the surface of the epidermis, possess a more delicate sensibility than the gums; and why the point of the tongue, whose *papillæ* even project with a thinner covering, is still more sensitive (compare, also, on the import of the axile Corpuscles, § 39). The epithelium is permeable outwards, as well as inwards, and permits of the passage of plasma from the vessels of the mucous membrane into the cavity of the mouth. In this manner, like the epidermis in relation to the cutaneous perspiration, it participates in the formation of the mucous fluid, which is yielded, not only by the glands which open into the oral cavity, but also by the whole surface of the mucous membrane.]

## B. OF THE TONGUE.

### § 131.

The *Tongue* is a mass of muscles attached to a particular bone, the *os hyoides*, and covered by the mucous membrane of the cavity of the mouth; its muscular elements, 0·009—0·023'' in breadth, are distinguished from those of the external transversely striated muscles, only by being interwoven in the most

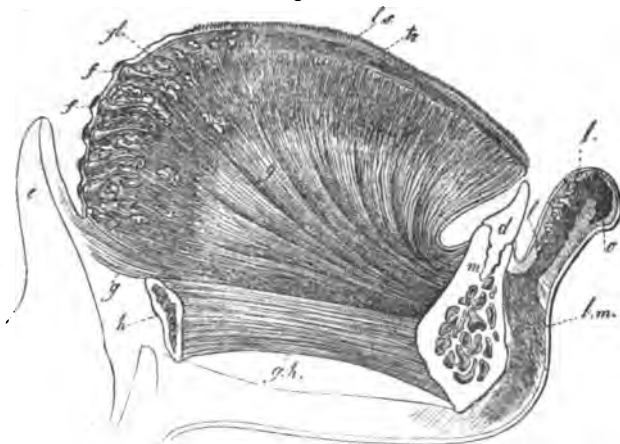
complex manner, so that in the interior of the tongue the lingual muscles cannot be separately demonstrated as such, but only as secondary bundles and fibres.

The frame-work of the tongue may be said to be formed by the two *genio-glossi*, the *musculus transversus linguae* and the *fibro-cartilage* of the tongue. The latter, which is also called the lingual cartilage (fig. 170, *e*), is a dense, whitish-yellow, fibrous lamella, placed perpendicularly in the middle of the tongue, between the two *genio-glossi*, extending through the whole length of the organ, and is not very appropriately named, inasmuch as it is composed of common tendinous or ligamentous tissue. It commences, low down, upon the body of the hyoid bone, in connection with a broad fibrous lamella, *membrana hyoglossa* (Blandin), which stretches from the hyoid bone to the root of the tongue, and covers the extremity of the *genio-glossus*, very soon attains the level of the *musculus transversus*, and, upon the anterior third of the tongue, gradually diminishes, as far as its point, where it terminates very low down. Superiorly, the *septum linguae*, as this fibrous mass, 0·12''' thick, might well be termed, ascends to within 1½—2''' distance from the dorsum of the tongue; inferiorly, it extends to where the *genio-glossi* become lost in the fleshy mass of the tongue, and terminates here, not with a defined border, but by passing into the *perimysium*, between the two *genio-glossi*. On each side of this *septum*, the *genio-glossi* spread out, fan-like, into the tongue (fig. 169, *g*, 170, *g*, 171, *f*), so that they occupy the middle of the organ from its point to its root, forming a long, moderately broad, fleshy mass, which, however, is anything but compact. The *genio-glossi*, in fact, when they have entered the tongue, exchange a few bundles here and there, along the lower edge of the *septum* and then break up on each side into a great number of *lamellæ*, which lie one behind the other, separated by small interspaces, in which are the transverse muscular fibres of the tongue; the *lamellæ* are, for the most part, perpendicular, but some curve forwards and backwards, towards the dorsum of the tongue.

The fibres of the *genio-glossus*, thus separated into distinct *lamellæ*, which have, on the average, a thickness of 0·06—0·14''' , extend as far as the *septum*, and then gradually take a new arrangement, so as to be directed from behind for-

wards. For whilst, previously, the *genio-glossi* were broken up into transverse *lamellæ*, by the bands of the *transversus*,

Fig. 169.



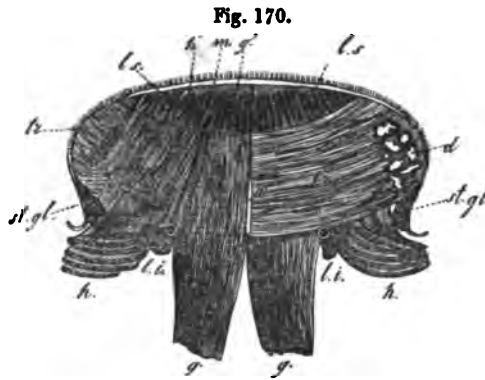
they are now separated longitudinally by the interposition of the bundles of the superior longitudinal muscle of the tongue, between their fibres. These perpendicular longitudinal *lamellæ* are very distinct in the two anterior thirds of the tongue, less so in the vicinity of the *papillæ circumvallatæ*, where, especially in the middle of the tongue, the *genio-glossus* passes, in more isolated bundles, to the mucous membrane; in the root of the tongue, finally, they cannot be demonstrated at all. The *genio-glossus* ends upon the upper surface of the tongue, in such a manner, that its primitive bundles, immediately beneath the mucous membrane, are continuous, in groups, with little tendinous streaks of connective tissue, which then partly become lost in the deeper, very firm layer of the mucous membrane, to be described presently, and partly run as far as the bases of the *pupillæ*. At the root of the tongue, the *genio-glossus* does not reach so far as the mucous membrane, which may here be easily dissected away, with its mucous sacs, from the more deeply

Fig. 169. Longitudinal section of the human tongue, nat. size; the outlines after Arnold *Icon. org. (sens.)*; *g.h.*, *genio-hyoideus*; *h.*, hyoid bone; *g.*, *genio-glossus*; *g'*, *glosso-epiglotticus*; *tr.*, *transversus linguae*; *l.s.*, *longitudinalis superior*; *e.*, *epiglottis*; *m.*, *maxilla inferior*; *d.*, incisor tooth; *o.*, *orbicularis oris*; *l.m.*, *levator menti*; *l.*, *glandulae labiales*; *f.*, *folliculi linguales*; *gl.*, *glandulae linguales cum ductibus*.



situated racemose glands, but ends upon and between the latter, uniting with them, or with a dense fibrous tissue between them, by means of tendinous striæ.

The *transverse muscle* or the *transverse fibres* of the tongue (*transversus linguae sive fibræ transversales*, fig. 169, *tr.*, 170, *tr.*, 171, *g*), consists of very numerous *lamellæ* belonging to each



half of the tongue, which penetrate with great regularity between the transverse *lamellæ* of the *genio-glossus*, and are to be found in all sections of the organ. Each *lamella* is 0.1 — 0.16" thick, and in the middle of the tongue  $\frac{2}{3}$ " deep; it is usually perpendicu-

lar, and its muscular fibres extend from the *septum linguae* to the lateral border of the tongue. They arise, so to say, directly from the whole surface of the *septum*, by the intermediation of a small quantity of a transverse tendinous tissue, distinct from its longitudinal fibres, and pass, united into small flat bundles, at first, directly outwards. In their further course, they curve upwards, and finally, the uppermost shortest fibres reach the sides of the dorsum of the tongue, the inferior longer ones, its proper lateral margin, where they also become attached to the mucous membrane by means of short bands of connective tissue. The other lingual muscles form, in a manner, the sheath of the organ and, in their course, partly follow the above, partly take their own special direction.

The *hyo-glossus* (*baseo-* and *cerato-glossus* of authors), has, at the sides of the tongue, nearly the same relations as the

Fig. 170. *Transverse section of the human tongue, a little in front of the papilla circumvallata: g, genio-glossus; l.i., longitudinalis inferior (lingualis) with the arteria ranina; tr., transversus, visible in its whole extent on the left side, on the right only at the edge and between the divaricating bundles of the genio-glossus; g', termination of the genio-glossus upon the mucous membrane; h', termination of the hyo-glossus; l.s., longitudinalis superior, with flat bundles interposed between the perpendicular fibres; d, glands of the margin of the tongue; st.gl., stylo-glossus.*

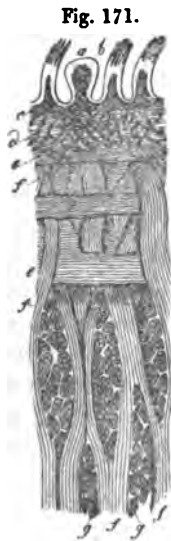
*genio-glossus*, in the middle. Its coarser bundles, in fact, break up when they have reached the lower surface of the margin of the tongue, into a great number of thin transverse *lamellæ*, which, more or less curved, penetrate superiorly between the *lamellæ* of the transverse muscle and in their further course, present exactly the same relations as those of the *genio-glossus*, to which they are applied externally, except, that as their fibres ascend towards the dorsum of the tongue, they take a slightly oblique direction inwards. Upon the dorsum of the tongue, the *hyo-glossus* lies between the *genio-glossus* and the upper edge of the *transversus*; it presents, like the former, longitudinal plates, with perpendicular fibres, between which the upper longitudinal fibres lie, and it finally, also, terminates in the mucous membrane. The expansion of the *hyo-glossus* is most distinct and strongest, in the middle of the tongue, where the chief mass of the *baseo-glossus* lies; it is only behind that it becomes more indistinct, the *lamellæ* of the *cerato-glossus* being here very delicate, and lying more horizontally; however, they still penetrate between those of the *transversus* and terminate upon the dorsum of the tongue.

The *stylo-glossus* (fig. 170, *st. gl.*), in general, divides into two bundles, which have totally different relations; the posterior, smaller one, passes between the *cerato-glossus* and *baseo-glossus*, and between the fasciculi of the latter, directly inwards, penetrating, in a few bundles, between the *lamellæ* of the *lingualis* and *genio-glossus*, as far as the *septum lingue*, where it becomes attached, in common with the somewhat superior fibres of the transverse muscle. The principal mass of the *stylo-glossus* passes inwards and downwards at the margin of the tongue, unites in front of the *hyo-glossus* with the *lingualis inferior*, and terminates in the mucous membrane of the lower surface of the apex of the tongue and of the point itself; the anterior bundles of the two muscles becoming united in an arch.

The *lingualis* of authors, which I shall call *lingualis* or *longitudinalis inferior* (fig. 170, *l. i.*), is a tolerably strong, longitudinal bundle of muscular fibres placed upon the lower surface of the tongue, between the *genio-glossus* and *hyo-glossus*, but whose commencement and termination are not readily discoverable. The posterior portion of the *lingualis inferior* appears at first to become lost in numerous superimposed flat bundles

between the transverse fibres of the *genio-glossus* (*glosso-pharyngeus*), of the *stylo-glossus*, and of the *transversus*, at the root of the tongue; more carefully traced, however, it is found that these, like the posterior portions of the *genio-glossus*, break up into many *lamellæ*, which ascend, slightly curved, between the transverse fibres, as far as the outer portions of the glandular layer of the root of the tongue; and finally, like the plates of the *genio-glossus*, which lie internal to them, end in it. Anteriorly the *lingualis inferior* unites with the larger bundles of the *stylo-glossus*; ending at the point of the tongue with them, and also, applying itself anteriorly to the *hyo-glossus*, it sends many delicate *lamellæ* between the transverse muscles as far as the dorsum of the tongue, presenting, in fact, at the border of the anterior third of the tongue, the same relations as the *hyo-glossus* further backwards.

Finally, there exist in man yet another *longitudinalis*, or *lingualis superior*, and isolated *perpendicular fibres*. The *longitudinalis superior* (figs. 169, 170, *l.s.*, 171, *e*),



constitutes a longitudinally fibrous layer placed between the uppermost fibres of the *transversus* and the mucous membrane, which occupies the whole breadth and length of the tongue and proceeds from the *chondro-glossus* (overlooked by most anatomists), which arises from the smaller *cornu* of the hyoid bone as a moderately large bundle, separated from the *baseo-* and *cerato-glossus* by the lingual artery and the glosso-pharyngeal nerve. It passes forwards, under the deep glandular layer of the root of the tongue, and in part through the midst of the termination of the *genio-glossus* and *lingualis inferior*; occupies, a little in front of the *papillæ circumvallatæ*, almost the entire half of the tongue, and thence passes forwards in the form of narrow bundles, united here and there at acute angles, immediately under the mucous membrane, between the ends

Fig. 171. Portion of a longitudinal section through the side of the human tongue: *a*, *papilla fungiformis*; *b*, *papilla filiformis*; *c*, mucous membrane; *d*, fibrous layer below it; *e*, *longitudinalis superior*; *f*, *genio-glossus*; *g*, *transversus*, cut across.

of the *genio-glossi* and *hyo-glossi*, as far as the point of the tongue, here to become lost in the integument on its upper surface. Since these longitudinal fibres become thicker anteriorly, it is probable that independent, superior longitudinal fibres, arising from the mucous membrane of the dorsum of the tongue, and ending upon it, become associated with them. I find *perpendicular fibres*, which do not arise from without, only in the apex of the tongue, where delicate bundles of them are stretched between the upper and lower layers of mucous membrane.

The lamellæ of the most anterior part of the *transversus* pass between the inner portions of these bundles, whilst between their extremities the *longitudinalis superior* and *inferior* and *stylo-glossus* penetrate with tolerable regularity, so that transverse sections exhibit an alternation of perpendicular and longitudinal fibres, such as that which appears in the dorsal part of the tongue in fig. 170.

It remains to be added, that the *palato-glossus* muscle becomes in part lost, together with the *cerato-glossus*, in the mucous membrane of the lateral borders of the tongue, and in part seems to unite with the larger bundles of the *stylo-glossus*.

If, after thus describing the separate muscles of the tongue, both external and internal, we consider the general structure of the organ, it appears that its proper substance presents essentially only three sets of muscular fibres, which may be denominated *perpendicular*, *transverse*, and *longitudinal*. The *perpendicular fibres* arise from the *genio-glossi* in the middle; from the *lingualis* and *hyo-glossus* laterally; at the apex, also, from the *perpendicularis*; and they form from the point to the root, a great number of transverse *lamellæ*, occupying nearly the entire breadth of the halves of the tongue, whose fibres pass in general from the lower surface to the upper. The *transverse fibres*, derived from the *transversus* and in part from the *stylo-glossus*, are inserted as so many, usually somewhat thicker, *lamellæ*, between the above named, commencing at the *septum* and ending at the lateral edges and partly upon the surface; the *longitudinal fibres*, lastly, belong to the *lingualis superior* (*chondro-glossus*), the *lingualis inferior* and *stylo-glossus*, cover the upper surface, the margin, and in part the

lower surface, and lie for the most part immediately beneath the mucous membrane. The various layers of muscles of the tongue are invariably separated from one another by a thin *perimysium*, and where larger vessels and nerves run, by thicker masses of connective tissue; besides which, there are in many localities, larger or smaller aggregations of common fat-cells, which especially abound between the *genio-glossi*, at the *septum*, at the root of the tongue, and under the mucous membrane.

Fig. 172.



[In the tongue of the Frog very beautiful instances of division of the transversely striated fibres occur (fig. 172), of which I have not been able to find any certain trace in man. Occasionally, however, it has seemed to me that the fibres of the *genio-glossus* exhibited divisions shortly before their passage into tendinous bands.]

### § 132.

On the dorsum of the tongue, from the *foramen cæcum* as far as its point, the mucous membrane differs from that of the rest of the oral cavity, in being very closely united with the subjacent muscular tissue, and in possessing a great number of processes, the well known *lingual* or *gustatory papillæ*. The 6—12 *papillæ circumvallatæ* consist, when they are well developed, of a central round papilla, flattened at the end, having a diameter of  $\frac{1}{4}$ —1" and  $\frac{1}{4}$ — $\frac{1}{3}$ ", or even  $\frac{3}{4}$ " high; and of a lower uniform *wall*,  $\frac{1}{3}$ — $\frac{1}{3}$ " broad, which closely surrounds the papilla, particularly at its base. These *papillæ*, however, vary much in number, size, and position, and occasionally pass into the fungiform kind; which is especially true of the posterior ones lying in the *foramen cæcum* or *Morgagnii*. The papillæ, anterior to the *circumvallatæ*, are arranged in more or less regular

Fig. 172. A branched primitive muscular bundle, of 0.018", from the tongue of the Frog,  $\times 350$ .

rows, which in general run parallel to the latter, and pass, upon the border of the tongue, into laminated, sometimes not even notched folds, which can no longer be considered as *papillæ*. The *papillæ fungiformes* or *clavatae* are 0·3'''—0·8''' in length, 0·2—0·5''' in breadth; they have smooth surfaces and, during life, are readily recognised by their red colour; they abound particularly upon the anterior half of the tongue, scattered over its surface at tolerably regular intervals of  $\frac{1}{4}$ —1''' and more; and at the point, indeed, they are often so thickly crowded as to be in contact; they are not absent, however, upon the posterior half, as far back as the *papillæ circumvallatae*. The *papillæ filiformes* or *conicae* of  $\frac{1}{3}$ —1 $\frac{1}{4}$ ''' length, and 0·1'''—0·2''' breadth, are rendered very obvious by their number and whitish colour; they occupy, in close contact with one another, the intervals between the fungiform kind, and invariably appear most densely crowded and best developed, with brush-like ends, in the concave side of the V of the circumvallate *papillæ*, and in the middle line of the centre of the tongue. Towards the edges and the point, the *papillæ* themselves, as well as their processes, become shorter, and to some extent more scanty, so that they gradually pass into the *laminae* to which we have referred, and also in many respects approximate the fungiform *papillæ*; from which, in fact, so far as the structure of their surface is concerned, they become hardly distinguishable.

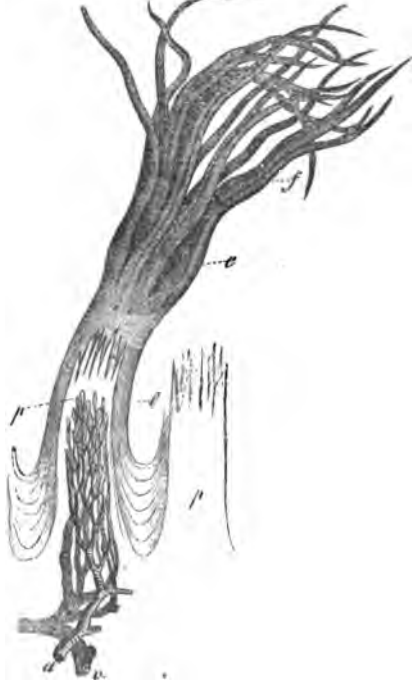Besides these *papillæ* which project freely, there may also be observed over the whole gustatory region of the tongue, smaller ones completely buried in the epithelium, which are perfectly similar to those of the non-gustatory parts of the organ.

With respect to the minuter structure of the mucous membrane of the tongue, that part of it which presents no projecting *papillæ*, differs in no respect from the mucous membrane of the oral cavity, and possesses, in fact, a laminated pavement epithelium of 0·045''' thickness at the root of the tongue, of 0·06—0·1''' on the lower surface of its apex, with simple small imbedded *papillæ* of 0·024—0·05''' length, 0·004—0·02''' breadth, which are not absent even upon the anterior surface of the *epiglottis*, and between it and the *papillæ circumvallatae*. In the proper gustatory region of the tongue the sub-mucous tissue is wholly absent, the mucous membrane being united with the muscular substance by means of a dense layer

of connective tissue (see above § 131); it has itself a dense and solid appearance, though in consequence of the presence of a considerable quantity of elastic tissue, of common fat cells of  $0.016-0.024''$ , and of its abundant vascular supply, it is tolerably elastic.

The *papille filiformes* or *conicæ* (fig. 173), are conical processes of mucous membrane beset either at their extremities

Fig. 173.



only, or over their whole surface, with a certain number (5—20) of smaller secondary *papille* of  $0.1-0.14''$  in length. The whole is invested with a thick epithelial coat drawn out at its extremity into a number of long, thin ( $0.01-0.02''$ ), fine and often subdivided, processes (fig. 173, *f*), which give the papilla the aspect of a fine brush, and may attain a length of as much as  $0.5-0.6-0.7''$ , with a breadth of  $0.02-0.028''$  at their base. The superficial layers of this epithelium resemble the epidermic plates in their long resistance to the action of acids and alkalies, and consist, especially the epi-

thelial processes, only of solid horny scales of  $0.022$  to  $0.028''$ , which frequently form a more solid axis, and of an external cortex composed of overlapping plates, so that the whole mass may, with some justice, be compared to a hair.

The primary *papilla* of the *p. filiformes* contains distinct con-

Fig. 173. Two *papille filiformes* of Man, one with its epithelium,  $\times 35$ , after Todd and Bowman: *p*, the *papille* themselves; *a*, *v*, arterial and venous vessels of *papilla*, together with the capillary loops, which, however, ought to enter the secondary *papille*.

nective tissue, and a very considerable number of elastic fibrils, which as 10—20 wavy threads of 0·0004—0·0008''', penetrate even to the points of the simple papillæ, and give to the whole cone and its processes a certain solidity and firmness which are not possessed by the simple papillæ of the mucous membraue. A minute artery ramifies in each filiform papilla, in such a manner, that every simple papilla contains a capillary loop of 0·004—0·005''', from whose reunion a small vein arises. It is difficult to discover the *nerves*, on account of the abundant elastic tissue; and in many papillæ they may be sought in vain. In the majority, however, at least at the base of the papillæ, they are quite distinct, in the form of one or two delicate trunks, with 5—10, dark edged primitive fibrils of 0·002—0·003''', which gradually become finer as they run towards the point. I have been unable to make out with certainty how the nerves terminate, yet everything appeared to indicate the existence of loops, not, however, in the simple papillæ, but at their base. In animals these loops are more distinct, as for example, in the Calf, where every filiform papilla receives 10—12 primitive fibrils, of 0·002—0·003''', which diminish to 0·001''', and do not enter the simple papillæ.

The *papillæ fungiformes* consist of a clavate primary papilla, whose entire surface is beset with closely placed, conical, secondary papillæ, 0·1—0·12''' in length, and invested with a simple epithelium, such as is met with elsewhere in the oral cavity, *without filiform processes, or any very horny cells*, and which, measured from their points, has a thickness of 0·04—0·05'''. The primary




Fig. 174.

Fig. 174. *A*, *papilla fungiformis*, with its secondary or simple papillæ, *p*, on one side still covered with epithelium, *e*,  $\times 35$ . *B*, the same, with only the outlines of the epithelium, *e*, and the vessels; *a*, artery; *v*, vein; *d*, capillary loops of the simple papillæ; *e*, capillaries in the simple papillæ of the mucous membrane at the base of the *p. fungiformis*;  $\times 18$  diam. After Todd and Bowman.

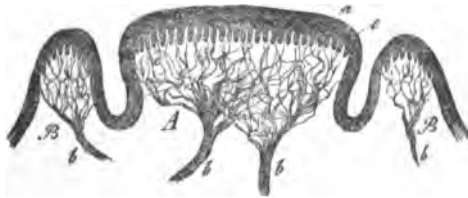


papilla contains far less elastic tissue than the *papillæ filiformes*, and it is almost wholly wanting in the secondary papillæ; on the other hand, a network of bundles of connective tissue of 0.002—0.003''' in breadth, is very distinct. The vessels present the same arrangement as in the *p. filiformes*, only that they are much more numerous; and as regards the nerves, one or two larger trunks of 0.04—0.08'', enter into every fungiform papilla, together with many minute filaments, which, spreading out in the form of a brush, and repeatedly anastomosing (see *Zeitschrift für Wiss. Zool.*, Band IV, Tab. IV), finally diverge in all directions towards the secondary papillæ, and their axile corpuscles (see § 37).

The nerves, which in the trunks measured 0.002—0.004'', on the average 0.003'', diminish in size during their course, so that at the base of the papillæ, their diameter is not more than 0.001—0.0015'', and they also exhibit distinct divisions; I have not yet observed their terminations with certainty, but have thought that in some cases I could detect loops, in others, free ends, without, however, pledging myself either to the one or the other.

In the *papillæ circumvallatæ* the central papilla, which may be regarded as a depressed *papilla fungiformis*, is closely covered

Fig. 175.



upon its plane terminal surface with simple conical elevations, and is invested externally by an epithelium of uniform thickness, without any special processes and prolongations.

The wall is a simple elevation of the mucous membrane, possessing a smooth epithelial investment, beneath which its upper border is produced into many rows of simple conical secondary papillæ. The elastic tissue is usually absent in the papillæ, otherwise, they have the same structure as the fungiform kind, only they are still more abundantly provided with nerves. Every proper *papilla circumvallata* contains in its lowest


Fig. 175. *Papilla circumvallata* of Man in section: A, proper papilla; B, wall; a, epithelium; c, secondary papilla; bb, nerves of the papilla and of the wall; x about 10.

portions several nervous trunks of 0.05—0.08''' in diameter, which, as they ascend, subdivide into a very elegant plexus, from which the nerves of the secondary papillæ radiate upon all sides. In other respects, they resemble the *p. fungiformes*, except that the nerve-tubules, even in the trunks, have not a greater average diameter than 0.002''' , and the largest not more than 0.003''' , while at the base of the secondary papillæ it is not more than 0.001—0.0015''' . The *walls* of these papillæ also contain many nerves, whose ultimate disposition appears to be exactly the same as in the papillæ themselves.

[The lingual papillæ present many varieties, the following of which are the most important: 1. The *papillæ filiformes* are all elongated, and provided with very considerable epithelial processes. The appearance of what is commonly called a gastric furred tongue, depends principally upon a growth of the epithelial processes of the *papillæ filiformes*, which, all directed backwards and in close apposition, form apparently a peculiar white coating. If the processes become longer, so that the *papillæ filiformes* measure  $1\frac{1}{2}$ '''—2''' , we have the *lingua hirsuta* or *villosa*, which is not uncommon in various disorders; and at length forms may be produced, in which the tongue looks as if it were covered with hairs 4—6''' long. 2. The *papillæ filiformes* possess very small epithelial processes, or none at all, and are hardly distinguishable from the smaller *p. fungiformes*. 3. The *papillæ filiformes* do not exist as special elevations, but are imbedded in a general epithelial investment of the dorsum of the tongue. Tongues may be observed, particularly in old people, which, without being furred, in some spots or over a large extent, present no papillæ at all, but have either a perfectly smooth surface, or exhibit only a few linear elevations, corresponding with the rows of papillæ which would, otherwise, exist there. In these places we find the epithelium more developed, and beneath it small papillæ, more of the ordinary form. Tongues which, with better developed papillæ, present a smooth surface, are again different from these; here the smooth or cracked surface is produced by the papillæ being glued together by superabundant epithelium, mucus, blood, pus-corpuscles, and mucedinous or yeast-like fungi. 4. The epithelial processes of the filiform papillæ are covered with mucedinous fungi. Every micro-

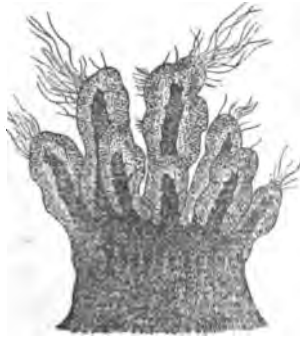scopist is doubtless acquainted with brownish, elongated bodies (0.12—0.24'' in length, 0.04—0.08''' in breadth), consisting of

Fig. 176.



a dark axis and a finely granular cortex, from the coating of the tongue. The centre of these bodies only is composed of cornified epithelial cells, which become isolated and swell up by the action of caustic potass and soda, especially with heat, and are derived from the epithelial processes of the *papillæ filiformes*; the granular cortex again, is nothing but the matrix of a mucedinous fungus of only 0.0006''' in diameter, which, agreeing completely with the well known filaments upon the teeth, is often rooted in immense quantities in it. In the dead subject we readily recognise the epithelial cells, covered with fungi, either with or

Fig. 177.



without projecting mucedinous filaments, even *in situ* (fig. 177);

Fig. 176. A mass of epithelial cells covered with the granular matrix of the fungus, *b*, from which a luxuriant growth of mucedinous filaments, *c*, proceeds;  $\times 350$ ; from Man.

Fig. 177. A *papilla filiformis*, whose, here, short epithelial processes are invested by the matrix of the fungus, from which also single filaments are growing out.

and in living persons, they may be procured in any quantity by scraping the tongue. In twenty or thirty healthy young people, I have hardly once failed to find the granular covering upon the epithelial processes, even in a perfectly clean, red tongue.

The more fur there is, the more abundant is the matrix, and the mucedinous filaments are also apparent, though they are rarely (three or four times in thirty cases) found so clear and distinct as in fig. 176, and in general are not met with in more than a third of those persons whose *papillæ filiformes* are not altogether in a normal condition.

The *physiological results* of the anatomical data which have been communicated, may be thus summed up: the *papillæ filiformes* are neither gustatory nor delicate tactile organs, since their thick, and what is more to the point, greatly cornified epithelium, is very little fitted to allow of the passage of fluids capable of being tasted, or of other influences, to the scattered nerves, which only attain to the base of the simple papillæ. With Todd and Bowman, I consider that the *p. filiformes* have a similar office to the lingual spines of animals, which are nothing but modified filiform papillæ, and I therefore ascribe to them a certain importance for the conveyance and retention of the morsels of food, and I consider that their epithelium serves, at the same time, as a protecting investment for the tongue. The two other kinds of papillæ subserve the sense of taste and are, besides, the seat of ordinary sensation (for mechanical irritation, temperatures, &c.), for which functions they are excellently fitted by their thin, soft epithelium, the softness of the tissue of their papillæ and by the superficial position (in the secondary papillæ), and the great number of their nerves. The sensibility of the tongue is most delicate where the *papillæ fungiformes* are most closely set, *i. e.*, at the apex, which, on that account, and also perhaps by reason of the solid axile corpuscles in many of the papillæ, is especially fitted for a tactile organ; at the root of the tongue it is more obtuse, and is accompanied by peculiar sensations; the sense of taste is much more acute at the root of the tongue than in the other regions, the point not excepted. The reason of this lies neither in the epithelium, nor in the fundamental structure of the papillæ, which are essentially similar in both the *papillæ circumvallatæ* and *fungiformes*, but is, very

possibly, to be sought for in the nerves. In the *p. circumvallatæ*, the nervous fibres are always finer, and not only absolutely, but also relatively, considerably more numerous than in the *fungiformes*, so that they possess more papillæ and nervous terminations in the same space. The fineness of the nerves especially, together with the smaller quantity of medullary sheath and the more superficial position of the axis-fibre, which indeed is the case in all the nerves of the higher senses, may perhaps explain why tastable substances act here not only more powerfully, but when they are no longer perceptible by more dense elements of the nerves. If this peculiarity be insufficient to account for the differences in the sense of taste possessed by the two kinds of papillæ, they can only be referred to the central organs, or ascribed to specific actions in the nervous fibres themselves, which, however, is only making a public confession of the *hiatus* in our knowledge.

Remak<sup>1</sup> discovered *microscopic ganglia* upon the expansion

<sup>1</sup> [Remak, 'Ueber die Ganglien der Zunge bei Säugethieren und beim Menschen.' The author finds ganglia upon the branches of the glosso-pharyngeal and of the gustatory nerves, and not upon those of the ninth nerve; small ganglia were sometimes observed near branches of the latter, but were never actually connected with them, and probably belonged to neighbouring branches of the gustatory. Remak compares these ganglia with those observed by himself in the heart, contractile wall of the bronchiæ, posterior wall of the urinary bladder, and muscular wall of the uterus, and with the ganglia of the cavernous plexus described by Müller; and his reasons against their connection with the nerves of sense appear to us sufficiently important to be given in his own words.

"The terminal branches of both nerves (glosso-pharyngeal and gustatory nerves) form a very dense plexus before entering the papillæ. Neither in this plexus, nor within the papillæ themselves, could ganglion-globules ever be detected. It must be remembered, further, that the ganglia upon the thicker branches of the glosso-pharyngeal and gustatory are always *hemiganglia*, that is, they do not occupy the whole thickness of the nerve—a bundle of tubules, which takes no share in the formation of the ganglia, passing over them. Those ganglia which lie in the neighbourhood of the papillæ have the same structure. Far more numerous are the *hologanglia*, *i. e.* those in which all the nervous fibres become lost between the ganglion globules (probably pass into them), but these are found only in the finest lateral branchlets. They are almost always multipolar, *i. e.* they are connected with more than two nervous trunks, and these are very widely different from the nerves which constitute the papillary plexus. While the latter present very delicate sheaths, and consist of evident dark-edged fibres, the processes of the *hologanglia* are closely surrounded and enveloped by very dense sheaths, and contain, particularly in the lingual branch of the fifth, both in man and in the sheep and calf, a very large quantity of the well-known nucleated fibres, so that it is at times difficult to find

of the *glosso-pharyngeal* nerve in the tongue, and these have been recently subjected by myself (Mikr. Anat. II, 2, p. 32), and by Remak (Müll. Arch., 1852) to a more exact investigation. Remak found such ganglia also upon the branches of the gustatory division of the fifth nerve in the Sheep and Calf, as far as close to the apex of the tongue, though they were smaller and more scanty than those upon the *glosso-pharyngeus*; whilst on the other hand, in man, they were wanting upon the thicker branches of the gustatory division of the fifth, and were to be found only as very minute ganglia upon the more delicate internal branches. Remak endeavours to demonstrate some relation between these ganglia and the lingual glands, and draws a functional parallel between them and the *ganglion linguale*, a view plausible enough, and against which I only have to remark, 1. That ganglia exist not only upon the branches distributed to the mucous membrane, but also upon those passing to the papillæ, and in regions of the tongue, (the point) where no glands are found; and, 2. That the glandular region of

a single dark-edged fibre in one of these nerves. In other cases, the processes of the ganglia are delicate nerves (of  $\frac{1}{350}$ "), which possess a solid sheath, and a single dark-edged nervous fibre inclosed by it. The fine lateral branches of the *hemiganglia* upon the thicker branches of the nerves present the same appearances. No fibres can ever be traced from a ganglion to the papillæ. Another circumstance which speaks against the relation of the ganglia to those fibres of the gustatory nerve which are distributed to the mucous membrane is, that I could never, in spite of every exertion, find ganglia upon the terminal branches of the gustatory nerve of the apex of the tongue of the sheep. I believe that a certain value may be attributed to this negative result, as I never failed to find ganglia upon the other branches of the gustatory nerve, up to within about an inch of the apex of the tongue."

Remak gives, further, the following reasons for believing that the ganglia are related to the mucous glands. "1. The lingual ganglia always occur in the neighbourhood of the mucous glands, or of their excretory ducts. 2. That the smaller number of mucous glands in the anterior region of the tongue (in the sheep or calf), corresponds with the smaller number of ganglia upon the branches of the gustatory nerve. 3. That little ganglia exist upon the branches of the gustatory nerve distributed to the maxillary glands, and to the *ductus Whartonianus*, whilst in man there is the well-known maxillary ganglion. 4. That in the point of the tongue of the sheep, in which he could find no ganglia on the branches of the fifth, there are no mucous glands. 5. That in the walls of the pharynx and larynx, upon which he also found small ganglia on the branches of the *glosso-pharyngeal* and superior laryngeal nerves (Med. Zeit., 1840, No. 2), the mucous glands are very numerous. 6. That in the sheep and calf he has observed little ganglia upon the surface of the *ductus Whartonianus*, which are connected with a plexus of delicate nerves investing the duct."—Eds.]

the root of the tongue, also, possesses gustatory sensibility. Upon these grounds, I think it is impossible, for the present, wholly to deny a relation of the ganglia in question, to the sensations.]

### C. OF THE GLANDS OF THE ORAL CAVITY.

#### 1.—MUCOUS GLANDS.

##### § 133.

The *mucous glands* of the oral cavity are yellowish or whitish racemose glands, usually of a rounded form and tuberculated surface of  $\frac{1}{3}$ —2'' in diameter, which in general lie immediately external to the mucous membrane and yield a mucous secretion.

According to the localities in which they are found, the mucous glands present somewhat different relations and receive different names.

1. The *labial glands*,  $\frac{1}{8}$ —1 $\frac{1}{4}$ ''' in diameter, lie between the muscular layer and the mucous membrane, are very numerous, and form an almost continuous glandular ring round the oral aperture, which commences at 3''' distance from the red edge of the lips, and possesses a breadth of about  $\frac{1}{4}$ ''.

2. The *buccal glands*, lying further outwards, covered by the buccinator muscle, are tolerably numerous but smaller; a few large glands appear at the aperture of Stenon's duct upon the buccinator muscle and still further backwards in the neighbourhood of the last molar tooth (*molar glands*).

3. The *palatine glands*.—Those of the hard palate are small and hardly pass beyond its middle anteriorly, while on the other hand, those of the soft palate form a considerable layer of glands upon its under side, which anteriorly measures as much as 3—4'', diminishing, however, somewhat towards the free edge and the *uvula*. On the posterior surface of the soft palate, also, glands exist, but they are much smaller, and do not always form a connected layer.

4. The *lingual glands*, among which I distinguish :

a. The *mucous glands of the root of the tongue*.—These form a stratum, in parts very thick, of glands  $\frac{1}{3}$ —2'' in diameter, beneath the simple mucous sacs of the root of the tongue, to

which we shall have to refer hereafter, and the *papillæ circumvallatæ*; it presents, especially beneath the former, a thickness of as much as 4''', and extends almost continuously from one tonsil to the other. In front of the *foramen cæcum* these glands are smaller and more scattered, but a few occur more or less deep in the muscular substance in front of the most anterior *papillæ circumvallatæ*; they are never found, however, further forwards than the middle of the tongue.

The excretory ducts of the glands, which are interwoven with the extremities of the *genio-glossus* and partly united with them, are as much as 6''' long in the posterior glands, and open, as E. H. Weber first showed, by a funnel-shaped expansion into the simple mucous sacs of the root; in the neighbourhood of the *papillæ circumvallatæ*, on the other hand, they open independently between the lingual papillæ, and into the clefts which surround the circumvallate papillæ, a few also on the walls of the *foramen cæcum*.

*b. The marginal glands of the root of the tongue.*—At the borders of the root of the tongue we find, at the level of the *papillæ circumvallatæ* many perpendicular laminated folds, to which reference has already been made and between them fine apertures, which belong to a special small group of glands lying in the midst of the expansion of the *hyo-glossus* and *transversus*. In animals, these glands, as well as the folds (Mayer's organ), are often very greatly developed. (See Brühl, l. c.)

*c. The glands of the point of the tongue.*—On the lower surface of the apex of the tongue, but still in the substance of the *lingualis inferior* and *stylo-glossus*, there lie, right and left, two elongated broad glandular masses 6—10''' long, 2—3''' thick, 3—4''' broad, where 5 or 6 excretory ducts open upon peculiar lobed folds of mucous membrane close to the *frænulum lingue*; these glands were long ago accurately described by Blandin, and have been recently rescued from oblivion by Nuhn.

#### § 134.

*Intimate structure of the mucous glands.*—All these glands agree in the essential characters of their intimate organisation and invariably consist of a certain number of glandular lobes with a branched excretory duct. The lobes, of which in the



simplest glands (fig. 178), only a few (4—8) exist, are in their circumference generally elongated, pyriform, or rounded, not

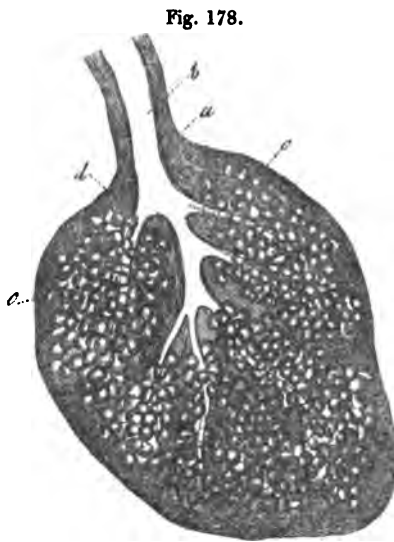


Fig. 178.

rarely, flattened, 0.5—0.72''' long, 0.2—0.48''' broad, and are each seated upon a branch 0.03—0.05''' thick, of the excretory duct, which measures 0.12—0.3''' , or even 0.5''' , (in the glands of the root of the tongue). They consist of a number of coiled canals presenting numerous simple or compound, vesicular diverticula (fig. 179), and appear to be the immediate continuations of the excretory ducts of the lobes, which, as soon as they have entered the latter, usually without

diminishing in diameter, break up successively into a certain number of them. What have been called the glandular vesicles or *acini*, are nothing more than the dilatations and terminations of these canals, or ultimate branches of the excretory ducts. Examined superficially, and under low magnifying

Fig. 179.



cles or *acini*, are nothing more than the dilatations and terminations of these canals, or ultimate branches of the excretory ducts. Examined superficially, and under low magnifying

Fig. 178. Racemose mucous gland from the floor of the oral cavity: *a*, investment of connective tissue; *b*, excretory duct; *c*, glandular vesicles; *d*, ducts of the lobes; from Man,  $\times 50$ .

Fig. 179. Diagram of two ducts of a lobe of a mucous gland: *a*, excretory duct of the lobe; *b*, secondary branch; *c*, the glandular vesicles upon it *in situ*; *d*, the same separated and the duct unfolded.

powers, they all appear uniformly rounded or pyriform; the exact analysis of a whole lobe, or still better of a dissected and injected gland, shows however, that their form is very various, rounded, pyriform, or elongated. It is impossible to describe at length all the forms which they assume; I will therefore only remark, that the ends of the glandular lobes frequently repeat, on a small scale, the figure and structure of the seminal vesicles, and refer to the subjoined diagrammatic figure.

All the finest glandular ducts and vesicles, whose diameter varies from 0.02 to 0.08 $''$ , consist of a peculiar, structureless coat, the *membrana propria*, of 0.0008—0.0012 $''$  in thickness, and of an epithelium (fig. 180), which, in fresh preparations, appears as a continuous investment of the glandular extremities, but is very readily detached, and then fills the glandular vesicles as a granular mass. The epithelial cells constitute a simple layer upon the *membrana propria*, have 3—6 sides, are often somewhat elongated, 0.005—0.006 $''$  broad, 0.003—0.004 $''$  thick, and invariably contain, besides a rounded or elongated nucleus of 0.002—0.003 $''$ , often presenting a distinct nucleolus, a certain number of larger or smaller granules, which sometimes simply resemble white fat, sometimes are coloured yellowish and brownish, and contribute to the hue of the glands themselves.

The elements of the glandular lobes which have been just described, though they are all applied very closely together, so, indeed, as not uncommonly to be flattened against one another, yet always present a small quantity of interposed connective tissue, by which the vessels of the lobes are supported. Besides this, the separate lobes and the entire glands are invested by dense coats of a connective tissue, with elastic fibres, which may, in addition, contain fat-cells. In small glands, such as fig. 178, the only distinguishable subdivisions are the lobes, glandular vesicles, and cæca, which have been described; in the larger, on the other hand, as in the glands of the lips

Fig. 180.




Fig. 180. Two glandular vesicles of a racemose mucous gland of Man,  $\times 300$ : *a*, *membrana propria*; *b*, epithelium, as it appears in the apparent section of a vesicle; *c*, the same seen upon its surface.

and palate, the smallest lobes are surrounded in groups by somewhat stronger sheaths of connective tissue, so that a certain number of secondary lobes are formed, each of which corresponds with a simple gland and also has the same size, *i. e.* about  $\frac{1}{3}$ — $1\frac{1}{3}$ '''.

The excretory ducts of the lobes have a coat of connective tissue, with networks of fine elastic fibres, and a simple layer of cylindrical cells 0·008—0·01''' thick. In the principal excretory ducts, the wall, which is very rich in elastic fibres, measures, even in the smallest glands, 0·02''' , in the larger as much as 0·03''' and 0·04''' , the epithelium 0·01—0·012''' . Of muscular fibres I saw no trace whatsoever, either in the glands themselves or in their excretory ducts; on the other hand, they possess many minute vessels, which penetrate with the excretory duct or otherwise between the lobes, and form, in the interior, a wide network of capillaries of 0·003''' , which encircle the separate cæca and vesicles, so that each of them is in contact with at least 3—4 capillaries. *Nerves* exist abundantly upon the excretory ducts and, occasionally, moderately fine tubules are found in the glands themselves.

The *secretion* of the racemose glands is a clear, yellowish mucus, with only accidentally intermingled granules, nuclei, and remains of cells, which coagulates in acetic acid and is insoluble in an excess of it, remaining as a viscid mass, striated, or deceptively similar to a fibrous tissue. It fills the excretory ducts and the other cavities of the gland to their ultimate extremities, being readily rendered obvious in them by acetic acid. I have never found the so-called *mucous corpuscles*, as they exist in the fluids of the mouth, in a mucous gland and I believe that, normally, the secretion of mucus goes on without the production of cells.

## 2.—FOLLICULAR GLANDS.

### § 135.

The *follicular glands* of the cavity of the mouth are: firstly, *simple follicles* at the root of the tongue and, secondly, *compound follicles* at the sides of the *isthmus faucium*,—the *tonsils*. These organs agree so perfectly in structure, that the tonsils may be

regarded as an aggregation of simple follicular glands, while, on the other hand, they are so widely different from the mucous glands that they can on no account be classified with them.

The *simple follicular glands* of the root of the tongue (fig. 169, *f*), form an almost continuous layer from the *papille vallatæ*, as far as the *epiglottis* and from one tonsil to the other, lying immediately under the mucous membrane, and above the mucous glands. Their position is so superficial, that the separate glands are visible from without, like little elevations upon the mucous membrane, and allow their number and arrangement to be recognised. When dissected out, we see that each follicle is a lenticular or globular mass of  $\frac{1}{3}$ — $2''$  in diameter, invested upon its outer surface by the mucous membrane, which is here very thin, lying loosely in the submucous tissue and receiving upon its under surface the excretory duct of a more deeply disposed mucous gland. In the midst of the free surface a punctiform aperture, often tolerably wide ( $\frac{1}{3}$ — $\frac{1}{2}''$ ), is easily perceived by the naked eye; it leads into a funnel-shaped cavity, which is remarkable on the one hand for its narrowness, in relation to the size of the sac, and on the other, for its thick walls, and is usually filled with a greyish mucous material.

Each follicle (fig. 181) is a thick-coated capsule, externally surrounded by a fibrous investment connected with the deep layers of the mucous membrane; internally, it is lined by a process of the mucous membrane of the oral cavity, with its papillæ and epithelium, and contains between the two, imbedded in a delicate, fibrous, vascular matrix, a certain number of large, completely closed *capsules* or *follicles* (fig. 181, *g*), which are about  $\frac{1}{10}$ — $\frac{1}{4}''$  in diameter, round or elongated in form,

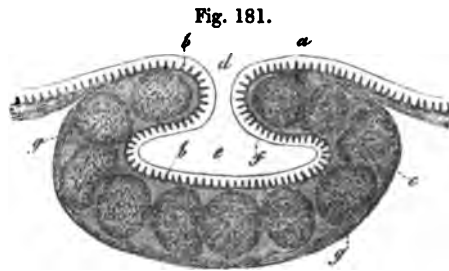


Fig. 181.

Fig. 181. Follicular gland from the root of the tongue in Man: *a*, epithelium lining it; *b*, papillæ; *c*, external surface of the follicular gland, with the coat of connective tissue; *e*, cavity of the gland; *f*, epithelium; *g*, follicle in the thick wall of the gland;  $\times 30$ .

present a whitish colour, and closely resemble the capsules of Peyer's patches, the solitary glands, the vesicles of the spleen and of the lymphatic glands. They consist of a tolerably solid coat, about 0·002—0·003''' thick, composed of more homogeneous connective tissue, without elastic fibres, and of greyish white contents, which, when the follicle is pricked, exude in the form of a drop, which becomes diffused through water, and consists of a fluid with formed particles. The former, alkaline in its reaction, is present in excessively small quantity, so that it appears to be merely the connecting medium of the latter, which consist of cells of 0·003—0·005''' and free nuclei of 0·002—0·0025''' without any determinate character. Acetic acid renders the cells granular, and thence communicates a whitish tinge to the contents; but it precipitates no mucus, the fluid differing decidedly in this respect from the ordinary mucous secretion and agreeing with that of the splenic corpuscles. The position of the follicles is usually such, that they form a connected, almost simple layer, between the external coat and the epithelium of the follicular glands, yet there are localities, at least in animals, where two follicles are found behind one another, or at greater intervals.

The *vessels* of the follicular glands are very numerous, and may often be traced naturally injected, in man. Small arteries enter from without, passing through the fibrous coat to the interior, ramify between the follicles, as they ascend, in an elegant arborescent manner, and terminate in the papillæ and on the follicles. The vessels of the former present the same relations as those of the other simple papillæ, and are either simple or complex loops; around the follicles they form an exceedingly elegant and abundant network, whose finest vessels, 0·004—0·006''' in diameter, take a wavy course, forming a moderately close network immediately upon the membrane of the follicle. The efferent veins converge from these two localities, and are wide and numerous. *Lymphatic vessels* also, according to E. H. Weber (Meckel's Archiv, 1827, p. 282), appear to proceed from these glands, and I have myself noticed *nerves* upon them.

The *tonsils* are, according to my investigations, nothing but an aggregation of a certain number (10 to 20) of compound follicular glands, which, intimately united and held together by a common investment, form a large hemispherical organ;

the apertures of the follicles frequently unite, so as ultimately to form only a small number. Each section of the tonsil, much as it may vary in the form of its cavity and its external appearance, has exactly the same structure. Proceeding from the oral cavity, we observe that its epithelium enters into the separate cavities of the tonsil and, becoming somewhat thinner, completely lines all the secondary cavities. Beneath it we find a greyish, soft, very vascular membrane  $\frac{1}{2}$ — $\frac{1}{3}$ " thick; and still more externally, a dense, relatively thick fibrous covering, which, when two lobes or sections of the tonsils are in contact, belongs to them in common, and is in contact at their outer extremities with the common coat of the organ. The soft thick layer between the epithelium and the fibrous investment has the same composition as the corresponding layer of the follicular glands of the root of the tongue. Here also we meet with conical or filiform, even slightly branched papillæ, of 0.06—0.08" length, 0.01—0.03" breadth, directed towards the epithelium; internally to these, round, completely closed *follicles* one close to the other, of the same size and possessing the same contents as those previously described; and finally, a soft fibrous tissue connecting them, and containing numerous vessels. The *vessels* are still more numerous than in the follicles of the tongue, though their ramifications are essentially similar, except that the papillæ frequently contain multiple loops, and the networks around the capsules are still closer (fig. 182). The fibrous investment, lastly, consists of connective tissue, with elastic fibres and receives certain muscular fibres from the superior constrictor of the pharynx. *Nerves* may be detected on the external surface of the tonsil, and in the papillæ, but, as in the case of the follicular glands of the root of the tongue, I have failed to observe them in the proper membrane of the follicles.

Fig. 182.

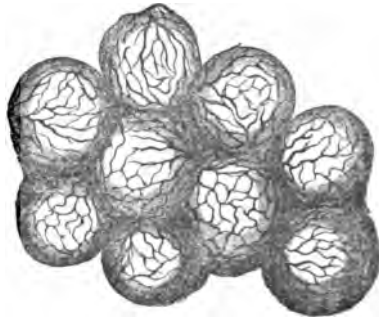


Fig. 182. Vessels of a few follicles from a human tonsil, seen from the cavity of a sac,  $\times 60$ .

Corresponding with their structural similarity is the resemblance in the secretion of the tonsils and that of the lingual follicles, though the former is not easily obtained pure on account of the tonsils also receiving the ducts of mucous glands. It is a greyish white mucous substance, which, however, so far as I have been able to observe, contains no mucus, but is composed either of cast-off epithelial plates alone, or of a mixture of these with cells and nuclei, perfectly identical with those contained in the parietal follicles of the tonsillar cavities. How these cells are formed and whence they arise, I know not. It would seem probable that they proceed from follicles which have burst, a process which may really occur in man, though from what is observed in animals we can hardly assume their dehiscence to be a normal process.<sup>1</sup>

[In man, it is quite impossible, in a vast number of cases, to find the follicles which we have described in the walls of the tonsils, a circumstance which appears to me to be explained by the frequent morbid changes to which these organs are subject. In fact, in the course of inflammations of the tonsils and their *sequelæ*, the contents of the follicles appear to alter, the follicles themselves becoming distended, and finally bursting. The closed sacs, filled with purulent or caseous masses, which are described in diseased tonsils, when they do not exceed a certain size, may be nothing else than such follicles; and by their bursting they may yield those masses of secretion which are accumulated in the larger cavities. It thus happens, that the normal structure is frequently no longer recognisable in the walls of the tonsils and that we find, at most, recently opened follicles, or more usually nothing but a granular mass interpenetrated by fibres and vessels, with remains of papillæ and of epithelium.

On the other hand, however, the frequent pathological degenerations have this advantage, that if we happen to hit upon

<sup>1</sup> [In the *Mikroskopische Anatomie*, B. II. H. II., p. 46, Professor Kölliker adds a few points to the account here given of the structure of the tonsils. In man, racemose glands are not unfrequently met with external to the tonsils, and probably open in them; and in the Calf, a considerable number of such glands may be found between the lobes of the organ. In opposition to Frerichs (*Wagn. Handw. III.*, p. 745), Kölliker states that he has "not yet" found solitary glands like those of the intestine in the mucous membrane of the mouth.—Eds.]

the right period, all the follicles may be seen enlarged, but still closed and beautifully injected, so that it is quite impossible to overlook them. An instance of such a hyperæmic tonsil, with distended, lingual follicular glands, the follicles attaining a size of 0.36—0.48", was what first led me to a conception of the true structure of these parts, which has been only verified by subsequent investigations. The difficulties attending the investigation in man disappear in many animals, and I can especially recommend the tonsils of the Pig and Sheep, the lingual follicular glands of the Ox and the tonsil-like organs at the entrance of the larynx in the Pig, Sheep, and Ox, in which the structure may be always readily made out, both in fresh organs and in those which have been hardened in strong alcohol.

With respect to the *secretion of the tonsils* in man, it is certainly abnormal in many cases, in the dead subjects which are accessible for investigation; for instance, when the cavities contain considerable quantities of a greyish, yellowish, or greenish, sometimes softer, sometimes more consistent mucus, if it may be so called, the constituents of these contents being larger and smaller cells, with a single nucleus, some of which have undergone a very obvious fatty metamorphosis, while others have cavities and thickened membranes; further, epithelium (not ciliated cylinders, as *Valentin* states, having probably confounded with such, the deepest, here very much elongated, cells of the pavement epithelium), occasionally abundant cholesterin crystals and mucedinous fungi. The secretion is more normal if it consist only of epithelium, of small cells without fat and of free nuclei, the two latter elements being perfectly similar to those in the follicles; such great masses of them, however, are often found, that we must suppose they have been developed in excess.

In any case I am disposed to consider such cells and nuclei as the proper secretion of the tonsils, inasmuch as, in animals, as for example, the Sheep, we find similar contents, though their amount is often small. It is difficult to decide whether they are afforded by the follicles or not; certain it is, that they are identical with the contents of the latter, and that in man the follicles burst, but the former might be accidental, and the latter only a morbid process.

In fact, however frequently the tonsils of animals are examined, no ruptured follicles are ever met with; they are



always entirely closed, and the epithelium extends them, so that one is led to the belief that the secretion is developed independently, out of a substance excreted into the cavity of the organ. That this is possible and actually takes place, indeed, elsewhere (*e. g.* suppuration upon mucous membranes which are still covered by their epithelium), is not to be denied; and the sole difficulty about such a hypothesis is, that in this case the import of the tonsillar and lingual follicular glands (for which, also, all that has been said, holds good), becomes highly problematical. If they do not occasionally burst, their function, as regards secretion, can only be to elaborate in their interior a fluid, which, when it subsequently enters the cavity of the gland, is especially fitted to form its proper secretion. For the rest, the similarity of the follicles in question, especially with those of the solitary and Peyerian glands, and also with those of the spleen<sup>1</sup> and lymphatic glands, would indicate another series of possibilities, into which, however, I will not enter, because in all the organs in question the anatomical facts and the physiological relations have hitherto been by no means completely determined.]

### 3.—SALIVARY GLANDS.

#### §. 136.

The *salivary glands*, *i. e.* the parotid, the submaxillary, the sublingual, and *Rivini's* glands, agree so closely in their structure with the racemose mucous glands, that it would be quite superfluous to enter into any detailed description of them. They are compound racemose glands, and they might be regarded as aggregations of numerous mucous glandules. In fact, the primary and secondary lobulations which are observed in these glands correspond, the latter to the entire mucous gland, the former to its lobes. The secondary lobulations then become united into still larger groups, and a certain number of these constitute the whole gland. The excretory ducts correspond with the number of the lobulations of the gland; they are more or less branched, and in their final relations resemble those of the mucous glands.

<sup>1</sup> [For some additional facts in favour of these resemblances, see notes § Spleen.—Eds.]

The more *intimate structure* of the salivary glands presents nothing remarkable. The glandular vesicles have about the same diameter—0·016—0·024—0·03''', in all three descriptions of glands; they are as variously formed as in the mucous glands, and proceed in a similar manner from the excretory ducts. Their *membrana propria* frequently presents a double contour, and is, internally, always clothed with a pavement epithelium, whose cells of 0·005—0·008''' have a single nucleus, and may be obtained in beautiful series by coarsely crushing the gland; they are distinguished by their greater proportion of fatty granules and pigment granules from those of most mucous glands, whence the glandular vesicles themselves present a somewhat dark appearance. Here, also, acetic acid makes the contents of the cells turbid, the addition of an excess even not restoring their clearness, and it is not therefore advisable to make use of it in our examinations; a very dilute solution of caustic soda, which allows the epithelial cells to be seen *in situ*, is more to be recommended.

The *excretory ducts* of the salivary glands possess a single layer of cylinder epithelium, whose cells measure 0·016''' in length. The remaining portion of the wall, which is very thick in *Stenon's* duct, but much thinner in the others, has a dense, solid structure, and consists of connective tissue, with a very close network of fine, and moderately thick, elastic fibres. It is only in *Wharton's* duct that we find, external to the epithelium, and to a double layer of elastic membranes whose elements are disposed transversely and longitudinally, a thin stratum of *smooth muscles*, which, however, can only be demonstrated and isolated with very great difficulty. They are disposed longitudinally, have short nuclei of 0·004—0·006''', at most 0·008''', and are covered externally by a layer of connective tissue with elastic fibres.

The *vessels* of the salivary glands are very numerous, and present the ordinary structure. The capillaries have a diameter of 0·003—0·004''', and form broad networks in which the glandular vesicles are imbedded, so that each vesicle receives its blood from several directions. A considerable number of vessels are distributed also to the excretory ducts. *Lymphatics* are found in the salivary glands, but their internal relations are unknown. *Nerves* proceed from the *plexus caroticus externus*, with

the vessels, into the interior of the glands; in addition, the *ganglion linguale* (*lingualis* and *chorda tympani*) supplies the two smaller pair of glands, and the facial nerve, probably with the anterior auricular, the parotid. I may remark, with regard to the distribution of these numerous nerves, that here also it is impossible to find any in the smallest lobules of the glands, while on the other hand they are readily discovered upon the larger vessels and the excretory ducts. In animals I found particularly rich nervous networks upon *Rivini's ducts*, the tubules having a diameter of 0.001—0.002'''.

The *secretion* of the salivary glands normally contains no formed elements, but may accidentally present cylindrical cells from the excretory ducts, or scattered, half-disorganised cells from the glandular vesicles. Its physical and chemical properties, in the different salivary glands, appear to differ in some respects. The parotid saliva is clear and fluid, and, like the glandular vesicles themselves, contains no mucus. Bernard and Jacobowitsch found the secretion of the sub-maxillary gland in the Dog to be viscid, and capable of being drawn out into threads; according to Bernard also, a watery extract of the gland itself contains mucus.

In man, the *ductus Whartonianus*, if laid open, is usually found to contain a small quantity of a kind of mucous fluid, which, however, consists chiefly of cylinder epithelium and broken up epithelial cells of the glandular vesicles themselves, containing only a very small amount of a substance which coagulates in acetic acid, and is, perhaps, mucus. The glandular vesicles, on the other hand, if crushed, usually yield a considerable quantity of mucus, which coagulates into threads by the action of acetic acid. The vesicles of the proper *sublingual gland* contain still more mucus, and the *ductus Bartholinianus* also commonly presents distinct evidence of it. With respect to *Rivini's ducts*, they are filled, in man and animals, with the same yellowish, viscid, amorphous fluid, coagulating into threads by the action of acetic acid, which is met with in the ducts of the small mucous glands, while the glandular vesicles themselves also contain abundant mucus. From all that has been said, it would seem that *Rivini's glands*, as I will call them, must be excluded from the class of salivary glands, and, as regards the three larger glands, their secretion does not appear to

be identical, but sometimes to contain mucus (submaxillary and particularly the sublingual), sometimes to want it (parotid).

[We may take this opportunity of making some observations with respect to the *salivary*, or *mucous corpuscles*, of authors; rounded cells of 0.005''', with one or many nuclei, which are always to be met with in the fluid of the mouth, and are usually supposed to be derived from the mucous or salivary glands, yet wrongly, since the examination of both these kinds of glands, and of their ducts, teaches us that they excrete no formed elements. In my opinion the mucous corpuscles are nothing but products of the mucous membrane of the oral cavity—not normal, although they are almost constant, but a kind of exudation- or pus-corpuscles, with which they have, as is well known, the closest possible resemblance in structure. Many authors consider them to be abortive epithelial cells of the oral cavity; but in that case the epithelium of the localities in which they are found must want the outermost layer of large, flattened scales, *which is by no means the case*. In my own person, at any rate, I find mucous corpuscles on the gums, the lips, cheeks, and tongue, in localities in which the epithelium is *wholly uninjured*; and by scraping with a knife I can often obtain entire lamellæ of epithelial plates, covered with mucous corpuscles. I do not mean to affirm by this, that in little sores, arising from whatever cause upon the gum, for instance, where the epithelium is wholly or partly wanting, or when it is lost more extensively, in consequence of disease, that mucus- or exudation-corpuscles may not be developed, as upon other sore surfaces, and then might be regarded as abortive epithelium-cells, but only, that this does not take place in the oral cavity under ordinary circumstances. I consider, therefore, that the so-called mucus, or salivary corpuscles, are exudation corpuscles, and consequently totally distinct from epithelial cells; and I regard their formation to be analogous to that of the pus-corpuscles in catarrh, which also very often takes place upon unbroken epithelial surfaces. It is thus readily explained how it is that they are almost entirely absent in many individuals, while in others who are subject to irritation of the mucous membrane of the mouth they are very abundant, and that they have been observed in saliva, *obtained from a fistulous*

---

*aperture* (Sebastian, in 'Van Setten, Diss. de Saliva.' 1837, p. 12).

The best *mode of examining* the oral mucous membrane is by making perpendicular sections of portions, either fresh, or dried, or hardened in absolute alcohol, in which the papillæ and epithelium are very distinct, and become still more so by the use of very dilute caustic soda; by the aid of which also the deepest perpendicular epithelial cells are rendered readily visible. The papillæ may be studied in macerated portions, or if it be only required to ascertain their position and form, in perpendicular or horizontal sections, treated with concentrated caustic potass, on which the epithelium is dissolved. The lingual papillæ may be treated in the same manner; the epithelium upon which, especially on the *filiiformes*, moreover, is often entirely absent. The nerves of all these parts are best seen under the use of dilute caustic soda; acetic acid is also frequently of service. The muscular substance of the tongue must be examined by minute dissection, a method which may be carried very far, especially in tongues which are half macerated from having long lain in spirit. Recent tongues are also of use, but are by no means so good, and it is usually necessary to boil them until they are quite soft; and to procure sections for the microscope the tongue may be dried or hardened by boiling, or by strong alcohol. In all three methods caustic soda is of great service in clearing up the tissue, although it undoubtedly attacks the muscular fibres a little. Perpendicular and longitudinal sections in various directions are to be recommended, especially in the glandular region. With respect to the glands, the most important points have been already stated.]

*Literature.*—W. Bowman, Art. 'Mucous Membrane,' in Todd's 'Cyclopædia of Anatomy,' April, 1842; E. H. Weber, 'Ueber die Schleimbälge und zusammengesetzten Drüsen der Zunge und über den Bau der Parotis,' in Meckel's 'Archiv,' 1827, pp. 276-280; A. Sebastian, 'Recherches anatomiques, physiologiques et pathologiques sur les glandes labiales,' Groningue, 1842; Nuhn, 'Ueber eine bis jetzt nicht näher beschriebene Drüse im Innern der Zungenspitze,' Mannheim, 1845; N. Ward, Art. 'Salivary Glands,' in Todd's 'Cyc. of Anat.,' Sept. 1848, part xxxiii, p. 421; C. Rahn, 'Einiges über die Speichelsecretion,' Zürich, 1850; C. Ludwig, 'Neue Versuche

über die Beihülfe der Nerven zur Speichelsecretion,' in 'Mitth. der Zürich. nat. Ges.,' 1850, Nos. 53 and 54, and 'Zeitschr. f. rat. Med.,' 1851; C. J. Baur, 'Ueber den Bau der Zunge,' in Meckel's 'Archiv,' 1822, p. 350; P. N. Gerdy, 'De la Structure de la Langue,' in 'Recherches d'Anatomie, de Physiologie, et de Pathologie,' Paris, 1823; P. F. Blandin 'Sur la structure de la Langue,' in the 'Archiv. génér. de Médecine,' 1823; J. Zaglas on the 'Muscular Structure of the Tongue of Man and certain Mammalia,' in the 'Annals of Anatomy and Physiology,' ed. by J. Goodsir, 1850, I, p. 1; H. Hyde Salter, Art. 'Tongue,' in Todd's 'Cycl. of Anat.,' iv, June and Sept., 1850; C. B. Brühl, 'Ueber den Bau der Zunge der Haussäugethiere,' in 'Kleine Beiträge zur Anatomie d. Haussäugethiere,' Wien 1850, pp. 1-6; Sappey, 'Ueber die Lymphgefäße der Zunge,' in 'Comptes rendus,' 1847, p. 26; and 'Froriep's Notizen,' 1848, vi, p. 88. Besides these, compare the anatomical works of E. H. Weber, Valentin (im Handw. d. Phys.), Todd and Bowman, Henle, Arnold, Huschke, Krause, and myself; the figures of Berres, Arnold, and Langenbeck.

## D. OF THE TEETH.

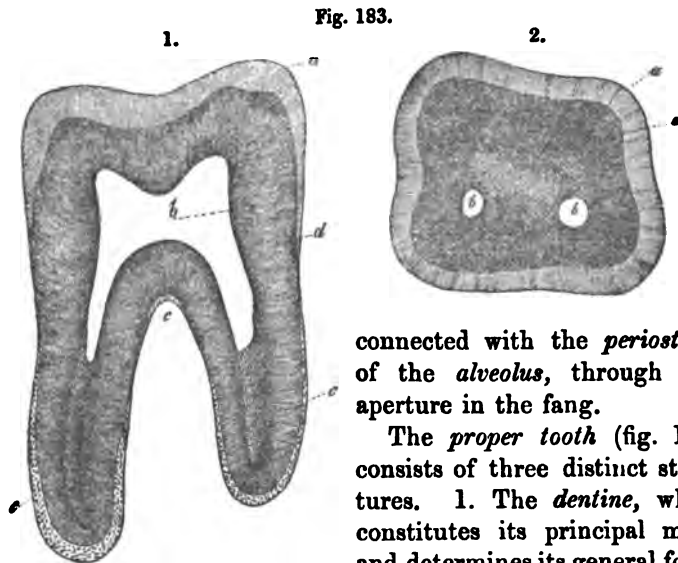
## § 187.

The *teeth* are hard organs inserted into the alveolar processes of the jaws, which although to some extent identical in structure with bone, and in other respects clearly allied to it, must, from their development, be regarded as modifications of the mucous membrane.

In every tooth we must distinguish *the tooth proper*, and the *soft structures*; the former consists of a free part, the *crown*, and of an imbedded portion, the simple or multiple *fangs*, whose special forms are treated of in anatomical works; they contain internally a small cavity, the *pulp cavity*, which extends through each fang as an elongated canal, opening at its point by a simple, or more rarely double (Havers, Raschkow), fine aperture.

Among the soft parts we may enumerate first, the *gum*, *gingiva*, a dense mass formed by the union of the mucous membrane and of the periosteum of the jaw, which surrounds

the lower half of the crown or the *neck* of the tooth. Secondly, the *periosteum of the alveolus*, which unites the tooth very closely with the alveolus. Finally, the *pulp*, a soft, vascular and nervous mass, which occupies the cavity of the tooth, and is



connected with the *periosteum* of the *alveolus*, through the aperture in the fang.

The *proper tooth* (fig. 183) consists of three distinct structures. 1. The *dentine*, which constitutes its principal mass, and determines its general form.

2. The *enamel*, which forms a tolerably thick investment to the crown; and 3. The *cement*, which covers the fang externally.

#### § 138.

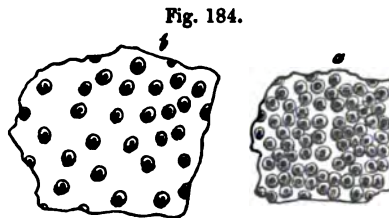
The *dentine* or ivory, (fig. 183, *d*) is yellowish-white and translucent or transparent, in thin sections of a recent tooth; when dry it has a silky or satiny aspect, in consequence of the reception of air into a special system of canals. It is considerably harder and more brittle than either the cement or bone, but, on the other hand, yields in these qualities to the enamel. With the exception of a very small spot in the root, the dentine forms the sole boundary of the pulp cavity, and in an uninjured tooth it is never exposed, inasmuch as it is covered,

Fig. 183. Molar tooth (human),  $\times$  about 5: 1, longitudinal; 2, transverse section: *a*, enamel; *b*, pulp cavity; *c*, cement; *d*, dentine, with its canals.

even upon the neck of the tooth, by a thin layer of enamel, and when this ceases by cement.

The dentine consists of a *matrix* and of a multitude of canals which traverse it, the *dentinal tubules or canals*. In the recent tooth, the former is, even in the finest sections, quite homogeneous, without the slightest trace of cells, fibres, or other elements. After the extraction of the calcareous salts from the dentine, it exhibits, however, a great tendency to tear up into coarse fibres, parallel to the dentinal canals; from these, finer fibres of 0·002—0·003''' may be detached, their irregular form, however, shows them to be artificial products, and in fact they owe their existence simply to the circumstance, that the dentinal canals run close together and parallel to one another through the dentine. The matrix exists in all parts of the dentine, but not everywhere to the same amount. In general there is less of it in the crown than in the root, and in the neighbourhood of the pulp cavity than in that of the enamel and cement.

The *dentinal canals* (fig. 184, 187) are microscopic tubules of 0·0006—0·001''' (in the root some reach 0·002'''), which commence by open mouths upon the wall of the pulp cavity, and traverse the whole thickness of the dentine to the cement and enamel. Each canal has a special wall, rather less in thickness than its diameter, which can only be observed in transverse sections, (and then not always), as a narrow, yellowish ring surrounding the cavity; in longitudinal sections, on the other hand, it is almost entirely invisible. During life the canals contain a clear fluid and they cannot therefore readily be detected in recent preparations; it is different in dry sections, when they become filled with air, and appear separately as black lines by transmitted light, and by reflected, as silvery threads. On account of the immense numbers of the dentinal canals, so great in some situations that their walls are almost in contact,



are almost entirely invisible. During life the canals contain a clear fluid and they cannot therefore readily be detected in recent preparations; it is different in dry sections, when they become filled with air, and appear separately as black lines by transmitted light, and by reflected, as silvery threads. On account of the immense numbers of the dentinal canals, so great in some situations that their walls are almost in contact,

Fig. 184. Transverse section of dentinal canals as they are commonly seen,  $\times 450$ : *a*, canals very close together; *b*, more dispersed.



dry sections appear milk-white, and if not very thin, are quite unfit for microscopic investigation, unless the air has been previously expelled from the canals by any clear and not viscid fluid.

Fig. 185.


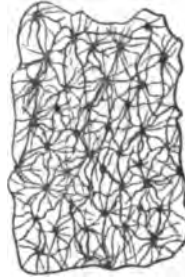


Fig. 186.



The dentinal canals present certain constant peculiarities in their *course* which may be best gathered from figs. 185 and 187; it is not straight but *wavy*, and in addition, they present numerous *ramifications* and *anastomoses*. Each canal describes, in general, two or three large *curvatures*, and a very great number (as many as 200 in 1"', according to Retzius) of *small curvatures*, which are sometimes more or less strongly marked and occasionally have even the appearance of actual

Fig. 185. Dentinal tubules from the root,  $\times 350$ : *a*, internal surface of the dentine, with scattered canals; *b*, their divisions; *c*, terminations with loops; *d*, granular layer, consisting of small dentinal globules at the boundary of the dentine; *e*, bone *lacuna*, one anastomosing with dentinal canals. From Man.

Fig. 186. Transverse section through the dentinal canals of the root, *a*, in order to exhibit their excessively numerous anastomoses,  $\times 350$ . From Man.

zigzags, or spiral windings. The *ramifications* of the canals (figs. 185 and 186), appear in the first place as *divisions*, and then as true *ramifications*; the former are very frequently to be met with close to the origin of the tubules from the pulp cavity and are almost always bifurcations, of such a kind that one canal divides at an acute angle into two of almost the original diameter. These divisions may be repeated 2—5 times altogether, and even still oftener, so that at last, 4—8—16, and even more canals, proceed from a single one. The canals, already somewhat narrowed after division, then run close together and tolerably parallel, towards the surface of the dentine, and excepting in the root, branch again only in its outer half or third; the ramifications appearing, in the root, as fine twigs given off from the principal canal, while in the crown, they more resemble dichotomous divisions. In the latter case, they are for the most part rare, in the former, it is otherwise; the branches, which are usually close together and given off at right or acute angles from the trunk canal, having sometimes the appearance of a feather, sometimes that of a brush, the latter being most common when the twigs are large and undergo further branchings. According to their more or less frequent ramification, are the *ends* of the dentinal canals more or less fine; frequently appearing merely as excessively fine, pale lines, like fibrils of connective tissue, and finally disappear. When they are distinct, they either become lost upon the surface of the dentine in a granular layer, which we shall have to consider presently, or they enter the innermost portions of the enamel and cement, or finally, they are connected in pairs by loops in the dentine (*terminal loops of the dentinal canals*). The *branches* of the principal canals are, almost always, very fine and usually simple, though sometimes ramified; they serve, as may be best seen in the root, where they are excessively numerous, to connect neighbouring or even distant canals; such anastomoses having either the form of simple, transverse canals or of loops. The ultimate branches present the same relations as the forked or simple terminations of the principal canals, and end either free or by loops, in the dentine, or are continued beyond it.

The chemical composition of dried dentine is, according to Von Bibra:

|   | <i>Molar of a<br/>Woman of 25.</i> | <i>Molar of a<br/>Man.</i> | <i>Incisor of the<br/>same Man.</i> |
|---|------------------------------------|----------------------------|-------------------------------------|
| Phosphate of lime, with some fluoride of<br>calcium . . . . . | 67.54                              | 66.72                      |                                     |
| Carbonate of lime . . . . .                                   | 7.97                               | 3.36                       |                                     |
| Phosphate of magnesia . . . . .                               | 2.49                               | 1.08                       |                                     |
| Salts . . . . .   | 1.00                               | 0.83                       |                                     |
| Cartilage . . . . .   | 20.42                              | 27.61                      |                                     |
| Fat . . . . .   | 0.58                               | 0.40                       |                                     |
|   | <hr/>                              | <hr/>                      |                                     |
|   | 100.00                             | 100.00                     |                                     |
|   | <hr/>                              | <hr/>                      |                                     |
| Organic substance . . . . .                                   | 21.00                              | 28.01                      | 28.70                               |
| Inorganic substance . . . . .                                 | 79.00                              | 71.99                      | 71.30                               |

In fresh teeth, Pepys found 28 p. c. cartilage, 62 inorganic matter, 10 water and loss; and according to Tomes, teeth, after the pulp is removed, lose in drying  $\frac{1}{8}$ — $\frac{1}{17}$  of their weight. The organic basis of the teeth, which may readily be obtained by treating them with hydrochloric acid, is identical in all respects with that of the bones and is readily changed into gelatin by boiling. This so-called cartilage of the tooth retains the exact form of the dentine and its external structure also; the tubules, however, are seen with difficulty. If it be macerated in acids or alkalies until quite soft, the matrix undergoes incipient solution, *but the dentinal tubules, with their walls, offer greater resistance, and may be readily and abundantly isolated*, (see 'Mikr. Anat.' ii, 2, p. 61, fig. 189). By still longer maceration, all is dissolved. If teeth be heated to redness, or treated with caustic alkalies, the inorganic portions likewise retain the form of the tooth. It follows, then, that the same intimate mixture of inorganic and organic parts occurs in the teeth, as in the bones, with which they so closely agree in their chemical composition.

[The apparent *walls* of the dentinal tubuli, which are commonly visible in transverse sections (fig. 184), are not the actual walls of the canals, but rings, which result from our invariably viewing a certain length of the canals in the always more or less thick sections, their undulated course giving the walls a greater apparent thickness than they really possess. If in any transverse section the apertures of the canals be exactly brought into focus, we perceive, instead of the dark ring, only a

very narrow yellowish border, which is what I consider to be the actual wall. That such is the case, appears from the examination of transverse and oblique sections of canals filled with fluid, in which short, yellow tubules and small rings of almost the same diameter as that of the cavities of the canals, may be clearly recognised.

The *dentine* occasionally presents indications of lamination in the form of arched lines running more or less parallel and at different distances, often quite close together (fig. 187); which in transverse sections appear as rings, and are especially distinct in the crown. These, the *contour lines* of Owen,<sup>1</sup> are not the same with the glistening, indistinctly defined *stræ* observed by Schreger, which run exactly parallel to the pulp cavity, and arise from the primary curvatures of the dentinal canals, and which are the expression of the laminar mode of deposit of the dentine. In animals they are at times singularly beautiful, especially in the Cetacea and Pachydermata (Zeuglodon, Dugong, Elephant), and also in the Walrus. Here as well as in fossil teeth we very frequently observe a breaking up of the dentine into

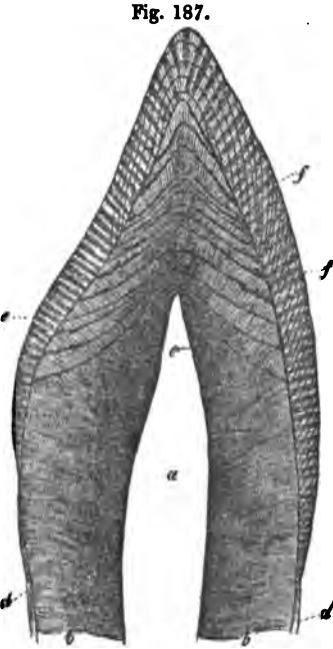


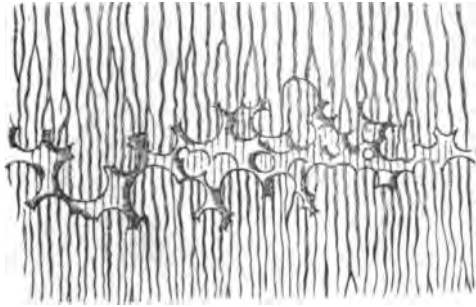
Fig. 187. Perpendicular section of the apex of an incisor tooth (human),  $\times 7$ : *a*, pulp cavity; *b*, dentine; *c*, arched contour lines, with interglobular spaces; *d*, cement; *e*, enamel, the various directions of the fibres being indicated; *ff*, lines of colour of the enamel.

<sup>1</sup> [This is not exactly correct. The term "contour lines," as used by Professor Owen ('Report of British Association' for 1838, p. 135, and 'Odontography,' pp. 460, 464, 641) includes both descriptions of markings mentioned in the text, but is more especially employed for Schreger's. The ordinary contour lines, in fact, are stated by Professor Owen to proceed from "a short bend" of the tubuli "parallel with the outer contour of the crown;" from these, the Professor distinguishes the "strong contour lines," in the ivory of the elephant's tusk, as being produced by "strata of extremely minute opaque cellulae." It should be observed, however, that Retzius had

lamellæ (Owen), indications of which may be found also in fresh human teeth and in the dental cartilage.

Upon the crown, the dentinal canals not unfrequently pass for some distance into the enamel, and expand here and there, into larger cavities (fig. 191), which should perhaps rather be regarded as pathological. Similar not quite normal formations are the *interglobular spaces* in the dentine itself (fig. 188).

Fig. 188.



Czermak has conferred this name upon certain very irregular cavities, bounded by globular processes of the dentine, which are, it may be said, never entirely absent in the teeth. In the crown they are found most frequently in the neigh-

bourhood of the enamel, and often form a thin curved layer, extending along its whole inner surface, which, upon close examination, is seen to be composed of a multitude of thin layers, receiving the ends of the contour lines (fig. 187). They also occur, however, more internally, but always in longitudinal sections, in lines which correspond with the contour lines. The spaces are sometimes very wide, intersecting or interrupting in their course many dentinal canals; sometimes they are very small, so that only a few canals are touched by them. In the former case, their limits are formed by distinct globular projections of 0.002—0.012" and more, which are pierced by dentinal

Fig. 188. A morsel of dentine with dentinal globules and interglobular spaces filled with air between them,  $\times 350$ .

---

long before drawn attention to these peculiar striæ. In his admirable memoir, published in Müller's Archiv, for 1837, he says, p. 507, "In the incisor teeth of the horse, also, many less transparent striæ running parallel with the *cavitas pulpæ* may be seen, like the annual rings in the trunk of a tree. They proceeded in this case, however, not merely from certain parallel flexures of the tubes, but especially from similar calcareous cells, which had accumulated in one zone for the greatest part of the length of the tooth. Tab. xxii, fig. 3." See also his explanation of the zones in the Elephant's tooth, at pp. 510-11.—Eds.]

canals, and have precisely the same aspect as the dentine, of which they are obviously nothing but portions; whilst in the latter, such *dentinal globules*, as I will term them, are not always distinct. This is especially true of the smallest spaces, which, on account of their notched form, and their communications with dentinal canals, might be taken for osseous *lacunæ*, and indeed have been so regarded; yet, at least in the crown, it is almost always easy to recognise their identity with the larger spaces. Greater difficulty is met with upon the fang, where small interglobular spaces and globules form a zone, (the *granular layer* of Tomes) which often appears like a layer of small osseous lacunæ or of simple granules. I have but rarely observed actual *lacunæ* in normal dentine; they were, when present, invariably situated at the boundary of the cement (fig. 185); on the other hand, interglobular spaces and dentinal globules are to be met with in the interior of the dentine of the root, and with especial distinctness on the walls of the pulp cavity, in which latter locality the globules often give rise to irregularities visible to the naked eye, or even to a botryoidal appearance. The interglobular spaces whose presence is normal in developing teeth, contain during life, not fluid, as might at first sight be expected, but a soft substance resembling tooth cartilage and possessing a canaliculated structure, like the dentine itself. It is remarkable that this substance offers a greater resistance to long maceration in hydrochloric acid than the matrix of the actually ossified tooth and therefore, like the dentinal canals, it may be completely isolated. In sections, this *interglobular substance* usually dries up in such a manner that a cavity is produced, into which air penetrates; it is properly only in reference to these, that interglobular spaces can be spoken of. Many teeth, indeed, exhibit no interglobular substance, but they occasionally present the outlines of dentinal globules, in the form of delicate arched lines.

Dentine containing Haversian canals, the so called '*vaso-dentine*' of Owen, which exists in many animals, is rarely found in man, and I am only acquainted with one case, observed by Tomes, (l. c., p. 225), in which the vascular canals were numerous; on the other hand, in the dentine, with irregular tubuli which is formed in obliteration of the pulp cavity, we occasionally meet with scattered Haversian canals and rounded

---

cavities, like osseous lacunæ, constituting the so-called *osteodentine* of Owen.<sup>1</sup>

<sup>1</sup> [Considerable discrepancies will be met with if we compare the various statements of authors who have described the ultimate structure of the dentine.

1. According to Retzius, the dentine contains *cells*, but these cells, in his view, are *cavities* analogous to bone *lacunæ*, in which the dentinal canals terminate.

2. Mr. Nasmyth took a totally different view from this. The matrix, or as he calls it, "interfibrinous substance of the dentine," is, he says, composed entirely of cells; but these cells are solid bodies, lie between, and form the boundaries of the canals. His "cells" and those of Retzius had exactly as much, or as little relation to one another, as the "osteal cells" of Tomes and De Morgan (to which we have referred in the note to § 107, p. 377, vol. I), have to osseous lacunæ.

3. Professor Owen likewise affirms, that the dentine is made up of "cells,"—his "dentinal cells,"—which, however, can hardly be identical with Czermak's "dentine globules" as stated in the text. We find it, in fact, somewhat difficult to understand what these "dentinal cells" are, inasmuch as we are unable to reconcile the various definitions of their nature which may be found in the 'Odontography.'; { In the first place, at p. 462, it is stated, in a note, that "the true dentinal or calcigerous cells include many tubes and intertubular spaces, and it is much more exact to say, that those cells contain a tubular structure, than that the interstitial space is cellular." In perfect accordance with this, we find, on referring to plate 123, fig. 1, which represents a section of human dentine, that the "dentinal cells" which are marked *d'd'*, are traversed by from seven to eleven dentinal tubules.

But at p. 463, the passage in which reference is made to this figure, runs thus: "the dentinal cells of the human tooth are subcircular, about  $\frac{1}{3000}$ th of an inch in diameter. They seem most numerous from being most conspicuous near the periphery of the dentine, as originally described by me in the dentine of the Crocodile.

And in the Introduction, p. xlv, we find: "The diameter of the dentinal or calcified primary cells of the pulp, is usually one fourth or one half larger than that of the blood discs manifest in them."

Now, how is it possible, that a body  $\frac{1}{3000}$ th of an inch in diameter, can have passing through it seven tubules, each of which is  $\frac{1}{70,000}$ th of an inch in diameter? To say nothing of the circumstance, that these tubules are at the very least  $\frac{1}{70,000}$ th of an inch apart. Halve the actual diameter of the tubules and arrange them close together, and they will barely squeeze into  $\frac{1}{3000}$ th of an inch. We conclude, therefore, as the definitions and the figures of these dentinal cells are at variance, that we are not justified in making any definite statement about them.

4. Mr. Tomes asserts in his lectures, that the "intertubular tissue is itself made up of minute granules closely united," which pass into those of his "granular layer;" an opinion which seems to us to be most nearly in accordance with fact. We may observe, that the dentine globules and interglobular spaces of Czermak, had been previously very carefully figured and described by Mr. Tomes, in his lectures, p. 45.

5. The views of Czermak are stated in the text. Mr. James A. Salter (On certain Appearances occurring in the Dentine, dependent on its mode of Calcification, 'Quarterly Journ. of Mic. Science,' vol. I, p. 252, 1853,) has confirmed Czermak's results, and has added some very interesting observations of his own. He considers that the contour lines, which he prefers to call "contour markings," may arise from various

## § 139.

The *Enamel, substantia vitrea*, forms a continuous layer investing the crown of the tooth; it is thickest upon the masticating surface, and gradually diminishes towards the roots until at last it terminates by a sharply defined or sometimes, slightly-notched, border, ceasing sooner upon the contiguous surfaces of the crowns, than upon their inner and outer sides. The external surface of the enamel appears smooth, but is always marked by delicate, close, transverse ridges, among which more marked circular elevations may occur.<sup>1</sup> A delicate membrane, discovered by Nasmyth, and which I will denominate the *cuticle of the enamel*, [*Nasmyth's membrane*, Eds.]<sup>2</sup> entirely

causes, not only from those pointed out by Czermak—curvings and local enlargements of the canals and interlobular spaces, but also from a difference in density without alteration of structure; and he states as a general law, that the curves of the contour markings are in proportion to the primary curves of the dentinal tubes at any particular spot, and cross them at right angles. No markings are more divergent than the outline of the tooth, and passing from within outward, they abut in succession upon the external surface of the dentine, under the enamel and *crusta petrosa*, in the form of granular patches. The outer extremities of these patches look like white rings on the surface of the tooth. They are composed of coarse globular dentine, and gradually thin out internally into mere streaks. When a tooth is macerated in acid, it may be broken up into cones (triangles in section), as Dr. Sharpey first indicated, formed by the normal dentine between the contour markings. In transverse sections, the cones become, of course, rings. Finally, Mr. Salter points out that the enamel is almost always imperfect opposite the "patches" at the outer ends of the contour lines.—Eds.]

<sup>1</sup> [Czermak (l. c. pp. 4, 5) states that the fine regular annular ridges and furrows upon the surface of the enamel, characterise the permanent teeth, and are not present upon the enamel of the milk set. The ridges are closest at the margin of the crown, and most distant towards its centre, where they finally disappear. In the space of a line, there were, at the margin of the enamel, 84—72 ridges; more internally, 36—30; and where they began to be indistinct, only 18—12.—Eds.]

<sup>2</sup> [We have ventured to substitute the name "Nasmyth's membrane," for that of the "cuticle of the enamel," used by Professor Kölliker, inasmuch as the latter term gives a false idea of the relations of this important structure, which is much more than a mere "cuticle of the enamel," and is in fact, as one of us has already shown, (Huxley, On the Development of the Teeth, 'Quarterly Journal of Mic. Science,' vol. I, p. 149, 1853), the *calcified membrana preformativa* of the whole pulp.

This structure was first described, in its true relation to the dental tissues, by Mr. Nasmyth, in a memoir read before the Medical and Chirurgical Society, in January, 1839, and which, illustrated with very good figures, was published in the twenty-second volume of the Society's Transactions (p. 310—328). Mr. Nasmyth states, that his



covers, but is so closely united with, the enamel, that it can be demonstrated only by the use of hydrochloric acid. According to Berzelius and Retzius,<sup>1</sup> a similar membrane exists between the internal usually irregular surface of the enamel, and the dentine, but I have been unable to find it. The enamel is bluish, trans-

attention had been drawn to fragments of a membrane which he found floating in the acid in which teeth had been macerated; "after a minute and careful examination, however, I was able to demonstrate with the greatest certainty, that they were derived from the external surface of the enamel, and that they were continuous with the structure covering the fang, which latter is itself continued into the chamber of the tooth. I afterwards succeeded in tracing this covering on the whole surface of the enamel and fang of the tooth in one continuous envelope; and eventually, I was enabled to remove it from the crown of the tooth in the form of a distinct coat or capsule; this covering, which I proved to exist externally to the enamel, I have termed 'the persistent dental capsule,' p. 312.

"In all cases where this covering has been removed by means of acid, it has, of course, the appearance of a simple membrane, in consequence of the earthy deposits having been dissolved, and of there being only present the animal tissue. The structure and appearance of the covering detached in this manner from the enamel, are the same in every respect as those observed in the capsule of the unextruded tooth; consisting, like it, of two layers, fibrous externally, and having on its internal surface the peculiar reticulated appearance common to both, and shown at Plate V, fig. 6," p. 313.

"On examining carefully fine sections of several teeth under the microscope, I perceived here also, that the structure in question was continuous with the *crusta petrosa* of the fang of the tooth," p. 313.

Mr. Nasmyth does not distinguish quite clearly in the text, between the proper capsular membrane on the fang and the *crusta petrosa* itself, though his figures (Pl. 5, figs. 4, 5.) exhibit the two structures as sufficiently distinct, and he hesitates, at p. 316, to decide what relation the outer layer of pale yellowish or brown substance in the cement of the teeth of the Elk, Ox, Bradypus, &c., may have to the "persistent capsule."

We have not retained Mr. Nasmyth's own term for his discovery, because, as one of us has endeavoured to show, (Huxley, l. c.) while he accurately described its *relations* to the other dental tissues, he mistook its true nature. (See Appendix, § 8, on the Development of the Teeth.) But, on the other hand, as no one has, before or since, distinctly described his "persistent capsule," we have thought it desirable, that his name should be associated with the structure.—Eds.]

<sup>1</sup> [Berzelius and Retzius obviously saw Nasmyth's membrane (Retzius, in Müll. Archiv, 1837, pp. 53-54). The latter says, that on macerating a large piece of enamel from the fossil tooth of a horse (dug out of a peat-moss) in dilute acid, he found after the enamel was dissolved, a membrane swimming in the fluid, "I examined it immediately under a considerable magnifying power; it appeared to be pierced by a multitude of closely arranged little holes, but exhibited no trace of fibres." But he states expressly, that this membrane was "internal to the enamel fibres, as Berzelius clearly points out," and therefore failed to recognise its true relations with the enamel.—Eds.]

parent in thin sections and much more brittle and harder than the other dental structures, so that it is hardly touched by the knife, and yields sparks with steel (Nasmyth). Chemically, it may be regarded as osseous substance, containing the smallest possible proportion of organic matter; but whether the latter belong to the class of collagenous substances or not is uncertain. According to Von Bibra, the enamel contains:

|   | <i>From a Molar of a<br/>Woman 25 years of age.</i> | <i>From a Molar of<br/>an adult Man.</i> |
|---|---|--|
| Phosphate of lime, with some fluoride<br>of calcium . . . . . | 81.63   | 89.82                                    |
| Carbonate of lime . . . . .                                   | 8.88  | 4.37                                     |
| Phosphate of Magnesia . . . . .                               | 2.55  | 1.34                                     |
| Salts . . . . .   | 0.97  | 0.88                                     |
| Cartilage . . . . .   | 5.97  | 3.39                                     |
| Fat . . . . .   | a trace   | 0.20                                     |
|   | <hr/> 100.00  | <hr/> 100.00                             |
| Organic matters . . . . .                                     | 5.97  | 3.59                                     |
| Inorganic matters . . . . .                                   | 94.03   | 96.51                                    |

The enamel, as its fibrous structure indicates, consists entirely of the so-called *prisms or fibres of the enamel*, (fig. 189); long, solid prisms of 0.0015—0.0022" breadth, irregular in shape, but commonly hexagonal or pentagonal, which usually occupy the whole thickness of the enamel, resting with one extremity upon the dentine, and with the other upon Nasmyth's membrane. In adult teeth, these elements may be very readily detected in transverse and longitudinal sections, but can hardly be isolated for any great length; it is otherwise in young or developing teeth, where the enamel is much softer and may be cut with a knife. In such isolated prisms, whose broken ends may by accident appear pointed, whence they have been called "enamel needles," the surfaces and edges may be very well seen. We may also very frequently observe upon them, particularly after the addition of dilute hydrochloric acid, more or less distinct transverse striæ 0.0014—0.002"

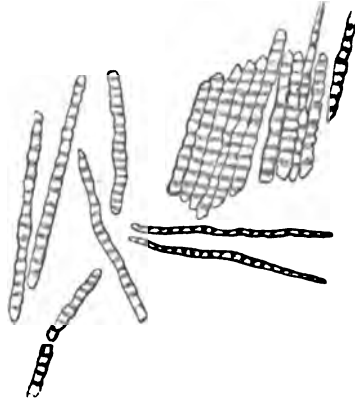
Fig. 189.



Fig. 189. Surface of the enamel, with the ends of the enamel prisms,  $\times 350$ . From the Calf.

apart, which arise from slight varicosities, and give the fibres a certain resemblance to muscular bundles, or rather

Fig. 190.



colossal muscular fibrils. They certainly do not indicate a cellular composition. If the action of the hydrochloric acid be allowed to go on, the fibres soon become quite pale, the transverse striation disappears, and nothing remains but a delicate framework corresponding with the previously solid fibres, and which often presents certain appearances of tubes. In the end this also becomes almost completely destroyed

by the action of the acid, so that in teeth which have been thus macerated hardly anything remains of the enamel, which does not, like the dentine, retain its form.

The prisms of the enamel are *united* very intricately without any intermediate substance. I have not been able to convince myself that canals constantly exist between the prisms,<sup>1</sup> but it is certain that cavities of various kinds may be not unfrequently found in the enamel. Such, for instance, are—1. The continuations of the dentinal canals into the enamel, to which reference has been made above, with the elongated cavities at the border of the dentine which arise from their expansion (fig. 191, c); and 2. The cleft-like gaps in the middle and external portions of the enamel (fig. 191), which are not in communication with the preceding, are never entirely absent in any enamel, and often occur in very great numbers, as narrower or wider spaces which, however, never contain air.

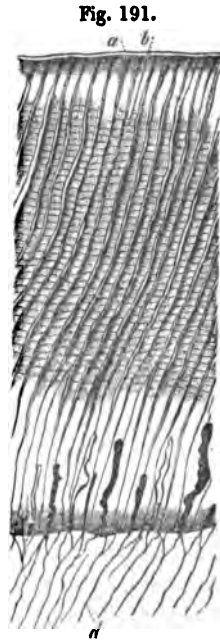
Fig. 190. Enamel prisms isolated, after the slight action of hydrochloric acid,  $\times 350$ . From Man.

<sup>1</sup> [With respect to this point, opinions differ; Todd and Bowman consider that canals normally exist between the enamel prisms. Tomes finds canals in the enamel prisms of young animals, and sometimes in a part or the whole length of them in old teeth. Kölliker (Mikr. Anat. 77) has not yet observed any such cases. Czermak (l.c. p. 13) believes that, in a few cases, he has observed "very numerous delicate enamel tubules arranged in close series."—Eds.]

The general *course* of the prisms of the enamel resembles that of the dentinal canals of the crown of the tooth, but extensive flexures are only to be met with towards the masticating surface. Most of the prisms extend through the whole thickness of the enamel, but this is not the case with all. They also decussate in a peculiar manner; thus, in some transverse sections, we observe annular layers of prisms, 0.08—0.12'' thick, extending from the dentine to the surface of the enamel, and corresponding with fine circular lines upon its exterior; in each layer, all the prisms take a similar direction, which is different from that of the prisms of the contiguous layers, so that perpendicular sections of such enamel, especially when moistened with hydrochloric acid, have a very singular striated appearance, arising from the dark transverse, and clear longitudinal sections of the prisms being alternately presented to the eye.

A similar decussation of the prisms occurs constantly at the masticating surface, and here the layers of enamel take a generally annular arrangement, so that they describe circles, in the molars, and ellipses in the incisor teeth; however, towards the centre of the masticating surface, irregularities occur which we are not yet in a condition to explain. Care must be taken not to confound the colourless *striae* which indicate these peculiar arrangements of the enamel fibres, with certain *brownish lines* or *coloured streaks* which cross the prisms in various directions and in perpendicular sections, appear like oblique ascending lines or arches (fig. 187); in transverse sections, like circles in the external layers of enamel, rarely extending through its whole thickness. These I regard as the expression of the lamellated development of the enamel.

Fig. 191. Dentine and enamel,  $\times 350$ ; Man: *a*, cuticle of the enamel (Nasmyth's membrane); *b*, enamel prisms with transverse markings and interposed clefts; *c*, larger cavities in the enamel; *d*, dentine.



*Nasmyth's membrane* is a calcified, structureless membrane, 0·0004—0·0008" thick, distinguished by the great resistance it offers to chemical re-agents, and its consequent appropriateness as a defence for the crown of the tooth. It is not altered by maceration in water, and is not dissolved by boiling in water, concentrated acetic acid, hydrochloric acid, sulphuric acid, and nitric acid; the latter only renders it yellow. In caustic alkalies it remains unchanged. Boiled with caustic potass and soda, it becomes white and somewhat disintegrated, but still forms a connected mass; the potass is rendered slightly turbid by the addition of hydrochloric acid, but clears with an excess. The membrane burns with an ammoniacal odour, and yields a calcareous spongy coal.

§. 140.

The *Cement, substantia ostoidea, cementum* (fig. 185), is a cortical layer of true osseous tissue, which covers the fangs, and in the many-fanged teeth, not uncommonly unites them all together. It commences where the enamel ceases, as a very thin layer, either simply abutting upon, or slightly overlapping it, increases in thickness lower down, and finally attains its *maximum* at the ends of the fangs, and on the alveolar surface of the molar teeth between the fangs. Its internal surface is, in man, very intimately united with the dentine, but without any connecting substance, so that frequently, at least under high powers, the limit of the two structures is not altogether sharply defined. The external surface is very closely surrounded by the periosteum of the alveolar cavity, but is not so firmly united with the gum; after the removal of these soft parts it is usually irregular, and is frequently marked with annular striations. The cement is the least hard of the three dental tissues, and is, chemically, almost identical with bone. Von Bibra found:

|                             | <i>In Man.</i> | <i>In the Ox.</i> |
|-----------------------------|----------------|-------------------|
| Organic matters . . . . .   | 29·42          | 32·24             |
| Inorganic matters . . . . . | 70·58          | 67·76             |
|                             | <hr/> 100·00   | <hr/> 100·00      |

The latter, thus composed .

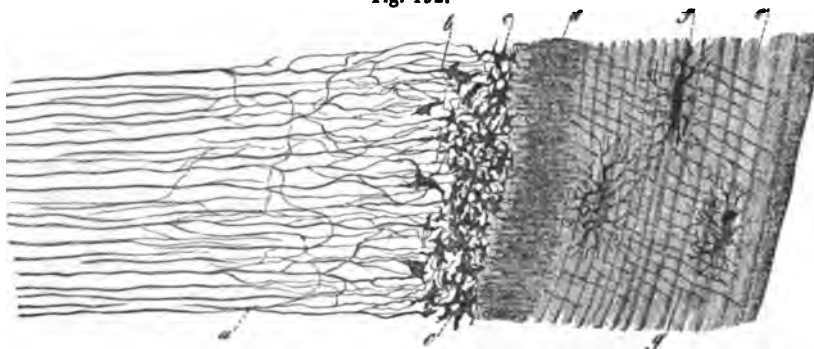
|   |        |
|---|--------|
| Phosphate of lime and fluoride of calcium . . . . . | 58.73  |
| Carbonate of lime . . . . .                         | 7.22   |
| Phosphate of magnesia . . . . .                     | 0.99   |
| Salts . . . . .                                     | 0.82   |
| Cartilage . . . . .                                 | 31.31  |
| Fat . . . . .                                       | 0.93   |
|   | <hr/>  |
|   | 100.00 |

The earthy salts are readily extracted from the cement by acids, a white cartilage remaining, which may easily be separated from the dentine, and usually, when boiled, yields gelatin.

Like bone, the cement consists of *matrix* and of *lacunæ*, but rarely contains Haversian canals and vessels. Besides these, peculiar canals analogous to those of the dentine are found, and other more abnormal cavities.

The *matrix* is sometimes granular, sometimes transversely striated, sometimes amorphous, and frequently laminated

Fig. 192.

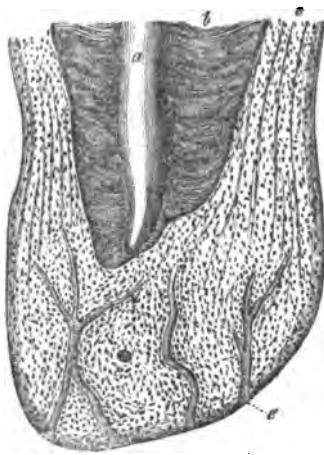


like bone. The *lacunæ* resemble in all essential characters those of the bones, so that any detailed description may be dispensed with. They are distinguished only by the great variety which they present in number, form, and size (0.005—0.02'', even to 0.03''), and the unusual number and length (as much as 0.03'') of their *canaliculi*. The majority are oval.

Fig. 192. Dentine and cement from the middle of the fang of an incisor tooth: *a*, dentinal canals; *b*, interglobular spaces, having the appearance of osseous *lacunæ*; *c*, smaller interglobular spaces; *d*, commencement of the cement, with many canals close together; *e*, its *lamellæ*; *f*, *lacunæ*; *g*, canals;  $\times$  350. From Man.

and lie parallel to the axis of the tooth, others are rounded and pyriform. Those are most remarkable which have a very elongated form, together with a narrow, canal-like cavity (fig. 185), inasmuch as their resemblance to the dentinal canals is unmistakable. The *canaliculi* often resemble feathers and brushes, and unless the *lacunæ* are altogether isolated, connect them with one another, and anastomose with the ends of the dentinal canals. In the thinnest part of the cement, towards the crown, the *lacunæ* are invariably absent; they are first met with, as a rule, about the middle of the fang, but are here scattered and solitary; towards the extremity their number gradually increases, and they not unfrequently take on a very regular arrangement, as in the external layer of the long bones, lying in series in the layers of the cement, and sending most of their canaliculi inwards and outwards, so as to give rise to an even, fine, transverse striation of the cement. The thicker layers of cement which occur in old teeth, present immense quantities of *lacunæ*, but these are to a great extent irregular, and have mostly the elongated form. Many *lacunæ* are bordered,

Fig. 193.



singly or in groups, by a very distinct, clear, yellowish, slightly undulated margin, which partially or entirely surrounds them; it has perhaps some relation to the cells from which the cavities are developed.

*Haversian canals* do not occur in young teeth, where the cement has only its normal thickness; but they are very common in old teeth, especially molars, and in *hyperostoses* one, three, or more enter the cement from without, branch out two or three times, and then terminate in blind extremities. Their diameter is too small (0.005—0.01") to contain medulla as well as blood-vessels, and they are commonly like those of the bones, surrounded by a few connective *lamellæ*.

Fig. 193. Cement and dentine of the root of an old tooth: *a*, pulp cavity; *b*, dentine; *c*, cement, with *lacunæ*; *e*, Haversian canals. From Man.

Besides these vacuities, the cement occasionally presents peculiar sinuous cavities, which are certainly pathological products (see Mikr. Anat., II, 2, p. 82, fig. 202); and frequently canals, like dentinal canals (fig. 192), which are sometimes closely set, at others more isolated, occasionally ramified, and very frequently connected with the ends of the dentinal canals, and with the *canaliculi* of the osseous *lacunæ*.

[In the cement of the *Solipedia*, the osseous *lacunæ* with their *canaliculi*, of the innermost layers, are frequently inclosed within actual cells, as Gerber first pointed out. If such cement be macerated in hydrochloric acid, these cells may be readily isolated, and present the following characters, which are not unimportant in their bearing upon the nature of the *lacunæ*: 1. The *lacunæ* frequently occur in twos and threes in a single cell, exactly as I have seen in rickety bones. 2. The substance which immediately surrounds the cavities and their processes, is not so readily soluble in hydrochloric acid as the other parts of the thickened cell. In fact, while the cells appear generally pale, a dark notched body, which often contains a very distinct cavity, is very obvious in their interior; and as we see by comparing it with these *lacunæ* of the cement, the contours of whose cells are no longer visible, is nothing else than the innermost portion of the thickened wall of the original cell. In the last-mentioned *lacunæ*, in fact, it is easy to demonstrate, by the aid of acetic acid, a special wall, which is at first thick, but subsequently becomes thinner; and occasionally such *lacunæ*, with walls which give off a few processes externally, may be isolated. These *lacunæ* are frequently empty, but in other cases they contain a substance which at first also resists hydrochloric acid, wherein, however, I could discover no nucleus.<sup>1</sup>]

<sup>1</sup> [The structure of the cement on the fang of the still uncut molar of the calf, is very peculiar and instructive. It is here a white, friable substance, about  $\frac{1}{16}$ th of an inch thick, bounded externally by a delicate Nasmyth's membrane. Its outer three fourths are composed of straight parallel fibres, resembling those of the enamel, but  $\frac{1}{16}$ th of an inch long. The inner fourth consists of similar fibres inextricably interlaced, cemented into a mass by a calcareous deposit, and containing here and there, spaces or *lacunæ*,  $\frac{1}{1000}$  of an inch in length, as it were left among the fibres. This structure appears to become obliterated with age, as the cement on the fang of the molar immediately in front of this, which had cut the gum, had the ordinary appearance. (Huxley, l. c.)—Eds.]



## § 141.

The *soft parts* of the teeth are: the *periosteum of the alveolus*, the *dental pulp*, and the *gum*. The *periosteum* of the *alveolus* is very intimately connected with the fangs of the tooth, and has the same structure as any other *periosteum*, except that it is softer, contains no elastic element and possesses an abundant nervous network, containing many thick fibres.

The *dental pulp*—the remains of the foetal dental papilla—arises from the *periosteum* at the bottom of the *alveolus*, enters the fangs, and, as a continuous, soft, reddish, very vascular and nervous substance, fills their canals and the pulp cavity in such a manner as to be everywhere in close adherence to the inner surface of the dentine. The pulp consists of an indistinctly fibrous connective tissue, totally destitute of the elastic element, but containing many dispersed, round and elongated nuclei; and except that it occasionally contains narrow bundles, almost like imperfect foetal connective tissue. A fluid may be expressed from it which, like mucus, is coagulated by acetic acid and is not dissolved in an excess; and, similarly, the entire pulp is rendered whitish by acetic acid, never becoming transparent like perfect connective tissue. This substance constitutes the principal mass of the pulp, so far as the vessels and nerves extend; but upon its surface we find, immediately beneath a delicate structureless membrane, a layer of 0.02—0.04'' thick, composed of many series of cells, 0.012'' long, 0.002—0.003'' broad, cylindrical or pointed at one end, with long narrow nucleolated nuclei of 0.005'', arranged perpendicularly to the surface of the pulp like a cylinder epithelium. More internally these regular series are no longer recognisable, but the cells, without losing their close radial arrangement, are more intermixed, and pass, finally, by shorter and rounder cells, without any sharp lines of demarcation, into the vascular tissue of the pulp. These cells correspond with the formative cells of the dentine, to be described presently, and they afford the materials for the deposits of dentine upon the walls of the pulp cavity, which take place even in the adult.

The *vessels* of the pulp are excessively numerous, whence its red colour. 3—10 small arteries enter each pulp of a simple tooth, and ultimately form, as well in its interior as upon its

surface, a loose plexus of capillaries, 0·004—0·006''' in diameter, which also exhibits here and there upon the surface distinct loops, from which the veins arise. The pulp appears to contain no *lymphatics*, but its *nerves*<sup>1</sup> are extremely abundant. Arising from the well-known *nervi dentales*, there passes into every fang a large trunk of 0·03—0·04, and besides, as many as six or more, fine branches of 0·01—0·02''', which contain fibres of 0·0016—0·003'''. They ascend at first without any considerable anastomoses and only giving off a few filaments; but in the thicker part of the pulp they form a rich plexus, with elongated meshes and divisions of the nerve tubules, and so gradually break up into fine primitive fibres of 0·001—0·0016'''. I am inclined to think their final termination is in loops, but I grant that so long as the primitive fibrils in those loops which unquestionably do occur, have not been traced from trunk to trunk, which no one has yet done, the subject is open to doubt.

The *gum*, *gingiva*, that portion of the oral mucous membrane which unites the alveolar margins of the jaw and the necks of the teeth, is a pale red vascular tissue, which is tolerably soft, but feels firm on account of the subjacent hard parts: it attains, where it lies upon the teeth, a thickness of  $\frac{1}{4}$ —1 $\frac{1}{8}$ ''' and possesses papillæ of a considerable size (of 0·15—0·8'''; in old people they even reach 0·7''' in length, and like the *papillæ filiformes* are covered with secondary papillæ), and a pavement epithelium, which, between the papillæ, has a thickness of 0·23—0·4'''. I could find no *glands* upon the gum, but care must be taken not to confound with them, certain rounded depressions of the epithelium of 0·08—0·15''' in diameter, with more cornified cells, which occur not unfrequently upon its upper portions.

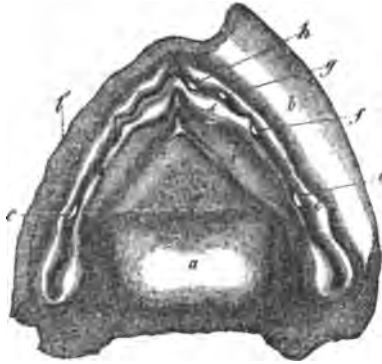
#### § 142.

*Development of the teeth.*—The development of the twenty milk teeth commences in the sixth week of foetal life, by the formation of a groove in the upper and lower margin of the jaws, in which, up till the tenth week, twenty dental papillæ gradually make their appearance. Partitions are now developed, so that

<sup>1</sup> [The nerves of the alveolar periosteum and of the pulp, are particularly described by Czermak (l. c. pp. 27, 28).—EDS.]

each papilla soon lies in a special cavity. In the course of the fourth month, these cavities gradually contract, the papillæ at

Fig. 194.



the same time assuming the forms of the future teeth, and finally they close up completely; this takes place, however, in such a manner, that a little cavity is developed above each "tooth sac," and thus "reserve sacs," in which pulps begin to be developed in the course of the fifth month, are formed for the twenty anterior permanent teeth.

Fig. 195.

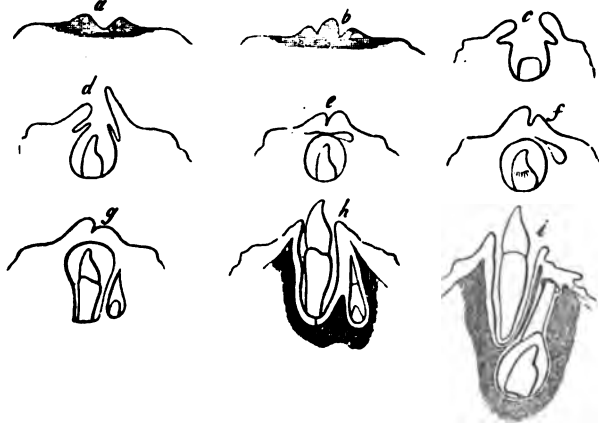


Fig. 194. Lower jaw of a human fetus, nine weeks old,  $\times 9$ : *a*, tongue thrown back; *b*, right half of the lip depressed; *b'*, left half of the lip cut off; *c*, outer alveolar wall; *d*, inner alveolar wall; *e*, *papilla* of the first molar; *f*, *papilla* of the canine; *g*, of the second; *h*, of the first incisor; *i*, folds where the *ductus Riviniani* subsequently open.

Fig. 195. Diagram of the development of a milk-tooth, and of its corresponding permanent tooth, after Goodsir: *a*, dental furrow; *b*, the same, with its *papilla*; *c*, the same beginning to close, with the rudiment of the reserve cavity; *d*, the same still more closed; *e*, tooth-sac completed, with a 'reserve cavity'; *f*, the reserve cavity moving backwards; *g*, the same become quite posterior, with a pulp; *h*, the *alveoli* of both sacs are forming, the milk-tooth has emerged; *i*, the permanent tooth forming, its deeper seated sac has a *gubernaculum*.

These "*reserve sacs*" at first lie above the milk sacs, but by degrees they retreat backwards, and are received into hollows of the bony *alveoli* as they are formed round the milk teeth (fig. 195, *g, h.*) Those of the incisors and canines eventually become completely separated from the alveoli of the corresponding milk teeth, but those of the premolars<sup>1</sup> open into the bottom of the alveoli of the deciduous molars.

The sacs of all these teeth are produced at their apices into a solid cord, which extends either to the gum, or, as in the two premolars, to the periosteum in the bottom of the *alveoli* of the two deciduous molars (fig. 195, *i.*), and has been erroneously described as a *gubernaculum*, or guiding cord for the teeth in their eruption.

The sac of the anterior of the three permanent molars, arises, together with its *papilla*, in the sixteenth or seventeenth week, quite independently, from the posterior extremity of the primitive dental groove, and closes in such a manner that a reserve sac remains between it and the mucous membrane (Mikr. Anat. fig. 206). It is not till the seventh or eighth month after birth that the latter elongates behind the first sac, arches into the margin of the jaw, produces a papilla from its base, and becomes constricted off into the sac of the second molar. The remainder of the cavity falls into a line with the other sacs, and forms that of the wisdom tooth.

The formation of *milk teeth* begins at about the fifth month

<sup>1</sup> [Instead of the loose phraseology "small" and "large" molars, &c., we have adopted the philosophical nomenclature of the teeth, introduced by Professor Owen, (see his Article on the Teeth, in Todd's Cyclopædia) and thus explained by him: "Those teeth which are implanted in the premaxillary bones, and in the corresponding part of the lower jaw, are called "incisors," whatever be their shape or size; the tooth in the maxillary bone, which is situated at or near to the suture with the premaxillary, is the "canine," as is also that tooth in the lower jaw, which in opposing it, passes in front of its crown when the mouth is closed. The other teeth of the first set, are the "deciduous molars;" the teeth which displace them vertically, are the "premolars:" the more posterior teeth which are not displaced by vertical successors, are the molars properly so called."

It results from this, that the so-called bicuspid and "first molar" of the permanent set in man (Professor Kölliker's "small molars") are the premolars; being, in fact, the third and fourth of the typical dentition; the first and second premolars and the third incisor of the typical dentition, not being developed in man. The nomenclature of the teeth, from being merely technical and arbitrary, has thus, by Professor Owen's recourse to development, become scientific.—EDS.]

of foetal life, and at the seventh, ossification has commenced in all of them. The first step is the formation of a little scale of dentine upon the apex of the pulp; in the molar teeth there are at first several of these scales, corresponding with the several elevations of the pulp, but they soon coalesce. Immediately after the appearance of this dentinal scale, a thin layer of enamel is deposited from the so-called enamel organ upon the roof of the sac, and which coalescing with the dentine, forms the first rudiment of the crown of the tooth. The scale of dentine extends over the pulp and becomes thicker, so that it soon rests like a cap upon the pulp, and finally forms a sort of capsule for it, which, as ossification proceeds and the pulp diminishes, closely and completely embraces it; the deposition of enamel goes on simultaneously, so that it soon proceeds from the entire surface of the enamel organ, and becomes more and more considerable. In this manner, the whole enamel is eventually deposited around the dentinal layer of the crown, while the enamel organ and the pulp gradually diminish, until the former is represented only by a delicate membrane; and the latter presents similar relations to that of the perfect tooth. As yet there exists no trace of either fang or cement; they are not formed till the crown is nearly complete, and the tooth is about to emerge. About this time the pulp undergoes a considerable longitudinal growth, while the enamel organ becomes atrophied; and upon the newly formed portion only dentine, that of the fang, is developed. The tooth, thus forced upwards, begins to press against the upper wall of its sac, and the firm gum which is closely united with it; in which an independent process of absorption also takes place, and the tooth finally makes its appearance. The gum now contracts around it, and the rest of the dental sac becomes closely applied to the fang, and constitutes the alveolar periosteum.

The milk-tooth attains completeness: 1. by the addition of the remainder of the fang, and the consequent elevation of the crown to its normal length; and 2. by a deposition which takes place from the sac, now united with the alveolar periosteum, which commenced even before eruption, and by which the cement is applied around the fang, while at the same time the tooth is thickened by internal deposition, the pulp diminishing to a corresponding extent. In teeth with several fangs, the pulp, which is at first simple, divides as it elongates,

near its point of attachment, a separate fang being developed around each portion. *The eruption of the milk teeth* takes place in the following order: central incisors of the lower jaw in the 6th—8th month; central incisors of the upper jaw a few weeks later; lateral incisors in the 7th—9th month, those of the lower jaw first; anterior molars in the 12th—14th month, those of the lower jaw first; canine in the 16th—20th month; second molars between the 20th and 30th months.

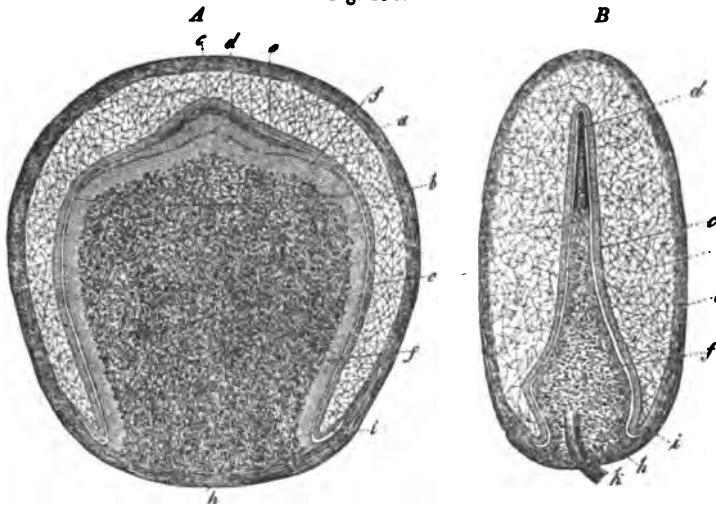
The *permanent teeth* are developed in precisely the same way as the milk-teeth. Their ossification begins, somewhat antecedent to birth, in the first molar, extends, in the first, second, and third years, to the incisors, canines, and pre-molars, and finally reaches the second molar; so that in the 6th—7th year there are 48 teeth co-existing in the two jaws, *i. e.*, twenty milk-teeth, and all the permanent set with the exception of the wisdom teeth (third molar). When the shedding of the teeth takes place, the bony partitions which separate the *alveoli* of the permanent, from those of the milk teeth are absorbed, and at the same time the fangs of the latter gradually disappear from below in a manner which is not yet understood. The permanent teeth, whose fangs in the meanwhile have elongated, thus become placed immediately under the loosened crowns of the milk teeth, which finally, as the others protrude, fall out and make way for them. The permanent teeth emerge in the following order: first molar in the seventh year, inner incisor in the eighth year, lateral incisor in the ninth year, first premolar in the tenth year, second premolar in the eleventh year, canine in the twelfth year, second molar in the thirteenth year, third molar (wisdom tooth), between the seventeenth and nineteenth years.

The *gum* in the fœtus, and especially in newly born infants before the eruption of the milk teeth, is whitish and very firm, almost cartilaginous, whence perhaps it has also been called gum-cartilage, although it has not the slightest resemblance to cartilage in structure, but consists of the ordinary elements of mucous membrane, but with a considerable admixture of a more tendinous tissue. The bodies of the size of millet-seed, contained in it, described by Serres, the so-called *glandule tartaricæ*, which were supposed to secrete the "tartar" of the

teeth, are aggregations of epithelium, and are probably pathological<sup>1</sup> (see Mikr. Anat. II. 2, p. 92).

[The *dental sacs* consist of connective tissue, in which vessels and nerves are distributed; from their base proceeds the *dental pulp*, which, in form, resembles the tooth to which it

Fig. 196.



belongs, and consists of an internal portion rich in vessels, and eventually in nerves also, and of a non-vascular external portion. The latter is bounded by a delicate structureless membrane, the *membrana præformativa* (Raschkow), which has no further relation to the development of the tooth. Beneath this, lie cells of 0.016—0.024<sup>'''</sup> in length, and 0.002—0.0045

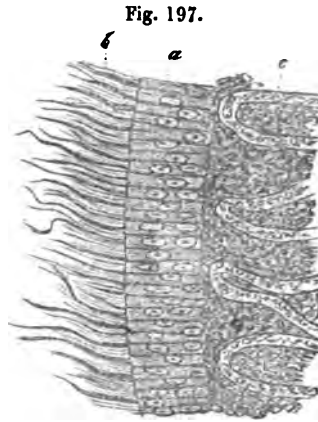
Fig. 196. *A*, tooth-sac of the second incisor of an eight-months' foetus, from the broad surface,  $\times 7$ : *a*, dental sac; *b*, enamel pulp; *c*, enamel membrane; *d*, enamel; *e*, dentine; *f*, dentinal cells; *g*, limits of the cap of dentine; *h*, dental pulp; *i*, free edge of the enamel organ. *B*, first incisor of the same embryo from the narrow surface: letters as before; *a*, dentinal cap *in toto*; *k*, nerves and vessels of the pulp.

<sup>1</sup> [They have a diameter of from 0.24—0.36<sup>'''</sup>, and are composed throughout of numerous concentric layers of ordinary epithelial plates, or of softer scales, with cholesterine crystals and granules. Besides these, microscopic bodies of 0.02—0.12<sup>'''</sup>, soft, and with only indications of lamination, are found in the gum (Kölliker, l. c.) The true nature of these glands was pointed out by Purkinje and Raschkow.—Eps.]

in breadth, with very beautiful, vesicular nuclei, and distinct, single or multiple nucleoli; they are arranged close together over the whole surface of the pulp (fig. 197), like an epithelium, though not so sharply defined internally as it would be, but gradually passing, at least apparently, by smaller cells, into the parenchyma. In vascular pulps (fig. 197), an additional boundary line may be traced, inasmuch as the capillary loops in which the vessels terminate, do not penetrate between the cylindrical cells, but end close to one another upon their inner surface; so that, considering that the dentine is produced by the cells in question, we might be justified in terming them the *dentinal membrane*, or *membrana eboris*. The internal portions of the pulp consist throughout of an originally granular or homogeneous, afterwards more fibrous *matrix*, containing many rounded or elongated nuclei, which must be regarded as a sort of connective tissue. *Vessels* are developed in great numbers in the pulp at the period when ossification commences; the most numerous perpendicular loops of capillaries of about 0.006" existing in contiguity with the ossifying surface. The *nerves* accompany the vessels, but are developed later; their number is very considerable and their distribution resembles that in the pulp of the perfect tooth.

The *enamel organ* (*organon adamantinæ*), is applied to the pulp like a cap by its internal, concave surface, and is connected externally with the dental sac, in such a manner, however, that at the base of the pulp it presents a very small free edge. Its structure is very peculiar. The principal mass consists of anastomosing stellate cells (fig. 196, *b.*), or reticulated connective tissue, containing in its meshes a great quantity of fluid, rich in albumen and mucus. This gelatinous

Fig. 197. Surface of the dentinal pulp of a newly-born infant: *a*, dentinal cells; *b*, their appendages; *c*, vascular part of the pulp;  $\times$  300.





connective tissue is most abundant immediately before the commencement of ossification, and in its earliest stages. Thus, in the fifth and sixth months it measures  $\frac{1}{10}$ — $\frac{1}{3}$  of a line; in the new-born infant, on the other hand, only 0.16—0.2". At this period it contains vessels in its outer third and its network is metamorphosed into true connective tissue, (Mikr. Anat. ii, fig. 211.) On the inner side of the spongy tissue of the enamel organ, lies the so-called *enamel membrane*, *membrana adamantinae* (Raschkow), a true cylinder epithelium, of which it need only be said that its cells measure 0.012" in length, and 0.002" in breadth, are finely granular and delicate, and possess nuclei frequently situated at the ends of the cells.

The *development of the dental tissues* has, hitherto, always been regarded as a very difficult subject. The simplest relations are presented in the enamel, where there can be no doubt whatever that the enamel-cells become, by their complete ossification, the enamel-fibres. As soon as only a small portion of the cells has become ossified (without the previous deposit of calcareous matter in a granular form), a little scale of enamel is recognizable upon the somewhat larger cap of dentine, which has also just been produced. The deposition of calcareous matter in the cells constantly advances outwards, until at last they are entirely converted into enamel fibres, and extends at the same time to other cells, so that the layer of enamel increases in width. During this process, the enamel membrane does not disappear in the locality in which ossification commenced, but retains, there and elsewhere, the same thickness, so long as the deposition of enamel continues; its ossifying part, therefore, must be replaced by the incessant development of new substance, which takes place apparently, not by the apposition of new cells, but by the continual growth of the old ones. The enamel organ has assuredly some very important relation to the development of the enamel; probably serving by the abundance of albumen and of mucus in its meshes, as a storehouse, out of which the enamel membrane, distant as it is from blood-vessels, is enabled to draw the materials for its increase. In fact, the spongy tissue is seen to decrease more and more during the development of the enamel, and finally, when the enamel is complete, to disappear.

In the development of the *dentine*, as in that of the enamel,

it is not the whole pulp which shares in the process, but only its most external, epithelium-like layer of cells, which appears to maintain a constant thickness by the elongation of the original cells, accompanied by a continual multiplication of their nuclei (Mikr. Anat. ii, 2, p. 103, *et seq.*) I by no means intend to assert that one and the same cell suffices for the whole duration of the development of the dentine, although this is not at all inconceivable; indeed, I consider it possible that the dentinal cells are from time to time replaced by others, which are formed upon their inner surface; but what I deny is, that the whole pulp is simply changed progressively, from without inwards, into dentinal cells and ossified, and I am of opinion that, like the spongy tissue of the enamel organ, the only import of the pulp in the development of the dentine is to support the vessels which are necessary to enable the dentinal cells to grow at all.

The diminution of the pulp, therefore, is very readily intelligible without supposing it to be ossified from without inwards; it takes place, like the diminution of the contents of the wide Haversian canals of fetal bones when the lamellæ are deposited upon their walls, by a gradual resorption of its tissue, which, as in the latter case, is soft and full of juices; and it is by no means necessary to suppose any extensive retrogressive metamorphosis of its vessels.

With regard to the *formation of the dentine* from the dentinal cells, it is certain that no other tissue than these cells contributes anything to its development and that they, like those of the enamel membrane, become dentine by the gradual reception of calcareous salts. The dentinal tubules are either the remains of the cavities of the dentinal cells, whose walls, in the course of ossification, thicken<sup>o</sup> and harden into them, but do not quite close, or they are developed from the elongated and coalesced nuclei of the dentinal cells whose cavity persists; or finally, they are the result of a process of resorption in the primarily homogeneous, dentinal tissue, analogous to the formation of the Haversian canals, or of those in the cement. Of these three hypotheses, the second would, at first sight, appear the most probable, if we consider that the dentinal tubules may be isolated, with distinct walls, that the dentinal cells are abundantly provided with nuclei, and that certain filiform pro-

elongations of the dentinal cells which I have noticed (figs. 9 and 197, and Mikr. Anat., II. 2, p. 105), might be regarded as elongated nuclei; but there is one very remarkable fact, *that no trace of any elongation of the nuclei can be discovered by the most careful investigation.* The third hypothesis is indeed conceivable, but in opposition to it, we find that pores and canals exist even in the youngest and softest dentine, when the development of the tooth is at all advanced and therefore, that they can hardly be regarded as secondary formations. In favour of the first supposition, on the other hand, it may be said, that it would, if true, indicate a close agreement between dentine and osseous tissue, structures which are in every case nearly allied, inasmuch as the dentinal tubules would be homologous with long and narrow, simple or possibly coalesced, osseous *lacunæ*. Certain objections may be urged, which are not, perhaps, so important as they at first appear. These are, in the first place, that the dentinal canals have special walls and may be isolated as tubes, which might be regarded as demonstrative evidence that they are developed out of peculiar vesicular structures, either nuclei or cells; and secondly, that upon this supposition, the filamentous appendages to the dentinal cells are not so readily interpreted. But as regards the former, we have recently learnt that the osseous *lacunæ* and *canaliculi* may also be isolated, with special walls which are not those of the original cells, and the same is true of the Haversian canals, whence it would be conceivable that the walls of the dentinal canals also, although originally and genetically not special structures, might eventually become so. Since, again, the processes of the dentinal cells may be nothing else than the still soft part of the cells in which ossification is commencing, this first hypothesis may be regarded as having a certain claim to consideration, the more so as the osseous *lacunæ* in the teeth, frequently assume forms, resembling those of the dentinal canals, often communicate with them, and, at least in animals, are interposed among them.

To sum up, it may be said, that in any case, the matrix of the dentine proceeds from the cylindrical cells investing the pulp of the tooth, which undergo a greater or less elongation, coalesce, and ossify. The dentinal canals either arise from the

nuclei of these cells, or are, and this at present appears to me to be more probable, the remains of the cavities of the cells, whose boundaries have undergone a greater consolidation, and therefore correspond with osseous *lacunæ*. The divisions of the canals are explained, if we conceive, either that the dentinal cells divide *longitudinally* from time to time, as I believe I have actually observed, or that a cell coalesces with two of its predecessors. As to the more delicate ramifications, we can only suppose that they are formed by a *secondary process of resorption* in already formed dentine, like that which must be assumed to occur in the osseous *lacunæ*, to account for the anastomoses of their *canaliculi*, and their communication with Haversian canals; at least, I see no possibility, whatever view we take, of explaining their formation in any other way, without coming into opposition with well-ascertained facts. No such process as the thickening and ossification of dentinal cells accompanied by the formation of pore-canals can be observed, so that the fine lateral branches appear to be entirely of secondary origin.

In the course of the ossification of the dentine, at least in man, we find that the deposition of calcareous salts in the recently formed, structurally characterised, though only slightly hardened dentine, takes place in such a manner that the whole appears to consist of *isolated globules*. These globules, which are visible not only at later periods, but in the earliest cap of dentine and are best seen at the edge of the root of a large tooth viewed externally, eventually disappear if development proceed normally, calcareous matter being deposited between them, so that the dentine becomes quite homogeneous and clear; in the opposite case, they persist in greater or less number, and the spaces between them, which are nothing but the interglobular spaces above described, contain unossified dentine.

According to my observations, the development of the *cement* takes place from that portion of the dental sac which lies between the pulp and the enamel organ and commences, even before the eruption of the teeth, contemporaneously with the formation of their fangs. About this time the dental sac elongates inferiorly, applies itself to the growing fang, yields, from its abundant vascular network, a soft blastema, in which nucleated cells are developed, and then ossification takes place.

The cement, therefore, is not formed by the ossification of the sac itself. I met with the first traces of it in newly-born infants, in the form of isolated, elongated or rounded scales, which were firmly attached to the dentine of the, as yet, very short fang, and looked exactly like the developing osseous substance in the cranial bones; the smallest exhibited distinct osseous *lacunæ* and a faint yellow tinge, but were quite soft and transparent, passing at their edges into a clear cellular blastema; in the larger ones, the margins were similar, but the centre was darker and firmer, and in this way every stage of transition to actual bone was presented, without any granular deposit of calcareous matter. With the elongation of the fang, new osseous scales of this kind were formed and gradually coalesced from above downwards into a single layer, to which continual additions were made from without, until the whole thickness of the cement was produced.

I am unacquainted with the manner in which the Nasmyth's membrane is produced. No structureless layer exists upon the enamel organ, by the ossification of which it might be supposed to be formed and therefore I should be inclined to regard it as a calcified, amorphous exudation secreted from the enamel organ immediately after the ossification of the last enamel cells, which glues together and protects the ends of the prisms of the enamel.

If we now, in conclusion, take a general view of the different structures in the teeth and their mutual relations, we perceive that although they agree in certain respects, yet they cannot be brought under one class. *Dentine and cement* are much more closely allied to one another, than to enamel, and should it prove to be correct that the dentinal canals are formed by the coalescence of the cavities of thickened, elongated cells, the dentine will correspond with an osseous tissue, whose matrix is constituted only by the thickened walls of the original cells, and whose *lacunæ* are all directly connected. Cement, or bone, and dentine, often have a very close external resemblance to one another, particularly, on the one hand, when the latter is traversed by numerous Haversian canals, and, as Retzius believes he has observed, contains osseous *lacunæ*; and, on the other hand, when, in bone the *lacunæ* are either greatly elongated, with numerous *canaliculi*, vascular canals also ex-

isting ; or when with few *lacunæ*, the *canaliculi* are numerous and parallel, like dentinal canals. This much is certain, that the two substances never become exactly alike and it is probable that their development is always to a certain extent different.

[The *enamel* may be best compared with a dentine whose cells are ossified throughout, and which, therefore, presents no canals, like that in the outermost layers of fishes' teeth ; at least the two substances agree in this, that they are entirely composed of elongated cells without any connecting matrix. When canals occur in the enamel, it acquires a very great similarity to dentine ; but these canals probably have a totally different import to those in the dentine, viz.—that of cavities which proceed from absorption. With the cement, the enamel has, in general, no analogy, though there is a kind of homogeneous cement with an indistinct transverse striation which, at least externally, looks somewhat like enamel, but has hardly, like the latter, arisen from elongated cells. If we consider the nature of the parts from which the various substances are developed, the dentine, formed from the vascular part of the mucous membrane of the mouth, is a *true product of the homologue of the derma (schleimhaut-production)*, the enamel an *epithelial structure*, and the cement an *investing substance*, afforded by the mucous membrane.]

#### § 143.

The substance of the perfect tooth, though hard, is by no means incapable of molecular change, as its various diseases best show. The functions of the *lacunæ* and their *canaliculi* in the bones are here performed by the dentinal canals with their ramifications, the *lacunæ* and *canaliculi* in the cement, and the fissures between the prisms of the enamel. All these cavities, during life, contain a fluid, derived on the one side, from the vessels of the pulp, on the other, from those of the alveolar *periosteum*, and permit of changes in the substance, though they may be slow. Nothing definite, however, is known about the latter, but from the circumstance that perfect dentine is not coloured when an animal is fed with madder (Hunter, Flourens, and others ; compare Henle, p. 878), it may be concluded, that they are far less active than in the bones, and perhaps take place in such a manner that the calcareous matters are not at all or

only very slowly renewed. The dentine is undoubtedly best provided with fluid supplies, from its being penetrated by very numerous and frequently anastomosing canals. We can as little suppose any regular circulation in it as in the bones; but it may be assumed that a certain movement takes place, proportionate to the amount of the exudative and absorptive processes in the pulp, of the waste in the tooth itself, and of the supply afforded to the enamel and cement and probably given off from the latter tissues externally. Though the *enamel* is not impermeable, it permits of the passage of fluids with difficulty, as is best shown by the circumstance that the nerves of the dental pulp are not affected by acids, so long as the coating of enamel is entire, but readily enough, when, as in the incisors, the dentine is exposed. The enamel, again, is the hardest dental tissue, possesses scarcely any organic matrix and no constant system of canals. Nasmyth's membrane, which is attacked with so much difficulty by chemical reagents, is, very probably, still more impenetrable than the enamel itself, and hence these two substances serve admirably to protect the teeth. The *sensibility* of the teeth arises from the nerves of their pulp; they are affected by contact, heat, cold, and chemical agents. Slight mechanical influences can only act by the vibrations which they may communicate to the substance of the tooth and thence to the pulp; it is therefore the more remarkable that the teeth have a certain sense of locality, so that it is possible to distinguish whether they are touched internally or externally, above or below, on the right or on the left side. The sensibility of the teeth is indeed tolerably delicate, especially on the masticating surface, where the smallest foreign bodies, as hairs, grains of sand, &c., are perceived when these surfaces are rubbed against one another; and as regards its acuteness, it is, in disease at least, excessive, which is sufficiently explained by the considerable number of nerves in the pulp and the readiness with which they may be compressed within their hard receptacle.

With age the teeth become denser; the pulp cavity is filled with a kind of irregular dentine and may be totally obliterated, which is, perhaps, the normal cause of their falling out. In certain cases observed by Tomes, the fangs in old age were quite transparent, like horn.

[The following remarks may be made upon the *pathology* of the teeth. Permanent teeth which have fallen out are sometimes replaced by a third dentition; but it must not be forgotten that the milk teeth occasionally remain beyond their time, and care must be taken not to confound a second tooth, late in its eruption, with a third. Teeth which have been extracted may be replaced (in fifteen months a canine tooth which had been extracted from the upper jaw was perfectly firm again). An abnormal development of the teeth takes place particularly in the *ovarium*, but also elsewhere. *Fractures* of the teeth may be re-united when they occur within the *alveoli*, by imperfect dentine or cement. Regeneration of the worn down parts takes place only in animals (Rodents, *e. g.*) in which the teeth constantly grow. *Hypertrophy* of the cement (the so-called *exostosis*), deposits of dentine in the walls of the pulp cavity and ossification of the pulp itself, are exceedingly common, and result from chronic inflammation of the *periosteum* and pulp. A partial disappearance of the fang is not uncommon. *Necrosis* of the teeth takes place when the periosteum has been stripped off, or the pulp has died. The teeth become rough and dark, even black, and finally fall out. The nature and causes of *dental caries* are doubtful. It attacks living and false teeth (Tomes), and always begins on the exterior, from Nasmyth's membrane (Ficinus), whence the fluids of the mouth have been supposed to have considerable influence upon it; it does not follow, however, that one living tooth may not be more disposed to it than another, being rendered less capable of resistance either by its chemical composition, or by the mode of its nutrition. Caries, however, is assuredly not a simple solution of the salts by the oral fluids, but a solution accompanied by a putrefactive decomposition of the organic elements of the tooth, which becomes covered with infusoria and fungi; in fact, according to Ficinus's observations, the latter growths would appear to play the more important part, inasmuch as the decay of the teeth usually commences in those localities in which undisturbed opportunity is given to these organisms to develop, as in the cracks and pits of the enamel, in the depressions of the molar teeth, in the clefts between the teeth, but not where the dentine is otherwise exposed, as on the masticating surface, in filed places, &c. The usual



course of caries is, that the discoloured spots of the cuticle of the enamel, covered with living and growing organisms (infusorial animalcules, similar to a *Vibrio*, which *Ficinus* calls *Denticola*, mucedinous fungi (Erdl, Klenke, Tomes), similar to those which are found upon the tongue, and which *Ficinus* wrongly refers to the *Denticolæ*) first lose their calcareous salts, and then break up into angular, cellular pieces, as if they had been treated with hydrochloric acid. The decay then penetrates through the enamel to the dentine, always first softening it, so that it yields not more than 10 per cent. of ash (*Ficinus*), and then decomposing it. The dentine is more affected by this process than the enamel, its canal first becoming filled with the fluids proceeding from its decomposition, which may reach the pulp and give rise to pain, unless, as Tomes found, the dentinal canals in the neighbouring healthy portions become obliterated by deposits, or the pulp is protected by new masses of dentine developed in the cavity<sup>1</sup> (*Ficinus*, Tomes). Eventually a brownish deposit takes place in the tubules and then the intermediate substance becomes completely broken up. In this manner the process of decomposition extends further and further, until at last the crown collapses, the root also becoming dissolved and finally falling out.

In jaundice, the teeth not uncommonly assume a yellow colour, which is occasionally almost as intense as in the skin, and in asphyxiated persons they are said frequently to be red; both facts being explicable only by the supposition that the colouring matter of the bile and of the blood transudes into the dentinal tubuli. In *rachitis* the teeth remain unaffected. In the *mucus upon the teeth*, an abundant growth of the mucedinous fungi which have been mentioned, is always to be met with in a finely granular *matrix*, surrounding mucus- or epithelium-corpuscles; besides which we find the infusoria of carious teeth and the earthy deposits of the oral fluids. If this

<sup>1</sup> ["It is worthy of mention, also, that in the teeth of the hare, the sow, and the stag, especially in the molars, stony masses are constantly found. They are semi-transparent, for the most part oval and rounded bodies, situated in the axis of the dental pulp, towards its apex, in irregular rows, never extending the whole length of the dental pulp, but only to a greater or less distance from the coronal extremity." Raschkow, Meletemata, &c., cited and translated in Nasmyth's 'Researches,' (1839), p. 139.]

mucus accumulates, it hardens and forms the *tartar of the teeth*, which consists, according to Berzelius, of earthy phosphates 79·0, mucus 12·5, ptyalin 1·0, organic matter, soluble in hydrochloric acid, 7·5.

The best *mode of examination* of the teeth is by making fine sections and preparations softened in hydrochloric acid. To obtain good specimens of the former it is necessary to employ only young and fresh teeth, as the enamel otherwise readily breaks off. A longitudinal or transverse slice should be first taken off with a fine saw, and may then be rubbed down, first upon a coarser and then upon a finer stone, as thin as possible; the section should then be cleaned and polished between two glass plates, until its surface is as smooth and shining as it can be made, and finally washed with ether in order to remove any impurities it may have contracted. When well polished and dried, all the dentinal canals and *lacunæ* will be filled with air, and the section may be preserved without further addition under a glass plate, cemented by some thick and quickly solidifying varnish. Such polished sections are preferable to any others, which, on account of their irregular surface, require to be covered with different fluids, as Canada balsam, oil of turpentine, &c., in order to be examined by high magnifying powers. It almost always happens, in fact, that some portion of these fluids enters the dentinal tubules, which then become quite clear and indistinct and invisible in their finer ramifications. A very viscid varnish alone is of any service. In preparing these sections of the teeth, the slices may also first be affixed to pieces of glass with Canada balsam, and then be rubbed down with a file and polished, on one side first, and then by warming the balsam and turning the section round, upon the other. When such a section has been washed with ether and dried, it is as good as one prepared with water only. Two sections made perpendicularly to one another through the middle of the crown and fang of a tooth, from before backwards, and from right to left, are sufficient to exhibit the most important features of the teeth; but sections ought also to be prepared, showing the surface of the pulp cavity and that of the enamel; and also different oblique and transverse sections through the commencement of the dentinal canals of the fangs, to exhibit the anastomoses of their branches. The *dental cartilage* is easily

demonstrable by maceration in hydrochloric acid, a process which requires a longer or shorter time according to the concentration of the acid and its more or less frequent renewal, taking 3—4 days in strong acid and in dilute, from 5—8. If it be desired to soften the tooth so much that the tubules may be isolated, it must be left for about eight days in concentrated hydrochloric acid; in thin sections of dental cartilage 12—24 hours' treatment with sulphuric and hydrochloric acid, and a few hours with dilute solutions of caustic potassa and soda, are sufficient for this purpose. It is very instructive also to macerate thin sections of teeth in acid and to examine them upon glass plates at intervals, until they entirely break up. The enamel prisms are readily isolated in developing enamel; the transverse lines are seen best when the object is moistened with hydrochloric acid, and the transverse sections of the prisms are seen exceedingly well in longitudinal sections, in some layers. The early development may be studied in embryos of two, three, or four months with the simple microscope and in transverse sections of parts hardened in spirit; the structure of the dental sac, and the development of the dental tissues in fœtuses of four, five, and six months, and in new-born infants, both in fresh subjects and, if it be desired to recognise the relations of the enamel organ, in spirit-preparations also, in which its structure is very well retained. The pulp of mature teeth is obtained by breaking them in a vice, and their nerves are best seen on the addition of dilute solution of caustic soda.

*Literature of the Teeth.*—L. Fränkel, 'De penitiori dentium humanorum structurâ observationes,' Vratislav, 1835; and Retzius, 'Bemerkungen über den innern Bau der Zähnen,' in Müll. 'Arch.,' 1837; J. Tomes, 'A Course of Lectures on Dental Physiology and Surgery,' London, 1848; R. Owen, 'Odontography,' London, 1840-45, 1 vol., with atlas of 150 plates; and article 'Teeth,' in 'Cyclopædia of Anatomy,' IV. p. 864, Krukenberg; 'Zur Lehre vom Röhrensysteme der Zähne und Knochen,' in Müll. 'Archiv,' 1849, p. 403; J. Czermak, 'Beiträge zur mikroskopischen Anatomie der menschlichen Zähne, in Zeitschr. für. wiss. Zool.' 1850, bd. II. p. 295; Arnold, in 'der Salzburger med. Zeitung,' 1831, p. 236; Raschkow, 'Meletemata circa dentium mammalium evolutionem,'

Vratisl, 1835; Goodsir, in 'Edinb. Med. and Surg. Journal,' 1838, No. XXXI. 1; and Froriep's 'Neue Notizen,' Nos. 199, 200, 202, 203; Marcusen, 'Ueber die Entwicklung der Zähne der Säugethiere,' aus dem 'Bulletin Phys. Math.' VIII., No. 20, Petersburg, 1850. On *Dental Caries* consult Erdl. in 'Allg. Zeitung für Chirurgie von Rohatzsch,' 1843, No. 19; Ficinus, in 'Journal für Chirurgie von Walther and Ammon,' 1846, p. 1; Klenke, 'Die Verderbniss der Zähne,' Leipzig, 1850. The *Comparative Anatomy* of the teeth is treated of microscopically in the works of Owen and Retzius above cited; also by Erdl, in the 'Abhandlungen der Math. Phys. Klasse, der Königl. Bayer. Akad.' bd. III, Abth. 2; Tomes, in the 'Phil. Trans.' 1849—50 (Marsupialia and Rodentia); Agassiz, in the 'Poissons fossiles,' Henle and J. Müller, 'Syst. Beschreibung der Plagiostomen,' 1838.

[To these should be added: Blake, 'Essay,' &c., 1801; Hunter, 'Treatise on the Natural History and Diseases of the Human Teeth,' edited by Thomas Bell. (Works by Palmer, 1835. Vol. ii.); Tomes, 'On the Structure of the Teeth, the Vascularity of those Organs, and their relation to Bone,' Proceedings of the Royal Society, June, 1838; Owen, 'On the Structure of the Teeth, and the resemblance of Ivory to Bone,' British Association Reports, 1838; Nasmyth, 'Medico-Chirurgical Transactions,' 1839; 'Proceedings of the British Association,' 1839; 'Researches on the Development, Structure, and Diseases of the Teeth,' 1849; Huxley, 'On the development of the Teeth,' 'Quarterly Journal of Micr. Science,' 1853; Salter, 'On certain appearances occurring in Dentine,' *ibid.* 1853.—Eds.]

## OF THE ORGANS OF DEGLUTITION.

## I. THE PHARYNX.

## § 144.

The alimentary canal assumes a greater independence in the pharynx, acquiring a special investment of transversely striated muscles, the *constrictores* and *levatores*, which, however, do not entirely surround it and arise for the most part from bones. The thickness of the walls of the pharynx is about 2'' on an average, depending principally upon this muscular layer, external to which there is a tense fibrous membrane, composed of connective tissue and elastic fibres, while internally it is separated by a layer of submucous connective tissue from the *mucous membrane*. The latter is paler than that of the oral cavity and its structure in the upper half of the pharynx differs considerably from that in the lower half. In the latter locality, that is, below the pharyngo-palatine arches, or in the region through which the food passes, it possesses a tessellated epithelium similar in structure and thickness to that of the oral cavity; above them, on the other hand, that is, on the posterior surface of the soft palate from its free edge, upon the upper surface of the uvula, in the region of the *choanae* and Eustachian tubes, and upon the vault of the pharynx, there is a ciliated epithelium like that in the nasal cavity and *larynx*, to the description of which, below, the reader may be referred. In this upper or *respiratory* section the mucous membrane is also redder, thicker, and more glandular than in the lower division, otherwise, however, its structure is pretty much the same, with the exception that it presents no papillæ, which however, in some parts of the lower division are very little developed and rare, and would even appear to be entirely wanting. Compared with that of the oral cavity I find the mucous membrane of the pharynx to possess much more and much stronger elastic tissue, which, in the deeper layers, forms connected, very dense, elastic membranes.

The pharynx contains two sorts of *glands*; 1. *racemose mucous glands* (*vide supra*, § 134), and, 2. *follicular glands*. The

former  $\frac{1}{3}$ —1''' in diameter, have distinct apertures and abound more particularly in the upper portions of the pharynx, where they form a perfectly continuous layer on the posterior wall, in the neighbourhood of the pharyngeal opening of the Eustachian tubes, and upon the posterior surface of the *velum*, diminishing in number lower down. *Follicular glands*, simple as well as compound, analogous to the tonsils, are met with in the vault of the *pharynx*, where the mucous membrane is closely attached to the base of the skull. Here a glandular mass, stretching from one Eustachian opening to the other, and from one to four lines thick, may constantly be met with; it is, upon the whole, smaller, but otherwise its structure resembles, in all essential respects, that of the tonsils (§ 135). Besides this mass, whose largest sacculations are situated in the middle of the roof of the pharynx, and in the recesses behind the Eustachian apertures, and which, in aged persons, frequently present enlarged cavities, filled with puriform masses, there occur round the apertures of the tubes, and upon them, towards the *choanæ*, on the posterior surface of the *velum palati*, and on the lateral walls of the *pharynx*, as far as the level of the *epiglottis*, more or less numerous, smaller and larger follicles, whose size is too great for apertures of the mucous glands, and which have in all probability the same structure as the simple follicles of the root of the tongue, and receive the excretory ducts of the mucous glands.

The mucous membrane of the *pharynx* is rich in *blood-vessels* and *lymphatics*. The former constitute superficially a network with elongated meshes, sending short loops into the rudimentary papillæ. The *nerves* are very numerous, form superficial and deep plexuses, the former with fine fibres of 0·001—0·0015'', which occasionally divide, and whose ultimate terminations escape the eye.

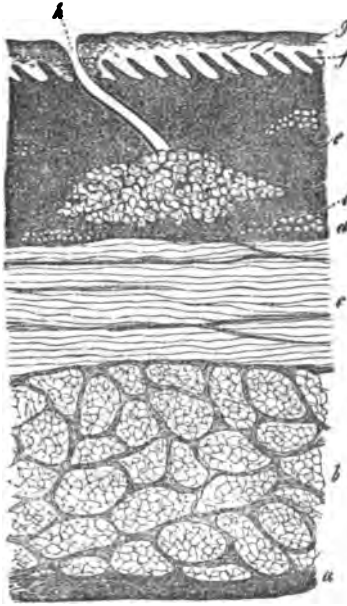## 2. THE ŒSOPHAGUS.

### § 145.

The wall of the œsophagus,  $1\frac{1}{3}$ —1 $\frac{3}{4}$ ''' thick, consists, externally, of a fibrous membrane composed of connective tissue, with exceedingly beautiful elastic fibres. To this succeeds a muscular

membrane  $\frac{3}{4}$ —1" thick, composed of an external, longitudinally fibrous layer, having a thickness of 0.5", and of an internal,

Fig. 198.



circularly fibrous layer of 0.24—0.3", which are in close apposition. From the *pharynx*, where the longitudinal fibres arise in two bundles from the *constrictor infimus*, united with a third from the cricoid cartilage, they extend as far as the stomach, with whose muscles they are partly continuous. In the upper third of *oesophagus*, as far as its entrance into the *thorax*, transversely striated muscles alone are found, arranged in bundles of 0.04—0.24", which sometimes distinctly anastomose. Further downwards *smooth muscles* of the same structure as those in the intestine (*infra*) make their appearance, in the first place

in the circular layer and subsequently, among the longitudinal fibres; the proportion of these gradually increases, until at last, in the lower fourth, smooth muscle altogether predominates. Isolated, transversely-striated muscles, however, are, according to Ficinus, to be met with as far as the *cardia*. Most internally we find, separated from the muscular coat by a white, soft layer of submucous connective tissue (*tunica nervea* of the ancients), the pale-red mucous membrane, which below takes on a whitish tint. Its total thickness 0.36"—0.45" is due, to the extent of about 0.1—0.12", to its laminated, tessellated epithelium, which presents the same structure as in the oral cavity, with the exception, however, that the actual epithelial plates constitute about a moiety of

Fig. 198. Transverse section from the middle of the *oesophagus* (Man),  $\times 1-2$ : *a*, fibrous investment; *b*, longitudinal muscles; *c*, transverse muscles; *d*, *tunica nervea*; *e*, longitudinal muscles of the mucous membrane; *f*, papillae; *g*, epithelium; *h*, aperture of a mucous gland; *i*, mass of fat.

the whole and, after a short maceration, or, as frequently happens in the dead subject, spontaneously, may be readily stripped off in large white sheets, either


alone, or accompanied by adherent portions of the deeper layers. The proper mucous membrane, measuring on the average 0·8''' , possesses numerous conical *papillæ* of 0·04—0·05''' in length, and consists of ordinary connective tissue, with fine elastic fibres, among which, however, as Brücke

and I have ascertained, a great quantity of *longitudinal* bundles of *smooth muscles*, and in addition, more isolated groups of ordinary fat cells and small *racemose mucous glands*, may be observed.

The *œsophagus* is moderately provided with *lymphatics* and *blood-vessels*; the latter send loops into the *papillæ* and form at their bases, a not very wide network, like that in the *pharynx*. *Nerves* may also be met with in considerable numbers in the mucous membrane, containing fine fibres of 0·0012'''—0·0015''' , but I have not yet succeeded in tracing them into the *papillæ*, nor in observing divisions, nor the modes in which they terminate.

*Literature.*—C. Th. Tourtual, 'Neue Untersuchungen über den Bau des Menschlichen Schlund-und Kehlkopfes,' Leipzig, 1846.

Fig. 199.



## OF THE ALIMENTARY CANAL.

## § 146.

Those parts which constitute what may, more strictly speaking, be called the *alimentary canal*, are the least fixed of all which compose the alimentary tract and are almost invariably attached by special membranous bands—the *mesenteria*—in the great cavity of the abdomen, lined by the peritonæum. With

Fig. 199. Muscular-fibre cells from the œsophageal mucous membrane of the Pig, after being treated with nitric acid of 29 per cent.,  $\times$  15.



the exception of a small portion of the *rectum*, the walls of the alimentary canal consist everywhere of three tunics: a *serous*—the *peritonæum*; a *muscular*—consisting of two or even three layers; and a *mucous* membrane, the latter containing a great number of glandular structures, which may be divided into three groups, *racemose mucous glands*, *tubular glands*, and *closed follicles*.

#### § 147.

The *peritonæum* is much thicker in its external or parietal, than in its internal or visceral layer (in the former case 0·04—0·06'', in the latter 0·02—0·03'') though its structure is essentially the same in each locality. It consists principally of *connective tissue* with distinct, variously interwoven bundles, and abundant reticulated elastic fibres, which are coarser in the parietal *lamina*. A loose *subserous* connective tissue, containing more or less fat, unites the *peritonæum* with the other organs, or, as in the mesenteric folds, connects its layers together; under the visceral *lamina*, however, it is very little developed except in certain localities (*colon*, *appendices epiploicæ*), and in certain folds of the *peritonæum*, it does not exist at all. The free surface of both lamellæ of the *peritonæum* is lined by a simple tessellated epithelium, whose slightly flattened, polygonal, nucleated cells measure, on the average, 0·01''; they are so closely united and so constantly kept moist, that the free serous surface appears perfectly smooth and shining.

The *peritonæum* is, in general, but scantily supplied with vessels; they are most abundant in the *omenta*, in the visceral layer and in the subserous tissue, in which last alone, *lymphatics* have as yet been found. The *nerves* are also but few, and are especially to be met with in the *omentum*, the *mesenteria*, and hepatic ligaments, where they accompany the arteries.

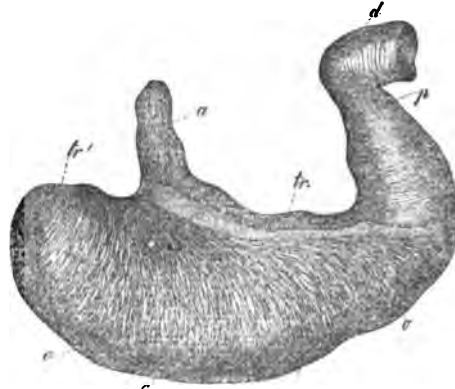
#### § 148.

*Muscular tunic of the alimentary canal.*—The whole alimentary tract, from the stomach to the *rectum*, possesses a special muscular coat, which, however, does not everywhere present the same conditions.

In the *stomach* the muscular tunic varies in thickness; at

the *fundus* it is thin ( $\frac{1}{4}$ — $\frac{1}{3}$ '''); in the middle, it has a thickness of about  $\frac{1}{3}$ '''; in the pyloric region, finally, about  $\frac{2}{3}$  or even 1''' . It consists of three incomplete layers : 1. most externally, *longitudinal* fibres, especially at the *cardia*, where they arise from the expansion of a part of the longitudinal fibres of the *œsophagus* ; and also at the *pylorus* and in the *pars pylorica*, whence, tensely

Fig. 200.



stretched, they are continued upon the *duodenum* ; 2. *circular muscles*, in the middle region, from the *fundus* to the *pylorus* ; where they are accumulated, constituting the so-called *sphincter* of the *pylorus* ; 3. most internally, *oblique fibres*, which, in connexion with the circular fibres, embrace the *fundus* as in a sling, and run obliquely upon the anterior and posterior walls of the stomach, towards its greater curvature, where they terminate upon the outer surface of the mucous membrane or unite together.

In the *small intestine*, the muscular coat is somewhat thicker in the *duodenum* and the upper portions, than in the lower ; it has, in general, a thickness of  $\frac{1}{4}$ — $\frac{1}{8}$ ''', and is composed only of longitudinal and transverse fibres. The former are always less developed and do not form a continuous layer, since they are very few or entirely absent along the attachment of the mesentery ; they are usually most distinct upon the free border, though even here they may be readily torn away with the serous membrane, so as, at once, to leave the second layer exposed. The latter is complete and continuous, consisting of circular bundles, which not uncommonly anastomose at very acute angles.

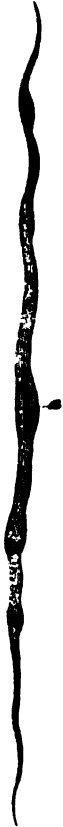In the *large intestine*, the longitudinal fibres are reduced to the three *ligamenta coli*, muscular bands of 4'''—6''' , or even 8''' broad, and  $\frac{1}{3}$ — $\frac{1}{3}$ ''' thick, which commencing upon the *cæcum* are

Fig. 200. Stomach of Man, reduced : *a*, œsophagus, with the longitudinal fibres ; *tr*, transverse fibres (second layer), for the most part dissected off ; *tr'*, transverse fibres of the *fundus* ; *o*, *fibræ obliquæ* ; *p*, *pylorus* ; *d*, *duodenum*.

united upon the sigmoid flexure, into a single longitudinally fibrous layer, which is continued upon the rectum. Beneath these bands there lies a continuous, circularly fibrous layer, thinner than in the small intestines and more especially developed in the duplicatures, which are known under the name of the *plicæ sigmoideæ*.

The *rectum* possesses a muscular layer of 1''' and more thick, in which the more abundant longitudinal fibres lie external to the circular. The ultimate, somewhat thickened extremity of the circular fibres is the *sphincter ani internus*, with which the transversely striated *sphincter externus* and *levator ani* are conjoined.

Fig. 201.



In their *elementary structure*, all the muscles of the proper alimentary canal belong to the so-called *smooth* or *not-striated* (vegetative, organic) muscles (see § 26). Their elements, the fibre-cells, are fusiform, on the average 0.002—0.003''' broad, and 0.06—0.1''' long, pale, flattened, and homogeneous, and provided with a nucleus 0.006—0.012''' long, and 0.001—0.0028''' broad.

Many of the fibres present knot-like enlargements and frequently zigzag flexures, which produce the *transversely striated* appearance of the entire bundles of such muscles so frequently met with in spirit preparations. The arrangement of the fibre-cells in the different strata is simply this; mutually applied in their length and breadth and coherent, they are united into thin muscular bands, which then, invested with a coating of connective tissue and, frequently, also united into secondary bundles, constitute the thinner or thicker muscular tunics of the different regions; which, again, are surrounded and separated from the contiguous parts, by considerable layers of connective tissue.


*Blood-vessels* are very abundant in the smooth muscles; and their capillaries, of 0.003—0.004''' , constitute a characteristic<sup>1</sup> network with rectangular meshes.

Fig. 201. Muscular fibre cell from the small intestine (human).

<sup>1</sup> [Hardly characteristic; the vessels are arranged in precisely the same way in the fascial aponeuroses; e. g., the *fascia lata* of the thigh.]—Eds.

Nothing is known about the *lymphatics*; nor are the relations of the *nerves* yet ascertained, except that Ecker has observed

Fig. 202.



the division of fine nervous tubules in the muscular tunics of the stomach of the Frog and Rabbit.

### MUCOUS MEMBRANE OF THE STOMACH.

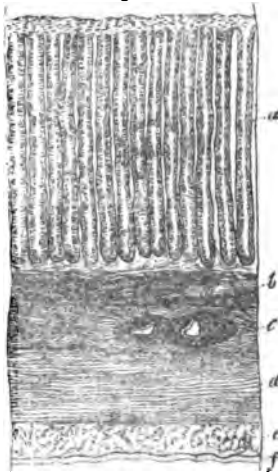
#### § 149.

The *gastric mucous membrane* is soft and loose in texture; and its colour, during digestion, is reddish-grey or bright red, at other times greyish. When the stomach is empty, the inner surface is thrown into longitudinal folds, which disappear in its distended state. Furthermore, it presents, especially

Fig. 202. Blood-vessels of the smooth muscles of the intestine,  $\times 45$ .

Fig. 203. Perpendicular section through the tunics of the Pig's stomach, from the pylorus,  $\times 30$ : *a*, glands; *b*, muscular layer of the mucous membrane; *c*, submucous tissue (*tunica nervea*), with divided vessels; *d*, transverse layer of muscles; *e*, longitudinal layer of muscles; *f*, serous membrane.

Fig. 203



in the pyloric region, around the apertures of the tubular or gastric glands, little reticulated folds or even isolated *villi* (*plicæ villosæ*, Krause) of 0·024—0·048''' or even 0·1''' ( $\frac{1}{30}$ — $\frac{1}{25}$ ''' Krause). Not unfrequently, also, the mucous membrane is marked out, especially upon the right side, by little shallow depressions, into slightly raised polygonal areas of  $\frac{1}{8}$ —2''', the so-called 'état mamelonné' of pathologists, which, however, is also exhibited by perfectly healthy stomachs. The mucous membrane is thinnest ( $\frac{1}{8}$ — $\frac{1}{4}$ '''), at the *cardia*, in the middle it becomes thickened to  $\frac{1}{3}$ ''', and in the pyloric region to  $\frac{2}{3}$  or 1''', which depends entirely upon the glandular layer, since the epithelium and muscular layer everywhere possess the same thickness. The submucous tissue is abundant and, as throughout the whole intestine, contains occasional fat-cells.

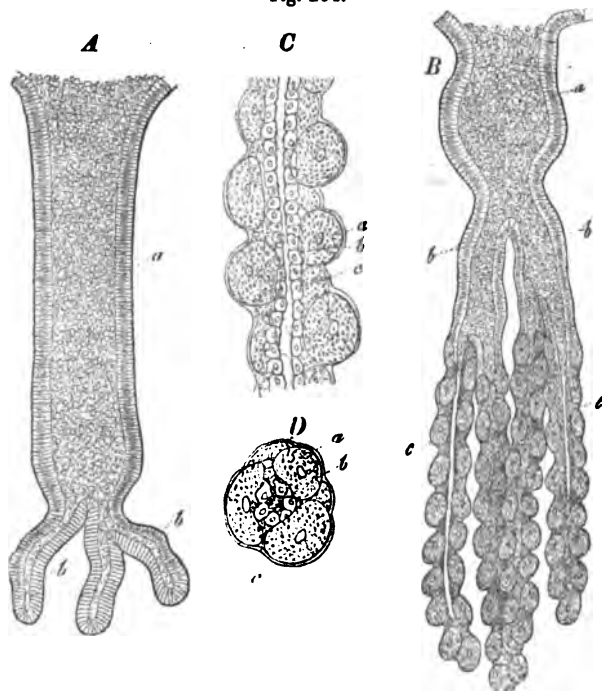
#### § 150.

*The gastric glands.*—The gastric glands—the most important part of the mucous membrane—are tubular glands which, set close together, pass straight through the entire thickness of the mucous membrane to its muscular layer, and therefore vary, in the different regions of the stomach, from  $\frac{1}{5}$  to  $\frac{3}{4}$ ''', or even 1''', but are on the average  $\frac{1}{3}$ ''' in length. Each of them commences as a cylindrical tube, of 0·03—0·04''' diameter, at the surface of the mucous membrane, diminishes inferiorly to as little as 0·014—0·02''', and terminates by a clavate or flask-shaped enlargement of 0·02—0·026—0·036'''. The lower third of the glands is usually undulated or even twisted into a corkscrew shape, especially at the *pylorus*; occasionally it gives off a shorter or longer cæcal branch before its termination. Every gastric gland is surrounded by a delicate *membrana propria* and possesses in its upper third, a cylindrical epithelium continuous with that of the surface of the stomach; for the inferior three fourths of its extent, on the other hand, it presents pale, finely granular, polygonal nucleated cells of 0·006—0·01''', which probably never constitute a distinct epithelium, but appear completely to fill the tubes.

[In animals, the gastric glands are more complicated than in man, frequently presenting dichotomous divisions and subdivisions of their free ends; in many genera, they are of two

very distinct kinds, the *mucous gastric glands*, with a cylinder epithelium and the *peptic gastric glands* (Magensaftdrüsen) with cells similar to those which exist in man. A more detailed description of some forms will be found in my 'Mikroskop. Anatomie' (II, 2, p. 140); and I here subjoin figures of the two forms of the glands in the dog, merely to render my meaning intelligible.

Fig. 204.



The *secretion* of the *gastric glands* has not been so completely examined in man, that we can say with certainty whether they all secrete gastric juice or not. A few experiments which I instituted with regard to this point, tend to

Fig. 204. *A*, mucous gastric gland of a Dog, from the *pylorus*, with cylinder epithelium: *a*, wide cavity of the gland; *b*, its caecal appendages. *B*, peptic gastric gland from the middle of the stomach: *a*, common trunk of the gland; *b*, its chief branches; *c*, terminal caeca;  $\times 60$ . *C*, a portion of the caeca,  $\times 350$ , and viewed longitudinally. *D*, the same viewed in transverse section: *a*, *membrana propria*; *b*, large cells close to it; *c*, small epithelium round the cavity.

show that here, as in animals, it is only particular glands—those in fact of the middle of the stomach—which yield the proper, active secretion; however, further observations must be made on stomachs in the freshest and most normal state, to confirm this result. In any case, the secretion of the glands is for the most part a fluid, though in the *mucus*, a small quantity of which usually covers the mucous membrane, we not only meet with half-destroyed cylinder epithelium, but almost invariably, with a certain quantity of proper glandular cells; and it is impossible to say whether these are essential, or only accidental constituents of the glandular secretion.

*In many animals there are two secretions with different properties corresponding with the two forms of gastric glands, a fact to which Bischoff and Wasmann first drew attention, and which I can confirm. In the Dog, glands with cylinder epithelium exist in the pylorus; those with round cells in the remainder of the stomach; there is the same arrangement in Ruminants and in the Rabbit; whilst in the Pig, it is only the middle of the stomach and especially the great curvature, which presents the latter glands. A series of experiments on artificial digestion, which were carried out by Dr. Goll, of Zurich, and myself, principally with the pig's stomach, afforded the distinct result, that, so far as their solvent powers are concerned, the glands present very different relations; those with round cells act upon protein compounds which have been coagulated by acids in a very short time, while those with cylinder epithelium, either have no action at all or take a long time to produce a slight effect. Furthermore a well-marked acid reaction is presented by that region of the stomach only in which the former glands are situated. The active organic substance, pepsin, is not contained in the gastric mucus, which, consisting of detached epithelium cylinders, often forms a thick covering over the mucous membrane, but in the finely granulated, rounded cells of the peptic gastric glands, to which therefore the term peptic cells (Labzellen, Frerichs)<sup>1</sup> may well be applied. According to my observations, however, these peptic cells do not necessarily become thrown off, nor take any direct share in digestion, but frequently exert their action simply by pouring the juice which they prepare into the glands.]*

<sup>1</sup> [Literally, "rennet-cells."—Eds.]

## § 151.

We have seen, that beside the glands, only a very *scanty tissue enters into the mucous membrane*. Around their extremities alone, do we find a dense, continuous, reddish layer 0·022—0·044'' in thickness, (Brücke) the *muscular layer of the mucous membrane*, consisting of bundles of common connective tissue and of smooth muscles, interwoven, the latter of which cross one another principally in two directions, and, in the Pig, even pass between the glands and into the *pllicæ villosæ*. In man, we meet only with vessels, and an amorphous connective tissue, without elastic fibrils, interposed between the glands, forming at the surface of the mucous membrane, a clear, perfectly homogeneous stratum, the *structureless membrane* of authors, which is continuous with the *membranæ propriæ* of the separate glandular tubes, but cannot, like them, be isolated.

The whole internal surface of the stomach from the *cardia*, (where the tessellated epithelium of the *œsophagus* terminates by a sharp notched edge), possesses a simple covering of cylindrical cells, about 0·01'' long on the average, which lie immediately upon the outermost homogeneous portion of the mucous membrane, without any interposed substance. During life, this *cylinder epithelium*—whose other relations will be treated of below, in describing the small intestine, where a layer of exactly similar nature is to be met with—is closely united with the mucous membrane, though not so intimately, but that its elements are, at times, detached to a larger or smaller amount, by the mechanical violence to which it is necessarily occasionally subjected in the stomach. After death this takes place so readily, that the cells can be seen *in situ*, in man, only under very favorable circumstances. Perhaps, also, detachment of the epithelium to a certain extent may take place normally, in one way or another, during digestion; at least, in animals the quantity of loose epithelial cells is often very great and they frequently almost entirely constitute the mucous coating which covers the surface of the stomach.

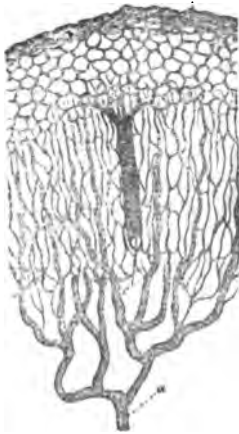
Besides the tubular glands, the stomach also contains, though they are inconstant and vary very much in number, *closed follicles*—the so-called *lenticular glands*, which are identical in



structure with the solitary follicles of the small intestine, and therefore need not be further described in this place.<sup>1</sup>

The *blood-vessels* of the gastric mucous membrane are very numerous, and their distribution is quite characteristic (compare fig. 205, representing the vessels of the large intestine,

Fig. 205.



whose arrangement is almost the same). The *arteries* begin to divide in the sub-mucous connective tissue, in such a manner, that only their finer branches reach the mucous membrane, in which, gradually breaking up into capillaries, they ascend in great numbers, perpendicularly, between the glands and form a network of fine capillaries of 0.002—0.003''', around the tubes, which extends as far as to the apertures of the glands. Here this network, which we may regard as continuous through the whole stomach, passes into a superficial reticulation of somewhat larger capillaries, of 0.004—0.008''', whose meshes, in man, are polygonal, 0.02—0.04''' in diameter and encircle the

Fig. 205. Vessels of the large intestine of a Dog, the mucous membrane being cut through perpendicularly: *a*, artery; *b*, capillary network of the surface, with glandular apertures; *c*, vein; *d*, capillary network round the glandular tubules in the thickness of the mucous membrane.

<sup>1</sup> ["Although it may be that the lenticular glands of the stomach are always present in children, they are certainly inconstant in adults, since in many cases no trace whatever can be discovered of them. In other instances they are exceedingly numerous, covering the whole surface of the stomach, but in this case, the invariably diseased state of the alimentary tract, suggests the idea, that they stand in some connexion with it. In many mammalia, no trace of such structure is to be found, while, according to Bischoff (Müll. Arch. 1838,) they occasionally exist in the dog, invariably in the pig, and so far as the latter animal is concerned, I can, with Wasmann, confirm this statement. They are here, as Bischoff supposes and as is evident from Wasmann's description, not isolated, but aggregated glands, true minute Peyer's glands. The aggregations measure 1—2 $\frac{1}{4}$ ''', are distributed especially upon the *cardia* and small curvature, and are readily seen upon stripping off the muscular and sub-mucous tissue. At first sight, they appear to lie entirely in the last-named layer, but if the attempt be made to detach them, it is found that this cannot be done without tearing the mucous membrane, to which they closely adhere. On the internal surface, small depressions are seen where these patches occur, and the gastric glands are here either absent or undeveloped." Külliker, Mikr. Anat. II, 2, p. 151.—Eds.]

apertures of the glands; it is more complicated or more simple, according to the breadth of the interspaces of the glands and the occurrence of elevations upon them, but seems never to consist of simple vascular rings. From this network the *veins*, which are relatively wide, arise by many radicles; they then, further apart from one another than the arteries, and receiving no more blood, penetrate the glandular layer, and upon the outer surface of the mucous membrane, enter, often at right angles, a wide venous network with partly horizontal vessels, in the submucous tissue.

The *lymphatics* of the stomach form a superficial fine network and a deep, coarse, one; and can only be demonstrated by injection. The numerous small branches which pass from the mucous membrane, their aggregation into larger trunks, and final penetration of the muscular tunic, are readily seen in large Mammalia, killed during digestion. The *nerves of the stomach*, derived from the *vagus* and sympathetic, are readily traced into the submucous tissue and they may also be observed entering the muscular layer of the mucous membrane; but it becomes impossible to follow them further, principally because, in the interior of the mucous membrane itself, they present no more dark edged tubules, but probably only the pale embryonic fibres.<sup>1</sup>

#### MUCOUS MEMBRANE OF THE SMALL INTESTINE.

##### § 152.

The mucous membrane of the *small intestine* is thinner than that of the stomach, but more complex in its structure, inasmuch as, besides the *tubular* or *Lieberkühnian glands*, it presents

<sup>1</sup> [In his 'Mikroskopische Anatomie,' B. II, 2, pp. 149, 153, 164, Professor Kölliker shows that the muscular layer of the mucous membrane of the stomach and intestine was discovered by Middeldorpf (De Glandulis Brunonianis, Vratial, 1846, c. tab.) but remained unnoticed until it was re-discovered by Brücke and himself. In the small intestine there are, when this muscular stratum is well developed, two layers, though they are not always complete; the external layer is composed of longitudinal, the internal of transverse fibres.

In the villi, the smooth muscular fibres have been found not only in many mammalia, but also in birds. The contraction of the villi which they effect appears to have been noticed by Lacauchie, Gruby and Delafond, so long ago as 1842.—EDS.]

a great number of permanent *folds* and *villi*; also, imbedded

Fig. 206.



in its substance, peculiar *closed follicles*, the so-called *solitary* and *Peyer's glands* and, in the submucous tissue of the *duodenum*, *Brunner's glands*.

The *mucous membrane* consists of connective tissue, which is internally homogeneous or indistinctly fibrillated; except where certain glands exist, there is but little *submucous tissue*, so that it is pretty closely connected with the muscular tunic. Upon the inner surface of the mucous membrane, there rests a cylinder epithelium, to which further reference will be made under the head of the *villi*; whilst externally, towards the submucous tissue, it is bounded by a *layer of smooth muscles*, discovered by Brücke, which measures, at most, 0·0177''; they are disposed longitudinally and transversely, but in man

their slight development renders it often very difficult to discover them.

### § 153.

The *villi of the small intestine* are small, whitish elevations of the innermost portion of the mucous membrane, readily distinguishable with the naked eye and which, distributed upon and between the *valvulæ conniventes* (*Kerkringian valves*) through the whole extent of the small intestine, from the *pylorus* to the sharp edge of the ileo-cæcal valve (*valvula Bauhini*), are set so close together as to give the mucous membrane its well-known velvety appearance. They are most numerous

Fig. 206. Section through the walls of the lowest portion of a Calf's *ileum*,  $\times 60$ : *a*, villi; *b*, Lieberkühn's glands; *c*, muscular layer of the mucous membrane; *d*, follicles of a *Peyer's patch*; *e*, remainder of the submucous tissue under them; *f*, circular muscles; *g*, longitudinal muscles.

(50—90 upon a square line) in the *duodenum* and *jejunum*, less so in the *ileum* (40—70 upon a square line). In the *duodenum* they are broader and less elevated, resembling folds and laminae  $\frac{1}{10}$ — $\frac{1}{4}$ ''' in height,  $\frac{1}{8}$ — $\frac{1}{4}$  or even  $\frac{3}{4}$ ''' in breadth. In the *jejunum*, they appear for the most part to be conical and flattened; frequently, they are even foliated or cylindrical, clavate or filiform, the three latter forms predominating in the *jejunum*. The length of the villi is from  $\frac{1}{5}$ — $\frac{1}{3}$ ''' ; the breadth from  $\frac{1}{8}$ — $\frac{1}{10}$ ''' , even  $\frac{1}{15}$ ''' ; the thickness in the flattened forms  $\frac{1}{16}$ ''' .

The villi are composed of two portions, a deeper, belonging to the *mucous membrane* and an *epithelial*, superficial coat. The contour of the former or *villus proper*, is similar to that of the entire villus; it is simply a solid process of the mucous membrane, containing

blood-vessels, lymphatics and smooth muscles, whose *matrix*, through which a variable number of roundish *nuclei* are scattered, in general exhibits no morphological character more decided than that of the mucous membrane itself, yet must most undoubtedly be regarded as a metamorphosed connective tissue, without any intermixture of elastic tissue. The *blood-vessels* of the villi (fig. 208) are so numerous,

Fig. 207.

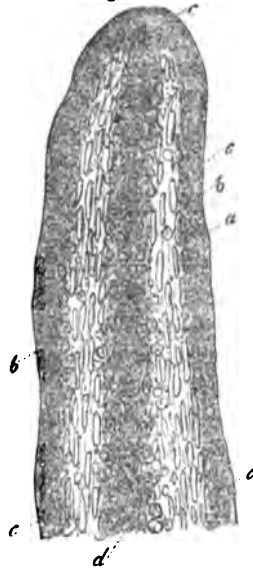


Fig. 208.

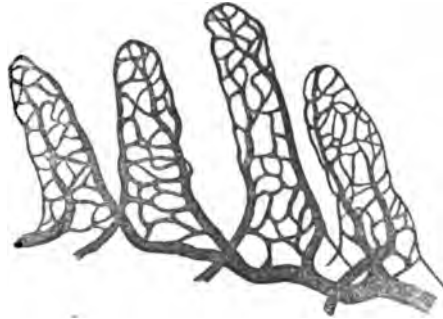


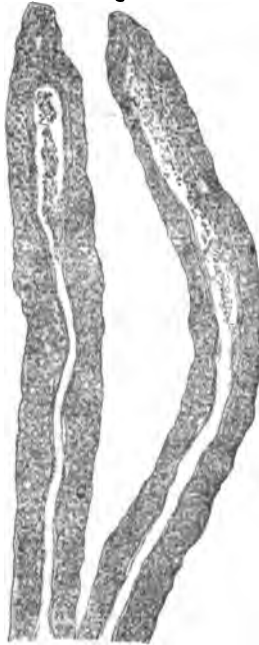Fig. 207. Intestinal villus of a young Kitten without its epithelium, to which acetic acid has been added: *a*, boundary of the villus; *b*, subjacent nuclei; *c*, nuclei of the smooth muscles; *d*, round nuclei in the centre of the villus.

Fig. 208. Vessels of a few villi of the Mouse, after one of Gerlach's injections,  $\times 45$ .

that when well injected, those whose epithelium has been detached become coloured throughout; and, in living animals, or those which have just been killed, each *villus*, if viewed from above, appears as a red dot surrounded by a clear ring. In man, every *villus* contains a close network of capillaries of 0·003—0·005", with rounded or elongated nuclei, which lies immediately beneath the homogeneous external layer of the *matrix*, and is supplied by 1, 2, or 3 small arteries of 0·01—0·016". The blood is usually carried back directly into the larger trunks of the submucous tissue, by a *vein* of 0·022", which does not arise, as in animals, by the arching round of the artery, but proceeds from the gradual confluence of the finest capillaries.

The relations of the *lacteals* in the *villi* of man, have not hitherto been perfectly made out; for although the majority of

Fig. 209.



investigators are inclined, like the older observers, to suppose that they commence by one or two cæcal branches, yet recently, more and more voices appear to be raised for the view that they originate in a plexiform manner. As to my own opinion, I can affirm nothing with respect to the human subject, since I have never succeeded in meeting with *villi* distended with chyle, and in empty ones, I have been unable to obtain any decisive evidence: on the other hand, in animals, I feel certain that in many cases only a single lacteal, which has a cæcal and frequently enlarged end, and whose diameter is much greater than that of the capillaries, traverses the axis of the *villus* (fig. 209).

For my own part in fact, I believe that all the narrow cylindrical and filiform villi will be found to present this condition, but that, on the other hand, the number and mode of origin of the lacteals may possibly

Fig. 209. Two villi without epithelium and with the lacteal in their interior, from the Calf,  $\times 350$ , and treated with dilute solution of caustic soda.

be different in the broad and foliaceous forms (see Mikr. Anat., ii, 2, p. 160).

In addition to these organs, the *villi* also contain, as Brücke discovered a short time ago, a thin layer of longitudinal smooth muscles situated more centrally round the lacteals; these, however, are not always distinct in man. They produce contractions of the *villi* (fig. 210), which are very evident immediately after death, and which, according to Brücke, are also perceptible in the living animal. They have, in all probability, an important influence over the propulsion of the chyle and of the venous blood in the *villi*—always supposing that there is no objection to the assumption that they perform repeated contractions during life. Nothing is known of *nerves* in the *villi*.

The *epithelium of the villi* and of the rest of the surface of the mucous membrane, although it is very intimately united with the deeper-seated parts during life, only becoming detached accidentally or by disease, separates very readily in the dead subject, and can only be observed in perfectly fresh portions of intestine. It consists everywhere of a simple layer of cylindrical cells slightly narrowed below, of 0.01—0.012<sup>mm</sup> in length and 0.003—0.004<sup>mm</sup> in breadth, whose contents are usually nothing but fine granules and an oval, clear, vesicular nucleus, provided with one or two nucleoli. During life, these cells, which agree in all their chemical characters with the deeper cells of the oral epithelium, are so intimately united, that even after death their contours, in a longitudinal view, are at first either not at all, or only indistinctly distinguishable, though on the surface they have the appearance of a beautiful mosaic. The cylinders only become quite distinct when they are either spontaneously or artificially detached, a process which usually takes place in such a manner that they hang together in continuous portions, all the cells covering a *villus*

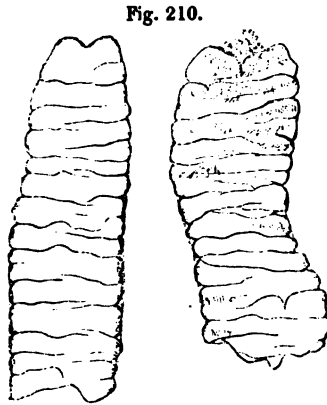
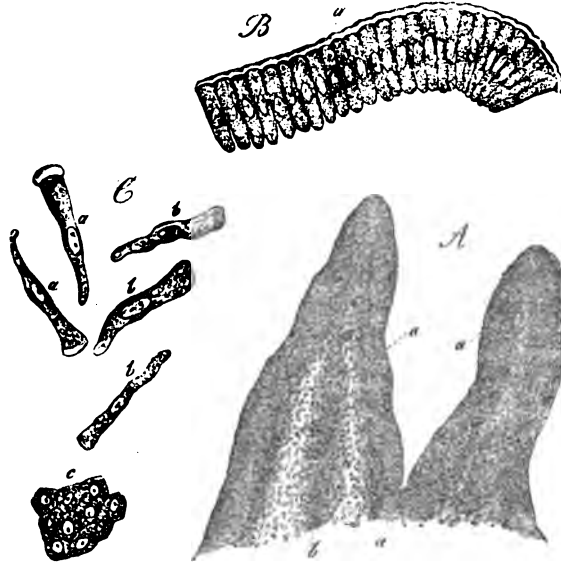


Fig. 210. Two intestinal *villi* of the Cat, contracted,  $\times 60$ .

sometimes coming off together like the *calyptra* of a moss. The addition of water to these cells produces a separation of

Fig. 211.



the cell contents from the broad end, giving rise, in separate cells, to the appearance of a membrane thickened upon one side and in series of cells or entire *villi*, to that of a peculiar structureless coat, like the cuticle of plants; by its longer action, however, or by that of the intestinal fluids, the bursting of the cells produces apertures in them, or they become distended into large pyriform clear vesicles.

[We may here refer to the *changes which the epithelial cells and the villi in general undergo during digestion*. The most striking circumstance is the occurrence of fat in different parts of the *villi*, which may always be observed during the formation of a fatty, milk white chyle. The succession of the morphological steps, at least as I have observed them in animals,

Fig. 211. *A*, two *villi*, with their *epithelium*, from the Rabbit,  $\times 73$ : *a*, *epithelium*; *b*, *parenchyma* of the *villus*. *B*, a detached sheet of *epithelium*,  $\times 300$ : *a*, membrane raised up by the action of water. *C*, single epithelial cells,  $\times 350$ : *a*, with, *b*, without, a raised-up membrane; *c*, a few cells from the surface.

is as follows: The fat contained in the chyme at first enters only isolated epithelial cells in different regions of the *villi*, so that in each we soon observe a large ovate shining drop. The number of these fat-cells rapidly increases, and then the *villi* acquire a very peculiar appearance, often as if beset with pearls, from the irregular alternation of cells filled with fat and consequently bright and shining, with those which are empty and pale. In the end, all the cells become filled with these drops and the epithelium appears quite dark by transmitted, but whitish by reflected light, giving its aspect to the whole *villus*. With the repletion of the entire epithelial covering of the *villus*, absorption commences, but up to this time nothing has entered the lacteals. This, however, soon takes place, and the first indication we observe, is the breaking up of the large drops of fat in the cells into many tolerably minute fatty molecules. When this has occurred, these drops penetrate by degrees, from all sides, into the parenchyma of the *villus* itself, fill it more and more and, at last, enter the central lacteal, whose whole length they eventually occupy. In the meanwhile, fresh fat has been continually passing in from the intestinal canal, not in the form of large drops, however, but henceforward, in small molecules or drops of the same kind as those which were at first developed secondarily in the cells. On the other hand, at a subsequent period, we not uncommonly meet, in the interior of the *villi*, with large round drops, which appear especially inclined to form considerable accumulations at their apex. In man, I have not yet had the opportunity of tracing the process of the absorption of fat, step by step, but we may here so frequently observe, on the one hand, cylindrical epithelial cells filled with fatty molecules, and on the other, collections of larger and smaller drops of fat in the parenchyma of the *villi*, especially at their points and in their axes, that I do not at all hesitate to suppose the process to be the same as in animals, without, however, wishing to imply that all the steps are identical. These observations demonstrate that fatty matters are absorbed as such and are not saponified; on the other hand, it cannot at present be certainly stated how it is possible that they penetrate the membrane of the epithelial cells, the parenchyma of the *villi*, and the walls of the lacteals. I should be most inclined to compare the whole process



to the imbibition of an emulsive fluid, such as milk, by a porous body; and I believe that the fatty molecules of the chyme are absorbed simply in consequence of their being carried along with its fluid part.

While digestion is going on, we frequently find the whole parenchyma of the *villi* densely filled with small nuclei, here and there surrounded by cell membranes, elements which are perhaps never entirely absent in a *villus*, but are at other times far fewer, and particularly are not to be distinguished in its interior.<sup>1</sup>]

<sup>1</sup> [One of the most important contributions to our knowledge of the anatomy of the villi and the general physiology of digestive absorption, which has appeared for a long time, is Professor Bruch's 'Beiträge zur Anatomie und Physiologie der Dünndarm-Schleimhaut,' in Siebold and Kölliker's 'Zeitschrift,' for April, 1853. We subjoin the principal results at which the Professor has arrived.

The epithelium is not cast off during normal digestion and in freshly killed animals it is somewhat difficult to detach it from the mucous membrane. The cells of the epithelium do not, as Weber stated, undergo any change of form during digestion and chylication, but they become filled with fat, which gradually passes on into the villi, &c., so that in the fasting state they are again free from any foreign contents.

The villi ordinarily contain two, but sometimes many, capillary trunks, which ramify principally at their apices, and superficially. Ramifications and anastomoses in the body of the villi are less common. In dogs, many parallel vessels often run undivided for a considerable distance, and have doubtless been confounded with a central lacteal.

In all the animals Bruch examined, and in man, he found that the villi had a striking uniformity of structure. *A single lacteal ran, without dividing, through the villus, and terminated shortly before reaching its apex, in a caecal commonly enlarged end (Lieberkühn's ampulla).* The lacteal had no wall, appearing to be a mere excavation in the villus. In cleft villi, the lacteal was cleft, each end terminating in a caecum. In very rare cases, there were in broad villi two lacteals, a shorter and a longer, terminating in distinct *ampullae*, side by side. In the mucous membrane itself, the lacteals form a wide superficial network.

Bruch accounts for the supposed lacteal network of the villi, by showing that the *blood-vessels are as capable of absorbing fat as the lacteals*, and when filled, of course acquire the appearance of a lacteal network. In some cases he found the superficial capillary network of a villus half red and half white, and it was frequently possible, when the fatty contents of the capillary network were hidden by the preponderating blood, to render them obvious by the action of water, which dissolved out the colouring matter and thus apparently converted a capillary, into a lacteal network.

Professor Bruch considers that the absorption of fat is a purely mechanical process, "just as quicksilver is pressed through leather," and he doubts altogether that the lacteals have any special absorbent function, or differ from ordinary lymphatics. However, we think that the mechanical nature of the process is open to very great question, and we should rather compare the manner in which fat enters a villus, to

## § 154.

*Glands of the small intestine.*—The small intestine contains only two kinds of true glands; viz., 1. *tubular glands*, which are disposed over the whole mucous membrane; and 2. *racemose glands*, in the submucous tissue of the *duodenum*.

The *racemose glands*, or as they are more commonly named, after their discoverer, *Brunner's glands*, form, at the commencement of the *duodenum*, upon the outer side of the mucous membrane, a continuous layer, which is best developed and thickest, close to the *pylorus*, where it constitutes a considerable glandular ring and extends about as far as the aperture of the biliary ducts. If the two layers of the muscular tissue be dissected off a stretched or distended *duodenum*, the glands may readily be recognised as yellowish, flattened bodies of  $\frac{1}{10}$ — $1\frac{1}{4}$ ''' (on the average  $\frac{1}{4}$ — $\frac{1}{2}$ '''), with their angles rounded off, which, enclosed within a little connective tissue, lie close to the mucous membrane and send short excretory ducts into it. In their minute structure, Brunner's glands, the terminal vesicles of which measure 0.03—0.06, even 0.08''', agree perfectly with the racemose glands of the oral cavity and *œsophagus*. Their secretion is an alkaline *mucus*, in which no formed elements are contained, having no digestive action upon coagulated protein compounds and probably merely subservient to mechanical ends.

The *tubular, or Lieberkühnian glands (cryptæ mucosæ)*, are distributed over the whole small intestine, including the *duodenum*, as innumerable, straight, narrow cæca, which occupy the entire thickness of the mucous membrane and are frequently slightly enlarged at their extremities, though hardly ever dichotomously divided. The best idea of their number is obtained by viewing the mucous membrane either from above or in vertical section, under a low power. In the latter case, we see the cæca standing close together, almost like palisades

that in which the *ingesta* enter an *Actinophrys*; one can as readily comprehend the existence of a selective power in the former as in the latter case. That some such faculty exists would seem to be indicated by the fact stated by Bruch, that the Lieberkühnian and Peyerian glands take no share in fatty absorption; though, on the other hand, it must be remembered that Kölliker found the eggs of Entozoa in the villi of rabbits ('Mikr. Anat.,' B. II, 2, 173).—Eps.]

(fig. 206); in the former, we observe that the glands do not occupy the whole surface, but only the interspaces between

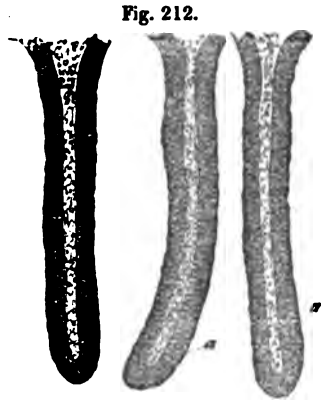


Fig. 212.

the villi; here, however, they exist in such numbers, as to leave no intervals of any width, the mucous surface between the villi appearing pierced like a sieve. Even on Peyer's patches and over the solitary follicles, these glands are to be met with; but in man, they leave those portions of the mucous membrane which lie immediately over the centre of the follicles free, and therefore are arranged like rings around the

follicles. The length of the Lieberkühnian glands equals the thickness of the mucous membrane and varies from  $\frac{1}{3}$ — $\frac{1}{7}$ ''; their breadth is 0·028—0·036''; that of their aperture, 0·02—0·03''. They are composed of a delicate homogeneous *membrana propria* and of a cylindrical epithelium, which, even during chylication, never, like that of the intestine, contains fat; their cavity is filled, during life, by a clear, fluid secretion, the so-called *intestinal juice*, which, however, becomes rapidly changed after death, or on the addition of water, so that the glands appear to be filled with cells, or with a granular mass.

The *vessels* of Brunner's glands have the same arrangement as those of the salivary, whilst around Lieberkühn's *cæca* they follow exactly the type of those of the stomach. A fine network of capillaries of 0·003'' passes up round the *cæca* and, upon the surface of the mucous membrane, enters an elegant polygonal reticulation of somewhat wider (0·01'') vessels, which communicates on one side with the vessels of the villi, on the other is directly continuous with veins, which, after communicating with those of the villi, run directly out of the mucous membrane. Hence, in this case also, the veins are connected only with the superficial network round the glandular apertures and with that in the villi, but not with that which surrounds the glands, so that, as in the stomach, the vessels which

Fig. 212. Lieberkühnian glands of the Fig,  $\times 60$ : a, *membrana propria* and epithelium; b, cavity.

supply the secretion immediately succeed the arteries, and precede those to which the absorbent function is more especially assigned (comp. Frei, cited below).

[Whence the small round cells, with a single nucleus, which are to be met with in the intestinal mucus, proceed, is doubtful. I have not found them in the glands and I can only refer them to the epithelium, whence I am inclined to suppose that these cells, which are usually few, arise upon the surface of the mucous membrane like the mucous corpuscles of the oral cavity.

In various, particularly intestinal, disorders, in inflammations, *typhus*, *peritonitis*, Böhm found a white viscid secretion in many Lieberkühnian glands (Gland. int., p. 34), which, as subsequent observations of the same author (Darmschleimhaut in der Cholera, p. 63) would indicate, was merely an epithelium detached from the walls of the cavity, and which had become aggregated into a compact plug. In cholera, according to Böhm, this epithelium, as well as that of the whole intestine, is thrown off.]

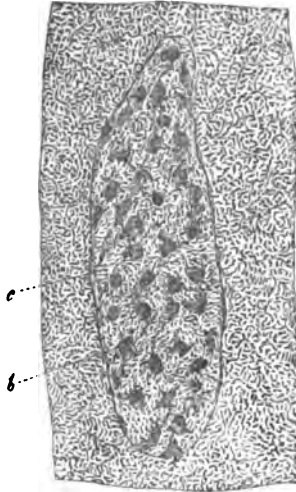
#### § 155.

*Closed follicles of the small intestines.*—Vesicles of a peculiar kind are found scattered, singly or in groups, over the walls of the small intestine, of whose anatomical and physiological import we have, as yet, attained no very clear idea and which may therefore, for the present, be most fittingly described under a general denomination.

The most important of these are *Peyer's patches* (*glandulae agminatæ*). They are rounded flattened organs, invariably situated along that surface of the intestine which is opposite to the mesentery; they are most distinct upon the inner surface, where they appear as rather depressed, smooth spots, without any very sharp definition, but they are also recognizable from the exterior, by the slight elevation to which they give rise; by transmitted light they look like more opaque portions of the membrane. These patches are usually most abundant in the *ileum*, but they are not uncommonly to be met with in the lower part of the *jejunum*:—occasionally they exist in its upper portion close to the *duodenum* and even in the inferior horizontal portion of the *duodenum* itself. Ordinarily

there are 20—30 of them; when they are found higher up there may be as many as 50—60; but they are always most

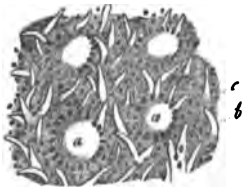Fig. 213.



closely set in the lowest portion of the *ileum*. The dimensions of the separate patches are in general the larger, the closer they are to the *cæcum*; their length is usually  $5''-1\frac{1}{2}''$ , but may diminish to  $3''$ , and increase to  $3-5''$ , or even  $1'$ , their breadth varies from  $3''$  to  $5''$  or  $9''$ . Where the patches lie, the *valvula conniventes* are usually interrupted; in the *jejunum*, however, these folds are also to be met with upon the Peyer's patches and in the *ileum*, rows of closely set *villi* often take their place.

More minutely examined, every *Peyer's patch* is seen to be an aggregation of *closed follicles*, of  $\frac{1}{8}-\frac{1}{3}-1''$  in diameter, either rounded or slightly conical towards the intestinal cavity, which

Fig. 214.



lie partly in the mucous membrane itself, partly in the submucous tissue, and are, on the one side not more than  $0.02-0.03''$  distant from the mucous surface, while on the other, they are in immediate contact with the muscular tunic, which is here somewhat more closely united with the mucous membrane. Viewed from the interior of the intestine, their most striking feature in Man is the presence of many small rounded depressions  $\frac{1}{3}''-\frac{1}{4}''-1''$  apart, which correspond with the separate follicles, and whose floor is, indeed, rendered slightly convex

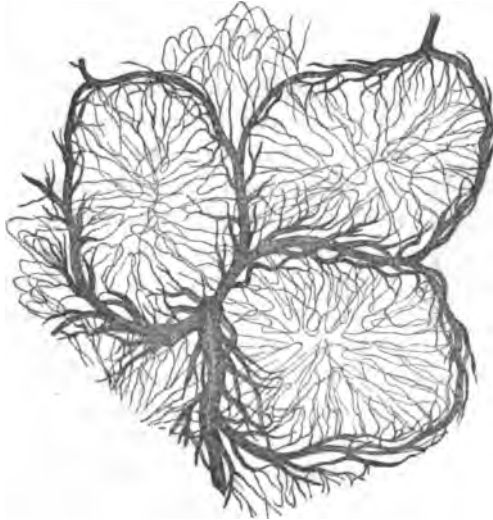
Fig. 213. A Peyer's patch (Man),  $\times 4$ : *a*, ordinary mucous surface, with villi; *b*, depressions upon the patches corresponding with the follicles; *c*, intermediate substance, with small villi.

Fig. 214. Portion of a Peyer's patch of an old Man, after Flouch: *a*, follicle surrounded by the apertures of the Lieberkühnian glands; *b*, villi; *c*, more isolated Lieberkühnian follicles.

by the latter, but which present no villi whatsoever. The remainder of the patch is occupied by *common villi*, or by reticulated folds and by the apertures of the Lieberkühnian glands; the latter are disposed around the slight elevations produced by the follicles, in circlets of 6—10 and more apertures, the *coronæ tubulorum* of authors.

Each *follicle* of a patch possesses a *perfectly closed*, thick and tolerably strong coat of indistinctly fibrillated connective tissue, with interspersed nuclei; within this are the *contents*, which are soft and greyish, (never milk-white). They become slowly diffused through water and consist of a little *fluid*, with innumerable nuclei and round cells of 0·004—0·008<sup>'''</sup>, which, when recent, appear quite homogeneous and of a dull grey colour, but are first cleared up and ultimately destroyed by the action of water and of acetic acid, the nuclei at the same time becoming granular and very distinct. Among these elements, which here and there also contain fatty granules, and

Fig. 215.



which, as the comparison of their various forms shows, are constantly undergoing progressive and retrogressive develop-

Fig. 215. Horizontal section from the middle of three Peyer's follicles of the Rabbit, in order to show their internal vessels. After an injection by Frei.

ment, Frei and Ernst have demonstrated the existence of numerous, but very fine blood-vessels of 0·0015—0·004''', which are connected with a rich vascular network surrounding the follicle, and may be readily recognised in the contents of the follicles of animals (Fig, *e. g.*), if they be quite fresh, and have been extracted with care.

Little is known of the *lymphatics* of Peyer's patches. This much is certain, however, that the *number of lacteals which may be traced during digestion from the Peyerian patches, is greater than that in other parts of the intestine*, although their villi are fewer and less developed; on the other hand, we know nothing of the internal relations of these vessels. They would seem to form networks around the separate follicles, at least we see that they encompass them externally; but they do not become inserted into, nor enter them, at any rate upon this surface, as their milk-white colour would render their detection easy. Although, then, Brücke has recently affirmed the direct communication of the follicles with lymphatics, I must, for these and other reasons (see Mikr. Anat. II, 2, p. 188), at present doubt the fact.

The *solitary follicles* (*glandulae solitariae*) resemble the separate elements of Peyer's patches so closely in size, contents (I have also seen the internal vessels in them), and general structure, that there is no reason for considering them as distinct, particularly since the number of the follicles is subject to all possible varieties; and since, in animals at least, we find Peyer's patches with 2—3—5 follicles. In man, as all writers justly agree, their number is exceedingly inconstant; sometimes not one can be found, whilst in other cases, the whole intestine, as far as the margins of the ileo-caecal valve, is thickly beset with them, or lastly, they may occur in the *ileum* and *jejunum*, but in no very great number. Their entire absence must probably be considered abnormal, since they are constant in newly-born children, being more abundant in the *jejunum* than in the *ileum*. The miliary vesicles, however, which are often met



Fig. 216. A solitary follicle, covered with villi, from the small intestine. After Böhm.

with in immense quantities in the small intestine and stomach, in catarrhal affections of the alimentary tract, may very probably be entirely or partially pathological, since the occurrence of such follicles has been demonstrated in other organs also (in the liver, according to Virchow). The solitary follicles have the same position as the elements of the patches, only they occur also in the mesenteric border and support villi upon their intestinal surface, which is usually somewhat convex.

[I consider it as quite certain, that the follicles of Peyer's patches have no apertures, but I may here adduce the following facts. 1. In animals examined while fresh, the capsules are invariably closed, as may be very readily seen in the well developed patches of the Pig, Sheep, Cat, Dog, &c., which I particularly recommend for the examination of these organs, because the patches in the human subject have so frequently undergone alteration. 2. The appearance of an aperture may proceed from the depression of the mucous membrane over the single follicles, especially when the projecting portion of the wall of the follicles is not very tense. 3. In man, the closed follicles of the intestine are subject to very many morbid changes; they are frequently ruptured and so altered, that in place of the patches nothing remains but a reticulated, indistinctly pitted surface. As Virchow was the first to show (*Med. Reform.* 1848, No. 10, p. 64), they may also burst after death, if they are allowed to stand in water or in a warm place; whence, perhaps, many of those apertures which are met with in the dead subject should be regarded as the result of putrefactive change.

It is easy to understand, that little can be said concerning the physiology of Peyer's follicles so long as their relations to the lymphatics are not understood. They, and the follicles of the intestine in general, appear to me to be closed glandular organs, analogous to the splenic follicles, the tonsils, and the lymphatic glands, which contain peculiar elements and a vascular network. In these a constant development of cells takes place and at the same time, substances are elaborated from the plasma, supplied by the blood-vessels and perhaps also from matters not of a fatty nature, absorbed from the intestine,



a part of which, in all probability, is at once taken up by the internal blood-vessels, while the larger proportion is excreted and absorbed by the lymphatics. The period of their greatest activity (when they become distended) coincides with that of the intestinal absorption, either because they absorb from the intestine or because they simply participate in the greater activity of the intestine at this time; and perhaps the more albuminous matters which they yield may be connected with the development of cells in the chyle. This hypothesis will hold good in its principal outlines, even if in future the direct connexion of the lymphatics with the follicles, or the occurrence of lacteals within them, should be demonstrated; at any rate, it will not be blamed for being too wide of the facts.]

#### § 156.

*Mucous membrane of the large intestine.*—The structure of the mucous membrane in the large intestine agrees so closely in essentials with that of the small intestine, that it may suffice here to draw attention to a few points only:

The mucous membrane of the large intestine, if we except the *rectum*, has no proper folds, for the transversely fibrous muscular layer also enters into the *plicæ sigmoideæ*. The *villi* also are absent, from the edge of the ileo-cæcal valve, into which the muscular tunic likewise enters, onwards; and the mucous surface, apart from some occasional, hardly perceptible, small, wart-like elevations, is even and smooth. It is difficult to detect the muscular layer of the mucous membrane in the human *colon*, though it is unquestionably present; it is more distinct in the *rectum*. In animals I find it well developed. According to Brücke, in the *colon* (of animals?) its longitudinally and transversely fibrous layers, which also exist here, are only 0·013''' thick, the diminution having taken place at the expense of the external longitudinal fibres, which are reduced to a three-fold or even only a two-fold stratum; in the *rectum*, the layers are again of equal thickness, and, taken together, measure about 0·022'', at the *anus* even 0·088''' and more.

The glandular organs of the large intestine are *Lieberkühn's* glands and *solitary* follicles; the former, also termed *glands of the large intestine*, are distributed over its whole surface from the ileo-cæcal valve to the *anus* and in the *processus vermicularis*.

They are closely set, and have exactly the same structure as those of the small intestine, only, in accordance with the greater thickness of the mucous membrane, they are longer and broader ( $\frac{1}{4}$ — $\frac{1}{3}$ '' long,  $\frac{1}{14}$ — $\frac{1}{30}$ '' broad.) Here also I have found, in man and in animals, in the fresh state, no formed contents besides a beautiful cylinder epithelium; so that we have no reason to suppose that the secretion is at all different from that in the glands of the small intestine, especially as the mucous membrane has, like that of the latter, an alkaline reaction, and, so far as my own experiments go, is equally devoid of digestive action.

The *solitary follicles* are arranged close together in the *processus vermicularis*, are very frequent in the *cæcum* and *rectum*, and are also usually more abundant in the colon than in the small intestine. They are distinguished from those of the latter locality by their larger size ( $\frac{3}{4}$ — $1$ — $1\frac{1}{3}$ ''') and by the circumstance that upon each of the little prominences of the mucous membrane to which the follicles give rise, there is a small pit-like, elongated or rounded aperture, of  $\frac{1}{5}$ — $\frac{1}{14}$ ''', which leads to a little depression of the mucous membrane above the follicles. These pits, which are totally absent in the normal follicles of the small intestine, led Böhm formerly to regard the follicles as cæcal glands provided with apertures: this, however, is incorrect, for at the bottom of this depression lies, as Brücke has also remarked, a closed, somewhat flattened follicle of exactly the same structure, even to the internal vessels, as those of the small intestine.

The *blood-vessels* of the glands and follicles of the large intestine present the same relations as in the small. Every Lieberkühnian aperture is encircled by a ring of vessels of

Fig. 217.

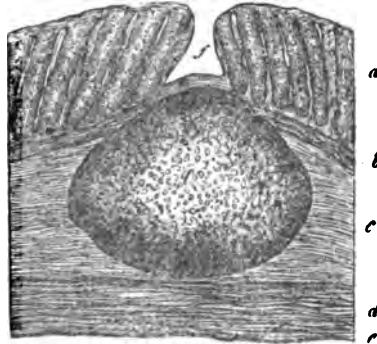


Fig. 217. Solitary follicle from the colon of a Child,  $\times 45$ : *a*, Lieberkühn's glands; *b*, muscular layer of the mucous membrane; *c*, submucous tissue; *d*, transverse muscles; *e*, serous membrane; *f*, depression of the mucous membrane above the follicle, *a*.

0.006—0.01''', which is sometimes single, sometimes, especially in the neighbourhood of the solitary follicles, multiple.

From these vessels wider venous trunks arise and penetrate deeply between the glands, which are themselves surrounded by a dense network of fine capillaries derived immediately from the arteries (fig. 205). Nothing is known of either the *lymphatics* or the *nerves* in the mucous membrane. The *epithelium* is precisely similar to that of the small intestine, and, at the *anus*, is separated by a pretty sharp line of demarcation, from the external *epidermis*.

#### § 157.

*Development of the intestinal canal.*—The *entire wall of the intestine*, various as its different structures may afterwards become, proceeds from two points of development: viz. in the first place from the inferior lamina of the germinal membrane (mucous layer of Pander and Baer; mucous tunic, Reichert; glandular layer or intestinal glandular layer, of Remak), which is not the foundation of the whole mucous membrane, but only of the intestinal epithelium and of the intestinal glands; and 2. from the middle layer of the germinal membrane (vascular lamina, Pander, *membrana intermedia*, Reichert), which gives rise, in addition to many other parts (muscles, bones, nerves, heart), to the vascular and nervous fibrous coats of the intestine, as well as to the vessels, nerves, and coats of the intestinal glands.

The *inner layer or the epithelial tube* consists from first to last of nothing but cells and becomes metamorphosed by their continual multiplication, superficially and perpendicularly, which, according to Remak, takes place by division, in the first place, into the future *epithelia*; and in the second, into the *glands* of the intestine. Of the latter, the Lieberkühnian follicles are from the first, hollow diverticula of the epithelium, whilst the salivary and Brunner's glands arise, like the sudoriparous glands, as solid processes, which only subsequently acquire cavities and become branched. The gastric glands and those of the large intestine also certainly arise from the primitive epithelial tube—whether as diverticula or as solid processes is not yet made out—and form at the commencement a layer completely separated from the fibrous *lamina* of the intestine; whence, also, the epithelium in their neighbourhood

appears much thicker than it subsequently is. At a later period, delicate vascular processes grow from the fibrous layer between the glands, until at length both layers, intimately united, constitute the proper mucous membrane. Similar and more considerable processes of the fibrous layer form the *villi*, whilst the muscular and serous tissues are developed from its external portion.

[The *examination* of the intestinal mucous membrane presents greater difficulties than that of other parts. The *epithelium* is usually in a good state of preservation only in quite fresh subjects, and generally breaks up into its elements with extreme ease. The *villi* are best seen in thin perpendicular sections, made with fine scissors, viewed with a low power, and illuminated from above. During absorption, they are usually found full of fat and nuclei, so that their separate portions are not perceived, with the exception of the lacteals, which become distinct by the use of acetic acid and still better by that of dilute caustic soda. At other times, the muscles of the *villi* are easily recognised by their nuclei, on the addition of acetic acid. Injections are required for the blood-vessels: the best are made by injecting from both arteries and veins at the same time, and should be preserved in fluid. The same holds good of the other parts of the intestine, for which perpendicular sections are especially instructive. For the glands, recent pieces of intestine are particularly required, although it is often, as in the stomach, exceedingly difficult to prepare them. Mucous membrane, hardened in alcohol, pyroligneous acid, or chromic acid, or boiled in acetic acid of 80 per cent. and dried, according to the method of Purkinje and Middeldorpf, or saturated with gum and dried, thin transverse and longitudinal sections being made with a sharp knife, according to Wasmann's method, may be used, being first rendered clear by a little soda. The analysis of the gastric mucous membrane into its elements, presents the greatest difficulties, especially when it is as thick, as in the Horse and Pig. In the Dog, Cat, Rabbit, and in Ruminants, the process is easier, since, frequently, by merely scraping the mucous membrane with the back of a knife, the epithelium of the glands may be drawn out in a connected state and affords all the information required as to their form and lining. Simple teasing out is also frequently sufficient to

reduce the mucous membrane of the animals in question into its elements.

*Brunner's glands* offer no difficulties except in their excretory ducts, which may, however, be clearly seen in perpendicular sections and in animals, by teasing out the mucous membrane. The Lieberkühnian glands, also, may generally be very readily isolated in their entire length; while the *closed follicles* should be carefully exposed from without, isolated and opened; or they may be studied in perpendicular sections. The muscular tissue of the mucous membrane must be exposed by removing the *tunica nervea* on its exterior and then separating it in small segments from the glandular layer; its elements may be very well seen by macerating it in nitric acid of 20 per cent.]

*Literature of the intestinal canal.*—Th. L. W. Bischoff, 'Ueber den Bau der Magenschleimhaut,' Mull. Arch. 1838, p. 503, with figures; Wasmann, 'De digestionem nonnulla,' Berol., 1839, cum tab.; L. Böhm, 'De glandularum intestinalium structurâ penitiori,' Berol., 1835, 8 c. tab.; and 'Die kranke Darmschleimhaut in der asiatischen Cholera,' Berl., 1838; J. Henle, 'Symbolæ ad anatomiam villorum intestinalium impr. eorum epithelii et vasorum lacteorum,' c. tab. Berol., 1837, 4to.; J. Flouch, 'Recherches sur la membrane muqueuse intestinale, in Mém. de la société d'histoire natur. de Strasbourg,' III, 3. Strasb., 1845; A. Th. Middeldorpf, 'De glandulis Brunnianis,' Vratisl. 1846, c. tab.; E. H. Weber, in 'Müller's Archiv,' 1847, p. 400; and in 'Berichte der Königlichen Sächsischen Gesellschaft der Wissenschaften,' Heft VII, 18 May, 1847, p. 245; Frerichs (and Frei), Article, 'Verdauung, in Wagner's Handw. d. Physiologie,' Bd. III, p. 738—755; R. O. Ziegler, 'Ueber die solitären und Peyer'schen Follikel,' Würzburg, 1850, Diss.; E. Brücke, 1. 'Ueber den Bau und die physiologische Bedeutung der Peyer'schen Drüsen, in Denkschriften der Wiener Akademie,' bd. II, 1850, p. 21, with 1 plate; 2. 'Das Muskelsystem der Schleimhaut des Magens;' und 3. 'Ueber ein in der Darmschleimhaut aufgefundenes Muskelsystem,' in the 'Berichten der Akademie,' 1851; Kölliker, 'Ueber das Vorkommen von glatten Muskelfasern in Schleimhäuten,' in 'Zeitschrift für wiss. Zoologie,' III. 1851, p. 106, und Nachtrag dazu. Heft II.; F. Ernst, 'Ueber die Anordnung der Blutgefäße in den Darmhäuten.' Zürich, 1851, Diss. c. tab.

[Brüch, 'Beiträge zur Anatomie und Physiologie des Dünndarm-Schleimhaut,' Siebold and Kölliker's 'Zeitschrift,' 1853; also three most important papers by Brücke, 'Ueber die Aufsaugung des Chylus,' Sitzungsberichte d. Wiener Akad. Dec. 1852. 'Ueber den Ursprung und den Verlauf der Chylusgefäße,' *ibid.* January, 1853, and 'Ueber die Chylusgefäße und die Fortbewegung des Chylus,' *ibid.*, March, 1853, which have come into our hands too late for further reference.—Eps.]

## OF THE LIVER.

## § 158.

The liver, a large gland, is at once distinguished from those compound glands, such as the salivary, which have hitherto been described, by the intimate connexion of its larger subdivisions and by the very peculiar structure of its secreting parenchyma, which elaborates the bile. The component parts are, *the secreting parenchyma*, consisting of the lobules or islets of the liver and of the networks of hepatic cells; the *biliary passages* which are formed in this and the *effluent biliary ducts*; very numerous *blood-vessels*; a considerable number of *lymphatics* and *nerves*; and finally, a *peritoneal investment*.

## § 159.

*Secreting parenchyma, hepatic lobes and hepatic substance.*—If the surface or a section of the liver be regarded, it generally exhibits a mottled appearance, which is usually of such a kind, that small, stellate, reddish or brown spots are enclosed within a more yellowish-red substance—medullary and cortical substance (Ferrein). This variegation proceeds from the usually unequal distribution of the blood in the smallest trunks and in the capillaries, and in healthy persons it is replaced by a uniform reddish-brown colour. The mottling of the surface of the liver is frequently so regular as to have given rise to the supposition that it consists of *lobes*, especially as in an animal which is a frequent subject of investigation,—the Pig,—they are very obvious; but, as E. H. Weber was the first to demonstrate, in 1842, in the human liver nothing of the kind exists; here, in fact, not only the secreting elements, but the most important parts of the vascular system, *i. e.* the capillary network between the portal and hepatic veins are intimately

connected together throughout the whole organ. Nevertheless, it would be very erroneous to suppose that the secreting parenchyma of the liver is everywhere homogeneous. Ultimate segments may be observed in it, which have a certain independence, although they are in nowise isolated. These *hepatic lobules*, as they may be called, if the term be used in its most general signification, or *hepatic islets*, are thus produced: 1. The smallest branches of the afferent and efferent blood-vessels, the *venæ inter- and intra-lobulares* (Kiernan) are distributed at pretty equal intervals through the whole liver, so that a portion of hepatic substance of  $\frac{1}{3}$ — $\frac{1}{4}$ — $1''$  in diameter, is always found to give origin in its interior, to a small twig of the hepatic vein receiving externally a certain number of the minutest branches of the portal vein and of the hepatic artery; and, 2. The hepatic ducts do not commence irregularly in the parenchyma, but are so disposed that they invariably arise at a distance of  $\frac{1}{7}$ — $\frac{1}{4}'''$  from the origins of the hepatic veins and take the same course as the finest ramifications of the portal vein. In this manner little masses, containing only secreting parenchyma, capillaries and the origins of hepatic veins, are marked out in the liver; whilst in their interspaces, together with parenchyma and capillaries, lie the ultimate branches of the portal vein and hepatic artery and the origins of the hepatic ducts, which, as they do not approach the masses from one, but always from many sides, and are also supported and partially united by connective tissue, form, if not complete, at all events partial zones around them.

[The livers of those animals which present lobes (Polar Bear, *J. Müller*, Pig), are of the greatest value in comprehending the structure of the organ and I therefore here subjoin an account of the structure of the Pig's liver. If we examine this organ in sections or otherwise, it is always seen to be divided into numerous small, rounded, polygonal, not very regular *areæ* of tolerably uniform size, ( $\frac{1}{3}$ — $1\frac{1}{4}'''$ ) which consist of the proper parenchyma of the liver and are bordered by whitish partitions, readily visible to the naked eye. If a cut surface be scraped with the handle of a scalpel, angular masses of liver, equal in size to these *areæ*, are detached, the capsules which surrounded them remaining behind as empty compartments, like a honeycomb. These become still more distinct if a thin

section of the liver is gently kneaded with the fingers in water, and then washed and examined on a black ground, in which case many compartments remain almost completely closed, and still more resemble closed capsules. It must not be supposed, however, that there are any complete special investments around each hepatic lobule. On the other hand, the membranes by which they are formed, always appertain to many lobules in common, so that the whole constitutes a cellulated substance continuous throughout, whose partitions are all simple and cannot be divided into a number of lamellæ. If we trace out the capsules, or as they might better be termed, the partitions of the lobes, we find that they are, for the most part, expansions of the connective tissue, which accompanies the *vena portæ*, &c., or of the so-called capsule of Glisson, but are also connected with the serous investment of the liver and accompany the larger hepatic veins. Kiernan was the first to take a just view of the relation of the lobules to the hepatic vessels, when he said, that they are seated upon the branches of the *hepatic vein*, like leaves upon their stalk. In fact we find, if a small branch of the hepatic vein be slit up, (fig. 218, *bbb*) that it is surrounded on all sides by the hepatic lobules and receives a single vein from each, so that they actually appear to be attached to it by short pedicles. Now since this takes place in exactly the same manner from the veins of moderate size up to the intra-lobular veins, the hepatic veins and lobules may, not without reason, be compared to a tree whose branches are so numerous and so closely beset with polygonal leaves that the foliation, so to speak, constitutes one mass. Imagine now, that another ramified system,

Fig. 218.

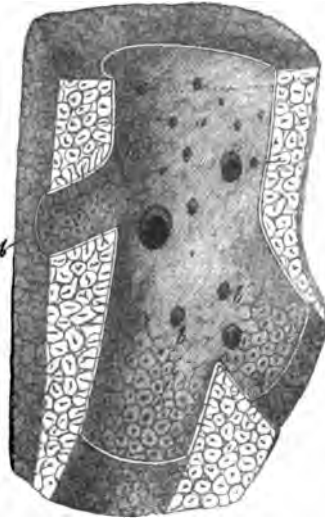
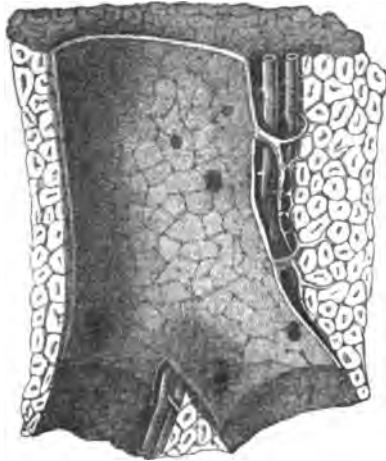


Fig. 218. Segment of a Pig's liver, with an hepatic vein laid open, somewhat magnified: *a*, large vein, into which as yet no intralobular veins open; *b*, its branches, with intralobular veins, and the bases of the lobes shining through. After Kiernan.



composed of vessels, is introduced into the expanded head of this tree, in such a manner that the larger vessels lie in the clefts

Fig. 219.



between its principal masses, the smaller and smallest, in those between the subordinate masses, ultimately penetrating into the lobules themselves, so that every lobule is connected with many of the finest twigs, receiving a coat from the connective tissue which accompanies them, and we shall have as distinct an idea as possible of the relations of the *vena portæ*. The hepatic duct and artery merely accompany the *vena portæ* and, therefore, require no special notice.

In *form*, the lobes of the Pig's liver are angular, usually presenting irregular four, five and six-sided figures in longitudinal and transverse sections.

In the human liver, but very little connective tissue accompanies the *vena portæ* between the hepatic islets, and the latter can neither be said to possess coats nor to be in any complete manner enclosed by the vessels. In *cirrhosis* of the liver, on the other hand, an enormous increase takes place in the amount of connective tissue contained in the parenchyma of the liver, and the individual secreting segments may become prominent or even form isolated lobules. The reddish brown hepatic substance is softer, because more macerated, and sinks in more than the rest, upon the surface and in sections; it may also be more easily scraped away and sometimes readily falls out in fine segments. The cortical layer, which forms a reticulation around the reddish brown spots, presents narrower places, *fissuræ interlobulares*, Kiernan, and wider, *spatia interlobularia*, in which not uncommonly a bloody point may be seen, arising from a portal vessel, but not so regularly as in the brown spots, where

Fig. 219. Portal vessel of the Pig, cut open, with its accompanying branches of the hepatic artery and duct. After Kiernan.

it arises from the *vena intralobularis* and often appears stellate.

By the more complete filling up of the capillary network, it may happen, and, according to Theile, this is in fact the usual case in the majority of human livers, that the *fissuræ interlobulares* disappear, the brown substance representing a network, and the yellow, occurring in isolated spots. I find, as I have stated above, that perfectly fresh livers are, for the most part, uniformly coloured throughout. Kiernan describes, in children, even a reversal of the colouring, which he considers to be dependent upon congestion, more particularly of the *vena portæ*, the external portions of the hepatic lobes being thus more injected. Neither Theile nor I have hitherto noticed this form.]

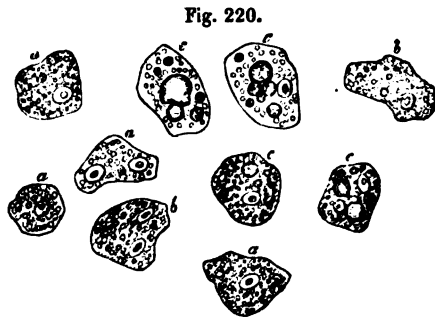
#### § 160.

*Hepatic cells and cell-networks.*—Every hepatic islet contains two elements; 1. a *network of capillaries*, which, on the one hand, is continuous with the finest portal branches, and on the other, unites into the intralobular vein, one of the roots of the hepatic vein; and 2. *an interlaced tissue of delicate columns*, composed of nothing but cells, the *so-called hepatic cells*, in close and immediate apposition. These two networks are so interwoven that the interstices of the one are *completely filled* by the solid portions of the other and leave no interspaces, at least when the vessels contain blood or are injected. Not a trace of biliary ducts is to be observed in this network: they are first met with at the periphery of the hepatic islets, where also the finest portal branches occur, without its having been possible, hitherto, to make out, directly, their connection with the hepatic-cell-network, which is indubitably the secreting portion of the liver.

The *hepatic cells*, which may be isolated with the greatest ease,<sup>1</sup> have a diameter of 0·008—0·012'' on the average,

<sup>1</sup> [This is true of the hepatic "cells" of Man and many Mammalia, but not of all. In the Rat, we could find no demarcation of the hepatic tissue into cells, the tissue resembling very nearly that of the spleen. In Fishes, Dr. Handfield Jones has pointed out the existence of all varieties in this respect, from free "nuclei," with oily and granular matter scattered through a matrix, up to perfectly formed "cells." In the Pigeon, the same author finds no fully formed cells, nor in the Duck; and he there-

0.006—0.016''' in extreme cases, and resemble tessellated epithelium-cells in form, except that they are more irregular. Their membrane is delicate, and perfectly closed, and their



contents, in perfectly normal livers, such as are rarely met with in man, but readily enough in animals, are a granular, yellowish, semifluid substance, which, as microscopic investigation shows, probably contains the essential element of the bile. In this lies a

round vesicular nucleolated *nucleus*, of 0.003—0.004''' ; and in many cells there are *two*. Besides these, fat-drops and pigment granules are frequently to be met with. The former (fig. 220 *e*) occur in all the cells, when the liver has undergone fatty degeneration, in such quantities that they become very similar to certain forms of fat-cells ; and generally, as a few large or many small drops, entirely fill the cell, so that the nucleus becomes invisible. Every transition may be traced from these well-marked forms to ordinary cells with a few minute drops or a single somewhat larger one ; and, in fact, these less fatty cells occur to a certain extent in almost every body ordinarily subjected to examination, so that if their absence in animals were not kept in mind, their occurrence, at least to a small amount, might be regarded as normal. The same may be said with respect to the pigment molecules (fig. 220 *b*). When these are very abundant they are certainly pathological ; but when few, they can only be regarded as a slight deviation from the normal state. They are small, hardly exceeding 0.001''' , of a yellow, or

Fig. 220. Hepatic cells of Man,  $\times 400$  : *a*, more normal cells ; *b*, with pigment ; *c*, with fat.

---

fore draws the general conclusion, "that the secreting process by no means requires the formation of perfect cells in order to effect its peculiar changes ; these may certainly occur in blastematous matter, if the nucleus only be present." 'Philosoph. Transactions,' 1849, p. 132.—EDS.]

brownish yellow colour; their chemical reaction are identical with those of the colouring matter of the bile as it occurs in the intestinal canal, inasmuch as they are not altered in colour by nitric acid, nor dissolved by caustic alkalies.

The hepatic cells are so arranged in the islets as to form a *network* by the simple apposition of their flat surfaces, without the assistance of any foreign connecting intermediate substance or investing coat. The simple or branched columns of hepatic cells, which are almost always to be found among scraped off particles of the liver and to which Henle drew attention (Allg. Anat., p. 903), are nothing but fragments of the hepatic cell-network, whose elements do not cohere very firmly. Taken altogether, the network of every hepatic islet presents more rounded meshes at the periphery, while in the centre they are constantly disposed radially, whence, in a transverse section through the interlobular vein, long ramified columns of hepatic cells are seen stretching from the latter on all sides and uniting by short lateral anastomoses, so that the intermediate meshes appear like narrow elongated clefts. The

*hepatic columns* consist of 1—3, more rarely of 4—5 rows of cells, have a diameter of 0.01—0.015", on the average, 0.006—0.02" in extreme cases, and are generally cylindrical or prismatic, but not at all regularly so; their surfaces are arched, plane, or, in some localities, depressed,

and have rounded or sharp angles. The meshes of the hepatic cell-network correspond with the diameters of the capillaries and of the larger vessels which border upon the hepatic islet, by which they are perfectly filled during life, and will be more thoroughly considered below.

Fig. 221.

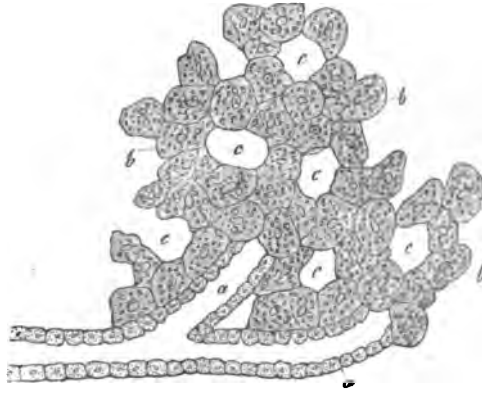


Fig. 221. Hepatic cell network, *b*, and finest *ductus interlobulares*, *a*, of Man, after nature, the union of the two, diagrammatic,  $\times 350$ ; *c*, vascular spaces.

If, as results from the above analysis, the secreting parenchyma of the liver consist of a *solid network of hepatic cells*, one cannot but be struck with its great difference from all the other glands of the body and the important question arises, how, with this arrangement, the secretion is conveyed from the interior of the cells, in which we suppose it to be formed and finally carried away. Anatomy here gives no sufficient reply; for although the ramifications of the hepatic ducts have been traced accompanying the *vena portæ* as far as the hepatic islets, yet, as respects the connexion of their finest twigs with the hepatic network of cells, no definite answer has been afforded; and indeed, up to the present time, no satisfactory account even of the structure of the former has been given. Without entering further, in this place, into the distribution of the hepatic ducts, I will only observe, that in carefully made microscopic preparations, we not unusually find fragments of the finer and finest ducts, the *ductus interlobulares* of Kiernan, between the hepatic islets, and readily obtain evidence that they are constructed according to the ordinary type of excretory ducts. The minutest of these canals, which I have met with, measured  $\frac{1}{100}$ ''' in diameter, possessed a cavity of 0.0033''', and were composed of a simple layer of common tessellated epithelium-cells, which were distinguished from the hepatic cells by their small size (0.004—5'''), their pale contents and the minuteness of their nuclei. I have frequently met with such ducts as these; they had no fibrous coat, perhaps because it had been stripped off in preparing them; but occasionally they seemed to possess a *membrana propria*, at least their external contours were sharply defined. Larger canals, of 0.004—0.005''', always possessed a coat, and the epithelium was more cylindrical, though not completely so, inasmuch as the cells, with a breadth of 0.0048—0.0056''' measured only 0.006—0.008''' in length. Often as I have sought for a direct communication of the finest canals with the hepatic networks, I have not yet directly observed it; which is, indeed, by no means surprising, if we consider the softness of the parts with which we have to do; but unfortunately the result is a *hiatus* in the minute anatomy of the parts, which can hardly be made good by hypotheses. As such, however, I would offer the supposition, that the finest ducts

impinge directly upon the columns of the network of hepatic cells, as the diagram in fig. 221 shows, so that their cavity is terminated by hepatic cells: and, judging from the scantiness of the finest branches of the hepatic duct, I believe that such communications exist, in no very great numbers, at the circumference of the hepatic islets.

Whatever view we may take of the connexion of the hepatic cell-networks with the efferent biliary canals, it is undeniable that any such connexion only takes place *upon the surface of the hepatic islets* and not in their interior and that, therefore, the bile which is formed here, *must be transmitted outwards from cell to cell*. Such a process of transmission through closed cells, involves, as vegetable physiology teaches us, no impossibilities; but it can hardly take place so rapidly as in those localities where actual canals subserve this purpose. Since the bile, as late investigations tend to show with increasing clearness, is not only excreted from the blood, but absolutely formed in the liver and is at the same time by far the most complicated of all the secretions, it may be presumed that the peculiar arrangement of the secreting parenchyma in the liver stands in relation with these peculiarities. In fact, the *plasma* of the blood, in passing through many cells and being subjected to the metabolic influence of each before it reaches the efferent duct, must undergo very different changes from those which it suffers when it is separated from the glandular canals only by a single layer of cells and one or two structureless membranes. The resulting necessary slowness of the secretion is compensated by the size of the organ and the elaboration of the product.

[If nitric acid be added to the hepatic cells, they assume a greenish yellow colour, as was originally stated by Backer. Sugar and sulphuric acid turn them red; water produces an abundant precipitate of dark granules in the cells, which are usually, readily and completely soluble in acetic acid, so that they become more or less pale, often to a considerable extent; the same thing occurs if the acid be added directly. If the liver be boiled, its parenchyma becomes hard and the cells acquire a concentrated and wrinkled appearance. Dilute caustic alkalies rapidly attack the hepatic cells in animals, and

dissolve them; in man they resist somewhat longer, but from the very first swell up to about twice their size, become very pale, and eventually also disappear. Ether and alcohol render the cells smaller and granular, as do sulphuric and nitric acids. The result of these and the above-mentioned facts is, that the hepatic cells contain a considerable quantity of nitrogenous substances, fat, colouring matter of the bile, and perhaps also its acids. The nitrogenous compounds are of several kinds: albumen; which is met with in the watery extract of the liver, and a substance which is precipitated by water, is readily soluble in acetic acid and resembles the casein-like matter found in the serum of the blood (Pannum in Virchow and Reinhard's Archiv, b. IV, 1). The existence of the colouring matter of the bile in the hepatic cells is not so much manifested by their reaction with nitric acid, which is also exhibited by many other cells, as by their general tint, and the frequent occurrence in them of precipitated colouring matter of the bile. The existence of the fatty acids of the bile in the hepatic cells is not directly demonstrable, since both albumen and fat become red by the action of sulphuric acid and sugar (Schultze), but is probable. Fat, however, certainly exists in them, even when it is not microscopically demonstrable, as the collective analyses of the liver show. Probably, also, the sugar which recent researches have demonstrated in the liver will be found to exist in the parenchyma; in the cells, therefore and not in the blood only.

As the principal mass of the liver is formed by the hepatic cells, I here add the results of one of the many analyses of the liver by Von Bibra ('Chem. Fragmente über die Leber und Galle,' Braunschweig, 1849). He found, in 100 parts of the substance of the liver of a young man who died suddenly—

|                                       |           |       |
|---------------------------------------|-----------|-------|
| Protein substance, insoluble in water | . . . . . | 9.44  |
| Albumen                               | . . . . . | 2.40  |
| Collagenous substance                 | . . . . . | 3.37  |
| Extractive matter                     | . . . . . | 6.07  |
| Fat                                   | , . . . . | 2.50  |
| Water                                 | . . . . . | 76.17 |

---

100.00

One hundred parts of the water yielded 3·99 of ash, containing especially phosphate of potash, then phosphate of lime, some silica and iron, and chloride of sodium. The protein-substance, insoluble in water, proceeds from the nuclei and membranes of the hepatic cells and from the contents to which we have referred. The albumen partly proceeds from the blood, but certainly from the cells also. Von Bibra found neither kreatin nor kreatinin in the extractive matters; the colouring matter which they contained did not present the same reaction as that of the bile, whence Von Bibra draws the conclusion that this ingredient does not exist as such in the cells. Finally, I may advert to the acid reaction of the parenchyma of fresh liver, which I discovered (Art. 'Spleen,' in Todd's Cyclopædia), and which, in this case, is even more remarkable than in the spleen. Von Bibra also found the watery extract of the Ox's liver to have an acid reaction (*l. c.*, p. 33), and has demonstrated the existence of lactic acid in it.

There is no subject of minute anatomy upon which opinions are so various, at the present time, as upon the structure of the secreting parenchyma of the liver; and yet, with the views which have been expressed in the preceding section, the only question that can arise is, whether the finest biliary ducts are intercellular spaces, canalicular spaces between the hepatic cells, as Henle and Gerlach consider, or whether they consist of the columns of hepatic cells surrounded by *membranæ propriae*. I have endeavoured to show, in my Mikr. Anat. II, p. 221, that these notions are untenable, and that nothing remains but to accept the view which has been offered, however paradoxical, as the only one which at all corresponds with nature.]

#### § 161.

*Excretory ducts of the liver.*—The *biliary duct* and its branches accompany the *vena portæ* and hepatic artery, so that on one side of a portal branch there is always a much smaller biliary duct and artery, which are included with it in a sheath of connective tissue, the so-called capsule of Glisson. The hepatic ducts ramify, in Man, with the *vena portæ* and may be dissected out for a long distance; and with the microscope they may, in fresh and injected livers, be traced as far as the lobules. Before reaching the latter, they either do not anastomose at all



or very sparingly; the *ductus interlobulares*, however, as they have been termed, appear to be continuous with each other and thus to invest the hepatic islets. From these ducts of  $\frac{1}{90}$ — $\frac{1}{120}$ ''' branches of  $\frac{1}{100}$ — $\frac{1}{120}$ ''' proceed, in no very great numbers, to the hepatic islets and become continuous with the hepatic network in the mode above described. Perhaps the very fine biliary ducts, which I have, as stated above, observed microscopically, with a diameter of 0.01''' and a cavity of 0.0033''', are identical with a part, at all events, of those which have been injected as the origins of the hypothetical lobular biliary ducts.

All the *biliary ducts*, down to those which have a diameter of 0.1''', possess a thick fibrous membrane, composed of dense connective tissue with many nuclei and elastic fibres, and a cylinder epithelium 0.01''' thick, which, in ducts under 0.04—0.05''', becomes gradually changed into a tessellated epithelium. The *ductus communis choledochus* and the *cystic duct* are similarly constituted, only their walls are thinner, and they may be readily separated into a fibrous and a mucous layer, the latter of which contains also a few *muscular fibre-cells*, but on the whole so sparingly, that these ducts cannot be said to possess any special muscular coat.

The *gall-bladder* has, between its *peritoneal covering* and the abundant subserous connective tissue, a delicate layer of *muscles*, whose fibre-cells 0.03'''—0.04''' long, take more particularly a longitudinal and a transverse direction and present only indistinct nuclei. The mucous membrane is distinguished by many reticulated, more or less prominent folds, which contain a capillary network, exactly like that of the foliaceous intestinal villi and it is also provided with a cylinder epithelium, whose cells are often, like the membranes of the gall-bladder, thoroughly stained with bile; their nuclei are not always distinct.

The walls of the biliary ducts contain a multitude of small, racemose, yellowish mucous glands, the *glands of the biliary ducts*, whose vesicles of 0.016—0.024''', differ in no essential respect from those of other racemose glands. In the *ductus hepaticus*, *choledochus*, and in the lower portion of the *cysticus*, the glands in the fibrous tunic and parts external to it, are very numerous,  $\frac{1}{4}$ —1''' in diameter, opening singly or many together by foramina of 0.1—0.14''' visible to the naked eye, which give the mucous membrane of those canals a reticulated

appearance. At the commencement of the cystic duct the glands are few, and in the gall-bladder itself, in which they are said to have been met with, their occurrence is certainly not constant. On the other hand, in the branches of the hepatic duct, down to  $\frac{1}{3}$ " in diameter, such glands are again met with, many of them opening by a double series of fine apertures which exist in these canals.

[We may refer here to certain peculiar ramifications of the biliary duct, *vasa aberrantia* (E. H. Weber). They exist: 1. in the *ligamentum triangulare sinistrum*, as 6—10 and more canals  $0\cdot006$ — $0\cdot027$ " in diameter, consisting of a fibrous membrane and small cells. Ferrein and Kiernan traced them as far as the diaphragm, though for the most part they only extend to the middle of the ligament, or not so far, branching out, forming networks, or anastomosing in loops. According to Theile, tolerably large biliary ducts frequently proceed as far as the edge of the left lobe of the liver without entering the triangular ligament. 2. *Anastomosing biliary ducts* are also to be met with in the membranous bridge which unites the *Spigelian* and right lobes behind the inferior *vena cava*, also in the membranous band which frequently covers the umbilical vein and at the edge of the cystic *fossa*. 3. In the transverse fissure of the liver, according to E. H. Weber, the right and left branches of the *ductus hepaticus* and their smaller twigs give off numerous fine ramuscles, which are distributed through the connective tissue of the capsule of Glisson covering the fossa and form a network, which unites the right and left hepatic ducts. Many small branches of these ducts terminate by enlarged ends of  $\frac{1}{35}$ "— $\frac{1}{18}$ ", and upon their walls a multitude of rounded elevations are met with, which, like the walls of the smallest *bronchiæ*, appear to be formed by flattened cells, which have coalesced with the canals and retain wide communications with their cavities. What Weber thus describes as *vasa aberrantia*, were subsequently described by Theile as *glands of the biliary ducts*. He says, that the elongated glands are not merely curved in various directions, but divide, the resulting branches re-uniting with one another and with the surrounding glands, as may be observed in the glands of the coarser and middle sized biliary ducts—especially, also, in the connective tissue of

the transverse fissure, where the glandular networks are connected with both branches of the biliary ducts. In opposition to these views, Weber, in his latest work, adheres to his former interpretation and shows, against Theile, that mucous glands and their ducts form networks and connect the ducts of other glands nowhere else; furthermore, that in the new-born infant, although the network of the biliary ducts exists in the transverse fissure, those branches which terminate in enlarged extremities are almost entirely absent.

The relations of the finest ramifications of the hepatic ducts, or of the *ductus interlobulares* of Kiernan, have not yet been perfectly made out, a subject which gave rise to many remarks in the previous section. I will only add here, that some, as more especially Guillot, suppose, not only that the *ductus interlobulares* anastomose, but also that their branches are inter-connected in many ways, whilst others, as Theile, describe their communications as scanty. For myself, though I have observed anastomoses of the interlobular ducts, I have as yet met with no communications between their branches, which, though they do not enter the hepatic islets, may be called *lobular branches*. If they occur, they are certainly few in number, for such branches may be isolated for a considerable distance, without any other trunks being seen either to be given off from or to join them. Upon the whole, the interlobular branches are anything but abundantly distributed and, therefore, the slowness of the biliary secretion is determined, not only by the peculiar structure of the hepatic parenchyma, but also by the small number of the excreting canals.

The *bile* is normally quite fluid, being only accidentally mixed with cylindrical epithelium-cells, derived from the coarser biliary ducts. I have never met with hepatic cells in them and the statements of those who have affirmed their existence have arisen, either from a mistake, or from confounding with them the polygonal cells of the epithelium of the *ductus interlobulares*. Constituents which, though abnormal, are very frequent, are—fat-drops, colouring matter of the bile in granules or granular masses, which, as in the hepatic cells, so also in the bile itself, are, occasionally, abundantly excreted; more rarely there are crystals of cholesterine, and especially

the reddish needles of *bilifulvin*, lately observed by Virchow, ('Mittheil d. Würzburg, Phys. Med. Ges.' I, p. 311.)<sup>1</sup>

<sup>1</sup> [The view which Professor Kölliker takes of the mode of termination of the hepatic ducts, can hardly be said to present any essential difference from that which Dr. Handfield Jones has ably advocated in several successive papers in the 'Philosophical Transactions' (for 1846, 1849, and 1853), and which we here subjoin in his own words :

"The liver, in all vertebrate animals, may be regarded as consisting of a secretory parenchyma and of excretory ducts.

"The size of the excretory apparatus bears only a small proportion to that of the secretory.

"These two portions of the liver are not continuous with one another, but are disposed simply in a relation of juxtaposition.

"The action of the liver seems to consist in the transmission of bile, as it is formed, from cell to cell, till it arrives in the neighbourhood of the excretory ducts, by which it is absorbed. This action is probably slow and very liable to be interfered with, contrasting remarkably with that of the kidney, where a particular apparatus is added to ensure completeness and rapidity of action.

"The secretion of the hepatic cells is very liable to be retained within the gland, either in the cells or in a free state.

"This circumstance, as well as its structural relations, seem to point out the liver as approximating to the class of ductless glands.

"For the same reason it is highly probable that a part of the secretion of the cells is directly absorbed into the blood which traverses the lobules" ('Phil. Trans.,' 1849, p. 132)."

From an extensive series of researches in all classes of the Vertebrata, Dr. H. Jones comes to the conclusion that the excretory system of the liver always terminates in closed tubes. The ducts of the Sheep's liver, which in all essential particulars agrees with that of Man and of the Pig, are thus described :

"In the minutest branches (of the biliary ducts) which seem to be approaching their termination, and which can sometimes be examined and isolated in the most satisfactory manner, the epithelial particles are remarkably modified; they can scarcely be said to exist as separate individuals, but rather their nuclei, which are often large and distinct, are set close together in a subgranular or homogeneous basis substance. In ducts where this condition of epithelium exists, there is seldom any distinct trace of basement membrane; the margin, though sufficiently even, yet exhibiting the bulging outlines of the component nuclei; still less is there any proper fibrous coat, though the ducts may be more or less involved in the filamentary expansions of the capsule of Glisson. Ducts of this character have usually a diameter of about  $\frac{1}{1000}$ th of an inch; they can sometimes be followed for a considerable distance without being seen to give off any branches, or to diminish much in calibre. Their mode of termination is various—several have been distinctly seen to terminate by rounded and closed extremities, which have nearly the same diameter as the duct itself; others seem to lose their tubular character, their nuclei become less closely set together, and the uniting substance more faintly granular and indefinite; the duct, in short, gradually ceases, losing all determinate structure. In some, of rather minute size,  $\frac{1}{3000}$ — $\frac{1}{2000}$ th of an inch in diameter, the exterior form remains distinct, but the canal

## § 162.

*Vessels and nerves of the liver.*—The arrangement of the blood-vessels in the liver distinguishes it from all other organs, inasmuch as, besides an artery and an efferent vein, it possesses an additional, afferent vein, the *vena portæ*. While the latter is appropriated to the supply of the secreting parenchyma, being directly continuous through the capillary network with the hepatic vein, the artery is more especially distributed to the walls of the biliary ducts and of the portal vein, to Glisson's capsule, and to the serous investment of the liver, taking only a subordinate share in supplying the capillary network of the hepatic islets. The ramifications of the *portal vein*, and of a few small veins of the stomach and gall bladder (see Weber, Ann. Acad. 1845), which enter the liver independently, take place for the most part dichotomously;

is almost obliterated by the close approximation of the nuclei of the opposite walls. These structures now described, I believe to be truly the terminal branches of the hepatic duct, from which they certainly originate. They seem gradually to lay aside the several component tissues of the larger ducts, the fibrous coat blending with the ramifications of Glisson's capsule, the basement membrane imperceptibly ceasing, and the epithelium becoming resolved at last into its simple fundamental nuclei" (l. c., p. 125).

It is important to remark, that in a Dog, Dr. H. Jones found biliary matter in the interlobular fissures.

From the fact that in the contents of the hepatic ducts of Man and the Sheep, extracted by means of a forceps and without injuring the organ, hepatic cells may be detected, Mr. Wharton Jones ('Phil. Trans.,' 1848) draws the conclusion that the hepatic cells are endogenous cells, answering to the epithelium of other glands—which was Henle's view. It is impossible to doubt a fact stated by so careful an observer; but, however these cells may have got into the large biliary ducts, it is quite clear, from a comparison of diameters, that they cannot enter the minutest ones—the total diameter of the latter being the same as that of the cells, viz.  $\frac{1}{1000}$ th of an inch.

We are strongly inclined to believe that the view taken by Dr. H. Jones is in the main correct—that the liver is essentially of the same order as the "ductless" glands and should be placed in the same category as the Peyerian follicles, spleen, &c. In fact, startling as this view may at first appear, a very clear transition between the Peyerian follicles, &c., and the liver, is afforded by the tonsils; which, on the one hand, are identical with Peyer's follicles, in so far as they are solid vascular networks, whose meshes are filled by a morphologically indifferent tissue; while, on the other hand, without differing from the liver in this respect, they resemble it in having these elements arranged around *diverticula* of the intestinal mucous membrane.—Eds.]

but both larger and smaller branches, besides the main trunk, into which they divide, give off a number of small vessels at right angles. The latter, often after a very short course, at once enter the hepatic islets contiguous to the largest vascular canals, while the larger portal branches, ramifying continually, and becoming finer and finer, have, according to their diameter, to take a longer or a shorter course through the hepatic parenchyma in the canals lined by the capsule of Glisson, before they enter the hepatic islets or lobules. Each of these receives, from one or other set of vessels, at least 3, usually 4—5, smaller vessels of  $\frac{1}{120}$ — $\frac{1}{50}$ ''' , which Kiernan calls *venæ interlobulares*. Such a vein, however, is never distributed to only one hepatic islet, but always to two, or even three. Their ultimate branches, the *rami lobulares* of Kiernan, 10—20 in number, enter the neighbouring hepatic islets, usually at a right angle, and divide immediately into the capillary network, without becoming, in man, directly united with one another. In fact, the branches of the portal vein nowhere anastomose, but are connected merely by the finest vascular network of the organ.

The *capillary network* of the islets (fig. 222) completely fills the interspaces of the hepatic cell network, so that the secreting parenchyma consists actually of only two elements, the hepatic cells and the capillaries. Exactly as the hepatic cell-network is continuous through the entire liver, though, being interrupted by the biliary ducts which pass off and the vessels which enter, at regular intervals, it is divided into separate, very minute *areæ*—so the capillary network of the blood-vessels passes from one hepatic islet to another, but is nevertheless discontinuous in certain spots.

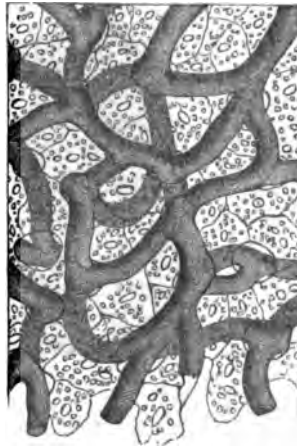

Fig. 222.

Fig. 222. Hepatic-cell network and its capillaries,  $\times 350$ , from the Pig. Spaces are purposely left here and there between the cells and capillaries, which do not exist in nature.

The diameter of the capillaries is, in general, somewhat less than that of the hepatic cell-network, though relatively considerable; in man it is, on the average, 0·004—0·0055", 0·002—0·01" in extreme instances; the wide vessels being more especially found in the neighbourhood of the afferent and efferent veins, the narrowest in the interval between them. The meshes of the network correspond, of course, in form, with the hepatic cell-network, and are thence more elongated in the interior of the hepatic islets, more rounded externally, whilst their breadth corresponds with that of the columns of the hepatic cells, being about 0·006—0·02".

The *hepatic veins* essentially resemble the portal vein, in so far as they possess no valves, branch out at acute angles and do not anastomose; their larger branches also receive numerous minute vessels, but these lie isolated in special canals in the hepatic substance to which they are firmly attached, whence they do not collapse when cut across, and, at least in their finer ramifications, possess no external investment of connective tissue, which is indeed but very rudi-

Fig. 223.



mentary, even in the largest trunks. The relations of the ultimate branches of the hepatic vein, termed by Kiernan *intra-lobular veins*, and by Krukenberg, *venæ centrales lobulorum*, are, however, totally different from those of the portal

Fig. 223. Segment of a very successful injection of the hepatic veins of the Rabbit,  $\times 35$ . One *vena-intralobularis* is visible in its entire course, but only the radicles of the other. The capillaries of the lobules partly coalesce and, in one place, two venous radicles do so.

ramuscles. These veins, which in Man are 0·012—0·03<sup>'''</sup> in diameter, are best studied in some animal whose liver breaks up into isolated lobules, as the Pig; after which Kiernan has given his somewhat diagrammatic figure. If we here open a small branch of the hepatic vein, polygonal areæ are described through the walls of the vessel—the outlines of those surfaces of the lobules which are turned towards the vein (fig. 218).

A minute vein which, in the centre of each of these surfaces, termed by Kiernan “bases of the lobules,” opens directly into the larger vessel leads, if we trace it in the opposite direction, into the interior of a lobule, where it arises from the capillary network; but under no circumstances is it continued into a second or third lobule. In this way only a single vein, which may thence be called *vena intra-lobularis*, arises in each lobule. The vessels into which these veins directly open are called by Kiernan *sublobulares*, because they run along the basal surfaces of the lobules. They are sometimes large, attaining as much as 1—2<sup>'''</sup> in the Pig, and then lie in canals which are surrounded by the basal surfaces of a certain number of lobules; at other times they are smaller, down to  $\frac{1}{35}$ <sup>'''</sup>, in which case they only pass between the lobules. The *sublobular veins* unite into larger veins, which continue to receive, directly, but few or no other intra-lobular veins and thence, are only partly or not at all bounded by the basal surfaces of the lobules, but only by their lateral or apical surfaces (‘capsular surfaces,’ Kiernan). Such veins, when they are smaller, still receive sublobular veins from the groups of lobules which immediately surround them; or, lastly, only larger veins, which have the same relations as themselves.

The *intra-lobular veins* are very simply arranged. Each of them penetrates directly into the axis of an hepatic islet, or lobule, dividing in the middle into two or three principal branches, which frequently again subdivide. The capillaries open, not merely into the terminations of these veins, but also into their trunks throughout their course; indeed, according to Theile, the origins of the sublobular veins also receive capillaries. In all those hepatic lobules or islets whose apices are turned either towards the surface of the liver, or to a large vascular trunk, the interlobular veins extend nearly to their extremities; whilst in others they stop more nearly in the



middle, so that they are always about half the diameter of the lobules distant from the nearest interlobular veins of the *vena portæ*.

The *hepatic artery*, for the most part, accompanies the portal vein and the biliary canals, is inclosed with the latter in Glisson's capsule, and, in its principal ramifications, presents precisely the same relations as the portal vein. It is finally distributed upon the vessels and biliary ducts, in Glisson's capsule, in the fibrous and serous coats of the liver, and in the hepatic islets, whence its branches are denominated *rami vasculares*, *capsulares*, and *lobulares*.

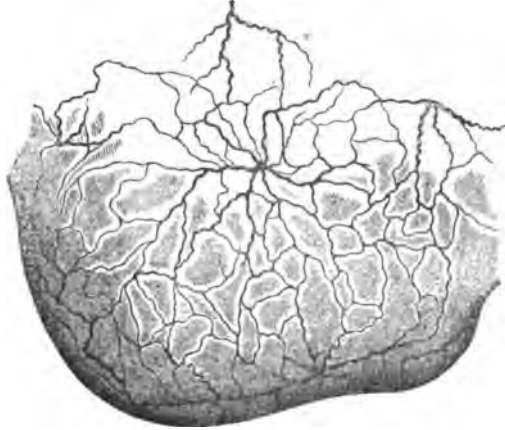1. *Rami vasculares*.—As it divides, in company with the *vena portæ*, the hepatic artery gives off numerous small branches, almost at right angles, which form a plexus in Glisson's capsule, from which some lobular branches for the parietes of the portal canal arise, on the side opposite to the arterial trunks; while many twigs proceed to the walls of the portal vein, the larger branches of the artery itself, the hepatic veins, Glisson's capsule and the biliary ducts. The distribution of the vessels is particularly remarkable in the latter canals, so that, in a good injection, they appear almost as red as the arteries themselves.

A moderately close capillary network exists around all these parts, even the glands of the biliary ducts, whence the *venæ vasculares* arise and open, as Ferrein discovered and as all the moderns since Kiernan have agreed, not into the hepatic vein, but into small portal twigs, as these are leaving the larger branches in Glisson's capsule, and are therefore to be regarded as *internal*, or *hepatic radicles of the portal vein*. From this cause the portal vein may be partially injected from the hepatic artery and conversely. Again, in injecting the hepatic artery and the portal vein, the vascular network in question may be filled from both sides; while it is not possible directly to force injection from the hepatic vein into them.

2. *Rami capsulares*.—Independently of a few branches given off by the artery, before its entrance into the liver, to the *fossa ductus venosi*, to the *ligamentum teres* and *suspensorium*, all the arterial twigs of the coats of the liver are the terminal prolongations of certain arteries which penetrate the liver and appear in different parts of its surface between the hepatic islets. At the points of exit, and even before reaching them,

these vessels, which have a diameter in the adult of  $\frac{1}{30}$ — $\frac{1}{40}$ ''' , in children as much as  $\frac{1}{3}$ ''' , break up into 3—5 radiated subordinate branches, take for the most part a remarkable, corkscrew-

Fig. 224.



like, coiled course, repeatedly anastomosing, and thus spread over the whole surface of the organ, as far as the great venous trunks (*venæ hepaticæ, vena portæ, cava inferior*), the *fossæ* of the liver and its edges, as an elegant arterial network. In the end, these arteries everywhere form a capillary plexus with wide meshes, from whence, in many parts—whether universally or not I do not know—veins arise, which run back parallel with the arteries, enter the liver and open into the portal branches. *Portal radicles*, or *venæ advehentes capsulares*, must be derived, therefore, from this region also. The arteries and veins of the hepatic coats are in their terminal expansion connected, on the one hand, with prolongations of the internal mammary, phrenic, cystic and even the right suprarenal and renal vessels (Theile), and anastomose, on the other side, in the hepatic *fossæ*, with those of Glisson's capsule, with the *vena cava* and hepatic vein.

3. *Rami lobulares*.—With every interlobular vein there runs a branch of the hepatic artery, of at most  $\frac{1}{130}$ ''' in diameter,

Fig. 224. Arterial network upon the convex surface of a child's liver. *Natural size.*

(Theile), which, in the Pig, divides between the hepatic islets, in the capsules of the lobules, into fine anastomosing twigs, and is directly connected with the peripheral part of the capillary network of the hepatic islets or lobules, formed, as stated above, by the portal vein. Arterial blood therefore takes a part, although perhaps a minor one, in the preparation of the bile and the hepatic artery is thus distinguished from the bronchial arteries, whose blood is carried away by special veins.

The *lymphatics* of the liver are very numerous, and may be divided into *superficial* networks, under the *peritoneum*; and *deep* vessels, which accompany the portal vein, and, in animals at least, the hepatic veins also. Both kinds of vessels are connected and proceed partly through the *diaphragm* into the *thorax*, partly to small lymphatic glands in the *porta hepatis* and to the intestinal plexus. The lymphatics of the *gall-bladder* are also exceedingly numerous.

The *nerves* of the liver are relatively very abundant. They arise from the sympathetic and, in a smaller proportion, from the *vagus*, and are chiefly distributed with the hepatic artery, around which they form closer and wider networks without ganglia. They always contain, together with many fine tubules and 'Remak's fibres,' a few thick fibres, and may be traced:— 1. to the *gall-bladder and large biliary ducts*; 2. in *Glisson's capsule*, as far as the interlobular arteries, where their finest twigs, of 0.008—0.010", contain only nucleated fibres; 3. to the *hepatic veins*; and lastly, 4. into the *coats and ligaments of the organ*.

#### § 163.

According to the latest observations, particularly of Bischoff and Remak, the development of the liver may thus be best understood. The primary rudiment of the liver, which appears at a very early period (about the 55—58 hour, in the Chick; in Mammals, after the Wolffian bodies and the *allantois*) consists of two masses of cells, an external, proceeding from the fibrous membrane of the intestine and an internal, epithelial, which at first form a simple, and afterwards a dichotomously divided sac. *Solid processes*, the *hepatic cylinders* of Remak, are now developed from the epithelial *lamina*, which, as in the intestine,

consists at first of round cells, probably in many layers, by the multiplication of its cells, and extend into the outer *lamina*, *branching out* and *anastomosing*, whilst, at the same time, the cells of the outer *lamina* included in the meshes of this network, multiply and become successively changed into vessels, nerves, connective tissue, &c. The difficulty is to say how this peculiar, reticulated parenchyma of cells and rudimentary vessels becomes ultimately arranged as we know it to be. In the first place, as regards the hepatic-cell-network and the islets or lobules of the complete liver. They evidently proceed from the further growth of the original hepatic-cell-network, to which by a continual new development of cells, fresh processes are added, which unite into new networks, so that the hepatic-cell-network of the adult liver is the direct progeny of the original reticulation. More detailed information concerning the separate steps of the formation of the hepatic-cell-network, is at present wanting; yet from what is known it would appear to take place in somewhat different modes. Sometimes, in the subsequent stages, free cylindrical processes of the hepatic-cell-network do not exist to any extent, but it would appear to increase by the continual addition of new meshes at its edges, perhaps also by the constant elongation of the existing columns of hepatic cells and the development of fresh anastomoses between them: this is, if I have observed rightly, the case in man, where even in the seventh week I did not succeed in clearly distinguishing free hepatic columns. At other times, free terminations of the hepatic columns are apparently developed for a considerable period, perhaps until the whole organ has nearly arrived at perfection, their formation appearing to precede by some time that of new anastomoses, as is the case in the Chick and other Birds, and according to J. Müller, in a few Mammals; in the latter of which, according to Müller's figures, the hepatic columns are grouped in lobes. These free, superficial hepatic columns may perhaps throw some light upon the meaning of Weber's and Krause's statements respecting the biliary ducts with caecal ends upon the surface of the liver. With regard to the *biliary ducts*, they are assuredly nothing but secondary excavations of a part of the primarily solid hepatic columns and of the larger internal tracts, which border upon the original epithelial *diverticulum* and which all consist

of many series of cells. The excavation commences in the common biliary duct, proceeds towards its branches, and must be considered to take place exactly as in other glands, *i. e.* either by solution of the inner cells of the rudimentary structures, or by the excretion of a fluid between them and the consequent production of a cavity. In this mode of regarding the matter, there is only one point for consideration; viz. that according to Remak, all the hepatic columns, even the largest, form anastomoses, whilst, as is well known, the biliary ducts ramify without anastomosing. The only solution of this difficulty, consists in assuming that the anastomoses of the primary, largest hepatic columns do not continue in the course of the further development, but that they are *re-absorbed*, a process which has its analogue in many phenomena of foetal growth. In Man alone might we find an exception, for it seems to me that the anastomoses of the right and left hepatic duct, in the *fossa hepatis*, described by E. H. Weber, are perfectly well explained by Remak's observations, and are simply the embryonic anastomoses of the rudiments of these canals, which have attained to some, though no very great development. The mode of origin of the fibrous membranes of the biliary ducts becomes readily comprehensible, if we reflect how the networks of hepatic columns and the fibrous layers of the liver interdigitate; so that layers of connective tissue, &c., might be readily formed around the hepatic cylinders from those elements of the fibrous layer which are nearest to them. The further development of the vessels, nerves, &c., presents no difficulties, taking place in the same way as in other organs. The *gall-bladder* in the Chick, according to Remak, is a process, at first solid, of one hepatic duct, which subsequently becomes hollow and rapidly increases in size. I saw the folds of its mucous membrane, as early as in the fifth month, in a human foetus.<sup>1</sup>

<sup>1</sup> [In his last memoir (Philosophical Transactions, 1853), Dr. Handfield Jones maintains that, in Fishes, Amphibia, and Birds, the liver is developed independently of the intestine, and, that the first rudiment of the excretory apparatus is the gall bladder, whence ducts extend on the one hand into the intestine, and on the other into the liver. He has not traced the development of the liver in Mammalia.

Vogt, however (Embryogenie des Saumons, p. 175), states that in *Coregonus palea*, the liver is at first a rounded, solid mass of cells, in contact with a diverticulum

[The investigation of the liver is best undertaken in the Pig, in which animal the distinct demarcation of the lobules greatly facilitates the comprehension of the relations of the secreting parenchyma, to the vessels and hepatic ducts. The hepatic cells may be isolated with the greatest ease in all animals, either singly, in series, or in reticulated fragments; but to comprehend rightly their collective arrangement no better means exist than the making of fine sections in a fresh liver with the double knife, for which, sections made off-hand with a razor, even in a liver previously hardened in alcohol, pyroligneous acid, chromic acid, &c., are by no means sufficient substitutes. We do not mean to say that the hepatic-cell network cannot be seen at all in this manner, for it is visible even in opaque sections of liver by reflected light, but merely that no complete view can thus be obtained. The finest hepatic ducts are not readily found, though a careful search in nearly all sections which include many lobules, will almost certainly detect scattered fragments of them, readily recognisable by their small polygonal cells, at the edges of the lobules, and long examination may perhaps eventually discover such a fragment in connexion with the hepatic-cell-network, which, however, I have not yet succeeded in doing. The coarser biliary ducts present no difficulties. Their glands are seen readily, partly with the naked eye, partly by the use of dilute caustic soda. Weber's anastomoses of the two hepatic ducts in the *fossa transversa*, are visible in good injections. The *vasa aberrantia*, in the left triangular ligament and in other localities, are readily perceived even without injection, on the addition of acetic acid or of caustic soda. The nerves and lymphatics of the liver are, except their finest portions, easily seen in Man. The blood-vessels require good injections, for which purpose, in the human subject, I especially recommend children's livers, in which the distribution of the *arteria hepatica* in the serous coat, on the vessels, &c., is beautifully distinct. The capillary network of the lobes may readily be filled with fine injection, and a series of excellent preparations of this kind, by various masters of the art, are everywhere to be met with.]

of the intestine—the future *ductus choledochus*; and that, in the course of development, the diverticulum grows into and ramifies in the mass—its ultimate branches terminating in *cæca*. The gall bladder is not formed till very late.—Eds.]

*Literature of the Liver.*—F. Kiernan, 'The Anatomy and Physiology of the Liver,' in 'Phil. Trans.,' 1833; E. H. Weber, 'Annotat. Anat. and Physiol.,' Prol. VI, VII, and VIII, Lips., 1841, and 1842, and 'Programmata collecta Fasc.,' II, Lips., 1851; 'Ueber den feineren Bau der menschlichen Leber,' in 'Müller's Archiv, 1843, p. 318; Zusätze zu seinen Untersuchungen über den Bau der Leber,' in 'Berichte d. K. Sächs. Ges. d. Wissensch. zu Leipzig,' 1850, p. 151; A. Krukenberg, 'Untersuchungen über den feineren Bau der menschlichen Leber,' in 'Müll. Arch.,' 1843; Joh. Müller, in his great Work on the Glands, in his 'Physiology,' and 'Müller's Archiv, 1843, p. 338; Theile, article 'Leber,' in R. Wagner's 'Handw. der Phys.' II, p. 308, 1844; C. L. J. Backer, 'De Structurâ subtiliori Hepatis sani et morborosi. Diss. Inaug. Trajecti ad Rhenum,' 1845; Natalis Guillot, 'Sur la Structure du Foie des Animaux vertébrés' Ann. d. Sc. Nat., 1848, p. 129; R. Retzius, 'Ueber den Bau der Leber,' in 'Müll. Arch.,' 1849, II, p. 141; C. Wedl, 'Ueber die traubenförmigen Gallengangdrüsen,' in 'Sitzungsbericht der Wiener Akad.,' 1850, Dec., p. 480, c. Tab.; N. Weja, 'Beiträge zur feineren Anatomie der Leber,' in 'Müll. Arch.' 1851, p. 79; E. Von Bibra, 'Chemische Fragmente über die Leber und die Galle.' Braunschweig, 1849. The more minute comparative anatomy of the Liver is treated of by H. Karsten, 'Disq. microsc. et chem. hepatitis et bilis Crustaceorum et Molluscorum,' in 'Nova Acta Acad. Cur.,' vol. XXI, 1, p. 295; T. F. G. Schlemm, 'De hepate et bile crustaceorum et molluscorum quorundam,' Diss. Berol., 1844; Williams, in 'Guy's Hosp. Rep.' 1846; H. Meckel, 'Mikrographie einiger Drüsenapparate der niederen Thiere,' in Müll. 'Arch.,' 1849, p. 1; Fr. Will. 'Ueber die Absonderung d. Galle,' Erlangen, 1849; H. Jones, 'Phil. Trans.,' 1846 and 1849.

[T. Wharton Jones, 'Phil. Trans.,' 1848; Handfield Jones, 'Phil. Trans.,' 1853.]

## OF THE PANCREAS.

## § 164.

The *pancreas* is a compound racemose gland, which so closely resembles the salivary glands, that a short exposition of its peculiarities will suffice. As in all such glands, larger, smaller and smallest lobes, may be very distinctly made out, the last being composed of microscopic glandular vesicles, which are here characterised by their moderate size 0.02—0.04" and their usually rounded form. They possess a *membrana propria* and a tessellated epithelium, whose cells are very frequently remarkable from the great number of fat granules, so that the glandular vesicles appear quite opaque and as if entirely filled with secretion. The excretory ducts, which, as elsewhere, are connected with the glandular vesicles, uniting into larger

Fig. 225.



canals and, eventually, into the *duct of Wirsung*, or pancreatic duct, are whitish and somewhat thin walled. They are composed of connective tissue and of elastic fibrils and all possess an epithelium with small cylindrical cells, scarcely exceeding

Fig. 225. Vessels of the pancreas of the Rabbit,  $\times 45$ .



0·006—0·008''' in length, and 0·002''' in breadth. In the walls of the pancreatic duct, and its larger branches, small racemose glands of 0·06—0·08''' with vesicles of 0·016—0·02''' , and a less fatty epithelium, are situated in considerable numbers; whether they are *mucous glands* analogous to those of the biliary ducts, or parts of the pancreas itself, I cannot say. The pancreas possesses the ordinary investing tissue of the glands, with more or less abundant fat cells, in which the vessels and nerves of the gland are distributed. The former present exactly the same relations as in the parotid, except that the lymphatics appear to be more numerous; the latter would seem only to accompany the vessels and arise from the sympathetic, possessing fine, and a few moderately thick tubules. The *secretion* of the pancreas is normally perfectly fluid, only accidentally containing formed constituents, as detached epithelium of the glandular vesicles and of the ducts.

The *development* of the pancreas commences by the formation of a *diverticulum* of the posterior wall of the *duodenum* and in its further progress, exactly resembles the salivary glands, except that the rudiment of the gland forms, from the first, a more compact mass and thence is not so readily made out in detail.

[The *examination* of the pancreas presents no difficulties, except that, in Man, the fat in the epithelial cells of the glandular vesicles offers some impediment and therefore the pancreas of Mammalia (Rabbit, Mouse), which usually contains less fat, should be made use of. The glandules in the ducts are best rendered visible by acetic acid.]

#### OF THE SPLEEN.

##### § 165.

The *spleen*, is a so-called blood-vascular gland, which is in some way concerned in the renewal of the blood and probably with the secretion of the bile also. It consists of a *fibrous and serous coat* and of a soft *parenchyma*, the latter being principally composed of reticularly interwoven solid bands, the *splenic trabeculæ*, inclosing a red substance, the *splenic pulp*.

In the latter we find, in addition, many peculiar white corpuscles, the *splenic or Malpighian corpuscles*, while abundant *vessels* and a certain number of *nerves* are distributed through its whole interior.

## § 166.

*Coats and trabecular tissue.*—The peritoneal investment covers the whole surface of the spleen, with the exception of the *hilus*, where, forming a sheath around the vessels and nerves, it passes on to the fundus of the stomach as the *ligamentum gastro-lienale*, and of the upper extremity, from which it becomes detached, as the *lig. phrenico-lineale*; it adheres so closely to the fibrous coat in Man (though not in Ruminants), that it can only be dissected from the organ in fragments.

The fibrous coat (*tunica albuginea seu propria*) completely surrounds the surface of the spleen, as a moderately thin and semi-transparent but very strong membrane and at the *hilus*, passes into its interior, like Glisson's capsule, accompanying the vessels in the form of peculiar sheaths, the *vaginae vasorum*. In Man, it is composed of common connective tissue, with abundant networks of elastic fibres, whilst in some animals—the Dog, Pig, Ass, Cat, (not in the Rabbit, Horse, Ox, Hedgehog, Guinea-pig, and Bat), I find it to contain *smooth muscles* in considerable numbers.<sup>1</sup>

The *trabeculae of the spleen* are white, shining, flattened or cylindrical fibres, having, on an average, a diameter of  $\frac{1}{10}$ — $\frac{1}{3}$ ''' , which are attached in great numbers to the inner surface of the fibrous coat, and less frequently to the outer surface of the sheaths of the vessels, and unite with similar *trabeculae* in the interior, into a network which extends through the whole organ. The interstices included in it all communicate, con-

Fig. 226.

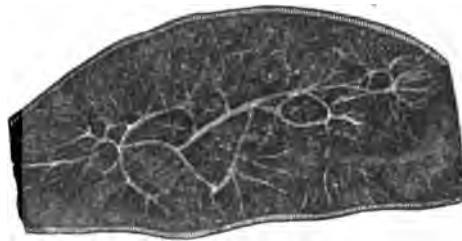


Fig. 226. Transverse section through the middle of an Ox-spleen, washed out, to show the trabeculae and their arrangement. Natural size.


<sup>1</sup> [The existence of these muscles in the ox's spleen was first pointed out by Dr. Sharpey. See Quain and Sharpey's Anatomy, p. 1086.—Eps.]

tain the red pulp of the spleen and the Malpighian corpuscles, and although no one exactly resembles another, yet all as regards form and size, present a certain similarity.

The older anatomists considered them to be regular cavities lined by a membrane, like those of the *corpora cavernosa penis*, to which, indeed, they are very similar in the arrangement of the liminary *trabeculae*, but there is nothing of this kind, as may be best demonstrated in sections of the spleen, in which pulp has been removed by washing. Such a preparation is best fitted for the study of the relations and connexions of the *trabeculae*; and it is readily seen, that although very various in size, they do not ramify after the fashion of vessels, but unite quite irregularly. Where 4, 5, or more of these unequally thick *trabeculae* unite, a flattened cylindrical enlargement, like a nervous ganglion, usually exists; these are more frequent towards the external surface of the organ than in its internal portions and at the *hilus*, where the large vessels already afford a sufficient support to the parenchyma and an intimate union of the *trabeculae* is less necessary.

The *structure* of the *trabeculae* of the human spleen perfectly resembles that of the fibrous coat; they consist of longitudinally

Fig. 227.



fibrous connective tissue, with intermingled fine elastic fibres. In animals, on the other hand, smooth muscles exist, as I shewed in the year 1846, sometimes in all the *trabeculae* (Fig, Dog, Cat), sometimes (Ox,) only in the smaller ones, with respect to whose distribution further particulars will be found in my 'Mikroskopische Anatomie,' II, 2, p. 256. In the *trabeculae* also, we find peculiar spindle-shaped fibres, of 0.02—0.03''' in length and 0.002''' in breadth, with undulated ends and prominent enlargements, in which rounded nuclei are situated. They are to be met with in great

numbers in the splenic pulp of Man (fig. 227 A), and I formerly, though as I now believe wrongly, took them to be

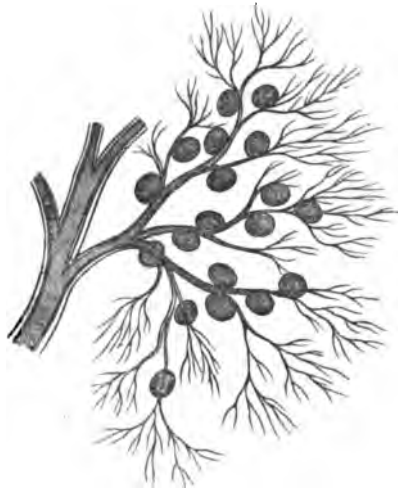Fig. 227. Peculiar fibres from the pulp of the human spleen: A, the same free B, one inclosed in a cell;  $\times$  350.

smooth muscles. What their nature is I cannot say, and I can only add that they are also found coiled up in cell-like bodies<sup>1</sup> (fig. 227 B).

§ 167.

*Malpighian corpuscles*, the *splenic corpuscles*, *Malpighian corpuscles* or *vesicles*, are white roundish bodies, which are im-

Fig. 228.



bedded in the red substance of the spleen and are connected with the smallest arteries. They are constant only in quite fresh and healthy subjects; but not at all, or rarely, in those who die of disease, or after long fasting. It hence becomes comprehensible that Von Hessling found the corpuscles only 116 times in 960 examinations. In subjects whose age was between the first and second year, they were present in every second individual; from the second to the tenth year, in every third; from the tenth to the fourteenth, in every sixteenth; and from the fourteenth onwards, only in every thirty-second. In the bodies of those who die suddenly, as in consequence of accidents, suicide, or judicial sentence (of the latter of whom I have examined three cases), they are probably never absent; and it is the same with the majority of children. In these cases they are as numerous and as distinct as in Mammalia. The size of the splenic corpuscles is liable to certain variations in Man and in animals and has hitherto, for the most

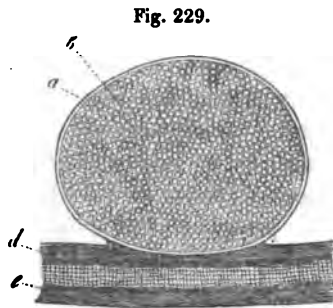
Fig. 228. A portion of a small artery, with a branch covered with Malpighian corpuscles. Dog,  $\times 10$ .

<sup>1</sup> [According to Mr. Wharton Jones ('British and Foreign Med.-Chir. Review,' Jan., 1853), these cells, containing "peculiar fibres," are nothing but the ordinary nucleated fibres of the pulp "circularly coiled, the coil being maintained by a tenacious intercellular substance filling up the middle space."—Eds.]

part, been over-estimated, in consequence of their having been incompletely isolated. Their diameter is from  $\frac{1}{10}$ — $\frac{1}{3}$ ''' , on the average  $\frac{1}{8}$ ''' ; and very probably depends upon the varying condition of the chylopoietic organs, so that the corpuscles are larger after food has been taken than at other times ; though, in confirmation of Ecker's statement, I can affirm that they are to be met with, beautifully developed, in fasting animals also. We have no data of any kind with regard to this point in Man.

The *Malpighian corpuscles*, though imbedded in the red pulp and hardly separable from it, are nevertheless always attached to a branch of an artery, in such a manner that they either rest laterally immediately upon a vessel, or are situated in its angle of division, or finally appear stalked ; in which latter case, however, the stalk itself, again, is usually a small artery. Their number is very considerable, arterial twigs of 0.02—0.04''' carrying 5—10 corpuscles, so that, extracted with them from the pulp, they present the figure of an elegant raceme (fig. 228). It appears to me that it would be rather under, than over estimating the number of the Malpighian corpuscles, to assume that every 1—1 $\frac{1}{2}$  cubic line of the pulp contains a corpuscle.

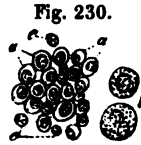With respect to its *minute structure*, every Malpighian corpuscle possesses a special coat and contents, and is therefore a *vesicle*. The membrane is colourless and transparent, 0.001—0.002''' thick, and everywhere exhibits a double contour, with occasional intermediate concentric lines ; it is intimately connected with the sheath of the vessel, with which it also agrees in structure, so far as it contains homogeneous connective tissue and elastic fibrils ; whilst, on the



other hand, the smooth muscles which are also present as longitudinal fibres in these sheaths, are entirely absent. In their interior, the Malpighian corpuscles contain no epithelium, but are entirely filled by a viscid, greyish, continuous substance,

Fig. 229. A Malpighian corpuscle from the spleen of an Ox,  $\times 150$ : *a*, wall of the corpuscle ; *b*, contents ; *d*, sheath ; and *e*, wall of the artery to which it is attached.

consisting of a small quantity of a clear, neutral fluid, coagulable by heat, and therefore albuminous; of many, rounded, larger and smaller (from 0.003—0.006"), pale cells, which usually possess a single nucleus and become granulated by the action of water and of a varying number of free nuclei. Beside these cells, which frequently contain single fat granules and offer the most distinct evidence that in the Malpighian corpuscles a constant development of cells is going on, we occasionally meet with blood-corporcules, either free or in cells and, as I am inclined to believe from a single observation in the spleen of a Cat, with fine blood-vessels, as in Peyer's follicles (see § 155).



The Malpighian corpuscles are completely closed and are not connected with the lymphatics, although this has been asserted by different authors—among the moderns by Huschke, Gerlach, Pölmann and Schaffner. Anatomically, they are perfectly similar to the follicles of Peyer's patches and of the solitary glands, described above and very closely agree with those of the tonsils and lymphatics, whence they may for the present be denominated *gland-like follicles*.

[Malpighian corpuscles have been discovered in all the Mammalia which have hitherto been examined and also occur in Birds. Among the scaly Amphibia they were found by Joh. Müller in one of the *Chelonia* and by myself in the Blind-worm, where the corpuscles were surrounded by an exceedingly elegant network of capillaries. In Frogs and Toads they are, according to Oesterlen, to be met with now and then; but I have not yet succeeded in finding any trace of them in the naked Amphibia, nor in the fresh-water fishes. Leydig, however, has observed them in the Plagiostomata (Beiträge zur Anat. der Rochen und Haie). Joh. Müller's supposition that the Malpighian corpuscles exist in all Vertebrata, is therefore not borne out, a fact which is not without weight in considering their physiological import. In a few Mammals the Malpighian corpuscles contain, though not constantly, the same forms of

Fig. 230. Contents of a Malpighian corpuscle from the Ox: a, small; b, large, cells; c, free nuclei.

retrograding blood corpuscles as will be described to occur in the pulp, in the following section.<sup>1</sup>

<sup>1</sup> [The *Malpighian follicles* of the spleen present three points of importance to the investigator. 1. Whether they have a capsule and what is its nature? 2. The arrangement of their vessels. 3. The structure of the substance which they contain.

1. *The capsule and its nature.*—We have been quite unable to convince ourselves of the existence of any such capsule as that described by Professor Kölliker, in the *Malpighian follicles* of Man, the Sheep, the Pig, the Cat (Kitten), or the Rat; in all of which we have made very careful investigations with regard to this point. In Man, in the Pig and in the Cat, we were unable to distinguish any boundary at all between the follicles and the surrounding red pulp—the substance of the one appearing to pass into the other. At the line of transition, however, the indifferent tissue of the follicle underwent a partial metamorphosis and broke up, when teased out, into spindle-shaped bodies, containing “nuclei,” or short delicate fibres with “nuclei,” exactly resembling, in Man, the structures described by Professor Kölliker as peculiar fibres and represented in fig. 227.

In the Rat this border zone of metamorphosed tissue was somewhat broader and firmer and when the follicle was compressed, appeared, particularly under a low power, like an indistinctly fibrous coat such as Professor Kölliker describes; but when closely examined, it was readily seen to be no distinct closed capsule, but to pass gradually, on the one hand, into the pulp and on the other, into the contents of the follicle. The same is true of the *Malpighian follicles* of the Sheep, where the appearance of a capsule, under a low power, is often very distinct; and where imperfect elastic fibres may be met with in it.

In fact, our own observations are perfectly in agreement with those of Mr. Wharton Jones (British and Foreign Med. Review, Jan., 1853), and have led us completely to the opinion of Remak (Ueber runde Blut-gerinnsel und über Pigment Kugelhaltige Zellen, Müller's 'Archiv,' 1852), that the capsules of the follicles are by no means their essential element, and that we must consider the spleen to be formed by two principal constituents; the first being the *parenchyma*—and the second, a superadded fabric of blood-vessels, nerves, lymphatics, elastic and contractile elements. The manner in which the latter are arranged in and about the *parenchyma* is, in a manner, accidental, and very variable. It may be, as Remak says, either *intercapillary*, as in the pulp; or *vaginal*, as in the sheaths of the arteries; or *encysted*, as at the angles of division of the arteries, in the *Malpighian follicles* of the Sheep.

To insist, therefore, upon the follicular arrangement of the spleen, or indeed of any other of the vascular glands, as Sanders (On the Structure of the Spleen, 'Annals of Anatomy and Physiology,' 1850) and Kölliker do, seems to us to mistake accidental for essential characters.

The results of comparative anatomical examination are strikingly in favour of this view of the matter.

The *Malpighian follicles* of Birds and Amphibia have no capsules (Remak, Leydig). In *Bombinator igneus*, according to Leydig, a white substance, the representative of the *Malpighian follicles*, lies in the middle of the spleen, surrounded by a red cortical pulp, into which it directly passes.

On the other hand, *Coluber natris*, a Reptile, presents the very opposite characters.

## § 168.

*The red substance of the spleen, the pulp, or parenchyma of the spleen,* is a soft reddish substance, which fills up all the in-

Here the red pulp is absent and the spleen has, as nearly as possible, the structure of an ordinary lymphatic gland, consisting of a fibrous *stroma*, containing cavities full of indifferent tissue, through which a capillary network, arising from the vessels of the *stroma*, is distributed (Leydig, 'Anatomisch-Histologische Untersuchungen über Fische und Reptilien,' 1853).

In Fishes the same variation occurs. In *Hexanchus* there are thick-walled Malpighian corpuscles (Leydig). In other Plagiostomes and many osseous Fish there are no distinct follicles, but the indifferent follicular tissue follows the sheaths of the arteries.

2. *The arrangement of the vessels of the Malpighian follicles.*—Johannes Müller, who gave the first good account of the Malpighian follicles of vegetable feeders (Müller's 'Archiv,' 1834), not only states that the follicles are, what all recent researches have shown them to be—the representatives of portions of the sheaths of the arteries, but also that the arterial twigs which supply them "sometimes run beside the Malpighian bodies without giving any branches to them, *sometimes pass straight through the corpuscles*" (p. 88). However, he appears to be inclined to the opinion that the arterial twigs pass "not so much through the middle of the corpuscles" as in the thickness of their walls.

All subsequent writers have affirmed that the arterial twigs pass over the surface and not through the substance of the Malpighian follicles, with the exception of Günsburg and of Dr. Sanders—who states, not in the paper we have cited, but in a subsequent communication to the Edinburgh Physiological Society (Jan. 31st, 1851), that by a peculiar method of preparation, he had observed arterial twigs passing diametrically through the substance of the follicles, "stains of blood also, often in linear arrangement, indicating capillaries, were seen in the interior of the sacculi." With regard to the latter point, it will be observed that, in the text, Professor Kölliker also records a single observation of minute blood-vessels in the Malpighian follicles of the Cat.

In all the Mammalian spleens we have examined (Man, Sheep, Pig, Cat, Rat), we have observed the passage of arteries through the Malpighian follicles and the existence of a capillary network in them, with the utmost ease; we are, indeed, at a loss to comprehend how it is that previous observers have so generally overlooked facts so patent. The method we have pursued has been merely to make a tolerably fine section, containing a Malpighian follicle, with a sharp knife—to spread it out with needles, *adding nothing but a little weak syrup* and then, placing a thin glass plate over it, we have examined it with both the simple and the compound microscope. The use of the former is especially to be recommended, because by manipulating the covering plate, the whole follicle may be readily rolled about under the eye, and the clearest evidence thus obtained that the arterioles pass through and not over the surface of, the follicles. Acetic acid should not be used, as it renders the contents of the follicle opaque; but the syrup is of great service, as it keeps the coloring matter of the blood in the capillaries and renders them extremely obvious.



terspaces between the larger trabeculæ and the coarser vessels, and is so soft as to be readily removed from a fragment of the organ. It consists of three elements; viz., of the most delicate blood-vessels of the spleen, of microscopic fibres and trabeculæ,

The walls of the capillaries are exceedingly delicate and often indistinguishable as distinct structures. Both the longitudinal inner coat and the transverse muscular coat of the arterioles are very well developed in Man.

3. *Structure of the "contents" of the Malpighian follicles.*—We have been unable to find either cavity or fluid in the contents of the Malpighian follicles. So far as we have seen, they are solid bodies—their outer portion or "wall" being constituted as above described; while the inner is, to use the accurate phraseology of Mr. Wharton Jones, composed of "nucleated granular corpuscles and nucleated cells, similar to those of the red substance, cohering together in a mass by means of a diffuent intercellular substance, and, interspersed among these, a few somewhat larger nucleated cells" (l. c., p. 35).

The idea that the Malpighian corpuscles were hollow bodies originated with Malpighi himself; but Müller, in opposition to him and to Rudolphi, asserts very justly that in the Pig, Sheep, and Ox, they are firm and resistant.

From all that has been said, it results very clearly that the only difference between the "pulp" and the "Malpighian follicles" of the spleen is one of degree, consisting in the greater or less development of the vascular network and the greater or less amount of metamorphosis, which the elements of the parenchyma have undergone. It is, furthermore, sufficiently obvious that the anatomical differences between a solitary follicle of the intestine, a Peyer's patch, a lymphatic gland and a spleen, are also questions of degree. It is impossible to distinguish, under the microscope, a minute lymphatic gland—such as may be met with in the mesentery of the Rat, for example—from one of the follicles of the Peyer's patches of the same animal. But as the intestinal follicles are aggregated to form the Peyer's patches, so the lymphatic follicles are aggregated to form the large lymphatic glands: increase the vascularity of the *stroma* of a lymphatic gland and we have a spleen.

On the other hand, we can state decidedly that the follicles of the tonsils, both in Man and in the Sheep, are traversed abundantly by capillaries, so that they come under the same category; differing, however, from the lymphatic glands and spleen, in that the follicles are arranged, not in solid masses, but around diverticula of the intestinal mucous membrane, which, in the tonsils (both in Man and in the Sheep), take the form of more or less irregularly ramified ducts. Starting, therefore, from the simple intestinal follicle, we have two series of vascular glands—the one, the *solid* series, reaching its utmost complexity in the spleen (and perhaps the supra-renal bodies and thymus); the other, the *diverticular* series. Does the latter, however, reach its highest complication in the tonsils? or rather do not these lead in the plainest way to the liver, which is, like them, essentially a solid meshwork of capillaries, filled by indifferent tissue and arranged around a complex diverticulum of the intestine? It appears to us that the structure of the tonsils affords, in this way, an analogical basis for the views of Dr. Handfield Jones; and tends greatly to support the doctrine that the liver is essentially one of the vascular glands. While adding the liver, however, we should exclude the thyroid; its structure being totally different from that of the rest of the class.—Eds.]

and of *peculiar cells of the parenchyma*. In Man and in Animals the occurrence of extravasated blood, in manifold stages of metamorphosis, is so frequent, that it may be almost regarded as a normal constituent. According to its amount and to the distension of the blood-vessels, the pulp appears sometimes of a brighter, sometimes of a darker blood-red; besides which, however, it must be noted that the pulp has also its own proper red colouring matter.

The fibres of the pulp are of two kinds. Firstly, there are *microscopic trabeculae*, answering completely to those visible with the naked eye and possessing the same structure, except that in many Mammals they contain more smooth muscles, or are even entirely composed of them. As a general rule, their diameter varies between 0.005 and 0.01''; in quantity they differ in different animals and in different parts of the spleen. In Man I find them to be more rare and broader than in other Mammals, and perfectly identical in their structure with the larger *trabeculae*. Other fibres which occur in the pulp are plainly the *terminations of the vascular sheaths*. They are very numerous, and usually have the appearance of delicate, indistinct, fibrous membranes, without any elastic element, which appear to connect the capillaries, and are, perhaps, continuous with the finest *trabeculae*.

The *cells of the pulp*, or *parenchyma-cells* of the spleen, round cells of 0.003—0.005'', with single nuclei, are for the most part so similar to those in the Malpighian corpuscles, that it is unnecessary to enter upon a more minute description of them; intermingled with them, and, indeed, in larger quantities than in the Malpighian corpuscles, we find *free nuclei*. Besides these, a few other elements may be met with:—1. pale round bodies, with a homogeneous aspect, somewhat larger than the corpuscles of the blood, which appear either as free nuclei, or as homogeneous nuclei, closely surrounded by a delicate investment; 2. larger cells, up to 0.01'' in diameter—both of the completely pale kind, with one or two nuclei, and also what I have called colourless granule-cells—that is, cells with more or fewer colourless, dark fat-granules. Each of these elements exists in the splenic corpuscles also, but never to so great an amount. The quantity of the different kinds of parenchyma cells and of free nuclei in the pulp, is so considerable,

that, together with a small amount of a reddish yellow fluid which unites them, they constitute probably one-half of the bulk of the spleen. They are not collected in large masses, but in small irregular aggregations of different sizes, which occupy the interspaces between all the *trabeculae* and vessels of every description, and surround the Malpighian corpuscles. The clearest conception of the arrangement is obtained, if we consider that every segment of the red substance included within the larger *trabeculae* has the same composition, on the small scale, as the whole spleen has on the large. In fact, the microscopic *trabeculae*, the terminations of the vascular sheaths and the finest vessels, present the same relations as the large *trabeculae* and vessels, while the small masses of parenchyma cells correspond with the apparently homogeneous masses of pulp, visible to the naked eye. There are no special investments around the parenchyma-cells, but they lie everywhere in direct contact with the sheaths of the vessels, the *trabeculae*, and the sheaths of the Malpighian corpuscles.

The red pulp of the spleen of Man and of Animals has a different colour at different times; or rather the blood-corpuscles which it contains and which, without the participation of any other element, give rise to its colour, present different conditions. In some animals, for instance, its colour is sometimes paler, more greyish-red, sometimes brown, or even blackish-red. In the latter case, a quantity of changed blood-corpuscles will be met with (to which we shall return subsequently); in the former, on the other hand, it may be microscopically demonstrated that the red colour proceeds from unchanged blood-corpuscles, which may also be readily expressed from the substance of the spleen and, on the addition of water, in a short time lose all their colouring matter. In other animals the spleen, although it always has about the same, usually dark colour, yet contains in addition, sometimes only unchanged blood-corpuscles, sometimes multitudes of them in every stage of metamorphosis. These are very striking, and in all animals consist essentially in this—that, 1. the blood-corpuscles, becoming smaller and darker and, in the lower Vertebrata, losing their elliptical form and taking a circular shape, agglomerate together into rounded masses, which either persist in this condition, or, combined with a certain amount

of the plasma of the blood, develop an envelope externally and a nucleus in their interior, thus passing into *round blood-corpuscule-holding cells*, of 0.005—0.015<sup>m</sup>, containing 1—20 blood-corpuscles; and 2. these masses and cells, their contained blood-corpuscles gradually diminishing in size and assuming a golden yellow, brownish-red, or black colour, either in their entire state or after breaking up into pigment granules, change into *pigment masses* and *pigmented granule cells*; and, finally, the latter, their granules gradually becoming pale, pass into perfectly colourless cells. In many cases the blood-corpuscles form no masses or cells, but pass through the above-described stages of coloration and disintegration, like the others.

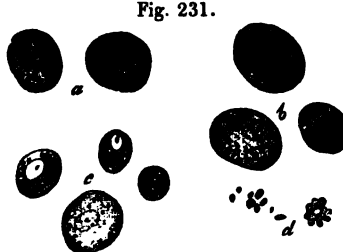


Fig. 231.

[The changes undergone by the blood in the spleen, a subject which is more fully treated of in my 'Mikr. Anat.,' II., 2, pp. 268-270, and which were observed and interpreted by Ecker, at the same time and in the same manner as by myself, have lately become the subject of much discussion. Gerlach, Schaffner, and lately O. Funke also (*l. c.*), who are completely at one with Ecker and myself as to the facts, differ altogether in their interpretation of them; and believe that, instead of their being the result of a dissolution of the blood-corpuscles, they proceed from a process of *development of new corpuscles*, and that therefore the spleen—as, indeed, was Hewson's opinion—is a formative organ for blood-corpuscles.

I have already, in another place (*Zeitsch. für wiss. Zool.*, p. 115), confuted Gerlach's views, and I therefore consider it to be unnecessary to enter, again, into this question, the less, as Ecker, after repeated, careful investigations, quite agrees with me; indeed no unprejudiced observation can tend to

Fig. 231. Blood-corpuscule-holding cells and their metamorphoses, from the spleen of the Rabbit,  $\times 350$ : *a*, two nucleated cells, with blood-corpuscles; *b*, similar cells metamorphosed into brown pigment cells; *c*, cells from which the colour has disappeared again; *d*, pigment granules which have arisen from metamorphosed free blood-corpuscles.

other conclusions than those at which we have arrived. Remak has recently brought forward an entirely new view (*l. i. c.*) From the known facts, that other pigment cells exist than those whose colouring matter is derived from blood-corpuscles, and that effused blood may form cell-like masses with blood-corpuscles, as Hasse and I have more particularly shown—facts which he has strengthened by new cases—Remak has allowed himself to be misled into asserting, not only that no cells with inclosed blood-corpuscles exist at all, but also, that in the spleen no blood-corpuscles are destroyed, *i. e.* change into pigment granules. This is so strong an assertion, that I see no necessity for my contradicting it; one might at last be required to demonstrate that there are such things as cells and blood-corpuscles. It will interest Remak to learn that Virchow, as he tells me, has satisfied himself of the existence of the cells in question, though he explains their origin in another mode, believing that the blood-corpuscles pass from without into already existing cells—a supposition with which, at present, I cannot exactly agree.

An important question arises, as to the *import* of the changes in the blood-corpuscles, whether they are *physiological* or *pathological*? On the one hand, very weighty reasons present themselves for considering the phenomena to be normal, particularly their *constant* occurrence, as it may be said, in so many living animals, especially in those living under natural conditions, as Amphibia and Fishes; secondly, the apparent continuance of perfect health, notwithstanding the enormous quantity of disintegrating blood-corpuscles; thirdly, the occurrence of blood-corpuscle-holding cells in blood-vessels which are not cut off from the general circulation, as may be demonstrated in the Amphibia; fourthly, the absence of similar, constant changes in the blood, repeated at short intervals, in other organs in the higher Vertebrata; and much more might be added. To these facts, however, careful observation opposes many others, which almost involuntarily lead to the idea, that perhaps all the changes of the blood-corpuscles in the spleen are abnormal, a view to which my observations in Fishes also tend. Here, 1. the metamorphoses of the blood-corpuscles in the spleen do not go on in the interior of blood-vessels, but in extravasations which resemble pathological *aneurismata spuria* (see 'Mikr.

Anat.,' II, 2; and Todd's 'Cyclopædia of Anatomy and Physiology,' Art. Spleen, fig. 533; Ecker, 'Icon. Phys.,' tab. vi, figs. 15, 16); 2. extravasations and metamorphoses of their blood-corpuscles occur, not only in the spleen, but in other organs, especially in the kidneys, where they are constant, and frequently also in the liver and *peritoneum*.

If to these facts we also add, that in certain animals, *e. g.* the Cat, the Sheep, &c., the changes of the blood-corpuscles in the spleen are very rarely met with—furthermore, that their progress is not always coincident with the stages of digestion—it becomes very difficult not to believe that the phenomena are abnormal, especially if we consider that similar phenomena certainly not physiological, such as the small effusions of blood into the lungs, bronchial glands and thyroid in Man, in the lymphatic glands of the mesentery of the Pig and Rabbit, &c., are also, on the one hand, almost as constant phenomena, and, on the other hand, are accompanied by perfectly similar metamorphoses of the blood-corpuscles. However, in the latter cases, the quantity of the metamorphosed blood-corpuscles is not to be compared to the immense number of those which are constantly undergoing disintegration in the spleen; and in the second place, it is also possible that effusion of blood may occur as a physiological phenomenon, as into the Graaffian follicles, and during menstruation and the detachment of the placenta. And although all animals do not present a microscopically demonstrable disintegration of the blood-corpuscles in their spleen, yet it does not follow that the process may not occur and that when it can actually be demonstrated, it is pathological. This much is at least certain, that congestions of blood in the spleen occur in all animals, without exception; and it is almost certain, that these congestions are, in Mammals, attended by extravasation. In these stagnations of blood, the blood-corpuscles may be disintegrated, in some cases *rapidly*, in others *slowly*, which would constitute an important difference for the observer; it is also conceivable that they and their consequences are physiological and have some great influence upon life, since it is a fact, that in many animals they are constant, and occur upon a very large scale.

For the present, therefore, so long as the pathological character of the phenomena in question is not conclusively

demonstrated, I must maintain their physiological nature and regard the disintegration of blood-corpuscles in the spleen as a normal occurrence.<sup>1</sup>]

§ 169.

*Vessels and nerves.*—As they enter the organ, the relatively very large splenic artery and the still larger splenic vein, are accompanied by those processes of the fibrous membrane, which have been referred to as the *vascular sheaths*. In Man these processes form complete investments around the vessels and nerves, somewhat after the fashion of the capsule of Glisson, so that the arteries and nerves especially, can be readily isolated, while the veins, which on the side opposite to the artery are more intimately connected with the sheath, are less easily se-

<sup>1</sup> [With respect to the "blood corpuscle-holding cells," the reader will do well to consult Remak's very valuable and elaborate paper, 'Ueber runde Blutgerinnel und über Pigment kugel haltige Zellen,' in Müller's 'Archiv,' for 1852, and Mr. Wharton Jones's article on the same subject in the 'British and Foreign Med. Chir. Review,' for 1853, to which we have already referred. Having carefully studied them, he will, we think, arrive very much at our own conclusion, that as the question now stands, the very existence of "blood corpuscle-holding cells" must be considered as highly problematical.

Mr. Wharton Jones found the blood of the splenic vein to contain nucleated corpuscles and fibres identical with those of the pulp, together with free nuclei similar to those of the nucleated corpuscles; on the occurrence of which, he considers the statements as to the abundance of colourless corpuscles in the blood of the splenic vein are founded. Some of these elements were traced as far as the *vena porta*, but in the hepatic veins they had mostly, though not entirely, disappeared. He appears to be inclined to draw the conclusion that some of the venous radicles of the spleen are connected with the pulp in the same way as the hepatic ducts with the parenchyma of the liver, and that the materials thus derived by the blood from the spleen may concur in fitting it for the secretion of bile. Moleschott ('Ueber die Entwicklung der Blutkörperchen,' Müller's 'Archiv,' 1853) gives some curious results obtained by extirpating the liver and spleen of Frogs. Normally, the cardiac blood of Frogs contains about 8 red corpuscles to 1 colourless; after extirpation of the liver, the proportion is 2—3 red corpuscles to 1 colourless. The blood of the spleen of Frogs contains, normally, six times fewer red corpuscles in proportion to 1 white, than that of the heart. After extirpation of the liver, there are 1—6 colourless corpuscles to 1 red corpuscle in the splenic blood. When the spleen alone has been extirpated, the proportion of red corpuscles is slightly increased. Moleschott concludes that the liver favours the metamorphosis of colourless into red corpuscles. However, we must confess that the results of the individual experiments, from the average of which his conclusions are drawn, vary so widely as to throw some doubt on the latter.—Eds.]

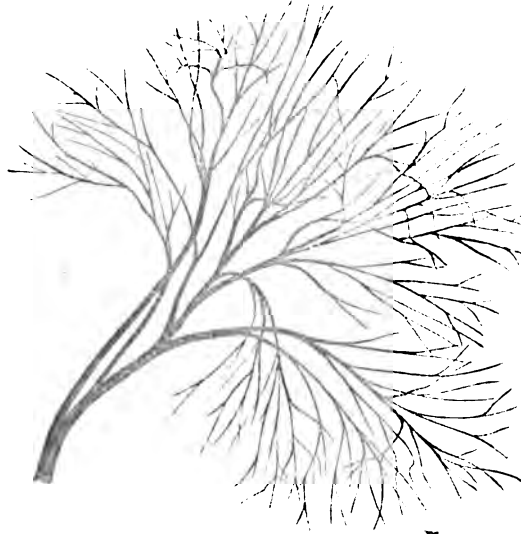
parable. At first the sheaths are as thick as the fibrous coat itself and they retain this thickness so long as they surround the principal branches of the vessels. The finer ramifications of the latter and even those small branches which are given off from the large ones, have finer and finer sheaths, until at last, when the vessels are quite minute, they become lost as thin membranes in the pulp. The thickness of any sheath is always less than that of the wall of the artery to which it belongs and greater than that of the vein, but after division the sheaths become relatively stronger. It was remarked above, that a number of the *trabeculae* are inserted into the vascular sheaths and they therefore take a share, together with the vessels which they inclose, in the formation of the dense network in the interior of the spleen. In Mammalia, as in the Horse, Ass, Ox, Pig, Sheep, &c., the sheaths present different relations, inasmuch as the smaller veins have none at all, and the larger possess them only on the side on which the arteries and nerves lie. Only the two principal venous trunks near the *hilus* have perfect sheaths, whilst the arteries, from the main trunks to the finest ramifications, all possess them. The structure of the sheaths is precisely that of the *trabeculae*, but muscles are not always found in the former when they are contained in the latter—*e. g.* in the Ox—while in the Pig they are also very distinct in the sheaths.

The splenic artery, immediately it enters the organ, and all its principal branches, divide and spread out into a great number of ramifications, the larger of which proceed towards the anterior margin of the organ, the smaller towards the posterior, forming no anastomoses with those of other principal branches. When they have diminished to the diameter of  $\frac{1}{5}$ — $\frac{1}{10}$ ''' , they separate from the veins, which till then had run in the same sheath with them, and become connected by branches of 0.01—0.02''' , with the Malpighian corpuscles in the manner which has been described above; perhaps, also, sending fine branches into their interior (see § 167). Then, often closely applied to the surface of the corpuscles, but, so far as I can observe, not passing through them, as Joh. Müller formerly supposed, they enter the red pulp and immediately break up into elegant bundles of minute arteries, the so-called *penicilli* (fig. 232), which finally subdivide into true capillaries



of 0.003—0.005<sup>m</sup>, which throughout the pulp, round the Malpighian corpuscles, as well as elsewhere, unite into a somewhat wider network.

Fig. 232.



With respect to the veins, I must especially express myself against the existence of the venous sinuses or spaces of ancient and modern anatomists, in the *human spleen*. The larger veins which still accompany arteries, present no peculiarities, except in their width; all possess a membrane, which is, at least upon the side of the artery, easy of demonstration, and, like the vascular sheath, gradually becomes thinner. Apertures of more minute veins, the so-called *stigmata Malpighii*, exist only in inconsiderable numbers in the largest of these veins, while in the smaller, they are more frequent. From the point of divarication of the arteries and veins, the relations of the latter become somewhat different. In the first place, they give off upon all sides a vast number of small veins, usually at right angles, whence their walls appear in places almost cribriform; and secondly, their membranes become completely coalescent with the sheaths of the vessels, so that ultimately the two constitute only a single very delicate wall, which, however, may

Fig. 232. An artery with its penicillate ends, from the spleen of the Pig,  $\times 25$ .

still be easily detected in the very smallest vessels that can be isolated by dissection. I find dilatations of any kind in no part of these veins, only, it is to be observed that they become narrowed more slowly than the arteries. Their continuity with the capillaries takes place in exactly the same manner as in all other organs and may be demonstrated without difficulty, by injecting the veins of a well preserved human spleen, especially of a child. Neither does any trace of dilatations present itself in this case.

The *capillaries* of the spleen have the ordinary structure, and a width of 0.003"—0.005"; they are very numerous, and exist throughout the pulp, where, round the Malpighian corpuscles, though not in their coats, and elsewhere, they form a tolerably close network continuous through the whole spleen, only interrupted by the minutest *trabeculae* and by the Malpighian corpuscles.

The human spleen possesses, relatively, very few *lymphatics*. The *superficial* set are distributed sparingly between the two coats, but can hardly be recognised, except in the neighbourhood of the *hilus* and in perfectly healthy spleens. The *deep* set may be discovered in the *hilus*, whence also, few in number and small in diameter, they accompany the arteries, but cannot be traced by any means so far as these. In the *hilus* both sets of lymphatics join, traverse a few small glands, which exist in this locality, and finally unite into a trunk which opens into the thoracic duct opposite the 11th or 12th dorsal vertebra. In diseased spleens no trace of the superficial lymphatics can ordinarily be detected.

The *nerves* of the spleen, consisting of many fine and a few thick tubules, with a moderate proportion of Remak's fibres, are derived from the splenic plexus, formed by two or three trunks which surround the splenic artery, and are continued on the arteries into the interior of the organ, each dividing into one or two branches, anastomosing here and there. In the Sheep and Ox, these splenic nerves are truly colossal, so that, taken together, they equal the empty and collapsed splenic artery, this size, however, being attributable principally to the unusual quantity of Remak's fibres.

In animals, these nerves, which never possess ganglia, may be followed into the spleen further than in Man; and, by the aid of the microscope, I have frequently met with them even

upon the arteries which support the splenic corpuscles. As to their terminations, I can only state that they pass into the pulp, and are still to be met with upon the arterial *penicilli*. Here they ultimately become as delicate as the finest capillaries, no longer possess dark edged tubules, and, according to Ecker's observations (l. c., p. 149, fig. 10), probably end in free dichotomous divisions. In the Calf, the nerves upon arteries of 1<sup>m</sup> measure 0·024—0·028<sup>m</sup>, on the *penicilli arteriarum* 0·0048—0·0056<sup>m</sup>, in the midst of the pulp 0·003—0·004<sup>m</sup>. In branches of 0·012—0·028<sup>m</sup>, I here still found a single dark edged nerve-tubule, whilst all the rest consisted of a striated nucleated tissue, which alone constituted the finer threads. It is improbable that this structure has here, as in the trunks, the import of Remak's fibres; I should rather, with Ecker, consider it to be embryonic nervous tissue, such as we are sufficiently acquainted with in other localities; and I am inclined to believe that the dark edged tubules of the trunks finally pass into pale fibres, as such compose entirely or almost entirely the ultimate twigs, and then terminate by branching out. In the *trunks* of the splenic nerves of the Calf, there are found, before their entrance into the spleen and within it, numerous dichotomous divisions of the dark edged, partly coarser and partly finer primitive tubules, such as I have not hitherto succeeded in detecting in Man.

[In regard to the structure of the veins, many of the Mammalia appear to resemble Man, while others, as the Horse, Ox, Sheep, Pig, present very wide differences. In these animals a special venous membrane and a vascular sheath are found only at the origins of the largest venous trunks, while further in, they are visible only upon the side of the arteries. In all the smaller veins, which run independently (without arteries), no further trace of two coats is to be met with, in fact, these veins appear to be mere excavations in the substance of the spleen, especially as a number of anastomosing *trabecule* with red pulp often forming projecting knobs between them, are apparent upon their walls. However, they always have a perfectly smooth and shining surface, arising from spindle-shaped, tessellated epithelium-cells of 0·005—0·01<sup>m</sup>, which are only microscopically demonstrable. This epithelium corresponds per-

fectly with that of the larger veins, only that here it no longer lies upon a special wall, but immediately upon the substance of the spleen, *i. e.* upon the *trabeculae* and upon a delicate membranous substance which bounds the pulp between them. Under these circumstances we may, with perfect justice, speak of *venous sinuses*; the more, if we consider that these, so to say, wall-less veins have a colossal width, and are pierced by innumerable veins which open into them. These smaller veins, again, may be traced for a considerable distance with the scissors, but I have as yet never been able to succeed in demonstrating in what manner they are continuous with the capillary network, proceeding from the *penicilli arteriarum*, which here also is very distinct. I can hardly believe that it will ever be possible to make out this continuity completely, for the finest veins, which are often bounded by but a few *trabeculae*, and indeed for the most part by the red pulp alone, are such delicate canals, that the slightest mechanical force, as in inflating or injecting them, destroys them; and even by the microscope they are not discoverable. It may always be observed, however, that they eventually become very minute, so small that it is impossible to consider their origins as enlargements. For my own part, I believe, that here also, the connection with the capillaries takes place quite in the ordinary manner, with this distinction, however, that the veins in arising from them possess only one membrane, an epithelium, and are therefore perhaps connected in some other manner with their structureless coat. Smaller series of more rounded epithelial cells, which are not unfrequently found on teasing out the pulp, probably belong to the smallest veins.

In *mammalia* the lymphatics are stated by all authors to be extremely numerous, and this is perfectly true for the superficial vessels, which in the Calf, for example, are exceedingly abundant and present numerous anastomoses in the subserous cellular tissue. *On the other hand, I find that the deeper lymphatics are scanty.* In the *hilus* of a calf's spleen, for instance, I found but four lymphatic trunks with a collective diameter of 0.17". The superficial and deep lymphatics would appear to be, to a certain extent, connected; inasmuch as a few scattered lymphatics, which are probably connected with those which proceed from the *hilus*, accompany the arteries which pass

from the interior of the spleen, to be distributed in its coats, and open into the superficial trunks. The latter may readily, in the Ox, be traced for a certain distance into the interior, so far that it can be seen that they not only at first, but subsequently, always accompany the arteries. Their origin is unknown, and I can only say, that in the Malpighian corpuscles and in the *penicilli*, as microscopic investigation shows, the arteries are no longer accompanied by lymphatics. They probably, as in the liver, belong only to the vascular sheaths. In structure, the splenic lymphatics present no peculiarities, and they have valves.

The arteries in the human spleen are exceedingly muscular, which sufficiently explains the dilatation and subsequent contraction of the organ observed 5 or 6 hours after the ingestion of food, noticed by many observers. In animals, besides these contractile elements, the muscles of the coats and *trabeculae* which I have discovered, may take some part in this process, and their presence further accounts for the circumstance that the spleens of Animals contract by galvanism, while that of man does not (*vid.* Mikr. Anat. II, 2, p. 265).]

#### § 170.

*Physiological remarks.*—The spleen is *developed* at the end of the second month, in the foetal mesogastrium, at the fundus of the stomach, from a blastema which, derived from the middle layer of the germ, independently of the stomach, the liver, or the pancreas, collects in this situation. It is, at first, a whitish, often slightly lobed body (0·72''' in length, 0·4''' in breadth, in the ninth to the tenth week), which gradually becomes red and is very soon as rich in blood and in vessels as in the adult. The roundish small cells, of which the spleen is at first entirely constituted, become, in the third month, partly developed into vessels and fibres, whilst another portion remains as parenchyma-cells. The Malpighian corpuscles are not formed till subsequently, but may always be found at the end of the foetal period, although considerably smaller than afterwards. I do not know how they are formed, but I presume that they proceed from simple masses of cells, whose external elements become metamorphosed into the coat of connective tissue, whilst the internal ones, partly persisting in their original condition, partly becoming metamorphosed into vessels, form the contents.

This is not the place to discuss at length the *functions* of the spleen; I must refer to my 'Mikroskopische Anatomie,' II, 2, p. 282, and content myself here with stating, that I consider the spleen to be an organ into whose parenchyma constituents of the blood enter bodily and at times in increased quantity, and, with the co-operation of cellular elements, which are in a state of continual formation and solution, undergo, more especially a *retrogressive*, but partly also a *progressive* metamorphosis, in the end to be taken up again by the blood and lymphatics, in order to be excreted from the body or further applied to the purposes of the organism.

[Up to a certain point the investigation of the spleen presents no difficulties; the pulp, the *trabeculae*, and the Malpighian corpuscles, are at once obvious. The latter are most readily examined in the Pig and Ox, where the coat and the contents may easily be isolated, and the connection with the vessels is also apparent. To see blood-corpuscle-holding cells, the addition of water must be avoided. The muscular fibres are beautifully seen in the finer *trabeculae* of the Ox, and in the *trabeculae* of the Pig and Dog; and here maceration in nitric acid, of 20 per cent., is of service. The arteries and capillaries are easily injected; the veins with great difficulty; most readily in Man. The nerves are found with ease on the arteries; the lymphatics may be best studied in the Ox.]

*Literature of the Spleen.*—M. Malpighi, 'De liene,' in 'Exercit. de visc. struct.,' Lond., 1669; J. Müller, 'Ueber die Structur der eigenthümlichen Körperchen in der Milz einiger pflanzenfressenden Thiere,' Müller's 'Archiv,' 1834 (the first good anatomical work since Malpighi); T. C. H. Giesker, 'Splenologie, I. anatomisch. physiologische Untersuchungen über die Milz,' Zürich, 1835 (a very elaborate treatise); Schwager-Bardeleben, 'Observationes micros. de gland. ductu excretorio carentium structurâ,' Berol., 1841; Th. von Hessling, 'Untersuchungen über die weissen Körperchen der menschlichen Milz,' Regensburg, 1842; A. Kölliker, 'Ueber den Bau und die Verrichtungen der Milz,' in Mittheil. 'Der Zürch. nat. Gesellschaft,' 1847, p. 120; 'Ueber Blutkörperchen haltige Zellen,' in 'Zeitsch. für wiss. Zool.,' Bd. I, p. 261, and Bd. II, p. 115; art. 'Spleen,' in Todd's 'Cyclopædia of

Anatomy,' June, 1849; A. Ecker, 'Ueber die Veränderungen, welche die Blutkörperchen in der Milz erleiden,' in 'Zeitsch. für Rat. Medicin,' VI, 1847, and art. 'Blutgefäßdrüsen,' in R. Wagner's 'Handw. der Phys.,' IV, 1, 1849; J. Landis, 'Beiträge zur Lehre über die Verrichtungen der Milz,' Zürich, 1847; Gerlach, 'Ueber die Blutkörperchen haltenden Zellen der Milz,' in 'Zeitschrift für Rat. Medicin,' VII, 1848; 'Gewebelehre,' p. 218; R. Sanders, 'On the structure of the Spleen,' in Goodsir's 'Annals of Anat.,' I, 1850; O. Funke, 'De sanguine venæ lienalis,' Lips., 1851.

[Gray, 'On the Development of the Ductless Glands in the Chick,' 'Phil. Trans.,' 1852.—Eds.]

---

## OF THE RESPIRATORY ORGANS.

### § 171.

Under the head of respiratory organs are usually enumerated only the *larynx*, *trachea*, and *lungs*; but I consider it as most suitable here to describe two organs connected genetically with those respiratory organs of the embryo, which remain undeveloped, that is to say, the branchial arches; and which, physiologically, perhaps, belong to the lungs—the *thyroid gland* and the *thymus*.

## OF THE LUNGS.

### § 172.

The structure of the lungs corresponds, in all respects, with that of a *compound racemose gland*, presenting, in the lobes, lobules, and air-cells, the proper glandular parenchyma; whilst the *bronchiæ*, *trachea*, and *larynx*, constitute the excretory apparatus. They differ from common glands in this, that since in the lungs a double process—an excretion and an absorption of matters—is carried on, which affects the whole mass of blood, the cavities are proportionately more capacious, and also, on account of the special nature of their

contents, of a peculiarly compact, and, at the same time, elastic structure.

§ 173.

The *larynx* is the most complex portion of what are termed the air-passages, and consists, in the first place, of a firm framework, the *cartilages of the larynx*, together with their ligaments; secondly, of numerous small *muscles* attached to them; and lastly, of a *mucous membrane*, abounding in glands, with which they are lined.

The *cartilages of the larynx* are not all alike in their structure, some being composed of *common cartilaginous tissue*, others of *fibro-cartilage*, whilst others, again, are constituted of the so-termed *reticular* or *yellow cartilage*. To the former belong the *thyroid-, cricoid-, and arytenoid-cartilages*; all of which present a more homogeneous, hyaline matrix, with scattered cartilage cells imbedded in it (fig. 20), and approach nearest to the costal among the other true cartilages. Most externally they contain flattened cells, to which succeeds a whitish layer, with numerous large parent-cells and a more fibrous fundamental substance; and, lastly, in the interior, a larger proportion of matrix and minute radiating cavities. The membranes of the cells are thickened, and, in their interior, a large oil-drop is most usually found. *Incrustations* of the cartilage-cells and of the matrix, with minute calcareous granules, are very frequent in the laryngeal cartilages; but besides these, true *ossifications* occur, which are always attended with the formation of larger cavities, filled with a well-marked, gelatiniform, vascular medulla. The *epiglottis* and the *cartilages of Santorini* and of *Wrisberg*, consist of *yellow* or *reticular cartilage* (*vide* § 22, fig. 21), presenting opaque, very closely interlaced fibres, which, in animals (*e. g.* the Ox), are much thicker than in Man, and clear cells, 0·01—0·02''' in size, in which Henle, in one instance, noticed a concentric disposition of such a kind that the remaining cavity of the cell resembled a simple bone-lacuna with a few prolongations (Allg. Anat., Tab. V, fig. 8). The *cartilago triticea* consists of connective tissue with scattered cartilage-cells, and is, consequently, common *fibro-cartilage*.

Of the *ligament* of the larynx, the *ligg. crico-thyreoideum*

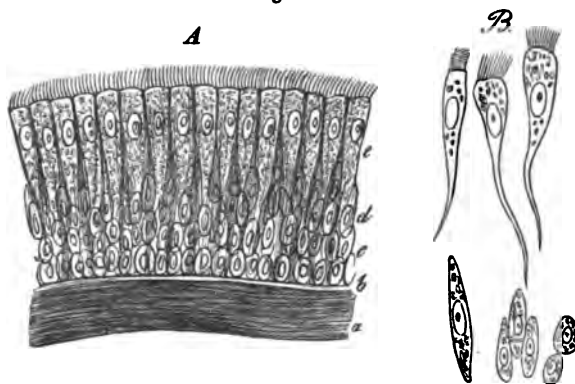


*medium* and *thyreo-arytænoidea inferiora* contain a preponderance of elastic tissue and are of a yellow colour; whilst others, such as the *thyreo-arytænoidea superiora*, *hyo-* and *thyreo-epiglottica*, and the *membr. hyo-thyreoides*, are characterised, at all events, by the great abundance of that element which they present. The elastic fibres of the laryngeal ligaments are of the finer sort, scarcely exceeding  $0\cdot001''$ , and are united in the usual manner into a very close elastic network; which, however, even where it is apparently most unmixed, contains some connective tissue. The *muscles* of the larynx are all transversely striated with fibres of  $0\cdot016$ — $0\cdot024''$ , and present the same structure as those of the trunk. They arise from the cartilages, and are inserted into them, and also into their elastic ligaments; the latter being the case with the *thyreo-arytænoideus*, which is for the most part lost on the concave side of the vocal ligaments.

The *mucous membrane* of the larynx, the continuation of that of the throat and mouth, is smooth, whitish red, and connected with the subjacent parts by the ordinary, in some places abundant submucous connective tissue. Except in the *glottis*, the mucous membrane, covered only by a ciliated *epithelium*, and presenting no *papillæ*, abounds in finer elastic fibrous networks, particularly in its deeper portions; whilst the innermost layer,  $0\cdot03$ — $0\cdot04''$  thick, consists principally of connective tissue, and ceases in an inseparable, homogeneous border of  $0\cdot004''$ . The *ciliated epithelium*, in the adult, commences at the base of the *epiglottis* and, above the upper vocal ligaments, is composed of several laminæ (*vide* § 21), on the whole  $0\cdot024$ — $0\cdot04''$  thick; with the exception of the vocal ligaments, which, as was discovered by H. Rheiner and I can confirm, have a squamose *epithelium*, it lines the rest of the larynx throughout. The proper *ciliated cylinders*  $0\cdot015$ — $0\cdot02''$  long. and  $0\cdot0025$ — $0\cdot004''$  broad in the mean, with elongated round nuclei of  $0\cdot003$ — $0\cdot0045''$ , and occasionally with a few fat-granules, are mostly much acuminate, frequently even prolonged into slender filaments, which may attain such a length that the entire cell may equal  $0\cdot024$ — $0\cdot027''$ . The *cilia* are fine, transparent, soft processes of the cell-membrane,  $0\cdot0016$ — $0\cdot0022$  long, which arise from it with a rather broader basis, and terminate in a pointed extremity.

Most usually they are placed close together, over the whole of the terminal surface of the cells, according to Valentin, on the

Fig. 233.



average, to the number of 10 to 22, which appears to be rather under the mark; more rarely they occur in smaller number, or even, as it is said, singly upon a cell. But in this case, care must be taken not to regard cohering cilia as single ones, as might happen, particularly in the embryo. In their chemical relations the cells of the ciliated epithelium correspond precisely with those of the cylinder-epithelium, and especially, the separation of the cell membrane on the addition of water, may also be remarked in them. The *cilia* are of much more delicate consistence than the cell membrane and are very readily detached upon any maceration of the epithelium; more or less altered by almost all reagents, they are, by many, at once destroyed; in chromic acid, however, they may be preserved pretty well. In man, the *ciliary motion* is directed, in the *trachea*, from below upwards and may often be perceived fifty-two or even fifty-six and seventy-eight hours after death (Biermer, Gosselin). There is nothing to show the occurrence, normally, of a desquamation of the ciliated epithelium of the larynx and air passages. Occasionally, it is true, isolated,

Fig. 233. Ciliated epithelium from the human trachea,  $\times 350$  diam. *A*, epithelium *in situ*: *a*, most external portion of the elastic longitudinal fibres; *b*, homogeneous, most external layer of the mucous membrane; *c*, deepest, rounded cells; *d*, middle, elongated cells; *e*, most superficial cells, supporting cilia. *B*, isolated cells from the various layers.

ciliated cylinders are thrown off and expelled with the mucus of the *trachea*, but of an extensive detachment of the ciliated cells there is no indication. Even in diseases of the respiratory passages, the detachment of the ciliated cells is by no means so common a phenomenon as is believed by many, and the *epithelium* may be frequently found uninjured under puriform mucus, or even beneath croupose exudations. The mode in which the ciliated cylinders that have been thrown off are replaced, is probably simply this: that the deep cells multiply, perhaps by division (*vide* § 12), and succeed them, the outermost again producing *cilia*.

The *laryngeal mucous membrane* contains a considerable number of *glandules*, all of which belong to the category of minute racemose glands; and, like those of the oral cavity, *pharynx*, &c., present rounded gland-vesicles of 0·003—0·04", with a tessellated epithelium, and excretory ducts lined with a cylinder-epithelium. They are situated, in part scattered as minute glandules of  $\frac{1}{10}$ — $\frac{1}{3}$ " on the posterior surface of the *epiglottis*, where they are frequently imbedded in depressions, which may even perforate the cartilage, and in the cavity of the larynx itself, where their orifices, such as might be produced by a needle, are easily seen; in part they occur at the entrance of the larynx, in front of the arytenoid cartilages, forming a large aggregate mass, a horizontal division of which envelopes the cartilage of Wrisberg, whilst a second dips down into the cavity of the larynx (*glandulæ arytenoidæ laterales*). Glandules are also placed upon the *arytenoideus transversus* and a considerable mass of them presents itself externally, in the ventricles of Morgagni, behind and above the sacciform ligaments. The *secretion* of these glands, as of the oral glands, is pure mucus, without any morphological elements.

The *larynx* is richly supplied with *vessels* and *nerves*. The former, in the mucous membrane, present the same conditions as in the *pharynx* and ultimately breaking up into capillaries, 0·003—0·004", form a superficial plexus. The *lymphatics* are numerous and are received by the deep cervical glands. Of the *nerves*, we learn from Bidder-Volckmann, that the more sensitive *laryngeus superior* contains a preponderance of fine fibres, whilst the *inferior*, whose properties are more of a motor nature, has more thick fibres. They terminate in the muscles, the *peri-*

*chondrium* and, especially, in the mucous membrane, in which they are disposed as in the *pharynx* (*vide* p. 393); the branches going to the *epiglottis* are also furnished with microscopic ganglia.

[The glands of the larynx and of the air-passages are frequently altered in catarrh, so that their vesicles measure as much as 0.08", or even 0.15", and are filled with minute, rounded cells, which may probably be compared with the mucous corpuscles formed on the surfaces of mucous membranes.]

§ 174.

The *trachea* and its branches are united to the contiguous parts by a connective tissue abounding in well-defined elastic fibres; they are then surrounded by a tough, elastic, fibrous tissue, which covers the cartilaginous rings, like a *perichondrium*, connects them together, and, in a somewhat thinner layer, invests the posterior membranous wall of the canal in question. To this layer succeed the *cartilages*, in front and on the sides, while posteriorly there is a layer of *smooth muscles*. The former,  $\frac{1}{3}$ — $\frac{1}{4}$ " thick, are constituted exactly like the larger cartilages of the larynx, but exhibit no tendency to become ossified. The muscles, on the contrary, from the *trachea* onwards, cease to be of the striped kind and constitute, on the posterior wall of the tube, only an

Fig. 234.

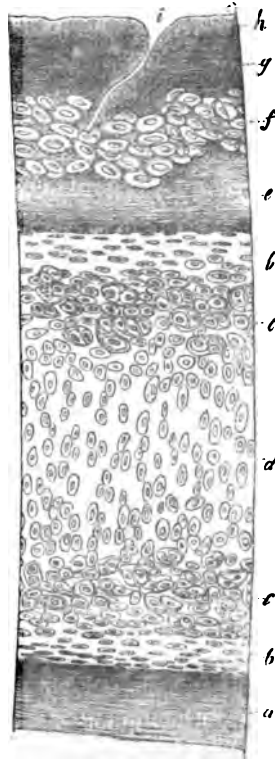


Fig. 234. Vertical section through the anterior wall of the human trachea,  $\times 45$  diam.: *a*, fibrous coat; *b*, *c*, *d*, cartilage; *b*, external layer, with flattened cells; *d*, internal layer, with elongated elements; *e*, submucous connective tissue; *f*, portion of a mucous gland; *g*, elastic longitudinal fibrous layer; *h*, *epithelium*, on which the cilia are not visible; *i*, glandular orifice.

incomplete layer, 0.3<sup>mm</sup> thick, composed of transverse fibres; on the outer aspect of which are isolated longitudinal bundles, whose elements, 0.03<sup>mm</sup> long and 0.002—0.004<sup>mm</sup> wide, are united into small fasciculi, which arise by delicate minute *tendons* of *elastic tissue*, in part from the inner surface of the ends of the tracheal rings; in part, particularly the longitudinal bundles, from the external fibrous membrane. (*vid.* Mikr. Anat. II, 2, fig. 277.)

On the inner aspect of the cartilages and muscles, which, to a certain extent, are to be regarded as one layer, we find a stratum about 0.12<sup>mm</sup> thick, of more common, close, connective tissue, and then the true *mucous membrane*. This consists of two layers; an external composed of connective tissue, 0.12<sup>mm</sup> in thickness; and an internal, yellow, of 0.09—0.1<sup>mm</sup>, almost wholly elastic, the plexiform fibres of which, 0.0015<sup>mm</sup> in diameter, run *longitudinally*, and in places, especially on the posterior wall, often constitute flattened fasciculi joined at acute angles. The innermost portion of the elastic layer, 0.024—0.03<sup>mm</sup> thick, is, particularly in the posterior wall, as in the larynx, frequently composed more of connective tissue with fine elastic fibrils; it may also be raised as a thin pellicle from the thicker elastic layer, and internally always presents a more homogeneous layer, 0.005<sup>mm</sup> thick. Upon this lies the *ciliated epithelium*, which is laminated and differs in no respect from that of the larynx. Numerous *glands* exist in the mucous membrane; these are: 1. smaller ones of  $\frac{1}{10}$ — $\frac{1}{4}$ <sup>mm</sup>, found especially on the anterior wall, within the mucous membrane and immediately exterior to the elastic layer; and 2. larger of  $\frac{1}{4}$ —1<sup>mm</sup>, which occur more in the posterior wall, externally to the muscles and the whole mucous membrane, or between the cartilages. These glands differ from those of the *larynx* only inasmuch as the larger of them alone have the usual tessellated epithelium in their vesicles; whilst the smaller, situated in the mucous membrane itself, and some of which are in the strictest sense simple, or only bifurcated cæcal follicles, present in their oval gland-vesicles, 0.02—0.03<sup>mm</sup> in size, a very narrow cavity and walls of 0.006—0.01<sup>mm</sup>, a thickness which may, perhaps, be referred altogether to the well marked cylinder-epithelium.

The *blood-vessels* of the *trachea* are very numerous, and, in

the mucous membrane, are especially characterised by the circumstance, that the larger branches run chiefly in a longitudinal direction, whilst the superficial capillary plexus, which is frequently met with above the elastic elements, close beneath the homogeneous layer, more commonly forms rounded-angular meshes. The trachea is abundantly furnished with *lymphatics*; and in one case I found their commencement in the mucous membrane, in

Fig. 235.



the form of wide-meshed plexuses 0.003—0.001''' broad, of thin-walled vessels, from which, here and there, isolated, caecal processes were given off (fig. 235). The *nerves* also of the *trachea* are numerous, and present the same conditions as those of the *larynx*.

## § 175.

*Lungs*.—The lungs are two large, compound, racemose glands, in which are to be distinguished: 1. a special serous coat—the *pleura*; 2. the secreting parenchyma, consisting of the *ramifications of the two bronchi*, with their terminations, the *air-cells*, and numerous *vessels* and *nerves*; and 3. an *interstitial tissue* interposed between these parts and uniting them into larger and smaller lobules.

The *pleura*, in their structure, entirely correspond with the *peritonæum*, as in which, the parietal layer is the thicker, and consist of connective tissue abounding in finer or coarser elastic elements, with a tessellated *epithelium*, to which constituents, on the walls of the *thorax*, as on the exterior of the *pericardium*, a more purely fibrous lamella is superadded. Vessels are seen most abundantly in the *pleura pulmonalis*, where, arising from the bronchial and pulmonary arteries, they ramify in the subserous tissue; whilst the parietal lamella is

Fig. 235. Commencement of the lymphatics in the tracheal mucous membrane of Man,  $\times 350$  diam.

more scantily supplied by the intercostal and mammary arteries. Luschka found *nerves* with finer and coarser fibres and traced them, in the outer portions of the membrane, to the phrenic and to the thoracic divisions of the sympathetic. In Man, I have myself also seen, in the *pleura pulmonalis*, nerves, as much as 0.036'' in diameter, accompanying the branches of the bronchial arteries, with middle-sized and thick fibres and occasionally large scattered *ganglion-globules*, which were derived from the *plexus pulmonalis*, and were probably afforded chiefly by the *vagus*.

§ 176.

*Air-vessels* and *cells*.—When the right and left bronchi have reached the root of the lungs, they begin to branch, like the excretory ducts of one of the larger glands, such as the liver, dividing, for the most part, dichotomously and at acute angles, into smaller and smaller branches; but giving off, at the same time, from the sides of the larger and middle-sized branches, numerous minute air-vessels, at a right angle, which, like the terminations of the main ramifications, subdivide in an arborescent manner. Thus is ultimately constituted an

extremely rich tree of air-vessels, whose finest terminations, never anastomosing, extend through the entire lung and are to be found in every part, on the surface as well as in the interior. With them, also, are connected the ultimate elements of the air-passages—the *air-cells* or *pulmonary vesicles* (*vesiculæ s. cellulæ aereæ s. Malpighianæ, alveoli pulmonum*, Rossignol), not, as was formerly believed, by each finest bronchial twig *terminating* in a single vesicle, but always by their communi-

cating with a whole group of air-cells. *These groups of vesicles*

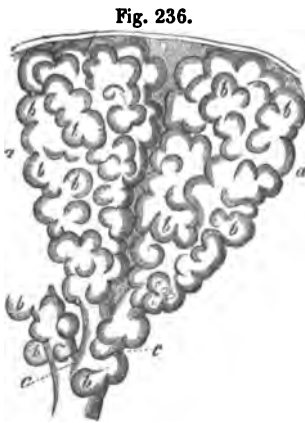

Fig. 236. Two small pulmonary lobules, *a a*, with the air-cells, *b b*, and the finest bronchial twigs, *c c*, upon which air-cells are also placed. From a new-born child,  $\times 25$  diam. Half-diagrammatic.

*correspond to the smallest lobules of racemose glands*, and consequently there is no occasion whatever to designate them under any other name, as was done by Rossignol, who calls them *infundibula*, although it must be allowed that their structure, in many respects, is peculiar. For, whilst in other glands the vesicles, if not quite so isolated from each other as has hitherto been supposed, still enjoy a certain degree of independence, the pulmonary elements corresponding to them,—the air-cells,—are, to a considerable extent, confluent with each other, so that all the vesicles belonging to one lobule open, not into ramifications of the finest bronchial twig going to it, but into a common space, from which the air-vessel is afterwards developed. That this is the true condition of these parts is most readily shown when sections, in various directions, of an inflated and dried lung are prepared, or a preparation injected with a coloured resinous material is corroded by hydrochloric acid. In preparations of this kind, vesicles either terminal or otherwise pedunculated, or opening independently, are never met with; on the contrary, they always open in such a way, one into the other, and coalesce to such an extent, as, in the aggregate, to form, most usually, a pyriform sacculus, with sinuous walls. These sacculi, which are also identical with the finest lobules, or the *infundibula* of Rossignol, must not, however, be regarded as sacs, furnished on their walls with closely placed simple cells or *alveoli*, the latter, on the contrary, being always grouped in such a way that many of them do not open directly in the larger space, but first into other *alveoli*, and through them into the common cavity. An idea of the whole relations of these parts may be best arrived at if each pulmonary lobule be viewed as an amphibian lung in miniature, or if it be conceived that the outer surface of the dilated extremities of the bronchial tubes is thickly beset with numerous racemose groups of vesicles, the constituents of which all open into one another and into the common cavity. Understood in this way, the structure of the lungs, then, does not differ in the least, in any important respect, from that of the other racemose glands, except that in the former, at all events in the adult, a partial confluence of the gland-vesicles or air-cells of a lobule, appears to have taken place, the dissepiments between them being here and there broken through and reduced to isolated *trabeculae*, as Adriani correctly




observes. The smallest air-vessels, 0.1—0.16<sup>'''</sup> in diameter, arising by simple narrowing from the most minute lobules, are at first still beset with simple air-cells, which may be termed *parietal*, and at first also, have sinuous walls, a character, however, which is soon lost, to be replaced by the usual smooth appearance which is afterwards retained. The *size* of the air-cells varies very considerably even in a healthy lung, amounting after death, and when they are wholly undistended with air, to  $\frac{1}{8}$ — $\frac{1}{10}$ — $\frac{1}{18}$ <sup>'''</sup>. But owing to its elasticity, every air-cell may be dilated to twice or three times its natural size without rupture, and is capable afterwards of returning to its pristine condition. It will not be wrong to assume, that, in life, when the lungs are filled with the average quantity of air, the air-cells are at least one third larger than we find them after death; and that, on the deepest possible inspiration, the expansion reaches, perhaps, to twice that dimension. In *emphysema*, dilatations to this and even to a much more considerable extent, are permanent, and ultimately lead to the rupture of the walls of the *alveoli* belonging to a lobule, or even to the confluence of the lobules themselves. The *form* of the *alveoli*, in a recent collapsed lung, is most usually rounded or oval and, in one that has been inflated or injected, in consequence of their mutual pressure, rounded-angular; the air-cells of the surface of the lung are invariably polygonal and their external sides are almost always nearly plane.

The *lobulated structure* of the lung is not nearly so distinct in the human adult as in younger individuals and in animals. It is therefore advisable, in the first instance, to seek for these conditions in the lungs of a child. In this case the separate lobules are still all distinctly parted from each other by connective tissue and admit of being isolated, so that the tolerably regular pyramidal form of the superficial, and the more irregular one of the interior lobules can be satisfactorily perceived. In the adult, also, these smallest lobules, in size  $\frac{1}{4}$ — $\frac{1}{8}$ — $1$ <sup>'''</sup>, still exist, but are so intimately united, that, even on the surface of the lung, their outlines are only perceived with difficulty and imperfectly; and, in the interior of the organ, a more homogeneous structure, something like that of the liver, is apparently presented. *Secondary lobules*, on the other hand, of  $\frac{1}{4}$ — $\frac{1}{8}$ — $1$ <sup>'''</sup> in size (lobules of authors) are, even in the adult,

most usually evident and the more so, because their boundaries are indicated by streaks of pigmentary matter, which, in course

Fig. 237.



of time, is deposited in the continuous interlobular, connective tissue. These lobules are ultimately united together by a more abundant interstitial tissue, so as to form the large well-known lobes.

Thus the lung consists entirely of larger and smaller groups of air-cells and smallest bronchial tubes, and accordingly the larger air-vessels also fall into certain definite groups, each of which stands in relation with only one of the former.

#### § 177.

The *intimate structure of the bronchie* and air-cells is as follows. The *bronchie* are in general constituted in the same way as the air-tubes and their branches, although from the very commencement some differences are presented, which become greater and greater in their further course. It is most proper to distinguish in them two membranes, a *fibrous*, still in part containing *cartilages*, and a *mucous*, with a *smooth muscular layer*. The former, constituted of connective tissue and elastic fibrils, is at first thick, as in the *bronchi*, but gradually becomes thinner and thinner; in *bronchie*, less than  $\frac{1}{3}$  in diameter, it is scarcely demonstrable with the scalpel;

Fig. 237. External surface of the lung of a Cow, with the air-cells injected with wax,  $\times 30$  diam., after Harting: *a a*, air-cells; *b b*, borders of the smallest lobules or infundibula (Rossignol).

and ultimately, in their terminations, it coalesces with the mucous membrane, and the more lax connective tissue uniting the *bronchiæ* with the parenchyma of the lung. In this membrane are lodged the *cartilages* of the *bronchiæ*, which, instead of being half-rings, are irregular angular plates, distributed around the entire circumference of the tubes. These cartilaginous plates, at first large and closely approximated, are soon more widely separated at the points of origin of the branches, and become smaller and smaller, until finally in tubes under  $\frac{1}{8}$ " in diameter they usually cease to exist (Gerlach would appear to have noticed some even in tubes of  $\frac{1}{16}$ " in diameter). The structure of these cartilages, which are not unfrequently of a reddish hue, is at first exactly like that of the tracheal rings, but in the smaller and smallest of them the differences between the superficial and deeper cells disappear and the tissue becomes homogeneous throughout, more like the interior of the larger cartilages. In the largest *bronchiæ* the *muscles* present the form of *circular* flattened fasciculi, which, except in old people, in whom larger and smaller interstices occur between them, constitute a completely continuous layer, and as they are still seen in twigs of  $\frac{1}{10}$ — $\frac{1}{12}$ " in diameter, probably exist even in the pulmonary lobules. The *mucous membrane* is intimately united with the muscles and at first, is of the same thickness as in the *trachea*, but this is gradually reduced, so that tubes of less than  $\frac{1}{8}$ " have only an extremely thin wall. This everywhere consists, externally, of elastic, longitudinal fibres, the bundles formed by which give the characteristic longitudinally striped aspect to the inner surface of the *bronchiæ*, and also produce a less distinct longitudinal plication of the mucous membrane; secondly, of a homogeneous layer 0.002—0.003" thick; and thirdly and lastly, of a *ciliated epithelium*, which, in the larger bronchial tubes and down to those of 1" in diameter, is distinctly composed of several laminae, but is gradually reduced to a single layer of ciliated cells 0.006" in length. The *bronchiæ* are at first also furnished with racemose *glands*, even in considerable number, which, however, are wanting in tubes of 1— $1\frac{1}{2}$ ".

In the *air-cells*, I cannot admit the existence of more than two layers—a *fibrous membrane* and an *epithelium*. The former is manifestly the much attenuated mucous membrane and

fibrous tunic of the *bronchiæ*, entirely deprived of the smooth muscles, and consisting of a homogeneous matrix of connective tissue, together with elastic fibres and numerous vessels. The *elastic fibres*, 0·0005—0·002" in size, present the form chiefly of separate *trabeculae* and filaments, running especially at the angles of the air-cells, which have been flattened in the distended condition, as well as around their openings; they anastomose with each other on every side and thus constitute a firm frame, on which the softer, vascular parts of the air-alveolæ, composed of connective tissue, are stretched. The structure of these elastic *trabeculae*, which, at the points where the air-cells abut upon each other, mutually coalesce, so that the boundaries of the separate cells cannot for the most part

be recognised, is almost everywhere one of the most close elastic networks possible, the interstices of which appear only as extremely narrow fissures, although occasionally the fibres are more loosely united, so that they are plainly recognisable as elastic elements of the usual kind. From the *trabeculae* also, but everywhere sparingly, elastic fibres, in part very fine, proceed into the remainder of the walls of the air-cells, in which, by their

union, they constitute a wide network. The *connective tissue* of the air-cells, which appears to be altogether *homogeneous*, is quite a subordinate element in their composition, compared with the elastic elements and vessels, presenting itself, as it may be said, only in the walls of the *alveolæ*, between the elastic

Fig. 238.

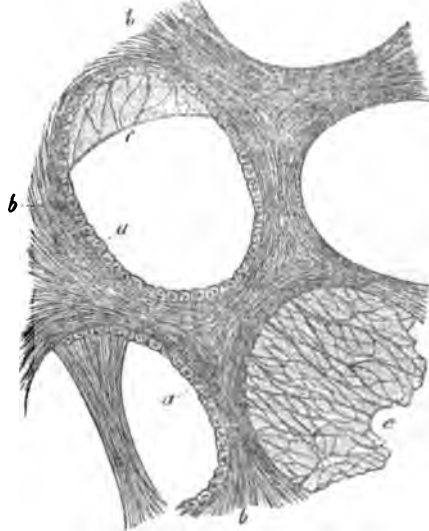


Fig. 238. Human air-cell, with the surrounding tissues,  $\times 350$  diam.: *a*, epithelium; *b*, elastic *trabeculae*; *c*, more delicate wall between the latter, with finer elastic fibres.

*trabeculae*, as a connective medium between the numerous capillaries.

The *epithelium* of the air-cells is of the common tessellated kind, without cilia, and composed of polygonal, pale, granular cells, in morbid states, containing fat, 0·005—0·007<sup>mm</sup> in diameter and 0·003—0·004<sup>mm</sup> in thickness, resting immediately upon the fibrous membrane of the air-cells. A regular detachment of this *epithelium* is not to be supposed, any more than with that of the *trachea* and *bronchiæ*, whilst it is indubitable, that by chance, or in diseases of the air-passages, its isolated elements may become mixed with the bronchial mucus. In Man, these cells are detached with remarkable readiness and then lie free in the air-cells and finest ramifications of the *bronchiæ*, although in almost every lung, at all events in some of the *alveolæ*, they may still be seen *in situ*; and in animals recently killed, the observation of their disposition presents no difficulty whatever.

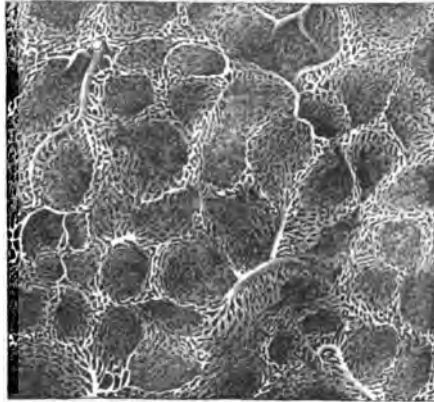
The *interlobular connective tissue* of the lungs, which is contained sparingly, even between the secondary lobules, and between the primary, exists in inappreciably minute quantity, consists of common connective tissue with fine elastic fibres and contains, in the adult, a larger or smaller quantity of *blackish pigment*, in the form of irregular, minute granules, aggregations of granules and also crystals, which, it may be said, are never enclosed in cells. The walls of the *alveolæ* themselves, also, very frequently contain this pigment, which, when it is deposited in smaller quantity and regularly, marks out very distinctly the contours of the secondary lobules, and not unfrequently also, to some extent, those of the primary.

#### § 178.

*Vessels and nerves of the lungs.*—As regards their blood-vessels, the lungs occupy a unique position, inasmuch as they possess two complete vascular systems, for the most part distinct from each other—that of the *bronchial vessels*, for the nutrition of certain portions and that of the *pulmonary vessels* for the fulfilment of their proper function. The branches of the pulmonary artery follow pretty nearly the course of the bronchial tubes, which are most usually placed below and behind them, with this difference, that they divide dichoto-

mously with greater frequency and consequently, diminish more rapidly in diameter. Ultimately, a twig goes to each secondary lobule, which then subdivides into still finer ramuscles, in general corresponding in number with the smallest lobules and supplying the individual air-cells. The course of these finest lobular arteries, as they may be termed, is very easily traced in injected, inflated and dried preparations; and it is apparent, that whilst traversing the uniting tissue between the lobules (*infundibula*), they supply, not one lobule alone, but always two or even three of them with finer twigs. These penetrate from without, upon and between the air-cells, divide repeatedly while running in the larger elastic *trabeculae*, anastomosing also occasionally, though not regularly, with each other, or with branches of other lobular arteries and finally, terminate in the *capillary plexus* of the air-cells. This plexus, which is one of the closest existing in Man, as estimated in moist preparations, presents rounded or oval meshes 0.002 — 0.008<sup>mm</sup> wide, and vessels of 0.003 — 0.005<sup>mm</sup> in diameter. It lies in the wall of the air cells, at a distance of about 0.001<sup>mm</sup> from the *epithelium*, in the middle of the fibrous tissue and is continuous, not only

Fig. 239.



over all the *alveolae* of one of the smallest lobules, but also, at all events in the adult, is partially in connexion with the plexuses of the contiguous lobules. The *pulmonary veins* arise from the above-described capillary plexus, with roots which lie more superficial than the arteries and more externally, on the smallest lobules, then run deeply between them and unite with other lobular veins into larger trunks, which proceed, in part with the arteries and bronchial tubes, in part more isolated by themselves, through the pulmonary parenchyma.

Fig. 239. Capillary plexus of the human air-cell,  $\times 60$  diam.

The *bronchial arteries* are distributed, firstly, to the greater *bronchiæ*, whose vessels present the same conditions as those of the *trachea*, then to the pulmonary veins and arteries, the latter of which, in particular, possess an extremely rich, vascular plexus, which may be traced as far as branches of  $\frac{1}{3}$ ''' and less; lastly, to the *pleura pulmonalis*, the branches destined for which are, some of them, given off even at the *hilus* and in the fissures between the main lobes, some also from the vessels accompanying the *bronchiæ*, coming out between the secondary lobules. Small vessels, moreover, which are not derived from the bronchial arteries, pass on the pulmonary ligaments to the *pleura*.

The *lymphatics* of the lungs are very numerous. The superficial lymphatic vessels run in the subserous connective tissue and in the interspaces between the larger and smaller lobules, forming a superficial, finer, and a deep, coarser, angular network, which covers the entire surface of the lungs, and on the one hand empties itself into special, superficial trunks accompanying the blood-vessels of the *pleura* towards the root of the lung, and on the other, opens into the deeper vessels by numerous trunks which penetrate between the lobules. These arise from the walls of the *bronchiæ* and blood-vessels, particularly those of the pulmonary arteries, running with those canals through the substance of the lung, and through some minute lymphatic glands (*glandulæ pulmonales*), towards the root of the lung, in order, ultimately, to communicate with the larger bronchial glands.

The *nerves* of the lungs are derived from the *vagus* and *sympathetic*, form the more scanty *plexus pulmonalis anterior*, and the richer *plex. p. posterior*, and are distributed principally with the *bronchiæ* and the pulmonary artery, occasionally, however, accompanying the pulmonary veins and *vasa bronchialia*. In the interior of the lung they are also furnished with microscopic ganglia, and may be traced nearly to the termination of the *bronchiæ*.

[It is very remarkable, that besides the air-cells, some other parts of the lungs are also supplied by the *vasa pulmonalia*, such as the *surface of the lungs* and the *finer bronchiæ*. With respect to the former, even in uninjected lungs, minute ramus-

cules of the pulmonary artery are apparent in various situations on the surface of the lungs, ramifying under the *pleura*. Reisseisen (p. 17) describes these vessels, and figures them very beautifully (Tab. IV, V); recently, Adriani has traced them in injected lungs and states that they penetrate into the interior, much convoluted and frequently anastomosing; they are considerably thicker, however, and form wider plexuses than those of the *alveoli*. The blood from these plexuses is conveyed away, on the one hand, by the superficial roots of the pulmonary veins, and on the other, through anastomoses with the ramifications of the *vasa bronchialia* in the *pleura pulmonalis*. That the pulmonary artery also supplies the *bronchiæ* to some extent, was stated by Arnold (Anat. II., p. 171); and to Adriani we are indebted for more precise information on this interesting subject. According to them, the pulmonary artery and veins chiefly participate in the formation of the capillary plexus on the surface of the *bronchiæ*, which is characterised by the elongated form of its meshes, and is constituted by vessels almost as fine as those of the air-cells (in Man, of 0·004—0·006 ), whilst the bronchial vessels are specially destined for the supply of the muscular and fibrous coats of those canals. It is comprehensible, also, that in this situation the two vascular systems are, to a certain extent, connected; and consequently the older anatomists, such as Haller, Sömmerring, and Reisseisen, who speak of a connexion between the two vascular systems of the lungs, were quite right. According to Adriani and Rossignol, the bronchial arteries and veins may be injected from the pulmonary veins, and inversely, the pulmonary veins from the bronchial arteries; but the bronchial vessels cannot be filled from the pulmonary arteries.

In accordance with these facts, a participation in the interchange of gases may be ascribed also to the finest *bronchiæ*, but, on account of the already somewhat increased thickness of the *epithelium* in them, and the rather wider capillary plexus, to a less extent than in the air-cells. Here also we might recall to mind the dilatation of the bronchial arteries and extension of their zone of distribution, in cases where the circulation through the pulmonary arteries is interrupted (*vide* Virchow, in his 'Archiv.' III, 3, p. 456), in which cases the bronchial arteries frequently wholly replace branches of the pulmonary artery, and become



respiratory vessels ; conditions which, from the occurrence of numerous normal anastomoses between the two vascular systems, it is not difficult to explain.

### § 179.

*Development of the lungs.*—In the Mammalia, the lungs appear a little after the liver, in the form of two hollow protrusions of the anterior wall of the *pharynx*, which are in close apposition and soon become furnished with a common peduncle—the rudiment of the *larynx* and *trachea*—and in the composition of which the epithelial tube and the fibrous membrane of the intestine take an equal share.

In the further course of development, there springs from the extremities of the original protrusions, a continually increasing number of arborescent processes, which differ entirely from what may be observed in most other glands. From their first formation they are always hollow, and in the sixth month the air-cells are developed from their invariably clavate, dilated extremities. During this growth of the glandular elements, the interior *epithelium* extends itself by spontaneous multiplication of its cylindrical cells (probably by division), whilst at the same time the fibrous layer surrounding them also grows, and finally constitutes the fibrous membrane of the *bronchiæ* and air-cells, together with the vessels and nerves. In the second month, in the human embryo, the large pulmonary lobes are already formed and besides them, smaller divisions also, 0·16''' in size, may be recognised, originating in the dilated extremities of the *bronchiæ*, which, even at this time, are considerably ramified. As development proceeds and the ramifications of the *bronchiæ* are multiplied, these *gland-granules*, as I have termed them, become more and more numerous, and ultimately, in the fifth month, are aggregated so as to form smaller lobules, of 0·24—0·48''' in size, each of which, in all probability, is produced from a single gland-granule, or bronchial termination of the second month. Each of the gland-granules of these lobules, which correspond with the secondary lobules of the future lung, by continued budding, finally constitutes a *primary lobule*, which, with air-cells of 0·025—0·03''' in size, first becomes distinctly visible in the sixth month, although, up to the time of birth, new *alveoli* are constantly superadded (*vide* Mikr. Anat.

II, 2, p. 323). In the new-born child the secondary lobules measure 2—3—4''; the *alveoli*, before they are filled with air 0·08'', and after the first inspiration 0·03—0·04—0·06''; the latter at this time appear to exist in the same number as in the adult, the further increase of the lungs proceeding only from the expansion of all its parts.

[The *investigation of the lungs* presents no real difficulty, except in one point; that is, with respect to the relation of the pulmonary cells to the terminations of the *bronchiæ*, but here the difficulties are very considerable. In recent preparations it is obvious that the air-cells communicate in many ways, and in any case, that they are not merely terminal on the extremities of the *bronchiæ*. If it be desired to investigate the whole subject, inflated and dried lungs (it is better in an inflated lung to tie off an end and dry it by itself), or corroded preparations, or lungs injected with uncoloured substances (wax and resin) are most suitable, and with such, a definite result will be obtained, after a series of observations.

Before the injection of the *bronchiæ* is proceeded with, the air must be exhausted in the air-pump, for which purpose, also, though less conveniently, a well-fitted syringe may be employed. The injection of the blood-vessels is readily effected and the preparations should be kept wet; sometimes, when injected with opaque material, sometimes, following the processes of Schröder and Harting, with transparent substances (Prussian blue, &c.), dried preparations are to be preferred. The air-cells and *bronchiæ*, the *larynx* and *trachea*, are readily examined. The epithelium of the air-cells is obtained in large quantity in every section through the lung, as well as ciliated cells. If it be wished to study the *alveoli*, the air must previously be carefully removed. These are best displayed in Man, in whom, also, all the other parts, such as cartilage, elastic elements, muscles, and glands, are easily obtainable.]

*Literature.*—M. Malpighi, 'De pulmonibus epistolæ II ad Borellum.' Bonon. 1661; F. D. Reisseisen, 'Ueber den Bau der Lungen, eine gekrönte Preisschrift,' Berlin, 1822; J. Moleschott, 'De Malpighianis pulmonum vesiculis,' Heidl. 1845, Diss. and, 'Ueber die letzten Endigungen der feinsten Bronchien,' in the *Holländischen Beiträgen*, I, p. 7; Rossignol, 'Recherches

sur la structure intime du Poumon, Brux.,' 1846; A. Adriani, 'De subtiliori pulmonum structurâ.' Trajecti ad Rhen. 1847, Diss.; Köstlin, 'Zur normalem und patholog. Anatomie der Lungen,' in Gries. 'Archiv,' 1848, Heft IV, p. 282, and 1849, Heft II, p. 167; E. Schultz, 'Disquisitiones de structurâ et texturâ canalium aëriiferorum,' cum tab., Dorpati Liv. 1850. Dissert.

## OF THE THYROID GLAND.

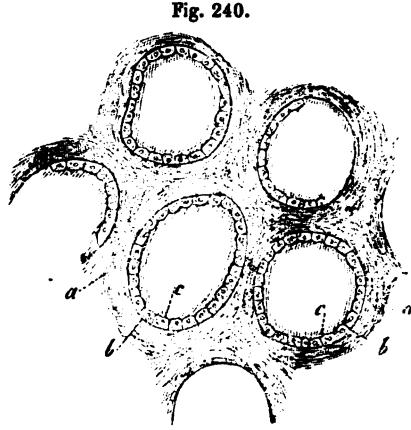
## § 180.

The *thyroid gland*, or *body* (*glandula thyroidea*), is a so-called 'ductless gland,' which in its external aspect much resembles the racemose glands, seeing that its round, closed *gland-vesicles*,  $\frac{1}{30}$ — $\frac{1}{30}$ ''' in size, are surrounded by a fibrous *stroma* and subdivided into rounded or elongated, often slightly polygonal *lobules*,  $\frac{1}{4}$ — $\frac{1}{3}$ ''' in size,—the *gland-granules* of authors;—and these again are associated into larger, though not completely separated, lobes, out of which the main divisions of the organ are then constituted; these have special, and indeed thicker coats, with which, lastly, a fibrous membrane investing the whole organ is conjoined.

## § 181.

With respect to its intimate structure, there is not much to be said about the *fibrous tissue* or *stroma* of the thyroid gland, inasmuch as it consists of common interlaced bundles of connective tissue, intermixed with fine elastic fibres and also, on the surface, contains a certain quantity of fat-cells. The *gland-vesicles* themselves, in Man, present such varied conditions of structure, that it is not easy to say what is their normal state. According to what I have observed in Man and also in animals, I must, with regard to this point, declare that, analogous to the true gland vesicles, for instance, of the mucous glands, they consist of a *membrana propria*, an *epithelium*, and fluid contents. The *membrane* is quite homogeneous, transparent, and delicate, 0.0008''' thick; and, like all membranes of the sort, is rendered more distinct by caustic alkalies, in which it swells up. On its inner surface lies a single layer of epithelium, composed of polygonal, finely granular,

transparent cells of 0.004—0.006<sup>m</sup>, with simple nuclei; whilst the space surrounded by these cells is occupied with a clear, somewhat viscous fluid, with a tinge of yellow in its colour, the behaviour of which towards alcohol and nitric acid and when the gland is boiled, clearly manifests the presence of much albumen. This is the character of the contents in the healthy thyroid gland of Man, particularly in children; if the organ, however, is but very little altered, conditions, in many respects

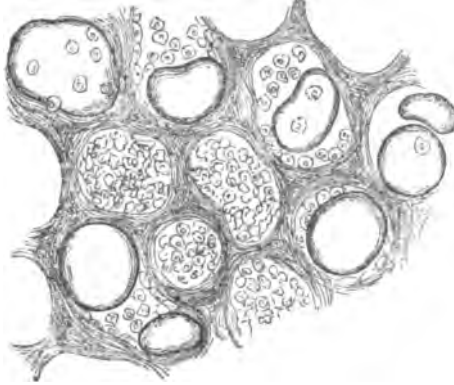


differently, are presented. Very frequently, instead of a regular epithelium, nothing is met with but a fluid mixed with minute, clearer or darker granules and free nuclei; although I am ignorant whether this condition of the contents does not take place until after death, or whether it is to be regarded as abnormal. For we so frequently observe, in the granular fluid, a greater or less number of the same cells, which at other times exist as *epithelium*, often pale and as if half dissolved, that it is impossible to avoid the conclusion, that in these cells we have an instance of that *post mortem* decomposition, so frequently observed in the human subject. On the other hand, the pathological nature of the change in the thyroid body and its vesicles, termed *colloid*, cannot be doubted, although this morbid condition is so frequent, in certain minor degrees, that many authors enumerate it under the physiological occurrences. In this degeneration, there is deposited in the gland vesicles, which increase in size at the same time, the *colloid substance*, which also occurs in other situations, in the form of transparent, amorphous, light yellowish, soft, solid, masses, by which they are more or less filled. In the lesser degrees of this change,

Fig. 240. Some gland-vesicles from the thyroid gland of a Child,  $\times 250$  diam.: a, connective tissue between them; b, membrane of the gland-vesicles; c, their *epithelium*.

the vesicles are but little enlarged, to as much as 0.05", in a transverse section, presenting the appearance of transparent

Fig. 241.



yellowish-white spots or granules, which have been very aptly compared, by Ecker, with boiled sago, and otherwise retaining the usual structure. In a higher degree, the vesicles containing colloid are transformed into larger cysts, of  $\frac{1}{10}$ — $\frac{1}{2}$ ", in which the *epithelium* is rarely any longer

distinct, but, together with the abnormal contents, rounded, pale cells, filled with colloid matter or granules, and *nuclei*, may occur; these cysts compress the *stroma* and ultimately, owing to a partial absorption of the walls, coalesce into still larger sinuous cavities, the contents of which are afterwards frequently altered in various ways, by extravasations and their metamorphoses. In Mammalia and Birds, the thyroid body also occasionally contains gland-vesicles slightly distended with colloid matter.

The *blood-vessels* of the thyroid gland are, as is well known, disproportionately numerous, but in their coarser ramifications present nothing worthy of remark. Each gland-vesicle is provided with some smaller arteries, the subordinate branches of which are distributed and sub-divided in the *stroma* between the vesicles, finally constituting around each of them a delicate capillary plexus, with rounded-angular and elongated meshes of 0.008—0.016", and vessels of 0.003—0.005", resembling that of the air cells, except that the interstices are wider. From this plexus the *veins* arise, which, in their further course, only partially accompany the arteries, which they much exceed in number. *Lymphatics* also occur in considerable number in the thyroid gland; the relations of which, however,

Fig. 241. Gland-vesicles of the thyroid gland, filled with colloid matter,  $\times 50$  diam.

in the interior, are unknown. The few *nerves*, lastly, are only vascular nerves and are derived from the cervical portions of the sympathetic.

[Ecker distinguishes the *struma*, which is by far the most frequent degeneration of the thyroid, into a *vascular* and a *glandular*. In the latter, the above-described changes of the gland-vesicles take place, whilst in the *vascular struma*, which is not regarded by Rokitansky as a special form, besides a hyperæmiated condition, numerous aneurismal dilatations of the smaller vessels, for the most part of those 0.030—0.040" in size, which Ecker looks upon as arteries and larger capillaries, are met with. From the bursting of these dilatations, apoplectic cysts, of various sizes, subsequently ensue, which may exhibit phases of the most various kinds, as the blood undergoes changes of one kind or another; fresh extravasations, and also exudations, are superadded, and even normal tissue becomes involved in them. In vascular *struma*, Ecker also very frequently met with a *cretification* of the vessels, consisting in the deposition of numerous scattered calcareous particles in the walls of the smaller and smallest, dilated or normal vessels, so that they appeared quite white; and when the affection had advanced to the highest stage, were obliterated and became concretions. In a certain form of *scrofula*, Rokitansky describes an *hypertrophy* of the thyroid gland, due to a multiplication of the normal glandular elements, taking place by the production of new gland-vesicles, sometimes independent, sometimes occurring in enlarged gland-vesicles, in growths inwards of their walls.

According to Remak, the thyroid body is *developed* by the constriction of a portion of the anterior wall of the *pharynx*, and the division of this into two halves. In a human embryo, at the third month, I found that the thyroid body was already composed of isolated vesicles 0.016—0.05" in size, consisting of a homogeneous envelope and rounded-angular cells in the interior, and I think I perceived that this follicle was multiplied by the formation of rounded buds and their separation by constriction. If this really be the case, the entire development, probably, of the thyroid gland would have to be regarded as a continued growth and division of the glandular follicles, of

which the fission of the primary vesicular rudiment, observed by Remak, would be merely the first phase. In this respect, also, a certain resemblance with the *thymus* would be established, only that in the latter, both the buds of the primary rudiment, as well as the later ones, are not detached, but all remain in connexion. The follicles of the thyroid gland, therefore, would not be any kind of enlarged cells, and still less metamorphosed *nuclei* (Rokitansky), but be equivalent to true gland-follicles.

The *investigation* of the vesicles of the thyroid gland has mainly been pursued in animals, especially in Birds, Amphibia, and in children; and sections obtained by means of the double-bladed knife, or glands that have been hardened, are most suitable for the purpose of studying the vesicles in detail, and in their mutual relations; but the same object may also be attained by minute dissection, and the teasing out of the structure. *Injections* are very easily made and run very finely in children; they best exhibit the plexuses around the vesicles, in sections taken from the surface.

*Literature.*—Schwager-Bardeleben, 'Obs. micr. de glandularum ductu excret. carentium structurâ,' Berol. 1841, Diss.; Panagiotides and K. Wagener, 'Einige Beobachtungen über die Schilddrüse,' in Froriep's 'N. Notiz.' Bd. XL, p. 193; and Panagiotides, 'De gland. thyreoidæ structurâ penitiori,' Diss. Berol., 1847; A. Ecker, 'Versuch einer Anatomie der primitiven Formen des Kropfes, &c.,' in 'Henle and Pfeuffer's Zeitschrift,' f. rat. Med. VI, Bd., p. 123, and Article 'Blood-vascular glands,' in Wagner's 'Handw. d. Physiol.' III; Rokitansky, in 'Zeitsch. d. Wiener Aerzte,' 1847, and 'Zur Anatomie des Kropfes,' in 'Denkschriften der kaiserl. Akad. zu Wien,' Bd. I, Wien, 1849.

#### OF THE THYMUS.

##### § 182.

The *internal thoracic gland* or *thymus*, also one of the so-termed blood-vascular glands, is a bilobate, elongated, flattened organ, broad inferiorly, invested and united to the

surrounding parts by a lax connective tissue. *Larger lobules*, measuring on the average 2—5<sup>mm</sup>, and of a rounded, oval or pyriform shape, though for the most part flattened figure, are very distinctly apparent, even on superficial inspection; these, although pretty closely approximated, are still united merely by a yielding connective tissue and may be separated without

Fig. 242.

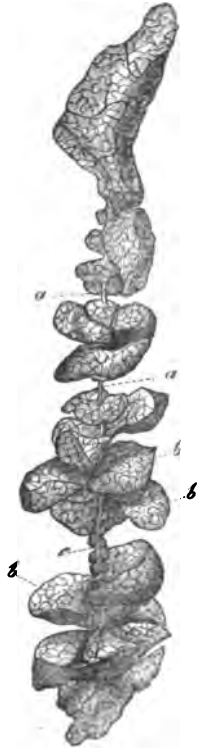
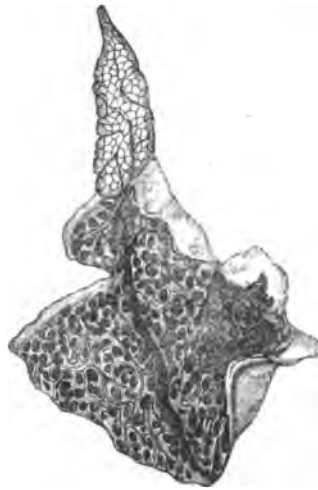
Fig. 243.



difficulty. If these lobules be traced from without inwards, it is easily perceived that they have no further mutual connexion, although they are invariably attached by a more slender portion, to a *canal*, which traverses the interior of the gland,

Fig. 242. Portion of the thymus of a Calf, unfolded: *a*, main canal; *b*, glandular lobules; *c*, isolated gland-granules, seated upon the main canal. Natural size.

Fig. 243. Half of the human *thymus*, with a large cavity in the inferior wide portion, and numerous orifices leading into the lobules.



and is in general, spirally convoluted, though not quite regularly so. When this canal, normally  $\frac{1}{2}$ — $1\frac{1}{2}$ " in diameter, is opened, there are found on its inner surface a great number of oval fissures or apertures, each of which leads to a lobule and constitutes the outlet of a cavity contained in it. The resemblance of this canal of the *thymus* and of the closely approximated lobules opening into it, to the excretory duct and the lobules of a true gland, is still further heightened by the circumstance, that the lobules are composed of smaller, also hollow subdivisions and the latter of rounded corpuscles,  $\frac{1}{2}$ — $\frac{1}{3}$ " in size, like gland-vesicles, the *gland-granules* (*acini* of authors), which may be recognised even on the exterior and, from their polygonal shape, give the surface of the lobules a delicate mosaic aspect, not unlike that of the lungs. These gland-granules, however, are not vesicles at all, such as the air-cells, which, among the elements of the true glands, approach nearest to them in size, but solid bodies, which, towards the cavity of the lobules or its accessory cavities, are intimately coherent, whilst on the outer side they are separated from each other. Each lobule may also be regarded as a thick-walled vesicle, with protrusions, whose inner surface is even and continuous, whilst the outer is subdivided into the above-mentioned gland-granules, by more or less deep fissures.

In many cases, a condition different from that just described is met with, inasmuch as, instead of a contracted canal, into which the cavities of the gland-lobules open, each *thymus* contains a larger though contracted *cavity*,  $\frac{1}{2}$ — $1$ " wide, with which the gland-lobules communicate by larger fissure-like openings. Many anatomists, and among the more modern, particularly Sir A. Cooper, consider the existence of this cavity as normal; whilst others, at the head of whom is Simon, are disposed to regard it as produced by the methods of investigation employed (injections, inflation). I believe that Simon is correct, when he asserts that in such a delicate structure as the *thymus*, injection or inflation, unless effected with the greatest care, necessarily lead to error and I am also satisfied, that many of the observed "reservoirs" in the *thymus* are only artificially produced; but, nevertheless, I am of opinion, that there really are thymus glands, containing, in life, a central cavity, because I have seen such cavities extending through the

entire *thymus* or only through separate segments of it, and this in cases where no preparation of any kind or injection had been used. I look upon the occurrence of a narrow central canal, as the original and usual condition, but believe, that in certain cases it may be expanded by a more abundant formation of the secretion, and ultimately be converted into a large cavity.

## § 183.

*Intimate structure of the thymus.*—When a lobule is stripped of its investing coat, consisting of common connective tissue, with fine elastic fibres of the finer sort and frequently with scattered fat-cells, its external surface, fissured in correspondence with the separate gland-granules, comes into view. Under strong magnifying powers, there is now presented a very thin (0·0005—0·001'), indistinctly fibrous, or almost homogeneous membrane, quite correctly described by Simon, which is continuous over an entire lobule or even the whole gland and must be placed in the same category with the wall of the follicles in Peyer's patches, the tonsils, &c. Within

this envelope, between it and the cavity of the lobule, lies a greyish white, soft, easily lacerable substance,  $\frac{1}{8}$ — $\frac{1}{3}$ ''' thick, which, when examined microscopically, appears to consist of nothing but free *nuclei* and minute cells, and on this account has, by agreement of all observers, hitherto been regarded as the secretion of the supposed gland-vesicles. But this substance cannot be washed away, which would have been the case had it lain loosely in the space enclosed by the delicate membrane; on the contrary, it

Fig. 244.

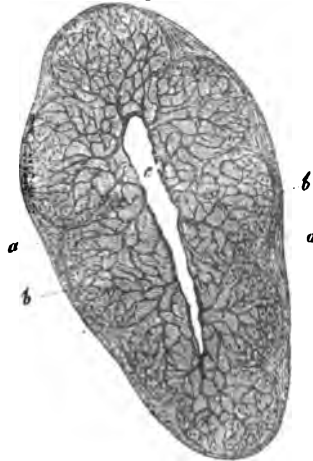


Fig. 244. Transverse section through the summit of an injected lobule of the *thymus* in a Child,  $\times 30$  diam.: *a*, membrane of the lobule; *b*, membrane of the gland-granules; *c*, cavity of the lobule from which the larger vessels branch out into the granules, on the surface of which they terminate, occasionally forming loops.

exhibits a considerable degree of toughness and resistance. When examined more closely, it is, by degrees, apparent that other elements, to some extent of quite an unexpected kind, enter into its composition; as for instance, *blood-vessels*, and also a smaller quantity of a *fibrous substance of the nature of connective tissue*, so that a structure not unlike that of the contents of the Peyerian follicles is presented.

Of the elements of the walls of the thymus-lobules, the *vesicular*, together with a small quantity of a connecting fluid, constitute the main bulk. Among these, *free nuclei* 0·002—0·005<sup>'''</sup> in size, of a round slightly flattened shape, with homogeneous, clear contents, which become troubled and granular in soda and acetic acid and with or without a *nucleolus*, are always present in very great numbers. Secondly, as I find, agreeing with Ecker but in opposition to Simon, *cells* also are never wanting, though existing of very various sizes, from 0·004<sup>'''</sup> to 0·01<sup>'''</sup>, and, though varying in number as well, still much less numerous than the *nuclei*. Their *nuclei* are for the most part simple and distinct, and the contents pale or with scattered fat-granules, or, and this Ecker says that he has noticed after the complete development of the organ, they are without *nuclei* and entirely filled with fat. In the midst of these elements run numerous *blood-vessels* of larger and smaller size. The main trunks running on the outer aspect and close upon the central cavity in the longitudinal direction of the organ, give off a large number of branches to the central cavity, which, penetrating its walls, reach its *internal surface*, and there ramify minutely in a delicate pellicle, composed of connective tissue, with which it is lined, anastomosing and also forming tolerably close capillary plexuses. From these arterial plexuses, at every point where the lobules open, numerous vessels arise and enter them, taking their course in the innermost portion of the thick boundary wall, and then ramify towards the exterior in the separate gland-granules, so as to constitute a capillary plexus entirely filling them, composed of vessels 0·003—0·005<sup>'''</sup> in diameter, and with meshes of 0·01—0·02<sup>'''</sup> (fig. 244). The distribution of these vessels, in Man, is so limited to the *interior* of the gland-granules, that, even when these have been most completely displayed, not a single vessel is found on the outer aspect of their structureless investing membrane; on the contrary they

are all seen terminating in loops close upon it. Besides these blood-vessels a small quantity of *connective tissue* also appears to enter into the formation of the thick walls of the glandular lobes; at all events, in their innermost portions, where the larger vessels are situated, we find, often with tolerable distinctness, a membrane supporting them, analogous to that lining the central cavity. In other cases, however, and especially in animals, an internal limiting membrane of this kind cannot be demonstrated and the cavities of the lobules are bounded immediately by the granular substance connecting the vessels, between which, only some delicate indications of fibres are apparent. In no case does there exist any epithelium lining the cavities and consequently, the comparison of the innermost part of their wall with a mucous membrane is untenable.

The *common cavity* or *central canal* of the *thymus*, presents the same structure as the lobules, except that externally there is a thicker fibrous layer and internally, a less thick granular stratum, with rather larger vessels. In a fully developed *thymus* it, as well as all the secondary cavities, contains a greyish-white or milky, faintly acid *fluid*, often in large quantity, in which, together with a clear fluid abounding in albumen, numerous *nuclei*, isolated cells and, under certain circumstances, also concentric corpuscles (*vide infra*) are contained. The *lymphatics* of the *thymus* are numerous and *nerves* may be readily demonstrated upon the arteries, although they cannot be traced as far as their terminations.

[Besides the above-described normal elements, there occur, especially at the period of involution of the organ, other peculiar spherical structures, which, with Ecker, I would term the *concentric corpuscles* of the *thymus*. They present very various forms, which, however, it seems to me may conveniently be reduced to two; viz. 1. *simple*, 0.006—0.01<sup>'''</sup> in size, with a thick concentrically striated membrane and a granular substance in the interior, sometimes appearing like a nucleus, sometimes as a cell; and 2. *compound*, as much as 0.04<sup>'''</sup> or even 0.08<sup>'''</sup> in size, and consisting of several simple corpuscles, surrounded by a common laminated envelope. These bodies, which were first noticed by Hassall and Virchow, and were further investigated by Ecker and Bruch, it appears to me arise

not from a direct metamorphosis of the *nuclei* and cells in the wall of the glandular lobule, but from the successive *deposition* of an amorphous material around them; and consequently that they are analogous in their mode of formation to the *corpuscula amylacea* of the brain, the prostatic concretions, &c. The laminated portion consists of a substance certainly not of a fatty nature which offers considerable resistance to alkalis, approaching the colloid substance and the substance of the prostatic concretions and *corpuscula amylacea*, being probably formed from a change in the albumen in the glandular walls. The situation of these concentric corpuscles is external to the secretion of the *thymus*, and principally in the innermost part of the glandular parietes, where the larger vessels occur.¹]

#### § 184.

*Development of the thymus.*—According to Remak, the *thymus* of the Chicken originates in the separation, by constriction, of the borders of the last two (third and fourth) branchial fissures, which are lined by the intestinal epithelium; and at the period when the last three aortic arches become detached from the walls of the *pharynx*, these follow them, and eventually lie as two elongated sacculi, on each side, between them.

In the earliest state observed in the Mammalia, *e. g.*, in the foetal Calf, 1" long, according to Bischoff the gland represents two delicate tracts of *blastema*, which descend from the *larynx* as far as the thorax and appear to be connected above with the thyroid body. Simon gives a similar description of the *thymus* in the foetal Calf and Swine,  $\frac{3}{4}$ —1 $\frac{1}{4}$ " long, except that he makes no mention of any connexion with the thyroid body, figuring the tract as a tube bounded by a delicate structureless membrane and filled with *nuclei* and a granular substance, which is further developed by becoming thicker and longer, whilst at the same time it pushes out, at first, simple and afterwards, more and more widely ramifying buds. Thus

¹ [Whatever may be the true nature of the Hassallian corpuscles, they do not seem to be an essential element of the *thymus* or its secretion, as they are not found in that body in Fishes (Skate, Ray, Sturgeon, *Zeus faber*); although present in the Reptilia. Leydig, 'Anat. histol. Untersuchung. ü. Fische und Reptilien,' pp. 21 and 66.—Eds.]

in foetal calves,  $2\frac{1}{3}$ —3''' long, wart-like and spherical, in part even shortly pedunculated offsets already existed, which subsequently increased in number, becoming produced, at first into two and four and afterwards, successively, into still more globular bodies, until ultimately the lobules were completed. In this way the primitive tube would be converted into the central cavity of the *thymus* and each offset of it, in course of time, into an entire lobule of the organ. In the *human* subject, as early as in the seventh week, I have seen the *thymus* lobate at the lower end and single above. In an embryo ten weeks old, the upper extremity was a delicate walled tube, 0.04—0.06''' in diameter, filled with polygonal cells; the lower portion, 0.16''' thick, presented several rounded outgrowths, in part isolated, in part grouped, to the number of from two to five together. The thicker, inferior portion of the gland, was entirely covered with further developed lobules 0.08—0.1''' in size, in which, again, more simple gland-granules, each with a structureless membrane and contained cells, were visible. In the twelfth week I found the *thymus* not much larger, but the horns broader, and, like the rest of the organ, covered with lobules 0.12—0.24''' in size. From this, although the first stages have not yet been observed in Man, there can be no doubt that the mode of development is the same as that observed by Simon in other Mammalia.

The later development of the *thymus* affords other interesting conditions. In the embryo it continues to grow slowly from the third month; in the sixth it extends as far as to the thyroid gland; and from and after the seventh month begins to contain a whitish secretion. After birth it is not stationary, as was formerly believed, but usually continues to grow until the second year, and, indeed, at first very considerably. After that period its growth ceases, though it still usually remains for some time longer unchanged, until ultimately it becomes atrophied, and finally disappears. The period at which these changes take place varies very much. Simon places the commencement of the atrophy between the eighth to the twelfth years, a statement which, from my own observations, and in accordance with those of Ecker, I cannot consider as universally correct; because, up to the twentieth year, the *thymus* is frequently met with in a good state of nutrition,

distended with fluid, without any fatty metamorphosis, and presenting the same structure as in children. It is still more difficult to assign the time of its complete disappearance, for which no determinate age can be indicated, although it is true that the *thymus* is usually not to be found after the fortieth year. The disappearance takes place in consequence of a gradual absorption, with a simultaneous development of fat in the gland-granules and of fat-cells in the interlobular connective tissue. At the same time, also, the concentric corpuscles multiply more and more and ultimately, according to Ecker, even connective tissue is developed in the lobules, the glandular structure being completely lost.

[The investigation of the *thymus* is not easy. I recommend, in the first place, *boiled* preparations, which of themselves are very well adapted for the investigation of the connexion of the lobes with the central canal, and the cavities in the lobules, and when hardened in spirit are convenient for the making of fine sections. Besides this, the hardening of recent preparations in alcohol, pyroligneous- and chromic acid, and the boiling of them in acetic acid, are advisable. The *thymus*, also, of small Mammalia, which is membranous at the edges, is well adapted to afford a general knowledge. But moreover, and above all, are *injections* of the human *thymus* indispensably requisite, without which no satisfactory conclusions can be arrived at.]

*Literature.*—S. C. Lucae, 'Anat. Untersuchung d. Thymus im Menschen und in Thieren,' Frankfurt am M. 1811 u. 12, 4to, und 'Anat. Bemerk. über die Divertikel am Darm. u. die Höhlen des Thymus,' Nurnb. 1813, 4to; F. C. Haugsted, 'Thymi in hom. et per ser. animal descrip.,' Hafn., 1832, 8vo; A. Cooper, 'Anatomy of the Thymus Gland,' Lond., 1832, 4to; J. Simon, 'A Physiological Essay on the Thymus Gland,' Lond., 1845, 4to; Ecker, Art. 'Blutgefäßdrüsen,' in Wagner's 'Handw. der Phys.' III.

## OF THE URINARY ORGANS.

## § 185.

The *urinary organs* consist of the two *kidneys*—true glands, having a tubular structure, which secrete the urine—and of the secretory urinary passages, the *ureters*, *bladder*, and *urethra*.

## § 186.

In the *kidneys*, are to be distinguished the *coats* and the *secreting parenchyma*. To the former belong the adipose capsule, as it is termed (*capsula s. tunica adiposa*), constituted of lax connective tissue abounding in fat cells, scarcely deserving the name of a special membrane, and the *fibrous tunic* (*tunica propria s. albuginea*), a thin but strong coat, of a whitish colour, composed of common connective tissue and numerous fine elastic networks, which closely invests the kidney, and, at the *hilus*, is in apposition with the pelvis of the gland and the vessels, but does not penetrate into the interior of the organ.

The *secreting parenchyma*, which is abruptly defined from the fibrous membrane, consists, as seen by the naked eye, of two portions, the *medullary* and the *cortical substance*, the former of which constitutes 8—15, isolated, conical, masses converging towards the *hilus*, the *pyramids* of *Malpighi*; whilst the latter forms the entire cortical part of the organ, and moreover, sends processes between the separate pyramids which extend as far as the *hilus*,—the *columnæ Bertini*,—and is apparently continuous throughout the gland. Examined microscopically, however, the cortical substance is found to be divided into as many segments as there are pyramids and the *kidneys*, therefore, may be regarded as made up of a certain number of large, though closely connected lobes.

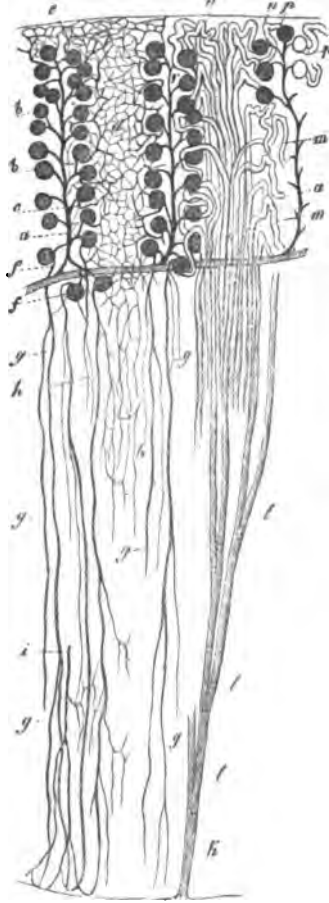
## § 187.

*Composition of the renal substance.*—Both portions of the *kidneys* consist, essentially, of the *uriniferous canals* (*tubuli*



*uriniferi*), cylindrical tubules, measuring, on the average, 0.016—0.025<sup>mm</sup>. They commence in each renal lobe or segment, in those portions of the pyramids which are surrounded by the *calices renales*, or on the renal papillæ, by, on the average, from 200 to 500 orifices, 0.024—0.1<sup>mm</sup> wide, scattered over the surface of those processes; they traverse the pyramids in nearly a straight line and in close contiguity, whence they are termed, in that situation, *tubuli recti* (or *Belliniani*) (fig. 245 *k*).

Fig. 245.



In this course, each of the straight canals divides repeatedly, most usually under very acute angles and at first with a considerable diminution of size, either into two (fig. 245 *l*), or more rarely into three or four, so that, ultimately, a complete bundle of finer tubules is produced from them; and in this way the continued increase in breadth of the pyramids towards the exterior is accounted

Fig. 245. Vertical section through a portion of a pyramid and the cortical substance belonging to it, of an injected Rabbit's kidney. The figure is half-diagrammatic; × 30 diam.

The vessels are represented on the left side, and on the right the course of the *tubuli uriniferi*: *a*, *arteria interlobulares*, with the *glomeruli Malpighiani*, *b*, and their *vasa efferentia*; *c*, *vasa efferentia*; *d*, cortical capillaries; *e*, *vasa efferentia* of the outermost corpuscles, proceeding to the superficial capillaries; *f*, *vasa efferentia* of the innermost *glomeruli*, continuous with the *arteriola recta*, *g g g*; *h*, capillaries of the pyramids which are formed out of the latter; *i*, a *venula recta*, commencing at the *papilla*; *k*, commencement of a straight canal at the *papilla*; *l*, divisions of the same; *m*, convoluted tubules in the *cortex*, their whole course not shown; *n*, the same at the surface of the gland; *o*, their continuation in the straight tubules of the *cortex*; *p*, their connexion with the Malpighian capsules.

for. At the same time, towards the base of the pyramids, the connexion of the ducts of Bellini is rendered less close, by the interpolation between them, at regular distances, of large vascular bundles (*arteriolaræ* and *venularæ rectæ*), and they become separated on all sides from each other, so that, in perpendicular sections, the pyramids (the *papillæ* of course excepted) in the entire circumference appear to spread out into numerous small bundles or pencils—the *pyramids of Ferrein* of authors—but which, as sections across them show, are only to be regarded as separate, sharply-defined fasciculi. The *tubuli uriniferi*, even here, assume a slightly undulating course, but this becomes much more manifest in the cortical substance, where they constitute the *convoluted uriniferous tubules (tubuli contorti s. corticales)*, which, at first sight, appear to be inextricably and irregularly interwoven, each terminating, ultimately, as Bowman discovered in the year 1842, in a vesicular, dilated extremity, 0.06—0.01" in diameter, containing a vascular plexus of a peculiar kind—the so-called Malpighian body. Upon more minute observation, however, it is easy to perceive that the convoluted *tubuli* are arranged in columnar masses,  $\frac{1}{3}$ — $\frac{1}{8}$ " wide, extending through the entire thickness of the cortical substance and in close apposition, which, notwithstanding their incomplete limitation from each other, may nevertheless be designated *fasciculi corticales*, or *lobuli renum* (or the "pyramids of Ferrein" of the older anatomists). In these columns (fig. 245), the *tubuli uriniferi* are disposed, in miniature, in the same way as in a renal lobe, so that in their interior, more especially at the periphery, convoluted canals may be distinguished. When the arrangement of these parts is accurately investigated, it is seen that the ducts of Bellini, entering a cortical lobule in a fascicular manner, at first run in perfectly straight lines (fig. 245 o). Soon, however, some, and further on, more and more, of the canals are curved laterally (fig. 245 m), in order to reach, in a serpentine course, the arterial twigs surrounding the cortical lobules; until, at last, the entire bundle of tubules is broken up, at some distance from the surface of the kidney (or of the centre of the *columnæ Bertini*), into convoluted canaliculi. The Malpighian bodies (fig. 245 b), from which the *tubuli uriniferi* arise, are found throughout the entire thickness of the cortical substance, from the pyramids to within

$\frac{1}{30}$ " from the surface, as well as in the *septa Bertini*, down to the sinus of the kidney and are disposed so regularly and in such numbers, around the cortical lobules, that every transverse section through the cortex always displays a red streak, caused by these corpuscles, between each two lobules. Usually each of these streaks consists of a minute artery, with from two to four, of Malpighian bodies supported by it, but not in regular series, some of which stand more in relation with the one, and others with the other cortical bundle. Each fasciculus of *tubuli uriniferi*, therefore, upon entering the cortical substance, is, from the first, entirely encompassed by the Malpighian bodies, and it is obvious that some of the *tubuli* quit it soon and others later, in order to reach their appropriate Malpighian bodies. For the rest, each cortical tubule, after its origin, is much convoluted, runs at first somewhat outwardly, and then returns upon itself, to join the straight tubules of the cortical fasciculus.

[The number of the convoluted *tubuli uriniferi* corresponds with that of the Malpighian bodies and is, consequently, in every instance, very considerable. According to Huschke, 200 tubuli exist in each *fasciculus corticalis*, and 700 such *fasciculi* in a pyramid; which calculation gives, in fifteen pyramids, more than two millions of commencements of *tubuli* and Malpighian bodies. Since each papilla has about 500 or even more orifices, it is possible that each cortical *fasciculus* proceeds from a single "duct of Bellini;" in any case, it is evident that in every straight tubule the divisions are repeated at least ten times.<sup>1</sup>]

#### § 188.

The *tubuli uriniferi*, are everywhere composed essentially of the same elements; viz. of a *membrana propria*, and a *tesse-lated epithelium*. The former is a perfectly structureless, trans-

<sup>1</sup> [It would scarcely be deduced, from what is said in the text, that the *tubuli uriniferi*, in the cortical part of the kidney, anastomose very freely and frequently, although the fact of their doing so has been long well known and often described. These anastomoses, however, and the general disposition of the tubules, are more particularly adverted to and well depicted by Toynbee ('Med. Chir. Transact.,' 2d ser., vol. XI, p. 308, pl. 7).—Eds.]

parent, thin (0.0004—0.0008<sup>m</sup>), but proportionally strong and elastic coat, which, particularly in the straight tubules, may be very easily isolated for a considerable extent, when it is very prone to fall into folds, which often present the striated aspect of connective tissue. On the inner surface of this coat, which in its chemical characters is very closely allied to the *sarcolemma* (*vid.* § 58), lies a single layer of polygonal, moderately thick cells, surrounding the cavity of the *tubulus*, which, from the readiness with which they alter, have given rise to many erroneous representations respecting the structure of the urinary ducts and their contents. For instance, in the usual mode of examination in water, they expand, owing to its absorption and become vesicularly distended, so that their polygonal form and regular arrangement are lost; the renal ducts, within the structureless membrane, appearing to be entirely filled with rounded larger cells and no longer to possess any cavity. The cells, also, frequently burst, in which case the *tubuli* contain nothing but a fine granular substance, with *nuclei* and clear albuminous drops escaped from the cells. In kidneys not quite fresh, these changes proceed spontaneously; and, therefore, it is, above all things, necessary to examine the organ as soon as possible after death and to avoid all additions capable of producing change. The contents of the epithelial cells are, besides round *nuclei* of the usual kind, a most usually, very finely-granular substance, which, on the addition of water, affords clear, light-yellowish drops, probably of albumen, but is not otherwise changed; under acetic acid the contents, together with the cell-membrane, are rendered pale, and soon dissolve; whilst the *nuclei* at the same time soon become pale, and finally, on the application of caustic alkalies, disappear in the same manner as the membrane. Besides these granules, which I do not hesitate to declare are a protein substance, and the albumen in solution in the contents, the cells very com-

Fig. 246.

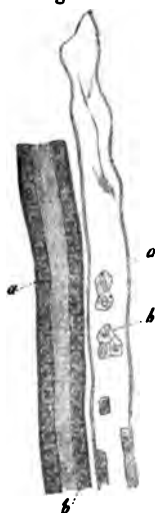


Fig. 246. Two straight tubuli uriniferi of Man, one with perfect epithelium, the other half empty: *a*, *membrana propria*; *b*, *epithelium*.

monly contain some dark oil-drops, and more rarely one or another, exhibits granules of yellow pigment.

The straight and convoluted canals, together with the general characters just described, present some differences. The former, although originally of the considerable width of even  $0.06-0.1'''$ , soon diminish, in consequence of the divisions they undergo, to a diameter of  $0.01-0.014-0.018'''$ , but in the "bundles of Ferrein," again acquire the size of  $0.02-0.24'''$ . With this diameter they enter the cortical substance, but subsequently, in the proper convoluted tubules, attain one of  $0.033'''$ , though again somewhat constricted close to their commencement. The *membrana propria* in the convoluted tubules is more delicate ( $0.0003-0.0004'''$ ) and isolated with more difficulty, the *epithelium*, on the contrary, is usually thicker, with cells measuring  $0.008-0.012'''$  in width, and  $0.004-0.005'''$  in thickness; whilst in the straight tubules the cells are not more than  $0.004-0.006'''$  wide, and  $0.004'''$  thick. Physiologically, it also seems to me worthy of remark,

that the last cells have clear, non-granular contents, whence, also, the medullary substance, in the bloodless condition, appears whitish, whilst the cortical exhibits a yellowish hue.

The Malpighian bodies present a very peculiar structure. They are to be regarded as appendages of the convoluted *tubuli uriniferi*, and contain imbedded in their *epithelium*, and, as it may be said, entirely filling their cavity, a compact, rounded vascular plexus—the *glomerulus Malpighianus*, the

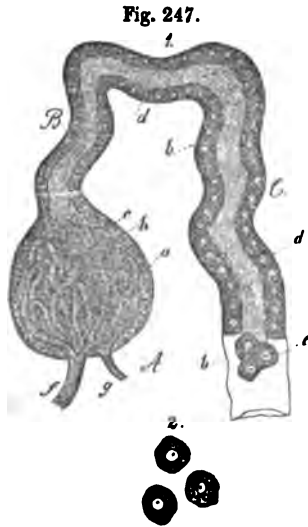


Fig. 247. 1, a Malpighian corpuscle, *A*, with the *tubulus uriniferus* springing from it, *B*, *C*; Human,  $\times 300$  diam.; figure half-diagrammatic: *a*, membrane of the Malpighian body, continuous at *b*, with the *membrana propria* of the convoluted tubule; *c*, epithelium of the Malpighian body; *d*, that of the tubule; *e*, detached epithelial cells from the convoluted tubule,  $\times 350$  diam.; *f*, *vas afferens*; *g*, *vas efferens*; *h*, *glomerulus Malpighianus*. 2, three epithelial cells from the convoluted tubule,  $\times 350$  diam.; one with oil-drops.

structure of which will be afterwards described. The same *membrana propria* which surrounds the *tubuli uriniferi*, also somewhat thickened, (0·0005—0·0008''') invests these bodies (fig. 247 a); and the *epithelium* is likewise continued into the capsules thus formed, only that its cells are smaller and less distinct and invest the vascular coil on the side directed towards the canal of the emergent *tubulus uriniferus*. This latter, generally somewhat constricted (fig. 247, B), is inserted into the Malpighian capsule, most usually on the opposite side to the afferent and efferent vessels; but in accordance with what has been said, its cavity penetrates into the capsule, only to an inconsiderable extent; inasmuch as the latter is almost entirely occupied by the vessels and the epithelium surrounding them.<sup>1</sup>

[The *ciliary motion* discovered by Bowman in the neck of the Malpighian bodies of the Frog and in the commencement of the *tubuli uriniferi*, with the direction of the stream towards the *ureter*, is readily confirmed, when the addition of water is avoided. It is absent, however, in Birds (Gerlach thinks he has

<sup>1</sup> [With respect to the question of the caecal termination, or commencement, as it might more properly be termed, of the *tubuli uriniferi* in the Malpighian capsules, there is an apparent discrepancy of opinion among anatomists. Bowman states that each tube commences in a Malpighian capsule; whilst Gerlach says that the capsules do not form the extremities of the uriniferous tubes, but are merely diverticula, which communicate by a small neck with the angle formed by the uriniferous tubes, winding through the cortical part of the kidneys; or, as the same thing is described by Leydig (l. c., p. 32), with respect to the kidney of the Sturgeon, two closely contiguous, uriniferous tubules, are connected with the (Malpighian) capsule and continuous with it; in other words, the tubules join in a loop, at the apex of which is a globose diverticulum, in which the *glomerulus* is lodged; and, according to him, the same arrangement obtains in the Reptilia. Now it seems that this discrepancy admits of an easy explanation, for if we suppose the constricted neck of the diverticulum to be lengthened into a tube, we have at once the disposition described by Bowman, viz. a tube commencing in a dilatation containing the *glomerulus* and afterwards anastomosing with another or with other tubules; and if the neck of the so-called diverticulum be very short, or, in other words, if the Malpighian capsule be sessile, we have the arrangement described by Gerlach, &c. Mr. Toynbee's notion that the *tubulus uriniferus* merely passes through the Malpighian capsule, forming a coil within it, appears to us to be wholly inadmissible; but many of the appearances depicted in his very carefully executed figures (l. c.) would serve to support the opinion that the Malpighian body is more often sessile than it would seem to be from Bowman's account.—Eds.]

seen it on one occasion in the Fowl) and other Mammalia, and was not noticed by me in the cases of two executed criminals, examined especially with respect to this point, whilst it is found in Serpents, in the *Salamander*, *Triton*, *Bombinator*, *Bufo*, and is very well marked in Fishes, and also, according to Remak's and my own observations, in the Wolffian bodies, which have the structure of kidneys, in the embryo of the Lizard; in the last two instances, they are also met with in the uriniferous ducts at a greater distance from the Malpighian bodies.

Of the very numerous *pathological* degenerations of the *tubuli uriniferi*, I will notice only the following: The *membrana propria* is frequently thickened to 0.001, or even 0.002''', when it often presents, on the inner aspect, very delicate, closely approximated transverse striæ. The epithelial cells, particularly in the cortical substance, frequently contain oil-drops in considerable quantity, so as often to present a deceptive resemblance to the cells of a fatty liver and at the same time, they are usually enlarged to a diameter of 0.02'''. Together with the oil, pigment granules (of the colouring matter of urine?) occur in them (also in the straight canals), whereas the concretions of uric acid and calcareous salts, which are so frequently met with in the canals of the tubules in the Vertebrata have not as yet been demonstrated with certainty in the cells themselves (in Fishes, Simon, '*Thymus*,' p. 69, often found crystals in the renal cells). Colloid-like, bright yellow masses are frequent in the epithelial cells, which then most usually increase in size, dilate into slender cysts as much as 0.05—0.072''' long, and finally, by bursting, empty themselves of the colloid substance, whence the latter is found free in the uriniferous ducts and also in the urine. A development of the epithelial cells into other cysts, as is stated to take place by J. Simon and also by Gildemeester (*Tijdschr. d. Nederl. Maatsch.* 1850) has not yet occurred to my observation, whilst I have noticed, as did Johnson, very distinctly, in an atrophied kidney, a partition of the convoluted tubules into closed cysts, to all appearance by a connective tissue developed between and constricting them. These cysts had the same structure as the tubules and were either of the same diameter, or distended into vesicles, 0.1''' in width. The Malpighian bodies also may expand into cysts, in which, together with a clear fluid, the atrophied

*glomerulus* is often visible on the wall. As abnormal contents, the *tubuli uriniferi* present: 1. *blood*, most frequently in the commencement of the convoluted tubules, especially the superficial, often in such quantity as to produce bloody points as big as a pin's head, and visible to the naked eye, which were formerly erroneously regarded as distended Malpighian bodies. 2. *fibrin*, in cylindrical masses, corresponding to the cavity of the tubules. 3. the above-mentioned *colloid-like substance*. 4. *concretions* in the ducts of Bellini, consisting, in the adult, chiefly of carbonate and phosphate of lime ("*Kalkinfarct*"); in new-born infants, of uric acid-salts ("*Harnsäureinfarct*," Virchow), which give the pyramids a brilliant gold-yellow colour, and, if not exclusively, still usually, occur only in children who have already respired (between the third and twentieth day after birth). In the later stages of "Bright's" disease, many *tubuli*, which have lost their epithelium in consequence of the exudations poured out in them, become atrophied, and ultimately disappear altogether, whilst groups of others are seen, filled with a fatty, broken-up exudation, and dilated into minute nodosities (granulations, Christison).]

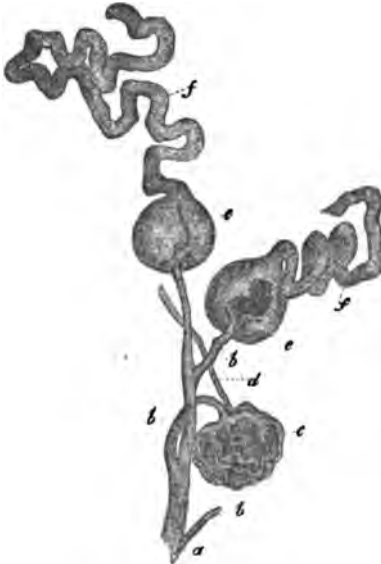#### § 189.

*Vessels and nerves*.—The large renal artery divides, in the pelvis of the kidney, into a certain number of branches, which, after supplying the parts lying in the *hilus*, enter, above and below the renal veins, the cortical substance interposed between the pyramids (the *columnæ Bertini*). From this point they are continued, repeatedly dividing, close upon the boundary of the two renal substances, so that around each pyramid a delicate ramification, but without any anastomoses, usually afforded only by two large arteries, is formed. From this ramification, on the side looking towards the cortical substance, there arise, with great regularity, and for the most part at right angles, smaller arteries, which after a few or more repeated divisions give off fine twigs, 0.06—0.1" in diameter, which run outwardly in a straight course between the cortical fasciculi or lobules, and are most fitly termed *arteriæ interlobulares* (fig. 245 a). It is these twigs which support the Malpighian bodies, and, with the exception of some branches to the coats of the organ, they terminate exclusively in the formation of their vascular coils.



In fact, each interlobular artery gives off, in its whole length, on two, three, or four sides, a great number of fine twigs possessing the structure of arteries and  $0.008-0.02''$  in diameter, which, after running a short distance, either directly or after dividing once, penetrate the tunic of the Malpighian body, becoming the *vasa afferentia* of its vascular coil. Each of these (fig. 247, 248) consists of a close convolution of fine

Fig. 248.



vessels  $0.004-0.008''$  in diameter, having the usual structure of capillaries (structureless coat and *nuclei*) and possesses, besides the afferent artery, an efferent vessel, the *vas efferens*. The mode in which these two vessels are connected is not that which usually obtains in arteries and veins, but corresponds with the arrangement presented in the bipolar *retia mirabilia*, as they are termed; the *vas afferens*, immediately after its entrance into the coil, dividing into 5—8 branches and each of these into a bundle of capillaries, which are much convoluted

and interlaced, without anastomosing, and ultimately, in the same way as that in which they were formed, re-unite into a single trunk. Usually the two main vessels enter and quit the *glomerulus* near together, opposite the origin of the urini-ferous duct, and its finest vessels of  $0.003-0.004''$ , the peripheral loops as it were, are invariably situated exactly at the commencement of the duct. In Birds, Amphibia, and Fishes, each glomerulus consists of a *single* convoluted vessel.

The *vasa efferentia*, although composed of capillaries, are

Fig. 248. From the Human kidney, after Bowman: *a*, extremity of an interlobular artery; *b*, afferent arteries; *c*, naked *glomerulus*; *d*, efferent vessel; *e*, *glomeruli*, surrounded by the Malpighian capsules; *f*, *tubuli uriniferi* springing from them;  $\times 45$  diam.

not veins, but in their nature, and to some extent in their structure, minute arteries, a character that they retain until, in their further course, they are merged in the *capillary plexus* of the kidney. This plexus exists in the cortical substance and in the pyramids, presenting somewhat different characters in these two situations. In the former (fig. 245, *d*) the *vasa efferentia* 0·004—0·008''' in size, after a short course, terminate in a very rich plexus of capillaries 0·002—0·004—0·006''' in diameter, the rounded-angular meshes of which, 0·005—0·015''' wide, encompass the convoluted *tubuli* on all sides and must be regarded as continuous throughout the whole cortical substance. The efferent vessels of the *glomeruli* in nearest contiguity to the Malpighian pyramids alone present an exception to this condition, inasmuch as, characterised by their more considerable size (0·01—0·016'''), they are distributed not in the cortical substance, but in the pyramids, and are distinguished by their long, straight course, and upon the whole, scanty ramifications. These vessels (fig. 245 *g*), which, with Arnold, I would term *arteriola rectæ*, penetrate around the entire circumference of the pyramids, in a straight course, between the ducts of Bellini, and descend, repeatedly dividing at acute angles, and gradually attenuated to the diameter of 0·004—0·01''', towards the *papillæ*, in which, as in the interior of the medullary substance (in the latter situation, either by their extremities or by twigs given off at right angles), they are continuous with the capillaries in those regions, measuring from 0·002 to 0·004'''. These capillaries are very importantly

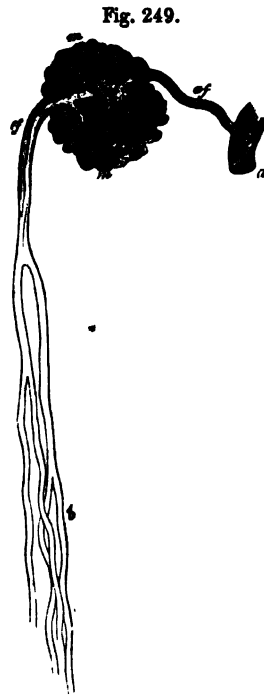


Fig. 249.

Fig. 249. *Glomerulus* from the innermost part of the cortex of the kidney of the Horse, after Bowman: *a*, *arter. interlobularis*; *af*, *vas afferens*; *m*, *glomerulus*; *ae*, *vas efferens* s. *arteriola recta*; *b*, divisions of the same in the medullary substance;  $\times 70$  diam.

distinguished from those of the cortical substance by their less number and the elongated figure of the meshes of the plexus which they form, although at the boundary of the pyramids the two sets are continuous with each other. The *renal veins* commence in two situations, viz. at the surface of the organ and at the apices of the papillæ. In that situation, minute venous radicles collect together from the outermost portions of the capillary plexus of the cortical substance, which either regularly surround each cortical lobule, and between them unite in a stellate manner (*stellulæ Verheyinii*) into somewhat larger roots, or, extending over several or numerous lobules, collect into larger trunks. These two sets of veins, forming the *venæ interlobulares*, then penetrate more deeply in company with the arteries of the same name, between the cortical fasciculi, where they are enlarged by the accession of numerous other venous radicles from the interior of the cortical substance, and proceed to join the larger veins, either directly or united into somewhat larger trunks, and for the most part at right angles. These lie, together with the larger arteries, around the periphery of the pyramids, ultimately opening into large veins without valves, as are all the renal veins, and which lying singly close to the arteries, quit the kidney in the same way. Previously to this, however, besides those of the *columnæ Bertini*, they receive the veins of the *pyramids*, which commence in a beautiful plexus surrounding the orifices of the *tubuli uriniferi* on the *papillæ*, and ascend between the *tubuli recti*, being strengthened by additional radicles; these united with the arteries of the pyramids, the *vasa efferentia* of the innermost *glomeruli* or the *arteriolæ rectæ*, into larger *vascular bundles*, lying between the "pyramids of Ferrein," open into the arched, wider, venous ramification which encompasses the pyramids.

The *vessels* of the *membranes of the kidney*, arise in part from the *art. renalis*, before it enters the *hilus*, and from the supra-renal and lumbar arteries, in part, also, they are branches of the *arteriæ interlobulares*, which, after supplying the Malpighian bodies, send on fine twigs to the fibrous coat, forming in it a wide-meshed capillary *plexus*, which is also continuous with that of the *capsula adiposa*.

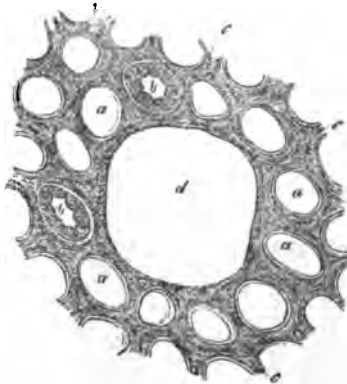
The kidneys present, proportionally, but few *lymphatics*. They run, in the interior, along the larger vessels, and do not appear

to extend further than the *vasa interlobularia*. In the *hilus*, they unite into a few small trunks, which also receive lymphatic vessels from the pelvis of the kidney and then open into the lumbar glands. Superficial lymphatics, which have been described by the older anatomists (Nuck, Cruikshank, Mascagni, &c.), I have as yet not seen, except in the *capsula adiposa*, but I am unwilling positively to deny their existence.

The *renal nerves*, from the celiac plexus of the sympathetic are tolerably numerous, form a plexus around the arteries, continue to present a few *ganglia* in the *hilus* and may be traced, in company with the vessels, as far as the *interlobular arteries*. Where and how they terminate is unknown.<sup>1</sup>

All these vessels and nerves are supported by a connective tissue, which, at the same time, serves as a *stroma* for the secreting elements and is much more developed in the medullary substance than in the cortical. At the surface of the gland, it is condensed into a membrane, often very distinct, 0.01—0.02" thick, which is but loosely connected with the fibrous tunic, partly supports the superficial capillary plexus, and is continuous with the internal stroma by numerous delicate processes.

Fig. 250.



[In *inflammations* and *exudations*, the *stroma* is frequently so

Fig. 250. Transverse section through some straight cortical tubules,  $\times 350$  diam.; from Man: *a*, transverse section of *tubuli uriniferi*, the *membrana propria* only of which remains; *b*, similar tubules, with the *epithelium* still remaining; *c*, *stroma* of connective tissue, with elongated nuclei; *d*, cavity in which a Malpighian corpuscle was contained.

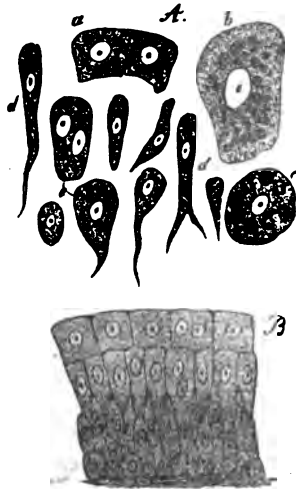
<sup>1</sup> [With respect to the termination of the nerves in the kidney, Mr. Toynbee (l. c., p. 805) makes the remarkable and very important observation that "the filaments end by becoming continuous with the parenchyma of the organ, precisely in the same way," he goes on to say, "as he has observed those in the tail of a Tadpole to become directly continuous with the radiating fibres of stellated corpuscles, and the filaments from the corpuscles to communicate with each other."—Eds.]

much condensed as to be apparent on the most superficial inspection, or even, more or less to compress the *tubuli uriniferi*. The additional elements consist chiefly of a fibrinous exudation, presenting various stages of transition into connective tissue, partly also of such forms as are peculiar to immature normal connective tissue, as fusiform cells, &c. In the case of the Malpighian bodies, these new formations present the form of concentric, often very thick deposits, which constrict the afferent and efferent vessels, thus inducing atrophy of the *glomerulus* and very essentially and prejudicially affecting the secretion of urine. In other cases the increase of the *stroma* is only apparent and depends upon the atrophy of the secreting elements.]

## § 190.

*Excretory urinary passages.*—The *ureters*, the *pelvis*, and *calices* of the kidney, are all composed of an external *fibrous membrane*, a *smooth muscular layer* and a *mucous membrane*.

Fig. 251.



inserted into the *papilla*.

The first, formed of common connective tissue and elastic fibres, chiefly of the finer kind, is continuous, at the point where the *calices* surround the *papilla*, with the fibrous tunic of the kidney. The *muscular layer* in the *ureters* is very distinct, with external, longitudinal and internal transverse fibres, to which, towards the bladder, internal longitudinal fibres also are superadded. In the *pelvis* of the kidney the two muscular layers are quite as thick as in the *ureter*, whilst in the *calices* they become thinner and thinner, ceasing where the latter are inserted into the *papilla*. The *mucous membrane* of all these

Fig. 251. Epithelium of the pelvis of the Human kidney,  $\times 350$  diam.: *A*, isolated cells; *B*, the same *in situ*: *a*, small; *b*, large tasselated cells; *c*, the same with nucleated corpuscles in the interior; *d*, cylindrical and conical cells from the deeper layers; *e*, transitional forms.

parts is thin, tolerably vascular, without glands or *papillæ*, and becoming very much thinner (0·005—0·01''' without epithelium), is also continued upon the renal papillæ, being likewise connected with their interior *stroma*. Its *epithelium*, 0·02—0·04''' thick, is laminated and characterised by the variety of form and size of its elements, of which the most deeply-seated cells are rounded and small, those in the middle cylindrical or conical, 0·01—0·02''' in length, and the superficial, rounded-polygonal scales 0·006—0·04''' in size, or more flattened, and reaching a diameter of 0·02''' . The frequent occurrence of two *nuclei* in these cells is a striking fact, as well as of clear darkish-coloured round granules 0·001—0·002''' in size, which often almost assume the aspect of *nuclei*.

The *urinary bladder*, besides its peritoneal investment, possesses the same membranes as the *ureters*. The muscular coat presents, externally, the well-known longitudinal fibrous layer (*detrusor urinæ*), with parallel bundles, from which isolated fibres are continued upon the *urachus*; beneath these is a plexiform arrangement of oblique and transverse, stronger and slenderer fasciculi, interwoven into a true *plexus*, which do not completely cover the entire mucous membrane, and, at the neck of the bladder, constitute a strong continuous circular fibrous layer (*sphincter vesicæ*). The *corpus trigonum*, in the fundus of the bladder, is a thick layer of whitish-yellow fibres, lying immediately beneath the mucous membrane, continuous with the longitudinal muscular fibres of the *ureters* passing through the muscular coat of the bladder, and contains chiefly longitudinal, but also some transverse fine elastic elements, connective tissue, and smooth muscular fibres. The *mucous membrane*, pale, smooth, and tolerably thick, except where the *corpus trigonum* is situated, presents an abundant submucous layer, and consequently, when the bladder contracts, is thrown into numerous folds. It presents no villi, is tolerably rich in *vessels*, especially at the fundus and neck, less so in *nerves*, which, however, especially in those two situations where they are more abundant, may be recognised as dark-bordered, fine and medium-sized fibres, and is covered with a laminated *epithelium* 0·03—0·05''' thick, whose deeper elements are usually fusiform, conical or cylindrical, the more superficial, rounded-polygonal or flattened. They exhibit the same want of uniformity in

size as those of the pelvis of the kidney, to which irregularity the numerous depressions of various depths on the under surface of the uppermost cells, for the reception of the ends of the deeper, elongated cells, much contribute; peculiar stellate and dentate forms being thence produced. In the neck of the bladder and towards the *fundus*, there occur minute *glands*, in the form of simple pyriform follicles or small aggregations of these (simple racemose glands). These glands, 0.04—0.24'' in size, have orifices of 0.02—0.05'', a cylindrical *epithelium*, and contain a clear *mucus*. In pathological conditions, as Virchow informs me, they are occasionally enlarged and filled with whitish mucous plugs.

The *male urethra* will be described with the sexual organs. That of the female presents a reddish *mucous membrane* with numerous vessels, especially in the form of much developed venous plexuses in the submucous tissue (which Kobelt, without any reason, has described as a *corpus spongiosum*), and a squamous epithelium, the deeper-seated cells of which are elongated, as in the bladder. There is an external muscular tunic united with the mucous membrane, consisting of a thin layer of longitudinal and transverse smooth muscles, intermixed with much connective tissue and elastic fibres, and of the thick substance of the *musculus urethralis*, the direction of the fibres in which is chiefly transverse. A certain number of larger and smaller racemose mucous glandules ("glands of Littre"), resembling in their structure those of the bladder, except that they are usually somewhat larger and more closely placed, pour their secretion into the *urethra*. Occasionally these glands occur of larger size (as much as 2''), and prominent, containing a colloid-like material in the distended vesicles.

#### § 191.

*Physiological remarks. Development of the urinary organs.*  
—According to Remak, the *kidneys*, in the Chicken, are formed as two protrusions of the intestine, in the constitution of which the epithelial and the fibrous layers both take part, and, like the lungs, grow by the ramification of their epithelial tube, and the augmentation in bulk of the fibrous layer (Unters. z. Entw. d. Wirbelth. Tab. II, fig. 83-85). In the Mammalia, the earliest stage of the development of the kidneys has not yet been

observed; but what we do know from the labours of Rathke, J. Müller, Valentin, and Bischoff, with respect to its subsequent conditions, perfectly accords with the statements of Remak, except that, in this case, the glandular canals appear to be developed upon the type of the salivary glands, and are not hollow from the commencement. The rudimentary kidneys, in the Mammalia, at first, present nothing but the pelvis and a certain number of clavate hollow protrusions continuous with it—the *calices*. From each of the latter is subsequently formed, by continued budding, a bundle of *tubuli uriniferi*, each of which bundles ultimately constitutes a Malpighian pyramid and the cortical substance appertaining to it; whilst, at the same time, the kidney expands into a corresponding number of lobes. The *tubuli uriniferi* are at first solid, composed solely of cells and without any *membrana propria*. In the course of development the latter arises, probably from a *plasma* afforded by the cells, and the cavity of the canal is formed, in consequence, it may be supposed, of the collection of a fluid between the cells; simultaneously with which the tubules begin to grow rapidly in length, and to become convoluted. The Malpighian bodies are originally nothing more than solid, clavate, thickened extremities of the rudimentary *tubuli uriniferi*. The interior cells of these pyriform or rounded bodies, subsequently become capillaries, which are continuous, at two points, with the vessels outside, whilst the most exterior form the *epithelium*, which joins that of the *tubulus uriniferus* and, like it, is invested with a *membrana propria*, which is of course deficient where the afferent and efferent vessels enter and emerge, at which point it may be said to be perforated. In the newborn child, according to Harting, the renal canals are three times more slender than in the adult, whence, as the kidney of the latter is only twice the size of that of the child, it is obvious that, at any rate after birth, no tubules are formed.

With respect to the *physiological* relations, I would merely offer the following remarks. There can be no question that the peculiar vascular conditions in the kidney, in accordance with which the blood circulates in special coils projecting into the commencement of the *tubuli uriniferi*, before it passes into the proper capillary plexus of the organ, are most intimately connected with the secretion of a large proportion of water in the



urine. The hinderance to the flow of the blood gives rise to a considerable lateral pressure in the *glomeruli*, and a large quantity of blood-plasma is forced through the thin opposing membrane (the walls of the capillaries and the *epithelium*). Since all the elements of the plasma are not found in the urine, and those that are, present in it totally different proportions to those in which they exist in the blood, it is obvious that the membrane in question does not act simply as a filter, but also, for reasons at present unknown, retains certain substances (protein-compounds, fat), whilst it allows others (*urea*, &c.) to pass through with peculiar facility. In this way there is formed in the commencements of the *tubuli uriniferi*, probably a very diluted urine, which afterwards, as it flows towards the pelvis of the kidney, reciprocally acts and is acted upon by the blood circulating around the *tubuli uriniferi*, receiving additional substances from it (perhaps more *urea*), but also yielding up certain of its own constituents (water and salts), and thus, at last, becomes true urine.

As regards the *chemical composition* of the kidney we know very little. Frerichs (l. c. p. 42) found, in a healthy kidney, 16·30—18% solid matter, 72—73·70 water. Of the former, the fat amounted to 0·63—0·1%, although, according to Owen Rees, it may amount to 1·86; the greater portion, however, is probably *albumen*, with regard to which, Ludwig especially has shown, that it exists in large quantity in the kidney, a fact that, from the micro-chemical characters of the epithelial cells of the *tubuli uriniferi*, cannot be wondered at.

[In the higher animals, the secretion of the urine takes place without any formation or dissolution of cells and consequently the normal urine just evacuated contains no morphological elements. It is only occasionally that *epithelial cells* from the urinary passages, especially from the bladder and *urethra*, occur in it; but we almost always find *mucus* from the same localities, forming clouds or a light sediment, occasionally with *mucus-corpuscles*; and lastly, *spermatic filaments* after emissions. In inflammations, hemorrhages, exudations, fatty kidney, we find *pus-corpuscles*, *oil-drops*, *blood-globules*, *blood*, and *fibrinous coagula*, moulded in the *tubuli uriniferi*, in the form of cylindrical casts, and *epithelium* from the *tubuli*, isolated or in

continuous strings or tubes. *Sedimentary deposits* of the salts of the urine are readily formed as the products of decomposition. All normal urine without sediment, at a mean temperature, undergoes an *acid fermentation*, under the influence of the *mucus* contained in it; and whilst fermentation and filamentary *fungi* are developed, forms, from the decomposition of the urinary colouring matter, lactic or acetic acid, in consequence of which *uric acid* is set free from its compounds and deposited, in the form of rhombic or prismatic crystals, coloured yellow or reddish by the colouring matter of the urine. Sooner or later the acid disappears, and from the decomposition of the *urea*, perhaps also of the colouring matter, the urine becomes *ammoniacal* and *alkaline*, with large colourless pyramidal prisms, or needles grouped in a stellate fashion and soluble in acetic acid, of the *triple phosphate* of magnesia and ammonia, which, intermixed with numerous *infusoria* (*vibriones* and *monades*), form a superficial pellicle, and with granules of *urate of ammonia*, and also, it may be, of *carbonate of lime*, a white sediment. Under conditions not as yet known, and rarely, hexahedral prisms of *cystin* appear in the urine; more frequently, after the use of drinks containing carbonic acid, and also in pregnant women, we find the octohedrons of *oxalate of lime* insoluble in acetic acid. If the quantity of *uric acid* be augmented, as after the inordinate use of nitrogenous food with deficient exercise, in impaired digestion, fevers, &c. a more or less abundant yellowish precipitate of *urate of soda*, in the form of isolated or aggregated granules, is formed as soon as the urine cools, and becomes re-dissolved when it is again warmed. If, under these circumstances, the acid fermentation is set up, very considerable sediments of coloured crystals of uric acid (brick-dust sediment) are often thrown down. In injuries of the bladder, the urine frequently becomes alkalescent with great rapidity, when the above-mentioned crystals of triple phosphate at once make their appearance; they are also very frequent in pregnancy; and when assuming the pellicular form above described, were at one time regarded as a peculiar substance (Kiestein).

The occurrence of albumen, fibrin, and fat, within the *tubuli uriniferi*, is, in my opinion, easily explained, upon the supposition that in such cases, the circulation is obstructed, and

an increased secretion of the elements of the blood takes place in the Malpighian bodies and *tubuli uriniferi*, in consequence of which the epithelium of those parts, which, as is well known, is found in these cases in considerable quantity in the urine, is washed away, whence, of course, any further hinderance to the continued passage of the above substances is removed. A permeation of fibrin through the epithelium is also conceivable, just as much, for instance, as upon the mucous membrane of the respiratory organs, although I do not believe, that an increased pressure of such a kind as to induce a transudation of fibrin could fail to affect the delicate epithelium. When the epithelium is once removed, it becomes an important question, whether it is quickly restored; and it appears to me, that the frequent occurrence of small quantities of albuminous matter in the urine, often depends simply upon local deficiencies of the epithelium caused in one way or another.

[*Investigation of the kidney.*—The *tubuli uriniferi* are readily isolated when the tissue of the organ is teased out; the *epithelium*, *membrana propria* and *canal*, being distinctly recognisable, if blood-serum, or a solution of albumen be employed to moisten it. Together with entire tubules, there will be found in every preparation numerous epithelial cells, separate or in groups, or even, as especially in the pyramids, in the form of long continuous tubules. The latter often present a peculiar aspect, for the most part collapsing, exhibiting somewhat flattened cells and resembling vessels. Equally frequent, are longer or shorter tubes of the *membrana propria*, which, when much plicated, cannot always at once be recognised. In the examination of the pyramids, the extremely numerous vessels must not be confounded with the “ducts of Bellini,” or the epithelial casts that have escaped from them. The connexion of the *tubuli uriniferi* with the Malpighian bodies, is easily discerned in the kidney of the Frog and of Fishes, upon careful teasing out of the structure; but in Mammalia, also, it will rarely be missed, in fine, hardened sections, and especially in injected preparations. The *glomeruli* themselves may frequently be recognised when naturally injected, and still better when artificially filled, which we may very readily succeed in doing with any fine material thrown in by the arteries. Similar injections, also, when successful, fill the whole capillary plexus

of the cortical substance and of the pyramids; when this portion of the circulatory apparatus, especially in perpendicular sections, may be very satisfactorily made out. For the same purpose, kidneys injected from the veins are employed, in which not only the capillary plexus, but the *glomeruli* are filled; and for the study of the *vasa efferentia*, preparations not completely filled from the arteries are suitable. The course of the *tubuli uriniferi* should be studied in fine sections of kidneys hardened by immersion in alcohol, by boiling in dilute nitric acid and drying (Wittich), or by chromic acid, and rendered transparent by acetic acid; or in sections, made with the double-bladed knife, of recent, as well as of injected kidneys, in which the most important conditions, even the divisions of the "ducts of Bellini," may be observed. Nevertheless, it is always expedient to inject the *tubuli uriniferi*; and for this purpose, among the Mammalia, the Horse appears to be best adapted. This filling may happen, in consequence of accidental extravasation into the Malpighian capsules; in the injection of the arteries by this means, however, rarely more than the convoluted tubuli are filled; or it may be effected by injection from the ureter with the aid of the air-pump (Huschke, Isis, 1826), or the pelvis of the kidney being kept filled, if an endeavour be made by the kneading of it with the hand, to force the material into the "ducts of Bellini," and beyond them (Cayla). By means of a very fine canula, the individual tubuli may also be injected directly from the *papillæ*.]

*Literature.*—M. Malpighi, 'De Renibus, in Exercit. de visc. struct.;' Al. Schumlansky, 'Diss. de structurâ renum, c. tab. Argentor. 1782, 4to; W. Bowman, 'On the structure and use of the Malpighian Bodies of the Kidney,' in 'Phil. Trans.,' 1842, I, p. 57; C. Ludwig, 'Beiträge zur Lehre vom Mechanismus der Harnsecretion,' Marburg, 1843; and Art. 'Niere,' in Wagner's 'Handw. d. Physiolog.,' II. p. 628; J. Gerlach, in 'Müller's Archiv.,' 1845 and 1848; Kölliker, in 'Müll. Archiv.,' 1845; Remak, in 'Froriep's N. Notiz.,' No. 786, 1845, p. 308; F. Bidder, in 'Müll. Archiv.,' 1845, and 'Untersuch. über die Geschlechts- und Harnwerkzeuge der Amphibien,' Dorpat, 1846; J. Hyrtl, in 'Zeits. d. Wien. Aerzte,' 1846; [Jos. Toynebee, 'On the Intimate Structure of the Human Kidney,' 'Med. Chirur. Transact.,' 2d Ser. vol. II,

p. 303, 1846;] C. v. Patruban, 'Beiträge zur Anatomie der menschlichen Niere,' in 'Prag. Viertelj.' 1847, III.; G. Johnson, Art. 'Ren,' in 'Cyclop. of Anat.,' May, 1848; V. Carus, in 'Zeitsch. f. wiss. Zool.,' II, p. 61; v. Wittich, in 'Arch. für path. Anat.' III, 1, 1849; v. Hessling, in 'Froriep's N. Notiz.,' 1849, p. 264, and 'Histologische Beiträge zur Lehre von der Harn-secretion,' Jena, 1851. Besides which should be consulted the usual Manuals of Anatomy, especially those of Henle, Valentin, J. Müller, and myself; the 'Memoirs on Development,' particularly of Valentin, Rathke, 'Abhand zur Entw.' II, p. 97; J. Müller, 'De Gland. sec. structurâ;,' and lastly, the 'Annual Reports of Reichert,' 1846 and 1849.

#### OF THE SUPRARENAL GLANDS.

##### § 192.

The *suprarenal glands or capsules*, (*glandulæ suprarenales*), are a pair of organs, in their structure approaching nearest to the blood-vascular glands, but whose function is as yet altogether unknown. Each consists of a moderately firm but thin coat composed of connective tissue, which closely invests the entire organ and is connected by numerous processes with the proper parenchyma, composed of a *cortical* and a *medullary substance*. The former, *substantia corticalis*, is more compact,  $\frac{1}{3}$ — $\frac{1}{4}$ ''' thick, tearing readily in the direction of its thickness, and, when torn, presenting a fibrous aspect. Its colour is for the most part whitish-yellow or yellow, in the innermost third, however, usually passing into brownish-yellow or brown, so that in a transverse section, two layers may be distinguished, an external, bright-coloured layer and an internal narrow, dark border. The *medullary substance* is, normally, of a brighter colour than the *cortical*, being of a greyish-white with a tinge of red, although when its numerous veins are full of blood, it may assume a darker and more venous hue. Its consistence is softer than that of the cortical substance, though not so much so as is usually believed, and with respect to its thickness, it is very inconsiderable ( $\frac{1}{8}$ — $\frac{1}{3}$ ''') at the thin borders and at the upper and outer extremity of the organ, whilst in

the middle, and in the lower and inner half, it amounts to as much as  $1'''$  or even  $1\frac{1}{2}'''$ . In the dead human subject, the cortical substance very readily becomes detached from the medullary, when the suprarenal gland presents a cavity, frequently occupying the entire organ, and containing a dirty, pultaceous substance derived from the half disintegrated brown layer of the cortex, mixed with blood, together with the less altered medullary substance; which, however, in more rare instances, also becomes broken up.

§ 193.

*Intimate structure.*—The cortical substance presents, as a foundation, a delicate mesh-work of connective tissue, which, in connexion with the tunic and the thin, mutually connected *laminae* proceeding from it, pervades the entire layer, and forms the boundaries of very numerous, closely-approximated compartments,  $0\cdot016$ — $0\cdot02'''$ , or even  $0\cdot03'''$  in diameter, which extend in a vertical direction from without to within, through the entire thickness of the *cortex*. In these compartments is lodged a granular substance, subdivided by delicate, oblique or transverse dissepiments, into larger and smaller aggregations, which Ecker describes as *gland-follicles*, and as containing, within a structureless membrane, a granular material mixed with nuclei or even cells. But in these "*cortical cylinders*," as I would term them, I have, in most instances, noticed nothing but rounded-angular cells,  $0\cdot006$ — $0\cdot012'''$  in size, and believe that Ecker, from the more rare occurrence of true follicles, has been induced to regard the compact aggregations of so-termed cells which occur in the interior of the *cortex*, and which are  $0\cdot024$ — $0\cdot048$ — $0\cdot06'''$  long, as special follicles. In fact, the cortical cells, which on the external and internal portions of the *cortex* are to be met with more isolated in the compartments, are in its interior, closely united into

Fig. 252.

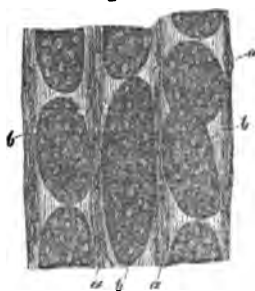


Fig. 252. Portion of a vertical section through the cortex of the suprarenal body in Man: *a*, septa of connective tissue; *b*, cortical cylinder, whose composition out of cells is more or less distinctly manifest;  $\times 300$  diam.

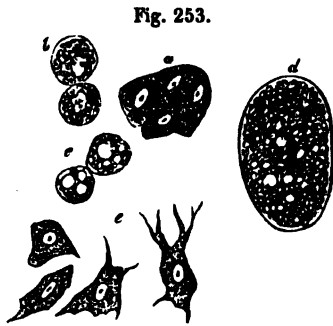
oval or cylindrical masses, in which the outlines of the cells have frequently coalesced into a single, general contour-line. I have never been able to detect any other membrane surrounding the cells besides the connective tissue of the corresponding compartment and I have almost always succeeded, by pressure, or the addition of alkalis, in isolating the cells, without bringing into view any special sac. True follicles, I have hitherto seen only in the inner portions of the cortex, in the form of round or oval vesicles 0.02—0.03" in diameter, within which, no cells like those of the cortical cylinders are formed, but only a collection of oil-drops could be recognised, and which I have been inclined to regard as enlarged cells. The contents of the cortical cells normally consist of fine granules of a nitrogenous substance; but to these are almost always added solitary fat-granules, which in many cases (in the yellow cortical substance), exist in such quantity, as entirely to fill the cells, which then assume a deceptive resemblance to those

of a fatty liver. In the brown layer of the *cortex*, the cells are entirely filled with brown pigment granules.

The *medullary substance* also has a *stroma* of connective tissue, which prolonged from the cortical lamellæ, pervades the whole interior, for the most part, in more delicate fasciculi, constituting a network with rather narrow, rounded meshes. In this network lies a pale, fine-granular substance, in which, in Man, by careful manipulation, and in recent preparations, I have almost always noticed pale cells of 0.008—0.16", which, in their fine-granular contents, occasionally presenting a few fat, or pigment-granules, their frequently very distinct *nucleus* with large *nucleoli*, their angular form, and occasionally single or multiple, or even branched processes,

round, rounded meshes. In this network lies a pale, fine-granular substance, in which, in Man, by careful manipulation, and in recent preparations, I have almost always noticed pale cells of 0.008—0.16", which, in their fine-granular contents, occasionally presenting a few fat, or pigment-granules, their frequently very distinct *nucleus* with large *nucleoli*, their angular form, and occasionally single or multiple, or even branched processes,

Fig. 253. From the suprarenal body of Man: *a*, five cells filled with pale contents, from the summit of a cortical cylinder; *b*, pigment-cells from the innermost layer of the cortex; *c*, fat-containing cells, from the yellow cortical layer; *d*, a larger cyst filled with fat, from a cortex of that kind (gland-follicle, Ecker); *e*, cells from the medullary substance, some with processes;  $\times 350$  diam.



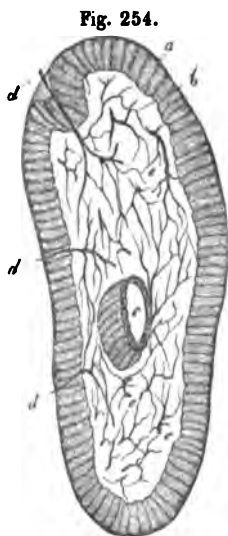
resemble the nerve-cells of the central organs, although they cannot definitively be declared to be such.

§ 194.

*Vessels and nerves.*—The blood-vessels of the suprarenal glands are numerous, lie in the stroma of connective tissue, and form two kinds of capillary plexuses; one in the *cortex* with elongated meshes, and one in the medullary substance with more rounded interstices. The arteries arise as numerous (amounting to twenty) small vessels from the neighbouring larger trunks (phrenic, cæliac, aortic, renal) and either penetrate directly into the medullary substance or ramify in the cortical. The latter, which are the more numerous, cover the outer surface of the organ with their multiplied ramifications, and form a wide capillary plexus even in the outer tunic. They then subdivide into numerous fine twigs, and dip down into the dissepiments of the *cortex*, in which, becoming more and more attenuated, they run straight towards the *medulla*, being mutually connected in their course by pretty numerous transverse anastomoses, so that the cortical cylinders are surrounded by blood on all sides. The extremities of these vessels extend to the interior of the *medulla*, where, in common with the arteries which penetrate directly to the same point (of which, however, according to Nagel, in the Sheep, some proceed from the medulla entirely to the *cortex*) they form a rich capillary plexus of rather large vessels. The *veins* arise chiefly from this latter plexus, and, within the medullary substance, join the principal vein of the organ,—the *v. suprarenalis*—which comes out on the anterior surface, at the so-termed *hilus*, emptying itself, on the right side, into the *vena cava* and on the left, into the renal vein. Besides these, a good many smaller veins arise from the *cortex*, which either accompany the arteries in pairs, or proceed independently and open into the renal and phrenic veins, and into the inferior *vena cava*. Of *lymphatics*, I have as yet noticed only a few small trunks on the surface of the organ, but none in the interior or coming out from it. The *nerves* of the suprarenal glands are, as was correctly stated by Bergmann, extremely numerous, arising from the semilunar ganglion and the renal plexus; according to Bergmann also, to a small extent, from the *vagus* and



phrenic nerves. In Man, in the right suprarenal gland, I have counted thirty-three trunks, 8 of  $\frac{1}{3}$ — $\frac{1}{16}$ ''', 5 of  $\frac{1}{14}$ — $\frac{1}{20}$ ''', 7 of  $\frac{1}{23}$ — $\frac{1}{33}$ ''', and 13 of  $\frac{1}{43}$ — $\frac{1}{50}$ ''', and found that, without exception, or at all events in a very preponderating proportion, they were constituted of dark-bordered, finer and medium-sized, or even thick fibres; were whitish or white and furnished with isolated, larger or smaller ganglia. They are especially apparent on the inferior half and inner border of the organ, and appear to be all destined for the medullary substance, in which, at least in the Mammalia, an *extremely rich plexus* of dark-bordered, finer fibres occurs, inclosed in the *trabeculae* and connective tissue, their terminations, however, being nowhere perceptible. In Man, the medullary substance is, in most instances, so altered, that the nerves cannot be traced farther than to their entrance into it, it being impossible to follow their farther distribution.



§ 195.

*Physiological remarks.*—The suprarenal glands are developed simultaneously with the kidneys and independently of them, from a blastema derived from the middle germinal lamella (Remak), the first appearance and growth of which is unknown, and are originally larger than the kidneys. In the third month the two organs are of equal size; in the embryo at six months, the weight of the suprarenal capsule is, to that of the kidney, as 2 to 5, in the mature embryo as 1 to 3, in the child at birth as 1 to 8 (Meckel). In other Mammalia the suprarenal glands are, from the first, smaller than the kidneys, and increase in the same proportion with them. Little is known with respect to the histological development of the

Fig. 254. Transverse section of the suprarenal body of the Calf,  $\times$  about 15 diam., treated with soda: a, cortex; b, medulla; c, central vein surrounded with some cortical substance; d, three entering nerves; e, nerves, and their distribution in the interior.

organ. I have, hitherto, investigated this only in an embryo of three months, in which, like Ecker, I found the *cortex* whitish, the medulla whitish-red, and both constituted of cells and fibres. The cells measured 0·012—0·02''' , had well marked, in part colossal *nuclei*, with distinct *nucleoli*, and in the cortical part also fatty molecules. Of the *nerves* at that period I saw nothing. In a newly-born Rabbit, Ecker observed no appearance of follicles, whilst in a foetal Calf, 1'6'' long, he found them very distinct, but small (0·05—0·15<sup>mm</sup>).

As regards the *functions* of the suprarenal glands, in the absence of all physiological indications, and so long as the course of the nerves in them is not much more accurately known, only very general observations can at present be offered. *I consider the cortical and medullary substances as physiologically distinct.* The former may, provisionally, be placed with the so-termed "blood-vascular glands," and a relation to secretion assigned to it; whilst the latter, on account of its extremely abundant supply of nerves, must be regarded as an apparatus appertaining to the *nervous system*, in which the cellular elements and the nervous plexus either exert the same reciprocal action as they do in the grey nerve-substance, or stand in a relation as yet wholly unascertained, towards each other. (For a more detailed account *vid.* Mikros. Anat. II. 2. zw. Hälfte.)<sup>1</sup>

<sup>1</sup> [The former and more recent researches of Leydig ('Anatomisch-histologische Unters. üb. Fische u. Reptilien,' 1853), appear satisfactorily to show the identity of the suprarenal glands of the Mammalia, with the yellow, vascular bodies seated, either on the kidney itself and its emulgent veins, or at a greater distance from those glands, on the veins near the epididymis or ovaries, or upon the sympathetic nerve. The study of these more simple forms has also thrown very considerable light upon the structure and true import of the more complicated organ in the Mammalia. In the Salamander, the ganglia of the sympathetic have a very remarkable structure, and contain cellular elements of two very distinct kinds. Each ganglion has a tunic of connective tissue which sends septa into the interior, which is thus divided into distinct and occasionally, perfectly separate compartments. The cells of both kinds are enclosed in these compartments, and are never intermixed in one and the same. In some of the compartments, or as they might almost be termed, vesicles, the cells are large, clear, and finely granular, with a vesicular *nucleus* and very transparent *nucleolus*. From some of these cells, nerve-fibres are distinctly seen to proceed, and they would appear to be of the bipolar kind of ganglion- or nerve-cells. The other kind of cells, contained in perfectly distinct compartments, are much smaller and their contents of a peculiar dirty yellow colour, owing to which the perfectly transparent nucleus is rendered very distinct.

These two kinds of cells occur in very variable proportions in different ganglia.

[In the investigation of the suprarenal glands, the larger Mammalia ought, in the first place, to be chosen, and not till afterwards should they be studied in Man. The cortical portion is readily examined when its elements contain but little fat, and, above all, perpendicular sections of fresh specimens, or of such as have been hardened in alcohol and in chromic acid, which are afterwards to be rendered transparent by soda, are to be recommended. The medullary substance, even in animals, is very easily disintegrated, so that its elements are either not to be seen at all in the normal state, or only partially, although they are occasionally very beautifully displayed without any addition, as well as in chromic-acid preparations. In animals, the *nerves* are very easily discerned in fine sections, after the addition of soda; and when their external visible points of entrance are exactly hit upon in the making of the section, their course through the cortical substance is readily brought into view. For the *vessels*, injections should be employed, which are best effected in the Sheep or sucking Pig, and which readily succeed when made, as well from the arteries as from the non-valvular veins.]

*Literature.*—Nagel, 'Diss. sistens ren. succent. mammal. descript.,' Berol., 1838, and Müll. 'Arch.,' 1836; C. Bergmann,

Now, if the dirty yellow-colored ganglion-globules of one of these sympathetic ganglia be compared, side by side, with the contents of one of the yellow bodies on the veins, or of the yellow granular masses on the kidney, it will be at once apparent, that by a gradual transformation, they directly pass into the fatty, granular cells of the so-termed *suprarenæ*. And the same transformation may take place even in the sympathetic ganglia.

According to Leydig, the *cortical* substance of the suprarenal capsules of the Mammalia corresponds to the yellow, granular and striped suprarenal bodies of Fishes and Amphibia; whilst the *medullary* substance of the Mammalian organ, which is abundantly supplied with nerves and cells, very like the ganglion-globules, represents the other divisions of the sympathetic ganglia: whence he concludes that Bergmann's view, according to which the suprarenal capsules are closely related to the nervous system, is undoubtedly correct, and that those organs bear the same relation to the ganglia of the sympathetic nerves, as the pituitary body bears towards the brain. Besides this relation to the nervous system, however, they have an intimate one with the vascular; and are, therefore, always pervaded by a very close capillary plexus. But in any case, he says, the suprarenal bodies must be removed from the category of the so-termed blood-vascular glands, which would then include only the thyroid and thymus, or should probably be abolished altogether, as an unmeaning term.—Eds.]

'Diss. de glandulis suprarenal,' c. tab. Gött., 1839; A. Ecker, 'Der feinere Bau der Nebennieren beim Menschen,' u. den 4 'Wirbelthierclassen,' Braunschweig, 1846, und Art. 'Blutgefäßdrüsen,' in Wagner's 'Handw. d. Physiologie,' Bd. IV, 1849; H. Frey, Art. 'Suprarenal Capsules,' in Todd's 'Cyclop. of Anat.,' Oct., 1849.

[H. Gray, 'On the development of the ductless Glands in the Chick,' 'Phil. Trans.,' 1852.—Eds.]

---

## OF THE SEXUAL ORGANS.

### A. MALE SEXUAL ORGANS.

#### § 196.

The *male sexual organs* consist. 1. Of two glands for the secretion of the *semen*, the *testes*, which, together with special tunics, the *tunicæ vaginales*, are contained in the *scrotum*; 2. of their efferent canals, the *vasa deferentia* and *ejaculatory ducts* with their appendages, the *vesiculæ seminales*; 3. of the copulatory organs, the *penis* and its muscles; 4. and lastly, of special accessory glands, the *prostate* and *Cowper's glands*.

#### § 197.

The *testicles, testes*, are a couple of true glands, containing within a special tunic, the *tunica albuginea s. fibrosa*, the secreting elements, in the form of complexly convoluted tubules, the spermatic tubes or *tubuli seminiferi*. The *tunic* is a white, dense and thick membrane, corresponding in structure, in all respects, with other fibrous membranes (the *dura mater* especially), and everywhere surrounding the parenchyma of the *testis* as a closed capsule. Its external surface, except where the *epididymis* is attached to the *testis*, is rendered smooth and glistening by a special covering, the *tunica adnata*, whilst the internal is united with the substance of the gland by a thin layer of loose connective tissue and moreover, sends a considerable number of processes into the interior; of which, the most important is the *corpus Highmori s. mediastinum testis*, a vertical lamella of dense connective tissue  $\frac{3}{4}$ —1" long, and thick at its commencement, which extends from the posterior

border of the *testis* to a depth of 3—4''' into the interior (fig. 255 *h*); but besides this, there are numerous lamellar processes (*septula testis*) (fig. 255 *s*) arising from the internal surface of the *tunica albuginea*,

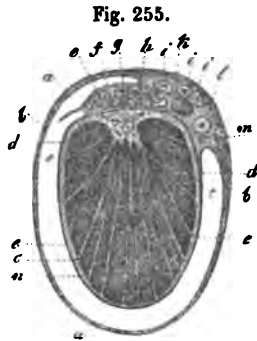


Fig. 255.

composed of more lax connective tissue, which, separating the divisions of the glandular structure from each other, and conveying the vessels belonging to them, converge from all sides towards the *corpus Highmori*, and are attached by their acuminate terminations to its surfaces.

The glandular substance of the *testis* is not absolutely homogeneous, but consists of a certain number (100—250) of pyriform lobules, *lobuli testis*, which are not, however, everywhere wholly separated from each other, and all converge with their points towards the *corpus Highmorianum*,

Fig. 256.



close to which they are shortest, whilst those between the borders of the organ are the longest (fig. 255 *n*, 257 *b*). Each of these lobules is formed of from 1 to 3 *seminal tubules* or *canaliculi*,  $\frac{1}{8}$ — $\frac{1}{15}$ ''' in diameter. These tubules, much convoluted, pretty frequently dividing and also, perhaps, anastomosing, in their course, form a compact substance and ultimately terminate at the thick end of the lobule, at a greater or less distance from the surface, either in cæcal ends or in loops (fig. 256 *g*). The spermatic canals of each particular lobule, although joined to each other by some connective tissue and vessels, may nevertheless, by careful dissection, be separated to a great extent, or even wholly isolated. Their length, according to Lauth,

Fig. 255. Transverse section through the right testis and its tunics, in Man: *a*, *t. vaginalis communis*; *b*, *t. vaginalis propria*, outer lamella; *c*, cavity of the *t. v. propria*, which does not exist in life; *d*, inner lamella of the *t. v. propria (adnata)*, coalescent with *e*, the *t. albuginea*; *f*, continuation of the *t. propria* on the *epididymis*, *g*; *h*, *corpus Highmorianum*; *i i i*, branches of the spermatic artery; *k*, *vena spermatica interna*; *l*, *vas deferens*; *m*, artery of the *vas deferens*; *n*, *lobuli testis*; *s*, *septula*.

Fig. 256. Diagram of the course of a spermatic tubule.

is from 13'' to 33''. At the pointed extremity of each lobule the spermatic canals become straighter, when each by itself, or the two or three arising in one lobule united into a simple canal, enter as the *ductuli recti*,  $1\frac{1}{10}$ ''' in diameter (fig. 257 c), the base of the *corpus Highmori*, where they form a very close plexus, 2—3''' broad and  $1\frac{1}{8}$ ''' thick, and extending the whole length of that body,—the *rete testis* (*r. vasculosum Halleri*) (fig. 257 d). From the upper end of this plexus, the canals in which measure from  $\frac{1}{13}$  to  $\frac{1}{33}$ ''' (0.03—0.08'''), proceed 7—15 efferent canals, *vasa efferentia testis* s. *Graafiana*, of  $\frac{1}{3}$ — $\frac{1}{8}$ ''' (0.16—0.18''') (fig. 257 e),

which, traversing the *t. albuginea* are continued into the *epididymis*. Here they contract to  $\frac{1}{8}$ ''' and  $\frac{1}{10}$ ''' , are convoluted in exactly the same way as the spermatic canals in the *lobuli testis*, but without presenting divisions or anastomoses, and thus produce a certain number of conical bodies, the apices of which are directed towards the *testis*,—the *spermatic cones* (*coni vasculosi* s. *corpora pyramidalia*) (fig. 257 f). These cones, united together by connective tissue, constitute the *head* (*globus major*) of the epididymis, at the upper and posterior border of which their canals gradually coalesce; and thus is formed the simple thick *duct* of the *epididymis*, 0.16—0.2'' in diameter (fig. 257, g). This duct, convoluted in a

Fig. 257.

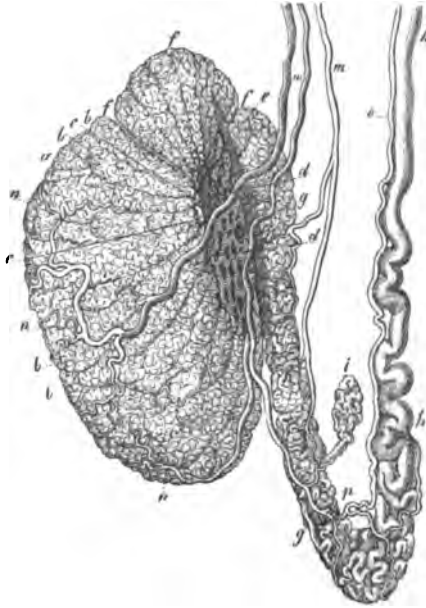



Fig. 257. Human *testis* and *epididymis*, after Arnold: a, *testis*; b, lobes; c, *ductuli recti*; d, *rete vasculosum*; e, *vascula efferentia*; f, *coni vasculosi*; g, *epididymis*; h, *vas deferens*; i, *vas aberrans*; m, branches of the *spermatica interna* of the *testis* and *epididymis*; n, ramification on the *testis*; o, *art. deferentialis*; p, anastomosis with a branch of the spermatic.

well-known manner, forms the body and tail (*globus minor*) of the *epididymis*, usually giving off at its inferior extremity a caecal prolongation, *vas aberrans Halleri* (fig. 257 *i*) and is ultimately continuous with the spermatic duct or *vas deferens*, which at first  $\frac{1}{4}$ — $\frac{1}{3}$ ''' in diameter and convoluted, soon increases, to a size of  $\frac{3}{4}$ —1''' , and becomes straight (fig. 257 *h*). The *epididymis*, moreover, has an extremely delicate fibrous tunic ( $\frac{1}{3}$ ''') of a greyish white colour.

### § 198.

*Structure of the seminiferous tubes.*—The seminal tubes of the *testis* are, in proportion to their diameter, rather more firmly constructed than other glandular canals and consist of a *fibrous membrane* and an *epithelium*. The former, from 0·0024—0·005''' , or in the mean 0·003—0·004''' thick, composed of an indistinctly fibrous connective tissue with longitudinal *nuclei*, without muscular fibres and rarely presenting an indication of elastic fibrils, is tolerably firm and extensible. A

Fig. 258.



simple layer of roundish, polygonal cells, of 0·005—0·008''' , occasionally with an indication of a *membrana propria* as a substratum, on the inner surface of this fibrous membrane, completes the vascular canal, which thus obtains a wall, 0·007—0·008''' in entire thickness. In younger subjects, these cells are pale and finely granular, but as age advances, a continually increasing number of fatty granules is collected in them,

whence the seminiferous tubes sometimes acquire a light yellowish, partially brownish colour, which is manifest very frequently in men even at the middle period of life, and invariably in old age. The *ductuli recti* present the same structure as the tubes; whilst in the *rete testis*, no special fibrous tunic can be distinguished, the canals in this portion of the gland appearing to be nothing more than cavities in the dense fibrous tissue of the *corpus Highmorianum*, lined by an *epithelium*. In the *coni vas-*

Fig. 258. Portion of a spermatic tube in Man,  $\times 350$  diam.: *a*, fibrous coat with longitudinal *nuclei*; *b*, clear border, probably a *membrana propria*; *c*, *epithelium*.

*culosi* the fibrous coat again makes its appearance, and to it there is now, also, added a layer of smooth muscles, which, in the form of transverse and longitudinal fibres, are recognisable even in canals of  $\frac{1}{3}$  to  $\frac{1}{8}$ " in diameter. The thicker portions of the canal of the *epididymis* are constructed in the same way as the *vasa deferentia* (*vid. infra*), with a cylindrical epithelium, which, moreover, commences even in the head of the epididymis.

The contents of the seminiferous tubes vary according to age. In Boys and young Animals the slender tubuli contain nothing but minute, clear cells, the most external of which might be regarded as epithelial cells, although not always clearly distinguishable from the others. At the age of puberty, together with the increased size of the *tubuli seminiferi*, the elements contained in them also increase in circumference; and when the formation of *semen* has actually commenced, they appear as clear, round cells and cysts of 0.005—0.03", which, according to their size, enclose a variable number of, from 1 to 10, or even 20, clear *nuclei* of 0.0025—0.0035" with *nucleoli*. At this time, in many cases, an epithelium is not manifest, the seminal tubes rather appearing to be occupied entirely and solely by the cells in question; at other

times, and particularly in advanced years, an epithelium is presented containing fat- or pigment-cells, and surrounding the other elements. The latter, whether they occur in the one way or the other, are the precursors of the *semen*, which, in the mature condition, entirely consists of an extremely small quantity of a viscid fluid, and of innumerable minute, linear corpuscles having a peculiar movement, the spermatic filaments or animalcules, *fila spermatica*, *spermatozoa* (also *spermatozoida*). These spermatic filaments are perfectly homogeneous, soft corpuscles, in which are distinguishable a thicker portion—the *body* or *head*,—and a filamentary appendage,—the *filament* or *tail*. The former is flattened and, viewed on the side, pyriform, with the acute end in front; on the surface oval, or even rounded ante-

Fig. 259.

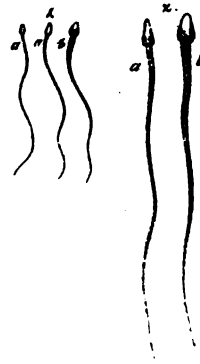



Fig. 259. Spermatic filaments (human); 1,  $\times 350$  diam.; 2,  $\times 800$  diam.: a, viewed on the edge; b, on the flat surface.



riorly, and also, though more towards the anterior part, slightly cupped; so that it sometimes appears clear in the middle, sometimes opaque. It is 0.0016—0.0024'' long, 0.008—0.0015'' wide, 0.0005—0.0008'' thick, and according as it lies on the surface or edge, does it appear clearer or more opaque, always presenting a peculiar fat-like, glistening aspect, and, particularly in a lateral view, dark borders. The pale filamentary portion has an average length of 0.02'', and at its anterior end, where it joins the broader extremity of the body, with a slight constriction, it is wider (0.0003—0.0005'') and also flattened, being gradually prolonged into an extremely fine point, scarcely visible even under the highest magnifying powers. In vigorous men the *semen*, throughout the *vas deferens* and in the *globus minor* of the *epididymis* is composed of these corpuscles, occasionally intermixed with isolated granules, *nuclei*, and cells, whilst in the upper part of the *epididymis* and in the body of the *testis* other elements, such as the above-described cells and cysts, preponderate more and more, and

Fig. 260.



finally constitute the entire secretion. These *spermatic cells* and *cysts*, as I term them, have a definite relation to the spermatic filaments, for in each *nucleus*, as was first shown by me, a spermatic filament is developed on the inner wall, in the form of a spiral

corpuscle with two or three turns. How this really arises is unknown; very probably as a sort of deposit from the contents of the nucleus, which at the same time become clear, in the same way as the spiral filaments of the vegetable cell are formed; but it may at all events be asserted as a positive fact, that the *testis* itself is the proper site of this development, so that, under normal conditions, developed, spermatic

Fig. 260. Development of the spermatic filaments in the Rabbit: *a*, parent-cell (cyst) with five *nuclei*; *b*, one with ten *nucleoli*, each of which contains a convoluted spermatic filament; *c*, an isolated nucleus with *nucleoli*; *d*, one with the spermatic filament; *e*, a cyst with a bundle of spermatic filaments; *ff*, *gg*, immature spermatic filaments, with enlargements in the filamentary portion; *h*, a perfect spermatic filament. *a*, *b*, *c*,  $\times 350$  diam.; *d*—*h*,  $\times 500$  diam.

filaments may always be found in the *nuclei*, in the internal portions of the gland, and frequently in every seminiferous tube without exception. But in the normal course of things the spermatic filaments in the *testis* itself do not become liberated at all, or in very small proportion, and the *tubuli seminiferi*, consequently, are by no means the situation in which spermatic filaments are to be sought for, although even here, on the addition of water, which causes the substance by which they are enclosed to burst, they will always be found. They do not occur in the free state before reaching the *rete testis* and *coni vasculosi*. First, the *nuclei* burst, and the filaments remain in the spermatic cells, in which, when numerous (10—20), they are very regularly disposed in close apposition, with the *heads* and *tails* together, in a curved bundle, or when in less number, confusedly aggregated. Ultimately these cells and cysts also burst, the filaments are liberated, and, forming a dense entangled crowd, entirely fill the *epididymis*, still in part associated in bundles, which, however, also are soon broken up, in part isolated. In the lower portion of the *epididymis*, the entire process of development is usually concluded, though it happens, not unfrequently, that isolated transitional forms are conveyed still farther, and are not completely developed before reaching the *vas deferens*.

The *semen*, regarded as a whole, as it is found in the *vas deferens*, is a whitish, viscid, inodorous material, consisting almost entirely of spermatic filaments, and containing between those bodies an extremely minute quantity of a connective fluid. The *chemical composition* of this unmixed *semen* has not yet been investigated in Man; but we know through Frerichs, with regard to the *semen* of the Carp, that the spermatic fluid contains no albumen, some little *mucus*, and, of salts, chloride of sodium, and a small quantity of alkaline sulphates and phosphates; whilst the spermatozoa consist of a protein compound (according to Frerichs, *binoxide* of *protein*), and contain besides 4.05% of a yellowish, butyraceous fat, and 5.21% of phosphate of lime. The *semen*, as *ejaculated*, is a mixture of pure semen and of the secretions of the *vesiculae seminales*, the *prostate* and *Cowper's glands*. It is, in this condition, colourless, opalescent, with an alkaline reaction and peculiar odour; when emitted, it is viscid and glutinous, like albumen, but on cooling becomes gelatinous, and after some time again

thinner and fluid. When examined microscopically it presents, besides the spermatozoa, a moderate quantity of a clear fluid, which, on the addition of water, presents irregular-sized whitish flocculi and fragments, and is undoubtedly derived principally from the *vesiculæ seminales*. This gelatinising substance, which Henle described as *fibrin*, and Lehmann regards as an albuminate of soda, has been described by Vauquelin, who analysed human emitted *semen*, together with the substance of the spermatic filaments, as *spermatin*, of which he found 6%, whilst besides it there were present 90% water, 3% earthy phosphates, and 1% soda. When *semen* is dried, innumerable crystals of the triple phosphate of magnesia and ammonia are formed among the undestroyed spermatozoa, which generally, owing probably to the considerable quantity of carbonate of lime contained in them, are not easily destructible. They may be demonstrated in seminal spots even after a long time, when they are moistened; resist putrefaction for a lengthened period in water and animal fluids (Donné observed them even after three months, in putrid urine), and retain their form unchanged even after incineration (Valentin). Acetic acid has but little effect upon the spermatic filaments. Caustic potass and soda render them pale, and dissolve them, after from 15 to 30 minutes. Nitric acid (20%) at first produces scarcely any change, afterwards dissolving them. In sulphuric acid their outline becomes extremely faint and they swell up, but are not entirely dissolved, as are, for instance, the epithelial cells of the seminal tubes. They are not coloured yellow by nitric acid and potass, nor red by sugar and sulphuric acid. Nitrate of potass in a solution containing 6 per cent. does not dissolve them. In the pure *semen* the filaments exhibit no *movements*, or scarcely any, when it is too much concentrated. Their movements are first visible in the contents of the *vesiculæ seminales*, and in ejaculated *semen*, or when pure *semen* is diluted. The movement of these bodies is effected solely by the alternate flexure and extension, or serpentine motion of the filamentary portion, in which way are produced such lively and various undulating, rotatory, quivering changes of place, during which the *head* or *body* always precedes, that these elements of the *semen* were formerly regarded as animals. The duration of the movements depends upon various circumstances. In the dead body they are not unfrequently perceptible even 12—24 hours after

death (on one occasion Valentin noticed faint motion at the end of even 84 hours), and in the female genital organs in the Mammalia, they exhibit motion even after seven or eight days. Water at first renders the motions more lively, but they soon cease, and the filaments are not unfrequently curved in a loop-like form. Blood, milk, mucus, pus, syrup, and a diluted saline solution usually have no injurious effect; but it is otherwise with urine and bile, the former particularly, when it is strongly acid or much diluted. All chemical reagents, acids, metallic salts, caustic alkalies, &c., cause the motion to cease, as do narcotics when they act chemically upon the filaments, or are too much diluted.<sup>1</sup>

The formation of the spermatic filaments and of the *semen*, it is true, usually ceases in old age, although they are not unfrequently found in men of 60, 70, or even 80 years of age, and even accompanied—though this, it must be confessed, is an unusual phenomenon—with the procreative faculty. After diseases, the spermatic filaments are as often found to be present as absent; and with respect to the cause of their deficiency only this much can be stated, that it appears to depend principally upon impaired nutrition.

#### § 199.

*Membranes, vessels, and nerves of the testis.*—The *testes*, together with their fibrous tunic, and a portion of the *epididymis*, are immediately invested by the *tunica vaginalis propria* (fig. 255 *b, d, f*), a delicate serous membrane, which, at one time, was a part of the *peritoneum*, and corresponds with it in structure. Its *epithelium*, constituted of a layer 0.005''' thick, of clear, polygonal cells, 0.005—0.008''' in size, with distinct *nuclei*, and occasionally with isolated, yellowish pigment-granules rests, on the *testis*, immediately upon the fibrous membrane, or at all events in this situation, is inseparably united with the fibrous coat constituting the *tunica adnata testis*, or the visceral lamella of the *t. v. propria*; whilst on the *epididymis* the serous coat, may be distinctly separated, and, like its parietal

<sup>1</sup> Chloroform exerts the same influence upon the spermatozoa as it does upon all motile tissues in animals and plants. The spermatozoa of the Frog, when exposed to the dilute vapour of chloroform, gradually cease to move, regaining their motile property upon exposure of the fluid to the air, (at any rate many of them) and the filaments thus revived, appear to retain all their impregnating power.—[Eds.]

portion, consists of dense connective tissue containing elongated *nuclei*. The *tunica vaginalis communis*, is a dense, tolerably thick membrane, consisting, on the *testis*, of firm connective tissue, and higher up, of a more lax reticulated tissue with elastic fibres; it closely surrounds the *tunica vaginalis propria*, and also invests the spermatic cord, and the lower end of the *epididymis*. Between it, the *tunica propria*, and the *epididymis*, and firmly connected with both tissues, is placed a layer of smooth muscles usually corresponding to the two lower thirds of the *testis*,—the *internal muscular tunic* of the *testis*; whilst on its outer side is inserted the *cremaster*, composed of transversely striated fibres. The *scrotum*, lastly, is formed by the *external muscular tunic* of the *testis*, which is more laxly connected with the *t. v. communis*,—the *tunica dartos*; with respect to which *vid.* § 34; and by the external integument, which is characterised by its thinness, the absence of fat, the colour of its epidermis, and its, mostly, large sebaceous and sweat-glands.

The blood-vessels of the *testis* and *epididymis* are derived from the long and slender *a. spermatica interna*, which, running in the spermatic cord, proceeds from its posterior aspect to the *testis*, and sometimes entering at once, the *corpus Highmorianum*, sometimes divided into numerous branches, ramifies in the fibrous tunic of the *testis* and on its inner surface, proceeding towards the anterior border of the gland. The coarser ramification in the parenchyma of the *testis* proceeds partly from the *corpus Highmorianum*, partly from the points of origin of the *septula testis* from the *tunica albuginea*, into the *septula*, from which, again, numerous more minute vessels penetrate into the interior of the lobules, constituting a rather wide-meshed plexus of capillaries, 0·003—0·008'' in diameter, around the *tubuli seminiferi*. In the *epididymis* there is a similar though less abundant plexus, in the formation of which the artery of the *vas deferens* also participates (fig. 257), whilst the *scrotum* and the *t. vaginalis* are richly supplied with vessels from the *aa. scrotales* and *spermatica externa*. The *veins* accompany the arteries, and with respect to the *lymphatics*, not only are those of the *scrotum* and vaginal tunics extremely numerous, but, according to the beautiful researches of Panizza ('Osservazioni,' Tab. VIII), confirmed by Arnold, those of the *testis* are also very much developed. They proceed partly from the interior, partly from the surface of the *testis* and

*epididymis*, form beneath the *tunica adnata* beautiful plexuses, ultimately connected by several trunks in the spermatic cord, and, together with those of the vaginal tunics, communicate with the lumbar glands.

The few *nerves* of the *testis* are derived from the internal spermatic plexus, and accompany the arteries to the gland. I have in vain endeavoured to follow their course in the interior, where it but rarely happens that dark-bordered nerves are seen, even accompanying the larger arteries of the parenchyma.

### § 200.

*Vasa deferentia, vesiculæ seminales, accessory glands.*—The spermatic ducts, or *vasa deferentia*, are cylindrical canals, having a mean width of  $1-1\frac{1}{2}$ ''' , the walls being  $\frac{1}{4}-\frac{1}{3}$ ''' thick, and the cavity  $\frac{1}{4}-\frac{1}{3}$ ''' in diameter, and composed, most externally, of a thin *fibrous membrane*, then of a strong, *smooth-muscular layer*, and most, internally, of a *mucous membrane*. The *muscular tunic*, which is  $0.88-0.6$ ''' thick, consists of an external, strong layer of longitudinal fibres, a middle one, also strong, of transverse and oblique fibres, and an internal, thinner longitudinal layer, constituting not more than  $\frac{1}{3}$ th of the whole muscular tunic. The tissue is constituted of stiff and pale fibre-cells, as much as  $0.1$ ''' in length, and having an average width of  $0.004-0.006$ ''' , intermixed with some connective tissue, and a few very pale elastic fibrils. The *mucous membrane*,  $0.12$ ''' thick, is white, longitudinally plicated, and in the last, broadest and widest portions of the duct, presents numerous larger and smaller *fossæ*, disposed in a reticular manner. Its external two-thirds are whiter, and contain one of the closest felted tissues of elastic fibrils with which I am acquainted; whilst towards the interior is found a more transparent, thinner layer, composed of an indistinctly fibrous connective tissue, with *nuclei*, upon which rests a single layer of *tesselated epithelium*, constituted of cells  $0.005-0.008$ ''' in size, and which almost invariably contain a certain number of brownish pigment-granules, from which the internal surface of the mucous membrane acquires a yellowish hue. The *vessels* of the *vas deferens* are very distinct in the external fibrous tunic, but also penetrate into the muscular and mucous coats, constituting in each, loose plexuses of capillaries  $0.003-0.005$ ''' in diameter. According to Swan ('Nerves of the Human Body,' Pl. V, 82; Pl. VI,

81), the *vas deferens* within the pelvis is surrounded by numerous, but fine nerves, which are in connexion with those of the lateral and median, vesical and rectal nerves, as well as with those of the hypogastric plexuses. I have myself also seen these nerves, which contain fine fibres, and "fibres of Remak," but have been unable to trace them in the interior.

The structure of the *ejaculatory ducts* and *vesiculæ seminales* appears to be the same as that of the *vasa deferentia*; the seminal vesicles, as is well known, being nothing more than appendages of the latter, furnished with wart-like, saccular, or even branched processes. The ejaculatory ducts, in their upper portions, present the same muscular structure as the spermatic canal, only that their walls are more delicate. As they approach the prostate, their membranes become still thinner; but nevertheless, even at the ultimate extremity, exhibit muscular fibres, mixed with a considerable quantity of connective tissue and elastic fibrils. The walls of the *vesiculæ seminales* are much thinner than those of the *vas deferens*, although they possess the same structure, except that the manifestly vascular mucous membrane is furnished throughout with reticular *fossæ*. Externally, the *vesiculæ seminales* are invested with a membrane, in part composed solely of connective tissue, in part, as on the posterior surface, distinctly muscular, which is continued between the separate convolutions of its canal, connecting them together; and, at the inferior end, passes from one *vesicula seminalis* to the other, in the form of a broad muscular band. The contents of the *vesiculæ seminales* are, normally, a clear, rather viscid fluid, which after death acquires a soft gelatinous consistence, though subsequently it becomes perfectly fluid; it contains a protein-compound very readily soluble in acetic acid and which is obviously identical with that contained in the ejaculated *semen*. With many other observers, I have so frequently seen spermatic filaments in the *vesiculæ seminales*, that I should describe their occurrence there as normal, and assign a double function to the seminal vesicles; together with its principal one, of affording a special secretion, that of also performing the part of seminal receptacles. The *nerves* of the *vesiculæ seminales* are derived from the sympathetic, and spinal cord, immediately from the rich *plexus seminalis*, the filaments of which, in part, penetrate the membranes of the vesicles, though they cannot be traced further, in part proceed

to the *prostate*, whose plexus—*plexus prostaticus*—receives additions also from the vesical and inferior pelvic plexuses.

The *prostate*, according to my observations, is a very muscular organ, so much so, that the glandular substance does not constitute more than one third or a half of the whole mass. Proceeding from within to without, there is presented in intimate connexion with the thin mucous membrane, the *epithelium* of which is always in two layers, though possessing a superficial lamella composed of cylindrical cells, a yellowish longitudinally fibrous layer, which extends from the *trigonum vesicæ* to the *caput gallinaginis*, is, in fact, unconnected with the muscles of the bladder, and is composed, in equal proportions, of connective tissue with elastic fibres, and of smooth muscles. To this succeeds a strong layer of circular fibres of a similar structure, continuous with the *sphincter vesicæ*, extending as far as the *caput gallinaginis*, and which I term the *sphincter prostateæ*. Beyond these different muscular layers, we come at last to the proper glandular tissue of the prostate, which consequently occupies, principally, the more external portions of the organ, although it is true that isolated lobules encroach upon the circular fibres; its numerous excretory ducts penetrate the longitudinal and transverse fibres, and open on both sides of the *caput gallinaginis*. The latter consists of a greyish-red, tolerably dense substance, which may be very readily split into fibres in the direction of the transverse diameter of the organ, or more accurately described, radiates on all sides of the upper surface of the organ, and is composed, in the first place, of variously-sized bundles of evidently *smooth muscle*, and secondly of the *glands* of the *prostate*. The latter are 30—50 compound, racemose glands, whose aggregate form is conical or pyriform, and which are distinguished from the usual kind of racemose glands by their more lax structure, their evident composition of numerous, pedunculate, glandular vesicles, and the slight development of the extremely minute glandular lobules, a condition which is partly connected with the abundant fibrous tissue interposed between the glandular elements. The *glandular vesicles* are pyriform or roundish, 0·05—0·1''' in size, and lined with polygonal or short, cylindrical epithelial cells, 0·004—0·005''' long, with brown pigment granules; whilst in the excretory ducts, the same cylinders are met with as exist in the prostatic portion of the *urethra*. The secretion



of the prostate appears to be similar to that of the *vesiculae seminales*; at all events, according to Virchow, the *prostatic concretions*, or *stones*, as they are termed—round, concentric concretions, 0·03—0·1", and more, in size, which are formed in the glandular vesicles—consist of the same protein-compound, soluble in acetic acid, which is found in the *vesiculae seminales*. The prostate possesses a fibrous coat, abounding in bundles of smooth muscles, and closely investing the glandular tissue, and tolerably numerous vessels, among which numerous capillaries surrounding the glandular elements, and a rich venous plexus under the mucous membrane of the urethra, are deserving of notice. The course of the *nerves* above described, in the interior of the prostate, is unknown.

The *uterus masculinus*, or *vesicula prostatica*, situated in the *caput gallinaginis*, in the middle, between the *ductus ejaculatorii*, presents in its whitish-yellow walls, lined with a cylinder-epithelium, principally connective tissue and elastic fibrils, with which, in the neck of the bladder, a few, and, at its base, pretty numerous flat, smooth muscles are intermixed.

The *glands of Cowper* are compact, compound, racemose glands, whose ultimate vesicles, 0·02—0·05" in size, are lined with a tessellated *epithelium*, whilst a cylindrical *epithelium* is found in the excretory canals. The delicate membrane with which the whole gland is invested, as well as the fibrous *stroma* in its interior, is tolerably rich in *smooth muscles*, which have lately been also found by me in the excretory canals,  $\frac{1}{4}$ " wide, as a delicate longitudinal layer. The secretion of these glands, which may be readily obtained from the excretory ducts, is common *mucus*.

#### § 201.

The *organ of copulation*, in Man, consists of the *penis*, an organ which is composed of three erectile, highly vascular bodies—the *corpora spongiosa s. cavernosa*; it is attached to the *pelvis*, and traversed by the *urethra*, invested by special fasciæ and by the external integument, and furnished with three proper muscles.

The *corpora cavernosa penis*, are two cylindrical bodies separated posteriorly, united anteriorly, and parted only by a single incomplete *septum*, in which are to be distinguished a special fibrous membrane (*tunica albuginea s. fibrosa*), and the internal spongy tissue. The former, which is a white, glisten-

ing, very strong membrane,  $\frac{1}{3}$ '' in thickness, constitutes both the external tunic of the spongy bodies and also, in its anterior half—as a thin lamella, partially broken up into separate fibres and laminæ—the *septum* between them; it consists of common fibrous tissue, like that of tendons and ligaments with numerous, well-developed, fine, elastic fibres. Within it lies the reddish *spongy substance*, consisting of innumerable fibres, bars, and laminæ united into a fine meshwork—the *trabeculæ corp. cavernosorum*; and with its minute, rounded-angular cavities, which anastomose on all sides, and, in life, are filled with venous blood, the *venous sinuses* of the spongy body—bears the most deceptive resemblance to a sponge. All the *trabeculæ*, without exception, present precisely the same structure. Externally they are covered by a simple layer of intimately connected tessellated *epithelium*, the cells of which frequently do not admit of being separated—the *epithelium* of the *venous spaces*;—to this succeeds the proper fibrous tissue, which is composed, on the one hand, of almost equal proportions of connective tissue and fine elastic fibres, and on the other of smooth muscles, and in many, but by no means in all the *trabeculæ*, encloses larger or smaller arteries and nerves. The elements of the trabecular muscles are not only at once distinctly recognisable from their wholly characteristic *nuclei*, on the addition of acetic acid, but may also be isolated in great numbers, and especially after treatment with nitric acid of 20 $\frac{0}{0}$ , appearing as fibre-cells 0.02—0.03'' long, 0.002—0.0025'' broad.

The *corpus cavernosum urethræ* (*corpus spongiosum*), is constructed essentially in the same way as that of the *penis*, except that, 1. the *fibrous membrane*, which in the bulb also forms the rudiment of a *septum*, is much thinner, less white, and more abundantly supplied with elastic elements; 2. the intertrabecular spaces are smaller, being smallest in the *glans*; 3. and lastly, the *trabeculæ* are more delicate, and, beneath the *epithelium*, richer in elastic fibrils; having, however, in other respects, the same structure as elsewhere.

This is the place also to speak of the *male urethra*, which at the *isthmus* is an independent canal, whilst at its commencement and termination it consists merely of a canal of mucous membrane, supported by the *prostate* and *corpus cavernosum urethræ*. The proper *mucous membrane*, beneath a longitudinal

layer of connective tissue abounding in elastic fibres, presents not only, as already mentioned, in the prostatic portion, but also in the membranous parts, although less developed, smooth muscles mixed with the usual fibrous tissue, disposed longitudinally and transversely; to which again succeed the animal fibres of the *musculus urethralis*. In the *pars cavernosa*, also, the submucous tissue still presents, here and there, muscles of the same kind, and at a certain depth longitudinal fibres are always found, with a greater or less intermixture of such, which, however, cannot be referred to the *corpus cavernosum*, seeing that there are no venous spaces between them; but which rather form a continuous membrane, bounding the true *corpora cavernosa*<sup>1</sup>, on the side towards the mucous membrane of the *urethra*. The *epithelium* of the *urethra* is formed of pale cylinders, 0·012" in size; beneath which, however, are found one, or perhaps two, layers of round or oval cells.

Fig. 261.



In the anterior half of the *fossa* of *Malpighi*, exist *papillæ* 0·03" long, and a tessellated *epithelium*, 0·04" thick. In the *isthmus* and *pars cavernosa urethræ* are found, in considerable number, the so-termed "glands of Littre,"  $\frac{1}{3}$ — $\frac{1}{4}$ " in size, which, speaking generally, rank with the racemose glands, although distinguished from

Fig. 261. "Gland of Littre," from the *fossa Morgagni*, in Man,  $\times 500$  diam.

<sup>1</sup> [Mr. Hancock published, in 1851, an account of the distribution of the organic muscular fibres of the *urethra*, essentially agreeing with the above. He states that this internal muscular coat of the *corpus spongiosum*, or, as Mr. Hancock prefers to call it, muscular coat of the urethra, unites with the external coat at the lips of the urethra, so as to form a sort of *sphincter*. Mr. Hancock also discovered and described the abundant organic muscles surrounding the vesicles and ducts of the prostate, which, though admitted in the text, were denied by Prof. Kölliker, in his Essay upon the distribution of the organic muscles in Siebold and Kölliker, *Zeitschrift*. Mr. Hancock further states that the muscular fibres of the membranous portion of the *urethra* are continued over the inner and outer surfaces of the prostate, into the muscular coat of the bladder, so that, according to his view, there is one continuous muscular coat, from the bladder to the end of the penis, which twice separates into two layers; posteriorly, to inclose the prostate, anteriorly, to envelope the spongy tissue of the *corpus spongiosum*.—See Hancock on the 'Anatomy and Physiology of the Urethra,' 1852.—EDS.]

them by their tubular form, and the frequently much convoluted course of the glandular vesicles, which are 0·04—0·08''' wide. More simple forms of glands of this kind (fig. 161) are occasionally met with intermixed with the others, and in the *pars prostatica*, instead of them, we find minute mucous follicles, similar to those which have been before described as occurring in the *cervix vesicæ*. The *epithelium*, both in the vesicles of the "glands of Littre" and in the excretory ducts, 1—2''' long, which are directed forwards, penetrating the mucous membrane obliquely, is cylindrical; in the former situation, however, more or less approaching the tessellated form (fig. 261); the secretion is common *mucus*, which in dilatations of the glandular follicles is, not unfrequently, collected in some quantity. Some minute, inconstant fossæ of the mucous membrane have been termed *lacunæ Morgagni*, in which I have been unable to detect anything of a glandular nature. The *fascia penis*, a tissue abounding in finer elastic fibres, surrounds the *penis*, from the root to the *glans*, being, in the former situation, in connexion with the perineal fascia, and that of the inguinal region, and also contributes to the formation of the *suspensory ligament* of the *penis*, a structure very rich in true elastic tissue, which extends from the *symphysis* to the *dorsum penis*. Externally it is continuous, without any line of demarcation, with the skin of the *penis*, which, up to the free border of the *prepuce*, a simple duplicature of it, possesses the nature of the common integument; though certainly characterized by its delicacy, and the presence of a layer of smooth muscles in the abundant, fat-less, subcutaneous tissue, a continuation of the *tunica dartos* (*vid.* § 34), which extends as far as into the prepuce. At the border of the prepuce the integument of the *penis* assumes more of the nature of a mucous membrane and is no longer furnished with hairs and sudoriparous glands, although it has well developed *papillæ*; it is still thinner than before, and on the *glans* is intimately connected with the spongy body, and covered with a softer cuticle (§ 42. fig. 56, 4), always, however, 0·055''' thick. With respect to the sebaceous glands (*gl. Tysonianæ*), which exist in this situation, and the formation of the preputial *smegma*, consult §§ 46, 74.

The *arteries* of the penis are derived from the *puhic*, and are peculiar only in the way in which they supply the *corpora*

*spongiosa*. In the *corp. cav. penis*, except a few small twigs from the *a. dorsalis*, the *a. profundæ penis* alone run near the *septum*, surrounded by a sheath of connective tissue continuous with the trabecular network, in fact directly forwards, but giving off a small twig to the bulbs of the *crura*. In this course they afford numerous, occasionally anastomosing branches to the spongy substance, which, running in a convoluted manner (except at the time of erection) in the axis of the *trabecula*, ramify in them, and ultimately, without the formation of capillary plexuses open into the venous spaces, by capillaries of 0.006—0.01'' in diameter. In the posterior part of the *penis* there are numerous minute arterial trunks, measuring 0.04—0.08'' in diameter, and for the most part lying from 3—10 together, as was first observed by J. Müller; they are contorted and convoluted in a peculiar, tendril-like manner (*arteriæ helicinæ*), and do not terminate in cæcal ends, but, as I have ascertained, give off from their clavate extremities minute vessels of 0.006—0.01'', which, like the other arterial prolongations, are continued further, and terminate in the venous spaces. The arterial ramification is precisely similar, in the *corpus cavernosum*

Fig. 262.



*urethræ*, which is furnished with its supply from the *art.*

Fig. 262. Arteries from the *corpora cavernosa penis* of Man, injected,  $\times 30$  diam. 1. one of the smaller arteries, with a lateral branch, dividing into two helicine arteries, from the extremities of which two very small vessels proceed, and are continued into the delicate *trabecula*; 2. five helicine arteries placed on a short stem of a larger arterial division; from two of these, fine vessels are seen to be given off, the others appear to terminate in cæcal ends: *a*, trabecular tissue, here presenting the form of sheaths to the arterial trunks and helicine arteries; *b*, wall of the arteries.

*bulbosæ*, *bulbo-urethrales*, and *dorsales*, and in the bulb there also exist *art. helicinae*. The *veins* commence, as it may be said, in the venous spaces which intercommunicate throughout; and from which, though not universally from the same situations, short efferent canals, or *emissaria*, receive the blood and convey it into the external veins furnished with special walls (*vena dorsalis*, *v. v. profundæ*, and *bulbosæ* in particular). The *lymphatics* form very close and delicate plexuses in the skin of the *glans*, the *prepuce*, and in the remainder of the integument, and communicate with the superficial inguinal glands through trunks accompanying the dorsal vessels. According to Mascagni, Fohmann, and Panizza, there are also numerous lymphatics in the *glans* surrounding the urethra, which run backwards on that canal, and proceed to the pelvic glands.

The *nerves* of the *penis* are derived from the *puddendal* and the *plexus cavernosus* of the *sympathetic*, the former of which are distributed principally to the skin and the mucous membrane of the *urethra*, and, in a small proportion only, to the *corpora cavernosa*, to which alone the latter set of nerves is destined. The terminations of the former nerves present the same conditions as those of the integuments; numerous divisions, in particular, and faint indications of axile corpuscles, occur in the *glans penis*; those of the latter nerves are not as yet known, although, in the *trabeculae* of the *corpora cavernosa*, nerves with fine fibres, and "fibres of Remak," are readily demonstrated.

[The smooth muscles of the *corpora cavernosa* are very distinctly shown in the *penis* of the Horse and Elephant, but are also not wanting in those of other Mammalia. The *art. helicinae*, since Valentin and Henle have declared them to be produced artificially, and to arise from the inrolling of *trabeculae* which have been cut across, or from the spontaneous retraction of certain arteries in stretched *trabeculae*, have been generally rejected, but *incorrectly*. They do exist; only I am satisfied that the circumstance, noticed even by J. Müller, of the extremity of one of these arteries, giving off an excessively delicate, almost capillary vessel, occurs very frequently, and consequently, that the caecal terminations are merely apparently such. That similar terminations do not exist at all, cannot, however, be

definitively proved, and it is very possible that Müller, in this respect also, may still be right. The *art. helicinae*, therefore, are not simple vascular loops, as which they are described by Arnold, although, in one instance, I have noticed such an arrangement in place of them.]

§ 202.

*Physiological remarks.*—The *development* of the *testes*, commencing in the second month, takes place, according to all that we know, from a *blastema* which appears independently on the inner side of the Wolffian body; and, at first, the form of the male sexual glands entirely resembles that of the ovaries. At a subsequent period, when the Wolffian body begins to waste, a portion of its fine canals, the Malpighian corpuscles of which disappear, become connected with the *testis*, and are formed into the *epididymis*, whilst at the same time the excretory duct of the Wolffian body constitutes the *vas deferens*.<sup>1</sup> Then, by a process not as yet accurately explained, the *testis*, with its peritoneal investment, descends into the *scrotum* under the agency of the *gubernaculum*, a process composed of transversely striated and smooth muscles; and by the growing together of the peritoneal protrusion contained in the *gubernaculum*—the *processus vaginalis peritonæi*,—with its own proper serous coat, acquires its *tunica vaginalis propria*. The *vesicula prostatica*, the analogue of the *uterus*, and probably of the *vagina*, is the remainder of the “Müllerian ducts,” two canals, descending on the external border of the Wolffian body, which, in the female, form the oviduct and by the coalescence of their extremities, the *uterus* and *vagina*; but in the male disappear, except the commencement, which becomes the “hydatids of Morgagni,” and the last portion. The *vesiculæ seminales* are protrusions of the *v. deferentia*; and the *prostate*, *Cowper’s*, and the smaller glands, are most probably formed, in analogy with other similar glands, from the *epithelium* of the *urethra*. The *penis* is developed from the pelvic bones outwards, and does not, till

<sup>1</sup> [It is a curious fact connected with this alleged origin of the epididymis distinctly from the rest of the gland, that, in cystic disease of the testicle, either of the innocent or malignant type, the affection is “the result of morbid changes in the ducts of the *rete testis*; this part of the gland being the sole seat of the disease.” (Curling, ‘Med. Chir. Transact.,’ XXXVI, p. 456, 1853.)—Eds.]

subsequently, include the urethra which is formed by the closure of a groove on its inferior surface.

With respect to the histological development of these parts little is known. The *testes* are constituted originally of a uniform cellular substance, which, however, soon begins to divide into transverse rows, forming the rudiments of the seminal tubes. These are, at first, straight caecal canals, extending from the outer border of the *testis* to the interior, which most probably originate as solid tracts of cells, and only subsequently acquire a cavity and *membrana propria*. From the continued growth, especially in length, of these primary channels, and the production of offsets from them, the later, convoluted and very long seminal tubes arise; it appearing, in fact, that an entire lobule of the *testis* is formed from each of them. The *tunica albuginea* of the *testis* and its internal prolongations arise from the primary blastema of the gland, and make their appearance at the same time with the seminal tubes.

With regard to the *physiological relations* of the male sexual organs, in the adult, I would here notice the following points. The *secretion* of *semen*, in animals, does not go on continuously, like that of the urine, but is intermittent, taking place only at the time of rutting or heat. In Man, the capability of producing semen, assuredly, always exists, although it does not appear to me to follow from this, that *semen* is being continually formed, and that what is not emitted undergoes absorption; and consequently it seems justifiable to suppose that the seminal tubes secrete *semen* only when the secretion has been partially evacuated externally, either in consequence of sexual congress, or of seminal emissions, and an excitement of the nervous system has caused an increased flow of blood to the *testis*. There are no certain facts in favour of an absorption of the semen when formed, which could only take place in the *vasa deferentia* and *vesicula seminales*; for what is observed in animals, after the rutting season is over, has no reference to this point; and the very circumstance, that in the situations above mentioned, no traces of a disintegration of the semen are ever found, appears to be very much opposed to such a supposition. At the same time, however, it is perhaps unquestionable, that without seminal evacuations, a formation of semen may be possible; for it is sufficiently established, that a rich, heating diet, and an



unsatisfied sexual excitement, often produce a turgescence of these organs, attended with painful sensations, and most probably with a formation of *semen*. The subsequent removal of this fulness does not, however, appear to me incontestably to prove any absorption, because a difference in the quantity of blood in the *testis*, and the passing of the *semen* into the *v. deferentia* are sufficient to account for the restoration of the usual condition. The fluid constituting a seminal emission is not pure *semen*, but in great part the secretion of the *vesiculæ seminales* and *prostate*, and affords no criterion by which to estimate the energy of the secretion of the *testes*. The formation of the *semen* itself certainly does not proceed rapidly and copiously, as might be concluded from the relatively small quantity of blood contained in the *testes*, and from its slow motion in them, necessarily consequent upon the anatomical conditions; and as is also evident from the fact, that after a few previous emissions, even in the most vigorous organisms, a certain time is requisite for the preparation of a fresh secretion. The secretions of the accessory glands are perhaps simply intended for the dilution of the *semen*.

That the *seminal filaments* are not *animalcules*, but elementary parts of the male organism, it is useless at the present time to attempt to demonstrate; although it is still as much as ever unknown, and will not easily soon be ascertained, what is effected by their curious movements, which are obviously intended to convey them to the *ovum*, from the *uterus*, which they probably reach in fruitful congress. Nor, from the experiments of Prévost, Dumas, Schwann, and Leuckart, and the later researches of Newport (Phil. Trans. 1851, 1.) can the least doubt be entertained that they are the true impregnating agent, and for the purpose of impregnation must necessarily come in contact with the *ovum*. The circumstance that motile spermatic filaments alone possess the fertilising property, and, according to Newport, that the effect upon the *ovum* takes place immediately upon the contact, although a short duration of the contact of the spermatic filament with the *ovum* is necessary to render it efficient, also shows, as it appears to me, that they do not act by affording any material substance to the egg, but in consequence of their exciting actions in it, as bodies in a state of peculiar activity. In my first work upon

the spermatic fluid, in which I expressed this view, in order to indicate a ground for discussion, I compared its influence upon the ovum to that of a nerve-fibre upon a nerve-cell, or of a magnet upon iron; and these comparisons, to which might be added the influence which a part of an organism exerts upon a self-organising exudation, or an entire organism upon a part in a state of self-regeneration, still appear to me the most suitable, if impregnation is in any way to be assimilated with other processes; but I have no objection to offer, should the chemical side of the question be advocated in preference, as by Bischoff, and the functions of the *semen* be referred to the category of catalytic phenomena.<sup>1</sup>

In the act of copulation, various motile phenomena are presented, of which we need discuss only those conducive to *ejaculation* and *erection*. In the former the *vasa deferentia*, provided as they are with a colossal muscular apparatus, are chiefly operative; these organs, as Virchow and I found in an executed criminal, shorten and contract with remarkable energy when excited by galvanism; as also do the *vesiculae seminales*, the highly muscular *prostate*, and, of course, the transversely striated muscular tissue of the *urethra* and *penis*. *Erection* is caused, as I have shown ('Würzb. Verh.' Bd. II.), by a *relaxation* of the muscular elements in the *trabeculae*

<sup>1</sup> [The later, most important researches of Dr. Neilson, respecting the impregnation of the ovum in *Ascaris mystax* ('Phil. Transact.,' 1852), and of Mr. Newport (op. cit.), with regard to that of the Frog, in which he has been compelled to abandon his former opinion, that the spermatozoa did not penetrate through the vitelline membrane, and has shown that, in that case, as in the one so ably described by Dr. Neilson, those bodies penetrated into the substance of the vitellus in large numbers, where they underwent changes, and finally disappeared—render much of the above speculation on the subject of their influence in impregnation futile. Whatever may be the *nature* of the influence conveyed to the *vitellus* by the spermatic filaments, it must now perhaps be regarded as an established fact, that it cannot be *communicated* except by an immediate contact between the motile filaments and the substance of the *vitellus*, which thereupon undergoes segmentation, and the series of changes is commenced, to terminate in the evolution of the embryo. Additional confirmation of the same fact would be afforded by Dr. Keber's researches on the entrance of the spermatozoon into the ovum of *Unio* ('De introitu Spermatozoorum,' &c., 1852), could full reliance be placed upon his results; but this, from some investigations of our own on the same subject—both in *Unio* and in *Pholas*—we consider extremely doubtful. The appearances he describes, much more resemble those noticed by Von Wittich and Carus in the ovum of Spiders.—Eps.]

of the cavernous and spongy bodies, and of the *tunica media* of the arteries of those parts; in consequence of which the tissue, like a sponge which has been compressed, expands and becomes filled with blood. The rigidity ensues so soon as the muscles are completely relaxed and the sinuses filled to the utmost, without there being any necessity that the return of the blood should be impeded and the circulation stopped. It ceases when the muscles again contract, the venous spaces become narrowed, and the blood is expressed from them. In the act of ejaculation, the *ischio-cavernosi*, and the *bulbo-cavernosus* muscles, which are formed of transversely striated fibres, increase the rigidity of the anterior parts by the compression of the root of the *penis* and dorsal veins; but under no circumstances can they, of themselves alone, contribute to the bringing about of the erection. I am not aware that any more important function can be assigned to the helicine arteries; this much being certain, that the erection does not depend upon them, because they do not occur in every part of the human *penis*, and are wanting in many animals.

[The *investigation* of the male sexual organs presents, generally speaking, no great difficulties. The *tubuli seminiferi* are very readily isolated, and when they are carefully unfolded some divisions are always met with. In order to trace their entire course, they must be injected according to the directions of Lauth or Cooper, which may be found quoted in all Manuals of anatomy. Lauth places the testicle for two or three hours in lukewarm water, then expresses the *semen* as completely as possible from the *epididymis*, and immerses the gland for 3—4 hours in a solution of carbonate of ammonia, or for 8—12 hours in a saturated solution of carbonate of potass, or a weak solution of caustic potass, which reagents partly dissolve the spermatic cells and *epithelia*; the *testis* is then again compressed, laid in alkaline water, and injected with quicksilver, at first under a weak and afterwards under a stronger pressure, a process requiring from 1½ to 2 hours. So soon as the quicksilver has penetrated into the *vas deferens*, the column must be lowered to 5", for otherwise the *tubuli seminiferi*, the filling of which demands some hours more, burst. Cooper injected from

the *vasa efferentia*, into which he introduced a fine *canula*. For microscopical investigation, Gerlach recommends a solution of gelatine, with carmine or chromate of lead. The *vas deferens* is best studied in transverse sections, after it has been hardened or dried, as are also the prostatic glands; whilst the muscles of the prostate and the *corpora cavernosa* can be distinctly made out only in the recent state, or after the application of nitric acid. The *helicine arteries* may be seen, even in fresh preparations, close to the larger arterial trunks, but still better after injection with fine materials.]

*Literature.*—A. Cooper, 'Obs. on the structure and diseases of the testis,' London, 1830, with twenty-four plates; E. A. Lauth, 'Mém. sur le testicule humain,' in 'Mém. de la société d'histoire naturelle de Strasbourg,' tom. I, 1833; C. Krause, 'Verm. Beobachtungen' (various observations), in Müll. 'Arch.,' 1837, p. 20; E. H. Weber, 'De arteriâ spermatica deferente, de vesica prostatica et vesiculis seminalibus,' Progr., 1836, editum in Progr. collecta, II, 1851, p. 178; 'Zusätze zur Lehre vom Bau und den Verrichtungen der Geschlechtsorgane' (Contributions to the knowledge of the structure and functions of the sexual organs), Leipsic, 1846; C. J. Lampferhoff, 'De vesicularum seminalium naturâ et usu,' Berol., 1835; Kölliker, 'Ueber die glatten Muskeln der Harn- und Geschlechtsorgane,' in 'Beiträge zur Kenntniss der glatten Muskeln' (On the smooth muscles of the urinary and genital Organs, (in Contributions to the knowledge of the smooth muscles), in 'Zeitsch. f. wiss. Zoologie,' I; Fr. Leydig, 'Zur Anatomie der männlichen Geschlechtsorgane und Analdrüsen der Säugethiere' (On the Anatomy of the male sexual Organs and anal glands of the Mammalia), in 'Zeits. f. wiss. Zoologie,' II; A. v. Leeuwenhoek, 'Arcana Naturæ,' p. 59; Prévost and Dumas, 'Ann. d. Sc. Nat.,' III, 1824, and 'Mém. de la Soc. d'Hist. Nat. de Genève,' tom. I, p. 180; R. Wagner, 'Die Genesis der Samenthierchen' (The genesis of the Spermatozoa), in Müll. 'Archiv,' 1836, and 'Fragmente zur Physiologie der Zeugung' (Fragments on the physiology of Generation), Munich, 1836; A. Donné, 'Nouv. Expér. sur les animalcules spermatisques,' Paris, 1837, and 'Cours de Microscopie,' Paris, 1844; A. Kölliker, 'Beiträge zur Kenntniss der Geschlechtsverhältnisse und der Samenflüssigkeit wirbelloser

Thiere' (Contributions to the knowledge of the sexual relations and the seminal fluid of the Invertebrata), Berlin, 1841, and 'Die Bildung der Samenfäden in Bläschen als allgemeines Entwicklungsgesetz' (The formation of the spermatic filaments in cells, as a general law of Development), in 'Denkschr. d. schweiz. naturf. Gesellsch.,' Bd. VIII, 1846; Krämer, 'Obs. microsc. et experimenta de motu spermatozoorum,' Gott., 1842; Fr. Will, 'Ueber die Secretion des thierischen Samens' (On the secretion of the *semen* of animals), Erlangen, 1849; R. Wagner and Leuckart, art. '*Semen*,' in Todd's 'Cycl. of Anat.,' Jan., 1849; Newport, 'On the impregnation of the ovum of the Amphibia,' in 'Phil. Trans.,' 1851, I; B. Panizza, 'Osservazioni anthropo-zootomico-fisiologiche,' Pavia, 1836; J. Müller, 'Entdeckung der bei der Erektion wirksamen Arterien' (Discovery of the Arteries which effect Erektion), 'Arch.,' 1835, p. 202; G. Valentin, 'Ueber den Verlauf der Blutgefässe in dem Penis des Menschen' (On the course of the blood-vessels in the human penis), Müll. 'Arch.,' 1838; Kobelt, 'Die Männlichen und Weiblichen Wollustorgane' (The male and female sexual organs), Freiburg, 1844; Herberg, 'De erectione penis,' Lips., 1844; Kölliker, 'Ueber das Anat. und Phys. Verhalten der Cavernösen Körper der Männlichen Sexualorgane' (On the anatomical and physiological relations of the corpora cavernosa of the male sexual organs), in 'Verhandl. der Würzb. Med. Phys.,' Ges., 1851. (H. Hancock, on the Anat. and Phys. of the Male Urethra, 1852.)—[EDS.]

## B. FEMALE SEXUAL ORGANS.

### § 203.

The female sexual organs consist, 1. of two follicular glands, in which the ova are formed—the *ovaries*—with the *par-ovaria*, and the two excretory ducts, which, however, are not directly connected with them,—the *oviducts*, or Fallopian tubes. 2. of the *uterus*, for the reception and nourishment of the *fœtus*; and 3. of the parts subservient to the expulsion of the *fœtus* as well as to copulation—the *vagina* and *external genitals*.

## § 204.

*Ovary, Parovarium.* The *ovaries, ovaria*, are constituted of special *tunics*, and of a *stroma* containing the *ova*, or the *parenchyma*. The former consist of a *peritoneal coat*, which covers all but the inferior border, and of a firm, white, *fibrous coat*, the *tunica albuginea s. propria*,  $\frac{1}{4}$ '' thick, which closely invests the whole *parenchyma*, and is intimately connected with it without any abrupt line of demarcation; but does not send any processes into the interior, like the corresponding coat of the *testis*, with which, otherwise, it precisely corresponds in structure. The *stroma* is a greyish-red substance, of tolerably firm consistence, composed of a nucleated, tough, fibrous, though not distinctly fibrillar, connective tissue, in which are lodged the *ovi-sacs* and the vessels of the organ. From the inferior border of the ovary, where the vessels enter, and *ovi-sacs* are never situated, the *stroma* extends, in the form of a compact lamella, into the interior of the ovary, from which it then radiates, in larger and more slender bundles, towards both surfaces and the free border of the organ, so that, in a transverse section, a penicillar arrangement is presented by them. The *ovi-sacs*, or *follicles*, usually termed *Graafian vesicles, folliculi ovarii s. Graafiani, s. ovi-sacci*, entirely closed, round follicles, from  $\frac{1}{4}$ '' to  $3$ '' in mean size (fig. 263 *a b*), are imbedded in the more peripheral portions of the *stroma*, so that, in a section, at all events, of well-developed and normal ovaries, the *parenchyma* separates, as it were, into a medullary and cortical substance, the latter of which only, as it may be said, contains the follicles. Ovaries in that condition, also, should alone be made use of, for the obtaining of a correct notion of the *size, position*, and number of the Graafian follicles. The latter amounts to 30—50—100 in each ovary, and in many cases may reach 200; whilst in arrested or degenerated

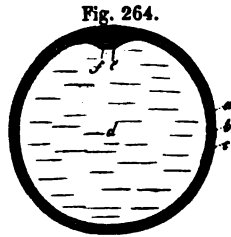
Fig. 263.



Fig. 263. Transverse section through the *ovary* of a woman dead in the fifth month of pregnancy: *a*, Graafian follicle of inferior, and *b*, of the superior surface; *c*, peritoneal lamella of the *lig. latum*, continued upon the ovary, and coalescing with *d*, the *t. albuginea*; in the interior, two *corpora albicantia* (old *corpora lutea*) are visible; *e*, *stroma* of the ovary.

ovaries, such as are frequent especially in old women, not more than 2 to 10, or even none at all, are often met with.

Each *follicle*, in the fully formed condition, consists of a membrane and contents. The former may be most aptly compared with a mucous membrane and presents: 1. a highly vascular fibrous layer, *theca folliculi* v. Baer, s. *tunica fibrosa*, of a proportionately not inconsiderable thickness, which is united to the *stroma* of the ovary by a rather loose connective tissue, and consequently can be readily stripped off in its totality. Its external, somewhat firmer, reddish-white layer (fig. 264 *a*), has been distinguished by v. Baer from the internal, thicker, softer, and redder portion



(fig. 264 *b*); but at the same time it should be remarked, that the inner layer also may be again divided, and that both *laminae* are composed of the same undeveloped, nucleated connective tissue, intermixed with numerous, mostly fusiform, formative cells. In young fol-

licles a delicate, structureless *membrana propria*, bounds the fibrous coat on the inner aspect and may, by the use of alkalis, even at a later period, frequently be demonstrated as a distinct membrane. 2. an *epithelium*, (*granular layer*, *membrana granulosa* of authors) (fig. 264 *b. c*). This membrane, 0.008—0.012'' or more, in thickness, lines the entire follicle, and on the side looking towards the surface of the ovary, where the *ovum* is situated, presents a wart-like thickening, projecting towards the interior and enveloping the *ovum*—the *germinal eminence*, *cumulus proligerus*,  $\frac{1}{3}$ '' broad (fig. 264 *e*). Its roundish, polygonal cells, 0.003—0.004'' in size, with proportionately large nuclei, and, frequently, some yellowish fatty granules, disposed in several layers, are extremely delicate, and after death soon become indistinct, in consequence of which the whole *epithelium* presents the appearance of a fine granular membrane with numerous *nuclei*. The interior of the follicles is occupied by a clear, light-yellowish fluid—

Fig. 264. Graafian follicle of the Sow,  $\times$  about 10 diam.: *a*, external; *b*, internal, layer of the fibrous membrane of the follicle; *c*, *membrana granulosa*; *d*, *liquor folliculi*; *e*, germinal eminence, a projection of the *membrana granulosa*; *f*, *ovum*, with a *zona pellucida*, *vitelus*, and germinal vesicle.

*liquor folliculi*—of the density of the serum of the blood, containing, almost always, isolated granules, *nuclei*, and cells, which are scarcely anything more than detached portions of the *membrana granulosa*, and do not originate in the fluid.

In the germinal eminence, close upon the fibrous membrane of the follicle, and therefore in the most prominent part of it, is placed the egg (*ovulum*), imbedded in the cells of which the eminence is composed, and retained in its position by them. When the follicle bursts, or is ruptured, the *ovulum* escapes, surrounded by the cells of the *cumulus*, and the contiguous part of the *epithelium*, which encompass it, as a sort of ring or disc (*discus proligerus*, *germinal disc*, v. Baer), enclosing it, however, entirely, and by no means only attached to it in its greatest breadth. The *ovulum* itself is a spherical vesicle, measuring when mature  $\frac{1}{8}$ — $\frac{1}{10}$ "", which, though in certain respects peculiar, nevertheless possesses the nature and constitution of a simple cell. The cell-membrane, or *vitelline membrane*, *membrana vitellina*, has the unusual thickness of 0.004—0.005"", and, in microscopical figures, surrounds the contents, or *yelk* (*vitellus*), as a clear, transparent ring, whence it has received the name of *zona pellucida*. It is structureless, very elastic, and firm, so as to support a considerable degree of extension without being torn; and in chemical characters corresponds, in every particular, with the *membrana propriae*, § 16. The light-yellow *yelk*, which in recent *ovula* completely fills the vitelline membrane, is composed of a viscid fluid, having numerous minute, pale granules dispersed in it, with which, in the mature *ova*, some fatty granules are also associated, and, in the fully-formed *ovum*, contains, excentrically, a well-marked vesicular *nucleus*, 0.02"", with clear contents, and a homogeneous, round, parietal *nucleolus*, 0.003"" in size, the *germinal vesicle*, *vesicula germinativa* (the "vesicle of Purkinjé"), and the *germinal spot*, *macula germinativa* (or "spot of Wagner") as they are here termed.

The *parovarium* (Nebeneierstock), a rudiment of the Wolffian

Fig. 265.

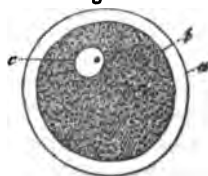


Fig. 265. Human *ovulum*, from a follicle of the average size,  $\times 250$  diam.: *a*, vitelline membrane (*zona pellucida*); *b*, external boundary of the yelk, and also internal boundary of the yelk-membrane; *c*, germinal vesicle, with the germinal spot.



body of the embryo, consists of a certain number of canals, 0.15—0.2" in diameter, diverging from the *hilus ovarii* into the 'bat's wing,' which in Man neither open into the *ovarium* nor are connected with any other parts, and contain nothing but a little clear fluid. The tubes are formed of a fibrous membrane, 0.020—0.024" thick, and of a single layer of pale, cylindrical, probably ciliated cells, and are of interest only as the remains of an embryonic structure.

The *arteries* of the ovary, derived from the *aa. spermatica* and *uterina*, and forming numerous minute trunks between the *lamelle* of the broad ligaments, enter from the inferior border of the ovary, run in a serpentine course in the internal portion of the *stroma*, and terminate partly in the *stroma* itself and in the *t. albuginea*, but chiefly in the walls of the Graafian follicles, where they form an exterior more coarse, and an inner finer plexus, which extends as far as the *membrana granulosa*. The *veins* arise in the same situation, are in Man, for the most part very beautifully displayed in the walls of the larger follicles, and terminate in the uterine and internal spermatic veins. A few *lymphatic vessels* come out from the *hilus ovarii*, and proceed, in company with the blood-vessels, to the lumbar, and pelvic glands. And with respect to the *nerves*, they arise from the spermatic plexus, enter as minute trunks with fine fibres, and "fibres of Remak," together with the arteries, into the ovary; but as respects their ultimate condition, they have not yet been investigated.

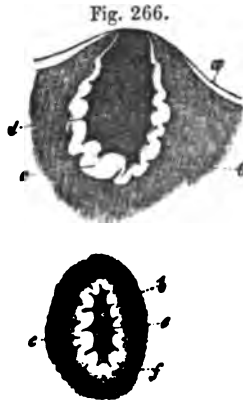
#### § 205.

*Detachment and re-formation of the ova,—corpora lutea.*  
From the commencement of puberty up to the period of involution, the ovaries are the seat of a *continual detachment of the ova by dehiscence of the Graafian vesicles*, which, independently of sexual congress, takes place in women and virgins, above all at the menstrual period, although it may and does frequently occur at other times, under conditions not yet accurately determined. In animals the same process is exhibited at the time of "heat," although sexual congress appears to afford a necessary impetus to its completion; and in them the anatomical processes may be more completely traced, whilst, in Man, the opportunity for such observations is much more rarely afforded.

When the Graafian follicles approach the time of bursting, they gradually enlarge to a circumference of 4''' to 6''' and more, and are continually brought more and more near to the surface, until they project beyond it, as wartlike or hemispherical elevations, covered only by a thin pellicle of the much attenuated *t. albuginea*, with its peritoneal lamella. At the same time their vessels are remarkably multiplied, and by the continual exudation from them, the *liquor folliculi* is rendered more and more abundant, whilst the fibrous coat of the follicle, at the bottom and sides, but not where the *ovulum* is situated, becomes thickened towards the interior; the *membrana granulosa* also swells a little, and contains larger cells (up to 0.01'''). When these processes have advanced to a certain point, the thin, opposing coats can no longer withstand the continued and ever-increasing pressure from the interior of the follicle; they give way at the most elevated, and most thinned point, exactly where the *ovulum* is situated, and this body surrounded by the cells of the germinal eminence, if the oviduct has applied itself exactly over the follicle, escapes into it. But the vital course of the Graafian follicle is not hereupon concluded, for now a series of partly new formations is presented in it, in consequence of which it at first becomes a *corpus luteum*, as it is termed and ultimately, disappears altogether.

These *corpora lutea* are displayed in the most complete state, when conception and pregnancy ensue upon the detachment of the *ovum* and, when in perfection, appear as roundish or oval, firm bodies, mostly rather larger than the former follicles, and are usually visible even on the exterior, as projections, exhibiting on the summit a stellate *cicatrix*, arising from the rupture of the Graafian follicle. Exteriorly these bodies are bounded, towards the *stroma* of the ovary, by a thin whitish fibrous membrane (fig. 266, 2 *f*), succeeded by a yellowish vascular lamella, which is much plicated, and consequently appears thicker (fig. 266 *c*); and in the interior is a larger or smaller cavity filled, either with coagulated blood (blood-clot), or with a somewhat gelatinous fluid tinged with blood (fig. 266 *d e*). With respect to the origin of these bodies, it is easily perceptible, that their 'nucleus' or contents consist of the blood poured out upon the rupture of the follicle, frequently mixed with some remains of the *liquor folliculi*, and that the outer fibrous mem-

brane is the external layer of the original fibrous coat of the follicle; and as regards the yellow plicated cortical layer, this



is referable for the most part to the internal layer of the fibrous membrane of the original follicle, which even before the expulsion of the ovum, becomes loosened in texture, and afterwards rapidly expanded to the thickness of  $\frac{1}{4}$ — $\frac{1}{3}$ ''' and more. The remains of the *epithelium*, or *membrana granulosa*, which were not expelled with the *ovum* from the follicle, also seem to contribute to this thickening, though in a subordinate degree, and by no means in the same proportion as the layer in question; the increased thickness of which is accom-

panied by the development of a vast number of smaller and larger cells, which are, in part, transformed into immature connective tissue and vessels, in part remain in the condition of cells, characterised by their size, which reaches as much as 0.01—0.2''', their well-marked, vesicular *nuclei* with *nucleoli*, and a greater or less number of yellow oil-drops in the interior. The *corpus luteum*, thus constituted, retains its original size for some time, up to the second or third month of pregnancy; because, whilst the contents (whether these are a blood-clot, or a reddish gelatinous substance with a small cavity in the interior) gradually diminish and lose their colour, the yellow cortical layer continues to increase in thickness, and, at the same time, its tissue to become more organized and more compact; this change taking place by the transformation, on the one side, of the internal substance into fibrous tissue, and on the other by the more intimate fusion of the yellow cortex with it, and the more abundant development of immature connective tissue in the former. In the fourth and fifth months the *atrophy* of the *corpus luteum* commences, and is slowly continued to the end

Fig. 266. Two *corpora lutea*, of the natural size, in a transverse section. 1, quite recent, eight days after conception; 2, at the fifth month of pregnancy: *a*, *t*, *albugeina*; *b*, *stroma ovarii*; *c*, thickened and plicated fibrous membrane of the follicle (inner layer); *d*, blood-clot within it; *e*, discoloured blood-clot; *f*, fibrous coat bounding the *corpus luteum*.

of pregnancy; so that in persons dead in childbed, it still measures 4''' on the average, but afterwards more rapidly, until ultimately, after some months, the metamorphosed Graafian follicle has entirely disappeared or become reduced to a diminutive, variously coloured corpuscle, which undoubtedly may still exist for a long time, and perhaps is not removed altogether for some years. Such arrested *corpora lutea* (*corpora albicantia* and *nigra*, of authors) at first retain a distinct limitation, a dentate nucleus, containing a minute cavity of a greyish white or red-brown, even black colour depending upon altered *hematin*, and a cortical substance presenting various tints of yellow or yellowish-white, or even quite white and often still distinctly plicated, but subsequently they become mere amorphous spots, coalescent with the *stroma* of the ovary. Their elements are fibres, more of an embryonic character, such as also form the ovarian *stroma*, together with various pigmentary molecules and coloured crystals (*hæmatoidin*), and a whitish-yellow fat, which latter at first occurs in the cortical substance still contained in larger, round, elongated, or fusiform cells, but is ultimately liberated by their rupture, and at last subjected to a more or less complete absorption.

In the *corpora lutea*, which are not formed at the time of a pregnancy, the same processes, in general, take place as in the others, but with much greater rapidity; so that these bodies have usually entirely disappeared in the space of one or two months, or left only the merest trace, whence they never possess the peculiar conformation of the others, which have been termed the *true corpora lutea*.

The place of the numerous follicles which disappear from the ovaries during the whole of the vigorous periods of life, is supplied by the constant production, even in the adult, of new ovi-sacs, which are developed into Graafian follicles. In animals, these new formations which take place at the time of heat, and were first noticed by Barry, Bischoff, and Steinlin, are very abundant and very easily observed, whilst in Man no opportunity has as yet been afforded of noticing them, and it is only from the circumstance, that in this case also in normal ovaries, follicles of the most various sizes are always met with, that a continual formation of them may be concluded to take place. In Man, it is also probable, that the times of conception

and of menstruation are those in which, especially, these productions take place, which in animals, as respects their histology, originate in exactly the same way as will be afterwards described when we speak of the first follicles of the embryo. [See Appendix, § *corpora lutea*.—Eds.]

§ 206.

*Oviducts and uterus*.—Of the three coats of the oviduct, the most external, which belongs to the *peritoneum*, presents nothing worthy of remark. The middle, or *smooth muscular coat*, is of tolerable thickness, especially in the internal half of the duct; and consists of external, longitudinal, and internal transverse fibres, the elements of which, even at the time of pregnancy, can be isolated with some difficulty, and are intermixed with much, more undeveloped connective tissue of the same form as in the *stroma* of the ovary. The innermost coat is the *mucous membrane*, a thin, whitish-red, soft layer, which is connected with the muscular tunic by a small quantity of submucous connective tissue, presents no glands or *villi*, though it has a few longitudinal folds, and consists of undeveloped connective tissue, with many fusiform formative cells. On its inner surface, from the *uterus* to the free border of the *fimbriæ*, lies a single layer of conical or filiform, ciliated cells, of 0.006—0.01", whose distinct *cilia* effect a current running from the *ostium abdominale* to the *ost. uterinum*, which probably assists in the locomotion of the *ovula*, but not of the spermatic fluid.

The *uterus* is constituted in the same way as the oviducts, except that the muscular coat and mucous membrane are much stronger, and, in some respects, differently constructed. In the pale red *muscular-coat*, three layers may, most conveniently, be distinguished, which, however, cannot, as elsewhere (in the intestine for instance), be sharply defined from each other. The *external layer* is composed of *longitudinal* and *transverse fibres*, the former of which, forming a continuous, thin stratum, intimately united to the serous coat, extend over the *fundus* and the anterior and posterior surfaces, as far as the *cervix*, whilst the stronger transverse fibres surround the organ, and are also, to some extent, continued beyond the *uterus*, into the *ligg. rotunda, ovarii, and lata*, and upon the

oviducts. The *middle layer* is the strongest, presents transverse, longitudinal, and oblique, flat bundles, which are interlaced in a complex manner, and contains larger vessels, chiefly veins, whence, especially in the pregnant uterus, it presents a spongy appearance. The *innermost layer*, lastly, is again thinner, and formed of a network of more slender, longitudinal, and of stronger, transverse and oblique fibres, which, at the openings of the oviducts, frequently form very distinct rings. In the *fundus*, where the uterus is thickest, the middle layer is strongest, and often appears to be composed of several laminæ; whilst, at the thinner *cervix*, transverse fibres especially, intermixed with isolated longitudinal ones, are met with. In the neighbourhood of the external *os uteri*, and in that part itself, highly developed transverse fibres lie immediately beneath the mucous membrane, and may be described as an *occludor* of it—*sphincter uteri*. As to the elements, all these layers consist of short (0·02—0·03'') fusiform fibre-cells, with elongated oval *nuclei*, which, on account of the great quantity of the nucleated embryonic connective tissue, of the same constitution as in the *stroma ovarii*, by which the layers are pervaded, can only with difficulty be isolated, and even with the aid of nitric acid, of 20%, are not brought into view so distinctly as elsewhere.

The *mucous membrane* of the *uterus* is of a white or whitish-red colour; it is closely united with the muscular coat, from which it cannot be raised; in transverse sections, however, it is distinguishable from it by its, mostly, brighter colour, though rarely presenting any marked line of demarcation. Except in its fundamental substance, consisting of the connective tissue which exists everywhere in the female genital organs, containing undeveloped *nuclei* and fibre-cells without elastic elements, and the *epithelium*, which throughout appears as a *ciliated epithelium* with pale cells, as much as 0·016'' in size, and delicate cilia which vibrate from without to within, the mucous membrane is differently constituted in the *body* and *fundus*, and in the canal of the *cervix*. In the former situations it is more delicate, redder, and thinner (from  $\frac{1}{4}$ —1''), smooth on the inner aspect, and without *papillæ*, but occasionally presenting a few large folds. In it are found very numerous minute glands, the *utricular glands of the uterus*, or *uterine glands* (*glandule utricularæ s. uterinæ*), which bear the closest resemblance to

the Lieberkühnian glands of the intestine; they exhibit the form of thickly placed follicles, either simple or bifurcated, and not unfrequently spirally contorted at the end, and in length correspond with the thickness of the mucous membrane, being 0.02—0.03''' broad. They consist of a very delicate structureless membrane, and a uniform cylinder-epithelium, and open either singly or two or three together, with orifices  $\frac{1}{36}$ ''' wide. Normally, these glands contain no morphological elements at all, but it is probable that their *epithelium* is very easily detached, and may appear as a greyish-white secretion filling them.

In the *cervix* the mucous membrane is whiter, denser, and thicker (1—1 $\frac{1}{2}$ '''), particularly on the anterior and posterior walls, where the well-known *plicæ palmatæ* are situated; between which are found larger and smaller, sinuous fossæ lined with cylinder-epithelium, and as much as 1''' and more in depth, and differing very essentially from common mucous follicles, although, as the secreting organs of the viscid, crystalline *mucus* of the *cervix uteri*, they may be designated the *mucous follicles* of the *uterus*. In this region also occur, in great abundance, closed vesicles,  $\frac{1}{3}$ —1—2''' and more in size, filled with the same secretion, and composed of a layer of connective tissue and short cylinder-cells, the so-termed *ovula Nabothi*, which, like the Graafian follicles, might perhaps be regarded as closed glandular vesicles, bursting periodically, but which probably are nothing more than dilated and closed mucous follicles, and in part also pathological new formations; they are likewise occasionally found in the mucous membrane of the body of the *uterus*. The inferior third or half of the cervical canal contains verrucose or filiform papillæ, 0.1—0.3''' long, clothed with ciliated cylinders, containing a single or several vascular loops, with very numerous minute *nuclei*, and also, perhaps, pale oil-drops in their interior.

The *distribution* of the *vessels* in the unimpregnated *uterus*, does not present much of a special nature. The larger arterial branches run in the muscular substance, and ramify thence on both sides in the muscular and mucous coats. The latter, as everywhere, has larger vessels in the deeper, and finer in the superficial portion, and these, after they have surrounded the glands with smaller capillaries, form an extremely rich and delicate plexus of larger vessels (0.006—0.01''') on the surface,

from which arise the wide, thin-walled veins, unfurnished with valves, which follow the course of the arteries towards the exterior. The *lymphatics*, probably commencing in the mucous membrane, are remarkably numerous, form coarser or finer networks under the peritoneal investment and proceed, in numerous, considerable trunks, accompanying the blood-vessels, in part to the pelvic glands, in part, with the *vasa spermatica*, to the lumbar plexus. The *nerves* of the *uterus*, containing numerous fine, and some thick nerve-fibres coming from the hypogastric and pudendal plexuses, and united in a plexiform manner, reach the *uterus* through the broad ligaments, and ramify, following principally the course of the vessels in the muscular substance, from the *fundus* to the *cervix*, in which latter situation they are the most abundant. They are white and, in the *uterus*, are not furnished with any ganglia; their condition in the mucous membrane, and their terminations elsewhere, are unknown.

Of the *ligaments* of the *uterus*, the *ligg. lata, anteriora, and posteriora*, are duplicatures of the peritoneum, which contain, together with the vessels and nerves passing to and from the *uterus*, a considerable number of smooth muscular fibres continued into them from the *uterus*. The same tissue also arising from the *uterus*, occurs more sparingly in the *ligg. ovarii*, and in very considerable number in the *ligg. rotunda*, in the form of longitudinal bundles surrounded by connective tissue, with which at the internal abdominal ring a good many *transversely striated muscular fibres, often extending nearly to the uterus*, are associated.

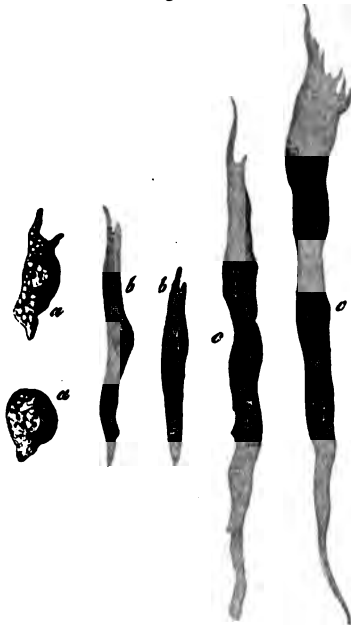
#### § 207.

*Changes in the uterus at the menstrual period and in pregnancy.*—At the menstrual period, the whole *uterus* enlarges, and its texture expands, which is perhaps to be attributed, chiefly, to the distension of the vessels, and the considerable infiltration of the entire organ with blood-plasma; at all events, beyond a greater facility in the demonstration of its elements, I have been unable to perceive any further alteration in the muscular coat. The mucous membrane, on the other hand, in many cases really increases, being thickened to 1—2''', or even 3''', or, in its projecting folds, even to 5—6'''; it becomes



softer and presents, in its tissue, well marked, easily isolated, utricular glands, 1—3'' long and 0·036—0·04'' broad, and numerous immature, round and fusiform cells. The blood-vessels of the mucous membrane, which chiefly afford the menstrual flux, are, throughout the *uterus*, and particularly in its body and *fundus*, extremely numerous and much distended, and this is especially the case with the superficial capillary plexus; whence also, the mucous membrane presents a bright red colour. With the escape of the blood from the superficial, ruptured capillaries, the *epithelium* of the mucous membrane is, in great measure, thrown off, except that of the *cervix*, and may always be found in large quantity in the mucus mixed with blood, which fills the cavity of the *uterus*; it is not, however, to be regarded as normal, if, after the menstrual period, or during it, the whole uterine mucous membrane

Fig. 267.



twenty-four times the original size (J. F. Meckel, 'Anat.,' IV,

Fig. 267. Muscular elements from the *uterus*, in the fifth month of pregnancy: *a*, formative cells of the muscular fibres; *b*, younger; *c*, developed, fibre-cells;  $\times$  350 diam.

or portions of it are detached. After the menstrual period, the parts rapidly regain their pristine condition, and the *epithelium* is restored.

Changes of a totally different kind are induced in the *uterus* by *pregnancy*, among which, however, in a microscopical point of view, the increased bulk of the organ only, is of interest. This enlargement, as is well known, depends upon a great augmentation of the circumference and of the cavity; at first with increased, and afterwards (usually from the fifth month onwards) with a diminished thickness of the walls, and an increase in bulk, amounting on the average to

691). The mode in which this change is brought about was, as regards the histological conditions, until a recent period, it may be said, entirely unknown; but, in the main points, is now sufficiently made out. The principal changes occur in the *muscular coat*, to which the increased volume of the *uterus* is chiefly to be assigned, and there are two processes which participate in common in its production: in the first place, an *enlargement of the pre-existing muscular elements*; and secondly, a *new formation* of them. The former is so considerable, that the contractile fibre-cells, instead of a length of  $0\cdot002$ — $0\cdot003$ "", and width of  $0\cdot002$ "", as elsewhere, in the fifth month present a length of  $0\cdot06$ — $0\cdot12$ "", and width of  $0\cdot0025$ — $0\cdot006$ "", or even  $0\cdot01$ "", and in the second half of the sixth month, a length of  $0\cdot1$ — $0\cdot25$ "", a width of  $0\cdot004$ — $0\cdot006$ "", and a thickness of  $0\cdot002$ — $0\cdot0028$ ""; consequently, their length is increased from seven to eleven times, and their width from twice to five times. The *new formation* of muscles may be observed in the first half of pregnancy, especially in the innermost layers of the muscular coat, where newly originating cells,  $0\cdot01$ — $0\cdot018$ "" in size, in all stages of transition into fibre-cells of  $0\cdot02$ — $0\cdot03$ "", always occur in great quantity; but it takes place also in the outer layers. After the sixth month, this origination of muscles seems to cease; at least in the twenty-sixth week, in the whole *uterus* I have found nothing but the above-mentioned colossal fibre-cells, and no longer any trace of their earlier forms. Like the muscles, the *fibrous tissue* which unites them also increases,

Fig. 268.



Fig. 268. *a*, muscular fibre-cell from a gravid uterus, at the sixth month; *b*, its middle portion, after treatment with acetic acid, exhibiting the appearance of a membrane; *c*, nucleus of the fibre-cell;  $\times 350$  diam.

and towards the end of pregnancy, occasionally exhibits distinct fibrils. Whilst the muscular coat grows in this way, the mucous membrane has also undergone manifold changes. It is in it, especially, that the metamorphoses of the gravid *uterus* commence, seeing that as early as the second week, it becomes thickened to 2—3", is softer, more lax, and redder, acquires more prominent *plicæ*, and is more distinctly defined from the muscular coat; peculiarities which, as time goes on, become more and more marked. Examined microscopically, it is apparent, that not only are the vessels more distended, but also that an abundant new formation of connective tissue has taken

place in its *parenchyma*, and a considerable enlargement of the utricular glands, which latter are, at this time, 2—3" long, and 0·04—0·11" broad, or, on the average, 0·08". As these changes proceed, the greater part of the hypertrophied mucous membrane is transformed into the well-known *decidua vera*, whilst another portion, at the point of attachment of the *ovum*, is converted into the *placenta uterina*, and by a growth from the border of this part, the *reflexa* is produced around the *ovum*; processes of which this is not the place to speak farther. It can only be remarked that the utricular glands, in the *decidua vera*, are gradually converted into wider follicles, the orifices of which give rise to the appearance, as it were, of a cribriform perforation in that membrane and the border of the *reflexa*; and moreover, that the *decidua*, from the second month onwards, though gradually diminishing, it is true, in thickness, nevertheless, on account of the enlargement of the internal surface of the *uterus*, are still far from ceasing to increase in bulk; and lastly, that their tissue at all times consists of larger and smaller, round cells, with large, often compound *nuclei*, in part




Fig. 269.

Fig. 269. A uterine gland from a Woman in the first pregnancy, eight days after conception.

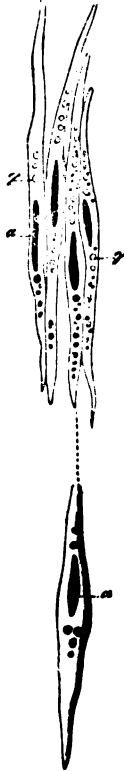of colossal fibre-cells with well formed large *nuclei*, and, particularly in the *decidua vera*, of vessels; whilst an *epithelium*, except in the first month, is no longer to be found upon the *decidua*. The *mucous membrane of the cervix* takes no part in the formation of the *decidua*, and retains its epithelium (without cilia) during the whole time of pregnancy. It also, however, swells, and its mucous follicles, especially, enlarge and secrete the well known mucous plug which fills up the entire canal of the *cervix*.

The *serous coat* also increases considerably in thickness, though not to the same extent as the mucous membrane; whilst the thickening of the uterine ligaments, particularly of the round ligaments, is very evident, and also depends upon changes in their smooth muscles similar to those described in the muscles of the *uterus*, and probably also, upon an increase of the transversely striated bundles. The growth of the *blood-vessels* and *lymphatics*, in length and calibre, is also very evident and is, in great part, to be referred to the enlargement and new formation of muscular elements, which, in the veins, are also demonstrable in the *t. adventitia* and *intima*. With respect to the *nerves*, they also become thickened, although it is doubtful whether new nerve-fibres are really produced in them. On the other hand, it is certain that the pre-existing elements increase in width and length, retain their dark borders for a greater distance, and may be traced further into the interior than at other times.

The lessening of the *uterus* after parturition, and its restoration to a condition, not, indeed, similar to the previous state, though closely approximated to it, does not take place in its various portions exactly in the same way. In the muscular coat, an atrophy of the contractile fibrous elements manifestly plays a principal part, since, as early as three weeks after parturition, these fibres are again as short (0·03''') as in the virgin *uterus*, fat, at the same time, being developed in their interior; but a complete absorption of certain muscular fibres is also probably superadded to this. A different process takes place in the mucous membrane, which, in the form of the *decidua* and *placenta uterina*, is completely thrown off after parturition, and consequently has to be entirely formed anew. The intimate nature of the processes accompanying this unique kind of

regeneration has not yet been traced, though it is more than probable that it is completed as early as within the first two or three months after parturition. It is evident that, besides this, the serous coat, the vessels and nerves of the *uterus*, return to their former condition, but the precise nature of this change in them has not yet been investigated.

Fig. 270.



[It has been generally assumed, since Tiedemann, that the *nerves* of the gravid uterus are thicker than in the virgin state; but quite recently this has been altogether disputed by Dr. Snow-Beck, and is only partially admitted by Jobert de Lamballe ('Compt. rend.,' 1841, Mai), inasmuch as that he states that it is the investing connective tissue, but not the nerves themselves, that is thickened. It is evident that very accurate microscopic investigations are alone competent to decide this question; but such investigations are wanting. No conclusion, in the first place, can be drawn from Remak's statement (l. c.), that the nerves, at the time of pregnancy, enlarge and acquire a *grey* colour, a change depending upon an increase of nucleated fibres, because no grounds exist upon which it can be decided whether these nucleated fibres are embryonic nerve-fibres, or a form of connective tissue. On the other hand, we are indebted to Kilian for careful researches in animals, which prove with certainty that the

uterine nerves, at the time of pregnancy, may be traced further into the substance of the uterus, in the form of dark-bordered fibres; whilst at an earlier period, in part even before they enter the *uterus*, in part when they have scarcely reached it, they possess the nature of embryonic non-medullated fibres. For this reason, Kilian succeeded also in tracing the nerves in the gravid *uterus* much further into the parenchyma than at other times. He perceived no evidence of a formation of new

Fig. 270. Muscular fibre-cell of the *uterus*, three weeks after parturition, four of them treated with acetic acid, and pale: a, nuclei; g, fat-granules;  $\times$  350 diam.

nerve-fibres in the trunks, and regards such an occurrence as improbable; for otherwise a new formation of ganglionic substance must also be assumed, which is unlikely. Something of the kind appears to me by no means impossible, because the multiplication of the ganglion-cells and of the fibres would only take place once—in the first pregnancy; it is also conceivable that newly formed nerve-fibres are added to the others *simply as branches*, and consequently it will be more prudent to wait and see upon which side Remak's statements, with respect to the human subject, incline. Upon this, however, I would also remark, that a thickening of the nerves may undoubtedly be produced by an increased size of the already existing fibres and an augmentation of the *neurilemma*, and that the nerves, by a multiplication of their ultimate divisions, are fully enabled to ramify over larger spaces than at other times.

The increased size of the *vessels*, both of the arteries, and, above all, of the veins, at the time of pregnancy, is very considerable; owing to which, at this period, the middle layer of the muscular substance, containing the larger vessels, is much more distinct from the other two. The alteration which takes place in the vessels of the mucous membrane, at the point where the *placenta* is formed, cannot here be entered upon; and I will only remark that I agree with those who believe that large vascular trunks exist in the human uterine *placenta*, at the border and on the convex surface, whilst in the interior there are only *lacunæ* without walls, between the *villi* of the *chorion* (*vide* Kiwisch, 'Geburtskunde,' I, p. 151, et seq.; C. Wild, 'Zur Physiologie d. Placenta,' Wurzh., 1849; Virchow, 'Archiv,' III, p. 449; Schröder v. d. Kolk, in the 'Verh. d. Nied. Instituts,' 1851). In the rest of the *decidua*, the capillaries are frequently excessively enlarged; according to Virchow ('Archiv. f. path. Anat.,' III, p. 436), its superficial capillaries, in the sixth week of pregnancy, reach the size of 0·027—0·045", and become extremely thin-walled, as are, probably, also those in the part where the *placenta* is situated, before their walls disappear and their cavity is thrown into that of the *lacunæ*. In the *venous trunks* of the gravid *uterus*, besides the circular muscular layer, with much enlarged fibre-cells, which exists also in other situations, I have found an external and internal longitudinal muscular layer with similar colossal elements;

so that here the increase of the walls may be directly demonstrated ('Zeitsch. f. wiss. Zool.,' I, 84).]

§ 208.

*Vagina and external sexual parts.* The walls of the *vagina*, 1'' thick, consist of an external *fibrous coat*, a middle *muscular layer*, and a *mucous membrane*. The thin white *fibrous coat* presents externally a more lax, towards the interior a more dense connective tissue, with numerous elastic fibres and venous plexuses, and passes, without any line of demarcation, into the second, redder layer, which, together with connective tissue and numerous veins, contains, particularly during pregnancy, a good many, developed, smooth muscular fibres, which, with their transverse and longitudinal bundles of fibre-cells, 0·04, 0·08'' long, constitute a true muscular membrane. The *mucous membrane* is of a pale red colour, with numerous larger and smaller folds and elevations—the *columnæ rugosæ*; it is composed of a dense connective tissue, without glands, and containing elastic elements in extreme abundance, to which its great firmness and extensibility are due. Its inner surface presents numerous conical or filiform papillæ, from 0·06 to 0·08'' in length, and 0·025 to 0·03'' in breadth, which are entirely imbedded in a tessellated epithelium, 0·07—0·09'' thick, of the same kind as that in the œsophagus, the uppermost scales of which, having a diameter of 0·01—0·015'', contain *nuclei* of 0·003''. The *hymen* is a duplicature of the mucous membrane of the *vagina*, and contains the same elements.

From the *vagina* the mucous membrane is also continued upon the external genitals, invests the *glans clitoridis* and the vestibule, with the orifice of the *urethra*; folds of it constituting the *preputium clitoridis* and *labia minora*. On the *labia majora*, it is continuous uninterruptedly with the external integument, which, on their inner side, and at the *commissura labiorum*, still bears a close resemblance to a mucous membrane; whilst on their border and outer surface, and on the *mons veneris*, it resembles the *cutis* in all respects. The matrix of the mucous membrane of the external genital organs, is a spongy, highly vascular, fatless connective tissue, containing, however, a good many elastic fibres, and which, in its condensed external layer,  $\frac{1}{4}$ — $\frac{1}{3}$ '' thick, corresponding to the

*corium*, is everywhere furnished with much-developed *papillæ*, in the *labia minora*  $\frac{1}{10}$ — $\frac{1}{20}$ "", and on the *clitoris*  $\frac{1}{24}$ — $\frac{1}{33}$ " in length; and with a squamose *epithelium* of 0·04—0·12"", the most superficial cells of which are 0·01—0·02"" in size (fig. 56, 4). The *labia majora*, in the structure of their coverings, correspond partly with the mucous membrane, in part approach the *cutis*, and contain, in the interior, common adipose tissue.

The external genital organs are furnished with various smaller and larger *glands*. Sebaceous glands, mostly of a rosette-form and considerable size ( $\frac{1}{3}$ —1""), occur in the *labia majora*, on the external and internal aspects, in connexion with larger and smaller hair-follicles; moreover, in larger quantity in the *labia minora*, for the most part without hairs and rather smaller (from  $\frac{1}{10}$  to  $\frac{1}{3}$ ""); occasionally, also, around the orifice of the *urethra*, and laterally at the entrance of the *vagina*. Common *racemose mucous glands*,  $\frac{1}{3}$ —1"" in size, with scarcely visible or tolerably wide openings, and having excretory ducts, either short, or as much as 6"" long, exist in very various number around the orifice of the *urethra*, in the vestibule and in the lateral portions of the entrance of the *vagina*. Lastly, the two "glands of Bartholini," corresponding to Cowper's glands in the male, are situated at the inferior extremity of the *bulbi vestibuli*; they are common racemose mucous glands, 6"" in size, with pyriform gland-vesicles lined with a tessellated *epithelium*, 0·02—0·05"" in diameter, and lodged in a compact nucleated connective tissue without muscular fibres. The excretory ducts of these glands, 7—8"" long and  $\frac{1}{3}$ " wide, have, external to their mucous membrane invested with a cylinder epithelium 0·01"" thick, a delicate longitudinal layer of smooth muscles, and always contain a viscous, amorphous, clear, yellowish mucus.

The *clitoris*, with its two *corpora cavernosa* and *glans* attached to the *bulbi vestibuli*, the divided *corpus cavernosum urethræ* of the female, present on a small scale precisely the same conditions as the corresponding parts and *corpora cavernosa* of the male; and in them the muscular elements are even more readily isolated than in the man.

The blood-vessels of the *vagina*, and of the external genital organs, present, upon the whole, nothing much worthy

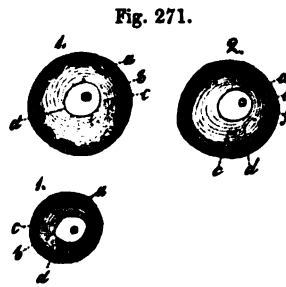


of remark. In the *papille* of the various situations where they occur, we find for the most part simple vascular loops, it is only when the papillæ are larger or compound, such as abound around the orifice of the *urethra*, that more complex loops occur. The *corpora cavernosa* have the same structure as in man; and, according to Valentin, helicine arteries also appear to exist in the *clitoris*. The venous plexuses in the walls of the *vagina*, above the *bulbi vestibuli*, are extremely rich; but by no means, as Kobelt assumes, represent true *corpora cavernosa*. The *lymphatics* of the external genital organs, and of the *vagina*, are numerous, and communicate partly with the inguinal glands, partly with the pelvic plexus. The *nerves*, lastly, are derived in part from the sympathetic, in part from the pudendal plexus, and are extremely numerous, especially in the *clitoris*, but are also found without difficulty in the mucous membrane of the *vagina*. In the latter situation they present divisions, and their terminations have as yet been but little investigated. I have never found nerves in papillæ containing vessels, whilst, in the *clitoris*, I have sometimes met with them in non-vascular, minute verrucosities, which also contained rudimentary axile corpuscles; and I think I have noticed here, as well as on the surface of the mucous membrane itself, finer and coarser, looplike terminations of nerves lying buried in the bodies resembling axile corpuscles, which are also occasionally met with in these situations. In the *clitoris* of the Sow, Dr. Nylander, of Helsingfors, found Pacinian bodies, which I have also seen; and looped terminations of the nerves in the *papille*.

#### § 209.

*Physiological remarks.*—In their development the internal female genital organs, as was noticed above in § 202, entirely correspond, originally, with those of the male; and it is not till after some time that a difference in the histological development of the sexual glands is manifested, consisting in this, that in the female, the Wolffian body, except that it forms the *parovarium*, stands in no farther relation to the genital apparatus, whilst the “ducts of Müller” are formed into the oviducts, *uterus*, and *vagina*. As regards the *histological* conditions, the *ovaries* alone seem to present any great interest. These bodies

are composed at first of common formative cells,  $0\cdot005$ — $0\cdot009''$  in size, which afterwards pass, in part into fibres and vessels, in part persist as cells, multiply spontaneously, probably by division, and serve for the formation of the Graafian follicles. These, according to Barry, at first appear as spherical agglomerations,  $0\cdot01''$  in size, of some few cells, which contain in the interior a clear vesicle—the germinal vesicle; but, by the formation of a delicate, structureless membrane on



the exterior, around the cells, which then represent an *epithelium*, soon assume the nature of follicles. Very young Graafian follicles of this kind (*ovisacs*, Barry) occur by thousands in the ovaries of nearly mature embryos, and of new-born children, in which the further development is very easily traced. Whilst the follicle increases by the multiplication of the cells of its *epithelium* (the *membrana granulosa*), and at the same time acquires an external vascular, fibrous coat; a clear substance, in Man containing but few granules, is collected in the interior, detaching the germinal vesicle,  $0\cdot0065$ — $0\cdot008''$  in size, with a germinal spot of  $0\cdot001$ — $0\cdot0015''$ , from the *epithelium*, to which at first it was closely applied, and forcing it into the centre of the follicle. When this has attained the size of  $0\cdot02''$ , a membrane in close apposition with the *membrana granulosa*, and surrounding the germinal vesicle and the whole contents of the follicle—the *vitelline membrane*—becomes evident; which is regarded by all authors as a secondary formation, although it probably exists, even in the very earliest rudiment of the follicle, as an extremely delicate membrane, closely surrounding the germinal vesicle. At first excessively delicate, and scarcely perceptible, the vitelline membrane, when the follicle has increased in size and contains more fluid, becomes more distinct, owing to its removal from the wall of the follicle, and rapidly thickens. In follicles of  $0\cdot04$ — $0\cdot05''$ ,

Fig. 271. Three Graafian follicles, from the ovary of a newly-born female child,  $\times 350$  diam. 1, without; 2, with, acetic acid: a, structureless membrane of the follicle; b, *epithelium* (*membrana granulosa*); c, yolk; d, germinal vesicle with spot; e, nucleus of the epithelial cells; f, vitelline membrane, very delicate.

the *ova* are perfectly distinct and disproportionately large, with a delicate *zona pellucida*, and still lying very close to the walls of the follicle. The further development is apparent of itself; and I will only remark that, in the new-born child, follicles visible to the naked eye will be more rarely found; whilst such make their appearance even before puberty, although they undergo no considerable development before that period.

According to what has been said, the mode of origin of the Graafian follicle ranks in every respect with that of the tubular glands. The former is an agglomeration of cells, at first, perhaps, without cavity or contents, to which the structureless membrane is added, not by the coalescence of the outermost cells, but probably as an excretion from them, and thus is formed the follicle, which therefore exactly corresponds with a closed gland-vesicle, or a section of a tubular gland-canal. How the germinal vesicle, and the vitelline membrane arise, is doubtful; the former is either a *nucleus* of new formation, originating in the minute cavity of the follicle, about which a certain amount of *vitellus* is subsequently collected, the cell, or vitelline membrane not being formed until after this, from a sort of cell formation "around portions of contents"; or the whole *ovum*, with the germinal vesicle, is nothing else than the central cell of the primordial rudiment of the Graafian follicle, and consequently coexistent with it. In any case it corresponds to a cell, and the germinal vesicle is nothing but the cell-nucleus.

[With respect to the *physiological* conditions of the mature, female sexual organs, much has already been remarked in the preceding pages; and it will, therefore, here be sufficient to say something about their movements and secretions. In the *ovaries*, whose *stroma* frequently presents a deceptive appearance of muscularity, I have in vain sought for muscles, with nitric acid of 20%, although in recent preparations microscopical appearances are occasionally obtained, which one is inclined to explain as belonging to that tissue. That the *oviducts* are capable of very active movements cannot be doubted, from the results of vivisections in animals, and microscopical researches in Man; and in opposition to V. Kiwisch ('Geburtskunde,' p. 96) I do not understand why their application to the ovaries should

not be brought about by movements in them, together with a kind of erection dependent upon increased fulness of the vessels, as has also been established by the experiments of Gendrin and Raciborski (l. c. p. 412—417), in two women dead during menstruation, and of Laahr ('De mutat. gen. mul. brevi post concept.' Halis, 1843) in the case of one who was killed shortly after *coitus*. As regards the movements of the *uterus*, they are, at all events during parturition, very energetic, but take place even at other times. The muscular tissue is so disposed, that at first a universal contraction of the uterine cavity, but afterwards local, more or less extensive contractions, also may be performed with great ease. Thus, in the act of parturition, the *cervix* and the *os uteri* are at rest, whilst the *fundus* and *body* contract, contractions of the former parts and of the *vagina* not ensuing till subsequently. In convulsions, the whole *uterus* contracts closely round the child; in retention of the *placenta*, the contraction is entirely local and confined to the *fundus*. It is probable that movements take place at the time of menstruation and in the act of congress, but the fact has not been ascertained. In the latter case, an opening of the *os uteri*, and a dilatation of the canal of the *cervix*, are commonly supposed to take place. If this is to be regarded as a spontaneous action of the *cervix*, it would be justifiable, with Kivisch (l. c. p. 103), to refuse assent to the supposition, for the radiating fibres described by Kasper, which alone could effect anything of the kind, do not exist; the fact, nevertheless, is conceivable, if we assume a relaxation of the muscular element in the *cervix* and *os*, together with a contraction, especially of the longitudinal fibres in the *fundus* and body. In comparing the *uterus*, as respects the disposition of its muscular element and its movements, with other organs, none affords so apt a comparison as the bladder, in which the muscular tissue is arranged essentially in the same way, and a physiological antagonism exists between the superior and inferior portions. The *sensibility* of the *uterus*, and of the internal parts of the female genital organs in general, is very slight; careful sounding of the uterine cavity causes no sensation; in like manner, contact with the vaginal portion is, frequently, scarcely felt, whilst these parts give pain upon more powerful pressure or traction, and when in a state of inflammation. The *sensibility* of the

*vagina* increases towards the inferior portion; and as regards the external organs, the *clitoris* is rendered especially susceptible of sensation, by its abundant supply of nerves, as is also the entrance to the *vagina*, particularly at the orifices of the glands of Bartholini or Duverney.

The secretions of the female genital organs, except those of the *ovarium*, are: 1. a whitish *mucus* in the *uterus* and *vagina*, which, in the former situation, is derived chiefly from the uterine glands, and probably differs in some respects from the other; 2. a transparent viscous mucus in the *cervix uteri* (*vide supra*); 3. the clear viscid secretion of the Bartholinian glands, which is poured out in large quantity in copulation; and upon excitation, as was noticed by Huguier and Scanzoni, it even frequently escapes in jets, which may be ascribed to the muscles of the excretory ducts; 4. the secretions of the minute sebaceous and mucous follicles of the external organs.

*Investigation of the female organs.*—The Graafian follicles should be examined as fresh as possible, when the *membrana granulosa* and *ova* will be seen in their natural relations. In ovisacs that have been longer kept, the former floats about in flocculi in the *liquor folliculi*, and the “germinal eminence” is also for the most part destroyed. In order to make sure of obtaining the *ovulum*, the position of which is readily perceived even in the still closed follicle, in certain animals, as in the Bitch, for example, a large carefully extracted follicle is opened under water, and the larger flocculi which escape are examined with a low magnifying power; it is also readily found when the contents of a follicle are carefully transferred to an object-bearer. In rough sections, or when the structure of the ovaries is teased out, *ova* are also always readily found, although this is not exactly the mode of seeking for them to be recommended. The muscular elements of the oviducts, *uterus*, *vagina*, &c. are investigated by means of careful dissection, as also in fine sections of parts that have been hardened. Kasper especially recommends that the uterus should be boiled for 10 minutes in water, and then placed for 24 hours in the most concentrated solution of carbonate of potass, or that it should be treated with pyroligneous acid, and the sections moistened with dilute acetic acid; whilst Schwartz, according to Reichert, dries the uterus hardened in

alcohol, and renders the muscular fibres distinct by acting upon them for a short time with nitric acid of 20%. The method, also, employed by Wittich (p. 486), should be used, according to Gerlach. The contractile fibre-cells are nowhere more beautifully displayed than in the gravid *uterus*. The uterine glands are best shown at the menstrual period and in the first months after conception. The ciliated *epithelium* is only to be seen in perfectly fresh subjects, and best in the Fallopian tubes; the non-ciliated cells, on the other hand, are readily seen. The preparation of the external parts presents no difficulty, and the directions already given are applicable to the glands, nerves, *papillæ*, and *epithelium*.]

*Literature.*—C. E. v. Baer, 'De ovi mammalium et hominis genesi, epist.,' Lips., 1827, and 'Commentarius,' in German, in Heusinger's 'Zeitsch.,' II; Coste, 'Recherches sur la génération des mammifères,' 1834; 'Embryogénie comparée,' Paris, 1837; 'Etudes ovologiques,' in 'Annal. Franc. et Etrang. d'Anat. et de Phys.,' II, 224, 1838; 'Histoire générale et part. du développement,' Paris, 1847; A. Bernhardt, 'Symbolæ ad ovi mam. hist. ante prægnat.,' Vrat., 1834, Diss.; R. Wagner, 'Ueber das Keimbläschen,' in Müller's 'Archiv,' 1835, p. 373; 'Prodromus hist. generationis,' Lips., 1836; 'Beiträge zur Zeugung u. Entwicklung,' in 'Denkschrift der bayr. Akad.,' Bd. II, 1837, p. 511; M. Barry, 'Researches in embryology,' Series I, II, III, in 'Philos. Trans.,' 1838-1840; Bischoff, 'Beweis der von d. Begattung unabhängigen Reifung u. Loslösung d. Eier d. Säugethiere und des Menschen,' Giessen, 1824; 'Ann. d. Sc. Nat.,' 3, Ser. II, 1844, 304; Pouchet, 'Théorie positive de l'ovulation spontanée,' Paris, 1847; Zwicky, 'De corpor. luteorum origine,' Turici, 1844; Kobelt, 'Der Nebeneierstock des Weibes,' Heidelberg, 1847; W. Steinlin, 'Ueber die Entwicklung der Graafschen Follikel und Eier der Säugethiere,' in 'Mittheil der Zürcher naturf. Gesellschaft,' 1847, p. 156; Fr. Tiedemann, 'Tabulæ nervorum uteri,' Heidelb., 1822; G. Kasper, 'De structurâ fibrosa uteri non gravidæ,' Vratisl., 1840; E. H. Weber, 'Zusätze zur Lehre vom Bau der Geschlechtsorgane,' Leipzig, 1846; A. Kölliker, 'Ueber die glatten Muskeln der weiblichen Genitalien,' in 'Zeitschr. für wissensch. Zool.,' I; Fr. Kilian, 'Die Structur des Uterus bei Thieren,' I, II, Art. in 'Zeit-

schr. f. ration. Med.,' Bd. VIII, IX, 1849 u. 1850; 'Die Nerven des Uterus,' *ibid.*, 1850, Bd. X, st. 41; R. Lee, 'Memoirs on the ganglia and nerves of the uterus,' London, 1849; Th. Snow-Beck, 'On the nerves of the uterus,' in 'Philos. Trans.,' II, 1846; Rainey, 'On the structure and use of the *lig. rotundum uteri*,' in 'Phil. Trans.,' II, 1850; V. Schwartz, 'Observ. microsc. de decursu muscul. uteri et vaginæ hominis,' Dorpat., 1850, Diss.; Robin, 'Mém. pour servir à l'hist. anat. et pathol. de la membrane muqueuse uterine,' in 'Arch. génér. de Méd.,' 1848, tom. XVII, pp. 258 à 405, tom. XVIII, p. 257; Kobelt, 'Die männlichen und weiblichen Wollustorgane,' Freib., 1844; Tiedemann, 'Von den Duverney'schen Drüsen des Weibes,' Heidelberg, 1840; C. Mandt, 'Zur Anatomie der weiblichen Scheide,' in 'Zeitschr. für rat. Med.,' VII, p. 1; Huguier, 'Sur les appareils secrets des organes génit. de la femme,' in 'Annal. d. Sc. Nat.,' 1850, p. 239.

### C. OF THE LACTEAL GLANDS.

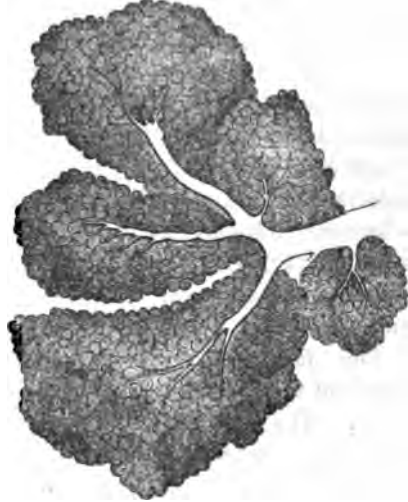#### § 210.

The *lacteal glands* (*glandulæ lactiferæ*) are a pair of compound racemose glands, which, in the male, are only rudimentary, but in the female fully developed, and, after parturition, secrete the milk.

With respect to their structure, the lacteal glands, in all essential particulars, completely correspond with the larger racemose glands, for instance the *parotid* and the *pancreas*. Each gland consists of 15—24 or more, irregular, flattened lobes,  $\frac{1}{4}$ " to 1" wide, with a rounded, angular outline, which, although their cavities are quite distinct from each other, cannot externally always be definitely separated. Each is composed of a certain number of *smaller* and *smallest* lobules, and these, lastly, of *gland-vesicles*. The latter are rounded, or pyriform, 0.05—0.07" in size, with a distinct constriction between them; and the smallest excretory ducts, as, for instance, in the small mucous glands, and as everywhere else, are formed of a structureless membrane and tessellated epithelium, which,

at the time of lactation, undergoes peculiar metamorphoses. All these glandular elements are surrounded by dense, white connective tissue, particularly abundant between the gland-vesicles and smaller lobules,

Fig. 272.



and are united into a compact, large glandular mass, which is ultimately covered by a quantity of adipose tissue, and in part by the skin. The lacteal glands are, properly speaking, not simple glands, but like the lachrymal, aggregations of these. From each glandular lobe, by the coalescence of the excretory ducts of the smaller and larger lobules, there ultimately proceeds a shorter or longer duct, 1—2''' in diameter,

the *lacteal duct* or canal (*ductus lactiferus s. galactophorus*), which, running towards the nipple, dilates beneath the *areola*, into an elongated *sacculus*, 2—4''' wide, the *lacteal sac* or *receptacle* (*sacculus s. sinus lactiferus*); afterwards contracting to 1''' or  $\frac{1}{4}$ ''' , it bends round into the nipple, and ultimately opens, at its apex, in an independent orifice, not more than  $\frac{1}{3}$ — $\frac{1}{5}$ ''' in diameter, between the *papilla* which exist in that situation. All these excretory ducts, besides an *epithelium*, which in the largest of them presents cylindrical cells, 0.006—0.01''' long, and in the finer ramifications, rounded, polygonal smaller cells, and a homogeneous layer beneath them, also possess a white dense fibrous membrane, longitudinally plicated in the larger canals, in which I have hitherto been unable to detect any indubitable muscular fibres, and nothing but a nucleated, longitudinally fibrous, connective tissue with fine elastic fibres. Henle, however, more recently, thinks that he has noticed longitudinal muscles in the lacteal ducts, not those of the nipple, but more deeply within the gland.

Fig. 272. A few of the smallest lobules of the lacteal gland of a puerperal female, with their ducts,  $\times 70$  diam. After Langer.



The *nipple* (*mamilla*) and the *areola*, present numerous smooth muscles, to which the contractility of those parts is owing (*vid.* § 34); a delicate cuticle, the horny layer of which, in the female, is not more than 0·006''' thick, whilst the Malpighian layer has a thickness of 0·04''' and is coloured in the deeper portion; and compound *papillæ*  $\frac{1}{10}$ — $\frac{1}{33}$ ''' long. On the breast itself, the *papillæ* are small ( $\frac{1}{60}$ — $\frac{1}{30}$ ''') and simple, and the *epidermis* still finer (0·032—0·04'''), although with a thicker horny layer of 0·02—0·024'''. In the *areola*, especially at its borders, but not on the nipple itself, there are large sudoriparous glands, often with peculiar contents, and large sebaceous follicles with fine hairs, which frequently form little *papillæ*, visible on the exterior (*vid.* §§ 68 and 73). In the male, I have seen sebaceous glands without hairs, also on the nipple.

The *blood-vessels* of the lacteal glands are numerous, and surround the gland-vesicles with a rather close plexus of capillaries. The *veins* in the *areola* constitute a circle, which is not always quite complete (*circulus venosus Halleri*). The *lymphatics* are equally abundant in the skin covering the gland, whilst in the gland itself they have not yet been demonstrated. The *nerves* of the skin covering the *mamma* are derived from the supraclavicular nerves, and the cutaneous branches of the second, third, and fourth intercostals. In the interior of the gland, no other nerves can be traced than a few fine twigs accompanying the vessels, whose termination is unknown.

At the time of lactation the gland enlarges very considerably. Its tissue is no longer uniform, whitish, and firm, but softer, granular, and lobate, with a yellowish-red, glandular *parenchyma*, distinctly bounded by the whitish, spongy interstitial tissue. The gland-vesicles and lactiferous ducts are wider, filled with milk, and the vessels excessively multiplied. In the external parts, the enlargement of the *areola* and of the nipple is especially worthy of remark; the cause of which appears to depend upon a growth of these parts, with all their elements, including the muscular fibres and minute glands; and not in a simple extension of the colour over a larger surface. In the male, the lacteal gland is quite rudimentary,  $\frac{1}{3}$ —2'' broad, and 1—3''' thick, not lobed, and firm. The

lacteal ducts have no sinuses, and are never so far developed as in the female, inasmuch as they either correspond in form with those met with in the new-born child, or, in larger glands, are more branched, and furnished with a certain number of terminal vesicles, which, on account of their considerable size (they are three times as large as the gland-vesicles in the female), are not to be regarded as true gland-vesicles. In rare, but well-established instances, the glands, even in the male, have become so much developed as to be capable of secreting milk.

§ 211.

*Physiological remarks.*—The lacteal gland, in its *development*, follows the same course as the other cutaneous glands, and is, as I find ('Mittheil. d. Zürcher nat. Gesells.,' 1850, No. 41) in accordance with Langer (l. c.), originally (in the fourth to the fifth month) nothing but a solid papillary projection of the mucous layer of the *epidermis*, which is invested by a layer of denser dermal tissue (fig. 273, 1). In the sixth to the seventh month, it throws out a certain number of buds, and in this way arise the first rudiments of the subsequent lobes (fig. 273, 2). These are, at first, nothing but minute pyriform- or flask-shaped processes of the common rudiment of the gland, which do not separate from each other until towards the end of foetal life, at which time they open externally; whilst, at the same time, rounded or elongated solid buds begin to appear at their ends, which at this time are also solid. At the period of birth, the gland measures from  $1\frac{1}{2}$ —4''' , and already distinctly

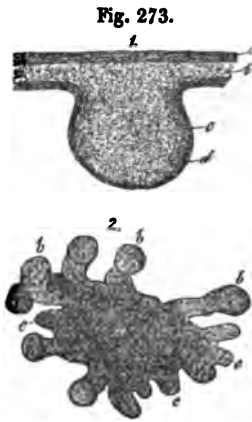


Fig. 273. Development of the lacteal gland. 1. rudiment of the gland in a male embryo, at five months: *a*, horny layer; *b*, mucous layer of the *epidermis*; *c*, process of the latter or rudiment of the gland; *d*, fibrous membrane around the same. 2. lacteal gland of a female fetus, at seven months, seen from above: *a*, central substance of the gland, with larger (*b*) and smaller (*c*) solid outgrowths, the rudiments of the large gland-lobes.

exhibits a certain number (12—15) divisions, of which the internal still approximate the rudimentary *papillæ*, in fact have either simple flask-like ends, or terminate in two or three sinuosities; whilst the others are in connexion with a greater number. The excretory duct of each of these rudimentary lobules, which is either simple or possesses two or three branches, is composed of a fibrous membrane of immature, nucleated connective tissue, and an *epithelium* of small cylindrical cells, and is manifestly hollow; whilst the dilated ends, which cannot in this case, any more than in other glands in the process of development, at this time be termed terminal vesicles, are still solid; being wholly composed, besides the fibrous tunic continued upon them from the ducts, of minute nucleated cells. From this very simple form, the later one is thus developed: by the long continued gemmation of the primary and subsequently formed, clavate ends, and their simultaneous excavation, a much branched duct, beset in its offsets with whole groups of hollow gland-vesicles, is at last formed. These processes, however, go on more slowly in the lacteal gland than in any other of the secretory organs. According to Langer, to whom we are indebted for careful researches upon this subject, true terminal vesicles are never met with in childhood, before menstruation is established, but, universally, only undeveloped ducts with clavate ends. On the occurrence of puberty, true gland-vesicles are formed, but at first only at the borders of the gland, until, ultimately, in the first pregnancy, the entire gland is fully developed. After the first lactation, it is true, the gland again diminishes in size, but all its constituent parts remain, and again enlarge in the succeeding occasions of conception, without the addition of any new parts. At the period of involution—probably also, if after a pregnancy, too long a time has elapsed without the functions of the gland being called into play—it undergoes a retrograde metamorphosis, until finally, in old age, all the gland-vesicles have disappeared, and nothing but the more or less persistent lactiferous ducts, with their epithelium in a state of fatty degeneration, are to be found in the adipose cushion which supplies the place of the glandular tissue.

The *milk*, the secretion of the mammary glands, consists of a fluid, the milk-plasma, and innumerable spherical, opaque

corpuscles, with the brilliant aspect of fat-drops, suspended in it. These corpuscles—the milk-globules—vary in size, from immeasurable minuteness up to 0·001—0·002''' and more, and most probably do not consist of the fatty part of the milk alone, but have also a delicate invest-

ment of *casein*, and it is to them that the whiteness of the milk is owing. With respect to the formation of the milk, it is to be remarked that, except

at the periods of lactation and pregnancy, the glands contain nothing but a small quantity of a yellowish viscid mucus, with a certain number of epithelial cells, and are lined up to their extremities by an epithelium, which in that situation is tessellated, but externally is more cylindrical. With conception, this state of things is altered. The cells of the gland-vesicles begin to develop, at first a little, and subsequently more and more fatty matter within them, and to enlarge, so as entirely to fill the terminal vesicles. To this is added, before the end of pregnancy, a new formation of fat-containing cells in them, by which the older cells are forced into the lactiferous ducts, which they gradually fill. Thus it happens, that although a true secretion is not at that time set up, still in the latter half of pregnancy a few drops of fluid may be expressed from the gland, which, as is shown by its yellow colour, is not milk, but nevertheless contains a certain number of fat-globules from the more or less disintegrated fatty cells, exactly resembling the subsequent milk-globules, and also contains such cells either with or without a tunic—the so-termed *colostrum corpuscles*. On the commencement of lactation after parturition, the cell-formation in the gland-vesicles proceeds with excessive energy, in consequence of which the secretion collected in the lactiferous ducts and gland-vesicles is evacuated, as the *colostrum* or immature milk, the true milk taking its place.

The latter, in the extremities of the gland, consists only of some fluid and cells entirely filled with fat-globules, which sometimes occupy the gland-vesicles alone, sometimes associated with pale epithelial cells, which, however, always contain more



Fig. 274.

Fig. 274. Elementary forms in milk,  $\times 350$  diam.: *a*, milk-globules; *b*, colostrum corpuscles; *c* *d*, cells with fat-globules from the colostrum, one (*d*) with a nucleus.

or less fat, and originate either in a free cell-formation or from epithelial cells, in a way analogous to that in which the cutaneous sebaceous matter is formed (*vid.* § 73), by their continued multiplication. These cells, which I would designate *milk-cells*, break up, so soon as they reach the lactiferous ducts, into their elements, the milk-globules; the membrane, and for the most part also, the *nucleus*, disappearing, without a vestige being left, so that the milk, when secreted, usually presents no indication of its mode of origin. At most, there occur in it a very few larger or smaller aggregations of milk-globules, which, from their similarity to those met with in the *colostrum*, may likewise be termed *colostrum-corpuscles*. The secretion of the milk, therefore, depends essentially upon a formation of fluid and fat-containing cells in the gland-vesicles, and consequently falls into the category of those secretions into the composition of which morphological elements enter; above all to the fatty secretions, such as the cutaneous sebaceous matter, in which cells of precisely similar kind occur to those met with in the gland-vesicles of the lacteal glands and in the *colostrum*.

In the new-born child, the mammary gland very frequently contains a small quantity of a fluid presenting the external and microscopical characters of milk, the origin of which is probably related to the formation of the glandular ducts.

[With respect to the *colostrum-corpuscles* and fat-globules of the *colostrum*, Reinhardt was the first to prove, that the supposition broached by Nasse and Henle, that these bodies are related to a formation of fat-containing cells in the mammary glands, and that the former in their more usual form are nothing but membraneless cells, and the latter oil-drops liberated from cells, is in every respect well founded, although he is inclined to distinguish the formation of the *colostrum* from the secretion of milk, and to regard the former as a pathological process, as a fatty metamorphosis, by which the old epithelial cells of the gland, previously to the formation of true milk, are evacuated externally, and particularly because, in the true milk-formation, he was unable to perceive any fat-containing cells. But since V. Bueren, especially, has found such cells, and consequently the formation of the milk and of the

colostrum, seem to be morphologically quite identical, such a separation of the two processes can no longer be defended; and, in cases of repeated parturition, the formation of *colostrum* can scarcely be viewed in any other light than as the introduction to that of the milk. On the other hand, I am quite of opinion, that the production of the first *colostrum* is connected with the excessive development of the lacteal gland coincident with the first pregnancy; and that it is in part derived from the internal cells of the originally solid rudiments which are removed, during the formation of the ultimate terminations of the gland. I explain, in a similar way, the formation of milk in the new-born child; in which case, surely, no true secretion can be thought of.

Donné, the discoverer of the *colostrum-corpules*, states, that in inflammations and tumefactions of the breast of nursing women, the milk acquires the nature of *colostrum*; which is, however, denied by d'Outrepoint and Münz ('Neue Zeitschrift für Geburtskunde,' Bd. 10); in the same way, according to Lehmann ('Phys. Chemie,' II, 327, [transl. II, p. 334]) it would appear, that, in acute diseases generally, and also in menstruation (Donné, d'Outrepoint), the milk exhibits *colostrum-corpules*, which, when they exist in larger quantity, are regarded by Donné as indicative of bad milk. In "hoof-murrain" ('Klauenseuche') Herberger and Donné found the milk to contain a good deal of *colostrum*. In *sour milk* the *casein* coagulates into granules, and the milk-globules gradually run together into larger drops. *Blue* and *yellow* milk, according to Fuchs (*vid.* Scherer, art. 'Milk' in 'Handw. d. Phys.', II, p. 470) contains colourless infusoria, which he terms *vibrio cyanogenus* and *xanthogenus*, which, when transferred to healthy milk also colour it; a fact which, as regards *blue milk*, is confirmed by Lehmann (l. c., p. 335, Eng. transl.); according to Bailleul ('Comptes rend.', t. 17, p. 1138), however, and Lehmann [once only], a filamentary fungus is also found in that sort of milk. *Red milk* has also been noticed by C. Nägeli, and vegetable, *protococcus*-like growths found in it.

For the *investigation* of the mammary glands, those of pregnant or nursing women, or of women who have borne children, should be preferably selected, because it is only in such that the gland-vesicles are well developed. When the

smallest lobules are teased out, their elements come readily into view; but if it be desired to examine into their arrangement, fine sections of glands boiled in acetic acid and dried are above all to be recommended, as well as injected preparations, which it is not difficult to make from the lacteal sinuses. For the study of the *development of the gland*, besides recent specimens, preparations made with acetic acid are necessary. The smooth muscles of the *areola* are found by mere dissection, although not always very easily, as, except during pregnancy, they are frequently very delicate.]

*Literature.*—Rudolphi, 'Bemerk. über den Bau der Brüste,' in the 'Abh. der Berliner Akademie,' 1831, p. 337; Astley Cooper, 'The Anatomy of the Breast,' London, 1839. 4to; C. Langer, 'Ueber den Bau und die Entwicklung der Milchdrüsen, mit 3 Taf.,' from the 'Denkschr. d. Wiener Akad.,' Bd. III, Wien, 1851; A. Donné, 'Du lait et en particulier du lait des nourrices,' Paris, 1837; 'Ueber die mikroskopischen Körperchen im Colostrum,' Müller's 'Arch.,' 1839, p. 182; 'Cours de Microscopie,' Paris, 1844; Fr. Simon, 'Die Frauenmilch, nach ihrem chemischen u. physiol. Verhalten dargestellt,' Berlin, 1838; 'Ueber die Corps granuleux 'von Donné,' in Müller's 'Arch.,' 1839, pp. 10 and 187; J. Henle, 'Ueber die mikr. Bestandtheile der Milch,' in Fror. 'Notizen,' 1839, No. 223; H. Nasse, 'Ueber die mikr. Bestandt. d. Milch,' Müller's 'Archiv,' 1840, p. 259; Reinhardt, in 'Arch. f. path. Anat.,' Bd. I, pp. 52—64; Lammerts van Bueren, 'Onderzoekingen over de Melkbolletjes,' in the 'Nederl. Lancet,' 2d ser., 4, Jaarg., p. 722, or 'Observat. microscop. de lacte,' Traject. ad Rhenum, 1849, Diss.; 'De Ontwikkeling van de Vormbestanddeelen der Melk,' in the 'Nederl. Lancet,' 2d ser., 5, Jaarg, p. 1; Fr. Will, 'Ueber die Milchabsonderung,' Erlangen, 1850, Programm. Besides which, should be consulted the 'General Anatomy' of Henle, J. Müller's work on the Glands, and the Atlases of Berres, Donné, and Mandl. [*Vid.* also, 'Observations on the muscular tissue of the Skin,' by Joseph Lister, M.B., 'Quart. Journ. Micros. Sc.,' vol. I, p. 262, 1853.]

## OF THE VASCULAR SYSTEM.

## § 212.

The *vascular system*, consisting of the *heart*, with the blood- and lymphatic vessels, contains in its interior the *blood* and the *lymph (chylus)*, with innumerable morphological particles. The lymphatic vascular system presents special organs--the lymphatic glands.

## 1.—OF THE HEART.

## § 213.

The *heart* is a thick, hollow, muscular organ divided into four compartments, invested externally by a serous membrane—the *pericardium*,—and lined internally by the *endocardium*, a continuation of the walls of the great vessels, particularly of the *tunica intima*.

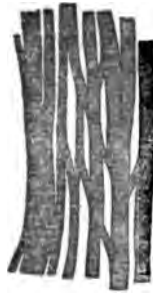
The *pericardium* does not differ in structure from other serous membranes, as, for instance, the *peritoneum*. The outer lamella is considerably the thicker; it is more fibrous towards the exterior, presenting, towards the interior, numerous fine, elastic networks, which are immediately covered with one or two layers of tessellated *epithelium*. Very numerous elastic networks of the same kind are found also in the inner thin lamella which is, partly, very intimately united with the muscular substance, and partly, especially in the *sulci*, separated from it by common adipose tissue, which, moreover, not unfrequently forms a subserous fatty layer, extending almost over the entire heart. The *vessels* present the same conditions as elsewhere; and with respect to the *nerves*, twigs from the phrenic and recurrent branch of the right *vagus* have been demonstrated in the outer lamella of the *pericardium* (Luschka).

The *muscular fibres* of the heart are red and transversely striated, but differ in many respects from those of the voluntary muscles. The individual fibres themselves are, on the average, about  $\frac{1}{3}$  more slender (0.004—0.01"), frequently more distinctly striated in the longitudinal than in the transverse direction, and pretty readily divisible into fibrils and



minute particles ("sarcous elements," Bowman); their *sarcolemma* is very delicate, or even wholly inappreciable; and in the fibres, there almost uniformly occur minute fatty granules, which, with the *nucleus*, are frequently disposed in a series in the axis of the fibre, and, where the muscular tissue is degenerated, appear most usually to be excessively multiplied, and also coloured. Much more, however, than by these characters, is the muscular tissue of the heart distinguished by the intimate union of its elements, which, except on the internal surface of the organ, not only never form manifestly distinct bundles, being everywhere in close apposition with each other, and separated only by a scanty connective tissue, but, as was discovered by Leeuwenhoek,<sup>1</sup> and I also have found (*vid.* p. 94,

Fig. 275.



vol. i), are directly united together in their elements. These anastomoses of the muscular fibres, which are a universal attribute of the cardiac muscular tissue, are effected in the human and mammalian heart generally, chiefly by short, oblique, or transverse, usually small fasciculi, and are extremely numerous, so that, in many places in the ventricles and auricles (whether universally I know not), numerous instances of them are presented in every minute portion. Besides these, there also exist true *divisions* or fibres, by which the thickness of separate portions of muscle may be rendered more considerable than it was originally.

The *course of the muscular fibres* of the heart is extremely complex, and a general outline only of it can here be given. The muscular structures of the ventricles and of the auricles are completely distinct from each other; both, however, have as their chief point of origin the *ostia venosa* of the ventricles, where tough, tendinous tracts—the so-called *annuli fibrocartilaginei*—are situated, two anterior, on the right and left of the aortal opening, and one posterior, which runs backwards also from the aorta to the border of the auriculo-ventricular *septum*, where it splits into two slender *crura*. In the auricles are found: 1. fibres, which are *common* to both, in the form

Fig. 275. Anastomosing primitive fasciculus from the human heart.

<sup>1</sup> [See note, p. 94, Vol. I.—Eds.]

of transverse, flattened bundles, which proceed chiefly anteriorly, but afterwards also superiorly and posteriorly, from one auricle to the other, and are continued in them as transverse fibres. 2. *special fibres*. These constitute, in the first place, complete rings at the origins of the great veins, and at the points of the *appendices*; and, in the second place, a *longitudinal layer* of some thickness beneath the *endocardium*, which springs from the auriculo-ventricular openings, and is especially developed in the right auricle (*musculi pectinati*). Besides these, there exist between the latter muscles, and also in the auricles, numerous other small fasciculi, which, on account of their irregularity, cannot be more particularly described. The *septum* is to some extent common to both auricles. Its muscles arise from the most anterior part of the upper border of the *septum* of the ventricles, immediately behind the aorta, from the posterior fibro-cartilage and arch to the right, around the *fossa ovalis*, in which only slender fibres exist, in a superior and posterior direction, in order to terminate, partly at the *vena cava inferior*, partly by forming a complete ring; whilst on the left, they surround the *fossa ovalis* in the opposite direction.

The muscular structure of the *ventricles* is disposed so that on the external and internal surfaces the fibres everywhere decussate; and in the intermediate portion, every stage of transition from the one direction to the other is presented. The muscular fibres arise at the *ostia venosa* and at the arterial openings, in part immediately, and partly with the intervention of short tendons, run more or less obliquely, (and some longitudinally or even transversely) and after they have surrounded a portion of the ventricle in the longitudinal or transverse direction, curve back again, and then terminate, some in the *musculi papillares*, and *chordæ tendineæ*, whilst others are again inserted in the points of origin above indicated, so that without being interrupted by tendons, they describe large involved loops or figure-of-8 turns of large size, and running in very numerous and diverse directions.

The *endocardium* is a whitish membrane, investing all the elevations and depressions of the internal surface of the heart, as well as the papillary muscles and their tendons, and the valves. It is most developed in the left auricle (as much as  $\frac{1}{4}$ "), and thinnest in the ventricles, so that the muscular substance

there presents its natural colour. As regards its structure, it consists of three layers; an *epithelium*, an elastic layer, upon which the varying thickness of the *endocardium* in different situations depends, and a thin layer of connective tissue. The first is a single, or, according to Luschka, perhaps a double layer of polygonal, usually elongated, clear, flattened, nucleated cells, 0.007''' to 0.012''' long, resting immediately upon the most superficial layer of the elastic membrane, which, may be said to consist of nothing but very fine, longitudinal, elastic fibres. The remainder of this middle layer is constituted of a matrix of common connective tissue with scattered *nuclei*, through which the very abundant finer and coarser elastic networks penetrate. This elastic element is so abundant, in fact, in the auricles, and even mixed with true fenestrated membranes (*vid.* § 23) that the *endocardium* of those cavities is rendered almost entirely a yellow, elastic membrane, consisting of several laminae. Most externally, there succeeds to this elastic layer, a stratum of connective tissue, of great tenuity indeed, but which nevertheless, both in the ventricles and in the auricles may easily be raised as an entire membrane. In the portion bordering upon the elastic tissue this layer contains fine elastic elements. It represents, in fact, a somewhat loose layer, like a subserous connective tissue, uniting the muscles and the true *endocardium*.

The auriculo-ventricular valves, are *laminae* springing from the fibrous rings of the *ostia venosa*, in the thicker parts of which, a middle layer of connective tissue with numerous elastic networks, and two *lamelle* of the *endocardium* united with it, may be clearly distinguished. Towards the free border, these three layers are conjoined so as to form a single one, composed of connective tissue and fine elastic networks, over which again the *epithelium* is continued. The semilunar valves present the same conditions as the free border of the others, and with respect to the *chordae tendineae*, they are constituted of common tendinous tissue, covered by a very thin layer of *endocardium*—consisting indeed merely of *epithelium* and a fine elastic *lamella*.

The blood-vessels of the muscular substance of the heart are very numerous, but differ in no respect from those of transversely striped muscle, (§ 77), except that the capillaries, owing to the slenderness of the muscular fibres, often encompass

several of them in common. The *endocardium* is tolerably well supplied with vessels in its layer of connective tissue, whilst they are more scanty in the proper *endocardium*. In the auriculo-ventricular valves a few vessels are readily seen, not only in animals but also in Man, (*vid.* Luschka, l. c., p. 182, fig. 1), some of which enter them from the papillary muscles, but chiefly from the basis of the valves, and are also distributed, in part, though sparingly, in their proper endocardial investment. The semilunar valves possess no vessels. Only a few *lymphatics* are found in the external *lamella* of the *pericardium*, whilst they occur in greater abundance on the inner *lamella* on the muscular substance, and may there be demonstrated readily enough, if the heart be placed for a few days in water, as Cruikshank correctly observes. Their trunks collect in the *sulci*, accompanying the blood-vessels, and terminate in the glands, behind and below the arch of the *aorta*, on the bifurcation of the *trachea*, to which the pulmonary lymphatics also proceed. Whether the substance of the heart and the *endocardium* are also furnished with lymphatics, as is asserted by some, is not yet determined. The *nerves* of the heart are numerous and proceed principally from the *cardiac plexus* formed by the *vagus* and sympathetic, beneath and behind the arch of the *aorta*. These nerves, forming the more scanty *plexus coronarius dexter*, and the richer *p. c. sinister*, accompany the vessels on the right and left ventricles and auricles, run, in part with the vessels, in part crossing them in various directions, toward the apex of the heart, and, whilst entering into numerous anastomoses with each other, usually at acute angles, enter the muscular substance at various points, some even in the coronary *sulcus*, in order to terminate, partly in the muscular substance, and partly to reach the layer of connective tissue of the *endocardium*. The cardiac nerves, in Man, are grey, and, except the largest, contain only fine and very pale fibres; the latter, however, in the greater number, and intermixed with not very numerous nucleated fibres. Although the nerves, even in the *endocardium*, retain their dark borders and are tolerably numerous, it has not hitherto been possible to discover their terminations in that situation, any more than in the muscular substance. *Ganglia* exist, not only in the cardiac plexus in various situations, but as Remak discovered in the Calf, also

in the muscular substance of the auricles and ventricles, which is likewise true of Man and other animals. These *ganglia* are best known in the Frog, in which they are situated, especially in the *septum*, and at the junction of the auricles with the ventricle, and contain apolar and unipolar cells, (Ludwig, Bidder, R. Wagner, myself). The minute fusiform enlargements on the external nervous branches, especially noticed by Lee, are not ganglia, being merely thickenings of the *neurilemma*.

[With respect to the particular directions of the muscular fibres of the ventricles, the following remarks may be offered. On the external surface of the ventricles there is a layer,  $\frac{1}{4}$ — $1$ " thick, which, on the left ventricle, runs obliquely downwards from the pulmonary artery, the anterior longitudinal sulcus and the left transverse sulcus, and in the middle of the wall of the ventricle, descends very abruptly, almost vertically. On the right ventricle, these fibres are oblique only on the *conus arteriosus*, whilst on the sides and posteriorly they are almost or quite transverse. At the longitudinal *sulci*, the superficial fibres are continued from one ventricle upon the other, so that a small portion of those of the left ventricle arise from the anterior side of the *ostium venosum dextrum* and the greater part of those belonging to the right ventricle from the posterior portion of the left *ostium venosum*. If the fibres of the *left ventricle* are traced, it will be found, with the exception of those which at the posterior longitudinal sulcus pass upon the right ventricle, that they (fig. 276 *a, a', a''*) run towards the apex of the heart, and there form the well known *vortex*, and then curve inwards, forming loops; and are continued as the innermost, for the most part longitudinal, fibres of the cavity of the ventricle, and either ascend as high as the venous openings, or terminate in the posterior papillary muscle. Upon removal of this set of fibres, a thick layer comes into view, interposed between its external and internal portions, the fasciculi in which, at first sight, appear to surround the cavity of the ventricle in an oblique and transverse direction, although they seem to arise, without exception, from the *ostia venosa*, and again to terminate in the same situation, and to describe a figure-of-8 turn, still more distinctly than the external muscular layer, as has been clearly shown by Ludwig. I find

that the bundles of this layer (fig. 276 *c, c', c'', c'''*), after their origin from the left border of the *aorta* and the anterior half of the *ostium venosum sinistrum*, extend obliquely downwards, and to the left (*c*), and then, before reaching the apex of the heart, curve towards the posterior wall of the ventricle (*c'*), whence they again ascend on the *septum* (*c''*) and the anterior wall (*c'''*), and are finally inserted in the whole extent of the venous opening, and also in the upper border of the *septum* (*c''''*). It is from these fibres in the free wall of the ventricle that are derived the deep layers which decussate with the superficial, and on the *septum* afford the fibres which, on the left side, run obliquely from below and behind, upwards and forwards.

On the *right ventricle*, there are much fewer independent fibres than on the left. Most of the superficial fasciculi are continued upon the left ventricle; both the anterior, which are continued over the anterior longitudinal sulcus and lost in the *vortex*, and also many of those which, at the posterior longitudinal sulcus, stretch from the left to the right ventricle. These latter fibres, consequently, completely encircle the right ventricle, part of them also entering the *vortex*, and part, in the anterior longitudinal sulcus, joining the middle muscular layers of the left ventricle. Independent, superficial fibres occur only: 1. at the *conus arteriosus*, arising from the *ostium venosum dextrum*, between the right auricle and the *aorta*, surrounding the *conus arteriosus*, and returning thence, from the left, back to their point of origin; 2. at the apex of the right

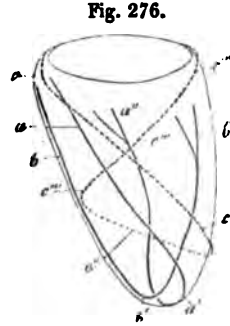


Fig. 276.

Fig. 276. Diagram of the left ventricle, with the septum, in order to show the course of the muscular fibres. *a, a', a''*, superficial fibres: *a*, on the anterior wall; *a'*, the turning inwards of them at the *vortex*; *a''*, their passage into the posterior papillary muscle. *b, b', b''*, septal fibres of the right side: *b*, their course, downwards and forwards; *b'*, their passage into the *vortex* and internal muscular layer of the left ventricle, as well as their termination in the anterior papillary muscle, *b''*. *c—c''''*, middle muscular layer: *c*, commencement at the right side of the *ostium venosum*, and course on the anterior wall obliquely downwards and backwards; *c'*, curvature on the *septum*, and course on it, *c''*; *c'''*, curvature on the anterior wall, and deep course in it, to the end of the *ostium venosum*, *c''''*.

ventricle, where not unfrequently a distinct, second *vortex* exists, in which case some of the superficial fibres arising from the left *ostium venosum* also curve inwards in that *vortex*, as they do in that of the left ventricle, and are continued into the superficial fibres of the right ventricle, but, on account of their intricate interlacement, cannot be traced further. Besides these, other *deeper fibres* exist in the right ventricle, which are disposed as follows: 1. From the upper border of the *septum*, and the left posterior side of the pulmonary opening, flattened bundles commence and run in the *septum*, downwards and forwards, towards the apex of the heart and the anterior longitudinal *sulcus*, where they join the superficial fibres, and are continued with them into the *vortex*, whence they may be traced as far as the anterior papillary muscle of the left ventricle, (fig. 276 *b, b', b''*). 2. With these fibres are associated others, running obliquely downwards and backwards, from the right side of the pulmonary opening and the right portion of the *ostium venosum dextrum*, beneath the superficial layer of fibres on the free wall of the ventricle, as far as the posterior longitudinal sulcus, where they curve abruptly towards the *septum*, in which they accompany the fibres described under (1), though more on the inferior half of the *septum*, to the apex of the heart, and terminate in a similar way. 3. With these fibres are also conjoined, to some extent, the elements of the great papillary muscle of the right ventricle, whilst those of the two smaller are continued into the fibres of the *septum* described under (1). Besides this, all these muscles furnish direct fibres, some of which descend from the *ostium venosum* and return upon themselves, and some proceed from the network of the *trabeculae carneae* and cannot be traced further.

It would appear therefore, that the auricles, as regards their muscular structure, are almost distinct; whilst in the ventricles, the entire superficial, tolerably thick muscular layer is continuous all round, and is disposed as if the heart had only a single cavity. Properly speaking, the left ventricle alone in this respect, is independent, in which there is not only beneath the superficial layer a very thick muscular mass arising and ending in it, to which, also, the greater part of the *septum* belongs, but which also receives nearly all the deeper muscular layers arising on the right side, in the free wall of the ventricle, and inserted

into the right portion of the *septum*. The heart, consequently, might be described as composed of two muscular sacs; the thinner of which is common to the whole; the other and thicker belonging only to the left division, and to some extent being interposed between the layers of the former. To the latter would belong the entire *septum*, and the middle muscular substance of the left ventricle; to the former, the superficial layers with their continuations in the innermost muscular strata, and especially the whole of the free portion of the right ventricle.]

## 2.—OF THE BLOOD-VESSELS.

## § 214.

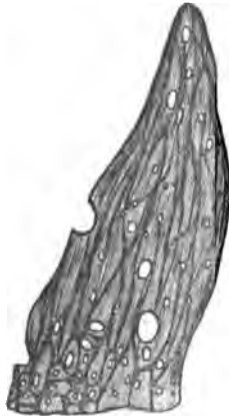As regards their structure, the blood-vessels are divided into *arteries*, *capillaries*, and *veins*; but these three divisions are by no means separated by definite limits, inasmuch as the capillaries are continuous with the veins on the one hand, as imperceptibly as they commence from the arteries on the other. At the same time it is true that both kinds of larger vessels, although in their rudiments presenting a general conformity of structure, are still sharply and definitely distinguished in many respects.

Concerning the *tissues* which enter into the composition of the vessels, and the mode of their *arrangement*, the following general remarks may be made. Whilst the true *capillaries* possess only a single perfectly structureless coat, in the *larger vessels*, with few exceptions, the number of tunics is increased to three, which may most suitably be described as the *tunica intima*, *t. media*, and *t. externa s. adventitia*. In these tunics there are found, of the fibrous tissues of the body, in the first place, the elastic and smooth muscular tissues, but the connective tissue, and even the transversely striped muscular tissue are also represented in them; besides which, there exist *epithelia*, peculiar homogeneous membranes, vessels, and even nerves; so that we have presented in them a complexity of structure which renders a general description almost impossible, and which can be made clear only by an accurate examination of each particular element; and the rather so, because the more



extensively distributed tissues assume very different forms. With respect to the arrangement and subdivision of these tissues, they may be said to exhibit a very strong tendency to lamination and, in the different layers, to the assumption of a constant direction in the course of their constituent elements. The former of these dispositions, however, rarely extends to the actual isolation of the individual layers; and to the latter, though more rarely, there are also exceptions. The *tunica intima* is the thinnest of the membranes of the vessels, and always consists of a cellular layer, the *epithelium*; most usually also of an elastic membrane in which a *longitudinal* direction of the fibres predominates; to which again may be superadded other layers of one kind or another, which also almost invariably retain the longitudinal direction. The *t. media* is for the most part a thick layer, and is especially the seat of the *transverse* elements and of the *muscles*, although in the veins it also contains numerous longitudinal fibres, and in all the larger vessels presents, in addition, elastic elements, and connective tissue in greater or less quantity. The *t. adventitia*, lastly, again exhibits a preponderating longitudinal fibrillation, is as thick as or thicker than the *t. media*, and consists, for the most part, only of connective tissue and elastic networks.

Fig. 277.

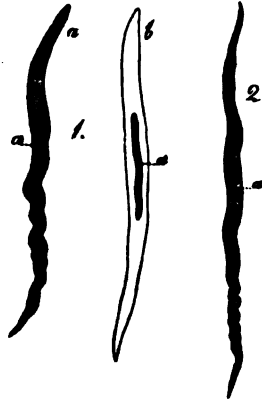


If the separate tissues of the vascular tunics are investigated somewhat more closely, it will be seen that the *connective tissue* appears almost universally fully developed, with fine and coarse bundles and distinct fibrils. It is only in the smallest arteries and veins that it is replaced by a nucleated, indistinctly fibrous tissue, and ultimately passes into a perfectly homogeneous, still occasionally nucleated, delicate membrane. The *elastic tissue* nowhere presents such manifold forms as it does in the vessels. From wide-meshed, lax networks of the finest, middle-sized, and thickest fibres (fig. 22, p. 62), up to the narrowest, closest, membraniform interlacements of these fibres, all

Fig. 277. Elastic membrane from the *tunica media* of the popliteal artery in Man, with an indication of fibrous networks,  $\times 350$  diam.

transitory forms are here met with ; and besides this, we may notice every degree of transformation of the latter, or of the *elastic reticulated membranes* into true *elastic membranes*, which either betray their derivation, in an elastic, more or less indistinct, fibrous network pervading them, and distant openings, or are transformed, either partially or entirely, into perfectly *homogeneous* plates, exhibiting more or fewer openings (fig. 25, vol. I, p. 62). In the smallest vessels, instead of the elastic elements, there occasionally occur, especially in the *t. adventitia*, fusiform cells, which can only be regarded as undeveloped formative cells of elastic tissue. *Transversely striped muscle* is found only at the

Fig. 278.



openings of the largest veins into the heart ; whilst, on the contrary, *smooth muscles* are extensively distributed, especially in vessels of a medium size, and also to some extent in the larger vessels. The elements of these muscles, or the contractile fibre-cells, in the majority of the vessels, present nothing peculiar, except that their length never exceeds 0.04''' , and that they are united, either directly, or with the intervention of connective tissue and elastic fibrils, into flattened bundles and muscular membranes, more rarely into reticulated muscular tissue. In the larger arteries, in place of these elements, we find shorter plates resembling epithelium cells, always with elongated *nuclei* ; and in the smallest arteries and veins, slightly elongated, or even roundish cells ; both which forms may be regarded as being in a less developed condition.

A peculiar fibrous tissue is contained in the *t. intima* of the larger vessels, which, since Henle, has generally been regarded as a metamorphosed *epithelium*. It consists of pale, usually striped, or it may be, homogeneous *lamellæ*, with elongated (long-oval) *nuclei* disposed parallel to the long axis of the vessel, and which may not unfrequently be broken up into

Fig. 278. Muscular fibre-cells from the human arteries,  $\times 350$  diam. 1, from the popliteal artery: *a*, without, *b*, with acetic acid. 2, from a twig,  $\frac{1}{3}$ ''' in diam., of the anterior tibial artery: *a*, *nuclei* of the cells.

slender nucleated fusiform fibres, similar to certain epithelial cells, or at all events, into fibres; but at other times are more homogeneous and without *nuclei*, or else appear to be transformed into extremely delicate fibrous membranes, like the closest and finest elastic networks. The similarity of these layers, which I shall term the *striped lamellæ* of the *t. intima*, or rather of the fibrous cells of which they are fundamentally constituted, to the *epithelium* of the vessels, is nevertheless insufficient to justify the supposition of their being derived from the latter, since there are no facts to shew that the true epithelial cells and the striped *lamellæ* stand in any genetic connexion of such a kind, as that the latter were at one time a true *epithelium* and the innermost layer in the vessel, being afterwards successively pushed back and their elements made to coalesce; on the contrary, it seems to be allowable to regard the epithelial cells and the formative cells of these layers as originally equivalent, and that in the course of development, the one set are transformed in one direction, and the other in another, and, in this way, ultimately become tissues of more or less different kinds.

The *epithelium* of the vessels (fig. 14, p. 55, vol. I) presents two forms: firstly, especially in the great veins, it appears under that of a *tesselated epithelium*, with polygonal, mostly somewhat elongated cells; and secondly, as in most of the arteries, as a *fusiform epithelium*, with acuminated, slender cells, 0·01—0·02'' long. Normally, it exists in all vessels, may almost always be pretty readily broken up into its elements, and like other simple *epithelia*, is not subject to any constant detachment and restoration. With Remak, we might describe the epithelium as the *cellular membrane* of the vessels, since it differs from other *epithelia* in this respect, that in the large vessels, it is often continuous with the striped *lamellæ*, without any line of demarcation, so that frequently it cannot be said where the one ceases and the others commence; but I should myself rather be inclined to retain the old name, both because the innermost cellular layer of the vessels presents in all respects the relations of a simple *epithelium* and is, in many situations (heart, smaller vessels) abruptly defined from the deeper tissues. Even the circumstance particularly adduced by Remak, that the vascular *epithelium* does not proceed from the embryonic epithelial membrane, is not with me decisive as to the propriety

of separating it from the other *epithelia*, inasmuch as the investments of the serous sacs and synovial capsules, which no one will be disposed to separate from the *epithelia*, are developed quite independently.

All the larger vessels down to those of  $\frac{1}{8}$ '' in diameter and less, possess *nutritive vessels* as they are termed (*vasa vasorum s. nutritia*), derived from minute contiguous arteries and ramifying chiefly in the *t. adventitia*, in which they constitute a rich capillary plexus with somewhat rounded meshes, from which again the veins accompanying the arteries arise, and which, in the case of the venous *vasa vasorum*, pour their blood directly into the vein to which they belong. The *t. media* of the larger arteries and veins, according to the concurrent testimony of many authors, also contains vessels, although in very small number, and only in the outer layers; whilst the internal layers and the *t. intima* have always appeared to me to contain none at all; but even in these situations some observers would seem to have noticed vessels (in the Ox, the *vena cava inferior* is richly provided with vessels up to the *t. intima*). *Nerves* derived from the *sympathetic* and spinal nerves may readily be seen going to many arteries, but frequently appear merely to accompany them. Where they enter the coats of a vessel they run only within the *t. adventitia*, and in favorable instances, in animals, divisions and free terminations of their fine fibres may be perceived (*vid. Mikros. Anat.*, II, 1, p. 532-33). Many arteries are wholly without nerves, as those of the cerebral and spinal substance, of the *t. chorioidea*, the *placenta*, as well as many arteries of muscles, glands, and membranes, whence it is obvious, that nerves are not as requisite for them as we have usually been inclined to believe. This may be said more decisively with respect to the veins, as it is only in the larger ones that a few fine nerves can be demonstrated. Such have been observed by Luschka in the sinuses of the *dura mater*, the veins of the vertebral canal, the *venae cavae*, the jugular, iliac, and crural veins, and in those of the liver by myself. They are derived both from the *sympathetic* and the spinal nerves, and with regard to their terminations have not yet been investigated. According to Luschka, they would appear to extend to the innermost vascular tunic; but this I have not as yet been successful in observing.

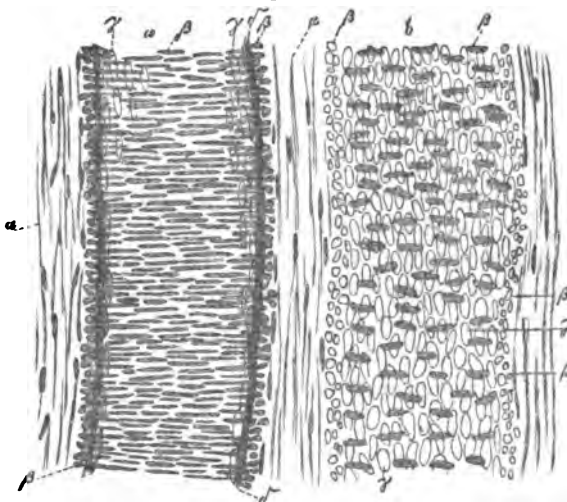
## § 215.

For more easy description, the *arteries* may be divided, according as the middle tunic is *purely muscular*, or *composed of muscular und elastic fibres intermixed*, or else chiefly *elastic*, into *small, medium sized, and large arteries*; and the more properly so, because, concomitantly with the variations in the structure of the middle tunic, the external and internal coats present a different conformation, at all events, in many respects. A general characteristic of the arteries is presented in the circumstance, that the middle tunic is very strong, and consists of numerous, regularly disposed *laminae*, the elements of which observe a transverse direction. In the largest arteries the *t. media* is yellow, highly elastic, and of great thickness; towards the periphery of the body it gradually diminishes in thickness, and becomes redder and more contractile, until, just before the capillaries are reached, it appears quite thin and subsequently inapparent. The whitish *t. intima* is always much thinner, and varies in thickness within narrower limits, but this is also regulated by the size of the vessel; whilst on the contrary, the *t. adventitia* of the largest arteries is absolutely considerably thinner than in those of a medium calibre, in which it often equals the *t. media* in thickness, or may even exceed it. In a special exposition of these points, it is best to begin with the smallest arteries as the simplest in structure; with these the others may be afterwards readily compared.

*Arteries under  $\frac{1}{8}$  or 1''' in diameter*, with few exceptions, present, until close to the capillaries, the following structure (fig. 279). The *t. intima* consists of only two *laminae*, an *epithelium*, and a peculiar, glistening, less transparent membrane, which I shall term the *elastic internal tunic*. The former contains well marked, fusiform, pale cells with long-oval *nuclei*, which are readily separated in connexion, in entire fragments, or even in the form of perfect tubes; but may also be isolated, and then present no small resemblance, on the one hand, with the fusiform cells of pathologists (also with the formative cells of the elastic fibres and of connective tissue), and on the other with contractile fibre-cells; from the former, however, they are distinguished by the less attenuation of their extremities and their paleness; and from the latter by their rigidity, by the *nuclei* never

having the rod-like form and by their chemical reactions. The *elastic tunic* is, on the mean 0.001" thick, and in the living

Fig. 279.



subject is smoothly stretched beneath the epithelium, whilst in empty arteries it almost always presents a greater or less number of usually strong folds, and frequently also, numerous, fine transverse *rugæ*, which give it, although perfectly homogeneous, a peculiar longitudinally striated aspect; in addition, it appears almost always as a *fenestrated membrane*, as it is termed, with various sized, distinctly marked reticulated fibres, and usually minute elongated openings; more rarely as a true but very close network, of chiefly longitudinal elastic fibres, with narrow, elongated fissures,—and completely corresponds in aspect, in its great elasticity, and its chemical reactions with the elastic *lamellæ* of the *t. media* of the larger arteries. The *middle tunic* of the small arteries is purely muscular, without the slightest admixture of connective tissue and elastic elements, and is stronger or weaker according to the size of the vessel (down to

Fig. 279. An artery, *a*, 0.062", and vein, *b*, 0.067" in diam., from the mesentery of a child, treated with acetic acid,  $\times 350$  diam.: *a*, *tunica adventitia*, with elongated nuclei; *b*, nuclei of the contractile fibre-cells of the *t. media*, viewed in part on the flat surface, in part in apparent transverse section; *c*, nuclei of the epithelial cells; *d*, elastic longitudinal fibrous membrane.

0.03'''). In vessels of  $\frac{1}{10}$ '' in diameter, the fibre-cells, which are united into *lamellæ*, may be pretty readily isolated by dissection, and in still smaller ones by boiling and maceration in nitric acid of 20 per cent., when they appear as delicate fibre cells 0.02—0.03'' long, and 0.002—0.0025'' broad. The *t. adventitia* consists of connective tissue and fine elastic fibres, and is usually as thick as the *t. media* or even a little thicker.

The above description of the structure holds good of arteries down to  $\frac{1}{4}$ '' in size, but nearer the capillaries the structure changes more and more (fig. 280). Even in arteries  $\frac{1}{10}$ '' in diameter, the *t. adventitia* contains no elastic tissue, being composed only of connective tissue with elongated *nuclei*, which at first still retains its fibrous character, but afterwards, though always nucleated, appears more homogeneous, and ultimately represents a thin, truly structureless membrane, which, in vessels under 0.007'' disappears altogether.

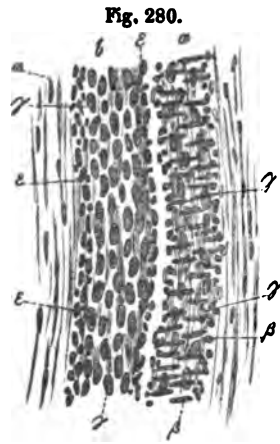


Fig. 280.

The *annular fibrous coat* in arteries less than  $\frac{1}{10}$ '' down to those having a diameter of  $\frac{1}{32}$ '' still presents 2—3 layers of muscles and a thickness of 0.005—0.008''; in smaller vessels it has but one layer, the elements of which at the same time become shorter and shorter; and finally, in vessels between 0.03—0.007'', appear only in the form of short, elongated or elliptical cells of 0.015—0.006'', with shorter *nuclei*. In vessels of 0.012'' in diameter, these more embryonic forms of contractile fibre-cells still constitute a connected lamina, but after that, they are gradually separated from each other (fig. 280) and become wholly lost.


The *t. intima*, in vessels more than 0.028—0.03'' in size, has an elastic inner membrane, which, however, in its earliest form, is very delicate, and does not appear to attain its full development in arteries less than 0.06—0.08'' in diameter. On the other hand, the epithelium may be traced in vessels of not more

Fig. 280. An artery, *a*, of 0.01'', and a vein, *b*, of 0.015'', from the mesentery of a child,  $\times 350$  diam., treated with acetic acid. The letters as in fig. 279: *e*, *t. media* of the vein, composed of nucleated connective tissue.

than 0.01''' or even of 0.007''' ; and it may at the same time be remarked, that its cells can no longer be isolated, and its presence only be recognised from the closely placed elliptical nuclei.

*Medium-sized arteries* above  $\frac{1}{3}$ ''' or 1''' , up to those of 2''' and 3''' in diameter, at first, present no great alterations in the external and internal tunics, whilst the *t. media* is not only always increased in thickness in proportion to the size of the vessel (from 0.05—0.12'''), but is also changed in structure. For now, in addition to muscular layers, the number of which constantly increases, but the elements of which are precisely

Fig. 281.



the same as before, we observe fine *elastic fibres*, which, united into wide-meshed networks, run, at first singly and with little regularity among the muscular elements; but in larger vessels of this category are accompanied by a certain amount of connective tissue, and here and there exhibit a disposition to form special layers alternating with the muscular, though not presenting the characters of a continuous network throughout the *t. media*. Thus, although the *t. media* is deprived of its eminently contractile structure, it must be allowed that the muscular fibres here also still retain a considerable preponderance. The *t. intima* in the medium-sized arteries has, not unfrequently, between the elastic inner membrane and the *epithelium*, several other layers, among which the above-described striped *lamellæ* are the most remarkable. These *lamellæ*, composed of fine elastic networks, wider towards the exterior, and lying in a homogeneous, granular or fibrillated connective substance, constitute the middle *lamina* of the *t. intima*, the elements of which also all run longitudinally, and are for that reason readily distinguishable from the muscular layers of the *t. media*, to which in some respects they bear a resemblance. The *t. adventitia*, lastly, in almost all these arteries exceeds the

Fig. 281. Transverse section of the *art. profunda femoris* of Man,  $\times 30$  diam.: a, *t. intima*, with the elastic layer (the *epithelium* is not perceptible); b, *t. media*, without elastic *lamellæ*, but with fine elastic fibres; c, *t. adventitia*, with elastic networks and connective tissue.

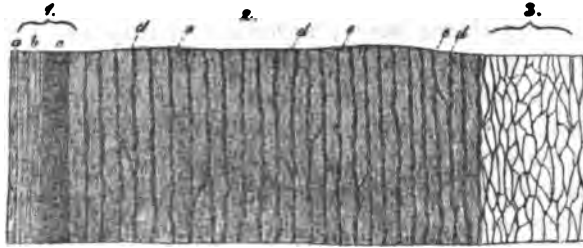


*t. media* in thickness, attaining 0.05—0.16". Its elastic fibres at the same time become stronger and stronger, and even in vessels 1" in diameter, a considerable aggregation of them, where it adjoins the *t. media* may be perceived; the line of demarcation between the two tunics, being in all these arteries extremely well defined. This elastic membrane of the *t. adventitia* is extremely well marked in the largest of the vessels belonging to the class now under consideration, as in the external and internal carotids, the crural, brachial, *profunda femoris*, mesenteric, and celiac, in which it measures from 0.013" to as much as 0.04", and more, and is to some extent very distinctly laminated, the structure of the *lamellæ* very often closely approaching that of the true elastic membranes. Besides this, the external layers of the *t. adventitia* also contain elastic networks, only that the elements of the latter are somewhat finer and constitute minute *lamellæ*, but are conjoined with less regularity. *The largest of the medium-sized arteries* exhibit an approach to the largest arteries, inasmuch as, in their *t. media* certain portions of the elastic networks constitute somewhat stronger elastic *lamellæ*, which, however, are continuous through the entire thickness of the tunic, and also, more rarely, form true elastic membranes, by which they are distinguished from the elastic plates of the annular fibrous coat of the largest arteries, yet to be described. *Lamellæ* of the former character are found in the inner layers of the *t. media* of the *aa. cruralis, mesenterica superior, celiaca, iliaca externa, brachialis*, and in the external and internal carotids; whilst they occur in a remarkable manner in the commencement of the *tibialis antica* and *postica*, and in the popliteal artery throughout the entire middle tunic; they are particularly well developed in the last-named vessel, which has also usually somewhat thicker walls than the crural.

From the conditions of the *t. media* above stated, and in other respects also, the transition from the medium-sized to the largest arteries is rendered extremely gradual. With respect to the *t. intima*, its epithelial cells in the latter are usually no longer so much elongated as in the smaller vessels, though still retaining their fusiform figure and a length of 0.006—0.01". The rest of this tissue does not necessarily increase in amount with the size of the vessel, although it

exhibits, especially in the *aorta*, a great proneness to become thickened, so that it is often difficult to determine its normal

Fig. 282.



thickness. As regards its structure, it consists chiefly of *lamellæ* of a clear, sometimes homogeneous, sometimes striated, or even distinctly fibrillated substance, presenting, for the most part the characters of connective tissue (Eulenberg obtained some *gelatin* from the *t. intima*), and is pervaded by finer and coarser longitudinal elastic networks. Usually these networks become more and more close from within to without, and their elements stronger, and on the side towards the *t. media* the inner membrane ceases, either with an elastic close network or a true fenestrated more or less fibrous membrane, obviously corresponding with the elastic inner membrane of the small arteries. Immediately beneath the *epithelium* the elastic networks are either very fine, or are replaced by one or several clear layers—the *striped lamellæ*,—which, when nucleated, often appear to consist of coalesced epithelial cells; and when homogeneous and without *nuclei*, to approach elastic membranes. In the *annular fibrous layer*, the largest arteries present, as a new element, peculiar *elastic membranes or plates*, which, except in the transverse disposition of their fibres, are constituted in all essential respects in the same way as the elastic inner membrane, particularly of the smaller arteries, and sometimes appear as very thick networks of strong elastic fibres, sometimes as true fenestrated membranes with a less evident fibrous structure. These

Fig. 282. Transverse section of the *aorta* below the superior mesenteric artery. 1, *t. intima*; 2, *t. media*; 3, *t. adventitia*; a, epithelium; b, striped lamellæ; c, elastic membrane of the *intima*; d, elastic lamellæ of the *t. media*; e, its muscles and connective tissue; f, elastic networks of the *t. adventitia*. From Man,  $\times 30$  diam., treated with acetic acid.

membranes 0.001—0.0012" thick, and the number of which may amount to from 50 to 60, regularly alternate, at distances of 0.003—0.008", with transverse layers of smooth muscle, which are pervaded by connective tissue and networks of medium-sized elastic fibres; nevertheless, they are not to be regarded merely as tubes inserted regularly one within the other and having the interspaces occupied by muscles; for, in the first place, they are connected with each other and with the finer elastic network pervading the muscular tissue, sometimes more frequently, sometimes more sparingly; and, in the second place, they are not unfrequently interrupted in spots, or replaced by common elastic networks. The plates are seen most

Fig. 283.



distinctly and most regularly disposed in the abdominal *aorta*, the *a. innominata*, the common carotid and the smallest of their immediate branches, although these conditions vary considerably in different individuals, so that in the want of very extended researches no general statement with respect to them can be propounded.

Another characteristic of the *t. media* is the slight development of its muscular element. Contractile fibre-cells, it is true, may be found also in the largest arteries throughout all the layers of the middle tunic; but, in the first place, compared with its other elements, the elastic plates, the connective tissue, and the finer elastic networks, they constitute only a very inconsiderable part of that membrane ( $\frac{1}{3}$ — $\frac{1}{4}$ ); and, secondly, are so undeveloped in their elements, that it appears very doubtful whether they possess any notable contractile power. For in the *aorta* and the trunk of the pulmonary artery, the fibre-cells in the inner layers of the *t. media* are often not longer than 0.01", and 0.004—0.006" broad, and quite flat, so that they are not unlike certain epithelial cells; at the same time their figure is irregular, rectangular, fusiform or clavate, though they still contain the well known, rod-like *nuclei*. In the outer layers the fibre-cells are more slender and more elongated, up to 0.02", and at the same time more like the

Fig. 283. Muscular fibre-cells from the innermost layer of the axillary artery in Man,  $\times 350$  diam.: *a*, without; *b*, with, acetic acid; *a*, *nucleus* of the fibres.

well-marked muscular fibre-cells of other organs, though even there retaining somewhat of a rigid and peculiar aspect. In the carotids, subclavian, axillary and iliac arteries, the contractile elements have become more developed, whence also the *t. media* of those arteries does not present the pure yellow colour of that of the largest vessels, but begins to assume a reddish tinge. The *t. adventitia* of the largest arteries is, relatively and absolutely, thinner than in the smaller, amounting to 0·04—0·02". Its structure, upon the whole, is the same as in other vessels, although the elastic inner layer is less developed, and also very indistinctly defined from the thick elastic elements of the *t. media*.

[The *t. intima* of certain arteries also contains *smooth muscles*, as I have found in the axillary and popliteal arteries in Man, and as has been lately demonstrated, particularly in the visceral arteries of the Mammalia. In the largest arteries in Man this tunic is very frequently thickened, in which condition a vast increase of the striped lamellæ in particular takes place. In the *t. media* of no artery is the muscular element wholly wanting, and Henle erroneously adduces the arteries of the *retina* in opposition to this, for it occurs in those arteries even in branches of 0·03", and is not absent in any above 0·02". In Animals the *t. adventitia* of the large arteries contains muscles, but not in Man.]

#### § 216.

*Veins*.—The *veins* also admit of being divided into three groups, *small*, *medium-sized*, and *large*, which, however, are not so abruptly defined as is the case with the arteries. The veins, without exception, have thinner walls than the arteries, which depends just as much upon their containing a less considerable quantity of contractile, as upon a more sparing development of the elastic elements; whence also the venous walls collapse more readily, and are less contractile. The *t. intima*, in the larger veins is frequently not thicker than it is in those of medium size; it is less developed than in the arteries, but in other respects, of the same structure. The *t. media*, which is never yellow, but usually greyish-red, contains far more connective tissue, fewer elastic fibres and muscles, and, what chiefly characterises it, always presents together with the *transverse*, *longitudinal*

*layers* also. It is in general thin, but absolutely stronger in the medium-sized veins than in the larger, and in these also the muscular element is most vigorously developed. The *t. adventitia*, lastly, is usually the thickest of the three coats, its relative and absolute thickness usually increasing with the size of the vessels. In constitution it precisely resembles that of the arteries, except that in many veins, especially of the *abdomen*, longitudinal muscles, occasionally very well developed, appear in it, and give the entire venous wall a peculiar character.

The smallest veins (fig. 280 *b*,) may be said to consist solely of a nucleated, indistinctly fibrous, or homogeneous *connective tissue* and an *epithelium*. The elements of the latter are elliptical or round, with oval or even rounded *nuclei*, whilst the former constitutes a proportionately strong *t. adventitia* and besides that, a thinner layer, which supplies the place of the *t. media* (fig. 280 *ε*), both having a longitudinal, fibrous arrangement. Below the size of 0.01''' the veins gradually lose the external connective tissue and the *epithelium*, the *t. media* appearing to pass into the structureless wall of the capillaries. A *muscular membrane*, and in general, a layer of annular fibres are first seen in veins more than 0.02''' in size, in the form, at first, of widely separated, transversely oval cells, with short-oval, sometimes even almost rounded, transverse *nuclei*. By degrees these cells become more elongated, and more numerous, and ultimately, in vessels of 0.06—0.08''' constitute a continuous layer (fig. 279 *β*), but which is always less developed than the corresponding arterial tissue. This continues to be the structure of veins up to the size of 0.1''; when elastic networks, at first fine, begin gradually to make their appearance externally to the *epithelium* in the *t.t. musculo-* and *adventitia*, whilst at the same time the muscular layers multiply, and even admit connective tissue and fine elastic fibres among their elements.

*Veins of the medium diameter* of 1—3—4'', such as the cutaneous veins, and deeper veins of the extremities up to the *brachial* and *popliteal*, the veins of the head and *viscera*, except the main trunks, are characterised (particularly those of the lower extremity), by the not inconsiderable development of their annular fibrous membrane, which, as in the arteries, is of a yellowish red

colour, and striped transversely. But even where thickest, it is far from equalling that of the corresponding arterial vessels; and in thickness never exceeds 0·06''' to 0·07''' . It consists not only of *transverse* but also of *longitudinal* layers, and in this respect likewise differs from that of the arteries. The *transverse* layers are composed of common, undulating *connective tissue*, with fine, loosely arranged, or rather isolated *elastic fibres* (nucleated fibres, as they are termed), and of a large quantity of *smooth muscles*, the fusiform elements of which, 0·02—0·04''' long, and 0·004—0·007''' broad, present the usual characters of contractile fibre-cells, whilst the longitudinal laminæ consist of true, thick, and very thick, reticulated *elastic fibres*. With respect to the mutual relations as *laminæ* of these tissues, it should be remarked that in certain veins (popliteal, *profunda femoris*, *saphena major* and *minor*), the *t. intima* is succeeded by a layer, formed solely of connective tissue and finer elastic networks, and having a longitudinal fibrillation—the *longitudinal lamina* of the *t. media*—whilst in other veins the muscular elements extend also into the innermost *lamina*. In this case, immediately external to the *t. intima*, there is a *transverse layer* of muscles, with connective tissue and elastic fibrils,

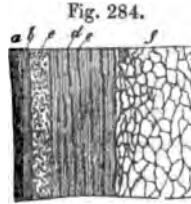


Fig. 285.

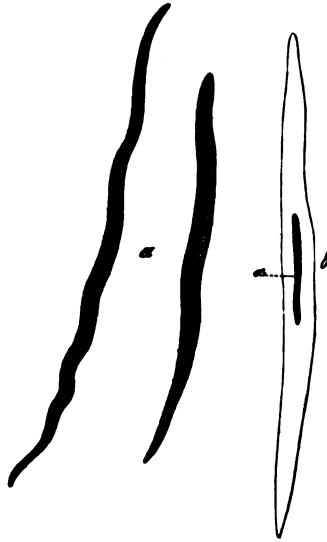


Fig. 284. Transverse section of the *vena saphena magna*, at the *malleolus*,  $\times 30$  diam.: *a*, striped *lamella* and *epithelium* of the *t. intima*; *b*, its elastic membrane; *c*, longitudinal, internal connective-tissue layer of the *t. media*, with elastic fibres; *d*, transverse muscles, and *e*, longitudinal elastic networks, disposed in a laminated manner; *f*, *t. adventitia*.

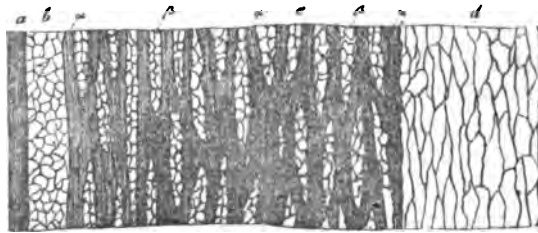
Fig. 285. Muscular fibre-cells from the renal vein of Man: *a*, without; *b*, with acetic acid;  $\alpha$ , nucleus of the latter;  $\times 350$  diam.

which three tissues, in these veins, always accompany each other; to this succeeds a regular alternation of longitudinal, elastic, reticulated membranes, always in a single layer, and transverse muscles with connective tissue, so that the *t. media* of these veins presents a laminated aspect, somewhat resembling that of the largest arteries. It should, however, be remarked, that the elastic, reticulated membranes, although frequently very closely interwoven, nevertheless never form homogeneous, elastic membranes; moreover, that they are occasionally interrupted, and, as longitudinal sections manifestly show, are invariably continuous with one another through the whole *t. media*. The number of these elastic *lamellæ* fluctuates between five and ten, and their interspaces vary in width from 0.004—0.01". The *t. intima* of the medium-sized veins is 0.01—0.04" thick, and consists, where it is thinner, only of an *epithelium* with shorter, though elongated cells, a *striated, nucleated lamella*, and an *elastic longitudinal membrane*, corresponding to the elastic inner membrane of the arteries, but which scarcely ever appears as a truly homogeneous, fenestrated membrane, but most usually as an extremely close, areolated network of finer and coarser elastic fibrils. Where the *t. intima* is thicker, the striated *lamellæ* are multiplied, and, above all, one or even several additional networks of elastic, fine fibres make their appearance on the inner aspect of the above-described elastic membrane, which forms the liminary portion of the *t. intima*. I have also seen smooth muscles in the *t. intima*, in the veins in the gravid *uterus*, as well as in the *saphena major* and popliteal vein; and Remak has confirmed their existence in the visceral veins of certain Mammalia. The *t. adventitia* of these veins, is almost invariably thicker than the *t. media*, often twice as thick, rarely of equal strength. Usually it contains only longitudinal, much interwoven, often very well marked elastic networks with thick fibres, and common connective tissue, but in the case of those visceral veins, the trunks of which have longitudinal muscles in the *t. adventitia*, similar muscular elements also extend for a certain distance into the branches (*vid. seq.*).

The *largest veins* are distinguished from those of the medium diameter chiefly by the sparing development of the *t. media*, and especially of its muscular elements; a deficiency, however, it is true, often counterbalanced by the presence of contractile elements

in the *t. adventitia*. The thickness of the *t. intima* is usually 0·01''', when it presents the same conditions as in the medium-sized veins. More rarely, as occasionally in the *vena cava inferior*, in the trunks of the hepatic veins, and in the *vena innominata*, it amounts to 0·02''' and 0·03'''', which increase of thickness is due to striped *lamellæ* with *nuclei*, and fine, elastic, longitudinal networks, never to those composed of muscles. The *t. media*, on the average, presents a thickness of 0·02—0·04''', but may occasionally, as at the commencement of the trunk of the *vena portæ*, in the uppermost part of the abdominal portion of the *v. cava inferior*, and at the orifices of the *hepatic veins*, measure 0·05—0·12''', or be *wholly wanting*, as in the greater part of the *v. cava inferior* in the liver, and in the further course of the largest hepatic veins. Its structure, in all essential particulars, is the same as in the previous class of vessels, except that the longitudinal elastic networks are intricately connected together, and less distinctly, or not at all, laminated; the transverse muscles, also, are scanty and indistinct, even where the *t. media* possesses the considerable thickness above stated, and are more abundantly intermixed with bundles of connective tissue. I have noticed the muscles to be most developed in the splenic vein and *v. portæ*; they appeared to me to be *wholly wanting* in the abdominal portion of the inferior *vena cava*

Fig. 286.



below the liver, in certain spots, and also in the subclavian vein, and in the terminal portions of the superior and inferior

Fig. 286. Longitudinal section of the inferior *vena cava*, in the liver,  $\times 30$  diam.: *a*, *t. intima*; *b*, *t. media*, without muscles, containing only connective tissue and elastic fibres; *c*, inner layer of the *t. adventitia*; *a*, its longitudinal muscles;  *$\beta$* , transverse connective tissue of the same layer; *d*, external portion of the *t. adventitia*, without muscles.



*vena cavae*. The *t. adventitia* of the largest veins, is almost invariably nearly twice as thick as the middle tunic, or even as much as five times as thick, and exhibits, in its structure, the important difference, at least in certain veins, as Remak correctly states, that it contains a considerable quantity of longitudinal muscles. These are very distinct, as was pointed out by Bernard ('Gaz. Med. de Paris,' 1849, 17, 331), in the hepatic portion of the inferior *vena cava*, where their fasciculi, 0.02—0.04'' thick, constitute a network pervading the inner half or two inner thirds of the external membrane, which, where the *t. media* is absent, rests immediately upon the *t. intima*, and may attain a thickness of as much as 0.22''. Besides this, I have found, as Remak has also done, these contractile, longitudinal bundles, (which never contain connective tissue, though probably a certain number of elastic fibres,) still very well developed, in the trunks of the hepatic veins, in that of the *vena porta*, and in the remaining portion of the inferior *vena cava*, and have traced them as far as the splenic, superior mesenteric, external iliac and renal veins. Some were also to be found in the *vena azygos*, whilst they were altogether absent in the superior veins. These muscles extended through the entire thickness of the *t. adventitia*, only in the renal vein and *vena porta*, whilst in the other veins above enumerated, a greater or less portion of it, contained no muscular element, and consisted as usual, of longitudinal connective tissue, and elastic networks composed of strong fibres. The muscular layer of the *t. adventitia* therefore appears to be a special membrane of the vessels, and occasion would be afforded to confound it with the undeveloped, or, as has been stated, even absent *t. media*; an error, however, which might be readily avoided by tracing the conditions of the smaller veins. The muscular layer of the *t. adventitia*, besides the contractile elements, having a length of 0.02—0.04'', which present the common character, and numerous elastic longitudinal networks, invariably contains a certain amount of connective tissue, which, as it seems, is always arranged *transversely*, so that the transverse elements, even in these large veins, are compensated for, though not exactly, by muscle. All the large veins, which open into the heart, are furnished, for a short distance, with an external annular layer of muscles similar to those of the heart itself,

and which also present anastomoses of the primitive *fasciculi*. According to Räschel, these muscles, in the region of the superior *vena cava*, extend as far as to the subclavian vein, and may be found also in the main branches of the pulmonary veins; and even, according to Schrant, in the former case, more in the interior of the wall of the vessels, and disposed longitudinally.

The veins in which the *muscular element* is *excessively developed* demand special notice, and also those in which that element is *wholly wanting*. To the former class belong the veins of the gravid *uterus*, in which besides the *t. media*, the *tt. intima* and *adventitia* also present muscular layers, longitudinal in the two latter, the elements of which in the 5th and 6th month exhibit the same colossal development as those of the *uterus* itself. The muscular element is wanting: 1. in the *veins of the maternal portion of the placenta*, in whose walls, externally to the *epithelium*, large cells and fibres, which I regard as undeveloped connective-tissue, occur. 2. in most of the *veins of the cerebral substance, and of the pia mater*. These veins consist of a roundish *epithelium* in a single layer, a thin longitudinal connective-tissue layer, with solitary elongated *nuclei*, which supplies the place of the *t. media*, and in the smaller vessels of a more homogeneous, and in the larger, of a fibrillated and nucleated *t. adventitia*. It is but rarely that a faint indication of muscles in the *t. media* is seen in the largest of these veins, as shown in fig. 279. 3. in the sinuses of the *dura mater* and the *veins of Breschet in the bones*, which are furnished with a layer of connective tissue, occasionally containing fine elastic fibres, external to a tessellated *epithelium*, and which layer is continuous with that of the *dura mater* and of the internal *periosteum*. 4. in the *venous sinuses of the corpora cavernosa* (*vid. sup.*), and of the spleen of certain Mammalia, (*vid. § 169*). 5. in the *veins of the retina*.

The *valves of the veins* consist chiefly of distinct connective tissue, which, at their free border, runs transversely, containing numerous elongated *nuclei*, and also isolated, undulating, usually fine, in part strong, elastic fibres. Their surface is covered either with nothing but an *epithelium*, with short cells, or in addition, there is beneath it, a very fine elastic network, the prevailing direction of which is longitudinal. The valves

may, therefore, be regarded as continuations of the middle and internal tunics, although muscular fibres, so far as I have seen, are wanting in them (Wahlgren states that he has found such fibres in the larger valves).

#### § 217.

*Capillaries (vasa capillaria).*—With the solitary exception of the *corpora cavernosa* of the sexual organs, and of the uterine *placenta*, the arteries and veins, in Man, are universally connected by the intervention of a rich plexus of microscopically fine vessels, which, on account of their slender dimensions, have been designated under the above name. They are everywhere composed of a single, structureless membrane, with cell-nuclei, and are thus very essentially distinguished from the larger vessels, although the transition from the one to the other is wholly imperceptible; so that at a certain point in the course of the vessels it is quite impossible to detect the characters of either of the classes into which Histology has been accustomed to divide them. Vessels of this kind may be best described as *venous* and *arterial transitional* vessels, according as they lie on the one side or the other, and without any further alteration of the common classification, may be referred to the capillaries.

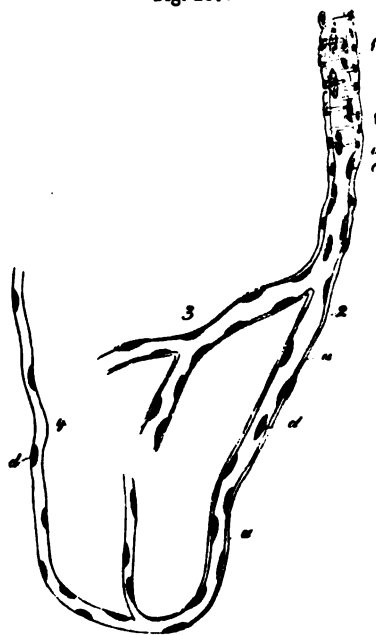
The *true capillaries*, when more closely examined, exhibit the following conditions. Their structureless membrane is perfectly clear and transparent, sometimes delicate and presenting a simple contour, sometimes thicker (0.0008—0.001<sup>m</sup>), and bordered by a double line. In its microscopical reactions, it corresponds entirely with older cell-membranes and the *sarcolemma* of the transversely striped muscles (*vid.* § 85), and as regards its other properties, it is perfectly smooth on both aspects and, notwithstanding its tenuity, tolerably resistant and elastic, although very probably not contractile. It invariably presents a certain number of elongated cell-nuclei, 0.003—0.004<sup>m</sup> in size, which are disposed with wide interspaces, usually alternately on opposite sides of the vessel, sometimes more approximated, or in close contiguity, though rarely in actual contact; and, when the capillary tunic is thin, are situated on its inner side, when thicker, within its substance, in such a way, however, as not unfrequently to

cause projections of it on the outer surface. The diameter of the capillaries, in Man, varies from  $0.002''$  to  $0.006''$ ; and, for the sake of description, they may be again subdivided into *finer*, of  $0.002$ — $0.003''$ , with few *nuclei* and thinner walls; and *coarser*, of  $0.004$ — $0.006''$ , with a thicker membrane and numerous *nuclei*; although in so doing it is not intended to draw any distinct limitation between them.

The capillaries, by their union, constitute the *capillary plexuses*, *retia capillaria*, which have already been described in

Fig. 287.

detail, in speaking of the individual organs and tissues, and, consequently, here, will be referred to only in brief and general terms. The forms presented in these plexuses, which, notwithstanding considerable diversities, are constant in the different organs, and according to their similarity or diversity, more or less characteristic, depend to some extent upon the disposition of the elementary parts, and are also in some degree dependent upon the energy of the functions. With respect to the former, there are in many organs certain tissues, into which vessels



never penetrate,—as the transversely striped muscular fibres, the bundles of connective tissue, nerve-fibres, cells of all kinds, gland-vesicles, and which, therefore, according to their form, trace out definite courses for the capillaries, so that

Fig. 287. Finest vessels on the arterial side of the capillaries. 1. an artery of the smallest size; 2, transitional vessel; 3, coarser capillary; 4, finer capillary: *a*, structureless coat, with a few nuclei, representing the *t. adventitia*; *b*, nuclei of the muscular fibre-cells; *c*, nuclei within the minute artery, probably still belonging to an *epithelium*; *d*, nuclei of the capillaries and transitional vessels. From the human brain,  $\times 300$  diam.

they sometimes present elongated meshes, sometimes rounded, narrower or wider reticulations. The physiological energy is still more influential, and it is a general rule, that the greater the activity of an organ, whether as regards contractions or sensations, excretion or absorption, so much the closer is the capillary network, and so much the more abundant the supply of blood. The capillary plexuses are closest in the secretory and absorbent organs, as in the glands, above all in the lungs, liver, and kidneys; next in the integuments and mucous membranes; much wider in the organs which receive blood only for the purpose of their own nutrition, as the muscles, nerves, organs of sense, serous membranes, tendons, and bones; although among these organs differences exist, as, for instance, the muscles, and the grey nerve-substance, are more abundantly supplied than the other parts above enumerated. The diameter of the capillaries themselves is almost directly in an inverse relation, and they have the thinnest walls and are smallest (0.002—0.003<sup>'''</sup>) in the nerves, muscles, *retina*, and Peyerian patches; in the external integument and mucous membranes they attain the size of 0.003—0.005<sup>'''</sup>, in the glands and bones, lastly, one of 0.004—0.006<sup>'''</sup>, and in the compact substance of the latter, although no longer having, in all respects, the structure of capillaries, even the diameter of 0.008—0.01<sup>'''</sup>. Physiology is not as yet in a condition to explain these differences in all particulars, inasmuch as information is wanting with respect to the laws of diffusion in the various capillary membranes; and also because the more minute conditions of the sanguineous circulation, in the separate organs, are wholly unknown.

The mode in which the capillaries pass into the larger vessels is difficult of investigation. On the arterial side it is found, that the capillaries, as they become wider, present more closely placed *nuclei*, and are then invested externally with a structureless *t. adventitia*, and solitary muscle-cells, whence, when they have reached the diameter of 0.007<sup>'''</sup>, they already exhibit the aspect of the finest arteries (fig. 287, <sup>1</sup>). Afterwards, the *nuclei* seem to be replaced by *epithelium* cells, whilst the capillary membrane either ceases or is continuous with the elastic inner membrane. The venous transitional vessels are less characteristic for a greater length. The first thing

that is superadded, on this side, to the capillary membrane, is an external, homogeneous, nucleated layer, which may be regarded as a sort of connective tissue, and whilst the *nuclei* of the capillary vessels become more closely approximated, gradually coalesces with their membranes. In vessels of  $0.01''$ , the internal *nuclei* have become so numerous, as clearly to represent the *epithelium*, and as at this time also, the external layer has likewise received the addition of a nucleated *lamina*—the *t. adventitia*—the now distinctly *laminated* vessel (fig. 280) may be termed a *vein*. It would consequently appear that the capillaries are transformed into the larger vessels by the addition of layers on the exterior and interior, whilst their proper membrane coalesces with these layers, and is probably continuous with the fibrous layer of the *t. intima*.

[Besides the finest capillaries, which, however, always admit of the passage of the very flexible blood-corpuscles, the older anatomists have admitted the existence of still finer vessels—the so-termed *vasa serosa*—which no longer allow of the passage of blood, but only of its plasma,—a notion which has been abandoned by most modern authors. Hyrtl alone thinks, that it is necessary to admit of the existence of vessels of this kind in the *cornea*, because the vessels at its border escape the sight without passing into veins, and are too small (in Man, when injected,  $0.0009''$ ) to be capable of conveying blood-corpuscles. He thinks, that still further on they are continued into *vasa serosa*, and probably are connected with the, as yet undemonstrated, lymphatics. In opposition to this, Brücke and Gerlach remark, that the corneal vessels terminate in true loops, and that it would thence appear that Hyrtl's statements are based upon incomplete injections. I am able, however, to state that something corresponding with the *vasa serosa* of authors does actually exist in the *cornea*, having noticed that, in the Dog, fine and the finest filaments are continued still further inwards, from the terminal loops pervious to the blood-corpuscles, which occur in that animal, as in all others, at the margin of the *cornea*; which filamentary prolongations were connected in a reticular manner, and were usually slightly dilated at the points of junction. Whether these filaments were hollow, and had any contents, and directly

communicated with the canals of the true capillaries, could not be determined, and I should not, therefore, at present definitively declare them to be pervious parts of the vascular system; whilst I have not the least hesitation, nevertheless, in referring them to that system, for although they may have no canal, they scarcely admit of any other possible interpretation, than as being derived from the vascular plexus, which covers almost the entire *cornea* in the child at birth, and as being obliterated capillaries. Should these corneal elements not turn out to be *vasa serosa*, I am acquainted, in the adult, with no situation in which such vessels exist, whilst vessels conveying *plasma* are everywhere present during the development of the capillaries, as a preliminary phenomenon (*vid. infra*), and it is therefore intelligible that, even at a subsequent period, scattered vessels of the kind should occasionally be met with, as in the brain of the Calf, according to Henle; or may perhaps exist in great quantity, just as in the distribution of the nerves, the terminations often retain the embryonic character.]

### 3.—OF THE LYMPHATICS.

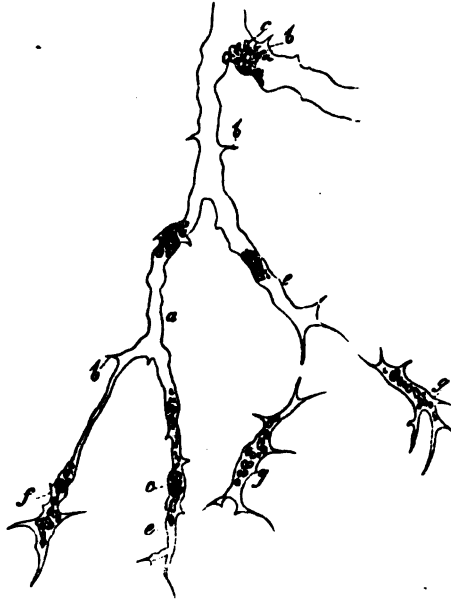#### § 218.

The *lymphatics*, except in their contents, correspond so closely with the veins, that a short exposition of their structure will suffice.

The *capillary lymphatics*, which, in the three situations in which they have hitherto been seen with certainty—in the small intestine, the tail of the Tadpole, and the mucous membrane of the *trachea*—commence partly with free prolongations, in part in networks. I have, in a single instance in the tracheal mucous membrane in Man, had an opportunity of investigation, and they were found to consist of a delicate structureless wall, without distinct *nuclei* after the addition of soda, and having a diameter of 0·003—0·005—0·01''' (fig. 235). The same structure is presented in the simple lacteals of the intestinal *villi* in Mammalia, except that these measure 0·012—0·026''' , and have a somewhat thicker wall. The lymphatics discovered by me in the tail of the Tadpole (fig. 288), on the contrary, correspond entirely

with the blood-capillaries, in the occurrence of *nuclei* on the inner side of the very delicate, structureless membrane, whilst

Fig. 288.



they differ from them in being furnished with short, jagged processes with prolongations. The diameter of the lymphatic capillaries in this situation is 0.002—0.015 $\mu$ , and the two main trunks of the tail, like those of the blood-vascular system itself, have a perfect capillary structure.

In what way these capillary lymphatics are changed into the larger lymphatic canals has not been seen by any one, or at all events has not been investigated. The finest vessels, which have elsewhere come under my observation, had a diameter of  $\frac{1}{10}$ — $\frac{1}{7}$ — $\frac{1}{8}$  $\mu$ , and these, except in the thickness of the individual layers, corresponded in all respects with the larger vessels of 1—1 $\frac{1}{4}$  $\mu$ . The latter, the *medium-sized lymphatics*, present three


Fig. 288. Capillary lymphatic from the tail of the Tadpole,  $\times 350$  diam.: *a*, membrane; *b*, processes formed by it; *c*, remains of the contents of the cells forming these vessels, in which *nuclei* are concealed; *e*, caecal terminations of the vessels; *f* one of these terminations, still pretty distinctly recognisable as a formative cell; *g*, isolated formative cells about to join with the actual vessels.



tunics. The *t. intima* consists of an epithelium, of elongated, although rather short cells, and of a single, rarely double *elastic reticulated membrane*, longitudinally fibrillated, which, as regards the thickness of its fibres, and the narrowness of the meshes, exhibits manifold diversities; but it never has thick fibres, nor does it ever constitute a true elastic membrane (according to Weyrich, this membrane is wanting in the lymphatics of the mesentery, whilst I have always found it in those of the lumbar plexus, and in those of the extremities). This is succeeded by a stronger, *t. media*, composed of *transverse smooth muscles*, with fine, also transverse *elastic fibres*; and lastly, there is a *t. adventitia*, with *longitudinal smooth-muscular fasciculi*. The latter I have found, in the extremities, upon vessels of not more than  $\frac{1}{10}$ ''', and I consider them a good distinctive character between lymphatics and small veins (*vid.* Mikrosk. Anat., II, p. 236).

The *thoracic duct* differs in some respects from the smaller lymphatics. The similarly constituted *epithelium* is succeeded

Fig. 289.



by some *striped lamellae*, and these by an *elastic reticular membrane*, longitudinally fibrillated, although the entire *t. intima* scarcely measures 0.006—0.01'''. The *t. media*, 0.025''' thick, commences with an extremely thin layer of longitudinal connective tissue, with fine elastic fibres, and consists, besides, of a transverse muscular layer, with fine elastic fibres. The *t. adventitia*, lastly, contains longitudinal connective tissue, together with elastic fibrils, and a few reticularly connected bundles of longitudinal muscles. The *valves* of this duct, and of the lymphatics in general, correspond completely with those of the veins.

The *blood-vessels* of the lymphatics present the same conditions in the thoracic duct as in the veins. No *nerves* have been found in them.

### § 219.

*Lymphatic glands.*—These glands (*glandulae lymphaticae*) differ very considerably from the rest of the blood-vascular

Fig. 289. Transverse section of the thoracic duct in Man,  $\times 30$  diam.: *a*, epithelium, striped lamellae, and elastic inner membrane; *b*, longitudinal connective tissue of the *t. media*; *c*, transverse muscles of the same tunic; *d*, *t. adventitia*, with *e*, the longitudinal muscles.

glands with which they are usually classed, and approach nearest to the Peyerian patches of the intestine, although they do not wholly correspond with them. Every normal lymphatic gland, within a thin but tough *sheath*, composed of nucleated connective tissue and fine elastic fibrils, presents a soft, whitish-red *parenchyma*, in which three elements, viz. a *fibrous tissue*, a soft, pultaceous *pulp*, and *blood-vessels*, are manifest. The *fibrous tissue*, formed partly of fibrous, and in part of more homogeneous connective tissue, with scattered fine elastic fibres, when the gland is well developed, as is not always the case in Man, but almost invariably in the Cat, Dog, Rabbit, Rat, &c., presents a large number of thin (0.004—0.005''' and more) *lamellæ* arising from the sheath, which are so regularly connected together as to constitute an elegant areolated structure pervading the entire gland, all of whose roundish spaces,  $\frac{1}{8}$ — $\frac{1}{3}$ ''' wide, openly communicate, it is true, with each other, but much less freely than is the case with the cells of the *corpora cavernosa*, for instance. Now, since all these spaces are occupied by the greyish-white pulp, the entire gland exhibits externally, and, in some degree, also in a transverse section, a coarsely granular, vesicular aspect, which was known even to the older anatomists, almost like that of the Peyerian patches, since there may be distinguished in it a great number of clear round bodies, like follicles, surrounded by narrow, somewhat darker borders. But upon proceeding to isolate these bodies we shall fail in the attempt, and the *septa* by which they are parted will be found to be always common to several, something like the walls of the *alveoli* in the adult lung. Consequently, notwithstanding the similarity in outward appearance, and as we shall find, in contents also, there is a very essential difference between the follicles of the Peyerian patches, as well as of the spleen, and of the tonsils, and the alveolar spaces in the lymphatic glands, on which account I shall describe the latter as "*alveoli*."

The greyish-white alkaline *pulp* which fills the spaces in question, agrees in nearly all respects with that contained in the Peyerian follicles, and consists of a certain proportion of *fluid*, and of very many morphological elements. The latter are, in part free *nuclei*, of 0.002—0.003''' , usually without distinct *nucleoli*, with homogeneous contents, which are never-

theless rendered turbid by water; in part true, pale, uninuclear, round *cells*, most of which measure from 0.003—0.004<sup>'''</sup>, with *nuclei* similar to those found in the free condition, a certain number of larger size (0.005—0.007<sup>'''</sup>), with larger, often distinctly vesicular *nuclei* and *nucleoli*, and occasionally a few fat-granules. These morphological elements also, to some extent, correspond entirely with the cells of the lymph and chyle; a circumstance in itself of no great significance, since no specific character can be assigned to either of them. The similarity of the contents of the *alveoli* of the lymphatic glands, with those of the follicles of the Peyerian patches, is still further increased by the circumstance, that they are also penetrated by a fine vascular network, as I at least have observed, and have already stated in another place (*Mikr. Anat.*, II, 2, p. 192). For the numerous blood-vessels of the lymphatic glands, which frequently penetrate into the interior at a depressed *hilus*-like spot, are not distributed merely in the *septa* of connective tissue, as has hitherto been generally asserted, but, as I have seen in Man, also *enter the pulp filling the alveoli*, where they run freely among the elements, and form a very fine capillary plexus, bearing the closest resemblance to that of the Peyerian follicles, except that in general it is rather wider, and frequently also varicose.

The most difficult part of the anatomy of these glands is the ascertaining of their connexion with the lymphatic vessels. After the majority of the most recent authors had agreed in the assumption, that the *vasa inferentia* and *efferentia* were connected by numerous anastomoses of convoluted and looped vessels, the proper parenchyma of the glands being thus frequently left in the background or altogether forgotten, the number of those has latterly been much increased, who advocate the view originally propounded by Malpighi, viz. that the lymphatic glands consist of an aggregation of anastomosing cells, into which the *vasa afferentia* open, and from which the *vasa efferentia* proceed; and, in particular, Ludwig and Noll have declared themselves most decidedly in favour of this view. As for myself, it will be apparent from the preceding account, that I am one of those who admit of the existence of a special glandular element in the lymphatic glands, and I consequently deny, in the most explicit terms, that they are composed merely

of a plexus of lymphatic vessels. As regards the relation of the lymphatics to the glandular part or *alveoli*, together with their contents, I formerly felt compelled to express myself in opposition to the notion propounded by Ludwig and Noll, although without having entered deeply into the subject, principally because, whilst it seemed to me improbable, that the *alveoli* of the glands in question should contain blood-vessels, and at the same time communicate with the lymphatics; and, in the second place, because in cases where the *vasa afferentia* and *efferentia* were full of milk-white chyle, I was never able to perceive similarly coloured contents in the *alveoli*. These facts, indeed, still retain all their weight with me; but they are now more than outweighed by further experience, so that it appears very doubtful whether they justify the conclusions which I formerly thought might be deduced from them. For I find, like Ludwig, in a considerable number of injections in the human subject, Dog (cervical glands), and Ox (lumbar glands), that it is impossible to fill lymphatic vessels in the interior of the glands, and that the injection either colours only the ramifications of the *vasa inferentia* upon the gland, or when it runs further, as it may be more easily made to do in animals than in Man, it enters the *alveoli*, which it fills according to their position in the series, and escapes through the *vasa efferentia*. Induced by the result of these experiments, I should now, without being desirous of giving a definitive opinion, be inclined to side with Ludwig, and to deny the existence of any direct connexion between the afferent and efferent lymphatics, or rather to view the *alveoli* of the glands as a specially modified part of them. In accordance with this notion, the lymph would be poured out into the *alveoli*, and flow through them in fine divided streams among the elements of which their contents are composed; and, to this circumstance, it is probably owing that it never has a milk-white colour. In this process it is possible that some of the cells of these contents, which so closely resemble the lymph-corpuscles, may be detached and become disintegrated, whence the chyle of the *vasa efferentia* abounds more in morphological elements, than the fluid conveyed by the *vasa afferentia*. At the same time, I am decidedly opposed to the view which would regard the morphological contents of the *alveoli* as directly appertain-

ing to the lymph, as *lymph-cells*—which are there formed, and subsequently conveyed away from the gland. I consider them rather as an independent, stationary, glandular element, standing, indeed, in the closest relation with the chyle, but not necessarily forming a part of it, or passing into the blood. If we ascribe to the *alveoli* of the lymphatic glands the function of inducing a metamorphosis and changes in the lymphatic fluid flowing through them, under the influence of the cells of its pulp, which are manifestly in a continual process of development, of such a kind probably, that its elements are rendered more capable of development, or new matters, such as *fibrin*, are mixed with it, the reason is at once evident, why the lymphatic fluid should form more cells after its passage through the glands than previously. The well known cases also of “white blood,” in which, together with an enormous increase in size of the lymphatic glands, a vast multiplication of the colourless blood-cells takes place (Virchow), may be explained in accordance with the above view; although, for the present, I am not disinclined to assume, that although no constant and total passage of the pulp of the lymphatic glands into the lymph takes place, which from the anatomical conditions is utterly impossible (considering the blood-vessels in the *alveoli*), nevertheless a sort of commixture of it from the *alveoli* contiguous to the *vasa efferentia* occurs, so that the lymphatic glands, after all, at least to some extent, appear to afford a site for the formation of lymph-corpuscles.

The lymphatics of the lymphatic glands retain all their tunics up to the gland. But as they ramify in an arborescent manner on the gland and become smaller, they lose the muscular membrane, and enter the *alveoli*, possessing only a layer of connective tissue with fine elastic fibres, and an *epithelium*. The glands, at all events the larger ones, always have some delicate *nervous filaments* composed of fine fibres, which enter in company with the blood-vessels, and are lost to sight in the interior. The ganglia in the lymphatic glands, mentioned by Schaffner (*Zeitsch. f. rat. Med.*, VII, 177), I have not been able to find, nor is that author's description of the kind to command much confidence.

[The above-described structure of the lymphatic glands does

not apply to all cases. In Man, and in other animals, there are small and smallest glands, of 3'''—2'''—1''', or even  $\frac{1}{4}$ ''' , in which the interior does not distinctly exhibit the alveolar structure, appearing, on the contrary, to be more continuous throughout, and homogeneous, notwithstanding a good many traces of fibrous structure, which always exist even in them. In the larger glands also, especially in certain animals, a similar condition of the contents is not unfrequently presented, which of course does not materially affect the above exposition of the structure of the lymphatic glands, since, in such cases, we simply see a less developed condition of the *septa*, and a more intimate union of the individual parts of the pulp.

O. Heyfelder has lately described (l. c.), in the lymphatic glands of the Mouse, the Rat, and, to some extent, of the Rabbit, a complete *muscular layer*. In the Bat also, the Dog, Sheep, Ox, Goose, and Fowl, smooth muscles are said to occur sparingly, and to be fewest in Man. Heyfelder also says that they pass into the internal *septa*, and that in the Rabbit he has noticed contractions of the glands upon electrical excitement, an experiment which has not yet succeeded with me.

The lymphatic glands are subject to numerous *degenerations*. The most frequent are *extravasations of blood* in the *alveoli*, and in consequence of these effusions, depositions of *pigmentary matter*, which may proceed to such an extent as to render the glands brownish-red, or even black (bronchial-glands); we also find thickenings of the sheath, and of the internal *septa*; *fatty deposits* in the blood-vessels; *hypertrophies*, with a uniform increase of all their parts; *tuberculosis* and *cancer*.]<sup>1</sup>

<sup>1</sup>[Professor Brücke, in a valuable communication read before the Vienna Academy, March 31, 1853 ('Ueber die Chylus-gefäße und die Fortbewegung der Chylus'), confirms the account given by Ludwig and Noll of the structure of the lymphatic glands, and states that the *vasa inferentia* break up into the porous, glandular tissue, out of which the *vasa efferentia* arise anew. In the glands themselves, a distinction must be drawn between the *cortical substance*, composed of round or ovate bodies, like the separate glandular bodies of Peyer's patches, and the *medullary substance*. The framework of the latter is formed by the large blood-vessels, with their *tunica adventitia*. One portion of their branches divides into capillaries in the medullary substance, the rest enter the cortical substance. The accompanying connective tissue becomes looser, the finer the branches. The fully developed connective fibres disappear more and more, and in their place cytoblasts appear, with closely investing cell-membranes, which run out into two or three pointed, sometimes flat, usually filiform

## 4.—OF THE BLOOD AND THE LYMPH.

## § 220.

Every part of the vascular system contains in its interior a special liquid, consisting of a fluid and numerous morphological particles, and which, according to its colour, its occurrence in one or other division of the system, and its other properties, is distinguishable on the one side into *white* and *red blood*, and *lymph* or *chyle*; and on the other, into *blood* in the more strict sense of the term. Histology is concerned only with the description of the morphological elements existing in these fluids, among which the blood- and lymph-corpuses are by far the most important, leaving the description of their other conditions to physiology.

## § 221.

The *lymph* and the *chyle*, like the blood, consist of a *plasma*, which coagulates out of the vessels; and of *morphological elements*, including *elementary granules*, *nuclei*, *colourless cells*, and *red blood-corpuses*, which, however, are not found in all parts of this vascular system, nor everywhere in equal quantity. The *elementary granules* are immeasurably minute granules, which, as has been shown by H. Müller, consist of fat and a protein-envelop, and are contained in vast numbers in milky chyle, *whose colour is owing to them alone*, whilst, in the more colourless lymph they are either wholly wanting, or are rare

processes, fitted together into a soft tissue, in which the capillaries of the medullary substance lie. Round cells in different stages of development follow them, resembling the lymph-corpuses, and forming the immediate limit of the fine, irregular, frequently anastomosing canals, which render the medullary substance as porous as a sponge. The whole gland is inclosed in a membrane, which, as Heyfelder observed, is composed of connective tissue and smooth fibre-cells, and sends sheaths in towards the medullary substance, whereby imperfect compartments are formed, in which the glandular elements lie. The chyle of the *vasa inferentia* traverses the glandular elements, enters the pores of the medullary substance, and passes thence on the opposite side, between the glandular elements to the *vasa efferentia*. "I have never" (says Brücke) "observed the fat-drops of the chyle enter into the interior of the glandular elements, which appear to be merely bathed with the fluid part of it. On the other hand, the cells which are formed in the glandular elements pass as lymph-corpuses into the chyle."—Eds.]

and scattered. *Free nuclei*, 0·001—0·002<sup>'''</sup> in size, and of a more homogeneous aspect, becoming vesicular and granular on the addition of water, I have hitherto noticed only in the commencements of the lacteals in the mesentery, and in the *vasa efferentia* of the mesenteric glands, though even there scantily, and never in the thoracic duct; whilst the colourless cells, which are identical in the chyle and in the lymph—the chyle- or lymph-corpuscles of authors—are found almost everywhere in the lymphatic vascular system in considerable quantity. These are rounded, pale cells, 0·0025—0·0055<sup>'''</sup> in diameter, which, when examined in their native fluid, appear homogeneous or finely granular, and contain a usually indistinctly transparent, homogeneous, slightly glistening, round *nucleus*; but on the addition of water, the *nucleus* and contents are rendered turbid by a granular deposit, and on that of acetic acid, become transparent and pale, exhibiting the strongly granulated contracted *nuclei* with extreme distinctness, bursting at the same time, and allowing the contents to escape; a change that also frequently takes place, especially in the smaller cells, on the addition of water, preceded by the appearance of clear albuminous drops. Otherwise dilute solutions, when the lymph-cells are already spherical, induce no very remarkable changes of form, whilst, in consequence of the evaporation of the fluid, and by concentrated liquids, a considerable contraction, and frequently also, a jagged outline, is caused in them (fig. 290 *a*).

In *size*, *quantity*, and *shape*, the lymph-corpuscles present diversities, according to situation. In the commencement of the lacteals, which are eminently adapted for such investigations, in the mesentery, and before it reaches the lymphatic glands, the chyle contains but few, and in the smallest mesenteric vessels which allow of being examined, frequently even no chyle-corpuscles at all. Where they do exist, which is always

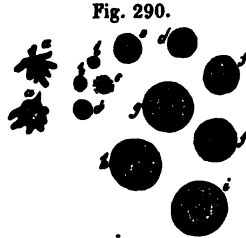


Fig. 290. Elements of the chyle: *a*, lymph-corpuscles become stellate by the escape of their contents; *b*, free *nuclei*; *c*, one such, surrounded by a few granules; *d*, *e*, minute lymph-cells, some with a distinct nucleus; *f*, *g*, larger cells, one with a visible *nucleus*; *h*, one such, after the addition of a little water; *i*, with the addition of acetic acid.



the case in the larger trunks, they usually appear small (0.002—0.003"), closely investing the minute nucleus, and often even, as it were, in process of formation by the apposition of granules. As the chyle traverses the mesenteric glands, the cells become more and more numerous and larger, so that in the lacteals at the root of the mesentery (and also in the larger lymphatic trunks), together with the small cells which are still present, we find numerous larger ones, up to 0.0055" in size. At the same time, at any rate in the Dog, Cat, and Rabbit, a multiplication of the lymph-corpuscles by division takes place more or less actively; in this process the larger cells elongate till they attain a length of 0.006—0.008", and when the *nucleus* has divided, are separated into two by a median, circular constriction. This proceeding does not usually occur at all in the thoracic duct, and consequently the larger cell-forms, of 0.004—0.0055", are here rare. In Animals, at all events, the majority of the cells in this situation are larger than the blood-corpuscles, that is to say, they are 0.0025—0.0035", whilst in Man, at least as observed by Virchow and myself in an executed criminal, they were invariably smaller (from 0.002" on the average). The *nuclei* of these lymph-corpuscles, which are imperceptible without the addition of acetic acid, were for the most part single and round, occasionally, also, horse-shoe shaped, or constricted in the middle, very rarely truly multiple. In other Mammalia, cells having *nuclei* disintegrated by acetic acid, or naturally constricted and multiple (3—5 fold) are very rare, omitting those in process of division; although occasionally such occur even in considerable quantity.

*Red blood-corpuscles* I have not as yet noticed in the human chyle, when it has been carefully taken, and under normal conditions; whilst in animals these corpuscles almost always occur in the thoracic duct in small quantity, and also frequently in the lymph of certain organs, as of the spleen. As they do not exhibit the slightest trace of a development within the lymphatics, I regard them as elements escaped from the blood-vessels, and indeed, am of opinion, so long as direct connexions between the two sets of vessels in the peripheral parts are not shown to exist, that this passage is an accidental occurrence, from the rupture of finer vessels, which, owing to the peculiar structure of certain organs, as the spleen and lymphatic glands,

may be very readily conceived ; and indeed, as I have shown in the Tadpole, may be directly observed. I would, however, remark that I have not unfrequently met with *brown, round granule-cells*, 0·004—0·005" in diameter, completely corresponding with those mentioned as found in the blood, and which are probably derived from the lymphatic glands.

From the above facts, it would seem not to admit of doubt that the lymph-corpuscles are formed, like cells, by the development of membranes around free *nuclei*, a process which is effected, in the first place, in the commencements of the lymphatic vessels, but also, and chiefly, in the *vasa efferentia* of the lymphatic glands. To this is superadded the multiplication of cells by division, which does not always take place. The total quantity of the corpuscles contained in the lymph, compared with that of the blood-corpuscles, is very inconsiderable, not only in the middle-sized and smaller trunks especially, of the lymphatics, but even in the thoracic duct itself is very far from being in an equal proportion ; and even there all the elements of the fluid may readily be perceived, without any dilution. More precise enumerations have not yet been instituted, and it can only be added that considerable diversities exist, and that a milk-white chyle is not always also rich in corpuscles.<sup>1</sup>

<sup>1</sup>[Professor Kölliker appears not to be thoroughly acquainted with the very accurate and extensive researches of Mr. Wharton Jones, embodied in his memoir on 'The Blood-corpuscle, considered in its different phases of development in the Animal Series,' 'Philosophical Transactions,' 1846 ; the publication of which will, we believe, be considered hereafter to constitute an epoch in our knowledge of the blood. It is shown in this Memoir that "the lymph-corpuscle of the Vertebrata is identical with the corpuscle of their blood. In the oviparous Vertebrata it occurs, like the corpuscle of their blood, in the two phases of granule-cell and nucleated cell ; whilst in Man and the Mammifera it occurs like the corpuscle of their blood in the three phases, of granule-cell, nucleated cell, and free cellæform nucleus.

"The only difference that exists between the corpuscle of the lymph and the corpuscle in the blood is, as regards the oviparous Vertebrata, the little degree of coloration which the coloured stage of the nucleated cell as yet presents, and, as regards the Mammifera, the small degree of coloration which the coloured stage of free cellæform nucleus has yet attained," (p. 82).

Mr. Wharton Jones first pointed out in this Memoir the true nature of the process which is described and figured in the text as the "bursting," &c., of the lymph-corpuscles. These changes of form, in fact, are not in general produced by any such cause, but they arise from the *amaba-like* motions of the corpuscles, observed by Mr. Jones in the Skate, Frog, and many Invertebrata, and which may be readily enough seen on a smaller scale in the colourless corpuscle of the human blood.

## § 222.

*Of the Blood.*—The blood, so long as it is circulating in the vessels, is a slightly glutinous fluid, in which only two elements, the blood-*corpuscles*, -*globules*, -*cells* (*corpuscula s. globuli s. cellulae sanguinis*), the majority of which are of a red colour while some are white, and the colourless *blood-plasma* (*liquor s. plasma sanguinis*), are to be distinguished; when excluded from the circulation, it usually coagulates entirely, by the solidification of the *fibrin* in solution in the *plasma*, and afterwards by the contraction of the coagulated constituent, divides into the “crassamentum” and “serum.” The former is of a deep red colour containing, together with the *fibrin*, almost all the coloured, and most of the colourless blood-*corpuscles*, with a portion of the still dissolved parts of the *plasma*, whilst the remainder of the latter, together with some of the colourless blood-*corpuscles*, constitutes the *serum*. In certain cases in Man, especially in disease, before the coagulation of the blood has taken place, the coloured corpuscles subside more or less deeply below the surface of the fluid,

The subjoined description of the phenomena presented by the colourless corpuscle (granule-cell, Jones) of the Skate will serve for all:

“My attention was first attracted to the phenomenon, by observing a granule-cell with the granules apparently escaping from it, as if burst (fig. 3). But the cell soon appearing again with all the granules collected together, I was led to watch, and soon perceived that the appearance of granules escaping as if from a burst cell, was owing to this: The transparent and colourless cell-wall bulged out on one side, leaving the granules still agglomerated and holding together, but this only for a short time; for soon, single granules were seen to separate and burst out from the rest, and to enter the hitherto empty compartment produced by the bulging out of the cell-wall. The regular manner in which this sometimes took place was remarkable. I have actually seen the granules enter the compartment by one side, and circulate along the bulging cell-wall to the other side, until the whole compartment became filled with granules. This having occurred, the bulging began to subside, but was succeeded by the bulging of another part of the cell-wall, into which again a flow of granules took place, and so on all round the cell.”

We have already pointed out the occurrence of similar *ameba-like* movements in the young cells of mucous membranes detached during slight inflammation, and in the cells of the gelatinous tissue of Medusæ; and we think that, very probably, it will eventually be found to be a property of all young periplastic substance.

MM. Guérin-Méneville (1849-51), Davaine (1850), and Robin (1853), appear also to have observed these *ameba-like* movements, without being acquainted with Mr. W. Jones's essay. (See the ‘Histoire nat. des Vegetaux parasites,’ by M. Robin, p. 567.)—Eds.]

when the *crassamentum* presents a superficial colourless, or whitish *stratum* (inflammatory crust), consisting only of the coagulated fibrin and colourless blood-cells, together with the fluid with which they are imbued.

The *coloured* or *red blood-globules*, or simply *blood-globules*, in which alone the colouring matter of the blood resides, are minute non-nucleated cells of a flattened, lenticular form, which are contained in the blood in such vast quantity, that, unless it be diluted with serum, they do not readily admit of exact investigation,<sup>1</sup> appearing of themselves to constitute the blood. However important it would

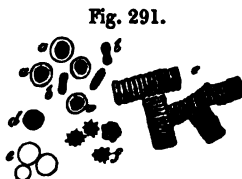

Fig. 291.

be to know accurately the proportion of the blood-globules to the *plasma*, their number and their volume, all researches hitherto have failed, owing to the difficulty of the subject; and even the very recent statements of Schmidt, according to which 47—54 parts of moist blood-globules exist in 100 parts of human blood, can only be described as approximative. One method only can be successful, consisting in the direct enumeration of the globules in accurately determined quantities of blood, and as precise a determination as possible of the volume of the individual corpuscles (Vierordt); but this method, if applied in such a way as to ensure correct results, demands so much time and trouble, that it cannot be expected to obtain general application, and we must be contented with an accurate investigation of the total quantity of blood-globules in a single or in some few instances, an undertaking in which Vierordt is now engaged.

The red blood-globules, more minutely examined, present the following characters: Their form is usually that of a biconcave or plane, orbicular disc, with rounded borders, and consequently they present a different aspect to the observer, according as the surfaces or borders are turned towards him.

Fig. 291. Blood-globules of Man: *a*, viewed on the flat surface; *b*, on the edge; *c*, united into rouleaux; *d*, rendered spherical by the addition of water; *e*, rendered colourless by the same agent; *f*, blood-globules shrunken by the drying up of the fluid.

<sup>1</sup> [We must caution the reader against being guided by this statement. Nothing is easier than the examination of the blood as it is,—nothing more likely to mislead than the practice of diluting it with any fluid whatsoever.—Eds.]

In the former case they are pale-yellow, orbicular corpuscles, in which, according to the focussing of the microscope, the slight central depression which almost always exists, is indicated, sometimes by a clear, sometimes by an opaque spot in the centre, the latter appearance admitting of being confounded with a *nucleus*. Viewed on the edge, on the other hand, they present the form of an elongated, narrow ellipse, or of an ellipse constricted in the middle. The blood-corpuscle is *constituted* of a very delicate, but nevertheless tolerably firm, and at the same time, elastic, colourless cell-membrane, composed of a protein-substance closely allied to *fibrin*, and of coloured viscid contents formed of *globulin* and *hæmatin*, which in the adult present no trace of morphological particles, of granules, or of a *cell-nucleus*; they are consequently vesicles, whence the name "blood-cells" is to be preferred. The elasticity, softness, and flexibility of the membrane is so considerable, that the corpuscles are rendered capable of passing through vessels of less diameter than themselves, and when by pressure under the microscope they have become elongated, flattened, or otherwise altered in shape, of reassuming their original form. The blood-globules are the better adapted for the former process, since their surface is perfectly smooth and slippery, so that they easily glide over the walls even of the smallest capillaries, which present the same conditions.

The size of the blood-globules may differ in different individuals; but these diversities, owing to the minuteness of the bodies concerned, are not altogether inconsiderable. As a general mean size, the most recent inquiries of Harting ('Rech. micrometr.'), from measurements of recent blood-corpuscles, give a width of 0.0033''' ( $\frac{1}{300}$ '''), and a thickness of 0.00062'''; and of Schmidt, from the estimation of dried blood-globules, a width of 0.0035'''; whilst, according to the former, the mean width in various individuals amounts to from 0.0028''' to 0.0036''', and according to Schmidt to 0.0032—0.0035''', with which numbers those given by other good observers essentially correspond. The differences in the same individual, found by Harting to exist between the two extremes, amount, as regards the width, to 0.0010—0.0017''', and for the thickness to 0.00009—0.0005''': the extremes observed in general were 0.0020—0.0040''', and 0.0005—

0·0009''; and Schmidt states, that in 100 blood-corpuscles 95—98 are of equal size. With respect to the size of the blood-globules in one and the same individual, it may be stated in general, that it necessarily differs at different times, and especially that it necessarily increases or diminishes according to the varying degrees of concentration of the blood-plasma; but on this subject we have scarcely any accurate researches. Harting only says, that the blood-corpuscles of the same individual, measured after an interval of three years, presented the same mean size, whilst in the same individual after a copious meal, somewhat less average dimensions were exhibited (by about 0·00013'') and more considerable extremes. It has been remarked that determinate data are wholly wanting as to the *number* of the blood-globules, and we must await the results of Vierordt's researches. But, at all events, from what has been ascertained with respect to the amount of solid constituents in the blood-globules, this much in general may be concluded, that they are more numerous in the male than in the female sex; moreover that, after repeated venesection, during pregnancy and after prolonged deprivation of food, they diminish in number; and in certain diseases, as *chlorosis* and *anæmia*, are also found to be much more scanty than usual. At the same time, however, it is certain, that all the possible variations are not as yet by any means exhausted, and it can scarcely be doubted, that in every individual the number of blood-cells is subject to numerous, even daily changes, according to the conditions of supply and waste, with which we have still to be made accurately acquainted. The *volume* of the blood-cells is estimated by Harting, regarding them as short cylinders, as that of a cell of 0·0763 cubic millimeters; and the *weight*, taking their specific gravity as equal to that of water, and abstracting their central depression, at  $\frac{1}{13,114,000}$  milligramme. If, with Schmidt, the blood is taken to contain 50 per cent. of corpuscles, and the whole quantity of blood be estimated at 10 kilogrammes, we have a total of 65 billions 570,000 millions. According to Schmidt, the specific gravity of the blood-corpuscles in men, is 1·0885—1·0889, and in women 1·0880—1·0886—numbers which must stand and fall with his statements respecting the quantity of blood-corpuscles. Compared with the other

constituents of the blood, the corpuscles are *heavier* than the *serum* and the *plasma*. In the former, and in defibrinated blood, they form, upon standing, a red sediment, whilst in the *plasma*, owing to its rapid coagulation, they do not usually subside below the level of the fluid. This subsidence of the blood-cells, which, according to their own density and that of the fluid in which they are suspended, may be slow or rapid, is favoured by their mutual *cohesion*, which is observed especially in inflammatory blood, in which, from the rapid subsidence of the blood-cells, part of the blood coagulates into a colourless mass; but it also takes place in perfectly healthy blood, and, in fact, constantly in little drops obtained by trifling injuries of the skin, and frequently also in the blood taken by venesection. The blood-globules in these instances apply themselves to each other by their flat surfaces, and form, as it were, columns or rouleaux, to the sides of which others may be again applied, so that very complicated branched figures, and even networks are in this way produced, covering the entire field of view (fig. 291 c).

Besides the *coloured*, the blood also contains a certain number of *colourless* elements, of two kinds—*elementary granules* of a fatty nature, and *true cells*. The former, which correspond entirely with those of the chyle (*vid.* § 221), occur in very varying number, sometimes very scantily or not at all, sometimes in greater or even in vast numbers, so as to give the *serum* a whitish or even milk-white colour. From all that we know, these must exist when fat is introduced into the blood through the chyle; thus also in common alimentation, 3—6 hours and longer after the taking of food, although in many cases they seem to disappear in the course of the pulmonary circulation; at all events Nasse (*vid.* Nasse, 'Wagn. Handw. d. Phys.,' I, p. 126) and others have never found them in the systemic blood of healthy persons, a fact which I can confirm as regards my own blood. In herbivorous Animals, on the contrary, in the Goose, and in sucking Animals, the occurrence of these molecules appears to be constant; in pregnant women, also, and after the free use of milk or alcoholic drinks, and also in famishing persons (in consequence of an absorption of the fat of the body), it seems to be, at all events, very frequent. The colourless cells of the *white blood-*

corpuscles are derived from the chyle; and may, consequently, be termed the *chyle-* or *lymph-corpuscles* of the blood. Some of them are *uninuclear*, and correspond in all respects with the small cellular elements of the chyle (*vid.* § 221); some *multinuclear*, having an average size of 0.005", in which case they so closely resemble pus-corpuscles, that it is quite impossible to distinguish the one from the other. The larger corpuscles are rarely as granular as the smaller, usually tolerably homogeneous, often with clear contents, so that their two or three, rounded, minute nuclei are at once apparent.<sup>1</sup> Should this not be the case, acetic acid or water brings




Fig. 292. Colourless blood-corpuscles, or lymph-corpuscles of the blood: *a*, *b*, smaller cells, such as are found in the thoracic duct, viewed on the side (*a*), and on the edge (*b*); *c*, *c*, the same with visible *nucleus*; *d*, *d*, larger cells with *nuclei* multiple *ab origine*; *e*, *e*, *e*, the same after having been acted upon by acetic acid, the *nuclei* disintegrated or becoming so.

<sup>1</sup> [With regard to the appearances presented by the "nucleus" of the colourless corpuscle, Mr. Wharton Jones, (l. c. p. 67 for the Frog, p. 72 for Man, the Horse, and the Elephant) shows very clearly that the singleness or multiplicity of this body depends entirely upon the strength of the acetic acid used to bring it out, and we can fully confirm his statement so far as our own observations have gone. If the blood of Man, in fact, be diluted first with water, and then only very dilute acetic acid be added, the "nuclei" of the colourless corpuscles will all, or almost all, be circular, with even edges. If, on the other hand, strong acetic acid be added at once, every variety of form, from mere notching, to apparent division into two, three, or four smaller ones, will be found. "I am satisfied, however, that this is, in both cases, (granule-cell and nucleated cell) merely an appearance produced by the shrivelling together of the walls of the single cellæform nucleus, in consequence of the action of the acetic acid.

"It is proper to observe, that I have come to this conclusion, only after having particularly tested the point by repeated, careful, prolonged, and varied observations. Nor is the determination of the point of small moment, as on the appearance of a multiple nucleus, which I have thus shown to be artificially produced, and on a similar, but I believe equally artificially produced appearance of a multiple nucleus in the pus-corpuscle, a particular view has been founded as to the first formation of the nucleus, and, indeed, as to cell-development generally." (Wharton Jones, l. c., pp 67-8.)

It will be observed that in the text Professor Kölliker admits that the multiple "nuclei" may be still further broken up by the action of reagents.

The existence of any difference of specific gravity between the colourless and the red corpuscles of the blood may be doubted; their relative positions in masses of blood, to which reference is made above, being fully accounted for by the aggregation of the red corpuscles into rolls.

With regard to the blood-corpuscles of the Invertebrata, Mr. Wharton Jones's



the *nuclei* distinctly into view by rendering the contents clear, of which occasionally a drop escapes from the ruptured cell; at the same time, at all events under the former reagent, the nuclei not unfrequently are farther disintegrated, and fall into irregular, jagged, and constricted corpuscles, or are even resolved into a greater number, 4, 5, 6, and more, of smaller granules, assuming at the same time a yellow colour, whilst the cell-membranes gradually disappear. The other reactions of these colourless blood-corpuscles are those of the common indifferent cells, and as regards their number, it is, compared with that of the blood-corpuscles, very small, though not always the same, being dependent upon the energy with which nutrition is going on, and therefore more considerable when a large quantity of chyle has entered the blood after a full meal. It is impossible to give any definitive statement as to their number, without perfectly accurate enumeration; but this much is certain, that the usual statement, that there is one colourless to every ten coloured blood-corpuscles, is quite incorrect. I find, with Henle and Donders, that they are much less numerous than this, and am of opinion, that when the latter, with Moleschott, reckons 5·1 colourless to 2000 coloured corpuscles, he is not far wrong. After meals, these authors found the number of the latter augmented to 6·2, whilst in fasting animals, as was also noticed by Heumann in Pigeons, they diminished in number; and after long fasting, at least in Frogs, they saw them disappear altogether. Their increase after venesections, not only relatively but even absolutely, is a very remarkable circumstance; and this, as in the Horse, after very copious abstraction of blood (as much as 50 lbs.), may proceed to such an extent, that the coloured and colourless corpuscles appear to exist in equal numbers. The white corpuscles are lighter than the coloured, and they are consequently more numerous in the upper *strata* of the *crassamentum*. When the latter presents a buffy coat, it always contains a great number of these corpuscles, and especially if their number has been augmented by previous venesections, so as in such cases to constitute even

Memoir above cited, should be consulted, as it contains the only complete account of them extant. The statement in the text that *Amphioxus* has no blood-corpuscles, is incorrect. It is, however, altogether exceptional among the Vertebrata, as its corpuscles are entirely of the colourless kind.—Eds.]

half of the buffy coat (Remak, Donders). Their less tendency to subside is, moreover, increased by the circumstance, that although they have an uneven surface and a disposition to cohere, they usually do not form any large aggregations and never constitute rouleaux.

*Condition of the blood-corpuscles in various kinds of blood.*— However sensitive the blood-cells, out of the body, are towards various reagents, they appear, within it, to be so constant, at all events as regards their shape, that not only within the bounds of the physiological condition, are no notable and uniform differences to be observed in them, in the arterial and venous blood and the blood of the different organs, but, even in the most various diseases, no visible alterations are presented. And yet it cannot be doubted that, as the colour and chemical composition of the blood-cells vary, so also are their forms subject to certain diversities and changes, according as the blood is more concentrated or diluted, and abounds more or less with one saline constituent or another, or with other substances; but these changes of form are so inconsiderable, that it cannot be wondered at, that we have not yet been in a condition to recognise them with certainty. At all events, with Henle, I must most expressly declare, that all these forms—the jagged blood-corpuscle on the one side, and the diminutive, spherical, coloured or pale—are never met with in the circulating blood. Slight degrees of flattening and distension may probably be noticed; but in such researches it should never be forgotten how quickly the blood-corpuscles change their form, and care must be taken not to view a condition set up out of the organism, as a natural one. The relations of the blood-cells, as to their number, appear to vary more than their forms. As respects the *coloured*, they are more numerous in the venous than in the arterial blood. In speaking of the venous blood, that of the hepatic veins stands pre-eminent, containing, according to Lehmann, far more blood-cells than that of the portal vein, and even exceeding in that respect the somewhat rich blood of the jugular vein. The colourless blood-cells, as I and Funke have found, exist in very great number in the splenic blood, and indeed sometimes more in the form of uninuclear cells, sometimes as multinuclear; and also in the blood of the hepatic veins, according

to Lehmann, in which they are characterised by their very various size (*vid.* § 223); I have noticed this, in many cases, though by no means invariably, but am unable to regard it as an exclusive character of the blood in the hepatic veins, because I have also found the same multitude of colourless cells, in perfectly healthy animals, in the portal blood, as Lehmann has done in one case, as well as in the blood of the pulmonary veins. Otherwise, however, the colourless cells are more abundant in the venous, than in the arterial blood (Remak). In the *vena cava superior*, and iliac vein of the Dog, Zimmermann noticed uninuclear cells, and, in the *v. cava inferior*, multinuclear ones.

. [Many experiments have already been made as to the influence of various *reagents* on the blood-globules, although the results obtained have in some measure been of very trifling importance; and I, therefore, here adduce, chiefly from my own researches on the subject of the human blood-corpuscles, only what may serve to illustrate their anatomical and physiological relations. *Water* at first renders the blood-globules spherical, and, owing to the diminution of the broad diameter, consequent upon the increased thickness, smaller (from 0.002—0.0024"), which may be best seen in corpuscles arranged in columns. The size then usually remains without further change, and the colouring matter and remainder of the contents slowly (sometimes suddenly, and by fits and starts) escape, so that the fluid becomes dark-red, the corpuscles at the same time losing their colour, and acquiring the aspect of colourless vesicles or rings, so faint, that it is often difficult to perceive them. But by the addition of tincture of iodine, which colours them yellow, or of salts (common salt, nitre, &c.), of gallic or chromic acid, which cause them to shrink, and to present a more defined outline, they may be readily brought into view; and it is thus satisfactorily shown that water, by no means dissolves, or destroys them. Some blood-globules always withstand the influence of the water for a longer time, and are still coloured when all the rest have lost their colouring matter; but it is not yet ascertained, whether these are to be regarded as of younger formation, as is commonly supposed, or of older. The latter notion seems to be favoured by the

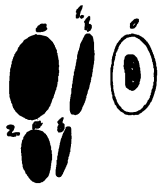
circumstance that older cells usually have firmer membranes than younger ones, and also that blood-corpuscles, left to their fate out of the circulation—for instance in extravasated blood—always, in time, become more resistant; but it must be allowed that, at present, no decisive opinion can be given either way. Many other substances act in the same manner as water, only more powerfully and even destructively, particularly *acids* and *alkalies*; although not all with equal energy. Gallic and pyroligneous acids, aqueous solutions of chlorine and iodine, sulphuric ether and chloroform, act very much in the same way as water. In the first three the blood-globules remain as distinct, pale rings, whilst in sulphuric ether they are instantaneously transformed into the most delicate and excessively faint rings,  $\frac{1}{3}$ — $\frac{1}{4}$  the original size, and which it is very difficult to perceive in the finely granular coagulum that is formed at the same time, although they are rendered more distinct by the addition of salts (nitre for instance). I have seen no evidence of an actual solution of the cells. Chloroform acts in the same manner, only more slowly, and the corpuscles first become considerably smaller, and of a glistening yellow colour. Acetic acid, of 10%, at once renders the corpuscles extremely faint, so as to be scarcely perceptible, but they are by no means dissolved, being visible, even at the end of several hours, in the form of delicate rings. A solution, containing 20 per cent. of acid, acts more energetically, and in glacial acetic acid, the cells are completely dissolved in the space of two hours, in the slimy brown blood. *Concentrated sulphuric acid* renders the blood black-brown. The corpuscles become pale, and although still retaining some colour, are scarcely recognisable, their contours running mutually together. On the addition of *nitre* or *water*, which latter throws down a white precipitate, they again become distinct as minute, dull-yellow, round corpuscles. After some hours' action of the acid all is dissolved. *Concentrated hydrochloric acid*, which colours the blood brown, and produces a white precipitate, contracts most of the cells, which are gradually dissolved, and renders many of them granular internally, also producing rents in some of them, so that the contents escape, in the form of a pale streak, appearing like a stalk to the corpuscle; subsequently they become so faint in colour as to be scarcely perceptible, without

the aid of some saline solution. After some hours many are dissolved, though a few offer a longer resistance. *Nitric acid*, when concentrated, renders the blood olive-brown, and the corpuscles greenish. The latter are corrugated, but are not rendered smaller, and are partly enclosed in the *coagulum*, which is formed at the same time, in part free, and lying above it. After several hours there is still no indication of a solution going on, but this takes place at the end of a day. Of the alkalis, *potass* acts the most powerfully. A solution containing 10 per cent. makes the blood black, and at once dissolves all the blood-cells, first rendering them spherical and smaller. The same thing takes place with a solution containing 20 per cent. of the alkali, except that some of the cells remain for a time as pale rings, whilst a concentrated solution of two parts potass and one part water does not attack the corpuscles, beyond making them very small; at the same time they remain spherical, or jagged and folded. The whole blood is coagulated by this solution, and acquires, at first, a brick-red, and afterwards, a bright brown colour. On the subsequent addition of water, the blood-corpuscles enlarge, as in no other reagent, to a size of 0.006''', remaining for the most part flat, and are then dissolved as in a dilute solution. *Caustic soda*, and *caustic ammonia*, in solutions containing about 10 per cent., act like the corresponding potass-solution, only that the action is a little weaker, whilst *concentrated caustic soda* ( $\frac{1}{3}$  part to 1 part water) acts precisely like caustic potass. The same phenomenon of a diminution of the *blood-cells*, as that caused by some of the reagents above noticed, is manifested also in many other instances, and may be referred to the abstraction of materials, chiefly water, from the cells, as it is always concentrated solutions which so act. In these cases, also, since the blood-globules reflect the light from more numerous points, the colour of the blood becomes brighter, usually of a brick-red. Even the mere concentration of the blood-plasma, by evaporation, causes the cells to shrink more or less, in consequence of which they become either round, dark, brilliant globules, 0.001—0.002''' in size, or jagged, stellate bodies, or, lastly, diversely bent and plicated discs. All concentrated solutions of metallic and other salts, act in the same way, unless, like nitrate of silver, they exert an imme-

diately destructive influence. Donders and Moleschott have carefully investigated the reactions, especially of such soluble salts as exist in the blood, and have found that a concentrated solution (1 part salt, 7 parts water) added to an equal volume of blood, diminishes all the cells, and reddens the blood. The cells are least affected by the hydrochlorates of soda and potass, much more by the phosphate and carbonate of soda, and nitrate of potass, most of all by the sulphates of soda and potass. When diluted (1 part salt, 17 parts water), all these salts colour the blood a dark wine-red, and produce a distension of the cells, rendering them pale, and completely dissolving them at the end of four or five hours; in this regard the soda-compounds, except common salt, which exerts no destructive action, prove more energetic than those of potass. I find changes similar to those caused by the salts, to take place on the addition of *alcohol, tincture of iodine, chromic acid, and creosote*, the first two of which merely render the blood-globules smaller and corrugated, the latter also causing them to become granular internally. In this respect the action of *creosote* is the most remarkable, which transforms the blood-corpuscles partly into perfectly opaque, even fat-like glistening granular and homogeneous granules and globules, and partly into very beautiful clear vesicles, which may even be rendered polygonal by their mutual pressure. Lastly, it is very important to notice the influence of oxygen and of carbonic acid on the blood, which by their reception into the interior of the cells, both in the body (in the pulmonary and systemic capillaries) as well as externally to it, as proved by experiment, produce sometimes a brighter, sometimes a darker colour in it. This takes place without any change of form in the blood-corpuscles (J. Müller, and Todd and Bowman, in opposition to Nasse and Harless), and the experiment may be alternately made several times in succession with the same blood without any alteration of the corpuscles (Magnus, Bischoff, De l'Espinasse, and Reuemann, in opposition to Harless). Those gases also act upon the colouring matter of the blood, when isolated, in the same way as upon the corpuscles (Magnus, Marchand), and it is probable that the change of colour is not connected with any chemical change in the *hæmatin*, but is a physical action of a peculiar kind, analogous to similar changes of colour in other fluids caused by the absorption of gases.

*Blood-corpuscles of other animals.*—The non-nucleated blood-corpuscles of the Mammalia do not differ in form from those of Man, except that in the Camel and Llama (*Auchenia Paco*, *A. Glama*, *A. Vicugna*) they are oval, and 0·0038''' long; they are mostly smaller than in Man, as in the Dog, 0·0031''', Rabbit, Rat, 0·0028''', Swine, 0·0027''', Horse and Ox, 0·0025''', Cat, 0·0024''', Sheep, 0·0022''', the smallest (0·00094''') in the Musk Deer; seldom larger (0·005''') as in the Elephant. All the lower Vertebrata have, almost without exception, *oval, nucleated* blood-corpuscles, of the shape of a melon-seed. Those of Birds are from 0·004''' to 0·008''' long, and contain roundish *nuclei*; those of the Amphibia measure between 0·008—0·025''' in length, have round and oval *nuclei*, and are largest in the naked Amphibia (Frog, 0·011—0·013''' long, 0·007—0·008''' broad; *Proteus*, 0·025''' long, 0·016''' broad; *Salamander*, 0·02''' long); those of Fishes, lastly, are mostly 0·005—0·007''' long, except that in the Plagiostomes they measure 0·01—0·015'''; in the *Lepidosiren* they are 0·020''' long, and 0·012''' broad. In *Myrine* and *Petromyzon* they are 0·005''' in diameter, round, and slightly biconcave. In *Amphioxus* the blood-corpuscles are absent.<sup>1</sup> The blood-corpuscles of the Invertebrata

Fig. 293.



resemble the colourless cells of the blood in the higher animals, and are almost always uncoloured.

The following should here be also noticed as *extraordinary* constituents of the blood: 1. *cells, enclosing blood-corpuscles*, noticed by Ecker and myself in the blood of the spleen and hepatic vessels, and elsewhere also in the blood (*vid. Mikroskop. Anat.*, II, 3, p. 369. et seq.) 2. *pigmented and colourless granule-cells*, observed by myself, Ecker, Meckel, Virchow, and Funke, particularly in cases of intermittent fever and diseases of the spleen (l. c.) 3. *pale, fine-granular, roundish aggregations*, in the blood of the splenic vein (Funke). 4. *peculiar concentric bodies*, three to four times larger than the white blood-cells, similar to those of the *thymus* (*vid. Henle, 'Zeitsch. f. rat. Pathol.,' Bd. VII, p. 44*), found by Hassall in fibrinous clots

Fig. 293. 1, blood-cells of the Frog: *a*, viewed on the side; *b*, on the edge; *c*, rendered colourless by water. 2, Blood-cells of the Pigeon: *a*, viewed on the side; *b*, on the edge.

<sup>1</sup> [*vid. Note, p. 330.—Ems.*]

in the heart. 5. *cells resembling pus-corpuscles*, in tumours of the spleen and leukæmia (Virchow); these bodies are found in vast quantities, but, in their form, cannot in any way be distinguished from the colourless blood-corpuscles. 6. *caudate, pale or pigmented cells* (Virchow, 'Arch.,' II). Besides these, should be noticed, the morphological elements which are formed in the blood without the body or in cases where the circulation has been obstructed—the fibrinous coagula and crystals. The former are seen in coagulated blood, usually in the form of fine, extremely closely interwoven fibrils, disposed irregularly; occasionally as stronger, straiter fibres, having a uniform width of 0.001—0.03"; not unfrequently also in the shape of plates resembling epidermis-scales (fibrinous flakes, Nasse). I noticed *crystals* of a red colour in normal blood in the year 1849 ('Zeitsch. für wiss. Zool.,' I, p. 266, Todd's 'Cyclop. of Anat.' Art. 'Spleen,' p. 792, and Mikros. Anat., II, p. 280), in the blood of the Dog, of Fishes, and of a *Python*; sometimes *within* the blood-globules, sometimes free in the blood, particularly of the liver and spleen. Their occurrence in the former situation especially, appeared to me to prove that they exist in the blood during life, and consist of a substance allied to *hematin* and *hematoidin* (Virchow); but I also showed that they were soluble in acetic and nitric acids, and in caustic alkalies, and consequently that they are not identical with *hematoidin*. Quite recently, Funke, without being acquainted with my observations, has independently noticed these crystals in the blood of the Horse, Dog, Man, and Fishes, and instituted very careful researches with respect to them ('*De sanguine venæ lienalis*,' Lips., 1851; also in Henle's 'Zeitsch. N. Folge,' Bd. I, p. 172, and 'Neue Beob. üb. d. Krystalle d. Milzvenen- u. Fischblutes,' *ibid.*, II, p. 199), by which it is rendered certain that these crystals arise *out of the body*. For more particulars concerning them reference may be made to the works cited, and I will here only further notice that the crystals are most readily formed, if a drop of blood covered with a piece of glass be allowed nearly to dry, and a small quantity of water be added; moreover, that the crystals are formed not only in the blood of the splenic vein, as it at first seemed, but in other kinds of blood also, in Man (I can obtain crystals in my own venous blood) and other animals. They assume the form of red or



pale needles, columns, and plates, probably belonging to the rhombic system (Funke), and also tetrahedral (in the Guinea Pig, Lehmann, Funke), and are characterised by their little permanency, since they perish in the air, are very soluble in water, and also in acetic acid, alkalies, and nitric acid. Those found by me in the blood of the Dog resisted the action of water, but I do not think that they were of a different nature, and I should be inclined to refer this difference to the greater resistance of the blood-globules themselves. Funke believes that they consist of the albuminous contents of the blood-cells in combination with *hematin*, relying, for support to this opinion, especially upon their numbers, their occurrence in blood-cells, their formation, as observed by him, from aggregations of blood-cells, and their absence from the serum of the blood; but I cannot regard this hypothesis as at present fully established, and it appears to me that further proof is required before we should admit the existence of crystals from the substances in question, and the more so, because colourless crystals are also formed in the blood, quite independently of the blood-cells. Robin and Verdeil, moreover, assert that they have also obtained crystals from the serum of the blood; and the quantity of the crystals is by no means opposed to the notion that they are derived from a salt of the blood merely tinged with *hematin*, since, in the case of *fibrin* we see that not much of a substance is required to occupy a large space.]<sup>1</sup>

<sup>1</sup> [Reichert was the first to draw attention to the occurrence and nature of crystallised, albuminous matters coloured with *hematin*, in his 'Beobachtungen über eine eiweissartige Substanz in Krystallform,' Müller's 'Archiv,' 1849. These were tetrahedrons of as much in some cases as  $\frac{1}{15}$ " long, and occurred upon the placenta and foetal membranes in a Guinea Pig. Their albuminous nature was confirmed by Schmidt and Buchheim; subsequently, 'Bericht,' Müller's 'Archiv,' 1852, Reichert states that he has again found the crystals in the same locality, and that he has convinced himself, by further experiments, that the difference observed between his crystals and those described by Kunde and Lehmann, arose entirely from the action of the spirit in which his first specimens had been preserved. Reichert observed the development of crystals of the same kind, though smaller, in fresh blood taken from the heart of the Guinea Pig.

In connexion with this subject, Dr. Ayres has recorded a very interesting observation with regard to the occurrence of prismatic, more or less red crystals, in a band of olive-green, almost black matter, having the appearance of coagulated blood at the margin of the placenta of the Bitch ('Quarterly Journal of Mic. Science,' vol. i, p. 299, with figures). See also the papers of Dr. Parkes ('Med. Times and Gazette,' 1852) and of Dr. Sieveking ('Brit. and For. Med.-Chir. Rev.,' 1853) on this subject.—Eds.]

## § 223.

*Physiological remarks.*—*The development of the blood-vessels* takes place, essentially on the same type, in the heart, arteries, and veins. The rudiments of all these vessels, and even of the heart, are *solid tracts of cells* of greater or less thickness, which, by the liquefaction of their interior substance, and the metamorphosis of the central cells into blood-globules, become *cavities*, which shortly coalesce, and constitute a continuous passage for the blood. The heart and vessels having remained for some time in this condition of cellular tubes, in which state the former, moreover, exhibits contractions, the cells composing the walls, with the exception of the innermost, begin to elongate into fibres, and to represent the divers fibrous tissues and tunics. At the same time the vessels become thicker and increase in circumference, which at first is still to be referred to an increase in the number of the cells, but subsequently, is brought about chiefly, or even solely, by the growth of their elements in length and thickness. In the fifth month of foetal life, all the larger and medium-sized vessels are formed, with their tunics and tissues, and it is impossible to perceive any vestige of formative cells. The tissues, however, appear to be still far from completion, the muscular fibres being short and delicate, and instead of the strong elastic fibrous networks, we perceive only finer and the finest fibrils, and in the place of the elastic membranes themselves, only layers of more or less coalescent, fusiform cells. The internal longitudinal fibrous membrane alone, in many vessels, is at this time demonstrable as a homogeneous elastic tunic immediately under the *epithelium*, but in the smaller vessels this is wanting, and is replaced by a layer of elongated cells, out of which it appears to be developed. It is thought that similar cells are occasionally to be seen also in the adult, in which the elastic inner membrane is likewise merged. The muscular fibres of the heart arise, as in other situations, from the union of cells, but I have not yet seen how their anastomoses are formed, whether from a branching of certain formative cells, or by the lateral apposition of small rows of cells—probably in both ways.

The mode in which the development of the *capillaries* is effected, differs *in toto* from that observed in the larger vessels.

The former, as Schwann and I have shown, proceed from the coalescence of single cells. At the primary origin of these vessels, tubules of some size are formed, at first by the successive apposition in a straight line and the coalescence of rounded-angular cells, and the subsequent absorption of the *septa* and of the contents, but not of the *nuclei*, which remain attached to the former cell-membrane, now become the capillary tunic. Delicate pointed processes then project from the walls of these little vessels, which rapidly elongate, and meeting similar pointed processes of stellate cells dispersed in the surrounding tissue, coalesce with them. At the same time, the other processes of these cells join, so that there is soon produced a network of stellate cells, continuous with the already formed capillary tube or tubes. This net, however, is never spread, for the prolongations, given off from already formed and pervious capillaries, and the neighbouring cells connected with them, are constantly and rapidly transformed into fresh capillaries, by the continual increase in size of the coalescing processes from their point of origin onwards, and their becoming hollow. In this way are produced vessels which are at first extremely fine, and admit only blood-plasma—true *vasa plasmatica s. serosa*; but they rapidly enlarge, until at last the blood-globules are transmitted through them, and the *capillaries* are perfected. Owing to the circumstance, that while these processes of the stellate formative cells thus enlarge, the bodies of the cells do not expand in a corresponding manner, but appear as simple nodular points in the vessels, all vestige of the original cellular network is gradually lost, and subsequently the situation of the bodies of the cells can only be determined by the position of the persistent *nuclei*. When finer tubules have once been formed from the previous larger capillaries, the facilities for the passage of the blood are continually undergoing augmentation, inasmuch as new stellate cells are constantly enlarging into vessels, whilst, at the same time, fresh vascular material is as constantly furnished by the apposition of new cells. New connexions also are frequently formed between capillaries which are already pervious, partly by the direct meeting of prolongations from them, partly also by the mutual connexion of formative cells lodged in their interstices, whence, of course, the original net is rendered closer. This

mode of development, so far as I have seen, obtains in all animals, without exception, in which capillaries exist, and the various objections offered to the exposition given by Schwann and myself, have chiefly arisen in the notion, that every network connecting the arteries and veins in embryos, is a capillary plexus. This, however, is by no means the case, and consequently the circumstance, that the wrongly termed capillaries of the germinal area arise after the type of the larger vessels, is not an objection of the least weight in opposition to us.

The capillaries of the lymphatic system, which may be readily traced in the tail of batrachian *larvæ* (fig. 228), exhibit, essentially, precisely the same mode of development as those of the blood-vascular system (fig. 294), except that anastomoses are rare in them, and its course is more limited to the mutual apposition of fusiform cells, or of cells furnished with three principal processes. Observations are wanting with respect to the larger trunks of this system, although it cannot be doubted, that they follow exactly the same course as the blood-vessels. Engel (l. c.) has lately treated of the *lymphatic glands*, and states, that they proceed from lymphatic vessels which throw out buds and are much convoluted.

Fig. 294.

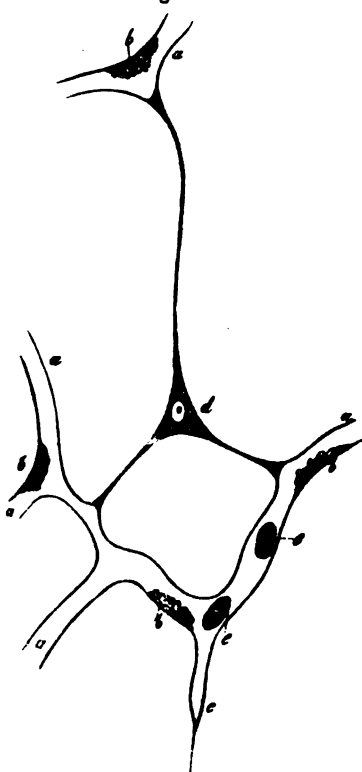



Fig. 294. Capillaries from the tail of a Tadpole: *a*, completed capillaries; *b*, cell-nuclei, and remains of the contents of the original formative cells; *c*, caecal process of a vessel; *d*, stellate formative cell, connected by three prolongations, with three processes of pervious capillaries; *e*, blood-globules, still retaining some granular contents;  $\times 350$  diam.

The *development of the blood-corpuses* is pretty accurately known, in the embryo, as concerns its principal stages. The first blood-corpuses, in the Mammalia and other Vertebrata in general, are nucleated, colourless cells, with granular contents; they are perfectly identical with the formative cells of every part of the young embryo, and arise in the originally solid rudiments of the heart and great vessels, in some situations very early, in others somewhat later, by the separation of the central cells contained in the rudiments, in consequence of the development of a fluid (the first blood-plasma) between them. The first perfect blood-corpuses arise from these colourless-cells, which lose their granules, and, except the *nucleus*, become filled with *hematin*. These colourless, nucleated, primary blood-cells are spherical, of a deeper colour than the blood-corpuses of the adult, and larger (in a foetal Lamb,  $3\frac{1}{2}''$  long, most of them were  $0.005$ — $0.0065''$ , the minority  $0.0025$ — $0.0035''$ ; in a human embryo,  $4''$  long, according to Paget,  $0.004$ — $0.007''$ ), but in all other respects present the same conditions, and, with their colourless formative cells, at first constitute the sole elements of the blood. But many of them soon begin to multiply by *division*; to this end they grow into elliptical, or even flattened cells,  $0.009''$  long,  $0.004$ — $0.006''$  broad, bearing a deceptive resemblance to the blood-corpuses of the Amphibia; produce 2, rarely 3 or 4,

Fig. 295.



rounded *nuclei*, and afterwards divide by one or several annular constrictions, into 2, 3, or 4 new cells. When the liver begins to be formed, this multiplication of the blood-cells in the entire mass of the blood ceases, and in a short time (in a foetal Lamb,  $11''$  long) all trace even of their development out of colourless formative cells is lost; whilst at the same time, as Reichert supposed and I have directly proved, a very active formation of blood-cells is set up in the *liver*, a reason for which

Fig. 295. Blood-corpuses of a foetal Lamb,  $3\frac{1}{2}''$  long: *a*, bi- and tri-nucleated, large, coloured blood-globules, in various stages of division; *b*, larger spherical, coloured blood-cells, one with a nucleus undergoing spontaneous division; *c*, a smaller one of the same kind;  $\times 300$  diam.

may be found in the circumstance that, at this time, all the blood from the umbilical vein, which supplies the embryo with new organisable materials, first flows into the liver, instead of entering the general circulation as before. In proportion to the extent in which this cell-formation in the hepatic vessels is carried on, does the self-multiplication of the blood-corpuscles become less and less considerable; and instead of it, a *new formation* of free colourless nucleated cells, having a mean size of 0.003—0.004<sup>'''</sup>, and an extreme diameter of 0.0015—0.006<sup>'''</sup>, is observed to take place in the blood and immediately around *nuclei*, which also occur in the free condition; and which cells afterwards, still for the most part in the liver, are transformed, by the development of colouring matter in their contents, into coloured, nucleated blood-cells, either immediately or after they have multiplied in a similar way to that which the coloured corpuscles had previously followed. This new formation of blood-corpuscles in the liver, with which the considerable size of, and the abundant supply of blood to, the embryonic liver, is perfectly in accord, continues probably throughout the foetal life; at all events, I have found it in quite old embryos in Mammalia, and also in newly-born children, although it probably diminishes, *pari passu*, in connexion with the appearance of the *ductus venosus* (which, according to Rathke, is a secondary formation) and its enlargement, because, through it, a considerable portion of the blood from the umbilical vein enters the circulation directly, and is diverted from the liver.

The further development of the nucleated, spherical blood-cells of the embryo, which have originated in either way, takes place in this manner: the cells gradually, and either directly or after they have multiplied in the mode above described, become more and more flattened, and even present slight excavations, whilst their nuclei manifestly diminish, and on the application of acetic acid, exhibit a great tendency to disintegration. Ultimately, the *nuclei* disappear altogether, and the blood-cells become *non-nucleated*, like those of the adult, of which they all soon assume the form, being at first somewhat irregular. With respect to the period at which these non-nucleated coloured cells make their appearance, it must be remarked that in a foetal Lamb, 3 $\frac{1}{4}$ ''' long, I could perceive none

of them, nor could Paget in a human embryo, measuring 4''', in the fourth week. In foetal Lambs, 9''' long, they were still very scanty, whilst in those 13''' in length they constituted by far the majority of the blood-cells; and in a human embryo, at three months, they formed, in the hepatic blood  $\frac{1}{4}$ , and elsewhere about  $\frac{1}{8}$ — $\frac{1}{5}$  of the coloured corpuscles. In still older embryos, they preponderate greatly, so that in foetal Lambs of 5—13''' in length, the nucleated coloured cells in the hepatic blood constituted not more than  $\frac{1}{4}$  or  $\frac{2}{3}$  of the blood-cells, and in the rest of the blood, in the larger embryos, did not occur more abundantly than the lymph-globules in the blood of the adult animal. At what time, in the human embryo, the nucleated coloured cells become more rare and disappear, is not yet ascertained, although Paget saw them still tolerably numerous in one instance in an embryo of five months. The blood of the larger Mammalian embryos contains, not only in the liver, but also elsewhere, besides the coloured blood-globules, other colourless cells in great number, and often as numerous as the coloured, which cells, there can perhaps be no doubt, are derived mainly from the liver, in which, even in foetal Lambs 13''' long, the colourless and slightly coloured, nucleated blood-cells constitute perhaps one third of the whole blood-corpuscles; and in the latter periods of foetal life, are probably also derived from the lymph. Whether these cells are metamorphosed into coloured ones, is by no means determined, this much only having been ascertained, that the transitional forms between the two, so numerous in the hepatic blood, are wholly wanting in the rest of that fluid.

*The origination of the blood-globules after birth and in the adult*, notwithstanding the great pains specially devoted to this point, still remains one of the most obscure parts in the history of the blood-cells; in my opinion, however, the notion which assumes that the red blood-cells proceed from the smaller chyle-corpuscles, which lose their nuclei, become flattened, and have *hematin* produced in them, is the one most deserving of credit. These cells are about of the same size as the blood-globules, or even rather smaller, have the same kind of membrane as the latter, are flattened, and not unfrequently of a faint yellow colour, and consequently may, as we see in the colourless blood-cells of the embryo, pass without any considerable change

into coloured cells. Where and how this takes place, no one has seen ; and notwithstanding all the trouble and care that I have devoted to the subject, I have never noticed a nucleated coloured blood-cell in the adult. The only thing of the sort that I have met with, has been this, that in the pulmonary veins, and occasionally also in other blood, the smaller lymph-corpuscles were in many instances pretty distinctly coloured, much more so than in the thoracic duct, so that, except from their faintly granular aspect, they were scarcely distinguishable from the true blood-cells lying on their flat side ; and the more so, because they contained somewhat smaller *nuclei* than elsewhere ; but even this circumstance is insufficient to decide the question. The following points, however, may be adduced as presenting very important analogies : 1. that in all the lower Vertebrata, very distinctly for instance in the Amphibia, even in adult animals, the origination of nucleated blood-cells from the lymph-corpuscles may be observed ; and 2. that, in the human embryo also, the formation of the coloured blood-globules from colourless cells very closely resembling the lymph-corpuscles, has been demonstrated by me in the most decisive way. If to this it be added, that there is not the slightest evidence of an independent, or other kind of origination of blood-cells, it may perhaps be considered quite justifiable if I maintain their origination from the lymph-corpuscles ; and, in order to explain the reason why the transition itself has not yet been observed, if I broach the supposition that it may take place too rapidly to be in any way obvious with our means of observation.

Although in what has been said, I express myself in favour of the formation of the red blood-cells from the elements of the lymph and of the chyle, I would by no means assert that *all* the elements of those fluids become blood-cells at *every* period of post-embryonic life. The microscopical investigation of the blood would rather show, that they invariably contain a certain number of larger pale cells with several *nuclei*, or a single *nucleus* disintegrated by acetic acid, of which, although they are certainly derived from the chyle, or are metamorphosed elements of it, it is perhaps impossible to suppose that they ever become blood-cells. This being established, it is a question whether the change of the blood-cells, their formation



and their dissolution, is not perhaps *much slower than is commonly assumed*, and whether they are not elementary parts of a more stable nature than is supposed. I am unable to throw any decided light upon this point, and will merely remark that in any case, so long as the growth of the body goes on, and the quantity of blood is augmented, an energetic formation of blood-cells must take place; in opposition to which it is quite unascertained whether, in this period of life, blood-cells are dissolved; on which account, also, it cannot be stated how many of the elements of the chyle undergo the metamorphosis into blood-corpuscles. In the adult, only this much should be regarded as certain, that when from any cause the quantity of blood has become diminished, it may be replaced together with the red blood-cells; whilst it is altogether unascertained whether, under the usual conditions, anything like an energetic solution and re-development of those cells takes place. As their formation cannot be definitively observed, nothing remains by which the question can be decided but observations respecting the dissolution of the blood-globules; these observations, however, have by no means tended to demonstrate the occurrence of a constant change of the elements of the blood, taking place at short intervals; for although in the spleen of many animals a vast quantity of blood-globules undergoing disintegration is met with, the frequent and regular recurrence of a dissolution of those bodies in that organ has not yet been proved. Taking everything into consideration, I am therefore of opinion, that the question as to when, and to what extent, blood-corpuscles perish and are again formed in the adult, cannot be definitively decided from the facts at present in our possession, although I am inclined to think that the elements of the blood are not altogether such perishable structures as is commonly believed.

I have still to mention, that, quite recently, the view that the blood-globules are formed independently in the blood, out of colourless cells, is advocated by various authorities. Lehmann and Funke rely, the former on the large amount of colourless cells in the blood of the hepatic veins, the latter on the similar condition of the blood in the splenic vein, and they both consider it probable, that a new formation of red blood-cells takes place within the blood-vessels of the liver and spleen. It

appears to me, that this question must be approached with very great care, so long as the transition of the colourless cells into blood-corpuscles has not been directly observed, which in this case has by no means been done. At present we are far too little acquainted with the vital relations of the colourless cells in the blood to conclude, merely from their existence, upon a formation of red blood-cells, and especially when we remember the facts stated; since, as I have elsewhere shown (*Mikros. Anat.*, II, 2, p. 292), it is very possible that the colourless cells in question, in the splenic and hepatic veins, are derived from the parenchyma of the spleen, are only accidental constituents of the blood, and as their frequently multiple *nuclei* seem to indicate, undergo no further developments, but are in a state of gradual removal.

The view propounded by Gerlach and others, that the cells containing blood-corpuscles, which are met with frequently in the spleen and occasionally in the blood, have a relation to the formation of blood-cells, must decidedly be rejected, since the blood-corpuscles of all these cells are in a state of dissolution.<sup>1</sup>

<sup>1</sup> [It is somewhat surprising that Professor Kölliker should not have thought it necessary to consider the doctrine advocated by Wharton Jones (l. c.), the truth of which the latter writer may, we think, be almost said to have demonstrated, viz. that the coloured corpuscle of the blood of Mammalia is the homologue of the "nucleus" of the colourless corpuscle of the same blood, and of the "nucleus" of the corpuscle of the blood of oviparous Vertebrata and of Invertebrata.

If we consider that it is admitted on all sides: 1. that the colourless corpuscle of Mammalian blood and the lymph-corpuscle are identical. 2. that these are identical with the colourless and lymph-corpuscles of other Vertebrata. 3. that in the latter, the coloured blood-corpuscle proceeds from the colourless corpuscle:—only three hypotheses can well remain with regard to the relation of the blood- and colourless corpuscles of Mammalia—viz.: that in the text; that which supposes that they have an independent origin; and that advocated by Wharton Jones. The two former of these hypotheses are deficient in all positive basis, and the first appears to us extremely improbable. On the other hand, the third theory appears to be in harmony with all the known facts, and opposed to none. It is, shortly, that in Vertebrate animals, the blood-corpuscle is found in three successive phases of development: that of a cell with granular contents—the granules being either fine or coarse; that of a cell without any contents except the "nucleus"—the cell being either colourless or coloured; and, finally, in that of a free cellæ-form "nucleus," which is either colourless or coloured. We have thus three *phases*, each of which has two *stages*. The phases of granule-cell and nucleated cell are met with in all Vertebrata; *Amphioxus* alone going no further than the colourless stage of the second phase. In the oviparous Vertebrata the blood-corpuscle presents the two first phases in both their stages. In the Mammalian cell, the phases exist in all their

[*The investigation of the heart*, as regards the muscular fibres themselves, is easy, and their anastomoses will be found without difficulty in every carefully made preparation. But great difficulties attend the tracing of the course of the fibres in that organ. Hearts that have been macerated in weak spirit are best adapted to this purpose; the boiling in water, also, of the recent heart, or of hearts that have been previously in salt for some weeks, has been long recommended, a method, instead of which Purkinjé and Palicki advise the boiling in a solution of common salt, or still better of sulphide of lime; whilst Ludwig, after removing the *pericardium*, lays the heart in water, and repeats this maceration each time after the removal of a layer of the muscular substance, using at the same time slight pressure. For the *blood-vessels*, the tearing of them into lamellæ with the forceps and scalpel, which alone was formerly employed, is not sufficient; the examination of transverse and longitudinal sections of the entire wall, being, in addition,

stages; but two of the latter, that of the coloured nucleated cell and that of the colourless free cellæ-form nucleus, occur but rarely and scantily. That the red corpuscle of Mammals is the cellæ-form "nucleus" of the nucleated-cell stage, set free by the bursting of this cell itself, and become filled and red by the secretion of globulin and colouring matter into its interior, is strongly evidenced by the correspondence in size between the "nucleus" and the red corpuscle, as the latter varies in different animals. In the Elephant the red corpuscle is very large, and in the Goat it is very small; the "nucleus" of the colourless corpuscle varies correspondingly. There is a similar correspondence in form; and it is remarkable that in the Paco, whose red corpuscles are, when fully formed, elliptical, while the nuclei of the colourless corpuscles are for the most part circular, younger less-coloured red corpuscles are met with, which are circular and correspond in all respects with the "nuclei" of the colourless corpuscles. In dealing with objections which might be raised from the chemical and physical differences between the red corpuscles and the "nuclei," Wharton Jones shows that these almost disappear if we select the youngest state of the red corpuscle as one term of the comparison.

It is rare to meet with the transition stage between the phase of nucleated cell and that of "free cellæ-form nucleus," in the blood of Man. We have, however, recently recorded an observation of the kind in unaltered blood ('Quarterly Journal of Micr. Science,' vol. i, p. 145), where a well marked red corpuscle was observed within what would otherwise have been regarded as a colourless corpuscle, and occupying the place of its "nucleus;" and we may add that the same subject has recently afforded, in blood taken from the finger one or two hours after breakfast, a very considerable proportion of such corpuscles with red "nuclei," affording every transitional stage between the ordinary colourless corpuscle and the free red cellæ-form nucleus. For these observations, however, water and very dilute acetic acid were added to the blood.—Eds.]

indispensably requisite. The best mode of proceeding is to dry portions of the vessel stretched out upon paper, in which condition sections may be made even of very small vessels, which are to be again moistened with water, and if it be wished to study the muscular structure, treated with acetic or nitric acid of 20 per cent. (Weyrich), or else with caustic soda, by which reagents the elastic tissue is also very beautifully displayed. For the speedy, isolated demonstration of the *epithelium*, the elastic inner membrane, and the muscular tunic, the larger vessels at the base of the brain have appeared to me to be the best adapted; the elastic membranes of the *t. media* are readily isolated by maceration in strong acetic acid. Its muscular fibres are always to be seen upon simple teasing out; or else readily, upon the addition of nitric acid. For the study of the capillaries, the brain, the *retina*, the Tadpole and embryos are above all to be recommended; for their development, the Tadpole, the *allantois* of embryos, and the vascular capsule of the *lens*. The *blood* should be examined, when it is possible, in the serum itself, afterwards with the various reagents above noticed; and regard must be paid to the great tendency to change possessed by its elements. I inject lymphatic glands with *carmine* and size, or with sealing-wax and resin dissolved in alcohol; I also recommend sections of preparations hardened in alcohol.]

*Literature.*—J. C. Fr. Wolff, in the ‘Memoirs of the Petersburg Academy,’ for the years 1780—92; J. Reid, Art. ‘Heart,’ and B. Searle, ‘Fibres of the Heart,’ in ‘Cyclop. of Anat.,’ II; Parchappe, ‘Du Cœur, de sa structure et de ses mouvements,’ Paris, 1844; C. Ludwig, ‘Bau der Herzventrikel,’ in ‘Zeits. für rat. Med.,’ Bd. VII, p. 189, and ‘Ueber die Herznerven der Frösche,’ in Müller’s ‘Archiv,’ 1848, p. 139; Luschka, ‘Das Endocardium und die Endocarditis,’ in Virchow’s ‘Archiv,’ IV, p. 171; Remak, ‘Ueber die Ganglien des Herzens,’ in Müller’s ‘Archiv,’ 1844, p. 463, and ‘Ueber den Bau des Herzens,’ *ibid.*, 1850, p. 76; R. Lee, ‘Memoir on the ganglia and nerves of the heart,’ London, 1851 [and ‘On the Nerves which supply the Muscular Structure of the Heart,’ ‘Proceed. Roy. Soc.,’ Nov. 17, 1853, vol. vi, No. 99, p. 337]; Bidder ‘Ueber die Nervencentra im Froschherzen,’ in Müller’s ‘Archiv,’ 1852, p. 163; R. Wagner, ‘Symp. Ganglien des

Herzens,' in 'Handw. d. Phys.,' part XIII, p. 360; F. Räschel, 'De arteriar. et venar. struct.,' Vratial., 1836, Diss.; Kölliker, 'Ueber die Muskulatur der Gefässe,' in 'Mitth. d. Zürch. naturf.,' Ges., 1847, and 'Zeits. f. wiss. Zool.,' I; 'Sur le developpement des vaisseaux capillaires sanguins et lymphatiques,' in 'Ann. d. Sc. Nat.,' 1846; C. Donders and H. Jansen, 'Unters. über die krankh. Veränder. d. Arterienwände,' in 'Archiv. f. phys.,' Heilk., VII, p. 361, also in 'Nederl. Lancet,' I, p. 473; Jaesche, 'De telis epithelialibus in gener. et de iis vasorum in specie,' Dorp., 1847; J. Engel, 'Beiträge zur Anatomie der Gefässe,' in 'Zeits. der Wiener,' Aerzte, 1847, pp. 152, 315, 428, 1849, p. 121; R. Remak, 'Histologische Bemerkungen über die Blutgefässwände,' in Müll. 'Arch.,' 1850; J. M. Schrant, 'Ontleedkundige Studien over de aderlijke bloedvaten,' in 'Tijdschr. d. Maatsch. tot bevord. d. geneesk.,' 1850, p. 2; M. Schultze, 'De arteriarum structurâ,' Gryph., 1850; H. Weyrich, 'De texturâ et structurâ vas. lymphatic.,' Dorpat, 1851; Fr. Wahlgren, 'Vensystemets allmänna Anatomi,' Lund., 1851; F. Noll (and Ludwig), 'Ueber den Lymphstrom u. die Anatomie der Lymphdrüsen,' in Henle's 'Zeits.,' IX, p. 52; Remak, 'Ueber blutleere Gefässe im Schwanze d. Froschlarven,' in Müll. 'Arch.,' 1850, pp. 79, 183; J. Engel, 'Bau u. Entwicklung der Lymphdrüsen,' in 'Prag. Vierteljahrsschrift,' 1850, p. 111; O. Heyfelder, 'Ueber den Bau der Lymphdrüsen,' Bresl., 1851; H. Nasse, Art. 'Chylus, Lymph, u. Blut,' in Wagner's 'Handw. d. Physiol.,' Bd. I.; H. Müller, 'Beiträge z. Morphologie des Chylus u. Eiters,' in 'Zeits. f. rat. Med.,' 1845; R. Wagner, 'Beiträge z. vergl. Physiologie d. Blutes,' Leipzig, 1833, and 'Nachträge zur vergl. Physiol.,' I, *ibid.*, 1838; J. C. Fahrner, 'De globulorum sanguinis origine,' Turici, 1845; A. Kölliker, 'Ueber die Blutkörperchen eines menschl. Embryo und die Entwickl. d. Blutk. b. Säugethieren,' in 'Zeitsch. f. rat. Med.,' Bd. IV. 1846, p. 42; C. Donders u. J. Moleschott, 'Untersuch. ü. d. Blutkörperchen,' in the 'Holländ. Beiträgen,' III, 360; Donders, in 'Ned. Lancet,' 1846; Wharton Jones, 'The blood-corpusele considered in its diff. phases of development,' in the 'Phil. Trans.,' 1846, II, p. 82. Besides which, should be consulted, the hand-books of E. H. Weber and Henle, and the recent embryological works of Vogt, Remak, Prévost, Lebert, and Courty.

## OF THE HIGHER ORGANS OF SENSE.

## I.—OF THE ORGAN OF VISION.

## § 224.

The *visual organ* consists of the *eye-ball*, or the proper sensitive apparatus, and the *accessory parts*, some for its protection, some for its movement: viz. the *eye-lids*, the *ocular muscles* and the *lachrymal organs*. The *eye-ball* itself is a very complex organ, into the constitution of which nearly all the tissues of the body enter. It is composed essentially of three tunics: a *fibrous*—the *sclerotica* and *cornea*, a *vascular*—the *chorioidea* and *iris*, and a *nervous*; and of two internal refractive media—the *vitreous humor* and the *crystalline lens*.

## A. OF THE EYE-BALL.

## § 225.

*Fibrous tunic of the Eye.*—The external envelope of the eye-ball is formed by a tough, fibrous membrane, composed chiefly of connective tissue, which, to outward appearance, is divisible into a smaller, anterior, transparent portion—the *cornea*; and a larger, opaque, posterior part—the *sclerotic*; but, as shown by its development and more intimate structure, is to be regarded as a membrane continuous throughout.

The *sclerotica*, also termed the *tunica albuginea*, is a white, very tough and strong, fibrous membrane, which gradually diminishes in thickness as it advances forwards from the posterior part of the eye, where it is directly connected with the sheath of the optic nerve, although it is again strengthened, in front, by the expanded tendons of the *recti* muscles, with which it is blended, afterwards becoming continuous with the *cornea*. When boiled, it affords common gelatin, and it consists of true connective tissue, the fibrils of which are very

distinctly manifest when the structure is teased out, or transverse sections are treated with acetic acid. The bundles themselves are straighter, in other respects as in the tendons,

Fig. 296.

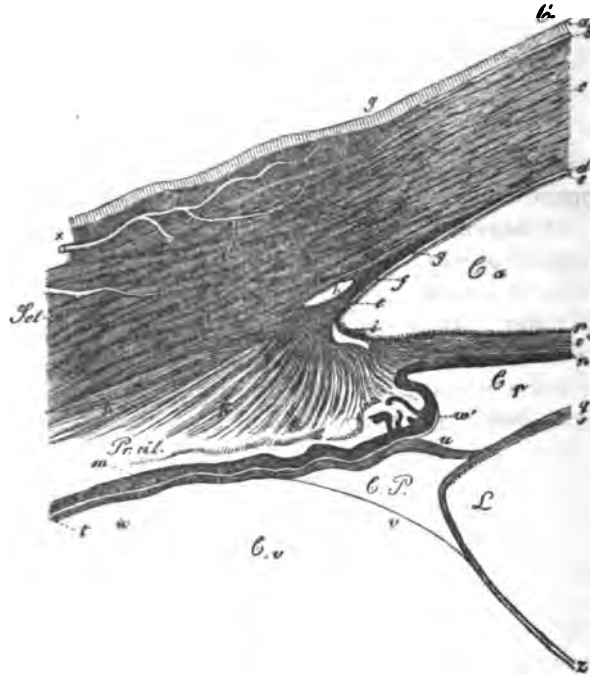


Fig. 296. Transverse section through the tunics of the eye, in the region of the ciliary processes,  $\times 12$  diam.: *Scl.*, sclerotica; *C.*, cornea; *Pr. cil.*, processus ciliaris; *C.a.*, anterior chamber; *C.p.*, posterior chamber; *C.v.*, corpus vitreum; *C.P.*, canalis Petitii; *L.*, lens; *I.*, iris; *a.*, conjunctiva cornea, epithelium; *b.*, homogeneous lamella beneath, continuous with the conjunctiva sclerotica, *x*; *c.*, fibrous layer of the cornea; *d.*, membr. Demoursii; *e.*, indication of its epithelium; *f.*, termination of the membrana Demoursii, and its transition into peculiar fibres, *g.*, which are continued at *i.*, upon the iris constituting the *lig. pectinatum iridis*; *h.*, canalis Schlemmii; *k.*, musculus ciliaris s. tensor chorioideæ springing from its inner wall, *l.*; *m.*, pigment layer of the ciliary processes; *n.*, the iris; *o.*, fibrous layer of the iris; *p.*, indication of its epithelium; *q.*, anterior wall of the capsule of the lens; *z.*, posterior wall; *s.*, indication of the epithelium of the capsule; *t.*, zonula Zinnii, or anterior thickened portion of the hyaloid membrane; *u.*, its free anterior lamina (proper zonula), inserted into the border of the lens; *v.*, its posterior lamina blended with the posterior wall of the lenticular capsule; *w.*, colourless epithelium of the ciliary processes; *w'*, anterior termination of this epithelium. In part after Bowman.

being intimately united and conjoined into larger, thinner or thicker, flattened bands, which are disposed in the transverse and longitudinal directions, alternating pretty regularly through the entire thickness of the tunic and consequently, in vertical sections, producing a lamellated structure. Truly independent *lamellæ*, however, nowhere exist, the various longitudinal layers having numerous points of connexion, as have also the transverse *laminae*. However, on the external, but more particularly on the internal surface of the *sclerotic* the longitudinal fibres are collected into somewhat thicker plates, and thus acquire a greater independence.

Numerous fine elastic elements pervade the connective tissue of the *sclerotic*, of the same form as those in the tendons and ligaments (§ 80), viz.: as a network of the finer or finest fibres, in which the sites of the original formative cells are indicated by enlargements with nuclear rudiments, so that the whole often very closely resembles anastomosing, fusiform and stellate cells. During life, the elements of this network occasionally appear still to possess cavities and fluid contents; at any rate in portions of a dried sclerotic, air is always to be seen in the bodies of all the cells (these are the cretaceous corpuscles of Huschke), and consequently, in this situation the opinion propounded by Virchow, that channels of this kind are a sort of nutritive canals, would appear to be completely justified, and the more so, because the vessels of this tunic are at all events very scanty. They are derived chiefly from the ciliary arteries and from those of the muscles of the eye-ball, and constitute, as I and Brücke have found, a tolerably wide-meshed network of capillaries of the last order. Bochdalek has recently described nerves (and also Rahm, in the Rabbit) in the sclerotic, but with Arnold and Huschke, I have hitherto been unable to satisfy myself that these are anything more than branches, on its inner side, running to the ciliary ligament.

The *cornea* (fig. 296 C) is perfectly transparent, still more compact and tough than the *sclerotic*, and is composed of three special layers, viz.: 1. of the *conjunctival membrane* (*conjunctiva corneæ*); 2. of the *proper cornea*; and 3. of the *membrane of Descemet*; the first and last of which are formed of an *epithelium* and a subjacent structureless membrane, and the middle one of a fibrous tissue of a peculiar kind.



The *proper cornea*, or the fibrous layer (fig. 296 *c*), by far the most important part of the whole tunic, consists of a fibrous substance closely allied to connective tissue, but which, according to J. Müller, affords when boiled, not *gelatin*, but *chondrin*. Its elements, pale bundles, 0.002—0.004" in diameter, in which, at least when teased out, finer fibrils are usually perceptible, sometimes more and sometimes less distinctly, are united into flat bundles. These bundles, which have their flat sides always parallel with the surface of the *cornea*, decussate in various directions, and exhibit, if not complete *lamellæ*, yet a distinctly laminated structure, owing to which the *cornea* is very readily torn and penetrated in the direction of its surfaces, and with great difficulty in that of its thickness. The correspondence of the corneal elements with connective tissue is also shown by the following circumstances: 1. that it is continuous at the border, by its elements, which in that situation follow principally a radiating direction, *directly and without interruption* with the similarly disposed fibres of the *sclerotic*, so that there cannot be the least question as to the non-existence of any natural demarcation between the two tunics; and 2. as Virchow was the first to show, that a great number of anastomosing, fusiform and stellate, nucleated cells lie among its bundles, just as they do in undeveloped elastic tissue (connective tissue-corpules of Virchow), which also exist in the *sclerotic*, though more branched. It can perhaps scarcely be doubted, that the nutritive fluid, with which the *cornea* is constantly imbued in considerable quantity, and which, in the large eyes of animals, may be directly demonstrated by expression, is in great measure conveyed and distributed in the interior, by the cells in question; a view which is only strengthened by the knowledge that these cells, in morbid conditions of the *cornea*, very frequently contain oil-drops, and occasionally, according to Donders, even pigment, in their interior. The "corneal tubes" injected by Bowman in the eye of the Ox and in that of Man must not be confounded with this cellular network, and are probably to be explained as artificial dilations of the minute interstices which normally exist between the structural elements of the *cornea*, and which it is thought may occasionally be perceived on microscopical examination.

The *conjunctival membrane* of the *cornea* (fig. 296 *a, b*) is

composed principally of a soft, laminated *epithelium*, 0·023—0·050'' thick, in which the deeper layers of cells are elongated and placed vertically upon the *cornea*, whilst the middle ones are more of a rounded form, and as they approach the surface, pass into a layer, 0·008—0·01'' thick, corresponding to the horny layer of the *epidermis*, composed of plates 0·01—0·14'' in size, though still nucleated and soft. Many of these latter cells, as I have shown ('*Zeitsch. f. wiss. Botanik*,' II, p. 80), in consequence of their mutual pressure, present larger or smaller pits, like certain cells in the urinary bladder, so as when viewed on the side often to exhibit a stellate figure, which induced Valentin, who first noticed this form, to regard them as cells with processes. Beneath the *epithelium*, which, after death, is very soon rendered opaque by both water and acetic acid, is a *structureless lamella*, first described by Bowman (anterior elastic *lamella*, of Bowman), 0·003—0·004'' thick, which is especially evident in vertical sections and in folds of thin superficial sections, upon the addition of alkalies, although it is by no means so sharply defined from the true *cornea* as the membrane of Descemet, nor does it seem to be of the same import as that membrane, but is perhaps no more than the remainder of the vascular layer of the corneal *conjunctiva*, which exists at an earlier period. Arched fibres, like rigid bundles of connective tissue or elastic fibres, are occasionally visible, given off from it, and penetrating the *cornea* to a certain distance, where they are lost.

The *membrane of Descemet* or *Demours*, also termed the *membrane of the aqueous humor* (*memb. Descemeti*, *s. Demoursii s. humoris aquei*) (fig. 296 *d*), consists of an *elastic membrane* rather laxly attached to the corneal tissue—the *proper membrane of Descemet* [*posterior elastic lamina of the cornea*, Bowman], and of an *epithelium* on its inner surface. The former is as clear as glass, brilliant, quite structureless, easily lacerable though tolerably firm, and so elastic, that when it is raised from the *cornea* by the scalpel and forceps, by boiling in water, or by maceration in alkalies, under which treatment, as under reagents in general, it does not lose its transparency, it always rolls up strongly and towards the front. Towards the border of the *cornea*, the membrane of Descemet, which is 0·006—0·008'' thick, and in chemical properties approaches

the homogeneous membranes (§ 16), passes into a peculiar system of fibres, first accurately described by Bowman. This set of fibres commences at a short distance from the margin of the *cornea* on the *anterior* surface of the membrane of Descemet (fig. 296 *g*), as an elongated network of fine fibrils, like the finer elastic fibrils, afterwards gradually increasing in thickness, until at the very margin of the *cornea*, the whole thickness of the membrane of Descemet is broken up into a network of thicker fibres and *trabeculae*, which turn over upon the border of the *iris* (fig. 296 *i*), and are blended with its anterior surface. Consequently, the membrane of Descemet, does not cease, as is usually stated, with a free border, but, on the contrary, is continued (fig. 296 *f*) all round the anterior chamber, by numerous free processes passing across it, upon the *iris*. The elements of this *ligamentum iridis pectinatum*, as it is termed by Hæck [*pillars of the iris*, Bowman], and which, according to Luschka, is much more distinct in the eyes of certain animals (Dog for instance) than in Man, were formerly ('*Zeitsch. f. wiss. Zool.*,' I, p. 54) referred by me to reticular connective tissue, at a time when I was acquainted with their form but not with their reactions; now, however, I should rather be inclined to describe them as an intermediate form between the connective and elastic tissues. The bundles in question correspond with those of connective tissue, in their width (0.004—0.012<sup>'''</sup>) and paleness, and also in the circumstance that still finer fibrils are usually to be distinguished in them, whilst in their rigidity and chemical reactions they approach the elastic tissue and the membrane of Descemet itself, of which latter, though probably differing from it genetically, they are, in the adult at any rate, an integral constituent.

The *epithelium* of the "membrane of Demours" (fig. 296 *e*), which, in Man, frequently does not retain the perfect condition, is a single layer, 0.002—0.003<sup>'''</sup> thick, of well formed, polygonal cells, 0.006—0.01<sup>'''</sup> in size, with extremely fine and pale granular contents, and round *nuclei* of 0.003—0.005<sup>'''</sup>. Towards the border of the *cornea* the cells of which the epithelium is constituted become smaller, and then ceases as a connected layer, whilst isolated indications, usually of elongated, or even fusiform epithelial cells, are continued, over the fibrous

network of the *lig. pectinatum* and surrounding its elements, upon the border of the *iris*, where a perfect *epithelium* is again met with.<sup>1</sup>

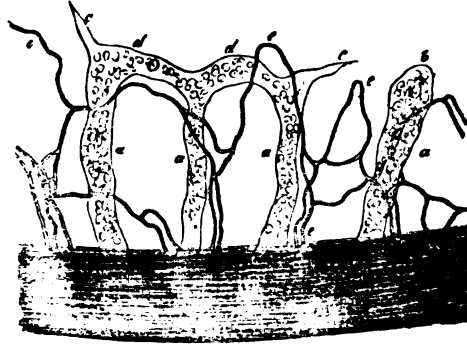
The *cornea* in the adult is nearly altogether *non-vascular*, whilst, as J. Müller and Henle first observed (*'De membr. pupill.'* p. 44), in the human embryo and foetal Lamb a rich capillary plexus exists in the *conjunctiva cornea*, but which does not appear to extend as far as the centre. Towards the end of foetal life and after birth, this plexus diminishes in breadth, in animals to a less extent than in Man, so that in the latter we find blood-vessels at the margin of the *cornea*, only in a zone of  $\frac{1}{8}$ " or at most of 1" in width. These vessels are for the most part the fine and finest capillaries of 0.002—0.004", forming one or several rows of arches, and thus terminating; they are lodged in the substance of the *conjunctiva*, which here extends, in the form of a distinct layer, for a short distance upon the *cornea*, ceasing in its anterior structureless *lamella*. In animals these *superficial* or *conjunctival vessels* also exist, but are usually much better displayed, and extend further towards the centre; frequently over half the radius, or even beyond it. Besides these, deeper capillaries derived from the sclerotic also occur in the substance of the *cornea*, usually accompanying the nervous trunks, in which they either form a single or a few very much elongated loops, or extend a little beyond them; they all terminate in loops, the finest vessels constituting which, like the superficial capillaries, measure scarcely more than 0.002". I have also noticed, in Man, these peculiar *corneal vessels* accompanying the nervous trunks, although not constantly and never so much developed.

Nothing certain is known of the *lymphatics* of the *cornea* (*vid.* also, Arnold, *'Anat.'* II, p. 988), though I have recently

<sup>1</sup> [This statement is directly opposed to Mr. Bowman's observations (*op. c.*, p. 22), who says, "that it would appear from what has been said concerning the conversion of the posterior elastic lamina at its border into fibrous tissue, which in part passes through the aqueous humor to the *iris*, that this epithelium must cease with the elastic *lamina*, since there is no longer any stratum upon which it can rest." He has been unable "to discover the smallest appearance of it upon the pillars of the *iris*, and conceives therefore that it is limited to the *cornea*." And according to the same accurate observer, the front of the *iris* has no true epithelial investment.—Eds.]

observed vessels in the *cornea* of a young Cat (fig. 297), which I can scarcely regard as anything else than lymphatics. In

Fig. 297.



this instance, at the margin of the *cornea*, together with the very distinct capillary loops containing blood-corpuscles, there were numerous wider vessels (of 0.01—0.02''' , or even 0.03''' ), which either extended singly into the *cornea* to the same distance as the blood-vessels, and terminated in dilated clavate ends, or in acuminate points, or two, three, or more together, formed simple loops, from which in like manner other cæcal processes were given off. Notwithstanding their capacity these vessels presented a delicate, structureless coat, with scattered, appressed *nuclei*, and contained a clear fluid, in which frequently a few, and occasionally even a good many clear spherical cells, exactly like lymph-corpuscles, were visible. If I had found these vessels in other animals as well, I should at once have declared them to be the commencements of the lymphatics of the *conjunctiva*, but it appears to me, at present, more prudent to regard this explanation perhaps as probable, but not as certain. For although, in this one instance of the Cat, the vessels in question were very manifest in both *corneæ*, so that I was able to point them out to many of my colleagues, particularly to R. Virchow and H. Müller, I have since been unable to perceive any decided indication of pale vessels of the same kind, either in the adult Cat or in the newly born Kitten,

Fig. 297. Capillaries and lymphatics (?) at the border of the *cornea* of a Kitten : *a a*, trunks of the colourless vessels; *b*, cæcal clavate extremity of one of these vessels; *c*, pointed prolongation; *d*, loops; *e*, blood-capillaries;  $\times$  250 diam.

or in the Dog, Ox, Sheep, Pig, and Rabbit. But it is now well known that the commencements of lymphatics, for once when they are distinct (in the intestinal *villi* for instance), escape the sight perhaps twenty or thirty times. Nevertheless, in this case there seems to be every reason for caution. Should the vessels in question not be lymphatics, they might be regarded as pathological excavations, or as transformations of earlier embryonic corneal vessels; but the manifest limitary membrane of the canals is opposed to the former supposition, and the latter is upset by the circumstance that they occurred in the same plane with true vessels, and did not enter into the least anastomosis with them.

The *nerves of the cornea* discovered by Schlemm, are derived from the *nervuli ciliares*, penetrate the *sclerotic* at its anterior border (in the Rabbit, according to Rahm, in the posterior half of the globe), and thence enter the fibrous layer of the *cornea*. In Man, they are readily found at the margin of that tunic, in the form of 24—36 finer and thicker twigs, but scarcely exceeding 0.02" in size. What especially characterises these nerves, is not so much their mode of distribution, which takes place with numerous bifurcations and anastomoses, so as to produce a wide nervous plexus extending throughout the *cornea*, as the circumstance that they still contain dark-bordered, though fine (0.001 — 0.002") primitive tubules, only at the margin of the *cornea*, in a zone not always of uniform width,  $\frac{1}{8}$ —1" broad, and in their further course present nothing but non-medullated, perfectly *clear* and transparent fibres, 0.0005—0.001" at most in diameter, so that they offer, at any rate, no more obstacle to the passage of the rays of light than the other corneal elements, as is evident from the difficulty with which they are traced under the microscope. The *trunks* of these nerves ex-

Fig. 298.



Fig. 298. Coarser ramifications of the nerves of the *cornea* of the Rabbit. Where the trunks are represented as dark, they contain dark-bordered primitive fibres.

hibit, though rarely, bifurcations of the primitive tubules, but divisions of this kind are never presented in the plexus formed by them, the conditions in which, however, on account of their paleness, scarcely admit of being quite certainly traced. This plexus is situated in the *proper cornea*, although nearer to its anterior surface, and from the absence of any indication of free terminations to the nerve-fibres, appears to consist altogether of anastomosing branches of the finest sort, so that, though not in the form of loops, a mutual connexion of the nerve-tubes may be assumed to exist.

[The blood-vessels of the *conjunctiva corneæ*, in the healthy condition of the organ, are very scanty, and the figures given by Römer (Ammon's 'Zeitsch.' V, 21, Tab. I, figs. 9, 11) and Arnold ('Icon. org. sens.' II, fig. 6), I regard as exceptional instances; but, as is well known, they may become so much developed, in inflammations, as almost to cover the entire *cornea*. The proper corneal vessels also, in such cases, appear to be developed more deeply in the interior. With regard to the *vasa serosa* of the *cornea*, *vid.* § 217. The statements that have been made respecting the blood-vessels of the *membrana Demoursii*, in inflammation of the eye (*vid.* Henle, 'De memb. pupill.' p. 53), appear still to demand confirmation; and Arnold's "serous vessels," in the normal condition of the membrane of Descemet ('Anat.' I, Tab. II, fig. 5, II, p. 1015), are nothing more than the anastomosing fibres of the *ligamentum pectinatum* of the *iris*. The *cornea*, although vascular only at its margin, is nevertheless not unfavorably circumstanced as regards its nutritive conditions. Wounds in it rapidly unite, portions of the *epithelium* or even of the fibrous layer when removed, are restored, and ulcers are filled up from the bottom with new corneal substance. Fatty deposits in its tissue, particularly in its cellular elements (especially above and below, or even all round), produce a yellow zone—the so-termed *arcus senilis* (*gerontoxon*).<sup>1</sup>]

#### § 226.

The *vascular tunic* (*tunica vasculosa*) or *uvea*.—The second tunic of the eye-ball is a highly vascular membrane, containing

<sup>1</sup> [As shown by Mr. Edwin Canton in his 'Observations on the *Arcus senilis*, or fatty degeneration of the Cornea.'—'Lancet,' vol. i. 1850, p. 560.—Eds.]

a great amount of pigmentary matter, and divisible into a larger posterior portion—the *choroid*, and a less extensive anterior segment—the *iris*.

The *choroid* is an easily lacerable membrane,  $\frac{1}{13}$ — $\frac{1}{30}$ '' thick, extending from the entrance of the optic nerve, where it is perforated by a rounded opening, nearly to the anterior border of the *sclerotic*, where it presents a thicker part—the *corpus ciliare*, and is then continuous with the *iris*. Its external surface is attached not only by larger vessels and nerves, but also otherwise, tolerably intimately, to the *sclerotic*, so that in exposing the *choroid* a portion of the membrane always remains more or less adherent to the *sclerotic*, in the form of a brown tissue. This is the so-termed *lamina fusca* of authors, which there is no ground for separating from the vascular tunic and regarding as a distinct membrane, although in many instances scattered pigment-cells, such as exist in it, are found to extend even into the connective tissue of the *sclerotic*. The inner surface of the *choroid* is smooth and, at the *ora serrata*, very closely connected with the *retina*, elsewhere more loosely; whilst anteriorly to the *ora serrata*, and particularly in the *processus ciliares*, it is very intimately united with the hyaloid membrane (*zonula Zinnii*), so that the two are never completely separable.

The *choroid* consists essentially of two portions, a *vascular, external thicker layer*—the *proper choroid*, and an inner distinctly coloured *lamina*—the *pigmentum nigrum*; the former, however, may be again subdivided into three, but by no means sharply defined layers, viz.: 1. an external, brown, soft *lamella*, supporting the ciliary nerves and long ciliary vessels, and, in front, containing the ciliary muscle—the *outer pigment-layer*; 2. the less deeply coloured, *proper vascular layer*, with the larger arteries and veins; and 3. a colourless, delicate, internal layer, containing an extremely abundant capillary plexus—the *membrana choriocapillaris*, which, however, does not extend further in front than the *ora serrata*. The tissue of which the *proper choroid* is constituted, except the vessels and nerves, which indeed make up a considerable part of it, and the *ciliary muscle*, is of a peculiar kind, and cannot conveniently be described under any particular head, but like the fibres of the *lig. pectinatum* of the *iris*, though in somewhat different respects, is intermediate between the connective and elastic



tissues. In the outer portions of the tunic, this *stroma* is formed of fusiform or stellate, very irregular, and extremely pale, or more or less brown nucleated cells, 0.008—0.02'' long, which anastomose frequently with each other by shorter or longer, usually very delicate (0.0005''), but rather rigid processes, and from their great number represent a lax membranous tissue. There would be nothing very peculiar in this, and these cellular networks might properly be classed with

Fig. 299.



other similar anastomosing pigment-cells, as for instance in the batrachian *larva* (most characteristic in *Alytes*); but in the inner layers of the *choroid*, and especially in the *membrana choriocapillaris*, they gradually pass into homogeneous, nucleated tissue, at first containing a little pigment, but afterwards none at all; and which, although in appearance very similar to homogeneous connective tissue, is distinguished from it by its resistance to acids and alkalis, and

approximates the elastic tissue, from which, however, it likewise differs in its trifling elasticity and paleness; whence it is better, at present, to regard it as *sui generis*.

The *ciliary ligament* of anatomists, or the *musculus ciliaris s. tensor chorioideæ* (fig. 296 *k*), the really muscular nature of which was recognised almost simultaneously by Brücke and Bowman, is a tolerably thick layer of radiating smooth muscular bundles, passing from the most anterior border of the *sclerotic* upon the ciliary body, and ceasing in its anterior half, opposite the part where the ciliary processes are placed, internally. More precisely described, the ciliary muscle arises where the *sclerotic* is grooved for the formation of the venous sinus of Schlemm, and, in fact, from a special, dense, smooth tract (fig. 296 *l*), which, forming the inner wall of the canal in question, coalesces with the *sclerotic*, and also receives a portion of the fibrous network, into which the *membrana Demoursii* is prolonged, the fibres of which are completely blended with the elements of the tract in question, and resemble the others in all respects except that they are much finer,

Fig. 299. Cells from the *stroma* of the *choroid*: *a*, pigment-cells; *b*, uncoloured fusiform cells; *c*, anastomoses of the former. Human;  $\times 350$  diam.

anastomose more closely, and run in a *circular* direction. The ciliary muscle terminates at the most adherent portion of the ciliary processes, though not in those processes themselves, and as regards the elements of which it is composed, they are rather shorter (0.02''') and broader (0.003—0.004''') than the common fibre-cells; being at the same time finely granular, soft and so perishable, as, in Man, not readily to admit of being isolated.

The *pigmentum nigrum* (fig. 296 *m*) is a continuous, purely cellular layer, completely investing the inner surface of the *choroid* and consisting, as far as to the *ora serrata*, of a single layer of well formed, almost regularly hexahedral, contiguous cells, 0.006—0.008''' in diameter, 0.004''' thick, disposed in an elegant mosaic manner, in which the large quantity of brownish-black pigment usually prevents the *nucleus* being apparent as more than a clear spot in the interior. On the side towards the *retina*, however, a narrow clear border is frequently left free of colour, showing that the cells must, at one time, have possessed contents or have had a thickened membrane. From the *ora serrata* onwards, the pigment-cells are disposed in several, at least two, layers, become rounded, smaller, and entirely filled with pigment, so that the *nuclei* even are scarcely visible.

All the pigment-cells have extremely delicate walls, and are very easily ruptured under pressure; the pigment is composed of minute, flattened, oval corpuscles, at most 0.0007''' long, and presenting, sometimes even while contained in the cell, but still better when liberated, the phenomenon of molecular motion in the most marked manner. The pigment of the *choroid* is wanting in the eyes of *albinos*, as well as, at any rate partially, in the region of the *tapetum* in animals; but the cells, which would elsewhere contain it, exist in both these instances, only perfectly colourless.

The *iris* differs from the choroid in containing true *connective tissue*, the delicate, lax fasciculi of which, partly radiating, in part circular, especially at the ciliary border, and much in-

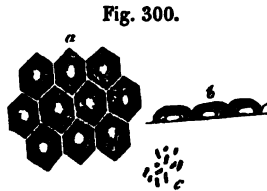


Fig. 300. Cells of the *pigmentum nigrum* of Man: *a*, viewed on the surface; *b*, on the side; *c*, pigment-granules.

terlaced, constitute the principal bulk of the *stroma* of this tunic, and, towards its surface, form a more homogeneous layer. It contains a large number of elongated *nuclei*, which, at any rate in part, are situated in fusiform *cells*, similar to those of the *choroid*, only smaller; and also a few rigid, pale fibres, which, as prolongations of the *ligamentum pectinatum* of the *iris*, or of the "membrane of Demours," are continued over a part of the anterior surface; lastly, the *smooth muscular fibres* of the *iris*, presenting exactly the same characters as those of the *choroid* [ciliary muscle]. In Man, these fibres constitute a very distinct *occlusor muscle of the pupil* (*sphincter pupillæ*), in the form of a smooth ring,  $\frac{1}{4}$ " wide, close to the pupillary margin of the *iris*, and somewhat nearer to the posterior surface, which, in a blue *iris*, may be readily recognised after the removal of the posterior pigment, with and without the application of acetic acid, and may also be torn up into its elements, 0.02—0.03" long. Besides this larger muscular ring, I find, close to the *annulus iridis minor*, another very narrow ring, nearer the anterior surface of the *iris*, not more than  $\frac{1}{40}$ " in breadth. Brücke traces the *dilatator pupillæ* as far as the *ligamentum pectinatum* and the border of the vitreous *lamella* of the cornea, but I am unable to do so; and it rather appears to me to commence in the substance of the *iris* at the ciliary margin. From what the difficulty of the investigation has allowed me to see of this muscle, it consists of numerous slender fasciculi, which, far from constituting a continuous membrane, run inwards, each separately between the vessels, and are inserted at the border of the *sphincter*.<sup>1</sup>

The *iris* differs from the *choroid* also, in possessing a cellular layer on the anterior and posterior surfaces. The latter, the so-termed *wea* of authors, or the *pigmentum nigrum* of the *iris* (fig. 295 n), is a stratum, 0.0089" thick, of minute, closely filled pigment-cells, like those of the ciliary body, with which they are also uninterruptedly connected, and which lines the whole of the posterior surface of the *iris*, extending as far as the border of the pupil. When the *iris* is folded, the pigmentary stratum, or its free surface, appears to be bounded by a delicate, but sharply defined line, which has been described

<sup>1</sup> [Compare Mr. Lister's 'Observations on the contractile tissue of the Iris,' 'Quarterly Journal of Micr. Science,' vol. i, p. 8, October, 1852.—Eds.]

by several authors as a special membrane (*membrana pigmenti*, Krause, *m. limitans*, Pacini [?], Brücke, M. Jacobi, Arnold), and, in fact, in eyes that have been kept some time, and on the addition of alkalies, may be raised in places from the pigment. But since, in such instances, the pigmentary layer is always without any defined outline, and its granules are exposed and dispersed, it appears to me that this membrane is nothing more than the conjoined outer cell-walls of the pigment-cells, which, as is known to be the case elsewhere (intestinal *villi* for instance), are raised in their totality, and apparently as a special membrane. The cellular layer of the anterior surface of the *iris* is a simple *epithelium* of rounded and much flattened cells, which, when viewed in a fold of the *iris*, are seen to constitute, not a continuous, clear border of uniform breadth throughout, but on the contrary, only distinct, slight elevations. This layer is better seen after the removal of the posterior pigment, in a horizontal view, and also by scraping or shaving off the anterior surface of the *iris*.<sup>1</sup> The colour of the *iris*, in blue eyes, depends simply upon the posterior pigment seen through its substance; whilst in brownish-yellow, brown, and black eyes, it is owing to a special *iris-pigment*, which is very unequally distributed, and thus produces the peculiar markings of the anterior surface. This pigment is seated, in the first place, in the *stroma* itself, and in fact, chiefly in its fusiform cells, but also, as it appears to me, occurs free among the fibres and vessels, and in the fibre-cells of the *sphincter pupillæ*; lastly, in the anterior epithelial layer, it consists of larger and smaller cells, gold-yellow or brownish irregular-sized granules, aggregations of granules and streaks, never of the regular pigment-granules of the true ocular pigment.

The vessels of the *tunica vasculosa* are extremely numerous, and are variously disposed in its different parts. The *choroid* receives its blood from the *short posterior ciliary arteries*, about twenty small vessels, penetrating the *sclerotic*, in the posterior part of the eye-ball, at a greater or less distance from the optic nerve, and which, dividing in a dichotomous manner in the middle or vascular layer of the *choroid*, run anteriorly, and subdivide into three sets of branches: 1. *external*, which, having attained a certain fineness by continued division,

<sup>1</sup> [Vid. note, p. 357.—Eds.]

pass directly into the *venæ vorticosæ*; 2. *internal*, which pass into a capillary plexus immediately beneath the pigment, in the so-termed *membrana choriocapillaris*, or *Ruyschiana*; and

Fig. 301.



3. *anterior*, which are continued into the ciliary body and *iris*. The above mentioned *capillary plexus* of the innermost layer of the *choroid*—which in animals having a *tapetum* lies upon its internal aspect, and may easily be demonstrated as a special membrane, as may also occasionally be done in Man—is one of the most elegant and closest that exists, inasmuch as its meshes, formed by vessels of  $0.004''$ , do not measure more than  $0.002$ — $0.005''$ , the capillaries arising from the larger vessels, as it were in a stelliform manner. It extends, as has been already said, only as far as the *ora serrata*, where it gives place to somewhat coarser convolutions of vessels,  $0.004''$  in diameter, which, proceeding from the anterior branches of the short posterior ciliary arteries, constitute the ciliary processes, and are so closely approximated that, besides

the vessels and a homogeneous sheath supporting the processes, the latter seem to contain no other tissue. From these various points and from the ciliary muscle, which likewise obtains some twigs from the same arteries, the blood is returned principally through the *venæ vorticosæ*, which, lying upon the arteries, constitute elegant vascular stars or *vortices*, two above and two below (or it may be five or six); and also at the back of the eye-ball, through some minute *venæ ciliares posticæ breves*, all of which veins penetrate the *sclerotic* in the same way as the arteries.

The *iris* receives its blood in the first place from the arteries of the choroid, and secondly from the long posterior and the anterior ciliary arteries. The former, with their anterior

Fig. 301. Vessels of the *choroid* and *iris* of a Child, after Arnold; viewed from within,  $\times 10$  diam.: *a*, capillary plexus of the posterior segment of the *choroid*, terminating at the *ora serrata*, *b*; *c*, arteries of the *corona ciliaris*, supplying the ciliary processes, *d*, and in part passing upon the *iris*, *e*; *f*, capillary plexus on the inner surface of the pupillary margin of the *iris*.

branches, in part immediately enter the iris, between the ciliary processes, and in part, after supplying the ciliary processes, form small trunks at their border and anterior extremity, which are also continued upon the *iris*. The *long ciliary arteries*, two in number, perforate the *sclerotic* on the right and left a little anterior to the short ciliary vessels, run in the external pigment layer of the choroid, as far as the *tensor chorioideæ*, where, each dividing into two branches and joining the *ciliares anticae*, which to the number of five or six penetrate the *sclerotic* in front, they constitute a superficial irregular arterial circle in that muscle—the *circulus art. iridis major*. From this circle, together with small vessels passing either from it or from the vessels forming it to the *tensor* muscle, very many convoluted branches, continued to the *iris*, are given off; which, with the arteries already mentioned from the *choroid*, divide, partly into a few true capillaries, a layer of which is found particularly at the posterior surface of the pupillary margin, beneath the pigment (Arnold), and partly run, continually dividing, as far as the pupillary margin, where, forming arched loops, they pass into fine, but still not capillary, venous trunks, after they have constituted a second, usually irregular *circulus arteriosus minor* close to the *annulus iridis minor*. The *veins* of the *iris* arise from the arteries and capillaries just mentioned, run, except frequent transverse anastomosing branches, also in a radiating manner, and open: 1. more from the posterior surface of the *iris* into the *vasa vorticosæ*; 2. into the *venæ ciliares posticae longæ*; and 3. according to Arnold and Retzius, also into the “canal of Schlemm,” a narrow annular channel situated between the *choroid* and *sclerotic* (fig. 295 h), from which the *venulæ ciliares anticae*, passing through the *sclerotic*, afterwards convey the blood outwardly.

The *nerves* of the *tunica vasculosa* are also very numerous, but destined solely for the ciliary muscle and the *iris*. They are the *nerveli ciliares*, which perforate the *sclerotic* posteriorly, then run forwards in the outer *lamella* of the *choroid*, partly in grooves in the *sclerotic*, and, before entering the ciliary muscle, divide with repeated bifurcations. Within the muscle they break up into a rich and close plexus, numerous filaments from which proceed to the muscle and to

the *cornea*, while others constitute the proper nerves of the *iris*. The latter accompany the vessels, dividing repeatedly, and with frequent anastomoses, especially in the *annulus minor*, to the pupillary margin, where their mode of termination is at present unknown. The elements of all these nerves are, in the trunks, of the medium and fine kinds, from 0·002—0·004''', and in the *iris* of not more than 0·001—0·002''' . I have never noticed ganglion-cells in them, nor in the ciliary muscle, where Bochdalek describes them as existing.

[Some authors, and among them, recently, Bochdalek, believe that they have seen scattered nerves in the choroid—a circumstance that I am unable to confirm from my own observations. Quite recently, Rainey ('Philos. Magaz.,' May, 1851, p. 420) describes a transversely striped *choroidal muscle*, occupying the posterior part of the choroid and extending through its entire thickness in the form of variously decussating layers, which he says may be most easily demonstrated in the eye of the Sheep. I agree with Henle in thinking that these statements rest upon deceptive grounds; at all events, in the situation in question, either in animals or in Man, I can discover nothing like muscular fibres.]

#### § 227.

*Nervous membrane (retina).*—The *retina* is the innermost of the five tunics of the eye-ball, and is in close apposition with the *choroid*, though not coextensive with it, ending at the *ora serrata* in an undulated margin (*margo undulato-dentatus s. ora serrata retinæ*), which is very intimately connected, on the one side with the *choroid*, and on the other with the *hyaloid membrane*. A continuation of the *retina* on the ciliary portion of the hyaloid membrane, which is described by many anatomists, does not exist.

The *retina* is a delicate membrane; when recent, almost perfectly transparent and clear, and after death whitish and opaque. It commences at the point of entrance of the optic nerve, with which it is, in part, continuous. Its thickness at first is 0·1''' , but as it extends anteriorly it soon diminishes to 0·06''' , until ultimately, close to the anterior border of the *retina*, it is not more than 0·04''' in thickness, and finally terminates quite

abruptly. Notwithstanding this various thickness, the following layers from without to within may be evidently distinguished in all parts of it: 1. the *layer of rods and cones* [bacillar layer]; 2. the *granular layer*; 3. the *layer of grey nerve-substance*; 4. the *expansion of the optic nerve*; and 5. the *limitary membrane*. These layers, with the exception of the innermost, which is of uniform thickness throughout, in general become thinner towards the front, in correspondence with the diminished thickness of the whole *retina*.

1. *The bacillar layer, stratum bacillarum s. memb. Jacobi* (fig. 302 *i, k*), presents a very remarkable structure, being composed of innumerable rod-like and conical corpuscles, disposed with the utmost regularity and reflecting the light very strongly. With the exception of H. Müller (*vid. infra*), this structure, in animals, has been understood quite erroneously; and even in Man it has been but very superficially known. It consists of two elements—the *rods, bacilli* (*k*), and the *cones, coni* (*i*), which together constitute a single layer, 0.036''' thick at the bottom of the eye, more anteriorly 0.024''', and quite in front not more than 0.015''' in thickness. In general these bodies are so arranged that the more numerous *rods* have their largest end directed outwards, whilst the *cones* are disposed in the reverse direction, whence the latter, when imperfectly examined, appear to constitute an inner, distinct, thinner layer, lying between the inner extremities of the "rods."

In Man, the *rods* (fig. 303, 1, *k, 2*) are cylindrical, slender,

Fig. 302.




Fig. 302. Vertical transverse section of the *retina* of Man, from the posterior portion of the membrane,  $\times 250$  diam.: *a*, hyaloid membrane with decumbent nuclei; *b*, *membrana limitans*; *c*, clear globules (*epithelium?*); *d*, expansion of the optic nerve; *e*, layer of grey nerve-substance; *f*, internal granular layer; *g*, fine-granular layer, in which the radiating fibres are more distinct than elsewhere; *h*, external granular layer; *i*, internal division of the bacillar layer, with the "cones;" *k*, external division, with the prolongations of the "cones" and the true "rods."



elongated corpuscles, in which a larger external end, the *proper rod*, is to be distinguished from a more slender internal portion,

Fig. 303.



the prolongation or *filament*. The former portion of the rods, which alone almost has hitherto been known to anatomists, is a cylinder, 0.0075—0.012—0.015" long, 0.0008" broad, and truncated at the outer end, whilst the inner is produced into a short point, 0.002—0.003" in length, which is often separated from the rest of the "rod" by a faint transverse line, and might even perhaps be assigned to the "filament." The latter is an

extremely delicate process, not more than 0.0002—0.0003" in thickness, of uniform width throughout, prolonged immediately from the point of the "rod," and, extending through the inner half of the bacillar layer; it is connected with the other elements of the *retina* in a manner to be afterwards described. This filament is so delicate that it is usually torn off near its origin on the slightest mechanical impression affecting the bacillar layer; on which account also it has happened that observers hitherto have been acquainted only with the "proper

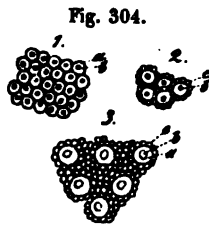
Fig. 303. Retinal elements of Man,  $\times 350$  diam. 1, "rods" and radiating fibres: *k*, proper "rod;" *r*, prolongation of its pointed inner extremity; *h*, "granule" (cell) of the outer granular layer; *l*, enlarged extremity of the radiating fibres proceeding from them to the surface of the optic layer; *k'*, "rod" seated on a "cone," *i*; *r'*, fibre proceeding from the latter, connected with the "granule," *f*, of the inner granular layer, and the terminal enlargement, *l'*, on the inner surface of the *retina*; *n*, one of the fibrous bundles in which the radiating fibres frequently terminate at their innermost extremity. 2, "rods" torn off from their fibres, in various states of curvature, &c. 3, fibres of the optic nerve: *a*, *b*, straight, coarser and finer fibres, with varicosities; *c*, without varicosities. 4, two "cones," *d*, torn off from their processes, *e*, with somewhat altered "rods," *a*, at their outer ends; *c*, nucleus of the "cones."

rods," and, although they had often seen the somewhat longer filaments attached to them, the latter were regarded merely as artificial products. Since Hannover, also, the points of these organs have been misplaced outwardly by all writers, which is wholly incorrect. The substance of the "rods" is clear, homogeneous with a faint glistening fatty aspect, very soft and flexible, and at the same time extremely fragile. Their delicacy is so great that they undergo the most manifold changes even in water, often even to their being rendered unrecognisable, bending, as it were, into a hook of various forms, curling and rolling up in all ways, or breaking up into two or more pieces, and allowing clear drops to escape, which are often met with on the external surface of the *retina* in vast quantity, derived partly from the "rods," partly from the ruptured pigment-cells of the *choroid*. One of the most usual changes consists in this, that the point, if it be not detached, which is very frequently the case, becomes distended in a varicose manner, and assumes a lancet-shape, or is even transformed into a sphere, on which the "filament" of various lengths is placed, in consequence of which, the obtuse end of the "rod" often presents a hook-like curve or a slight enlargement. The "rods" are almost invariably very much altered by reagents; and, above all, the proper "rods," which, notwithstanding their greater bulk, yet offer less resistance than the "filaments." Ether and alcohol cause them to contract and shrivel up, often rendering them unrecognisable, but do not dissolve them. In acetic acid of 10 per cent. they are immediately shortened very considerably, swelling out in several places, and disintegrating into clear drops, which at first offer some resistance, but afterwards disappear. Concentrated acetic acid dissolves them in a short time, as do alkalies and mineral acids; whilst diluted chromic acid, although it causes them to shrink a little, is the best preservative of them.

The "cones" (fig. 303 '4) are "rods" which instead of a filament are furnished at their inner extremity with a conical or pyriform body, the length of which equals half the thickness of the bacillar layer (from 0.007—0.015'''), and whose breadth is from 0.0025''' to 0.0045'''. Each of these "cones" consists of an external, thicker and longer, finely granular extremity,

often more or less ventricose, which, gradually diminishing in size, passes into a common "rod" without a point, and of a shorter inner portion, somewhat constricted from the other by a slight incurvation, in which an elongated or pyriform, more opaque and brilliant body, 0.002—0.003" in length, is enclosed. On the internal aspect, these "cones," in which I can see nothing but a cell with a *nucleus*, are, like the "rods," continued into the succeeding layers of the *retina*, where we shall again have to consider them, by fine filaments, 0.0004—0.0006" in size, similar to those of the "rods."

The "rods" and "cones" are arranged vertically upon the *retina*, like palisades, in close apposition, and consequently, one of their ends is directed towards the *choroid* and the other towards the granular layer. Close to the *macula lutea* the "cones" form an almost continuous stratum (fig. 304<sup>a</sup>), so that the "rods" are placed only in single series between them, but more anteriorly they are wider apart, the distance between them at first being about 0.002—0.003", and in the anterior portions of the *retina* even 0.0004—0.005" (fig. 304<sup>b</sup>), thus affording room for more "rods" in the interspaces. Viewed



from without, the bacillar layer, when its outermost surface is brought into focus, exhibits rounded spaces, placed at a greater or less depth, filled with a clear substance, which also occupies elsewhere the interspaces between the elements of this layer. These clear spaces, corresponding to the "cones," present an internal, dark, smaller circle, the terminal surface or apparent transverse section of the "rod" which is seated upon the "cone," and are surrounded by the closely crowded terminal surfaces of the "proper rods," disposed in a sort of mosaic manner, their outlines being indicated by the single, double, or multiple series of reticulations (fig. 304).

2. The *granular layer, stratum granulosum* (fig. 303 *h, f*), is composed of opaque, granular corpuscles, reflecting the light

Fig. 304. Bacillar layer from without. 1, at the "yellow spot" (only "cones"); 2, at the border of the same; 3, from the middle of the *retina*: *a*, "cones," or vacuities corresponding with them; *b*, "rods" of the "cones," whose terminal surface is often placed rather more deeply than that of the proper "rods," *c*;  $\times$  350 diam.

tolerably strongly, of a round or oval figure, and 0.002—0.004<sup>'''</sup> in size, sometimes looking like free *nuclei*, sometimes like minute cells almost entirely filled by large *nuclei*, although, according to my observations, they should all be referred to the latter category. For I find, especially in preparations made with chromic acid, that from both sides of every granule very fine filaments, 0.002—0.003<sup>'''</sup> thick, are regularly given off, which in many cases may be distinctly seen to proceed from a pale border surrounding the granule, so that the whole is very like a bipolar ganglion-cell in miniature. In Man, the granules, in the greater part of the *retina*, are disposed in two layers—an outer, thicker, of 0.013—0.016<sup>'''</sup> (*h*), and an inner, thinner (*f*), of 0.006—0.008<sup>'''</sup>—which are parted from each other by a clear, fine-granular, and, to some extent, vertically striated layer (*g*), 0.006—0.008<sup>'''</sup> thick; whilst, towards the *ora serrata*, the two constitute a single stratum of not more than 0.015<sup>'''</sup> in thickness. The granules of the inner layer are a trifle larger than those of the outer, and when they are oval, as is most usually the case, I find that they are placed with the long axis in the direction of the thickness of the *retina*, so that their processes, like those of the external layer, run directly outwards and inwards.

8. The layer of *cineritious cerebral substance* (fig. 302 *e*) is pretty sharply defined on the side of the granular layer, and less so towards that of the fibres of the optic nerve, between the elements of which it penetrates more or less. It is composed of a finely granular *matrix*, corresponding exactly with that of the grey substance on the surface of the *cerebrum* and *cerebellum*, and of numerous *nerve-cells* scattered in it.

Of the latter, some, particularly in the outer half of this layer, which is 0.008—0.012—0.02<sup>'''</sup> thick, are small (0.003—0.006<sup>'''</sup>), inconspicuous, and in fresh preparations recognisable

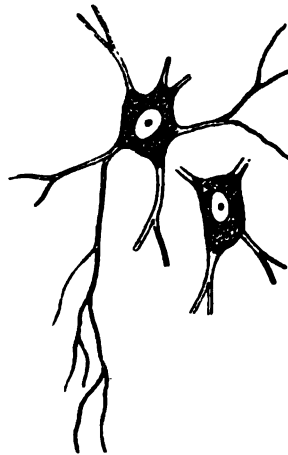


Fig. 305.

Fig. 305. Nerve-cells with processes from the *retina* of the Ox,  $\times 350$  diam.

only by their beautiful vesicular *nuclei*; whilst another portion, forming an almost continuous layer on the inner side, are of larger size (0.006—0.016"). These cells are usually pyriform or rounded, or occasionally prolonged into 3—5 angles; and most of them, perhaps all, are furnished with pale processes like those of the central nerve-cells—which were first noticed by Bowman ('Lectures,' &c., pp. 84 and 125), and afterwards also described by Hassall, Corti, and myself.<sup>1</sup> The processes occur either single or in numbers varying from two to six and more; are at first as much as 0.002" wide, but in their further course continually diminish in size, under repeated divisions, till they are reduced to fine filaments of scarcely 0.0004" in diameter, which, in isolated cells, terminate in torn ends. In every case in which I have noticed these nerve-cells distinctly *in situ*, their processes were given off towards the exterior, and afterwards in their further course, without entering the granular layer, appeared to be curved, in order to ramify in the grey nervous layer itself. The *nuclei* of these nerve-cells, which behave towards reagents like those of the *cerebrum*, measure 0.003—0.005", and usually present a very distinct *nucleolus*.

4. On the inner aspect of the layer in question we find the *expansion of the optic nerve (d)*. This nerve, after quitting the *chiasma* (concerning which *vid.* p. 444, vol. I) and till it reaches the eye, presents the same conditions as a common nerve; its dark-bordered fibres, 0.0005—0.002" in diameter, much disposed to become varicose, and between which, according to Hassall, nerve-cells would also seem to occur, but which I have not yet noticed, form polygonal bundles, 0.048—0.064" thick, surrounded by a neurilemma of the usual kind. When the optic nerve has reached the eye, its sheath is lost in the *sclerotic*, which tunic is perforated for the entrance of the nerve by a funnel-shaped opening, the narrower part being inward; and the internal *neurilemma* also ceases on a level with the inner surface of the same tunic, where it may be artificially displayed, as a cribriform lamella (*lamina cribrosa* of authors), so that the fibres of the optic

<sup>1</sup> [Pacini appears to have been the first to perceive the existence and true nature of the caudate cells in this layer of the *retina*. ('Sulla tessitura int. dell. Retina,' 1844, p. 32.)—Eds.]

nerve enter the eye, each independently, without their sheaths of connective tissue. Within the canal of the *sclerotic*, and as far as the slight eminence, the *colliculus nervi optici*, visible on the inner surface of the *retina* opposite its point of entrance, the optic nerve retains its white colour, and continues to present dark-bordered tubules; but, from that point onwards, its elements, in Man and in many animals, become perfectly clear, yellowish or greyish, and transparent, like the finest tubules in the central organs, measuring on the average not more than 0·0006—0·0008''' and a good many only 0·0002—0·0004''', whilst some, it is true, have a size of 0·001—0·0015''' or even of 0·002'''. What chiefly distinguishes these from other pale nerve-terminations, is the absence of *nuclei* in their course, a somewhat greater refractive power, and the frequent occurrence of varicosities, which two latter particulars would seem to indicate, if not exactly a nerve-medulla as in the common nerves, still the existence of partially semi-fluid and perhaps fatty contents and assimilate the nerve-fibres of the *retina* to the most delicate elements of the *cerebrum*. I have not yet been able to demonstrate axis-fibres and sheaths in the fibres of the *retina*, although I would not from that circumstance at present conclude that they do not exist.<sup>1</sup> At any rate, the retinal fibres are not composed solely of nerve-medulla, for, if they are treated never so thoroughly with ether, they always remain, smaller indeed, but more distinct and more opaque than previously. Fibres which have been thus treated enlarge again in cold acetic acid, and dissolve in alkalies, and consequently consist, perhaps without doubt, chiefly of a nitrogenous substance.

As respects the *course* of the nerve-fibres in the *retina*, this much is certain, that they radiate on all sides from the *colliculus nervi optici* and constitute a continuous membranous expansion, which extends as far as the *ora serrata retinae*, and presents any considerable interruption only in the situation of the *macula lutea*. In this true nervous membrane the fibres

<sup>1</sup> [Here again, Professor Kölliker is at variance with Mr. Bowman, who gives as one of the peculiar characteristics of the fibres of the optic nerve in the *retina*, that they have lost "the tendency to fall into the varicose or beaded state; in a word, that the fibres of the nerve, in expanding into the retina, lose their white substance, but retain the axis- or central fibre."—Eds.]

are associated into larger and smaller compressed bundles, usually 0·01—0·012''' wide, which either mutually anastomose at very acute angles or run for considerable distances parallel with each other. Notwithstanding all that has been stated by various authors, it may be boldly asserted that the terminations of these nerves are as yet wholly unknown; and, as more will be said upon this subject afterwards, I shall here merely remark that, in any case, they exist not only in front, but in every part of the *retina*, because the layer of nerve-fibres becomes visibly thicker from before to behind. I have estimated its thickness, in Man, at the bottom of the eye at 0·036'', two lines beyond the yellow spot at 0·006—0·008'', and near the *ora serrata* at 0·002''.

5. The *limitary membrane*, *membrana limitans*<sup>1</sup> (*b*), is a delicate membrane, 0·0005''' thick, intimately united with the rest of the *retina*, which, when that structure is teased out, and on the application of reagents, is frequently detached in large shreds, and then appears perfectly structureless. On its inner aspect, towards the hyaloid membrane (*a*), when the *retina* is folded, flattened cell-nuclei are occasionally perceptible, which certainly cannot be referred to an *epithelium*, and scarcely to the vitreous body, as the latter is always readily separable from the *retina*. It seems to be different with regard to a clear, light yellowish border, 0·002—0·003''' wide, situated on the outer side of the *membrana limitans*, which, in folds of a perfectly fresh *retina*, appears, as it were, to be completely blended with the limitary membrane, but occasionally exhibits, more or less distinctly, the contours of excessively clear and transparent spherical bodies (*b*), 0·002—0·003''' in size. At a longer interval after death, as well as on the addition of water, a large number of transparent globules, like drops of albumen, are afforded by the clear border of the *retina*, which then disappears altogether, except the *membrana limitans*, frequently also, together with it. Todd and Bowman describe the clear bodies above noticed as cells and also figure a minute nuclear corpuscle in them; and I will not directly contradict this notion, although I have not as yet been in any way able to satisfy myself of the existence of *nuclei* and true cells in this layer.

<sup>1</sup> [So named by Pacini (l. c., p. 22).—Eps.]

The condition of the retinal elements at the "yellow spot" is in many respects peculiar. In the first place, any continuous layer of optic fibres is there wholly wanting, and the *stratum* of nerve-cells, which are in close mutual apposition, lies immediately upon the *membrana limitans*. Between these cells, however, nerve-fibres run equally from the sides and the internal end of the spot into it, either isolated or in very minute bundles, and terminate in a way that cannot be accurately determined. In the centre of the *macula lutea* there is a thin uncoloured spot in which the granular layer is wanting, from 0.08—0.1" in diameter, through which the pigment of the *choroid* is visible—the so-termed *foramen centrale*. The *plica centralis* never exists during life; but this is not the case, probably, with the yellow colour, which depends upon diffused pigment pervading all the parts of the *retina*, except the "rods." The latter, in this situation, assume the form of "cones" exclusively, inasmuch as the "proper rods," as Henle ('*Zeitsch. f. rat. Path.*,' 1852, II, p. 307) correctly states, are wholly wanting in the "yellow spot" and its immediate neighbourhood. Instead of them, the "cones" form a perfectly continuous layer, are more slender than elsewhere (not more than 0.002—0.0024" in breadth), and support at their outer end, here as elsewhere, not short points, as Henle states, but the usual "rods," which in this situation are not more than 0.0006—0.0007" broad (fig. 304<sup>1</sup>).

After this description of the elements of the various retinal layers, it will be as well to cast a glance upon their mutual *connexion*. I have ascertained, in the human eye, that the fibres proceeding from the "rods" and "cones" inwards, and from the "granules," on both sides, are connected, and simply constitute parts of a fibrous system of the *retina*, as yet not recognised as a connected whole, except by H. Müller. This system, the greater number of whose elements are vertical, penetrates the entire thickness of the tunic, and might be termed the *radiating fibre-system* (*radial fibres*, H. Müller), in contradistinction to the *horizontal*, referable to the expansion of the optic nerve. Proceeding from the bacillar layer, it is obvious, that the fine filaments arising from the "rods" and "cones" are directly continuous with the similar processes given off from the external side of the "granules," in such a



way that the filaments of the "rods" (fig. 303<sup>1</sup>, *rr*) are connected with the "granules" of the outer granular layer, and those of the "cones" (fig. 303<sup>1</sup>, *r'*) with the "granules" of the inner layer; in fact, each "cone" or "rod" is in connexion with a granule, the latter also perhaps with several. The filaments which run inwards from both kinds of "granules," which may be pretty readily traced in vertical sections, are continued in a straight line, or slightly curved, through the layer of grey nerve-substance without any connexion with its elements, and enter the expansion of the optic nerve, where, as especially in the posterior part of the eye, in which situation the layer of nerve-fibres is thick, it is easy to perceive that they run in the narrow interstices between the nervous bundles, in a fascicular manner towards the *membrana limitans*. I have taken much pains in the investigation of their relations at the surface of the *retina*, and have arrived at the following results. If the inner surface of the *retina* be examined under a strong magnifying power, in its posterior half, where the fibrous bundles of the optic nerve are still very distinct, a peculiar marking will be observed between them, consisting of series of points, of minute stelliform figures, or of little streaks, which often (also in animals, as the Ox for instance) regularly converge towards each other from the bundles of fibres like the rays of a feather. If these structures are traced in vertical sections, it is easily seen that they are nothing but the extremities of the radiating fibres dipping down between the nervous bundles, and presenting a somewhat peculiar aspect. For, whilst in the deeper part of the *retina* they are simple pale fibres, of at most 0.0008''' in size, they are here so modified that some of them simply expand, and terminate in a triangular pale corpuscle, 0.0015—0.003''' in length and breadth (fig. 303<sup>1</sup>, *l*), from the internal angles of which, one or two horizontal fibres are again given off; whilst the others, without expanding, end in a complete bundle of 5—9 or more fine fibres (fig. 303<sup>1</sup>, *n*), which also turn to the sides and continue in the plane of the nervous expansion. What further becomes of these latter, *innermost* processes of the radiating fibre-system, I have not yet been fortunate enough to observe, however zealously I have investigated the matter, and regret that the decision of this very important point in the

anatomy of the *retina* must still be left in abeyance. The radiating fibres either actually terminate in the filaments observed by me on the surface of the expansion of the optic nerve, or they are continuous with the true fibres of that nerve, or at any rate are in connexion with them. In a physiological point of view the latter supposition would, in any case, be the most plausible; and in support of it, it may be stated, that in the true fibrous bundles of the *retina*, together with the varicose nerve-tubules (fig. 303<sup>3</sup> *a, b*), there are fibres of another sort (fig. 303<sup>3</sup> *c*), which, although of equal size, agree in all respects with the radiating fibres in the absence of varicosities, and in their less straight or more serpentine and irregular course. It may be that these fibres are the direct continuations of the horizontal terminal processes of the radiating fibres, which subsequently, in their further progress towards the optic nerve, acquire more and more of the character of common nerve-tubules, and follow a more direct course. However interesting this notion may be, according to which the "rods" would be the terminations of the optic fibres, the considerable difficulties attending it must not be concealed; among which not the least is the circumstance, that, although the "rods" and "cones" are certainly fifty times more numerous than the fibres of the optic nerve, yet the radiating fibres arising from the former, on their passage into the optic fibres, subdivide, and, as it must probably be assumed, are continuous with several of them—a difficulty, which might indeed be removed on the hypothesis, that a single optic fibre receives or gives off numerous radiating fibres, but is nevertheless of such a kind that I do not consider it advisable to proceed any further upon a basis unsupported by facts.

In spite of the obscurity which, from what precedes, still hangs over a very important point in the anatomy of the *retina*, physiology may nevertheless even at present draw some useful conclusions from the facts in our possession. In the first place, since the demonstration by H. Müller and myself of its connexion with the radiating fibre-system and the "granules," the bacillar layer appears in quite a different light from that in which it was previously held, and it is now obviously impossible to regard it, with Brücke, as a catoptric, reflecting apparatus. I look upon the "rods" and "cones," which may

also be said to correspond in all chemical characters with the nerve-fibres of the *retina*, and the whole of the radiating fibre-system of the *retina*, as *true nervous* elements; and venture at the same time to broach the bold supposition, founded upon a less established basis, which has been already thrown out, that the "rods" and "cones" are the *true percipients of light*, and that they communicate their condition to the fibres of the optic nerve, by means of the direct or indirect connexion of their fibrous processes with the former, through which again the impressions are conveyed to the *sensorium*. That the optic-fibres in the nervous expansion of the retina, do not perceive light, appears to me to be proved by the circumstance: 1. that the point of the *retina*, where those fibres alone, and no other elements of the *retina*, are found, viz. at the entrance of the optic nerve, is not sensitive to light; 2. that the optic fibres are *superimposed upon each other in such numbers*, in almost every part of the *retina*, and above all in the neighbourhood of the *macula lutea*, that it is impossible they should perceive light, inasmuch as each luminous impression, owing to the transparency of the fibres, must in any case always affect many of them, and consequently would of necessity give rise to confused sensations; and 3. because the part of the *retina* in which there is no continuous layer of nerve-fibres on the inner surface, that is to say, the "yellow spot," is the most sensitive to luminous impressions. Under this notion, the import of the "rods," and their remarkable arrangement, would be intelligible, and the almost inexplicable correspondence in the size of the images of the smallest distinguishable interspaces between two objects, with the diameter of the "rods" and "cones," be placed in its true light. I consider it impossible to say anything with respect to the import of the other elements of the *retina*, for although the "granules" may be compared to minute bipolar ganglion-corpuscles, and their continuity with the radiating fibres is known, this affords as little ground for discussion as to their function, as is given by the knowledge of the fact that the large nerve-cells of the inner layers have numerous processes and probably free terminations.

The vessels of the *retina* are derived from the *art. centralis retinæ*, which enters the eye inclosed in the optic nerve, and begins to ramify from the centre of the *colliculus nervi optici*

in 4 or 5 main branches. Lodged at first only beneath the *membrana limitans*, these vessels penetrate through the layer of nerve-fibres into that of grey nerve-substance, ramify in an elegant arborescent manner as far as the *ora serrata*, and pass by their terminal prolongations on all sides into a rather wide-meshed network of very fine capillaries (0.002—0.003"), which is lodged chiefly in the grey layer, but partly also in the expansion of the optic nerve. In animals, the veins commence with a complete circle, *circulus venosus retinae*, at the *ora serrata*, accompany the arteries in single trunks, and converge to the *vena centralis*, which quits the eye together with the artery. No large vessels exist in the "yellow spot," where there are only numerous capillaries. I have never yet met with nerves on the retinal vessels, whilst on the outside of the larger vessels I have occasionally noticed traces of an accompanying fibrous tissue, approaching nearest to the embryonic, reticular connective tissue.

[The radiating fibre-system of the *retina*, though known in its separate parts to older and more recent observers, had not been comprehended in its connexion, and we are very greatly indebted to H. Müller for his accurate investigations into this important structure in animals of every class. I have repeated Müller's observations in the human eye, which was not investigated by him, and have been enabled to confirm in it all that he has stated, and in some respects to carry the observations further. The reason why the radiating fibre-system and the relation of the "rods" to it has hitherto remained unknown, is because no one except Bowman, so far as I am aware, has engaged in the indispensable study of vertical sections of the *retina*, and moreover, because no one had thought of applying chromic acid to that tunic, which has elsewhere in the nervous tissues been of such important service, and although I had particularly shown that the multipolar retinal cells were well preserved in it. If parts still fresh be taken for examination, in transverse sections and chromic acid preparations, very satisfactory views of the structures above described will be obtained, and it will excite surprise that such numerous fibres pervading the entire *retina* should have been hitherto overlooked. A wholly new investigation of the *retina* has commenced with

what has been made known by Müller and myself, but it will still demand much time and pains before it can be conducted to any certain results. Future inquirers should take up particularly the relations of the radiating and optic fibres in the eye, also the point whether the latter subdivide in the *retina*, as is asserted by Hassall and Corti, and lastly, whether the nerve-cells are directly connected with the nerve-fibres (Corti) or not.]

§ 228.

The *crystalline lens* is a perfectly transparent body, in relation by its posterior surface with the vitreous humor, and laterally with the termination of the hyaloid membrane, the *zonula Zinnii*; and in which are to be distinguished the *lens*, properly so termed, and its *capsule*.

The *capsule* of the *lens* consists of two elements—the *proper capsule* and the *epithelium*. The former is a perfectly structureless and transparent, highly elastic membrane, enclosing the *lens* on all sides, as if moulded to it, and parting it from the neighbouring structures. If the *lens* with its capsule be placed in water, the latter becomes considerably distended by imbibition, whence it is apparent, that membranes of that kind, notwithstanding their homogeneous structure, are yet very permeable, so that the nutrition of the non-vascular *lens* is provided for without difficulty, by means of materials penetrating from without. The lenticular capsule, measuring in its anterior wall, 0·005—0·008", and posteriorly to the attachment of the *zonula Zinnii*, where it is abruptly thinned, not more than 0·002—0·003", may be readily torn, punctured, or incised, whilst it offers considerable resistance to a blunt instrument. If an uninjured capsule be punctured, it contracts to such an extent, owing to its elasticity, that the *lens* not unfrequently escapes spontaneously. In its micro-chemical reactions the capsule of the *lens* behaves exactly like other transparent membranes, except that, according to Strahl ('Archiv f. phys.,' Heilk., 1852), it would appear to be dissolved by boiling in water. The *epithelium* of the capsule is placed, not on the outer surface, as Brücke states, but on the *inner*, towards the *lens*, lining the *anterior half* of the capsule with a single layer of beautifully clear, polygonal cells, of 0·006

—0.01", with round *nuclei*. After death its elements are readily separated, expand into transparent spherical vesicles, many of which burst and together with a few drops of aqueous humor which have penetrated into the interior, constitute the so-termed *aqua Morgagni*, which during life, when the *epithelium* is accurately applied to the surface of the *lens*, does not exist at all.

The *lens* itself consists entirely of elongated, flat, hexahedral elements, 0.0025—0.005" broad, and 0.009—0.0014" thick, of a perfectly transparent aspect, very flexible and soft,

and having a considerable degree of toughness, which have usually been described as the *fibres of the lens*, although they are nothing more than *thin-walled tubes* with clear, viscous, albuminous contents, which, when the tubes are torn, escape from them in the form of large irregular drops, and consequently might suitably be described as the *tubes of the lens*.

As concerns the microscopic characters of these bodies, they are distinguished

by the circumstance of their becoming opaque and more distinct in all reagents by which albumen is coagulated; consequently reagents of that kind, particularly nitric acid, alcohol, creosote, and chromic acid, are especially suitable for the investigation of the *lens*; but in caustic alkalies they are quickly dissolved, and they are also speedily attacked by acetic acid. The union of the tubes, which are more solid, slender, and opaque in the more compact inner layers of the *lens*—the so-termed *nucleus*—than in the softer external portions, is brought about simply by their apposition. They

Fig. 306.

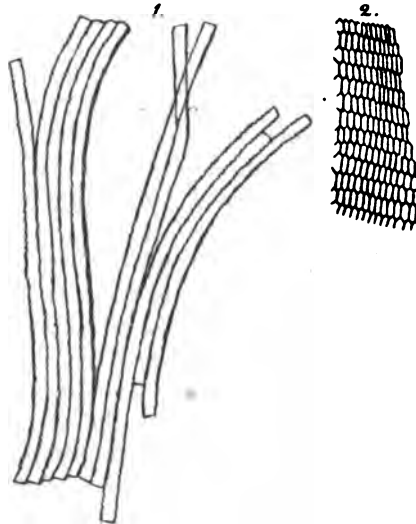


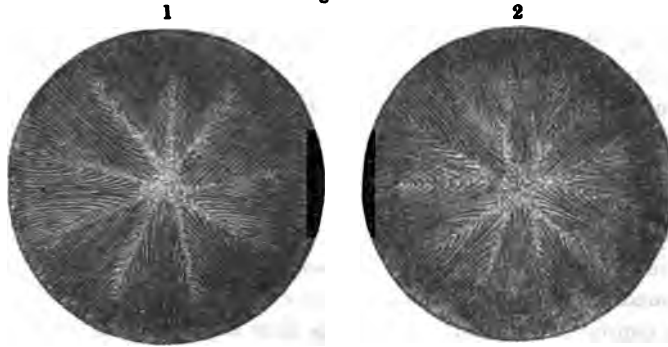
Fig. 306. Fibres or tubes of the *lens*. 1, from the Ox, with slightly toothed borders; 2, transverse section of the lenticular tubes of Man;  $\times 350$  diam.

invariably lie with their sides parallel to the surface of the lens, regularly interdigitating with each other by their acute borders, so that, as is shown in fig. 306<sup>2</sup>, in the interior of the lens, each tube is surrounded by six others, and their transverse section presents the aspect of a wall built up of hexagonal bricks. As the edges and corresponding surfaces of the tubes are usually somewhat uneven, or even toothed (in animals, particularly Fishes, beautifully so) their lateral union is rendered more intimate than it is between their broader surfaces, and on this account also the structure is more readily torn into lamellæ in the direction of the surfaces, than into vertical plates in that of its thickness. For the same reason also, a lamellar structure may be assigned to the *lens*, as is commonly done, seeing that it is constituted of concentric laminæ like an onion, only it must not be forgotten that these laminæ are not regularly defined layers, and never consist of a single *stratum* of tubes, and moreover, what may prove of great physiological importance, that the elements of the *lens* are, properly, still more regularly disposed in the direction of its thickness, so that, throughout the *lens*, they cover each other, and the latter might be regarded as consisting of very numerous vertical segments, the thickness of which would correspond with the width of a single fibre. [Bowman, l. c., p. 69.]

The *course* of the tubes of the *lens* in the separate lamellæ is in general such that both the superficial and the deeper, in the centre of the lens, radiate towards the margins, and then curve round upon the other surface, anterior or posterior, but in such a way that no fibre extends through the entire semicircumference of the *lens*, or reaches, for instance, from the middle of the anterior surface to that of the posterior. More precisely described, the tubes on the anterior and posterior surfaces of the lens do not proceed exactly to the middle, but terminate in a *stelliform figure* which exists in that situation. In the *fœtus* and in the new-born child, each of these stelliform figures of the lens, which are readily seen by the naked eye, presents three rays, which usually meet, regularly, at angles of 120°; in the anterior star, two of the rays are directed, the one upwards and the other downwards; the reverse being the case with the posterior "star," which, therefore, as compared with the anterior, appears as it were turned round in an

arc of  $60^\circ$ . Now, the tubes arising from the middle of the anterior "star" extend, on the posterior aspect, only as far as the extremities of the three rays; and, on the other hand, those commencing from the posterior pole do not reach the middle of the anterior. Similar conditions obtain in all the tubes situated between these two points, so that none of them reach entirely round; and all the tubes in a layer are of equal length. Now precisely the same thing also exists in the "nucleus" of the lens in the adult, whilst in the superficial *lamelle*, and on the surface itself, we observe a more complex "star," with from nine to sixteen rays of various

Fig. 307.



lengths and rarely quite uniform, among which, however, three principal rays may be distinguished. The course of the fibres is consequently rendered more complex, and the rather so, because fibres attached to the sides of the rays converge in an arched manner, so that the latter appear, as it were, *feathered*, or form whorls (*vortices lentis*); but, notwithstanding this, the course of the fibres remains essentially the same in all respects as that above described, inasmuch as in this case also the anterior and posterior "stars" do not correspond with each other, and no fibre extends from the one pole to the other. In the "stars" the substance of the lens is not formed of tubes as elsewhere, but is in part finely granular, in part homogeneous; and consequently, since the "stars" involve all the layers, three or more, vertical, non-fibrous lamellæ

Fig. 307. Lens of the adult, after Arnold, to show the "star." 1, anterior aspect; 2, posterior.



("central planes," Bowman) exist in each half of the *lens*. Moreover, the tubes themselves in the neighbourhood of the "stars" become less distinct, are gradually fused together, and ultimately lost, without any line of demarcation, in the substance in question.

§ 229.

The *vitreous body or humor*, occupies the entire space between the *lens* and the *retina*; its relations being such that excepting at the point of entrance of the optic nerve, where the connexion is rather more intimate, it is only in loose apposition with the *retina*, whilst it is very closely united with the *corona ciliaris* and the *lens* itself. The membrane enclosing the vitreous body, or the *hyaloid membrane*, which behind the *ora serrata* constitutes an extremely fine and delicate, perfectly transparent membrane scarcely perceptible under the microscope, in front of that part becomes rather firmer (fig. 296 *t*), and is continued to the border of the *lens* as the *pars ciliaris hyaloideæ s. zonula Zinnii* ("suspensory ligament of the lens," Bowman [and Retzius]), where it becomes blended with the capsule of that body. In doing this it splits into two *lamellæ*, a posterior (*v*), which is blended with the capsule of the *lens* a little behind its border, and cannot be traced further, so that beyond that point the posterior wall of the lenticular capsule and the vitreous body are directly in contact; and an *anterior* (*u*) connected with the ciliary processes,—the *zonula* in the more restricted sense,—which is attached to the capsule of the *lens* a little in front of its margin. Between the two *lamellæ* and the border of the *lens*, there is left a space surrounding the latter in an annular manner, and, in a transverse section, of a triangular form—the *canal of Petit*;—which, though containing a little clear watery fluid, yet during life is very narrow, inasmuch as its anterior wall or the *zonula Zinnii* so long as it is continuous with the ciliary processes, like them presents the aspect of a much plicated membrane, and consequently is brought into close approximation with the posterior wall, at as many points as there are ciliary processes. These folds, however, are still visible where the *zonula*, quitting the ciliary processes, is continued independently upon the border of the *lens*, as a part of the posterior wall of the posterior chamber of the eye; and it

is therefore attached to the capsule, not in a straight but in a slightly undulating line.

With respect to the structure of the parts in question, much pains have recently been bestowed upon the elucidation of that of the proper vitreous body; although it cannot be asserted that at present the truth has been arrived at. Brücke's view, according to which the vitreous body, like an onion, consists of concentric lamellæ parted by a gelatinous fluid, was contradicted by Bowman, who has shown, that the concentrated solution of acetate of lead used by Brücke for the exposition of these *lamelle*, produces the appearance of lamination not only on the superficial surface but also on that of any section whatever, but without rendering true lamellæ manifest. Hannover's opinion, according to which, after treatment of the vitreous body with chromic acid, numerous dissepiments are found in it, running from the surface towards the axis, so that in a vertical section a number of "rays" are perceptible proceeding from the central point, and the whole resembles an orange laid open, appears to have more in its favour, inasmuch as, at any rate, the vitreous body of the new-born child, according to Bowman (Lectures, p. 100, and fig. 5, p. 97), when treated with chromic acid, very distinctly exhibits an areolated aspect of the kind described, but it should be remarked that from the same author's observations, the conditions are widely different in the eye of the adult, for, in this instance, in chromic acid preparations, a few concentric *lamelle* are found externally, to which succeed very irregular radiating *septa*, and lastly an irregular central cavity. If to this it be added that these *lamelle* formed by chromic acid also cannot be demonstrated as true membranes, and that in the fresh vitreous body no trace of them is perceptible, the appearances produced by this second reagent can likewise not be considered as proving much.

A more correct notion of the constitution of the *vitreous body* would appear to be derivable from the study of its development. It has been long known that the vitreous body in the *fœtus* has vessels on its surface and in the interior; it might thence have been concluded that some tissue for the support of these vessels must also exist—but no one has, till recently, sought farther information with the aid of the microscope. Bowman was the first (l. c., p. 100 and p. 97, fig. 7)

to remark, that the vitreous body of the new-born child exhibited a very distinct and peculiar fibrous structure, consisting in fact of a close network of fibres, presenting at nodular enlargements [where the fibres join] "minute nuclear granules resembling oil-particles, but not soluble in ether;" the whole exhibiting "a peculiar fibrous texture not at all unlike that of the enamel pulp" in the foetal tooth-sac, that is to say, to its gelatiniform connective tissue. This agrees pretty nearly with what Virchow has recently found. According to the latter author, the vitreous body of a foetal Pig, 4" long, consists of a homogeneous substance, containing mucus, and faintly striated at distant spots, in which round nucleated granular cells lie, scattered at regular distances apart. This substance is surrounded by a delicate membrane, with very elegant vascular networks and a fine fibrous areolated mesh-work containing *nuclei* at the nodular intersections, and also enclosing in its meshes a gelatinous mucus with rounded cells. Consequently, and also because he found mucus in the vitreous body in the adult, Virchow believes that the tissue of the foetal *corpus vitreum* should be ranked with what he terms "mucous tissue," corresponding with my gelatinous connective tissue (§ 24); and that it might be assumed that, in the course of development, the structure may so change that the cells disappear and the intercellular substance alone remains. As regards my own views, I can only partially agree with these authors. In the vitreous body of the human foetus and of that of animals, I can perceive nothing but a homogeneous matrix containing *mucus* and numerous round or elongated granular, nucleated cells, 0.004—0.01" in size, dispersed in it at pretty regular distances of 0.01—0.02", or even 0.03" apart. It is true I have also noticed stelliform anastomosing cells also, but only on the outer side of the hyaloid membrane, and which, when the vessels once began to convey blood, could be easily shown to communicate with them, and to be, in fact, capillaries in process of development. Of membranes, such as Hannover describes, I have never seen any certain indication with the microscope; and yet such membranes, did they exist, would incontestably be as easily recognised, where they are folded, as the excessively delicate hyaloid membrane itself. In the vitreous body of the adult, of the previous conditions there was

usually nothing left but the homogeneous *matrix*, the cells having disappeared; I noticed the latter, however, in many instances, though rare and indistinct, particularly in those parts of the organ bordering upon the *lens* and the hyaloid membrane in general. From these observations I conclude that the vitreous body, at an early period probably presents a sort of structure most nearly approximated to embryonic cellular tissue, but that subsequently all trace of such a structure is normally lost, and it consists merely of a more or less consistent *mucus*.

*Zonula Zinnii*.—At the *ora serrata*, the hyaloid membrane comes into intimate contact with the *retina*, and the latter again with the *choroid*, so that it is extremely difficult to display the relations of the above-noticed *zonula Zinnii*. If this part be exposed from the outside, some of the *pigmentum nigrum* of the ciliary processes is almost always left adherent at certain spots and often over a considerable extent. If the places where this is not the case are examined, it is evident that the outermost lamina of the *zonula* is a greyish layer, extending exactly so far as the *processus ciliares* are in connexion with the *zonula*, and ceasing anteriorly in a slightly toothed, irregular border. Under the microscope there are always visible in this layer, even when the zone appears quite clear, and particularly towards the front, a good many rows of pale pigment-cells belonging to the *choroid*, which are situated principally in the folds in which the *processus ciliares* were contained, and give the entire zone a striped aspect. On the inner side of this lies a single layer of clear, frequently very pale, polygonal, nucleated cells, of 0.006—0.012''' in size, but which is never entire, being always partially removed, together with the ciliary processes, on which Henle and others have noticed it. This layer of cells does not belong to the *retina*, as most authors assume, and still less to the hyaloid membrane, but to the *choroid*, and is nothing more than a *stratum* of cells not containing pigment, lying immediately upon the *corona ciliaris*, internally to the pigment (fig. 296 *w, w'*); it does not, however, in any way appear to be a distinct epithelial layer, but only the uncoloured part of the pigmentary stratum, to which it would stand in the same relation as the colourless epidermis-cells to the coloured, in dark skins. This *colourless epithelium* of the

*corona ciliaris*, as I shall term these cells, is most distinctly shown on the ciliary processes, as a clear border sharply defined on the inner side, and often 0·006—0·008''' broad, whose large, frequently shortly cylindrical cells, may usually be recognised without any trouble, and are always rendered distinct by acetic acid; whence it is evident that the boundary is composed only of them, and is not a special membrane. Posteriorly, this cellular *stratum* reaches as far as the *ora serrata*, extending anteriorly to the termination of the ciliary processes (fig. 296 *w'*), and on either side it is continuous, without any line of demarcation, with the pigmentary layer, the clear cells being gradually replaced by cells containing pigment.

Excepting these cells, the *zonula* is a thin, transparent but tolerably firm membrane, stretching from the *ora serrata retinæ* as far as the border of the lens, and appearing to be a continuation of the hyaloid membrane. It consists of peculiar, pale fibres, already very well characterised by Henle, resembling certain forms of reticular connective tissue, except that they are more rigid, usually present no distinct fibrils, and are less swollen in acetic acid. They commence, very fine, a little behind the *ora serrata retinæ* on the outer side of the hyaloid membrane, although most intimately connected with it, in part like fibrils of connective tissue, then run forwards, forming a layer at first more lax, and becoming more and more dense, and increasing in thickness (up to 0·004—or even 0·01''' and more), with numerous divisions and anastomoses, and for the most part parallel with each other, until they constitute, at the free portion of the *zonula*, a perfect, continuous layer—though still containing a few isolated bundles, and are ultimately blended with the capsule of the lens. From the *ora serrata* to the commencement of the “canal of Petit,” no hyaloid membrane besides the fibres of the *zonula*, can be any longer distinguished, whilst at the canal itself, where the substance of the vitreous body is separated from the fibrous layer, it is again furnished with a limiting membrane, only thinner than before, which constitutes the posterior wall of the “canal of Petit,” and extends no farther than to the border of the *lens*, where it ceases as a special membrane, the vitreous body being most intimately united with the posterior *lamina* of the capsule of the lens.

[M. Langenbeck, some years ago described, in the free portion of the *zonula Zinnii*, what he believes to be a muscular ring, and terms the *musculus compressor lentis s. accommodatorius* ('Klinisch. Beiträge zur Ophthalmol.,' 1849, p. 66), of which I have been unable to perceive any indication. He has probably confounded the zonular fibres with such a structure.]

## B. ACCESSORY ORGANS.

## § 230.

The *eye-lids* are supported by the so-termed *tarsal cartilages* (*tarsi*), thin, semilunar, flexible, but tolerably elastic plates, attached internally and externally by the fibrous, *tarsal ligaments*,—and belonging, as far as their structure is concerned, to the solid, fascicular, connective tissue, though occasionally containing a certain number of minute cartilage cells. These plates, 0·3—0·4''' thick, the fibres in which chiefly run parallel with the borders, are covered externally by the *orbicularis palpebrarum* and the integuments, and internally by the *conjunctiva*. The *skin* is here very thin ( $\frac{1}{3}$ — $\frac{1}{8}$ '''), with scanty, subcutaneous connective tissue containing no fat, a delicate cuticle, 0·055—0·058''' thick, and short *papillæ* (of 0·60—0·066'''); but it is furnished throughout with minute sudoriparous glands (of  $\frac{1}{10}$ — $\frac{1}{13}$ ''') and almost invariably, with numerous minute hairs (frequently, with contiguous sebaceous glands, but whether always so provided I do not know). At the edges of the *palpebræ* these hairs are more considerably developed and constitute the *eye-lashes*, which are also furnished with sebaceous follicles. Agreeing in all respects, in structure and secretion, with the sebaceous glands, the Meibomian glands, nevertheless, differ somewhat in form. They are imbedded in the tarsal cartilages, to the number of from twenty to forty, in the form of elongated, white, delicate, parallel, racemose follicles, disposed in such a direction that the long axes of the glands, cut those of the tarsal cartilages at a right angle. Each of these glands, which are visible at once upon inverting the eye-lid, and do not occupy the entire width of the *tarsi*, consists of a straight excretory duct, 0·04—0·05''' wide, which

at its orifice on the inner edge of the free palpebral border, is lined with common *epidermis*, including the horny and the mucous layers, and more internally presents the usual structure observed in the sebaceous glands. This canal, throughout its length, is beset with round or pyriform, shortly pedunculated, gland-vesicles, 0·04—0·07—0·01''' in diameter, either isolated or aggregated several together, in which, in a mode similar to that already described in speaking of the sebaceous glands (§ 74), a constant production of spherical, adipose cells, 0·005—0·01''' in size, takes place; the cells differing from the sebaceous cells, only in the circumstance that the oil-drops contained in them do not usually run together into a single large drop, but remain separate. As these cells advance towards the excretory duct they gradually break up into a whitish pul-taceous substance composed of oil-drops, and form the so-termed *lema s. sebum palpebrale*. The *orbicularis palpebrarum*, constituted of transversely striped, though rather slender and pale muscular fibres, lies immediately beneath the skin, its *stratum internum* being separated from the *tarsi* by a layer of lax, and to some extent adipose connective tissue, so that it may be readily raised into a fold together with the integuments. It is only towards the free margin that this muscle is more closely attached to the *tarsi*, and there presents a bundle of fibres situated at the very verge of the eye-lid, which is parted from the rest of the muscle by the follicles of the *cilia*—the so-termed *ciliar muscle* (*musculus ciliaris*, Riolan).

The *conjunctiva*, (a mucous membrane) commences at the free palpebral margin, as an immediate continuation of the external integument, lines the posterior surface of the eye-lids, and is then reflected upon the eye-ball, investing the anterior part of the *sclerotic* and the entire *cornea*. The palpebral *conjunctiva* is a reddish membrane, 0·12—0·16''' thick, very intimately connected with the posterior surface of the *tarsi*, and consisting of a dense layer of connective tissue corresponding to the *cutis*, 0·08—0·11''' thick, and of a squamose *epithelium*, 0·04'' in thickness, containing deeper cells of an elongated form, and more superficially, polygonal, slightly flattened, nucleated, and (so far as I have seen in Man) non-ciliated cells. *Papillæ* also, similar to those of the *cutis*, are met with in the palpebral *conjunctiva*, some of which are smaller and

more cylindrical, whilst others, particularly towards the point of reflection of the membrane where it is generally thicker, are larger, (as much as  $\frac{1}{10}$ ''' long), more verrucose and fungiform. At the line of reflection itself, Krause describes minute racemose mucous glands,  $\frac{1}{3}$ — $\frac{1}{28}$ ''' in size, but which do not always exist. The *conjunctiva sclerotica*, is white, less dense and thinner than that of the lids, tolerably rich in fine elastic fibres, and loosely and moveably attached to the sclerotic by an abundant submucous connective tissue, containing more or fewer fat-cells. *Papillæ* are wholly wanting in this portion, except at the line of reflection, as well as glands, whilst the *epithelium* is well developed, as on the *conjunctiva cornea*, and beneath it there is not unfrequently an outermost layer of the proper mucous membrane, in the form of a very distinct structureless, narrow seam. At the margin of the *cornea*, particularly in elderly persons, the *conjunctiva sclerotica* forms a slight annular elevation  $\frac{1}{2}$ — $1$ ''' broad,—the *annulus conjunctivæ*, which encroaches a little upon the *cornea* at the lower, and especially at the upper border. The *corneal conjunctiva* has been already described, and it only remains to notice the *plica semilunaris*, or the third *palpebra* at the inner *canthus* of the eye. This is a simple duplicature of the sclerotic *conjunctiva*, which rises in front into a conical elevation—the *caruncula lachrymalis*,—in which are seated about a dozen fine hairs, surrounded by an equal number of rosette-like sebaceous follicles  $\frac{1}{3}$ — $\frac{1}{2}$ ''' in size, encompassed by numerous fat-cells.

The *lachrymal apparatus* consists, in the first place, of the *lachrymal glands*—a certain number of larger and smaller compound racemose glands, disposed in two groups—termed the *superior* and *inferior lachrymal glands*, and in the structure of the larger and smaller lobules, as well as in the rounded gland-vesicles, 0·02—0·04''' in diameter, precisely resembling the salivary and mucous glands (§§ 134, 135). The excretory ducts of these glands, 6—12 in number, perforate the *conjunctiva* in the fold between the outer part of the eye-lid and the globe of the eye; they are excessively fine *canaliculi*, composed of connective tissue, with a few *nuclei* and elastic fibrils, and of a cylindrical *epithelium*. It is extremely difficult to display these canals in man, whilst in animals (the Ox, for instance) they are easy of demonstration. The passages by which the tears



are conveyed away from the eye are constructed in the same simple manner as the excretory ducts of the lachrymal glands, consisting merely of a dense *connective tissue* with numerous networks of fine elastic fibres, particularly abundant in the lachrymal canals, which appears to be a continuation of the mucous membrane of the nose and of the *conjunctiva*, and of an *epithelium* which, in the lachrymal canals, is of the squamous kind, and in the lachrymal sac and nasal duct is furnished with vibratile cilia, as in the cavity of the *nares*. The muscles of the globe of the eye and of the eye-lids, as well as the *musculus Horneri*, are all composed of transversely striped muscular fibres, and together with their tendons, present no differences from those of the trunk and extremities. The *fascia bulbi oculi s. Tenoni* is a true fibrous membrane, and the *trochlea* is formed principally of dense, connective tissue, in which only a few cartilage cells can be seen.

The *vessels* of the organs described in this section present little worthy of remark. Excepting those of the muscles and skin, they are most abundant in the palpebral *conjunctiva*, in which they chiefly enter the *papillæ*, and in the next place in the lachrymal glands and the *caruncula lachrymalis*. The sclerotic *conjunctiva* also contains numerous vessels, and the Meibomian glands within the *tarsi* are also surrounded by a few. Except in the skin of the eye-lids, *lymphatics* have only been demonstrated by Arnold in the *conjunctiva scleroticæ*, where they form, at the border of the *cornea*, a closer, and more externally a looser plexus, passing outwards in several small trunks. The *palpebræ* and *conjunctiva* are everywhere well supplied with *nerves*, but their relations have been minutely examined only in the *conjunctiva*. In this membrane, in Man, I have found terminal plexuses as in the external integument, with numerous divisions of fibres, 0.001—0.006" thick, extending up to the margin of the *cornea*, together with pretty clear indications of loops and free terminations. Besides which, in one instance, there were presented, towards the palpebral *conjunctiva*, peculiar "nerve-coils," 0.02—0.28" in size, into which a single nerve-fibre usually entered, whilst 2—4 were given off from it (*vid.* Mik. Anat. II, 1, p. 31, fig. 13. A, 3). The relations of the nerves of the lachrymal apparatus are entirely unknown.

## § 231.

*Physiological remarks.*—The *eye-ball* is not developed from a single point as a whole, but arises from the conjunction of formations, proceeding on one side from the central nervous system, on another from the skin, and, thirdly, from the parts lying between the two. In the Chick, the *primitive ocular vesicles* arise before the commencement of the second day, from the primitive cerebral vesicle or the anterior *cerebrum*, in the form of two protrusions, at first sessile, but afterwards having a hollow peduncle—the rudiment of the optic nerve. At the beginning of the third day, the formation of the *lens* commences, from the skin of the face covering these vesicles, by the thickening on the inner aspect, and inversion of the *epidermis*, in consequence of which the anterior wall of the primitive ocular vesicle is also inverted, and becomes applied to the posterior wall, so that the cavity of the vesicle is wholly obliterated. Now, at first, this *secondary ocular vesicle* encompasses the *lens*, which in the meantime has been separated by constriction from the *epidermis*, and comes into exact apposition with it beneath, like a cup; subsequently, however, the *vitreous body* is developed between the two, in a special new cavity. How the latter is formed has not yet been ascertained, although, as Schöler observes, it is most probable that it also grows in from the skin,—in fact, from the region below and behind the *lens*,—and participates with the latter in the inversion of the primitive ocular vesicle. According to Remak, the *retina* is formed from the inner, thicker wall of the inverted or secondary ocular vesicle, and from the outer and thinner, the *choroid*, from the anterior border of which the *iris* is not produced till afterwards. The *sclerotic* and *cornea* are applied from without upon the eye-ball thus constituted, the former being to some extent a production of the skin.

An interesting phenomenon is presented in the *vessels* existing in the foetal eye, even in the transparent *media*. The vitreous body, on its outer surface, between the hyaloid membrane and the *retina*, presents a tolerably wide meshed vascular plexus, which is supplied by branches of the *arteria centralis retinae*, given off from it at its entrance into the eye, and anteriorly, at the border of the *lens* on the *zonula Zinnii*, forms

a vascular circle, the *circulus arteriosus Mascagnii*, from which again vessels are given off to the *membrana capsulo-pupillaris*, presently to be described. Besides this, a special *arteria hyaloidea*, also derived from the central artery of the *retina*, runs in the so-termed *canalis hyaloideus*, in a straight line through the vitreous body, to the *lens*, and ramifies in the most elegant arborescent manner, at very acute angles, in a membrane closely applied to the posterior wall of the lenticular capsule. This is nothing else than a portion of an *external vascular capsule*, which at first very closely surrounds the *lens*, and in its anterior wall is supplied by the continuations of the hyaloid artery, coming round the border of the *lens* towards the front, with which branches of the *circulus arteriosus Mascagnii* and of the anterior border of the *uvea* are connected. Afterwards, when the *lens* retreats from the *cornea*, with which it is, at first, in close apposition, and the *iris* buds out from the border of the *uvea*, the anterior wall of the vascular lenticular capsule is divided into two portions: one central and anterior, which, arising from the border of the *iris*, and connected with that membrane by vessels, closes the pupil—the *membrana pupillaris*; and another, external and posterior, extending backwards from the same points upon the border of the *lens*—the *membrana capsulo-pupillaris*. The latter becomes more and more distinct as the *iris* and aqueous chambers are developed and the *lens* retreats, until at last it represents a delicate membrane stretching across the posterior chamber. The venous blood from all these parts is returned through the veins of the *iris*, and from the outer surface of the vitreous body, also through those of the *retina*, and perhaps through a *vena hyaloidea*, said to take the same course as the artery, but of the existence of which many authors doubt, and which I have never myself seen. With respect to the genetic import of the vascular capsule, nothing has as yet been ascertained. I find it to be composed of a homogeneous tissue, with a few scattered cells, and regard it as a structure corresponding to the *cutis*, which, in the formation of the *lens*, is detached from the skin, together with a portion of the *epidermis*, and remains in the eye. The vitreous body, then, may be understood as modified subcutaneous connective tissue,—a supposition not at all incongruous with the observations above

adduced, and the more so, because, as I have shown (§ 24), all the subcutaneous connective tissue of the fœtus is at one time perfectly gelatinous, and, like the enamel organ which also belongs to the same tissue *in specie*, strikingly resembles the vitreous body in aspect and consistence.

Concerning the *histological* development of the eyes, the following only need be remarked. At an early period they consist in all their parts of formative cells of uniform size, which, in process of time, are metamorphosed into the various tissues. In the fibrous coat, in the second and third month, the cells are developed, in the mode already described (§ 24), into connective tissue, and at the same time the distinction is set up between the *cornea* and *sclerotic*, which are at first, externally, exactly alike, and constitute only a single membrane. In the *uvea* the cells are for the most part employed in the formation of vessels; another portion goes to the formation of the inner and outer pigment-layers, pigment-granules being deposited in them at the commencement of the third month, whilst another is transformed into muscles, nerves, the *epithelia* and connective tissue of these membranes. The development of the nerve-cells and of the so-termed "granules" from embryonic cells, may be readily traced. I have observed the same thing also with respect to the "cones;" and I think that, in the Frog, it may be assumed with respect to the "rods" likewise, that they are nothing but elongated cells; whilst in the Mammalia, the formation of the "rods," and of the nerve-fibres themselves, has not yet been traced. The *lens*, lastly, is originally composed entirely of cells, which, in course of time, are transformed into the tubes. The precise nature of the processes attending these changes has not yet been investigated, although I agree with H. Meyer in the conclusion, that since the tubes, both in the fœtus and child, present only a single *nucleus*, each of them is developed out of a single cell. These *nuclei*, taken as a whole, constitute a thin layer, extending from the borders of the *lens*, through the middle of its anterior half, and slightly convex in front ("nuclear zone," Meyer); the *nuclei* being smaller in the interior portions, and as it were in progress of solution, whence it may certainly be concluded that the *lens* increases by the apposition of thin layers from without. The formative cells of

the tubes of the lens are those which exist on the anterior half of the capsule and the starting point of the formation of the lenticular elements, according to my observation, is the *entire anterior surface and the border of the organ*. *Nuclei* are visible in the tubes even in the *lens* of the adult, as was known to Harting, though only at its margin.

[With respect to the vessels of the foetal eye, Dr. Thiersch has quite recently communicated to me a mass of interesting details, accompanied by beautiful injections, to which I shall refer in the concluding part of my 'Microscopical Anatomy.'

*Investigation of the visual organ.* The *fibrous tunic* of the eye should be examined in the recent condition, and in moistened sections of dried preparations, which latter, especially of the *cornea* and at its point of transition into the *sclerotica*, afford very useful information. If, after the removal of the vitreous body and *lens*, the *iris* and *choroid* are dried, their connexion with each other and with the fibrous tissue may be studied. In order to view the *nerves and vessels of the cornea*, the latter is removed by a circular section in the recent eye, together with the margin of the *sclerotic*, the whole is divided into three or four segments, which, in order that they may lie the better, have little incisions made into them around the edge, are moistened with the aqueous humour, and covered with a thin plate. The nervous trunks, which are here usually opaque, are then sought for at the border of the *cornea*, first with a low power, and afterwards traced under a higher. The nerves are beautifully displayed in the eye of the Rabbit, where I can perceive their trunks with the naked eye, though they may usually be readily found in other eyes also, but are always traced with difficulty towards the centre. If the epithelium is cloudy, it must be removed by caustic soda, which at first does not affect the nerves. The *vessels* under these circumstances are usually full of blood, and consequently present no difficulties. The corneal *epithelium* is visible on the surface in sections of dried preparations, and is very well shown when the surface is scraped. The "membrane of Demours" is very distinct in sections, and frequently its *epithelium* also; otherwise the latter is well seen on the surface and in detached shreds of the membrane. The passage of this membrane into the *ligamentum pectinatum*

of the *iris*, may be seen in sections and by careful dissection. In the latter case, the inner wall of the "canal of Schlemm" should be carefully removed, together with the *iris* and *choroid*, and an attempt made to raise from it portions of the *membrana Demoursiana*, which is not unfrequently successful. The *uvea* offers no difficulty. The pigment-cells of the *stroma*, with their processes, and the inner pigment are readily seen; the latter at the margin of folds and in carefully detached portions. For the investigation of the ciliary muscle, a fresh eye is requisite, as its elements very soon become unrecognisable. The muscles of the *iris* should be studied in a blue eye, and best in that of a child, after removal of the posterior pigment; and also in the eye of a white Rabbit, in which the *sphincter pupillæ* may be readily seen without farther trouble on the application of acetic acid. The same preparation should be employed in order to examine the nerves of the *iris*, but a perfectly fresh eye and a dilute solution of soda are indispensable. The *retina* should be examined in the recent state, on the surface, in vertical sections, and at the edges of folds, moistened with aqueous humour, and without any covering glass; and also with the aid of slight compression and by the teasing out of the tissue. Chromic acid preparations are very important in the study of this structure. This reagent, it is true, affects the "rods" to some extent, but preserves the other parts so much the better, and without its aid Müller and I should never have arrived at the results above stated, although Hannover, on account of its influence upon the "rods," erroneously considered it an unfit agent to employ. The most advantageous mode of applying it, is to treat a fresh *retina* at once with chromic acid, and to trace all the stages of its effect step by step. If the solution be much diluted, the elements are very little changed, and in particular may be easily isolated; and if more concentrated, sections through the *retina* may be prepared, without which no complete view of the structure of that tunic can be arrived at. I apply it by extending a portion of the *retina* upon an object-bearer, with a little chromic acid, in such a way that it should lie flat and not float. Extremely fine slices may then be taken by a sharp convex scalpel or razor from any sectional surface, by pressing downwards, which, with a little pains, may be done

easily enough. It is as well, however, to guide the cutting scalpel by the handle of another held in the other hand, until the edge of the former is brought immediately over the border of the *retina*. When the nervous layers, which are very well defined from each other, have been studied in sections of this kind, which should be taken especially from the neighbourhood of the *macula lutea*, as well as from other situations in the transverse and longitudinal directions, and which when useful necessarily exhibit only a few layers of the elements, they may be carefully teased out or rendered more transparent by *soda*, which last, however, is not generally of much use, since it makes the elements pale. The hyaloid membrane is posteriorly always very readily detached from the *retina*, together with the vitreous body, and may be recognised in every eye, in sections from the surface of that body, examined under the microscope, and, in folds, occasionally by the naked eye. The *zonula Zinnii*, on the other hand, in the recent eye, is always so covered by detached pigment and the colourless *epithelium* of the ciliary processes, and at its posterior border by the *retina*, that it cannot well be recognised in that situation, and almost only in its free, most anterior portion. In such preparations, also, after the removal to the greatest possible extent of the adherent parts by means of a hair pencil, pretty good views of it may be obtained, particularly if, in addition to the viewing of the external and internal surface of segments of the *zonula* detached from the vitreous body, and of preparations made by the teasing out of the structures, the borders of folds, especially of the inner surface, are also examined, which, with some care, may be obtained to the whole extent of the *zonula* and of its points of connexion with the *retina*. The *zonula* in connexion with the hyaloid membrane, is very beautifully and distinctly isolated from the *retina* and the cells of the ciliary processes, in half-putrid eyes and in macerated preparations of the vitreous body; and preparations of this kind are especially adapted to show that the *zonula* is a part of the hyaloid membrane, as well as the mode of origin and course of its fibres. For the study of the zonular fibres I can also particularly recommend chromic acid preparations, in which they become quite opaque and glistening, almost like elastic fibres. The capsule of the *lens* and its *epithelium* present no

difficulties. The *tubes of the lens*, when fresh, are very transparent, but in dilute chromic acid they are rendered *quite* distinct. Sections of the *lens* may be easily procured from preparations made in alcohol, or chromic acid, or from dried and hardened preparations, which may be rendered transparent again by means of acetic acid. The accessory organs of the eyes require no particular remark, unless, with respect to the Meibomian glands, it may be stated, that they are best seen in *tarsi* which have been cleanly dissected and treated with acetic acid and alkalies, and in longitudinal and transverse sections of similar preparations, dried.]

*Literature.*—THE "EYE" AS A WHOLE: Valentin, in his 'Repert.,' 1836 and 1837, and 'Handw. d. Physiol.,' I, p. 748; S. Pappenheim, 'Gewebelehre d. Auges,' Berlin, 1842; E. Brücke, 'Anat. Beschreib. d. menschlichen Augapfels,' Berlin, 1847; W. Bowman, 'Lectures on the parts concerned in the operations on the eye and on the structure of the Retina and Vitreous Humor,' London, 1849; A. Hannover, 'Bidrag til Ojets Anatomie, Physiologie og Pathologie,' Copenhagen, 1850. SCLEROTICA: M. Erdl, 'Disquisit. anat. de oculo,' I. 'De m. scleroticâ,' Monach., 1839; Bochdalek, 'Ueber die Nerven der Sclerotica,' in 'Prag. Viertelj.,' 1849, IV, 119. CORNEA: Kölliker, 'Ueber die Nerven der Hornhaut,' in 'Mitth. d. naturf. Ges., in Zürich, 1848, No. 19; Rahn, 'Ueber die Nerven der Hornhaut,' in 'Mitth. d. naturf. Ges., in Zürich, 1850, No. 45; Luschka, 'Die Nerven der durchsichtigen Augenhaut,' in 'Zeitsch. f. rat. Med.,' X, p. 20, and 'Die Structur der serösen Häute des Auges,' in 'Str. d. serösen Häute,' Tubingen, 1851; Strube, 'Der normale Bau der Cornea,' Diss., Wurzburg, 1851. CHOROID AND IRIS: C. Krause, 'Ueber die Pigmenthaut, in Müller's 'Arch.,' 1837, p. 33; E. Brücke, 'Ueber den *Musc. cramptonianus* u. d. Spannungsmuskel der *Chorioidea*,' in Müll. 'Archiv,' 1846; Bochdalek, 'Beiträge zur Anatomie des Auges,' 'Prag. Viertelj.,' 1850, I. RETINA: G. Treviranus, 'Ueber den Bau der Netzhaut,' in his 'Beiträgen,' Bremen, 1835 and 1837; C. M. Gottsche, 'Ueber d. Nervenausbreitung d. *Retina*,' in Pfaff's 'Mittheil. a. d. Geb. d. Med.,' 1846 [and 'Ueber die *Retina* im Auge der Grätenfische,' in Müll. 'Archiv,' 1835, p. 457,]; A. Michaelis, in Müller's 'Archiv,' 1837, p. 12, and 'N. Acta,' T. XIX,



1842; B. Langenbeck, 'De retinâ observat.,' Gott., 1836; R. Remak, 'Zur mikrosk. Anatomie der *Retina*,' in Müll. 'Archiv,' 1839; B. Lersch, 'De retinæ struct. microsc.,' Berolini, 1840; A. Burow, 'Ueber den Bau der *macula lutea*,' in Müll. 'Archiv,' 1840; F. Bidder, 'Zur Anatomie der *Retina*,' in Müller's 'Archiv,' 1839 and 1841; R. Hannover, 'Ueber die Netzhaut,' in Müller's 'Archiv,' 1840 and 1843, and 'Recherches microsc. sur le syst. nerveux,' Copenh., 1844; E. Brücke, 'Ueber die physiologische Bedeutung der stabförmigen Körper,' in Müller's 'Archiv,' 1844, p. 444, and 'Anat. Untersuchung über die sog. leuchtenden Augen,' *ibid.*, 1845, p. 337; F. Pacini, 'Sulla tessitura intima della retina,' in 'Nuovi Annali delle scienze naturali di Bologna,' 1845; H. Müller, 'Zur Histologie des Netzhaut,' in 'Zeitsch. für wissenschaft. Zool.,' 1851, p. 234; Corti, 'Beitrag zur Anatomie der *Retina*,' in Müller's 'Archiv,' 1850, p. 274. VITREOUS BODY: E. Brücke, 'Ueber den innern Bau des Glaskörpers,' in Müll. 'Archiv,' 1843, p. 345, and 1845, p. 130; Hannover, 'Entdeckung des Baues des Glaskörpers,' in Müller's 'Archiv,' 1845, p. 467; W. Bowman (op. cit.), and in 'Dublin Quarterly Journal,' Aug., 1845, p. 102; Virchow, 'Notiz über den Glaskörper,' in 'Arch. f. path. Anatomie,' IV, p. 468, and in 'Verh. d. Würzb. phys. med.,' Gesellsch., II, p. 317. LENS: W. Werneck, 'Mikr. Betracht. der Wasserhaut u. des Linsensystems,' in Ammon's 'Zeitsch.,' Bd. IV and V; R. Hannover, 'Beobachtungen über den Bau der Linse,' in Müll. 'Archiv,' 1845, p. 478; Harting, 'Histolog. Anteeckennigen,' 1846, pp. 1—7, and 'Recherch. micrométriques.' DEVELOPMENT OF THE EYE: H. Schöler, 'De oculi evolutione,' Mitav., 1849, Diss.; Remak, in his large work, 'Ueber Entwicklungsgeschichte,' 1850-51; Gray, 'On the development of the retina and the optic nerve,' in 'Phil. Trans.,' I, 1850; Henle, 'De membr. pupillari,' Bonn., 1832; Reich, 'De membr. pupillari,' Berolini, 1833; J. Müller, also Arnold, and Henle, on the 'M. capsulo-pupill.,' in Ammon's 'Zeitsch.,' II, p. 391, III, p. 37, IV, pp. 23 and 28. Besides which, see Arnold, 'Org. sensuum.'

## II.—OF THE ORGAN OF HEARING.

## § 232.

The auditory organ consists of the *proper sentient parts* with the expansion of the acoustic nerve, which are contained in the osseous substance of the labyrinth; and of special accessory apparatus, the *external* and *middle ear*, intended chiefly for the reception and conduction of the undulations of sound.

## § 233.

*External and middle ear.*—The *auricle (pinna)* and the cartilaginous external auditory canal, are supported by the *cartilage of the ear (cartilago auris)*,  $\frac{1}{3}$ — $1''$  thick, and while retaining the thick *perichondrium* very flexible, but otherwise extremely brittle, and the form of which is well known. This *cartilage*, in its more intimate structure, approaches the yellow or reticular cartilages, though it is distinguished by a considerable preponderance of cartilage-cells,  $0\cdot01''$  in diameter, in the striated *matrix*. It is covered by the *external integument*, which, except in the lobule, contains no fat and on the concave side of the auricle is closely adherent to the cartilage, where it is characterised by a great abundance of *glands*. These are, in the first place, common *sebaceous follicles*, which are most developed in the *concha* and *fossa scaphoidea*, where they attain the diameter of  $\frac{1}{4}$ — $1''$ ; secondly, minute *sudoriparous glands* of  $\frac{1}{18}''$  on the convex side of the *pinna*; and, lastly, the *ceruminous glands*, already described (§ 71, 72), in the cartilaginous, external auditory canal itself. In the latter, the *cutis* measures  $\frac{1}{3}$ — $\frac{1}{8}''$  in thickness, without the *epidermis*, which is  $\frac{1}{75}$ — $\frac{1}{50}''$  thick; and presents, besides the *glandulæ ceruminosæ*, hairs and sebaceous follicles in a dense subcutaneous tissue, whilst in the osseous part of the passage it is very thin, contains no organs of any kind, and is blended very intimately with the *periosteum* of the canal.

The *middle ear*, in all its cavities, together with the ossicles, tendons and nerves contained in it, is lined with a delicate mucous membrane, which, in the mastoid cells and on the

*ossicula auditus*, where it also forms the *memb. obturatoria stapedis*, and on the *membrana tympani*, is still more delicate than in the accessory sinuses of the nose, being thickest in the Eustachian tube. In the latter situation, its *epithelium* is of the squamose, ciliated kind, 0.024''' thick, whilst in the tympanic cavity it is changed into a thin, tessellated *epithelium*, composed of one or two layers, extending as far as the accessory cavities. The *membrana tympani*, which, according to Todd and Bowman, is furnished with a ciliated *epithelium*, consists of a middle fibrous plate, which, at the *sulcus tympanicus*, in connexion with the *periosteum* of the cavity of the *tympanum* and of the osseous *meatus* and with the *cutis* lining the latter, commences in a dense tract of chiefly annular fibres—the so-termed *annulus cartilagineus*,—and further inwards is composed principally of slender radiating *fasciculi* converging towards the centre, where the handle of the *malleus* is inserted into this membrane, and in part reticulated, with undeveloped fine elastic fibres ("connective tissue corpuscles," Virchow). Externally, this membrane is covered by a delicate continuation of the *epidermis* of the external *meatus*, and internally it is lined by a fine investment of the mucous membrane of the *tympanum*.

The *ossicula auditus* are composed principally of spongy osseous substance, with a thin compact *cortex*; and their articulations and ligaments resemble, in miniature, those of other similar organs in all respects, even down to the cartilaginous layer, consisting of scarcely more than a single stratum. Their *muscles*, like those of the external ear, are transversely striped. The Eustachian tube has in part, as a foundation, a *cartilage* which in structure approaches the true cartilages; usually, however, presenting a pale, fibrous *matrix*; and containing, in the cartilaginous portion, especially towards the aperture, numerous racemose mucous glands, of precisely the same conformation as those of the *pharynx*, in the mucous membrane of which organ that of the Eustachian tube is imperceptibly lost. The *external ear* is supplied with *vessels* and *nerves*, in the same manner as the external integuments. In the *middle ear*, the mucous membrane, especially of the walls of the *tympanum*, is highly vascular, as is also the Eustachian tube and the *membrana tympani*, in which latter

the largest arteries and veins run along the *manubrium* of the *malleus* in the middle coat, constituting arterial and venous circles around the periphery of the membrane, and also ramifying abundantly in the mucous membrane. The *nerves* are derived principally from the ninth and fifth pairs, and upon the whole are scantily distributed in the mucous membrane and *membrana tympani*. With their terminations we are unacquainted, whilst it is known that the tympanic nerve contains numerous large ganglion-cells, either isolated or aggregated into small *ganglia*.

### § 234.

The inner surface of the *vestibule* and of the *osseous semicircular canals* is lined by an extremely thin *periosteum*, consisting of a rigid, finely-fibrous connective tissue, without elastic fibres, but with numerous *nuclei* and in many respects resembling the forms of fibre met with in the inner wall of the "canal of Schlemm" in the eye. On the surface of this *periosteum* rests a tessellated *epithelium* in a single layer, with delicate, polygonal, nucleated cells of 0.007—0.009", which, as well as its certainly not very numerous vessels, stands in relation to the *perilymphe s. aqua Cotunni*, filling the osseous labyrinth. By the conjunction of the *periosteum* of the labyrinth and the lining of the *tympanum*, are produced the *membranæ tympani secundariæ*, which, like the proper *membr. tympani*, are composed of a middle fibrous layer with vessels and scattered nervous filaments, and two epithelial layers.

The *two sacculi* and *canals*, contained in the interior of the vestibule and of the osseous semicircular canals, all essentially present the same structure. Their firm, transparent, and elastic walls, which are tolerably thick in proportion to the minuteness of the parts (0.012—0.15" in the *canals*, and 0.016" in the *sacculi*), present, most externally, a membrane composed of reticulated, fine fibres, approaching very nearly to the outer coloured layer of the *choroid* or the *lamina fusca*, like which it also occasionally contains irregular brownish

Fig. 308.

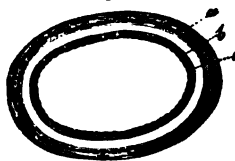


Fig. 308. Transverse section of a semicircular canal,  $\times 250$  diam.: *a*, fibrous membrane with *nuclei*; *b*, homogeneous membrane; *c*, epithelium. From the Calf.

pigment-cells. This is succeeded by a transparent, glassy membrane, sharply defined, especially on the inner aspect, 0.004—0.008" thick, presenting in parts a distinct, delicate, longitudinal striation, and on the addition of acetic acid always exhibiting a multitude of elongated *nuclei*, and which consequently cannot well be placed in the same class with the *membrana propria*, the capsule of the lens, &c., although it very nearly approaches them in its chemical reactions. The innermost layer, lastly, is a simple, readily disintegrated, tessellated *epithelium*, 0.003", with sometimes larger, sometimes smaller (0.004—0.008") polygonal cells, lining all the spaces in question, and inclosing the so-termed *endolymph. s. aquula vitrea auditiva*, in which, in Fishes, Barruel has ascertained the presence of *mucus*.

The *vessels* of the membranous labyrinth are tolerably numerous, and are distributed in minute arteries and veins and abundant capillary net-works, on the fibrous membrane and vitreous tunic of these parts, being most abundant near the terminations of the nerves. Of these, we are acquainted only with that of the acoustic nerve, which, with the *nervus vestibuli*, supplies the three membranous canals and the elliptic *sacculus*, and, with a branch of the cochlear nerve, the round *sacculus*. In the semicircular canals, the nerves are distributed only on the *ampullæ*, and, indeed, enter each, as Steifensand has shown, in an inversion or duplicature of the wall situated on the concave side of the canal, which appears, viewed on the inside, as a transverse projection extending through about one third of the circumference. Within these folds, the nerves divide at first into two principal branches, which, diverging towards both sides, penetrate into the vitreous membrane of the *ampullæ*, where each of them breaks up into a rich bundle of smaller, frequently anastomosing ramuscules, which ultimately appear to terminate free, in fine twigs, composed of from two to ten primitive fibres, 0.001—0.0015" thick. In the *sacculi*, the distribution of the nerves is the same, except that it occupies a larger space, and does not occur in a projection of the wall. In this situation, also, I think I have noticed free prolongations of the attenuated nerves, although it may be very possible, as Todd and Bowman point out, that they are continuous with very pale fibrils, in which they ultimately ter-

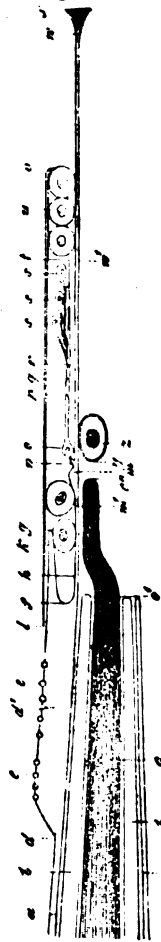
minate. In the situation of the nervous expansion, we find, in each of the *sacculi*, a sharply defined spot, as white as chalk, and readily seen by the naked eye, which is attached to the inner wall of the *sacculus* by a perfectly clear membrane, 0.01''' thick, and probably epithelial. These are the so-termed *otoconia* of Breschet, or *otolithes*, which are constituted of innumerable corpuscles, 0.0004—0.005''' long, and (in the largest) 0.001—0.002''' broad, of a rounded or elongated form, or distinctly pointed at each end, probably hexahedral prisms, suspended in a homogeneous substance. They are composed of carbonate of lime, and are said to leave a residuum of some organic matter; but this I have not succeeded in observing.

#### § 235.

*Cochlea*.—The canal of the *cochlea*, filled by the fluid of the labyrinth, is lined in both its *scalæ* by a *periosteum*, here and there presenting a small quantity of pigment, and which is constituted precisely like that of the vestibule, and also partially invests the *lamina spiralis ossea*. An *epithelium*, 0.0005''' thick, with delicate, flattened polygonal cells, 0.007—0.009''' in size, covers this ligamentous membrane, and is also continued upon the *lamina spiralis membranacea*, where its nature is, to some extent, altered. The most important part of the *cochlea* is the *lamina spiralis*, which, in its osseous zone, contains narrow-meshed anastomosing canals for the reception of the cochlear nerves, which canals, towards the free border of the *lamina*, coalesce so as to form a fissure-like cavity and consequently, in this situation, the osseous spiral *lamina* actually consists of two plates. The *membranous* zone, having a constant width of 0.2'', is again subdivided into a *zona denticulata* and a *zona pectinata*, the former of which constitutes about the inner two thirds, and the latter the outer third of the breadth of the membranous *lamina*, and are both characterised by a great complexity of structure, the importance of which was first, in more recent times, pointed out by Corti (*l. c.*) (*vid.* figs. 309, 310).

1. The *zona denticulata* (*d-v*) may be again subdivided into two portions, an internal, the *habenula interna s. sulcata* (*d-g*), and an external, the *habenula externa s. denticulata* (*h-l*). The

Fig. 309.



former is developed at *d*, as an immediate continuation of the *periosteum* of the *lamina spiralis ossea*, and, in fact, only from that portion of it which looks towards the *scala vestibuli*, increasing in width and thickness from the commencement to the termination of the cochlear canal. In the first and second turns of the *cochlea*, its under surface supplies the place of the *periosteum* upon the most external portion of the osseous zone, whilst in the last half turn it is bounded only by the expansion of the nerve, so that the *habenula sulcata*, in the strict sense of the word, properly constitutes, in this situation, only a part of the so-termed membranous spiral *lamina*. On the upper surface of this layer, and on the outer border of it, there is an uninterrupted series of clear, peculiarly glistening, elongated, slightly clavate processes (*g*), the "teeth," as they are termed "of the first series," which, in the first spiral turn of the cochlea, are 0.004—0.005" wide, and 0.003" thick, at their origin, whilst in the last turn they are not more than 0.015" long and 0.003" broad. They project, free, into the *scala vestibuli*, and arch over the commencement of the *habenula*

Fig. 309. Vertical section of the *lamina spiralis*, at 6" from its commencement,  $\times$  circa 225 diam. (Cat or Dog); the epithelial layer investing its upper and lower surfaces is removed: *a*, periosteum of the osseous zone; *b*, the two lamellæ of the osseous zone near its free border; *c*, *c'*, *c''*, termination of the auditory nerves; *d-w*, *lamina spiralis membranacea*; *d-w*, *zona denticulata*; *d-d'-f*, *habenula sulcata*; *d*, place where the *periosteum* is thickened; *e*, granules in the groove of the *habenula sulcata*; *f-g*, "teeth of the first series;" *g-f-h*, *sulcus s. semicanalis spiralis*; *h*, its inferior wall; *k*, epithelial cells at the entrance of the *sulcus spiralis*; *h-w*, *habenula denticulata*; *h-m*, apparent teeth; *n-t*, "teeth of the second series;" *n-p*, their posterior joint; *o*, nucleated enlargement upon them; *p-q* and *q-r*, articular portions; *r-t*, anterior joint of the second row; *s s s*, three cylinder-cells, placed upon them; *l-v*, membrane covering the *habenula denticulata*; *u*, one of the epithelial cells underneath; *w-w*, *zona pectinata*; *x*, *periosteum*, attaching the *lamina spiralis* (*musc. cochlearis*, Todd and Bowman); *y*, *vas spirale internum*; *z*, its inner coat. After Corti.

*externa*, so that between the two a tolerably deep *sulcus*, *semicanalis spiralis* (Huschke), opening externally, is left. Towards the axis of the *cochlea* the so-termed "teeth" are directly continuous, with similarly constituted, elongated ridges or *costæ* (fig. 309 a a), which are occasionally conjoined in pairs, or divided into two, and still further inwards break up into divisions, which become shorter and shorter and smaller and smaller, being at first elongated and afterwards rounded. In the longitudinal and transverse grooves between these *costæ* and tubercles and the teeth, there usually exists, in single series, rounded or elongated, opaque glistening corpuscles (*e*), 0.0015—0.002—0.003" in size, which, on the addition of acetic acid, prove to be *nuclei*; and by the same reagent, nuclei-form *striæ* occasionally become distinct in the pale and somewhat swollen "teeth" and *costæ*, which parts, consequently, as well as those presently to be described, I am inclined to regard as belonging to the connective-tissue group.

The *habenula externa s. denticulata* (*h-t*) arises under the base of the "teeth" of the first series, directly from the just-described *habenula sulcata*, and constitutes at first the bottom of the *spiral sulcus* noticed above. In most places its thickness does not amount to more than 0.001", which is also that of

Fig. 310.

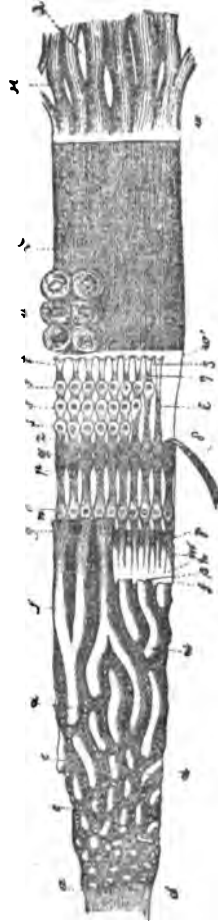


Fig. 310. Vestibular surface of the *lamina spiralis membranacea*,  $\times 225$  diam. The letters are in part the same as in fig. 309: a a, cylindrical elevations of the *habenula sulcata*;  $\beta$ , spot where a "tooth of the first series" originates;  $\gamma$ , spaces between the "apparent teeth;"  $\delta$ , anterior portion of a "tooth of the second series" thrown back;  $\epsilon$ , the same in its natural position, without its epithelial cells;  $\zeta$ , the same with only the lowermost epithelial cells;  $\eta$ , the same with two of the lowermost cells;  $\theta$ , streaks or slight elevations of the *zona pectinata*;  $\kappa$ , periosteum, by which the *lamina spiralis* is attached, with spaces,  $\lambda$ , between the bundles. After Corti.



the rest of the membranous spiral *lamina*, that is to say, of the *zona pectinata*, and its width increases towards the *cupola* in proportion to the decreasing breadth of the *habenula sulcata*, so that it measures at first, not more than 0.05", and ultimately, 0.1". With respect to its structure, it presents, on the side of the *scala vestibuli*, a considerable number of elevations, whilst towards the *scala tympani* it is perfectly smooth and even. These elevations, proceeding from within to without, are as follow:—first, come the so-termed "apparent teeth" ("dents apparents," Corti), a crowded series of elongated projections, 0.08" long, 0.002" broad, which, separated from each other by shallow grooves, are slightly raised at the outer end, and then suddenly depressed. Externally to these processes which, in the first turn of the *cochlea*, are still situated on the *zona ossea*, beneath the "teeth of the first series," and in that situation present minute elongated hollows between their outer ends (fig. 309,  $\gamma$ ), but in the second and third turns are placed more externally than the "teeth of the first series," being bounded on the under surface only by the nerves, succeed in equal number the "teeth of the second series," (Corti) (*n-t*), very remarkable structures, of which the adjoining figure will afford a better exposition than any description. Each of them represents a little rod, somewhat compressed from above to below, and lies free and moveable on the membranous spiral *lamina*, to which it is affixed only by the inner extremity, as a continuation of which, therefore, these teeth must be regarded. Viewed more closely, each of them presents three joints. The innermost (*n-p*), an attached joint, resembles a cell of cylinder *epithelium*, and contains in its somewhat dilated internal extremity (*o*) a round *nucleus*, 0.005" in size; to this succeed the middle joints (*p, q, r*), two equal, elongated, quadrangular segments, 0.0044" long, of the same homogeneous and glistening substance as that of which all these "teeth" in general are composed (the *coni articulares* of Corti), which are connected with each other and with the internal and external joints, so as to allow the latter a certain extent of motion up and down. The last joint, finally (*r-t*), is at first attenuated, but towards the extremity again becomes wider and bifurcate, and supports three nucleated segments attached to its inner extremity, resembling pe-

dunculated cells (*s, s, s*), one above the other, the undermost being the longest, which may be termed "teeth of the third series," ("cylinder epithelium-cells," Corti). The *habenula denticulata*, as far as to the "teeth of the second series," is covered by round or oval *epithelium* cells (*h*) which also occupy the spiral *sulcus* below the "teeth of the first series," though lying free and separate in immediate contiguity, and forming a continuous layer only on the *hamulus membranaceus*. Upon these cells and over the entire *habenula denticulata*, we then find a peculiar, thin, finely striated membrane (*l-v*), which externally projects a little over the commencement of the *zona pectinata*, though separated from it by some large epithelial cells (*w*), and passing internally upon the *habenula sulcata*, where it is gradually thinned and ultimately lost. This membrane, covered by the *epithelium* of the cochlear canal, can hardly be viewed as anything but a continuation of the *habenula sulcata*, and may be most suitably compared with the *zona pectinata*.

2. The *zona pectinata* (Todd and Bowman) (*w'-w*), is the outer portion of the membranous spiral *lamina*, smooth on both the upper and under surfaces, and affixed, at the outer side, on a projection of the external wall of the cochlear canal. It is a perfectly homogeneous *lamella*, but, except at the borders, appears to be very closely ribbed, and thence assumes a fibrous aspect. At its outer edge this lamina, which seems to be opened out in a narrow border, receives a peculiar fibrous substance (*x*) arising from the wall of the *cochlea*, which there presents a minute osseous ridge (the *lamina spiralis accessoria*), Huschke; which Todd and Bowman describe as a cochlear muscle, but in which I can perceive nothing but a form of nucleated connective tissue, whence I shall term it the *ligamentum spirale*.

The *nerves of the cochlea* enter the cavities of the osseous zone from the canal of the *modiolus*, and there form a close plexus of dark-bordered fibres, 0.0015''' in diameter, throughout its whole length, and which, as discovered by Corti, contains, at a very definite spot not far from the border of the zone, an aggregation, at first, 0.1''' in width, of bipolar, oval, minute, (0.011—0.016''' long, 0.0066—0.0097''' broad), and pale ganglion-cells, which it is very probable intercept all the fibres of the

cochlear nerves in their course. The dark-bordered fibres proceeding from the external side of these cells, are again disposed in anastomosing, and afterwards in simply parallel, flattened bundles, which become less and less close as they approach the

Fig. 311.



*hamulus*, so that, upon that process, the fibres may be perceived forming a single layer, and even separated by interstices. The end of these nerves, in all the parallel bundles and fibres, is always in the same line, but in the first spiral turn will be found nearer to the outer wall of the *cochlea* than it is higher up. Besides this, there are terminations, also situated between the two plates of the osseous zone, although exactly at its border; in the second turn, in an extent of 0.02—0.03'', and even outside it, on the under surface of the commencement of the *habenula denticulata*, consequently within the *scala tympani*; in the third half turn, lastly, they appear in the form of a nervous border, 0.08—0.09'' broad, also on the under surface of the *habenula sulcata*. The actual termination of the nerve-fibres which are reduced to 0.001'' in diameter, appears to me, as well as to Corti, to take place by their first becoming pale, and

still finer, and afterwards ceasing—and I must here express myself as decidedly opposed to the notion of the existence of loops.

The *vessels* of the *cochlea*, though fine, are yet very numerous; they are distributed, in the first place, to the parietal periosteum of the cochlear canal, and secondly, to the *lamina spiralis*. In the former situation, besides the capillary plexus, which is found throughout, they constitute a peculiar vascular tract in the *scala vestibuli*, immediately under the *ligamentum spirale*,—the *stria vascularis* of Corti, and which, though continuous with the vessels of the *periosteum*, still lies above it, imbedded, as it were, in the partially coloured *epithelium*. In the *zona spiralis*, we find in the osseous portion, but also in the nervous expansion itself, a rich capillary plexus, continuous with a *vas spirale* running on the under or vestibular surface of the *zona membranacea*, through the whole extent of the *cochlea*. This vessel, which is probably

Fig. 311. Bipolar ganglion-globules from the *zonula ossea* of the *lamina spiralis* of the Fig. × 350 diam. After Corti.

venous, lies immediately under the *habenula denticulata*, sometimes more towards the interior, sometimes more externally, becoming, in the last half turn of the *cochlea*, a capillary vessel of not more than 0.004''' in diameter; but towards the base, it gradually enlarges to 0.013''' , and is distinctly composed of two coats. In rare instances, there are two capillary *vasa spiralia* in the situation above indicated, and on two occasions, in Man and in the Sheep, Corti also noticed an external *vas spirale*, near the *ligamentum spirale* on the *zona pectinata*, which, however, did not communicate with the internal vessels, so that, speaking generally, the *zona pectinata* is non-vascular.

Lastly, we have to consider the *acoustic nerve*. The fibres of its trunk, in Man, measure 0.002—0.005''' , are very readily destroyed, and have only a delicate neurilemma. Among these, in the trunk itself and in the vestibular and cochlear nerves, there occur numerous bipolar, apolar, and unipolar, pale and coloured ganglion-cells, measuring, in the Mammalia and in Man, 0.02—0.07''' , of which the two latter forms are, as Stannius correctly observes, probably only truncated bipolar cells, inasmuch as, particularly in Fishes, the acoustic nerve contains cells of this kind only or nearly so. Similar cells, but smaller, are also met with, as already mentioned, in the *cochlea*, as well as in the nervous twigs in the vestibule (Pappenheim, Corti). Divisions of the fibres of the auditory nerve were noticed by Czermák in the ultimate ramifications in the *ampullæ* and *sacculus* of the Sturgeon, by myself and Harless in the Frog, and by Leydig in the *Chimæra*.

Of the *development* of the auditory organ, it need here merely be mentioned, that according to Huschke's discovery, confirmed by Reissner and Remak, the membranous portions of the labyrinth are formed from the external integument, simply by its inversion, and consequently in their origin may be compared with the lens and vitreous body. To this inversion, in which the cellular layers corresponding to the *epidermis*, principally, but not alone, as Remak believes, take part, the auditory nerves are afterwards continued from the brain; and from the middle germinal layer are afforded the hard tissues and the rest of the soft parts in order to complete the sentient organ. With respect to the histological development of the soft parts of the labyrinth, nothing of consequence is known.

[In the description of the *cochlea*, I have altogether followed Corti, having formerly satisfied myself of the correctness of his statements, when that zealous and intelligent observer pursued his investigations in Wurzburg; and having also, recently, confirmed the greater part of them by the examination of the human *cochlea*. At the same time the parts of the *habenula denticulata*, which are so difficult of investigation, have always appeared to me to demand further consideration, and particularly with respect to the ascertaining of the kind and mode of the movements of its processes, the relations of the *epithelium*, and of the investing, structureless membrane. So long as these points are not ascertained, all suppositions respecting the function of these delicate structures are without any secure basis, and the physiology of the cochlea, otherwise so difficult, is rendered only still more perplexed (*vid.* Harless, l. c.). As regards the nature of the so-termed "teeth," they are certainly, as Corti assumes, nothing more than developments of the periosteum of the cochlear canal, and may, in my opinion, although in chemical respects very similar to the vitreous membranes, yet be regarded as belonging to the connective-tissue group. Whether the three so-termed cylinder epithelium-cells (Corti) on the *habenula denticulata* are really epithelial, as Corti supposes, still demands investigation. These bodies, notwithstanding their great delicacy, appear to me rather to be referable to the category of the other tissues of the *habenula denticulata*; and on that account I have termed them "teeth of the third series."

For the *investigation* of this organ, which, however, presents any very considerable difficulties only in the labyrinth, perfectly fresh objects are indispensable, and are best taken from animals just killed. For the moistening of them, serum or syrup should be employed, when it is desirable to view the parts in a perfectly normal condition. Successful results will be obtained, especially if a certain amount of practice, in the exposing and dissection of the delicate tissues with which we have to do, be combined with great patience, seeing that it is often a matter of chance whether any given relations are brought into view. In order to see the nervous plexus of the osseous zone of the *cochlea*, the latter must be deprived of its calcareous constituents by dilute muriatic acid; whilst in the

case of the ganglion-cells in that situation, the only means of attaining our object consists in a careful breaking down of the osseous zone in a neutral medium.]

*Literature.*—E. Huschke, in 'Frör. Not.,' 1832, No. 707; 'Iris,' 1833, No. 18, 34; K. Steifensand, 'Untersuchungen über die Ampullen des Gehörorgans,' in Müller's 'Archiv,' 1835; S. Pappenheim, 'Die specielle Gewebelehre des Gehörorgans,' Breslau, 1840, and Froriep's 'Not.,' 1838, Nos. 141, 194, and 195; G. Breschet, 'Recherches sur l'organe de l'ouïe dans l'homme et les animaux vertébrés,' 2d ed. Paris, 1840; E. Krieger, 'De otolithis,' Berol. 1840; Wharton Jones, 'The Organ of Hearing,' in Todd's 'Cyclopædia,' Vol. II. p. 529; J. Hyrtl, 'Ueber das innere Gehörorgan des Menschen und der Säugethiere,' Prag., 1845; A. Corti, 'Recherches sur l'organe de l'ouïe des mammifères,' in Zeitsch., f. wiss. Zool. III, p. 109; Reissner, 'De auris internæ formatione,' Dorpat, 1851; E. Harless, Art. 'Hören,' in Wagner's 'Handw. der Physiol.' IV, p. 311, and 'Münchn. Gel. Anzeiger' 1851, No. 31 and 37; Stannius, 'Ueber die gangliöse Natur des *Nervus acusticus*,' in Gött. Nachr., 1850, No. 16; *Ib.*, 1851, No. 17. Besides which should be consulted the general works of Krause, Huschke, Arnold, Todd and Bowman, Remak (Entwicklungsgeschichte), and the '*Icones org. sensuum*,' of Arnold.

### III.—OF THE OLFACTORY ORGAN.

#### § 236.

The *olfactory organ* consists of the two *nasal cavities*, or *fossæ*, supported by bones and cartilages, and lined by a mucous membrane, and of a certain number of accessory cavities, *viz.*, the *frontal*, *sphenoidal*, and *ethmoidal sinuses* and the *antrum Highmori*. Of all these cavities, however, only the uppermost portions of the nasal fossæ, where the olfactory nerve is distributed, are subservient to the sense of smell itself, the others being either simple conducting canals, and participating as well in the action of respiration, or at any rate having no direct relation to the olfactory sense.

The hard structures, just named, present nothing much

worthy of remark ; and of the bones it need merely be mentioned, that the thinnest parts of the ethmoid consist only of a fundamental substance and bone fibres, without any Haversian canals. The nasal cartilages are true cartilages, and most nearly approach those of the *larynx*, except that the contents of the cartilage-cells are usually very pale, and without fat, the cell walls little thickened, and the matrix finely granular. Beneath the *perichondrium* there is, also in this situation, a layer of flattened cells, which, on the septum attains a thickness of 0.024", whilst in the interior the cells are more rounded, larger, and disposed in rows, in the direction of the thickness of the septum.

With respect to the coverings of these parts, the *integument* of the nose may be first noticed : it is characterised by a thin *epidermis* 0.024—0.032" thick, a dense *cutis* of  $\frac{1}{4}$ " with minute undeveloped *papillæ* of  $\frac{1}{16}$  —  $\frac{1}{64}$ " and fine hairs, as well as by a close adipose tissue 1" thick, intimately united with the cartilage, containing large sebaceous follicles, extending into the latter, and minute sudoriparous glands  $\frac{1}{16}$  —  $\frac{1}{12}$ " in diameter. This external integument, with its sebaceous follicles, and with stronger hairs (*vibrissæ*) also extends a short distance into the nasal *fossæ*, but not quite so far as the point where the cartilaginous portion of the nose terminates, passing imperceptibly into the mucous membrane of the olfactory organ, by which all the remaining cavities are lined, though it does not everywhere present the same conditions. As was discovered by Todd and Bowman, and I can fully confirm, this mucous membrane is subdivided into a *ciliated* and a *non-ciliated* portion, the latter being limited to the uppermost parts of the nasal *fossæ*, where the olfactory nerve is distributed, and consequently should perhaps be termed the *olfactory mucous membrane* in the stricter sense, whilst the other might retain the old name of "Schneiderian membrane."

Upon first viewing the latter, it will be found that, although the *epithelium* vibrates throughout, still that its structure is not everywhere the same, and that we may conveniently distinguish in it the *thicker* glandular mucous membrane of the proper nasal *fossæ* from the *thinner* membrane of the accessory sinuses, and of the interior of the spongy bones. The *epithelium*, in both situations, is squamose and ciliated, like that of

the *larynx* (fig. 311<sup>3</sup>), measuring, in some places, 0·018—0·020'' in thickness, and in others as much as 0·042'''. In Man it presents pale, fine-granular cells, of which the outermost ciliated ones attain a length of 0·03''', and in animals produce a current running from before to behind. To this succeeds, a true *m. mucosa*, wholly without elastic elements, or at all events very scantily supplied with them, and composed chiefly of common connective tissue. In the proper nasal *fossæ* there are imbedded in this membrane very numerous larger and smaller, racemose mucous glands of the usual kind, with gland vesicles of 0·02—0·04''', so that, in places, especially at the borders of the septal cartilage, and on the inferior spongy bones, it presents a thickness of 1—2'''. The thickness of the mucous membrane of these regions, however, does not depend upon the glands alone, but also, especially at the border and posterior extremity of the inferior spongy bone, upon *abundant, almost cavernous venous plexuses* in its interior. In the accessory cavities, the glands are almost wholly wanting, and I have as yet only occasionally found them in the *antrum Highmori*, where their excretory ducts and gland-vesicles are sometimes dilated into cysts containing *mucus*,  $\frac{1}{3}$ ''' in diameter. Except in these places, the mucous membrane of the accessory cavities is extremely delicate and inseparable, as a distinct membrane, from the *periosteum* lining them; and the same may be said of it in the nasal *fossæ* themselves, particularly in the glandular parts, notwithstanding the intimate connexion of the two. A remarkable appearance presented itself to me in the body of a youth aged 15, (who, as I was informed by Virchow, also exhibited ossifications in the lungs), consisting in the deposition—in the mucous membrane, in all these accessory cavities, as well as in the similarly constituted mucous membrane on the concave side of the spongy bones, immediately beneath the *epithelium*—of calcareous salts, to such an extent, that its uppermost layer was transformed into a peculiar ossified though still flexible membrane, in which there existed, in places, larger and smaller, often very regularly disposed openings, but no evidence of a special structure. Under this layer, which, where well developed, appeared perfectly white, like a membrane filled with air-vesicles, as which I at first regarded it, there always occurred a looser connective tissue with vessels, of which latter,



however, some were also incrustrated; and in the deeper parts of the epithelial layer itself, there were scattered, smaller, simple or aggregated concretions, like "brain-sand" in miniature.

The proper *olfactory mucous membrane* of all the divisions of the organ, occupies only the uppermost parts of the *septum*

and of the walls of the proper nasal *fossæ*, where the superior spongy bones are situated, to a distance of about  $\frac{3}{4}$ —1" downwards from the *lamina cribrosa*. It is distinguishable, even by the naked eye, from the contiguous ciliated membrane, by its greater thickness and its colour, which is sometimes yellowish, as in Man, the Sheep, and Calf; sometimes yellowish-brown or brown, as in the Rabbit and Dog; and, when examined microscopically, it is seen to be bounded by a tolerably well-defined, toothed or undulated border. The differences of the structure depend

upon the condition of the *epithelium*, the occurrence of numerous peculiarly constructed glands, which I shall term "Bowman's glands," and upon the relations of the nerves. The epithelium is *not ciliated*, of which I have most fully satisfied myself, not indeed in Man, in whom I have never yet met with the epithelium of the true olfactory region in a perfect condition, although the ciliated epithelium occurred frequently enough still in a state of vibration, but in the animals just named. It is also much *thicker*, so that in the Sheep, in which the ciliated *epithelium* is 0.03"', it measures 0.05"', and in the Rabbit, the one is 0.04"' thick, and the other 0.07"'. Notwithstanding this thickness, which is con-

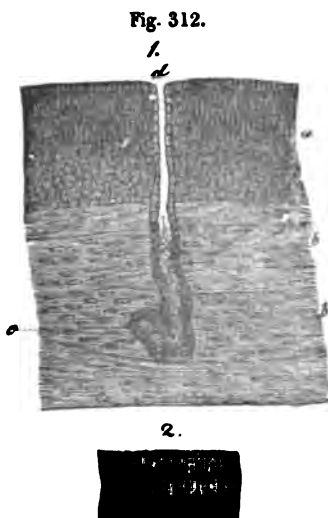


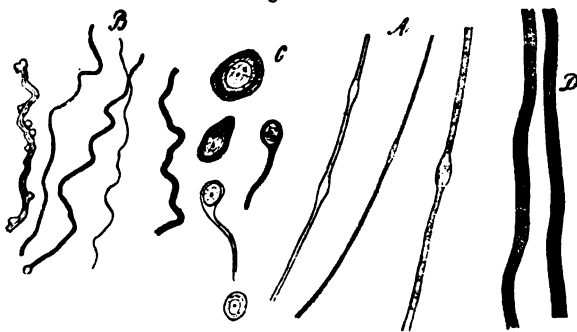
Fig. 312. From the nasal mucous membrane of the Sheep,  $\times 150$  diam. 1, from the *regio olfactoria*, transverse section of the mucous membrane: *a*, epithelium without *cilia*; *b*, olfactory nerves, with a dividing, pale, nucleated fasciculus; *c*, one of "Bowman's glands;" *d*, its orifice. 2, ciliated epithelium of the Schneiderian membrane.

siderable for a mucous membrane, it is remarkably delicate and soft, and is so much affected by almost all reagents as to allow of its being studied only with considerable trouble. According to my observations, it should be described as a *squamose cylinder-epithelium*; at all events, in opposition to Todd and Bowman, I always find as its outermost layer, one or two strata of slender, vertical cells, 0·005—0·007''' long, whilst it must be allowed that, more deeply, spherical elements, of 0·003—0·004''' , alone appear to exist. All these cells have minute, round *nuclei*, usually pale, finely granular contents of a brownish hue in the deepest layer only in the Rabbit and Dog, and such delicate membranes, that in water they instantly burst. Although the ciliated cells of the nasal *fossæ* are much more readily affected by water than those of other situations, this is true to a much greater extent as regards the cells of the olfactory region; and the destructive effect of the filling of the nasal cavities with water (E. H. Weber) and other fluids is thus easily accounted for, as well as, on the other hand, is the ready transition of volatile substances through the epithelium rendered intelligible. For the moistening and protection of this *epithelium* throughout the region in which it exists, it is furnished with a great number of the "glands of Bowman," which is the more remarkable, because the immediately contiguous, ciliated mucous membrane is but scantily supplied with glands, or is wholly without them. These glands are simple cylinders, either straight or slightly convoluted at the lower end and 0·08—0·1''' in length, or elongated pyriform follicles, situated principally between the larger branches of the olfactory nerves, in crowded rows, in part, however, more isolated, as at the lower boundaries of the olfactory region. They most nearly approach certain forms of the Lieberkühnian glands, and the sudoriparous glands of the *fœtus*. I have never yet noticed divisions of the follicles, although it is very possible that I may have overlooked them, since these organs are extremely delicate, and easily altered. Their canals, 0·014—0·025''' wide, are lined by a beautiful, simple *epithelium*, composed of rounded polygonal cells, 0·006—0·008''' in size, containing more or fewer yellowish or brownish pigment-granules, to which is due the varying colour of the olfactory mucous membrane. Their excretory ducts are rather more contracted

(0.008—0.012''') than the glandular canals and ascend, always lined by rounded larger cells, straight through the *epithelium*, in order to terminate on the surface with rounded orifices, 0.01''' in diameter, surrounded by a few large cells. The tissue beyond these glands is, as in other regions, soft connective tissue, without elastic elements.

The mucous membrane, in the proper nasal cavities, is very richly supplied with *vessels*, and less so in the accessory sinuses. The terminal branches of these vessels form loose plexuses around the glands, and in the trunks and branches of the olfactory nerves; while on the surface of the mucous membrane itself, they constitute a more close network with numerous horizontal loops, at first sight leading to the supposition of the presence of *papillæ*, which, however, do not exist. The branches, also, of the arteries and veins enter into numerous anastomoses, and constitute (the latter especially) on the inferior spongy bones, the abundant spongiform plexus already noticed. Nothing is known of the *lymphatics* of the nasal mucous membrane. The nerves are, in the first place, branches of the fifth pair (ethmoidal, posterior nasal, and a branch of the greater anterior dental nerve), which supply

Fig. 313.



especially the ciliated region of the organ, presenting there the same conditions as the nerves in other sentient mucous membranes (of the *pharynx* for example), but also extend to the proper olfactory region; and, as I noticed in one instance in the

Fig. 313. From the olfactory nerve of Man,  $\times 350$  diam.: *A*, nerve-tubes from the *tractus*, in water; *B*, in syrup, appearing contracted; *C*, nerve-cells, from the *bulb*; *D*, nerve-fibres, from the branches in the olfactory organ.

Calf, send scattered dark-bordered primitive fibres in the course of the branches of the olfactory nerves. The *olfactory nerve*, in its *tract* and *bulb*, contains dark-bordered fibres and nerve-cells, of which we have already spoken (vol. I, p. 444). The *nervi olfactorii*, on the other hand, in Man and in other Mammalia, even in the main trunks given off from the olfactory bulb, present no white medullated fibres at all, but are wholly constituted of pale, slightly granular flattened fibres, 0·002—0·003''' wide with elongated *nuclei*, which are closely adherent and retained in connexion by common sheaths of connective tissue, which are somewhat thicker and therefore whiter in the *rami ad septum*. With respect to the origin of these fibres, which very closely resemble the embryonic nerve-elements, whether they are derived from the olfactory *bulb* or from the *cerebrum* itself, has by no means been as yet ascertained in Man, or in other Mammalia, although, from the observations of Leydig in the 'Plagiostomata,' ('Beiträge,' p. 34, Tab. I, fig. 6), it is probable that the former is the case. The termination of these nerves is yet more doubtful. This much is readily seen, that the *nervi olfactorii*, in their course in the mucous membrane of the olfactory region, are gradually attenuated as they descend, in consequence of numerous divisions at acute angles, and form a plexus which may also, in Mammalia, be traced almost throughout the olfactory region; but shortly before reaching its border, these plexuses are always lost to sight, nor is any other indication of terminal branches presented; so that, as regards the main fact, I remain quite in the dark. At present it appears to me most probable that the terminal distribution takes place throughout the non-ciliated region, and above all at its border; at any rate I have never yet been able to detect the filaments of the olfactory nerves in the ciliated *epithelium*, although they can be traced down to twigs of the size of 0·005—0·01'''. I have not seen the ganglion-globules on the inner surface of the finer plexus mentioned by Valentin ('Nervenlehre,' p. 303), and the rather strange looking "glands of Bowman," might have been mistaken for such bodies.

[In the investigation of the olfactory organ, the chief difficulty arises from the softness of the *epithelium*, and on this

account a solution of albumen, or *humor vitreus*, only should be employed to moisten it. Vertical sections in detached portions of the mucous membrane, are best made with the scissors; and the edges of folds not unfrequently afford good sectional views. The mucous glands, are found in sections; those of Bowman on teasing out the structure. Chromic acid cannot be recommended for the olfactory nerves: teasing out the membrane is the most suitable mode of proceeding; as well as the compression of fresh preparations or of preparations moistened with soda or acetic acid; lastly, the examination of mucous membrane macerated in water, in which the nerves are preserved for a long time.]

*Literature.*—Todd and Bowman (op. cit., II). [Horn, 'Ueber die Endschlingen des Geruchsnerven,' Müll. 'Archiv,' 1850. Dr. Horn professes to have discovered looped terminations of the olfactory nerve in the Frog.—Eds.]

---

## APPENDIX.

---

### § 1.

THE first section of the Appendix should, according to promise, have been constituted of an exposition of the views which we have taken with regard to the Cell-theory. Finding, however, that it would be inexpedient to extend this already somewhat voluminous work by the amount of space and number of illustrations which would be necessary for a more complete discussion of the subject than has already appeared in the pages of the 'British and Foreign Medico-Chirurgical Review' (October, 1853), we must refer the reader to the article in question.

We hope, however, in the course of a short time, to treat of the whole subject at length in another place.

*Corpuscula tactûs and Pacinian bodies.*—In an essay on this subject, contained in the 'Quarterly Journal of Microscopical Science,' for October, 1853, we have endeavoured to show that papillæ which contain "*corpuscula*" may also possess a vascular loop and that there is, at any rate, no inverse relation between nerves and vessels in the papillæ, since in the Frog, the terminations of the nerves in the fungiform papillæ of the tongue, first described by Dr. Waller ('Phil. Trans.,' 1848), take place in obviously vascular papillæ. We regard the '*corpusculum*' as no peculiar body, but simply as embryonic connective tissue, differing from that of the rest of the papilla only in the regular

arrangement of its elastic element; it is, in fact, the dilated termination of the neurilemma of the nerve of the papilla.

With regard to the mode of termination of the nerves, while not venturing to deny the existence of loops, we doubt it; on the other hand, repeated instances of the so-called free termination of dark-contoured nerve-tubules on the surface of the *corpuscula* are described and figured (l. c., p. 3, fig. 4). The termination is not really "free," inasmuch as the tubules become continuous, both here and in the Frog's tongue, with the imperfect, reticulated, elastic fibrils of the papillæ.

As respects the Pacinian bodies, we stated, at that time in opposition to all authorities, that their central portion is solid and not hollow, and that in Birds and in the human hand, the fluid supposed to exist between the concentric laminæ was equally hypothetical. In structure, the Pacinian body, in fact, is identical with the *corpusculum tactûs*—being a solid mass of connective tissue, whose apparent lamination depends on the regular disposition of its elastic elements. We stated further, that the central nerve-tubule gradually terminates, passing into the central solid axis of the Pacinian body. In reality, the Pacinian bodies are also nothing more than thickened processes of the neurilemma of the nerve to which they are attached, and differ from the tactile corpuscles only in the circumstance that in the latter the thickening takes place on one side of the nerve-fibril, while in the Pacinian body it takes place on both sides.

In the meanwhile, contemporaneous observations on this subject were made by Leydig ('Ueber die Vater-Pacinischen Körperchen der Taube') and by Kölliker ('Einige Bemerkungen über die Pacinischen Körperchen'), and were published in Siebold and Kölliker's 'Zeitschrift,' B. V, H. 1.

Leydig and Kölliker's results are, in the main, in accordance with our own, especially as respects the solidity of the Pacinian body. The "central cavity" is given up by both, but Kölliker still maintains the existence of a fluid between the outer layers, at least in the Cat. Leydig regards the central solid axis of the Pacinian body in the Bird as the expanded termination of the nerve itself.

Wagner had already drawn attention to the resemblance between the *corpuscula tactus* and the Pacinian bodies; Leydig

further shows that the latter form one series with the Savian bodies and the so-called muciparous canals of osseous and cartilaginous Fishes. We ventured, in the paper in question, to add the "tactile hairs" or "*vibrissæ*" of Mammalia to this series of cutaneous organs, by showing that they are but a further development of the muciparous canals—pointing out, at the same time, that even the highest organs of sense, the Eye and the Ear, are constructed upon the same principle.

### § 2.

*Malpighian bodies of the spleen.*—Having recently carefully investigated the structure of these organs, we have arrived at the following conclusions (*vid.* 'Quarterly Journal of Micr. Science,' Jan., 1854).

1. In the various animals examined (Man, Sheep, Pig, Rat, Kitten), we find, as Dr. Sanders had already demonstrated in the Pig, that the minute arterial twigs supplying the Malpighian bodies are not only distributed over, but enter and ramify in them, breaking up into their fine penicillate branches as they pass out.

Furthermore, connecting these arterioles, there is a network of fine capillaries, whose walls are hardly distinguishable, but which are readily detected by using syrup, which retains the colouring matter in their contained blood-corpuscles.

The pulp of the Malpighian body stands, as Remak pointed out, in the relation of *tunica adventitia* to the arterioles; it is composed of indifferent tissue, consisting of endoplasts imbedded in a homogeneous periplast, and which may or may not become surrounded by cell-walls.

The Malpighian body has no wall, but passes insensibly, as Wharton Jones had already shown, into the fusiform fibres of the red pulp.

We adduce evidence from Remak and Leydig that the Malpighian bodies of other Vertebrata present similar relations, and that the spleen, lymphatics, Peyer's patches and the *glandula solitaria*, the supra-renal capsules, thymus, and pituitary body, belong to the category of the so-called "vascular" glands, all consisting essentially of masses of indifferent tissue contained in a vascular plexus.

We proceed to show that the follicles of the tonsil are not



closed, but are traversed by capillaries; and that it is a gland of the same class, distinguished from a Peyer's patch only in the fact of its elements being aggregated, not on a plane, but round a diverticulum of mucous membrane.

Finally, we suggest that the liver itself is but a huge tonsil—a vascular gland, with what might be termed a false duct; and we indicate the agreement of this doctrine with the view taken by Dr. H. Jones with regard to this organ, and we may add, with the recent beautiful researches of Bernard.

### § 3.

*Corpora lutea*.—Professor Kölliker does not appear to be acquainted with the exact description of the structure of the *corpora lutea*, given by Mr. Wharton Jones so long ago as 1843-4, in his 'Report on the Ova of Man and the Mammifera before and after Fecundation,' 'Brit. and For. Med. Review,' 1843, and in a paper entitled 'Microscopical Examination of an early *Corpus Luteum*,' in the 'London Med. Gazette' for 1844. From the latter we extract the following passages, premising that to the naked eye a section of this *corpus luteum* presented the appearance of a dark clot with a central membranous shred from which processes radiated.

"The body in question (early *corpus luteum*) is of a lenticular form, about  $\frac{6}{10}$  in. in diameter, and about  $\frac{1}{10}$  in. thick, and projects on the surface of the ovary by somewhat more than half its diameter. The prominent part being covered merely by the *indusium* of the ovary, the dark-brown red colour of the body shines through. Examined microscopically the central membranous shred was found to present the following structure:

1. On its free surface a fine film of tessellated epithelium.
2. Invested by this epithelium was a stratum of finely interwoven transparent fibres, with dark contours, somewhat like elastic tissue.
3. Outside all was a layer identical in structure with the stroma of the ovary, the same structure as that composing the principal thickness of the walls of Graafian follicles.

"The membranous processes possessed a similar structure, and were found to be continuous with the stroma of the ovary. That part of the body next the substance of the ovary, had, by

its pressure, so condensed the stroma at the place, that the latter looked somewhat like an external capsule sending processes inwards, which met and interwove with those sent outward by the central membranous striæ. But that this appearance of external capsule was the result simply of the matting of the stroma of the ovary by pressure, is shown by the circumstance that it was absent at the peripheral part of the clot-like body, there being there, as already said, merely the *indusium*.

“As to the microscopical characters of the clot-like matter itself, this was found to consist of granulous corpuscles somewhat like so-called compound inflammation globules closely aggregated, and red blood-corpuscles interspersed amongst them. The latter had lost some of their colouring matter, but the granulous corpuscles were tinged red, as if they had imbibed it.

“The conclusion which is to be drawn as to the nature of the body from this investigation is, that it is a true corpus luteum in an early stage; that the central membranous shred is the wall of the Graafian follicle, from which the ovum had escaped; and that the clot-like mass (which would by and by have acquired the characteristic yellow appearance of the corpus luteum, traces of which could indeed in some deep places be detected), together with the membranous processes extending through it from the central shred to the stroma of the ovary, is the stroma surrounding the Graafian follicle infiltrated with bloody-looking matter.”

With regard to the important question of the nature and reason of the differences between true and false *corpora lutea*, Mr. Wharton Jones observes:

“If in the human female, Graafian follicles burst periodically, independently of coitus, why is there no *corpus luteum* left? The explanation which might be given of this is:

“By a slow, natural, and regular process, a Graafian follicle matures, points, bursts, and is evacuated like a small healthy abscess or pimple, and like this the part quickly cicatrises. A Graafian follicle, at the time of coitus, not happening to be in this fully matured state, its bursting is hastened by the process of congestion, exudation, and extravasation

above described ; but when burst, the lymph and blood in an altered state remain for a while in the form of a corpus luteum, which may thus be compared to the hard base of an abscess evacuated prematurely. Though true *corpora lutea*, there is reason to believe, are formed only after coitus, impregnation may take place without the formation of a corpus luteum. How is this ? The explanation which might be offered of such rare cases is this : Coitus may have chanced to take place at the very time when a Graafian follicle, having become mature, had spontaneously given way and expelled the ovum. No congestion, exudation, and extravasation, would in this case take place, but the part would quickly close and cicatrise.

4. Lastly, what explanation can be given of the origin of false *corpora lutea* ? To this it might be answered, that from some circumstance or other, effusion of blood takes place into the interior of a Graafian follicle, perhaps on the point of bursting spontaneously. This blood coagulates and remains filling and distending the Graafian follicle, even although its walls may have subsequently given way. But besides this effusion of blood, an exudation of lymph takes place on the inner surface of the walls of the Graafian follicle, in consequence of the irritation produced, which, becoming organised, presents the same yellow appearance as the substance of the true corpus luteum formed outside the walls of the Graafian follicle.

“ In conclusion, I would remark, that, though *physiologically* one may be permitted to speculate, as I have done, on the relation between the occurrence of corpora lutea in the ovaries and preceding coitus, it would be rash and unwarrantable in any one to pronounce positively from the occurrence of a corpus luteum in the ovaries that coitus had taken place. The discovery of an ovum in the uterus, in process of development, could alone, in the present state of knowledge, warrant such an affirmation in a court of law. But, on the other hand, the absence of a corpus luteum could not warrant the affirmation that coitus had not taken place.”

#### § 4.

*Development of the Teeth.*—In an Essay on this subject in the ‘Quarterly Journal of Microscopical Science,’ for April, 1853, we have taken a very different view from that advocated

by Professor Kölliker, and which amounts to this, that all the tunics of the teeth are the result of calcareous deposition from the pulp, the so-called "enamel organ" taking no direct share whatever in the process. This view was based upon observations made upon the teeth of all the principal orders of the Vertebrata, *i. e.*, the Mackerel, the Skate, the Frog, the Calf, and Man; and subsequent observations on these and on other animals, have only confirmed our belief in the substantial truth of the *matters of fact* there stated.

The keystone of the theory of dental development there enunciated is the fact, that, in all the orders of the Vertebrata, a membrane homologous with the so-called "persistent capsule," discovered, in 1839, by Mr. Nasmyth, and which we have therefore denominated "*Nasmyth's membrane*," can be demonstrated covering the enamel of the teeth and extending over the dentine, to be continuous with the *membrana preformativa* and *basement membrane* of the sac, in an incompletely formed tooth; or with the surface of the cement, in a fully developed one. Nasmyth's membrane, in fact, *is* at first the *membrana preformativa* more or less altered.

We hold this statement to be incontrovertible, nor less so the correlated doctrine, that the enamel and cement, as well as the dentine, are developed *beneath* Nasmyth's membrane, between it and the pulp; that the enamel is, consequently, during the whole course of its formation, separated from the enamel-organ by Nasmyth's membrane; and that, therefore, the direct conversion of the long cylinders of the epithelium into the fibres of the enamel, strongly as their mutual resemblance may suggest the notion, is, to say the least, highly improbable.

Thirdly, we have met with no facts in opposition to what we have stated with regard to the mode of development of dentine and the relation of the latter to the pre-existing elements of the pulp, and we believe that there is every reason to regard what we have there called the "Deposition theory," as an established position. According to this theory, the dentine is *not* the result of the *conversion* of the elements of the pulp; the endoplasts of the latter never becoming engaged in the calcareous deposit, as they are in bone; but the young dentine is formed by a deposit of transparent calcareous granules in a thin layer between the pulp and the *membrana preformativa*.

It must be understood, however, that the latter two structures are continuous, and that when the dentine is said to be deposited between them it is not meant that any real interval exists, but only that the outer portion of the periplast of the pulp, of which the *membrana preformativa* constitutes a part, increases and receives a calcareous deposit without any corresponding implication of the endoplasts of the pulp.

The thinnest and youngest layer of the dentine appears to be structureless, which may, however, arise from the small quantity of calcareous matter which it contains: subsequently, minute cavities, irregular in form, and  $\frac{1}{3000}$ th of an inch apart, appear in it; and these corresponding with one another in successive layers of the dentine, become the dentinal tubuli. The appearance of walls, &c., to these tubuli, we consider to be the result of a subsequent differentiation in the dentine.

A careful study of the mode in which the dentine-like tegumentary organs of many of the lower animals (Fishes, Articulata, Mollusca) are formed, has afforded the fullest confirmation of this theory of the development of dentine, and we would recommend those who have any doubt upon the subject to study the development of the spines of the Skate, or that of shell of the Crab or Lobster.

The mode of development of the enamel appears to us to be a very difficult subject, and requires to be most carefully studied. Taking into consideration the facts that a distinction of a superficial and a deep layer of calcified tissue is very general in the tegumentary organs—that in a Molluscan shell, for instance (*e. g. Trigonina*), we may have a superficial membranous layer corresponding with Nasmyth's membrane, a deeper prismatic layer, whose prisms precisely resemble those of enamel on a large scale, and an internal laminated tubular layer, corresponding with dentine; and knowing, further, that these varieties of structure thus arranged are (whatever view we take of shell-structure) nothing but the result of the different modes in which calcific deposit has successively taken place in the same organ, it is sufficiently obvious that there are abundant analogical grounds for considering the enamel and the dentine as modifications of one and the same tissue.

Nor does the structure of the enamel in the Fish or the

Batrachian present any difficulty in the way of this view. It is, at most, indistinctly fibrous and contains so large a quantity of calcareous matter in proportion to the dentine, that the differences between the two may well be supposed to arise—as we believe they do—from this circumstance alone.

In the higher Vertebrata, however, when the enamel in its young state consists of definite fibres composed of organic substance, which are added to the surface of the tooth only *after* the formation of a subjacent scale of dentine, it becomes more difficult to comprehend the development of the former. There appears to be three possibilities :

1. What we call the primary scale of dentine is not, on the crown of the tooth, dentine at all, but young enamel, becoming converted into the latter structure, and not into the former, as development proceeds. This appears, as first sight, a startling hypothesis enough ; but there are, so far as we know, no means of disproving it. Young dentine can only be known to be such by its relations ; in structure it is neither like perfect dentine nor like perfect enamel ; but might readily be supposed to be converted into either by variation in the quantity and mode of deposition of its calcareous element. If this deposit be comparatively small, leaving much of the organic basis, and not encroaching upon the existing cavities, we have dentine ; increase the quantity of calcareous salts, and break up the organic basis at the same time into fibres, and enamel would be produced.

2. The enamel is the *indirect* product of the prismatic cells of the enamel organ, whose inner extremities pass into successive layers of membrane, which are applied upon and indistinguishably unite with the *membrana preformativa* over the whole surface of the developing enamel. The laminated membrane thus formed receives a calcareous deposit, and breaks up into the prisms of the enamel.

This hypothesis likewise, at first sight, appears somewhat improbable, but it may be strictly paralleled with what occurs in the formation of prismatic shell substance, where a laminated membranous substance is produced from the cellular epidermis of the mantle, and subsequently breaks up into the characteristic, large, transversely striated prisms.

3. The enamel is neither the result of the modification of

the primary "dentine," nor superimposed on this from the enamel organ, but a *tertium quid*, the product of the growth and metamorphosis of that excessively thin layer of organic matter which lies between the dentine and the enamel.

In support of this view, also, a very close analogy may be found in the mode of development of the shaft of the hair—a structure which exhibits the closest correspondence with the teeth. The fibrous cortex of the hair is in fact homologous with dentine; it is a horny dentine containing rudimentary canals. External to this substance we find two layers, the inner composed of parallel horny structureless plates, closely united and set obliquely on the shaft, in fact, a rudimentary horny enamel; the outer consisting of a tough areolated membrane, *outer layer of the cuticle*, whose resemblance to Nasmyth's membrane cannot be overlooked. Now, if we trace the development of these layers in the long hairs of the head, we find that they pass on the bulb into a structureless limiting membrane, beneath which lie the endoplasts of the pulp; this is, in fact, a *membrana preformativa* of the hair pulp. Passing from the base towards the apex of the hair, the deep endoplasts become surrounded by the horny matter and the pigment-granules of the cortex, while the superficial layer remains free from the latter, but gradually becomes horny, and loses its endoplasts. Its outer portion then becomes the areolated outer (Nasmyth's membrane) cuticular layer, while its inner portion breaks up into the parallel plates of the inner (enamel) cuticular layer. So far as we have been able to observe in the long hair, however, the disappearance of the endoplasts takes place *before* the areolation and lamination of the periplast which corresponded to them, so that, as we have already stated (note p. 182, vol. I), the cuticle does here pass into an apparently structureless layer. This, however, is not, as it seemed, a real discrepancy from Prof. Kölliker's views, for in the short thick hairs, such as those of the nostril, the endoplasts persist longer, and we see that, as he states, the areolations of the outer cuticle are the representatives of the cell-cavities of the outer layer of the pulp; while the laminæ of the inner layer are the result of the lamination of the next layer of the pulp, whose endoplasts may be seen gradually disappearing, whilst its periplast breaks up into plates.

Now in the long hairs we have a relation of the outer cuticle to the cortex very similar to that of Nasmyth's membrane to the dentine before the development of the enamel, and the conclusion is obvious, that as the development of the inner layer of the cuticle takes place by the differentiation of the intermediate substance between the cuticle and cortex, so that of the enamel may take place in the same way in relation to Nasmyth's membrane and the dentine.

These would appear to be the alternatives concerning the development of the enamel. At present facts would seem to be wanting to determine definitely which should be accepted.

Finally comes the question of interpretation of the phenomena of development of the dental tissues, and the determination of the homologies of the latter with the pre-existing elements of the mucous membrane. Professor Kölliker's views are stated in the text. He considers the dentine and the cement to be the calcified corium of the mucous membrane, while the enamel is the calcified epithelium.

The view we have ourselves taken is that cement, dentine, and enamel, are calcifications in the same constituent of the mucous membrane, and, in fact, that they entirely belong to its corium or dermal element. Taking for granted that the *membrana preformativa* was a basement membrane, and furthermore, the received doctrine that a basement membrane marks the boundary between the dermal and epidermal elements of integument or mucous membrane, it was, in fact, impossible to come to any other conclusion. An extensive study of the integumentary organs, however, has led us to reflect more closely upon this matter, and to inquire what is a basement membrane, and what is the real distinction between the epidermic and the dermic elements of a membrane? We cannot here enter into the grounds for our conclusions (which will be stated in full in a forthcoming article on the 'Tegumentary System,' in Todd's 'Cyclopædia of Anatomy and Physiology'), but must be content merely to state our conclusions that the existence of a basement membrane, *i. e.*, of a structureless membrane, internal or external to it, proves nothing with regard to the dermic or epidermic nature of an organ, but that we must be guided entirely by the direction of its growth and metamorphosis.



Every integument and every mucous membrane may, in fact, be distinguished into three portions; a central plane of indifferent tissue, from which growth and metamorphosis take place externally, to constitute the representative of epidermis or epithelium, to which we propose to give the name of *ecderon*; while internally, growth and metamorphosis take place from the central plane, so as to constitute the representative of the derm or "mucosa," which we have termed the *enderon*.

Now the dental pulp is a process of the whole integument, and its outer surface, although bounded by a "basement membrane," truly represents the deepest layer of the *ecderon* of ordinary integument, while its inner substance belongs to the *enderon*. Although, therefore, the dentine is not a calcified cellular epidermis, it is a calcified *ecderon*, and grows in the same manner as an *ecderon* would do. The cement follows the dentine, and whatever the view we take of the development of the enamel, it also belongs to the *ecderon*. Although, therefore, the teeth are not, in the ordinary sense, epidermic structures, they are homologous with the *ecderon*, and not with the true derma or *enderon* of the mucous membrane.

END.



RETURN TO the circulation desk of any  
University of California Library  
or to the  
NORTHERN REGIONAL LIBRARY FACILITY  
Bldg. 400, Richmond Field Station  
University of California  
Richmond, CA 94804-4698

31

ALL BOOKS MAY BE RECALLED AFTER 7 DAYS

- 2-month loans may be renewed by calling (510) 642-6753
- 1-year loans may be recharged by bringing books to NRLF
- Renewals and recharges may be made 4 days prior to due date.

DUE AS STAMPED BELOW

MAY 06 1997

~~NOV 08 2004~~

12.000 (11/95)

LEY

U. C. BERKELEY LIBRARIES



CD45842267



