

593
K95_a

MBL/WHOI



0 0301 0021489 6

Manual of
HUMAN PROTOZOA

Manual of
HUMAN PROTOZOA

*With Special Reference to
Their Detection and Identification*

By

RICHARD R. KUDO, D.Sc.

*Associate Professor of Zoology
The University of Illinois*



CHARLES C THOMAS · PUBLISHER

1944

Springfield · Illinois

Baltimore · Maryland

All rights reserved,
including the right of reproduction
in whole or in part, in any form.

Published by CHARLES C THOMAS

Copyright, 1944, by CHARLES C THOMAS
220 EAST MONROE STREET, SPRINGFIELD, ILLINOIS

First Edition

PRINTED IN THE UNITED STATES OF AMERICA



Preface

THIS MANUAL is based upon the author's laboratory notes that have been in use in an emergency course offered at the University, in which the detection and identification of protozoan parasites of man and simple microscopical technique employed for this purpose, are studied and practised. There are now available several excellent treatises on parasitic protozoa of man which deal comprehensively with the morphological and developmental details, incidence of infections, geographical distribution, pathological changes brought about on human body, diagnosis, treatment, etc. As no one of these meets the need of the class, the present manual has been prepared. It contains only the essential information in order to serve as a practical guide or companion book in detecting and identifying the human protozoa.

The text has been compiled from the materials which have been accumulated by the author in the last twenty-five years. In addition, the author has consulted the works of Mr. C. Dobell, Dr. R. P. Strong, Dr. C. M. Wenyon, and many others, to whom he expresses his indebtedness. To supplement the descriptions in the text, a number of original drawings which have been especially prepared for this work, are inserted. Except the living specimens, all drawings were made with the aid of a drawing apparatus under an oil immersion objective, and depict precisely as the specimens appeared under the microscope. The author is under obligation to the authors of papers that contain the illustrations from which all or parts of figures 7, 8, 14, 15,

16, and 28 have been redrawn. He further wishes to express his appreciation to Mr. Charles C Thomas for his whole-hearted cooperation and thorough care in the making of the booklet.

RICHARD R. KUDO

Urbana, Illinois

January, 1944

Contents

| | |
|--|----|
| PREFACE | v |
| CHAPTER | |
| 1 Introduction | 3 |
| 2 Protozoa parasitic in the digestive tract | 8 |
| Sarcodina | 8 |
| 1 Entamoeba histolytica | 9 |
| 2 Entamoeba coli | 15 |
| 3 Entamoeba gingivalis | 19 |
| 4 Iodamoeba bütschlii | 21 |
| 5 Endolimax nana | 24 |
| 6 Dientamoeba fragilis | 26 |
| Keys to the genera and species of human amoebae | 28 |
| Differential diagnosis of the intestinal amoebae | 30 |
| 3 Protozoa parasitic in the digestive tract (con- tinued) | 31 |
| Flagellata | 31 |
| 1 Retortamonas intestinalis | 31 |
| 2 Enteromonas hominis | 34 |
| 3 Tricercomonas intestinalis | 35 |
| 4 Chilomastix mesnili | 36 |
| 5 Trichomonas hominis | 38 |
| 6 Trichomonas elongata | 41 |
| 7 Giardia intestinalis | 41 |
| Keys to the genera and species of flagellates living in the digestive tract | 45 |
| Differential diagnosis of intestinal flagellates .. | 46 |

| | |
|---|----|
| 4 Protozoa parasitic in the digestive tract (continued) | 47 |
| Sporozoa | 47 |
| 1 Isospora hominis | 47 |
| Ciliata | 49 |
| 1 Balantidium coli | 49 |
| 5 Technique for detection and identification of protozoa parasitic in the digestive tract | 53 |
| Collection of material | 53 |
| Microscopical examination | 54 |
| Fresh preparation | 55 |
| Permanent preparation | 58 |
| 6 Coprozoic protozoa and objects present in the faeces | 62 |
| Coprozoic protozoa | 62 |
| Objects present in the faeces | 67 |
| 7 Protozoa parasitic in the circulatory system | 72 |
| Flagellata | 72 |
| Trypanosoma | 72 |
| 1 Trypanosoma gambiense | 73 |
| 2 Trypanosoma rhodesiense | 75 |
| 3 Trypanosoma cruzi | 76 |
| Leishmania | 78 |
| 1 Leishmania donovani | 79 |
| 2 Leishmania tropica | 81 |
| 3 Leishmania brasiliensis | 82 |
| 8 Protozoa parasitic in the circulatory system (continued) | 83 |
| Sporozoa | 83 |
| Plasmodium | 83 |
| 1 Plasmodium vivax | 86 |

CONTENTS

ix

| | | |
|----|---|-----|
| 2 | Plasmodium malariae | 89 |
| 3 | Plasmodium falciparum | 92 |
| 4 | Plasmodium ovale | 94 |
| | Differential diagnosis of the three common species of Plasmodium, as seen in Giemsa- stained thin blood films | 96 |
| 9 | Technique for detection and identification of protozoa parasitic in the circulatory system | 97 |
| 10 | Objects which may be confused with blood-in- habiting protozoa in stained films | 102 |
| 11 | Protozoa parasitic in the muscle and the repro- ductive organ | 106 |
| | In the muscle | 106 |
| | 1 Sarcocystis lindemanni | 106 |
| | In the reproductive organ | 108 |
| | 1 Trichomonas vaginalis | 108 |
| | Reference books | 110 |
| | Index | 111 |



Manual of
HUMAN PROTOZOA

Chapter 1

Introduction

UNFORTUNATELY man is host to some twenty-seven species of parasitic organisms that are known as protozoa or unicellular animals. These protozoa nourish themselves by absorbing the body fluids or by feeding directly on tissue cells or on solid particles present in the digestive tract. They grow and multiply and the daughter individuals in turn grow and multiply. This phase of a protozoan is called the trophozoite or vegetative stage (Fig. 1, 1-4).

The body of a trophozoite is made up of the nucleus and cytoplasm. The nucleus is vesicular in structure, except in *Balantidium coli*, a ciliate, in which the macronucleus is a large compact one (Fig. 13, 2). The vesicular nucleus (Fig. 1, 2-4) is composed of the nuclear membrane which encloses the nucleoplasm. The chromatin granules are either attached to the inner surface of the membrane or suspended in the nucleoplasm. In addition there is usually an endosome which is a conspicuous body and stains differently in various protozoa. The endosome is either suspended in the nucleoplasm or attached to the nuclear membrane.

The cytoplasm is frequently differentiated into an outer layer, the ectoplasm, and an inner mass, the endoplasm (Fig. 3, 1, 2). The nucleus, food vacuoles, etc., are ordinarily located in various parts of the endoplasm. In Sarcodina, Flagellata, and Ciliata, the trophozoite moves about ac-

tively by means of pseudopodia, flagella, and cilia respectively. The fluid food substances are taken in through the entire body surface, while the solid food particles may be engulfed by pseudopodia or taken in through a permanent opening, the cytostome. The osmotic regulation is also carried on through the body surface in the majority, and there occurs no contractile vacuole in the human protozoa except in *Balantidium coli* (Fig. 13, 1).

The trophozoite multiplies as a rule by binary fission which produces two daughter individuals. The species of *Plasmodium* however multiply by multiple division or schizogony (Figs. 21, 22). In this, the nucleus divides repeatedly without cytoplasmic division so that several to many nuclei are produced within a trophozoite, and finally each nucleus becomes the center of a daughter individual. When the parent body breaks up, there are formed many daughter trophozoites. On this account, this type of trophozoite is called a schizont.

After multiplying a certain number of times, the trophozoites of the protozoa which depend on man as the only host and not transmitted by invertebrates, encysts. It becomes gradually less active, and secretes a resistant wall. Thus the cyst (Fig. 1, 5-9) is formed. The cyst wall thus produced protects the inner protoplasm against low temperature, desiccation, and other unfavorable external conditions which the cyst encounters after being voided in the faeces from the intestine. When a cyst finds its way into the digestive tract of man in food or water, excystment takes place, and young organism emerges and develops into the trophozoite. The encystment however does not take place in forms such as *Trypanosoma*, *Leishmania*,

and Plasmodium, which live in man and also in blood-sucking invertebrates.

In the human protozoa which belong to Sarcodina and Flagellata, sexual reproduction is not known, asexual reproduction by the trophozoite and in some in the cyst, being the sole mode of multiplication. In the ciliate, *Balantidium coli*, conjugation has been reported to occur by some observers. In Plasmodium in addition to the schizogony mentioned above, certain schizonts develop into macrogametes and microgametes which unite in pairs and produce numerous zygotes. The zygote formation and subsequent development into an oocyst take place in the female anopheline mosquito.

As to the effects of the protozoa upon the human body, information is at present not complete for all of them. In the broad sense of the term, all protozoa living in man are parasites. However, a true parasite is one which actually lives at the expense of human body and brings about certain pathological conditions in it. The true protozoan parasites of man and the diseases for which they are responsible are as follows:

| | |
|--------------------------------|--------------------------------------|
| <i>Entamoeba histolytica</i> | Amoebic dysentery, amoebiasis |
| <i>Balantidium coli</i> | Balantidial dysentery, balantidiosis |
| <i>Trypanosoma gambiense</i> | Central African sleeping sickness |
| <i>Trypanosoma rhodesiense</i> | East African sleeping sickness |
| <i>Trypanosoma cruzi</i> | Chagas' disease |

| | |
|--------------------------------|---|
| <i>Leishmania donovani</i> | Kala-azar, visceral leishmaniasis |
| <i>Leishmania tropica</i> | Oriental sore, cutaneous leishmaniasis |
| <i>Leishmania brasiliensis</i> | Espundia, naso-oral leishmaniasis |
| <i>Plasmodium vivax</i> | Benign tertian malaria |
| <i>Plasmodium malariae</i> | Quartan malaria |
| <i>Plasmodium falciparum</i> | Subtertian or malignant tertian malaria |
| <i>Plasmodium ovale</i> | Ovale or mild tertian malaria |
| <i>Isospora hominis</i> | Coccidiosis |
| <i>Sarcocystis lindemanni</i> | Sarcosporidiosis |

The remaining thirteen species of human protozoa appear not to invade any living tissues of host. While undoubtedly absorbing a certain amount of fluid substances in human systems, they seem to subsist also on microorganisms which abound in the lumen of the intestine. As far as we can find, they do not bring about any noticeable damage upon the host, and are therefore to be called the commensals. *Giardia intestinalis* inhabits the duodenum and other parts of the small intestine by being attached, when not swimming about, to the gut epithelium, and thus may cause abnormal conditions of the gut epithelium over a wide area. A number of observers are inclined to think that this flagellate is a pathogenic protozoan.

The known protozoa which inhabit the human body represent all four major groups of protozoa. Here they will

be considered for convenience under the following three headings:

1. Protozoa parasitic in the digestive tract.
2. Protozoa parasitic in the circulatory system.
3. Protozoa parasitic in the muscle and the reproductive organ.

Chapter 2

Protozoa parasitic in the digestive tract

THERE are fifteen species of protozoa which have been reported to inhabit the digestive tract of man. Of these six belong to Sarcodina, seven to Flagellata, and one each to Sporozoa and Ciliata.

Sarcodina

The amoebae which inhabit the human body all belong to the group Amoebina, and are parasites of the digestive system. The trophozoites absorb fluid nourishment and also engulf solid food particles. They multiply by binary fission. If the trophozoites leave by accident the human intestine, they perish within a short period of time. Encystment takes place in four species. The cysts are capable of remaining alive outside the host body in the faeces, water, etc., for a considerable length of time and become the source of infection. When they are taken into the human mouth in contaminated water or food, the cysts pass through the stomach unharmed and excyst in the intestine. The emerged amoebae, if not uninucleate, divide to form uninucleate individuals and develop into trophozoites.

The first three amoebae described in the following pages, have been in recent years designated by several writers as *Endamoeba* apparently in accordance with the opinion expressed by no. 99 of the International Commission on Zoological Nomenclature (1928). This manual does

not follow this opinion, since the structures of the resting nuclei in *Endamoeba*, *Entamoeba*, *Iodamoeba*, *Endolimax*, and *Dientamoeba*, are distinctly different from one another. Unless all five genera are combined under one, these genera should be considered as distinctive. Therefore, the generic name, *Entamoeba*, is retained here.

1. *Entamoeba histolytica* Schaudinn 1903

Synonym: *Endamoeba histolytica* (Schaudinn)

This is the pathogenic amoeba of man and commonly referred to as the "dysentery amoeba." The amoeba lives in the lumen and tissues of the colon wall, producing a typical ulceration and, in case of acute infection, it brings about dysentery, although in chronic infection there may not be any symptoms at all. It frequently enters the liver by way of portal veins, and produces abscess in it. Other internal organs, such as the lung, brain, etc., have also been known to be invaded by this amoeba. The trophozoites are found in dysenteric or diarrhoeic faeces, and cysts usually in formed faeces.

Trophozoites

1. *Living specimens.* When seen in freshly obtained dysenteric or diarrhoeic faeces, the trophozoite (Fig. 1, ¹) is a typical amoeboid organism with the well differentiated cytoplasm. When undergoing progressive movements, it changes its body form little by forming a single pseudopodium as broad as the body itself. Others may be seen changing their body forms continuously by actively forming lobose pseudopodia in an eruptive manner in which the hyaline ectoplasm plays a leading part, followed by

a rapid flowing-out of the grayish granulated endoplasm. The amoebae vary in diameter 15-35 μ . The monopodal individuals may be longer. On a warm stage, the activity may continue for hours if the cover-glass is sealed to the slide by vaseline or paraffin. But sooner or later, the amoeba will become less and less active and assumes a more or less rounded form. The formation of the pseudopodia and change of body form may continue for some time. Finally the organism becomes immobile. With the decrease in activity, the ectoplasm and endoplasm may often become more clearly differentiated in many individuals. The ectoplasm may be more voluminous than before, while the endoplasm becomes alveolated. In the endoplasm are found a nucleus and food particles. The nucleus is seldom seen in actively moving amoebae, but may be faintly seen as a ring of small granules, about 5 μ in diameter, in sluggish individuals. The food consists of host tissue cells and tissue and body fluids which are absorbed through the body surface. The amoeba takes in erythrocytes and fragments of tissue cells, which give the organism a characteristic appearance. The number of erythrocytes found in an individual varies a great deal and not all individuals contain them. Bacteria and other microorganisms which are freely taken in by other species of *Entamoeba* mentioned in the following pages, are only seldom engulfed by *E. histolytica*.

2. *Stained specimens.* When fixed and stained (p. 58), the trophozoites (Fig. 1, 2-4) appear more or less rounded and their cytoplasm is reticulated. In some individuals the cytoplasm may be differentiated into the clearer ectoplasm and denser endoplasm (Fig. 1, 3). The erythrocytes pres-

ent in the endoplasm are usually at various stages of disintegration (Fig. 1, 2-4). The nucleus is spherical, circular in outline, and measures 4-7 μ in diameter. It is highly

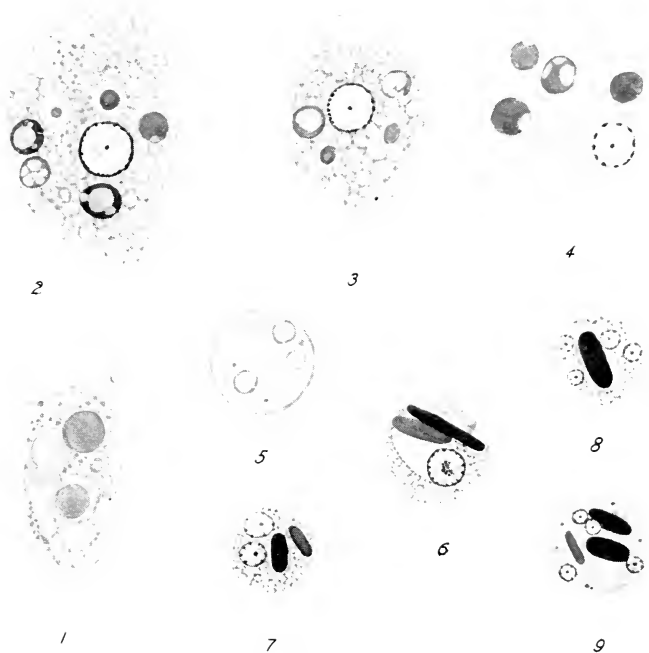


FIG. 1. *Entamoeba histolytica*. $\times 1150$. (original)

1. A living trophozoite.
- 2-4. Stained amoebae, highly spread out.
5. A fresh cyst.
- 6-9. Stained cysts.

vesicular. There is a centrally located endosome which may be surrounded by an ill-defined achromatic reticulum. The chromatin granules are evenly distributed over the inner surface of the nuclear membrane, and often referred

to as the peripheral chromatin granules. These granules are smaller than those of *E. coli* (p. 16-17). The most commonly observed specimens are 20-30 μ in diameter.

The trophozoites are usually found only in dysenteric or diarrhoeic faeces and occasionally in the mucus apparently eroded from amoebic ulcers voided in formed stools. While the majority of the amoebae are uninucleate, there may be a few binucleate ones which are undergoing division that ordinarily takes place in the tissues of the colon.

Precystic forms

The trophozoites become transformed into cysts. The transition form is known as the precystic form. Some observers believe that the trophozoites which occupy the superficial position in the lesions of the intestine may be unable to grow after division, because of lack of fresh tissue cells or fluid, and remain small. Such amoebae secrete cyst walls and develop into cysts. The nucleus contains frequently larger chromatin granules and on this account it is not possible to distinguish *E. histolytica* from *E. coli* in this stage.

Cysts

1. *Living specimens.* The cyst (Fig. 1, 5) is nearly spherical in form, and its outline is almost always circular, though sometimes ovoid. It is highly refractile and appears somewhat greenish, and therefore could be recognized with a little practice under a low power objective. The homogeneous cyst wall is comparatively thin (about 0.5 μ thick), and the protoplasm fills the space within the wall. The nuclei vary in number from one to four, depending upon stages of development, and are difficult to make out, although

sometimes recognized as indistinct rings. In addition, there may be seen a vacuole, and refractile, colorless rods which become deeply stained in permanent preparation and are known as chromatoid bodies. The cysts measure 5-20 μ in diameter.

When the cysts are stained with Lugol's solution (p. 57), the cytoplasm becomes tinted in grayish brown color and the nuclei are easily recognized. In many cysts there may be found one or more ill-defined masses which are stained reddish brown (the glycogen bodies), while the rod-like chromatoid bodies remain colorless. Thus Lugol's solution facilitates greatly the identification of the cyst.

2. *Stained specimens.* When the cysts (Fig. 1, 6-8) are fixed and stained (p. 58), the cyst wall remains unstained and is not noticeable as its index of refraction is nearly the same as that of the mounting medium, Canada balsam. The cytoplasm appears finely reticulated and may show vacuolation especially in young uninucleate cysts (Fig. 1, 6). Such vacuoles as a rule contain glycogen. There are seen one to several rod-like bodies which stain intensely black. These are the so-called chromatoid bodies which in this species are almost always with rounded extremities. The nucleus in young uni- and bi-nucleate cysts may appear somewhat different in structure from that of the trophozoite described above, as in many cases the nuclei are preparing for, or completing, division (Fig. 1, 6). But when the nuclear divisions are completed, there are seen four small nuclei, about 2 μ in diameter, of the structure more closely resembling that of the trophozoite (Fig. 1, 8, 9). Some of the four nuclei may divide once more on rare occasions so that cysts with six to eight nuclei may be seen. These are con-

sidered abnormal and comparatively small in number. Tetranucleated mature cysts are typical of *Entamoeba histolytica*. In the faeces, the cysts do not undergo any further changes. The most commonly seen cysts measure about 7-16 μ in diameter.

Viability of cysts

The dysentery amoeba is transmitted by viable cysts in contaminated food or water. The cyst-passers or carriers do often not show any symptoms of infection. According to Yorke and Adams (1926), cysts kept in faeces at 16-20°C. in the laboratory, begin to die rapidly and all are dead within about 10 days. Keeping the faeces in an ice box at 0°C. gives approximately the same result. Washed suspensions of the cysts live 17-21 days when kept at 0°C., and 10-11 days at 16-20°C. Chang and Fair (1941) state that the cysts are viable 90 days at freezing point, but only 30, 10 and 3 days at 50°, 68°, and 86°F. respectively.

Yorke and Adams state that the cysts survive a temperature of 45°C. for 30 minutes, but are killed within 5 minutes at 50°C. The lethal strengths of various chemicals and drugs when allowed to act upon the cysts for 30 minutes at 20-25°C. and 37°C. are as follows:

| | 20-25°C | 37°C |
|------------------------|------------------|------------------|
| HCl | 7.5% | 5% |
| NaOH | 2.5% | 2.5% |
| Cl (sat. aq. solution) | 1/64 | 1/320 |
| HgCl ₂ | 1:2500 | — |
| Potassium permanganate | 1% does not kill | 1% does not kill |
| Formaldehyde | 0.5% | 0.5% |
| Carbolic acid | 1% | 1% |
| Lysol | 1% | 0.5-1% |
| Yatren | 5% does not kill | 5% does not kill |
| Emetin HCl | 5% does not kill | 5% does not kill |

2. *Entamoeba coli* (Grassi 1879)

Synonym: *Endamoeba coli* (Grassi)

This is an amoeba which lives in the lumen of the colon and is looked upon as a commensal. It is a very common amoeba in the human intestine and easily mistaken for *E. histolytica* because of the morphological similarity. Trophozoites and some cysts occur in fluid or semifluid faeces, but formed faeces contains only cysts.

Trophozoites

1. *Living specimens.* This amoeba (Fig. 2, 1) resembles *E. histolytica* in size, but the average individual appears to be slightly larger than the latter. It measures 15-40 μ in the largest diameter, but the majority are about 20-35 μ . Even in freshly obtained material, it is less active than *E. histolytica*. The cytoplasm is not well differentiated. The ectoplasm is thin and ill-defined and merges into the voluminous endoplasm. The endoplasm is usually vacuolated or alveolated, and contains numerous bacteria, yeasts, other microorganisms of large size in addition to various debris that occur in the lumen of the colon. The erythrocytes are normally not taken in by this amoeba, although instances of ingestion of erythrocytes by it especially *in vitro* have been reported. For diagnostic purpose, therefore, one can place a great emphasis on the presence or absence of the erythrocytes in the endoplasm as suggestive of *E. histolytica* or *E. coli*. The nucleus is more easily seen than that of *E. histolytica*, especially in the specimens in which a comparatively small number of food particles are present. It appears as a ring of coarse refractile granules with a large granule located near, but not in, its center.

2. *Stained specimens.* In the majority of individuals (Fig. 2, 2-5), the body outline is more or less rounded and the cytoplasm is generally reticulated. Some individuals

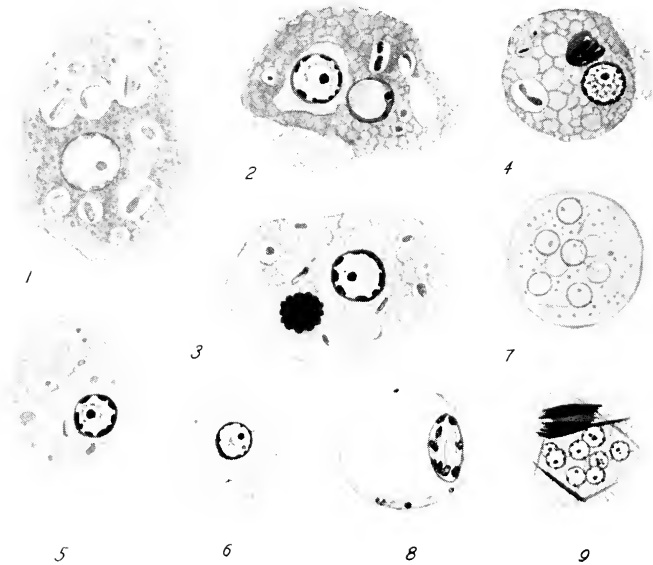


FIG. 2. *Entamoeba coli*. $\times 1150$. (original)

1. A living amoeba.
- 2-5. Stained trophozoites.
3. A trophozoite infected by *Sphaerita*.
6. A precystic amoeba.
7. A fresh cyst.
8. A stained young cyst with a large glycogen vacuole.
9. A stained mature cyst.

(Fig. 2, 2, 4) may show the division between the ectoplasm and endoplasm. In the food vacuoles are found chiefly bacteria, numerous inorganic faecal debris, and also microorganisms which co-exist in the lumen of the colon. The

nucleus is characterized by a thicker membrane than that of *E. histolytica*. The peripheral chromatin granules are coarser and often in block-form, and the endosome is a much larger body, about 1μ in diameter, and located usually eccentrically. The clear ring around the endosome may be narrow or wide, and smaller chromatin granules may be lodged on the achromatic network present in the nucleoplasm. The nucleus is about $5-8\mu$ in diameter. Although the typical nucleus of this amoeba is quite different from that of *E. histolytica*, there occur invariably atypical or degenerating individuals with nuclei which may appear intermediate between the two. If undecided, one must look for many typical individuals in which a positive identification can be made.

Precystic forms

Prior to encystment, the amoebae (Fig. 2, 6) become much smaller through division and transform themselves into precystic amoebae. These are usually rounded and more sluggish than the trophozoites. The cytoplasm does not contain food material. The amoeba resembles closely that of *E. histolytica*, but may be slightly larger. It is $8-20\mu$ in diameter. The nucleus shows a typical appearance, but may show a structure somewhat resembling that of *E. histolytica*. Therefore, it is quite difficult, as was stated already, to differentiate the two species of *Entamoeba* in precystic forms.

Cysts

1. *Living specimens*. The cyst (Fig. 2, 7) is usually spherical, but often ovoid in form. It measures $10-30\mu$ in

the largest diameter. It is refractile and could be readily detected under a low power objective, although species identification is of course not possible under it. The cyst contents are granulated and often contain a large homogeneous body particularly in uni- or bi-nucleate forms. It stains reddish brown with Lugol's solution and is considered as a glycogen body. The nuclei are faintly visible. In uni- or bi-nucleate cysts, the nucleus may be seen as a ring pushed against the glycogen body. In older cysts with four or eight nuclei, not all of them may be seen. In addition, colorless needle-like bodies (chromatoid bodies in stained smears) may be present.

When the cysts are treated with Lugol's solution, the nuclei become plainly visible, and the glycogen body stains reddish brown, while the filamentous bodies remain unstained.

2. *Stained specimens.* The cyst wall is not recognizable. The cytoplasm is finely reticulated, and in young cysts with one or two nuclei, there may be present a large well-defined vacuole in which glycogen body occurs. This vacuole may be very large in some cysts so that the cytoplasm forms a narrow ring enclosing the nucleus (Fig. 2, 8). The chromatoid bodies are less abundant as compared with those of *E. histolytica*, and when present they are filamentous or irregularly shaped fragments with sharply pointed extremities (Fig. 2, 9). There are usually 1, 2, 4, or 8 nuclei, as in each of the second and third division, the nuclei divide simultaneously. Sometimes because of irregular divisions cysts containing 3, 5, or 7 nuclei of unequal sizes may be seen. Very rarely cysts with more than eight nuclei may also be seen. All these cysts are more or

less abnormal, and are insignificantly small in number as compared with the normal mature eight-nucleated cysts in routine work. The glycogen body appears to disappear before the cyst is mature, and may be entirely lacking even in young cysts.

3. *Entamoeba gingivalis* (Gros 1849)

Synonym: *Endamoeba gingivalis* (Gros)

This is the amoeba of human mouth. It lives in carious teeth, in tartar and debris accumulated around the roots of teeth, and in abscesses of gum, tonsils, etc. Although held by some as the cause of pyorrhoea alveolaris, exact evidence for its pathogenicity is still lacking. It has been found in healthy gum and in false teeth, and is generally looked upon as a commensal. Only the trophic stage is known, cysts not having been observed up to the present time. It is of common occurrence.

Trophozoites

1. *Living specimens.* As seen in fresh material in saliva under a sealed cover glass the amoeba (Fig. 3, 1, 2) is as active as *E. histolytica* (p. 9). The cytoplasm is well differentiated. In some a broad single pseudopodium is formed at one end, which results in progressive movement, similar to the monopodal forms of *E. histolytica* or free-living limax amoebae; in others several pseudopodia composed chiefly of the ectoplasm are formed in quick succession (Fig. 3, 1). The endoplasm is often vacuolated and contains a large number of food particles and a nucleus which is frequently seen as a ring about 3-4 μ in diameter. The food particles are almost always charac-

teristically pale greenish and mostly rounded, each being enclosed in a food vacuole. They are probably the nuclei of leucocytes, pus cells, or other degenerating host cells found outside the gum tissues. Erythrocytes have however not been observed in this amoeba. Bacteria are also found in food vacuoles. The amoeba measures 8-30 μ in diameter,

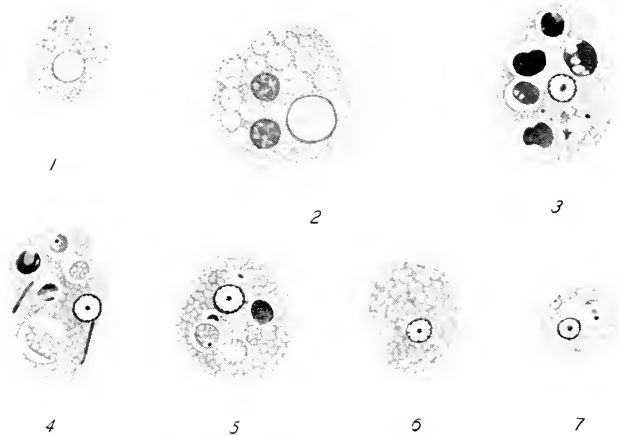


FIG. 3. *Entamoeba gingivalis*. $\times 1150$. (original)

1, 2. Living trophozoites.
3-7. Stained amoebae.

but the most commonly seen individuals are 10-20 μ in diameter.

2. *Stained specimens*. The amoeba (Fig. 3, 3-7) appears more rounded and somewhat contracted than in life, the majority having withdrawn their pseudopodia at the time of fixation. The cytoplasm shows a little differentiation into the ectoplasm and endoplasm. The whole is finely granulated or vacuolated and food vacuoles are very conspicu-

ous. The various food particles seen in life are stained black to gray, in some of which reticulation is visible. Many bacteria occur also as food particles. The spherical nucleus is vesicular and measures about 2-4 μ in diameter. There is a small endosome near the center, while the peripheral chromatin granules are small and compactly packed along the inner surface of the membrane so that the latter frequently appears as a uniformly thick ring. Depending on the degree of decolorization, there may be seen a clear zone around the endosome and the rest occupied by an achromatic network. The stained specimens are a little smaller than the living ones.

Although this amoeba is the very first parasitic amoeba seen by man and has been studied by numerous workers, encysted forms have, as stated already, not yet been observed. Therefore, the transmission appears to be carried on by the trophozoite. Koch (1927) found the effects of desiccation and varied temperatures upon the amoeba, as follows: The amoeba is killed at 0°C. in 18 hours; 5°C. in 24 hours; 10°C. in 48 hours; 45°C. in 20 minutes; 50°C. in 15 minutes; 55°C. in 2 minutes. At 40°C. survival is possible for an indefinite length of time. Complete desiccation of the medium or immersion in water at 60°C. kills the amoeba. She considered that *E. gingivalis* may be disseminated both by direct contact and by an intermediate contaminated article.

4. *Iodamoeba bütschlii* (Prowazek 1912)

Synonym: *I. williamsi* (Prowazek 1912)

This amoeba is intermediate in size between the two intestinal amoebae already described and the two smaller

ones which follow, and is an inhabitant of the lumen of the colon. Like *Entamoeba coli*, it does not invade the tissues of the colon wall and live by absorbing fluid substances and feeding on bacteria. Thus it is considered as a commensal. This amoeba is not as common as the amoebae already stated. The trophozoite and cyst are usually found together in diarrhoeic faeces, while the formed faeces contains cysts only.

Trophozoites

1. *Living specimens.* This amoeba (Fig. 4, 1) measures about 6-25 μ in its largest diameter, but the average individuals are 8-15 μ . It is a fairly active amoeba, and when seen soon after being voided, it shows a monopodal progressive locomotion, but presently rounds itself up and forms small pseudopodia, which reminds one of the sluggish amoeboid form-change of *Entamoeba coli*. There is no sharp demarcation between the ectoplasm and endoplasm, but the ectoplasm is often well recognizable in pseudopodia. The endoplasm is granulated and contains bacteria in food vacuoles. Large food particles which are commonly found in *E. coli* are ordinarily not present. The nucleus is usually not distinctly seen, but the large endosome may be seen surrounded by a clear circle around it in some individuals.

2. *Stained specimens.* The trophozoites (Fig. 4, 2-5) appear as composed of reticulated or alveolated cytoplasm, depending upon the extent of degeneration (Fig. 4, 4, 5), in which are present bacteria taken in as food material. The vesicular nucleus measures about 3-4 μ in diameter. The endosome which is about one-half the diameter of the

nucleus, is typically surrounded by small spherules that do not take stains so that the achromatic interspherule substance may appear as a reticulum (Fig. 4, 3). There

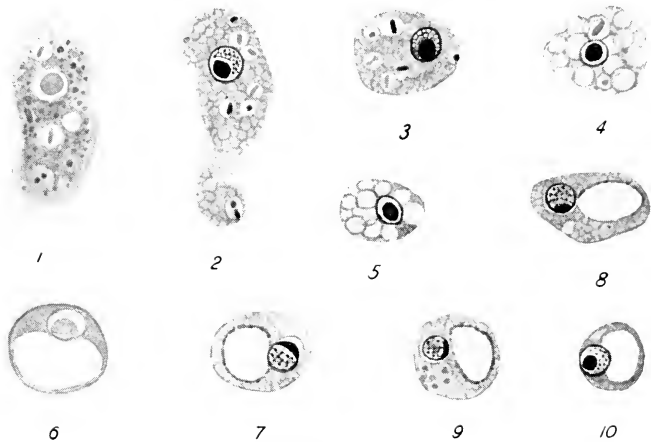


FIG. 4. *Iodamoeba bütschlii*. $\times 1150$. (original)

1. A living amoeba.
- 2-5. Stained amoebae.
- 4, 5. Somewhat degenerated trophozoites.
6. A fresh cyst.
- 7-10. Stained cysts.

may be small chromatin granules in this area. The endosome is found in various parts of the nucleus, and may stain homogeneously or show a more deeply stained cortical layer. The well developed nuclear membrane is free from chromatin granules.

Cysts

1. *Living specimens*. Although spherical cysts occur, the majority are ovoid, ellipsoid, triangular, pyriform, or square

in form, which is a characteristic feature of this amoeba (Fig. 4, 6). Naturally the cysts vary a great deal in dimensions. More or less rounded cysts measure usually 6-15 μ in diameter. The contents appear hyaline, but there is a conspicuous clear sharply outlined body which stains reddish brown with Lugol's solution and is considered as a glycogen body. It may be one-third to one-half the diameter of the cyst. Because of the presence of this glycogen body, the cysts had formerly been called "I cysts," before their relation to the trophozoite became known. Unlike the glycogen body present in the cysts of other amoebae already described, it persists in the majority of cysts in the present species, although it may become smaller when the cysts are kept in the faeces for several days. The nucleus is ordinarily faintly seen in a living cyst, but when treated with Lugol's solution, it may be recognized more clearly because of the characteristic endosome.

2. *Stained specimens.* The contents of the cyst (Fig. 4, 7-10) are reticulated and one (sometimes two) large clear vacuole is invariably noticed, which is the glycogen vacuole. The nucleus is usually situated close to the vacuole at one point. The endosome is often attached to the nuclear membrane and may be crescentic in shape. There is a single nucleus. Binucleate cysts are of rare occurrence and considered to be abnormal forms.

5. *Endolimax nana* (Wenyon and O'Connor 1917)

This is one of the two smallest amoebae living in man and inhabits the lumen of the colon. It has not been seen to invade colon tissues and is therefore considered as a

commensal. It is another very common amoeba and widely distributed.

Trophozoites

1. *Living specimens.* This amoeba (Fig. 5, 1) is considerably smaller than the four species already described. It measures 6-15 μ in the largest diameter. The organism is a fairly active amoeba as seen in fresh material. It pro-

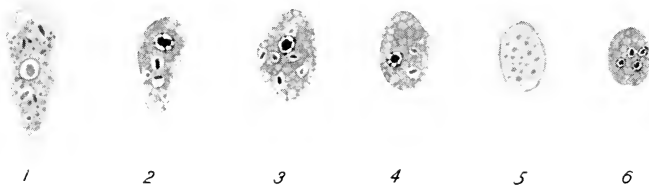


FIG. 5. *Endolimax nana*. $\times 1150$. (original)

1. A living amoeba.
- 2-4. Stained amoebae.
5. A fresh cyst.
6. A stained cyst.

gresses slowly by forming a broad pseudopodium in the direction of movement. When stationary, pseudopodia are formed at different points of the body surface. In these forms, the ectoplasm appears clearly differentiated from the endoplasm which is granulated and contains bacteria as solid food particles. The nucleus is not clearly visible in living specimens because the endosome assumes varied appearances.

2. *Stained specimens.* The body is rounded (Fig. 5, 2-4). The reticulated cytoplasm contains bacteria, and is sometimes infected by *Sphaerita* (p. 69). There is a vesicular nucleus which measures about 1.5-3 μ in diameter. The

nuclear membrane is delicate and a few peripheral chromatin granules are attached to it. The size, form, and location of the endosome vary a great deal among different individuals. In the majority, the endosome is of triangular, square, or irregularly angular in shape, and may be in the center, toward one side, or attached to the membrane of the nucleus. In the latter case, a strand may be seen connecting it with a smaller chromatin mass on the opposite side of the nucleus. The endosome in well differentiated specimens may be seen as composed of a less deeply staining matrix in which are imbedded 3-5 chromatin granules.

Cysts

1. *Living specimens.* Usually ovoid in form, the cyst (Fig. 5, 5) appears as a hyaline and homogeneous body with a few small granules. In some there may be seen an irregularly shaped vacuole which stains red brown with Lugol's solution (glycogen body) which however disappears as the cyst matures. The nuclei are rarely seen in living cysts, but may be observed in Lugol-treated specimens. The cysts measure 5-12 μ in diameter, the majority being about 7-10 μ .

2. *Stained specimens.* The cyst (Fig. 5, 6) is finely reticulated. The nuclei vary in number from 1 to 4. Their structure varies as in the nucleus of the trophozoite, but appears to be characterized by an angular endosome and its variable location within the nucleus.

6. *Dientamoeba fragilis* Jepps and Dobell 1918

This small amoeba appears to be another inhabitant of the lumen of the colon and considered as a commensal.

It is widely distributed, but usually of rare occurrence, although in certain areas the infection rate seems to be high. It has been seen only in the trophic stage in dysenteric or diarrhoeic faeces, and encysted forms have not yet been found.

Trophozoites

1. *Living specimens.* This active amoeba (Fig. 6, 1, 2) undergoes progressive movement by forming a few broad



FIG. 6. *Dientamoeba fragilis*. $\times 1150$. (original)

- 1, 2. Living trophozoites.
3. A stained uninucleate amoeba.
- 4, 5. Stained binucleate amoebae.

and thin pseudopodia. The cytoplasm is well differentiated in actively moving individuals. The endoplasm is highly granulated and contains cocci or bacilli in food vacuoles. The nucleus is ordinarily faintly visible. The amoeba measures 4-18 μ in diameter, but the majority are 5-12 μ in diameter.

2. *Stained specimens.* The body is elongate round. The cytoplasm is reticulate and bacteria occur in food vacuoles. The amoebae (Fig. 6, 3-5) possess one or two nuclei. The ratio of uni- and bi-nucleate forms varies among different faecal specimens. In some binucleate forms may be 80% or more, while in others uninucleate forms may be predominant. The nucleus is a small vesicle and about 1-2.5 μ

in diameter. There is a delicate membrane. The endosome is comparatively large and more than one-half the diameter of the nucleus itself. The ground mass of the endosome stains less deeply and is made up of plastin material. On its periphery are arranged 4-8 chromatin granules and occasionally a central granule.

Degenerating trophozoites often develop vacuoles which coalesce into a large one and may resemble *Blastocystis hominis* (p. 69-70). Transmission is apparently by the trophozoite. According to Wenrich (1940), the amoeba, if kept in faeces, remains viable up to 48 hours at room temperature, but disappears, apparently by disintegration, in 2 hours at 3.5°C.

Keys to the genera and species of human amoebae

A. The trophozoites in fresh and stained smears

- | | | |
|-------|---|---|
| 1(10) | Active trophozoite in dysenteric or diarrhoeic faeces. | 2 |
| 2(5) | Trophozoites large, 20-30 μ in diameter | 3 |
| 3(4) | Trophozoites contain often erythrocytes; nucleus with a small central endosome and comparatively small peripheral chromatin granules; more actively amoeboid. | |
| | <i>Entamoeba histolytica</i> (p. 9-14) | |
| 4(3) | Trophozoites do not ingest erythrocytes; nucleus with a large eccentric endosome and large peripheral chromatin granules; less active. | |
| | <i>Entamoeba coli</i> (p. 15-19) | |
| 5(2) | Trophozoites smaller, average less than 20 μ in diameter. | 6 |
| 6(7) | Trophozoites with 1 or 2 nuclei; endosome central, composed of plastin matrix and coarse chromatin granules; nuclear membrane without chromatin. | |
| | <i>Dientamoeba fragilis</i> (p. 26-28) | |
| 7(6) | Trophozoite with only one nucleus. | 8 |
| 8(9) | Trophozoite sluggish, 6-25 μ in diameter; nucleus with a large endosome, surrounded by a reticulum. | |
| | <i>Iodamoeba bütschlii</i> (p. 21-24) | |
| 9(8) | Trophozoite actively amoeboid, 6-18 μ in diameter; nucleus with an endosome of varied forms and location. | |
| | <i>Endolimax nana</i> (p. 24-26) | |

- 10(1) Trophozoite in the material around teeth.....
*Entamoeba gingivalis* (p. 19-21)

B. The cysts in fresh and stained smears

Of the six known human amoebae, *Entamoeba gingivalis* and *Dientamoeba fragilis* have not yet been seen in encysted condition

- 1(2) Mature cysts minucleate and of various shapes; nucleus with a large endosome often attached to membrane; cytoplasm with a large glycogen body *Iodamoeba bütschlii* (p. 21-24)
- 2(1) Mature cysts with more than one nucleus.....3
- 3(4) Mature cyst with 8 nuclei; body spherical or oval, about 10-30 μ in diameter; chromatoid bodies if present filamentous, acicular, or irregular with sharply pointed ends
*Entamoeba coli* (p. 15-19)
- 4(3) Mature cyst with 4 nuclei.....5
- 5(6) Mature cyst spherical, about 5-20 μ in diameter; chromatoid bodies numerous, rod-shaped with rounded ends; nuclei composed of a small central endosome and peripheral chromatin granules*Entamoeba histolytica* (p. 9-14)
- 6(5) Mature cyst often ovoidal, small, about 5-12 μ in diameter; chromatoid body rarely found; nuclei with a large angular endosome variable in position ...*Endolimax nana* (p. 24-26)

DIFFERENTIAL DIAGNOSIS OF THE INTESTINAL AMOEBAE

| | <i>Entamoeba histolytica</i> | <i>E. coli</i> | <i>Iodamoeba butschlii</i> | <i>Endolimax nana</i> | <i>Dientamoeba fragilis</i> |
|----------------------------|------------------------------------|---|--|---|------------------------------------|
| Trophozoite | 1. Living specimens a. Diameter | 15-35 μ | 6-25 μ | 6-18 μ | 4-18 μ |
| | b. Movement | Active progressive movements; eruptive formation of pseudopodia | Less active amoeboid movements | Progressive movements | Progressive movements |
| | c. Cytoplasm | Hyaline; erythrocytes, tissue cells taken in as food particles | Granulated; bacteria, yeasts, faecal debris in food vacuoles | Granulated; bacteria in food vacuoles | Hyaline; bacteria in food vacuoles |
| | d. Nucleus | Faintly visible ring | Visible as a ring of coarse granules | Faintly seen | Rarely seen |
| 2. Stained specimens | a. Nucleus | Fig. 1, 2-4 | Fig. 4, 2-5 | Fig. 5, 2-4 | Fig. 6, 3-5 |
| | b. Inclusions | Erythrocytes, fragments of tissue cells | Bacteria, faecal debris, etc. | Bacteria | Bacteria |
| Cyst | 1. Living specimens a. Form | Spherical; circular in outline | Circular, often oval | Often oval to ellipsoid | Unseen |
| | b. Diameter | 5-20 μ | 10-30 μ | 5-12 μ | — |
| 2. Lugol-treated specimens | | Cytoplasm greenish yellow; glycogen diffuse; 1, 2, or 4 nuclei | Cytoplasm yellowish brown; glycogen often large; 1, 2, 4, or 8 nuclei | Cytoplasm greenish yellow; glycogen scanty, diffused; 1, 2, or 4 nuclei | — |
| | 3. Stained specimens | 1, 2, or 4 nuclei; chromatoid bodies with rounded extremities | 1, 2, 4, or 8 nuclei; chromatoid bodies few, acenular or irregular with pointed ends | 1, 2, or 4 nuclei; chromatoid bodies very small if present | — |

Chapter 3

Protozoa parasitic in the digestive tract (continued)

Flagellata

THE FLAGELLATES which inhabit the digestive tract of man are all minute organisms. They live in the lumen of the intestine or in the mouth, by absorbing fluid substances as well as by engulfing solid food particles. The trophozoites are able to move about only in fluid or semi-fluid contents of the intestine, and under favorable circumstances multiply in large numbers. There is however no definite evidence to suppose that any of these flagellates is the cause of diarrhoeic condition. When the faeces become normal, the flagellates disappear, and the cysts appear in their stead. As in Sarcodina, the trophozoite encysts. The cysts are voided in the faeces and able to live outside the human host for variable lengths of time. Infection begins when viable cysts enter the mouth of a person in contaminated food or water. In the species in which the encystment does not take place, the trophozoite appears to be able to bring about new infection.

1. *Retortamonas intestinalis* (Wenyon and O'Connor 1917)

Synonym: *Embadomonas intestinalis* (Wenyon and O'Connor)

This flagellate appears to inhabit the lumen of the

intestine. It is widely distributed, but of comparatively rare occurrence. Fluid faeces contain both the active trophozoites and cysts, while formed faeces cysts only.

Trophozoites

1. *Living specimens.* The flagellate (Fig. 7, 1-3) is highly plastic, and therefore polymorphic. It is 4-9 μ long by 3-4 μ

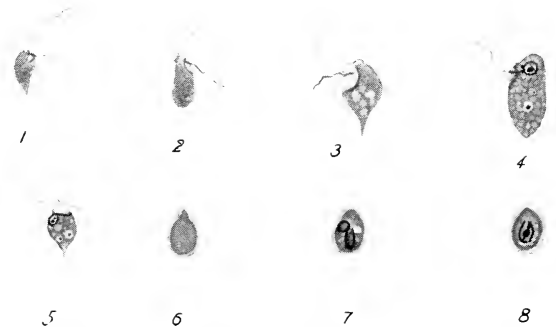


FIG. 7. *Retortamonas intestinalis*. $\times 1150$

1-3. Living trophozoites.

4, 5. Stained trophozoites.

6. A fresh cyst.

7, 8. Stained cysts.

(1-4, modified after Wenyon and O'Connor; 5, after Dobell and O'Connor; 7, modified after Jepps; 6, 8, original.)

broad. It undergoes continued jerky movements. The body is often pyriform or ovoid. The anterior end is broadly rounded, and the posterior end is either attenuated or rounded. The body length is usually about twice (or sometimes three times) the body width. Near the anterior end, there is seen a clear area which is the cytostome. The cytoplasm is granulated or slightly reticulated. There are

two flagella on each individual; but to see them clearly a dark field illumination is needed. When treated with Lugol's solution, the flagella can be seen. One flagellum which vibrates more actively is directed forward, and about as long as the body, while the second flagellum is shorter, but thicker and lies above or in the cytostome.

2. *Stained specimens.* The cytoplasm is finely reticulated or alveolated, and contains as a rule bacteria in food vacuoles (Fig. 7, 4,5). The nucleus is located near the anterior end. It is spherical and shows the central endosome clearly. Very close to the anterior margin of the nucleus, may be seen the insertion points of the two flagella. At one side of the nucleus, there is the cytostome. The ridge surrounding the mouth is marked by a delicate fibril. Mingled among numerous uninucleate individuals, binucleate forms with four flagella may be seen. They are dividing individuals.

Cysts

1. *Living specimens.* The cyst (Fig. 7, 6) is a colorless refractile pyriform body. It measures 4.5-7 μ long by 3-4.5 μ broad. The contents are granulated and details cannot be made out because of the presence of a comparatively thick cyst wall.

2. *Stained specimens.* The cyst (Fig. 7, 7,8) surrounded by a distinct membrane, appears granulated and contains an ellipsoidal area which is marked by a looped fibril. The nucleus lies near the center of the cyst. In general appearance, the cyst resembles that of *Chilomastix mesnili* (p. 36), but is much smaller than the latter.

2. *Enteromonas hominis* da Fonseca 1915

This is a small flagellate of comparatively rare occurrence. It probably inhabits the lumen of the intestine.

Trophozoites

1. *Living specimens.* A small rounded or ovoid flagellate moves about actively with its three flagella. The body is

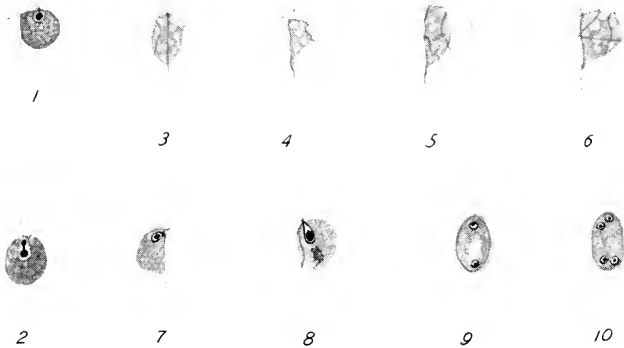


FIG. 8. 1, 2. Stained trophozoites of *enteromonas hominis*. $\times 1150$ (modified after da Fonseca).

3-10. *Tricercomonas intestinalis*. $\times 1150$ (modified after Wenyon and O'Connor).

3-6. Living trophozoites.

7, 8. Stained trophozoites.

9, 10. Stained young and mature cysts.

hyaline, but at times granulated, and contains a few granules. The flagellate is about $4-6\mu$ in diameter.

2. *Stained specimens.* The flagellate (Fig. 8, 1, 2) appears more or less spherical. The reticulated cytoplasm contains granules. The rounded nucleus is located close to the anterior end. Its nuclear membrane is moderately thick, and the endosome central and very large. The three flagella

originate in the blepharoplasts attached to the anterior margin of the nuclear membrane.

Encysted individuals have not yet been observed. Not all protozoologists agree on the validity of the species. Dobell (1935) examined da Fonseca's preparations and observed 4 flagella as well as encysted forms; and considered this flagellate and *Tricercomonas intestinalis* identical; while Wenyon (1926) is inclined to think that this flagellate is a small form of *Chilomastix mesnili* (p. 36).

3. *Tricercomonas intestinalis* Wenyon and O'Connor 1917

This is also a minute flagellate which has been found in diarrhoeic faeces and appears to inhabit the lumen of the intestine. Though widely distributed, it is of rare occurrence. The trophozoites and cysts occur in fluid or semi-fluid faeces, but in formed faeces only cysts are found.

Trophozoites

1. *Living specimens.* The flagellate (Fig. 8, 3-6) is highly plastic, but usually pyriform in shape. The anterior end is broadly rounded, while the posterior end is drawn out. The cytoplasm is granulated and contains vacuoles. In a freshly made preparation, the flagella lash very actively and therefore it is difficult to observe them. There are three anterior flagella which produce jerky movements of the organism. The fourth flagellum runs along the flattened body surface and extends out freely at the posterior tip of the body. The flagellate measures 4-10 μ long by 3-6 μ broad, but the majority are about 7 or 8 μ long.

2. *Stained specimens.* The stained trophozoites (Fig. 8,

7, 8) are more rounded than living ones. The cytoplasm is finely reticulated. The nucleus located close to the anterior margin is spherical or pyriform, and composed of a large endosome and a sharply defined membrane. The four flagella take their origin in the anterior border of the nucleus.

Cysts

1. *Living specimens.* The cyst is a small ovoid body, surrounded by a distinct cyst wall. Its cytoplasm is homogeneous, and contains small granules. There are 1, 2, or 4 nuclei which are not easily seen in life. The cyst measures 6-8 μ by 4-6 μ .

2. *Stained specimens.* The cyst wall is recognizable in stained specimens. The nuclei become clearly visible. Young cysts contain 1 or 2 nuclei (Fig. 8, 9), but mature cysts show 4 nuclei (Fig. 8, 10). The nuclei are spherical or ellipsoidal and highly vesicular, each with an endosome. The refractile granules seen in life are somewhat eosinophile.

Some authors hold that this flagellate is the same as *Enteromonas hominis* in which the fourth flagellum was overlooked.

4. *Chilomastix mesnili* (Wenyon 1910)

This is a somewhat larger flagellate which inhabits the lumen of the colon and caecum. Some hold that it also inhabits the lower small intestine. Its solid food is exclusively bacteria and other microorganisms, and the organism is considered a commensal. The trophozoites and cysts occur in diarrhoeic faeces, and the formed faeces contains cysts only.

Trophozoites

1. *Living specimens.* The body (Fig. 9, 1) is oval or pyriform in outline, and measures about 5-20 μ long. The commonly seen individuals are about 10-15 μ in length. The anterior end is invariably bluntly rounded, while the posterior end is usually drawn out into a tapering process. The flagellate moves about in jerky fashion by means of

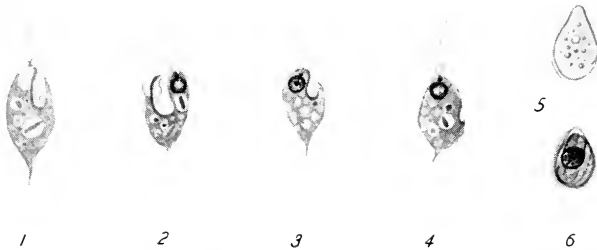


FIG. 9. *Chilomastix mesnili*. $\times 1150$. (original)

1. A living trophozoite.
- 2-4. Stained trophozoites.
5. A fresh cyst.
6. A stained cyst.

the three lashing flagella which are hard to be seen in life. The organism is less plastic than *Trichomonas hominis* (p. 38) which it superficially resembles. In the anterior one-third to one-half of the body is found a conspicuous cytostomal cleft which is somewhat spirally twisted and in which is located a short flagellum. The body itself is also frequently twisted.

2. *Stained specimens.* The body form is pyriform, with the bluntly rounded anterior and the long drawn-out posterior end (Fig. 9, 2-4). The cytoplasm is reticulated and contains bacteria in food vacuoles. A spherical vesicular

nucleus is located very close to the anterior tip. It is characterized by a distinct membrane to which chromatin granules are attached. The three flagella arise from a point anterior to the nucleus, and are of the same length (about 7-10 μ long). The fourth flagellum is about one-half the length of the other flagella and lies in the cytostomal cleft. The ridge of the cytostome is supported by two fibrils of which one on the right side is usually longer and makes a loop at the posterior margin.

Cysts

1. *Living specimens.* The cyst (Fig. 9, 5) usually occurs with the trophozoite. It is pyriform and resembles a melon seed. It is about 7-10 μ long. Its contents appear homogeneous except a few coarse granules. In general appearance, it is similar to the cyst of *Retortamonas intestinalis* (p. 31), but noticeably larger than the latter.

2. *Stained specimens.* The uniformly thin, but distinctive cyst wall is clearly recognized (Fig. 9, 6). The reticulated cytoplasm contains a spherical to ovoid nucleus located near the narrow end. The chromatin material is usually concentrated on a portion of the nuclear membrane. Surrounding or near the nucleus, may be seen the two cytostomal fibrils and the short flagellum.

5. *Trichomonas hominis* (Davaine 1860)

This is one of the commonest flagellates of the human intestine. It appears to inhabit the lumina of the colon and ileum. The organism frequently appears in large numbers in diarrhoeic faeces, but its presence is considered as a

result and not the cause of the diarrhoea. It is widely distributed, but more common in the tropics and subtropics. The trophozoite only is known.

Trophozoites

1. *Living specimens.* This is an actively motile flagellate (Fig. 10, 1) which shows a jerky or spinning movement. It measures 5-20 μ in length. The organism is highly plastic, and assumes various body forms in life. It is however generally ovoid or pyriform in body outline. Its anterior end is usually rounded, while the posterior end often tapers into a point through which the axostyle protrudes. A cytostome is located close to the anterior tip. On the opposite side of the body is seen the undulating membrane which extends slightly spirally towards the posterior end. The axostyle and undulating membrane are structures which distinguish this flagellate from *Chilomastix mesnili* (p. 36) in life. Over a dark field condensor, the flagella become clearly visible. There are typically five flagella in all, inserted at the anterior end of the body. Of these four are equally long, directed anteriorly, and lash freely, while the fifth flagellum makes the outer border of the undulating membrane. After being on the slide for some time, or when held stationary by debris in the preparation, the organism may become rounded and the undulating membrane becomes spread along the margin of the body and continues to undulate. Such an individual may simulate an amoeba.

2. *Stained specimens.* The majority of the stained specimens are more or less pyriform in shape, with the rounded

anterior and the pointed posterior end (Fig. 10, 2, 3). A large ovoid vesicular nucleus is located near the anterior end. It is characterized by a distinct membrane which surrounds an endosome and reticulated achromatic substance in which chromatin granules are suspended. Four flagella arise from the blepharoplasts present near the anterior mar-

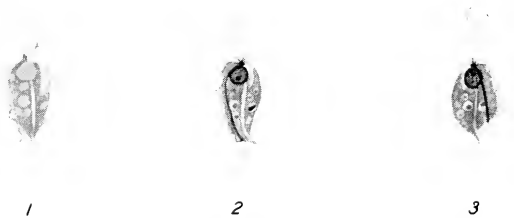


FIG. 10. *Trichomonas hominis*. $\times 1150$. (original)

1. A living trophozoite.
- 2, 3. Stained trophozoites.

gin of the nucleus. The fifth flagellum bordering the undulating membrane also takes its origin in a blepharoplast. The line of attachment of the undulating membrane is marked by a fibril which is known as costa. Unlike the flagellates already described, *Trichomonas hominis* has an endoskeleton, the axostyle, which is colorless or only faintly stained so that it appears a clear median line. The posterior portion of the axostyle usually extends beyond the body surface. The cytostome is a clear crescentic area along the side of the nucleus opposite the undulating membrane. The body cytoplasm is granulated or alveolated, and often contains bacteria in food vacuoles. Some observers noticed erythrocytes in this flagellate in bloody

faeces or in culture media, but there is no evidence to show that the flagellate ingests erythrocytes still in tissues.

This flagellate has not yet been observed in encysted condition. What were considered cysts years ago, are now known to be *Blastocystis hominis* (p. 69). Transmission is obviously by the trophozoites, some of which have been shown to withstand the gastric digestion and pass into the small intestine alive.

6. *Trichomonas elongata* Steinberg 1862

Synonym: *T. buccalis* Goodey 1917

T. tenax (O. F. Müller)

This flagellate is found in the human mouth, especially in tartar, and in pyorrhoeic sockets. It has also been observed in the sputum and pus of tonsils. Morphologically it is similar to *T. hominis*, and therefore description given for the latter will apply for the present species also. Whether these two species and *T. vaginalis* (p. 108) are identical or not, is still unknown, although some of the recent observations seem to indicate that *T. hominis* and *T. vaginalis* are physiologically distinct species. As in *T. hominis*, *T. elongata* is known only in the trophic stage. Transmission is apparently by the trophozoites which are transferred in food or water or by direct contact to another person.

7. *Giardia intestinalis* (Lambl 1859)

Synonym: *G. lamblia* Stiles 1916

This is the most conspicuous flagellate of the human intestine and seems to be the commonest one. It lives in the duodenum and other parts of the small intestine. In the

diarrhoeic faeces, both the trophozoite and cyst occur, but in formed faeces only cysts are present. In severe cases of infection with this flagellate, an enormous number of trophozoites appear to lie attached to the mucous membrane of the duodenum so that there may occur disturbances in the affected portion of the intestine. In some cases, the flagellate has been reported from the gall bladder. But there is no definite evidence that it destroys the intestinal epithelium.

Trophozoites

1. *Living specimens.* While the flagella lash actively, the organism progresses a little forward with a sidewise rocking motion. It is broadly pyriform (Fig. 11, 1), and about 9-20 μ long by 5-10 μ broad. The anterior end is broadly rounded and the posterior part tapers into a usually upturned sharp point. Seen from side, one (dorsal) side is convex, while the other (ventral) side is flat or slightly concave (Fig. 11, 2). The anterior half of the ventral side is concave and acts as a sucking disc for attachment of the organism to the intestinal epithelium. The pellicle appears delicate, but the body form changes little, except the contraction and expansion of the sucking disc and bending of the posterior prolongation. The body cytoplasm is hyaline and seldom contains any solid food particles. The four pairs of flagella which in actively moving individuals cannot be seen without a dark field condenser, lash continuously. They may however be seen in less active individuals. Lugol's solution brings them out fairly distinctly and at the same time the two nuclei may

become clearly noticeable near the center of the sucking disc.

2. *Stained specimens.* The bilateral symmetry of the flagellate is clearly revealed (Fig. 11, 3, 4). Along the median line of body there are seen two parallel rods running

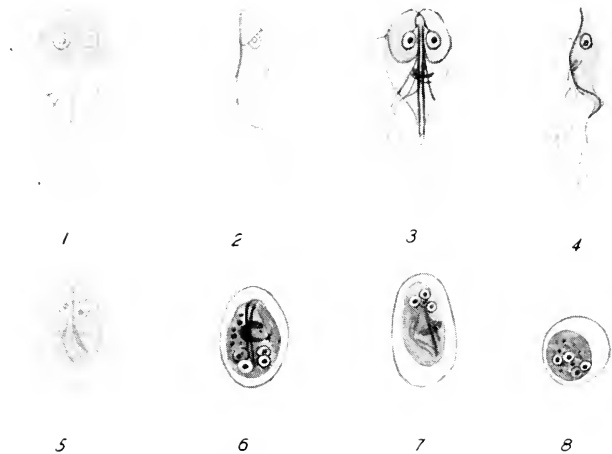

FIG. 11. *Giardia intestinalis*. $\times 1150$. (original)

- 1, 2. Living trophozoites in front and side views.
- 3, 4. Stained trophozoites in front and side views.
- 5. A fresh cyst.
- 6, 7. Stained cysts.
- 8. A stained cyst in an end view.

lengthwise. These are axostyles. Near the anterior end of the axostyles, there is an ovoid nucleus on either side. The two nuclei are similar in size and for the most part in structure. The nuclear membrane is comparatively thick and there is ordinarily one endosome in the center of the nucleus. There is sometimes present a deeply staining rod-

like body lying across the axostyles near the posterior third of the body. The four pairs of flagella are usually arranged in the following manner: The anterior pair are inserted in the blepharoplasts located near the anterior end of the axostyles, cross each other near the anterior tip of body, follow the antero-lateral margin of the sucking disc, and become free flagella. The second pair originate in the anterior part of the axostyles, travel backward along the latter structure, and become divergent by following partly the inner posterior margin of the sucking disc, leaving the body about one-third from the posterior end. The third (ventral) pair are thicker than others, and originate in the axostyles at points behind the disc, remaining free throughout. The fourth (caudal) pair arise from the posterior tips of the axostyles.

Cysts

1. *Living specimens.* The cyst (Fig. 11, 5) is ovoid in form and refractile. It measures 8-14 μ by 6-10 μ . The cyst wall is thin, but distinctive, and there is ordinarily a narrow space between it and the inner protoplasmic mass. Two or four rings and fibrils may be faintly seen. They are the nuclei, axostyles, fibrils of sucking disc, and some of the flagella. With Lugol's, these structures are more clearly visible.

2. *Stained specimens.* In stained cysts (Fig. 11, 6-8), the cyst wall is distinctly visible. Separated from it, is a granulated ovoid body of the flagellate. A young cyst contains two nuclei, each of which divides once, so that an older and mature cyst is tetranucleate. The axostyles, fibrils, flagella, are usually stained conspicuously.

DIFFERENTIAL DIAGNOSIS OF INTESTINAL FLAGELLATES.

| | <i>Retortamonas intestinalis</i> | <i>Enteromonas hominis</i> | <i>Tricomonas intestinalis</i> | <i>Chilomastix mesnili</i> | <i>Trichomonas hominis</i> | <i>Giardia intestinalis</i> |
|------------------------|--|--|--|---|---|---|
| Trophozoite | | | | | | |
| 1. In life or in Lugol | 2 flagella | 3 flagella | 1 posterior, 3 anterior flagella | 3 anterior flagella; 1 cyto-stomal flagellum | 4 anterior flagella; 1 flagellum along border of undulating membrane | 8 flagella in 4 pairs |
| 2. Stained specimens | Ovoid; 4-9 μ by 3-4 μ ; nucleus with an endosome, surrounded by chromatin granules; a few bacteria; 2 flagella | Rounded; 4-6 μ long; nucleus with a large endosome | Pyriform; 4-10 μ long; nucleus with a large endosome | Pyriform; 5-20 μ long; large mouth near anterior end with a short flagellum; bacteria in food vacuole | Pyriform; 5-20 μ long; nucleus oval with an endosome; axostyle; undulating membrane; cyto-stome small; bacteria | Pyriform; 9-20 μ long; 2 nuclei; 2 axostyles; without bacteria in food vacuoles |
| Cyst | | | | | | |
| 1. In life | Pyriform; 4.5-7 μ long | Cyst unknown | Ovoid; 6-8 μ long; with a few granules | Pyriform; 7-10 μ long; a few granules | Cyst unknown | Ovoid; 8-14 μ long; faint nuclear rings |
| 2. Stained specimens | A vesicular nucleus; a looped fibril | — | 1, 2, or 4 nuclei | A prominent nucleus, with eccentric chromatin block on membrane; 2 cyto-stomal fibrils with a short flagellum | — | 2 or 4 nuclei; axostyles; fibrils |

Chapter 4

Protozoa parasitic in the digestive tract (continued)

Sporozoa

1. *Isospora hominis* (Rivolta 1878)

THIS is the sole coccidian parasite of man, and occurs in the faeces in the oocyst stage. Judging from the developmental cycle of other species parasitic in various mammals, it is assumed that the organism undergoes schizogony as well as sporogony in the epithelial cells of the small intestine, thus destroying host's intestinal cells.

Oocysts

The oocyst (Fig. 12, 1-4) is fusiform in general outline, but as a rule asymmetrically drawn out at the two extremities. One end may be bluntly pointed, while the other often truncated. It is 20-33 μ long by 10-16 μ wide. The wall is composed of two membranes and is remarkably resistant to fixatives and stains, and therefore it can be far more satisfactorily studied in fresh or unstained conditions than in a stained smear. When freshly passed, the contents either fill up the oocyst completely (Fig. 12, 1) or more often appear as a spherical mass whose diameter coincides with the inner width of the cyst wall (Fig. 12, 2). The protoplasm is filled with refractile granules of various dimensions, among which the nucleus may appear as a clear granule-free area. If a portion of the faeces contain-

ing such oocysts is kept in a covered container at room temperature, the spore formation is completed within the oocyst in about 48 hours. At the end of the first day, the oocyst contents divide into two sporoblasts (Fig. 12, 3) and by the end of another day each sporoblast develops into a spore, measuring 10-16 μ long by 7-10 μ broad (Fig. 12, 4). Each spore contains four sporozoites and residual

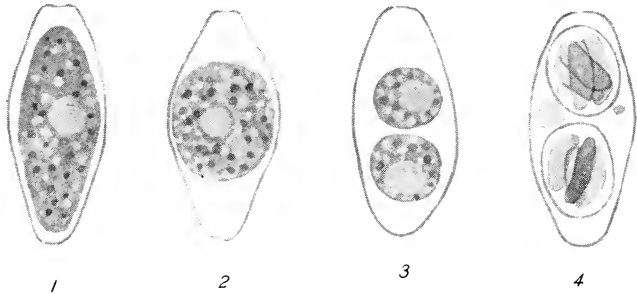


FIG. 12. *Isospora hominis*, unstained. $\times 1150$. (original)

1. A young oocyst.
2. An oocyst in which the protoplasmic mass has contracted.
3. An oocyst with two sporoblasts, one of which shows the division of contents.
4. A mature oocyst with two tetrazoic spores.

masses. Further changes would take place when the oocyst finds its way into the human intestine in contaminated food or water.

This coccidian has been observed in Europe, North and South America, Africa, and Asia, but appears not to be of common occurrence. It is a cytozoic parasite in the intestinal epithelium and may be considered as pathogenic. However, no definite information on the effect (coccidiosis) of this organism upon human host is available except

that of Connal (1922) who described the course of an accidental oral infection by viable mature oocysts, as follows: The incubation period was about six days, the onset sudden, and the duration over a month. The cure was spontaneous. The symptoms were diarrhoea, abdominal discomfort, flatulence, lassitude, and loss of weight. During the first three weeks of the illness no oocysts were found, but then oocysts appeared in the faeces for nine days. On the 10th, they were not seen, but reappeared on the 11th and 12th days, after which they were not found again. The acute signs of illness abated within one week of the finding of the oocysts. The faeces contained a large amount of undigested material, particularly fat which gave it a thick oily consistency, showing signs of slow gaseous formation. Although *Isospora hominis* is considered pathogenic to man in some cases, it appears to bring about no lasting disturbances in the majority of cases.

Ciliata

1. *Balantidium coli* (Malmsten 1857)

This ciliate lives in the lumen as well as the wall of the colon and caecum, and is a pathogenic parasite. It has a wide geographical distribution, having been reported from Europe, Asia, Africa, and South and North America. In the United States a number of infections have been reported in recent years. But in the Philippine Islands more cases perhaps have been reported than anywhere else. *Balantidium coli* occurs more often in persons who come in contact with the pig in which it is a common parasite. Chimpanzee is also host to this ciliate. A heavy infection with this organism brings about a chronic dysentery. Dysenteric

or diarrhoeic faeces contains the trophozoites and occasionally cysts, but the formed faeces cysts only. Man becomes infected with the ciliate by taking in viable cysts through mouth.

Trophozoites

1. *Living specimens.* The large protozoan (Fig. 13, 1) is ovoid in form. The entire body is covered by numerous slightly obliquely longitudinal rows of cilia by means of which the organism swims about actively. Its size varies considerably, but the average specimens are 48-80 μ long by 30-60 μ broad. In slowly moving specimens, a short narrow peristome may be seen near the anterior end, which is lined by somewhat coarser cilia. The cytostome is located at its posterior end and is continuous with the cytopharynx through which solid food particles are taken in. The food particles are of various kinds, including the host's intestinal cells, erythrocytes, and leucocytes. Faecal debris of various types which occur abundantly in the gut lumen, are also ingested. The food vacuoles are found in various parts of the body. The cytoplasm is granulated. Near the posterior tip of the body, there is a narrow slit, the cytopyge, through which indigestible solid matter is thrown out. Unlike the other groups of protozoa already mentioned, this ciliate possesses contractile vacuoles, one near the center of the body and the other near the cytopyge. There are two nuclei, of which the large macronucleus is usually visible as a refractile sausage-shaped body.

2. *Stained specimens.* In the stained individuals (Fig. 13, 2) the structures seen indistinctly in life, may be clearly visible. The macronucleus is stained black and conspicu-

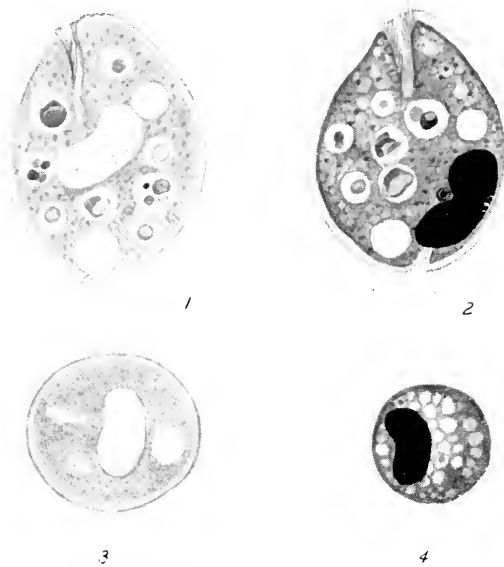


FIG. 13. *Balantidium coli*. $\times 530$. (original)

1. A living trophozoite.
2. A stained trophozoite.
3. A fresh cyst.
4. A stained cyst.

ous. The micronucleus may also be seen. Food particles of different kinds are stained in different tones.

Cysts

1. *Living specimens*. The cysts (Fig. 13, 3) are rounded or ovoid and appear slightly yellowish or greenish in color. They are about 40-60 μ in diameter. The wall is composed of two membranes. In a newly formed cyst, the ciliate may be seen actively revolving inside the wall, with the posterior contractile vacuole contracting rhythmically.

cally. In older cysts, the movement ceases. The protoplasm of the cyst is hyaline, but granulated and does not usually contain any solid food particles. The macronucleus, peristome and a contractile vacuole are often noticeable in the cyst.

2. *Stained specimens.* Not much advantage is obtained by staining cysts (Fig. 13, 4). The macronucleus appears to be the most conspicuous structure. Two individuals may occasionally encyst together.

Chapter 5

Technique for detection and identification of protozoa parasitic in the digestive tract

THE DETECTION and identification of the protozoa inhabiting the digestive tract are done under ordinary circumstances by examination of the faecal matter.

Collection of material

Natural movement should be collected. Do not use oily purgatives in obtaining faecal specimens, as they make the microscopical examination extremely difficult by the presence of numerous oil droplets in the microscopic field. The receptacle must be thoroughly cleaned and dry, and provided with a cover. The urine or water must be excluded completely. Avoid also using antiseptics for cleaning the container. And if they are used, the container should be cleaned and dried completely. The faeces must be examined as soon as possible, since the active trophozoites degenerate quickly once outside the human intestine. If dysenteric or diarrhoeic faeces are to be examined, they must not be older than one hour or two. In case this is not possible, wrap the container with a woolen cloth while transporting and keep it in an incubator at 37°C. The organisms may live for several hours. Care should however be exercised during the microscopical examination, since there unavoidably will be present a large num-

ber of sluggishly moving individuals as well as degenerating ones.

The faecal specimen should be quickly examined with the naked eye. If it is formed, it should be examined mainly for the encysted form. If mucus, pus, or blood is present in the specimen, examine it for active trophozoites. In diarrhoeic or dysenteric faeces, one should look for trophozoites and occasional cysts.

Microscopical examination

Microscopical examination of the faecal matter is conducted as far as possible on fresh material, but in making out certain body structures which enable one to identify the protozoan under observation, permanent preparations are also necessary.

The microscopic slides of standard size, 3" by 1", should be of white glass and preferably thin, about 0.75 mm. thick (No. 1). For dark field illumination thin slides are essential. No. 1 cover-glasses should only be used for both fresh and permanent preparations. They are about 0.13-0.17 mm. thick. The most convenient size is about $\frac{3}{8}$ " square covers, which are preferred to circular ones. The slides and cover-glasses must be cleaned thoroughly before being used. Immerse them in a concentric mineral acid (nitric acid is best fitted) for about 10 minutes. Pour off the acid, wash the slides and covers for about 10 minutes in running water, rinse in distilled water, and keep them in 90-95% alcohol. When needed they are dried one by one with clean cheesecloth. Handle slides and covers with a pair of forceps. If thumb and fingers are used, hold them by edges or ends.

Fresh preparation

If the faeces is dysenteric, a small portion is placed by a toothpick or platinum loop on a slide and covered with a cover-glass. Before placing the cover, all large particles must be removed so that the smear preparation will be uniformly thin. If the faeces is diarrhoeic, then the smear is made in a similar manner. But if the faecal specimen is semiformed or formed, a small drop of warm (37° C.) 0.85% sodium chloride solution which has been boiled beforehand, is first placed on the slide, and by means of a toothpick, a small portion of the faeces, particularly mucus, pus, or blood, is emulsified in it and a cover is placed over the whole. The smear should not be too thick or too thin for a satisfactory observation. If the smear is too thick, it will be impossible to distinguish objects clearly, and on the other hand, if it is too thin, there will unavoidably be a great deal of time lost in detecting widely scattered protozoa. The optimum thickness of the smear is one through which the print on this page can be read.

Place the preparation on the stage of the microscope and examine with a moderately low power objective, by moving the slide systematically by hand or by a mechanical stage. Recognize the active trophozoites by the refractility and the change in body form or movement, and in case of cysts by their form and size. The determination of the size of a microscopical object can be done quickly and easily, if ocular micrometer divisions have been calculated in combination with different objectives. When trophozoites or cysts are recognized, examine them one by one under a high dry objective, and identify them. If necessary, an

oil immersion objective should be used to make out finer details.

The objectives used depend upon the training and experience of the one who carries on the examination. A low power objective must be used as far as possible. The lower the magnification, the brighter and the larger the field. The success of examination depends almost entirely on continued practice, since the faecal matter contains myriads of objects which may resemble protozoa that themselves may quite often be at various stages of degeneration and disintegration. Experienced observers can recognize most of the protozoa described in the preceding pages easily in a low power objective field.

It is important to examine the fresh preparations carefully and thoroughly. If no protozoa here mentioned are found, make several more preparations from different parts of the specimen and examine. Often it is necessary to obtain and examine specimens on several successive days from a person, before a positive or negative diagnosis can clearly be established. Remember demonstration of either the trophozoite or the cyst is absolutely necessary for a positive diagnosis of a protozoan parasite.

The flagella of the actively moving flagellates are difficult to recognize in an ordinary bright field, but the peculiar movement in combination with the finding of certain structures such as cytostome, undulating membrane, etc., will suggest that the organism is flagellated. In order to see actively moving flagella, a dark field condensor is necessary. But when this is not possible, treat the specimens with Lugol's solution (p. 57).

The cysts are as a rule distributed throughout the formed

faeces, and therefore are difficult to detect in small portions of the naturally voided faeces. Flecks of mucus in the fluid faeces obtained by use of a saline purge may contain more cysts than naturally passed one. In the ordinary formed faeces, the following concentration method is frequently advantageous in revealing more cysts. Emulsify thoroughly a small mass of faeces, about the size of a lump of sugar in a mortar by adding a small amount of once-boiled tap water. Add to it about 500 cc. of water and pour the whole emulsion into a glass cylinder and let it stand for about 15 minutes. Remove the scum floating on the surface and draw off the turbid fluid into another cylinder, leaving the sediment and a little fluid above it untouched. The majority of cysts are suspended in the drawn-out part of the emulsion. If a centrifuge is available, centrifugalize the fluid, pour off the supernatant fluid and add water. Centrifugalize again. Repeat this three or four times until the supernatant fluid is clear. The deposit will contain many cysts which now can be examined and identified. If no centrifuge is on hand, let the glass cylinder stand for about 20 hours and examine the sediment for cysts. The cysts will be more numerous than in untreated specimen.

The cysts are frequently more satisfactorily identified if one or two drops of Lugol's solution is well mixed with the faecal matter on a slide. This solution is composed of potassium iodide 1.5 grams, water 25 cc., and iodine 1 gram. As the solution deteriorates easily, fresh solution should be prepared about every two weeks. Lugol's solution of course kills all protozoa in the preparation. After about 5 minutes, examine the smear. The flagella become

stained, the nuclei are much more clearly visible, and glycogen bodies are stained reddish brown, while the chromatoid body remains unstained.

Permanent preparation

Permanent preparations are employed to aid in identification of living protozoa, and not as substitutes for fresh preparations. Smears are made on cover-glasses, and not on slides as in fresh preparations; mark with India ink, wax pencil, etc., the unsmear side of the covers. Instead of trying to place all data, simply write the number, and enter on a record card all necessary data, such as the name of the person, date, condition of the specimen, fixative, stain, and any other remarks.

The smears should be left horizontally with the smeared side up for a short while. Place a jar above them to exclude dust, flies, etc. The purpose of leaving the slide for a few minutes is not to dry the smear, but to allow the active trophozoites to become attached to the cover by pseudopodia or flagella and at the same time to allow the fluid to evaporate a little. Smears made from dysenteric or fluid faeces should be fixed almost immediately, and those made from diarrhoeic or formed faeces emulsified in warm salt solution should be left for a few minutes. In any case, do not let the smear dry, except a narrow peripheral zone.

The smears are next to be fixed. For fixation, Schaudinn's fixative is most widely used and advocated here exclusively, though any good histological or cytological fixatives will do. Schaudinn's fluid is made up as follows: Mercuric chloride (HgCl_2 or corrosive sublimate) 6-7% (cold saturated) aqueous solution 6 cc., 95% or absolute alcohol 3 cc.,

and glacial acetic acid about 4 drops. The first two can be kept mixed without deterioration, but the glacial acetic acid should be added just before fixation. Fix at room temperature. The fixative is put in a Petri (preferably square) dish or a wide stendor dish. The smear is gently dropped on the fixative with the smeared surface facing downward. With a little practice, air bubbles can be avoided and make the smear float on the surface of the fixative. After about one minute, turn the smear around and let it stay on the bottom of the container for 5 more minutes. If the smear is too thick, it will not float on the fixation. A thin coat of vaseline on the unsmeared side will allow the cover to float. About six cover-glass smears can be fixed in an ordinary Petri dish simultaneously.

The cover-glasses are now transferred into a coplin jar or better Columbia staining jar for cover-glasses, containing 50% alcohol for 10 minutes, and then two changes for 10 minutes each. Transfer next the smears into a jar containing 30% alcohol for 5 minutes, and then into a jar with water which is now placed under gently running tap water for 15 minutes. Rinse the smears in distilled water. They are ready for staining.

The most dependable staining which is widely used for staining intestinal protozoa is Heidenhain's iron haematoxylin. It requires a mordant, ammonio-ferric sulphate (iron alum) and a dye, haematoxylin. Crystals of iron alum become yellow and opaque very easily; select clear violet crystals and prepare 2% watery solution which will keep for a long time. 0.5-1% haematoxylin must be well "ripe." The most convenient way of preparing it is to make 10% absolute alcohol solution. By diluting this stock solution

with distilled water, prepare 0.5-1% slightly alcoholic solution which will be ready for immediate use and which can be used repeatedly.

The smears are now placed vertically in iron alum solution and left in it for 1-3 hours. Wash with running water for 5 minutes and rinse in distilled water. Immerse the smears in haematoxylin solution for 1-3 hours. Smears are now washed for 5 minutes in running water and placed face up in a Petri dish containing a weak (0.25%) iron alum solution for decolorization which must be controlled under a compound microscope. If all smears are of uniformly the same thickness and meant for the same protozoa, one of the smears may be watched continuously. If the smear contains, for example, the trophozoites of *Entamoeba histolytica*, the whole amoeba will look black at the beginning, but the cytoplasm becomes gradually decolorized, leaving the nucleus and the cytoplasmic inclusions still dark. As the process is continued, further decolorization takes place, and finally the nucleus may appear as a ring. Often it is necessary to control the last stage of the process under a high dry objective. For this purpose, flood the well in a depression slide with the iron alum solution and place a representative smear over it with the smeared side facing downward. Such a smear could be observed with a high dry objective and will be better controlled. Optimum staining will be attained by repeated practice.

When the decolorization is completed, the smears are washed gently in running water for about 15 minutes in order to insure the complete washing of the iron alum. Rinse in distilled water and transfer to 30%, 50%, and 70%

alcohol in order for 5 minutes each. Then if counter-staining is desired, dip in 1% eosin in 95% alcohol for a few seconds, and then transfer the smears to two changes of plain 95% alcohol, two changes of absolute alcohol, and finally two changes of xylol. The smears can now be mounted one by one in a drop of Canada balsam-xylol which is placed in the center of a slide. The technique involved is simple and with a little practice, satisfactory smears can be prepared. Before examining the slides under the microscope they should be placed in a drying oven at about 60°C. for a little while. As in the case of fresh smears, microscopical examination of permanent preparation should be done as far as possible under low magnifications.

Chapter 6

Coprozoic protozoa and objects present in the faeces

Coprozoic protozoa

NUMEROUS free-living protozoa which inhabit waters containing abundance of organic matter or decomposing organic matter, may sometimes be found in stale faeces. These have been collectively called coprozoic protozoa. With food or water, the cysts of these protozoa may enter the human mouth and pass through the intestine unharmed. In the old faeces, they excyst and the trophozoites may develop in a larger number. Furthermore, the trophozoites or cysts of certain free-living protozoa which live in fresh, brackish, or salt water, may be introduced into the faeces after it has been voided and if conditions are favorable, numerous trophozoites may appear in it. The coprozoic protozoa are, of course, not seen in the trophic stage in freshly voided faeces, but develop in old specimens. Therefore, if old faeces contains actively moving protozoa which were not present in the specimen when examined fresh, they are most certainly coprozoic and not parasitic protozoa. But when the faecal material is not examined fresh, and examined a few to several days later, one cannot tell without careful examination if the protozoan observed is parasitic or coprozoic.

Coprozoic protozoa belong to all of the three major groups, Sarcodina, Flagellata, and Ciliata. Here a few forms will be mentioned.

1. *Hartmannella hyalina* (Dangeard 1900)

Trophozoites. It is an actively amoeboid organism with flattened pseudopodia (Fig. 14, 1), and is 5-20 μ in diameter. The cytoplasm is well differentiated. The endoplasm contains a contractile vacuole and bacteria taken in as food. When stained, the nucleus, 3-4 μ in diameter, becomes visible. It is composed of a distinct membrane, a large endosome, and chromatin granules distributed in the nucleoplasm.

Cysts. Spherical; 10-15 μ in diameter (Fig. 14, 2). The inner cyst wall is thin, but the outer one is thick, brownish, and much wrinkled. The cyst wall has no pores. It contains a single nucleus.

2. *Dimastigamoeba gruberi* (Schardinger 1899)

This amoeba has both amoeboid and flagellate stages (diphasic). It is ordinarily seen in amoeboid form, but when the medium becomes more fluid, it changes into flagellate form. Cysts also occur.

Trophozoites. 1. Amoeboid stage. The active amoeba (Fig. 14, 3) forms a few broad lobopodia which are composed mostly of ectoplasm. In the endoplasm of a living amoeba can be seen a vesicular nucleus with a large endosome, a contractile vacuole, and bacteria taken in as food. The amoeba measures about 10-20 μ in length. When stained, the nucleus (about 3-4 μ in diameter) shows a central endosome and scattered chromatin granules between it and the membrane.

2. Flagellate stage. When distilled water is added to the medium in which amoeboid forms occur, the latter become flagellated (Fig. 14, 4). The body is ovoid to pyri-

form, and measures 10-30 μ long. There are two equally long flagella at the narrow end, near which is located a nucleus. A contractile vacuole is present near the posterior end. Stained individuals show that the flagella arise from points just in front of the nucleus.

Cysts. The cyst (Fig. 14, 5) is spherical and about 7-14 μ in diameter. The cyst wall may show 3-8 small pores. The nucleus may be faintly seen near the center. When stained, the cyst wall is seen double-layered. The pores are surrounded by slight thickenings of the wall. The majority of cysts are uninucleate.

3. *Bodo caudatus* (Dujardin 1841)

This is a small biflagellated organism which is very common in stagnant water and moist soil.

Trophozoites. Actively motile; body polymorphic, but usually elongate. About 10-20 μ long (Fig. 14, 6, 7). Its anterior end is bluntly pointed, while its posterior end is attenuated. The body is somewhat compressed. There are a vesicular nucleus with a large endosome near the center of body, and bacteria in food vacuoles. Two flagella arise in the anterior end. The anterior flagellum is short, but the trailing flagellum is long. A small slit, the cytostome, and a small contractile vacuole are located near the flagellated end. When fixed and stained, the body becomes more rounded. The nucleus contains a large central endosome and there are seen radiating strands between the latter and the membrane. The anterior flagellum is about the body length, but the posterior one is about twice the body length. Near the blepharoplasts there is a large rounded parabasal body.

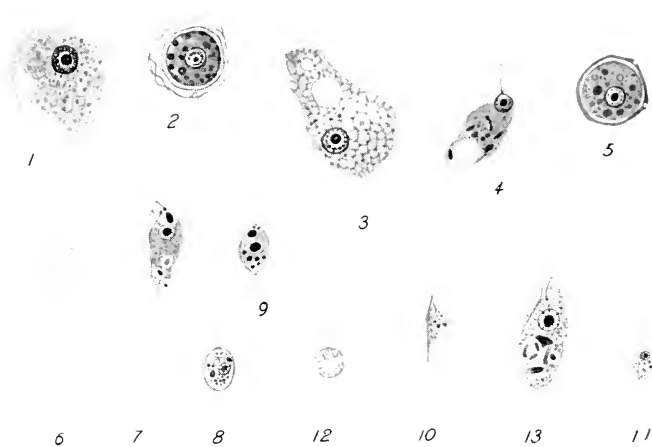

FIG. 14. Coprozoic protozoa. $\times 1000$ (modified after Dobell and O'Connor).

- 1, 2. *Hartmannella hyalina*.
 1. A stained trophozoite.
 2. A stained cyst.
- 3-5. *Dimastigamoeba gruberi*.
 3. A stained amoeboid form.
 4. A stained flagellate form.
 5. A stained cyst.
- 6-8. *Bodo caudatus*.
 6. A living trophozoite.
 7. A stained trophozoite.
 8. A stained cyst.
9. A stained trophozoite of *Bodo cdax*.
- 10-12. *Cercomonas longicauda*.
 10. A living trophozoite.
 11. A stained trophozoite.
 12. A fresh cyst.
13. A stained trophozoite of *Copromonas subtilis*.

Cysts. The cyst (Fig. 14, 8) is oval, surrounded by a thin wall, and about $5-7\mu$ in diameter. In the granulated cytoplasm are found a nucleus and a parabasal body.

Somewhat similar to this is *Bodo edax* Klebs 1892 (Fig. 14, ⁹) which is less frequently seen in faeces. The trophozoite is more stumpy and a little smaller, being about 6-15 μ long. The body is much more rounded in cross-section. The two flagella are nearly equal in length and both are longer than body. Cysts resemble closely those of *B. caudatus*.

4. *Cercomonas longicauda* Dujardin 1841

Trophozoites. Body plastic and amoeboid, engulfing bacteria by pseudopodia (Fig. 14, ¹⁰). About 5-10 μ by 5-7 μ . The nucleus is located near the flagellated anterior end, pyriform in shape, and contains a central endosome. Of the two flagella, the anterior one is about 3-4 times the body length, but the posterior flagellum adheres to body surface and extends a little beyond the body (Fig. 14, ¹¹).

Cysts. Spherical, about 4-6 μ in diameter. Uninucleate (Fig. 14, ¹²). Coarse granules are often grouped around the nucleus.

5. *Copromonas subtilis* Dobell 1908

Trophozoites. Body elongated pyriform (Fig. 14, ¹³), the pellicle is comparatively thick so that there is little change of body form. It is 7-20 μ long. The anterior end is bluntly pointed, while the posterior end is rounded. A single flagellum takes its origin in the anterior end, near which are seen a contractile vacuole and a reservoir. The vesicular nucleus with a large endosome is near the center of body. At the anterior end, the cytostome opens and is continuous with a long tubular cytopharynx. The cytoplasm usually contains bacteria.

Cysts. Thinly enveloped cysts are rounded or oval in form, and measure 7-8 μ in diameter. They are uninucleate.

Objects present in the faeces

An enormous number of different kinds of objects occur in the faecal matter, some of which may resemble superficially intestinal protozoa and thus may be mistaken for them. These objects are derived from foods, microorganisms present in drinking or cooking water, or the digestive tract itself. To deal with all of them is beyond the scope of the present manual. The best information will be obtained by frequent examinations of one's own faeces. Here only a few examples will be mentioned.

Neutral fats. Fats often occur as spherical bodies of various sizes. They are highly refractile and may resemble superficially cysts of amoebae. However, they do not have any wall and do not show the differentiation of the contents of a cyst. A little care will easily allow one to realize the real nature of fats. They stain with sudan III. In stained smears, the fat droplets are usually dissolved and do not appear.

Coccidia. Coccidia are common parasites of animals that are important sources of human foods, and consequently are often found in the faeces. The oocysts of *Eimeria sardinae* Thélohan (Fig. 15, 1) parasitic in the testis of sardines, mackerel, herrings, etc., and of *E. clupearum* Thélohan (Fig. 15, 2), a parasite of the liver of mackerel, herrings, etc., are sometimes passed in human faeces. Both oocysts are spherical, but the former are 33-55 μ in diameter and contain four fusiform spores, while the latter measure about 20 μ in diameter and contain four oval spores. The

digestive tracts of various birds are often infected by *Eimeria* and *Isospora*. English sparrows are frequently hosts for *Isospora lacazei* Labbé (Fig. 15, 3). The oocysts are ovoid and measure 18.5-30 μ long. They contain two spores when mature as in the case of *I. hominis* (p. 47). Drinking

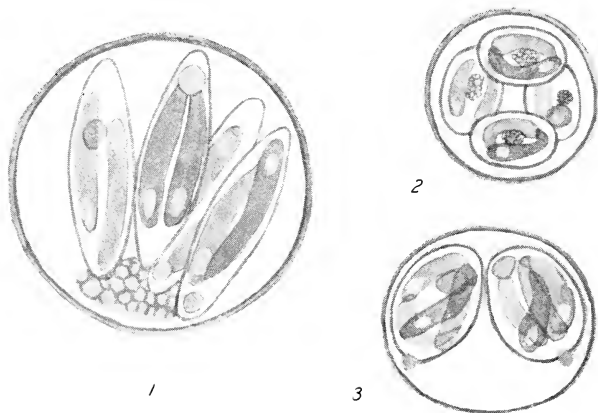


FIG. 15. Coccidian oocysts found in the stool. $\times 1150$ (1, 2, modified after Thomson and Robertson; 3, original).

1. A fresh mature oocyst of *Eimeria sardinae*.
2. A fresh mature oocyst of *E. clupearum*.
3. A fresh mature oocyst of *Isospora lacazei*.

water contaminated with the droppings of infected birds may introduce the oocysts in the faeces.

Yeasts and molds. These are exceedingly common in the faeces. Yeasts are spherical, ovoid or ellipsoidal bodies and measure about 5-15 μ in diameter. Surrounded by a distinct membrane, the cytoplasm contains one or more refractile granules and a vacuole. Yeasts must not be confused with the cysts of *Endolimax nana*. Mold spores sometimes simulate also protozoan cysts under low power ob-

jective, but the walls are colored and sculptured in various ways.

Sphaerita and Nucleophaga. These vegetable organisms are occasionally found parasitic in intestinal amoebae, especially coelozoic forms such as *Entamoeba coli*, *Iodamoeba bütschlii*, and *Endolimax nana*. *Sphaerita* (Dangeard 1895) occurs in the host's cytoplasm as small spherical bodies which are made up of compactly packed spores (Figs. 2, 3 and 16, 1). Because of high refractility, they are very conspicuously noticed in living amoebae. The spheroidal spores are 0.5-1 μ in diameter. When stained with Heidenhain's iron haematoxylin, they are stained black, but when differentiated, the spores appear to be made up of a deeply staining cortical layer and a less deeply staining core. The spherical group of spores is sometimes about the size of the nucleus of the infected amoeba. *Nucleophaga* (Dangeard, 1895) is a very closely related form, but apparently develops in the nucleus of the host amoeba (Fig. 16, 2). The spores appear as dark-stained granules and therefore have occasionally been mistaken for chromatin granules of the host nucleus. When heavily infected, the host nucleus becomes hypertrophied and completely disintegrates.

Blastocystis hominis. This is an extremely common plant organism, considered to be a fungus, occurring in human and various animal excrements. It is as a rule spherical in shape (Fig. 16, 3-5) and is about 5-25 μ in diameter, the commonest forms being about 8-12 μ . Within a very thin membrane, there is a narrow peripheral cytoplasmic layer in which 1-2 nuclei and several refractile granules are present. This cytoplasmic ring encloses a

large homogeneous body which is not iodophilous, but when fixed and stained is more or less eosinophilous. In some individuals, the cytoplasmic ring may be thick and the enclosed body very small. This organism has often been confused with the cysts of intestinal protozoa. Divid-

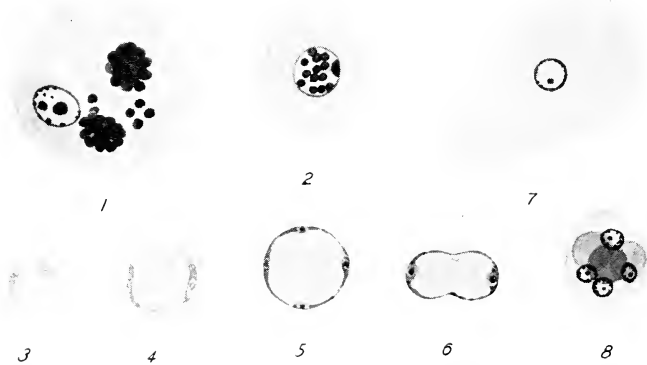


FIG. 16. 1. Sphaerita in a stained trophozoite of *Entamoeba coli*.
 2. Nucleophaga in a stained trophozoite of *Iodamoeba bütschlii*.
 3, 4. Fresh specimens of *Blastocystis hominis*.
 5, 6. Stained specimens of *Blastocystis hominis*.
 7. An epithelial cell found in faeces.
 8. A polymorphonuclear leucocyte with three ingested erythrocytes.
 All $\times 1150$ (1, after Nöller; 2, after Brug; 3-8, original).

ing forms may appear peanut-shaped (Fig. 16, 6). It is considered as a harmless organism.

Helminth eggs. In faeces of persons infected by various helminth parasites, eggs of the worms occur commonly. Some of these eggs, especially of nematodes, may resemble superficially the oocysts of *Isospora hominis* (p. 47-49) in general form and appearance, but can easily be distin-

guished, since the worm eggs are much larger than the coccidian oocyst. Eggs of the nematodes, *Heterophyes heterophyes* and *Clonorchis sinensis* measure about 30μ long, thus approximating the size of the oocyst of *Isospora hominis*. But these eggs are flask-shaped, the shell is thick and yellowish, and the truncate end is operculated.

Algae. Some of the algae which abound in fresh, brackish, and marine water, are occasionally found in the faeces. They are covered by a conspicuous siliceous shell which is variously sculptured and the body is usually flattened.

Cellular elements of the intestine. In the faeces there occur an enormous number of various cells derived from the intestinal wall of the host. As seen in fresh smear, there may occur squamous epithelial cells in various stages of degeneration, sometimes with an irregular "amoeboid" outline and a vesicular nucleus located near the center (Fig. 16, 7). But these cells are flat as seen edgewise and the nucleus is relatively small. It should be borne in mind that no matter how closely the object may resemble an amoeba, if there is no movement, it is most probably not an amoeba. Polymorphonuclear leucocytes may contain erythrocytes and simulate *Entamoeba histolytica* (Fig. 16, 8). Do not become confused with them.

Free-living protozoa. If salt solution or distilled water used for making fresh or permanent preparations of semi-fluid or formed faeces are contaminated with free-living protozoa, the preparation will naturally show them and confusion may result. Therefore, the solution or water must be renewed frequently with boiled ones.

Chapter 7

Protozoa parasitic in the circulatory system

Flagellata

Trypanosoma

TRYPANOSOMES are slender flagellates with tapering extremities. There is a vesicular nucleus located usually near the middle of the body. The posterior end is less attenuated than the anterior end. Near the posterior end is present a small refractile body, the blepharoplast, which stains deep red with Giemsa's stain. Originating in this or a small granule located near it, there is a flagellum which follows the outer border of an undulating membrane to the opposite end and projects beyond freely. The organism nourishes itself by absorption of liquid nourishment through its body surface. It multiplies by binary fission in the human blood and gives rise to polymorphic individuals.

When a blood-sucking insect (*Glossina*, *Triatoma*, etc.) sucks the blood of a person infected with *Trypanosoma*, the latter undergoes a series of change and multiplication in its digestive tract. During this development, the blepharoplast may shift its position toward the anterior end, and the body may assume crithidia form. Finally in *Glossina* engorged with the blood containing *Trypanosoma gambiense* or *T. rhodesiense*, the flagellates enter into and continue to multiply in the salivary gland. These flies are now infectious and when they feed on a human victim, the trypanosomes enter the blood. In *Triatoma* infected by

T. cruzi, the trypanosomes appear, after undergoing a series of divisions and form changes, in small trypanosome forms in the rectum of the bug, and are voided in the faeces at the time when the latter feeds on a human host. It is believed that infection in man is established by scratching the site of the insect bite and introducing the organisms into the subcutaneous tissue.

1. *Trypanosoma gambiense* Dutton 1902

This trypanosome is confined to Africa and especially to its equatorial zone. It is the causative organism of the Gambian or Central African sleeping sickness or trypanosomiasis. It is found in the blood, lymph, and cerebrospinal fluid of the human host, and of various domestic and wild animals (reservoir hosts). The flagellate is transmitted by biting flies belonging to *Glossina*, especially *G. palpalis*, in the digestive tube of which it undergoes certain developmental changes and in the salivary glands of which the infective metacyclic trypanosomes become finally lodged for inoculation into a new host individual. The trypanosome occurs in the human body as active flagellates only.

Trypanosoma gambiense (Fig. 17) is an exceedingly active flagellate, and is hardly seen in life, although in fresh blood preparation its presence may be seen indirectly by the movement and agitation among erythrocytes under a low power objective. In routine detection, stained blood smears (p. 97-100) are used.

The body is elongate and tapers towards both ends. It is usually sinuous in general outline. There is a nucleus in the approximate center of body. Near the less attenuated

posterior end, is a blepharoplast, a small granule, in which originates a flagellum. The flagellum runs forward along the outer border of the undulating membrane which is a somewhat spiral thin expansion of the pellicle and which arises near the blepharoplast and extends to the anterior end. The active waving movements of the undulating mem-

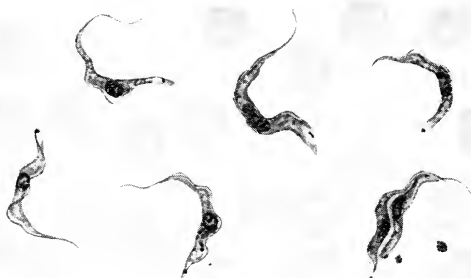


FIG. 17. *Trypanosoma gambiense* in a stained blood smear of an inoculated rat. Two individuals are in the process of division. $\times 1150$. (original)

brane aid the organism in moving about in the blood plasma. The flagellum extends beyond the membrane at the anterior end and becomes a free flagellum. The body is 15-30 μ long by 1-3 μ broad. Some are long and slender, others short and broad. Between these extremes are found intermediate forms. The long forms are those in which binary fission is taking place, while the short individuals are thought to be recently divided forms.

Thick and thin smears of peripheral blood (p. 97) should be examined. In the majority of cases, the trypanosome is very scanty and may not be found until after several smears have been examined. Some advocate the examination of

fresh blood preparation (under a cover-glass) with a low power dry objective and look for the disturbance among the erythrocytes, which may suggest the presence of the trypanosome. But absolute identification must be made on stained smears under a high power objective. Others advocate centrifugalization of the citrated blood. If lymphatic glands are enlarged, gland-puncture should be examined in stained smears. In the advanced stage of infection and also in cases where an early nervous symptom is present, cerebro-spinal fluid should be drawn out, centrifugalized and the sediments examined in stained smears. If this examination is also negative, some portion of the sediment may be inoculated intra-peritoneally into a rat or a monkey, the blood of which will reveal the trypanosomes if periodic examinations are made.

2. *Trypanosoma rhodesiense* Stephens and Fantham 1910

This trypanosome is considered the causative organism of Rhodesian or East African sleeping sickness which is more virulent than Gambian form and runs a course of only a few months. It is confined in its distribution to the southeastern coastal region of Africa.

Trypanosoma rhodesiense (Fig. 18) is indistinguishable from *T. gambiense* in human blood smears. But when inoculated into rat, the position of the nucleus shifts in a certain proportion of the individuals (usually less than 5%), toward the posterior end, near or behind the blepharoplast, together with the shortening of body.

Some investigators maintain that *T. rhodesiense* is the human strain of *T. brucei* (of cattle and game animals),

others hold that it may be a more virulent race of *T. gambiense* or transmitted by different species of *Glossina*. In nature, this trypanosome appears to be transmitted chiefly by *Glossina morsitans*.

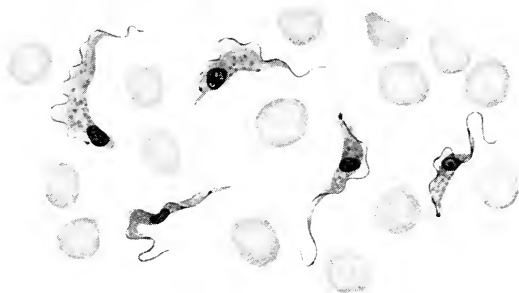


FIG. 18. *Trypanosoma rhodesiense* in a stained blood film of an inoculated rat. $\times 1150$. (original)

The method of detecting the flagellate is similar to that given for *T. gambiense*.

3. *Trypanosoma cruzi* Chagas 1909

Synonyms: *Schizotrypanum cruzi* Chagas 1909

Trypanosoma escomeli Yorke 1920

This trypanosome is the cause of Chagas' disease or South American trypanosomiasis which is mainly a children's disease, and which is widely distributed in Brazil, Argentina, Uruguay, Peru, Venezuela, Colombia, Panama, Salvador, Guatemala, and Mexico. The trypanosomes are found in the blood and the leishmania-forms (p. 78) in various tissue cells. The organism is transmitted by reduviid bugs, *Triatoma megista* and *T. infestans*, etc., in the digestive tract of which it undergoes developmental changes.

The trypanosome as seen in a stained smear of the peripheral blood, is a curved (in the form of the letter C or U) spindle-shaped organism with a sharply pointed posterior end, near which a conspicuously large ovoid blepharoplast is present (Fig. 19, 1). The organism measures



FIG. 19. *Trypanosoma cruzi*. $\times 1150$. (original)

1. Five trypanosomes seen in a very thin stained blood film of an inoculated rat.
2. Leishmania forms found in skeletal muscle cells of a patient.
3. Flagellating individuals seen in a host cell.

about 20μ in length. The nucleus is located in the middle of the body. The undulating membrane is narrow and only slightly convoluted. Both slender and short-broad forms occur. Dividing forms are usually not found in the human blood.

The trypanosome enters the tissue cell: muscles, central nervous system, bone marrow, lungs, thyroid, etc., and transforms into an ovoid body, the leishmania form (Fig. 19, 2), by discarding the flagellum and undulating membrane. Here, it undergoes repeated binary fission, and increases in number. The host cell becomes distended.

Sooner or later, each individual elongates and develops a flagellum (Fig. 19, 3) and later an undulating membrane. These young trypanosomes are set free in the blood.

Trypanosoma cruzi should be looked for in thick and thin stained blood films. In acute febrile stage, it is present in the peripheral blood. Sometimes it is necessary to centrifugalize the citrated blood and sediment to be examined in stained smears. Although the trypanosomes are ordinarily not found in the lymphatic glands, it has been reported to occur in some cases in the spinal fluid. If all results are negative, 5-10 c.c. of the blood may be inoculated into guinea pigs in which after about two weeks the trypanosomes will appear in the blood. Examination of excised muscle for leishmania forms of the trypanosome has also been used by some. Brumpt advocates to allow laboratory-bred (therefore free from *T. cruzi*) *Triatoma* to feed on the suspected subject and examining in about two weeks the digestive tract of the bugs for the flagellate.

Leishmania

The three species of *Leishmania* are morphologically alike. In human host, they are represented by small ovoid leishmania bodies. They invade various leucocytes of the reticulo-endothelial system. Each trophozoite is a small protoplasmic mass in which are found a nucleus, a blepharoplast, and sometimes a rhizoplast. All indications point to the species of sandflies (*Phlebotomus*) as the vectors. In the flies as well as in culture tubes, the leishmania bodies become enlarged and elongate, and the blepharoplast gives rise to a long flagellum, the whole assuming a leptomonad form. In the mid-gut of the sandfly, the flagellate forms

increase in number by division, and the mass population shifts to the anterior portion of the gut. By about the tenth day after feeding on the infected person, the flagellates are often lodged in the proboscis of the fly. It is assumed that these are introduced into man when the fly feeds again. Adler and Ber (1941) succeeded in producing leishmaniasis in 5 out of 8 human volunteers by bites of laboratory-bred *Phlebotomus papatasi* which were infected artificially with *Leishmania tropica*.

1. *Leishmania donovani* (Laveran and Mesnil 1903)

Synonym: *L. infantum* Nicolle 1908

This is the causative organism of Kala-azar or visceral leishmaniasis which is widely distributed in parts of Europe, Africa, and Asia. In Europe it occurs in the southern region which borders the Mediterranean Sea, such as Portugal, Spain, Italy, Malta, Greece, and southern Russia. In Africa it has been reported from Morocco, Algeria, Tunisia, Libya, Abyssinia, Sudan, Northern Kenya, Nigeria, while in Asia south-eastern area of India, north of Yangtze River in China, Turkestan, etc. The leishmania body occurs in the macrophages, mononuclear leucocytes, polymorphonuclears, etc., of the reticulo-endothelial system of various organs such as the spleen, liver, bone marrow, intestinal mucosa, lymphatic glands, etc. When the infected host cells are destroyed, the organisms will become free in the blood plasma (Fig. 20, 2).

The organism as seen in stained smears of spleen puncture, is a rounded ($1-3\mu$ in diameter) or ovoid ($2-4\mu$ by $1.5-2.5\mu$) body (Fig. 20, 1-3). Its cytoplasm is homogeneous except one or more minute vacuoles. The nucleus is a com-

paratively large rounded body, stained red with Giemsa's stain. But in ordinary films, the body may be flattened to various extents, and the nucleus also becomes flattened and is of various shapes. The blepharoplast is stained more deeply, and is an oval or elongate body, much smaller




FIG. 20. *Leishmania donovani*. $\times 1150$. (original)

- 1-3. Forms found in a stained spleen puncture film.
1. An infected polymorphonuclear leucocyte.
2. *Leishmania* bodies scattered in the blood plasma.
3. A large endothelial cell heavily infected by the organism.
- 4-6. Flagellate forms which developed in the first five days of cultivation in blood-agar medium.

than the nucleus. When the smear is deeply stained, there may be seen a short thread extending between the blepharoplast and the periphery. This is the rhizoplast. The number of parasites in a host cell varies greatly. A newly invaded host cell may show a single parasite, while host cells with 200 or more parasites are sometimes seen, this being a result of repeated binary fission. No flagellate forms occur in the human host. Dogs suffer also infection by this organism.

When citrated blood or culture tube with blood-agar (p. 10) is inoculated with *Leishmania* and incubated at 20-24°C., the leishmania bodies become elongate and the rhizoplast develops into a flagellum in about 48 hours (Fig. 20, 4-6). Thus *Leishmania* develops into leptomonad flagellate.

The transmission is most probably carried on by *Phlebotomus* spp., sandflies, in the digestive tube of which flagellates identical with the cultural forms, develop after ingestion of the blood of a suspected subject.

To detect *Leishmania donovani*, smears of peripheral blood should be made and examined (p. 97). The number of the organisms in the blood is ordinarily very small, but it is the simplest method and should be the first step to be taken. Look for the parasites in large mononuclear leucocytes. The best result is of course obtained by examining stained smears of spleen puncture. The organisms are far more numerous there than in the blood smear and the detection is easily done.

2. *Leishmania tropica* (Wright 1903)

This is the causal organism of the Oriental sore or cutaneous leishmaniasis. It has been reported from Africa (mainly regions bordering the Mediterranean Sea), Europe (Spain, Italy, France, and Greece), Asia (Syria, Palestine, Armenia, southern Russia, Iraq, Iran, Arabia, Turkestan, India, Indo-China, and China), and Australia (northern Queensland). The organism occurs in the endothelial cells in and around the cutaneous lesions, located on hands, feet, legs, face, etc.

Leishmania tropica is morphologically indistinguishable

from *L. donovani*, but some believe that it shows a wider range of form and size than the latter. In addition to rounded or ovoid forms, elongate forms are often found, and even leptomonad forms have been reported from the scrapings of lesions. This organism is also transmitted by sandflies (p. 79).

For detection of the organism, smears should be made from the lesions. If the lesion is not ulcerated, the fluid taken from it by puncture may be examined in stained smears for the intracellular parasites. If the lesion is ulcerated, material should be obtained by puncturing the margin of the ulcer, as the superficial part of the ulcer itself contains pus cells, bacteria, and abnormal forms of *Leishmania*. In case the parasites are very scanty, cultivation in blood-agar may aid the detection of the organism.

3. *Leishmania brasiliensis* Vianna 1911

This causes Espundia or South American or naso-oral leishmaniasis, which seems to be confined to South and Central America. It has been reported from Brazil, Peru, Paraguay, Argentina, Uruguay, Bolivia, Venezuela, Ecuador, Colombia, Panama, Costa Rica, and Mexico.

Its morphological characteristics are identical with those of *L. tropica*, and a number of investigators combine the two species into one. However, the lesions are mainly in the mucous membrane of the nasal passage, mouth, and other parts. Transmission is also probably carried on by sandflies as is the case with the other two species.

For detecting the organism use the method given for *L. tropica*.

Chapter 8

Protozoa parasitic in the circulatory system (continued)

Sporozoa

Plasmodium

THE SPOROZOAN parasites of the human blood are all malarial organisms and placed in the genus *Plasmodium*. Although there are certain morphological differences which characterize the different species, the general cycle of development is nearly identical. The malarial organisms of man are transmitted by female mosquitoes belonging to the genus *Anopheles*. Asexual and sexual reproduction takes place in man and mosquito respectively.

When an infected anopheline mosquito feeds on man sporozoites are introduced (Fig. 21, 1). The immediate change the sporozoites undergo is unknown. But during about six days after the bite of an infected mosquito, no parasites can be seen in the peripheral blood and quinine has no effect. Judging by what has been observed in early phase of *Plasmodium* infection in birds, it is now supposed that there probably occurs exoerythrocytic development of the organism. Sooner or later, however, the organisms enter erythrocytes (Fig. 21, 2) and become schizonts (Fig. 21, 3). At the beginning the schizonts are ring-form. They grow in size and finally divide into 12-24 or more merozoites (Fig. 21, 4, 5) which are finally set free in the plasma (Fig. 21, 6). This schizogony takes place in 48 to 72 hours.

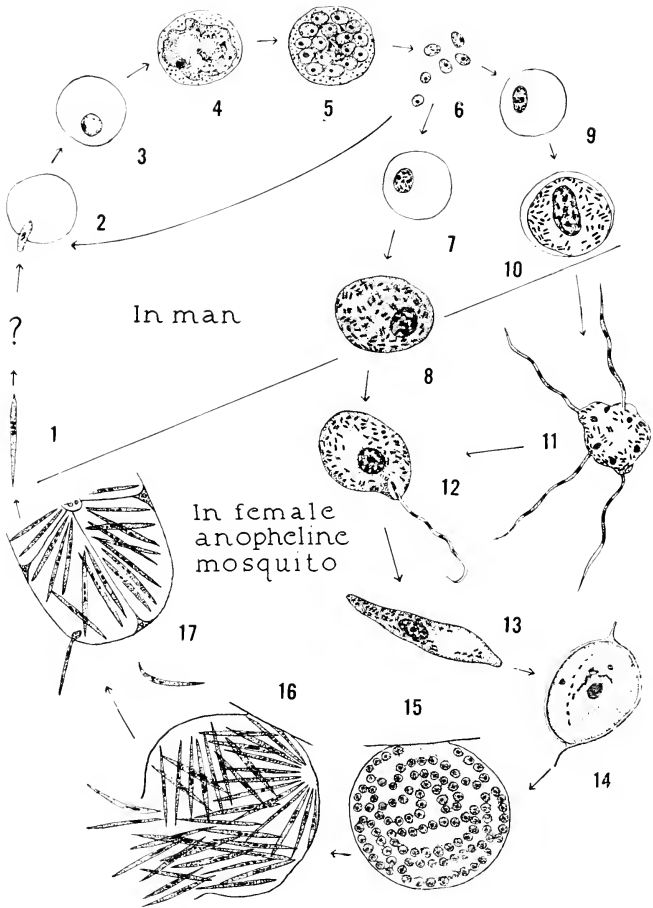


FIG. 21. A diagram showing the life-cycle of *Plasmodium vivax* (from Kudo).

(See next page for description)

These merozoites will, if not ingested by leucocytes, enter again and repeat the schizogony in erythrocytes. After repeated and simultaneous schizogony in geometric progression, a large number of infected erythrocytes will be destroyed, setting free an ever-increasing amount of toxic substance. The onset of the malarial chill and fever corresponds with the time of liberation of merozoites.

Some of the merozoites develop into gametocytes instead of schizonts in erythrocytes (Fig. 21, 7-10). When fully formed they can be differentiated into macro- and microgametocytes, but remain as such while in the human blood. When a female anopheline mosquito sucks blood containing the gametocytes, microgametocytes develop into microgametes (Fig. 21, 10, 11) and macrogametocytes into macrogametes (Fig. 21, 8, 12) in the stomach. An ookinete is formed when a microgamete fuses with a macrogamete (Fig. 21, 12, 13). The ookinetes are mobile, penetrate through the stomach wall, and become rounded into

DESCRIPTION OF FIG. 21

1. A sporozoite entering human blood.
2. Sporozoite entering an erythrocyte.
3. Young schizont.
- 4-6. Schizogony.
- 7, 8. Macrogametocytes.
- 9, 10. Microgametocytes.
11. Microgamete-formation in the stomach of a mosquito.
12. Union of gametes.
13. Zygote or ookinete.
14. Young oocyst.
15. Oocyst in which sporozoites are developing.
16. Mature oocyst from which sporozoites are emerging.
17. Sporozoites entering the salivary gland.

oocysts between the base of the epithelium and outer membrane of the stomach (Fig. 21, 14). Within the oocysts, repeated nuclear divisions produce many sporozoites (Fig. 21, 15). When fully mature, the oocysts rupture and the sporozoites are set free in the haemolymph through which they migrate to the salivary glands (Fig. 21, 16, 17). The sporozoites finally make their way through the gland epithelium and enter the duct of hypopharynx. They are now ready to infect a human victim when the mosquito goes after another blood meal. The development in the mosquito is completed in about 8-14 days.

1. *Plasmodium vivax* (Grassi and Feletti 1890)

This organism is the cause of the benign tertian malaria. It is seldom fatal. The schizogony is completed in 48 hours. Thus chill and fever appear every third day. It is the most widely distributed species in the tropical and subtropical regions as well as in the temperate zone. It has been reported as far north as the Great Lakes region in North America, England, southern Sweden and northern Russia in Europe, and as far south as Argentina, Australia, and Natal in Africa. Generally speaking this species predominates in the spring and early summer more than the other species of *Plasmodium*. In routine detection and identification, stained blood films are examined for the organisms.

Schizonts

1. *Ring forms*. Usually found soon after the characteristic malarial attack has passed off. The young merozoite which has entered an erythrocyte recently is a ring form

(Fig. 22, 1) which is about one-fourth to one-third the diameter of the erythrocyte. The unevenly narrow peripheral portion is stained blue and encloses a clear vacuole. A small compact nucleus is stained dark red and appears




FIG. 22. *Plasmodium vivax*. $\times 1150$. (original)

1. A young ring form.
- 2, 3. Growing schizonts.
4. Two schizonts in an erythrocyte.
- 5, 6. Large schizonts.
- 7-9. Schizogonic stages.
10. Fully formed merozoites.
11. A macrogametocyte.
12. A microgametocyte.

prominently. The infected erythrocyte at this stage does not differ appreciably from uninfected cells, measuring about 7.5μ in diameter.

2. *Growth period*. In about six hours the ring-form has now become larger and often assumes irregular amoeboid

forms (Fig. 22, 2). In life, amoeboid movement is clearly visible. The infected cells may be a bit larger, stain slightly paler, and begin to show fine red dots known as Schüffner's dots (Fig. 22, 3, 4).

3. *Grown schizonts.* In about another 20 hours, the schizonts (Fig. 22, 5, 6) are considerably larger and occupy about two-thirds of the erythrocytes which may now be as much as 12μ in diameter and distinctly paler than uninfected erythrocytes. Schüffner's dots appear to increase. The schizonts are of irregular outline, enclosing one or more large vacuoles and in addition pigment (haemozoin) granules appear in the cytoplasm. The haemozoin granules are brownish in color in this species. A compact large nucleus is easily recognized, often located at a point in periphery.

4. *Schizogonic or segmentation stage.* The schizont nucleus soon afterwards begins to divide (Fig. 22, 7) and the division is repeated. Often some 16 daughter nuclei are produced. The division of some of the nuclei are somewhat irregular (Fig. 22, 8) so that there may be 12-24 nuclei in a schizont (Fig. 22, 9). These multinucleate schizonts measure about $8-9\mu$ in diameter. Presently around each of the nuclei becomes differentiated a small cytoplasmic mass, and thus many young schizonts or merozoites are produced (Fig. 22, 10). The haemozoin granules present in the schizont assume a loose mass and are completely excluded from the merozoites. The merozoites are somewhat irregularly rounded and measure about 1.5μ in diameter. These changes take place between 40 to 48 hours after the malarial attack. The infected erythrocytes now rupture and the merozoites are set free in the blood plasma.

Gametocytes

Young gametocytes which originate in ring forms are difficult to identify, but they are less amoeboid, and more rounded. Mature gametocytes can easily be identified. They may appear during early phase of the malarial attacks. The development of ring forms to mature gametocytes has been estimated as requiring some four days. They are smoothly rounded and occupy almost the whole of the enlarged erythrocytes which may show Schüffner's dots. Brown haemozoin granules are numerous. The differences between the mature macro- and micro-gametocytes are as follows:

| | Macrogametocytes (Fig. 22, 11) | Microgametocytes (Fig. 22, 12) |
|-----------|---|--|
| Size | Large, 9-10 μ in diameter | Small, 7-8 μ in diameter |
| Cytoplasm | Stains more deeply | Stains less deeply |
| Nucleus | Compact and smaller, staining dark red | Large, composed of many chromatin granules which stain less deeply |

No further change takes place in human erythrocytes. If fresh blood containing microgametocytes, is kept at room temperature on a slide under a sealed cover-glass, formation of microgametes may be seen.

2. *Plasmodium malariae* (Laveran 1881)

This species is the cause of the quartan malaria in which the attacks of fever occur at intervals of 72 hours or every fourth day which is the time necessary for completion of schizogonic cycle. It is distributed in the tropics and subtropics, though it is the rarest of the three common species of malarial parasites. As a rule in an area where all three species of *Plasmodium* occur, *Plasmodium malariae* seems

to appear later in the year than the other two. The entire schizogony can be seen in the peripheral blood.

Schizonts

1. *Ring forms*. The ring form is similar to that of *P. vivax*. Large ring forms may be about one-third the diam-



FIG. 23. *Plasmodium malariae*. $\times 1150$. (original)

1. Ring form.

2-5 Band-form schizonts.

6-8. Schizogonic stages.

9, 10. Merozoite formation.

11. A macrogametocyte.

12. A microgametocyte.

eter of erythrocytes (Fig. 23, 1). The cytoplasm stains more deeply than that of *P. vivax*.

2. *Growth period*. The schizont is less amoeboid and, as a rule, rounded in outline in stained smears, although somewhat irregular forms may occur. In about 6-10 hours, haemozoin granules begin to appear in the cytoplasm.

These are coarse granules and of much darker color than those of *P. vivax*. For about 24 hours, the growth of the schizonts is relatively slow; now may measure about one-half the diameter of the host cell which remains unchanged, except sometimes they may be slightly smaller and stain more deeply than uninfected ones. As the growth continues, the schizonts tend to be stretched into band-form across the erythrocytes. The younger schizonts are narrow bands (Fig. 23, 2), while the older are broad bands (Fig. 23, 3-5). This "band-form" is one of the characteristics of this species and possesses a high diagnostic value. Dots comparable with Schüffner's dots do not occur ordinarily in this species.

3. *Mature schizonts and schizogony.* In about 48 hours, the schizont nearly fills the erythrocyte. It is rounded and haemozoin granules first scattered, begin to collect into a mass. At about this time, the nucleus divides into 6-12 daughter nuclei by repeated binary fission (Fig. 23, 6-8). These nuclei are often arranged in a circle, and soon a ring of 6-12 merozoites are formed with the pigment mass in the center. These merozoites (Fig. 23, 9, 10) appear to be the largest of the three species. A little before the attack of fever, the infected erythrocytes rupture and set the merozoites free in the blood plasma.

Gametocytes

The development of gametocytes takes place in the peripheral blood, but it is difficult to distinguish them from growing schizonts, since the latter are more or less compact and rounded in this species. The mature gametocytes are spherical and fill the erythrocytes which are normal in

dimensions. They are uninucleate and contain haemozoin granules. The two kinds of gametocytes can be distinguished from each other as follows:

| | Macrogametocytes (Fig. 23, 11) | Microgametocytes (Fig. 23, 12) |
|--------------------|-------------------------------------|--------------------------------------|
| Cytoplasm | Denser, stains more deeply | Stains less deep blue |
| Nucleus | Small, compact; more deeply stained | Large, elongate; less deeply stained |
| Haemozoin granules | Coarser | Finer; abundant |

3. *Plasmodium falciparum* (Welch 1897)

Synonyms: *Laverania malariae* Grassi and Feletti 1890
Plasmodium tenue Stephens 1914

This is the causative organism of the most malignant malaria, known as subtertian, malignant tertian or aestivo-autumnal fever. It is widely distributed in the tropics. In the subtropical region, it is more prevalent in late summer or early autumn. It is, however, relatively rare in the temperate zone. The chill and fever appear every 36 to 48 hours, the schizogonic cycle being somewhat irregularly periodic.

Schizonts

1. *Ring forms.* Young ring forms are much smaller than those of the other species (Fig. 24, 1). They measure about 1.5μ in diameter. Quite often marginal forms are encountered, and also multiple (2-6) infection (Fig. 24, 1) often occurs in this species. The nucleus of the ring form appears as a short rod or is divided into two granules (Fig. 24, 1). In deeply stained smears, the infected host cells may show red-stained granules (Fig. 24, 2-6), the

Maurer's dots, which are coarser in size and fewer in number than Schüffner's dots found in the erythrocyte infected by *P. vivax*. In about 12 hours after the attack of fever, these schizonts disappear from the peripheral blood.

2. *Growth and schizogonic stages.* These are found only

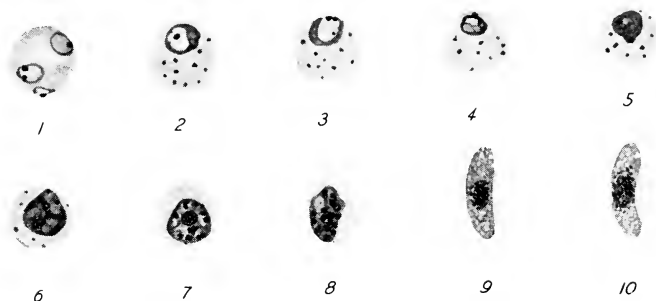


FIG. 24. *Plasmodium falciparum*. $\times 1150$. (original)

1. Three ring forms in an erythrocyte.
2. A somewhat grown schizont in an erythrocyte with Maurer's dots.
- 3-6. Growth and schizogonic stages.
- 7, 8. Merozoite formation.
9. A macrogametocyte.
10. A microgametocyte.

in the capillaries of various internal organs. As the schizonts grow, the cytoplasm becomes denser. Haemozoin granules which are much darker than those in other species, become grouped into a compact mass (in contrast to the scattered granules in the other two species). When the schizont reaches the size about two-thirds of the infected erythrocytes (about 5μ), nuclear division begins and finally 8-24 or more nuclei are produced (Fig. 24, 5, 8). Thus 8-24 small merozoites are formed. When these merozoites are

liberated into the blood plasma and enter erythrocytes, the ring forms reappear in the peripheral blood.

Gametocytes

The gametocytes develop from the ring form in the internal organs, especially the spleen and bone marrow. Mature gametocytes which appear in the peripheral blood and therefore are present in ordinary blood smears, are characteristically crescentic or sausage form ("crescents") and have an important diagnostic value. They are about 10-12 μ by 2-3 μ . The macro- and micro-gametocytes may be distinguished as follows:

| | Macrogametocytes (Fig. 24, 9) | Microgametocytes (Fig. 24, 10) |
|-----------|----------------------------------|---|
| Cytoplasm | Stains deeper blue | Hyaline, stains less deeply or reddish |
| Nucleus | Small, compact; deep red | Large, chromatin closely set; less deeply stained |
| Pigment | Coarser, around the nucleus | Less coarse, more widely scattered |

4. *Plasmodium ovale* Stevens 1922

This is considered as the cause of mild tertian or *Ovale* tertian fever which appears to be confined to Africa and Asia (Philippine Islands and India). The validity of the species is still disputed among malariologists. Its schizogony is completed in about 48 hours and its morphological characters resemble both *P. vivax* and *P. malariae*. The whole schizogony and gametocyte formation occur in the peripheral blood.

Schizonts

1. *Ring forms*. They are similar to those of *P. vivax* and *P. malariae*. Schüffner's dots appear early (Fig. 25, 1).

2. *Growth period.* The infected erythrocytes are more or less oval with irregular fimbriated margins or outline (Fig. 25, 2-4). There seems to be a slight increase in size also. The schizonts are not actively amoeboid, and sometimes seen in band form with brownish-black haemozoin




FIG. 25. *Plasmodium ovale*. $\times 1150$. (original)

1. A ring form.
- 2, 3. Growing schizonts.
- 4-6. Schizogonic stages.
7. A macrogametocyte.
8. A microgametocyte.

granules, resembling those of *P. malariae*. Schüffner's dots are usually abundant.

3. *Schizogonic stage.* The fully grown schizont is smaller than the erythrocyte (Fig. 25, 5), and produces 6-12 merozoites (Fig. 25, 6), which resemble those of *P. malariae*. Schüffner's dots appear abundantly.

Gametocytes

The gametocytes do not fill the erythrocytes, and resemble closely those of *P. malariae*. But in *P. ovale*, the host cells show Schüffner's dots and seem to be slightly enlarged (Fig. 25, 7, 8).

DIFFERENTIAL DIAGNOSIS OF THE THREE COMMON SPECIES OF PLASMODIUM AS SEEN IN GIEMSA-STAINED THIN BLOOD FILMS

| | <i>P. vivax</i> | <i>P. malariae</i> | <i>P. falciparum</i> |
|-----------------------|---|---|--|
| Ring forms | About $\frac{1}{4}$ diameter of erythrocytes; marginal forms rarely seen | Similar to <i>P. vivax</i> but cytoplasm slightly denser | Smaller, $\frac{1}{6}$ – $\frac{1}{5}$ diameter of erythrocytes; marginal forms frequent; multiple infection common |
| Infected erythrocytes | Larger, up to 12μ , in size and paler in color than normal erythrocytes (7.5μ in diameter); Schüffner's dots | Not enlarged; sometimes slightly smaller than normal ones; usually no dots | Normal; some contracted and distorted in later schizogonic stage; Maurer's dots |
| Growing schizonts | Irregularly amoeboid; vacuolated; pale blue; brown haemozoin granules small | Not amoeboid; oval, rounded, band-form, rarely irregular; less vacuolated cytoplasm stains deeper blue; dark brown pigment numerous | Partly grown ring forms often with a rod-shaped nucleus or 2 compact nuclei. Further development only in inner organs |
| Fully grown schizonts | Irregular form; $\frac{2}{3}$ the enlarged erythrocytes; vacuolated; brown haemozoin granules | Nearly fill erythrocytes; less irregular, rounded; cytoplasm deeper blue; dark brown pigment | In internal organs, $\frac{2}{3}$ of erythrocytes; dark haemozoin granules compactly massed |
| Schizogonic stages | 12–24 nuclei; later merozoites; irregularly arranged; brown haemozoin granules | 6–12 nuclei, later merozoites which are largest of all, typically arranged in a circle with pigment mass in center | In internal organs, 8–24 or more nuclei, later merozoites which are smallest of all; irregularly arranged; dark pigment mass eccentric |
| Gametocytes | Almost fill enlarged erythrocytes; rounded or ovoid; brown pigment | Fill normal-sized erythrocytes; round or ovoid, much smaller; dark brown pigment | Crescentic or sausage-shaped |

Chapter 9

Technique for detection and identification of protozoa parasitic in the circulatory system

Thin film. The finger tip or ear-lobe is cleaned with 70% alcohol. Prick it with an aseptic blood lancet or a sterilized needle. Wipe off the first drop with gauze and receive the second drop on a thoroughly cleaned (p. 54) slide about half an inch from an end (Fig. 26, 1). Use care not to let the slide touch the finger or ear-lobe itself. Quickly bring a second slide, one corner of which had been cut away, to the inner margin of the blood drop (Fig. 26, 1), and let the blood spread along the edge of the second slide. Next push the second slide over the surface of the first slide at an angle of about 45° towards the other end (Fig. 26, 2). Thus a thin film of blood is spread over the slide (Fig. 26, 3). Let the smear lie horizontally and dry. It should be covered with a glass cover to prevent dust particles from falling on it and to exclude flies or other insects. If properly made, the film is made up of a single layer of blood cells with smoothly rounded natural outlines.

Thick film. Often parasites are so few that to find them in a thin film involves a great deal of time. In such cases, a thick film is advocated. For this 4-6 drops of blood are placed in the central area of about $\frac{1}{2}$ square inch, and with a needle or a corner of slide, spread them into an even layer. Let the smear dry, protecting it from dust or flies.

With a little practice, a satisfactory thick smear without crackling or peeling of the blood film can be made. It will take two hours or more to dry. Do not dry by heat, but

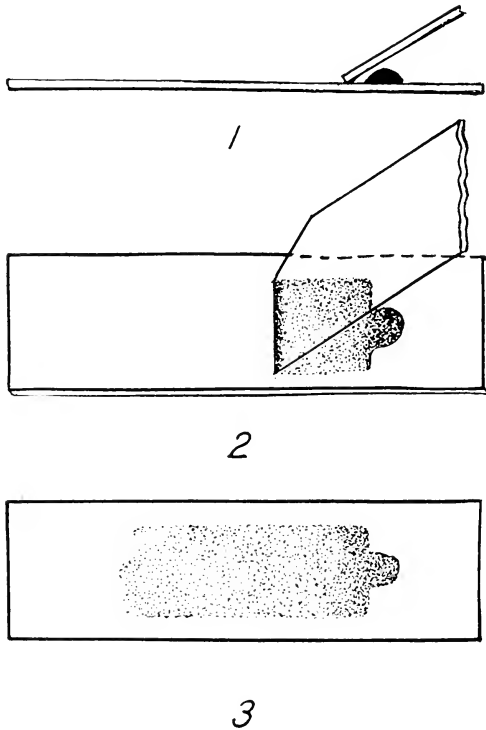


FIG. 26. Diagrams showing how a thin blood film is made.

placing it in an incubator at 37°C . will hasten the drying. When it is thoroughly dry, immerse it in water and dehaemoglobinize it. Air dry again.

Thin and thick film. Sometimes it is time-saving if thin and thick films are made on a single slide. Place a single drop

of blood near the center and make a thin film of it toward one end of the slide. About one-fourth from the other end, place drops of blood in a small area and make a thick film. Dry. When thoroughly dry, immerse the thick film part in distilled water and dehaemoglobinize it. Let the slide dry.

The blood films must be stained as soon as possible to insure a proper staining, as lapse of time or summer heat will often result in poor staining especially of thick films.

Staining. Of numerous blood stains, Giemsa's and Wright's stains are used here. For staining with Giemsa's solution, the thin film is fixed after thorough drying in absolute methyl alcohol for 5 minutes. Wash the film in running water and rinse well in neutral distilled water. After shaking the stock Giemsa's stain (obtained from reliable makers) well, dilute it with neutral distilled water in a ratio of one drop of stain to 1-2 c.c. of water. Mix the solution and the film is placed in it for one-half to 2 hours or longer if desired. It is now placed in neutral distilled water and excess of stain washed off the slide. Rinse it in fresh distilled water and then wipe off water with a tissue paper from the underside and edges of the slide. Let the slide stand on end to dry. When thoroughly dry, place a drop of xylol and a drop of cedar wood oil (used for immersion objectives) and cover with a cover-glass. For thick film the square cover-glass will cover the entire film, but for a thin film use two such cover-glasses side by side if a rectangular one (40 by 20 mm.) is not available. The mounting medium should be absolutely neutral. Do not use Canada balsam for mounting, as acid in it promptly spoils the staining.

For Wright's staining, fixation is not necessary. With a

medicine dropper, cover the dried blood film with drops of undiluted Wright's stain, and let the film stand horizontally for 3-5 minutes; then the same number of drops of neutral distilled water is added to the stain and the whole is left for 10-30 minutes. The stain is then poured off and the film is rinsed in neutral distilled water. Dry. Mount in xylol and cedar wood oils as stated for Giemsa's stain.

Use of cover-glasses on a stained blood film is advocated, since a cedar wood oil mounted slide allows the use of dry objectives which in the hand of an experienced worker would give enough magnification for species determination of Plasmodium, and which will very clearly reveal any trypanosome present in the film. Furthermore the film is protected against scratches and contamination by many objects which may bring about confusion in detecting protozoa.

The splenic pulp smears for Leishmania and Trypanosoma are also similarly treated and prepared.

When the parasites are very few in the blood, the thick film is highly useful for detection of ring forms and gametocytes of Plasmodium and of trypanosomes, as the organisms are much concentrated, and the haemoglobin is completely absent. On the other hand, the thick film brings about a great deal of abnormalities in the organism so that many of the specimens may be variously distorted. Therefore, species identification is usually difficult. Thick films should be used for detection of organisms and identification should be made on thin films.

In diagnosis of Trypanosoma and Leishmania, it is necessary often to use culture method. The oldest medium is

that first advocated by Novy, MacNeal and Nicolle (or N N N). This is prepared as follows: Dissolve 7 grams of agar-agar and 3 grams of NaCl in 450 c.c. of distilled water by heating. Place 5 c.c. of the mixture while still hot into each test tube and apply a cotton plug. Autoclave the tubes for 30 minutes under 15 lbs. pressure. Let the tubes cool down to about 50°C., and add to each tube 15-20 drops of rabbit's blood with care to prevent bacterial contamination. The tubes are rapidly evolved to bring about mixture without forming bubbles, and sloped. When the medium is solid, place rubber caps over the cotton plugs and incubate the tubes at 37°C. for 24 hours. The testing blood is inoculated into the condensation water.

Chapter 10

Objects which may be confused with blood-inhabiting protozoa in stained films

CERTAIN artifacts and extraneous objects occur frequently in stained blood films. In spite of the precautions taken during the preparation, there will be seen a number of objects not present in the blood originally, because of chance contaminations of the blood film by various animal or plant organisms, dust particles, particles suspended in reagents and stains, etc.

Free-living protozoa. They may occur in long-standing distilled water, especially in warmer climate, and if it is used for dilution of the stain, some of them may adhere to the blood film and be stained. If flies or other insects drop faecal matter on the drying blood film, intestinal flagellates and other microorganisms may contaminate it.

Dust particles. Dust particles from air or suspended in water, stain, etc., may adhere to the film and simulate malarial pigment. Scratches or breaks in the slide may take up the stain, and resemble trypanosomes.

Plant organisms. Yeasts, fungi, and bacteria may be found in the film, often originating in the skin or air. Blood films made post-mortem, may contain them as they may have invaded the blood shortly before or just after death. They may be confused with young stages in Plasmodium.

Erythrocytes. Normal erythrocytes are circular in outline

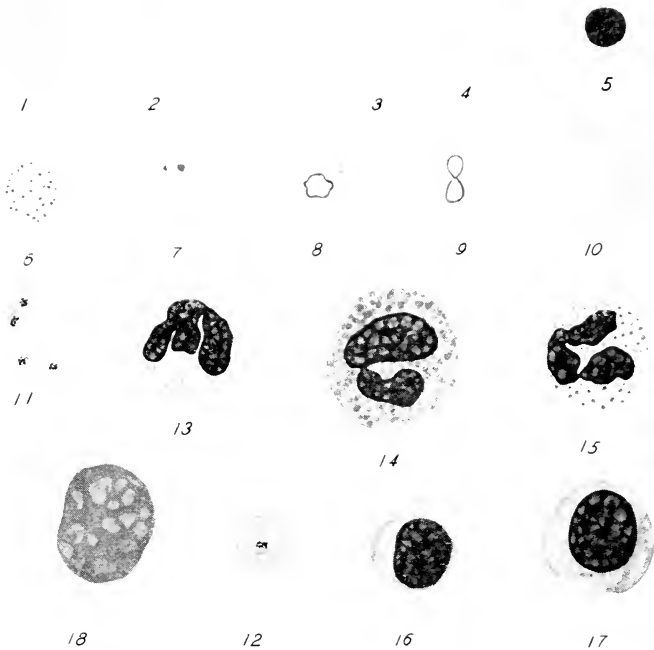


FIG. 27. Various blood cells found in stained blood films. $\times 1150$. (original)

1. A normal erythrocyte.
2. A crenated erythrocyte.
3. A macrocyte.
4. A microcyte.
5. A normoblast.
6. A basophilic erythrocyte.
7. An erythrocyte with chromatin dots.
- 8, 9. Erythrocytes with Cabot's rings.
10. Semi-lunar erythrocyte.
11. Blood platelets.
12. A thrombocyte superimposed on an erythrocyte.
13. A neutrophilous polymorphonuclear leucocyte.
14. An eosinophile leucocyte.
15. A basophile leucocyte.
16. A small lymphocyte.
17. A large lymphocyte.
18. A large mononuclear leucocyte.

and bi-concave, and stain homogeneously, except the central area which is lighter in color (Fig. 27, 1). They are about 7.5μ in diameter. Some erythrocytes show small knob-like projections from their surface. These are crenated erythrocytes (Fig. 27, 2), and appear in drawn-out normal blood. In addition to the normal erythrocytes, macrocytes, about $10-14\mu$ in diameter (Fig. 27, 3) and microcytes, $2-6\mu$ in diameter (Fig. 27, 4) may be present in the blood of persons suffering from anaemia including subtertian malaria. Some erythrocytes may be nucleated (Fig. 27, 5); they are called normoblasts. Some erythrocytes may show basophilic dots (Fig. 27, 6), others chromatin dots (Fig. 27, 7), and still others Cabot's rings, either irregularly rounded (Fig. 27, 8) or in form of an 8 (Fig. 27, 9). Sometimes in the blood of tertian malaria patients may appear large erythrocytes with a very large eccentrically placed vacuole, resembling half moon in shape with a somewhat undulating outline, which simulates a trypanosome (Fig. 27, 10).

Blood platelets. Thrombocytes are rounded disc-shaped bodies with indistinct margins and are $1-3\mu$ in diameter. They may be found singly in clusters, or in chains (Fig. 27, 11). They stain bluish with red-stained granules in center. Occasionally filamentous processes may be seen. When an isolated platelet is attached to an erythrocyte, it may simulate a young schizont of Plasmodium, but there is always a clear zone around the platelet by which it can be identified as such (Fig. 27, 12).

Leucocytes. There are many kinds. The main types are as follows:

Neutrophile polymorphonuclear leucocytes (Fig. 27, 13).

Normally 60-70% of leucocytes. When rounded as is usually seen in a stained blood film, the cell is about 10μ in diameter. The nucleus is of irregular shape and often tri-lobed. The cytoplasm is stippled with fine neutrophilic granules.

Eosinophile leucocytes (Fig. 27, 14). Normally 2-4% of leucocytes. These cells are about $12-14\mu$ in diameter. The nucleus is bi- or tri-lobed. The cytoplasm is filled with coarse red-stained granules. These cells increase in number in cases of helminth infection.

Basophile leucocytes (Fig. 27, 15). Normally about 0.5%. These cells are about 10μ in diameter and similar to neutrophile, but the granules are stained purplish or blue.

Lymphocytes. Normally 20-30% of leucocytes. The nucleus is large and compact, and stains deep dark red. The cytoplasm is comparatively scanty and stains blue. Small lymphocytes (Fig. 27, 16) are about $5-8\mu$ in diameter, while larger ones (Fig. 27, 17) measure $8-10\mu$ in diameter.

Large mononuclear leucocytes (Fig. 27, 18). Normally 3-6%. They are the largest blood cells and measure $12-20\mu$ in diameter. The nucleus is rounded, elongate, or reniform, and chromatin material is loosely packed so that the stained nucleus is much lighter than that of the lymphocytes. The cytoplasm is voluminous and stains a clear pale-blue. In malaria and trypanosomiasis these leucocytes increase in number and in the former they may show ingested haemozoin granules.

Chapter 11

Protozoa parasitic in the muscle and the reproductive organ

In the muscle

1. *Sarcocystis lindemanni* (Rivolta 1878)

THIS sporozoan is responsible for the sarcosporidiosis in man which is very rare, and has been reported from the tropical regions. It invades the muscle cells of man. Information on the species which attack the human body is very incomplete. The questions such as what species occur in man and how man is infected, etc., are unanswered at present. The published records indicate that there is a wide morphological variation among the organisms observed by different workers.

The organism is oval to spindle form and imbedded in the muscle cell of larynx, biceps, tongue, heart, chest, etc. The infected muscles seem to become distended owing to the growth of the parasite within. The infected muscles may be seen white-streaked to the naked eye. Seen in sections, the body of the organism (Fig. 28) may be divided into numerous compartments. The size of the organisms varies a great deal according to different observers: 16 mm. by 170 μ , 5.3 cm. by 320 μ , 84 μ by 27 μ . Near the peripheral zone are found rounded sporoblasts and in the central area crescentic or banana-shaped spores occur usually in abundance. The size of the spores also differs among different cases: 8-9 μ long; over 10 μ long; 8.33 μ by 1.6 μ ; 4.25 μ

by 1.75μ . The spores are rounded at both ends or more often one end is more rounded than the other. There is a nucleus near the broader end, and the cytoplasm near the

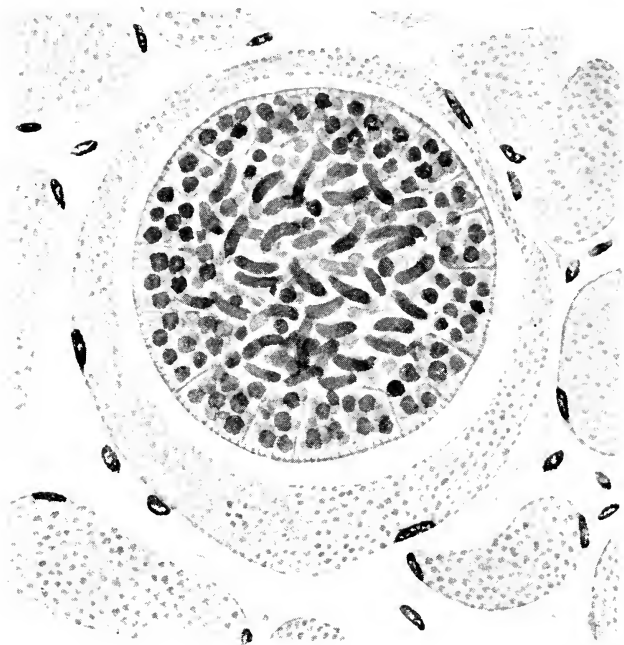


FIG. 28. *Sacrocystis lindemanni* in human musculae. $\times 1150$ (modified from the drawings and description of Baraban and St. Rémy).

other end stains darkly and contains several granules.

The detection of the organism must be carried on fresh preparation of excised muscle cells or sectioned permanent preparation of muscle tissue.

In the reproductive organ

1. *Trichomonas vaginalis* Donne 1837

This flagellate occurs in the vagina in which the reaction of the secretion has changed from alkaline to acid. There are some investigators who consider it as the causative organism of vaginitis, but definite information to support this view is still missing. As in the other two species of human *Trichomonas*, encysted forms have not yet been found.

Trophozoites

1. *Living specimens.* The organism (Fig. 29, 1) resembles *T. hominis*. General body form is broadly pyriform or fusi-

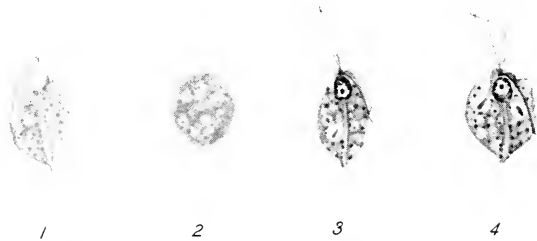


FIG. 29. *Trichomonas vaginalis*. $\times 1150$. (original)

1. Living trophozoite.
2. A degenerating amoeboid trophozoite in life.
- 3, 4. Stained trophozoites.

form, but may be varied, as it is extremely plastic. It measures $10-30\mu$ long by $10-20\mu$ broad. When the preparation is a few hours old, many degenerating forms appear (Fig. 29, 2). In such forms active amoeboid form-change together with the continued movement of flagella and

undulating membrane will be noticed. Further degenerated forms are rounded and are with or without flagella. The undulating membrane in larger individuals, does not usually reach the posterior end of body.

2. *Stained specimens.* The general morphological feature (Fig. 29, 3, 4) is similar to that of *T. hominis* (p. 38). But the costa is less conspicuous in the present form. The nucleus is pyriform or oval. The cytoplasm contains bacteria and numerous granules.

The detection of the flagellate can be done easily by examining fresh smears of vaginal secretions in bright and dark field under the microscope. For permanent preparation, use either Heidenhain's iron haematoxylin in the way the faecal smears are handled (p. 59) or Giemsa's stain as given for blood-inhabiting protozoa (p. 99).

Reference Books

For further information concerning protozoa parasitic in man not dealt with in the present work, the reader is referred to the following works.

- Craig, C. F. 1934 Amebiasis and amebic dysentery. Springfield, Illinois; Charles C Thomas.
- Craig, C. F. 1942 Laboratory diagnosis of protozoan diseases. Philadelphia; Lea & Febiger.
- Dobell, C. and F. W. O'Connor 1921 The intestinal protozoa of man. London: John Bale, Sons and Danielsson, Ltd.
- Kudo, R. R. 1939 Protozoology. Springfield, Illinois; Charles C Thomas.
- Manson-Bahr, P. 1940 Manson's tropical diseases. Toronto: Cassell & Co.
- Strong, R. P. 1942 Stitt's diagnosis, prevention and treatment of tropical diseases. 6th edition. 2 vols. Philadelphia; The Blakiston Co.
- Wenyon, C. M. 1926 Protozoology. 2 vols. London: Baillière, Tindall & Cox

Index

- Algae in faeces, 71
Amoeba, dysentery, 5, 9-14, 28, 29, 30
Amoebae, coprozoic, 63-64
 free-living, 19, 63-64
 intestinal, 5, 9-19, 21-30
 oral, 19-21
Amoebiasis, 5, 9
Amoebic dysentery, 5, 9
Amoebina, 8-30, 63-64
Anopheles, 83, 85
Axostyle, 39, 40, 43, 44, 108
- Bacteria as food of Protozoa, 6, 15, 19, 22, 25, 27, 30, 33, 37, 39,
 41, 108
Balantidial dysentery, 5, 49
Balantidium coli, 3, 4, 5, 49-52
Balantidiosis, 5, 49
Bandform schizont, 90, 91, 95
Basophile leucocyte, 105
Binary fission, 3, 4
Blastocystis hominis, 28, 41, 69-70
Blepharoplast, 72, 74, 75, 77
Blood agar culture medium, 81, 101
Blood films, 74, 97-100
 making of, 97-99
 staining of, 99-100
 thick, 97-98, 100
 thick and thin, 78, 98-99
 thin, 97, 100
Blood platelets, 104

- Blood-sucking insects, 5, 72, 73, 76, 78, 79, 81, 83, 84, 85, 86
Bodo caudatus, 64-65, 66
 edax, 65, 66
- Cells in blood films, 102-105
 faecal smears, 70, 71
- Centrifuge, 57, 75, 78
- Cercomonas longicauda*, 65, 66
- Chagas' disease, 5, 76
- Chill and fever, 85, 89, 92, 93
- Chilomastix mesnili*, 33, 35, 36-38, 39, 45, 46
- Chromatin, 3, 9, 17
- Chromatoid body, 13, 18
- Cilia, 4, 50
- Ciliata, 3, 8, 49-52, 62
- Cleaning of cover-glasses, 54
 slides, 54
- Clonorchis sinensis*, 71
- Coccidia in birds 68
 intestine, 6, 47-49
 faeces, 6, 47-49, 67, 68
 fishes, 67
 sparrow, 68
- Coccidiosis, 6, 47-49
- Collection of blood, 97
 faeces, 53-54
- Commensals, 6, 15, 19, 22, 25, 26, 31, 36
- Conjugation, 5
- Contractile vacuole, 4, 50, 51
- Copromonas subtilis*, 65, 66-67
- Coprozoic Protozoa, 62-67
- Costa, 40, 109
- Cover-glasses, 54, 99, 100

- Crescents, 94, 96
- Crithidia form, 72
- Cyst, 4, 8, 31, 56, 57
- carriers, 14
 - chemicals on, 14
 - concentration of, 57
 - drugs on, 14
 - formation of, 4, 12
 - of *Balantidium coli*, 51-52
 - Cercomonas longicauda*, 66
 - Chilomastix mesnili*, 33, 38, 45, 46
 - Copromonas subtilis*, 67
 - Dimastigamoeba gruberi*, 64
 - Endolimax nana*, 26, 29, 30
 - Entamoeba coli*, 17-19, 29, 30
 - histolytica*, 12-14, 29, 30
 - Giardia intestinalis*, 44, 45, 46
 - Hartmannella hyalina*, 63
 - Iodamoeba bütschlii*, 23-24, 29, 30
 - Retortamonas intestinalis*, 33, 38, 45, 46
 - Tricercomonas intestinalis*, 36, 45, 46
 - passers, 14
 - temperature on, 14
 - viability of, 8, 14
- Cytopharynx, 50
- Cytoplasm, 3
- Cytopyge, 50
- Cytostome, 4, 32, 37, 38, 40, 50
- Darkfield illumination, 33, 39, 42, 54, 56, 109
- Dehaemoglobinization, 98, 99
- Detection of
- haematozoa, 74-75, 76, 78, 81, 82, 86

Detection of (continued)

intestinal protozoa, 53-61

Sarcocystis, 107

Trichomonas vaginalis, 109

Dientamoeba, 9

Dientamoeba fragilis, 26-28, 29, 30

Differential diagnosis of

intestinal amoebae, 30

flagellates, 46

Plasmodium, 96

Dimastigamoeba gruberi, 63-64, 65Diseases caused by protozoa, 5, 6, 9, 48, 49, 73, 75, 76, 79, 81,
82, 86, 89, 92, 94, 106

Dust particles on blood films, 102

Dysentery, 5, 9, 49

Dysentery amoeba, 9-14

Ectoplasm, 3, 9, 10

Eimeria clupearum, 67*sardinae*, 67*Embadomonas intestinalis*, 31

Encystment, 4, 8, 31

Endamoeba, 8, 9

Endamoeba coli, 15*gingivalis*, 19*histolytica*, 9

Endolimax, 9

Endolimax nana, 24-26, 28, 29, 30, 69

Endoplasm, 3, 10, 11

Endosome, 3

Entamoeba, 9

Entamoeba coli, 12, 15-19, 22, 28, 29, 30, 69*gingivalis*, 19-21, 29*histolytica*, 5, 9-14, 15, 17, 19, 28, 29, 30, 71

- Enteromonas hominis*, 34-35, 36, 45, 46
- Eosin, 61
- Eosinophile leucocytes, 105
- Epithelial cells in faeces, 70, 71
- Erythrocytes, 102-104
- crenated, 104
 - dots in, 104
 - in protozoa, 10, 40, 41, 50
 - macrocytes, 104
 - microcytes, 104
 - normal, 102-104
 - normoblast, 104
 - semilunar, 104
 - with basophilic dots, 104
 - Cabot's ring, 104
 - chromatin dots, 104
- Espundia, 6, 82
- Examination of slides, 55-57, 61
- Exoerythrocytic development, 83
- Excystment, 4, 8
- Faeces, blood in, 54, 55
- collection of, 53-54
 - fresh preparation of, 55-58
 - microscopical examination of, 54-61
 - mucus in, 12, 54, 55, 57
 - objects present in, 67-71
 - permanent preparation of, 58-61
 - pus in, 54, 55
- Fixation of blood films, 69
- faecal smears, 58-59
- Flagella, 4, 42, 56, 62
- Flagellata, 3, 4, 5, 8, 31-46, 72-82, 108-109
- blood-inhabiting, 72-96

Flagellata (continued)

coprozoic, 64-67

free-living, 64-67

intestinal, 31-46

oral, 41

vaginal, 108-109

Food substances, 4, 8

Free-living protozoa, 19, 62-67, 71, 102

Fungus, 69-70, 102

Gametocytes, 5, 85, 89, 91-92, 94, 95, 96, 100

Giardia intestinalis, 6, 41-44, 45, 46*lamblia*, 41

Giemsa's stain, 72, 80, 99, 109

Glossina, 72, 73, 76

Glossina morsitans, 76*palpalis*, 73

Glycogen body, 13, 18, 19, 24, 26, 58

Haematoxylin, 59-60

Haemozoin granules, 88, 89, 90-92, 93, 95, 105

Hartmannella hyalina, 63, 65

Heidenhain's iron haematoxylin, 59-60, 109

Helmith eggs, 70-71

Heterophyes heterophyes, 71

I cysts, 24

Illustrations of

Balantidium coli, 51*Blastocystis hominis*, 16, 70

Blood cells, 70, 103

Blood film, making of, 98

Bodo caudatus, 65*edax*, 65

Illustrations of (continued)

- Cercomonas longicauda*, 65
- Chilomastix mesnili*, 37
- chromatoid bodies, 11, 16
- cilia, 51
- compact nucleus, 51
- Copromonas subtilis*, 65
- Coprozoic protozoa, 65
- Dientamoeba fragilis*, 27
- Dimastigamoeba gruberi*, 65
- Endolimax nana*, 25
- Eimeria clupearum*, 68
 - sardinae*, 68
- Endosome, 11, 16, 20
- Entamoeba coli*, 16, 70
 - gingivalis*, 20
 - histolytica*, 11
- Enteromonas hominis*, 34
- Epithelial cell, 70
- Giardia intestinalis*, 43
- Hartmannella hyalina*, 65
- Iodamoeba bütschlii*, 23, 70
- Isospora hominis*, 48
 - lacaiei*, 68
- Leishmania donovani*, 80
- Leucocytes, 103
- Nucleophaga, 70
- Nucleus, vesicular, 11, 16, 51, 108
- Plasmodium, life cycle of, 84
- Plasmodium falciparum*, 93
 - malariae*, 90
 - ovale*, 95
 - vivax*, 87
- Retortamonas intestinalis*, 32

Illustrations of (continued)

Sarcocystis lindemanni, 107

Sphaerita, 16, 70

Tricercomonas intestinalis, 34

Trichomonas hominis, 40

vaginalis, 108

Trypanosoma cruzi, 77

gambiense, 74

rhodesiense, 76

Intestinal amoebae, 9-19, 21-30

flagellates, 31-46

Iodamoeba, 9

Iodamoeba bütschlii, 21-24, 28, 29, 30, 69

williamsi, 21

Iodine, 57

Iodine solution, 57

Iron alum, 59

Isopora hominis, 6, 47-49, 68, 70, 71

laczeyi, 68

Kala azar, 6, 79

Keys for genera and species of

intestinal amoebae, 28-29

flagellates, 46

Laverania malariae, 92

Leishmania, 4, 78-82, 100

Leishmania brasiliensis, 6, 82

donovani, 6, 79-81

infantum, 79

tropica, 6, 79, 81-82

Leishmania forms, 76, 77, 78

Leishmaniasis, cutaneous, 6, 81

naso-oral, 6, 82

- Leishmaniasis (continued)
 South American, 82
 visceral, 6, 79
- Leptomonad form, 78, 81
- Leucocytes, 104-105
 basophile, 105
 eosinophile, 105
 lymphocytes, 105
 neutrophile, 104-105
 mononuclear, 79, 105
 polymorphonuclear, 71, 79, 81
- Life cycle of intestinal amoebae, 8
 flagellates, 31
 Leishmania, 78-79
 Plasmodium, 83-86
 Trypanosoma, 72-73
- Lugol's solution, 13, 18, 24, 26, 33, 42, 57
- Lymphocytes, 105
-
- Macrocytes, 104
- Macrogametes, 5, 85
- Macrogametocytes, 85, 89, 92, 94, 95
- Macronucleus, 3, 50, 52
- Macrophages, 79
- Malaria, 83-96, 105
 aestivo-autumnal, 92
 benign tertian, 6, 86-89
 malignant tertian, 6, 92
 mild tertian, 6, 94
 Ovale tertian, 6, 94
 quartan, 6, 89
 subtertian, 6, 92, 104
 tertian, 86-89

- Material, collection of, 53-54, 97
- Maurer's dots, 93
- Mercuric chloride, 14, 58
- Merozoites, 83, 85, 88, 91, 93
- Methyl alcohol, 99
- Microcytes, 104
- Microgametes, 5, 85
- Microgametocytes, 85, 89, 92, 94, 95
- Micronucleus, 51
- Microscopic cover-glasses, 54, 99, 100
slides, 54
- Microscopical examination of
blood, 97-105
faeces, 54-61
- Molds in blood films, 102
faeces, 68
- Mononuclear leucocytes, 79, 105
- Mordant, 59
- Mosquito, anopheline, 5, 83, 85
- Mounting media, 61, 99
Canada balsam, 61
cedar wood oil, 99
- Mucus in faeces, 12, 54, 55, 57
- Multiple division, 4, 5, 83-85, 88, 91, 93, 95, 96
- N N N medium, 101
- Neutral fat, 67
- Neutrophile leucocytes, 104-105
- Nitric acid, 54
- Nucleophaga, 69, 70
- Nucleoplasm, 3
- Nucleus, 3, 10, 11, 15
- Objectives, microscopic, 55, 56

- Objects in blood films, 102-105
 faecal smears, 56, 62-71
 Oocyst of *Eimeria clupearum*, 67
 sardinae, 67
 Isospora hominis, 47-48
 latazei, 68
 Plasmodium, 5, 86
 Ookinete, 85
 Oriental sore, 6, 81
- Parasites of protozoa, 25, 69, 70
 Peripheral chromatin granules, 12, 17
 Peristome, 52
 Permanent preparation, 58-61
 Phlebotomus, 78, 81, 82
Phlebotomus papatasi, 79
 Plasmodium, 4, 5, 83-96, 100, 104
Plasmodium falciparum, 6, 92-94, 96
 malariae, 6, 89-92, 94, 95, 96
 ovale, 6, 94-95
 tenue, 92
 vivax, 6, 84, 86-89, 90, 94, 96
 Polymorphonuclear leucocytes, 71
 Potassium iodide, 57
 Precystic amoebae, 12, 17
 Protozoa, free-living, 19, 62-67, 71, 102
 Protozoa in blood, 9, 72-96
 bone marrow, 79, 94
 brain, 9, 73, 75, 76
 cerebro-spinal fluid, 73, 78
 circulatory system, 9, 72-96
 cutaneous tissues, 81, 82
 digestive tract, 8-52

Protozoa in (continued)

- duodenum, 6, 41, 42
- gall bladder, 42
- gum, 19-21, 41
- intestinal wall, 9, 49, 79
- intestine, 9-19, 21-52
- liver, 9, 79
- lung, 9
- lymph, 73, 79
- mouth, 19, 41, 82
- muscles, 106
- reproductive organ, 108
- spleen, 79, 94
- sputum, 41
- tartar, 41
- tonsile, 41
- vagina, 108

Pseudopodia, 4, 9, 10, 19

Pus, 54, 55

Pyorrhoea alveolaris, 19

Reproduct, asexual, 3, 4, 5

sexual, 5, 84-86

Reservoir hosts, 49, 73, 75, 80

Reticulo-endothelial system, 78, 79, 81

Retortamonas intestinalis, 31-33, 45, 46

Rhizoplast, 78, 80

Ring forms, 83, 86-87, 90, 100

Salt solution, 55

Sand flies, 78, 81, 82

Sarcocystis lindemanni, 6, 106-107

Sarcodina, 3, 5, 8, 9-30, 62

- Sarcosporidiosis, 6, 106
 Schaudinn's fixative, 58
 Schizogony, 4, 5, 83-85, 88, 91, 93, 95, 96
 Schizonts, 4, 5, 83-85, 86-88, 90-91, 92-95, 96
Schizotrypanum cruzi, 76
 Schüffner's dots, 88, 89, 93, 94, 95
 Sleeping sickness, Central African, 5, 73
 East African, 5, 75
 Gambian, 73
 Rhodesian, 75
 Slides, microscopic, 54
 Smears, blood, 97-101
 faecal, 55-61
 Sodium chloride, 55
 Sphaerita, 25, 69, 70
 Spleen puncture, 79, 81, 100
 Spores of *Eimeria clupearum*, 67
 sardinae, 67
 Isospora hominis, 48
 lacazei, 68
 Sarcocystis lindemanni, 106-107
 Sporoblasts of *Isospora hominis*, 48
 Sarcocystis lindemanni, 106
 Sporozoa, 8, 47-49, 83-96
 Sporozoites, 48, 68, 83, 86
 Staining of blood films, 99-100
 faecal smears, 59-61
 Trichomonas vaginalis, 109
 Sucking disc, 42, 44
 Sudan III, 67

 Technique for protozoa in
 blood, 97-101

- Trypanosoma brucei*, 75
 faeces, 53-61
 muscles, 107
 vagina, 109
- Thick blood films, 97-98
- Thin blood films, 97
- Thrombocytes, 104
- Toxic substances, 85
- Trichomonas buccalis*, 41
 elongata, 41, 45
 hominis, 37, 38-41, 45, 46, 108, 109
 Tenax, 41
 vaginalis, 41, 108-109
- Trophozoites, 3, 4, 8
- Trypanosoma, 4, 72-79, 100
- Trypanosoma brucei*, 75
 cruzi, 5, 73, 76-78
 escomeli, 76
 gambiense, 5, 72-75, 76
 rhodesiense, 5, 72, 75-76
- Trypanosomiasis, 5, 72-79, 105
- Tricercomonas intestinalis*, 35-36, 45, 46
- Triatoma, 72, 78
- Triatoma infestans*, 76
 megista, 76
- Ulcers, 9, 12
- Undulating membrane, 39, 74, 77, 78, 109
- Use of cover on blood smears, 100
- Vaginitis, 108
- Vegetative stage, 3, 4
- Vesicular nucleus, 3

- Viability of cysts, 14
 trophozoites, 8, 21, 28
- Wright's stain, 99-100
- Yeasts in blood films, 102
 faecal smears, 68
- Zygotes, 5

This Book

Manual of
HUMAN PROTOZOA

By RICHARD R. KUDO, D.Sc.

was set, printed and bound by The Collegiate Press of Menasha, Wisconsin. The type face is Linotype Caledonia, set 11 point on 13 point. The type page is 23 x 35½ picas. The text paper is 80 lb. White Deep Falls Enamel. The binding is Bancroft Linen Finish No. 70. The jacket is Hammermill, Antique, Sepia.



With THOMAS BOOKS careful attention is given to all details of manufacturing and design. It is the publisher's desire to present books that are satisfactory as to their physical qualities and artistic possibilities and appropriate for their particular use. THOMAS BOOKS will be true to those laws of quality that assure a good name and good will.



