



TREASURY ROOM

COL. GEORGE WASHINGTON FLOWERS  
MEMORIAL COLLECTION



DUKE UNIVERSITY LIBRARY  
DURHAM, N. C.

PRESENTED BY  
W. W. FLOWERS



Digitized by the Internet Archive  
in 2010 with funding from  
Duke University Libraries

720.  
A MANUAL

OF

MILITARY SURGERY.

PREPARED FOR THE USE OF THE

CONFEDERATE STATES ARMY.

ILLUSTRATED.

*Quise*  
-----  
BY ORDER OF THE SURGEON-GENERAL.  
-----  
*Confederate States Army* *W.S.*

159104

RICHMOND:

AYRES & WADE,

ILLUSTRATED NEWS STEAM PRESSES.

1863.

Entered according to the Act of Congress, in the year 1863, by

AYRES & WADE,

In the Clerk's Office of the District Court of the Confederate States for the  
Eastern District of Virginia.

cont  
12000  
#3 C.2

6/30  
Flowers Collection  
Tr.  
J. W. Co.  
\$ 3.50

# PREFACE.

A convenient Manual of Operative Military Surgery has been much needed in the army of the Confederate States. To supply this deficiency, the Surgeon-General has directed the preparation of the present brief collection of papers. Unambitious of authorship, the officers to whom this duty was confided have sought only to supply, in the briefest possible period, the most comprehensive and, as near as they could, the most convenient hand-book for the use, more particularly, of medical officers in the field. They have not, therefore, hesitated to use freely any material which their restricted opportunities and the state of the country permitted. Throughout the work such opinions as have been derived from their personal experience, acquired either before or during the war, have been freely, though briefly, expressed. At the beginning or in the body of each article, ample acknowledgment will be found for the selections to the several authors from whom they have been derived. The work does not profess to be even a complete manual, far less an elaborate treatise on Military Surgery. It will hence be observed that it treats of but few of the diseases incidental to the camp and hospital. The selection of these few subjects have been strictly confined to those affections most

intimately connected with gun-shot wounds and operations, as Shock, Tetanus, Hospital Gangrene, Pyæmia, &c.

The outline lithographs at the end of the volume have been carefully selected, and, the difficulties attending such work at this time being taken into view, in most instances accurately executed. It is hoped they will aid much in the elucidation of the text.

RICHMOND, VA., *October*, 1863.



# A MANUAL

OF

# MILITARY SURGERY.

---

## CHAPTER I.

### SURGICAL DISEASES.

#### SHOCK—COLLAPSE.

Shock is a sudden and powerful impression produced upon the heart through the medium of the nervous system, manifesting itself in a general depression of the vital forces. This depression may be more or less profound, involving sometimes the speedy destruction of life; at other times causing only a momentary impression upon the system. Between these extremes the experience of the surgeon will afford every possible shade of difference. When death results from shock, there is no room to doubt that its mode of approach is through the heart; for post-mortem observations have revealed the fact, that that organ is, under these circumstances, constantly and largely distended with blood, and that the fatal issue is due, not to the absence of its wonted stimulus, but to paralysis of its muscular fibres, in consequence of the suspension of nervous influence.

The symptoms of *collapse* (a term employed to denote an extreme degree of shock) are substantially those of syncope, save that in the latter the loss of consciousness and sensibility is more pronounced than in the former. The patient presents a pale, shrunken and anxious face; a cold and clammy surface, and a lack-lustre eye; his respiration is accelerated, imperfect and often sighing; his pulse quick and feeble; at times, intermitting; at times, wholly wanting. The intel-

lectual faculties are occasionally obscured or aberrated, though not unfrequently the mind affords no manifestation of sympathy with the general disturbance. The stomach usually evidences its participation by nausea, vomiting and hiccough. The duration of this condition is very variable; at times, passing off promptly and entirely, leaving the patient in the possession of his accustomed health; at other times, continuing for many hours and terminating either in death or tardy recovery. When recovery awaits the patient, *re-action*, as it is termed, must sooner or later be experienced. The vital functions, hitherto depressed and almost extinguished, are re-established; the pulse resumes its volume and loses its frequency; the respiration, at first sighing and oppressed, becomes deeper and freer; the surface regains its temperature and the countenance its accustomed expression. But this re-actionary effort may and often does transcend the limits of safety, and febrile disturbance with vascular excitement succeeds; or, in lieu of this, we encounter Travers's *prostration with excitement*. This is the traumatic delirium of certain authors, differing in no respect from delirium tremens, save that the limits of cerebral disturbance are wider in the former than in the latter affection.

*Causes.*—The causes of shock are resolvable into two classes: those which operate primarily upon the mind, as violent mental emotions, and those which act directly upon the body, as severe and sudden, or extensive injuries. The shock consequent upon gun-shot wounds usually illustrates the operation of both, these causes acting in conjunction, and in such sort that the precise measure of each in the given result cannot be determined. As a general rule, the greater the importance of the organ injured, the greater will be the amount of constitutional commotion. And although there is no constant relation between the amount of shock and the severity of the injury, yet the presence or absence of the former affords a valuable diagnostic indication in determining the gravity of the latter. It is true, however, that this indication is not wholly reliable, for we often find that, owing to some peculiarity of constitution, a degree of shock is manifested to which the accompanying injury bears no just proportion. It should be borne in mind, too, that while hemorrhage is itself a frequent source of shock, its presence never fails to aggravate that condition, from whatsoever other source it may

arise. McLeod says that "the commotion," *i. e.*, shock, "succeeding gun-shot wounds, is greater when the lower extremities are injured than when the arms suffer, and this is more especially seen if the person be in an erect position when the injury is inflicted." It is affirmed, too, that the shock is greater when the ball strikes a muscle in action than when it impinges upon one which is relaxed.

The *prognosis* will be favorable or otherwise, according as the collapse is more or less complete. Unqualifiedly bad when the manifestations of life are wholly suppressed, it should be guardedly unfavorable when re-action is long delayed and imperfectly established. But while a long delay in this process may well awaken fears for the safety of the patient, a somewhat tardy re-action warrants a more favorable prognosis than when it quickly supervenes and is strongly developed. If the patient be advanced in years, or of feeble powers, it will be remembered that in these conditions there is a defect of vital resilience, and the prognosis will accordingly be cautiously expressed.

*Treatment.*—The treatment of the disorder will depend upon its violence, as well as upon its duration. When the shock is slight, the patient having been placed in a recumbent position, with the head low, the case may safely be left to the unassisted powers of nature. If re-action be long delayed, a gentle filip may be imparted to the flagging energies of the system, by means of warmth externally applied, light frictions, and even some of the milder diffusible stimulants. When symptoms of collapse appear, recourse must at once be had to active stimulants, care being taken so to temper their exhibition that re-action be not thereby unduly accelerated or exaggerated. Among the many stimulants with which the surgeon's armamentarium is supplied, there are few more acceptable to the stomach than brandy, and none as well calculated to fulfil the indications which here present themselves. There are limits, however, beyond which its use cannot be judiciously carried. A wine-glassful or two will do all that may be expected of this drug, and should the system fail to respond to its influence in such quantity, nothing will be gained by oppressing the stomach with it; for being unable to appropriate it, the organ seeks relief by the expulsion of its irritating contents. Opium is much lauded for the energy with which it combats this condition of the system,

and, given with this view, it is recommended that the dose be large, and repeated according to circumstances. But, though salutary in its operation when the affection assumes the form of syncope, its use would be manifestly injudicious when the symptoms of coma predominate.

Should vomiting occur as a symptom of shock, it may be relieved by causing the patient to swallow pellets of ice, by mustard plasters to the epigastrium, by the use of soda water or the effervescing draught.

The military surgeon is often forced to decide upon the propriety of performing a capital operation upon a person who is the subject of shock from recent injuries or wounds. Though the question is not without perplexing difficulties, and gave rise formerly to much excited controversy, it has been at length definitively settled. When the prostration is great, delay in the operation is demanded; but it is neither necessary nor judicious to wait till re-action be fully developed. Larrey, indeed, says that the shock, so far from contra-indicating primary amputation, ought to determine the surgeon thereto. McCod affirms that "if the constitutional depression be the result of an injury, which remains as a source of irritation, then the removal of such must manifestly be a great point gained." The admissibility of chloroform in such cases is a vexed question among medical men, though the ample experience of this war strongly favors its use.

## TETANUS.

Tetanus is an affection characterized by tonic or permanent spasm of the voluntary muscles. The spasm may be general or partial; and when limited to the muscles of the inferior maxilla, it is called *trismus*, or, more commonly, *locked jaw*.

*Symptoms.*—The prodromic or precursory symptoms of the disease, as given by Larrey and others, are pronounced by more recent observers to be neither constant nor reliable, and are therefore omitted. When, however, the attack is declared, the muscles of the lower jaw and neck are the first to signal its onset. The patient begins to complain of soreness of the throat, stiffness of the jaws, and rigidity of the neck; mastication and deglutition are not performed with their accustomed facility, the tongue is with difficulty protruded, the

voice becomes husky and indistinct, and the throat clogged with a viscid mucus, which is excreted only after repeated efforts. As the disease progresses the countenance assumes a ghastly grin, *risus sardonicus*—in consequence of the contraction of the facial muscles; a severe pain is felt in the pit of the stomach, passing backwards to the spine, corresponding with the situation of the diaphragm; the breathing becomes laboured, conveying at times a sense of impending suffocation; the muscles of the trunk and extremities are involved, and the body becomes forcibly and unalterably curved backwards, forwards or laterally. When the disease has reached its acme the patient presents a most appalling spectacle. The head is thrown back, the extremities are rigidly fixed, and the body, if placed in the supine posture, rests upon the occiput and heels. The abdomen is hard, unyielding and resonant, under percussion; the bowels are obstinately confined; the urine is either wholly retained, or is expelled only in small quantity during the violence of a paroxysm; an offensive perspiration covers the skin; the saliva, which can no longer be swallowed, flows from the angles of the mouth; the countenance is haggard, the features horribly distorted, and when the spasm has reached its height, cries of anguish are extorted from the sufferer.

From the onset of the disease to its termination, no intermission of muscular rigidity is known, but on the contrary it is liable, ever and anon, to violent exacerbations, which may be determined oftentimes by a touch of the patient's body, a slight shock of his bed, a draught of cold air, or even the tones of a familiar voice.

When the disease approaches a fatal issue, a relaxation of the muscles is sometimes, though rarely observed, but it is the relaxation of exhaustion, and cannot be thought to be token amendment.

Notwithstanding the violence of these symptoms, the intellect rarely suffers impairment, and the senses are often preternaturally acute. The pulse and respiration, save during a paroxysm, are usually tranquil, and display no sympathy with this terrible commotion of the system till the hour of dissolution approaches, when laryngismus supervenes, and the heart's action becomes feeble and irregular.

Sleep, unless artificially procured, is wholly denied to the sufferer, who lives in the momentary dread of a paroxysm of

spasm, which sooner or later justifies his fears by terminating his existence.

In the above sketch an effort has been made to portray the features of *acute traumatic tetanus*, and the resemblance of any given case to that picture will be more or less marked as it approaches to or recedes from that variety of the disease.

*The modes of death in tetanus* are various, though by far the most frequent is that by asphyxia. Death begins in the lungs, and is speedily ushered in when the respiratory muscles and those of the larynx are invaded by the disease.

Occasionally death begins at the heart, and is then due to spasm of its muscular fibres, which, under such circumstances, are shown to be rigidly contracted. But the fatal termination is sometimes delayed till exhaustion or inanition puts a period alike to the life and sufferings of the patient.

*Causes.*—The causes of tetanus are of a two-fold character; they are remote or predisposing, and proximate or exciting. Among the former are usually classed age, constitution, sex, climate and race, though no time of life, habit of body, country, tribe or sex is exempt from its inroads.

Of *traumatic tetanus* the exciting causes are wounds of all kinds, contusions, luxations, burns, frost-bite, surgical operations, and indeed every conceivable form of physical lesion.

The idiopathic variety is supposed to depend upon exposure to cold and damp, intestinal irritation, intense mental excitement, or the suppression of certain natural secretions or adventitious drains.

The proportion of cases of tetanus among the wounded is computed by Alcock to be one in every seventy-nine, though we have the authority of more recent writers for saying that the number falls very far short of that estimate. Out of 7,740 wounded in the English army in the Eastern Campaign, but 23 cases of the disease are reported to have occurred; while the hospitals of Italy afforded only 80 cases during the campaign of 1859. (Legouest.) The experience of the war in which we are now engaged amply corroborates this conclusion, and proves that in this climate, at least, the complication is rare.

The situation and character of the wound doubtless exert a decided influence in determining the development of tetanus, for observation teaches that it results most frequently from punctured or lacerated wounds, especially of parts covered

with dense structures and liberally supplied with nerves; of such are the feet and hands.

Post-mortem researches have failed to demonstrate any special anatomical lesion peculiar to this affection, and hence its pathology is involved in obscurity. There is reason, however, to believe that it consists essentially of peripheral irritation transmitted through the spinal cord to the muscular system.

*Diagnosis.*—When tetanus is fully developed, its character is too clearly defined to admit of its being confounded with any other disease, though in its onset it has been mistaken for post pharyngeal abscess and rheumatism of the cervical muscles, and later in its progress for hydrophobia and spinal meningitis, from which, however, it is readily distinguishable.

If the distinction drawn between tetanus and *traumatic spasm* be recognized, the differential diagnosis may be arrived at thus: The latter is characterized at its onset by sudden and painful spasms in the wounded part itself, by localized contractions appearing under the form of paroxysms, repeating and prolonging themselves more and more, and passing speedily from their first seats to the neighboring parts, and finally, to all the voluntary muscles. (Legouest.) Tetanus, on the other hand, makes its appearance first in the muscles of the neck and jaw, without regard to the situation of the wound; it knows no intermission of its spasm, and is not relieved by amputation of the limb which we are informed is the proper remedy for traumatic spasm.

The average *duration* of acute traumatic tetanus is three days, though death may result from it in four or five hours, or be delayed for twenty or thirty days.\*

*Prognosis.*—In forming an opinion as to the probable result of a case of tetanus, it will be necessary to consider the variety as well as the violence of the disease. In the acute traumatic form, a speedily fatal termination may certainly be prognosticated, and so general is the assent of the profession to this conclusion, that the citation of authorities to establish it is deemed unnecessary.

When the disease is idiopathic in its origin, or exceeds twelve

---

\* The apocryphal case of death in fifteen minutes, reported in Rees's Encyclopædia, is purposely omitted.

days in duration; when the muscles of respiration and the larynx are not involved in the spasm; when it is intermittent in type, and the heart's action undisturbed, strong hopes of recovery may be entertained.

*Treatment.*—To enumerate the means used for the relief of tetanus would require a volume, to record those entitled to confidence does not demand a line. So varied and often conflicting are the remedies used—each one, too, claiming its measure of successes—that to the mind of the impartial observer there must arise a doubt whether any line of practice is capable of influencing materially the progress or termination of this affection. Under treatment, the most opposite, it will often be seen, that acute cases die, and the sub-acute and chronic cases recover. Nevertheless, experience has pronounced a qualified judgment in favor of certain measures, which therefore, until superceded by more efficacious ones, are entitled to consideration. These are both local and general. The former consists in a careful exploration of the wound, the removal of foreign bodies from it, and the use of mild and unirritating dressings.

The constitutional resources, after judicious purgation has been premised, are comprised in a supporting diet, and the free exhibition of opium, with some of the more potent sudorifics. As extreme exhaustion has been shown to be one of the sources of danger to the patient, the tendency to death in that direction has been sought to be obviated by the most nutritious and bracing food, administered by the mouth, through a tube introduced by the nostril into the stomach, or by enema, as the circumstances or necessities of the case may dictate. Brandy and opium are called for to mitigate pain and relieve spasm, and to this end should be administered in large and repeated doses.

Amputation of the limb, section of the nerves communicating with the wounded part, cauterization, vesication and free incisions (save for the extraction of foreign matter) have fallen into merited disuse. Chloroform, employed locally, internally and by inhalation, haschisch, woorara, quinia, lobelia, tobacco, mercury, iodide of potassium, alcoholic stimulants pushed to ebriety, tonics, anti-spasmodics, purgatives and anodynes, electricity and galvanism, have each in turn disappointed the hopes of the surgeon. So that, after a careful review of the treatment recommended, we are not surprised to hear the



practitioner of our own day proclaim with John Hunter "for tetanus I know of no internal medicine."

## ERYSIPELAS.

Erysipelas has been defined to be a diffused inflammation of the skin, or skin and cellular tissue, with a tendency to spread. (Druitt.) If this definition be accepted, it is with the qualification that the affection is not necessarily limited to the cutaneous or sub-cutaneous structures, but is liable with these to involve most of the tissues of the body, but especially the mucous and serous.

The subject has been variously divided, according to the views or caprices of successive writers; but that division by which the demands of convenience, as well as practical utility, are most fully met is in *idiopathic*—the effect of extraneous causes, or general influences acting upon the economy from without—and *traumatic*—when the result of wounds, injuries or local irritation. These forms are subdivided into *simple* or *cutaneous*, *phlegmonous* or *cellulo-cutaneous*, and *cellular*.

*Simple erysipelas* may make its advent without any precursory symptoms, though its approach is usually announced by anorexia, lassitude, pain in the head and back, and rigors more or less pronounced. The skin, in strongly-marked cases, speedily acquires an elevated temperature, and becomes dry; the tongue is broad, indented with the teeth, furred and flabby; and the pulse is accelerated, but usually soft and compressible.

When these premonitory symptoms, which are sometimes so slight as wholly to escape observation, have continued for an indefinite period of from three or four hours to as many days, the *local symptoms* manifest themselves. The skin of the affected parts, presents a sharply-defined, bright, almost scarlet redness, which, though readily disappearing under the pressure of the finger, as promptly returns. The swelling is inconsiderable, but may be detected by passing the hand lightly from the unaffected to the affected surface. Pain, though not invariably present, is rarely escaped, and is of a smarting, burning or stinging character, never pulsatile. Minute vesicles sometimes appear upon the inflamed surface, filled with transparent serum.

The disease early manifests a tendency to spread by invading the contiguous surfaces, and this tendency may be shown in one particular direction or in all directions at the same time. When different portions of the body are successively attacked, the term *erratic erysipelas* has been employed to denote it.

Phlegmonous erysipelas is ushered in by the same precursory symptoms which have been shown to precede the milder variety of the disease, though their intensity is not in a direct and constant ratio with the violence of the attack. This form of the disease is much more dreaded by the surgeon than cutaneous erysipelas, and justly so, for here we find not only the skin involved but the subjacent structures also, and the constitutional disturbance correspondingly greater. The pulse is quick, though compressible, and may become irregular or intermitting; the skin, hot and dry at first, conveying to the hand a sensation of pungent heat, declines in temperature as the disease advances, and is, at times, moist and clammy; the tongue is dry, brown and fissured, the bowels confined, and the urine scanty, high-colored and acid, containing an excess of urea, and is sometimes albuminous. The affected part is swollen from effusion of serous fluid into the cellular tissue, is soft and admits of pitting; the redness is deeper than in simple erysipelas and does not disappear entirely on pressure, and the pain is more acute and deep-seated. Soon, however, the swelling is greatly increased, and if seated in a limb, its size speedily rivals that of the trunk, it no longer pits, but is tense, hard and unyielding, and presents a dusky red or purplish hue. About the sixth or eighth day large vesicles or bullae stud the surface, and giving way, cover it with scabs or moist incrustations. In debilitated subjects, in whom the powers of life have been enfeebled by previous disease, the vesicles sometimes lose their transparency and assume a dark, purple color in consequence of the escape into them of the coloring matter of the blood. This is an untoward indication and augers badly for the patient in whom it evidences a vitiation of the circulating fluid. If, at this stage of the disease, resolution is not reached, diffuse suppuration with sloughing of the cellular tissue results. The parts become pale, soft, quaggy and doughy, though distinct fluctuation cannot be detected for the reason that the pus is not contained in a sac or limited by the deposit of plastic material. This pulpy, in-

elastic and doughy condition is a certain indication that suppuration is going on in the diseased tissues.

When erysipelas attacks a wound or ulcerated surface its condition and actions undergo marked changes; its lips or edges become puffed and swollen, discharging a thin, sanious matter; if previously suppurating it ceases to do so, and the granulations, pale and lifeless, soon disappear. If pain had existed in the wound it now becomes greatly aggravated, and is tense, throbbing and burning.

*Causes.*—Erysipelas is essentially a constitutional disease—a local manifestation of a poisoned condition of the blood, and acknowledges, in its production, the operation of two distinct classes of causes, the *predisposing* and the *exciting*.

A predisposition to the disease is engendered by certain atmospheric conditions, exposure to wet and cold, intemperance, bad diet, chronic affections of the liver and kidneys, and above all, to what Dr Gregory terms *ochlesis*, or the poison emanating from the bodies of the sick in closely crowded apartments

The exciting causes are wounds or injuries of any description, in any portion of the body, but especially those of the scalp, and gun-shot, lacerated, contused, punctured and poisoned wounds of the extremities—infection and contagion.

“The *modus operandi* of certain of these causes cannot be doubted, they are *zymotic*; that is, they act like ferments on the blood, and communicate to it a disposition to undergo the same changes in composition which they are themselves undergoing. The blood so poisoned deposits in the affected parts of the body an unhealthy plasma, which causes wide-spreading irritation and exudation.”

The disease is liable to epidemic prevalence, and it is then that it is exceedingly prone to assume its most intractable and fatal form, though we not unfrequently see the different varieties of the disease co-existing epidemically in the same community. When an epidemic tendency of the atmosphere exists, the most trivial injury or the smallest abrasion is sufficient to light up the disease, and hence no surgeon would, at such time, attempt any operation which the most imperious necessity did not demand.

*Terminations.*—Cutaneous erysipelas may run its course in from five to seven days, and terminate in resolution with desquamation of the cuticle, but where *phlyctæna* exist, the cure

is delayed in consequence of the superficial ulcerations to which they give rise.

Instead of running its course with regularity, and terminating in the time and manner prescribed, it sometimes assumes the *erratic* form, and, advancing gradually from site to site, declining at one point as it progresses at another, the entire cutaneous surface may, sooner or later, become involved in the disease. When it takes on this ambulant or wandering form, its duration is indefinitely prolonged, and its course should be regarded with suspicion, for though it is of the cutaneous variety, and never ends in suppuration, and rarely in vesication, its subjects are those of feeble constitution, and, for the most part, the victims of chronic organic disease. But the progress and termination of the affection may be modified by a metastatic tendency—a disposition to sudden recession of the inflammation at one point, with an equally sudden development of it at another and, it may be, remote point, or to its translation from the external surface to the internal organs.

In phlegmonous erysipelas, when the inflammation does not yield to treatment by the sixth or eighth day, sloughing and suppuration of the sub-cutaneous, and also the inter-muscular areolar tissue, take place. Cellular tissue, thus destroyed, is not re-produced, and the skin in such cases contracts adhesions with the aponeuroses or muscles, or it may even be with the bone itself, by means of an adventitious, or, as Delpech terms it, *inodular* tissue, whence result deformity and the abolition of the functions of the part.

Even where suppuration, with extensive loss of substance, is not experienced, the intensity of the morbid action may be such, that the softness and mobility of the skin are for a long period impaired or permanently destroyed, and the cellular tissue is converted, by effusion of plastic lymph, into a brawny and inelastic mass. It sometimes happens that the disease runs on to the destruction of both the skin and cellular tissue of an entire limb, and in such cases, if recovery take place, loss of function is inevitable.

Death by *coma* may terminate the disease in consequence of its extension to the brain or its meninges. Or the mucous membrane of the pharynx and larynx becoming involved, serious effusion may take place into the sub-mucous tissue, and death by *apnoea* result from œdema of the glottis. Death

sometimes begins at the heart, especially when the attack is prolonged and the patient imperfectly nourished and much debilitated by previous disease. The *prognosis* of erysipelas must depend upon a variety of circumstances, as the age, habits, constitution and surroundings of the patient, the condition of the atmosphere, and the seat of the disease, as well as upon the form which it assumes.

Where the malady affects only the skin, and does not involve the integument of the head or face—where the inflammation is not of the erratic form, and the patient is young, vigorous and temperate—a favorable opinion may be unreservedly expressed; but should the disease prove phlegmonous or œdematous in character—should the head and face become implicated, especially in an old and feeble subject—should it attack the throat or brain, or should the accompanying fever prove to be of a typhoid type—the prognosis should be guardedly pronounced.

*Preventive treatment.*—Since the agency of impure air, unwholesome food, intemperance, crowded hospitals, contagion and infection, is recognized in the production of erysipelas, it behooves the military surgeon, to whom is entrusted the preservation of the health of the soldier, to look well to the character of the locality chosen for his camp or hospital, to take care that it be not low, damp, or malarious; that the tents be so pitched, with reference to each other, as to admit of a free circulation of air between them; that the hospitals be freely ventilated; that they be not crowded with inmates—an area of not less than 1500 cubic feet being allotted to each—that their walls be frequently whitewashed, and their floors dry-scrubbed. A frequent use of the warm bath, by promoting a healthy action of the skin, will greatly diminish the tendency to this disease. Should it make its appearance, those affected by it should at once be isolated either in tents or small rooms. The practice of establishing large wards for erysipelas, though doubtless convenient, is nevertheless reprehensible, as tending to increase its violence, by intensifying the conditions favorable to its development and spread.

In describing the treatment of erysipelas, it will be convenient to consider, first, those measures which are adapted to the relief of its milder or cutaneous variety, calling attention to the constitutional, and afterwards to the local remedies. Venesection, though formerly much in vogue in the treat-

ment of this affection, is now no longer countenanced. Emetics are of far less doubtful utility, but may, unless the stomach be oppressed with ingesta or vitiated secretions, be advantageously superceded by purgatives. Constipation, which has been shown to be one of the symptoms of the disease in all its varieties, must be met by the timely use of cathartics, and for this purpose eight or ten grains of calomel, with as many of rhubarb or jalap, should be given and repeated daily, so long as the alvine evacuations are dark-colored, liquid, and offensive. But even here the military surgeon should bear in mind the exceeding proneness to ulceration of the intestines which exists among soldiers in the field, and exercise a wise discretion in the use of this class of remedies. Refrigerants, as acetate of ammonia, or the effervescing mixture, are grateful to the patient, and may be employed to advantage, if there be much febrile disturbance. Tincture of the sesqui-chloride of iron has acquired almost the reputation of a specific in the treatment of erysipelas in all its forms, and may be given in quantities of from two to eight, or ten drachms in the twenty-four hours. In that form of the disease now under consideration, it will suffice to give twenty or thirty drops in a wine-glassful of water every four hours. When the condition of the patient demands tonics—and it is rare that it does not—two grains of quinine may be advantageously combined with each dose of the foregoing preparation. The diet of the patient should be nourishing and supporting, without being stimulating. If the patient has accustomed himself to the daily use of ardent spirits, they should not now be wholly interdicted, lest the vital powers, already depressed by the disease, be still farther reduced through the defect of their accustomed stimulus. Opium may be given, especially at night, to allay restlessness and promote sleep, provided there be no head symptoms present.

The *local remedies* for cutaneous erysipelas are, for the most part, mild and unirritating in their action. They consist in warm fomentations with decoction of poppy heads, enveloping the inflamed surface with carded cotton, or dredging it with flour. Advantage sometimes results from painting the diseased parts twice daily with the tincture of iodine, diluted with an equal quantity of alcohol; the application should encroach somewhat upon the sound skin. The sulphate of iron has enjoyed, since its introduction to the notice of the

profession by Velpeau, a wide reputation as a local remedy in erysipelas. For this purpose a solution containing an ounce of the salt to a pint of water is applied to the inflamed surface by means of compresses moistened with it. The efficacy of blisters in cutting short this morbid action is much insisted upon by certain writers—but experience would restrict their use to the erratic form of the disease, in which they sometimes exert a promptly beneficial effect. The nitrate of silver is frequently applied to the skin of the affected part, either by pencilling it with a strong solution, or by bringing the solid caustic, previously moistened, in contact with every portion of it. This is a measure of dubious propriety, for the blackening which results from the application of this substance, and the consequent concealment of the surface from further observation, is scarcely atoned for by the amount of benefit resulting from it.

A less doubtful use of the nitrate of silver is its employment in limiting the spread of the disease by belting the affected part with a saturated solution of the salt, or with the solid caustic. - To render this effectual, the caustic should be applied upon the sound skin in such manner as completely to circumscribe the diseased portion. Collodion, creasote, acetate of lead, tincture of iron, sulphate of copper, mercurial ointment, are a few of the many topical remedies advised, and convenience or necessity may sometimes dictate a recourse to one or other of them. In cutaneous erysipelas incisions are not called for, though, when the swelling, pain and redness are great, benefit will inure to the patient from numerous minute punctures, as recommended by Dobson—from one-fourth to one-fifth of an inch in depth, made with the point of a lancet or bistouri, as by this means the overloaded capillaries are relieved, and the tension thereby greatly diminished. Compression, by means of the roller bandage, though recommended by Velpeau, and practised by some surgeons, can only be used to advantage when the inflammation begins to decline, and the parts are left in an unhealthy and swollen condition.

The influence of position in combatting inflammatory action is nowhere more clearly demonstrated than in the treatment of erysipelas. Throughout the entire progress of the case, the affected limb should be elevated and maintained perfectly at rest.

The *constitutional treatment of phlegmonous erysipelas* must be determined and regulated by the stage of the disease, or rather by its attendant symptoms. At its onset, when for a brief period, as has been stated, the fever is of the sthenic type, purgatives, with saline diaphoretics are indicated. When typhoid symptoms appear—and their approach is always announced by an increased frequency and loss of force in the pulse, as well as by dryness and brownness of the tongue—the patient's strength should be sustained by the most nutritious food, conjoined with alcoholic stimulants, carbonate of ammonia and quinine. Beef essence, milk punch or toddy, wine whey, or the egg and brandy mixture of the British Pharmacopœia, should be administered *ad libitum*. Should nausea or vomiting supervene, it may often be relieved by brandy and soda water, the effervescing mixture, or a pill of crude opium, with or without a minute portion of calomel.

In phlegmonous erysipelas, however, as in the simple variety, much reliance is placed upon the muriated tincture of iron, in doses of from thirty to sixty drops, repeated at intervals of one, two or three hours, according to the violence of the inflammation.\* This drug has been pushed to the extent of two ounces in the twenty-four hours, in cases threatening a speedily fatal termination, with good results. To attain the beneficial effects of this preparation, it will be necessary that the alimentary canal be previously evacuated, and its secretions altered and improved. To the neglect of this precaution is doubtless due the disappointment which some practitioners have experienced in its employment. Quinine may conveniently, as well as advantageously, be combined with the iron in such manner that each dose of the latter shall contain a proportion of the former.

The *local remedies* for cellulocutaneous erysipelas are substantially those recommended for the milder affection, save that in the former greater promptness is necessary in their adoption, and greater energy in their application. Incisions, after the manner of Dr. Hutchison, made through the diseased structures, are most salutary in their effects, and cannot, at certain stages of the inflammation, be dispensed with. A

---

\* When the iron, given in these doses, irritates the bowels, causing catharsis, the dose should be lessened or the medicine pretermitted.



timely recourse to this expedient may not only contribute largely to the recovery of the patient, but may suffice to cut short the disease, and wards off the fearful consequences of diffuse suppuration and sloughing. These incisions to be effectual should be made "through the cellular tissue, down to the deep-seated fascia, which should not be divided in the first instance." (Guthrie.)

When the parts are hard, tense and brawny, and the skin deeply congested or purple, much good may be anticipated from this measure as affording an outlet to the infiltrated fluids which, by their pressure upon the vessels, threaten strangulation and gangrene of the part. Guthrie says "as soon as the inflamed part communicates the springy, fluctuating sensation approaching, but not yet arrived at the quagmire feel alluded to, an incision should be made into it, when the areolar or cells of the cellular tissue will be seen of a bright, leaden color and of a gelatinous appearance, arising from the fluid secreted into them, being now nearly in the act of being converted into pus."

At a still later period, when the parts have become boggy, soft and semifluctuating, incisions are indispensable to give exit to the pent up pus and sloughing cellular tissue. The resulting hemorrhage should be controlled by the pressure of the fingers, or a compress applied to the wounds and the elevation of the part, after which it should be fomented or enveloped in cloths wrung out of a warm decoction of poppies or chamomile flowers. So great is the importance of the period at which the incisions should be made, that the following rule upon that subject has been given by a recent author: "In the early stages of phlegmonous erysipelas, in the course of the first two or three days, attempts may be made to arrest the course of the inflammation by the means which are found most effective in the simple forms. Should these not be found of any avail in checking it, incisions should be at once resorted to freely and decisively; and they should be resorted to afterwards whenever it may be found that pus is lodged, or that the cellular tissue has been destroyed in parts removed from the neighborhood of those previously made." The incisions should be made in the direction of the longitudinal axis of the limb, to avoid doing injury to the muscles, nerves and arteries; they should not be more than two inches in length, nor should the spaces between them exceed three.

The objections to the long incisions recommended and practiced by Lawrence are; that the hemorrhage is excessive, having, in some instances, proved fatal, and in others, rendering necessary the ligation of the main artery of the limb; that the shock attending their infliction is very considerable, and is badly borne by those among whom the disease is most frequently encountered; and that the swelling and tension of the inflamed parts are not more effectually relieved by them, than by well-planned short incision. South recommends that they be made diamond shape, thus :



and maintains that by this means more relief is afforded than by incisions, which involve even the entire length of the limb. If suppuration has already commenced, the discharge will be very copious for some days, during which much care and frequent dressings will be necessary. When shreds of disorganized tissue or gangrenous masses are seen, they should, if possible, be removed, since their presence is a source of irritation, and their extrusion, if left to nature, must be long delayed. The subsequent treatment consists in the application to the parts, of moistened lint or linen, which should be retained in position by means of a roller bandage, so applied as to exert a very gentle pressure, and afford an equable support. Should the process of separation be sluggish, and local stimulation become necessary, the lint may be saturated with the "red wash," than which there is nothing better for this purpose. The formula for its preparation is as follows :

Take of Sulphate of zinc, grs. xvi.  
 Compound spirits of lavender, ℥ij.  
 Spirits of rosemary, ℥ij.  
 Water, ℥viij.

The application may, however, be varied to meet the necessities of the case, or the fancy of the surgeon. Convalescence is usually slow, and recovery is often for a long period very

partial. Pending such a result, a generous diet, with wine, iron and some of the vegetable tonics should be prescribed. Gentle exercise in the open air, as soon as the strength of the patient admits of it, will contribute much towards his restoration to health.

*Cellular erysipelas*, or, as it is more frequently called, *cellulitis*, or *diffuse inflammation of the cellular tissue*, is, for the most part, traumatic in its origin, though predicated upon a depraved state of the blood, as shown by the typhoid character of its symptoms. Its local manifestations are somewhat peculiar, and serve to distinguish it from cellulocutaneous erysipelas, with which it is nearly identified in its origin, development, terminations and treatment. The skin, not being implicated in the disease, save as a consequence of the destruction of the subjacent tissues, suffers no change of color, beyond, at times, a slight erythematous blush; the swelling is great, though undefined; and the limb is tense, shining, brawny and painful, but very presently becomes soft, and crepitating. The progress of the disease is rapid, and sometimes ends in the destruction of the patient, even before suppuration is established, the vital forces being overwhelmed by the accumulated poison of the blood. Where such an event does not take place, the case may not the less surely, though more tardily, terminate in death, in consequence of the extensive sloughing and profuse suppuration to which it gives rise.

When cellular erysipelas makes its appearance in a wound—it matters not how otherwise trivial—it becomes at once invested with the gravest import, and should awaken apprehensions the most serious; for, though the disease may terminate in resolution, such an issue is exceedingly rare, and should not be reckoned upon.

Its treatment differs from that of phlegmonous erysipelas only in respect to the date of the incisions, which, in the cellular variety, should be made so soon as the character of the disease is declared, without waiting for those local signs that elsewhere determine to their use.

It is not thought necessary to consider separately the special forms of erysipelas given by most authors, as that of the orbit, the head, the scrotum, &c., for the reason that they are all of them—with perhaps some slight modifications—amenable to the rules already laid down.

## PYÆMIA.

The terms pyæmia, pyohæmia, purulent infection, purulent resorption, purulent diathesis, purulent phlebitis, and purulent fever, have all been employed, according to the views of each individual writer, to designate the same disease, or some of its modifications, and are only valuable as setting forth in a word the different opinions which are entertained of its nature. They all imply a vitiation of the blood by the admixture with it of pus.

Without an unqualified endorsement of the pathology involved in the foregoing denominations, the term pyæmia is here employed to signify that systematic poisoning which results from the introduction of septic matters into the circulation, and is characterized by a tendency to purulent deposits in one or more of the organs or tissues of the body.

Though it does not comport with the limits or design of this work to enter upon the interesting and still unsettled etiological questions involved in this subject, yet it cannot be omitted to state, that recent observations have failed to detect, with certainty, the presence of pus in the blood; that the secondary manifestations of the disease are sometimes wholly independent of primary local suppuration; and, lastly, that the abscesses which are developed at various portions of the frame are not at first purulent in their character.

These conclusions, if corroborated by further investigation, must overthrow the recently received views on the subject of pyæmia. And it remains to be seen how far the newly ventilated theory that the secondary deposits or collections of pus are due to mechanical obstruction, caused by the entanglement in the lesser veins of the debris of disintegrated clots or detached portions of fibrin, will be sustained when submitted to the same test.

*Cause.*—The causes of pyæmia are both predisposing and exciting. Among the former are reckoned habits of life, temperament, physical condition of the patient, and epidemic constitution of the atmosphere. Those of temperate habits, equable temper and vigorous constitution are rarely the subjects of this disease, whilst the feeble, desponding and dissipated are especially liable to its attacks, if long confined within the crowded wards of an hospital.

The life of the soldier—its hardships, privations and exposures, its sudden alternations of excitement and despondency—is well calculated to engender that condition of the fluids of the system which predisposes to pyæmia.

The exciting causes are wounds or injuries of any portion of the frame, but especially of the veins and bones.

We find it supervening upon surgical operations, both great and small, resections, amputations and disarticulations, though the subjects of surgical operations are more liable to its attacks than those who have sustained gun-shot wounds.

*Symptoms.*—The symptoms of pyæmia are local and general, though the local symptoms are not of great significance. If the wound is suppurating at the time of the attack, it no longer does so, but becomes dry, and the adjacent surface assumes a livid or dusky aspect. These symptoms are not constant, for the disease frequently declares itself without any local threat of the coming trouble. A sign to which Legouest (*Chirurgie d' Armee,*) attaches importance, is pain along the course of the veins, which, he says, however, is frequently wanting.

The general symptoms, when the disease assumes the acute form, are ushered in by severe rigors or shiverings which may last an hour or even more. The hot stage, with acceleration of pulse, then supervenes, but is of brief duration, and is speedily followed by copious, exhausting and long continued sweats. A period of tranquility succeeds, during which the patient expresses himself as greatly better, and is sustained in that belief by his attendants, who, unless familiar with the treacherous character of this malady, are apt to consider these phenomena as the paroxysm of an intermittent fever. But, ere long another chill is experienced, and is speedily followed by another and another, each it may be more intense and protracted than its predecessor, and separated from each other by short and irregular intervals. The pulse becomes quick, small, thready; the respiration short and hurried, attended with dry cough; the physiognomy altered; the skin clammy and often jaundiced; the tongue dry and furred; the teeth and lips not unfrequently covered with sordes. The patient now begins to experience pain, sometimes in the chest, sometimes in the right hypochondrium, and sometimes, it may be, in the vicinity of the larger joints. These pains point to the formation of the so-called metastatic abscesses, which are liable to be de-

veloped in various portions of the system. Abscesses, however, may and often do occur without such premonition, and even attain a large size before their presence is suspected.

Concurrently with the formation of these purulent collections, there is more or less hebetude manifested by tendency to sleep, though such sleep is neither refreshing nor profound, but is attended with a constant muttering. When roused, however, the patient evinces no impairment of intellect. If, now, the stethoscope be applied to the chest, crepitation is distinctly heard over the greater portion of its parietes, whilst percussion affords a corresponding diminution of resonance.

Death by asthenia usually closes the scene in from five to ten days, though when the disease is slowly developed, it may last for fifteen or even twenty days. Occasionally, this fearful malady runs its course with yet greater celerity. "Within twenty-four hours in *acute* cases there are rigors, vertigo and general uneasiness. Then follow heat, perspiration and increased rapidity of pulse. The seat of inoculation is dusky, indurated, often pustular, or, if it had been before secreting pus, the discharge ceases. Radiating from this centre, the integument is distended with a serous effusion, presently to be mingled with thin sanious pus. The swelling, generally somewhat elastic, is hard and tense over enlarging and painful glands. The blood, deranging the heart's action, is circulated violently and rapidly through the system; exuding from its vessels, as in purpura, it stains the surrounding tissues, forms ecchymoses in internal organs, or is poured out upon mucous surfaces, and is then chiefly removed with purging or vomiting. In another twenty-four hours, the patient—flushed, anxious, restless, even delirious, is in a hopeless condition, with prostration and rapid sinking." (See Callender, Art. Pyæm: Holmes' System. Surgery.) When the disease thus rapidly runs its course there is an entire suppression of local symptoms, and it then assumes the character of typhoid fever, and might, with propriety, be called pyogenic fever.

*Prognosis.*—When it is known that pyæmia is the cause of death in 43 per cent. of all fatal primary amputations, and in 25 per cent. of all fatal secondary amputations; when it is shown that 10 per cent. of all amputations terminate in death from the same cause, (Bryant,) the fatal character of this terrible scourge will be vindicated. Lalleron tells us that of

539 amputations performed by him at Constantinople, he lost nearly one-fourth from pyæmia; and of those performed in the continuity of bone, his loss was one in two and a half. In the hospitals of Brescia, in Italy, 1839, the mortality from this source, after amputation, was 52 per cent.; at Milan something over 27 per cent.

There is little room to doubt, when the symptoms of systemic poisoning are accompanied by its secondary manifestations in the form of purulent abscesses, that the disease must terminate fatally. Now and then an instance of recovery is recorded, but this is so rare in comparison with the whole number of cases, as to leave no rational ground of hope for such a result. When the symptoms are tardy of development, and the constitution of the patient is not seriously impaired; when the purulent collections are limited to the cellular planes, and do not involve the viscera or their cavities, experience teaches that judicious treatment may sometimes, though rarely, effect a cure.

To arrest the ravages of this terribly fatal disease, we may readily conceive has taxed the ablest talent of the profession, and the amplest resources of the materia medica. No means, whether prophylactic or curative, general or local, which afforded a prospect of benefit, have been overlooked, and yet its mortality is fearfully great, fully justifying the language of a recent writer, (Holmes' Syst. Surgery,) when he states that "practical surgeons acknowledge that very little chance remains for the patient who, after an operation, (or gun shot wound?) is attacked with the symptoms of this disease."

The treatment employed is both preventive and curative. Under the head of the former we find measures, some of which are simply valueless, whilst others are positively mischievous. Thus, we find one surgeon (Teissier) recommends the internal use of aconite; another, sub-cutaneous amputations; another, the use of the actual cautery instead of the knife, in amputations; and yet others—among whom is Legouest—warn us of the danger of seeking union by the first intention! Of these measures the aconite treatment is certainly the least injurious, though the propriety of its daily administration to all the wounded of an hospital, may well be questioned, when it is known that the experience of the profession is adverse to its efficacy.

Something, however, may be effected in the way of preven-

tion, and to such means every attention should be paid. These consist in observing scrupulous cleanliness about the person and apartment of the patient. The room should be freely ventilated, and the wound carefully washed and dressed as often as its condition requires; and in doing this, avoid the use of sponges, as the most prolific source of contagion known to the hospital surgeon. All depressing causes, both mental and physical, should, as far as possible, be removed. Patients should not be crowded together, for experience teaches that they fare better in tents, or even in the open air, than when immersed in the poisoned atmosphere of a crowded hospital.

When the disease has once made its appearance, recourse is had to local, as well as general treatment. As local remedies, we are advised to employ blisters, escharotics—as nitrate of silver, chloride of zinc, per-chloride of iron, the mineral acids, and the actual cautery. The weight of authority is here in favor of the liquor of the per-chloride of iron, diluted or not, according to the degree of effect which it is sought to produce. The liquid should be brought, and retained, in contact with the entire surface of the wound, reaching into its sinuses and depressions, by means of masses of charpie, or lint previously saturated with it. Unless the condition of the wound is particularly unfavorable, manifesting a tendency to diffuse cellulitis, one such dressing suffices for twenty-four hours.

When evidences of amendment appear, the fluid may be further diluted, until its use is superseded by simple dressings. To condemn amputation as a remedy for pyæmia, though recommended and even practiced by some surgeons, it is only necessary to mention it.

The constitutional measures are such as look to the support of the patient's strength, and the improvement of his general condition. It is almost needless to say that depressing remedies of every kind are inadmissible, and that so far from bleeding, purging and vomiting a patient in whom the vital powers are enfeebled by a subtle blood-poison, we should seek to sustain his strength till nature resumes her sway and establishes re-action. To carry out the indications, milk toddy, wine, beef tea, and quinine, are especially worthy of reliance. The salt may be given to the extent of fifteen or twenty grains daily, with or without some of the preparations of iron. Opium may often be employed to advantage, when pain and restlessness



are experienced. And with this view the nightly exhibition of Dover's powder has been strongly recommended.

When secondary abscesses present themselves, they should be freely opened, and subsequently treated on general principles.

## HOSPITAL GANGRENE.

This affection, under the names *Sloughing Phagedæna*, *Pulpy Gangrene*, *Phagedæna Gangrenosa*, *Putrid Degeneration*, *Pourriture d'Hopital*, *Humid Gangrene*, *Diphtherite of Wounds*, and *Traumatic Typhus*, has long been known to the profession, and especially to the military surgeon. Though sporadic cases are now and then met with by the general practitioner, its peculiar *habitat*, as its name implies, is the hospital, in which it formerly prevailed to such an extent as to lead its early historian, Pouteau, seriously to inquire, "Are hospitals, then, more pernicious than useful to humanity?" With the modern improvements in sanitary regulations, however, it has nearly disappeared from civil practice, and confines its ravages, in a great measure, to the wounded inmates of the over-crowded, illy-ventilated, and often filthy, extemporaneous hospitals of the military surgeon. So well recognized is the effect of "over-crowding" in causing this fatal disease, that from its earliest notices, through successive generations of writers, especial stress is laid upon it by each; and Legouest, writing in April of the present year, says, after reviewing the supposed agency of various other causes, "But the veritable cause of hospital gangrene appears pre-eminently to reside in over-crowding. It oscillates and vibrates, in short, with the movements of the sick; declining and disappearing when their number diminishes; returning and increasing in virulence when it is augmented." If to this cause be added the operation of contagion and infection, the predisposing influence of all depressing agencies, both moral and physical, together, possibly, with certain atmospheric conditions, or epidemic tendencies, all that is at present known of the origin of this disease will have been said.

*Symptoms.*—In describing the characteristics of the milder form of hospital gangrene McLeod says, "the earliest symptom was pain in the part, which sometimes preceded the ulcerative process by a couple of days. The edges of the

wound did not swell up, but remained thin, as they were undermined. The pain generally continued during the process of destruction. It appeared chiefly in the lower extremities, and in wounds whose progress towards cure had been for some time stationary. It seldom burrowed far into the intermuscular tissue, but confined its ravages to the surface and the circumference of the wound." This is the usual mode in which the disease presents itself when it occurs in isolated cases, and under favorable circumstances of hygiene. But when the predisposing and exciting causes conspire to give it intensity, its progress towards destruction is fearfully rapid. The same author says of the disease in this more malignant form, "The cases of all of those who died in my wards seemed to be doing perfectly well up to sixteen hours, at the farthest, before death. During the night previous to death, the patient was restless, but did not complain of any particular uneasiness. At the morning visit, the expression seemed unaccountably anxious, and the pulse was slightly raised. The skin was moist, and the tongue clean. By this time the stump felt, as the patient expressed it, heavy like lead, and a burning, stinging pain had begun to shoot through it. On removing the dressings, the stump was found slightly swollen and hard, and the discharge had become thin, gleetty, colored with blood, and having masses of matter, like gruel, occasionally mixed with it. A few hours afterwards, the limb would be greatly swollen, the skin tense and white, and marked along its surface by prominent blue veins. The cut edges of the stump looked like pork. Acute pain was felt; a cold sweat covered the body; the stomach was irritable, and the pulse weak and frequent. The respiration became short and hurried. The heart's action gradually and surely got weaker till, from fourteen to sixteen hours from the first bad symptom, death relieved his sufferings." Guthrie, in describing the disease, uses the following graphic language: "A wound attacked by hospital gangrene, in its most concentrated and active form, presents a horrible aspect after the first forty-eight hours. The whole surface has become of a dark-red color, of a ragged appearance, with blood partly coagulated, and apparently half-putrid, adhering at every point. The edges are everted, the cuticle separating from half to three-quarters of an inch around, with a concentric circle of inflammation extending an inch or two beyond it; the limb is usually swollen for some distance,

of a shining, white color, and not peculiarly sensible except in spots; the whole of it being, perhaps, œdematous or pasty. The pain is burning, and unbearable in the part itself, whilst the extension of the disease, generally in a circular direction, may be marked from hour to hour; so that, in from another twenty-four to forty-eight hours, nearly the whole of the calf of a leg, or the muscles of a buttock, or even of the wall of the abdomen, may disappear, leaving a deep, great hollow, or hiatus, of the most destructive character, exhaling a peculiar stench, which can never be mistaken, and spreading with a rapidity quite awful to contemplate. The great nerves and arteries appear to resist its influence longer than the muscular structures, but these at last yield; the largest nerves are destroyed, and the arteries give way, frequently closing the scene, after repeated hemorrhages, by one which proves the last solace of the unfortunate sufferer. \* \* \* The joints offer little resistance; the capsular and synovial membranes are soon invaded, and the ends of the bones laid bare. The extension of the disease is, in the first instance, through the medium of the cellular structure of the body. The skin is undermined and falls in; or a painful, red, and soon black, patch or spot is perceived at some distance from the original mischief, preparatory to the whole becoming one mass of putridity, whilst the sufferings of the patient are extreme."

To this picture, drawn by the hand of the great apostle of military surgery, it is needless to add; though, as has been already said, the disease does not always assume a character of such intense malignity. Instead of this rapidly destructive gangrenous variety, we sometimes encounter its sloughing, pulpy, or, as it has been called, diphtheritic form. This is characterized by the formation of a thick semi-concrete, greyish or greenish mass, which attaches itself firmly to the ulcer, the edges of which are sharply defined, everted and circular in form. There is much stinging and lancinating pain experienced, and the discharge is thin, sanious, or greenish brown, and excessively offensive. When these pseudo-membranous masses, or rather sloughs, are detached, there remains a raw, bleeding surface, which may be partially concealed beneath a stratum of thin, greenish yellow, and offensive pus. The parts thus exposed are exceedingly liable to be transformed into the same substance as before, and this, in turn, being thrown off, the limits of the morbid action are gradually ex-

tended. Should a large artery be encountered, its vitality is retained, and its integrity preserved, for a short period, but yielding finally to the resistless nature of the attack, a copious, and, it may be, fatal hemorrhage results, for no effort is here made by nature to seal up the vessel, or to plug its extremity with a coagulum.

Death from hospital gangrene may take place in the rapid and inevitable manner shown by McLeod, through the overwhelming effect of the poison upon the system; or, the disease progressing more tardily, the patient may succumb from exhaustion, hemorrhage, hectic or pyæmia.

*Treatment.*—The treatment of this “child of the typhus,” as it has been called, comprises both prophylactic and preventive measures. The latter, unfortunately, are little under the control of the field surgeon, who is often compelled, by the necessities of war, to do violence to all his ideas of sanitary propriety, by crowding large numbers of sick and wounded soldiers into very circumscribed, and, it may be, damp and ill-ventilated apartments. Neither can he guard those under his care against the more remotely predisposing causes of this disease, such as excessive fatigue, exposure, insufficient or improper food, and much less can he ward off the depressing effect of a sudden reverse of arms.

The precautions against hospital gangrene consist in affording to each patient an ample space—1600 cubic feet is the area allowed in the best-ordered European hospitals—with free ventilation and pure air; cleanliness should be observed in the minutest particular; the latrines should be so constructed—over running water, if practicable—and so remote, as to leave no chance of atmospheric contamination from that source. The general condition of the patient should claim attention; if febrile action be present, mild antiphlogistics, with purgatives and refrigerants, are indicated; if irritation be manifested, it should be calmed by anodynes and sedatives. The wound should be carefully dressed as often as is necessary to meet the requirements of cleanliness, and, if convenient, disinfectants, such as the chlorides of lime and soda, freely used. When the disease makes its appearance, *nothing short of complete segregation of each case, as it occurs, with a liberal use of disinfectants, can give a promise of security against its further spread.*

The curative treatment is both general and local. As the

attendant fever is of a low grade, a generous diet, with a judicious use of stimulants, will be required throughout the management of each case. McLeod says he derived much advantage from the exhibition of muriated tincture of iron, in half-drachm doses, three times daily. To each dose of the iron, five grains of quinine may be added, with a reasonable prospect of benefit.

The *local treatment* may be summed up in a very few words. The strongest possible escharotic should be applied to the entire gangrenous surface. The mineral acids, the actual cautery—Fowler's solution of arsenic, and the chloride of zinc—have each their advocates, and, perhaps, advantages. But the practitioner of the present day can have no hesitation in giving the preference to chemically pure nitric acid, unless hemorrhage be present, when the actual cautery should be substituted. As its application is attended with much pain, chloroform should be previously administered. The acid is applied by means of a dossil of lint attached to a bit of whalebone or wood, and should be brought in direct contact with every portion of the diseased surface, so as to form an eschar equal to the dimensions of the sore. The use of the cautery should be followed by a full anodyne, which should be repeated, if the sufferings of the patient are great. When the eschar is thrown off, the ulcerated surfaces should be treated upon general principles, taking care to uphold the patient by nourishing food, and a liberal use of wine or brandy.\*

## AFFECTIONS OF STUMPS.

In considering the affections to which stumps are liable, it will be necessary to bear in mind the several structures which enter into their formation. These are skin, cellular tissue,

---

\* The oil of turpentine has recently been employed, both internally and as a local application, in the treatment of ill-conditioned ulcers and sloughing wounds; and it is claimed that the results of the experiments are such as to entitle it to further trial.

The per-sulphate and the per-chloride of iron have each been recommended as escharotics in hospital gangrene, but their efficacy in this respect must be confirmed by the test of a wider experience before they can be pronounced worthy to supersede the mineral acids.

muscles, aponeuroses, tendons, nerves, arteries, veins, bone, and medulla. Each occasionally has morbid changes impressed upon it during the healing process, which are modified and determined by the character and susceptibilities of the particular tissue involved.

It is here proposed to discuss only such of these morbid conditions as are found more frequently to present themselves as accidents in the history of stumps resulting from the casualties of the battle-field. Convenience of description has divided these accidents into primary and secondary; the primary embracing hemorrhage—venous and arterial—spasm, pain, medullitis, and necrosis; whilst the secondary comprises osseous vegetations, neuralgia, and aneurismal enlargement of the arteries.

When *arterial hemorrhage* takes place from the stump within a short period after the removal of a limb, it will generally be found to proceed from one of the smaller arteries which had been overlooked during the operation, or it may be that the ligature has been placed too low down, the vessel having been cut obliquely, as is necessarily the case when the flap amputation is performed. Should the bleeding occur still later, it may be found to arise from ulceration of the artery at the seat of ligature. Whatever be the cause, ligation of the bleeding vessel is the remedy, and, in order to effect this, the stump should be freely laid open when necessary.

If the *hemorrhage be venous*, elevation of the limb, cold applications, and proper compression, will usually suffice to restrain it. Failing these, we are advised carefully to dissect the vein from the surrounding tissues, and to convey its extremity through an aperture made therefor in one of the adjacent muscles. It is sought by this expedient to close the vessel through the constriction exerted upon it by the contraction of the muscular fibres. When these expedients are unsuccessful, or impracticable, recourse must be had, without further loss of time, to the ligature.

*Spasmodic twitchings of the muscles* of the stump, with acute pain in it, are exceedingly common results of amputations, and liable to be developed so soon as the patient has recovered from the shock of the operation. Occurring at this period, opium is our chief reliance and should be given freely; though where the stump has been properly supported by a roller bandage spasm is of rare occurrence.

*Medullitis* or osteomyelitis—inflammation of the marrow of the bone—is very prone to happen when the bone has sustained a violent shock, either in consequence of the injury, which calls for the operation, or during its section by the surgeon. The occurrence of this event is known when, within a few days after amputation, the marrow of the bone, if seen, presents a dark-greenish or brown color; is separated from the bone, and emits a most offensive odor. For this condition little can be done, but to meet the constitutional indications in each particular case, observing, at the same time, much care and cleanliness in dressing the stump. It has been suggested that nitrate of silver might prove serviceable if freely applied to the parts.

*Necrosis*.—Necrosis is a serious and not unfrequent effect of amputations, and may be the result of otitis or medullitis, or the bone may perish through lack of nutrition, in consequence of the stripping off of its membranous covering. This disease must be left to nature, in the hope that it may be arrested and the dead portions detached. Any attempt at their removal, before their separation has been thus effected, is liable to be seriously resented by the system. Amputation of the bone for necrosis has repeatedly resulted in the destruction of the patient.

*Protrusion of the bone* is a very untoward, though not uncommon accident, after amputation of the limbs. It is sometimes due to carelessness on the part of the operator in not leaving a sufficiency of flap to protect the bone; at other times, as occasionally happens in amputations through the thigh, the most judiciously planned and skillfully performed operation will not suffice to guard against it. It is commonly due, when it presents itself as a primary affection, to retraction of the muscles, and much may be done towards its prevention by the use of the roller bandage during the treatment. After this condition has once arisen, something may yet be done by the application of long strips of adhesive plaster, supported by a roller applied from above, downwards, the stump being elevated and supported in such manner as to relax its muscles. Should these means fail, it has been advised to dissect out the bone from its attachments, and to saw off so much of it as is necessary to secure for it a proper covering. But as this procedure is attended with great risk to life, and is hardly less grave, in its effects upon the system

than amputation itself, it should only be resorted to when all other means fail.

*Conical*, or, as they are sometimes called, *sugar-loaf stumps*, may be classed among the secondary effects of amputations. These are due to an insufficiency of soft parts to cover the extremity of the bone. This insufficiency, when it arises from retraction of the muscles, and does not depend upon any defect of the operation, is especially apt to occur in the thigh, when the soft parts have been attacked with inflammation prior to the operation. In such cases, either the flaps fail to unite, and leave an intractable ulcer corresponding with the situation of the end of the bone, or, if union is effected, there results a delicate, irritable, and painful cicatrix, which will not sustain the weight of the body.

This accident, like the primary affection just considered, protrusion of the bone, with which it is so nearly identified in its origin and development, is more easily prevented than cured. Here, too, as in the former case, the tendency to such a result is sought to be counteracted by a judicious and prolonged use of the roller bandage. When, however, this condition is established, the only remedy lies in the removal of a segment of the bone.

*Osseous vegetations*, or *stalactites*, as they have been called, are sometimes encountered among the secondary affections of the stump; and after amputations of the fore-arm and leg, we often find the bones firmly united by a deposit of osseous material between them, or by the approximation of their divided extremities. In such cases, nervous filaments are liable to be pressed upon by the vegetations, or to become entangled in the bony arches or osseous deposits above alluded to, and thus to give rise to one form of neuralgia of the stump. But this is not the only mode in which such growths give rise to inconvenience and suffering, for we presently find them assuming hygrometric functions, and announcing atmospheric vicissitudes with painful accuracy.

To relieve this morbid condition, when it gives rise to the inconveniences just detailed, section of the diseased portions of the bone, and amputation of the limb at a higher point, have each been advised. But since neither of these expedients is free from hazard, recourse to them is not recommended, unless the grievance can no longer be borne.

It will be remembered, that after amputation of a limb, the



extremities of the truncated nerves undergo a bulbous expansion, which, within certain limits, gives rise to no inconvenience. Developed beyond these limits (and they sometimes attain the size of an English walnut), they constitute veritable neuromata, which, by their presence, and the pressure brought to bear upon them, create much suffering.

We find, too, that a similar hypertrophy, with not less distressing results, may arise from the looping together of the extremities of the divided nerves. Another and frequent source of neuralgia in the stump is the involvement of some of the smaller nerve branches in the cicatrix. Pressure, in such cases, is productive of much pain, and an artificial limb cannot be borne till this condition of the parts be removed.

But neuralgia may present itself in yet another form, and as a local manifestation of a constitutional vice. The cases now referred to are met with among those of irritable fibre, and of what is termed "nervous" habit. Here the sensibility of all the nerves of the stump is exalted, and, together with hyperæsthesia, we have acute pain and spasmodic twitching of its muscles.

The two conditions first described are sometimes amenable to excision of the nervous bulbs, or resection of the limb. The last form yields only to constitutional remedies which tend to build up the powers of the system. Of these, the chalybeates, with quinine, are most to be depended upon. As local applications, lead plasters and anodyne liniments have been advised, and may sometimes prove beneficial. The stump should be protected from sudden changes of temperature by wrapping it in flannel or furs.

## CHAPTER II.

# GUN-SHOT WOUNDS.

[This essay is principally a condensation from a recent contribution by Professor Thomas Longmore to Holmes's System of Surgery. It is so admirable in itself, that it has been accepted with but very slight additions or alterations.]

*Gun-Shot Wounds.*—Wounds by fire-arms are, properly speaking, but wounds by contusion.

They have been distinguished from ordinary contusions and contused wounds by reason of the causes which produce them, the particular appearance that they present, the local and general phenomena that they give rise to, the special complications that affect them, the indications that they point out, the ulterior results which flow from them, and, finally, the conditions under which they are habitually observed.

*Character of Gun-Shot Wounds.*—When a cannon-ball at full speed strikes in direct line a part of the body, it carries away all before it. If the head, chest or abdomen are exposed to the shot, an opening corresponding with the size of the ball is effected, the contiguous viscera are scattered, and life is at once extinguished. If it be part of one of the extremities which is thus removed, the end remaining attached to the body presents a stump with nearly a level surface of darkly-contused, almost pulpified, tissues. The skin and muscles do not retract, as they would had they been divided by incision. Minute particles of bone will be found among the soft tissues on one side, but the portion of the shaft of the bone remaining *in situ* is probably entire.

In ricochet-firing, or in any case where the force of the cannon-shot is partly expended, the extremity, or portion of the trunk, may be equally carried away, but the laceration of the remaining parts of the body will be greater. The surface of the wound will be less even. Muscles will be separated from each other and hang loosely, offering at their divided ends little appearance of vitality; spiculæ of larger size will

probably be found among them, and the shaft may be found shattered and split far above the line of its transverse division. The injury to nerves and vessels may be proportionately higher and greater.

If the speed be still further diminished, so that the projectile becomes what is termed a "spent ball," there will not be a removal of the parts of the body struck, but the external appearances will be limited usually to ecchymosis and tumefaction, without division of surface; or even these may be wanting, notwithstanding the existence of serious internal disorganization.

Should the cannon-ball strike in a slanting direction, the external appearances of the wound will be similar to those just described, according to its velocity; modified only in extent by the degree of obliquity with which the shot is carried into contact with the trunk or extremity wounded.

Large fragments of heavy shell generally produce immense laceration and separation of the parts against which they strike, but do not carry away or grind as round shot. Ordinarily, the line of direction in which they move forms an obtuse angle with the part of the body wounded. When they happen to strike in a more direct line, so as to penetrate, the external wound is mostly much smaller than the fragment itself, from the projectile not having had force enough to destroy the vitality and elasticity of the soft parts through which it enters.

Small projectiles, with force enough to penetrate the body, leave one or more openings; the external appearances of which also vary according to their form and velocity. The appearance of a wound from a rifle-ball, at its highest rate of speed, may be sometimes witnessed in cases of suicide. The muzzle is usually applied beneath the chin. In such a case, a circular hole, without any puckering or inversion of the marginal skin, together with dark discoloration of the integument for several inches round, is observed at the wound of entrance.

When the musket-ball strikes at a distance from the weapon by which it was propelled, but still preserves great velocity, the appearances of the wound are changed. An opening is observed, irregularly circular, with edges generally a little torn, and the whole wound is slightly inverted. There may be darkening of the margin of a livid-purple tinge, from the effects of contusion, or it may be simply dead-like and pale.

Should the ball have passed out, the wound of exit will be probably larger, more torn, with slight eversion of its edges and protrusion of the subcutaneous fat, which is thus rendered visible. These appearances are the more easily recognised, the earlier the wound is examined. They are more obvious if a round musket-ball has caused the injury than when it has been inflicted by a cylindro-conoidal ball. Indeed, with the latter, when it has simply passed through the soft tissues of an extremity of the body at full speed, it is usually very difficult to distinguish by its appearance the wound of entrance from that of exit.

A musket-ball ordinarily causes either one wound, as when, after entering, it lodges, or, as sometimes happens, from its escaping again by the wound of entrance; or two wounds, from making its exit at some point remote from the spot where it entered; but occasionally leads to a greater number of openings. This last result may happen from the ball splitting into two or more portions within the body, and causing so many wounds of exit.

The number of wounds made by one ball may be increased by its traversing two adjoining extremities of the same person, or some distant parts of the body from accidental relative position at the time of the injury.

The two openings made by one ball may hold such a relative situation as to lead to the mistake of their being supposed to be caused by two distinct balls. Length of traverse, and consequent distance between the two openings, parts of the body brought into unusual relations from peculiarities of posture and peculiar deflections of the ball, may be sources of this error.

The appearances of wounds resulting from penetrating missiles of irregular form, as small pieces of shells, musket-balls flattened against stones, and others, differ from those caused by ordinary bullets, in being accompanied with more laceration, according to their length and form. Being usually projected with considerably less force than direct missiles, such projectiles ordinarily lead only to one aperture, that of entrance.

*Symptoms of Gun-Shot Wounds: Pain.*—A gun-shot wound by a musket-ball is attended with an amount of pain which varies very much in degree, according to the kind of wound, condition of mind, and state of constitution of the

soldier at the time of its infliction. It will sometimes happen in simple flesh wounds, that patients will tell the surgeon they were not aware when they were struck. Sometimes the pain from the shot is described as a sudden smart stroke of a cane; in other instances, as the shock of a heavy, intense blow. Occasionally the pain will be referred to a part not involved in the track of the wound. Immediately after the transit of a ball, the sensibility of the track and parts adjoining is found to be partially numbed, so that examination is borne more readily for a short time after the accident than at any later period. Of course, after re-action sets in, or when inflammation has been established, the pain of the wound is proportionably increased. When a ball does not penetrate, but simply inflicts a contusion, the pain is described to be more severe than where an opening has been made by it.

*Shock.*—When a bone is shattered, a cavity penetrated, an important viscus wounded, a limb carried away by a round-shot, pain is not so prominent a symptom as the general perturbation and alarm which supervene on the injury. This is generally described as the “shock” of a gun-shot wound. The patient trembles and totters, is pale, complains of being faint, perhaps vomits. His features express anxiety and distress. This emotion is in great measure instinctive; it is sympathy of the whole frame with a part subjected to serious injury, expressed through the nervous system.

As a general rule, the greater the injury, the greater and more persistent is the amount of shock. A rifle-bullet, which splits up a long bone into many longitudinal fragments, inflicts a very much more serious injury than the ordinary fracture effected by the ball from a smooth-bore musket, and the constitutional shock bears like proportion. When a portion of one or both lower extremities is carried away by a cannon-ball, the higher towards the trunk the injury is inflicted, the greater the shock, independent of the loss of blood. The practical experience of every army surgeon teaches him, that where a ball has entered the body, though its course is not otherwise indicated, the continuance of shock is a sufficient evidence that some organ essential to life has been implicated in the injury.

*Primary Hemorrhage.*—Primary hemorrhage of a serious nature from gun-shot wounds does not often come within the sphere of the surgeon’s observations. If hemorrhage occur

from one of the main arteries, it probably proves rapidly fatal. When a part of the body is carried away by round-shot or shell, the arteries are observed to be nearly in the same state as they are found to be in when a limb is torn off by machinery. The lacerated ends of the middle and inner coats are retracted within the outer cellular coat; the calibre of the vessel is diminished, and tapers to a point near the line of division; it becomes plugged within by coagulum; and the cellulo-fibrous investing sheath, and the clot which combines with it, form on the outside an additional support and restraint against hemorrhage. When large arteries are torn across, and their hemorrhage thus spontaneously prevented, they are seldom withdrawn so far but that their ends may be seen protruding and pulsating among the mass of injured structures; yet, though the impulse may appear very powerful, further hemorrhage is rarely met with from such wounds. There is more danger of continued hemorrhage from wounds by pieces of shell, as the arteries are liable to be wounded without complete transverse section of their coats. Primary but indirect hemorrhage, in consequence of a gun-shot injury, usually occurs as a complication of fractured long bones, the sharp points and edges of which, extensively torn up as they now are by conical bullets, are well calculated to cause such injuries.

*General Treatment.*—When the circumstances of a battle admit of the arrangement, the wounded should receive surgical attention preliminary to their being transported to the regimental or general field hospital in the rear. The provisional treatment should be of the simplest kind, and chiefly directed to the prevention of additional injury during the passage to the hospital, where complete and accurate examination of the nature of the wound can alone be made, and where the patient can remain at rest, after being subjected to the required treatment. The removal of any missiles or foreign bodies which may be readily obvious; the application of a piece of lint to the wound; the arrangement of any available support for a broken limb; protection against dust, cold, or other objectionable circumstances likely to occur in the transit; if shock exist, the administration of a little wine, aromatic ammonia, or other restorative, in water—need little time in their execution, and may prove of great service to the patient. If hemorrhage exist, from injury to a large

vessel, it must, of course, receive the surgeon's *first* and most earnest care. He should not trust to a tourniquet, but secure it at once by ligature.

On arrival at the hospital, the following are the points to be attended to by the surgeon: firstly, examination of the wound, with a view to obtaining a correct knowledge of its nature and extent; secondly, removal of any foreign bodies which may have lodged; thirdly, adjustment of lacerated structures; and fourthly, the application of the primary dressings.

The *diagnosis* should be established as early as possible after arrival at hospital. An examination can then be made with more ease to the patient, and more satisfactorily to the surgeon, than at a later period.

One of the earliest rules for examining a gun-shot wound is to place the patient, as nearly as can be ascertained, in a position similar to that in which he was in relation to the missile, at the time of being struck by it. In almost every instance, the examination will be facilitated by attention to this precept.

When only one opening has been made by a ball, it is to be presumed that it is lodged somewhere in the wound, and search must be made for it accordingly. But even when two openings exist, and evidence is afforded that these are the apertures of entrance and exit of one projectile, examination should still be made to detect the presence of foreign bodies. Portions of clothing, and other harder substances, are not unfrequently carried into a wound by a ball; and, though it, itself, may pass out, these may remain behind, either from being diverted from the straight line of the wound, or from becoming caught and impacted in the fibrous tissue through which the ball has passed.—The inspection of the garments worn over the part wounded may often serve as a guide in determining whether foreign bodies have entered or not, and, if so, their kind, and thus save time and trouble in the examination of the wound itself.

Of all instruments for conducting an examination of a gun-shot wound, the finger of the surgeon is the most appropriate. By its means the direction of the wound can be ascertained with least disturbance of the several structures through which it takes its course. The index finger naturally occurs as the most convenient for this employment; but

the opening through the skin is sometimes too contracted to admit its entrance, and in this case the substitution of the little finger will usually answer all the purposes intended. When the finger fails to reach sufficiently far, owing to the depth of the wound, the examination is often facilitated by pressing the soft parts from an opposite direction towards the finger end.

It was formerly the custom to enlarge the external orifice of all gun-shot wounds by incision; and not merely the opening, but the walls of the wound itself, as soon after the injury as possible. This was not done as a means of rendering the examination easier, but as a prophylactic measure. Dilatation was also employed, by tents and various other means, with a view to secure the escape of sloughs and discharges. English surgeons have, however, generally discarded the practice, excepting only in cases where it is required to allow of the extraction of some extraneous body; to secure a wounded artery; to replace parts in their natural situation, as in protrusion of viscera in wounds of the abdomen; or, in short, when anything can be done to the part wounded, after the opening is made, for the present relief of the patient, or the future good arising from it.

It does not happen that it is necessary to enlarge the openings of wounds to remove balls, although a certain amount of constriction of the skin may be expected from the addition of the instrument employed in the extraction; but if much resistance is offered to their passage out, it is better to divide the edges of the fascia and skin to the amount of enlargement required, than to use force. In removing fragments of shells or detached pieces of bone, the fascia and skin have almost invariably to be divided to considerable extent.

When the finger is not sufficiently long to reach the bottom of the wound, even when the soft parts have been approximated by pressure from an opposite direction, and when the lodgment of a projectile is suspected, a long silver probe, that admits of being bent by the hand, if required, is the best substitute. Elastic bougies or catheters are apt to become curled among the soft parts, and do not convey to the sense of touch the same amount of information as metallic instruments do. The probe should be employed with great nicety and ease, for it may inflict injury on vessels or other structures which have escaped from direct contact with the



ball, but have returned, by their elasticity, to the situation from which they had been pushed or drawn aside during its passage. The above directions for examining wounds apply more particularly to such as penetrate the extremities, or extend superficially in other parts of the body. When a missile has entered any of the important cavities, search for it is not to be made, but the surgeon's attention is to be directed to matters of more vital importance, to be hereafter noticed.

*Removal of Foreign Bodies.*—As soon as the presence of a ball or other foreign body is ascertained, it should be removed. If it be lying within reach from the wound of entrance, it should be extracted through this opening by means of the various instruments advised for this purpose. Instruments of two blades, or scoops, with ordinary hinge action, dilate the track of the wound injuriously before the ball can be grasped by them. The way to the removal of a bullet may often be smoothed by judiciously clearing away the fibres, among which it is lodged, during the examination by the finger; and sometimes, by means of the finger in the wound, and external pressure of the surrounding parts, the projectile may be brought near to the aperture of entrance, so that its extraction is still further facilitated.

Such foreign substances, as pieces of cloth, can usually be brought out by the finger alone, or by pressing them between the finger and a silver probe, inserted for the purpose. Sometimes a long pair of dressing forceps, guided by the finger, is found necessary for effecting this object. Caution must be used in employing forceps, when the foreign substance is out of sight, and of such a quality that the soft tissues may be mistaken for it.

In some instances, when the foreign body has not completely penetrated, but is found lying beneath the skin, away from the wound of entrance, an incision must be made for its extraction. Before using the knife, the substance to be removed should be fixed *in situ*, by pressure on the surrounding parts. In the instance of a round ball, the incision should be carried beyond the length of its diameter; an addition of half a diameter is usually sufficient to admit of the easy extraction of the ball. In removing conical balls, slugs, fragments of shells, stones, and other irregularly shaped bodies, the surgeon cannot be too guarded in arranging that the fragment is drawn away with its long axis in line with the

track of the wound. By proper care in this respect, much injury to adjoining structures may be avoided.

If balls are impacted in bone, as happens in the spongy heads of bones, in bones of the pelvis, and occasionally, though rarely, in other parts of long bones, they should be removed. This can be effected by means of a steel elevator, of convenient size; or, should this fail, from the ball being too firmly impacted, a thin layer of the bone, on one side of the ball, may be gouged away, so that a little purchase may be obtained for the elevator, in effecting its removal. The fact is now fully established, that, although in a few isolated cases, balls remain lodged in bones without sensible inconvenience, in the majority the lodgment leads to such disease of the bony structures as often to entail troublesome abscesses, and, in some instances, eventually to necessitate amputation. The lodgment of balls will not often occur, without extensive fracture in warfare, where rifled arms of such force as the Minnie and Enfield are the chief weapons employed.

Should there be reason for concluding that a ball or other foreign body has lodged, but after manual examination and observation, as well by varied posture of the part of the body supposed to be implicated, as by indications derived from the patient's sensations, effects of pressure or injury to nerves, and all other circumstances which may lead to information, should the site of the lodgment not be ascertained, the search should not be persevered in to the distress of the patient. Neither, although the site of lodgment be ascertained, if extensive incisions are required, or if there is danger of wounding important organs, should the attempts at extraction be continued. Either during the process of suppuration, by some accidental muscular contraction, or by gradual approach towards the surface, its escape may be eventually effected; or, if of a favorable form, and if not in contact with nerve, bone, or other important organ, it may become encysted and remain without causing pain or mischief. Extensive experience has shown that not only is the risk of subsequent ill results greater in those cases where foreign bodies remain lodged than where they have been cut out; but also that the advantages of a second opening for the escape of the necessary sloughs and discharges greatly preponderate over the disadvantages connected with it, as regards the additional extent of injured surface.

*Local Treatment.*—When a gun-shot wound has been accompanied with much laceration and disturbance of the parts involved in the injury, it is necessary, after the removal of all foreign substances that can be detected, to re-adjust and secure the disjoined structures as nearly as possible in their normal relations to each other. The simplest means—strips of adhesive plaster, light pledgets of moist lint, a linen roller, favorable position of the limb or part of the body wounded—should be adopted for this purpose. Pressure, weight and warmth should be avoided as much as possible in these applications, consistent with the end in view. It must not be forgotten, in thus bringing the parts together, that the purpose is not to obtain union by adhesion, which can not be looked for, but simply to prevent avoidable irritation and malposition of parts, during the subsequent stages of cure by granulation and cicatrization. In all gun-shot wounds much discomfort to the patient is prevented by carefully sponging all blood and clot from the surface adjoining the wound, and by adopting measures to prevent its spreading again in consequence of oozing. This can be readily done with the aid of a little warm water and arrangement when the wound is first dressed, but can only be accomplished with considerable inconvenience after the thin clots have become hard and firmly adherent to the skin.

When the parts of a lacerated gun-shot wound have been brought into apposition, as in simple, penetrating wounds, the only dressing necessary is moistened lint. It should be kept moist either by the renewed application of water dropped upon it, or by preventing evaporation by covering it with oiled silk. The sensations of the patient may be consulted in the selection of either of these; and climate and temperature will be often found to determine the choice. M. Boudens and Dr. Stemeyer have strongly recommended the topical application of ice placed in bladders; others, the continued irrigation of the wound with tepid water. When much local inflammation has set in, and when there is much constitutional fever even without unusual local irritation, the non-evaporating or warm applications will be found to be the most advantageous.

When suppurative action has been fully established, the surgeon must be guided by the general rules applicable to all other such cases. Care must be taken to prevent the accumulation of pus, lest it burrow, and sinuses become estab-

lished; not an unfrequent result of want of sufficient caution in this regard. If much tumefaction of muscular tissues beneath fascia occurs, or abscesses form in them, free incisions should be at once made for their relief. In wounds where the communication between the apertures of entrance and exit is tolerably direct, occasional syringing with tepid water may be useful, by removing discharges and fibres of cloth which may be lying in the course of the wound. Weak astringent solutions are occasionally employed in a similar way, with a view to improving the tone of the exhalants and exciting a more vigorous action in the process of granulation.

The strictest attention to cleanliness and the complete removal of all foul dressings are essentially necessary, not merely for the comfort of the patient, but to prevent the accumulation of noxious effluvia, and also to obviate the access of flies to the wounds. Cloths dipped in weak solutions of creasote or disinfecting fluid, laid over the wound, are found necessary for this purpose when the insects abound in great numbers.\*

*Constitutional Treatment.*—The constitutional treatment in an ordinary gun-shot wound, uncomplicated with injury of bone or structures of first importance, should be very simple. The avoidance of all irregularity in habits tending to excite febrile symptoms or to aggravate local inflammation, attention to the due performance of the excretory functions, and support of the general strength, are chiefly to be considered. Bleeding, with a view to prevent the access of inflammation in such cases, is now never practised. The diet should be nutritious, but not stimulating. A pure fresh atmosphere is a very important ingredient in the means of recovery. If from previous habits of the patient, or from circumstances to which he is unavoidably exposed, the local inflammation has become aggravated—indicated by pain, increased swelling, and redness about the wound—topical depletion, by leeches or cupping, bleeding from the arm, saline and antimonial medicines, and strict rest in the recumbent position, must be had recourse to, the extent being regulated by the circumstances of each case. In instances such as these, when the inflammation has become diffused, the purulent secretion is

---

\* *Inf. sambuci* has been recently highly recommended, also to paint the ulceration over with a thin layer of honey.

not confined to the track of the wound, but is liable to extend among the areolar connexions of the muscles; and if the cure be protracted, attention will be necessary to prevent the formation of sinuses. If stiffness or contractions result, attempts must be made to counteract them by passive motion and friction, with appropriate linaments; if a tendency to œdema and debility remain in a limb after the wound is healed, the cold water douche will be found to be one of the most efficient topical remedies. In French practice, the administration of perchloride of iron as a tonic, or diluted, as an injection, in wounds threatening to assume an unhealthy character, is very highly praised. It is stated, that under the conjoined employment of this remedy internally and externally, in wounds of a pallid, unhealthy aspect, accompanied by nervous irritability and symptoms of approaching pyæmia, the granulations have assumed a red and healthy appearance, and the general state of health become rapidly favorable.

### Gun-Shot Wounds in Special Regions of the Body.

*Gun-shot Wounds of the Head.*—No injuries met with in war require more earnest observation and caution in their treatment than wounds of the head. The vital importance of the brain; the varied symptoms which accompany the injuries to which this organ may be subjected, directly or indirectly; the difficulty in tracing out their exact causes; the many complications which may arise in consequence of them; the sudden changes in condition which not unfrequently occur without any previous warning; all these circumstances will keep a prudent surgeon, who has charge of such wounds, continually on the alert. Injuries of this class, the most slight in appearance at their onset, not unfrequently prove most grave as they proceed, from encephalitis and its consequences, or from plugging of the sinuses by coagula, leading to coma, paralysis or pyæmia; and the converse sometimes holds good with injuries presenting at first the most threatening aspects, where care is taken to avert these serious results. Mr. Guthrie has laid down as a rule that injuries of the head, of apparently equal extent, are more dangerous on the forehead than on the side or middle portion, and still more so than those on the back part; and that a fracture of the vertex is infinitely less important than one at the base of the cranium.

When the injuries are caused by rifle balls, however, these considerations are rarely of much avail, for the power of injury is such that it can scarcely ever be confined to the immediate neighborhood of the part directly struck.

*Wounds of the Scalp and Pericranium.*—These wounds are usually inflicted by projectiles which are brought into contact at a very acute angle, so that little direct injury to the brain or its membranes is inflicted, and the surgeon's attention need only be directed to the same considerations as must occur in any contused wounds of the scalp from other causes than gun-shot. But, even in these accidents, though appearing to be simple flesh wounds, serious cerebral concussion and other lesions are occasionally met with. The usual stupor and other signs of concussion may be very evanescent, or may last for several days, disappearing gradually and wholly, or entailing subsequent evils at more or less remote periods. It must not be forgotten that when the pericranium is removed by a musket ball, however superficial the injury may seem, there is always a certain degree of injury and bruising to the bone from which it is torn, and necessary laceration of the vessels which inosculate with the nutritive capillaries of the diploe, and through them of the vessels of the meninges with which they are connected. The injury to this vascular system almost invariably leads to necrosis of the portion of the skull from which the coverings are carried away; and, sometimes, even when the pericranium is not torn off, sufficient injury is inflicted to lead to a like result. The death of the bone is generally limited to a thin layer of the outer table, which in due time exfoliates. The injury to the vessels ramifying between the inner surface of the cranium and dura mater, may lead to serious results. There may be rupture of a sinus, leading to compression, or fatal results may ensue from inflammation and suppuration.

*Treatment.*—The treatment of an ordinary gun-shot wound of the scalp should be very simple. Cleansing the surface of the wound, removing the hair from its neighborhood for the easier application of dressings, lint moistened with clean water, very spare diet, and careful regulation of the excretions, are the only requirements in most cases. The patient must be closely watched, so that measures may be taken to counteract inflammatory symptoms in their earliest stages. Even after one of these wounds has healed, and the patient, to all

appearance, has quite recovered, it is necessary to enjoin continued abstinence from excesses of all kinds. Instances are frequently quoted where intoxication, a long time after the date of injury, has induced symptoms of apoplexy and death.

*Wounds Complicated with Fracture, but without Depression on the Cerebrum.*—In these injuries there may be a simple furrowing of the outer table, without injury to the inner; or there may be fissure extending to a greater or less degree of length, or radiating in several lines; or both tables may be comminuted in the line the ball has traversed in such small portions, that they lie loose on the dura mater, without much alteration in the general outline of the cranial curve. The chief and only means, in many cases, of concluding that no depression upon the cerebrum has taken place, is the absence of the usual symptoms of compression; for it is well known that simple observation of the injury to the outer table, whether by sight or touch, will, by no means, necessarily lead to a knowledge of the amount of injury, or change of position, in the inner table.

When simple removal of a portion of the outer surface of the skull has been caused by the passage of the ball or other missile, the wound will sometimes heal, under judicious treatment, without any untoward symptom. A layer of the exposed surface of bone will probably exfoliate, and the wound granulate and become closed without further trouble. But such injuries, for reasons before named, are very likely to be followed by inflammation, and not improbably by abscess, between the internal table and dura mater; and further, as a consequence of the vascular supply being stopped, and perhaps also partly from the effect of the original contusion, by necrosis of the inner table itself. Care must be taken not to mistake one of these injuries for a depressed fracture, as it is not unlikely to happen when the excavation effected by the projectile is rather deep, and the edges of the bone bordering the excavation are sharp.

Fissured fractures, when the fissure extends through the skull, usually result from injuries by shell. The passage of a ball may fracture and very slightly depress a portion of the outer table of the cranium, and then the line of fracture will very closely simulate fissured fracture, extending through both tables, and the diagnosis between them be excessively doubtful. When fissured fracture exists, the distance to

which it may be prolonged is often quite unindicated by symptoms, and its extent is very uncertain. Fissures often extend to long distances. They may occur at a part remote from the spot directly injured. Fissured fracture of the inner table may also occur from the action of a ball, without external evidence of the fracture. The cases where comminution has resulted from the track of a ball across the skull, generally present less unfavorable results than those where a single fissured fracture, extending through both tables, exists. The small, loose fragments can be removed, and if the dura mater be intact, the case, with proper care to prevent inflammatory action, may not improbably be attended with a favorable recovery.

*Wounds Complicated with Fracture and Depression on the Cerebrum.*—Such wounds are most serious, and the prognosis must be very unfavorable. They must not be judged of by comparison with cases of fracture, with depression, caused by such injuries as are usually met with in civil practice. The severe concussion of the whole osseous sphere by the stroke of the projectile, the bruising and injury to the bony texture immediately surrounding the spot against which it has directly impinged, as well as the contusion of the external soft parts, so that the wound cannot close by the adhesive process, constitute very important differences between gun-shot injuries, on the one side, and others caused by instruments impelled by muscular force on the other. So, also, the injury to the brain within, and its investments, is proportionably greater in such injuries from gun-shot. The experience of the Crimean campaign shows, that when these injuries occurred in a severe form, they invariably proved fatal.

*With Penetration of the Cerebrum.*—It is obvious that when a projectile has power not only to fracture, but also to penetrate the cranium, it will rarely be arrested in its progress near the wound of entrance. Either splinters of bone, or the ball, or a portion of it, will be carried through the membranes into the cerebral mass. Sometimes a ball, if not making its exit by a second opening in the cranium, will lodge at the point of the cerebral substance opposite to that of its place of entrance; but the course a projectile may follow within the cranium is very uncertain.

*Treatment.*—Formerly, a gun-shot wound of the head was



supposed to be in itself a sufficient indication for the use of the trephine. Modern surgeons, however, generally have made use of the trephine only when there was reason for concluding that depressed bone was leading to *permanent* interruption of cerebral function, or that an abscess had formed within reach, and was capable of evacuation. Preventive trephining has been proved to be useless, as well as dangerous, and is no longer an admissible operation. The tendency of the most recent experience has been to limit the practice of trephining to the narrowest sphere, and when the great difficulty of making accurate diagnosis in these cases considered—whether as to the distinguishing signs of compression; the precise seat of the cause, if the compression exist; the space over which the cause, when ascertained, may extend; its persistent or temporary character; its complications; and certain dangers connected with the operation itself—no wonder need be excited that this tendency should exist. Besides, the numerous cases which have been noted where bone has evidently been depressed, but the brain has accommodated itself to the pressure without serious disability being caused, or when compression from effusion has been removed by absorption, under proper constitutional treatment, are farther causes of hesitation in respect to trephining. Where irregular edges, points or pieces of bone, are forced down and penetrate—not merely pressing upon—the cerebral substance, or when abscess manifestly exist in any known site, or a foreign substance has lodged near the surface, and relief cannot be afforded by the wound, trephining may be resorted to for the purpose; but the application of the operation, even in these cases, will be very much limited, if certainty of diagnosis be insisted upon. In all other cases, it seems now generally admitted, that much harm will be avoided, and benefit more probably effected, by employing long-continued constitutional treatment, viz: all the means necessary for controlling or preventing the diffusion of inflammation over the surface of the brain and its membranes—the most careful regimen, very spare diet, strict rest, calomel and antimonials, occasional purgatives, cold applications locally, so applied as to exclude the air from the wound, and free depletion by venesection, in case of inflammatory symptoms arising. Similar remarks will apply in case of lodgment of a projectile within the brain. If the site of its lodgment is obvious, it should be removed with as little dis-

turbance as possible; but trephining for its extraction on simple inference is unwarrantable.

*Gun-shot Wounds of the Spine.*—Gun-shot wounds of the spine are closely associated with similar injuries of the head. In both, classes corresponding considerations must be entertained by the surgeon in reference to the important nerve-structures, with their membranes, which are likely to be involved in the injury to their osseous envelope; in both, the effects of concussion, compression, laceration of substance, or subsequent inflammatory action, chiefly attract attention.

In injuries of the vertebral column and spinal cord occurring in military practice, the mischief is usually so complicated and extensive, and the medulla itself so bruised, that the cases must be very rare indeed in which the operation of trephining, if justifiable in any case, can offer the slightest prospect of benefit.

*Gun-shot Wounds of the Face.*—Wounds of the face from gunshot, grape, and small fragments of shell are usually more distressing from the deformity they occasion than dangerous to life. The absence of vital organs, the natural divisions among the bones, and their comparatively soft structure rendering them less liable to extensive splitting; the copious vascular reticulation and supply rendering necrosis so much less likely, and repair so much easier than in other bones; the limited amount of space occupied by the osseous structure between their respective periosteal investments, and the opportunities from the number of cavities and passages connected with this region for the escape of discharges—lead to this result. On the other hand, the vascularity of this region leads to danger both of primary, and especial secondary, hemorrhage—a circumstance which in all deep wounds of this region must be looked for as a not improbable complication. The other complications of these gun-shot wounds are lesions of the organs of special sense, injury to the base of the skull, paralysis from injury to nerves. Wounds of glands, their ducts, and of the lachrymal apparatus.

*Treatment.*—In the treatment of gun-shot wounds of the face where the bones are splintered and torn, the surgeon should always retain and replace as many of the broken portions as possible. It is often surprising how small connexions with neighboring soft parts will suffice to maintain vitality and lead to restored union in this region. In case a ball has

to be removed, when practicable, it should always be extracted through the mouth. Great care should be used, both by position and attention to dressing, to prevent the swallowing of the secretions from wounds of these parts, as it may lead to great constitutional irritation, and fever of a low typhoid and fatal character. Should secondary hæmorrhage supervene from the deep branches in this region, it will be necessary to ligate the main trunk, the local method of ligation not being applicable from the difficulty experienced in reaching the vessels.

*Gun-shot Wounds of the Chest.*—Gun-shot wounds of the chest may conveniently be divided into two classes, viz: *non-penetrating* and *penetrating*.

*Non-penetrating* wounds become subdivided into simple contused wounds of the soft parieties; contused and lacerated wounds; the same accompanied with injury to bones or cartilage; and lastly, those complicated with lesion of some of the contents of the chest, the pleura remaining unopened, or, if opened, without a superficial wound.

*Penetrating* wounds may exist without wound, or with wounds of one or more of the viscera of this cavity. Among the more serious complications with which the latter may be accompanied is the lodgment of the projectile or other foreign bodies, as of fragments of bone, within the chest. As wounds of the heart and great vessels are almost invariably at once fatal, and as the organs of respiration occupy the greater part of the cavity of this region, it is in reference to the latter that the treatment of chest wounds is chiefly concerned.

*Non-penetrating Wounds.*—Of the simpler wounds, in which the soft parieties only are involved, little need be observed, excepting that the healing process is often prolonged by the natural movements of the ribs to which the wounded structures are attached, especially when the ball has taken a circuitous course beneath the skin, and that the surgeon must be on his guard to watch for pleuritis arising as an occasional consequence of these injuries. When the force has been great, as when fragments of shell or rifle balls strike at full speed against a man's breast-plate, not only may troublesome superficial abscesses and sinuses follow, but the lungs may have been compressed and ecchymosed at the time of the injury, and hæmoptysis be one of the symptoms presented.

When the projectile has been of large size, although no

opening of the parieties or fracture exists, death sometimes ensues by suffocation, as the direct result of pulmonary engorgement. The danger of pleuritis or pneumonia will, when the injury has been so severe as to cause division of bone or cartilage, and the subsequent suppuration and process of exfoliation, will not unfrequently prove very tedious and troublesome. Although the pleura has not been opened, the lung may be lacerated, either by the force of contusion, or, as in a case recorded by Dr. Macleod, by the edges of the fractured ribs, which may afterwards return to their normal relative positions, so as to leave no indication during life of the means by which the lung had been wounded. Such an injury would be rendered much more probable by the existence of old adhesions, connecting the pulmonary and costal pleuræ opposite to the site of injury.

Notwithstanding a projectile has not penetrated the parieties of the chest, a pleural cavity may be opened, as in injuries from other causes, and the lung wounded by the sharp edges of fractured ribs. This will be indicated by emphysema, pneumothorax, hæmoptysis, probably signs of internal hemorrhage and inflammation. Such wounds will generally be the result of injuries from fragments of shell.

*Penetrating Wounds.*—These wounds, especially when the lung is perforated or the projectile lodges, are necessarily exceedingly dangerous. Fatal consequences are to be feared, either from hemorrhage, leading to exhaustion or suffocation; from inflammation of the pulmonary structure or pleuræ; from irritative fever accompanying profuse discharges; or from fluid accumulations in one or both of the pleural sacs.

In gun-shot injuries a penetrating wound of the chest is, in most instances, readily obvious to the sense of sight or touch; but it will be found by no means easy always to decide whether a lung has been penetrated or otherwise. The train of symptoms usually described as characterizing wounds of the chest must not be expected to be all constantly present; they are each liable to be modified by a great variety of circumstances, and may each severally exist in penetrating wounds of the chest where the lung has escaped perforation. Nor is it always easy to determine whether the ball has lodged or not; or, the ball having passed through, whether fragments of bone, or other substances, have remained behind. When the chest has been opened by a projectile, the following signs may

be expected in addition to the external physical evidences of the injury : a certain amount of constitutional shock, collapse from loss of blood, and, if the lung be wounded, effusion into the pleural cavity, hæmoptysis, dyspnœa, and an exsanguine appearance. These will generally, but not invariably, be followed, after twenty-four hours or later, by the usual signs of inflammation in some of the structures injured.

The shock of penetrating wounds of the chest, apart from the collapse consequent on hemorrhage, is not generally so great as happens in extensive injuries to the extremities, or in penetrating wounds of the abdomen. There is often much more shock where a ball has not penetrated ; but, having met with something to oppose its course, has nevertheless inflicted a violent percussion of the whole chest and its contents.

When loss of blood occurs without the lung being wounded, the hemorrhage is probably proceeding from a wound of one of the intercostal arteries, which has been torn by the sharp ends of fractured bone. Serious hemorrhage, however, is exceedingly rare from vessels external to the cavity of the chest.

When blood is effused in any large quantity into the pleural sac—as indicated by the exsanguine appearance of the patient, increasing dyspnœa, occasional hæmoptysis, and the stethoscopic signs of auscultation—the inference is that the lung has been opened, and that it is from its structure the blood is flowing. The amount of hemorrhage in wounds of the lung will greatly vary according to the direction of the track of the ball ; for the large vessels cannot here glide away from the action of the projectile, as they may in the neck or extremities of the body. Wounds, therefore, near the root of each lung, where the pulmonary arteries and veins are largest, are attended with the greatest amount of hemorrhage ; and as coagula can hardly form sufficiently to suppress the flow of blood, are generally fatal.

Hæmoptysis indicates injury to the lung, but does not give assurance that this organ has been penetrated. It generally accompanies gun-shot wounds of the lung in a greater or less degree, no doubt always when a bronchial tube of large size is penetrated ; but, as may be ascertained by careful perusal of recorded cases, is sometimes wholly absent, even though the patient may be troubled by cough.

Dyspnœa is a frequent accompaniment of wounds pene-

trating the lung, but not as a constant symptom before inflammatory action has set in. When dyspnoea is great in the early period, it will often be found to depend upon the injuries to the parieties, and to the pain caused on taking a full inspiration; as a sign of subsequent mischief in the progress of the case, it is, of course, very constantly present. It is now known that the opening of the pleura does not necessarily induce collapse of the lung, even though unfettered by adhesions during life. It was formerly supposed that the escape of air by the wound was a sufficient proof that the lung had been opened by the projectile; but it is evident that it is not so, as the air may enter by the wound and be forced out again by the expansion of the lung in inspiration, or by the action of the chest on expiration. If air and frothy mucus, with blood, as noticed in one of the cases recorded in the Crimean campaign, escape by the wound, there can be no doubt of the nature of the injury. Emphysema is not common in penetrating gun-shot wounds, but occasionally happens. The free opening generally made by the projectile sufficiently explains the fact.

*Treatment.*—The object of the surgeon's care must be, in the first place, to arrest hemorrhage; afterwards, to remove pieces or jagged projections of bone, or any other sources of local irritation; and to adopt means to prevent interference with the natural process of cure which takes place by adhesion of the opposite pleural surfaces near the wound in the first instance, and subsequently by cicatrization of the wound itself. Although the shock may happen to be considerable, attempts to rally the patient, if any be made, should be conducted very cautiously; the prolongation of the depressed condition may be valuable in enabling the injured structures to assume the necessary state for preventing hemorrhage. Hemorrhage from vessels belonging to the costal parieties should be arrested by ligation, as in other parts, if the source from which it proceeds can be ascertained, and if the flow of blood be so free as not to be controlled by the ordinary styptics. Operative interference of this kind is chiefly called for on account of secondary, not primary, hemorrhage.

Hemorrhage from the lung itself must be treated on the general principles adopted in all such cases; the application of cold to the chest, perfect quiet, the administration of opium, and, if the patient be sufficiently strong, bleeding from

a large vein until *syncope* supervenes. When blood has accumulated in any large quantity, and the patient is much oppressed, the wound should be enlarged, if necessary, so as, with the assistance of proper position, to facilitate its escape. If the effused blood, from the situation of the wound, cannot be thus evacuated, and the patient is in danger of suffocation, then the performance of paracentesis, as directed for the relief of empyema, must be resorted to.

The extensive bleedings formerly recommended in all penetrating gun-shot wounds of the chest, are now practised with much greater limitations; indeed, should never be employed simply with a view to prevent mischief from arising. Venesection, carried to a great extent, does harm by lessening the restorative powers of the frame. It appears to interrupt the process of adhesion between the pleural surfaces and the steps taken by nature to repair the existing mischief, while it leads the injured structures into a condition favorable for gangrene, or encourages the formation of ill-conditioned purulent effusions. When inflammation has arisen, venesection may be joined with other means to control its excessive action, and to give relief, which it certainly does, to the patient; and when hemorrhage is manifestly going on internally, it may be practised with a view of draining the blood from the system and more speedily inducing faintness, to give an opportunity to the pulmonic vessels to become closed; but, even when thus applied, the general state of the patient will not be unconsidered by a judicious surgeon, nor caution neglected lest the venesection cause him to sink more rapidly from the additional shock to the system and abstraction of restorative force. Taking away blood certainly does not prevent pneumonia from supervening, but occasionally seems to give the inflammation, when it arises, more power over the weakened structures, or even to cause it to be accompanied by typhoid symptoms.

To remove splinters of bone, and re-adjust indented portions of the ribs, the finger should be introduced into the wound, and care taken that in so doing no pieces of cloth or fragments be separated and projected into the pleural sac. Notice must, at the same time, be taken of any bleeding vessel requiring to be secured. A pledget of lint should be laid on the wound, and a broad bandage placed around the chest, just tight enough to support the ribs and in some degree to restrain their movements, but with an opening over each wound large enough to

permit the ready access of the surgeon to it, if necessary. If the patient's comfort admits of it, he should be laid with the wound downwards, with a view to prevent accumulation of fluid in the pleura; and if there be two openings, as will be most frequently the case in rifle-ball wounds, one wound should be thus placed, and the upper be kept covered. In gun-shot wounds, closure of the parieties by adhesion is of course not to be looked for. The diet, beverages, and medicines must constantly have reference to the avoidance of inflammatory action; and should this occur, it must be combated on general principles.

If the presence of a ball within the cavity be ascertained, efforts should be made for its removal. But any attempt to determine where the ball has lodged should be made very cautiously, as more harm may result from the interference than from the lodgment of the foreign body. The existence of old adhesion will modify the effects of a penetrating wound, by excluding the track of the ball from the general pleural cavity, and may influence the result of the injury, especially if there be hemorrhage, or lodgment of foreign bodies, which may thus be brought within the sphere of removal more readily.

Wounds of the heart seldom come to the military surgeon's notice, as they ordinarily prove fatal on the battle-field.

*Gun-shot Wounds of the Neck.*—Gun-shot wounds of this region do not appear to be so fatal as might be anticipated from the large vessels and important canals leading to the thorax and abdomen, which at first sight appear to be so exposed and unprotected. In no region are so many examples offered of large vessels meeting, but escaping from balls in their passage, as in this, because the cause which operates elsewhere, ready mobility among long and yielding structures, exists in a greater degree in the neck than in any other part. When the large vessels happen to be divided, death must follow almost immediately. Superficial wounds of the neck offer no peculiarities. The larynx and trachea being the organs most prominent and most frequently injured, are those which chiefly attract the surgeon's notice in warfare.

*Gun-shot Wounds of the Abdomen.*—Gun-shot wounds of the abdomen are, like those of the chest, divided into *non-penetrating* and *penetrating*.

*Non-penetrating* may be either simple flesh-wounds, or may



be accompanied with fracture of some of the pelvic bones, or with injury to some of the contained viscera. In penetrating wounds the peritonæum only, or, together with it, one or more of the abdominal viscera, may be wounded; or, in comparatively rare cases, a viscus may be penetrated without the peritonæum being involved. It is in the regional cavity of the abdomen that the proportion of penetrating wounds is the greatest. The cranium, from its form, structure and coverings, serves as a strong defence even against gun-shot. The osseous, yet elastic and moveable ribs, the sternum, and muscular parieties, greatly protect the contents of the cavity which they enclose; but the extensively exposed surface of the abdomen, anteriorly and laterally, has no power of resistance to offer against a projectile directly impinging it; and when the important cavity is once penetrated by these means, death is the almost inevitable result. Even the changes of a favorable termination which may exist in wounds from other causes are generally wanting; and much of their treatment, such as the use of sutures, and other means to insure the apposition of cut edges, is inapplicable—from the parts to a certain distance being almost necessarily deprived of their vitality—to injuries from gun-shot wounds.

*Non-penetrating Wounds.*—If, although the viscera have been contused, the injury does not amount to being mortal, the patient should be subjected to perfect quiet, extreme abstinence, and, only when inflammation arises, to the necessary treatment for its control.

If the parieties have been much contused, abscess and sloughing may be expected, and a tendency to visceral protrusion must be afterwards guarded against.

When portions of the pelvic parieties are fractured by heavy projectiles, very protracted abscesses generally arise, connected with necrosed bone; and the vital powers of the patient are greatly tried by the necessary restraint and confinement. The great force by which these wounds must be produced, and the general contusion of the surrounding structures, cause a large proportion, sooner or later, to prove fatal, notwithstanding the peritoneal cavity may have escaped. Even apparently slight cases, as where a portion of the crest of the ilium is carried away by a shell, or ball lodged in one of the pelvic bones, often prove very tedious from the long-continued exfoliations and abscesses which result.

*Penetrating Wounds.*—A penetrating wound of the abdomen, whether viscera be wounded or not, is usually attended with a great amount of “shock.” The prognosis will be extremely unfavorable if there is reason to fear the projectile has lodged in the cavity of the peritonæum; and in all cases the danger will be very great from inflammation of this serous investment. The liability to accumulation of blood in the cavity, from some vessel of the abdominal wall being involved in the wound, must not be forgotten.

When, in addition to the cavity being opened, viscera are penetrated, and death does not directly ensue from rupture of some of the longer arteries, the shock is not only very severe, but the collapse attending it is seldom recovered from up to the time of the fatal termination of the case. This is sometimes the only symptom which will enable the surgeon to diagnose that viscera are perforated. The mind remains clear, but prostration, oppressive anxiety, and restlessness, are intense, and, as peritonitis supervenes, pain, dyspnœa, diffused tenderness, irritability of the stomach, distension, and the other signs of this inflammation, are superadded. In ordinary wounds from musket-shot, scarcely any matter will escape from the opening in the parieties, the margin of which becomes quickly tumefied, but if any escape, it will probably indicate what viscus has been wounded. If the stomach has been penetrated, there will probably be vomiting of blood from the first. If the spleen or liver be wounded, death from hemorrhage is likely to follow quickly. In some instances patients, however, recover after gun-shot wounds involving these viscera.

If the small intestines have been perforated, and death follows soon after from peritonitis, the bowels usually remain unmoved, so that no evidence is offered of the nature of the wound from evacuations; but in any case of penetrating wound of the abdomen, when the opportunity is offered, steps should be taken to isolate and examine all evacuations which may follow. If the kidneys or bladder are penetrated, the escape of urine into the abdomen is almost a certain cause of fatal result. The latter viscus may, however, be penetrated without the peritoneal cavity being opened, and, as experience proves, the wound is by no means of a fatal character. Musket balls sometimes lodge in the bladder. In all such cases it is probable that the bladder has been pene-

trated at some part uncovered by the peritonæum, so that the cavity of the abdomen has not been opened; or, if otherwise, the foreign body has found its way in by ulceration, after adhesion has been established, and thus circumscribed the openings of communication. Small bodies may also pass into the bladder by the ureters.

When the abdominal parieties have been opened by shell or passage of large shot, protrusion of omentum and intestine will probably be one of the results. This does not always happen. Sometimes a wound caused by a large projectile, which was at first not penetrating, will indirectly become so, from the severe contusion and consequent sloughing, to such an extent as to denude the viscera. Curious instances are recorded, in which balls have passed directly through the abdomen, without perforating any important viscus, as proved by examination after death.

Gun-shot wounds of the colon, especially of the sigmoid flexure, appear to be less fatal, probably from structural causes, as well as circumstances of position, than wounds of the small intestines; they sometimes lead to fæcal fistula, and thus save life for a time.

*Wounds of the Diaphragm.*—Musket balls occasionally pass through the diaphragm; and Mr. Guthrie has remarked that these wounds, in instances where the patients survive, only become closed under rare and particular circumstances. Hence the danger of portions of some of the viscera of the abdomen, or the stomach or colon, passing into the chest, and thus forming diaphragmatic herniæ; and of these, eventually, from some cause becoming strangulated. The direction of the ball, hiccough, dyspnœa, accompanied with spasmodic inspiration and inflammatory signs, more particularly connected with the chest, will be the usual indications of such a wound; and in case of recovery, the risk of hernial protension and strangulation must be explained to the patient.

Should the strangulation occur, it can hardly be expected that division of the structure could be performed without the operation itself leading to equally certain fatal results.

*Treatment.*—In the general treatment of penetrating wounds of the abdomen, the surgeon can do little more than to soothe and relieve the patient by the administration of opiates, and to treat symptoms of inflammation, when they arise, on the

same principles as in all other cases. The usual directions to attempt agglutination of the opposite portions of peritonæum by favorable posture cannot generally be carried out, the attempts being defeated by the restlessness of the patient. The collapse which attends such injuries may be useful in checking hemorrhage; and the exhibition of stimulants is further contra-indicated by the risk of exciting too much reaction should the wound not prove directly fatal. If the wound be caused by grape-shot, or a piece of shell, and the intestine protrudes, it must be returned; if the intestine be wounded, sutures are inapplicable, as in an incised wound, without previously removing the contused edges. When the bladder is penetrated care must be taken to provide for the removal of the urine, either by an elastic catheter, or, if this cannot be retained, perineal incision.

*Gun-shot Wounds of the Perinæum and Genito-urinary Organs.*—From the position of these parts of the body, uncomplicated gun-shot wounds of them are comparatively rare. Perineal wounds are not unfrequently caused by shells bursting and projecting fragments upwards; but they are generally mixed with lesions of viscera of the pelvis, or fracture of its structure, or injuries about the upper parts of the thighs or buttocks.

*Gun-shot Wounds of the Extremities.*—Gun-shot wounds of the extremities divide themselves into flesh wounds and contusions, and those complicated with fracture of one or more bones. Flesh wounds may be simple, and these offer few peculiarities, whatever their site; or they may be accompanied with lesions to nerves, or blood-vessels, or both, and these usually increase in gravity in proportion as they approach the trunk.

When complicated with fracture, the lesion is usually rendered compound by the direct contact of the projectile with the bone injured; but the fracture is sometimes simple when caused by indirect projectiles, such as stones or splinters, or by spent balls. These injuries are liable to become further aggravated by the fracture extending into, or being complicated with, an opening of one of the joints. Joints may be contused or opened by projectiles without apparent lesion of any portion of the bones entering into their composition; but these are exceptions to the usual order of such cases from gun-shot.

Simple flesh wounds have already been referred to, both in respect to their nature and treatment in the commencement of this essay. It is in connexion with fractures of bones and their proper treatment that the interest of the surgeon is chiefly attracted in gun-shot wounds of the extremities. From the nature of the injuries to which bones are subjected by the modern weapons of war, together with the irreparable nature of the wound in the softer structures, except after a long process of suppuration and granulation, as well as from the usual circumstances of military life, it might be anticipated that difficulty would often arise in determining which of the double set of risks and evils—those attending amputation, and those connected with attempts to preserve the limb with a profitable result—would be least likely to prove disadvantageous to the patient. Experience in such injuries has established certain rules which are now generally acted upon; some still remain *sub judice*.

*Upper Extremity.*—Fractures of the bones of the arm are well known to be very much less dangerous than like injuries in the corresponding bones of the lower extremity. Unless extremely injured by a massive projectile, or longitudinal comminution exists to a great extent, especially if also involving a joint, or the state of the patient's health be very unfavorable, attempts should always be made to preserve the upper extremity after a gun-shot wound.

In these injuries, when the bone is much splintered, the detached portions, and any fragments which are only retained by very partial periosteal connexions, should be removed; projecting spiculæ sawn or cut off; the wound being extended at the most dependent opening where two exist, or fresh incisions being made for this purpose, if necessary; light water dressing applied; the limb properly supported, and the case proceeded with as in cases of compound fractures from other causes. The same general rules also apply to the preserving as much of the hand as possible in gun-shot injuries.

If the shoulder or elbow joint be much injured, but the principal vessels have escaped, the articulating surfaces and broken portions should be excised. Care should be taken to see that the projectile has wholly passed out, or been removed. The results of excision practiced in the shoulder and elbow joints, especially the former, after gun-shot wounds, have been

exceedingly satisfactory. These operations present no peculiarities in the mode of performance or their after treatment, as compared with similar resections in civil practice.

*Lower Extremity.*—Gun-shot wounds of the lower extremity vary much more greatly in the gravity of their results, as well as in the treatment to be adopted, according to the part of the limb injured, than happens in those of the upper extremity. As a general rule, ordinary fractures below the knee, from rifle balls, should never cause primary amputation; while, excepting in certain special cases, in fractures above the knee, from rifle balls, amputation is held by most military surgeons to be a necessary measure. The special cases are gun-shot fractures of the upper third of the femur; especially when the hip-joint is implicated, for in these the danger attending amputation itself is so great that the question is still open whether the safety of the patient is best consulted by excision of the injured portion of the femur, by simple removal of detached fragments and trusting to natural efforts for union, or by resorting to amputation. The decision of the surgeon must generally rest upon the extent of injury to the surrounding structures, the condition of the patient, and other circumstances of each particular case. If the femoral artery and vein have been lacerated, any attempt to preserve the limb will certainly prove fatal.

Attention was specially directed in the late Crimean campaign, to the question of the proper treatment of these injuries, and expectations were generally held that the advanced experience in conservative surgery would lead to many such cases, terminating favorably, with preservation of the limb, which previously would have been subjected to amputation. Towards the latter part of the war, all the circumstances of the patients were as favorable for testing this practice as they had been in the various *emeutes* in Paris, with the advantages of immediate attention and all the appliances of the best hospitals close at hand. Yet, in the *Surgical History of the Campaign*, it is stated that only fourteen out of one hundred and seventy-four cases of compound fracture of the femur among the men, and five out of twenty among the officers, recovered without amputation being performed; that those selected for the experiment of preserving the limb were patients where the amount of injury done to the bone and soft parts was comparatively small; that where recovery ensued, it always proved

tedious, and the risks during a long course of treatment, numerous and grave; and that the proportion of recoveries would not appear even so large as the above, if the deaths of those who, after long treatment, were subjected to amputation as a last resource, were included. Amputations of the thigh, however, were very fatal in their results also, the recoveries being stated to be, among the men, in the upper third, 12 9-10; in the middle third, 40; in the lower third, 43 3-10 per cent. of cases treated. Among the officers the proportion was rather more favorable. But this per centage includes those cases in which attempts had been made to preserve the limb, and failure resulting, amputation was resorted to as a last chance of saving the patient, so that they ought to have been excluded from the lists of amputations, both primary and secondary, as commonly interpreted. On account of this comparatively indifferent success of amputation, resection of portions of the shaft of the femur was sometimes practised, but the records state that no success attended the experiment, every case, without exception, having proved fatal.

In considering the results of gun-shot fractures of the femur, the situation of the injury is a matter of great importance, whether as regards chances of recovery without or with amputation. Dr. Macleod, in his Notes, remarks that he has only been able to discover three cases in which recovery followed a compound fracture in the upper third of the femur without amputation. A case, however, was under the care of the writer, not included in the above, nor appearing in the official history of the war; and one, judging from the results described in Dr. Macleod's Notes, more fortunate in its issue than at least two of the number he mentions. Dr. Macleod says that, after many inquiries respecting cases of this nature in the hospitals of *other* armies engaged in the war, excepting one presented by Baron Larrey to the *Societe de Chirurgie* in 1857, he never could hear of any other but that of a Russian, whose greatly shattered and deformed limb he often examined. It united almost without treatment. Two cases of united fractures of the femur in the upper third have arrived from the late mutiny in India, and in both, Dr. Williamson records, a good and useful limb had resulted, one with shortening of one and a-half and the other three and a-half inches. Still more recently, M. Jules Roux, of the St. Maudrier Hospital, at Toulon, has given a list of no less than twenty-one cases

of gun-shot injuries of the upper third of the femur, which he had examined on their return from the Italian war of 1859.

The proportion of recoveries in amputations of the upper third of the femur in the Crimean war was under 13 per cent. Amputations at the hip-joint, both in the French and English armies, in all instances proved fatal. Resection of the upper part of the femur, including the head, and two inches below the small trochanter, was performed once, but the patient died from pyæmia. The operation in this instance was performed three weeks after the injury.

M. Legouest, in a recent essay in the *Memoirs of the Society of Surgeons*, at Paris, maintains that amputations at the hip-joint should be reserved for cases of fracture, with injury to the great vessels, and that when the vessels have escaped, resection should invariably be performed. He also inculcates, as a general principle, not to perform immediate *primary* amputation at the hip-joint in any case; but, even in the severest forms of injury, to postpone the operation as long as possible. For the *consecutive* results of gun-shot wounds, the operation presents a less unfavorable aspect than for immediate injuries. M. Jules Roux has recently, at Toulon, performed amputation at the hip-joint six times, for the consequences of wounds received during the war in Italy, and of these, four have been successful.

With regard to gun-shot fractures in the middle and lower third of the femur, the experience of the French and English armies in the Crimea has tended to confirm the doctrine of the older military surgeons, that many lives are lost which might be otherwise preserved, by trying to save limbs; and that, of the limbs preserved, many are little better than incumbrances to their possessors. In the late Italian battles, the practice of trying to save lower extremities, after comminuted fractures in these situations of the thigh, appears to have been abandoned. Eight cases of union, after compound gun-shot fractures of the femur in these situations, have, however, returned from the late mutiny in India, and this is a much larger proportion than was that of the recoveries from the Crimea. But wounds generally, when proper care is taken, heal more favorably in Southern latitudes, East or West, probably owing to the climate admitting of much more free access of fresh air, by day and night, to the patient,



that can be afforded, without inconvenience, in colder or more variable climates.

In fractures of the leg, where neither the knee or ankle-joints are implicated, the results of conservative attempts have been more favorable. Where the fracture is comminuted, and implicates the knee or ankle joint, opening the capsule, amputation is necessary. The knee-joint was once excised in the Crimea, but the patient died; as was the case in the only other instance where this operation is known to have been performed for gun-shot injury in the Schleswig-Holstein campaign. In the treatment of fractures of the leg, when it has been determined to seek union, the same remarks apply as those made above, in respect to fractures in the upper extremity. In wounds of the foot, it is especially necessary to remove, as early as possible, all the comminuted fragments of the bone injured, or tedious abscesses, and much pain and constitutional irritation, are likely to ensue.

### CHLOROFORM AS AN ANÆSTHETIC.

Chloroform is a limpid, colorless, volatile, neuter liquid, having a bland, ethereal odor, and hot, aromatic, saccharine taste. It neither reddens nor bleaches litmus paper. It is but slightly soluble in water. Its specific gravity is 1.49 United States, 1.48 London, 1.496 Dublin. It boils at 142°. It is not inflammable, but renders the flame of an alcohol lamp yellow and fuliginous. It burns, however, with a smoky flame when mixed with an equal volume of alcohol. When pure, it has no action on potassium. It is scarcely acted on by sulphuric acid in the cold, but dissolves readily in alcohol and ether. A strong alcoholic solution is decomposed by abundance of water, the chloroform separating and subsiding, and the alcohol mixing with the water.

*Impurities and Tests.*—Chloroform is liable to contain alcohol and ether; both of which lessen its specific gravity. To determine the presence of impurities which have this effect on its density, Soubieran recommends that a drop of the suspected chloroform be added to a mixture of equal weights of concentrated sulphuric acid and water. Such an acid, when cold, will have the specific gravity of 1.38, and good chloroform, being of greater density, will sink in it.

M. Miahle has proposed the following test for the presence of alcohol: drop into distilled water a small quantity of the chloroform. If pure, it remains transparent at the bottom of the glass; but, if it contain even a small proportion of alcohol, the globules acquire a milky appearance. The most injurious impurities are the chlorinated pyrogenous oils. When the vapor of the oils is inspired, or even smelt, it causes, according to Dr. Gregory, distressing headache and sickness. These pyrogenous oils are detected by the action of pure and strong sulphuric acid. Pure chloroform, when mixed with an equal volume of the acid, does not color it; but, when contaminated with these oils, gives the acid a color, varying from yellow to reddish-brown, according to the amount of impurity present. In applying this test, several fluid ounces of chloroform should be used, as a slight change of color cannot be easily seen in a test tube. If the chloroform, thus contaminated, be poured upon the hand, it quickly evaporates, leaving the oily impurities, recognizable by their peculiar offensive smell, which is no longer covered by that of the chloroform. Pure chloroform, poured upon white paper, evaporates entirely without leaving any tache.

All new agents, that are presented for a place upon the primary list of the pharmacopœia, are viewed with prejudice and suspicion by the profession. In regard to chloroform, the feeling of distrust was very strong, whilst, on the other hand, the public eagerly seized upon and employed it, of course ignorantly and incautiously, and fatal results often followed. Every such case was gladly reported by the sensation press of the day, and thus, perhaps, we have more of the fatal cases resulting from the use of chloroform recorded, than from any other therapeutic agent. Very many more of the fatal cases were due to unskilfulness in its preparation and carelessness in testing for its impurities. The single case, cited in the British *Surgical History of the Campaign in the Crimea*, was due to these causes. But, perhaps, the greatest number of accidents have occurred with our own profession, and in cases, where we would least expect them,—in its administration for minor operations. A satisfactory explanation of this anomaly has been found in the fact that, in all these cases, the operator, in attempting to avoid danger by giving very little of the anæsthetic, has allowed "shock" to be pro-

duced, and death has been the result of it. If the anæsthetization had been pushed further, shock would have been entirely prevented. Other cases have occurred, with the profession, from inattention to the condition of the respiratory functions. We do not object to the attention paid to the pulse, but would insist upon greater being given to the respiration, since death results, in a majority of fatal cases, from obstruction to this latter function.

Some unfortunate results have been attributed to its employment in the most desperate cases, where, but for its aid the surgeon would have considered it madness to have operated. Still other, to want of special care in certain cases, as where there has been excessive hemorrhage, the chloroform being in such instances absorbed at once, owing to the emptiness of the veins; in cases of debility, where the accustomed stimulant is neglected before commencing or during the inhalation; and in that still larger class where it is not given to the required extent.

Whatever may be thought of it by civil practitioners, army surgeons cannot fail to give it their implicit confidence, when they consider the results of experience in its use, and the weight of authority demanding its employment. A computation has been made that one fatal case has occurred in every 16,000 in which it has been employed. Mr. Syme has used it in 5,000 cases with favorable results in every instance. Professor Simpson has administered it in over 15,000 cases without a single accident. In the Crimean war it was inhaled 25,000 times with no unfavorable result. Not a single case is reported from its employment in the late Italian war; and the same may be said of its use in our own service for nearly three years.

Professor Longmore says, "the complete applicability of chloroform, on the field, to injuries caused by gun-shot wounds as to all others in civil practice, is established among continental surgeons, and among a majority of British surgeons." Dr. Scriver, Chief of the French Medical Department of the East, writes, "of all the therapeutical means employed in the surgical art, none has been so efficient, and none has succeeded so well as chloroform; under no circumstances, in its employment with thousands, did it cause the slightest accident." Surgeon Major M. Armand says: "During the Italian war,

chloroform was as extensively used and was as harmless as in the Crimea." Macleod strongly recommends it; "for my own part, I have never had reason, for one moment, to doubt the unfailling good and universal applicability of chloroform in gun-shot injuries, *if it be properly administered.*" Guthrie advises its use in the gravest of capital operations—amputation at the hip-joint. Deputy Inspector-General Alexander, of the British service, reports that "no operations whatever, of any consequence, has been performed in the Light Division without first placing the patient under the influence of chloroform, and in no single instance have either the medical officers of the division or myself seen any bad results follow, or had to reject its use, but quite the contrary. It should, therefore, be always employed, being careful only as to its purity and the mode of its administration.

*Mode of Administration, &c.*—A bed for the patient should be prepared, preferably in the open air, if the weather will permit, or in a room which may be quickly and freely ventilated by currents of fresh air. The patient, placed upon it, should have the head supported but by a single pillow, as it is very important that he be put and kept in the horizontal posture, and on no account be raised during the inhalation lest syncope supervene. The clothes should be loosed from about the neck, chest and abdomen, in order that the respiratory movements may be unimpeded; for the same reason the stomach should not be full, as it might interfere with the play of the diaphragm, which is the principle agent in respiration during the second stage of anæsthetisation. Vomiting would most likely result also, and might prove very inconvenient. The best time is, possibly, soon after the patient has digested a light, but nutritious meal—as the stomach is then empty and the patient strong. All special instruments of inhalation have been discarded, and a towel or napkin, folded into a cone, by having its corners turned down, is now almost universally employed for the purpose. The chloroform, about a drachm, is poured into this cone, and is held over the patient's mouth and nostrils, which should previously have been anointed. When the inhalation is about to commence, the surgeon should address a few kind and encouraging remarks to the patient, telling him that all that is required of him is to be still, and breathe naturally, and that the uncomfortable feeling of suffocation,

which is frequently experienced, will soon pass off; upon the assistants he should enjoin silence, and upon the administrator the strictest attention to the condition of the respiration, pulse and countenance. The administrator will now gradually bring the inhaler towards the patient's face, until it is within half an inch, and should never carry it further for fear of producing vesication, and excluding entirely the air. A proper admixture of air is always required in the inhalation of chloroform. It has been recommended, in the case of the feeble and timid, always to precede the inhalation by the administration of brandy, or brandy and a few drops of laudanum, and if the operation is long continued, to allow the patient to sufficiently recover to have it repeated. It has become an almost universal practice with surgeons in our own service to use the brandy in all cases before resorting to the anæsthetic. The practice is a safe one, and should not be omitted.

The phenomena produced by the anæsthetic have been divided into two stages: the first, one of excitement; the second, one of unconsciousness, insensibility and relaxation. The excitement is first shown upon the brain as the organ of intellect and sensation, when we have the mutterings, the wild eye, the cries, the exalted imagination, displaying themselves according to the peculiarities of the patient or the impressions made by circumstances. We have next the voluntary motions interested, as expressed by violent struggles, attempts to rise, and rigid contraction. The rigidity may extend to the muscles of the larynx, and thereby cause obstruction to the respiration. The reflex functions are the last to be influenced, as is exhibited by the spasmodic closure of the eye-lids upon the slightest touch. The actions of the nervous centres are, in the same regular gradation abolished, and we have unconsciousness, insensibility and relaxation of the voluntary muscles. The patient cannot be aroused, call him ever so loud, nor move, inflict what we may; the eye-lids no longer contract when the conjunctiva is touched,—the reflex functions are suspended, and the organic nerve centres alone are active. The inhalation has been carried as far as is either necessary or safe. It is maintained by the occasional repetition of the inhalation. Insensibility of the conjunctiva is perhaps the best test of perfect anæsthetisation, since by it we see that the reflex functions of the cerebro-spinal axis are suspended. There is,

however, a remarkable and most fortunate exception to this suspension—the nervous centres presiding over the lungs and heart are still active, though much less so than in the normal condition of the system. We find the pulse slow, small and weak, the respiration shallow and feeble; as they have only the organic acts to subserve, their force is diminished. In some instances, the stage of excitement is very transient, and the patient seems at once to fall into a quiet slumber; in other cases the first stage is much prolonged. During the whole time of administration the strictest attention should be paid to the respiration. Should obstruction come on in the first stage, as already noticed; it is probably due to the rigidity extending to the muscles of the larynx, and the effects are the same as those arising from spasm of the glottis. A suspension of the inhalation will allow the patient to respire fresh air, and, after a few inspirations, he will fall back unconscious and relaxed. Should the obstruction not thus readily yield, restorative means should be employed. When obstruction occurs in the second stage, it depends upon muscular relaxation, which allows the epiglottis to fall upon the glottis, and thus close the rima glottidis. Mr. Lister, however, says that this explanation is not satisfactory, and that the obstruction is caused by the arytaeno-epiglottidean mucous membrane, which is carried forward and touches the base of the epiglottis.

The snoring respiration is due to the relaxation of the muscles of the soft palate, allowing the velum palate to flap and vibrate; whilst the stertorous breathing is laryngeal. Mr. Lister attributes this last to the vibrations of the mucous membrane upon the apices of the arytenoid cartilages.

When obstruction occurs in the second stage, we have most frequently stertorous breathing, though occasionally the respiratory movements take place silently. There is also lividity and profound alteration of the countenance, turgescence of the neck, dilatation of the pupil, and coolness of the general surface. If this condition continue, the respiratory movements soon cease, and then those of the heart. The treatment, to be efficacious in such extreme cases, must be very prompt. The inhalation must be suspended; the tongue, seized by the hook, tenaculum, forceps or fingers, must be drawn *forcibly* forwards, so as to clear the rima glottidis of the ob-

struction. Artificial respiration is to be instituted by either Marshall Hall's ready method, by Sylvester's, or by that of Prof. Campbell, of Georgia. Fresh, cold air is to be admitted to the patient, and water dashed upon his face and chest. Stimulating enemata are administered, and, if to be had at once, electricity is applied. In cases less grave, the dragging forwards of the tongue and the suspension of the inhalation will be all that is required. The after effects of chloroform usually pass off as soon as the patient has had a good sleep.

## CHAPTER III.

### ON THE ARTERIES.

#### HEMORRHAGE.

The arteries are interesting to the military surgeon chiefly on account of the danger and frequent occurrence of *hemorrhage* in wounds and surgical operations. "Three-fourths of those who die on the field of battle," says Morand, "perish from hemorrhage." Hemorrhage, then, as first in importance among the accidents of battle, takes precedence of them all, in its claims upon the surgeon. The means of arresting the flow of blood from wounded arteries, is an object of the highest moment. With it are connected some of the surgeon's most responsible duties, often under circumstances in which time is not allowed for either study or preparation of any kind. No class of operations demands a more accurate knowledge of anatomy than those upon the arteries; no class, in which perfect equanimity is so important to the surgeon; and no class, the attendants of which are more calculated to alarm, disconcert and confuse him. A familiar and exact knowledge of the parts to be operated on, a thorough understanding of conditions in each instance, and a clear idea of the course to be pursued, are his only, but sure safeguards against mortification and well-merited blame. The well established results of experience, therefore, from whatever source they may be gathered, should be in the hands of every one having charge of the wounded soldier, with rules to guide, and principles to govern, in this most frequent and frightful emergency of both the field and the hospital.

Every lesion of the soft parts is attended with more or less effusion of blood, which occurs generally at the moment of injury; at other times, it appears at a period more or less remote from the accident. This difference in time has given rise to the division of hemorrhage into primary and secondary



or consecutive. A large number of cases have been grouped, by some, into classes termed retarded and intermediary, which terms also have reference to the time at which the effusion takes place, and which distinctions we shall retain with certain definite restrictions to be indicated hereafter.

**PRIMARY HEMORRHAGE.**—Primary hemorrhage is more frequent in injuries from edged weapons than from gun-shot wounds, which are more apt to be followed by consecutive bleeding. It may be capillary, venous or arterial; infiltrated through the meshes of the cellular tissue or collected into a mass or clot.

*Capillary Hemorrhage.*—The loss of blood arising from the division of capillary vessels hardly deserves the name of hemorrhage, and seldom engages the attention of the surgeon except in cases of that peculiar condition of the system known as the "hemorrhagic diathesis," where there is always a troublesome tendency to sanguineous extravasations, and may often be observed in those whose constitutions have been impoverished by privations and fatigues. M. Legouest, whose valuable work we have freely used in these preliminary observations, justly remarks that this form of effusion "shows itself more frequently among soldiers towards the end, than at the beginning, of a campaign." We have observed also during the present war, that certain diseases seem capable of establishing the hemorrhagic constitution—especially has this been observed after the epidemic of measles, so wide-spread in our army during 1861 and 1862. The blood oozing from the general surface of the wound in these cases, re-appears as rapidly as it is wiped away, and we are unable to detect any precise point from which it comes. The blood itself is generally thin and resembles that of a chlorotic female—cherry juice—the clot, if any, is soft and of feeble tenacity. These cases, of course, are more suitable to the hospital than to the treatment of the camp, and come more properly under the supervision of the medical man than the surgeon, though, when the hemorrhage is from the gums or nostrils, we are tempted into operative measures, which, indeed, seldom accomplish anything.

*Venous Hemorrhage* is apt to occur in all wounds of the soft parts, but only requires attention when the lesion involves large vessels or veins whose calibre is kept open by their attachment to aponeuroses or the fibrous tissues they traverse,

the blood flows generally from the end of the vessel communicating with the capillaries. It is poured out by a continuous jet of more or less force, increased by pressure above, and diminished by pressure below, the point of lesion. The blood is black and slowly forms into friable and diffuent clots.

*Arterial Hemorrhage.*—The history of arterial hemorrhage is inseparable from that of wounds of the arteries. It is this form which has deserved and received most attention from the profession, both because it is more dangerous to the patient and more frequently demands operative measures for its relief.

When an artery of an appreciable size has been opened, the blood issues by the cardiac end of the divided vessel, in interrupted oscillatory jets of a bright vermilion color, synchronous with the pulsations. Pressure made between the heart and the wound generally arrests the hemorrhage.

Arteries may be incised, punctured, contused or lacerated. Each of these forms of injury is attended with results peculiar to itself, which, though they necessarily modify the history of the case, influence but little the principles which govern the treatment. Incised and punctured wounds of arteries give rise to primary hemorrhage; lacerated, more frequently to retarded or intermediary, when they bleed at all; while contused wounds of the vessel, either result in secondary hemorrhage or in traumatic aneurism.

The form and seat of the wound, and the extent and character of the division, cause also important modifications in the flow of blood. In clean and open wounds, both ends of the divided vessel are said to furnish a stream of blood; that from the superior end being of a bright vermilion color, while the recurrent stream from the lower end partakes, it is said, somewhat of the appearance and characters of venous blood; the jets being also less decided. The surgeon seldom has opportunity to observe this distinction, as in deep wounds, the two streams become mixed and the force of the respective pulsations is broken by the streams coming in contact with the walls of the wound in the soft parts leading to the orifice.

The location of the arterial lesion modifies the symptoms in other respects: thus, when a considerable vessel or the principal trunk of a limb happens to be wounded, if very high up and near the body, there will be no pulsation in the limb below, and the manner and character of the blood discharged

will indicate that only the cardiac end is bleeding; if lower down, where the collateral communications are abundant, pulsations will be perceptible, and the bleeding will probably arise from both the cardiac and distal end, or even altogether from the distal end.

This observation of M. Legouest's, relating to the influence which the locality of the lesion exercises on the symptoms, a little reflection will show to be of great practical importance. It has a bearing on that valuable doctrine of Mr. Guthrie, so generally applicable that it is now rapidly becoming the invariable and imperative rule of the profession, viz : That scarcely under any circumstances is it allowable to ligate a bleeding artery in its continuity above the wound, or elsewhere than at the point of lesion, and that, when this rule is departed from, the occasional success is "only a matter of accident." From the foregoing it will be seen that what has been considered accidental is the result of conditions and anatomical relations, which can be estimated previous to each operation, viz : the position of the wound, and the paucity or abundance of the collateral communications with the trunk to be operated on. The circumstances in which it may be desirable to depart from this important rule laid down by Mr. Guthrie, though but few, are yet of very frequent occurrence during every active campaign, where even the most unusual peculiarities repeat themselves so often and in such rapid succession. The advantage, therefore, of being able to recognize the cases in which we may safely depart from any given rule, when circumstances and the good of the patient seem to demand it, is worthy of some consideration. These cases will be referred to more fully when the surgical treatment of hemorrhage is in discussion.

The section of the walls of an artery may be complete or incomplete, transverse or longitudinal :

The complete transverse section of an artery of large calibre is apt to be immediately fatal, for it gives rise to a gush of blood which ceases only with life. In the most fortunate cases of this class, syncope and the other natural processes by which hemorrhage is arrested spontaneously, may even permanently close the wound. Most frequently, however, these barriers giving way, the effusion of blood re-appears after a longer or shorter interval, when it is known under the name of secondary or, more properly, *consecutive* hemorrhage.

The incomplete transverse section of an artery gives rise to phenomena of different kinds, according as it involves a fourth, a half, or three-fourths, of its calibre; the blood issues in part from the wound, and continues in part its course along the inferior portion of the vessel. The quantity of the blood which escapes being less than in the preceding case, the arterial pulsations are observed below the wound, and, though weakened in proportion to the extent of the orifice, still preserves somewhat of their normal characters. Pressure made above the wound arrests the flow, while it is augmented by pressure below, which last causes the entire contents of the artery to be thrown upon the orifice.

Ordinarily, the hemorrhage is more difficult to arrest when a vessel has been divided in part, than when completely severed. When the fourth only of the vessel has been cut, the wound is enlarged by the elasticity of the arterial tunics and by the flow of the blood; but, as its stream is not very large, nor very violent, it may, especially in the case of the smaller arteries, be stopped by the formation of a clot or by the effusion of plastic lymph. When half the circumference of the vessel is involved, the effusion is still more increased, and a loss of blood is sustained which is almost uniformly fatal. Death, of course, is still more certain when three-fourths of a large trunk is divided, unless, perchance, the remaining part should break under the efforts at retraction made by the arterial tunics, when the case will enjoy the scarcely more hopeful chances occasionally found in complete transverse section. Incomplete transverse sections are, therefore, more serious than the complete, because the obstacle to retraction and contraction of the vessel, which the undivided portion presents, keeps the wound permanently open.

Longitudinal sections of arteries, when not very extensive, are much less serious than any of the transverse, and spontaneous cures are by no means uncommon in this form of lesion.

It is always important to distinguish the kind of hemorrhage we have to deal with. The characters which have been assigned above are not so well defined, nor can they always be, as to leave no doubt on the mind of the surgeon when the wounds are deep and ragged, or when the bleeding, instead of occurring externally, takes place in the cavities. True, it is well known that blood coming from an artery

escapes with more force and in much greater quantity than when flowing from a vein ; again, that arterial blood is much redder than venous, and that the first issues per saltum, while the latter escapes in a continuous stream ; but still each of these guides is liable to its own peculiar fallacy. Thus, the bleeding may be arterial, and yet internal, most of the blood being retained in some cavity, or infiltrated among the meshes of the cellular tissue, while but a small quantity escapes to meet the eye of the surgeon. As examples of this kind of obscurity, it is not uncommon to observe, after the removal of large tumors, as the mamma, that hemorrhage comes on, after the dressing has been completed, from some small artery neglected at the bottom of the wound ; on the removal of the bandage, a small opening is made somewhere along the line of recent union, and the blood issues in a jet upwards, sometimes five or six inches, the column being sustained by the elasticity of the skin, made tense by the accumulation of fluid blood ; again, several times during the present war, have we seen, in the Georgia hospitals at this post, arterial hemorrhage some hours after amputation, or, as in one instance, many days after, when union had become pretty firm and the bleeding was secondary. In this instance, as in the one just stated, the blood, accumulated in the pocket formed by the flaps, was forced out of the small opening in a continuous jet, the elastic force of the skin overcoming the interrupted force with which the artery replenished the contents of the sac. Here the *supply* was arterial, the *color* red, but the *manner of the flow* was venous. Again, venous hemorrhage may simulate the interrupted jet of an arterial bleeding by the proximity of a large artery communicating its pulsations to a wounded vein. This is sometimes observed when the median-basilic is the vessel selected for venesection ; the pulsations of the brachial artery beneath may cause the blood to issue per saltum. Secondly, if we depend on the quantity discharged for our criterion, we may still be deceived, as it is well-known that pressure on the vein between the wound and the heart will increase the abundance of the venous flow. Thirdly, the color is not a safe criterion for other reasons than those just given ; the rapidity of the circulation may cause the blood to course with such celerity through the capillaries that, though it issue from a wounded vein, the change of hue not having been effected, it may be mistaken for arterial blood.

And, finally; we should remember that, in the hemorrhage which occurs during *operations under chloroform* and immediately after, the arterial blood is almost invariably of a dark venous color—sometimes nearly black—owing to the fact of the chloroform vapor having replaced the atmospheric air; and, though this seems to sustain respiration, it does not change the color of the venous blood in the lungs. This fact is, we suppose, pretty generally known; yet, on several occasions during the present war, we have seen patients lose an exhausting amount of blood after amputations, from the operator mistaking *dark arterial* blood, under these circumstances, for *venous*, and waiting for the spontaneous cessation of the flow, as he would be justified generally in doing were the hemorrhage really venous. For the same reason as given above—absence of oxygen—do we find the arterial blood of patients laboring under impeded respiration, as in extreme compression of the brain or apoplexy, dark enough to be taken for venous blood:

A soldier was brought to the Fourth Georgia Hospital with a wound in the temporal region. At first, there was only confusion of intellect, with partial hemiplegia—symptoms certainly not warranting the use of the trephine. After some days, the paralysis began to increase. He soon became comatose, the case now declaring itself one of compression from effusion—probably purulent. The symptoms increased so rapidly after trephining was determined on, that his respiration sank to *six in the minute*, and during the operation, as will be seen, ceased several times altogether; his face was turgid and very dark, lips and tongue blue. A deep incision, to the bone, was made in the temporal region in order to raise the fascia and muscle for the trephine. Of course, the temporal artery was cut; the blood was poured out abundantly *per saltum*, and it was black like venous blood. At this time respiration ceased entirely, and we supposed him to be dead. The heart being found still to beat, though feebly, “artificial respiration in the sitting posture,” was applied. The vigor of the pulse was at once restored, and the color of the blood changed from that of venous to bright vermilion. The countenance also became natural during artificial respiration. With the finger on the pulse, the operation was rapidly proceeded with, but had to be interrupted frequently to apply the artificial respiration

whenever the pulse was becoming extinct. The effort was always the same during the whole period—more than an hour—occupied by the operation, viz: improvement in the heart's action, and *complete restoration of the arterial color of the blood*, as shewn whenever there was any bleeding. On the removal of the bone the dura mater was found greatly distended, and a puncture gave exit to a large quantity—ounces—of pus. Contrary to our hopes, and, indeed, expectations, spontaneous respiration never returned, though he was sustained, and his face kept of the natural color for hours after the pus was evacuated. The heart's action began to flag soon, even under the artificial respiration, and he must have died after a while, but his death was probably completed, we have suspected, by the fumes of ammonia, injudiciously and irregularly applied to excite natural respiration. The whole time, during and after the operation, he did not perform a single spontaneous act of respiration. The case is related somewhat in full because of its many points of interest, but our present use for it ends with the illustration of one single point—*the coloration of the blood resulting from a gun-shot wound*.

When hemorrhages, instead of being external, take place in the substance of the tissues or in the cavities, they give rise, on the one hand, to infiltration, and, on the other, to effusions of blood. The diffusion of blood among the tissues is seldom observed in arterial lesions. It is evidenced by rapid augmentation of the volume of the parts in which it occurs, by an unpleasant feeling of tension and weight, by the marbled and black coloration of the skin which covers the effusion, and by the more or less deep and wide-spread pulsations in the neighborhood of the wound. Sometimes the hemorrhage appears on the surface; at others, it is completely enclosed when the extravasation constitutes what is known as diffused traumatic aneurism.

If the effusion takes place in some cavity, the appearance, more or less promptly, of the signs of internal hemorrhage and the patient's own sensations indicate clearly the means of diagnosis. These symptoms and sensations vary in accordance with the character of the special organ disturbed or impressed by the collection. Thus: if in the cranium, symptoms of cerebral compression become manifest; if in the cavity of the pleura, dyspnoea is observed; while, for collections in the

cavity of the peritonæum, the patient is apt to experience an unusual and ineffectual desire to evacuate either the rectum or bladder, caused by external pressure of the accumulating blood on the parietes of these organs. In connection with these special symptoms, however, the rapidly progressive or complete collapse seldom fails to declare positively, to the experienced observer, the existence of internal hemorrhage.

**CONSECUTIVE HEMORRHAGES.**—If there is any one accident of gun-shot wounds more alarming than primary hemorrhage, that accident is secondary hemorrhage; for, to all the frightful phenomena that assemble in the first, we have most frequently added in this last, the disconcerting element of surprise. Whenever the soft parts are wounded, a free discharge of blood, even to a dangerous amount, is not an unlooked for occurrence; but secondary hemorrhage often gushes out, under circumstances least calculated to forewarn. In gun-shot wounds, this is especially the case; the projectile is often devious in its course, and it is well known that the line, between entrance and exit, does not always represent the true track of the ball. Cases have not been wanting to illustrate this among our own troops. The situation of the wound, and the apparent course of the ball, may have suggested no suspicion that any important vessel had been approached, and yet an outburst of secondary hemorrhage in some cases, or the sudden formation of traumatic aneurism in others, even when the wound had nearly healed, may unexpectedly reveal the fact, that an artery of the largest size is involved. To the patient, the danger is always imminent; to the surgeon, the position is often perplexing. Few of us will deny the assertion of Legouest, that “secondary hemorrhages are the terror of the surgeon, as well as of the patient.”

Even at the present day, much confusion seems to exist as to the terms used to indicate the varieties of consecutive hemorrhage. An exact nomenclature and a determinate classification are greatly needed for the methodical study of the subject. With the exception of the term primary hemorrhage, all the words used to indicate the differences in the *time of the bleeding*, which is the basis of classification adopted, are of the most indefinite and uncertain signification. Thus, the term “retarded hemorrhages” has long been in dispute; Dupuytren classes them with the primary, whilst others, before and since his time, place them among the consecutive



effusions. The term "intermediary" is not more fixed in its meaning, while those of "secondary" and "consecutive" are most unsettled of all; because mutually convertible, and because both of them are constantly applied to a wide range of cases illustrating great varieties of conditions. In the mind of no one do they establish any very definite time for the bleeding. When the terms which are intended to distinguish things are so loosely applied, confusion must necessarily follow.

We understand by *Consecutive Hemorrhages* the entire class of sanguineous effusions which appear at a period more or less remote from the moment of injury, and which are capable of placing in imminent danger the life of the patient. Using the term, then, in a general sense, it will embrace *all hemorrhages which occur after the period of the primary*, and, among these, secondary hemorrhage will be comprised as the most prominent and important variety. We shall recognize three others, viz: the retarded, or delayed, the intermediary and the indeterminate. The classification when arranged, in brief tabular form, will appear thus :

Consecutive Hemorrhages.	{	1st. Retarded Hemorrhages.
		2d. Intermediary Hemorrhages.
		3d. Secondary Hemorrhages.
		4th. Indeterminate Hemorrhages.

We have arranged the above classification for the convenience of the Confederate army, preferring it to the unsettled and indefinite application of terms now in use—and for the following reasons: first, because of its exposition of the actual facts of the history of hemorrhage; second, because such a classification will admit of the clear and accurate record of cases, and can be soon generally understood throughout the army; and, thirdly, because we confidently believe that the observation of those who have enjoyed the largest experience in the surgery of this war, will accord with our own, and gain for it an unhesitating assent. All have felt the inconvenience of a deficient classification.

*Retarded Hemorrhages.*—When the soft parts have sustained a severe gun-shot or other contused wound, if a large artery has been opened, death, as we have seen, is apt rapidly to follow; but when vessels of less considerable size have been wounded, especially in gun-shot wounds, the primary

hemorrhage soon begins gradually to lessen, and finally ceases altogether; or there may have been only a sudden spurt of blood at the moment of injury, succeeded by no further effusion. Sometimes, this sudden check constitutes the permanent arrest of the hemorrhage, but most frequently otherwise—the effusion, in the case of the larger vessels, almost certainly returns in the period of from six to ten hours—and it is to this effusion, which cannot properly be called either primary or secondary, *whether it had been preceded by bleeding at the time of wound or not*, that the name of “retarded or delayed” hemorrhage has been given. In many cases, the wound from which the bleeding proceeds had not bled at all at the moment of injury.

The conditions which give rise to delay in hemorrhages are: crumpling of the vessels; contusion; fraying of the soft parts; fright, syncope and concussion; exposure or contact with the air, and consequent rapid formation of clot. All these causes of delay are of a nature liable to be overcome by that restoration of the nervous system, and of the circulation, known under the name of “re-action,” when the vessels bleed with great vigor, and call for the immediate attention of the surgeon. These hemorrhages seldom occur till after the patient has been removed from the field, and has been placed in the hospital or infirmary. During the engagements around Richmond, from the several battle-fields of Seven Pines, Mechanicsville, Gaines’ Farm and Malvern Hill, large numbers of wounded crowded our hospitals. Some of the wounds had been carefully dressed by the surgeons at the field infirmaries; others came in to be attended to, for the first time, in the general hospital here, often less than five miles from the scene of action. The surgeons could not have failed to observe the very large number, comparatively, whose wounds began to bleed freely after arriving at the hospital. Such was the case, at least, to a remarkable extent, at the four Georgia hospitals, crowded at that time with the wounded from those bloody fields. These were all cases of *retarded hemorrhage*, taking place from eight to ten hours after the receipt of the injury. The bleeding in these cases was most probably due to the excitement and disturbance of transportation, and to the removal from the open air of the field to the closed walls of the hospital. Reckoning together the trivial and the serious effusions of this class, retarded hemorrhages may be

considered as by far the most numerous of all the consecutive bleedings which attend upon gun-shot wounds.

*Intermediary Hemorrhages.*—We cannot say to whom the profession is indebted for the term “intermediary hemorrhage.” It is of rather recent date in surgical language; and as yet, seems to have acquired no very determinate significance; thus Legouest (*Traite de Chirurgie d’Armee*, 1863,) defines intermediary hemorrhages as “those appearing suddenly tolerably long (*assez long temps*) after the injury, without being preceded by any other hemorrhage,” and is disposed to agree with Dupuytren and class them with the primary hemorrhages. Mr. Ferguson, referring to them as they occur in civil practice, defines them as “those bleedings which take place in the period between the first dressing of the wound at the conclusion of an operation and the coming on of inflammatory action, and which occur in the first eight hours afterwards,” thus confounding them with retarded hemorrhages. Our purposes of classification require us to give the term a more certain and exact meaning, which shall connect this class of bleedings with a definite time, and with a set of circumstances and conditions, if not peculiar to them, at least very generally attendant upon them.

In order to comprehend these circumstances and conditions, it is only necessary to recount a few of the facts which make up the history of the first four or five days of the inflammation consequent upon a gun-shot wound in which an artery of considerable size is involved. At first, there is bleeding; then the formation of a clot, under the influence of retraction and contraction of the vessel and other tissues, aided by syncope; shortly after, the processes of congestion and inflammation begin; and finally, as these progress to the point when the swelling has attained its height, which is generally about *from the third to the fifth day*, the pressure exerted upon the vessel, and the accelerated condition and turgescence of the circulation, cause disturbance of the clot located in the mouth of the vessel;—it is forced away—when a sudden, and sometimes dangerous, hemorrhage takes place. This occurs just in the midst of that period of the inflammatory process in which the tissues are most sensitive and least favorable for any operative procedure—a fact which renders these hemorrhages more embarrassing to the surgeon than either the primary, the retarded, or even the secondary cases.

*Secondary Hemorrhages.*—Secondary hemorrhage is a bleeding not only occurring at a particular period and in a particular order, as the name justly implies, but it is one attended by a peculiar set of circumstances, conditions and causes which even more fully distinguish it from all other forms than either of these, and which, when properly considered, must be seen to exert a most important and instructive influence over the history, the treatment and the prognosis of the accident; over its history, as shown in the nearly uniform period at which the bleeding occurs, and also the much greater liability to dangerous complications in this form than in the others; over its treatment, because the feeble condition of the patient and the often tumid and inflamed state of the parts to be operated on introduce important considerations of practice, both operative and medical; and lastly, these attendants of secondary hemorrhage exert an important influence over the *prognosis*, either for or against the patient, because, as will be seen, the observation and experience of the present war have shown that though on the one hand there are often fever, inflammation and great turgescence to contend with, yet the very existence of these conditions, for so considerable a time, may be regarded as promotive of a favorable issue in the case of ligation, by the previous gradual establishment of the collateral circulation so necessary to success. In this place it may be stated that the operation itself has been found, under the above circumstances, a valuable means of relief, by moderating and controlling this inflammation, effectually restricting it within the bounds of a safe and healthy activity. Marked illustrations of these results may be adduced in the proper connection.

Although doubtless sometimes it may happen, in accordance with the statement of M. Legouest, that secondary hemorrhage is the result of a subsidence of the tumefaction surrounding the arterial lesion, the disturbance of parts removing the clot, this is by no means the rule applicable to the gun-shot wounds of large arteries, as observed in our own military hospitals. Indeed, a decidedly contrary condition of the tissues seemed to prevail, in most of the cases requiring ligation. The inflammation, so far from receding—"the parts shrinking and recovering themselves"—was, in nearly all instances, *rapidly advancing*, and, in some, had reached what appeared to be the utmost limit of intensity, consistent with

structural organization, at the time the hemorrhage took place. How far this difference, in the stages and character of the inflammation, may be due to the difference in climate and circumstances, and the latter-day ingenuity displayed in the projectiles producing many of our wounds, it would be difficult to estimate, but doubtless all these combine to render many features in the surgery of the present prolonged, gigantic and unprecedented struggle, widely aberrant from any rules deducible from the brief campaigns of European wars. Our men have been now, over two years under the privations and exposure of the field, and though veterans in morale, and heroes in valor and endurance, still that peculiar trait of the soldier's physique, which, for want of a better name, we hope to be understood in calling "the scorbutic constitution," has been deeply impressed upon them. For however stalwart and active the soldier may appear, the inflammation from the Minnie-ball wound defies all comparison with familiar precedents, shows little or no tendency to resolution, and a strong proclivity, to septic termination—the entire course of its sad history being painfully diversified by strange episodes of irregular and unexpected occurrences.

*Indeterminate Hemorrhages.*—In the foregoing paragraphs it has been seen, how and at what period the various forms of consecutive hemorrhages are occasioned; thus retarded hemorrhage more frequently comes in within from five to twelve hours after the receipt of the wound, and simultaneous with re-action or recovery from the general or local shock;—intermediary, within from three to five days, with the dislodgment of the occluding clot and the increased circulation, consequent upon advancing inflammation and tumefaction;—while secondary takes place from the eighth to the fifteenth day, according to the artery wounded, and is occasioned, either by the separation of a slough opening into the calibre of a vessel previously injured, or by softening of the fibrinous adhesion in the mouth, or by the giving way of the walls of a traumatic aneurism. But there are still other cases of hemorrhage which admit of classification with none of these, and which are aberrant, both from the uncertainty attending the periods at which the bleeding occurs, and the variety of causes giving rise to it. These can only be classed under a common head, "*indeterminate hemorrhages*," by their one common feature, *their irregularity*, both as to the time of their occurrence and the

## TABLE

*Showing the period at which CONSECUTIVE HEMORRHAGE occurred in thirty-four cases of Gun-Shot Wound.*

No.	Name of Patient.	Age.	Battle.	Date of Wound.	Artery involved.	Date of Consecutive Hemorrhage.	Time elapsed.
1	B. Creecy,	—	Chancellorsville,	May 3d, 1863,	Hyoid,	May 12th, 1863,	9 days.
2	A. D. Councill,	37	"	"	Axillary,	May 17th,	14 "
3	John Shaffner,	30	"	"	Femoral,	May 12th,	9 "
4	W. H. Moxley,	27	"	"	"	"	9 "
5	Absalom Strunk,	35	"	"	"	May 10th,	7 "
6	Corporal H. Day,	49	"	"	"	May 24th and 28th, 1863,	21 "
7	Serg't G. Wallen,	23	"	"	Anterior and pos- terior tibial,	May 20th, 1863,	17 "
8	W. A. Wiley,	21	"	May 2d,	"	May 9th,	7 "
9	T. A. Davis,	22	"	May 3d,	Radial or interos- seal,	May 17th,	14 "
10	W. H. Butler,	27	"	May 4th,	Deep palmar arch,	May 18th,	14 "
11	W. P. Anderson,	24	"	May 3d,	Radial or ulnar,	May 14th,	11 "
12	W. H. Hager,	—	—	Dec. 31st, 1862,	Popliteal,	Jan. 29th,	29 "
13	J. W. Jones,	23	Chancellorsville,	May 3d, 1863,	Radial,	May 13th,	10 "
14	J. J. Stewart,	30	"	"	External carotid,	June 7th,	35 "
15	M. Roan,	35	"	"	Radial,	May 10th,	7 "
16	A. Carter,	24	—	Amp. 2d June, '63,	Radial and ulnar,	June 16th,	14 "
17	F. M. Chance,	26	Chancellorsville,	May 3d, 1863,	Radial,	June 18th.	15 "
18	Hosea McMurray,	—	"	"	Femoral,	"	15 "
19	H. R. Polk,	21	Gettysburg,	July 2d,	Palmar arch,	July 20th,	18 "

20.	John F. Endy,	23	Gettysburg,	July 3d, 1863,	Sub-clavian,	July 17th, "	14
21	T. K. Lewis,	21	Fredericksburg,	Dec. 13th, 1862,	Femoral,	Dec. 19th, 1862,	6
22	C. Burch,	25	"	"	Brachial,	Dec. 23d, "	10
23	W. A. Robanett,	—	Chancellorsville,	May 2d, 1863,	Femoral,	June 6th, 1863,	35
24	Noah Gray,	—	—	May 10th, "	Femoral in ampu- tation,	May 14th, "	4
25	R. H. Hapgood,	—	Chancellorsville,	May 4th, "	Shoulder,	May 12th, "	8
26	W. H. Barnard,	—	"	May 2d, "	Femoral,	"	10
27	Z. M. McCatherine,	—	"	May 3d, "	Lower jaw,	"	6
28	W. McBeth,	—	Charleston,	—	Amputation thigh,	—	11
29	M. McDaniel,	51	Chancellorsville,	June 9th, 1863,	Femoral in ampu- tation,	June 26th, 1863,	17
30	J. M. Orr,	18	Richmond,	June 27th, "	Anterior tibial,	July 11th, "	14
31	C. A. Ried,	17	Seven Pines,	May 31st, "	Aneurism of femo- ral,	June 2d, "	3
32	S. A. Willingham,	17	Richmond,	June 26th, "	Peroneal,	July 9th, "	12
33	Drury B. Early,	18	Seven Pines,	June 1st, "	Anterior tibial,	June 10th, "	10
34	T. Roach,	31	—	June 7th, "	Radial,	July 11th, "	3

manner of their production. The bleeding usually takes place, in gun-shot wounds, at a late period, when the danger of consecutive hemorrhage is supposed to have passed—in twenty, thirty or forty days, or indeed at any time during the advanced stages of a severe wound. The causes, as has been said, are various. Most frequently from attrition of the artery by contact with spiculæ of bone, or from ulceration of the arterial tunics, or even from the advancement of mortification; though this last seldom gives rise to hemorrhage. Cases of undeterminate hemorrhage seldom admit of ligation at the seat of lesion, as their occurrence always involves such a condition of the surrounding parts, as to preclude operative procedure, unless at a considerable distance above.

In concluding this portion of the subject, we deem it of sufficient practical interest to present the experience of our own surgeons, as exemplified in the hospital reports sent to the Surgeon-General. The preceding tabular view of cases of consecutive hemorrhage, we have arranged out of the valuable materials found in the office of the Inspector of Hospitals.

The foregoing cases resulted principally from the fields of Chancellorsville and Gettysburg, the record being begun after the removal of the patients to the General Hospital. Hence no cases of retarded hemorrhage appear among them. These occur, as has been seen, more frequently either on the battlefield, or at the field infirmaries, and within a certain number of *hours* after the injury. The periods in the above table range, as will be seen, from three to thirty-five days, and among the cases will be found examples of each of the other varieties of consecutive hemorrhage. The largest proportion may be classed as secondary; some few intermediary; while cases 6, 7, 12, 14, 19, 23 and 29 all more properly come under the head of indeterminate hemorrhage, as the long period elapsed, between the receipt of the wound and the effusion, indicates plainly that other causes, besides those which occasion secondary bleeding, were at work in its production.

*Treatment of Hemorrhage.*—We have several times referred to the *natural processes* by which hemorrhage is arrested. These are syncope, general and local shock, the retraction and contraction of the arterial tunics, the gradual formation of a clot, and the final union of the edges of the wound as in the lesion of other parts. By one or other of these means, or by several combined, arteries of considerable size



sometimes heal permanently. Such occurrences, however, serve rather as rare accidents for the consideration of the student; but are seldom to be depended on by the surgeon; certainly *never* unless under the strictest watching and completest preparedness, in case it should be required to adopt more efficient hæmostatic measures.

The means of arresting hemorrhage are of two kinds: the temporary or provisional, and the permanent or operative. The *provisional means* consist in all those agents and appliances which the surgeon may command on his first introduction to the case, and are intended to prevent the exhaustion of the patient during the time necessary either, to remove him from the field or to prepare for an operation. These means are few and simple in the hands of a good surgeon. Pressure on the main arterial trunk of the limb, under some form or other, is the principal, most reliable, and, when practicable, the *first to be applied*, of all these means. Position or the elevation of the wounded part (in case of one of the extremities), local styptics, the application of cold, by ice or cold water, making access for cold air to the part, and the administration of sedatives, are all valuable adjuncts in certain cases, never forgotten by the thoughtful practitioner.

*Pressure* is made either by the hand or by the application of the tourniquet, over the course of the main artery at some convenient point above the wound. The object is to flatten the vessel, and, for the time, to obliterate its calibre. If possible, such a direction should be given to the force as to compress the vessel between the fingers and the bone—as in the *upper extremity*; the brachial artery, (see Plate 1, Fig. 1, Arteries,) the point selected, is where the vessel is in close relation with the *humerus*. A moderate degree of pressure with the fingers and thumb will, if judiciously applied, effectually arrest the circulation for the time. When the seat of the wound will not admit of pressure being made against the humerus, the *subclavian artery* may be compressed with the thumb, just within the clavicle as it passes, rather deeply, over the *first rib*. The ring of a large key, wrapped with a piece of roller, is often conveniently used for this purpose.

In hemorrhages from the *lower extremity*, the pressure may be applied to the *femoral artery* at the *brim of the pelvis* where that vessel passes over the *pubic bone*. In wounds below the knee, if the patient is not too fleshy, it may be

applied in the *popliteal region*. Pressure with the hand can be applied to all the superficial vessels, as the *facial*, where it ascends over the inferior maxilla, the *temporal* and *occipital* upon the cranium, the *primitive carotid* upon the transverse processes of the cervical vertibræ, and recently even the *abdominal aorta* has been effectually flattened against the bodies of the lumbar vertibræ, to delay the fatal issue in a wound of one of the illiac arteries.

A very effectual mode of applying pressure with the fingers is often apparently forgotten or omitted by the surgeon, perhaps from a species of timidity, viz: pressure *directly upon the bleeding orifice*, by passing the finger into the wound, down to the artery. When applied in this way, very little force is required; it causes little or no fatigue to the surgeon, and, of all methods, is the one most certain to control the bleeding.

Pressure with the tourniquet is less fatiguing and more trustworthy than with the fingers. A good many modifications of the instrument have been suggested, some of them admirably adapted to certain specific purposes for which they were devised; we prefer, however, for the temporary arrest of hemorrhage, from wounds of the extremities, the ordinary tourniquet of Petit, (Plate 1, Fig. 2, Arteries,) with perhaps a somewhat larger pad than that in ordinary use. Though one of the oldest forms of the instrument, it is more readily applied, occupies less space, maintains its place on the vessel better, and is more reliable than any of its more modern competitors. As in pressure with the fingers, the pad of the tourniquet should be adjusted, if possible, so as to compress the trunk of the main vessel *against the bone* (Plate 1, Fig. 3, Arteries,); but, with a pad of sufficient size, it may be effectually applied at any portion of the limb which can be encircled by the band of the instrument. Care should be taken to have *no greater* constriction than necessary to arrest the circulation in the main trunk, and to keep up the application *no longer* than actually necessary, for fear of increasing the tendency to gangrene thereby, after the ligation of the artery. As a substitute for the regular tourniquet, every one is familiar with the use of the handkerchief, either smooth or with a knot, and made tight by twisting with a stick, bayonet or ramrod passed between it and the limb. This is a valuable extemporaneous means of compression.

*Local Styptics.*—These, though here classed among the temporary means of arresting hemorrhage, often serve the purpose of permanent measures, and obviate the necessity of an operation. They act both by changing the condition of the blood in the mouth of the arterial wound, and by stimulating retraction and contraction of the vessel when completely divided. The most powerful agents of this class are found among the *preparations of iron*, especially the persulphate and perchloride. They contract all the tissues about the surface of the wound, close the mouths of all the small vessels, and change the fluid blood into a firm, dense clot, which often plugs up completely an opening of considerable size in vessels of even large calibre. The persulphate of iron may be applied in solution, of a strength varying from ten to sixty grains to the ounce of water. Pledgets of lint, saturated with the fluid, may be stuffed into a deep wound; or laid upon the surface, when the source of the effusion is superficial. An objection made to its application, in certain cases, is that it prevents union by first intention. The sulphates of *zinc* and *alumina* are older remedies, which possess much inferior power to the above, but are similar in their mode of operation. *Ice*, *creosote*, *tannin*, and a variety of valuable agents of secondary power, so often applied in civil practice, and attainable in the hospitals, cannot be relied on for field practice, and are, therefore, out of the question, except under rare circumstances.

*Admission of Air.*—Too little value, ordinarily, is attached to the admission of air into the wound in a bleeding vessel. Vessels of a moderate size, as the anterior tibial, the radial, or the ulnar, often bleed most obstinately, till the wound in the soft parts has been widely opened, the clots turned out, and the cold air admitted—when the hemorrhage is apt to cease immediately. In wounds of the mouth, the hemorrhage is often alarming—sometimes the extraction of a tooth produces exhausting discharges of blood. In these cases, the removal of the clot, and the direction, to *keep the mouth open*, often arrests the hemorrhage without further efforts from the surgeon.

In penetrating wounds of the *chest*, where the lung is wounded and bleeding, the patulous condition of the external wound may be considered favorable to the arrest of the hemorrhage; it affords exit to the confined blood, and at each

effort at inspiration air enters the cavity of the pleura; on its first introduction the air is cold and acts as a *local styptic*, but, as with each inspiration the quantity increases, and also expands from the warmth of the cavity, the wounded lung is subjected to an equal and powerful *compression*, as by a tight and evenly applied bandage, is made to retire up to its bronchial and vesicular attachments near the spinal column—it can no longer dilate to receive the laryngeal current, its circulation is consequently greatly diminished, it obtains, or is compelled into, that “*rest*” which “is the condition of recovery.” The hemorrhage ceases, the external wound closes, and by a gradual process, whether of absorption or otherwise, the pleural emphysema is removed. But, in the meantime, the wound in the lung has firmly cicatrized, and, in gradually resuming its functions, all danger of hemorrhage has passed away. Such has been the result of our observation of chest-wounds of the kind referred to above during the present war. Men are frequently brought to the hospitals with these penetrating wounds of the chest. They are suffering from dyspncea; percussion shows extensive pleural emphysema; auscultation detects no respiratory murmur anywhere on that side—the lung is evidently compressed. Many of these cases have been left on the field all night without the attention of any surgeon, and most of them recover under treatment in the hospitals. Reflection, in such cases, would lead to the precept: *to leave the chest-wound open for a considerable time, and so far from dreading and preventing the entrance of air into the pleura, to favor it on account of its hæmostatic effect.* Compression of one lung produced in a gradual manner, seldom destroys life; hemorrhage often does.

*Constitutional Hæmostatics.*—Reputed remedies of this class are quite numerous; many of them are supposed to have considerable power, but have gained their reputation in arresting sanguineous discharges of a very different nature from the hemorrhages resulting from lesion of large vessels, with which the military surgeon has to deal. They are applicable rather to the accidents of the *hemorrhagic diathesis* than to traumatic effusions. The largest class of them therefore are tonics and astringents; as the preparations of iron, zinc and lead. Ergot is supposed to be possessed of some virtue, though its action is not at present well understood. The class of *sedatives* are much more answerable to the purposes of the surgeon. It is

but rarely that the sedation produced by nauseants such as antimony and ipecac. can be of judicious application in a case of profuse traumatic hemorrhage threatening a fatal termination. Such remedies depress the vital powers too decidedly, and yet often fail to arrest the sanguineous flow. Antimonial preparations are often injurious, if long continued, by their disorganizing effects upon the blood.

*Venesection.*—Equally unphilosophical and more injurious, in our opinion, than even the use of the last class of sedatives, is the time-honored absurdity of venesection. It comes to us embalmed in the dicta of “the highest authority,” and consecrated by the owlish wisdom of “the ancients,” and, until recently, the precept has met with submissive and unquestioning acquiescence. We are gratified to find that, in all the cases of arterial hemorrhage collected in the office of the inspector, *not one* is reported wherein the expedient was practised by a surgeon of the Confederate States. The measure is one which has doubtless been transferred from civil practice, where it has been found of the greatest value, but in a very different kind of hemorrhage from that to which some military surgeons have sought to apply it. It is the great reliance—the sheet-anchor—in the *spontaneous* hemorrhages resulting from *general plethora* or local *visceral engorgements*. For these, too much cannot be said in its praise. But for *traumatic* pulmonary hemorrhage, the measure appears to us, not only hazardous, but actually injurious. All the circumstances are different—the cause of the bleeding entirely dissimilar—and hence the *result* of the remedy is, doubtless, often fatally adverse to the ill-founded expectation on which it was applied. Exotics, however vigorous, seldom continue to thrive. So have we found that the *traditions* of civil practice, however reliable, will not always answer as *principles* of military surgery.

*Opium.*—So far, we have seen that all the constitutional hæmostatics are either unattainable to the field surgeon, or, if applicable, of feeble power and totally unreliable in cases of serious hemorrhage. Most happily, there is a single blessed exception. Opium is the one indispensable drug on the battlefield—important to the surgeon, as gunpowder to the ordnance officer—for besides the ages of pain for which it is the relieve as an anodyne, it saves rivers of blood as a hæmostatic. The value of the remedy may depend somewhat on the pre-

paration used. The tincture or the gum itself seems preferable to any of its salts. The preparations of morphia relieve pain more quickly, but are more certainly and more rapidly succeeded by the stage of depression incident to some constitutions. They, also, seem to possess less power than laudanum in quieting the arterial excitement in the manner that arrests hemorrhage. For the object under consideration, the mode of administration most convenient is in *doses of from twenty to sixty drops*, repeated at *intervals of from two to six hours*, having reference always to the urgency of the symptoms and the constitutional peculiarities and habits of the patient. At the field infirmaries, where many wounded are crowding upon the medical officers, a *decided dose* of opium, or one of its preparations, may be safely administered to *all* the more severely wounded. All of these require the remedy for the relief of pain; in some of them, with undetected arterial lesions, impending hemorrhages will be delayed, till time shall be allowed for thorough examination of each particular case. We have found the remedy valuable in cases of *diffused traumatic aneurism*, whether bleeding had yet occurred or not. These cases arrive at the General Hospital often in the night; the administration of a full dose of laudanum lessens greatly the risk of that tempting, and indeed warrantable, *delay till morning*, which all good surgeons practice whenever admissible.\*

*Quinine*.—To some, the suggestion of quinine, as one of the *adjuncts* in the treatment of hemorrhage, will appear a most extraordinary proposition. Not so to those who have carefully noted the progress of many cases. Consecutive hemorrhage does not always—indeed seldom—bursts out in such a manner as to destroy the life of the patient at the first or at any single bleeding. There is generally a premonitory period marked by interrupted discharges, of more or less profuseness, which forehadow the serious or fatal bleeding. The prudent surgeon, of course, in case the artery involved is a large one, needs no further warning, but promptly performs

---

\* *Veratrum Viride*.—We have been surprised at not finding, among the reports in the office of the Surgeon-General, some experience in the use of this valuable sedative, as applied to arterial hemorrhage. Careful experiments with this powerful agent may prove fruitful of good practical results.

ligation to prevent unnecessary exhaustion. It is in the case of *smaller* vessels, in which the danger is not imminent, and where there is hope of avoiding an operation, that it is important to consider the value of *every* remedy and the grounds for its application.

The febrile excitement, which attends upon the early stages of a gun-shot wound, is generally of the paroxysmal form, and it is during these *paroxysms* of arterial agitation that the bleeding is most apt to take place. In the cases above described, the use of quinine, *in antiperiodic doses*, during the intermissions, is a valuable adjunct to more specific treatment.

OPERATIVE TREATMENT OF HEMORRHAGE.—“The great principles of surgery to be observed,” says Mr. Guthrie, “in cases of wounded arteries, and which ought never to be absent from the mind of the surgeon, are two in number :

“1st. That no operation ought to be performed on a wounded artery unless it bleed.

“2d. That no operation is to be done for a wounded artery, in the first instance, but at the spot injured, unless such operation not only appears to be, but is, impracticable.”

I. The propriety of a rigid adherence, in nearly every case, to the first of these rules is obvious. We have seen that the natural processes for the arrest of hemorrhage are so often reliable that, they may be depended on until the bleeding actually occurs. The nature of the arterial lesion in gun-shot wounds is such as greatly to favor the occurrence of a spontaneous arrest. The wound is often both contused and lacerated, the general and local shock deters re-action, and the formation of a firm clot, with subsequent adhesion of the arterial tunics, where the division is complete, is by no means an unreasonable hope, even in case of the largest trunks, as the axillary and the femoral. No case of even *suspected* arterial lesion, notwithstanding all this, should ever pass from under the immediate care of the surgeon; without the most particular instructions to *intelligent* attendants, as to the momentary danger of hemorrhage and the most efficient method of applying the means for its temporary suppression. The patient himself should also be calmly informed of his danger, in order that he may avoid unnecessary muscular efforts and be prompt in calling assistance at the first moment of the bleeding. It must be remembered that, to produce hemorrhage, it is not always necessary that the artery shall be opened, and also

that the necessity for *close watching* does not cease with the expiration of a few hours, or a few days; for the slightest *brush* by a passing ball against an arterial trunk is apt to lay the foundation of consecutive hemorrhage, by the subsequent falling away of a slough from the wall of the vessel. Experience has shown that the period of bleedings from this cause is generally from ten to fifteen days, though care may be recommended for a much longer time.

II. The principle upon which the successful ligation of arteries is based depends upon the existence of *collateral vessels*, capable of sufficient enlargement to sustain the nutrition of the parts beyond the point at which the ligature is applied. The arteries and their branches seem to enter into combinations with each other at every possible opportunity; every artery of the trunk, except some in the *viscera*, anastomoses with its fellow; every artery anastomoses with the vessel immediately above and below it, and every artery anastomoses with *itself* by a chain of communications established between its branches. It is this intercommunication of arteries, more abundant in some situations than in others, that is known under the name of the collateral circulation.

While this free communication of arterial branches is the very foundation of ultimate success in all operations interrupting the blood-currents in the main trunk, it has yet been found, when *too direct* or *too abundant*, seriously to interfere with the attainment of the proposed end, in ligations for the arrest of hemorrhage. This failure to arrest the hemorrhage by ligation, between the wound and the heart, is caused by what is known as the *recurrent* circulation—the blood passing through the capillaries of the collateral vessels into the lower portion of the main trunk, and being poured out at the wound from the lower end of the divided artery. Indeed so constantly does this abundance of collateral circulation exist, and so frequently has it been found to give rise to the reflux hemorrhage just referred to, that Mr. Guthrie's second proposition, that "*no operation is to be done for a wounded artery but at the spot injured*," has become the acknowledged rule of action, in all cases of *traumatic hemorrhage*. Anel, and more particularly Mr. Hunter, had practised ligation in the continuity of the vessel above, successfully for the cure of *aneurism*, and surgeons, up to the time of Mr. Guthrie, had practised the same method, with a varying and uncertain suc-



cess, in cases of hemorrhage. Since the publication of Mr. Guthrie's views, it has been seen that the Hunterian operation, so successful in the treatment of *aneurism*, is, in the majority of instances, unsafe and inapplicable to *traumatic hemorrhage*, on account of the great liability that exists, especially in the upper extremity, to the recurrence of hemorrhage from the wound by the *lower end* of the divided artery. His views are thus stated :

“Whenever the collateral vessels are not capable of carrying on the circulation of the limb, mortification or death of the part ensues ; and whenever this collateral circulation is sufficient to maintain the life of the limb, blood must pass into the artery below the wound, and must, as a general rule, pass up and out through the lower end of the divided artery, unless prevented by the application of a ligature, or by some accidental circumstance forcing an exception to the rule, but not the rule itself.

“The cause of difference in the success of the Hunterian operation in aneurism and in the case of arterial lesion is, that in the one case, the *sac* receives and *retains* the blood brought into it by the collateral circulation, while, in the other, there is no aneurismal sac to receive and retain it, and the patient bleeds, perhaps, to death, unless surgery comes to his assistance.

“The absence, then, of the aneurismal sac renders the application of *two ligatures* absolutely necessary ; one on each end of the divided artery, or *one above* and *one below the wound*, if the artery should not be divided. This is the principal point to be attended to in the treatment of wounded arteries.”

Such, briefly stated, are Mr. Guthrie's views on the most important points of interest connected with arterial hemorrhage. They are worthy to command from all, unlimited confidence, and have, indeed, already become, as has been said, the cardinal principles of practice for military surgeons, every where. It has been seen, however, that the occasional success of the Hunterian operation for hemorrhage, which he regards as due to “some accidental circumstance,” is rather the result of well-ascertained anatomical facts, viz: the greater or less abundance of the collateral circulation, and to the situation of the wound along the course of the arterial trunk. This is a circumstance worthy to be taken into account in de-

termining upon the course to be pursued in cases either of unusual difficulty, or where, for some important object independent of such embarrassment, the surgeon may desire to adopt the plan of Hunter in preference to this. One of the most desirable, and, at the same time, most difficult, of these objects is to save a limb, as the superior or inferior extremity, in case of fracture of the bone, complicated with consecutive hemorrhage.

We have already intimated that, singular combinations of circumstances repeat themselves often, in every battle. This, however, can scarcely be considered a singular one. A ball cannot well fracture the femur, for instance, in certain portions of its diaphysis without endangering the femoral artery. How often do we see our hopes of a promising ease of fracture of the thigh, dashed by the sudden occurrence of either a secondary or indeterminate hemorrhage. In such a case, no necessity more to be regretted could arise, than that of being compelled to make the deep incisions, and enter into the tedious search among the inflamed and tender soft parts necessary to find and secure the bleeding vessel at the seat of injury; converting our *comparatively* simple case into one of additional, and most serious complications—all pertaining to the immediate seat of the fracture. Here we remember that, *according to rule, and not by accident*, large arteries, when wounded *high up*, are not quite so subject to recurrent hemorrhage as when wounded near the extremity of the vessel; because the collateral communications, though sufficient for the purposes of nutrition, are not in such abundance as to produce hemorrhage by the recurrent circulation. The Hunterian operation then may be legitimately performed somewhere below the profunda, and the patient saved the greater evil of being operated on in the tissues about the fracture, or what, in our opinion, would be less objectionable, amputation.

*Hunterian Ligation to Prevent Destructive Inflammation.*—After the battle of Seven Pines, May 31st, 1862, many of the wounded in the General Hospital at this place suffered from the most violent and uncontrollable inflammation. The inflammation from gun-shot wounds for sufficient causes, viz: the shock or jar to all the tissues, especially the nerves and blood vessels of the part, is apt to be more intense than in other wounds of the same parts. Wounds of both the

upper and lower extremities resisted all ordinary measures of treatment. Suppuration in many had ceased, and, in its place, a bloody water was discharged from the openings and abrasions. The swelling in these cases was immense.

Six of the above cases,\* under our observation, were the subjects of arterial lesion. The arteries wounded in the lower extremity of three of these cases were, severally: in one, the peroneal, close to its origin; in the other two, the anterior tibial, near the middle of the leg. Profuse secondary hemorrhage occurred in all these cases, (see table, page 91, cases 30, 32 and 33,) respectively, on the 14th, 12th and 10th day. Ligation was determined on. The extreme swelling and inflammation of the limb, extending even above the knee in all, and in one, No. 30, marked by large patches of *incipient gangrene* on the foot, presented great embarrassments to the operation at the seat of lesion. It was not the difficulties, however, which caused Mr. Hunter's operation to be preferred in all of these cases to Mr. Guthrie's, notwithstanding the risk of recurrent hemorrhage. There was a desirable *incidental benefit* hoped to be attained, which was of even deeper interest, if possible, than the arrest of the hemorrhage. The idea pursued in departing from the rule was no less than *the experimental effort to cure the inflammation in the limb by cutting off its arterial supply, by ligation of the main trunk which supported that inflammation*. The femoral artery was tied in each case near the apex of Scarpa's triangle. The hemorrhage ceased immediately in all three of the cases, the swelling began to decline within twelve hours, and, in three or four days, the limbs were reduced to very nearly their natural size, the discharge having changed from the bloody water, to healthy pus.

*Results.*—Case 30 recovered slowly, on account of the sloughing out of the patches of gangrene, *which had shown themselves previous to the ligation*. These surfaces granulated healthily and cicatrized firmly. The suppuration was profuse and long continued.

In case 33, the result was most satisfactory and complete; the swelling had disappeared in three days—the appearance of the wound wonderfully improved—the discharge became

---

\* See reports of 1st, 2d and 4th Georgia Hospitals in office of the Surgeon General—Ligation of arteries.

healthy, and the subsequent progress of the case rapid and favorable, ending in entire recovery.

In case 32 it was discovered, after the complete subsidence of the swelling, that the fibula was broken. Still the case progressed well. The inflammation was entirely subdued. On the tenth day after the ligation, *recurrent hemorrhage supervened*, causing great infiltration below the knee and in the popliteal space and rupture of the nearly cicatrized gun-shot wounds. This patient was greatly exhausted and was not thought to be able to bear the ligation of the peroneal artery. Amputation above the knee was determined on. Only one artery, superficial and of small size, required tying in the stump. It is worthy of remark, that the stump healed *by the first intention*—a most unusual result of a *secondary amputation*. It is not unfair to presume that the previous ligation favored this rapid recovery of the stump.

In the three cases of arterial lesion in the superior extremity, in which ligation of the main trunk in its continuity was preferred, *in order to subdue inflammation*, the arteries wounded, respectively, were the brachial, near elbow, in one, and the radial, in both the others. The inflammation was greatly modified, though not in so marked a manner—except in one of them—as in those of the lower extremities. The patients all recovered; and in two of them, recurrent hemorrhage took place, but was controlled without resorting to further ligation. In the exception mentioned, no recurrent hemorrhage occurred, and the inflammation seemed to be completely *strangled* throughout the hand and forearm by the ligation of the brachial artery.\*

---

\* As the subject has only a relative bearing on the main object of the present paper, attention is called, only in a note, to the above practice of ligation to subdue or control inflammatory action. We believe that the cases of Privates C. A. Reid and Drury B. Early, (see table, page 91, cases 31 and 33,) ligation in the one, June 5th, in the other, June 11th, 1862, are the first cases on record in which this measure was adopted with reference to the proposed result. In all of the six cases, the Hunterian operation was chosen *with the distinct end in view of combatting and checking, if possible, the destructive progress and, in some, the septic tendency of the inflammation*. In all of these, the pain, the swelling and turgescence were almost immediately relieved, and the most remarkable change was soon presented, as seen in the character of the discharges.

Surgeon A. C. Thom, of the Confederate States Army, has kindly

It will be observed that, in the above six cases, in which the rule of Mr. Guthrie was departed from, recurrent hemorrhage took place in three of them, but only in one, in such degree as to require an operation. The advantages gained in departing from the established rule would be more apparent from a detail of the cases than in the above very condensed notes. The cases are referred to more in illustration of the circumstances in which departure from the rule may be considered justifiable, than with any view of advocating the Hunterian practice in opposition to the more reliable one of Mr. Guthrie.

And lastly; though there are doubtless many other considerations which may justify the ligation of an artery in its continuity in the treatment of hemorrhage, we will refer to but one more: For instance, suppose a patient in a state of extreme exhaustion, whether from hemorrhage or other causes:—Consecutive hemorrhage in some inaccessible artery, for instance, as the peroneal or posterior tibial high up, occurring in a patient of this kind, especially if complicated with great tumefaction and consequent change in the histology of the parts, would present a case, even for the most practised operator, of unavoidable delay. A prolonged and trying—we had almost said a blind—search among clots and fibrinous masses and condensed infiltrated tissues, every one who has tried it knows full well, is sometimes the only route to the open mouth of the bleeding vessel in such cases. This greatly exhausts the strength of the patient, and lessens—indeed destroys—his chance of life. Under such circumstances, the Hunterian operation would be preferable, especially in a wound of the lower extremity. In the first

---

furnished us notes of a case, in which he subsequently practised Hunterian ligation of the femoral, and in which the same beneficial results were exhibited in the most marked degree—"the inflammation relieved, as by magic."

The application of the ligature, in cases of elephantiasis and for malignant diseases of the face, does not, it appears to us, interfere with any originality which the principle here practised may possess. The present operations, besides being applied with an entirely different object, fully answered the proposed end, while the others did not. We feel confident, that this practice will become one of frequent application in the treatment of otherwise unmanageable inflammation, under a variety of circumstances authorizing its adoption.

place, it arrests the hemorrhage for the time being at least, and affords a *chance* of even permanent arrest; and secondly, by cutting off the main stream from the support of the inflammation and general turgescence, the condition of the limb may be so improved that, in case the recurrent hemorrhage should return, a less embarrassing state of things will attend this more desirable operation. The adoption of the one operation gives a chance for life; we think we have seen the adoption of the other, under just such circumstances, take it away.

**THE LIGATION OF ARTERIES.**—Under this head, we shall consider those operations necessary to the exposing of an artery in its continuity, its isolation from surrounding parts, and the arrest of the circulation through it by the application of a ligature. We shall also describe the application of ligatures to arteries in gun-shot wounds and aneurism, presenting such guides as are at present recognized in this more difficult surgical procedure. That whole class of ligations which are necessary during the course of amputations, resections, and other operations, together with those required to arrest consecutive hemorrhage, sometimes attendant upon them, have received no particular attention anywhere in the present chapter, as their consideration comes more properly under the head of those several operations, or of the accidents incident to them. All that is necessary on these subjects will be found under Amputations, Resections, and the Diseases of Stumps.

No class of operations have received more particular attention, or have the advantage of more definite rules for every step in their procedure, than those required in the ligation of arteries. They are thought more to resemble the lessons of the dissecting-room, than any other class of operations on the living subject; and certain it is, that their previous rehearsal on the dead will often save much mangling and pain to the living.

**GENERAL RULES FOR LIGATION OF ARTERIES.**—Lisfranc, Malgaigne, and a variety of French writers, furnish valuable definite rules for operations upon the arteries, which, in one form or another, constitute the basis of the directions to be found in all works on operative surgery. Though the arterial walls have been more elaborately studied by the histologist, for all the practical purposes of the surgeon, it is only necessary to recollect that, they consist of three coats; the internal, known as the *serous*, the middle or *musculo-elastic*, and the

outer or *areolo-fibrous*; that each artery is surrounded by a special cellular sheath, that it is accompanied by one or more veins and nerves, and is under the enveloping aponeurosis.

1st. In determining the *position* of an artery, its known anatomical relations are greatly assisted, often in the living body, by the pulsations of the vessel, though the tumefaction and the natural depth of the artery, in many instances, deprive the operator of this great advantage.

2d. *The Incisions*.—These are properly but two, viz: through the skin and through the aponeurosis, though supplementary cuts are frequently necessary. In making the first, the fingers and thumb of the left hand should be placed perpendicularly and firmly upon the surface to be operated on, care being taken not to draw the skin away from the seat of the artery, or to slide it, so as to alter its relations in the attempt to make it tense. If the artery is superficial, the *direction* of the incision may be parallel with its course and its *extent*, moderate; but, if the vessel is large and deeply seated, it is more convenient and safe to make an ample incision, and that its course traverse that of the artery obliquely, in order to avoid the accident of falling too much to one or the other side. The skin and superficial fascia having been divided, the aponeurosis presents itself, and is of a whitish and sometimes glistening appearance. This may be pinched up with the forceps, and a small opening made into it, the knife being held flatwise to the artery. The director is then introduced first upwards and then downwards along the course of the artery, and the bistoury, with the back of its point in the groove, run along so as to divide this membrane in both directions, to the full extent of the opening in the integuments.

Malgaigne directs that, when the artery lies immediately under the aponeurosis, the incision be made to one side, in order to avoid wounding the vessel; but when the groove director is used, and it should be in all cases, this precaution is unnecessary.

3d. *Separation of the Muscles, &c.*—The muscles now present themselves, and generally their interstices are sufficiently apparent; but, if not, such movements may be produced in the limb as will contract them, especially the satellites, when the depression will be recognized. Having now arrived almost in the very presence of the sheath enclosing the artery, its accompanying vein, and perhaps an important nerve, the

blade of the bistoury will not be used, but the separation will be made with the fingers, or with the groove director, or the handle of the knife. If necessary, the muscles should be drawn aside from the course of the artery, either with the hand or with bent spatulas, so as to bring the enveloping sheath into full view; or it may be necessary even to *cut the muscle*. It is better to avoid this; but the measure is preferable to that of allowing it to obscure the position of the vessels and embarrass the further proceedings.

At this stage of the operation, we may sometimes find that we have been at fault in our incision, the appearance of the parts presented, after dividing the fascia, seeming unfamiliar and different from that which was anticipated. Under such circumstances, the operator should not enter into a blind search after the vessel, into first one and then another intermuscular space, but should pause and carefully study the parts as they are found in the incision he has made. By producing contractions of the several muscles traversing the wound, he will soon comprehend the exact relation of the parts presented to the point he desires to attain. Each step in the operation should have its own definite end in view, and the surgeon should not occupy himself in attempting to find the artery on making the *first* incision, as this cannot be attained till the *last* has been completed.

4th. *Isolation of the Artery*.—The sheath of the artery should be opened by raising a fold of it with the dissecting forceps and nicking it carefully with the bistoury, held parallel to the artery and *never turned towards it*. Now laying aside the bistoury, but retaining his hold on the fold of the sheath held by the forceps, the surgeon should introduce into the opening the point of the groove director. With this, he should endeavor to loosen the connections between the artery and the sheath, taking care not to extend the separation more than a few lines, and also to introduce the instrument *between the artery and the vein*, so that the latter shall not be exposed to injury from the point of the director as it passes beneath the artery. Should the artery be deep, it may be found necessary to curve the director in order to pass it beneath it. Sometimes, in arteries of large size, the vessel will flatten before the point of the director or blunt-curved needle, in which case it may be punctured. To avoid this, the forefinger and thumb of the left hand should be applied above and below



the point where the pressure is made, so as to facilitate the rolling of the vessel over the point of the instrument.

If the director has raised any important structure with the vessel, a second director or probe may be used to complete the isolation before withdrawing the first. The artery having been thus placed upon the director, we feel for the pulsations, in order to assure ourselves, to the last degree, that there is no mistake as to its identity. We cannot mistake the artery for a vein, as the color of the latter alone will prevent such an error. The accompanying nerve is sometimes nearly as large as the artery, as in the case of the median, in ligation of the brachial, but can always be easily distinguished by its color and cord-like solidity.

*Application of the Ligature.*—The thread for the *ligature* should be a small round cord, of silk or hemp, from twelve to fifteen inches long, so as to admit of secure holding, and possessed of sufficient strength to allow of considerable force being used in drawing a compact noose and forming a firm knot. It should be carefully waxed to prevent slipping. The ligatures used by the surgeons of the Confederate States army are of the material known as saddler's silk, of such medium fineness as will serve single, for the small branches and, when twisted double, answer for the larger trunks. We have used strands of cotton-thread twisted to the proper size, but prefer the saddler's silk.

Having ascertained, by careful examination, that the artery alone has been raised on the director, a common eyed-probe, slightly curved and armed with the ligature, may be used in case the aneurism needle is not at hand. This may be passed along the groove of the director and under the artery, till the armed eye is presented on the opposite side. The ligature should then be extricated from the eye with a hook or the forceps, and both the probe and director withdrawn. Most surgeons, however, use the common aneurism needle (plate I. fig. 4, Arteries) when the director will not be required in the introduction of the thread. Others use the needle, both to isolate the vessel and to pass the ligature, to which no particular objection is seen—indeed, we most frequently practise it.

Various forms of aneurism needles are at present in use. A short blunt-curved needle, held firmly in the artery forceps, was used by Dr. Physic; or the same, attached by a screw to

a staff, known as the American needle, (plate I. figs. 5 and 6,) attributed to Dr. Mott. This latter instrument is managed as the ordinary aneurism needle, till the ligature has been introduced; then the blunt hook of figure 6 is introduced into the eye—this holding it steadily, while the staff is unscrewed. The needle is then drawn through by the hook and removed, leaving the thread in position. For arteries still more deeply seated, as the anterior or posterior tibial, or especially for the internal iliac—which operation would have failed on one occasion except for its use—is the very admirable needle figured in plate I. figure 7, which has been delineated, for this work, from the instrument in our possession. It is somewhat on the plan of Bellocq's tube. The principle, it is said, being first applied to ligation by Professor Gibson, the father of Surgeon Gibson of our army. In application, the curved tube (*a*) is passed under the vessel, as the ordinary aneurism needle; the slide (*c*) is then pushed down with the index finger, causing the delicate hooked watch-spring (*b*) to be projected, and to rise from the bottom of the wound, in most cases, above the tegumentary surface and within easy reach of the operator. The ligature is then *looped into* the hook and the spring drawn within the tube, carrying the ligature securely against its edges, holding it fast. The whole instrument is now withdrawn and removed, leaving the thread in proper position under the artery.

Having raised the artery, by drawing gently on the ligature, to be sure that the circulation is arrested and that we have not included a nerve or a tendon, as *has* been done, the ligature is firmly secured with a double knot. It should be tied directly across the vessel, as an oblique loop, by slipping on one side, might fail to make sufficient compression. When the vessel is deep, each fold of the knot must be firmly tightened, and so held as to avoid slipping, till the entire knot is completed. One end of the ligature is then removed, and the other brought to the surface by the most direct route.

The ligature, when properly applied, as is well known, divides the two inner coats of the vessel, and, subsequently also, the remaining coat by ulcerative absorption. A clot, extending to the first collateral branch above, having formed, the vessel is completely plugged; but it is now understood that the adhesion of the coats of the vessel is fully as effectual as the clot, in preventing the recurrence of hemorrhage. The

enlargement of the collateral branches secures the nutrition of the limb beyond the ligature.

*Dressing and After Treatment.*—The dressing of the wound should be simple, having for its object, as far as practicable, union by the first intention. The lips should be brought together with adhesive straps, and lightly secured with a compress and roller. If the loss of temperature is persistent under the use of woollen wrappings, stimulating liniments may be used till the time is afforded for the establishment of the collateral circulation. This is apt to be very deficient in ligations for primary hemorrhages, better in those for the consecutive forms, and quite abundant whenever an aneurism has existed for a considerable time. The wound should not be disturbed by frequent dressings. The ligature should be left untouched for eight or ten days, in case of the smaller arteries, and for two or three weeks in that of larger ones; at which time it may be tried by gentle traction. It frequently separates and begins to protrude spontaneously, as will be shown by the projection of a half-inch or more of the clean white thread beyond the surface of the skin. Throughout the treatment, the limb should be placed in such a position as will moderately relax the muscles and favor the escape of the discharges from the wound.

**THE LIGATION OF ARTERIES AT THE SEAT OF LESION.**—The lessons of the amphitheatre, the study of anatomical details, the descriptions by authors and the stress laid on the surgical relations of arteries, as well as, in most instances, the rules enunciated for their ligation, have, until a very recent period, contemplated tying, *only in the continuity of the vessel*; consequently, the whole science of the subject, so to speak, has been adjusted and is more applicable to the treatment of aneurism, than to that of traumatic hemorrhage. It has been plainly shown that, for the treatment of hemorrhage, the operation of Hunter is unsafe and entirely inapplicable, however often we may be forced to use it as a temporary means, or adopt it for the control of concomitant inflammation threatening the life or limb of the patient.

As the doctrine of ligation, by two ligatures at the point of injury, is here acknowledged in its fullest acceptation, an embarrassing incongruity would be avoided could we furnish reliable directions for operating on the principle so strongly urged. It must be acknowledged, however that, as compared

with the ligation in the continuity of the vessel, the operation at the wound, while in itself it is far more difficult and embarrassing, is yet less clearly treated in the works of authors, and sadly needs that clearness of description and systematized programme of procedure which has rendered the other so easy—we had almost added—positively attractive. In consequence of the comparatively recent and sudden change wrought in the practice by the convincing and brilliant experience of Mr. Guthrie, time has scarcely been allowed for that thorough study and well-considered teaching which a new, and certainly more difficult method requires; nor for the enunciation of such rules as will safely guide, and above all, give confidence to, the inexperienced. Nevertheless, the facts are overwhelming, the necessity imperative, our duty unmistakable. We must cast about for principles, or, in their default, even operate without them. Otherwise, condemnation awaits us from without, and worse still—self-accusings from within.

The records of surgery, however, are not wholly without very useful hints in this mode of operating. It must be recollected that, previous to the time of Anel and Hunter, this, or something very similar to it, which we now call the new method, was then the old and only one at command of operating surgeons whenever they were heroic enough to attempt the surgical treatment of aneurism; and there may be found, scattered up and down along the annals of medicine, both before their time and since, occasional cases wherein ligation at the seat of lesion was successfully accomplished.

In the consideration of this particular aspect of the subject the cases presented may be divided into two classes: 1st. Cases of hemorrhage with simple arterial lesion; and 2d. Arterial lesion complicated with diffused aneurism.

I. *Ligation in Simple Arterial Lesion.*—The nature of this injury has been already fully described. The time, above all others, at which we may hope to find the opening in the artery entirely uncomplicated with clots or matted fibrine is immediately after the receipt of the wound and when the vessel is to be ligated for primary hemorrhage. In these cases, the wound is apt to be still patulous at the time of the bleeding, and as little or no barrier is presented to the easy outflow of the blood no infiltration occurs, and the clots formed, if any, are confined entirely within the walls of the fleshy tube punched

by the projectile in its progress through the structures towards the artery. Even in retarded hemorrhage, the same clean condition of the tissues about the arterial lesion may sometimes be found, unless the movements of the patient have so disturbed the relation of the superimposed muscular layers as to interrupt the exit of the blood. Unless the situation of the wound is a very unusual one, the immediate anatomical relations of the artery and the descriptions for the Hunterian operations can be made easily available in reaching the vessel in simple arterial lesion.

*External Wounds and Tracks of Projectiles.*—A consideration of these is important, as they have reference to, and, in a measure, determine the line and position of the incisions. It will be understood that any classification of wounds or the course of balls here found, is made specially and purely in reference to, and on the *one* principle of, *their connection with the arterial lesion*, and is not intended to be considered as an arrangement of gun-shot wounds in any other relation whatever. We would ask to be allowed, for a moment, to conceive the *track of the ball* as the tunnelled highway through a solid mass, crossed, at some portion of its course, by a tubular stream—a culvert, which, when entire, conducts a living tide, to a glowing region beyond, but now, breached and interrupted, the stream is diverted—and, wasted at one or other end of the tunnel, leaving pools and sediment, here and there, throughout its course. All along this highway, the anatomist has his beacons, his finger-posts, and his mile-stones, by which he shapes his course and measures his distances, in seeking any particular point. There is but one point of absorbing interest—the wound in the artery—all pointers and measurements tend onward to this centre.

Balls producing arterial lesions approach the vessels in every conceivable direction: Directly, obliquely, sometimes longitudinally from above, sometimes, from below; they pass through the body or limb in a straight line, or they diverge in an angle or by a curve; or, again, they may enter on the outer side, distant from the vessels, traversing the limb towards the inner aspect, wounding some large trunk—as the femoral or brachial, or axillary as from the shoulder, coming to the vessel thus from the *rear*, but making no wound of exit, are *incomplete*. We cannot consider all of these; we select but three for description, which we shall take the liberty of

naming respectively: 1st, the direct; 2d, the oblique; and 3d, the posterior incomplete track.

The two first of these are selected because they are very frequent; and the third—not much less frequent—because its bleeding is apt to be obscure, and because it requires careful consideration always, whenever it gives rise to hemorrhage.

It doubtless for a moment occurs to the mind of some one, that this classification might be extended. We agree that it might, but with little or no advantage to *our* subject, and we cannot see that such a basis of classification could be made to elucidate any other connected with gun-shot wounds. It may be asked are there not posterior *complete* tracks, and *anterior* incomplete; and, if so, why are they not considered? Without doubt, there are both of these varieties, for balls do often pass *entirely* through limbs from behind, and they sometimes pass *partly* through from the front, but we only recognize their tracks, for our purposes, when they happen to wound an artery, and then we view them altogether, and only from the antero-internal or *vascular* aspect of the limb; therefore, they both become either direct or oblique tracks, so far as we are concerned, and are so considered in our operations. We have no interest in these tracks except, either *as a route* from the surface of the *vascular* aspect\* of the wounded man, to the bleeding vessel, or *as a line in reference to which* we make a route to the bleeding vessel from that portion of the surface least removed from it. Briefly, here is our object, and method of attaining it: We wish to reach the bleeding artery—we know that the *track* has crossed it somewhere, and at the very place which is bleeding, for in the making of the track, the wound was made; we know, also, the general course and position of the artery. Now, if either *end* of this track happens to be the shortest route leading directly to the opening in the artery, we enlarge it to reach the vessel—but if there is any much

---

\* We mean by "vascular aspect," that surface in relation to which the artery is most superficial. It is generally, as is known, for the primary trunks, on either, the anterior or internal aspect of the body, as in the neck the carotids; in the superior and inferior extremities, the axillary, brachial, radial and ulnar; femoral and anterior tibial, &c. But in the case of those arteries that approach nearer to the posterior plane of the body, the vascular aspect is reversed, as in the case of the posterior tibial, peroneal, gluteal, and ischiatic arteries, and also some arteries of the shoulder.

more direct route through the sound skin and muscle, we cut down and bi-sect the track, as nearly parallel with the course of the wound as we can, the track greatly assisting us in finding the arterial wound. Thus far, *the track* is our great rallying point, and has the most important value in the operation—beyond that, none at all.

*Operation.*—We shall have reference to these tracks in connection with the *incision* and *search* for the arterial lesion. We prefer completing the description of the operation in connection with the incision of the *oblique track*, because that one, we conceive, to be of the most frequent occurrence, and the one which seems to present more clearly, a *type* of ligation at seat of lesion than either of the others.

*1st. Instruments.*—A tourniquet, a straight, a convex and probe-pointed bistoury, a female catheter or straight sound, probes, forceps, bent spatulas, needles, sponges, and the dressings, complete the preparations.

*2nd. Digital or Instrumental Compression.*—In case the tourniquet or other means of compression is not already applied, the surgeon having prepared for the operation, should see that the main trunk leading to the wound about to be disturbed, is securely compressed, either by that instrument or by the fingers of a perfectly reliable assistant. Never begin the operation without some form of compression.

*3d. The Incision.*—The circulation being controlled, time is now allowed to consider well the circumstances of the wound, the *relations peculiar* to the particular and perhaps *unusual* portion of the vessel he has to reach, and also by which wound, if there are two, he should attempt to approach it, or whether the incision should traverse the wound *in the skin at all*, in order to reach the arterial wound.

*Direct Track.*—When the course of the ball is *direct*, the entrance being near the line of the artery, the incision should traverse that wound, whether of entrance or exit, which is nearest to the general course of the artery and most accessible to it. The catheter may be used to follow the course of the ball during its search for the artery, as it is certain that the wounded vessel will be found *somewhere in its track*. We should at no time lose sight of the anatomical guides of the particular region in which we operate.

*Oblique Track.*—The ball may have penetrated the artery very *obliquely* in such a manner that, both its wound of en-

trance and exit may be far removed from the known course of the vessel which it has traversed, in this case, the incision should be made perpendicularly to the course of the ball, bisecting it near its middle and parallel with the known course of the artery. Here the introduction of the female catheter or sound through the wound, from one opening to the other, will be found of great assistance as indicating the level or plane of the wounded artery.

Under these circumstances, make an ample incision in the skin, especially if the vessel is deep. Divide the aponeurosis as heretofore described on the director, and proceed cautiously, directing the assistant to make such movements with the sound—pressing it upwards, &c.—as will indicate the approach of the operator to it; or he may feel for it through the tissues in the bottom of the incision. As the seat of the wound is approached, the stained appearance of the tissues, together with the prominence of the sound will guide to the track of the ball. The particular satellite muscle must be recognized, and the relation of the artery to it, considered. Having arrived at the level of the instrument, the sheath of the vessels should be carefully searched for—in this, the clots about the wound will materially assist. Sometimes the sheath may be protruded, which will indicate the vicinity of the cut in the artery. Having approached thus near to the vessel or to the wound itself, if there is any difficulty, scraping with the handle of the knife or raking with the point of the director or probe, and picking in the suspicious places with the forceps, will be apt to plough up the vessel. If not now found, or even before this stage, the surgeon should direct the tourniquet to be relaxed, when the beating of the vessel will indicate its course and the flow of blood, divulge perhaps the very point of the opening. When one end has been found—most frequently the upper on account of its pulsations, the lower or distal end should be looked for. In vessels of considerable size, where the sound or catheter is used, the cardiac end of the artery is on one side and the distal end on the other, the instrument occupying the space between them, caused by retraction. If the vessel is not completely divided, the search may be somewhat shortened.

*Application of the Ligature.*—This requires no very particular description. If the vessel is only partially divided, the common aneurism needle (plate I. fig. 4, Arteries,) may be used,



as in ligation in the continuity of the artery. When completely severed, the cardiac end will be found to have contracted for some lines from its mouth, resembling, as described by some, the neck of a claret bottle. It will also be found to have retracted within its sheath. The mouth of the distal portion of the artery will probably be found less, and perhaps not at all contracted, and also less drawn within its sheath. This end is much more apt to bleed afterwards, if neglected, than the upper end. Either the forceps or tenaculum may be used. The forceps are supposed to be more suitable for the trunks and the tenaculum for the branches. If the forceps are used, seize the upper end of the vessel in such a way as to *flatten* its calibre, and not introducing one branch into its mouth, as recommended by Dessault. If the tenaculum is used, it is better to *traverse* the vessel, and *not introduce the point into its calibre*—this, we think, often gives rise to imperfect ligation in amputations. The vessel, thus seized, is pulled a little out of its sheath, an assistant passes a thread beneath the forceps or tenaculum, surrounds it, and makes a knot, taking care, before tying, to push it over the vessel and as close to the surface from which it emerges as possible. Then, in the same manner, apply another ligature to the lower end. Both ends being ligated, the instrument is withdrawn from the vessel, and the pressure on the main trunk is relaxed, in order to ascertain whether the ligation is effective. The pulsations of the vessel will be observed moving the ligature. Sometimes small branches in a wound bleed so as to give trouble, and yet are difficult to isolate—a sharp-pointed aneurism needle, (see plate I. figure 5, Arteries,) armed with a thread, may be passed into the structures under it, including a little muscular fibre, &c., with it, in a *common* ligature.

*Dressing.*—Sponge out the wound to remove all clots, and dress and place in position as heretofore described, adjusting the parts for union by the first intention.

In *posterior-incomplete tracks*, it will be recollected, that the ball enters at some point distant from the artery, penetrates to it, or a little beyond, and wounds the vessel, but makes no exit.

This form of track is seldom found in connection with simple arterial lesion and free external bleeding, but is the one which is more apt to be characterized by diffused aneurism. Partly, for this reason, have we deferred its consideration till we ap-

proach that more complex portion of our subject. Still, inasmuch as cases do occur in which the more simple operation is required, we describe here some of the details of the procedure, especially as these details easily lead on, as by gradual approach, to the perplexities of that uninviting operation.

Suppose, for instance, the ball to have entered the middle of the thigh posteriorly, as before described, wounding the artery and lodging in the limb—an alarming hemorrhage from the wound results, and ligation is determined on. Here, as in the oblique wound, we wish to use the *track* to assist in finding the arterial lesion. The general precept, to “enlarge the wound and tie both ends of the bleeding vessel,” of course, cannot here be carried out, and it would be simply absurd to *follow that track* in reaching the artery. Yet the track may be made very useful as a *guide*, though not as a route. Effectual compression being made, and the limb being placed in such a position as will make all parts of the track coincide, the sound is introduced and pushed to the bottom of that canal. If it has approached near to the surface, the point can be made prominent through the skin in front. Knowing the course of the vessel, the incision may now be made by the *side* of the point, if the prominence does not exactly correspond with it, or directly *upon* the end of it, if it does. We may then follow the sound downwards to the plane of the vessel, and we will probably find the gap in the artery, either very near the side of the sound, on the same vertical plane, or perhaps *traversed by it*. The lesion being thus arrived at, the operation does not differ in general principles, nor even in its details, from the one just described.

Although it may happen that there exist no aneurism with wide-spread pulsations and an ampullated space, still an arterial wound, so circumstanced, cannot fail to present complications approaching to aneurismal characteristics; there are apt to be more or less infiltration, and a large number of clots, while the confusion of tissue simulates the matted and stiffened condition of the parts—unless the bleeding is primary—observed in diffused aneurism. The simplest of them belong to that indefinite order known as “transition cases,” embarrassing every classification, and which here bridge over the chasm between the uncomplicated and the complex, overlapping the boundaries of one grand division with the confusing outskirts of another.

**LIGATION IN TRAUMATIC ANEURISM.**—The Hunterian operation of ligation in the continuity of the vessel, facilitated as it is by the normal condition of the structures and guided by undisturbed anatomical relations, is seldom, in itself, a difficult procedure. Even ligation at the wound, in simple arterial lesion; though the tissues are altered more or less by the extravasation, always in some degree present, is still an operation, the performance of which the surgeon may contemplate with complacency, and which he may hope to accomplish successfully in most instances, without meeting serious embarrassment at any stage of the procedure. His anatomical guides and the course of the artery itself being well considered, he avails himself of *the track* and finds that he has, *crossing each other at angles*, varying in different cases, *two lines*, one longitudinal, the other oblique or transverse—the *intersection* of which *must rest* at a point, not very distant from the arterial wound. The transverse or oblique line is the track, a straight, narrow tube, undilated in any portion of its extent, which offers easy and certain transit to his sound, from the wound of entrance to that of exit, or the reverse indifferently—that when this is accomplished, he knows that the vessel rests somewhere against the side of the instrument, crossing it. He considers the superimposed layers of muscles, if there be any, their number, their thickness, and thus he arrives at the depth at which the arterial wound rests from the cutaneous surface; and with his mind and his eye familiar with every object he is to encounter, he starts out, not on a voyage of discovery, but with a clear conception of his end, guided, at every step of his course, by pointers and beacons, which illumine every portion of his way

If, then, such are the guides—in the one case, rendering the wound in the artery easily attainable—what, it will be asked, is the new condition which so alters the situation as to make traumatic aneurism, perhaps in the very same region, the dread of the surgeon and its surgical treatment, the most difficult and embarrassing of all the operations of modern practice—the whole field of surgery not presenting a more difficult operation, nor one requiring greater judgment, nerve and dexterity? \* A consideration of the circumstances and condition of parts involved in diffused traumatic aneurism

---

\* Druitt.

will enlighten us as to the reason why these operations are generally considered so difficult.

This form of aneurism, if we may so term it, resulting either from the obstruction presented by the partial agglutination of the wound or sinuous course of its track, consists of an effusion of blood poured out by, and communicating with, a wounded artery. It has no distinct sac and is only limited in its extent by the pressure of the surrounding parts. Even these do not form for it a distinct wall, but, as long as the accumulation continues, they are themselves subjected to infiltration, till each organ surrounding the accumulation becomes soaked and stiffened by the fibrine and discolored by the red particles of the blood. The accumulation, beginning at the arterial wound, sometimes dilates and presses before it the sheath of the vessel; at others, passing through a free opening in the sheath, it makes for itself outside of it, in the intermuscular space immediately overlying the vessel, a dilating cavity—of which the distended track also forms a part—of constantly increasing dimensions, imperfectly and irregularly lined with layers of clotted blood and fibrine. In the centre, or more frequently lying against one wall of this irregular cavity, is the wounded artery; the blood from which is being constantly poured into the sac, so that the entire space is filled with fluid blood, momentarily increasing with each pulsation of the vessel. The pulsations are accompanied by dilatations of this pseudo-sac. The accumulation continuing, some portion of the wall of clotted blood and fibrine gives way; if the rupture is opposite the partially healed external wound, profuse hemorrhage follows, relieving the distension for a time, to be repeated again and again, till the vessel is secured; but if at some other portion of the wall, the blood is still farther extravasated among the muscles, under the aponeurosis, and in the meshes of the cellular tissue, till, for an indefinite distance around the wounded vessel, all the structures are distended, compacted, matted and consolidated, and the tissue of each particular organ infiltrated and stained with blood as just described. In certain portions of the body, where the distensibility of the parts is great, the artery being large, the accumulation is sometimes so abundant as to produce syncope by the sudden diversion of so large an amount of blood from the current of the circulation.

From the above statement of the facts, connected with

traumatic aneurism, as briefly presented as clearness will permit, it will be seen that the great advantage afforded by the anatomical relations of the region, so valuable to us in the other two operations, is, in a great measure, withdrawn in this. On laying open the cavity to reach the vessel, the mass of clotted blood and of fibrine—partly effused from the tissues and partly deposited from the blood—obscures the view of all the parts familiar to us in our dissections; and the altered appearance of everything throughout the entire region, does not fail to embarrass the operator, and to make each step uncertain and hesitating. A wilderness of matted, confused and unfamiliar structures bounds all the cavity from which he has removed the blood, and he looks in vain for something he has ever seen before, to direct him to the place where the artery, at least, *ought to be* located. Again; to add to the difficulties which present themselves, we know by experience, that, however well our pressure may be applied to the main trunk, we cannot always be secure against a certain oozing of blood from the turgid vessels of the parts, which, though it does not damage the patient always, will continue still farther to confuse and embarrass the operation.

For the condition of things above described—and in many systematic works, the difficulties are more graphically amplified than in the above brief sketch—it is surprising, how little detail of directions is given for the operation. Some writers simply recommend “the old operation for aneurism,” and, with a few additional directions, pass on to some other subject. Others complacently and tritely advise to “lay open the sac, turn out the clots, and secure both ends of the artery”—these teachers had certainly never operated—while John Bell, whose evident experience determined him to recommend boldness as better than caution, thus dashingly describes his operation—which seems to have been performed without a tourniquet—and which, in cases where pressure *cannot be made*, is perhaps the best that can be recommended:

“Run your bistoury upwards and downwards, so as to slit up the tumor quickly; plunge your hand suddenly down towards the bottom; turn out the great clots of blood with your fingers till, having reached the bottom entirely, *you begin to feel the warm jet of blood*; and, directed by that, clap your finger upon the wounded point of the artery; as

it has but a point, your finger will cover it fairly, and your feeling of the artery assures you that all is now safe."

The objections to the above mode of procedure, in cases where a more careful and deliberate operation can be performed, are many. Most operators could not safely trust themselves, especially in a first operation, to *remove the protection which the pseudo-sac affords against the frightful hemorrhage which would follow, and which would continue to gush out while they pursued the search for the artery, if compression is neglected, the finding of which, many occurrences may present to interfere with.*

In diffused aneurisms, situated in parts in which pressure is impracticable or in such as are fed by small arteries, the bold measure of John Bell, may be the best that can be adopted, but those who have operated on these effusions know full well that sometimes, even where pressure is used and no hemorrhage embarrasses the surgeon, there is often an unavoidable amount of delay in finding and securing the vessel which is apt to disconcert the surgeon and materially depreciate the strength of the patient and lessen his chances of ultimate recovery. It must be recollected, that many patients who require the operation have suffered at least one, and perhaps several, exhausting bleedings, and they can illy bear the additional loss of blood *as a part of the operation.*

Others, however, and among them Vidal, Nelaton and Erichsen, describe their several procedures with more particularity, recommending, very properly, as the first step in the operation, either the careful application of the tourniquet, or that efficient compression of some kind be exerted on the main trunk leading to the vessel to be operated on.

Both Vidal\* and Nelaton† recommend the female catheter to be used in the operation; not, however, to re-establish the track, and to make it available to the operator throughout the whole process, but to be introduced into the mouth of the upper and lower end of the severed vessel, for the purpose of elevating them and separating them from the accompanying vein and nerve. The ligature is passed over the vessel encircling the instrument, which is slipped out as the thread is

---

\* *Traite de Pathologie Externe et de Medicine Operatoire.*

† *Elemens de Pathologie Chirurgicale.* Paris, 1844.

tightened. Erichsen\* recommends the use of a probe, to be used as a centre, on which to make the incisions. Too much minuteness, in our opinion, cannot be observed in the detail of description for every portion of this, sometimes, tedious operation; for no duty the surgeon has to perform requires more careful reflection, a closer study of each particular step, more forethought to anticipate accidents, or promptness in meeting them, than this one of ligation in diffused aneurism.

*The Operation in Diffused Aneurism.*—For the control of the circulation in the ligation of any large artery supplying a diffused aneurism, the fingers of an assistant should not be relied on whenever the tourniquet can be applied. This instrument should be applied with great care, and in cases where it is impracticable, two assistants should be assigned the care of the main trunk, that they may relieve each other in case of a prolonged operation. The surgeon having assured himself that all circulation has ceased in the limb, proceeds deliberately with the further steps of the operation.

*Re-establishing the Track.*—As we have shown in the ligation in simple arterial wounds, so, for a still greater reason, is it important to re-establish the original track of the ball in diffused aneurism. For this purpose, an ordinary probe is recommended by some—we prefer a female catheter; but in many instances it will be found too short to traverse the diameter of the thigh. A better instrument than either would be a straight steel sound,  $\frac{3}{8}$  of an inch in thickness and eight or ten inches in length. If the track is *direct*, the ball having penetrated the limb, the surgeon should pass the sound into that wound *which is nearest the vessel*, continuing it on till it emerges from the opposite wound, in its course breaking up the partial adhesion of the soft parts.

If the track is *oblique* or *indirect* the instrument should, in the same manner, be passed through its entire course, from one opening to the other. In case there is but one wound, traverse the course of the vessel as nearly as possible in the track of the ball.

In case the track is of the *posterior-incomplete* kind, having no opening anywhere in the neighborhood of the course of the vessel, the instrument should be passed as directed in case of the same track in simple arterial lesion, viz: through the full

extent of the wound, its point being pushed towards, or past the normal position of the vessel, and it being made to become prominent on the surface near the line of its course. If the ball has not approached near enough to the surface for this, the instrument must be pushed *towards* the line described.

The original track of the ball having been thus re-established by the introduction of the sound, which now represents it, the operator may consider the normal course and position of the vessel, which is the *other bearing* by which he is to arrive at the exact site of the arterial wound. He will recollect that if the sound has been properly introduced, and especially if there be two wounds, notwithstanding the ampullated area into which the track has been distended and the vast accumulation of both clotted and fluid blood which surrounds it in that cavity, his sound still coincides with at least *one plane of the vessel*, and, whether he cuts down *by the side of it*, as in both the direct and posterior-incomplete tracks, or *crosses it* with his incision, as in the transverse or oblique track, he must reach the plane of the vessel, and the close vicinity of the arterial wound, by arriving at the point *where these two lines intersect*—where the course of the vessel crosses the track of the ball.

*The Incisions.*—An assistant must see that the sound remains in the track, holding it if necessary. The normal position of the vessel being borne in mind, the incisions must coincide with the usual direction of the vessel, no matter what may be the amount of swelling produced by the accumulation. They should equal, if not exceed the limits of the tumor, in order to give free discharge to the clots and fluid blood, but more particularly to allow ample room for the operator to make the movements necessary to search for, expose and separate the wounded vessel. At the first cut, the skin and fascia overlying the tumor, should be divided; the second divides the aponeurosis, under which, generally, is found lying the clotted mass of blood and fibrine, irregularly moulded to the elevations and depressions of the surrounding organs. This forms the pseudo-sac of the aneurism. The external appearance of this mass varies somewhat in accordance with the length of time during which the sac has been forming; if but recent, the color of the outside is dark, like the clot of venous blood, but if the tumor has existed for some time, from two to five weeks, the color is changed by the accumulation of lymph



upon its surface, effused from the surrounding structures with which the clot had been in contact.

*Search for the Arterial Wound.*—The sides of the wound must now be held widely apart with bent spatulas, so as to afford ample room for the operator. The mass of clotted blood should be broken into and the cavity reached. A large quantity of fluid blood will be discharged, notwithstanding the pressure on the main trunk. If the flow is rapid, showing that it is from the artery supplying the sac, an endeavor should be made to reach the orifice within the sac, so as to cover it with the finger, till the compression can be made effectual, the jet of warm blood will indicate its position. The clots should be removed, and the fluid blood sponged out by an assistant. The operator should, in *direct* tracks, follow the sound to the bottom of the cavity, and search *there* for the vessel, or somewhere *along the length* of that instrument. In *transverse* or *oblique* tracks he should seek the sound *where it traverses* the cavity, or on the floor of it, looking for the gapped or divided vessel running in a line *across* it. In most aneurisms, after the interior soft clots are removed, the more external portion of the tumor will be found laminated, increasing in density as we approach their periphery from within, which is apt to be formed, as before stated, by a layer more fibrinous than the internal ones. This laminated feature, like the fibrinous character, depends much upon the length of time the aneurism had been forming at the time of the operation. The last layer appears to be closely agglutinated to the surrounding tissues, so that when removed, there yet appears to be a quantity of the fibrinous clot still adhering, and the surfaces of muscles are covered with it, and the muscular tissue itself, deeply infiltrated and stiffened, and densified with the same agglutinating material.

The fibrine must be cleared away from the surface of the muscles with the handle of the knife—the inter-muscular spaces will thus be defined, and the edges of the *satellite* recognized. This must be raised, and the sheath containing the artery vein and nerve will be found either under it, or lying along its edge. The search will be made more particularly and with more confidence, in the immediate vicinity of the sound representing the track than elsewhere. Should neither the artery nor its wound present, the tourniquet should be relaxed for a moment; the pulsations will indicate the course

of the vessel within its sheath, and the bleeding will soon begin, revealing the opening in it. The sheath being recognized, the opening made by the projectile must be sought for, and the director introduced so as to open it both up and down for a few lines, when the ligature may be applied as in simple arterial lesion. The lower end is generally more difficult to secure, and its importance is such, that it is recommended by some, that rather than close the wound without tying it, even the actual cautery should be applied. It appears to us, however, that if we approach near enough to apply the cautery, we might continue our efforts and secure the vessel. The lower mouth is generally found open. The spots of greenish yellow fibrine, described by some excellent authorities as being found accumulated around the open ends of the severed vessel, serving to indicate their situation, we have never particularly observed in cases operated on by us, and cannot, therefore, undertake to estimate their value. Doubtless they will be found to assist those who have learned to distinguish them among the masses of clot and fibrine which are apt to be found, in all directions, about the wound and track, in even simple arterial lesion—and more abundantly in diffused aneurism.

*Recapitulation.*—Apply compression; introduce the sound; make an ample incision; clear the wound of clots and fluid blood; dilate with bent spatulas; seek first the portion of sound in contact with the vessel; look next for the satellite muscle, if any; next, for the sheath; then search for the opening in the sheath; relax the pressure if necessary; introduce the director, and divide the sheath carefully; now look for the wound in the vessel, *not before*; seize each end, and apply the ligatures.

*Dressing.*—Cold water may be used in the often, extensive wound left by the above operation; but we prefer that it be applied in form of a wetted pad laid on the wound. Adhesive straps should be applied to bring the edges in apposition to prevent wide gaping, to which these wounds seem much disposed. A roller is valuable for the compression it exercises; thus favoring the discharge of the extensive infiltrated clot, dissolving from among the tissues, and which discharge we have known to continue for more than a week, producing the impression that the hemorrhage had returned. After this, pure pus makes its appearance, and the wound

heals satisfactorily, but not by the first intention, or, at most, only in part.

*Chloroform.*—The administration of chloroform has not been referred to in any of the foregoing operations. Its value in all surgical operations is, with but few exceptions, so well established, that it was not deemed necessary to urge its applicability here. It may be suggested, however, that inasmuch as the subjects of hemorrhage are often more or less debilitated, and the operations, especially those at the seat of lesion, often prolonged and tedious, the administration of the anæsthetic should not be commenced *till the surgeon is fully ready to begin*; and if the search is unusually long and difficult, the application should be remitted at intervals, to allow a partial subsidence of its effects. We think that patients, in exsanguined and feeble conditions, are sometimes overwhelmed with the too free use of chloroform, which, under such circumstances, may seriously retard re-action after the arrest of the hemorrhage.\*

## THE LIGATION OF PARTICULAR ARTERIES.

In this second portion of the present chapter, we propose to describe, briefly, the ligation of the individual arteries wherever they have been found accessible to the efforts of the surgeon.

Any general system of descriptions must necessarily contemplate, as we have heretofore remarked, only ligation in the continuity of the vessel as the basis of the directions

---

\* As, in the foregoing considerations, the deficiency of *Data*, on many unsettled points connected with hemorrhage, has been referred to, we may briefly suggest, the keeping of a **SYNOPTICAL RECORD** of all cases, in which shall be noted, among others, such as the following interesting particulars: *Time elapsed* between the receipt of the wound and the occurrence of consecutive hemorrhage; *Condition of limb*, or other part, at *period* of consecutive hemorrhage; Whether the ligation was performed *at the wound*, or in the *continuity* of the vessel; How the *inflammation* was affected, by *reducing the supply of blood* in the part, by ligation. The columns might be so extended as to include *every fact* in the history of each case worthy of registration, and Tables, similarly constructed, would be found to apply conveniently, to the statistical investigation of all other subjects in the domain of military practice. For the form of the Synoptical Record, see pages 90-91.

given. Ligation at point of lesion can only refer to *special cases*, either actual or supposed. We shall, however, keep constantly in view the more frequent accidents of the several vessels, adding such special descriptions as may be deemed useful.

The operations will be grouped in the following manner: Arteries of the Superior Extremity; Arteries of the Head and Neck; and Arteries of the Inferior Extremity.

### Arteries of the Superior Extremity.

The artery which supplies the superior extremity continues as a single unbifurcated trunk from its origin, within the cavity of the thorax, to a point generally, a little below the elbow. The several portions of it have received different names, corresponding to the region through which it passes. That part of the vessel, which extends from its origin to the outer border of the first rib, is called the subclavian artery; beyond this point, to the lower border of the axilla, it is termed the axillary artery; and from the lower margin of the axilla, to the bend of the elbow, it is known as the brachial. The single trunk here terminates by dividing into the radial and ulnar, very similar in arrangement to that which is found to exist in the lower extremity.

**THE ULNAR ARTERY.**—From the division of the Brachial, the ulnar artery runs downwards and inwards along the ulnar side of the fore-arm. Passing in front of the wrist between the two portions of the annular ligament, on the radial side of the pisiform bone, it enters the palm of the hand where it terminates in the palmar arch, *anastomosing* with the *superficialis volæ* and *radialis indicis* of the radial. The line which the vessel describes is, first, a curve inwards from near the tubercle of the radius—marked in the living subject by the lower tendon of the biceps—to the junction of the upper and middle thirds of the ulnar, then directly downward to the pisiform bone.

*Relations.*—The artery is deep in the upper third of the fore-arm, being covered by the superficial layer of muscles, but in the lower two-thirds, it is superficial, being covered only by the integument and fascia, and by the tendon of its *satellite* muscle, the *flexor carpi ulnaris*, the muscle lying upon its inner or ulnar side. The *ulnar nerve* accompanies it,

on the *inner* side, for its lower two-thirds; at the wrist, it gets somewhat behind the artery. The *venæ comites*, one on either side, accompany it throughout its whole course.

If wounded, the vessel should be ligated in any portion of its course. The three following portions are most frequently operated on :

I. AT THE WRIST.—The ligature is to be applied near the point at which the vessel terminates in the superficial palmar arch. (Plate II. Fig. 8.) This is not a desirable operation, unless the vessel is here wounded.

*Operation.*—The wrist being made prominent by extending the hand, a slightly curved incision of about two inches, concavity looking inwards, is made on the radial side of the pisiform bone, through the skin and superficial fascia. The strong tendinous arch thrown over the vessel from the pisiform bone should be divided on the groove director, and the artery isolated with the point of that instrument. The needle should be introduced from the ulnar side to avoid the nerve which lies somewhat behind the vessel.

*Explanation.*—Plate II. figure 8, Arteries : *a*, the artery ; *b*, the ulnar veins ; *c*, the ulnar nerve.

II. IN THE LOWER THIRD OF THE FORE-ARM.—The artery is here covered by the skin and the superficial and deep fasciæ, and lies rather under the edge of the tendon of the *flexor carpi ulnaris*, with the nerve on its ulnar side and the *flexor sublimis digitorum* on its radial side.

*Operation.*—The arm is placed in the supine position, and the tendon of the *flexor carpi ulnaris* made prominent by extending the hand. An incision, about two inches in length, divides the skin and superficial fascia along the radial border of that muscle. The deep fascia being divided on a director, the tendon of the *flexor carpi ulnaris* will be seen and must be drawn to the inner side. The artery will be found between its accompanying veins in a common sheath and the nerve on its inner side. The needle may be introduced from the inner side, but it will be found more convenient to pass it from the radial side, as the vessel is overlaid by the muscle. Mr. Holmes\* considers it a matter of indifference whether the *venæ comites* are included in the ligatures or not. Flexing the hand upon the fore-arm, during the operation, will facili-

\* System of Surgery, Theoretical and Practical. London, 1862.

tate the isolation of the vessel and the introduction of the needle.

*Explanation.*—Plate II. figure 9, Arteries, represents the parts exposed in the operation: *a*, tendon of the flexor carpi ulnaris; *b*, the satellite veins; *d*, the artery between them; *c*, the skin; *e*, the cellular tissue.

III. IN THE UPPER THIRD OF THE FORE-ARM.—The tying of this artery in its upper third, where it is covered by the superficial layer of muscles of the fore-arm and the median nerve, is more difficult than either of the preceding operations. For a wound at this point, attended with serious hemorrhage, the operation should be performed without hesitation. Ligation of the brachial would fail, from its *free anastomosis* with the radial, in the hand, and also from that between its recurrent branches and the profunda arteries of the brachial. Both the upper and lower ends would be liable to bleed. This portion of the vessel makes a curve, with the convexity, towards the ulnar border, from near the tubercle of the radius to the border of the ulnar, at the junction of its upper and middle third; thence, it passes down on the ulnar side of the fore-arm. It is covered, near its origin, by the semilunar fascia of the biceps, and crossed, obliquely from within outwards, by one head of the pronator radii teres and the median nerve, and lower down, it is covered by the other muscles of the superficial layer. The veins accompany the artery, but the ulnar nerve is not in relation with this portion.

*Operation.*—Place the fore-arm in a state of forcible supination. A number of different incisions are advised in this operation; the one preferred is that which crosses the course of the artery at the region operated on and runs nearly parallel with the intermuscular spaces. This incision should be about three inches in length and situated about *one-fourth the width of the fore-arm from its ulnar margin*. This will fall very nearly upon the natural division which exists between the flexor carpi ulnaris and flexor sublimis digitorum, or, when the aponeurosis has been divided, the operator will easily find it. The incision should be extended low enough to reach the tendinous portion of these muscles, where the separation is distinct. The skin being drawn aside with hooks or bent spatulas, the surgeon continues the separation of the intermuscular space upwards, using the knife and director as he

approaches towards their origin, if necessary. Continuing the separation outwards and working his way towards the radial border of the fore-arm, he will find his finger beneath the flexor sublimis and resting on the profundus. *Upon this last, the artery rests, about an inch and a-half from the ulnar border of the fore-arm.* The ulnar nerve will be first seen near the border, running parallel with the bone; this will assist in finding the artery. In searching for the vessel, the operation will be greatly facilitated by flexing the fore-arm moderately and the hand strongly, so as to relax the muscles to be separated. When found, the artery should be isolated and the needle introduced from within outwards.

*Explanation.*—Plate II. figure 10, Arteries: *a*, shows the flexor sublimis drawn outwards; *b*, the ulnar nerve, running parallel with the bone at some distance from the portion of the vessel operated on; *c*, the flexor carpi ulnaris drawn inwards, so as to expose the artery; *d*, the two venæ comites; *e*, the ulnar artery.

In case of hemorrhage from a *gun-shot wound*, the incision would, of course, be modified by the track of the ball. The use of the sound, applied as directed in a former paragraph, will be found to assist in reaching the opening in the vessel.

IV. NEAR ITS ORIGIN.—“If the ulnar artery be wounded near its origin, through the radial side of the pronator teres muscle,” says Mr. Guthrie,\* “an incision should be made through the integuments and the aponeurosis of the biceps muscle; the pronator muscle, being then exposed, is to be drawn inwards and downwards, or towards the ulnar, and the dissection continued until the median nerve is brought into view. The probe, introduced through the original wound, will lead to the artery—the pulsation of which will be felt and the bleeding seen. When the nerve crosses the artery, the vessel will be found above, to the radial side of it and to the ulnar side below. It may be tied above, without dividing a single muscular fibre; but at the point where the nerve crosses, and below it, some fibres of the pronator teres must be divided, and in some cases the whole of them, before the artery can be properly secured by two ligatures; but this division is of little or no consequence, as the muscular fibres re-unite without difficulty.”

---

\* Commentaries, p. 294. London, 1855.

**THE RADIAL ARTERY.**—As has been seen, the brachial artery bifurcates near the coronoid process of the ulnar into the radial and ulnar arteries. The former of these, although the smaller of the two, runs more in the direction of the parent trunk. From its origin, the radial artery descends, along the radial side of the fore-arm to the wrist, nearly parallel with a line drawn, from *the centre of the elbow to the base of the metacarpal bone of the thumb*, immediately above which it winds round the outer surface of the carpus, descends a little beneath the extensors of the thumb, turns forwards, passes between the heads of the first and second metacarpal bones, and sinking deep into the hand, it becomes the deep palmar arch. The vessel is superficial throughout the greater portion of its course. In the upper third, it is overlapped by the convergence of the pronator radii teres and *supinator longus*, which latter muscle accompanies the vessel on its radial side, from the elbow to the wrist, and is considered its *satellite*. It has two venæ comites; but the radial or musculo-spiral nerve is in relation with it *on the outer side*, only in its *middle third*. It can be reached anywhere in the fore-arm without the division of muscular fibres; ligation is usually described, however, in but three places.

I. **AT THE WRIST.**—At this point, the vessel winds round the outside of the carpus and crosses the external lateral ligament of the wrist; then passes under the tendons of the extensor metacarpi and primi internodii pollicis, between which and the tendon of the extensor secundi internodii it may be felt during life. The vessel may be tied at several points in this restricted region; near the styloid process of the radius, while between the extensor tendons of the thumb—"surgeon's snuff-box"—or just before it dips into the palm between the two heads of the abductor indicis. None of the operations are advisable unless the vessel be wounded and bleeding at one of these points. As an expedient for arresting hemorrhage from the palmar arches, it is unreliable—first, on account of the large *anostomosis* between the radial and ulnar; and, secondly, because the superficialis volæ—often a considerable branch—is given off above this region and would continue to supply the bleeding vessel after the ligation. We here describe one of these ligations—at the commencement of the palmar arch:

*Operation.*—Determine the position of the tendon of the



*extensor secundi internodii* by producing forced extension of the thumb; make an incision, little over an inch in length, along its inner border and parallel to it. The centre of this incision should correspond with the proximal end of the first interosseous space; by dividing the deep fascia on a director, the artery will be exposed as it passes through the first interosseous space to reach the palm of the hand. Two veins accompany the artery. Isolate the artery with the needle or the director, and pass the ligature beneath it. Bringing the hand somewhat toward the radial side will facilitate the latter part of the operation.

*Explanation.*—Plate II. figure 11, Arteries: *a*, the *extensor ossis metacarpi pollicis* drawn inward to expose the vessel; *d*, the *extensor secundi internodii* drawn outwards; *c*, the artery exposed, with a ligature passed under it; *b*, *venæ comites*.

II. IN THE LOWER THIRD OF THE FORE-ARM.—This is, perhaps, the ligation most easily performed in the whole body. The artery just above the wrist, and for some distance up the fore-arm, is superficial, covered only by the integument and the superficial and deep fasciæ. It lies between the tendons of the *supinator longus* and the *flexor carpi radialis*, each of which is considered its satellite muscle. Its *venæ comites* lie on either side of it; but the radial nerve is not in relation with it, having diverged from it, four inches above the wrist, and passed under the *supinator*, to reach the posterior aspect of this region. The pulsations are easily detected—it is “the pulse.”

*Anomalies.*—One of the anomalies of the radial, pertaining to this region, is so frequent, that it deserves mention, as it might cause embarrassment if not remembered. This vessel not unfrequently deviates from its normal course down the lower third of the fore-arm and winds over the radius, two or three inches above, the original course of the artery being continued by the *superficialis volæ*, a small branch comparatively. In case such an anomaly should exist, and the object was to ligate the radial for bleeding in the palm, the operation would, of course, fail, by the true vessel escaping ligation.

*Operation.*—The arm should be supinated. The line of the vessel may be traced along the inner margin of the tendon of the *supinator longus*, where the pulsation may be felt. In the groove between this tendon and that of the *flexor carpi*

radialis, the skin may be carefully divided for about two inches. The superficial veins and nerves crossing the wound should be drawn aside, and the fasciæ divided on a groove director. The sheath of the vessel being exposed, it is carefully divided, the artery isolated, and the ligature passed from within outwards.

*Explanation.*—Plate II. figure 12, Arteries: *a*, the deep fascia divided and drawn aside; *c*, the artery with the ligature passed under it; *b*, the venæ comites; *d*, intended for the nerve, is an error of the cut from which the present has been taken; there is no nerve in that place.

III. IN THE UPPER THIRD OF THE FORE-ARM.—In the upper third of the fore-arm the radial artery is deeply seated, being overlapped by the belly of the *supinator longus* on the outer side, rather overhung by that of the *pronator radii teres* on the outer side. It can be reached, however, without the division of any muscular fibres. It is covered by the superficial and deep fasciæ, and, with its venæ comites, rests upon the *supinator brevis* and lower portion of the *pronator radii teres*. The radial nerve has not yet joined the artery, and is, therefore, not interested in the operation. In making the incision, the median vein, which passes over it, should be avoided if possible.

*Operation.*—To expose the vessel, make an incision along the inner border of the *supinator longus*, of three inches in extent, beginning near the middle of the bend of the arm. The line of incision may be made plain by putting the *supinator* in action in flexing the fore-arm. This will divide the skin and superficial fascia. It would be safer to divide the deep fascia on the groove director, and to pursue the isolation of the artery afterwards without the edge of the knife; ordinarily, the beating of the vessel will lead to its exact location. The *supinator* must be drawn slightly outward to expose the artery. The ligature is passed indifferently from without or from within.

*Anomalies.*—The radial, it will be remembered, is subject to anomalies of origin and course. In the observation of Professor Quain, the high division of the brachial occurs in one case out of five, the vessel dividing anywhere between the armpit and its normal point of bifurcation below the elbow. The radial is not always deep seated, as above described, but varies much in this respect; it is even sometimes found on

the outside of the aponeurosis for a great portion of its course; fortunately, when this is the case, it can be detected. Much circumspection is necessary in operations upon this vessel on account of these various anomalies.

*Explanation.*—Plate III. figure 13, Arteries, is a greatly improved copy of the original which *misrepresents* the operation; *a*, intended to represent the supinator longus drawn aside; *b*, is the artery exposed, with the ligature under it.

THE PALMAR ARCHES.—It has been seen that, the *ulnar artery*, after passing the outer side of the pisiform bone, runs into the palm of the hand upon the tendons of the superficial flexor, and is covered by the palmaris brevis and palmar fascia; that it crosses the hand towards the radial side, to unite with a branch of the radial, forming the *superficial palmar arch*; and further, that the *radial artery* also dips between the first and second metacarpal bones, to form the *deep palmar arch*, which rests upon the metacarpal bones and interosseous muscles, being covered by the flexor tendons of the hand, and freely communicating with the ulnar artery by a large inosculating branch. Whenever either of these arches are wounded, ligation of either, the radial or ulnar, has been found inadequate to arrest the bleeding, on account of the perfect *community of circulation*, established through them, in all the vessels of the hand and fore-arm.

Operations in the palm, with a dread that seems to be traditional, are deprecated by most writers, on account of the large number of nerves and tendons and of the thick fascia of the part. Tying both, the radial and ulnar, has been resorted to, often without success, on account of the free supply by the interosseal artery; till finally, it is recommended, to ligate the brachial in case the bleeding cannot be suppressed by pressure. This is objected to by Mr. Guthrie, except after efforts have been made to reach the wounded artery in the palm. "When there is a large open wound, and the bleeding end or ends of the vessel can be seen, a ligature should be applied on each." When the search has been made by incisions, such as the nerves and tendons will allow, and we fail to find the bleeding point, he directs, that pressure at the wrist, on first one and then the other artery, be made, in order to detect the point of lesion. All the coagula should then be removed, "when a piece of lint, rolled tight and hard, but of a size only sufficient to cover the bleeding point, should be

laid upon it. A second and a larger hard piece should then be placed over it, and so on, until the compresses rise so much above the level of the wound, as to allow pressure to be continued and retained on the proper spot, without including the neighboring parts."

*Operation.*—If the gradual compression above recommended, together with due pressure on the radial and ulnar arteries at the wrist, should fail to arrest the bleeding from the wound in the palm, the same author advises that, the two muscles, forming, what may be called the web, between the thumb and fore-finger, should be divided, until the wounded artery can be seen. "If a man in opening an oyster," says he, "were to divide these muscles by an accidental thrust of his knife, it would not be considered a serious accident, and yet, some surgeons are dismayed if desired to divide them surgically, to expose this artery at the spot where it has been wounded."

**THE BRACHIAL ARTERY.**—This vessel, the continuation of the axillary, commences at the lower margin of the *teres major* and *latissimus dorsi* muscles, it passes downwards, forwards and outwards, lying first on the inner surface of the arm, then on its anterior surface; it descends below the elbow joint, where it sinks into a triangular fossa, bounded by the *supinator longus* and *pronator radii teres*, and terminates opposite the *coronoid process* of the ulna, by dividing into the radial and ulnar arteries. Throughout its entire course, the vessel is superficial, being covered only by the integuments and brachial aponeurosis. It rests successively on the *triceps*, *coraco-brachialis*, *brachialis anticus* and tendon of the biceps. To the inner side, is the internal cutaneous and ulnar nerve; to the outer side, the *coraco-brachialis* and *biceps muscles*. It is crossed very obliquely by the *median nerve* which rests upon it during most of its course, but gets to its ulnar side at the elbow. It has two venæ comites in its sheath, and the basilic vein also corresponds with its course. Ligation at three points may be described:

I. **AT THE ELBOW.**—In front of the elbow is a triangular space formed externally by the *supinator longus* and internally by the *pronator radii teres*. The brachial artery runs through the middle of this space, resting upon the *brachialis anticus*, having the *median nerve* half an inch to its inner side, and the *tendon of the biceps* on its outer side. It is covered by the skin and superficial fascia and is separated from the *median*

*basilic vein* by the semilunar aponeurosis of the biceps. The *tendon of the biceps* is our satellite at this point; the artery on its *inner side*.

*Operation*.—An incision, a little over two inches in length, will be made along the internal edge of the tendon of the biceps, inside the median basilic vein. This divides the skin; then carefully lay bare and put aside the vein which rests upon that aponeurotic expansion of the tendon of the biceps called its semilunar fascia. Make an opening into this carefully; introduce the groove director and divide the aponeurosis to the extent of the first incision. This exposes the tendon of the biceps, sinking deeply into the triangular space heretofore described; feel on its internal edge and the artery will certainly be perceived on the loosening of the tourniquet. It has a *satellite vein* on either side, and the *median nerve* is a quarter or half an inch towards the ulnar side. Now flex the fore-arm a little to facilitate the isolation and introduction of the needle, and then pass the ligature from within outwards, excluding the satellite veins. If the incision should be made about two inches higher up, it must be recollected that the median nerve is here in contact with the artery resting upon it, somewhat to its internal side.

*Explanation*.—Plate III, figure 14; *e*, the deep fascia; *c*, the tendon of the biceps; *a*, the artery at the inner side of the tendon, with the ligature passed under it; *b*, the median nerve; *d*, the skin.

II. IN THE MIDDLE OF THE ARM.—The vessel lies in the upper portion of its course to the inner side of the *coraco brachialis*; lower down, on the inner side of the biceps, being somewhat overlapped by it. The *median nerve* lies along the external and anterior side of the artery, and being exposed, is one of the best guides to the vessel after the aponeurosis is incised. The "directing line" given by Sabatier for the whole vessel is from the middle of the axilla to a point just within the middle of the elbow. The vessel is sufficiently superficial to feel its pulsations in the living subject, which is always a valuable guide.

*Operation*.—Place the patient in a recumbent posture with the arm abducted and rotated outwards, make an incision about three inches long, in a line with the inner edge of the biceps muscle, through the integuments and superficial fascia, taking care to avoid, as much as possible the superficial ves-

sels and nerves; cut through the aponeurosis on a director and separate the artery from the median nerve which will be found here, lying somewhat above and in front of it, and from the venæ comites. The vessel is secured in the usual manner.

*Explanation.*—Plate III. figure 15; *d*, the biceps muscle drawn aside to expose the artery; *b*, the median nerve drawn up with a blunt hook; *c*, the artery; *a*, the venæ comites.

III. IN THE UPPER THIRD OF THE ARM.—The vessel, as we have seen here, lies to the inner side of the coraco-brachialis muscle, and somewhat upon its brachial attachment. The median nerve is on its outer, and the ulnar nerve on its inner side. The other relations are not altered.

*Operation.*—The incisions, made as in the last operation, are carried along the inner border of the coraco-brachialis muscle for about two and a half or three inches. The vessel should be isolated with the needle or director and the ligature passed so as to exclude everything but the artery.

*Anomalies.*—As the brachial artery frequently divides high up in the arm, into the radial and ulnar arteries, it may happen that the operator, in performing any of the preceding operations, will meet with two vessels running parallel, or may possibly meet with but one, and that perhaps, the vessel which does *not* require the ligature. This will remind the surgeon of the necessity of ascertaining always, by compressing it between his fingers, previously to tightening his ligature, whether the vessel, he is about to tie, commands the bleeding or aneurismal pulsation, as the case may be. Should it do so, the artery may at once be secured. In this anomaly it may be necessary to tie both vessels as they frequently communicate by a transverse branch in their course down the arm, which would render the tying of one, perfectly useless.

In the arm, much more even than in the lower extremity, does the necessity always exist of tying the wounded vessel at the seat of lesion with two ligatures, one to the upper and one to the lower end of the open artery. The anastomosis in the upper extremity is so abundant that there is scarcely ever any danger that the nutrition of the limb will not be kept up, but on the other hand, in case of a bleeding wound, or even in true aneurism, ligation in the continuity of the vessel, is apt to fail on account of the too abundant collateral circulation, establishing a reflux stream, which in the case of the wound,

flows out of the lower end, and in the case of aneurism prevents the changes necessary for its cure. In several cases of secondary hemorrhage, in which the Hunterian operation was chosen with the view of *controlling the inflammation* in the fore-arm and hand, all but one of the operations was followed by recurrent hemorrhage. In primary hemorrhage the brachial artery should *never* be tied except at the seat of lesion.

**THE AXILLARY ARTERY.**—The axillary artery, the continuation of the subclavian, commences at the lower margin of the first rib, from which it passes downwards, outwards and backwards, across the axilla and along the inner and upper part of the arm, until it arrives at the lower margin of the tendons of the teres major and latissimus dorsi muscles, where it becomes the brachial. In this course, it forms a curve, the convexity of which is turned upwards and outwards. It is closely accompanied by the axillary or brachial plexus of nerves, and by the axillary vein, which last lies, at first to the inner side, and then in front of the artery, obscuring it from view. Near the middle of the axilla, it is embraced by the two heads of the median nerve. The vessel is crossed in its course by the narrow portion of the pectoralis minor muscle, passing to its coracoid attachment. This has resulted in its division, for the purposes of description, into three portions, viz: 1st, that above the lesser pectoral muscle, and *just below the clavicle*; 2d, that under or behind the muscle; and 3d, that below the lesser pectoral muscle. This vessel may be tied in its first and third stages only, either for the cure of aneurisms, or in cases of wounds in these situations.

**I. BELOW THE PECTORALIS MINOR.**—In this portion of its course the axillary artery extends from the lower edge of the pectoralis minor to the inferior edge of the latissimus dorsi and teres major tendons. It here rests on the insertion of the subscapularis muscle; and below this, on the tendons of the latissimus dorsi and teres major; a plexus of veins covers it, as in the second stage, the axillary vein lying in front of the artery, and the branches of the brachial plexus of nerves are related to it as follows: to its *outer* side are the median and external cutaneous; to its *inner*, the internal cutaneous and ulnar; and *behind* it are the musculo-spiral and circumflex nerves. It is covered by the integuments and pectoralis major

muscle, and may be exposed from the axilla, by cutting through the integuments and axillary fascia only.

*Operation.*—Place the patient in the recumbent position, with the arm rotated outwards, raising it from the side; make an incision in the line of the artery, about three inches in length, through the integuments and fascia, and opposite the head of the humerus, between the folds of the axilla, but a little nearer to the posterior one; tear cautiously through a quantity of loose cellular tissue, and the *axillary vein* or *veins*, with the branches of the brachial plexus of nerves, will be exposed, concealing the artery. Great caution must be used now in isolating the vessel, to avoid wounding the vein which lies before it, and is the first object which meets our view. The vein must be pushed backwards with the brachial plexus. The median nerve must then be sought for, and on the inner side or beneath it, the artery is found. The pulsations of the vessel are valuable in guiding to its position. In order to isolate the artery, the elbow must be bent so as to relax the nerves, and permit their more easy separation from the vessel. The needle must be passed from behind forwards. In case any small arterial branches are cut in the first incision, they should be tied, or torsion applied, to prevent embarrassment to the surgeon.

*Explanation.*—Plate III. figure 16, Arteries: *g*, the coracobrachialis muscle; *b*, the skin divided; *a*, the axillary vein; *c*, the median nerve; *e*, the internal cutaneous nerve; *d*, the ulnar nerve; *f*, the artery.

II. BELOW THE CLAVICLE.—This operation is frequently improperly referred to as ligation of the subclavian below the clavicle. It is properly ligation of the axillary in its first stage. As the number of gun-shot wounds of the shoulder has been found to be great, the necessity for ligations of the axillary is therefore frequent. The present operation requires deep cutting, but when the vessel is wounded in this portion of its course, ligation of the subclavian above the clavicle, though an operation so much easier, will not answer the purpose of restraining the hemorrhage. In its first stage, the artery lies above the pectoralis minor muscle, and is covered by the great pectoral and a dense fascia, the costo-coracoid membrane from which the vessele emerges, as it passes from under the clavicle. It is separated from the pectoralis major by a layer of adipose tissue containing numerous small veins



and arteries. The axillary vein is situated in front and to the inner side of the artery, but is not in immediate contact with it in this portion of its course. More superficially the *cephalic vein* passes upward in the intermuscular space between the deltoid and pectoralis major, *crossing* the axillary artery just above the superior border of the pectoralis minor, and empties into the axillary vein. The nerves of the brachial plexus lie behind and somewhat above the artery; the *superficial thoracic nerve* crosses the course of the artery, sometimes in front and sometimes behind, to be distributed to the pectoralis major muscle.

*Explanation.*—Plate IV. figure 17, Arteries, is a representation of the surgical anatomy of the region above described, taken from the work of MM. Bernard and Huette. A portion of the clavicle has been sawn through, and the upper part of the pectoralis major cut away to expose the vessel and its relations; *j*, the pectoralis minor muscle; *i*, the pectoralis major cut away with a portion of the clavicle; *a*, the suprascapular artery, a small branch of the subclavian, crossing the base of the neck and brachial nerves just above the clavicle; *b*, the brachial nerves; *c*, the brachial plexus; *h*, the axillary vein on the inner side of the artery, with the cephalic vein emptying into it; *g*, the axillary artery, as it emerges from under the clavicle, with the vein in front and the nerves behind it; *f*, the sterno-mastoid muscle, with the external jugular vein passing down over its surface; *d*, the omo-hyoid muscle.

*Operations.*—Four methods of performing this operation have been in practice. 1st, the ordinary method of cutting through the pectoralis major, by a nearly transverse incision; 2d, Desault's method; 3d, Lisfranc's method; and 4th, Chamberlayne's method.

1st. *The Ordinary Method.*—The muscles of the shoulder being perfectly at rest, the elbow slightly separated from the trunk, and the head inclined to the opposite side, an incision, three inches in length, is made about three-quarters of an inch below the clavicle, and parallel with it. This incision divides the skin, platysma and subcutaneous cellular tissue, and extends from the septum, between the deltoid and pectoralis major, to within two inches of the sterno-clavicular articulation. The muscular fibres of the pectoralis major are successively divided and pushed aside, till the posterior fascial

investment of this muscle is brought into view. The shoulder should now be depressed to favor the separation of the edges of the wound, and the fascia torn through with the point of the director. When the finger is now introduced into the wound, to press downwards and outwards the pectoralis minor, by feeling carefully, the following parts will be recognized: 1st, the axillary vein distended with blood; 2d, the axillary artery pulsating, farther on the outside and behind the vein; the nerves of the brachial plexus, still higher up and farther behind; the needle is introduced between the vein and the artery, and it is important that the vein should be pressed to the inner side with the finger, in order that it may be protected from injury from the point of the director or needle.

Malgaigne thinks this is one of the most difficult of all ligations. Dupuytren was obliged to tie, on one occasion, twelve or thirteen small vessels before he reached the axillary artery. Many of these small vessels, however, though they spirt freely when first cut, cease bleeding if compressed, for a little while, between the finger and thumb. In extirpation of the mamma they seldom require ligation.

2d. *Desault's Method*.—This has been modified by Delpech in which form we here present it. Lay the patient on his back, with his arm separated from his body, at an angle of about 45 degrees; make an incision through the integuments two inches and half long, commencing beneath the clavicle, at the union of the external and middle third, and descending obliquely towards the humerus in the direction of the interstice mentioned in the last operation. Separate and strongly draw apart, the deltoid and pectoralis major, and the pectoralis minor will be exposed, divide it completely near its insertion into the coracoid process. Then carry the index finger to the bottom of the wound and follow the surface of the serratus magnus until stopped by the scapula; then bring back the finger bent, pressing it between the subscapularis and the entire mass of nerves and vessels and raise them on it to the surface of the wound. The artery is seen at once, exposed just before it passes between the roots of the median nerve, having the vein on its *internal side* and almost all the *plexus* on its *outer side*. It is now easy to press the director or needle under it. In this operation, we must look for the superior thoracic artery, the first branch of the axillary, which passes in front of the pectoralis minor, to the walls of the

chest, and secure it either before or after its division, as its bleeding would embarrass the operation.

3d. *Lisfane's Method* consists in giving an oblique direction to the incision downwards and outwards, following the interstice between the sternal and clavicular portions of the pectoralis major, the arm being strongly abducted to make the depression more apparent. This plan has the advantage of not dividing any of the fibres of either muscle, but it is said not to expose the artery high enough up, which renders the operation difficult. It is also suggested by Malgaigne that the contraction of the pectoralis major would prevent the free discharge of pus, and favor the formation of abscesses and sinuses.

4th. *Chamberlayne's Method*.—Make an incision three inches in length below the clavicle, and join it by another of the same extent, corresponding with the intermuscular space between the deltoid and pectoralis major. It will be seen that this method unites the incision of the *ordinary* method, viz: make the first incision *three-quarters of an inch below the clavicle, beginning two inches from its sternal end and terminating at the muscular interspace* between the deltoid and pectoralis major—make the second incision three inches in length *along the muscular interspace* between the deltoid and pectoralis major. The result of these two incisions is a *triangular flap* which is turned downwards in proceeding with the operation. The clavicular portion of the pectoralis major being detached in this flap, and the cellular tissue overlying the vessels torn through, the search should be made first for the vein which is most anterior—this is the infallible landmark—drawing the vein gently inwards we find the artery pulsating to the outer side and a little behind it. The nerves are seen still further outwardly and further still, behind the artery. The needle, of course, is introduced between the vein and artery, avoiding the nerves lying behind the latter.

*Explanation*.—Plate IV, figure 18, arteries, is intended to represent Chamberlayne's operation. The line of incision, however, does not correspond with our description, *g* and *b*; the clavicular portion of the pectoralis major cut through and detached and turned down; the cellular tissue being torn through *c*; the pectoralis minor is exposed also; *d*, the margin of the deltoid muscle; *e*, the axillary artery, with *a*, the vein, lying in front, and *f*, the brachial nerves, lying outwardly and behind.

*As Applied to Wounded Arteries.*—Of the four methods described, Chamberlayne's will be found most frequently the preferable operation. The double incision exposes the vessel better and affords room for the movements necessary to introduce the ligature. In any of the methods, the operator will find great advantage in the use of bent spatulas to draw the lips of the wound apart, and that changing the position of the limb in the several stages of the operation, will relax the muscles and facilitate the isolation of the vessel and the introduction of the needle. In gun-shot wounds it is well to consider in each case, before the operation begins, the possible necessity, as the procedure advances, of having to modify its method, on account of the development of the individual character of the wound. Thus, an operation, begun on *Desault's method*, with the incision along the inter-muscular space, may be changed to Chamberlayne's by adding the horizontal incision of the *ordinary method*; and so, the ordinary method, after being begun, may be also changed to Chamberlayne's by adding Desault's incision along the line above mentioned. Again, we may find, after removal of the clots form a diffused aneurism in this region, that the *wound is below* the pectoralis minor; in that case the division of the muscle, as described in Delpech's modification of Desault, may be found necessary to get at the wound. It must be recollected, as we have said in the first portion of this chapter, that all these descriptions refer to ligations for true aneurism, somewhere below the point of ligation; when they come to be applied, in the case of arterial lesion, or still worse, in the cure of diffused aneurism, the altered circumstances may embarrass and disconcert the operator, unless he has maturely deliberated *on all the possibilities* of the operation he has gone into. Balls which wound the axillary artery most frequently *pass through* the shoulder, making a *complete track*. When this is the case, the surgeon can have the advantage of the introduction of the sound, as recommended on page 123, to re-establish the track in the same manner as though the missile had passed through the limb lower down, or through the thigh or leg. In case of wounds, there will be found large quantities of clot and matted tissues about the vessel, which will obscure and confuse the parts, to an embarrassing degree. The surgeon should secure the most intelligent and reliable one of his assistants, to *compress the subclavian artery*,

as it passes over the first rib, and in case the compression cannot be made effectual without it, it has been recommended by some to make an incision above the clavicle, as if to expose that vessel so as to allow the finger to come in contact with it. This certainly cannot often be necessary.

**THE SUBCLAVIAN ARTERY.**—The subclavian artery arises on the right side, from the arteria innominata, opposite the sterno-clavicular articulation; and, on the left, from the arch of the aorta; these two vessels, therefore, necessarily differ, in the first part of their course, in their length, their direction, and their relation to surrounding parts. These differences will be considered, when necessary, in connection with the description of the several operations. The vessels ascend from their respective origins, pass between the scaleni muscles, and curving in the form of an arch, cross the first rib, at the lower border of which, they take the name of the axillary arteries. This short trunk has been divided, for the purposes of description, into three stages: the *first* or *ascending*, extends from the origin of the vessel to the inner border of the scalenus anticus muscle; the *second* or *transverse*, or *middle* stage, is the portion of the vessel which lies between the scaleni muscles; while the *third* or *descending* stage, extends from the outer border of the scalenus anticus muscle to the lower margin of the first rib, when the vessel terminates in the axillary artery. It has been ligated in each one of these three stages.

**I. OUTSIDE THE SCALENI MUSCLES.**—In its third stage, the subclavian artery lies in the posterior inferior triangle of the neck, bounded by the omo-hyoid muscle externally, the sterno-mastoid and scalenus anticus muscles internally, and the clavicle inferiorly; it is covered only by the integuments, platysma and a quantity of cellular membrane, which contains several branches of the cervical and brachial plexus, the subclavian, external jugular, and other veins, and the transversalis colli and humeri arteries; it rests on the *first rib*, which separates it from the pleura; the *brachial plexus* lies above and posterior to it; the *subclavian vein* lies anterior and inferior to it.

*Operation.*—This portion of the artery is the most favorable for the application of the ligature. To secure it in this situation, place the patient in the horizontal position, with the

head and neck turned towards the opposite side, and the shoulder depressed as much as possible; the skin over the parts being drawn down upon the clavicle, so as to have a firm surface to cut upon, make an incision along the clavicle, commencing at the outer edge of the *sterno-mastoid* muscle, or a little internal to the centre of the bone, and terminating near its acromial end at the anterior border of the *trapezius* muscle; in this, the integuments, platysma, and a few of the supra-clavicular branches of the cervical plexus will be divided. A quantity of loose cellular tissue is now exposed, filling the posterior inferior triangle of the neck; in this are contained some branches of the cervical and brachial plexuses, lymphatic glands and a number of small veins, crossing from the posterior part of the neck, to terminate in the *external jugular vein*, which lies close to the outer margin of the *sterno-mastoid* muscle. Tear through the cellular tissue, taking care to avoid, if possible, the several parts just mentioned, especially the external jugular vein. In some subjects, the clavicular portions of the *sterno-mastoid* muscle encroaches on the space, and will require partial division.

On continuing the dissection more deeply, the *omo-hyoid* muscle will be brought into view, crossing the upper part of the space; this being drawn upwards, the *subclavian vein* and *transversalis humeri artery* will be exposed in the base of the triangle, and the *transversalis colli artery* in its apex; separate these parts, and expose the outer edge of the *scalenus anticus* muscle; pass the finger downwards along this, and it will thus be conducted to the *subclavian artery*, where it rests on the upper surface of the first rib. As the *brachial plexus* lies in close contact with the artery, it is possible that one of its branches, and most likely the central one, from its running a long course before it joins the plexus and from its proximity to the artery, may be mistaken for the *subclavian artery*. Detach the artery from its surrounding connections, and pass the aneurism needle from below upwards and a little from within outwards. Sometimes it is difficult to pass the needle in this direction from the position of the clavicle; it may then be passed in the contrary direction. Throughout the operation, the *subclavian vein* must be remembered and carefully avoided, both in making the incisions and in introducing the ligature. After the first incision, the knife should be aban-

done, and the operation continued with the handle or the director as much as possible; if the knife is required at all, it should be used only on the groove director.

If the external jugular is cut, it must be pressed by the fingers of an assistant at both ends for a while, till the bleeding is arrested, or ligatures may be applied, *to be removed* after the operation is completed. The upper end is apt to bleed profusely, and a greater danger attends the *lower end*, which being open, air is sometimes drawn through it into the heart, when the patient dies instantly.\* Should the transversalis humeri or colli artery be wounded, they should be sought for and tied at once, for their bleeding would not only embarrass the operation, but weaken the patient—they are of considerable size.

*Explanation.*—Plate IV. figure 19, Arteries: *a*, the brachial plexus, above and behind the artery; *b*, the artery; *c*, the subclavian vein, in front and somewhat below the artery; *d*, the border of the scalenus muscle, with the artery emerging from behind it—the vein should have been represented *in front* of the muscle; *e*, the external border of the sterno-mastoid muscle. Figure 17, on the same plate, represents a dissection of the parts, together with a portion of the axillary artery, the clavicle being sawn away.

*Different Methods.*—The operation we have described is very nearly that recommended by Lisfranc. He recommended the division of the external portion of the sterno-mastoid, and advises that the external jugular should be drawn inwards, with a blunt hook, to keep it from being injured. The tubercle of the first rib is his “rallying point” in finding the artery—we prefer the scalenus anticus, which *conducts us to it*—the elevation on the rib is occupied by the insertion of the muscle, and cannot always be felt. Roux has proposed an incision perpendicular to the clavicle, Marjolin, a  $\perp$  incision with the base inferior, and Physic a  $\vee$  incision. The operation described above, besides the great advantage of simplicity, we

---

\* We witnessed the death of a valuable horse, some years ago, from this cause. The ordinary phlebotomy not being at hand, a thumb lancet was used, which, in passing out, opened the orifice, or elevated one edge of it—a peculiar gurgling was heard for a moment, when he fell down and died instantly, from the air being sucked into the right auricle of the heart.

have found it to expose the vessel sufficiently to answer all useful purposes.

II. BETWEEN THE SCALENI.—In the second or *middle* stage, the subclavian artery rests on the scalenus medius muscle and the cone of the pleura; the brachial plexus lies above and posterior to it; in front of it are the integuments, platysma, sterno-mastoid and scalenus anticus muscles; on the anterior surface of this last are the subclavian vein, the transversalis colli and humeri arteries, and the phrenic nerve, which runs parallel with and in front of the scalenus anticus muscle.

*Operation.*—The patient must be placed as in the preceding operation. Make an incision about three inches long and a little above the clavicle, commencing at a short distance from its sternal end; divide the integuments, the platysma, the fascia, and the clavicular portion of the sterno-mastoid muscle, the last on the director; the subclavian vein, transversalis colli and humeri arteries are exposed; and the phrenic nerve on the anterior surface of the scalenus anticus muscle. These several parts having been drawn out of the way, pass a director behind the scalenus anticus muscle and divide it; the subclavian artery will now be brought into view; pass the aneurism needle from below upwards, taking care to avoid the cone of the pleura, which lies behind the artery, and the brachial plexus of nerves.

III. WITHIN THE SCALENI.—The difference in origin, length and direction in the arteries of the two sides has given rise to a corresponding diversity in the relations of their first portion. The *first* portion on the *right side* is in relation *in front* with the internal jugular and vertebral vein, and is *crossed* by the pneumogastric nerve, phrenic nerve, and one or two branches of the sympathetic. *Behind* and beneath, it is invested by the pleura, is crossed by the right recurrent laryngeal nerve, and is in relation further back with the sympathetic nerve, longus colli muscle, and transverse process of the seventh cervical vertebra. The *first* portion on the *left side* is in relation *in front* with the pleura, internal jugular vein, vena innominata, and pneumogastric and phrenic nerves, which lie parallel to it. To its *inner side* is the left carotid artery, trachea, œsophagus and thoracic duct; to its outer side, the pleura; and *behind*, the œsophagus, thoracic duct, longus colli and vertebral column.



The chief points of difference may thus be summed up : the right arises from the arteria innominata, the left from the arch of the aorta ; the right is larger but shorter than the left, is more superficial and takes a more transverse course, and differs in its relation to the par vagum and vena innominata ; the left only is related to the thoracic duct and œsophagus and is more closely connected with the pleura.

This operation on both the right and left side has been almost abandoned by the profession, even for aneurism, on account of the small space allowed on the right side for the formation of the occluding clot, and the almost insurmountable difficulties presented on the left, in the isolation of the vessel. Brasdor's distal ligation is recommended in cases of aneurism when ligation in the first stage is debated, so difficult has the operation been found, and so uniformly fatal has been the result. In the case of gun-shot wounds, it is not probable that our surgeons would have the trying opportunity of ligating the first portion of either the right or the left subclavian, as any wound which would involve this portion of the artery would be so speedily fatal, generally, as to allow no time for such an operation ; indeed, we know of but one contingency under which the military surgeon might have to consider the necessity of operating on the subclavian artery within the scaleni as a consequence of any of the casualties of battle ; that is, in case a ball, in passing through this portion of the body, should brush or graze the artery somewhat beyond this place, so as to weaken its coats and give rise to the formation of a circumscribed traumatic aneurism. Even in this rare case, we would not advise the operation. Brasdor's plan to ligate beyond should be here applied to the third portion of the subclavian, or, if it should be on the right side, even ligation of the innominata, hopeless as it is, would be a preferable operation. Here, however, are the directions as we have condensed them from one or two systematic works, for the guidance of any one who may conceive it his duty to perform either of these operations :

*Operation on the Right Side.*—The patient is to be placed upon his back, with his chest moderately elevated, his head turned to the opposite side, and the shoulder carried downwards and backwards as much as practicable, in order to tense the skin fascia and muscles. Make an incision <sup>to make</sup> three inches in length along and a little above <sup>the clavicle,</sup> <sub>the clavicle,</sub>

commencing at its sternal end ; from the inner extremity of this, carry another along the external margin of the sternomastoid muscle to the extent of about two inches and a half ; in these incisions, the integument platysma and fascia are divided ; raise a triangular flap so as to expose the lower part of the sternomastoid muscle, behind which pass a director and cut through it ; the sterno-hyoid and sterno-thyroid are now exposed, with a few branches of the descendens noni nerve ; they may be divided in like manner, and drawn inwards. By a little farther dissection, the right vena innominata, formed by the junction of the internal jugular and subclavian veins, is exposed. Tear through some cellular substance found here and the artery will be brought into view. Now draw the par vagum, recurrent nerve and the sympathetic filaments to the inner side, (if they are drawn to the outer side the recurrent nerve will certainly get under the ligature,) depress the vena innominata towards the thorax, and pass the aneurism needle from below upwards, taking care to avoid the parts which lie behind the vessel. It is seldom that the phrenic nerve is exposed in performing this operation, as it lies either on or close to the scalenus anticus muscle. There is only a space of about three quarters of an inch between the origin of the vessel and the place where it gives off its branches, where the vessel can be safely reached. The ligature should be applied about midway between these two points, or perhaps a little nearer the first branch, so as to allow as much space as possible for the formation of the internal clot. It has been suggested by Mr. Hayden to ligate the common carotid at the same time, so as to secure, if possible, the obliteration of the arteria innominata by arresting the circulation in both its branches.

*On the Left Side.*—The operation on the left side does not differ so much from that on the right as to require a separate description. On this side it will be recollected, that this portion of the vessel is more intimately connected with the pleura ; has the subclavian vein in front of it and the thoracic duct behind it. The operation has been performed two or three times, and the nearest approach to success, so far as we remember, was the case of Mr. Colles, of Dublin, whose patient survived the operation about nine days. Sir Astley Cooper had to abandon the operation once on account of its great difficulty.

Ligations of the subclavian, even in the external third of its course, cannot be regarded as a very reliable means of arresting hemorrhage from gun-shot wounds of the axillary or its branches. Mr. Guthrie deprecates the operation in hemorrhage, except in cases where the artery is *wounded at the point ligated*, and one of his precepts is: "Never commit the error of ligating the subclavian above the clavicle, for a wound of the axillary below it." The circles of anastomosis are very abundant around the shoulder, and the communications large, amounting to inosculation. The re-establishment of the circulation may, therefore, be expected to be rapid, and bleeding is apt to follow quickly by the reflux current. The operation is of great value in axillary circumscribed aneurisms, but not to be trusted in axillary traumatic hemorrhage.

*Branches.*—Some of the branches of the subclavian are of sufficient size to require ligation when wounded and accessible to the surgeon. Operations on the internal mammary and the inferior thyroid are selected for description.

I. THE INTERNAL MAMMARY ARTERY.—This vessel, arising from the under surface of the subclavian, nearly opposite the point where the vertebral is given off, passes downwards and forwards behind the phrenic nerve, and enters the cavity of the thorax to its outer side. It has a long course in the thorax, descending along the outer margin of the anterior mediastinum, behind the sternal extremities of the costal cartilages; it is covered by the triangularis sterni muscle and the pleura till it arrives at the diaphragm. It here enters the sheath of the rectus and descends in it along the posterior surface of the muscle, and finally, arriving opposite the umbilicus, terminates by anastomosing with the epigastric, a branch of the external iliac. Dr. Harrison has remarked upon the number of the inosculations of this artery and the distant parts of the arterial system which they serve to connect. The two arteries anastomose with each other, and their inosculations with the aorta, completely encircle the body, and, besides other inosculations, they connect the main trunk of the superior with that of the inferior extremity.

*Operation.*—This vessel may require ligation in penetrating wounds of the chest, when the operation may be performed as follows: It may be tied best in the second, third or fourth intercostal space in case of a wound. Make an incision in either one of these spaces, beginning at the edge of the ster-

num, and carrying it outwards, for the distance of an inch and a half or two inches, along the middle of the space between the costal cartilages. Divide the intercostal muscle cautiously on a director; the artery will be found lying upon its aponeurosis, which is stretched between the ribs; it is easy to isolate it from the veins and to tie it without injuring the pleura. If the vessel is wounded higher up, it may be tied, as recommended by Scarpa, between the first and second ribs, in which case the pectoralis major will have to be divided, as well as the intercostal muscle. In this position, it lies very close to the edge of the sternum, which increases the difficulty of the operation.

II. THE INFERIOR THYROID ARTERY.—The thyroid axis, of which this vessel is a branch, arises close to the inner border of the scalenus anticus muscle. The *inferior thyroid* ascends obliquely, in rather a serpentine course, *behind the sheath* of the carotid vessels, and in front of the longus colli muscle, to the inferior and posterior part of the thyroid body, to which it is distributed.

*Operation.*—Sir Everard Home recommended the ligation of these vessels, together with the superior thyroids, branches of the external carotid, for the cure of bronchocele; the operation has long since been abandoned for this purpose, on account of its difficulties, and still more on account of the unsuccess attending the practice.\* Place the patient in the

---

\* In these cases the cause of failure is, that the abundant anastomosis of the supplying arteries soon re-established the excess of nutrition, and the tumor continued to grow, because its *feeder* could not be *permanently* cut off. Indeed, so long as a part exists, we cannot *permanently* diminish its blood supply, and hence, whenever the case depends upon that, it fails—the collateral circulation in time certainly enlarges, so as to be adequate to even the *morbid* appetite of the hypertrophic parts. The measure of ligation, as applied to *inflammation*, is different; here the morbid demand for blood is evanescent, existing only so long as the causes of irritation at the wound remain—if its *feeder*, the main trunk, is cut off, the diminution in the supply, though not permanent, is not *required* to be—still it is sufficiently so to allow of the recovery of the parts, before the collateral circulation can be fully established. If inflammation was of a nature to demand for its cure the permanent diminution of the blood-supply, then ligation of the main trunk would be of no avail. It is most fortunate, in the general interests of humanity, that we cannot cure tumors and other morbid conditions dependant upon excessive nutrition, by cutting off their arterial supply. The

recumbent posture; then, turning the head towards the opposite side and moderately extending the neck. make the incision, about three inches in length, along the inner edge of the sterno-mastoid, commencing close to the sternum. All the steps in the operation are nearly the same as those necessary to reach the primitive carotid in its first stage, to be described presently. The sheath and its contained structures are drawn aside with a blunt hook or curved spatula, and the vessel will be found behind it, ascending by the side of the trachea to reach the thyroid body. The inferior or recurrent laryngeal nerve, lying behind it, must be avoided in the application of the ligature.

**THE ARTERIA INNOMINATA.**—Ligation of the arteria innominata, like that of the subclavian in its first stage, experience has so far shown to be a hopeless and useless operation. Nine failures in the one case and seven in the other have served to secure for them general condemnation, and convinced the profession of their inutility.

The arteria innominata is the first branch given off from the arch of the aorta, being the common trunk of the right carotid and subclavian arteries, into which it bifurcates. It is generally not more than an inch and a half in length, and ascends obliquely from the right side of the arch of the aorta, to the right sterno-clavicular articulation. It has, in front of it, the sternum, the sterno-hyoid and sterno-thyroid muscles and the left vena innominata or transverse vein, which crosses it. On the right side, the right vena innominata and the pleura; on the left, the left carotid and the remains of the thymus gland; behind, the trachea and right pneumogastric nerve.

*Operation.*—The patient is laid on his back, his head thrown backwards, with his face inclined a little to the left shoulder. The surgeon stands on the right side and makes a horizontal incision from the median line of the neck, directed outwards for two and a half inches, at about half an inch above the clavicle. Another incision of the same length traces the in-

---

possession of that power would involve a denial to us of one far more important, viz: that of ligating to cure aneurism and to arrest hemorrhage—for, in that case, wherever the main trunk of a limb was ligated, for any object whatever, its nutrition would be permanently destroyed, and the organ it supplied would consequently perish.

ternal border of the right sterno-mastoid, and falls on the extremity of the first. In the same direction the sternal end of the muscle is cut, and most of the clavicular portion also, which is turned upward and outward. The sterno-hyoid and sterno-thyroid are cut on a director carefully passed under them. With the director and fingers, the veins and cellular tissue which cover the artery may be separated, and the vessel may be isolated and tied.

Of course the above operation could scarcely, in any event, be debated for the arrest of hemorrhage. The singular circumstance that in two cases wherein the operator, after exposing the vessel failed to apply the ligature, the pulsations in the tumor gradually diminished, and in one the patient recovered, suggests that this partial procedure may perhaps hereafter become the method for treating certain forms of aneurism, wherein the vessel was formerly ligated.

*Explanation.*—Plate IV. figure 20: *d*, the arteria innominata isolated and with the ligature passed under it; *b*, the pneumogastric nerve; *c*, the internal jugular vein; *a*, the phrenic nerve; *e*, the sterno-mastoid with the sterno-hyoid and sterno-thyroid muscles beneath it, all divided.

*M. Sedillot* makes an incision which he thinks is convenient for the ligation of both the primitive carotid and the subclavian in the first stage. The patient is placed in the position described in the last operation. The incision is then made, three inches in length, in the depression, observable in the living subject, between the sternal and clavicular portions of the sterno-mastoid muscle. The head being now flexed, the two portions of the muscle are separated, the sterno-hyoid and thyroid muscles divided on a director, and the vessels exposed, as in the operations above described.

*Explanation.*—Plate V. figure 21<sup>a</sup>, Arteries: *d*, exhibits the parts as exposed in *M. Sedillot's* operation; *a*, internal portion of the sterno-mastoid muscle; *b*, the sterno-hyoid and thyroid muscles divided; *h*, the arteria innominata; *e*, the common carotid; *d*, the pneumogastric and recurrent laryngeal nerves; *g*, the origin of the subclavian; *c*, the vertebral artery and thyroid axis.

### Arteries of the Head and Neck.

The arteries of the head and neck are derived principally from divisions of the primitive carotid. The branches of the respective sides anastomose freely with each other, and also with the corresponding branches of the opposite side, which results in a complete mesh-work of communications, both in the scalp and on the interior of the cranium.

THE PRIMITIVE CAROTID ARTERIES.—Like the subclavians, the two primitive carotid arteries differ in their origin on the two sides of the body. The *right*, as we have seen, arises from the arteria innominata opposite the right sternoclavicular articulation; the *left* from the arch of the aorta, between the origins of the arteria innominata and left subclavian. From these different origins, the vessels ascend backwards and outwards into the neck, being enclosed with the pneumogastric nerve and internal jugular vein in a common sheath. Arriving opposite the os hyoides or the upper edge of thyroid cartilage, each divides into the external and internal carotid arteries. Only in the first part of their course do the relations of the two vessels differ. Being derived from the aorta, the left carotid at first, lies within the thorax, and is covered by the sternum, the transverse vein and the remains of the thymus gland, resting on the trachea a little above its bifurcation. Escaping on the left side of the trachea, it rests on the thoracic duct and œsophagus, whence, ascending into the neck, it resembles the right carotid. It is longer than the right, lies deeper in the neck, and is generally somewhat smaller.

The course of the common carotid arteries in the neck is, divided into a superficial and deep stage, by the omo-hyoid muscle, which crosses the neck obliquely. In the deep stage, the artery, enveloped in its sheath, lies in the anterior inferior triangle of the neck, covered by the skin, platysma, fascia, sterno-mastoid, hyoid and thyroid muscles; to its inner side, lie the trachea and left recurrent nerve; on the left side the œsophagus; to its outer side, the par vagum and internal jugular vein; and behind it, and behind its sheath, are the inferior thyroid artery, the recurrent and sympathetic nerves, the longus colli and rectus anticus muscles. On the left side, the internal jugular vein overlaps the artery as it descends to

join the subclavian, which increases the difficulty in securing the carotid on this side.

In its superficial or upper stage, the common carotid lies in the anterior superior triangle of the neck; it is only covered by the skin, platysma and cervical fascia, and by its sheath, on the outer surface of which, are the filaments of the descendens noni nerve. Sometimes this nerve is within or behind the sheath. The larynx, pharynx, superior thyroid artery, and superior laryngeal nerve are to its inner side, the par vagum and internal jugular vein to its outer side, enclosed in its sheath; while behind it are the sympathetic nerve and longus colli, and rectus anticus major muscles. Numerous lymphatic glands accompany the artery which, when enlarged, may somewhat obscure its appearance. The vessel rests posteriorly on the cervical portion of the spinal column, and in cases of hemorrhage, may, for a short time, be compressed against it. The artery cannot be long compressed here, as the internal jugular is necessarily compressed with it, thus obstructing the return of blood from the brain.

The primitive carotid can be tied in any portion of its course; two operations are generally described.

I. AT THE BASE OF THE NECK.—The vessel, as we have seen, is here covered by the skin and fascia, the platysma, sterno-hyoid and thyroid muscles, having the trachea and recurrent nerve to its inner side; its immediate relations being the same as before mentioned.

*Operation.*—The patient is placed in the recumbent posture, with the head turned towards the opposite side, and the neck moderately extended. An incision, about three inches in length, is then made along the inner edge of the sterno-mastoid muscle, beginning at the sternum, and cutting through the skin and platysma myoides muscle. The fascia is then cut through, avoiding any veins that may present. The inner edge of the sterno-mastoid, and also the sterno-hyoid and thyroid muscles are exposed with a few branches of the descendens noni nerve; draw the mastoid muscle to the outer side, the others to the inner or tracheal side; or, if necessary, cut across some of their fibres on a groove director. The sterno-thyroid, from its greater breadth, overlaps the artery, and is most likely to require division. The sheath will now be brought into view, having the omo-hyoid muscle crossing it at the upper part of this region. Pinch up a small portion



of the sheath to make an opening for the director, and divide the sheath on it, to the required extent. The carotid artery will be exposed with the vein and nerve. The artery must be gently detached from its connections within the sheath, and the needle passed under it from without, inwards; in doing so, the pneumogastric nerve and the vein on the outer side, the sympathetic nerve and inferior thyroid artery behind, and the recurrent nerve on the inner side, must be avoided. If the left carotid be the artery operated on, the thoracic duct and œsophagus must also be guarded against.

All the large veins at the root of the neck are emptied when inspiration takes place, and distended during the act of expiration; motion also is communicated to the blood by the regurgitation from the right auricle; these changes cause the internal jugular vein alternately to flap over, and recede from, the artery, causing more or less embarrassment to the surgeon. Should this become troublesome, the vein should be compressed both above and below.

*Explanation.*—Plate V. figure 21<sup>b</sup>, Arteries, does not represent the operation as described, but that of Sedillot, as applied to the carotid in this region, the incision being made between the sternal and clavicular portions of the sterno-mastoid. We prefer the operation above described; *c*, the internal portion of the muscle drawn inwards; *a*, the external portion drawn outward, with bent spatulas or hooks; *b*, the internal jugular vein; *e*, the pneumogastric nerve, lying between the vein, and *f*, the carotid artery.

II. IN THE SUPERFICIAL STAGE.—Where the vessel is crossed obliquely by the omo-hyoid muscle, or just above that point, in the anterior superior triangle of the neck, is the point of election for tying the primitive carotid artery, as it is here most easily reached. Its immediate relations are nearly the same as those mentioned above, viz: the internal jugular on the outer side, the pneumogastric nerve between and somewhat behind both, enclosed in a common sheath. The vessel here bi-sects the triangle, passing under the edge of the sterno-mastoid, and being crossed by the omo-hyoid muscle. The descendens noni is upon its sheath, and covering it, are the fascia, platysma, and the skin.

*Operation.*—Place the patient in the recumbent posture, with the head turned to the sound side, slightly extending the neck; make the incision, about three inches in length,

along, and a little internal to, the anterior margin of the sterno-mastoid muscle, extending from a little below the angle of the jaw, to the side of the cricoid cartilage. In this, the integuments and platysma are divided, and the cervical fascia exposed. This must be cautiously divided on a director, care being taken to avoid the veins which cross this part of the neck, the facial or labial vein being one of them. The descendens noni nerve will soon appear lying on the surface of the sheath; open the sheath to one side of this nerve, introduce the director and divide carefully with the knife for a short distance; pass the needle from without inwards, leaving out the par vagum and internal jugular vein. If the lips of the wound are held well apart with bent spatulas, any parts outside of the sheath cannot be in much danger of being included in the ligature. The trunk of the sympathetic nerve is behind the sheath, and the superior laryngeal nerve and superior thyroid artery are on its inner side. The ligature should be applied some distance from the bifurcation of the vessel, to allow the better opportunity for the formation of the coagulum. Should the sterno-mastoid artery, a branch of the external carotid, be cut, and bleed much, it should be ligated, as it may obscure the further steps of the operation. It is a small muscular branch, crossing the sheath of the vessel and inner edge of the muscle, to be distributed to its posterior surface.

*Explanation.*—Plate V. figure 22: Arteries, exhibits the parts exposed by the operation. The incision as represented, does not extend high enough for the operation in the superior triangle; *a*, the omo-hyoid muscle; *b*, the carotid artery crossed by filaments of the descendens noni nerve, which, before the dissection, were on the outside of the sheath; *c*, the internal jugular vein, external to the artery; *d*, the pneumogastric nerve, drawn from its position a little forward, so as to appear between the vein and artery; *e*, the inner border of the sterno-mastoid muscle drawn backwards.

*Anastomoses.*—To the anastomosing communications of the primitive carotid artery, with surrounding vessels, attach surgical considerations of unusual importance. These relate, both to the success of ligation in the various cases in which it may be practised, and to the influence of that operation upon the important parts within the cranium. Especially do these considerations force themselves upon us in military practice, where the operation requires to be so frequently debated for

hemorrhage resulting from gun-shot wounds of this vessel, or some one of its branches. Even more abundant than the arterial communications of the superior extremity, those of the head and neck present almost an impossibility of permanently arresting the circulation through any of their trunks, and in ligation of the primitive carotid, pulsation readily re-appears beyond the point at which the vessel is tied. The vertebral, the internal carotid, the thyroid, the lingual, facial and temporal of the opposite sides, communicate freely, while the superior and inferior thyroid and the princeps cervicis, and the profunda cervicis, keep up the communication between the subclavian and external carotid on the side on which the vessel may be tied.

*Results and Effects of Ligation.*—On account of the abundant anastomosis above described, it has been found that whenever the common carotid has been tied for aneurism, the pulsation, as we have said, returns in the vessel above the ligation in a very short time, and if tied for hemorrhage, the sanguineous effusion takes place by the recurrent circulation. For this reason, ligation of the primitive carotid for anastomotic aneurism of the branches of the external carotid, a practice once quite popular, has been nearly abandoned at the present day, and, for a stronger reason, ligation of this vessel for hemorrhage from any of its divisions or for bleeding from the trunk itself, except at the seat of lesion, is peremptorily condemned by the highest authorities.\* It is a vessel very liable to become the subject of frequent and ineffectual ligation, on account of its easy accessibility and its apparent availability for the trying emergency of alarming and persistent traumatic hemorrhage. We have tested, by repeated trials, how frequently this ligation is inefficient, both in the case of erectile tumor and in hemorrhage from its branches.

Considering the freedom of collateral communication between the circulation of the various regions of the head and neck, it is surprising how frequently ligation, of one common carotid artery, is attended with serious cerebral disturbance,

---

\* Mr. Guthrie says, "No fact can be more satisfactorily shown, than that, in every case of wounded—not aneurismal—artery of the neck, one ligature should be applied above and another below the opening in the wounded vessel, and not, one alone on the common trunk, even if that should be the part injured."—*Commentaries*, page 252.

and how invariably the simultaneous arrest of circulation in both, has been followed by death. The experiments of Meyer, Jobert and others to throw light on this subject were inconclusive on account of the varying relative importance of the common carotid to the brain in the lower animals as compared with man. Observations on the human subject go to show that out of 149 cases, in which the vessel was tied for various objects, 33 proved fatal, and of these, 18 died of cerebral disease, showing that the most frequent cause of death after ligation of the common carotid is this cerebral disease induced by the operation. The *successive* ligation of both carotids, with a *considerable interval* between the operations, has been attended with no greater cerebral disturbance than that following the single operation. While the *simultaneous* ligation† of both has invariably ended fatally. Mr. Erichsen thus sums up his conclusions on this subject: 1. Ligature of one carotid artery is followed by cerebral disturbance in about one-fifth of the cases, more than one-half of which are fatal. 2. When both carotids are ligated *simultaneously*, death has hitherto always resulted, as in the two cases in which Mott and Langenbeck ligatured these vessels with an interval of but a few minutes between each operation. 3. When the two carotids are ligatured, *with an interval of some days or weeks*, the operation is not more frequently followed by cerebral disturbance than when only one is tied.

The symptoms arising from this cause are either *immediate* or *remote*. The first are syncope, trembling, giddiness, impairment of sight, and hemiplegia—then the remote symptoms appear, which are such as result from impairment of the nutrition of the brain and softening of that organ, ending generally in convulsions, paralysis and death.

**THE EXTERNAL CAROTID ARTERY.**—This vessel extends from the division of the primitive carotid, opposite the upper border of the thyroid cartilage, to the neck of the lower jaw, where it divides into its two terminal branches, the temporal and internal maxillary. *In front* of it, crosses the posterior belly of the digastric and the stylo-hyoid and platysma myoides muscles. The facial nerve passes over its upper part while in the parotid gland, and the hypoglossal nerve over its lower part near its origin. *Behind* it, is the internal carotid artery,

---

† The Science and Art of Surgery. London, 1861.

with the glosso-pharyngeal nerve, the stylo-glossus and stylo-pharyngeus muscles and part of the parotid gland intervening. It has been divided into *three stages*: 1st, below the digastric muscle; 2d, from this point to the parotid gland; and, 3d, where it is lodged in that gland. The vessel is seldom tied in its third stage, except during extirpation of the parotid, or in an open wound. In the first or second stage, it may be tied in the following manner:

*Operation.*—The patient must be placed in the position for ligating the primitive carotid. Make an incision, about three inches in length, through the skin, platysma and fascia, extending from beneath the lobe of the ear downwards towards the cornu of the os-hyoides. This is in the direction of, and overlying, the digastric muscle, and will expose it. The muscle guides the operator at once to the artery, which may be brought into view, either above or below it, by a little dissection. The hypoglossal nerve should be carefully avoided in every stage of the operation, and the needle introduced from without inwards. The external carotid should only be tied for a wound of that trunk itself, and then two ligatures should be applied. The operation is seldom performed, on account of the numerous branches of the vessel rendering it unfavorable for the formation of a clot.

**THE SUPERIOR THYROID ARTERY.**—This artery arises from the external carotid, a little below the cornu of the os-hyoides. It first passes upwards and inwards, then curves downwards and forwards, by the inner side of the common carotid artery, to the edge of the thyroid body, in which it is distributed. Besides the gland, the superior thyroid sends branches to supply the mucous membrane and muscles about the larynx. It is accompanied, for a short distance, by the *superior laryngeal nerve*, which lies posterior to it, and the *hypoglossal* above it.

*Operation.*—This operation was formerly practised by Sir Everard Home, Walther, Theden, Langenbeck, and others, for the cure of bronchocele, hoping to produce atrophy of the gland. It is now abandoned for this purpose, on account of its invariable failure. In case of wound, it may be performed as follows: The head is extended; make an incision, about two inches in length, along the internal border of the sternomastoid muscle, letting the centre of it correspond with the cornu of the thyroid cartilage. By this, the skin, platysma

and fascia are divided. The sterno-mastoid may be drawn outwards, exposing the omo-hyoid muscle, underlying which are the sheath, and its contents, of the primitive carotid artery. The artery we are seeking lies, in this situation, between the carotid sheath and the lobe of the thyroid gland. It should be carefully isolated with the point of the director and ligated in the usual manner.

**THE LINGUAL ARTERY.**—The lingual artery has a very tortuous course from its origin, on the inner side of the external carotid, to the base of the tongue, when it becomes the ranine artery. It first ascends somewhat obliquely to reach the cornu of the os hyoides, along which it runs parallel for some distance under the hyo-glossus muscle, when it ascends to the base of the tongue. In this course, it is covered by the tendon of the digastric and the stylo-hyoid muscle; then by the hyo-glossus, which separates it from the hypo-glossal nerve; and in the third part of its course, it rests between the hyo-glossus and genio-hyo-glossus muscles.

*Operation.*—First find the position of the cornu of the os hyoides; make an incision, somewhat over an inch in length and about half an inch above it, through the skin, cellular tissue and platysma; this incision will expose the lower border of the submaxillary gland, under which the shining tendon of the digastric may be seen; less than a line below this, lies the hypoglossal nerve. Now look for the outer border of the *hyo-glossus muscle*, pass a director carefully under it, and make a transverse incision through its fibres, when the artery will be exposed in a situation in which it is unaccompanied by any nerve or vein. The needle may be passed under it from either side. The main point to be recollected in reaching the vessel is, that it is under the hyo-glossus muscle, parallel with and a little above the cornu of the os hyoides.

*Explanation.*—Plate V. figure 23, represents the operation above described. The hypoglossal nerve is seen running parallel with the artery, but superficially to it and to the hyo-glossus muscle, which has been divided; *a*, refers to the artery, with the ligature passed under it.

**THE FACIAL ARTERY.**—The facial or external maxillary artery passes forwards from its origin, a little above the lingual, and becomes embedded in the submaxillary gland. It then curves around the body of the lower jaw, close to the anterior inferior angle of the masseter muscle, where it may be felt

beating during life or effectually compressed in hemorrhage; ascending to the angle of the mouth and thence to the cornu of the eye, it becomes the angular artery. The facial vein lies to its outer side.

*Operation.*—In case of wound, the artery may be ligated below the jaw, either before or after it enters the submaxillary gland, by enlarging the opening and seeking for the vessel within the border of the inferior maxilla. It is more frequently tied, as it passes over the ramus, at the foot of the masseter muscle. Feel for the pulsation, and then make an incision a little over an inch in length obliquely over the course of the vessel, dividing the skin, fascia and platysma—using the director, if necessary, to divide the fibrous tissue surrounding the vessel. Pass the needle from without inwards.

*Explanation.*—Plate V. figure 24: *a*, the masseter muscle; *b*, the vein; *c*, the facial artery, with filaments of the portio dura passing over it and the ligature passed under it.

**THE TEMPORAL ARTERY.**—The temporal is one of the terminal branches of the external carotid. It arises opposite the neck of the lower jaw, in the substance of the parotid gland, passes over the zygoma, in front of the ear. It shortly divides into an anterior and posterior branch, anastomosing with the occipital and opposite temporal.

*Operation.*—Find the vessel by its pulsations just in front of the external ear, a little above the zygoma; make an incision, about an inch in length, through the skin, in the direction of the artery; divide the dense cellular tissue on the director, and introduce the needle from without inwards, avoiding the vein and neighboring nerve.

*Explanation.*—Plate V. figure 24: *a*, the temporal artery exposed, with ligature passed; *b*, the temporal vein.

**THE OCCIPITAL ARTERY.**—This vessel arises from the back part of the external carotid, opposite the facial. The hypoglossal nerve hooks round it near its origin, about opposite the angle of the jaw. The artery passes behind the parotid gland, under the posterior belly of the digastric and trachelo-mastoid and sterno-mastoid, and ascends between the splenius and complexus, from under the posterior border of which it emerges, to perforate the trapezius and supply the back of the head. The vessel, like the temporal, can be easily compressed and

seldom requires ligation in the scalp. It is tied in two other places :

I. AT ITS ORIGIN.—It is in relation here with the hypoglossal nerve, and lies under the stylo-hyoid and digastric muscles.

*Operation*—Make an incision, about two inches in length, along the upper portion of the inner border of the sternomastoid muscle. Divide the deep fascia carefully on a director, expose and isolate the artery carefully, avoiding the hypoglossal nerve.

II. BEHIND THE MASTOID PROCESS.—The artery is here covered by the sternomastoid and splenius muscles, and lies in the occipital groove of the mastoid portion of the temporal bone.

*Operation*.—Make an incision through the skin, full an inch and a-half long, half an inch behind and a little beneath the mastoid process, obliquely upwards and backwards; the aponeurosis, sternomastoid and splenius muscles are to be divided, layer by layer, carefully on a director, till the artery is reached. The pulsations must be felt for, as the operation advances. The vessel must be carefully isolated from any branches of the great occipital nerve which may be lying near it.

*Explanation*.—Plate VI. figure 25: *a*, the occipital artery with the ligature passed under it; *b*, the obliquus capitis superior muscle exposed; *c*, the thin tendon of the sternomastoid cut through and drawn apart.

THE INTERNAL CAROTID ARTERY.—The internal carotid artery curves slightly from the bifurcation of the common carotid, and ascends, by the side of the pharynx, to the carotid foramen of the temporal bone. It has *behind* it, the rectus anticus major muscle, the superior cervical ganglion, and the pharyngeal and superior laryngeal nerves; *internally*, is the pharynx, tonsil, and ascending pharyngeal artery; *externally*, the internal jugular vein, the glosso-pharyngeal, pneumogastric and hypoglossal nerves; and, *in front*, the stylo-glossus and stylo-pharyngeus muscles, the stylo-hyoid ligament, glosso-pharyngeal nerve and parotid gland.

A vessel thus deeply situated, is ordinarily equally secure from injury, and out of the reach of the surgeon; its lesion, however, is not an uncommon occurrence, as one of the acci-



dents of battle. Balls entering the mouth frequently divide or open the internal carotid, making their wound of exit near or above the angle of the lower jaw. Though, perhaps, the very most difficult ligation of the whole body, yet the vessel has been reached and secured on several occasions. Mr. Guthrie describes two processes by which the operation may be performed; one from without, by external incision, and the other from within the mouth, by division of the lower jaw. In regard to the first, his remarks are as follows: "The internal carotid, when wounded near the bifurcation of the common carotid, is to be secured by two ligatures, and the steps of the operation are the same as those for exposing the external carotid, the surgeon recollecting that the internal is more deeply seated and to the outside of the external." In case the injury should encroach on the bifurcation, he recommends *three ligatures*, one to each division, and one to the common trunk, considering nothing less sufficient to secure the patient against recurrent hemorrhage.

In regard to the operation recommended below by Mr. Guthrie,\* it may be said that, it is nearly equal to a resection of a portion of the inferior maxilla, yet we subject patients to this constantly, for dangers often much more remote than the fatal hemorrhage which must follow a wound of the internal carotid.

*Operation from within the Mouth.*—An incision is to be begun opposite to, and on the outside of, the extremity of the lobe of the ear, and carried downwards in a straight line, until it crosses a little below the angle of the jaw, at the distance of nearly half an inch, more or less, as may be found most convenient from the form of the neck. This incision exposes the parotid gland without injuring it. A second is then to be made from the extremity of the first, extending at a right angle forwards; under or along the base of the lower jaw, until the end of it is opposite the first molar tooth. This incision should divide the skin, superficial fascia, platysma myoides muscle, and the facial artery and vein. The second molar tooth should then be removed and the jaw sawn through at that part. Then cut through the deep fascia, the mylohyoideus muscle, and the mucous membrane of the floor of the mouth, exposing the insertion of the internal pterygoid muscle,

---

\* Commentaries, page 256.

which is to be divided. The surgeon will next be able to raise and partially evert the angle of the jaw, and thus obtain room for the performance of the remaining part of the operation, which should be effected by the pointed but blunt edge of a scalpel, or other instrument, chosen for the purpose of separating but not cutting. The styloid process of the temporal bone may then be readily felt and exposed, by the separation of a little mucous membrane, and with it the stylohyoid muscle, which is to be carefully raised and divided. The external carotid artery will thus be brought into view, together with the stylo-pharyngeus muscle and glosso-pharyngeal nerve attached to it. These are to be drawn aside by a blunt hook, when, if care be taken to avoid the pneumogastric nerve, the internal carotid artery may be felt, seen, and secured by ligation, with comparative facility, outside the tonsil, there being between them, the superior constrictor of the pharynx, which, in case, of wound through the mouth, must have been divided. The pneumogastric nerve should be drawn outwards, and the external carotid artery also, if in the way. The division of the jaw will not lead to further inconvenience, as the bone always re-unites when divided, with little difficulty.

### Arteries of the Inferior Extremity.

The main artery, supplying the inferior extremity, arises from the aorta, within the cavity of the abdomen, by a common trunk, the primitive iliac, which also supplies parts within, and external to, the pelvis. The crural division, like the main artery of the upper extremity, proceeds as a single vessel, through several successive surgical regions before it divides, receiving from each one a corresponding designation. That portion of the vessel which extends from its origin to the femoral arch, is called the external iliac artery; beyond this line, to the opening in the adductor magnus, it is termed the femoral artery; and from the termination of Hunter's canal, to the lower border of the popliteus muscle, it bears the name of the popliteal artery. The vessel here terminates by dividing into the anterior and posterior tibial arteries for the supply of the tissues of the leg and foot.

**THE DORSALIS PEDIS ARTERY.**—This vessel is the continuation of the anterior tibial upon the dorsum of the foot. It runs along the inner side of the dorsum, from the middle

of the ankle to the base of the metatarsal bone of the great toe.—It here gives off the *dorsalis hallucis* and then dips into the first interosseous space to communicate with the deep plantar arch. In this course, it lies along the outer border of the tendon of the *extensor proprius pollicis* and has the innermost tendon of the *extensor longus digitorum* to its fibular side being crossed, near its termination, by one of the tendons of the *extensor brevis*. It is accompanied by *venæ comites* and has the continuation of the anterior tibial nerve to its outer side.

*Operation.*—Make an incision, about two inches in length, along the external border of the *extensor proprius pollicis* muscle, which line may be made prominent by directing the patient to extend his big toe. The deep fascia should be divided on a director. The artery will be found about a quarter of an inch or more from the outer border of the *extensor proprius* tendon, with a collateral vein on either side and the anterior tibial nerve on its fibular side. Isolate the artery and pass the needle from within outwards.

*Explanation.*—Plate VI. figure 26: *c*, the *extensor proprius pollicis* tendon; *a*, the *extensor brevis digitorum* drawn outwards; *d*, the *dorsalis pedis* artery, with the ligature passed under it; *b*, the *venæ comites*.

**THE ANTERIOR TIBIAL ARTERY.**—This artery passes directly forwards from the bifurcation of the popliteal, through the opening in the upper part of the interosseous membrane of the leg, close to the inner side of the neck of the fibula, thus gaining the anterior aspect of the leg. It then descends inwards in front of, and resting upon, the interosseous membrane, and passes over the ankle-joint, beneath the annular ligament. It here becomes the *dorsalis pedis*, which, as we have seen, crosses the dorsum of the foot near its inner edge and plunges between the first and second metatarsal bones. A line drawn from a little within the head of the fibula, to the base of the great toe, will run nearly parallel to the course of both the anterior tibial and *dorsalis pedis* artery. In its upper third, it is situated between the *tibialis anticus* and *extensor longus digitorum*: lower down, between the *tibialis anticus* and *extensor proprius pollicis*; and just before it reaches the ankle, it is crossed by the tendon of the *extensor proprius pollicis*, and is placed between that tendon and the tendons of the *extensor longus digitorum*. In its course down the leg,

it rests on the interosseous membrane and is bound down to it by a little tendinous arch thrown over it. Its immediate relations are its venæ comites and the anterior tibial nerve. The nerve lies, at first, to its outer side; about the middle of the leg, in front of it; and at the ankle is again on its outer side. This artery, though deeply situated in its upper two-thirds, can be reached in any portion of its course without the division of the muscular fibres—though, to isolate the vessel and introduce the ligature conveniently, it may be necessary to divide the muscles at the point ligated, by a crucial incision. Three operations are described :

I. AT THE LOWER THIRD OF THE LEG.—The artery is here crossed by the tendon of the extensor proprius pollicis, and lies between the tendon of this muscle and that of the extensor longus digitorum. The anterior tibial nerve lies to its outer side. It is here superficial.

*Operation.*—The leg being placed with its anterior surface upwards, the foot is extended so as to make prominent the line of the tibialis anticus. An incision, three inches in length, extending not quite to the annular ligament, is made along the external border of that muscle; carefully divide the deep fascia on the director, find the space between the tibialis anticus and extensor proprius pollicis, flex the foot so as to separate the two muscles with the index finger. The artery, here resting on the anterior surface of the tibia, may be felt pulsating, isolated and secured. Draw the nerve inwards and pass the ligature from within outwards. This place should not be selected for the operation, on account of its proximity to the joint.

II. AT THE MIDDLE THIRD.—Through its upper and middle thirds, the artery lies very deep in the intermuscular space upon the interosseous membrane, is covered by the skin and superficial fascia and the deep fascia, which is very thick and aponeurotic. On its inner side is the tibialis anticus, and externally, the extensor longus digitorum and the extensor proprius pollicis. The nerve is in front and the veins on either side.

*Operation.*—Make an incision, over three inches in length, over the intermuscular space between the tibialis anticus and extensor longus. This line is from an inch to an inch and a-half, varying with the subject and the position incised, from the spine of the tibia. The incision should be carried low

enough to strike the distinct separation of the muscles, so that it may be traced up to the fusion, if necessary. In case it is made higher, the line of fusion of the muscles may be recognized by its whiteness as it runs upwards, uniting their heads. This must be carefully dissected apart down to the interosseous membrane, upon which, first the nerve, and then the artery and its two veins, will be found covered by the tendinous arch before described. The foot must be flexed to relax the muscles, and a crucial incision made across their bellies, if necessary, to give room for the isolation of the vessel. The instrument figured in plate I. figure 7, will be found convenient for a vessel so deeply seated and so overhung by muscles.

*Explanation.*—Plate VI. figure 27: *a*, the skin, deep fascia and muscles drawn outwards to dilate the wound; *b*, the tibialis anticus pressed inwards; *c*, the venæ comites; *d*, the artery. The nerve should be represented smaller, running upon its surface.

III. IN ITS UPPER THIRD.—Here the artery is almost inaccessible, deeply situated between the tibialis anticus and extensor longus digitorum. The muscles are fused together, and the white line between them is the best guide to the artery when the deep fascia has been cut into. The nerve lies to the outer side of the artery and the venæ comites on either side.

*Operation.*—Make an incision, about four inches long, through the integument and superficial fascia, about one inch from the spine of the tibia. Then divide the deep aponeurotic fascia, making a crucial incision in it to allow of its easier separation. Now seek for the white line of the intermuscular septum, which is the first from the tibia. The white line is better marked at the lower part of the incision. The foot should be flexed to relieve the tension of the muscles; these may be separated with the index-finger and held apart with blunt hooks or spatulas. The muscle may be cut across, if necessary, to reach the vessel, which will be found between its veins, with the nerve on the outer side. Pass the needle from without inwards.

In gun-shot wounds near the knee, it is difficult sometimes to determine whether the anterior tibial or upper part of the posterior tibial is injured. The anterior tibial, when severed

very high up, sometimes retracts through the opening in the interosseous membrane, in which case, the membrane should be divided or the artery sought from behind.

**THE POSTERIOR TIBIAL ARTERY.**—The posterior tibial is much larger than the anterior. Beginning at the lower border of the popliteus muscle, it passes obliquely downwards, along the tibial side of the leg, to the concavity of the os calcis, where it enters the sole of the foot, between the two heads of the abductor pollicis muscle, and divides into the internal and external plantar arteries. In this course, it is covered by the intermuscular fascia, which separates it, above, from the soleus muscle, and, below, from the deep fascia and the integument. It is accompanied by venæ comites and by the posterior tibial nerve, which lies to its inner side at first, and to its outer side for the rest of its course. In its upper two-thirds, the vessel is deeply situated, being covered by the gastrocnemius and soleus muscles and the intermuscular fascia above-mentioned. It rests successively on the tibialis posticus, on the flexor longus digitorum, and, below this, on some fat and cellular tissue, which separates it from the tibia and internal lateral ligament of the ankle-joint. Three operations on this artery are usually described :

**I. IN ITS LOWER THIRD.**—The artery here descends at first parallel with the tendo-achillis, but soon diverges from it behind the internal malleolus, and occupies a position midway between the internal malleolus and the os calcis. In the fossa between these two eminences are the following: tibialis posticus tendon, flexor longus tendon, posterior tibial artery and venæ comites, posterior tibial nerve, flexor longus pollicis tendon, plantaris tendon, and tendo-achillis. The skin and a very dense process of the deep fascia covers all these parts. The artery is here comparatively superficial, and may be felt pulsating in the hollow of the heel.

**Operation.**—The limb must be everted and the foot flexed so as to make prominent the tendo-Achillis. Make a somewhat semilunar incision over the course of the artery, and nearly midway between the two bony prominences of the os calcis and internal malleolus, but a little nearer to the ankle. This divides the integument and superficial fascia for about two and a half inches. The deep fascia is then divided on a director, to the same extent. The artery can soon be

brought into view, with the end of the director, in company with its nerve and veins. Secure the vessel by passing the aneurism needle from behind forwards, to avoid the nerve.

*Explanation.*—Plate VI figure 28, Arteries: *a*, the deep fascia; *b*, the posterior tibial nerve; *c*, the venæ comites; *d*, the posterior tibial artery, with the ligature passed under it.

II. IN ITS MIDDLE THIRD.—This is considered quite a difficult operation, as the posterior tibial artery in its upper two-thirds lies very deeply situated between the superficial layer of muscles and in close proximity to the bone. The vessel is very frequently wounded in these situations as an accident of battle, and the hemorrhage is apt to be complicated with diffused aneurism on account of the depth at which the vessel lies and the dense fascia covering it. Re-establishing the track by the introduction of the sound—entering it at one wound and passing it out of the other—we have found, greatly facilitates the finding of the wound in the vessel. The artery here rests, with its two venæ comites, upon the tibialis posticus and flexor longus digitorum, and has the posterior tibial nerve to its outer side, covered by the deep fascia and the gastrocnemius and soleus muscles.

*Operation.*—In case of hemorrhage or traumatic aneurism\* in the middle third of the posterior tibial artery, the vessel must be tied with two ligatures at the point of lesion. The tourniquet must be carefully applied either to the femoral or popliteal artery; then introduce the sound into the track traversing the artery, from one wound to the other, if there are two, giving it in charge of an assistant. The limb having been placed on its outer side, with the knee somewhat flexed, make an incision over four inches in length, according to the extent of the tumor, if there is aneurism. This incision

---

\* We must here explain that the precept, "never ligate an artery unless it bleeds," is not violated by ligating in cases of diffused aneurism before any *external* effusion of blood takes place. In such cases the artery of course is bleeding, only the surrounding tissues retain the effused blood. We always recommend, and have acted upon the principle—*ligation of the vessel as soon as the traumatic aneurism is discovered.* It would be useless to wait for the external bleeding when a trunk of large size is pouring blood into the tissues in the form of a traumatic aneurism. This practice we have pursued both in the case of the posterior tibial in its upper third and also in the femoral artery.

must be made about an inch behind, and along the inner edge of the tibia. It will divide the integuments and probably expose the internal saphena vein, which must be drawn to the inner side; now divide the fascia to the extent of the first incision, exposing the inner edge of the gastrocnemius muscle. This muscle must be raised and drawn outwards, when the origin of the soleus from the oblique line of the tibia will present itself. The artery lies under this muscle and about one inch from the inner edge of the tibia, covered by the deep fascia of the leg. Some recommend now to introduce the director and cut the soleus from its attachment at the oblique line; we prefer the following: make an incision cautiously through to the soleus, about three-quarters of an inch from the edge of the tibia, using the director, if it is thought necessary, to divide the fibres, layer by layer; in doing this, be careful not to mistake the *shining* fibres of the aponeurotic attachment of the soleus for the deep fascia *which is not yet reached* and which has a *pearly* appearance. The soleus having been raised from its attachment, or divided, must be drawn aside. The fingers may be passed now between the two layers of muscles—that is, under the soleus—and the posterior tibial can be felt pulsating under the fascia, provided the accumulation of clotted blood and fibrine do not interfere. The fascia may now be divided on the director, the sound will be seen and the opening in the vessel found, and the aneurism needle passed from without inwards. In case of large accumulations of blood, these must be removed as the operation advances, and the sound felt for on raising the soleus muscle; the wounded artery will be found on the same level with the sound—the sound resting between the two ends of the severed vessel. The posterior tibial nerve on its outer side and the venæ comites must be avoided. From the depth at which the artery lies, and its proximity to the bone, much difficulty is sometimes experienced in passing the ligature. This will be somewhat increased if the artery is completely severed. Each end must be sought for on either side of the sound, seized with the forceps and isolated, and the two ligatures applied.

Mr. Guthrie\* recommends “an incision six or seven inches long through the gastrocnemius and soleus muscles, down to

---

\* Commentaries, page 277.



the deep fascia." This we regard as an unnecessary cutting of muscular fibres, risking a crippling of the limb. When we are certain that the posterior tibial is the artery wounded, it can be more easily reached by the incisions above recommended, and with less injury to the important muscles concerned. If there is *doubt* whether the bleeding vessel be the peroneal or posterior tibial, Mr. Guthrie's recommendation should be adopted. There are two great objections to dividing extensively the muscular fibres: first, the injury to the muscle which, though it finally perfectly recovers, remains a long time stiff and consolidated after being cut; and secondly, to cut through the calf, gives rise to embarrassing hemorrhage during the operation from division of the sural arteries.

*Explanation.*—Plate VI. figure 29, Arteries: *a*, the fascia of the leg; *b*, the venæ comites; *c*, the posterior tibial artery; *d*, the internal edge of the gastrocnemius. The nerve is to the outer side, and pulled out of the way.

III. AT THE UPPER THIRD OF THE LEG.—Quite high up, the artery rests upon the tibialis posticus and is covered by the deep fascia, the soleus and gastrocnemius muscle. The nerve is here to the inner side of the artery and its accompanying veins.

*Operation.*—This operation does not differ greatly from the one just described. Malgaigne's method is thus described by Bernard and Huette: At the distance of two-thirds of an inch from the internal border of the tibia, make an incision at least four inches in length, through the integuments and deep fascia, carrying the index finger into the wound, detach and push outwards the internal head of the gastrocnemius muscle, and divide also the attachments of the soleus, thus exposed, from the posterior surface of the tibia; whilst an assistant keeps this muscle held backwards and outwards with a blunt hook, divide the layer of aponeurosis upon a director and search for the vessel immediately beneath it; lastly, detach the artery and pass the ligature beneath it with the artery needle.

The operation of ligating the posterior tibial *above the ankle*, in the upper part of the lower third is sometimes described as the operation in the *middle* third. The vessel is here easily reached without dividing the soleus; it is here found about three-quarters of an inch from the inner border of the tibia, and the incision is made midway between the internal border

of the tibia and the tendo-achillis. The muscles are drawn outwards, the deep fascia cut through on a director and the vessel secured as in the preceding operations.

**THE PERONEAL ARTERY.**—This artery arises from the posterior tibial a short distance below the popliteus muscle; it is nearly as large as the anterior tibial artery, and passes outwards to the fibula. It then runs downwards along the inner border of this bone to its lower third, being closely applied to the interosseous membrane, and a little above the ankle, it divides into the anterior and posterior fibular arteries. It is very deeply situated, resting on the tibialis posticus muscle, on the inner side of the fibula, and is covered by the soleus, intermuscular fascia and flexor longus pollicis muscle.

This vessel most frequently is injured in gun-shot wounds, the circumstances of which, leave considerable doubt on the mind of the surgeon as to whether the bleeding vessel is the peroneal or the posterior tibial, or sometimes even, the popliteal. In this remark many surgeons of our army will coincide. This doubt existing, it is better to perform such an operation as will admit of the ligation of either the peroneal or posterior tibial, or which, being modified, may be made subservient in reaching the popliteal. The following is Mr. Guthrie's method.\*

*Operation.*—An incision, from six to seven inches long, should be made rather nearer to the inner edge of the leg than to the centre, and should be carried through the gastrocnemius muscle, the plantaris tendon and soleus muscle, down to the deep fascia, under which the arteries lie, with their accompanying veins, having the posterior tibial nerve on the fibular side of the artery. If the incision is made in the upper part of the calf of the leg, the *peroneal artery* will be exposed by it; but if it be certain that the peroneal is the vessel injured, the incision should be made towards the fibular side of the leg. When the fascia has been divided the peroneal artery will be found covered by the fibres of the flexor longus pollicis muscle at any distance, below three inches and a half, from the head of the fibula. These fibres being divided, the artery will be found close to the inner side of the bone. Above that part, the peroneal is under the fascia and upon the tibialis

---

\* Commentaries, page 277.

posticus muscle. It has no accompanying nerve. Both arteries will be readily found by either of the incisions if the surgeon be acquainted with their situation.

**THE POPLITEAL ARTERY.**—The popliteal region is a diamond-shaped space, comprehending about the inferior fourth of the thigh, and superior sixth of the leg on their posterior aspect, formed by the approximation, base to base, of two triangles, the one above caused by the divergence of the hamstring muscles, and that below by the union of the two heads of the gastrocnemius. Stretched between the boundaries of this space, are the skin, the superficial fascia and the deep fascia, and beneath this last a large quantity of fat, in which the vessels and nerves of the region are embedded, besides a number of lymphatic glands. The popliteal artery, the continuation of the femoral, enters this space from above, through the opening in the adductor magnus, and with its accompanying vein, joins the nerve and descends through the centre of it into the leg. When at the lower border of the popliteus muscle, it terminates in the anterior and posterior tibial arteries. In the cellular tissue under the skin, the external saphena vein ascends through the middle of the space, and perforating the deep fascia, terminates in the popliteal vein. Besides cutaneous branches of nerves and the veins, the relation of the more important of the contained parts to each other is the following: 1st, the *popliteal artery* traverses the space resting on the posterior surface of the femur and ligament of the knee-joint; 2d, the *popliteal vein*, superficial and a little external to the artery, and closely united to it by dense areolar tissue; 3d, the *internal popliteal nerve*, the continuation of the sciatic, crosses both vessels, superficially and obliquely, from the superior external, to the inferior internal boundary of the space. With the patient in the prone position, the order of superposition is: saphena vein, popliteal nerve, popliteal vein, and lastly, popliteal artery. This artery may be ligated by the following operations:

I. *By Lateral Incision.*—This method proposes to reach the popliteal artery under the inner margin of the gastrocnemius muscle.

*Operation.*—Place the patient on his back or side, with the limb abducted, slightly flexed and laid on its outer border, the knee being supported by a pillow. Now find the groove be-

tween the inner border of the gastrocnemius and the internal margin of the tibia. In this groove, make an incision, three inches in length, beginning just below the tendons of the inner ham-string muscles; the internal saphena vein and nerve, being exposed, are drawn forwards, and the superficial fascia and the deep-seated thick aponeurosis of the leg are divided on a director. The internal head of the gastrocnemius, now exposed, is to be separated and drawn strongly outwards. At about the depth of an inch, the popliteal artery may be found. The vein lies nearest, the artery being to the external side, the nerve being behind them both. The vein should be separated from the artery and carefully drawn backwards and outwards by the fingers of an assistant. The artery may now be felt and seen resting on the popliteus muscle, where it may be raised and the ligature applied.

*Explanation.*—Plate VI. figure 30, Arteries: *a*, the internal edge of the gastrocnemius muscle; *c*, the popliteal vein, drawn backwards and outwards; *e*, the popliteal nerve; *d*, the popliteal artery, with ligature under it; *f*, the internal saphena vein, exposed by the incision in the skin.

The artery is tied in two places, above and below, by posterior incisions:

II. The vessel should never be interfered with in this situation, unless wounded and bleeding, on account of the depth at which it lies and its proximity to the knee-joint.

*Operation.*—The patient should be laid on his face, with the limb extended. The bleeding and the pulsations will point to the exact situation of the artery, between the two heads of the gastrocnemius muscle. Make an incision; about three inches long, somewhat external to the median line. The integument and superficial fascia, having been divided, the external saphena vein and nerve are to be avoided and drawn aside; carefully divide the deep fascia on a director and draw apart the heads of the gastrocnemius muscle; first the nerve, then the vein, and, lastly, *the artery*, will be found deeply situated and surrounded by fat and cellular tissue. The nerve in this situation should be drawn inwards and the vein outwards, in order to introduce the ligature.

*Explanation.*—Plate VII. figure 31, Arteries: *a*, the deep fascia divided—exposing (*c*) the popliteal nerve, (*b*) the popliteal vein, and (*d*) the popliteal artery, somewhat external

and most deeply seated; *f*, the external saphena vein, penetrating the deep fascia and winding round the nerve to empty into the popliteal vein.

III. IN ITS UPPER THIRD—The vessel here enters the popliteal space, from the inner side of the thigh, and lies along the outer side of the inner ham-string. The nerve is external and superior to it, and the vein rather upon its inner side, but superficial to the artery.

*Operation.*—The most convenient posture for the patient is on the face. Make an incision, three inches in length, along the outer border of the semi-membranosus muscle, through the skin and superficial fascia; divide the deep fascia, as before, on a director; flex the leg, to relax the tension of the parts; feel for the artery along the inner ham-string; the nerve will first be found, then the vein, and, lastly, the artery. Isolate the vessel with the fingers and director, and introduce the ligature from within outwards.

In connection with wounds of the popliteal artery, it may be well to remember, that the dense aponeurotic popliteal fascia has the effect, by the resistance it offers, of preventing the enlargement of aneurismal tumors posteriorly, and they are forced to ascend into the lower and inner part of the thigh. Popliteal abscesses, also from this cause, point in the above region.

THE FEMORAL ARTERY.—The external iliac, emerging from beneath Poupart's ligament, assumes the name of the femoral artery. It then passes obliquely downwards, backwards and inwards—at first being superficial, but gradually becoming more deeply seated—till, at the junction of the middle and lower thirds of the femur, it passes through the tendinous opening of the adductor magnus, where the vessel again changes its name to that of the popliteal artery. The artery in this course bi-sects the isosceles triangle, called Scarpa's, formed externally by the sartorius muscle and internally by the adductor longus. It is covered by the skin, superficial and deep fascia of the thigh, and has enclosed with it, in a dense sheath, which is a prolongation of the abdominal fasciæ, the femoral vein and internal saphenous nerve, a branch of the anterior crural. Below, the vessel is covered by the sartorius muscle, and soon after enters Hunter's canal, to pass through the opening in the adductor magnus. A line drawn from the centre of Poupart's ligament, to the inner

surface of the internal condyle, will very nearly indicate the course of the artery. The femoral is accessible in any portion of its course. The following are the operations thought worthy of description :

I. **IN HUNTER'S CANAL.**—For a case of popliteal aneurism, Mr. Hunter first tied the femoral artery in the tendinous canal, formed between the adductors and vastus internus muscle. The operation at this point, though abandoned at the present time for aneurism, is often required for hemorrhage from gun-shot wounds. It is more difficult than that in Scarpa's triangle, but, in case of hemorrhage, there is no choice.

*Operation.*—The limb should be placed in the semi-flexed position and turned on its outer side. Make an incision, about four inches in length, along the anterior margin of the sartorius muscle as it winds over the internal surface of the thigh. The internal saphena vein must be sought for by pressure above; it lies a little internal to the line of incision. The integuments and superficial fascia are cut through, and the fascia lata divided on a director. The anterior margin of the sartorius will be exposed; draw the muscle to the inner side, and the tendinous wall of Hunter's canal will be seen stretching from the adductor longus to the vastus internus muscle; introduce carefully the groove director, and cut through the tendinous fibres. The nerve will be found in front of the artery and the vein behind it. The union between the artery and the vein at this point is very intimate; they should be cautiously separated and the aneurism needle passed round the artery, excluding the nerve. The anastomotica magna artery sometimes may be wounded in this operation. It should be tied to avoid the embarrassment its bleeding would occasion. If the femoral is wounded in the canal, both ends should be secured, as the free anastomosis with the popliteal, just below this point, through the articular arteries, will ensure recurrent hemorrhage.

*Explanation.*—Plate VII. figure 32: *a*, the fascia lata divided; *b*, Hunter's canal laid open; *c*, the sartorius muscle, drawn upwards and outwards; *d*, the femoral artery, lifted on a director, with the ligature passed under it.

II. **NEAR THE APEX OF SCARPA'S TRIANGLE.**—The vessel here begins to be over-lapped by the sartorius muscle, and is somewhat more deeply seated than in the middle and upper

part of the thigh. The femoral vein is here behind it and somewhat to its outer side, the long saphenus nerve is closely applied to the artery, within the sheath, rather upon its anterior and internal side, and a pretty large *muscular branch* of the anterior crural, supplying the vastus internus, follows the course of the vessel on the surface of the sheath. The skin, superficial fascia and fascia lata cover the region, and the trunk of the saphena vein generally runs immediately in the line of the incision.

*Operation.*—Place the limb on its outer side, with the leg semi-flexed and the thigh a little elevated; make an incision, about four inches in length, along the line of the artery, being guided somewhat by the prominence of the sartorius muscle, through the skin and superficial fascia. The saphena vein, which now appears, must be avoided. Open the fascia lata and introduce the director, dividing it in the line of the first incision. The inner border of the sartorius muscle will be exposed, overlying the artery; lift this out of the way, if necessary, and divide the deep layer of its sheath on a director, if it obscures the vessels. The sheath of the femoral vessels will now appear, with a muscular branch of the anterior crural nerve lying upon it; avoid this and carefully open the sheath, introduce the director and slit it a few lines; feel for the pulsations of the artery and introduce the needle from within outwards, avoiding injury to the vein, and excluding the long saphenus nerve from the ligature.

III. AT ITS MIDDLE AND UPPER PORTION.—The relations of the vessel do not differ materially in the middle and upper portions. The sartorius, while it can still be used as a guide, being the outer boundary of Scarpa's triangle, no longer serves as the directing line for the incision. The true line is found midway between the sartorius and adductor longus muscle—from the middle of the base, formed by Poupart's ligament, to the apex of the triangle at the crossing of the two muscles. The saphena vein—always directly in the way—runs, here too, along the course of the artery, superficial to the fascia lata.

This is a region very much exposed in action, and the artery is here constantly found wounded in the course of ball-tracks traversing the limb in every variety of direction; direct, oblique, transverse, and sometimes longitudinal tracks plough through the artery and leave wide gaps between the proximal

and distal ends. From the denseness of the fascia lata, and probably from the fact that many of the wounds are received when the soldier is advancing, the anterior muscles contracted, preventing the track from being uniform, arterial wounds in this region are frequently complicated with diffused aneurism, obscuring the relation of parts and increasing the difficulties attending ligation. The importance of using the sound to re-establish the track, in searching for the arterial lesion, as described in a former paragraph,\* apply usefully, we think, to the present region. To economize space, we here describe the simple operation.

*Operation.*—Place the patient in the recumbent posture, the limb being in a state of easy extension, rotated somewhat outwards and a little abducted. The course of the vessel being ascertained—by its pulsation or by rule—an incision, four inches in length, is made through the middle of Scarpa's triangle, beginning one or two inches, according to the situation of the wound, below Poupart's ligament. This divides the skin and superficial fascia, and, if high enough, exposes the superficial lymphatic glands of the groin. The internal saphena vein is more conveniently left in the internal side of the incision. Separate the edges of the wound and expose the fascia lata; open into it, introduce the director and divide upon it, the fascia to the full extent of the first incision. By the use of blunt instruments and sponges, the sheath of the vessels will soon be brought into view and the pulsations of the artery felt on relaxing the tourniquet. Pinch up a portion of the sheath with the fingers, to the outer side of the artery; make a small opening in it—unless, in case of wound, there is one—introduce the director through this and slit the sheath for a few lines. The femoral artery being thus exposed, it should be carefully isolated from the vein on the inner side and the saphenous nerve on the outer side,† and the ligature passed from within outwards.

*Explanation.*—Plate VII. figure 33, Arteries, exhibits the

\* Re-establishing the track, page 123.

† Expressions of pain on the part of the patient, when the ligature is tightened, are no certain indication that the nerve is included. The artery *itself* is sensitive. We scarcely ever ligate for secondary hemorrhage, when there is always more or less arteritis near the wound, that the patient does not manifest pain, unless deeply quieted by anæsthetics.



operation somewhat higher up than described above, the artery being represented too near the sartorius muscle for the region figured: *a*, the fascia lata divided; *b*, the sartorius muscle; *c*, the femoral vein; *d*, the femoral artery, with the ligature passed.

IV. BENEATH POUPART'S LIGAMENT.—The relations of the femoral artery, under Poupart's ligament, are the following: The vessel passes from the abdominal cavity under the centre of Poupart's ligament, enclosed in a dense infundibuliform sheath, derived from the abdominal and pelvic fasciæ. The artery is placed externally to the vein, with fibrous septa separating them from each other and the vein from the crural ring. The anterior crural nerve passes out half an inch externally to the artery, but a branch of the genito-crural nerve passes out upon its upper surface. In addition to the fascia superficialis and lata, the vessels are overlain in the groin, with quantities of loose cellular tissue and fat, besides numerous lymphatic glands. The pulsations of the artery are here, however, more distinct than elsewhere. The proper sheath of the vessels is, for some distance down the limb, larger than its contained structures. The trunk here passes over the pubic bone.

*Operation.*—Place the patient on his back, with the pelvis a little elevated and the thigh somewhat extended. The position of the artery being determined by rule and by its pulsations, the surgeon makes an incision, from two to three inches, in the course of the artery, beginning at the middle of Poupart's ligament; this divides the skin, superficial fascia and fat, and exposes the lymphatic glands—perhaps cuts one or two of them, which does no particular harm. Profuse bleeding is apt to follow this incision, from the numerous small vessels here given off from the femoral; these should be tied or twisted, and the fascia lata carefully opened and divided on a director—here, another bleeding is apt to occur—the deep external pudic lies generally under the fascia lata and is apt to get on the director. The funnel-shaped sheath of the vessels, formed by the descending abdominal fascia, is now exposed. This should be carefully opened in front of the artery on a director; the proper use of blunt instruments will now easily isolate the artery, when the ligature may be applied, without endangering the vein, or including the filament of the genito-crural nerve generally, closely connected with

the artery. The anterior crural nerve is not usually endangered in the operation, as it is ordinarily half an inch external to the artery, in the groove between the psoas and iliacus muscles.

*Remarks*—The operation just described, while it is sufficiently easy of performance, is yet one of the most dangerous—indeed, fatal—of all the ligations of the lower extremity. Military surgeons are compelled to ligate arteries at the seat of lesion often, even when the chances of success are of the faintest kind; we cannot, therefore, fully coincide with Mr. Erichsen in saying that ligations of the common femoral should be banished from surgery. The operation, however, should never be performed when it can possibly be avoided. The causes of its almost constant unsuccess are of two classes: 1st, failure in formation of internal clot, endangering, in so large a vessel, fatal subsequent hemorrhage;\* and 2d, failure of collateral circulation ensuring fatal gangrene of the entire limb. This artery, both before and after its exit from the abdomen, gives off a number of vessels, which endanger the success of ligation at this point; above Poupart's ligament, the deep circumflexa ilii and deep epigastric, and also, sometimes, the obturator, as branches of the external iliac. Just after the trunk has passed the crural arch, numerous vessels also spring from it: the superficial epigastric, and the superficial and deep external pudic arteries, all have their origins clustering around the point, where the clot would have to form; and, if arrest of blood-movement is necessary for the formation of a coagulum, we certainly cannot expect one under such circumstances. Of twelve cases on record, in which the common femoral was tied, only three were successful; all the other nine being followed by secondary hemorrhage. Most of these twelve cases underwent the ligation for *spontaneous aneurism*, which dis-

---

\* We are perfectly familiar with Mr. Guthrie's original observations and ingenious reasoning on the subject of the internal coagulum and the healing of the arterial coats after ligation. "A coagulum," says he, "contrary to the usually received opinion, is not necessary to the permanent closure of the artery, though it certainly assists in maintaining it." The question is otherwise determined by statistics, however, at least in regard to this particular artery at the region in question; and while we regard Mr. Guthrie's discovery and doctrine on this subject as of high value, we cannot deny that it seems to fail in application to the present case.

ease, from its long obstruction to the main channel, fully establishes the collateral circulation, and obviates, in a great measure, the danger of a deficient blood-supply.

But, in cases of *hemorrhage*, with which the military surgeon has almost exclusively to deal, there is a more immediate and more inevitable disaster attending this ligation, than any failure of occlusion at the point of ligature—almost certain and fatal gangrene of the entire limb. The vessel in this case is here blocked up above the origin of both the great nutrient channels of the extremity. There is no profunda now left to re-inforce the obstructed superficial femoral, and the lesser avenues of collateral supply, thus suddenly called upon, cannot be soon enough dilated to furnish an adequate supply for so large and, in great part, so distant a region. That innervation necessary to blood-movement fails for want of the normal stimulus of nutrition, a universal paralysis of the circulation takes place throughout the limb, even the veins seem to fail to return the blood; general œdema takes place, the surface becomes cold and mottled, and a progress of degeneration, both local and constitutional, the most rapid that can be described, soon terminates the case.

The present war has doubtless afforded, in many instances, the undesirable opportunity of witnessing the results above described where ligation of the common femoral was unavoidable. At the present moment the notes of only our own cases are before us. We mention them briefly in view of the paucity of records on this subject in surgical works. These are two cases in which we were called in consultation and requested to operate. One in General Hospital No 13,\* the other in the First Georgia Hospital.† In both of them, the circumstances of the hemorrhage, it seemed to all present, were such as to preclude the adoption of any other measure than the one practised. Both were cases of comminuted fracture in the upper third of the femur; there was great tumefaction in the limb above the injury; both patients had been greatly exhausted, and the hemorrhage proceeded from a wound of the femoral, near the seat of fracture. The condition of each of these patients was plainly such as to forbid either, ligation at the seat of injury or ligation of the external

---

\* In charge of Surgeon W. D. Hoyt.

† In charge of Surgeon J. A. S. Milligan.

iliac, or the amputation of the limb; any one of which three alternatives, though more formidable in the first place, would have been gladly preferred by us, if practicable. The result of both operations—for they were much alike in all important points—has been faithfully described in the foregoing paragraph.

**THE PROFUNDA ARTERY.**—This vessel, when bleeding, should be cut down upon and tied with two ligatures, and the attempt should not be made to arrest the hemorrhage by ligating the common trunk, above it.\* The deep femoral is nearly as large as the superficial, and arises from the outer and back part of the common femoral, about one or two inches below Poupart's ligament. It first runs along the outer side of the sheath of the femoral vessels, but after some distance, passes beneath it and beneath the femoral vein, to the inner side of the femur, finally, passing through the adductor magnus. It rests, first on the iliacus, then on the adductor brevis, and lastly on the adductor magnus muscle. It is covered by the superficial fascia and the fascia lata, and has passing over it, a number of branches of the anterior crural nerve. Ligation of the profunda is seldom described in surgical works from the fact that it is not often the subject of spontaneous aneurism. As it is apt to require ligation in gun-shot wounds, we describe the operation as we have performed it in one case of hemorrhage, that of a wounded soldier in the First Georgia Hospital, and repeatedly, but a few hours ago, on the dead subject.

*Operation.*—Place the patient in the recumbent posture, with the thigh extended and somewhat abducted. An incision, beginning just below Poupart's ligament, and extending

---

\* Finding no satisfactory description of this operation, and having performed it but once, we made three dissections, with the view of securing accuracy in our description. The relation of the profunda, to the *femoral sheath* and to the *lash of anterior crural nerves*, did not vary, but, in the two subjects examined, the point at which the common femoral bifurcated did not agree—in one only an inch, and in the other, nearly two inches, from the crural arch. We also proved the practicability of Mr. Guthrie's proposition to ligate the internal carotid by dividing the lower jaw. The stylo-hyoid ligament was much in the way, but did not actually require division. It seemed more convenient also to draw the *par vagum outwards*, instead of inwards, as Mr. Guthrie recommends. We think the internal pterygoid should be spared, if possible.

fully four inches down the thigh, should be made, as if to expose the common and a portion of the superficial femoral artery, *except* that to expose the profunda, the incision should be somewhat more external, its whole course being kept to the outer side of saphena vein. The superficial and deep fascia are now divided in a director. The fasciæ and integument being held apart with bent spatulas, the sheath of the common femoral will appear in the centre of the wound. Feel now, first for the pulsations of the femoral, and then, less than half an inch external to it, for the profunda. This latter pulsation will be found generally, to begin at little over an inch from Poupart's ligament. Only blunt instruments should now be used to search for the vessel. The cellular tissue immediately around the profunda is quite tough and dense. We first come across many branches of the anterior crural nerve, running nearly parallel with the vessel, and rather external to it; by continuing the search between these branches and the femoral artery, we soon expose the trunk of the profunda. The isolation may be carried up to its origin or down the thigh, past the point where the two circumflex vessels are given off—but the situation of the wound must determine the point at which to apply the ligatures. The needle should be introduced from within outwards to avoid the femoral vein and profunda vein which are on the inner side and somewhat in front of the artery. The branches of the anterior crural nerve are easily excluded. Assisted by the sound in the track, the operation is even more simple than above described, unless the vessel be wounded very deeply in the neighborhood of the bone.

**THE EXTERNAL ILIAC ARTERY**—The external iliac artery, on each side, passes obliquely downwards and outwards from the division of the primitive iliac, along the inner border of the psoas muscle as far as Poupart's ligament, where it becomes the femoral artery. In this course the external iliac vessels are behind the abdominal muscles and the peritoneum and are enveloped by a thin layer of fascia derived from the iliac fascia, serving as their proper sheath. The artery is crossed at its *commencement* by the ureter, and near Poupart's ligament by the genital branch of the genito-crural nerve and by the circumflex ilii vein. It is separated *externally* from the psoas muscle by the iliac fascia; and *posteriorly*, it is in relation with the external iliac vein, which, at Poupart's lig-

ament, lies on its inner side. Lymphatic vessels and a few glands lie in the course of the artery. The trunk is free from branches till about to pass under the femoral arch when it gives off two of considerable size, the deep epigastric and deep circumflexa iliac. The course of the external iliac is indicated by a line drawn from a point a *little external to the umbilicus* to a point midway between the anterior superior spinous process of the ilium and the symphysis pubis.

There are several methods of operating recommended, but only two can be said to be of frequent practice—the one originally practised by Mr. Abernethy, and the other that of Sir Astley Cooper. The original operations are seldom performed without some modification, yet one or other of the two methods is generally adopted.

*Mr. Abernethy's Method.*—The patient should be laid on his back, but a little inclined to the opposite side, that the intestinal mass may gravitate away from the region to be operated on; the shoulders should be elevated and the limbs somewhat flexed. Make an incision three and a half or four inches in length in the course of the artery, beginning on a plane somewhat below and external to the umbilicus. This will be nearly perpendicular to the centre of Poupart's ligament, terminating about half an inch outside the external abdominal ring, falling short of the ligament. The skin and superficial fascia having been cut through, the external oblique should be divided on a director. The instrument should now be passed beneath the lower edge of the internal oblique and transversalis muscles, and these divided successively and cautiously to the extent of the first incision. The transversalis fascia being thus exposed, must also be similarly divided. The peritoneum now being reached, must be gently raised with the fingers, out of the iliac fossa, and pressed inwards toward the linea alba, when the artery will be felt pulsating along the inner side of the psoas muscles. The vessels are enveloped in a dense cellular membrane connecting it with the vein on the inner side; this must be torn through with the nail and the aneurism-needle passed between the vein and artery, and the point made to emerge on the outer side of the latter. It is safest to secure the vessel at some distance above the origins of the epigastric and circumflexa ilii arteries. The anterior crural nerve is out of the way, being on the outer edge of the psoas muscles.

*Sir Astley Cooper's Method.*—The patient being placed in a position somewhat similar to the above, a similar incision, about four inches in length, is made, with its concavity directed upwards and inwards towards the umbilicus. This should extend from a little above and internal to the anterior superior spinous process of the ilium to the outer side of the external abdominal ring; by this, the skin and superficial fascia are divided and the external oblique tendon exposed. Make a hole in this, external to the outer column, and divide it on a director, thus exposing the inguinal canal, and the lower edge of the internal oblique and transversalis may be pushed upwards. The internal abdominal ring being now brought into view, is gently dilated and the finger, passed through this space, is directly applied upon the artery above the origin of the epigastric and circumflexa ilii arteries. It is recommended to introduce the ligature from without inwards in the operation, but Mr. Guthrie prefers that it should be applied from within outwards, as he has seen the vein injured by the opposite proceeding.

*Explanation.*—Plate VII. figure 34, does not represent either of the above operations, but a modification described by Bernard and Huette: *a*, the internal oblique and transversalis muscles divided; *b*, the external iliac artery, with the ligature under it, and the vein to its inner side; *c*, the aponeurosis of the external oblique divided; *d*, the peritoneum pressed towards the median line. See also figure 35, plate VIII. for the anatomical relations of this vessel, and for the several lines of incision: *a*, Mr. Abernethy's line of incision; *c*, Sir A. Cooper's line of incision; *b*, dotted, showing Bogros's line of incision; *f*, the external iliac.

The points chiefly to be guarded against in ligation of the external iliac are: wound of the epigastric artery, or of some of the constituents of the spermatic cord, or laceration, or too great disturbance of the peritoneum, or puncture of the external iliac vein, or including the genito-crural nerve in the ligature. The epigastric, if wounded, can be secured, but its ligation would close, as remarked by Dr. Holmes,\* an important anastomosis, and the chance of gangrene would be increased, though Mr. Guthrie† thinks it is not a very serious matter.

\* Op. citat. volume iii. page 515.

† Commentaries, page 269.

**THE EPIGASTRIC ARTERY.**—This artery arises from the inner side of the external iliac, near Poupart's ligament and passing inwards between the peritoneum and transversalis fascia, it ascends to the margin of the sheath of the rectus abdominis muscle, and passes up the abdomen, in a line drawn from a point a little external to the umbilicus to about the middle of Poupart's ligament. It is behind the inguinal canal and on the inner side of the spermatic cord at the internal abdominal ring. The operation for its ligation resembles somewhat that for reaching the external iliac, though it is not so extensive.

*Operation.*—An incision about two inches long should be made parallel with and a little above Poupart's ligament. The centre of this incision should be at an equal distance from the spine of the ilium and symphysis pubis. The skin and cellular tissue being divided, introduce a director and divide the aponeurosis of the external oblique in the same direction. Follow the spermatic cord to the internal abdominal ring, which must be dilated with the finger. The epigastric may be felt on its inner edge; it has a vein on either side of it. The cord may be pressed a little outwards and the artery isolated and secured in the usual manner.

**THE PRIMITIVE ILIAC ARTERY.**—The common iliac arteries, the terminal branches of the abdominal aorta, are about two inches in length, and extend generally from the body of the fourth lumbar vertebra, divergently at each side, to the margin of the pelvis, opposite the sacro-iliac symphysis, where they each divide into the internal and external iliac arteries. The relations of the two vessels differ on the two sides of the body. The *right* is in relation in front with the peritoneum, and is crossed at its bifurcation by the ureter, behind with the two common iliac veins, and externally with the psoas magnus. The *left* is also in relation in front, with the peritoneum and ureter, but, in addition, is crossed by the rectum and superior hemorrhoidal artery. It is in relation only with the left iliac vein, which is behind it, and with the psoas muscle externally. Gun-shot wounds of the primitive iliac are generally immediately fatal, only the fortunate accident of traumatic aneurism ever allowing the opportunity for ligation as a result of such injuries.

*Operation.*—Place the patient in a position similar to that in which the external iliac is tied. Make a slightly curved



incision four or five inches in length, extending one half above, the other half below the anterior superior spinous process of the ilium. This divides the skin and superficial fascia down to the external oblique muscle, and should commence nearly on a level with, and external to, the umbilicus. The muscles should then be carefully cut through in succession on a director till the fascia transversalis is arrived at; this also must be very cautiously opened and the director slipped between it and the peritoneum, so as to divide it to the requisite extent. Now draw the peritoneum upwards and inwards, towards the umbilicus. The *ureter* should be raised with the peritoneum from over the vessels that it may be out of the way of the ligature. The common iliac artery may now be felt and seen, if the wound is properly held apart; the vessel should be carefully isolated, with the fingers, and the aneurism needle passed from within outwards on the left side, and from without inwards on the right, to avoid injury to the vein in its varying relation to the artery on the two sides. The ligature should be applied a short distance—little over half an inch—above the bifurcation of the trunk. See plate VIII, figure 35: *d*, the common iliac; *r*, line of incision for common iliac.

The exact location of the incision, so far as reaching this artery or the external iliac, is not of vital importance, but it is best not to make it too perpendicular on account of the bulging or the bag of the peritoneum with the intestines, which seems greater as the incision approaches the median line. The quill-suture or silver wire, will be found the best mode of stitch to be used in closing these wounds.

**THE ABDOMINAL AORTA.**—The aorta enters the abdomen between the two pillars of the diaphragm. In its course downwards it rests on the vertebral column to the left of the median line terminating on the fourth tendon vertebra, in the common iliac arteries. It has the vena cava on its right side, and on its left side a number of veins and sympathetic nerves. The vessel has been exposed and ligated, as is well known, by Sir Astley Cooper and several other surgeons—each time with a fatal result.

**Operation.**—The vessel could be reached by an incision similar to the one recommended for the ligation of the common iliac. Sir Astley Cooper made an incision along the linea alba, about three inches in length, a little to the left of the umbilicus. After opening the peritoneum, he pushed aside

the intestines, detected the vessel by its pulsations, and tore through the intervening layer of serous membrane, with his finger-nail, on the left side, then carried the finger under the vessel, and introduced the needle from left to right. The vessel may be ligated about an inch above its division. It is difficult to conceive of any circumstances, of either the field or hospital, which would justify this last and most desperate resort for the staunching of hemorrhage.

**THE INTERNAL ILIAC ARTERY.**—The other terminal trunk of the primitive iliac is intended to supply the viscera and walls of the pelvic cavity. The internal iliac is a short, thick vessel, about an inch and a-half in length, extending from the point of bifurcation of the common iliac downwards, to the upper margin of its great sacro-sciatic foramen, where it divides into an anterior and a posterior trunk. Like the primitive and external iliac arteries, it has the peritoneum spread over it in front and near its origin, the ureter crosses it to reach the lower fundus of the bladder. On the other side is the psoas magnus muscle, and behind it is the internal iliac vein, lumbo-sacral nerve and pyriformis muscle. The artery has been tied a number of times, for aneurism of one or other of its branches.

*Operation.*—The patient is placed, as in the preceding operations, on the primitive and external iliac. Make an incision, about five inches in length, slightly convex outwards, commencing about half an inch to the outer side of the external abdominal ring and an inch above Poupart's ligament, so as to avoid the spermatic cord. The line of incision should be nearly parallel with the course of the epigastric artery, but a half or three-quarters of an inch to its outer side, and should terminate little over an inch above, and to the inner side of, the anterior superior spinous process of the ilium. The skin and superficial fascia being divided, the several muscular strata should be divided on a director. It is probable certain branches of the superficial epigastric and superficial circumflexa ilii may require tying in the course of the incision. The transversalis fascia having been reached, it must be carefully opened by pinching through it with the finger-nail, and the director introduced upwards and downwards, so as to divide it to the required extent. The peritoneum is then to be carefully separated on the iliac side with the index-finger, and drawn, with the bag of intestines towards, the linea alba. Continue

now carefully to separate the membranes towards the sacro-vertebral articulation, with the left hand, following up the movement with the thumb and finger of the right hand, till the external iliac artery is reached. This is our guide, first to the bifurcation, and secondly to the descending trunk of the internal iliac, which we are seeking. The point at which this divergence takes place is nearly opposite the centre of a line drawn from the anterior superior spinous process of the ilium to the umbilicus. Use the left fore-finger to isolate the artery on its inner side, and the right for the outer side. It then may be either hooked up with the left fore-finger, or picked up between the fore-finger and thumb of the right hand, and pulled inwards from the wall of the pelvis. In passing the ligature, an object of particular care is to avoid the ureter, which is near the origin of the artery and on its inner face. The instrument, best adapted for introducing the ligature in a vessel so deeply seated, is that heretofore described (page 110) and represented on plate I. figure 7. The ligature should be passed, from within outwards, to avoid injury to the veins. The fore-fingers of both hands should be deeply introduced into the wound, back to back, so as to secure strangulation of the vessel in tightening the ligature. The parts should be properly drawn together afterwards and united with the quill-suture or with silver-wire. See plate VIII. figure 35, Arteries: *e*, the internal iliac artery, given off from the primitive; *h*, the ureter, passing over the vessel; *m*, the psoas magnus muscle.

Some of the branches of the internal iliac are interesting, on account of the frequency of gun-shot wounds of the buttock:

THE GLUTEAL ARTERY.—This is a short, thick trunk, which passes downwards to the upper part of the great sacro-sciatic foramen. Escaping from the pelvis, above the upper border of the pyriformis muscle, it immediately divides into a superficial and deep branch. The *trunk* of the gluteal is deeply situated, being covered by the gluteus maximus and medius muscles, and often, by a very great thickness of dense fat; besides this, to reach it, we will encounter probably many of its muscular branches, the bleeding from which will much obscure the operation. The two *branches* of the gluteal, the *superficial* lying between the gluteus maximus and medius, and the *deep*, along the superior curved line of the ilium are

even more liable to be wounded than the main trunk. They are neither of them so deeply seated. A line, drawn from the posterior superior spine of the ilium to the trochanter major, marks the course of this vessel.

*Operation.*—Neither this artery, or its branches, should ever be searched for, except in case of their being wounded and bleeding. For aneurism, the ligature is applied to the internal iliac. In case of a gun-shot wound, the vessel can be best found by introducing the sound to re-establish the track of the ball. Then either follow the sound, or cut transversely to it, as near as possible the line of the branch suspected to have been wounded. The accumulation of clots will lead to the situation of the wound along the line of the sound. If the superficial branch is wounded, it will be found by reaching the intermuscular layer, between the gluteus maximus and medius muscle, and extending the separation up towards the crest of the ilium, till the beating of the vessel, or the fibrinous accumulation about the wound, shall indicate its position.

Mr. Guthrie\* gives the following description of the operation: Place the body on the face, turn the toes inwards; commence the incision, one inch below the posterior spinous process and one inch from the sacrum; carry it on towards the great trochanter, in an oblique direction, to the extent of five inches. Divide the gluteus muscle and the aponeurosis beneath it, and seek for the artery as it escapes through the upper and anterior part of the sciatic notch, lying close to the bone. If the vessels of the gluteus muscle bleed so as to be troublesome and cannot be stopped by compression, they must be secured.

Plate VIII. figure 36, Arteries, exhibits the incision and the artery raised on an instrument.

**THE SCIATIC ARTERY.**—The sciatic artery is also distributed to the muscles on the back of the pelvis. It emerges from the pelvis, through the lower part of the great sacrosiatic foramen, between the pyriformis and coccygeus muscles. It then descends in the interval, between the trochanter major and tuberosity of the ischium, in company with the sciatic nerves, and covered by the gluteus maximus muscle, dividing into two branches, which supply the deep muscles at the back of the hip, one branch accompanying the great sciatic nerve

---

\* Commentaries, page 269.

some distance down the thigh. A line drawn from the posterior superior process of the ilium, to the tuberosity of the ischium, will traverse the point of exit of the artery at its centre.

*Operation.*—The patient should be laid with the body face-downwards, with the foot inverted. Let the centre of a vertical incision, over three inches long, fall upon the point of exit of the artery as given above. This incises the skin, cellular tissue and fat, down to the coarse fibres of the gluteus maximus—dividing as few as possible—over the lower part of the sciatic notch. The sciatic nerve will soon be seen, which, being followed up, will lead to the artery which is found at its inner side, the vein is also to its inner side but somewhat posterior. There will be no difficulty in isolating and securing the vessel, provided the wound is held open with blunt spatulas.

Mr. Guthrie advises that an incision similar to, and in the same direction as that used to reach the gluteal be made to expose the ischiatic artery. only that it must be made an inch and a half lower down than the one for the gluteal. It must be recollected, however, that the two operations just described contemplate the ligation of each vessel *at a particular part* of its course. This selection is only allowable when these vessels are to be tied for aneurism; when they are wounded it is advisable to ligate the vessel in the track of the wound at whatever portion that may traverse it, applying two ligatures, one to each end of the divided vessel, otherwise recurrent hemorrhage is apt to prove the operation perfectly useless. The sound should be introduced if practicable—we know then that it transverses the arterial wound, and our duty is to cut through, by the nearest and most practicable route, all intervening tissues not endangering life, so as to arrive at and secure the bleeding vessel.

**THE INTERNAL PUDIC ARTERY.**—The internal pudic is one of the terminal branches of the internal iliac. It descends to the lower part of the great sacro-sciatic foramen, through which it emerges from the pelvis between the lower border of the pyriformis and the coccygeus muscles. It here crosses the spine of the ischium, re-enters the pelvis through the lesser sacro-sciatic foramen, passes forward over the tuberosity of the ischium, about an inch from its border, to the ramus; now, ascending along the ramus of the ischium and pubis, it pierces the triangular ligament near the symphysis, and divides into

its two terminal branches the cavernous artery and the dorsalis penis. Like the gluteal and ischiatic arteries, it is covered by the gluteus maximus muscle while external to the pelvis, and is consequently very deeply seated. The artery may be reached at two places should it be deemed necessary to ligate it.

I. ON THE SPINE OF THE ISCHIUM.—The vessel is here, for a short distance—half an inch—on the outside of the pelvis, but it is most frequently covered by some of the dense fibres of the greater sacro-sciatic ligament. Place the patient on the face. Make an incision from about an inch below the posterior spinous process of the ilium for five inches towards the trochanter major, through gluteus maximus, and search for the vessel on the spine of the ischium, which separates the lesser from the greater sacro-sciatic foramen. Some of the fibres of the ligament overlying the vessel must be cut through and the artery may be isolated and tied as it crosses the outer surface of the spine of the ischium. It will be found here without fail.

II. IN THE PERINEUM.—The artery here is just within the ascending ramus of the ischium. The patient should be placed in the position for lithotomy. The rami of the pubis and ischium may be felt beneath the skin below the symphysis pubis; make an incision vertically along this line of projection dividing the fascia carefully, then feel, just within the inner border of the ramus, for the pulsation of the vessel. It may here be found and secured, care being taken to include nothing but the artery in the ligature.

*Explanation.*—Plate VIII, figure 38, Arteries, is a representation of the operation for ligation of the internal pudic in the perineum.

ANASTOMOSES.—The anastomotic communications of the inferior extremity although, in general, not so abundant and direct as those of either the superior extremity or of the head and neck, are still sufficiently so to render the measure of ligation of the main trunks warrantable in almost every region of the limb, so far as the apprehension of a non-supply of nutrition is concerned. Indeed, unless for some object worthy the risk, as to combat destructive inflammation or to avoid increased peril to the patient, this freedom of inosculation is such as to render ligation in the continuity a somewhat doubtful measure in wounds of arteries, for fear of recurrent hemorrhage. In the foot and ankle we have seen that the anterior and posterior

tibial and the peroneal communicate freely through the plantar arch and the perforating and the mallcolar arteries; at the knee, these vessels of the leg combine with those of the thigh to form a network of communications—a universal and most interesting *rete*—which enmeshes the joint externally and penetrates into the interior of the bone, making its cancellous structure, perhaps, the most vascular of any part of the osseous system, and accounting for the obstinacy and destructiveness of inflammation in this joint, by inosculations between the recurrent and muscular branches with the articular arteries of the popliteal.\* All along the thigh, a collateral chain establishes by-channels for the blood, from the upper to the lower region, by the perforating branches of the profunda; and lastly, around the hip-joint the communication seems so abundant, that the internal iliac and its branches may be almost considered the *grand anastomotie trunk* between the body and the lower limb, accomplishing between the two, a thorough *community of circulation*. The gluteal, the ischiatic, the internal pudic and the obturator anastomose freely with each other, and by communication with arteries above and below constitute an unfailing collateral circulation.

In consequence of this very free communication, anastomotic aneurisms of the gluteal region are of frequent occurrence, and ligation of the affected trunk does not always succeed in curing them. For the same reason, has it been found necessary in gun-shot wounds of these arteries to apply two ligatures at the point of lesion. We should not be deterred from cutting down upon and searching for, either the gluteal or ischiatic when bleeding, by the depth and frightfulness of the incision required to reach them. We all know with how little ceremony and how indiscriminately a fragment of shell often ploughs through and tears away a large portion of these muscles, and also how little permanent injury is sustained, and also how rapidly nature will replace the deficiency by granulation, when she has the blood to do it with; certainly, no amount of judicious cutting by the surgeon, to save this blood, could be more irreparable than this.

In the surgical treatment of hemorrhage, *impossibilities*

---

\* These articular vessels enlarge greatly during inflammation of the knee-joint; and when amputation is necessary, after it has long existed, a large number of them require ligation.

sometimes stare us in the face, and the most conscientious discharge of duty may prove entirely unavailing. When we have faithfully carried out, however, the well considered determinations of an *enlightened* judgment, we are free from blame for the result, no matter how disastrous or however much to be deplored. Suppose, in some extreme case, life should give out in the very midst of our earnest efforts to save it—even this sad event will be less painful to the military surgeon and to the *true man*, than the enduring, bitter reflection that, he had either carelessly, or indolently, or ignorantly, or procrastinatingly, or even timidly, *allowed* a wounded fellow-soldier—  
TO BLEED TO DEATH.



## CHAPTER IV.

### AMPUTATIONS IN GENERAL.

An amputation is the complete removal of all the structures of a part, or of the whole of a limb. This may be effected either at a joint, or at any intermediate point. In the first case the knife suffices for the separation, and the amputation is said to be *in the contiguity*. In the last, or an amputation *in the continuity*, a perfect section demands the use of the saw or bone pliers. Whatever the seat of the operation, due care must be taken to preserve enough of the soft structures to cover, without tension, the cut or articular end of the bone.

In the standard methods of amputation, the integument is divided by circular, elliptical or hemi-elliptical incisions; or by a combination of the first and last forms.

In the first method, the soft structures are necessarily incised in succession from without inwards, or from the surface towards the centre. This plan may be pursued in the execution of the other methods; but they may also be wholly or partially completed by cutting out after transfixing the limb on the opposite sides of the bone at points *not quite* co-incident. The whole operation being effected on this plan, or by combining this with the cut from within outwards.

These standard methods have received names from the shape of the resulting wound. Hence the terms circular, flap and oval amputations. See figures 1, 2, 3, 6, plate I.

ARRANGEMENTS.—As in all operations, the necessary instruments, dressings, &c., should be placed in order, and within easy reach of the surgeon. The patient should occupy the required position. In all cases, that giving the operator entire command of the seat of amputation. The skin must be shaved for several inches above and below the line of incision. The assistants should take place as directed by the surgeon, and should, as far as possible, retain their relative posi-

tions to the end of the operation. Two points must be carefully attended to before the slightest wound is inflicted. If an anæsthetic is used at all, see that the patient is *fully* under its influence. Be sure the chief artery of the limb is commanded either by hand, or by the tourniquet. When the tourniquet can be applied, *prefer* it to all other means of controlling the local circulation, no matter what the surgeons theoretical views with regard to the advantages of other kinds of pressure. Be certain that the instrument is so applied that no struggles of the patient will impair its power. The direction is sometimes given to place the tourniquet as *far* as possible from the seat of operation. This is not a rule for general guidance. The precept would be better enunciated thus: Adjust the instrument so that it may compress the artery against a bony surface, and let it be as *near* the line of incision as may be compatible with a proper retraction of the soft parts, and perfect freedom of action on the part of the surgeon. When the command of a single large trunk will not entirely arrest the circulation through the parts to be sacrificed, be careful not to tighten the instrument until the moment before the incisions are begun. When the condition of the patient demands the greatest economy of blood, elevate the limb, and bandage tightly from its distal end to the point where the artery is to be compressed. In screwing up the tourniquet let the movement be as rapid as possible.

The directions here given are somewhat precise and detailed, because the success of an amputation, both as regards the life of the patient and the quality of the stump, will more often be secured by the strict observance of these simple suggestions, than by the mode of amputation selected, or the dexterous manipulation of the operator. One ounce more, or less, of vital fluid, retained in the vessels, will often go far to decide the issue. These preliminaries settled, the surgeon may proceed at once to amputate in accordance with the method previously selected.

**THE CIRCULAR METHOD** (Figures 1, 2, plate I).—Whatever the seat and mode of operation, if the patient is to be anæsthetized, he should occupy the recumbent posture, and should lie at length upon a table of such dimensions as will exact the least possible restraint in the movements of the operator.

The part to be removed, in the case of the larger amputa-

tions, should project beyond the edge of the table, and should be supported and controlled by an assistant. In the circular method the surgeon always stands on the right of the diseased limb in such manner, that his left hand may rest upon and command the part to be saved. An assistant, grasping the whole circumference of the integument a short distance above the seat of operation, steadily and evenly stretches the skin, by pulling in the direction of the body. If it has been found advisable to adjust the tourniquet near the line of incision, the retraction of the integument may be made previous to its application. The operator stooping, and encircling the limb with his right arm, holds the long amputating knife like a sword, so that its point presents downwards and towards himself—the heel of the instrument resting on the upper part of the skin to be divided. Here the incision begins, and is continued with a gently sawing motion, drawing the blade from heel to point, completely around the limb, to the spot where the cut commenced. At first the hand is prone and extended, subsequently supine, and lastly, prone and strongly flexed. During the progress of this procedure the surgeon rises, and at its termination has resumed the erect posture. The first incision should divide the skin and superficial down to the deep fascia. Many prefer to make two *semi-circular* cuts, whose extremities coincide. This proceeding is more easily managed, and is equally efficient, although it does not tickle the fancy of critics. In either case the integument should be cut at right angles to its general surface.

The question whether this and subsequent incisions shall be made transverse or oblique, with reference to its long axis, is decided by the comparative length of the muscular fibres on the different aspects of the limb. When these are nearly equal, the cut should be transversely, when unequal, obliquely circular. In other words, the divided skin and muscles should be longer on the side of greatest retraction, which will always correspond to the longest muscular fibres. In amputations of the thigh, for instance, at its middle or lower third, a transversely circular division of the soft parts will give an oblique or pointed stump. Here the long fibres of the sartorius, gracilis and great adductor retract more than those of the quadriceps, and carry the skin with them.

The next step in the circular method will depend somewhat on the point of amputation. In the thigh and arm,

where there is but one bone, and where the tissues are healthy, and slide easily on one another, two more circular incisions are made, in accordance with the directions already given. The one divides the more superficial layer of muscles; the other reaches to the bone. Each is made in a line with the margin of the superjacent structures, when strongly retracted by an assistant. The edge of the knife in these last incisions is somewhat inclined towards the proximal end of the limb. So, that as a result of the whole proceeding, there is a hollow conoidal wound, at whose apex the bone is divided by the saw. (Figure 2, plate I.)

Where there are two bones, or the soft structures, as in many secondary amputations, are too adherent to admit an even and thorough retraction, it is found better, before severing the muscles, to dissect and turn up the skin like a coat cuff. (Figure 1, plate) In such cases endeavor as far as possible to hollow out the muscular layers by the proper use of the knife. If they should prove very untractile, dissect the deep layer back from its periosteal attachments for an inch or more before the bone is sawed. When two bones are involved in the amputation, the section of the soft tissues between them forms a distinct step in the operation, and care should be taken not to introduce the knife with the edge upwards. The interosseous soft parts should be incised close to the seat of proposed bone section. When the conformation of the limb does not admit the ready reversion of the skin cuff, as just above the ankle, wrist or knee, in muscular subjects, it may be necessary to make a longitudinal cut, equal in length to the skin to be turned up, and meeting the margin of this at some point in its circumference—usually over a bone. The distance of the skin incision from the point at which it is intended to saw, the hard textures must be decided by reference to the dimensions of the limb. One-fifth the circumference of the latter will give the required length.

**FLAPS,** (Figures 37, 38, 39.)—In amputating by this method, the operator stands on the side most convenient to himself. Either side presents its advantages. If his position brings his left hand in relation with the proximal end of the limb, he can more readily grasp and elevate the structures, out of which the flap is to be fashioned, and can conveniently make with his thumb and fingers the points of entrance and exit for the trans-fixing knife. On the other hand, if his position

is reversed, he is better able to control and steady the parts to be removed during the latter stages of the operation; and he may thus, it is thought, prevent the binding of the saw or the splintering of the bone.

Flaps may be single or double; may be cut from within outwards, or by the reverse method; and they may be cut from either or both opposed aspects of the part to be amputated.

In making double flaps by transfixion, the operator grasps the soft parts with his left hand, his fingers and thumb being so placed on the opposite sides of the limb as to correspond usually to the extremities of its transverse axis. These points, with the intervening structures, are so elevated as to permit the ready passage of the blade on the side of the bone from which the flap is to be cut. A long bladed, sharp pointed knife is then thrust transversely, or obliquely (having due regard for the precepts already given concerning the unequal retractility of the muscles) through the part, an inch or two below the point elected for the bone section. The knife should graze the bone, and is made to cut its way gently downwards and outwards, so as to fashion a flap, whose length, without stretching, shall equal one-half the diameter of the proposed stump. In some cases it is found advisable to graze the bone in a downward line until sufficient length of the flap is obtained, and then to cut abruptly outwards. The withdrawn knife is again entered one or two inches below the original point of transfixion, and traverses the limb on the opposite side of the bone. A second, similar and opposed flap is thus made. The flaps are turned up, and, as in the circular method, the tissues are strongly retracted. An encircling sweep of the blade divides the remaining muscular substance and the periosteum close to the separated angle of the retracted flaps. The bone is sawed at the same point. When the flaps, owing to parcify of skin, are likely to be at all deficient, it will be well to dissect back the deep muscles from their periosteal connections (as already advised in cases of circular amputation) before using the saw.

It is evident that any proportion between the flaps may be obtained, according to the will of the operator or the exigencies of the case. It being always remembered, that in order to secure a good stump, one flap must be increased in length just in the same ratio that the other is reduced. These altered relations may be carried to the extreme, resulting in a single

flap on one side and a transverse cut on the other; giving a combination, so to speak, of the two principal methods just described.

In very muscular subjects better results may be sometimes obtained by cutting the flaps from the surface towards the centre. In such, too, one or other of the following plans may be adopted: Semi-elliptical skin flaps may be dissected and turned up, while the muscles are divided close to their base by a circular sweep down to the bone; or the skin flaps, made as before, may be simply retracted, and the muscular structures incised by transfixing and cutting outwards from their retracted margin; or the redundant tissue may be pared, as an after step in the ordinary flap operation.

Mr. Teale, of Leeds, has proposed a modified flap operation, (figures 4 and 5, plate I.) which presents the advantage (if it be an advantage) of withdrawing the line of cicatrix from the face of the stump, and for which he claims an extended success. Two flaps are cut from opposite aspects of the limb. Each is to possess a rectangular outline. They are to be of unequal length. The long one is to be a square, whose sides shall measure half the circumference of the part to be incised. The short flap is to be one-fourth of the length of its fellow. Their outline is to be traced with ink previous to the operation, as in figure 4. He directs the longitudinal cuts to be made first, and only through the skin. The transverse incisions are cut at once to the bone. Each flap is completed by dissecting upwards close to the periosteum; care is taken to select the long flap from that side of the limb *not* containing the larger nerve trunks and blood vessels. The bone is sawn transversely at the base of the flaps. The long one is doubled on itself, so as to appose its free end to that of the short one. These and the other margins of the resulting wound are held in apposition by sutures alone. No other dressing is used. The stump is elevated on a cushion, covered with a wire cage, and cleansed by sponging from time to time. The appearance of the lines of incision, when brought in contact in the manner described, will be understood by reference to figure 5, plate I. Theoretically, at least, we would be inclined to reject Mr. Teale's procedure, especially in field amputation. It produces a larger wounded surface and a more extended cicatrix than any of the usual methods.

OVAL METHOD, (figure 5, plate I.)—This name is given

to an amputation in which the line of incision presents two limbs parting from the same point, to give the figure of an inverted V on one-half the limb, which, being rendered continuous, circumscribes the remaining half with a semi-circular outline. The apex of the  $\Lambda$  is made to correspond to the seat of the desired bone section or disarticulations, and should, if possible, lie opposite to the great nerves and arterial trunks. The division of the soft parts is made at once to the bone, cutting from the surface; or, still better, the skin may be first divided, making a second step of the separation of the deeper tissues. In disarticulations at some of the larger joints, and in some amputations in the continuity, it is found easier and every way better to connect the limbs of the V by transfixing at their terminus, and cutting from without inwards.

AMPUTATIONS IN THE CONTIGUITY.—The nature of these operations has already been mentioned. They are also called disarticulations. While their performance requires fewer instruments than those just described, it involves the observance of the same general rules as to preparations, arrangements and character of incisions. Due regard must be had to the conformation of the joint, the seat of operation, and every care must be taken to secure a sufficient covering of soft tissue. An accurate anatomical acquaintance with the parts concerned is an essential prerequisite to the dexterous accomplishment of the proposed task.

The recognition of the articular line is to be derived from its constant and invariable relation to bony prominences, skin creases and tendinous attachments, visible through the integument, which, at the joints, fits more closely upon the hard structures than in the continuity of the limb, and permits us, in the healthy state, to ascertain without difficulty the line of junction between any two segments of the skeleton. When swelling masks these guides, it is possible, ankylosis being absent, to gain the desired information by moving the parts to be amputated upon that to be preserved, while the latter is rendered fixed and immovable. The line separating the points of motion and quiescence, ascertained by firm pressure during the manipulation mentioned, will, of course, give the seat of articulation. When this and other expedients fail, we have, with rare exceptions, an opportunity for comparison with the opposite limb. An accurate measurement of the distance from parts plainly seen on both sides of the median plane will give

the desired knowledge. The exact position of the joint ascertained, the configuration of the articular surfaces, the attachment, shape and extent of the ligamentous and tendinous bonds of union must be present to the mind in effecting a speedy and skillful separation of the injured and healthy segment.

The covering for the bony stump is obtained by the practice of such incisions of the soft structures as are used in amputations in the continuity, due allowance being made for the retractility of the soft tissues, which, in the muscles, is always in exact ratio to the length of the fibres connecting the parts to be separated. As specific rules will be furnished on this point in the description of the individual disarticulations, it is not deemed necessary to anticipate them in a consideration of the general principles to be observed.

From what precedes we have learned that all amputations may be performed by one of two principal methods, or by their combination. These are the circular method and the method of double flaps. The single flap mode and "*methode ovulaire*" may be justly regarded an association of steps derived from the two first. The former, giving a semi-circular cut on one aspect of the limb; the latter, presenting at one end two distinct flaps; at the other, a continuous line of incision.

Formerly, much time was spent in contrasting the relative value of the flap and circular operations. Now, a recital of all the arguments on both sides is almost useless. The majority of leading surgeons seem to have quieted themselves with the conviction, that, "*cæteris paribus*," the circular operation is *par excellence* the operation to be selected whenever the circumstances of the case will permit. This statement, perhaps, carries greater weight in military than in civil practice. Still it will not be amiss if the surgeon will consent to forget the business of the advocate and look somewhat into both sides of the question. He will do well, until he attains the requisite facility, to practice each of the operations named whenever a suitable opportunity presents, because what may be true as a general rule admits of undoubted exceptions. Thus, in amputation at the hip, the double or single flap operation will be found preferable. In the removal of the fingers and toes, and the extreme metacarpal and metatarsal bones, the oval method should be selected. Let him bear in mind, in all amputations, that he sacrifices a part to save life, and that, in doing this,



it is desirable to save as much limb as possible. A circular operation makes a smaller wound and cuts the arteries transversely. For the first reason, it shocks less and gives a less extensive suppurating surface—makes a more compact stump, and, therefore, bears the jars of transportation better. For the second reason, the small arteries will either contract permanently, or will be certain to show themselves at once and permit ligation, and will thus guard against subsequent hemorrhage. The single, or even the double flap, method may permit us to save more limb. Both may be performed with great rapidity, and both, under favorable circumstances, provide a thicker cushion for the bony stump. The first is a questionable advantage if chloroform be used—the last is not a certain result. But, as before indicated, it is not desirable to be too obstinate in our prejudices in favor of either method, since, in full practice, we will certainly encounter conditions where we shall only be able to do full justice to the patient when capable of adapting one's self to the special exigencies of the case. In other words, the surgeon should be prepared to undertake any variety of amputation.

All amputations involve at least four steps: I. The incision of the soft parts. II. The bone section, or disarticulation. III. The ligation of the vessels. IV. The dressing of the resultant wound. *The division of the soft structures* is governed by the principles already given.

*The bone section* is effected by the saw, in the case of the larger bones—by the bone pliers, in the case of the smaller bones. Previous to the use of the saw, the periosteum should be cleanly incised by a circular knife cut. The circumference of the bone section should coincide with this periosteal groove. If there is but one bone, the saw may be applied horizontally, and should first be drawn from heel to point with a firm, steady pressure, the blade being meanwhile guided and supported by the thumb-nail. This begins a cut, in which the instrument may be worked backwards and forwards rapidly, with a light, sweeping movement. During progress, it is well to change its direction from horizontal to oblique, and, by the termination of this step, it is best to work the saw vertically. Where two bones are to be cut, the saw is applied to both simultaneously, but the section of the more slender, or most movable, is first to be completed. In the leg, the fibula—in the forearm, the radius—is first to be divided.

*The disarticulation* presents differences dependant on the seat of the amputation. It includes the division of all the immediate bonds of union constituting the articulation, but especially the section of the ligaments, which bear constant relation to the nature of the joint and the character of its movements. This division can only be performed with celerity when we know where, how and what we ought to cut.

*Ligation of the Vessels.*—As a general rule, the arteries alone require ligation. When bleeding from a vein is obstinately persistent, despite the elevation of the part, a ligature may be applied. It is well to avoid the use of this resource. All arteries seen to bleed had better be secured with ligatures, which should always be smooth, round, and as small as may be consistent with sufficient strength, provided the arterial coats are healthy. Usually one end of the ligature is cut off close to the knob. This is really unnecessary trouble. The sharp, cut extremity is a source of as much, if not more, irritation than the smooth, continuous thread.

*The Dressings.*—Hemorrhage having entirely ceased, and the raw surface being thoroughly cleansed by the free use of cold water and the sponge, the lips of the wound are to be adjusted and held in apposition by ligatures, adhesive strips or bandages, or by a combination of two or more of these means as the case may require. In the circular operation, any direction may be given to the line of union. That is, it may be made transverse, vertical or oblique, in either sense. When free suppuration is to be anticipated, it is found better to facilitate the draining off of the discharges by favoring their gravitation to one angle of the wound. The line of union is therefore generally made oblique. In the flap or oval operations no choice is permitted. We are per force controlled by the line of incision. In any case the ligatures are arranged in groups, to be drawn out at the nearest angle of the wound. The interrupted suture is most in use; the distance between individual stitches being governed by our views as to the probability of immediate union, and the consequent necessity of close apposition. Metallic sutures are preferable. Strong, even, well waxed silk thread will answer very well. Flax or cotton may be substituted when neither of the former can be obtained. If not contraindicated, keep up the administration of the anæsthetic during the introduction of the sutures. The patient will thereby be saved much undoubted and unneces-

sary suffering. The application of adhesive strips will depend partly on the degree of support needed to prevent dragging on the sutures, and partly on the size of the wound. In *small* wounds, where the arteries have ceased to bleed *without* ligature, adhesive strips, *accurately* closing the line of incision, constitute an essential first dressing. Sutures may here be entirely omitted, and immediate union is sought by the perfect apposition of the edges of the incised integument, and the careful exclusion of air. This refers to amputation through *healthy* tissues. In the larger amputations a certain amount of supuration is almost inevitable under the most favorable circumstances, and must be anticipated. If from no other surface, it will be certain to occur along the track of the ligature groups. Provision must be made to permit the free exit of this pus by leaving the corresponding points uncovered by anything except an absorbent material. In these cases where the patient is to be subjected, at once, to the jars of transportation, interrupted adhesive stripping or a supporting bandage is demanded. *Wet* dressing is unnecessary in amputations through normal textures. And it is well to remember that we should endeavor to secure the immediate union of as much of the line of incision as possible, and that this end can only be attained by a perfect opposition of the corresponding integumental edges.

### Amputation of the Upper Extremities.

Observation would seem to teach that the hazard of an amputation is *cæteris paribus* in direct relation with the dimensions of the resulting wound, and the length of the part removed. Differently expressed, the larger the wound and the nearer it is to the proximal end of the limb, the greater the risk to life. The inference is that we should always endeavor to save as much of the diseased or injured segment as possible. This rule of general acceptance is especially applicable to the upper extremity, and especially to its terminal segments. In nothing, perhaps, are surgeons so much in accord as with reference to the duty of preserving, within certain limits, the smallest fragments of the fingers. Hence, short as are the phalanges, it is customary, whenever possible, to cut in the continuity as well as to disarticulate. In either case, it is well to note a brief outline of the structure of the parts concerned.

The skeleton of each finger is a jointed column (figures 7, 8, plate I.; figures 9, 10, 11, plate II.) composed of three long segments surmounting the heads of the metacarpal bones, and joined end to end. Each is shorter than the other, proceeding from the upper to the terminal phalanx. The extremities of each segment are broader than the intermediate portion, which is convex in both directions on its dorsal, concave in both on its palmar aspect, and tapers slightly from above downwards. There are three joints in each finger; one between the basal phalanx and the metacarpal bone, the other two, resulting from the apposition of phalanges. The metacarpal joint is condyloid. The articular surfaces are more or less elliptical. The metacarpal is convex in both senses and prolonged towards the palm, so that its long diameter is antero posterior and opposed to the short diameter of the corresponding end of the phalanx, whose articular extremity is concave. (Figure 11, plate II.) The phalangeal articulations are both of the ginglymus variety. These are formed by the distal end of the second and middle phalanges, each bearing a surface fashioned like the segments of a pulley, and the proximal extremities of the second and terminal phalanges, conversely figured. That is, bearing a central antero-posterior ridge, flanked on either side by a glenoid depression. (Figure 10, plate II.) In each case the long diameter of the joint is transverse. In each case, too, this diameter of the upper end of the more distant phalanx exceeds somewhat in dimensions the opposed extremity of the bone it joins. The bonds of union between all these segments are two strong lateral ligaments, attached to non-articular depressions, flanking the extremities of the contiguous bones; while the flexor and extensor tendons cross and are closely applied to the palmar and dorsal aspects of the joints. The sublimis attaching itself to the palmar margins of the second, and the profundus, to the bases of the terminal phalanges; the common extensor getting connection with similar points of the dorsum. The principal blood vessels and nerves, two for each finger, skirt the junction between the lateral and palmar surfaces. The integument clothing the parts is thin and loose, laterally and behind; thick and regularly marked in front. Where we find with tolerable constancy three a principal and distinct transverse creases or lines bearing a nearly invariable relation to the joints just described. (Figure 8, plate I.; figure 9, plate II.) The middle line *corresponds*

to the joint between the metacarpal and second phalanges. The line nearest the metacarpal bone is twelve or thirteen lines *below* the articulation of that bone with the basal phalanx; while the terminal skin crease is about one line and a half *above* the distal phalangeal joint; (*f*, figure 42.)

AMPUTATION OF THE FINGERS—*between the joints*—may be performed by the circular, double or single flap methods. In the circular operation the skin and areolar tissue are divided by the first cut, and retracted to a sufficient distance, when a second sweep incises the theca tendons and periosteum. Bone pliers or a fine saw will cut the phalanx. (Figure 12, plate II.) Double flaps may be dorsal and palmar or lateral. Each is semi-elliptical, with its convexity downwards. In the first case, the palmar cut may be made by transfixing and grazing the phalanx. The other flaps can only be fashioned by incising from without inwards. One may be so increased in dimensions as to furnish alone a sufficient skin covering for the stump, the other being altogether omitted and replaced by a transverse division of the tissues. When this single flap is palmar, it gives the best possible result, throwing the line of cicatrix in the dorsal aspect of the finger. But little art is needed in the performance of these amputations. The great point is to make **such** calculation for retraction as will bring the bases of the flaps to coincide with the point where it is desired to cut the bone. Otherwise, we shall have to sacrifice an unnecessary amount of phalanx, just what we wish to save.

DISARTICULATIONS OF THE PHALANGES.—In these, as in all amputations in the continuity, the first step is to recognize the articular line. A due regard to the general precepts and anatomical outline of the parts, already given, will conduct to the desired end. Here, as in the operations between the joints, the two principal methods, with their obvious modifications, may be practised. Such accuracy of eye and judgment, as may be required to make allowance for retraction of the soft parts, will be especially needed. Remember that it is easy to pare redundant integument, while one cannot shorten the bone and at the same time preserve its articular end. The position of the joint certainly ascertained, the circular division of the skin at the proper level presents no peculiarities; the lateral ligaments are divided, and the joint may be entered from either aspect, cutting first either the dorsal or palmar tendon; finishing the separation by the

division of its opponent. Flaps may be fashioned, as for amputations, in the continuity. The palmar flap, when required, by transfixing one or two lines below the articular junction, and cutting downwards and outwards. Where a single palmar flap is proposed, it may be made, as suggested, previous to, or after, disarticulation. In the first method, (figure 14, plate II.) the hand is to be held supine. The flap is commenced by transfixion. When finished, it is turned up and retracted. The lateral ligaments, flexor and extensor tendons, and dorsal integument are incised by an almost continuous movement from within; traction being made by the surgeon upon the part to be removed, to render tense the fibrous bonds of union and facilitate disarticulation, while retraction of the skin secures its sufficient preservation. If it is proposed to disarticulate before carving the palmar flap, the skin must be first incised transversely a line below the joint, (figure 13, plate II.) the ends of this cut coinciding with the level of the palmar aspect of the articulation; the hand meanwhile being prone and the part to be removed somewhat flexed. The joint is traversed as before, but from behind forwards. The same tractions are exercised, and disjunction being effected, the knife is passed in front of the phalanx, which, at this moment, is to be extended, to begin the palmar flap, completed in the usual way.

AN ENTIRE FINGER may be removed at the metacarpal joint by either of the standard methods.

*The circular* is the least desirable in practice. In this, the line of incision of the soft tissues is made to correspond with the upper transverse palmar skin crease *c*, Figure 8, Plate I. Subsequent dissection and disarticulation complete the operation.

*Double flaps* should be lateral. In this and in the oval method, first recognize the articulation. When there is little or no swelling, the ligaments and tendons will so yield to strong traction as to permit a slight separation of the bones. The atmospheric pressure on the soft tissues, will force them into the joint, whose line is then indicated by a slight depression, visible at the sides and behind. Where the condition of the parts will not admit this procedure, the distance of the joint from the transverse palmar crease, (rarely wholly effaced) about one inch may be measured. The other fingers being held aside by an assistant, the parts to be ampu-

tated prone and somewhat bent, is fixed by the left hand of the operator. The incision begins over, or a little above, the back of the articulation, and is carried obliquely downward to the web between the fingers. This cut is prolonged to a corresponding point on the palm. The soft parts on the opposed side are divided in the same manner. This cut, like the first, beginning and terminating at the point already mentioned; so that both incisions coincide at their extremities. Disarticulation is then effected by a division of the lateral ligaments and the tendons. In Lisfranc's operation, the joint is entered and the bones are separated after the completion of one flap; the second being formed by cutting from within outwards. The dotted lines diverging from *a*, figure 15, plate II. show the line of incision on the dorsal aspect of the part; *c*, *b*, figure 16, plate III, show the flaps where fashion and where disjunction has been completed. While making this palmar cut, the finger is to be extended, and the hand so elevated as to permit the eye to guide the knife.

*In the oval method*, the diverging dorsal incisions, instead of converging to a point on the palm opposite to where they began, are made to coincide and become continuous with the palmar transverse skin crease. The knife, on reaching the web, follows the direction of the skin-line, while the finger is extended, and reaching its opposite extremity mounts again on the dorsum, retracing its steps to the point whence it started; the finger, meanwhile, resumes the semi-flexed position. The dorsal view, before disarticulation, is traced in figure 15, plate II. by the lines *a*, *c*, *b*, *a*. The appearance when the amputation is finished, is seen in figure 16, plate III. *a'*, *b'*, *c'*, *d'*.

The expanded head of the metacarpal bone is quite a prominent object after this operation. With a view to the production of a more agreeable and convenient looking hand, many surgeons of eminence counsel the removal of this head, thus converting what was intended as a disarticulation into an amputation in the continuity; performing, in fact, a double operation to accomplish a single object. All must admit that the extent of and the risks of the operation are thereby augmented. In the case of the middle and ring fingers, where appearance is most to be served, this last step involves greater difficulty and more violence to the soft structures, than in the case of the index and little fingers. The writer would always

prefer to leave the metacarpal head of the fore-finger undisturbed. Its opposition to the thumb is too valuable to throw away for appearance sake. In the other fingers, a certain amount of atrophy will at last occur; so that it is, all things considered, a matter of some doubt whether it is good surgery to do more than mere disarticulation, where it can be avoided. If the taste of the surgeon, the wishes of the patient, or the nature of the injury or disease necessitate a further sacrifice of bone, it may be effected by prolonging *ab initio* the dorsal incisions to a point above the site of the desired section. The bone is cleared by close dissecting along its sides and palmar surface, and bone pliers are used for its division.

AMPUTATION OF FOUR FINGERS at the junction, between the phalanges and the metacarpal bones, may be done in *Lisfranc's method*, figure 17, plate III. The hand to be operated on is held prone. The fingers, slightly flexed, are grasped by the operator, while he steadies the part and abducts the thumb. An incision through the skin, whose curve is parallel with the articular line, is made on the dorsum, half an inch below the joints. The assistant meanwhile retracts the integument. The exposed extensor tendons are cut in succession on a level with the metacarpal heads. The lateral ligaments and flexor tendons are then divided; the knife, (figure 17, plate III.) passed in front of the disjointed phalanges, cuts out a palmar flap, ending at the margin of the web. A slight modification of this operation will answer for two or more contiguous fingers.

THE PHALANGES OF THE THUMB may be removed by methods and rules similar to those given for the fingers.

SINGLE METACARPAL BONES can be amputated *in their continuity*, at any point, by extending upwards the dorsal portion of the incisions practised in the disarticulation of the proximal phalanges. Care must be taken to cut close to the periosteal surface in dissecting the soft textures, that the larger palmar nerves and blood vessels may escape injury. Bone pliers must be used for the middle and ring fingers. A saw may be applied to the little and fore fingers, subsequent to the adjustment of a retractor. These last should be cut obliquely downwards from the corresponding margin of the hand, *a*, figure 18, plate III. The metacarpal bone of the thumb, however, is to be divided at right angles to its long axis.



THE FOUR METACARPAL BONES of the fingers may simultaneously be amputated *in continuity* by the single or double flap methods. The flaps are dorsal and palmar, or only palmar. The last may be made by transfixion, although its margin can be more neatly fashioned by cutting from without inwards. After the bones are cleared, a five-tailed retractor protects the soft parts during the application of the saw, (figure 19, plate V.)

#### AMPUTATIONS AT THE CARPO-METACARPAL JOINTS.—

The upper extremities of the five metacarpal bones form an irregular articular line with the second row of the carpus, whose general direction gives a curve with the convexity downwards. The metacarpal bones of the fingers are also connected with one another. Leaving the thumb out of consideration, these joints are all of the arthrodiar variety and permit but slight movement of the several pieces entering into their composition. The immediate bonds of union are short fasciculated filaments, attaching the dorsal and palmar aspects of the bones, with dense interosseous fibres crossing between the opposed surfaces, (figures 20, plate III., 28, plate IV.) give a general idea of the mutual relations of the several pieces. The carpo-metacarpal joint of the thumb is distinct and independent. It is an articulation by mutual reception, in which the trapezium and metacarpal bone offer surfaces alternately convex and concave in opposite directions, with the short diameters of each opposed to the long diameter of the other. The ligamentous connection is a loose fibrous capsule, permitting all varieties of motion except rotation. Here the synovial membrane is also distinct, while in the other carpo-metacarpal and inter-metacarpal joints it is a mere dependence of the common synovial membrane of the whole carpus. The extremities of the general articular line (*h, j*, figure 28, plate IV.) can usually be recognized with facility, unless swelling marks the configuration of the parts. Forced adduction and opposition of the thumb produces a dorsal prominence of its carpal end. The corresponding extremity of the fifth metacarpal bone projects sufficiently in any position, beyond the ulnar margin of the unciform, to be manifest to the touch in ordinary conditions. Besides, when the hand is between abduction and adduction, each of the points referred to is about one and a quarter inches below the styloid processes of the radius and ulna. Remembering the direction of the curve, formed by the joints between

the two, no great error can arise in ascertaining their position. Removal of the metacarpal bone of the thumb is always a separate operation. The other pieces of the series may be taken away separately or together.

THE FIRST METACARPAL BONE may be conveniently amputated by either the flap or the oval methods.

*Flap Operation.*—An assistant commands the fingers and supports the hand. The operator abducts the thumb to be sacrificed. All the structures connecting the thumb and forefinger are divided by an incision, carried from the centre of the connecting web to the base of the metacarpal bone. Care should be taken to graze the bone as the blade approaches its upper end. Otherwise, the radial artery, as it traverses the first interosseous space, will be wounded. The edge of the knife, arrested by the trapezium, is directed towards and opens the joint. Disarticulation is effected by light touches of its point. The blade, passed around the upper end of the bone, is then made to cut downwards and outwards, so as to detach an antero-external flap large enough to cover in the surface laid bare by the first incision. Figure 21, plate III. shows the position of the hand and knife just before the disarticulation is begun. The dotted line indicates the shape of the outer flap. To obtain the desired extent of covering, the bistoury is carried beyond the junction of the phalanx and metacarpal bone before cutting out.

*The oval method* of Malgaigne, as modified from Scoutetten. An incision starts six lines above the joint on its dorsal aspect. An inch below, it divides into two slightly diverging branches, whose greatest separation corresponds to the width of the thumb at its phalangeal end of the metacarpal bone. Here, each cut approaches the palmar surface, across which the two coincide at the level of the web. This incision may be practised by a continuous movement of the knife down one side, across the palm and up the other, to the point where it meets itself. Clearing the bone by close dissection and disarticulation form the last steps of the operation. *a, b* and *c*, figure 22, plate IV. show the line of dorsal incision. In figure 23, plate IV. disarticulation is being effected; *a*, shows where the cut divides.

*Liston's method* is more elegant than either of those just described, and agrees with the last in avoiding a palmar cicatrix. It is thus given by Erichsen, "The point of a long

narrow-bladed bistoury should be introduced well on the palmar aspect of the carpo-metacarpal articulation, carried over this, which it opens, and the dorsum of the hand as far as the web. The point of the knife should then be pushed downwards through the ball of the thumb, transfixing this and issuing where the incision commenced. It is next made to cut outwards, keeping next to the metacarpal bone, which is readily twisted out, the remaining attachments being separated by a few touches of the knife." In order to avoid an awkward crossing of the hands, on the part of the operator, who is not ambidextrous, in amputating the right thumb, the steps of the operation are reversed. The ball is first transfixed to make the palmar cut; next, we have the dorsal incision and disarticulation.

THE SECOND METACARPAL BONE is usually removed by the oval method. A glance at figure 20, plate III. will show how this bone joins three pieces of the carpus, and, on the ulnar side, with the third metacarpal. The direction and extent of the several articulations, when viewed from behind, are seen in the plate. A point, one and a quarter to one and a half inches below the styloid process of radius, marks the level of the joint with the trapezium. The dorsal incisions practised in this operation are shown in figure 20, plate III. *a*, *b* and *c*. These begin just above the joint, descending to the margin of the interdigital web within and to a corresponding point without, become continuous by following the palmar skin crease. The sides of the bone are cleared by close dissection; the dorsal, external, interosseous and palmar bonds of union are severed in succession; and lastly, the wound being opened by an assistant, who commands the thumb and fingers, the knife is laid flat side in front of the osseous segment, whose remaining connections are then divided by cutting downwards. The last step of the operation is given in figure 25, plate III. where *a* marks the point of the bistoury and *b* the radial edge of the metacarpal bone. Some surgeons prefer, in this operation, to practise a longitudinal cut over the radial margin of the bone, which divides near its head into two diverging branches. One of these crosses the dorsum in an oblique curve to the interdigital web; the other, the palm, to the same point.

THE THIRD AND FOURTH METACARPAL BONES may be disarticulated by incisions and dissections similar to those just

described. The difference in the number and direction of their carpal joints may be learned by consulting figure 20, plate III.

THE FIFTH METACARPAL BONE may be removed either by the oval or single flap operations. The joint is most easily found by tracing downwards the ulnar margin of the bone upwards. A prominence, surmounted by a distinct depression, is encountered. The point of junction between the two corresponds to the joint. Here, or a little above, in the *oval method*, the incision is begun, and is carried nearly as far down as the head of the bone, where it divides into two branches. One crosses the dorsum of the proximal phalanx and descends on its radial side in an oblique curve, to terminate at the margin of the interdigital web, while the other is carried as far as the ulnar end of the palmar skin crease, whose direction it then follows, and so meets the first. The separation of the soft tissues and the division of the ligaments are steps easily accomplished. The joint is entered from within and behind, the edge of the knife being directed obliquely downwards and outwards. In figures 26 and 27, plate IV. are respectively traced the line of incision and the resulting cicatrix.

The *flap operation* is performed thus: The hand being prone, the structures of the hypothenar eminence are grasped by the fingers and thumb of the operator, who lifts them beyond the ulnar margin of the bone; close to this, and on a level with the carpal joint, the knife is thrust in somewhat obliquely from back to palm; and the flap fashioned by cutting downward, hugging the bone all the way, should end opposite the margin of the interdigital web. This is turned back. The skin is dissected and sufficiently retracted to completely clear the upper end of the interosseous space, when the knife is again entered, its point passing out at the same spot as before. Grazing the radial margin of the metacarpal bone, all the interdigital textures are divided. Disarticulation is accomplished as in the former case. The flap will be found adapted to cover the exposed surface.

The *metacarpal bones of the four fingers* may be simultaneously separated from their carpal connections by Maingault's method. The operation is thus described in Bernard and Huette (figures 29 and 30, plate V.):

1st. The hand being held in a position of forced supina-

tion, recognize at its outer border the articulation of the first metacarpal bone with the trapezium, and at its internal side the articulation of the unciform with the fifth metacarpal. 2d. Introduce a small straight knife between the bones and the soft parts, carrying it a little below the projections formed by the unciform and the trapezium, so as to bring out its point below the thumb. 3d. Carry the blade of the knife along the anterior surfaces of the metacarpal bones, and cut out a large flap of an elliptical outline. 4th. Then turn the hand in the prone position, and make a semicircular incision across its back, two-thirds of an inch below the line of the articulation, and carrying the knife through the tissues, connecting the thumb with the index finger, join the first incision. Whilst an assistant is drawing the integuments upwards, the surgeon, holding the metacarpus in his left hand, proceeds with the disarticulation from the front of the hand, commencing with the metacarpal bone of the index or little finger, according as he is operating upon the right or left hand.

AMPUTATION AT THE WRIST-JOINT.—The radio-carpal articulation is a condyloid joint. The articular surface at the lower end of the radius, taken together with the triangular-fibro cartilage, connecting this with the ulna, gives a shallow elliptical concavity whose long diameter is transverse. This is opposed and accurately adapted to the convexity presented by the contiguous upper faces of the scaphoid, lunar and cuneiform bones of the carpus. The joint is flanked within and without by the styloid processes of the ulna and radius, from whose extremities proceed strong lateral ligaments. Anterior and posterior fibrous bands cover the front and back of the joint and complete its ligamentous connections. The articulation is still farther strengthened on these aspects by the flexor and extensor tendons of the hand and fingers, confined by their respective annular ligaments. The radial and ulnar arteries, their accompanying and the median nerve cross the junction between the hand and fore-arm. The skin behind is loose, thin, and covered with more or less hair, that in front thicker and less moveable. Figure 28, plate IV. presents an outline of the skeleton of these parts; *c* and *d* marking the extremities of the joint in question. The recognition of this joint is usually attained without difficulty by tracing downward the outline of the radius and ulna, until the position of the styloid processes is distinguished. Malgaigne states that

the joint is two and a half lines below their level. When the hand is strongly flexed, the transverse ridge on the front of the radius may be felt on the outside of the radial flexor tendon. The articular line is just below this. Strong flexion of the hand will also produce a rounded prominence at the back of the wrist. The summit of this projection is just below the joint. There are usually three transverse skin-creases in front of the wrist. According to Velpeau, the middle one overlies the articulation.

The circular and flap methods are both in use for the removal of the hand.

*Flaps* may be single or double. The former may be cut from either dorsum or palm. The single flap operation of Denonvillier's is performed as follows: The hand being prone and the skin strongly retracted towards the elbow by an assistant, the thumb and index finger of the surgeon are placed as guides on the styloid processes. A curved dorsal incision, with the concavity downwards, is made through the skin and areolar tissue, parallel with and two lines below the joint. Farther retraction of the skin and flexion of the hand expose the subcutaneous structures. Another cut similar, in direction to the first, divides the fascia tendons and posterior ligaments. The lateral ligaments are incised, and the knife, passed into the articulation and in front of the carpus, fashions an anterior flap two inches or more in length. Care should be taken to avoid the pisiform bone by the direction given to the edge of the knife. The tendons, if too long, should be clipped before adjusting the parts for suture. Avoidance of the pisiform is easier in theory than in practice. It may be safely stated that a neater result can be obtained by cutting on both sides from without inwards, whether in making one or two flaps. In figure 32, plate V. the palmar line of incision is traced. Figure 33, plate V. shows the position of the parts at the moment disarticulation is effected.

*Circular Method.*—One assistant supports the hand; another holds the fore-arm midway between pronation and supination, and retracts the integument. A circular cut is made through the skin at the base of the thenar and hypothenar eminences. The skin is dissected back and turned up high enough to expose the joint. A second incision at this point incises the fascia and tendons. The joint is opened from behind, and all its connections severed. The lips of the wound

are brought together transversely. In these operations the brachial artery must be compressed. The radial and ulnar always, and the interosseous sometimes require ligature. Figure 31, plate V. shows the knife applied to make the second incision. Some surgeons prefer to remove the styloid processes. They may be cut with bone pliers.

AMPUTATION OF THE FORE-ARM, says Legouest, may be performed at any height. The rule is to save as much as possible, although Larrey only favored operations above the lower third, as avoiding the danger of inflammation of the tendinous sheaths. Any of the standard methods may be adopted, but the circular is preferable in the opinion of most surgeons in the lower half. Baudens recommends the flap operation in muscular subjects, because of the difficulty of reflecting the skin. One or more lateral incisions, however, as already explained, in no wise injurious to the result, will obviate this objection. The French statistics show these to be the most successful of the larger amputations. In all cases the circulation in the brachial artery should be well commanded. And, on account of the free anastomosis of its branches, the tourniquet is found the best means of compression.

*Circular Method.*—The fore-arm is placed midway between pronation and supination, and held by an assistant, who retracts the skin. A second assistant supports the hand. The surgeon, armed with a double-edged, sharp-pointed knife, makes a circular cut through the skin and areolar tissue down to the deep fascia, two or three fingers' breadth below the point at which it is desired to saw the bone. The integument is detached from the fascia and turned up. A second circular cut is made to sever the muscles with a sawing motion, close to the margin of the reflected integument. The interosseous structures are cleanly divided on the same level, by transfixing the space obliquely on opposite sides of the limb; and the periosteum is incised as high as the retraction of the muscles, assisted by a three-tailed retractor, passed between the bones, will permit. The saw is applied to both bones at once, completes *first* the section of the radius. The radial, ulnar and interosseous arteries are tied, and the lips of the wound so applied as to give a transverse cicatrix. In figure 34, plate V. the knife is seen as applied for the second incision.

*The double flap operation* is thus described by Mr. Joseph

Lister: "In front, when the muscles are in large amount, transfixion may be adopted. Behind, the presence of the two bones prevents this, except near the wrist, where it may be effected, provided the soft parts have their natural laxity, by pinching up the skin and passing the knife as close to the radius and ulna as possible. When, after the integument has fallen back to its usual position, the extremities of the wound will be placed so far forwards, that the knife can be introduced through them in forming the anterior flap." "The surgeon standing on the (patient's) left side of the limb, [a matter of taste,] and holding it with the dorsal surface towards him, enters the knife a little to the palmar side of the bone that is further from him, and cuts through the skin and fat, so as to shape a rounded dorsal flap, terminating a little to the palmar side of the nearer bone, where he at once pushes in the point of the knife, so that it may pass in front of the bones, and emerge at the place where the operation was commenced, and cuts out a fleshy palmar flap downwards and outwards. He then dissects up the dorsal flap; and the soft parts being drawn back by an assistant, clears both bones thoroughly about three-quarters of an inch higher up, and applies the saw. If the median or ulnar nerve is exposed in the palmar flap, it should be shortened with the scissors to prevent the occurrence of painful symptoms as the stump heals."

DISARTICULATION AT THE ELBOW-JOINT.—This operation can be performed expeditiously only by those who are familiar with the configuration of the articular surfaces and the position of the ligamentous and tendinous connections. The joint is a ginglymus, into whose formation the humerus and both bones of the fore-arm enter. Figures 36, 37, plate VI. *a, c, d*. The lower end of the humerus presents within, an articular trochlea, surmounted in front and behind, by the coronoid and olecranon cavities, for the reception of the ulnar processes of the same name, whose larger sigmoid depression is adapted to the trochlea; without, a rounded head, which corresponds to a cup-like depression at the upper end of the radius. A groove separates the two. The antero-posterior curves of these surfaces are all segments of circles, varying in diameter. Marked non-articular prominences, easily distinguished through the skin, flank the parts just described. These projections, distinguished as the internal and external condyles



of the humerus, give attachment to the upper extremities of the strong lateral ligaments of the joint, whose lower ends are respectively connected with the inner margins of the coronoid and olecranon processes, and with the annular ligament. The latter is a fibrous band, thrown around the head of the radius to bind it to the lesser sigmoid cavity. Anterior and posterior ligaments also fasten the bones of the fore-arm to the humerus. The brachialis muscle is applied to the front of the joint, which is crossed by the tendon of the biceps and in part by the muscles, taking origin at the inner condyle. The brachial artery and median nerve descend on the same side, the radial nerve trunk lying without. The posterior aspect is in part covered by the anconeus and the extensor muscles of the fingers coming from the outer condyle. The ulnar nerve trunk crosses within the olecranon, which process forms a prominent sub-aponeurotic projection, rising half an inch above the interarticular line during extension of the fore-arm, and giving attachment to the triceps muscle, is to be distinguished through the integument, no matter how great the swelling. The recognition of the articular interline is generally derived from reference to the condyles. Its outer end is three and its inner six lines below the corresponding projection. As the condyles form the extremities of a horizontal line, the general transverse direction of the joint is oblique from without and above, downwards and inwards. Figure 36, plate VI. gives a front view of the elbow joint, in which *a* marks the humerus, *c* the radius, *d* the ulna, *b* the radial tuberosity of the humerus, *f* the trochlea, *e* the articular interline.

*Circular Operation.*—The articulation recognized, the brachial artery commanded and the fore-arm held extended and supine, a circular cut through the integument fat and superficial, down to the deep fascia, is made about three fingers' breadth below the joint. (Legouest recommends that this incision shall descend lower behind than in front.) This is dissected up and reflected on a level with the articulation. The muscles in front are divided; the lateral and anterior ligaments incised; the joint entered from before; disarticulation is effected, and the operation completed by severing the attachments of the triceps. The brachial is the only large arterial trunk cut.

*Flap Operation.*—A good single flap may be obtained from

the fleshy mass before the joint. In doing this, the fore-arm is supine, and at first slightly flexed. The part is transfixed on the palmar side of the bones by a sharp pointed straight blade, making its entrance and exit half an inch below the external, and an inch below the internal condyles, cutting downwards and forwards, a curved flap at least three inches long is obtained—this is turned up. The fore-arm being now extended and the integument drawn towards the shoulder, a transverse cut behind the limb connects the points of transfixion. Disarticulation is performed, as in the circular operation. The radial and ulnar arteries will demand ligation.

*The double flap operation* of Guerin may, under some circumstances, be found advantageous. This surgeon transfixes the fore-arm obliquely, entering the knife in front of the radius, carries it across the neck of that bone on the outside, making exit beyond its posterior surface, cutting a fleshy flap from the antero-external portion of the limb. The other is obtained from the opposite aspect, and is shaped by incising from the skin towards the bone. It is stated that a good stump may thus be made.

AMPUTATION OF THE ARM.—Here, as elsewhere, we attempt to save as much as possible, although Larrey favors separation at the shoulder-joint in preference to amputation near the tuberosities. Even French statistics, however, show the former operation to be more fatal, and Guthrie is so impressed by his experience as to counsel section below the joint whenever possible.

The English and Eastern surgeons select the method by flaps. The circular operation is the choice of the French. In this it is directed that the cut shall descend to a lower level behind than in front, when the amputation is high up. The front and back of the humerus are well covered by soft parts, which encroach on the inner margin, along its lower half, leaving the outer edge nearer to the integument. At the upper third, most of the muscles, except the deltoid, are inserted more or less at right angles to the long axis of the bone, and tend to separate from it as soon as cut. A single large artery traverses the whole length of this segment of the limb. The arm is well adapted to the *circular operation*—whose performance here presents no peculiarities, except that in a healthy state of the tissues, it is unnecessary to reflect the skin like a cuff. Slight dissection permits it to be retracted.

The more superficial muscular fibres are incised close to its margin; farther retraction permits a higher division of the deep muscular substance, giving the desired hollow cone. The bone is sawed at its apex.

*The flap operation* may be double or single. Flaps of equal, or unequal dimensions, are cut from the front and back of the limb by transfixing on opposite sides of the humerus. The patient being in the recumbent posture, the arm is extended at right angles to the body. The surgeon grasps and lifts, with his left hand, the soft parts, which are pierced with the catlin an inch, at least, below where the bone is to be sawed. Cutting downwards obliquely until the desired length is obtained, from two to three inches, the knife is turned suddenly outwards to finish the rounded end of the first flap. This is not reflected at once. The same process is repeated on the opposite side. To avoid an encounter between the bone and the knife-point, and to secure a more even margin to the second flap, it is found best to transfix somewhat below the original points in beginning its formation. The flaps are now turned up and well retracted by an assistant. A circular sweep of the knife divides all the textures between their bases down to and through the periosteum. The bone-section finishes the amputation. Great expedition is attained by transfixing to make a single large flap on one side, whilst the remaining tissues are incised circularly.

*The oval method* is recommended by Guthrie in amputating just below the tuberosities. While the subclavian artery is controlled and the limb extended, an incision is begun two fingers' breadth below the acromion process; it descends obliquely in the front of the arm just beyond the attachment of the pectoralis major, crosses on the inner side of the limb, and meets the end of, or is continued to make, another cut behind similar to, and starting from, or terminating at, the same point where the operation begun. The skin is retracted, the muscles divided, the bone cleared to the desired height, and the saw applied. The nerves should be shortened with the scissors before closing the wound.

The rectangular method of Mr. Teale has been practised with good result. In figure 44, plate VII. Teale's rectangular incisions are traced. For a description of the operation, see "general considerations."

In figure 42, plate VI. the appearance of double flaps is in-

licated. Figure 44 shows transfixion and the line of section for an anterior flap.

**AMPUTATION AT THE SHOULDER-JOINT.**—According to Legouest, the mortality is 12 per cent. greater in this operation than in amputations of the arm in continuity. Yet the results are most satisfactory, for his compatriot Larrey saved ninety out of a hundred cases.

The shoulder joint is an enarthrodial articulation, in which the large spheroidal head of the humerus is applied to the shallow glenoid cavity of the scapula. A loose fibrous capsule, strengthened in front by the expansion of the coracohumeral ligament, connects the circumference of the cavity with the anatomical neck of the os brachii. The tendons of the four rotator muscles are also blended with this capsule in proceeding to attach themselves to the humeral tuberosities. The upper tendons of the biceps coraco-brachialis, and triceps, surround the articulation. The long head of the former lies within the capsule. These parts being all capped externally behind and in front by the thick fleshy mass of the deltoid, are overhung and roofed in by the outer end of the clavicle and the prominent acromion process of the scapula. The latter, easily seen and felt, form excellent guides to the position of the joint. Within the acromion, with which it is connected by a ligament, and from which it is separated by a short space, is found the coracoid process, whose tip can be felt just below the collar bone. The axillary vessels and nerves cross the joint on its inner side. Figure 45, plate VII. is intended to show the skeleton of the parts described.

Of the various methods proposed for amputation at the junction of the humerus and scapula, Lisfranc's and Larrey's yet hold the first place in the esteem of surgeons. The one is a double flap, the other an oval operation. Malgaigne, Jacob and Bourguery, Bernard and Huette, Guthrie, with others who have followed, differ, among themselves, as to the steps advised by Lisfranc, and are by no means so clear in their account of his operation as might be wished. It is the most expeditious, and may be easily performed, circumstances favoring, in accordance with the following directions:

*Lisfranc's Method.*—The arm is raised from the side, so as to relax the deltoid, a long straight knife is entered below the clavicle, between the coracoid and acromion processes, and is passed around the joint, above and behind, so as to emerge

close in front of the posterior axillary fold. If the left limb is the subject of operation, the direction of the transfixing knife is reversed. A large postero-external flap is rapidly cut. This is elevated and held up. The arm being now depressed and carried inwards and forwards, disarticulation is effected by incising the tendons about the joint and the capsular ligament. The head of the bone is next withdrawn from its socket, that the knife may pass around it and descend along the inner surface of its shaft. During this last step, the humerus is again elevated, while the hand of an assistant follows the blade, to grasp the structures between it and the axilla and compress the artery before its division and the completion of the short antero-internal flap.

This operation is rarely available in civil and, perhaps never, primarily, in military practice. Its satisfactory performance demands the continuity and leverage of the humerus.

“On the other hand,” says Mr. Joseph Lister, (Art. Amputation, Holmes’ System of Surgery,) “Larrey’s mode of operating by lateral flaps of equal size, proved almost always applicable in his cases of gun-shot wound, while it was as secure against hemorrhage as that of Lisfranc. Thrusting the point of a knife, of moderate length, down to the bone immediately below the acromion process, Larrey first made a longitudinal incision, about two inches in length, from the extremity of which he cut in a curved line at each side of the limb to the fold of the axilla; then dissected up the flaps so as to expose the articulation completely, a finger of an assistant being placed on the divided circumflex artery; and having severed the connexion of the head of the humerus, passed the knife around it, and kept the instrument close to the inner side of the bone, till, turning the edge towards the surface, he last of all divided the tissues intervening between the axillary folds, containing the artery, previously commanded by the hand of an assistant following the knife.”

Dupuytren transfixed at the base of the deltoid, horizontally, beneath the acromion process, and cut a single long external flap. Guerin makes a flap from the same parts by cutting from without inwards. The circular operation may occasionally be practised with good result; but circumstances often arise for which no specific rules can be given. The surgeon, governed by his judgment, must turn to the best advantage the soft parts that are available for covering in the

necessary wound ; and, even when these are deficient, he may hopefully trust to the granulating process, as shown in some of Larrey's cases, which terminated satisfactorily, despite extensive loss of tissue and the removal of parts of the scapula.

Figure 46, plate VII. shows the primary line of incision, and figure 47, the terminal step in Larrey's operation.

In figure 48, the mode of disarticulation, and figure 49, the line of incision for the external flap of Guerin.

Figures 50, 51, plate VIII. indicate the first and last steps in Lisfranc's operation. *C* and *a*, figure 51, correspond to the points of transfexion ; *b* is the outline of the flap.

### Amputations of the Lower Extremity.

The general rule, with regard to saving as much as possible, is, within certain limits, as applicable to the foot as to the hand. The observance is carried so far by some surgeons, that the distal and middle phalanges of the lower limb are cut in their continuity ; although, except in the case of the great toe, it was at one time thought useless even to disarticulate beyond the tarsal joint.

The conservative inclination of the operators of the present day is good. It is well to recollect that the loss of several toes impairs the facility of locomotion, and that the value of the parts increases from the fifth to the great toe. The last-named is the most important of the series. The head of its metatarsal bone, contrary to the precepts of Dupuytren, should always be preserved. It forms one abutment of the plantar arch. When the amputation of three or four of the larger toes is imperative, Legouest (*Chirurgie d'Armee*) recommends the removal of the whole range, as affording a more convenient organ.

In all amputations of the inferior extremity, unless otherwise stated, the patient is supposed to be placed in the dorsally recumbent posture. In operations in front of the ankle-joint, the parts to be sacrificed do not necessarily project beyond the margin of the operating table. When the separation of the foot or its segments is in question, the circulation may be controlled by pressure on the popliteal artery. Some of the British surgeons, however, prefer so to adjust the tourniquet as to act especially on the two tibial vessels.

The foot is constructed on the same type as the hand, with such modifications as adapt it more particularly to the functions of progression and support. Solidity and great increase of dimensions distinguish the tarsus. The several pieces of the metatarsus are arranged on the same transverse plane and are connected at both extremities; while the terminal segment appears, so to speak, atrophied, when compared with the corresponding part in the upper limb. The phalanges and metatarsal bones are the same in number and in the general configuration of their shafts and articular ends. The arrangement of the ligaments, tendons and other soft parts is so similar as to render farther consideration unnecessary, unless to remark that the *metatarsal* heads are farther from the interdigital web than are the *metacarpal*.

Figure 52, plate VIII. shows the skeleton of the foot and ankle: *a, b*, the bones of the leg; *c*, the astragalus; *d*, the os calcis; *e*, the scaphoid bone; *f*, the cuboid; *g, h, i*, the three cuneiform. The numbers indicate the several pieces of the metatarsus, and *k, k, &c.*, the phalanges.

THE AMPUTATION OF THE PHALANGES, whether in the continuity or in the contiguity, beyond the metatarsal articulations of the first row, may be conducted on the principles applicable to like operations on the fingers.

DISARTICULATION OF A SINGLE TOE.—In this operation, the oval and flap methods are in use.

*Oval Method.*—This is similar to the one practised on the fingers. While the toe is commanded by the thumb and fingers of the left hand and slightly flexed, an incision, begun on the dorsum behind the metatarsal joint, is carried obliquely forwards to one side and descends to the web, or to its level. It then follows the transverse depression of the skin, and rising on the opposite side, joins itself a short distance in front of the articulation. The successive division of the tendons and ligaments sets free the bone to be removed.

*Double lateral flaps* are objectionable on account of the consequent plantar cicatrix. Figures 53, 54, plate VIII. sufficiently indicate the nature of the procedure requisite to their formation. A *dorsal and plantar flap* may be obtained, in the case of the great and little toes, by traversing the dorsal and plantar surfaces, each with a curved incision, convex forwards, starting from the interdigital web and meeting its fellow on the opposite side, just behind the metatarsal joint. A

somewhat similar result is obtained by dividing, with a circular cut, the soft structure clothing the proximal phalanx on a line with the web—which section is met by a straight, antero-posterior incision along the margin of the foot, near its dorsum—sufficiently prolonged to permit disarticulation, after the consequent flaps are detached and reflected. The last operation presents the advantage of ensuring an abundant covering for the expanded head of the first metatarsal bone.

Figure 53, plate VIII. shows the formation of lateral flaps in disarticulation of the great toe. The dotted line traces the proper length of the outer flaps. In figure 54, the last stage of a similar operation on the little toe is represented.

DISJUNCTION OF ALL THE TOES demands for its performance the same steps as the disarticulation of the four fingers. The unequal length of the metatarsal bones gives a curved direction to the general articular interline, whose concavity looks backwards. The ends of this line are usually recognized with facility. An incision, parallel with the joints and two lines in front of them, descends at its extremities as low as the plantar surface of the phalanges. This divides skin, fasciæ and tendons. The knife passed beneath the bones, after disarticulation, shapes a plantar flap, whose margin reaches almost to the web. If the tissue of the sole is deficient, a dorsal flap is furnished by advancing the line of the first incision, while its ends are prolonged horizontally to the site of the extreme joints. The plantar flap may be also fashioned by cutting from without, as practised by Guerin. The *circular method* has been applied in this region. Figure 55, plate IX. traces the dorsal cut. In figure 56, the sole of the foot is presented, while the margin of the plantar flap is being shaped.

AMPUTATION OF THE METATARSUS IN THE CONTINUITY.—Transfix horizontally the plantar structures, in front of the line on which it is intended to saw the bones, cutting forwards until the desired extent of tissue is detached, turn the edge of the knife down and finish the flaps. The dorsal division is made from the skin towards the bone. Incise the interosseous soft parts, clear the bones, apply a six-tailed retractor and use the saw. Figure 57, plate IX. shows the application of the saw and retractor.

SINGLE METATARSAL BONES may be cut in their continuity with bone-pliers, the chain, or metacarpal saw, after the prolongation backwards of the dorsal or marginal incisions



practised for the removal of the toes at their roots, and the dissection required to clear the bones.

**DISARTICULATION OF THE METATARSAL BONES.**—Fracture generally demands the section of these bones in front of their carpal extremities. After frost-bite, it is regarded better surgery to disarticulate. They may be separated isolatedly or collectively.

At their bases the metatarsal bones resemble the metacarpal. They are tied together by dorsal, plantar and interosseous ligaments, and form an irregular line of junction with the anterior pieces of the tarsus, whose general articular curve is interrupted by the forward projection of the two extreme cuneiform bones. There results therefrom a deep recess for the reception of the second metatarsal bone. The inner cuneiform advancing thrice as far as the outer, proportionately overlaps the second metatarsal segment, with which it is connected by a strong, interosseous ligament. The external cuneiform also sends interosseous fibres to the second, as well as to the third metatarsal bone. Dorsal, plantar and lateral ligaments cover in the whole circumference of this compound joint. The individual articular surfaces are so nearly plain as to require no special description; and the general arrangement of the enveloping soft textures so closely assimilates to that of the analogous segment of the hand, as to do away with the practical necessity of a more detailed notice.

The extremities of the articular interline are thus recognized. Trace backwards with the finger the fibular margin of the fifth metatarsal bone—a very considerable prominence will be encountered belonging to the tarsal end of that bone, which projects a little behind the outer limit of the joint. A similar manœuvre on the opposite side of the foot reveals two slight projections close together. The depression between them marks the inner end of the articulation. As the prominences last mentioned are not always well developed, and as tumefaction will mask their existence, it is well to bear in mind that the desired point will be found nearly five-eighths of an inch in front of a transverse line reaching from the tuberosity of the fifth metatarsal bone, which process can nearly always be felt; and is also one inch in advance of the plantar process of the scaphoides. The movements which the first metatarsal piece can be caused to execute, will afford further assistance in the search for the joint.

**THE FIRST METATARSAL BONE.**—The carpal articular surface of this bone is a slight concavity, with the long diameter vertical, adapted to the convexity of the corresponding cuneiform. A line drawn through the joint across the foot will strike the shaft of the fifth metatarsal at its middle. *The oval*, or, more correctly, the battledore incision (*incision en raquette*) may be practised for its entire removal, as seen at figure 58, plate IX. After the ligaments are divided, and the disarticulation is complete, section of the strong tendon of the peroneus longus will be required to set free the bone.

It is desirable to avoid the dorsalis-pedis artery, where it descends in the first interosseus space to communicate with the plantar arch. Dissection close to the bone, while clearing it, will usually prevent this accident.

In Lisfranc's method a single internal flap is made by transfixing from back to sole, to cover the section of the interosseus structures accomplished by the same manœuvre.

No operation on the foot can be commended, which (as this does) gives a plantar cicatrix. It is only properly admissible when the character of the injury to the sole precludes the adoption of other methods.

**THE DISARTICULATION OF THE FIFTH METATARSAL BONE** is executed on the same principles as that of the first. The joint is found by reference to the prominent extremity of the bone to be excised, easily felt through the integument. The articular surfaces are flat. A line drawn through the joint across the foot will strike the proximal end of the first phalanx of the great toe. In this operation the tendons of the two shorter peroneal muscles are cut. The lines of incision for the *oval method* are given at *a b*, *a c*, figure 59, plate IX.

**THE SECOND, THIRD AND FOURTH METATARSAL BONES** are removed, by preference, in accordance with the directions for the *oval method* of disjoining the same bones of the metacarpus. *A, b, c*, figure 60, plate IX. mark the dorsal cuts.

The oval operation is said to be applicable to the simultaneous disarticulation of the two outer metatarsal bones. The loop of the cut, embracing the roots of both toes, is shown at figure 61, plate IX. But Beclard has proposed an ingenious means for the concurrent disjunction of the first and second of these bones, which may be applied with equally good result to the removal of the fourth and fifth. Two incisions are begun on the dorsum of the foot, on a line with the joints

to be opened, separated by a distance nearly equal to the combined width of the carpal ends of the bones to be removed. Each of these cuts proceeds obliquely forward, so that the two cross about midway between the tarso-metatarsal joints and the roots of the toes—the one descending to the interdigital web, the other to a corresponding point on the outside of the little, or the inside of the great toe, (in accordance with the bones to be excised.) The two join in front on the plantar aspect, by following the web and skin creases. The triangular dorsal flap, embraced by the posterior half of these incisions, is detached to and turned back. This step exposes freely the articulations. They are entered, disjunction is accomplished, and the bones isolated. The flap is now laid down, and the lips of the wound beyond brought into apposition. The two cuts form a St. Andrew's cross on the back of the foot, and the consequent cicatrix is like a Y, with an oblique lower limb.

**THE DISARTICULATION OF THE WHOLE METATARSUS.—**  
*Lisfranc's Method.*—This is an operation performed without much difficulty, if the operator retains a distinct remembrance of the character of the articular interline of the tarso-metatarsal joint. See page 229. The surgeon grasps the sole of the foot in front, and applies the fore-finger and thumb as guides over the extremities of the joint, whose position is discovered by the means already indicated. A curved cut, convexity forwards, dividing all the soft tissues, is made across the dorsum, half an inch in advance of the articulation. Care should be taken that it starts and terminates just below the level of the bones. Disjunction is best begun on the outside, and is carried as far as the second metatarsal bone. The first metatarsal bone is next separated, leaving the second still in place. The point of the amputating knife is thrust obliquely downwards and backwards between the inner cuneiform and the bone in question; keeping the point fixed, the handle is pushed back until the instrument is perpendicular to the foot. This procedure divides the strong, interosseus ligament on the inside, and is repeated at the outside. Disarticulation is now easily effected. All the bones being dislocated, the knife is passed below their bases and the front of the foot is raised to its natural level; when a plantar flap is fashioned by cutting forwards almost to the web on the inside, and to a less advanced point without. Some of the British surgeons direct transfexion

across the sole, immediately after the dislocation of the first and fifth metatarsal bones. The disarticulation of the fourth, third and second, forming a subsequent stage of the operation.

Lisfranc's method of dividing the interosseous ligaments is an unnecessarily violent process, and is not unapt, even in skillful hands, to separate the cuneiform bones. A stout scalpel is well adapted to their section. It is only requisite to push the blade steadily back to the desired depth.

Mr. Hay, of Leeds, saws off the rather unsightly projection of the inner cuneiform. Mr. Skey avoids the disarticulation of the second metatarsal, and cuts it with bone pliers on a level with the cuneiform surfaces. Either of the proceedings just indicated affords a more regular bone stump, obviates the difficulty experienced in ossification of the ligaments, and prevents the formation of a pus pocket. Guerin traces a plantar flap accurately through the skin by an incision reaching to the sesamoid bones of the great toe on the inside, and on the outside to the junction of the middle and anterior thirds of the fifth metatarsal bone. It is finished by transfixing and cutting forward to divide the subcutaneous structures. Figure 62, plate X, indicates the position and direction of the dorsal cut; figure 63, the division of the interosseous ligaments, according to Lisfranc. In figure 64 the knife is shaping the anterior margin of the plantar flap. Figure 65 gives Guerin's method of tracing this flap.

**TARSAL DISARTICULATIONS.**—Two principal operations are performed on the tarsus; one called the *medio-tarsal* amputation, the other the sub-astragalian operation. After the first, the os calcis and astragalus, both retain their position. After the second, the astragalus alone remains.

The tarsus consists of seven pieces, differing in dimensions, and unlike in conformation, arranged in two groups placed one behind the other. The posterior group embraces the two largest bones, the astragalus and the os calcis; the former resting upon and articulating with the latter. In the anterior group are five bones—the scaphoid, the cuboid and the three cuneiform. The first two lie side by side, and form, with the bones of the posterior group, the medio-tarsal joint, the general direction of whose interline is transverse. Viewed more closely, however, and from above, this line, like the clavicle, presents a double curve. Its inner half traces the junction between the elliptical convex head of the astragalus, opposed

to the less extensive concavity of the scaphoides, while its outer half bounds the reciprocal surfaces of the os calcis and cuboides. The last-named surfaces are sinuous. The os calcis encroaches on the dorsum of the cuboid internally, and the cuboid on the plantar aspect of the os calcis externally.

The cuboides is bound to the calcaneum by four ligament: two are plantar; one, dorsal; the fourth, internal, interosseous and very strong. The os calcis is also attached to the scaphoides by two fibrous bands; one above, the other below. The last is a dense ligament. It stretches from the inner and front part of the os calcis to the contiguous margin of the scaphoid bone. Its upper surface, serving to complete the concavity intended for the reception of the astragalian head, is lined by a synovial membrane. A single broad, but feeble band connects the dorsum of the scaphoid with the astragalus.

The medio-tarsal joint is recognized by reference to the plantar projections of the scaphoid and cuboid bones. These occupy the opposite margins of the foot, and, when swelling is absent, can generally be distinguished by the touch. The ends of the inter-articular line are found immediately in the rear of these prominences.

The *inner* extremity of the articulation is also placed one inch *in front* of the corresponding malleolus; the *external*, half an inch *behind* the tuberosity of the fifth metatarsal bone. Forced extension of the anterior tarsal bones will render manifest the head of the astragalus. The consequent prominence will mark the middle of the joint.

**THE MEDIO-TARSAL AMPUTATION.**—*Chopart's Method.*—Chopart practised a transverse dorsal incision, two inches in front of the malleoli, descending along the margins of the foot. The resultant flap was elevated and the articulation opened. Two lateral cuts, starting from the ends of the first, and meeting on the plantar region far enough forwards to secure a sufficient covering for the exposed cartilages, circumscribed the remaining soft parts. Subsequent sections of the deeper structures set the bones free. (*Vidal, op cit.*)

*Modern Process.*—As in disarticulation of the metatarsus, the operator's left hand grasps the sole of the foot, resting the thumb and index finger on the respective tuberosities of the scaphoid and cuboid bones. Behind these points, a curved dorsal cut, dividing the soft structures half an inch in advance of the joint, is made to begin and end. The articulation may

be attacked at either side, but is more easily entered at its inner aspect, care being taken to apply the knife two lines behind the process of the scaphoides, and to direct the edge of the instrument obliquely forwards and outwards. The division of the dorsal and interosseous ligaments, combined with downward pressure on the bones to be removed, will cause the joint to open widely. The blade, passed in, divides at a single cut the plantar bands, slips beneath the bones and shapes an inferior flap, almost as long as in the tarso-metatarsal operation.

A too great advance of the dorsal cut on the inner side, sometimes leads to the separation of the cuneiform bones. The scaphoides, thus left in position, should not be retained. Its preservation, by sparing the tendon of the tibialis posticus, would involve an increased tendency to permanent elevation of the heel.

*Sedillot's Method.*—The site of the articulation is determined as before. A transverse incision is carried from the outside of the calcaneo-cuboid joint, to the same side of the anterior-tibial tendon, over the back of the foot. From the termination of this, a curved cut passes obliquely forwards and downwards, to within two fingers' breadth of the distal end of the fifth metatarsal bone, descends on the inner margin and crosses the sole of the foot, to reach the point at which the operation was begun. The flap embraced in the line of incision is dissected up to the joint and the operation completed by the separation of the bones.

**THE SUB-ASTRAGALEAN AMPUTATION.**—The two bones of the first row of the tarsus are placed one above the other. The astragalus rests upon and articulates with the front part of the os calcis. The articular surfaces of the latter bone, two in number, are separated by an oblique groove, directed backwards and inwards. Of the two facettes presented to be astragalus, the posterior is broad and convex; the anterior, narrow and concave. Conversely fashioned facettes, of similar outline, are found on the under surface of the astragalus, also parted by a groove.

When the two bones are *in situ*, the opposed grooves form a canal, filled, in the recent state, by dense interosseous fibres, constituting a strong bond of union between them. A special external ligament belongs to this joint and a posterior is also described. The lateral ligament of the ankle crosses and pro-

fects the inside of the articulation. The tendons of the toes and foot surround and consolidate the parts.

Malgaigne, Roux, Verneuil and Nelaton are each reported to prefer a different line of incision in the performance of the operation in question. By each, a flap is circumscribed and dissected up before the joint is attacked.

Malgaigne severs the skin and tendo-Achillis, grazing the upper margin of the calcaneum by a horizontal cut, which continues its direction on the outside, passing one-third of an inch below the malleolus, then turns abruptly over the back of the foot, an inch in front of the ankle-joint, to descend within and reach to the middle of the sole. At this point, it is met by an incision prolonged from its place of commencement across the inside of the foot, so as to outline an internal inferior flap, four or five inches wide at its base and two or three at its rounded termination.

The incisions of Roux, Verneuil and Nelaton are all of more or less elliptical, or rather of battledore, outline. Each is begun and ended on the outside of the os calcis, near its upper margin, and half way between its posterior extremity and the outer malleolus; each crosses the dorsum of the foot in an oblique curve and descends on the tibial side of that organ. Roux retraces on the sole the cut on the back, advancing on both surfaces half an inch in front of the junction between the astragalus and scaphoid bones. Verneuil carries forward his dorsal cut to within an inch of the fifth metatarsal bone on one side, and over the middle of the first cuneiform on the other. He makes the plantar part of the incision more decidedly oblique. Nelaton crosses the sole more transversely. All the incisions referred to, divide the soft structures down to the bone, and all have for their object the conservation of a well-nourished covering for the face of the stump, well adapted to sustain pressure without detriment to its integrity.

Observing Malgaigne's directions, the following steps succeed the detachment and elevation of the flap. The surgeon, assured of the lateral limits of the medio-tarsal articulation, opens widely the scapho-astragalean joint, so wielding the knife as to incise, at the same time, the outer ligament of this joint and enter the anterior synovial cavity beneath the astragalus. He should also cut that part of the inner ankle ligament which descends to the calcaneum and open the posterior articulation of the latter bone with the astragalus. Subsequently, the long flexor tendons are severed.

The interosseous ligament, which occupies the calcaneo-astragalean canal, still remains untouched. Its destruction is thus accomplished: The point of the knife, with the blade held flatwise and the edge directed backwards and outwards, enters and is pushed beyond the anterior joint of the os calcis with the astragalus. The section of a few fibres of the ligament attacked causes the others to yield and complete separation of the bones is soon effected. The arteries tied, the flap is adjusted and the margins of the wound sutured. Malgaigne highly lauds his process, which he practised with success in two cases, and which has been repeated by other surgeons. The method of Malgaigne gives easy access to the joint, but Legouest (*Chirurgie d'Armee*) seems to prefer the incisions of Verneuil.

In figure 68, plate XI, the line of Roux's incision is traced.

The partial amputations of the tarsus, although rarely fatal, have fallen into disfavor with many surgeons, because of their ultimate results.

The medio-tarsal operation is especially reprehended as of doubtful propriety, because of the disposition of the stump to dip in front and rise behind. This tilting throws the weight of the body more or less on its anterior extremity, producing pain and lameness; and where the cicatrix is too low, causes ulceration and other unpleasant complications.

As section of the tendo-Achillis, either during or after the operation, does not prevent the permanent elevation of the heel, Legouest concludes this deviation from the natural condition to be the effect of a general retraction of the fibrous tissues behind the tibio-tarsal joint. (*Chirurgie d'armee.*) He seems to forget that the post-tibial and long peroneal tendons, folded over the end of the bony stump in bringing up the plantar flap, very probably gain, from their new attachments, a considerable leverage, which may be manifest after division of the tendo-Achillis. The degree of power with which the foot is extended after complete ablation of the os calcis, affords some foundation for this belief. The writer, with all proper modesty, suggests the clipping of the tendons of the tibialis and peroneus, in addition to division of the tendo-Achillis, as a possible means of preventing the deformity and consequent interference to easy progression referred to.

The necessarily tedious character of the sub-astragalean operation, does not recommend it for field-practice.



Pirogoff's resection is performed with greater facility, gives as long a stump, and so far as at present known, is quite as successful.

**AMPUTATION AT THE ANKLE-JOINT.**—The astragalus tibia and fibula enter into the formation of this joint. The lower surface of the tibia rests upon the astragalus, and the two malleoli embrace its sides.

Three strong fibrous fasciculi descend from the outer malleolus. The anterior and posterior attach the astragalus, the middle one connects the os calcis with the fibula. The three taken together constitute the *external* lateral ligament. The *internal*, broader below than above, is called the deltoid ligament, and ties the inner malleolus to both bones of the posterior-tarsal group.

A feeble fibrous band closes the front of the joint, which is crossed by the tendons of the tibialis anticus, peroneus tertius, and long extensors of the toes, as well as by the anterior tibial vessels and nerve.

The tendons of the two longer peroneal muscles, of the tibialis posticus and long flexor of the toes, descend laterally: the former behind the outer, the latter in the rear of the *inner* malleolus. The proper flexor of the big toe grooves behind, both tibia and astragalus. The post-tibial and peroneal arteries are placed at opposite sides in the rear.

The principal methods of amputating at the tibio-tarsal articulation, are two in number. Each is a candidate for the favor of the profession. Each has its advocates. One is a Russian, the other a Scotch invention. They bear the names of the surgeons who have suggested and practised them. One is called Syme's, and the other Pirogoff's operation. As will be learned from their description, neither is necessarily a tibio-tarsal disarticulation. The operation of Mr. Syme is one of such theoretical excellence, and gives, when successful, so useful a stump, that we prefer to transcribe bodily the account of its different steps furnished by Joseph Lister, Professor of Surgery in the University of Glasgow. (Holmes' System of Surgery.)

*Syme's Ankle Operation.*—"In the amputation of the ankle, devised by Mr. Syme, the bones of the leg are divided just *above* the malleoli; a covering for the osseous surface being provided from the integuments of the heel, fitted by the character of its epidermic investment and subcutaneous cushion, for bearing the weight of the body.

“Hence, the end of the stump becomes as capable of sustaining pressure as the natural sole; and when the deficient spring of the arch of the foot is compensated by some elastic material contained in a very simple boot, the limb proves nearly as useful as in the normal condition. At the same time, the parts likely to originate carious disease are completely got rid of, so that this operation is calculated to supersede entirely that of Chopart, beside taking the place of amputation of the leg in the majority of cases formerly supposed to demand it.

“The operation should be performed as follows: Provision being made against hemorrhage from the anterior and posterior tibial arteries, by pressure of the thumb and finger of an assistant, placed respectively on the middle of the fore part of the limb and behind the tibia, about two inches above the joint, or by a tourniquet applied over two rollers, occupying these situations, and the foot being held at right angles to the leg, the surgeon puts his left hand behind the heel, with the finger and thumb on the places where the incisions are to commence and terminate; these being the tip of the external malleolus, and the point exactly opposite on the inner side, *i. e.* not at the tip of the internal malleolus, but considerably below and behind it. With a knife short and strong, both in blade and handle, he now cuts down to the bone across the sole, from one of these points to the other, in a plane not quite vertical, but sloping slightly toward the heel, especially when that part is unusually prominent; and then, extending the foot, joins the horns of this incision by another, running as straight as possible across the front of the ankle.”

He next dissects up the posterior flap from the os calcis, keeping the edge of the knife close to the bone, with the guidance of the left thumb nail, till the point of the calcaneum is fairly turned, when he proceeds to open the joint in front, divides each lateral ligament with the knife applied between the malleolus and the astragalus, and completes the removal of the foot by severing the tendo-Achillis. He then prepares the bones of the leg for the application of the saw, taking care, when cutting behind the tibia, to keep close to its surface, from which the posterior tibial artery is separated only by a little loose cellular tissue; and lastly, he takes off the malleoli, with a thin slice of the intervening part of the tibia, sawing perpendicularly to the axis of the limb.”

“It is a common mistake to make the inner end of the incision at the internal malleolus, instead of opposite to the extremity of the outer one. This has two bad effects: it renders the flap unsymmetrical, and what is far worse, it makes it unnecessarily long, and thus introduces an element of difficulty and risk into an easy and safe operation. For when the incision is carried forwards to the hollow of the foot, it becomes a most troublesome task to turn back the integument over the prominence of the heel, and the knife being thrust, the operator knows not where, the subcutaneous tissue, on which the skin depends for its nourishment, is punctured and scored; and perhaps the point of the instrument appears occasionally through the skin itself, while the flap is subjected to violent wrenching in the effort to draw it back over the bony projection. Under such a combination of unfavorable circumstances, it is but natural that it should slough.

“On the other hand, when the flap has been made as above recommended, it applies itself with perfect uniformity to the surface it is designed to cover, and has no disposition to shift to one side in the after progress of the case; and every stroke of the knife by which it is raised being made under the eye of the surgeon, without any forcible traction, it is as little liable to slough as any other portion of integument, with an equally broad base and equally rich vascular supply. Even the integrity of the posterior tibial artery, though desirable, is by no means essential, provided the rest of the subcutaneous tissue has been left uninjured. Many persons, in discussing the merits of this operation, seem to assume as an axiom, that the sloughing of the flap must occasionally take place; but I am persuaded, from very extensive experience, especially in Mr. Syme’s practice, that if the skin of the heel be sound, such an occurrence will always be the fault of the operator

“Traumatic cases, in which the integuments are thinner than in chronic disease, are considered the most unfavorable; but though I have had occasion to perform the operation in several cases of this kind, *I have never met with the slightest sloughing.* The last instance was that of a young man, who, lying in a state of intoxication with his feet upon a rail, had the fore parts of both crushed by a train, and I amputated both at the ankle. The last intelligence that I have received of him is, that he was able not only to walk, but to run, and even to dance the Highland fling.”

Quain, Handyside, McKenzie, Teale, Roux, Baudens, Sedillot has each proposed his own method of limiting the integument in the amputation of the foot. Quain's first incision resembles that of Syme, but is met by a horizontal cut over the outside of the os calcis, reaching to the tip of the heel. Handyside makes two lateral flaps which join in front of the tibio-tarsal articulation, and on the back of the calcaneum. Teal divides the plantar structures transversely, three quarters of an inch in advance of the malleoli, and bi-sects the parts in the rear of this section as far back as the tendo-Achillis. Roux limits the tissues to be retained by two incisions, beginning one inch and a half behind the outer malleolus, and terminating three lines in front of the inner malleolus. One crosses the dorsum just before the ankle-joint, the other descends to the sole and slopes obliquely backwards.

McKenzie also practises two cuts. The first courses beneath the malleolus externus, stretching from the tendo-Achillis to the inner side of the tibialis anticus, two inches in advance of the malleolus internus. At these points, it joins the second, which outlines a large rounded flap on the sole, of sufficient extent to afford an abundant covering for the stump. Sedillot fashions a quadrilateral flap from the inner and plantar regions, while the outer and anterior structures are divided just below the joint.

The condition of the integument makes it occasionally necessary to adopt one or the other variety of incision just mentioned, or demands of the ingenuity of the operator an extemporaneous method for the adaptation of the uninjured parts to the ends in view. The incisions which will not expose the line of cicatrix to pressure, and which give a covering of the *plantar* integument for the face of the stump, are to be preferred.

Figures 69, 70, plate XI. are opposite aspects of the same foot, the dotted lines tracing in each the incisions of Syme. In figure 71, plate XI. the operation is seen at an advanced stage. The heel flap is turned up and disarticulation has begun. Figure 72, plate XII. indicates the position of the foot and the inner cut adopted by McKenzie; figure 73, the outer cut of the same surgeon; figure 74 is the inside view of a foot removed in accordance with Roux's method; figure 75 shows the stump after the ankle-joint operation.

*Pirogoff's method* is thus translated from the description

given by its inventor in the *Medical Times and Gazette*. I commence my incision close in front of the outer malleolus, carry it vertically downwards to the sole of the foot, then transversely across the sole, and obliquely upwards to the inner malleolus. Thus, all the soft parts are divided at once quite down to the os calcis. I now connect the outer and inner extremity of the first incision by a second semilunar incision, the convexity of which looks forwards, carried a few lines anterior to the tibio-tarsal articulation. I cut through all the soft parts at once down to the bones, and then proceed to open the joint from the front, cutting through the lateral ligaments, and thus exarticulate the head of the astragalus. I now place a small, narrow amputation saw obliquely upon the os calcis, behind the astragalus, exactly upon the sustentaculum tali, and saw through the os calcis, so that the saw passes into the first incision through the soft parts. Saw carefully, or the anterior surface of the tendo-Achillis, (posterior tibial artery,) which is only covered by a layer of fat and a thin fibrous sheath, might be injured. I separate the short anterior flap from the two malleoli, and saw through them at the same time close to their base. I turn this flap forwards, and bring the cut surface of the os calcis in apposition with the articular end of the tibia.

Croft, of the Dreadnought hospital, (*London Lancet*), adopts the following modifications of Pirogoff: The tissues are first divided across the front of the joint, carrying the ends of the requisite curved incision to opposite points *behind* both malleoli. The second cut, connecting the extremities of the first, *advances* toward the toes before traversing the sole, and is, therefore, *oblique forwards* during its descent to the plantar surface. After disarticulation, the soft parts are sufficiently detached from the os calcis to permit its section in the direction of a line connecting the posterior margin of its larger facet with the under edge of the articular surface for the cuboid.

It has also been proposed to saw off the back part of the calcaneum immediately after making the cut across the sole. Figure 75, plate XII. is an external view of the os calcis, the dotted lines indicating the different sections that have been practiced; *b, f*, is that proposed by Pirogoff; *a, e*, is Croft's line. Figure 77 shows the clearing of the bones previous to the application of the saw, according to Pirogoff.

It will be observed by the reader that Syme *always* saws the *tibia*. Handyside imitates him, and Pirogoff recommends the section of this bone in some cases, although he is usually satisfied to remove the malleoli. The difference is only three or four lines in the length of the resulting stump. A very natural question hence arises as to the necessity for disarticulating in the performance of either operation. The interrogation is especially pertinent when the removal of a slice of the tibia is demanded by the condition of its articular surface. Why subject the patient to the tedium of two operative procedures, when one will suffice? Disjunction at the ankle has already been proved not a pre-requisite to the section of the calcaneum. It is, indeed, even of doubtful convenience to the operator. The saw can be more easily steadied, and the bone to be cut more firmly supported previous to than after the separation of the foot from the leg. Why not, therefore, in *all* cases of Syme's operation, shorten the bones *without entering the ankle joint*? Will it not also be better to modify the process of Pirogoff, by always sawing both tibia and calcaneum, *without disturbing the articulation*?

In estimating the relative value of the operations of Syme and Pirogoff, it is well to refer to Mr. Lister's views, given above, (see page 238,) in relation to the sloughing of the heel flap, after the amputation of Syme. If this can be avoided by proper care in its dissection, Pirogoff's method will still recommend itself to the field surgeon as a more expeditious procedure. The comparative length of stump furnished by the latter is not, however, so advantageous as might be supposed. Some mechanical aid will be demanded in either case to bring the limbs to the same level. The piece of the os calcis, retained by the Russian surgeon, is said to encroach inconveniently on the space to be occupied by an artificial foot; besides which, the bone in question, in virtue of its structure and exposed position, is very subject to carious degeneration and other disturbances of nutrition exacting its entire removal. Lastly, while the stump of Mr. Syme is covered with integument, adapted by nature to sustain the weight of the body, that of Prof. Pirogoff presents tissues unaccustomed to constant pressure.

The very oblique line of section for the os calcis, adopted by Croft and others, tends to throw the line of support behind the axis of the tibia; and, by so much, to assist the power of

the extensor muscles connected with the tendo-Achillis, in straining the new structures which bind the fragment of the calcaneum to the bones of the leg. The experience of the profession, with regard to the relative merit of these operations, is not sufficiently extended to warrant an appeal to statistics.

AMPUTATION OF THE LEG in the continuity may be performed at any point between the tubercle of the tibia and the ankle-joint. The French place "the point of election" at from two to four fingers' breadth below the tubercle of the tibia. The English surgeons, in the Eastern campaign, are said to have paid but little attention to this point, usually operating as low as the nature of the injury would permit. The proclivity of the latter toward conservatism, seems to have been followed by no bad result as to mortality. They lost only *thirty-three* per cent. of their cases, while the French per centage amounted to *fifty-four*.

Along its upper half the muscular structures of the leg are greatly accumulated behind. In front the soft tissues project but little beyond the bones. The two peronei give a slender covering to the fibula without, while the tibia is sub-aponeuritic from knee to ankle. Tendons form a large part of the subcutaneous mass on the lower third of the limb.

The anterior and posterior tibial arteries always, and the peroneal usually, are cut in amputation at or below the point of election. When the bones are sawed as high as the tubercle of the tibia, the popliteal may be the only vascular trunk requiring ligature. The tourniquet may be applied over the popliteal just above the knee, or if this be found inconvenient, to the femoral artery. The patient is placed on a table of sufficient height, with the part to be removed well projected beyond its edge, and supported by an assistant. The circular, double and single flap, and oval method of amputation, has each been practised on the leg.

SUPRA MALLEOLAR AMPUTATION.—This expression is intended to include all operations on the lower half of the limb. *The circular method* has to be modified in this region. The skin, divided by a circular cut, is with difficulty reversed. Lenoir, therefore, counsels a vertical incision along the crest of the tibia, reaching the level of the intended bone section. The integument is then dissected up obliquely, and reflected in the form of an open collar. (Figure 78, plate XII.) The

musculo-tendinous parts are severed down to the bones on a line with the reflected collar, and drawn up. The interosseous mass is transversely divided, a retractor introduced, and the bones sawed on the same level. (Section of the fibula in this, and all other amputations of the leg, is completed first.) The edges of the vertical cut are sewed, and the integument is then adjusted as after the usual circular operation.

*Flaps.*—Guerin transfixes *close* behind the bones and cuts a flap of four fingers' length. An anterior curved incision terminates, on either side, at its base. The flap is dissected and reversed. The other steps are as for the circular method.

Mr. Teale has applied his rectangular flap method (see page 223) to the lower part of the leg. Double semi-elliptical flaps are sometimes made by transfixing behind, and cutting from the skin in front. Figure 78, plate XII. shows Lenoir's operation. The skin collar is laid open, and the muscular division begun. Figure 79 traces Guerin's incisions. Figure 80, the usual double flap method, and Figure 81, Mr. Teale's rectangles.

AMPUTATION AT THE "POINT OF ELECTION"—*Circular Method.*—1st. The skin, superficial fascia and fat are divided three or four inches below where the bones are to be sawed. The circular incision begins and ends on the crest of the tibia, and is made without removing the knife. The integument is dissected one and a half to two inches, and then reflected. 2d. The muscles are cut circularly down to the bones at the margin of the skin cuff, with a sawing motion of the knife. 3d. The interosseous structures are divided transversely. A three-tailed retractor is applied, the soft parts drawn up, and the periosteum incised around each bone. 4th. The saw is applied to the tibia, which it first grooves before the fibula is attacked. The section of the latter, as before mentioned, is first completed. 5th. The arteries are tied, and the lips of the wound brought together.

The following directions are given for the severance of the interosseous mass and the clearing of the bones, (although, to say the truth, the writer can scarcely conceive that the necessary steps would not suggest themselves to the mind of any operator :) The heel of the knife is applied to the outer surface of the fibula, and the instrument is drawn across the front of both bones. The interosseous space is next pierced from before backwards, with the blade held transversely to



the long axis of the limb. The opposite edges of the catlin are made to act alternately on the opposed surfaces and margins of either bone. The knife being withdrawn, is now applied to the inner aspect of the tibia, and drawn across the back of both bones. The interosseous space is transfixed from behind, and there is a reversed repetition of the steps already indicated. This is the method of Guerin, figure 83, plate III. The dotted lines, *a, b, c, &c.*, and Nos. 1, 2, are intended to mark the different positions assumed by the catlin.

When the bones are sawn transversely, the angle formed by the crest of the tibia, with its cut surface, is very sharp.

This prominence is unsightly, and, what is worse, disposes the integument covering it to ulceration. Therefore, some surgeons remove the bony angle *after* the transverse section of the hard tissues is completed, while others *precede* this cross cut with an oblique application of the saw to the *inner surface* of the tibia.

*The Single Flap Operation.*—The operator, standing on the right of the limb, gathers up and grasps the integument over its posterior aspect, so as to stretch evenly the skin in front. The fingers and thumb mark the points of transfixion. The knife is thrust transversely and *horizontally* from side to side, grazing the fibula, (which occupies a plane somewhat in the rear of the other bone,) or, in very muscular subjects, still farther back. A flap, four or five inches long, is now cut. A slightly curved, or perfectly transverse incision, divides the structures on the fore part and sides of the leg, at the base of the flap. The latter is turned up and retracted. The remaining steps proceed as in the circular operation.

*The double flap operation* of the English surgeons, as practised by Luke, Guthrie and others, is similar to that described above, except that the integument is not stretched backwards; the knife in transfixing is made to graze *both* bones, and an anterior flap, by cutting from the surface, is shaped, equal in length to the fleshy one behind.

Mr. Skëy transfixes horizontally three-quarters of an inch *above the palm of the left hand*, used to support the calf of the limb to be sacrificed; thus spreading out and flattening the soft parts behind and against the bones. This manœuvre is said to rid the posterior flap of an unwieldy bulk of muscular fibre, while sufficient integument is preserved to form a thorough covering for the stump. The grasping of the skin,

as above directed, with transfixion on a plane posterior to the bones, effects the same end. A similar result is obtained by first tracing through the skin the outline of the desired flap. After the retraction of the integument, the muscles are transfixed and cut in contact with its margin.

AMPUTATIONS ABOVE THE POINT OF ELECTION are executed by one or other of the methods just described. In these Larrey removed the fragment of the fibula, a proceeding deprecated by Liston and Syme, as destroying the attachments of the external lateral ligament, and as sometimes opening the synovial cavity of the knee-joint. The bone section should in no case be made above the tubercle of the tibia.

DISARTICULATION AT THE KNEE.—The statistics of both French and English armies in the Crimea would seem to demonstrate *this* to be a less successful operation than section in the lower third of the femur; indeed, it is almost as fatal as amputation at the middle of the thigh. A more extended comparison, however, of the results of European and American practice, military and civil, gives a per centage of six and a half in favor of the knee-joint operation. Its advocates claim that the liability to hurtful retraction of the soft structures, to ulceration of the cicatrix, and to pyæmia, is not so great as when the femoral condyles are removed; and that, when successful, it gives a longer and more useful stump.

The knee-joint, although a somewhat complex structure in an anatomical point of view, is, when considered with reference to amputation, sufficiently simple. Usually, the line of articulation is readily recognized, the joint is easily entered, and the bones forming it are separated with facility. The femur, tibia and patella furnish the articular surfaces. The os femoris presents below two condyles, adapted, by the interposition of fibro cartilages, to two shallow elliptical cavities on the upper end of the tibia. The femoral condyles are separated by a deep notch behind, but join in front to be prolonged upwards, and form a trochlea, fitted to the posterior surface of the patella.

The immediate bonds of union are a broad ligament, closing in the posterior aspect of the articulation; an internal ligament, tying the inside condyle to the tibia; an external ligament, connecting the fibula and outer condyle; and a very stout continuation of the rectus femoris tendon to the tubercle of the tibia, called ligamentum patellæ. Filling up the in-

tervals that would otherwise exist between the last three fibrous bands, are found expansions from the vasti muscles, blended with the fascia femoris.

Beside the circumferential fastenings just enumerated, there are two other ligaments within the joint, which descend from the opposed sides of the intercondyloid notch, and attach themselves, one in front of the other, to spaces between the glenoid cavities of the tibia. These are the crucial ligaments.

The articulation is still farther strengthened and crossed by the muscles of the leg and foot. In addition to the vasti and rectus, whose arrangement has already been indicated, the sartorius, gracilis, semi-tendinous and semi-membranous muscles descend within, to seek connection with the tibia; the biceps cruris without, to be inserted on the fibula.

The respective condyles of the femur give origin to the corresponding heads of the gastrocnemius; and the outer one, also, to the plantaris and popliteus muscles. Traversing behind the joint are the popliteal vessels and nerves.

Three bony prominences and the lower end of the patella form the guides of the articular interline. These are the tuberosities of the os femoris and the tubercle of the tibia. The two former project from the respective femoral condyles, attach the lateral ligaments, and of course occupy opposite lateral aspects of the limb; the latter is on the fore part of the tibia. The tuberosities are said to be each half an inch above, and the tubercle three-quarters of an inch below the joint, while the lower margin of the patella exactly overlies it.

All the standard methods of amputating have been applied by operators at the tibio-femoral articulation. Unless injured or diseased, the patella is usually retained.

*The circular operation* in this region implies a circular division of the integument four fingers' breadth below the joint, the skin being previously retracted, and subsequently reflected to its level. The joint is entered from the front by division of the ligamentum patellæ. The leg *extended* during the cut, though the skin is slightly *flexed* pending the division of the anterior ligament.

*Oval Method.*—In this an incision from without inwards traverses the front and sides of the limb, reaching at its centre two inches below the tubercle of the tibia, terminating laterally within two fingers' breadth of the joint. The integu-

ment thus circumscribed is turned up, the leg bent, the anterior and lateral ligaments cut, the joint entered, the crucial bonds divided, and the parts behind transversely severed from within. This gives, in effect, an anterior flap.

*Posterior Flap.*—Syme prefers to make a posterior flap, and saws off the condyles. Fergusson recommends the operation, which is thus performed: The limb being extended, a lunated cut, convex downwards, is made by drawing the knife from over one condyle across to the other, on a level with the middle of the patella. The short lip thus fashioned is drawn up, the extensor tendons are divided above the knee-pan, the parts behind the joint transfixed at the extremities of the first incision, and a six inch flap shaped from the fleshy part of the gastrocnemius. This retracted, a circular sweep of the knife clears the femur, just above the condyles, and permits the application of the saw. A similar division of the soft tissues lower down may be combined with disarticulation.

The condition of the tissues may demand two flaps of equal or unequal dimensions. These can be easily shaped from opposite sides of the part, although it is always desirable, if pressure is to be borne by the face of the stump, to have the line of cicatrix at its margin. A single long flap begets this result. Figure 86, plate XIII. shows the oval or anterior flap operation at the moment the joint is entered. Figure 87 traces the cuts in the posterior flap method.

**AMPUTATION OF THE THIGH.**—The os femoris, constituting the skeleton of this segment of the lower extremity, is well clothed with soft parts in nearly every aspect. It is proper, however, to bear in mind, that the fibres of the muscles on its inner and posterior regions are very *long*, reaching in some, as in the case of the sartorius from the pelvis to the knee. Since the retraction of a muscle after section is just in proportion to the length of those fibres, which retain their attachment, we may anticipate what may always be observed in practice: 1st, that the nearer amputation is to the leg, the greater must be the allowance made for muscular recession; 2d, that as the ascent of the tissues will be most obvious in the regions embracing the longest fibred muscles, an *evenly* shaped stump can only be secured by an *oblique* section of the limb. The cut should incline toward the knee in traversing the more *retractile* structures.

In all amputations of the thigh the tourniquet, if used to

control the circulation, should be applied as *far* as possible from the seat of operation. The skin should be strongly and evenly retracted by a careful assistant, previous to and pending its division; and, in order to secure more certainly against protrusion of the bone, it is well to detach the deep tissues from the periosteum an inch or more above their point of section. Here, as in the arm, the easy sliding of the skin in its healthy state upon the subjacent parts, ordinarily obviates the necessity for its reflection in the performance of the circular operation. The French surgeons rarely turn up a skin cuff. The English generally reverse about two inches of integument. The superficial and deep tissues are separately incised at different levels, the edge of the knife being slightly directed towards the proximal end of the limb, so as more effectually to shape the hollow cone, at whose apex the bone is to be sawed. Many operators divide with a *single* circular sweep of the knife, the whole muscular thickness of the limb.

A *single flap* may be fashioned by transfixing on one side of the bone, and dividing all the tissues on the opposite semi-circumference of the limb by a transverse cut. If this flap be taken from behind, the line of cicatrix will be drawn to the face of the stump; because of the superior retractility of the flexors of the leg. On the other hand, and for the same reason, if shaped from the front of the limb, it will hug and pad the end of the bone. In amputation in the upper third, where the bone is tilted forward by the action of the psoasiliac, a good anterior flap is regarded as especially desirable.

Mr. Guthrie, in his surgical commentaries, manifests a decided partiality for the *double flap operation*, as practised by Mr. Luke. He describes it at length. The following paraphrase will give the substance of his directions: The patient is so placed that the thigh projects beyond the table. The surgeon stands on the *right* of the limb to be removed. The knife to be used should be narrow, pointed, and two or three inches longer than the diameter of the limb at the seat of operation. The posterior flap is first to be formed by transfixing "transversely" behind the bone, and "midway" between the upper and lower surfaces of the thigh. The anterior flap is fashioned by repeated cuts from without inwards, curving evenly across the front of the limb and terminating at either end "near" the base of the first flap. The length of the anterior flap is determined by that of the posterior,

and varies accordingly "from four to six inches." The remaining soft tissues are incised by a circular sweep of the knife "where it is intended to saw the bone." The flaps being retracted, the bone is divided by the saw.\*

*Double skin flaps* are preferred by Mr. Skey. He directs that they should not be redundant. After their detachment and reflection, the long-fibred muscles are *first* severed and allowed to *recede*, when the remaining mass is divided by a firm circular sawing movement on a line with their retracted extremities.

*Mr. Teale's rectangular operation* is said to have been practised, with excellent results, at the lower third of the thigh. The specific directions for its performance will be found in the general considerations. (See page 202.) In figure 88, plate XIII. the upper dotted lines indicate the character of the anterior and posterior flaps. The lower lines trace lateral flaps. In figure 89, A, E, G, D, show the posterior flap and cut in Mr. Luke's operation. G, F, his anterior incision.

AMPUTATION AT THE HIP.—The hip, like the shoulder-joint, is an enarthrodial articulation. The os innominatum and the os femoris furnish the articular surfaces. The one presents a hemispherical concavity, (the acetabulum or cotyloid cavity,) deepened by a circumferential fibro-cartilage; the other, a spheroidal head, supported by a compressed neck, set at an angle of  $125^{\circ}$  to the shaft of the thigh bone.

One bond of union, the ligamentum teres, lies in the joint, and attaches its extremities near the centre of the respective articular surfaces; another, the capsular ligament, embraces the margin of the acetabulum and the neck of the femur.

A large muscular mass clothes the inner, outer and posterior aspects of the joint. At its fore part the articulation is comparatively superficial. Here, in thin subjects, the femoral head can be distinguished by the touch during the movement of the limb. Six bony prominences are found in the neighborhood of this joint. Two are deep seated and concealed; four are subcutaneous and easily recognized. The former are the trochanter minor and the anterior inferior spine of the ilium; the latter, the trochanter major, the anterior superior spine of the ilium, the spine of the pubes, and the tuberosity

---

\* It will be found better to transfix *obliquely*, so that the knife shall enter, or emerge lower on the inside than without.

of the ischium. These last, with the pubic symphysis, are generally regarded as points of reference in seeking the position of the joint. The trochanter major is not a good guide, because its position and relations are modified by the posture of the limb. When the weight of the body is equally supported by both extremities, and the toes are directed slightly outwards, the heels nearly touching, its most projecting point is two and a half inches outside of a vertical line drawn through the centre of the articulation, and is two inches below the level of the anterior margin of the acetabulum.

The other points of reference are relatively immoveable, and furnish reliable indications. The following statements are made by some authorities :

The anterior superior spine of the ilium is one and three-quarter inches above the upper margin of the cotyloid cavity, and three-quarters of an inch to its outer side.

A straight line, connecting the superior iliac spine and ischial tuberosity, crosses the acetabulum at the junction of its posterior with its anterior two-thirds.

The skin of the pubis is from one to one and a quarter inches from the anterior margin of the cotyloid cavity.

A line, coinciding with the axis of the horizontal pubic ramus, has one-third of the acetabulum above it.

The following measurements, obtained from a fully developed male skeleton, five feet nine and a half inches in height, are also presented :

The anterior superior spine of the ilium is two and a quarter inches above the highest point of the cotyloid cavity, and half an inch in advance of its anterior margin. The spine of the pubis is two inches, and the symphysis pubis three inches from the inmost point of the acetabulum. Both are one inch in advance of the joint.

The most dependent part of the ischial tuberosity is one inch and a half beneath the lower margin of the acetabulum.

As these data are all the result of observation made upon the bones, some allowance must be added for the possible thickness of the fascial and integumental coverings.

The three gluteal muscles and all the outward rotators get insertion on the trochanter major. The psoas-iliac, passing beneath Poupart's ligament (with the crural nerve in front of it) to seek attachment at the trochanter minor, covers the fore part of the fibrous capsule, and winds its tendon around the

neck of the os femoris. The femoral vessels descend vertically within the margin of this compound muscle, and approach the femoral shaft, forming, meanwhile, with it and the neck of the femur, a triangle of surgical value.

The obturator artery, escaping from the pelvis under the horizontal branch of the pubis, and the ischiatic, descending behind, between the ischial tuberosity and the greater trochanter, form with one another, with the circumflex and perforating vessels, numerous and free anastomoses, which preclude the power to control the circulation, at the upper part of the thigh, by pressure on the *femoral* artery.

Although formidable, on account of the immense wound inflicted, the size and number of the vessels cut, the usual incomplete command of the circulation of the part, the consequent unavoidable and sometimes profuse hemorrhage, the great attendant nervous shock, and the demonstrated fatality of its results, the removal of the whole lower limb at the hip presents the surgeon with as few difficulties as does the analogous operation on the upper extremity. Every variety of method has been practised in disarticulation at the coxo-femoral joint, each mode possessing some special advantage in the eye of the operator who recommends it. Here, however, as elsewhere, it is improper to advocate, with unyielding tenacity, the exclusive adoption of any one process, because it is clearly impossible to foresee what special conditions may arise demanding its modification or rejection. The standard methods are each and all applicable to amputation at this articulation. But when the state of the soft parts will permit, a single flap operation is to be preferred.

AN ANTERO-INTERNAL FLAP is thus obtained: The patient, on his back, is supported with his hips projecting beyond the margin of the table. The thigh to be removed slightly flexed, and the other, with the scrotum, withdrawn and protected, the operator takes position on the side most convenient to himself. If he prefer to stand on the outside, the limb is transfixed, from a line connecting the superior front spine of the ilium with the great trochanter, to a point one inch in front, and the same distance below the ischial tuberosity. The knife enters nearer to the ilium than to the trochanter. But if the surgeon stand on the inside, the points of entrance and emergence for the knife are reversed. In traversing the limb, the knife should graze the lower margin



of the femoral neck, and enter the surgical triangle already indicated. As a consequence, the chief artery will not be cut at the base of the flap, but some distance lower down.

After transfixion, the knife is carried downwards, with a rapid sawing movement, to cut its way out *at least* six inches below. During this step, the fingers of an assistant's hand follow the blade, and are thrust into the wound to support the femoral artery, which is compressed upon them, previous to its section, by the thumb placed on the anterior integument.

Both of the assistant's hands may be thus employed if thought necessary. So soon as completed, the flap is elevated and retracted, (the hands continuing to grasp the artery,) the head of the femur is rendered prominent, and the capsule of the joint stretched by abduction and outward rotation of the limb. The knife incises the capsule over the femoral head, the joint is entered, the bone dislocated, the ligamentum teres severed, the knife passed behind the bone, and the postero-external mass divided as quickly as possible from the centre toward the surface. If the flap first formed be deficient in length, the section of the tissues of the posterior region is made obliquely downwards; if full and sufficient, transversely outwards.

In the first case a second flap is shaped, varying in dimensions in accordance with the length of its fellow. The arteries severed *after* disarticulation generally first engage the surgeon's attention, the femoral being subsequently tied. If, however, the assistant who grasps this vessel is unreliable, it is best to secure it as soon as possible; perhaps, previous to entering the joint.

We have the authority of Larrey and Delpsch for tying the artery before commencing the operation. Some surgeons vary the operation just described by making a posterior transverse or circular cut at the base of the reflected flap *previous* to disarticulation. The division of the ligaments and separation of the limb forms the last step of their process. The English surgeons seem to have a special fancy for two flaps. The necessary modification for the formation of the one behind has already been described. Lisfranc made double lateral flaps.

*Lisfranc's Method*—The patient is dorsally recumbent, with the ischial tuberosities projected beyond the operating table. The limb is neither adducted nor the reverse. The

knife is entered vertically between the superior iliac spine and greater trochanter, and passed obliquely around and behind the femoral head to make exit below the tuberosity of the ischium. The tissues over the trochanter are grasped and slid backwards, and the knife is carried outwards and downwards to form an external flap. The structures within are next grasped and elevated. The knife passed "below the head of the femur" across the front and inner side of its neck, emerges at the same point as before, and is again made to cut out, avoiding the trochanter minor. The flaps being elevated and retracted, the arteries are at once secured, and division of the ligaments, with dislocation of the femoral head, completes the operation. In this operation the circulation in the femoral artery is controlled by pressure, where it escapes from the pelvis.

Mr. Guthrie, in his surgical commentaries, makes most judicious reflections on the methods of operating at the hip. He also gives an account of his own practice in a successful case, with good suggestions as to the character of the injury, compelling the sacrifice of the whole lower limb. So much practical sagacity, and such commendable regard for the welfare of the patient are manifested, that it is thought advisable to offer the substance of his remarks.

"It may be laid down as a principle," says this apostle of military surgery, "in all cases of accident, whether from shot, shell, or railway carriages, that no man should suffer amputation at the hip-joint when the thigh bone is entire. It should never be done in cases of injury when the bone can be sawn through immediately below the trochanter major, and sufficient flaps can be preserved to close the wound. An injury warranting this operation should extend to the neck or head of the bone;" and it may even be possible to avoid it, by the removal of the bony fragments.

The usual instructions of the books are apt to be drawn from post-mortem experiments on subjects which have not sustained injury in the neighborhood of the articulation. Thus; for instance, the recommendation for the varied rotations of the limb, most excellent in theory, would be practically impossible, because "no person should suffer this operation who has a knee or half a thigh, or even a third of one, to move by the rotatory process." Where choice of integument permits, a large anterior flap is best, but the necessary soft

parts are apt to be deficient in cases demanding primary amputation.

*Guthrie's Oval Method.*—The patient is placed on a low table in a horizontal position. The femoral artery is pressed against the pubis. The surgeon stands on the inside of the limb. The incision dividing the integuments is begun three or four inches beneath and on a line with the anterior superior iliac spine, and is carried around the thigh obliquely inwards, backwards and outwards, the same distance below the ischial tuberosity to a point “exactly opposite” to where it was begun. A second cut, one-third the length of the first, whose extremities it connects, ascends in a gentle curve behind the great trochanter. The divided integuments are retracted and the glutei incised to the bone. The knife, now placed in contact with the margin of the skin, severs the whole mass on the inner and front part of the thigh. The femoral artery is ligated, the capsular ligament opened, the ligamentum teres cut, and the knife passed behind the dislocated bone, completes the section of the remaining soft tissues, care being taken not to preserve too much muscle. The obturator, ischiatic, and other bleeding vessels, are secured. The nerves are clipped short, the wound cleansed, and its lips confined with “three or more soft leaden sutures.” The dressing must be light.

The imperfect control of the circulation attained by pressure upon the femoral artery at the pubes, and the necessity for husbanding the vital fluids in the successful infliction of so serious and large a wound, would seem to demand the utmost possible celerity in its execution as a chief feature in any method of operation to be practised at the hip-joint; yet, it will be observed, that Mr. Guthrie's process, for which the advantage of special applicability to the circumstances warranting the removal of the whole limb is claimed, is a slow process. In this connection we must again refer to Mr. Joseph Lister, of Glasgow. This surgeon has caused a large horse-shoe tourniquet to be made, and, with it, he finds he can thoroughly command the whole pelvic circulation. The instrument is used to compress the lower part of the abdominal aorta against the vertebral column, which it is said to do without causing much pain to the patient. The idea was suggested by the account of an American amputation at the hip for bony tumor, exacting a slow dissection. The aorta in

this case was successfully compressed by the fingers of an assistant. The name of the operator does not transpire.

Figure 93, plate XIV. shows the catlin entered for the antero-internal flap operation. The dotted line (*arrow C*) indicates the position first assumed by the instrument, according to Guerin and Malgaigne, who pierce the joint before carrying the knife through the limb. C, B, traces the subsequent curve of the knife's point in its descent and before its emergence. In figure 94 the transverse cut behind the limb is begun. Figure 95 gives the position of Lisfranc's flaps. Figure 96 outlines the double flap of Mr. Fergusson.

## CHAPTER V. ON RESECTIONS.

Malgaigne, in his work on Operative Surgery, says: "We comprise under this title the removal of the articular extremities of bones, the resection of long bones in their continuity, and, lastly, the extirpation of certain bones without amputation of the soft parts."\*

Excepting a slight alteration in the position of words, the same definition is given by Mr. Pirrie, F. R. S. E., professor of surgery in the University of Aberdeen; surgeon to the Royal Infirmary, &c., &c. 2d ed., London, 1860.

Accepting Malgaigne's comprehensive appreciation of the term, we shall proceed to give a brief history of the operation in general, and then describe the operative procedure as applicable to special cases ordinarily falling under care of the surgeon.

The first operation of the kind on record was performed, as it is reported, by Filkin, of Liverpool, who excised the knee-joint in 1762. After this, Vigaroux and David removed the head of the humerus, but no publication of their operations was made until after the upper part of the same bone had been removed by White, of Manchester, 1768. Mr. Park, of Liverpool, was the first to propose, but the celebrated Moreau was the first who performed excision at the elbow-joint.

The foregoing is almost a *verbatim* extract from Mr. Pirrie's "Principles and Practice of Surgery."

Resections may be performed at either one of three distinct periods, viz:

1. Upon the field.
2. In hospital, to which, immediately after action, the patient has been removed, in consequence of want of time, or appliances upon the field; or
3. At a more remote period the result of such injuries, inflicted during transportation to hospital, as to direct the surgeon's care en-

---

\* Operative Surgery, based on Normal and Pathological Anatomy, by J. P. Malgaigne, Professeur Agrégé de la Faculté de Médecine de Paris, Chirurgien de l'Hôpital de Lariboisière, Chevalier de la Légion d'Honneur, et du Mérite Militaire de Belgique. Translated from the French, by Frederick Britton, M. D., &c., &c. 1861.

tirely to that constitutional restitution which would enable recovery after resection.

Without undertaking to decide, we simply ask, if, in moving armies upon such a continent as this, it be not better, *in order to save life, to amputate immediately* upon the field, rather than leave the patient the chance of having his *limb* preserved by the removal to a distant hospital? When we reflect that the present is a war of immense distances, over huge mountains and along rugged roads, and in which transportation of even the *best* character is attended with pain, annoyance, sleeplessness, hunger and thirst to the wounded soldier, should not such an operation as will most probably save *life*, rather than one which preserving *limb* for a few days, and finally ending in death from either pyæmia, erysipelas or nervous exhaustion, be performed?

In cases hereinafter to be reported, we will find that amputation is best suited to transportation, and resection to absolute rest and care.

The reasons, as justly inferred for this last remark, are based upon the facts that—

1. Resections are of slow performance.
2. They should be well rested after operation.
3. Careful attendance and watchfulness should be for a long time kept over them.
4. Transportation destroys proper adjustment.
5. Long and continued jolting creates suppuration.
- 6 This, added to want of nervous and muscular power, creates that state of constitution that finally,
7. Ends in death by the causes above enumerated.

## RESECTIONS OF THE CRANIUM.

Under the title resections, removal of bone from the head will be first considered and described. The removal of bone from the cranium or the trepanning operation must of course be performed under the circumstances immediately calling for it, whether on field or elsewhere.

TREPANNING.—The circumstances necessitating trepanning are wounds of the cranium, attended with depression of the internal plate, or such diseases of bones of the cranium as give rise to enlarged growth, infringing upon the superficies of the cerebrum itself. The methods of operating, not vary-

ing to any considerable extent, may be stated in a general way, to be the election of such place for applying the trephine as not to injure the important blood-vessels coursing within the cranial cavity, and to avoid entering the sinuses. In military surgery but little discretion can be left to the surgeon—the wounds occurring at the will of the fickle course of balls and shells, or inflicted by the uncertain wield of sabres, the bayonet's puncture, or the sudden fall upon some sharp projecting body. As these causes give rise to different characters of wound, we may here state that the *immediate* necessity for surgical interference may not occur to all minds alike, and hence, while the comminuted fracture would, under the symptoms attending it, at once suggest an operation, the punctured wound on the contrary might pass by unnoticed until such manifestations occurred as to render the application of the trephine useless. The anatomical difference in structure of the two plates of the cranium is such, that while the outer one may be punctured, the extent of injury corresponds entirely with that of the body inflicting it. The reverse, however, prevails in case of wound occurring to the inner or vitreous plate. Here *stellation* is the result, and hence great apprehension of fatal end by depressed and detached spiculæ, though the effect is not so readily exhibited. Wounds, therefore, of this latter variety should be cautiously examined, and the surgeon at once proceed to remove the portions of bone resting upon the brain.

Figure 1, plate I. gives an idea of distribution of the arteries and sinuses, and suggests what place is preferable for the application of the trephine. When possible, such precaution should be taken as to avoid the evil results consequent upon internal hemorrhage

Figure 2, plate I. exhibits the patient under the trephine. The flaps have been made and dissected up—the scalpel has cut close to the bone, and so much only of the peri-cranium has been removed as was necessary to give purchase to the bit and circular saw of the instrument.

The improvement made by Mr. Galt, of Virginia, upon the old trephine, renders its employment much less dangerous, and prevents wounding the membranes by a too rapid motion or incautious pressure. An author thus describes it:

“It consists of a truncated cone, with spiral peripheral teeth and oblique crown-teeth. When applied, the peripheral

teeth act as wedges, so long as counteracting pressure exists on the crown; upon removal of that pressure of the cranial walls, its tendency is to act on the principle of a screw; but owing to its conical form, and the spiral direction of its peripheral teeth, its action ceases. In repeated trials the membranes of the brain have not been injured."

Such conveniences then being within the surgeon's reach, and no danger existing of wounding the cerebral membranes, the remarks of Malgaigne may be here inserted. He says, in his *Operative Surgery*, (Brittan's translation, 1851, page 179 :) "We may trepan on all the accessible points of the cranium. The sutures, the frontal sinuses, or the presence of the temporal muscle, are no longer obstacles with the modern practitioner. But we must avoid touching the confluence of these sinuses opposite the occipital protuberance, and in general go as far as possible from the thickest points of the cranium, from the course of the venous sinuses and the middle meningeal artery.

"Some have said that it is easy to recognize, when we have perforated the diploe by the redness of the groove, caused by the saw; and again, when we have reached the internal table, by the whiteness and dryness of the bone dust. This distinction holds good on the subject, but on the living patient the blood continues to flow from the diploe, and prevents our drawing any inference. The more rapid progress of the saw in the diploe has also been vainly given as an indication. But, to judge of the distance we are from the dura mater, we have no other resource, than frequently measuring the depth of the groove with the end of a pen, and especially examining whether the bone is perforated in any one part of the circle before the other. The disc of bone having been removed, and the edges levelled with a lenticular knife, the operation may be continued according to the end proposed. If we want to raise bits of depressed bone, slip an elevator between the cranium and dura mater, without dividing that membrane. If an effusion exists beneath, divide it longitudinally, or crucially, very carefully, carrying the point of the bistoury perpendicularly on it.

"Dupuytren did not fear, in an urgent case, to plunge his bistoury even into the cerebral substance, to more than an inch in depth.

"The mode of dressing varies. If the external wound must



be left open on account of some effusion, carry into the sac a very thin band of linen, cover the wound with a bit of linen riddled with holes, in the same way as an ordinary wound, taking care not to pass this linen between the bone and dura mater, as some advise. Some lint over that, with compresses and a moderately tightened bandage, completes the dressing,

“If there is no effusion, re-unite the flaps by first intention. by means of adhesive plaster.”

In applying the trephine, the surgeon should pay strict attention to the anatomical peculiarities which exist at the different regions of the skull. The author above quoted gives the following valuable rules to guide us in the operation :

“1. When we trepan on the temporal fossa, Sabatier advises making a V-shaped incision, the base upwards, in order to respect the fibres of the temporalis muscle. Velpeau very properly remarks, that by so doing we cut, just the same, all the fibres comprised in the base of flap. To respect these fibres as much as possible, we would advise making two incisions in the direction of the muscular fibres, and re-uniting them inferiorly by a transverse incision, so as to form a V incision, reversed and cut off at the top; on the one hand, the division of these fibres, and the cicatrix that results, are less extensive; and on the other, the transverse incision, affecting more or less the deep aponeurosis on which most of its fibres terminate, we should divide really less muscular fibre.

“2. When we have to traverse the frontal sinus, the internal table of the bone not being on the same plane as the external, in performing the operation as usual, the dura mater would be torn at one point before the second table was cut through at the opposite. To cut the second table, then, a smaller crown should be used than that employed in sawing the first.

“3. When we trepan on the sagittal suture, or opposite the venous sinusses, we run a great chance of opening them; the hemorrhage generally stops of itself, or yields to a little plugging.

“4. Lesion of the middle meningeal artery is more serious, on which account it has long been forbidden to trepan at the anterior angle of the parietal bone, under which the artery lies. If hemorrhage occurs, it may be compressed with a bit of lint placed inside the cranium, and retained by a thread

outside (Physick); or with a plate of lead bent so as to embrace both surfaces of the bone; or it may be plugged with a bit of wax, if it is shut in a complete bony canal; or touched with a steel probe, heated to whiteness (Larrey); or even tied, in which Dorsey once succeeded."

*Operation.*—The patient being placed in the recumbent or semi-recumbent position, the hair having been closely and neatly removed, an incision having a semi-circular form or that of a V, T, Λ or X is made down to the bone; this being well scraped, the operator seizes the handle of the trephine with his right hand, and fixing the perforator by its screw, so that it protrudes slightly beyond the teeth, he places the same in the centre of the disc of bone to be removed; the instrument is now worked in a rotary manner, alternately backwards and forwards, until the teeth have cut a groove sufficiently deep to receive them; the perforator is then loosened and slid up in the shaft and *fixed*, to avoid wounding the membranes; great care should be taken to maintain the instrument in a position perpendicular to the part operated upon, in order to avoid its penetrating more deeply on one side than the other, and thus suddenly and unawares wounding the cerebral membranes. (See rule No. 2 of Malgaigne, previously laid down.) It is important to examine the depth of the groove frequently with a quill, cut in form of a tooth-pick, to ascertain how nearly the instrument has completed the section of bone; the teeth of the trephine should be cleaned frequently with a small brush or wet sponge, to avoid clogging with bone dust, which impedes easy action of the instrument, and might create unfortunate pressure. The disc of bone should be raised with the elevator, and the edges remaining smoothed with the lenticular knife, usually found at the other end of it.

In fractures with depression there are frequently projecting points of bone which it is desirable to remove; this may be done with the bone nippers (*rongeur*) or with Hey's saw.

## RESECTIONS OF THE FACE.

RESECTIONS AND REMOVAL OF SUPERIOR MAXILLA. (Plate I., figures 3 and 4.)—Many surgeons have attempted, more or less, extensive resection of this bone; but the rules for the operation must entirely depend on the disease.

*Anatomy.*—In attentively examining the face of a skeleton, we see that the superior maxillary bone is attached to the others in but three principal points. First, by its ascending process and articulations with the *os unguis* and *ethmoid*; second, by the orbital border of the *malar*, as far as the sphenomaxillary fissure; third, by the articulation of the two maxillary bones and *palate bone* with each other. There is a fourth point of contact behind, with the pterygoid process and palate bone, which yields easily by simple depression of the maxillary bone into the interior of the mouth. In detaching these different points, no large vessel is injured; the trunk of the internal maxillary artery may be avoided, or in any case easily ligated after the removal of bone. Should unforeseen hemorrhage occur during the operation, we have a resource in compression of the carotid against the transverse process of the seventh cervical vertebra. As for the nerves, only one important trunk need be divided—the superior maxillary, which may be easily cut before the bone is removed.

*Operation.*—The patient is either seated on a chair of moderate height, or placed in a semi-erect position upon an operating table—his head thrown a little backwards and leaning on the breast of an assistant. According to Gensoul's method, a vertical incision is first made, extending from the inner angle of the eye to the upper lip, which is divided on a level with the canine tooth.

Another incision, dividing the first, is made from nearly the base of the nose and prolonged to within half an inch anterior to the lobe of the ear; a third extends from half an inch outside the external angle of the eye to the point of termination of the second. The result is a quadrilateral flap, which is turned back upon the forehead.

The bone being thus laid bare, begin with a chisel and mallet the section of the external orbital arch near the suture that unites the malar with the external orbital process of the frontal bone; then cut the zygomatic process of the malar. Next attack its upper and internal attachments, apply a chisel below the internal angle of the eye, and cut through the inferior part of the *os unguis* and the orbital surface of the *ethmoid*. The ascending process is, in like manner, separated from the corresponding nasal bone; then detach, with a knife, all the soft parts that unite the ala of the nose to the superior maxilla; extract the first incisor tooth of the side operated

on and slip a chisel between the two bones directly from before backwards, but by the mouth, working it from side to side; lastly, to separate the articulations and adhesions to the pterygoid process, and, above all, to cut the superior maxillary nerve, pass a chisel flatly between the soft parts and floor of the orbit, from above downwards and from before backwards, so as to cut the nerve well back and at the same time to get a good purchase on the bone to depress it into the mouth. It only now remains to divide, with the curved scissors or knife, all the soft parts that still hold the bone, and especially the attachments of the velum palati to the palate bone, so as to leave the soft portion of this velum extended between the pterygoid process and the other side of the mouth.

The cavity resulting from the operation is formed on the inside by the septum nasi; outside, by the cellular tissue, which is found in so great abundance under the buccinator muscle; above, by the depressor oculi and the adipose tissue of the orbit; behind, you see the back of the throat; above, the velum palati. Leave the wound open for a half hour or an hour, employ sutures and adhesive strips and cold-water applications. Union takes place very rapidly, and the restored symmetry soon forms a singular contrast with the hideous chasm immediately resulting from the operation.

Velveau makes but one incision, which commences at the labial commissure, and, being extended outwards and upwards, terminates at the temporal fossa of the side affected. The operation is reported by some surgeons to be attended with less subsequent deformity and equal celerity of performance.

Another modification is suggested by M. Nelaton. This surgeon, whose success has been eminent and whose skill equals his success, a man thoroughly versed in anatomy and its application to removal of structure with as much preservation of important parts as possible to the patient, prefers the multiple to the simple incision of Velveau and others. The simple incision begins at the labial commissure and terminates at the union of the malar bone with the zygomatic process or thereabouts, depending entirely upon whether the operator designs the removal of the entire malar bone or not. In this incision, the filaments of the facial and tri-facial nerves are cut, From this may result a facial neuralgia (tri-facial injury), and there always does result a facial paralysis (injury of facial nerve) to a greater or less degree, so that the side operated

upon always contrasts badly with the sound side. The muscles lose their tension; there is ptosis of the inferior palpebra; the side looks dull and *dead*. Besides this the duct of Steno incised and the cut surfaces not uniting exactly, a salivary fistula may be created.

The multiple incision is made from the root of the nose a little externally to the median line towards the affected side. The flap is dissected upwards, close to the bone, (carrying with it one *ala nasi*) until a further dissection is prevented by want of room caused by the superior end of the incision being too confined. This is remedied by letting fall another incision (perpendicular or oblique) proceeding from near the inner angle of the eye to the superior end of the first.—Though there results more than one cicatrix in this case, the deformity is not so great as in the others in consequence of less injury being inflicted upon the nerves. The flap having been dissected back to the limits desired, the subsequent steps are the same as in Velpeau's operation. The operation as above described, was performed by M. Nelaton in his amphitheatre at the *Clinique de la Faculte* in Paris, in 1853; and two years afterwards it required close observation to reveal an ablation of the superior maxilla. In this case the incisor teeth were left by sawing the bone obliquely above them in a line extending from the interspace between the second incisor and the canine teeth upwards towards the septum. The teeth were at first loose, but afterwards became firmly fixed in their sockets. Neither the voice nor articulation was impaired, nor was the patient at all incommoded by food getting into the cavity left after the operation.

In this operation, in order to preserve as much symmetry as possible, it is always desirable to leave that portion of the ascending process of the superior maxilla which extends upwards from a line drawn from the inferior border of the nasal to the same border of the os unguis and terminates in union with the frontal bone. Hence, in giving the anatomy of the bone, this portion was omitted, inasmuch as it should be retained if possible.

*Description of Figures.*—Figure 4 represents an operation described by Guerin, but answers very well in describing Gensoul's method, as given by Malgaigne. Guerin's first incision (slightly convex) commenced at the ala of the nose, its convexity looking backwards, and terminated at the cor-

responding commissure of the lip following the naso-labial fold or furrow. He then dissected up the two flaps formed by the incision, until the nostril, on the one hand, and the malar process on the other, were well exposed; this process was then divided from above downwards and a little from within outwards, with a small saw held in the right hand. The soft palate was next detached from the posterior border of the palatine bone by a transverse incision departing from the posterior border of the last molar and terminating at the median line of the roof of the mouth. An incisor tooth was then drawn, and the horizontal portion of the maxilla divided from before backwards, with Liston's forceps, the branches being placed one in the mouth, the other in the nose. A final section of bone is now made transversely by the forceps in a line corresponding with the point of insertion of its lower branch and the divided malar bone, (as represented in figure) the bone is then firmly seized and removed.

Figure 3 is noticed out of order because it merely represents the points at which the chain saw is introduced and its lines of action after the instruments described in Guerin's operation have been, to a greater or less degree, employed in Velpeau's modification, of which this figure is a representation.

Syme, Liston and others have their modifications also, but they are not described in this chapter because, for all practical purposes, those already mentioned are deemed sufficient for the military surgeon, who, in many cases, must adapt his own election to the immediate exigencies surrounding him—in other words, must *modify for himself*.

RESECTION OR ABLATION OF BOTH SUPERIOR MAXILLÆ.—The remarks upon resection of one superior maxilla already made, if rightly comprehended by means of the text and figures, will readily suggest to the surgeon a proper method for the removal of both.

In *Cooper's Surgical Dictionary* the operations of Heyfelder and Dieffenbach are described. The patient occupying the same posture as in the foregoing operation, Heyfelder made an incision from the outer angle of each eye to the labial commissure of each side respectively, and closely dissected up all the softer parts to the inner angles of the eyes and the nasal bones. The flap was then turned over the forehead and the orbital margin clearly exposed along its inferior ridge.

By means of a chain saw introduced through the inferior orbital fissure, he separated the maxillæ from the malar bones. By a similar procedure, the maxillæ were separated from the nasal bones. A bone forceps was next employed to disentangle the upper maxillary from its further bony connexions, and the soft palate was then dissected from its union with bone. Pressure from above downwards then being practised, the two maxillæ were entirely loosened, and a little further dissection completed the operation. The subsequent dressings were the same as used in a less extensive operation.

Dieffenbach made an incision from the root of the nose through the centre of the upper lip; if required, other incisions extend upwards on either side of the nose to the angles of the eyes; two flaps are thus formed, which are reflected and the bones exposed.

RESECTIONS OF THE INFERIOR MAXILLA.—This bone may be entirely ablated or only resected in part.

RESECTION OF THE BODY OR CENTRAL PORTION.—The muscular attachments to this portion of the bone on either side of its symphysis are those of the levator menti, depressor labii inferioris, depressor anguli oris, and platysma myoides, all of which are osseo-cutaneous muscles. Besides these, we have other attachments existing between the hyoid bone and inferior maxillary, viz: those of the genio-hyoglossus and the genio-hyoideus on either side. In performing the above operation these attachments must, necessarily, be severed, but the deformity which inexperience might cause to be inferred is practically very slight; in fact, all of these operations, whether for partial or total removal of the lower jaw-bone, are attended with great rapidity of reunion and restoration of symmetry.

*Operation.*—Figure 5, plate I, represents the method adopted by Dupuytren, and is thus described by Bernard and Huette: The patient is placed in a chair sufficiently elevated to prevent his feet from touching the floor and getting a purchase thereon.\* An assistant placed at the back holds the patient's

---

\* This position applies only in those cases in which chloroform is not administered. The semi-recumbent posture is best suited to the employment of anæsthetics. The writer has seen them employed in various instances of removal of the body, or one entire half of the lower jaw-bone, and in no case have they proved detri-

head closely and firmly against the breast, and at the same time makes pressure upon each facial artery at the point where it crosses the lower maxilla. The operator, standing in front, seizes one of the angles of the lower lip with his left hand and an assistant draws the other angle from the bone, thus putting the whole lip on the stretch. A vertical incision is at once made which divides all the soft tissues down to the bone, in a line corresponding with its symphysis, and is then extended as far as the hyoid bone. The two flaps, *a b*, are next dissected back and the knife kept as close as possible to the bone *c*. This last having been sufficiently exposed and the points at which it is to be sawn through decided upon, an incision is made through the periosteum and a tooth corresponding with each of these points is extracted. When dividing the bone Dupuytren stood behind the patient and used a small Hey's saw, as represented in the figure. Should the chain-saw be preferred the surgeon's position will be in front of the patient. The bone being divided on both sides an assistant pushes back the tongue with a spatula, to protect it from the knife, and the operator holding the detached piece with his left hand, introduces a probe-pointed bistoury, held perpendicularly, and, keeping as closely as possible to bone-surface, divides all the tissues attached to its concavity. After this division the tongue will sometimes fall backwards and suffocation be threatened. This, however, is easily remedied by holding the head forwards, which position throws the tongue in the same direction and prevents its backward tendency.

If, in consequence of the extent of disease, the first incision does not suffice, make another along the base of the bone joining the first at right angles. When only a small portion of bone is removed, the saw may be used perpendicularly; but when resection of a large piece is demanded, in order to bring the fragments better together, it would be well for the section to be more or less oblique, according to the thickness of the bone structure. In this case begin to trace the groove for the saw by four or five perpendicular strokes, and afterwards incline it so as to have the required obliquity; in all cases a

---

mental. The tongue was grasped with a volcellum or forceps, or retained in proper position by means of a strong ligature passed through its tip.



firm support may be obtained by applying the inferior against the superior maxilla, at least in the beginning of the section.

*Modifications.*—If the portion requiring excision be so large as to demand removal with it of integument, Dupuytren recommends two incisions to be made—one on each side of the *raphe* of the lip—and meet at an acute angle formed at the upper border of the hyoid bone, in the shape of the letter V, so that the cut surfaces when approximated for sutures may form a line corresponding with the median.

This is termed the *ordinary operation* to be performed in such cases as the foregoing, and Gensoul objects to it because the cicatrix is in the median line. He remarks that when the bones no longer support the skin of the chin, there results a line of inodular fibrous tissue extending from the lip to the hyoid bone, whose tendency is always to retract, to draw the lip downwards and flatten the new-formed chin. Hence, Gensoul makes his *first incision*—as is ordinarily done—*median*; having completed his resection, if he finds that too much integument is left, he removes as much of it as he deems proper, *but from one side only of his median incision*, so that the resulting cicatrix inclines laterally and leaves the chin free from the evil results attending, in his opinion, the ordinary operation. The cicatricial line may then be said to lie between the *second* point of section of one half of the lip and the terminal end of the *first*, viz: os hyoides, and the operation be termed the *half-V* or *V-operation*. Malgaigne, not objecting to Gensoul's method, asks if it may not be proper, in such cases, always to make the first incision lateral, so that the benefit of such a line of union as above described, may be secured to the patient whether subsequent removal of integument becomes necessary or not?

The removal of the bone having been completed, the metallic or silk suture may be used—always the latter, should the hare-lip suture be preferred.

Whether the fragments should be brought in contact or not, must depend upon the amount of bone removed. If the surgeon, having removed but a moderate portion on each side of the symphysis, deems it best to approximate the sawn surfaces, he can do so by either employing a metallic thread through the bony fragments themselves, or, by using the same around the teeth corresponding on each side. Malgaigne says that, in general, neither is necessary.

In order to create as little deformity as possible, and leave the dental surfaces of the fragments in their natural relations with those of the superior maxilla, it behooves the surgeon to pay the strictest attention to their proper adjustment. This is best done by using a non-corrosive metallic plate, or one made of vulcanized India-rubber, and adjusting it in such manner to the corresponding teeth of either side so that the interspace caused by removal of bone may be exactly preserved, while adventitious tissue is forming and filling it up. This latter having arrived at a sufficient degree of maturity, substitutes the artificial means employed and which may now be removed.

As a substitute for all the foregoing operations, in which the subsequent cicatrix and its results seem to be the points of difference among authors, it has been proposed to make but one incision along the inferior border of the bone corresponding with the extent of injury, and dissect the two flaps, (one *up*, the other *back*), until sufficient room for the chain saw is procured. The remaining portion of the procedure is then accomplished as heretofore described. This leaves a concealed horizontal cicatrix, and adds much to the symmetry of the lip and chin. By many surgeons of high note it is deemed the best mode of operating, and we concur in their belief.

The preceding rules given for removal of the body of the inferior maxilla, or only the central portion of it, are considered sufficiently explicit as to do away with a detailed account of the mode of operating in case one-half of the horizontal portion should require resection. The muscular attachments to be severed, the vessels and nerves to be divided, the deformity resulting, the manual procedure, and the subsequent treatment are, with a few variations, the same as already mentioned, and the operator will readily recognize them.

**RESECTION OF ONE-HALF OF THE LOWER MAXILLA.**—This operation, as usually described, applies to those cases which are the result of chronic bone disease. In military surgery the necessity requiring surgical interference is, we may say, immediate, in comparison with the length of time during which bony tumors are developed. Hence, the various modifications and operations described by different authors do not need mention here. The operation being demanded by a traumatic injury, must, of course, be adapted

to the cause inflicting the lesion. When practicable, it may be performed in two ways, viz: by flap or by a single incision, not involving the labial commissure. As the latter better assures symmetry, it is preferred whenever it can be practised.

Figure 6, plate II. taken from the work of Bernard and Huette, represents the operation as follows: A horizontal incision is made along the inferior border of the bone extending from the symphysis to the angle; to the extremities of this incision two others are let fall vertically, one internal, dividing the lower lip on the median line, the other external, beginning at the zygomatic arch and passing behind the ramus. This gives a quadrilateral flap, which is dissected up and turned inwards. The saw is next applied upon the median line, the bone divided, and the soft parts detached from its posterior surface with a bistoury closely grazing it from symphysis to angle; reaching the articulation, a probe-pointed bistoury is inserted behind the coronoid process below the zygomatic arch, and the tendon of the temporal muscle is divided, while traction upon the bone is made downwards in order to disengage the condyloid process from the glenoid cavity. The pterygoid muscle is next detached, and while drawing the bone firmly towards him, the surgeon severs the ligamentous connexions. This latter precaution is recommended for the purpose of avoiding the vessels neighboring the ramus of the bone and the internal maxillary artery.

When circumstances permit, it is always advisable to leave the coronoid and condyloid processes, and to saw the bone below its ligamentous attachments, thus avoiding the facial paralysis resulting necessarily from entire ablation of one-half.

*Explanation of Figure 6, Plate II.*—*F*, *b*, *a*, represent the flap; *d*, the median line; *c*, the bone.

### Resections of the Superior Extremity.

RESECTION OF THE CLAVICLE, (Figure 7, plate II.)—This bone may be resected in whole or part. Travers, Davie, Mott and Syme have published cases of successful result. It has been operated upon by many others, and with equal success; but these operations were demanded in consequence of *chronic disease of bone*, and this not appertaining to the pur-

pose of the chapter devoted to *immediate* resections, or those made necessary by gun-shot injury, renders their description useless, as the mode of procedure must always be modified according to the extent and relations of the part to be removed. The incision may be curved, linear or crucial. Velpeau, in removing the scapular extremity, adopted the last, and describes it as follows: First, make a crucial incision, each limb of which should extend about two inches from the centre; dissect up and turn back the flaps, and keep them well separated; next divide the acromio-clavicular ligaments, and as much of the attachments of the deltoid and trapezius muscles as may be necessary; then, by means of a wooden lever, introduced into the articulation, raise the bone and detach the healthy tissues; carry the chain saw from below upwards; divide the bone and remove the diseased portion. Velpeau suggests another operation which he deems preferable to the first. It is performed by making an incision parallel with the clavicle, and a few lines below it, which terminates at the acromion process; another and shorter cut is carried backwards from the outer extremity of the first, at right angles, making a triangular flap. The ordinary or chain saw may be used, and the danger of the operation is proportionate to the point at which section is practised. The nearer we approach the middle of the bone, the closer we get to the axillary vessels; hence, the chain saw is more desirable.

The operation for removal of the sternal extremity varies but little from the foregoing, and the following mode of procedure explains the ordinary operation: Make an incision, corresponding with the long axis of the clavicle, two or three inches in extent; divide the ligamentous attachments with a bistoury or narrow bladed knife, taking care to follow well the line of articulation; slip a piece of sole-leather under the bone, and with a small strait saw, or the chain saw, divide it at the point selected. In military surgery, the bone being fractured, a section of the inner extremity of the portion left, if scapular, should be made. If the sternal portion be preserved, then its outer end should be smoothly sawn off. The further attachments must now be severed, and the knife kept closely to the bone on its superior and posterior surface; the sterno-cleido-mastoid and sterno-hyoid muscles are detached from the bone to be removed; a section of some of the fibres of the pectoralis major will be rendered necessary on its ante-

rior aspect. The important parts thus avoided, and which are in near relation with the clavicle posteriorly, are the pleura, internal mammary artery, sub-clavian vessels, and transverse cervical artery. On the right side the innominate, and on the left the thoracic duct, merit the surgeon's consideration.

The entire clavicle may be removed. The operation has been successfully performed, and is thus briefly described: A curvilinear incision, with an inferior convexity, is made from one articular extremity to the other; another is made upwards, extending from the acromion process to the outer border of the external jugular vein, the platysma myoides and a portion of the trapezius are cut through; a grooved sound is passed under the bone near the acromion, and serves as a guide to conduct the chain saw, which accomplishes the section externally.

In order to facilitate this operation, it has been recommended by Velpeau and Malgaigne to make three incisions, giving a quadrilateral flap with a superior base, which being cautiously dissected, is turned upwards, and the resection continued as above described.

The preceding methods were suggested by the existence of a large tumor of long growth, which had altered to a great degree, the relations of parts, and particularly those of the articular extremities. In very recent injuries, there being no enlargement of bone, and no abnormal adhesions contracted, the military surgeon may proceed to act under more favorable circumstances; and in such cases, provided the soft tissues have not been injured or carried away to any considerable extent, the operation is very much simplified by making use of the horizontal linear incision, or some slight modification of it.

The after treatment should be, as much as the cause will admit of, that of fractured clavicle, complicated with external injury.

RESECTION OF THE SCAPULO-HUMERAL ARTICULATION, (Figures 9, 10, 11, plates II. and III.)—That portion of the humerus enclosed within the capsule, when disconnected from the shaft, becomes a foreign body, and, if left within its *envelope*, gives rise to great inflammation, which subsequently involves all the bones neighboring the joint. Unlike the head of the femur, when fracture occurs within the coxo-femoral articulation, that of the humerus has no source of nutrition

through a ligamentum teres, and hence is left to die within its cavity. No chance for ligamentous re-union of fragments existing, the superior one becomes a foreign body, and, if not removed in time, will do such mischief to the surrounding parts as will ultimately demand an operation of more dangerous result.

Articular diseases, requiring surgical interference, are the results of inflammation, chronic affections, or injuries of some kind, whether of recent or remote date, such as fractures or lodgment of foreign bodies. The object which the surgeon hopes to attain is conservation to the patient of a partially useful limb, which the above-mentioned accidents have rendered useless at the joint involved. In many instances, mobility has been restored, and in many also a surgical ankylosis, produced in a line of direction different from that of the accidental ankylosis, has rendered useful a limb which before was an incumbrance. It may be laid down, as a general rule, that restoration of articular motion may be expected in most cases where, after operation, extensor, flexor and ligamentous attachments are, in whole or in part, preserved. In all others, ankylosis must result.

In the operation now under consideration, it would be prudent not to resect below the inferior attachment of the deltoid muscle. Various procedures by which it may be accomplished have been proposed, but they may all be reduced to two principal modes, viz: by a simple and vertical incision or by forming a flap.

The latter method may be performed in several different ways. Moreau preferred making the flap quadrilateral, with its base downwards. Manne, the same, with base upwards. Sabatier made it triangular, with superior base, and, moreover, he excised it. Morel practised a semi-lunar incision, with base upwards. Syme operated by making, first, a longitudinal incision, of four inches, corresponding with the middle line of the deltoid, and next another, extending from the inferior extremity of the first and passing backwards as far as the posterior border of the axilla. Baudens incised over the anterior border of the deltoid in a vertical line, commencing a little below the coracoid process; at each extremity of this incision he made a transverse cut, dividing the fibres of the deltoid, but not involving the skin; the object being to have a wider opening through which to incise the capsule and

expose the head of the bone. Malgaigne vaunts highly the method proposed by Lisfranc and says it is incontestably superior to all others. It is the same as that practised by him in amputating at the scapulo-humeral articulation. He terms the operation of Baudens a *multiple operation*, and hence excludes it from the method by *simple incision*.

If any rule can be suggested in regard to a choice between the two methods, it may be briefly stated, that the simple linear incision will suffice when the head of the bone is crushed or comminuted; but, in most cases, where the operation is performed for the removal of diseased bone, the flap method will be found to be preferable. Should the latter be practised, the following description will serve as a guide to the operator: Make a vertical incision from the apex of the acromion, along the middle of the deltoid, to near its insertion, and, from the lower extremity of this incision, make another upwards and backwards, cutting in a semi-lunar direction, towards the posterior border of the axilla; raise up the flap, which will comprehend the external portion of the deltoid; open the joint; detach the muscles which are inserted into the tuberosities; open the bicipital groove and avoid the tendon of the biceps; thrust out the head of bone and carefully employ the saw. It is reported that, in fourteen cases in which this operation was performed, only one proved fatal.

The subsequent treatment should be entire rest, flexure of forearm, and close approximation of arm to thorax by long adhesive strips.

*Explanation.*—Figure 9, plate II. represents the straight or simple incision. Figure 10, plate III. represents the V-shaped incision of Sabatier. Figure 11, plate III. represents the U-shaped incision recommended by Erichsen.

If considered necessary, the glenoid cavity may be removed together with the humeral head, and the same operative procedure be employed. In all cases it should be the surgeon's care to keep the knife as close as possible to the bone in executing the last *manœuvre*, viz: that of ablation of the cardiac fragment. The distal end (if severance of bone demands the operation) must be neatly sawn through, while due care is paid to the axillary vessels and nerves.

The lower extremity of the humerus may be excised or resected, or a portion of its shaft can be removed. The first is best done by the method for removal of the elbow-joint,

and the second by an external linear incision, care being taken, if the upper portion is removed, to avoid the circumflex artery and nerve, and, if the lower, to cut along the outer border of the brachialis anticus and not involve the external cutaneous nerve.

RESECTION AND ABLATION OF THE SCAPULA, (Figure 8, plate II.)—This figure represents Syme's mode of operating in which he makes an incision from the acromion process to the posterior edge of the scapula, *f, e*, and another extending downwards from the centre of the first to the inferior angle of the bone, *c, g*. Having dissected up the flaps and turned them back he separates the attachments of the deltoid and divides the acromio-clavicular connexions. Should the sub-scapular artery be divided, it must be seized and tied immediately. He next enters the scapulo-humeral articulation and rounds the glenoid cavity, then hooks his finger under the coracoid process and makes traction which facilitates the division of the muscular and ligamentous attachments—and this should be done, he says, with rapid sweeps of the knife.

Other methods have been suggested, as exhibited in the figure, viz: a flap formed by the incisions, *a, b*, and *b, h*, or *A, d*, joined at the extremities by *b, h*, and *A, E*. Chassaignac advises a single curved incision.

Janson operated upon the infra-spinous portion of the scapula by making two semi-elliptic incisions. Having turned out his flaps he discovered that the articular portion was not diseased and, by means of a saw, removed the diseased part. The patient recovered with use of the shoulder-joint.

The entire removal of the scapula was performed by Mr. Fergusson in King's College Hospital, in February, 1847. The arm had been previously removed at the shoulder-joint and a portion of the glenoid cavity and adjacent bone had been taken away with it. The patient was reported as doing well a month after the operation.\*

RESECTIONS AT THE HUMERO-CUBITAL ARTICULATION, (Figures 12, 13, 14, plate III.) This articulation may be entirely removed, or only a portion of it be resected. The mode of proceeding will depend upon the character of the wound and the extent of time which the disease may have occupied. If an entire removal be demanded, the humerus, as well as the

---

\* Drutt's Modern Surgery.



ulna and radius, must be involved. The figures 12, 13, 14, plate III. are intended to represent the different ways by which these operations may be performed according to the part or parts involved and the circumstances calling for surgical action. In describing the operation, most surgeons lose sight of the fact that ankylosis may have occurred in such way as to put the arm and forearm in one and the same straight line; hence, flexure at the joint would be impossible before section is practised, and hence the recommendation to "place the patient in a prone position, with the *elbow semi-flexed*," must depend upon circumstances, and cannot be a *rule*.

Pirrie advises as follows: "The patient having been placed in the prone position, with the elbow semi-flexed on the edge of a table, and presenting its posterior aspect to the surgeon, the joint is conveniently exposed by a wound in form resembling the letter H; and the performance of the operation is exceedingly easy, if that form of incision be adopted. The parallel portions of the wound may be two inches long, and the transverse portion should extend from the very margin of the outer tuberosity of the humerus along the upper part of the olecranon process to as near the inner tuberosity as may be without endangering the ulna nerve. The two square-shaped flaps having been detached from the subjacent parts, the soft parts behind the condyles deflected laterally without injuring the ulnar nerve, and the bones brought into view, the olecranon process should be cut through with the bone-forceps and the lateral ligaments divided. After which, the humerus can easily be made to protrude, and be sawn off through the tuberosities. The head of the radius and portion of the sigmoid cavity of the ulna left after the division of the olecranon process should be removed by the bone-forceps or saw, and bleeding having been arrested, the edges of the wound should be brought together, and the arm secured in a semi-flexed position. A most useful joint, formed by ligamentous union, is the usual result. I have now performed this operation thirty-five times, and, with one exception, all the patients have done well. I have practised every form of incision, and, although the H incision makes the performance of the operation very easy, I now invariably prefer the single longitudinal incision. By this form of incision the soft parts are left in the best possible state for steadying the cut ends of the bones."

Figure 12, plate III. represents the single straight incision which Chassaignac recommends. It is made on the external and posterior part of the elbow, from *a* to *c*, and commencing about three inches above the joint, is carried as low as may be necessary. The head of the radius is exposed, its shaft divided with the chain saw and the upper extremity removed. The extremity of the humerus, *b*, is now exposed and the chain saw applied at the point selected; the fragment of bone is easily made to protrude and disarticulation is effected. At this juncture, the ulnar nerve must be cautiously avoided. The upper extremity of the ulna is now brought within reach and easily sawn through.

Figure 13, plate III. is a modification of the foregoing and is the straight incision made use of in removal of the extremity of the humerus alone. It is practised on the posterior and external part of the arm to an extent which admits a free exposure of bone. The same precautions apply in this case as in total resection, and due regard must be paid to the brachial artery and ulnar nerve.

Figure 14, plate III. is descriptive of Moreau's quadrilateral flap, with base upwards, and shows the action of the saw upon the humeral extremity, while a slip of wood or metal is carried under it to prevent injury to the soft parts on the anterior aspect of the arm.

Other resecting operations may be performed at or near the humero-cubital articulation, and the preceding descriptions are deemed sufficient as a guide to the military surgeon.

The rules and descriptions which have been given above serve for removal of the entire bone or only a portion of its shaft between the articular surfaces. The only modification worthy of note here is that of adding a transverse incision backwards to each extremity of the longitudinal cut, thus giving more room for action by forming a quadrilateral flap.

**RESECTION AND ABLATION OF THE RADIUS.**—As the heading indicates, this bone may be operated upon in whole or some part of its continuity. Its articular surface in relation with the humerus is easily managed by the surgeon; while the inferior or radio-carpal surface is more complicated and justifies a brief mention.

The wrist-joint is enarthrodial. The parts entering into its formation are the lower end of the radius, and under surface of the triangular interarticular fibro-cartilage above; and

the scaphoid, semilunar and cuneiform bones below. The articular surfaces of the radius and interarticular fibro-cartilage form a transversely elliptical concave surface. The radius is subdivided into two parts by a line extending from before backwards; and these, together with the interarticular cartilage form three facets, one for each carpal bone. The three carpal bones are connected together and form a rounded convex surface, which is received into the cavity above mentioned. All the bony surfaces of this articulation are covered with cartilage, and connected together by the ligaments known as external and internal lateral, anterior and posterior, and these are invested with synovial membrane.

It will be perceived from the above description, given by Gray, that the manœuvring of the knife is more difficult at the carpo-radial than at the humero-radial extremities.

*Resection of the Inferior Extremity of the Radius* is represented by figure 15, plate IV, and may be thus described: Make a straight incision along the outer and posterior part of the bone (where it is nearest the surface) and parallel with its longitudinal axis. Keeping the knife close to its surface, detach the soft parts and introduce the chain saw. As soon as section is accomplished, the knife should graze the ulnar side of the radius, and the surgeon, grasping in his left hand the part to be detached, disarticulates it while carefully avoiding the artery and preserving the tendons.

Another step in the operation for the same purpose is shown by figure 16, plate IV., where, after denuding the bone and sawing through its shaft, the left hand of the operator seizes the cardiac or proximal extremity of the portion to be removed, while the right, properly using the point of the knife at the articulation, *b*, opens it and avoids the artery, *a*.

RESECTIONS AND ABLATION OF THE ULNA.—Like the radius, the ulna may be removed entirely or in part. It may be resected at either extremity or any part of its continuity. The superior articular surface of the bone having several inequalities, becomes more difficult of removal than the inferior, and requires more time and caution.

The lower extremity of this bone articulates with the radius externally, an anterior and posterior ligament binds it to the same, while a lateral ligament connects its styloid process with the carpus. The operation for its removal is performed as follows: Place the hand in a supine position and forcibly ab-

duct it—this stretches the lateral ligament; make a longitudinal incision along the internal border of the ulna and a transverse incision over the dorsal part of the articulation, forming a right angle outwards, with the inferior extremity of the first. The triangular flap, thus formed, is carefully dissected up, the bone properly denuded and disarticulated, while an aid cautiously draws aside the tendons, and the operator avoids both them and the vessels and nerves. A spatula or any flat instrument is next carried under the extremity of bone, and final section and removal are readily accomplished by a small straight or chain saw.

In preference to the foregoing, other surgeons prefer the single linear incision, parallel with the longitudinal axis of the bone. Others again prefer making the transverse incision inwards. The figures will explain the lines of incision.

Figure 17, plate IV. represents the ordinary operation by a single longitudinal incision. Figure 18, plate IV. is the modification of figure 17, by making the transverse incision above alluded to: *a* is the angle of triangular flap turned outwards; *b*, the bone; *c*, the spatula or slip of wood or ivory; and *d*, the saw acting at the point of section.

RESECTION OF THE UPPER EXTREMITY OF THE ULNA.—This operation, as well as that for removal of the olecranon, is performed in a manner very similar to the processes above-mentioned, and the surgeon will readily discriminate between the propriety of the flap and the longitudinal incision, avoiding at the same time the nerve and vessels. The operations upon the shaft are usually performed by making a linear incision parallel with the longitudinal axis of the bone, and the cutting edge of the knife is kept in close contact with the bone, in order to preserve as much periosteum as possible and prevent injuring important soft parts.

RESECTION OF THE LOWER ENDS OF BOTH BONES, (Figure 19, plate IV.)—An incision, of a length suitable to the circumstances demanding the operation, is made along the inner border of the ulna and the outer border of the radius, in the same way as if the lower end of either bone were to be removed; these two incisions are connected on a level with the line of articulation by a transverse dorsal one, and the flap is then dissected up. Due care should then be taken to avoid the tendons, vessels and nerves; the bones are divided with the chain saw, and, while both the anterior and posterior

tendons are carefully displaced, the surgeon manipulates the articulation with the point of the knife, according to rules already given. Some surgeons prefer not to employ the transverse incision, but simply to resect each bone separately, by cutting on either side in a line with the longitudinal axis of the fore-arm.

Figure 19, plate IV. *a, b, c, d*, represents the outlines of the bones—their articular relations, their direction, the radio-carpal joint and the lines of incision.

A modification of the methods above referred to was suggested by Roux, who made two longitudinal incisions similar to those already mentioned and *two transverse*, extending backwards from the lower ends of the first to either side of the extensor tendons that partly cover the posterior surface of the articulation. Two V shaped flaps are thus obtained, which are reflected, and the tendons that glide in the bony grooves are carefully respected. He isolated these and then (as a protection) passed a compress, spatula or piece of card between them and the bone, and while an assistant turned the hand outwards, after sawing the ulna, he detached this fragment of bone from its articular connexions. The hand was next turned inwards and the end of the radius managed in a similar way.

This operation, as performed by Roux, was intended to involve the entire wrist-joint, but, as it may stop short of the carpus, it might be of service in the removal of the lower ends of the radius and ulna.

RESECTION OF THE ENTIRE CARPUS, (Figure 20, plate IV.)—Blackburn says, that “excision is advisable in the shoulder and elbow, and that it is inadmissible, except under very peculiar circumstances, in the wrist.” Pirrie says, “I have twice performed the operation of excision of the wrist-joint; once in the Aberdeen Hospital and once in private practice. The result was a serviceable hand, with three of the fingers decidedly bent, in the latter case. In the former case, I made a long and straight incision behind, deflected the tendons to each side and removed the whole of the carpal bones along with the extremity of the radius, and the gratifying result was that the patient had a most serviceable hand and enjoyed the full use of all her fingers.”

Without undertaking to advise the operation or counsel the adoption of either one of the methods proposed, the surgeon

who undertakes it may find a guide to his incisions in the figure above-mentioned.

Figure 20, plate IV. represents the curved incision of Chas-saignac with a downward convexity. Another method is that of parallel incisions; one on the radial, *b*; another on the ulnar border, *e*; and these two incisions are joined by one made transversely over the dorsal surface of the carpus. The flaps are then properly dissected and the tendons cared for. The figure, being intended to represent the various operations at the wrist-joint, needs no further explanation than to state that *c*, *g*, mark the limits of Butcher's curvilinear incision, in which he divided all the tendons except those of the thumb, and that *f* and *d* are the points limiting his incisions in a case demanding removal of all the carpal, with the fourth and fifth metacarpal bones. The flap thus formed is raised from the dorsum of the hand, beginning a little below and outside the second extensor of the thumb, over the junction of the first and second carpal range, and terminating at a point nearly opposite to where the incision commenced. In order to expose the metacarpal bones sufficiently, a straight incision had to be carried along the fourth metacarpal, *d*, and a flap dissected outwards.

CARPAL RESECTIONS have been practised upon single bones, and, by some, the entire carpus has been removed. It is a matter of doubt among surgeons whether operations of this character are legitimate. Should an attempt at removal however be determined upon, the performance of it may be facilitated by reference to figure 21, plate V., which is a vertical section through the articulations at the wrist, showing the five synovial membranes. As it is incumbent upon the surgeon to avoid, as much as possible, entering any one of these synovial sacs not involved in disease or wound, this *map* of the membranous reflexion has been here inserted.\*

---

\* Sir Astley Cooper successfully extracted the scaphoid, in a case of luxation of this bone, occasioned by an accident from machinery. He lays it down as a principle, that when, in an analogous case, one or two bones of the carpus are displaced, they must be removed; but if the injury be more extensive, amputation is necessary. Velpeau was obliged, in a similar case, to remove the injured bone with the two metacarpal bones. After having cut their dorsal attachments to the neighboring bones, he passed a spatula into the articular intervals, using it as a lever for separation. In this way,

**METACARPAL RESECTIONS**, (Figures 22, 23, 24, 25, plate V.)—The complete or partial excision of these bones is rendered comparatively easy in consequence of the superficial condition of their dorsal aspect and the facility of detecting the tendons coursing over it. These latter, being simply subcutaneous, are readily put aside and as readily avoided by making a lateral incision. If a complete resection be demanded, the carpal bone, with which the metacarpal is articulated, must also be removed. In such cases, the longitudinal incision is made to the extent required, the tendon drawn aside, the bone closely denuded, the saw applied at the proper point and the portion to be removed carefully disarticulated. The carpal bone is then extirpated. Figure 22, plate V. explains the operation.

*Resection of an entire metacarpal bone* may become necessary, and, according to the one injured, surgeons recommend different lines of incision or that amputation be preferred.

The anatomical relations of the thumb will at once suggest the proper cut to be made when circumstances demand the removal of its metacarpus. The operation was successfully performed by Troccon in 1816, and subsequently by Roux and Blandin. The rule most usually adopted is to make an incision along the radial border (if it be the metacarpus of the thumb or index finger involved) of the bone, passing half an inch beyond each of its two articulations; detach with caution the skin and extensor tendon from its dorsal surface and the muscles from its palmar. Let an assistant hold the edges well apart; then carry the point of the bistoury on the external side of the carpal articulation; divide the tendon of the long abductor, which is attached to the metacarpal bone, and traverse the articulation; then try to luxate the bone outwards, and pass the knife along its internal surface to completely separate it from all adherent soft parts. Lastly, destroy the metacarpo-phalangeal articulation by dividing the internal, external, lateral, and the anterior ligaments. The radial artery may be easily avoided, but, if divided, can be readily ligated. Lint or graduated compresses should be employed from before

---

he got a bistoury well inserted and completed the section of the palmar ligaments. The dissection of the unciform process, under which the artery and nerve pass, requires an increase of precaution lest they be injured.—MALGAIGNE.

backwards, in order to secure rapid union, and the thumb kept in its natural position. After cure, there is a temporary uselessness of the thumb and also shortening, but, by degrees, it regains almost all its natural movements. In case the first incision does not suffice, add others to its extremities.

Figure 23, plate V. represents the removal of the entire carpus of the middle finger. Figure 24, plate V. is intended to show the method of removal of the metacarpo-phalangeal joint of the same. Figure 25, that of the thumb.

It may not be inappropriate to state, in this connexion, that surgeons of much celebrity counsel against performing such operations as the foregoing, where disease or traumatic injury involves the metacarpus of the index or little finger. It is given as a reason for such advice, that the "probable shortening of these fingers would leave a deformity, perhaps as great as that of amputation, and would doubtless injure the strength of the hand more."

The metacarpal bones of the middle and ring fingers are differently conditioned, and may, therefore, be operated upon to greater advantage. These fingers might be retained in position by their connection with those bordering them on each side and the hand preserve its normal strength. In case of operation an incision should be made along the dorsal surface of the bone to the side of the extensor tendon, which should not be injured on any account, and the disarticulation commenced at the phalangeal joint.

Modifications of operations have been suggested, but it is conceived that the figures already alluded to will serve every purpose the surgeon may stand in need of should the knife and saw or bone-scissors be required.

**RESECTION OF THE PHALANGES.**—It frequently becomes necessary to ablate a phalanx, whether disease should have attacked it or an immediate injury require operation. Paronychia is of frequent occurrence in military surgery, and the hand, being very much exposed, is often wounded in one or the other of its parts. A blow is frequently received upon a finger, inflammation supervenes and suppuration occurs. Death of bone ensues and its removal is demanded. It is extremely rare that necrosis or caries takes place, under ordinary circumstances, in paronychia of the first or second phalanx. It rarely fails to be the case when the third or ungual phalanx is involved. M. Velpeau explains this by referring



to the coverings of the first two as compared with those of the last. In the first, we have skin, subcutaneous cellular tissue, tendon, sheath and bone; in the latter, there is scarcely an interruption of tissue, the skin, subcutaneous structure and bone being closely adherent, one to the other, and forming what is known as the *pulp*. Here, then, an inflammation arising goes on without interference and invades the series of structures thus closely combined. M. Nelaton adopts Velpeau's explanation and thus accounts for the infrequency of necrosis or caries in whitlow, occurring in the first two phalanges and its frequency in the terminal or unguis phalanx.

In paronychia, it not rarely happens that pus, following the course of the tendons, forms sacs either in the hand or on the anterior aspect of the fore-arm. Once reaching the fore-arm, it burrows its way between muscle and muscle, and finally produces a very grievous affection to the patient and an embarrassing one to the surgeon. This, however, is not the result of a paronychia indiscriminately located. In order that such purulent infiltration may occur, the primary source of pus must reside in either the thumb or little finger; if occurring in the other fingers, its flow will be arrested on a level with a line drawn across the middle of the palmar surface or a little above it.

If the hand be dissected and the tendinous sheaths of the fingers be inflated, a ridge will be formed by the air distending the synovial membrane; that of the thumb and little finger will extend as far as the annular ligament and follow the tendons of the flexor muscles; whereas, distension of the remaining three sheaths will cease at the line above indicated. This proves that the synovial membrane lining the flexor sheaths of the thumb and little finger extends the length of their tendons and communicates with that of the common flexors of the hand. Pus following this tract will ultimately lodge in the anterior part of the fore-arm and become sacculated. Hence, dissecting abscesses may result from paronychia of the two fingers alluded to, while that of the other three, should pus gravitate, will be arrested in the palm. If removal of bone is decided upon, a simple median palmar incision will suffice for the last phalanx; a lateral or bilateral incision will answer for removal of the others, and care should be taken to preserve the tendons within their sheaths and to adjust the parts properly after operation. In removal of the unguis pha-

lanx, the nail should be left. The periosteal bed having been preserved to as great an extent as possible, there exudes an adventitious structure, which, after awhile, fills up the space formerly occupied by bone, and, passive motion being exerted, a very useful joint results. There are numerous instances of success in such cases.

### Resection of the Ribs.

This operation was performed, according to Malgaigne, by Aymar de Grenoble in the seventeenth century and at a much later period by Richerand. The bone, or that portion of it to be removed, is laid bare by an incision, which may be straight, crucial, curved, or by three incisions, giving a quadrilateral flap. The intercostal muscles, above and below the bone, are next detached by sliding in a grooved sound and cutting down upon it, or carrying the knife along its channel and cutting outwards; the pleura is now separated from the rib by a cautious use of the smooth handle of the scalpel and the bone resected by means of the chain or Hey's saw.

When the disease has lasted long enough to become chronic, adhesions form between the visceral and parietal reflexions of the membrane, so that introduction of air into the sac is but little to be feared. In some cases, however, the pleura is in a normal state, or its thickening may be of such a character as to require excision of it. Under such latter circumstances, scissors, curved on the cutting surface, should be used; and the suffocating effect of a rapid introduction of air into the thoracic cavity should be relieved by either closing the wound immediately or covering it with a broad compress thoroughly smeared with cerate. The rules for operating in cases of empyema will be of service, in a modified form, when the resection of the rib is performed partially or entirely.

Richerand feared frightful flow of blood from section of the intercostal artery, but, as it is one of very small calibre from the end of the posterior third of the rib, his fear was baseless.

### Resections of the Lower Extremitly.

Authors differ very much as to the practicability of performing these operations at certain articulations. The joints subject to surgical interference in consequence of long con-

tinued disease or recent injury are the coxo-femoral, tibio-femoral, tibio-tarsal, tarso-metatarsal, metatarso-phalangeal, and inter-phalangeal. The propriety of resection is commensurate with the amount of injury, the length of time it has occupied, and the general condition of the patient. In recent gun-shot wounds, which are attended with compound comminuted fracture of joints, the question arising in the mind of the surgeon is: shall resection or amputation be performed? The decision must depend upon the character and extent of wound and its entire condition as regards both the soft and hard tissues. As a substitute for excision of bone, some surgeons have recommended, in cases where joints are involved, the mere use of mechanical force by which to overcome the opposing cause. This method is entirely employed in cases chronic and ankylosed. Yet it is not out of place to give it some consideration. Ankylosis, as now accepted, means a stiffened joint, whether bent or straight, though the word from which it is derived signifies *crooked*. The operations which it requires are more often performed, according to the joint involved, upon the straight than the crooked limb; but the term is significant to every surgeon, and uselessness of joint in consequence of synovial adhesion, bony fusion, osseous deposit in the ligaments, or muscular retraction, accompanied with fibrous deposits in the textures external to the joint, gluing them to each other, all come under the general head ANCHYLOSIS.

According to what has preceded, it will be readily inferred that ankylosis may be complete or partial, and the displacement which it sustains must decide the operation to be performed. In such chronic cases as we now consider the question very naturally arises, whether a subcutaneous incision of tendons should be first practised, the wound allowed to heal, and force be subsequently employed, or whether force should be employed without previous division of tendons. This will depend upon the fact in the case. An author of much celebrity has divided ankylosis into true and false, or bony and fibrous. He says, "generally, when true ankylosis exists, the sensation, when grasping the limb above and below the joint, and endeavoring to move one part on the other, is unmistakable; the sensation of solidity, which is communicated under these circumstances, is never felt when the adhesions are fibrous. Yet, as bony ankylosis is the exception,

and fibrous adhesions exist so commonly, as to constitute the rule, the full effect of chloroform should always be obtained before ankylosis is pronounced to be bony. I know no certain test which will enable true and false ankylosis to be at once distinguished, except the peculiar and unmistakable sensation which is communicated by solid bony union. But this is certain, that when the slightest motion exists, union is not bony. And again, when the muscles about a joint are rigid, or the tendons are tense, union is not bony.\*" If the adhesions be fibrous, they may be ruptured by forcible extension, and motion be successfully restored. If, together with fibrous adhesions, muscular contractions exist to such an extent as to prevent forcible extension having any effect, then the tendons and fasciæ should be divided subcutaneously, and extension be afterwards made use of. The after treatment consists in placing the limb in any easy and properly adjusted splint, keeping it preserved at perfect rest until all inflammation has subsided and pain been removed; after this, passive motion should be employed.

The author, above quoted, furnishes a statistical table of thirty-two cases occurring under the one or the other of his two divisions, as already mentioned—those requiring and those not requiring sub-cutaneous section previous to using forcible extension. He says, "of thirty-two cases which I have submitted to rupture, the following has been the result: in eleven instances, complete power of motion, or nearly complete power, has been gained; in fourteen, partial but useful motion has been restored; and in seven, the limb has been rendered straight and the joint has remained stiff. Of the eleven first-mentioned cases, eight were of the hip, one of the shoulder, one of the elbow and one of the ankle. Of the fourteen in the second series, five were of the knee, four of the hip, two of the elbow, one of the shoulder and two of the ankle; and of the remaining seven, four were of the knee, one of the hip, one of the ankle and one of the elbow.

If the above treatment should be deemed of no avail, then the surgeon must resort to other measures, and if the object aimed at, in the treatment of certain articular diseases, is to obtain *ankylosis*, the maintaining of the limb in a serviceable position should be strictly enjoined.

---

\* Bradhurst, (*Treatment of Ankylosis.*)

RESECTION OF THE COXO-FEMORAL ARTICULATION, (Figs. 26, 27, 28, plate VI.)—Mr. Guthrie informs us that, in his opinion, the above operation should be invariably practised in cases where the bone, though injured, is entire. He also says that it should always be done in cases of injury, when the bone can be sawn through immediately behind the trochanter major, and sufficient flaps can be preserved to close the wound thus made.

The operation, we are told, "was first performed by Mr. Anthony White, in 1821, with perfect success, although Sir E. Home and the medical officers of St. George's Hospital gave it as their opinion that it would be useless, impracticable and fatal." So many cases of success have been made known, that it may now fairly rank among the established operations of surgery; and, as an argument in its favor, it may be stated, that whether the acetabulum be involved or not, it frequently sets up a process of repair and becomes filled with fibrous tissue as soon as it is relieved of the head of the femur.

Various modes of incising the superjacent soft parts have been suggested and practised, as the figures will show. Malgaigne prefers the simple longitudinal incision, extending from the crest of the ilium to three inches below the trochanter major, in consequence, he says, of the favorable results attending a similar incision when the head of the humerus is excised. Many surgeons, however, are of an opposite opinion in regard to both operations—shoulder and hip—and contend that the straight incision, from above downwards, is followed by the burrowing of pus and the subsequent formation of deep-seated abscesses, giving rise to pyæmia, erysipelas or exhaustion, either of which may result fatally. Should the surgeon prefer this mode, he will make the incision as above indicated, clear away from the bone the soft tissues, apply the chain saw below the trochanter, and grasping, with a proper forceps, the upper fragment, remove the head of bone by entering the capsule and keeping the knife in close contact with its surface, in order to avoid injuring the important vessels and nerves, which an incautious manipulation might involve. After the operation, the limb must be brought into the straight position and kept at rest by means of a long splint, and the case be treated on general principles. If every thing goes on well, the patient will recover with a useful limb, having a

considerable degree of motion at the hip and can walk comfortably with a high-heeled shoe.

The same precautions appertain to the after treatment in all cases, it matters not what the incision—straight, curved or semilunar.

Figure 26, plate VI. represents the last step in the operation, which is performed by making a curved cut, as seen at figure 28. In this latter figure, which serves to show the mode of procedure before the bone has been divided by the saw, the incision has its convexity backwards, and embraces the posterior part of the great trochanter, its limits being the iliac crest and two inches below the process mentioned; the bone, *b*, is next reached, and the chain-saw, *g*, is applied at the point of section and passed under it with the needle, *d*, held in the right hand, *f*; the index finger of the left hand, *e*, is passed under the external side to free the point; after sawing the bone, the lower end of the upper fragment, *a*, figure 26, is grasped with forceps, or a *tire-sond*, *b*, and disarticulation practised with caution by properly employing the point of the knife, *c*.

Figure 27, plate VI. exhibits the method of operating by making a semilunar flap with an upward convexity. The incision is marked by *a*, *b*, *c*. It surrounds the trochanter, *d*, except on its lower part. The flap is dissected from above downwards, muscular attachments are severed, the capsular ligament freely opened, the femur is carried towards the median line by an aid, who, at the same time, should rotate it inwards, and thus dislodge its head. The ligamentum teres is cut, and a flattened piece of wood, a spatula, or any similar article, being placed between the bone and subjacent soft structures, section is readily accomplished by the chain or other saw.

Various modifications of the foregoing operations have been proposed, and as Malgaigne very properly says: "If you prefer the method with flaps, you may cut a triangular flap on the outside (Rossi), or a semilunar, with the convexity downward, extending from the spine of the ilium to the sciatic tuberosity (Velpeau); or, lastly, any variety of external flap proposed for the coxo-femoral disarticulation."

The femur may also be resected at any point between its two articular extremities and, the rules already given, with

those which follow, in regard to the operations at its inferior jointures, are sufficiently explicit to guide the operator, whether he considers total ablation of a portion of the shaft necessary, or whether his aim be to remove involucra of bone from their casement in new growth, as evidenced by inserting the probe into the cloacæ or openings of fistulous character, caused by the long residence of carious bone acting as a foreign body. In the latter case, the removal of a portion of new growth to an extent sufficient to allow the surgeon to extract the dead spiculæ or portions of bone, will be sufficient; and the wound being well stuffed with lint, will rapidly granulate, and perhaps several small fragments, which were not at first discovered, will come away during the granulating process. The cavity will soon fill up, and continuity and usefulness of the bony shaft be restored. In the former instance the hiatus left between the upper and lower fragments should be a matter of serious consideration, lest false joint result.

RESECTIONS OF THE FEMORO-TIBIAL ARTICULATION, (Figs. 29, 30, plate VI. and 31, 32, plate VII.)—The object of this operation is to produce a firm and useful limb, slightly shortened and with entire bony ankylosis, or fibrous union at the situation of the joint. But all cases are not suitable for excision, as, for example, where the *quantity* of bone to be removed is too great, or where the *quality* of diseased bone is such as experience has shown to be incompatible with the exudation of healthy material of repair. (Druitt.) Mr. Price, surgeon to the Great Northern Hospital, London, says that if the "white swelling" has begun with disease of the synovial membrane or so-called ulceration of cartilage, the diseased joint-surfaces may be cut off and the case will do well; or if there be scrofulous exudation into the bone-structure and it be in one or more *circumscribed* masses, bounded by a layer of lymph and healthy bone, these masses, when laid bare by the section of the bone, may be gouged out, as a dentist would deal with a carious tooth, and, if sound bone be left, the patient will do well.

If, however, there should be an infiltration, throughout the cancellous structure, of strumous deposit—if the bone becomes enlarged and softened, and its periosteum thickened and separating from it—excision would be unadvisable, because the whole disease can scarcely be removed, and diseased bone is left, incapable of healthy exudation. Low inflamma-

tion and repeated abscesses will be the certain result, and if the patient do not die of exhaustion or pyæmia, he must go through amputation at last.

Since there are no absolute diagnostic marks of the various forms and degrees of joint-disease, it may happen that a decision can only be made after exposing the articular surface or removing a portion of bone connected with the joint.

Mr. Butcher, of Dublin, in his "Second Memoir on Excision of the Knee-Joint," gives the following rule: The patient, whilst under chloroform, suffers no prolonged shock, and, if the bones are found extensively diseased, amputation should be performed at once. This has been done in many cases. The patient loses nothing by an attempt to save his limb, and pedantry only, complaining of such as "disturb her ancient melancholy reign," could object to the proceeding.

The surgeon, governed by the attending circumstances, will either select for himself or adopt one of the operative procedures represented by the figures above-mentioned. It is not necessary, in all cases, to subject the entire articular surface to removal. The extremity of either one of the bones concurring to form the joint may be solely involved, and hence should be alone interfered with. Figure 29, plate VI. is taken from the work of Bernard and Huette. It represents Syme's mode of resecting the joint under consideration and is thus described: The leg flexed at a right angle with the thigh, the operator makes a curved incision above the patella, with a superior convexity, extending from one lateral ligament to the other. The articulation should be entered by this single cut. Another curved incision is made below the patella, with an inferior convexity, meeting the two ends of the first. The patella is thus circumscribed in an elliptical flap and removed. The lateral and deeper ligaments are next divided with the point of the knife; the extremities of the femur and tibia are then turned out successively, after due care has been practised in removing from them the soft parts, in order not to injure the popliteal vessels. A flat instrument, *b, c*, it matters not what, is passed under each bone at the point of section as a support to the saw, *d*, and a protection to structures subjacent, which should also be withdrawn by a split bandage or retractor, *e*. The exposed end of the femur is shown by *a*. Figure 36, plate VI. is intended to show the lines of section made by different surgeons in cases of ankylosis of various



characters and directions. In making section, when true ankylosis exists, it is advisable to unite the bones at a slight angle anteriorly; the section, therefore, should be nearly in the lines, *h, h,* and *i, j.*

It has been suggested to saw the bones very obliquely when a portion of the shaft is involved in disease. The femur and tibia may be resected when disease extends to the anterior part of the lower portion of the former and the lines of section are marked by the corresponding horizontal lines, as mapped off in the skeleton figure just referred to. The lines will be reversed when the anterior and upper portion of the tibia is diseased. The *parallel lines* may be termed the lines of *bony apposition*, and, whether one or other operation be performed, they must accord with each other.

It is a matter of discussion in regard to removal of the patella. If it is removed, there can be found very good authority for the propriety of the operation.

RESECTION OF THE PATELLA is performed by the crucial or H incision, taking care to remove the bone, and to preserve, to as great an extent as possible, the tendinous expansion. It is well known that there are cases of congenital absence of this bone, and not the slightest impairment of the function of locomotion attending it. This fact alone would rather invalidate the arguments of those who contend that it should never be ablated. Too much care cannot be taken to preserve the longitudinal continuity of the ligament.\*

Figure 31, plate VII. illustrates the method of operating, by making a semilunar flap anteriorly, and shows the manner in which the saw is applied to the part or parts to be removed.

Figure 32, plate VII. exhibits the first steps in the same operation. A curved incision is made which sweeps around the lower end of the patella. It should commence at or near the point of insertion of the internal lateral ligament into the inner condyle of the femur, and terminate at a corresponding point exteriorly. The flap is then dissected up, (figure 32,)

---

\* In the volume of *American Transactions*, for the year 1851, will be found the report of a case of congenital absence of both patellæ, presented by Prof. H. F. Campbell. In this case (a grown negro man) the subject walked, ran, leaped and performed all the various functions of locomotion without the slightest inconvenience.

the patella removed, and division of the ligaments next practised. In order to isolate the soft structures, a bandage of sufficient width should be passed under the end of bone to be sawn off; and while an aid draws firmly on it, the operator applies the saw, first to the end of the femur and next to the head of the tibia—(figure 31.) Due care should be observed in not wounding the arteries coursing around the joint, by making the incision lower than as above recommended.

Modifications of the preceding methods have been proposed. Some surgeons recommend that the flap be carried below the tuberosity of the tibia, where the quadriceps extensor has its insertion.

If immediate interference be required for partial or entire removal of either bone of the leg, the foregoing remarks and quotations, with reference to the plates and figures, will probably be of some service to the surgeon who may possess this manual. We are informed that each bone has been removed in totality and the result been one of perfect success. As the superior extremity of the tibia and fibula has each been considered in the operation termed *resection of the knee-joint or femoro-tibial articulation*, it would be useless to mention the steps to be taken in removing the upper end of either bone, except to say that the head of the fibula has a synovial reflexion independent of the general capsule of the joint, and hence may be removed without involving the latter. Some authors are of a different opinion.

RESECTIONS OF THE TIBIO-TARSAL ARTICULATION, (Figures 33, 34, 35, plate VII. and figures 36, 37, plate VIII.)—The knee-joint having been disposed of, and a brief allusion made to the resecting of the superior articular extremities or portions of the bony shaft of either the tibia or fibula, another case occurs wherein disease of long growth or immediate injury may involve the ankle-joint or its close neighborhood, while the rest of the foot may be entirely healthy. The astragalus has been excised; the astragalus and os calcis have been successfully removed; the astragalus, os calcis, and cuboid bone have been removed with equal success; and the only question which the surgeon has to decide for himself is the one of resection or amputation. If the former be preferred, a reference to the history of the case must not be overlooked, nor a careless examination of shattered bone be visited upon the operator.

Surgeon Henry Hancock, of Charing Cross Hospital, London, says: "This operation was first performed by Moreau, and subsequently by Jüger and others abroad; but, I believe, I am justified in stating that, with the exception of those I have done myself, there is not a single instance upon record in which excision of the ankle-joint has been performed in this country for disease."

The success of the operation depends, in a great measure, upon leaving the anterior and posterior tibial arteries intact, and on no account to open the sheaths of the tendons.

Commence the incision about two inches above and behind the external malleolus, and carry it across the instep to about two inches above and behind the internal malleolus. Take care that this incision merely divides the skin and does not penetrate beyond the fascia. Reflect the flap so made and next cut down upon the external malleolus, carrying the knife close to the bone, both behind and below the process. Dislodge the peronei tendons and sever the external lateral ligamentous attachments. This accomplished, cut through the fibula with the bone nippers, about an inch above its lower end, and remove the fragment, after dividing the inferior tibio-fibular ligament. Dissect, carefully, the tendons of the tibialis posticus and flexor communis digitorum, from behind the internal malleolus, and expose the joint. Carry the knife close around this latter process and detach the internal lateral ligament. The lower end of the tibia being now turned outwards, the diseased portion is sawn off, and afterwards, with a small metacarpal saw, placed back of the astragalus and between it and the tendo-Achillis, remove the former by cutting from behind forwards. Replace the parts *in situ*, close the wound on the inner side and front of the ankle, and leave a free exit for discharge on the outer side; the last step is to place the limb on a splint applied externally, and fenestrated or bored, so as to allow the escape of pus. Water dressings are best adapted to such operations. Four cases of entire success, by the foregoing method, are reported by an English surgeon, and he says his patients could "walk, run and jump without any inconvenience."

The figures referred to will guide the operator, whether entire or partial resection be required, and the foregoing description of the manner in which the whole articular surface may be removed does away with the necessity for describing mi-

nutely the partial operations at this joint. Preservation of the tendons and arteries should, however, be always kept in mind.

In 1858, the writer of this chapter assisted Professor A. E. Peticolas in an operation which he deemed advisable to be performed upon the ankle-joint, but one in which only the os calcis was involved. The cause was caries of this bone, but the mode of extirpating it and the result are worthy of notice.

The whole heel was enlarged and distorted. The foot had been poulticed and frequently lanced. Pieces of bone had been removed. Treatment availed but little. The patient became a confirmed cripple and his general health was failing. It was determined to extirpate the os calcis. Two incisions were made through the integument—one vertical, the other horizontal—the latter, reaching from the outer side of the articulation with the cuboid, encircled the posterior end of the calcaneum, and stopped an inch behind the same joint on the inside of the foot. The former descended vertically, from a point an inch and a half above the lower attachment of the tendo-Achillis, to the latter. This tendon was severed and the outer surface of the os calcis exposed. The tendons of the two peronei were liberated and turned forwards, and the middle fasciculus of the external lateral ligament was cut. The posterior calcaneo-astragaloid articulation was entered, the strong inter-ossous ligament divided, and the anterior joint of the same name penetrated. The calcaneum was next freed from its connections with the cuboid and the short extensor muscle, and its under surface exposed. Lastly, the bone was separated from its attachments to the internal malleolus and scaphoid, and removed. No ligatures were required, and vessels, nerves and tendons were all avoided. The three flaps resulting were brought together and secured by suture and adhesive plaster. Cold-water dressings were employed, and, sixty days after the operation, the patient was walking about with a single crutch. He subsequently recovered complete use of his foot, and none but those who attended the operation would have imagined that the calcaneum had been ablated.

Figures 36 and 37, plate VIII. are illustrative—one, of the partial resection of the os calcis—the other, of the inter-articular tarsal surfaces and tarso-metatarsal line of joint. The case of removal of the entire calcaneum above reported, together with the figure 36, which represents Chassaignac's

curvilinear incision, whether made on the internal or external aspect of the bone, serves to show the result of operation, the importance of abstaining from total removal of foot, and the benefit which conservative surgery may yield the patient.

The same precautions in these operations upon the lower extremity should be observed as in those of the carpal and metacarpal joints, and a repetition of the rules, in regard to avoiding tendons, nerves, vessels and sheaths, is useless.

Figures 38 and 39 are descriptive of operations intended for removal of entire metatarsal bones. The resection of the first and fifth is accomplished by first making a curved incision with a downward convexity—*a, b, c*, figure 38—and extending it beyond the articulation of both extremities. The middle of the shaft is sawn through, after the soft parts have been carefully detached, and each fragment properly removed. The after-treatment is easily conducted by means of lint and cold-water dressings.

The phalanges of the foot are removable like those of the hand, and, as a general rule, should be attacked upon the plantar surface, if the last be involved, and the dorsal aspect, should either one of the others need excision.

Received of Mr. J. B. Smith  
the sum of \$100.00  
for rent of premises  
situated at No. 123  
Main Street, New York  
City, for the month of  
January, 1870.

Witness my hand and seal  
this 1st day of January,  
1870.

J. B. Smith  
Landlord

John Doe  
Tenant

123 Main Street  
New York City

1870

Received of Mr. J. B. Smith  
the sum of \$100.00  
for rent of premises  
situated at No. 123  
Main Street, New York  
City, for the month of  
January, 1870.

Witness my hand and seal  
this 1st day of January,  
1870.

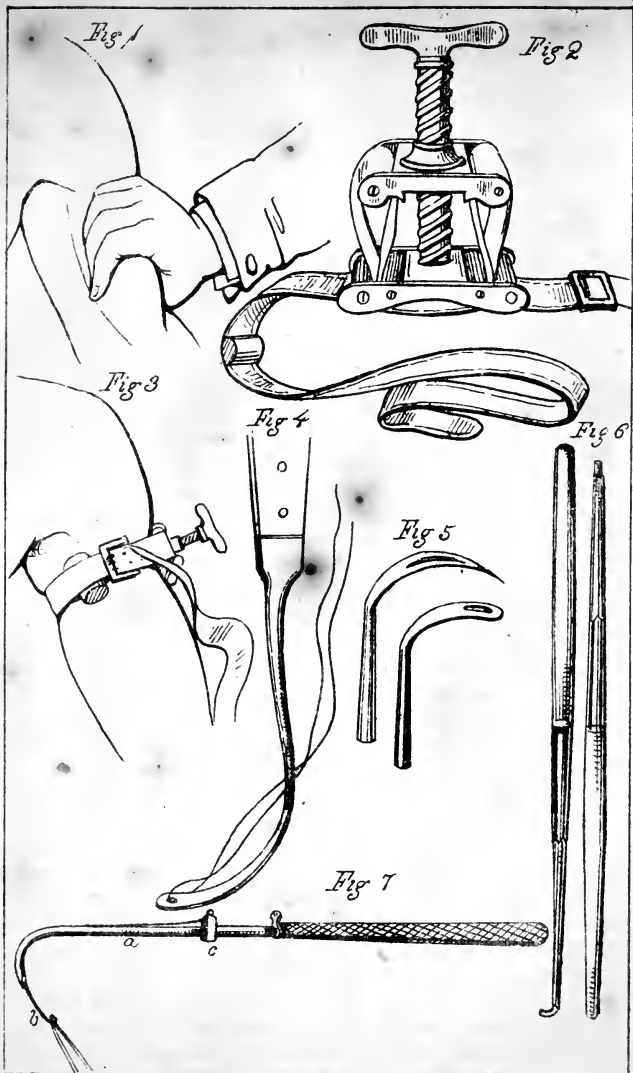
J. B. Smith  
Landlord

John Doe  
Tenant









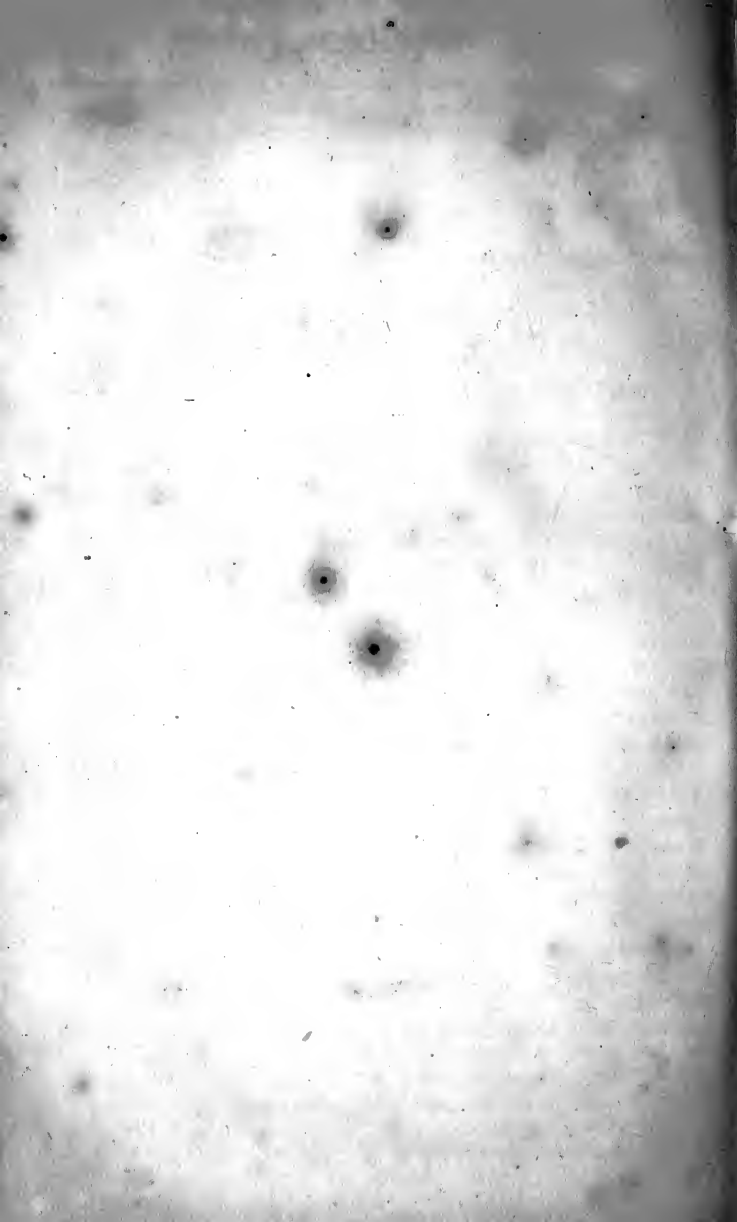




Fig 8

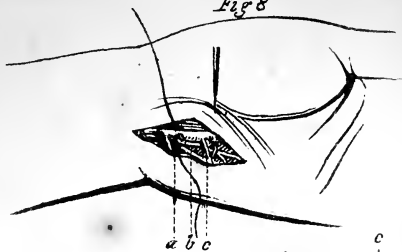


Fig 9

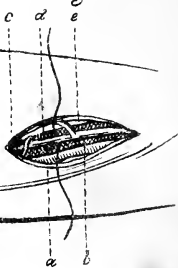


Fig 10

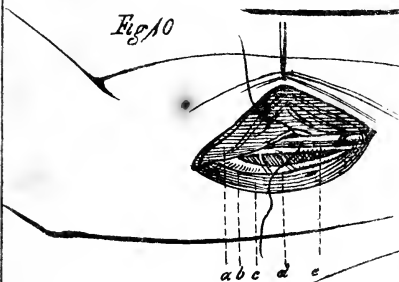


Fig 11

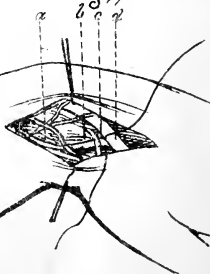
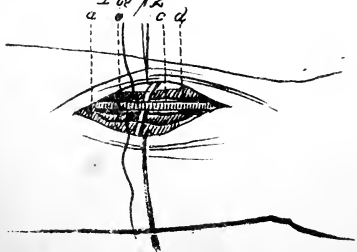
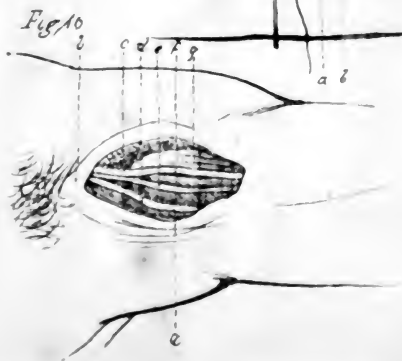
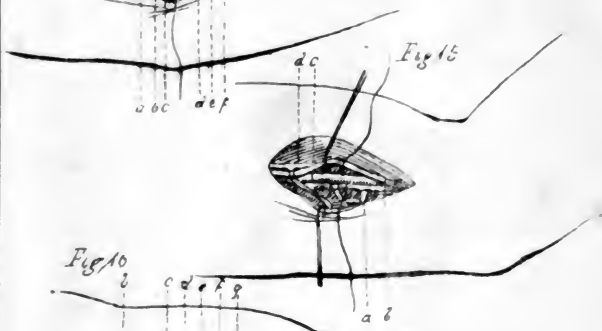
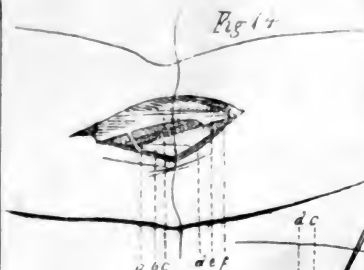
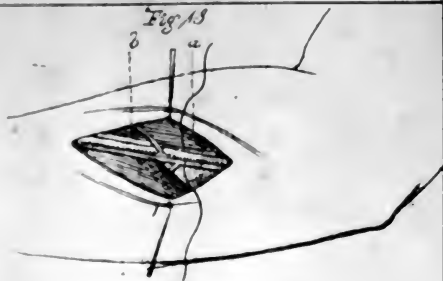


Fig 12









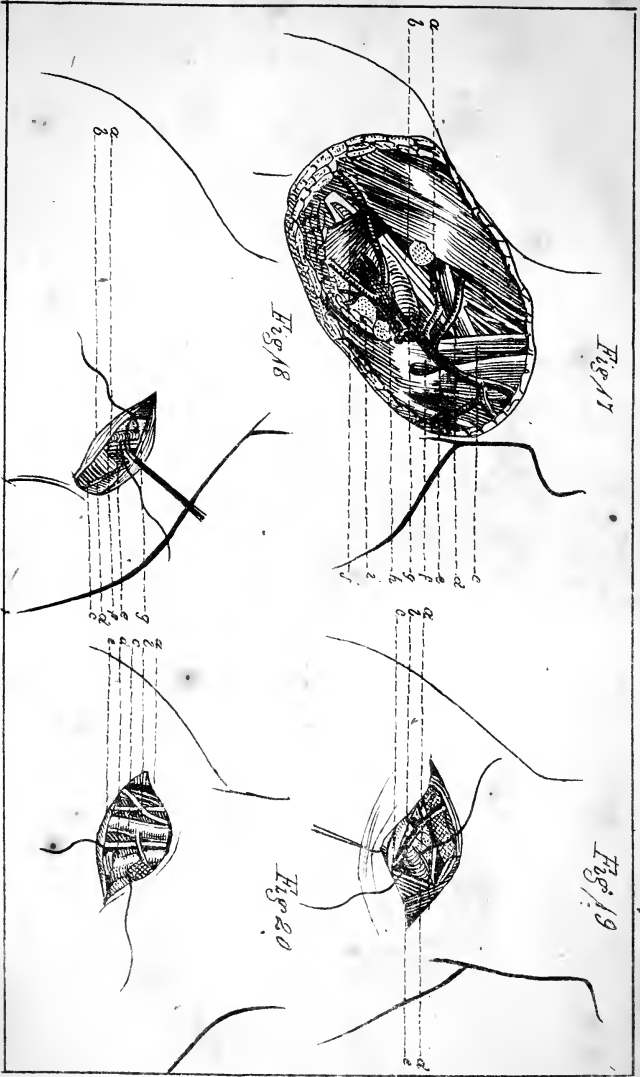


Fig 17

Fig 18

Fig 19

Fig 20



Fig 21

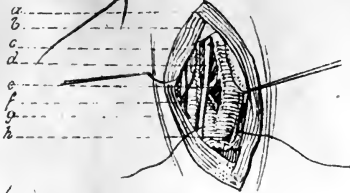


Fig 21

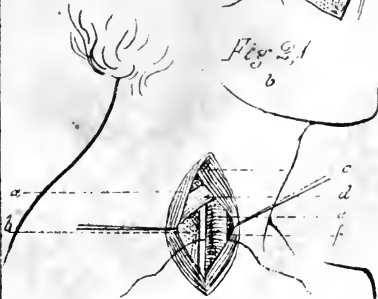


Fig 22

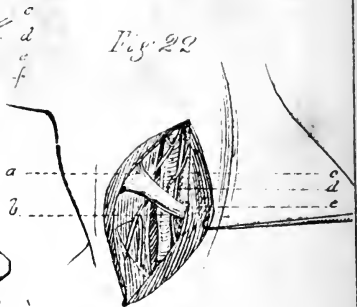


Fig 23

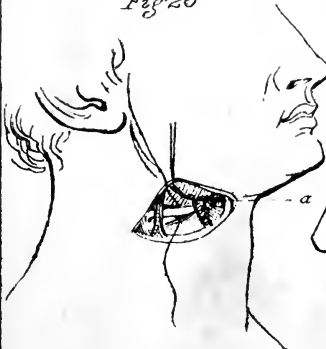
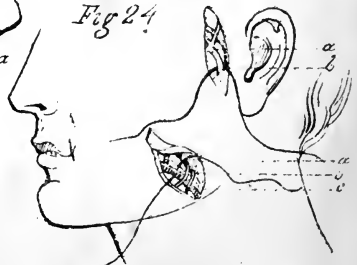


Fig 24










Fig 25

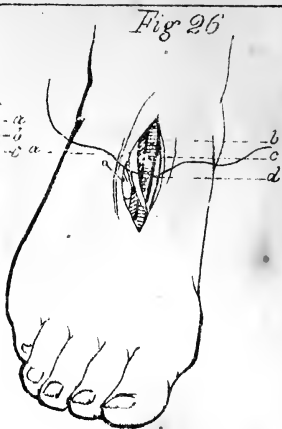


Fig 26

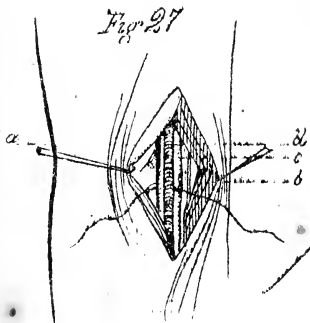


Fig 27

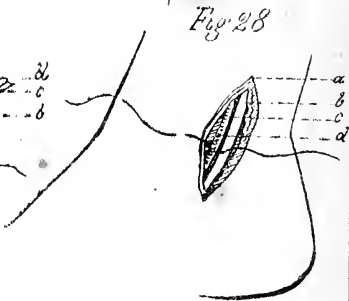


Fig 28

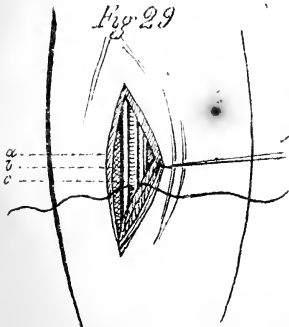


Fig 29

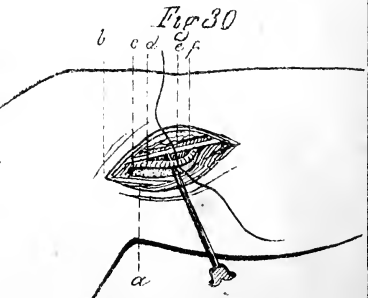


Fig 30

Fig 31

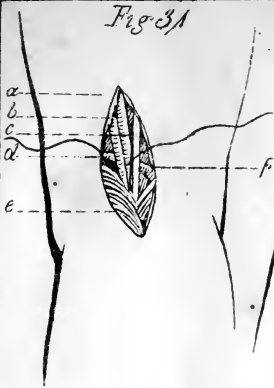


Fig 32 b a

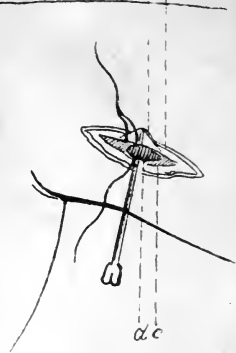

Fig 33


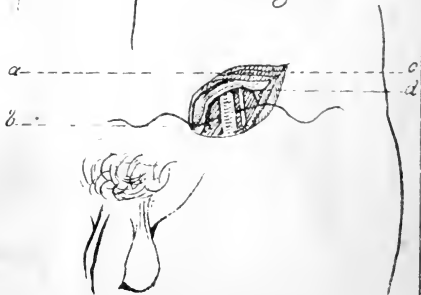


Fig 34








Fig 35

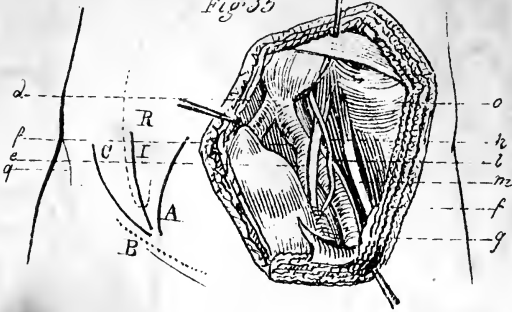


Fig 36

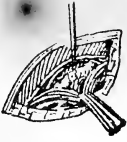

Fig 37

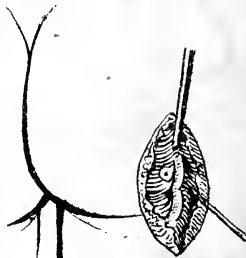
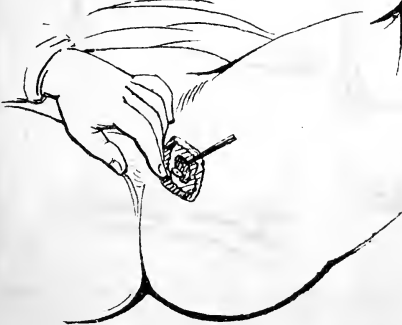
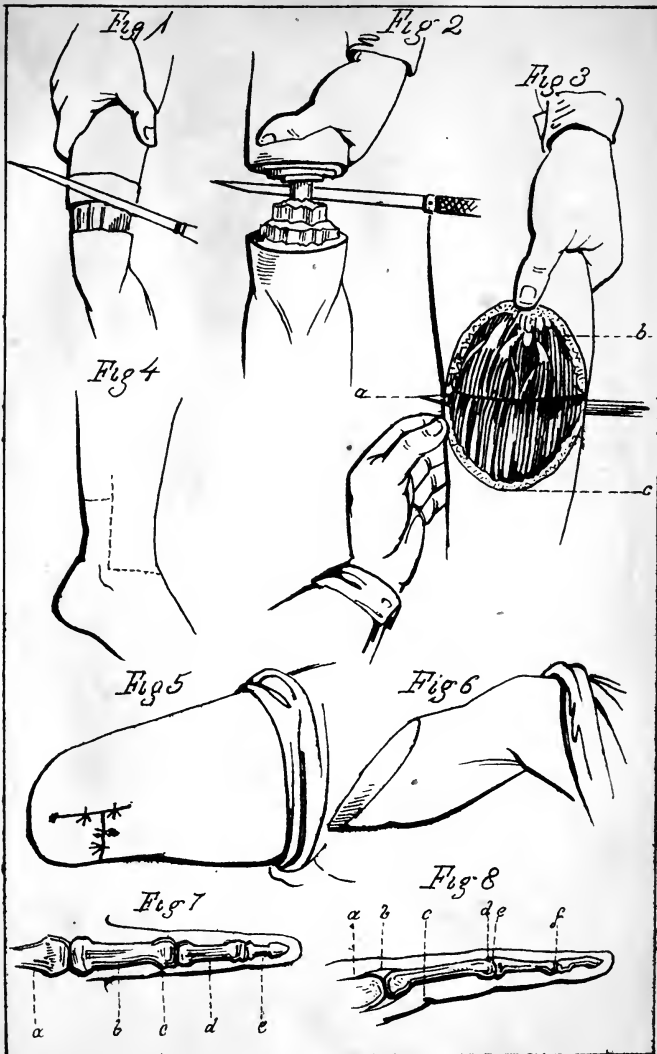


Fig 38











# AMPUTATION

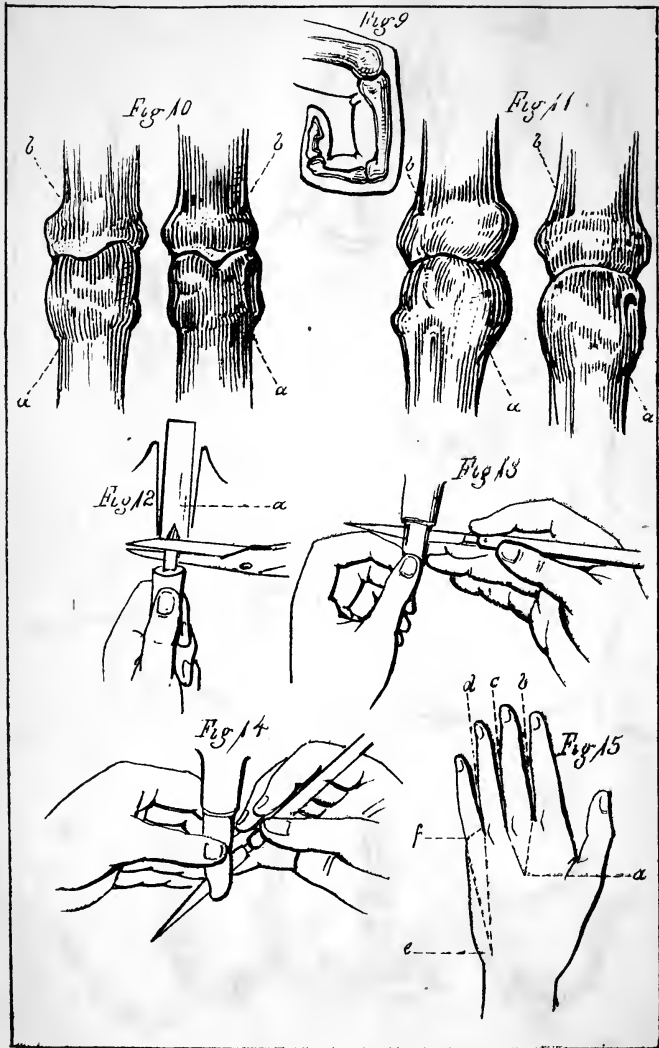


Fig 16

Fig 17

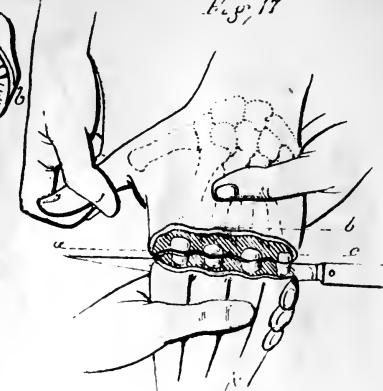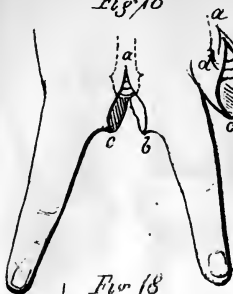


Fig 18

Fig 19

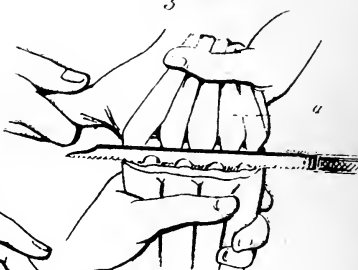
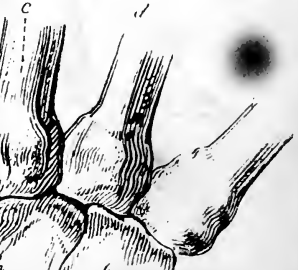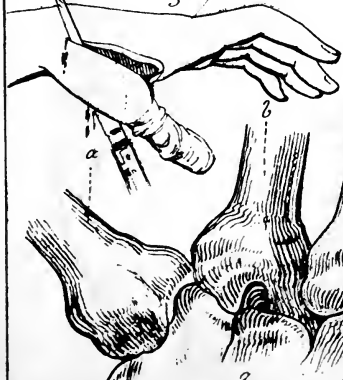


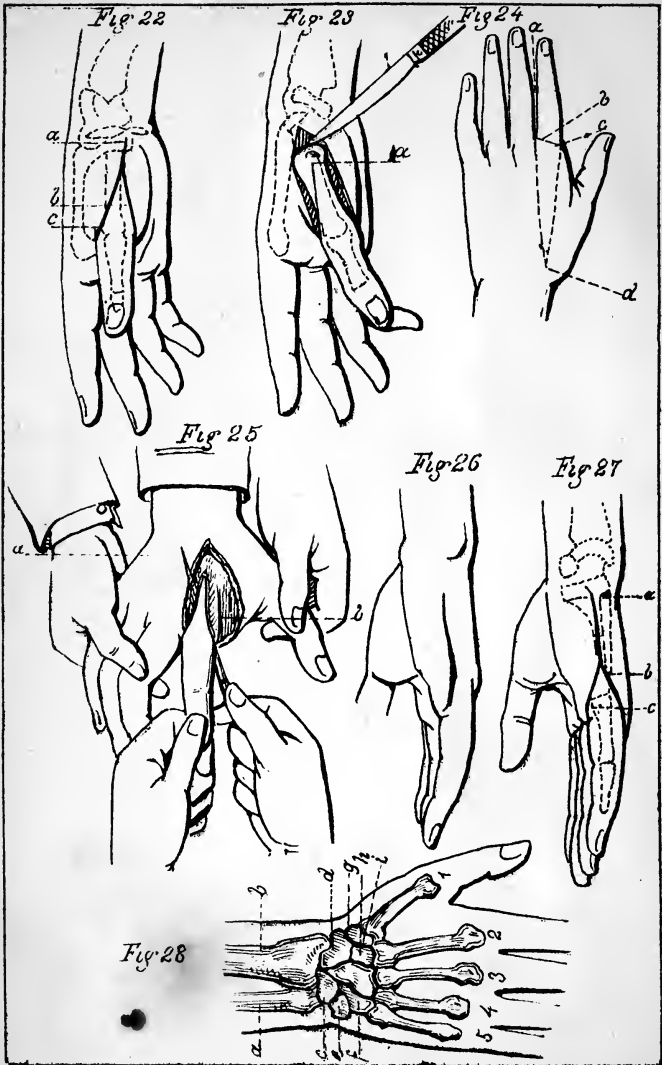
Fig 21

Fig 20

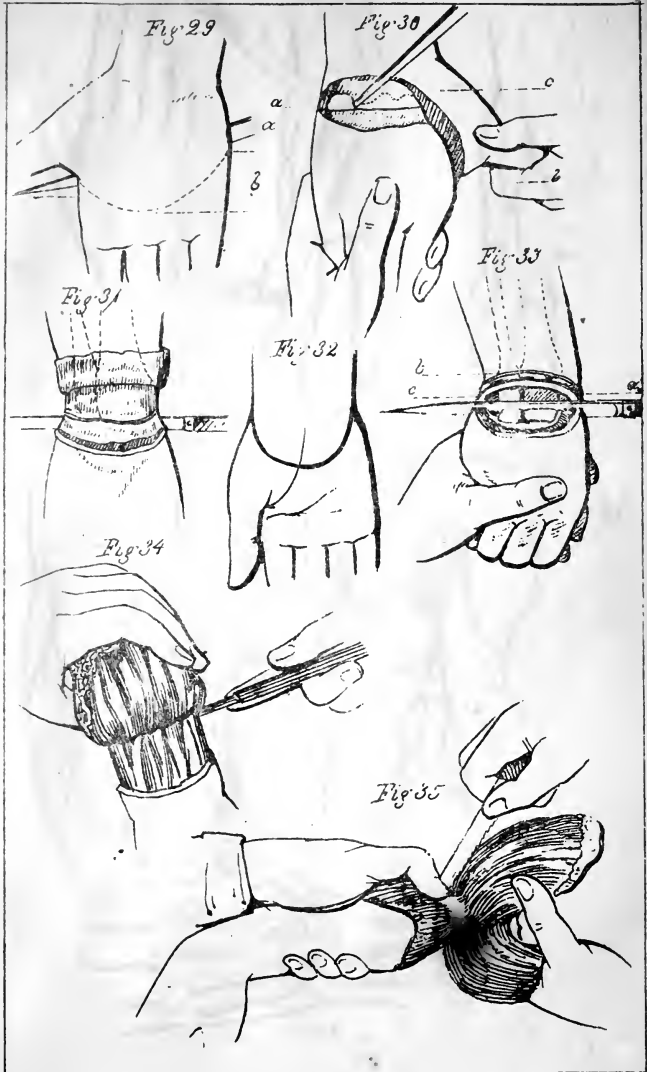

















Fig 36

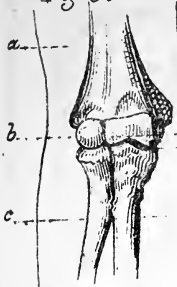


Fig 37

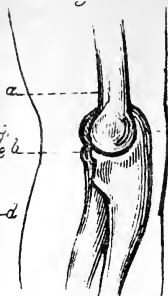


Fig 38

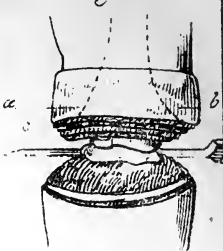


Fig 39

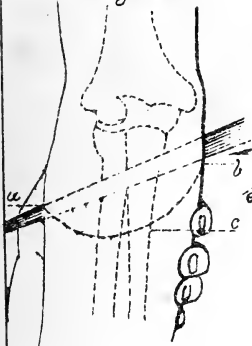


Fig 40

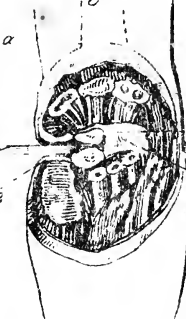


Fig 42

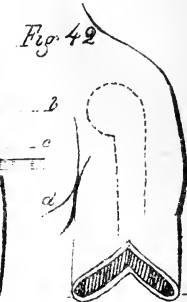

Fig 41

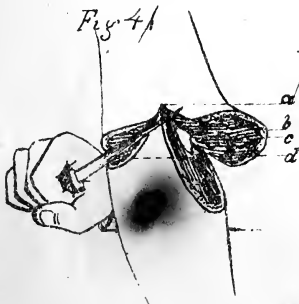
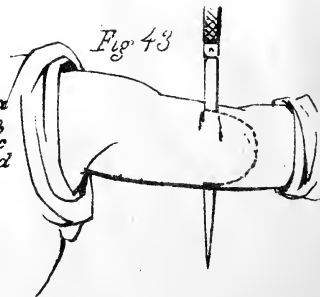


Fig 43



# AMPUTATION

PL 7

Fig 44

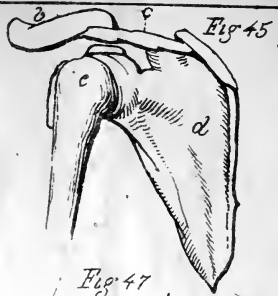
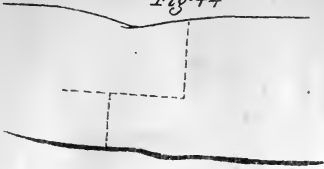


Fig 46

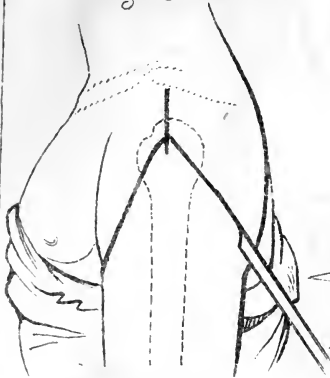


Fig 47

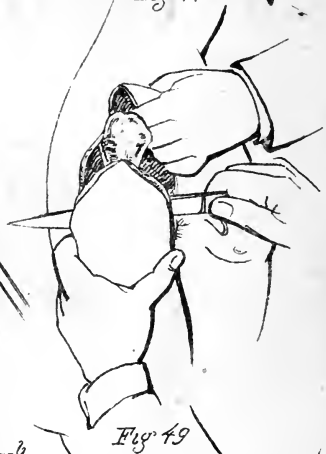


Fig 48

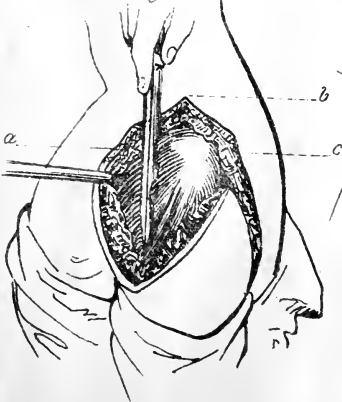


Fig 49

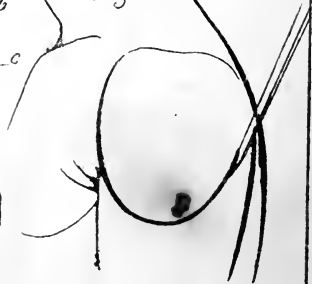





Fig 50

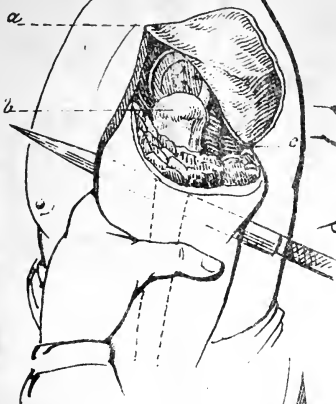


Fig 51

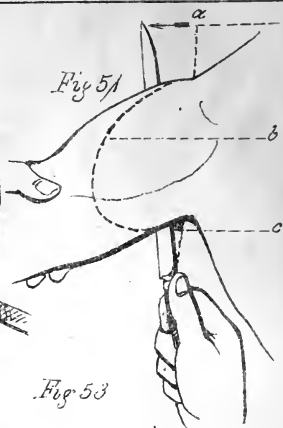


Fig 53

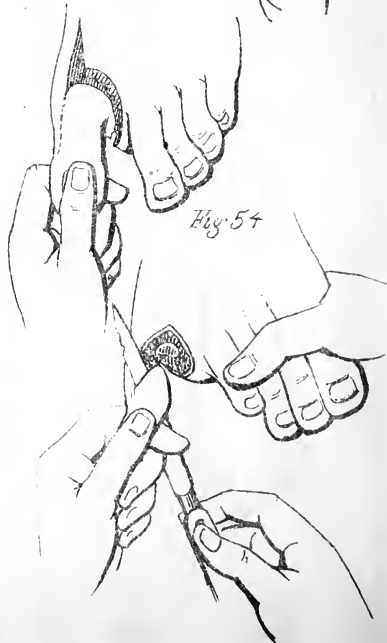

Fig 52




Fig 54



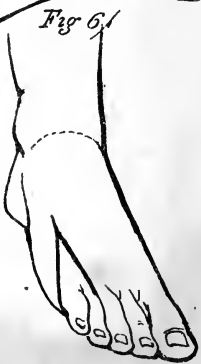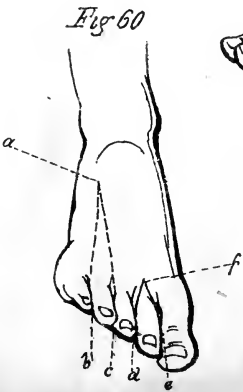
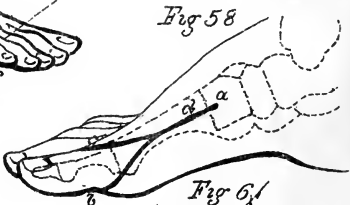
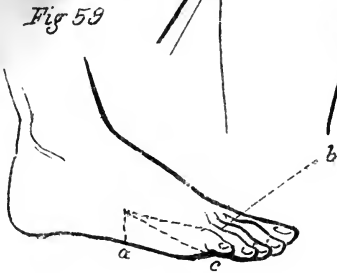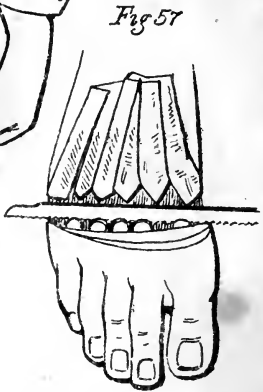
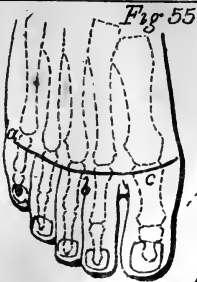






Fig 62

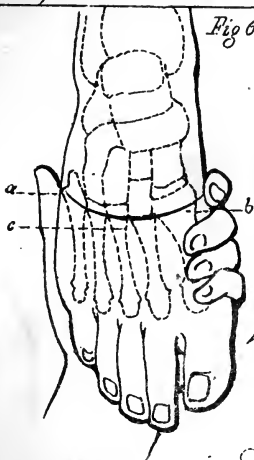


Fig 64

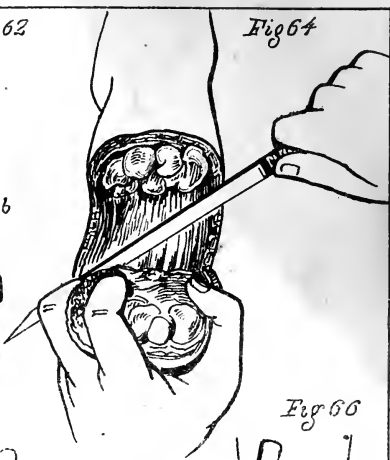


Fig 66

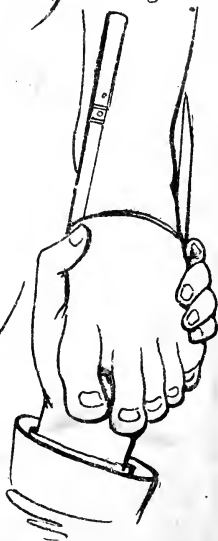

Fig 63

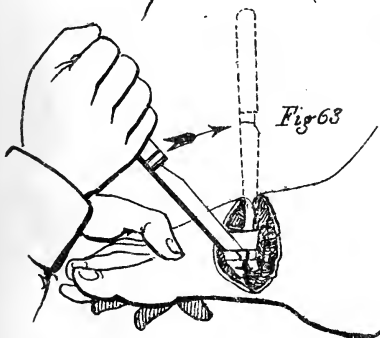
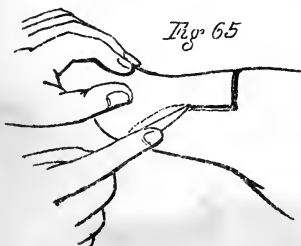


Fig 65



# AMPUTATION

12/11

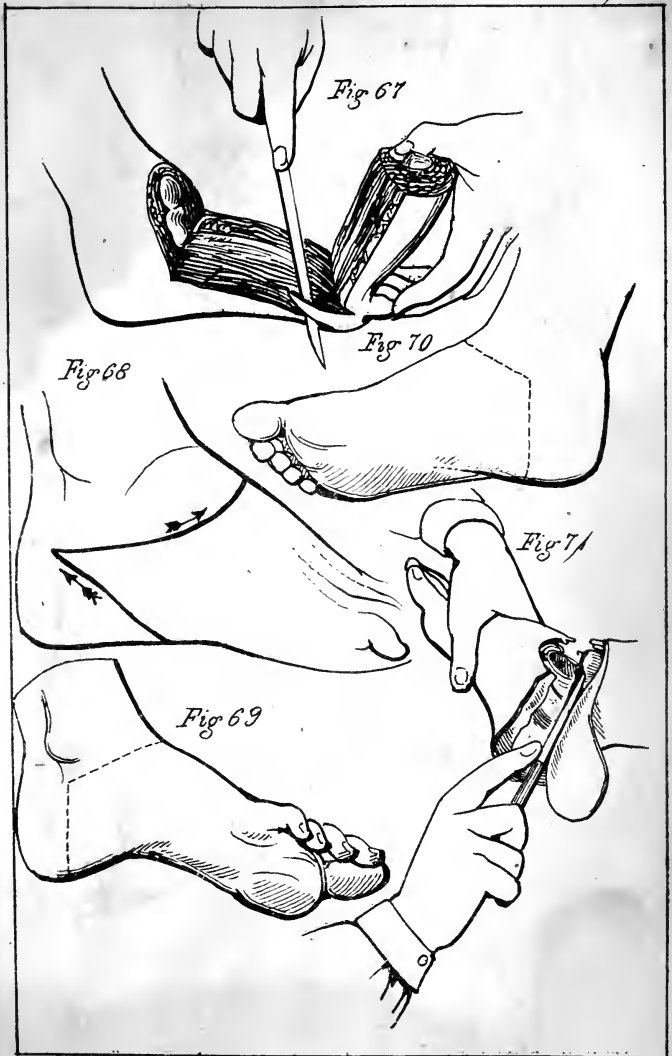






Fig. 72

Fig 15

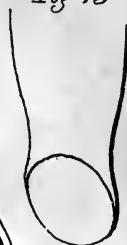

Fig 73

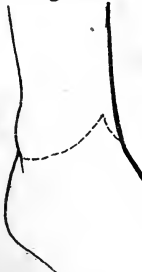

Fig 76

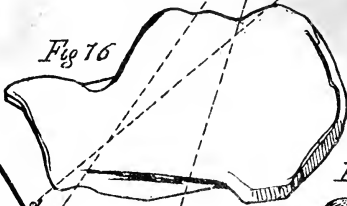


Fig 74



Fig 77

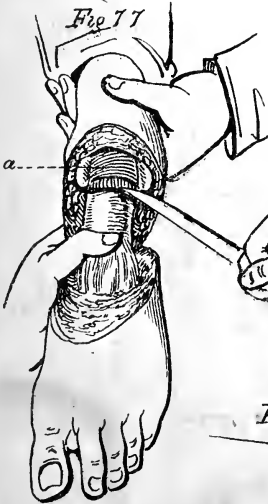


Fig 78



Fig 79

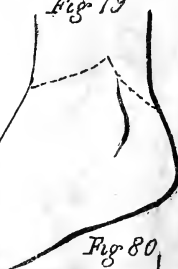

Fig 80

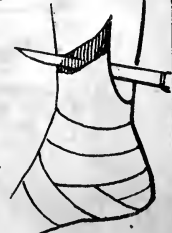
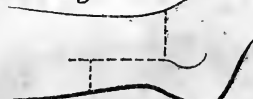
Fig 81





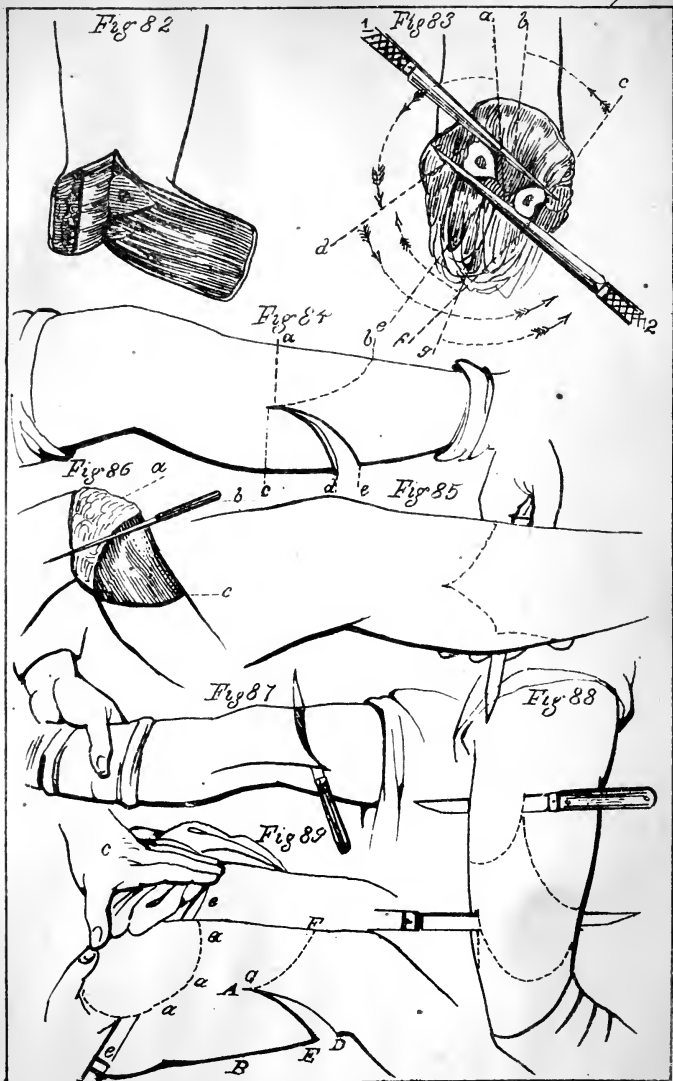






Fig 90

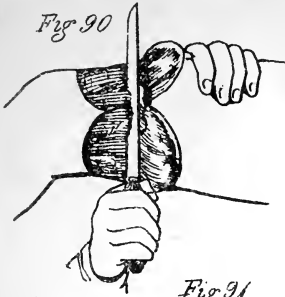


Fig 91

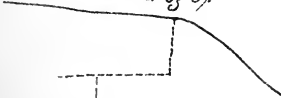


Fig 93

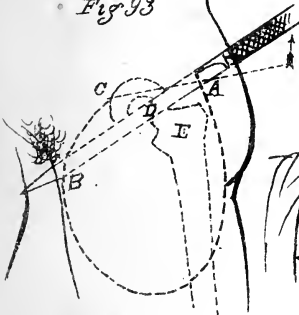


Fig 92

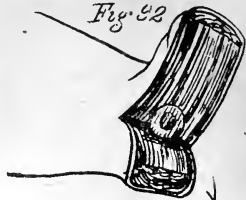

Fig 94

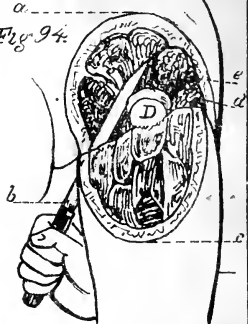


Fig 96

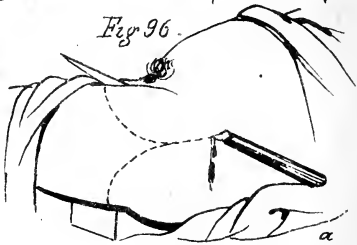

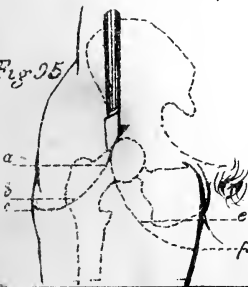
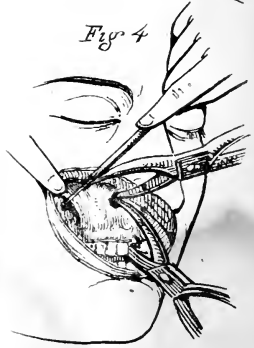
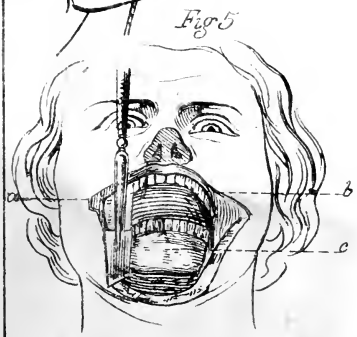
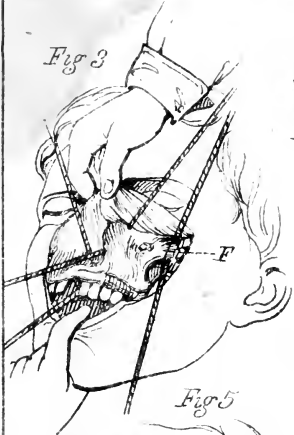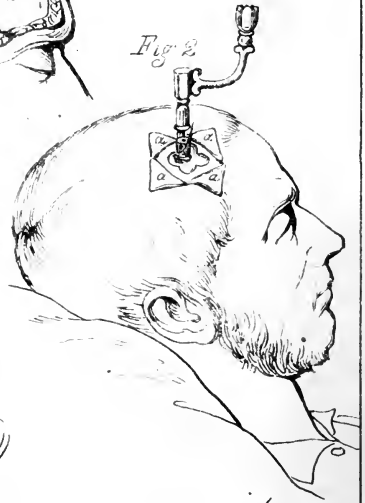
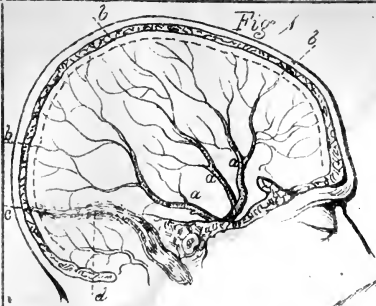



Fig 97

Fig 95



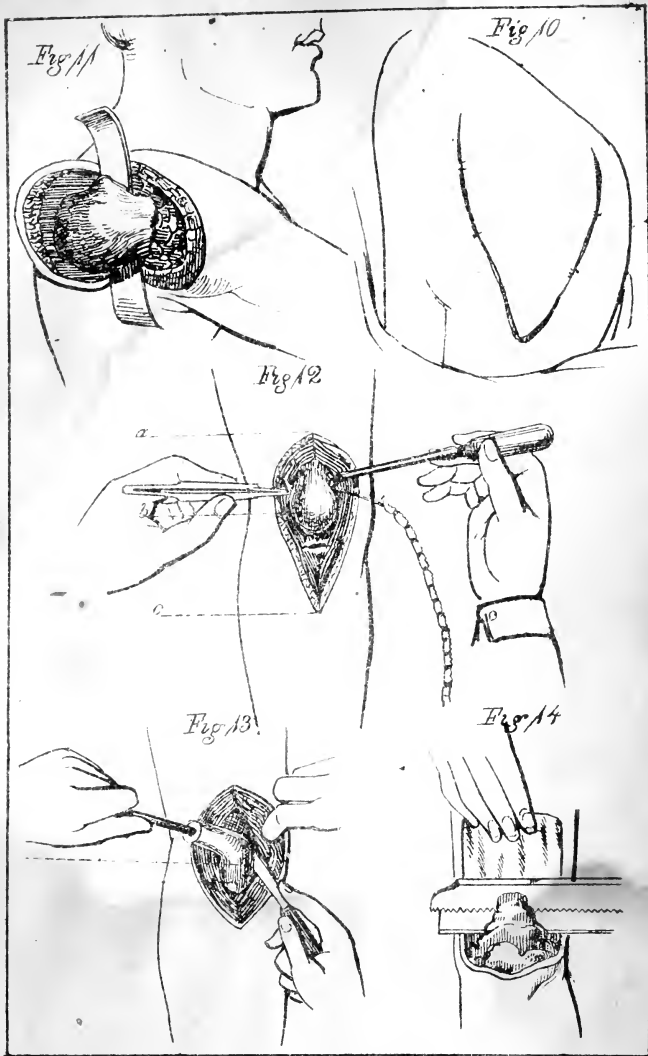


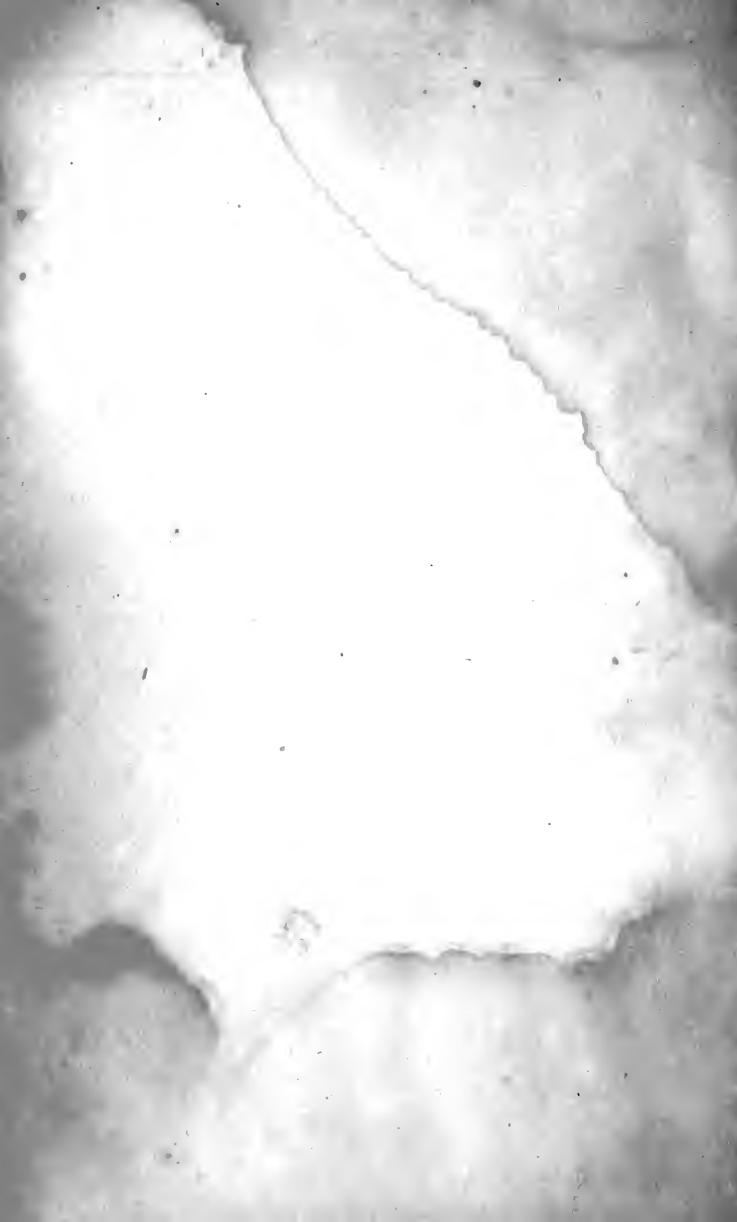













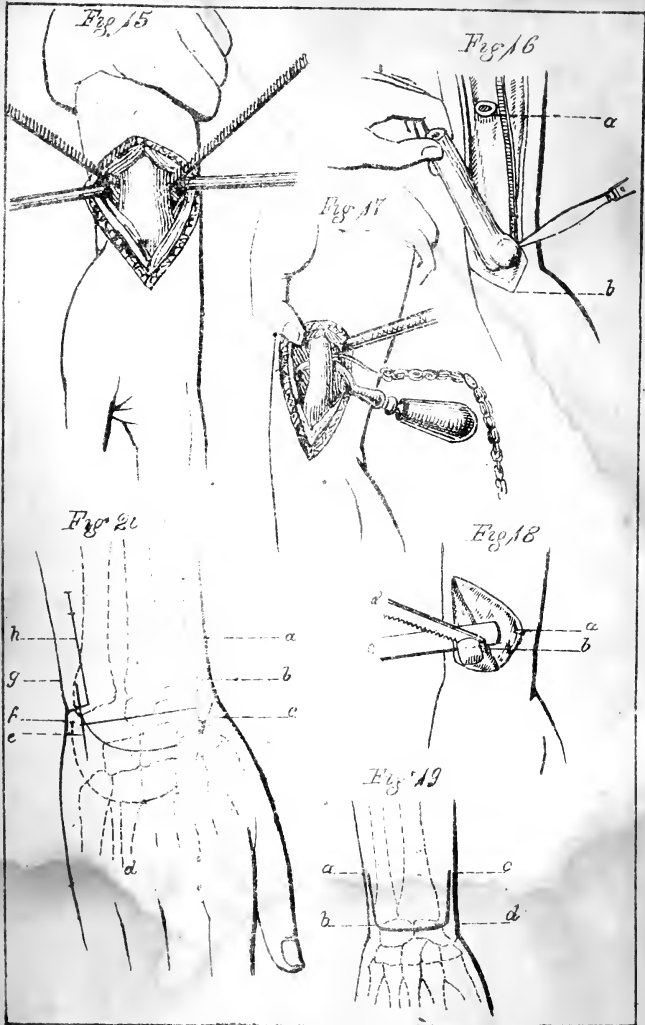


Fig 21

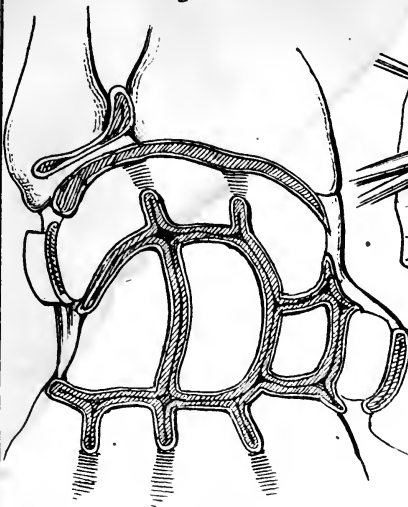


Fig 23

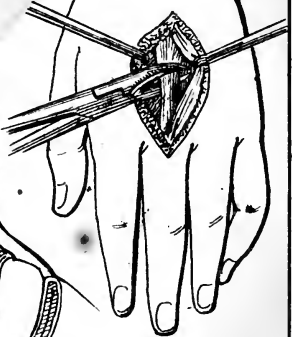


Fig 22

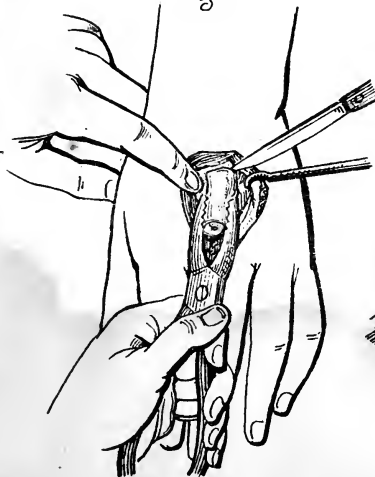


Fig 24

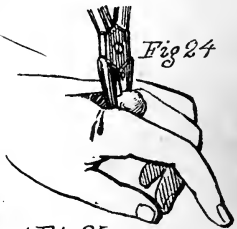


Fig 25

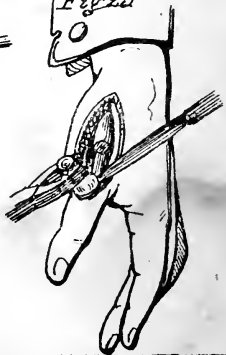






Fig 26

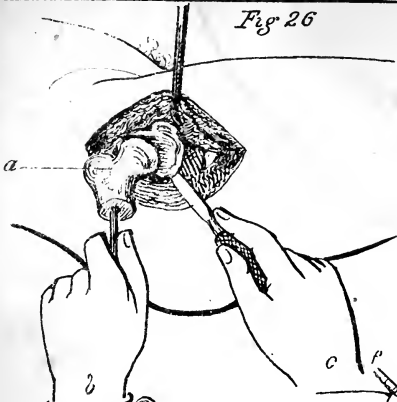


Fig 27




Fig 28

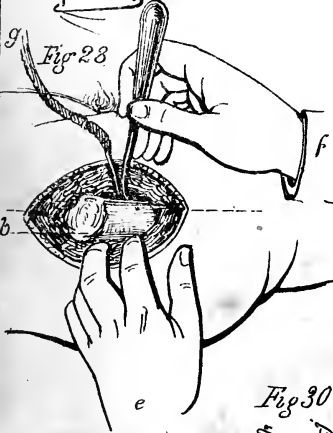

Fig 29

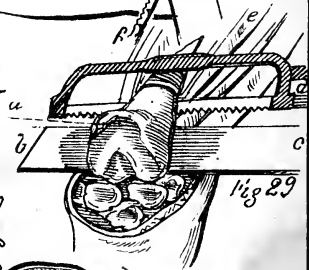


Fig 30

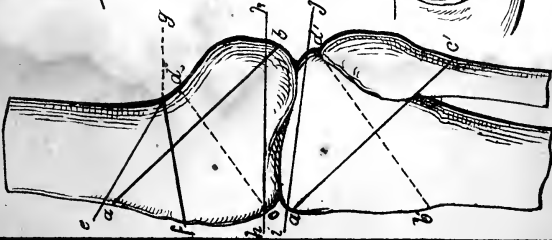




Fig 31

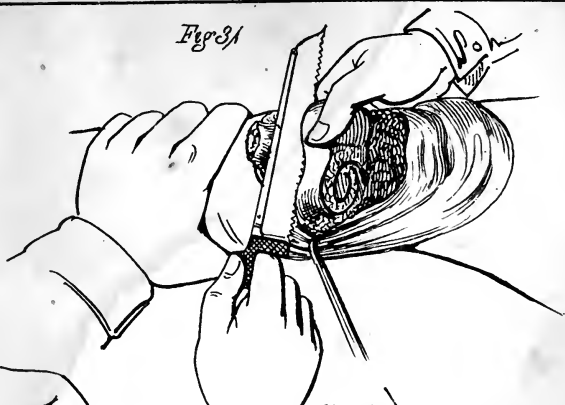


Fig 32

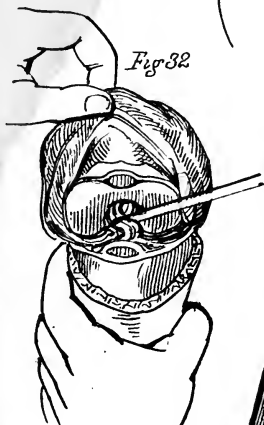


Fig 33

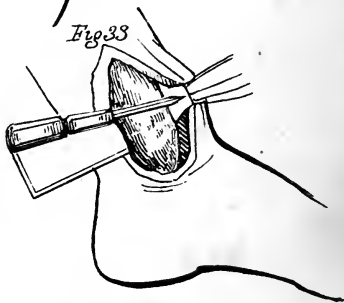


Fig 34

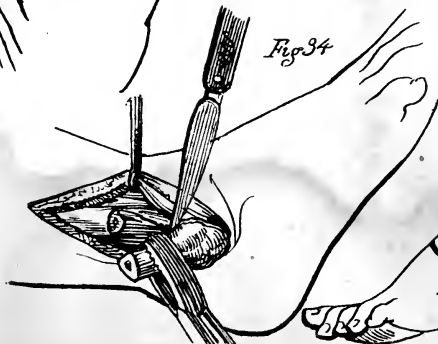
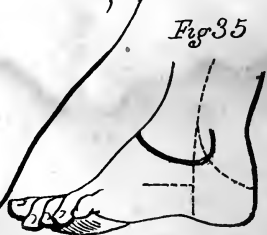


Fig 35







6.

Fig 37

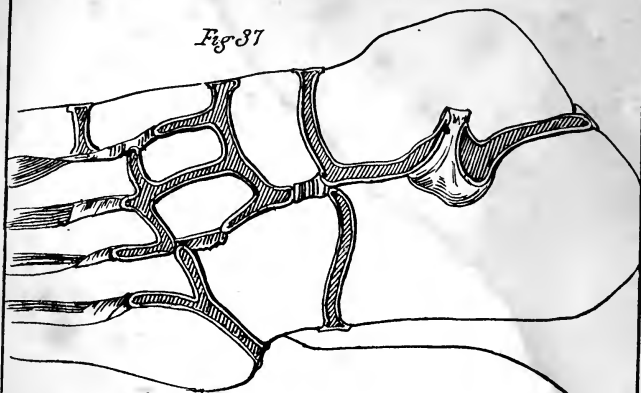


Fig 36

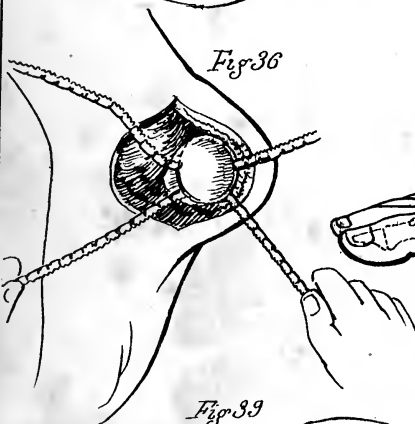


Fig 38

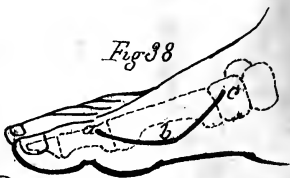


Fig 39

