

COLUMBIA LIBRARIES OFFSITE
HEALTH SCIENCES STANDARD



HX00016268

RECAP

G. M. 23


C 912


v. 1 1896
Copy 1

Columbia University
in the City of New York

College of Physicians and Surgeons
Library







Digitized by the Internet Archive
in 2010 with funding from
Columbia University Libraries

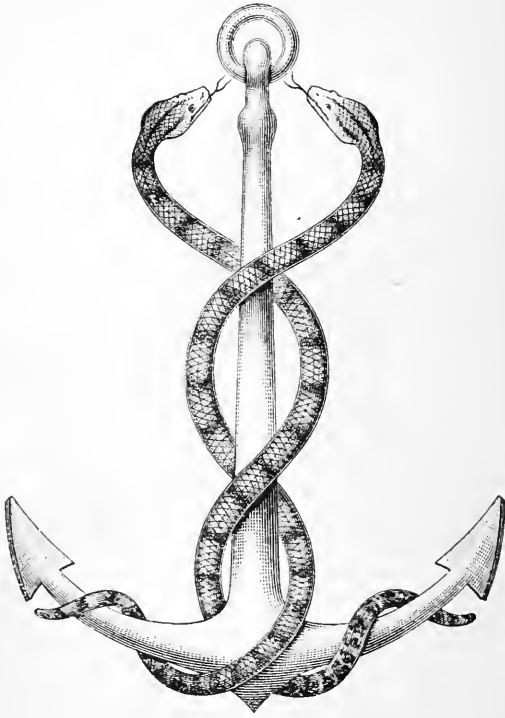


Pentland's Students' Manuals.

LIBRARY OF THE
ALUMNI ASSOCIATION,
COLLEGE OF PHYSICIANS AND SURGEONS
COLUMBIA UNIVERSITY
NEW YORK



MANUAL OF ANATOMY.



NUNQUAM ALIUD NATURA, ALIUD SAPIENTIA DICIT.

Nature never said one thing and wisdom another.

Hugh A. Stewart
New University.
MANUAL *Edinburgh*
OF

PRACTICAL ANATOMY

BY

D. J. CUNNINGHAM,

M.D. (EDIN. ET DUBL.), D.SC., LL.D., D.C.L. (OXON.), F.R.S.,
PROFESSOR OF ANATOMY AND CHIRURGERY, UNIVERSITY OF DUBLIN

VOLUME FIRST.

UPPER LIMB; LOWER LIMB; ABDOMEN

SECOND EDITION.

ILLUSTRATED WITH ENGRAVINGS.

EDINBURGH AND LONDON:
YOUNG J. PENTLAND.

1896.

QM23

C912

1896

v.1

Copy 1

EDINBURGH: PRINTED FOR YOUNG J. PENTLAND, 11 TEVIOT PLACE, AND
38 WEST SMITHFIELD, LONDON, E.C., BY R. AND R. CLARK, LIMITED.

tomy. Sectional anatomy is the true
 only be appreciated and understood
 by dissection.

P R E F A C E. made to deal with
 ordinary

THE order of dissection which is recommended in this Manual of Practical Anatomy is much the same as that which has been followed for many years in the Practical Anatomy Department of the Edinburgh University, and in the numerous schools which have been officered from it. As time has gone by many changes in this method of dissection have been adopted. As it has been handed from one teacher to another it has undergone development and improvement, so that it differs at the present day from the practice in the time of the Monros, or of Goodsir.

The first volume deals with the Limbs and the Abdomen, the second volume contains the method of dissection and the description of the Thorax and the Head and Neck.

Our conception of the topographical anatomy of the cavities of the body has of late years undergone very considerable modification. This has largely been brought about by the study of sections of the frozen body, and by the publication of the beautiful series of models by Professor His of Leipzig. In so far as the topography of

is too strongly urged alike in the relation of ^Q even in the same individual are produced during life, both in the and in the form of the organs, by different conditions of the hollow viscera. Such being the case, the author is well aware that in the present state of our knowledge it is impossible in every case to state dogmatically the average condition of the various organs and viscera ; still, in the short description which he has given, he has striven to approach as nearly as possible to the truth, by the careful study of specially prepared specimens and models.

The topographical anatomy of the abdominal cavity offers at the present moment a most promising field for research, and the author has little doubt that in a short time more definite and exact knowledge will be obtained upon the effect which different degrees of enlargement or distension of particular organs may exercise upon neighbouring viscera.

It is right that the student should not lose sight of the fact that in the course of an ordinary dissection the parts which are displayed are artificially separated from each other, and in consequence their true relations are disturbed. It is necessary to correct, therefore, impressions gained by dissection by the study of sections of the frozen body. The one form of study is the complement of the other ; both are required for the acquisition of a proper knowledge

of topographical anatomy. Sectional anatomy is the true anatomy, but it can only be appreciated and understood by the key which is supplied by dissection.

In the present work no attempt is made to deal with the minute anatomy of the organs. Under ordinary circumstances the microscope is out of place in the dissecting-room. It is a matter for regret, however, that students so very generally neglect the opportunities which are afforded them during their dissections of gaining a practical knowledge of the general architecture of the different organs which come under their notice. The connecting link between the dissecting-room and the histological laboratory is thereby lost. The spleen offers us a good example ; it is only when we deal with such an organ as a whole, and not with thin slices suited for the microscope, that we can obtain a proper appreciation of its framework, and the general disposition of its constituent parts.

The Committee appointed some years ago by the Anatomical Society of Germany with the view of obtaining some uniformity in anatomical nomenclature has recently published its report. Where the terminology recommended by this Committee differs from that in common use in this country, the author has, in most cases, introduced the German terms into the text, within parentheses.

Most of the illustrations are new, but many have also been borrowed from the writings of well-known authors.

In every case the source from which the latter have been obtained is acknowledged in the text. The author has specially to thank Dr. Symington and Professor Paterson for the generous manner in which they have supplied him with original drawings and wood-blocks.

TRINITY COLLEGE, DUBLIN,
25th December 1895.

CONTENTS.



THE UPPER LIMB.

	PAGE
INTRODUCTORY,	I
DISSECTION OF THE BACK,	3
PECTORAL REGION AND AXILLARY SPACE,	15
THE AXILLA,	23
SCAPULAR REGION,	45
FRONT OF THE ARM,	58
BACK OF THE ARM,	79
SHOULDER JOINT,	84
FOREARM AND HAND,	90
FRONT AND INNER BORDER OF THE FOREARM,	94
WRIST AND PALM,	106
BACK AND OUTER BORDER OF THE FOREARM,	129
DORSAL ASPECT OF THE WRIST AND HAND,	138
ARTICULATIONS,	145

THE LOWER LIMB.

GLUTEAL REGION,	164
POPLITEAL SPACE,	183
BACK OF THE THIGH,	195
FRONT OF THE THIGH,	200
SUPERFICIAL DISSECTION OF THE FRONT OF THE THIGH,	202
DEEP DISSECTION OF THE FRONT OF THE THIGH,	213
INNER SIDE OF THE THIGH,	239
HIP-JOINT,	248
THE LEG,	254

	PAGE
ANTERIOR TIBIO-FIBULAR REGION—DORSUM OF THE FOOT, .	256
PERONEAL REGION,	271
TIBIAL REGION,	273
POSTERIOR TIBIO-FIBULAR REGION,	274
SOLE OF THE FOOT,	288
THE KNEE-JOINT,	307
THE ANKLE-JOINT,	319
TIBIO-FIBULAR JOINTS,	321
THE ARTICULATIONS OF THE FOOT,	324

ABDOMEN.

MALE PERINEUM,	336
RECTAL TRIANGLE,	338
UROGENITAL TRIANGLE,	346
THE FEMALE PERINEUM,	364
RECTAL TRIANGLE,	370
UROGENITAL TRIANGLE,	370
ABDOMINAL WALL,	377
SURGICAL ANATOMY OF THE ABDOMINAL WALL,	421
ABDOMINAL CAVITY AND ITS CONTENTS,	430
VESSELS ON THE POSTERIOR WALL OF THE ABDOMEN,	530
FASCIA AND MUSCLES ON THE POSTERIOR WALL OF THE ABDOMEN,	537
NERVES ON THE POSTERIOR WALL OF THE ABDOMEN,	540
PELVIS,	546
MALE PELVIS,	548
PELVIC ARTICULATIONS,	605
FEMALE PELVIS,	612
INDEX,	639

LIST OF ILLUSTRATIONS.



PLATE I. Posterior wall of the abdomen after the removal of
viscera. (After GOUBAROFF), . . . *facing page 466*

FIG.	PAGE
1. Lines of incisions for reflection of skin from dorsal aspect of subject,	3
2. Cutaneous nerves and superficial muscles of the back,	5
3. Diagram of the lumbar fascia,	10
4. Lines of incisions for reflection of skin from ventral aspect of the subject,	17
5. Diagram to show the structure of the mammary gland	20
6. Section through the axilla of the left side,	25
7. Transverse section through the right shoulder, and apex of the axilla,	27
8. Transverse section through the right axilla,	28
9. Diagram illustrating the arrangement of the main branches of the brachial plexus,	32
10. Diagram of the costo-coracoid membrane,	33
11. Diagram of the axillary artery and its branches,	37
12. Diagram of the brachial plexus,	40
13. Dissection of the posterior scapular region,	48
14. Diagram of the circumflex vessels and nerve,	51
15. Posterior view of the upper limb, with the elbow-joint fully extended. (LUSCHKA),	59
16. Posterior view of the upper limb, with the elbow-joint flexed (LUSCHKA),	59
17. Diagram of the cutaneous nerves on the front of the upper limb,	62

FIG.	PAGE
18. Diagram of the cutaneous nerves on the posterior aspect of the upper limb,	64
19. Superficial dissection of the region in front of the right elbow. (LUSCHKA),	66
20. Diagram to show the arrangement of the intermuscular septa in the arm. (After TURNER),	68
21. Transverse section through the lower third of the right upper arm,	69
22. Transverse section through the right upper arm about its middle,	71
23. Dissection of the anticubital fossa,	78
24. Coronal or vertical transverse section through the left shoulder-joint. (Viewed from behind),	85
25. Transverse section through the upper third of the left forearm,	97
26. Diagram to show the relation of the skin markings of the palm to the arteries and bones of the hand. (TREVES),	108
27. Diagram of the median and ulnar nerves in the palm,	115
28. Transverse section through the wrist at the level of the second row of carpal bones to show the carpal tunnel,	117
29. Diagram to illustrate the arrangement of the synovial sheaths around the flexor tendons,	120
30. Flexor tendons of the finger, with the vincula accessoria. (REEVES),	122
31. Diagram of the anastomosis around the elbow-joint,	136
32. Diagrammatic section through the lower end of the forearm to show the compartments of the posterior annular ligament. (REEVES),	141
33. Arrangement of the flexor and extensor tendons of the middle finger. (LUSCHKA),	142
34. Vertical antero-posterior section through the humerus and ulna at the elbow-joint,	145
35. Vertical antero-posterior section through the humerus and radius at the elbow-joint,	147
36. Socket formed by radius and triangular fibro-cartilage for upper row of carpal bones,	150
37. Vertical section through the flexed wrist-joint in the line of the middle finger,	151
38. Coronal section through the carpal joints,	157
39. Cutaneous nerves on the back of the lower limb,	167

FIG.	PAGE
40. Dissection of the gluteal region,	174
41. Dissection of the right popliteal space,	187
42. Transverse section through the popliteal space of the right lower limb,	188
43. Diagram of the popliteal artery and its branches,	192
44. Dissection of the back of the right thigh,	197
45. Diagram of the cutaneous nerves on the front of the lower limb	208
46. Diagram to show the arrangement of the three intermuscular septa and the three osteo-fascial compartments of the thigh. (TURNER),	212
47. Dissection of the femoral sheath and Hunter's canal,	216
48. Parts which pass behind Poupart's ligament. (LUSCHKA),	218
49. Dissection of the femoral sheath and Hunter's canal,	226
50. Transverse section through Hunter's canal,	228
51. Transverse section through the middle of the thigh,	229
52. Diagram to illustrate the distribution of the obturator nerve and the general disposition of the adductor muscles of the thigh. (PATERSON),	244
53. The ilio-femoral band isolated from the capsule of the hip-joint,	250
54. Diagrammatic representation of the fascia of the leg,	260
55. Transverse section through the calf of the leg,	263
56. Dissection to show the plantar arterial arch from the dorsal aspect of the foot,	267
57. Transverse section through the leg immediately above the ankle-joint,	270
58. Transverse section through the leg immediately above the ankle-joint,	284
59. Diagrammatic representation of the fascia of the leg,	285
60. Dissection of the inner ankle,	286
61. Diagram to show the different planes occupied by the external plantar artery. (PATERSON),	293
62. Diagram of the accessorius muscle and the tendons of the flexor longus hallucis and flexor longus digitorum in the sole of the foot,	297
63. Vertical section through the foot. (LUSCHKA),	299
64. Anastomosis on the anterior aspect of the knee-joint,	305
65. Vertical antero-posterior section through the knee-joint,	312
66. Articular surface of the lower end of left femur, with the crucial ligaments attached,	314

FIG.	PAGE
67. Upper articular surface of right tibia showing attachments of semilunar cartilages and crucial ligaments, . . .	318
68. Socket for the astragalus,	320
69. Vertical section through the foot. (LUSCHKA), . . .	324
70. Outlet of pelvis,	337
71. Lines of incisions for reflection of skin in the dissection of the perineum,	339
72. Diagram of the pelvic fascia,	342
73. Dissection of the perineum,	345
74. Diagram of the three parts of the penis, and their relation to the pubic arch and the triangular ligament, . . .	350
75. Deep dissection of the perineum,	354
76. Diagram of the triangular ligament,	355
77. " " " " " " " " " " " " " " " " "	356
78. Vertical transverse section through the pubic arch to show the two perineal compartments and their contents, . . .	360
79. Deep dissection of the perineum. (GRAY),	362
80. Outlet of pelvis,	365
81. External genitalia of the female. (SYMINGTON), . . .	367
82. The clitoris and the bulb of the vestibule. (GEGENBAUR),	374
83. Lines of incision for reflection of skin from the ventral aspect of the subject,	379
84. Superficial dissection of abdominal wall,	383
85. Diagram to show the connections of the lower part of the aponeurosis of the external oblique muscle,	388
86. The obliquus abdominis internus. (HEITZMANN), . . .	393
87. Diagram to illustrate the relation of the lower border of the internal oblique muscle,	394
88. Diagram of the muscles and aponeuroses of the abdominal wall,	398
89. Dissection of the abdominal wall. (HEITZMANN), . . .	399
90. Diagram of the muscles and aponeuroses of the abdominal wall,	402
91. Diagram of the aponeuroses in the lower part of the front wall of the abdomen,	403
92. Diagram to illustrate the relation of the lower portions of the internal oblique and transversalis muscles to the inguinal canal,	404
93. Diagrams illustrating the descent of the testicle and the derivation of the tunica vaginalis from the peritoneal lining of the abdominal cavity,	412
94. Transverse section through the left side of the scrotum and the left testicle,	416

FIG.	PAGE
95. Diagram illustrating the structure of the testicle. (GEGEN- BAUR),	419
96. Diagram to show the different peritoneal relations in an ordinary inguinal hernia and a congenital inguinal hernia	424
97. Diagram to illustrate the four different varieties of infantile hernia. (After LOCKWOOD),	426
98. Outline of the abdominal cavity as seen in mesial section, .	432
99. Subdivision of the abdominal cavity,	433
100. Diagram showing the exact portions of the liver in the different sections of the costal zone,	437
101. Anterior surface of the liver from the model by HIS, .	439
102. The form of the spleen as seen from its visceral aspect, .	442
103. Position of viscera as seen in a female subject,	444
104. The recess or space in the abdominal cavity which is occupied by the stomach,	445
105. Position of viscera in relation to the under surface of the diaphragm. (BRAUNE),	448
106. From a tracing of a transverse section through the abdomen, at the level of the fourth lumbar vertebra,	453
107. Diagram to illustrate the continuity of the peritoneum in the vertical direction,	456
108. Section through the peritoneal cavity at the level of the foramen of Winslow,	460
109. Section at the level of the umbilicus through the inter- vertebral disc between the third and fourth lumbar vertebræ,	461
110. Section through the abdominal cavity of a young subject at the upper border of the twelfth dorsal vertebra, above the level of the foramen of Winslow. (LUSCHKA),	462
111. Diagram of the peritoneal ligaments of the liver,	465
112. Diagram of the superior mesenteric artery and its branches. (GRAY),	471
113. Diagram of the inferior mesenteric artery and its branches. (GRAY),	475
114. The cœliac axis and its branches. (GRAY),	484
115. The splenic artery and vein. (GRAY),	487
116. The duodenum, pancreas, kidneys, etc., from the model by HIS,	491
117. Position of duodenum, with reference to kidney in three different subjects. (BROOKS),	492


FIG.		PAGE
118.	The pancreas as seen in a subject in which the abdominal viscera were hardened by repeated injections of Müller's fluid and spirit,	495
119.	The pyloric orifice of a child in which the sphincter is tightly contracted,	503
120.	Peritoneal and muscular coats removed from the pylorus and upper part of duodenum to show the constriction and Brunner's glands. (GEGENBAUR),	504
121.	Inferior surface of the liver, from the model by HIS,	507
122.	Posterior surface of the liver, from the model by HIS,	509
123.	Liver, right kidney, spleen, and stomach, as seen from behind,	510
124.	Lower and posterior surfaces of a liver which has lost its proper form from being placed on a plane surface. (GRAY),	511
125.	Cystic and hepatic ducts. (GEGENBAUR),	512
126.	Section through abdomen at the level of the second lumbar vertebra,	517
127.	{ A. Anterior surface of a model of the right kidney of a child of two years old,	519
	{ B. Anterior surface of a model of the left kidney of a child of two years old,	519
128.	Transverse section through abdomen at the level of the first lumbar vertebra,	520
129.	Peritoneal relations of the kidneys,	521
130.	Two different forms of the pelvis of the ureter. (GEGENBAUR),	522
131.	Two renal papillæ. (LUSCHKA),	522
132.	Posterior surface of the anterior wall of the thorax and abdomen, to show the costal and sternal origins of the diaphragm on the left side. (LUSCHKA),	526
133.	Diagram of the lumbar plexus,	543
134.	The lumbar plexus,	545
135.	Side view of pelvic viscera. (WILSON),	549
136.	Diagram of the pelvic fascia	552
137.	Dissection to expose pelvic fascia from the outer side,	553
138.	Dissection of the pelvic fascia	554
139.	Relation of blood-vessels, etc., to the parietal pelvic fascia,	558
140.	Diagram of the pelvic fascia as seen in a vertical transverse section through the pubic arch,	559
141.	Diagram of the pelvic fascia,	560
142.	„ „ „ „	561

FIG.	PAGE
143. Diagram representing the pelvic fascia in antero-posterior section,	562
144. Dissection of the rectum, from behind, by Mr. C. Paton,	566
145. Coronal section through the whole length of the anal canal. (SYMINGTON),	569
146. Mesial section through the pelvis of an adult male,	572
147. Mesial section through a male pelvis, in which the bladder is greatly distended,	574
148. Mesial section through pelvis of a newly-born full-time male infant,	575
149. Seminal vesicle and vas deferens on the base of the bladder. (GEGENBAUR),	578
150. View of the posterior aspect of the anterior wall of the abdomen and pelvis of a foetus, to show the hypogastric artery. (LUSCHKA),	580
151. Sacral and sacro-coccygeal plexuses as seen from behind. (EISLER),	588
152. Mucous membrane lining the anal canal. (LUSCHKA),	595
153. Diagram of the urethra and bladder,	599
154. Section through the sacro-iliac joint. (LUSCHKA),	608
155. Horizontal section through the symphysis pubis. (LUSCHKA),	610
156. Mesial section through the pelvis of a virgin. (LEGENDRE),	613
157. Horizontal section through the urethra, vagina, and anal canal, a short distance above their terminations. (HENLE),	614
158. The uterus, with the broad ligament stretching out from either side of it. (GEGENBAUR),	615
159. Two forms of the empty female bladder as seen in mesial section. (DISSE),	618
160. Mesial section through a female pelvis,	619
161. Vertical section through the female pelvis; bladder distended. (PIROGOFF),	620
162. Diagram of the vulva, vagina, and uterus with its appendages. (SYMINGTON),	625
163. The uterus, with the broad ligament stretching out from either side of it. (GEGENBAUR),	626
164. Sagittal section through the pelvis of a female child two years old,	628
165. The ampulla and fimbriated end of the Fallopian tube; the ovary and the parovarium. (GEGENBAUR),	630
166. Interior of the uterus. (LUSCHKA),	635



LIBRARY OF THE
ALUMNI ASSOCIATION,
COLLEGE OF PHYSICIANS AND SURGEONS
COLUMBIA UNIVERSITY
NEW YORK

MANUAL OF ANATOMY.



MANUAL

OF

PRACTICAL ANATOMY.



THE UPPER LIMB.

THE dissector of the upper limb begins work on the third day after the subject has been placed in the dissecting-room. He will then find the subject stretched out at full length upon its face, with the pelvis and chest supported by blocks (Fig. 1); and while the body remains in this position he must examine those structures which connect the limb to the posterior aspect of the trunk.

Surface Anatomy.—Before proceeding to the actual dissection of any region, the student should make it an invariable rule to familiarise himself with the bony prominences within its area. It is by using these as landmarks that the surgeon is enabled to establish the position of the component parts of the body in the living subject. Their importance can hardly be exaggerated. In the middle line of the back there will be little difficulty in recognising the spines of the vertebræ, which follow each other in consecutive order. If the finger be passed over them, it will be observed that they do not, in every case, occupy the mesial plane;

some of them may be deflected, in a slight degree, to one side or the other. The spines of the vertebræ are the only parts of the vertebral column which come to the surface; they alone yield direct information, by touch, to the surgeon as to the condition of the spine. At the lower end of the neck, the spine of the seventh cervical vertebra (*vertebra prominens*) makes a visible projection; and the spines of the first two dorsal vertebræ are likewise very prominent. As a rule, the most evident of the three is that of the first dorsal vertebra. At a lower level, in subjects of good muscular development, a mesial furrow is produced by the prominence of the erector spinæ muscle on each side, and the spines of the vertebræ may be felt at the bottom of this groove. It attains its greatest depth in the upper part of the lumbar region, and it fades away below at the level of the spine of the third sacral vertebra. The finger should next be passed along the crest of the ilium as it pursues its sigmoid course forwards and outwards. Note that the posterior superior spine of the ilium lies in a slight depression on a level with the second sacral spine. The scapula is for the most part thickly covered by muscles; but, in spite of this, its general outline can be made out. The scapula covers a considerable area on the upper portion of the chest on its posterior aspect. With the hand by the side its superior angle corresponds with the second intercostal space, whilst its inferior angle reaches down as far as the seventh, or even the eighth, rib. It is very mobile—moving more or less with every movement of the limb. The spine and acromion process of the scapula will be seen to be subcutaneous throughout. It is important to make out accurately the angle which is formed by the meeting of the lower border of the spine with the outer margin of the acromion. This very apparent bony point is selected by the surgeon as the upper limit in making measurements of the limb.

DISSECTION OF THE BACK.

In this dissection the following are the parts which require to be examined :—

1. The cutaneous vessels and nerves of the back.
2. The trapezius muscle.
3. The latissimus dorsi muscle.
4. The rhomboid muscles and their nerve of supply.
5. The levator anguli scapulae muscle.
6. The spinal accessory nerve and the nerves from the cervical plexus which supply the trapezius.
7. The transversalis colli artery and its two terminal branches (viz. the posterior scapular and the superficial cervical).
8. The posterior belly of the omo-hyoid muscle.
9. The suprascapular artery and nerve.

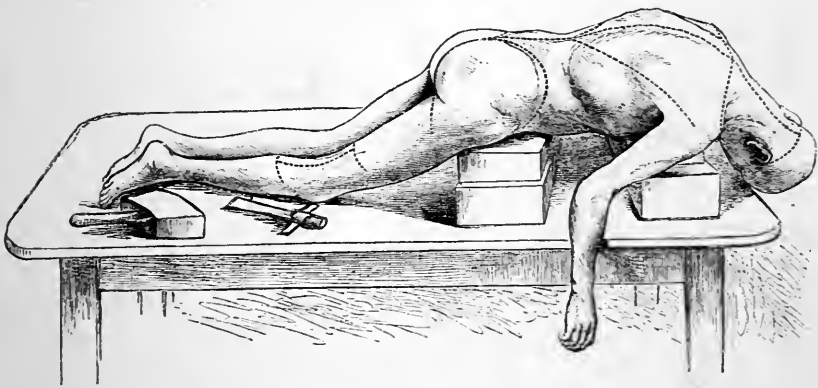


FIG. 1.

This dissection must be completed *in two days*, in order that the dissector of the head and neck may be enabled to continue the deeper dissection of the back. The *first day's work* should comprise—(1) the reflection of the skin; (2) the dissection of the cutaneous nerves and vessels; and (3) the cleaning of the latissimus dorsi and trapezius muscles. The remainder of the dissection can be undertaken on *the second day*.

Reflection of the Skin.—The following incisions are necessary :—

1. From the tip of the coccyx upwards, along the middle line of the body to the spine of the seventh cervical vertebra.
2. From the upper end of the foregoing mesial incision transversely outwards, to the inner border of the acromion process of the scapula.
3. From the lower extremity of the mesial incision in a curved direction outwards and forwards, along the crest of the ilium, to within two inches of the anterior superior iliac spine.
4. An oblique incision from the spine of the first lumbar vertebra, upwards and outwards, to the outer border of the acromion process.

The two large flaps which are now mapped out upon the back must be carefully raised from the subjacent fatty tissue. Reflect the upper triangular flap first, and then deal in the same way with the lower flap.

Superficial Fascia.—The fatty layer which is now exposed is termed the *superficial fascia*. It constitutes the cushion upon which the skin rests, rounds off the angularities of the body, and varies in thickness according to the obesity of the subject. In subjects that have lain for some time on the back it is usually more or less infiltrated with fluid which has gradually gravitated into its loose meshes. The superficial fascia constitutes the bed in which the cutaneous vessels and nerves ramify before they enter the skin; and it is separated from the muscles by a tough, but thin, layer of fibrous tissue, devoid of fat, which forms an investment for the body. This aponeurotic membrane receives the name of the *deep fascia*; it can be readily demonstrated by making an incision in the superficial fascia, and raising a small portion of it.

Dissection.—In searching for a cutaneous nerve, cut boldly down through the superficial fascia in the direction in which the nerve runs, until the plane at which the superficial and deep fasciæ blend is reached. It is here that the main trunks are to be found; and in a well-injected subject the cutaneous arteries constitute the best guides. A more rapid way of finding the cutaneous nerves in this region is to reflect in one layer both the superficial and the deep fascia outwards from the vertebral spines. The nerves are seen piercing the muscles. This plan, however, should only be adopted by the senior student.

Cutaneous Vessels and Nerves.—The *cutaneous nerves*

of the back are derived from the posterior primary divisions of the spinal nerves. As the latter pass backwards, they

divide into external and internal branches. Both of these supply twigs to the muscles amongst which they lie ; but one or other also contains some sensory fibres which come to the surface to supply the skin.

In the *dorsal region* the *upper six or seven* cutaneous nerves are the terminations of the internal branches of the posterior primary divisions of the spinal nerves. They become superficial close to the vertebral spines, and are to be sought for near the mesial plane. It is not uncommon to find one or more of them piercing the trapezius one or two inches external to the line of emergence of the others. The branch which comes from the second dorsal nerve is the largest of the series ; and it may be traced outwards beyond the spine of the scapula. The *lower five or six* cutaneous nerves in the *dorsal region* are the terminal twigs of the external branches

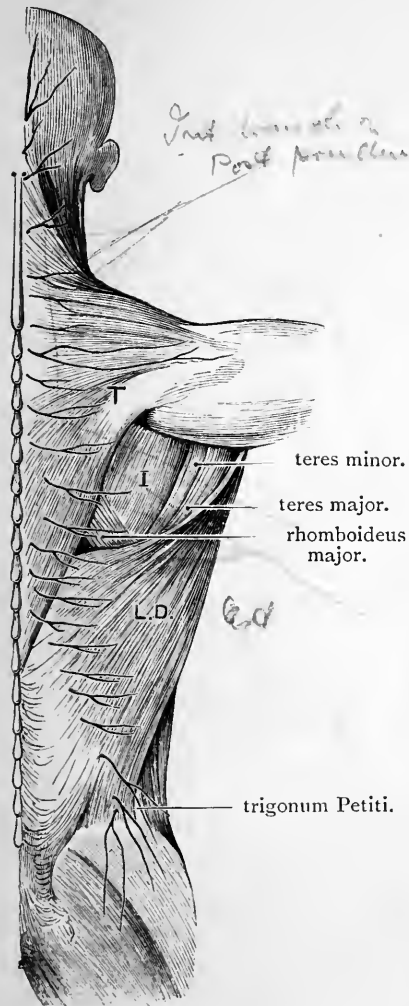


FIG. 2.—Cutaneous nerves and superficial muscles of the back.

- T. Trapezius.
I. Infraspinatus.
L.D. Latissimus dorsi.

of the posterior primary divisions of the spinal nerves ; and, consequently, they must be looked for at a short

distance from the middle line of the back. They reach the surface by piercing the latissimus dorsi muscle on a line with the angles of the ribs and outer margin of the erector spinæ muscle. In every case the cutaneous branches derived from the dorsal nerves turn outwards in the superficial fascia, and may be traced for a varying distance in this direction.

It is important to note that the area of skin supplied by these cutaneous nerves is in each case placed at a lower level than the origin of the posterior primary division from which they arise.

In the *lumbar region* three cutaneous nerves reach the surface by piercing the lumbar aponeurosis at the outer margin of the erector spinæ, a short distance above the ilium. They are the terminal twigs of the external branches of the posterior primary divisions of the three upper lumbar spinal nerves; and they differ from those above, inasmuch as they turn downwards over the crest of the ilium to supply the skin of the gluteal region.

The *cutaneous arteries* which accompany these nerves come from the dorsal branches of the intercostal and lumbar arteries.

Muscles connecting the limb to the dorsal aspect of the trunk.—These are five in number, and are arranged in two strata. Two form the superficial stratum, viz., the trapezius and the latissimus dorsi. Both are broad, flat muscles which cover the greater part of the dorsal aspect of the trunk, from the occiput above to the ilium below. The trapezius lies over the back of the neck and the chest. The latissimus dorsi is placed lower down. The deeper stratum of muscles, composed of the levator anguli scapulæ and the two rhomboid muscles, is placed under cover of the trapezius.

Dissection.—The trapezius muscle should now be cleaned. This muscle belongs only in part to the dissector of the upper limb. The portion of it which lies above the prominent spine of the seventh cervical vertebra is the property of the dissector of the head and neck, and must be dissected by him. Let the two dissectors work in con-

junction with each other; and when the entire muscle is exposed, let each give the other an opportunity of studying it in its entirety.

In cleaning the trapezius the limb must be placed in such a position as will render the fibres of the muscle tense. If the dissection is being made on the *right* side, the arm must be placed close to the trunk, and drawn downwards, whilst the scapula is dragged well forwards over the side of the block which supports the chest. A transverse cut is now to be made through the superficial and deep fasciæ, from the seventh cervical spine outwards. This incision will be found to coincide with the direction of the fibres at this level. From this point gradually work downwards, raising both fasciæ in a continuous layer from the surface of the muscle. The knife must always be carried in the direction of the muscular fibres: and care must be taken to leave none of the thin, filmy, deep fascia behind. If this rule be attended to, it will be found that, as the dissection progresses, the knife is not, as at first, carried transversely, but obliquely, in accordance with the alteration in the direction of the fibres of the lower portion of the muscle. When this stage is reached, a change in the position of the arm is required in order that the lower oblique fibres may be stretched to the full extent. The scapula must still be kept as far forwards as possible; but the limb must be carried upwards, and placed parallel to the neck. In the case of the *left* trapezius, the student must make the incision through the fascia, along the lower margin of the muscle, and work upwards to the level of the seventh cervical vertebra. In the first instance the limb must be extended, and, at a later stage, placed by the side, as the transverse fibres of the muscle are reached. In removing the fascia from the trapezius, and indeed throughout the whole dissection of the back, the cutaneous nerves must be carefully preserved, in order that the dissector of the head and neck may have an opportunity of establishing their continuity with the trunks from which they arise.

The Trapezius is a flat, triangular muscle, which lies in its entire extent immediately subjacent to the deep fascia. It has a very wide origin, which extends along the mesial plane, from the occiput above to the level of the last dorsal vertebra below. It arises from—(1) the inner third or less of the superior curved line of the occipital bone and the external occipital protuberance; (2) the ligamentum nuchæ and the spine of the seventh cervical vertebra; (3) the tips of the spines of all the dorsal vertebræ, as well as the supraspinous ligaments which bridge across the intervals between them.

The *cranial* or *occipital* origin is by short tendinous fibres, which

are interlaced with aponeurotic bands, connecting it to the adjacent attachment of the sterno-mastoid. The *cervical* and *dorsal* origin is, for the most part, also effected by short tendinous fibres, which are not very apparent, owing to the fact that they are almost immediately replaced by the fleshy fasciculi; but in the lower cervical and upper dorsal regions they lengthen out so as to form a manifest flat tendon, which, taken in conjunction with the corresponding aponeurosis of the opposite side, exhibits an oval outline.

As the fibres of the trapezius pass outwards, they converge to gain an insertion into the two bones of the shoulder-girdle. The occipital and upper cervical fibres incline downwards, and turning forwards over the shoulder, are inserted into the outer third of the posterior border of the clavicle; the lower cervical and upper dorsal fibres pass more or less transversely outwards, to gain an insertion into the inner border of the acromion process and the upper margin of the spine of the scapula; while the lower dorsal fibres are directed upwards and, at the base of the scapula, end in a flat, triangular tendon, which plays over the smooth surface at the root of the scapular spine, and is inserted into a rough tubercle on the spine of the scapula immediately beyond this. To facilitate the movement of the tendon upon the bone a small synovial bursa intervenes between them.

Dissection.—The latissimus dorsi is now to be dissected. It is a difficult muscle to clean, not only on account of the varying direction of its fibres, but also because its upper part is generally very thin, and its upper border ill-defined. Near the spines of the vertebræ it is overlapped in its upper part by the trapezius, but in its greater extent it is subcutaneous. Both layers of fascia should be raised together from its surface, and its fibres may be stretched by raising the arm and folding it under the neck. The origin of the latissimus dorsi in the lumbar region is effected through the medium of the superficial lamina of the lumbar fascia, a dense tendinous aponeurosis, which covers the erector spinæ in the loins (Fig. 3). Clean this structure thoroughly. The attachment of the muscle to the crest of the ilium, and its slips of origin from the lower ribs, must be carefully defined; at the same time, the posterior and lower part of the external oblique muscle of the abdomen should be cleaned, so that its relation to the latissimus dorsi may be studied. As the latissimus dorsi sweeps over the inferior angle of the scapula it receives an accession of fibres

from that bone. This fleshy slip may be brought into view when the muscle is cleaned by relieving the tension of the muscular fibres, and then turning the upper margin of the muscle outwards. It is apt to be mistaken for a piece of the *teres major* muscle upon which it lies.

The Latissimus Dorsi is a wide, flat muscle, which covers the back from the level of the sixth dorsal vertebra down to the crest of the ilium. It arises—(1) from the tips of the spinous processes of the lower six dorsal vertebræ and the supraspinous ligaments in connection with them; (2) from the superficial lamella of the lumbar fascia (Fig. 3); (3) by a thin tendinous origin from a small extent of the outer lip of the crest of the ilium in front of the lumbar fascia; (4) by three or four digitations from the lower three or four ribs; and (5) by a fleshy slip from the dorsal aspect of the inferior angle of the scapula. By means of its origin from the posterior lamella of lumbar fascia, it receives an indirect attachment to the spines of the lumbar and upper sacral vertebræ, and also to the posterior part of the crest of the ilium. The costal slips of origin interdigitate with the lower digitations of the external oblique muscle of the abdominal wall.

The fibres of the *latissimus dorsi* converge rapidly as they approach the lower part of the scapula. The highest fibres pass almost horizontally outwards towards this point; the lowest fibres ascend almost vertically; whilst the intermediate fibres show varying degrees of obliquity. As a result of this convergence of fibres, the muscle is greatly reduced in width; and it sweeps over the inferior angle of the scapula in the form of a thick, fleshy band which winds round the lower margin of the *teres major* muscle, to gain insertion, by means of a narrow, flat tendon, into the bottom of the bicipital groove of the humerus. This insertion cannot be studied at present, but will be seen later on. With the *teres major* muscle the *latissimus dorsi* forms the posterior fold of the axilla. At first placed on the dorsal aspect of the *teres major*,

the latissimus dorsi is folded round its lower border, and finally at its insertion comes to lie in front of it. To this peculiar relationship of the two muscles is due the full, rounded appearance of the posterior axillary fold.

Two Intermuscular Spaces.—A triangular space mapped out by the lower border of the trapezius, the upper

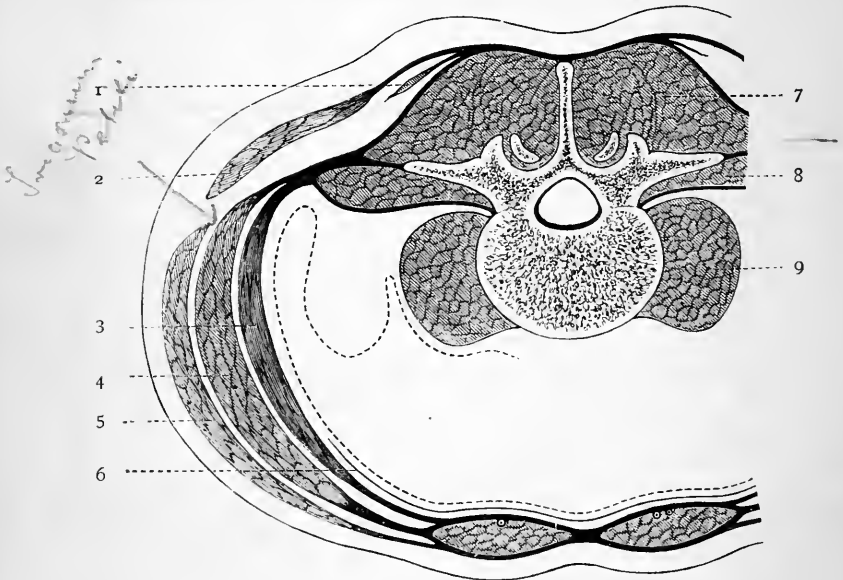


FIG. 3.—Diagram of the lumbar fascia.

- | | |
|--------------------------------|--------------------------|
| 1. Serratus posticus inferior. | 6. Fascia transversalis. |
| 2. Latissimus dorsi. | 7. Erector spinæ. |
| 3. Transversalis abdominis. | 8. Quadratus lumborum. |
| 4. Obliquus internus. | 9. Psoas. |
| 5. Obliquus externus. | |

border of the latissimus dorsi, and the base of the scapula, will now be noticed (Fig. 2). Within these limits a small portion of the rhomboideus major will be seen, and also a varying amount of the chest wall—a part corresponding to the sixth intercostal space and the borders of the ribs which bound it above and below. It is well to note that this is the only part of the thoracic

parietes on the posterior aspect of the trunk which is uncovered by muscles. Further, between the last rib and the crest of the ilium the anterior border of the latissimus dorsi will generally be observed to overlap the posterior border of the external oblique muscle of the abdominal wall. Sometimes, however, a narrow triangular interval exists between the two muscles, in which is seen a small part of the internal oblique muscle. This space is termed the *trigonum Petiti* (Fig. 2).

Reflection of the Trapezius.—On the *second day* the dissector should begin by reflecting the trapezius. This should be done, if possible, in conjunction with the dissector of the head and neck. Divide the muscle about two inches from the spines of the vertebræ, and throw it outwards towards its insertion. The trapezius is very thin at its origin, and the greatest care must therefore be taken not to injure the subjacent rhomboid muscles. The small *bursa* between the tendon of insertion of the lower part of the trapezius and the triangular root of the spine of the scapula must not be overlooked.

Nerves and Vessels of Supply to the Trapezius.—A dissection of the deep surface of the reflected muscle will reveal the following structures:—

- a. The spinal accessory nerve.
- b. Two or three nerves from the cervical plexus.
- c. The superficial cervical artery.

These constitute the nervous and vascular supply of the trapezius.

The nerves have already been displayed by the dissector of the head and neck, as they cross the posterior triangle of the neck. The branches from the cervical plexus come from the third and fourth cervical nerves. On the deep surface of the trapezius they join with branches of the spinal accessory to form the *subtrapezial plexus*, from which twigs proceed into the substance of the muscle. The terminal twig of the spinal accessory nerve can be traced nearly to the lower margin of the trapezius.

The *superficial cervical artery* which accompanies the spinal accessory nerve must be followed to the anterior

border of the trapezius, where it will be seen to spring from the *transversalis colli artery*.

Dissection.—The posterior belly of the omo-hyoid and the suprascapular artery and nerve can now be displayed by dissecting towards the upper margin of the scapula, and removing carefully the loose fatty tissue in this locality. The dissector of the head and neck must take part in this dissection, and it is well not to expose these structures for more than an inch from the upper margin of the scapula.

Omo-hyoid.—Suprascapular Artery and Nerve.—The slender *posterior belly of the omo-hyoid muscle* will be seen to arise from the upper border of the scapula immediately behind the suprascapular notch. It also derives fibres from the ligament which bridges across this notch. The *suprascapular artery* will be noticed to enter the supraspinous fossa of the scapula by passing over the suprascapular ligament, whilst the *suprascapular nerve* proceeds into the fossa under cover of that ligament.

Dissection.—Draw the scapula well over the edge of the block which supports the chest of the subject. The two rhomboid muscles are thus rendered tense, and the cleaning of the fleshy fasciculi greatly facilitated. The *nerve to the rhomboids* should be secured at this stage, so that it may be preserved from injury in the further dissection of the region. It can best be detected by dissecting in the interval between the rhomboideus minor and the levator anguli scapulae about one inch to the inner side of the superior angle of the scapula. It is accompanied by the posterior scapular artery, and it will afterwards be traced upon the deep surface of the rhomboid muscles when they are reflected.

The Rhomboid Muscles constitute a thin quadrangular sheet of muscular fibres, which proceeds from the spinous processes of the vertebræ to the base of the scapula.

The *rhomboideus minor* is a narrow, ribbon-like fleshy band which runs parallel to the upper border of the greater rhomboid. It springs from the lower part of the ligamentum nuchæ, the spine of the seventh cervical vertebra, and frequently also from the spine of the first dorsal vertebra. It is inserted into the base of the scapula opposite the triangular surface at the root of its spine. It is entirely covered by the trapezius.

The *rhomboides major* arises from the upper four or five dorsal spines, and the corresponding part of the supraspinous ligament. Its fibres run obliquely downwards and outwards, and end in a tendinous cord, which receives insertion into the base of the scapula close to the inferior angle. From this point, up to the commencement of the spine, the tendinous cord is firmly bound to the base of the scapula by areolar tissue. The greater part of the *rhomboides major* is covered by the trapezius; only a small portion near the inferior angle of the scapula lies immediately subjacent to the deep fascia.

The Levator Anguli Scapulæ (*musculus levator scapulæ*) is an elongated muscle which arises by four more or less tendinous slips from the posterior tubercles of the transverse processes of the upper four cervical vertebræ, and passes downwards and backwards to be inserted into the base of the scapula from the superior angle to the spine.

Dissection.—In cleaning the levator anguli scapulæ muscle care must be taken of the nerve which pass to it from the cervical plexus, and also of the nerve to the rhomboids and the posterior scapular artery which lie under cover of it near the base of the scapula. The dissector of the head and neck has an interest in the levator anguli scapulæ, and when it has been studied by both dissectors it should be divided midway between its origin and insertion, and the lower portion turned outwards. The nerve to the rhomboids has already been secured in the interval between the *rhomboides minor* and the levator anguli scapulæ, and it has still further been exposed by the reflection of the latter muscle. It may now be displayed in its whole length, together with the posterior scapular artery, which it accompanies, by reflecting the rhomboid muscles. These should be detached from the ligamentum nuchæ and the vertebral spines, and thrown outwards towards the base of the scapula. In doing this take care of the serratus posticus superior, a thin muscle which lies subjacent, and is apt to be injured.

The Nerve to the Rhomboids (*nervus dorsalis scapulæ*) is a long slender twig which arises in the neck from the fifth cervical nerve, and usually in common with the upper root of the nerve of Bell. It pierces the scalenus medius, and then proceeds downwards under cover of the levator anguli scapulæ to the deep surface of the rhomboid muscles

to which it is distributed. The nerve to the rhomboids likewise supplies one or two twigs to the levator anguli scapulæ.¹

The Posterior Scapular Artery is a branch of the transversalis colli, and takes origin in the lower part of the neck close to the outer margin of the levator anguli scapulæ. At first it proceeds backwards under cover of this muscle, but soon changing its direction it runs downwards along the base or vertebral border of the scapula under cover of the rhomboid muscles. It gives numerous branches to both ventral and dorsal aspects of the scapula, and its terminal twigs may enter the latissimus dorsi. One large branch usually passes backwards in the interval between the rhomboid muscles, or through the greater rhomboid, to reach the trapezius muscle, and another branch, the *supraspinal*, is given to the supraspinatus muscle, and the structures superficial to it.

Reflection of Latissimus Dorsi.—Divide the muscle by carrying the knife from its upper margin, about three inches from the vertebral spines, obliquely downwards and backwards to a point a little way behind its digitation from the last rib. In raising the inner portion of the muscle care must be taken of the subjacent serratus posticus inferior. The attachment of the latissimus dorsi to the crest of the ilium and to the lumbar aponeurosis can now be verified. The outer part of the muscle is next to be thrown forwards, so that the three costal digitations may be seen from their deep aspect, and also for the purpose of displaying the termination of the *subscapular artery* and the *long subscapular nerve*. These are found upon the deep surface of the muscle at the inferior angle of the scapula.

Lastly, replace the outer portion of the latissimus dorsi muscle, and fix it in position by a stitch or two around one or more of the ribs. This is done so as to preserve the posterior fold of the axilla.

The dissector of the arm now stops work for two days. He has completed the dissection of all the dorsal structures which are allotted to him, and he has nothing further to do until the body is turned.

¹ The nerve to the rhomboids sometimes pierces the levator anguli scapulæ in two or more branches, which unite in a plexiform manner.

PECTORAL REGION AND AXILLARY SPACE.

On resuming work the dissector will find the body lying upon its back. The chest is raised to a convenient height by means of blocks. A long board is placed under the shoulders for the purpose of supporting the arms when they are abducted from the sides (Fig. 4).

In dissecting the axilla and chest it will be found advantageous if the dissectors of the arm and of the head and neck arrange to work at different hours. The dissector of the head and neck at this stage is engaged at the posterior triangle of the neck, and this dissection cannot be well done unless the arm be placed close to the side and the shoulder depressed. For the dissection of the axilla the arm should be stretched out at right angles to the chest. A compromise between these two positions always results in discomfort to both dissectors.

Four Days are allowed for the dissection of the pectoral region and the axillary space. The arm must then be removed, so as to allow the dissector of the thorax to commence the dissection of the thoracic wall. The following Table may be found useful in regulating the amount of work which should be undertaken each day:—

First Day.—(a) Surface Anatomy; (b) reflection of skin; (c) cutaneous vessels and nerves of the chest, both on its anterior and lateral aspects; (d) cleaning of the pectoralis major muscle; (e) reflection of the axillary fascia; (f) cleaning of that part of the serratus magnus muscle which lies below the fourth rib.

Second Day.—Dissection of the axillary space from below. This includes the boundaries and contents of the space, in so far as they can be got at without the reflection of any muscle.

Third Day.—(a) Reflection of the clavicular portion of the pectoralis major; (b) the costo-coracoid membrane and the structures piercing it; (c) removal of the membrane; (d) the dissection of the upper part of the axilla; (e) reflection of the sternal part of the pectoralis major.

Fourth Day.—(a) Reflection of pectoralis minor muscle; (b) general revision of the space and study of the axillary vessels and nerves; (c) removal of the middle third of clavicle; (d) subclavius muscle; (e) brachial plexus; (f) nerve of Bell and serratus magnus muscle; (g) separation of limb from the trunk.

Surface Anatomy.—The entire length of the clavicle can be felt under the skin, and as the student follows its

curves with his finger, he can recognise the origins of the pectoralis major and deltoid muscles along its anterior border. In a few instances these muscles may present an unbroken line of origin from the sternal to the acromial end of the bone, but in the vast majority of cases a triangular interval is left between them. This is marked on the surface by a shallow depression, termed the *infra-clavicular fossa*, and it is rendered all the more apparent by the prominence of the shoulder on its outer side, and the sharp backward curvature of the clavicle immediately above it. If the finger be placed in this fossa, and pressed backwards and outwards, it will rest upon the inner side of the coracoid process of the scapula. The articulations of the clavicle should also be examined. Little or no prominence is formed by the outer end of the clavicle—its upper surface passes continuously on to the upper surface of the acromion process of the scapula. By moving the limb, however, the joint can easily be detected. In strong contrast to this is the sterno-clavicular joint, where the inner end of the clavicle can be felt as a marked projection, although this is masked to the eye by the sternal part of the sterno-mastoid muscle. The suprasternal notch on the upper border of the manubrium sterni between the clavicles should next be felt, and then the finger can be carried downwards in the middle line and in front of the sternum. A prominent ridge, crossing the bone transversely at the level of the second costal cartilages, indicates the junction between the body and manubrium sterni. The portion of the sternum uncovered by the two greater pectoral muscles is narrow above, but it widens out below, and suddenly, at the lower end of the meso-sternum, the finger sinks into a depression between the cartilages of the seventh pair of ribs, and rests upon the ensiform cartilage. This is termed the *infrasternal fossa*, or pit of the stomach. The costal arches below the first are easily recognised, but the first rib lies deeply under the clavicle, and can only be felt in front at its junction with the manubrium sterni. The arm should now be abducted

(*i.e.*, carried outwards from the trunk), when the hollow of the armpit will be brought into view, as well as the two rounded folds which bound it in front and behind. The anterior fold of the axilla is formed by the lower border of the pectoralis major, and to a small extent also by the lower border of the pectoralis minor. The posterior fold is formed by the latissimus dorsi as it winds round the teres major muscle. Note at this stage that it is carried downwards to a lower level than the anterior fold. This, as we shall see later on, is a most important point in connection with the anatomy of the axilla. If the finger be

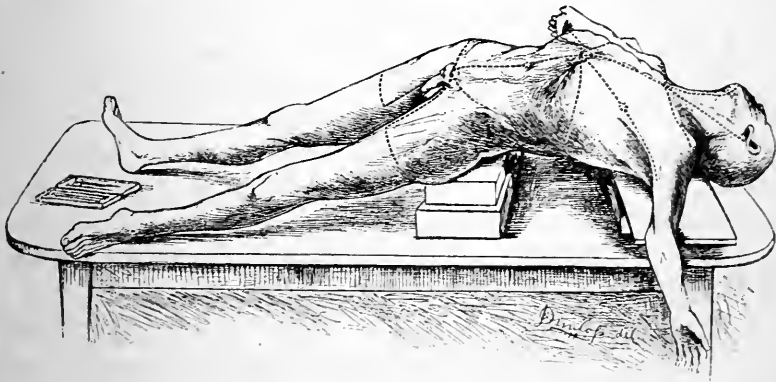


FIG. 4.

pushed upwards into the axilla, the globular head of the humerus can be felt when the arm is rotated. One other point demands the attention of the student before the dissection is commenced, and that is, the position of the nipple. As a rule it lies superficial to the interspace between the fourth and fifth ribs, and it is situated rather more than four inches from the middle line.

Reflection of Skin.—Incisions—(1) Along the middle line of the body from the upper margin of the manubrium sterni to the tip of the ensiform cartilage; (2) from the lower end of this vertical incision transversely outwards round the side of the body; (3) from the upper extremity of the primary incision outwards along the clavicle to the extremity of the acromion process; (4) from the lower end of the

vertical and mesial incision (*i.e.*, tip of the ensiform cartilage) obliquely upwards and outwards along the anterior fold of the axilla to the point at which this joins the upper arm. This last incision may, with advantage, be carried vertically down the arm for two and a half or three inches.

Two triangular flaps of skin are marked out by these incisions, and these are now to be raised from the fatty superficial fascia. It is well to encircle the areola and nipple with the knife, and leave the skin covering them undisturbed.

Superficial Fascia.—The superficial fascia presents here, as elsewhere, the usual characters, but, as a rule, the fat is not so plentiful. As it passes over the clavicle to the upper part of the chest and summit of the shoulder, it will be seen in most cases to present a faintly ruddy striated appearance. Should this not at first be apparent, the removal of some of the superficial fat will render it visible. This appearance is due to the presence of a number of sparse scattered muscular fasciculi which stream down over the clavicle, to obtain origin in the superficial fascia over the pectoralis major and deltoid muscles. In the neck they form a thin, cutaneous, fleshy stratum, called the platysma myoides. The superficial fascia in this region is also peculiar in so far as it has developed within it the mammary gland. It should now be dissected with the view of exposing the gland as well as the cutaneous vessels and nerves which make it their bed before entering the skin.

Cutaneous Nerves and Arteries.—There are three distinct groups of cutaneous nerves for the supply of the skin on the anterior and lateral aspects of the chest. These are—

1. The descending cutaneous—from the cervical plexus.
2. The anterior cutaneous, } from the intercostal nerves.
3. The lateral cutaneous, }

The descending cutaneous nerves arise in the neck from the third and fourth cervical nerves, and, spreading out as they descend, they cross the clavicle under cover of the platysma myoides. They are classified according to their position into the suprasternal, the supraclavicular, and the supra-acromial branches. The suprasternal branch is the

smallest of the series, and crosses the inner part of the clavicle to end in the skin immediately below. The supra-clavicular branches pass over the middle of the clavicle, and extend downwards for some distance, in the superficial fascia over the pectoralis major. The supra-acromial branch crosses the outer third of the clavicle, and will be afterwards followed to the skin of the shoulder.

These nerves can readily be found by cutting down upon the clavicle through the platysma muscle, and in the direction of its fibres.

The anterior cutaneous nerves are the minute terminal twigs of the intercostal trunks, and they become superficial by piercing the pectoralis major muscle and deep fascia close to the margin of the sternum. One will be found in each intercostal space, and they are accompanied by the perforating branches of the internal mammary artery, which (when injected) serve as the best guides to the nerves. They give slender twigs to the skin over the sternum, and larger branches which are directed outwards, and may be traced as far as the anterior fold of the axilla.

The lateral cutaneous nerves, much larger than the preceding, arise from the intercostal nerves, and appear on the side of the chest, along a line situated a little behind the anterior fold of the axilla. They pierce the chest wall in the interspaces between the ribs, and divide into anterior and posterior branches under cover of the serratus magnus muscle. These will be found appearing between the digitations of the serratus magnus. The anterior branches come out, as a rule, about an inch in front of the corresponding posterior branches, and then proceed forwards over the lower border of the pectoralis major muscle. From the lower members of this series some minute twigs are given off, which enter the superficial surface of the digitations of the external oblique muscle of the abdomen. The posterior branches run backwards to the dorsal aspect of the trunk over the anterior border of the latissimus dorsi muscle.

Do not attempt to secure the two highest lateral cutaneous nerves (*i.e.*, those issuing from the second and third intercostal spaces) in the meantime. They are best dissected along with the other contents of the axillary space.

Dissection.—If the subject be a female the dissector should endeavour to make out the connections, and also something of the structure of the mammary gland. The small area of skin which has been left over the areola, should be raised towards the summit of the

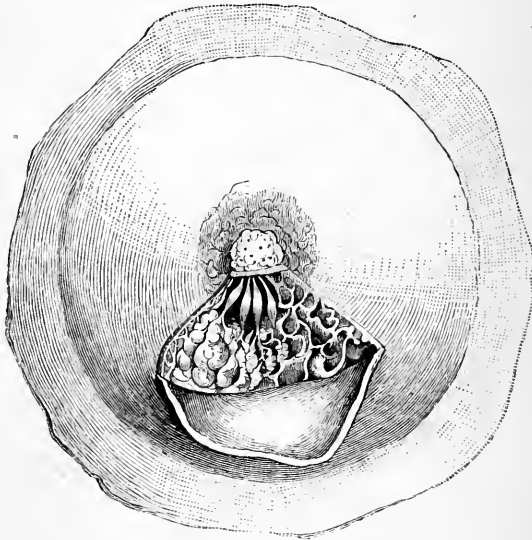


FIG. 5.—The Mammary Gland of a young woman who died during parturition. The dissection shows the trabecular arrangement of the connective tissue, the lobules, and the milk-ducts, with their dilatations or ampullæ.

nipple, and bristles may be introduced through the external orifices which will be seen on its surface. Further, by removing the fat which surrounds the organ, the true glandular tissue will be rendered more apparent, although it is only in favourable circumstances that the milk-ducts in the nipple and their ampullæ in the region of the areola can be isolated and rendered apparent.

If the subject be a young female the senior student is recommended to conduct the dissection in the following manner:—Remove the gland with the skin and superficial fascia which cover it, and, after dissecting away the fat from its deep surface, introduce a pad of tow underneath the gland; then fasten the skin firmly with tacks to a small board, and place the board under water. Next reflect a small portion of skin, in the manner shown in the figure, remove the superficial fat, and proceed

to unravel the glandular substance. By this means the milk-ducts can generally be demonstrated. A cork-lined tray is very useful for this purpose.

Mammary Gland (mamma).—The mammary gland in the female is a smooth rounded prominence, which extends in a horizontal direction from the side of the sternum to the axillary border of the pectoralis major muscle, and in a vertical direction from the third to the sixth or seventh costal arch. It should be clearly understood that it lies within the superficial fascia and that its smooth contour is largely due to the invasion of its substance by the fatty tissue of this layer. It is separated from the great pectoral muscle by the deep fascia, and also by a thin layer of the superficial fascia. } NB

A little below its mid-point, and at a level which usually corresponds to the fourth intercostal space, the mamma is surmounted by a conical elevation—the nipple or mammilla (*papilla mammae*). This is surrounded by a circular patch of coloured integument, which is termed the areola mammae. In the nipple, and immediately subjacent to the areola, there is no fat. A curious change of colour occurs in this region during the second month of pregnancy. Of a delicate pink tint in the virgin, the nipple and areola become brown from the deposition of pigment at this time, and they never again resume their original appearance.

Although the mammary gland is placed within the superficial fascia, it is nevertheless completely isolated by a dense fibrous capsule, which sends trabeculae into its substance. These subdivide the organ into loculi, in which the glandular lobules are placed. From the lobules the ducts (ductus lactiferi) converge towards the nipple. Look for them particularly in the region of the areola. Here they become much dilated, and form pouches or ampullae (*sinus lactiferi*) which serve as temporary reservoirs for the milk (Fig. 5). At the base of the nipple the lactiferous ducts again contract and run forwards in its substance towards its summit, upon which they open.

In a well-injected subject, twigs from the intercostal arteries, and also from the perforating branches of the

internal mammary, may be traced into the mammary gland, and another vessel, called the *external mammary artery*, may be seen winding round the edge of the greater pectoral muscle, or piercing its lower fibres to reach the gland.

By means of lymphatic vessels the mammary gland is brought into connection with the sternal glands, and also more directly with the axillary glands. The latter connection is one of much importance to the surgeon in cases where it is necessary to remove the organ for malignant disease.

In the male the mamma (*mamma virilis*) is extremely rudimentary. The nipple is small and pointed, and the areola is surrounded by sparse hairs.

The **Deep Fascia** of the pectoral region is a thin membrane which closely invests the pectoralis major. It is attached superiorly to the clavicle, and is firmly connected in the middle line to the front of the sternum. Below, it is continuous with the deep fascia covering the abdominal muscles. Its strongest fibres are directed outwards, parallel to the clavicle, and, at the lower border of the great pectoral muscle, it is continuous with the axillary fascia. At the infraclavicular fossa a process from its deep surface dips in to join the costo-coracoid membrane, whilst, beyond this, it becomes continuous with the fascia covering the deltoid muscle. The axillary fascia and the costo-coracoid membrane will be separately described later on.

Dissection.—The pectoralis major muscle must now be cleaned, and its division into sternal and clavicular parts clearly made out. The muscular fibres are rendered tense by abducting the arm from the side. On the right side the dissector begins at the lower border of the muscle, whilst on the left side he commences at the upper border. Clean also the anterior margin of the deltoid. In the interval between it and the portion of the pectoralis major which arises from the clavicle, the *cephalic vein*, and, subjacent to this, the *humeral thoracic artery* will be discovered.

The Pectoralis Major extends from the anterior aspect

of the chest to the humerus. It is divided by a deep fissure into a clavicular and a costo-sternal portion. This fissure penetrates through the entire thickness of the muscle, the clavicular and costo-sternal portions being thus distinct, except close to their insertion. The *clavicular portion* arises by short tendinous and muscular fibres from an impression on the inner half of the anterior surface of the clavicle. The *costo-sternal portion* takes origin by fleshy fibres from the anterior surface of the sternum, from the aponeurosis of the external oblique muscle, and occasionally from the sixth rib near its cartilage. Under cover of this more superficial origin, and partially independent of it, a variable number of muscular slips spring from the cartilages of the upper six ribs.

The pectoralis major is inserted by a flattened bilaminar tendon into the outer lip of the bicipital groove of the humerus (pectoral ridge), and the fibres of the muscle undergo a re-arrangement as they converge upon this tendon. The greater part of the clavicular portion joins the anterior lamina of the common tendon; some of the innermost clavicular fibres, however, are inserted directly into the humerus below the tendon, whilst a few gain attachment to the deep fascia of the arm, and become adherent to the adjacent part of the deltoid.

The fibres of the costo-sternal portion of the muscle take different directions as they proceed to join both laminae of the tendon of insertion; thus the upper fibres descend slightly, the intermediate fibres pass horizontally outwards, whilst the lower fibres ascend, and, at the same time, gain the deep surface of the rest of the muscle. A smooth, full and rounded lower border is in this way formed which constitutes the anterior fold of the axilla. The bilaminar tendon of the pectoralis major is the direct continuation of the axillary fold, and its two laminae are thus united, or, in other words, continuous below. The precise manner in which it is attached will be more fully studied at a later stage of the dissection.

The Axilla may be defined as being the hollow or recess

between the upper part of the side of the chest and the upper part of the arm. When the limb is abducted from the trunk, and the areolo-fatty tissue which occupies the armpit is removed, the space presents a distinctly pyramidal form. The apex, or narrow part of the space, placed immediately to the inner side of the coracoid process, is directed upwards towards the root of the neck, whilst the wider part or base looks downwards. But the space is not absolutely pyramidal in form, for the inner wall formed by the chest is of greater extent than the outer wall formed by the arm. It follows from this, therefore, that the anterior and posterior walls converge as they proceed outwards. Before engaging in the dissection of the space, it is necessary that the student should have some knowledge of its boundaries, and the manner in which its contents are disposed in relation to these.

Boundaries of the Axilla.—The *anterior wall* is formed by the two pectoral muscles and the costo-coracoid membrane. The pectoralis major constitutes the superficial stratum, and is spread out over the entire extent of the anterior wall. The pectoralis minor, which lies subjacent to the greater pectoral muscle, is only in relation to about one-third of the anterior boundary, whilst the interval or gap between this muscle and the clavicle is filled up by the costo-coracoid membrane. The lower border of this wall of the axilla constitutes its *anterior fold*, as already explained. This is formed by the lower margin of the pectoralis major, with a small part of the lower border of the pectoralis minor, which comes into view near the side of the chest.

The *posterior wall* of the axilla is somewhat longer than the anterior wall. It is formed from above downwards by the subscapularis muscle, the tendon of the latissimus dorsi, and the teres major muscle. The subscapularis, lying upon the venter of the scapula, takes by far the largest share in the formation of this boundary. The narrow tendon of the latissimus dorsi lies in front of the teres major, so that only the lower border of the latter muscle is seen below it.

The *posterior fold* of the axilla is formed by the lower border of this wall.

The *inner wall* is constituted by the upper four or five ribs with the intervening intercostal muscles; it is clothed by the corresponding digitations of the serratus magnus muscle.

The *outer wall* is formed by the humerus and the conjoined origin of the coraco-brachialis and short head of the biceps.

The *apex* of the space corresponds with the narrow

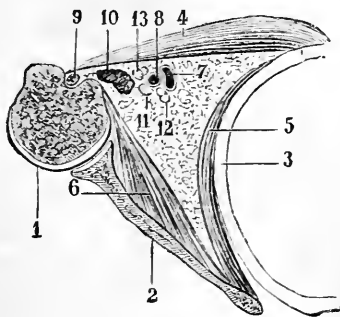


FIG. 6.—Diagram of section through the axilla of the left side.

- | | |
|--|---|
| <p>1. Upper end of humerus.
2. Scapula.
3. Rib.
4. Pectoralis major.
5. Serratus magnus.
6. Subscapularis.</p> | <p>7. Axillary vein.
8. Axillary artery.
9. Long head of biceps.
10. Conjoined origin of short head of biceps and coraco-brachialis.
11, 12, 13. Brachial nerves.</p> |
|--|---|

communication between the axilla and the root of the neck. It is a triangular interval (which can readily be investigated by the finger when the space is dissected) bounded by the clavicle, first rib, and upper margin of the scapula, and through it pass from the neck the great axillary vessels and brachial nerves. The wide vaulted *base* of the armpit is closed by the axillary fascia.

Contents of the Axilla.—The axillary artery and vein, with the great brachial nerves, constitute the most important contents of the armpit. Except at the summit of the space, they lie closely applied to the outer wall, and follow it in all

the movements of the upper arm. Of the branches which spring from the axillary artery, *two* (viz., the thoracic axis and the long thoracic) are related to the anterior wall; *two* (viz., the posterior circumflex and subscapular) to the posterior wall; *one*, the superior thoracic, to the inner wall; and *one*, the anterior circumflex, to the outer wall.

The *thoracic axis artery* arises high up in the space, and at once proceeds forwards through the costo-coracoid membrane. The *long thoracic artery* runs inwards along the lower border of the pectoralis minor. The *posterior circumflex artery* arises from the posterior aspect of the main trunk, and at once leaves the space by passing backwards through the posterior wall in the interval between the subscapularis and the teres major muscles. The *subscapular artery* runs inwards along the lower border of the subscapularis muscle. The *anterior circumflex*, a small vessel, proceeds outwards upon the humerus, under cover of the coraco-brachialis and short head of the biceps. The *superior thoracic artery*, also a small vessel, ramifies upon the first intercostal space high up in the axilla.

In making an opening into the axilla from below, for the purpose of allowing a collection of pus to escape, or for any other purpose, it is manifestly absolutely necessary to bear these relations in mind. The outer wall, where the great axillary vessels are, must be most carefully avoided; so also must be the anterior and posterior walls, where there would be a risk of injuring the long thoracic and subscapular arteries. The inner wall, however, is, comparatively speaking, free from danger, as the small thoracica suprema is placed high up in the space. Therefore enter the knife with the sides of the blade towards the anterior and posterior walls of the space, and with the back of the blade towards the outer wall and axillary vessels. The knife may then be carried inwards towards the chest. So as to insure the lungs.

But there are various nerves in relation to the walls of the axilla. Entering the deep surface of the anterior wall are the *two anterior thoracic nerves* for the supply of the two pectoral muscles. Upon the posterior wall are the *three subscapular nerves*, which supply the three muscles which constitute this boundary. Running downwards upon the inner wall is the nerve of Bell, or posterior thoracic nerve,

while piercing it are the *intercosto-humeral* and upper *lateral cutaneous nerves*.

In addition to the contents already enumerated, numerous lymphatic glands are lodged in the fat of the axillary space.

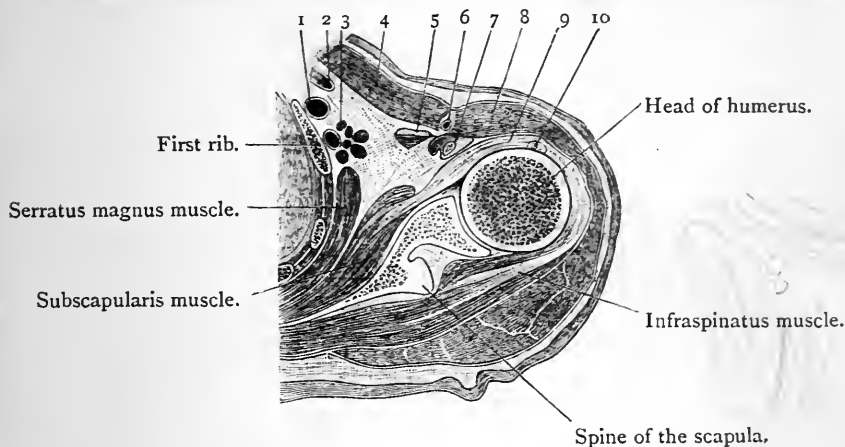


FIG. 7.—Transverse section through the right shoulder, and apex of the axilla.

- | | |
|--|--|
| <ol style="list-style-type: none"> 1. Subclavian vein. 2. Subclavius muscle. 3. Subclavian artery and brachial nerves. 4. Pectoralis major. 5. Pectoralis minor. 6. Cephalic vein. | <ol style="list-style-type: none"> 7. Tip of coracoid process, surrounded by the conjoined origin of the coraco-brachialis and short head of the biceps. 8. Deltoid muscle. 9. Capsule of the shoulder-joint. 10. Long head of the biceps. |
|--|--|

Note the connection between the capsule of the shoulder-joint and the tendons of the subscapularis and infraspinatus. The opposing rotatory action which these muscles exercise upon the humerus can be easily understood by an examination of this section.

Before proceeding with the dissection the student will do well to refer to Fig. 7. It represents a horizontal section through the right shoulder and axillary region, near the apex of the latter. The axilla appears as a triangular space, occupied for the most part by fat, but on its inner side the brachial plexus of nerves, the subclavian artery, close to the point at which it becomes the axillary artery, and the corresponding part of the subclavian vein may be seen. These structures are all cut transversely, as the section was made with the arm close to and parallel with the body. On the *inner wall* the first, second, and third ribs are seen in section with the intercostal muscles and serratus magnus; on the *outer wall* the coraco-brachialis and biceps muscles

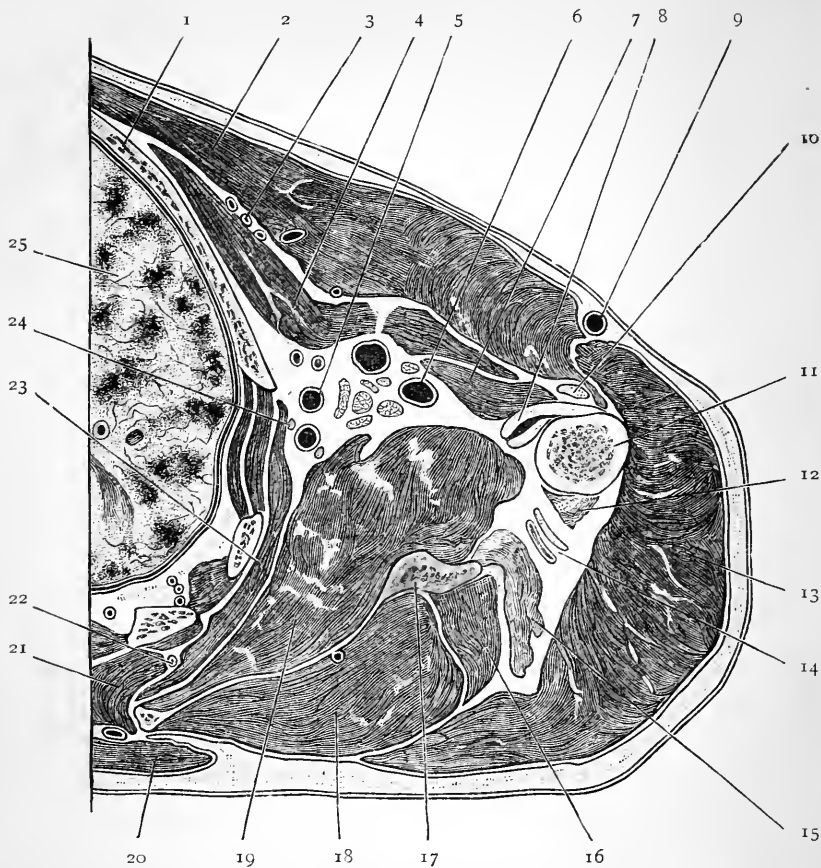


FIG. 8.—Transverse section through the right axilla.

- | | |
|--|---|
| 1. Third rib. | 13. Deltoid. |
| 2. Pectoralis major. | 14. Posterior circumflex artery and circumflex nerve. |
| 3. Pectoral thoracic arteries. | 15. Long or scapular head of triceps. |
| 4. Pectoralis minor. | 16. Teres minor. |
| 5. Subscapular artery. | 17. Axillary border of scapula. |
| 6. Axillary artery. | 18. Infraspinatus. |
| 7. Coraco-brachialis; short head of biceps immediately in front of this. | 19. Subscapularis. |
| 8. Tendons of latissimus dorsi and teres major. | 20. Trapezius. |
| 9. Cephalic vein. | 21. Rhomboideus major. |
| 10. Long head of biceps. | 22. Posterior scapular artery. |
| 11. Humerus. | 23. Serratus magnus. |
| 12. Outer head of triceps | 24. Nerve of Bell. |
| | 25. Right lung. |

appear. *Anteriorly*, the pectoralis major, the pectoralis minor and subclavius close in the space; *posteriorly*, the subscapularis is seen. The student should bear in mind that it is only in frozen sections that the exact relations of the parts can be accurately studied. Much can be learned from a properly dissected axilla; but the large open space which is thus displayed differs widely from the small, triangular, intermuscular recess which is seen in a frozen section.

Figure 8 gives a view of a transverse section through the axillary space at a lower level, and with the arm still by the side. The triangular outline of the space is seen; the boundaries and contents are also apparent. The great vessels and nerves will be observed to have shifted more to the outer side of the recess. Note further the tendons of insertion of the latissimus dorsi and teres major, which are cut in front of the shaft of the humerus.

The Axillary Fascia is a dense felted membrane which stretches across the base of the armpit. It is continuous in front with the deep fascia covering the pectoralis major, behind with the sheaths of the latissimus dorsi and teres major muscles, and internally with the deep fascia over the serratus magnus. Notice that it is drawn upwards towards the hollow of the axilla. This is chiefly due to the connection of its deep surface with the sheath of the pectoralis minor, but also to its attachment to the areolar tissue which fills the space. In a well-injected subject a small artery, from the lower part of the axillary trunk, may be observed ramifying upon the fascia.

Dissection.—Begin the dissection of the axilla from below by carefully separating the deep fascia from the lower edge of the pectoralis major muscle, so as to expose and clean the anterior fold of the axilla. Then grasp the edge of the fascia with the hand and pull it backwards, teasing out with the point of the knife the areolar tissue, which holds it in place. By this means the axillary fascia is reflected in one piece, and the upper lateral cutaneous nerves are put on the stretch, and can be followed out.

Lateral Cutaneous Branches of the Second and Third Intercostal Nerves.—As a rule, the first intercostal nerve does not give off a lateral cutaneous nerve. That which springs from the second intercostal nerve is the largest of the series, and differs from the others in not dividing into an anterior and posterior branch. It is termed the

intercosto-humeral nerve, on account of its being distributed to the skin on the inner and back aspect of the upper part of the arm. To reach this destination it crosses the axilla and pierces the deep fascia. But before doing so it establishes communications and forms a plexiform arrangement in the axilla with the nerve of Wrisberg (the lesser internal cutaneous nerve) and the lateral cutaneous branch of the third intercostal nerve.¹

The *lateral-cutaneous branch* of the third intercostal nerve divides into an anterior and posterior part, and these are distributed in the ordinary way. From the posterior branch twigs are given to the skin of the axilla, and the terminal twigs are distributed to the integument on the upper part of the inner aspect of the arm.

Lymphatic Glands.—In the subsequent dissection of the axilla the lymphatic glands must be removed as they are brought into view. The position which they occupy in the space should, however, in the first place, be carefully noted. They are disposed in three groups—(a) a group lying close to the axillary vessels which receives the lymphatic vessels ascending from the limb; (b) a group of pectoral glands placed along the lower border of the *pectoralis minor*, which are joined by the lymphatics from the mammary gland and the front of the chest; (c) a group of subscapular glands, situated along the lower border of the *subscapularis* muscle on the posterior wall of the axilla, and into which the lymphatics of the back pour their contents.

Dissection.—The loose areolar tissue and fat must now be cautiously removed from the hollow of the armpit. Begin by dissecting out the *subscapular artery* and the *long subscapular nerve*. The guide to their position is the lower margin of the *subscapularis* muscle. In relation to the lower border of the *pectoralis minor* muscle the *long thoracic artery* will be found. A vertical incision along the inner wall, a short distance anterior to the point where this joins the posterior wall, will

¹ This plexus may be joined by another twig, which is occasionally present, viz., the minute lateral cutaneous branch of the first intercostal nerve.

display the *external respiratory nerve*, or the *nerve of Bell*, upon the axillary surface of the serratus magnus. These structures being secured, the dissector may proceed with his work more boldly, as the remaining contents of the space are not so liable to injury. The *axillary artery and vein* and the great *brachial nerves* may next be exposed. Note the close manner in which they cling to the outer wall of the axilla in the various movements of the limb, and then isolate them thoroughly by removing their areolar sheaths, and establish their individual identity. In dissecting these structures care must be taken to secure the small *internal cutaneous* branch of the *musculo-spiral nerve*. This nerve is generally given off within the axilla in common with a muscular branch to the long head of the triceps, and it crosses the latissimus dorsi and teres major tendons on a deeper plane than the branches of the intercosto-humeral nerve. The *lowest subscapular nerve* must now be looked for upon the surface of the subscapularis muscle.

Axillary Artery (*arteria axillaris*).—It is the third part of the axillary artery which is now exposed, and the vein will be seen to lie upon its inner side, and also partly in front of it. It is important to note the position of the large nerves, with reference to the artery, before they are much disturbed by the dissection. The *ulnar nerve* lies in direct contact with its inner side. The *nerve of Wrisberg* (*the lesser internal cutaneous nerve*) is also internal to the artery, but is separated from it by the axillary vein, to which it is closely applied. The *internal cutaneous nerve*, and the *inner head of the median*, lie in front of the artery; the *musculo-spiral* and *circumflex nerves* are directly behind it; while the *median* and *musculo-cutaneous nerves* are placed upon its outer side. The latter nerve soon leaves the artery, by deviating outwards and entering the substance of the coraco-brachialis muscle. Its branch of supply to that muscle should be secured at this stage.

In this part of its course the axillary artery gives off three branches—the *subscapular*, which has already been found; the *posterior circumflex*, which arises from its posterior aspect; and the *anterior circumflex*, a small vessel which runs outwards under cover of the coraco-brachialis, and is apt to be injured in cleaning the nerves.

Dissection.—The axillary space must now be dissected from the front. This is done by reflecting the clavicular part of the pectoralis

major. The sternal portion of the muscle is not to be disturbed at present. Divide the clavicular part close to its origin from the clavicle, and throw it downwards and outwards. This must be done with care, because some twigs from the *external anterior thoracic nerve*, and also some of the *pectoral thoracic branches* of the thoracic axis artery, enter its deep surface. These must be cleaned and preserved.

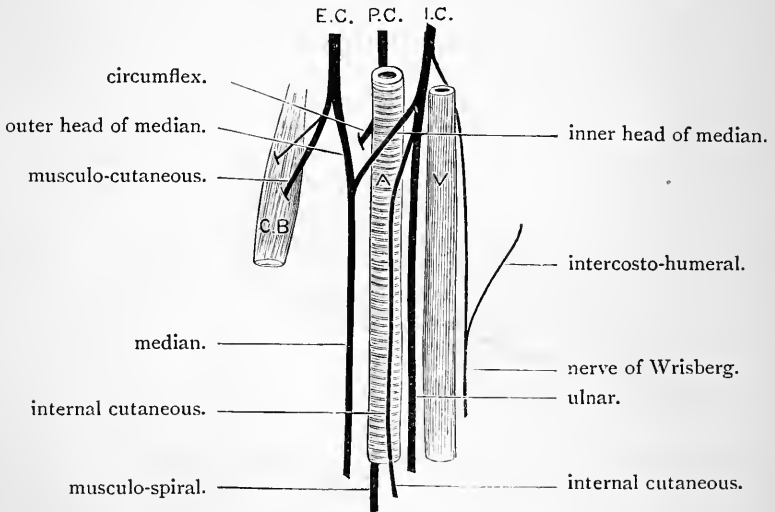


FIG. 9.—Diagram of the manner in which the main branches of the brachial plexus are arranged around the third part of the axillary artery.

E. C.	External cord.	A.	Axillary artery.
P. C.	Posterior cord.	V.	Axillary vein.
I. C.	Internal cord.	C.B.	Coraco-brachialis muscle.

Costo-Coracoid Membrane.—A space or gap between the clavicle and pectoralis minor is now exposed. This gap, however, is closed by the costo-coracoid membrane, the connections of which must be studied. Trace it outwards to its attachment to the coracoid process, and inwards to its attachment to the first rib. Above it constitutes the sheath of the subclavius muscle by splitting into an anterior and a posterior layer. These, passing upwards, enclose the muscle, and are attached, the one to the anterior border of the clavicle, and the other to the posterior border of the bone.

But how can the two layers be demonstrated? Divide the anterior lamina transversely close to the clavicle, and throwing it downwards, pass the handle of the scalpel upwards behind the muscle. The posterior attachment can in this manner be verified, and at the same time the nerve to the subclavius will be seen sinking into the deep surface of the muscle.

Observe that the density of the membrane diminishes almost immediately below the subclavius, and this so abruptly that a crescentic margin is formed, which, on account of its being thicker and stronger than the rest of the membrane, is

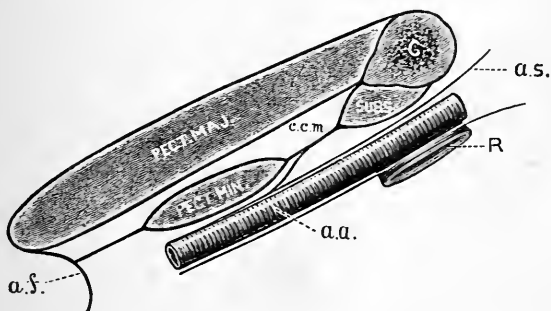


FIG. 10.—Diagram of the costo-coracoid membrane.

- | | | | |
|--------|-----------------------------|------|------------------|
| C. | Clavicle. | R. | First rib. |
| SUBS. | Subclavius. | a.a. | Axillary artery. |
| c.c.m. | Costo-coracoid membrane. | a.f. | Axillary fascia. |
| a.s. | Sheath of axillary vessels. | | |

sometimes called the costo-coracoid, or bicornuate ligament. The lower connections of the membrane are somewhat indefinite, and difficult to establish with precision. In a good subject, however, it will be seen to join the sheath of the axillary vessels, and also to give a process of fascia to the sheath of the pectoralis minor.

Four structures pierce the costo-coracoid membrane, and these should now be cleaned. They are:—(1) the thoracic axis artery, breaking up into pectoral, clavicular, acromial, and humeral branches; (2) the thoracic axis vein; (3) the cephalic vein; (4) and lastly, the external anterior thoracic nerve.

Dissection.—The costo-coracoid membrane should be removed, and the axillary space entered from above. With a little dissection the con-

tents of the upper part of the space may be exposed. These are the axillary artery, with the axillary vein on its inner side, and partly overlapping it. To the outer side, and to some extent above the vessels, are placed the great brachial nerves. All these important structures are enveloped in a loose, funnel-shaped sheath, which is prolonged into the axilla from the deep cervical fascia. Crossing behind the artery, and therefore lying very deeply, is the external respiratory nerve, or nerve of Bell. A small branch, called the superior thoracic, takes origin from this part of the axillary artery, and must be followed out. Lastly, the cephalic and thoracic axis veins must be traced to their junction with the axillary vein. *they have in front of it*

The sternal part of the pectoralis major muscle may now be divided about its middle, and the two portions thrown outwards and inwards. Several nerves will be observed entering its deep surface, and these must be preserved. They come from the external and internal anterior thoracic nerves. One or more from the latter pierce the pectoralis minor, and are now seen emerging from its anterior surface. The pectoralis minor must be cleaned and its attachments defined.

The Pectoralis Minor is a fan-shaped muscle, which extends from the thoracic wall to the scapula. It arises by three flat, tendinous slips from the third, fourth, and fifth ribs, close to their cartilages. Between the ribs these slips are prolonged into the anterior intercostal aponeuroses. From this origin the fibres proceed outwards and upwards, and converge upon a stout tendon, which is inserted into the front part of the inner border and upper surface of the coracoid process. The pectoralis minor is supplied by the internal anterior thoracic nerve.

Dissection.—The axillary vessels and the brachial nerves can now be cleaned throughout their entire extent, but the pectoralis minor muscle should not be reflected until the relations of these important structures have been thoroughly studied.

The Axillary Artery (arteria axillaris) is a portion of the great arterial trunk which carries blood for the supply of the upper limb. It begins above at the outer border of the first rib, where it is continuous with the subclavian artery, and it ends below at the lower border of the teres major muscle, where it becomes continuous with the brachial artery. Its course through the axilla varies with the position of the limb. When the arm is abducted from

the trunk (as it is when the axilla is being dissected), a straight line, drawn from the centre of the clavicle to a point below the anterior fold of the axilla, and immediately to the inner side of the slight prominence caused by the coraco-brachialis muscle, will, with tolerable accuracy, indicate the course pursued by the vessel.

The relations of the axillary artery vary very much as it traverses the armpit; and with the view of obtaining a greater precision of description, anatomists are in the habit of arbitrarily dividing the vessel into three parts. *The first part* extends from the outer border of the first rib to the upper border of the pectoralis minor; the *second part* lies under cover of that muscle; the *third part* extends from the lower border of the pectoralis minor to the lower border of the teres major.

The *first part* of the axillary artery lies very deeply. It is covered by the skin, superficial fascia, deep fascia, clavicular part of the pectoralis major, and the costo-coracoid membrane. But, even when these are removed, the vessel is not completely exposed, because it is enveloped, along with the axillary vein and great nerves, by a funnel-shaped sheath, which is prolonged upon them from the deep cervical fascia. Further, it is crossed by the cephalic and thoracic axis veins, and the loop of communication between the two anterior thoracic nerves likewise lies in front of it. *Posteriorly* this part of the vessel is supported by the first intercostal space and the first digitation of the serratus magnus muscle, and the nerve of Bell crosses behind it. To its *inner side*, and somewhat overlapping it, is the axillary vein, whilst *above* and to its *outer side* are the large brachial nerve-trunks.

The *second part* of the axillary artery is placed behind the two pectoral muscles, and has the three cords of the brachial plexus disposed around it. Thus the inner cord lies upon its inner side, the outer cord upon its outer side, and the posterior cord behind it. The axillary vein is still upon its inner side, but is separated from the artery by the inner nerve-cord. Strictly speaking, it is not in apposition

with any muscle posteriorly, being separated from the subscapularis muscle by a quantity of areolo-fatty tissue.

The *third and longest part* of the axillary artery is superficial in its lower half. This is due to the fact that the posterior wall of the axilla extends lower down than the anterior wall. Whilst, therefore, it is covered in its upper half by the pectoralis major, below this it is only covered by the integument and fasciæ. *Behind* it rests, from above downwards, on the subscapularis, the tendon of the latissimus dorsi, and the lower margin of the teres major. To its outer side is the coraco-brachialis muscle; whilst to its inner side is the axillary vein. The brachial nerve-cords have now given place to their large branches, and these are disposed around the vessel. The precise positions which they occupy in the undisturbed condition of parts, and when the arm is abducted from the side, has been already described on page 31.

The Branches of the Axillary Artery have been observed at different stages of the dissection. They may now be more fully examined. They are:—

Superior thoracic, . . .	from the first part.
Thoracic axis, . . .	} from the second part.
Long thoracic, . . .	
Alar thoracic, . . .	
Subscapular, . . .	} from the third part.
Anterior circumflex, . . .	
Posterior circumflex, . . .	

The Superior Thoracic Artery (arteria thoracica suprema) is a small branch which springs from the axillary at the lower border of the subclavius muscle and ramifies upon the upper part of the inner wall of the axilla. It supplies twigs to the serratus magnus muscle, the intercostal muscles, and the pectoral muscles.

The Thoracic Axis (arteria thoracicoacromialis) is a short wide trunk, which is usually described as arising from the first part of the axillary artery. As a rule, however, it takes origin under cover of the pectoralis minor, and winds round the upper border of that muscle. Piercing the

costo-coracoid membrane, it immediately divides into numerous branches, which diverge widely from each other. These receive different names, and are arranged as follows :—(a) The clavicular branch (ramus clavicularis), a small twig, runs upwards to the clavicle and then turns inwards along that bone between the clavicular part of the pectoralis major and the costo-coracoid membrane. (b) The pectoral branches (rami pectorales), of larger size, proceed downwards between the two pectoral muscles, give branches to both, and anastomose with the long thoracic and inter-

CHAN

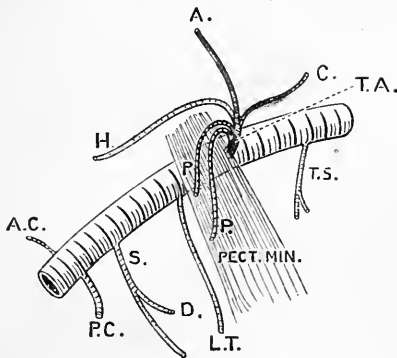


FIG. II.—Diagram of the axillary artery and its branches.

- | | |
|-------------------------|----------------------------|
| T.A. Thoracic axis. | L.T. Long thoracic. |
| C. Clavicular branch. | S. Subscapular. |
| A. Acromial branch. | D. Dorsalis scapulae. |
| H. Humeral branch. | P.C. Posterior circumflex. |
| P. Pectoral branches. | A.C. Anterior circumflex. |
| T.S. Superior thoracic. | |

costal arteries. (c) The acromial branch (ramus acromialis), runs outwards upon the tendon of the pectoralis minor and the coracoid process. Some of its twigs supply the deltoid, whilst others pierce it to reach the upper surface of the acromion process. It anastomoses with the suprascapular and posterior circumflex arteries. (d) The humeral branch (ramus deltoideus), as a rule, takes origin from a trunk common to it and the preceding artery, and it runs downwards in the intermuscular interval between the pectoralis major and the deltoid. To both of these muscles it gives twigs.

The Long Thoracic Artery (*arteria thoracica lateralis*) takes the lower border of the pectoralis minor as its guide, and proceeds downwards and inwards to the side of the chest. It gives branches to the pectoral muscles, the serratus magnus, and the mammary gland, and anastomoses with twigs from the intercostal arteries. It gives off, as a rule, an *external mammary* branch, which winds round or pierces the lower border of the pectoralis major to reach the mammary gland.

The Alar Thoracic supplies the fat and lymphatic glands in the axilla, and rarely arises as a separate branch from the axillary artery. Its place is usually taken by twigs from the subscapular and long thoracic arteries.

Subscapular Artery (*arteria subscapularis*).—This is the largest branch of the axillary artery, and it arises opposite the lower border of the subscapularis muscle. Following this, it runs downwards and backwards, in company with the long subscapular nerve, to the inferior angle of the scapula, where its terminal twigs anastomose with the posterior scapular artery. Not far from its origin the subscapular artery gives off a large branch, the *dorsalis scapulae* (*arteria circumflexa scapulae*) which winds round the axillary border of the scapula, in close contact with the bone, to reach its dorsal aspect. Numerous smaller twigs are given to the neighbouring muscles, viz., the subscapularis, latissimus dorsi, and serratus magnus.

Circumflex Arteries.—These are two in number, and as a rule they both arise from the axillary at the same level, a short distance below the origin of the subscapular artery. The posterior circumflex (*arteria circumflexa humeri posterior*) is much the larger of the two. Only a small portion of it can be seen at the present stage. It springs from the posterior aspect of the axillary, and at once proceeds backwards with the circumflex nerve close to the inner and under aspect of the head of the humerus, and in the interval between the subscapularis and teres major muscles. The small *anterior circumflex artery* (*arteria circumflexa humeri anterior*) takes origin from the outer aspect

of the axillary, and runs outwards in front of the surgical neck of the humerus, under cover of the coraco-brachialis and short head of the biceps. Reaching the bicipital groove it divides into two branches. Of these one is directed upwards with the long head of the biceps to the shoulder-joint; the other continues onwards to the under surface of the deltoid, and finally anastomoses with some of the terminal twigs of the posterior circumflex artery.

Axillary Vein (*vena axillaris*).—This venous trunk is the continuation upwards of the basilic vein of the upper arm. Beginning at the lower border of the *teres major*, it becomes the subclavian vein at the outer margin of the first rib. At the lower margin of the *subscapularis* it receives the two *venæ comites* of the brachial artery, and above the level of the *pectoralis minor* it is joined by the cephalic vein. Its other tributaries correspond, more or less closely, to the branches of the axillary artery.

The Subclavius Muscle may now be cleaned and its attachments defined. It is a small muscle, placed below the clavicle, and it is enclosed in a stout sheath derived from the costo-coracoid membrane. It takes origin by a short rounded tendon, from the upper surface of the first costal arch at the junction of the rib with its cartilage, and the small fleshy belly is inserted into the shallow groove on the under surface of the clavicle. Its nerve of supply comes from the fifth and sixth cervical nerves and has been previously noticed, p. 33.

Dissection.—The middle third of the clavicle should now be removed, and the subclavius muscle reflected, in order that a connected view of the structures which pass from the side of the neck into the axilla may be obtained. The dissector of the head and neck should also take part in this dissection. At the same time the *pectoralis minor* may be divided about an inch and a half from its insertion, and the two parts thrown inwards and outwards. In doing this care must be taken of the internal anterior thoracic nerve which pierces its deep surface. When the continuity of the axillary and subclavian vessels has been satisfactorily displayed they may be ligatured in two places at the level of the clavicle and then divided between the ligatures. By throwing the axillary vessels

downwards the examination of the brachial nerves will be greatly facilitated. The dense connective tissue which surrounds these large

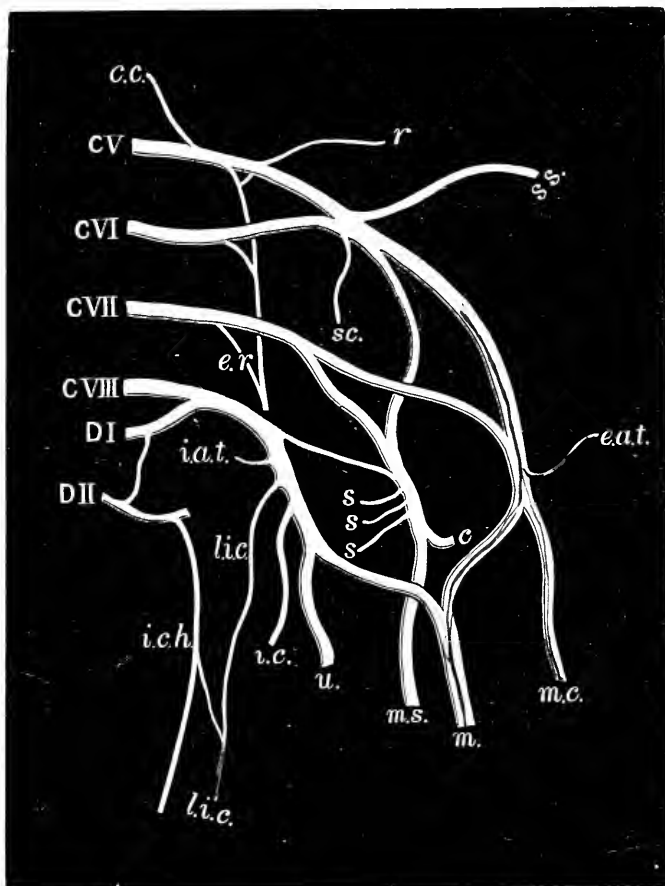


FIG. 12.—Diagram of the brachial plexus.

CV, CVI, CVII, CVIII, The four anterior primary divisions of the cervical spinal nerves which take part in its formation. DI and DII, The anterior primary divisions of the first two dorsal nerves. *c.c.*, Communicating twig from the fourth cervical nerve. *r.*, Nerve to rhomboids. *s.s.*, Suprascapular nerve. *s.c.*, Nerve to subclavius. *e.r.*, External respiratory nerve, or nerve of Bell. *e.a.t.*, External anterior thoracic nerve. *m.c.*, Musculo-cutaneous nerve. *m.*, Median nerve. *i.a.t.*, Internal anterior thoracic nerve. *l.i.c.*, Lesser internal cutaneous nerve, or the nerve of Wrisberg. *i.c.h.*, Intercosto-humeral nerve. *i.c.*, Internal cutaneous nerve. *u.*, Ulnar nerve. *s, s, s*, The three subscapular nerves. *c.*, Circumflex nerve. *m.s.*, Musculo-spiral nerve.

nerves should be completely removed and the arrangement of the brachial plexus studied.

The Brachial Plexus (*plexus brachialis*) is formed by the anterior primary divisions of the four lower cervical nerves and the greater part of the large anterior primary division of the first dorsal nerve. Above, the plexus is further reinforced by a small twig of communication which passes from the fourth to the fifth cervical nerve, whilst below, a similar connecting twig not infrequently passes upwards, in front of the neck of the second rib, from the second to the first dorsal nerve. The manner in which these great nerves unite to form the plexus is very constant. The fifth and sixth nerves unite to form an *upper trunk*; the *seventh* remains single and proceeds downwards as a *middle trunk*; whilst the *eighth cervical* and *first dorsal nerves* join close to the intervertebral foramina to constitute a *third* or *lower trunk*. A short distance above the clavicle each of these three trunks splits into an *anterior* and a *posterior division*. Raise the three anterior divisions on the handle of the knife, and it will be seen that all the three posterior divisions unite to form the *posterior cord* of the plexus, and, further, that the innermost of these divisions is much smaller than the other two. Of the three anterior divisions the *two outer* join to constitute the *outer cord*, whilst the *innermost* is carried downwards by itself as the *inner cord* of the plexus. From the three cords of the plexus are given off the branches which supply the upper limb.

From the above description it will be seen that the plexus, from changes which are effected in the arrangement of its fibres, may be divided into four stages:—

- | | | |
|----------------------|-----|--|
| <i>First stage,</i> | . . | Five separate nerves (viz., four lower cervical and first dorsal). |
| <i>Second stage,</i> | . . | Three nerve-trunks (viz., an upper, middle, and lower). |
| <i>Third stage,</i> | . . | Three anterior divisions and three posterior divisions. |

Fourth stage, . . . Three nerve-cords (viz., an outer, inner, and a posterior).

The first two of these stages are generally observed in the lower part of the posterior triangle of the neck, and the two last behind the clavicle and in the upper part of the axilla. It must be understood, however, that the points at which division and union of the different parts of the plexus take place are subject to variation.

Infraclavicular Branches of the Brachial Plexus.—The branches of the brachial plexus are usually classified into two groups, viz., those which arise above the level of the clavicle, and those which take origin within the axilla. The latter group of nerves must now be studied by the dissector of the upper limb. They consist of a number of short branches, which end in the muscles forming the anterior and posterior walls of the axilla, and a series of large terminal branches, which are prolonged downwards into the upper arm. They are:—

1. *Axillary branches*—

- From outer cord :
 - External anterior thoracic.
- From inner cord :
 - Internal anterior thoracic.
- From posterior cord :
 - Three subscapular nerves.

2. *Brachial branches*—

- From outer cord :
 - Musculo-cutaneous.
 - Outer head of median.
- From inner cord :
 - Inner head of median.
 - Ulnar.
 - Internal cutaneous.
 - Lesser internal cutaneous.
- From posterior cord :
 - Circumflex.
 - Musculo-spiral.

The Anterior Thoracic Nerves (nervi thoracici anteriores)

are the branches of supply to the pectoral muscles, or, in other words, to the two muscles which form the anterior wall of the axilla. The *external anterior thoracic nerve* springs from the outer cord of the plexus, pierces the costocoracoid membrane above the level of the pectoralis minor, and breaks up into branches which sink into the deep surface of the pectoralis major. The *internal anterior thoracic nerve*, somewhat smaller, arises from the inner cord of the plexus, and passing forwards between the axillary artery and vein enters the deep surface of the pectoralis minor. After supplying this muscle its terminal filaments emerge from its anterior surface, and sink into the pectoralis major. The pectoralis major is therefore supplied by both anterior thoracic nerves; the pectoralis minor by the internal anterior thoracic nerve alone. Close to their origin the two nerves are usually united by an arch or loop, thrown over the front of the axillary artery; in other cases they may join in a plexiform manner, before proceeding to their destinations.

Subscapular Nerves (nervi subscapulares).—The three subscapular nerves spring from the posterior cord of the plexus, and supply the three muscles which form the posterior wall of the axilla. The *upper subscapular nerve* is placed high up in the axilla. It is very short, sometimes double, and it sinks into the substance of the subscapularis muscle. The *long* or *middle subscapular nerve* accompanies the subscapular artery and supplies the latissimus dorsi. The *lower subscapular nerve* gives twigs to the lower border of the subscapularis muscle, and ends in the teres major.

Dissection.—The cords of the brachial plexus may now be divided. Begin with the inner and outer cords, because when these are thrown downwards a better view of the posterior cord and the three subscapular nerves will be obtained. When the posterior cord is cut the arm should be forcibly dragged away from the trunk, so as to put the serratus magnus on the stretch.

Posterior Thoracic Nerve (nervus thoracicus longus).—The *external respiratory nerve of Bell*, or the posterior

thoracic nerve, as it passes downwards upon the outer surface of the serratus magnus, may now be studied in its whole length. It is the nerve of supply to the serratus magnus, and it arises in the root of the neck by three roots from the brachial plexus. The upper two roots (one from the fifth cervical and the other from the sixth cervical nerve) pierce the scalenus medius, and uniting into one stem give off branches to the upper part of the serratus magnus. The third root takes origin from the seventh cervical nerve, and passes in front of the scalenus medius. It runs downwards for a considerable distance on the surface of the serratus magnus, before it unites with the other part of the nerve. The entire nerve, thus formed, can be followed to the lower part of the serratus, giving twigs to each of its digitations.

Serratus Magnus Muscle.—The serratus magnus arises by fleshy digitations from the upper eight or nine ribs, about midway between their angles and cartilages. These slips are arranged on the chest-wall, so as to present a gentle curve convex forwards. The lower three or four interdigitate with the external oblique muscle of the abdomen. The serratus magnus is inserted into the entire length of the vertebral border of the scapula. The muscle falls naturally into three parts. (a) The *upper part*, composed of the large first digitation alone, arises from the first and second ribs, and from a tendinous arch between them. The fibres converge, to be inserted into a somewhat triangular surface on the ventral aspect of the superior angle of the scapula. (b) The *middle part* consists of two digitations which take origin from the second and third ribs. The upper slip is very broad, and springs from the lower border of the second rib. The fibres diverge to form a thin muscular sheet, which is inserted into the anterior lip of the vertebral border of the scapula, between the insertions of the upper and lower portions. (c) The *lower part* is formed by the remaining digitations of the muscle. These converge to form a thick mass, which is inserted into a rough surface upon the ventral aspect of the

inferior angle of the scapula. The deep surface of the serratus magnus is in contact with the chest wall.

Removal of the Arm from the Body.—Draw the arm forcibly from the side and cut through the serratus magnus, the omo-hyoid, and the latissimus dorsi muscles, also the suprascapular artery and nerve, and the vessels and nerves in relation to the trapezius and rhomboids, if these have not been previously divided. The arm will then be found to be free, and it may be carried to one of the tables which are reserved for the dissection of separate parts. ✕

SHOULDER—SCAPULAR REGION.

In the dissection of this region the following parts must be studied :—

1. Cutaneous nerves of the shoulder.
2. Deep fascia.
3. Deltoid muscle.
4. Sub-acromial bursa.
5. Anterior and posterior circumflex vessels.
6. Circumflex nerve.
7. Dorsalis scapulæ artery.
8. Subscapularis muscle.
9. Supraspinatus, infraspinatus, teres minor, and teres major muscles.
10. Bursæ in connection with the shoulder-joint.
11. Suprascapular nerve and artery.
12. Acromio-clavicular joint, and the coraco-acromial arch.

Muscles Inserted into the Clavicle and Scapula.—The insertions of the muscles which have already been divided should first engage the attention of the student. These should be carefully defined and the precise extent of each studied. Begin with the omo-hyoid, which springs from the superior border of the scapula : then deal in the same way with the levator anguli scapulæ, rhomboideus minor and major, which are attached to the vertebral border of the bone, and the serratus magnus, which is inserted into the ventral aspect of the superior and inferior angles, and the intervening portion of the vertebral border of the scapula. The insertion of the pectoralis minor into the coracoid process, and of the trapezius into both clavicle and scapula should also be thoroughly examined. When this has been done these

divided muscles may be removed, with the exception of about half an inch of each, which it is advisable to leave attached to the bones for future reference.

Dissection.—A block should now be placed in the axilla, and the skin removed from the upper and outer aspects of the shoulder as low down as the insertion of the deltoid. Commence in front and proceed from before backwards, taking care to leave the fatty superficial fascia in its place.

Cutaneous Nerves.—In the superficial fascia, which is thus laid bare, cutaneous nerves from two different sources must be secured and traced, in order that the area of skin supplied by each may be recognised. They are :—

1. Supra-acromial branches from the third and fourth cervical nerves.
2. Cutaneous branches from the circumflex nerve.

The supra-acromial branches have already been observed crossing the outer third of the clavicle and the insertion of the trapezius under cover of the platysma. They have been divided in removing the limb. If the cut ends be secured and followed, they will be found to spread out over the outer and back part of the upper portion of the deltoid region.

The cutaneous branches of the circumflex nerve consist—(a) of a large branch which turns round the posterior border of the deltoid muscle, and (b) of several fine filaments from the same source, which pierce the substance of the deltoid muscle, and appear at irregular intervals on its surface. The latter are difficult to secure, but the main branch can be easily found by carefully dividing the superficial fascia along the posterior border of the deltoid. On everting this border very little dissection is required to expose the nerve hooking round it about two and a half inches above the deltoid insertion. It breaks up into branches which supply the skin over the lower portion of the deltoid region.

Deep Fascia.—A firm but thin fascia covers the subscapularis muscle. Into this some of the fibres of the serratus magnus will usually be found inserted at the

vertebral border of the scapula. The strongest and most conspicuous fascia in this region is that which covers the exposed part of the infraspinatus muscle. It is firmly attached to the limits of the fossa in which that muscle lies, and presents other very apparent connections. Thus a strong septum will be noticed to dip in between the infraspinatus and teres minor, and then as it proceeds forwards it gives a thin covering to the teres minor, teres major, and the deltoid. Indeed it may be said to split into two lamellæ—a superficial and a deep—which as they pass forwards enclose between them the deltoid muscle.

Dissection.—Depress the scapula and retain it in this position by means of hooks. The fibres of the deltoid are thus rendered tense, and the coarse fasciculi of the muscle may be cleaned.

Deltoid Muscle.—The deltoid muscle, as its name implies, is triangular in form. It is composed of coarse fasciculi and covers the shoulder-joint. It arises from the anterior border of the outer third or half of the clavicle, from the outer border of the acromion process, and from the lower border of the spine of the scapula. Its origin closely corresponds with the insertion of the trapezius. The fasciculi of which the muscle is formed converge rapidly as they are traced downwards, and finally they present a pointed tendinous insertion into the deltoid eminence on the middle of the outer surface of the shaft of the humerus.

Dissection.—The limb should now be placed on its posterior aspect, and the posterior circumflex artery and the circumflex nerve traced backwards through the quadrilateral space. The boundaries of the space at the same time should be defined and cleaned.

Quadrilateral and Triangular Spaces.—The quadrilateral space is purely the result of dissection; it has no real existence until the parts are artificially separated from each other. When viewed from the front, the boundaries will be seen to be formed by—(a) the upper part of the shaft of the humerus externally; (b) the long head of the triceps

internally; (c) the lower margin of the subscapularis *above*; (d) and the upper border of the teres major *below*. When viewed from behind, the *upper boundary* of the quadrilateral

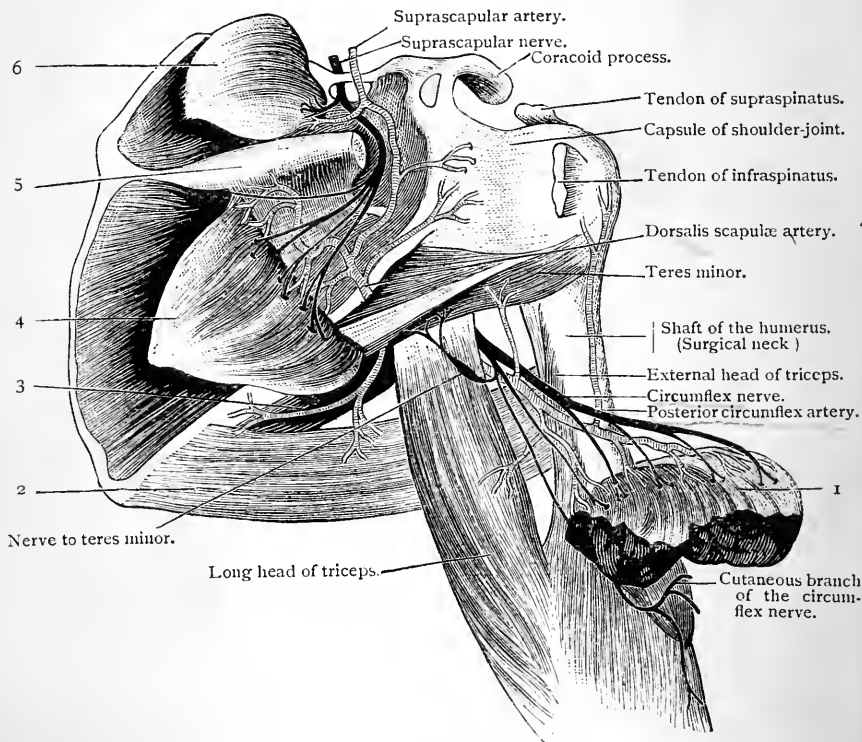


FIG. 13.—Dissection of the posterior scapular region.

- | | |
|---|--|
| 1. Deltoid. | 4. Infraspinatus. |
| 2. Teres major. | 5. Spine of scapula. (The acromion process has been sawn off.) |
| 3. Infrascapular branch of dorsalis scapulæ artery. | 6. Supraspinatus. |

Note the triangular and quadrilateral spaces as seen from behind.

space will be seen to be formed by the teres minor; the other boundaries are the same as those seen from the front.

The term *triangular space* is the name given to another intermuscular interval which becomes apparent when the muscles in this region are cleaned and separated. It is

placed nearer the inferior angle of the scapula, and the long head of the triceps intervenes between it and the quadrilateral space. It is bounded *above* by the subscapularis ; *below* by the teres major ; and *externally* by the long head of the triceps. The *dorsalis scapulae* artery should be followed into this space, and cleaned up to the point where it disappears around the axillary border of the scapula under cover of the teres minor.

Dissection.—Having now traced the posterior circumflex artery and the circumflex nerve as far as possible through the quadrilateral space, the position of the limb should be reversed. Turn it so that its dorsal surface is uppermost, and everting slightly the posterior border of the deltoid, define the boundaries of the space as they are seen from behind. At the same time clean the circumflex vessels and nerves as they issue from the space to reach the deep surface of the deltoid muscle. Care must be taken not to injure the branch which the circumflex nerve gives to the teres minor.

The deltoid muscle may now be divided close to its origin and thrown downwards ; in doing this preserve the acromial branch of the thoracic axis which runs in the line of incision beneath the deltoid. A large bursa which lies between the deltoid and upper aspect of the capsule of the shoulder-joint must also be kept intact.

Parts under cover of the Deltoid.—The deltoid covers the upper part of the humerus, and is wrapped round the shoulder-joint so as to envelop it behind, externally, and in front. The full rounded appearance of the shoulder will now be seen to be due to the muscle passing over the expanded upper end of the humerus. When the head of the bone is displaced the muscle passes more or less vertically downwards from its origin, and the dislocation is recognised by the squareness or flatness of the shoulder. Behind, the deltoid covers the muscles which arise from the dorsal aspect of the scapula as they pass outwards to reach the great tuberosity of the humerus ; in front, it covers the upper part of the biceps muscle, and overlaps the coracoid process and the muscles attached to it. In relation also to the deep surface of the deltoid are the circumflex vessels and nerves.

Subacromial Bursa.—This is a large bursal sac which intervenes between the acromion process and deltoid above, and the upper aspect of the capsule of the shoulder-joint below. It facilitates the play of the upper end of the humerus with its capsule, on the under aspect of the acromion process and deltoid. Pinch a portion of it up

with the forceps and make an incision into it.¹ The finger may then be introduced into its interior and its extent and connections explored. In some cases it is divided by internal partitions into two or more chambers or loculi.

Dissection.—The branches of the posterior circumflex artery and the circumflex nerve should now be dissected out on the deep surface of the deltoid muscle.

Circumflex Vessels.—The *posterior circumflex artery* (arteria circumflexa humeri posterior) has been already observed to arise within the axilla from the posterior aspect of the axillary artery a short distance below the subscapular branch. It at once proceeds backwards through the quadrilateral space, and winding round the surgical neck of the humerus, it is distributed in numerous branches to the deep surface of the deltoid muscle. Several twigs are also given to the shoulder-joint and the integument. It anastomoses with the acromial branch of the thoracic axis and the anterior circumflex artery, and also by one or more twigs which it sends downwards to the long head of the triceps, with the superior profunda branch of the brachial artery.

The termination of the *anterior circumflex artery* (arteria circumflexa humeri anterior) can now be more satisfactorily studied, and its anastomosis with the posterior circumflex established if the injection has flowed well. By this anastomosis the arterial ring which encircles the upper part of the shaft of the humerus is completed.

The Circumflex Nerve (nervus axillaris) accompanies the posterior circumflex artery, and supplies—(a) *muscular branches* to the deltoid and teres minor; (b) *cutaneous branches* to the skin over the lower part of the deltoid; and (c) an *articular twig* to the shoulder-joint. The following is the manner in which it is distributed. It springs from the posterior cord of the brachial plexus,

¹ If the wall of the bursa be quite entire a blowpipe may be thrust into it. It can then be distended, and if unilocular it may be inflated to about the size of a hen's egg. It varies, however, much in size in different individuals.

and turning round the lower border of the subscapularis, proceeds backwards with the posterior circumflex artery in the quadrilateral space. Reaching the posterior aspect of the limb, it divides into an anterior and a posterior division. The *articular branch* takes origin from the trunk of the nerve, and enters the joint below the subscapularis muscle. The *posterior division* gives off the branch to the teres minor, and after furnishing a few twigs to the posterior part of the deltoid, is continued onwards as the cutaneous nerve which has already been dissected in the superficial

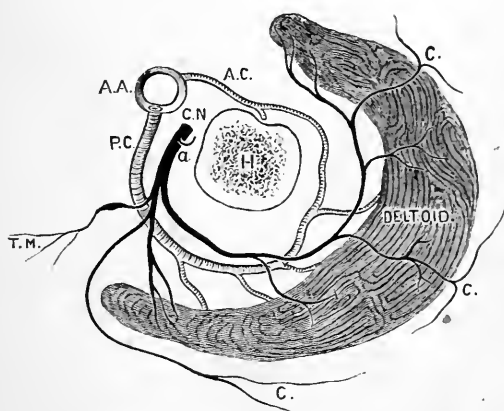


FIG. 14.—Diagram of the circumflex vessels and nerve.

- | | |
|--|---|
| <p><i>H.</i> Transverse section of the humerus immediately below the tuberosities.</p> <p><i>A.A.</i> Axillary artery.</p> <p><i>P.C.</i> Posterior circumflex artery.</p> | <p><i>A.C.</i> Anterior circumflex artery.</p> <p><i>C.N.</i> Circumflex nerve.</p> <p><i>a.</i> Articular branch.</p> <p><i>T.M.</i> Branch to teres minor.</p> <p><i>C.</i> Cutaneous branches.</p> |
|--|---|

fascia over the lower part of the deltoid (Fig. 14). The nerve to the teres minor is distinguished by the presence of an oval gangliform swelling upon it. The *anterior division* proceeds round the humerus with the posterior circumflex artery, and ends near the anterior border of the deltoid. It is distributed by many branches to the deep surface of this muscle, whilst a few fine filaments piercing the deltoid reach the skin.

Teres Major.—The part which the teres major plays

in the formation of the quadrilateral and triangular spaces has already been seen. It arises from the oval surface on the dorsum of the scapula close to the inferior angle of the bone, and also from the septa which the fascia infraspinata sends in to separate it from the infraspinatus and teres minor muscles. It is inserted into the inner lip of the bicipital groove on the upper part of the humerus. *Nerve supply. Lower Subscapular.*

Insertions of Latissimus Dorsi and Pectoralis Major.—The narrow, band-like tendon of the latissimus dorsi lies in front of the insertion of the teres major. From the lower margin of this a small fibrous slip will be observed passing downwards, beyond the lower margin of the teres major, to find attachment to the long head of the triceps. This is a rudiment of the dorsi-epitrochlearis muscle of the lower animals. The tendons of the teres major and latissimus dorsi should now be separated from each other. They will be found to be more or less adherent, and a small bursa will be discovered between them. The insertion of the latissimus dorsi into the bottom of the bicipital groove of the humerus may now be satisfactorily studied.

The tendon of insertion of the *pectoralis major*, which is attached to the outer lip of the bicipital groove may also be conveniently examined at this stage (p. 23). A separation of the sternal and clavicular portions of the muscle will bring into view the two laminae which constitute the tendon, and the following points may be noted in connection with these:—(a) that they are continuous with each other below, or, in other words, that the tendon is simply folded upon itself; (b) that the posterior lamina extends upwards on the humerus to a higher level than the anterior, and that a fibrous expansion proceeds upwards from its superior border, to seek attachment to the capsule of the shoulder-joint and the lesser tuberosity of the humerus; (c) that the lower border is connected with the fascia of the upper arm.

Acromio-clavicular Articulation.—This is a diarthrodial joint, and the ligaments which bind the bones together are:—

Ligaments proper to the joint,	{	1. <u>Superior</u>	} capsule.
	}	2. <u>Inferior</u>	
Accessory ligaments—	{	<u>Coraco-clavicular</u>	} trapezoid. conoid.

The *superior acromio-clavicular ligament* is a broad band, composed of stout fibres, which is placed on the

upper aspect of the joint. The *inferior acromio-clavicular ligament* which closes the joint below is not so strongly developed. In front and behind these ligaments are connected with each other so as to constitute a capsule. The joint should now be opened, when it will be seen to be lined by a synovial membrane. An imperfect *interarticular fibro-cartilage* is also usually present. It is wedge-shaped, and connected by its base to the superior ligament, whilst its free margin is directed downwards between the bones.

The Coraco-clavicular Ligament is very powerful. It binds the under surface of the clavicle to the base of the coracoid process. When thoroughly cleaned and defined it will be seen to consist of two parts, which are termed the conoid and the trapezoid ligaments.

The *conoid ligament* (ligamentum conoideum), placed upon the posterior and inner aspect of the trapezoid, is broad above where it is attached to the conoid tubercle of the clavicle, and somewhat narrower below at its attachment to the inner part of the root of the coracoid process. The *trapezoid ligament* (ligamentum trapezoideum) is the anterior and external part. Above it is attached along the trapezoid line of the clavicle, whilst below it is fixed to the upper aspect of the coracoid process. In the recess between these two ligaments a bursa will usually be found.

Coraco-acromial Arch.—It is necessary to examine this arch at the present stage, as the next step in the dissection will, in a great measure, destroy it. It is the arch which overhangs the shoulder-joint and protects it from above. It is formed by the coracoid process, the acromion process, and a ligament—the coraco-acromial—which stretches between them.

The *coraco-acromial ligament* is a strong band of a somewhat triangular shape. By its base it is attached to the outer border of the coracoid process, whilst by its apex it is attached to the extremity of the acromion.

The coraco-acromial arch plays a very important part

in the mechanism of the shoulder; it might almost be said to form a secondary socket for the humerus. We have already noted the large bursa which intervenes between the acromion and the capsule of the shoulder-joint, to facilitate the movements.

Dissection.—The supraspinatus, infraspinatus, and teres minor muscles which arise from the dorsum scapulæ, and the subscapularis, which takes origin from the venter scapulæ, may now be examined. In order to obtain an uninterrupted view of the supraspinatus muscle, the acromion process must be divided with the saw close to its junction with the spine of the scapula (Fig. 13).

Further, divide the fascia which covers the teres minor muscle, and reflect it towards the infraspinatus. By this means the septum from the fascia infraspinata, which dips in between the two muscles, will be demonstrated, and their separation rendered easy. Care must be taken not to injure the dorsalis scapulæ artery which passes between the teres minor and the bone.

The Supraspinatus Muscle arises from the inner two-thirds of the supraspinous fossa, and also to a slight degree from the fascia supraspinata which covers it. From this origin the fibres converge as they pass outwards, and, proceeding under the acromion process, they end in a short, stout tendon, which is inserted into the uppermost of the three impressions on the great tuberosity of the humerus. This tendon is closely adherent to the capsule of the shoulder-joint. The supraspinatus is covered by the trapezius, and in the loose fat which intervenes between this muscle and the fascia supraspinata some twigs of the superficial cervical artery ramify.

The Teres Minor is the small muscle which lies along the lower border of the infraspinatus. It arises from an elongated flat impression on the dorsal aspect of the axillary border of the scapula, and from the septa of the fascia infraspinata which intervene between it, the infraspinatus and teres major muscles. It is inserted into the lowest of the three impressions on the great tuberosity of the humerus, and also, by fleshy fibres, into the shaft of the bone for about half an inch below this. Towards its

insertion it is separated from the teres major by the long head of the triceps.

The Infraspinatus arises from the whole of the infraspinous fossa, with the exception of a small part of it near the neck of the scapula. It also derives fibres from the fascia which covers it. Its tendon of insertion is closely adherent to the capsule of the shoulder-joint, and is attached to the middle impression on the great tuberosity of the humerus.

The Subscapularis arises from the whole of the subscapular fossa, with the exception of a small portion near the neck of the scapula; it also takes origin from the groove which is present on the ventral aspect of the axillary border of the bone. Its origin is strengthened by tendinous intersections, which are attached to the ridges which are present on the venter scapulæ. The fleshy fibres thus derived converge upon a stout tendon, which is inserted into the lesser tuberosity of the humerus; a few of the lower fibres, however, gain independent insertion into the shaft of the humerus below the tuberosity.

As the muscle proceeds outwards to its insertion, it passes under an arch formed by the coracoid process and the conjoined origin of the short head of the biceps and coraco-brachialis. By dissecting between the upper border of the muscle and the root of the coracoid process, a bursa of some size will be discovered. This bursa communicates with the cavity of the shoulder-joint through an aperture in the capsular ligament: in other words, it is directly continuous with the synovial membrane which lines the joint. This can readily be ascertained by making an incision through its wall. An instrument can then be passed into the joint.

Dissection.—The suprascapular artery and nerve must now be followed to their distribution on the dorsum of the scapula. They have already been traced to the upper border of the scapula. Divide the infraspinatus muscle about an inch and a half from its insertion, taking care not to injure the subjacent vessels. Pull the muscle cautiously backwards, and its nerve of supply with the terminations

of the suprascapular and dorsalis scapulæ vessels will be exposed. Treat the supraspinatus muscle in a similar manner (Fig. 13).

The Suprascapular Artery (arteria transversa scapulæ) enters the supraspinous fossa by passing over the ligament which bridges across the suprascapular notch. It divides, under cover of the supraspinatus muscle, into a *supraspinous* and an *infraspinous branch*. The former supplies the supraspinatus muscle, and gives off the chief nutrient artery to the scapula; the latter proceeds downwards in the great scapular notch, and under cover of the spino-glenoid ligament, to reach the deep surface of the infraspinatus muscle to which it is distributed.

At the upper border of the scapula the suprascapular artery gives off a branch (the *subscapular*) which enters the subscapular fossa under cover of the subscapularis muscle.

The Suprascapular Nerve accompanies the artery of the same name, but it enters the supraspinous fossa by passing through the suprascapular notch, under cover of the suprascapular ligament. It supplies the supraspinatus, and ends in the infraspinatus muscle. It usually sends *two articular twigs* to the posterior aspect of the shoulder-joint, viz., one while in the supraspinous fossa, and the second as it lies in the infraspinous fossa.

Dorsalis Scapulæ Artery (arteria circumflexa scapulæ).—This vessel has already been observed to arise from the subscapular branch of the axillary, and enter the triangular space. While here, it supplies one or two *ventral branches*, which pass under cover of the subscapular muscle to the venter scapulæ, and a larger *infrascapular branch* which runs downwards in the interval between the teres major and teres minor to the inferior angle of the scapula (Fig. 13). After these branches are given off, the dorsalis scapulæ leaves the triangular space by turning round the axillary border of the scapula, under cover of the teres minor. It now enters the infraspinous fossa, where it ramifies and supplies branches to the infraspinatus muscle.

Anastomosis around the Scapula.—A very important and

free anastomosis takes place around the scapula. Three main blood-vessels take part in this, viz.—(a) the suprascapular; (b) the posterior scapular; and (c) the subscapular.

The *posterior scapular artery* runs downwards in relation to the base or vertebral border of the scapula, and dispenses branches upon both the dorsal and ventral aspects of the bone. The *subscapular artery* runs downwards and inwards along the axillary border of the scapula, and at the inferior angle some of its terminal branches anastomose with the terminal twigs of the posterior scapular. The *suprascapular artery* at the upper margin of the scapula is brought into communication with the posterior scapular by an anastomosis in the neighbourhood of the superior angle of the bone.

But still more distinct anastomoses take place upon the dorsal and ventral aspects of the bone. In the supraspinous fossa branches of the suprascapular inosculate with twigs from the posterior scapular; whilst in the infraspinous fossa free communications are established between the dorsalis scapulæ, the suprascapular, and the posterior scapular.

On the ventral aspect of the scapula, the ventral branch of the (suprascapular,) the ventral branches of the dorsalis scapulæ, and the ventral branches of the posterior scapular, join to form a network.

The importance of this free communication between the blood-vessels in relation to the scapula will be manifest when it is remembered that two of the main arteries, viz., the posterior scapular and the suprascapular, spring indirectly from the first part of the subclavian; whilst the third, viz., the subscapular, arises from the third part of the axillary. When, therefore, a ligature is applied to any part of the great arterial trunk of the upper limb, between the first stage of the subclavian and the third part of the axillary, this anastomosis affords ample means of re-establishing the circulation.

Dissection.—Detach the subscapularis from the scapula and lift it outwards to its insertion. This will afford a better view of its relation to the capsule of the shoulder-joint, and also of the subscapular bursa. In a well-injected subject the ventral anastomosis can likewise be made out.

Suprascapular and Spino-glenoid Ligaments.—These are two ligamentous bands, which are placed in relation to the suprascapular artery and nerve. The *suprascapular* or *transverse ligament* bridges across the suprascapular notch of the scapula, and converts it into a foramen. It lies between the artery and nerve: the former being placed above it, and the latter below it. Not infrequently it is ossified. The *spino-glenoid ligament* is a weaker band, which bridges across the suprascapular artery and nerve as they pass through the great scapular notch. On the one hand it is attached to the spine of the scapula, and on the other to the upper part of the neck of the scapula. 7

FRONT OF THE ARM.

In this dissection the following parts have to be studied:—

1. Cutaneous vessels and nerves.
2. Brachial aponeurosis.
3. Brachial artery and its branches.
4. Median, ulnar, musculo-spiral, and musculo-cutaneous nerves and the branches of the last two.
5. Biceps, coraco-brachialis, and brachialis anticus muscles.

In conjunction with this dissection, it is convenient to study the triangular space in front of the elbow, and also to trace the cutaneous nerves to their ultimate distribution in the skin of the forearm.

Surface Anatomy.—In a muscular limb the prominence formed by the biceps muscle along the front of the upper arm is very apparent. Every one is familiar with the rounded swelling which it produces when powerfully contracted in the living subject. On either side of the biceps there is a feebly-marked furrow, and ascending in each of these there is a large superficial vein. In the outer furrow is the cephalic vein; in the inner furrow the basilic vein. The

humerus is thickly clothed by muscles ; but towards its lower part the two supracondyloid ridges, leading down to the condylar eminences, may be felt. The external ridge is the more salient of the two, and therefore the more evident to touch.

But by far the most important objects for us to distinguish are the bony points around the elbow. It is by a proper knowledge of the normal relative positions of these that the surgeon is able to distinguish between the different

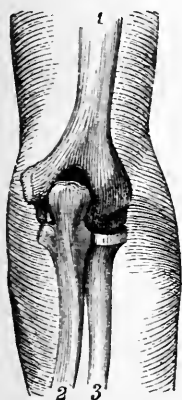


FIG. 15.—Posterior view of the upper limb, with the elbow-joint fully extended (Luschka).

1. Humerus.
2. Ulna.
3. Radius.

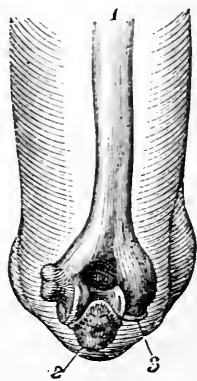


FIG. 16.—Posterior view of the upper limb, with the elbow-joint flexed (Luschka).

1. Humerus.
2. Ulna.
3. Radius.

forms of fracture and dislocation which so frequently occur in this region. First note the internal condyle of the humerus. This constitutes a prominence, appreciable to the eye ; grasp it between the finger and thumb, and note that it inclines backwards as well as inwards. In a well-developed arm, when fully extended, the external condyle does not form a projection on the surface, but can be felt at the bottom of a slight depression on the posterior aspect of the limb. It becomes apparent to the eye as a prominence when the elbow is semi-flexed. The olecranon pro-

cess of the ulna produces a marked projection on the back of the elbow between the two condyles. It is placed slightly nearer to the internal than to the external condyle. This is more especially the case in children—an important practical point, seeing that in the young injuries of the elbow are particularly common. The loose skin which covers the olecranon moves freely over its subcutaneous surface, owing to the interposition of a synovial bursa. The different positions which are assumed by the olecranon, in relation to the condyles of the humerus in the movements of the forearm at the elbow-joint, must be carefully studied and considered. This can best be done by placing the thumb on one condyle, the middle finger on the other, and the forefinger on the olecranon. The limb should then be alternately flexed and extended, so as to make clear the limits of the excursion performed by the olecranon. In full extension at the elbow-joint the three prominences are placed on the same straight line; when the forearm is bent at a right angle the three bony points are placed at the angles of an equilateral triangle, the apex of which points downwards.

When the arm is extended the head of the radius may be easily felt on the back of the limb, immediately below the external condyle, and when the movements of pronation and supination are alternately induced it will be felt to roll under the finger.

As the skin of the forearm must be reflected in the pursuit of the cutaneous nerves, it is well, at this stage, to study also the external anatomy of this segment of the limb. In its upper half the radius is deeply imbedded in muscles, but in its lower half it can be felt, and its styloid process on the outer side of the wrist can be readily distinguished. The sinuous posterior border of the ulna is subcutaneous, and may be followed by the finger throughout its entire length. In cases of suspected fracture, therefore, it affords valuable information. The styloid process may be detected, and it should be observed that this does not extend so low down as the corresponding process of the radius. The

rounded lower end of the ulna makes a marked projection on the inner and posterior aspect of the limb immediately above the wrist-joint.

Reflection of Skin.—The skin should be removed from the limb as far down as the wrist-joint. It is necessary to do this in order that a connected view may be obtained of the cutaneous nerves and the superficial veins. But at the same time the skin should not be cast aside, as it forms a most efficient protective wrapping for the part even after it has been detached. Make one long incision along the middle of the fore aspect of the arm and the forearm down to the wrist. A second incision carried transversely round the lower end of the forearm, immediately above the wrist-joint, will enable the dissector to reflect the skin in two large flaps, outwards and inwards. In the fatty superficial fascia which is then exposed, the superficial structures may be traced. It is well to begin with the nerves, as these are not so apparent, and therefore more liable to injury than the veins. But the dissection of the veins should be carried on concurrently with that of the nerves.

Cutaneous Nerves.—These are very numerous, and are derived from several sources. In addition to the two internal cutaneous nerves, and the terminal cutaneous part of the musculo-cutaneous, which spring from the brachial plexus, there are three branches derived from the musculo-spiral, and one—the intercosto-humeral—from the second intercostal nerve. These seven nerves may be classified into an inner and an outer group as follows:—

- | | |
|--|---|
| 1. Upper external cutaneous branch
of musculo-spiral, | } Distributed mainly
upon the outer
aspect of arm
and forearm. |
| 2. Lower external cutaneous branch
of musculo-spiral, | |
| 3. Cutaneous part of musculo-cutaneous, | |
| 1. Intercosto-humeral, | } Distributed mainly
upon the inner
aspect of arm
and forearm. |
| 2. Internal cutaneous branch of musculo-spiral, | |
| 3. Lesser internal cutaneous, | |
| 4. Internal cutaneous, | |

The two external cutaneous branches of the musculo-spiral pierce the deep fascia about the middle of the outer surface of the upper arm immediately below the insertion of the

deltoid, and in close relation to the external inter-muscular septum. The *upper and smaller branch* appears a short

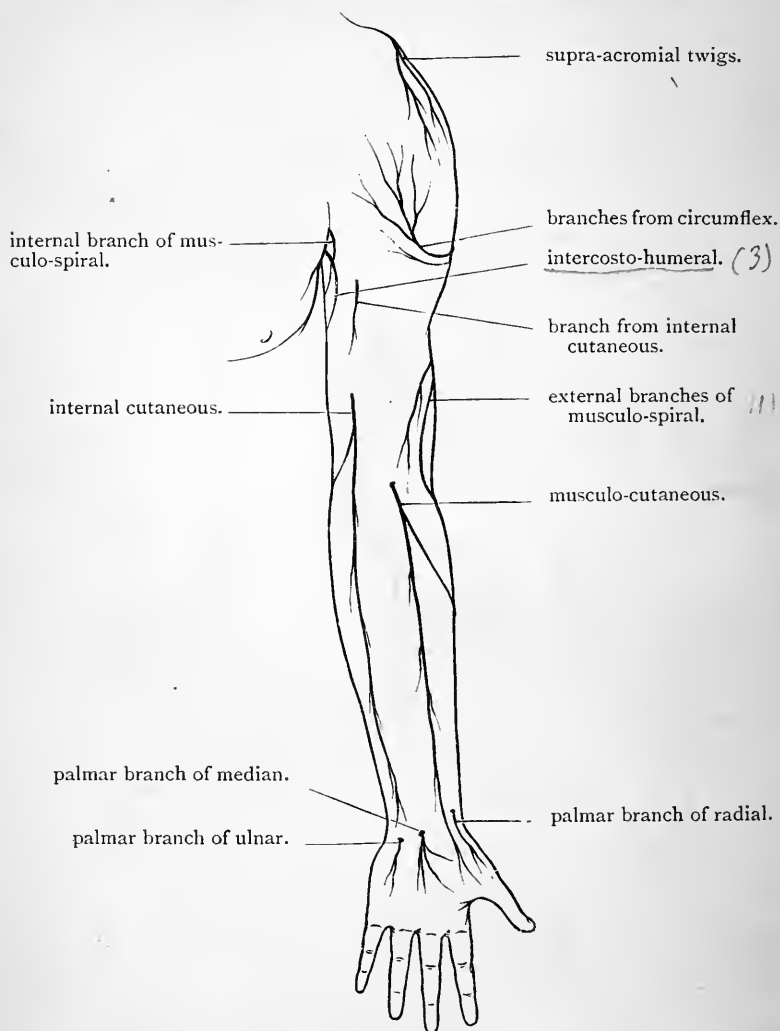


FIG. 17.—Diagram of the cutaneous nerves on the front of the upper limb.

distance above the other. It follows the cephalic vein, and can be traced downwards as far as the elbow. Its filaments

The upper external cutaneous branch of the musculo-spiral nerve accompanies the cephalic vein.

are distributed to the skin over the outer and anterior part of the lower half of the upper arm. The larger lower branch can be followed as far as the wrist, and not infrequently its terminal filaments may even reach the dorsum of the hand. It supplies the skin on the dorsal aspect of the forearm.¹

The terminal cutaneous branch of the musculo-cutaneous will be found in front of the elbow-joint. It pierces the deep fascia on the outer side of the tendon of the biceps. It is a large nerve, and proceeds downwards behind the median cephalic vein. The skin both upon the anterior and posterior aspects of the outer side of the forearm is supplied by this nerve, and it is distributed by two main branches. The anterior and larger branch can be traced as far as the skin over the ball of the thumb. A few of its terminal twigs pierce the fascia above the wrist, and join the radial artery, by which they are conducted to the back of the carpus. The posterior branch may be followed on the dorsal aspect of the limb as far as the wrist.

The intercosto-humeral nerve can usually be traced half way down the upper arm; but the area of skin which it supplies is somewhat variable. The internal cutaneous branch of the musculo-spiral proceeds downwards and backwards on a deeper plane, and crosses under the intercosto-humeral. Its filaments extend upon the back of the upper arm as low as the elbow-joint.

The small internal cutaneous nerve, or nerve of Wrisberg, will be found piercing the deep fascia, to become superficial, half-way down the inner side of the upper arm. Its twigs may be followed, in the superficial fascia, as far as the olecranon process.

On the inner side of the upper arm, on its dorsal aspect, three nerves therefore have been traced. From within

¹ It should be borne in mind that the skin on the outer aspect of the limb, above these nerves and over the deltoid, is supplied by the cutaneous branches of the circumflex nerve and the supra-acromial branches of the cervical plexus (p. 46).

all the cutaneous branches of the musculo-spiral reach on same side of the forearm.

outwards these are : the nerve of Wrisberg, the intercosto-humeral, and the inner cutaneous branch of the musculo-spiral (Fig. 18).

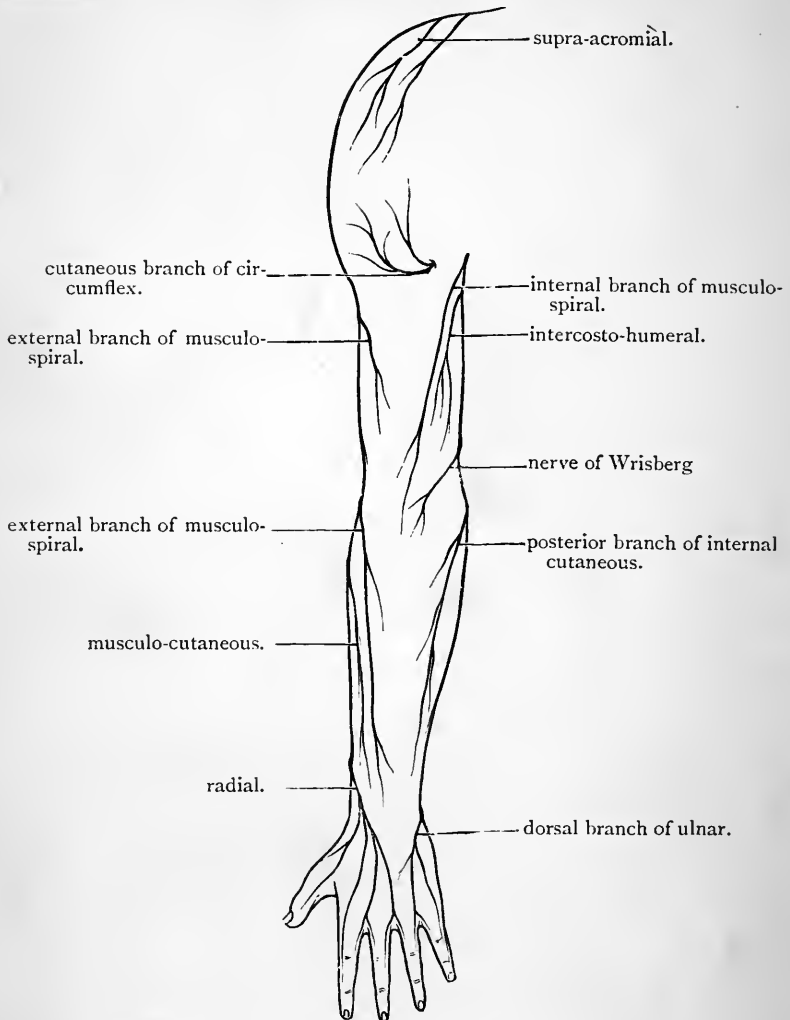


FIG. 18.—Diagram of the cutaneous nerves on the posterior aspect of the upper limb.

The internal cutaneous nerve is chiefly destined for the supply of the skin of the forearm. It appears through the

deep fascia half-way down the inner side of the upper arm close to the basilic vein, and a short distance in front of the nerve of Wrisberg. It at once divides into an anterior and a posterior branch. The *anterior branch* runs downwards behind (but sometimes in front of) the median basilic vein, and it is distributed to the skin over the inner and anterior aspect of the forearm. The *posterior branch*, inclining inwards, proceeds downwards in front of the internal condyle of the humerus, to reach the skin on the inner and dorsal aspect of the forearm.

A small twig is frequently given by the internal cutaneous nerve to the skin over the biceps muscle. This pierces the deep fascia close to the axilla.

Superficial Veins.—The superficial veins in front of the forearm and upper arm may now be followed; but in all probability they are already for the most part exposed.

Four veins will be seen ascending upon the anterior and lateral aspects of the forearm, viz., the radial vein upon the outer border; the anterior and posterior ulnar veins upon the inner border; and the median vein upon the front of the forearm. When the median reaches the hollow in front of the elbow, it is joined by a short wide vein, which appears through the deep fascia, and establishes a connection between the median and the deep veins of the forearm. This connecting trunk is called the *profunda vein*. After receiving this tributary, the median at once divides into two branches, which diverge widely from each other, like the limbs of the letter V. The inner branch is called the *median-basilic*; the outer the *median cephalic*.

The *median-basilic* is a short wide vessel which passes upwards and inwards, and as it approaches the front of the internal condyle of the humerus it is joined by the two ulnar veins. These may enter it separately; but more commonly the anterior ulnar vein joins the larger posterior ulnar vein in the upper part of the forearm, so as to form a common trunk, with a single opening into the median-basilic. The large vein, resulting from the union of the median-basilic and the two ulnar veins, is termed the basilic vein. The

median-basilic is the vein which is commonly selected when the surgeon has recourse to venesection, and formerly, when the practice of bloodletting was more common than it is now, the relations of this vein were a matter of high importance.¹ The dissector should observe the following points in regard to it:—(1) that it crosses a thickened piece of the deep fascia, termed the bicipital fascia; (2) that this fascia separates it from the brachial artery, which

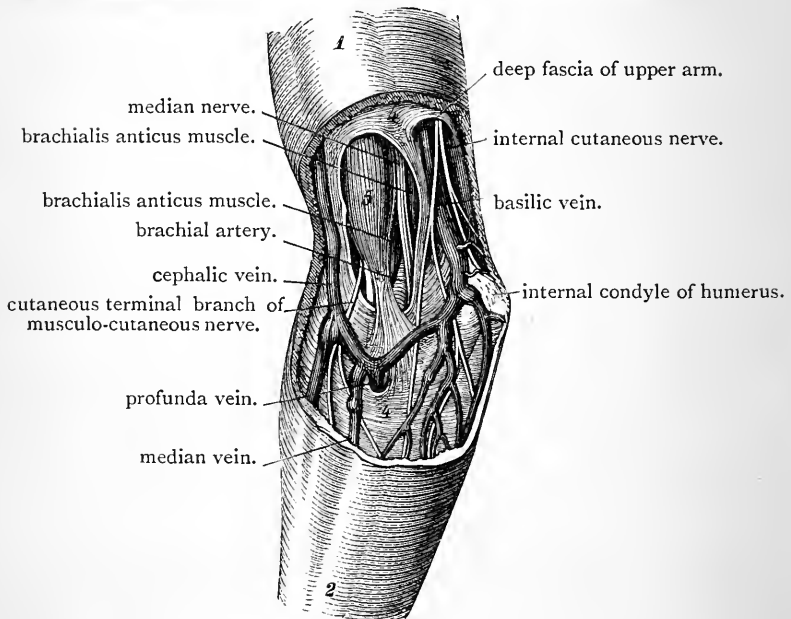


FIG. 19.—Superficial dissection of the region in front of the right elbow (Luschka).

- | | | |
|------------------------------|--|-----------------|
| 1. Prominence of the biceps. | | 4. Deep fascia. |
| 2. Forearm. | | 5. Biceps. |

it also crosses; and (3) that the anterior part of the internal cutaneous nerve lies behind it, although in many cases it may cross in front of it.

¹ Many surgeons prefer the median-cephalic vein for the purpose of venesection, because, although it is smaller than the median basilic, and does not yield so free a flow of blood, it may be opened with much less risk.

The *median-cephalic* vein is not so large as the median-basilic, and it generally ascends with a greater degree of obliquity. It crosses in front of the cutaneous branch of the musculo-cutaneous nerve, and is joined by the radial vein. The resulting trunk is called the *cephalic vein*.

The *basilic vein* runs upwards on the inner aspect of the upper arm in the slight furrow which marks the limb along the inner margin of the biceps. Half-way up the upper arm it disappears by piercing the fascia close to the spot where the internal cutaneous nerve emerges. At the lower border of the posterior wall of the armpit the basilic forms the axillary vein.

The *cephalic vein* ascends in the groove along the outer margin of the biceps. Its further course has been previously noted. It extends upwards in the interval between the deltoid and the clavicular part of the pectoralis major. It dips backwards through the costo-coracoid membrane, crosses the first part of the axillary artery, and finally opens into the axillary vein.

Lymphatic Glands.—If the superficial fascia be searched upon the inner side of the limb, and immediately above the elbow, one or two minute lymphatic glands in relation to the basilic vein will be found. These are of interest to dissectors, as they are the first to enlarge and become painful in cases of dissection-wound.¹

Brachial Aponeurosis (*fascia brachii*).—The deep fascia should now be cleaned by the removal of the fatty superficial layer. It forms a continuous envelope around the upper arm, but at no point does it show a great density or strength. Above, it is continuous with the axillary fascia, and the fascia covering the pectoralis major and the deltoid. The tendons of these two muscles are closely connected with it—a certain proportion of their tendinous fibres running directly into it. Below, it is firmly fixed to the bony prominences around

¹ It may be well to state here, however, that "dissection-wounds," obtained in the dissecting-room, are exceedingly uncommon. The subjects are so carefully preserved that the danger is reduced to a minimum.

the elbow, and in front it receives an accession of fibres from the tendon of the biceps. These fibres constitute the bicipital or semilunar fascia, and form a very distinct band which, continuous with the fascia above and below, bridges across the brachial artery, and is lost upon the pronator radii teres muscle on the inner side of the forearm.

The brachial aponeurosis may be reflected by making an incision through it along the middle line of the front of the arm. In throwing the inner portion inwards, the dissector must leave the bicipital fascia in position. This may be done by separating it artificially from the general aponeurosis by an incision above and below it.

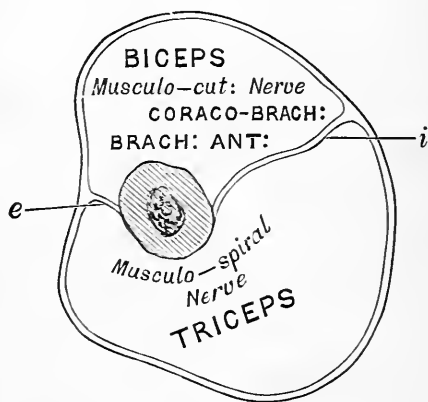


FIG. 20.—Diagram (after Turner) to show how the upper arm is divided by the intermuscular septa and bone into an anterior and posterior compartment. These compartments are represented in transverse section. *e*, External intermuscular septum; *i*, Internal intermuscular septum.

As the foregoing dissection is proceeded with, it becomes evident that septa or partitions pass in between the muscles from the deep surface of the investing brachial aponeurosis. Two of these possess a superior strength, and obtain direct attachment to the humerus. They are the external and internal intermuscular septa. The connections of these cannot be fully studied at present, but it is important that the student should understand their relations at this stage.

In the course of the dissection of the upper arm they will gradually be displayed.

The *internal intermuscular septum* is the stronger and more distinct of the two. It is attached to the internal supracondyloid ridge, and may be followed upwards as high as the insertion of the coraco-brachialis muscle. The *external intermuscular septum* is fixed to the external supracondyloid ridge, and extends up the arm as high as the insertion of the deltoid. The dissector should note that

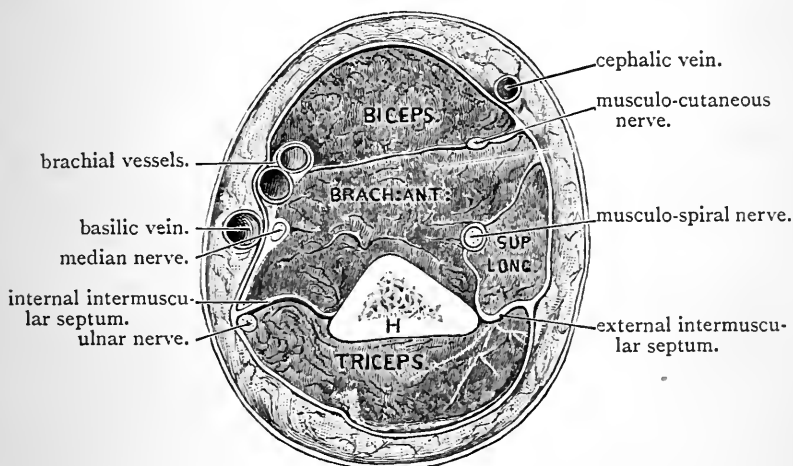


FIG. 21.—Transverse section through the lower third of the right upper arm.

H. Humerus.

these septa divide the upper arm into an anterior and a posterior osteo-fascial compartment.

Structures in the Anterior Compartment.—The anterior osteo-fascial compartment of the upper arm has been opened into by the reflection of the front part of the brachial aponeurosis. The three muscles which specially belong to this region are the biceps, brachialis anticus, and the coraco-brachialis. The biceps is the most superficial muscle: under cover of it, and closely applied to the anterior aspect of the humerus, is the brachialis anticus; whilst the coraco-brachialis is the slender muscular belly

which lies along the inner side of the biceps in its upper part. But, in addition, two muscles of the forearm will be observed extending upwards into the arm, to seek origin from the external supracondyloid ridge of the humerus: they are the supinator longus and the extensor carpi radialis longior. They are closely applied to the outer side of the brachialis anticus. The brachial artery, with its venæ comites, extends through the region in relation to the inner margin of the biceps, and all the terminal branches of the cords of the brachial plexus, with the exception of the circumflex, will be found for some part of their course in this region. The musculo-spiral, it is true, almost at once proceeds to the back of the limb, but it again comes to the front, and may be found in the lower part of the outer side of the arm, by separating the origins of the supinator longus and extensor carpi radialis longior from the brachialis anticus, and dissecting in the interval between them.

Dissection.—In carrying out this somewhat extensive dissection, the main object of the dissector should be to keep the brachial artery as undisturbed as possible until he has satisfied himself as to its relations. He is therefore, in the first instance, advised to clean only those parts of the muscles which are in immediate relationship to the vessel and its branches. The divided brachial nerves, with the axillary artery and vein, should be arranged in proper order, and then tied to a small piece of wood about $1\frac{1}{2}$ inches long (*e.g.*, a piece of a penholder), held transversely. By means of a loop of string this can then be fastened to the coracoid process. By this device the dissection of the upper arm will be greatly facilitated. The dissection of the entire length of the brachial artery should be carried out at one and the same time, and its termination in the radial and ulnar arteries should be defined. ✎

Brachial Artery (*arteria brachialis*).—The brachial artery is the direct continuation of the axillary trunk into the upper arm. It therefore begins at the lower border of the teres major, and it proceeds downwards to a point a short distance below the bend of the elbow, where it ends opposite the neck of the radius by dividing into two terminal branches—the radial and the ulnar arteries. The course which it pursues is not a straight one: at first

it lies upon the inner side of the limb, but it gradually, as it descends, inclines outwards so as to lie finally in front of the arm.

This change of direction must be borne in mind when pressure is applied to the vessel, with the view of controlling the flow of blood within it. Thus, above, the pressure must be directed in an outward and backward direction, so that it may be caught between the fingers and the bone; whilst below, the pressure must be applied in a backward direction.

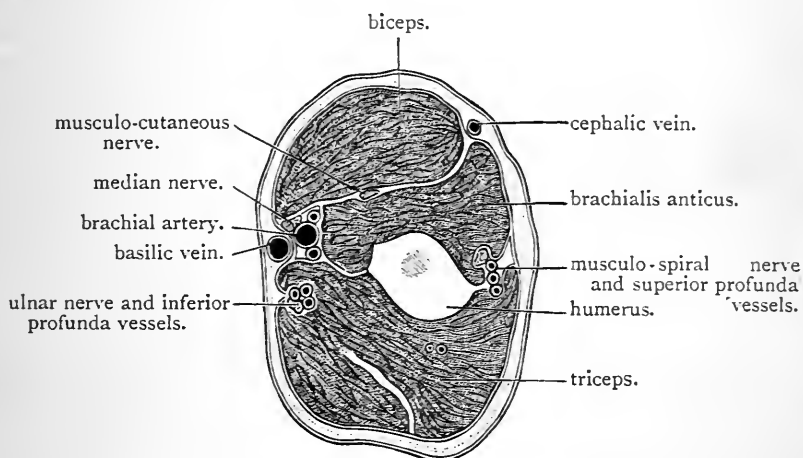


FIG. 22.—Transverse section through the right upper arm about its middle.

At this level it will be seen that the brachial artery and the median nerve lie in a deep furrow on the inner side of the limb bounded by the biceps, triceps, and brachialis anticus, reminding one somewhat of Hunter's canal in the lower limb.

Throughout its whole length, the brachial artery is superficial: in other words, in order to expose the vessel the skin and fascia alone would require to be removed. The inner margins of the coraco-brachialis and the biceps muscles, however, which lie along its outer side, overlap it to a considerable extent, and finally, in the anticubital fossa, it sinks deeply in the interval between the supinator longus on the outside, and the pronator radii teres on the inside. The extent to which the brachial artery is overlapped by the biceps may be seen in the accompanying

woodcut (Fig. 22). At the bend of the elbow it is crossed by the bicipital fascia, which, as previously stated, intervenes between it and the median-basilic vein. The basilic vein, in its lower part, is separated from the artery by the deep fascia. It does not lie immediately over it, but to its inner side (Figs. 21 and 22). Higher up, after the vein has pierced the fascia, it comes into closer relationship with the artery. Two venæ comites are closely applied to the brachial artery, and the numerous connecting branches which pass between these veins cross over and under the vessel, so as to make the relationship still more intimate.

Behind, the brachial artery is supported by a succession of structures, as we trace it from above downwards. First, it lies in front of the long head of the triceps, but here the musculo-spiral nerve and the superior profunda artery are interposed; next, it rests upon the inner head of the triceps; then upon the insertion of the coraco-brachialis; and lastly, for the remainder of its course, upon the brachialis anticus.

With the exception of the musculo-cutaneous, all the large nerves of the arm will be seen to lie, for a certain part of their course, in relation to the brachial artery. The *median* accompanies it closely throughout its whole length. At first it lies in front, and to the outer side of the vessel; towards the middle of the arm it crosses superficially to the vessel; from this onwards it is placed along its inner side. The *ulnar* and *internal cutaneous nerves* lie close to its inner side, as far as the insertion of the coraco-brachialis, and then they leave the artery. The former inclines backwards, and, piercing the internal intermuscular septum, enters the posterior compartment of the arm. The internal cutaneous nerve, on the other hand, inclines forwards, and becomes superficial by piercing the brachial aponeurosis. The *musculo-spiral*, for a very short distance, is placed behind the brachial artery, as it lies in front of the long head of the triceps, but soon it leaves the vessel by disappearing in the interval between the long and inner heads of the triceps.

Branches of the Brachial Artery.—A considerable number of branches spring from the brachial artery. Those which arise from its outer aspect are irregular in number, origin, and size. They are termed the external branches, and are distributed to the muscles and integument on the front of the arm. The series of internal branches which proceed from the inner and posterior aspect of the parent trunk are named as follows as we meet them from above downwards :—

- | | | |
|--|--|--|
| 1. Superior profunda.
2. Inferior profunda. | | 3. Nutrient.
4. Anastomotica magna. |
|--|--|--|

The *superior profunda* (arteria profunda brachii) is the largest of the branches which spring from the brachial trunk. It takes origin about an inch or so below the lower margin of the teres major, and associates itself with the musculo-spiral nerve, which it accompanies to the back of the arm. Consequently, only a short part of the vessel is seen in the present dissection. It soon disappears from view between the long and inner heads of the triceps.

The *inferior profunda* (arteria collateralis ulnaris superior) is a long slender artery, which can be recognised from the fact that it follows closely the course which is pursued by the ulnar nerve. Its origin is somewhat uncertain. As a general rule, it issues from the brachial artery opposite the insertion of the coraco-brachialis, but very frequently it will be seen to arise in common with the superior profunda. It pierces the internal intermuscular septum, with the ulnar nerve, and descends behind this aponeurotic partition to the interval between the olecranon and the internal condyle of the humerus.

The *nutrient artery* to the humerus (arteria nutritia humeri) may arise directly from the brachial trunk, or take origin from the inferior profunda. It should be sought for at the lower border of the coraco-brachialis, and the dissector should not be satisfied until he has traced it into the medullary foramen of the bone. When the nutrient artery is not seen in its usual position, it will probably be

found in the dissection of the back of the arm, taking origin from the superior profunda.

The *anastomotica magna* (arteria collateralis ulnaris inferior) arises about two inches above the bend of the elbow, and runs inwards upon the brachialis anticus. It soon divides into a small anterior and a larger posterior branch. The *anterior branch* is carried downwards in front of the internal condyle of the humerus in the interval between the brachialis anticus and the pronator radii teres. It anastomoses in this situation with the anterior ulnar recurrent artery. The *posterior branch* pierces the internal intermuscular septum, and will be seen later on in the posterior compartment of the arm.

The two Internal Cutaneous Nerves.—Very little more requires to be said about these nerves. Their origin within the axilla has already been noted, and they have been traced to their distribution from the points where they pierce the investing brachial aponeurosis. It only remains for the dissector to examine them in that part of their course in which they lie under cover of the brachial aponeurosis. It will be observed that they both lie along the inner side of the brachial artery. The *nerve of Wrisberg*, or *lesser internal cutaneous nerve*, gives off, as a rule, no branches in this situation, except one or more twigs of communication to the intercosto-humeral. The *internal cutaneous* gives off the branch which pierces the fascia to supply the skin in front of the biceps.

The Median and the Ulnar Nerves.—These large nerve-trunks do not furnish any branches in the upper arm. The *median* (nervus medianus) arises in the axilla by two heads from the outer and inner cords of the brachial plexus. It proceeds downwards upon the outer and superficial aspect of the axillary and brachial arteries, until it approaches the level of the insertion of the coraco-brachialis. Here it lies in front of the artery. Finally, it reaches the inner side of the vessel, and maintains this position for the rest of its course in the upper arm.

The *ulnar nerve* (nervus ulnaris) is the largest branch of

the inner cord of the brachial plexus. It descends upon the inner side of the axillary and brachial arteries, and at the insertion of the coraco-brachialis it encounters the inferior profunda artery. Accompanied by this vessel, it now leaves the brachial artery by passing backwards through the internal intermuscular septum, and it is continued downwards upon the posterior aspect of this aponeurotic partition, to the interval between the olecranon and internal condyle of the humerus.

Dissection.—The muscles should now be thoroughly cleaned, and the musculo-cutaneous nerve and its branches dissected out.

Musculo-cutaneous Nerve (*nervus musculocutaneus*). The musculo-cutaneous nerve arises from the outer cord of the brachial plexus, at the lower border of the pectoralis minor. Inclining outwards, it perforates the coraco-brachialis, and appears between the biceps and the brachialis anticus. It proceeds obliquely downwards between these muscles until it reaches the bend of the elbow, where it comes to the surface at the outer border of the tendon of the biceps. From this point onwards it has already been traced as a cutaneous nerve of the forearm (p. 63).

In the upper arm the musculo-cutaneous supplies branches to the three muscles in this region. The branch to the coraco-brachialis is given off before the parent trunk enters the substance of the muscle; the branches to the biceps and brachialis anticus issue from it, as it lies between them.

The Coraco-brachialis is an elongated muscle, which takes origin from the tip of the coracoid process in conjunction with the short head of the biceps. It proceeds downwards along the inner margin of the biceps, and obtains insertion into a linear ridge situated upon the inner aspect of the shaft of the humerus about its middle.

The Biceps (*musculus biceps brachii*) arises from the scapula by two distinct heads of origin. The *short* or *inner head* (*caput breve*) springs from the tip of the coracoid process in conjunction with the coraco-brachialis. The

long or *outer head* (caput longum) is a rounded tendon, which occupies the bicipital groove of the humerus. Its origin cannot be studied at this stage of the dissection, because it is placed within the capsule of the shoulder-joint. Suffice it for the present to say, that it arises from an impression on the scapula immediately above the glenoid fossa. Both heads swell out into elongated fleshy bellies, which are closely applied to each other, and afterwards unite in the lower third of the arm. Towards the bend of the elbow the fleshy fibres converge upon a stout, short tendon, which is inserted into the posterior part of the tuberosity of the radius. This insertion will be more fully examined at a later period, but it may be noticed in the meantime that the tendon is twisted so as to present its margins to the front and back of the limb, and further, that a synovial bursa is interposed between it and the anterior smooth part of the radial tuberosity.

The dissector has already taken notice of the *bicipital* or *semilunar fascia*, and has separated it artificially from the brachial aponeurosis above, and from the deep fascia of the forearm below. Observe now that it springs from the anterior margin of the tendon of the biceps, and that it likewise receives some muscular fibres from the short head of the muscle.

The Brachialis Anticus (musculus brachialis) arises from the entire width of the anterior surface of the lower half of the shaft of the humerus, from the internal intermuscular septum, and from a small part of the external intermuscular septum above the supinator longus. The origin from the bone is prolonged upwards in two slips which partially embrace the insertion of the deltoid. The fibres converge to be inserted into the base of the coronoid process of the ulna by a short, thick tendon. The muscle lies partly under cover of the biceps, but projects beyond it on either side. It is overlapped on its inner side by the pronator radii teres, and on the outer side by the supinator longus and extensor carpi radialis longior. Its deep surface is closely connected to the anterior ligament of the elbow-

joint. Its chief nerve of supply, from the musculo-cutaneous, has already been secured, but it also receives one or two small twigs from the musculo-spiral, which are given off under cover of the supinator longus.

Dissection.—Separate the supinator longus muscle from the brachialis anticus, and dissect out the musculo-spiral nerve, and the anterior terminal branch of the superior profunda artery, which lie deeply in the interval between them. Here also the anastomosis between the superior profunda and the radial recurrent arteries may be made out, in a well-injected subject; and the twigs which are given by the musculo-spiral nerve to the brachialis anticus, supinator longus, and extensor carpi radialis longior, looked for.

Triangular Space in front of the Elbow (antecubital fossa).—This is a slight hollow in front of the elbow-joint. It corresponds to the popliteal space of the lower limb, and within its area the brachial artery divides into its two terminal branches. In the first instance, let the dissector consider the structures which cover it. These have already been removed, and consist of skin, superficial fascia, and deep fascia. In connection with the latter is the semilunar fascia, whilst within the superficial fascia are the median-basilic and median-cephalic veins, the anterior division of the internal cutaneous nerve and the cutaneous part of the musculo-cutaneous nerve. These structures constitute the *coverings* of the space.

The space is triangular. Its *base* is directed upwards, and is usually regarded as being formed by a line drawn between the two condyles of the humerus. Its *inner boundary* is the pronator radii teres, and its *outer boundary* the supinator longus. The meeting of these two muscles below constitutes the *apex*. The boundaries should now be thoroughly cleaned, and then the *contents* of the space may be dissected.

Within the space, as we have already stated, there is the termination of the brachial artery, and the radial and ulnar branches into which it divides. To the outer side of the main vessel is placed the tendon of the biceps, and to its inner side the median nerve. A quantity of loose

fat is also present. The ulnar artery leaves the space by passing under cover of the pronator radii teres; the radial artery is continued downwards beyond the apex of the space, overlapped by the supinator longus. The median nerve disappears between the two heads of the pronator radii teres, and the tendon of the biceps inclines backwards

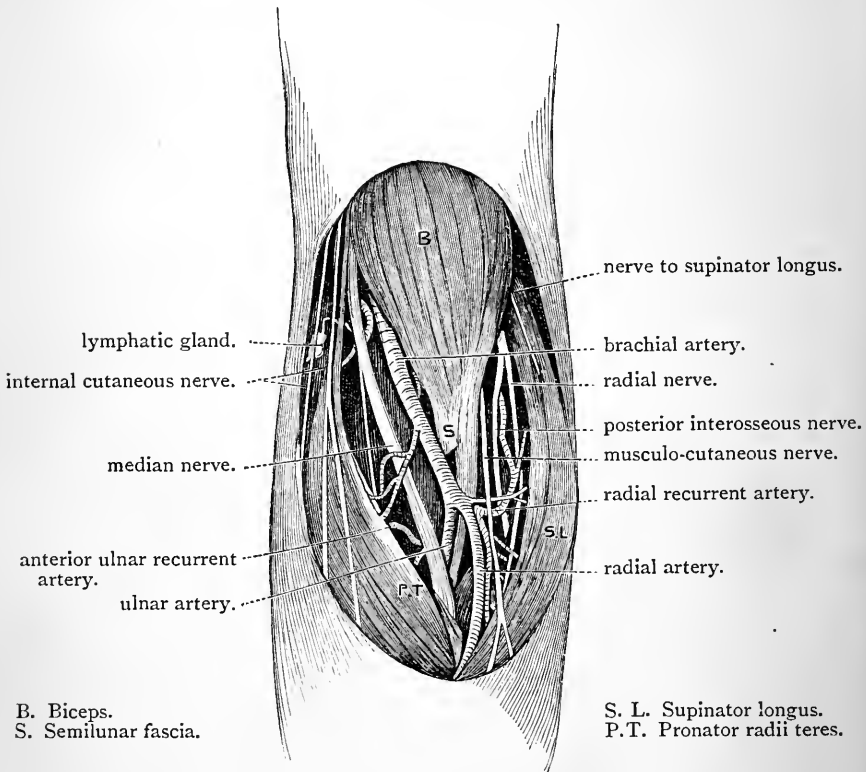


FIG. 23.—Dissection of the anticubital fossa.

between the two bones of the forearm, to reach its insertion into the radial tuberosity.

When the fatty tissue has been thoroughly removed the floor of the space will be revealed. This is formed by the brachialis anticus and the supinator brevis muscles. In this situation the brachialis anticus is closely applied

to the anterior aspect of the elbow-joint, whilst the supinator brevis is wrapped round the upper part of the radius.

Now divide the bicipital fascia, and separate the bounding muscles widely from each other. Other structures come into view, but they cannot, strictly speaking, be regarded as lying within the space proper. They are—(1) the musculo-spiral nerve, the anterior branch of the superior profunda artery, and the radial recurrent branch of the radial artery, lying deeply in the internal between the supinator longus and the brachialis anticus; (2) the anterior branch of the anastomotica magna, and the anterior ulnar recurrent branch of the ulnar artery, placed under cover of the pronator radii teres.

BACK OF THE ARM.

In this region the following are the structures which require to be studied:—

1. The triceps muscle.
2. The superior profunda artery, and the musculo-spiral nerve.
3. The inferior profunda artery, and the ulnar nerve.
4. The posterior branch of the anastomotic artery.
5. The subanconeus muscle.

Dissection.—The skin has already been removed from the back of the arm. The deep fascia should now be raised from the surface of the triceps muscle, and its three heads cleaned and isolated from each other. To place the muscle on the stretch, the inferior angle of the scapula should be raised as high as possible, and the forearm flexed at the elbow-joint. The musculo-spiral nerve, together with the superior profunda artery, must at the same time receive the attention of the dissector. They should be followed backwards between the heads of the triceps, and all their branches should be carefully preserved.

Triceps (musculus triceps brachii).—This muscle occupies the entire posterior osteo-fascial compartment of the upper arm. It arises by a *long* or *middle head* from the

scapula, and by two short heads, *outer* and *inner*, from the humerus. The fleshy fibres of these three heads join a common tendon, which is inserted into the top of the olecranon process of the ulna. The superficial part of the muscle is, for the most part, formed by the long scapular head and the outer humeral head of the muscle. The inner humeral head is deeply placed; only a very small portion of it appears superficially in the lower part of the arm on each side of the common tendon of insertion.

The *long* or *scapular head* (caput longum) of the triceps arises by a flattened tendon, from the rough triangular impression on the upper part of the axillary border and the lower aspect of the neck of the scapula. This tendon takes origin in the interval between the teres minor and subscapularis muscles. From the lower border of the tendon of the latissimus dorsi muscle an aponeurotic slip proceeds, which joins the long head of the triceps upon its inner aspect. This slip has been already alluded to as a remnant of the dorsi-epitrochlearis muscle of the lower animals.

The *two humeral heads* take origin from the posterior aspect of the humerus, and if it be borne in mind that no fibres arise from the musculo-spiral groove, and that this groove intervenes between the origins of these heads, their connections will be easily understood. The dissector should provide himself with a humerus, and, having first identified the musculo-spiral groove, proceed to map out the areas of attachment of the humeral heads of the triceps as they are exhibited in the dissected part.

The *outer head* (caput laterale) of the triceps arises from the outer and posterior aspect of the shaft of the humerus, above the level of the musculo-spiral groove. It takes origin, by short tendinous fibres, along a line which descends vertically from the insertion of the teres minor above to the upper border of the musculo-spiral groove below. **2** But it also derives fibres from a strong aponeurotic bridge or arch, which is thrown over the groove, so as to give protection to the superior profunda

artery and the musculo-spiral nerve. The strength and position of this arch can be tested by thrusting the handle of the knife downwards and outwards in the musculo-spiral groove, and along the course of the nerve and artery under the external head of the triceps. (3) By its lower end the arch is connected with the external intermuscular septum.

The *inner head* (*caput mediale*) of the triceps is placed below the musculo-spiral groove. It sends upwards, on the posterior aspect of the humerus, and along the inner margin of the groove, a narrow pointed fleshy slip, which obtains origin from the bone as high as the insertion of the teres major muscle. Below, it widens out and arises by short fibres from the entire breadth of the posterior surface of the humerus. It also springs from the posterior surface of the internal intermuscular septum, and from the lower part of the corresponding surface of the external intermuscular septum. The inner head of the triceps, therefore, has very much the same origin from the back of the bone that the brachialis anticus has from the front of the bone.

The dissector should now study the *common tendon of insertion* of the triceps. The long and the outer heads end in a broad, flat tendon, which is inserted into the back part of the upper surface of the olecranon process, and at the same time gives off, on the outer side, a strong expansion to the fascia of the forearm as it covers the anconeus muscle. The short fleshy fibres of the inner head are, for the most part, inserted into the deep surface of the common tendon, but a considerable number find direct attachment to the olecranon, whilst a few of the deepest fibres are inserted into the loose posterior part of the capsule of the elbow-joint. These latter fibres have been described as a separate muscle under the name of *subanconeus*.

Dissection.—In order that the musculo-spiral nerve and the superior profunda artery, may be fully exposed, the external head of the triceps must be divided. Thrust the handle of a knife along the musculo-

spiral groove, and under the muscle. This will give the direction in which the outer head of the triceps should be severed. Beyond cleaning the nerve and its branches, and the superior profunda artery, as they lie in the groove, no further dissection is necessary.

The Musculo-spiral Nerve (*nervus radialis*) is the direct continuation of the posterior cord of the brachial plexus after it has furnished in the axilla the three subscapular and the circumflex nerves. In the first instance, the musculo-spiral proceeds downwards behind the lower part of the axillary artery and the upper part of the brachial artery. It soon leaves the front of the arm, however, and, inclining backwards with the superior profunda artery, enters the interval between the long and the inner heads of the triceps, and reaches the musculo-spiral groove. In this it is conducted round the back of the shaft of the humerus, under cover of the outer head of the triceps, and on the outer side of the limb it pierces the external intermuscular septum and appears in the anterior compartment of the arm. Here it has already been exposed. It lies deeply in the interval between the brachialis anticus on the inside, and the supinator longus and extensor carpi radialis longior on the outside. It ends in front of the external condyle of the humerus by dividing into two terminal branches, viz., the radial and the posterior interosseous. The musculo-spiral nerve presents therefore very different relations as it is traced from its origin to its termination: (1) between the subscapularis, latissimus dorsi, teres major, and long head of the triceps which support it behind, and the axillary and brachial arteries which are placed in front of it; (2) between the long and inner heads of the triceps; (3) in the musculo-spiral groove between the bone and the outer head of the triceps; (4) in the interval between the brachialis anticus on the inside, and the supinator longus and extensor carpi radialis longior on the outside.

The branches which proceed from the musculo-spiral nerve are partly *muscular* and partly *cutaneous*.

The *cutaneous branches* are three in number, and have already been traced. They are—(1) the *internal cutaneous*,

which, as a rule, arises within the axilla, in common with the branch which supplies the long or scapular head of the triceps; (2) the *upper external cutaneous*, and (3) the *lower external cutaneous*, which come off on the outer side of the arm close to the outer margin of the external intermuscular septum (p. 61).

The *muscular branches* go to the three heads of the triceps, to the anconeus, to the brachialis anticus, to the supinator longus, and to the extensor carpi radialis longior. The branches to the three last muscles spring from the main trunk after it has pierced the external intermuscular septum.

The branch to the inner head of the triceps is sometimes termed the ulnar collateral nerve. It is a long slender filament, which runs downwards to supply the lower fibres of the inner head of the triceps, and it receives this name from the close manner in which it is applied to the ulnar nerve in the lower part of its course.

The *branch to the anconeus* is also a long slender twig, which enters the substance of the internal head of the triceps, and appears at first sight to terminate there, but, if traced downwards, it will be found to end in the anconeus.

Superior Profunda Artery (*arteria profunda brachii*).—This artery has been already observed to take origin from the brachial trunk, immediately below the lower margin of the *teres major* muscle. It accompanies the musculo-spiral nerve, and its relations to the three heads of the triceps and the musculo-spiral groove of the humerus are exactly the same as those of the nerve. When it reaches the external intermuscular septum, at the outer side of the arm, it ends by dividing into two terminal branches—an anterior and a posterior. The *anterior and smaller branch* accompanies the musculo-spiral nerve through the septum, and follows it downwards to the anterior aspect of the external condyle of the humerus, where it anastomoses with the radial recurrent

artery. The *posterior larger branch* proceeds downwards on the posterior surface of the external intermuscular septum, and anastomoses on the back of the external condyle of the humerus with the posterior interosseous recurrent artery.

The branches which proceed from the superior profunda artery are chiefly distributed to the three heads of the triceps muscle. One twig runs upwards between the long and outer heads of the muscle, and anastomoses with the posterior circumflex artery. In this way, a link is established between the axillary and brachial systems of branches.

Dissection.—The ulnar nerve, with the inferior profunda artery, and the slender ulnar collateral nerve, can now be advantageously followed, as they proceed downwards upon the posterior aspect of the internal intermuscular septum. They are covered by a thin layer of fleshy fibres belonging to the internal head of the triceps. The posterior branch of the *anastomotica magna*, after it has pierced the internal septum, should also be dissected out. As a rule, a transverse branch passes between this vessel and the posterior terminal part of the superior profunda. It lies upon the back of the humerus, immediately above the elbow-joint, and can be exposed by dividing the triceps muscle a short distance above the olecranon. At the same time the fleshy fibres of the internal head of the triceps, which are inserted into the posterior ligament of the joint, and constitute the *subanconeus muscle*, should be examined. Lastly, raise the lower piece of the triceps from the elbow-joint, and look for a small bursa between the deep surface of the triceps tendon and the upper aspect of the olecranon.

SHOULDER-JOINT (ARTICULATIO HUMERI).

Before proceeding to the dissection of the forearm it is advisable to study the shoulder-joint, because if this is deferred too long the ligaments are apt to become dry.

In no joint in the body is the movement so free, and so varied in its character, as in the shoulder-joint. This is rendered necessary by the many functions which are performed by the upper limb.

Freedom of motion is provided for in two ways—(1) by the large size of the head of the humerus, in comparison with the small dimensions and shallow character of the glenoid fossa—the socket in which it moves; (2) by the great laxity of the ligamentous structures which connect the humerus with the scapula. These

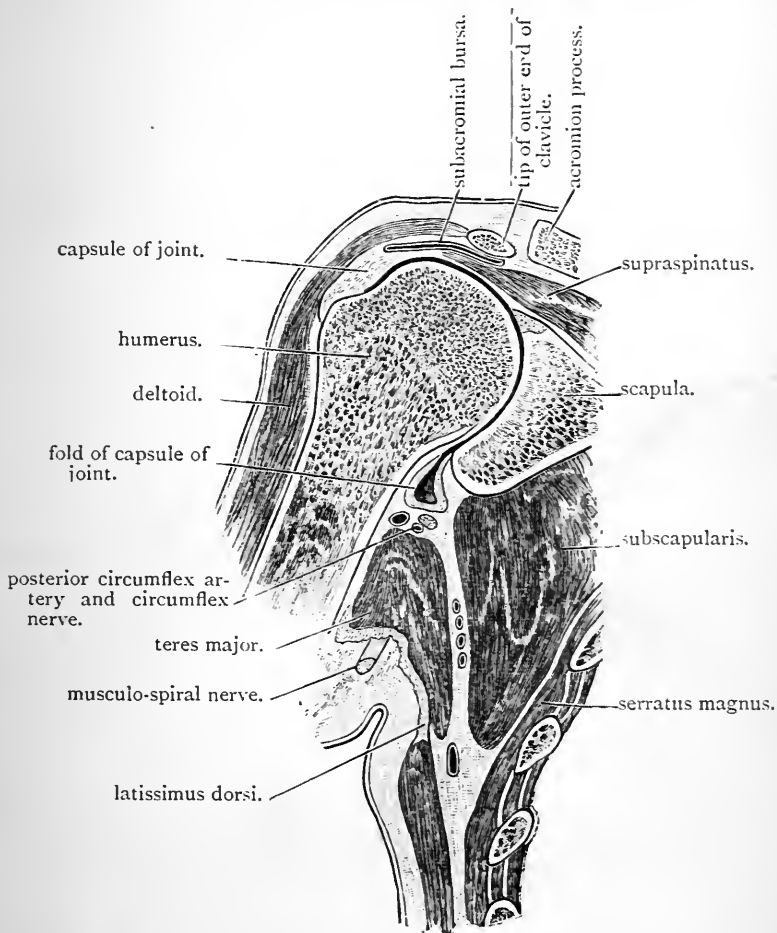


FIG. 24.—Coronal or vertical transverse section through the left shoulder-joint. (Viewed from behind.)

provisions for allowing an extensive range of movement at this articulation might, at first sight, lead one to doubt the security of the joint. Its strength certainly does not lie in the adaptation of the bony surfaces to one another, nor in the power of its ligaments.

It lies—(1) in the intimate manner in which the scapular muscles are arranged around it; (2) in the overhanging coraco-acromial arch which forms, as it were, a secondary socket for the head of the humerus, and effectually prevents any displacement in an upward direction; and (3) in atmospheric pressure, which exercises a powerful influence in keeping the opposed surfaces in contact with each other.

From all points of view, except over a small area below, the loose, ligamentous capsule which envelops the shoulder-joint is supported by muscles, the tendons of which are more or less intimately connected with it. *Above*, it is covered by the supraspinatus; *behind*, the infraspinatus and teres minor are applied to it; *in front* is the subscapularis. *Below*, the capsule is to a certain extent unsupported by muscles, and here it is prolonged downwards, in the form of a fold, in the ordinary easy dependent position of the limb (Fig. 24). When, however, the arm is abducted, this fold is obliterated, and the head of the bone rests upon the inferior part of the capsule, which now receives partial support from two muscles which are stretched under it, viz., the long head of the triceps and the teres major. Still, this must be regarded as the weakest part of the joint, and consequently dislocation of the head of the humerus, downwards into the axilla through the inferior part of the capsule, is an occurrence of considerable frequency.

Dissection.—Detach the axillary vessels and brachial nerves from the coracoid process to which they have been tied, and throw them downwards. Then proceed to remove the muscles. Divide the conjoined origin of the short head of the biceps and the coracobrachialis close to the coracoid process, the teres major about its middle, and the long head of the triceps about an inch or two below its origin, and turn them aside. Next deal with the muscles more immediately in relation to the joint, viz., the supraspinatus, the infraspinatus, the teres minor, and the subscapularis. These must be removed with great care and deliberation, because their tendons are closely connected with the subjacent ligamentous capsule. They are not incorporated with the capsule, however, although at first sight they appear to be so, and thus they can be dissected from it. In the case of the subscapularis a protrusion of the synovial membrane, forming a bursa, will be found near its upper border, close to the root of the coracoid process. The capsule of the shoulder-joint may now be cleaned, and its attachments defined.

The Ligaments in connection with the shoulder-joint are:—

- | | | |
|---------------------------|--|-----------------------|
| 1. The capsular ligament. | | 3. The gleno-humeral. |
| 2. The coraco-humeral. | | 4. The glenoid. |

The Capsular Ligament (*capsula articularis*) is a dense and strong ligamentous structure, which envelops the shoulder-joint on all sides. It is attached to the scapula around the glenoid cavity, but only above is it directly fixed to the bone. Elsewhere it springs from the fibrous ring or glenoid ligament, which serves to deepen the articular cavity; indeed, in its lower part, it appears to be nearly continuous with the border of the glenoid ligament. Externally it is fixed to the outer part of the anatomical neck of the humerus. The width of the capsule is not uniform throughout. It will be noticed to expand as it passes over the enclosed head of the humerus, and to contract as it reaches its scapular and humeral attachments. The great laxity of the capsule of the shoulder-joint will now be apparent. When the muscles are removed, and air is admitted into the joint, the bony surfaces fall away from each other—the head of the humerus sinking downwards, when the part is held by the scapula, to the extent of an inch.

The capsule of the shoulder-joint is not complete upon all aspects. Its continuity is interrupted by two, and sometimes three, apertures. The largest of these is an opening of some size, which is placed upon its inner or anterior aspect, near the root of the coracoid process. Through this aperture an extensive protrusion of the synovial membrane takes place in the form of a synovial bursa, which, from its position under the upper part of the subscapularis muscle, receives the name of the *bursa subscapularis*. It is important to note the position and character of this opening, seeing that in some cases the head of the bone may be driven through it in dislocation of the joint. The *second aperture* is smaller and more distinctly defined. It is placed between the two tuberosities of the humerus, at the upper part of the bicipital groove, and it is through this that the long tendinous head of the biceps gains admission to the interior of the capsule. The synovial membrane also protrudes from this opening, and lines the bicipital groove as low as the insertion of the pectoralis

major. It is not often that the *third opening* is seen. It is situated, when present, on the outer or posterior aspect of the capsule, and allows a pocket of synovial membrane to bulge out in the form of a bursa under the infraspinatus muscle.

At certain points the capsule of the shoulder-joint is specially thickened by the addition of fibres, which pass from the scapula to the humerus. Two of these thickened portions receive the names of the *coraco-humeral* and the *gleno-humeral* ligaments. A third is placed on the inferior aspect of the capsule, where it is not supported by muscles, viz., between the long head of the triceps and the subscapularis muscles. It is against this thickened portion of the capsule that the head of the humerus rests when the arm is abducted from the side, and it is sometimes spoken of as the *inferior accessory ligament, or inferior gleno-humeral ligament.*

The Coraco-humeral Ligament (ligamentum coraco-humerale) is placed upon the upper aspect of the joint. It is a broad band of great strength, which is more or less completely incorporated with the capsule. Above, it is fixed to the root and outer border of the coracoid process of the scapula, and it passes from this obliquely downwards and outwards, to gain attachment to the two tuberosities of the humerus. It forms a strong arch over the upper part of the bicipital groove, under which the tendon of the biceps passes.

The Gleno-humeral Ligament can only be seen when the joint is opened. The dissector should therefore, at this stage, remove the posterior part of the capsule, and, drawing the bones well apart from each other, look forwards into the cavity. The tendon of the biceps will be observed arching over the head of the humerus, to reach its insertion on the upper aspect of the glenoid cavity. Immediately internal to this, and parallel to it, will be noticed a ridge on the inner aspect of the capsule projecting into the joint. This band is the gleno-humeral ligament (of Mr. Flood). It is inserted into a faintly-marked pit on the anatomical

neck of the humerus, close to the upper end of the bicipital groove.

Dissection.—Complete the division of the capsular ligament, and drawing the tendon of the biceps through the intertubercular aperture in the capsule, separate the two bones from each other.

Glenoid Ligament (labrum glenoidale).—The glenoid ligament is the dense fibro-cartilaginous band which surrounds the margin of the glenoid cavity of the scapula, and is attached to its rim. It deepens, and at the same time serves to extend, the articular socket of the scapula. The intimate connection which it presents with the capsule of the joint can now be studied. Two tendons are also closely associated with it, viz., the long head of the triceps below, and the long head of the biceps above.

The Long Head of the Biceps is an important factor in the construction of the shoulder-joint. Entering the capsule through the opening between the two tuberosities of the humerus, it is prolonged over the head of the bone to the top of the glenoid cavity. Its insertion at this point should now be examined. It will be seen to divide into three portions, viz., a large intermediate part, which obtains direct attachment to the scapula, and two smaller lateral parts, which diverge from each other and blend with the glenoid ligament. The long head of the biceps, by its position within the capsule, and in the deep groove between the tuberosities of the humerus, serves to keep the head of the bone in place, and to steady it in the various movements at the shoulder-joint.

Synovial Membrane.—The synovial membrane lines the interior of the capsular ligament, and is reflected from it upon the anatomical neck of the humerus as far as the articular margin of the head of the bone. The bursal protrusion of the synovial membrane (*bursa subscapularis*) under the tendon of the subscapularis muscle has already been noticed. The tendon of the biceps, as it traverses the joint, is enveloped in a tubular sheath of the membrane,

which bulges out through the opening of the capsule in the form of a bursa, which lines the bicipital groove, and receives the name of *bursa intertubercularis*.

The Articular Surfaces.—The smooth, glistening articular cartilage, which coats the head of the humerus, is thickest in the centre, and thins as it passes towards the edges. In the case of the glenoid cavity the reverse of this will be noticed. The cartilaginous coating is thinnest in the centre, and becomes thicker as it is traced towards the circumference.

Movements at the Shoulder-joint.—The shoulder is a ball and socket joint, and consequently movement in every direction is permitted, viz.—(1) *flexion*, or forward movement; (2) *extension*, or backward movement (checked in its extent by the coraco-humeral ligament); (3) *abduction*, or outward movement (checked by the coraco-acromial arch); (4) *adduction*, or inward movement (limited by the coraco-humeral ligament). In addition to these different forms of angular movement, *rotation* to the extent of a quarter of a circle and *circumduction* are permitted.

The **muscles** chiefly concerned in producing these movements are—*flexion*—the pectoralis major and the anterior part of the deltoid; *extension*—latissimus dorsi, posterior part of the deltoid, and the teres major; *abduction*—the deltoid and supraspinatus; *adduction*—pectoralis major, coraco-brachialis, teres major, and latissimus dorsi; *rotation inwards*—subscapularis, pectoralis major, latissimus dorsi, teres major; *rotation outwards*—supraspinatus, infraspinatus, and teres minor; *circumduction* is produced by the action of different combinations of these muscles.

FOREARM AND HAND.

Dissection.—The skin has already been removed from the front and back of the forearm. It should now be raised from the dorsum of the hand by making incisions along the radial and ulnar borders. This is done in order that the superficial structures in this region may be examined in connection with those of the forearm.

Superficial Veins.—On the dorsum of the hand a plexus of superficial veins will be seen. In defining this, care must be taken of the fine cutaneous twigs from the radial nerve and the dorsal branch of the ulnar nerve. From the

outer part of the venous plexus the large radial vein takes origin, whilst from its inner part springs the posterior ulnar vein. Both of these vessels have already been traced along the forearm to their terminations. While still upon the dorsum of the hand each communicates with the deep veins in the palm of the hand.

Cutaneous Nerves.—Several cutaneous nerves have already been traced to the integument of the forearm, viz., the anterior and posterior branches of the internal cutaneous nerve to the inner aspect, and the cutaneous part of the musculo-cutaneous and lower external cutaneous branch of the musculo-spiral upon the outer aspect of the limb. Some additional twigs make their appearance by piercing the fascia in the lower third of the forearm (Figs. 17 and 18).

- | | | |
|--|---|-----------------------|
| <ol style="list-style-type: none"> 1. The palmar cutaneous branch of the
— ulnar nerve, 2. The palmar cutaneous branch of the
median nerve, 3. The palmar cutaneous branch of the
radial nerve, | } | on the front aspect. |
| <ol style="list-style-type: none"> 1. The dorsal branch of the ulnar
nerve, 2. The radial nerve, | } | on the dorsal aspect. |

The Palmar Cutaneous Branches are small twigs which supply the skin of the palm. The *twig from the ulnar nerve* takes origin about the middle of the forearm, but it does not at once pierce the deep fascia. It proceeds downwards on the ulnar artery, and becomes superficial immediately above the annular ligament, and close to the outer side of the insertion of the flexor carpi ulnaris tendon into the pisiform bone. It is here, therefore, that it must be sought for (Fig. 17, p. 62).

The *palmar cutaneous branch of the median nerve* appears through the deep fascia in the interval between the tendons of the flexor carpi radialis and the palmaris longus muscles, immediately above the wrist. It is continued downwards into the palm (Fig. 17, p. 62).

The *palmar branch of the radial nerve* runs close to the outer border of the lower part of the forearm. It does not spring from the trunk of the radial nerve, but from that branch of it which goes to the outer margin of the thumb. It is joined by a twig from the musculo-cutaneous nerve, and proceeds downwards in front of the tendon of the extensor ossis metacarpi pollicis, to end in the skin covering the ball of the thumb (Fig. 17, p. 62).

Dissection.—In tracing the nerves which appear on the back of the limb, it will be necessary to remove the skin from the dorsal aspect of the thumb and fingers. The great flap of skin which is still attached at the roots of the fingers may be detached, and an incision can then be made along the middle of the dorsal aspect of each digit. The skin should be carefully raised from each finger in two flaps and thrown outwards and inwards.

Dorsal Cutaneous Branches.—The *dorsal branch of the ulnar nerve* winds round the inner margin of the wrist to reach the dorsum of the hand. It will be found immediately below the prominence formed by the lower end of the ulna, and it at once divides into three main terminal branches. Of these, *the innermost* runs along the ulnar margin of the dorsum of the hand, and is continued onwards along the inner margin of the little finger. The *second branch* proceeds towards the cleft between the little finger and the ring finger, and divides into two twigs which supply the contiguous sides of these digits. The *third branch* joins a twig from the radial, and the nerve thus formed runs towards the interval between the ring finger and the middle finger, and divides to supply their adjacent margins. Each of these three main branches give several minute filaments to the integument on the dorsum of the hand (Fig. 18, p. 64).

The *radial nerve* will be found winding round the outer margin of the forearm, about two inches above the extremity of the styloid process of the radius. It at once gives off a long twig which proceeds along the radial margin of the hand and thumb. A little further on the radial nerve breaks up into four terminal branches, which are distributed

as follows: the *first* supplies the ulnar side of the thumb; the *second* goes to the radial side of the index finger; the *third* divides to supply the adjacent sides of the index and middle fingers; whilst the *fourth* joins with a twig from the dorsal branch of the ulnar (as already described) to supply the contiguous margins of the middle and ring fingers.

It should be noted that, except in the cases of the thumb and little fingers, the dorsal collateral nerves do not reach the extremities of the digits. The skin on the back of the lower parts of the digits is supplied by twigs, which proceed backwards from the palmar collateral nerves. As already stated, it is from the branch of the radial, which goes to the outer side of the thumb, that the *radial palmar cutaneous nerve* arises.

Numerous fine filaments are given to the skin on the dorsum of the hand, and a certain amount of crossing of the adjacent ulnar and radial twigs takes place in this locality; in other words, twigs from the one nerve invade the territory which is occupied by the other nerve.

The Deep Fascia, which envelops the forearm, should now be cleaned by removing the subcutaneous adipose tissue. It is an aponeurosis of great strength and density. More particularly is this the case on the posterior aspect of the limb, and also in the lower third of the forearm, where the fleshy bellies of the subjacent muscles give place to the tendons. In its upper part it receives an accession of fibres from the tendon of the biceps in the form of the bicipital or semilunar fascia. Some fibres are also given to it by the tendon of the triceps. Near the elbow it serves as a surface of origin for the numerous muscles which spring from the condyles of the humerus, and from its deep aspect dense septa pass between the fleshy bellies. These partitions are indicated on the surface by a series of white lines. At the wrist it becomes continuous in front with the *anterior annular ligament*, whilst behind it forms an obliquely placed, thickened band, the *posterior annular ligament*. On the dorsum of the hand the deep fascia is very thin.

FRONT AND INNER BORDER OF THE FOREARM.

In this dissection the following structures will be brought under the notice of the student:—

1. The radial and ulnar arteries and their branches.
2. The median and ulnar nerves and their branches.
3. The posterior interosseous and the radial nerves.
4. The group of pronator and flexor muscles.

Dissection.—With the exception of the palmar cutaneous nerves, the superficial veins and nerves on the front of the forearm may now be turned aside. The deep fascia should also be removed, and on dissecting it inwards round the ulnar border of the forearm it will be found to be firmly attached to the posterior border of the ulna. Near the elbow, as already stated, it gives origin by its deep surface to the group of muscles which spring from the internal condyle of the humerus. Where this is the case, it should be left *in situ*. Attempts to dissect it off will only result in laceration of the surface of the subjacent fleshy bellies. The radial artery should be followed out before the muscles are much disturbed, and at the same time the various muscles which lie upon the anterior surface of the radius, and upon which the vessel rests, should be cleaned.

The Radial Artery (*arteria radialis*) is the smaller of the two terminal branches of the brachial artery, but the direction which it takes gives it the appearance of being the continuation of the parent trunk into the forearm. It takes origin in the anticubital fossa opposite the neck of the radius, and it proceeds downwards along the outer side of the front of the limb until it reaches the lower end of the bone. Here it turns round the outer aspect of the wrist and leaves the present dissection. At first it lies between the pronator radii teres and the supinator longus, and is overlapped to some extent on the outer side by the fleshy belly of the latter muscle (Fig. 25). Lower down it is placed between the supinator longus on the outside and the flexor carpi radialis upon the inner side, and this position it maintains as far as the wrist. Where these muscles are fleshy the artery lies at some depth from the surface; but when the tendons make their appearance it assumes a superficial position, and is merely covered by

the integument and fasciæ. Throughout its whole length it is closely accompanied by the *venæ comites*, and the radial nerve lies along its outer side in the middle third of the forearm. Above this, the nerve is separated from the vessel by a slight interval, whilst below, the nerve leaves the artery by turning round the outer margin of the forearm under cover of the supinator longus.

Posteriorly the radial artery is supported by the muscles which clothe and find attachment to the front of the radius. At its origin it rests upon the tendon of the *biceps*; next it lies in front of the *supinator brevis*, with some adipose tissue intervening; from this downwards it is in contact with the *pronator radii teres*, the thin radial head of the flexor sublimis, the *flexor longus pollicis*, the *pronator quadratus*, and lastly, the lower end of the radius.

The radial artery is usually selected for the determination of the *pulse*. By placing the tips of the fingers upon the lower part of the forearm, in the interval between the tendons of the *supinator longus* and *flexor carpi radialis*, the pulsations of the vessel in the living person can readily be felt.

Branches of the Radial Artery.—In the forearm the radial artery gives off the following branches, viz. :—

1. The radial recurrent.
2. The superficialis volæ.
3. The anterior radial carpal.
4. Muscular.

The *muscular branches* (*rami musculares*) are very numerous, and proceed from the radial artery at irregular points throughout its whole course in the forearm.

The *radial recurrent artery* (*arteria recurrens radialis*) is a branch of some size. It takes origin close to the commencement of the radial artery, and in the first instance runs outwards between the *supinator longus* and the *supinator brevis*. Here it comes into relation with branches coming from the musculo-spiral nerve, and gives off several twigs for the supply of the muscles arising from the external condyle of the humerus. Somewhat reduced

in size, it now turns upwards in the interval between the supinator longus and brachialis anticus, and ends in front of the external condyle of the humerus by anastomosing with the anterior terminal branch of the superior profunda artery.

The *superficialis volæ artery* (ramus volaris superficialis) is a small, variable branch, which arises a short distance above the wrist, and runs downwards to end in the muscles of the ball of the thumb. Sometimes, however, it attains a larger size and a special importance, from its being continued into the palm to complete the superficial palmar arch on the outer side.

The *anterior radial-carpal* (ramus carpeus volaris) is a minute twig which springs from the radial at the lower border of the pronator quadratus muscle. It runs inwards under cover of the flexor tendons, and joins the corresponding branch of the ulnar artery to form the *anterior carpal arch.*

Radial and Posterior Interosseous Nerves.—The musculo-spiral nerve has already been observed to end in front of the elbow, under cover of the supinator longus muscle, in its two terminal branches, the radial and the posterior interosseous. These nerves may now be studied in so far as they lie on the front of the forearm. The *posterior interosseous nerve* (nervus interosseus dorsalis) soon disappears from view by passing backwards on the outer side of the radius through the fibres of the supinator brevis muscle.

The *radial nerve* (nervus cutaneus antibrachii dorsalis) proceeds downwards under cover of the fleshy belly of the supinator longus. In the middle third of the forearm it lies along the outer side of the radial artery, and then leaves it by winding round the outer margin of the limb, under cover of the tendon of the supinator longus. It has been traced in its further course (p. 92). The radial is a purely cutaneous nerve, and gives off no branches until it gains the dorsal aspect of the lower end of the forearm.

Muscles.—The muscles on the front and inner border of

the forearm are arranged in a superficial and a deep group. They comprise the flexors of the wrist and fingers, and also the pronators. In the *superficial group* we find the pronator radii teres, the flexor carpi radialis, the palmaris longus, the flexor sublimis digitorum, and the flexor carpi ulnaris, in that order from without inwards. The fleshy belly of the flexor sublimis only partially comes to the surface; the chief bulk of it is placed upon a deeper plane than the others.

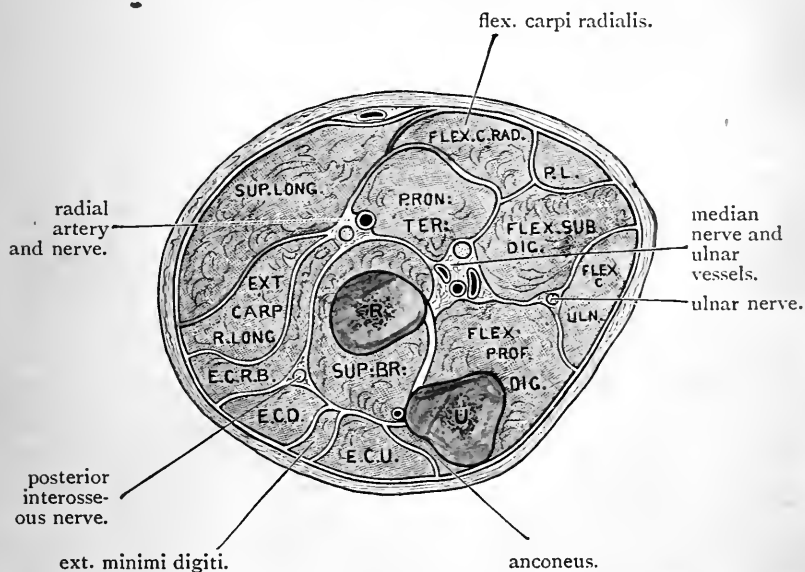


FIG. 25.—Transverse section through the upper third of the left forearm.

- P. L. Palmaris longus.
 E. C. D. Ext. communis digitorum.
 E. C. U. Ext. carpi ulnaris.
 E. C. R. B. Ext. carpi radialis brevior.

The *deep group* is composed of three muscles, placed in contact with the bones and interosseous membrane of the forearm, viz., the flexor profundus digitorum in relation to the ulna, the flexor longus pollicis in relation to the radius, and the pronator quadratus closely applied to the lower ends of both bones.

Dissection.—The superficial group of muscles should now be dissected. The supinator longus, which lies along the outer side of the

forearm, may be cleaned at the same time. In the lower part of the forearm the dissector will observe that the flexor tendons are enveloped by a loose bursal sac as they pass into the palm, under cover of the anterior annular ligament. A good view of this may be obtained by pulling the tendons upwards. If possible, the sac should be retained uninjured, in order that its full extent may be studied when the palm of the hand is opened up. At this stage it is also well to define the anterior annular ligament which bridges across the front of the carpus. The tendon of the palmaris longus passes in front of it, whilst close to the pisiform bone the ulnar artery and nerve are placed upon its anterior surface, and give the dissector the key to its depth. This vessel, with its accompanying nerve, are bound down to the ligament by a slip of fascia, which passes over them from the pisiform bone, and which the student is very apt to mistake for the annular ligament itself. This should not be disturbed in the meantime. ✕

Common Origin of the Superficial Muscles.—The five muscles which constitute the superficial group are very closely associated with each other at the elbow—indeed they may be said to arise by a common origin from the front of the internal condyle of the humerus. In addition to this they all derive fibres from the investing deep fascia of the limb near the elbow, and the strong fibrous septa which pass into the forearm from the deep surface of this in the intervals between them. The pronator radii teres, the flexor sublimis, and the flexor carpi ulnaris, have likewise additional heads of origin.

The Pronator Radii Teres (musculus pronator teres) crosses obliquely the upper half of the front of the forearm. It arises by two heads, viz., a humeral and a coronoid. The *humeral head* constitutes the chief bulk of the muscle, and it springs from the upper part of the internal condyle of the humerus, and also slightly by fleshy fibres from the lower part of the internal supracondyloid ridge. The fascia covering it and the fibrous septum on its inner side also contribute fibres. The *coronoid head* is placed deeply, and it may be recognised from the fact that it intervenes between the median nerve and the ulnar artery. To bring it into view the superficial humeral head must be drawn well inwards. The coronoid head is very variable in size. As a rule, it is a small fleshy slip, but sometimes it is

chiefly fibrous. It arises from the inner aspect of the coronoid process of the ulna, and soon joins the deep surface of the humeral head. The muscle thus formed is carried obliquely downwards and outwards, and ends in a tendon which gains insertion into a rough impression upon the middle of the outer surface of the radius. This attachment is placed on the summit of the chief curve of the radius, an arrangement which enables the muscle to exercise its pronating action at a great advantage. Close to its insertion the pronator radii teres is crossed by the radial artery and is covered by the supinator longus muscle.

The Flexor Carpi Radialis arises from the common tendon, from the fasciæ of the forearm and the fibrous septa which intervene between it and the adjacent muscles. Its fleshy belly gives place a short distance below the middle of the forearm to a long flattened tendon, which at the wrist traverses the groove on the front of the trapezium in a special compartment of the anterior annular ligament. It is inserted into the palmar aspect of the base of the metacarpal bone of the index, and slightly also into the base of the metacarpal bone of the middle finger. Its relations to the annular ligament, and also its attachment to the metacarpus, will be exposed and studied at a later stage of the dissection.

The Palmaris Longus is a long slender muscle, which is not always present. It springs from the common origin, the aponeurotic investment of the forearm and the fibrous septum on either side of it. Its tendon pierces the deep fascia immediately above the wrist, and then proceeds downwards in front of the annular ligament to join the strong palmar fascia of the hand. Very frequently it gives a slip to the abductor pollicis muscle.

The Flexor Carpi Ulnaris arises by two heads. One of these is incorporated with the common origin from the humeral condyle; the other springs from the inner aspect of the olecranon process of the ulna, and likewise by an aponeurotic attachment from the posterior border of the same bone in its upper two thirds. Fibres are also derived

from the investing fascia and the intermuscular septum on its outer side. The two heads of origin of the flexor carpi ulnaris bridge across the interval between the internal condyle of the humerus and the olecranon process, and between them the ulnar nerve is prolonged downwards into the forearm. The tendon appears upon the anterior border of the muscle, and is inserted into the pisiform bone.

The Flexor Sublimis Digitorum receives this name from, its being placed upon the superficial aspect of the flexor profundus. For the most part it lies deeper than the other superficial muscles (Fig. 25). It is a powerful muscle which arises from the internal condyle of the humerus by the common tendon, but it also takes origin from the internal lateral ligament of the elbow-joint, from the inner margin of the coronoid process of the ulna, the front of the radius, and the fascial intermuscular septa in relation to it. The radial head of origin is a thin fleshy stratum which is attached to the oblique line of the radius and the anterior border of that bone for a variable distance below the insertion of the pronator radii teres. Four tendons issue from the fleshy mass. These enter the palm by passing under cover of the anterior annular ligament, and go to the four inner digits. Their insertions will be seen later on, but in the meantime note that at the wrist and for a short distance above it they are enveloped by the bursal sac previously mentioned, and also that as they pass behind the annular ligament they lie in pairs—the tendons to the ring and middle fingers being placed in front of those for the index and little fingers.

Dissection.—The ulnar artery and at the same time the ulnar and median nerves should be followed in their course through the forearm. The artery in the upper part of its course lies very deeply, but its relations can be fully studied and its branches traced by simply slitting up the intermuscular septum between the flexor sublimis digitorum and the flexor carpi ulnaris.

The Ulnar Artery (arteria ulnaris) is the larger of the two terminal branches of the brachial trunk, and it takes

origin in the anticubital fossa opposite the neck of the radius. At first it inclines obliquely downwards and inwards, and having gained the front of the ulnar side of the forearm, it proceeds vertically downwards to the wrist. Here it enters the palm by passing in front of the anterior annular ligament. In the upper oblique portion of its course the vessel is deeply placed, and is crossed by both heads of the pronator radii teres, the flexor carpi radialis, the palmaris longus, and the flexor sublimis digitorum. In its lower vertical part it is overlapped on the inner side by the flexor carpi ulnaris, but a short distance above the wrist it becomes superficial, and lies in the interval between the tendon of the flexor carpi ulnaris on the inside and the tendons of the flexor sublimis on the outside. On the annular ligament it is placed close to the outer side of the pisiform bone, and is covered by a strong slip of fascia, which passes from that bone to the front of the ligament. Throughout its entire course it is accompanied by two *venæ comites*. It likewise presents relationships with the median and ulnar nerves. The *median nerve*, which lies upon its inner side at its origin, soon crosses it, but as it does so it is separated from the artery by the deep head of the pronator radii teres. The *ulnar nerve* in the upper third of the forearm is separated from the vessel by a wide interval, but in the lower two thirds of the forearm it closely accompanies the artery, and lies on its inner side.

In the anticubital fossa the ulnar artery rests upon the brachialis anticus; beyond this it is in contact behind with the flexor profundus digitorum; whilst at the wrist the artery lies upon the anterior surface of the anterior annular ligament.

Branches of the Ulnar Artery.—In the forearm the ulnar artery gives off the following branches:—

- | | | |
|-------------------------------|--|----------------------------|
| 1. Anterior ulnar recurrent. | | 4. Anterior ulnar carpal. |
| 2. Posterior ulnar recurrent. | | 5. Posterior ulnar carpal. |
| 3. Common interosseous. | | 6. Muscular twigs. |

The *muscular twigs* are of small size, and come off

at variable points for the supply of the neighbouring muscles.

The *anterior ulnar recurrent artery* is the smaller of the two recurrent branches. It runs upwards in front of the internal condyle of the humerus, in the interval between the pronator radii teres and the brachialis anticus muscles, and it anastomoses with the anterior terminal branch of the anastomotica magna.

The *posterior ulnar recurrent* passes inwards under cover of the flexor sublimis digitorum, and then turns upwards between the two heads of origin of the flexor carpi ulnaris to gain the interval between the internal condyle of the humerus and the olecranon process on the posterior aspect of the limb. Here it comes into contact with the ulnar nerve, and anastomoses with the posterior terminal branch of the anastomotica magna and with the inferior profunda artery.

It is not uncommon to find the two recurrent arteries arising from the ulnar trunk by a short common stem.

The *common interosseous artery* (arteria interossea communis) is a short, wide trunk, which takes origin immediately below the recurrent branches, about an inch or so below the commencement of the ulnar artery. It proceeds backwards, and at the upper margin of the interosseous membrane it divides into two terminal branches, viz., the *anterior* and the *posterior interosseous arteries*.

The *ulnar carpal branches* are two small arteries, which partially encircle the wrist. The *anterior ulnar carpal* (ramus carpeus volaris) runs outwards, under cover of the tendons of the flexor profundus digitorum, and anastomoses with the anterior radial carpal artery. From the arch thus formed small twigs are given to the front aspect of the carpal bones and joints. The *posterior ulnar carpal artery* (ramus carpeus dorsalis) gains the dorsal aspect of the carpus by winding round the ulnar margin of the limb immediately above the pisiform bone, and under cover of the tendon of the flexor carpi ulnaris.

Ulnar Nerve.—The ulnar nerve, which was traced in the dissection of the arm as far as the interval between the olecranon and internal condyle of the humerus, enters the forearm between the two heads of the flexor carpi ulnaris. It proceeds downwards upon the flexor profundus digitorum, and under cover of the flexor carpi ulnaris along the front of the ulnar side of the forearm. Close to the wrist it becomes superficial upon the outer side of the tendon of the flexor carpi ulnaris, and it reaches the palm by passing in front of the anterior annular ligament. In the upper third of the forearm the ulnar nerve is separated from the ulnar artery by an interval, but below this it is closely applied to the inner side of the vessel.

In the forearm the ulnar nerve gives off:—

1. Articular branches to the elbow-joint.
2. Muscular branches, { to the flexor carpi ulnaris and the
inner part of the flexor profundus.
3. Cutaneous branches, { palmar cutaneous.
dorsal cutaneous.

The *articular filaments* come from the ulnar nerve as it lies in the interval between the olecranon and internal condyle of the humerus.

The *muscular branches* are given off high up in the forearm, and supply the flexor carpi ulnaris and the inner part of the flexor profundus digitorum.

The *ulnar palmar cutaneous branch* is a minute twig, which has already been seen piercing the fascia of the forearm immediately above the annular ligament. It arises about the middle of the forearm and proceeds downwards upon the ulnar artery, to the coats of which it gives fine filaments.

The *ulnar dorsal cutaneous branch* is a nerve of some size which springs from the ulnar trunk about two and a half or three inches above the wrist. It winds round the ulnar margin of the forearm under cover of the flexor carpi ulnaris, and reaches the dorsum of the hand immediately below the prominence formed by the lower end of the

ulna. From this point onwards it has been traced in the superficial dissection (p. 92).

The Median Nerve, as its name implies, passes down the middle of the forearm, and to obtain an unbroken view of it, it is necessary to reflect the condylar head of the pronator radii teres and the radial head of the flexor sublimis digitorum.

In the upper part of the forearm the median nerve lies in the anticubital fossa upon the inner side of the ulnar artery. It leaves this space by passing between the two heads of the pronator radii teres, and as it does so it crosses the ulnar artery, but is separated from the vessel by the coronoid or deep head of the muscle. From this point the median nerve is carried downwards between the flexor sublimis and the flexor profundus digitorum. Near the wrist it becomes superficial, and lies in the interval between the tendons of the flexor sublimis on the inside and the flexor carpi radialis on the outer side. Finally it leaves the forearm by passing behind the anterior annular ligament of the wrist. A small artery, the *median branch* of the anterior interosseous, accompanies the median nerve. Sometimes this vessel attains a considerable size.

As the median nerve enters the forearm it gives off numerous branches for the supply of muscles, and near the wrist it supplies the *median palmar cutaneous nerve*, which has already been dissected.

The *muscular branches* supply the pronator radii teres, the flexor carpi radialis, the palmaris longus, and the flexor sublimis digitorum—all the muscles of the superficial group therefore, with the single exception of the flexor carpi ulnaris.

It likewise supplies a long slender twig—the *anterior interosseous*—which goes to the deep muscles on the front of the forearm.

Deep Structures on the front of the Forearm.—The connections of the deep muscles must now be studied, and at the same time the anterior interosseous artery and nerve must be followed. The flexor profundus is the large muscle

which clothes the anterior and inner aspects of the ulna ; the flexor longus pollicis is placed upon the anterior surface of the radius ; while the pronator quadratus is a quadrate fleshy layer closely applied to both bones immediately above the wrist. The artery and nerve proceed downwards in the interval between the flexor profundus and flexor longus pollicis.

The Flexor Profundus Digitorum springs from the anterior and internal surfaces of the ulna in its upper three fourths. It likewise derives fibres from the anterior surface of the interosseous membrane and the aponeurosis by which the flexor carpi ulnaris takes origin from the posterior border of the ulna. The fleshy mass gives place to four tendons for the four inner digits, but only one of these—that for the forefinger—becomes separate and distinct in the forearm. They proceed downwards behind the anterior annular ligament into the palm.

The Flexor Longus Pollicis arises from the anterior surface of the radius over an area which extends from the oblique line above to the upper border of the pronator quadratus below. It also takes origin from the adjacent part of the anterior surface of the interosseous membrane. A rounded tendon issues from the fleshy belly, and proceeds into the palm, under cover of the anterior annular ligament.

In many cases the flexor longus pollicis will be observed to have an additional slender head of origin, from the inner side of the coronoid process of the ulna, or the internal condyle of the humerus.

The Pronator Quadratus takes origin from the anterior surface of the ulna in its lower fourth, and is inserted into the front aspect of the lower end of the radius.

The Anterior Interosseous Artery (arteria interossea volaris) has been seen to arise from the common interosseous. It runs downwards upon the front of the interosseous membrane, in the interval between the flexor longus pollicis and the flexor profundus digitorum. At the upper border of the pronator quadratus it pierces the

interosseous membrane, and gains the posterior aspect of the limb.

It supplies *muscular twigs* to the three deep muscles with which it is in contact. In addition to these it gives off the following branches:—

1. Median.
2. Medullary.
3. Anterior communicating.

The *median artery* is a long delicate vessel, which accompanies the median nerve. The *medullary arteries* are two in number—one for the radius, the other for the ulna. They enter the nutrient foramina of these bones. The *anterior communicating* is a slender artery, which runs downwards, behind the pronator quadratus, to join the anterior carpal arch.

The Anterior Interosseous Nerve (*nervus interosseus volaris*) is a branch of the median, and accompanies the artery of the same name. It does not follow it, however, through the interosseous membrane, but is distributed entirely upon the front of the limb. It is the nerve of supply for the flexor longus pollicis, the outer part of the flexor profundus digitorum,¹ and the pronator quadratus, whilst its terminal filament proceeds downwards, behind the last-named muscle, to help in the supply of the carpal joints.

WRIST AND PALM.

In this dissection we meet with the following structures:—

1. Palmaris brevis and the palmar cutaneous nerves.
2. Palmar fascia.

¹ The flexor profundus digitorum is therefore supplied by two nerves, viz., the ulnar and the median. The precise range of supply by each of these nerves is somewhat variable. As a general rule the division of the muscle which belongs to the index finger is supplied by the median and the part belonging to the little finger by the ulnar; whilst the portions belonging to the middle and ring digits receive filaments from both nerves.

3. Superficial palmar arch and its branches.
4. Median and ulnar nerves and their branches.
5. Anterior annular ligament, the flexor tendons, and the flexor sheaths.
6. Lumbrical muscles.
7. Short muscles of the thumb and little finger.
8. Deep palmar arch and its branches.
9. Arteria princeps pollicis and arteria radialis indicis.

Surface Anatomy.—In the centre of the palm the depression, known as the “hollow of the hand,” may be remarked. Along the ulnar border of the palm this is bounded by a rounded elevation, called the *hypothenar eminence*, which is produced by the subjacent short, intrinsic muscles of the little finger. The *thenar eminence*, or ball of the thumb, formed by the short muscles of that digit, is the marked projection which limits the palmar hollow above and on the outer side; whilst the transverse elevation above the roots of the fingers, which corresponds to the metacarpo-phalangeal articulations, constitutes the lower boundary of the central palmar depression. Two pronounced bony projections on the front of the wrist cannot fail to attract attention when the hand is bent backwards. The more prominent of the two is situated at the upper extremity of the thenar eminence, and is formed by the tubercle of the scaphoid bone and the vertical ridge on the front of the trapezium; the other is placed at the upper end of the hypothenar eminence, and is somewhat obscured by the soft parts attached to it. It is caused by the pisiform bone, and when taken firmly between the finger and thumb a slight degree of gliding movement can be communicated to it. Traversing the thick integument of the palm, three strongly-marked furrows are apparent. One of these begins at the elevation formed by the scaphoid and trapezium, and curves downwards and outwards around the base of the thenar eminence to the outer margin of the hand. A second crosses the palm transversely. Commencing at the middle of the outer border of the hand, where the first furrow ends, it runs inwards, but, as a general rule, it fades away upon the

hypothenar eminence. The third furrow begins near the cleft between the index and middle fingers, and proceeds inwards with a gentle curve across the hypothenar eminence

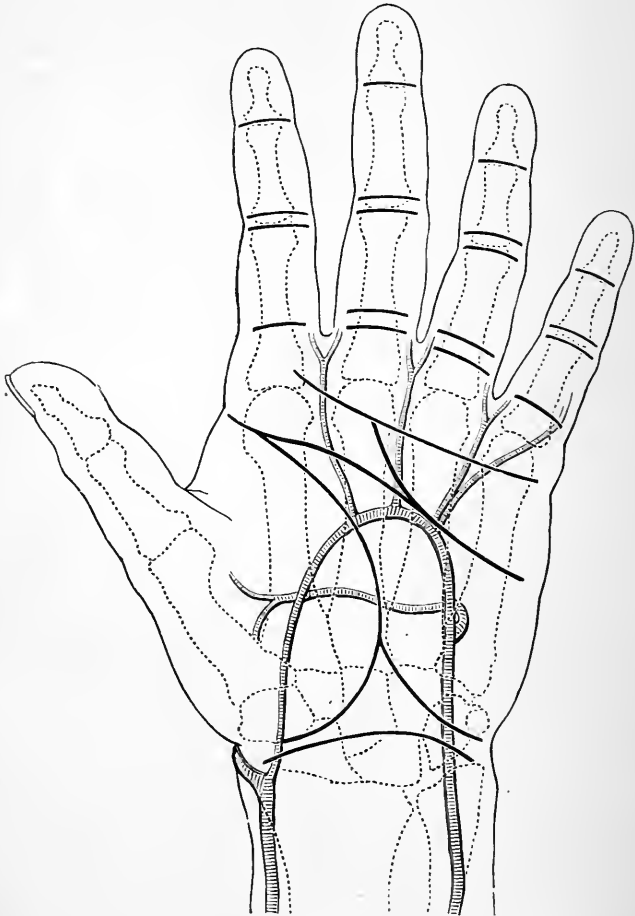


FIG. 26.—Diagram to show the relation of the skin markings to the arteries and bones of the hand. (From Treves.)

to the inner margin of the hand. The transverse cutaneous furrows at the roots of the fingers, and on the palmar aspects of the interphalangeal joints, should also be noticed, and it should always be remembered that, except

in the case of the proximal interphalangeal joints, these do not correspond accurately with the subjacent articulations. The furrows at the roots of the fingers are placed at least one inch below the metacarpo-phalangeal joints, whilst the distal interphalangeal furrows lie slightly higher than the corresponding interphalangeal joints. The upper of the two furrows in front of each of the proximal interphalangeal joints is placed immediately over the articulation.

Reflection of Skin.—In the first instance the skin should only be raised from the palm. Two incisions are required, viz.—(1) a vertical incision along the middle line of the palm; (2) a transverse cut across the roots of the fingers from the ulnar to the radial margin of the hand. The skin is tightly bound down to the subjacent deep fascia, and it must be raised with care. More especially is it necessary to proceed with caution at the roots of the fingers in order that some transverse fibres constituting a superficial cutaneous ligament may be preserved. In reflecting the inner flap of integument it is well not to lift it quite as far as the ulnar border of the hand, because it is into this portion of skin that the *palmaris brevis* is inserted.

Superficial Structures.—The *superficial fascia* over the central part of the palm is dense and thin. The fat is subdivided into small lobules by fibrous septa which bind the skin to the subjacent palmar fascia. Towards the ulnar and radial margins of the hand the fat becomes softer, and the amount of fibrous tissue in its midst diminishes. In connection with the superficial fascia of the palm we have to study—(1) the palmaris brevis; (2) the superficial transverse ligament; and (3) the palmar cutaneous nerves.

The *palmaris brevis* is a small cutaneous muscle embedded in the superficial fascia which covers the upper part of the hypothenar eminence. If it has not already been exposed by the reflection of the skin, carry the knife transversely through the granular fat on the ulnar margin of the palm immediately below the anterior annular ligament. The fleshy bundles of the muscle will come into view. When these have been cleaned, the muscle will be seen to consist of a series of distinct fasciculi,

which in its lower part are frequently separated from each other by intervals of varying width. It constitutes a thin fleshy layer, which covers an inch and a half or more of the hypothenar eminence. Externally it takes origin from the anterior annular ligament and inner border of the central part of the palmar fascia, whilst internally its fasciculi are inserted into the skin over the ulnar margin of the hand.

The *palmar cutaneous nerves* are three in number, and they arise, as already noted, from the ulnar, median and radial nerves. They should now be traced to their ultimate distribution in the palm of the hand.

The *transverse superficial ligament* is a band of fibres which extends across the palm at the roots of the fingers. It is intimately connected with the skin, and is enclosed within the folds of integument in the clefts between the fingers.

Dissection.—The palmaris brevis should be reflected by detaching its fasciculi from their origin, and turning them inwards. In raising the muscle care must be taken of the ulnar artery and nerve, which lie under cover of it, and a little nerve-filament from the latter should be traced into its substance. The granular fat should next be removed from the palm, and the dense palmar fascia cleaned. Towards the roots of the fingers the digital vessels and nerves, together with the lumbrical muscles, appear in the intervals between the slips into which the palmar fascia divides. These should be defined, and it will be seen that they pass downwards under cover of the superficial transverse ligament. Having noted this point, remove the ligament. The digital arteries and nerves for the inner side of the little finger, and the outer side of the index, appear beyond the area of the central part of the deep fascia, higher up than the others, and are consequently liable to injury, unless it be remembered that they occupy this position.

Palmar Fascia.—The deep fascia of the palm is composed of three portions—a central and two lateral. The *lateral parts* are thin and weak, and are spread over the muscles which constitute the thenar and hypothenar eminences on the outer and inner margins of the palm. The *central portion* of the palmar fascia, on the other hand, is exceedingly strong and dense, and is spread out over the middle of the palm. It counteracts the effect of

pressure in this region, and effectually protects the vessels, nerves and tendons, over which it is stretched. Its strength differs considerably in different hands, and it is seen to best advantage in the horny hand of a labourer, or of a mechanic who has been in the habit of handling heavy implements. In shape it is triangular. Above, it is narrow and pointed, and at the wrist it is attached to the anterior annular ligament, and receives the insertion of the flattened tendon of the palmaris longus. As it approaches the heads of the metacarpal bones it expands, and finally divides into four slips, which separate slightly from each other, and pass to the roots of the four inner digits. It gives no slip to the thumb. For the most part it is composed of longitudinal fibres, but, where it divides, a series of strong and very evident transverse fibres pass across it in relation to its deep surface, and bind together its diverging slips.

NB

In the three intervals between the digital slips of the palmar fascia, the digital arteries and nerves, together with the corresponding lumbrical muscles, make their appearance.

The connections of the four digital slips of the palmar fascia must be closely examined. Each lies in front of the two flexor tendons proceeding to the finger with which it is connected, and each will be observed to divide into two portions, so as to form an arch under which these tendons pass. This arch is connected with the flexor sheaths, which bind the tendons to the front of the finger, and the two portions which form it are carried backwards, to obtain attachment to the transverse metacarpal ligament, which stretches transversely across the front of the heads of the metacarpal bones. These relations can only be satisfactorily made out by dividing the arch, and slitting the slip of fascia in an upward direction.

Fascial Compartments of the Palm.—Two weak septa proceed into the palm from the margins of the strong central portion of the palmar fascia. They join a layer of fascia, which is spread out over the interosseous muscles and the deep palmar arch, and they thus subdivide the

palm into three fascial compartments, viz., a central, containing the flexor tendons, the lumbrical muscles, the superficial palmar arch, and the terminal branches of the median nerve; an inner, enclosing the short muscles of the little finger; and an outer, enclosing the short muscles of the thumb.

Dissection.—Raise the central part of the palmar fascia. Divide its narrow upper part, throw it downwards, and finally remove it completely. The superficial palmar arch is the most superficial of the structures now exposed. Trace the ulnar artery into it, and follow the digital branches which it gives off. The slip of fascia which binds the ulnar artery to the front of the annular ligament may now be removed. The median and ulnar nerves must also be dissected. The muscular branches, which the median gives to the muscles of the thenar eminence, are especially liable to injury. They come off in a short, stout stem, almost in a line with the lower margin of the anterior annular ligament, and at once turn outwards to reach the short muscles of the thumb, to some of which they are distributed. The nerve twigs to the two outer lumbricals must also be looked for. They spring from [the digital branches of the median, which go to the radial side of the index and to the cleft between the index and middle fingers.

In order that the digital vessels and nerves may be traced to their distribution, the skin must be reflected from the fingers. This can be done by making an incision along the middle of each digit, and turning the integument outwards and inwards. As the skin is raised from the lateral aspects of the different digits the cutaneous ligaments of the phalanges (Cleland) will come into view. These are fibrous bands, which spring from the edges of the phalanges behind the digital vessels and nerves. They are inserted into the skin so as to form a strong fibrous septum on each side of each finger. They retain the integument in proper position during the different movements of the digits.

Superficial Palmar Arch (*arcus volaris superficialis*).—The ulnar artery, when traced into the palm, is found to form the superficial palmar arch—an arterial arcade, which lies immediately subjacent to the deep fascia.

The ulnar artery enters the palm by passing downwards in front of the annular ligament, close to the outer side of the pisiform bone. A short distance below this it curves outwards, across the palm, and, near the middle of the thenar eminence, it is joined by the superficialis volæ branch of the radial, or, more frequently, by a twig from

the arteria radialis indicis or arteria princeps pollicis. The convexity of the arch is directed downwards towards the fingers, and its lowest point corresponds with a line drawn across the palm from the lower border of the outstretched thumb.

Throughout its entire extent the superficial palmar arch lies very near the surface. Its inner part is covered by the palmaris brevis muscle; beyond this it is placed immediately behind the central part of the palmar fascia. As it is followed from the inner to the outer side of the hand it will be seen to rest upon—(a) the anterior annular ligament; (b) the short muscles of the little finger; (c) the flexor tendons, and the digital branches of the median nerve.

Branches of the Superficial Palmar Arch.—Small branches proceed from the superficial palmar arch for the supply of the integument and adjoining short muscles of the palm. As the ulnar artery leaves the surface of the anterior annular ligament it gives off its *profunda branch*; whilst from the convexity of the arch proceed four digital branches.

The *profunda artery* is a small vessel, which at once disappears from view by passing backwards in the interval between the abductor minimi digiti and the flexor brevis minimi digiti. It will be traced to its termination in the deep dissection of the palm.

The *four digital arteries* form the palmar collateral branches for both sides of each of the three inner fingers and for the ulnar side of the index finger. The *first digital artery* runs downwards upon the short muscles of the little finger, to which it gives twigs, and then it is carried along the ulnar side of the little finger. The *second digital artery* proceeds towards the interval between the roots of the little and ring fingers, and divides into two branches (*collateral arteries*), which run along the contiguous sides of these digits. The *third digital artery* supplies in like manner the adjacent sides of the ring and middle fingers; whilst the *fourth digital artery* deals similarly with the contiguous margins of the middle and index fingers.

There are certain points in connection with these digital arteries, during their course in the palm and along the sides of the fingers, which must be noted. In the *palm* the undivided trunks lie in the intervals between the flexor tendons and in front of the digital nerves and the lumbrical muscles. Along the sides of the *fingers* they show a different relation to the nerves: the nerves are now in front, and the arteries behind. Upon the terminal phalanx the two collateral branches join to form an arch, from which proceed great numbers of fine twigs, to supply the pulp of the finger, and the bed upon which the nail rests.

Each digital artery at the point at which it divides is joined by the corresponding interosseous branch of the deep palmar arch. The collateral branches give a liberal supply of twigs to the integument, sheaths of the tendons, and joints of the fingers.

Median Nerve.—The median nerve enters the palm by passing *behind* the anterior annular ligament with the flexor tendons. In this part of its course it is enveloped by the synovial sheath which is wrapped around the tendons. Further, before it emerges it assumes a flattened form, and divides into two portions. Of these, the *external division* is slightly the smaller of the two, and gives off—(1) a stout short branch to some of the intrinsic muscles of the thumb; (2) three digital branches which go to the two sides of the thumb and the radial side of the index finger.

The *muscular branch* takes origin at the lower border of the annular ligament, and at once turns outwards to supply the abductor pollicis, the superficial head of the flexor brevis pollicis, and the opponens pollicis.

The *digital nerves* which run along the ulnar side of the thumb, and the radial side of the index, give several branches to the fold of integument which stretches between the roots of these digits; whilst the long digital branch to the radial border of the index gives a minute twig to the first or outermost lumbrical muscle.

The larger *internal division* of the median nerve divides into two branches. Of these one runs towards the cleft between the index and middle fingers, and splits into the collateral branches for the adjacent sides of these digits. From this nerve a twig to the second lumbrical muscle is

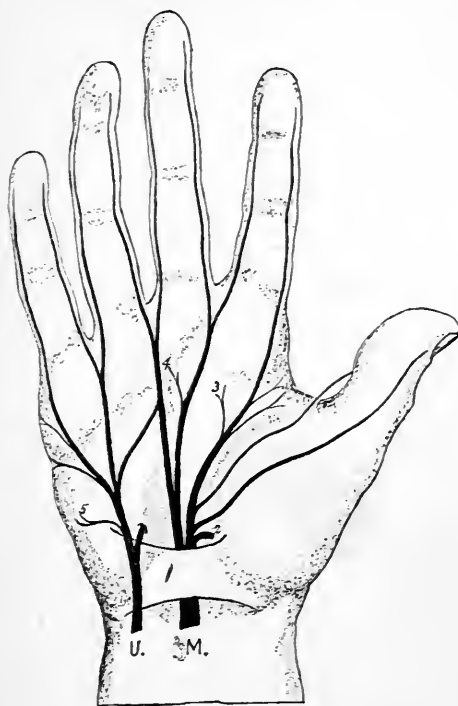

FIG. 27.—Diagram of the median and ulnar nerves.

U. Ulnar nerve.

M. Median nerve.

1. Anterior annular ligament.

2. Muscular branch of median.

3 & 4. Branches to the two outermost lumbrical muscles.

5. Branch to palmaris brevis.

given off. The second branch of the internal division of the median proceeds towards the cleft between the middle and ring fingers, and divides into the collateral branches for their contiguous margins.¹

¹ In some instances this nerve supplies a twig to the third lumbrical muscle.

In the palm the digital branches of the median proceed downwards behind the superficial palmar arch, but as they approach the fingers they come to lie in front of the digital arteries which, in many cases, may be observed to pass through, or perforate, the nerves. As the digital nerves lie upon the sides of the fingers, numerous branches are given to the integument; and if the dissector exercises sufficient patience and care in the dissection, he will notice attached to the nerve twigs numerous minute, oval, seed-like bodies. These are the *Pacinian bodies*. At the extremity of the fingers the digital nerves divide into two terminal branches. Of these, one ramifies in the pulp, whilst the other inclines backwards to reach the bed upon which the nail rests.

The Ulnar Nerve enters the palm by passing *in front* of the anterior annular ligament. It lies secure from the effects of pressure under the shelter of the pisiform bone, and upon the inner side of the ulnar artery. At this level it divides into two terminal branches—a superficial and a deep.

The *deep branch* of the ulnar is continued downwards upon the annular ligament, and associates itself with the profunda branch of the ulnar artery. It leaves the present dissection by passing backwards between the abductor and the flexor brevis muscles of the little finger.

The *superficial branch* of the ulnar nerve runs downwards under cover of the palmaris brevis, to which it gives a branch of supply, and then divides into two digital branches. One of these proceeds obliquely over the short muscles of the little finger to gain the inner side of that digit; the other descends to the cleft between the little and ring fingers, and divides into the collateral branches for the adjacent sides of these digits. A branch of communication passes from the second digital branch of the ulnar nerve to the adjoining digital branch of the median nerve.

The digital branches of the ulnar nerve are distributed on the sides of the figures in precisely the same manner as those derived from the median.

Anterior Annular Ligament.—This is a thick, dense, fibrous band, which stretches across the front of the carpal arch, so as to convert it into an osteo-fibrous tunnel for the passage of the flexor tendons into the palm. On each side it is attached to the two piers of the carpal arch, viz., on the *outer side* to the tubercle of the scaphoid and the ridge of the trapezium, and on the *inner side* to the pisiform bone and the hook of unciform. Its upper margin is in a measure continuous with the deep fascia of the forearm, of which it may be considered to be a

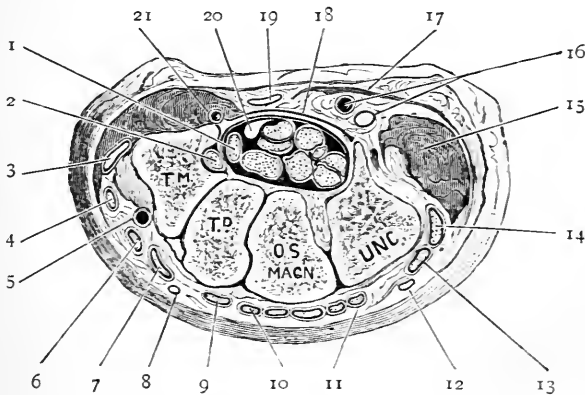


FIG. 28.—Transverse section through the wrist at the level of the second row of carpal bones to show the carpal tunnel. The tendons of the flexor sublimis, flexor profundus digitorum and flexor longus pollicis are seen within the carpal tunnel.

- | | |
|--|---|
| <p>1. Tendon of the flexor longus pollicis.</p> <p>2. Tendon of flexor carpi radialis.</p> <p>3. Tendon of the extensor ossis metacarpi pollicis.</p> <p>4. Tendon of the extensor primi internodii pollicis (extensor brevis pollicis).</p> <p>5. Radial artery.</p> <p>6. Extensor secundi internodii pollicis (extensor longus pollicis).</p> <p>7. Tendon of extensor carpi radialis longior.</p> <p>8. Radial nerve.</p> <p>9. Tendon of extensor carpi radialis brevior.</p> | <p>10 & 11. Tendons of extensor communis digitorum and the extensor indicis.</p> <p>12. Dorsal branch of the ulnar nerve.</p> <p>13. Tendon of the extensor minimi digiti.</p> <p>14. Tendon of extensor carpi ulnaris.</p> <p>15. Short muscles of little finger.</p> <p>16. Ulnar nerve and artery.</p> <p>17. Palmaris brevis muscle.</p> <p>18. Anterior annular ligament.</p> <p>19. Tendon of palmaris longus.</p> <p>20. Median nerve.</p> <p>21. Superficialis volæ artery.</p> |
|--|---|

thickened part, whilst below, it is connected with the palmar fascia.

Upon the anterior surface of the annular ligament the expanded tendon of the palmaris longus is prolonged downwards to the central part of the palmar fascia, whilst on each side several of the short muscles of the thumb and little finger take origin from it. Close to its inner attachment the ulnar artery and nerve find their way into the palm by passing in front of the ligament, and a strong slip of fascia which bridges over these may be looked upon as an accessory attachment of the ligament, seeing that it springs from the pisiform bone and tendon of the flexor carpi ulnaris, and joins the front of the annular ligament beyond the artery and nerve.

The tunnel which the anterior annular ligament forms with the palmar concavity of the carpus is transversely oval in shape, and below it opens into the middle compartment of the palm. Through it pass the tendons of the flexor sublimis, the flexor profundus digitorum, the tendon of the flexor longus pollicis, and the median nerve. The relation of the tendon of the flexor carpi radialis to the annular ligament is peculiar. It pierces the outer attachment of the ligament, and proceeds down in the groove of the trapezium in a special compartment provided with a special synovial sheath.

Synovial Sheaths of the Flexor Tendons.—As the flexor tendons and the median nerve pass through the carpal tunnel they are enveloped by two synovial sheaths, which at the same time line the walls of the canal, and thus greatly facilitate the free play of the tendons behind the anterior annular ligament. As we have stated, these sheaths are two in number. One is wrapped around the tendon of the flexor longus pollicis; the other invests the tendons of the flexor profundus and flexor sublimis. Both are prolonged upwards into the forearm for an inch or more, and both are carried downwards into the palm in the form of diverticula upon the diverging tendons. The diverticula in relation to the tendons which go to the index, middle, and ring fingers,

end near the middle of the palm. Those upon the tendons of the thumb and little finger, however, are prolonged downwards into these digits, and line the flexor sheaths which confine the tendons upon the palmar aspects of the phalanges.

[It is not likely that these synovial sheaths have been preserved intact throughout the previous dissection of forearm and palm, but should they turn out to be uninjured, a very striking demonstration may be obtained by inflating them with air by means of the blow-pipe. The apertures through which the air is introduced should be made at the upper margin of the annular ligament.

It is said that the synovial sac which invests the tendons of the flexor sublimis and flexor profundus is divided by a vertical partition into two compartments, and that the outer of these communicates, by means of a small aperture near the upper border of the annular ligament, with the synovial sheath of the tendon of the flexor longus pollicis.

Flexor Tendons.—Open the carpal tunnel by making a vertical incision through the anterior annular ligament at its middle. The arrangement of the flexor tendons can now be studied, and the synovial sheath dissected from the surface of each. The tendon of the *flexor longus pollicis* occupies the outer part of the canal, and gaining the palm turns outwards to reach the phalanges of the thumb. The four tendons of the *flexor sublimis* are arranged in pairs behind the annular ligament; those for the little and index fingers lying behind those for the ring and middle fingers. Of the tendons of the *flexor profundus*, only that for the index finger is distinct and separate, the other three as a rule remain united until they emerge from under cover of the annular ligament.

In the central compartment of the palm the flexor tendons diverge from each other, and two, viz., one from the flexor sublimis, and one from the flexor profundus, go to each of the four fingers. From the tendons of the flexor profundus, the lumbrical muscles take origin, and these, with the digital nerves and arteries, will be seen

occupying the intervals between the tendons as they approach the roots of the fingers.

In the *fingers* the two flexor tendons run downwards upon the palmar aspect of the phalanges, and are held in position by the flexor sheaths. These, therefore, must be studied before the insertions of the tendons can be examined.

Flexor Sheaths.—The flexor sheaths of the fingers lie

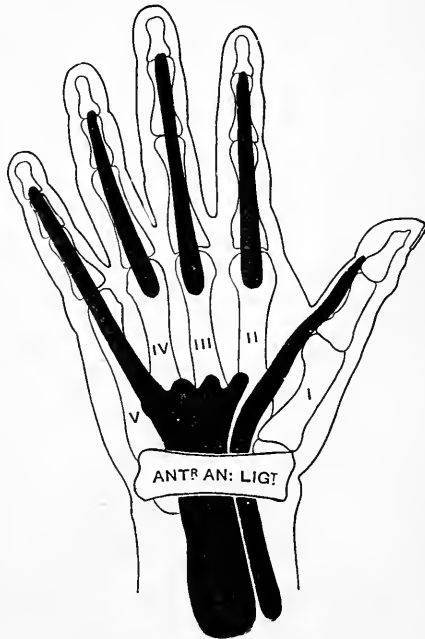

FIG. 29.—Diagram to illustrate the arrangement of the synovial sheaths around the flexor tendons.

immediately subjacent to the skin and superficial fascia, and the digital vessels and nerves run downwards upon each side of them. Each of these sheaths, with the phalanges of the fingers, forms an osteo-fibrous canal or tube. The posterior wall of the tube is formed by the flat palmar surfaces of the phalanges; the front wall is composed of the fibrous sheath which bridges over the tendons, and is attached on each side to the sharp lateral

margins of the phalanges. The strength of this sheath differs very much at different points. Opposite the centre of each of the two proximal phalanges it is composed of transverse fibres, and it acquires a great thickness and density, forming a distinct arch, called the *vaginal ligament*. Such an arrangement over the joints, however, would seriously interfere with the free flexion of the fingers, and therefore in front of the articulations between the phalanges the sheath is exceedingly thin, and is strengthened by oblique interlacing fibres.

The flexor tubes in front of one or more of the fingers may now be opened. They will be seen to be lined by a synovial sheath, which is reflected over the enclosed tendons so as to give each a separate investment. The synovial sheath of the little finger has been seen to be a direct prolongation from the carpal synovial sheath; the other three are distinct from this, and are carried upwards into the palm. They envelop the tendons of the ring, index, and middle fingers, as far as a line drawn across the palm immediately above the heads of the metacarpal bones.

If the flexor tendons be raised from the phalanges certain synovial folds will be noticed connecting them to the bones. These are termed the *vincula accessoria*. Of these we distinguish two kinds, viz., *ligamenta brevia* and *longa*. In the accompanying illustration (Fig. 30) the connections of these may be seen. The *ligamenta brevia* (5 and 6) are triangular folds, which connect the tendons near their insertions to the anterior face of the phalanx. The *ligamenta longa* (4) are not invariably present. They are placed higher up, and are narrow, weak folds which pass between the tendons and the bones.

Insertions of the Flexor Tendons.—The insertions of the two tendons can now be studied. In front of the first phalanx the tendon of the flexor sublimis becomes flattened and folded round the subjacent cylindrical tendon of the flexor profundus. It then splits into two parts, which pass behind the tendon of the flexor profundus, and allow the latter to proceed onwards between them. Behind the

deep tendon the two portions of the tendon of the flexor sublimis become united by their margins, and then they diverge, to be inserted into the borders of the shaft of the second phalanx.¹ By this arrangement the flattened tendon of the flexor sublimis forms a ring, through which the tendon of the flexor profundus is allowed to pass onwards to the base of the unguis phalanx, into which it is inserted. In each of the four fingers the same arrangement is found; the tendon of the flexor sublimis is inserted by two slips into the sides of the second phalanx, whilst

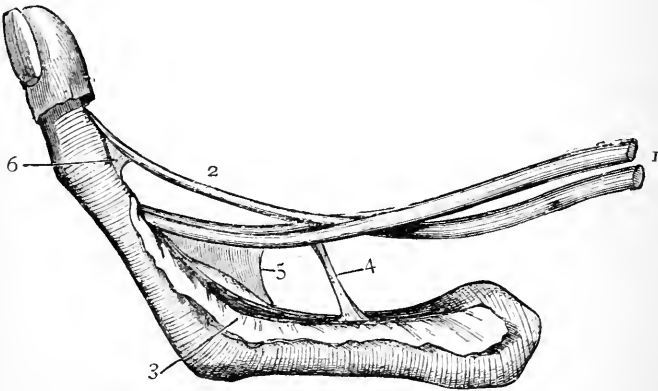


FIG. 30.—Flexor tendons of the finger, with the vincula accessoria. (From Reeves.)

- | | |
|--------------------------------|---------------------------|
| 1. Flexor sublimis tendon. | 4. Ligamentum longum. |
| 2. Flexor profundus tendon. | 5. & 6. Ligamenta brevia. |
| 3. Flexor sheath turned aside. | |

the tendon of the flexor profundus is inserted into the anterior aspect of the base of the terminal phalanx.

Tendon of the Flexor Longus Pollicis.—This tendon proceeds downwards in the interval between two of the muscles of the thumb (*viz.*, the superficial head of the flexor brevis pollicis, and the adductor obliquus pollicis), and also in the interval between the two sesamoid bones

¹ Where the margins of the two slips of the tendon of the flexor sublimis are united behind the tendon of the flexor profundus, a decussation of fibres takes place between the two slips, which greatly strengthens the insertion.

which play upon the head of the metacarpal bone. Reaching the proximal phalanx, it enters a fibrous sheath constructed upon a similar plan to those of the fingers. When this is opened, the tendon will be observed to be inserted into the front of the base of the terminal phalanx of the thumb. The synovial sheath which surrounds the tendon during its passage through the carpal tunnel is continuous with the sheath which invests the tendon in front of the phalanges.

Dissection.—Throw forwards the superficial palmar arch. Divide it on the inside below the origin of the profunda artery, and on the outside at the point where it is joined by the superficial volar artery. The median nerve may also be severed and its branches turned aside, but care should be taken to preserve the two branches which it gives to the lumbrical muscles, and also the stout branch which enters the muscles of the thenar eminence. Lastly, cut through the fleshy belly of the flexor sublimis in the forearm, and raising its tendons from the carpal hollow, throw them as far down as possible. The tendons of the flexor profundus and the attached-lumbrical muscles are now fully displayed.

The Lumbrical Muscles are four slender fleshy bellies which arise from the tendons of the flexor profundus digitorum as they traverse the palm. The *first lumbrical* arises from the outer side of the tendon for the index finger; the *second lumbrical* springs from the radial border of the tendon for the middle finger; whilst the *third* and *fourth lumbricals* take origin from the adjacent sides of the tendons between which they lie (viz., the tendons for the medius, annularis, and minimus). The little muscles pass downwards and end in delicate tendons on the radial sides of the fingers. Each is inserted into the outer margin of the dorsal expansion of the extensor tendon, which lies upon the posterior aspect of the proximal phalanx.

Dissection.—The flexor profundus may be divided in the forearm and thrown downwards. Great care must be taken in raising the tendons and lumbrical muscles from the palm, because slender twigs from the deep branch of the ulnar nerve enter the two inner lumbrical muscles on their deep aspect. These can easily be secured if ordinary caution be observed. The deep palmar arch and the deep branch of

the ulnar nerve are now exposed, and a favourable opportunity is given for studying the short muscles of the thumb and little finger.

Short Muscles of the Thumb.—The *abductor pollicis* forms the most prominent and external part of the ball of the thumb. The *superficial head of the flexor brevis pollicis* lies immediately to the inner side of the abductor, and by separating the one from the other, the *opponens pollicis* will be exposed. These three muscles lie to the outer side of the tendon of the flexor longus pollicis. To the inner side of this tendon, and placed deeply in the palm, is a fan-shaped muscular sheet imperfectly separated into an upper and lower part by the radial artery as it enters the palm. The upper muscle is the *adductor obliquus pollicis*, the lower muscle is the *adductor transversus pollicis*.

In dissecting these muscles the muscular branch of the median nerve must be traced to those which lie upon the outer side of the long flexor tendon of the thumb, and the deep branch of the ulnar must be followed, and its branches to the two adductors of the thumb secured.

The *abductor pollicis* arises from the front of the annular ligament and the trapezium. It is inserted into the radial side of the base of the first phalanx of the thumb, and slightly into the extensor tendon on the dorsum of the first phalanx. Its nerve of supply comes from the median.

The *superficial head of the flexor brevis pollicis*¹ takes origin from the annular ligament, and is inserted into the outer side of the base of the proximal phalanx of the thumb. It is supplied by the median nerve.

The *opponens pollicis* springs from the annular ligament and the ridge on the front of the trapezium. Its fibres spread out, and are inserted into the entire length of the radial border of the metacarpal bone of the thumb. Its nerve of supply is derived from the median.

The *adductor obliquus pollicis* arises from the bases of the

¹ The term *superficial head*, applied to this muscle, suggests the presence of a *deep head*. Such a head is present. It is the *interosseus primus volaris* of Henle (v. p. 144).

second and third metacarpal bones, and likewise from the os magnum, the trapezoid, the trapezium and the sheath of the flexor carpi radialis. From this origin the muscle proceeds downwards along the inner side of the tendon of the flexor longus pollicis, and is inserted into the ulnar side of the base of the proximal phalanx of the thumb. A strong slip will generally be seen to deviate outwards from the outer border of the muscle. This passes under cover of the long flexor tendon, and joins the superficial head of the flexor brevis pollicis. The adductor obliquus is supplied by the deep branch of the ulnar nerve.

The *adductor transversus pollicis* has a wide origin from the anterior face of the lower two-thirds of the shaft of the middle metacarpal bone, and from the fascia covering the interosseous muscles. Its fibres converge as they pass outwards, and are inserted along with the adductor obliquus into the ulnar side of the base of the first phalanx of the thumb. It is supplied by the deep branch of the ulnar nerve.

Two sesamoid bones are developed in connection with the tendons of the short muscles of the thumb as they are inserted on either side of the base of the proximal phalanx.

Short Muscles of the Little Finger.—The *abductor minimi digiti* lies on the inner and superficial aspect of the hypothenar eminence, and the *flexor brevis minimi digiti* upon its outer side. On separating these from each other, the *opponens minimi digiti* is seen on a deeper plane, and in the interval between them.

The *abductor minimi digiti* (abductor quinti digiti) arises from the pisiform bone, and is inserted into the ulnar side of the base of the proximal phalanx of the little finger. It is supplied by the deep branch of the ulnar nerve.

The *flexor brevis minimi digiti* (flexor digiti quinti brevis) is composed of a single fleshy belly which springs from the hook of the unciform bone and the annular ligament, and is inserted into the ulnar side of the proximal phalanx of the little finger, in common with the abductor. This muscle

is sometimes much reduced in size, and frequently more or less completely incorporated with the opponens. Its nerve supply comes from the deep branch of the ulnar nerve.

The *opponens minimi digiti* (*opponens digiti quinti*) arises from the annular ligament, and the hook of the unciform bone and its fibres spread out to obtain insertion into the entire length of the ulnar margin of the metacarpal bone of the little finger. The deep branch of the ulnar gives it its nerve of supply.

The Deep Branch of the Ulnar Nerve springs from the parent trunk on the anterior aspect of the annular ligament, and gives off a branch which supplies the three short muscles of the little finger. Accompanied by the deep branch of the ulnar artery, it then sinks into the interval between the abductor and flexor brevis minimi digiti, and turns outwards across the palm under cover of the flexor tendons. Near the radial border of the palm the deep branch of the ulnar nerve breaks up into terminal twigs, which supply the adductor transversus pollicis, the adductor obliquus pollicis, and the first dorsal interosseous muscle. In its course across the palm it lies along the concavity or upper border of the deep palmar arch, and sends three fine branches forwards in front of the three interosseous spaces. These supply the interosseous muscles in those spaces, while the two inner also give branches to the deep surfaces of the two inner lumbrical muscles.¹

The deep branch of the ulnar may, therefore, be said to supply all the muscles of the palm which lie to the inner side of the tendon of the flexor longus pollicis, whilst the median supplies the three muscles which lie to the outer side of that tendon. There are two exceptions to this generalisation, viz., the two outer lumbrical muscles, which lie upon the inner side of the tendon, and are yet supplied by the median nerve.

¹ The third lumbrical has frequently a double nerve supply, as it is not uncommon to find a second twig from the median entering its superficial aspect.

Deep Palmar Arch (*arcus volaris profundus*).—The artery which takes the chief part in the formation of this arch is the radial. This vessel enters the palm, by coming forwards through the upper part of the first interosseous space between the two heads of the first dorsal interosseous muscle. In the present state of the dissection it makes its appearance between the contiguous margins of the adductor obliquus and adductor transversus pollicis. It runs inwards upon the interossei muscles and the metacarpal bones immediately below their bases. As it approaches the fifth metacarpal bone it is joined by the deep branch of the ulnar artery, and in this manner the deep palmar arch is completed.

The deep palmar arch does not show so strong a curve as the superficial arch, and it is placed at a higher level in the palm. It is closely accompanied by the deep branch of the ulnar nerve; and is separated from the superficial palmar arch by the group of flexor tendons, the lumbrical muscles, the branches of the median nerve which occupy the middle compartment of the palm, and also at its inner part by the flexor brevis minimi digiti, under which the deep branch of the ulnar artery passes to join the radial.

The *branches* which spring from the deep palmar arch are: (1) the *recurrent*—a few small twigs which run upwards in front of the carpus to anastomose with branches of the anterior carpal arch; (2) *superior perforating*, which pass backwards in the upper parts of the interosseous spaces to anastomose with the dorsal interosseous arteries; and (3) the *palmar interosseous*—three in number—which pass forwards in front of the interosseous spaces and unite near the roots of the fingers, with the corresponding digital arteries from the superficial palmar arch. Sometimes one or more of these branches enlarge and take the place of the corresponding digital arteries.

Dissection.—To bring the *arteria radialis indicis* and the *arteria princeps pollicis* into view, the adductor transversus, and the

adductor obliquus pollicis must be detached from their origins and turned outwards. The radial artery is now seen coming forwards between the two heads of the first dorsal interosseous muscle.

Arteria Radialis Indicis, and Arteria Princeps Pollicis.—These arteries spring from the radial as it proceeds forwards between the first and second metacarpal bones.

The *arteria radialis indicis* runs downwards between the adductor transversus pollicis and the first dorsal interosseous muscle to the radial border of the index, along which it proceeds as its outer collateral branch.

The *arteria princeps pollicis* takes a course downwards and outwards under cover of the adductor obliquus pollicis, and gains the front of the metacarpal bone of the thumb. Here it lies behind the tendon of the flexor longus pollicis, and divides into the two collateral branches of the thumb. These branches make their appearance, in the interval, between the adductor obliquus and the superficial head of the flexor brevis pollicis, and are carried forward on either side of the tendon of the long flexor.

Surgical Anatomy of the Palm and Fingers.—When an abscess forms in the middle compartment of the palm early surgical interference is urgently called for. The dense palmar fascia effectually prevents the passage of the pus forwards, whilst an easy route upwards into the forearm is offered to it by the open carpal tunnel, through which the flexor tendons enter the palm. It is absolutely necessary, therefore, that before this can occur the surgeon should make an opening in the palm by means of which the pus can escape.

In making such an incision it is a matter of the utmost importance to bear in mind the position of the various vessels which occupy the middle compartment of the palm. As we have stated, the level to which the superficial palmar arch descends can be indicated by drawing a line transversely across the palm from the lower margin of the outstretched thumb. The deep palmar arch lies half an inch higher. The digital arteries, which spring from the convexity of the superficial arch, run in a line with the clefts between the fingers. An incision, therefore, which is made below the superficial arch, and in a direction corresponding to the central line of one of the fingers, may be considered free from danger in so far as the vessels are concerned.

The loose synovial sheath which envelops the flexor tendons as they pass behind the anterior annular ligament has been noticed to extend upwards into the lower part of the forearm, and downwards into the palm. When this is attacked by inflammatory action it is apt to become distended with fluid (thecal ganglion) and the anatomical arrangement of parts at once offers an explanation of the appearance which is presented. There is a bulging in the palm, and a bulging in the lower part of the forearm, but no swelling at all at the wrist. Here the dense annular ligament resists the expansion of the synovial sheath, and an hour-glass constriction is evident at this point.

The fingers are very subject to an inflammatory process, termed *whitlow*, and, in connection with this, it is essential to remember that the flexor fibrous sheath ends on the base of the distal phalanx in each digit. When the whitlow occurs below this, in the pulp of the finger, the vitality of the distal part of the unguis phalanx is endangered, but the flexor tendons may be regarded as being tolerably safe. When the inflammation occurs above this, and involves the flexor sheath, as it generally does, sloughing of the tendons is to be apprehended, unless an immediate opening is made. And no slight superficial incision will suffice. The knife must be carried backwards in the centre of the finger, so as to freely lay open the sheath containing the tendons. Early interference in cases of whitlow of the thumb and little finger is even more urgently required than in the case of the other three digits, because, as we have seen, the digital synovial sheaths of the former are, as a rule, offshoots from the great carpal bursa, and offer a ready means for the upward extension of the inflammatory action.

Every amputation of the fingers above the insertion of the tendons of the flexor profundus involves the opening of the flexor sheaths, and this no doubt explains the occasional occurrence of palmar trouble after operations of this kind. The open tubes offer a ready passage, by means of which septic material may travel upwards into the palm, and, in the case of the thumb and little finger, into the carpal tunnel and lower part of the forearm.



BACK AND OUTER BORDER OF THE FOREARM.

The cutaneous nerves and vessels in this region have already been studied. The parts which still require to be examined are:—

1. The deep fascia.
2. The supinator and extensor muscles.

3. The posterior interosseous artery.
4. The perforating or terminal branch of the anterior interosseous artery.
5. The posterior interosseous nerve.

Deep Fascia.—The deep fascia on the posterior aspect of the forearm is stronger than that which clothes it in front. At the elbow it is firmly attached to the condyles of the humerus and the olecranon process, and it receives a reinforcement of fibres from the tendon of the triceps muscle. Here also it affords origin to the extensor muscles, and sends strong septa between them. At the wrist a thickened band—the *posterior annular ligament*—is developed in connection with it. This can readily be distinguished from the thinner portions of the fascia with which it is continuous above and below, and it will be observed to stretch obliquely from the styloid process of the radius inwards and downwards across the wrist to the inner side of the carpus.

Dissection.—The deep fascia should now be removed, but that portion of it near the elbow, which gives origin to the subjacent muscles, should be left in place. The posterior annular ligament should also be artificially separated from it, and retained *in situ*.

Superficial Muscles.—The muscles in this region consist of a superficial and a deep group. The *superficial muscles*, as we proceed from the outer to the inner border of the forearm, are:—the supinator longus, the extensor carpi radialis longior, the extensor carpi radialis brevior, the extensor communis digitorum, the extensor minimi digiti, the extensor carpi ulnaris, and the anconeus. This group therefore comprises one supinator, three extensors of the wrist, two extensors of the fingers, and a feeble extensor of the forearm at the elbow-joint, viz., the anconeus. In the lower part of the forearm the extensor communis digitorum is separated from the extensor carpi radialis brevior by a narrow interval, and in this appear two muscles belonging to the deep group. These turn round the outer border of the forearm upon the surface of the radial extensors of the wrist, and end

in tendons which go to the thumb. The upper muscle is the extensor ossis metacarpi pollicis, and the lower muscle the extensor primi internodii pollicis. They are placed in close contact, and so intimately are their tendons connected that in many cases they appear at first sight to be blended together by their margins.

Four of the superficial muscles arise by a common origin from the front of the external condyle of the humerus, and at the same time derive fibres from the investing fascia and the septa it sends in between them. These are the extensor carpi radialis brevior, the extensor communis digitorum, the extensor minimi digiti, and the extensor carpi ulnaris. The superficial muscles should be cleaned, and isolated as far as possible from each other.

The Supinator Longus (brachio-radialis) lies more on the front than on the back of the forearm. It takes origin in the upper arm from the upper two thirds of the external supracondyloid ridge of the humerus and from the external intermuscular septum. Near the middle of the forearm a flat tendon emerges from its fleshy belly, and this proceeds downwards to gain insertion into the outer aspect of the expanded lower extremity of the radius close to the base of the styloid process.

The Extensor Carpi Radialis Longior is placed behind the supinator longus. It arises from the lower third of the external supracondyloid ridge of the humerus, and from the external intermuscular septum. From the fleshy portion of the muscle a long tendon proceeds which passes under cover of the posterior annular ligament, and is inserted into the radial side of the base of the metacarpal bone of the index finger.

The Extensor Carpi Radialis Brevior is closely associated with the preceding muscle. It arises by the common extensor tendon from the external condyle of the humerus; it also derives fibres from the external lateral ligament of the elbow-joint, from the investing

deep fascia, and the fibrous septa in connection with it. The tendon of the muscle accompanies that of the long radial extensor under cover of the posterior annular ligament, and is inserted into the radial side of the base of the third metacarpal bone immediately beyond the root of its styloid process:

The Extensor Communis Digitorum takes origin by the common tendon from the outer condyle of the humerus. The deep fascia and the intermuscular septa in relation to it also contribute fibres. Its fleshy belly in the lower part of the forearm sends out four tendons, which pass under cover of the posterior annular ligament. On the dorsum of the hand they diverge and proceed onwards to the four fingers. Their arrangement and attachments on the dorsum of the hand and fingers will be afterwards considered.

The Extensor Minimi Digiti is a slender fleshy belly which at first sight appears a part of the preceding muscle, but its tendon passes through a special compartment in the posterior annular ligament. It arises in common with the extensor communis digitorum.

The Extensor Carpi Ulnaris arises, by means of the common extensor tendon, from the outer condyle of the humerus, from the fascia of the forearm, and from the intermuscular septum between it and the extensor minimi digiti. In the middle third of the forearm it may also receive some fibres from the strong fascial layer which binds it to the posterior border of the ulna. The tendon does not become free from the fleshy fibres until it approaches close to the wrist. It occupies the groove on the posterior aspect of the lower end of the ulna, between the head and styloid process, and passing under cover of the annular ligament is inserted into the tubercle on the base of the metacarpal bone of the little finger.

The Anconeus is a short triangular muscle placed on the posterior aspect of the elbow-joint. It is frequently more or less directly continuous with the triceps, and this,

together with the fact that it gets a special branch of supply from the musculo-spiral nerve, has led some anatomists to regard it as a piece of the triceps muscle. This is not the case, however; it belongs to, and is therefore properly classified with, the group of muscles on the extensor aspect of the forearm.

The *anconeus* presents a narrow origin from the posterior aspect of the external condyle of the humerus. From this its fibres spread out—the upper fibres passing transversely inwards, whilst the others proceed inwards and downwards, with an increasing degree of obliquity towards its lower border. It is inserted into the outer surface of the olecranon process, and into the upper third of the posterior surface of the shaft of the ulna.

The nerve of supply to the *anconeus* has already been dissected. It is a long slender branch from the musculo-spiral, which descends to its destination in the substance of the internal head of the triceps. In addition to this, the lower part of the muscle usually receives a twig from the posterior interosseous nerve.

Dissection.—Reflect the *extensor communis digitorum* and the *extensor minimi digiti*. Divide the fleshy belly of each about its middle, and throw them upwards and downwards. In doing this care must be taken to secure and preserve the nerve-twigs from the posterior interosseous nerve which enter these muscles on their deep surface. The posterior interosseous artery and nerve, together with the deep muscles, are now exposed, and may be fully dissected. In the lower part of the forearm the terminal part of the posterior interosseous nerve dips under cover of the *extensor secundi internodii pollicis*, to reach the interosseous membrane and the back of the carpus. In following this part of the nerve, the terminal or perforating branch of the anterior interosseous artery will be seen appearing on the back of the forearm, under cover of the *extensor secundi internodii pollicis*.

Deep Muscles.—These are—(1) The *supinator brevis*; (2) the *extensor ossis metacarpi pollicis*; (3) the *extensor primi internodii pollicis*; (4) the *extensor secundi internodii pollicis*; and (5) the *extensor indicis proprius*.

The *supinator brevis* will be recognised from the close manner in which it is applied to the upper part of the

shaft of the radius. The other muscles take origin from above downwards in the order in which they have been named. The attachments of the supinator brevis cannot be satisfactorily studied at present. They will be described at a later stage of the dissection.

The Extensor Ossis Metacarpi Pollicis (abductor longus pollicis) arises from both bones of the forearm, and from the interosseous membrane which stretches between them. Its origin from the radius corresponds to the middle third of its posterior surface; its origin from the ulna is at a higher level from the outer part of the posterior aspect of the shaft immediately below the oblique line which marks the lower limit of the insertion of the anconeus. The muscle proceeds downwards and outwards, and comes to the surface in the interval between the extensor communis digitorum and the extensor carpi radialis brevis. Closely accompanied by the extensor primi internodii pollicis it crosses the two radial extensors. The tendon which issues from it at this point is continued downwards over the outer side of the expanded lower end of the radius, and under cover of the posterior annular ligament. It is inserted into the radial side of the base of the metacarpal bone of the thumb.

The Extensor Primi Internodii Pollicis (extensor brevis pollicis) is placed along the lower border of the preceding muscle. It arises from a small portion of the posterior aspect of the radius, and also from the interosseous membrane. Its tendon is closely applied to that of the extensor ossis metacarpi pollicis, and accompanies it under the posterior annular ligament. It may be traced on the dorsal aspect of the metacarpal bone of the thumb to the base of the proximal phalanx, into which it is inserted.

The Extensor Secundi Internodii Pollicis (extensor longus pollicis) takes origin from the outer part of the posterior surface of the shaft of the ulna in its middle third, and also from the interosseous membrane. It to some extent overlaps the preceding muscle, and it ends in a tendon which passes under cover of the posterior annular

ligament. Here it occupies a deep narrow groove on the back of the lower end of the radius. On the carpus it takes an oblique course, and, crossing the tendons of the two radial extensors and the radial artery, reaches the thumb. It is inserted into the base of the distal phalanx of that digit.

When the thumb is powerfully extended in the living person the tendons of its three extensors become prominent on the outer aspect of the wrist. The oblique course of the tendon of the extensor secundi internodii is rendered evident, and a distinct depression between it and the other two tendons is seen.

The Extensor Indicis Proprius arises below the preceding muscle from a limited area on the posterior surface of the ulna and from the interosseous membrane. Its tendon accompanies those of the extensor communis under cover of the posterior annular ligament, and will afterwards be traced to its insertion on the index finger.

Posterior Interosseous Artery (arteria interossea dorsalis).—This vessel arises in the front of the forearm, from the common interosseous branch of the ulnar artery. It at once proceeds backwards between the two bones of the forearm, in the interval between the upper border of the interosseous membrane and the oblique ligament. In the present dissection it makes its appearance between the contiguous borders of the supinator brevis and the extensor ossis metacarpi pollicis, and then it extends downwards between the superficial and deep muscles on the back of the forearm. It gives branches to these, and by the time it has reached the lower end of the forearm it is greatly reduced in size. In a well-injected limb it will be seen to end on the back of the carpus by anastomosing with the anterior interosseous and the posterior carpal arteries. In addition to the branches which it supplies to the muscles, it gives off one large branch called the *posterior interosseous recurrent*.

The *posterior interosseous recurrent artery* (arteria interossea recurrens) takes origin from the parent trunk as it appears between the supinator brevis and the extensor ossis meta-

carpi pollicis, and turns upwards, under cover of the anconeus muscle, to reach the posterior aspect of the outer condyle of the humerus. The anconeus should be detached

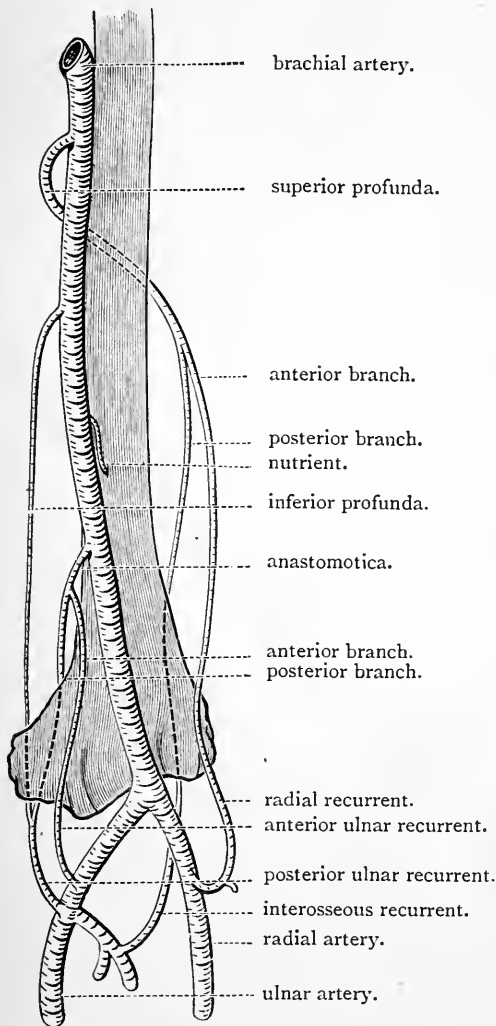


FIG. 31.—Diagram of the anastomosis around the elbow-joint.

from its origin and thrown inwards, in order that the artery may be traced to its termination. The interosseous recurrent artery will then be seen to end by anastomosing with the posterior terminal branch of the superior profunda artery.

The Anastomosis around the elbow-joint should now be reviewed as a whole. A distinct inosculation will be found to take place upon both the anterior and posterior aspect of each condyle of the humerus. Behind the external condyle the *posterior interosseous recurrent* joins the *posterior branch* of the *superior profunda*: in front of the same condyle the *anterior branch* of the *superior profunda* communicates with the *radial recurrent*. On the inner side of the joint the *anterior* and *posterior ulnar*

recurrent arteries anastomose with the *anterior* and *posterior ulnar*

recurrent arteries ascend respectively in front of and behind the internal condyle, and anastomose, the former with the *anterior branch of the anastomotica*, and the latter with the *posterior branch of the anastomotica* and the *inferior profunda*.

In this sketch of the anastomosis around the elbow-joint only the leading inosculation is mentioned. Rich networks of fine vessels are formed over the olecranon process and the two condyles of the humerus. One very distinct and tolerably constant arch requires special mention. It is formed by a branch which crosses the posterior aspect of the humerus immediately above the olecranon fossa, and connects the posterior branch of the superior profunda with the posterior branch of the anastomotica.

The Posterior Interosseous Nerve (*nervus interosseus dorsalis*) is one of the two terminal branches of the musculo-spiral, and it reaches the back of the forearm by traversing the substance of the supinator brevis, and at the same time winding round the outer aspect of the shaft of the radius. It emerges from the supinator brevis a short distance above the artery of the same name, and is carried downwards between the superficial and deep muscles on the back of the forearm. Reaching the upper border of the extensor secundi internodii pollicis, it leaves the posterior interosseous artery, dips under cover of that muscle, and joins the anterior interosseous artery on the posterior aspect of the interosseous membrane. It will afterwards be traced to the back of the carpus, where it ends, under cover of the tendons of the extensor communis digitorum, in a gangliform enlargement.

The *branches* which spring from the posterior interosseous nerve in the forearm are given entirely to muscles. Before it pierces the supinator brevis it gives branches both to it and to the extensor carpi radialis brevior. After it appears on the back of the forearm it supplies the extensor communis digitorum, the extensor minimi digiti, the extensor carpi ulnaris, the three extensors of the thumb, and the extensor indicis. It therefore supplies all the muscles on the outer and back aspects of the forearm, with the exception of

the supinator radii longus and the extensor carpi radialis longior, which derive their nerve-supply directly from the musculo-spiral. The anconeus also derives its main nerve of supply from the musculo-spiral, but it also frequently obtains a second twig from the posterior interosseous nerve.

Terminal Branch of the Anterior Interosseous Artery.—

The terminal or perforating branch of the anterior interosseous artery is a vessel of some size. It appears through the interosseous membrane, about two inches or so above the lower end of the forearm. Accompanied by the posterior interosseous nerve, it runs downwards, under cover of the extensor secundi internodii pollicis, and ends on the back of the carpus by anastomosing with the posterior carpal arch and the posterior interosseous artery.

DORSAL ASPECT OF THE WRIST AND HAND.

Upon the dorsal aspect of the wrist and hand we have still to examine—

1. The radial artery and its branches.
2. The posterior annular ligament.
3. The extensor tendons of the fingers.

Radial Artery.—It is only a small portion of the radial artery that is seen in this dissection. At the lower end of the radius the vessel turns backwards below the styloid process, and upon the external lateral ligament of the radio-carpal joint. Having gained the dorsal aspect of the carpus, it runs downwards upon the scaphoid and trapezium, and finally disappears from view by turning forwards through the upper part of the first interosseous space, and between the heads of origin of the first dorsal interosseous muscle. In the palm it takes the chief share in the formation of the deep palmar arch.

While the radial artery rests on the external lateral ligament, it is deeply placed, and is crossed by the tendons

of the extensor ossis metacarpi and the extensor primi internodii pollicis. On the carpus it lies nearer the surface, and is crossed obliquely by the third extensor tendon of the thumb, viz., the tendon of the extensor secundi internodii pollicis. It is accompanied by two *venæ comites* and some fine filaments from the musculo-cutaneous nerve which twine around it.

The *branches* which spring from the radial artery in this part of its course are of small size. They are—

1. The posterior radial carpal.
2. The first dorsal interosseous.
3. The two arteriæ dorsales pollicis.
4. The arteria dorsalis indicis.

The *posterior radial carpal artery* takes origin on the outer aspect of the wrist, and runs inwards upon the carpus, to join the corresponding carpal branch of the ulnar artery. The arch thus formed is placed under cover of the extensor tendons, and gives off two branches which run downwards in the third and fourth intermetacarpal intervals. They are termed the *second* and *third dorsal interosseous arteries*.

The *first dorsal interosseous artery* arises, as a rule, from the radial trunk, although not infrequently it may be seen to spring from the posterior carpal arch. It extends downwards in the second intermetacarpal interval.

The three dorsal interosseous arteries are brought into connection with the arteries in the palm by communicating branches. They are joined by the three perforating twigs of the deep palmar arch. These make their appearance on the dorsum between the heads of the three inner dorsal interosseous muscles. Further, at the lower ends of the interosseous spaces the dorsal interosseous arteries usually send *inferior perforating branches* to join the corresponding digital arteries in the palm.

The *two dorsal arteries of the thumb* run downwards upon either side of that digit.

The *dorsal artery of the index* is distributed on the radial side of the index.

Posterior Annular Ligament.—This has been seen to be an aponeurotic band which stretches obliquely across the wrist. It is merely a thickened portion of the deep fascia, and its attachments are so arranged that it does not interfere with the free movement of the radius and hand during pronation and supination. On the outer side it is fixed to the outer margin of the lower end of the radius, whilst on the inner side it is attached to the cuneiform and pisiform bones, and also to the palmar fascia. In the case of the anterior annular ligament one large compartment, or tunnel, is formed for the flexor tendons; not so in the case of the posterior annular ligament. Partitions or processes proceed from its deep surface, and these are attached to the ridges on the dorsal aspect of the lower end of the radius, so as to form a series of six bridges or compartments for the tendons. Each of these is lined by a special synovial sheath, to facilitate the play of the tendons within it. The different compartments may now be successively opened up, so that the arrangement of the tendons with reference to the posterior annular ligament may be studied.

The *first compartment* is placed on the outer side of the base of the styloid process of the radius, and corresponds with the broad oblique groove which is present in this part of the bone. It contains two tendons, viz., the tendons of the extensor ossis metacarpi and the extensor primi internodii pollicis. The *second compartment* corresponds with the outermost groove on the dorsal aspect of the radius. This is broad and shallow, and it holds the tendons of the extensor carpi radialis longior, and of the extensor carpi radialis breviar. The *third compartment* is formed over the narrow deep intermediate groove on the back of the lower end of the radius, and through it the tendon of the extensor secundi internodii pollicis passes obliquely. The *fourth compartment* is placed over the wide shallow groove which marks the inner part of the dorsal aspect of the lower end of the radius. It is traversed by five tendons, viz., the four tendons of the

common extensor and the tendon of the extensor indicis. The *fifth compartment* is situated over the interval between the lower ends of the radius and ulna. It contains the slender tendon of the extensor minimi digiti. The *sixth and innermost compartment*, which corresponds with the groove on the back of the lower end of the ulna, encloses the tendon of the extensor carpi ulnaris.

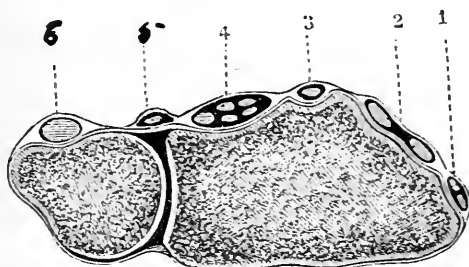


FIG. 32.—Diagrammatic section through the lower end of the forearm to show the compartments of the posterior annular ligament. (From Reeves, slightly modified.)

1. First compartment, with the tendons of the extensor ossis and extensor primi internodii pollicis.
2. Second compartment, with the tendons of the two radial extensors.
3. Third compartment, with tendon of extensor secundi internodii pollicis.
4. Fourth compartment, with the tendons of the extensor communis and extensor indicis.
5. Fifth compartment, with the tendon of the extensor minimi digiti.
6. Sixth compartment, with the tendon of the extensor carpi ulnaris.

Extensor Tendons of the Fingers.—The four tendons of the *extensor communis digitorum*, when they emerge from their compartment in the posterior annular ligament, diverge on the dorsum of the hand to reach the four fingers. The tendon of the ring finger will be seen to be connected by a tendinous slip with the tendon on either side of it. This explains the small degree of independent movement in a backward direction which the ring digit possesses. The arrangement of the tendons on the fingers is the same in each case. Upon the dorsal aspect of the first phalanx the tendon expands so as to cover it completely. Into the margins of this “*dorsal expansion*,” the delicate

tendons of the lumbrical and interosseous muscles are inserted. Near the first interphalangeal joint the expansion separates into three portions—a central and two lateral. The *central part*, which is the weakest, is inserted into the dorsal aspect of the base of the second phalanx. The *stronger lateral portions* unite into one piece beyond this, and gain an insertion with the base of the ungual phalanx.

The tendon of the *extensor indicis* joins the expansion of the extensor tendon on the dorsal aspect of the first phalanx of the index finger.

The tendon of the *extensor minimi digiti* splits into two parts. Of these the *outer* joins the tendon of the common extensor which goes to that digit, whilst the *inner* ends in the dorsal expansion.

Posterior Interosseous Nerve.—The terminal filament

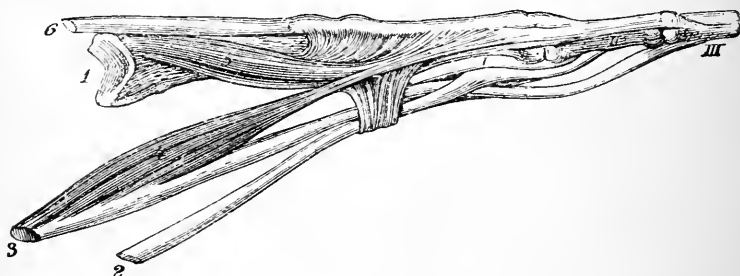


FIG. 33. (From Luschka.)

- | | |
|--------------------------------|---------------------------------------|
| 1. Middle metacarpal bone. | 4. Second lumbrical muscle. |
| 2. Tendon of flexor sublimis. | 5. Second dorsal interosseous muscle. |
| 3. Tendon of flexor profundus. | 6. Extensor tendon. |

I., II., and III. The three phalanges.

of this nerve can now be traced downwards to the dorsal aspect of the carpus. It passes under cover of the extensor indicis, the tendons of the extensor communis, and the posterior annular ligament. On the carpus it ends in a gangliform swelling, from which proceeds fine twigs for the supply of the numerous joints in the vicinity.

Dissection.—The limb should now be turned round, so that the

transverse metacarpal ligament which stretches across the palmar surface of the heads of the metacarpal bones may be examined previous to the dissection of the interosseous muscles.

Transverse Metacarpal Ligament.—The transverse metacarpal ligament is a strong band composed of transverse fibres, which is placed upon the palmar aspect of the heads of the four metacarpal bones of the fingers. Commencing on the outer side upon the distal extremity of the index metacarpal, it ends at the inner margin of the hand upon the head of the metacarpal bone of the little finger. It is not directly attached to the bones, but is fixed to the powerful anterior ligaments of the four inner metacarpophalangeal joints, and it effectually prevents excessive separation of the metacarpal bones from each other.

Dissection.—To obtain a satisfactory view of the interosseous muscles the adductor transversus pollicis, if not previously reflected, should be detached from its origin, and thrown outwards towards its insertion into the thumb. The transverse metacarpal ligament must also be divided in the intervals between the fingers.

The Interosseous Muscles occupy the intervals between the metacarpal bones. They are seven in number ; and are arranged in two groups, viz., a dorsal and a palmar.

The dorsal interossei (musculi interossei dorsales) are four in number, and are more powerful than the palmar muscles. They are best seen on the dorsal aspect of the hand, but they are also visible in the palm. They act as abductors of the fingers from a line drawn through the middle digit, and their insertions are arranged in accordance with this action. Each muscle arises by two heads from the contiguous surfaces of the two metacarpal bones between which it lies, and the fibres converge in a pennate manner upon a delicate tendon. In the case of *the first or outermost dorsal interosseous muscle*, this tendon is inserted into the radial side of the base of the first phalanx, and also into the radial margin of the dorsal expansion of the extensor tendon of the index. The *second and third dorsal interosseous muscles* are inserted in a similar manner upon either side of the base of the first

phalanx of the middle finger; whilst the *fourth* has a corresponding insertion upon the ulnar aspect of the base of the first phalanx of the ring finger.

The first dorsal interosseous muscle is frequently termed the *abductor indicis*, and between its two heads of origin the radial artery enters the palm. Between the heads of the other three muscles the small posterior perforating arteries pass.

The three *palmar interosseous muscles* (*musculi interossei volares*) can only be seen on the palmar aspect of the hand. They act as adductors of the index, ring, and little fingers towards the middle digit, and each muscle is placed upon the metacarpal bone of the finger upon which it acts. The *first palmar interosseous muscle* therefore arises from the metacarpal bone of the index finger, and its delicate tendon is inserted upon the ulnar side of that digit, partly into the base of the first phalanx, and partly into the extensor expansion. The *second palmar interosseous muscle* springs from the metacarpal bone of the ring finger, and has a similar insertion into the radial side of that digit. The *third palmar interosseous muscle* takes origin from the metacarpal bone, and presents a corresponding insertion into the radial side of the first phalanx and extensor expansion of the little finger. The interosseous muscles are supplied by the deep branch of the ulnar nerve.

Deep Head of the Flexor Brevis Pollicis (*interosseus primus volaris* of Henle).—This minute muscle can best be displayed from the dorsal aspect of the hand by reflecting the radial head of the first dorsal interosseous muscle. It arises from the base of the metacarpal bone of the thumb, and is inserted into the ulnar sesamoid bone of that digit. It is deeply placed, and is entirely covered from the front by the adductor obliquus pollicis.

Tendon of the Flexor Carpi Radialis.—The tendon of this muscle should now be traced through the groove on the front of the trapezium to its insertion into the base of the metacarpal bone of the index. It presents also a minor attachment to the base of the middle metacarpal bone.

Dissection.—All the muscles around the elbow-joint should be removed. In raising the brachialis anticus and the triceps from the front and back of the articulation, some care is required to avoid injury to the anterior and posterior ligaments. It is advisable to remove the supinator brevis last, because it is only when this muscle is completely isolated that a proper idea of its attachments and mode of action can be obtained.

Supinator Radii Brevis.—The supinator brevis envelops the upper part of the shaft and the neck of the radius, covering it completely, except on its inner side. It arises from the deep depression below the lesser sigmoid cavity of the ulna, and also from the external lateral ligament of the elbow and the orbicular ligament of the radius. From this origin the fibres sweep round the posterior, outer and anterior surfaces of the radius, and clothe its shaft as far down as the insertion of the pronator radii teres. The posterior interosseous nerve traverses the substance of the muscle, and separates it into two layers. ✕

ARTICULATIONS.

Elbow-joint (articulatio cubiti).—At the elbow-joint the trochlear surface of the humerus is grasped by the greater

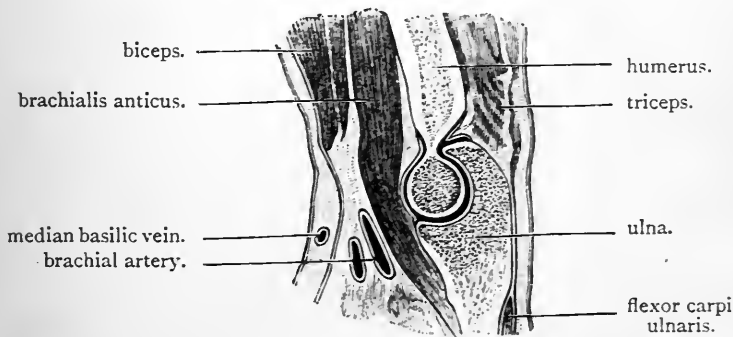


FIG. 34.—Vertical section through humerus and ulna at the elbow-joint.

sigmoid cavity of the ulna. The shallow depression on the upper surface of the head of the radius rests upon the

capitellum of the humerus, and its slightly raised rim occupies the groove on the lower end of the humerus between the capitellum and the trochlea.

The *ligaments* of the elbow-joint are arranged in the form of a capsule which surrounds the articulation on all sides. From the differences which this exhibits in strength and attachments four portions are recognised. These are—

1. The external lateral ligament.
2. The internal lateral ligament.
3. The anterior ligament.
4. The posterior ligament.

The External Lateral Ligament (*ligamentum collaterale radiale*) is a strong but short ligamentous band which is attached above to the lower aspect of the external condyle of the humerus. Below, it is fixed to the orbicular ligament of the radius, and also to the outer side of the olecranon process of the ulna behind this. The orbicular ligament, as we shall afterwards see, is a strong ligamentous collar which surrounds the head of the radius, and retains it in the lesser sigmoid cavity of the ulna.

The Internal Lateral Ligament (*ligamentum collaterale ulnare*) is fan-shaped. By its upper pointed part it is attached to the internal condyle of the humerus. Inferiorly it spreads out to find insertion into the coronoid and olecranon processes of the ulna. When carefully dissected it will be noticed to consist of three portions, viz., an anterior, a posterior, and a transverse.

The *anterior part* springs from the lower and front part of the humeral condyle, and is attached to the inner margin of the coronoid process of the ulna. The *posterior part* is attached above to the lower and back part of the humeral condyle, whilst below it is fixed to the inner border of the olecranon process. The *transverse part* consists of a narrow band of fibres, which bridges across the notch between the olecranon and the coronoid processes, and is attached to both.

The Anterior Ligament is broad, and composed of

fibres which take an irregular course over the anterior aspect of the joint. It is attached to the front of the humerus above the coronoid fossa, whilst below it is inserted into the margin of the coronoid process of the ulna, and also into the orbicular ligament of the radius.

The Posterior Ligament is weaker than the anterior. It has a loose attachment to the back of the humerus, above the olecranon fossa, and inferiorly it is fixed to the olecranon and the orbicular ligament of the radius.

Synovial Membrane.—The joint should be opened by

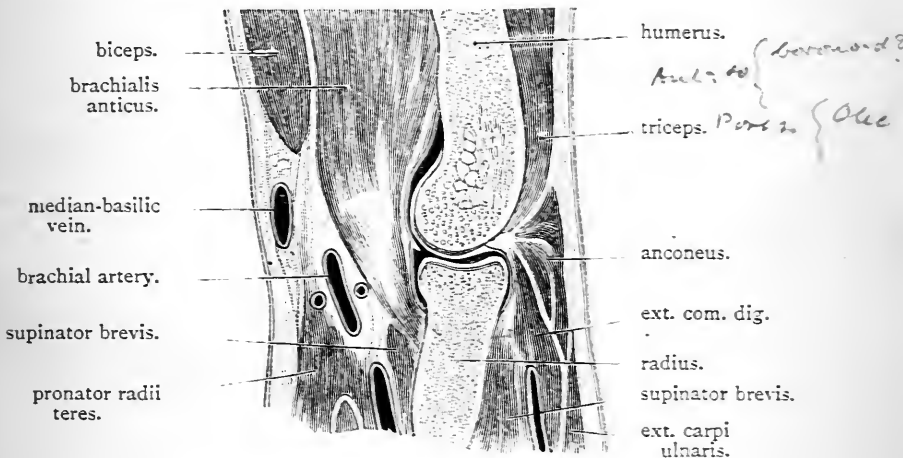


FIG. 35.—Vertical antero-posterior section through the humerus and radius at the elbow-joint.

making a transverse incision through the anterior ligament. The synovial membrane will be seen lining the deep surface of the ligamentous capsule, and to be reflected from this upon the non-articular parts of the bones which are enclosed within the ligaments. In front of the humerus it lines the radial and coronoid fossæ, and behind it is prolonged upwards in the form of a loose diverticulum into the olecranon fossa. In these fossæ a quantity of soft oily fat is developed in connection with the synovial membrane. In this way pliable pads are formed which occupy the recesses when the bony processes are withdrawn from them.

Inferiorly the synovial membrane of the elbow-joint is prolonged downwards into the superior radio-ulnar joint, so that both articulations possess a single continuous synovial cavity.

Movements at the Elbow-joint.—The movements at the elbow-joint must not be confounded with those that take place at the superior radio-ulnar joint. At the elbow-joint two movements, viz., *flexion*, or forward movement of the forearm, and *extension*, or backward movement of the forearm, are permitted.

The muscles which are chiefly concerned in flexing the forearm upon the upper arm at the elbow-joint are the biceps, the brachialis anticus, the pronator radii teres, and the supinator longus. The muscles which extend the forearm at this articulation are the triceps and anconeus.

Dissection.—It is advisable to study the radio-carpal, or wrist-joint, before the articulations between the two bones of the forearm are examined. The anterior and posterior annular ligaments, together with the extensor and flexor tendons, should be completely removed from the wrist. No attempt, however, should be made to detach the extensor tendons from the back of the fingers and thumb. The short muscles of the thenar and hypothenar eminences must also be taken away.

Radio-carpal Joint (articulatio radiocarpea).—In the radio-carpal joint, the under surface of the radius, with a triangular plate of fibro-cartilage on its inner side, forms a shallow socket for the scaphoid, semilunar, and cuneiform bones. The ulna does not take part in this articulation, as the triangular fibro-cartilage is interposed between its lower end and the carpus.

The ligaments which retain the opposed surfaces in contact with each other are four in number, viz.—

- | | | |
|---------------|--|--------------|
| 1. Anterior. | | 3. Internal. |
| 2. Posterior. | | 4. External. |

The Anterior Ligament (ligamentum radiocarpeum volare) is strong and broad, and it is composed of fibres which run in different directions, although those which pass obliquely downwards and inwards predominate. Above it is attached to the lower border of the inferior expanded extremity of the radius; and below, it is inserted into the bones which constitute the first row of the carpus.

with the exception of the pisiform, viz., into the scaphoid, semilunar, and cuneiform. Some of the fibres may be traced beyond the first carpal row on to the os magnum.

The Posterior Ligament (ligamentum radiocarpeum dorsale) is weak in comparison with the anterior ligament. The direction of its fibres is for the most part downwards and inwards. It arises above from the posterior aspect of the lower end of the radius, and is attached below to the scaphoid, semilunar, and cuneiform bones.

The External Lateral Ligament passes from the tip of the styloid process of the radius to the scaphoid bone.

The Internal Lateral Ligament is round and cord-like. It stretches from the styloid process of the ulna to the cuneiform and pisiform bones.

The four ligaments which we have described in connection with the radio-carpal joint are directly continuous with each other, and in consequence they form a capsule around the articulation.

Articular Surfaces.—Divide the anterior and lateral ligaments of the radio-carpal joint by a transverse incision carried across the front of the articulation. The hand can now be bent backwards, so as to expose fully the articular surfaces opposed to each other in this joint.

The *carpal surface* is composed of the superior articular facets of the scaphoid and semilunar bones, and a very small articular facet on the extreme outer part of the upper surface of the cuneiform bone. Two interosseous ligaments stretch across the narrow intervals between these bones—one on either side of the semilunar—and complete the carpal surface. Formed of these factors, the carpal surface is convex both from before backwards and from without inwards. Further, it should be observed that it extends downwards to a greater extent behind than in front.

The *upper surface* or *socket* (Fig. 36), is elongated from side to side, and concave in both directions, viz., from before backwards and from without inwards. The greater part of it is formed by the lower end of the radius, but to the inner side of this the triangular fibro-cartilage of the inferior radio-ulnar

joint likewise enters into its construction. The lower surface of the radius is divided by a low ridge into an outer triangular and an inner quadrilateral facet. The outer facet, in the ordinary position of the hand, is in contact with the greater extent of the superior articular surface of the scaphoid. The inner facet of the radius, with the triangular fibro-cartilage, forms a much larger surface, triangular in outline, which is opposed to the superior articular surface of the semilunar. When the hand is placed in line with the forearm no part of the upper articular surface is allotted to the cuneiform: its small articular facet rests against the inner part of the capsule of the joint. When the hand is moved

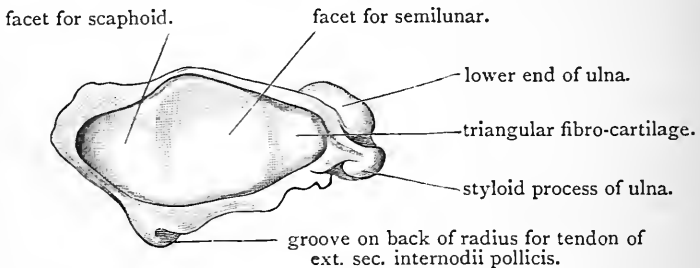


FIG. 36.—Socket formed by left radius and triangular fibro-cartilage for the upper row of carpal bones.

inwards (*i.e.*, adducted), however, the cuneiform bone travels outwards, and its articular surface comes into contact with the under surface of the triangular fibro-cartilage. The semilunar bone at the same time crosses the bounding ridge on the lower surface of the radius, and encroaches on the territory of the scaphoid, whilst a considerable part of the scaphoid surface leaves the radius, and comes into contact with the outer part of the capsule.

Synovial Membrane.—The synovial membrane of the radio-carpal joint lines the deep surfaces of the ligaments forming the capsule, and between the carpal bones it covers the upper surfaces of the two interosseous ligaments which complete the carpal surface. Sometimes the triangular fibro-cartilage is imperfect, and in these cases the synovial membrane of the radio-carpal joint becomes continuous

with the synovial membrane of the inferior radio-ulnar joint.

Movements at the Radio-carpal Joint.—The hand can be moved in four directions at the radio-carpal joint. Thus we have—(a) forward movement, or *flexion*; (b) backward movement, or *extension*; (c) inward movement, or *adduction*; (d) outward movement, or *abduction*. In estimating the extent of these movements in the living person the student is apt to be misled by the increase of range which is contributed by the carpal joints. Thus, flexion at the radio-carpal joint is in reality more limited than extension, although by the combined action of both carpal and radio-carpal joints the hand can be carried much more freely

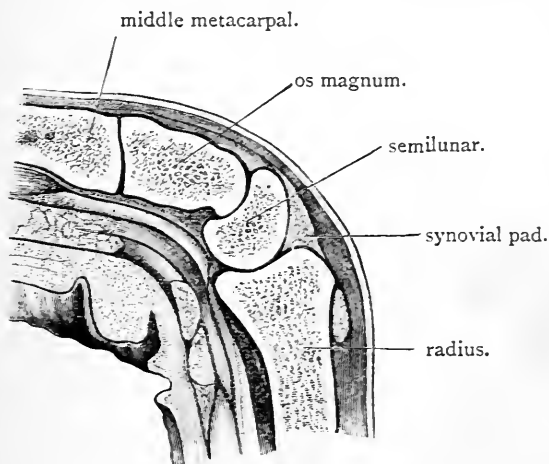


FIG. 37.—Vertical section through the flexed wrist-joint in the line of the middle finger. It shows that a greater degree of movement has taken place at the transverse carpal joint than at the radio-carpal joint.

forwards than backwards (Fig. 37). Adduction, or ulnar flexion, can be produced to a greater extent than abduction, or radial flexion.

In both cases the extent of movement at the radio-carpal joint proper is very slight but the range is extended by movements of the carpal bones. The styloid process of the radius interferes with abduction. The *muscles* which are chiefly concerned in producing these different movements of the hand at this joint are the following:—(a) *flexors*—the flexor carpi radialis, the palmaris longus, and the flexor carpi ulnaris; (b) *extensors*—extensor carpi radialis longior, the extensor carpi radialis brevior, and the extensor carpi ulnaris; (c) *abductors*, or *radial flexors*—flexor carpi radialis, extensor carpi radialis longior, extensor ossis metacarpi pollicis, and the extensor primi internodii pollicis; (d) *adductors*, or *ulnar flexors*—extensor carpi ulnaris and flexor carpi ulnaris.

Radio-ulnar Joints.—At the radio-ulnar joints the movements of pronation and supination take place. They are two in number, viz., a superior and an inferior. At the *superior radio-ulnar articulation* (articulatio radioulnaris proximalis), the inner part of the head of the radius fits into the lesser sigmoid cavity of the ulna; at the *inferior radio-ulnar joint* the small rounded extremity of the ulna is received into the sigmoid cavity on the inner side of the lower end of the radius. In connection with these joints there are special ligaments which retain the bones in apposition. These are—(1) for the superior radio-ulnar joint, *the orbicular ligament*; and (2) for the inferior radio-ulnar joint, (a) an *anterior and posterior ligament*, and (b) a connecting *triangular fibro-cartilage*.

In addition there are other ligaments which pass between the shafts of the two bones of the forearm, and are therefore common to the two articulations, viz., *the oblique ligament* and the *interosseous membrane*.

To expose these ligaments the muscles on the front and back of the forearm must be completely removed.

Orbicular Ligament (ligamentum annulare radii).—This is a strong ligamentous collar which encircles the head of the radius, and retains it in the lesser sigmoid cavity of the ulna. It forms four-fifths of a circle, and is attached by its extremities to the ulna, in front and behind the lesser sigmoid cavity. It is somewhat narrower below than above, so that under no circumstances could the head of the radius be withdrawn from it in a downward direction, and it is braced tightly upwards towards the elbow, and greatly strengthened by certain ligaments of the elbow-joint which become incorporated with it along its upper border. These are, on the outer side, the external lateral ligament of the elbow, in front a portion of the anterior ligament, and behind a portion of the posterior ligament of the elbow-joint. Its lower border is free, and protruding downwards below this will be seen a reflection of the synovial membrane.

The Anterior and Posterior Inferior Radio-ulnar Ligaments are weak, imperfect bands which can have little influence in retaining the bones in apposition at the inferior radio-ulnar joint. They pass between the radius and ulnar in front and behind the articulation, and close in the synovial membrane upon these aspects of the joint.

The Triangular Fibro-cartilage is the true bond of union at the inferior radio-ulnar joint. It has already been noticed in connection with the radio-carpal joint, where it extends the radial articular surface in an inward direction, and is interposed between the lower end of the ulna and the semilunar bone. It is a thick, firm plate, attached by its base to the margin on the inner and lower end of the radius which intervenes between the sigmoid cavity for the ulna, and the facet on its lower surface for the semilunar bone. Its apex is directed inwards, and is fixed to the depression on the lower end of the ulna at the root of the styloid process. It intervenes between the inferior radio-ulnar joint and the radio-carpal joint.

Synovial Membranes.—The synovial membrane of the superior radio-ulnar joint is continuous with that of the elbow-joint. It is prolonged downwards so as to line the orbicular ligament, and it protrudes beyond this for a short distance upon the neck of the radius.

In the inferior radio-ulnar joint the synovial membrane is remarkable for its laxity. It is called the *membrana sac-ciformis*, and extends upwards in the form of a loose sac for some distance between the radius and ulna. The synovial cavity is also prolonged inwards in a horizontal direction between the lower end of the ulna and the triangular fibro-cartilage.

Sometimes the triangular fibro-cartilage is perforated; and when this is the case, the inferior radio-ulnar joint-cavity communicates with the cavity of the radio-carpal joint.

The Interosseous Membrane (*membrana interossea antibrachii*) is a fibrous membrane which stretches across the interval between the two bones of the forearm, and is

attached to the interosseous border of each. Superiorly it is deficient. Its upper border does not reach higher than a point about an inch below the tubercle of the radius. The fibres which compose it run for the most part obliquely downwards and inwards from the radius to the ulna, although several slips may be noticed taking an opposite direction. The posterior interosseous vessels pass backwards between the two bones of the forearm immediately above its upper margin, whilst the terminal branch of the anterior interosseous artery pierces it about one and a half inches above its lower end. This ligament, in addition to bracing the two bones together in such a manner that to some extent forces may be transmitted from the radius to the ulna, extends the surface of origin for the muscles of the forearm. By its anterior surface it gives origin to the flexor profundus and the flexor longus pollicis muscles, whilst by its posterior surface it contributes fibres to the three extensor muscles of the thumb and to the extensor indicis.

The Oblique Ligament (*chorda obliqua*) is a weak slip which springs from the outer part of the coronoid process of the ulna, and extends obliquely downwards and outwards to find an attachment to the radius immediately below its bicipital tubercle. It crosses the open space between the bones of the forearm above the upper border of the interosseous membrane. The oblique ligament is often absent, and unless the utmost care be taken in removing the muscles in the preparation of the ligaments it is apt to be injured.

Movements at the Radio-ulnar Joints.—At the radio-ulnar joints the movements of pronation and supination take place. When the limb is in a condition of complete supination the palm of the hand is directed forwards, the thumb outwards, and the two bones of the forearm are parallel, the radius lying along the outer side of the ulna. In the movement of pronation the radius is thrown across the ulna, so that its lower end comes to lie on the inner side and in front of it. Further the hand follows the radius in this movement, and the dorsal aspect of both is directed to the front, and the thumb is turned inwards.

The dissector should analyse, as far as possible, in the part upon

which he is engaged, the movements at the two radio-ulnar joints which produce these effects. At the same time it should be remembered that results obtained from a limb, in which the dissection has proceeded so far, are apt to be deceptive.

In the case of the superior radio-ulnar joint the movement is simple enough. The head of the radius merely rotates within the orbicular ligament, and accuracy of motion is obtained by the cup-like depression on the upper end of the radius, resting and moving upon the rounded capitellum of the humerus. But it should be noticed that the head of the radius does not fit accurately upon the capitellum in all positions of the elbow-joint. In extreme extension and extreme flexion of the elbow it is only partially in contact with it. Therefore the semi-flexed condition of the elbow-joint places the radius in the most favourable position for free and precise movement at the superior radio-ulnar joint.

At the inferior radio-ulnar joint the lower end of the radius revolves around the lower end of the ulna, and carries the hand with it. In this movement the triangular fibro-cartilage moves with the radius, and travels backwards on the lower end of the ulna in supination, and forwards in pronation.

But the question may be asked, Does the ulna move during pronation and supination? When the elbow-joint is extended to its fullest extent the ulna remains almost immovable. When, however, pronation and supination are conducted in the semi-flexed limb, the ulna does move. A small degree of lateral movement at the elbow-joint is allowed, and the lower end of the ulna during pronation is carried slightly backwards and outwards, and in the reverse direction during supination.

The muscles which are chiefly concerned in producing *supination* of the forearm are—the biceps, the supinator longus, and the supinator brevis. The biceps, from its insertion into the back part of the radial tubercle, is placed in a very favourable position, in so far as its supinating action is concerned. The muscles which act as *pronators* of the limb are—the pronator radii teres, the pronator quadratus, and, to a certain extent, the flexor carpi radialis. The pronator radii teres, from its insertion into the point of maximum outward curvature of radius, can exercise its pronating action to great advantage. The balance of power is in favour of the supinators, and this is due to the preponderating influence of the biceps.

Dissection.—The ulna should be sawn through at the junction of its middle and lower thirds, and the interosseous membrane where it binds the lower portion of the bone to the radius divided in a downward direction. By drawing the lower fragment of the ulna inwards and opening the membrana sacciformis, the upper surface of the triangular fibro-cartilage of the wrist will be displayed and its attachments more fully appreciated.

Carpal Joints.—In studying the articulations of the carpal bones we recognise—

1. A joint between the pisiform and cuneiform bones.
2. Two joints between the remaining bones of the first row, viz., the scaphoid, semilunar, and cuneiform.
3. Three joints between the bones of the second row, viz., the trapezium, trapezoid, os magnum, and unciform.
4. A transverse carpal joint between the two rows of carpal bones.

The pisiform joint is distinct and separate. All the others present a single joint-cavity. Further, this common cavity is continued into the articulations between the metacarpal bones of the four fingers and the carpus, and also into the intermetacarpal articulations.

Pisiform Joint.—The pisiform bone is fixed to the cuneiform by a capsular ligament which surrounds the joint. There is a separate synovial membrane for this articulation.

The dissector has previously noted that the tendon of the flexor carpi ulnaris is inserted into the upper aspect of the pisiform bone. The capsular ligament by itself would be insufficient to withstand the strain to which this muscle subjects the articulation. Certain accessory ligaments are therefore provided, which anchor the pisiform firmly in its place. These consist of two strong ligamentous bands which pass from its lower surface to the hook of the unciform bone, and to the base of the fifth metacarpal bone. Additional security is frequently given by bands which connect it with the bases of the fourth and third metacarpal bones.

First Row of Carpal Bones.—*Two dorsal, two palmar, and two interosseous* ligaments pass transversely from the semilunar to the scaphoid and cuneiform bones which lie on either side of it.

The two interosseous ligaments are composed of short stout fibres which pass between the non-articular portions of the opposed surfaces of the three bones. They are readily seen from above, where they complete the carpal surface of the radio-carpal joint.

The Second Row of Carpal Bones.—*Three palmar, three*

dorsal, and *three interosseous* ligaments pass transversely between the adjacent bones.

The interosseous ligament between the os magnum and unciform is very powerful and strong; that between the os magnum and trapezoid is weak, and sometimes absent.

At the present moment the interosseous ligaments are hidden from view, but they can be studied when the transverse carpal joint between the two rows of bones is opened.

Transverse Carpal Joint (between the two rows of carpal bones).—*Two lateral ligaments*, which pass between the

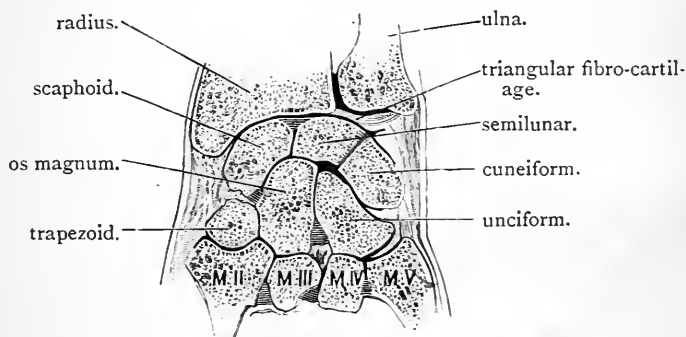


FIG. 38.—Coronal section through the carpal joints.

scaphoid and trapezium on the outer side, and the cuneiform and unciform bones on the inner side, together with a series of *palmar* and *dorsal bands*, and *one interosseous ligament*, connect the two rows of carpal bones together.

The *palmar ligaments* show a tendency to converge upon the os magnum, whilst the *dorsal ligaments* are very irregular. The *interosseous ligament* is placed between the os magnum and scaphoid bones, but is not always present.

Dissection.—To display the articular surfaces and interosseous ligaments of the second row it is necessary to open the transverse carpal joint. This can be done by dividing the two lateral and the dorsal ligaments. The interosseous ligament between the scaphoid and os magnum, if present, will now come into view, and it must be cut, to allow the thorough separation of the two rows of carpal bones.

Articular Surfaces.—The os magnum and unciform form

a high convexity, which fits into the concavity of the upper row, whilst the convex lower surface of the scaphoid is received into a concavity formed by the trapezium and trapezoid. The two opposing surfaces, therefore, are concavo-convex from side to side, and adapted the one to the other.

Movements at the Carpal Joints.—The movements at the carpal joints supplement those at the radio-carpal joint, and tend greatly to increase the range of movement at the wrist (Fig. 37). Between the individual bones of each row the movement is of a gliding character, and very limited. At the transverse carpal joint forward and backward movement (flexion and extension) is alone allowed.

By the multiplicity of joints in this part of the limb, strength and elasticity is contributed to the wrist.

Dissection.—The interosseous muscles should now be removed from the metacarpal bones. At the same time the flexor tendons and lumbrical muscles may be detached from the fingers. The extensor tendons, however, should be left in position on the dorsal surface of the metacarpo-phalangeal and interphalangeal joints. The ligaments which connect the carpus and metacarpus, and those which pass between the bases of the four inner metacarpal bones, should be cleaned and defined.

Intermetacarpal Joints.—The four metacarpal bones of the fingers articulate with each other by their basal or proximal extremities, and are united together by strong ligaments. The metacarpal bone of the thumb stands aloof from its neighbours, and enjoys a much greater freedom of movement.

The ligaments which bind the four inner metacarpal bones to each other are—

1. A series of *palmar* and *dorsal* bands which pass transversely, and connect their basal extremities.

2. *Three stout interosseous ligaments*, which occupy the intervals between the basal ends of the bones.

3. The *transverse metacarpal ligament*, which connects the heads or distal extremities of the bones (p. 143). This ligament has been removed in the dissection of the interosseous muscles.

The *interosseous ligaments* cannot be seen at present, but can be

studied later on by separating the bases of the metacarpal bones from each other.

Carpo-metacarpal Joints.—The *metacarpal bone of the thumb* articulates with the trapezium by a joint which is quite distinct from the other carpo-metacarpal articulations. A *capsular ligament* surrounds the joint, and is sufficiently lax to allow a very considerable range of movement. On the dorsal and outer aspects of the articulation it is specially thickened. It encloses a separate synovial membrane.

The *four inner metacarpal bones* are connected to the carpus by *palmar* and *dorsal ligaments*, and by *one interosseous ligament*.

Each of these metacarpal bones, with the exception of the fifth, possesses, as a rule, two dorsal ligaments and one palmar ligament. The articulation of the fifth metacarpal bone is also closed on the inner side by ligamentous fibres.

The *interosseous ligament* springs from the contiguous lower margins of the os magnum and unciform, and passes to the inner side of the base of the third metacarpal bone.

Dissection.—To display this ligament, divide the bands which connect the bases of the third and fourth metacarpal bones, and sever the dorsal ligaments which bind the two inner metacarpal bones to the carpus. The metacarpal bones thus set free can then be forcibly bent forward, when the ligament in question will come into view.

Synovial Membranes of the Carpal, Carpo-metacarpal and Intermetacarpal Joints.—The pisiform joint, and the carpo-metacarpal joint of the thumb, possess each a separate synovial membrane. The other carpal, and carpo-metacarpal and also the intermetacarpal articulations present one continuous joint cavity, and possess a single synovial membrane. This complicated and extensive synovial membrane may be seen to pass upwards in the intervals between the three bones of the first row (scaphoid, semilunar, and cuneiform) as far as the interosseous

ligaments. It lines the under surfaces of these, and is excluded by them from the radio-carpal joint. In a downward direction it may be traced between the four bones of the second row to the carpo-metacarpal joints of the four fingers, and from these it finds its way into the three intermetacarpal articulations.

In some cases the interosseous ligament which connects the base of the third metacarpal to the os magnum and unciform shuts off the articulation of the unciform with the two inner metacarpal bones, and also the innermost intermetacarpal articulation from the general joint-cavity. In such cases a separate synovial membrane is provided for these articulations.

Dissection.—To display the articular surfaces of the carpo-metacarpal articulations, the metacarpus should be detached from the carpus. The interosseous ligaments between the carpal bones of the second row, and also between the bases of the four inner metacarpal bones, can likewise be demonstrated by carrying the knife between the bones, and dividing the ligaments.

Articular Surfaces.—The base of the metacarpal bone of the index will then be seen to be hollowed out for the reception of the trapezoid. On the outer side it likewise articulates with the trapezium, and on the inner side with the os magnum. The base of the third metacarpal rests on the os magnum alone. The base of the metacarpal bone of the ring finger rests upon the unciform, but also articulates slightly with the os magnum. The fifth metacarpal bone articulates with the unciform.

Movements of the Metacarpal Bones.—The opposed saddle-shaped surfaces of the trapezium and thumb-metacarpal allow very free movement at this joint. Thus the metacarpal bone of the thumb can be moved—(1) backwards and outwards (extension); (2) forwards and inwards (flexion): inwards towards the index finger (adduction); (4) outwards (abduction): (5) inwards across the palm towards the little finger (opposition). The muscles which operate upon the thumb are—(1) the three extensors (extensor ossis metacarpi, extensor primi internodii, and the extensor secundi internodii), producing *extension*; (2) the flexor brevis pollicis and the opponens pollicis, producing *flexion* and *opposition*, two movements which are similar in character; (3) the

abductor pollicis, which produces *abduction*; (4) and the two adductors (adductor obliquus and the adductor transversus), which give rise to *adduction*.

The metacarpal bones of the middle and index fingers possess very little power of independent movement. The metacarpal bone of the ring finger, and more especially the metacarpal bone of the little finger, are not so tightly bound to the carpus. In clenching the fist they both move forwards. The metacarpal bone of the little finger is provided with an opponens muscle, and has a feeble power of advancing forwards and outwards to meet the thumb.

Metacarpo - phalangeal Articulations.—The slightly cupped base of the first phalanx of each digit articulates with the rounded head of the corresponding metacarpal bone, and is held in position by three ligaments, viz., a palmar and two lateral.

The *palmar ligament* is a dense fibrous plate placed on the fore aspect of the joint. It is firmly attached to the base of the phalanx, but only slightly connected with the metacarpal bone. Occupying the interval between the two lateral ligaments, it is united to both by its margins, so that the three ligaments are more or less directly continuous.

The palmar ligament also exhibits a close connection with the transverse metacarpal ligament which stretches transversely across the heads of the metacarpal bones, and its palmar surface is grooved for the flexor tendons as they proceed downwards over the joint. Further, the flexor sheath which bridges over the tendons is fixed to its borders.

The *lateral ligaments* are placed one on either side of the joint. They are strong, thick, and short bands, which are attached on the one hand to the tubercle and depression on the lateral aspect of the head of the metacarpal bone, and on the other to the base of the phalanx.

Dissection.—The extensor tendon should now be raised from the dorsal aspect of the joint. By this proceeding the joint is opened, and a demonstration is afforded of the fact that the metacarpo-phalangeal joints are destitute of dorsal ligaments.

A *synovial membrane* lines the deep surfaces of the liga-

ments in each joint, and also the deep surface of the extensor tendon, as it passes over the articulation and takes the place of a dorsal ligament.

Movements at the Metacarpo-phalangeal Joints.—The movements of the first phalanx at these joints are—(a) *flexion*, or forward movement; (b) *extension*, or backward movement; (c) *abduction*; and (d) *adduction*.

During flexion of the fingers, the first phalanx travels forwards with the thick palmar ligament upon the head of the metacarpal bone. The *interosseous* and *lumbrical* muscles are chiefly instrumental in producing this movement.

The first phalanges of the fingers in the movement of extension can only be carried backwards to a very slight degree beyond the line of the metacarpal bones. The *extensor communis* and the *special extensors of the index and little finger* are the muscles which operate in this case.

Abduction and adduction are movements of the first phalanx away from and towards a line prolonged downwards through the middle finger, and are seen when the fingers are spread out and again drawn together. The *abductor minimi digiti* and the *dorsal interosseous* muscles act as abductors of the fingers at these joints, whilst the *palmar interosseous* muscles operate as adductors of the little, ring, and index fingers. In the case of the middle digit, the *second and third dorsal interosseous muscles* act alternately as abductors and as adductors. In connection with the movements of abduction and adduction, it should be noticed that in the extended position of the fingers they are very free; but if flexion be induced, the power of separating the fingers becomes more and more restricted, until it becomes absolutely lost when the hand is closed. An examination of the lateral ligaments will afford the explanation of this. These “are attached far back on the metacarpal bones, so as to be much nearer to their inferior ends than to their palmar aspects” (Cleland). Consequently, whilst they are comparatively lax in the extended position of the fingers, the further flexion advances the tighter they become, and in this way they interfere with the lateral movements of the first phalanges.

The first phalanx of the thumb has only a limited range of movement at the metacarpo-phalangeal joint.

Interphalangeal Joints.—The ligaments connecting the phalanges are arranged upon a plan identical with that already described in connection with the metacarpo-phalangeal joints. This should not be made an excuse, however, to slur them over.

Movements.—From the manner in which the articular surfaces are

adapted to each other, flexion and extension are the only movements which can take place at the interphalangeal joints. Flexion of the second phalanges of the fingers is brought about by the flexor sublimis, and of the unguis phalanges by the flexor profundus. Extension of the phalanges at the interphalangeal joints is largely produced by the interosseous and lumbrical muscles acting through the extensor tendons, into which they are inserted. These muscles, therefore, whilst they flex the first phalanx at the metacarpo-phalangeal joints, extend the second and unguis phalanges at the interphalangeal joints.

In the case of the thumb, the long flexor and the extensor secundi internodii pollicis operate at the interphalangeal joint. ✕

THE LOWER LIMB.

ON the morning of the third day, after the subject has been brought into the dissecting-room, it is placed upon the table with its face downwards and its chest and pelvis supported by blocks (Fig. 1, p. 3). In this position it is allowed to remain for *four* days, and during this time the dissector of the lower limb has a very extensive dissection to perform. He has to dissect—(1) the gluteal region; (2) the popliteal space; and (3) the back of the thigh. With so much work before him, and being limited as to the time in which it must be done, it is very necessary that he should apportion the four days at his disposal so as to complete the dissection before the body is turned. The *first two days* he should devote exclusively to the study of the gluteal region; the *third day* may be given to the popliteal space; and on the *fourth day* he should undertake the dissection of the back of the thigh, and revise the work of the three preceding days.

GLUTEAL REGION.

In this region the following are the parts which will be displayed in the course of the dissection :—

1. Superficial fascia.
2. Cutaneous nerves and blood-vessels.
3. Deep fascia.
4. Muscles, . . . {
 - The gluteus maximus ; (and after this has been reflected).
 - Three synovial bursæ.
 - Gluteus medius and minimus.
 - Pyriformis.
 - The two gemelli and the tendon of the obturator internus.
 - The tendon of the obturator externus.
 - The quadratus femoris.
 - Upper border of the adductor magnus.
 - The origin of the hamstrings from the tuberosity of the ischium.
 - The upper part of the vastus externus.
5. The great sacro-sciatic ligament.
6. Blood-vessels, {
 - Gluteal.
 - Sciatic.
 - Internal pudic.
 - Internal circumflex.
7. Nerves, . . . {
 - Superior gluteal.
 - Great sciatic.
 - Small sciatic.
 - Internal pudic.
 - Nerve to obturator internus.
 - Nerve to quadratus femoris.
 - Special branches to gluteus maximus (inferior gluteal nerve).

Supposing that *two days* are allowed for the above dissection, the **first day's work** should consist—(1) in the dissection of the parts superficial to the gluteus maximus ; (2) in the cleaning and reflecting of this muscle ; (3) in tracing and defining the various nerves and blood-vessels which enter its deep surface. **On the second day** the parts which are exposed by the reflection of the gluteus maximus should be dissected.

Surface Anatomy.—Before the skin is reflected, the surface markings of the gluteal region require examination.

On each side, the prominence of the nates is seen to form a round, smooth elevation. Below, the nates are separated, in the middle line, by a deep fissure—the *natal cleft*. This cleft, if traced upwards, almost disappears over the prominence formed by the coccyx and lower part of the sacrum. The crest of the ilium can be felt along its whole length, and, in well-formed individuals, it appears as a groove—the *iliac furrow*. Traced forwards, the crest terminates in the anterior superior spine of the ilium; traced backwards, it ends in the posterior superior spine of the ilium. The position of the latter is indicated by a faint depression which lies on a level with the second spine of the sacrum, and it corresponds with the middle of the sacro-iliac articulation. The prominence of the nates is chiefly formed by the gluteus maximus muscle, covered by a thick layer of fat. A deep transverse groove, produced by a fold of skin and fascia, limits the gluteal elevation below. This is called “the fold of the nates” (gluteal sulcus), and is sometimes said to correspond with the lower border of the gluteus maximus muscle. It can easily be shown that this is not the case. Its inner end lies below the lower margin of the muscle, but as it proceeds transversely outwards it crosses the muscle-border, and finally comes to lie on the surface of the muscle. In disease of the hip-joint, the buttock loses its prominence, whilst the fold of the nates becomes faint. The tuberosity of the ischium may be felt below the lower border of the gluteus maximus by placing the fingers in the inner part of the fold of the nates and pressing upwards. A line drawn from the most prominent part of this tuberosity to the anterior superior spine of the ilium is called *Nelaton's line*. This line passes over the top of the great trochanter and crosses the centre of the acetabulum. It is used by the surgeon in the diagnosis of dislocations and other injuries of the hip-joint. The great trochanter of the femur may be felt at a point about six inches below the highest part of the crest of the ilium. It can be seen in thin subjects, but it does not form so projecting a feature of this region as might be expected from an inspection

of the skeleton, because the thick tendon of the gluteus medius is inserted into its outer surface, and it is moreover covered by the aponeurotic insertion of the gluteus maximus.

Reflection of Skin.—*Incisions.*—(1) From the posterior superior spine of the ilium in a curved direction along the crest of the ilium, as far forwards as the position of the body will permit; (2) from the posterior extremity of this curved incision obliquely downwards and inwards to the middle line of the sacral region, and then perpendicularly downwards to the tip of the coccyx; (3) from the tip of the coccyx obliquely downwards and outwards over the back of the thigh. When properly carried out, this incision intersects the fold of the nates at about its middle point, and terminates a little below the upper third of the thigh (Fig. 1, p. 3).

A large flap of skin is thus marked out, and this must be raised from the subjacent superficial fascia and thrown outwards. On the right side of the body, the dissector begins at the crest of the ilium and works downwards and forwards; whilst on the left side he commences over the coccyx and works upwards and forwards.

Superficial Fascia.—The superficial fascia is now exposed, and it is seen to partake of the same characters as the corresponding layer of fascia in other parts of the body. Notice, however, its special peculiarities in this region. How it is much more heavily laden with fat—especially in the female; how it thickens over the lower and upper margins of the gluteus maximus, and how it becomes tough, elastic, and stringy over the ischial tuberosity, so as to form a most efficient cushion upon which this bony prominence rests while the body is in the sitting posture.

Cutaneous Nerves (Fig. 39).—The superficial fascia forms a bed in which the cutaneous nerves ramify before they enter the skin. In this region the cutaneous nerves are very numerous, and they are derived from a great variety of sources. Some proceed from the posterior primary divisions of the spinal nerves, whilst others are branches of the anterior primary divisions of the spinal nerves.

From the posterior primary divisions there are usually six

—three from the sacral nerves, and three from the lumbar nerves. The three sacral nerves reach the surface by pierc-

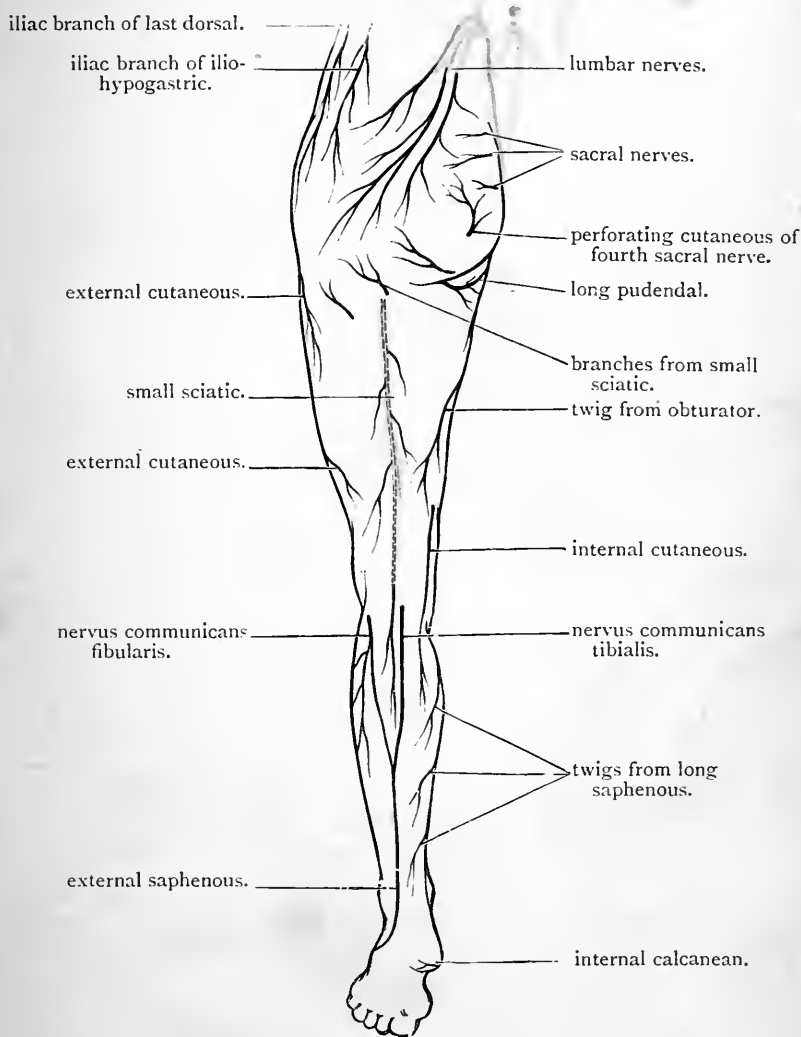


FIG. 39.—Cutaneous nerves on the back of the lower limb.

ing the gluteus maximus muscle close to its origin from the sacrum and coccyx. They are usually of small size and pierce the muscle in a line drawn from the posterior

superior iliac spine to the tip of the coccyx. The largest is found opposite the lowest piece of the sacrum, the highest about an inch above this, and the lowest about the same distance below it.

Owing to the coarseness of the muscular fasciculi between which they appear, they are somewhat difficult to find. In looking for them, it is best to cut right down through both superficial and deep fasciæ, so as to secure them as they emerge from the muscle.

The three lumbar nerves are easily found. They cross the crest of the ilium at a point corresponding to the outer limit of the attachment of the erector spinæ to the innominate bone. They pass downwards and slightly forwards in the superficial fascia, and run in different planes, the larger trunks being placed deeper than the smaller branches. They communicate with one another and with the sacral nerves. A few twigs may be followed as far as the great trochanter.

The cutaneous twigs which come from the anterior primary divisions of the spinal nerves may be classified under three headings—(1) those which pass downwards over the crest of the ilium; (2) those which pass backwards over the insertion of the gluteus maximus into the fascia lata; (3) those which turn upwards around the lower margin of the gluteus maximus.

The nerves which cross the crest of the ilium are—(1) the iliac branch of the ilio-hypogastric nerve; and (2) the iliac branch (i.e., the lateral cutaneous branch) of the last dorsal nerve.

The iliac branch of the ilio-hypogastric nerve pierces the external oblique muscle at its attachment to the ilium. It usually crosses the iliac crest opposite a tubercle which projects from the outer lip of the crest about two and a half inches from the anterior superior spine, but it may emerge at any point between this tubercle and the anterior border of the iliac origin of the latissimus dorsi. The iliac branch of the last dorsal nerve pierces the external oblique muscle of the abdominal wall, a short distance in front of

6 from Prof. P. B. D.

the ilio-hypogastric branch, at a point situated from one to two inches above the iliac crest. Both nerves, after crossing the iliac crest, run downwards in the thick superficial fascia over the upper part of the gluteus medius, and spread out into a great number of fine twigs, which ramify over the insertion of the gluteus maximus. Certain of them reach downwards as far as the level of the great trochanter.

The nerves which pass backwards over the insertion of the gluteus maximus are a few small branches of the posterior division of the *external cutaneous nerve* of the thigh. They are found above the level of the great trochanter.

The cutaneous twigs which hook round the lower margin of the gluteus maximus muscle, to reach the skin over this region, are a few offsets from the small sciatic nerve and the perforating cutaneous branch of the fourth sacral nerve. The former appear external to the tuberosity of the ischium, and are accompanied in some cases by twigs from the sciatic artery. The latter comes into view internal to the ischial tuberosity, and is accompanied by small branches of the inferior hæmorrhoidal artery.

These nerves can most readily be found by everting the lower border of the gluteus maximus; but in doing this, care must be taken not to injure the trunk of the small sciatic nerve, as it passes from under cover of the gluteus maximus and runs vertically down the thigh.

The Deep Fascia is brought into view by removing the remnants of the superficial fascia. The fatty tissue should be cleared away not only from the deep fascia as it is spread over the gluteus maximus, but also from the area in front of this. In the latter situation a dense opaque pearly white aponeurosis is by this means exposed. This covers the anterior part of the gluteus medius, and is firmly attached above to the crest of the ilium. It stands in marked contrast with the deep fascia over the gluteus maximus which is thin and transparent. Subsequent dissection will show that the dense fascia over the anterior

gluteal aponeurosis

part of the gluteus medius when it reaches the anterior border of the gluteus maximus, splits into two lamellæ which enclose that muscle between them.

Dissection.—Now proceed to clean the gluteus maximus muscle. If it is the right limb, begin at the anterior or upper margin of the muscle; but if it is the left, commence the dissection at the posterior or lower border. In undertaking this dissection, the dissector must keep clearly before him the rules which have already been laid down regarding the cleaning of a muscle:—(1) render the fibres as tense as possible by rotating the limb *inwards*; (2) remove the fascia in one continuous layer; (3) always cut in the direction of the muscular fibres; (4) define very carefully the borders of the muscle.

The gluteus maximus is a difficult muscle to clean, the fasciculi are so exceedingly coarse. To do it well, it is not sufficient to remove the fascia which covers the muscle, but it is necessary at the same time to follow, for a short distance, the septa which penetrate between the fasciculi, and to remove them also. Do not remove the thick opaque fascia which covers the insertion of the muscle.

The dissector of the left limb, on reaching the anterior margin of the muscle, will observe that the fascia which he holds in his hand is continuous with the strong aponeurosis which covers the gluteus medius; and further, if he now frees the anterior border of the muscle from subjacent parts, he will notice that the layer of fascia upon which the gluteus maximus rests is also continuous with the same aponeurosis. In other words, he will in this manner be able to satisfy himself that the strong fascia which covers the anterior part of the gluteus medius splits into two layers to enclose the gluteus maximus. The small sciatic nerve lies in very close relation to the deep surface of the muscle, and is apt to be injured in the subsequent steps of the dissection, unless it is secured at once by everting the lower border of the muscle.

The Gluteus Maximus arises from a narrow, rough area on the dorsum ilii, which is included between the superior curved line and the outer lip of the crest; from the sides of the lower two pieces of the sacrum and the upper three pieces of the coccyx; from the entire posterior surface of the great sacro-sciatic ligament; and slightly from the posterior layer of the lumbar aponeurosis, at the attachment of the latter to the crest of the ilium.

From this extensive origin the coarse fasciculi of the muscle proceed obliquely downwards and forwards towards the upper portion of the femur, but only a comparatively small proportion of them receive direct insertion into that

bone. The greater part of the muscle is inserted into the fascia lata. To be more precise, we may say that the whole of the fibres belonging to the upper half of the muscle, and the superficial stratum of fibres of the lower half of the muscle, are inserted into the fascia lata. The deeper fibres of the lower half of the muscle, however, are directly attached to the "gluteal ridge" on the back of the femur (*i.e.*, the ridge which extends from the great trochanter to the linea aspera).

Reflection of the Gluteus Maximus.—This is by no means an easy dissection. It is best to detach the muscle from its origin and throw it downwards towards its insertion. It should be dissected completely away from the various surfaces from which it arises. By this means the general outline of the pelvis becomes more apparent, and the dissector obtains distinct bony landmarks which are most useful in enabling him to localise the various structures he is expected to expose. Let us suppose we are dealing with the left lower limb. As a preliminary step, the two borders of the muscle should be freed and the left hand gently insinuated under the fleshy mass. The muscle must, in the first instance, be detached from the ilium. When the surface on the dorsum ilii from which it springs is cleared, we reach the upper margin of the great sciatic notch. Here the dissector must proceed with caution, because through this pass the gluteal vessels, branches of which enter the deep surface of the gluteus maximus muscle. Having secured these we next detach the muscle from the side of the sacrum, and the pyriformis muscle emerging from under cover of the sacrum comes into sight. The muscular fibres may now be raised from the surface of the great sacro-sciatic ligament and separated from the side of the coccyx. In doing this, care should be taken to preserve the three sacral cutaneous nerves intact, in order that they may be subsequently traced to their origins. As the surface of the great sacro-sciatic ligament is gradually laid bare, a number of small arteries (the coccygeal branches of the sciatic artery) will be seen piercing it and immediately sinking into the substance of the gluteus maximus. These cannot be retained. It is necessary to sever them in order that the muscle may be freed. The perforating branch of the fourth sacral nerve, which winds round the lower border of the gluteus maximus near the coccyx, must also be remembered and traced to the great sacro-sciatic ligament which it will be seen to pierce.

The gluteus maximus is now completely separated from the parts from which it arises, but it cannot be thrown downwards towards its insertion. It is still tied to its place by the blood-vessels and nerves which enter its deep surface. These are (1) the branches of the superficial division of the gluteal artery which we have already seen

above the level of the pyriformis; (2) branches of the sciatic artery and the inferior gluteal nerve below the level of the pyriformis. The veins may at once be removed, but the arteries and nerves must be systematically cleaned as they come into view, and traced into the substance of the gluteus maximus. Finally, to allow of the complete reflection of the gluteus maximus, these vessels and nerves must be cut, and it is advisable to leave in connection with the cut end of each a small portion of muscle-substance in order that they may be readily recognised in the further steps of the dissection. The whole muscle may now be thrown forwards, and after a little dissection an admirable view is obtained of its insertion. Piercing the lower part of this there will be seen a few small twigs of the first perforating artery—a branch of the profunda femoris.

In the case of the right limb the procedure adopted in reflecting the gluteus maximus is the same as detailed above, with this exception, that we begin by detaching it from the coccyx and great sciatic ligament and work upwards towards the ilium.

Although we have recommended that the gluteus maximus should be reflected from above downwards, it is right to mention that an equally instructive view of the subjacent parts may be obtained by detaching it from its insertion and throwing it upwards towards its origin. The senior student would do well to adopt this method.

Bursæ under cover of the Gluteus Maximus.—Two bursæ are found in relation to the insertion of the gluteus maximus. The one—a large loose sac—is interposed between the aponeurosis, into which the upper part of the muscle is inserted and the great trochanter of the femur. It allows the bone to play freely on the deep surface of the muscle. The second bursa lies immediately below this and in front of the part of the muscle which is inserted into the gluteal ridge of the femur. A slight touch of the knife is sufficient to open it, and then the glistening tendon of the vastus externus comes into view. The bursal sac intervenes between this tendon and the aponeurotic insertion of the gluteus maximus.

(2)
(3) A third bursa is situated between the gluteus maximus and the tuber ischii. In all probability this has already been explored by the dissector of the perineum. It lies over the inferior aspect of the bony prominence and is interposed more between the tough superficial fascia and the bone, than between the muscle and the bone.

Dissection.—On the *second day* the dissector undertakes the dissection

of the remaining structures which are displayed by the reflection of the *gluteus maximus*. The vessels and nerves which have been partially exposed in the previous day's dissection must now be followed up towards the pelvis, and the remaining vessels and nerves, together with the muscles, must be defined and cleaned by removing the loose areolar tissue which covers and passes between them.

Parts under cover of the *Gluteus Maximus*.—As we proceed from the dorsum ilii downwards towards the tuber ischii and the back of the thigh, the following muscles may be recognised:—(1) The *gluteus medius* lying over the greater part of the dorsum ilii; (2) the *pyriformis*, issuing from the pelvis through the great sacro-sciatic foramen; (3) the tendon of the *obturator internus* coming through the small sacro-sciatic foramen, with the *gemellus superior* attached to its upper border and the *gemellus inferior* to its lower border; (4) the *quadratus femoris* passing from the tuber ischii to the upper end of the femur; (5) the upper border of the *adductor magnus*. By separating the contiguous margins of the *gemellus inferior* and *quadratus femoris* widely from each other, and looking into the interval between them, the tendon of the *obturator externus* will be revealed as it passes round the neck of the femur to reach the digital fossa. By dealing similarly with the adjacent margins of the *quadratus femoris* and the *adductor magnus*, the small trochanter of the femur will be exposed. Lastly, the origin of the hamstring muscles from the tuber ischii and the upper part of the *vastus externus* arising from the root of the great trochanter of the femur on its outer aspect should be noted.

In each interval formed by the adjacent margins of the muscles exposed, blood-vessels and nerves, or blood-vessels alone, are to be found.

Before proceeding to the dissection of these, however, it is well that the student should renew his acquaintance with the skeletal peculiarities of this region. Let him obtain a dried pelvis with the ligaments *in situ*, and study carefully the position and boundaries of the great and small sciatic notches, and how they are converted into foramina by the small and great sacro-sciatic ligaments. Through these foramina most important structures issue from the interior of the pelvis into the gluteal region.

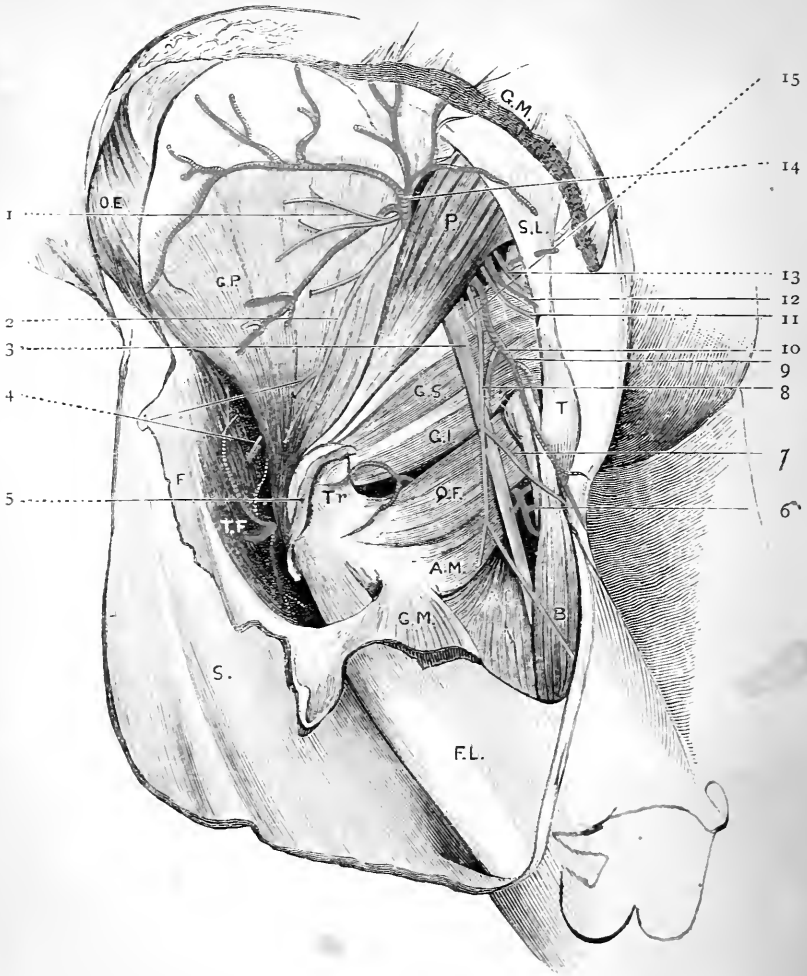


FIG. 40.—Dissection of the gluteal region. The gluteus maximus and gluteus medius have been reflected. *del. et. nat.*

G.M. Gluteus maximus.
 P. Piriformis.
 O.E. External oblique.
 G.P. Gluteus minimus.
 S.L. Great sciatic ligament
 T. Tuber ischii.
 B. Biceps.
 G.S. Gemellus superior.
 G.I. Gemellus inferior.
 Q.F. Quadratus femoris.
 A.M. Adductor magnus.
 Tr. Great trochanter.
 T.F. Tensor fasciæ femoris.
 F.L. Deep fascia.
 S. Skin.

1 & 2. Superior gluteal nerve.
 3. Great sciatic nerve.
 4. Branch from superior gluteal nerve to the tensor fasciæ femoris.
 5. Tendon of gluteus medius.
 6. Internal circumflex artery.
 7. Long pudendal nerve.
 8. Small sciatic nerve.
 9. Obturator internus.
 10. Sciatic artery.
 11. Nerve to the obturator internus.
 12. & 13. Internal pudic artery and nerve
 14. Gluteal artery.
 15. Nerve to the quadratus femoris.

In the interval between the contiguous margins of the gluteus medius and the pyriformis muscles, the gluteal artery and the superior gluteal nerve issue from the pelvis through the great sacro-sciatic foramen. In the interval between the pyriformis and the gemellus superior, two arteries and six nerves must be looked for as they emerge through the lower part of the sacro-sciatic foramen, viz. :—



- | | | |
|-----------|---|---|
| Arteries, | { | <ol style="list-style-type: none"> 1. Sciatic. 2. Internal pudic. |
| Nerves, | { | <ol style="list-style-type: none"> 1. Great sciatic. 2. Small sciatic. 3. Internal pudic. 4. Inferior gluteal. 5. Nerve to the obturator internus. 6. Nerve to the quadratus femoris. |

The huge great sciatic nerve, together with the sciatic artery and small sciatic nerve, proceed downwards in the hollow between the great trochanter of the femur and the tuber ischii.

In the interval between the gemellus inferior and the quadratus femoris, the small ascending terminal branch of the internal circumflex artery will be seen, whilst between the contiguous margins of the quadratus femoris and the adductor magnus the larger transverse terminal branch of the same artery makes its appearance.

The Inferior Gluteal Nerve (nervus gluteus superior) is the nerve of supply to the gluteus maximus. It springs from the sacral plexus, and enters the gluteal region through the lower part of the great sacro-sciatic foramen. During the reflection of the gluteus maximus it has been seen to break up into numerous twigs which enter the deep surface of the muscle.

Sciatic Artery (arteria glutea inferior).—The sciatic artery, which issues from the pelvis through the great sacro-sciatic foramen below the pyriformis muscle, proceeds downwards with the sciatic nerves under cover of the gluteus maximus. Finally reaching the lower border of that muscle, it is continued as a fine cutaneous twig to

the back of the thigh, in company with the small sciatic nerve. It gives off numerous branches in the gluteal region. Of these the large muscular offsets to the gluteus maximus, and the cutaneous twigs that accompany the branches of the lesser sciatic nerve which turn round the lower border of that muscle, have been already studied. The following three branches remain to be examined:— (1) the coccygeal branch, which passes inwards between the greater and lesser sacro-sciatic ligaments to reach the integument and fascia in the region of the coccyx; a number of twigs derived from this branch have been previously noticed piercing the greater of the two ligaments and ending in the gluteus maximus; (2) comes nervi ischiadici, a minute artery, which runs downwards on the great sciatic nerve and finally penetrates into its substance; (3) the artery to the quadratus femoris, which accompanies the nerve to that muscle, and will be found lying on the innominate bone under cover of the great sciatic nerve.

In a well-injected body the anastomosis between the sciatic artery, the two terminal branches of the internal circumflex, and the first perforating artery may be made out.

The Small Sciatic Nerve (nervus cutaneus femoris posterior) arises from the sacral plexus within the pelvis. After escaping through the great sacro-sciatic foramen it extends downwards with the sciatic artery under cover of the gluteus maximus. Reaching the lower border of this muscle it proceeds vertically downwards on the back of the thigh, immediately subjacent to the deep fascia. It will afterwards be traced to the posterior aspect of the calf.

In the gluteal region it gives off several cutaneous branches, viz.—(1) twigs which wind round the lower border of the gluteus maximus to supply a limited area of the skin of the buttock; (2) a few twigs to the skin on the inner side of the thigh; and (3) the long pudendal nerve of Sœmmerring.

The long pudendal nerve turns inwards round the origin of the hamstring muscles to reach the perineum.

The Great Sciatic (*nervus ischiadicus*)—the largest nerve in the body—comes from the sacral plexus, and enters the gluteal region through the lower part of the great sacro-sciatic foramen. At first it has the form of a flattened band, but soon it becomes oval or round, as seen in section. Covered by the *gluteus maximus*, the great sciatic nerve traverses the gluteal region in the interval between the great trochanter of the femur and the *tuber ischii*. From above downwards it lies on the innominate bone (at the lower margin of the great sciatic notch), the tendon of the obturator internus with its two gemelli muscles, the quadratus femoris, and the adductor magnus. In this region it does not, as a rule, give off any branch, but occasionally the nerves to one or more of the hamstring muscles issues from the main trunk as high as the level of the *quadratus femoris*.

The great sciatic nerve frequently escapes from the pelvis in the form of two trunks, which enclose between them a portion of the *piriformis* muscle.

Dissection.—The student should flex the knee and raise it on a block in order to relax the great sciatic nerve. By pulling this great nerve-trunk outwards, the dissector will expose the nerve to the *quadratus femoris* lying directly upon the bone. Internal to this he will find the pudic vessels and nerve with the nerve to the *obturator internus* crossing the spine of the ischium. These structures require to be carefully cleaned. The twig from the nerve to the *obturator internus* to the *gemellus superior* is especially liable to injury. The dissection will be improved by scraping off the periosteum from the small area of bone which is in relation to the above-mentioned vessels and nerves.

The Pudic Vessels and Nerve, and the Nerve to the Obturator Internus, emerge from the great sacro-sciatic foramen below the *piriformis*, and are only exposed in the present dissection for a very short part of their course. They pass out of view by entering the lesser sacro-sciatic foramen. *The nerve to the obturator internus* is placed most externally. It lies on the base of the ischial spine, and furnishes a twig to the *gemellus superior*. The *internal pudic artery* (*arteria pudenda interna*) with a companion

vein on each side, crosses the tip of the spine. The *internal pudic nerve* (*nervus pudendus*) is placed most internally, and lies on the lesser sacro-sciatic ligament close to its attachment to the spine. In some cases, however, the pudic nerve unites in a plexiform manner with the nerve to the obturator internus, so that the whole, or a part, of it may lie external to the pudic vessels.

External Rotator Muscles of the Thigh.—Under this heading we include the *pyriformis*, the *obturator internus*, the *gemelli*, the *obturator externus*, and the *quadratus femoris*. They are all inserted into or in the neighbourhood of the great trochanter of the femur, and they are applied to the posterior surface of the capsule of the hip-joint.

The *pyriformis* arises within the pelvis from the three middle pieces of the sacrum, and slightly from the upper margin of the great sciatic notch of the innominate bone. The sacral origin cannot be seen at present, but the iliac origin should be made out. After passing through the great sacro-sciatic foramen, the muscle is directed downwards, outwards, and forwards. Its fibres rapidly converge, and end in a rounded tendon, which crosses the common tendon of the obturator internus and gemelli, and is inserted into a small impression on the highest part of the great trochanter of the femur. It is closely adherent to the obturator tendon for some distance.

The *obturator internus* and *gemelli* together constitute a tricipital muscle with one intra-pelvic belly (*obturator internus*), and two extra-pelvic bellies (*gemellus superior* and *inferior*). The common tendon of this tricipital muscle is inserted into an impression on the upper part of the great trochanter of the femur immediately in front of the insertion of the pyriformis.

The *gemellus superior* arises from the spine of the ischium at the upper margin of the lesser sciatic notch. Its fibres pass outwards along the superior border of the tendon of the obturator internus, and are inserted obliquely into that tendon. The *gemellus inferior* arises from the tuberosity of the ischium at the lower margin of the lesser sciatic notch,

and is inserted into the inferior border of the obturator tendon, in a similar manner to the gemellus superior. Close to their origins the gemelli meet under cover of the obturator tendon, and form a fleshy bed, on which it lies; near the trochanter the fibres of the gemelli overlap the obturator tendon, and tend to cover its superficial surface.

The tendon of the obturator internus should be freed from the gemelli for some little distance from its point of exit from the small sacro-sciatic foramen. It may then be divided and raised from the bed in which it lies. Its deep surface will be seen to consist of four or five rounded slips separated by deep grooves or furrows. The surface of the small sciatic notch on which this tendon glides is coated with smooth cartilage, which is raised into ridges corresponding to the grooves on the surface of the tendon. A large synovial bursa is interposed, which still further facilitates the play of the tendon round the notch.

The quadratus femoris lies between the gemellus inferior and the adductor magnus. It is a flat oblong muscle which arises from the outer border of the tuber ischii, and proceeds horizontally outwards to gain insertion into the tubercle of the quadratus and into a line which extends downwards on the back of the femur for two inches below this.

Dissection.—The nerve to the quadratus femoris should now be traced to its termination. This can be done by reflecting the two gemelli muscles under which it runs. When followed as far as the inferior gemellus, care should be taken to secure the little twig it gives to that muscle. Lastly, reflect the quadratus femoris by detaching it from the femur and throwing it towards the ischial tuberosity. By this dissection not only is the whole length of the nerve to the quadratus femoris exposed, but also a considerable portion of the posterior aspect of the capsule of the hip-joint is laid bare, and the obturator externus muscle and the termination of the internal circumflex artery are brought into view.

The Nerve to the Quadratus Femoris runs vertically downwards on the innominate bone and passes successively under cover of the following structures: the great sciatic nerve, the gemellus superior, the tendon of the obturator

internus, the gemellus inferior. It gives the nerve of supply to the gemellus inferior and a twig to the hip-joint, and ends by sinking into the deep surface of the quadratus femoris.

The Obturator Externus Muscle can now be observed winding round the neck of the femur and finally ending in a rounded tendon which is implanted into the digital fossa of the femur. Its origin will be seen at another time.

The Internal Circumflex Artery (*arteria circumflexa femoris medialis*) comes to an end at the upper border of the adductor magnus by dividing into its ascending and transverse terminal branches. The *ascending branch* runs obliquely upwards and outwards under cover of the quadratus femoris and upon the surface of the obturator externus. Its terminal branches ramify in the neighbourhood of the digital fossa, where they anastomose with twigs from the sciatic and gluteal arteries. The *transverse branch* passes backwards between the quadratus femoris and the adductor magnus. It anastomoses with the terminal twig of the middle division of the external circumflex artery, which in a well-injected subject will be noticed appearing from midst the fibres of the vastus externus at its upper part. An arterial circle is thus completed around the upper part of the femur which communicates above with the sciatic artery and below with the first perforating artery. This series of inosculations is sometimes spoken of as the crucial anastomosis of the thigh.

Dissection.—The dissector has now examined all the structures in the gluteal region which lie below the level of the pyriformis. He should, in the next place, turn his attention to that portion of the dissection which lies above the level of that muscle. Here are found a number of parts in close relation to the dorsum ilii. These are the gluteus medius, the gluteus minimus, and the tensor fasciæ femoris muscles, together with the blood-vessel and nerve which supplies them, viz., the gluteal artery and the superior gluteal nerve.

The gluteus medius muscle is only covered in its hinder part by the gluteus maximus. In front it is invested by the dense aponeurotic layer already referred to. This fascia must be removed in order that a satis-

factory view of the muscle may be obtained. It will then become evident that numerous fleshy fibres arise from the deep surface of the fascia. Care must be taken not to injure the origin of the tensor fasciæ femoris which overlaps the anterior part of the gluteus medius, and is partially adherent to it.

Gluteus Medius.—The gluteus medius arises from that part of the dorsum ilii which is bounded above by the superior curved line and the anterior four-fifths of the crest of the ilium, and below by the middle curved line; it also derives fibres from the strong fascia which covers its upper and anterior part. The fibres converge to form a flattened band, partly fleshy and partly tendinous, which is inserted into an oblique line on the outer aspect of the great trochanter of the femur, as well as into the surface immediately above it.

Dissection.—The gluteus medius must now be reflected. This dissection is complicated by the fact that in its upper and anterior part the gluteus medius is partially blended with the subjacent gluteus minimus and the tensor fasciæ femoris. Begin by rotating the limb well outwards. Then seizing the gluteus maximus with left hand, pull it well outwards, and divide the glistening aponeurosis into which it is inserted for two or three inches in a downward direction. This will bring very conspicuously into view the upper part of the vastus externus. Next, grasp the cut edge of the fascia lata from which the gluteus maximus has been separated, and, dragging it forcibly outwards, dissect in the interval between it and the gluteus medius. The tensor fasciæ femoris, which is intimately associated with this portion of the fascia lata, is pulled outwards with it, and the deep surface of that muscle clothed by a strong deep lamella of fascia comes into view. Very little dissection is required to expose its nerve of supply—a branch from the superior gluteal—which emerges from the anterior border of the gluteus minimus, and sinks into its deep surface. An artery will also be noticed ramifying on the deep surface of the tensor fasciæ femoris; this is the ascending branch of the external circumflex. Seeing that the anterior borders of the gluteus medius and gluteus minimus are adherent, it is well to separate them from behind forward by introducing the fingers between their posterior borders. When the gluteus medius is completely isolated, it may be divided about two inches above the great trochanter of the femur, and the two portions thrown respectively upwards and downwards. A small bursa between the muscle and the upper part of the great trochanter will thus be brought into view, and the exact insertion of the tendon will be rendered evident. As the upper part of the muscle is raised, a

number of vessels and nerves between it and the gluteus minimus will be exposed. These must be carefully cleaned and followed to their destinations. They are derived from the gluteal artery and the superior gluteal nerve.

Gluteal Artery (*arteria glutæa superior*).—This is a large vessel which escapes from the pelvis through the upper part of the great sacro-sciatic foramen above the level of the pyriformis.

Immediately after its exit, it divides into a superficial and a deep division. The *superficial* division has been already seen during the reflection of the gluteus maximus. It is distributed to the deep surface of that muscle, and is placed between it and the gluteus medius.

The *deep division* bifurcates close to its origin into a superior and an inferior branch; both of these lie between the gluteus medius and minimus. The *superior branch* follows accurately the middle curved line on the dorsum ilii, and at the anterior superior spine terminates by anastomosing with the superficial and deep circumflex iliac arteries, and with the ascending branch of the external circumflex. The latter has already been noticed passing upwards under cover of the tensor fasciæ femoris. The *inferior branch* runs downwards and forwards towards the great trochanter. It gives twigs to the two gluteal muscles between which it lies, and some terminal offsets to the hip-joint.

The Superior Gluteal Nerve (*nervus glutæus superior*) emerges from the pelvis in company with the gluteal artery, and passing forwards between the gluteus medius and minimus, gives branches to both these muscles. Its terminal branch pierces the anterior fibres of the gluteus minimus, and ends in the tensor fasciæ femoris.

The Gluteus Minimus arises from the broad area on the dorsum ilii, which is included between the middle and inferior curved lines. The muscular fibres pass gradually into an aponeurotic tendon, which covers the superficial surface of the lower part of the muscle. This tendon as it descends narrows into a flattened band, which is inserted into a special impression on the anterior aspect of the

great trochanter of the femur. It is intimately connected at its insertion with the capsule of the hip-joint.

Parts under cover of the Gluteus Minimus.—The last step in the dissection of the gluteal region consists in the reflection of the gluteus minimus muscle. It must be detached from its origin and thrown downwards. Three objects are revealed by this dissection—(1) the capsular ligament of the hip-joint; (2) a bursa which intervenes between the tendon of the muscle and the great trochanter; (3) the reflected tendon of the rectus femoris.

The capsular ligament will be seen to be only loosely attached to the posterior aspect of the neck of the femur, but very firmly to the acetabular brim. The *synovial bursa* should be opened and examined. The *reflected tendon* of the *rectus femoris* occupies a groove situated just above the upper margin of the acetabulum. It is partially concealed by some fibres of the capsular ligament, which are prolonged upwards over it. It should be cleaned by repeatedly drawing the point of the knife over it in a direction parallel to its fibres.

POPLITEAL SPACE.

Before the muscles on the back of the thigh are disturbed, it is well to dissect the popliteal space. In this way the boundaries of the space are maintained in position during our examination of the structures which lie within it.

During the dissection of the popliteal space the following structures are brought into view:—

1. Superficial fascia.
2. External saphenous vein.
3. Small sciatic nerve.
4. Popliteal fascia.
5. Muscles which bound the space.

{	Biceps.
	Semitendinosus.
	Semimembranosus.
	Gastrocnemius.
	Plantaris.

6. The internal and external popliteal nerves and their branches.
7. The popliteal artery and vein and their branches.
8. A few lymphatic glands.
9. A slender branch from the obturator nerve. (*Nervus Browni*)
10. The popliteus muscle.

Surface Anatomy.—The space which lies immediately above the knee-joint, and between the hamstring muscles, is termed the ham. It is depressed when the knee is flexed, but forms a slight prominence when the joint is fully extended. By pressing deeply into the interval between the hamstrings, the (injected) popliteal artery may be distinguished, and its pulsations can sometimes be distinguished in this situation in the living subject. The tendon of the adductor magnus can be readily detected on the inner side of the limb, and should be traced downwards to the adductor tubercle on the inner condyle of the femur. It can be rendered distinct by slightly flexing the knee-joint, and at the same time forcibly abducting the limb. The tuberosities of the femur may be seen and felt: the internal is the more prominent of the two. The articulation between the femur and the head of the tibia can seldom be seen, but can always be felt. Below the knee-joint the head of the fibula forms a prominence on the outer side, and, by flexing the knee and pressing deeply between the fibula and the external condyle of the femur, the cord-like external lateral ligament can be distinguished. The external popliteal nerve may be felt as it crosses the outer side of the neck of the fibula, just before it pierces the peroneus longus muscle. The two heads of the gastrocnemius form prominent objects in muscular subjects.

The back of the thigh presents a smooth, rounded surface. In thin subjects indications of the bellies of the hamstring muscles may be seen.

Reflection of Skin.—Before beginning the dissection a good-sized block should be placed under the knee so as to support the limb and render the muscles which bound the space tense. *Incisions*—(1) a vertical incision along the middle line of the limb, beginning about five inches above, and terminating about four inches below, the bend

of the knee ; (2) a transverse incision at the upper end of the mesial incision ; (3) a transverse incision at the lower extremity of the mesial incision. The two transverse incisions should extend almost half-way round the limb.

Two flaps of skin are thus mapped out, and these must be raised and thrown, the one inwards and the other outwards.

Superficial Fascia—External Saphenous Vein—Branches of Small Sciatic Nerve.—The fatty layer upon which the skin rests is now brought into view, and the cutaneous nerves and vessels must be secured. First look for a small nerve—a *branch of the small sciatic*—which passes downwards over the space near the middle line, and when this is found, dissect out the *external saphenous vein*. This vessel ascends in the middle line of the leg, and on tracing it upwards it will be found to disappear from view by piercing the deep fascia, and entering the lower part of the popliteal space. The *terminal branch* of the *small sciatic nerve* pierces the popliteal fascia at the lower part of the space, and here it will be seen lying close to the external saphenous vein.

In removing the superficial fascia care must be taken of the deep popliteal fascia which is somewhat thin.

Popliteal Fascia.—Although thin, the deep fascia possesses considerable strength, owing to the transverse fibres which are interwoven amidst its proper aponeurotic fibres. In removing this fascia the dissector will notice that it is firmly attached on each side to the tendons of the muscles which bound the popliteal space. Above it is continuous with the fascia lata of the thigh.

Before opening up the popliteal space the dissector is recommended to read the two following paragraphs, which deal generally with its contents and boundaries.

Contents of the Space.—The principal objects within the popliteal space are the *popliteal artery* and *vein* with their branches. They are placed deeply in the space, and in close contact with each other—the vein being superficial to the artery throughout. The *two popliteal nerves*—

external and internal—also traverse the space. With the exception of the small sciatic nerve which descends immediately subjacent to the deep fascia, the *internal popliteal nerve* is the most superficial structure in the popliteal space. It lies over the popliteal vessels, and is readily found by separating the adipose tissue in the middle line of the space. The *external popliteal nerve* will be exposed by dissecting along the upper and outer boundary of the space. It lies under shelter of the biceps muscle. Both of these large nerves give off branches. The majority of these are easily secured and readily followed. The articular twigs, however, are very delicate, and great care is required in their dissection.

In intimate relation to the popliteal artery is the *geniculate branch of the obturator nerve*. It descends in close apposition with the coats of the artery. As the fat is being cleared out from the space the dissector will not fail to observe a few small *lymphatic glands* in relation to the great vessels.

Boundaries.—The popliteal space is diamond-shaped. Above and to the outside it is bounded by the *biceps* muscle; whilst above and to the inside are the *semi-tendinosus* and the *semimembranosus* muscles, the former lying upon the surface of the latter. On the inner side of the knee and in front of the semimembranosus, the *gracilis*, *sartorius*, and the tendon of the *adductor magnus*, can be exposed. Below, the space is bounded by the converging heads of the *gastrocnemius*. In the formation of the lower and outer boundary, the outer head of the *gastrocnemius* will be seen to be assisted by the small *plantaris* muscle.

Dissection.—In cleaning the muscles which bound the popliteal space there are certain points to be attended to. In the case of the outer head of the *gastrocnemius*, care must be taken not to remove the *nervus communicans fibularis*, which passes downwards and inwards upon its surface. In the groove between the heads of this muscle will be seen the *nervus communicans tibialis*. Further, the dissector must not overlook the synovial bursa which intervenes between the tendon of the semimembranosus and the inner head of the gastrocnemius.

This bursa sometimes communicates with a second synovial sac, which will be brought into view by lifting the inner head of the gastrocnemius from the internal condyle of the femur.

The dissection may be carried in a forward direction on the inner aspect of the limb a little beyond the inner boundary of the space, in order to expose the superficial division of the anastomotica artery, the

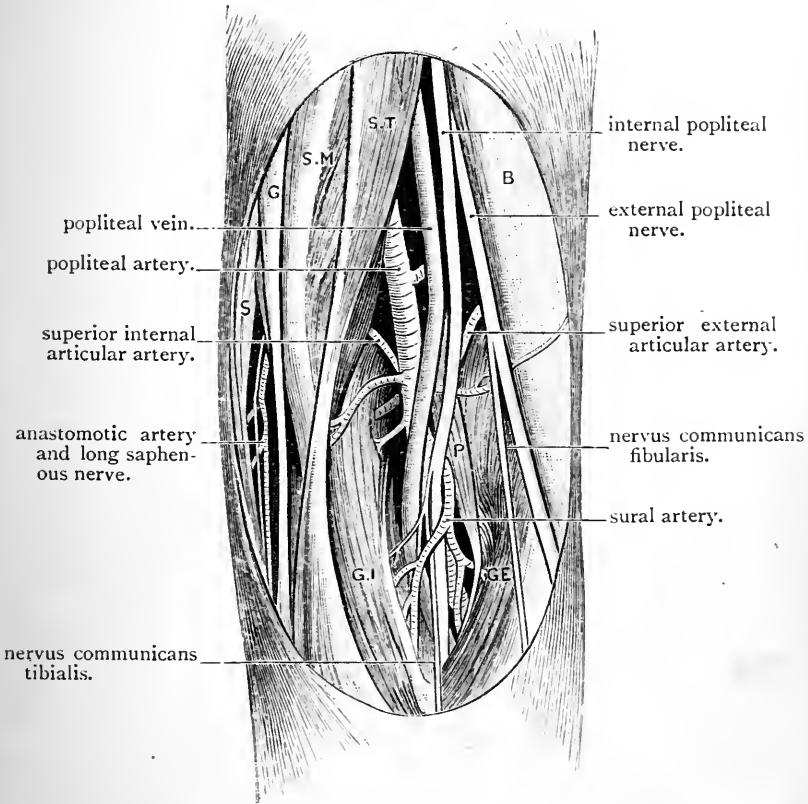


FIG. 41.—Dissection of the right popliteal space.

- | | |
|-----------------------|-----------------------------------|
| S.T. Semitendinosus. | B. Biceps. |
| S.M. Semimembranosus. | P. Plantaris. |
| G. Gracilis. | G.E. Outer head of gastrocnemius. |
| S. Sartorius. | G.I. Inner head of gastrocnemius. |

internal saphenous nerve and vein, and the posterior division of the internal cutaneous nerve. The *internal saphenous nerve* accompanied by the *superficial part* of the *anastomotica artery* will be found under cover of the sartorius. They afterwards come to the surface at its

posterior border. The *internal saphenous vein* ascends on the surface of that muscle, whilst the *posterior division* of the *internal cutaneous nerve* courses downwards along the posterior border of the same muscle, and comes to the surface a short distance behind the *internal saphenous nerve*. Properly speaking, these structures belong to the thigh, but it is convenient to secure them at this stage. They will be afterwards noticed more fully. When the boundaries of the space are thoroughly defined and cleaned, the contents should be dissected by removing the soft fat which surrounds them.

The dissection of the space should be carried out over the entire area

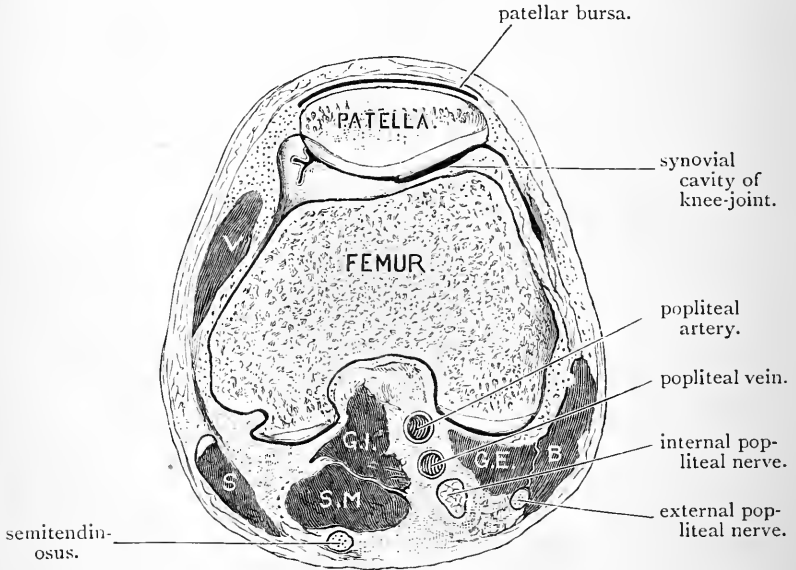


FIG. 42.—Transverse section through the popliteal space of the right lower limb.

V. Vastus internus.
S. Sartorius.
S.M. Semimembranosus.

G.I. Inner head of gastrocnemius.
G.E. Outer head of gastrocnemius.
B. Biceps.

at the same time. The heads of the gastrocnemius muscle, therefore should be well separated from each other. It is here that the dissection becomes tedious, because the numerous branches of the nerves and vessels to the muscles on the back of the leg require time and care for their dissection.

The floor of the space must now be cleaned. Scrape the fatty tissue from the popliteal surface of the femur with the handle of the knife.

It is during this stage of the dissection that the articular branches of

the popliteal artery are liable to injury, as they lie in close contact with the floor. Be especially careful not to injure the azygos articular artery which pierces the posterior ligament of the knee-joint, and the superior articular arteries which wind round the femur, immediately above the condyles. The fascia covering the popliteus muscle should be left in position.

Popliteal Space as seen in a Section through the Frozen Knee.—

The diamond-shaped space on the back of the knee-joint which is brought into view by dissection, differs widely from the condition which is observed when transverse sections are made through this part of the frozen limb (Fig. 42). Before the integuments and fasciæ are removed all the parts are tightly braced together, and the popliteal space is merely represented by a small intermuscular interval between the lower parts of the hamstring muscles, where they are separated from each other by the condyles of the femur. The space in this condition is rather under an inch wide at its broadest part. The popliteal artery, therefore, which traverses the space, is covered by muscles throughout its whole course, with the exception of a very small part immediately above the knee-joint.

The Floor of the Space.—The floor is formed from above downwards by—(1) the popliteal surface of the femur; (2) the posterior ligament of the knee-joint; and (3) by the strong fascia which covers the popliteus muscle.

The Small Sciatic Nerve (*nervus cutaneus femoris posterior*) enters the popliteal space at its upper angle, and proceeds downwards immediately subjacent to the popliteal fascia. It gives one or two twigs through the fascia to the skin, and finally pierces the fascia in the lower part of the space. Its terminal twigs are distributed to the skin over the upper part of the calf of the leg.

The Internal Popliteal Nerve enters the popliteal space by emerging from under cover of the biceps muscle, and it runs vertically downwards so as to bisect the space longitudinally. It is one of the two terminal branches of the great sciatic nerve, and it arises a little below the middle of the thigh. At the lower border of the popliteus muscle it becomes continuous with the posterior tibial nerve. The superficial position of the internal popliteal nerve has already been referred to. At first upon the outer side of the popliteal vessels it crosses them superficially, and in the lower part of the space it is placed upon

their inner side. Its *branches* may be classified into cutaneous, muscular, and articular.

The *nervus communicans tibialis* is its cutaneous branch. It arises about the middle of the space, and proceeds downwards in the furrow between the two heads of the gastrocnemius. It will afterwards be seen to unite with the *nervus communicans fibularis*, a little below the middle of the calf of the leg, to form the external saphenous nerve.

The *muscular branches* supply both heads of the gastrocnemius, the plantaris, the soleus, and the popliteus: they come off in the lower part of the space. The branch to the popliteus requires special notice. It arises lower down than the others, and crosses the superficial surface of the popliteal artery to reach the outer side of that vessel. It then runs downwards on the posterior surface of the popliteus muscle, and gains its deep or anterior surface by winding round its lower border. This will be better seen when the muscle itself is dissected.

The *articular branches* are three in number. They are given off by the internal popliteal nerve in the upper part of the space, and they accompany the azygos and the two internal articular arteries. That which accompanies the internal inferior articular artery is larger than the other two, and can be easily discovered as it runs along the upper border of the popliteus muscle.

The External Popliteal Nerve is the smaller of the two terminal branches of the great sciatic, and it ends on the outer side of the neck of the fibula by dividing into the anterior tibial and the musculo-cutaneous. It does not traverse the entire length of the popliteal space. It runs downwards and outwards along the inner side of the biceps, and leaves the space by following closely the tendon of this muscle. It now lies in the interval between the outer head of the gastrocnemius and the biceps, and finally turning forwards round the neck of the fibula, it ends under cover of the upper part of the peroneus longus. It gives off cutaneous and articular branches.

The *cutaneous branches* are two in number, viz., the *nervus communicans fibularis*, and one to the skin on the anterior and outer aspect of the leg in its upper part. They frequently take origin by a common trunk. The *nervus communicans fibularis* arises from the external popliteal nerve in the popliteal space, and is continued downwards over the outer head of the gastrocnemius. It ultimately unites with the *nervus communicans tibialis*, to form the external saphenous nerve.

The *articular branches* are three in number. They accompany the external articular branches of the popliteal artery, and the anterior recurrent tibial branch of the anterior tibial artery. They are of small size, and difficult to dissect. The *recurrent articular nerve* springs from the termination of the external popliteal nerve, and will be dissected at a later stage.

Popliteal Artery (*arteria poplitea*).—The popliteal artery is the terminal part of the great arterial trunk of the lower limb. It begins at the opening in the adductor magnus, where it is continuous with the femoral artery, and it ends at the lower border of the popliteus muscle by dividing into the anterior and posterior tibial arteries. This division is at present hidden from view by the upper border of the soleus muscle, but it will be exposed in the dissection of the leg.

The course which the popliteal artery takes through the popliteal space is not straight. In the first instance it inclines obliquely downwards and outwards, so as to gain the middle of the space between the two condyles of the femur. From this point to its termination it takes a vertical course downwards. Throughout the greater part of its length it is placed deeply. In the upper part of the space it is covered by the semimembranosus, but when it gains the interval between the two condyles it is simply covered by the integuments and fasciæ. This superficial part of the vessel is very short, however—not more than about an inch—because it at once passes onwards between the two heads of the gastrocnemius, is crossed by the



plantaris, and finally at its termination sinks under cover of the upper border of the soleus. Throughout its whole course the popliteal artery rests upon the floor of the popliteal space.

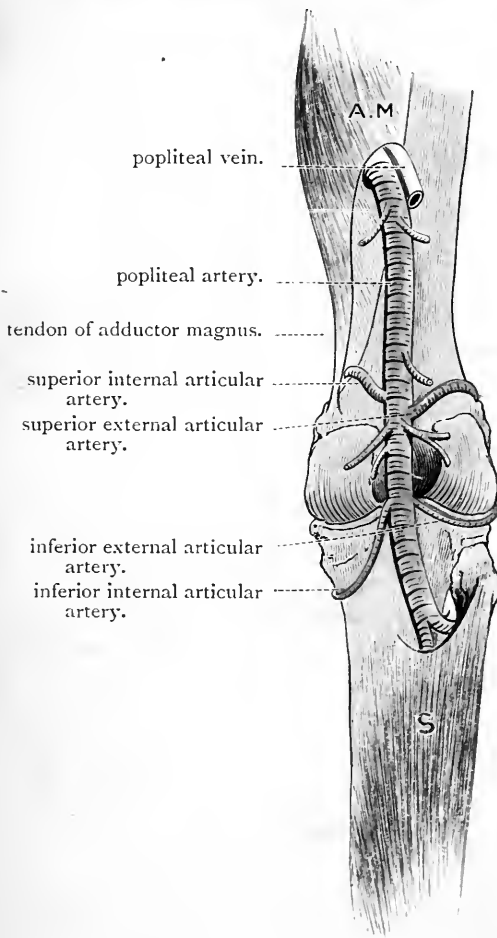


FIG. 43.—Diagram of the popliteal artery and its branches.

A.M. Adductor magnus. S. Soleus.

In its upper part it is separated from the femur by some fatty tissue; then it crosses the posterior ligament of the knee-joint, and lastly it comes into contact with the fascia covering the popliteus muscle.

The *popliteal vein* is placed upon a more superficial plane, and crosses the artery. In the upper part of the space it is placed upon the outer side of the artery, whereas in the lower part it is situated upon its inner side. The two vessels, however, are in close association throughout, and are bound together by a dense

fibrous sheath. The *internal popliteal nerve* is superficial to both vessels, and crosses the artery from without inwards; in the upper part of the space it lies a short distance to

the outer side of the artery, but in the lower part it lies on the inner side.

The Branches of the Popliteal Artery are :—

1. Muscular.
2. Cutaneous.
3. Articular.

The *muscular branches* consist of an upper and a lower set. The *upper branches* are distributed to the hamstring muscles near their insertions. The *lower branches*, termed the *sural arteries*, end chiefly in the two heads of the gastrocnemius; but small twigs also go to the soleus and plantaris.

The *cutaneous branch*, called the *superficial sural*, usually arises from one of the sural muscular branches, and supplies the integument over the upper part of the calf of the leg. It lies in the groove between the two heads of the gastrocnemius with the nervus communicans tibialis.

The *articular arteries* are five in number, viz., two superior, two inferior, and one median or azygos.

The Superior Articular Arteries spring from the main trunk as it passes between the condyles of the femur. One proceeds from each side of the popliteal, and they are called *internal* and *external*, according to the direction which they take. They will be found resting directly upon the back of the femur, and will be observed to incline slightly upwards, and then to wind round the bone immediately above the condyles. The *external* artery is the larger of the two. The student is apt to mistake a muscular branch for one or other of these vessels; but their close apposition to the femur should in all cases be sufficient to distinguish them.

The *superior external articular artery* (arteria genu superior lateralis) runs outwards under cover of the biceps, and disappears from the popliteal space by piercing the external intermuscular septum and entering the substance of the crureus muscle. The *superior internal articular* (arteria genu superior medialis) proceeds inwards under cover of

the semimembranosus, and leaves the popliteal space by passing forwards under cover of the tendon of the adductor magnus to reach the deep surface of the vastus internus muscle. *No intermuscular septum here*

The Inferior Articular Arteries arise from the popliteal as it lies on the lower part of the posterior ligament of the knee-joint. The *inferior external articular artery* (arteria genu inferior lateralis) takes a transverse course outwards, under cover of the plantaris and outer head of the gastrocnemius, to gain a point on the outer side of the knee, immediately above the head of the fibula. It proceeds onwards under cover of the external lateral ligament of the knee-joint. The *inferior internal articular artery* (arteria genu inferior medialis) takes a very oblique course downwards and inwards, under cover of the inner head of the gastrocnemius, and along the upper border of the popliteus muscle, to gain the inner side of the tibia below the internal tuberosity. Here it turns forwards under cover of the internal lateral ligament of the knee-joint.

The Azygos Articular Artery (arteria genu media) springs from the popliteal as it lies upon the posterior ligament of the knee-joint. It pierces this ligament to reach the synovial membrane.

Popliteal Vein.—The popliteal vein is formed near the lower border of the popliteus muscle by the union of the venæ comites of the anterior and posterior tibial arteries. It runs upwards through the popliteal space, and, entering Hunter's canal through the opening in the adductor magnus, it becomes the femoral vein. The relations which it presents to the popliteal artery have already been detailed. In addition to tributaries corresponding to branches of the artery, it receives the external saphenous vein, which has been seen piercing the popliteal fascia to join it. By slitting it open with the scissors the dissector will see that it possesses three (sometimes four) valves in its interior.

Obturator Nerve.—This minute nerve will be found lying upon the inner side of the popliteal artery. Trace it upwards, and it will be seen to enter the space by

piercing the lower fibres of the adductor magnus; follow it downwards, and it will be observed to enter the knee-joint by penetrating the posterior ligament.

BACK OF THE THIGH.

The dissection of the back of the thigh must be completed on the fourth day. The following are the structures which are brought into view:—

1. Superficial fascia.
2. Cutaneous nerves.
3. Deep fascia.
4. Muscles, {
 - Biceps.
 - Semitendinosus.
 - Semimembranosus.
 - Adductor magnus.
5. Nerves, {
 - Small sciatic.
 - Great sciatic.
6. Arteries, Four perforating.

Reflection of Skin.—A vertical incision must be made in the middle line of the thigh through the belt of skin which still encircles the limb posteriorly. The two flaps can then be reflected, the one outwards and the other inwards.

Superficial Fascia—Cutaneous Nerves.—In the fatty superficial fascia thus brought into view cutaneous twigs from four sources must be looked for—(1) Along the *middle line* of the limb a few minute branches from the *small sciatic* may be discovered; (2) Towards the *outer side* of the thigh some twigs from the *external cutaneous nerve* may be detected; (3) Lastly, towards the *inner aspect* of the limb endeavour to find some offsets from the *internal cutaneous* and *obturator nerve*.

Deep Fascia.—On removing the superficial fascia the deep fascia will be observed to be exceedingly thin. It must now be turned aside, and in doing this be careful of the trunk of the small sciatic nerve, which passes down in the middle line of the limb immediately subjacent to the fascia.

Hamstring Muscles.—The hamstring muscles are three in number, viz., the biceps, the semitendinosus, and the semimembranosus. They stretch from the tuberosity of the ischium to the upper ends of the tibia and fibula. The *biceps* is recognised from its diverging outwards to form the outer and upper boundary of the popliteal space. The *semitendinosus* and *semimembranosus* extend downwards on the inner side of the posterior aspect of the thigh, the former on the superficial aspect of the latter. In cleaning these muscles the dissector should proceed cautiously to work, otherwise he is certain to injure the arterial and nervous twigs which enter them. The latter may be easily secured by pulling upwards the upper part of the great sciatic nerve, and at the same time gently separating the muscles with the fingers.

The Biceps Flexor Cruris (*musculus biceps femoris*) arises by two heads—a *long*, or *ischial*, and a *short*, or *femoral*,—and is inserted chiefly into the head of the fibula. The *long head* arises from the ischium by a tendon which is common to it and the semitendinosus. This is implanted into the inner of the two impressions which mark the upper part of the tuber ischii. Some fibres from the great sacro-sciatic ligament are continued into it. The *short head* arises from the back of the femur below the insertion of the gluteus maximus, viz., from the outer lip of the linea aspera, from the upper half of the external supracondyloid ridge, and from the external intermuscular septum. Its parallel fibres run obliquely downwards and outwards, and join the anterior and inner surface of the tendon of insertion. This tendon, on the outer aspect of the knee-joint, is split into an anterior and a posterior part by the external lateral ligament. Both are inserted into the head of the fibula in front of the styloid process, but the posterior slip gives an aponeurotic extension to the fascia of the leg, whilst the anterior part gives off a slip (in some cases strong; but generally feeble) to the adjacent part of the outer tuberosity of the tibia.

The Semitendinosus arises from the inner impression on

the upper part of the tuberosity of the ischium by a tendon common to it and the long head of the biceps, and also by

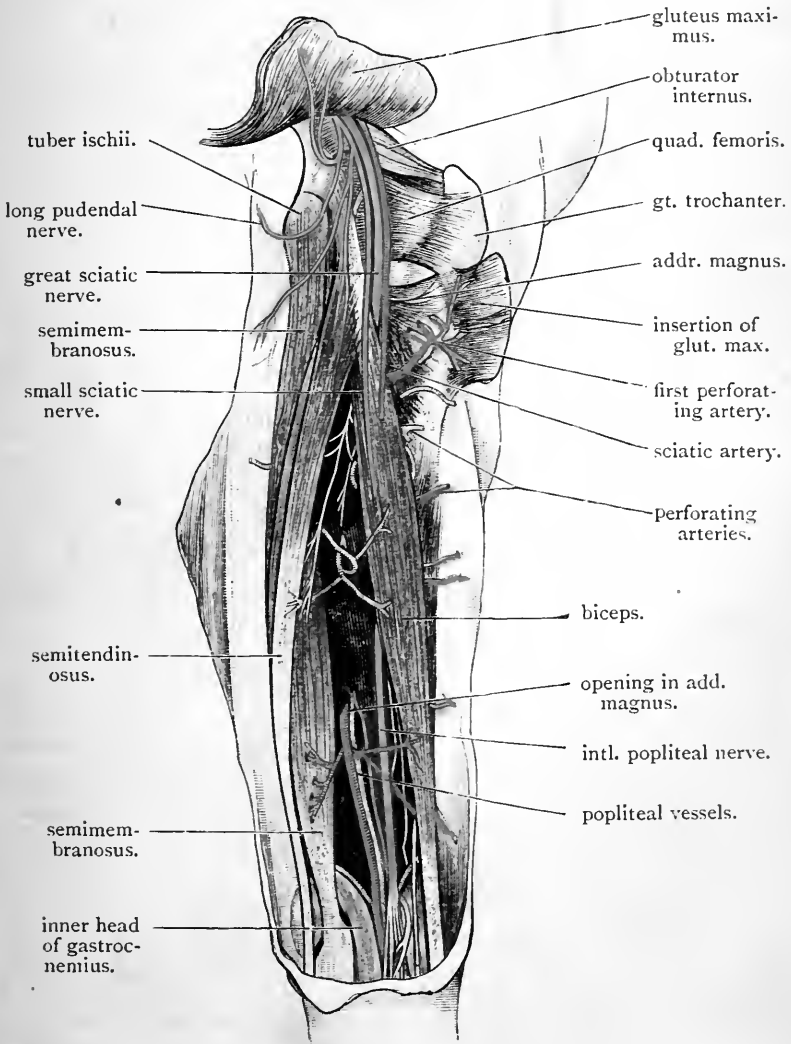



FIG. 44.—Dissection of the back of the right thigh.

fleshy fibres directly from the bone. A narrow tendinous intersection appears on the posterior surface of the muscle about the middle of the thigh, and is directed obliquely



downwards and outwards. The muscular belly ends in the lower third of the thigh, in a long cylindrical tendon which passes downwards on the semimembranosus muscle. On the inner side of the knee the tendon bends forwards, crosses the internal lateral ligament of the knee-joint, and, becoming flattened, is inserted into the upper part of the internal surface of the shaft of the tibia, near the anterior border of that bone, and immediately below the tendon of the gracilis. From its lower border aponeurotic fibres pass into the deep fascia of the leg; its upper border is adherent to the gracilis for about half an inch from its insertion, and both tendons are concealed by the expanded insertion of the sartorius. A synovial bursa lies between the three tendons and the internal lateral ligament of the knee-joint.

The Semimembranosus arises from the outer impression on the upper part of the tuberosity of the ischium, behind the quadratus femoris. The tendon of origin is broad at its attachment to the bone, and narrows as it passes inwards beneath the origin of the biceps; it then expands again, assuming a remarkable shape, something like the blade of a razor, the outer border being thick and rounded, the inner thin and membranous. This tendon passes downwards and inwards under cover of the semitendinosus, and is folded in such a manner as to form a groove, in which the latter muscle lies. The muscular fibres pass obliquely downwards and inwards from the tendon of origin to the tendon of insertion. The main mass of the latter tendon is inserted into the groove on the back of the internal tuberosity of the tibia, under cover of the internal lateral ligament of the knee-joint. Three additional attachments, however, require to be noted. These are effected by aponeurotic extensions from the tendon—(1) to the back of the knee-joint, forming a considerable part of the posterior ligament; (2) to the surface of the popliteus muscle, which is covered by the expansion; and (3) to the internal lateral ligament of the knee-joint.

This enters thigh at lower border of Quadratus

The Great Sciatic Nerve (*nervus ischiadicus*) commences at the lower border of the great sacro-sciatic foramen, and terminates a little below the middle of the thigh by dividing into the internal and external popliteal nerves. Its relations in the gluteal region have already been studied. In the thigh it lies on the posterior surface of the adductor magnus muscle, and is covered by the long head of the biceps. It gives branches to both heads of the biceps, to the semitendinosus, to the semimembranosus, and to the adductor magnus; the branches to the two last-named muscles arise by a common trunk. In a few cases it may be observed to give off a long articular twig, which enters the popliteal space and takes the place of the superior external articular nerve which, as a rule, comes from the external popliteal nerve.

Perforating Arteries (*arteriæ perforantes*).—Four perforating arteries, branches of the profunda femoris, will be found emerging from the surface of the adductor magnus muscle close to the linea aspera of the femur. They are called *first, second, third, and fourth*, according to the level at which they appear from above downwards. The *fourth*, is the terminal branch of the profunda artery of the thigh, and it makes its appearance about an inch above the opening in the adductor magnus muscle through which the popliteal artery enters the popliteal space. The perforating arteries and their branches must be thoroughly cleaned, together with the apertures in the adductor magnus through which they pass. It will then be seen that they do not pierce the fleshy substance of the muscle. Prepared for each is a tendinous archway, and they reach the back of the thigh by passing between these and the linea aspera, to which the piers of the various arches are attached.

These openings lie in the same line, and are in all respects analogous to the large opening in the adductor magnus muscle for the popliteal artery. The result obtained is the same in each case. When the muscle contracts, the vessels are protected from pressure.

Emerging from the tendinous arches the perforating

arteries wind round the back of the femur so as to gain its outer aspect, and reach the vastus externus in which they end. In this part of their course they pierce the short head of the biceps. The highest member of the series, which lies above the level of the femoral attachment of the biceps, pierces, as we have already seen, the insertion of the gluteus maximus.

Dissection.—To bring the adductor magnus muscle more fully into view, and at the same time to facilitate the process of cleaning its radiating fibres, it is well to reflect the hamstring muscles from their origins. First divide the conjoined tendon of the biceps and semitendinosus. This displays the precise origin of the semimembranosus, and when the dissector has again examined this under the present more advantageous circumstances he should divide it also.

Anastomosis on the Posterior Aspect of the Limb.—In a well-injected subject a chain of anastomoses, in which every link is complete, can be traced from the gluteal region down the back of the thigh to the popliteal space. The present is the best time to study this. Commencing above, we find the gluteal artery anastomosing with the sciatic, and the sciatic with the internal circumflex. In the back of the thigh this chain is carried downwards by the internal and external circumflex arteries anastomosing with the first perforating, each perforating artery inosculating with the one below it, and lastly, the lower perforating arteries effecting junctions with the muscular branches which the popliteal artery gives to the hamstrings.

FRONT OF THE THIGH.

The body is now turned round so as to lie on its back. The pelvis is supported by two blocks, and the lower limbs are stretched out at full length upon the table (Fig. 4, p. 17).

Surface Anatomy.—The anterior superior spine of the ilium should in the first place be recognised, and the crest

of the ilium traced as it proceeds outwards and backwards from this. The boundary line between the front of the thigh and the region of the abdomen is formed by Poupart's ligament, which stretches from the anterior superior spine of the ilium to the spine of the pubis. Its course and position are marked on the surface by a faint groove. By running the finger along this when the thigh is fully extended the ligament may be felt. At its inner end the spine of the pubis should be determined, and then the finger may be carried inwards on the crest of the pubis to the symphysis pubis. The rami of the pubis and ischium, leading downwards and backwards to the tuberosity of the ischium, constitute the upper boundary of the thigh on its internal aspect, and their relation to the surface must therefore be ascertained. Below Poupart's ligament in the extended position of the thigh, there is a faint depression corresponding in position to Scarpa's triangle.

In the dissection of the front of the thigh, the skin is also reflected from the anterior aspect of the knee. The dissector should therefore take the present opportunity of studying the surface anatomy of this articulation. The patella forms a marked prominence in front of the joint. When the limb is extended and the extensor muscles on the front of the thigh are relaxed, the patella will be found to be freely movable when grasped firmly between the finger and thumb. Note its change of position when the leg is flexed on the thigh at the knee-joint. It passes downwards, and comes to lie in front of the interval between the femur and tibia. The patellar surface of the femur can now be felt. The powerful ligamentum patellæ which passes vertically downwards from the patella to the anterior tuberosity of the tibia can be easily distinguished. The massive condyles of the femur should next be studied and compared. The internal condyle is the more prominent of the two, and immediately above its tuberosity the adductor tubercle can be recognised. The articular interval between the condyles of the femur and the head

of the tibia is not visible on the surface, but it can readily be felt by the finger. The three tuberosities of the tibia should likewise be studied, and the position of the head of the fibula on the posterior and lower aspect of the external tuberosity ascertained.

SUPERFICIAL DISSECTION.

This dissection comprises the examination of the following parts:—

1. Superficial fascia.
2. Internal saphenous vein, and its several tributaries.
3. Arteries, {
 - Superficial pudic.
 - Superficial epigastric.
 - Superficial circumflex iliac.
4. Lymphatic glands and vessels.
5. The saphenous opening.
6. Cutaneous nerves.
7. The fascia lata.
8. The bursa patellæ.

Reflection of Skin.—*Incisions.*—(1) From the anterior superior spine of the ilium along the line of Poupart's ligament to the symphysis pubis; (2) from the inner extremity of this line downwards, round the scrotum, and along the inner aspect of the thigh for four inches; (3) from the lower extremity of this vertical incision transversely outwards, across the front of the thigh, to the outer aspect of the limb (Fig. 4. p. 17).

The quadrilateral flap of skin thus traced out must be raised carefully from the subjacent superficial fascia and turned outwards.

Superficial Fascia.—The fatty superficial fascia which is now exposed is continuous with the corresponding layer on the front of the abdomen, and it is regarded by some anatomists as being composed of two layers. This subdivision we consider needless and artificial. In the lower part of the abdominal wall, above Poupart's ligament, it is true the superficial fascia presents two distinct strata—one a fatty layer continuous over Poupart's ligament, with the superficial fascia on the front of the thigh, and sometimes termed *the fascia of Camper*; the other, a deeper layer, firm and membranous and devoid of fat, called *the fascia*

of Scarpa. As this latter fascial stratum is attached to the fascia lata (deep fascia of the thigh), immediately below Poupart's ligament, it is necessary that it should receive some attention.

To demonstrate the fascia of Scarpa the dissectors of the lower limb and abdomen should work in conjunction with each other. A transverse incision should be made through the entire thickness of the superficial fascia on the front of the abdomen, from the anterior superior spine of the ilium to the middle line of the body. On raising the lower edge of the divided fascia the two layers can be easily distinguished. Insinuate the fingers between the fascia of Scarpa and the pearly-looking tendon of the external oblique. Little resistance will be encountered, as it is only bound down by some lax areolar tissue. The fingers can be readily carried downwards behind the fascia of Scarpa as far as Poupart's ligament. Here it will be found that they can force their way no farther. The passage of the hand into the thigh is barred by the blending of the fascia of Scarpa with the fascia lata. At this level therefore it ceases to exist. The fatty superficial layer of Camper, however, as we have said, is continued onwards as the superficial fascia of the thigh.

But it is necessary to study more closely the line along which the fascia of Scarpa unites with the fascia lata. Its direction does not correspond with that of Poupart's ligament; it is more nearly horizontal. Internally the union takes place along the line of Poupart's ligament; but as it is traced outwards, it will be seen to fall somewhat below the ligament. When urine is effused under the superficial fascia of the anterior abdominal wall, this attachment of the fascia of Scarpa prevents its passage downwards in front of the thigh.

Dissection.—In the superficial fascia blood-vessels, glands, lymphatic vessels, and nerves are embedded, and these must now be dissected out. First look for the large internal saphenous vein. It will be found extending up the thigh a little way internal to the middle line of the limb. Trace it upwards till it reaches a point about two inches from

Poupart's ligament. At this point it dips through the deep fascia, and joins the femoral vein. It is not desirable to define the opening in the fascia lata through which it passes until a later stage of the dissection. Several tributaries join the internal saphenous vein at this point, and these should be dissected along with the small superficial arteries of the groin which accompany them.

The large lymphatic glands of the groin must also be dissected out from the fatty tissue in which they lie. In doing this care must be taken to preserve as many of the minute thread-like lymphatic vessels which enter and leave the glands as possible. A small artery and vein should also be traced to each gland.

Superficial Inguinal Vessels.—Three minute arteries, termed the superficial epigastric, the superficial external pudic, and the superficial circumflex iliac, pierce the deep fascia below Poupart's ligament, and radiate from each other for the supply of the glands and integument of the groin. They all spring from the femoral artery immediately after it enters the thigh.

The superficial external pudic comes forward through the cribriform fascia (a thin fascial layer, which is spread over the saphenous opening), and runs inwards and upwards across the spermatic cord. It supplies the skin of the scrotum and penis.

The superficial epigastric turns upwards and leaves the thigh by crossing Poupart's ligament about its middle. It is distributed chiefly to the skin on the front of the abdomen.

The superficial circumflex iliac is very minute, and courses upwards and outwards along Poupart's ligament towards the anterior superior spine of the ilium.

The veins which accompany these arteries converge towards the saphenous opening and join the internal saphenous vein near its termination.

Lymphatic Glands and Vessels.—The disposition of the lymphatic glands into two groups will now be evident—an upper inguinal group along the line of Poupart's ligament, and a lower femoral group, which extends for a short way down the thigh along the line of the internal saphenous vein.

In a spare subject, or better still, in a dropsical subject,

the general arrangement of the lymphatic vessels may also be made out. To the femoral group of glands proceed the vessels of the lower limb; to the inguinal glands go the lymphatic vessels from the genitals, perineum, and the surface of the abdomen. These are termed the *afferent vessels*. In addition to these, numerous vessels pass between the various glands and connect them with each other. The lymphatic vessels which lead the lymph away from the glands are called the *effluent vessels*. A large number of these pass through the saphenous opening, others pierce the deep fascia. They join the glands which lie in relation to the femoral and external iliac arteries.

Dissection.—It requires an experienced dissector to display in a satisfactory manner the saphenous opening, or, in other words, the aperture in the deep fascia through which the saphenous vein passes to join the femoral vein. Begin by removing the lymphatic glands. In doing this bear in mind that the *crural branch* of the genito-crural nerve pierces the fascia lata in the middle line of the thigh about an inch or so below Poupart's ligament. Take care also of the two divisions of the *middle cutaneous nerve*, which make their appearance in the same line about three inches below Poupart's ligament.

To define the saphenous opening, the dissector should commence by cautiously removing the superficial fascia from the fascia lata over the upper parts of the adductor longus and pectineus muscles. The deep fascia at this point is called the *pubic portion* of the fascia lata, and as it is cleaned, from within outwards, it will be observed to recede gradually from the surface and to be continued behind the femoral vessels. The clearly-defined inferior cornu of the saphenous opening will now be brought into view, curving under the internal saphenous vein, and blending with the *pubic portion of the fascia lata*. The *cribriform fascia*, a thin and imperfect layer which is spread over the aperture, must be removed so as to display the outer boundary of the opening. In doing this take great care of the subjacent sheath of the femoral vessels to which it is more or less firmly attached. To a certain extent this dissection is artificial, seeing that the cribriform fascia is merely a continuation inwards of the outer lip of the opening. The outer boundary is usually very much broken up by the superficial branches of the femoral artery which pierce it, and its definition is a matter of some difficulty. In a spare subject, however, the line of demarcation between the *cribriform fascia* and the *iliac portion of the fascia lata*¹ may be distinguished.

¹ This is the name which is given to that part of the fascia lata which lies external to the opening.

Saphenous Opening.—This is the opening in the deep fascia through which the saphenous vein passes to effect its junction with the femoral vein. A thin fascia, called the *cribriform fascia*, is spread over the opening. This fascia has received the name of “cribriform,” because it is pierced by the saphenous vein and by numerous lymphatic vessels. Some difference of opinion exists as to what this fascia really is. It is regarded by many as being a part of the superficial fascia, but it is more correct to look upon it as being a thin layer of fascia lata carried over the opening, or, in other words, a prolongation inwards of the outer margin of the opening.

The importance of the saphenous opening consists in the fact that it is through it that a femoral hernia makes its way to the surface. It is oval in shape and very narrow, being not more than half an inch in width; but it is at least one and a half inches long. Its inner boundary is formed by the receding *pubic portion* of the fascia lata, and lies on a deeper plane than the outer boundary. The outer boundary is crescentic, and is known as the *falciform edge* of the opening. It is formed by the *iliac portion* of the fascia lata. The *inferior cornu* of the falciform edge curves inwards under the saphenous vein, in the form of a very distinct process which joins the pubic part of the fascia lata. The *superior cornu* (sometimes called Hey’s ligament), not so well defined, sweeps inwards in front of the upper part of the subjacent femoral sheath, and joins the front of Gimbernat’s ligament.

Reflection of Skin.—The next step in the dissection consists in reflecting the skin from the lower two-thirds of the front of the thigh, and also from the anterior aspect of the knee. This is effected by extending the vertical incision, which has already been made upon the inner aspect of the thigh downwards to the internal tuberosity of the tibia, and then carrying a transverse incision from the lower end of the vertical cut outwards over the front of the leg to its outer aspect. In raising the skin from the front of the knee take care not to injure the patellar plexus of nerves and the patellar bursa. In reflecting the integument from this extensive area, we have two objects in view—Firstly, the dissection of the cutaneous nerves and vessels of the thigh; and secondly, the examination of the entire extent of the fascia lata.

Internal Saphenous Vein (*vena saphena magna*).—The internal saphenous vein should be dissected in the superficial fascia to the lower limit of the area from which the skin has been reflected. It is the largest superficial vein of the lower limb. Taking origin on the dorsum of the foot, it extends upwards on the leg. On the inner side of the knee it will be seen to be placed very far back. As it reaches the thigh it inclines somewhat forwards, and runs upwards on the front and inner aspect of the limb to the saphenous opening in the fascia lata. Through this aperture it passes to join the femoral vein.

In its course along the thigh it receives several tributaries. Two of these are of large size, viz., an *anterior branch*, which collects the blood from the front and outer aspects of the limb, and a *posterior branch*, which performs a similar office for the posterior and inner aspects of the thigh. They both enter the internal saphenous vein near its termination. In addition to these, the *three small veins* corresponding to the superficial inguinal arteries converge towards the saphenous opening, and join the saphenous trunk as it disappears through it.

Cutaneous Nerves.—The cutaneous nerves are now to be looked for in the superficial fascia. The main stems are six in number, and are derived from two sources. *Three* come directly from the *lumbar plexus*, and *three* are branches of the *anterior crural nerve*:—

From lumbar plexus,	{	Ilio-inguinal.
		Crural branch of genito-crural.
		External cutaneous.
From anterior crural,	{	Middle cutaneous.
		Internal cutaneous.
		Long saphenous.

The *ilio-inguinal nerve* will be found as it escapes from the external abdominal ring in company with the spermatic cord. Its branches go for the most part to the scrotum, but some are distributed to the skin on the upper and inner side of the thigh.

The *crural branch* of the *genito-crural nerve* pierces the

fascia a little way below Poupart's ligament, and to the outer side of the femoral artery. With a little care a communication between this nerve and the middle cuta-

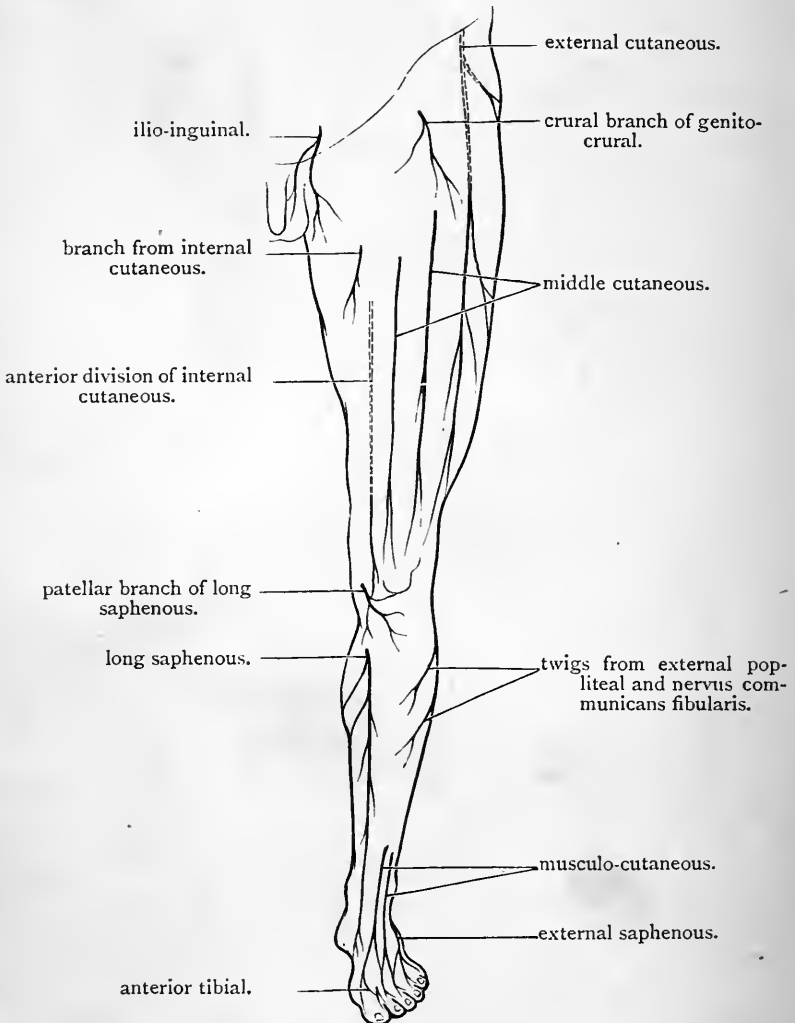


FIG. 45.—Diagram of the cutaneous nerves on the front of the lower limb.

neous may be made out. It supplies a limited area of skin on the upper part of the front of the thigh.

The external cutaneous is distributed on the outer aspect of the thigh. It pierces the deep fascia in two parts. Of these, one—the posterior division—appears about two inches below the anterior superior iliac spine, and proceeds backwards and downwards. Some twigs of this nerve may be followed to the lower part of the gluteal region. The anterior division comes to the surface about two inches lower down. It is the larger of the two, and has a wide area of distribution. It extends as low as the knee-joint. Previous to its division the external cutaneous nerve lies in a prominent ridge of the fascia lata, which descends vertically from the anterior superior spine of the ilium. This may be split up to expose it.

The middle cutaneous nerve pierces the fascia lata in the middle line of the thigh about three or four inches below Poupart's ligament. It usually appears as two nerves which perforate the fascia at two points a short distance apart from each other. Both branches extend downwards as low as the knee, which they reach on its inner aspect.

The internal cutaneous nerve, following the example of the external cutaneous and the middle cutaneous, divides into two portions—an anterior and a posterior—which perforate the deep fascia on the inner aspect of the limb, and at some distance apart from each other. The anterior division makes its appearance through the fascia lata in the lower third of the thigh, a short distance in front of the internal saphenous vein. It descends towards the knee, and its terminal branches turn forwards and outwards in front of the patella. The posterior division reaches the surface on the inner side of the knee, behind the long saphenous nerve, and proceeds downwards to supply the integument on the inner side of the upper part of the leg. But the main stem of the internal cutaneous nerve, before it divides, likewise sends a few twigs through the fascia lata to reach the skin on the upper and inner aspect of the thigh. These make their appearance along the line of the internal saphenous vein.

The long saphenous nerve becomes cutaneous on the

inner side of the knee by perforating the fascia between the tendons of the sartorius and gracilis muscles. The guide to it is the superficial branch of the *anastomotîc artery* which descends alongside of it. It follows the course of the internal saphenous vein into the leg. Before it pierces the fascia it gives off a *patellar* branch.

The *patellar branch* of the long saphenous nerve pierces the sartorius muscle and the fascia lata on the inner side of the knee, and turns outwards and forwards in front of the joint below the level of the patella.

Four of the cutaneous nerves of the thigh have been noticed to send twigs to the skin over the knee-joint, viz., the anterior division of the external cutaneous, the middle cutaneous, the anterior division of the internal cutaneous, and the long saphenous. These nerves communicate with each other and form an interlacement which is situated over the patella, the ligamentum patellæ, and upper part of the tibia. It is termed the *patellar plexus*.

On the inner side of the thigh two minute cutaneous nerve-twigs sometimes make their appearance which do not belong to any of the above main cutaneous trunks. One appears below the ilio-inguinal nerve, and is a twig from the long pudendal branch of the small sciatic; the other pierces the deep fascia half-way down the inner side of the thigh, and comes from the obturator nerve.

Fascia Lata.—This is the name which is given to that portion of the general aponeurotic investment of the lower limb which clothes and preserves the figure of the thigh. It should be carefully cleaned by removing the remains of the superficial fascia. This being done, the dissector will be struck with the marked difference in strength which it shows on the outer and inner aspects of the thigh. Externally it is so dense and strong that it appears to be more tendinous than aponeurotic in its character. The reason of this is, that the tensor fasciæ femoris muscle and the greater portion of the gluteus maximus are inserted into it upon this side of the limb. The strong band thus formed goes under the name of the *ilio-tibial band*, from its being attached above to the crest of the ilium, and below

to the outer tuberosity of the tibia and to the head of the fibula. It acts as a powerful brace on the outer aspect of the limb, which in the erect posture helps to steady the pelvis, and at the same time keep the knee-joint firmly extended. Internally, the fascia lata is so exceedingly delicate and thin that the subjacent muscular fibres shine through it, and it is very apt to be removed with the superficial fascia unless care be exercised in the dissection.

Superiorly, around the root of the limb, the fascia lata is attached to Poupart's ligament and the bones of the pelvis. *Behind*, it is continuous with the gluteal aponeurosis, and through this it is fixed to the coccyx, sacrum, and crest of the ilium. On the *outer side*, it is attached to the crest of the ilium; and on the *inner side*, to the body of the pubis, the side of the pubic arch, and to the tuberosity of the ischium. *In front*, its upper attachment is complicated by the presence of the saphenous opening. This aperture separates the fascia lata into an outer or iliac portion and an inner or pubic portion. This subdivision only extends downwards to the lower border of the saphenous opening. The *iliac portion* is attached along the whole length of Poupart's ligament. Its inner crescentic margin bounds the saphenous opening externally and forms its falciform edge. The superior cornu of this edge blends with Gimbernat's ligament, whilst its inferior cornu joins the pubic portion of the fascia lata. The *pubic portion* clothes the upper portions of the adductor longus and pectineus muscles. It recedes from the surface as it is traced outwards and passes behind the femoral vessels. In this situation it forms the posterior wall of the femoral sheath and is continuous above with the fascia iliaca¹ which covers the ilio-psoas muscle in the iliac fossa. To the inner side of the femoral vessels the pubic portion of the fascia lata is attached above to the ilio-pectineal line

¹ The dissector must keep clearly before him the distinction between the *fascia iliaca* and the *iliac portion of the fascia lata*. The former is a part of the general aponeurotic lining of the abdominal cavity; the latter is a part of the aponeurotic investment of the thigh.

of the pubic bone. The *cribriform fascia*, as previously stated, is to be regarded as a thin piece of the fascia lata, stretched across the saphenous opening. Externally, it is continuous with the falciform edge of the iliac portion of the fascia; internally, it blends with the front of the pubic portion.

In the neighbourhood of the knee the fascia lata is continuous behind with the popliteal fascia, whilst on the lateral and front aspects of the joint it is attached to the various bony prominences and to the different tendons in this locality. Here it helps to strengthen and support the capsular ligament of the knee-joint.

Intermuscular Septa.—But the fascia lata has other

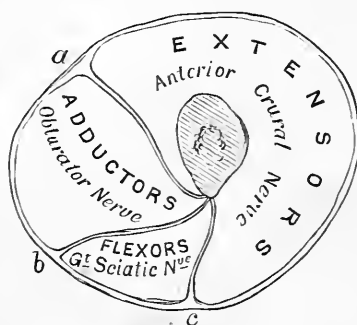


FIG. 46.—Diagram to show the arrangement of the three intermuscular septa and the three osteo-fascial compartments of the thigh. (After Turner.)

- a.* Internal intermuscular septum. *b.* Posterior intermuscular septum.
c. External intermuscular septum.

offices to perform besides that of forming a continuous investment for the thigh. From every part of its deep surface processes pass off which penetrate the limb and constitute sheaths for the muscles and other structures which compose it. Three of these are especially strong, and form distinct septa or partitions which reach the femur and are attached to the linea aspera on its posterior aspect. These partitions are termed the intermuscular septa, and are so disposed that they intervene between the three great

groups of muscles in this region. The external intermuscular septum is placed between the extensor muscles in the front of the thigh and the hamstring muscles on the posterior aspect of the thigh; the internal intermuscular septum intervenes between the extensor muscles and the adductor muscles on the inner aspect of the limb; whilst the posterior intermuscular septum, very weak and inconspicuous in comparison with the other two, is interposed between the adductor and the hamstring muscles. These partitions will be disclosed in the subsequent dissection. In the meantime merely observe that the internal and the external septa show on the surface of the fascia in the lower part of the thigh as white lines. The thigh is in this manner divided into three osteo-fascial compartments, viz., *an anterior*, containing the extensor muscles and the anterior crural nerve; *a posterior*, holding the hamstrings and the great sciatic nerve; and *an internal*, for the adductors with the obturator nerve (Fig. 46).

Patellar Bursa.—This is situated upon the superficial aspect of the patella (Fig. 42, p. 188). Pinch up the fascia lata as it passes over this bone with the forceps, and make a transverse incision through the wall of the sac large enough to admit the finger. The bursa will then be seen to extend downwards for a short distance upon the ligamentum patellæ. It is usually intersected by fibrous bands and cords.

DEEP DISSECTION.

In this dissection, the following parts require to be examined:—

1. The femoral sheath.
2. Crural branch of genito-crural nerve.
3. External cutaneous nerve.
4. Sartorius muscle.
5. Anterior crural nerve and its branches.
6. Femoral vessels and their branches.
7. Ilio-psoas muscle.

8. Quadriceps extensor, { Rectus femoris.
Vastus internus.
Crureus and subcrureus.
Vastus externus.
9. Tensor fasciæ femoris muscle.
10. Deep layer of the ilio-tibial band of fascia lata.
11. The external and internal intermuscular septa.

Poupart's Ligament—Gimbernat's Ligament.—Although, properly speaking, both of these ligaments belong more to the abdominal wall than the thigh, it is very essential that the dissector should obtain some knowledge of their connections before he proceeds further with the dissection. *Poupart's ligament* is merely the thickened lower border of the aponeurosis of the external oblique muscle of the abdominal wall folded backwards upon itself. It thus presents a rounded surface towards the thigh, and a grooved surface towards the abdomen. By its outer extremity it is fixed to the anterior superior spine of the ilium. Internally, it has a double attachment, viz.—(1) to the spine of the pubis; (2) through the medium of Gimbernat's ligament to the inner part of the ilio-pectineal line. Poupart's ligament pursues an oblique course between its iliac and pubic attachments, and at the same time describes a gentle curve, the convexity of which is turned downwards. By its lower border it affords attachment to the fascia lata, and when this is divided it loses its curved direction.

Gimbernat's ligament is a small triangular piece of aponeurotic fascia which occupies the interval between the inner part of Poupart's ligament and the inner inch of the ilio-pectineal line—being attached by its margins to both. Its base is sharp, crescentic, and free, and abuts against the femoral sheath. Gimbernat's ligament occupies a very oblique plane; its femoral surface looks downwards and outwards whilst its abdominal surface is directed upwards and inwards.

Dissection.—The exposure of the femoral sheath is the next step in the dissection of the thigh. To attain this object the *iliac portion* of

the fascia lata must be partially reflected. Divide the superior horn of the outer crescentic margin of the saphenous opening, and then carry the knife outwards along the lower border of Poupart's ligament, so as to sever the attachment of the fascia lata to this thickened band. This incision should extend to within an inch of the anterior superior spine of the ilium. The piece of fascia marked out by the incision above, and by the outer free margin of the saphenous opening internally, must be carefully raised from the subjacent femoral sheath and thrown downwards and outwards. On the removal of a little loose fat, the *femoral sheath* will be brought into view as it enters the thigh under Poupart's ligament. Isolate it carefully from adjacent and surrounding parts, by carrying the handle of the knife gently round it—insinuating it first between the sheath and *Poupart's ligament*, then between the sheath and *Gimbernat's ligament*, which lies internal to it.

Femoral Sheath.—The funnel-shaped appearance of the femoral sheath will now be apparent—the wide mouth of the membranous tube being directed upwards into the abdomen, and the narrow inferior part gradually closing upon the vessels, and fusing with their coats about the level of the lower limit of the saphenous opening. Whilst it presents this appearance, however, it should be noticed that its sides do not slope equally towards each other. The outer side of the sheath indeed is nearly vertical in its direction, whilst the inner wall proceeds very obliquely from above downwards and outwards. If the dissection has been successfully performed, the *crural branch* of the *genito-crural nerve* should be seen piercing the outer wall of the sheath, whilst the internal saphenous vein, and some lymphatic vessels, perforate its anterior and inner walls. Further, if the subject be spare, and the fasciæ well marked, the dissector will in all probability notice that the anterior wall of the sheath in its upper part is strengthened by some transverse fibres which pursue an arched course across it. To these fibres the name of *deep crural arch* is given, in contradistinction to the term *superficial crural arch*, which is frequently applied to Poupart's ligament. In favourable circumstances the deep crural arch may be observed to spring from the under surface of Poupart's ligament about its middle. After traversing the front of the sheath the band expands somewhat, and is attached by its inner

extremity to the ilio-pectineal line of the pubic bone behind Gimbernat's ligament.

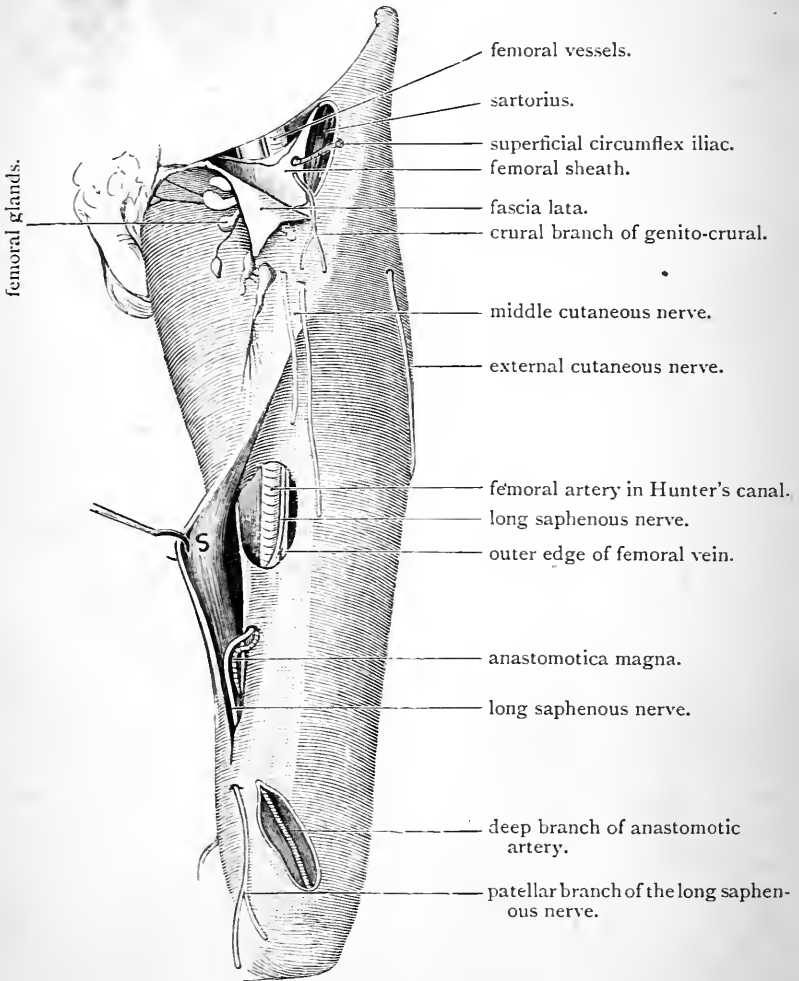


FIG. 47.—Dissection of the femoral sheath and Hunter's canal.

S. Sartorius with its fascial covering pulled aside.

Constitution of the Femoral Sheath.—The source from which the femoral sheath is derived, and the manner in which it is formed, must next be considered. This entails

the study of some of the structures concerned in the construction of the abdominal wall. Unfortunately it is not likely that at this period the dissection of the abdomen is in a sufficiently advanced state for their examination. A small portion of the inner part of the interval between Poupart's ligament and the portion of the innominate bone over which it stretches is filled up by Gimbernat's ligament. Immediately to the outer side of this the femoral vessels, enclosed within the femoral sheath, enter the thigh from the abdominal cavity, whilst to the outer side of these the interval is occupied by the ilio-psoas muscle. Three nerves also find their way into the thigh through this interval, viz., the crural branch of the genito-crural, which passes downwards in the femoral sheath; the anterior crural nerve, which occupies the interval between the psoas and iliacus muscles; and the external cutaneous nerve, which runs behind Poupart's ligament close to its iliac attachment.

The arrangement of the aponeurotic lining of the abdominal cavity with reference to this interval of communication between abdomen and thigh also requires attention. The lower part of the posterior wall of the abdomen, immediately above the thigh, is formed by the iliacus and psoas muscles. These are covered by that part of the aponeurotic lining of the abdomen which receives the name of the *fascia iliaca*. The anterior wall of the abdomen is lined in like manner by a portion of the general lining, termed the *fascia transversalis*. To the outer side of the femoral vessels these two fascial layers become continuous with each other, and at the same time are attached to the back of Poupart's ligament. It is behind this that the ilio-psoas, the anterior crural nerve, and the external cutaneous nerve, are carried downwards into the thigh. But the external iliac vessels (the femoral vessels in the thigh) with the genito-crural nerve lie in front of the fascia iliaca, or, in other words, within the fascial lining of the abdomen, and, as they proceed downwards behind Poupart's ligament, they carry with them a funnel-shaped prolongation of the lining. This, then, is the femoral

sheath, and the dissector will now readily understand that the *front wall* of the sheath is formed of *fascia transversalis* from the anterior wall of the abdomen above Poupart's ligament, while the *posterior wall* is formed of *fascia iliaca*, prolonged downwards from the posterior abdominal wall.

Posterior Wall of the Femoral Sheath.—There are still some additional facts relating to the posterior wall of the femoral sheath which require to be mentioned. It is

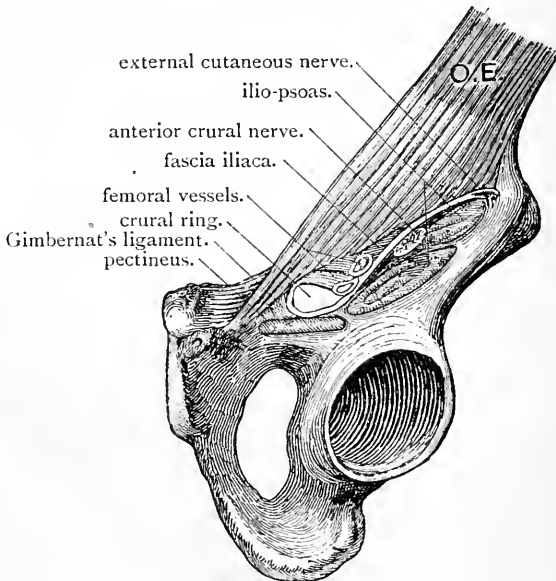


FIG. 48.—Parts which pass behind Poupart's ligament.
(After Luschka.)

formed, as stated above, by the fascia iliaca; but as this enters the thigh it becomes continuous with the pubic layer of the fascia lata, and further, it is firmly fixed in position by certain connections which it establishes in the thigh. Thus beyond the femoral sheath it is prolonged in an outward direction over the ilio-psoas muscle, whilst from its posterior aspect a lamina is given off which passes behind that muscle and joins the capsule of the hip-joint.

Dissection.—The femoral sheath should be opened, in order that

the arrangement of parts inside may be displayed. Make three vertical and parallel incisions through the anterior wall—one over the femoral artery which occupies the outer part of the sheath, another over the femoral vein, and the third about half an inch internal to the second. The first two should begin at the level of Poupart's ligament, and should extend downwards for an inch and a half. The most internal of the three incisions should commence at the same point, but should only be carried downwards for half an inch or less.

Interior of the Femoral Sheath.—A little dissection will show that the sheath is subdivided by two vertical partitions into three compartments. The femoral artery and crural branch of the genito-crural nerve occupy the *outermost* compartment; the femoral vein fills up the *middle* compartment; whilst in the *innermost* compartment is lodged a little loose areolar tissue, a small lymphatic gland, and some lymphatic vessels. This last compartment, from its relation to femoral hernia, has the special name of *crural canal* applied to it.

Crural Canal.—The boundaries and extent of this canal must be very thoroughly studied. The best way to do this is to introduce the little finger into it and gently push it upwards. Its length is not nearly so great as that of the other two compartments. Indeed it is not more than half an inch long. Inferiorly it is closed, and it rapidly diminishes in width from above downwards. Its superior aperture lies on the outer side of the base of Gimbernat's ligament, and is called the *crural ring*. It is closed by the closely-applied extra-peritoneal fatty tissue. The parts which immediately surround this opening can be readily detected with the finger; externally the *femoral vein*, internally the sharp crescentic base of *Gimbernat's ligament*, anteriorly *Poupart's ligament*, and posteriorly the *pubic bone* covered by the *pectineus muscle*. The portion of the extra-peritoneal fatty tissue which closes the ring is called the *septum crurale*. On the abdominal surface of the septum crurale is the peritoneal lining of the abdominal cavity, and when examined from above both are seen to be slightly depressed into the opening so as to produce the appearance of a dimple.

Femoral Hernia.—Femoral hernia is the name applied to a pathological condition which consists in the protrusion of a viscus or part of a viscus from the abdominal cavity into the region of the thigh. In its descent it passes behind Poupart's ligament along the *crural canal*, or *innermost compartment* of the femoral sheath. The arrangement of the parts which occupy the interval between the innominate bone and Poupart's ligament has been carefully considered, and the dissector should therefore be in a position to understand how the occurrence of such a protrusion is rendered possible. To the inner side of the femoral sheath the interval is closed by Gimbernat's ligament, which, by its strength and firm connections, constitutes an impassable barrier in this locality. To the outer side of the femoral sheath a hernial protrusion is equally impossible. Here the fascia transversalis on the anterior wall of the abdomen becomes continuous with the fascia iliaca on the posterior wall of the abdomen, and along the line of union both are firmly attached to Poupart's ligament.

It is in the region of the femoral sheath, then, that femoral hernia takes place. Its three compartments open above into the abdominal cavity, but there is an essential difference between these three openings. The two outer, which hold the artery and the vein, are completely filled up by their contents. The crural canal, or innermost compartment, is not; it is much wider than is necessary for the passage of the fine lymphatic vessels which traverse it. Further, its widest part is the upper opening or *crural ring*. It has been noted that this is wide enough to admit the point of the little finger. Here then is a weak point in the parietes of the abdomen, and a source of weakness which is greater in the female than in the male, seeing that in the former the distance between the iliac and pubic spines is proportionally greater, and in consequence the crural ring wider. Femoral hernia, therefore, is more common in the female.

When attempts are made to reduce a femoral hernia, it is absolutely necessary that the course which the protrusion has taken should be kept constantly before the mind of the operator. In the first instance it descends for a short distance in a perpendicular direction. It then turns forward and bulges through the saphenous opening. Should it still continue to enlarge, it bends upwards over Poupart's ligament, and pushes its way outwards towards the anterior superior spine of the ilium. The protrusion is thus bent upon itself: if reduction is to be carried out successfully it must be made to retrace its steps. In other words, it must be drawn downwards, and then pushed gently backwards and upwards. The position of the limb during this procedure must be attended to. When the thigh is fully extended and rotated outwards, all the fascial structures in the neighbourhood of the crural canal are rendered tight and tense. When the limb is flexed at the hip-joint and rotated inwards, on the other hand, the superior cornu of the falciform edge of the saphenous opening, and even Gimbernat's

ligament, are relaxed. This, then, is the position in which the limb should be placed during the reduction of the hernia.

As the hernia descends it carries before it the various layers which it meets in the form of coverings. First it pushes before it the peritoneum, and this forms the *hernial sac*. The other coverings from within outwards are—(1) the septum crurale; (2) the wall of the femoral sheath (if it does not burst through one of the apertures in this); (3) the cribriform fascia; (4) and lastly, the superficial fascia and skin.

The crural canal, as we have noted, is surrounded by very unyielding structures. Stricture in cases of femoral hernia is therefore a matter of very common occurrence. The sharp base of Gimbernat's ligament and the superior cornu of the falciform edge of the saphenous opening are especially apt to bring about this condition.

The Abnormal Obturator Artery.—But our account of the surgical anatomy of femoral hernia would not be complete if we omitted to mention the relation which the obturator artery frequently bears to the crural ring. In two out of every five subjects the obturator artery on one or on both sides takes origin from the deep epigastric. In these cases it passes backwards to gain the obturator canal in the upper part of the thyroid foramen. According to the point at which it arises from the epigastric trunk, it presents different relations to the femoral ring. In the majority of cases it proceeds backwards in close contact with the external iliac vein and on the outer side of the femoral ring. In this position it is in no danger of being wounded in operations undertaken for the relief of a strictured femoral hernia. In about thirty-seven per cent, however, of the cases in which it exists, the artery is placed less favourably. In these, it either proceeds backwards across the septum crurale which closes the opening into the crural canal, or it arches over it and turns backwards on the inner side of the ring upon the deep aspect of the base of Gimbernat's ligament. In the latter situation it is in a position of great danger, seeing that it is the base of Gimbernat's ligament against which the surgeon's knife is generally directed for the relief of strictured femoral hernia.

Dissection.—Scarpa's triangle may now be dissected. To bring its boundaries into view the deep fascia must be removed from the anterior aspect of the upper third of the thigh. In the lower two-thirds of the thigh, the fascia lata should be left undisturbed, so as to maintain as far as possible the natural position of parts.

Scarpa's Triangle.—This is the name which is given to the triangular hollow which lies in the upper part of the thigh below Poupart's ligament.

The *outer boundary* is formed by the *sartorius muscle* as it runs downwards and inwards across the thigh from the anterior superior spine of the ilium; and the *inner*

boundary is constituted by the prominent internal margin of the *adductor longus muscle*. These muscles meet below to form the *apex* of the triangle. *Poupart's ligament* forms the *base* of the triangle.

The *contents* of the space must now be displayed by removing the fatty areolar tissue which surrounds them. The *femoral vessels* should first be cleaned. Remove the remains of the femoral sheath and define the various branches which proceed from the vessels in so far as they are seen within the limits of the triangular space. Be careful not to injure the small twig which springs from the anterior crural nerve, and passes inwards behind the vessels, a short distance below Poupart's ligament, to supply the pectineus muscle. In this part of its course the femoral artery gives off—(1) the *three superficial inguinal vessels*, which have already been observed ramifying in the superficial fascia of the groin; (2) the *deep external pudic*, which runs inwards over the pectineus; (3) the large *profunda femoris*.

The *profunda femoris* comes off from the outer side of the femoral artery about one and a half inches below Poupart's ligament. It inclines downwards and inwards behind the femoral trunk, and soon leaves the space by passing under cover of the adductor longus. The *external* and *internal circumflex arteries* will be seen to arise from the profunda femoris within Scarpa's triangle.

The *external circumflex* should be traced outwards as it passes amongst the branches of the anterior crural nerve, to disappear under cover of the outer boundary of the space. The *internal circumflex* is lost to view shortly after its origin by sinking backwards through the floor of the space between the pectineus and psoas muscles. The veins corresponding to these arteries must be cleaned at the same time.

Certain nerves are also to be found in this space, viz.—(1) the *crural branch* of the *genito-crural*; (2) the *external cutaneous*; and (3) the *anterior crural*. The *crural branch* of the *genito-crural* descends in the outermost compartment

of the femoral sheath on the outer side of the femoral artery. It pierces the external wall of the sheath and the fascia lata a short distance below Poupart's ligament, and has already been traced to its distribution (p. 207). The *external cutaneous nerve* passes into the thigh behind Poupart's ligament, close to the anterior superior spine of the ilium. It soon leaves the triangle by crossing the sartorius and piercing the fascia lata. It has already been traced in its ramifications in the superficial fascia on the outer aspect of the thigh. The *anterior crural nerve* will be detected lying deeply in the interval between the psoas and iliacus muscles, about a quarter of an inch to the outer side of the femoral artery. Insinuate the handle of a knife under the main trunk, so as to raise it above the level of the muscles between which it lies, and render it tense, and then follow the numerous branches into which it breaks up as far as the limits of the space will allow. The minute twig to the pectineus muscle must be looked for. It passes inwards behind the femoral vessels.

The *floor* of Scarpa's triangle slopes backwards both from the inner and the outer boundary of the space. To the inner side of the femoral artery it is formed by the *adductor longus* and the *pectineus*; in some cases a small portion of the *adductor brevis* may be seen in a narrow interval between these two muscles. To the outer side of the artery are the *psoas* and *iliacus*. The adductor longus is placed in an oblique plane the inner border being nearer the surface than the outer border; and thus it is that this muscle not only forms the inner boundary of the triangle, but also takes part in the formation of the floor. These muscles should be cleaned in so far as they stand in relation to Scarpa's triangle.

When a transverse section is made through the frozen thigh in the region of Scarpa's triangle, the space appears more in the shape of a deep intermuscular furrow, bounded on the inner side by the adductor longus and pectineus, and on the outer side by the sartorius and rectus femoris, whilst behind it is separated from the bone by the ilio-psoas. The femoral vessels and the anterior crural nerve pass downwards in

this groove—the profunda femoris being placed very deeply, whilst the femoral artery lies nearer the surface.

Femoral Artery (*arteria femoralis*).—The femoral artery, the great arterial trunk of the lower limb, is the direct continuation of the external iliac. It begins at Poupart's ligament, behind which it enters the thigh, and it extends downwards to the opening in the adductor magnus, through which it gains the popliteal space and becomes the popliteal artery. This opening is situated on the inner aspect of the lower third of the thigh, and the course which the vessel pursues may be marked on the surface, when the thigh is slightly abducted and rotated outwards, by an oblique line drawn from a point midway between the anterior superior iliac spine and the symphysis pubis to the internal condyle of the femur.

The relations which the artery bears to the femur are important. As it enters Scarpa's triangle it passes from the brim of the pelvis and comes to lie in front of the inner part of the head of the femur, from which it is separated by the psoas muscle. Although its relation to the bone is tolerably intimate, this situation should not be chosen for applying compression. On account of the mobility of the head of the bone there is a liability for the vessel to slip from under the fingers. It is much safer to compress it against the brim of the pelvis. Below the head of the femur, during the remainder of its course through Scarpa's triangle, the artery is not in direct relation to the bone. It crosses in front of the angular interval between the neck and shaft of the femur. Towards the apex of the space, however, it comes into relation with the inner side of the shaft of the femur, and this position it holds to its termination.

In the present condition of the dissection it is only that part of the femoral artery which traverses Scarpa's triangle which comes under the notice of the dissector. The length of this part varies with the development of the sartorius muscle, and the degree of obliquity with which this crosses the front of the thigh. It measures from three to four inches in length, and is comparatively superficial through-

out its entire course. At the apex of the triangle it disappears under cover of the sartorius and takes up a deeper position in the limb.

In Scarpa's triangle the femoral artery is enveloped in its upper part by the femoral sheath, and is separated from the surface by the skin, superficial fascia, and deep fascia, whilst below it is crossed by the internal cutaneous nerve, which runs along the inner border of the sartorius muscle. Behind the vessel is the psoas, and then the pectineus muscle. It rests directly upon the psoas—the femoral sheath and the nerve to the pectineus, as it crosses inwards, alone intervening; but it is separated from the pectineus by an interval occupied by fatty areolar tissue, and here also the profunda artery crosses behind it, and the femoral vein is seen to have a position posterior to it. Upon the outer side of the femoral artery is the anterior crural nerve—but not in apposition with it, as a small portion of the psoas intervenes. The femoral vein changes its position with reference to the artery, as it is traced from above downwards. In the upper part of the space it lies on the same plane and to the inner side of the artery, but lower down it becomes more deeply placed and gradually assumes a position posterior to the artery.

The branches which the femoral artery gives off in Scarpa's triangle have already been enumerated (p. 222). One of these, viz., the deep external pudic, may now be traced to its destination.

The Deep External Pudic Artery is a small twig which arises from the inner side of the femoral, a short distance below Poupart's ligament. It extends inwards upon the pectineus and adductor longus muscles, and, piercing the fascia lata, ends, according to the sex, in the integument of the scrotum or of the labium pudendi.

Dissection.—The fascia lata may now be removed from the lower two-thirds of the thigh. This can best be effected by dividing it along the middle line of the limb, and throwing it outwards and inwards. Preserve undisturbed the thickened band of fascia on the outer side of the thigh.

In cleaning the sartorius muscle several of the nerves of the thigh will be found intimately related to it, and must be carefully dissected. The middle cutaneous nerve frequently pierces its upper border, and then proceeds downwards in front of it; the anterior branch of the

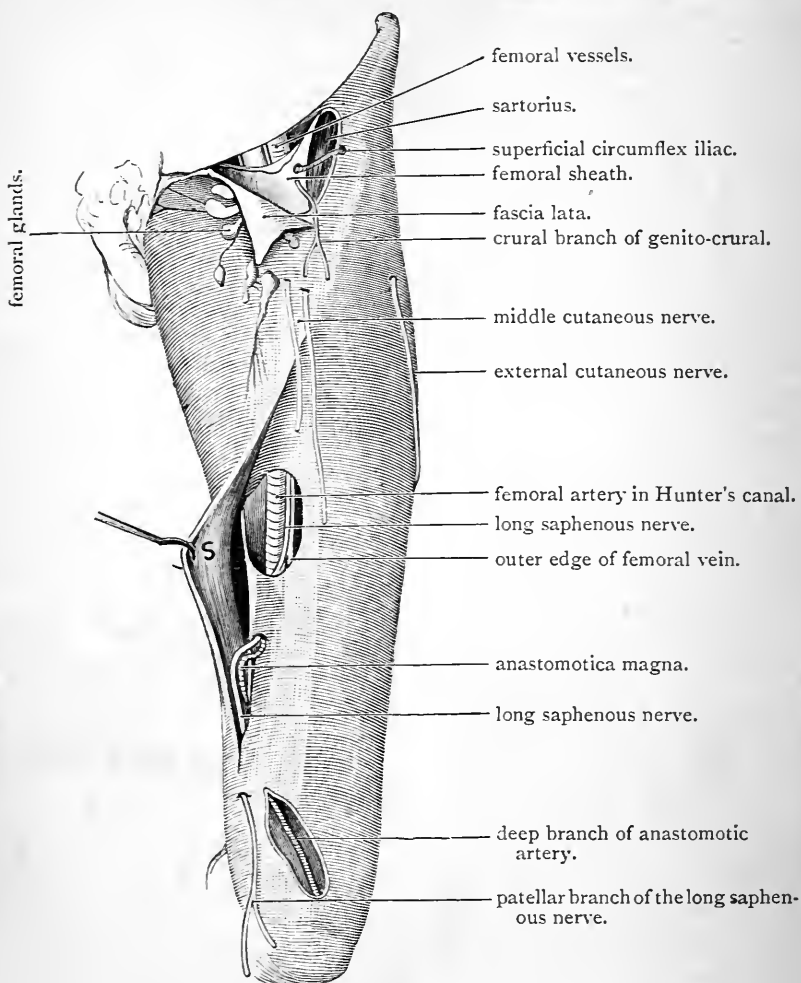


FIG. 49.—Dissection of the femoral sheath and Hunter's canal.

S. Sartorius with its fascial covering pulled aside.

internal cutaneous crosses it at a lower level, whilst the posterior branch of the same nerve is carried downwards along its posterior border. Near the knee it lies over the long saphenous nerve, which

ultimately comes to the surface between it and the gracilis. A short distance above this the sartorius is pierced by the patellar branch of the long saphenous. Lastly, about the middle of the thigh, there is formed under cover of the sartorius an interlacement of fine nerve twigs derived from the posterior branch of the internal cutaneous, the long saphenous, and the obturator. On raising the sartorius from subjacent parts this must be looked for.

The different portions of the quadriceps extensor muscle must also be cleaned, and the branches which the anterior crural nerve gives to them, as well as the descending branch of the external circumflex artery, traced to their terminations.

Sartorius.—The sartorius is a long slender muscle, which arises from the anterior superior spine of the ilium and the upper part of the notch and the anterior border of the bone immediately below. It crosses the front of the upper third of the thigh obliquely, and gaining the inner side of the limb, it takes a nearly vertical course downwards to a point beyond the inner prominence of the knee. Here it turns forwards, and ends in a thin, expanded aponeurotic tendon, which is inserted into the inner surface of the shaft of the tibia, behind the anterior tubercle. By its lower border this tendon is connected with the fascia of the leg, whilst by its upper border it is joined to the capsule of the knee-joint.

In its upper oblique part the sartorius muscle forms the outer boundary of Scarpa's triangle, and lies in front of the iliacus, the rectus femoris, and the adductor longus muscles. Below this, it is placed over the femoral vessels as far as the opening in the adductor magnus. At its insertion its expanded tendon lies in front of, and covers, the tendons of insertion of the gracilis and semitendinosus, but is separated from them by a bursa.

Hunter's Canal (canalis adductorius Hunteri).—When the femoral artery leaves Scarpa's triangle it is continued downwards on the inner side of the thigh, in a deep furrow, which is bounded in front by the vastus internus muscle, and behind by the adductor muscles. If this furrow be traced upwards, it will be seen to run into the deeper, wider, and more apparent hollow, which has

been described as Scarpa's space. Further, this intermuscular recess is converted into a canal, triangular on transverse section, by a strong fibrous membrane which stretches across it, and upon the surface of which the sartorius muscle is placed (Fig. 50). The tunnel thus formed is called "Hunter's Canal." When the fibrous expansion which closes in the canal is traced upwards, it is seen to become thin and ill-defined as it approaches Scarpa's triangle; when traced in the opposite direction,

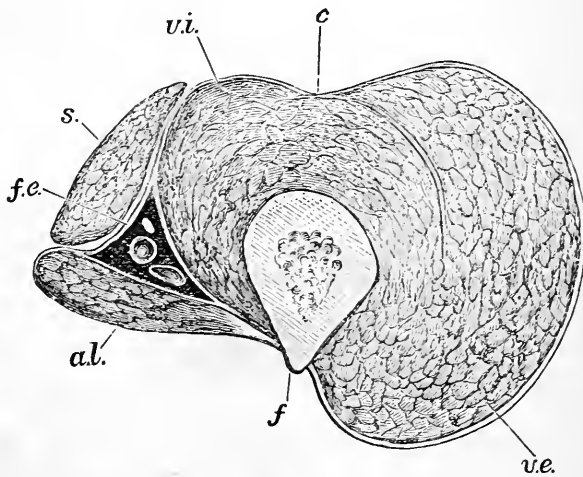


FIG. 50.—Transverse section through Hunter's canal.

- | | |
|--|------------------------------|
| <i>f.</i> Femur. | <i>s.</i> Sartorius. |
| <i>a.l.</i> Adductor longus. | <i>v.i.</i> Vastus internus. |
| <i>f.e.</i> Femoral vessels and long saphenous nerve in the canal. | <i>c.</i> Crureus. |
| | <i>v.e.</i> Vastus externus. |

however, it becomes dense and strong, and opposite the opening in the adductor magnus it presents a thick, sharply-defined margin. It stretches from the tendons of the adductor longus and the adductor magnus behind to the vastus internus in front. In its lower part the posterior wall of the canal, where it is formed by the adductor magnus, presents a deficiency or aperture which leads backwards into the popliteal space. The appearance and

construction of this aperture will be studied at a later stage. It is called *the opening in the adductor magnus*.

The femoral vessels and the long saphenous nerve traverse Hunter's canal. In this part of its course the artery gives off some muscular twigs and the *anastomotica magna* branch. The femoral vessels leave the canal at its lower end by inclining backwards through the opening in the adductor magnus and entering the popliteal space.

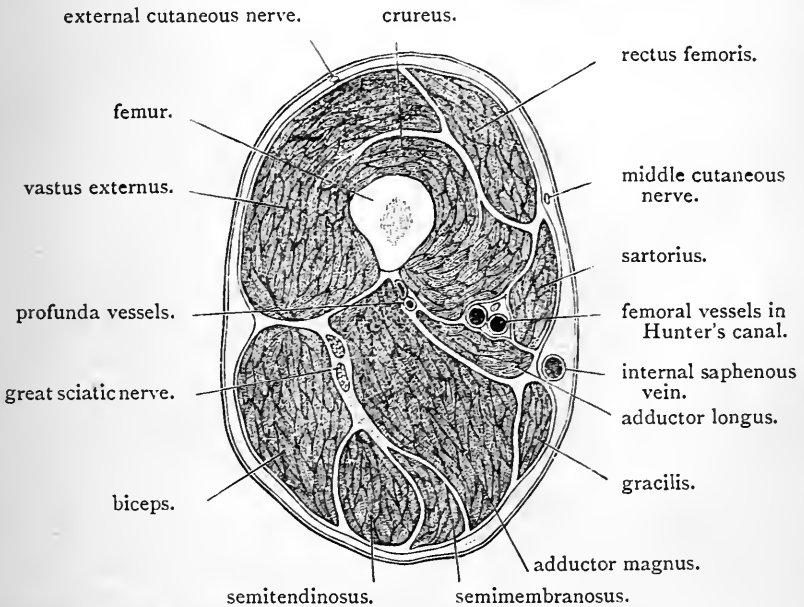


FIG. 51.—Transverse section through the middle of the thigh. The relationship of the parts in Hunter's canal is seen.

The long saphenous nerve, accompanied by the superficial branch of the *anastomotica magna* artery, escape from the canal by passing under cover of the lower thickened margin of the fibrous expansion which closes it in. They can be seen in the present stage of the dissection in this situation.

Dissection.—The fibrous expansion which is stretched across Hunter's canal under cover of the sartorius muscle should now be

divided, in order that the arrangement of the parts within the canal may be studied.

Lower Portion of the Femoral Artery.—The entire length of the femoral artery is now exposed. Below the apex of Scarpa's triangle it enters Hunter's canal, and is separated from the inner surface of the thigh by the fibrous expansion which closes the canal, the sartorius muscle, the fascia lata, and the integument. The long saphenous nerve at first lies to the outer side of this portion of the vessel and then in front of it. From above downwards the artery rests upon the pectineus, the adductor brevis, the adductor longus, and the adductor magnus. In its upper part, however, it is separated from these muscles by the femoral vein, which lies behind it; lower down, the vein, which inclines outwards, comes to lie on its outer side. The relation of parts in the lower portion of Hunter's canal is seen in Figs. 50 and 51. The two vessels are placed side by side, whilst the long saphenous nerve is in front of the artery.

From the femoral artery, as it traverses Hunter's canal, proceed muscular twigs and the anastomotic branch.

The *muscular branches* are irregular in number and in their mode of origin. They supply the vastus internus, the adductor longus, and the sartorius.

The Anastomotic Artery (*arteria genu suprema*) springs from the femoral trunk a short distance above the point where it enters the popliteal space by passing through the opening in the adductor magnus. It almost immediately divides into a superficial and a deep branch: very frequently, indeed, these branches take separate origin from the femoral artery.

The *superficial branch* accompanies the long saphenous nerve, and leaves Hunter's canal by passing under cover of the lower border of the fibrous expansion which is stretched over the canal. On the inner side of the knee it appears between the gracilis and sartorius, and it ends in branches to the integument on the inner aspect of the upper part of the leg.

The *deep branch* enters the substance of the vastus internus and proceeds downwards in front of the tendon of the adductor magnus (Fig. 49). It gives some twigs to the vastus internus and others which spread out over the upper and inner aspect of the knee-joint, and anastomose with branches of the internal articular arteries. One well-marked branch runs outwards above the patella to anastomose with the superior external articular artery.

The Femoral Vein (*vena femoralis*) is the direct continuation upwards of the popliteal vein. It begins at the opening in the adductor magnus, through which it enters Hunter's canal, whilst above it passes behind Poupart's ligament, and becomes continuous with the external iliac vein. It accompanies the femoral artery, but the relations of the two vessels to each other differ at different stages of their course. In the lower part of Hunter's canal the vein lies on the outer side of the artery, but it inclines inwards as it ascends, and in the upper part of the thigh it lies on its inner side and on the same plane. The crossing from one side to the other takes place behind the artery and is very gradual, so that for a considerable distance the femoral vein lies directly behind the femoral artery. For a distance of two inches below Poupart's ligament it is enclosed within the femoral sheath, of which it occupies the middle compartment.

In its journey up the thigh the femoral vein receives tributaries which for the most part correspond with the branches of the femoral artery. At the saphenous opening it is joined by the internal saphenous vein. The dissector should slit it open with the scissors. Several valves will then be seen. One is almost invariably found immediately above the entrance of the vein which corresponds to the profunda artery.

Anterior Crural Nerve (*nervus femoralis*).—The anterior crural nerve is a large nerve which arises within the abdomen from the lumbar plexus. It enters the thigh by passing downwards in the interval between the psoas and iliacus muscles and behind Poupart's ligament and

the fascia iliaca. In the upper part of the thigh it lies to the outer side of the femoral artery, and is separated from it by a small portion of the psoas muscle and the femoral sheath. A short distance below Poupart's ligament it divides into an anterior and a posterior portion, which at once resolve themselves into a large number of cutaneous and muscular branches. The following is a list of these :—

Anterior division,	{	Muscular branches,	{	To the pectineus.
				,, sartorius.
		Cutaneous branches,	{	Middle cutaneous.
				Internal cutaneous.
Posterior division,	{	Muscular branches,	{	To the rectus femoris.
				,, vastus internus.
				,, vastus externus.
				,, crureus.
				,, subcrureus.
		Cutaneous branch,		Long saphenous.
		Articular branches.		

With the exception of the long saphenous, which is distributed upon the inner side of the leg and foot, the distribution of the cutaneous branches of the anterior crural has been already examined (p. 209).

The *nerve to the pectineus* arises a short distance below Poupart's ligament and turns inwards behind the femoral vessels to reach its destination. The *branches to the sartorius* are two or three in number. As a rule they take origin by a common trunk with the middle cutaneous nerve.

The *middle cutaneous nerve* sometimes pierces the upper border of the sartorius. It divides into two branches which perforate the fascia lata about three or four inches below Poupart's ligament.

The *internal cutaneous nerve* inclines downwards and inwards, and crosses in front of the femoral artery. It divides into an anterior and a posterior portion, which become superficial at different levels on the inner side of the limb. From the trunk of the nerve a few cutaneous twigs are given to the skin over the upper and inner part

of the thigh. The anterior branch crosses the sartorius muscle and makes its appearance through the fascia lata in the lower part of the thigh, a short distance in front of the saphenous vein. The posterior branch runs downwards along the posterior border of the sartorius, and pierces the deep fascia on the inner side of the knee behind that muscle and the long saphenous nerve.

A short distance below the middle of the thigh the posterior branch of the internal cutaneous nerve forms, with filaments from the obturator nerve and the long saphenous nerve, a plexiform interlacement, the *sartorial plexus*, which is placed under the sartorius muscle, as it lies over Hunter's canal. The twig from the obturator nerve appears at the inner border of the adductor longus.

The *long saphenous nerve* is the largest branch of the anterior crural. It springs from the posterior division of that nerve and extends downwards on the outer side of the femoral artery. Entering Hunter's canal with the femoral vessels it comes to lie in front of the artery. At the lower end of the canal it emerges, by passing under cover of the thickened border of the fibrous expansion which stretches between the vastus internus and the adductor muscles, and, accompanied by the superficial branch of the anastomotic artery, it escapes from under cover of the sartorius and pierces the deep fascia at the inner side of the knee. It gives off the *patellar branch* after it quits Hunter's canal. This branch pierces the sartorius and appears on the surface of the fascia lata on the inner side of the knee.

Several large branches of the posterior part of the anterior crural nerve enter the four factors which compose the great quadriceps extensor muscle of the thigh. From certain of these articular filaments are given to the hip and knee-joints.

The *branch to the rectus femoris* sinks into the deep surface of this muscle. It supplies an articular twig to the hip-joint. The large *branch to the vastus internus* accompanies the long saphenous nerve, and enters with it the upper part of Hunter's canal. It can readily be dis-

tinguished from its sinking into the inner aspect of the vastus internus about the middle of the thigh. In the substance of this muscle it extends downwards, and near the knee joins the deep branch of the anastomotic artery. It gives an articular nerve to the synovial membrane of the knee-joint. The *nerve to the vastus externus* is associated with the descending branch of the external circumflex artery. Very frequently it gives an articular twig to the knee-joint. The *nerves to the crureus* are two or three in number, and they sink into its anterior surface. The innermost of these is a long slender nerve, which can be traced downwards under the anterior border of the vastus internus to the subcrureus. Its terminal twigs are given to the synovial membrane of the knee-joint.

One filament then from the anterior crural goes to the hip-joint; two, and frequently three, filaments go to the knee-joint.

Ilio-tibial Band of Fascia Lata.—The thick band of fascia lata on the outer side of the thigh which receives this name should now be examined, and its connections ascertained. It has been preserved for this purpose. Inferiorly it is attached to the outer tuberosity of the tibia and to the head of the fibula. On tracing it upwards on the outer surface of the vastus externus it will be observed to split at the junction of the middle and upper thirds of the thigh into two lamellæ—a superficial and a deep. The tensor fasciæ femoris is enclosed between these layers, and when they are disengaged from its surfaces the muscle will be seen to be inserted into the fascia at the angle of splitting. The *superficial lamina* of the ilio-tibial band is attached above to the crest of the ilium, and is continuous posteriorly with the gluteal aponeurosis where this covers the gluteus medius. The *deep lamina* can be followed upwards on the outer surface of the rectus femoris to the capsule of the hip-joint, with the upper and outer part of which it blends. It is also connected with the reflected tendon of the rectus femoris. This layer is perforated by the ascending twigs of the external circumflex artery.

Tensor Fasciæ Femoris (musculus tensor fasciæ latæ).—This is a small muscle which is placed on the outer and anterior aspect of the upper third of the thigh. It lies between the two lamellæ of the ilio-tibial band of fascia, in the interval between the sartorius muscle in front and the gluteus medius muscle behind. On turning the muscle outwards so as to display its deep surface, a little dissection will bring into view its nerve of supply which comes from the *superior gluteal nerve*. This nerve, however, has in all probability been already exposed in the dissection of the gluteal region. A few arterial twigs from the external circumflex also sink into its deep surface.

The *tensor fasciæ femoris* arises from a small portion of the anterior part of the crest of the ilium; from the upper part of the notch below the anterior superior spine of the ilium; and by some fibres from the aponeurosis covering the gluteus medius. It extends downwards with a slight inclination backwards, and is inserted into the ilio-tibial band of fascia lata at its angle of splitting.

The External Circumflex Artery (arteria circumflexa femoris radialis) is the largest branch which proceeds from the profunda femoris. It arises near the origin of the latter from the femoral artery, and runs outwards between the divisions of the anterior crural nerve and under cover of the sartorius and rectus femoris muscles. It ends by dividing into ascending, transverse, and descending branches.

The ascending branch reaches the dorsum ilii by passing under cover of the tensor fasciæ femoris. Its terminal twigs anastomose with the gluteal artery. The transverse branch is of small size and passes to the deep surface of the vastus externus. It reaches the back of the thigh, and inoscules with the internal circumflex and the first perforating arteries. The descending branch gives twigs to the crureus and rectus femoris and one long branch, which may be traced downwards amid the fibres of the vastus externus to the knee, where it anastomoses with the superior external articular artery.

The Intermuscular Septa.—Divide the *ilio-tibial band* of

fascia lata below the point at which it splits to enclose the tensor fasciæ femoris. This is done so as to obtain a better view of the vastus externus, and in order to demonstrate satisfactorily the external intermuscular septum. Take hold of the lower portion of the ilio-tibial band, and draw it forcibly outwards; at the same time push inwards the vastus externus muscle, and a strong fibrous septum will be seen passing inwards from the fascia lata towards the linea aspera. This is the *external intermuscular septum* of the thigh, a partition interposed between the vastus externus and the short head of the biceps. Follow it upwards and downwards with the finger. The fibres of the vastus externus are seen arising from it, but little difficulty will be experienced in making out its attachment to the linea aspera of the femur. It extends in an upward direction as far as the insertion of the gluteus maximus, whilst below it reaches the external tuberosity of the lower end of the femur. Immediately above the external condyle of the femur it is pierced by the superior external articular vessels and nerve. The *internal intermuscular septum* is interposed between the adductors and the vastus internus, and should also be examined. It is thin in comparison with the external septum.

Quadriceps Extensor Cruris (musculus quadriceps femoris).—This muscle is composed of four portions. The rectus femoris, which is placed on the front of the thigh, is quite distinct from the others, except at its insertion; the vastus externus, the crureus and the vastus internus clothe the shaft of the femur on its outer, anterior and inner aspects, and are more or less blended with each other.

The Rectus Femoris arises by two tendinous heads of origin, which may be exposed by dissecting deeply in the interval between the iliacus and tensor fasciæ femoris. The *anterior* or *straight* head springs from the anterior inferior spine of the ilium; the *posterior* or *reflected head* arises from a marked impression on the outer surface of the ilium, immediately above the upper part of the rim of the acetabulum, and is connected both with the capsule

of the hip-joint and the deep lamina of the ilio-tibial band of fascia lata. The two heads of origin of the rectus femoris join at a right angle immediately beyond the margin of the acetabulum, and form a strong flattened tendon, which gives place to a fusiform, fleshy belly. The tendon of origin spreads out on the anterior surface of the muscle in its upper part in the form of an aponeurosis. About three inches above the knee-joint the rectus femoris ends in a strong tendon of insertion, which is prolonged for some distance upwards on its deep surface in the form of an aponeurosis. As it nears the patella, this tendon is joined by the other tendons of the quadriceps, and through the medium of a common tendon finds insertion into the upper border of that bone.

The Vastus Externus (*musculus vastus lateralis*) forms the prominent muscular mass on the outer side of the thigh. Its surface is covered by a glistening aponeurosis. The descending branch of the external circumflex artery constitutes the best guide to its anterior border, and when this margin is raised it will be seen that the muscle lies upon, and is partially blended with, the crureus.

The vastus externus arises—(1) from the upper part of the anterior intertrochanteric line; (2) from the front of the great trochanter, anterior to the insertion of the gluteus minimus; (3) from the root of the great trochanter below the insertion of the gluteus medius; (4) from the outer part of the gluteal ridge in front of the insertion of the gluteus maximus; (5) from the upper part of the linea aspera; and (6) from the external intermuscular septum. The fleshy fibres are for the most part directed downwards and forwards. By means of the common tendon of insertion the muscle gains insertion into the patella, and at the same time gives an expansion to the capsule of the knee-joint.

The Vastus Internus (*musculus vastus medialis*) is intimately connected with the crureus, but not to such an extent as might be inferred from a superficial inspection. In its upper part the anterior border, which is fleshy, is

either contiguous or blended with the crureus ; below, the anterior border is tendinous and overlaps the crureus, but it is not fused with it.

“ A line drawn from the middle of the anterior intertrochanteric line downwards and slightly outwards to the middle of the upper border of the patella will define accurately the thick anterior border of the vastus internus.”—(Williams.) Divide the rectus femoris about its middle, and pull the lower part forcibly downwards. The narrow interval between the tendons of the crureus and vastus internus will then become apparent, and may be followed upwards. A still further guide is the long, slender nerve of supply to the subcrureus, which runs along the inner edge of the crureus. When the anterior border of the vastus internus is raised from the crureus, the inner surface of the shaft of the femur will be seen to be perfectly bare. No muscular fibres arise from this bony surface. The fleshy mass of the vastus internus may now, with advantage, be divided transversely about two inches above the patella. The muscle can then be thrown inwards, and its origin studied.

The vastus internus arises—(1) from the lower part of the anterior intertrochanteric line of the femur ; (2) from the line leading from this, below the small trochanter, to the linea aspera ; (3) from the inner lip of the linea aspera ; (4) from the upper part of the internal supracondyloid line as low down as the opening in the adductor magnus ; (5) **AD.** from the rounded tendon of the adductor magnus. The fleshy fibres are directed downwards and forwards, and end in the common tendon of the quadriceps muscle. By this it is inserted into the patella, and becomes connected with the capsule of the knee-joint.

The Crureus (*musculus vastus intermedius*) covers the anterior and outer aspects of the shaft of the femur, from both of which, as well as from the lower part of the external intermuscular septum, it takes origin. It is inserted into the patella through the medium of the common tendon.

Common Tendon of the Quadriceps.—It should now be noticed that the common tendon of the quadriceps muscle closes the knee-joint above the patella. It is inserted into the upper border of that bone, and is intimately connected with the capsule of the knee-joint. Some fibres are carried downwards into the ligamentum patellæ upon the surface

of the patella. A pouch of synovial membrane is prolonged upwards beyond the level of the patella, between the quadriceps and the bone. Into this some of the lower and deeper fasciculi of the crureus muscle are inserted. They constitute the *subcrureus muscle* (musculus articularis genu).

The crureus should be divided in a vertical direction, so as to bring this little muscle into view, and at the same time the long, slender nerve-filament which runs along the inner border of the crureus, may be traced to the subcrureus and the synovial membrane of the knee-joint.

The *ligamentum patellæ*, which connects the patella with the anterior tubercle of the tibia, and through which the quadriceps is attached to that bone, will be studied in connection with the knee-joint.

INNER SIDE OF THE THIGH.

The group of adductor muscles on the inner aspect of the thigh, together with the blood-vessels and nerves associated with them, must next be dissected. In this dissection the following are the structures which are displayed:—

Muscles,	{	Pectineus.
		Adductor longus.
		Adductor brevis.
		Adductor magnus.
		Gracilis.
		Obturator externus.
Arteries,	{	Profunda femoris and its branches.
		Obturator.
Nerves,	{	The two divisions of the obturator.
		Occasionally the accessory obturator.

The adductor muscles are disposed in three strata. The superficial stratum is formed by the adductor longus and the pectineus, which lie in the same plane. Above they are placed side by side, but below, as they approach

their insertions, they are separated from each other by a narrow interval. The second stratum is formed by the adductor *brevis*; and the third, or deep layer, by the adductor *magnus*. The *gracilis* muscle, also an adductor, extends along the inner aspect of the thigh. It is a long, strap-like muscle, applied against the adductor *brevis* and adductor *magnus*. Interposed between these muscular layers, are the two divisions of the obturator nerve. The anterior division is placed between the superficial and middle layers, whilst the posterior division lies between the middle and deep layers. In other words, the two divisions of the nerve are separated from each other by the adductor *brevis*, which intervenes between them. At the lower border of the adductor *longus*, a fine branch from the anterior division of this nerve makes its appearance to take part in the formation of the sartorial nerveplexus already dissected. The profunda artery and its branches are also to be followed. For a part of its course this vessel is placed between the anterior and middle muscular strata.

The Adductor Longus is placed on the inner side of the pectineus. It is somewhat triangular in shape, being narrow at its origin and expanded at its insertion. It arises by a short, but strong, tendon from the front of the body of the pubis, immediately below the pubic crest, and it is inserted into the inner lip of the linea aspera of the femur by a thin, tendinous expansion.

Dissection.—The adductor *longus* may now be reflected. Divide it close to the round tendon of origin, and throw it outwards. In doing this be careful of the anterior division of the obturator nerve, which lies under cover of it, and gives to it its nerve of supply. On approaching the linea aspera of the femur its aponeurotic tendon will be found intimately connected with the vastus internus in front and with the adductor *magnus* behind. Separate it from these as far as possible, in order that the profunda femoris vessels may be fully displayed as they proceed behind it.

Arteria Profunda Femoris.—This large vessel is the chief artery of supply to the muscles of the thigh. It

arises in Scarpa's triangle from the outer and posterior aspect of the femoral artery, about an inch and a half below Poupart's ligament. At first it is placed on the iliacus, but it inclines inwards as it proceeds downwards, and thus it crosses behind the femoral artery, and comes to lie on the pectineus. Reaching the upper border of the adductor longus, it passes behind that muscle, and is continued downwards close to the shaft of the femur upon the adductor brevis and adductor magnus. Numerous large branches spring from the profunda femoris, so that it rapidly diminishes in size. Ultimately it is reduced to a fine terminal twig, which turns backwards, through the adductor magnus, and receives the name of the *fourth perforating artery*. The following, then, are the relations of the profunda femoris:—(1) It lies on the iliacus to the outer side of the femoral artery. (2) It rests on the pectineus, behind the femoral artery, but separated from it by the femoral vein. (3) It is placed on the adductor brevis, and lower down on the adductor magnus; the adductor longus lies in front of this portion of the vessel and separates it from the femoral artery. (4) The terminal twig, called the fourth perforating artery, pierces the adductor magnus at the junction of the middle and lower thirds of the thigh.

The *branches* which spring from the profunda femoris are: the two circumflex arteries, the four perforating arteries, and some muscular branches.

The *external circumflex* arises from the outer aspect of the profunda, close to its origin. It has already been followed to its distribution (p. 235). The *internal circumflex*, which takes origin at the same level, but from the inner and back aspect of the profunda, will be studied when the pectineus muscle is reflected. The *muscular branches* are irregular both in origin and size. They supply the adductor muscles, and give twigs which pierce the adductor magnus to reach the hamstring muscles.

The internal circumflex artery frequently arises from the common femoral trunk.

The Perforating Arteries arise in series from the main trunk, and pass backwards through the adductor muscles to the back of the thigh. They may be recognised from the close relation which they bear to the *linea aspera* of the femur. The *first perforating artery* (*arteria perforans prima*) comes off at the level of the lower border of the *pectineus*. It proceeds backwards through the *adductor brevis* and *adductor magnus*. The *second perforating artery* (*arteria perforans secunda*) takes origin a short distance lower down, or perhaps by a common trunk, with the first perforating. It pierces the same muscles, viz., the *adductor brevis* and *adductor magnus*. The *third perforating* (*arteria perforans tertia*) springs from the *profunda* below the *adductor brevis*, and passes backwards through the *adductor magnus*. The *fourth perforating*, as we have noted, is the terminal branch of the *profunda femoris*, and pierces the *adductor magnus*.

The *chief nutrient artery* to the femur may come from either the second or the third perforating branch. A *second nutrient twig* is frequently derived from the fourth perforating artery.

When the *adductor magnus* is more fully exposed, it will be seen that the perforating arteries, as they pierce its tendon, have a series of fibrous arches thrown over them.

The Pectineus Muscle is placed between the *adductor longus* and the *ilio-psoas*. It is flat and somewhat broader at its origin from the brim of the pelvis than at its insertion into the femur. It has a fleshy origin, from the *ilio-pectineal line*, and from the surface of bone in front of it. Some fibres are likewise derived from *Gimbernat's ligament*. It descends obliquely outwards and backwards, and gains insertion into the femur behind the *small trochanter*, and to a certain extent also into the line which leads from this prominence down to the *linea aspera*.

Dissection.—The *pectineus* may be detached from its origin, and thrown downwards and outwards. In separating the muscle from the pubis the dissector must bear in mind that in some cases an *accessory obturator nerve* descends into the thigh, over the brim of the pelvis, and

under cover of its outer margin. Care must also be taken not to injure the anterior division of the obturator nerve which lies behind it, or the internal circumflex artery which passes backwards in contact with its outer border.

The Accessory Obturator Nerve when present arises within the abdomen from the obturator trunk near its origin. In the thigh it gives a branch to the hip-joint and joins the anterior division of the obturator nerve. It is very rare to find a twig given to the pectineus either by it or by the trunk of the obturator nerve itself.

The Internal Circumflex Artery (*arteria circumflexa femoris medialis*) arises from the inner and back aspect of the profunda femoris at the same level as the origin of the external circumflex. It proceeds backwards between the psoas and pectineus, and then between the upper border of the adductor brevis and the obturator externus to gain the back of the limb. Close to the small trochanter of the femur it divides into two terminal branches—a transverse and an ascending. From the main trunk before it divides are given off several *muscular branches* to the adjoining muscles, and an *articular branch*, which enters the hip-joint through the cotyloid notch.

The *terminal branches* of the internal circumflex have already been examined in the dissection of the gluteal region (p. 180).

Branches of the Femoral Artery.—In every region of the thigh the dissector has met with branches of the femoral artery. It is well now that he should revert to this vessel and study its branches systematically. The following Table may aid him in doing this:—

Femoral.	{	Superficial pudic.	}	Superficial inguinal.	
		Superficial epigastric.			
Superficial circumflex iliac.					
Deep external pudic.					
Femoral.	{	Profunda, or deep femoral.	{	External circumflex.	} Nutrient.
				Internal circumflex.	
				First perforating.	
				Second perforating.	
				Third perforating.	
Fourth perforating, or terminal.					
Femoral.	{	Muscular.			
		Anastomotica magna.			

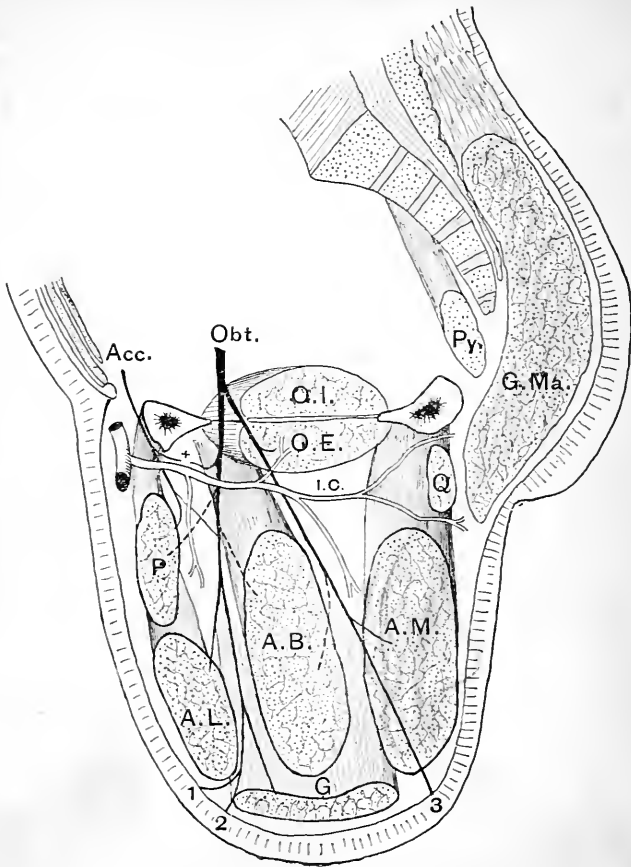


FIG. 52.—Diagram by Professor Paterson to illustrate the distribution of the obturator nerve and the general disposition of the adductor muscles of the thigh.

Acc. Accessory obturator nerve.
 Obt. Obturator nerve.
 O.I. Obturator internus.
 O.E. Obturator externus.
 Py. Piriformis muscle.
 G.Ma. Gluteus maximus.
 Q. Quadratus femoris.
 A.M. Adductor magnus.
 P. Pectineus.

A.B. Adductor brevis.
 A.L. Adductor longus.
 G. Gracilis.
 ×. Branch to hip-joint.
 I.C. Internal circumflex artery.
 1. Cutaneous branch.
 2. Twig to walls of femoral artery
 3. Branch to knee-joint.

The Adductor Brevis lies behind the adductor longus and the pectineus. It arises below the origin of the adductor longus from the anterior aspect of the body and the descending ramus of the pubis. As it descends it inclines backwards and outwards, and it is inserted behind the pectineus into the whole length of the line which extends from the small trochanter to the linea aspera.

Dissection.—Reflect the adductor brevis by cutting it close to its origin, and throwing it downwards and outwards. The posterior division of the obturator nerve is now exposed, and should be traced upwards to the thyroid foramen, and downwards to its distribution upon the adductor magnus.

Obturator Nerve (nervus obturatorius).—The obturator nerve is a branch of the lumbar plexus, and escapes from the pelvis by passing with its companion vessels through the upper part of the thyroid foramen of the innominate bone. While still within the foramen it divides into an anterior and a posterior division.

The anterior division of the obturator nerve enters the thigh over the upper border of the obturator externus muscle, and proceeds downwards upon the anterior surface of the adductor brevis. In front of it are the pectineus and adductor longus muscles. It gives branches to three muscles, viz., the adductor longus, the adductor brevis, and the gracilis. Very rarely it will be observed to supply a twig to the pectineus. In addition to these it supplies an *articular branch* to the hip-joint (Fig. 52, x); a fine twig which appears at the lower border of the adductor longus to join the sartorial plexus (Fig. 52, 1); and a *terminal twig* which goes to the femoral artery—(Fig. 52, 2)—and breaks up into fine filaments upon its walls.

The posterior division of the obturator nerve as it enters the thigh pierces the upper border of the obturator externus. It extends downwards between the adductor brevis and the adductor magnus, and is chiefly expended in the supply of the latter muscle. It gives also, however, a branch to the obturator externus and an *articular branch* to the knee-joint (Fig. 52, 3). The latter branch pierces

the lower part of the adductor magnus close to the linea aspera, and has already been seen in the popliteal space lying upon the popliteal artery.

The Gracilis is a long, strap-like muscle, which is situated along the inner aspect of the thigh and knee. It springs by a thin tendon from the lower half of the body of the pubis, close to the symphysis, and also from the upper half of the pubic arch. It ends in a slender, rounded tendon which inclines forwards below the knee, and then expands to find insertion into the upper part of the inner surface of the tibia, under cover of the tendon of the sartorius, and at a higher level than the insertion of the semitendinosus. A synovial bursa separates the expanded tendon of the gracilis from the internal lateral ligament of the knee-joint, and is prolonged above it, so as to intervene between it and the tendon of the sartorius.

The Adductor Magnus is one of the most powerful muscles of the thigh. It forms a flat fleshy mass, which springs from the anterior surface of the entire length of the pubic arch, and from the lower part of the tuberosity of the ischium. *The fibres which arise from the pubic arch* spread out as they approach the back of the femur. The upper fibres are nearly horizontal in their direction; below this they descend with increasing degrees of obliquity. They are inserted into the posterior surface of the femur, immediately internal to the gluteal ridge, into the linea aspera, and into a small portion of the upper part of the internal supracondyloid ridge. *The fibres which take origin from the ischial tuberosity* descend almost vertically and form the thick inner border of the muscle. In the lower third of the thigh they end in a strong, rounded tendon, which is inserted into the adductor tubercle on the inner tuberosity of the femur. This tendon is further attached to the femur by the internal intermuscular septum which stretches between it and the internal supracondyloid line. Close to the linea aspera the dissector will notice that fibrous arches are formed in connection with the insertion of the adductor magnus for the passage of the perforating

arteries. The opening through which the femoral artery enters the popliteal space lies in series with these. It is a gap between the two portions of the muscle, and is situated in the lower third of the thigh.

The adductor magnus has a double nerve supply. Behind, it is supplied by branches from the great sciatic, whilst in front it receives the greater part of the posterior division of the obturator.

Dissection.—The adductor magnus should now be detached from its origin, in order that the obturator externus muscle and the obturator artery may be more fully examined.

Obturator Externus—Obturator Artery.—The *obturator externus* is a flat, fan-shaped muscle, which is placed over the front of the thyroid foramen of the innominate bone. It springs from the inner half of the membrane which closes the foramen, and also from the inner and lower part of its bony margin. It proceeds backwards and outwards below the neck of the femur and the capsular ligament of the hip-joint, and ends in a stout tendon which obtains insertion into the digital fossa at the root of the great trochanter. This tendon has already been noticed in the dissection of the gluteal region.

The *obturator artery* (arteria obturatoria) appears in the thigh through the upper part of the thyroid foramen of the innominate bone. It at once divides into two terminal branches, which diverge from each other, and form an arterial circle upon the thyroid membrane, under cover of the obturator externus. This muscle must therefore be detached in order that these vessels may be followed. Both branches give twigs to the neighbouring muscles, whilst the *outer branch* (i.e., the branch which runs round the outer side of the foramen (sends an *articular twig* through the cotyloid notch of the acetabulum into the hip-joint. When the joint is opened this twig may be followed, in a well-injected subject, along the ligamentum teres into the head of the femur.

Psoas and Iliacus.—These muscles arise within the

abdomen and enter the thigh behind Poupart's ligament. A tendon appears on the outer side of the psoas, and into this the fibres of the iliacus are for the most part inserted. The conjoined tendon of the ilio-psoas is implanted into the small trochanter of the femur, but a certain proportion of the fleshy fibres of the iliacus obtain direct insertion into the shaft of the femur below and in front of that prominence.

Dissection.—Divide the femoral vessels, and the anterior crural nerve, about an inch below Poupart's ligament, and having tied them together with twine throw them downwards. Now cut through the sartorius and the rectus femoris about two inches from their origin and turn them aside. The tendon of the ilio-psoas must next be detached from its insertion and the muscle thrown upwards. This will expose the anterior surface of the capsule of the hip-joint. An intervening bursal sac will also be displayed. Open this and ascertain its extent by introducing the finger. It facilitates the play of the ilio-psoas upon the front of the hip-joint, and in some rare cases it will be found to be directly continuous with the synovial membrane of this articulation through an aperture in the capsular ligament. The intimate connection which exists between the capsule of the hip-joint and the tendon of the gluteus minimus, the reflected head of the rectus femoris, and the deep layer of the ilio-tibial band, should be noticed. Lastly, reflect the tensor fasciæ femoris, and carefully clean the capsule of the hip-joint.

HIP-JOINT (ARTICULATIO COXÆ)

It is necessary that the hip-joint be studied at this stage, as the further dissection of the limb can only be satisfactorily carried out after its removal from the trunk.

The hip-joint is the most perfect example of an enarthrodial or ball and socket joint in the body. It does not allow so free a range of movement as that which takes place at the shoulder-joint, but what it loses in this respect it gains in strength and stability. Its great strength and security depend: (1) upon the depth of the cotyloid cavity and the thorough manner in which the head of the femur is received into it; (2) upon the tension and power of the ligaments; (3) upon the length and oblique direction of the neck of the femur; and (4) upon atmospheric pressure,

The Ligaments in connection with the hip-joint are :—

- | | | |
|----------------------|--|----------------|
| 1. Capsular. | | 3. Cotyloid. |
| 2. Ligamentum teres, | | 4. Transverse. |

The capsular ligament and the ligamentum teres are attached to both bones entering into the construction of the joint. The transverse and the cotyloid ligaments are connected with the acetabular cavity; the former partially fills up the notch or deficiency in its inferior part, whilst the latter surrounds its circumference in a ring-like fashion, and serves to still further deepen it.

Capsular Ligament (*capsula articularis*)—This is exceedingly strong, and surrounds the joint on all sides. *Superiorly*, it is attached around the acetabulum; above and behind, directly to the innominate bone, just outside the rim of the cavity; in front, to the outer aspect of the cotyloid ligament; and below, to the transverse ligament. *Inferiorly*, it clasps the neck of the femur. In front, it is attached to the whole length of the anterior intertrochanteric line, and to the root of the great trochanter. This attachment is very firm and strong. Behind and below, it falls short of the posterior intertrochanteric line by about half an inch, and it presents a weak attachment to the posterior and inferior surfaces of the neck of the femur.

If the capsule of the hip-joint has been carefully cleaned it will be seen that the fibres which compose it run in two different directions. The majority pass in a longitudinal direction from one bone to the other; others, however, may be observed to take a more or less transverse or circular course. The latter are only seen to advantage on the posterior aspect of the capsule, whilst the longitudinal fibres are massed on the front of the joint. Certain thickened portions of the capsule, with more or less distinct attachments, are described as the *accessory ligaments* of the joint. These are :—

- | | | |
|------------------|--|----------------------|
| 1. Ilio-femoral. | | 3. Ischio-capsular. |
| 2. Pubo-femoral. | | 4. The zonular band. |

The *ilio-femoral band* (ligamentum iliofemorale) is placed over the front of the articulation, and constitutes the thickest and most powerful part of the capsule. It springs from the anterior inferior spine of the ilium, and from a depressed surface on the bone immediately to the outer side of this. As it proceeds downwards in the capsule, it divides into two limbs, which diverge slightly from each other. The outer portion is implanted into the upper part of the anterior intertrochanteric line, close to the

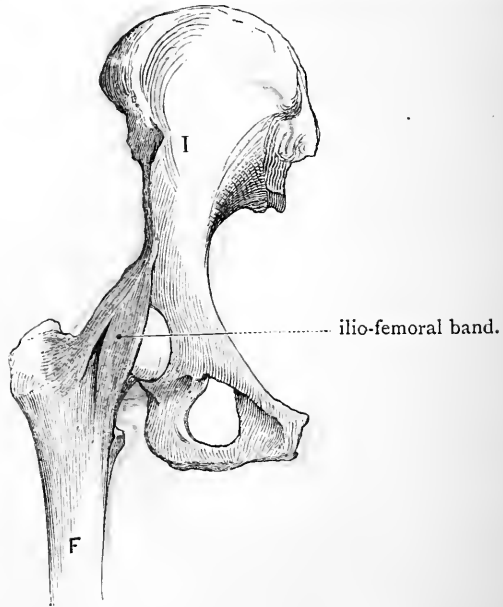


FIG. 53.—The ilio-femoral band isolated from the remainder of the capsule of the hip-joint.

F. Femur.

I. Ilium.

great trochanter; the inner portion, longer and almost vertical in direction, descends to find attachment into the lower end of the anterior intertrochanteric line. The interval between these two diverging parts of this ligament is occupied by a thinner portion of the capsule. The ilio-femoral band is sometimes called the *Y-shaped ligament*,

but, in making use of this term, remember that the shape it presents is that of an inverted Λ .

The *pubo-femoral band* (ligamentum pubocapsulare) is the name applied to several fasciculi of no great strength, which spring from the pubic bone and the thyroid membrane, and join the lower and anterior aspect of the capsule. In cases where the bursa under the ilio-psoas is continuous with the synovial membrane of the joint, the aperture of communication is placed between this band and the ilio-femoral band.

The *ischio-capsular band* (ligamentum ischio capsulare) is stronger. It takes origin from the ischium below the acetabulum, and passes into the lower and posterior aspect of the capsule.

The *zonular band* (zona orbicularis) is composed of circular fibres, and will be observed on the posterior aspect of the capsule. It encircles the neck of the femur behind and below, but is lost as it is traced forwards towards the upper part and the front of the capsule.

The dissector has already observed the close connection which is exhibited between the capsule of the hip-joint and the tendons of the gluteus minimus, and the reflected head of the rectus. Reinforcing fibres are contributed to the capsule by both of these tendons.

Movements permitted at the Hip-joint.—Before the capsule of the joint is opened the range of movement which is permitted at the hip-joint should be tested. *Flexion*, or forward movement, is very free, and is only checked by the anterior surface of the thigh coming into contact with the abdominal wall. *Extension*, or backward movement, is limited by the ilio-femoral band. This powerful ligament has a most important part to play in preserving the upright attitude with the least possible expenditure of muscular exertion. In the erect posture the line of gravity falls slightly behind the line joining the central points of the two hip-joints. In this position the ilio-femoral bands are tight, and prevent the pelvis from rolling backwards on the heads of the femora. *Abduction*, or outward movement of the thigh, is checked by the pubo-femoral band. *Adduction*, or inward movement (*e.g.*, as in crossing one thigh over the other), is limited by the upper portion of the ilio-femoral band and the upper part of the capsule. *Rotation inwards* tightens the ischio-capsular band, and is therefore in a measure

restrained by it. *Rotation outwards* is limited by the outer portion of the ilio-femoral band. In *circumduction*, which is combination of the movements of flexion, abduction, extension, and adduction, different parts of the capsular ligament are tightened at different stages of the movement.

The *flexor muscles*, which operate on the femur at the hip-joint, are chiefly—(1) the ilio-psoas, and (2) the pectineus; the *extensors* are—(1) the gluteus maximus, and (2) the gluteus medius; the *abductors*—(1) the upper part of the gluteus maximus, (2) the gluteus medius, (3) the gluteus minimus; the *adductors*—(1) the three adductors, (2) the pectineus, (3) the lower part of the gluteus maximus, and (4) the obturator externus; the *inward rotators*—(1) the anterior part of the gluteus medius, (2) the anterior part of the gluteus minimus, (3) the tensor fasciæ femoris, and (4) the ilio-psoas; the *outward rotators*—(1) the two obturator muscles, (2) the gemelli, (3) the piriformis, (4) the quadratus femoris, and (5) the gluteus maximus.

Dissection.—The hip-joint may now be opened, and in doing this it is advisable to remove in the first instance the whole capsule, with the exception of the ilio-femoral band. The enormous strength of this portion of the capsule can in this way be appreciated. It is fully a quarter of an inch thick, and a strain varying from 250 lbs. to 750 lbs. is required for its rupture (Bigelow). It is very rarely torn asunder in dislocations, and consequently the surgeon is enabled in most cases to reduce the displacement by manipulation. The ilio-femoral band may now be removed.

The Cotyloid Ligament (*labrum glenoidale*) is a firm fibro-cartilaginous ring, which is fixed to the brim or margin of the acetabulum. It bridges across the notch, and thus completes the circumference of the cavity, deepens it, and at the same time narrows slightly its mouth. The cotyloid ligament fits closely upon the head of the femur, and acting like a sucker, exercises an important influence in retaining it in place. Both surfaces are covered by synovial membrane; its free margin is thin, but it is much thicker at its attachment to the acetabular brim.

The Transverse Ligament (*ligamentum transversum acetabuli*) is composed of some transverse fibres which bridge across the notch in the inferior part of the acetabulum, and are attached to its margins. The more superficial of these fibres are more or less directly connected with the deep surface of the cotyloid ligament as it

stretches across the notch, but they do not fill up the entire gap; a narrow interval is left between the transverse ligament and the bone for the entrance of blood-vessels and nerves into the joint.

The Ligamentum Teres (*ligamentum teres femoris*) is not round, as its name might lead one to expect, but somewhat flattened and triangular in shape. Its narrow femoral extremity is implanted into the upper margin of the pit which marks the head of the femur, whilst its flattened acetabular end is bifid, and is fixed to the margins of the notch in the lower part of the acetabulum, and also to the transverse ligament. This attachment can be defined by removing the synovial membrane and some areolar tissue. The ligamentum teres is completely surrounded by synovial membrane, and a small artery runs along it to the head of the femur. It is difficult to understand the part which the ligamentum teres plays in the mechanism of the hip-joint. It presents very different degrees of strength in different individuals. It becomes very tense when the thigh is slightly flexed and then adducted.

Synovial Membrane and Interior of the Joint.—A mass of soft fat occupies the non-articular bottom of the acetabular cavity. Upon this the ligamentum teres is placed, and blood-vessels and nerves enter it by passing through the notch under cover of the transverse ligament. The vessels come from the internal circumflex and the obturator arteries, and the nerves come from the anterior division of the obturator nerve and from the accessory obturator, when it is present. A nerve-twig is also supplied to the back of the joint by the nerve to the quadratus femoris.

The synovial membrane lines the interior of the capsule. From this it is reflected on to the neck of the femur, and it clothes the bone as far as the margin of the articular cartilage which covers the head. Along the line of reflection some fibres of the capsular ligament proceed upwards on the neck of the femur and raise the synovial

membrane in the form of ridges. These fibres are termed the *retinacula* or *cervical ligaments*.

These ligaments are of some surgical importance. In intracapsular fracture of the neck of the femur they may escape rupture, and they may then to some extent help to retain the fragments in apposition. Hence examinations of this class of fracture must be conducted gently, lest by rupturing this ligamentous connection, the fragments be permanently displaced.

At the acetabular attachment of the capsular ligament the synovial membrane is reflected on to the cotyloid ligament and invests both its surfaces. It also covers the articular surface of the transverse ligament and the cushion of fat which occupies the bottom of the cavity. Lastly, it gives a tubular investment to the ligamentum teres.

Removal of the Limb.—The limb may now be removed from the trunk by dividing the ligamentum teres. It should then be taken to one of the tables set aside for the dissection of separate parts. Before proceeding to the dissection of the leg it is advisable to study the attachments of the various muscles to the femur. The bulk of these may be removed, but a small portion of each should be left, so that their connections may again be revised, should it be found necessary to do so at a later period.

THE LEG.

Surface Anatomy.—The relation of the tibia and fibula to the surface should be carefully investigated. The sharp anterior border of the tibia or shin does not form a projection visible to the eye, but nevertheless it is subcutaneous, and can be very distinctly felt when the finger is passed along it. It pursues a slightly sinuous course, and in its lower part becomes rounded-off and indistinct. The broad flat internal surface of the shaft of the tibia is also subcutaneous below the level of the insertion of the sartorius, and the inner border of the bone can be followed by the finger very readily throughout its entire length. The fibula is more deeply placed, and the upper

half of its shaft cannot be felt from the surface owing to the manner in which it is surrounded by muscles. The head of the bone, however, is very evident where it articulates with the outer and back part of the tuberosity of the tibia: and for a short distance above the external malleolus the shaft of the fibula is subcutaneous over a triangular area which is interposed between the peroneus tertius muscle in front and the peroneus longus and peroneus brevis muscles behind.

The two malleoli form marked projections in the region of the ankle. The internal malleolus is the broader and more prominent of the two; it does not descend so low down, however, and when viewed from the front it is observed to reach further forwards. This latter appearance is due to its greater breadth, because when examined from behind the posterior borders of the two projections are seen to occupy very nearly the same plane.

On the posterior aspect of the leg the prominence known as the "calf of the leg" is visible. This is largely due to the fleshy bellies of the gastrocnemius muscle. Below the calf and immediately above the heel the powerful tendo Achillis can be felt. In front of this tendon a slight hollow is apparent on either side of the limb.

As the skin is reflected from the dorsum of the foot during the dissection of the leg, the present opportunity should be seized for studying the surface anatomy of the foot. The individual tarsal bones cannot be recognised through the integuments which cover the dorsum of the foot; but if the foot be powerfully extended the head of the astragalus will be brought into view in the shape of a slight prominence. The margins of the foot require very careful study, because it is by the recognition of certain bony projections in these that the surgeon is enabled to determine the point at which to enter the knife when he is called upon to perform partial amputation of the foot. Examine the inner margin first. Begin behind at the projection formed by the internal tuberosity of the os calcis, and proceed forwards. About one inch below the internal

malleolus the inner edge of the sustentaculum tali may be recognised, and about one inch or a little more in front of this we recognise the tubercle of the scaphoid. Then comes the internal cuneiform bone, and this is succeeded by the first metatarsal bone. None of these bony points can be said to form distinct prominences on the surface of a well-developed foot. In order to distinguish them the inner margin of the foot must be judiciously manipulated by the fingers. On the outer margin of the foot the tubercle on the base of the fifth metatarsal bone stands out as a distinct landmark. Behind this is the cuboid, and still further back the outer surface of the os calcis, which is almost completely subcutaneous. When present in a well-developed form the peroneal tubercle on this surface may be distinguished about one inch below and a little in front of the external malleolus. If the foot be strongly inverted the anterior end of the os calcis will be seen to project on the surface.

Subdivision of the Leg into Regions.—In the dissection of the leg four distinct regions may be recognised, viz. :—

1. *An anterior tibio-fibular region*, in which are placed those structures which lie in front of the interosseous membrane, and between the two bones of the leg.
2. *A tibial region*, corresponding to the subcutaneous or inner surface of the shaft of the tibia.
3. *A peroneal region*, which includes the parts in relation to the outer surface of the fibula.
4. *A posterior tibio-fibular region*, in which are placed the parts on the back of the leg which lie behind the interosseous membrane and the two bones of the leg.

ANTERIOR TIBIO-FIBULAR REGION—DORSUM OF FOOT.

The anterior tibio-fibular region should be dissected first, and it is usual to conjoin with this the dissection of the dorsum of the foot. The following parts are exposed in this region :—

- | | |
|---|--|
| <ol style="list-style-type: none"> 1. Superficial veins. 2. Cutaneous nerves. 3. Deep fascia, with its inter-muscular septa, and annular ligaments. 4. Tibialis anticus. 5. Extensor longus digitorum. 6. Peroneus tertius. 7. Extensor longus hallucis. | <ol style="list-style-type: none"> 8. Anterior tibial vessels. 9. Anterior peroneal artery. 10. Anterior tibial nerve. 11. Recurrent articular branch from the external popliteal nerve. 12. Extensor brevis digitorum. 13. Dorsalis pedis artery. |
|---|--|

Reflection of Skin.—To place the limb in a convenient position for the dissection of this region, a block should be introduced beneath the knee, and the foot should be extended and fastened firmly to the table by means of hooks. The skin should be reflected from the *tibial* and *peroneal* regions at the same time. *Incisions*:—(1) a vertical cut along the middle line of the leg and dorsum of the foot to the base of the middle toe; (2) a transverse incision across the ankle-joint; (3) a transverse incision across the dorsum of the foot at the roots of the toes.

The four flaps of skin thus mapped out must now be raised from the subjacent fatty tissue, and the superficial veins and nerves dissected out.

Superficial Veins.—The *venous arch* on the dorsum of the foot, which receives the digital veins, should in the first place be dissected. From the inner extremity of this arch the *internal saphenous vein* will be seen to take origin, whilst from its outer end the *external saphenous vein* proceeds. Trace these vessels upwards. The former will be found to pass *in front* of the internal malleolus, whilst the latter ascends *behind* the external malleolus. Each is associated with the nerve which bears its own name.

Cutaneous Nerves.—The following are the cutaneous nerves which must be secured in this dissection:—

1. A branch from the external popliteal.
2. External saphenous.
3. Internal saphenous.
4. Musculo-cutaneous.
5. Anterior tibial.

The branch from the *external popliteal* frequently arises in common with the ramus communicans fibularis. It turns forwards, and is distributed upon the outer and anterior aspect of the leg in its upper part. The *external*

saphenous nerve can be readily found. It reaches the outer margin of the foot by passing behind the external malleolus in company with the vein of the same name. Trace it forwards, and it will be found to end upon the fibular side of the little toe. On the dorsum of the foot a connecting twig passes between the external saphenous and the outer division of the musculo-cutaneous nerve. The *internal* or *long saphenous nerve* should be looked for in front of the inner malleolus. It descends in company with the internal saphenous vein. It can with care be followed half-way along the inner margin of the foot, but there it ends. Above the ankle-joint several minute twigs from this nerve may be found passing forwards to reach the front of the leg.

The *cutaneous portion* of the *musculo-cutaneous nerve* appears in the lower third of the leg. It pierces the deep fascia a short way to the outside of the middle line of the limb. Almost immediately it splits into an inner and an outer part. The *inner division* extends forwards on the dorsum of the foot, and sends one branch to the inner side of the great toe, and a second to supply the adjacent sides of the second and third toes. It likewise gives a number of twigs to the skin upon the inner margin of the foot, and effects a junction with the anterior tibial and internal saphenous nerves. The *outer division* is smaller than the inner part. It gives several twigs to the skin on the dorsum of the foot, communicates with the external saphenous nerve, and then divides into two branches, which supply the contiguous margins of the third, fourth, and fifth toes. Therefore, with the exception of the adjacent sides of the great toe and the second toe, which are supplied by the anterior tibial nerve, and the outer side of the little toe, which is supplied by the external saphenous nerve, the musculo-cutaneous nerve furnishes twigs to the two margins of each of the toes.¹

¹ Very frequently the distribution of the musculo-cutaneous nerve is more restricted, and in these cases the external saphenous nerve will, in all probability, be found to supply the outer two and a half toes.

The *anterior tibial nerve*, or rather its *internal terminal branch*, pierces the deep fascia on the dorsum of the foot in the interval between the first and second metatarsal bones. It receives a communicating branch from the inner part of the musculo-cutaneous, and ends by dividing into two twigs, which go to supply the adjacent margins of the great toe and the second toe.

Deep Fascia.—The fatty superficial fascia should be removed in order that the deep fascia may be displayed. This aponeurosis does not form a complete investment for the leg. It is absent over the internal subcutaneous surface of the tibia, and is attached to the anterior and internal borders of that bone. It is also absent over the triangular subcutaneous surface on the lower part of the fibula, being attached to the ridges which limit this area in front and behind. It is not equally dense throughout. In the upper part of the front of the leg it is thick and strong, but it thins as it is traced downwards, and on the dorsum of the foot it becomes exceedingly fine. Its great strength in the upper part of the front of the leg is due to the fact that here it gives origin to subjacent muscles. In the neighbourhood of the ankle-joint it forms the thickened bands or annular ligaments which retain the tendons in position during the action of the muscles. Two of these may be examined at this stage, viz., the anterior and the external annular ligaments.

The *anterior annular ligament* consists of two portions—an upper and a lower. The *upper part* is a strong, broad band which stretches across the front of the leg immediately above the ankle-joint. By one extremity it is attached to the fibula, and by the other to the tibia. The *lower part* is placed over the ankle-joint. Externally it presents the appearance of a narrow, well-defined band, which is fixed firmly to the anterior part of the os calcis. As this is traced inwards it will be observed to divide into two diverging limbs. Of these the upper is attached to the inner malleolus, whilst the lower passes to the inner margin of the foot, and becomes connected with the

plantar fascia. The different parts of the anterior annular ligament are continuous with the deep fascia, but can readily be distinguished on account of their greater density and thickness.

The *external annular ligament* is short and narrow, and

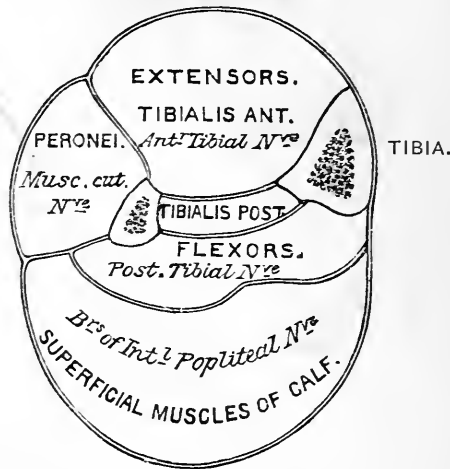


FIG. 54.—Diagrammatic representation of the fascia of the leg. The fascia of the tibialis posticus is more a muscular aponeurosis than a true fascial septum; but it is convenient for descriptive purposes to regard it as one of the partitions.

bridges over the hollow between the external malleolus and the posterior prominence of the os calcis.

Intermuscular Septa.—As the deep fascia of the leg passes backwards over the fibular region, two strong intermuscular septa are given off from its deep surface. These are distinguished as the anterior and posterior peroneal septa. The *anterior peroneal septum* intervenes between the peroneal muscles and the extensor muscles, and is attached to the anterior border of the fibula. The *posterior peroneal septum* is interposed between the peroneal muscles and the muscles on the back of the leg, and is attached to the external border of the fibula. The leg is thus subdivided into three osteo-fascial compartments, corre-

sponding to the anterior tibio-fibular, peroneal, and posterior tibio-fibular regions. The *anterior compartment* is bounded by the investing deep fascia, the anterior peroneal septum, the anterior part of the inner surface of the fibula (that part which lies in front of the interosseous line), the interosseous membrane, and the external surface of the tibia. The *outer compartment* is bounded by the external surface of the fibula, the investing fascia, and the two peroneal septa. The *posterior compartment* is much the largest, and its walls are formed by the posterior surface of the tibia, the hinder part of the internal surface and the whole of the posterior surface of the fibula, the interosseous membrane, the posterior peroneal septum, and the investing deep fascia. This compartment is still further subdivided by two partitions; but these will be studied later on.

Dissection.—The anterior compartment of the leg should now be opened by removing the deep fascia. The two portions of the anterior annular ligament, however, must be retained, and their borders should be defined and separated artificially by the knife from the deep fascia, with which they are continuous. In the upper part of the leg it will be found impossible to raise the fascia from the subjacent muscles without lacerating their surfaces. It should therefore be left in position. At a lower level it can readily be separated. Divide it in a longitudinal direction midway between the tibia and fibula. On throwing the inner piece inwards, its firm attachment to the anterior border of the tibia will become evident; and as the outer piece is turned outwards, the anterior peroneal septum will come into view.

Contents of the Anterior Tibio-fibular Compartment.—

Four muscles are brought into view by the above dissection, viz., the tibialis anticus, the extensor longus digitorum, the extensor longus hallucis, and the peroneus tertius. The *tibialis anticus* lies in relation to the tibia; the *extensor longus digitorum* is placed along the fibula; and on separating these muscles from each other, the *extensor longus hallucis* will be observed in the interval between them. The *peroneus tertius* lies upon the lower portion of the fibula, and in most cases is incorporated with the extensor longus digitorum. The *anterior tibial vessels* and *nerve* proceed

downwards in this compartment. At first they are deeply placed, but as they approach the ankle they come nearer to the surface.

Dissection.—To expose the anterior tibial vessels and nerve in their entire course on the front of the leg, the *tibialis anticus* and the *extensor longus digitorum* must be separated from each other along the line of a strong intermuscular septum, which dips backwards between them, and affords a surface of origin to each. The knife should be carried upwards along the plane of this septum. By drawing aside the *peroneus tertius* muscle, the *anterior peroneal artery* will be seen piercing the interosseous membrane. It is a small artery which descends upon the lower end of the fibula. As the structures in the anterior tibio-fibular compartment are being exposed and cleaned, the dissector should at the same time carry on the dissection of the dorsum of the foot. Here the tendons of the muscles on the front of the leg must be followed to their insertions, and the *extensor brevis digitorum muscle* defined. The *dorsalis pedis artery* and the *anterior tibial nerve* should also be followed, and their branches traced to their various destinations.

The Tibialis Anticus (*musculus tibialis anterior*) is a powerful muscle, which takes origin from the lower part of the external tuberosity of the tibia, and from the upper half of the external surface of its shaft. It likewise derives many fibres from the deep fascia which covers it, from the fascial septum between it and the *extensor longus digitorum* and the portion of the interosseous membrane on which it rests. In other words, it springs from the structures which form the walls of the inner portion of the osteo-fascial compartment in which it lies.¹ A strong tendon issues from its fleshy belly in the lower third of the leg, and this reaches the dorsum of the foot by passing through both portions of the anterior annular ligament.

¹ To understand the attachments of the muscles of the leg, it is necessary to bear in mind that the interosseous membrane, which stretches across the interval between the two bones of the leg, and thus extends the surface of origin for these muscles, is attached to the *outer* border of the tibia (*i.e.*, between its outer and posterior surfaces) and to the interosseous line of the fibula. This interosseous line traverses the inner surface of the fibula, so as to divide it into an anterior and a posterior part. The anterior part gives origin to the extensor muscles and the posterior part to the flexor muscles.

Here it inclines inwards, and, turning round the inner margin of the foot, gains insertion by two slips into the inner and lower part of the internal cuneiform bone, and into the adjoining part of the base of the first metatarsal bone. The tibialis anticus is supplied by the anterior tibial nerve.

The Extensor Longus Digitorum arises, for the most part, from the structures which form the outer portion of the

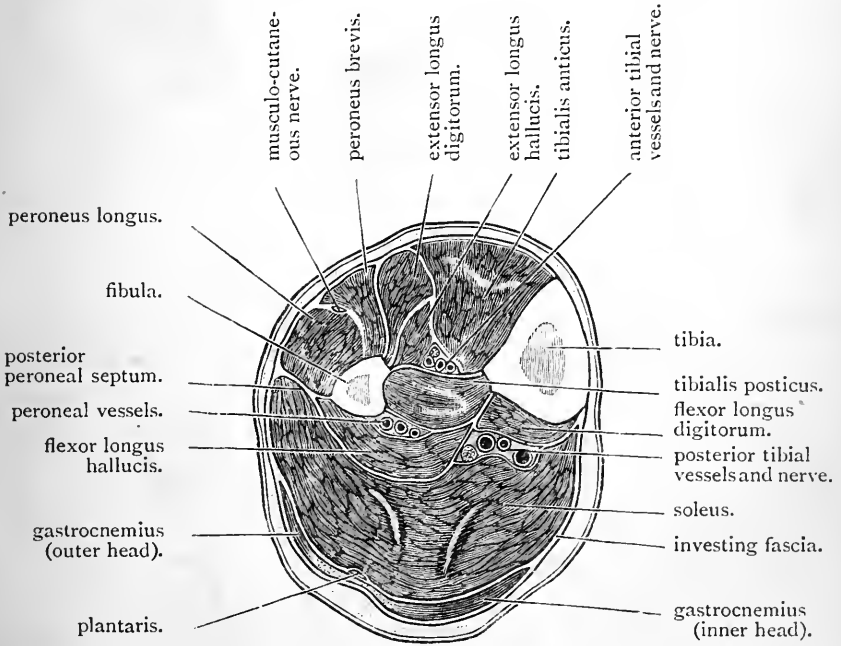


FIG. 55.—Transverse section through the calf of the leg.

wall of the anterior tibio-fibular compartment. Thus it springs from the upper part of the outer tuberosity of the tibia, from the head of the fibula, and from the anterior part of the inner surface of the shaft of the fibula in its upper three-fourths. It also takes origin from a small portion of the upper part of the interosseous membrane, the deep fascia, the anterior peroneal septum, and the intermuscular septum, which dips backwards between it and

the tibialis anticus. The tendon of the extensor longus digitorum descends in front of the ankle-joint, and, passing through the anterior annular ligament, divides into four pieces, which diverge from each other on the dorsum of the foot to reach the four outer toes. On the dorsum of the first phalanx each of the inner three slips is joined on the outer side by a tendon from the extensor brevis digitorum.

The manner in which the four tendons of the extensor longus digitorum are inserted on the dorsal surfaces of the four outer toes is so similar to that in which the corresponding tendons of the fingers are attached, that a very brief description will suffice. An expansion is formed on the dorsal surface of the first phalanx; this is joined by the slender tendons of the lumbrical and interosseous muscles, and divides into a central and two lateral slips. The central slip is inserted into the base of the second phalanx, whilst the stronger lateral slips are prolonged onwards, and, uniting with each other, gain insertion into the base of the unguis phalanx.

The Extensor Longus Hallucis is placed in the interval between the tibialis anticus and the extensor longus digitorum. In its upper part it is hidden from view by these muscles, but near the ankle it comes to the surface. It takes origin behind the extensor longus digitorum, from the anterior part of the inner surface of the shaft of the fibula in its middle two-fourths, and also from the adjoining part of the interosseous membrane. Its tendon crosses the lower part of the anterior tibial artery, and reaches the dorsum of the foot by passing downwards in front of the ankle-joint and through the anterior annular ligament. It is inserted into the dorsal aspect of the base of the unguis phalanx of the great toe.¹ It is *not joined* by the innermost tendon of the extensor brevis digitorum.

The Peroneus Tertius is a small muscle which is con-

¹ In most cases it likewise gives a slip to the base of the proximal phalanx.

tinuous at its origin with the extensor longus digitorum. It arises from the lower fourth of the anterior part of the inner surface of the fibula, and from a corresponding extent of the interosseous membrane. It also receives fibres from the lower part of the anterior peroneal septum which intervenes between it and the peroneus brevis. Its slender tendon is inserted into the dorsal surface of the expanded base of the fifth metatarsal bone. It is supplied by the anterior tibial nerve.

Anterior Tibial Artery (arteria tibialis anterior).—The anterior tibial artery is the smaller of the two terminal branches of the popliteal. It takes origin on the back of the leg, at the lower border of the popliteus muscle, and it gains the anterior tibio-fibular compartment by passing forwards through the opening in the upper part of the interosseous membrane. In this part of its course it lies close to the inner side of the neck of the fibula, and appears in the present dissection immediately below the outer tuberosity of the tibia. On the front of the leg it takes a straight course downwards to the ankle-joint. Here it reaches the dorsum of the foot, and receives the name of *dorsalis pedis*.

In the upper two-thirds of the leg the anterior tibial artery is very deeply placed. It lies upon the interosseous membrane in the interval between the tibialis anticus on the inner side, and the extensor longus digitorum and the extensor longus hallucis on the outer side. In the lower third of the leg where the muscles give place to their tendons the artery comes nearer to the surface. In this part of its course it rests upon the tibia and is overlapped on the outer side by the extensor longus hallucis. Immediately above the ankle-joint the tendon of that muscle crosses the artery and comes to lie on its inner side.

Two *venæ comites* closely accompany the anterior tibial artery, and send short communicating branches both in front of it and behind it. The *anterior tibial nerve* is also intimately related to it. It joins the artery a short

distance below the knee and soon takes up a position in front of the vessel. Near the ankle-joint the nerve as a rule assumes a place on the outer side of the artery.

On the front of the leg the anterior tibial artery gives off the following branches:—

- | | | |
|-------------------------------|--|------------------------|
| 1. Muscular. | | 3. External malleolar. |
| 2. Anterior recurrent tibial. | | 4. Internal malleolar. |

The *muscular branches* are numerous and come off at irregular points along the whole length of the artery. They supply the muscles on the front of the leg.

The Anterior Recurrent Tibial Artery (*arteria recurrens tibialis anterior*) springs from the anterior tibial immediately after it reaches the front of the leg. It turns upwards on the external tuberosity of the tibia in the fibres of the tibialis anticus muscle. Its terminal twigs reach the front of the knee-joint, and anastomose with the inferior articular branches from the popliteal artery.

The Malleolar Arteries take origin immediately above the ankle-joint. The *external malleolar* (*arteria malleolaris anterior lateralis*) is the larger of the two, and passes outwards under cover of the tendons of the extensor longus digitorum and peroneus tertius, to reach the outer surface of the external malleolus. It anastomoses with the anterior peroneal and tarsal arteries. The *internal malleolar* (*arteria malleolaris anterior medialis*) runs inwards under cover of the tendons of the extensor longus hallucis and tibialis anticus. It inosculates with branches from the posterior tibial artery.

Arteria Dorsalis Pedis.—The dorsal artery of the foot is the continuation of the anterior tibial. It begins in front of the ankle-joint at a point midway between the two malleoli, and it extends forwards upon the forepart of the astragalus, the scaphoid, and the middle cuneiform bones to the posterior part of the interosseous space between the metatarsal bones of the great toe and the second toe. Here it leaves the dorsum of the foot by dipping downwards between the two heads of the first dorsal interosseous

N.F.

muscle to reach the sole and unite with the external plantar artery in the formation of the plantar arch. Its relations on the dorsum of the foot are very simple. (1) It lies in the interval between the tendon of the extensor longus hallucis on the inner side and the innermost

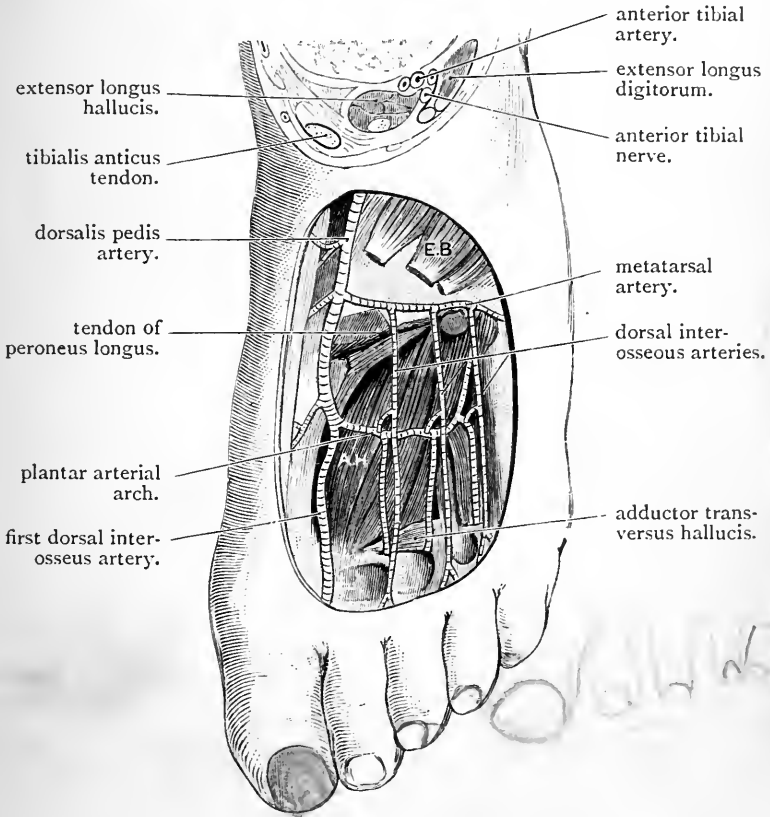


FIG. 56.—Dissection to show the plantar arterial arch from the dorsal aspect of the foot. The second, third, and fourth metatarsal bones have been removed.

E.B. Extensor brevis. | A.H. Adductor obliquus hallucis.

tendon of the extensor longus digitorum on the outer side. (2) At its commencement it is crossed by the lower part of the anterior annular ligament, whilst near its termination it is crossed by the innermost tendon of the extensor

brevis digitorum; with these exceptions the vessel is simply covered by the integument and fascia. (3) The internal terminal branch of the anterior tibial nerve lies along its outer side, and two *venæ comites* accompany it.

As the *dorsalis pedis* artery traverses the dorsum of the foot it gives off several twigs to the inner margin of the foot, and also three named branches:—

1. The tarsal.
2. The metatarsal.
3. The first dorsal interosseous.

Tarsal and Metatarsal Arteries.—The *tarsal artery* arises opposite the scaphoid bone, and the *metatarsal artery* near the bases of the metatarsal bones. They both run outwards under cover of the extensor brevis digitorum to reach the outer margin of the foot. There they anastomose with branches of the external plantar artery. The tarsal artery also anastomoses with the external malleolar and peroneal arteries.

From the arch which is formed by the metatarsal artery three dorsal interosseous arteries proceed, one to each of the three outer interosseous spaces. At the clefts between the toes these divide and supply dorsal digital twigs to the adjacent sides of the second, third, fourth, and fifth toes. From the outermost interosseous artery a twig is also given to the outer side of the little toe.

The First Dorsal Interosseous Artery takes origin from the *dorsalis pedis* at the point where it turns downwards to reach the sole of the foot. It continues forwards upon the first dorsal interosseous muscle, and divides into dorsal digital branches for the inner side of the great toe and the adjacent sides of the great toe and second toe.

The Anterior Peroneal Artery is one of the two terminal branches of the peroneal branch of the posterior tibial. It reaches the front of the leg by piercing the interosseous membrane about one and a half or two inches above the outer malleolus, and it descends upon the lower

part of the fibula under cover of the peroneus tertius. It is distributed on the outer side of the tarsus, where it anastomoses with the external malleolar and the tarsal arteries.

The Extensor Brevis Digitorum may now be examined. It arises from the anterior part of the os calcis, and also from the lower part of the anterior annular ligament. It splits into four fleshy bellies, which extend forwards and inwards on the dorsum of the foot, and end in four slender tendons for the four inner toes. The innermost tendon crosses the dorsalis pedis artery near its termination, and is inserted into the dorsal aspect of the base of the first phalanx of the great toe; the remaining three tendons join the long extensor tendons which go to the second, third, and fourth toes. The extensor brevis digitorum is supplied by the external branch of the anterior tibial nerve.

Anterior Tibial Nerve (nervus peroneus profundus).—The anterior tibial nerve is one of the terminal branches of the external popliteal. It arises on the outer side of the neck of the fibula, and, piercing the upper part of the extensor longus digitorum obliquely, joins the anterior tibial vessels a short distance below the external tuberosity of the tibia. These it accompanies for the remainder of its course. In the first instance it is placed in front of them, but near the ankle-joint it lies on their outer side. Passing behind the anterior annular ligament, it ends by dividing into an internal and an external branch.

In its course through the leg the anterior tibial nerve gives *muscular branches* to the extensor longus digitorum, tibialis anticus, the extensor longus hallucis, and the peroneus tertius; likewise a fine *articular twig* to the ankle-joint.

The *internal terminal branch* of the anterior tibial nerve is continued forwards upon the dorsum of the foot along the outer side of the dorsalis pedis artery. Reaching the first interosseous space it pierces the deep fascia, and divides to supply the contiguous margins of the great toe and the second toe (p. 259). Before it reaches the

surface, it furnishes *articular twigs* to the tarso-metatarsal and metatarso-phalangeal joints of the great toe, and frequently also a fine *muscular twig* to the dorsal surface of the first dorsal interosseous muscle.

The *external terminal branch* of the anterior tibial nerve turns abruptly outwards under cover of the extensor brevis digitorum, and ends on the dorsum of the foot in a gangliform enlargement. From this branches proceed for the supply of the extensor brevis digitorum, and the numerous articulations in the neighbourhood. One fine

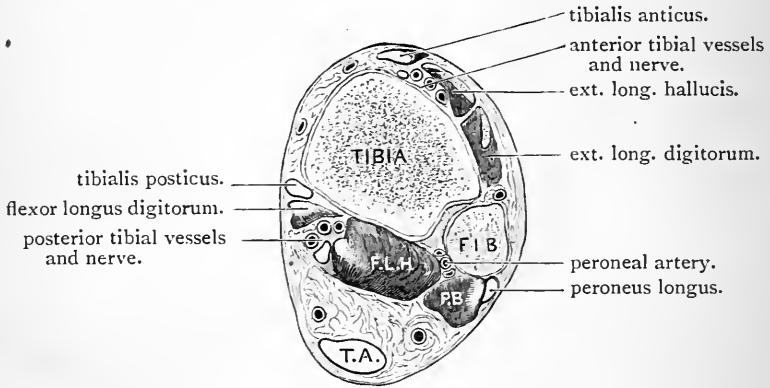


FIG. 57.—Transverse section through the leg immediately above the ankle-joint.

FIB. Fibula.
T.A. Tendo Achillis.

F.L.H. Flexor longus hallucis.
P.B. Peroneus brevis.

filament can, in most cases, be traced to the second dorsal interosseous muscle. The terminal swelling resembles closely the corresponding enlargement in which the posterior interosseous nerve of the upper limb ends.

Anterior Annular Ligament.—The dissector should again examine this ligament, and the arrangement of the structures which pass under it. The *upper portion* is attached to the fibula by its outer end, and to the tibia by its inner extremity. By dividing its fibular attachment, and throwing it inwards, it will be seen to give a separate and distinct sheath to the tibialis anticus.

The *lower portion* is the more important of the two. Its attachments have already been noted (p. 259). Examine the manner in which it holds the tendons in their place. It consists of two layers, and these, by separating at certain points and becoming re-united at others, form three distinct compartments. Through the *innermost* passes the tendon of the tibialis anticus; through the *middle* one passes the tendon of the extensor longus hallucis; and through the *outermost* are transmitted the tendons of the extensor longus digitorum and peroneus tertius. On opening up these sheaths each will be seen to be lined by a synovial membrane. Lastly, note the position of the anterior tibial vessels and nerve as they pass under cover of the ligament. They lie between the extensor longus hallucis and the extensor longus digitorum.

PERONEAL REGION

The peroneal or outer compartment of the leg should now be opened by dividing, in a longitudinal direction, the fascia which covers it. Enclosed within it are :—

1. The peroneus longus.
2. The peroneus brevis.
3. The termination of the external popliteal nerve.
4. The musculo-cutaneous nerve.

The Peroneus Longus arises from the head and from the outer surface of the shaft of the fibula in its upper two-thirds. A surface of origin is also afforded to it by the fascia which covers it, and by the two peroneal intermuscular septa. It ends a short distance above the ankle in a long tendon, which is continued downwards behind the external malleolus. Gaining the outer margin of the foot, it proceeds forwards to the groove on the under surface of the cuboid, which conducts it transversely into the sole. Its insertion will be examined at a later period.

The **Peroneus Brevis** arises from the lower two-thirds of the outer surface of the shaft of the fibula, below and in front of the peroneus longus, and from the peroneal intermuscular septum on either side of it. Its tendon descends behind the external malleolus, and then turns forwards on the outer surface of the os calcis to gain an insertion into the projecting base of the metatarsal bone of the little toe.¹ On the back of the external malleolus the tendon of the peroneus brevis lies directly under cover of the tendon of the peroneus longus, and therefore in contact with the bone. On the outer surface of the os calcis the tendon of the peroneus brevis is placed at a higher level than that of its fellow muscle.

As the tendons of the two peronei muscles proceed downwards in the hollow between the external malleolus and the posterior prominence of the os calcis they are held in place by the *external annular ligament*, and their movements are facilitated by the presence of a common synovial sheath. On the outer surface of the os calcis each tendon is retained in position by a separate fibrous sheath, into which the common synovial membrane is prolonged. The peroneal tubercle of the os calcis intervenes between these two sheaths.

External Popliteal Nerve (*nervus peroneus communis*) This nerve has previously been traced as far as the neck of the fibula. At this point it disappears from view by passing forwards between the peroneus longus muscle and the bone. The muscle must therefore be carefully turned aside from its origin in order that the nerve may be followed out. It will be found to give off a small *recurrent articular nerve* to the knee-joint, and then to divide into the *anterior tibial* and *musculo-cutaneous nerves*.

The *recurrent branch* accompanies the anterior recurrent tibial artery. It turns upwards in the fibres of the tibialis

¹ A small tendinous slip will, as a general rule, be observed to proceed forwards from the tendon of the peroneus brevis to join the tendon of the long extensor on the dorsum of the little toe. This is the *peroneus quinti digiti*.

anticus. To the upper part of this muscle it gives several twigs, whilst its terminal filaments gain the front of the knee-joint.

The *anterior tibial nerve* pierces the upper part of the extensor longus digitorum to reach the front of the leg, where it has already been dissected.

The Musculo-cutaneous Nerve (*nervus peronæus superficialis*) proceeds downwards in the substance of the peroneus longus. It reaches the interval between the two peronei muscles, gives branches to both, and lastly comes to lie between the peroneus brevis and the extensor longus digitorum. In the lower third of the leg it pierces the fascia, and becomes cutaneous.

TIBIAL REGION.

This region corresponds to the subcutaneous or inner surface of the tibia. The deep fascia blends with the periosteum of the bone, and the only structures which have to be examined are:—

1. The internal saphenous vein.
2. The internal saphenous nerve.
3. The expanded tendons of insertion of the sartorius, semitendinosus, and gracilis.
4. Internal lateral ligament of the knee-joint.
5. Inferior internal articular artery and nerve.

The *internal saphenous nerve and vein*, as they pass from the anterior to the posterior tibio-fibular region, cross obliquely over the lower third of the inner surface of the tibia.

The insertion of the *sartorius*, *gracilis*, and *semitendinosus* into the upper part of the inner surface of the tibia should again be examined. Observe how the sartorius overlaps the tendons of the other two, and how the tendon of the gracilis overlaps the upper part of the tendon of the semitendinosus. A synovial bursa separates these tendons from each other.

The *internal lateral ligament* of the knee-joint will be seen extending downwards for a short distance upon the inner aspect of the shaft of the tibia. Passing forwards under cover of this ligament, so as to gain the anterior aspect of the knee, are the *inferior internal articular vessels* and *nerve*.

POSTERIOR TIBIO-FIBULAR REGION.

The following is a list of the structures which are met with in this dissection:—

1. Superficial veins, { Internal saphenous.
External saphenous.
2. Cutaneous nerves.
3. Deep fascia.
4. Superficial muscles of the calf, { Gastrocnemius.
Plantaris.
Soleus.
5. Tendo Achillis and its bursa.
6. Posterior tibial vessels.
7. Posterior tibial nerve.
8. Deep muscles, { Popliteus.
Flexor longus hallucis.
Tibialis posticus.
Flexor longus digitorum.
9. Internal annular ligament.

Reflection of Skin.—The limb must now be placed on its anterior aspect, and the muscles of the calf rendered tense by flexing the foot at the ankle-joint. This position should be maintained by the aid of hooks, fastened to the toes and to the under surface of the table.

Incisions.—(1) A longitudinal incision along the middle line of the leg on its posterior aspect to the extremity of the heel. (2) A transverse incision at the lower end of this, extending along the inner and outer margins of the foot for about two inches on either side.

The two flaps of skin thus marked out must be raised and turned outwards and inwards.

Superficial Veins.—The *internal* and *external saphenous veins* must be traced in the substance of the fatty superficial fascia. Both of these vessels have been seen in

previous steps of the dissection. The *internal saphenous vein* has been observed to arise from the inner extremity of the venous arch on the dorsum of the foot, and it has been followed upwards for a short distance in front of the inner malleolus, and then upon the inner aspect of the lower part of the tibia. It has also been dissected upon the inner aspect of the thigh and knee. It can now be exposed in its course along the inner side of the calf of the leg. It lies a short distance behind the internal border of the tibia. The *external saphenous vein* has been seen to arise from the outer end of the dorsal arch and to pass upwards behind the outer malleolus. It may now be followed as it ascends along the outer side of the tendo Achillis to the back of the leg, where it lies over the interval between the two heads of the gastrocnemius muscle. When it gains the lower part of the popliteal space it pierces the deep fascia and joins the popliteal vein.

Associated with each of these veins are certain cutaneous nerves, which must be displayed at the same time. The *small sciatic* is closely related to the external saphenous vein in its upper part, and the *external saphenous nerve* accompanies it in the lower half of the leg. In company with the *internal saphenous vein* we find the *internal* or *long saphenous nerve*.

Cutaneous Nerves.—These are very numerous. On the *inner side* of the leg are—(1) the *internal* or *long saphenous*; (2) the *posterior branch* of the *internal cutaneous*; and (3) the *internal calcanean*.

The guide to the *internal saphenous nerve* is the vein of the same name. It may now be exposed in its entire course along the inner side of the leg. The *posterior branch* of the *internal cutaneous* proceeds downwards a short distance behind the preceding nerve. It usually ends about the middle of the leg. The *internal calcanean* is a branch of the posterior tibial nerve. Dissect for it in the interval between the prominence of the heel and internal malleolus. It pierces the internal annular ligament nearer the former

than the latter. Its branches of distribution to the skin of the heel and sole will be seen in a future dissection.

In the *middle line* of the leg two nerves will be found, viz.—(1) the *small sciatic*, and (2) the *nervus communicans tibialis*. They have both been previously seen in the dissection of the popliteal space. The *nervus communicans tibialis*, a branch of the internal popliteal, descends in the interval between the two heads of the gastrocnemius and pierces the deep fascia midway between the knee and ankle. A short distance below this it is joined by the *nervus communicans fibularis*, and then acquires the name of *external saphenous*.

On the *outer side* of the posterior aspect of the leg is the *nervus communicans fibularis*, a branch of the external popliteal. It descends upon the outer head of the gastrocnemius, and, perforating the deep fascia, unites with the *nervus communicans tibialis* a short distance below the middle of the leg, to form the *external saphenous nerve*. The latter has already been traced behind the external malleolus to the outer margin of the foot and little toe.

Deep Fascia.—A continuous view of the deep fascia on the back of the leg can now be obtained by removing the remains of the superficial fat. Observe how thin and transparent it is in the upper part of the leg, and how it thickens as it is followed downwards towards the heel. At no point, however, is it very dense. As it passes over the interval between the heel and the internal malleolus it forms the *internal annular ligament*. It is continuous above with the popliteal fascia, and a short distance below the knee, on the inner side, it receives a reinforcement of fibres from the tendons of the sartorius, the gracilis, and the semitendinosus.

Dissection.—Divide the fascia along the middle line and turn it outwards and inwards. Leave the internal annular ligament intact. On raising the inner part of the fascia it will be seen to be attached to the internal border of the tibia. In fact, it blends with the periosteum covering the inner subcutaneous surface of this bone. On turning the

outer portion of fascia outwards it will be observed to be directly continuous with the fascia on the front of the leg : further, the strong intermuscular septum (posterior peroneal septum) which passes in to join the external border of the fibula between the peroneal muscles and the muscles on the posterior aspect of the leg will be demonstrated. In this manner, then, the large posterior osteo-fascial compartment is formed, and, as the dissection goes on, two partitions will be noticed to stretch across it so as to subdivide it into three portions. The most superficial of these holds the superficial muscles of the calf ; the intermediate portion contains the flexor muscles with the posterior tibial vessels and nerve : whilst the deepest part encloses the tibialis posticus muscle (Figs. 54 and 55).

One of these partitions may be exposed at the present moment by removing the fat which is usually accumulated under cover of the tendo Achillis. Subjacent to this tendon is the layer of fascia in question. It stretches between the tibia and fibula, and separates the superficial from the deep group of muscles. In this locality it will be seen to be very dense, and to be strengthened by numerous transverse fibres. It becomes continuous on the inner side of the ankle with the internal annular ligament—indeed, the dissector will not fail to observe that it takes a more prominent part in the formation of this ligament, than the investing aponeurosis of the limb. In the upper part of the leg it becomes very thin.

Superficial Muscles.—The superficial muscles of the calf of the leg are three in number, viz., the gastrocnemius, the plantaris, and the soleus. The gastrocnemius is the most superficial ; the soleus is placed under cover of the gastrocnemius ; whilst the slender plantaris extends downwards and inwards between them. The tendons of insertion of the gastrocnemius and soleus unite to form the tendo Achillis.

The Gastrocnemius arises by two heads from the posterior aspect of the lower end of the femur. These heads have been already studied in connection with the popliteal space, which they bound in its lower part. The *outer head* springs from an impression on the outer surface of the external condyle of the femur, and also from a small portion of the posterior surface of the bone immediately above the condyle. The *inner head* takes origin from the upper part of the internal condyle, and likewise from the inferior portion of the internal supracondyloid ridge of the

femur. The two fleshy bellies swell out as they descend, and end near the middle of the leg in a thin aponeurotic tendon. They do not blend with each other. They are usually separated by a furrow, at the bottom of which the flattened tendon, to which the fasciculi of both heads are attached, may be seen. The internal head is the more bulky of the two, and it extends lower down than the external head. The flattened tendon in which they terminate narrows slightly as it descends, and a short distance below the middle of the leg it blends with the stouter tendon of the soleus to form the tendo Achillis.

Dissection.—The aponeurotic tendon of the gastrocnemius may be divided in the middle of the leg, and the two heads of origin thrown upwards towards the back of the femur. The sural arteries from the popliteal trunk, and the branches of supply from the internal popliteal nerve which enter the heads of the gastrocnemius, can thus be preserved. On raising the upper portion of the inner head, a bursa which intervenes between it and the condyle of the femur will be brought into view. On opening this with the knife it will, in all probability, be found to communicate with the interior of the knee-joint. The smooth and tendinous opposed surfaces of the gastrocnemius and the soleus, and the narrow tendon of the plantaris, which passes downwards and inwards between them, are now displayed.

Plantaris.—The small fleshy belly of the plantaris is not more than three or four inches long. It lies along the inner side, and partly under cover of the outer head of the gastrocnemius, and it arises from the posterior surface of the femur immediately above its external condyle. It ends in a slender tendon which is remarkable for its great length. This proceeds downwards and inwards between the gastrocnemius and soleus, and then runs along the inner side of the tendo Achillis to gain insertion into the posterior aspect of the os calcis. It is frequently closely connected with the tendo Achillis, and sometimes becomes blended with it or with the fascia of the leg before it reaches the os calcis.

The plantaris is supplied by a branch from the internal popliteal nerve.

Dissection.—The plantaris may now be reflected.

The Soleus is a flat, thick, and powerful muscle which arises from both bones of the leg, as well as from a strong fibrous arch which is thrown across the posterior tibial vessels. Its *fibular origin* is from the posterior surface of the head and the upper third of the posterior surface of the shaft of the bone; by its *tibial origin* it is attached to the oblique line of the tibia below the popliteal surface, and to the internal border of the bone below this as far down as the middle of the leg. The soleus ends in a strong stout tendon which joins with the tendon of the gastrocnemius to form the tendo Achillis. Branches from the internal popliteal nerve supply the soleus.

The Tendo Achillis (tendo calcaneus) is the most powerful tendon in the body. It narrows as it descends, but near the heel it again expands slightly. It is inserted into the middle portion of the posterior surface of the os calcis. The fleshy fibres of the soleus are continued downwards on its deep surface to within a short distance of the heel. A synovial bursa intervenes between the tendo Achillis and the upper part of the posterior surface of the os calcis.

Dissection.—Divide the soleus muscle transversely at the level at which it is joined by the gastrocnemius tendon, and turn downwards the tendo Achillis. Next make a vertical incision through the substance of the soleus in the middle line, so as to divide it into two lateral portions. By this dissection the tendinous arch which is thrown across the blood-vessels is exposed in the upper part, and both the tibial and fibular origins with the blood-vessels and nerves which enter them are preserved. The two portions of the fleshy belly of the muscle may now be turned outwards and inwards, and the branches which the muscle receives from the peroneal and posterior tibial arteries may be cleaned.

The deep fascial septum which stretches across from the tibia to the fibula between the superficial and deep muscles on the back of the leg may now be removed. In doing this note the manner in which it becomes continuous below with the internal annular ligament. On no account interfere with this ligament. The posterior tibial vessels and nerve, with their branches, should be dissected with as little disturbance to the deep muscles as possible. The muscle which lies on the fibula is the flexor longus hallucis; the muscle on the tibia is the flexor longus digitorum; whilst the third muscle between and on a deeper plane than the other two is the tibialis posticus.

Termination of the Popliteal Artery.—The termination of the popliteal artery lies under cover of the upper border of the soleus. It should now be cleaned, and it will be seen to end at the lower margin of the popliteus muscle by dividing into the *anterior* and *posterior tibial arteries*. Further, the venæ comites which accompany these vessels will be observed to join at this point to form the large popliteal vein.

The Anterior Tibial Artery (arteria tibialis anterior) passes forwards between the two heads of the tibialis posticus muscle to the front of the leg, where it has already been dissected. In this part of its course the anterior tibial artery gives off the posterior recurrent tibial and the superior fibular branch. The *posterior recurrent tibial* is a small twig which is not always present. It runs upwards under cover of the popliteus muscle to the back of the knee-joint. The *superior fibular* runs outwards on the neck of the fibula, and is distributed to the muscles and integument in the neighbourhood.

The Posterior Tibial Artery (arteria tibialis posterior) is the larger of the two terminal branches of the popliteal trunk. It takes origin at the lower border of the popliteus muscle and ends in the hollow on the inner side of the os calcis, under cover of the abductor hallucis, and at the level of the lower border of the internal annular ligament, by dividing into the external and internal plantar arteries. In the first instance the artery is placed between the two bones of the leg upon the tibialis posticus muscle; but as it descends it inclines gradually inwards, and at its termination it lies midway between the prominence of the os calcis and the internal malleolus.

In its upper two-thirds the posterior tibial artery is situated very deeply, being covered by the superficial muscles of the calf. In the lower third of the leg it appears between the tendo Achillis and the inner border of the tibia, and is merely covered by the integument, two layers of fascia, and lower down by the internal annular ligament. From above downwards it rests upon the

tibialis posticus, the flexor longus digitorum, the tibia, and the posterior aspect of the ankle-joint.

Throughout its entire course the posterior tibial artery is closely accompanied by two *venæ comites*. The *posterior tibial nerve* is at first on its inner side, but it soon crosses the vessel, and then proceeds down on its outer side.

The following are the branches which issue from the posterior tibial artery:—

- | | | |
|--------------|--|------------------------|
| 1. Muscular. | | 4. Cutaneous. |
| 2. Nutrient. | | 5. Internal calcanean. |
| 3. Peroneal. | | 6. Communicating. |

The *muscular branches* supply the deep muscles on the back of the leg, and one or two of large size enter the soleus.

The *cutaneous branches* are given to the skin on the inner aspect of the leg.

The *nutrient artery* (arteria nutritia tibiæ) springs from the posterior tibial close to its origin, and after giving some twigs to muscles enters the nutrient foramen of the tibia. It is remarkable on account of its large size.

The *communicating branch* (ramus communicans) is given off about an inch above the lower end of the tibia. It passes transversely outwards under cover of the flexor longus hallucis, and joins the peroneal artery.

The *internal calcanean branch* (rami calcanei mediales) pierces the internal annular ligament, and accompanies the nerve of the same name to the skin of the heel and the sole.

The *peroneal artery* (arteria peronea) is a large branch which proceeds from the posterior tibial about one inch or so below its origin. In the present stage of the dissection it is seen running obliquely downwards and outwards upon the tibialis posticus to reach the fibula. It is covered by the soleus, and is accompanied by the nerve to the flexor longus hallucis. It cannot be traced further at present, as it sinks into the substance of that muscle.

Posterior Tibial Nerve (nervus tibialis).—This is the continuation into the back of the leg of the internal popliteal

nerve. It begins at the lower border of the popliteus muscle and ends in the hollow between the heel and the internal malleolus by dividing into the external and internal plantar nerves. It accompanies the posterior tibial vessels, and presents the same relations. For a short distance in the upper part of the leg it lies on the inner side of the posterior tibial artery, but it soon crosses it, and is then continued downwards for the remainder of its course on the outer side of the vessel.

It supplies—(a) *muscular branches* to the tibialis posticus, flexor longus hallucis, and flexor longus digitorum; (b) a *cutaneous twig*, the *internal calcanean*, which springs from it close to its termination, and pierces the internal annular ligament to reach the integument of the heel and sole of the foot; and (c) *articular filaments* to the ankle-joint.

Deep Muscles.—The *popliteus muscle* will be seen lying upon the posterior aspect of the knee-joint and upon the posterior surface of the tibia above the oblique line. Its tendon of origin lies within the capsule of the knee-joint, and can only be properly studied when this articulation is dissected.

Note the strong fascia which covers the posterior surface of the popliteus, and trace it upwards and inwards to the inner side of the knee. Here it will be observed to be continuous with the tendon of the semimembranosus, and through it, therefore, the semimembranosus may be regarded as having an insertion into the oblique line of the tibia.

The *flexor longus hallucis* is placed upon the posterior aspect of the fibula, and its tendon will be noticed to groove deeply the posterior border of the astragalus as it passes forwards to gain the sole of the foot. The *flexor longus digitorum* lies upon the tibia. The *tibialis posticus* rests upon the interosseous membrane upon a deeper plane and between the fleshy bellies of the two flexors.

The Aponeurosis covering the Tibialis Posticus is the second partition which crosses the posterior osteo-fascial compartment of the leg. It is a strong aponeurosis, which is attached on the one hand to the internal border of

the fibula, and on the other to the vertical ridge which descends from the oblique line on the posterior surface of the tibia. To demonstrate these attachments, the flexor muscle of the toes must be pushed inwards and some of its fibres divided. The flexor longus hallucis must in like manner be pushed outwards. The aponeurosis will then be seen to serve as a surface of origin for both of these muscles; and, on its removal, it will also be observed to give fibres by its deep surface to the subjacent tibialis posticus.

The Popliteus arises by a stout narrow tendon, within the capsule of the knee-joint, from the front of the popliteal groove on the outer surface of the external condyle of the femur. The fleshy fibres are directed inwards and downwards, and spread out to obtain insertion into the posterior surface of the tibia above the oblique line, and also into the aponeurosis which covers the muscle.

The nerve to the popliteus has already been seen to arise from the internal popliteal trunk. It can now be seen hooking round the lower margin of the muscle to reach its deep surface.

The Flexor Longus Hallucis is a powerful muscle which arises from the posterior surface of the fibula below the origin of the soleus, from the posterior peroneal septum, and from the surface of the aponeurosis covering the tibialis posticus. Its tendon occupies a deep groove on the posterior border of the astragalus, and turns forwards under cover of the internal annular ligament to gain the sole of the foot.

The Flexor Longus Digitorum arises from the posterior surface of the shaft of the tibia below the popliteus, and internal to the vertical ridge, which descends from the oblique line. It also derives fibres from the surface of the aponeurosis which covers the tibialis posticus. Crossing the lower part of the tibialis posticus, its tendon grooves the back of the internal malleolus on the outer side of the tendon of that muscle. It is continued under cover of the internal annular ligament into the sole of the foot.

The Tibialis Posticus takes origin from the posterior surface of the interosseous membrane, from the posterior part of the inner surface of the shaft of the fibula, from the posterior surface of the shaft of the tibia on the outer side of the flexor longus digitorum, and from the aponeurosis which covers it. In Fig. 59 the compartment which it occupies is shown in a diagrammatic manner, and the surfaces from which it takes origin are indicated. Towards the lower part of the leg the tibialis posticus inclines inwards under cover of the flexor longus digitorum.

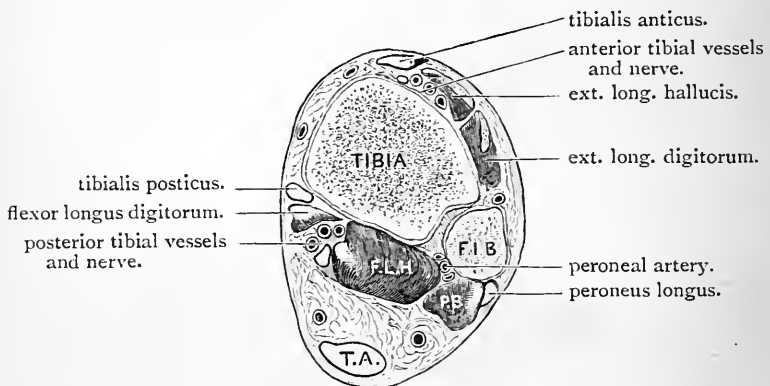


FIG. 58.—Transverse section through the leg immediately above the ankle-joint.

F.I.B. Fibula.
T.A. Tendo Achillis.

F.L.H. Flexor longus hallucis.
P.B. Peroneus brevis.

and its strong flattened tendon grooves the back of the internal malleolus to the inner side of the tendon of that muscle. Continued under cover of the annular ligament, its tendon is inserted into the tubercle of the scaphoid, and also by a number of slips into certain of the tarsal and metatarsal bones. These will be dissected later on.

Peroneal Artery (arteria peronea).—This vessel may now be traced downwards as it runs along the fibula under cover of the flexor longus hallucis. It is accompanied by two *venæ comites*. About an inch or an inch and a half above the ankle-joint it ends by dividing into its two

terminal branches—the anterior and the posterior peroneal arteries.

In addition to these it gives off—

1. Muscular branches.
2. The nutrient artery to the fibula.
3. The communicating artery.

The *muscular branches* supply the muscles around it. The *nutrient artery* (arteria nutritia fibulae) enters the

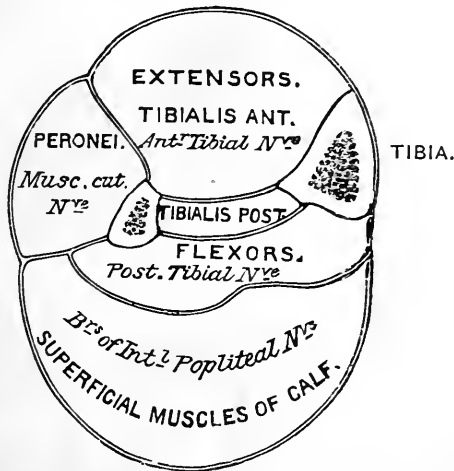


FIG. 59.—Diagrammatic representation of the fascia of the leg. The fascia of the tibialis posticus is more a muscular aponeurosis than a true fascial septum; but it is convenient for descriptive purposes to regard it as one of the partitions.

nutrient foramen on the posterior surface of the fibula. The *communicating artery* (ramus communicans) arises a short distance above the ankle-joint, and runs transversely inwards under cover of the flexor longus hallucis to join the posterior tibial artery.

The *anterior peroneal artery* (ramus perforans) passes forwards through the interosseus membrane, and has already been dissected on the front of the leg.

The *posterior peroneal artery* is continued downwards behind the external malleolus, and ends on the outer

surface of the os calcis, where it anastomoses with the external malleolar, tarsal, and anterior peroneal vessels.

Internal Annular Ligament.—The connections of this thickened band of deep fascia should be carefully studied, and also the arrangement of the structures which pass under cover of it into the sole of the foot. It bridges across the hollow between the prominence of the os calcis and the internal malleolus, and it is attached to both. Above, it is chiefly connected with that layer of the deep

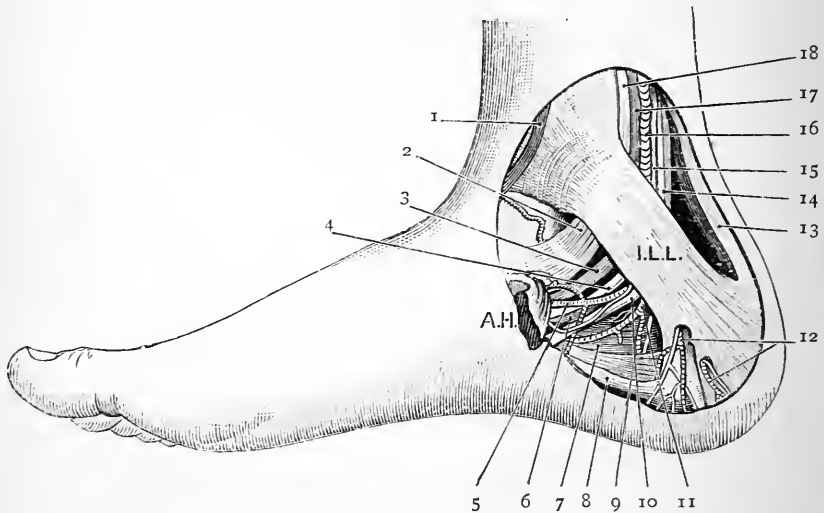


FIG. 60.—Dissection of the inner ankle.

A.H. Abductor hallucis, thrown forwards from its origin.
I.L.L. Internal annular ligament.

- | | |
|---|---|
| 1. Internal saphenous vein. | 10. External plantar nerve. |
| 2 & 18. Tibialis posticus tendon. | 11. External plantar artery. |
| 3 & 17. Flexor longus digitorum tendon. | 12. Internal calcanean arteries and nerves. |
| 4. External plantar nerve. | 13. Tendo Achillis. |
| 5. Internal plantar artery. | 14 & 6. Tendon of flexor longus hallucis. |
| 6 & 14. Flexor longus hallucis tendon. | 15. Posterior tibial nerve. |
| 7. Accessorius muscle. | 16. Posterior tibial artery. |
| 8. Plantar fascia and flexor brevis digitorum. | 17 & 3. Tendon of flexor longus digitorum. |
| 9. Origin of the abductor minimi digiti from the inner tuberosity of the os calcis. | 18 & 2. Tendon of tibialis posticus. |

fascia which intervenes between the superficial and deep muscles on the back of the leg, but it is also continuous with the general aponeurotic investment of the limb. Inferiorly, its lower margin gives origin to the abductor hallucis, and is connected with the inner portion of the plantar fascia.

Passing under cover of this ligament the dissector will observe—(a) the posterior tibial vessels and nerve; (b) to the outer side of these, the tendon of the flexor longus hallucis; (c) to their inner side, the tendons of the flexor longus digitorum and tibialis posticus. From within outwards these structures lie in the following order:—

1. Tendon of tibialis posticus.
2. Tendon of flexor longus digitorum.
3. Posterior tibial vessels.
4. Posterior tibial nerve.
5. Tendon of flexor longus hallucis.

The tendons are isolated from each other and from the vessels and nerve by septa, which pass from the deep surface of the ligament to ridges on the bones. These septa can be demonstrated by slitting up the ligament, for a short distance, in the line of each of the tendons: each of the three sheaths will then be seen to be lined by a glistening synovial membrane.

Anastomosis around the Ankle-joint.—The dissector should next satisfy himself with regard to the anastomosis of arteries which takes place around the ankle-joint. On the *outer aspect* of the joint he will observe inosculation taking place between branches of the following arteries:—(a) external malleolar; (b) anterior peroneal; (c) posterior peroneal; and (d) tarsal.

On the *inner aspect* of the joint the internal malleolar branch of the anterior tibial anastomoses with small twigs from the internal calcanean branch of the posterior tibial.

SOLE OF THE FOOT.

In this dissection the dissector will meet with the following structures:—

1. Superficial fascia and cutaneous vessels and nerves.
2. Deep plantar fascia.
3. Superficial muscles,

{	Abductor hallucis.
	Flexor brevis digitorum.
	Abductor minimi digiti.
4. External and internal plantar vessels.
5. External and internal plantar nerves.
6. Tendons of flexor longus hallucis and flexor longus digitorum.
7. Musculus accessorius and lumbrical muscles.
8. Flexor brevis hallucis, adductor obliquus hallucis, and adductor transversus hallucis.
9. Flexor brevis minimi digiti.
10. Plantar arterial arch.
11. Arteria magna hallucis.
12. Tendons of peroneus longus and tibialis posticus.
13. Interosseous muscles.

Reflection of Skin.—The limb should be placed upon the table, with the sole of the foot facing the dissector, and the ankle supported by a good-sized block. Two incisions are required—(1) a longitudinal incision along the middle line of the sole, from the heel to the root of the middle toe; (2) a transverse cut, at the digital extremity of the mesial incision, across the sole at the roots of the toes. The skin should also be reflected from the plantar surface of each of the toes. This can be done by means of a longitudinal incision along its middle line.

Superficial Fascia.—When the flaps of skin which are mapped out by the above incisions are reflected, the peculiar characters of the thick layer of superficial fascia become apparent. It is tough and granular, and in some respects resembles the superficial fascia which covers the tuber ischii. Traversing it are tough fibrous bands, which subdivide the fatty tissue into small lobules, and connect the thick skin of the sole with the plantar fascia.

Dissection.—The *internal calcanean nerve*, which has already been found piercing the internal annular ligament, should be traced to its distribution. It supplies the skin of the sole in the neighbourhood of the heel.

The superficial fascia may now be removed. Divide it along the middle line of the sole, and turn it outwards and inwards, cleaning at the same time the deep fascia. As the dissector approaches the outer and inner margins of the foot respectively, he will observe two furrows to extend forwards on each side of the central part of the deep fascia. Along the line of these a number of blood-vessels and some nerves will be seen piercing the deep fascia in order to reach the skin. Towards the heads of the metatarsal bones the digital vessels and nerves are unprotected by the deep fascia, and here the dissector must proceed cautiously. The nerves and vessels which go to the tibial side of the hallux and to the fibular side of the little toe are especially liable to injury, as they perforate the fascia further back than the others. A band of transverse fibres, which crosses the roots of the toes and lies over the digital vessels and nerves, should be noticed. It is the *superficial transverse ligament of the toes.* It is closely connected with the skin, where it forms the cutaneous webs between the toes. By forcibly separating the toes its connections will become evident, When the relations of this ligament have been studied it may be removed.

Plantar Fascia.—The plantar fascia, which is now brought into view, will be noticed to consist of three portions—(a) a central, and (b) two lateral parts. This subdivision is indicated by a difference in the density of the three parts and by two shallow furrows which traverse the foot in a longitudinal direction, one upon either side of the strong central portion of fascia. Each of the three portions of fascia is in relation to a subjacent muscle. The *central portion* covers the flexor brevis digitorum; the *external lateral part* clothes the abductor minimi digiti; and the *internal lateral part* covers the abductor hallucis.

The *central portion* of the plantar fascia stands out in marked contrast to the lateral portions in point of strength and density. Behind, where it is attached to the internal tuberosity of the os calcis, it is narrow, but it expands as it passes forwards, and, near the heads of the metatarsal bones, splits into five processes, which are bound together by transverse fibres. In the intervals between the digital slips the digital vessels and nerves and the lumbrical muscles appear. Trace these processes forwards. One goes to the root of each toe, and there divides into two slips, which embrace the flexor tendons and become fixed

to the flexor sheaths and to the transverse metatarsal ligament on either side of the toe. In its arrangement, therefore, this portion of the plantar fascia closely resembles the central part of the palmar fascia.

The lateral parts of the plantar fascia are weak in comparison with the central portion. They simply constitute aponeurotic coverings for the muscles which lie subjacent. A strong band is to be noted in connection with the outer part. It stretches between the prominence formed by the base of the fifth metatarsal bone and the external tuberosity of the os calcis.

In connection with the plantar fascia two intermuscular septa have also to be studied. These pass upwards into the sole, along the longitudinal furrows which mark off the central portion of the fascia from the lateral parts. They consequently lie one upon either side of the flexor brevis digitorum, and form partitions which separate it from the abductor hallucis on the one side, and the abductor minimi digiti on the other.

Dissection.—To demonstrate these septa, make a transverse incision through the central portion of the plantar fascia about an inch in front of the internal tuberosity of the os calcis, and also a longitudinal cut through the same piece of fascia, extending from the first incision along the middle line of the foot. Now raise the divided fascia and throw it outwards and inwards. Some difficulty will be experienced in effecting this, owing to its affording a surface of origin in its upper part to the subjacent flexor brevis digitorum. As we approach the margins of this muscle the septa are brought into view.

Muscles and Tendons of the Sole.—It is customary to look upon the muscles and tendons which we find in the dissection of the sole as being disposed in four strata, viz. :—

First layer.	{ Abductor hallucis. Flexor brevis digitorum. Abductor minimi digiti.	3
Second layer.	{ Tendon of flexor longus digitorum. Musculus accessorius. Lumbrical muscles. Tendon of flexor longus hallucis.	4

Third layer.	{ Flexor brevis hallucis. Adductor obliquus hallucis. Adductor transversus hallucis. Flexor brevis minimi digiti.
Fourth layer.	{ Interosseous muscles. Tendon of the peroneus longus, Tendon of the tibialis posticus.

Dissection.—The lateral portions of the plantar fascia should be raised from the subjacent muscles. The three superficial muscles of the sole are then exposed to view and their connections can be studied. The *flexor brevis digitorum* is placed in the middle, the *abductor minimi digiti* extends along the outer margin of the sole, and the *abductor hallucis* along the inner margin of the sole. In the interval between the abductor hallucis and flexor brevis digitorum the internal plantar nerve and artery will be found. Follow the nerve toward the toes and dissect out its four digital branches. In doing so, care must be taken of the muscular twigs which are given to the flexor brevis, hallucis and the innermost lumbrical muscle. Slender branches of the internal plantar artery accompany the digital nerves. Now trace the trunk of the *internal plantar nerve* backwards, by carefully separating the flexor brevis digitorum and the abductor hallucis along the line of the internal intermuscular septum. It will be found to give a branch of supply to each of these muscles. In the next place, separate the contiguous borders of the flexor brevis digitorum and abductor minimi digiti. The *external plantar artery and nerve* lie for a short portion of their course in the interval between these muscles. Approaching the prominent base of the fifth metatarsal bone, the artery disappears from view by turning inwards under cover of the flexor tendons. At the same point the external plantar nerve divides into its superficial and deep divisions. The *deep division* of the external plantar nerve cannot be dissected at present, as it accompanies the external plantar artery. The *superficial division*, however, should be traced to its distribution.

The Flexor Brevis Digitorum arises from the internal tubercle of the os calcis, from the deep surface of the central part of the plantar fascia, and from the intermuscular septum on either side of it. About the middle of the sole the fleshy belly divides into four slips, which end in slender tendons for the four outer toes. These enter the fibrous flexor sheaths of the toes, and will be afterwards studied.

The Abductor Hallucis takes origin from the inner aspect of the internal tubercle of the os calcis, from the

internal intermuscular septum, from the lower border of the internal annular ligament, and from the lateral part of the plantar fascia which covers it. A strong tendon issues from the fleshy belly. This is joined on its outer and deep surface by fibres of the internal head of the flexor brevis hallucis, and is inserted into the inner aspect of the base of the proximal phalanx of the great toe.

Abductor Minimi Digiti (musculus abductor quinti digiti).—The origin of this muscle extends inwards under cover of the flexor brevis digitorum. The latter muscle must therefore be detached from the os calcis and turned forwards. The abductor minimi digiti is then seen to have a broad origin from both the inner and outer tubercles of the os calcis, from the external intermuscular septum, and the lateral part of the plantar fascia which covers it. Its tendon is inserted into the outer aspect of the base of the proximal phalanx of the little toe.

Dissection.—The origin of the *abductor hallucis* from the os calcis and from the internal annular ligament should be divided and the muscle turned inwards. With a little dissection the mode and place of origin of the *plantar arteries* and *nerves* will be made manifest. They are the terminal branches of the *posterior tibial artery* and *nerve*, and they arise in the hollow of the os calcis under cover of the origin of the abductor hallucis. But further, we are now in a position to trace the *external plantar artery* and *nerve* as they pass outwards upon the musculus accessorius to the point where they were first seen—viz., in the interval between the abductor minimi digiti and the flexor brevis digitorum. In following the external plantar nerve, the branches which it gives to the musculus accessorius and the abductor minimi digiti must be secured. The latter nerve lies close to the os calcis.

Internal Plantar Artery (arteria plantaris medialis).—This is the smaller of the two terminal branches of the posterior tibial artery. It arises in the hollow between the internal malleolus and the prominence of the os calcis at the lower border of the internal annular ligament. At first it is placed under cover of the abductor hallucis, but as it proceeds forwards it appears in the interval between this muscle and the flexor brevis digitorum. Finally, at the

root of the great toe it ends by joining the digital branch to the inner side of the hallux.

The *branches* which proceed from the internal plantar are small but very numerous. They are—(1) three twigs which accompany the digital branches of the internal plantar nerve to the clefts between the four inner toes. These end by joining the corresponding digital arteries; (2) a series of cutaneous branches to the skin of the sole, which

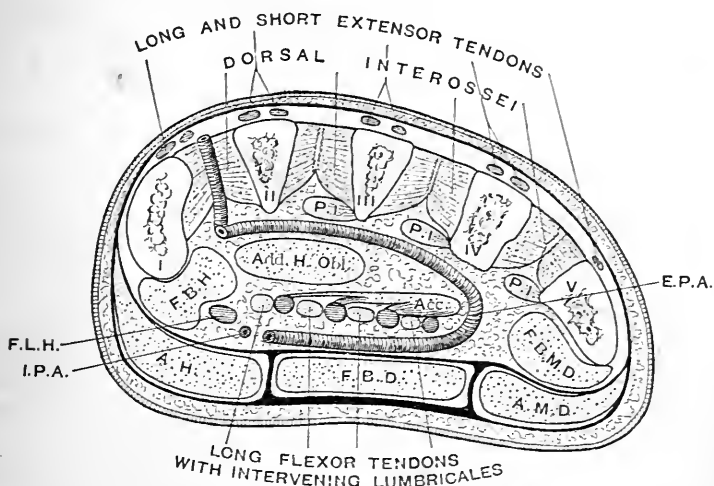


FIG. 61.—Diagram, by Prof. Paterson, to show the different planes occupied by the external plantar artery. (It must be clearly understood that the representation is purely schematic, as no transverse section through the foot would give a continuous view of this vessel.)

I. to V. Five metatarsal bones.

P.I. Palmar interosseous muscles.

F.B.H. Flexor brevis hallucis.

Add. H. Obl. Adductor obliquus hallucis.

Acc. Accessorius.

F.B.M.D. Flexor brevis minimi digiti.

E.P.A. External plantar artery.

F.L.H. Tendon of flexor longus hallucis.

I.P.A. Internal plantar artery.

A.H. Abductor hallucis.

F.B.D. Flexor brevis digitorum.

A.M.D. Abductor minimi digiti.

pierce the deep fascia in the furrow between the internal lateral and central parts of the plantar fascia; (3) a number of branches to the muscles in the vicinity; (4) some offsets which pass inwards under cover of the abductor hallucis to reach the inner border of the foot.

The External Plantar Artery (*arteria plantaris lateralis*) is much larger than the internal plantar. It is accompanied by the external plantar nerve and two *venæ comites*. From its origin in the hollow of the *os calcis* it proceeds outwards across the sole to reach the interval between the *flexor brevis digitorum* and the *abductor minimi digiti*. In this interval it is continued forwards for a short distance, and then at the base of the fifth metatarsal bone it turns suddenly inwards, and crosses the sole a second time, under cover of the flexor tendons, to form the plantar arch. In the present stage of the dissection it is only displayed as far as the base of the fifth metatarsal bone. Between its origin and this point its relations are as follows:—(1) it is placed between the *abductor hallucis* and the hollow of the *os calcis*; (2) it lies between the *flexor brevis digitorum* and the *musculus accessorius*; (3) it occupies the interval between the *flexor brevis digitorum* and the *abductor minimi digiti*. In this latter situation it is near the surface, and is merely covered by the integument and *fasciæ*.

The *branches* which proceed from this part of the vessel are—(1) twigs to the neighbouring muscles; (2) *internal calcanean* branches which arise near its origin, and gain the heel by piercing the origin of the *abductor hallucis*; (3) cutaneous branches which appear through the deep fascia along the line of the external intermuscular septum; (4) twigs to the outer margin of the foot which anastomose with the tarsal and metatarsal branches of the *dorsalis pedis*.

The Internal Plantar Nerve (*nervus plantaris medialis*) is the larger of the two terminal branches of the posterior tibial, and it takes origin in the hollow of the *os calcis* under cover of the internal annular ligament. It accompanies the internal plantar artery, and presents the same relations. After it emerges from under cover of the *abductor hallucis*, it gives off the digital branch to the inner side of the hallux, and then ends in the interval between the *abductor hallucis* and the *flexor brevis digitorum* by dividing into three digital branches.

The *branches* of the internal plantar nerve are :—

1. Cutaneous twigs to the skin of the sole.
2. Muscular branches.
3. Four digital branches.

The *cutaneous twigs* to the integument of the sole spring from the trunk of the nerve, and pierce the deep fascia in the line of the internal intermuscular septum.

The *four digital branches* supply both sides of the hallux and of the second and third toes, and also the tibial side of the fourth toe. The *first or innermost digital nerve* goes to the inner side of the great toe. The *second* divides to supply the contiguous margins of the great toe and the second toe. The *third* deals similarly with the second and third toes; whilst the *fourth* supplies the adjacent sides of the third and the fourth toes. In its digital distribution, therefore, the internal plantar nerve closely resembles the median nerve in the hand. To the *fourth or outermost digital branch* a twig of communication is given by the superficial division of the external plantar nerve.

The digital nerves should be traced along the toes. They are arranged in a manner very similar to that of the corresponding nerves of the fingers.

The *muscular branches* go to four muscles of the sole, viz., the abductor hallucis, the flexor brevis digitorum, the flexor brevis hallucis, and the innermost or first lumbrical muscle. The branches which supply the abductor hallucis and the flexor brevis digitorum arise from the trunk of the internal plantar nerve a short distance from its origin. The other two spring from the inner two digital nerves: thus, from the first digital nerve proceeds the branch to the flexor brevis hallucis; from the second, the branch to the first lumbrical.

The External Plantar Nerve (nervus plantaris lateralis) corresponds to the ulnar nerve in the palm of the hand. It accompanies the external plantar artery and presents the same relations. In the interval between the abductor

minimi digiti and the flexor brevis digitorum, opposite the base of the fifth metatarsal bone, it divides into a deep and a superficial part. The *deep division* follows the plantar arch under cover of the flexor tendons. The *superficial division* divides into two digital branches.

From the trunk of the external plantar nerve proceed *two muscular branches*, viz., to the musculus accessorius and to the abductor minimi digiti.

The *first or outer digital branch* of the superficial part of the external plantar nerve goes to the outer side of the little toe. It also gives muscular twigs to the flexor brevis minimi digiti and the interosseous muscles in the fourth intermetatarsal space.

The *second digital branch* divides to supply the adjacent sides of the fourth toe and little toe. It likewise sends a twig of communication to the fourth digital branch of the internal plantar nerve.

Dissection.—The abductor minimi digiti should be completely detached from its origin, and turned forwards in order that a good display may be obtained of the structures composing the second stratum of the sole.

Second Layer of Muscles and Tendons.—As the tendon of the *flexor longus hallucis* enters the sole it grooves the under surface of the sustentaculum tali and inclines inwards towards the great toe. The tendon of the *flexor longus digitorum*, on the other hand, inclines outwards to reach the middle of the foot, where it divides into four tendons for the four outer toes. Moreover, the tendons of these two muscles cross each other in the sole—the tendon of the flexor digitorum lying upon the plantar surface of the tendon of the flexor longus hallucis, and receiving from it a strong tendinous slip.

Sir William Turner has called attention to the fact that this slip, which passes from the tendon of the flexor longus hallucis to the tendon of the flexor longus digitorum, varies greatly in magnitude and in the manner in which it is connected with the flexor tendons of the toes. In the majority of cases it goes to the tendons of the second and third toes; in some cases, however, only to the tendon of

the second toe, or to the tendons of the second, third, and fourth toes. Very rarely does it divide so as to bring all the tendons of the flexor longus digitorum into connection with the tendon of the flexor longus hallucis.

The *musculus accessorius*, which is inserted into the tendon of the long flexor of the toes, and also the four *lumbrical muscles* which arise from the flexor tendons, can now be distinguished. Note the position of the long plantar ligament between the two heads of origin of the accessorius.

Fibrous Flexor Sheaths.—Before tracing the flexor tendons forwards on the toes, it is necessary to examine the sheaths which retain them upon the plantar aspect of the phalanges. In their construction these fibrous sheaths are precisely similar to the corresponding sheaths of the fingers. They are not so strongly marked, but they present the same thickenings over the shafts of the phalanges and the same want of strength opposite the interphalangeal joints. They may now be opened in order that the enclosed tendons may be examined. A synovial sheath is present in each to facilitate the play of the flexor tendons within them.

Insertions of the Flexor Tendons.—Two tendons, one from the flexor brevis digitorum, and one from the flexor longus digitorum, enter the flexor sheath of each of the four outer toes. Of these, the

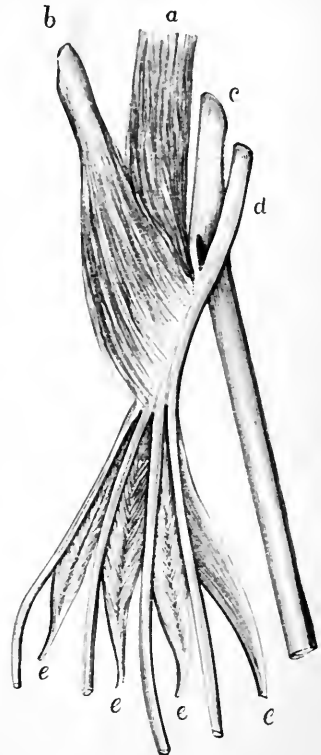

FIG. 62.—Diagram of the accessorius muscle and the tendons of the flexor longus hallucis and flexor longus digitorum in the sole of the foot.

- a. Inner head of accessorius.
- b. Outer head of accessorius.
- c. Tendon of flexor longus hallucis.
- d. Tendon of flexor longus digitorum.
- e. Lumbrical muscles.

one from the flexor longus digitorum, enter the flexor sheath of each of the four outer toes. Of these, the tendon of the former

muscle corresponds with a tendon of the flexor sublimis in the hand, whilst the tendon of the flexor longus digitorum corresponds with a tendon of the flexor profundus. Further, they are inserted in exactly the same manner. The tendon of the flexor brevis, which is the more superficial, divides into two slips, and between these the tendon of the flexor longus proceeds forwards to its insertion into the plantar aspect of the base of the unguis phalanx. The two slips of the tendon of the flexor brevis are joined by their margins on the deep surface of the long flexor tendon, and then separate again to obtain insertion into the sides of the shaft of the second phalanx about its middle.

The Tendon of the Flexor Longus Hallucis, after giving its slip to the tendon of the flexor longus digitorum, is prolonged forwards to the great toe. On the plantar aspect of the hallux it is retained in place by a flexor sheath, and finally it is inserted into the base of the terminal phalanx.

The Musculus Accessorius (musculus quadratus plantæ) takes a course straight forwards from the heel, and acts as a direct flexor of the toes. It also tends to bring the tendons of the long flexor muscle into a line with the toes upon which they operate. It arises by two heads, which embrace the os calcis and the long plantar ligament. The *inner head*, wide and fleshy, springs from the inner concave surface of the os calcis; the *outer head*, narrow, pointed, and tendinous, takes origin from the outer surface of that bone, and also from the long plantar ligament. The musculus accessorius is inserted into the tendon of the flexor longus digitorum in the middle of the sole. It is supplied by a branch from the external plantar nerve.

The Lumbrical Muscles of the foot are not so strong as the corresponding muscles in the palm of the hand. They are four in number, and arise from the tendons of the flexor longus digitorum. The outer three lumbricals spring from the adjacent sides of the tendons between

which they lie ; the first or innermost muscle takes origin from the tibial side of the tendon of the long flexor which goes to the second toe. The slender tendons of the lumbrical muscles proceed to the tibial side of the four outer toes, and are inserted into the expansions of the extensor tendon on the dorsal aspect of the proximal

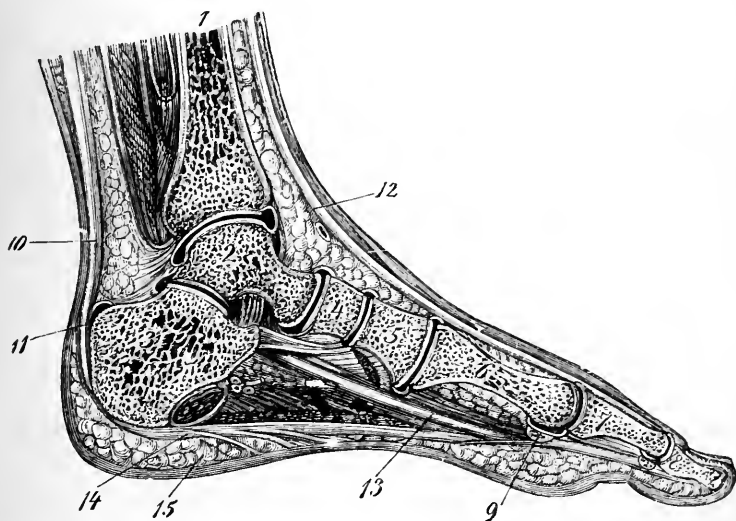


FIG. 63.—Vertical section through the foot, along a line stretching from the centre of the heel behind to the centre of the great toe in front. (From Luschka.)

- | | |
|-----------------------------|---|
| 1. Tibia. | 10. Tendo Achillis. |
| 2. Astragalus. | 11. Bursa between tendo Achillis and os calcis. |
| 3. Os calcis. | 12. Tendon of extensor longus hallucis. |
| 4. Scaphoid. | 13. Tendon of flexor longus hallucis. |
| 5. Internal cuneiform. | 14. Plantar fascia (central part). |
| 6. First metatarsal. | 15. Thick superficial fascia of heel. |
| 7 & 8. Phalanges of hallux. | |
| 9. Sesamoid bone. | |

phalanges. The first or innermost lumbrical is supplied by the internal plantar nerve ; the others by the external plantar nerve.

Dissection.—To bring the third layer of muscles into view we require to make the following dissection :—Divide the two heads of the accessorius and draw the muscle forwards from under the external

plantar vessels and nerve. Sever also the tendons of the flexor longus digitorum and the flexor longus hallucis at the point where they emerge from under cover of the internal annular ligament. Upon cutting the branch which is given by the external plantar nerve to the accessorius these structures can be thrown forwards towards the toes. On raising the lumbrical muscles, the twigs which are furnished to the *second, third, and fourth* by the deep division of the external plantar nerve must be looked for. That for the second lumbrical muscle will be seen to take a recurrent course around the adductor transversus hallucis muscle. Lastly, cut the internal plantar nerve close to its origin and turn it aside.

Third Layer of Muscles.—The *flexor brevis hallucis* lies along the outer side of the abductor hallucis.

The *adductor obliquus hallucis* has a very oblique position in the sole, and hides to a great extent the interosseous muscles. It lies to the outer side of the flexor brevis hallucis.

The *transversus pedis*, or *adductor transversus hallucis*, is placed transversely across the heads of the metatarsal bones.

The *flexor brevis minimi digiti* may be recognised from its lying upon the fifth metatarsal bone.

The deep division of the external plantar nerve and the plantar arterial arch are partially exposed, but they will be more fully displayed at a later stage.

The Flexor Brevis Hallucis arises from the cuboid bone and from the slip from the tendon of the tibialis posticus muscle, which goes to the middle and outer cuneiform bones. It is narrow and tendinous at its origin, but it soon divides into two separate fleshy bellies, which are ultimately inserted upon either side of the base of the proximal phalanx of the great toe. In the tendons of insertion two large sesamoid bones are developed. The inner head of the flexor brevis hallucis is closely connected with the tendon of the abductor hallucis, and is inserted in common with it. The flexor brevis hallucis is supplied by the internal plantar nerve.

The Adductor Obliquus Hallucis arises from the sheath of the peroneus longus muscle and from the bases of the

second, third, and fourth metatarsal bones. It tapers as it approaches the root of the hallux, and is inserted, with the outer head of the flexor brevis hallucis, into the fibular aspect of the base of the proximal phalanx of the great toe. It is supplied by the deep division of the external plantar nerve.

The Adductor Transversus Hallucis is a second special adductor of the great toe. It springs by a series of slips from the inferior metatarso-phalangeal ligaments of the third, fourth, and fifth toes, and proceeds transversely inwards under cover of the flexor tendons to find insertion into the fibular side of the base of the proximal phalanx of the great toe in common with the adductor obliquus hallucis. Its nerve of supply comes from the deep division of the external plantar.

The Flexor Brevis Minimi Digiti is a single fleshy slip, which springs from the base of the fifth metatarsal bone and the sheath of the peroneus longus tendon. It is inserted into the fibular side of the base of the proximal phalanx of the little toe. Its nerve supply comes from the superficial division of the external plantar nerve.

Dissection.—The adductor obliquus hallucis and the flexor brevis hallucis must now be detached from their origins and thrown forwards, in order that the entire length of the plantar arterial arch, and the deep division of the external plantar nerve, may be displayed. In raising the adductor hallucis the branch which is given to it by the deep division of the external plantar nerve must be secured and retained.

The Plantar Arterial Arch (arcus plantaris) is the continuation of the external plantar artery. It extends across the sole from the base of the fifth metatarsal bone to the posterior part of the first intermetatarsal interval, where it is joined by the dorsalis pedis artery. The plantar arch is deeply placed, it rests upon the interosseous muscles close to the bases of the metatarsal bones, and it is covered by the flexor tendons, the lumbrical muscles, and the adductor obliquus hallucis. It is accompanied by the deep division of the external plantar nerve and by two *venæ comites*.

The *branches* which proceed from the plantar arch are:—

1. Articular.
2. Posterior perforating.
3. Digital.

The *articular twigs* arise from the concavity of the arch, and run backwards to supply the tarsal joints.

The *posterior perforating branches* are three in number. They proceed upwards in the back parts of the outer three intermetatarsal spaces. Each artery occupies the interval between the heads of the corresponding dorsal interosseous muscle. They end on the dorsum of the foot by joining the three dorsal interosseous branches of the metatarsal artery.

The *digital branches* are four, in number, and are arranged in the same manner as the digital branches of the superficial palmar arch in the hand. The *first* or *outermost* goes to the fibular side of the little toe; the *second* proceeds forwards in the fourth interosseous space, and divides to supply the contiguous sides of the fourth and little toes; *the third* bifurcates at the cleft between the third and fourth toes, and gives the collateral branches to their adjacent sides; and *the fourth* is disposed in a similar manner, and furnishes collateral branches to the contiguous margins of the second and third toes.

Each of the inner three digital arteries, at its point of division, sends upwards in the interosseous space a minute *anterior perforating branch*, to join the corresponding dorsal interosseous branch of the metatarsal artery.

Upon the sides of the toes the collateral branches are distributed in exactly the same manner as the corresponding arteries of the fingers.

The Arteria Magna Hallucis (the *plantar digital branch* of the dorsal artery of the foot) corresponds with the *arteria radialis indicis* and the *arteria princeps pollicis* of the hand. It arises from the dorsal artery of the foot in the back part of the first interosseous space, and proceeds forwards to the cleft between the great toe and the second

This artery completes the ~~step~~^{plate} arch internally

toe. Having supplied a branch to the inner side of the hallux, it divides into the collateral branches for the adjacent sides of the great toe and the second toe.

The Deep Division of the External Plantar Nerve accompanies the plantar arch in its inward course across the sole, and ends in the deep surface of the adductor obliquus hallucis. In addition to this muscle, it supplies all the interosseous muscles, with the exception of those in the fourth space, the adductor transversus hallucis, and the three outer lumbrical muscles. The twig to the second lumbrical takes a recurrent course around the anterior border of the adductor transversus hallucis.

Transverse Metatarsal Ligament.—The adductor transversus hallucis should now be detached from its origin, and thrown inwards towards the hallux. This brings into view the transverse metatarsal ligament—a strong fibrous band which stretches across the heads of the five metatarsal bones. It is attached to the inferior ligaments of the metatarsophalangeal joints. It differs from the corresponding ligament of the hand, inasmuch as it includes within its grasp the metatarsal bone of the hallux.

Dissection.—A satisfactory display of the *interosseous* muscles cannot be obtained unless the transverse metatarsal ligament be divided between the heads of the metatarsal bones. The toes can now be separated more freely from each other, and the interosseous muscles traced to their insertions. It is well also to reflect at this stage the flexor brevis minimi digiti.

D.A.B. & PAD ~~PAF~~

The Interosseous Muscles.—The *plantar interosseous muscles* are three in number, and are so placed that they adduct the three outer toes towards a line drawn through the second toe. They arise from the plantar aspects of the outer three metatarsal bones, and are inserted one upon the tibial side of each of the corresponding toes. The *dorsal interosseous muscles* are four in number. They occupy the four intermetatarsal spaces, and consequently they must be dissected both upon the plantar and dorsal aspects of the foot. They are arranged so as to abduct the second, third, and fourth toes from a line drawn

through the second toe. They are inserted, therefore, as follows: *the first* upon the tibial side of the second toe; *the second* upon the fibular side of the same toe; *the third* upon the fibular side of the third toe; and *the fourth* upon the fibular side of the fourth toe. The slender tendons of the interosseous muscles are only very slightly attached to the bases of the proximal phalanges. They are for the most part inserted into the expansions of the extensor tendons on the dorsal aspect of the toes.

Tendons of the Tibialis Posticus and Peroneus Longus.

—Before leaving the sole of the foot the dissector must determine the precise insertions of the tendons of the tibialis posticus and of the peroneus longus. The tendon of the *tibialis posticus* is not merely inserted into the tubercle of the scaphoid. Fibrous slips are seen to spread out from it, and these may be traced to every bone of the tarsus with the exception of the astragalus, and also to the bases of the second, third, and fourth metatarsal bones. As it lies under the head of the astragalus, the tendon of the tibialis posticus has developed within it a sesamoid nodule of fibro-cartilage, or perhaps a sesamoid bone.

The tendon of the *peroneus longus* turns round the outer margin of the foot, and runs inwards in the groove on the under surface of the cuboid bone across the sole, to reach the base of the first metatarsal bone. As it traverses the sole it is enclosed in a fibrous sheath. This sheath is mainly formed by fibres derived from the long plantar ligament. Open the sheath and its smooth, glistening, internal surface will be displayed. This appearance is due to the synovial membrane which lines it. The tendon is inserted into the inferior part of the base of the first metatarsal bone, and also to a slight degree into the adjacent part of the internal cuneiform bone. It likewise, in some cases, sends a slip to the base of the second metatarsal bone. As the tendon winds round the cuboid bone it is thickened, and contains a nodule of fibro-cartilage, or perhaps a sesamoid bone.

Dissection.—The dissection of the sole of the foot is brought to an end by sawing through the first metatarsal bone close to its base, and removing its proximal extremity. A good view is thus obtained of the continuity between the dorsalis pedis artery and the plantar arch.

Anastomosis around the Knee-joint.—The most important of the anastomoses around the knee-joint are placed on the anterior aspect of the articulation, and take the form of three transverse arches. The uppermost of these arterial arcades passes through the superficial fibres of the quadriceps extensor close to the upper border of

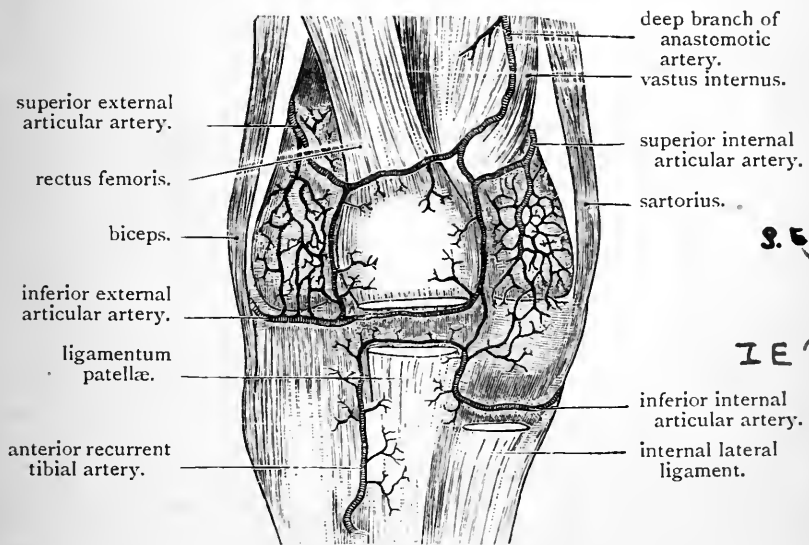


FIG. 64.—Anastomosis on the anterior aspect of the knee-joint.

the patella, and is formed by the union of a branch from the superior external articular artery with another from the deep branch of the anastomotica: the middle and lower are both placed under cover of the ligamentum patellæ. The middle arch runs across in the fatty tissue close to the lower end of the patella. The inferior external articular artery, with a branch which results from the union of a twig from the anastomotica, and another from the superior internal articular artery, enters into

its formation. The lowest arch lies on the tibia immediately above its tubercle, and results from the anastomosis of the recurrent tibial and inferior internal articular arteries. The upper and middle of these transverse arches are connected, on each side of the patella, by ascending and descending branches, which anastomose with one another, and thus enclose the patella in an irregularly quadrilateral arterial framework. From all sides of this arterial enclosure, twigs are given off which enter small foramina on the anterior surface of the patella to supply the osseous substance. Six arteries therefore take part in the formation of this system of anastomoses, on the front and lateral aspects of the joint, viz., the deep branch of the anastomotica, the two superior and the two inferior articular branches of the popliteal and the anterior recurrent branch of the anterior tibial. In addition to the twigs which proceed from these to form the arterial arches, numerous branches are given which spread over the bones in the form of a close meshwork. During the dissection of the articulation these vessels will become apparent.

The knee-joint is supplied on its posterior aspect by twigs derived from all the articular branches of the popliteal. These twigs are variable in their origin, and the anastomoses which are formed between them are unimportant and inconstant. They are sometimes supplemented by another artery, the *posterior recurrent tibial*. This small vessel is a branch of the anterior tibial before it leaves the back of the leg. It ascends under cover of the popliteus muscle, ramifies over the lower part of the ligamentum posticum Winslowii, and inosculates with the two inferior articular branches of the popliteal.

The *azygos articular artery* is chiefly destined for the supply of the interior of the joint. It pierces the posterior ligament, passes forwards between the crucial ligaments, and ramifies in the fatty tissue in that situation. Its terminal twigs usually anastomose with the intermediate arch in front of the knee-joint. It will be dissected at a later stage in the interior of the joint.

Articular Nerves.—The knee-joint is richly supplied with nerves. No less than ten distinct branches may be traced to it. The anterior crural, the external popliteal,

and the internal popliteal trunks, contribute three twigs apiece to this articulation, and the obturator furnishes a filament to its posterior aspect. The anterior crural supplies the joint through branches which proceed from the nerves to the vastus externus, vastus internus, and subcrureus. These nerves pierce the fibres of the quadriceps muscle, and are distributed to the upper and anterior part of the articulation. The articular branch from the nerve to the vastus internus is of larger size than the other two, and it accompanies the deep branch of the anastomotic artery. The external popliteal nerve gives off—(1) the superior and inferior external articular nerves: these accompany the arteries of the same name, and end in fine filaments, which pierce the capsule of the joint; and (2) the recurrent articular nerve which accompanies the anterior recurrent tibial artery. This nerve ends chiefly in the tibialis anticus muscle; but a fine twig may reach the lower part of the anterior aspect of the knee-joint. The internal popliteal nerve furnishes the knee-joint with superior and inferior internal articular and azygos articular nerves, which accompany the arteries of the same name. The branch from the obturator nerve descends on the posterior aspect of the popliteal artery as far as the back of the knee-joint. At this point it leaves the artery and, inclining forwards, breaks up into several filaments which separately pierce the posterior ligament.

ARTICULATIONS.

The dissection of the knee-joint, the ankle-joint, the tibio-fibular joints, and the various articulations of the foot, may now be proceeded with. It is possible that the ligaments may have become hard and dry. If this be the case, soak the joints in water for an hour or two.

Knee-joint (*articulatio genu*).—In this joint three bones are in apposition, viz., the lower end of the femur, the

upper end of the tibia, and the patella. It is the largest and most complicated articulation in the body; and if the bones be examined in the skeleton, the joint presents an apparent insecurity, because the bony surfaces show little adaptation the one to the other. In reality, however, it is very strong, and very rarely suffers dislocation on account of the strength of the ligaments which retain the bones in place. The ligaments on the exterior of the knee-joint are:—

1. The capsular ligament.
2. Two lateral ligaments—external and internal.
3. The ligamentum patellæ (or anterior ligament).
4. The posterior ligament.

Dissection.—The popliteal vessels and nerves, and the muscles surrounding the knee-joint, must be removed. Portions of the tendons of the biceps, semimembranosus, sartorius, semitendinosus, gracilis, and popliteus, together with small pieces of the heads of the gastrocnemius, should be left in place in order that their connection with the ligaments of the joint may be studied. The quadriceps extensor may be divided about three inches above the patella, and the lower part allowed to remain in position. Further, the various articular arteries which surround the joint should be followed to their terminations.

The Capsule (capsula articularis) of the knee-joint, together with the internal and posterior ligaments, form a complete investment for the articulation. In the upper and front part of the joint it is deficient, but here its place is taken by the common tendon of the quadriceps extensor muscle. The capsule may be regarded as an aponeurotic expansion on the front of the articulation, which fills up the intervals between the two lateral and the anterior ligaments. The fascia lata and expansions from the surrounding tendons enter into its formation. Thus, on the outer aspect, it is largely composed of the ilio-tibial band of fascia lata as this proceeds downwards to its attachment to the tibia. Traced backwards, the capsule will be seen to be prolonged over, and to hide from view, the external lateral ligament. On the inner side of the limb it receives expansions from the sartorius

and semimembranosus, and fuses with the internal lateral ligament.

The Ligamentum Patellæ forms the anterior ligament of the knee-joint, and constitutes, at the same time, the tendon of insertion of the quadriceps extensor muscle. By the removal of the capsular expansion from its surface it may be fully exposed and its margins defined.

The *ligamentum patellæ* is a strong band, about two inches long, which is attached above to the apex and lower border of the patella, and below to the lower part of the anterior tubercle of the tibia. Its superficial fibres are directly continuous over the surface of the patella with the central part of the common tendon of the quadriceps extensor. Its deep surface rests upon the infrapatellar pad of synovial fat, and upon a small bursa which intervenes between it and the upper part of the anterior tubercle of the tibia. The two lower arterial anastomotic arches of the knee are placed under cover of it.

Dissection.—The external lateral ligament may be exposed by removing the part of the capsule which is formed by the ilio-tibial band of fascia lata, and also the prolongation which this gives backwards over the ligament. By this proceeding the inferior external articular artery will be displayed as it extends forwards to the front of the joint.

The External Lateral Ligament (*ligamentum collaterale fibulare*) is rounded and cord-like. It stands well away from the joint, and is attached above to a tubercle on the outer tuberosity of the femur. Below, it is fixed to a depression on the head of the fibula in front of the styloid process. It is closely associated with the tendon of the biceps and the tendon of the popliteus. It splits the tendon of the biceps into two pieces, and extends vertically downwards to its fibular attachment between them. The tendon of the popliteus takes origin from the outer tuberosity of the femur below and in front of the femoral attachment of the external lateral ligament. As the tendon proceeds backwards it is placed under cover of the ligament.

An additional slip is sometimes described as the *posterior part* of the external lateral ligament. When present it is attached to the femur, under cover of the outer head of the gastrocnemius, in connection with the posterior ligament. Below, it is implanted into the styloid process of the fibula.

The Internal Lateral Ligament (ligamentum collaterale tibiale) is a long flat band, broader in the middle than at either extremity, which springs from the inner tuberosity of the femur below the adductor tubercle. As it descends, it inclines slightly forwards, and finally it gains attachment to the upper part of the shaft of the tibia below the internal tuberosity. The main part of the tendon of the semimembranosus extends forwards under cover of its posterior border to gain an insertion into the tuberosity of the tibia, whilst lower down the inferior internal articular vessels are carried forwards between it and the bone. The tendons of the sartorius, gracilis, and semitendinosus, lie upon its superficial surface, but are separated from it by an intervening bursa.

The Posterior Ligament stretches from the external to the internal lateral ligament. Above, it is fixed to the upper margin of the intercondyloid notch, whilst on either side it becomes incorporated with the corresponding head of the gastrocnemius. Below, it is attached to the posterior border of the upper end of the tibia. A strong slip derived from the tendon of the semimembranosus strengthens the ligament on its posterior aspect. This band passes upwards and outwards towards the external condyle of the femur.

Sometimes the term "posterior ligament" (ligamentum posticum Winslowii) is restricted to this oblique band from the semimembranosus, and the remainder of the ligament as described above is then regarded as a portion of the capsule.

The posterior ligament presents a number of apertures for the entrance of blood-vessels and nerves into the interior of the joint. The azygos artery is the most conspicuous of these vessels. An opening may likewise sometimes be observed over the upper part of the internal condyle of the femur. Through this protrudes a pouch of synovial membrane which forms a bursa under the inner head of the gastrocnemius. As a rule, however, this bursa is independent of the knee-

3.) joint, and the aperture in the ligament is absent. Another opening is situated in the outer part of the ligament, and gives exit to the tendon of the popliteus.

Dissection.—A vertical incision should be made into the joint on either side of the patella and ligamentum patellæ, in order that the common extensor tendon and the patella may be thrown downwards over the upper end of the tibia. The joint is now opened from the front, and the parts in the interior may be observed.

Interior of the Joint.—First note the great pad of soft fat which is placed on the deep surface of the ligamentum patellæ. In vertical section this fatty mass is triangular in form (Fig. 65). It is termed the *infra-patellar pad*, and it fills up the interval between the patella, femur, and tibia, and adapts itself to the varied forms which this recess adopts in the different movements of the joint. It is separated from the interior of the joint by a covering of synovial membrane, and from its surface a band of this membrane extends backwards and upwards to the intercondyloid fossa of the femur, where it is attached. This band is termed the *ligamentum mucosum*. As it approaches the femur it becomes narrow and slender; but, before it fairly rises from the surface of the infra-patellar pad, it is broad and triangular, and presents two free margins which extend along the lateral borders of the patella in its lower part, and receive the name of ligamenta alaria (plicæ alares). It must be clearly understood that these are not ligaments in the ordinary sense of the word, but merely folds of synovial membrane.

Within the joint the dissector is now able to recognise :

1. The two crucial ligaments.
2. The two semilunar cartilages.

Synovial Membrane.—This is the most extensive membrane of the kind in the body. It lines the deep surface of the ligamentous structures which surround the joint, and extends upwards for at least an inch beyond the articular surface of the femur, in the form of a great *cul-de-sac*, under cover of the common tendon of the quadriceps. By its upper part this pouch usually communicates by an orifice

of greater or less width with a large bursa which lies at a higher level upon the front of the femur. The synovial membrane covers both surfaces of the semilunar cartilages, gives a partial investment to the crucial ligaments, and contributes a pouch-like prolongation along the tendon of the popliteus. The synovial investment of

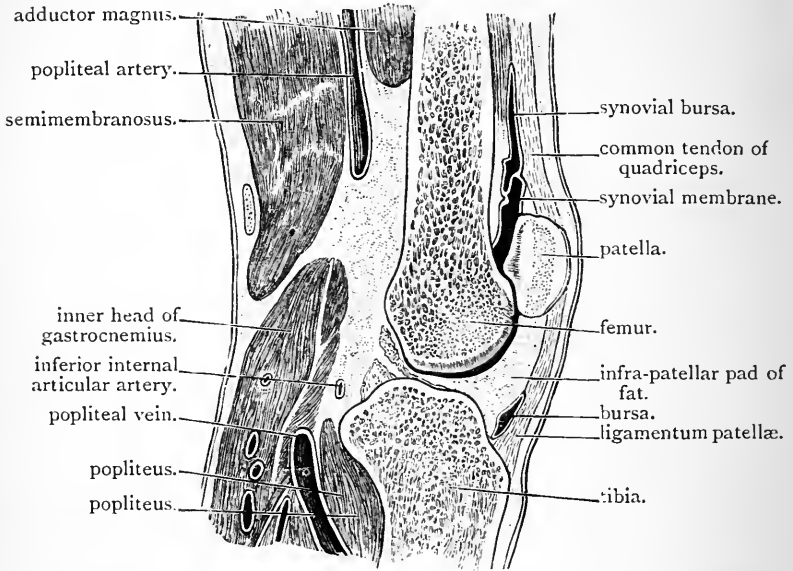


FIG. 65.—Vertical antero-posterior section through the knee-joint.

the crucial ligaments is not complete, and is carried forwards upon them from the posterior wall of the joint. The prolongation upon the tendon of the popliteus extends downwards between the external semilunar cartilage and the back part of the upper end of the tibia. It facilitates the play of the tendon over that bone, and comes very close to the upper part of the superior tibio-fibular joint. Indeed, the synovial membrane of this joint may, in some cases, be found continuous with it.

Dissection.—Divide the ligamentum mucosum and remove the infrapatellar pad of fat. The bursa between the ligamentum patellæ and the upper part of the anterior tubercle of the tibia may now be

opened and examined. Next dissect away the posterior ligament of the joint and trace the azygos articular artery, which pierces it, forwards to the crucial ligaments. It will now be seen that the posterior surface of the posterior crucial ligament is not covered by synovial membrane, and that it is connected by areolar tissue to the deep surface of the posterior ligament. Define the attachments of the crucial ligaments by removing the synovial membrane which is wrapped round them and the areolar tissue in connection with them. The semilunar cartilages should also receive the attention of the dissector, and the manner in which their fibrous pointed extremities are fixed to the tibia must be studied. At this stage the changes produced in the degree of tension of the crucial ligaments, and the change brought about in the position of the semilunar cartilages by movements of the joint, should be examined.

Movements at the Knee-joint.—The movements of the knee-joint are those of flexion and extension. The leg can be bent back until the prominence of the calf comes into contact with the posterior aspect of the thigh; but in extension the movement is brought to a close when the leg comes into a line with the thigh. In this position the joint is firmly locked, and the anterior crucial, the lateral and the posterior ligaments being fully stretched, the leg and thigh are converted into a rigid column of support. In flexion, however, the lateral and posterior ligaments are relaxed, and a certain amount of rotation of the tibia upon the femur is allowed.

But the movements of flexion and extension at the knee-joint are by no means so simple as at first sight they might appear to be, and to obtain some appreciation of them it is necessary to subject the opposed articular surfaces to a close scrutiny. Flex the joint acutely, and examine the cartilage-covered surface of the lower end of the femur. It consists of an anterior trochlear portion for the patella, and two condylar surfaces which move on the tibia. The trochlea is separated from the surface of the external condyle by a faintly marked groove, which takes a slightly curved course from the external border of the lower end of the femur inwards and backwards to the fore part of the intercondyloid fossa. At either extremity this groove widens out into a distinct depression. In full extension the outer depression rests upon the anterior part of the external semilunar cartilage, whilst the inner depression rests upon the anterior border of the external tubercle of the spine of the tibia (Bruce Young). The line of demarcation between the trochlea and the lower surface of the internal condyle of the femur is not so distinct. Close to the inner margin of the bone there is a depression which, in full extension, rests upon part of the anterior horn of the internal semilunar cartilage (Bruce Young): but external to this the trochlear surface is prolonged backwards for a certain distance along the anterior and inner margin of the intercondyloid fossa. A portion of the internal condyle is thus included in the trochlear surface,

Ligaments tense in Extension

Anterior Crucial

External Lateral

Internal Lateral

viz., the portion skirting the inner border of the anterior part of the intercondyloid fossa, and this is termed the "crescentic facet" of the internal condyle.

The deep surface of the patella may next be examined, and its movements in connection with flexion and extension of the knee-joint studied. A high vertical ridge divides its deep surface into a large external and a smaller internal area. Each of these is still further subdivided by faint ridges in the cartilage which coats the surface. A faint line upon the inner area of the patella descends in a vertical direction so as to mark off a narrow strip close to the inner border of the bone. This strip is called the *internal perpendicular facet*. Two horizontal lines extend outwards from the outer border of the internal perpendicular facet to the outer border of the bone, and subdivide the remainder of the inner area and the whole of the outer area into three facets each. In a well-marked patella, therefore, the deep cartilage-

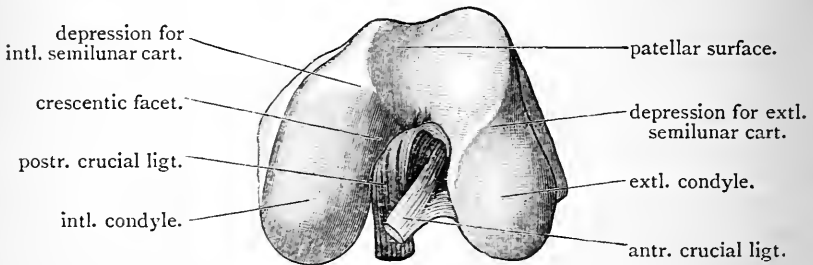


FIG. 66.—Articular surface of the lower end of left femur, with the crucial ligaments attached.

covered surface shows seven facets, viz., an upper pair, an intermediate pair, a lower pair, and an internal perpendicular facet (Goodsir).

The faceted appearance of the deep surface of the patella indicates that in the movements of this bone upon the trochlear surface of the femur the entire articular surface is never in contact with the femur at the same time. In flexion and extension of the knee, the patella moves downwards and upwards in a curved path, the concavity of which looks upwards, backwards, and outwards. The different facets come into contact and break contact with the femur in regular succession. Let us suppose the knee-joint to be acutely flexed: in this condition of the limb the internal perpendicular facet of the patella rests upon the crescentic facet of the internal condyle of the femur, while the outer of the two upper patellar facets is in contact with the outer lip of the trochlear surface of the femur. No part of the patella touches the inner lip of the trochlear surface. As the leg is moved from the fully flexed to the fully extended position, the two upper facets, then the two intermediate facets, and, lastly, the two lower facets, come

successively into contact with the trochlear surface of the femur (Goodsir). In Fig. 65 the position of the patella in the fully extended knee is exhibited.

Now examine the condylar surfaces of the femur. The posterior two-thirds of the internal condyle will be seen to be of equal extent with, and parallel to, the external condyle. The anterior third of the internal condyle, however, turns obliquely outwards to join the trochlear surface. The external condylar surface has no part corresponding with this, and its presence in connection with the internal condyle gives rise to the "screw-home" movement, which is so characteristic of the knee-joint when fully extended. At the commencement of flexion and at the completion of extension there is a screw movement, or a movement of rotation of the tibia and femur on each other. As the leg is moved forwards from the condition of acute flexion, the condyles of the femur roll and glide over the surfaces on the upper end of the tibia until the surface of the external condyle, and the corresponding part of the internal condyle, are exhausted. This movement of the femoral condyles has been compared to that of "a wheel partially restrained by a drag" (Goodsir). Any additional movement beyond this point must necessarily take place in connection with the anterior oblique third of the internal condyle. This produces a rotation or screw-like motion of the femur inwards. The internal condyle travels backwards round the spine of the tibia, and the anterior part of the intercondyloid notch comes into contact with the anterior crucial ligament and the internal tubercle of the tibial spine (Bruce Young). The joint is now "screwed home" or locked. In the initial stage of flexion the reverse movement must be accomplished. The unlocking of the joint can only be brought about by a rotation inwards of the tibia, or a rotation outwards of the femur.

When fully extended, as we have seen, the joint is locked, and the posterior, lateral, and anterior crucial ligaments are tense. The limb is converted into a rigid column, and the upright posture is thereby maintained with the smallest possible degree of muscular exertion.

The muscles which operate upon the bones of the leg so as to produce flexion and extension of the limb at the knee-joint are:—(1) *extensors*, the four parts of the quadriceps extensor; (2) *flexors*, the biceps, popliteus, sartorius, gracilis, semitendinosus, and semi-membranosus. Of these, only one is inserted on the outer side of the limb, viz., the biceps. The other five are inserted into the tibia on the inner side of the leg.

Dissection.—In order to obtain a proper view of the attachments of the crucial ligaments the following dissection should be made:—The femur must be sawn across about two inches above its lower articular surface. When this is done the saw should be applied to the cut surface of the lower part of the bone, and a vertical cut made through it so as to divide it into a right and a left lateral portion. The saw-cut

should be planned to end inferiorly in the intercondyloid fossa between the condyles and between the upper attachments of the two crucial ligaments. By this procedure the crucial ligaments can be studied singly, or together, and their relation to the lateral ligaments of the joint can be examined. It will be seen that the external lateral ligament and the anterior crucial ligament, constitute a pair of ligaments appropriated by the external condyle, to either side of which they are fixed; while the internal lateral and the posterior crucial ligaments belong to the internal condyle of the femur, and are attached on either side of it. When this relationship is observed, the internal lateral ligament may be divided. This will, in a measure, set free the internal condyle, and give greater space for the study of the crucial ligaments.

The Crucial Ligaments (*ligamenta cruciata genu*) are well named, because they cross each other like the limbs of the letter X in the interval between the two condyles of the femur. This crucial arrangement is seen whether they are viewed from the side, by the removal of the lower part of one condyle, or from the front or the back of the joint. The anterior crucial ligament is attached to the external condyle, whilst the posterior is fixed to the internal condyle of the femur. They are consequently sometimes termed *external* and *internal*.

The *anterior crucial ligament* springs from the intermediate rough area on the upper surface of the tibia, immediately in front of the inner tubercle which surmounts the tibial spine. From this it proceeds upwards, backwards, and outwards, to gain attachment to the posterior part of the inner surface of the external condyle of the femur.

The *posterior crucial ligament* springs from the posterior sloping part of the intermediate rough area on the upper surface of the tibia, behind the tibial spine, and behind also the attachments of the posterior horns of both semi-lunar cartilages. It proceeds upwards, forwards, and somewhat inwards, and, crossing the anterior crucial ligament, is attached in the fore part of the intercondyloid fossa to the outer surface of the anterior oblique portion of the internal condyle. It receives one, or sometimes two, strong slips from the posterior horn of the external semi-lunar cartilage.

The anterior crucial ligament is tight in extension, and




the posterior crucial ligament is tight in flexion of the knee-joint.

Semilunar Cartilages.—These are two crescentic plates of fibro-cartilage which are placed on the condylar surfaces of the tibia. They deepen the surfaces upon which the condyles of the femur roll, and, being movable, they fill up the gaps which would otherwise arise during the movements of the joint. Each cartilage presents two fibrous extremities, or horns, which are attached to the rough intermediate surface on the upper end of the tibia. They are thick towards the circumference of the joint, but thin away to a fine free concave edge in the opposite direction. Both surfaces are smooth and covered with synovial membrane. They do not cover the entire extent of the condylar surfaces of the tibia. The central parts of the latter, as well as the sloping surfaces of the tubercles of the tibial spine, are free. On raising the cartilages from the surface upon which they rest, distinct impressions similar in shape and extent are seen on the subjacent encrusting cartilage of the tibia.

Dissection.—Carefully define the attachments of the fibrous horns of the semilunar cartilages.

The *external semilunar cartilage* (meniscus lateralis) is usually somewhat thicker around its circumference than the internal cartilage. It forms the segment of a smaller circle, and its horns being fixed to the tibia close together, a very nearly complete circle is formed. The anterior fibrous horn is attached, immediately in front of the tibial spine, to the outer side of and partly under cover of the attachment of the anterior crucial ligament. The posterior horn is fixed to the summit of the tibial spine in the interval between the two tubercles. It likewise gives a strong slip to the posterior crucial ligament. The external lateral ligament is not in contact with the external semilunar cartilage. It is separated from it by the tendon of the popliteus, and the impress of the tendon is left on the cartilage in the form of a faint smooth groove on its



outer and posterior border. Behind, its circumference is attached to the posterior ligament.

The *internal semilunar cartilage* (meniscus medialis) is semicircular in form, and forms the segment of a much larger circle than the external cartilage. Its anterior fibrous horn is fixed to the fore part of the intermediate rough area of the tibia in front of the attachment of the anterior crucial ligament; its posterior horn is attached to the back part of the intermediate rough area of the tibia, behind the tibial spine, and in front of the attachment of the posterior crucial ligament. The circumference of this cartilage is closely connected with the deep surface of the internal lateral ligament.

The Transverse Ligament (ligamentum transversum genu) is a fibrous band which stretches across from the fore part of one semilunar cartilage to the corresponding part of the other, constituting thereby a bond of union between them.

Dissection.—The condyles of the femur should now be detached by dividing the external lateral ligament and the crucial ligaments close to their femoral attachments.

Attachment of Parts to Upper Surface of the Tibia.—

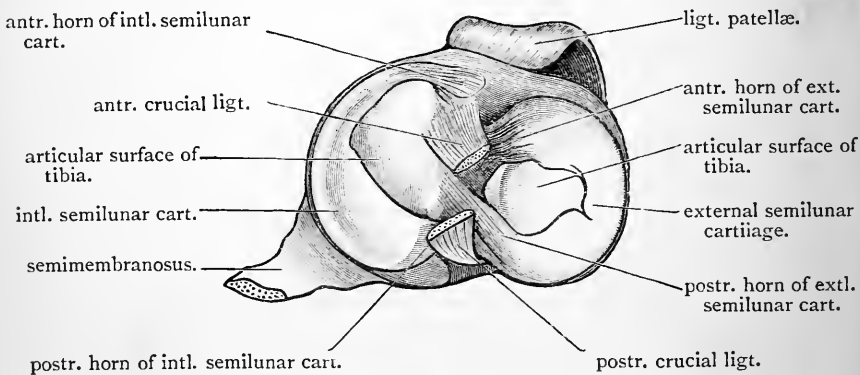


FIG. 67.—Upper articular surface of right tibia showing attachments of semilunar cartilages and crucial ligaments.

The ligamentous structures are attached to the intermediate area on the upper surface of the tibia in the following order from before backwards:—(1) The anterior

horn of the internal semilunar cartilage on the inner side of the extreme anterior part of the area. (2) The anterior crucial ligament and the anterior horn of the external semilunar cartilage: these are placed side by side, but the attachment of the former, which lies to the inner side, overlaps that of the external semilunar cartilage. (3) The posterior horn of the external semilunar cartilage on the summit of the tibial spine between its two tubercles. (4) The posterior horn of the internal semilunar cartilage immediately behind the tibial spine. (5) The posterior crucial ligament at the hinder part of the area.

The Ankle-Joint (*articulatio talocruralis*).—The ankle-joint is a diarthrodial articulation of the ginglymus or hinge variety. The articulation takes place between the bones of the leg and the astragalus, and the weight of the body is transferred through it to the foot. It is a joint of great strength; its stability being ensured not only by the powerful ligaments which surround it, but also by the close interlocking of the articulating surfaces.

The bones which enter into the formation of the ankle-joint are the lower ends of the tibia and fibula and the superior surface of the astragalus. The lower ends of the leg bones are very firmly united together by an interosseous and other ligaments which give the joint a certain amount of elasticity or spring. They form a deep hollow resembling a mortice. The upper surface of the astragalus is received into this cavity.

The ligaments of the ankle-joint are:—

- | | |
|--------------------------|--------------------------|
| 1. The anterior. | 2. The posterior. |
| 3. The external lateral. | 4. The internal lateral. |

Dissection.—The remains of the annular ligaments, together with the tendons which are in relation to the joint, should be removed and the ligaments defined. The anterior and posterior ligaments should be first dissected. They may then be removed in order to bring the powerful external and internal lateral ligaments more fully into relief, and at the same time display the articulating surfaces, and thus permit the play of these surfaces to be seen when the joint is flexed and extended.

The Anterior and Posterior Ligaments are feeble bands which are placed in front of and behind the joint. They are attached to the margins of the articulating surfaces, except in front and below, where the anterior ligament is fixed to the neck of the astragalus. The fibres of these ligaments have for the most part a transverse direction.

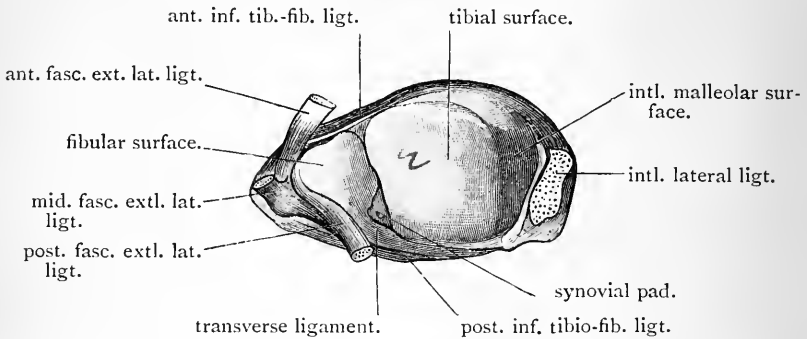


FIG. 68.—Socket for the astragalus; right ankle-joint. Note how the transverse ligament forms a part of this socket. On the articular surface of the astragalus a corresponding facet may be distinguished.

The External Lateral Ligament is divided into three distinct bands—an anterior, a middle, and a posterior. The *anterior fasciculus* (ligamentum talofibulare anterius) is a flattened band which passes from the anterior border of the lower end of the fibula to the outer and back part of the neck of the astragalus. The *middle fasciculus* (ligamentum calcaneo-fibulare) round and cord-like, passes from a point a little in front of the tip of the external malleolus to the external surface of the calcaneum. The *posterior fasciculus* (ligamentum talofibulare posterius) the strongest of the three, is a powerful band of fibres which proceeds almost horizontally inwards from the deep pit behind the lower articular surface of the fibula to a prominent tubercle on the back of the astragalus.

This tubercle is sometimes detached, and forms a supernumerary tarsal bone which may represent the *os trigonum* found in some mammals. In such cases it has been mistaken for a fracture.

The Internal Lateral Ligament (ligamentum deltoideum)

ant - Astin
 Mid - Cal
 Post - Ashr

is of a triangular form. Its apex is directed upwards and is attached to a shallow pit on the under border of the inner malleolus. Its fibres diverge as they descend, and are attached in a continuous layer from before backwards to the scaphoid, astragalus, sustentaculum tali, and behind this to the astragalus again.

The Synovial Membrane lines the ligaments above described, and sends a small process upwards between the tibia and fibula. It is thrown into a transverse fold in front, when the joint is flexed, and into a similar fold behind when the joint is extended.

Movements.—The movements which take place at the ankle-joint are—(1) flexion (dorsal-flexion); (2) extension (plantar-flexion); and (3) a very limited degree of lateral movement (abduction and adduction) when the foot is fully extended. The two principal movements (flexion and extension) take place around a horizontal axis, which is not transverse, but which is directed outwards and backwards, so that it is inclined to the median plane of the body at an angle of about 60° (Krause). This horizontal axis passes through or near the interosseous canal between the os calcis and astragalus (Henle). As the articular cavity formed by the tibia and fibula, and also the part of the astragalus which plays in it, are broader in front than behind, it follows that the more completely the ankle-joint is flexed the more tightly will the astragalus be grasped between the two malleoli. In the erect position the astragalus is held firmly in the bony socket, and portions of its articular surface project both in front of and behind the tibia. The centre of gravity is placed in front of the ankle-joint, and in this way the bones are kept firmly locked. When, on the other hand, the ankle-joint is fully extended (as when we rise on tip-toe) the narrower posterior part of the astragalus is brought into the socket, and thus a limited amount of lateral movement is allowed. In *flexion* the middle and posterior fasciculi of the external lateral ligament, the greater part of the internal lateral ligament and the posterior ligament are put on the stretch. In *extension* the anterior fasciculus of the external lateral ligament, the anterior fibres of the internal lateral ligament, and the anterior ligament, are rendered tense.

The Muscles principally concerned in producing dorsi-flexion of the foot at the ankle-joint are the tibialis anticus and the peroneus tertius; those which operate as plantar-flexors are the superficial muscles of the calf, the tibialis posticus, and the peroneus longus and brevis.

Tibio-fibular Joints.—The fibula articulates with the tibia by both its upper and lower extremity. Each of

these joints is provided with a synovial membrane and possesses its own appropriate ligaments. The interosseous membrane which occupies the interval between the shafts of the bones may be regarded as a ligament common to both joints.

Dissection.—Preparatory to the examination of the tibio-fibular joints the foot must be removed by dividing the internal lateral ligament and the three parts of the external lateral ligament of the ankle-joint. The muscles must also be detached from both aspects of the interosseous membrane and the bones of the leg. The ligaments may now be defined.

Interosseous Membrane (*membrana interossea cruris*).—This is a strong membrane which stretches across the interval between the two bones of the leg, and greatly extends the surface for the origin of muscles. It is attached on the one hand to the external border of the tibia, and on the other to the interosseous ridge which descends on the internal surface of the fibula. It is composed of strong oblique fibres, which take a direction downwards and outwards from the tibia to the fibula. An oval opening in its upper part, immediately under the external tuberosity of the tibia, is present for the passage of the anterior tibial vessels, whilst a small aperture a short distance above the ankle-joint marks the point where the membrane is pierced by the anterior peroneal artery.

Superior Tibio-fibular Joint (*articulatio tibiofibularis*).—At this joint the bones are held in apposition by an *anterior* and a *posterior ligament*, which pass from the outer tuberosity of the tibia downwards and outwards to be attached to the head of the fibula. The posterior ligament is the weaker of the two, and upon its upper part the tendon of the popliteus with its synovial investment rests. This investment is a prolongation from the synovial membrane of the knee-joint, and in some cases it will be found to be directly continuous with the synovial membrane which lines the superior tibio-fibular joint.

The relation of the tendon of the biceps to this joint

must not be lost sight of. Attached for the most part to the head of the fibula, its fibres stretch over the front of the joint. Some of its tendinous fibres also obtain insertion into the outer tuberosity of the tibia. Firm support is in this way contributed to the superior tibio-fibular joint.

The Inferior Tibio-fibular Joint (syndesmosis tibio-fibularis) is constructed upon a stronger plan, because upon its security the strength of the ankle-joint very largely depends. Only a very narrow strip of the lower part of each of the opposing surfaces of the bones is articular and coated with cartilage. Above this, the surfaces are rough, and are held together by an exceedingly strong *interosseous ligament*, composed of short fibres which pass directly between the bones.

In addition to this interosseous ligament there are :

1. An anterior ligament.
2. A posterior ligament.
3. An inferior transverse ligament.

The *anterior and posterior ligaments* are flat strong bands which pass from the tibia to the fibula, in an oblique direction, outwards and downwards.

The *transverse ligament* lies under cover of the lower part of the posterior ligament, and to see it properly the latter should be divided. It is a strong narrow band of yellowish fibres, which takes a transverse course on the back of the joint and is firmly attached to both tibia and fibula, filling up the interval between them. It forms a part of the tibio-fibular socket for the astragalus at the ankle-joint.

Dissection.—To see the interosseous ligament of the inferior tibio-fibular joint the bones of the leg may be sawn through about two inches above the lower end of the tibia, and then divided with the saw from above downwards in a vertical-transverse, or coronal direction. This cut should be planned so as to pass through the inferior tibio-fibular joint. The short strong fibres of the interosseous ligament will then be seen, and also the short narrow articular interval between the lower portions of the opposing surfaces of the bones. The synovial membrane which lines this is a continuation upwards of the synovial membrane of the ankle-joint.

The Articulations of the Foot.—The articulations of the foot are very numerous. They consist of:

1. The tarsal, tarso-metatarsal, and the inter-metatarsal joints.
2. The metatarso-phalangeal joints.
3. The interphalangeal joints.

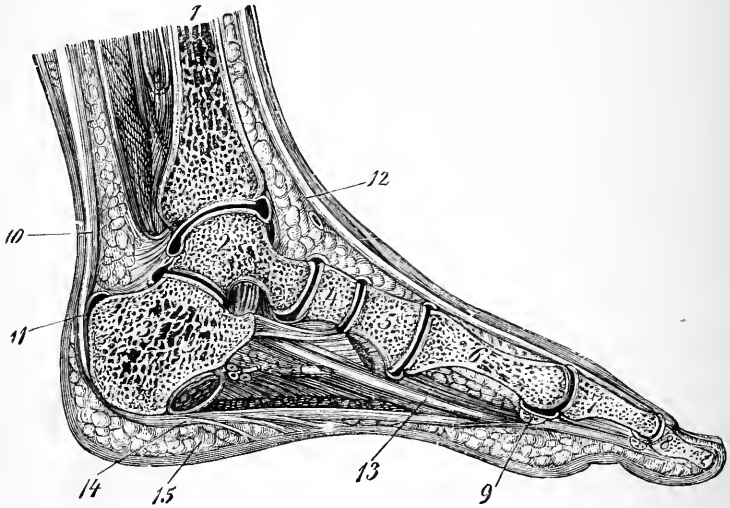


FIG. 69.—Vertical section through the foot, along a line stretching from the centre of the heel behind to the centre of the great toe in front. (From Luschka.)

- | | |
|--|---|
| <ol style="list-style-type: none"> 1. Tibia. 2. Astragalus. 3. Os calcis. 4. Scaphoid. 5. Internal cuneiform. 6. First metatarsal. 7 & 8. Phalanges of hallux. 9. Sesamoid bone. | <ol style="list-style-type: none"> 10. Tendo Achillis. 11. Bursa between tendo Achillis and os calcis. 12. Tendon of extensor longus hallucis. 13. Tendon of flexor longus hallucis. 14. Plantar fascia (central part). 15. Thick superficial fascia of heel. |
|--|---|

The bones which enter into these articulations are the seven tarsal bones, the metatarsal bones, and the phalanges. The tarsal and metatarsal bones are bound together by interosseous, plantar, and dorsal ligaments, and are disposed in the form of two arches, viz., a longitudinal and a transverse. The integrity of these arches is main-

tained partly by the tension of the ligaments and partly by the direction of the articulating surfaces of the bones.

The longitudinal arch presents a greater height and a wider span along the inner than along the outer side of the foot. The astragalus is placed on the summit of this arch and forms its keystone. The posterior pillar of the longitudinal plantar arch is short and solid, being formed by the os calcis alone; the anterior pillar, much longer, is composed of several bones, viz., the scaphoid, the cuboid, the three cuneiforms, and the metatarsus. Further, the anterior pillar may be considered as being formed of an inner column composed of the scaphoid, the three cuneiform, and the three inner metatarsal bones, and an outer column composed of the cuboid and the two outer metatarsal bones. The weight of the body is transmitted to the summit of the arch through the astragalus, and the most important ligaments concerned in the prevention of excessive flattening of the arch are the inferior calcaneo-scaphoid, the two plantar calcaneo-cuboid ligaments, and the various slips of the tendon of the tibialis posticus as they pass to find attachment to the different tarsal and metatarsal bones. The plantar fascia also acts powerfully in this way: connecting as it does the extremities of the two pillars of the plantar arch, it operates, as Sir George Humphry has pointed out, in the same manner as the "tie-beam" of a roof. The transverse arch of the foot is seen to best advantage across the line of the tarso-metatarsal articulations.

Dissection.—The muscles and tendons which have hitherto been only partially detached from the bones of the foot should now be completely removed and the ligaments defined.

Astragaloid Articulations.—The astragalus articulates by means of the large posterior facet on the under surface of its body with the corresponding posterior facet on the upper surface of the os calcis. Its head, on the other hand, is received into a large socket which is formed for it by the sustentaculum tali of the os calcis, the scaphoid, and

two ligaments which pass between the os calcis and the scaphoid bone, viz., one below, the inferior calcaneo-scapoid, and another on the outer side, the external calcaneo-scapoid ligament. These two astragaloid articulations are quite distinct, and each is provided with a separate synovial membrane.

The ligaments which hold the astragalus in its place are four in number. Three are attached to the os calcis and one to the scaphoid bone. They are :

1. An interosseous astragalo-calcanean.
2. An external lateral astragalo-calcanean.
3. A posterior astragalo-calcanean.
4. A dorsal astragalo-navicular.

The *interosseous ligament* is by far the most powerful. It occupies the tarsal canal, and consists of strong fibres attached below to the groove between the articular facets on the upper surface of the os calcis, and above to the corresponding groove on the under surface of the astragalus.

The *external ligament* is a short band of fibres which proceeds from the outer surface of the astragalus to the outer surface of the os calcis. It is parallel with the middle fasciculus of the external lateral ligament of the ankle-joint, but it is placed on a deeper plane, and lies somewhat in front of it.

The *posterior ligament* passes from the posterior border of the astragalus to the os calcis. It closes the posterior calcaneo-astragaloid articulation behind.

The *dorsal astragalo-navicular ligament* extends on the dorsum of the foot from the head of the astragalus to the scaphoid bone. It is thin and membranous.

The two lateral ligaments of the ankle-joint help to keep the astragalus in its place.

Dissection—The astragalus should now be removed by dividing the various ligaments which hold it in place. By this proceeding the different parts which form the socket for the head of the astragalus will be brought into view ; and the posterior astragalo-calcanean articulation will be seen to be completely cut off from the anterior articulation by the interosseous astragalo-calcanean ligament. The great strength of

this ligament can now be appreciated, and the facets on the head of the astragalus studied. These are :—(1) a convex surface which looks forwards and articulates with the scaphoid ; (2) an elongated facet on its under aspect (sometimes divided into two), which rests upon the sustentaculum tali ; and (3) between these, a triangular facet which corresponds with the upper surface of the inferior calcaneo-scaphoid ligament. In the recent state (and indeed usually also in the macerated condition of the bone) these three facets are very distinctly mapped off from each other by intervening ridges.

Calcaneo-navicular Ligaments.—Although the os calcis does not directly articulate with the scaphoid bone, it is connected with it by two powerful and important ligaments, viz., an inferior and an external.

The *inferior calcaneo-scaphoid ligament* is brought into view by the removal of the astragalus. It fills up the angular gap between the sustentaculum tali and the scaphoid bone, and enters into the formation of the socket for the head of the astragalus. Its upper surface therefore is smooth and covered with synovial membrane ; its lower surface is supported by the tendon of the tibialis posticus. This ligament has an important part to play in maintaining the integrity of the longitudinal arch of the foot. Posteriorly it is attached to the fore border of the sustentaculum tali, whilst in front it is fixed to the under surface of the scaphoid bone.

The *external calcaneo-scaphoid ligament* also forms a small part of the socket for the head of the astragalus. It is placed deeply in the anterior part of the depression between the os calcis and the head of the astragalus. It is composed of short fibres which are attached in front to the outer side of the scaphoid bone, and behind to the upper aspect of the fore part of the os calcis, immediately to the outer side of the facet on the sustentaculum tali. An elongated narrow facet may sometimes be noticed in correspondence with this ligament, along the posterior and outer margin of the articular surface of the head of the astragalus. In such cases four facets mark the head of the astragalus—one for each factor which enters into the formation of the socket in which it lies.

Calcaneo-cuboid Articulation.—In this joint the concavo-convex surface on the fore aspect of the os calcis articulates with the corresponding surface on the posterior aspect of the cuboid. It is a distinct joint, and is provided with a separate synovial membrane. The *ligaments* which bind the two bones together are:—

1. The inferior or plantar calcaneo-cuboid (long and short).
2. The dorsal calcaneo-cuboid.
3. The internal calcaneo-cuboid.

In the maintenance of the longitudinal arch of the foot the *plantar ligament* has an importance which is surpassed only by the inferior calcaneo-scapoid ligament. It is disposed in two layers which are respectively termed the long and the short plantar ligaments, and which are separated from each other by some fatty areolar tissue.

The *superficial* or *long plantar ligament* springs from the under surface of the os calcis, in front of the internal and external tuberosities, and extends forwards to the inferior surface of the cuboid. Here it broadens out, and is for the most part attached to the prominent ridge on the under surface of that bone. Numerous strong fibres, however, are prolonged forwards over the tendon of the peroneus longus to find attachment to the bases of the three middle metatarsal bones. The long plantar ligament therefore extends over the greater part of the outer portion of the tarsus, and it constitutes the longest of the tarsal ligaments. Further, it forms the greater part of the sheath of the tendon of the peroneus longus muscle.

The *short plantar ligament* is placed under cover of the long plantar ligament. Slip the knife in between them, and carry the cutting edge backwards so as to detach the long ligament from the under surface of the os calcis. On throwing the detached band forwards, the short plantar ligament comes into view, and little dissection is required to make its connections apparent. It is composed of short but strong fibres, not more than an inch in length. These spring from the anterior tubercle on the under surface of

the os calcis, and are attached in front to the inferior aspect of the cuboid behind its ridge. This ligament is broader than the long plantar ligament, and is apparent along its inner border even before the latter is reflected.

The *dorsal* and *internal ligaments* connect the os calcis and cuboid bones upon the superior and inner aspects of the joint. The internal ligament, sometimes called *interosseous*, is to be sought for in the deep pit between the head of the astragalus and the fore part of the os calcis.

The joint between the astragalus and scaphoid bone, and that between the os calcis and the cuboid bone, are sometimes referred to as the "transverse tarsal joint." It is here that the movements of eversion and inversion of the foot chiefly take place, and it should be noted that all the ligaments which connect these two segments of the tarsus together, with the exception of one, are attached posteriorly to the os calcis. They are—

Inferior calcaneo-scaphoid,	}	Attached behind to the os calcis.
External calcaneo-scaphoid,		
Long plantar,		
Short plantar,		
Dorsal calcaneo-cuboid,		
Internal calcaneo-cuboid,		
Dorsal astragalo-scaphoid,	{	Attached behind to the astragalus.

Inter-cuneiform Articulations.—The three cuneiform bones are held together so firmly that very little individual movement is permitted. The chief uniting structures are *two strong interosseous ligaments* which pass between the non-articular portions of their opposed surfaces. These can only be seen when the bones are separated from each other. *Dorsal inter-cuneiform ligaments* are also present. These are short flat transversely-placed bands.

Scapho-cuneiform Articulation.—The three cuneiform bones articulate with the anterior surface of the scaphoid. They are held in position by *dorsal ligaments*, which pass from the dorsal surface of the scaphoid to the dorsal surface of each of the cuneiform bones, and by *plantar ligaments*, which are similarly disposed. The strength of the plantar ligaments is greater than that of the dorsal ligaments and

they are very largely formed by slips from the tendon of the tibialis posticus.

The dissector may now divide freely all the dorsal, and the innermost of the plantar scapho-cuneiform ligaments. The scaphoid bone can then be drawn backwards so as to expose the interior of the joint. The knife may also be carried round the outer side of the external calcaneo-scaphoid ligament. A much better view of this ligament is thus obtained, although this dissection entails the division of the dorsal scapho-cuboid ligament.

The convex anterior articular surface of the scaphoid fits into a transversely concave socket, which is formed for it by the posterior surfaces of the three cuneiform bones, and often by a small facet on the inner surface of the cuboid bone as well. The articular surface of the scaphoid is divided by prominent ridges into areas or facets corresponding with the different parts of the socket in which it lies. The synovial membrane which lines this joint is prolonged forwards into the intercuneiform joints.

Scapho-cuboid and Cubo-cuneiform Articulations.—It has been noted that the anterior pillar of the longitudinal arch of the foot consists of an outer and an inner column. The tarsal portions of these are connected together by the scapho-cuboid and the cubo-cuneiform articulations.

It is only occasionally that the scaphoid bone touches and articulates directly with the inner surface of the cuboid bone. When it does so, the facet on the cuboid bone lies in series with the articular surfaces on the hinder ends of the cuneiform bones, and forms with them the socket for the anterior surface of the scaphoid. *The ligaments* which bind the scaphoid to the cuboid bone are disposed transversely, and consist of—(1) a series of short strong *interosseous* fibres which bind the opposed surfaces together; (2) a dorsal band; and (3) a plantar band.

The dorsal band has previously been divided in exposing the interior of the scapho-cuneiform joint and in defining the external calcaneo-scaphoid ligament, but the interosseous and plantar ligaments may be readily displayed.

The cuboid, by an oval facet on its inner surface articulates with the external cuneiform bone. *Interosseous, dorsal, and plantar ligaments* bind them together. By dividing the dorsal ligament and insinuating the knife between the two bones the interosseous ligament may be detected. It is the strongest of the three ligaments.

The synovial membrane which lines the scapho-cuneiform articulation is prolonged into the cubo-cuneiform joint and also into the scapho-cuboid joint when this exists.

Tarso-metatarsal Articulations.—The bases of the five metatarsal bones articulate with the three cuneiform bones and the cuboid bone, and are very firmly attached to them by dorsal, plantar, and interosseous ligaments.

The *dorsal ligaments* are flat distinct bands which can readily be defined. *One* such ligament passes to the base of the first metatarsal from the internal cuneiform; *three*, one from each of the cuneiform bones, proceed to the base of the second metatarsal; *one* extends from the external cuneiform to the base of the third metatarsal; *two*, of which one proceeds from the external cuneiform, and the other from the cuboid, go to the base of the fourth metatarsal; and *one* passes from the cuboid to the base of the fifth metatarsal.

The *plantar ligaments* are not so regularly disposed. Those in connection with the first and second metatarsal bones are very strong. Some of the bands have an oblique direction, and those which go to the bases of the three middle metatarsal bones are more or less connected with the sheath of the tendon of the peroneus longus, and therefore with the long plantar ligament.

To bring the *interosseous ligaments* into view, divide freely the dorsal ligaments, and then forcibly bend the metatarsus downwards upon the tarsus. The interosseous ligaments will resist this proceeding, and on looking into the joints they will be seen stretched and tense. If the force be continued they will rupture. The interosseous ligaments are three in number, viz., an internal, a middle, and an external.

The *internal interosseous ligament* is an exceedingly strong band, which passes forwards and outwards from the anterior part of the outer surface of the internal cuneiform bone to the adjacent surface of the base of the second metatarsal bone. The *middle interosseous ligament* is small, and passes forwards between the anterior part of the inner surface of the external cuneiform and the adjacent surface of the base of the second metatarsal. The *external interosseous ligament* passes from the outer surface of the external cuneiform bone to the outer side of the base of the third metatarsal. One interosseous ligament therefore passes from the internal cuneiform bone and two from the external cuneiform, and of these two are attached to the base of the second, and the third to the base of the third metatarsal bone.

Tarso-metatarsal Articular Surfaces.—The manner in which the metatarsus is implanted upon the tarsus should now be examined. The first metatarsal rests upon the internal cuneiform, and this joint possesses a separate synovial membrane. The second metatarsal rests upon the middle cuneiform, but its base is grasped by the projecting anterior ends of the internal and external cuneiform bones, with both of which it articulates, and with both of which it is connected by interosseous ligaments. No wonder then that this metatarsal should possess so little power of independent movement, and present a difficulty to the surgeon when he is called upon to amputate the fore-part of the foot through the tarso-metatarsal articulation (Hey's operation). The third metatarsal rests upon the external cuneiform. The synovial membrane which lines the joints between the tarsus and the second and third metatarsal bones is continuous with that which is present between the internal and middle cuneiform bones, and through this with the scapho-cuneiform synovial membrane. The bases of the fourth and fifth metatarsal bones are supported by the cuboid, but that of the fourth, by its inner margin, articulates also with the external cuneiform. A separate synovial membrane is present in

the articulation between the two outer metatarsal bones and the tarsus.

Intermetatarsal Joints.—The bases of the metatarsal bones, with the exception of the first, articulate with each other, and are very firmly bound together.

The ligaments which connect the bases of the four outer metatarsal bones are *dorsal*, *plantar*, and *interosseous*. To bring the interosseous ligaments into view it is necessary to divide the dorsal ligaments, and then forcibly separate the bases of the bones from each other. They are strong bands which pass between the non-articular portions of the basal parts of the bones. They constitute the chief bond of union.

In addition to these basal ligaments, the strong *transverse metatarsal ligament* unites the distal extremities of the metatarsal bones. This ligament has been previously described (p. 303).

Synovial Cavities of the Foot.—There are six separate synovial cavities in connection with the tarsal, tarso-metatarsal, and inter-metatarsal articulations, viz.—(1) in the joint between the posterior facets of the astragalus and os calcis; (2) in the calcaneo-cuboid joint; (3) in the joint formed by the head of the astragalus, the scaphoid, the sustentaculum tali, and the two calcaneo-scaphoid ligaments; (4) a complicated synovial membrane which lines the scapho-cuneiform articulations, and is prolonged forwards between the cuneiforms, and also between the cuboid and external cuneiform bones. This synovial membrane, however, is not confined to the tarsus, but reaches forwards into the articulation between the second and third metatarsal bones and the tarsus, as well as into the joints between the bases of the second, third, and fourth metatarsal bones;¹ (5) a separate synovial lining for the joint between the first metatarsal and the internal

¹ The external interosseous tarso-metatarsal ligament, which passes from the external cuneiform bone (frequently from the cuboid bone) to the base of the third metatarsal bone, separates the articulations of the fourth and fifth metatarsal bones from the general tarsal articular cavity.

cuneiform; (6) a distinct synovial membrane for the articulations between the cuboid and the two outer metatarsal bones. This is prolonged forwards into the joint between the bases of these two metatarsals.

Metatarso-phalangeal and Interphalangeal Joints.—These joints are constructed upon a plan almost identical with that of the corresponding joints of the upper extremity. For the detailed description the student is therefore referred to p. 161. In the metatarso-phalangeal joint of the great toe the thick *inferior ligament* or *fibrous plate* holds two large sesamoid bones, which slide upon grooved surfaces on the head of the metatarsal bone.

Movements.—The movements which take place in the tarso-metatarsal, intermetatarsal, and in the majority of the tarsal joints, are of a gliding character. In the joints between the astragalus and scaphoid, and also between the os calcis and the cuboid, movements of a wider range are possible. It is here that the movements of *inversion* and *eversion* of the foot chiefly take place.

The first and the fifth metatarsal bones enjoy a considerable degree of mobility. The second metatarsal is so tightly grasped by the internal and external cuneiform bones, and so firmly bound to the tarsus by its basal ligaments, that only a slight degree of movement is possible.

At the metatarso-phalangeal joints, flexion, extension, abduction, and adduction, are allowed; whilst the inter-phalangeal joints only permit of flexion and extension.

In the erect posture the parts of the foot which are chiefly concerned in transmitting the weight of the body to the ground are the heel, the head of the first metatarsal bone, and the shaft of the fifth metatarsal bone. Rather more than the middle third of the inner border of the foot is raised above the ground. The outer border of the foot is more or less in contact with the ground in its entire extent, whilst the tips of the toes rest lightly on the ground. In walking—(1) the heel is brought down; (2) the sole and toes follow; (3) the heel is raised, and the weight of the body is transferred to the heads of the metatarsal bones and the toes. In the second and third parts of this operation the arches of the foot are flattened to a certain extent, but more especially in the third part of the process is the transverse arch spread out. Great elasticity is thus given to the step.

The muscles which are chiefly concerned in producing *eversion* of the foot are the three peroneal muscles; those which operate as *invertors* of the foot are the tibialis anticus and the tibialis posticus.

The *extensors of the toes* are the extensor longus hallucis, the extensor brevis digitorum, and the extensor longus digitorum. The lumbrical muscles, and the interosseous muscles, through their insertions into the extensor tendons of the four outer toes, operate as extensors of the second and third phalanges.

The *flexors of the proximal phalanges* are the lumbricales, interossei, flexor brevis hallucis, and flexor brevis minimi digiti. The *flexor of the second phalanges* is the flexor brevis digitorum; whilst the *flexors of the distal phalanges* are the flexor longus digitorum, the musculus accessorius, and the flexor longus hallucis.

Abduction and adduction of the toes at the metatarso-phalangeal joints are produced by the interosseous muscles, the abductor hallucis, the adductor obliquus hallucis, the adductor transversus hallucis, and the abductor minimi digiti. The movements of abduction and adduction take place with reference to a line drawn through the second toe.

ABDOMEN.

WHEN the body is brought into the dissecting-room, it is first placed in the lithotomy position (Fig. 71). A stout cord or bandage is doubled and passed in the form of a running noose over each hand of the subject, so as to grasp the wrist when tightened. The hands are then drawn downwards and the feet upwards until the palm of each hand rests upon the outer aspect and dorsum of the corresponding foot. In this position they must be securely fixed by passing the cord once or twice round the instep, and then tying a knot upon the inner aspect of the foot. The subject must now be drawn towards the end of the table until the breech projects slightly over the edge. A block is introduced under the pelvis, and the cords carried downwards and fastened on each side to the leg of the table, so as to keep the lower limbs well apart from each other. A third cord must next be passed behind the flexed knee-joints, and then round the neck of the subject,

and tightened so as to flex the thighs upon the abdomen. The body is retained for two days in this posture, and during this time the dissector of the abdomen is expected to dissect the *perineum*.

MALE PERINEUM.

To prepare the part for dissection, a staff should first be introduced into the bladder. The dissector must stand upon the *left* side of the subject. Having smeared the instrument with oil, hold it lightly in the right hand and guide it gently along the upper and right wall of the urethra. When the point of the instrument reaches the triangular ligament—a strong aponeurotic structure which is stretched tightly across the pubic arch—depress the handle, but use no force. Should any difficulty be experienced, introduce the forefinger of the left hand into the rectum to guide the point of the instrument along the membranous and prostatic portions of the urethra. The most dependent part of the scrotum should now be stitched to the prepuce of the penis, and dragging both penis and scrotum forwards upon the staff, they should be fixed by means of the twine to its handle. Lastly, fasten the handle of the staff to the cord which passes behind the flexed knee-joints of the subject.

The rectum should then be *moderately* distended with tow, and the orifice of the anus stitched up.

Boundaries of the Perineum.—The perineal space may be said to correspond to the inferior aperture or outlet of the pelvis. It is absolutely necessary, then, that the student should renew his acquaintance with this part of the skeleton before he begins the dissection. Let him obtain a pelvis with the ligaments *in situ*. He will observe that he has to deal with a diamond-shaped space, and that it has the following boundaries: *in front*, the symphysis pubis and the subpubic ligament; *behind*, the coccyx; and *on each side* from before backwards, the rami of the pubis and ischium, the tuberosity of the ischium and the great sacro-sciatic ligament. If he now turns his attention to the subject before him he can readily identify these limits. The great sacro-sciatic ligament, however, is somewhat obscured, from its being covered by

the gluteus maximus muscle, but it can be felt by pressing deeply in a line between the ischial tuberosity and the coccyx.

In the undissected body the superficial area of the perineum is very limited; indeed, when the limbs are extended and approximated, it merely consists of a narrow groove running forwards between the thighs from the coccyx towards the pubis. In this groove are placed the

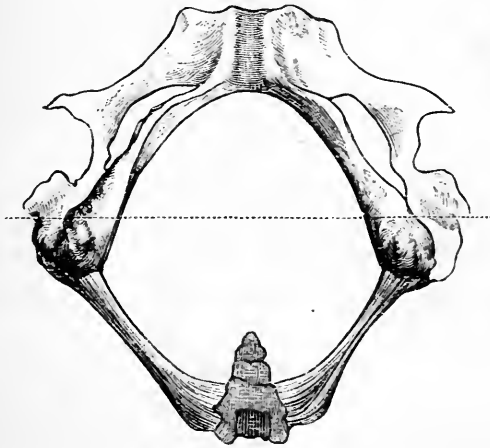


FIG. 70.—Outlet of pelvis.

anus or orifice of the rectum and the roots of the scrotum and penis, whilst in the middle line a cutaneous ridge—the *median raphe*—may be observed. This raphe can be traced from the anus forwards over the scrotum and along the under surface of the penis.

Subdivision of the Space.—The perineal space has, therefore, a diamond-shaped form, and it is customary to subdivide it arbitrarily into two portions by drawing an imaginary transverse line between the anterior parts of the ischial tuberosities immediately in front of the anus. Two triangles are thus mapped out. The anterior of these may be appropriately called the *urogenital triangle*, because the most important objects which it contains are the urethra and the root of the penis; the posterior may be distin-

guished as the *rectal triangle*, from its containing the lower end of the rectum.

Reflection of Skin.—Two incisions are required:—(Fig. 71) (1) a transverse incision along the line which separates the *rectal* from the urogenital triangle—*i.e.*, in front of the tuberosities of the ischium; (2) an incision at right angles to this in the line of the median raphe. This incision should begin well forwards on the scrotum and be continued back a little beyond the point of the coccyx. At the anus the knife should be carried round it so as to encircle it.

The four triangular flaps which are marked out should now be reflected close to the anal orifice. Some difficulty will be experienced in raising the skin. This is due to the presence of a number of fasciculi of involuntary muscle which radiate outwards from the opening. The term *corrugator cutis ani* is applied to this muscle. The *superficial fascia* and the *external sphincter muscle* are now exposed.

RECTAL TRIANGLE.

The dissection of this portion of the perineal space will disclose the following parts (Fig. 73, p. 345):—

1. The superficial fascia.
2. The external sphincter ani muscle.
3. The lower part of the rectum covered by the levator ani muscle and the anal fascia.
4. The parietal or obturator layer of pelvic fascia.
5. The lower border of the gluteus maximus muscle and the great sacro-sciatic ligament.
6. The coccygeus muscle.
7. The inferior hæmorrhoidal vessels and nerve.
8. The perineal branch of the fourth sacral nerve.
9. The commencement of the two superficial perineal nerves.
10. The perforating cutaneous branch of the fourth sacral nerve.

Superficial Fascia.—The student should examine the superficial fascia as it is spread over the entire extent of the perineal space. It shows great differences in character and texture in different positions. At the side of the anus it is remarkable for the large quantity of fat it holds in its meshes. This fat is soft and lobulated, and passes upwards upon each side of the rectum in the form of a pliable and elastic pad. Over the tuberosities of the

ischium the superficial fascia undergoes a striking alteration. Here it becomes tough and stringy; dense fibrous septa separate the lobules of fat from each other and connect the skin with the subjacent bone. Make a deep incision into it with the knife, and a bursa will be displayed intervening between the fascia and bone. This bursal sac is frequently intersected by strong fibrous bands

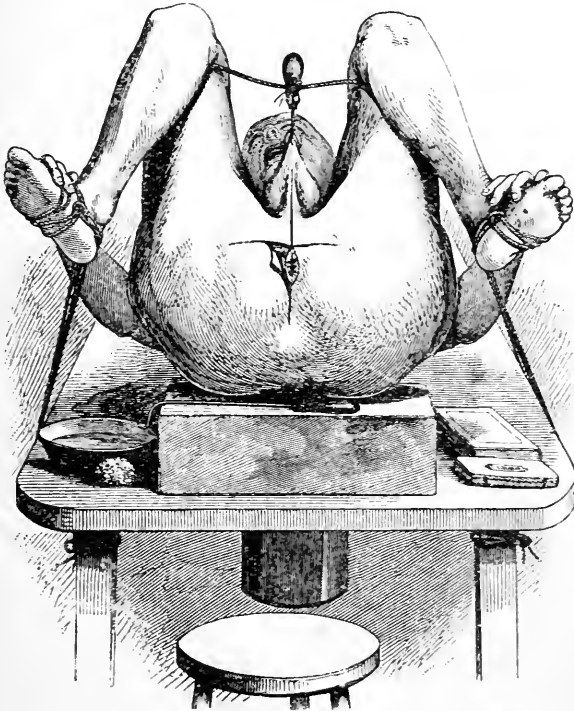


FIG. 71.

or cords. In this locality the superficial fascia acts as a cushion on which the tuber ischii rests when the body is in the sitting posture.

But, again, if the superficial fascia be now followed forwards over the urogenital triangle, another change in its character becomes manifest. The further forwards we proceed, the scarcer becomes the fat which it contains in

its meshes, and in the scrotum the fat entirely disappears and gives place to a thin layer of involuntary muscular fibres. These constitute the *dartos muscle*, and are recognised by their ruddy colour. The rugosity of the scrotal integument is caused by the contraction of these fibres.

Over the urogenital triangle the superficial fascia can be shown to consist of two very definite layers. The *superficial layer* is fatty and is not confined to this region. In fact it is simply a portion of the general fatty covering of the body. Behind it is continuous with the plugs of fat which fill up the ischio-rectal fossa; on either side it leaves the perineum and becomes continuous with the fatty tissue on the inner aspects of the thighs. The *deep layer* is of an altogether different nature. It is a dense membranaceous stratum, devoid of fat, which is spread over the urogenital triangle. It is called the *fascia of Colles*. This sheet of fascia forms very definite attachments around the limits of the urogenital triangle. Thus, on either side it is fixed to the anterior lips of the rami of the pubis and ischium, whilst inferiorly it is tucked round the two transverse perineal muscles and blends with the base of the triangular ligament. A pouch is thus formed, which is bounded *in front* by the fascia of Colles, *behind* by the triangular ligament, *laterally* by the attachment of these to the sides of the pubic arch, whilst *below* it is closed by the union of the fascia of Colles with the base of the triangular ligament (Fig. 73, p. 345). Within this pouch certain important parts are placed—viz., the superficial perineal muscles, vessels, and nerves, the long pudendal nerves, the bulb and crura of the penis, and the termination of the pudic artery. It is partially divided into two lateral parts by a median septum, which dips backwards from the superficial fascia. This septum is very perfect posteriorly, but becomes incomplete towards the scrotum. Traced forwards, the fascia of Colles passes over the scrotum, penis, and spermatic cords, to the front of the abdomen, where it becomes continuous with the fascia of Scarpa.

How to verify these facts.—The student can verify these facts in two ways, viz.—(1) by inflating the pouch with air, and (2) by dissection. Make a longitudinal incision, large enough to admit the nozzle of the bellows, into the superficial fascia towards the back part of the pouch and a little to one side of the middle line. This cut must be carried through the fascia until the fibres of the superficial perineal muscles are exposed. In using the bellows, the margins of the opening into the pouch must be held tightly around its nozzle. The air which is introduced passes forwards, and is first confined to one side of the pouch. Reaching the scrotum, however, where the septum is incomplete, it forces its way across the middle line, and inflates the opposite side of the pouch. The pouch is now rendered prominent, and the attachments of the fascia become very evident. The air cannot pass into the rectal triangle owing to the union of the fascia of Colles to the base of the triangular ligament; it cannot pass down the inner aspect of the thighs from the attachment of the fascia to the sides of the pubic arch; it can only force its way forwards under the superficial fascia and dartos muscle of the scrotum, and from this on to the penis and along the spermatic cords to the anterior aspect of the abdomen. By this means the dissector obtains a very striking view of the course which would be taken by urine escaping from a rupture in the urethra in front of the triangular ligament.

The attachments of the fascia of Colles are so important that the student should also test them by dissection. To do this it is necessary to make two incisions through the superficial fascia. Enter the knife in the middle line at the root of the scrotum, and carry it backwards and outwards to the tuber ischii on each side of the body. A central Λ -shaped flap and two lateral flaps of fascia are thus marked out. By raising and turning backwards the central portion, the septum of the pouch is brought into view, and the attachment of the fascia to the base of the triangular ligament is demonstrated, and by throwing each lateral flap outwards, it will be seen to be firmly fixed to the side of the pubic arch. In effecting this dissection the utmost care is demanded on the part of the student. In the areolar tissue immediately subjacent to the superficial fascia are the *superficial perineal vessels and nerves*, which are certain to be injured, or perhaps even reflected with the fascia, unless the greatest caution be exercised.

Sphincter Ani Externus.—When this muscle is cleaned it will be seen to consist of a thick ring of muscular fibres surrounding the orifice of the rectum. *Behind*, it is attached by a pointed tendon to the tip and posterior surface of the terminal part of the coccyx; *in front*, it blends with other perineal muscles in the central point of

the perineum. The fibres, in passing between these two points of attachment, encircle the anal orifice and constitute a true sphincter muscle. Some of the superficial fibres, both in front and behind the anal opening, are directly attached to the skin. It draws its nervous supply from two sources, viz., the *fourth sacral nerve* and the *inferior hemorrhoidal nerve*.

Ischio-rectal Fossa.—Although the rectum is the largest

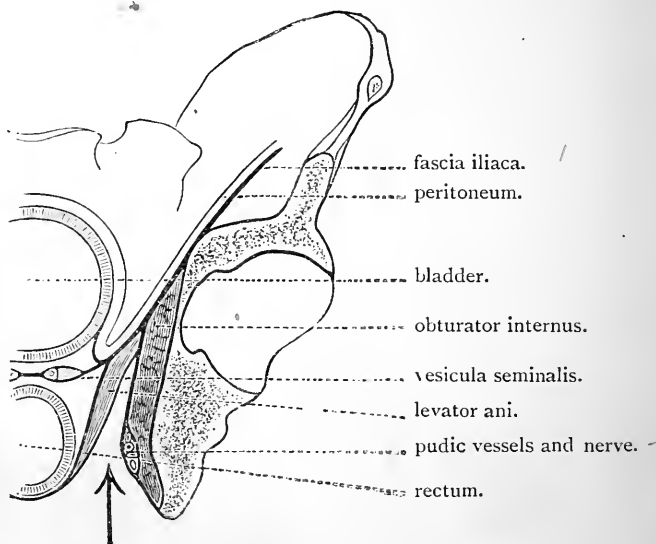


FIG. 72.—The arrow is directed upwards into the ischio-rectal fossa. The parietal pelvic fascia is seen upon the inner surface of the obturator internus. Observe also the anal fascia clothing the outer surface of the levator ani and the rectal fascia upon its inner surface.

and most important object which is contained within the posterior portion of the perineum, it does not fill up the entire extent of the rectal triangle. An interval or recess is left upon each side of the rectum—between it and the ischium—and to this recess is given the name of the *ischio-rectal fossa* (Fig. 73, p. 345).

In shape the ischio-rectal fossa is pyramidal, the apex of the pyramid being directed upwards towards the pelvic

cavity, and the base downwards towards the integuments. The inner wall of the space is sloping, whilst the outer wall is steep and perpendicular.

Boundaries.—Whilst the term "*ischio-rectal*" is applied to this fossa, it must be borne in mind that neither the ischium nor the rectum enter directly into the formation of its walls. Both are separated from the space by fascial and muscular layers. Upon the inner aspect of the ischium is the obturator internus muscle, and this again is covered by the parietal or obturator layer of the pelvic fascia as it is continued down to be attached to the tuberosity of the ischium and the great sacro-sciatic ligament. On the other hand, the rectum is clothed from without inwards by—(1) the anal fascia, a thin aponeurotic membrane which invests the outer surface of the levator ani; (2) by the levator ani muscle; and (3) by the rectal portion of the visceral layer of the pelvic fascia (Fig. 72). Strictly speaking, therefore, the perpendicular *outer* or *ischial wall* of the fossa is formed by the parietal layer of the pelvic fascia, and the sloping *inner* or *rectal wall* by the anal fascia. *In front* the space is limited by the triangular ligament—whilst *behind* it is bounded by the posterior or lower margin of the gluteus maximus and the great sacro-sciatic ligament.

Contents.—The ischio-rectal fossa is completely filled up by a mass of fat which is prolonged upwards into it from the superficial fascia. The soft pliable nature of this fat readily allows of the distension of the rectum. Embedded in its midst are certain blood-vessels and nerves. Crossing the fossa from its outer to its inner wall are the *inferior hæmorrhoidal vessels and nerve*; entering the fossa at its posterior part is the *perineal branch* of the *fourth sacral nerve*; turning round the lower border of the gluteus maximus, not far from the coccyx, is the *perforating cutaneous branch* of the fourth sacral nerve; whilst in the anterior part of the space will be found the commencement of the *two superficial perineal nerves* (Fig. 73).

Dissection.—Begin by exposing the posterior margin of the *gluteus*

maximus muscle. Take a point a short distance to the outside of the tuber ischii and another in the middle line about an inch above the tip of the coccyx, and cut boldly down through the superficial fascia, in a line between these points, until the fleshy fibres become visible. Winding round the lower margin of the muscle so as to gain its superficial aspect, there are a few small arteries and nerves. The arteries are derived from the *inferior hæmorrhoidal vessels*, or from the *sciatic artery*, whilst the nerves are the *perforating cutaneous branch* from the fourth sacral nerve and some offsets from the *small sciatic nerve*. Both are destined for the supply of the skin on the lower part of the gluteal region. The perforating cutaneous nerve turns round the margin of the gluteus maximus close to the coccyx, whilst the cutaneous branches from the small sciatic nerve appear on the outer side of the tuber ischii. Having secured these vessels and nerves, clean the lower margin of the gluteus maximus, and then proceed to dissect the ischio-rectal fossa. If the subject is obese, a considerable quantity of fat may be removed at once without endangering the inferior hæmorrhoidal vessels and nerve. Take the surface of the gluteus maximus and the margin of the external sphincter as guides, and transfix the fat with the knife in this plane. The adipose tissue superficial to this plane may be removed *en masse* with safety. The *hæmorrhoidal vessels and nerve* may be found by dissecting cautiously in the fat and carrying the knife in a transverse direction from the outer to the inner wall of the space. The branch from the *fourth sacral nerve* appears by the side of the coccyx.

Roof of the Space.—When the contents of the space are secured, continue to remove the fat from the fossa until its walls are fully displayed. On passing the finger upwards, its passage into the pelvis is prevented by the junction of the anal fascia with the parietal or obturator layer of the pelvic fascia (Fig. 72. p. 342). Further, if the anal fascia be removed, its entrance into the pelvis is still resisted by the visceral layer of the pelvic fascia, which at this level passes inwards from the parietal pelvic fascia, and also by the levator ani muscle which lies on the lower surface of the visceral pelvic fascia and takes origin from the line of union between these two layers of fascia.

Internal Pudic Vessels and Nerve.—The dissector should now pass his finger upwards and downwards over the surface of the parietal or obturator layer of the pelvic fascia, which covers the obturator internus muscle and forms the outer wall of the ischio-rectal fossa. About an

inch and a half above the lower border of the ischial tuberosity he will feel very distinctly the pudic vessels and nerve as they pass forwards to gain the urethral triangle. In this position they are enclosed in a tube or sheath formed by the parietal pelvic fascia. This fascial tunnel is called Alcock's canal. The student must for the present be satisfied with this partial view of these structures. To expose them would necessitate the division of the parietal

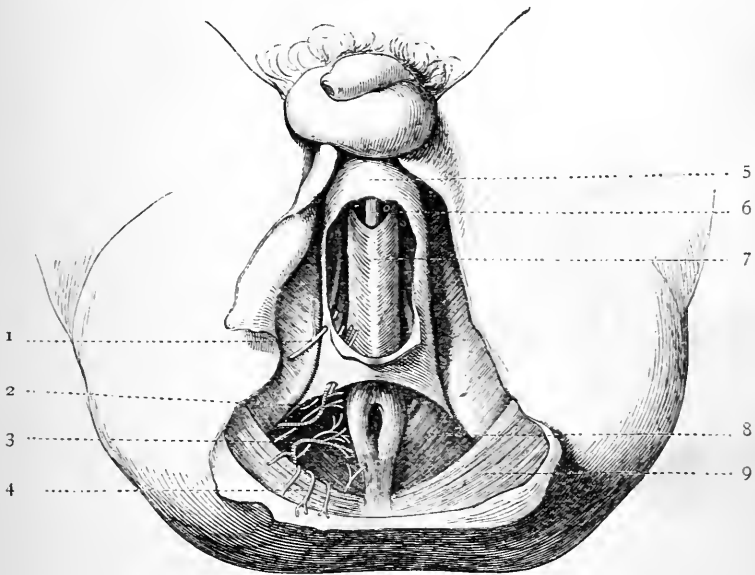


FIG. 73.

- | | |
|--|---|
| <p>1. Long pudendal nerve.
 2. Superficial perineal vessels and nerves.
 3. Hæmorrhoidal vessels and nerve.
 4. Perforating cutaneous nerve.
 5. Superficial fascia.</p> | <p>6. Corpus spongiosum.
 7. Accelerator urinæ.
 8. Levator ani.
 9. Gluteus maximus.</p> |
|--|---|

pelvic fascia, and this should be kept entire until the pelvic fascia can be studied as a whole.

Inferior Hæmorrhoidal Vessels (arteria hæmorrhoidalis inferior). The inferior hæmorrhoidal arteries are branches of the internal pudic. They are usually two or three in number, and, piercing the inner wall of Alcock's canal,

they pass inwards through the fat of the ischio-rectal fossa to supply the lower end of the rectum and the muscles in connection with it, as well as the skin around the anus. They anastomose with the corresponding arteries of the opposite side, and with branches from the middle and superior hæmorrhoidal arteries. They likewise send a few twigs round the lower border of the gluteous maximus, in company with the perforating cutaneous nerve to supply the skin in the lower part of the buttock.

The Inferior Hæmorrhoidal Nerve accompanies the vessels of the same name. It may proceed directly from the sacral plexus, but more frequently it is a branch of the internal pudic nerve. Perforating the inner wall of Alcock's canal, it enters the ischio-rectal fossa, and then it breaks up into muscular, cutaneous, and communicating branches. The *muscular twigs* supply the external sphincter: the *cutaneous offsets* are given to the skin which surrounds the anus, while the *communicating filaments* pass forwards to join the long pudendal nerve and the superficial perineal nerves.

Perineal Branch of Fourth Sacral Nerve.—This small nerve enters the ischio-rectal fossa by piercing the coccygeus muscle at the side of the coccyx. It is distributed to the skin between the anus and coccyx, and to the external sphincter muscle.

Ano-coccygeal Body.—An indefinite mass of muscular and fibrous tissue which lies between the tip of the coccyx and the anus receives the name of *ano-coccygeal body*. It is best seen in sections through the pelvis, and it requires notice on account of the support which it gives to the rectum in front of the coccyx. The muscular tissue which enters into its constitution belongs to the levator ani and the external and internal sphincter muscles (Symington).

UROGENITAL TRIANGLE.

The superficial fascia in this locality has already been

studied. The following is a list of the structures which still require to be examined:—

1. The superficial perineal vessels and nerves.
2. The long pudendal nerve.
3. The root of the penis } The bulb and the crura.
4. The superficial perineal muscles. { *a.* Transversus perinei.
 b. Ejaculator urinæ.
 c. Erector penis.
5. The triangular ligament.
6. The internal pudic vessels and nerve and their branches.
7. The compressor urethræ muscle.
8. Cowper's glands.
9. The membranous portion of the urethra.
10. The deep layer of the triangular ligament (*i.e.*, the parietal pelvic fascia opposite the pubic arch).

Superficial Perineal Vessels and Nerves.—The superficial perineal vessels and nerves must now be followed out. There are two arteries and three nerves to be looked for:—

- | | | |
|-----------|---|---|
| Arteries. | { | 1. Superficial perineal artery. |
| | { | 2. Transverse perineal artery. |
| Nerves. | { | 1. Posterior or external superficial perineal nerve. |
| | { | 2. Anterior or internal superficial perineal nerve. |
| | { | 3. The long pudendal nerve or the nerve of Soemmerring. |

The *superficial perineal artery*, a branch of the pudic, first pierces the inner wall of Alcock's canal, and then the base of the triangular ligament, so as to gain the interior of the perineal pouch of fascia. It now crosses the transversus perinei muscle, and is continued forwards in the interval between the ejaculator urinæ and erector penis to the scrotum, to the dartos muscle and integuments of which it is distributed in the form of numerous long, slender branches. Before it reaches the scrotum, it supplies twigs to the superficial perineal muscles. It is accompanied by the superficial perineal nerves.

The *transverse perineal artery* is a small vessel which usually springs from the pudic by a common root of origin with the preceding. It pierces the base of the triangular ligament, and, gaining the surface of the transversus

perinei muscle, proceeds transversely inwards to the interval between the rectum and the bulb, where it ends by supplying the parts in this locality, and by anastomosing with the corresponding vessel of the opposite side.

The *posterior superficial perineal nerve*, a branch of the perineal division of the pudic nerve, has already been seen in the anterior part of the ischio-rectal fossa, where it effects a communication with the inferior hæmorrhoidal nerve. It leaves the fossa by piercing the base of the triangular ligament, and is continued forwards with the superficial perineal artery to the scrotum.

The *anterior superficial perineal nerve*, also derived from the perineal part of the pudic nerve, supplies a few twigs to the levator ani, and, piercing the base of the triangular ligament, is prolonged forward with the posterior nerve to the scrotum. In some instances this nerve passes under cover of the transversus perinei muscle.

Dissection.—Instead of searching for the long pudendal nerve at the point where it becomes superficial, and then following it towards its distribution, it is much easier to find it after it has entered the perineal pouch of fascia. Here it will be discovered lying in close relation to the two preceding nerves, but to their outer side. Trace it forwards and backwards. The long pudendal communicates with the inferior hæmorrhoidal nerve, and also with the posterior superficial perineal nerve.

The *long pudendal nerve* is derived from an altogether different source. It is a branch of the small sciatic nerve, and pierces the deep fascia of the thigh a short distance in front of the tuber ischii, and about an inch and a half to the outer side of the margin of the pubic arch. As it proceeds forwards it inclines inwards, and, piercing the attachment of the superficial fascia to the margin of the pubic arch, it accompanies the other vessels and nerves to the scrotum, the outer and front part of which it supplies.

Dissection.—Divide the superficial perineal vessels and nerves, and throw them aside.

Root of the Penis.—At this stage of the dissection the student should consider the position of the triangular ligament, and the relation which it bears to the root of the penis. The *triangular ligament* is a strong aponeurotic membrane which stretches across the pubic arch, and subdivides the urogenital portion of the perineum into a superficial and a deep area. The *root of the penis* is placed altogether in front of it, in the superficial area of this region. With the handle of the knife clear away for a short distance the loose tissue which surrounds the body of the penis. The *body of the penis* is then seen to consist of three cylindrical masses which are chiefly composed of erectile tissue, and are placed in close apposition with each other. These are the two corpora cavernosa and the corpus spongiosum.

The *corpora cavernosa* constitute the chief bulk of the organ. They are placed side by side and form the dorsum and sides of the penis. They are partially blended with each other along the middle line,—indeed the only surface indication of the double nature of this portion of the penis are two median longitudinal grooves which run one along its upper and the other along its lower aspect. The *corpus spongiosum* is slender in comparison with the corpora cavernosa, and is lodged in the groove which extends along the lower aspect of these bodies. On account of this, the body of the penis has a somewhat prismatic form. The corpus spongiosum is traversed throughout its whole extent by the urethra.

If these three constituents of the body of the penis be traced backwards, the student will observe that opposite the lower part of the symphysis pubis they separate from each other and become attached to parts in the superficial area of the urogenital triangle. The *corpora cavernosa* diverge widely from each other, and now they receive the name of the *crura* of the penis. Each crus is fixed firmly to the corresponding side of the pubic arch by an attachment which extends from the sub-pubic ligament backwards to the tuberosity of the ischium. Close to the point where

it becomes continuous with the corresponding corpus cavernosum it shows a slight dilatation or bulging; from this to its posterior extremity it gradually tapers away. The *corpus spongiosum* is continued backwards in the middle line of the body to within a short distance of the anus, and it gradually expands so as to form a bulbous posterior extremity. The corpus spongiosum, as it lies in the interval between the diverging crura, is therefore termed the *bulb* of the penis. The bulb rests upon the superficial aspect of the triangular ligament, and it is firmly

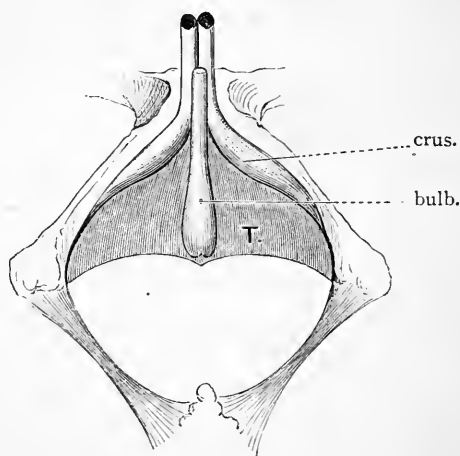


FIG. 74.—Diagram of the three parts of the penis, and their relation to the pubic arch and the triangular ligament.

T. Triangular ligament.

bound down to this by an aponeurotic investment, which is prolonged over it from the ligament. The posterior extremity of the bulb is notched in the middle line—an indication of its originally double constitution.

The bulb and the two crura together constitute *the root of the penis*, and each is provided with a special muscle, which at present hides it from view. Clothing the bulb the student will recognise a bipenniform muscle called the *ejaculator urinæ*, whilst moulded upon the surface of

each crus is the *erector penis muscle*. These muscles should now be cleaned and their connections examined.

Superficial Perineal Muscles.—Under this heading are included not only the ejaculator urinæ and erector penis muscles, but also the transversus perinei. The superficial perineal muscles have been seen to lie within the pouch formed by the superficial fascia and the triangular ligament. When the superficial fascia is removed each will be found to be invested by its own delicate aponeurotic layer.

The *transversus perinei muscle* (*musculus transversus perinei superficialis*) is a narrow slip of muscular fibres which arises from the inner aspect of the ascending ramus of the ischium close to the tuberosity. It passes inwards and unites with the corresponding muscle of the opposite side in the central point of the perineum. From this blending of the two muscles in the middle line it has occurred to some anatomists to describe them as together forming one digastric muscle, and certainly this mode of description is calculated to give a better idea of their action. By their simultaneous contraction they steady the central point of the perineum, and give support to the anus during defæcation.

The central point of the perineum.—But what is the central point of the perineum? It is a tendinous septum situated in the middle line of the body close to the posterior end of the bulb and a short distance in front of the anus. Towards this point, a number of the perineal muscles converge to obtain attachment. *On each side* it gives attachment to the transverse perineal muscles, *behind* to the sphincter ani, *in front* to the posterior fibres of the ejaculator urinæ, whilst *from above* the anterior fibres of the levator ani descend to reach its upper aspect.

Ejaculator urinæ (*musculus bulbo-cavernosus*).—This muscle is spread over the bulb and posterior part of the corpus spongiosum. It is composed of two symmetrical halves, and its fibres take origin from the central point of the perineum and from a fibrous median raphe which is

prolonged forwards between the two halves of the muscle. The insertion differs according to the point at which the muscle is examined. The *posterior fibres* are simply attached to the superficial aspect of the anterior triangular ligament; the *middle fibres* constituting the greater part of the muscle, sweep around the corpus spongiosum so as to invest it completely, and are inserted into a common aponeurosis upon the upper surface of this portion of the penis; lastly, the *anterior fibres* form two long narrow muscular bands which diverge from each other like the limbs of the letter V, and, passing forwards over the sides of the corpora cavernosa, are inserted into an aponeurosis on the dorsum of the penis. Thus the posterior fibres partially embrace the bulb; the middle fibres embrace the corpus spongiosum; whilst the anterior fibres embrace the body of the penis. The ejaculator urinæ supports the urethra during micturition, and by its contraction it ejects the last drops of urine or semen from the passage.

The *erector penis* (musculus ischio-cavernosus) lies upon the crus penis. It arises by fleshy fibres from the inner aspect of the tuber ischii, and is inserted by an aponeurotic expansion into the lower and outer surface of the anterior portion of the crus.

Perineal Nerve.—This is one of the two terminal branches of the pudic nerve. It supplies twigs to the skin, to the muscles of the perineum, and to the bulb of the penis. The *cutaneous branches* have already been followed out. They are the posterior and anterior superficial perineal nerves. *Muscular twigs*, occupying a deeper plane, may be traced to each of the three superficial perineal muscles and to the levator ani, whilst a few minute offsets pierce the triangular ligament to supply the compressor urethræ muscle. The *nerve to the bulb* is a small branch which breaks up into filaments which enter the hinder part of the corpus spongiosum.

Perineal Triangle.—If the superficial perineal muscles be now examined in regard to the relations which they hold to each other, the student will observe that they con-

stitute the boundaries of a small triangular space upon each side of the middle line. The *base* of the triangle is formed by the transversus perinei; *externally* it is limited by the erector penis, and *internally* by the ejaculator urinæ. Let the student now place the point of his finger within this space and press upwards and backwards. He will perceive that it rests upon a strong resisting membrane. This is the triangular ligament, which therefore forms the floor of the space.

Dissection.—To bring the triangular ligament of the urethra fully into view, it is necessary in the first place to remove the superficial perineal muscles. When this is done the three divisions of the root of the penis are exposed to view, and their manner of attachment (which has already been described, p. 349) can be studied. Detach in the next place the crura penis from the sides of the pubic arch, and turn them aside. This must be affected with care, so as not to destroy the attachment of the ligament to the sides of the pubic arch, or to injure the pudic artery and dorsal nerve of the penis which pierce the ligament in its upper part.

The Triangular Ligament¹ is now seen to be a strong aponeurotic membrane which stretches across the pubic arch. It must be regarded as lying in the same morphological plane as the bony and ligamentous wall of the pelvis, and as completing the pelvic wall in front in the same manner as the thyroid membrane fills up the gap formed by the thyroid foramen.

Upon each side the triangular ligament is attached to the margins of the rami of the pubis and ischium. Its base is somewhat indefinite, and has already been seen to blend along the lower borders of the transversus perinei muscles with the fascia of Colles. In addition to this attachment, however, a careful dissection in a good subject will show that the central part of the base projects backwards and downwards in the form of a short process or peak, which joins the central point of the perineum. Near the symphysis pubis some transverse fibres, in association with the

¹ To avoid confusion, it may be as well to mention that the terms "*deep perineal fascia*" and "*sub-pubic fascia*" are also applied to this structure.

triangular ligament, pass from one side of the pubic arch to the other, and form a more or less distinct band, called the *transverse perineal ligament*. Between the upper border of

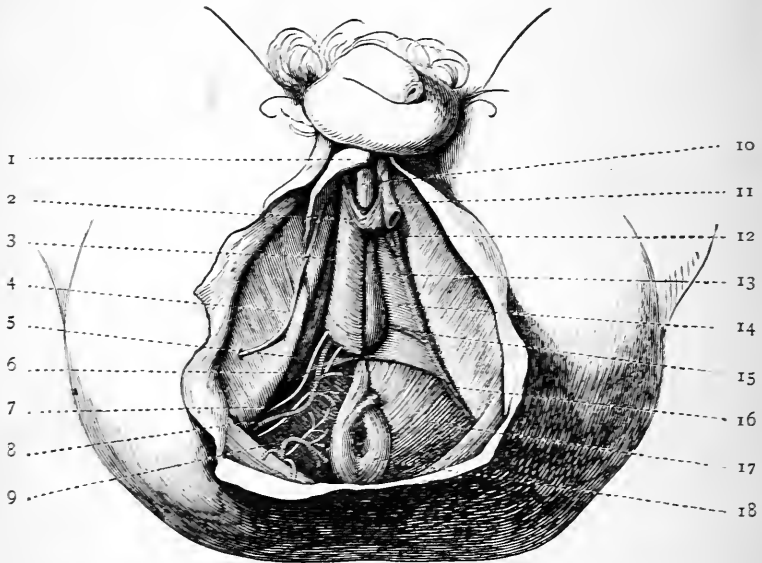


FIG. 75.—Superficial fascia removed; also one-half of the ejaculator urinæ to show the bulb. On the left side the transversus perinei, the erector penis, and the crus penis have been taken away to display the triangular ligament.

- | | |
|--|--|
| 1. Fascia of Colles. | 12. Terminal branches of the pudic artery. |
| 2. Ejaculator urinæ. | 13. Bulb. |
| 3. Erector penis. | 14. Triangular ligament. |
| 4. Long pudendal nerve. | 15. Artery to bulb (shining through the triangular ligament). |
| 5. Transversus perinei. | 16. Internal pudic artery and nerve (shining through the triangular ligament). |
| 6. Anterior superficial perineal nerve. | 17. Levator ani. |
| 7. Posterior superficial perineal nerve. | 18. Sphincter ani externus. |
| 8. Superficial perineal artery. | |
| 9. Hæmorrhoidal vessels and nerve. | |
| 10. Corpus spongiosum. | |
| 11. Crus penis (divided). | |

this band and the sub-pubic ligament an oval gap is left for the passage of the dorsal vein of the penis.

In the erect posture of the body the superficial surface of the triangular ligament looks downwards and forwards,

whilst its deep surface looks upwards and backwards towards the cavity of the pelvis. In close contact with its superficial surface are the parts which constitute the root of the penis, viz., the bulb and the two crura and the muscles which are associated with them, also the transversus perinei muscles. The structures which are in relation to its deep surface will be studied when it is reflected.

The triangular ligament is not an unbroken continuous layer of fascia. It is pierced—(1) by the urethra; (2) by the pudic arteries; (3) by the dorsal nerves of the penis; (4) by the arteries to the bulb; (5) and lastly, at its base,

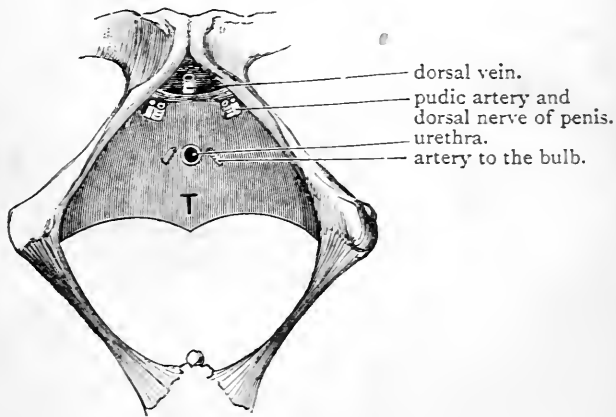


FIG. 76.—Diagram of the triangular ligament.

T. Triangular ligament.

where it blends with the superficial fascia, by the superficial perineal vessels and nerves. The *aperture for the urethra* is situated in the middle line, one inch below the symphysis pubis. It is not a clean cut hole with sharp edges. The margins of the opening are prolonged over the bulb of the penis so as to form for it an aponeurotic capsule. As soon as the urethra gains the superficial aspect of the ligament, it sinks into the bulb, and is carried forwards through the entire length of the corpus spongiosum to its external opening on the glans penis. On either side of the urethral aperture there is a small opening in the ligament which

gives passage to the corresponding *artery to the bulb*. Half an inch further forwards the *dorsal nerve of the penis* and the *internal pudic artery* pierce the ligament on either side, close to the margin of the pubic arch, and under cover of the corresponding crus penis.

The term "*inferior or superficial layer*" of the triangular ligament is frequently applied to this membrane, which implies that there is a deeper or superior layer to be studied in connection with it; and so there is. But whilst these layers are very intimately connected, they must be looked upon as

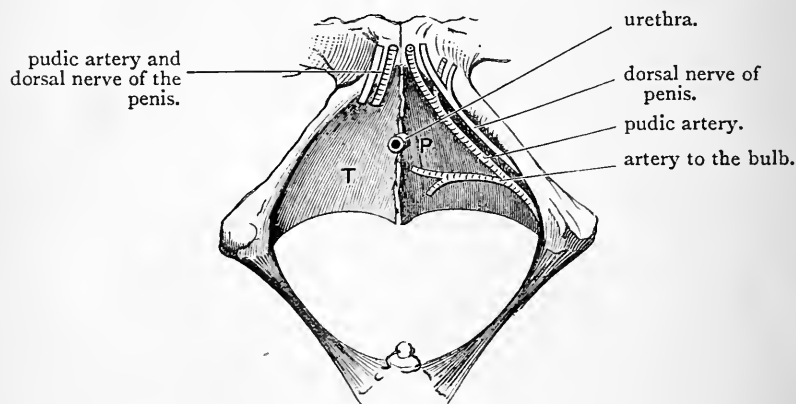


FIG. 77.—Diagram of the triangular ligament. The inferior layer or true triangular ligament is represented as having been removed on the left side.

T. Triangular ligament.

P. Superior or deep layer of the triangular ligament.

being distinct structures. The superficial or inferior layer or the triangular ligament proper is in the same morphological plane as the bony wall of the pelvis and the thyroid membrane, and, in fact, completes the pelvic wall in front. The *superior or deep layer* is simply the parietal layer of the pelvic fascia carried round to the front of the pelvis. Consequently the connections of this layer can be examined very much better in conjunction with the pelvic fascia. Suffice it for the present to say that inferiorly it is blended with the base of the triangular ligament, but that

it recedes from the surface as it passes upwards, so that a space or interval is left between the two aponeurotic strata. Contained within this interval are the following structures :—

1. The membranous portion of the urethra.
2. The dorsal vein of the penis.
3. The compressor urethræ muscles.
4. Cowper's glands.
5. The internal pudic vessels, the dorsal nerves of the penis, and the artery to the bulb.

Dissection.—To expose these parts, the superficial layer of the triangular ligament must be raised upon one side of the body. It should be carefully preserved upon the opposite side, for in the subsequent dissection of the pelvis it is required as a landmark. On the side selected detach the ligament from the margin of the pubic arch, and, cautiously raising it from the subjacent structures, throw it inwards towards the bulb.

Membranous Portion of the Urethra.—The canal of the urethra is subdivided for descriptive purposes into three parts, according to the structures which are in relation to its walls as it passes from the bladder to its termination on the glans penis. These are—(1) the prostatic portion; (2) the membranous or muscular portion; and (3) the spongy portion. Each of these subdivisions has a very definite relation to the triangular ligament; the prostatic part is placed behind this ligament; the membranous part is situated between the two layers of the ligament, whilst the spongy portion lies in front of the ligament.

Now that the superficial layer of the triangular ligament is removed upon one side, the student can readily feel with the point of the finger the staff as it lies within the membranous portion of the urethra. He should examine also its surroundings. It is the shortest subdivision of the urethra, and is distant about one inch from the symphysis pubis. Throughout its entire extent it is enveloped by the fibres of the compressor urethræ, and on this account it is sometimes called the muscular part of the urethra. On each side, and at a lower level, are Cowper's glands, whilst between it and the symphysis pubis is the dorsal vein of

the penis as it extends backwards between the two layers of the triangular ligament.

The Compressor Urethræ (*musculus transversus perinei profundus*) is a fan-shaped muscle. It has a narrow tendinous origin from the pubic arch close to the junction of the pubic and ischial rami. Expanding as it passes inwards towards the urethra, its fibres arrange themselves into two layers, which enclose between them the entire extent of the membranous portion of the urethra. The muscles of opposite sides meet therefore in the middle line, and the muscular fibres which compose the two layers are inserted into a median raphe, both upon the upper and lower aspects of the urethra. This muscle is supplied by one or two delicate twigs from the perineal division of the pudic nerve.

Cowper's Glands (*glandulæ bulbo-urethrales*).—As a general rule, these glands can readily be detected by raising the lower fibres of the compressor urethræ. They are small lobulated bodies of a deep yellow colour, and resemble peas both in size and shape. They are placed one on each side of the middle line, immediately below the membranous part of the urethra, and are overlapped by the posterior part of the bulb—separated from it, however, by the triangular ligament. From each a minute duct proceeds, but this duct does not open into the membranous portion of the urethra. It passes forwards between the wall of the urethra and the substance of the bulb for the distance of one inch, and opens on the floor of the spongy part of the urethra.

Internal Pudic Artery (*arteria pudenda interna*).—The pudic artery is a branch of the internal iliac. It is met with in three different regions of the body—viz. (1) within the cavity of the pelvis; (2) in the gluteal region, where it lies upon the spine of the ischium; and (3) in the perineal space. It is consequently described as consisting of a *pelvic*, a *gluteal*, and a *perineal* part. The *perineal* or *third part* of the pudic artery enters the perineum by passing through the small sacro-sciatic foramen. At first it is

placed deeply ; but, as it is traced forwards, it is found to become more superficial, and, at the same time, to incline inwards, so that, at its termination, it lies close to the middle line of the body.

In the rectal triangle the pudic artery is contained within a sheath, termed Alcock's canal, which is formed by the splitting of that part of the parietal pelvic fascia which forms the outer wall of the ischio-rectal fossa. It lies fully an inch and a half above the level of the lower border of the ischial tuberosity, and is accompanied by two veins and the two divisions of the pudic nerve. Of the latter the dorsal nerve of the penis lies above it and the perineal nerve below it. Reaching the base of the urethral triangle, the pudic artery insinuates itself between the two layers of the triangular ligament, and, gradually emerging from under cover of the bone, proceeds forwards along the edge of the pubic arch to a point about half an inch below the symphysis, where it pierces the superficial layer of the triangular ligament, and immediately ends by dividing into two branches under cover of the crus penis—viz. (1) the artery to the corpus cavernosum, and (2) the dorsal artery of the penis (Fig. 79, p. 362).

Branches of the Pudic Artery.—The pudic has already been seen to give off the *inferior hæmorrhoidal*, the *superficial perineal*, and the *transverse perineal arteries*, and to divide into its two terminal branches—the *dorsal artery of the penis* and the *artery to the corpus cavernosum*. Between the layers of the triangular ligament it gives origin to the *artery to the bulb*.

The *artery to the bulb* is a short wide vessel which springs from the pudic about a quarter of an inch above the level of the base of the triangular ligament. It passes transversely inwards between the two layers of this ligament, and, giving a small twig to Cowper's gland, it enters the substance of the bulb. It supplies the bulb and corpus spongiosum with blood.

The *artery to the corpus cavernosum* pierces the inner

aspect of the crus penis, and is carried forward in the substance of the corpus cavernosum, which it supplies with blood.

The *dorsal artery of the penis* runs forward in the interval between the crura penis, and, passing between the two layers of the suspensory ligament, gains the dorsum of the penis, where it will be afterwards traced.

The Pudic Nerve (nervus pudendus).—The pudic nerve

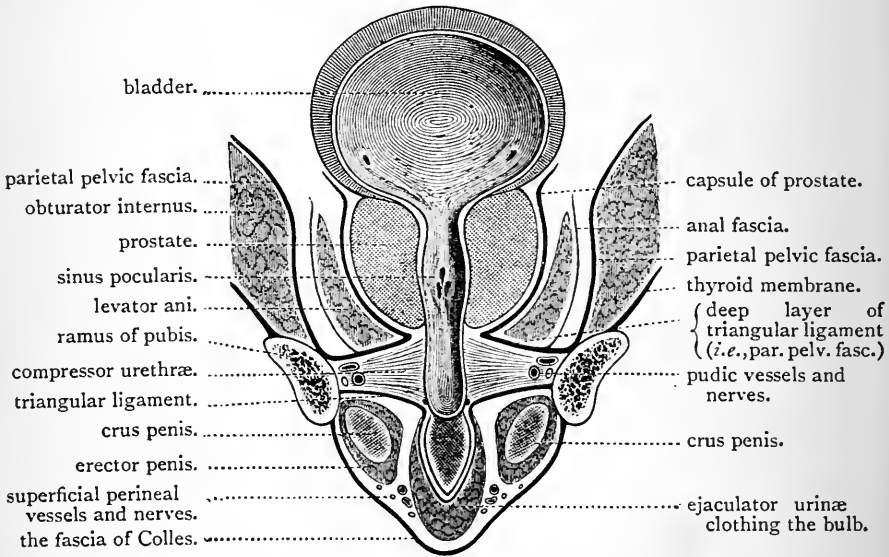


FIG. 78.—Diagram. Vertical section through the pubic arch to show the two perineal compartments and their contents.

is a branch of the sacral plexus. Following the internal pudic artery it enters Alcock's canal, and after giving off the *inferior hæmorrhoidal nerve*, it divides into two terminal divisions—viz. (1) the perineal nerve, and (2) the dorsal nerve of the penis.

The *perineal nerve* has been seen to break up into the following branches:—

- Cutaneous.* { 1. The posterior superficial perineal.
2. The anterior superficial perineal.

- Muscular.* {
1. The ejaculator urinæ.
 2. The erector penis.
 3. The transversus perinei.
 4. The compressor urethræ.

It also supplies one or two branches to the bulb and the corpus spongiosum penis.

The *dorsal nerve of the penis* follows the pudic artery between the two layers of the triangular ligament, where it lies more completely under shelter of the side of the pubic arch than the artery. Finally, piercing the superficial layer of the triangular ligament, about half an inch below the symphysis pubis, it accompanies the dorsal artery of the penis. At the root of the penis it supplies one or two twigs to the corpus cavernosum.

The dissection of the perineum is now completed, but whilst the body is in the lithotomy position, and the various parts of the perineum exposed, the student should consider what structures still cover the perineal aspect of the prostate gland. Three layers would still require to be removed to bring the prostate into view—viz. (1) the compressor urethræ muscle; (2) the parietal pelvic fascia or the deep layer of the triangular ligament; (3) the anterior fibres of the levator ani muscle. Such being the case, it will be apparent that within the limits of the urogenital triangle, and dissecting from the surface towards the prostate gland, we meet with an alternation of *muscular* and *fascial* strata, viz. :—

1. The fascia of Colles.
2. *Superficial perineal muscles.*
3. Triangular ligament.
4. *Compressor urethræ muscle.*
5. Parietal pelvic fascia or deep layer of triangular ligament.
6. *Levator ani muscle.*
7. Capsule of prostate.

Further, the fasciæ of the urogenital triangle are so arranged that they form a superficial and a deep compartment, and within one or other of these all the structures of this division of the perineum are contained (Fig. 78).

The *superficial compartment* is bounded *in front* by the fascia of Colles, *behind* by the triangular ligament, *laterally* by the attachment of these to the margins of the pubic arch, and *inferiorly* by the blending of the fascia of Colles with the base of the triangular ligament. For the contents of this compartment see p. 340 (Fig. 78).

The *deep compartment* is the interval between the triangular

ligament and the parietal pelvic fascia, and the structures which it contains are enumerated at p. 357 (Fig. 78).

Surgical Anatomy of Perineum.—In the rectal triangle the fatty tissue which fills up the ischio-rectal fossa is very liable, under certain circumstances, to inflammation. When pus forms, a knowledge of the

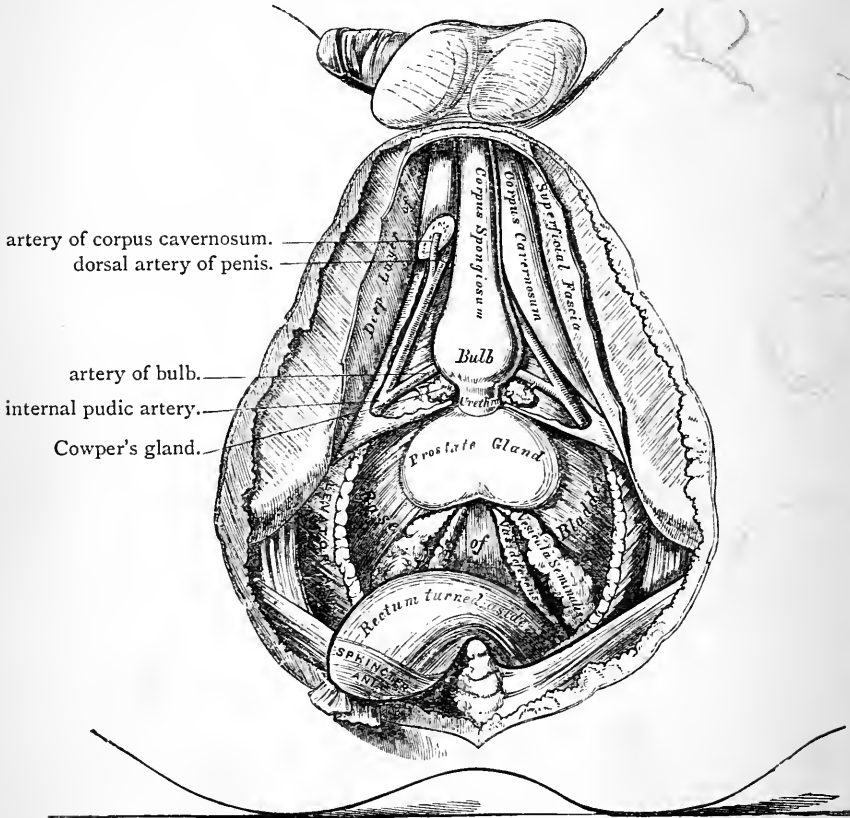


FIG. 79.—Deep dissection, in which the lower portion of the levatores ani muscles have been removed, and the external sphincter detached from the central point of the perineum, and the rectum turned back.—(From GRAY'S *Anatomy*.)

structures which compose the walls of the fossa will show why *fistula in ano* so frequently results. The pus cannot pass upwards into the pelvis on account of the union of the visceral and parietal parts of the pelvic fascia; its passage outwards is resisted by the strong parietal layer of the pelvic fascia; whilst inferiorly the dense integuments of

the hip prevent it from pointing towards the surface. The inner wall of the space, however, offers a weak resistance. Here the gut is guarded, it is true, by the rectal layer of the pelvic fascia, but in the lower part of the rectum this is very thin, and soon gives way before the continued pressure of the pus. The wall of the rectum then becomes thinned, and ultimately perforated, and the pus is voided through the anal orifice, giving rise to fistula. The lesson to learn from this is, that in every case of inflammation of the ischio-rectal fat an early incision should be made into the fossa so as to give free vent to the pus, and thus prevent its burrowing through the wall of the rectum.

In the *lateral operation of lithotomy* an accurate knowledge of the anatomy of the perineum is of great importance to the surgeon. He should know not only the structures which require to be divided, but also those which he must avoid, and how to avoid them. In the first incision, which begins in the middle line an inch and a half in front of the anus, and extends backwards and outwards into the left ischio-rectal fossa midway between the anus and ischial tuberosity, the following parts are cut :—(1) skin and superficial fascia ; (2) transversus perinei muscle and the transverse perineal artery ; (3) the lower or posterior edge of the triangular ligament ; (4) the inferior hæmorrhoidal vessels. The forefinger of the left hand is introduced into the middle of the wound and pushed upwards behind the triangular ligament until the groove of the staff, as it lies in the membranous part of the urethra, is felt. The point of the knife is now placed in the groove, and the blade lateralised. The knife is then carried steadily along the groove into the bladder. In this incision the structures divided are—(1) the membranous and prostatic portions of the urethra ; (2) the deep layer of the triangular ligament ; (3) the compressor urethræ muscle ; (4) the anterior fibres of the levator ani muscle and the left lateral lobe of the prostate.

The dangers of this operation may be considered to be three in number—(1) the artery to the bulb ; (2) the pudic artery ; (3) the rectum. Division of the artery to the bulb is an exceedingly awkward accident. The hæmorrhage resulting is very profuse, and exceedingly difficult to check on account of the short course of the vessel, its depth, and also its close connection with the layers of the triangular ligament which prevent it from retracting freely when cut. When this artery is in its normal position—*i.e.*, from a quarter to half an inch above the base of the triangular ligament—there should be little difficulty in avoiding it. In the first part of the operation it is merely the lower or posterior edge of the triangular ligament which is cut. Again, when the finger is introduced, so as to feel the staff in the membranous part of the urethra, the artery should lie in front of and superficial to it. When the artery to the bulb arises further back, as it sometimes does, it will, in all probability, be cut ; and there is no way of avoiding this, seeing that there are no means by which we can discover this abnormal origin beforehand.

The pudic artery runs no danger until it has given off the artery to the bulb, and has left the shelter of the pubic arch to lie between the layers of the triangular ligament. The risk of wounding this vessel is very slight, and it could only occur in the careless withdrawal of the knife. The superficial perineal branch of the pudic is frequently cut in the early stages of the operation, but under ordinary circumstances there is little difficulty in securing it. It has been stated, however, that if it should happen to be divided close to its origin, it might retract within Alcock's canal. The accident might then be very nearly as awkward an occurrence as a wound of the main vessel itself.

Although the rectum lies in close proximity to the membranous and prostatic parts of the urethra, it is very rarely injured. It is the invariable practice of the surgeon to empty the rectum by an enema prior to the operation.

A pad of tow, soaked in a mixture of spirit and carbolic acid, should be placed in the perineum, and the flaps of skin carefully stitched over it. On the *third day*, after the body has been brought into the Rooms, it is placed upon its face, and the dissectors of the abdomen stop work until the subject is turned, which is done *four days* later.

THE FEMALE PERINEUM.

The boundaries of the female perineum are identical with those in the male. The region, however, is wider and of greater extent. For purposes of description, it is subdivided by an imaginary transverse line drawn in front of the anus and the tuberosities of the ischium into a *posterior rectal triangle* and an *anterior urogenital triangle*.

External Anatomy.—The rectal triangle presents the same points for consideration as in the male. The external anatomy of the urogenital triangle demands the careful study of the student, because here we find the external organs of generation. They are—

- | | | |
|----------------------|--|--------------------------|
| 1. The mons Veneris. | | 4. The clitoris. |
| 2. The labia majora. | | 5. The urethral opening. |
| 3. The labia minora. | | 6. The vaginal orifice. |

All these parts are included under the common term of **Vulva**.

The **Mons Veneris** is a marked cushion-like eminence situated in front of the pubes. This projection is due to a collection of adipose tissue under the integument. It is covered with short crispy hair.

The **Labia Majora** correspond to the scrotum in the male, cleft along the middle line. They are two rounded folds, which commence in front at the mons Veneris and

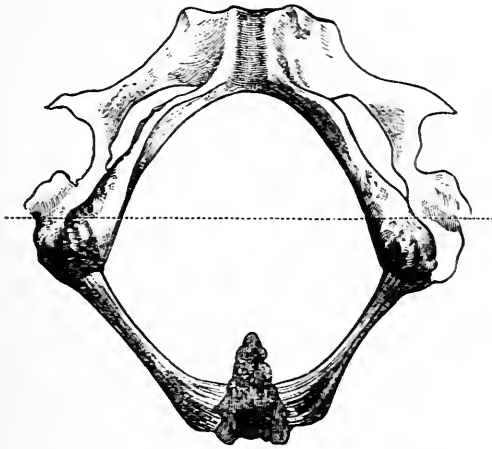


FIG. 80.—Outlet of pelvis.

extend downwards and backwards towards the anus. They diminish in thickness as they proceed backwards, and anteriorly they unite to constitute the *anterior commissure*. Externally, they are covered by skin studded with scattered hairs, whilst internally they are coated with smooth humid integument, the free surface of which is lubricated by an unctuous semi-solid secretion, derived from numerous sebaceous glands which open upon it. During parturition, the labia majora are unfolded, and thus give the vagina a greater capability of dilatation.

The labia majora enclose an elliptical fissure, which is termed the *puddental cleft*, or the *urogenital fissure*, on

account of its containing the apertures of the urethra and vagina. Within this fissure a slightly marked crescentic fold of integument stretching between the hinder parts of the labia majora will be observed. This fold receives the name of the "*fourchette*" or "*frænulum pudendi*," It is usually ruptured in first labours.

Between the fourchette and the entrance to the vagina there is a depression which is known as the *fossa navicularis*.

It may be well for the student to bear in mind that the term "perineum" in the language of the obstetric surgeon is used in a very restricted sense. It is given to the narrow interval which exists between the anus and the fourchette.

The Labia Minora or Nymphæ represent the male prepuce. They are two pendulous folds of integument which lie within the labia majora. To display them fully the labia majora must be pulled apart. They are placed one on each side of the vaginal orifice. As they proceed forwards they become more prominent, and at the same time converge so as to approximate to each other more closely. Reaching the clitoris, each terminates by splitting into two divisions or folds. The smaller and lower fold is attached to the under surface of the clitoris, and receives the name of *frænulum clitoridis*. The upper fold arches over the clitoris like a hood, and unites with the corresponding fold of the opposite side to form the *præputium clitoridis*.

The Clitoris is the homologue of the penis, and, notwithstanding its diminutive proportions, it presents a close resemblance to the male organ both in appearance and structure. It is a minute elongated projection placed below the anterior commissure, and surmounted by a sensitive rounded tubercle called the glans, but it is not traversed by the urethra. The manner in which its prepuce and frænulum are formed has already been described. To obtain a proper view of the clitoris the student must lay hold of the glans with the forceps and draw it out from the prepuce.

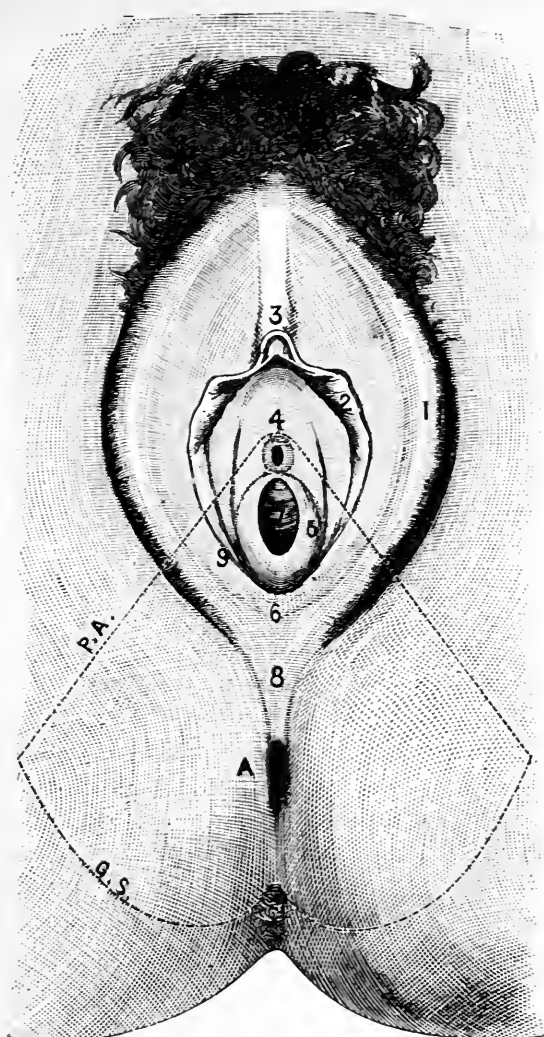


FIG. 81.—External genitalia of the female. (From Symington). The outlet of the pelvis is indicated by dotted lines.

1. Labium majus.
2. Labium minus or nympha.
3. Clitoris.
4. Vestibule (figure placed immediately above urethral opening).
5. Hymen.
6. Fourchette.

7. Vagina.
9. Opening of the duct of Bartholin's gland.
- A. Anus.
- G.S. Line of great sciatic ligament.
- P.A. Inner border of pubic arch.

Vestibule.—The dissector should next take note of a smooth triangular interval which exists between the clitoris and the entrance to the vagina. The term *vestibule* is given to this area. It is bounded laterally by the nymphæ, and towards its lower part or base is seen the orifice of the urethra.

The triangular outline of the vestibule is only seen when the labia are forcibly drawn apart from each other. In the natural condition of parts the labia are in close apposition, and the vestibule is then a deep recess which represents the bottom of the pudendal cleft, between the clitoris and the vagina.

The Urethral Orifice lies close to the opening of the vagina, about one inch below the clitoris. It is circular in form, and the mucous membrane around it is prominent, pouting and slightly puckered, so that when the tip of the finger is passed over the vestibular area the opening can readily be distinguished by touch.

The Vaginal Orifice, in the virgin, is partially closed by the *hymen*—a semilunar fold of mucous membrane attached to the posterior aspect and sides of the entrance to the vagina, and presenting a free concave margin towards the pubes. The form of the hymen, however, is very variable. Sometimes it is present in the shape of a septum attached around the entire circumference of the vaginal entrance, but pierced in the centre by a circular opening or a vertical slit; again, it may be cribriform or fringed along its free margin. Lastly, it may constitute a complete septum across the opening of the vaginal canal. In this case awkward results ensue from the retention of the menstrual fluid. After it has been ruptured its position is marked by certain rounded elevations which have received the name of *carunculæ myrtiformes*.

Passage of Catheter and Examination of Os Uteri.—The dissector should now practise the passing of the female catheter, and afterwards introduce a speculum into the vagina, so as to obtain a view of the os uteri.

The difficulty in passing the catheter arises from the fact

that the operation must be conducted without any exposure of the person. Place the forefinger of the left hand in the orifice of the vagina, with its palmar surface directed upwards towards the pubes. If the instrument be now passed along this finger, and the point raised slightly when it reaches the entrance to the vagina, a little manipulation will cause it to enter the urethra.

When the speculum is introduced into the vagina, the points to be noted in connection with the os uteri are:—(1) the small size of the opening; (2) the two rounded and thick lips which bound this aperture. In the virgin the opening is circular, but in women who have borne children it is somewhat transverse and often scarred. Note further that the anterior lip is the thicker and shorter of the two, whilst the posterior lip is the longer.

Reflection of Skin.—The rectum should be moderately filled with tow, and the vulva and anal orifice stitched up.—*Incisions*—(1) A transverse incision should, in the first place, be carried from one ischial tuberosity to the other, in front of the anus; (2) The urogenital fissure and the orifice of the anus should next be closely encircled by incisions, and these joined by a cut along the middle line. (3) Lastly, carry an incision forwards from the second or third piece of the coccyx along the middle line to the cut which surrounds the anus.

Four flaps are thus marked out; the two anterior may be thrown forwards and outwards, and the two posterior backwards and outwards.

Superficial Fascia.—The superficial fascia of the perineum is now laid bare. In the rectal triangle it agrees in every particular with the same portion of fascia in the male. In the anterior or urogenital triangle, however, owing to the difference in the external organs of generation, there is a slight modification. It presents the same two layers. In the superficial fatty layer, where it covers the labia majora, there are *dartos fibres* similar to those in the scrotum of the male. The deeper layer has the same attachments as in the male, viz., to the anterior lips of the pubic arch, and to the base of the triangular ligament; but it is not so membranaceous, and consequently does not form so distinct a stratum. The two fascial pouches are

also present in the female, and are sometimes spoken of as the *vulvo-scrotal sacs*. Their separation along the middle line is not due to the interposition of a median septum, as in the male, but to the presence of the urogenital fissure.

RECTAL TRIANGLE.

Nothing need be added to what has already been written regarding this portion of the perineal space in the male. In both sexes the steps of the dissection and the parts found are precisely the same (*vide* p. 338).

UROGENITAL TRIANGLE.

Superficial Perineal Vessels and Nerves.—Under this heading we include *two arteries* and *three nerves*, viz.:—

<i>Arteries.</i>	{	The superficial perineal artery.
	{	The transverse perineal artery.
<i>Nerves.</i>	{	The posterior superficial perineal nerve.
	{	The anterior superficial perineal nerve.
	{	The long pudendal nerve.

They have precisely the same disposition as the corresponding vessels and nerves in the male, with this exception, that they are somewhat smaller, and are distributed to the labium majus, instead of to the scrotum. For a detailed description of these structures, the student may refer to p. 347.

Dissection.—The superficial perineal vessels and nerves should now be divided and thrown backwards, and the superficial perineal muscles cleaned. These are three in number, viz., the transversus perinei, the erector clitoridis, and the sphincter vaginæ. The two first have a similar position to the corresponding muscles in the male; the sphincter vaginæ lies upon the side of the vagina close to its orifice. To obtain a good view of these muscles the superficial fascia and the labia should be dissected away.

In cleaning the muscles the dissector should look for the small nervous twigs which are given to each by the perineal division of the internal pudic nerve.

Superficial Perineal Muscles.—*The transversus perinei* has the same disposition as in the male, but it is rare to find it so well marked in the female. In most subjects its fibres are pale, and it is very difficult to define. It is a slender fasciculus which takes origin from the inner surface of the ramus of the ischium close to the tuberosity, and passes obliquely forwards and inwards to its insertion into the central point of the perineum.

In the female the central point of the perineum is placed behind the vaginal orifice.

The erector clitoridis corresponds with the erector penis in the male. It is a small muscle which arises from the inner aspect of the ischial tuberosity, and is inserted by a tendinous expansion on the surface of the crus clitoridis.

The sphincter vaginae is the representative of the ejaculator urinæ of the male. It is a true sphincter muscle, and consists of two halves, which are placed one on each side of the vaginal orifice and vestibule, and are closely adapted to the surfaces of the two halves of the vaginal bulb. Posteriorly the fibres of opposite sides unite behind the vaginal opening, and are attached to the central point of the perineum, some of the fibres intermixing with those of the sphincter ani. Anteriorly the two portions of the muscle become narrower, and, converging towards the middle line, are attached to the sides of the clitoris. In some cases a small fasciculus on each side may be observed to reach the dorsum of the clitoris, and there gain insertion into a tendinous expansion which lies superficial to the dorsal vein. This fasciculus is comparable with the anterior fibres of the ejaculator urinæ in the male, which embrace the circumference of the body of the penis.

The Perineal Triangle.—The dissector should now observe that the three perineal muscles form the sides of a small triangle, the floor of which is constituted by the superficial layer of the triangular ligament.

Perineal Body.—It has been already stated that the term “perineum” is confined by the obstetrician to the narrow interval between the fourchette and the anus.

Now that this part has been dissected, it will be seen to consist of an indefinite mass of fibrous and muscular tissue, which occupies the interval between the rectum and the vagina. This is known as the *perineal body*. Muscular tissue belonging to the sphincter ani, levatores ani and sphincter vaginæ, together with the central point of the perineum, enter into its constitution.

Dissection—The sphincter vaginæ should now be carefully raised from the surface of the bulb, and the erector muscle from the surface of the crus clitoridis. The transversus perinei muscle may be removed at the same time.

Bulb of the Vestibule.—The bulb of the vestibule is now displayed. It consists of two oblong bodies, composed of erectile tissue, placed one on each side of the vestibule and entrance to the vagina. Somewhat narrow in front, they expand as they pass backwards, and each is invested by a fibrous capsule derived from the triangular ligament, upon the anterior surface of which they rest. Externally they present a rounded convex surface which is coated with the sphincter vaginæ muscle, whilst internally, each erectile mass rests upon the deep surface of the mucous membrane of the vagina. In front of the urethra, between it and the clitoris, the two halves of the bulb are brought into direct communication with each other by a small venous plexus called the *pars intermedia*, which in turn is continuous with the erectile tissue of the glans clitoridis. To obtain a proper idea of these connections, it is necessary to study specimens which have been specially injected and prepared.

The arrangement of erectile tissue in the female corresponds more or less closely with the condition present in the male. The apparent dissimilarity is due to the presence of the urogenital fissure and orifice of the vagina. Let us suppose for a moment that the latter is obliterated, and that the vestibule is closed in the form of a canal which carries the urethra forwards to the extremity of the clitoris. The two halves of the bulb would then be in contact with

each other, and its entire surface would be covered by a muscular stratum, after the manner of the bulb and ejaculator urinæ in the male. Further, the urethra would be surrounded by erectile tissue, and the *pars intermedia* would be seen to correspond to some extent to that portion of the corpus spongiosum which in the male lies in front of the bulb, and becomes continuous with the glans.

Dissection.—If the stitches uniting the lips of the pudendal cleft have not been already removed they should now be taken away. The crura clitoridis have been exposed by the removal of the erector muscles. To obtain a good view of the entire organ, strip the mucous membrane from the body of the clitoris, and clear away the loose tissue which surrounds it. In doing this, however, remember that on its dorsal aspect certain vessels and nerves run forwards to reach the glans, and that suspending it to the front of the pubes there is the suspensory ligament.

Clitoris.—The *body of the clitoris* is composed of two cylindrical erectile bodies called the *corpora cavernosa*, which correspond with the structures that bear the same name in the male. Along the middle line they are united by their inner surfaces, and the erectile tissue of the one is separated from that of the other by an imperfect *pectiniform septum*. The body of the clitoris is about an inch and a half long. Anteriorly it terminates in a small rounded tubercle, which bears the name of the *glans clitoridis*. The glans, however, is not structurally continuous with the corpora cavernosa. It is a little mass of erectile tissue continuous with the *pars intermedia*, and fitting into a slight concavity which is formed for its reception on the extremities of the corpora cavernosa. Posteriorly, opposite the lower part of the symphysis pubis, the corpora cavernosa separate, and diverging widely from each other, form the *crura clitoridis*. Each crus is attached by its deep surface to the rami of the pubis and ischium, and is covered by its own erector muscle.

The clitoris, then, consists of three parts:—(1) a *glans* continuous with the *pars intermedia*; (2) a *body* composed

of two corpora cavernosa lying side by side and united along the middle line; and (3) *two crura* attached to the sides of the pubic arch. We have seen that the *pars intermedia* corresponds with the corpus spongiosum in the male. This apparatus in the female, therefore, closely resembles the penis in the male, the chief differences being the diminutive size of the clitoris, and the fact that the glans clitoridis is not perforated by the urethra.

Dissection.—Detach the crura clitoridis from the sides of the pubic arch and throw them aside. This dissection requires care, because the pudic arteries, the dorsal nerves of the clitoris, and the small arteries

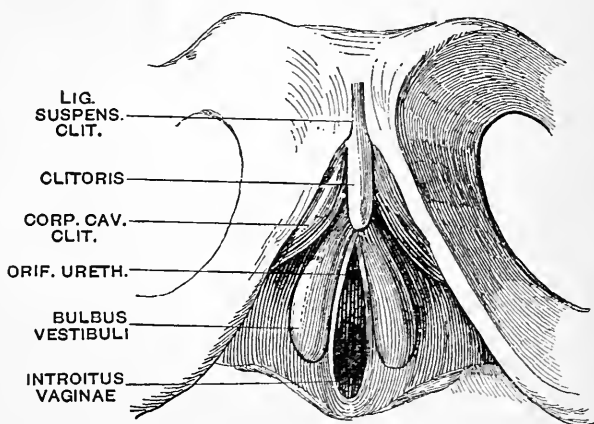


FIG. 82.—The clitoris and the bulb of the vestibule.
(From Gegenbaur.)

which enter the crura, are very apt to be injured. The pudic vessels and the dorsal nerve will be seen piercing the triangular ligament about half an inch below the symphysis pubis, and a little way external to the middle line.

The Triangular Ligament.—A good view is now obtained of the triangular ligament. Owing to the greater width of the pubic arch, it is a more extensive membrane than in the male. It does not possess the same strength, however, and is not so perfect, seeing that it is pierced by the vaginal canal.

In the middle line it is pierced fully an inch below the symphysis pubis by the urethra, and immediately below the urethral opening by the wide vaginal canal. Its base is perforated by the superficial perineal vessels and nerves, whilst the internal pudic artery and the dorsal nerve of the clitoris pierce it about half an inch below the symphysis.

The dorsal vein of the clitoris passes backwards through an oval opening between the transverse perineal ligament and the subpubic ligament.

The so-called *deep layer of the triangular ligament* is really a part of the parietal layer of the pelvic fascia. Opposite the pubic arch the deep layer of the triangular ligament by its lower border fuses with the base of the triangular ligament. As it is traced upwards, however, it recedes from the triangular ligament, and consequently a space or interval is left between them.

Dissection.—The triangular ligament should be reflected upon one side. Detach it from the margin of the pubic arch and throw it inwards. The pudic vessels and the dorsal nerve of the clitoris, together with the compressor urethræ muscle, may now be examined.

Urethra.—The female urethra is a short canal, which extends from the neck of the bladder to its orifice on the vestibule. It measures about one and a half inches in length, and has an oblique and slightly curved course from above downwards and forwards. The concavity of the curve is directed forwards. So close is its relation to the anterior wall of the vagina, that it may almost be said to be embedded in it.

At the present stage of the dissection, the urethral canal is seen to be covered by the fibres of the compressor urethræ muscle.

The leading peculiarity of the female urethra is its great dilatability. Cases are on record in which vesical calculi weighing from two to four ounces have traversed it, and thus escaped from the bladder. It thus happens that in the extraction of foreign substances from the female bladder, it is rarely necessary to have recourse to the knife.

Compressor Urethræ.—This muscle differs somewhat

from the corresponding muscle in the male. It has the same origin (viz., from the inner aspect of the pubic arch at the junction of the pubic and ischial rami), and it also divides into two bundles; but these have not the same intimate relation to the urethra. The upper or anterior bundle spreads out upon the upper or anterior surface of the urethra, whilst the lower or posterior bundle spreads out upon the wall of the vagina.

The Vagina will be fully described in connection with the pelvic viscera.

Bartholin's Glands.—These glands are the representatives in the female of Cowper's glands in the male. They are two round or oblong bodies about the size of a horse-bean, placed one upon each side of the entrance to the vagina immediately behind the rounded end of the bulb, and under cover of the sphincter vaginae. A long duct proceeds from each gland, and opens in the angle between the nymphæ and the hymen or carunculæ myrtiformes (Fig. 81, p. 367).

Internal Pudic Vessels and Nerve.—The internal pudic vessels and nerve have a precisely similar disposition to the corresponding vessels and nerve in the male (p. 358). If anything, they are somewhat smaller.

The student must therefore look for the *artery to the bulb*, a branch of the internal pudic, which in this case is given to the bulb of the vagina, and the two terminal branches of the internal pudic artery, viz., the *dorsal artery of the clitoris*, and the *artery to the corpus cavernosum*.

The internal pudic nerve ends by dividing into the perineal nerve and the dorsal nerve of the clitoris.

The *perineal nerve* gives off—(1) the anterior and posterior superficial perineal branches to the skin covering the labium majus; (2) muscular twigs to all the perineal muscles; and (3) a branch to the bulb of the vagina.

The *dorsal nerve of the clitoris* gives a twig to the corpus cavernosum, and runs forwards with the artery of the same name between the crura to reach the dorsum of the clitoris.

Dorsal Vessels and Nerves of the Clitoris.—On the dorsum of the clitoris a little dissection will display the *dorsal vein* occupying the groove in the middle line, with a *dorsal artery* and *nerve* lying upon each side of it.

The arteries and nerves should be traced forwards to their distribution in the glans.

The *dorsal vein* takes origin in the glans. As it proceeds backwards it receives certain superficial veins and also tributaries from the corpora cavernosa. At the root of the clitoris it dips downwards between the crura, and, passing between the triangular and the subpubic ligaments, is continued backwards into the pelvis to join the plexus of veins around the neck of the bladder.

ABDOMINAL WALL.

On the fifth day after the dissection of the perineum is completed, the body is placed upon its back, with blocks under the chest and pelvis, and the dissectors of the abdomen begin the dissection of the abdominal wall (Fig. 83).

External Anatomy.—It is well, however, before proceeding to the actual dissection of the part, that some attention should be paid to the general configuration and bony prominences of the region. If the subject is obese the abdomen presents a smooth, rounded, and protuberant appearance; if, on the other hand, it is spare, the abdominal wall is depressed, and the lower margin of the thorax above, and the pubes, crest of the ilium and Poupart's ligament below, stand out in marked relief. In the middle line, the student will notice a linear depression extending downwards towards the symphysis. This corresponds with the *linea alba* or the interval between the two recti muscles. It is a most important line to the surgeon, because here the wall of the abdomen is thin and devoid of blood-vessels, and, in consequence, it is chosen as the site for the incisions in the operations of ovariotomy, Cæsarean section,

and suprapubic lithotomy. In the same line the trocar is introduced into the abdomen in the operation of paracentesis abdominis or tapping.

In this linear depression, rather nearer the pubes than the ensiform cartilage, is the *umbilicus* or *navel*. This is a depressed and puckered cicatrix, the floor of which is raised in the form of a little button-like knob. It results from the closure of an opening in the abdominal wall of the fœtus, through which passed the constituents of the umbilical cord—viz., the umbilical vein, the two allantoic or hypogastric arteries, and the urachus.

In powerful well-developed subjects the rectus muscle stands out on each side of the middle line, and its outer margin gives rise to a curved line, the concavity of which is directed inwards. This line corresponds to the *linea semilunaris*—i.e., the line along which the aponeurotic tendon of the internal oblique muscle splits to enclose the rectus. The *linea semilunaris* is also frequently selected by the surgeon as the site for incisions through the abdominal wall.

The student should now place his finger upon the upper part of the symphysis pubis and carry it outwards, over the pubic crest, to the pubic spine; from this he should follow the line of Poupart's ligament to the anterior superior spine of the ilium, and, having identified these parts, let him next endeavour to determine the position of the external abdominal ring. This is easily done in a male subject. Immediately external to the spine of the os pubis the spermatic cord can be felt as it passes over Poupart's ligament to reach the scrotum. Taking this as a guide, push the loose skin of the scrotum upwards before the finger. The tip of the finger enters the opening, the sharp margins of which can now be felt.

The spermatic cord, as it passes downwards into the scrotum, should be taken between the finger and thumb. On pressure being applied the vas deferens can be easily distinguished at the back of the cord, by the hard whipcord-like feel that it conveys to the fingers.

The crest of the ilium, as it proceeds upwards and backwards from the anterior superior spine, can be easily felt. Indeed, in most cases it is visible to the eye for a distance of about two and a half inches. At the point where it disappears from view a prominent tubercle is developed on its outer lip, and it is here that the outline of the trunk joins the ilium. It is the highest point of the iliac crest, therefore, that can be seen from the front. As we shall see later on, use is made of this fact in subdividing the abdominal cavity into regions.

In females who have borne children the skin over the lower part of the abdomen is wrinkled and scarred.

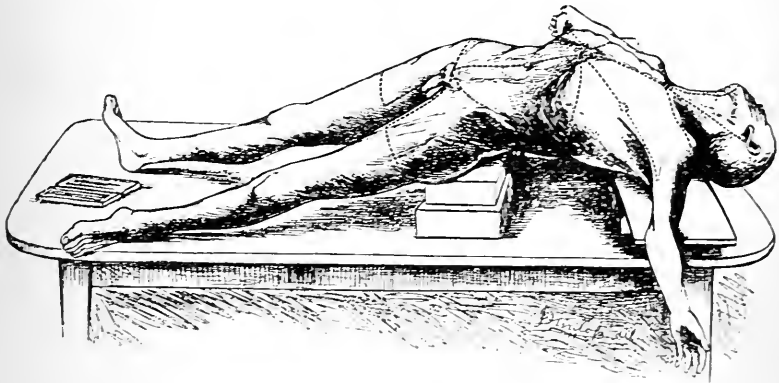


FIG. 83.

Parts to be dissected.—A dissection of the abdominal wall will display the following parts:—

1. Superficial fascia.
2. Cutaneous vessels and nerves.
3. The external oblique muscle.
4. The internal oblique muscle.
5. The lower six intercostal nerves and accompanying vessels ; the ilio-inguinal and ilio-hypogastric nerves.
6. The transversalis muscle.
7. The rectus and pyramidalis muscles and the sheath of the rectus.
8. The transversalis fascia.
9. The deep epigastric and deep circumflex iliac arteries.
10. The superior epigastric and musculo-phrenic arteries.

11. The spermatic cord.
12. The inguinal canal.
13. The extra-peritoneal fat.
14. The parietal peritoneum.

Reflection of Skin.—*Incisions*—(1) Along the middle line of the body from the ensiform cartilage to the symphysis pubis. At the navel the knife should be carried round so as to surround it with a circular incision. (2) From the ensiform cartilage transversely outwards around the chest, as far back as the knife can be carried. (3) From the symphysis pubis outwards along the line of Poupart's ligament to the anterior superior spine of the ilium, and then backwards along the crest of the ilium (Fig. 83).

The large flap of skin thus mapped out should be carefully raised from the subjacent superficial fascia and turned outwards. If the abdominal wall is flaccid, the dissection may be facilitated by inflating the abdomen. Make an incision through the umbilicus large enough to admit the nozzle of the bellows, and when the walls are quite tense secure the opening with twine, which has previously been *sewn* round the lips of the incision.

The Superficial Fascia.—The superficial fascia which is now laid bare is seen to present the same appearance, and possess the same characters as in other localities. Above, it is thin and weak, and is directly continuous with the corresponding fascia over the chest. Following it downwards, it will be noticed to become more strongly marked, and to acquire a greater density. Towards the lower part of the abdomen it consists of two layers—a fatty superficial stratum called *Camper's fascia*, and a deep membranaceous stratum termed *Scarpa's fascia*.

There is another point, however, in which the superficial fascia differs somewhat from the same fascia in other parts of the body. It is more elastic, and this elasticity is due to the presence of elastic fibres in its deeper membranaceous part. Over the lower part of the linea alba the elastic tissue is generally seen collected in the form of a distinct band. A reference to comparative anatomy gives interest to this fact. In the human subject this elastic band is the rudimentary representative of a continuous and distinct layer of yellow elastic tissue (*the abdominal tunic*), which is present in the horse.

But what becomes of the two layers of the superficial fascia if we follow them downwards from the front of the abdomen? The fatty layer of Camper is carried over Poupart's ligament, and becomes directly continuous with the fatty superficial fascia on the front of the thigh. The relations of the fascia of Scarpa are very different. In the region of the pubes it is carried continuous downwards over the spermatic cords, the penis and scrotum, into the perineum, where it becomes continuous with the fascia of Colles. On either side of this it proceeds downwards, and ends immediately below Poupart's ligament by blending with the fascia lata of the thigh.

These connections of the fascia of Scarpa are so important that it is necessary to undertake a special dissection, in order that they may be demonstrated. As this encroaches somewhat upon the region of the thigh, it must be done in conjunction with the dissection of the lower limb. A transverse incision should be made through the entire thickness of the superficial fascia on the front of the abdomen from the anterior superior spine of the ilium to the middle line of the abdomen. On raising the lower edge of the divided fascia the two layers can be easily distinguished. Insinuate the fingers between the fascia of Scarpa and the subjacent pearly-looking tendon of the external oblique muscle. Little resistance will be met, as the fascia of Scarpa is only bound down by some lax areolar tissue. As the superficial fascia is thus raised from the aponeurosis of the external oblique, the hypogastric branch of the ilio-hypogastric nerve will be seen piercing the aponeurosis, a little way above the external abdominal ring, and then sinking into the deep surface of the superficial fascia. The fingers can be readily carried downwards behind the fascia of Scarpa as far as Poupart's ligament. Here it will be found that they can force their way no further. The passage of the hand into the thigh is barred by the blending of the fascia of Scarpa with the fascia lata of the thigh. At this level it ceases to exist; it loses its identity by becoming fused with the deep fascia of the thigh. A little manipulation will show that this attachment stretches almost horizontally across the front of the thigh; that internally it coincides with Poupart's ligament, but that externally it falls below the line of this ligament.

Towards the pubes the finger can be pushed downwards behind the fascia of Scarpa and along the spermatic cord into the perineum. No barrier opposes the passage of the finger in this direction. The continuity of the fascia of Scarpa and the fascia of Colles is thus demonstrated.

If the dissector now recall the fact that in the urethral triangle of the perineum the fascia of Colles is attached laterally to the margins of the pubic arch, and posteriorly to the base of the triangular ligament, whilst anteriorly towards the abdomen it is free, he will have little difficulty in understanding the course which urine takes when extravasated from a rupture of the urethra in front of the triangular ligament. The effused fluid is directed upwards over the scrotum and penis, and along the spermatic cords to the front of the abdomen. From the abdomen it cannot pass downwards to the front of the thighs, owing to the attachment of the superficial fascia to the fascia lata. Unless vent be given to it by early and free incisions, it will continue to ascend over the abdomen.

Cutaneous Nerves.—A dissection must now be made of the cutaneous nerves of the abdomen. These are arranged on the same plan as the cutaneous nerves of the chest. We have therefore to look for an anterior and a lateral series.

- | | | |
|------------------|---|--|
| Anterior series. | { | <ol style="list-style-type: none"> 1. Anterior cutaneous nerves. 2. Hypogastric branch of the ilio-hypogastric nerve. 3. The ilio-inguinal nerve. |
| Lateral series. | { | <ol style="list-style-type: none"> 1. Lateral cutaneous nerves. 2. Lateral or iliac branch of last dorsal nerve. 3. Iliac branch of ilio-hypogastric nerve. |

The anterior cutaneous nerves are the small terminal twigs of the lower four or five intercostal nerves, and also of the last dorsal nerve. They pierce the aponeurotic sheath of the rectus muscle at variable points, some close to the middle line, and others a little distance from it. Entering the superficial fascia, they run for a short distance outwards.

To find these nerves, the best plan to adopt is to divide the superficial fascia along the middle line, and reflect it cautiously outwards. The small arteries which accompany the nerves serve as guides.

The hypogastric nerve is the terminal twig of the ilio-

hypogastric, and it lies in series with the preceding. In the dissection of the superficial fascia it has been seen piercing the aponeurosis of the external oblique immediately above the external abdominal ring.

The ilio-inguinal nerve comes out through the external abdominal ring, and is distributed to the integument of the scrotum and the inner aspect of the thigh.

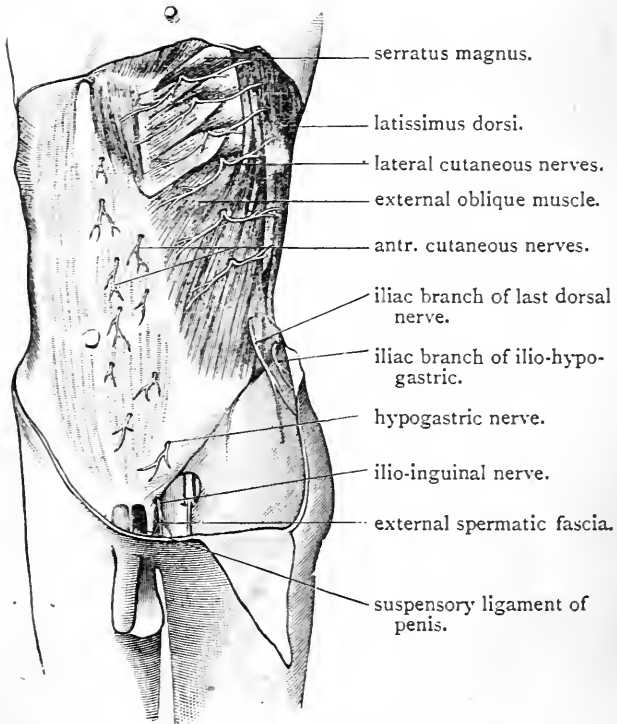


FIG. 4.—Superficial dissection of abdominal wall.

The lateral cutaneous nerves are branches of the five lower intercostal nerves. They become superficial between the digitations of the external oblique muscle, and then each divides into an anterior and posterior division. The posterior divisions are small, and are directed backwards over the latissimus dorsi. The anterior divisions run for-

ward, and a careful dissector may trace them as far as the outer margin of the rectus.

The iliac branch of the last dorsal corresponds with the lateral cutaneous branches of the intercostal nerves. It differs from the other members of the series in not dividing into an anterior and a posterior branch, and in being destined for the supply of the integument over the gluteal region. It pierces the external oblique muscle in a line with the other lateral nerves, and is then directed downwards over the crest of the ilium. It crosses the iliac crest from one to two inches behind the anterior superior spine.

The iliac branch of the ilio-hypogastric nerve is also distributed to the skin of the gluteal region. It pierces the external oblique immediately above the iliac crest, which it usually crosses opposite the tubercle which projects from the outer lip of the crest, about two and a half inches behind the anterior superior spine of the ilium.

Cutaneous Vessels.—Cutaneous arteries are found accompanying the cutaneous nerves. Those which are associated with the lateral cutaneous nerves are branches of the aortic intercostal arteries, whilst those in relation to the anterior cutaneous nerves are derived from the deep and superior epigastric arteries, and also from the aortic intercostal arteries.

In addition to these, three small branches of the femoral artery ramify in the superficial fascia of the groin.

These are—

- | | |
|---|--------------------------------------|
| } | 1. The superficial pudic. |
| } | 2. The superficial epigastric. |
| } | 3. The superficial circumflex iliac. |

They take origin in the thigh, a short distance below Poupart's ligament, and, piercing the fascia lata, diverge from each other in the superficial fascia.

The superficial pudic is directed inwards over the spermatic cord, and gives branches to the skin of the scrotum and under surface of the penis.

The superficial circumflex iliac proceeds outwards and upwards along the line of Poupart's ligament, and ends in the skin in the neighbourhood of the anterior superior spine of the ilium.

The superficial epigastric takes a vertical course upwards, and, crossing Poupart's ligament, ramifies in the superficial fascia over the lower part of the abdomen. Its branches extend as high as the level of the umbilicus.

The small *veins* which accompany these arteries open into the internal saphenous vein.

The Muscles of the Abdominal Wall.—The abdominal wall is formed anteriorly and laterally by *five pairs of muscles*, and by the aponeuroses which constitute their tendons. *In front* are the two recti muscles and the two pyramidales muscles. The recti are placed parallel to the middle line, and extend in a vertical direction from the pubic bones to the lower margin of the thorax. *On each side* three fleshy and aponeurotic strata are met with as we dissect from the surface towards the abdominal cavity. These strata are—(1) the external oblique muscle; (2) the internal oblique muscle; (3) the transversalis muscle. The direction taken by the muscular fibres which compose each of these layers is different. The external oblique corresponds in this respect with the external intercostal muscles; the fibres proceed obliquely downwards and forwards. Again, the internal oblique resembles the internal intercostal muscles in the direction of its fibres; they are directed upwards and forwards, and thus the fibres of the two oblique muscles cross each other like the limbs of the letter X. Lastly, the fibres composing the transversalis muscle pursue a horizontal or transverse course.

This difference of direction in the fibres which compose these three strata is a source of strength to the fleshy part of the abdominal wall, and offers an insurmountable barrier to the protrusion of any of the abdominal contents. The two oblique muscles and the transversalis are prolonged forwards to the middle line in the form of aponeuroses.

The union of these with the corresponding aponeuroses of the opposite side forms the linea alba—a strong band which extends in the median line from the symphysis pubis to the ensiform cartilage.

Dissection.—Remove the superficial fascia from the front of the abdomen. This will expose the aponeurosis of the external oblique muscle. Towards the thorax this aponeurosis is very thin, and is liable to injury, unless the dissection be performed with care. Proceed cautiously also at the lower part of the abdomen, above the inner end of Poupart's ligament. Here the aponeurosis is pierced in the male by the spermatic cord. The lips of the opening thus formed are prolonged downwards upon the cord in the form of a thin membrane called the *external spermatic fascia*. In defining this the blade of the knife must not be used. Work entirely with the handle. The thin layer of deep fascia which is spread over the muscular part of the external oblique muscle must also be removed. In doing this it is not necessary to carry the knife in the direction of the fleshy fasciculi. Indeed, the muscle can best be cleaned by carrying the knife at right angles to the general direction of the fibres. In front, the deep fascia will be seen to blend with the aponeurosis of the muscle, along the line of junction between the tendinous and fleshy fibres. The slips of origin of the external oblique muscle from the eight lower ribs must each be carefully defined.

The Obliquus Abdominis Externus arises by *eight* pointed processes or digitations from the outer surfaces and lower borders of the eight lower ribs (Fig. 84). Of these, the *upper five* interdigitate with the digitations of the serratus magnus, and the *lower three* with those of the latissimus dorsi. From this origin the fibres proceed downwards and forwards with varying degrees of obliquity. The *posterior fibres* have a nearly vertical direction, and are inserted into the anterior half of the outer lip of the crest of the ilium. The *superior fibres* are almost horizontal, and the *intermediate fibres* are directed obliquely downwards and forwards, and both end in a strong aponeurosis called the *aponeurosis of the external oblique*.

Superiorly, the aponeurosis of the external oblique is very thin, and is carried forwards to be attached to the ensiform cartilage. It is from this part of it that the pectoralis major derives fibres of origin. *Inferiorly* it is attached to Poupart's ligament, which, indeed, is simply the

nerve supply. Lower six intercostal nerves (Kathal branches) and last dorsal blood supply. Aortic intercostal art

thickened lower border of the aponeurosis folded back upon itself. *Between these attachments* it proceeds forwards over the rectus, and is inserted into the linea alba and into the front of the os pubis.

In connection with this aponeurosis note that it is broadest and strongest inferiorly, that it is narrowest about the level of the umbilicus, but that it widens somewhat again towards the ribs. Superiorly it is so thin that the fibres of the rectus muscle shine through it.

External Abdominal Ring (annulus inguinalis subcutaneus) (Fig. 84).—In the male, the aponeurosis of the external oblique is pierced immediately above the pubes by the spermatic cord; and in the female it is pierced, at the same point and in the same manner, by the round ligament of the uterus. The aperture which is thus formed receives the name of the external abdominal ring. At the present stage of the dissection this opening is not visible, because a thin fascial covering is carried downwards from its lips upon the spermatic cord or round ligament of the uterus. This is called the external spermatic or the intercolumnar fascia. If the cord be raised and rendered tense, this covering will be observed to invest it completely, and to be somewhat funnel-shaped—wide above, but closing upon the cord as it is traced downwards.

With the point of the knife divide the external spermatic fascia round the cord, and then, with the handle, define the margins of the external abdominal ring. When this is done, the dissector will observe that the term “ring,” as applied to this opening, is calculated to convey to the mind an erroneous impression. It is not circular, but triangular, in shape. The direction of the opening is very oblique, the base of the triangle being formed by the crest of the pubes, whilst the apex is directed outwards and slightly upwards.

The external abdominal ring, therefore, is merely a small gap or interval left between that portion of the aponeurosis of the external oblique muscle which is inserted into Poupart’s ligament, and that portion which is inserted

into the front of the pubic bone. The margins of the aperture are termed *the pillars or crura of the ring*. The *internal or superior pillar* (crus superius) is flat and broad, and is attached to the symphysis pubis. Some of its fibres cross the middle line, decussate with the corresponding fibres of the other side, and are inserted into the front of the opposite pubic bone. The *external or inferior pillar* (crus inferius) is simply the inner end of Poupart's ligament.

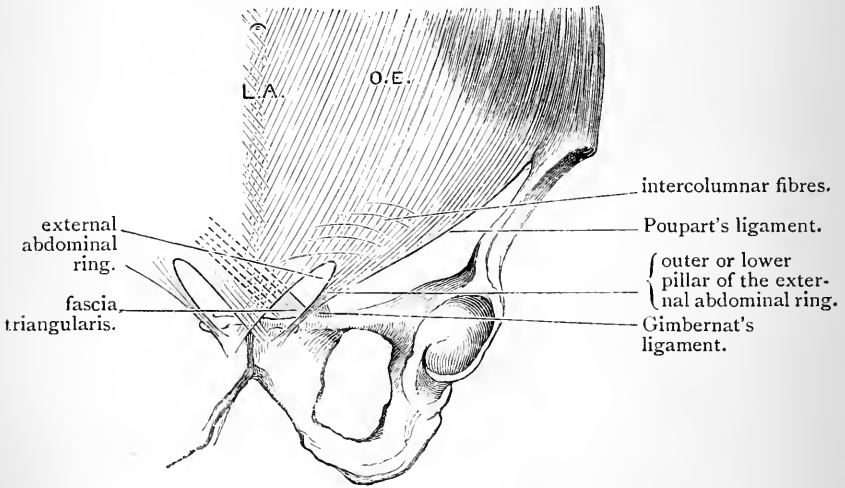


FIG. 85.—Diagram to show the connections of the lower part of the aponeurosis of the external oblique muscle.

O.E. Aponeurosis of external oblique. L.A. Linea alba.

It is, therefore, thick and strong, and is fixed to the pubic spine. The spermatic cord, as it issues from the external abdominal ring, rests upon the external pillar.

The *size* of the external abdominal ring is very variable. In the male the average length may be said to be one inch, and the breadth about half an inch. In the female it is much smaller. In the female the round ligament of the uterus will be found to end in the superficial fascia of the groin.

On a close inspection of the lower part of the external

abdominal aponeurosis, the student will observe a number of cross fibres arching over its surface. These are called the *intercolumnar fibres* (fibrae intercrurales), and in some cases they are very strongly marked. They begin at Poupart's ligament close to the iliac spine, and arch upwards and inwards above the external abdominal ring. The function of these fibres is very evident, and the term "*intercolumnar*" is derived from the part which they play. They bind together the two pillars of the ring, and prevent their further separation or divarication. There is a direct continuity between the intercolumnar fibres and the external spermatic fascia which clothes the cord, and consequently, as we have already seen, the term "*intercolumnar*" is frequently applied to the latter.

Reflection of the Obliquus Externus.—The external oblique muscle should now be reflected. Begin by detaching each digitation from the rib to which it is fixed. Between the last rib and the crest of the ilium the posterior border of the muscle will be found free; sometimes it is slightly overlapped by the latissimus dorsi, but in other cases a small portion of the internal oblique muscle can be observed in a triangular interval between them (trigonum Petiti). These points can only be seen by tilting the body slightly over on its opposite side. Raise the posterior border of the muscle from the subjacent internal oblique, and divide the fleshy fibres which are inserted into the crest of the ilium close to the bone. Next divide the aponeurosis horizontally in a line leading from the anterior superior spine of the ilium to the outer border of the rectus. The entire muscular portion, and the greater part of the aponeurotic portion of the external oblique can now be thrown forward. On approaching the outer border of the rectus, the dissector must proceed with care, because a little beyond this the anterior lamella of the aponeurosis of the internal oblique fuses with the deep surface of the aponeurosis of the external oblique. Define the line of union, and notice that it does not extend beyond the lower margin of the thorax. Above this the rectus is simply covered by the aponeurosis of the external oblique; the outer margin of the muscle in this locality is bare, and the hand can be freely passed between it and the costal cartilages.

On the *left side* of the body, the parts below the horizontal line drawn from the anterior superior iliac spine to the outer border of the rectus, and along which the aponeurosis of the external oblique muscle has been divided, should be preserved intact for the special study of those parts which are related to inguinal hernia. On the *right side* of the body divide the lower part of the aponeurosis along the outer

border of the rectus to the pubes. This incision should pass to the inner side of the internal pillar of the external abdominal ring, so that this opening may be preserved. The triangular flap of aponeurosis may now be thrown downwards and outwards. By this proceeding we can study more successfully Poupart's ligament, the entire extent of the internal oblique muscle, and the cremaster muscle.

Poupart's Ligament (ligamentum inguinale).¹—Poupart's ligament is merely the thickened lower border of the aponeurosis of the external oblique folded backwards upon itself. It thus presents a rounded surface towards the thigh and a grooved surface towards the abdominal cavity. The manner in which it is attached by its outer and inner extremities deserves the close study of the dissector. *Externally* it is fixed to the anterior superior spine of the ilium; *internally* it has a double attachment—viz. (1) to the pubic spine, which may be considered as its attachment proper; (2) through the medium of Gimbernat's ligament to the ilio-pectineal line.

Poupart's ligament does not pursue a straight course between its iliac and pubic attachments. It describes a curve, the convexity of which is directed downwards and outwards towards the thigh. By its lower border it gives attachment to the fascia lata. When this is divided Poupart's ligament at once loses its curved direction.

Gimbernat's Ligament (ligamentum lacunare) (Fig. 85) is a triangular process of aponeurotic fascia. Raise the spermatic cord, and place the finger behind the inner end of Poupart's ligament, and press downwards. The structure upon which the finger rests is the ligament in question, and the student should note that at this point it offers a barrier to the passage of the finger into the thigh. With the handle of the knife its shape and connections can be easily defined. Its *apex* is fixed to the pubic spine; by *one margin* it is attached to the inner part of Poupart's ligament; by its *other margin* it is inserted for the distance of an inch into the ilio-pectineal line. Its *base* is sharp,

¹ The term *superficial crural arch* is frequently applied to this ligament.

crescentic, and free, and is directed outwards towards the femoral sheath. The dissector should thoroughly realise that Gimbernat's ligament is not an independent structure. It is merely the inner part of the folded back margin of Poupart's ligament which, in the vicinity of the pubic spine, obtains an attachment to bone.

Gimbernat's ligament occupies an oblique plane, its lower femoral surface looking downwards and slightly forwards and outwards, whilst its upper abdominal surface looks upwards and slightly backwards and inwards. It is of importance that the student should note the precise relation which this ligament bears to the spermatic cord. Taken in conjunction with Poupart's ligament and the aponeurosis of the external oblique, it forms a gutter or groove in which the cord lies.

The Triangular Fascia (Fig. 85) is a small triangular piece of fascia which springs from the attachment of Gimbernat's ligament to the inner end of the ilio-pectineal line. It passes upwards and inwards under cover of the internal pillar of the external abdominal ring, and is inserted into the linea alba. If the fibres which compose it are followed through the linea alba, they will be found to be continuous with the fibres of the aponeurosis of the external oblique muscle of the opposite side. It must, therefore, be considered as an additional insertion of this muscle. It is frequently so poorly developed, that its true relations and connections are demonstrated with difficulty.

Dissection.—The internal oblique muscle should now be cleaned. Towards its lower part it will be seen to be pierced by certain nerves, and these must be preserved. Close to the iliac crest the *iliac branches* of the ilio-hypogastric and last dorsal nerves will be noticed emerging from the midst of its fleshy fibres, whilst in front it is pierced by the *hypogastric branch* of the ilio-hypogastric and by the *ilio-inguinal nerve*. The former of these appears near the anterior superior iliac spine, and then proceeds forwards under cover of the external oblique aponeurosis, which it soon pierces. The ilio-inguinal nerve will be found perforating the internal oblique a little way in front of the hypogastric nerve and at a lower level. It becomes superficial by passing through the external abdominal ring.

Care must be taken in defining the lower margin of the muscle to preserve its relations to the spermatic cord, and not to injure the muscular fasciculi which it gives to the cremaster muscle.

The Obliquus Abdominis Internus (Fig. 86) *arises*—(1) from the abdominal grooved surface of Poupart's ligament in its outer half; (2) from the middle lip of the anterior two-thirds of the iliac crest; (3) from the lumbar aponeurosis. From this origin the muscular fibres radiate, but the general direction is from below upwards and forwards. *The posterior fibres ascend, and are inserted into the lower borders of the cartilages of the lower four ribs.* These fibres occupy the same plane as the internal intercostal muscles—indeed, they will be observed to be directly continuous with the fibres of the internal intercostal muscles of the two lower spaces. *The lower fibres, or those springing from Poupart's ligament, arch downwards and inwards, and join with the lower fibres of the transversalis in a flat tendon, called the conjoined tendon, which is inserted into the pubic crest, and into the ilio-pectineal line behind Gimbernat's ligament, for fully half an inch of its extent* (Fig. 87). *The intermediate fibres proceed upwards and forwards, and end in a strong aponeurosis, which extends from the lower margin of the chest to the pubis. By this aponeurosis they gain insertion into the lower borders of the seventh and eighth ribs and the ensiform cartilage, and into the linea alba throughout its entire length.* The manner, however, in which the aponeurosis reaches the middle line requires special description.

At the outer margin of the rectus muscle the aponeurosis of the internal oblique splits into two layers—a superficial and a deep. The *superficial aponeurotic layer* passes in front of the rectus, and has already been seen to fuse with the aponeurosis of the external oblique muscle. The *deep layer* is carried inwards behind the rectus, and becomes incorporated with the subjacent aponeurosis of the transversalis muscle. But this arrangement does not hold good lower down than a point about midway between the umbilicus and the pubes. Below this point the tendon

does not split, but passes entirely in front of the rectus, to join the aponeurosis of the external oblique.

It is important to mark exactly the relation which the

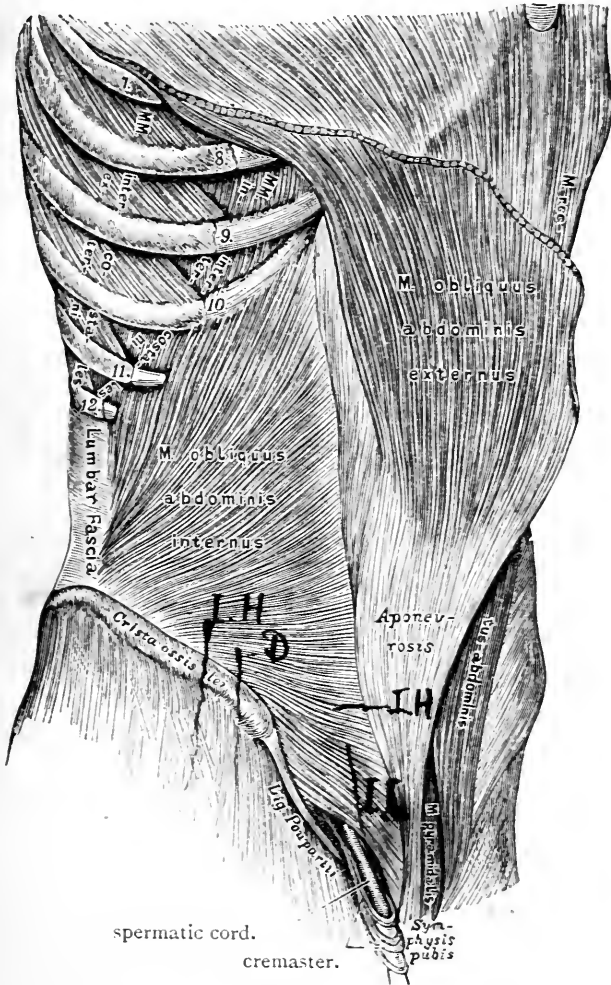


FIG. 86.—From HEITZMANN'S *Anatomy* (slightly modified).

lower part of the muscle bears to the spermatic cord. At first the cord lies under cover of the fleshy fibres, but it soon emerges, clothed by the cremaster muscle, and as

it is continued downwards and inwards to the external abdominal ring, it lies in front of the conjoined tendon. Especially note the position of the conjoined tendon in relation to the external abdominal ring. It lies immediately behind it, and gives strength to this otherwise weak point in the abdominal parietes.

Cremaster Muscle.—This muscle supports the testicle and spermatic cord, and is consequently peculiar to the male. It *arises* from the inner part of Poupart's ligament, and also derives fibres from the lower border of the internal

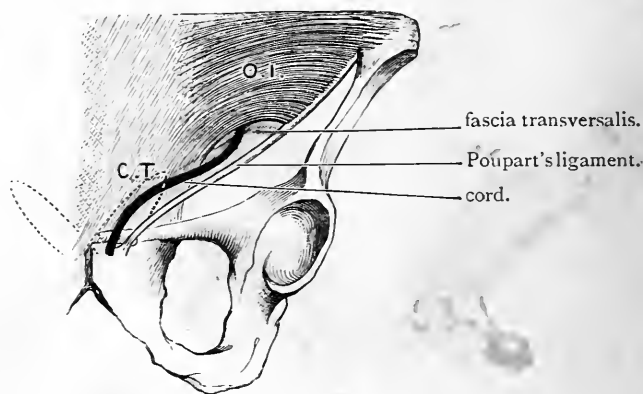


FIG. 87.—Diagram to illustrate the relation of the lower border of the internal oblique muscle to the cord, the conjoined tendon, and the inguinal canal.

O.I. Internal oblique muscle.
C.T. Conjoined tendon.

The position of the external abdominal ring is indicated by a dotted outline.

oblique (rarely from the lower border of the transversalis muscle). The fleshy fibres descend upon the outer and anterior aspects of the cord in the form of loops, the concavities of which are directed upwards. The depth to which these loops descend varies. Some reach the tunica vaginalis of the testicle, and the scrotum should now be opened up on the right side, in order that they may be traced downwards to this point; the majority of the fibres, however, do not reach so far down, some going no further

than the external abdominal ring. Upon the posterior aspect of the cord the loops are directed upwards, and some reaching the os pubis, obtain a tendinous insertion into its spine and crest.

It will be noticed that the cremasteric fleshy loops do not form a complete investment for the cord and testicle. The intervals between the fasciculi are occupied by areolar tissue, and this combination of muscular and areolar tissue is sometimes termed the *cremasteric fascia*.

Reflection of Internal Oblique.—On the *right* side of the body the entire muscle may be reflected, but on the left side preserve the lower portion of it (*i.e.*, that part which is still covered by the aponeurosis of the external oblique) *in situ*. Begin below by dividing the muscular fibres along the crest of the ilium. The depth to which the knife should be carried is indicated by the dense areolar tissue which lies between it and the subjacent transversalis muscle. An ascending branch from the deep circumflex iliac artery will also serve as a guide. This vessel emerges from the fibres of the transversalis close to the fore part of the iliac crest, and is then directed upwards upon its surface. Although this vessel has not attained the dignity of a name, it is a very constant branch. On the right side the fibres springing from Poupart's ligament should also be severed, but on the left side carry the knife horizontally inwards, from the anterior superior spine of the ilium to the outer margin of the rectus. Now turn to the upper part of the muscle, and make an incision through it along the lower margin of the thorax, from the outer border of the rectus to the last rib. Lastly, carry the knife downwards, from the tip of the last rib to the crest of the ilium.

The muscle freed in this manner can be thrown forwards towards the outer border of the rectus. In doing this the dissector must proceed with caution, because he has reached the plane of the main trunks of the nerves of the abdominal wall and the arteries which accompany them. These pass forwards between the internal oblique and transversalis, and, in raising the former muscle, they are apt to adhere to its deep surface and be cut.

In all probability the student will experience considerable difficulty in separating the lower part of the internal oblique from the corresponding portion of the transversalis. At this level these two muscles are always closely connected, and in some cases they may be even found to be partially blended.

The *cremaster muscle* should also be reflected from the spermatic cord. This can best be done by making a longitudinal incision along it. Entering the deep surface of the cremaster is a small *branch of the deep epigastric artery* and the *genital branch of the genito-crural nerve*. These constitute its vascular and nervous supply, and must, if

possible, be secured. Now clean the transversalis muscle, and dissect out the vessels and nerves which lie upon it.

Nerves of the Abdominal Wall.—Running forwards upon the transversalis muscle, the dissector will find the following nerves:—

- | | | |
|---|--|---|
| 1. The anterior portions of the lower six intercostal nerves. | } The anterior primary divisions of the lower seven dorsal nerves. | |
| 2. The last dorsal nerve. | | |
| 3. The ilio-hypogastric nerve. | | } From the anterior primary division of the first lumbar nerve. |
| 4. The ilio-inguinal nerve. | | |

The *six lower intercostal nerves* issue from the anterior ends of the six lower intercostal spaces, and then proceed forwards, between the internal oblique and transversalis muscles, to the outer border of the rectus. Here they disappear by piercing and passing within the sheath of this muscle. In a future dissection they will be observed sinking into the substance of the rectus, supplying it with twigs, and then turning forwards to pierce the sheath a second time. They end on the front of the abdomen as the *anterior cutaneous nerves*. Midway between the spine and the linea alba they give off the *lateral cutaneous nerves*. They likewise supply offsets to the transversalis and two oblique muscles. Minute arteries accompany these nerves.

The *last dorsal nerve* has the same relation in the abdominal wall as the preceding nerves. It gives off the same branches, but in addition supplies a branch to the *pyramidalis muscle*. Its *lateral cutaneous* or *iliac branch*, however, goes to the skin of the buttock.

The *ilio-hypogastric* and *ilio-inguinal* are the two lowest nerves of the series. They are directed forwards between the internal oblique and the transversalis close to the crest of the ilium.

The ilio-hypogastric is the higher of the two, and gives off an *iliac* or *lateral branch*, which pierces the two oblique muscles and then crosses the crest of the ilium to reach the skin of the gluteal region. The *hypogastric portion* of the nerve perforates the internal oblique a short distance

in front of the anterior superior spine of the ilium, and then runs forwards towards the linea alba. It becomes superficial by piercing the aponeurosis of the external oblique immediately above the external abdominal ring.

The *ilio-inguinal nerve* gives off no lateral branch. It pierces the internal oblique, to which it gives branches, a short distance above Poupart's ligament, and it becomes superficial by passing through the external abdominal ring.

Transversalis Muscle (*musculus transversus abdominis*).—This is the deepest of the three muscular strata which enter into the formation of the wall of the abdomen. It has a threefold origin—viz., from the pelvis, from the vertebral column, and from the costal cartilages. By its *pelvic origin* it is attached to the outer third of Poupart's ligament and to the anterior two-thirds of the inner lip of the crest of the ilium; by its *costal origin* it arises from the inner surfaces of the costal cartilages of the lower six ribs by a series of slips or digitations which interdigitate with the slips of origin of the diaphragm; by its *vertebral origin* it is attached through the medium of the lumbar fascia to the spinous processes, transverse processes, and bodies of the lumbar vertebræ. In point of fact, the lumbar fascia constitutes the posterior aponeurosis of this muscle. But the manner in which this fascia is attached to the vertebræ requires further explanation. As it approaches the spine it splits into three layers or lamellæ; of these the *posterior lamella* is attached to the tips of the spinous processes, the *anterior lamella* to the bodies of the vertebræ at the roots of the transverse processes, and the *intermediate lamella* to the tips and adjacent sides of the transverse processes. Two aponeurotic compartments are thus formed, the posterior of which is occupied by the erector spinæ, whilst in the anterior is placed the quadratus lumborum. These are points which cannot be demonstrated in this dissection, but a reference to Fig. 88 will help the student to understand the arrangement.

Anteriorly the fibres of the transversalis muscle end in

a strong aponeurosis, which is inserted into the linea alba, the pubic crest, and the ilio-pectineal line. Towards this aponeurosis the fleshy fibres for the most part run in a transverse direction. The lower fibres, however, take a curved course downwards and inwards, so that the muscle presents an arched lower margin.

The dissector has already seen that the lower portions of the aponeuroses of the internal oblique and the trans-

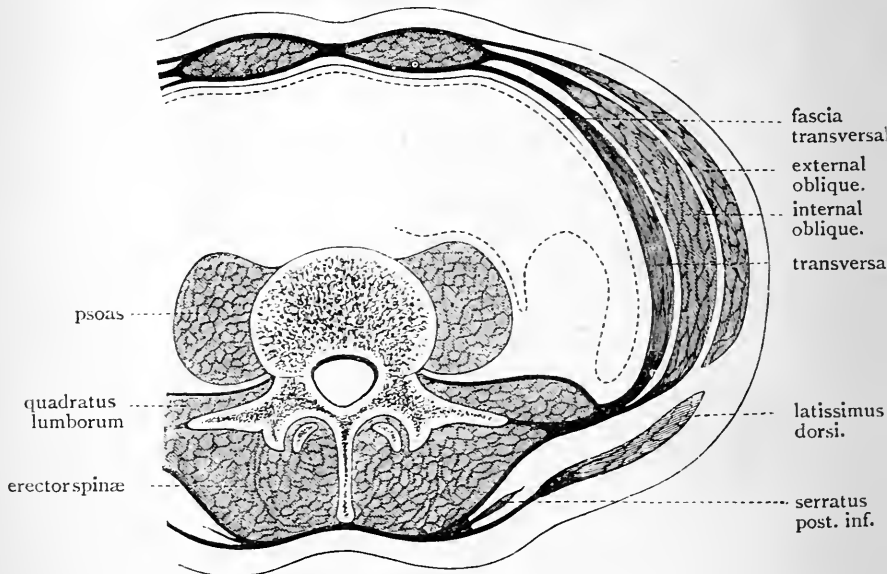


FIG. 88.—The dotted line represents the peritoneum.

versalis muscles blend to form the *conjoined tendon*. It is through the medium of this tendon that the transversalis gains its insertion into the pubic crest and into the ilio-pectineal line. The aponeurosis of the transversalis constitutes the greater portion of the conjoined tendon—indeed, whereas the internal oblique aponeurosis has an attachment to the ilio-pectineal line of little more than half an inch, the aponeurosis of the transversalis is fixed to fully an inch of this line.

Above the level of the conjoined tendon the aponeurosis

of the transversalis is inserted into the linea alba, but in passing inwards to this insertion it presents two different

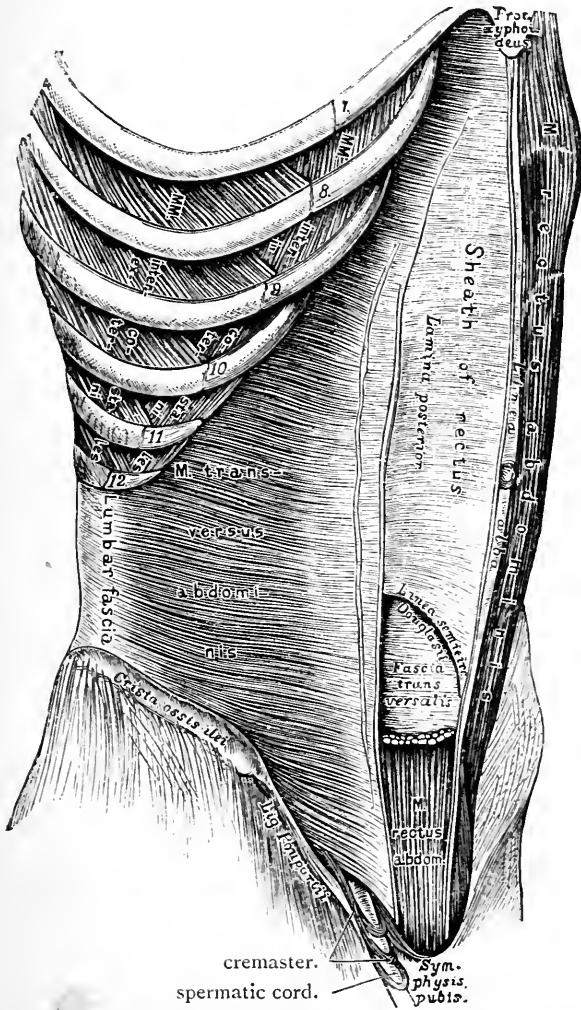


FIG. 89.—External oblique, internal oblique, anterior lamella of rectal sheath, and upper portion of rectus removed.—(From HEITZMANN'S *Anatomy*—slightly modified.)

relations to the rectus muscle. Down to a point midway between the umbilicus and pubes it passes *behind* the

rectus, and blends with the posterior lamella of the aponeurosis of the internal oblique. Below this point it passes *in front* of the rectus, and blends with the aponeuroses of the internal oblique and external oblique.

Dissection.—The sheath of the rectus should now be opened on both sides of the body by a vertical incision along the middle line of the muscle. The divided anterior lamella should then be carefully raised from the surface of the muscle and turned outwards and inwards. At the *lineæ transversæ* this can only be done with difficulty, so close is the connection between the sheath and the tendinous intersections of the muscle.

Contents of the Sheath of the Rectus.—Within the rectal sheath we find the following structures :—

1. The rectus muscle.
2. The pyramidalis muscle.
3. The terminal portions of the six lower intercostal nerves, and the last dorsal nerve.
4. The deep epigastric artery.
5. The superior epigastric artery.

In cleaning the rectus keep in mind the intercostal nerves and the last dorsal nerve. These will now be seen to enter the sheath and sink into the rectus. After supplying it with twigs, they come forward from its substance as the *anterior cutaneous* nerves of the abdomen.

Rectus Muscle (*musculus rectus abdominis*).—This is a broad band of muscular fibres which stretches between the chest and the pubes, on each side of the *linea alba*. Inferiorly it *arises* by two heads; of these, the external and larger is attached to the pubic crest, whilst the internal and smaller is fixed to the ligaments in front of the symphysis pubis. Towards the chest the muscle widens and becomes thinner, and its *insertion* is effected by three large slips into the anterior aspect of the costal cartilages of the *fifth, sixth and seventh ribs*.

The rectus muscle is broken up into portions by irregular tendinous intersections—the *inscriptiones tendineæ* or *lineæ transversæ*. These are usually three in number, and are placed, one at the level of the umbilicus, another

opposite the ensiform cartilage, and a third midway between. A fourth intersection is sometimes found below the umbilicus. We have seen that these tendinous intersections are closely adherent to the sheath of the rectus in front. Raise the muscle, and it will be apparent that they have no attachment to the sheath behind.

Pyramidalis Muscle.—This is a small triangular muscle—not always present—which springs from the front of the pubes and the ligaments of the symphysis, and is inserted into the linea alba. It lies upon the lower part of the rectus, and is supposed to act as a tensor of the linea alba.

The nerve of supply to the pyramidalis comes from the last dorsal nerve. To bring it into view the muscle must be carefully detached from the linea alba and turned downwards towards the pubes. The nerve will be exposed entering its deep surface.

Sheath of the Rectus (*vagina recti abdominis*).—The dissector is now in a position to study the manner in which the rectal sheath is formed. An examination of the relations which the aponeuroses of the three flat muscles of the abdomen bear to the rectus, will show that the sheath is incomplete, in so far as the rectus is concerned. It is deficient *posteriorly*, both above and below.

From the lower margin of the thorax to a point midway between the umbilicus and pubes, it encloses the rectus upon all sides. Here the *anterior wall* or *lamella* is formed by the aponeurosis of the external oblique fused with the anterior layer of the aponeurosis of the internal oblique, whilst the *posterior wall* or *lamella* is formed by the fusion of the posterior layer of the aponeurosis of the internal oblique with the aponeurosis of the transversalis.

Superiorly, the rectus muscle rests directly upon the costal cartilages, and the sheath is merely represented by the aponeurosis of the external oblique, which covers the muscle anteriorly. *Inferiorly*, the posterior wall of the sheath is also absent, and the rectus rests on the transversalis fascia. Here, however, the anterior wall is formed by a blending of all three aponeuroses (Fig. 91).

The lower free margin of the posterior lamella of the sheath can be easily defined by raising the rectus and working with the handle of the knife. It usually presents a sharp lunated edge, the concavity of which is directed downwards to the pubes. It is called the *semilunar fold of Douglas* (linea semicircularis). The deep epigastric artery will be observed to enter the sheath by passing upwards in front of this free border.

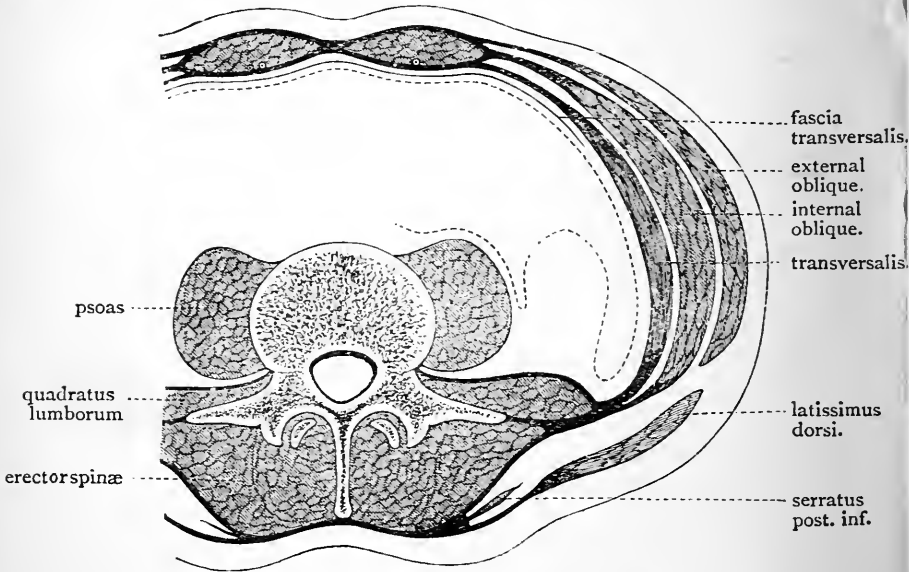


FIG. 90.—The dotted line represents the peritoneum.

The semilunar fold of Douglas is often rendered indistinct by the presence of scattered tendinous bundles crossing behind the lower part of the rectus.

Linea Alba.—The linea alba can now be studied to the best advantage. It is a dense fibrous cord or band which extends perpendicularly between the ensiform cartilage and the symphysis pubis. It is formed by the union and decussation of the fibres composing the aponeuroses of the two oblique and the transversales muscles of opposite sides. Above the umbilicus it is somewhat broader than

in its lower part. A close examination will show that it is pierced by several small round openings for the transmission of blood-vessels, and from some of these the dissector may even observe minute fatty masses protruding. A little below its middle is the umbilicus, but the foramen, of which this is the remains, is now completely closed; indeed, in the adult the linea alba is stronger at this point than elsewhere.

Fascia Transversalis.—This is a thin layer of fascia which is spread out upon the deep surface of the transversalis muscle. The fascia of one side is directly continuous with the fascia of the opposite side, and it forms a part of an extensive fascial stratum which lines the entire abdominal wall, and is placed between the abdominal

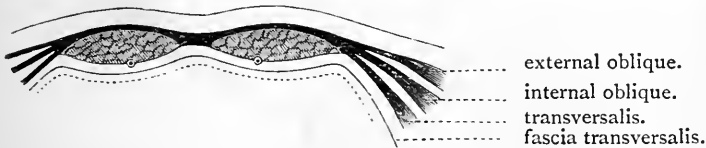


FIG. 91.

muscles and their aponeuroses on the one hand, and the extra-peritoneal fatty tissue on the other.

Traced upwards, the fascia transversalis becomes thin, and at the margin of the thorax it is directly continuous with the fascia which lines the lower surface of the diaphragm. Towards the inguinal region it plays an important part as a constituent of the abdominal wall. Here, then, it must be studied with great care.

In the present state of the dissection (on the right side of the body), a small gap or interval is seen to exist between the lower arched border of the transversalis muscle and Poupart's ligament. The membrane which fills up this interval is the *transversalis fascia*. At no part of the abdominal wall is the fascia stronger than here, and this accession of strength is obviously for the purpose of compensating for the deficiency in the internal oblique and

transversalis muscles, which, at this point, do not descend so low as Poupart's ligament. In this interval the transversalis fascia has an important relation to the spermatic cord. Here the fascia is pierced by the cord, but as yet no opening is visible. Take hold of the cord and draw it downwards and inwards. The margins of the aperture through which it passes will be observed to be prolonged downwards upon the cord in a funnel-shaped manner, so

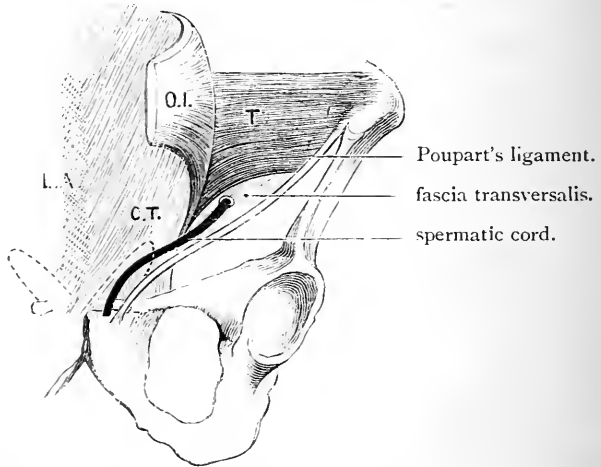


FIG. 92.—Diagram to illustrate the relation of the lower portions of the internal oblique and transversalis muscles to the inguinal canal. The position of the external abdominal ring is indicated by a dotted line.

- | | |
|---|------------------------|
| O.I. Lower part of the internal oblique thrown forward. | C.T. Conjoined tendon. |
| T. Lower part of transversalis. | L.A. Linea alba. |

as to invest it upon all sides with a tube of fascia. This investment, which is thus seen to come directly from the fascia transversalis, is called the *infundibuliform* or *internal spermatic fascia*.

Dissection.—It must now become the object of the dissector to demonstrate the more important attachments of this fascia. For this purpose divide the fibres of the transversalis muscle along the outer part of Poupart's ligament and along the crest of the ilium, and, raising the muscle from the subjacent fascia, throw it upwards. It is not necessary to reflect the entire muscle.

Attachments of the Fascia Transversalis.—When the fascia is cleaned with the handle of the scalpel, it will be seen to be attached *laterally* to the inner lip of the iliac crest. Along the line of this attachment, which is by no means firm, it becomes continuous with the *fascia iliaca*—that portion of the same fascial stratum which covers the iliacus and psoas muscles in the iliac fossa. Close to the crest of the ilium the fascia transversalis is pierced first by the ascending branch and then by the terminal branches of the deep circumflex iliac artery. *In front*, in the inguinal region, its connections are more complicated, and must be studied at three different points—(1) between the anterior superior iliac spine and the femoral artery, where it will be seen to be attached to Poupart's ligament; along this line also it becomes continuous with the fascia iliaca; (2) opposite the femoral vessels, where it is carried downwards into the thigh behind Poupart's ligament, to form the anterior part of the femoral or crural sheath (*vide* p. 215); (3) internal to the femoral vessels, where it is attached to the ilio-pectineal line and the pubic bone, behind the conjoined tendon, with which it is partially blended.

Internal Abdominal Ring (*annulus inguinalis abdominalis*).—We have seen that the transversalis fascia is pierced by the spermatic cord. The opening through which it passes is called the *internal abdominal ring*. This opening can only be defined from the front by an artificial dissection—viz., by dividing the infundibuliform fascia around the cord, and pushing it upwards with the handle of the knife. The ring thus defined will be observed to lie about half an inch above Poupart's ligament, at a point midway between the symphysis pubis and the anterior superior spine of the ilium. Through the opening the dissector can see the extra-peritoneal fat upon which the transversalis fascia rests, and immediately internal to the opening he will notice the deep epigastric artery, pursuing its oblique course upwards and inwards, and shining through the fascia. If the handle of the knife be now introduced into the ring and carried outwards between the fascia and extra-peritoneal

fat, the attachments of the fascia to Poupart's ligament and to the iliac crest can be very clearly shown.

Canalis inguinalis.—The dissector has observed that the spermatic cord in the male and the round ligament in the female pierces the abdominal wall above Poupart's ligament. The passage which is formed for their transmission receives the name of the *inguinal canal*. Now, as this canal is a source of weakness to the abdominal wall, and as it is in connection with it that inguinal hernia occurs, the student will understand how necessary it is that he should examine it carefully from all points of view.

The *inguinal canal* is a narrow channel of about one inch and a half in length. It begins at the internal abdominal ring, which may be spoken of as its inlet, and ends at the external abdominal ring, which constitutes its outlet. It is, consequently, very oblique, having a direction almost directly inwards, with a slight inclination downwards and forwards. So much for its length and direction; we have still to make out in connection with it (1) a floor; (2) an anterior wall; and (3) a posterior wall.

The *floor* is formed in the first part of the canal by the upper grooved surface of Poupart's ligament. Towards the outlet, however, the floor becomes broader and more definite; here it is formed not only by Poupart's ligament, but also by Gimbernat's ligament. At this point, as the student has already observed, the cord rests directly upon the abdominal surface of the latter ligament. The parts which enter into the formation of the *anterior wall* are—(1) the aponeurosis of the external oblique throughout the entire extent of the canal; and (2) the lower border of the internal oblique in the outer third of the canal. These facts can be readily verified by restoring the structures to their original positions. The parts which compose the *posterior wall* are still *in situ*. Naming them in order, from the inlet to the outlet, they are—(1) the fascia transversalis; (2) the conjoined tendon; and (3) the triangular fascia, when it is strongly developed.

But it may be asked, Does the transversalis muscle take

no part in the formation of the inguinal canal? The student can readily satisfy himself as to this point. He will notice that the arched lower border of this muscle does not descend so low as that of the internal oblique, that, in fact, it stops short immediately above the internal abdominal ring. The canal is closed superiorly by the approximation of the anterior and posterior walls above the cord and by the intervention between these walls of the lower borders of the transversalis and internal oblique.

There is still another point to be noted, viz., the relation which the deep epigastric artery bears to the posterior wall of the canal. This vessel can be felt (and, indeed, in most cases seen) extending obliquely upwards and inwards behind the transversalis fascia to the outer border of the rectus. A triangular space is thus mapped out by the artery, Poupart's ligament, and the outer border of the rectus. This receives the name of the *triangle of Hesselbach*. The floor of the space is formed by the posterior wall of the inguinal canal, and chiefly by that part of it which is composed of the conjoined tendon.

In the female the inguinal canal is much smaller than in the male. It has the same boundaries, and it is traversed by the round ligament of the uterus.

Arteries of the Abdominal Wall.—In the abdominal wall we find the following arteries:—

1. The intercostal and lumbar arteries.
2. The deep epigastric.
3. The deep circumflex iliac.
4. The superior epigastric.
5. The musculo-phrenic.

The *intercostal arteries* of the three lower spaces are prolonged forwards between the internal oblique and the transversalis. They have already been noted accompanying the corresponding nerves. In front they anastomose with the epigastric arteries, whilst inferiorly they effect communications with the lumbar arteries.

The *abdominal branches* of the *lumbar arteries* ramify between the same two muscles as the preceding vessels,

but at a lower level in the abdominal wall. Anteriorly they anastomose with the deep epigastric artery; above with the intercostal arteries; and below with the deep circumflex iliac and the ilio-lumbar.

1064 The Deep Epigastric Artery (arteria epigastrica inferior), a branch of the external iliac, is a vessel of some size, and takes origin about a quarter of an inch above Poupart's ligament. At present it is seen shining through the fascia transversalis and forming the outer boundary of Hesselbach's triangle. Divide the fascia transversalis along its course and it will be observed to be accompanied by two veins. Study the course and relations of this vessel. At first it runs inwards for a short distance between Poupart's ligament and the internal abdominal ring, and then changing its direction it is carried upwards and inwards on the inner side of the ring. Reaching the deep surface of the rectus it enters the rectal sheath, and proceeding vertically upwards, ends near the lower margin of the thorax in branches which sink into the substance of the muscle and anastomose with the superior epigastric and the intercostal arteries.

In the first part of its course, the deep epigastric lies in the extra-peritoneal fat between the peritoneum and the fascia transversalis. It soon, however, pierces the fascia, and, passing in front of the fold of Douglas, ascends between the rectus muscle and the posterior lamella of its sheath. These are its immediate relations, but there are others of equal importance, viz. (1) as it runs upwards it lies close to the inner side of the internal abdominal ring; (2) as the spermatic cord traverses the inguinal canal it lies in front of the artery, only separated from it by transversalis fascia; (3) as the vas deferens passes from the inguinal canal into the abdominal cavity it hooks round the outer side of the artery.

The branches which spring from the deep epigastric are—

1. Cremasteric.
2. Pubic.
3. Cutaneous.
4. Muscular.

The *cremasteric* is a small twig which supplies the cremaster muscle and anastomoses with the spermatic artery. The *pubic*, also insignificant in size, goes to the back of the pubes, where it anastomoses with a small branch from the obturator. The importance of this branch arises from the fact that the anastomosis which it establishes sometimes becomes so large as to take the place of the obturator artery. *The muscular branches* are given to the substance of the rectus, and the *cutaneous offsets* pierce the abdominal muscles and anastomose with the superficial epigastric artery.

The Deep Circumflex Iliac (*arteria circumflexa ilii profunda*) springs from the outer side of the external iliac artery, about the same level as the deep epigastric, and runs outwards behind Poupart's ligament to the anterior superior spine of the ilium. From this point onwards it takes the crest of the ilium as its guide, and ends by anastomosing with the ilio-lumbar artery. At first it is placed in the extra-peritoneal fat, and consequently it lies between the fascia transversalis and the peritoneum. Its course behind Poupart's ligament is indicated by a whitish line, which marks the union of the fascia transversalis and fascia iliaca; and if the former fascia be now divided along this line, the deep circumflex iliac will be exposed. At the crest of the ilium the vessel pierces the fascia transversalis, and lies between this and the transversalis muscle; and lastly, about the middle point of the iliac crest it pierces the transversalis muscle, and its terminal twigs ramify between it and the internal oblique. In this manner, then, the artery gradually approaches the surface as we trace it from its origin to its termination, and its relations may be expressed thus:—

1. Between fascia transversalis and peritoneum.
2. Between fascia transversalis and transversalis muscle.
3. Between transversalis muscle and internal oblique muscle.

The dissector has already seen the *ascending branch* which it sends upwards between the internal oblique and transversalis muscles.

The Superior Epigastric and Musculo-phrenic Arteries are the two terminal branches of the internal mammary. The *superior epigastric* (arteria epigastrica superior) will be found behind the rectus muscle and within the upper part of its sheath. It gives twigs to the rectus, and anastomoses with the deep epigastric.

The *musculo-phrenic* (arteria musculophrenica) can only be seen by reflecting the transversalis from the ribs. It will be found at the level of the eighth rib. From this it proceeds downwards and backwards, along the attachment of the diaphragm, to the last intercostal space. It gives branches to the diaphragm and others (the anterior intercostals), which enter the lower intercostal spaces.

Dissection.—When the transversalis fascia is reflected the only layers which intervene between the dissector and the abdominal cavity are the extra-peritoneal fatty tissue and the parietal peritoneum.

If the subject be a male, now is the best time for the student to examine the constitution of the scrotum, spermatic cord, and testicle. This can only be done at present on the right side, as the parts on the opposite side must be kept *in situ* for the study of hernia. After this, however, the dissection can be repeated on the left side.

The dissector works at a great disadvantage when he attempts to unfold the coverings of the cord and unravel its constituent parts while they are attached to the body. The cord and testicle of the right side should be removed by dividing the former with its coverings at the level of the external abdominal ring. The specimen should then be placed in a cork-lined tray and dissected under water. Having fastened the cord and testicle with pins to the bottom of the tray, little difficulty will be experienced in displaying and recognising the different layers, and a splendid demonstration will be afforded of the constituent parts of the cord.

Scrotum.—This is a pendulous purse-like arrangement of the skin and superficial fascia for the lodgment of the testicles. The skin composing it is of a dark colour and rugose, and is traversed along the middle line by a *median raphe* or ridge, an indication of its bilateral character.

When the skin is removed the superficial fascia is observed to possess certain characters peculiar to itself. It has a ruddy colour, and is totally devoid of fat. The ruddy tint is due to the presence of involuntary muscular

fibres, which take the place of the fat, and constitute what is called the *dartos muscle*. The rugosity of the scrotal skin is maintained by these muscular fibres. But further, the superficial fascia forms in the interior of the scrotum an imperfect septum or partition, which divides it into two chambers—one for each testicle. These points in connection with the construction of the scrotum have all, to a certain degree, been noted in the dissection of the perineum.

But these two scrotal tunics are not the only coverings of the testicle. Each constituent of the abdominal wall has been seen to contribute an investment to the spermatic cord, and these in turn are continued down so as to clothe the testicle. Presuming, then, that the skin and superficial fascia are reflected, the testicle and cord within the scrotum will still be found to be invested by—

1. The external spermatic or intercolumnar fascia from the aponeurosis of the external oblique.
2. The cremasteric fascia—the muscular element of which is partly derived from the internal oblique.
3. The infundibuliform fascia from the fascia transversalis.

The dissector will find it difficult to demonstrate in every case these different investments of the testicle. In cases of large herniæ of old standing, however, they become thickened, and are more readily recognisable.

From the above description the student will understand that there is only *one* tunic common to both testicles—viz., the integument; that the superficial fascia and dartos, and the investments derived from the abdominal wall, constitute special tunics for each testicle.

Spermatic Cord.—The spermatic cord has been traced in its course through the inguinal canal, and has been observed to issue from it through the external abdominal ring. It is now seen as it lies within the scrotum suspending the testicle.

Before dissecting out the constituent parts of the cord, examine the extra-peritoneal fatty tissue which lies behind the internal abdominal ring. Note that a process of this

tissue is prolonged downwards with the cord. Now with the handle of the knife gently separate the extra-peritoneal fat from the subjacent peritoneum. Behind the internal abdominal ring the peritoneum shows a slight bulging forwards, and a slender fibrous band may be detected passing into the cord from the most prominent part of this bulging. This fibrous cord is the remains of the tube of

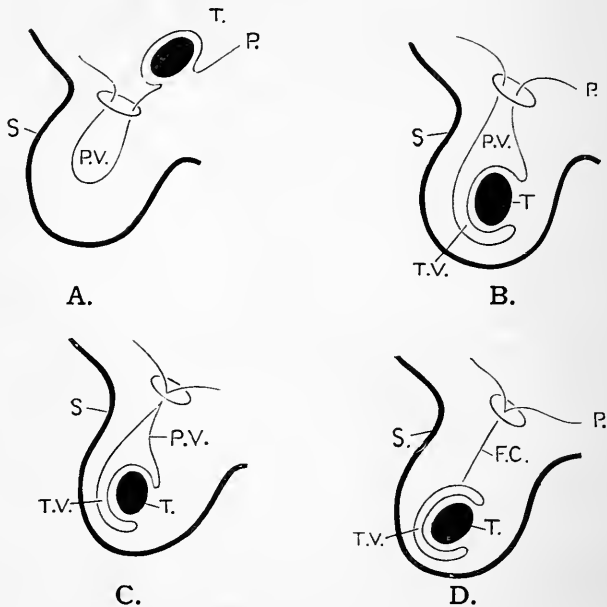


FIG. 93.—Diagrams illustrating the descent of the testicle and the derivation of the tunica vaginalis from the peritoneal lining of the abdominal cavity. The inguinal canal is represented by a ring.

P. Peritoneum.
T. Testicle.
S. Scrotum.

P.V. Processus vaginalis.
T.V. Tunica vaginalis.
F.C. Fibrous cord or thread.

peritoneum, which in the fœtus connected the serous investment of the testicle (the tunica vaginalis) with the general peritoneal lining of the abdomen. In some cases it may be traced as far as the testicle, but more commonly it only extends down the cord for a short distance; indeed it is frequently absent.

To obtain a proper conception of this fibrous thread, it is necessary that the student should understand that the testicle is not developed within the scrotum. Up to a comparatively late period of intra-uterine life the testicle is situated within the cavity of the abdomen. It lies upon the psoas muscle, immediately below the kidney, and is not only invested by peritoneum, but is connected to the posterior wall of the abdomen by a short fold of that membrane, which receives the name of the *mesorchium*.

As development proceeds, the testicle gradually descends on the posterior wall of the abdomen. It retains its peritoneal investment, and in the seventh month it reaches the internal abdominal ring. Prior to its entrance into the inguinal canal, a test-tube-like process of peritoneum, termed the *processus vaginalis*, is carried into the passage (Fig. 93, A.). The testicle with its peritoneal covering enters this tubular recess, and during the eighth month it traverses the inguinal canal. Finally, towards the end of the ninth month, it reaches the bottom of the scrotum (Fig. 93, B.). Throughout the whole journey it is preceded by the *processus vaginalis*, which, as it were, prepares the way for it.

The testicle, therefore, in its descent has a double relation to the peritoneum—viz. (1) it carries with it into the scrotum its own proper investment; (2) it is preceded in its passage into the inguinal canal and the scrotum by a tubular prolongation of the parietal peritoneum, which forms a diverticulum of the general peritoneal sac within the scrotum. In those quadrupeds in which the testicle reaches the scrotum, this diverticulum or *processus vaginalis* remains open, and freely communicates with the abdominal cavity. In man, the lower part of the diverticulum which holds the testicle is alone retained; the upper part is obliterated, and no trace is left, beyond, perhaps, the fibrous cord mentioned above. In this manner, then, the *tunica vaginalis* of the testicle is formed, the original peritoneal investment remaining as the *visceral* or *testicular* part, and the lower part of the *processus vaginalis* being retained as the *parietal* or *scrotal* part (see description of *tunica vaginalis*, p. 415).

The orifice by which the abdominal peritoneal cavity communicates with the scrotal peritoneal diverticulum is usually closed before birth (Fig. 93, C.), and the upper part of the *processus vaginalis*, from the internal abdominal ring to the upper end of the testicle is generally obliterated in the first month of extra-uterine life (Fig. 93 D.).

The *gubernaculum testis* is the active agent in bringing about the descent of the testicle. This is a band of involuntary muscular fibres which traverses the inguinal canal, and establishes important connections both within and without the abdominal cavity. Below, three main attachments of the *gubernaculum* may be recognised—viz. (*a*) to the abdominal wall; (*b*) to the pubis; (*c*) to the bottom of the scrotum. Above, the gubernacular fibres are chiefly connected with the testicle; but many of them are also attached to the peritoneum on the posterior

wall of the abdomen. By the traction which the gubernaculum exerts on the testicle the descent of that organ is brought about. By the portion attached to the abdominal wall the testicle is pulled down to the internal abdominal ring, the pubic portion drags it through the inguinal canal, whilst the scrotal part finally leads it into the scrotum.

The formation of the processus vaginalis is accounted for in the same way. Some of those gubernacular fibres which are inserted into the peritoneum drag down the peritoneal diverticulum which lines the inguinal canal and scrotum, and prepares the way for the testicle.

It is but right to state that the active part we have ascribed to the gubernaculum in the process of testicular descent is not admitted by all anatomists. Some of our most eminent embryologists deny that it exerts any active traction upon the testicle. They consider that through the gubernaculum failing to keep pace with the general growth of surrounding parts, it anchors the testicle to a particular level, and by this means finally lands it in the scrotum.

Dissection.—The coverings of the spermatic cord should now be removed, and the parts which enter into its formation isolated from each other.

Constituent Parts of the Spermatic Cord.—The following are the structures which form the spermatic cord:—

1. The vas deferens.
2. Blood-vessels. $\left\{ \begin{array}{l} \text{Arteries.} \\ \text{Veins.} \end{array} \right. \left\{ \begin{array}{l} \text{The spermatic.} \\ \text{The cremasteric.} \\ \text{The artery to the vas deferens.} \\ \text{The spermatic plexus of veins.} \end{array} \right.$
3. Lymphatics.
4. Nerves. $\left\{ \begin{array}{l} \text{Genital branch of the genito-crural.} \\ \text{Sympathetic twigs.} \end{array} \right.$

These are all held together by loose areolar tissue, which intervenes between them, and also by the investments which are given to the cord by the abdominal wall.

The *cremasteric artery* is a branch of the deep epigastric, and has already been seen entering the cremaster muscle. The *genital branch* of the genito-crural nerve has a similar destination. It has also been displayed in a previous stage of the dissection.

The *spermatic artery* arises within the abdomen from the front of the aorta, and entering the cord at the internal abdominal ring, proceeds to the testicle, into the posterior

border of which it sinks, after dividing into several smaller twigs. The *spermatic veins* issue from the testicle at its posterior border, and as they pass upwards they form in the cord a bulky plexus, which is termed the *spermatic* or *pampiniform plexus*. A single vessel issues from this, which enters the abdomen through the internal abdominal ring. On the right side it pours its blood into the inferior vena cava; on the left side it joins the left renal vein.

The *vas deferens* (ductus deferens) the duct of the testicle, can always be distinguished by the hard, firm, cord-like sensation which it gives when the spermatic cord is held between the finger and thumb. It ascends along the posterior part of the cord. At the internal abdominal ring, however, it separates from the spermatic vessels, and lies to their inner side, and as it enters the abdomen it hooks round the deep epigastric artery.

The *artery to the vas deferens* is a small branch from the superior vesical. It follows the duct to the testicle.

The *sympathetic filaments* extend downwards upon the spermatic artery. They come from the renal and aortic plexuses.

The *spermatic lymphatics* enter the abdomen through the internal abdominal ring, and join the lumbar glands.

The Testicle (testis).—The testicle should next be examined. First note its position in the scrotum. It lies somewhat obliquely, with its upper end directed forwards and outwards, and its lower end backwards and inwards. The left testicle hangs at a lower level than the right.

Each testicle is enveloped by the *tunica vaginalis testis*.

The *tunica vaginalis* is a serous sac, and consequently presents a *parietal* or *scrotal* portion, and a *visceral* or *testicular* portion. Its extent can be demonstrated in a striking manner by making a small aperture in the parietal part, and then introducing a blow-pipe into the serous cavity and inflating it with air. It will be seen to be considerably larger than the gland which it envelops. It ascends for some distance upon the spermatic cord, and it even descends beyond the testicle. When flaccid, the

parietal part is simply wrapped loosely over the visceral portion which adheres to the surface of the testicle.

Dissection.—Open into the sac of the tunica vaginalis by running a pair of scissors along the anterior aspect of the parietal part. On folding back the parietal portion of the tunica vaginalis the form of the testicle may be studied, and also the manner in which the testicle is clothed by the visceral layer.

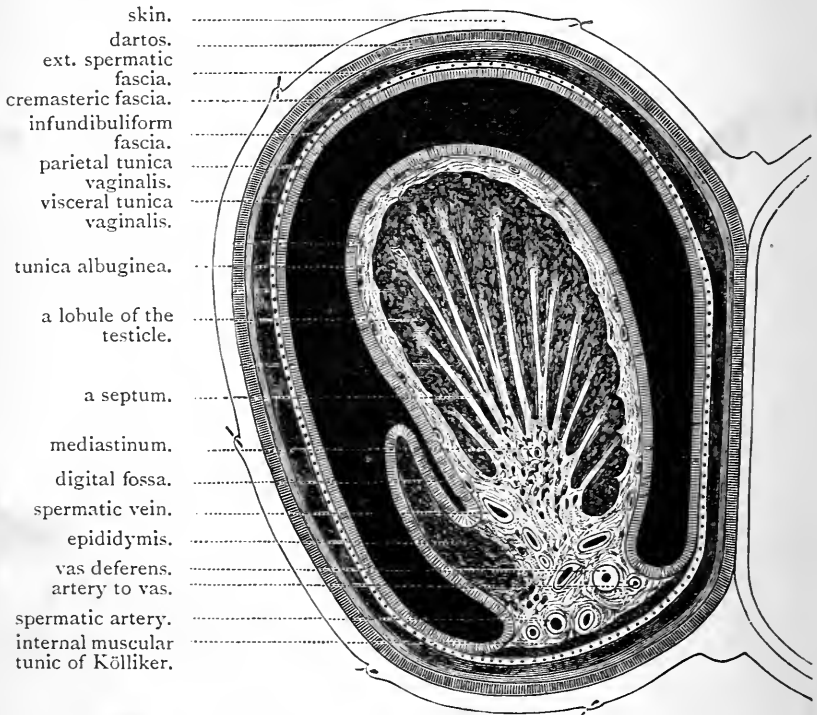


FIG. 94.—Transverse section through the left side of the scrotum and the left testicle. The sac of the tunica vaginalis represented in a distended condition.

The Body and Epididymis of the Testicle.—The testicle is an oval body, with flattened sides. The posterior border is also somewhat flattened, and here we see the *epididymis*. This is an elongated and arched structure, which is adapted to the upper end and outer side of the posterior border of the testicle. Its upper end is enlarged, and is termed

the *globus major* (caput epididymis); its lower end is called the *globus minor* (cauda epididymis), and the intervening portion, which is narrow, receives the name of the *body of the epididymis* (corpus epididymis). The *globus major* is directly attached to the upper end of the testicle, which it surmounts like a helmet, by the *vasa efferentia*, which pass from the one into the other. The *globus minor* is merely fixed to the back of the testicle by areolar tissue, whilst the *body* is free, and is separated from the body of the testicle by an involution of the serous covering which forms the *digital fossa*.

If the upper end of the body of the testis be carefully examined, two minute structures will be observed attached to it close to the *globus major*. These are the "*hydatids of Morgagni*," remnants of an embryonic canal called Müller's duct. One of the hydatids is usually pear-shaped and stalked; the other is smaller and generally sessile.

The vas deferens emerges from the lower end of the *globus minor*, and then passes upwards upon the posterior border of the testicle on the inner side of the epididymis. By this relation, the side to which a given testicle belongs can be readily detected. The vessels have already been seen entering and emerging from the posterior border of the testicle.

Visceral Layer of the Tunica Vaginalis Testis.—Having learned the foregoing points concerning the testicle, the student is in a position to trace the visceral layer of the tunica vaginalis upon its surface. Observe that it envelops it closely on every side, with the exception of the posterior border, where the vessels enter and emerge. The posterior aspect of the epididymis is also, to a certain extent, left bare. On the outer surface of the organ it forms a little *cul-de-sac* between the body of the epididymis and the body of the testicle. This is called the *digital fossa*. Note particularly that it is along the posterior border of the testicle that the parietal part of the tunica vaginalis becomes continuous with the visceral part.

Dissection.—Some of the main facts relating to the structure of the

testicle may be learned by a careful naked-eye examination of its different parts. For this purpose place it in a cork-lined tray and dissect it under water. Having fixed it with pins to the bottom of the tray, begin by tracing the vessels into the gland. In doing this a quantity of involuntary muscular tissue spread over the posterior border of the testicle and the epididymis becomes apparent. This is the *inner muscular tunic of Kölliker*. The intimate manner in which the visceral tunica vaginalis clings to the surface of the testis should next be ascertained by endeavouring to raise it as a distinct layer. Remove now the parietal tunica vaginalis and free the globus minor and body of the epididymis from the back of the gland. This can be easily done by cutting the serous covering as it passes from one to the other, and breaking through the fibrous tissue which intervenes between the globus minor and the lower part of the body of the testis. Do not interfere with the globus major. Turning the epididymis aside, the body of the gland may be divided transversely with a sharp knife about its middle into an upper and a lower portion.

Structure of the Testicle.—The cut surface of the lower part of the body of the testis may now be studied. The dense, tough fibrous coat which envelops it under cover of the visceral tunica vaginalis first attracts attention. It is called the *tunica albuginea*. At the posterior border of the gland it will be seen to be projected into the interior in the form of a thick fibrous elevation. This extends along the whole length of the posterior border, and receives the name of the *mediastinum testis* (corpus Highmori). It is traversed by the vessels that pass into and out from the gland, and it is also tunnelled by a plexus of seminal canals, called the *rete testis*.

From the front and sides of the mediastinum testis radiating fibrous lines will be seen passing into the substance of the testis. These are the cut margins of incomplete fibrous lamellæ or septa which extend towards the deep surface of the tunica albuginea and become connected with it (Fig. 94). By means of these partitions and the mediastinum testis, the space enclosed by the tunica albuginea becomes broken up into a large number of loculi or compartments, the walls of which are imperfect. Such is the fibrous framework of the body of the testicle.

The blood-vessels have a very definite arrangement

with reference to this framework. Passing in through the mediastinum they spread out on the deep surface of the tunica albuginea, and upon both surfaces of the fibrous lamellæ which bound the testicular compartments. The vascular mesh-work thus formed is sometimes called the *tunica vasculosa*.

The proper glandular substance of the testis is lodged within the compartments described above. It consists of an enormous number of fine hair-like tubes, termed the

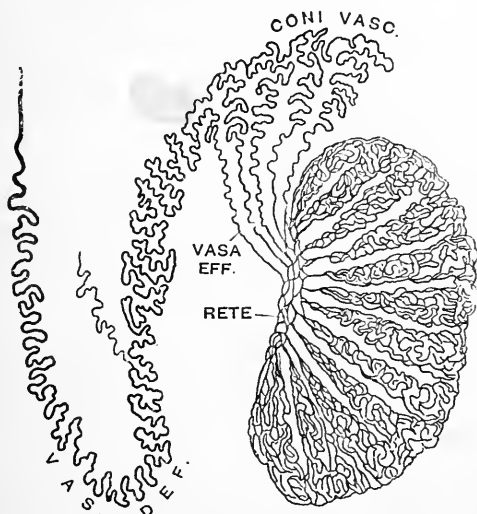


FIG. 95.—Diagram illustrating the structure of the testicle.
(From Gegenbaur.)

seminiferous tubules. Two or more occupy each compartment, and constitute what is called a *testicular lobule* (lobulus testis). In this they are closely packed and are coiled and convoluted to an extraordinary degree. The dissector should now endeavour to unravel some of these tubuli seminiferi under water. It will be impossible to open them out in their whole length, but a sufficiently good demonstration may be obtained to make their general arrangement apparent. The length of these tubes is remarkable. They average two feet in length.

Approaching the mediastinum testis the tubuli seminiferi join each other at acute angles and form a smaller number of tubes, which finally become straight and considerably reduced in diameter. These are called the *tubuli recti*. They enter the mediastinum and join the *rete testis*.

Dissection.—The tubuli seminiferi should now be removed from the lower part of the gland. This can be done with the forceps under a stream of water. A good view is then obtained of the fibrous framework of the testicle. The strength of the tunica albuginea becomes evident, whilst the mediastinum testis and the lamellæ which proceed from it are seen to great advantage.

The dissector must next endeavour to ascertain the manner in which the secretion of the testicle passes from the rete testis into the epididymis. For this purpose the upper part of the testicle with the attached epididymis must be examined. Gently raise the globus major from the surface of the body of the testis by dividing the visceral part of the tunica vaginalis which binds them together, and carefully break down the intervening connective tissue. Under favourable circumstances the *vasa efferentia* may be seen.

Structure of the Epididymis.—The *vasa efferentia* (ductuli efferentes testis) are fifteen to twenty delicate ducts which leave the upper part of the rete testis, pierce the tunica albuginea, and pass into the globus major. In this body the vasa efferentia become coiled and form a series of small conical masses, called the *coni vasculosi*. Ultimately these ducts open into a single convoluted canal, termed the *canal of the epididymis* (ductus epididymis). The globus major is thus composed of the coni vasculosi and the coiled canal of the epididymis. The body and globus minor of the epididymis are formed of the continuation of the same canal coiled and convoluted upon itself to a remarkable degree.

The intricacy of its flexuosities will be better understood by simply stating that if it were completely opened out it would be found to measure twenty feet or more. At the lower end of the globus minor the canal of the epididymis becomes continuous with the vas deferens.

Dissection.—The dissector should endeavour to unravel a part of the canal of the epididymis. The coils are held together by areolar tissue and the dissection is very tedious.

Surgical Anatomy.—To the surgeon the anatomy of the abdominal wall presents a very special interest from the bearing which it has upon **Hernia** or **Rupture**.

Hernia abdominis may be defined as being the protrusion of any viscus or portion of a viscus, or the protrusion of any portion of a peritoneal fold (*e.g.*, great omentum) through the wall of the abdomen. There are three localities in which, from natural weakness of the parietes, this protrusion is specially liable to occur—(1) through the external abdominal ring, which gives passage to the spermatic cord in the male, and the round ligament of the uterus in the female; (2) through the crural canal or innermost compartment of the femoral sheath, within which certain lymphatic vessels ascend from the thigh into the abdominal cavity; (3) through the umbilicus or the foramen in the linea alba of the foetus, which transmits the constituents of the umbilical cord. These different forms of hernia are distinguished by the terms—*inguinal*, *femoral*, and *umbilical*.

There are other situations at which hernial protrusions occur, but so rarely that it would be out of place to take notice of them here.

Inguinal Hernia.—The inguinal canal is not so great a source of weakness to the abdominal wall as might, at first sight, be expected, and this chiefly on account of its obliquity of direction. The inlet or internal abdominal ring is situated a long way (fully an inch and a half) to the outer side of the outlet or external abdominal ring. The canal is therefore distinctly valvular; the greater the force with which the viscera are pressed directly against the inguinal part of the abdominal parietes, the more firmly will the posterior wall of the canal be pressed against the spermatic cord and the anterior wall.

On the *left side* of the body the parts related to inguinal hernia have been retained in position. The student should, therefore, make a dissection of the inguinal region, with special reference to hernia. Begin by reflecting the aponeurosis of the external oblique. Make a vertical incision through it parallel to the outer border of the rectus, and carry it downwards on the inner side of the internal pillar of the external abdominal ring. The aponeurosis can thus be thrown downwards and outwards, and the external ring, at the same time, preserved. The internal oblique, cremaster, and conjoined tendon should now be cleaned, and their precise relations to the spermatic cord studied. Notice that the fleshy lower border of the internal oblique overlaps the upper part of the cord, whilst, towards the outlet of the inguinal canal, the conjoined tendon lies behind the cord. Next replace the aponeurosis of the external oblique, and, introducing the point of the forefinger into the external abdominal ring, press directly backwards. Observe that it rests upon the conjoined tendon; that, in fact, this tendon and the fascia transversalis alone intervene between the finger and the extra-peritoneal fatty tissue and the peritoneum. The lower part of the internal oblique muscle should now be separated from the transversalis by insinuating the handle of the knife between

them. When this is done, divide the internal oblique close to Poupart's ligament, and throw it forwards. At the same time, make a longitudinal incision through the cremaster muscle, and turn it aside from the surface of the cord.

All further dissection must be effected from the inside. Divide the abdominal wall horizontally, from side to side, at the level of the umbilicus. Raising the lower part of the abdominal wall, and examining its posterior surface, the student will observe three peritoneal ridges or falciform folds radiating from the umbilicus as from a centre, and proceeding downwards towards the brim of the pelvis. These are caused by the presence of three fibrous cords,—the urachus and the two obliterated hypogastric arteries,—in the extra-peritoneal fatty tissue. The *urachus* occupies the middle line, and extends downwards to the apex of the bladder. The *obliterated hypogastric artery* proceeds downwards and outwards on each side so as to gain the side of the bladder. It lies a short distance to the inner side of the internal abdominal ring.

There is still another peritoneal ridge or fold on this aspect of the abdominal wall. It is formed by the deep epigastric artery as it passes upwards and inwards to reach the deep surface of the rectus abdominis muscle. It is placed a short distance to the outer side of the fold which corresponds to the obliterated hypogastric artery, and runs more or less parallel to it.

By these three peritoneal folds three fossæ, which vary greatly in depth in different subjects, are formed on either side of the middle line, close to Poupart's ligament. They are termed the external, middle, and internal inguinal pouches, and are very generally regarded as determining, to a certain extent, hernial protrusions in this region. The *internal inguinal fossa* lies between the folds formed by the urachus and the obliterated hypogastric arteries, and the external abdominal ring or the outlet of the inguinal canal corresponds to its outer and deepest part. The *middle inguinal fossa*, very narrow but frequently very deep, is situated between the peritoneal folds which enclose the obliterated hypogastric artery and the deep epigastric arteries. The bottom of this fossa corresponds to the outer part of the posterior wall of the inguinal canal, or, in other words, to that part of the posterior wall which is formed by the fascia transversalis. The *external inguinal fossa* is placed to the outer side of the deep epigastric artery, and its lower, inner, and deepest part corresponds to the internal abdominal ring.

The student has already seen, in the dissection of the abdominal wall, that the deep epigastric artery, together with Poupart's ligament and the outer border of the rectus, bound a triangular space termed Hesselbach's triangle. Recalling this fact, he will understand that the obliterated hypogastric artery, which lies to the inner side of the deep epigastric, must ascend in relation to the posterior aspect of the floor of the triangle and cut the space into two.

Having determined these points, the dissector can proceed as follows :—Divide the lower part of the abdominal wall in a vertical direction along the *linea alba*, from the umbilicus to the pubes. Make this incision a little on one side of the urachus, and, on nearing the pubis, be careful not to injure the bladder, which may project upwards beyond it. On throwing the left flap downwards and outwards, it may be possible to detect the position of the internal abdominal ring from the fact that in some cases the peritoneum is slightly dimpled into it. This dimple or depression is termed the *digital fossa*. Now strip the peritoneum from the flap as far down as Poupart's ligament. This can be easily done with the fingers, as its connection with the extra-peritoneal fatty tissue is very slight. Next separate the extra-peritoneal fatty tissue from the fascia transversalis with the handle of the knife, proceeding with great care as Poupart's ligament is approached. The *internal abdominal ring*, or the inlet of the inguinal canal, is now seen from within. From this point of view the opening is more like a vertical slit in the fascia transversalis than a ring. Its lower and external margin will be seen to be specially strong and thick. Note the deep epigastric artery passing upwards and inwards close to its inner margin. Further, observe the vas deferens and the spermatic vessels entering it, the former, as it disappears into the canal, hooking round the deep epigastric artery. Introduce the tip of the little finger into the opening and push it gently downwards in the direction of the inguinal canal. On raising the flap of the abdominal wall and looking at its front aspect, a very striking demonstration of the infundibuliform fascia can thus be obtained.

There are *two* forms of *Inguinal Hernia*,—viz, *oblique* and *direct*. *Oblique inguinal hernia* follows the course of the spermatic cord. The protrusion traverses the entire length of the inguinal canal, entering at the inlet or internal abdominal ring, and emerging (when the hernia is complete) at the outlet or external abdominal ring. *Direct inguinal hernia* only traverses the lower part of the inguinal canal. It pushes before it or bursts through that part of the posterior wall of the canal which forms the floor of Hesselbach's triangle, and, having thus gained the interior of the canal by a short cut, it emerges like the oblique variety at the external abdominal ring.

The *deep epigastric artery* bears a different relation to each of these forms of hernia. This vessel lies close to the inner margin of the internal abdominal ring, and it forms the outer boundary of Hesselbach's triangle ; consequently, in oblique inguinal hernia, the protrusion, as it enters the inguinal canal, lies *external* to the vessel, whilst, in direct inguinal hernia, it lies *internal* to it. So important are these relations, that the terms *external* and *internal* are frequently employed to denote the two forms of inguinal hernia instead of *oblique* and *direct*.

It is also essential that the student should determine the relation which these forms of hernia hold to the inguinal pouches of peritoneum.

In *oblique inguinal hernia* the protrusion invariably leaves the abdominal cavity at the lower and inner part of the *external inguinal pouch*. It is here that the internal abdominal ring is situated.

In the case of *direct inguinal hernia* the protrusion may leave the abdominal cavity either from the *middle* or from the *internal inguinal pouch*, both of which are in relation to the floor of Hesselbach's triangle.

In almost every case a hernial protrusion in passing to the surface carries before it a portion of the parietal peritoneum, which constitutes its immediate covering, and is termed by surgeons the *sac* of the hernia (Fig. 96 left side). In *oblique inguinal hernia* the other coverings which the protrusion acquires are identical with those of the spermatic cord. Entering the internal abdominal ring, it receives an investment from the infundibuliform fascia; emerging from the lower border of

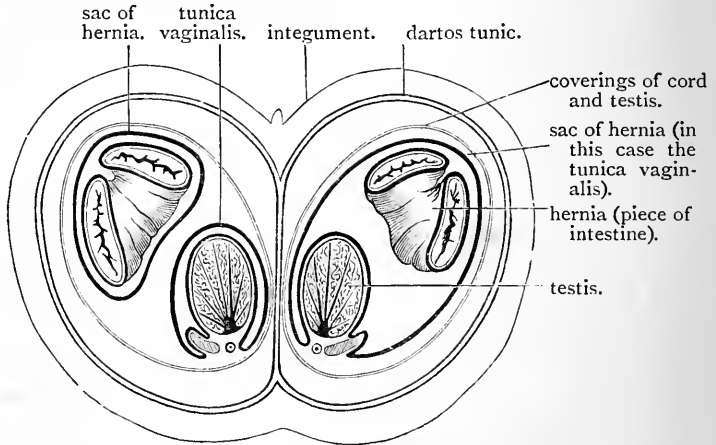


FIG. 96.—Diagram to show the different peritoneal relations in an ordinary inguinal hernia (left side) and a congenital inguinal hernia (right side).

the internal oblique, it acquires a cremasteric covering; and, coming out through the external abdominal ring, it obtains the external spermatic or intercolumnar fascia. From the surface, then, to the peritoneal sac, the following are the coverings of an oblique inguinal hernia:—

1. Skin and superficial fascia.
2. Intercolumnar or external spermatic fascia.
3. Cremasteric fascia.
4. Infundibuliform fascia.
5. Extra-peritoneal fatty tissue.
6. Parietal peritoneum, constituting the hernial sac.

In *direct inguinal hernia* the coverings of the protrusion differ according to the part of Hesselbach's triangle through which it projects. If the student examine the floor of this triangular area, he will observe that the conjoint tendon does not stretch over its entire extent; that,

towards the outer part of the space, the transversalis fascia alone forms the floor. When a direct hernia leaves the abdomen from the middle inguinal pouch, it is through this outer part of Hesselbach's triangle that it protrudes, and, in this case, the coverings are almost identical with those of oblique hernia.

1. Skin and superficial fascia.
2. Intercolumnar or external spermatic fascia.
3. Cremasteric fascia (as a general rule).
4. Transversalis fascia.
5. Extra-peritoneal fatty tissue.
6. Parietal peritoneum or sac.

This form of direct hernia is comparatively rare. The more common form of direct hernia leaves the abdomen from the internal inguinal pouch, and pushes its way through the inner part of Hesselbach's triangle. It therefore acquires a covering from the conjoined tendon. The following are its investments :—

1. Skin and superficial fascia.
2. Intercolumnar or external spermatic fascia.
3. Conjoined tendon.
4. Transversalis fascia.
5. Extra-peritoneal fatty tissue.
6. Parietal peritoneum or hernial sac.

When the conjoined tendon is feeble, or when a direct hernia takes place suddenly, the protrusion may burst through it, in which case it does not obtain a covering from this source.

There are two special varieties of oblique inguinal hernia which it is necessary to mention—viz., *congenital hernia* and *infantile hernia*.

Congenital Hernia.—We have seen that the passage of the testicle from the abdomen into the scrotum is accompanied by a protrusion of parietal peritoneum, which lines the inguinal canal and the scrotal sac. This diverticulum is called the *processus vaginalis*. Under ordinary circumstances the lower part persists as the *tunica vaginalis*, whilst the upper part becomes obliterated so as to completely shut off the communication between the general peritoneal cavity and the cavity of the *tunica vaginalis*. In certain cases this closure fails to take place, and an open pathway from the peritoneal cavity into the *processus vaginalis*, is the result (Fig. 97, B.). Such a condition is favourable to the occurrence of a hernial protrusion into the open *processus vaginalis*, and a hernia of this nature is distinguished by the term *congenital*. (Fig. 96 right side).

Infantile Hernia.—The conditions favourable to the occurrence of an infantile hernia are also due to faults in the developmental process, by which the testicle acquires its serous investment. They may be said to owe their origin to an excess of zeal on the part of the gubernaculum. The *processus vaginalis* remains patent, or is only partially closed. The gubernacular tissue in relation to the parietal

peritoneum draws down into the inguinal canal a second test-tube-like diverticulum of the membrane behind the true processus vaginalis (Fig. 97, S.). This is altogether an abnormal peritoneal recess which is thus produced, and it gives rise to a dangerous condition, because at any time an abdominal content may be forced into it. When this takes place an infantile hernia is the result. Four varieties are recognised according to the state of the true processus vaginalis. These are indicated in the diagram (Fig. 97).

Femoral Hernia.—This consists in the protrusion of an abdominal

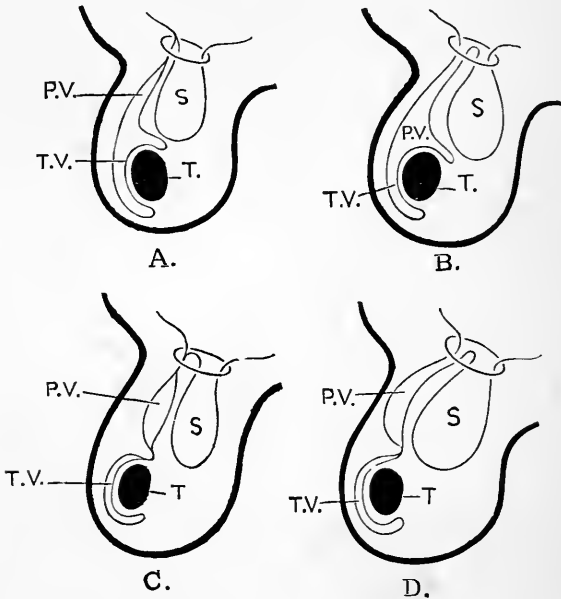


FIG. 97.—Diagram to illustrate the four different varieties of infantile hernia. (After Lockwood.)

- | | |
|---|---|
| <p>A. Processus vaginalis closed above.</p> <p>B. Processus vaginalis closed above and below, but open in intermediate part.</p> <p>P.V. Processus vaginalis.</p> <p>T.V. Tunica vaginalis.</p> | <p>C. Processus vaginalis open throughout its entire extent.</p> <p>D. Processus vaginalis closed below, but open above.</p> <p>T. Testicle.</p> <p>S. Hernial sac.</p> |
|---|---|

content from the abdominal cavity into the region of the thigh. In its descent it passes *behind* Poupart's ligament along the *crural canal* or *innermost compartment* of the femoral sheath. It is consequently mainly the duty of the student who is engaged in the dissection of the lower limb, and within whose domain the femoral sheath lies, to investigate the anatomical connections of this variety of hernia (p. 220).

Still it is essential that the dissector of the abdomen should examine, from its abdominal aspect, the *crural ring* or aperture of communication between the crural canal and the abdominal cavity, and give the dissector of the lower limb an opportunity of doing so likewise.

The *crural ring* is placed immediately behind Poupart's ligament, in the interval between the external iliac vein and the base of Gimbernat's ligament. If the peritoneum is still in position at this point it may exhibit a slight digital depression as it passes over the ring. Strip the peritoneum from the greater part of the iliac fossa. The extra-peritoneal fatty tissue, which stretches over the crural ring, will be observed to be denser, stronger, and more fibrous than elsewhere. A special name is applied to this small portion of the extra-peritoneal fatty tissue. Seeing that it is applied to the ring in such a manner as to close the crural canal at its abdominal end, it is called the *septum crurale*. The extra-peritoneal fatty tissue should now be dissected back with the handle of the knife, to the same extent as the peritoneum. The *fascia iliaca* clothing the iliacus and psoas muscles is thus exposed, and the dissector should note that the external iliac vessels lie *upon* and not *behind* this fascia.

The student is now in a position to study the manner in which the *crural ring* is formed. Let him follow the fascia iliaca and the fascia transversalis towards Poupart's ligament. If the dissection has been carefully performed, he will observe that to the outer side of the external iliac vessels these two fasciæ become directly continuous with each other, and, further, that along the line of union they are both firmly attached to Poupart's ligament. It is evident, then, that no hernial protrusion could leave the abdominal cavity behind Poupart's ligament and external to the iliac vessels.

Opposite the iliac vessels the arrangement of the fascia will be found to be very different. Here the fascia iliaca is carried downwards behind the vessels, whilst the fascia transversalis is prolonged downwards in front of the vessels and behind Poupart's ligament. In the region of the thigh they together constitute a funnel-shaped sheath for the femoral artery and vein, and for some lymphatics ascending to the abdomen. This sheath is divided into three compartments by two vertical partitions. The femoral artery occupies the outermost compartment, and the vein the middle compartment, whilst the innermost compartment, called the *crural canal*, is occupied by the lymphatics, and sometimes by a small lymphatic gland.

An essential difference between these compartments is this—that whilst the two outer are completely filled up by the artery and vein, the crural canal is much wider than is necessary for the passage of its contents. Gauge the width of the crural ring by introducing the point of the little finger. It is readily admitted within the opening. Here, then, is a source of weakness to the abdominal wall, and one which is greater in the female than in the male, seeing that the distance between the iliac and pubic spines is proportionally greater, and, in consequence, the crural ring wider.

When the finger is within the ring, mark the structures which surround it—*in front*, Poupart's ligament, with the spermatic cord or round ligament of the uterus; *behind*, the ramus of the pubis, giving origin to the pectineus muscle, which is covered by the pubic portion of the fascia lata; *internally*, the sharp crescentic free border of Gimbernat's ligament; and *externally*, the external iliac vein.

It is still more necessary to note the relations of the blood-vessels to the crural ring. The *external iliac vein* has been seen to lie to its outer side. The *deep epigastric artery*, as it ascends on the posterior aspect of the abdominal wall, is close to its upper and outer margin, and sends its *pubic* branch inwards in front of it. More important than any of these is the relation of the *obturator artery*, when it takes origin from the deep epigastric. This anomalous vessel may adopt one of three courses—(1) It may follow the course of the pubic artery, an enlarged form of which it in reality is, and pass inwards *in front* of the ring, and then descend along its *inner* margin. In this case, the ring is surrounded on all sides, except posteriorly, by important vessels. (2) It may pass downwards and backwards across the crural ring. (3) It may run downwards between the ring and the external iliac vein (*vide* p. 221).

Internal to the crural sheath the passage of a hernia protrusion behind Poupart's ligament is effectually prevented by Gimbernat's ligament.

Femoral hernia is more common in females, and inguinal hernia in males; and for the very evident reason, that in the female the crural canal is relatively larger, whilst in the male the passage of the spermatic cord weakens the inguinal region more than the passage of the small round ligament of the uterus.

Umbilical Hernia.—This form of hernia consists in the protrusion of an abdominal content through the umbilical ring in the linea alba. When it occurs in the foetus the hernia passes into the umbilical cord, and the three vessels are separated by it. More than one case has occurred in which the bowel has been cut in dividing the cord at the birth of the child. In the adult the fibrous cords in connection with the umbilicus are related to the lower border of the ring, and the hernia escapes through its upper part (Treves).

The Penis.—The penis has already, to a certain extent, been studied in the dissection of the perineum (p. 349). It has been seen to be composed of the *two corpora cavernosa* and the *corpus spongiosum*. Posteriorly, the corpora cavernosa separate from each other, become tapered and are attached to the sides of the pubic arch under the name of the *crura penis*; anteriorly, they together form a blunt rounded extremity, which is covered by the glans penis.

The corpus spongiosum, when traced backwards into the perineum, expands into the *bulb of the penis*, which is attached, in the mesial plane, to the anterior aspect of the triangular ligament; traced forwards to the extremity of the penis, it is again found to expand into the *glans penis*, which fits like a cap upon the rounded ends of the corpora cavernosa. The glans penis is somewhat conical in shape, and the projecting margin of its base is termed the *corona glandis*. The urethra opens at the extremity of the glans by a vertical fissure, called the *meatus urinarius*.

The *integument of the penis* is remarkable for its great delicacy and elasticity, and the absence of hairs. It has a brownish tint, and is freely movable over the organ. At the glans the skin leaves the body of the penis, and, passing for a variable distance over the glans, is folded back upon itself so as to form the *prepuce*. The deep layer of the prepuce reaches the penis again behind the corona glandis, and is then reflected forwards over the glans to become continuous with the mucous membrane of the urethra at the meatus urinarius. A slight fold will be observed on the under surface of the glans, extending from the lower angle of the urinary orifice to the prepuce; this is the *frænum preputii*.

Dissection.—Reflect the integument from the surface of the penis by making a longitudinal incision along the middle line of the dorsum. The superficial fascia will then be seen to be composed of a quantity of loose areolar tissue. We never find fat in the meshes of this tissue. The suspensory ligament and the dorsal vessels and nerves of the penis should now be dissected.

Suspensory Ligament.—The suspensory ligament is a strong fibro-elastic band of a triangular shape. By its posterior border it is attached to the symphysis pubis. Towards the penis it separates into two lamellæ, which join the body of the organ, and between which are placed the dorsal vessels and nerves.

Dorsal Vessels and Nerves.—On the dorsum of the penis, in the groove which extends along the middle line between the two corpora cavernosa, is the *dorsal vein*; on each side

of this is the *dorsal artery*, and superficial and external to the artery is the *dorsal nerve*. On the dorsum of the penis, therefore, we find *one* vein, *two* arteries, and *two* nerves.

The *dorsal vein* of the penis begins by several twigs from the glans and prepuce. It extends backwards in the middle line, and disappears between the two layers of the suspensory ligament. It gains the pelvis by passing under the sub-pubic ligament, and ends by joining the prostatic plexus of veins.

The *dorsal arteries* are the terminal twigs of the internal pudic vessels. Piercing the triangular ligament, they pass forward between the two layers of the suspensory ligament, and, continuing their course on the dorsum of the penis, they terminate in branches for the glans penis.

The *dorsal nerves* are branches of the internal pudic. They have a similar course to the arteries, and end in fine twigs to the papillæ of the glans.

ABDOMINAL CAVITY.

The abdominal cavity may now be opened completely by carrying an incision from the umbilicus upwards to the ensiform cartilage. On throwing the two flaps thus formed upwards and outwards over the lower margin of the thorax, a strong fibrous cord, the *obliterated umbilical vein*, will be observed extending from the umbilicus to the under surface of the liver. The obliterated umbilical vein also receives the name of the *round ligament, or ligamentum teres, of the liver*. As it ascends towards that organ, it gradually recedes from the posterior surface of the anterior abdominal wall, taking with it a fold of peritoneum, termed the *falciform ligament* of the liver.

Shape and Boundaries of the Abdominal Cavity.—The abdominal cavity is ovoid in shape, its vertical diameter being the longest. Superiorly, it is roofed by the dome-

shaped diaphragm, which presents a deep concavity towards the abdomen. Inferiorly, it is floored by the pelvic diaphragm, which is also concave towards the abdominal cavity. It is formed by the levatores ani and the coccygei muscles. Neither the roof nor the floor are complete and unbroken. The diaphragm is perforated by certain structures which pass between the thorax and the abdomen. The continuity of the pelvic diaphragm is broken by the passage of certain structures between the pelvic division of the abdominal cavity and the perineum. The upper part of the abdominal cavity extends upwards for a considerable distance under the shelter of the lower ribs and their costal cartilages. The protection which is thus afforded to the viscera in this portion of the cavity is most complete laterally and behind. In front, as the costal cartilages ascend towards the sternum, a wide Λ -shaped gap is left between those of opposite sides. The level to which the costal arches descend on either side varies greatly in different subjects, but in the great majority of cases a narrow belt of abdominal wall, from one to two inches wide, is left between the lower border of the chest wall and the highest point of the iliac crest, which receives no skeletal support beyond that which is afforded by the vertebral column.

Inferiorly, the expanded iliac bones give support to the abdominal walls posteriorly and laterally, whilst, in its lowest part, the pubic, ischial, sacral, and coccygeal bones form very complete bony boundaries for the cavity.

Whilst the abdominal cavity, therefore, is very fully protected, posteriorly and laterally, by skeletal parts, the front wall is almost entirely formed by the muscles and aponeuroses which have been dissected in this region.

From this it will be seen that the roof, floor, and the greater part of the abdominal wall are composed of muscular structures, the contraction of which would diminish the capacity of the cavity, and subject the contained viscera to compression.

Subdivision of the Abdominal Cavity.—In dealing with

so large a cavity, and one which contains such a diversity of contents, it is absolutely necessary for anatomists to subdivide it into regions, in order that the precise position of each viscus may be accurately defined. In making the first subdivision, we take advantage of the brim of the true pelvis. That part of the cavity which is situated above this is termed the abdomen proper; whilst that part which lies below it is called the pelvic cavity. These two portions of the general abdominal cavity do not lie the one directly over the other. The long axis of the abdomen proper is very nearly vertical; that of the pelvic cavity is very oblique, and directed backwards and downwards. Indeed, the pelvic cavity presents the appearance of a recess leading backwards and downwards from the lower and back part of the abdominal cavity (Fig. 98).

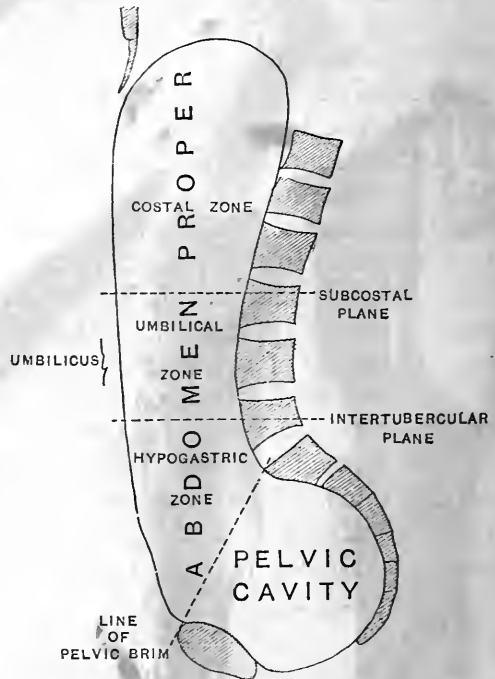


FIG. 98.—Outline of the abdominal cavity as seen in mesial section. The planes of subdivision are indicated by dotted lines.

The abdomen proper is still further subdivided by means of four arbitrary planes of section. Two of these are supposed to pass through the body in a horizontal direction, and two in a vertical direction. The former are termed the subcostal and the intertubercular planes of subdivision, and the position of each is determined as follows:—A hori-

zontal line is drawn around the body at a level corresponding to the most dependent parts of the tenth costal arches. This gives the position of the subcostal plane. A second line is drawn horizontally around the trunk so as to pass through the highest point on the iliac crest on

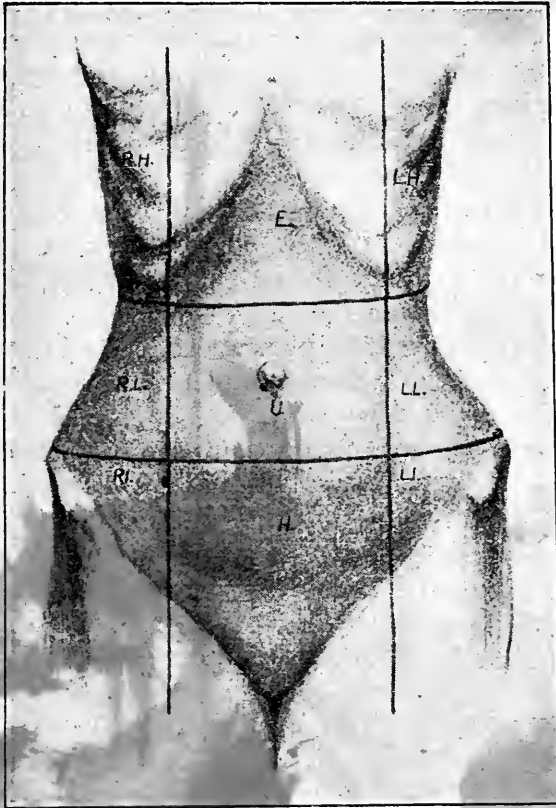


FIG. 99.—From a photograph of a female subject in the erect posture. The mid-Poupart lines were ascertained by letting two plumb-lines drop from a height in front of the subject.

- R.H. Right hypochondrium.
- R.L. Right lumbar region.
- R.I. Right iliac region.
- E. Epigastric region.
- U. Umbilical region.

- H. Hypogastric region.
- L.H. Left hypochondrium.
- L.L. Left lumbar region.
- L.I. Left iliac region.

each side that is seen from the front. This point is always easily determined, as a prominent tubercle juts out from the outer lip of the iliac crest at that spot. It is situated rather more than two inches behind the anterior superior iliac spine, and it marks the point where the outline of the body meets the iliac crest. The line which encircles the body at this level indicates on the surface the position of the intertubercular plane of subdivision.

The two horizontal planes, thus placed, map out the abdomen into three districts or zones, which are termed from above downwards—(1) the *costal*, (2) the *umbilical*, and (3) the *hypogastric zone*.

The two vertical planes of subdivision are called the *right* and *left mid-Poupart planes*, seeing that they correspond on the surface to two perpendicular lines reared from the mid-points of Poupart's ligaments.

By these mid-Poupart planes, each of the three zones determined by the horizontal planes of section is subdivided into three.

The costal zone is mapped off into a central *epigastric region* and a *right* and *left hypochondriac region*; the umbilical zone into a central *umbilical region* and a *right* and *left lumbar region*; and the hypogastric zone into a central *hypogastric region* and a *right* and *left iliac region*.

Contents of Abdomen Proper.—Within the abdominal cavity we find the following structures:—

1. Abdominal part of the alimentary canal.

{	Stomach.
{	Small intestine.
{	Large intestine.
2. Glands situated outside the walls of the alimentary canal and pouring their secretions into it.

{	Liver with its gall-bladder or reservoir.
{	Pancreas.
3. The spleen.
4. The two kidneys, the ureters, and the two suprarenal bodies.
5. Lymphatic glands, lymphatic vessels, the receptaculum chyli, and the commencement of the thoracic duct.
6. The abdominal aorta, with its various visceral and parietal branches.

7. The inferior vena cava and its tributaries, and the commencements of the venæ azygos major and minor.
8. The vena portæ and its tributaries.
9. The lumbar plexuses of nerves.
10. The abdominal portion of the sympathetic nervous system.
11. The peritoneal membrane which lines the cavity and invests the viscera.

A mere glance is sufficient to distinguish between the three primary parts of the alimentary canal within the abdominal cavity. The *stomach* is the dilated bag-like portion which lies in the left part of the costal zone. The *small intestine* succeeds the stomach, and presents a striking contrast to the *large intestine*. The following are the leading points of difference:—(1) The calibre of the small intestine is usually smaller than that of the large intestine. Sometimes, however, the large intestine is very much contracted, so this feature cannot be regarded as an infallible guide. (2) The walls of the small intestine are smooth and uniform, whereas the walls of the great intestine are puckered and sacculated. (3) The longitudinal muscular fibres in the wall of the great intestine are not disposed uniformly around the tube as in the small intestine, but are collected into three bands, which are separated from each other by intervals, and are distinctly visible to the naked eye. These bands are shorter than the tube itself, and this is the reason of its walls being puckered. (4) Attached to the great intestine are *appendices epiploicæ*. These are small peritoneal pouches or folds, which hang from the gut and contain fat.

On opening the abdominal cavity, the student obtains a very partial view of the contained viscera, so long as they are left undisturbed. On the right side of the costal zone the sharp margin of the liver may be observed projecting slightly below the ribs, whilst opposite the ninth costal cartilage the fundus of the gall-bladder is seen peeping out from under cover of this organ, and projecting slightly beyond its anterior border. In the same zone to the left of the liver, a portion of the stomach is visible, whilst extending downwards from the lower border of this viscus

is a broad fold of peritoneal membrane, called the *great omentum*. This usually contains a quantity of fat in its meshes, and is spread out like an apron, so as to hide from view the viscera which occupy the two lower zones. Sometimes, however, the great omentum is narrow and short; or, again, it may be turned more or less completely upwards or to the side. In either case some of the coils of the small intestine will be seen, and also, in all probability, those parts of the great intestine which occupy the right and left iliac fossæ. That part lying in the right iliac fossa is called the *cæcum*, whilst the part situated in the left iliac fossa is the *sigmoid flexure*. It may also chance that the bladder is full, in which case its apex will be observed projecting above the pubes. Lastly, in pregnant females the gravid uterus will be visible, reaching a height in correspondence with the period of gestation.

Raise the great omentum and turn it upwards over the lower margin of the thorax. By this proceeding the coils of the small intestine are fully exposed, and a part of the great intestine which extends across the cavity of the abdomen will be seen shining through the posterior layer of the great omentum. This is the *transverse colon*.

The position and connections of the various viscera should now be studied.

Liver (hepar).—The liver is the largest gland in the body. It is a solid pliant organ, the chief bulk of which lies in the epigastrium. It also occupies the right hypochondrium, and extends for a variable distance into the left hypochondrium. Further, the lower right margin crosses the subcostal plane, and enters for a short distance into the upper part of the right lumbar region. The accompanying diagram shows the extent of the parts of the liver which occupy these regions of the abdominal cavity when the hollow viscera in its vicinity are empty.

The liver has the shape of a right-angled triangular prism (Symington), but its substance is so pliant that its natural configuration can only be preserved when special measures are adopted for this purpose. It presents five

surfaces, viz., a superior, an anterior, an inferior, a posterior, and a right lateral surface. For the most part, these surfaces pass insensibly into each other by means of rounded borders. A sharp attenuated margin, however, separates the inferior surface from the right lateral, from the anterior, and, at the left extremity of the organ, from the superior surface. This margin constitutes a prominent feature of the liver.

At the present moment, with the organ *in situ*, the connections of the liver are such that the posterior surface

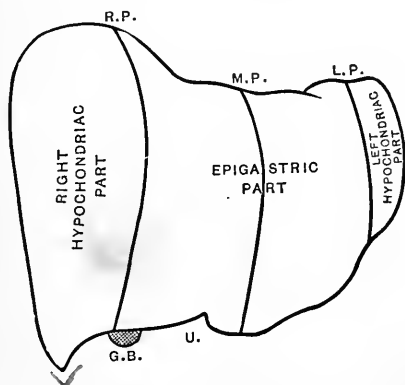


FIG. 100.—Outline of a model of the liver prepared by the reconstruction method. The vertical lines show the exact portions of the organ in the different sections of the costal zone.

R.P. Right mid-Poupart plane.
 M.P. Mesial plane.
 L.P. Left mid-Poupart plane.

U. Umbilical notch.
 G.B. Fundus of gall-bladder.

cannot be studied at all, and the inferior surface only partially. The other three surfaces and the sharp margin can be fully examined. The right lateral surface forms an area of some extent, which passes vertically downwards in relation to the lateral portions of the seventh, eighth, ninth, tenth, and eleventh costal arches. It is separated from these, however, by the diaphragm and the thin basal margin of the right lung. It is convex from before backwards, and is adapted to the curvature of the ribs, under the shelter of which it lies. This surface passes insensibly by means of

rounded borders into the superior, anterior, and posterior surfaces. Inferiorly, however, the sharp margin of the liver marks it off in the most distinct manner from the inferior surface. This portion of the sharp margin constitutes the most dependent part of the liver, and extends for a variable distance below the subcostal plane into the right lumbar region.

The *superior surface* is adapted accurately to the under surface of the diaphragm. Its right portion rises in the form of a high convexity, which occupies the right cupola of the diaphragm. Immediately to the left of this is a depressed slightly concave area (*impressio cardiaca*), which corresponds to the heart and pericardium on the upper surface of the diaphragm; whilst, still further to the left, the superior surface of the liver again shows a convexity, but not so pronounced as that on the right side, which fits into the left cupola of the diaphragm. Full rounded borders separate this surface from the right lateral, from the anterior, and from the posterior surfaces of the liver. At the left extremity of the organ, the superior surface is separated from the inferior surface by the left portion of the sharp margin.

The *anterior surface* of the liver, which looks directly forwards, presents a triangular outline. The base of the triangle is formed by the rounded border which separates this surface from the right lateral surface; the upper limit is formed by the rounded border which intervenes between the superior and anterior surfaces; and the lower limit by the anterior sharp margin of the liver. The apex of this triangular area points to the left, and corresponds with the left extremity of the organ. The greater part of the anterior surface lies against the diaphragm, and under cover of the lower ribs and costal cartilages of the right side. Its left part lies under shelter of the costal arches of the left side; whilst in the Λ -shaped interval between the costal cartilages of opposite sides it lies behind the ensiform cartilage, and, for a variable distance below this, in direct relation to the posterior surface of the anterior abdominal wall.

Attached to the anterior and superior surfaces of the liver will be seen the broad peritoneal *falciform ligament* (*ligamentum falciforme hepatis*), which maps out the organ into a right and a left lobe. The smooth glossy appearance of the three surfaces we have examined is due to the peritoneal investment of the organ. If the hand be passed backwards over the upper surface of the liver, its posterior surface will be observed to be in contact with the diaphragm,

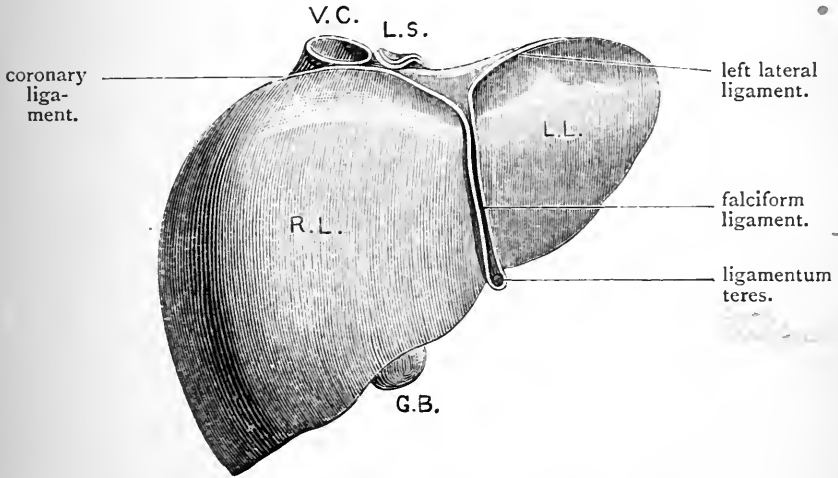


FIG. 101.—Anterior surface of the liver. (From the model by His.)

V.C. Vena cava inferior.
 L.S. Lobulus Spigelii.
 R.L. Right lobe.

L.L. Left lobe.
 G.B. Gall-bladder.

and bound to it by the peritoneum which passes from the one to the other.

The *posterior* and *inferior surfaces* of the liver can only be satisfactorily studied after the removal of the organ. Still, there are several very important points in connection with the inferior surface which can be best ascertained under the present conditions. This surface is very oblique; it slopes from the right inferior sharp margin upwards to the left extremity of the organ, so that it looks very nearly as much to the left as downwards. It follows

from this that the vertical depth of the liver diminishes rapidly as it extends to the left. In relation to this sloping inferior surface there are a number of important structures, all of which leave their imprint upon it in the shape of fossæ of greater or less depth. Thus the left lobe is moulded over the stomach, whilst in contact with the inferior surface of the right lobe are:—(1) the gall-bladder, which is bound down to it by peritoneum; (2) the pyloric end of the stomach and the duodenum or commencement of the small intestine; (3) the hepatic flexure of the colon; and (4) the right kidney. The precise relations of these organs to the liver will be studied more fully at a later stage.

The *sharp margin of the liver* forms a continuous attenuated border, although it is convenient to speak of it as consisting of a *right inferior part* intervening between the right lateral surface and the inferior surface; an *anterior part*, which separates the anterior surface from the inferior surface; and a *left portion*, which turns round the left lobe and forms its left fine edge or extremity. The anterior part of the sharp margin presents a slight deficiency where it is adapted to the fundus of the gall-bladder, and a notch (*incisura umbilicalis*) of varying depth where the falciform ligament meets the *ligamentum teres* or obliterated umbilical vein.

Even in health the position and shape of the liver is subject to considerable variation. From its intimate connection with the diaphragm it is easy to understand how it must rise and fall with every respiratory act. Further, the full or empty condition of the neighbouring hollow viscera affects not only its form, but also its position. Displacement of the liver from artificial causes, such as tight-lacing in females, is by no means uncommon. A gravid uterus, also, as it gradually ascends in the abdominal cavity, exercises a marked influence upon the shape of the liver.

The Gall-Bladder (*vesica fellea*).—The gall-bladder should be examined in connection with the liver. This small pyriform sac lies in the epigastric region close to the right mid-Poupart plane. Its fundus, covered by peritoneum, peeps out from under cover of the anterior

margin of the liver, but in the rest of its extent it is bound down by a partial peritoneal investment to the under surface of the right lobe of that organ.

The Spleen (lien).—The spleen is a solid organ, which lies deeply in the left part of the costal zone, and is altogether out of sight in the undisturbed condition of the viscera. By drawing the stomach to the right, and thrusting the hand into the left hypochondrium, it can readily be discovered and pulled forwards for inspection. It lies very obliquely in the abdominal cavity, its upper end being much nearer the mesial plane than its lower end. Its long axis is directed from above downwards and outwards, and also slightly forwards. For the most part it lies in the left hypochondrium, but its upper end extends inwards beyond the left mid-Poupart plane, so that fully a third of the organ is situated in the epigastric region.

What has been said in regard to the difficulty of preserving the liver in its natural form applies with even greater force to the spleen. Special methods have to be adopted for this purpose, and it is seldom that the natural form of the spleen is seen in the dissecting-rooms.

The spleen has the shape of an irregular tetrahedron with its apex above and its base below. The upper extremity or *apex* is curved to some extent forwards on itself, and approaches close to the left suprarenal capsule.

Of the four surfaces the most extensive is the *diaphragmatic* (superficies diaphragmatica), which looks backwards and outwards and rests upon the diaphragm. By this it is separated from the ninth, tenth, and eleventh ribs—to the curvature of which it is adapted. It is well to remember that the upper part of this surface is also separated from the chest-wall by the thin basal margin of the left lung, which intervenes at this level between the diaphragm and the ribs.

The remaining three surfaces are turned towards the cavity of the abdomen, and are closely applied to the neighbouring viscera. These three surfaces meet at a blunt but usually conspicuous prominence which may be termed the *internal basal angle*. From this as from a

centre three ridges radiate. One, a salient and prominent border (*margo intermedius*), ascends to the apex and separates an extensive anterior gastric area from a posterior renal surface; a second short ridge or border passes backwards to the posterior basal angle and intervenes between the renal and the basal surfaces; whilst the third ridge, less distinctly marked, proceeds

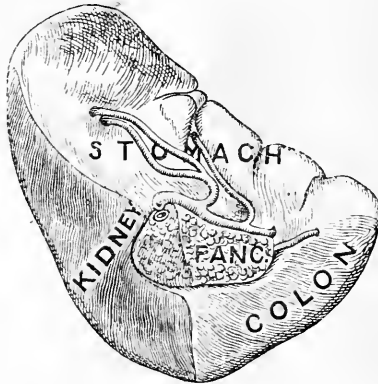

FIG. 102.—The form of the spleen as seen from its visceral aspect: drawn from the model of the spleen of a child prepared by the reconstruction method.

forwards to the anterior basal angle and separates the gastric and the basal surfaces from each other. The two last-named ridges, together with the lower border of the organ, map out a triangular area which may be distinguished as the basal surface.

The *gastric surface* (*superficies gastrica*) is the most extensive of the three visceral districts. It is deeply concave and moulded upon the fundus of the stomach. Within its area and about half an inch to the outer side of the *margo intermedius* is situated a longitudinal slit, frequently broken up into two or more pieces, and termed the *hilum*. This gives passage to the vessels and nerves which enter and leave the organ.

The *renal surface* (*superficies renalis*) is flat and even, and varies somewhat in its extent. It is applied to the

anterior surface of the upper part of the kidney close to its outer border.

The peritoneal relations of the spleen are such that the renal surface cannot be studied unless the posterior border of the organ is pulled forwards, so that we can see behind it.

The *basal surface* (*superficies basalis*) is smaller than the other two visceral areas. It is triangular in form, and looks downwards and inwards. It is related to the tail of the pancreas and the colon. The area of contact with the pancreas is in the neighbourhood of the internal basal angle, and is subject to considerable variation; sometimes, indeed, there may be seen, as in the case of the spleen figured on p. 442, a marked pancreatic depression. The portion of the basal surface of the spleen which is not in apposition with the pancreas presents a varying relation to the colon.

Of the several borders which separate the different surfaces of the spleen from each other, the anterior, the inferior, and the posterior are the most prominent and conspicuous. The *anterior border* (*margo crenatus*) is notched or crenated, and intervenes between the diaphragmatic surface and the gastric surface. The *inferior border* separates the diaphragmatic surface from the basal surface; whilst the *posterior border* (*margo obtusus*) intervenes between the renal and diaphragmatic surfaces. The other margins which separate the visceral areas from each other radiate out from the internal basal angle, and have been already noticed.

A very characteristic feature of the typically formed spleen is the great prominence of the anterior basal angle. It forms the most anteriorly placed part of the spleen.

Peritoneal Connections of the Spleen.—Passing from the fundus of the stomach to the gastric surface of the spleen along the line of the hilum is a fold of peritoneum known as the *gastro-splenic omentum*; whilst tying the visceral aspect of spleen down to the surface of the kidney is another short fold called the *lieno-renal ligament*.

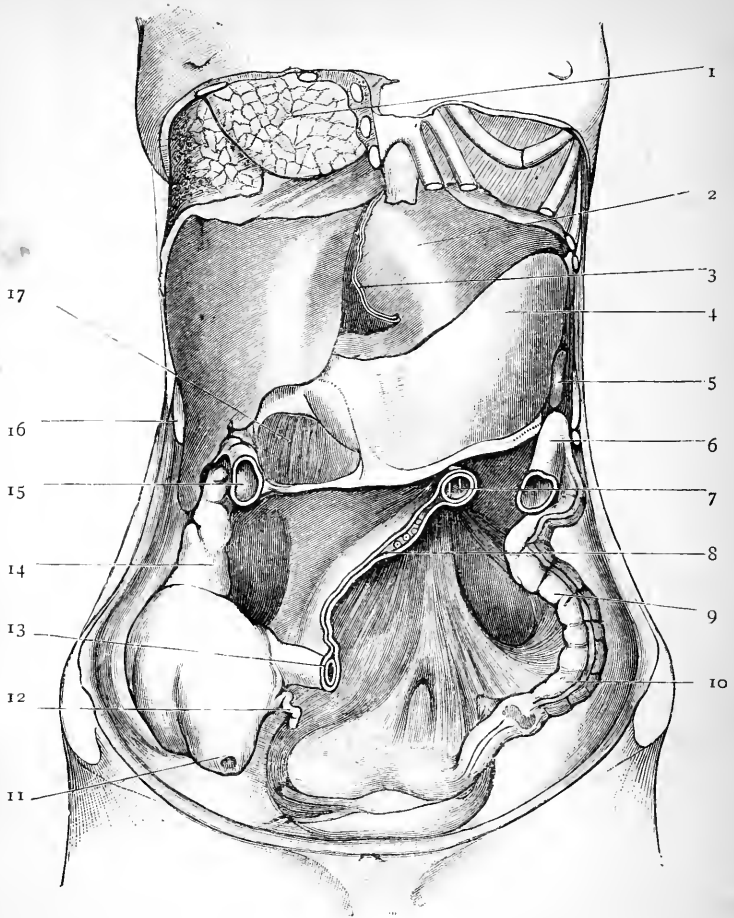


FIG. 103.—Position of viscera as seen in a female subject, which was hardened by repeated injections of Müller's fluid and spirit for a period of six weeks. The great omentum, the transverse colon, and the coils of the small intestine have been removed.

- | | |
|------------------------------------|---|
| 1. Right lung. | 10. Sigmoid flexure. |
| 2. Liver. | 11. Caecum greatly distended. |
| 3. Falciform ligament. | 12. Vermiform appendix. |
| 4. Stomach. | 13. Termination of ileum. |
| 5. Anterior basal angle of spleen. | 14. Ascending colon. |
| 6. Splenic flexure of colon. | 15. Hepatic flexure of the colon. |
| 7. Commencement of jejunum. | 16. Tenth costal arch. |
| 8. Root of mesentery. | 17. Depression in which a coil of small intestine was placed. |
| 9. Descending colon. | |

The Stomach (ventriculus).—The stomach is the most dilated part of the alimentary canal, and constitutes the receptacle for the food after it has been masticated and swallowed. The gullet or œsophagus opens into it above, whilst below it becomes continuous with the duodenum or first part of the small intestine. Its form and position are greatly influenced by the amount of food it contains.

In the dissecting-room the stomach is usually seen in a relaxed and empty condition. The walls are then

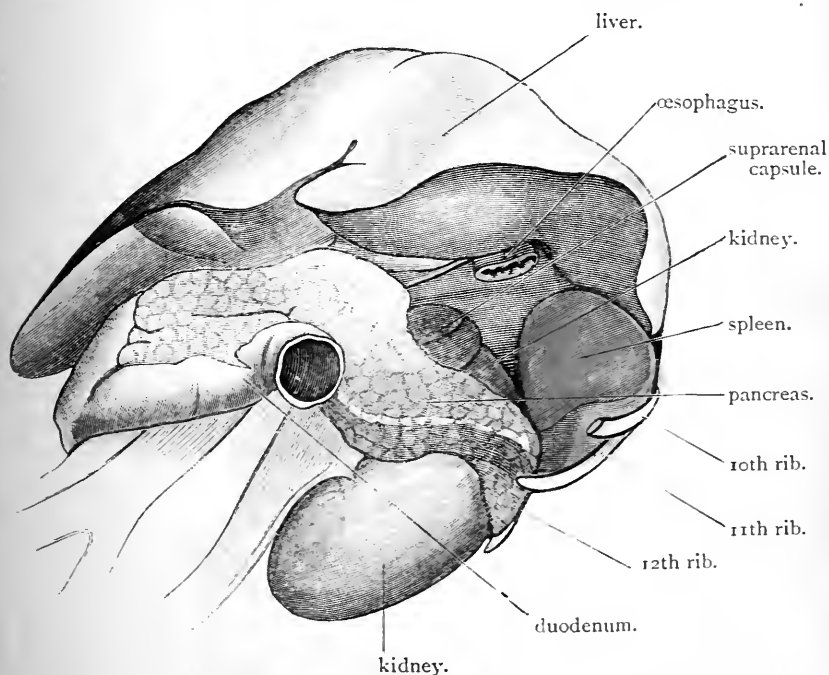


FIG. 104.—The recess or space in the abdominal cavity which is occupied by the stomach. Drawn from a preparation in which the viscera were hardened *in situ* by repeated injections of Müller's fluid and spirit.

in apposition with each other, and, if healthy, the viscus will probably lie altogether to the left of the mesial plane. When distended the stomach assumes a pyriform shape, and is curved upon itself. Its upper end, which is

large, full, and rounded, forms a bulging called the *fundus*, which is directed upwards so as to rest on the under surface of the left cupola of the diaphragm. Its lower part becomes much smaller and is termed the *pyloric portion*. Just before it gives place to the duodenum it usually shows a slight dilatation, which receives the name of *antrum pyloricum*. To the right of the fundus, and about two inches or more below its highest point, is the œsophageal or *cardiac orifice*. At this point it is joined by the gullet.

The *pyloric orifice*, or the opening into the duodenum, is at the lower end of the stomach, and is directed backwards in the natural condition of parts. Its position is rendered evident by a slight constriction which marks the junction of the stomach with the small intestine.

The surfaces of the distended stomach are convex. The *anterior surface*, which bulges more than the posterior surface, looks forwards and upwards. It is largely covered by the liver, but below the sharp margin of that organ it is in apposition with the diaphragm, which separates it from the lower costal arches of left side, and also with the posterior surface of the anterior abdominal wall. The *posterior surface* looks downwards and backwards, and rests upon the spleen, the upper part of the left kidney, the left suprarenal capsule, the pancreas and the transverse meso-colon (Fig. 104).

The borders of the stomach are termed its curvatures. The right or upper border forms the *lesser curvature*. It extends from the cardiac orifice to the pylorus, and is concave. From this curvature passes a fold of peritoneum, called the gastro-hepatic omentum, which connects the stomach to the under surface of the liver. The left or lower border, called the *greater curvature* on account of its great length, is convex, and from this hangs downwards the peritoneal fold, termed the great omentum.

Position of the Stomach.—It is a difficult matter to say anything definite regarding the position of the stomach, as the space which it occupies within the abdominal cavity varies so much with the amount of food which it contains. It lies in the left hypochondriac and the epigastric regions.

When empty, about equal parts are contained in these regions, and the pyloric opening corresponds, as a rule, to the mesial plane. The greater part of the viscus, under these conditions, is nearly vertical in its direction. This vertically-placed portion of the organ may be said to comprise three-fourths of its bulk. The pyloric fourth is more or less horizontal, and its opening is situated about half an inch above the subcostal plane, and about four and a half inches below the lower end of the gladiolus.

As the stomach becomes filled it changes its position. It becomes more oblique in its direction, and the pyloric opening moves to the right until it comes to lie in close relation to the neck of the gall-bladder. The cardiac opening is the only part which is more or less fixed in its position. It is placed opposite the tenth dorsal vertebra, and on the surface of the body its situation may be indicated by placing the finger on the seventh costal cartilage of the left side, about one inch from its junction with the sternum. The slight range of movement which is allowed to this part of the stomach is due to the manner in which it is fixed by the œsophagus to the diaphragm.

• **Œsophagus.**—The portion of the gullet which is placed within the abdomen is very short, and occupies a groove on the back aspect of the left lobe of the liver. By pulling this part of the liver aside the gullet will be seen joining the stomach.

Relations between Thoracic and Abdominal Organs.—At this stage it is useful to consider the relations which exist between the abdominal and thoracic organs which lie upon the different aspects of the diaphragm. We have seen that the right lobe of the liver occupies the right vault of the diaphragm, whilst the left lobe of the liver, the fundus of the stomach and the spleen occupy the left vault. The base of the right lung is in relation to the right lobe of the liver. The pericardium, in by far the greater part of its extent, lies above the left lobe of the liver, which therefore intervenes between it and the stomach; only a limited portion of the apex of the heart extends over the region of the stomach.

The base of the left lung lies over the left lobe of the liver, the fundus of the stomach and the spleen (Fig. 105).

The Small Intestine (intestinum tenue) is that part of the alimentary canal which succeeds the stomach. It begins in the epigastric region at the pylorus, and ends in the lower part of the right lumbar region by joining the great

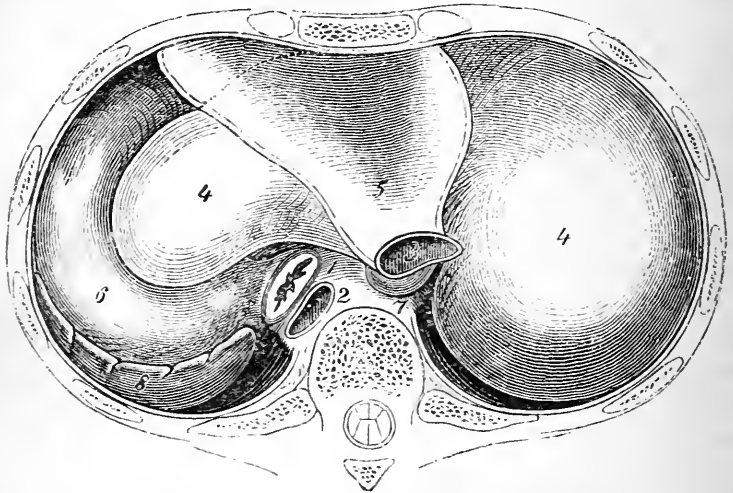


FIG. 105.—Position of viscera in relation to the under surface of the diaphragm. The dotted line marks off that part of the pericardium which lies directly above the stomach. (From Braune.)

- | | |
|---------------|---------------------------------------|
| 1. Œsophagus. | 5. Pericardiac part of the diaphragm. |
| 2. Aorta. | 6. Fundus of stomach. |
| 3. Vena cava. | 7. Lobulus Spigelii. |
| 4. Liver. | 8. Spleen. |

intestine. Its average length is somewhere about twenty-three feet, and as it is traced towards its termination it will be seen to diminish slightly in calibre. It is divided into three portions, viz. :—

1. The duodenum.
2. The jejunum.
3. The ileum.

The *duodenum* is the name which is given to the first part of the small intestine. It is about ten inches long, and extends from the pylorus to the left side of the body

of the second lumbar vertebra. As it lies deeply in the greater part of its extent, and as dissection is necessary to bring out its relations, it is better to defer its description till later on.

The *jejunum* and *ileum* constitute the coils of the small intestine, and are more or less completely covered by the great omentum. The jejunum begins where the duodenum ends, viz., on the left side of the body of the second lumbar vertebra; and the ileum ends in the lower part of the right lumbar region by joining the cæcum or the commencement of the great intestine. The subdivision of the small intestine is of the most arbitrary kind. After mapping off the duodenum it is customary for anatomists to look upon the upper two-fifths of the remainder as being jejunum, and the lower three-fifths as being ileum. There is no hard-and-fast line of demarcation between the lower two divisions—the one passes insensibly into the other; and as the chief distinction is to be found by an examination of the interior of the tube, the student will not in the meantime see much difference between them.

To expose the commencement of the jejunum, the great omentum should be thrown upwards with the enclosed transverse colon over the lower margin of the thoracic wall. The coils of the small intestine should then be drawn over to the right. The junction between the duodenum and the jejunum will now be seen on the left side of the vertebral column, at the level of the second lumbar vertebra. The termination of the duodenum is fixed, and the jejunum bends suddenly forwards and downwards upon it, forming the *duodeno-jejunal flexure*. To bring the termination of the ileum into view, the coils of the intestine should be turned over to the left. The terminal part of the ileum, which has no great latitude of movement, will be seen passing upwards across the iliac vessels and upon the psoas muscle, to join the cæcum immediately above the inter-tubercular plane, and close to the right mid-Poupart plane in the lower part of the right lumbar region.

The coils formed by the jejunum and ileum are suspended

from the posterior wall of the abdomen by a wide fold of peritoneum, called the mesentery. They are thus freely movable within the cavity. Owing to the manner in which the mesentery is attached to the posterior wall of the abdomen (Fig. 103), they tend to lie more in the left portion of the cavity than in the right part, and they occupy the umbilical, hypogastric, lumbar, and iliac regions. A few coils extend downwards into the pelvis, and not uncommonly some coils of the jejunum may be found in the left hypochondrium.

The Large Intestine (intestinum crassum).—The large intestine, although possessing a much wider calibre than the small intestine, is not nearly so long. It extends from the right iliac fossa to the anus, and it rarely measures more than five or six feet in length. Like the small intestine, it is widest at its commencement, and gradually diminishes in diameter as it advances towards its termination. It is subdivided arbitrarily into the following parts :—

The cæcum.	}	Ascending colon.
		Hepatic flexure.
		Transverse colon.
The colon.		Splenic flexure.
		Descending colon.
		Sigmoid flexure.
The rectum.		

The *cæcum* is the blind commencement of the great intestine. It lies in the right iliac fossa, on the ilio-psoas muscle, and being as a rule completely enveloped by the peritoneum, it is allowed some latitude of movement. When distended it is in contact with the anterior abdominal wall, and its most dependent part corresponds to Poupart's ligament in its outer part. The ileum opens into it upon its inner and hinder aspect about two and a half inches above its blind end, and marks the point where it becomes continuous with the ascending colon. This junction, as we have already noted, takes place in the lower part of the

right lumbar region, in the immediate neighbourhood of that part of the iliac crest which lies behind it.

On the surface of the anterior abdominal wall the position of the ilio-cæcal orifice may be determined by the fact that it lies close to the right side of the right mid-Poupart plane, and immediately above the intertubercular plane.

In connection with the cæcum the dissector will find the *vermiform appendix* (processus vermiformis). This is a narrow cæcal tube, which has a diameter slightly greater than that of a goose quill, and a length which varies from three to five or six inches. It opens into the cæcum upon its inner and back aspect below the termination of the ileum. It is held in position by a minute peritoneal fold, which constitutes its mesentery.

The orifice of the appendix may be determined on the surface by placing the finger upon the right mid-Poupart line immediately below the intertubercular plane.

The *ascending colon* (colon ascendens) extends vertically upwards through the right lumbar region, until it reaches the under surface of the right lobe of the liver. It is continuous below with the cæcum, whilst above it becomes the hepatic flexure. It is usually clothed anteriorly and laterally by peritoneum, whilst posteriorly it is bare; and this bare surface rests upon the fascia covering the quadratus lumborum muscle and upon the lower part of the anterior surface of the right kidney, with each of which it is connected by a little loose areolar tissue. In certain cases the peritoneum may surround the tube, and form behind it a short meso-colon.

The *hepatic flexure* (flexura coli dextra) is the bend which connects the ascending colon with the transverse colon. When the colon reaches the inferior surface of the right lobe of the liver, it bends slightly forwards and then turns suddenly to the left, and this curvature constitutes the flexure. The summit of the curve lies in the right hypochondrium. It occupies a marked depression on the under surface of the liver to the right of the gall-

bladder, and is placed in front of the lower part of the kidney. Like the ascending colon, it is only partially covered by peritoneum. Its posterior surface is more or less bare, and in direct contact with the kidney.

The *transverse colon* (colon transversum) continuous on the one hand with the hepatic flexure, and on the other with the splenic flexure, stretches across the abdominal cavity. At first it descends into the umbilical region, and then ascends into the left hypochondrium. It takes an arched course, the summit of the arch being nearer the anterior wall of the abdomen, and at the same time at a lower level in the body, than its extremities. The transverse colon possesses greater freedom of movement than any other part of the great intestine. It is attached to the posterior abdominal wall by a wide peritoneal fold, called the *transverse meso-colon*. Its right extremity lies in front of the duodenum, whilst its left extremity is in close relation to the lower surface of the pancreas. The transverse colon is the longest subdivision of the great intestine.

The *splenic flexure* (flexura coli sinistra) is the term applied to the bend which the colon takes in the left hypochondrium, before proceeding downwards as the descending colon. It is placed at a higher level and gains a deeper plane in the abdominal cavity than the hepatic flexure, and it receives its name from the fact that it lies in more or less intimate relation with the basal surface of the spleen. A fold of peritoneum, with a free, crescentic border, binds it to the diaphragm opposite the tenth or eleventh rib. This fold is called the *phrenico-colic* ligament or the *sustentaculum lienis*.

When the stomach is empty and the colon distended with gas, the splenic flexure may rise so high as to occupy a position against the vault of the diaphragm, beside the fundus of the stomach. In such a case it intervenes between the stomach and the thoracic wall, and would yield a tympanitic note upon percussion.

The *descending colon* (colon descendens) takes a vertical course downwards through the left lumbar region, and, on gaining the crest of the ilium, becomes continuous with the

sigmoid flexure. Its anterior surface and its sides are covered by peritoneum, but its posterior surface is usually bare, and rests upon the lower part of the kidney and the fascia over the quadratus lumborum muscle, to which it is connected by loose areolar tissue.

It is into the lower part of this division of the colon that the surgeon opens in the operation of Lumbar Colotomy. The opening is made into the posterior aspect of the tube, so as to avoid wounding the

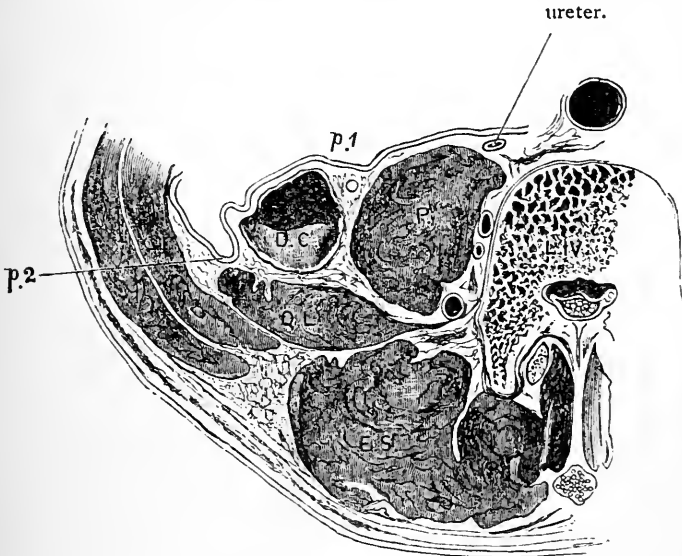


FIG. 106.—From a tracing of a transverse section through the abdomen, at the level of the fourth lumbar vertebra.

p.1 and *p.2* indicate the points at which the peritoneum is reflected from the descending colon on to the posterior wall of the abdomen.

D.C. Descending colon.

Q.L. Quadratus lumborum.

P. Psoas.

E.S. Erector spinae.

L.IV. Fourth lumbar vertebra.

peritoneum. It is therefore essential that the posterior relations of the descending colon should be laid down with more than usual precision. At the level of the third lumbar vertebra, where the colon is in relation to the kidney, it lies along the outer border of the quadratus lumborum. Between the lower end of the kidney and the crest of the ilium (where the operation is performed) the quadratus lumborum is placed behind the colon, and must be divided, or pushed aside, in order to reach it. It may be noted that the outer edge of the erector spinae usually

corresponds with the bare posterior surface of the colon at this level (Fig. 106).

The *sigmoid flexure* (colon sigmoideum) extends from the crest of the ilium to the brim of the true pelvis, where it becomes continuous with the rectum at a point corresponding to the left sacro-iliac articulation. It forms a long single loop of intestine, which is bound to the left iliac fossa by an extensive fold of peritoneum, called the *sigmoid meso-colon*. The sigmoid flexure may, therefore, be defined as being that part of the great gut which is attached to the wall of the false pelvis; whilst the rectum is that part of the bowel which is fixed to the posterior wall of the true pelvis. The subdivision is somewhat arbitrary, seeing that the sigmoid meso-colon runs continuously into the meso-rectum, or the fold of peritoneum which binds the rectum, to the front of the sacrum. The sigmoid loop of intestine possesses considerable latitude of movement, owing to the length of its mesentery. It lies in the left iliac fossa, and in the true pelvis; but a portion of it may also be found in the hypogastric region.

The *rectum* will be described with the pelvic viscera.

Adaptation of the Abdominal Walls to the Viscera, and of the Viscera to each other.—The abdomen is an air-tight cavity, and the atmospheric pressure acts upon its mobile walls so as to keep them constantly in accurate apposition with the viscera, and also the viscera in accurate contact with each other. During life, and in the undissected subject, no space of any kind is left vacant. The external configuration of the solid organs within the abdomen is determined by this close adaptation of walls to contents, and of viscus to viscus. The liver is the best example of this—every structure with which it is in contact leaves its mark upon it, in the form of a depression, whilst its upper surface presents an exact mould of the under surface of the diaphragm. During life the hollow viscera are constantly undergoing changes of form, and they react upon the pliable solid organs modelling them in such a manner that they also undergo striking alterations of form.

The Peritoneum.—The peritoneum is the serous membrane which lines the walls of the abdominal cavity, and gives more or less complete coverings to all the viscera within it. In the male it is a *closed sac* like other serous membranes. In the female, however, there is a small opening at the extremity of the Fallopian tube, by means of which the lumen of this tube communicates with the interior of the sac. It differs from other serous sacs in its great size, and also in its many complications. Take, for example, the pleura or the serous pericardium, or the tunica vaginalis; in these cases the serous membrane lines a cavity which holds a single viscus, and the reflection of the membrane from the walls of the cavity on to the viscus, and from the viscus again on to the walls, can be followed with the greatest ease. The peritoneal sac, on the other hand, belongs to a cavity which contains numerous viscera, the majority of which have undergone striking changes in position during development, and this is the reason why it is so very complicated.

In opening the cavity of the abdomen, the peritoneal sac has been laid open, and the inner surface of the membrane is observed to present the usual smooth, polished, and glistening appearance. The part which lines the walls of the abdomen is termed the *parietal peritoneum*; that which is reflected on to viscera is called the *visceral peritoneum*.

Before tracing the peritoneum through its many foldings, it is well that some terms which are applied to certain of its folds should be explained. The term *omentum* is employed to denote a fold of peritoneum which connects the stomach with neighbouring viscera. Thus we have the *great* or *gastro-colic omentum* connecting it with the transverse colon; the *small* or *gastric-hepatic omentum* connecting it with the liver; and the *gastro-splenic omentum* connecting it with the spleen. The term *mesentery* is applied to any fold of peritoneum which attaches the intestinal tube to the posterior wall of the abdomen, as, for example, the *mesentery proper* in connection with the small intestine, the *transverse meso-colon*, the *sigmoid meso-colon*, the *meso-rectum*, the

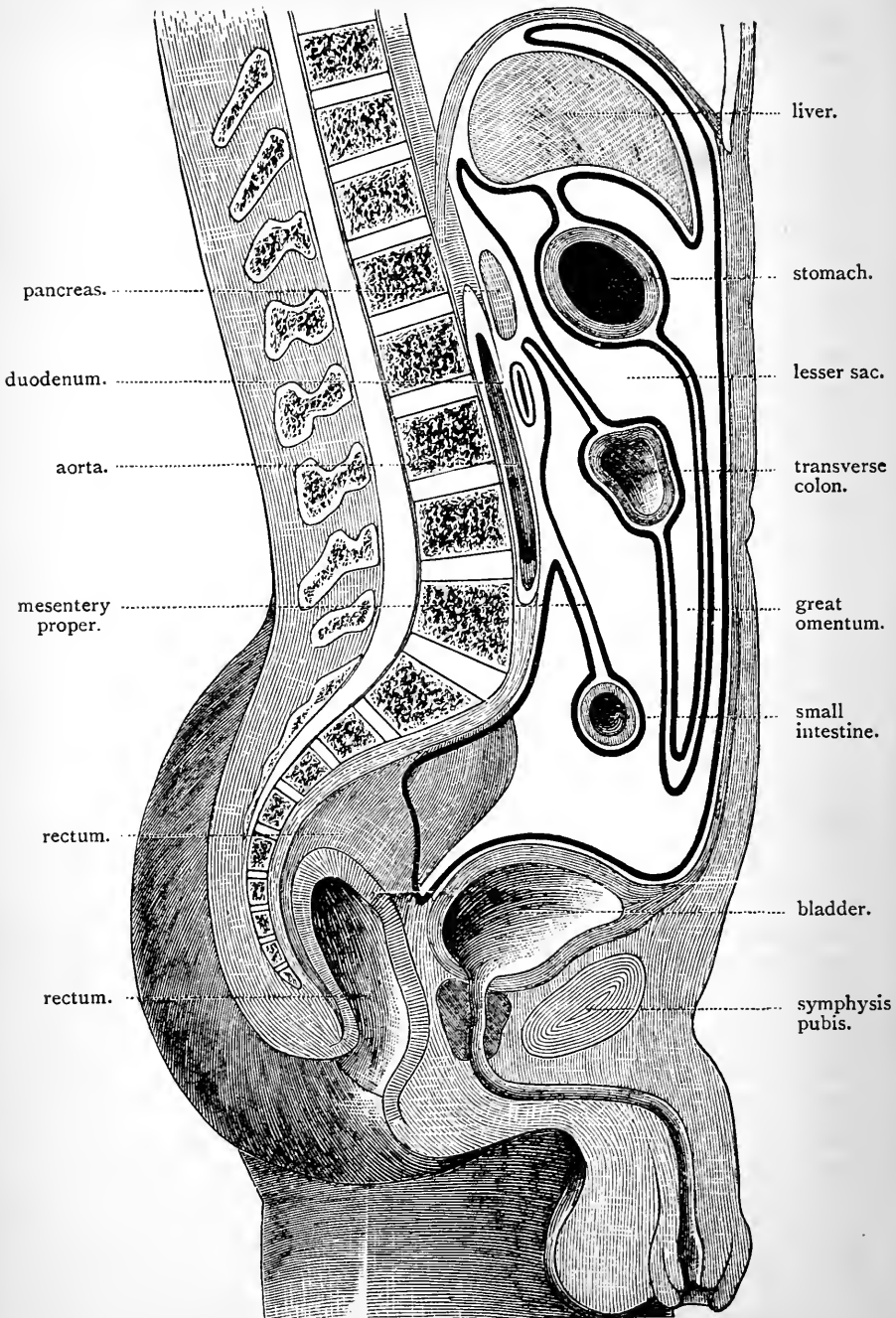


FIG. 107.—Diagram to illustrate the continuity of the peritoneum in the vertical direction.

mesentery of the vermiform appendix, and the mesenteries occasionally found in connection with the ascending and descending portions of the colon. The term *ligament* is given to folds which connect viscera which are not parts of the intestinal canal to the walls of the abdomen, or which bind viscera of any kind to the diaphragm. Examples of these are to be found in the peritoneal ligaments of the liver, bladder, and uterus, and also in the *lieno-renal*, the *phrenico-colic*, and the *gastro-phrenic* ligaments.

Let us now endeavour to follow the peritoneal membrane in the vertical direction (Fig. 107). The best point to start from is the *great omentum*, or large apron-like fold which hangs down from the stomach, and is spread out over the coils of the small intestine. This omentum is composed of *four* layers—two anterior layers and two posterior layers, and these are continuous with each other at the lower free margin of the fold. Trace the two anterior layers upwards. They lead to the greater curvature of the stomach, and here they separate from each other so as to enclose this viscus between them—one passing in front and the other passing behind it. The smooth glistening appearance presented by the surface of the stomach is due to the peritoneal coating which it thus acquires. At the lesser curvature of the stomach the two layers come together, and are prolonged upwards to the liver as a distinct fold, which receives the name of the *gastro-hepatic* or *lesser omentum*. Reaching the transverse fissure of the liver the two layers again separate, this time to enclose the liver. The one layer is directed forwards over the under surface of the organ round its anterior border, and then onwards over its anterior and superior surfaces. On reaching the point where the liver and diaphragm are in contact, it is reflected on to the diaphragm, and proceeds forwards upon its under surface to reach the anterior wall of the abdomen. The other layer turns backwards, and, clothing the lobus Spigelii on the posterior surface of the liver, is reflected on to the back part of the diaphragm, and turns downwards on the posterior wall of the abdomen. We shall now leave these layers for

a little and trace the *two posterior* layers of the omentum. For this purpose it is necessary to turn up the great omentum over the ribs. Its two posterior layers in proceeding upwards come to the transverse colon. This they enclose, the one passing in front and the other behind, and coming in contact with each other again on the other side of the gut, they are prolonged backwards to the posterior wall of the abdomen, as the *transverse meso-colon*. They reach the back wall of the abdomen along the antero-inferior border of the pancreas, and here they separate. The one layer turns upwards over the pancreas to become continuous with the layer which we left upon the posterior wall of the abdomen. The other turns downwards over the third part of the duodenum, and is almost immediately led away from the posterior wall of the abdomen by the superior mesenteric vessels, which, spreading out in a fan-like manner, conduct it to the small intestine. Turning round the gut so as to invest it, the peritoneum proceeds upwards upon the posterior aspect of the superior mesenteric vessels to the spine. In this manner the *mesentery proper* is formed. The peritoneum is now carried downwards over the posterior abdominal wall into the pelvis, where it may be traced over the rectum and bladder,¹ to both of which it gives partial coverings, and then on to the anterior abdominal wall, where it becomes continuous with the layer which we left there.

The *two anterior layers* of the great omentum therefore proceed upwards to the under surface of the diaphragm, and there separate, the one passing forwards over the anterior portion of its under surface to reach the anterior wall of the abdomen, whilst the other is directed backwards over the posterior part of its under surface to reach the posterior wall of the abdomen. On their way up to the diaphragm these layers enclose the stomach, form the gastro-hepatic omentum, and partially enclose the liver. On the other hand, the *two*

¹ In the female it also gives a covering to the uterus, but the disposition of the peritoneum in the pelvis, both male and female, will be fully described in connection with the pelvic viscera.

posterior layers are directed backwards to the spine, and there separate. In passing back, they enclose the transverse colon, and form the transverse meso-colon. The one layer then ascends to become continuous with the layer on the posterior abdominal wall. The other layer passes downwards, doubles upon itself to enclose the small intestine and form the mesentery proper, enters the pelvis, and then reaches the anterior abdominal wall.

A reference to Fig. 107 will show that the peritoneal sac is arranged in two pouches,—a *large pouch* in front and a *smaller pouch* situated behind it. The large pouch is the one into which we have opened in opening the cavity of the abdomen. Now it must be clearly understood that these are simply compartments of *one* serous sac, and that they communicate freely with each other through a narrow channel called the **Foramen of Winslow** (foramen epiploicum). The best way to find the foramen of Winslow is to lay hold of the fundus of the gall-bladder with the left hand, and then pass the forefinger of the right hand backwards along it towards its neck. The finger will slip behind the gastro-hepatic omentum into the foramen.

The foramen of Winslow has the following boundaries :—*in front*, the right free margin of the gastro-hepatic omentum, between the two layers of which are the hepatic artery, the portal vein, the hepatic duct, and some nerves ; *behind*, the vena cava inferior, and the right crus of the diaphragm, covered by the layer of the transverse meso-colon, which passes upwards on the posterior wall of the abdomen ; *below*, the duodenum and hepatic artery ; and *above*, the lobus caudatus of the liver.

The lesser bag of the peritoneum extends *downwards* into the omentum, *upwards* to the posterior surface of the Spigelian lobe of the liver and back part of the diaphragm, and *to the left* as far as the spleen. It is closed in the following manner :—*in front*, by the two anterior layers of the great omentum, by the stomach, by the gastro-hepatic omentum, and the lobus Spigelii of the liver ; *behind*, by the two posterior layers of the great omentum, by the

transverse colon, by the transverse meso-colon, and by the layer which ascends on the posterior wall of the abdomen over the pancreas, left kidney, left suprarenal capsule, and diaphragm : on *the left side*, by the spleen and gastro-splenic omentum.

In a favourable subject these points can be made out by dividing the two anterior layers of the great omentum along the greater curvature of the stomach, and introducing the hand into the lesser sac. The entire

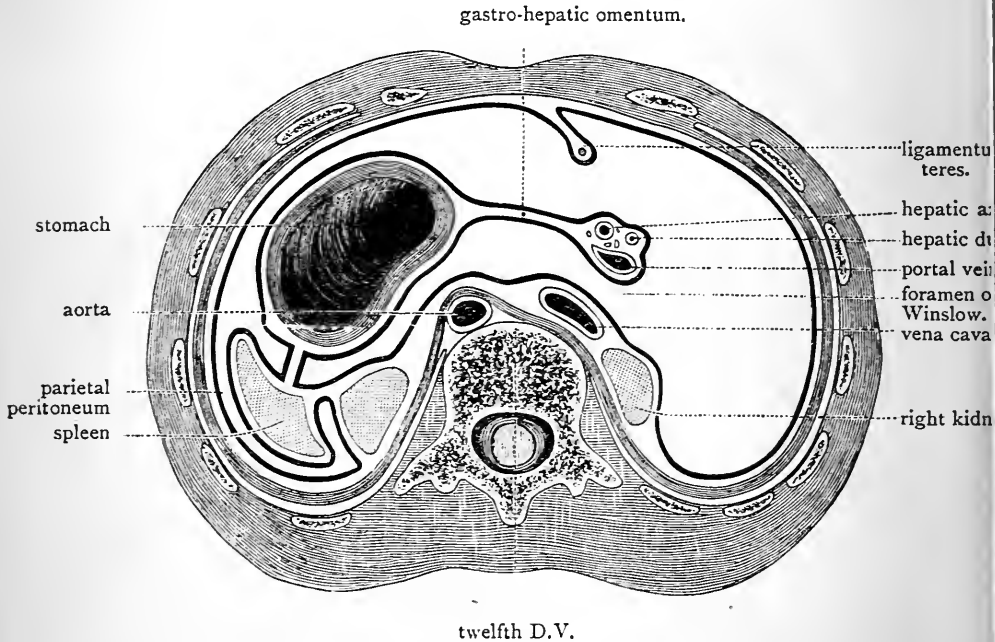


FIG. 108.—Section through the peritoneal cavity at the level of the foramen of Winslow.

extent of the pouch can thus be explored, and its continuity with the greater bag demonstrated, by turning the forefinger to the right and bringing it out through the foramen of Winslow, or by passing the forefinger of the other hand into the foramen of Winslow, and making the two fingers meet behind the gastro-hepatic omentum.

The peritoneal lining of the abdomen must also be traced in the transverse direction at different levels. Fig. 108 gives a diagrammatic view of the manner in which it is arranged

at the level of the foramen of Winslow or the twelfth dorsal vertebra. Taking the gastro-hepatic omentum as the starting-point, follow the two layers of which this is composed to the right. They become continuous around the hepatic artery and duct and the portal vein forming the right free border of this omentum and the anterior boundary of the foramen of Winslow. Following them to the left, they separate to

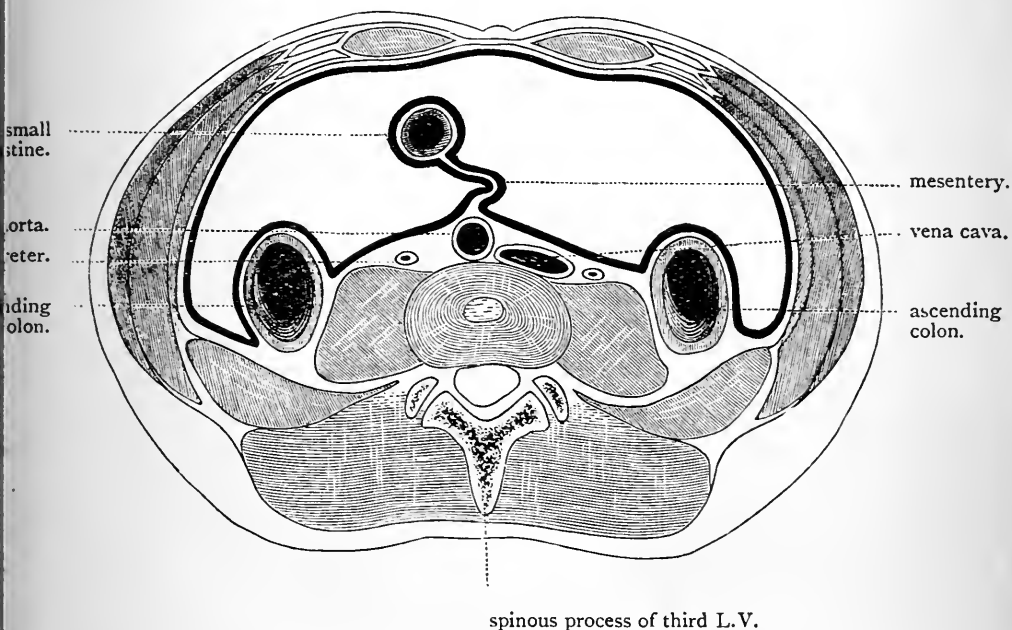


FIG. 109.—Section at the level of the umbilicus through the intervertebral disc between the third and fourth lumbar vertebræ.

enclose the stomach, and then, coming in contact again, they are prolonged to the spleen in the form of the *gastro-splenic omentum*. Here they separate, and the posterior of the two layers is reflected backwards to the anterior surface of the left kidney, so as to form the right layer of a fold called the *lieno-renal ligament*. Upon the kidney it turns to the right, and is continued over the posterior wall of the abdomen until it reaches the foramen of Winslow, of

which it forms the posterior boundary. Here it covers the vena cava inferior, and is then carried onwards over the right kidney on to the lateral and the anterior wall of the abdomen. The anterior layer of the gastro-splenic omentum, which we left at the spleen, turns round this organ so as to give it its serous covering, and, reaching again its inner aspect, it is reflected backwards to the left kidney, forming

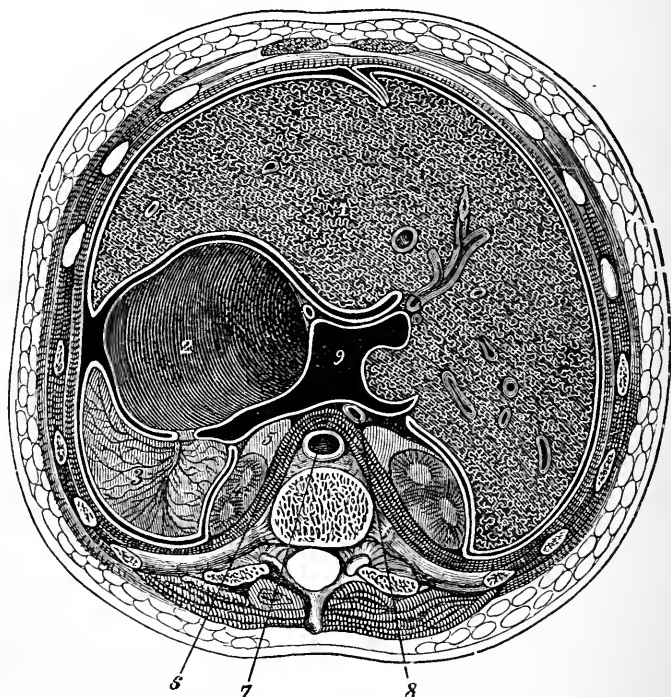


FIG. 110.—Section through the abdominal cavity of a young subject at the upper border of the 12th dorsal vertebra, above the level of the foramen of Winslow. From this it will be seen that the lobus Spigelii is the only part of the posterior surface of the liver which is clothed by the lesser sac. (From LUSCHKA'S *Anatomy*.)

- | | |
|------------------------|------------------------------|
| 1. Liver. | 6. Diaphragm. |
| 2. Stomach. | 7. Aorta. |
| 3. Spleen. | 8. Vena Cava. |
| 4. Kidney. | 9. Lesser bag of peritoneum. |
| 5. Suprarenal capsule. | |

the left layer of the *lieno-renal ligament*. Upon the anterior surface of the kidney it turns to the left, and, reaching the wall of the abdomen, is continued round this to become continuous with the layer which we left there. Observe that at this level the peritoneum is borne off the anterior wall of the abdomen by the obliterated umbilical vein, so as to form a distinct fold, called the *falciform ligament* of the liver.

In the diagram which is given to illustrate the continuity of the peritoneum at this level (Fig. 108), the continuity of the lesser and greater bags of the peritoneum through the foramen of Winslow is seen. The gastro-splenic and the lieno-renal folds which connect the spleen to the stomach and to the left kidney are also exhibited.

Opposite the umbilicus, at the level of the intervertebral disc, between the third and fourth lumbar vertebræ, the peritoneum may be followed in the transverse direction with the greatest ease (Fig. 109). Turn the great omentum with the enclosed transverse colon upwards over the ribs, and, taking the *mesentery proper* as the starting-point, trace its two layers towards the small intestine. They will be observed to be continuous around it. Now follow them backwards to the spine, and here they will be observed to separate—the one turning to the right, and the other to the left over the posterior wall of the abdomen. In the lumbar regions they meet the ascending and descending portions of the colon. These they clothe anteriorly and laterally, as we have already seen, and then they are carried on to the anterior wall of the abdomen, where they become continuous.¹

Peritoneal Ligaments.—In the abdomen proper, the student must specially examine—(1) the gastro-phrenic ligament; (2) the lieno-renal ligament; (3) the phrenicocolic ligament; and (4) the hepatic ligaments.

¹ As we have previously observed, the ascending and descending portions of the colon may be completely enveloped by peritoneum, and even connected by mesenteries to the posterior wall of the abdomen. Symington states, with good reason, that the frequency of these mesenteries has been much exaggerated by recent writers.

The *gastro-phrenic ligament* is an insignificant fold which connects the fundus of the stomach with the under surface of the diaphragm. It is placed close to the œsophageal opening, on its left side, and is formed by that layer which ascends over the anterior surface of the fundus of the stomach to reach the diaphragm. It is simply a reduplication of this layer.

It is interesting to note that the stomach is not completely covered by peritoneum. There is a small triangular area situated on its posterior surface immediately below the œsophagus, which is bare, and rests directly upon the left crus of the diaphragm.

The *lieno-renal ligament*, formed of two layers of peritoneum, passes from the visceral face of the spleen to the front surface of the left kidney. It is a short fold, and between its two layers the branches of the splenic artery reach the hilum of the spleen (Fig. 108).

The *phrenico-colic ligament* has been already noticed (p. 452).

The *ligaments of the liver* are five in number—viz. (1) the ligamentum teres; (2) the falciform ligament; (3) the coronary ligament; (4) the right lateral; and (5) the left lateral ligaments.

The *ligamentum teres* is not a peritoneal ligament, but it is convenient to describe it with them. It is a fibrous cord, in fact the obliterated umbilical vein, which extends from the umbilicus upwards, backwards, and to the right, to the anterior part of the longitudinal fissure on the under surface of the liver. It ends by joining the wall of the left terminal branch of the portal vein.

The *falciform ligament* (*ligamentum falciforme hepatis*), is a double layer of peritoneum of a triangular shape. By its *anterior border* it is attached to the anterior wall of the abdomen, and to the under surface of the diaphragm, whilst by its *posterior border* it is fixed to the upper and anterior surfaces of the liver, so as to mark it off into a right and left lobe. Its *lower border* or *base* is free, and contains between its two peritoneal layers the ligamentum

teres. Along the line of its attachment to the liver the two layers separate—the one spreading over the left lobe and the other over the right lobe. When followed backwards these leave the liver as upper layers of the coronary and lateral ligaments (Fig. III).

To understand the *coronary ligament* (ligamentum coronarium hepatis) aright, it must be borne in mind that an irregular area on the posterior surface of the right

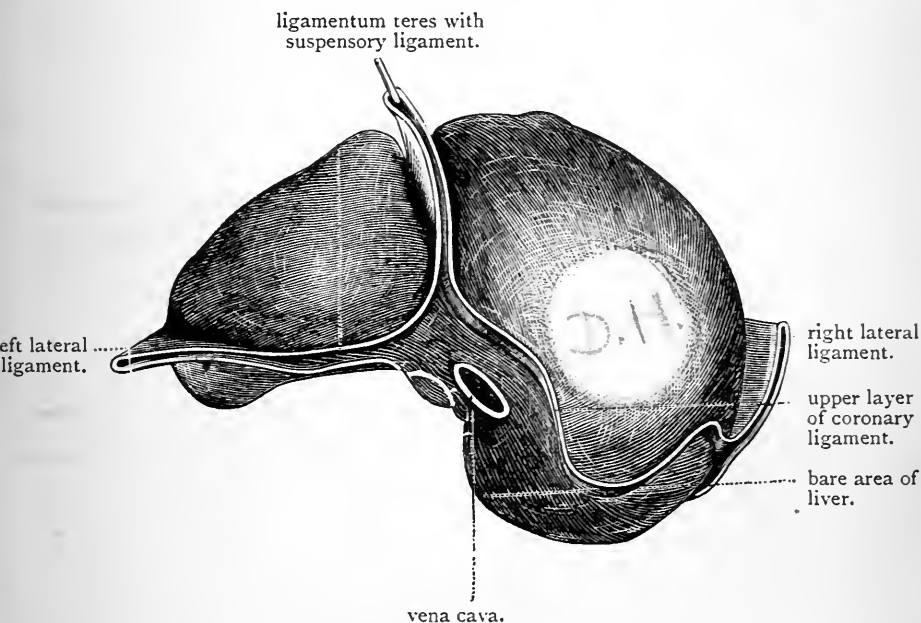


FIG. III.—Diagram of the peritoneal ligaments of the liver.

lobe of the liver is devoid of peritoneum, and that this area is in direct apposition with the diaphragm, to which it is connected by some loose areolar tissue. The peritoneum covering the upper surface of the liver is reflected at the upper limit of this bare area directly on to the diaphragm; this reflection constitutes the *upper layer* of the coronary ligament (Fig. III). The *lower layer* of the ligament is formed at the lower limit of the bare area by the reflection of the peritoneum from the under surface of

the liver on to the upper part of the right kidney and the vena cava inferior. The two layers, therefore, of the coronary ligament are not in contact with each other, but are separated by a distance equal to the breadth of the bare surface of the liver (Fig. 111).

The *right lateral ligament* (ligamentum triangulare dextrum) will be brought into view by dragging the right lobe of the liver to the left and looking into the interval between the back part of its right surface and the diaphragm. It is a very small free fold, formed by the apposition of the two layers of the coronary ligament at the right extremity of the bare area of the liver (Fig. 111).

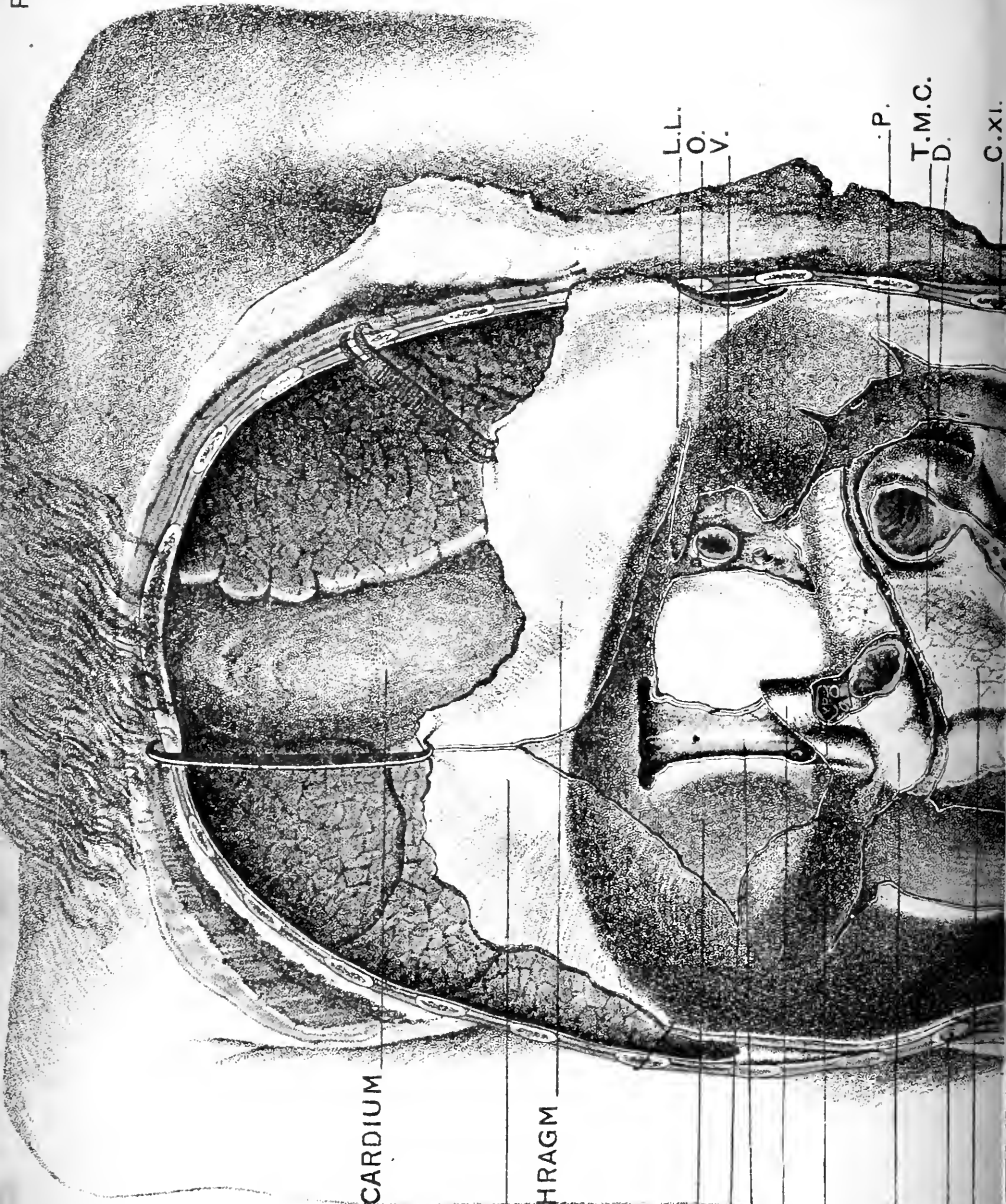
The *left lateral ligament* (ligamentum triangulare sinistrum) is a much more extensive fold, which passes from the under surface of the diaphragm to the posterior part of the upper surface of the left lobe of the liver. It is triangular in form, and its basal margin is crescentic and free and directed to the left. When the ligament is traced to the right its upper layer is seen to become continuous with the left layer of the falciform ligament, whilst the lower layer becomes continuous with the front layer of the gastro-hepatic omentum (Fig. 111).

Peritoneal Omenta.—We have seen that these are three in number—viz., the great omentum, the small omentum, and the gastro-splenic omentum.

The *great omentum* (omentum majus) is by far the largest free fold of peritoneum in the abdomen. It is formed by the two layers which invest the stomach and first part of the duodenum passing downwards for a variable distance and then being folded backwards upon themselves to gain the transverse colon. In the adult, especially towards its lower free margin, the four layers have become blended, so that it is impossible to separate them. The cavity of the lesser peritoneal bag is carried downwards into it. In obese people the whole structure becomes loaded with fat.

The *small* or *gastro-hepatic omentum* (omentum minus) formed of two layers, leaves the lesser curvature of the





PERICARDIUM

S.L.

DIAPHRAGM

H.

R.L.

V.C.

F.

V.P.

D.

C.XI.

P.

L.L.

O.

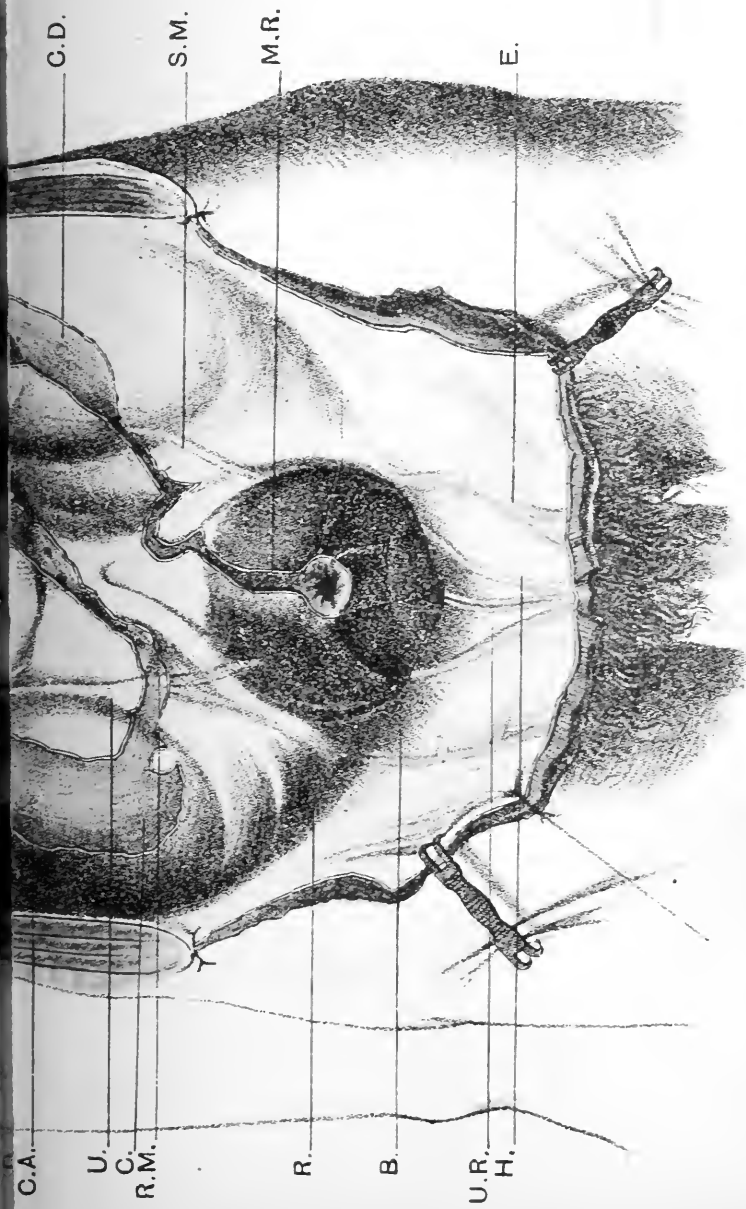
V.

P.

T.M.C.

D.

C.XI.



Posterior wall of the abdomen after the removal of viscera. It shows the lines along which the peritoneum is reflected on to the viscera. (This plate is reduced by permission from a drawing by Dr. GODAKOFF of the Anatomical School in Moscow.)

- | | | | |
|--|---|--|--|
| <p>S.L. Attachment of suspensory or falciform ligament of liver.
 H. Bare area on diaphragm in contact with bare area of liver.
 R.L. Right lateral ligament of liver.
 V.C. Vena cava inferior.
 F. Position of the foramen of Winslow.</p> | <p>V. Vena portae with hepatic artery and common bile duct.
 D. Duodenum.
 C.XI. Eleventh rib.
 P. Pancreas.
 C.A. Surface devoid of peritoneum for ascending colon.
 U. Ureter shining through the peritoneum.</p> | <p>C. Surface for upper part of the posterior surface of the caecum.
 R.M. Root of the mesentery.
 R. Rectum.
 B. Bladder.
 U.R. Utrachus.
 H. Obliterated hypogastric artery.
 E. Deep epigastric artery.</p> | <p>M.R. Meso-rectum.
 S.M. Sigmoid meso-colon.
 C.D. Surface devoid of peritoneum for descending colon.
 R.S. Left kidney.
 T.M.C. Transverse meso-colon.
 V. Bare surface on diaphragm for stomach.
 L.L. Left lateral ligament of liver.</p> |
|--|---|--|--|

stomach and the first part of the duodenum, and proceeds upwards as a free fold towards the liver. Above it is attached along the transverse fissure of the liver, the posterior part of the longitudinal fissure of the liver (*i.e.*, that part which contains the obliterated ductus venosus) (Fig. 122), and also to the diaphragm in the immediate vicinity of the oesophagus. It presents a right free margin, which extends from the transverse fissure of the liver to the duodenum, and forms the anterior boundary of the foramen of Winslow. Over the greater part of its extent it is very thin; the two layers are fused, and often it is fenestrated. The two layers, however, become evident along its lines of attachment, and also in the portion adjoining its right free edge.

The *gastro-splenic omentum*, composed of two peritoneal layers continuous with the two anterior layers of the great omentum, forms a short fold, which connects the fundus of the stomach with the spleen. Between its two layers the vasa brevia of the splenic artery gain access to the stomach.

The Mesenteries of the Great Intestine.—Under ordinary circumstances these are three in number—*viz.*, the transverse meso-colon, the sigmoid meso-colon, and the meso-rectum.

The *transverse meso-colon* (*mesocolon transversum*) stretches from the transverse colon to the posterior wall of the abdomen, to which it is attached along the antero-inferior border of the pancreas (Pl. I., also Fig. 116, p. 491). It is an extensive fold, formed by the two posterior layers of the great omentum after they have enclosed the colon, and containing between them the blood-vessels which go to this portion of the gut. It is longest in the mesial plane of the body, and shortens as it is traced to the right and to the left, until finally at the two flexures which mark the limits of the transverse colon it ceases to exist as a free fold.

The *sigmoid meso-colon* (*mesocolon sigmoideum*) is a long mesentery, composed of two layers of peritoneum, which binds the sigmoid flexure of the colon to the left

iliac fossa. At its root it is narrow, but it widens out as it is traced to the gut, and it contains within it the blood vessels which supply this portion of the intestine. The line of attachment of its root is oblique, and extends from the highest point of the iliac crest across the iliac fossa to the left sacro-iliac articulation where it crosses the iliac vessels (Pl. I., also Fig. 103, p. 444). Towards both ends the fold rapidly shortens, and inferiorly it becomes continuous with the meso-rectum. The loop of intestine which is enclosed in sigmoid meso-colon when held up presents a somewhat pedunculated appearance, and cases of intestinal obstruction through the twisting of this loop of gut around its own base are not unknown.

The *meso-rectum* will be examined in connection with the pelvis.

The Mesentery Proper.—By this we mean the extensive fold of peritoneum by which the jejunum and ileum are suspended from the posterior wall of the abdomen. To obtain a proper view of the mesentery proper, it is necessary to throw up the great omentum and the transverse colon over the lower margin of the chest. It is attached along an oblique line, which extends from the left side of the body of the second lumbar vertebra downwards, and to the right into the right iliac fossa (Fig. 103, p. 444). This attachment is called the “root” of the mesentery, and as it is traced downwards it will be seen to cross obliquely the third part of the duodenum, the aorta on the front of the spine, and the psoas muscle (Pl. I.). The “root” of the mesentery is thus, comparatively speaking, narrow (about six inches), but, as the fold approaches the coils of the small intestine, it widens out enormously, so that when it reaches the gut its width equals the length of the jejunum and ileum. This great width is not at first apparent, because the mesentery is thrown into folds like a goffered frill. The coiled condition of the gut is due to this arrangement.

The two layers of the mesentery are not in apposition with each other. They are separated by a variable amount of fat, and also certain important structures which lie

between them. These are (1) the superior mesenteric vessels and their branches to the jejunum and ileum; (2) the superior mesenteric nerves; (3) great numbers of lymphatic glands and lacteal vessels; (4) the gut itself.

Occasional Peritoneal Fossæ.—It is necessary to take notice at this stage of three little peritoneal pockets or blind recesses which are occasionally present in different positions on the posterior wall of the abdomen. The importance of these fossæ depends upon the fact that one or other of them may become the site of a form of hernia, termed *retro-peritoneal hernia*, through a knuckle of the small intestine becoming engaged within it. From their position they are termed (1) the fossa duodeno-jejunalis: (2) the fossa subcæcalis, and (3) the fossa intersigmoidea. In every abdomen that is opened in the dissecting-room these fossæ should be looked for before the peritoneal folds are dissected.

The *fossa duodeno-jejunalis*, if present, will be brought into view by throwing the omentum with the transverse colon upwards over the ribs and drawing the coils of the small intestine well to the right. The little fossa lies on the left side of the commencement of the jejunum. It is bounded below by a free projecting semilunar peritoneal fold, and it passes for a short distance behind the parietal peritoneum. Cases are known in which this small peritoneal pocket has become so distended through the entrance of the small intestine that it has formed a hernial sac into which the whole of the jejunum and ileum has passed.

When the *fossa subcæcalis* exists it will be brought into view by drawing the cæcum forwards and to the right. It is a small peritoneal pocket which ascends for a short distance behind the ileo-cæcal junction. It is right to mention that there are several varieties of this fossa.

The *fossa intersigmoidea* is very rarely seen in the adult. When present it will be found by raising the sigmoid loop of the great intestine. Its mouth lies about the middle of the under surface of the root of the sigmoid mesentery, over the interval between the psoas and iliacus muscles (Henle).

Dissection.—The structures which are included between the two layers of the mesentery proper and between the two layers of the transverse meso-colon must now be dissected. The great omentum being thrown well up over the lower margin of the chest, remove the entire anterior layer of the mesentery from its root down to where it is attached to the gut. Begin at the upper end of the jejunum at the left side of the second lumbar vertebra, and gradually travel downwards to the lower end of the ileum, stripping off the peritoneum and cleaning the structures exposed. To display all the branches of the superior mesenteric artery it is necessary to remove also the inferior layer of the

transverse meso-colon and the peritoneum which proceeds on the posterior wall of the abdomen towards the cæcum and ascending colon. Follow the main trunk of the superior mesenteric artery upwards to its origin from the aorta, by raising the lower border of the pancreas.

Superior Mesenteric Artery (*arteria mesenterica superior*).

—The superior mesenteric artery springs from the front of the abdominal aorta about a quarter of an inch below the cœliac axis. At its origin it is covered by the pancreas, and crossed by the splenic vein. Emerging from under cover of the pancreas, it crosses the third part of the duodenum, close to the duodeno-jejunal flexure, and then enters the mesentery proper. Between the two layers of the mesentery the artery is placed at a short distance from the mesenteric root, and pursues a slightly curved course towards the right iliac fossa, where it ends by anastomosing with one of its own branches. The convexity of the curve which it describes is directed to the left, and the concavity to the right. It is accompanied by the superior mesenteric vein, which lies upon its right side, and by the superior mesenteric plexus of nerves which surrounds it closely.

The following branches proceed from the superior mesenteric artery :—

- | | |
|--|--|
| 1. Inferior pancreatico-duodenal. | |
| 2. Branches to the jejunum
and ileum. | } Rami intestini tenuis. |
| 3. Branches to the great
intestine. | |
| | } Ileo-colic.
Right colic.
Middle colic. |

The *inferior pancreatico-duodenal* (*arteria pancreatico-duodenalis inferior*) takes origin from the superior mesenteric under cover of the pancreas. It has a curved course round the head of this gland, between it and the duodenum, and gives branches to both. It ends by anastomosing with the superior pancreatico-duodenal artery.

The *rami intestini tenuis* (*arteriæ intestinales*) spring from the convexity or left side of the superior mesenteric, and proceed obliquely downwards and to the left, between

the layers of the mesentery, to supply the jejunum and ileum. They are very numerous, from twelve to fifteen,

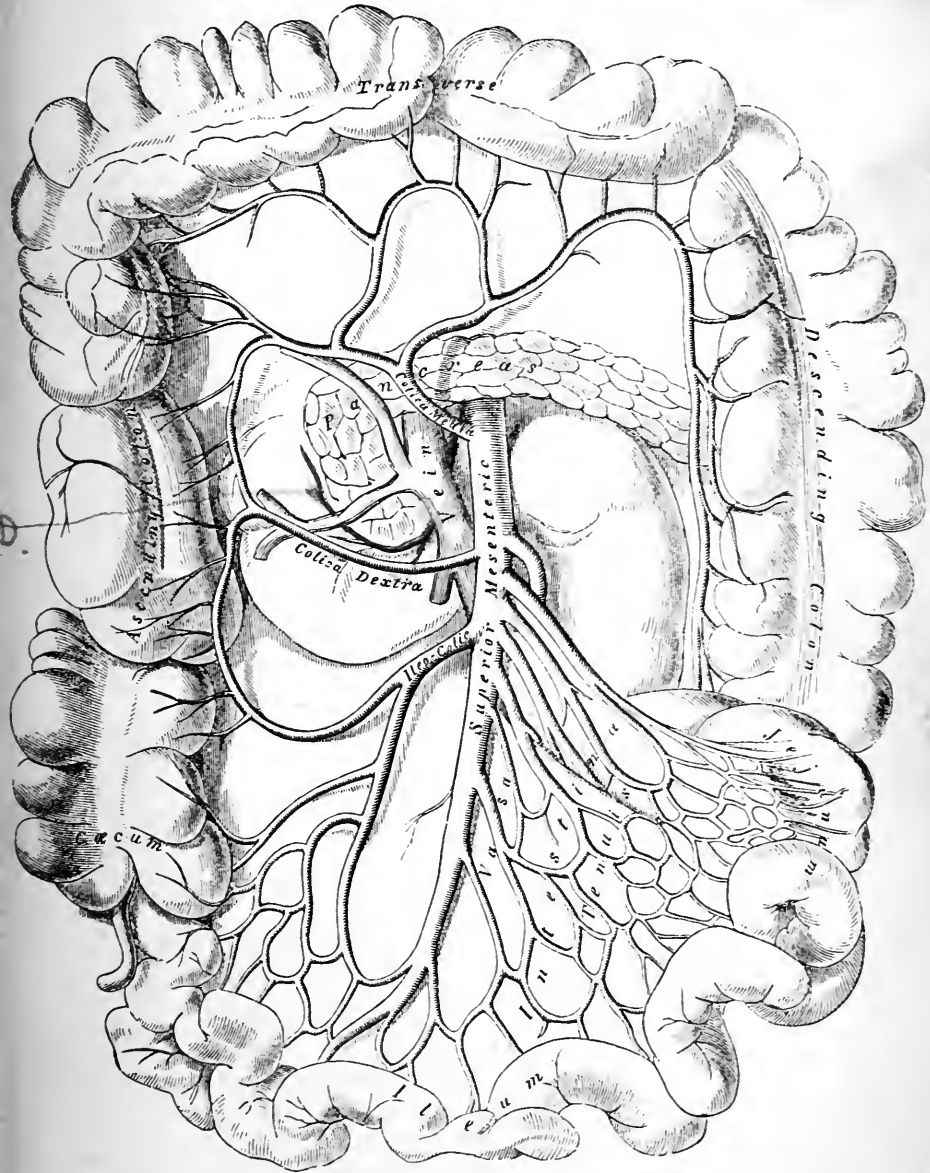


FIG. 112.—Diagram of the superior mesenteric artery and its branches.
(From GRAY'S *Anatomy*.)

or even more, in number, and, by their mutual inosculation, they form a very remarkable series of arches before they finally reach the bowel. At first they run parallel to one another, but soon they divide into two branches, each of which joins its neighbour, and in this way a succession of arterial arcades is formed. From these smaller twigs proceed, which divide and unite in a similar manner to form a second series of arches, and so on, until three, four, or perhaps even five tiers of arterial arcades are produced. From the lowest arches a multitude of minute twigs pass directly to the wall of the intestine.

The *colic branches* (arteriæ colicæ) spring from the concavity or right side of the superior mesenteric artery.

The *ileo-colic artery* (arteria ileo-colica), the lowest of the three branches which go to the great intestine, proceeds downwards, between the two layers of the mesentery, towards the right iliac fossa, and divides into a descending and an ascending branch. The *descending* branch joins the terminal part of the superior mesenteric, and from the arch thus formed twigs are given to the lower end of the ileum, the vermiform appendix, and the cæcum. The *ascending* branch inosculates with a branch of the right colic, and sends offsets to the ascending colon.

The *right colic artery* (arteria colica dextra) frequently arises in common with the ileo-colic. Escaping from the root of the mesentery it takes a horizontal course to the right, behind the parietal peritoneum on the back wall of the abdomen, and divides into two branches, a superior and an inferior. The superior branch ascends between the two layers of the transverse meso-colon to inosculate with the middle colic; whilst the *inferior branch* joins the ascending part of the ileo-colic. From the convexity of these arches twigs proceed to the colon.

The *middle colic artery* (arteria colica media) is the highest of the three branches which spring from the concavity of the superior mesenteric. It passes between the two layers of the transverse meso-colon, and divides into a right and a left branch. The *right branch* joins the superior

part of the right colic, whilst the *left branch inosculates with the ascending part of the left colic artery*, which is derived from the inferior mesenteric.

The Superior Mesenteric Vein (vena mesenterica superior) lies to the right of the artery and receives tributaries, which come from those parts of the intestinal canal which are supplied by branches from the superior mesenteric artery, and also the right gastro-epiploic vein from the great curvature of the stomach. Leaving the mesentery, it passes upwards in front of the duodenum, and then disappears under cover of the pancreas. Here it unites with the splenic vein to form the *vena portæ*.

The Superior Mesenteric Nervous Plexus (plexus mesentericus superior) is a dense plexus of sympathetic twigs, which surrounds the superior mesenteric artery like a sheath. From it filaments are prolonged to the gut along the various branches of the artery. As the nerves approach the bowel, some of the twigs leave the vessels and effect a series of communications with each other in the intervals between the arteries.

The superior mesenteric plexus is an offshoot from the *solar plexus*, and it distributes twigs to the jejunum, ileum, and to the right half of the great intestine.

Mesenteric Lymphatic Glands (lymphoglandulae mesentericae).—These are very numerous, indeed considerably over a hundred in number. In health they rarely attain a size greater than that of a bean or a pea, and they are scattered between the two layers of the mesentery. The larger glands lie along the superior mesenteric artery, whilst the others are placed in the intervals between its branches. It should be noted that they are most numerous opposite the jejunum, and that the mesentery in the immediate vicinity of the gut is free from them.

A few lymphatic glands will also be noticed in connection with the great intestine.

The *lacteal vessels* enter the mesentery from the walls of the intestine in enormous numbers. As they proceed upwards they pass through the succession of glands which

they meet, and greatly reduced in numbers, although considerably enlarged in calibre, they usually terminate near the origin of the superior mesenteric artery in one or perhaps more large trunks which pour their contents into the receptaculum chyli of the thoracic duct.

Dissection.—The coils of the small intestine must now be pulled over to the right side of the body, and the peritoneum carefully removed by the fingers from the lower part of the aorta and the left side of the spine and psoas muscle. The inferior mesenteric artery is thus exposed, and its branches can be followed to their distribution. The *ureter* and the *inferior mesenteric vein* will be seen lying upon the psoas muscle.

The Inferior Mesenteric Artery (*arteria mesenterica inferior*), considerably smaller than the superior mesenteric, springs from the left side of the abdominal aorta, about an inch and a half above its terminal bifurcation, and descends with a slight inclination to the left, towards the left iliac fossa. At first it is applied to the left side of the aorta, to which it is bound by peritoneum; it then crosses the left common iliac artery and enters the pelvis, where it receives the name of *superior hæmorrhoidal*. Before leaving the abdomen proper it gives off the *left colic* and the sigmoid branches.

The *left colic artery* (*arteria colica sinistra*) proceeds to the left, over the left kidney, and divides into two branches, of which one ascends in the transverse meso-colon to inosculate with the middle colic, whilst the other descends behind the peritoneum lining the posterior wall of the abdomen to unite with the sigmoid. From the arches thus formed twigs are supplied to the colon.

The *sigmoid arteries* (*arteriæ sigmoideæ*) proceed obliquely downwards, and, entering the sigmoid meso-colon, break up into several branches. These form arches with each other, from which twigs are ultimately given to the sigmoid flexure of the colon. The upper arch is in connection with the lower branch of the left colic, whilst the lower arch inosculates with the superior hæmorrhoidal artery. The arcading of the sigmoid vessels resembles that of the *vasa intestini tenuis* of the small intestine, and the extent

to which it is carried varies with the length of the sigmoid meso-colon.

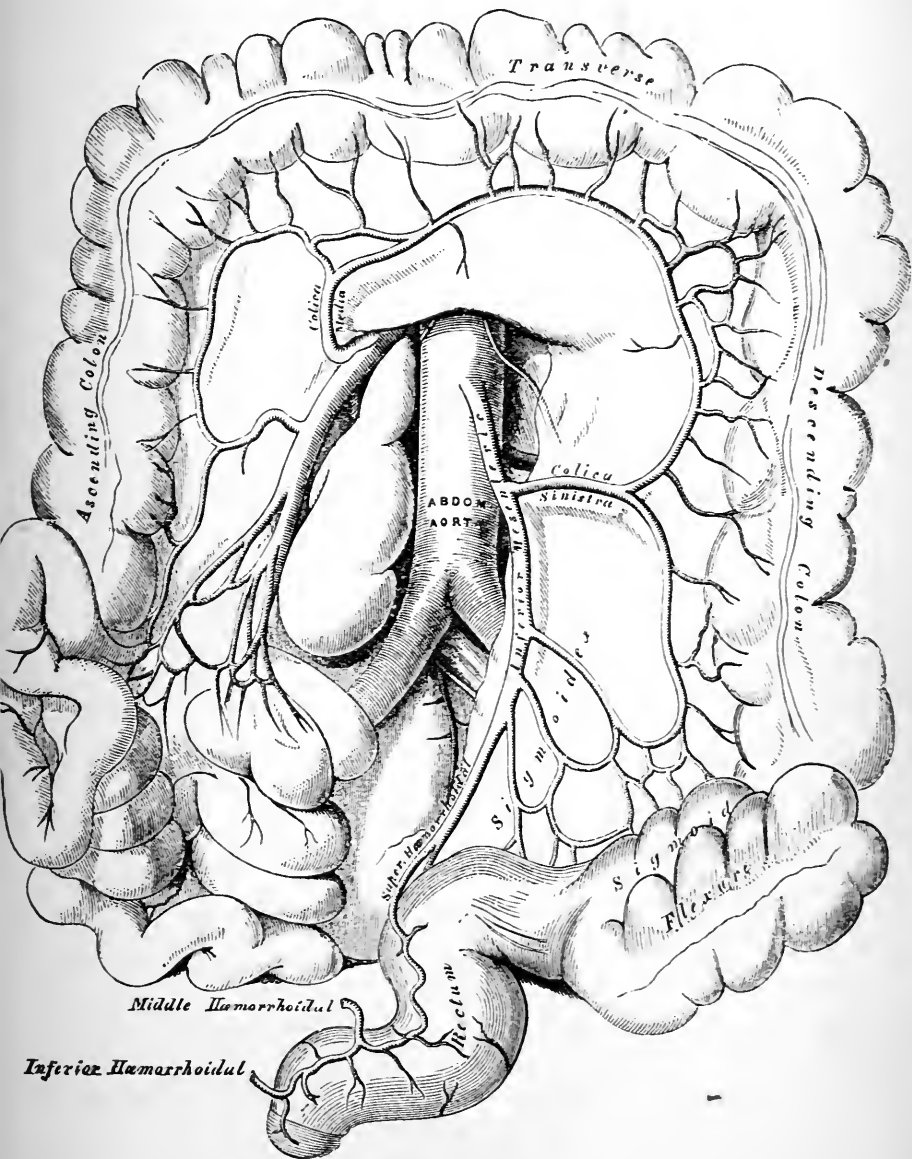


FIG. 113.—Diagram of the inferior mesenteric artery and its branches. (From GRAY'S *Anatomy*.)

Most frequently in place of one there are two or three sigmoid arteries, each with an independent origin from the inferior mesenteric artery.

The *superior hæmorrhoidal artery* will be followed out in the dissection of the pelvis.

The Inferior Mesenteric Vein (*vena mesenterica inferior*) receives tributaries corresponding with the branches of the inferior mesenteric artery. It passes upwards upon the psoas muscle under cover of the peritoneum, to the left of, and at some distance from, the artery, and, disappearing behind the pancreas, it ends in the splenic vein.

The Inferior Mesenteric Plexus of Nerves (*plexus mesentericus inferior*) is an offshoot from the left side of the aortic plexus. It closely surrounds the artery, and sends twigs along the branches of the vessel to supply the left half of the great intestine.

Dissection.—If the peritoneum has been carefully stripped off the lower part of the aorta, there will be little difficulty in recognising and following out the delicate nerves which form the aortic plexus. Raise the third part of the duodenum from the surface of the aorta, and trace these nervous twigs upwards.

The Aortic Plexus of Nerves (*plexus aorticus abdominalis*) is placed upon the aorta between the origins of the two mesenteric arteries. It is more strongly marked upon the sides of the artery than in front of it. Superiorly it will be found to be continuous with the solar and renal plexuses, whilst inferiorly it sends numerous large branches downwards in front of the common iliac arteries to join the hypogastric plexus—a plexus which is situated in front of the fifth lumbar vertebra, and which will be afterwards dissected. Upon each side the aortic plexus will be observed to be reinforced by several small twigs from the gangliated cord of the sympathetic. The *inferior mesenteric plexus* accompanying the artery of that name, and the *spermatic* (or *ovarian*) *plexus* of nerves which accompanies the spermatic (or ovarian) artery, are offsets from it.

Removal of the Intestines.—The jejunum, ileum, cæcum, and colon may now be removed from the abdominal cavity. Apply two

ligatures around the upper end of the jejunum, about an inch or so below the duodeno-jejunal flexure, and divide the gut between them; then place two ligatures around the sigmoid flexure at the brim of the pelvis, and divide it in like manner. The entire intestinal canal, with the exception of the duodenum and rectum, can now be taken away by carefully severing the blood-vessels and peritoneal folds which hold it in position. In cutting through the two layers of the great omentum, which extend from the transverse colon to the stomach, keep the knife close to the gut so as to avoid injury to the vessels in relation to the greater curvature of the stomach.

As soon as the intestines are detached they should be taken to the sink and the ligatures removed. The small intestine should be separated from the great intestine by dividing the ileum about six inches from the point where it enters the cæcum, and, the remains of the mesentery having been taken away from the small intestine by means of the scissors, both should be thoroughly cleaned out by allowing the water from the tap to run freely through them.

The coats of the small intestine should be dissected under water. Take a few inches of the intestine from the upper end of the jejunum, and, having opened it up with the scissors along the mesenteric line of attachment, pin it out, with its mucous surface downwards, upon the bottom of a cork-lined tray, which has been previously filled with clean water. The jejunum is chosen because its wall is thicker than the ileum, and consequently more easily dissected. Carefully remove the thin serous coat in order that the subjacent layer of longitudinal muscular fibres may be studied. Then turn the specimen round and pin it down with its mucous surface uppermost. Now remove the mucous membrane with the subjacent flocculent submucous coat with the scissors in one layer. The circular muscular fasciculi will come into view.

Coats of the Small Intestine.—The small intestine has five coats or strata entering into the formation of its walls, viz. :—

- | | |
|---------------|---------------|
| 1. Serous. | 4. Submucous. |
| 2. Subserous. | 5. Mucous. |
| 3. Muscular. | |

The *serous coating* of the jejunum and ileum is complete, except along the line of the mesenteric attachment. It is exceedingly thin—much thinner than the layers of the mesentery, with which it is continuous. Unless great care be taken in stripping it off, some of the subjacent muscular fibres will be taken away with it. The *subserous coat* is a scarcely appreciable amount of areolar tissue which inter-

venes between the peritoneum and the muscular coat. It need not be taken into account in this dissection. The *muscular coat* is composed of involuntary non-striated muscular fibres. These are disposed in two layers, viz., an *external stratum* of longitudinal fibres, and an *internal stratum* of circular fibres. Of these the circular layer is the thicker and more distinct of the two. The external longitudinal fibres are spread out in the form of a very thin uniform layer all round the circumference of the gut. In that part of the wall opposite the mesenteric attachment they are more thickly disposed than elsewhere. The *sub-mucous coat* is composed of loose areolar tissue which binds the muscular to the mucous coat. It is more firmly connected with the latter. The *mucous coat* must be examined throughout the whole length of the jejunum and ileum.

Dissection.—The student has noticed that externally no distinction can be drawn between the jejunum and ileum, with this one exception, viz., that as the tube descends it diminishes slightly in its calibre and in the thickness of its walls. It is necessary, therefore, that he should open it up along its whole length, with the view of determining what differences exist internally. Before doing this, about twelve inches of the upper part of the jejunum should be removed and inflated with air. It should then be hung up to dry in order that the folds of mucous membrane, called *valvulæ conniventes*, may be studied in their continuity. The best way to open the remainder of the intestine is to tie a ligature around the lower cut end of the ileum, and fill the gut as full as possible with water. The scissors can now be easily carried along the *line of the mesenteric attachment*, and the intestine slit open in its entire length. The intestine can be laid open with much greater ease if a piece of costal cartilage be impaled upon that blade of the scissors which is introduced into the gut.

The Mucous Membrane of the Small Intestine.—The *valvulæ conniventes* (*plicae circulares*) are the most conspicuous objects on the inner wall of the small intestine. These are folds of the mucous membrane placed more or less transversely to the long axis of the gut. Note particularly that they are *permanent folds*, and that no amount of stretching or distension of the walls will cause their obliteration. On careful study of the dried specimen three main varieties of *valvulæ conniventes* may be

recognised. The great majority are in the form of crescentic folds, which extend for a variable distance round the wall of the gut; others form complete rings around the interior of the intestine; whilst the third variety, and usually the least numerous, are arranged in a spiral manner, and take from one to three spiral turns around the wall of the gut (Brooks and Kazzander). Each fold consists of two layers of mucous membrane, with a little intervening areolar tissue derived from the submucous coat. The other coats of the intestine take no part in the formation of the *valvulæ conniventes*. In the upper part of the jejunum the *valvulæ conniventes* are strongly developed, and placed so closely together that the intervals between them are hardly greater than the thickness of one of the folds. As we follow them down, however, they gradually diminish in numbers, become more widely separated, more oblique in their direction, and not nearly so prominent. Approaching the middle of the ileum, they become exceedingly sparse and far between, and a little beyond this they usually disappear altogether.

The chief function of the *valvulæ conniventes* is to increase the absorbing and secreting surface of the small intestine.

Another peculiarity characteristic of the mucous lining of the small intestine is the presence of *villi* (*villi intestinales*). These are minute projections of the mucous membrane, varying in length from one-fourth to one-third of a line. They occur in enormous numbers over the entire extent of the inner surface of the gut, not only upon the *valvulæ conniventes*, but also in the intervals between them, and they give to the mucous membrane a velvety or fleecy appearance.

To obtain a proper view of these minute villous processes it is necessary to float out a portion of the small intestine in water after it has been carefully cleansed from adhering mucus, and examine it with an ordinary pocket lens. If a portion of the upper end of the jejunum be placed side by side with a portion of the lower part of the ileum, and in-

spected in this manner, the student will readily detect that the villi are, if anything, larger, and that they are decidedly more numerous in the jejunum than in the ileum. They diminish gradually in number and in size as we pass down the small intestine.

Peyer's patches and *solitary glands* must also be looked for. Frequently they are difficult to find, but by holding the bowel up to the light they can generally be detected. In our examination of the Peyer's patches it is better to begin at the lower end of the ileum and pass upwards.

A *Peyer's patch* (*noduli lymphatici aggregati*) consists of a large number of lymphoid follicles grouped together so as to present to the eye a patch of an elongated, oblong figure. The patches are placed upon that aspect of the gut which is opposite to the line of the mesenteric attachment, and the long axis of each corresponds in its direction with that of the gut itself.

In the lower part of the ileum the patches may present a length of one, two, or even four inches, and a breadth of about half an inch, but, as we follow them up the tube into the jejunum, they become much smaller and not nearly so numerous. The total number varies much, but the average number may be stated to be about thirty. They are more numerous in the young, and not so abundant nor so distinctly marked out in later periods of life. Indeed, in very old individuals they may disappear almost entirely.

The *solitary glands* (*noduli lymphatici solitarii*) are isolated lymphoid follicles, scattered everywhere over the mucous membrane of the small intestine. They are minute, rounded or ovoid, opaque white bodies, about the size of a millet seed, and they usually cause a slight bulging of the mucous membrane at the points where they occur.

The *valvulæ conniventes*, the *villi*, and *Peyer's patches* are the only special peculiarities of the mucous membrane of the jejunum and ileum which are visible to the naked eye, and from what has been said regarding them the dissector will understand that although they are not arranged in

such a way as mark off by a clear line of demarcation the jejunum from the ileum, they are sufficient to enable him to distinguish between characteristic portions of each—*i.e.*, between portions taken at some distance from the arbitrary line of division. The following are the essential points of difference which would guide him in deciding which is ileum and which jejunum :—

JEJUNUM.

ILEUM.

Valvula Conniventes.

Numerous and well marked.

Few in number and poorly developed, and, in its lower part, absent altogether.

Villi.

Numerous and large.

Not so numerous and not so large.

Peyer's Patches.

Few in number, small in size, and, as a rule, nearly circular in outline.

More numerous, of large size, and oblong in form.

Dissection.—Ligature the great intestine about four inches above the entrance of the ileum, and divide the gut above this point. The nozzle of the bellows should now be introduced into the attached portion of ileum, and the cæcum inflated until its walls are tense. This portion of the intestine should then be hung up to dry. Next slit open the colon in the same manner as the small intestine, and examine its inner surface.

Great Intestine.—Transverse and oblique ridges or folds, corresponding to the constrictions which separate the sacculi are everywhere apparent on the inner surface of the large intestine. If the longitudinal bands of muscular fibres be removed or divided at short intervals, and the gut stretched, both sacculi and constrictions disappear, and the wall of the bowel becomes uniform. The mucous membrane of the great intestine is absolutely destitute of villi, but *solitary glands* are present in considerable numbers. If the mucous surface be examined with a lens,

its surface will be seen to be studded over with the round mouths of tubular glands, which are embedded in the mucous membrane (*crypts of Lieberkühn*). The same glands are present in the mucous membrane of the small intestine, but they are not so large.

Dissection.—The coats of the large intestine must be dissected in the same manner as in the case of the small intestine.

Coats of the Large Intestine.—In connection with the *serous coat*, the student has already taken notice of the *appendices epiploicæ*. The *external longitudinal* muscular fibres have also been observed to be disposed in three flat bands. These begin on the cæcum at the base of the vermiform process. From this they diverge, so as to take up positions on different aspects of the gut. They are placed as follows:—(1) One in relation to the attached surface; (2) the second upon the anterior aspect; (3) and the third along the inner aspect of the gut, but, in the case of the transverse colon, this band is in relation to the inferior aspect of the tube. The *internal circular* muscular fibres are most distinct in the constrictions between the sacculi, but constitute a thin uniform layer over the entire extent of the gut. The *submucous coat* is in no respect different from the corresponding coat in the small intestine.

Dissection.—When the distended cæcum is dry, the ileo-cæcal valve should be examined. This can best be done by removing the outer wall of the cæcum with a pair of scissors. A window is thus made into the gut, through which the opening of the ileum into the cæcum can be seen.

Ileo-cæcal Valve (*valvula coli*).—The ileo-cæcal aperture is a narrow transverse slit placed on the inner aspect of the gut. The aperture is narrow and pointed behind, but more open and wider in front. It is guarded by a valve which consists of two crescentic segments or folds. The upper and smaller segment is placed horizontally, whilst the lower one is perpendicular. At the extremities of the aperture these folds unite, and are prolonged round the inner surface of the wall of the great intestine in the form of two ridges, which are termed the *fræna* or *retinacula*

of the valve. The ileo-cæcal opening is placed in the lower part of the lumbar region, immediately above the intertubercular plane of subdivision, and close to the mid-Poupart plane.

The function of this valve is obvious. It is so arranged that the free passage of materials from the ileum into the cæcum is in no way impeded, but when the cæcum becomes distended, and there is consequently a tendency to regurgitation, the fræna of the valve are put upon the stretch, and the free borders of the segments brought into firm contact. In this way reflux of the contents of the cæcum into the ileum is effectually prevented.

Dissection.—The cœliac axis, the artery which supplies blood to the stomach, liver, duodenum, spleen, and pancreas, should now be dissected. Pull the stomach downwards, and tear through the two layers of peritoneum which form the gastro-hepatic omentum. The artery will be found by dividing the layer of peritoneum which forms the posterior wall of the lesser sac along the upper border of the pancreas. This dissection will be facilitated if the liver is first raised and then fixed in this position, by stitching it to the lower margin of the thorax.

The Cœliac Axis (*arteria cœliaca*) is a short, wide vessel, which springs from the front of the aorta, between the two crura of the diaphragm, opposite the lower border of the body of the last dorsal vertebra, and in immediate relation to the upper margin of the pancreas. It is directed horizontally forwards, and after a course of little more than half an inch divides into three large branches, viz. :—(1) the coronary; (2) the hepatic; and (3) the splenic, which radiate from each other like the spokes of a wheel. The cœliac axis is surrounded by a thick, matted plexus of nerves, called the *cœliac plexus*, which sends numerous nervous twigs with the three branches which spring from the axis. The cœliac plexus must be left undisturbed, and in following the coronary, hepatic, and splenic arteries the nerves which accompany them must be carefully preserved.

The Coronary Artery (*arteria gastrica sinistra*), the smallest of the three branches of the cœliac axis, proceeds upwards and to the left, behind the lesser sac of peritoneum, to the œsophageal opening of the stomach. Here it changes its

direction, enters between the two layers of the gastro-hepatic omentum, where this is attached to the diaphragm, and

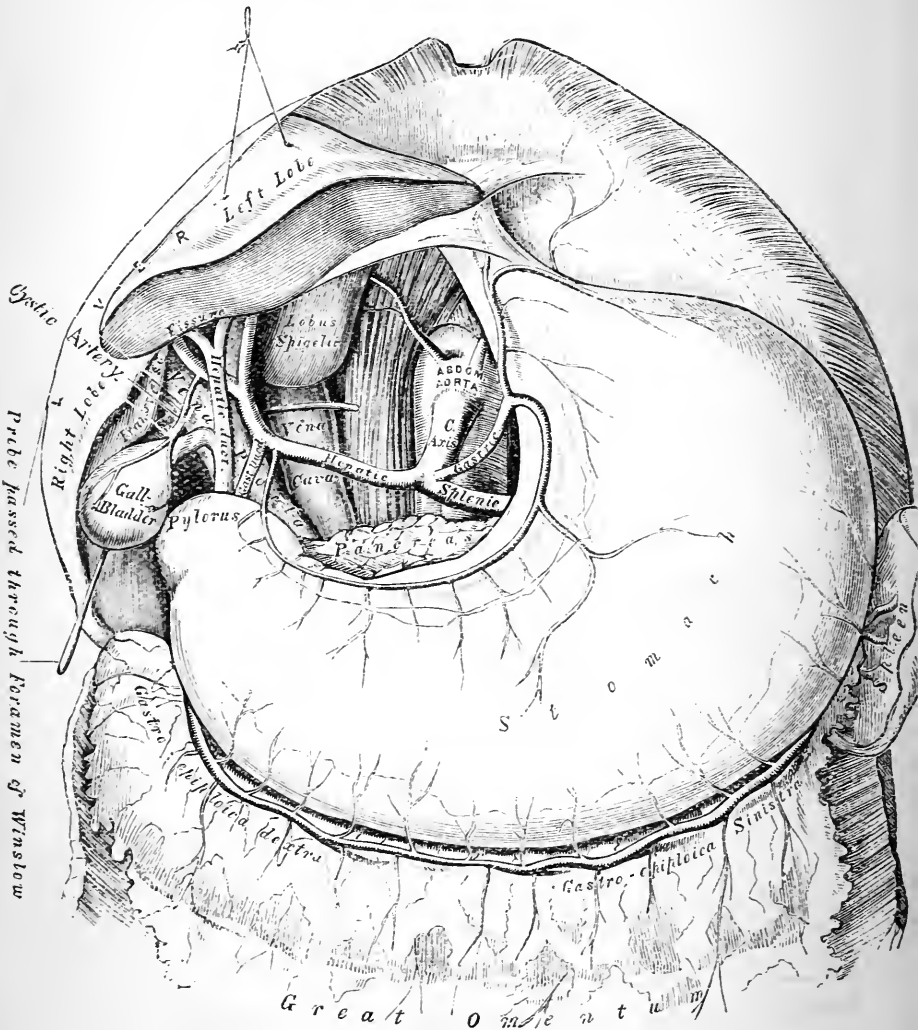


FIG. 114.—The celiac axis and its branches. The gastro-hepatic omentum has been taken away and the liver raised. (From GRAY'S *Anatomy*.)

runs from above downwards and to the right along the lesser curvature of the stomach. Near the pylorus it ends

by anastomosing with the pyloric branch of the hepatic artery.

The branches of the coronary artery are :—

1. Œsophageal.
2. Gastric.

The *œsophageal arteries* (rami œsophagei) spring from the coronary at the point where it reaches the stomach. They pass upwards upon the posterior aspect of the gullet, through the œsophageal opening of the diaphragm, and anastomose with the œsophageal branches of the thoracic aorta.

The *gastric branches* take origin from the coronary as it runs along the lesser curvature of the stomach, and are distributed to both surfaces of this viscus.

The **Coronary Vein** (vena coronaria ventriculi) lies by the side of the artery of the same name. It passes from right to left along the lesser curvature of the stomach. Reaching the œsophagus it turns to the right and joins the portal vein.

The **Hepatic Artery** (arteria hepatica), intermediate in size between the coronary and splenic, at first takes a transverse course to the right. At the pyloric end of the stomach it changes its direction, and, turning forwards below the foramen of Winslow, ascends between the two layers of the gastro-hepatic omentum. Near the transverse fissure of the liver it ends by dividing into *right* and *left hepatic arteries*. The hepatic artery is accompanied by numerous large nervous twigs derived from the cœliac plexus, and, as it passes upwards to the liver, it is in close relationship with the bile duct and the portal vein. The duct lies upon the right side of the artery, and the vein lies behind both. (Figs. 114 and 108).

The following are the branches of the hepatic artery :—

1. Pyloric.
2. Gastro-duodenal. { Superior pancreatico-duodenal.
 { Right gastro-epiploic.
3. Hepatic. { Right. { Cystic.
 { Left.

The *pyloric* (arteria gastrica dextra) is a small artery which springs from the hepatic at the pylorus, and then runs from right to left along the lesser curvature of the stomach between the two layers of the gastro-hepatic omentum. It ends by inosculating with the coronary.

The *gastro-duodenal* (arteria gastro-duodenalis) arises close to the pyloric artery, and is directed downwards behind the first part of the duodenum, at the lower border of which it ends by dividing into the superior pancreatico-duodenal and the right gastro-epiploic.

The *superior pancreatico-duodenal* (arteria pancreatico-duodenalis superior) takes a curved course round the head of the pancreas, between it and the duodenum, to both of which it gives branches. It ends by inosculating and forming an arch with the *inferior pancreatico-duodenal branch* of the superior mesenteric artery.

The *right gastro-epiploic* (arteria gastro-epiploica dextra) is directed from right to left, along the greater curvature of the stomach, and between the two anterior layers of the great omentum. It gives branches upwards to both surfaces of the stomach, and downwards to the great omentum, and ends by anastomosing with the *left gastro-epiploic*, a branch of the splenic.

The *right* and *left hepatic* arteries, the terminal branches of the hepatic, diverge from each other, and sink into the liver at the two extremities of the transverse fissure. From the right hepatic a small branch called the *cystic* is given to the gall-bladder. This divides into two twigs, one of which ramifies in the areolar tissue between the liver and gall-bladder and the other upon the opposite surface of the gall-bladder immediately subjacent to its peritoneal covering.

The *cystic vein* joins the vena portæ or its right branch.

The Splenic Artery (arteria lienalis), the largest branch of the celiac axis, takes a wavy or tortuous course behind the lesser sac of the peritoneum to the left side, and ends near the spleen by dividing into five or six branches, which enter the organ on its concave surface.

To obtain a good view of the splenic artery, it is necessary to throw the stomach upwards towards the ribs.

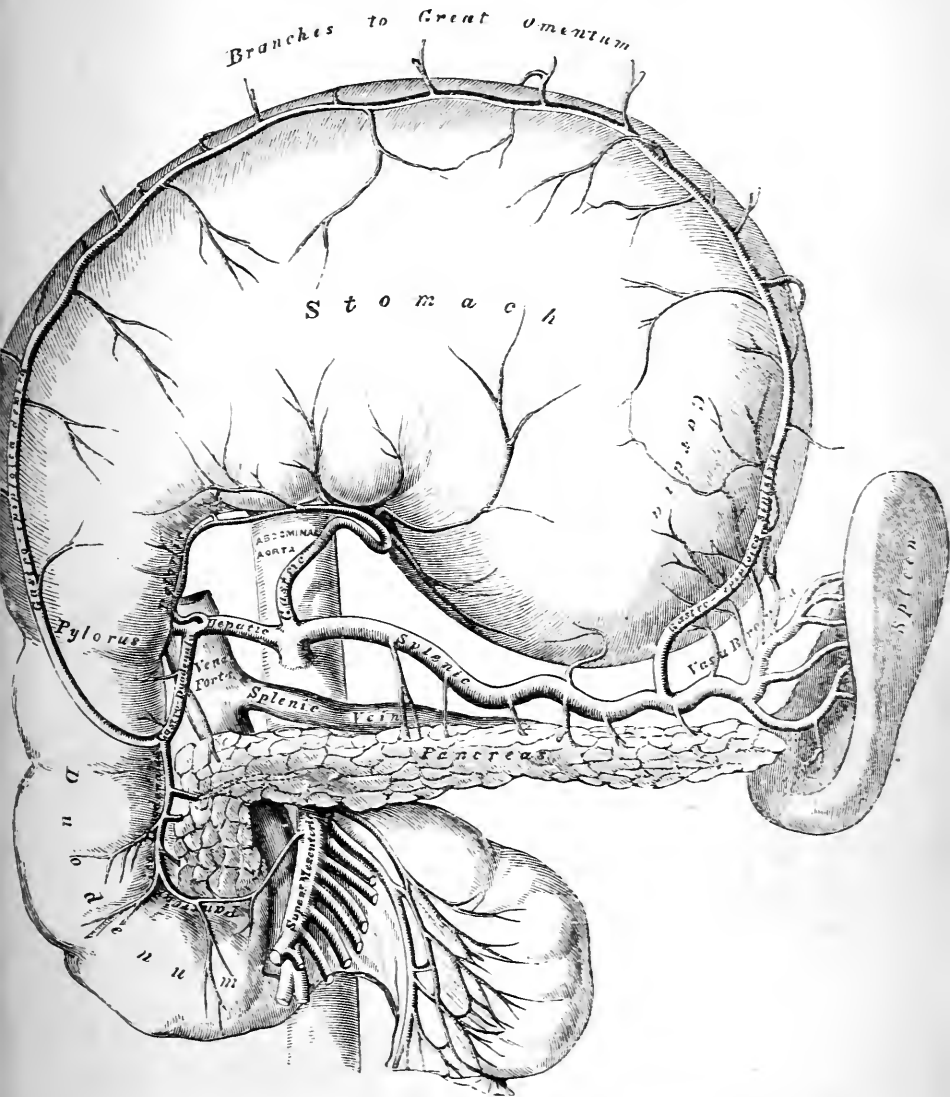


FIG. 115.—The stomach has been thrown upwards to show the celiac axis and its branches; the pancreas is drawn downwards to exhibit the splenic vein. (From GRAY'S Anatomy.)

The vessel will then be seen to run along the upper border of the pancreas, which somewhat overlaps it. It is accompanied by the splenic vein, which, however lies at a lower level, and therefore altogether behind the pancreas.

The following are the branches of the splenic artery:—

- | | |
|----------------|-------------------------|
| 1. Pancreatic. | { Pancreaticæ parvæ. |
| | { Pancreatica magna. |
| 2. Gastric. | { Vasa brevia. |
| | { Left gastro-epiploic. |
| 3. Splenic. | |

The *arteriæ pancreaticæ parvæ* are small twigs which come off at various points for the supply of the pancreas. The *pancreatica magna* is a larger branch which arises from the splenic artery near its termination. It sinks into the pancreas, and is directed from left to right in the gland substance in company with the duct of the gland.

The *vasa brevia* (*arteriæ gastricæ breves*) are five or six small arteries, of which some arise directly from the splenic, whilst others take origin from its terminal branches. They run towards the stomach between the two layers of the gastro-splenic omentum, and are distributed to the cardiac end of this viscus, anastomosing with the coronary and left gastro-epiploic arteries.

The *left gastro-epiploic* (*arteria gastro-epiploica sinistra*) takes origin from the splenic near the spleen, and is directed from left to right, along the greater curvature of the stomach, between the two anterior layers of the great omentum. It gives branches which ascend to supply both aspects of the stomach, and others which descend into the great omentum, and it ends by anastomosing with the right gastro-epiploic artery.

The *splenic* or *terminal branches* of the splenic artery reach the spleen by passing between the two layers of the lieno-renal ligament. The *vasa brevia* and the *left gastro-epiploic artery* take the same route to gain the interval between the two layers of the gastro-splenic omentum.

From the above description of the branches of the cœliac axis it will be seen that the stomach is remarkably rich in

blood-vessels. *Two* proceed from *left to right*—viz., the *coronary* along the lesser curvature, and the *left gastro-epiploic* along the greater curvature; *two*, both branches of the hepatic, are directed from *right to left*—viz., the *pyloric*, in relation to the lesser curvature; and the *right gastro-epiploic*, in relation to the greater curvature. The arterial circle is completed on the left by the *vasa brevia*, which connect the coronary artery with the left gastro-epiploic.

The Splenic Vein (*vena lienalis*) formed by the union of the veins which issue from the spleen, runs from left to right behind the pancreas, and at a lower level than the artery of the same name. After crossing the aorta and the root of the superior mesenteric artery, it ends by joining the superior mesenteric vein to form the *vena portæ*. In its course between the spleen and the *vena portæ* it receives the following tributaries:—(1) veins corresponding to the *vasa brevia*; (2) the left gastro-epiploic vein; (3) pancreatic veins; (4) the inferior mesenteric vein.

Vena Portæ.—This is a remarkable vessel. It arises after the manner of a vein, by gathering, by means of its rootlets, the blood from the capillaries of the entire abdominal portion of the alimentary canal (with the exception of the lower end of the rectum), the spleen, pancreas, and gall-bladder, whilst it ends in the liver after the manner of an artery, by pouring its blood into the hepatic capillaries. The blood which flows in the portal vein, therefore, passes through two series of capillaries before it is returned to the heart—viz. (1) the capillaries of the organs from which it is derived; (2) the hepatic capillaries.

The *portal vein* is formed between the neck and the head of the pancreas, by the union of the splenic and superior mesenteric veins. From this it ascends, with an inclination to the right, and ends near the right extremity of the transverse fissure of the liver by dividing into a *right and left branch*, one for each lobe of this organ. After emerging from under cover of the neck of the pancreas, it lies first behind the first part of the duodenum, and then between the two layers of the gastro-hepatic omentum,

close to its right free margin. In the latter situation it is placed behind the hepatic artery and the bile duct, and is accompanied by the hepatic nerves and lymphatics. The vena portæ receives the coronary, pyloric, and cystic veins. The last-named vein, however, may join its right branch.

The branches of the portal venous system are devoid of valves. This is a great predisposing cause in the production of hæmorrhoids.

Dissection.—The connections of the duodenum should next be studied, and the dissector will find it advantageous in doing this to partially inflate with air both it and the stomach.

The Duodenum, or first part of the small intestine, is wider and more fixed in its position than either the jejunum or ileum. It is ten to twelve inches in length, and extends from the pylorus of the stomach to the left side of the second lumbar vertebra. Here it bends forwards on itself in the form of the duodeno-jejunal flexure and becomes continuous with the jejunum (Fig. 116). The duodenum is adapted to the front of the vertebral column, and describes a U-shaped curve around the head of the pancreas the concavity of which is directed upwards. For convenience in description it is divided into a *first part*, a *second part*, and a *third part*.

The *first part of the duodenum* (pars superior) is two inches in length, and is contained in the epigastric region. It is enveloped by the same two layers of peritoneum which invest the stomach, and consequently enjoys a limited degree of movement. Its position and relations are dependent upon the degree of distension of the stomach. When that viscus is empty, and the pylorus, in consequence, occupies the mesial plane, the first part of the duodenum passes backwards and to the right, with a slight inclination upwards, until it reaches the neck of the gall-bladder. Here it ends by bending suddenly downwards into the second part. Under these circumstances the first part of the duodenum lies in close apposition with the lobus quadratus of the liver. When the stomach, on the other hand, is distended, the pylorus comes into relation with

the lobus quadratus, and the first part of the duodenum is pushed to the right, and occupies a depression on the under surface of the right lobe of the liver, behind and to the right of the transverse fissure. The relations of the first part of the duodenum are as follows: *above*, the under surface of the liver; *below*, the pancreas; *behind*, the

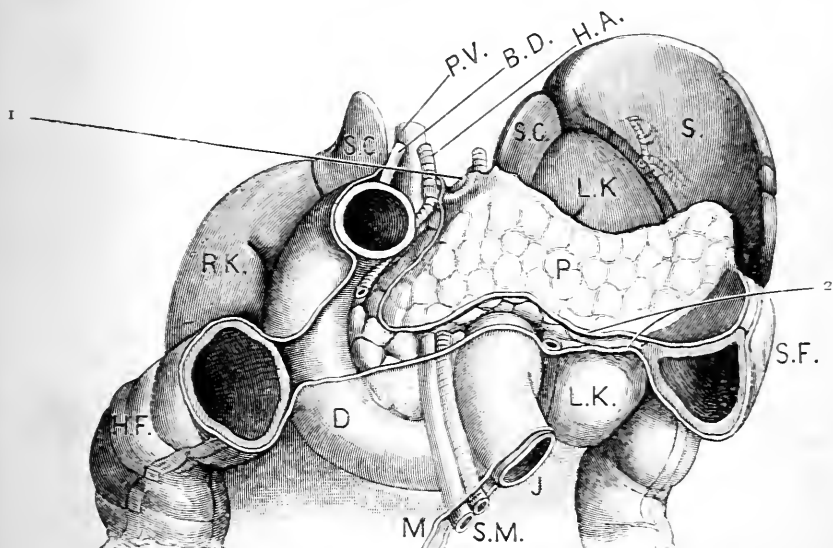


FIG. 116.—Duodenum, pancreas, kidneys, etc. (From the model by His.)

1. Foramen of Winslow. 2. Two layers of the transverse meso-colon.

P. V. Portal vein.	P. Pancreas.
B.D. Common bile-duct.	D. Duodenum.
H.A. Hepatic artery.	H.F. Hepatic flexure of the colon.
S.C. Suprarenal capsule.	S.F. Splenic flexure of the colon.
S. Spleen.	M. Mesentery.
R.K. Right kidney.	S.M. Superior mesenteric vessels.
L.K. Left kidney.	J. Jejunum.

common bile-duct, the gastro-duodenal artery, and the portal vein.

The *second part of the duodenum* (pars descendens) is usually about from three to four inches in length, and takes a downward course from the under surface of the liver. Placed at its commencement in the epigastric region, it

descends into the umbilical region, lying close to the right mid-Poupart plane. Reaching the level of the third lumbar vertebra, it turns across the spine and enters upon the third stage of its course. The second stage of the duodenum is immovably fixed in its position. It is covered by peritoneum on its anterior surface only, and is crossed by the commencement of the transverse colon, which, in this part of its course, does not possess a mesentery (Fig. 116). *Behind*, it rests upon the vena cava and presents a variable relation to the renal vessels and the anterior surface of the right kidney in the neighbourhood of the hilum. *To the right* is the hepatic flexure of the colon; and *to the left* is the head of the pancreas, which is moulded upon the inner side of this part of the duodenum.

The common bile-duct and the pancreatic duct open into the inner and back aspect of the second part of the duodenum a little below its middle.

The accompanying outline drawings exhibit the varying relations of the duodenum and kidney in different subjects (Fig. 117). The

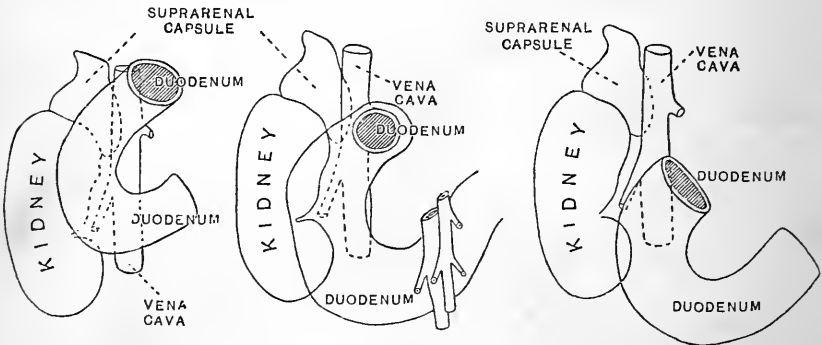


FIG. 117.—Position of duodenum with reference to kidney in three different subjects. (From drawings by Dr. Brooks.)

duodenum, moulded, as it is, on the front of the vertebral column, and around the head of the pancreas, is not subject to much variation in its position. The differences seen in the figures are probably chiefly due to variations in the position of the kidney.

The *third part of the duodenum* (pars ascendens) is

somewhat longer than the second part, and may be regarded as being composed of two portions, viz., an oblique and a vertical. The oblique portion begins on the right side of the third lumbar vertebra and extends across the spine from right to left with a decided inclination upwards. It is moulded upon the vena cava and aorta which lie behind it, and it is crossed by the superior mesenteric vessels. The pancreas is adapted to its upper aspect. The vertical portion commences on the left side of the aorta; here the duodenum changes its direction and proceeds vertically upwards upon the psoas muscle for an inch or more. Having gained the left side of the body of the second lumbar vertebra, the duodenum suddenly bends forwards upon itself and forms the duodeno-jejunal flexure. The lower surface of the body of pancreas is moulded on the summit of this flexure.

At its commencement the third portion of the duodenum is placed in the umbilical region, but it gradually crosses the subcostal plane, and its terminal part is situated in the epigastric region. The third part of the duodenum is fixed in its position. It is covered by peritoneum on its anterior surface, and is crossed obliquely by the root of the mesentery proper.

As already mentioned the duodenum forms a U-shaped curve, the convexity of which is directed downwards and the concavity upwards, whilst its two upper extremities are bent in a forward direction. "The right upper end which is also inclined towards the median plane is represented by the first part of the duodenum; the left extremity is formed by the flexura duodeno-jejunalis. The right limb of the U corresponds to the second part of the duodenum; the loop and the left limb of the U are formed by the third part of the duodenum" (Ballowitz).

Suspensory Muscle of the Duodenum and Mesentery Proper. (Lockwood.) The flexura duodeno-jejunalis and the root of the mesentery are held in position and prevented from slipping down on the posterior wall of the abdomen by a band of involuntary muscular fibres, which fixes them to the diaphragm. This band is

called the suspensory muscle of Treitz. It is attached above to the diaphragm, on the right side of the oesophageal aperture. From this it proceeds downwards on the left side of the coeliac axis artery to the flexura duodeno-jejunalis, into which a large number of its fibres are inserted. The remaining fibres enter the mesentery and find attachment to the peritoneum. In the child the suspensory muscle is well marked and easily isolated, but in the adult it loses its distinctly muscular character, and becomes more or less blended with neighbouring tissues.

Pancreas.—The pancreas is an elongated gland which stretches transversely across the posterior wall of the abdomen behind the stomach. For the most part it is situated in the epigastric region, a small portion only of its left extremity being placed in the left hypochondriac region. As in the case of the other solid organs contained within the abdominal cavity, its form is greatly modified by the condition of the hollow viscera in its immediate vicinity, and its true shape can only be ascertained by preserving it *in situ* by repeated injections of some hardening reagent. It may be described as consisting of a *head*, a *neck*, a *body*, and a *tail*.

The *head of the pancreas* is a flattened portion of the gland which lies in front of the spine and occupies the concavity of the duodenum. It rests upon the inferior vena cava and to some extent also upon the aorta, whilst its anterior surface is covered by the layer of peritoneum, which forms the posterior wall of the lesser sac. As a rule its margins tend to overflow the duodenal boundary: in other words, its marginal lobules show a tendency to wander over the anterior surface of the second and third parts of the duodenum so as to overlap the gut in the vicinity of its concavity. Two other relations may be noticed in connection with the head of the pancreas, viz.: (1) the common bile-duct passes down behind it in close relation to the second part of the duodenum; and (2) the vena portæ is formed in front of it.

The *neck of the pancreas* (Symington) is a narrow constricted portion of gland-substance which springs from the anterior aspect of the head, nearer its upper than its lower margin. It constitutes the link of connection between the head and the body of the pancreas, and as it proceeds to the left it lies in front of the commencement of the vena portæ and of the termination of the superior mesenteric vein. These vessels intervene

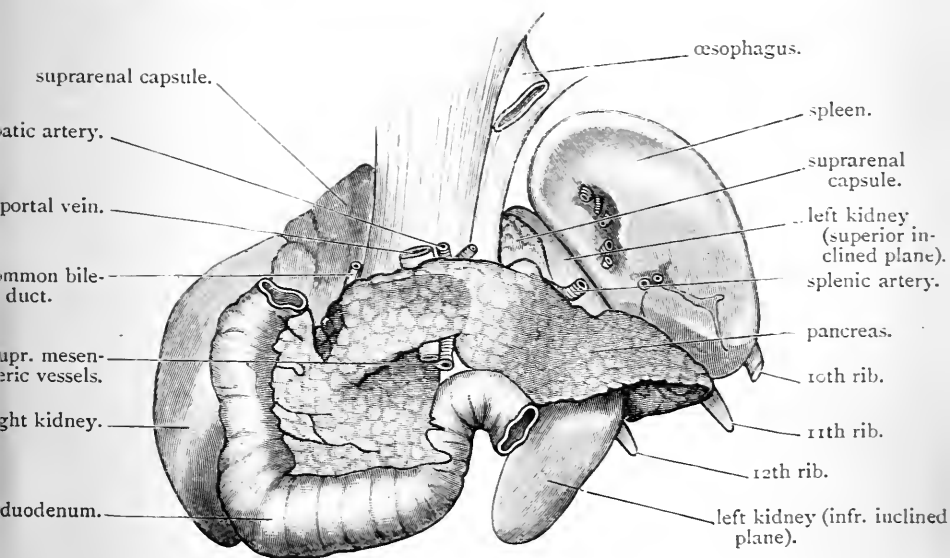


FIG. 118.—The pancreas as seen in a subject in which the abdominal viscera were hardened by repeated injections of Müller's fluid and spirit.

between the neck and the front surface of the head of the pancreas. The anterior surface of the neck is covered by that layer of peritoneum which forms the posterior wall of the lesser sac, and is usually somewhat depressed by the pyloric end of the stomach which rests upon it.

The *body of the pancreas*, where it becomes continuous with the neck of the organ, lies in front of the superior mesenteric artery and the aorta. From this it stretches

backwards, and to the left over the lower part of the left supra-renal capsule, and the front of the left kidney. It presents an anterior, a posterior, and an inferior surface separated from each other by a superior, an antero-inferior, and a postero-inferior border. The *posterior surface* is moulded upon the structures upon which it rests, and the splenic vein runs towards the portal vein under cover of it. The *anterior surface* looks upwards and forwards, and is covered by the layer of peritoneum which forms the posterior wall of the lesser sac. This surface of the pancreas in the greater part of its extent supports the posterior aspect of the stomach, and is consequently deeply hollowed out for its reception. Immediately adjoining the neck a smooth rounded prominence on the anterior surface of the pancreas juts upwards and forwards above the pyloric portion of the lesser curvature of the stomach, and abuts against the gastro-hepatic omentum. This is called the *tuber omentale* (His). Above this prominence and partly under cover of it the coeliac axis extends forwards from the aorta, and breaks up into its three branches. The *inferior surface* of the body of the pancreas looks downwards and rests upon the flexura duodeno-jejunalis, the transverse meso-colon and the transverse colon close to the splenic flexure. It varies greatly in extent: this variation being due to the varying degrees of intestinal pressure to which the pancreas is subjected from below.

The gastric pressure exerted on the pancreas from above, and the counter-pressure which is exerted by the intestine on the inferior surface of the organ from below, varying as they do in the same individual, according to the condition of these hollow viscera, determine, in a great measure, the shape of the body of the pancreas.

The splenic artery pursues a wavy course along the superior border of the pancreas, whilst the transverse meso-colon is attached posteriorly to the pancreas along its antero-inferior border.

The tail of the pancreas when well developed is folded

backwards round the outer border of the kidney, and may come into relation with the lateral wall of the abdomen in the region of the 11th rib. The base of the spleen rests on its upper surface; whilst its lower surface is moulded on the colon.

The Duct of the Pancreas, called the *canal of Wirsung*, is embedded in the gland substance. It begins at the tail and runs towards the head, somewhat nearer the lower than the upper border. By dividing the gland, therefore, horizontally along this line, little difficulty will be experienced in discovering it. The extreme whiteness of its walls, and the fact that it is accompanied by the *pancreatica magna* artery, are a great help to the student in this dissection. As it approaches the head of the gland it will be observed to gain considerably in diameter, from its being joined by the small ducts which come from the various groups of lobules. A large tributary takes origin in that part of the lower extremity of the head of the pancreas which lies behind the mesenteric vessels. This passes upwards in the substance of the gland to join the main duct. Close to the duodenum the pancreatic duct comes in contact with the common bile-duct, and bending downwards they both pierce in company the coats of the descending part of the duodenum upon its posterior and inner aspect, and open into the gut by a common orifice.

The Hepatic Ducts may next be examined (Fig. 123). Leaving the transverse fissure of the liver, the student will notice two ducts, called respectively the *right* and *left* hepatic ducts. These soon unite to form the *hepatic duct*, which in turn is shortly joined by the *cystic duct* of the gall-bladder. The junction of the cystic and hepatic ducts gives rise to the *common bile-duct*, or the *ductus communis choledochus*, and this descends between the two layers of the gastro-hepatic omentum to the right of the hepatic artery and in front of the *vena portæ*. Passing behind the duodenum and the head of the pancreas, it ends by opening, as we have already seen, into the second part of the duodenum.

Dissection.—The attention of the student should now be directed to

the ending of the vagi nerves within the abdominal cavity, and also to the great epigastric or solar plexus of the sympathetic. For the proper display of these it is necessary to divide the gastro-duodenal artery, the common bile-duct, and the portal vein at the level of the upper border of the first part of the duodenum, and then, having allowed the air to escape from the stomach and duodenum, to throw both, along with the pancreas, over to the left side of the body. The dissection of the solar plexus is a very tedious one, because mingled with the nerves, which are soft and easily broken, are several lymphatic glands and a quantity of tough areolar tissue.

Pneumogastric or Vagi Nerves.—These enter the abdomen through the œsophageal opening of the diaphragm. The *left vagus* will be found lying upon the anterior aspect of the gullet. Trace it downwards and notice that it breaks up into branches, the great bulk of which spread out upon the anterior wall of the stomach; a few, however, run to the right, along the lesser curvature, and establish communications with the *coronary plexus*, whilst others ascend between the two layers of the gastro-hepatic omentum to reinforce the *hepatic plexus*. The *right vagus* lies upon the posterior aspect of the gullet, and at once breaks up into numerous branches which ramify upon the posterior wall of the stomach; it also sends twigs to the *celiac plexus* and to the *splenic plexus*.

The Solar or Epigastric Plexus.—In connection with the sympathetic system three large plexuses are formed in front of the vertebral column—viz., the *cardiac plexus* in the thorax, the *solar plexus* in the upper part of the abdomen proper, and the *hypogastric plexus* in the lower part of the abdomen proper. These receive the name of the pre-vertebral plexuses.

The *solar plexus* is by far the largest of the three. It is situated behind the stomach, in front of the aorta and the pillars of the diaphragm. Upon each side it extends as far as the suprarenal capsule, whilst inferiorly it passes downwards behind the pancreas. On each side of the body, where it lies upon the crus of the diaphragm, a large ganglionic mass, called the *semilunar ganglion*, is developed in its midst.

Distinctive terms are applied to different parts of the plexus. The portion which connects the semilunar ganglia and surrounds the cœliac axis is called the *cœliac plexus*. To the outer side of each ganglion the plexus ends in numerous branches for the suprarenal body and kidney, and these are classified under the terms of *suprarenal* and *renal plexuses*. Inferiorly, the plexus has already been seen to send downwards large offshoots which accompany the aorta and the superior mesenteric artery; these are the *aortic* and *superior mesenteric plexuses*. Lastly, a small offset from the upper part of each semilunar ganglion is termed the *diaphragmatic plexus*.

Semilunar Ganglia (ganglia cœliaca).—These are so large that they are usually mistaken by students for lymphatic glands. The ganglion of the right side is placed under cover of the vena cava inferior, and both lie in close relation to the cœliac axis. When thoroughly defined, they will be observed to be of a very irregular shape, and to show little of the outline from which their name is derived. The upper extremity of each ganglion is joined by the great splanchnic nerve, whilst into its lower part, which is often more or less detached, may be traced the *small or second splanchnic nerve*.

The Cœliac Plexus (plexus cœliacus).—This plexus of nerves connects the two semilunar ganglia with each other, and surrounds the cœliac axis so closely that it almost completely hides its trunk from view. It is reinforced by twigs from the *right vagus*. Three secondary plexuses—viz., the coronary, the hepatic, and the splenic—take origin from the cœliac plexus.

The *coronary plexus* (plexus gastricus superior) accompanies the artery of the same name along the lesser curvature of the stomach, and distributes twigs to both aspects of the viscus.

The *hepatic plexus* (plexus hepaticus) follows the hepatic artery, the vena portæ, and the bile-duct to the transverse fissure of the liver. It is joined by twigs from the left pneumogastric, and it gives origin to the *pyloric*,

right gastro-epiploic, superior pancreatico-duodenal, and cystic plexuses, which accompany the arteries of the same names.

The *splenic plexus* (plexus lienalis) is prolonged along the splenic artery to the spleen. It is joined by twigs from the right pneumogastric, and gives off branches to the pancreas and to the fundus of the stomach, and also the left gastro-epiploic plexus.

Renal Plexus (plexus renalis).—This consists of numerous nerves which spring chiefly from the outer part of the semilunar ganglion. Some will be found, however, coming from the cœliac, and others from the aortic plexus. The smallest or third splanchnic nerve, when it is present, joins this plexus. Thus constituted, the filaments of the renal plexus run with the renal artery to the hilum of the kidney, and are distributed to the gland substance. Several twigs are likewise given to the spermatic plexus. A few scattered ganglia are usually found in connection with the renal plexus.

Suprarenal Plexus (plexus suprarenalis).—The dissector will, no doubt, be struck with the large number of nerves which supply the suprarenal body. The plexus seems altogether out of proportion to the small organ to which it is distributed. The nerves composing it are chiefly derived from the semilunar ganglion, but many come from the cœliac plexus. Below, it is directly continuous with the renal plexus, and above, it is connected with the diaphragmatic plexus. The smallest splanchnic nerve usually contributes a branch to this plexus, and the point at which it joins is marked by a small ganglion.

Diaphragmatic Plexus (plexus phrenicus).—The filaments composing this plexus take origin from the upper part of the semilunar ganglion, and are distributed with the phrenic artery to the under surface of the diaphragm, but they do not follow rigorously the branches of this vessel. At first they lie subjacent to the peritoneum, but soon they penetrate between the fleshy fasciculi and establish communications with the phrenic nerve. On the right side a small ganglion is formed on the under surface of the diaphragm

at the point of junction between this plexus and the phrenic. In addition to its diaphragmatic branches, it contributes filaments to the suprarenal plexus, and, on the right side, to the hepatic plexus.

Dissection.—Apply two ligatures to the œsophagus, where it enters the stomach, and divide it between them. The stomach, duodenum, pancreas, and spleen may now be removed by dividing the vessels, nerves, and peritoneal folds which still hold them in position.

The Spleen.—Several important points in connection with the internal structure of this organ may be recognised in the dissecting-room. It is enveloped by two coats—(1) serous; (2) fibro-elastic. The *peritoneal investment* adheres so closely to the subjacent fibrous coat that it can only be removed with difficulty. With regard to the *fibro-elastic tunic*, it should be noted that processes proceed from its deep surface and dip into the substance of the organ. These are the *trabeculae*, and they constitute the supporting framework of the *gland-pulp*. On account of this arrangement, it will be found utterly impossible to strip off the fibrous coat of the spleen without at the same time lacerating its surface. Make a section through the organ, and carry a portion of it to the tap. By squeezing it and allowing the water to run freely over it, a view of the trabecular framework may be obtained.

Dissection.—Detach the pancreas from the duodenum, but leave a portion of the duct in connection with the gut. Next clean out the stomach and duodenum by allowing water to run freely through them, and then render their walls tense by inflating them with air.

The Coats of the Stomach should now be examined. They are five in number, viz :—

- | | |
|---------------------------|---------------|
| 1. Peritoneal, or serous. | 4. Submucous. |
| 2. Subserous. | 5. Mucous. |
| 3. Muscular. | |

The *serous coat*, derived from the peritoneal membrane, can be best stripped off with the fingers. The *subserous coat* is composed of a little areolar tissue which intervenes

between the muscular and serous strata. The branches of the two pneumogastric nerves can now be followed, as they spread out upon both surfaces of the stomach.

The *muscular coat* consists of involuntary or unstriped muscular fibres, and these are disposed in three layers—each layer being distinguished by the direction of its fibres. The *external layer* is composed of longitudinal fibres. These are best seen at the curvatures and towards the pylorus. At the cardiac orifice they become continuous with the longitudinal fibres of the œsophagus, and at the pyloric orifice they mix with the longitudinal fibres of the duodenum. Very few longitudinal fibres can be detected on the anterior and posterior surfaces of the viscus. The *middle layer* is composed of circular fibres, and these constitute a uniform coating for the stomach. Very thin at the fundus, this layer becomes gradually thicker as we approach the pylorus, and, at the point where the stomach gives place to the duodenum, they are aggregated into a circular band, called the *pyloric sphincter*. The *internal layer* consists of oblique fibres, which give a very partial covering to the stomach. They are continuous with the circular fibres of the gullet, and are best seen on the fundus of the stomach to the left of the œsophageal opening. From this they spread out upon both surfaces of the viscus, and embrace the œsophageal opening.

The *submucous coat* is composed of loose areolar tissue. It intervenes between the muscular and mucous tunics, and binds the one to the other.

The *mucous coat* must be studied from the inside of the stomach. Open up the viscus by running the scissors along the lesser curvature. The duodenum may be laid open at the same time. The gastric mucous membrane will now be seen to be thick, soft and pulpy. In the dissecting-room the student cannot obtain a proper idea of its natural colour. In infancy it is rosy red, but as life advances it gradually becomes paler, and in old age it always presents a brownish hue from the presence of pigment. When the mucous membrane is cleansed and examined with a pocket

lens, its surface is observed to present a pitted appearance. Innumerable polygonal depressions are brought into view, and these are observed to be larger and better marked in every way near the pylorus than in the vicinity of the fundus. At the bottom of these pits are the mouths of the minute tubular glands of the gastric mucous membrane.

When the stomach is empty, the mucous membrane is thrown into longitudinal folds or rugæ, but these disappear when the organ is distended. During life the mucous

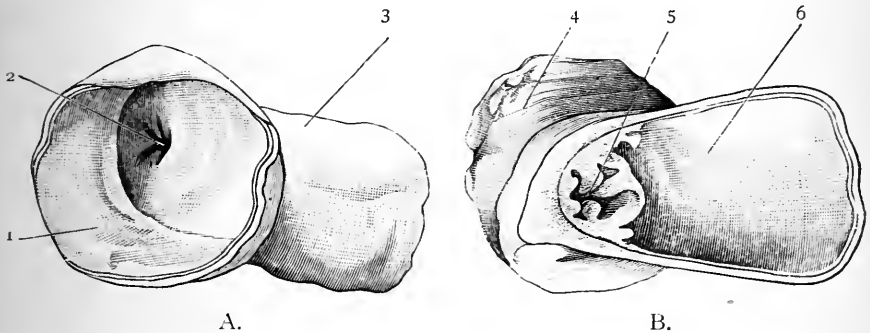


FIG. 119.—The pyloric orifice of a child in which the sphincter is tightly contracted.

- A. Opening as seen from the duodenal side.
- B. Opening as seen in section from the cardiac side.

- | | |
|---|--|
| <ul style="list-style-type: none"> 1. Cavity of duodenum. 2. Pyloric orifice. 3. Pyloric end of stomach. | <ul style="list-style-type: none"> 4. Duodenum. 5. Pyloric opening. 6. Cavity of stomach. |
|---|--|

membrane of the stomach is thickest at the cardiac end, but after death it is always thinned at this point by *post-mortem* digestion. At the pylorus the mucous membrane is raised into a remarkable circular fold, called the *pyloric valve*. This fold contains between its two layers the sphincter pylori muscle. If the mucous membrane be removed from the fold, the thick band of fibres which forms the sphincter becomes very apparent. This dissection had best be done under water.

When the sphincter of the pylorus is tightly contracted,

the pyloric opening, viewed from the duodenal side, presents a striking resemblance to the os uteri externum. (Fig. 119, A.)

Coats of the Duodenum.—In connection with the duodenum, note that the valvulæ conniventes begin about one or two inches beyond the pylorus, about the commencement of its second part; that the mucous membrane is covered by villi; and that usually no Peyer's patches are to be seen. Pass a probe along the bile-duct, and another along the pancreatic duct. These ducts will then be observed to pierce the coats of the duodenum, side by side, very obliquely, and to open by a common orifice, which is placed on the summit of a papillary projection of mucous membrane.

The duodenum should now be pinned down with its mucous surface undermost to the bottom of a cork-lined tray filled with water. Its coats may then be dissected. They are in all respects similar to those already examined in connection with the jejunum (p. 477). If the

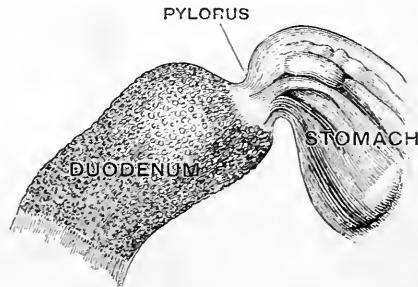


FIG. 120.—Peritoneum and muscular coats removed from the pylorus and upper part of duodenum to show the constriction and Brunner's glands. (From Gegenbaur.)

dissection is carried on until the deep surface of the submucous coat is exposed by the removal of the entire muscular coat, a view of Brunner's glands may be obtained. They appear as whitish specks, about the size of hemp-seed, in the submucous tissue (Fig. 120). They are most numerous close to the pylorus and gradually disappear about two inches beyond this.

Removal of the Liver.—The student has already examined the position and connections of the liver (p. 436). It should now be removed from the abdominal cavity, in order that its form and the

manner in which the vessels are distributed in its substance may be studied. Begin by dividing the ligamentum teres and the falciform ligament. Then drawing it downwards, cut through the lateral ligament on each side and the upper layer of the coronary ligament. Having done this, the bare area on its posterior border can be separated from the diaphragm with the handle of the knife. Observe that this portion of the liver is merely connected to the diaphragm by areolar tissue. Soon the vena cava inferior will be exposed, emerging from the posterior surface of the liver, and then piercing the central tendon of the diaphragm. This must be severed. On dividing the lower layer of the coronary ligament, the liver will be free from all the surrounding parts, except the vena cava, at the point where it first comes in contact with the organ. The vena cava must, therefore, be cut a second time, and thus a portion of the vessel is taken away with the gland.

The Liver (hepar).—In the adult male the weight of the liver will be found to vary from 50 to 60 ounces, and in the adult female from 40 to 50 ounces. It represents about $\frac{1}{36}$ th of the weight of the whole body. In infancy and childhood it is relatively larger than in later life.

In form the liver has been seen to resemble, while *in situ* and supported by surrounding viscera, a right-angled triangular prism (Symington), and to present a basal or right lateral surface, a superior surface, an anterior surface, an inferior surface, and a posterior surface. When removed from the abdomen and placed on the table before the dissector, it in a great measure loses this shape. It becomes flattened, the distinction between the anterior and superior surfaces is lost, and the inferior and posterior surfaces also tend to run into each other. It is necessary, therefore, to correct the impressions which we receive from such a disfigured organ by reference to a specimen which has been specially prepared.

Longitudinal Fissure.—The *inferior* and *posterior surfaces* of the liver alone remain to be studied. Upon these the demarcation of the organ into a right and a left lobe is effected by the *longitudinal fissure*. This furrow pursues a course which corresponds with the line of attachment of the falciform ligament on the superior and anterior surfaces. The portion of the longitudinal fissure, which

traverses the inferior surface, extends from the anterior border, where it begins in a notch, in a straight direction backwards to the left extremity of the transverse fissure. It lodges the obliterated umbilical vein or ligamentum teres, and is in consequence termed the *umbilical fissure*. Sometimes it is more or less completely bridged over by liver substance, so that a portion, or perhaps the whole of it, is converted into a tunnel or canal. In these cases, the overlying piece of liver substance constitutes a link between the right and left lobes, and receives the name of *pons hepatis*. The continuation of the longitudinal fissure on the posterior surface begins at the left extremity of the transverse fissure, and takes a vertical course upwards. It lodges the slender fibrous cord which represents in the adult the ductus venosus of the foetus. It is consequently called the *fissure of the ductus venosus*.

Inferior Surface of the Liver.—Having recognised the boundary line between the two main lobes of the liver, the dissector should examine carefully the inferior and posterior surfaces. The *inferior surface*, when the liver was *in situ*, has been seen to be very oblique, and to look as much to the left as in a downward direction. It is to some extent also slightly hollowed out, or concave, and it bears upon itself the impress of the various organs with which it is in contact. Thus the left lobe presents a concavity of greater or less extent according to the degree of distension of the stomach upon which it is moulded (impressio gastrica). It also exhibits, in the neighbourhood of the longitudinal fissure, a smooth rounded boss or eminence, termed by His the *tuber omentale*. This prominence lies above and to the right of the lesser curvature of the stomach, and consequently in contact with the anterior surface of the gastro-hepatic omentum (Fig. 121).

The inferior surface of the right lobe of the liver is much more extensive than that of the left lobe. Upon it we recognise the transverse fissure and the fossa for the gall-bladder (Fig. 121).

The *transverse fissure* (porta hepatis) is the deep depres-

sion or hilum within which the portal vein and the hepatic artery and nerves enter the liver, and the lymphatics and bile-ducts leave the liver. It is sometimes spoken of as the "porta" or "gate" of the gland. Beginning at the posterior extremity of the umbilical fissure it extends

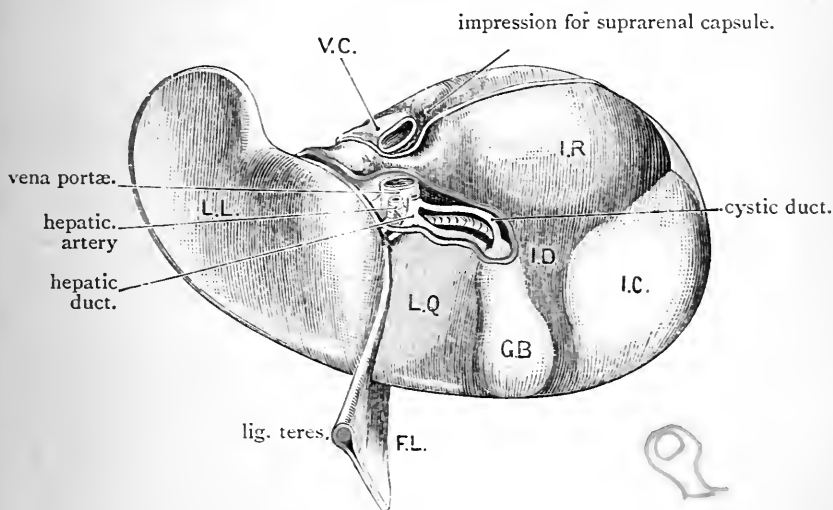


FIG. 121.—Inferior surface of the liver. (From the model by His, slightly modified.)

- | | | |
|--|---|---------------------------|
| V.C. Vena cava inferior. | } | G.B. Gall-bladder. |
| F.L. Falciform or suspensory ligament. | | I.R. Renal impression. |
| L.L. Left lobe showing depression for stomach. | | I.C. Colic impression. |
| L.Q. Lobus quadratus. | | I.D. Duodenal impression. |

transversely to the right for a distance of two inches, and then ends abruptly.

The *fossa for the gall-bladder* (*fossa vesicæ felleæ*), parallel to the umbilical fissure, extends upon the under surface of the right lobe from the anterior sharp border to a point close to the right extremity of the transverse fissure. In this the gall-bladder is lodged, and it varies in depth and extent with the condition of that sac.

By means of the transverse fissure and the fossa for the gall-bladder, the inferior surface of the right lobe of

the liver is subdivided into three unequal portions. These are—(1) the lobus quadratus; (2) the lobus caudatus; and (3) an extensive area which lies to the right of these, and forms the greater part of the under surface of the right lobe.

The *lobus quadratus* is an oblong quadrilateral area, cut off on all sides from the adjoining liver surface. It is bounded behind by the transverse fissure, in front by the anterior sharp margin of the organ, on the left by the umbilical fissure, and on the right by the gall-bladder and its fossa. The surface of the lobus quadratus is usually somewhat depressed, and when the liver is in position and the stomach empty, it is in contact with the first portion of the duodenum. When the stomach is full the pylorus as well as the commencement of the duodenum are in apposition with it.

The *lobus caudatus* is a narrow ridge of liver substance which lies behind the transverse fissure and connects the under part of the lobus Spigelii with the inferior surface of the right lobe of the liver. It is placed immediately above the foramen of Winslow, of which it forms the upper boundary, and intervenes between the portal vein, which lies in front of it, and the inferior vena cava, which is placed behind it.

The greater extent of the inferior surface of the right lobe of the liver lies to the right of the gall-bladder and the lobus caudatus. It presents three concave impressions or hollows, viz., an anterior, a posterior, and a small internal impression. The anterior impression is called the *impressio colica*, because it corresponds to the summit of the hepatic flexure of the colon. It is shallow, and looks almost directly downwards. The posterior impression, the *impressio renalis*, is moulded upon a variable extent of the anterior surface of the right kidney. It is much deeper than the colic impression, and it looks more backwards than downwards. When the hollow viscera in the vicinity are empty, and the abdominal wall is in consequence retracted, this hollow becomes so deep that the kidney might almost be said to be sunk into the liver substance. The small internal

impression, the *impressio duodenalis*, lies immediately to the inner side of the renal fossa. It is produced by contact with the duodenum.

The **Posterior Surface of the Liver** may now be studied (Fig. 122). It is moulded upon the front of the vertebral column, from which it is separated by the diaphragm. It presents, therefore, a deep hollow corresponding to the bodies of the vertebræ. Immediately to the left of the fissure of the ductus venosus there is a smooth notch or groove which leads downwards into the gastric fossa on the under surface of the left lobe (*impressio*

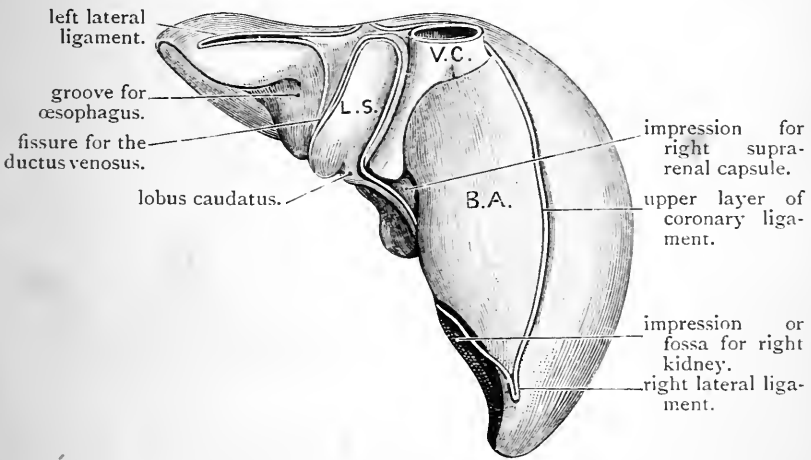


FIG. 122.—Posterior surface of the liver. (Drawn from the model of His, slightly modified).

V.C. Vena cava inferior. | B.A. Bare area of liver.
L.S. Lobus Spigelii.

œsophagea). This groove lodges the œsophagus. Beyond the œsophageal groove the posterior surface of the left lobe merges with the sharp margin of the organ. On the posterior surface of the right lobe—(1) the lobus Spigelii; (2) the fissure for the inferior vena cava; and (3) an extensive bare area uncovered by peritoneum, may be recognised.

The *lobus Spigelii* is the portion of liver substance which lies between the fissure of the ductus venosus and the

inferior vena cava. Its lower end appears on the under surface of the liver immediately behind the transverse fissure, and runs into the lobus caudatus (Fig. 121). The Spigelian lobe forms the bottom of the vertebral hollow,

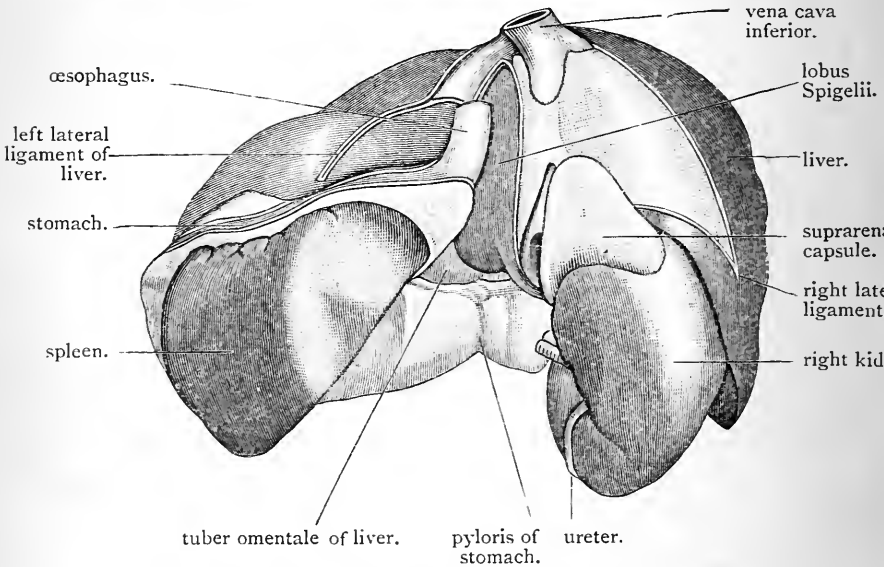


FIG. 123.—Liver, right kidney, spleen, and stomach, as seen from behind. Drawing taken from a model prepared by the reconstruction method.

and lies in front of the tenth and eleventh dorsal vertebræ. Its posterior surface is consequently slightly depressed.

The *fissure for the inferior vena cava* (*fossa venæ cavæ*) is a deep groove placed on the right side of the Spigelian lobe. It ascends almost perpendicularly, and sometimes it is converted into a tunnel by a bridge of liver substance which passes over the vein from the one side to the other.

The *bare area* of the posterior surface of the liver is triangular in form, and lies to the right of the vena cava. It forms the greater part of the posterior surface of the right lobe, and is bounded above and below by the lines of reflection of the coronary ligament. For the most part it is convex, and connected with the diaphragm by loose areolar tissue, but close to the lower end of the fissure for the vena

cava there is a well-marked depression which lodges the right suprarenal capsule. D. B.

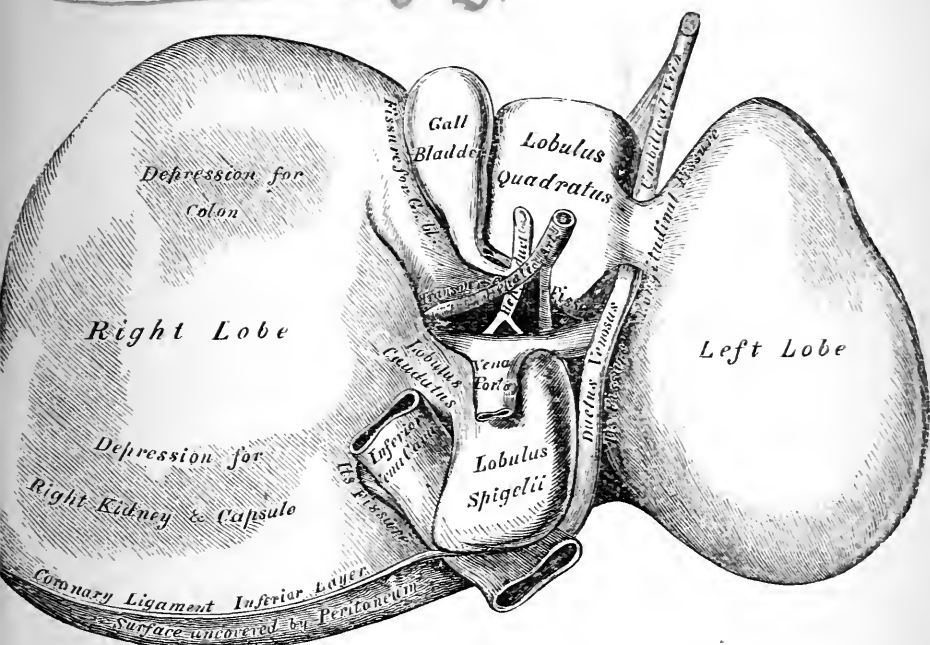


FIG. 124.—Lower and posterior surfaces of a liver which has lost its proper form from being placed on a plane surface. (From GRAY'S *Anatomy*.)

Gall-Bladder and Bile Ducts.—The gall-bladder is a pyriform membranous bag placed in a depression on the under surface of the right lobe of the liver. Its form and position can be seen to best advantage by inflating it with air through the bile duct. It lies somewhat obliquely, its great end or *fundus*, free and covered by peritoneum, being directed downwards, forwards, and to the right, so as to project slightly beyond the anterior border of the liver, whilst its narrow extremity or *neck* ends near the right end of the transverse fissure, by making a double bend like the letter S, and then becoming continuous with the *cystic duct*. The *upper surface* is in contact with the liver, to which it is connected by areolar tissue. The *under surface*

is clothed by peritoneum, and is in relation in front to the transverse colon, and behind to the first part of the duodenum.

The *cystic duct* (ductus cysticus) has already been observed to proceed downwards and to the left to join the hepatic duct, and thereby form the common bile duct. The *right* and *left hepatic* ducts issue from the extremities of the transverse fissure, and unite to form the hepatic duct. To see these points, it will be necessary to remove a sheath of areolar tissue which surrounds the hepatic ducts and vessels, and which is termed *Glisson's capsule*.

If the dissector now investigates the composition of the wall of the gall-bladder, he will find that, in addition to its partial serous covering, it has—(1) a strong coat composed of muscular and white fibrous tissue, and (2) an internal mucous coat. The first can be seen by stripping off the peritoneum, and the second is best displayed by laying open the gall-bladder with a pair of scissors. The mucous membrane will then be seen to be elevated into ridges which join with each other so as to form an alveolar arrangement—the meshes or depressions having a polygonal form. The cystic duct should also be laid open, when the mucous membrane in this will be observed to be raised into oblique crescentic folds, which, when viewed collectively, have a spiral appearance.

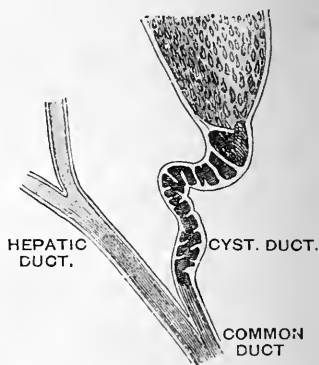


FIG. 125. — Cystic and hepatic ducts. (From Gegenbaur, modified.)

Dissection.—The umbilical fissure, the fissure for the ductus venosus, and the transverse fissure of the liver should now be opened up, and the structures contained within them dissected out.

The Vessels of the Liver.—Blood enters the liver—(1) by the *hepatic artery*, (2) by the large *portal*

vein; whilst it is led away from the liver by the *hepatic veins*.

The *hepatic artery* is a branch of the coeliac axis, and carries arterial blood for the nourishment of the liver substance. It divides into two branches which enter the liver at the extremities of the transverse fissure.

The *portal vein* carries venous blood, which it has gathered from the entire length of the abdominal portion of the alimentary canal (with the exception of the lower end of the rectum), from the spleen, pancreas, and gall-bladder. It reaches the under surface of the liver at the right extremity of the transverse fissure. Here it divides into its two terminal branches. The right branch is a short wide vessel, which immediately sinks into the liver; the left branch, much longer and considerably smaller, extends to the left along the bottom of the transverse fissure, and at the left extremity of this furrow it enters the liver substance. Near this point the coats of the left branch of the portal vein are joined in front by the obliterated umbilical vein, whilst behind it has also attached to it the obliterated ductus venosus. The terminal part of the portal vein, just before it divides, is slightly expanded, forming the *sinus of the portal vein*.

Note the relative position of the *vein, artery, and duct* at the transverse fissure. The duct is placed *in front*, the vein *behind*, whilst the artery is *intermediate* in position. They and their branches are all enveloped in a common fibrous sheath called Glisson's capsule. Trace them into the liver substance for a short distance. The portal vein branches like an artery, and wherever it divides, there also will the hepatic artery and hepatic duct be found to divide. The branches of these three structures, therefore, traverse the liver substance in company, and Glisson's capsule is prolonged into the liver with them, and follows them in their ramifications. The student is now in a position to understand the meaning of the term "*portal canal*." It is employed to denote a channel in the liver substance lined by a prolongation of Glisson's capsule, and holding in its

interior a branch of the portal vein, a branch of the hepatic artery, and a branch of the hepatic duct.

The *hepatic veins* which lead the blood out of the liver have an arrangement altogether different from the vessels which enter at the transverse fissure. They converge towards the fossa for the vena cava on the posterior surface of the organ, and cannot be said to have any course outside the liver, as they open directly into the vena cava inferior. The vena cava should be slit open, when the wide gaping mouths of the terminal hepatic veins will be displayed. Trace these veins for a short distance into the substance of the gland. They are remarkable for the tenuity of their walls, and also for the very small quantity of areolar tissue which separates them from the hepatic substance; indeed this is so scarce that it is hardly appreciable to the naked eye. In the case of the smaller veins it is altogether absent, and the hepatic lobules rest directly upon their walls.

A section should now be made through the liver substance and the cut surface examined. The portal veins can be readily distinguished from the hepatic veins. The following are the points of difference:—

PORTAL VEINS.	HEPATIC VEINS.
<ol style="list-style-type: none"> 1. Are always accompanied by a branch of duct and a branch of hepatic artery. 2. Mouths usually collapsed. 3. Walls thicker. 4. Walls separated from the liver substance by Glisson's capsule. 	<ol style="list-style-type: none"> 1. Are solitary and not accompanied by any other vessel. 2. Mouths usually open and gaping. 3. Walls exceedingly thin. 4. Walls apparently in direct apposition with the liver substance.

Structure of the Liver.—Very little of the structure of the liver can be learned in the dissecting-room. It is completely enveloped by a fibro-areolar coat. This is thick where the peritoneum is absent; but very thin where that membrane is spread over the gland. The liver substance presents a mottled appearance, and when torn or ruptured

the surface exhibits a granular aspect. The minute particles which give rise to this appearance are the hepatic lobules. In the human liver these are not completely separated from each other. Each lobule may be regarded as a miniature liver; they are all built up of the same constituents, but these can only be made out by the aid of the microscope.

The Kidneys.—The kidneys are situated behind the peritoneum, against the posterior wall of the abdomen—one on either side of the vertebral column. They are enveloped by a capsule of loose areolar tissue, the meshes of which are at certain points loaded with soft pliable fat. Clear this away, and be careful not to remove at the same time the *suprarenal body*, which lies upon the upper end of each kidney.

The *kidney* is placed opposite the bodies of the last dorsal and the upper three lumbar vertebræ. It extends from the upper border of the last dorsal vertebra to the middle of the body of the third lumbar vertebra, and it lies obliquely—its upper end being somewhat nearer the mesial plane than its lower end. The kidneys lie for the most part in the hypochondriac and epigastric regions. As a rule the left kidney is entirely confined to these districts; but the right kidney, which occupies a slightly lower level, crosses the subcostal plane so that a small portion of its inferior extremity comes to lie in the right lumbar and the adjoining part of the umbilical region. This difference on the two sides is probably due to the great bulk of the right lobe of the liver. The twelfth rib lies behind both kidneys. The right kidney does not, as a rule, extend beyond the upper border of this rib; the left kidney may reach the lower border of the eleventh rib. The lower end of each organ is separated by a short interval, of varying extent, from the crest of the ilium.

The average length of the kidney is four inches; its breadth two and a half inches; and its average weight four and a half ounces in the male, but somewhat less in the female. It is a solid organ, very pliable, and of a brownish-

4 11
4
4

red colour. The left kidney is, as a rule, slightly longer and narrower than the right kidney.

The Form of the Kidney is so characteristic that the term "reniform," or "kidney-shaped," has become common in descriptive language. The *anterior surface* looks outwards and forwards, and presents impressions corresponding to the viscera in contact with it; whilst the *posterior surface* is directed inwards and backwards, and is moulded accurately upon the parts which support it. The *extremities* are round, but the superior end is usually thicker and more massive than the inferior. The *external border*, smooth and convex, is directed backwards and outwards; whilst the *internal border* is concave, and looks inwards and forwards. The true form of the kidneys can only be seen in cases where they have been carefully hardened *in situ*.

The kidneys present many changes in form, according to the amount and the kind of pressure which is exerted upon them by contiguous viscera. In every case, however, and on both sides there is on the anterior surface of the organ a point of maximum convexity—a place where the kidney substance is raised in the form of a marked prominence or bulging. Above and below this eminence the anterior surface falls away towards each extremity, in the form of an inclined or sloping plane of greater or less obliquity (Fig. 118). These impressed districts indicate pressure exercised on the anterior surface of the kidney in two directions, and the intervening eminence is the result of this pressure and counterpressure.

Upon the upper inclined plane of the anterior surface of the *left kidney* is placed the left suprarenal capsule, the stomach, the spleen, and the pancreas. These exercise a downward and backward pressure, chiefly through changes in the condition of the stomach. Upon the inferior inclined plane of the left kidney the counterpressure is produced by the intestinal canal, which, as a rule, presses upwards and backwards.

Resting upon the upper inclined plane of the *right kidney* is the liver, whilst in contact with the lower inclined

area is the colon. The colon presses on the kidney in an upward and backward direction. To this pressure the liver offers a passive resistance, except perhaps in the case of the slight influence which it conveys in a downward direction from the diaphragm, and in a backward direction from the anterior abdominal wall.

This pressure and counterpressure, which produces so marked a conformation of the anterior surface of the two kidneys, must also exercise an important influence in maintaining the organ in its place, and securing it in that part of the abdominal cavity in which it lies.

Hilum of the Kidney.—The internal border of the kidney presents a longitudinal fissure called the *hilum*, for the

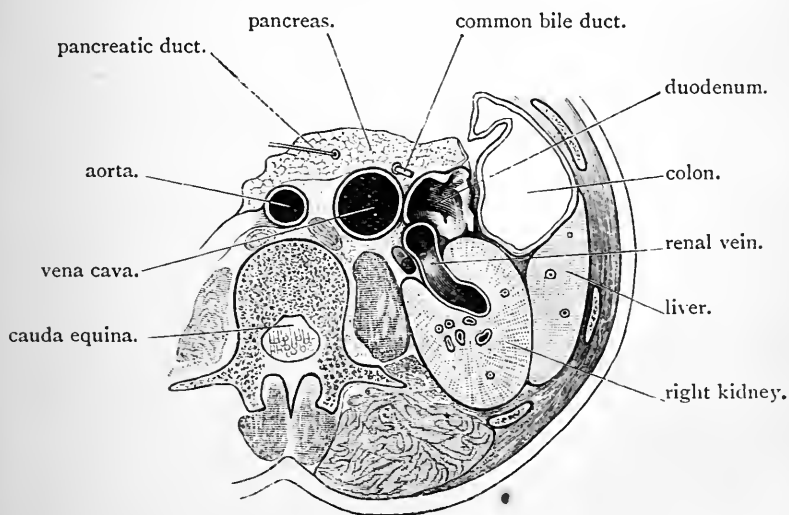


FIG. 126.—Section through abdomen at the level of the second lumbar vertebra.

admission and egress of the vessels, nerves, lymphatics, and duct (Fig. 126). This is bounded anteriorly and posteriorly by a thick lip and leads into a deep recess or cavity in the kidney, which is termed the *renal sinus*. The ureter and the renal vessels enter the kidney between the lips of the

hilum. They will be found to have the following position from before backwards: (1) branches of the renal vein; (2) branches of the renal artery; (3) ureter or renal duct.

Anterior Surface of the right Kidney.—The anterior surface of the right kidney presents three impressions, viz., a hepatic, a colic, and a duodenal. The *hepatic impression*, which indicates the area of contact with the under surface of the right lobe of the liver, occupies almost the whole of the upper two-thirds of the anterior surface, and corresponds to the upper inclined plane. Over this district the kidney is sometimes sunk deeply into the substance of the liver. The suprarenal capsule, which rests, as a rule, on the upper extremity of the right kidney, extends downwards for a very short distance on the anterior surface of the organ between it and the liver. With the exception of this narrow strip immediately adjoining the superior extremity, the hepatic impression on the anterior surface of the kidney is covered by peritoneum. The *colic impression* corresponds to the inferior inclined plane, and sometimes it exhibits a marked degree of obliquity. The hepatic flexure of the colon and the commencement of the transverse colon are in contact with this area. The posterior surface of these portions of great gut is devoid of peritoneum, and bound to the kidney by areolar tissue. The *duodenal impression*, or area of contact with the second part of the duodenum, is in the neighbourhood of the hilum, and varies greatly both in position and extent (*vide* Fig. 117, p. 492).

Anterior Surface of the left Kidney.—The suprarenal capsule, the spleen, the stomach, and the pancreas are in contact with the upper inclined plane on the anterior surface of the left kidney. The *suprarenal capsule*, as a rule, occupies a narrow district along the inner border from the level of the hilum to the summit of the organ. The *spleen* is in contact over an area immediately adjoining the outer convex border. The extent of this splenic field varies considerably in different subjects, and in a carefully hardened kidney it is apparent to the eye, as a distinct impression. The *pancreas* stretches across the left kidney either imme-

diately above, or perhaps exactly over the eminence which intervenes between the two sloping surfaces on the anterior aspect of the kidney, and the area which it occupies is not unfrequently indicated by a faint impression. The *stomach* is in contact with the left kidney over the triangular interval which is left between the suprarenal capsule, the spleen, and the pancreas.

The inferior sloping surface on the anterior aspect of the left kidney presents a varying relation to the intestinal canal. The *descending colon*, and as a rule some coils of the *small intestine* are in relation to it.

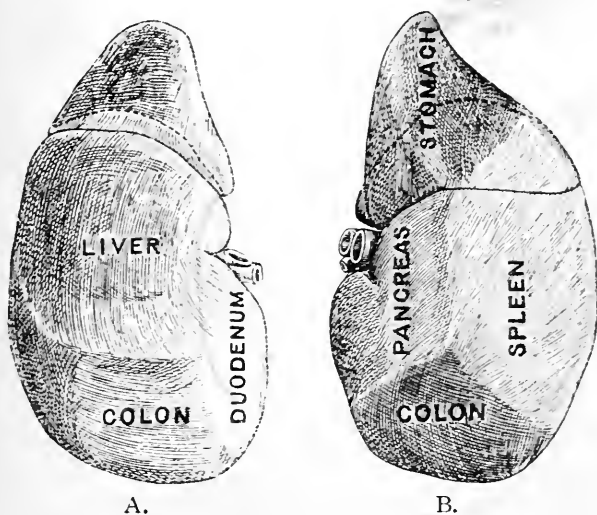


FIG. 127.—Models of the kidneys of a child of two years old prepared by the reconstruction method.

- A. Anterior surface of the right kidney.
 B. Anterior surface of the left kidney. In this the suprarenal capsule does not hold the usual place, and owing to this and to the very extensive surface of contact for the spleen, the stomach did not, in this case, come into direct apposition with the kidney.

The Outer Convex Border of each Kidney presents a marked thickening opposite the eminence on the anterior surface. From this it narrows in an upward and downward direction towards each extremity. On the left kidney,

somewhere in the neighbourhood of this marginal thickening a faint groove may indicate where the outer border is clasped by the last rib; on the right kidney such a marking is rarely visible, but a narrower furrow which corresponds with the ligamentum arcuatum externum may be detected.

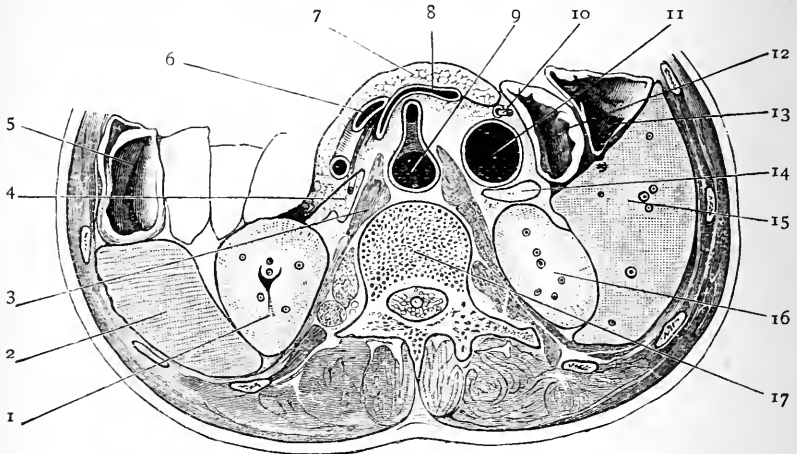


FIG. 128.—Transverse section through abdomen at the $\frac{1}{4}$ level of the first lumbar vertebra.

- | | |
|--|---|
| 1. Left kidney. | 9. Aorta giving off the superior mesenteric artery. |
| 2. Spleen. | 10. Rod in bile-duct. |
| 3. Crus of diaphragm. | 11. Inferior vena cava. |
| 4. Suprarenal capsule. | 12. Duodenum. |
| 5. Colon. | 13. Colon. |
| 6. Splenic artery. | 14. Suprarenal capsule. |
| 7. Pancreas. | 15. Liver. |
| 8. Splenic vein joining the portal vein. | 16. Right kidney. |
| | 17. 1st lumbar vertebra. |

The Posterior Surface of the Kidney is very distinctly mapped out into an internal and an external district. The *internal district* is the narrower of the two, and looks directly inwards. It is in apposition with the psoas muscle and the crus of the diaphragm, and a rounded ridge, which corresponds with the posterior margin of the psoas, separates it from the external district. The *external district* looks backwards. In its upper third it rests on the diaphragm, and in its lower two-thirds upon the quadratus lumborum. On the right kidney these two muscular areas are frequently

mapped off from each other by a furrow corresponding to the ligamentum arcuatum externum.

In spare individuals, when the kidneys have been carefully hardened *in situ*, dimples, corresponding to the tips of the transverse processes of the first, second, and third lumbar vertebrae, and a shallow groove for the last rib may sometimes be detected on the posterior surface of the kidney.

The Peritoneal Relations of the two kidneys are seen in the accompanying diagrams (Fig. 129).

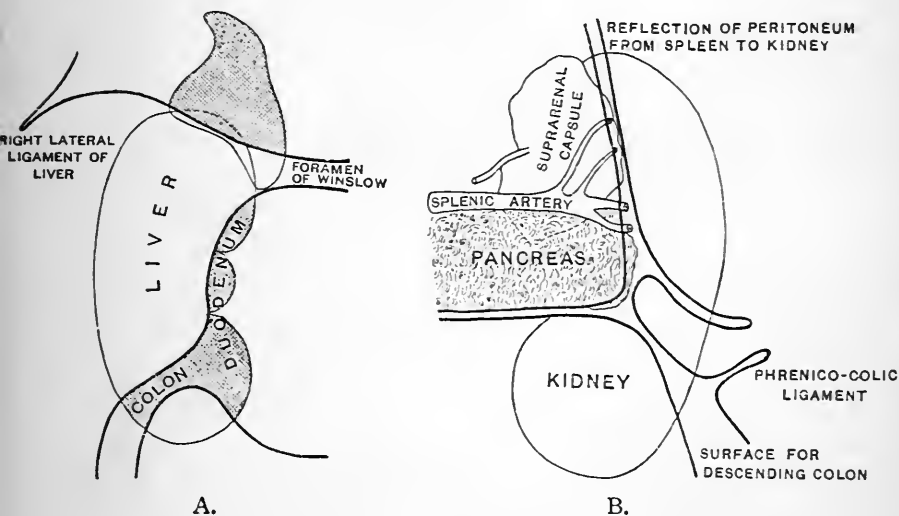


FIG. 129.—A. Diagram of the anterior surface of the right kidney to illustrate the relation of the peritoneum and the areas in contact with the LIVER, COLON, DUODENUM, and CAPSULE. The areas which are not covered by the peritoneum are shaded. The heavy dark lines indicate the lines of peritoneal reflection.

B. Diagram, by Dr. Brooks, to illustrate the relations of the peritoneum, etc., to the anterior surface of the left kidney. The dark lines indicate the lines of peritoneal reflection.

The student should never experience any difficulty in determining the side to which a given kidney belongs. Even allowing that the upper end cannot be distinguished from the lower end, or the anterior surface from the posterior surface, by differences in their appearance (which is generally the case in a dissecting-room kidney), the ureter

alone is sufficient for the purpose. It shows the posterior surface from its position at the hilum, and the lower end from its curving downwards towards it.

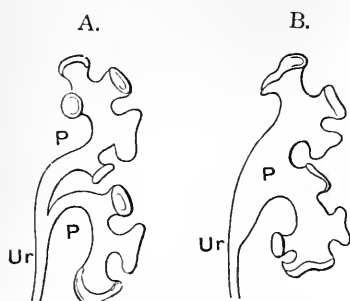


FIG. 130. — Two different forms of the pelvis of the ureter. (From Gegenbaur.)

- A. Pelvis (P) dividing into two main parts.
 B. Pelvis (P) dividing directly into the infundibula or calices.
 Ur. Ureter.

expands into a wide funnel-shaped portion called the *pelvis*.

This enters the sinus and divides into two, or perhaps three, large primary branches, and these again break up into a large number of short stunted secondary divisions called *calices* or *infundibula*, which are attached to the walls of the sinus.

The kidney should now be cut into two in the longitudinal direction. Use a large knife, and, entering it at the external border, carry it steadily through the gland substance to the hilum.

An examination of the cut

Kidney Capsule and Kidney Substance.—The kidney is invested by a strong fibrous coat, which can be easily stripped from its surface. Divide this capsule along the outer margin of the organ and peel it off towards the hilum. Here it enters the sinus and becomes continuous with the sheaths of the vessels entering the gland, and also with the external coat of the ureter.

Examine the manner in which the ureter or duct is connected with the kidney. As it approaches the hilum it

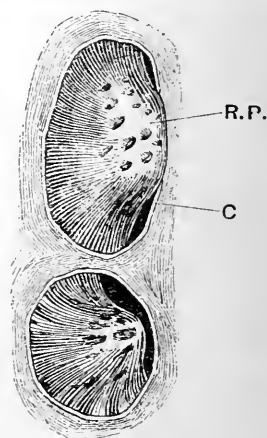


FIG. 131. — Two renal papillæ.

R. P. Renal papilla.

C. Cut edge of a calix of the pelvic portion of the ureter.

surface of the kidney will show that its substance is arranged in two parts—a medullary and a cortical. The *medullary portion* is seen to consist of dark-coloured, faintly-striated pyramidal masses, the bases of which are directed towards the periphery, whilst their apices are free and project into the sinus. On the sinus wall each of these appears in the form of a prominent mammillary projection, called a *renal papilla*, which projects into one of the calices of the pelvis of the ureter. If the kidney be squeezed, fluid will be seen to exude from these papillæ, showing that the tubuli uriniferi open upon their surface. The number of pyramids and renal papillæ vary from eight to twenty. Usually there are more than twelve. A single calix of the ureter may surround one, two, or even three renal papillæ, and receive the urine which issues from the papillary ducts which open on their surface. The *cortical substance* constitutes the peripheral part of the gland, and also sends prolongations inwards between the pyramids. These are called the *columns of Bertin* (*columnæ renales*).

The Ureter.—This is the duct which carries the urine from the kidney to the bladder. The relations of its expanded upper end or pelvis at the hilum of the kidney have already been noted. Leaving the gland, it turns downwards and becomes contracted, so that when it reaches the level of the lower end of the organ it has acquired the appearance of a cylindrical tube. The ureter extends downwards and inwards upon the psoas muscle, and, crossing the common or external iliac artery, it enters the pelvis, where it will be afterwards followed. In the abdomen proper it is placed immediately behind the peritoneum, and is crossed obliquely by the spermatic vessels. Before entering the pelvis it passes behind the ileum on the right side, and the sigmoid flexure of the colon on the left side.

The Suprarenal Capsules (*glandulæ suprarenales*) are two small flattened triangular bodies, each of which is placed upon the upper end of the corresponding kidney.

It surmounts the kidney after the fashion of a helmet, and is prolonged downwards for a short distance upon its anterior surface. The suprarenal body lies in the epigastric region, and rests upon the diaphragm. On the *right side* its anterior face is in relation to the posterior surface of the liver, and may receive a very slight covering in its lower or basal part from the peritoneum. On the *left side* its anterior surface is covered more or less completely with peritoneum, and is in relation to the stomach, the pancreas, and possibly the spleen. The student has already observed its abundant nerve supply from the solar plexus. Its blood supply is equally rich. No fewer than three arteries enter its substance—viz., the *superior, middle, and inferior capsular arteries*. On the anterior surface of the suprarenal capsule of each side there is a slit, called the *hilum*, from which a large vein emerges.

When a section is made through the suprarenal capsule it is seen to consist of an external firm portion termed the *cortex*, and of a soft pulpy dark-coloured internal substance called the *medullary part*.

Dissection.—Having now disposed of all the viscera within the cavity of the abdomen proper, the student should, in the next place, direct his attention to the diaphragm—the great muscle which constitutes a movable partition between the thoracic and abdominal cavities. Stripping the peritoneum from its lower concave surface, clean the muscular fibres and the central tendinous expansion towards which they ascend. In making this dissection be careful to preserve the phrenic arteries which ramify upon this aspect of the diaphragm and also the nerves which accompany them.

The Diaphragm is, after the heart, the most important muscle in the body. It forms the dome-shaped roof of the abdomen, and the highly arched and convex floor of the thorax. It is the chief muscle of respiration. Each respiratory act is accompanied by a descent and ascent of its muscular part, and in this way the capacity of the thoracic cavity is alternately increased and decreased in the vertical direction. The vault or cupola of the diaphragm is higher on the right side than upon the left side

of the body. In forced expiration it rises on the right side as high as the upper margin of the fourth rib, close to the sternum; whereas, on the left side, it only reaches the upper border of the fifth rib.

The *central portion* of the diaphragm is tendinous. From this the fleshy fibres will be observed to radiate, and, at the same time, to arch downwards, so as to obtain attachment to the circumference of the lower aperture or outlet of the thorax. In front, it takes origin from the back of the lowest segment of the sternum; behind, it springs by two partly fleshy and partly tendinous processes called the crura, from the bodies of the upper three lumbar vertebræ, and upon each side of these from two ligamentous arches, termed the ligamenta arcuata; laterally, it arises from the lower six costal arches. Examine each of these attachments in turn.

Anterior Attachment.—The sternal origin consists of two slips which spring from the back of the xiphoid cartilage. These are separated from each other by a narrow linear interval filled by areolar tissue, and comparable with the wider interval in the mesial plane behind, which separates the two crura of the diaphragm.

The Lateral Attachment.—The costal origin consists of six pointed and fleshy slips which spring from the deep surfaces of the lower six costal cartilages. These interdigitate with the digitations of the transversalis abdominis. The sternal and costal origins of the diaphragm are separated by a small triangular interval, in which the pleural and peritoneal membranes are merely separated from each other by some loose areolar tissue. Through this gap the superior epigastric branch of the internal mammary artery descends into the abdominal wall.

The Posterior Attachment.—The *ligamentum arcuatum externum* is a fibrous band which stretches from the last rib to the transverse process of the first lumbar vertebra. It arches in front of the quadratus lumborum, and is merely the thickened upper part of the fascia which covers this muscle, *i.e.*, the anterior lamella of the lumbar fascia. By

pressing the rib backwards the arch will be rendered more prominent. The *ligamentum arcuatum internum* arches

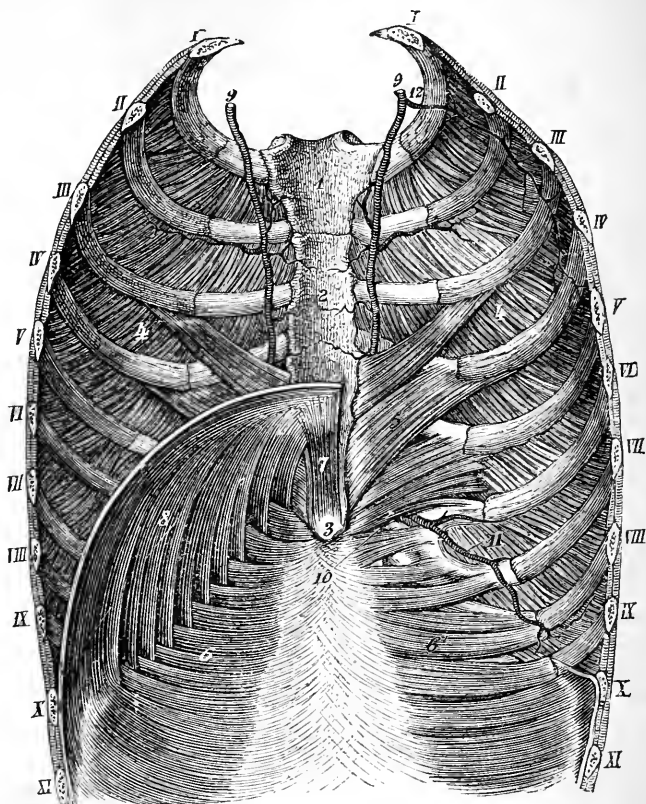


FIG. 132.—Posterior surface of the anterior wall of the thorax and abdomen, to show the costal and sternal origins of the diaphragm on the left side. (From LUSCHKA'S *Anatomy*.)

- | | |
|----------------------------------|---|
| 1. Manubrium sterni. | 8. Costal origin of diaphragm. |
| 2. Body of sternum. | 9. Internal mammary artery. |
| 3. Ensiform cartilage. | 10. Superior epigastric artery. |
| 4. Internal intercostal muscles. | 11. Musculo-phrenic artery. |
| 5. Triangularis sterni. | 12. An occasional branch of the internal mammary. |
| 6. Transversalis abdominis. | |
| 7. Sternal origin of diaphragm. | |

over the psoas muscle, and, like the external ligament, is simply a thickening of the fascia which covers that muscle.

It is the stronger of the two, and is attached by one extremity to the tip of the transverse process of the first lumbar vertebra, and by the other to the body of the second lumbar vertebra and the tendinous part of the crus. Fleishy fibres arise from both of these arcuate bands; those from the internal ligament are more numerous and better marked than those which take origin from the external ligament, and they are continuous with the fleshy fibres of the crus. Very frequently a gap or interval exists between the fibres which spring from the ligamentum arcuatum externum and those which arise directly from the last rib. The anterior, lateral and posterior attachments of the diaphragm are therefore in this manner marked off from each other.

The *crura* of the diaphragm are two thick fleshy processes which descend upon the bodies of the upper lumbar vertebræ, tapering as they proceed downwards, and finally ending in pointed tendinous extremities. The *right crus* is the larger and longer of the two. It takes origin from the bodies of the upper three lumbar vertebræ, and the intervertebral discs which intervene between them. The *left crus* springs from the left side of the bodies of the first two lumbar vertebræ. It is much smaller, and lies upon a posterior plane to the right crus. Follow the crura upwards; opposite the last dorsal vertebra they will be observed to be connected across the middle line by a strong fibrous band which arches over the aorta. From the upper border of this fibrous arch fleshy fibres arise which join both crura, and on this account we give it the name of *ligamentum arcuatum medium*.¹

Above this level the fleshy fibres of the crura diverge and ascend to join the posterior border of the central

¹ It may be regarded as a universal law that wherever an artery pierces the origin or insertion of a muscle, and comes to lie between bone and muscular fibres, it is protected by a fibrous arch. Of this nature is the arch in question, and also the fibrous arch thrown over the superior profunda artery on the back of the humerus, and the fibrous arches in the adductor magnus for the passage of the perforating arteries, and the femoral artery itself.

tendon. The innermost fibres of each crus, however, decussate so as to separate the aortic from the œsophageal openings. The decussating fasciculus of the right crus is always the larger of the two, and moreover it usually passes in front of the decussating fasciculus of the left crus.

Central Tendon.—The central tendon is exceedingly strong. It is composed of strong tendinous bundles running in different directions, and closely woven together so as to give it a plaited appearance. This is well seen by an inspection of its abdominal surface. In shape the central tendon resembles a trefoil leaf, of which the right lobe is the largest, and the left lobe the smallest. Upon all sides it is surrounded by muscular fibres. Those which spring from the sternum are much the shortest.

Foramina of the Diaphragm.—The continuity of the diaphragm is broken by *three* large openings, and by some smaller apertures or fissures for the passage of the splanchnic nerves, and the vena azygos minor. The three main openings receive the names of the most important objects which they transmit. They are—

1. The aortic.
2. The vena caval.
3. The œsophageal.

The *aortic opening* is in the mesial plane in front of the first lumbar vertebra, and between the crura of the diaphragm. It is bounded in front by the fibrous band which arches across the middle line and connects the tendinous portions of the two crura. Behind, a fibrous expansion is prolonged inwards on each side, so as to limit the aperture posteriorly, and in this manner an almost complete fibrous ring may be formed around the aorta. The structures which pass through the aortic opening are—(1) the aorta, (2) the thoracic duct, and (3) the vena azygos major—in this order from left to right.

The *vena caval opening* is at a higher level, being situated opposite the disc between the eighth and the ninth dorsal vertebræ, in front and slightly to the right of the aortic

Aorta 1st Lumbar
 Ven. Caval. 9th Dorsal
 œsoph. 10th Dorsal

opening. Note that it is placed in the back part of the central tendon at the junction between its middle and right lobes. Its form is somewhat quadrangular, and its margins are prolonged upon the walls of the vena cava as it passes through it. The contraction of the muscular fibres of the diaphragm will therefore tend to increase the size of this opening and the calibre of the vein which it holds.

In addition to the vena cava, one or two minute twigs from the right phrenic nerve may be transmitted through the vena caval opening.

The *œsophageal opening* is an oval or elliptical foramen in the muscular part of the diaphragm. It lies in front and slightly to the left of the aortic aperture, and also at a higher level, being placed opposite the tenth dorsal vertebra. In some cases its anterior border is tendinous, and formed by the posterior margin of the central tendon. Posteriorly it is separated from the aortic opening by the decussation of the internal fibres of the crura.

The *œsophageal opening* transmits the gullet and the two pneumogastric nerves.

The three large openings of the diaphragm, therefore, present very different features. The *aortic opening* is a fibrous ring behind the diaphragm, and it can in no way be affected by the contraction of the muscular fibres. The *vena caval opening* is in the central tendon, and its margins are attached to the wall of the vessel which it transmits; contraction of the diaphragm must therefore have a tendency to widen this aperture. The *œsophageal opening* is placed in the muscular part, and consequently it is highly probable that the fibres which surround it may be capable of exercising a constricting influence upon the *œsophagus*, and in this way help to prevent regurgitation of food during the descent of the diaphragm.

Little need be said regarding the smaller foramina. Each crus is pierced by the *three splanchnic nerves*, and the left crus is likewise perforated by the *vena azygos minor*. The *superior epigastric artery* descends in the interval between the sternal and costal attachments of the dia-

phragm, and the *musculo-phrenic artery* pierces the costal attachment opposite the eighth or ninth rib.

VESSELS ON THE POSTERIOR WALL OF THE ABDOMEN.

Dissection.—The abdominal aorta and its branches and the vena cava must now be cleaned. In doing this, care should be taken of the gangliated cord of the sympathetic which extends downwards on the vertebral column along the anterior border of the psoas. It is necessary to bear in mind that the lumbar branches of the aorta, as they proceed outwards, pass *behind* this. Separate the right crus of the diaphragm from the aorta, and dissect in the interval between them. Here the *receptaculum chyli* and the *vena azygos major* will be found. A chain of lymphatic glands, termed the *lumbar glands*, will be noticed in relation to the aorta. The only branches of the aorta which are liable to injury are the *spermatic arteries*. These are two slender arteries which spring from the front of the vessel a short distance below the renal arteries. They are so small that they are apt to be overlooked.

The Abdominal Aorta (*aorta abdominalis*).—The abdominal aorta is the direct continuation of the thoracic aorta, and enters the abdomen through the aortic opening of the diaphragm. It begins in the mesial plane in front of the last dorsal vertebra, and it ends upon the left side of the body of the fourth lumbar vertebra by dividing into the two *common iliacs*. It therefore pursues an oblique course—slightly inclining to the left as it proceeds downwards. A line drawn between the highest points of the iliac crests would indicate the level of the bifurcation of the abdominal aorta; it takes place opposite the left side of the umbilicus.

Most of the structures which lie *in front* of the abdominal aorta have been removed. In immediate relation to it from above downwards are:—(1) The solar plexus and the layer of peritoneum which forms the posterior wall of the lesser bag. (2) The pancreas and splenic vein. (3) The third part of the duodenum and the left renal vein. (4) The peritoneum and the aortic plexus of nerves. Superficial to these it is covered by the liver, the gastro-hepatic omentum and the stomach, the transverse colon and its

mesentery, and by the great omentum and the coils of the small intestine. *Behind*, the abdominal aorta rests upon the bodies of the lumbar vertebræ and the intervertebral discs, separated from them, however, by the anterior common ligament and the left lumbar veins. *On each side* it is related in its upper part to the crus of the diaphragm. On the *right side* the inferior vena cava lies close to the aorta as high as the second lumbar vertebra, but above this it is separated from it by the fleshy part of the right crus. In the interval between the right crus of the diaphragm and the vessel, the student has already noted the receptaculum chyli and the vena azygos major. On the *left side*, the left gangliated cord of the sympathetic is in relation to the artery below the level of the left crus.

Branches of the Abdominal Aorta.—The branches of the abdominal aorta may be described under two heads, viz.—(1) Those which come off *in pairs*. (2) Those which arise *singly*.

PAIRED BRANCHES.

1. Inferior phrenic arteries.
2. Middle capsular arteries.
3. Renal arteries.
4. Spermatic or ovarian arteries.
5. Lumbar arteries.

SINGLE BRANCHES.

1. The cœliac axis.
2. The superior mesenteric.
3. The inferior mesenteric.
4. The middle sacral.

The *single branches* have already been described, with the exception of the *middle sacral*, which arises from the extremity of the aorta between the two common iliacs. It will be studied in connection with the pelvis. The *paired branches* may now be examined.

The Inferior Phrenic Arteries (arteriæ phrenicæ inferiores) have already been noticed upon the under surface of the diaphragm. They are two in number, and are the first branches which spring from the abdominal aorta. Diverging from each other, the artery of the right side passes behind the inferior vena cava, whilst the artery of the left side goes behind the œsophagus. Near the posterior border of the central tendon of the diaphragm

each divides into an external and an internal branch. The *external branch* proceeds outwards to anastomose with the intercostal arteries, whilst the *internal branch* curves forwards in front of the central tendon, and ends by anastomosing with its fellow, and with the terminal branches of the internal mammary artery. Each phrenic artery, in addition to the branches which it supplies to the diaphragm, gives a twig, called the *superior capsular artery*, to the suprarenal body. On the left side it also sends a few minute branches to the œsophagus.

The *phrenic veins* open into the inferior vena cava.

The Middle Capsular Arteries (arteriæ suprarenales mediæ) are two small vessels which arise one from each side of the aorta at the same level as the superior mesenteric. They run outwards and upwards in front of the crura of the diaphragm to the suprarenal bodies, into the substance of which they sink. On the right side, the middle capsular artery passes behind the inferior vena cava. They anastomose freely with the superior and inferior capsular arteries.

The *right capsular vein* opens into the inferior vena cava, whilst the *left vein* ends in the renal or phrenic vein.

The Renal Arteries (arteriæ renales), when compared with the organs which they supply, are disproportionately large. Only a small part of the blood which they carry to the kidneys is used for the nourishment of the gland substance. The kidneys are the great excretory organs for the waste nitrogenous materials of the body, and it is necessary that the blood should pass to them in large quantity in order that it may be purified.

The renal arteries take origin about a quarter of an inch below the superior mesenteric. Each artery proceeds outwards at right angles to the aorta, and, approaching the kidney, breaks up into four or five branches, which enter the hilum, and pass deeply into the sinus before sinking into the kidney substance. It is overlapped by the accompanying vein. Seeing that the aorta lies a little to the left of the mesial plane, the right renal artery is the

longer of the two; the right artery is also placed at a slightly lower level, and passes behind the vena cava. Again examine the relation of parts at the hilum. From before backwards we find:—(1) Veins; (2) arteries; (3) ureter.

The renal artery gives a small branch—the *inferior capsular*—to the suprarenal body, and also numerous fine twigs to the connective tissue around the kidney.

The *renal veins* join the inferior vena cava. The vein of the left side crosses in front of the aorta, and is the longer of the two. Both receive tributaries from the suprarenal bodies, and the left vein is also joined by the left spermatic or ovarian vein.

The Spermatic Arteries (*arteriæ spermaticæ internæ*) are two long slender vessels which spring from the front of the abdominal aorta, a short way below the renal arteries. Diverging from each other, each artery passes obliquely downwards and outwards behind the peritoneum, to the internal abdominal ring, where it joins the other factors of the spermatic cord. As it descends, it rests upon the psoas, and crosses the ureter and the external iliac artery. On the right side, the spermatic artery passes in front of the vena cava inferior.

In the female, the corresponding arteries go to the ovaries, and are consequently termed the *ovarian arteries*. Within the abdomen proper they have the same relations as the spermatic arteries. In the dissection of the female pelvis they will be followed to their destination.

The *right spermatic vein* joins the vena cava directly, whilst the *left vein* terminates in the left renal vein. The *ovarian veins* end in the same manner.

The Lumbar Arteries (*arteriæ lumbales*)—five in number on each side—spring from the posterior aspect of the abdominal aorta, in series with the intercostal arteries. At present they are only seen in a very short part of their course. They proceed outwards upon the bodies of the last dorsal and upper four lumbar vertebrae, behind the gangliated cord of the sympathetic, and then disappear

under the cover of the psoas muscle. The three upper arteries also pass behind the crura of the diaphragm, and on the right side they are crossed by the inferior vena cava.

The *lumbar veins* join the inferior vena cava, and those of the left side pass behind the aorta.

Vena Cava Inferior.—This is the large vein which collects, by means of its tributaries, the venous blood from the lower limbs, the abdominal viscera, and a great part of the abdominal parietes. It is formed on the right side of the body of the fifth lumbar vertebra by the union of the two *common iliac veins*. As it ascends, it lies in the first place upon the vertebral column, close to the right side of the aorta: above the level of the second lumbar vertebra it lies upon the fleshy part of the right crus of the diaphragm, which intervenes between it and the aorta; lastly, it is contained in a deep groove, on the posterior surface of the liver, and leaves the abdomen by passing through the vena caval opening of the diaphragm, to open into the right auricle of the heart.

As it passes upwards it receives the following tributaries:—

1. The common iliac veins.
2. The lumbar veins.
3. The right spermatic or ovarian vein.
4. The renal veins.
5. The right middle capsular vein.
6. The inferior phrenic veins.
7. The hepatic veins. N 13

The Common Iliac Arteries (*arteriæ iliacæ communes*). The two terminal branches of the aorta should next be examined. They arise upon the left side of the body of fourth lumbar vertebra, and, diverging from each other, proceed downwards and outwards upon the vertebral column. After a course of about two inches, each vessel ends opposite the lumbo-sacral articulation by dividing into the *external and internal iliac arteries*; of these the former is the larger of the two, and appears to be the continuation

of the parent trunk, whilst the latter passes downwards into the pelvis.

The common iliac artery of each side is covered by peritoneum, and overlapped by coils of the small intestine ; furthermore, it is crossed by the large sympathetic twigs which connect the aortic and hypogastric plexuses, and, close to its termination, by the ureter. On the left side the superior hæmorrhoidal artery also passes down in front of the common iliac artery.

Venæ Iliacæ Communes.—The position of the corresponding veins should be carefully noted. This differs on the two sides of the body. The *left common iliac vein* is in relation to both arteries. It first lies along the *inner* or *right* side of its companion artery, and then crosses *behind* the upper part of the right artery to reach the vena cava inferior. The *right common iliac vein* at first lies *behind* its companion artery, but, as it ascends, it gradually comes to lie upon its *right* side, and here it joins the vena cava. Each common iliac vein is formed by the junction of the external and internal iliac veins.

No collateral branches of any consequence proceed from the common iliac artery.

The common iliac vein of each side is joined by the *ilio-lumbar vein*. The left common iliac vein also receives the *middle sacral vein*.

The External Iliac Artery (*arteria iliaca externa*) is the first or abdominal portion of the great arterial trunk which carries blood to the lower limb. It begins, as we have seen, opposite the lumbo-sacral articulation, and extends obliquely downwards and outwards along the brim of the true pelvis to Poupart's ligament, behind which it passes into the thigh, and becomes the *femoral artery*. Its course can be indicated on the surface with tolerable accuracy by drawing a line from a point a little below and to the left side of the umbilicus to a point midway between the symphysis pubis and the anterior superior spine of the ilium.

Like the common iliac artery, the external iliac is

closely covered by peritoneum. On the right side it passes behind the terminal part of the ileum, whilst on the left side it presents a similar relation to the sigmoid flexure of the colon. Towards its termination it is crossed by an artery, a vein, and a minute nerve, viz. the spermatic artery, the deep circumflex iliac vein, and the genital branch of the genito-crural nerve. At first it rests upon the inner margin of the psoas muscle, but close to Poupart's ligament it comes to lie directly in front of that muscle. The artery is separated from the muscle, however, by the iliac fascia, to which it is bound down by a condensed part of the extra-peritoneal tissue, which passes over it. The genito-crural nerve lies along the outer side of the artery, and the companion vein is placed on its inner side; on the right side, however, the vein, as it passes upwards, gradually comes to lie behind the artery.

The external iliac gives off two large branches to the abdominal wall, viz., (1) the deep epigastric; (2) the deep circumflex iliac. They arise close to Poupart's ligament, and have both been examined (pp. 408, 409). The veins corresponding to these arteries open into the external iliac vein.

Deep Lymphatic Glands.—The dissector has, doubtless, noticed a chain of lymphatic glands in connection with the external iliac artery, the common iliac artery, and also extending upwards upon the vertebral column in relation to the aorta and inferior vena cava. The *external iliac glands* receive the efferent vessels which proceed from the inguinal glands. As we proceed upwards, the lymphatic vessels which connect the various glands become greatly diminished in number, but much increased in calibre, until at last they resolve themselves into four or five trunks, which join the lower part of the receptaculum chyli.

Receptaculum Chyli (cisterna chyli).—This is the dilated commencement of the thoracic duct. It is placed upon the body of the second lumbar vertebra, in the interval between the right crus of the diaphragm and the aorta.

To bring it into view, it is necessary to separate the right crus from the lumbar vertebræ and pull it aside. When fully displayed, the receptaculum chyli is seen to be a narrow elongated sac about an inch in length, which receives by its lower end several large lymphatic vessels, whilst superiorly, it contracts and becomes the thoracic duct. Near its upper end it is joined anteriorly by the lacteal vessels. The vena azygos major lies along its right side, but the receptaculum chyli is easily distinguished from this by the whiteness of its walls. The thoracic duct enters the thorax by passing through the aortic opening of the diaphragm.

Azygos Veins.—The *right azygos vein* or *vena azygos major* usually takes origin in the right ascending lumbar vein. It will be found in the interval between the right crus of the diaphragm and the aorta, upon the right side of the receptaculum chyli, and it will be noticed to enter the thorax by passing through the aortic opening of the diaphragm.

The *vena azygos minor inferior* is more difficult to discover. It originates on the left side of the spine, in the left ascending lumbar vein, and enters the thorax by piercing the left crus of the diaphragm.

FASCIA AND MUSCLES ON THE POSTERIOR WALL OF THE ABDOMEN.

The muscles on the posterior wall of the abdomen are three in number, viz. (1) The *psaos*, an elongated fleshy mass extending downwards on the side of the spine: (2) The *quadratus lumborum*, a quadrate muscle external to the psaos, and stretching between the crest of the ilium and the last rib; (3) The *iliacus*, situated in the iliac fossa. The fascia which covers these muscles must, in the first place, be studied.

Quadratus Lumborum Fascia.—Follow this inwards and it will be found to be attached to the anterior aspect

of the roots of the transverse processes of the lumbar vertebræ. Trace it outwards and it will be noticed to join the posterior aponeurosis of the transversalis abdominis muscle. From these connections the dissector will understand that this fascia is simply the anterior lamella of the lumbar fascia. But what are its superior and inferior attachments? Above, it is fixed to the last rib, and is thickened so as to form the *ligamentum arcuatum externum*; whilst inferiorly, it is attached to the ilio-lumbar ligament. The quadratus lumborum muscle, therefore, is enclosed in a sheath formed anteriorly by the anterior lamella of the lumbar fascia, and posteriorly by the middle lamella of the lumbar fascia (Fig. 90, p. 402).

The Fascia covering the Psoas and Iliacus is one continuous aponeurotic sheet. Above the level of the crest of the ilium, where it is merely in relation to the psoas, it is thin and narrow. Here it is attached externally to the fascia covering the quadratus lumborum, whilst internally it is fixed to the spine by a series of fibrous arches which bridge over the lumbar arteries. Superiorly, it has been seen to form the thickened band termed the *ligamentum arcuatum internum*. Below, the fascia expands so as to cover both the psoas and the iliacus, and, at the same time, it becomes much denser and thicker. Here it receives the name of the *fascia iliaca*, and presents most important connections. The external iliac vessels lie upon it, whilst the anterior crural nerve lies behind it. The genito-crural nerve pierces it, and comes into relation with the external iliac artery. Externally it is firmly fixed to the crest of the ilium, whilst internally it sweeps over the psoas, and is attached to the brim of the true pelvis. These attachments can be easily demonstrated by dividing it in the vertical direction, over the iliacus, a short way to the outer side of the psoas. It is very loosely attached to the subjacent muscles, so that the fingers can readily be passed behind it, first in an outward and then in an inward direction. Note that no perceptible fascial partition dips backwards from it between the psoas and iliacus.

The inferior connections of this fascia have already been studied (pp. 217 and 427). On the outer side of the iliac vessels it has been seen to become continuous with the fascia transversalis, and, at the same time, to be attached to Poupart's ligament; whilst behind these vessels it is carried downwards into the thigh, to form the posterior wall of the femoral sheath.

Dissection.—The muscles should now be cleaned and their attachments defined; but, in doing this, certain points must be attended to. The inner portion of the fascia iliaca must be carefully preserved, in order that its relation to the pelvic fascia may be afterwards made out. In the case of the psoas muscle, great care must be taken not to injure—(1) the sympathetic cord, which lies along its anterior margin; (2) the genito-crural nerve, which runs downwards in front of it; (3) the ilio-inguinal, and the external cutaneous nerves, which appear at its outer border, and the anterior crural nerve, which lies in the interval between it and the iliacus muscle. In the case of the quadratus lumborum, bear in mind that the last dorsal nerve runs outwards in front of this muscle, close to the lower border of the last rib, and that the ilio-hypogastric and ilio-inguinal nerves cross it obliquely at a lower level.

Quadratus Lumborum.—This muscle *arises* from the ilio-lumbar ligament and from the crest of the ilium behind it. It likewise receives two or three slips from the transverse processes of a corresponding number of the upper lumbar vertebræ. Narrowing slightly as it passes upwards, it is *inserted* into the inner half of the last rib, behind the ligamentum arcuatum externum, and by four tendinous slips into the tips of the transverse processes of the four upper lumbar vertebræ.

Psoas Magnus.—This muscle has three distinct modes of origin from the side of the vertebral column:—(1) by five fleshy processes from the anterior surfaces and lower borders of the transverse processes of the lumbar vertebræ close to their roots; (2) by five slips, each of which arises from the intervertebral disc and the contiguous margins of the bodies of two vertebræ—the first slip springing from the last dorsal and the first lumbar vertebræ and the intervening disc, and the last slip from the two lower

lumbar vertebræ and their intervening disc ; (3) from the tendinous arches which bridge over the lumbar arteries and protect these vessels from the pressure of the contracting muscle.

The psoas tapers somewhat as it extends downwards along the brim of the pelvis, and a tendon appears on its outer border, which affords attachment to the fibres of the iliacus. Passing behind Poupart's ligament, it is inserted into the small trochanter of the femur.¹

Iliacus.—This muscle arises from the upper part of the iliac fossa, the anterior ilio-sacral ligament, and the base of the sacrum. It is inserted into the tendon of the psoas magnus. Some of its fibres, however, have a separate insertion into an impression below the small trochanter of the femur.

NERVES ON THE POSTERIOR WALL OF THE ABDOMEN.

The nerves on the posterior wall of the abdomen are the gangliated cord of the sympathetic and the anterior primary divisions of the spinal nerves, with the branches which proceed from them. These should now be dissected.

Gangliated Cord of the Sympathetic.—This enters the abdomen behind the ligamentum arcuatum internum, and extends downwards upon the bodies of the lumbar vertebræ along the anterior border of the psoas muscle. *Above,* it is continuous with the thoracic portion of the cord, whilst *below,* it passes behind the common iliac artery and enters the pelvis. In the thorax, it is placed upon the heads of the ribs ; here, however, it lies nearer the middle line, being carried forward by the psoas muscle. On the right

¹ Another muscle, called the *psoas parvus*, is occasionally present. This springs from the bodies of the last dorsal and first lumbar vertebræ, and the intervertebral disc between them, and, stretching downwards upon the anterior and inner aspect of the psoas magnus, it ends in a tendon which is inserted into the ilio-pectineal eminence and ilio-pectineal line.

side, it is in great part covered by the inferior vena cava, and on both sides the lumbar vessels pass outwards behind it. As a general rule, a small oval ganglion is formed upon the body of each lumbar vertebra. An *external* and an *internal* series of branches will be observed to spring from these ganglia.

The *external branches* connect the ganglia with the anterior primary divisions of the lumbar spinal nerves. Two will be found accompanying each lumbar artery. Trace them carefully backwards by cutting through the fibrous arches which bridge over these muscles, and scraping away the fibres of the psoas muscle. They join the lumbar nerves close to the intervertebral foramina.

The *internal branches* are chiefly given to the aortic plexus, but some will be found passing downwards in front of the common iliac artery to join the hypogastric plexus. Several twigs are also given to the vertebræ and their ligaments.

Dissection.—To bring the anterior primary divisions of the lumbar nerves into view, it is necessary to scrape away the psoas muscle. This has already been partially done in following the connecting sympathetic twigs backwards. An occasional branch, the *accessory obturator*, is liable to injury unless it be secured at once. When present, it will be found descending along the inner border of the psoas.

Lumbar Nerves.—The anterior primary divisions of the lumbar nerves are five in number, and pass outwards in the substance of the psoas muscle. They increase in size from above downwards, and each nerve is joined by two twigs from the sympathetic cord. Branches are given by them to the psoas and quadratus lumborum muscles.

The first three lumbar nerves, with a part of the fourth, unite in a loop-like manner to form the lumbar plexus, whilst the remaining part of the fourth joins the fifth to form the lumbo-sacral cord.

Lumbar Plexus (plexus lumbalis).—This plexus is placed in front of the transverse processes of the lumbar vertebræ in the substance of the psoas. Above, it is usually connected with the last dorsal nerve by a small twig which

descends in the substance of the quadratus lumborum to the first lumbar nerve; *below*, it is brought into communication with the sacral plexus by the branch of the fourth nerve, which enters into the formation of the lumbo-sacral cord.

The following are the branches which proceed from the lumbar plexus:—

- | | | |
|------------------------|---|----------------------------------|
| 1. Ilio-hypogastric, | } | derived from 1st lumbar nerve. |
| 2. Ilio-inguinal, | | |
| 3. Genito-crural, | „ | 1st and 2nd lumbar nerves. |
| 4. External cutaneous, | „ | 2nd and 3rd lumbar nerves. |
| 5. Obturator, | „ | 2nd, 3rd, and 4th lumbar nerves. |
| 6. Anterior crural, | „ | 2nd, 3rd, and 4th lumbar nerves. |

The manner in which these nerves spring from the plexus must be carefully studied. The *first lumbar trunk* breaks up into four branches, viz., the ilio-hypogastric, the ilio-inguinal, the upper root of the genito-crural, and a communicating branch to the second lumbar nerve. The *second, third, and fourth lumbar trunks* each divide into an anterior and a posterior division. The three anterior divisions are smaller than the others, and they unite to form the obturator nerve; the three large posterior divisions unite to form the anterior crural nerve. But other branches come off from certain of these divisions. Thus, the lower root of the genito-crural springs from the anterior division of the second lumbar nerve, whilst the two roots of the external cutaneous nerve take origin from the posterior divisions of the second and third lumbar trunks.

The *ilio-hypogastric nerve* emerges from the outer border of the psoas, and crosses the quadratus lumborum obliquely. Reaching the crest of the ilium, it leaves the abdomen by piercing the transversalis muscle. Its further course has already been studied (p. 396). It is distributed by an *iliac branch* to the skin of the gluteal region, and by a *hypogastric branch* to the skin over the lower part of the abdominal wall.

The *ilio-inguinal nerve* is smaller than the ilio-hypogastric, and leaves the psoas almost at the same point. It runs

obliquely downwards and outwards over the quadratus lumborum and the upper part of the iliacus, and disappears from view by piercing the transversalis muscle a little way in front of the ilio-hypogastric. It is distributed to the

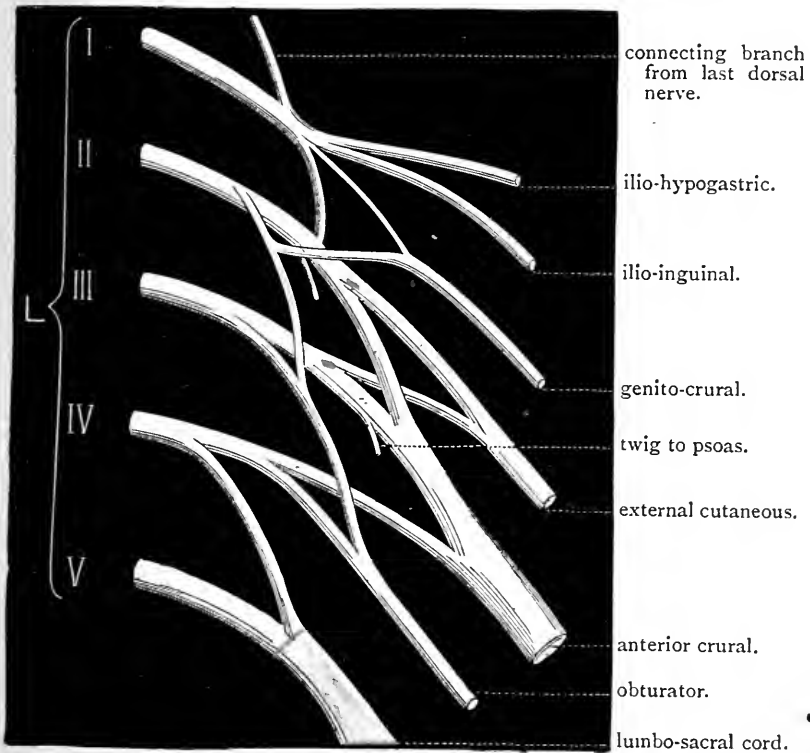


FIG. 133.—Diagram of the lumbar plexus.

integument of the scrotum and the inner aspect of the thigh (p. 382).

The *genito-crural nerve* (*nervus genitofemoralis*) is directed forwards through the psoas, and, appearing upon its anterior aspect, ends by dividing into a *genital* and a *crural* branch. The *genital branch* proceeds downwards and inwards, and, crossing the external iliac artery, reaches the internal abdominal ring. Here it joins the other constituents of the spermatic cord, and, leaving the abdomen, is distributed

to the cremaster muscle. In the female the genital branch is very small, and ends in the round ligament of the uterus and the labium pudendi. The crural branch runs downwards along the outer side of the external iliac artery, and, crossing the deep circumflex iliac artery, passes behind Poupart's ligament. It supplies a limited portion of the integument in front of the thigh.

The *external cutaneous nerve* of the thigh emerges from the outer border of the psoas about its middle, and descends obliquely across the iliacus muscle to the anterior superior spine of the ilium. At this point it leaves the abdomen by passing behind Poupart's ligament. It supplies the skin upon the outer aspect of the thigh.

The *anterior crural nerve* (nervus femoralis) is the largest branch of the plexus. It runs downwards in the interval between the psoas and iliacus, and passes from the abdomen behind Poupart's ligament. It will be observed to give twigs to the iliacus muscle, and a branch to the upper part of the femoral artery.

The *obturator nerve* emerges from the inner border of the psoas, where this muscle reaches the brim of the pelvis, and extends forwards upon the inner wall of the pelvis a short way below the ilio-pectineal line of the innominate bone. At the upper part of the thyroid foramen it joins the artery of the same name, and, escaping from the pelvis, enters the thigh.¹

Lumbo-sacral Cord (truncus lumbosacralis).—This large nervous trunk is formed by the union of the anterior primary division of the fifth lumbar nerve with a branch from the fourth lumbar nerve. It passes downwards over the base of the sacrum into the pelvis, and joins the sacral plexus.

¹ A small nerve, the *accessory obturator*, is occasionally to be found. It may either spring directly from the obturator or from the third and fourth lumbar nerves. It proceeds downwards along the inner side of the psoas, and it enters the thigh by passing over the pubic bone under cover of the pectineus. Here it gives branches to the hip joint, and unites with the obturator nerve. It also occasionally supplies a twig to the pectineus muscle.

The Last Dorsal Nerve.—The anterior primary division of this nerve will be found running outwards in front of the quadratus lumborum, and under cover of the fascia spread over that muscle, along the lower border of the last rib. Near the spine it sends a small offset downwards to the first lumbar nerve, and at the outer border of the quadratus lumborum it pierces the aponeurosis of the transversalis

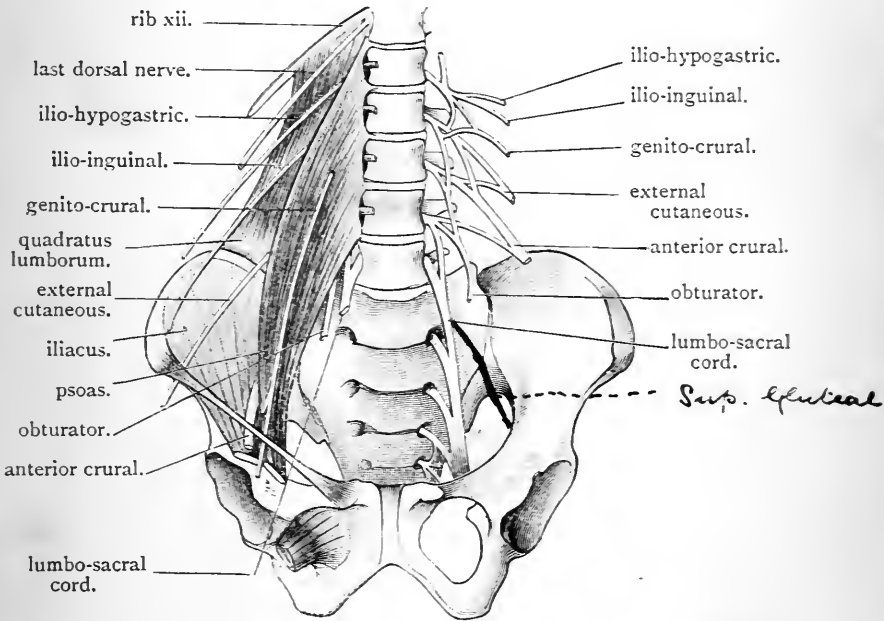


FIG. 134.—The lumbar plexus.

abdominis, and then passes forwards in the abdominal wall between this muscle and the internal oblique. Its course and distribution in the wall of the abdomen have already been described (pp. 384, 396).

Lumbar Arteries (arteriæ lumbales).—These have been traced to the inner border of the psoas. They are now observed to pass backwards behind this muscle to the intervals between the transverse processes of the vertebræ. Here each ends by dividing into a dorsal and an abdominal branch.

The *dorsal branch* runs backwards between the transverse processes, and, after giving a *spinal branch*, which enters the spinal canal through the intervertebral foramen, ends in the muscles and integument of the back.

The *abdominal branches*, with the exception of the first, proceed outwards behind the quadratus lumborum, and are then directed forwards between the abdominal muscles, where they anastomose, above with the intercostal arteries, below with the deep circumflex iliac and ilio-lumbar arteries, and in front with the superior and deep epigastric arteries. The first abdominal branch passes in front of the quadratus lumborum, in company with the anterior primary division of the last dorsal nerve.

The Lumbar Veins (venæ lumbales) accompany the corresponding arteries, and pour their blood into the inferior vena cava. The veins of the left side pass behind the aorta. In front of the transverse processes of the vertebræ, cross branches link together the different lumbar veins on each side of the vertebral column, and form a continuous longitudinal vessel, called the *ascending lumbar vein*. By its upper end this venous trunk is connected with the corresponding azygos vein.

Dissection.—The lower limbs having, by this time, been removed from the trunk, the pelvis may also be detached. Place a ligature around the aorta and vena cava at the level of the bifurcation of the former, and divide them immediately above this point. Then carry the knife through the intervertebral disc which intervenes between the third and fourth lumbar vertebræ, and, having cut the nerves and soft parts, complete the separation of the pelvis from the remainder of the trunk by means of the saw.

PELVIS.

The pelvis is the basin-shaped lower part of the abdominal cavity. It has already been defined as being that portion of the general cavity of the abdomen which lies below and behind the ilio-pectineal lines of the innominate bones. Its walls are, for the most part, rigid

and composed of bone; *behind*, it is bounded by the sacrum and coccyx; whilst *in front* and *laterally*, it is bounded by the two ossa innominata. The bony wall, however, is deficient at certain points; thus, *posteriorly*, there is an interval on each side, between the sacrum and the os innominatum, which is partially filled up by the sacro-sciatic ligaments; again, *laterally*, there is the wide thyroid foramen, which is closed by the thyroid membrane; and, *in front*, there is the gap left by the pubic arch, which is occupied by the triangular ligament of the urethra.¹

Upon the inner aspect of these boundaries of the pelvis there are placed certain muscles. *Posteriorly*, upon the anterior aspect of the sacrum, are the two *pyriformes muscles*; *laterally*, upon the inner aspect of each innominate bone, is the *obturator internus muscle*; whilst, *in front*, lying against the deep surface of the triangular ligament, is the *compressor urethræ muscle*. But, in addition, there is a strong aponeurotic membrane, called the *parietal layer of the pelvic fascia*, which forms a complete lining for the pelvis, and is placed upon the deep surface of these muscles.

The pelvic wall may therefore be regarded as consisting of three strata, each composed of parts which lie in the same morphological plane, viz. :—

1. A bony, ligamentous, and membranous stratum.
2. A muscular stratum.
3. An aponeurotic stratum.

The pelvic cavity is closed below, and separated from the perineum by the *visceral layer of the pelvic fascia*, which passes inwards to the viscera from the parietal layer of the same aponeurosis, and also by the *pelvic diaphragm*, which is placed upon the under surface of the fascia. This diaphragm consists of the two *levatoris ani muscles* and the

¹ Let it be clearly understood that it is the inferior or superficial layer of the triangular ligament to which we refer, and not the "deep layer."

two *coccygei muscles*. The pelvic and abdominal cavities are directly continuous above and in front through the pelvic inlet.

The contents of the pelvic cavity differ in the two sexes; in both, however, the bladder occupies the fore part, and the rectum the back part of the space. The difference is to be found in the generative organs. It is necessary, therefore, to describe the male and female pelvis separately.

MALE PELVIS.

Within the male pelvis we find the following structures:—

- | | | |
|----------------|---|---|
| Viscera. | { | <ol style="list-style-type: none"> 1. The rectum. 2. The bladder, with the lower portion of the ureters, the prostate, and the prostatic portion of the urethra. 3. Vasa deferentia and the vesiculæ seminales. |
| Blood Vessels. | { | <ol style="list-style-type: none"> 1. The internal iliac vessels and their branches. 2. The superior hæmorrhoidal vessels. 3. The middle sacral vessels. 4. Certain venous plexuses in connection with the viscera. |
| Nerves. | { | <ol style="list-style-type: none"> 1. The sacral plexuses and their branches. 2. The obturator nerves. 3. The pelvic part of the sympathetic. |

The peritoneum dips into the pelvis, and gives a partial covering to the rectum and the bladder.

General Position of Viscera.—The *rectum* occupies the posterior part of the cavity. It takes a curved course downwards upon the sacrum and coccyx, to the concavity of which a portion of it is adapted. The *bladder* is placed in the fore part of the cavity, and lies against the pubic bones. Behind the bladder, between it and the rectum, are the *vesiculæ seminales* and the *vasa deferentia*, whilst embracing its neck is the *prostate*. At present, however, the bladder and the rectum are the only viscera visible.

Peritoneum.—The peritoneum is continued from the

posterior wall of the abdomen into the pelvis. Here it comes into relation with the rectum, to which it gives a partial covering. The first part of the rectum it invests completely, and connects by means of a fold called the *meso-rectum* to the anterior surface of the sacrum. Gradually it leaves the gut, first disappearing from its posterior surface, then from its lateral, and finally from its anterior surface, and passes on to the lower and back part of the bladder. The point at which the peritoneum departs from

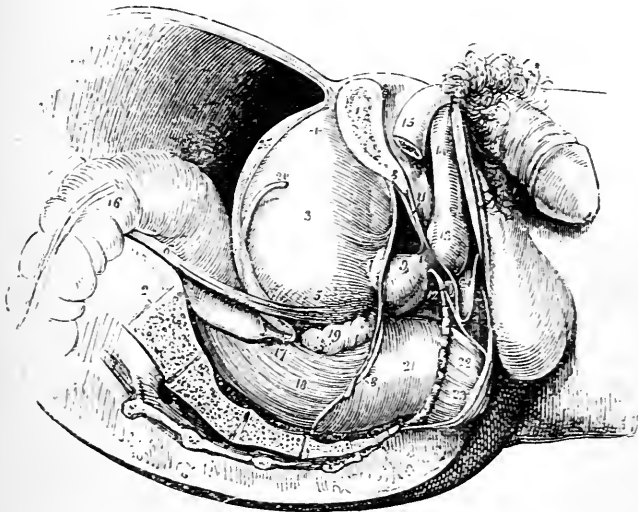


FIG. 135.—Side view of pelvic viscera. Subject in the horizontal position.—(From WILSON'S *Anatomy*.)

- | | |
|---|---|
| <ol style="list-style-type: none"> 1. Section of pubic bone. 2. Section of sacrum and coccyx. 3. Bladder. 4. Apex of bladder. 5. Base of bladder. 6. Ureter. 7. Neck of bladder. 8. Visceral pelvic fascia. 9. Prostate. 10. Membranous portion of urethra. 11. Parietal pelvic fascia. 12. Cowper's gland. 13. Bulb of penis. 14. Corpus Spongiosum. | <ol style="list-style-type: none"> 15. Right crus of penis. 16. Rectum (first part). 17. Recto-vesical pouch of peritoneum. 18. Rectum (second part). 19. Right seminal vesical. 20. Right vas deferens. 21. Pelvic fascia covering rectum. 22. Levator ani. 23. Sphincter ani externus. 24. Interval between the triangular ligament and the fascia of Colles. 25. Line of reflection of the peritoneum from the side of the bladder. |
|---|---|

the rectum may be stated to be about three inches above the anus, or, in other words, along a line connecting the middle points of the two vesiculæ seminales—somewhat less than an inch from the base of the prostate. This is a point, however, which is subject to variation. It is not uncommon to find the peritoneum passing lower down; and, in rare instances, it may even be seen to reach the base of the prostate before it is continued on to the bladder.

The peritoneum now ascends upon the back of the bladder, and, reaching its apex, is conducted from it by the urachus on to the posterior aspect of the anterior abdominal wall. On each side of the viscus it extends outwards as far as the obliterated hypogastric artery, along the line of which it quits the bladder, and is continued round the pelvic wall.

Recto-vesical Pouch.—As the peritoneum passes from the posterior wall of the pelvis to the back of the bladder, it is raised in the form of two semilunar ridges or folds by the obliterated hypogastric arteries. These folds extend forwards one on each side of the rectum, and they limit laterally a deep peritoneal pouch or recess between the rectum and bladder, which, from its position, is called the *recto-vesical pouch*.

False Ligaments of the Bladder.—Wherever the peritoneum leaves the bladder, to reach the pelvic or abdominal wall, it is termed “a false ligament.” Of these, *five* are described—viz. two posterior, two lateral, and one superior.

The *posterior false ligaments*, or *recto-vesical folds*, are the two semilunar folds which limit the recto-vesical pouch laterally. They are produced, as we have seen, by the peritoneum being stretched over the obliterated hypogastric artery as it passes forwards to reach the bladder. Within each of these folds future dissection will reveal, in addition to the impervious hypogastric artery, the ureter and the superior vesical artery accompanied by some minute nerves.

The *lateral false ligament* is the name given to the peritoneum as it passes from each side of the bladder to the wall of the pelvis and the iliac fossa. This reflection has been seen to take place along the line of the obliterated hypogastric artery as it lies upon the lateral aspect of the bladder.

The *superior false ligament* is the portion of peritoneum which is continued from the summit of the bladder on to the posterior aspect of the anterior abdominal wall. It is led away from the viscus by the urachus and the two obliterated hypogastric arteries.

Hypogastric Nervous Plexus (plexus hypogastricus).—This is the lowest of the three great prevertebral plexuses, and is the main source from which the pelvic viscera are supplied with nerves. It is a dense flattened plexus, which lies in front of the body of the last lumbar vertebra in the interval between the two common iliac arteries. *Superiorly*, it is joined by numerous large filaments, which proceed downwards from the aortic plexus and the lumbar ganglia. *Inferiorly*, it ends by dividing into two lateral parts which are continued downwards on the back wall of the pelvis, and along the inner side of the internal iliac vessels to the pelvic plexuses.

Pelvic Fascia.—Now is the time to study the pelvic fascia, and it is a work which will require some care and patience on the part of the dissector. Much of the difficulty which is involved in the study of the pelvic fascia will be removed if the student will constantly keep before him two facts regarding it, viz., (1) That it constitutes a continuous lining for the inner surface of the pelvic wall. (2) That it sends across the pelvic cavity a layer which acts as a partition between the pelvis proper and the perineum. The lining-portion of the fascia may be termed the *parietal part*, and the partition-portion the *visceral part*. If the pelvis contained no viscera, the arrangement would be exceedingly simple, and might be represented diagrammatically as in Fig. 136.

The visceral layer, however, comes into relation with the viscera, and the connections which it forms with these give rise to the complexity of the membrane.

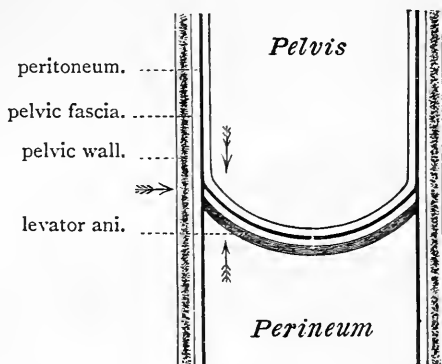


FIG. 136.

In order to obtain a proper display of the pelvic fascia, it is necessary to dissect it from three different aspects, viz, (1) From above; (2) From below; (3) From the side. The arrows in the diagram indicate the directions in which the dissection must be made. Seeing that the first part of the rectum lies to the left of the mesial plane it is best to make the dissection on the right side.

Dissection from above.—This dissection is undertaken with the view of exposing the pelvic aspect of the fascia. Strip the peritoneum from the *right side* of the pelvic wall by means of the fingers. It should also be partially removed from the same side of the bladder. On carefully scraping away the loose fatty extra-peritoneal tissue with the handle of the knife, or better still, with the finger nails, the pelvic fascia will be brought into view. To expose it in front, the bladder must be forcibly dragged backwards from the pubic bones, and the intervening areolar tissue taken away. At this point the pelvic fascia will not be encountered until we have descended to within half an inch or so from the lower end of the symphysis. Here it is so thick that it is beyond injury so long as we work with the fingers, or the handle of the knife, but laterally it is thin, and great care must be taken. The extra-peritoneal tissue which surrounds the internal iliac vessels must also be removed, and the relation of their parietal branches to the fascia made out.

Dissection from below.—The object of this dissection is to expose the perineal surface of the fascia. The pelvis must be placed so that

the outlet looks upwards. The fat having previously been removed from the ischio-rectal fossa, divide the inferior hæmorrhoidal vessels and nerves if they are still present, and then raise the levator ani muscle from the side of the rectum. To do this the muscle must be cut transversely about an inch above the anus. At first the levator ani will be observed to rest upon the side of the gut, separated from it, however, by a well-marked layer of fascia (the rectal layer of pelvic fascia), but, as the dissector proceeds with the dissection, the muscle

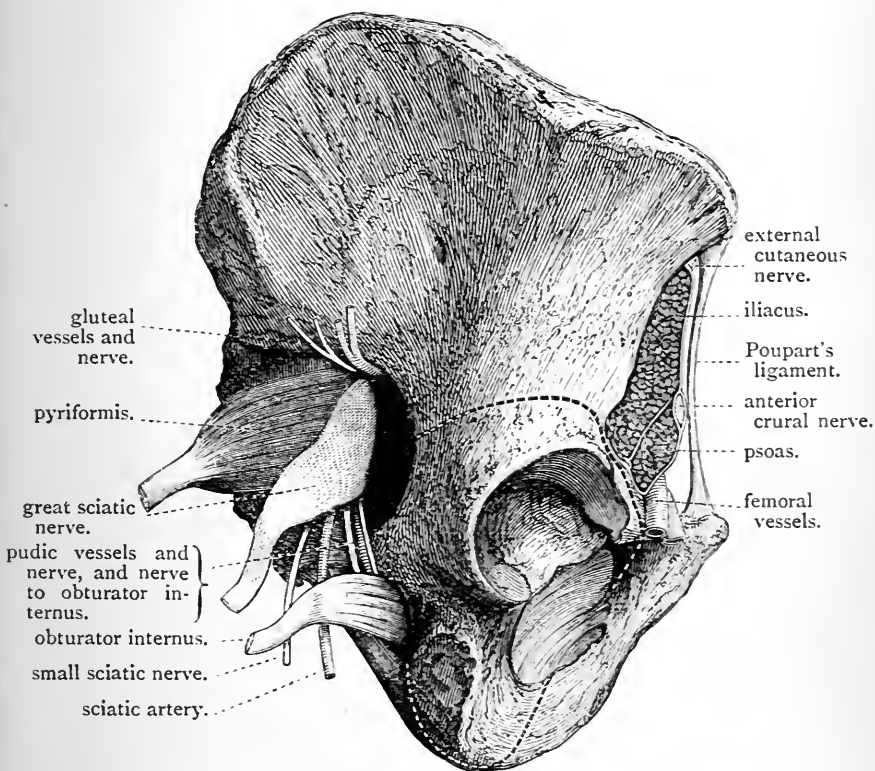


FIG. 137.—The dotted lines indicate the directions in which the saw must be carried through the bone.

will be found higher up to be in close contact with the under surface of the visceral layer of the pelvic fascia. Lastly, he will come to the line of origin of the muscle from the pelvic fascia, *i.e.*, the line along which the visceral layer leaves the parietal layer—and here he must stop.

In the dissection of the ischio-rectal fossa (p. 342), the parietal pelvic fascia was exposed and recognised as forming the outer wall of the space. The entire inner surface of the parietal portion, both in its

pelvic and perineal parts, is, therefore, now displayed, and, if the levator ani be drawn outwards and the pelvis held up to the light, the visceral pelvic fascia will be seen passing inwards from the parietal part of the aponeurosis to the viscera.

But it is also necessary to obtain a view of the outer aspect of the parietal pelvic fascia, and, for this purpose, the following dissection must be made.

Dissection from the side.—To reach the pelvic fascia from this

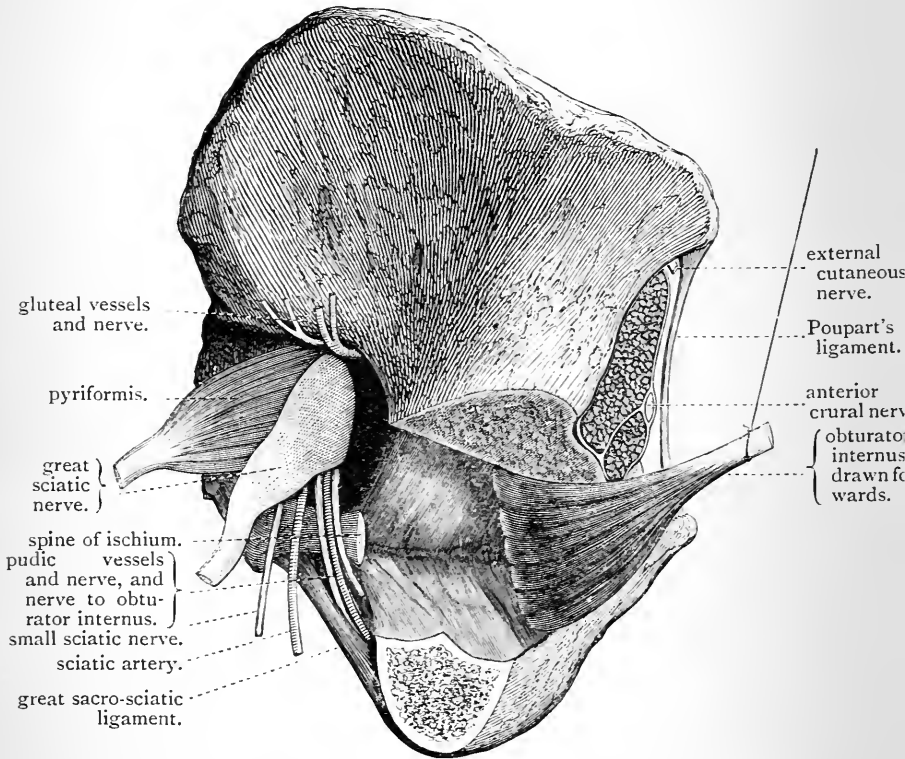


FIG. 138.—The white line of the pelvic fascia is seen in shadow.

aspect a portion of the bony wall of the pelvis must be removed, and the obturator internus muscle raised from its position. The outer aspect of the innominate bone must first be thoroughly cleaned, by removing the remains of the obturator externus muscle and all adhering portions of muscle from the pubic and ischial bones; carefully preserve, however, the obturator nerve and artery as they emerge from the upper part of the thyroid foramen. The membrane which closes the thyroid foramen may also be taken away, with the exception of a small portion

immediately adjoining the canal under the pubic bone, through which the obturator vessels and nerve emerge. This will expose a part of the outer surface of the obturator internus muscle, and the parietal pelvic fascia will be observed arching over the border of the muscle to join the thyroid membrane below the obturator vessels. Next, define the great and small sacro-sciatic foramina and the structures which emerge from and enter the pelvis through these apertures.

The section of the bone may now be made. This simply consists in taking away that portion of the innominate bone which bears the acetabulum. The first step is to saw through the spine of the ischium, close to its base. The bone must then be sawn through above and below the acetabulum—(1) the first cut should pass through the ischial tuberosity from the lower end of the thyroid foramen to the lower end of the small sciatic notch; (2) the second cut should extend from the upper part of the thyroid foramen to the upper part of the great sciatic notch. The direction in which the saw is to be carried in making these sections is indicated by dotted lines in Fig. 137. In the case of the second section, the direction will be somewhat influenced by the depth of the acetabulum. In no case, however, is it wise to enter the saw lower than the anterior inferior spine of the ilium. This is the point at which the cut should be commenced. In all probability it will be found necessary to complete this section in front by means of the bone pliers, as there are many cases in which it is impossible to bring the saw out at the two points indicated. The greatest care must be taken not to break the ascending ramus of the pubic bone. In carrying out the first or lower section, the dissector will meet with no difficulty whatever.

The section of bone being successfully performed, the detached portion should be raised from the subjacent obturator internus. The fibres of this muscle take origin from the deep surface of the bone, and it will thus be necessary to use the knife in effecting the separation. Lastly, clean the obturator internus, and, grasping its tendon, draw it gently outwards and upwards, as in Fig. 138. The outer aspect of the parietal pelvic fascia comes into view. By this dissection the student is afforded a striking illustration of the three morphological planes, the bony, muscular, and the aponeurotic, referred to on p. 547, as entering into the composition of the pelvic wall.

Description of the Pelvic Fascia.—The dissector has already taken note of a continuous fascia lining the interior of the abdomen proper, and placed between the muscles on the one hand, and the extra-peritoneal fatty tissue and peritoneum on the other. In relative position the pelvic fascia is identical with the abdominal fascia, and the visceral layer of the former, which passes inwards upon the

upper surface of the pelvic diaphragm, may be compared with the thin cellular layer which clothes the under surface of the abdomino-thoracic diaphragm; the one completes the aponeurotic wall of the great abdominal cavity below, whilst the other completes it above. But, whilst this is the case, it must be borne in mind that the abdominal and pelvic fasciæ are only directly continuous with each other over a very limited part of the posterior portion of the ilio-pectineal line.

Parietal Pelvic Fascia.—The parietal or lining portion of the pelvic fascia must be examined from three different points of view, viz.—(1) posteriorly; (2) laterally; (3) anteriorly. On the *posterior wall* of the pelvis, the parietal pelvic fascia is of little importance. It is simply represented by a thin cellular membrane, covering the anterior aspect of the pyriformes muscles, and the sacral plexus of nerves. It is in consequence frequently described under the name of the *fascia of the pyriformis*.

Laterally, it is strong and dense, and in this situation it covers the inner surface of the obturator internus muscle. Superiorly, it is attached for a distance of about one inch to the back part of the ilio-pectineal line, where it will be observed to be directly continuous with the fascia iliaca, which is inserted into the same line; but the attachment of both to the bone is weak; so that by passing a probe down behind the latter the continuity of the two membranes can be determined. In front of this, the line of attachment of the parietal pelvic fascia leaves the ilio-pectineal line; it descends obliquely along the superior border of the obturator internus muscle to the upper margin of the thyroid foramen, and, opposite the groove on the under surface of the ascending ramus of the pubic bone, there is a break in its bony attachment. At this point it turns over the margin of the obturator internus, and, joining the thyroid membrane on the other side, converts the groove into a canal. From this onwards the line of attachment gradually sinks upon the posterior aspect of the body of the pubis, and, in front, it is found as low as the inferior

border of the symphysis. There is thus a considerable part of the inner surface of the pelvis below the level of the ilio-pectineal line, and the crest of the pubis devoid of fascial lining. Here no continuity can be shown to exist between the iliac and pelvic fasciæ, except through the medium of the periosteum. This part of the pelvic wall is therefore merely lined by extra-peritoneal tissue and the peritoneum.

From the line of attachment thus indicated the parietal pelvic fascia descends upon the inner or deep surface of the obturator internus muscle, and is attached inferiorly to the tuberosity of the ischium through the medium of the falciform edge of the great sciatic ligament, and also behind this to that ligament itself. Traced forwards, it will be found to be fixed to the rami of the pubis and ischium (*i.e.*, the side of the pubic arch) in front of the obturator internus. In this manner, therefore, it may be said to have an attachment to the pelvic outlet from the symphysis to the sacrum. When followed backwards, the fascia will be noticed to pass over and close the great sacro-sciatic foramen, and then to turn inwards at an angle to reach the parts on the front of the anterior aspect of the sacrum, or, in other words, to form the *fascia of the pyriformis muscle*.

From the close relation which this lateral piece of the parietal pelvic fascia presents to the obturator internus muscle—covering it and having its extent very nearly determined by the area occupied by the muscle—it is very commonly called the *obturator fascia*.

We have previously seen that the parietal pelvic fascia gives off from its inner surface a layer called the *visceral layer*, which proceeds inwards towards the viscera, and acts as a partition between the pelvis and the perineum. The line along which this takes origin extends around the pelvic wall, from the spine of the ischium behind to a point in front, a little above the level of the lower end of the symphysis. This line receives the name of the *white line*. It can always be seen by an examination of the outer surface

of the pelvic fascia (Figs. 138 and 139). If the white line be inspected from the inside of the pelvis by pulling the bladder well over to the opposite side, it will be noticed that the fascia is specially thickened along this line by a band which springs from the back of the pubis, and which may be traced backwards to the ischial spine. But the

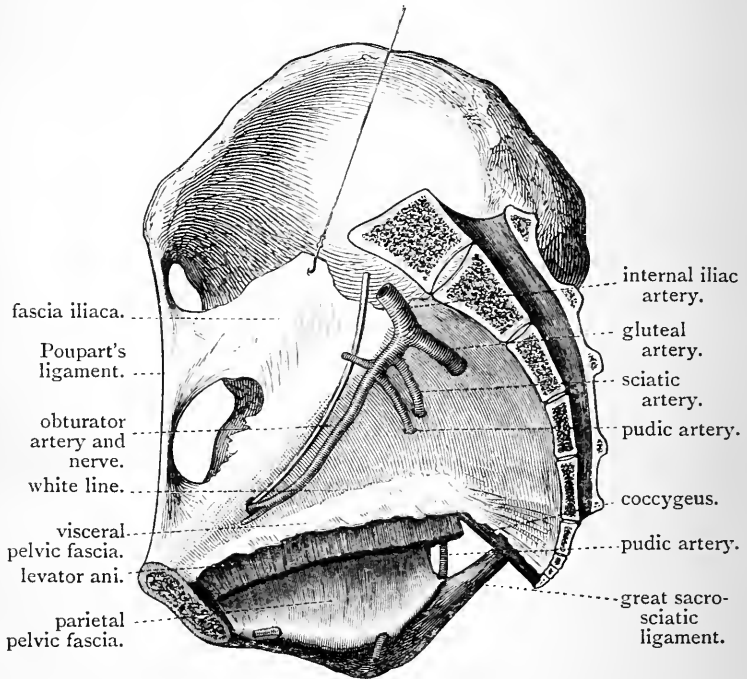


FIG. 139.

“white line” has a still wider significance. It also indicates the fascial origin of the levator ani muscle. It must be admitted, however, that in many cases the fibres of this muscle pass upwards beyond the “white line,” and separate the visceral and parietal layers of the pelvic fascia from each other for a variable distance.

Above the “white line,” the parietal pelvic fascia is in relation to the pelvic cavity, and its inner surface is clothed by peritoneum; below the line, the parietal pelvic fascia

belongs to the perineum, and forms the outer wall of the ischio-rectal fossa, where its inner surface is in relation to the fat which fills up this space. About an inch and a half above the tuberosity of the ischium, the internal pudic vessels and nerves pass forwards in a tube formed by this fascia (p. 359), which receives the name of Alcock's canal.

The student has now examined the parietal pelvic fascia posteriorly and laterally. He must next study its disposition *in front* of the pelvis—*i.e.*, opposite the pubic arch.

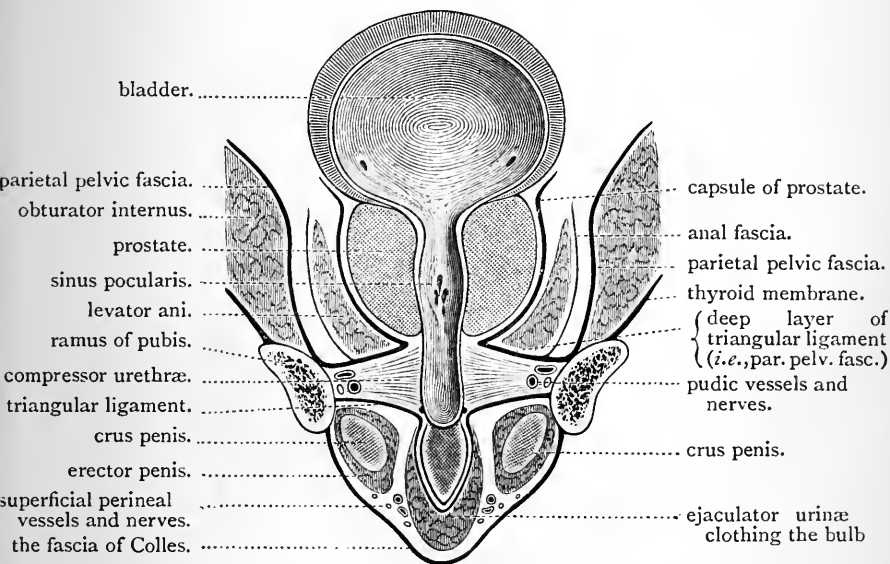


FIG. 140.—Diagram. Vertical section through the pubic arch to show the two perineal compartments and their contents.

He must not suppose, because it has an attachment to the side of the pubic arch, that it stops there. It is continued onwards behind the compressor urethræ muscle, across the arch, and in this situation it is generally known as *the superior or deep layer of the triangular ligament*. This consists of two lateral halves, each of which on reaching the urethra sweeps backwards around the anterior border of the levator ani, and joins the visceral layer (Fig. 140).

Inferiorly, it is attached to the base of the triangular ligament, which, as we have seen, is on the same morphological plane as the bone; consequently this attachment is quite in keeping with the attachment of the fascia further back, to the tuberosity of the ischium, and to the sciatic ligaments.

Visceral Layer of Pelvic Fascia.—In the greater part of its extent the visceral pelvic fascia springs from the inner surface of the parietal pelvic fascia, along the *white line*. In front, however, it has an attachment to the back of the

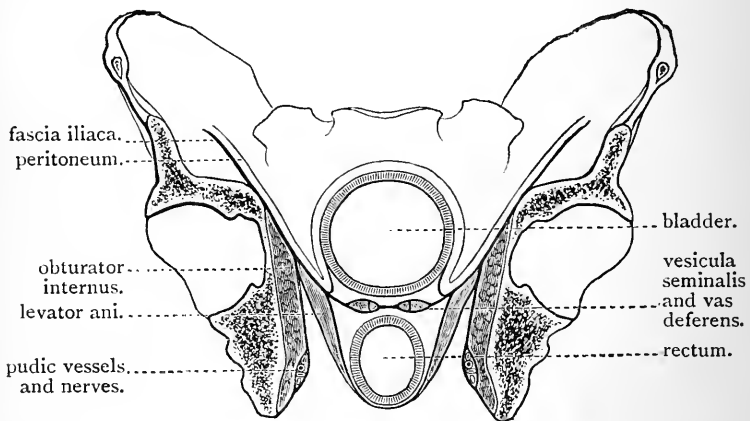


FIG. 141.

body of the pubic bone *above* the attachment of the parietal layer. It is from the portion of bone between these layers that the anterior fibres of the levator ani arise. The visceral pelvic fascia now passes inwards upon the pelvic surface of the levator ani muscle to the side of the prostate and the base of the bladder, and divides into *three layers* termed—(1) the vesical; (2) the recto-vesical; and (3) the rectal. These have different connections, according to the point at which they are examined.

In the region of the bladder (Fig. 141), the splitting of the visceral pelvic fascia takes place at the outer margin of the vesicula seminalis, and the *vesical*, or *highest layer*, turns

upwards upon the lower part of the side of the bladder, and constitutes its "*lateral true ligament.*" Upon the wall of this viscus the vesical prolongation gradually thins away until it is ultimately lost upon its coats. The *recto-vesical*, or *intermediate layer*, is carried inwards between the bladder and the rectum, and, in the mesial plane, it becomes continuous with the corresponding layer of the opposite side. As it proceeds inwards it splits to enclose and form a capsule for the vesicula seminalis and the vas deferens. The *rectal*, or *lowest layer*, is prolonged downwards upon

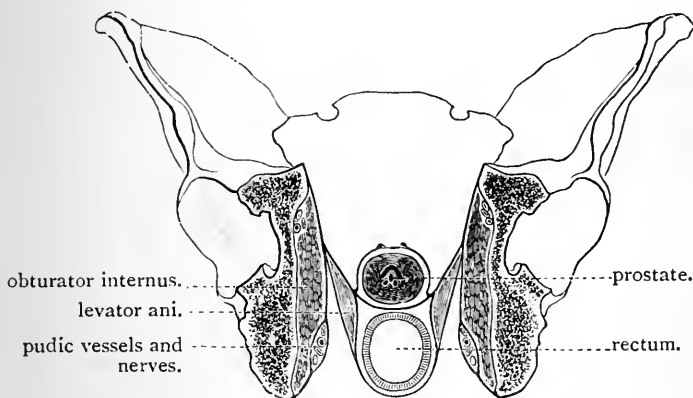


FIG. 142.

the side of the rectum—between it and the levator ani muscle—and then, turning backwards behind the gut, it becomes continuous with the same layer of the other side. The rectum is thus enclosed in a sheath formed by the recto-vesical and rectal layers of the pelvic fascia.

Proceeding forwards to the region of the prostate and the neck of the bladder, the connections of the three layers will be found to be somewhat altered. Substitute the prostate for the bladder, and carry the vesical layer over it, so as to meet its fellow of the opposite side, and the arrangement will be understood (Fig. 142). The prostate is thus enclosed in a capsule, the walls of which are exceedingly strong and dense. But at this point the

lower part of the rectum passes backwards to reach the surface, and as it does so it pushes itself through the rectal layer, and carries downwards upon its walls a thin tubular prolongation of the rectal layer of the fascia (Fig. 143).

The arrangement of the visceral pelvic fascia in front of the pelvis must next be studied. The student has already noted that here the visceral layer has a direct attachment to the posterior aspect of the body of the

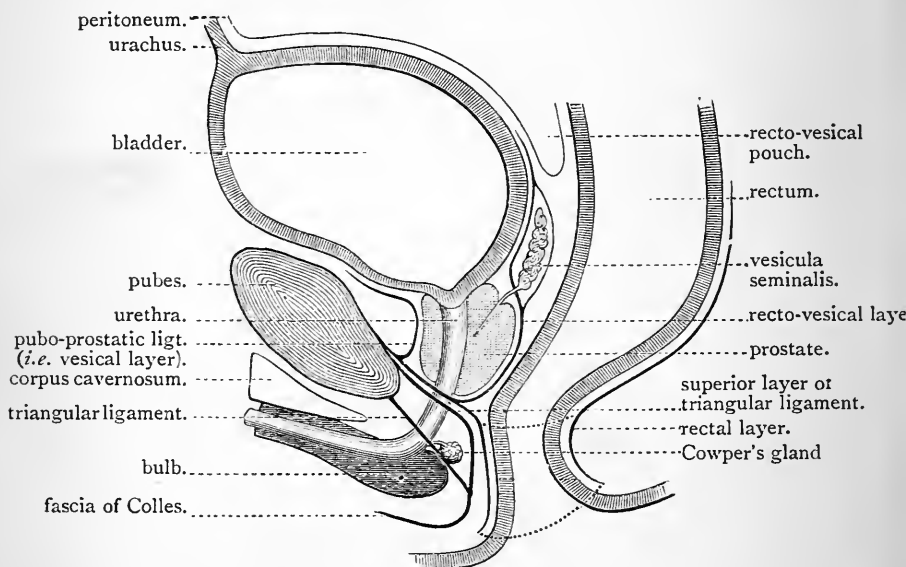


FIG. 143.—This diagram represents the pelvic fascia in section a short distance to the outer side of the mesial plane, beyond the point at which the parietal and visceral layers blend; hence both are seen in section.

pubic bone a short distance above the lower end of the symphysis, and above the bony origin of the anterior fibres of the levator ani, and the attachment of the parietal pelvic fascia. Draw the bladder backwards and look down between it and the pubic bones. The *vesical layer* will be seen to pass backwards on each side of the symphysis, in the form of a strong, rounded, and cord-like band, which proceeds over the anterior surface of the

prostate to the bladder. These cord-like bands are the *anterior true ligaments of the bladder*, or, if they are looked at merely in their relations to the pubis and the prostate, they are called the *pubo-prostatic ligaments*. In the middle line there is a very evident interval or recess between them, so deep in some cases that the tip of the little finger can be introduced into it. The dorsal vein of the penis passes backwards in this groove. The fascia is not deficient at the bottom of this furrow. It is prolonged from one side to the other over the dorsal vein, so as to hide it from view. In the accompanying diagram (Fig. 143), which represents a sagittal section through the pelvis a short distance to the outer side of the mesial plane, the attachment of the visceral layer of the pelvic fascia to the back of the pubic bone, a short distance above the attachment of the parietal pelvic fascia (superior layer of the triangular ligament), is exhibited. The anterior true ligament of the bladder is seen passing backwards from the visceral layer in front of the prostate, whilst the recto-vesical layer is shown passing below the prostate, and then between it and the rectum. In the interval between this layer and the superior layer of the triangular ligament (parietal pelvic fascia) is placed the anterior border of the levator ani (not represented in the diagram), around which these two layers become continuous (*v.* Fig. 142). In this manner the capsule of the prostate is brought into anatomical continuity with the superior or deep layer of the triangular ligament on either side of the urethra.

Anal Fascia.—It is necessary, before leaving the pelvic fascia, to take notice of a layer which has already been studied in connection with the perineum—*viz.*, the *anal fascia*. This is a thin and delicate aponeurosis which covers the perineal or lower surface of the levator ani, and which is connected with the pelvic fascia along the *white line* (Fig. 141). In consequence of this attachment, it is usually described as a distinct layer of the pelvic fascia, whereas it is merely the aponeurosis of the muscle. The levator ani is thus enclosed between two aponeurotic

lamellæ—viz., the visceral pelvic fascia and the rectal fascia above, and the anal fascia below.

Relation of Blood-Vessels and Nerves to the Pelvic Fascia.—The blood-vessels of the pelvis are placed on the peritoneal aspect of the fascia. It follows, therefore, that the parietal branches of the internal iliac artery, in passing out from the pelvis, pierce the membrane, and they always carry with them a prolongation from it which blends with their sheaths. There is an exception to this rule—viz., the *obturator artery*. It has been observed to pass over the upper border of the parietal pelvic fascia. The nerves, on the other hand, lie *outside* or *behind* the fascia, and do not require to pierce it in emerging from the pelvis. This difference in the relation of the nerves and blood-vessels can be well studied by looking at the fascia as it passes over the great sacro-sciatic foramen.

The arrangement of the pelvic blood-vessels with reference to the lining fascia is a matter of some practical interest. The margins of the apertures in the fascia through which the vessels pass are usually strengthened by some encircling fibres. Sciatic hernia consists in the escape of a portion of gut through the sciatic notch. It makes its way through the parietal pelvic fascia by means of one of these apertures. It may be placed above or below the pyriformis muscle. In the former case, it escapes through the aperture of the gluteal artery; in the latter case, it forces its way through the aperture of the sciatic or internal pudic artery.

A hernia may also occur through the thyroid foramen (obturator hernia). In this case, the gut follows the obturator artery over the upper border of the parietal pelvic fascia through the canal that is formed between this and the under surface of the pubic bone.

Dissection.—The *right* innominate bone should now be removed, in order that a side view of the pelvic viscera may be obtained. The first step to take is to divide the visceral layer of the pelvic fascia from behind forwards, about half an inch from the white line. Next, saw through the pubic bone, half an inch external to the symphysis, and divide the great sacro-sciatic ligament close to the sacrum. The further separation of the bone should be effected at the sacro-iliac articulation by means of the saw.

In connection with the detached innominate bone, a good view may be obtained of the fascial origin of the levator ani (Fig. 139, p. 558), and also of the origin of the obturator internus. It is better, however,

to defer the description of these muscles until the viscera are removed.

The dissector should, in the next place, turn his attention to that portion of the visceral layer of the pelvic fascia which has been left attached to the viscera. Follow it as far as possible in its reflections upon them, but preserve intact the capsule of the prostate. When its connections have been recognised, remove what remains of the fascia on the right side, and clean the viscera, taking care not to injure the blood-vessels and nerves which supply them. This dissection will be facilitated if the rectum be moderately stuffed with tow, and the bladder partially inflated with air. In the case of the rectum, first cleanse it thoroughly by allowing water from the tap to run freely through it, and, in the case of the bladder, pass a staff into it through the urethra, and having placed a ligature around the penis, introduce the air through a blow-pipe thrust into one of the ureters.

When the vesical layer of fascia is divided, a plexus of large veins will be discovered upon the bladder. These veins ramify over the entire organ, but are especially numerous towards the base and in the angle between the vesical and recto-vesical layers of pelvic fascia. These veins constitute what is termed the *vesical plexus*.

The vesiculæ seminales must be carefully defined, and the obliterated hypogastric artery and the vas deferens followed upon the side of the bladder.

Rectum (intestinum rectum).—This is the terminal part of the great intestine. It begins at the left sacro-iliac articulation, where it is continuous with the sigmoid flexure, and ends on the surface a short distance in front of the coccyx, in an orifice termed the *anus*. Its length is about eight inches, and it does not present a uniform diameter throughout. At first, its calibre corresponds with that of the lower part of the colon, but, as it descends, it gradually dilates. A short distance above its termination it again contracts to form a narrow passage which leads to the anus. In its course through the pelvis, the rectum is adapted to the concave anterior surface of the sacrum and coccyx, and is divided, from changes in its direction and connections, into three parts. This subdivision is purely arbitrary, and merely adopted for the purpose of rendering the description more exact.

The *first part* of the rectum, about three and a half inches long, extends from the left sacro-iliac articulation obliquely downwards, backwards, and to the right, and ends

in the mesial plane upon the body of the third sacral vertebra. In its upper part this portion shows sacculations similar to those of the colon; but, as it proceeds downwards in the pelvis, the three bands of longitudinal fibres begin to spread out upon its walls, and the gut assumes a more uniform appearance. The first part of the rectum is completely clothed by peritoneum, and is connected to the

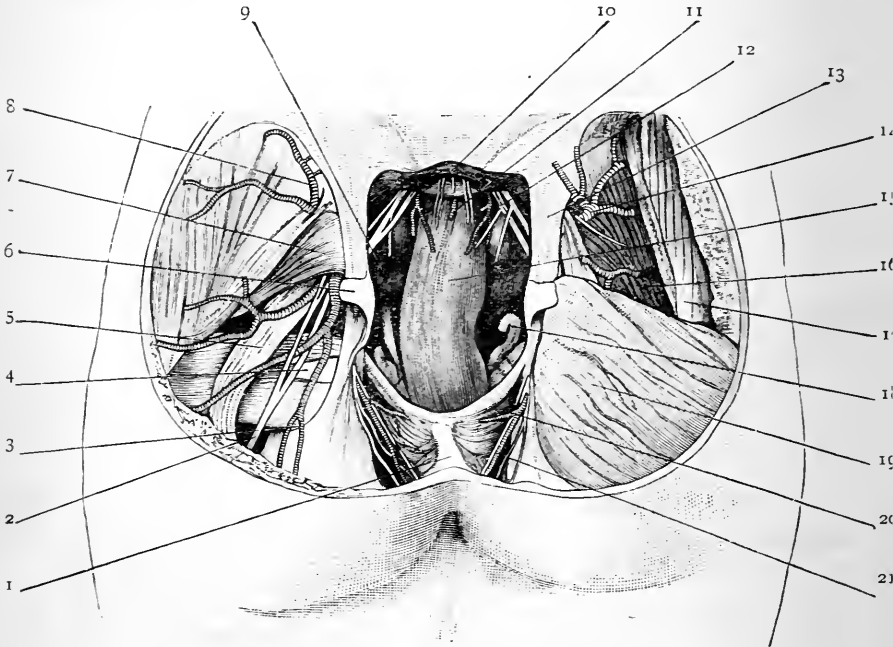


FIG. 144.—Dissection of the rectum from behind by Mr. C. Paton. A portion of the sacrum has been removed.

- | | |
|--|---|
| 1. Ano-coccygeal body. | 11. Middle sacral artery. |
| 2. Small sciatic nerve. | 12. Lateral sacral artery. |
| 3. Sciatic artery. | 13. Great sciatic ligament. |
| 4. Obturator internus. | 14. Gluteal artery. |
| 5. Great sciatic nerve. | 15. Rectum. |
| 6. Small sciatic ligament. | 16. Gluteus medius. |
| 7. Pyriformis. | 17. Gluteus maximus |
| 8. Superficial gluteal artery. | 18. Vasa deferentia and seminal vesicles. |
| 9. Recto-vesical reflection of peritoneum. | 19. Gluteus maximus. |
| 10. Filum terminale. | 20. Levator ani. |
| | 21. Hæmorrhoidal vessels and nerves. |

anterior surface of the sacrum by a short peritoneal fold called the meso-rectum. Between the two layers of this fold, the superior hæmorrhoidal artery will be observed descending to supply the gut. The first part of the rectum is in relation posteriorly to the sacrum, the left pyriformis muscle, and the left sacral plexus of nerves, separated from them, however, by the peritoneum. In relation to its left side are the left ureter and branches of the left internal iliac vessels. *In front* it is separated from the posterior surface of the bladder by the recto-vesical peritoneal pouch, and, it may be, by some coils of small intestine contained within this pouch.

The *second part* of the rectum is usually the most dilated portion of this section of the gut, and measures about three inches in length. It occupies a median position and extends from the third piece of the sacrum to a point fully an inch beyond the tip of the coccyx. Here the rectum bends backwards upon itself and enters upon its third stage.

In its upper two-thirds the second part of the rectum is adapted to the anterior surface of the sacrum and coccyx, and is firmly fixed in position. It consequently describes a curve, the concavity of which is directed forwards. Beyond the coccyx the lower part of this portion of the rectum is supported behind by a dense mass of tissue, partly muscular, and partly fibrous, which fills up the interval between the coccyx and the anus, and to which the term of *ano-coccygeal body* is applied (Symington) (Fig. 144, 1). The relations which the peritoneum presents to the second part of the rectum are of high importance. It clothes the gut at first both on its anterior and lateral aspects, leaving its posterior surface bare; soon, however, the peritoneum passes away from the sides of the gut, and finally, about one inch above the base of the prostate, it quits the rectum altogether and is reflected on to the bladder. This reflection forms the bottom of the recto-vesical pouch of peritoneum, and it is usually placed opposite the middle of the fifth piece of the sacrum. Below the

reflection of the peritoneum, the anterior surface of the rectum is in relation to the base of the bladder and the posterior surface of the prostate. It must be borne in mind, however, that the recto-vesical layer of the pelvic fascia extends across the pelvis between the gut and these viscera, and that only a small triangular portion of the bladder is in close relation to the rectum. Interposed between the gut and the bladder there are on each side of this area the seminal vesicle and the vas deferens.

Lying, as it does, between the bladder and prostate in front, and the concavity of the sacrum and coccyx behind, the second part of the rectum when empty and collapsed has its anterior wall pressed against its posterior wall. In this condition, therefore, its lumen appears in transverse section in the form of a transverse slit. Behind the apex of the prostate, at the point where the gut bends so as to enter upon its third stage, the anterior wall in the distended condition of the rectum frequently shows a slight bulging or *cul-de-sac* which gains a lower level than the prostate.

The *third part* of the rectum is the narrow passage which leads from the second part of the gut to the anus. Except during the passage of fæces it is always tightly closed by the application of its lateral walls to each other. In coronal sections of the pelvis, therefore, it appears in the form of a longitudinal slit (Fig. 145). It is very different in its surroundings and functions from the other parts of the rectum, and may appropriately be distinguished by the special term of *anal canal* (Symington).

The anal canal begins at the apex of the prostate and proceeds downwards and backwards to the anal orifice. In length it measures from one to one and a half inches. It is totally destitute of peritoneum, but it is supported and clothed by a prolongation from the rectal layer of the pelvic fascia. It is closely surrounded by strong muscles which keep constant guard over it, and only allow its lateral walls to separate from each other during defæcation. Thus, the internal sphincter encircles it in very nearly its whole length; the external sphincter surrounds the anal orifice and lower part of the wall; whilst above this we have on

each side support given to the walls of the anal canal by the levator ani. The membranous portion of the urethra and the bulb of the penis are placed in front of the anal

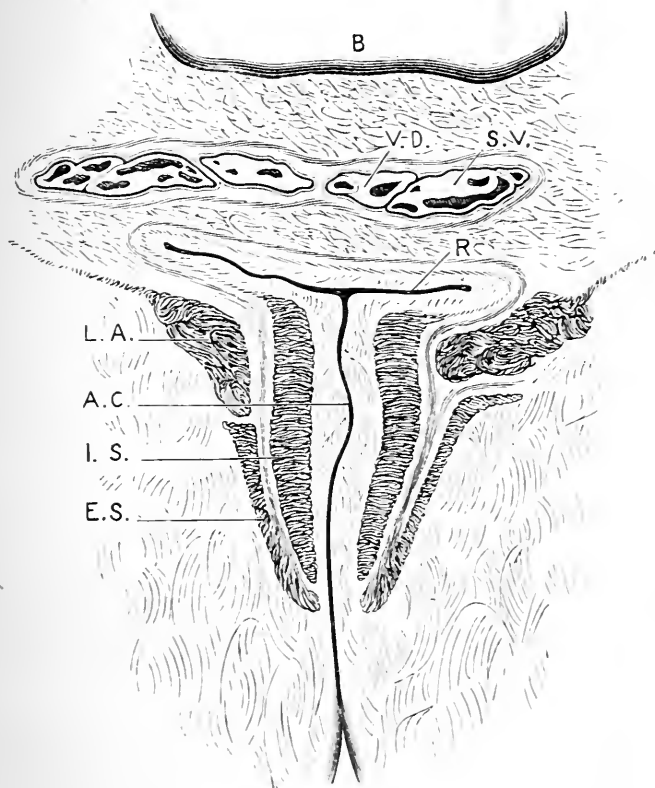


FIG. 145.—Coronal section through the whole length of the anal canal (Symington).

- | | |
|---|--|
| <p>B. Bladder.
V.D. Vas deferens.
S.V. Seminal vesicle.
R. Terminal portion of the second part of the rectum (note the apposition of its anterior and posterior walls).</p> | <p>L.A. Levator ani.
A.C. Anal canal (note the apposition of its lateral walls).
I.S. Sphincter ani internus.
E.S. Sphincter ani externus.</p> |
|---|--|

canal, but, owing to the backward inclination of the gut, these are not in contact with it, but are separated from it by an angular interval.

The staff, which has been introduced into the bladder, being held in the middle line, the student should pass the forefinger of the right hand into the rectum, and endeavour to distinguish by touch the parts in relation to the anterior aspect of the gut. Passing beyond the bulb, the staff, as it lies in the membranous part of the urethra, will be felt very distinctly; next, the prostate will be encountered; and, immediately behind this, the finger, provided it is carried upwards exactly in the middle line, will rest upon the small triangular surface of the base of the bladder, which is in contact with the rectum—the recto-vesical layer of pelvic fascia alone intervening.

The Bladder (*vesica urinaria*).—This is a hollow viscus, with strong muscular walls, which acts as a temporary reservoir for the urine, before it is emitted from the body by the process of micturition. As will be readily understood, its form, and in a great measure its position and relations, are influenced by the quantity of fluid which it contains. When moderately distended, it assumes an ovoid shape. In this condition it presents for examination an apex and base; a superior, inferior, and two lateral surfaces; and a neck. The long axis of the organ is nearly horizontal and is directed from before backwards, from the apex to the base.

The *apex* or *summit* of the bladder is directed forwards, and rests upon the posterior aspect of the anterior abdominal wall immediately above the pubis. From its centre a strong fibrous cord, the *urachus*, proceeds upwards in the middle line to the umbilicus.¹ The peritoneum gives a partial covering to the apex; it clothes it as far forwards as the urachus, which conducts it to the abdominal wall. The base of the bladder looks backwards towards the concavity of the second part of the rectum. It is not in actual contact with the gut, however; above,

¹ This is an interesting structure from a developmental point of view. It is the remains of that connection which exists between the bladder and the allantoidal sac of the embryo. At an early stage of development the allantois consists of an extra-abdominal and an intra-abdominal portion, which are continuous with each other through the umbilicus. In course of time the extra-abdominal part disappears. The fate of the intra-abdominal part is different; its lower portion is developed into the bladder, whilst its upper portion shrivels and becomes the urachus.

it is separated from it by the lower part of the recto-vesical pouch of peritoneum, and below this by the recto-vesical layer of pelvic fascia, the vasa deferentia, and the vesiculæ seminales (Fig. 141). The ureters open into the upper part of the base.

The inferior surface, which looks downwards, is devoid of peritoneum, and rests directly upon the pubic bones in its fore part. Further back, however, it is separated from the symphysis by a triangular interval, which is filled with a little pad of soft pliable fatty-areolar tissue. This is termed the retro-pubic pad, and it occupies a space bounded below by the pubis, above by the bladder, and behind by the anterior true ligaments of the bladder (Fig. 146). The superior surface is directed upwards, and is covered by peritoneum. Resting upon this aspect of the bladder are some coils of the small intestine, and probably also a loop of great intestine formed by the first part of the rectum and the lower part of the sigmoid flexure. Upon the lateral surface the obliterated hypogastric artery and the vas deferens will be found. As the latter descends towards the base, it will be noticed to cross the obliterated hypogastric artery. This aspect of the bladder is clothed by peritoneum as far downwards as the obliterated hypogastric artery; along the line of this fibrous cord it quits the viscus and passes to the iliac fossa and the lateral wall of the pelvis.

The neck or cervix of the bladder is that part from which the urethra issues. It is surrounded by the base of the prostate, and is directed downwards.

When the urine is ejected from the bladder the superior wall descends until it becomes approximated to the inferior wall and the basal wall. The viscus, therefore, becomes flattened from above downwards, and comes to lie entirely within the cavity of the true pelvis. When such a bladder is examined in a mesial section of the pelvis, and in a subject from whom the urine has been expelled shortly before death, the walls of the bladder are thick and firm, and the lumen of the viscus may be reduced to a mere slit. The part of the lumen which lies behind the urethral opening, formed by the approximation of the superior wall with the basal wall, is spoken of as the posterior limb, whilst that part formed

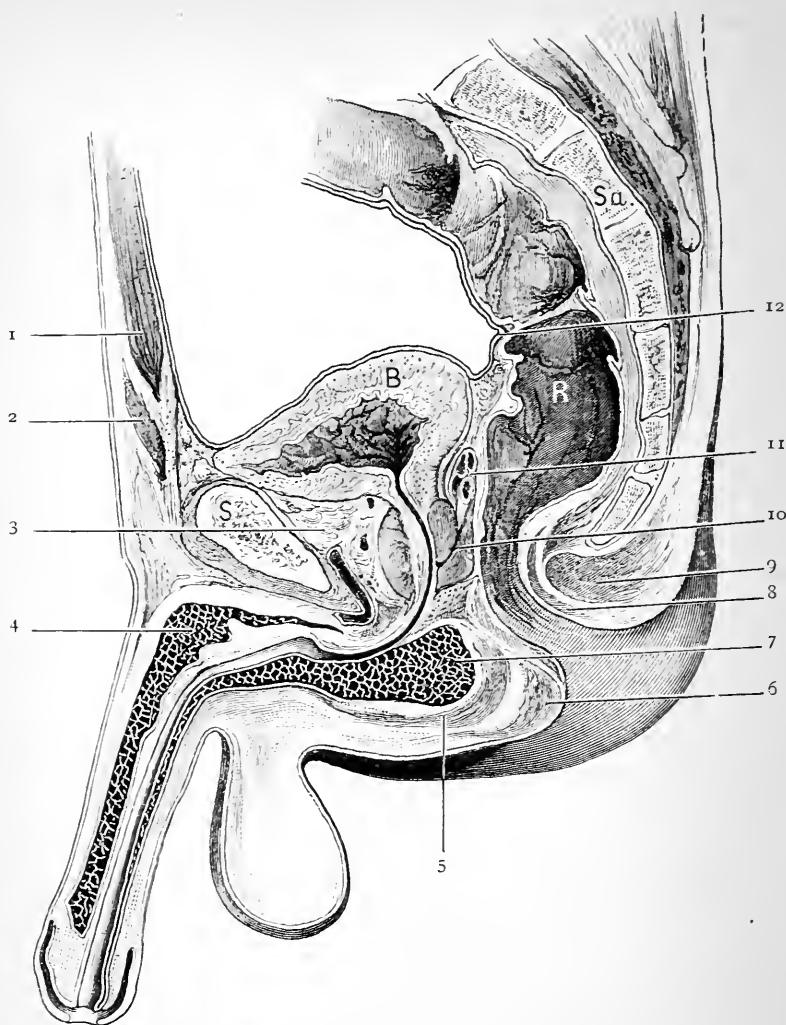


FIG. 146.—Mesial section through the pelvis of an adult male. The bladder is nearly empty, and the urethra is divided along its whole length.

Sa. Sacrum.

R. Rectum.

S. Symphysis.

1. Rectus abdominis.
2. Pyramidalis muscle.
3. Retro-pubic pad of fat.
4. Corpus cavernosum.
5. Ejaculator urinæ.
6. Sphincter ani externus.

7. Bulb.
8. Sphincter ani internus.
9. Sphincter ani externus.
10. Prostate.
11. Vas deferens.
12. Peritoneum.

by the approximation of the superior and inferior walls of the viscus in front of the urethral opening is called the *anterior limb* of the cavity. The anterior limb of the cavity is long and nearly horizontal. The posterior limb is short, and sometimes barely recognisable; further, it is oblique or perhaps vertical, and joins the anterior limb at the urethral opening at an angle. Viewed, therefore, in mesial section, the lumen of the perfectly empty bladder usually forms a Y-shaped figure with the lumen of the upper part of the urethra.

In other cases the empty bladder is firm and rounded, and when divided in the mesial plane its cavity is seen to present only the one limb or slit continuous with the lumen of the urethra.

As the bladder becomes gradually filled by the entrance of urine into it through the ureters, the superior wall is raised from the inferior and basal walls, and gradually ascends in the cavity of the pelvis. The bladder now assumes the egg-shaped form, and the apex appears above the symphysis pubis. As the distension goes on, the organ rises higher and higher into the hypogastric region, and a greater extent of its wall becomes applied to the abdominal wall above the pubis. In connection with this relation it is important to note that the peritoneal reflection from the apex is raised along with the organ, so that now there is a considerable area of bladder wall applied directly to the anterior abdominal wall above the pubis without the intervention of peritoneum.

When the bladder is excessively distended it assumes a spherical form, or perhaps an ovoid form with the enlarged end at the apex (Fig. 147). In the latter case the long axis is no longer horizontal, but very oblique, being directed from above downwards and backwards.

The neck of the bladder is very firmly fixed in position. This is chiefly due to the manner in which it is grasped and held in place by the base of the prostate, and also to the connections which we have seen are established between it and the visceral layer of the pelvic fascia. The prostate is securely anchored in its place by the strong capsule which it derives from the pelvic fascia. As the bladder becomes distended the neck therefore suffers very little change of position. This can readily be proved by drawing a straight line backwards from the lower border of the symphysis pubis through the urethral opening, and extending it onwards to the back wall of the pelvis. In the empty state of the bladder such a line strikes the second piece of the sacrum; in the hyper-distended condition of the organ it strikes the lower border of the third, or perhaps the fourth sacral vertebra. The neck of the bladder therefore sinks slightly in the pelvic cavity when the viscus becomes greatly distended.

We have noted how the reflection of the peritoneum from the apex of the bladder on to the posterior aspect of the anterior abdominal wall is raised as the organ becomes distended. It may therefore very well be asked: Does the reflection of the peritoneum from the rectum to the base of the bladder undergo a like displacement? It would appear that it does not (Fig. 147). When the second part of the rectum becomes

distended, the recto-vesical reflection assumes a higher level, but this is not due to any change in the relative position of the bladder and peritoneum, but to the entire bladder with the reflection being pushed upwards and forwards by the loaded gut.

In the new-born infant the form and position of the bladder is very different from what is found in the adult. It is more or less pyriform in shape, the narrow end gradually passing into the urethra, and there

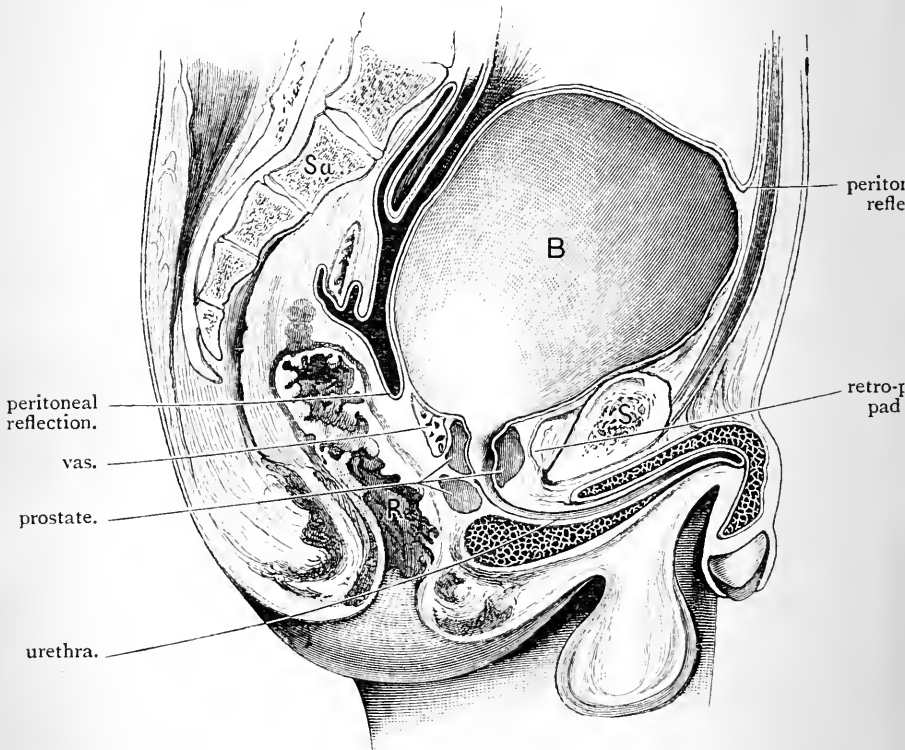


FIG. 147.—Mesial section through a male pelvis, in which the bladder is greatly distended.

B. Bladder.
R. Rectum.

S. Symphysis pubis.
Sa. Sacrum.

is little or no appearance of a basal portion (Fig. 148). Further, it is placed very much higher. The urethral orifice is situated at the level of the upper border of the symphysis pubis, and the anterior surface of the organ, entirely uncovered by peritoneum, is in contact with the lower two-thirds of that part of the posterior surface of the anterior ab-

dominal wall which lies between the symphysis pubis and the umbilicus (Symington). As growth goes on "the urethral orifice sinks rapidly from the period of birth up to the beginning of the fourth year, and more slowly from that period up to the beginning of the ninth year; it now remains stationary until the commencement of puberty, and then it sinks slowly until it ultimately attains its normal adult position" (Disse). One other point may be noted in connection with the infantile bladder, viz., the recto-vesical reflection of peritoneum corresponds to the base of the prostate.

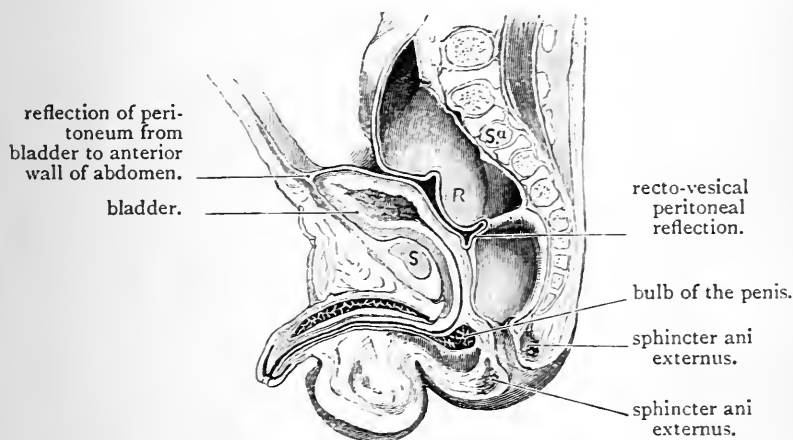


FIG. 148.—Mesial section through pelvis of a newly-born full-time male infant.

R. Rectum.
 Sa. Sacrum.
 S. Symphysis pubis.

The Ureters.—After entering the pelvis, the ureter of each side proceeds towards the base of the bladder in the posterior false vesical ligament at a lower level than the obliterated hypogastric artery. It enters the bladder about two inches behind the prostate, and about the same distance from its fellow of the opposite side.

The Prostate (prostata).—This is a solid body, partly glandular and partly muscular, which embraces the neck of the bladder and surrounds the first part of the urethra.

In shape, it is conical, and somewhat resembles a Spanish chestnut—its base being directed upwards, and its apex

downwards. *In size*, it is variable ; but its average dimensions are commonly stated to be about one inch and a quarter from base to apex, and one inch and a half from side to side at its broadest part. The prostate rests upon the anterior aspect of the second part of the rectum. It is about one inch and a half distant from the anus, whilst its anterior surface lies three-quarters of an inch behind the lower part of the symphysis pubis.

The prostate has already been noticed to be enclosed within a dense capsule derived from the pelvic fascia, and when the constitution of this capsule is analysed, it will be seen that the vesical, recto-vesical, and parietal layers of this fascia all enter into its composition. The vesical layer, in which the pubo-prostatic or anterior true ligaments of the bladder are developed, forms the anterior part ; the recto-vesical layer closes it behind ; whilst the same layer and the parietal pelvic fascia complete it below. These points are brought out in a diagrammatic manner in Figs. 140, 142, and 143. This capsule prevents the prostate altering its position in response to the continual changes which occur in the state of distension of the bladder.

Open into the capsule, and lay bare the prostate. It will be found to be surrounded within the capsule by a dense network of veins. This is the *prostatic plexus*, and it will be noticed that the veins are chiefly massed upon the lateral aspects and around the base of the gland. The dorsal vein of the penis passes upwards in relation to the anterior or pubic surface of the prostate, and, after dividing into two, joins the plexus.

Two median grooves, one upon its anterior or pubic surface, and the other upon its posterior or rectal surface, indicate the subdivision of the prostate into *two lateral lobes*. This is further marked by a median notch in the posterior aspect of the base. A *third* or *middle lobe* (lobus medius) is also present. It is a small piece interposed between the lateral lobes on the one hand, and the posterior aspect of the neck of the bladder and first part of the urethra on the other. This lobe can only be dis-

played by detaching the vesiculæ seminales and the vasa deferentia from the base of the bladder, and throwing them backwards. On tracing the slender common ejaculatory ducts, they will be observed to pass into the base of the prostate between the middle lobe and the lateral lobes. The middle lobe of the prostate is very variable in size, and may even be absent (Griffiths).

Anteriorly, the prostate is in relation to the pubo-prostatic ligaments and the dorsal vein of the penis; *posteriorly*, it rests upon the second part of the rectum; *laterally*, it is supported by the anterior fibres of the levator ani, which, from this relation, receive the name of levator prostatae; *inferiorly*, the urethra emerges from its apex, and the gland is in close relation to the superior layer of the triangular ligament; whilst *superiorly*, its base embraces the neck of the bladder, and the common ejaculatory ducts are received into the interval between its middle and lateral lobes.

Vesiculæ Seminales.—These are two sacculated receptacles for the semen, which intervene between the base of the bladder and the second part of the rectum. Conical or somewhat pyriform in shape, each seminal vesicle presents a narrow inferior end in close proximity to the base of the prostate, and an expanded or blunt superior end in relation to the recto-vesical pouch of peritoneum and the entrance of the ureter. Inferiorly, they are near to each other and the mesial plane, but they diverge widely as they proceed upwards, so that posteriorly they are separated by a considerable interval. The vas deferens lies along the inner side of each. In length, the vesicle measures about two inches. By introducing a blow-pipe into the narrow anterior extremity, and inflating it with air, a demonstration of its capacity may be obtained.

Each vesicula seminalis is in reality a closed tube, five or six inches long, coiled upon itself and held in its present form by dense areolar tissue. When unravelled, several diverticula will be observed to proceed from the main tube. The narrow anterior end of the vesicle joins

the vas deferens at an acute angle to form the *common ejaculatory duct*.

Vas Deferens (ductus deferens).—The vas deferens, or duct of the testicle, has already been traced to the internal abdominal ring, through which it enters the abdomen. Separating itself from the other factors of the spermatic cord, it now hooks round the deep epigastric artery, and descends upon the inner side of the external iliac artery into the pelvis. Here it is continued downwards upon the lateral surface of the bladder, and crosses the obliterated hypogastric artery. Then passing to the inner side of the ureter, it reaches the base of the viscus, where it becomes dilated and slightly sacculated, and lies upon the inner side of the seminal vesicle. As it proceeds onwards, it gradually inclines towards the mesial plane, and at the base of the prostate it is joined by the narrow end of the vesicula seminalis of its own side.

Triangle on the Base of the Bladder.—A line drawn from the middle of one seminal vesicle to a corresponding point in the other, would, under ordinary circumstances, indicate the line along which the peritoneum is reflected from the anterior aspect of the rectum on to the back of the bladder; or, in other words, the bottom of the rectovesical *cul-de-sac* of peritoneum. This line, taken in conjunction with the converging vasa deferentia and vesiculae seminales, maps off a triangular space upon the base of the bladder—the apex of which is at the base of the prostate, whilst the base is formed by the reflection of the peritoneum.

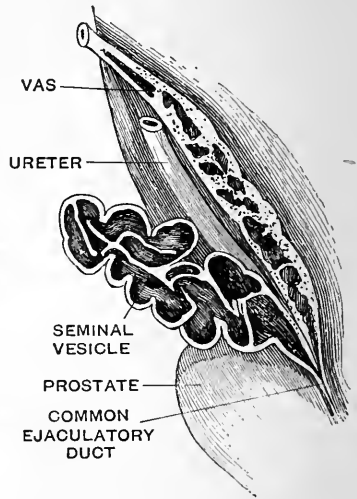
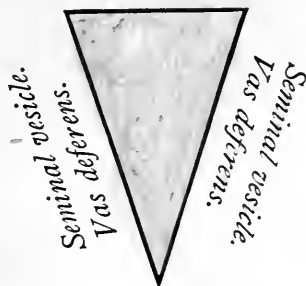


FIG. 149.—Seminal vesicle and vas deferens on the base of the bladder. (From Gegenbaur.)

Within the limits of this triangle the base of the bladder

Reflection of peritoneum.



Prostate.

is separated from the rectum by the recto-vesical layer of pelvic fascia alone.

It occasionally happens that in retention of urine, it is impossible to pass a catheter into the bladder to relieve the distension. In these cases it becomes necessary to puncture the bladder with a trocar and cannula. The foregoing facts concerning the relations of this viscus will show that the operation may be performed at two points without injury to the peritoneum—viz. (1) in the middle line immediately above the pubic symphysis; (2) through the rectum and within the limits of the small triangular space on the base of the bladder. In the distended condition of the bladder, the peritoneum is absent from its walls at both of these points. The middle line must be adhered to rigorously in both methods.

Dissection.—The blood-vessels of the pelvis should now be followed out. For this purpose it is necessary to remove the stuffing from the rectum, and allow the air to escape from the bladder. The peritoneum upon the left side and the loose tissue around the vessels must be dissected away. Accompanying the arteries the dissector should notice numbers of fine nervous twigs from the pelvic plexus, and from the third and fourth sacral nerves. Preserve these as far as it is possible to do so. Upon the right side the blood-vessels are more or less injured, and some of them severed, by the removal of the innominate bone; on the left side, however, they are intact.

Pelvic Blood-Vessels.—The pelvic arteries are the following:—

1. The internal iliac and its branches (upon each side).
2. The middle sacral
3. The superior hæmorrhoidal } (in the mesial plane).

The Internal Iliac Artery (arteria hypogastrica).—This is a short, wide vessel, which commences opposite the lumbo-sacral articulation, at the bifurcation of the common iliac. It proceeds downwards and backwards into the pelvis, and ends near the upper part of the great sciatic

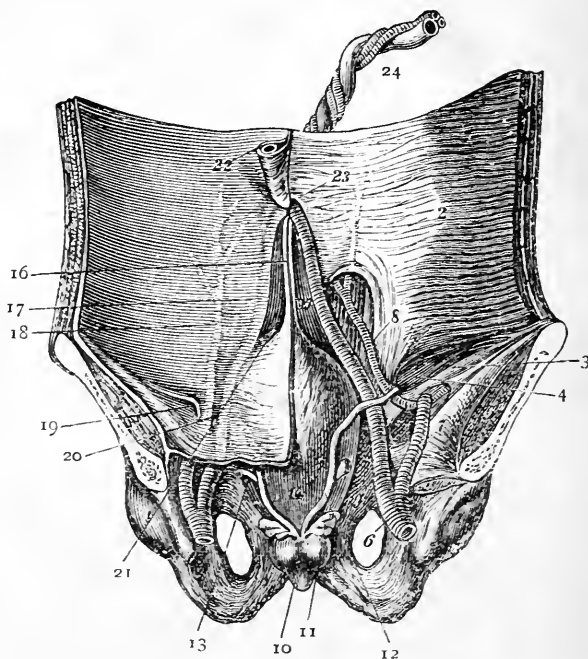


FIG. 150.—View of the posterior aspect of the anterior wall of the abdomen and pelvis of a fœtus to show the hypogastric artery. On the right side the peritoneum and fascia transversalis have been removed.—(From LUSCHKA'S *Anatomy*.)

- | | |
|-----------------------------|---|
| 1. Os innominatum. | 14. Bladder. |
| 2. Transversalis muscle. | 15. Urachus. |
| 3. Poupart's ligament. | 16. Fold of the urachus. |
| 4. Internal abdominal ring. | 17. Hypogastric artery covered by peritoneum. |
| 5. Iliacus muscle. | 18. Deep epigastric artery covered by peritoneum. |
| 6. Common iliac artery. | 19. External inguinal pouch. |
| 7. External iliac artery. | 20. Middle inguinal pouch. |
| 8. Deep epigastric artery. | 21. Internal inguinal pouch. |
| 9. Thyroid foramen. | 22. Umbilical vein. |
| 10. Prostate. | 23. Umbilicus. |
| 11. Vesicula seminalis. | 24. Umbilical cord. |
| 12. Vas deferens. | |
| 13. Ureter. | |



notch by dividing into an *anterior* and *posterior division*. In length it measures about one inch and a half, and its calibre in the adult is considerably smaller than that of the external iliac. *In front*, it is clothed by the peritoneum, and crossed by the ureter; whilst *behind*, it rests upon the inner border of the psoas muscle, the sacrum, the lumbo-sacral cord, and the internal iliac vein. The impervious hypogastric artery extends forwards from its extremity.

Condition in the Fœtus.—Very different is the condition of the internal iliac artery in the fœtus. It is termed the *hypogastric artery*, and is twice as large as the external iliac. Instead of terminating at the sciatic notch, it extends forwards to the side of the bladder, upon which it ascends to reach the abdominal parietes. Continuing its course upwards upon the posterior aspect of the anterior wall of the abdomen, it gains the umbilical orifice, through which it passes in company with its fellow of the opposite side and the umbilical vein. Outside the abdominal cavity the hypogastric arteries enter the umbilical cord, and, twining spirally around the umbilical vein, they reach the placenta, where the impure blood which they carry is brought into relation with the maternal blood.

After birth, when the umbilical cord is divided and a ligature placed around it, the hypogastric arteries become filled with clot, which is gradually absorbed. At the same time the vessels shrivel, and after a few years they are merely represented by the fibrous cords which we have examined in the adult. A small portion of this cord, close to the internal iliac artery, usually remains patent, and from this the superior vesical artery takes origin.

Branches of the Internal Iliac.—The branches of this artery spring from the two divisions into which it divides, and may be tabulated thus:—

ANTERIOR DIVISION.		POSTERIOR DIVISION.	
Parietal.	Visceral.	Parietal.	Visceral.
1. Obturator.	1. Superior vesical.	1. Ilio-lumbar.	...
2. Internal pudic.	2. Inferior vesical.	2. Gluteal.	...
3. Sciatic.	3. Middle hæmorrhoidal.	3. Lateral sacral.	...

Superior Vesical (arteriæ vesicales superiores).—Under this name are included two or three small twigs which spring from the pervious part of the obliterated hypogastric artery, and proceed forwards in the posterior false ligament of the bladder to the coats of that viscus. They supply the apex and the greater part of the body of the bladder, and from one of them a minute twig, the *artery to the vas deferens* (arteria deferentialis), is given to the seminal duct. Although exceedingly slender, this branch can be followed along the vas as far as the testicle.

Inferior Vesical (arteria vesicalis inferior).—This artery will be recognised from its distribution. It ramifies upon the base of the bladder, and sends twigs to the vesiculæ seminales. A branch called the *vesico-prostatic* also takes origin from the inferior vesical, and runs downwards upon the lateral lobe of the prostate to supply its substance.

The *middle hæmorrhoidal* (arteria hæmorrhoidalis media) almost invariably proceeds from the inferior vesical. It is given to the coats of the rectum, and anastomoses above with the superior hæmorrhoidal branch of the inferior mesenteric, and below with the inferior hæmorrhoidal twigs from the internal pudic.

The *obturator artery* (arteria obturatoria) proceeds forwards upon the inner aspect of the pelvic wall to the upper part of the thyroid foramen. Here it comes into relation with the nerve of the same name, and both leave the cavity by passing above the pelvic fascia and below the groove upon the under surface of the ascending ramus of the pubic bone. Within the pelvis it lies in the extra-peritoneal fatty tissue, between the peritoneum and the parietal pelvic fascia; the obturator nerve is placed at a higher level, whilst the vein lies below it. In this part of its course the obturator artery furnishes a small *iliac branch* to the parts in the iliac fossa, and a minute *pubic branch*, which ramifies upon the back of the pubic bone and anastomoses with a similar branch from the deep epigastric artery.

The *pudic artery* (arteria pudenda interna) is now seen

in the *pelvic part* of its course. It proceeds downwards upon the pyriformis muscle and sacral nerves, and reaching the lower part of the great sacro-sciatic foramen, it leaves the pelvis by passing through it. In the gluteal region it appears between the pyriformis and the superior gemellus.

The *sciatic artery* (arteria glutæa inferior) can be recognised from its being the largest of the branches which spring from the anterior division of the internal iliac, and also from its generally lying a little behind the pudic. It proceeds downwards upon the pyriformis muscle and sacral nerves, and quits the pelvis for the gluteal region through the lower part of the great sacro-sciatic foramen.

The *ilio-lumbar artery* (arteria ilio-lumbalis) is directed upwards, outwards, and backwards behind the obturator nerve, the external iliac vessels, and the psoas muscle, to the iliac fossa, where it divides into a lumbar and an iliac branch. The *lumbar branch* (ramus lumbalis) runs upwards and ramifies in the substance of the psoas and quadratus lumborum muscles, where it anastomoses with the lower lumbar arteries. It gives off a small spinal branch (ramus spinalis), which enters the spinal canal through the intervertebral foramen between the last lumbar vertebra and the sacrum. The *iliac branch* (ramus iliacus) breaks up into twigs, which run outwards, some in the substance of the iliacus muscle, and others between it and the bone; of the latter set, one will be observed to enter the nutrient foramen in the iliac fossa. Reaching the crest of the ilium, the terminal branches of this vessel anastomose with the deep circumflex iliac and lumbar arteries.

The *gluteal artery* (arteria glutæa superior) is the largest of the branches of the internal iliac. It has a very short course within the pelvis. Passing downwards between the lumbo-sacral cord and the first sacral nerve, it leaves the pelvis through the upper part of the great sacro-sciatic foramen, and appears in the gluteal region in the interval between the pyriformis and gluteus minimus muscles.

The *lateral sacral* (arteria sacralis lateralis) is usually

represented by two arteries, which extend downwards upon the pyriformis muscle and sacral nerves, external to the anterior sacral foramina and the sympathetic cord. They furnish twigs to the parts upon which they lie, and branches which enter the sacral foramina (*rami spinales*). The latter, after supplying the membranes and nerve-roots within the sacral canal, emerge behind, through the posterior sacral foramina, and there anastomose with branches of the gluteal artery. The lower of the two lateral sacral arteries inosculates inferiorly with the middle sacral.

The Superior Hæmorrhoidal Artery (*arteria hæmorrhoidalis superior*).—This is the continuation into the pelvis of the inferior mesenteric artery. It descends behind the rectum, between the two layers of its mesentery, and soon divides into two branches which extend downwards, one upon each side of the gut. Upon the second part of the rectum these branches break up into several twigs which surround the intestine. Approaching the anal canal they pierce the muscular coat and continue downwards, subjacent to the mucous membrane, and at the anus they end in a series of anastomosing loops. The superior hæmorrhoidal anastomoses freely with both the middle and inferior hæmorrhoidal arteries.

Middle Sacral Artery (*arteria sacralis media*).—The middle sacral has already been observed springing from the posterior aspect of the termination of the abdominal aorta, between the two common iliac arteries. It runs downwards upon the body of the last lumbar vertebra and under cover of the left common iliac vein. Reaching the sacrum, it continues its downward course in the mesial plane till it arrives at the coccyx. Here it ends by anastomosing with the lateral sacral arteries, and by sending minute branches to the coccygeal body. From each side it gives off small twigs, which ramify upon the anterior aspect of the sacrum and inosculate with branches of the lateral sacral arteries.

Veins of the Pelvis.—The arrangement of the veins in the pelvis corresponds in a great measure with that of the

arteries ; still there are some important points of difference, viz. :—

(1.) The *dorsal vein of the penis*, instead of joining the pudic vein, proceeds backwards, divides into two, and enters the prostatic plexus of veins.

(2.) The *ilio-lumbar* and the *middle sacral veins*, as a general rule, pour their blood into the common iliac veins.

(3.) The veins around the prostate, bladder, and lower end of the rectum are exceedingly large and numerous, and constitute dense plexuses, which freely communicate with each other. The *prostatic* and *vesical plexuses* have already been noticed. They are directly continuous, and the blood is drained from them by the vesical veins. The *hæmorrhoidal plexus* surrounds the lower third of the rectum subjacent to the mucous membrane. From this the blood is drained away by three different veins—viz., the inferior hæmorrhoidal, which carries it to the pudic vein ; the middle hæmorrhoidal, which leads it to the internal iliac vein ; and the superior hæmorrhoidal vein, which is one of the rootlets of the portal vein. The hæmorrhoidal plexus may therefore be regarded as being the link between the systemic and portal systems of veins. This has an important bearing upon the production of hæmorrhoids, which consist in a varicose condition of the hæmorrhoidal veins. As we have seen, the portal vein and its tributaries are devoid of valves ; consequently, anything retarding the flow of blood through the portal system will react upon the hæmorrhoidal plexus, cause its distension, and predispose to hæmorrhoids.

The *internal iliac vein* (*vena hypogastrica*) proceeds upwards behind the artery of the same name, and joins the common iliac vein. With the exception of the ilio-lumbar vein, it receives tributaries corresponding to the branches of the artery.

Dissection.—The diaphragm of the pelvis should next be examined. It is composed of two muscles upon each side—viz., the *levator ani* and the *coccygeus*. Draw the viscera as far as possible to the right, and remove what remains of the visceral layer of the pelvic fascia upon

the left side. This will expose the upper surface of the levator ani, the connections of which can now be studied. In cleaning the coccygeus, be careful not to injure the fifth sacral nerve and the coccygeal nerve, both of which pierce it near its insertion.

Levator Ani.—The levator ani is a thin sheet of muscular fibres, which forms the anterior and greater part of the pelvic diaphragm. It has a triple origin. The *anterior fibres* spring from the back of the body of the pubic bone between the attachments of the visceral and parietal layers of pelvic fascia; the *posterior fibres* arise from the pelvic surface of the ischial spine; whilst the *intermediate fibres*, constituting the greater part of the muscle, take origin from the “white line” of the pelvic fascia, in the angle between the perineal portion of the parietal layer and the visceral layer.

The insertion of the levator ani must also be looked at from three points of view. The *anterior fibres* proceed downwards upon the lateral aspect of the prostate; and from the support which they give to it, they are sometimes spoken of under the name of *levator prostatae*. Behind the prostate they meet in the mesial plane, with the corresponding fibres of the opposite side, and are inserted into the central point of the perineum. The *intermediate* and largest portion of the muscle descends upon the side of the rectum, into which it is inserted, some of the fibres mingling with those of the external sphincter. The *posterior fibres* pass downwards and inwards and are inserted into a median raphe behind the anus, and also into the side of the lower end of the coccyx.

The levator ani draws its nervous supply from the *fourth sacral nerve* and the *inferior hæmorrhoidal nerve*.

Coccygeus.—This is a small triangular muscle which lies behind and upon the same plane as the levator ani—indeed, their margins are contiguous. It arises by its narrow end from the pelvic surface of the ischial spine, and from the parietal pelvic fascia above the spine. Expanding as it passes inwards, it is inserted into the margin of the lower piece of the sacrum and the margin and anterior

aspect of the coccyx. It is supplied by twigs from the fourth and fifth sacral nerves.

Pelvic Spinal Nerves.—The anterior primary divisions of the spinal nerves in the pelvis are *six* in number—viz., five sacral and one coccygeal. These should be dissected, and the various branches which they give off followed to their distribution, or the point where they quit the pelvis. It is well to begin by cleaning the lumbo-sacral cord and securing the upper root of the superior gluteal nerve which springs from its posterior aspect. The upper four sacral nerves appear through the anterior sacral foramina; the fifth sacral nerve comes forward in the interval between the sacrum and coccyx; and the coccygeal a little lower down at the side of the coccyx. The two latter are very minute, but they can be easily found by following downwards a twig from the *fourth* to the *fifth* sacral nerve, and another twig which connects the *fifth* nerve with the *coccygeal*.

The first and second sacral nerves are very large, and almost equal in size; the third sacral nerve is much smaller than these, and the fourth still smaller than the third. Each spinal nerve is joined by two twigs from the sympathetic cord.

The first three sacral nerves unite to form the sacral plexus. This is joined above by the lumbo-sacral cord, and below by a branch from the fourth sacral nerve.

The fifth sacral nerve and the coccygeal nerve, with the descending branch of the fourth sacral nerve, unite to form the sacro-coccygeal plexus.

Sacral Plexus (plexus sacralis).—When the nerves which enter the sacral plexus are dissected they will be seen to resolve themselves into two flattened bands—viz., an upper sciatic and a lower pudendal. The sciatic band is very large, and is formed by the union of the lumbo-sacral cord with the first sacral nerve and the greater portion of both the second and the third sacral nerves. It proceeds downwards and outwards to the lower part of the great sacro-sciatic foramen, and, here much reduced in

width and increased in thickness, it enters the gluteal region below the level of the pyriformis muscle as the *great sciatic nerve*. This nerve indeed may be regarded as the

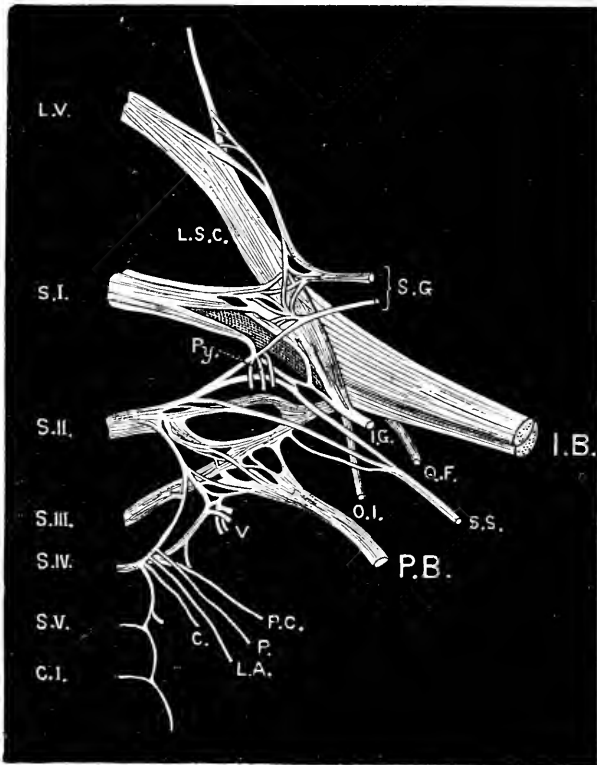


FIG. 151.—Sacral and sacro-coccygeal plexuses as seen *from behind*. (Modified from Eisler.)

- | | | |
|-----------------------------|---------------------------------|-----------------------------------|
| | I.B. Ischiadic or sciatic band. | |
| | P.B. Pudendal band. | |
| L.S.C. Lumbo-sacral cord. | | C. Nerve to the coccygeus. |
| Py. Branches to pyriformis. | | O.I. Nerve to obturator internus. |
| V. Visceral branches. | | Q.F. Nerve to quadratus femoris. |
| P.C. Perforating cutaneous. | | I.G. Inferior gluteal nerve. |
| P. Perineal branch. | | S.G. Superior gluteal nerve. |
| L.A. Nerve to levator ani. | | S.S. Small sciatic nerve. |

direct continuation of the sciatic band of the plexus into the thigh. The *pudendal band* is small and lies at a lower

level than the sciatic band. It takes origin by roots which spring from the second, third, and fourth sacral nerves, and unite in a plexiform manner to form the band. It leaves the pelvis through the lower part of the great sacro-sciatic foramen, below the pyriformis, and is continued directly into the *internal pudic nerve*.

The sacral plexus rests upon the pyriformis muscle; whilst, anteriorly, it is clothed by parietal pelvic fascia, which separates it from the branches of the internal iliac artery.

In addition to the two terminal branches of the sacral plexus (great sciatic and internal pudic) which have been seen to be continuations of the two bands into which the plexus resolves itself, there are various other twigs given off from it—viz.,

1. Superior gluteal.
2. Inferior gluteal.
3. Small sciatic.
4. Nerve to the obturator internus and superior gemellus.
5. Nerve to the quadratus femoris and inferior gemellus.
6. Branches to the pyriformis muscle.
7. Branches to the pelvic viscera.

The *superior gluteal nerve* (nervus glutæus superior) arises on the posterior aspect of the plexus by three roots from the lumbo-sacral cord and the first and second sacral nerves. It leaves the pelvis with the gluteal vessels through the upper part of the great sacro-sciatic foramen, and in the gluteal region is distributed to the gluteus medius, gluteus minimus, and tensor fasciæ femoris muscles.

The *inferior gluteal nerve* (nervus glutæus inferior) is the special branch of supply to the gluteus maximus. It arises upon the posterior aspect of the plexus, from the lumbo-sacral cord and from the first and second sacral nerves, and gains the gluteal region through the lower part of the great sciatic foramen below the level of the pyriformis muscle.

The *small sciatic nerve* (nervus cutaneus femoris posterior) is often closely associated at its origin with the

preceding branch. It arises on the posterior aspect of the plexus by two or more roots from the second and third sacral nerves, and leaves the pelvis through the lower part of the great sacro-sciatic foramen.

The *nerve to the obturator internus* springs from the anterior aspect of the sacral plexus. It accompanies the pudic nerve through the great sacro-sciatic foramen into the gluteal region, where it gives a twig to the superior gemellus. It reaches the obturator internus by passing through the small sacro-sciatic foramen, and ends by sinking into the inner aspect of this muscle.

The *nerve to the quadratus femoris* arises from the upper part of the anterior aspect of the plexus, and enters the gluteal region by passing through the lower part of the great sacro-sciatic foramen. It also supplies the gemellus inferior and a branch to the hip-joint.

The *twigs to the pyriformis* usually spring from the second and third sacral nerves.

The *visceral branches* come from the third and fourth sacral nerves.

Sacro-Coccygeal Plexus.—The *fourth sacral nerve*, as we have seen, sends upwards a branch to join the sacral plexus; it also sends a twig downwards to unite with the fifth sacral nerve. But in addition to these connecting branches, it gives off *muscular* and *visceral branches*, and also the *perforating cutaneous nerve*.

The *muscular branches* are distributed to three muscles—viz., the levator ani, the coccygeus, and the sphincter ani externus. The last of these has already been dissected in the perineum, under the name of the “perineal branch of the fourth sacral nerve.”

The *visceral branches* are numerous, and are directed inwards towards the viscera. Here they join with the pelvic plexus of nerves. Some, however, may be found entering the viscera directly. The third sacral nerve also gives off visceral branches.

The *perforating cutaneous nerve* pierces the great sacro-sciatic ligament and then winds round the lower border of

the gluteus maximus to gain the skin over the lower and inner part of that muscle.

The *fifth sacral nerve* pierces the coccygeus. After being joined by the branch from the fourth sacral nerve, it turns downwards and unites with the coccygeal nerve. It supplies one or two minute filaments to the coccygeus muscle.

The *coccygeal nerve* is a very delicate filament. It emerges from the lower end of the sacral canal, and makes its appearance by piercing the sacro-sciatic ligaments and the coccygeus muscle. It is now joined by the fifth sacral nerve and runs downwards. Near the tip of the coccyx it is directed backwards through the coccygeus muscle, and ends in the skin in this neighbourhood.

Dissection.—The dissector should, in the next place, make out the distribution of the sympathetic nerves within the pelvis. These have, no doubt, been considerably injured in previous dissections, but those which remain must be carefully traced.

Pelvic Plexuses of the Sympathetic.—The hypogastric plexus has been observed to end inferiorly by dividing into two lateral portions, which are prolonged downwards, one upon each side of the rectum. These are termed the *pelvic plexuses*, and each consists of a dense mesh-work of sympathetic nerves. In addition to the branches from the hypogastric plexus, they receive numerous twigs from the sacral spinal nerves, more especially from the third and fourth, and the points at which these unite with the sympathetic filaments are marked by minute ganglia. The pelvic plexuses also acquire branches from the sacral portion of the sympathetic cord.

Prolongations from the pelvic plexus upon each side are sent along the various branches of the internal iliac artery. There are thus formed various secondary plexuses—viz., the *vesical plexus*, to the coats of the bladder, to the seminal vesicle and the vas deferens; the *hæmorrhoidal plexus* to the rectum; and the *prostatic plexus* to the prostate.

The prostatic plexus proceeds forwards between the prostate and the levator ani, and sends twigs to the erectile tissue of the penis. These latter are termed the *cavernous nerves*.

Gangliated Cord of Sympathetic.—The sympathetic cord as it enters the pelvis is considerably reduced in size. It proceeds downwards in front of the sacrum, along the inner side of the anterior sacral foramina. *Above*, it is continuous with the lumbar portion of the sympathetic cord, whilst *below*, it ends in the mesial plane in front of the coccyx in a minute ganglion, termed the *ganglion impar*, which acts as a bond of union between the cords of the two sides. The ganglia are very variable in number, but as a general rule there are five—one in relation to each sacral vertebra. Each of these is brought into connection with the spinal nerves by two short twigs.

The branches of these ganglia are chiefly distributed upon the anterior surface of the sacrum and around the middle sacral artery. A few filaments, however, are given to the pelvic plexuses, and some minute twigs proceed from the ganglion impar to the parts about the coccyx and to the coccygeal body.

Coccygeal Body.—This is a minute lobulated body about the size of a small pea, and situated in front of the tip of the coccyx. In structure it is almost entirely vascular, being composed of a plexus of minute arteries in connection with the terminal twigs of the middle sacral artery. It receives minute filaments from the ganglion impar. The function of this little body is quite unknown. Possibly it has none. Most likely it is vestigial, and has a developmental significance.

Removal of the Viscera.—The viscera must now be removed from the pelvic cavity. Begin by dividing the vessels and nerves which enter them, the levator ani, and the anterior true ligaments of the bladder. Then sever the parts which hold the membranous portion of the urethra and the bulb of the penis to the pubic arch. Great care must be taken at this stage not to injure the delicate walls of the urethra, or to lose sight of Cowper's glands. Lastly, separate the rectum from its connections with the coccyx. Laying aside the viscera for a little, the dissector should study the muscles in relation to the pelvic wall—viz., the obturator internus and the pyriformis.

Obturator Internus.—This muscle clothes the lateral

wall of the pelvis upon its inner aspect. Remove the parietal layer of the pelvic fascia, and it will come into view. It is a fan-shaped muscle, and has an extensive origin, viz.—(1) from the circumference of the thyroid foramen, except above, where the obturator vessels and nerve quit the pelvis; (2) from the deep surface of the membrane which extends across the foramen; and (3) from the surface of bone behind the thyroid foramen as far back as the great sciatic notch. A few fibres are also derived from the parietal pelvic fascia which covers it. From this origin the fibres converge towards the small sciatic notch, and end in a tendon which issues from the pelvis through the lesser sacro-sciatic foramen. Entering the gluteal region, it is inserted in conjunction with the gemelli muscles into the upper part of the great trochanter of the femur. The small sciatic notch, over which the tendon glides, is coated with smooth cartilage, and this is raised into three or four parallel ridges, which fit into fissures upon the deep surface of the tendon. A synovial bursa intervenes between them.

The obturator internus is supplied by a special branch from the upper part of the sacral plexus.

The Piriformis is placed against the anterior aspect of the posterior wall of the pelvis. It arises by three processes, from the anterior surface of the second, third, and fourth sacral vertebræ between the sacral foramina; it also takes origin from the innominate bone, where it forms the upper part of the great sciatic notch, and from the great sacro-sciatic ligament. The muscle leaves the pelvis through the great sacro-sciatic foramen, and is inserted by a rounded tendon into the top of the great trochanter of the femur. It is supplied by branches from the sacral plexus.

Coats of the Rectum.—Turning now to the viscera, separate the rectum from the bladder and prostate, and, having stuffed it with tow, or inflated it with air, proceed to dissect its walls. It presents the same coats as the colon, viz. :—

- | | | |
|---------------|------------|---------------|
| 1. Serous. | | 3. Muscular. |
| 2. Subserous. | | 4. Submucous. |
| | 5. Mucous. | |

The *serous coat* has already been examined. It is complete in the first part of the rectum, partial in the second part, and altogether absent from the third part. The *subserous coat* is the loose areolar tissue which intervenes between the peritoneum and the muscular coat. In its lower part the rectum derives a sheath from the rectal layer of pelvic fascia.

The *muscular coat* is composed of two strata of involuntary non-striated muscular fibres—viz., an *external* longitudinal and an *internal* circular layer. The *longitudinal fibres* are continuous above with the three longitudinal bands of the colon. These bands are usually distinct over a greater or less part of the first portion of the rectum, but they always spread out so as to form a continuous and uniform covering before they reach the second part. They terminate near the anus. The *circular fibres* extend transversely around the gut, and near the anus they are collected into a distinct circular band which surrounds the anal canal, and is termed the *sphincter ani internus*.

The *submucous coat* differs in no respect from the same coat in the colon.

To see the mucous membrane, it is necessary to slit open the rectum along its anterior wall. The gut may then be placed with advantage in the dissecting tray under water.

The *mucous membrane* is somewhat thicker than that of the colon, and is more freely movable upon the muscular tunic. In consequence of this mobility, it is thrown into irregular folds or *rugæ* when the gut is empty. Owing to the contraction of the two sphincter muscles, and the narrowing of the anal orifice, the folds in this part of the gut are longitudinal, and are termed the *columns of Morgagni*, or the *columnæ recti*. When the anal canal is distended, these *rugæ* disappear. In addition to the effaceable *rugæ*, there are three permanent oblique folds which must be

noticed. These folds contain some fibres from the circular layer of the muscular coat, and are usually named after Houston. The most constant fold is placed on the anterior wall of the rectum, opposite the base of the bladder, and about three inches above the anal orifice; another is situated near the upper end of the rectum in relation to

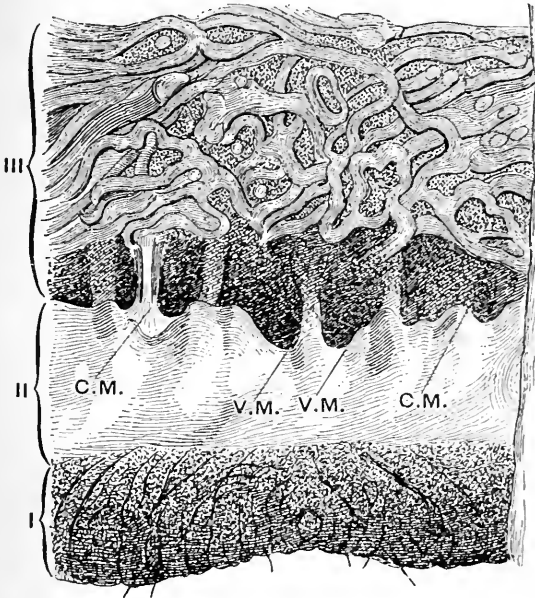


FIG. 152.—Mucous membrane lining the anal canal.
(After Luschka.)

- C.M. Columns or rugæ of Morgagni. | V.M. Valves of Morgagni.
 I. Integument at verge of anus.
 II. Mucous membrane of anal canal.
 III. Mucous membrane above the anal canal, with large tortuous veins.

its right lateral wall; whilst the third is intermediate in position, and juts out from the left lateral wall of the gut.

Immediately above the anal orifice a series of faintly marked semilunar folds may be seen connecting the lower ends of the columns of Morgagni. When these are strongly developed, they form a number of little pocket-like recesses between the vertical columns (sinus Morgagni).

It is here that the scaly epithelium of the integument merges into the columnar epithelium of the gut. These semilunar folds are of importance in connection with the condition known as "fissured anus" (Ball).

Dissection.—The bladder must be fully distended with air before the dissection of its walls is commenced.

Coats of the Bladder.—The bladder presents the same coats as the intestine, viz :—

- | | | |
|---------------|------------|---------------|
| 1. Serous. | | 3. Muscular. |
| 2. Subserous. | | 4. Submucous. |
| | 5. Mucous. | |

The *serous covering* is partial and confined to its superior part. The *subserous coat* consists of a thin stratum of areolar tissue which binds the peritoneum to the muscular coat. The vesical layer of pelvic fascia may be considered to thin away into this coat.

The *muscular tunic* presents three layers of non-striated muscular fibres, viz :—

1. External longitudinal fibres.
2. Circular fibres.
3. Internal longitudinal fibres.

The *external longitudinal fibres*, frequently termed the *detrusor urinæ*, give a continuous covering to the bladder, but are most apparent upon its inferior and superior surfaces. They may be considered to spring from the back of the pubic bones, the anterior true ligaments of the bladder, and the base of the prostate. From this they mount upwards and spread out upon the inferior surface of the bladder. At the apex, a few pass on to the urachus, but the majority are carried backwards over the superior aspect and base of the bladder to the prostate, to which they are attached.

The *circular fibres* give a very thin and sparse covering to the bladder. In direction they are more oblique than transverse. At the neck of the bladder they become continuous with the fibres of the prostate.

The *internal longitudinal fibres* constitute a very feeble layer. Over the basal part of the bladder the stratum is tolerably complete; but, as it is followed forwards, the fibres open out and become oblique.

The *submucous coat* is the loose areolar bed in which the blood-vessels and nerves ramify before they enter the mucous membrane. It connects the mucous and muscular coats, and has a considerable amount of elastic tissue entering into its composition.

Dissection.—The *mucous membrane* which lines the bladder should now be examined, and, for this purpose, it is necessary to open up the viscus by an incision along its anterior aspect from the apex to the neck. It is better to lay open the first portion of the urethra at the same time by carrying the incision along the mesial plane through the anterior part of the prostate.

Mucous Membrane of the Bladder.—When the mucous membrane is washed, it will be observed to be highly rugose, except over a triangular area immediately behind the urethral orifice. This rugosity is due to the loose manner in which the membrane is bound by the submucous layer to the muscular coat. When the bladder is distended, the folds are effaced, and the mucous lining becomes smooth and even.

Orifices of the Bladder.—The *orifice of the urethra* (orificium urethræ internum), or the canal which conducts the urine from the bladder, is situated at the neck. Immediately above this, the mucous membrane will be noticed to be elevated so as to form a slight prominence, which bulges forwards into the aperture. This elevation is termed the *lucette*, or the *uvula vesicæ*, and it results from an accumulation or thickening of the submucous tissue at the spot. Probes should now be passed along the ureters into the interior of the bladder. By this means the dissector will be able to see how very obliquely these ducts pierce the walls of the bladder. Indeed, they traverse the wall for more than three-quarters of an inch before they reach the internal orifices. This arrangement, whilst it permits the passage of urine from the ureter into the

bladder; exercises a valvular action in distension of the viscus, and prevents any backward flow of the urine into the ureters. The *openings of the ureters* (orificia ureterium) are two slit-like apertures, which are placed about an inch and a half apart from each other, and about the same distance from the luette or urethral orifice.

Trigone of the Bladder.—The three orifices of the bladder constitute the angles of an equilateral triangle, which is termed the *trigone*, the boundaries of which are formed by lines drawn between the openings of the ureters and from each of these forwards to the luette. The mucous membrane over this area presents a marked contrast to the same membrane in other parts of the bladder. Here it is always smooth, in whatever condition the viscus may be, and this is due to its being tightly bound down to the subjacent muscular coat. It is also said to be more sensitive than in other parts of the bladder.

It is important to note that the trigone in the interior of the bladder corresponds with the triangular area on the exterior of the base, which is bounded by the vasa deferentia, the vesiculæ seminales, and the recto-vesical peritoneal reflection.

Dissection.—The bladder should now be pinned out on the bottom of a cork-lined tray filled with water. When this is done the mucous membrane over the trigone may be carefully raised. A band of muscular fibres will be observed to take a curved course, at the base of the trigone, between the two ureters. In certain cases another band may be traced from the ureter along each side of the trigone towards the luette. These muscular bands form the slightly marked ridges which bound the trigone.

Urethra (urethra virilis).—The urethra is the canal through which the urine, the semen, and the secretions of the vesiculæ seminales, the prostate, and Cowper's glands are emitted from the body. It commences at the neck of the bladder and ends on the glans penis, and its average length is somewhere about eight or nine inches. It is customary to divide the urethra into three parts, from the

different character of the structures which it traverses. The *first* or *prostatic portion* (pars prostatica) is contained within the substance of the prostatic gland; the *second* or *membranous portion* (pars membranacea) extends from the apex of the prostate to the bulb of the corpus spongiosum penis, and is surrounded by the fibres of the compressor urethræ muscle; whilst the *third* or *spongy part* (pars

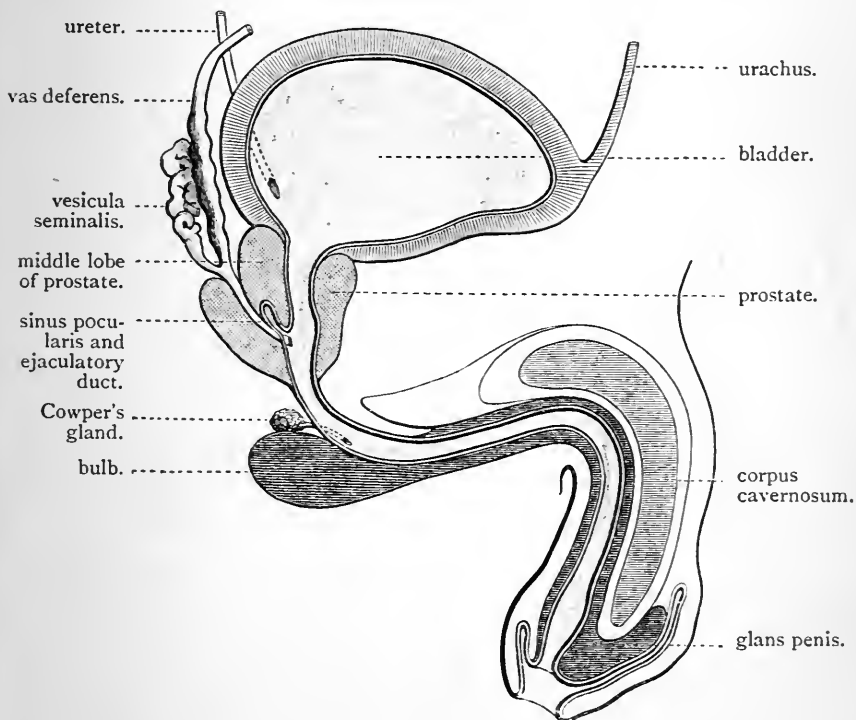


FIG. 153.

cavernosa) traverses the entire length of the corpus spongiosum.

Dissection.—The urethral canal must now be laid open throughout its whole length, in order that its various parts may be studied. Lay the bladder and penis upon a block, and extend the incision which has already been made through the prostate, along the upper wall of the membranous portion of the urethra, and along the dorsum of the penis

between the two corpora cavernosa and through the glans. This cut must be made as far as possible in the mesial plane.'

Prostatic Portion of the Urethra.—This part of the urethra is about one inch and a quarter in length. It traverses the prostate in front of its middle lobe, and is therefore nearer the anterior than the posterior surface of this structure. It is the *widest* and at the same time the *most dilatable* part of the canal, and further, it is *fusiform*, being wider in the middle than at either its commencement or termination.

In connection with the floor of the prostatic portion of the urethra, there are certain very important features to be noted. The mucous membrane along the mesial plane is raised into a prominent ridge called the *verumontanum*.¹ This commences a short distance in front of the uvula vesicæ, and extends forwards for about three-quarters of an inch. Posteriorly, it rises to a considerable height, but anteriorly, it gradually fades away. On each side of the verumontanum, the floor of the urethra is hollowed out into a longitudinal depression, termed the *prostatic sinus*, into which numerous *prostatic ducts* open. This may be rendered evident by squeezing the prostate, when fluid will be observed to exude into the two sinuses. These ducts belong to the lateral lobes of the prostate. A close inspection of the floor of the urethra behind the verumontanum, will reveal the apertures of the ducts of the middle lobe of the prostate.

Immediately in front of the highest part of the verumontanum, the mucous membrane dips backwards and upwards behind the middle lobe of the prostate, and between the lateral lobes, so as to form a small recess or *cul-de-sac*. This is the *sinus pocularis* or the *utriculus*. Gauge its extent by means of a probe. It will be observed to be from a quarter to half an inch long, and to be very

¹ Other terms are applied to this mesial ridge on the floor of the urethra — viz., *crest of the urethra*, *colliculus seminalis*, and *caput gallinaginis*.

narrow at its orifice, but to widen out considerably towards its blind extremity. It is of interest, both from a developmental and a surgical point of view. It is the representative, in the male, of the uterus and vagina in the female. Practically, it is important, because in some cases it is large enough to entangle the point of a small catheter or bougie.

The dissector should now pass bristles along the *common ejaculatory ducts*. They will be observed to run downwards between the middle and lateral lobes of the prostate. Finally, entering the wall of the sinus prostaticus, they open by slit-like apertures, just within the margin of its orifice.

Owing to the presence of the verumontanum on the floor of the canal, and the prostatic sinus upon each side of it, a transverse section of the prostatic portion of the urethra presents a crescentic figure—the convexity of the crescent being directed forwards and the concavity backwards.

As old age approaches, the prostate is very liable to become enlarged, and the most important result of this is the effect which it exerts upon the urethra. When the enlargement is uniform, the prostatic portion of the canal is simply elongated; when, however, the enlargement is confined to one lobe or part of a lobe, it impinges upon the urethra, and produces an alteration in its direction, and a consequent difficulty in micturition. When the middle lobe alone is increased in size, it projects forwards into the bladder so as to close the commencement of the canal.

The Membranous Portion of the Urethra.—This is the *narrowest* and the *shortest* division of the urethra. It extends from the apex of the prostate to the bulb of the penis, and describes a gentle curve from above, downwards and forwards, behind the lower border of the symphysis pubis, from which it is distant about one inch. Its length is fully three-quarters of an inch, and its concavity is directed forwards and upwards, and its convexity backwards and downwards. Throughout its entire extent it is enveloped by the fibres of the compressor urethræ muscle,

whilst towards its termination Cowper's glands are placed behind it—one on each side.

The relation of the membranous part of the urethra to the triangular ligament and the parietal pelvic fascia is very important. As it emerges from the prostate, the parietal pelvic fascia (*i.e.*, the superior layer of the triangular ligament) sweeps backwards upon it to take part in the formation of the prostatic capsule. At its termination it pierces the triangular ligament proper about an inch below the symphysis pubis. It may therefore be looked upon as lying in the interval between these membranes.

Immediately subjacent to the mucous membrane the membranous part of the urethra is surrounded by a thin coating of erectile tissue, outside which there is a muscular tunic composed of involuntary fibres arranged circularly.

The Spongy Portion of the Urethra.—This is the *longest* division of the urethra. It is embedded throughout in the substance of the corpus spongiosum penis, and shows considerable differences in its calibre as it is followed forwards to the glans. At each expansion of the corpus spongiosum there is a corresponding dilatation of the urethra. Thus the canal presents two dilatations—(1) in the bulb, and (2) in the glans; between these it is of uniform diameter, and slightly wider than the membranous part. The dilatation of the urethra in the glans is termed the *fossa navicularis*. At its orifice, which is termed the *meatus urinarius*, the canal is much contracted, and is even narrower, than any part of the membranous portion. This aperture is a vertical slit, the lower end of which is connected with the prepuce by a fold of mucous membrane, termed the *frænum preputii*.

In the bulb and in the glans penis the erectile tissue of the corpus spongiosum is disposed very unequally around the urethra. In the former it is chiefly massed below or behind the tube, whilst in the glans it is chiefly placed in front and upon each side, a very thin layer covering it posteriorly.

The *ducts of Cowper's glands* open into the spongy portion of the urethra by piercing its floor about an inch in front of the triangular ligament. These orifices are extremely minute, and very difficult to find. By making a small hole in the wall of the duct as it emerges from the gland, and passing a fine bristle along it, the dissector may be able to detect the opening in the urethral floor. He will notice that the ducts proceed in the first place through the erectile tissue of the bulb, but towards their termination they lie immediately subjacent to the mucous membrane.

The walls of the urethra are always in apposition except when urine is flowing through it. A transverse section through the spongy portion, except at its anterior part, would give the appearance of a transverse slit. In the fossa navicularis, however, the slit becomes vertical.

Mucous Membrane of the Urethra.—The mucous lining of the urethra is continuous posteriorly with that of the bladder, and anteriorly with the integument covering the glans penis. It is likewise continuous with the mucous membrane which lines the various ducts which open into the urethra. It is everywhere studded with the mouths of minute recesses, called *lacunæ*. These are particularly plentiful on the floor of the spongy part, and, as a general rule, they are directed forwards towards the meatus urinarius. One recess, specially deserving the attention of the student on account of its large size, is called the *lacuna magna*; it is placed on the roof of the fossa navicularis. Its orifice in rare cases is large enough to admit the point of a small bougie or catheter.

Direction of the Urethral Canal.—The prostatic portion is directed downwards and very slightly forwards; the membranous part describes a slight curve behind the symphysis, the concavity of which looks forwards; whilst the spongy part at first ascends, and then curves downwards. The urethra, therefore, in the flaccid condition of the penis, takes a course in which there are two curves, like the letter *o* reversed. In the erect condition of the penis

the curve in the spongy part of the canal is obliterated, and there is now only one curve, the concavity of which is directed upwards.

Structure of the Prostate.—In the course of an ordinary dissection it is hardly to be expected that the dissector will be able to make out the structure of the prostate in all its details. It is mainly composed of involuntary muscular tissue, which is so arranged that it exercises a powerful sphincter action on the first part of the urethra. This tissue forms a layer on the outside of the organ, and also gives a coating to the urethra as it traverses the prostate. The outside and inside fibres are continuous in front—indeed, the greater part of the anterior portion of the prostate is muscular. The fibres surrounding the urethra are also continuous above with the circular fibres of the bladder, and below with the circular fibres of the membranous part of the urethra; further, they radiate out transversely into each lateral lobe. The glandular substance is interspersed amidst the muscular tissue, but none is to be seen in front of the urethra.

Structure of the Penis.—In the dissection of the urethra the corpora cavernosa penis have been separated from each other. Each will be seen to be enveloped in an exceedingly strong fibro-elastic sheath. In the mesial plane the sheaths become continuous with a strong septum, which intervenes between the two cylindrical masses. This septum receives the name of *septum pectiniforme*, because in front it is very imperfect, being broken up by vertical slits into a series of processes like the teeth of a comb. The two fibrous cases thus constructed are filled with erectile tissue. Fibrous lamellæ and bands proceed from the deep surface of each sheath and join with each other to form a spongy framework. The interstices of this framework freely communicate with each other, and are filled with venous blood. By taking the penis to the tap and washing out the blood some idea of the trabeculæ may be obtained.

The corpus spongiosum has a similar structure. The

enclosing sheath, however, is very delicate, and the trabeculæ are much finer.

Vesiculæ Seminales.—If the dissector has not already unravelled the vesiculæ seminales, he should now do so, and, at the same time, endeavour to make out the composition of their walls. This can best be done under water. In addition to the recto-vesical fascia which ensheathes them, each vesicula has a strong dense fibrous tunic and a certain proportion of transverse and longitudinal non-striated muscular fibres. Open them up and expose the *mucous lining*. This is remarkable for its honeycomb or reticular appearance. In this respect, therefore, it is not unlike the mucous membrane of the gall-bladder, only the meshes are finer and the pits smaller.

PELVIC ARTICULATIONS.

The pelvis is attached to the last lumbar vertebra, and its several parts are held together by the following articulations:—(1) Lumbo-sacral; (2) Sacro-coccygeal; (3) Coccygeal; (4) Sacro-iliac; (5) Pubic.

Dissection.—The nerves and blood-vessels of the pelvis must now be removed, and all adhering portions of muscle detached from the left innominate bone and the front and back of the sacrum. When this is done, the pelvis should be soaked for some time in warm water. By this proceeding the dissection of the ligaments will be rendered much easier.

Lumbo-sacral Articulations.—The last lumbar vertebra is joined to the sacrum by one *amphiarthrodial joint*, which connects the body of the vertebra to the base of the sacrum, and by two *diarthrodial joints*, between the two pairs of articular processes.

Capsular ligaments (capsulæ articulares) surround the articulations formed by the apposition of the articular processes, and each is lined by a synovial membrane.

The *anterior common ligament* (ligamentum longitudinale anterius) of the vertebral column is continued downwards

over the anterior aspect of the body of the last lumbar vertebra to the anterior aspect of the first segment of the sacrum. In a similar manner the *posterior common ligament* (ligamentum longitudinale posterius) is prolonged downwards within the spinal canal, over the posterior aspect of the body of the last lumbar vertebra, to the upper part of that portion of the sacrum which forms the anterior wall of the sacral canal.

Ligamenta subflava (ligamenta flava) are also present. These are two short bands of yellow elastic tissue placed one on each side of the mesial plane. Superiorly they are attached to the anterior aspect of the lower borders of the laminae of the last lumbar vertebra; whilst inferiorly they are fixed to the posterior aspect of the upper margins of the laminae of the first sacral segment.

An *interspinous ligament* (ligamentum interspinale) connects the lower border of the spinous process of the last lumbar vertebra with the upper border of the spinous process of the first sacral vertebra. A *supraspinous ligament* (ligamentum supraspinale) bridges across between the extremities of the same spinous processes.

So far, then, the ligaments of the lumbo-sacral articulations are identical with those which, above the level of the sacrum, bind the several segments of the spinal column together. Two additional ligaments—viz., the lumbo-sacral and the ilio-lumbar, must now be examined.

The *lumbo-sacral ligament* is the representative of the superior costo-transverse ligaments. It is a strong triangular fibrous band attached by its apex to the tip and lower border of the transverse process of the last lumbar vertebra. Expanding as it proceeds downwards, it is fixed below to the posterior part of the base of the sacrum, where some of its fibres intermingle with those of the sacro-iliac ligaments.

The *ilio-lumbar ligament* (ligamentum iliolumbale) may be considered to be a thickened and specially developed part of the anterior lamella of the lumbar fascia. It lies in the same plane and is directly continuous with it. It is

triangular in shape, and is fixed by its apex to the tip of the transverse process of the last lumbar vertebra. Proceeding horizontally outwards, it is inserted into the inner lip of the iliac crest at the posterior part of the iliac fossa.

The *amphiarthrodial joint*, between the body of the last lumbar vertebra and the base of the sacrum, corresponds in every respect with the similar articulations above, between the bodies of the vertebræ. The opposed bony surfaces are each coated by a thin layer of hyaline cartilage, and are firmly united by an intervening disc of fibro-cartilage, which is dense and laminated externally, soft and pulpy towards the centre. The dissector should observe that this disc is the thickest of the series, and further, that it is wedge-shaped, being thicker in front than behind.

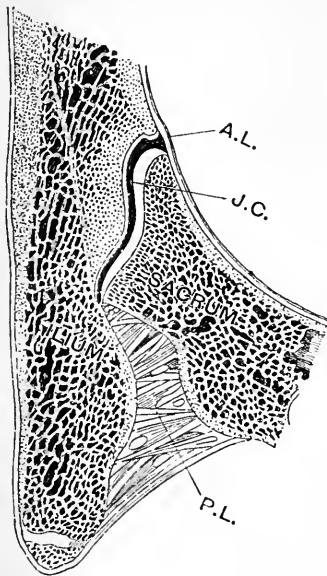
Sacro-coccygeal Articulation.—This is an amphiarthrodial joint. The articulating surfaces are each covered by a thin cartilaginous plate, and these are united by a disc of fibro-cartilage. The joint is strengthened in front by an *anterior ligament*, which extends downwards from the front of the sacrum to the anterior aspect of the coccyx, and by a *posterior ligament* which, attached above to the posterior border of the lower aperture of the sacral canal, proceeds downwards upon the posterior aspect of the coccyx. The latter ligament is much the stronger of the two. In addition, fibrous bands will also be found passing between the cornua of the sacrum and the coccyx, and also between the lateral angles of the sacrum and the transverse processes of the first piece of the coccyx.

As regards the *coccygeal joints* (when such exist), the union of the different segments of the bone is brought about by intervening cartilaginous discs and anterior and posterior ligaments.

Dissection.—The student should now saw through the sacrum and coccyx in the mesial plane. By this proceeding he will obtain a view of the structure of the intervertebral discs, and at the same time be enabled to make out to better advantage the attachments of the posterior common vertebral ligament and of the ligamenta subflava.

Sacro-iliac Articulation.—The sacrum is wedged in

between the two innominate bones, and is held fast in this position by the sinuous form of the opposed articular surfaces and the strong ligaments which pass between the bones. These ligaments are—



1. The anterior sacro-iliac.
2. The posterior sacro-iliac.
3. The oblique sacro-iliac.
4. Great sacro-sciatic.
5. Small sacro-sciatic.

The *anterior sacro-iliac ligament* (ligamentum sacroiliacum anterius) is by no means strong. It is composed of a series of short fibres stretching across in front of the joint, and connecting the bones anteriorly.

The *posterior sacro-iliac ligament* (ligamentum sacroiliacum interosseum) is exceedingly strong. It consists of fibrous bands, which connect the rough surface on the posterior part of the lateral aspect of the sacrum with a corresponding rough surface on the ilium, behind the auricular surface. Upon the

FIG. 154.—Section through the sacro-iliac joint. (After Luschka.)

A.L. Anterior sacro-iliac ligament.
P.L. Posterior sacro-iliac ligament.
J.C. Joint cavity.

posterior sacro-iliac ligaments the strength of the articulation chiefly depends. As the sacrum narrows towards its dorsal surface it cannot be regarded in any sense as forming the keystone of an arch. It may be regarded as being in a great measure suspended from the iliac bones by these ligaments.

The *oblique ligament* is simply a specially thickened part of the posterior sacro-iliac ligament. Above, it is fixed to the posterior superior spine of the ilium; whilst, inferiorly, it is inserted into the lateral tubercle of the third piece of the sacrum.

The *great sacro-sciatic ligament* (ligamentum sacrotuber-
osum) has a wide attachment to the posterior inferior iliac
spine and to the side of the sacrum and coccyx. Narrow-
ing considerably as it proceeds downwards and forwards,
it again expands, and is inserted into the inner border of
the tuberosity of the ischium. From this it sends upwards
a sharp *falciform edge*, which extends forwards for a short
distance upon the ascending ramus of the ischium, and
gives attachment to the parietal pelvic fascia. It should
be noticed that at its ischial attachment, some of its fibres
pass continuously into the tendon of the biceps muscle.

The *small sacro-sciatic ligament* (ligamentum sacrospin-
osum) is triangular in form. By its base it is fixed to the
side of the sacrum and coccyx in front of the great sacro-
sciatic ligament, the fibres of both mingling together; by
its apex it is attached to the spine of the ischium. The
pelvic surface of this ligament presents an extremely in-
timate connection with the coccygeus muscle; indeed, it
is generally believed that the ligament is derived from the
superficial part of the muscle by the fibrous degeneration
of its fasciculi.

The two sacro-sciatic ligaments convert the sciatic
notches of the innominate bone into foramina. Through
the great sacro-sciatic foramen pass the gluteal vessels and
superior gluteal nerve, the pyriformis muscle, the sciatic
vessels and nerves, the inferior gluteal nerve, the internal
pudic vessels and nerve, the nerve to the obturator
internus, and the nerve to the quadratus femoris.

The small sacro-sciatic foramen transmits the obturator
internus muscle, the pudic vessels and nerve, and the
nerve to the obturator internus.

A *synovial cavity* is present in the sacro-iliac joint.
The ligaments of the joint should now be divided, and the
two bones forcibly wrenched asunder. By this proceeding
each articular surface will be seen to be covered with a
plate of cartilage, between which a small synovial space
may be observed, which partially separates them.

The sacro-iliac joint is not immovable, as is sometimes

stated. A slight amount of movement can take place—the sacrum moving round an imaginary line drawn transversely through its second piece from one side to the other. In the erect posture the promontory of the sacrum is withdrawn to the full extent from the symphysis; in bending the body forwards, it approaches, in a small degree, the symphysis, and, in consequence, the tension of the sacro-sciatic ligaments is increased.

Symphysis Pubis.—This is an example of an amphiarthrodial joint. In addition to the intervening disc of

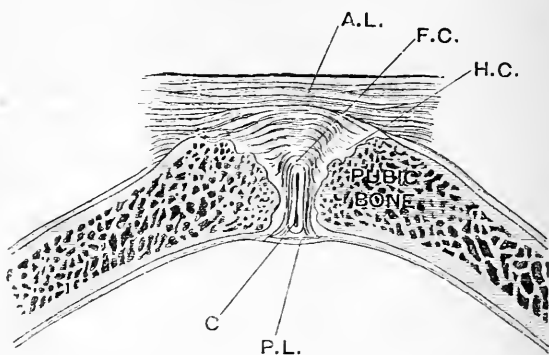


FIG. 155.—Horizontal section through the symphysis pubis. (After Luschka.)

A.L. Anterior ligament.
F.C. Fibro-cartilage.
H.C. Layer of hyaline cartilage.

C. Synovial cavity.
P.L. Posterior ligament.

fibro-cartilage which connects the cartilage-covered opposing surfaces of the two pubic bones, *four* ligaments are present, viz. :—

- | | |
|---------------------|-------------------------|
| 1. Anterior pubic. | 3. Supra-pubic. |
| 2. Posterior pubic. | 4. Infra- or sub-pubic. |

The *anterior pubic ligament* is strongly marked, and consists of two layers of fibres—a superficial and a deep. The *superficial fibres* are oblique, and cross each other like the limbs of the letter X, mingling with the decussating fibres of the internal pillars of the external abdominal ring.

The *deep fibres* are transverse, and extend across from one bone to the other.

The *posterior pubic ligament* consists of a very few fibres on the posterior aspect of the joint.

The *supra-pubic ligament*, like the preceding, is weak. It is placed upon the upper aspect of the symphysis, and stretches between the crests of the two pubic bones.

The *infra- or sub-pubic ligament*, which is situated on the lower aspect of the joint, rounds off the apex of the pubic arch. It is a strong band, somewhat triangular in shape, which is attached on each side to the descending ramus of the pubic bone, and above, to the fibro-cartilaginous disc. Between the crescentic lower margin of this ligament and the upper border of the transverse perineal band of the triangular ligament of the urethra, there is an oval aperture through which the dorsal vein of the penis passes backwards.

Dissection.—The saw should now be used, and a portion sliced off from the front of the joint. The intervening plate of fibro-cartilage can in this way be studied. It will be seen to be thicker and denser in front than behind. As a general rule, a small synovial cavity will be found towards its back part, and nearer its upper than its lower end.

The Obturator or Thyroid Membrane.—This is the membrane which stretches across the thyroid foramen. It is attached to the circumference of the foramen, except at its upper part, where it bridges across the groove on the under surface of the horizontal ramus of the pubic bone, and converts it into a foramen for the escape of the obturator vessels and nerves. At this point it is continuous over the upper border of the obturator internus muscle with the parietal pelvic fascia.

FEMALE PELVIS.

The contents of the female pelvis are the following :—

<i>Viscera.</i>	{	1. The rectum.	
		2. The bladder and urethra.	
		3. The uterus and vagina.	
		4. The uterine appendages.	{ Fallopian tubes. Ovaries, etc. Round ligament.
<i>Blood-vessels.</i>	{	1. Internal iliac vessels and their branches.	
		2. The superior hæmorrhoidal vessels.	
		3. The middle sacral vessels.	
		4. The ovarian vessels.	
		5. Certain venous plexuses in connection with the viscera.	
<i>Nerves.</i>	{	1. The sacral and sacro-coccygeal plexuses and their branches.	
		2. The obturator nerves.	
		3. The pelvic part of the sympathetic.	

The peritoneum is continued into the pelvis, and clothes some of the viscera completely and others partially.

General Position of the Viscera.—The *rectum*, as in the male, occupies the posterior part of the pelvic cavity, and is adapted to the concavity of the sacrum and coccyx. The *bladder* and *urethra* are situated in front, the former lying against the posterior aspect of the pubic bones. The *uterus* and *vagina* are intermediate in position; whilst the *uterine appendages* are placed laterally. Three tubes or canals are thus directed downwards to open on the surface within the limits of the perineum, viz. (*a*) the urethra; (*b*) the vagina; (*c*) the rectum. (Figs. 156 and 157).

Peritoneum.—The peritoneum, as it proceeds downwards from the posterior abdominal wall into the pelvis, comes into relation with the rectum, and gives it a partial covering. The first part of the gut it clothes completely and connects by means of a distinct fold, called the *mesorectum*, to the anterior surface of the sacrum. Gradually it quits the rectum, leaving first its posterior surface, then its

lateral, and finally its anterior surface. The peritoneum is now reflected on to the posterior wall of the upper part

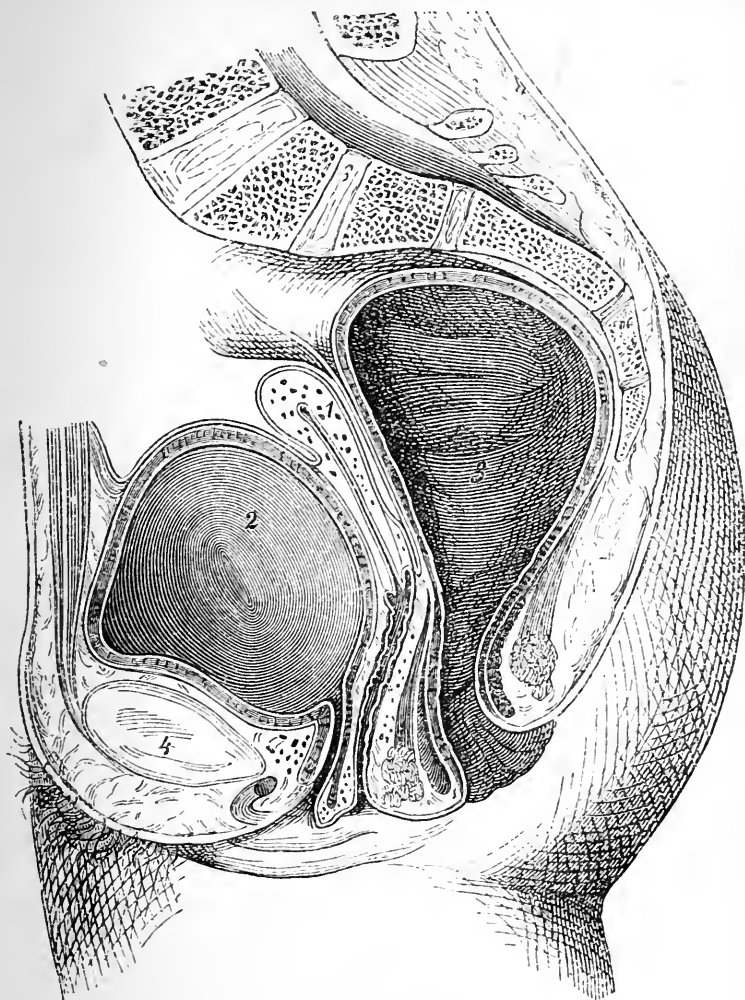


FIG. 156.—Mesial section through the pelvis of a virgin (after Legendre). The uterus is smaller than usual. (From BRAUNE'S *Atlas of Topographical Anatomy*.)

- | | | |
|-------------|--|---------------|
| 1. Uterus. | | 3. Rectum. |
| 2. Bladder. | | 4. Symphysis. |

of the vagina, upon which it ascends to the posterior surface of the uterus, which it covers completely. Reaching the

fundus of the uterus, it turns over this and descends upon the anterior aspect of the organ. This surface of the uterus it only invests in its upper three-fourths, and is then reflected on to the posterior aspect of the bladder. Whilst the vagina, therefore, receives a partial investment from the peritoneum posteriorly, it is altogether destitute of it anteriorly; and, again, whilst the entire posterior surface of the uterus is covered, the lower fourth of its anterior surface is bare, in so far as this membrane is concerned. From each lateral border of the uterus the peritoneum stretches outwards in the form of a wide fold, called the *broad ligament*. This connects the organ to the lateral wall of the pelvis and the iliac fossa.

Upon the bladder the peritoneum is carried upwards, and at its apex is conducted to the posterior aspect of the anterior abdominal wall by the urachus. On each side of the viscus it extends outwards as far as the obliterated hypogastric artery, along the line of which it quits the bladder, and is continued on to the pelvic wall. An important point to notice is, that the peritoneal membrane is much more adherent to the wall of the uterus than it is to the wall of the bladder.

Broad Ligament of the Uterus (ligamentum latum

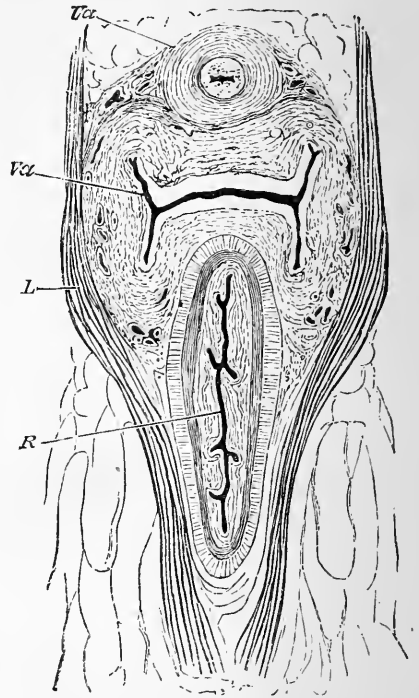


FIG. 157.—Horizontal section through the urethra, vagina, and anal canal, a short distance above their terminations. (Henle.)

Ua. Urethra.		L. Levator ani.
Va. Vagina.		R. Rectum.

uteri).—This is a wide fold composed of two layers of peritoneum which stretches from each lateral border of the uterus to the opposite part of the pelvic wall and iliac fossa. The *superior border* of the ligament is occupied by the *Fallopian tube*, the fimbriated free outer extremity of which opens into the peritoneal cavity. Here, therefore, a continuity is established between the mucous lining of the tube and the peritoneal membrane. At a lower level than the Fallopian tube two secondary folds will be observed in

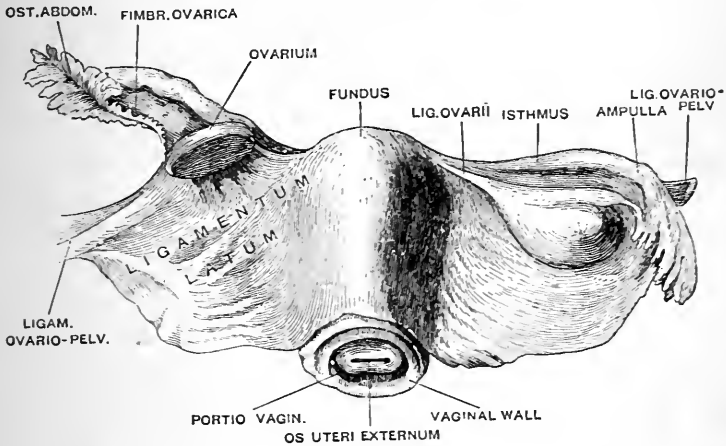


FIG. 158.—The uterus, with the broad ligament stretching out from either side of it (from Gegenbaur). The line which leads from LIGAM. OVARIO-PELV. on the left side points to the round ligament of the uterus. The peritoneal fold immediately beyond this is the ligamentum ovario-pelvicum.

connection with the broad ligament. Of these one projects backwards, and contains between its layers the *ovary and its ligament*, whilst the other is directed forwards, and contains the *round ligament of the uterus*.

In addition to these more conspicuous objects, the two layers of the broad ligament include between them other structures, viz.—(1) the *parovarium*; (2) the *uterine and ovarian vessels, nerves, and lymphatics*.

The part of the broad ligament which extends from the

upper end of the ovary to the iliac fossa in the neighbourhood of the external iliac vessels receives the special name of the *ovario-pelvic ligament*, or the *suspensory ligament of the ovary*. It contains between its two layers the ovarian vessels and nerves.

Recto-Vaginal Pouch, or the Pouch of Douglas.—This corresponds with the recto-vesical pouch in the male. *In front*, it is bounded by the peritoneum clothing the vagina and uterus; *behind*, by the membrane investing the rectum; whilst, *on each side*, it is limited by a semilunar fold of peritoneum which proceeds forwards from the side of the rectum to the side of the uterus. Some importance is attached to the fact that this pouch is slightly deeper on the left than upon the right side.

The Utero-vesical Pouch is much shallower than the preceding. It is placed between the uterus and the bladder, and it is limited laterally by two slight antero-posterior folds of peritoneum, termed the utero-vesical folds, which pass between these viscera.

False Ligaments of the Bladder and Uterus.—The false ligaments of the bladder are *five* in number, viz., one superior, two lateral, and two posterior.

The *two posterior false ligaments* of the bladder are the utero-vesical folds, which extend between the uterus and bladder, and limit the utero-vesical pouch laterally.

The *superior false ligament* is that portion of the peritoneum which passes from the apex of the bladder on to the anterior wall of the abdomen. It is led away from the viscus by the urachus and the two impervious hypogastric arteries.

The *lateral false ligament* is the term applied to the peritoneum as it passes from each side of the bladder to the wall of the pelvis and the iliac fossa. This reflection has been seen to take place along the line of the obliterated hypogastric artery.

The false ligaments of the uterus are *four* in number—*two anterior* and *two posterior*. These are simply other names applied to the recto-uterine and utero-vesical folds.

The recto-uterine folds, or folds of Douglas, contain a considerable quantity of involuntary muscular tissue between their layers.

Hypogastric Nervous Plexus.—In no respect does it differ from that of the male (*vide* p. 551).

Pelvic Fascia.—For a description of the pelvic fascia and the manner in which it should be dissected the student is referred to page 551. The *parietal portion* is identical with that of the male, except in so far that in front it sweeps backwards upon the urethra and vagina, instead of the prostate, to join the visceral part. The *visceral portion* differs inasmuch as it gives a sheath to the vagina. Reaching the lateral aspect of the viscera, it thus divides into four layers, viz.—(1) A *vesical layer*, which forms the lateral true ligament of the bladder; (2) A *vesico-vaginal layer*, which passes between the bladder and vagina; (3) A *recto-vaginal layer*, which proceeds inwards between the vagina and rectum; and (4) A *rectal layer*, for the lateral and posterior aspects of the rectum.

Dissection.—The right innominate bone should now be removed, in accordance with the directions given at p. 564, and the visceral layer of the pelvic fascia followed out in its various reflections upon the viscera. When thoroughly satisfied upon this point, remove the remains of the fascia and clean the viscera, taking care not to injure the blood-vessels and nerves which supply them. This dissection will be rendered easier if the rectum and vagina be cleansed and moderately stuffed with tow. It is better also to partially inflate the bladder, but it is a difficult matter to retain the air when introduced; still it can be accomplished by sewing a fine thread round the urethral orifice, and tightening it like a purse-string as the blow-pipe is withdrawn.

Rectum (*intestinum rectum*).—A detailed account of the rectum, as it is found in the male, is given at p. 565. It is only necessary, therefore, to mention here the points of difference in the female.

The relations and extent of the *first part* are similar in every respect, with one exception—viz., that the peritoneal *cul-de-sac* in front separates it, not from the bladder, but from the uterus.

The *second part* is also separated, for a short distance,

by the recto-vaginal *cul-de-sac* of peritoneum from the uterus and vagina. Below this, however, it is in apposition with the posterior wall of the vagina—a layer of pelvic fascia (the recto-vaginal) alone intervening. The connection between the rectal and vaginal walls is at first very loose, but afterwards much more intimate. This has an important bearing upon the manner in which prolapsus uteri takes place. It should be noted that whilst the greater part of this portion of the rectum is supported by the sacrum and coccyx, there is fully an inch of its lower portion which rests upon the *ano-coccygeal body* (Fig. 160).

The *third part* or *anal canal* bends downwards and backwards about one inch in front of the coccyx, so that

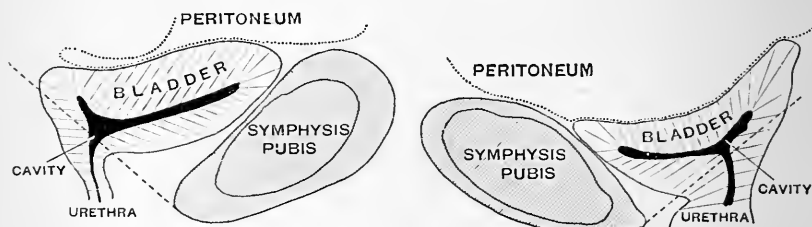


FIG. 159.—Two forms of the empty female bladder as seen in mesial section. (After Disse.)

an angular interval is left between the gut and the vagina—an interval to which the term *perineum* is restricted by the obstetrician, and which is occupied by a pyramidal mass of firm fibro-muscular tissue, called the *perineal body* (Fig. 160).

The Bladder (*vesica urinaria*).—The female bladder, when distended, is rounder and not so ovoid in shape as in the male. The base, which is directed backwards, is in relation to the neck of the uterus and the vagina. In the female, there is no prostate surrounding its neck, no *vas deferens* upon its side and base, and no *vesiculæ seminales* in relation to its base. The relations which it presents to the peritoneum, the walls of the pelvis, and the obliterated hypogastric arteries, are so similar to those present in

the male (*vide* p. 570) that a second description is unnecessary.

The position of the bladder is not quite the same as in the male. It is placed at a lower level in the pelvis. We have noted that a line carried from the inferior margin of the symphysis pubis backwards through the urethral orifice of the bladder strikes the posterior pelvic wall in the male at the level of the lower part of the second sacral

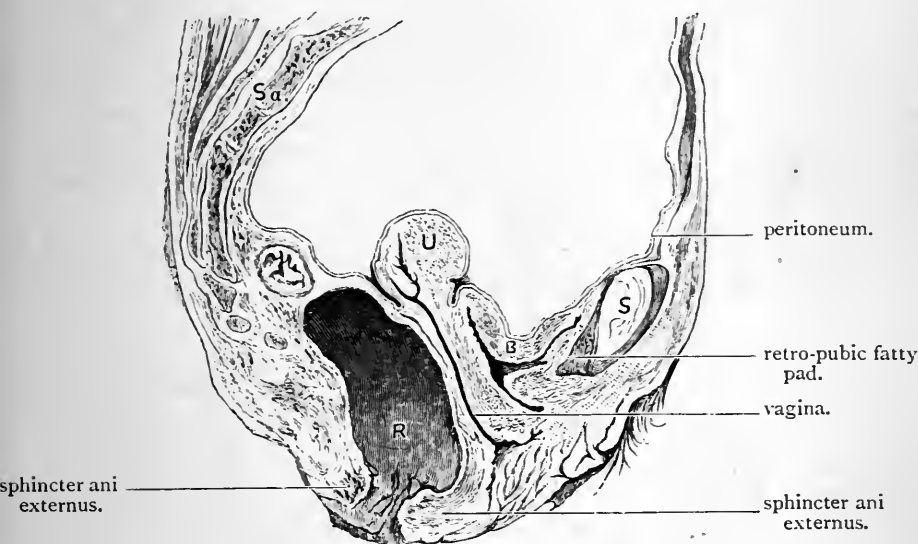


FIG. 160.—Mesial section through a female pelvis.

Sa. Sacrum.
R. Rectum.
U. Uterus.

B. Empty Bladder.
S. Symphysis.

The uterus is anteflexed, and, as it inclines to the right side, the section in the upper part does not cut it into two equal and symmetrical portions.

Note the rectal *cul-de-sac* above the anal canal.

vertebra. In the female, such a line would probably strike the lower border of the fifth sacral vertebra (Disse). Of course in making this observation we must not lose sight of the fact that the symphysis pubis is relatively shorter in the female than in the male.

The female bladder, when empty, usually becomes flattened from above downwards, so as to obliterate in a great measure its vertical diameter. Taken in conjunction with the urethra, it presents, when seen in a mesial section, an outline something like the letter Y. The vertical limb of the letter represents the urethra (Figs. 159 and 160).

The empty bladder may assume a different form. In place of being flattened from above downwards, it may be small, rounded, and exceedingly firm to the touch. In such cases, on mesial section, the bladder cavity forms a slit continuous with the lumen of the urethra. It has been suggested that this rounded form of bladder represents the organ in systole; whilst the flattened form with the Υ -shaped cavity represents it in diastole (Hart). The former condition is more common in the male; the latter, in the female.

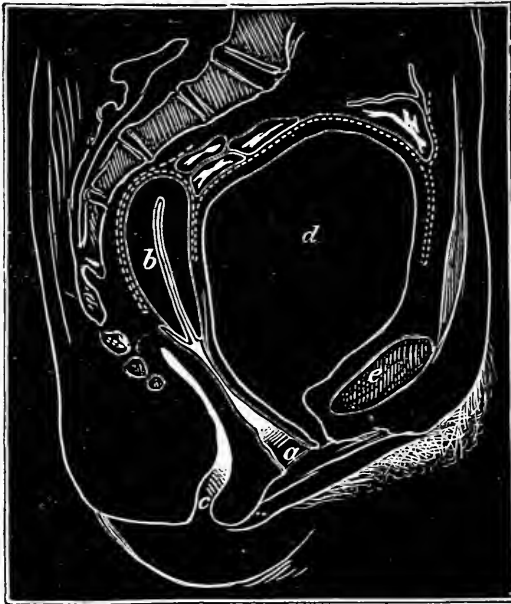

FIG. 161.—Vertical section through the female pelvis; bladder distended. (After Pirogoff.)

a. Vagina.

b. Uterus.

c. Rectum.

d. Bladder.

e. Symphysis.

The dotted line represents the peritoneum.

Ureters.—The pelvic portions of the ureters are longer in the female than in the male. They cross the internal iliac artery, and then extend forwards, one upon each side of the neck of the uterus. As the ureter approaches the base of the bladder, it lies for a very short part of its course in relation to the upper part of the side wall of the

vagina. As in the male, it pierces the bladder wall very obliquely.

Urethra (urethra muliebris).—The urethra is the canal along which the urine escapes from the bladder. Its walls are always in close apposition, except when the passage is opened by the flow of urine through it. In length, it measures about one inch and a half, and it takes a slightly curved course from the neck of the bladder downwards and forwards to the vestibule, where it opens on the surface by an aperture, called the *meatus urinarius*. This has been examined in the dissection of the perineum (p. 375). The relation of the female urethra to the anterior wall of the vagina is so intimate that it may almost be said to be embedded in it.

Uterus.—The uterus is the organ into which the ovum is received, and in which it is retained until the foetus is fully developed. It is placed in the interval between the rectum and the bladder, below the general mass of the small intestine, and above the vagina. *In shape*, it is pyriform or flask-shaped, flattened from before backwards. *In length*, it is about three inches; *in breadth*, at the broadest point, two inches; and *in thickness*, nearly an inch. The broader upper end of the uterus is directed upwards and forwards, whilst its narrow lower end looks downwards and backwards, and forms, with the vagina, an obtuse angle, which is open towards the pubis.

It is customary to describe the uterus as being composed of three parts—viz., a fundus, a body, and a neck or cervix (Fig. 158).

The *fundus* (fundus uteri) is the rounded upper end. The Fallopian tube enters the organ on each side at its upper angle, and a line drawn transversely between these is arbitrarily fixed upon as the limit between the fundus and the body of the uterus. It is completely covered by peritoneum.

The *body* (corpus uteri) diminishes in breadth as it proceeds downwards towards the neck. In front and behind, it is smooth and convex, the convexity of the

posterior surface, however, being much more marked, especially in its upper part, than that of the anterior surface. Upon each side it is joined immediately below the entrance of the Fallopian tube, in front, by the *round ligament*, and behind, by the *ligament of the ovary* (Fig. 162). Inferiorly, the body of the uterus is marked off from the neck by a slight constriction, which is very apparent in the infant, but which becomes less distinct as puberty approaches, and usually disappears altogether after parturition. This constriction is called the *isthmus*.

The *neck* or *cervix* (*cervix uterina*) about an inch in length, is narrower than the body, and more cylindrical in form. It projects into the upper end of the vagina, the walls of which are attached to the uterus around it. To obtain a satisfactory view of the cervix uteri, it is necessary to slit up the vagina along its lateral aspect and to remove the stuffing. The posterior wall of the vagina will then be seen to ascend to a higher level upon the cervix than the anterior wall; or, in other words, the anterior wall of the vagina will be observed to be shorter than the posterior wall (Fig. 160). On the lower extremity of the cervix, which is full, rounded and knob-like, there is an aperture called the *os uteri externum* (*orificium externum uteri*). In the virgin this opening is small and circular, but in females that have borne children it is usually transverse and somewhat irregular in outline. It is bounded by two thick rounded lips. Comparing these it will be noticed that the anterior lip is the thicker of the two, whilst the posterior is the longer. Although the anterior lip is the shorter it should be noted that, on account of the oblique position of the uterus, it is placed at a lower level in the vagina. The greater length of the posterior lip is due to the fact that the wall of the vagina passes higher up on that aspect of the uterus. The part of the cervix which projects into the vagina is called the *portio vaginalis*; the part above is termed the *portio supravaginalis* (Fig. 158).

As the mucous membrane which lines the vagina passes from its anterior wall on to the anterior lip of the os uteri,

it forms a shallow angular recess between the two, called the *anterior fornix*. The same is seen behind in connection with the posterior lip of the os uteri, but, owing to the higher attachment of the posterior vaginal wall, the *posterior fornix* is very deep. A most important relation should be made out at this stage, viz., that when the finger is placed in the posterior fornix it is merely separated from the peritoneum lining the pelvic cavity by the posterior vaginal wall (Fig. 160). This is owing to the fact that the recto-vaginal *cul-de-sac* of peritoneum descends so as to cover the upper part of the posterior vaginal wall.

The *relations* of the uterus should next be studied. *Posteriorly*, it is invested completely by peritoneum, and is separated from the rectum by the recto-vaginal *cul-de-sac*. Within this peritoneal pouch there are always more or less of the sigmoid flexure and a few coils of small intestine. *Anteriorly*, it is covered in its upper three-fourths by peritoneum, and is in apposition with the bladder.

Position of the Uterus.—In women who have borne no children (*nulliparæ*) and in whom the bladder and the rectum are both empty, the uterus is normally strongly anteflexed and anteverted (Waldeyer). When we say that the uterus is anteflexed, we mean that it is bent forwards upon itself at the isthmus, so that the body and the cervix meet at an angle which is open to the front. This forward flexion of the uterus depends upon two circumstances—viz., (1) upon the greater pliability of the body as compared with the firmer consistence and greater rigidity of the cervix; and (2) upon the fact that the cervix is more or less held in position by its attachments to the anterior vaginal wall and the base of the bladder in front, and to the posterior vaginal wall behind. By the term “anteversion,” we mean that the whole uterus—both body and cervix—is inclined forwards so as to form an angle of greater or less magnitude with the vertical axis of the trunk. In this position of the uterus the coils of the small intestine and a loop of the sigmoid flexure rest upon its posterior surface, whilst its anterior surface is supported

by the bladder. It is very rare indeed that a coil of small intestine is found between the uterus and the bladder in the utero-vesical pouch of peritoneum. In multiparæ (women who have borne children) the anteflexion of the uterus is not so marked as it is in nulliparæ.

But the uterus possesses a great degree of mobility, and consequently we find that its position is constantly liable to change. Intra-abdominal pressure, and distension of the bladder or rectum, are the chief agencies at work in producing these effects. Every breath that is taken, every movement of the body, is followed by a slight alteration in the position of the uterus. When the bladder fills the uterus is raised with it; the anteflexion and the anteversion become less marked, and, in cases of hyper-distension of the bladder, the uterus may assume an almost erect position (Fig. 161). With this change of position the relation of the uterus to the rectum becomes more intimate, through the forcing of the small intestine out of the pouch of Douglas. When the rectum becomes distended the uterus is pushed forwards and to the right side.

Under no circumstances is it usual to find the uterus occupying an accurately median position. It would appear that it is more frequently inclined to the left than to the right (Waldeyer).

Vagina.—The vagina is the passage which leads from the uterus to the vulva. In length it is about four and a half or five inches, and in the empty condition of the bladder and rectum it pursues a very nearly straight course from above downwards and forwards. In the erect posture of the body its long axis may be said to be nearly parallel to the plane of the pelvic brim. Superiorly, its walls are firmly attached to the substance of the uterus around its neck, upon which it ascends to a higher level behind than in front; on account of this, the cervix uteri has the appearance of piercing its anterior wall. The vagina is wider in the middle than at either end, and the anterior and posterior walls are closely applied to each other, so that in no respect can the vagina be regarded as an open

tube or canal. In section, therefore, it appears simply as a transverse or longitudinal slit, according to the direction in which it is divided (Figs. 157 and 160).

Posteriorly, the upper end of the vagina is in relation to the bottom of the recto-vaginal pouch of peritoneum.

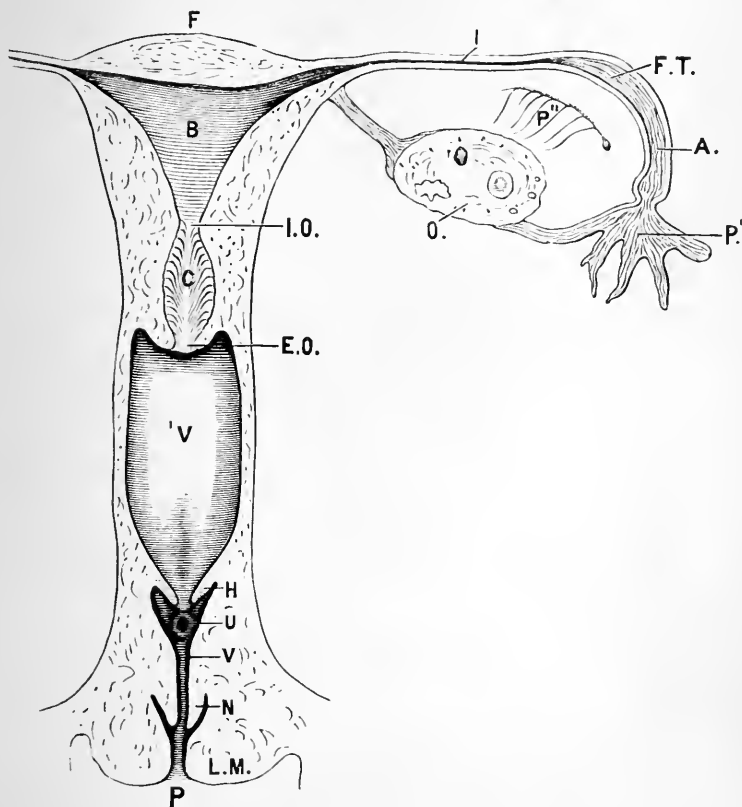


FIG. 162.—Diagram of the vulva, vagina, and the uterus, with its appendages (Symington).

- F. Fundus of the uterus.
- B. Body of the uterus.
- I.O. Os internum.
- C. Cervical canal.
- E.O. Os externum.
- V. Vagina.
- H. Hymen.
- U. Urethral opening.
- P. Pudendal cleft.

- N. Nympha.
- L.M. Labium majus.
- I. Isthmus of the Fallopian tube.
- F.T. Fallopian tube.
- A. Ampulla of Fallopian tube.
- P'. Fimbriated end of Fallopian tube.
- P''. Parovarium.
- O. Ovary.

Below this it is in apposition with the second part of the rectum, the recto-vaginal layer of pelvic fascia intervening. Still lower down, it is separated from the third part of the rectum by an angular interval, which is occupied by the perineal body. *Anteriorly*, it is related to the base of the bladder and to the urethra—indeed, the latter may almost be said to be embedded in its wall. *Upon each side* of the vagina, the levator ani muscle descends and gives it support, whilst its lower end is embraced by the sphincter

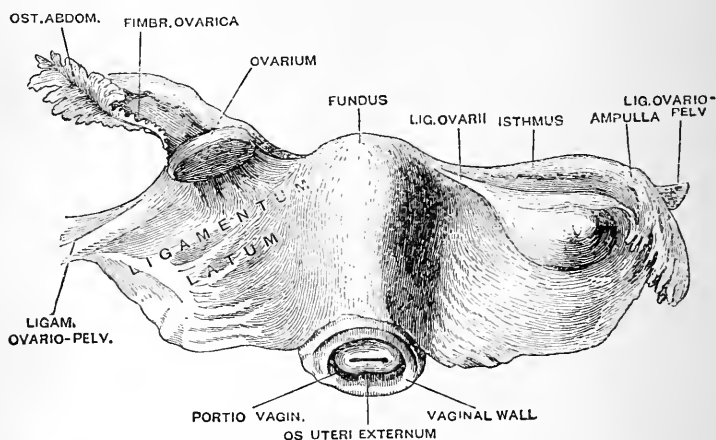


FIG. 163.—The uterus, with the broad ligament stretching out from either side of it (from Gegenbaur). The line which leads from LIGAM. OVARIO-PELV. on the left side points to the round ligament of the uterus. The peritoneal fold immediately beyond this is the ligamentum ovario-pelvicum.

vaginæ. Close to the neck of the uterus the ureter is in contact with the vagina on each side for a very limited part of its course.

Ovaries.—The ovaries are two small solid bodies contained within the posterior secondary folds of the broad ligaments. Each ovary is oval or oblong in figure, slightly compressed from side to side, and having a size somewhat similar to that of a pigeon's egg.

The ovary presents two flattened surfaces, two extremities

or poles, and two borders. Its natural or typical position can only be studied in young women who have borne no children. When pregnancy occurs the ovaries become displaced, and it is questionable if they ever regain their original place within the pelvis. In the young virgin and in the erect posture of the body the ovary lies with its long axis vertical (Waldeyer and His). It occupies a peritoneal fossa on the posterior part of the side wall of the pelvis, immediately below the external iliac vessels (Fig. 164). This recess is termed the *fossa ovarii* (Claudius). From the *upper pole* of the ovary the ovario-pelvic fold of peritoneum passes outwards to the wall of the pelvis. To the same extremity the mouth of the Fallopian tube is attached by one of its fimbriæ; from the latter connection the term *tubal pole* (*extremitas tubaria*) is frequently applied to the upper end of the ovary. The lower extremity is connected with the uterus by a round cord-like structure, *the ligament of the ovary*, which is included between the two layers of the broad ligament. This end of the ovary is consequently sometimes called the *uterine pole* (*extremitas uterina*). The two surfaces of the ovary look outwards and inwards, and the two borders are directed forwards and backwards. The *anterior border* is thinner and straighter than the posterior border, and is very commonly called *the attached border* or the *hilum*. The term "attached" is applied to it because it is along this margin that the two layers of the broad ligament which enclose the ovary leave it. Everywhere else it presents a free surface. The name of "hilum," on the other hand, is given to this margin because the vessels, nerves, and lymphatics enter and leave the organ along its whole length. The *posterior border* of the ovary is free, and looks slightly inwards towards the rectum as well as backwards. The Fallopian tube in the natural position of the pelvic organs encircles the greater part of the circumference of the ovary.

It may be well to state here that anatomists are by no means unanimous on the question of the typical position of the ovary. Kölliker considers that it lies obliquely, with its long axis parallel to the external

iliac vessels. Hasse believes that the long axis is directed forwards and outwards; whilst Schultze figures the ovaries with their long axes directed from before backwards. The author has given preference to

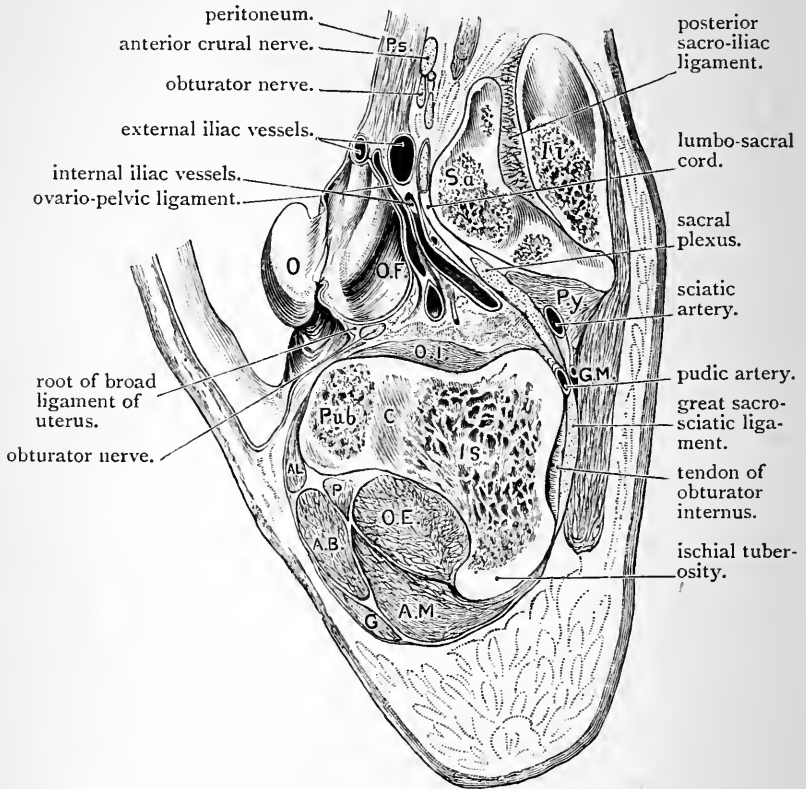


FIG. 164.—Sagittal section through the pelvis of a female child two years old, in a plane midway between the right mid-Poupart plane and the mesial plane. The ovary has been turned forwards out of the ovarian fossa.

Il. Ilium.
 Sa. Sacrum.
 Ps. Psoas.
 O. Ovary.
 O.F. Ovarian fossa.
 O.I. Obturator internus.
 Py. Pyriformis.
 G.M. Gluteus maximus.
 Pub. Pubic bone.

C. Acetabular cartilage.
 Is. Ischium.
 A.L. Adductor longus.
 A.B. Adductor brevis.
 P. Pectineus.
 G. Gracilis.
 O.E. Obturator externus.
 A.M. Adductor magnus.

the views of His and Waldeyer, because they are in accordance with his own observations.

The ovary is completely surrounded by peritoneum, except along its hilum. The membrane, however, does not present so highly polished an appearance as in other parts of the abdominal cavity. This is due to a change in the form of the surface epithelium, which is placed over the ovary. Before puberty the surface of the ovary is smooth and uniform. After this period, however, it becomes scarred and puckered from the breaches which are made by the escape of the ova, from the Graafian follicles.

Parovarium, or the Organ of Rosenmuller.—This structure is of interest because it is the representative of the epididymis in the male. It is somewhat triangular in form, and will be discovered by an attentive examination of that portion of the broad ligament of the uterus which stretches between the ovary and the Fallopian tube. Its apex is directed towards the former, and its base towards the latter; but it lies free between the two layers of the ligament, and is not connected with either. In structure it will be seen to consist of a number of tubules which radiate from the apex of the body and are joined together by a longitudinal tube (the homologue of the duct of Gartner in the cow, etc), which extends along its base.

The Fallopian Tubes or Oviducts (*tubæ uterinæ*).—These are two tubes which have as their function the conveyance of the ova or eggs from the ovary to the uterus. Each duct is about three or four inches long, and is contained within the superior free border of the broad ligament of the uterus. Its inner extremity pierces the uterus at its superior angle, whilst its outer end is situated about an inch beyond the ovary and opens into the peritoneal cavity by a constricted orifice (*ostium abdominale*), surrounded by numbers of fringe-like processes, called *fimbriæ*. By one of these fimbriæ, termed the *ovarian fimbria* (*fimbria ovarica*), it is attached to the tubal pole of the ovary. The calibre of the Fallopian tube is by no means uniform. As it is traced outwards from the

uterus it is at first extremely narrow. This portion is called the *isthmus* (*isthmus tubæ uterinæ*). In the neighbourhood of the ovary it dilates considerably, and receives the name of the *ampulla* (*ampulla tubæ uterinæ*). The ovarian fimbria is longer than the others; it is attached along its whole length to the broad ligament, and shows on its surface a gutter-like groove leading from the constricted mouth of the tube to the ovary (Fig. 165).

In the typical position of parts the Fallopian tube proceeds horizontally outwards on the pelvic floor. It then

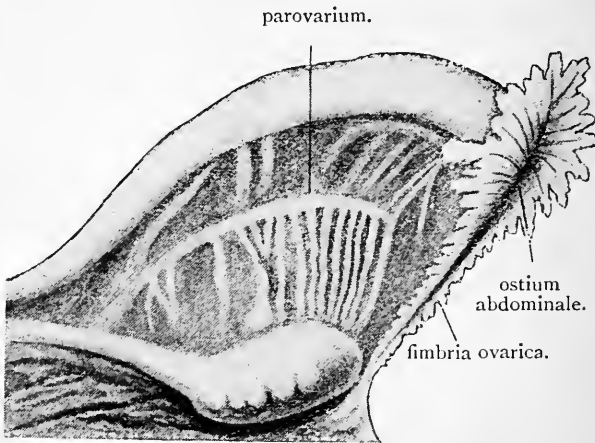


FIG. 165.—The ampulla and fimbriated end of the Fallopian tube; the ovary; and the parovarium. (From Gegenbaur, modified.)

turns vertically upwards along the hilum or attached border of the ovary, and gaining the tubal pole, it bends upon itself and turns downwards upon the posterior free border and the inner surface of the ovary, both of which it in great part covers (Waldeyer). It may, therefore, be considered to consist of three parts:—(1) *the first* in relation to the floor of the pelvis; (2) *the second* in relation to the anterior border of the ovary; (3) *the third* in relation to the posterior border and inner surface of the ovary.

Round Ligament of the Uterus (*ligamentum teres*

uteri).—The round ligaments are two cord-like bands largely composed of involuntary muscular fibres, which are attached to the body of the uterus immediately in front of and a little below the entrance of the Fallopian tube—one on each side. From this, each ligament is directed outwards and forwards between the layers of the broad ligament and in front of the oviduct, to the internal abdominal ring. It has already been examined within the inguinal canal. In the young subject the peritoneum is usually prolonged along with it into this canal in the form of a tubular process termed the “*Canal of Nuck.*” Later on this becomes obliterated.

PELVIC BLOOD-VESSELS.

The manner in which the blood-vessels of the pelvis should be dissected is described at p. 579. In the female three additional arteries will be found, viz.—

- 1. The uterine, } branches of the internal iliac.
- 2. The vaginal, }
- 3. The ovarian, from the abdominal aorta.

The Uterine Artery (*arteria uterina*) springs from the anterior division of the internal iliac artery, and proceeds downwards and inwards to the neck of the uterus. At this point it gives several small branches to the vagina and bladder, and, changing its direction, extends upwards in a tortuous manner along the lateral border of the uterus and between the two layers of the broad ligament. Reaching the fundus, it sends several twigs outwards into the broad ligament; of these, one accompanies the round ligament, another goes with the Fallopian tube, and several proceed to the ovary, and anastomose with twigs from the ovarian artery. Whilst, in contact with the lateral border of the uterus, the uterine artery gives numerous branches to this organ.

The Vaginal Artery (*arteria vaginalis*) also springs from

the anterior division of the internal iliac, but it is not unusual for it to arise in common with the uterine artery, or the middle hæmorrhoidal artery. It is distributed to the vagina, and sends twigs to the rectum and bladder.

The Ovarian Artery (*arteria ovarica*).—The course which this vessel takes within the abdomen proper is described at p. 533. When it arrives at the pelvis, it insinuates itself between the two layers of the broad ligament of the uterus, where this forms the ovario-pelvic fold. It is highly tortuous, and runs along the anterior border of the ovary, and from thence onwards to the fundus of the uterus into which its terminal branches sink. It follows, therefore, the course of the Fallopian tube to which it gives several branches, and in the neighbourhood of the ovary a crowd of small twigs enter along the hilum of that organ. It likewise supplies an offset which follows the round ligament, and it anastomoses freely with branches of the uterine artery.

The other arteries of the female pelvis are identical with those of the male, and therefore it is needless to repeat the description which will be found at p. 580.

Veins of the Pelvis.—Very few facts require to be added to those which are given regarding the veins of the male pelvis (p. 584). Of course there is no prostatic plexus of veins in the female, and therefore the *dorsal vein of the clitoris* joins the vesical plexus.

Both the vagina and uterus are surrounded by large tortuous veins, constituting a *vaginal* and a *uterine plexus*. From the former, the blood is drained away into the internal iliac vein, whilst from the uterine plexus it is chiefly carried away by the ovarian veins.

PELVIC DIAPHRAGM.

This is described at p. 586. The dissector should note, however, that the anterior fibres of the *levator ani* muscle, which in the male are connected with the prostate, pass

downwards upon the lateral aspect of the vagina and give it support (Fig. 157).

NERVES OF THE PELVIS.

Very little requires to be added to what has already been said regarding the nerves of the male pelvis (p. 587). There is no *prostatic plexus*; but a *vaginal plexus*, an *ovarian plexus*, and numerous *uterine nerves* are present in addition to those mentioned in the male.

The *uterine nerves* proceed from the pelvic plexus, before it is joined by the twigs from the third and fourth sacral nerves. They ascend between the two layers of the lateral ligament along with the uterine artery, but, in their distribution to the uterus, they do not rigorously accompany the branches of this vessel.

The *vaginal plexus* is an offset from the pelvic plexus, and the nerves which compose it are not plexiform in their arrangement.

The *ovarian plexus* is derived from the aortic and renal plexuses, and, accompanying the artery of the same name, is distributed to the ovary.

Coccygeal Body.—*Vide* p. 592.

Removal of Viscera.—The viscera should now be removed from the pelvic cavity. Begin by cutting the various nerves and vessels which enter them, the levator ani and the anterior true ligaments of the bladder. Then carefully divide the parts which hold the urethra and vagina to the arch of the pubis. Lastly, separate the rectum from its connections with the sacrum and coccyx.

The *obturator internus* and *pyriformis muscles* should now be studied. They are described at page 592.

The viscera should next be separated from each other, but the vagina must be left attached to the uterus, and the urethra to the bladder.

Coats of the Rectum.—The coats of this portion of the intestinal canal are identical in both sexes. The student may, therefore, refer to p. 593, where the wall of the male rectum is described.

Bladder.—Particulars regarding the coats of the bladder may be obtained by turning back to p. 596. In slitting open this viscus the urethra should be laid open along its upper surface at the same time.

Urethra.—The external meatus is the narrowest part of this tube. As the urethra is traced upwards, it will be seen to expand before joining the neck of the bladder, and close to the meatus its floor will be noticed to be somewhat depressed so as to form a slight hollow.

Dissection.—The uterus with its appendages should now be laid upon its posterior surface on a block. The round ligaments and the ligaments of the ovaries should be isolated and their attachments defined, and then the uterus may be opened by a longitudinal mesial incision, extending from the fundus to the os uteri externum. A slight cut should also be made outwards from the upper end of this incision towards the entrance of each Fallopian tube. The cut edges may now be pared so as to extend the view of the interior of the uterus.

Wall of the Uterus.—The *round ligament* will now be seen to be attached to the body of the uterus immediately in front of and a little below the entrance of the Fallopian tube. The *ligament of the ovary*, a much more slender band, is a fibrous cord containing some muscular tissue derived from the wall of the uterus. It extends from the lower uterine pole of the ovary to the body of the uterus, which it joins immediately behind and a little below the entrance of the Fallopian tube. In all its length, it is enclosed between the two layers of the broad ligament.

The wall of the uterus is very thick, and presents three well-marked coats, viz., a serous or peritoneal, a muscular, and a mucous. The *serous covering* has already been fully studied. The *muscular part* of the wall constitutes its chief bulk. It is composed of involuntary muscular tissue, with a considerable admixture of areolar tissue. It is not equally thick throughout. Thus it becomes distinctly thinner towards the angles at the entrance of the Fallopian tubes. The *mucous lining* will be studied after the interior of the organ has been examined.

Interior of the Uterus (cavum uteri).—The cavity in the interior of the uterus is much smaller than would be naturally expected from the size of the organ. It is subdivided arbitrarily into an *upper part*, which occupies the body, and a *lower or cervical part*, which occupies the cervix.

The *upper portion* is the larger of the two, and is triangular in form. The anterior and posterior walls are in contact with each other, and the sides of the triangle are incurved, the base being directed upwards. At the two extremities

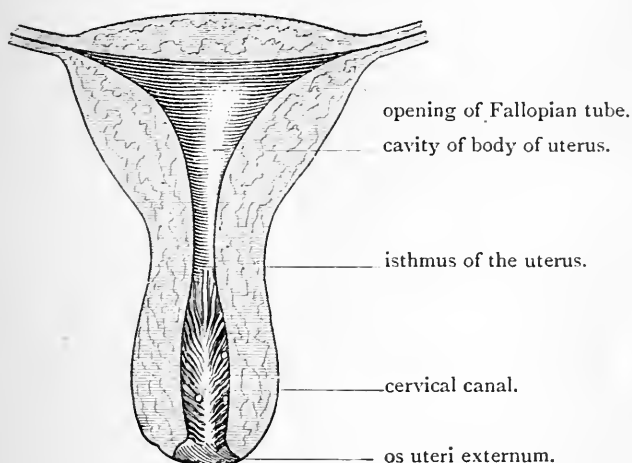


FIG. 166.—Interior of the uterus. (Luschka.)

of the base are the constricted openings of the Fallopian tubes.

The *lower cervical portion* is fusiform or spindle-shaped in form, being also slightly compressed from before backwards. Above, it is somewhat constricted, and at the junction of the body with the cervix of the uterus it becomes continuous with the upper triangular part of the cavity. This narrow opening is termed the *os uteri internum* (orificium internum uteri). Below, the cavity of the uterus opens into the vagina by the *os uteri externum*.

Mucous Membrane of the Uterus.—The dissector will

not fail to note a striking difference between the mucous lining of the uterus in the triangular cavity of the body and in the fusiform cavity of the cervix. In the former it is smooth and even, and tightly bound down to the subjacent muscular tissue. In the cervix it presents a remarkable disposition, which, from its appearance, has been termed the *arbor vitæ*. This consists of a series of prominent folds or rugæ arranged in a definite manner. Thus, there is an anterior and posterior median fold or raphe, and from this secondary folds branch off and pass obliquely upwards and outwards. The *arbor vitæ* is more marked upon the anterior than upon the posterior wall.

The student should look between the folds of the *arbor vitæ* for *ovula Nabothi*. These are minute vesicles filled with a yellowish liquid. They are merely follicles distended with mucus.

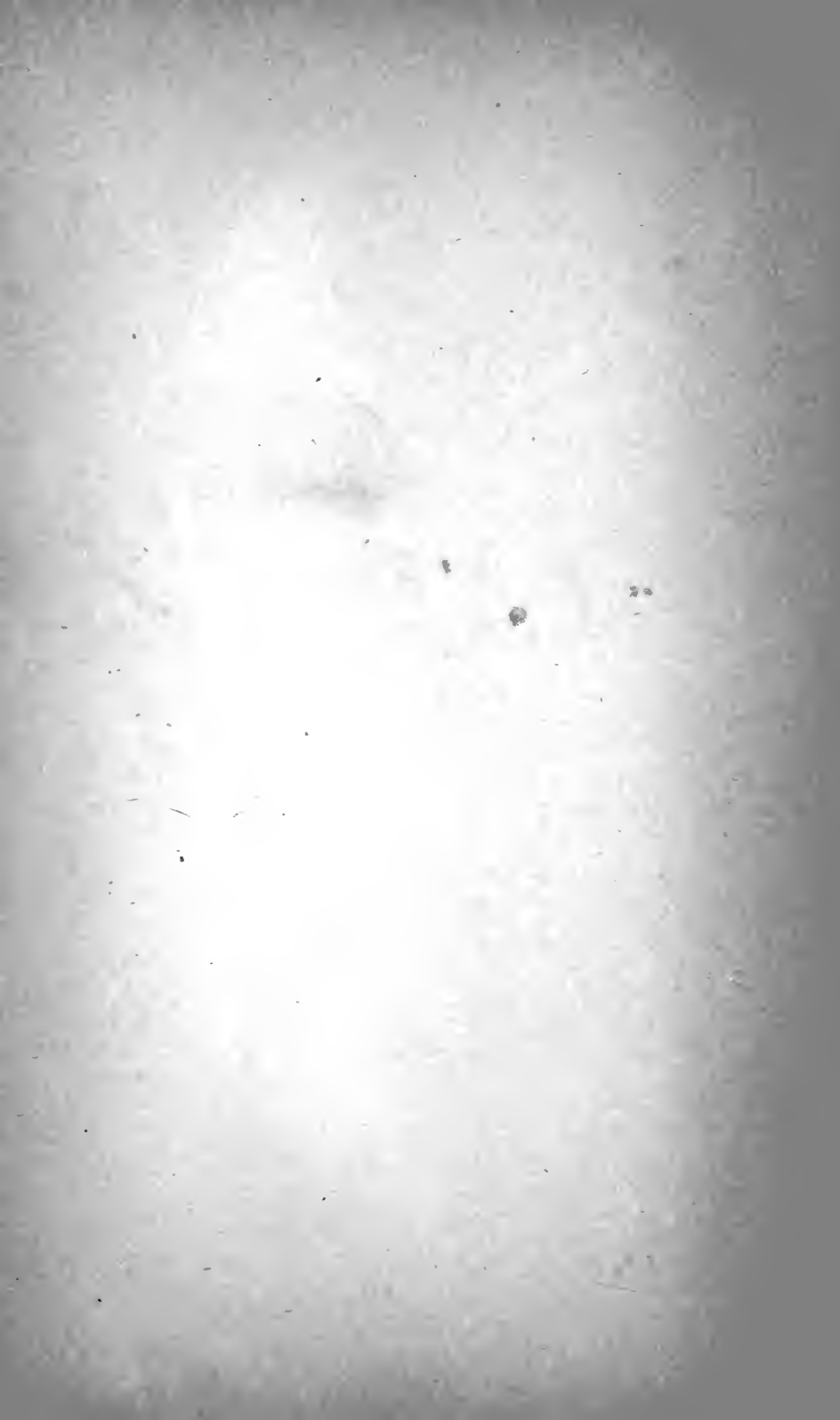Fallopian Tubes.—The Fallopian tube has an external serous, an intermediate muscular, and an internal mucous coat. The aperture by which it opens into the uterus is exceedingly small, and will barely admit a bristle. The expanded ampulla, however, may be opened up. In this part of the tube the mucous membrane will be seen to be arranged in longitudinal folds. To obtain a proper idea of the fimbriæ which surround the *ostium abdominale*, the tube should be immersed in water, when the fringes will float out and separate from each other.

Coats of the Vagina.—Outside the mucous lining there is a thin layer of erectile tissue, and spread over this the proper muscular coat of the vagina. The mucous lining will be observed to present special peculiarities. Two well-marked median and longitudinal folds extend upwards, one upon the anterior and the other upon the posterior wall. These are termed the *columnæ rugarum*, and from each side they send off numerous transverse rugæ, which are arranged so that those on the anterior wall fit in between those on the posterior wall. These folds are best marked near the vaginal orifice, and are absent at the upper end of the canal.

PELVIC ARTICULATIONS.

These are described at p. 605. In the later months of pregnancy the ligamentous tissues of the various pelvic joints become softened, thickened, and infiltrated. The pelvic bones are thus partially separated from each other, and the width of the pelvic circle is increased.

INDEX.



	PAGE		PAGE
Aorta,	530	ARTERIES— <i>Continued.</i>	
,, Abdominalis,	530	Bulb of Penis, Artery to,	359
Aortic Nervous Plexus,	476	,, Vestibule, Artery to,	376
,, Opening in Diaphragm,	528, 529	Capsular, Inferior,	524, 533
Aponeuroses, Brachial,	67	,, Middle,	524, 532
,, of External Oblique,	386	,, Superior,	524, 532
,, of Internal Oblique,	392	Cœliac Axis,	483
,, of Transversalis,	398	Colic,	472
Appendices Epiploicæ,	435	Collateral Arteries of the	
Arbor Vitæ of Uterus,	636	Fingers,	113
Areola of Mamma,	21	Common Iliac,	530, 534
Arteria Magna Hallucis,	302	Common Interosseous,	102
,, Princeps Pollicis,	128	Coronary,	483
,, Radialis Indicis,	128	Corpus Cavernosum Penis,	
ARTERIES—		Artery to,	359
Acromio-thoracic,	36	,, ,, Clitoridis,	
Alar-thoracic,	38	Artery to,	376
Anastomosis around Ankle,	287	Cremasteric,	409, 414
,, ,, Elbow,	136	Crucial Anastomosis,	180
,, ,, Knee,	305	Cutaneous of Abdominal	
,, ,, Scapula,	56	Wall,	384
,, on Back of		,, of Back,	6
Thigh,	200	,, of Chest,	18
Anastomotica of Arm,	74	Cystic,	486
,, Thigh, 210, 230,		Deep Circumflex Iliac,	409
305		,, Epigastric, 402, 408, 423,	428
Anterior Carpal Arch,	96	,, External Pudic,	225
,, Circumflex, 26, 31, 38		,, Palmar Arch,	127
,, Interosseous, 102, 105,	138	Digital,	113, 302
,, Peroneal,	268, 285	Dorsal of Clitoris,	376
,, Radial Carpal,	96	,, of Penis,	359, 429
,, Tibial Artery, 265, 280		,, Interosseous,	139, 268
,, ,, Recurrent,	266	Dorsalis Indicis,	139
,, Ulnar ,,	102	,, Pedis,	265, 266
Aorta,	530	,, Pollicis,	139
,, Abdominalis,	530	,, Scapulæ,	56
,, ,, Branches of,	531	External Circumflex, 222, 235,	
Arteria Magna Hallucis,	302	,, Iliac,	241
,, Princeps Pollicis,	128	,, Mammary,	22
,, Radialis Indicis,	128	,, Plantar,	294
Articular Arteries of Knee,	193, 305	Femoral,	224, 230
Axillary,	31, 34	Gastro-duodenal,	486
,, Branches of,	36	Gluteal,	182, 583
Brachial,	70	Hepatic,	485, 513
,, Branches of,	73	Hypogastric,	581
		Ileo-colic,	472
		Iliac Branch of Obturator	582
		Inferior Hæmorrhoidal,	345

	PAGE
<i>ARTERIES—Continued.</i>	
Inferior Mesenteric, . . .	474
,, Pancreatico-duo- denal, . . .	470
,, Phrenic, . . .	531
,, Profunda, . . .	73
,, Vesical, . . .	582
Intercostal, . . .	407
Internal Calcanean, . . .	281
,, Circumflex, 180,	222,
,, Iliac, . . .	243
,, Iliac, . . .	580
,, Plantar, . . .	292
,, Pudic, 177, 344,	358,
,, Pudic, . . .	376, 582
Lateral Sacral, . . .	583
Left Colic, . . .	474
,, Gastro-epiploic, . . .	488
Long Thoracic, . . .	38
Lumbar, . . .	407, 533, 545
Malleolar, . . .	266
Median, . . .	106
Metatarsal, . . .	268
Middle Colic, . . .	472
,, Hæmorrhoidal, . . .	582
,, Sacral, . . .	584
Musculo-phrenic, . . .	410, 530
Nutrient of Femur, . . .	242
,, Fibula, . . .	285
,, Humerus, . . .	73
,, Radius, . . .	106
,, Tibia, . . .	281
,, Ulna, . . .	106
Obliterated Hypogastric, . . .	422
Obturator, . . .	247, 428, 564, 582
,, Abnormal origin of, . . .	221
Ovarian, . . .	533, 632
Pancreatica Magna, . . .	488
Pancreaticæ Parvæ, . . .	488
Perforating of Foot, . . .	302
,, of Thigh, . . .	199, 242
Peroneal, . . .	281, 284
Plantar Arch, . . .	301
Popliteal, . . .	191, 280
,, Branches of, . . .	193
Posterior Circumflex, . . .	38, 50
,, Interosseous, . . .	135
,, ,, Recurrent, . . .	135
,, Peroneal, . . .	285

	PAGE
<i>ARTERIES—Continued.</i>	
Posterior Scapular, . . .	14
,, Tibial, . . .	280
,, Ulnar Recurrent, . . .	102
Profunda Branch of Ulnar, 113,	127
,, Femoris, . . .	222, 240
Pubic, . . .	409, 582
,, Branch of Obturator, . . .	582
Pyloric, . . .	486
Radial, . . .	94, 128, 138
,, Branches of, . . .	95
,, Recurrent, . . .	95
Rami Intestini Tenuis, . . .	470
Renal, . . .	532
Right Colic, . . .	472
,, Gastro-epiploic, . . .	486
Sciatic, . . .	175, 583
Sigmoid, . . .	474
Spermatic, . . .	414, 533
Splenic, . . .	486
Subscapular, . . .	14, 26, 31, 38
Superficial Cervical, . . .	11
,, Circumflex Iliac, ,, Circumflex Iliac, . . .	204, 385
,, Epigastric, . . .	204, 385
,, External Pudic, . . .	204, 384
,, Inguinal, . . .	204, 384
,, Palmar Arch, . . .	112
,, Perineal, . . .	347, 370
Superficialis Volæ, . . .	96
Superior Epigastric, . . .	410, 529
,, Hæmorrhoidal, . . .	584
,, Mesenteric, . . .	470
,, Pancreatico-duo- denal, . . .	486
,, Profunda, . . .	73, 83
,, Thoracic, . . .	36
,, Vesical, . . .	582
Suprascapular, . . .	56
Tarsal, . . .	268
Thoracic axis, . . .	36
Transversalis Colli, . . .	12
Transverse Perineal, . . .	347, 359
Ulnar, . . .	100, 112, 126
,, Carpal, Anterior, . . .	102
,, ,, Posterior, . . .	102
Uterine, . . .	631
Vaginal, . . .	631
Vas Deferens, Artery to, 415,	582

	PAGE		PAGE
ARTERIES— <i>Continued.</i>		Capsular Ligament of Shoulder, . . .	87
Vasa Brevia,	488	" Veins,	532
Articular Arteries of Knee, 193,	306	Capsule of the Kidney,	522
" Nerves of Knee,	306	Caput Gallinaginis,	600
Articulations of the Foot,	324	Cardiac Orifice of Stomach,	446
Ascending Colon,	451	Carpal Joints,	156
" Lumbar Vein,	546	Carpo-metacarpal Joints,	159
Astragaloid Articulations,	325	Carunculæ Myrtiformes,	368
Axilla,	23	Central Point of Perineum,	351
Axillary Artery,	31, 34	" Tendon of Diaphragm,	528
" Glands,	30	Cephalic Vein,	34
" Space,	15	Cervix Uteri,	622
" Vein,	39	Cervix Uteri, Portio Vaginalis,	622
Azygos Articular Artery, 194,	306	Circumflex Nerve,	50
		" Vessels,	50
Bare Area of Liver,	510	Clitoris,	366, 373
Bartholin's Glands,	376	Coats of Bladder,	596
Basilic Vein,	65	" Duodenum,	504
Bertin, Columns of,	523	" Gall-bladder,	511
Biceps Brachii,	75, 89	" Great Intestine,	482
" Femoris,	196	" Large "	482
Bicipital Fascia,	66, 76	" Rectum,	593
Bile Ducts,	511	" Small Intestine,	477
Bladder,	548, 570, 618	" Stomach,	501
" in Distended Condi-		" Vagina,	636
tion,	571, 619	Coccygeal Body,	592
" in Empty Condi-		" Nerve,	591
tion,	571, 619	Coccygeus Muscle,	586
" in the Infant,	574	Coeliac Axis,	483
" Orifices of,	597	" Plexus of Nerves,	499
" Trigone of,	598	Collateral Arteries of Fingers,	113
Body of Clitoris,	373	Colles, Fascia of,	340
" of the Penis,	349	Colliculus Seminalis,	600
" of Testicle,	416	Colon,	451
Brachial Aponeurosis,	67	Colotomy,	453
" Artery,	70	Columnæ Rectæ,	594
" Plexus,	41	" Rugarum,	636
Brachialis Anticus Muscle,	76	Columns of Bertin,	523
Brunner's Glands,	504	" of Morgagni,	594
Bulb of the Penis,	350, 429	Common Bile Duct,	497
" Vestibule,	372	" Ejaculatory Duct, 578,	601
Bulbo-cavernosus Muscle,	351	" Iliac Arteries,	534
		" " Veins,	534
Cæcum,	450	Communicans Fibularis,	190
Calcaneo-cuboid Articulation,	328	" Tibialis,	190
Calices of Ureter,	522	Compartments of Femoral	
Camper, Fascia of,	202, 380	Sheath,	219
Canal of the Epididymis,	420	" of Perineum,	361
Capsular Ligament of Hip,	249	Congenital Hernia,	425
" " Knee,	308	Coni Vasculosi,	420

	PAGE		PAGE
Conjoined Tendon, . . .	392	Dartos Muscle, . . .	340, 369, 411
Conoid Ligament, . . .	53	Deep Circumflex Iliac, . . .	409
Constrictor Urethræ, 358, 375, 547		„ Crural Arch, . . .	215
Coraco-acromial Arch, . . .	53	„ Epigastric Artery, 408, 423, 428	
„ „ Ligament, . . .	53	„ External Pudic Artery, 225	
„ -brachialis Muscle, . . .	75	„ Layer of Triangular Ligament, . . .	356, 375
„ -clavicular Ligament, . . .	53	„ Palmar Arch, . . .	127
„ -humeral Ligament, . . .	88	Deltoid Ligament, . . .	320
Corona Glandis Penis, . . .	429	„ Muscle, . . .	47
Coronary Artery, . . .	483	Descending Colon, . . .	452
„ Ligament of Liver, 465		Descending Cutaneous Nerves, 18	
„ Plexus, . . .	499	Descent of the Testicles, . . .	413
„ Vein, . . .	485	Detrusor Urinæ, . . .	596
Corpus Caverosum Clitoridis, 373		Diaphragm, . . .	524
„ „ Artery to, 359		Diaphragmatic Plexus of Nerves, 500	
„ „ Penis, 349, 428		Digital Arteries, . . .	113, 302
„ „ Artery to, 359		„ Fossa of Tunica Vaginalis, . . .	417
„ Highmori, . . .	418	„ „ of Inguinal Canal, 423	
„ Spongiosum Penis, 350, 428		„ Nerves, 114, 116, 295, 296	
Cortical Part of Suprarenal Capsule, . . .	524	Direct Inguinal Hernia, . . .	423
„ Portion of Kidney, . . .	523	DISSECTION OF—	
Costal Zone of Abdomen, . . .	434	Abdomen, . . .	335
Costo-coracoid Membrane, . . .	32	Abdominal Cavity, . . .	430
Cotyloid Ligament, . . .	252	„ Wall, . . .	377
Cowper's Glands, . . .	358, 603	Adductor Region of Thigh, 239	
„ „ Ducts of, . . .	603	Anterior Tibio-fibular Region, . . .	256
Cremaster Muscle, . . .	394	Axillary Space, . . .	15
Cremasteric Artery, . . .	409, 414	Back, . . .	3
„ Fascia, . . .	395, 411	„ and Outer Border of Forearm, . . .	129
Crest of the Urethra, . . .	600	„ of Arm, . . .	79
Crucial Anastomosis of Thigh, 180		„ of Thigh, . . .	195
„ Ligaments, . . .	316	Dorsal Aspect of Wrist and Hand, . . .	138
Crura Clitoridis, . . .	373	Dorsum of the Foot, . . .	256
„ of Diaphragm, . . .	525	Female Perineum, . . .	364
„ of the External Abdominal Ring, . . .	388	Forearm, . . .	90
„ Penis, . . .	349, 428	Front of Arm, . . .	58
Crural Branch of Genito-crural Nerve, . . .	207, 215, 544	„ and Inner Border of Forearm, . . .	94
„ Canal, . . .	219, 220, 426	„ of Thigh, . . .	200
„ Ring, . . .	219, 220, 426	„ „ Deep, . . .	213
Crureus Muscle, . . .	238	„ „ Superficial, 203	
Cubo-cuneiform Joint, . . .	330	Gluteal Region, . . .	164
Cutaneous Nerves of Arm, . . .	61	Hand, . . .	90
„ „ Forearm, 61		Inner Side of Thigh, . . .	248
Cystic Artery, . . .	486		
„ Duct, . . .	497, 512		
„ Vein, . . .	486		

	PAGE		PAGE
DISSECTION OF— <i>Continued.</i>		Extensor Ossis Metacarpi Pol-	
Leg,	254	licis,	134
Lower Limb,	163	,, Primi Internodii Pol-	
Male Perineum,	336	licis,	134
Palm,	106	,, Secundi Internodii	
Pectoral Region,	15	Pollicis,	134
Pelvis,	546	External Abdominal Ring,	387
Peroneal Region,	271	,, Annular Ligament of	
Popliteal Space,	183	Ankle,	260, 272
Posterior Tibio-fibular Re-		,, Anterior Thoracic	
gion,	274	Nerve,	42
Scapular Region,	45	,, Circumflex Artery,	235, 241
Shoulder,	45	,, Cutaneous Nerve of	
Sole of Foot,	288	Thigh, 169, 209, 223,	544
Tibial Region,	273	,, Iliac Artery,	534, 535
Upper Limb,	1	,, ,, Glands,	536
Wrist,	109	,, ,, Vein,	428
Dorsal Artery of Clitoris,	376	,, Inguinal Fossa,	422
,, ,, of Penis,	429	,, Lateral Ligament of	
,, Nerve of ,,	429	Ankle,	320
,, Vein of ,,	429, 585	,, Lateral Ligament of	
,, Branch of Ulnar Nerve,	92, 103	Knee,	309
Dorsalis Pedis Artery,	266	,, Plantar Artery,	294
,, Scapulæ Artery,	56	,, ,, Nerve,	295
Douglas, Pouch of,	616	,, ,, Deep	
,, Semilunar Fold of,	402	,, ,, Division of,	303
Ductus Communis Choledochus,	497	,, Popliteal Nerve, 190, 272	
,, Venosus,	506	,, Respiratory Nerve,	134
,, ,, Fissure of,	506	,, Saphenous Nerve,	258
Duodeno-jejunal Fossa,	469	,, ,, Vein, 185, 257, 274	
Duodenum,	448, 490, 504	,, Spermatic Fascia,	387
Ejaculator Urinæ Muscle,	351	Falciform Ligament of Liver,	464
Elbow-joint,	145	Fallopian Tube,	615, 629, 636
Epididymis,	416, 420	False Ligaments of Bladder,	550, 616
Epigastric Region,	434	,, ,, of Uterus,	616
Erector Clitoridis,	371	FASCIÆ—	
,, Penis,	352	Anal,	563
Extensor Brevis Digitorum,	269	Axillary,	29
,, Carpi Radialis Brevior,	130	Bicipital,	76
,, ,, ,, Longior,	131	Brachial,	67
,, ,, Ulnaris,	132	Costo-coracoid,	32
,, Communis Digi-		Cremasteric,	395, 411
torum,	132, 141	Cribriform Portion of Fascia	
,, Indicis Proprius,	135, 142	Lata,	205, 206, 212
,, Longus Digitorum,	263	Deep Fascia of Forearm, 93, 130	
,, ,, Hallucis,	264	,, ,, Gluteal Region, 169	
,, Minimi Digniti,	132, 142		

PAGE

FASCIÆ—Continued.

Deep Fascia of Leg,	259, 276
„ „ Pectoral Region, 22	
„ „ Scapular „ „	46
„ „ on back of Forearm,	130
„ „ on Back of Thigh,	195
External Spermatic,	387
Fascia Iliaca,	217, 538
„ Lata,	210
„ Transversalis,	403
Fascial Compartments of Palm,	III
Iliac Portion of Fascia Lata,	205, 206, 211
Ilio-tibial Band,	234
Infundibuliform,	404, 411
Intercolumnar,	387
Intermuscular Septa,	69, 212, 235, 260, 290
Internal Spermatic,	404
Lumbar,	397
Obturator,	557
of Camper,	202, 380
of Colles,	340
of Psoas Muscle,	538
of Piriformis Muscle,	556
of Quadratus Lumborum,	537
of Scarpa,	202, 380
of Tibialis Posticus,	282
Palmar,	110
Parietal Pelvic,	551, 556, 617
Pelvic,	547, 551, 558, 617
Popliteal,	185
Pubic Portion of Fascia Lata,	205, 206, 211
Rectal,	560, 617
Recto-vaginal,	617
„ -vesical,	560
Superficial of Abdominal Wall,	380
„ Back	4
„ Back of Thigh,	195
„ Female Perineum,	369
„ Front of Thigh,	202
„ Gluteal Region,	166
„ Male Perineum,	338
„ Palm,	109

PAGE

FASCIÆ—Continued.

Superficial of Pectoral Region,	19
„ Sole of Foot,	288
Transversalis,	217, 403, 405
Triangular,	391
Vesical,	560, 617
Vesico-vaginal,	617
Visceral Pelvic,	560, 617
„ „ Rectal Layer,	560, 617
„ „ Recto-vesical Layer,	560
„ „ Vesical Layer,	560, 617
Femoral Artery,	224, 230
„ Hernia,	220, 426
„ Sheath,	215
„ Vein,	231
Fissure for Vena Cava in Liver,	510
Flexor Brevis Digitorum,	291, 297
„ „ Hallucis,	300
„ „ Minimi Digniti,	125, 301
„ „ Pollicis,	124, 144
„ Carpi Radialis,	99, 144
„ „ Ulnaris,	99
„ Longus Digitorum,	283, 296
„ „ Hallucis,	283, 296, 298
„ „ Pollicis,	105, 119, 122
„ Profundus Digitorum,	105, 119
„ Sheaths of Fingers,	120
„ „ of Toes,	297
„ Sublimis Digitorum,	100, 119
„ Tendons of Fingers,	119, 121
Flexura Duodeno-jejunalis,	449, 493
Fold of the Nates,	165
Folds of the Axilla,	17
Fossa for Gall-bladder,	507
„ Navicularis,	366, 602
„ Ovarii,	627
Fourchette,	366
Fræna of Ileo-cæcal Valve,	482
Frænulum Clitoridis,	366
„ Pudendi,	366
Frænium Preputii Penis,	429, 602
Fundus of Stomach,	445
„ Uteri	621

	PAGE		PAGE
Gall-bladder,	440, 511	Hymen,	368
Gastrocnemius Muscle,	277	Hypochondriac Regions,	434
Gastro-duodenal Artery,	486	Hypogastric Artery,	580
„ -hepatic Omentum, 455, 466		„ Plexus,	551
„ -phrenic Ligament,	457	„ Region,	434
„ -splenic Omentum, 455, 467		„ Branch of Ilio-hypo-	
Gemelli Muscles,	178	gastric Nerve,	382
Genital Branch of Genito-		„ Zone of Abdomen, 434	
crural Nerve,	414, 543	Hypothenar Eminence,	107
Genito-crural Nerve,	543	Ileo-cæcal Valve,	482
Gimbernat's Ligament, 214, 219, 390		Ileo-colic Artery,	472
Glans Clitoridis,	373	Ileum,	449, 480
„ Penis,	429	Iliac Branch of Last Dorsal	
Gleno-humeral Ligaments,	88	Nerve,	384
Glenoid Ligament,	89	„ „ of Obturator	
Glisson's Capsule,	512	Artery,	583
Globus Major,	417, 420	„ Fascia,	217, 538
„ Minor,	417, 420	„ Furrow,	165
Gluteal Aponeurosis,		„ Regions,	434
„ Artery,	182, 583	Iliacus,	247, 540
„ Region,	164	Ilio-hypogastric Nerve,	396, 542
„ Sulcus,	165	„ -inguinal Nerve, 382, 396, 542	
Gluteus Maximus,	170	„ -lumbar Artery,	583
„ „ Bursæ under cover of, 172		„ „ Ligament,	606
„ „ Parts under cover of, 173		„ „ Vein,	535, 585
„ Medius Muscle,	181	„ -tibial Band of Fascia Lata,	
„ Minimus Muscle,	182	210, 234, 235	
„ „ Parts under cover of, 183		Impressio Colica on Liver,	508
Gracilis Muscle,	246	„ Duodenalis on Liver, 509	
Great Omentum,	436, 455, 466	„ Renalis on Liver,	508
„ Sacro-sciatic Ligament, 609		Infantile Hernia,	425
„ Sciatic Nerve, 177, 199, 588		Inferior Acromio-clavicular	
„ Splanchnic Nerve, 499, 529		Ligaments,	53
Greater Sac of Peritoneum,	459	„ Articular Arteries of	
Gubernaculum Testis,	413	Knee,	194, 305
Hepatic Artery,	485, 513	„ Calcaneo-scaploid	
„ Duct,	497, 513	Ligament,	327
„ Flexure of Colon,	451	„ Capsular Artery, 524, 533	
„ Ligaments,	463	„ Gluteal Nerve,	175, 589
„ Lobules,	515	„ Hæmorrhoidal Artery, 345	
„ Veins,	514	„ „ Nerve, 346	
Hernia Abdominis,	421	„ „ Vein, 345	
Hesselbach's Triangle,	407, 424	„ Mesenteric Artery,	474
Hilum of Kidney,	517	„ „ Vein, 476	
„ of Ovary,	627	„ „ Nervous	
„ of Spleen,	443	Plexus, 476	
Hip-joint,	248	„ Pancreatico-duodenal	
Hunter's Canal,	227	Artery,	470
Hydatids of Morgagni,	417	„ Phrenic Arteries,	531

	PAGE		PAGE
Inferior Profunda Artery, . . .	73	Internal Pudic Artery,	
„ Tibio-fibular Joint, . . .	323	177, 344, 358, 376, 582	
„ Vesical Artery, . . .	582	„ „ Nerve, 344, 376, 589	
Infra-clavicular Fossa, . . .	16	„ „ Vein, . . . 344, 376	
„ -patellar Pad of Fat of		„ Saphenous Vein, 257, 274	
Knee,	311	„ Spermatic Fascia, . . . 404	
„ -spinatus,	55	Interosseous Arteries, 105, 135, 138	
„ -sternal Fossa,	16	„ Membrane of	
Infundibula of Ureter,	522	Forearm, 153	
Infundibuliform Fascia,	404, 411	„ „ of Leg, 322	
Inguinal Canal,	406, 423	„ Muscles, 143, 303	
„ Hernia,	421, 423	Interphalangeal Joints, . . . 162, 334	
„ Lymphatic Glands,	204	Intersigmoid Fossa, 469	
„ Peritoneal Fossæ,	423	Interspinous Ligaments, . . . 606	
Inscriptiones Tendineæ,	400	Intertubercular Bursa, 90	
Intercolumnar Fascia,	387	„ Plane, 432	
„ Fibres,	389	Intestine, 447	
Intercostal Arteries,	407	Ischio-cavernosus Muscle, . . . 352	
„ Nerves,	396	„ -rectal Fossa, 342	
Intercosto-humeral Nerve,	29, 63	Isthmus of Fallopiian Tube, . . . 630	
Intercuneiform Joints,	329		
Intermetacarpal Joints,	158	Jejunum, 449, 481	
Intermetatarsal Joints,	333		
Intermuscular Septa of Arm,	69	Kidney-capsule, 522	
„ „ Foot, 290		„ -substance, 522	
„ „ Leg, 260		Kidneys, 515	
„ „ Thigh, 212, 235		Knee-joint, 307	
Internal Abdominal Ring, 405, 423		Kölliker, Internal Muscular	
„ Annular Ligament of		Tunic of, 418	
Ankle, 276, 286			
„ Anterior Thoracic Nerve, 42		Labia Majora, 365	
„ Calcanean Artery, 281		„ Minora, 366	
„ „ Nerve, 275		Lacuna Magna, 603	
„ Circumflex Artery, 180, 222, 243		Lacunæ of Urethra, 603	
„ Cutaneous Nerve (upper		Lamellæ of Lumbar Fascia, . . . 397	
limb), 31, 72, 74		„ of Rectal Sheath, 401	
„ „ Nerve of		Large Intestine, 435, 450, 482	
Thigh, 209		Last Dorsal Nerve, 396, 545	
„ Iliac Artery, 580		Lateral Cutaneous Nerves, 19, 27, 383, 396	
„ „ Vein, 585		Latissimus Dorsi Muscle, 9, 52	
„ Inguinal Fossa, 422		Left Colic Artery, 473, 474	
„ Lateral Ligament of		„ Gastro-epiploic Artery, 486, 488	
Ankle, 320		„ Hepatic Artery, 485, 486	
„ „ „ of Knee, 274, 310		„ „ Duct, 512	
„ Plantar Artery, 292		„ Lateral Ligament of Liver, 466	
„ „ Nerve, 294		Lesser Sac of Peritoneum, 459	
„ Popliteal Nerve, 189		Levator Anguli Scapulæ Muscle, 13	
		„ Ani Muscle, 547, 586, 632	
		„ Prostatae, 586	

	PAGE		PAGE
Lieberkühn, Crypts of, . . .	482	LIGAMENTS— <i>Continued.</i>	
Lieno-renal Ligament, 444, 461,	464	Great Sacro-sciatic, . . .	609
Ligamenta Alaria, . . .	311	Hepatic,	463
,, Brevia,	121	Ilio-femoral,	250
,, Longa,	121	,, -lumbar,	606
,, Subflava,	606	Inferior Acromio-clavicular,	53
LIGAMENTS—		,, Calcaneo-cuboid, . . .	327
Acromio-clavicular Interar-		,, ,, scaphoid,	327
ticular Fibro-cartilage, . .	52	,, Transverse Tibio-	
Anterior Annular, of Ankle,		fibular,	323
	259, 270	Intercuneiform,	329
,, ,, of Wrist,	117	Intermetacarpal,	158
,, Common Vertebral, . . .	605	Intermetatarsal,	333
,, of Ankle,	320	Internal Annular, of Ankle,	
,, of Elbow,	146		276, 286
,, True, of Bladder,	563	,, Calcaneo-cuboid, . . .	328
Broad Ligament of Uterus, .	614	,, Lateral of Ankle, . . .	320
Capsular of Hip,	249	,, ,, Elbow,	146
,, of Shoulder Joint, . . .	87	,, ,, Knee, 274, 310	
Capsule of Knee,	308	Interosseous Astragalo-cal-	
Carpal,	156	canean,	326
Carpo-metacarpal,	159	,, Membrane of	
Conoid,	53	Forearm,	153
Coraco-acromial,	53	,, ,, of Leg,	322
,, -clavicular,	53	,, Tibio-fibular,	323
,, -humeral,	88	Interphalangeal,	162, 334
Coronary, of Liver,	465	Interspinous,	606
Cotyloid Ligament,	252	Ischio-capsular,	251
Crucial,	316	Lateral True, of Bladder, .	561
Cubo-cuneiform,	330	Left Lateral, of Liver, . .	466
Deep Layer of the Triangu-		Lieno-renal,	444, 464
lar Ligament,	356, 375	Ligamenta Alaria,	311
Deltoid,	320	,, Brevia,	121
Dorsal Astragalo-navicular,	326	,, Longa,	121
,, Calcaneo-cuboid,	329	Ligamentum Arcuatum Ex-	
External Annular, of Ankle,		ternum, 525, 538	
	260, 272	,, ,, Internum,	
,, Calcaneo-scaphoid, . . .	327		526, 538
,, Lateral Astragalo-		,, ,, Medium,	527
calcanean,	326	,, Inguinale,	391
,, Lateral, of Ankle,	320	,, Mucosum,	311
,, ,, of Elbow,	146	,, Patellæ,	239, 309
,, ,, of Knee,	309	,, Posticum Wins-	
Falciform Ligament of Liver,	464	lowii,	310
False Ligaments of Bladder,		,, Teres of Hip,	253
	550, 616	,, ,, Liver,	
Gastro-phrenic,	464		430, 464
Gimbernats,	214, 390	Long Plantar,	328
Gleno-humeral,	88	Lumbo-sacral,	606
Glenoid,	89	,, ,, Capsular,	605

	PAGE		PAGE
LIGAMENTS—Continued.		LIGAMENTS—Continued.	
Lumbo-sacral Disc,	607	Transverse, of Knee,	318
Metatarso-phalangeal,	334	" Perineal,	354
Oblique Ligament of Fore- arm,	154	" Superficial of Palm,	110
Obturator Membrane,	611	Triangular, of Urethra,	353, 374
Orbicular,	152	Zonular Band of Hip,	251
Ovarian,	615, 622, 634	Ligamentum Arcuatum Exter- num,	525, 538
Ovario-pelvic,	616	" " Inter- num,	526, 538
Phrenico-colic,	464	" " Medium,	527
Posterior Annular, of Wrist,	130, 140	" " Mucosum,	311
Posterior Astragalo-calcaneal,	326	" " Patellæ,	239, 309
" Common Vertebral,	606	" " Teres of Hip,	253
" of Ankle,	320	" " of Liver,	440
" of Elbow,	147	Linea Alba,	402
" of Knee,	310	Lineæ Transversæ,	409
Poupart's,	214, 390	Liver,	436, 505
Pubic,	610	Lobules of Testicle,	419
Pubo-femoral,	251	Lobulus Caudatus of Liver,	508
" -prostatic,	563	" Quadratus of "	508
Radio-carpal,	148	" Spigelii of Liver,	510
" -ulnar,	152	Longitudinal Fissure of Liver,	505
Rhomboid,	52	Long Plantar Ligament,	328
Right Lateral of Liver,	466	" Pudendal Nerve,	176, 348
Round Ligament of Liver,	430	" Saphenous "	209, 233
" " of Uterus,	615, 630, 634	" " Thoracic Artery,	258, 275
Sacro-coccygeal,	607	Lower Limb,	163
" -iliac,	607	Luette of Bladder,	597
Scapho-cuboid,	330	Lumbar Arteries,	407, 533, 545
" -cuneiform,	328	" Colotomy,	453
Semilunar Cartilages,	317	" Nerves,	541
Short Plantar,	328	" Plexus,	541
Small Sacro-sciatic,	609	" Regions,	434
Spino-glenoid,	58	" Veins,	535, 546
Subflava,	606	Lumbo-sacral Cord,	541, 544
Superficial Layer of the Tri- angular Ligament,	356	" Disc,	607
Superior Acromio-clavicular,	52	" Joints,	605
Suprascapular,	58	" Ligament	606
Supraspinous,	606	Lumbrical Muscles,	123, 298
Suspensory, of Ovary,	616	Malleolar Arteries,	266
" of Penis,	429	Mammary Gland,	21
Tarso-metatarsal,	331	Meatus Urinarius,	429, 602
Thyroid Membrane,	611	Median Basilic Vein,	65
Tibio-fibular,	321, 322	" Cephalic Vein,	67
Transverse Metacarpal,	143	" Nerve,	74, 104, 114
" Metatarsal,	303	" Vein,	65
" of Hip,	252	Mediastinum Testis,	418

	PAGE		PAGE
Medullary Part of Suprarenal Capsule, . . .	524	Mucous Membrane of Stomach, . . .	502
„ Portion of Kidney, . . .	523	„ „ Urethra, . . .	603
„ Pyramids of Kidney, . . .	523	„ „ Uterus, . . .	635
Membrana Sacciformis, . . .	153	Müller's Duct, . . .	417
Membranous Urethra, . . .	357, 601	MUSCLES—	
Mesenteric Glands, . . .	473	Abductor Hallucis, . . .	291
„ Lacteals, . . .	473	„ Longus Pollicis, . . .	134
„ Nervous Plexus, . . .	473	„ Minimi Digiti, . . .	125, 292
Mesentery Proper, . . .	455, 468	„ Pollicis, . . .	124
Mesorchium, . . .	413	Accessorius of Foot, . . .	298
Meso-rectum, . . .	549, 612	Adductor Brevis, . . .	223
Metacarpo-phalangeal Joints, . . .	161	„ Longus, . . .	240
Metatarsal Artery, . . .	268	„ Magnus, . . .	246
Metatarso-phalangeal Joints, . . .	334	„ Obliquus Hallucis, . . .	300
Middle Capsular Artery, . . .	524, 532	„ „ Pollicis, . . .	124
„ Colic Artery, . . .	472	„ Transversus Hal-	
„ Cutaneous Nerve of		lucis, . . .	300
Thigh, . . .	205, 209, 232	„ „ Pollicis, . . .	125
„ Hæmorrhoidal Artery, . . .	582	Anconeus, . . .	132
„ Inguinal Fossa, . . .	422	Biceps Flexor Cruris, . . .	196
„ Sacral Artery, . . .	531, 584	„ „ Brachii . . .	75, 89
„ „ Vein, . . .	535, 585	Brachialis Anticus, . . .	76
Mid-Poupart Planes, . . .	434	Brachio-radialis, . . .	131
Mons Veneris, . . .	365	Bulbo-cavernosum, . . .	351
Morgagni, Columns of, . . .	594	Coccygeus, . . .	548, 586
„ Sinus of, . . .	595	Common Origin of Super-	
Movements at Ankle-joint, . . .	321	ficial Muscles on front of	
„ Carpal Joints, . . .	154	Forearm, . . .	98
„ Elbow-joint, . . .	148	Compressor Urethræ, . . .	358, 375, 547
„ Hip-joint, . . .	251	Conjoined Tendon, . . .	392
„ Interphalangeal		Constrictor Urethræ, . . .	358, 375, 549
Joints, . . .	160	Coraco-brachialis, . . .	75
„ Joints of the		Cremaster, . . .	394
Foot, . . .	334	Crureus, . . .	238
„ Knee-joint, . . .	313	Deltoid, . . .	47
„ Metacarpo-phalan-		Detrusor Urinæ, . . .	596
geal Joints, . . .	158	Diaphragm, . . .	524
„ Radio-carpal		Ejaculator Urinæ, . . .	351
Joint, . . .	151	Erector Clitoridis, . . .	371
„ „ -ulnar		„ Penis, . . .	352
Joints, . . .	154	Extensor Brevis Digitorum, . . .	269
„ Shoulder-joint, . . .	90	„ „ Pollicis, . . .	133, 134
„ of Metacarpal Bones, . . .	160	„ Carpi Radialis	
Mucous Membrane of Bladder, . . .	597	Brevior, . . .	131
„ „ Great In-		„ „ „ Longior, . . .	131
testine, . . .	482	„ „ Ulnaris, . . .	132
„ „ Rectum, . . .	594	„ Communis Digi-	
„ „ Small In-		torum, . . .	132, 140
testine, . . .	478	„ Indicis Proprius, . . .	135, 142

PAGE

PAGE

MUSCLES—*Continued.*MUSCLES—*Continued.*

Extensor Longus Digitorum,	263
„ „ Hallucis,	264
„ „ Pollicis,	134
„ Minimi Digiti,	132, 142
„ Ossis Metacarpi	
Pollicis, . . .	134
„ Primi Internodii	
Pollicis, . . .	134
„ Secundi Internodii	
Pollicis, . . .	134
Flexor Brevis Digitorum,	291, 297
„ „ Hallucis,	300
„ „ Minimi Digiti,	
.	125, 301
„ „ Pollicis,	124, 144
„ Carpi Radialis,	99, 144
„ „ Ulnaris,	99
„ Longus Digitorum,	
.	283, 296
„ „ Hallucis,	
.	283, 296, 298
„ „ Pollicis,	
.	105, 109, 122
„ Profundus Digi-	
torum,	105, 119, 122
„ Sublimis Digitorum,	
.	100, 119, 122
Gastrocnemius,	277
Gemelli,	178
Gluteus Maximus,	170
„ Medius,	181
„ Minimus,	182
Gracilis,	246, 273
Hamstrings,	196
Iliacus,	247, 540
Infraspinatus,	55
Interosseous Muscles of Foot,	303
„ „ of Hand,	143
Ischio-cavernosus,	352
Latissimus Dorsi,	9, 52
Levator Anguli Scapulæ,	13
„ Ani,	547, 586, 632
„ Prostatæ,	586
Lumbricales (Foot),	298
„ (Hand),	123
Obliquus Abdominis Externus,	
.	386
„ „ Internus,	
.	392

Obturator Externus,	180, 247
„ Internus,	177, 547, 592
Omo-hyoid,	12
Opponens Minimi Digiti,	126
Palmaris Brevis,	109
„ Longus,	99
Pectineus,	242
Pectoralis Major,	22, 52
„ Minor,	34
Pelvic Diaphragm,	547, 632
Peroneus Brevis,	272
„ Longus,	271, 304
„ Tertius,	264
Plantaris,	278
Platysma Myoides,	18
Popliteus,	283
Pronator Quadratus,	105
„ Radii Teres,	98
Psoas Magnus,	247, 539
Pyramidalis,	401
Pyriformis,	178, 547, 593
Quadratus Femoris,	179
„ Lumborum,	539
Quadriceps Extensor Cruris,	
.	236, 238
Rectus Abdominis,	399
„ Femoris,	236
Rhomboideus Major,	13
„ Minor,	12
Sartorius,	227
Semimembranosus,	196, 198, 273
Semitendinosus,	196, 273
Serratus Magnus,	44
Soleus,	279
Sphincter Ani Externus,	341
„ „ Internus,	594
„ Pylori,	503
„ Vaginæ,	371
Subcrureus,	239
Subscapularis,	55
Superficial Perineal,	351, 371
Supinator Brevis,	145
„ Longus,	131
Supraspinatus,	54
Suspensory of Duodenum	
and Mesentery,	493
Tendo Achillis,	279
Tensor Fasciæ Femoris,	235
Teres Major,	51

	PAGE		PAGE
MUSCLES—Continued.		NERVES—Continued.	
Teres Minor,	54	Cutaneous of Circumflex,	46
Tibialis Anticus,	262	,, of Front of Leg,	257
,, Posticus,	284, 304	,, ,, Thigh,	207
Transversalis,	397	,, of Gluteal Region,	166
Transversus Pedis,	301	,, of Upper Limb,	61
,, Perinei,	351, 371	,, of Scapular Region,	45
Trapezius,	7	Deep Branch of Ulnar,	116, 126
Triceps Extensor Cubiti,	80	Descending Cutaneous,	18
Vastus Externus,	237	Diaphragmatic Plexus,	500
,, Internus,	237	Digital,	114, 116, 295, 296
Muscular Coat of Bladder,	596	Dorsal Branch of Ulnar,	92, 103
,, ,, Rectum,	594	,, Cutaneous, of Hand,	92
,, ,, Stomach,	502	,, Nerve of Clitoris,	376
Musculo-cutaneous Nerve of		,, Nerve of Penis,	361, 429
Arm,	63, 75	External Cutaneous of Mus-	
,, ,, of Leg,	258, 273	culo-spiral,	61
,, -phrenic Artery,	410, 530	,, Cutaneous of Thigh,	169, 209, 544
,, -spiral Nerve,	31, 82	,, Plantar,	295, 303
		,, Popliteal,	190, 272
		,, Respiratory,	34
		,, Saphenous,	258, 275
Natal Cleft,	165	Fifth Sacral,	591
Neck of Bladder,	571	Genito-crural,	543
NERVES—		,, Crural Branch	
Nerve of Bell,	26, 34	of,	207, 215, 544
,, of Wrisberg,	31	,, Genital Branch,	414, 543
,, to Obturator Internus,	177	Great Sciatic,	177, 199, 588
,, to the Rhomboids,	13	,, Splanchnic,	499, 529
Accessory Obturator,	243, 544	Hæmorrhoidal Plexus,	591
Anterior Crural,	231, 544	Hypogastric,	382, 396
,, Cutaneous,	19, 382	,, Plexus,	617
,, Interosseous,	106	Iliac Branch of Ilio-hypo-	
,, Thoracic,	42	gastric,	168, 384, 396
,, Tibial,	259, 269, 273	,, ,, of Last Dorsal,	168, 384, 396
Aortic Plexus,	476	Ilio-hypogastric,	396, 542
Articular of Knee,	306	,, -inguinal,	207, 382, 396, 542
Brachial Plexus,	41	Inferior Gluteal,	175, 589
Cavernous,	591	,, Hæmorrhoidal,	346, 586
Circumflex,	31, 46	,, Mesenteric Plexus,	476
Coccygeal,	587, 591	Intercostal,	396
Coeliac Plexus,	483, 499	Intercosto-humeral,	29, 63
Communicans Fibularis,	191, 276	Internal Calcanean,	275
,, Tibialis,	190, 276	,, Cutaneous of Mus-	
Cutaneous of Abdominal		culo-spiral,	63
Wall,	382	,, ,, of Thigh,	209
,, of Arm,	61	,, ,, of Upper Limb,	31, 72
,, of Back,	4		
,, of Back of Forearm,	91		
,, ,, Thigh,	195		

	PAGE
NERVES—Continued.	
Internal Plantar,	294
,, Popliteal,	189
,, Pudic, 177, 344, 376, 589	
Last Dorsal,	396, 545
Lateral Cutaneous, 19, 383, 396	
Long Pudendal,	176, 348
,, Saphenous,	209, 233, 258, 275
Lumbar,	542
,, Plexus,	542
Lumbo-sacral Cord,	542, 544
Median,	74, 104, 114
Middle Cutaneous of Thigh,	
205, 209, 232	
Musculo-cutaneous,	
75, 258, 273	
,, -spiral,	31, 82
Obturator,	194, 245, 544
of the Abdominal Wall,	396
of Supply to Trapezius,	11
Ovarian Plexus,	633
Palmar Cutaneous of Radial,	
92, 110	
,, ,, Median,	
91, 110	
,, ,, Ulnar, 91,	
103, 110	
Patellar Plexus,	210
Pelvic,	587
,, Plexuses,	591
Perforating Cutaneous of the	
Fourth Sacral,	169, 590
Perineal,	352, 360, 376
,, Branch of Fourth	
Sacral,	346
Phrenic,	529
Pneumogastric,	498
Posterior Interosseous, 96, 137,	
142	
,, Primary Branches	
of the Spinal	
Nerves,	5, 166
,, Thoracic,	43
,, Tibial,	281
Prostatic Plexus,	591
Pudendal Band,	588
Radial,	92, 96
Renal Plexus,	500
Sacral Plexus,	587

	PAGE
NERVES—Continued.	
Sacro-coccygeal Plexus,	590
Sartorial Plexus,	230
Sciatic Band,	587
Smallest Splanchnic,	500, 529
Small Internal Cutaneous, 63, 74	
,, Sciatic, 176, 185, 189, 589	
,, Splanchnic,	500, 529
Solar Plexus,	473, 498
Spermatic Plexus,	476
Spinal Accessory,	11
Subscapular,	43
Superficial Perineal,	347, 370
Superior Gluteal,	182, 589
,, Mesenteric Plexus, 473	
Supra-acromial,	19, 46
,, clavicular,	19
,, renal Plexus,	500
,, scapular,	12, 56
Suprasternal,	18
Sympathetic, Gangliated Cord,	
540, 592	
to Obturator Internus,	590
to Pyriformis,	590
to Quadratus Femoris,	590
Ulnar,	31, 74, 103, 116
,, Collateral,	83
Uterine Plexus,	632
Vaginal ,,	632
Vagus,	498
Vesical Plexus,	591
Visceral Branches of Sacral	
Nerves,	590
Nipple,	21
Nuck, Canal of,	631
Nymphæ,	366
Oblique Inguinal Hernia,	423
,, Ligament of Fore-	
arm,	154
,, Sacro-iliac Ligament, 608	
Obliquus Abdominis Externus, 386	
,, ,, Internus, 392	
Obliterated Hypogastric Artery, 581	
,, Umbilical Vein,	430
Obturator Artery, 247, 428, 564, 582	
,, Externus,	180, 247
,, Fascia,	557
,, Internus Muscle, 177, 547	
592	

	PAGE		PAGE
Obturator Internus, Nerve to,	177,	Patellar Branch of long Saphen-	
	590	ous,	210
,, Membrane, . . .	611	,, Bursa, . . .	213
,, Nerve, . . . 194, 245,	544	,, Plexus, . . .	210
Œsophagus, . . .	447, 528	Pectineus Muscle, . . .	223, 442
Œsophageal Groove in Liver,	509	Pectiniform Septum, of Clitoris,	373
,, Opening in Dia-		,, Penus,	604
phragm, . . .	529	Pectoralis Major Muscle,	22, 52
Omenta, . . .	455, 466	,, Minor ,, . . .	34
Omo-hyoid Muscle, . . .	12	Pectoral Region, . . .	15
Opening in Adductor Magnus,	229	Pelvic Blood-vessels, . . .	579, 631
Openings in Diaphragm, Aortic,	528	,, Cavity, . . .	432
,, ,, Œsophageal,	528	,, Diaphragm, . . .	547, 632
,, ,, Vena Caval,	528	,, Fascia, . . .	551, 555
Opponens Minimi Digiti, . . .	126	,, Joints, . . .	605, 637
Orbicular Ligament, . . .	152	,, Nerves, . . .	587
Osteo-fascial Compartments of		,, Peritoneum, . . .	548, 612
Arm, . . .	69	,, Plexuses of Sympathetic,	591
Osteum Abdominale, . . .	629, 636	Pelvis of the Kidney, . . .	522
Os Uteri Externum, . . .	368, 622	Penis, . . .	349, 428, 604
,, ,, Internum, . . .	635	Perforating Arteries of Foot, . . .	302
Ovarian Arteries, . . .	533, 632	,, ,, Thigh,	199,
,, Fimbria, . . .	629		242
,, Ligament, 615, 622,	634	,, Cutaneous Nerve,	169,
,, Veins, . . .	533, 633		590
,, Vessels, . . .	615, 627	Perineal Body, . . .	371, 618
Ovario-pelvic Ligament, . . .	616	,, Branch of Fourth	
Ovary, . . .	615, 626	Sacral Nerve, . . .	346
Ovula Nabothi, . . .	636	,, Nerve, . . .	352
		,, Triangle, . . .	352, 371
Pacinian Bodies, . . .	116	Perineum, Female, . . .	364
Palmar Arch, Deep, . . .	127	,, Male, . . .	336
,, ,, Superficial, . . .	112	Peritoneal Fossæ, . . .	469
,, Cutaneous Nerves, . . .	110	,, Ligaments, . . .	455, 463
,, Fascia, . . .	110	,, Mesenteries, . . .	455, 467,
Palmaris Brevis Muscle, . . .	109		468
,, Longus ,, . . .	99	,, Relations of Kidneys,	521
Pampiniform Plexus of Veins,	415	Peritoneum, 455, 521, 548,	612
Pancreas, . . .	494	,, Greater Sac of, . . .	459
Pancreatic Duct, . . .	497	,, Lesser Sac of, . . .	459
Pancreatica Magna Artery, . . .	488	Peroneal Artery, . . .	281, 284
Pancreaticæ Parvæ Arteries, . . .	488	Peroneus Brevis, . . .	272
Parietal Pelvic Fascia, . . .	547, 551,	,, Longus, . . .	271, 304
	556, 617	,, Tertius, . . .	264
Parovarium, . . .	615, 629	Peyer's Patches, . . .	480
Pars Intermedia, . . .	373	Phrenic Nerve, . . .	529
Passage of Catheter, in Female,	368	Phrenico-colic Ligament, . . .	452
,, ,, Male, . . .	336	Pisiform Joint, . . .	156
,, Vaginal Speculum, . . .	368	Plantar Arterial Arch, . . .	301
		,, Fascia, . . .	289

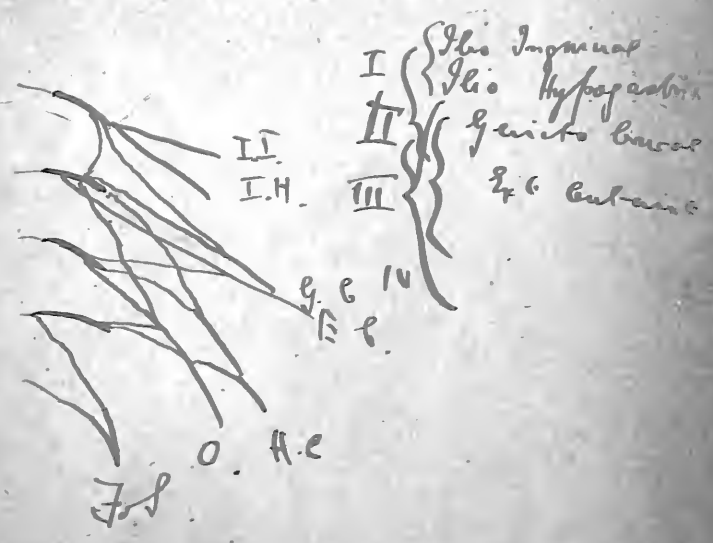
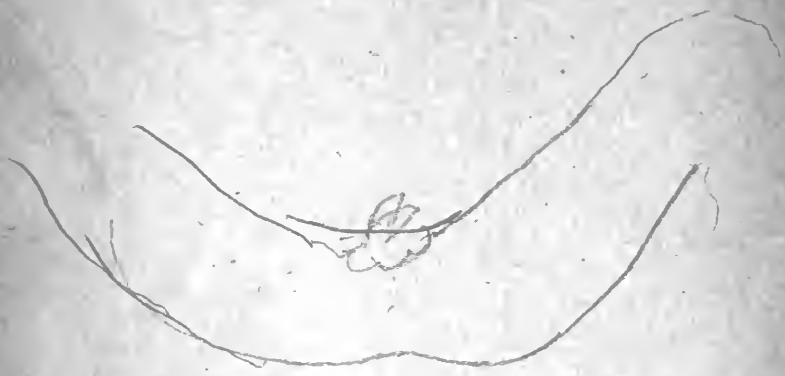	PAGE		PAGE
Plantaris Muscle, . . .	186, 278	Prostatic Urethra, . . .	600
Platysma Myoides Muscle, . . .	18	Psoas Muscle, . . .	223, 247
Pneumogastric Nerves, . . .	498	Pubic Branch of Deep Epi- gastric Artery, 409,	
Pons Hepatis, . . .	506	" " of Obturator	
Popliteal Artery, . . .	191, 280	Artery, . . .	582
" Fascia, . . .	185	Pubo-prostatic Ligaments, . . .	563
" Space, . . .	183	Pudendal Cleft, . . .	365
" " Boundaries of, 186		" Nerve-Band, . . .	588
" " Contents of, 185		Pyloric Artery, . . .	486
" " Floor of, . . .	189	" Portion of Stomach, . . .	445
" Vein, . . .	192, 194	" Sphincter, . . .	502
Popliteus Muscle, . . .	283	" Valve, . . .	503
Portal Canal, . . .	513	Pyramidalis Muscle, . . .	401
" Fissure of Liver, . . .	506	" " Nerve to, . . .	401
" Vein, . . .	489, 513, 514	Pyramiformis Muscle, . . .	178, 547, 593
Posterior Annular Ligament of		Quadratus Femoris Muscle, . . .	179
Wrist, . . .	130	" " Nerve to, 179, 590	
" Circumflex Artery, 26, 31,	38	" Lumborum Muscle,	
" Common Vertebral		537, 539	
Ligament, . . .	606	" " Fascia of, 537	
" Fornix of Vagina, . . .	623	Quadriceps Extensor Cruris, 236, 238	
" Interosseous Nerve, . . .	96, 137, 142	Quadrilateral Space, . . .	47
" " Recur-		Radial Artery, . . .	94, 128, 138
rent Artery, . . .	135	" Nerve, . . .	92, 96
" Ligament of Knee, . . .	310	" Recurrent Artery, . . .	95
" Peroneal Artery, . . .	285	" Vein, . . .	65
" Radial Carpal Artery, . . .	139	Radio-carpal Joint, . . .	148
" Scapular Artery, . . .	14	" -ulnar Joints, . . .	152
" Superficial Perineal		Rami Intestini Tenuis, . . .	470
Nerve, . . .	348	Raphe of Perineum, . . .	337
" Thoracic Nerve, . . .	43	" Scrotum, . . .	410
" Tibial Artery, . . .	280	Receptaculum Chyli, . . .	536
" " Nerve, . . .	281	Rectal Fascia, . . .	561, 617
Poupart's Ligament, . . .	214, 390	" Triangle, . . .	338, 370
Præputium Clitoridis, . . .	366	Recto-vaginal Fascia, . . .	617
Prepuce of the Penis, . . .	429	" " Pouch, . . .	616
Processus Vaginalis Testis, . . .	415	" -vesical Fascia, . . .	561
Profunda Branch of Ulnar Artery, 113		" " Folds, . . .	550
" Femoris Artery, 222, 240		" " Pouch, . . .	550
" Vein of Forearm, . . .	65	Rectum, . . .	548, 565, 617
Pronator Quadratus Muscle, . . .	105	Rectus Abdominis Muscle, . . .	399
" Radii Teres Muscle, . . .	98	" Femoris, . . .	236
Prostate, . . .	548, 575	Renal Artery, . . .	517, 532
" Capsule of, . . .	561, 576	" Papillæ, . . .	523
" Lobes of, . . .	576	" Plexus of Nerves, . . .	500
" Structure of, . . .	604	" Veins, . . .	517, 533
Prostatic Ducts, . . .	600	Rete Testis, . . .	418, 420
" Sinus, . . .	600		

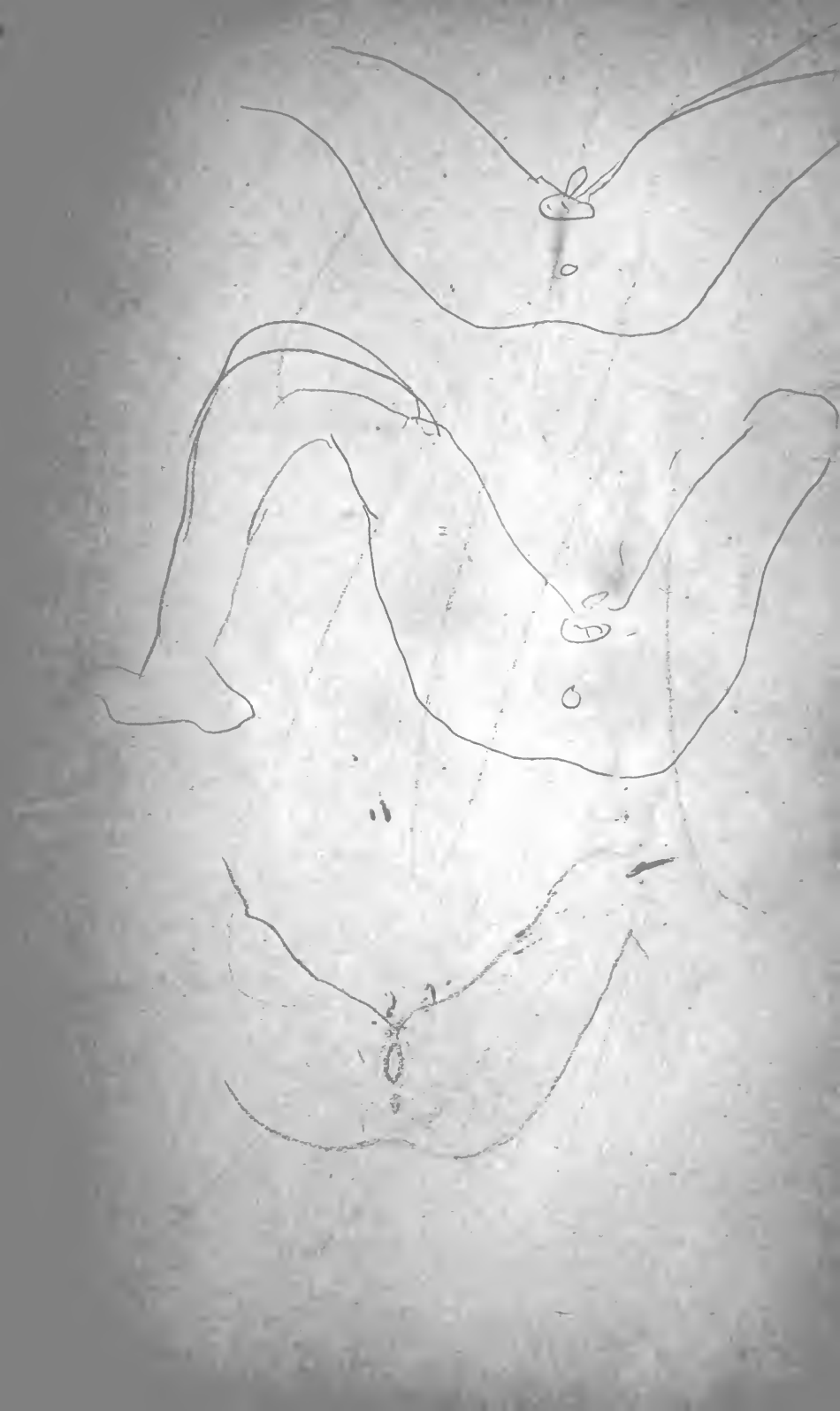
	PAGE		PAGE
Retinacula of Ileo-cæcal Valve,	482	Sinus of Morgagni,	595
Retro-peritoneal Hernia,	469	,, of Portal Vein,	513
,, -pubic Pad,	571	,, Pocularis,	600
Rhomboid Muscles,	12	Small Internal Cutaneous Nerve,	63, 74
Right Colic Artery,	472	,, Intestine,	435, 447, 519
,, Gastro-epiploic Artery,	486	,, Omentum,	455, 466
,, Hepatic Artery,	485, 486	,, Sacro-sciatic Ligament,	609
,, ,, Duct,	512	,, Sciatic Nerve,	185, 189, 589
,, Lateral Ligament of		,, Splanchnic Nerve,	500, 529
Liver,	466	Solar Plexus,	473, 498
Root of Mesentery,	468	Soleus Muscle,	279
,, of Penis,	349	Solitary Glands,	480
Rosenmüller, Organ of,	629	Spermatic Artery,	414, 533
Round Ligament of Liver,	430, 506, 513	,, Cord,	411, 414
,, ,, Uterus,	615, 630	,, Lymphatics,	415
		,, Sympathetic Plexus,	415
		,, Veins,	415, 533
Sacral Nerves,	586	Sphincter Ani Externus,	341
,, Plexus,	587	,, ,, Internus,	594
Sacro-coccygeal Joint,	607	,, Pylori,	503
,, ,, Plexus,	590	,, Vaginæ,	371
,, -iliac Joint,	607	Spinal Accessory Nerve,	11
,, -sciatic Foramina,	609	Spino-glenoid Ligament,	58
Saphenous Opening,	206	Spleen,	441, 501, 518
Sartorius Muscle,	221, 227	Splenic Artery,	486, 488
Scapho-cuneiform Ligaments,	328	,, Flexure of Colon,	452
Scapular Region,	45	,, Vein,	489
Scarpa, Fascia of,	202, 380	Spongy Urethra,	602
Scarpa's Triangle,	221	Stomach,	435, 444, 501
Sciatic Artery,	175, 583	,, Position of,	446
,, Nerve-Band,	587	Structure of the Liver,	514
Scrotum,	410	Subacromial Bursa,	49
Semilunar Cartilages,	317	Subcæcal Fossa,	469
,, Fascia,	66, 76	Subclavius Muscle,	39
,, Ganglion,	499	Subcostal Plane,	432
Semimembranosus Muscle,		Subcrureus Muscle,	239
	196, 198, 273	Subpubic Ligament,	611
Seminiferous Tubules,	419	Subscapular Artery,	14, 26, 31, 38
Semitendinosus Muscle,	196, 273	,, Bursa,	89
Septum Crurale,	219, 427	,, Nerve,	14, 26
Serratus Magnus Muscle,	44	Subscapularis,	55
Sheath of the Rectus,	399, 401	Sub-trapezial Bursa,	11
Short Plantar Ligament,	328	,, Plexus,	11
Shoulder,	45	Superficial Cervical Artery,	11
,, -joint,	84	,, Circumflex iliac	
Sigmoid Arteries,	474	Artery,	204, 385
,, Flexure of Colon,	436, 454	,, Crural Arch,	215
,, Meso-colon,	454, 467	,, Epigastric Artery,	204, 385
Sinus of Kidney,	516, 520		

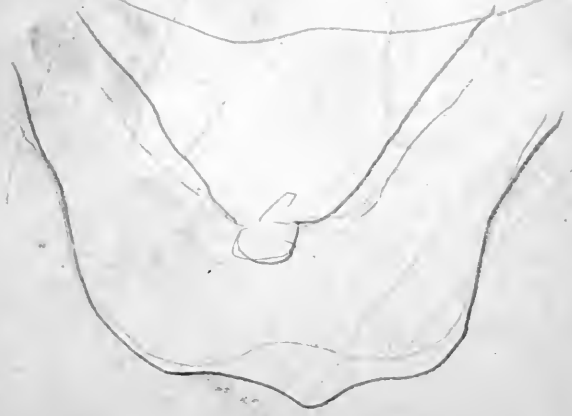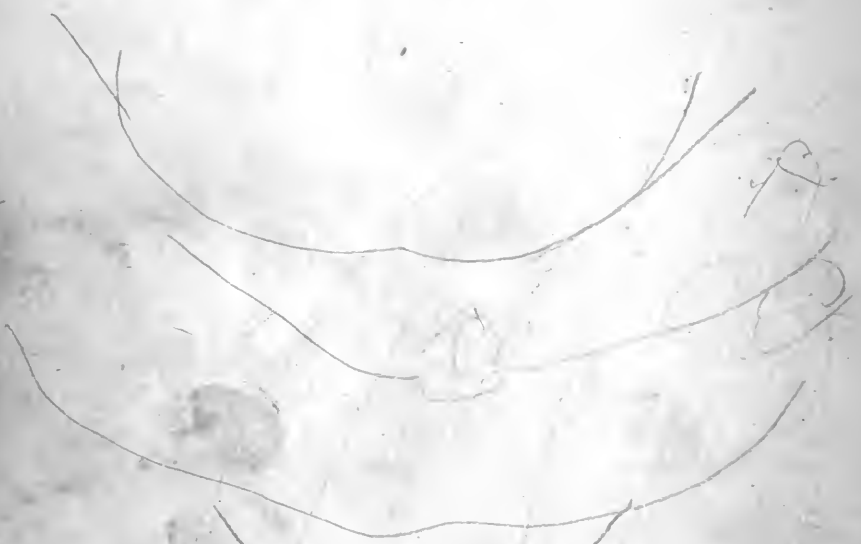
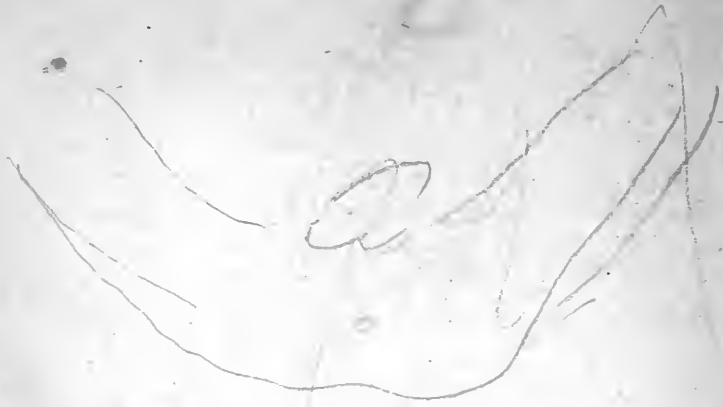	PAGE		PAGE
Superficial External Pudic Artery,	204, 384	SURFACE ANATOMY— <i>Continued.</i>	
„ Layer of Triangular		of Forearm,	6c
„ Ligament,	356, 375	Front of the Abdomen,	377
„ Palmar Arch,	112	„ of Thigh,	200
„ Perineal Artery,	347, 370	Gluteal Region,	164
„ „ Muscles,	351, 371	Leg,	254
„ „ Nerves,	347, 370	Male Perineum,	336
Superficialis Volæ Artery,	96, 112	Pectoral Region,	15
Superior Acromio-clavicular		Popliteal „	184
Ligament,	52	Wrist and Palm,	107
„ Articular Arteries of		Surgical Anatomy of Abdominal	
„ Knee,	193, 306	Wall,	421
„ Capsular Artery,	524, 532	„ „ Palm and	
„ Epigastric Artery,		„ „ Fingers,	128
„ „	399, 410, 529	„ „ Perineum,	362
„ Gluteal Nerve,	175, 182,	Suspensory Ligament of Ovary,	616
„ „	587, 589	„ „ Penis,	429
Hæmorrhoidal Artery,	474, 584	„ „ Muscle of Duodenum	
„ Mesenteric Artery,	470	and Mesentery,	493
„ „ Nervous		Sustentaculum Lienis,	452
„ „ Plexus,	473	Sympathetic Gangliated Cord,	
„ „ Vein,	473	„	540, 592
„ Pancreatico-duodenal		Symphysis Pubis,	610
Artery,	486	Synovial Cavities of the Foot,	333
„ Profunda Artery,	73, 83	„ Membrane of Ankle,	321
„ Thoracic Artery,	26, 34	„ „ Carpal Joints,	159
„ Tibio-fibular Joint,	322	„ „ Carpo-meta-	
„ Vesical Artery,	582	„ „ carpal Joints,	159
Supinator Brevis,	145	„ „ Elbow-joint,	147
„ Longus,	131	„ „ Hip-joint,	253
Supra-acromial Nerves,	19, 46	„ „ Intermetacar-	
„ -clavicular Nerves,	19	„ „ pal Joints,	159
„ -renal Capsules,	518, 523	„ „ Knee,	311
„ „ Plexus,	500	„ „ Metacarpo-	
Suprascapular Artery,	56	„ „ phalangeal	
„ Ligament,	58	„ „ Joints,	161
„ Nerve,	12, 56	„ „ Radio-carpal	
Supraspinatus Muscle,	54	„ „ Joint,	150
Supraspinous Ligament,	606	„ „ „ -ulnar	
Suprasternal Nerve,	18	„ „ Joints,	153
SURFACE ANATOMY—		„ „ Sacro-iliac	
of Ankle,	253	„ „ Joint,	607
Arm,	58	„ „ Shoulder-joint,	89
Axilla,	18	„ „ Sheaths of Flexor	
Back,	1	„ „ Tendons of Fingers,	118
Elbow,	59	Tarsal Artery,	268
Female Perineum,	364	Tarso-metatarsal Joints,	331
Foot,	256	Tendo Achillis,	279
		Tensor Fasciæ Femoris,	234

	PAGE		PAGE
Teres Major Muscle,	51	Tubuli Recti of Testicle,	420
„ Minor, „	54	„ Uriniferi,	523
Testicle,	415	Tunica Albuginea of Testicle,	418
„ Structure of,	418	„ Vaginalis Testis,	415, 417
Thenar Eminence,	107	„ Vasculosa of Testicle,	419
Thoracic and Abdominal Viscera,		Ulnar Artery,	100, 112, 126
Relations of,	447	„ Carpal Arteries,	102
„ Axis Artery,	276	„ Collateral Nerve,	83
„ Duct,	529	„ Nerve,	31, 74, 103, 116
Thyroid Membrane,	611	„ Recurrent Arteries,	102
Tibialis Anticus,	262	„ Veins,	65
„ Posticus,	284, 304	Umbilical Fissure of Liver,	506
Tibio-fibular Joints,	321, 322	„ Hernia,	428
Trabeculæ of Spleen,	501	„ Region,	434
Transversalis Fascia,	217, 403, 405	„ Zone of Abdomen,	434
„ Muscle,	397	Umbilicus,	378
Transverse Carpal Joint,	157	Upper Limb,	I
„ Colon,	436, 452	Urachus,	422, 570
„ Fissure of Liver,	506	Ureter,	518, 523, 575, 598, 620
„ Ligament of Hip,	252	Urethra, Female,	375, 621, 634
„ „ Knee,	318	„ Male,	357, 597, 598, 601
„ Meso-colon,	452, 455	Urethral Orifice (Female),	368
„ „	467	Urogenital Fissure,	365
„ Metacarpal Liga-	143	„ Triangle,	337, 346, 370
„ Metatarsal Liga-	303	Uterine Appendages,	612
„ Perineal Artery,	347	„ Artery,	631
„ Perineal Ligament,	354	„ Vessels,	615
„ Superficial Ligament	110	Utero-vesical Folds,	616
„ of Palm,	110	„ Pouch,	616
Transversus Pedis,	301	Uterus,	612, 621, 623, 634
„ Perinei Muscle,	351, 371	Utricle,	600
Trapezoid Ligament,	53	Uvula Vesicæ,	597
Trapezius Muscle,	7	Vagina,	612, 624
Triangle of Hesselbach,	407, 424	Vaginal Artery,	631
Triangular Fascia,	391	„ Orifice,	368
„ Fibro-cartilage of	153	Vagus Nerves,	498
„ Wrist,	153	Valvulæ Conniventes,	478, 480
„ Ligament of Urethra,	353	Vasa Brevia,	488
„ Space,	47	„ Efferentia of Testicle,	417, 420, 548
„ „ of Elbow,	77	Vas Deferens,	415, 420, 548, 578
Triceps Extensor Cubiti,	80	„ Artery to,	415, 582
Trigone of Bladder,	598	Vastus Externus,	237
Trigonum Petiti,	11	„ Internus,	237
True Ligaments of Bladder,	561	VEINS—	
„ „ Anterior,	563	Arch on Dorsum of Foot,	257
„ „ Lateral,	561	Ascending Lumbar,	546
Tuber Omentale of Liver,	506	Axillary,	34, 39
„ „ Pancreas,	496		

	PAGE		PAGE
<i>VEINS—Continued.</i>		<i>VEINS—Continued.</i>	
Basilic,	65	Splenic,	489
Capsular,	532, 534	Superficial Inguinal,	204
Cava Inferior,	510, 528, 532	,, of Arm and Fore-	
Cephalic,	34	arm	65
Common Iliac,	534	,, Perineal,	347
Coronary,	485	Superior Hæmorrhoidal,	585
Cystic,	486	,, Mesenteric,	473
Dorsal, of Clitoris,	377, 632	Ulnar,	65
,, Penis,	429, 585	Uterine Plexus,	632
External Iliac,	428	Vaginal ,,	633
,, Saphenous, 185, 257, 274		Vena azygos Major,	528, 537
Femoral,	219, 231	,, Minor,	528, 537
Hæmorrhoidal Plexus,	591	,, Caval Opening in Dia-	
Hepatic,	514	phragm,	528
Ilio-lumbar,	535, 585	,, Cava Inferior,	528, 534
Inferior Hæmorrhoidal, 346, 586		,, Portæ,	489
,, Mesenteric.	476	Vesical Plexus,	591
,, Phrenic,	532	Vermiform Appendix,	451
Internal Iliac,	585	Vertebra Prominens,	2
,, Pudic,	344, 376	Verumontanum,	600
,, Saphenous, 207, 257, 273		Vesical Fascia,	617
Lumbar,	535, 546	Vesico-vaginal Fascia,	617
Median,	65	Vesiculæ Seminales, 548, 577, 605	
,, -basilic,	65	Vestibule of Vulva,	368
,, -cephalic,	67	Villi of Small Intestine,	479, 480
Middle Hæmorrhoidal,	585	Vincula Accessoria,	121
,, Sacral,	535, 585	Visceral Pelvic Fascia,	547, 551,
of Pelvis,	584, 632	557, 560	
on the Dorsum of Hand,	93	Vulva,	365
Ovarian,	533, 633	White Line of Pelvic Fascia,	557,
Popliteal,	194	560, 563	
Portal,	489, 513, 514	Winslow, Foramen of,	459
Profunda,	65	,, Ligamentum Posti-	
Prostatic Plexus,	576, 585	cum of,	310
Radial,	65	Wirsung, Canal of,	497
Renal,	517, 532	Wrisberg, Nerve of,	31, 63, 74
Spermatic,	415, 533		







YOUNG J. PENTLAND'S PUBLICATIONS.

SYSTEM of GYNECOLOGY and OBSTETRICS. By AMERICAN AUTHORS. Edited by MATTHEW D. MANN, A.M., M.D., Professor of Obstetrics and Gynecology in the Medical Department of the University of Buffalo, N.Y.; and BARTON COOKE HIRST, M.D., Associate Professor of Obstetrics in the University of Pennsylvania; Obstetrician to the Philadelphia Maternity Hospital; Gynecologist to the Orthopædic Hospital. In 8 very handsome volumes, Royal 8vo, Cloth, of about 400 pages each, fully Illustrated with Engravings and Coloured Plates. Price 12s. 6d. each, nett. For sale by Subscription only.

TEXT-BOOK of GENERAL BOTANY. By Dr. W. J. BEHRENS. Translation from the Second German Edition. Revised by PATRICK GEDDES, F.R.S.E., Professor of Botany in the University of Dundee. 8vo, Cloth, pp. viii., 374, with 408 Illustrations, finely engraved on Wood, and 4 Analytical Tables, New Edition, Price 5s. (1893.)

THE ELEMENTS OF OPHTHALMOSCOPIC DIAGNOSIS. FOR THE USE OF STUDENTS ATTENDING OPHTHALMIC PRACTICE. By GEORGE A. BERRY, M.B., F.R.C.S.ED., Ophthalmic Surgeon, Edinburgh Royal Infirmary; Lecturer on Ophthalmology, Royal College of Surgeons, Edinburgh. Crown 8vo, Cloth, pp. xii., 83, Price 3s. 6d. (1891.)

DISEASES of the EYE. A PRACTICAL TREATISE FOR STUDENTS OF OPHTHALMOLOGY. By GEORGE A. BERRY, M.B., F.R.C.S.ED., Ophthalmic Surgeon, Edinburgh Royal Infirmary; Senior Surgeon, Edinburgh Eye Dispensary; Lecturer on Ophthalmology, Royal College of Surgeons, Edinburgh. Second Edition revised and enlarged. 8vo, Cloth, gilt top, pp. xvi., 730, illustrated with many Coloured Plates and Wood Engravings. Price 25s. (1893.)

(Pentland's Medical Series, Volume Second.)

THE NATIONAL MEDICAL DICTIONARY. INCLUDING ENGLISH, FRENCH, GERMAN, ITALIAN, AND LATIN TECHNICAL

TERMS USED IN MEDICINE AND THE COLLATERAL SCIENCES, AND A SERIES OF TABLES OF USEFUL DATA. By JOHN S. BILLINGS, A.M., M.D., LL.D., Harv. and Edin., D.C.L., Oxon., Member of the National Academy of Sciences, Surgeon, U.S.A., &c. With the collaboration of W. O. ATWATER, M.D., FRANK BAKER, M.D., JAMES M. FLINT, M.D., R. LORINI, M.D., S. M. BURNETT, M.D., J. H. KIDDER, M.D., H. C. YARROW, M.D., WILLIAM LEE, M.D., C. S. MINOT, M.D., WASHINGTON MATTHEWS, M.D., W. T. COUNCILMAN, M.D. In Two very handsome Imperial 8vo volumes, containing about 1600 pages, Price 50s. nett. (1890.)

DISEASES of the HEART and THORACIC AORTA. By BYROM BRAMWELL, M.D., F.R.C.P.ED., Lecturer on the Principles and Practice of Medicine, and on Practical Medicine and Medical Diagnosis, in the Extra-Academical School of Medicine, Edinburgh; Assistant Physician, Edinburgh Royal Infirmary. Large 8vo, Cloth, pp. xvi., 783. Illustrated with 226 Wood Engravings, and 68 pages of Lithograph Plates, exhibiting 91 Figures—317 Illustrations in all. Price 25s. (1884.)

INTRACRANIAL TUMOURS. By BYROM BRAMWELL, M.D., F.R.C.P.ED., Lecturer on the Principles and Practice of Medicine in the Extra-Academical School of Medicine, Edinburgh; Assistant Physician to the Edinburgh Royal Infirmary. 8vo, Cloth, pp. xvi., 270, with 116 Illustrations, Price 14s. (1888.)

ILLUSTRATIONS of the NERVE TRACTS in the MID AND HIND BRAIN, AND THE CRANIAL NERVES ARISING THEREFROM. By ALEXANDER BRUCE, M.D., F.R.C.P.ED., Lecturer on Pathology in the School of Medicine, Edinburgh; Assistant Physician (formerly Pathologist), Edinburgh Royal Infirmary; Pathologist to the Royal Hospital for Sick Children. Oblong 4to, Cloth, in a series of 27 Coloured Plates from Original Drawings, with Descriptive Letterpress, and 27 Engravings throughout the Text. Price 50s. nett. (1892.)

DISEASES and INJURIES of the EAR: THEIR PREVENTION AND CURE. By CHARLES HENRY BURNETT, A.M., M.D., Aural Surgeon to the Presbyterian Hospital. Crown 8vo, Cloth, pp. 154, with 5 Illustrations. Price 4s. 6d. (1889.)

DISEASE in CHILDREN: A MANUAL FOR STUDENTS AND PRACTITIONERS. By JAMES CARMICHAEL, M.D., F.R.C.P.ED., Physician, Royal Hospital for Sick Children; University Lecturer on Disease in Children, Edinburgh. Crown 8vo, Cloth, pp. xvi., 520. Illustrated with Charts. Price 10s. 6d. (1892.)

(Pentland's Students' Manuals.

TUBERCULOUS DISEASE of the BONES and JOINTS.

By W. WATSON CHEYNE, M.B., F.R.S., F.R.C.S., Professor of Surgery, King's College, London. 8vo, Cloth, pp. xvi., 374. Illustrated with numerous Wood Engravings throughout the Text. Price 14s. nett. (1895.)

SUPPURATION and SEPTIC DISEASES. THREE LECTURES DELIVERED AT THE ROYAL COLLEGE OF SURGEONS OF ENGLAND.

By W. WATSON CHEYNE, M.B., F.R.S., F.R.C.S., Professor of Surgery, King's College, London. 8vo, Cloth, pp. xii., 102, with 4 Illustrations, Price 5s. (1889.)

THE TREATMENT of WOUNDS, ABSCESSSES, and ULCERS.

By W. WATSON CHEYNE, M.B., F.R.S., F.R.C.S., Professor of Surgery, King's College, London. Second Edition. Crown 8vo, Cloth, pp. xvi., 200. Price 3s. 6d. *In Press.*

ATLAS of the DISEASES of the SKIN. By H. RADCLIFFE

CROCKER, M.D., F.R.C.P., Physician to the Department for Diseases of the Skin, University College Hospital, London. In 16 Fasciculi, containing 96 plates, exhibiting 238 Figures in colours from Original Drawings specially prepared for the work, with Descriptive Letterpress. Price 21s. each nett. Or in 2 Large Handsome Folio Volumes, Half Morocco, gilt tops. Price £18, 18s. nett.

* * *Subscribers' Names are now being Received.*

MANUAL OF PRACTICAL ANATOMY. By D. J. CUN-

NINGHAM, M.D., Professor of Anatomy and Chirurgery, University of Dublin. Second Edition. In two Vols., Crown 8vo, Cloth. Volume First—Upper and Lower Limb; Abdomen. Volume Second—Thorax; Head and Neck. Illustrated with 372 Engravings and 2 full-page Plates. Price 12s. 6d. each. (1896.)

(Pentland's Students' Manuals.

HYGIENE AND DISEASES OF WARM CLIMATES,

IN A SERIES OF ARTICLES BY EMINENT AUTHORITIES. Edited by ANDREW DAVIDSON, M.D., F.R.C.P.ED., late Visiting and Superintending Surgeon, Civil Hospital; Professor of Chemistry, Royal College, Mauritius; Author of "*Geographical Pathology.*" Royal 8vo, Cloth, pp. xvi., 1016. Illustrated with Engravings throughout the Text and full-page Plates. Price 31s. 6d. (1893.)

GEOGRAPHICAL PATHOLOGY.

AN INQUIRY INTO THE GEOGRAPHICAL DISTRIBUTION OF INFECTIVE AND CLIMATIC DISEASES. By ANDREW DAVIDSON, M.D., F.R.C.P.ED., late Visiting and Superintending Surgeon, Civil Hospital; Professor of Chemistry, Royal College, Mauritius. Two vols. Large 8vo, Cloth, pp. xvi., 1008. Illustrated with Maps and Charts. Price 31s. 6d. (1891.)

TEXT-BOOK of NERVOUS DISEASES

BY AMERICAN AUTHORS. Edited by FRANCIS X. DERCUM, M.D., PH.D., Clinical Professor of Nervous Diseases in the Jefferson Medical College of Philadelphia. Royal 8vo, pp. xvi., 1056, with 341 Engravings in the Text, and 7 Coloured Plates. Price 25s. nett. (1895.)

THE "COMPEND" SERIES

A Series of Handbooks to assist Students preparing for Examinations.

COMPEND of HUMAN ANATOMY,

INCLUDING THE ANATOMY OF THE VISCERA. By SAMUEL O. L. POTTER, M.A., M.D., Cooper Medical College, San Francisco. Fifth Edition, revised and enlarged, Crown 8vo, Cloth, pp. 233, with 117 Engravings and 16 full-page Plates. Price 5s.

COMPEND of the PRACTICE of MEDICINE.

By DANIEL E. HUGHES, M.D., late Demonstrator of Clinical Medicine in the Jefferson Medical College of Philadelphia. Fourth Edition, revised and enlarged, Crown 8vo, Cloth, pp. 328. Price 7s. 6d.

COMPEND of OBSTETRICS.

By HENRY G. LANDIS, A.M., M.D., late Professor of Obstetrics and Diseases of Women in Starling Medical College. Fourth Edition, thoroughly revised, enlarged, and improved, Crown 8vo, Cloth, pp. 118, with 17 Illustrations. Price 4s. 6d.

COMPEND of SURGERY. By ORVILLE HORWITZ, B.S., M.D., Chief of the Outdoor Surgical Department, Jefferson Medical College Hospital. Fourth Edition, revised, Crown 8vo, Cloth, pp. 272, with 136 Illustrations. Price 5s.

COMPEND of GYNÆCOLOGY. By HENRY MORRIS, M.D. late Demonstrator of Obstetrics and Diseases of Women and Children, Jefferson Medical College, Philadelphia. Crown 8vo, Cloth, pp. 178, with 45 Illustrations. Price 4s. 6d.

COMPEND of GENERAL PATHOLOGY and MORBID ANATOMY. By H. NEWBERY HALL, Ph.G., M.D., Professor of Pathology and Medical Chemistry, Post Graduate Medical School; Surgeon to the Emergency Hospital, &c., Chicago. Crown 8vo, Cloth, pp. 204, with 91 Illustrations. Price 4s. 6d.

COMPEND of DISEASES of CHILDREN. By MARCUS P. HATFIELD, A.M., M.D., Professor of Diseases of Children, Chicago Medical College. Crown 8vo, Cloth, pp. 186, with Coloured Plate. Price 4s. 6d.

COMPEND of DENTAL PATHOLOGY and DENTAL MEDICINE. By GEO. W. WARREN, D.D.S., Clinical Chief, Pennsylvania College of Dental Surgery. Crown 8vo, Cloth, pp. 109, Illustrations. Price 4s. 6d.

CYCLOPÆDIA of the DISEASES of CHILDREN, MEDICAL AND SURGICAL. The Articles written especially for the Work by American, British, and Canadian Authors. Edited by JOHN M. KEATING, M.D. In 8 Vols., Royal 8vo, of about 500 pages each, Illustrated with Wood Engravings in the Text, and numerous full-page Plates. Price 12s. 6d. per Volume nett, Carriage Free.

* * *Detailed Prospectus on application.*

EDINBURGH HOSPITAL REPORTS. PUBLISHED UNDER THE SUPERVISION OF AN EDITORIAL COMMITTEE ELECTED BY THE MEDICAL AND SURGICAL OFFICERS OF THE ROYAL INFIRMARY, ROYAL HOSPITAL FOR SICK CHILDREN, AND ROYAL MATERNITY AND SIMPSON MEMORIAL HOSPITAL. Edited by G. A. GIBSON, M.D., D.Sc., C. W. CATHCART, M.A., M.B., JOHN THOMSON, M.D., and D. BERRY HART, M.D. To be issued annually, 8vo, pp. xvi., 650 or thereby, handsomely printed, illustrated with full-page Plates and Engravings. Price per Volume, 12s. 6d. nett. Carriage free. Volumes I. to IV. now ready.

DISEASES of the STOMACH. By 'DR. 'C. A. EWALD, Extraordinary Professor of Medicine at the University of Berlin; Director of the Augusta Hospital. Authorised Translation, with Special Additions by the Author, by MORRIS MANGES, A.M., M.D., Attending Physician, Mount Sinai Hospital, New York City. 8vo, Cloth, pp. xvi., 498, with 30 Illustrations. Price 16s. (1892.)

EXAMINATION QUESTIONS, SET FOR THE PROFESSIONAL EXAMINATIONS IN EDINBURGH UNIVERSITY DURING THE PAST TEN YEARS, SELECTED FROM THE CALENDARS. By W. RAMSAY SMITH, M.B., C.M., B.Sc., Formerly Demonstrator of Anatomy, Edinburgh School of Medicine, Minto House; late Senior Assistant to the Professor of Natural History, University of Edinburgh.

NATURAL HISTORY, arranged and annotated, Price 1s.

BOTANY, arranged and annotated, Price 1s. 6d.

CHEMISTRY, answered and annotated, Price 2s.

ANATOMY, answered and annotated, Price 2s.

PHYSIOLOGY, answered and annotated, Price 2s.

MATERIA MEDICA, answered and annotated, Price 2s.

MIDWIFERY AND GYNECOLOGY, answered and annotated,
Price 1s. 6d.

SURGERY, answered and annotated. Price 1s. 6d.

PRACTICE OF PHYSIC, answered and annotated. Price 1s. 6d.

MEDICAL JURISPRUDENCE AND PUBLIC HEALTH, answered and annotated. Price 2s.

* * *Other Volumes to follow.*

DISORDERS of the MALE SEXUAL ORGANS. By EUGENE FULLER, M.D., Instructor in Genito-Urinary and Venereal Diseases, New York Post-Graduate Medical School. Large 8vo, pp. viii., 241, with Full-Page Plates and Illustrations in the Text. Price 9s. (1895.)

THE FUNDUS OCULI, with an OPHTHALMOSCOPIC ATLAS, ILLUSTRATING ITS PHYSIOLOGICAL AND PATHOLOGICAL CONDITIONS. By W. ADAMS FROST, F.R.C.S., Ophthalmic Surgeon, St. George's Hospital; Surgeon to the Royal Westminster Ophthalmic Hospital, London. In one handsome 4to volume, extra Cloth, gilt top, with 47 Plates, exhibiting 107 beautifully Coloured Figures and numerous Engravings in the Text. Price £3, 3s. nett. (1896.)

PHYSICAL DIAGNOSIS: A GUIDE TO METHODS OF CLINICAL INVESTIGATION. By G. A. GIBSON, M.D., D.Sc., F.R.C.P.ED., Assistant Physician, Edinburgh Royal Infirmary; Lecturer on the Principles and Practice of Medicine in the Edinburgh Medical School; and WILLIAM RUSSELL, M.D., F.R.C.P.ED., Assistant Physician, Edinburgh Royal Infirmary; Lecturer on Pathology and Morbid Anatomy in the Edinburgh Medical School. Second Edition, thoroughly revised, Crown 8vo, Cloth, pp. xvi., 383, with 109 Illustrations, some Coloured, Price 10s. 6d. (1893.) *(Pentland's Students' Manuals.*

HYDATID DISEASE IN ITS CLINICAL ASPECTS. By JAMES GRAHAM, M.A., M.D., late Demonstrator of Anatomy, Sydney University; Medical Superintendent, Prince Alfred Hospital, Sydney. 8vo, Cloth, gilt top, pp. xvi., 204, with 34 full-page Coloured Plates, Price 16s. (1891.)

PHYSICAL AND NATURAL THERAPEUTICS: THE REMEDIAL USES OF ATMOSPHERIC PRESSURE, CLIMATE, HEAT AND COLD, HYDROTHERAPEUTIC MEASURES, MINERAL WATERS, AND ELECTRICITY. By GEORGES HAYEM, M.D., Professor of Clinical Medicine in the Faculty of Medicine, Paris. Edited by HOBART AMORY HARE, M.D., Professor of Therapeutics and Materia Medica, Jefferson Medical College, Philadelphia. Large 8vo, Cloth, pp. 426, with 113 Illustrations in the Text. Price 14s. (1895.)

A SYSTEM OF PRACTICAL THERAPEUTICS. By Various Authors. Edited by HOBART AMORY HARE, M.D., Clinical Professor of Diseases of Children, and Demonstrator of Therapeutics in the University of Pennsylvania; Physician to St. Agnes's Hospital, Philadelphia. 3 Vols., Royal 8vo, of about 1000 pages each, Price per vol. 22s. 6d. *nett*, carriage free.

HANDBOOK OF OBSTETRIC NURSING. By F. W. N. HAULTAIN, M.D., F.R.C.P.ED., Physician to the Royal Dispensary; late Clinical Assistant to Physician for Diseases of Women, Royal Infirmary, Edinburgh; and J. HAIG FERGUSON, M.D., F.R.C.P.ED., Physician to the New Town Dispensary; late Resident Physician, Royal Maternity Hospital, Edinburgh.

Second Edition, Revised and Enlarged, Crown 8vo, Cloth, pp. xvi., 244, with Coloured Plate and 33 Wood Engravings, Price 5s. (1894.)

HUMAN MONSTROSITIES. By BARTON COOKE HIRST, M.D., Professor of Obstetrics in the University of Pennsylvania; and GEORGE A. PIERSOL, M.D., Professor of Embryology and Histology in the University of Pennsylvania. In 4 Fasciculi, folio size, illustrated with Engravings and full-page Photographic Plates from Nature, Price 25s. each Fasciculus. *Sold only by Subscription.*

THE URINE AND THE COMMON POISONS, MEMORANDA, CHEMICAL AND MICROSCOPICAL, FOR LABORATORY USE. By J. W. HOLLAND, M.D., Professor of Medical Chemistry and Toxicology, Jefferson Medical College, Philadelphia. Second Edition, Revised and Enlarged, oblong Crown 8vo, Cloth, pp. 65, with 28 Illustrations, Price 4s. (1889.)

DISEASES OF THE SKIN: A MANUAL FOR STUDENTS AND PRACTITIONERS. By W. ALLAN JAMIESON, M.D., F.R.C.P.ED., Extra Physician for Diseases of the Skin, Edinburgh Royal Infirmary; Consulting Physician, Edinburgh City Hospital; Lecturer on Diseases of the Skin, School of Medicine, Edinburgh. Fourth Edition, Revised and Enlarged, 8vo, Cloth, pp. xvi., 676, with Coloured Illustrations. Price 21s. (1894.)

(Pentland's Medical Series, Volume First.)

BOTANY: A CONCISE MANUAL FOR STUDENTS OF MEDICINE AND SCIENCE. By ALEXANDER JOHNSTONE, F.G.S., Lecturer on Botany, School of Medicine, Edinburgh. Crown 8vo, Cloth, pp. xvi., 260, with 164 Illustrations and a series of Floral Diagrams, Price 6s. (1891.) *(Pentland's Students' Manuals.)*

A NEW PRONOUNCING DICTIONARY OF MEDICAL TERMS. By JOHN M. KEATING, M.D., Fellow of the College of Physicians of Philadelphia, Visiting Obstetrician to the Philadelphia Hospital, and Lecturer on Diseases of Women and Children. Handsome 8vo, Cloth, pp. 818, Price 18s. (1892.)

CLINICAL GYNÆCOLOGY, MEDICAL and SURGICAL. By AMERICAN AUTHORS. Edited by JOHN M. KEATING, M.D.,

LL.D., and HENRY C. COE, M.D., M.R.C.S., Professor of Gynæcology, New York Polyclinic. Two Volumes, Royal 8vo, Cloth, pp. xviii., 994, Illustrated with Full-page Plates and Engravings in the Text. Price 25s. nett. (1895.)

TEXT-BOOK of ABDOMINAL SURGERY: A CLINICAL MANUAL FOR PRACTITIONERS AND STUDENTS. By SKENE KEITH, F.R.C.S.Ed.; assisted by GEORGE E. KEITH, M.B. 8vo, Cloth, gilt top, pp. xvi., 508, Price 16s. (1894.)

(Pentland's Medical Series, Volume Fourth.)

THE ESSENTIALS of MEDICAL ANATOMY. By H. R. KENWOOD, M.B., C.M., L.R.C.P. (Lond.) 12mo, Cloth, pp. 52, Price 2s. (1889.)

THE PARASITES of MAN, AND THE DISEASES WHICH PROCEED FROM THEM. A TEXT-BOOK FOR STUDENTS AND PRACTITIONERS. By RUDOLF LEUCKART, Professor of Zoology and Comparative Anatomy in the University of Leipsic. Translated from the German, with the Co-operation of the Author, by WILLIAM E. HOYLE, M.A. (Oxon.), M.R.C.S., F.R.S.E., Curator of the Museums, Owens College, Manchester. NATURAL HISTORY OF PARASITES IN GENERAL—SYSTEMATIC ACCOUNT OF THE PARASITES INFESTING MAN—PROTOZOA—CESTODA. Large 8vo, Cloth, pp. xxviii., 772, Illustrated with 404 Engravings, Price 31s. 6d. (1886.)

FIRST AID to the INJURED and MANAGEMENT of the SICK. By E. J. LAWLESS, M.D., Surgeon-Major, 4th V.B., E. Surrey Regiment. Crown 8vo, Cloth, pp. xvi., 262, Illustrated with numerous Wood Engravings. Price 3s. 6d. (1894.)

TRAUMATIC INFECTION. HUNTERIAN LECTURES DELIVERED AT THE ROYAL COLLEGE OF SURGEONS OF ENGLAND. By CHARLES BARRETT LOCKWOOD, F.R.C.S., Hunterian Professor, Royal College of Surgeons of England; Assistant Surgeon to St. Bartholomew's Hospital; Surgeon to the Great Northern Central Hospital. Crown 8vo, Cloth, pp. xii., 138, Illustrated with 27 Wood Engravings in the Text. Price 3s.

ASEPTIC SURGERY. By CHARLES BARRETT LOCKWOOD, F.R.C.S. Crown 8vo, Cloth, pp. xvi., 233. Price 4s.

STUDENTS' POCKET MEDICAL LEXICON, GIVING THE CORRECT PRONUNCIATION AND DEFINITION OF ALL WORDS AND TERMS IN GENERAL USE IN MEDICINE AND THE COLLATERAL SCIENCES. By ELIAS LONGLEY. New Edition, 18mo, Cloth, pp. 303, Price 4s. (1891.)

DISEASES of the THROAT, NOSE, and EAR. By P. M'BRIDE, M.D., F.R.C.P.Ed., Lecturer on the Diseases of the Ear and Throat, Edinburgh School of Medicine; Aural Surgeon and Laryngologist, Royal Infirmary, Edinburgh; Surgeon, Edinburgh Ear and Throat Dispensary. Second Edition, thoroughly revised. 8vo, Cloth, pp. xvi., 682, with Coloured Illustrations from Original Drawings. Price 25s. (1894.)

(Pentland's Medical Series, Volume Third.)

REGIONAL ANATOMY IN ITS RELATION TO MEDICINE AND SURGERY. By GEORGE M'CLELLAN, M.D., Lecturer on Descriptive and Regional Anatomy at the Pennsylvania School of Anatomy. In Two Handsome Volumes, large 4to, Illustrated with 100 full-page facsimile Chromo-lithographic Plates, reproduced from Photographs taken by the Author of his own Dissections, expressly designed and prepared for this work, and coloured by him after nature. Price 42s. each, nett.

ATLAS of VENEREAL DISEASES. A SERIES OF ILLUSTRATIONS FROM ORIGINAL PAINTINGS, WITH DESCRIPTIONS OF THE VARIED LESIONS, THEIR DIFFERENTIAL DIAGNOSIS AND TREATMENT. By P. H. MACLAREN, M.D., F.R.C.S.ED., Surgeon, Edinburgh Royal Infirmary; Formerly Surgeon in Charge of the Lock Wards, Edinburgh Royal Infirmary; Examiner in the Royal College of Surgeons, Edinburgh. In One Handsome Royal 4to Volume, Extra Cloth, Price 63s. nett.

FUNCTIONAL and ORGANIC DISEASES of the STOMACH. By SIDNEY MARTIN, M.D., F.R.S., F.R.C.P., Assistant Physician and Assistant Professor of Clinical Medicine at University College Hospital; Assistant Physician to the Hospital for Consumption and Diseases of the Chest, Brompton. 8vo, Cloth, pp. xvi., 506, Illustrated with numerous Engravings throughout the Text. Price 16s. (1895.)

(Pentland's Medical Series, Volume Fifth.)

A SYSTEM OF GENITO-URINARY DISEASES, SYPHILOLOGY, AND DERMATOLOGY. Edited by PRINCE A. MORROW, M.D. 6 vols., large 8vo, of about 550 pages each, fully Illustrated, Price per vol. 14s., carriage free.

PRESCRIBING and TREATMENT IN THE DISEASES OF INFANTS AND CHILDREN. By PHILIP E. MUSKETT, L.R.C.P. & S.Ed., late Surgeon to the Sydney Hospital; formerly Senior Resident Medical Officer, Sydney Hospital. Third Edition, Revised and Enlarged, 18mo, pp. xx., 336, in Flexible Leather binding for the pocket. Price 6s. 6d. (1894.)

PRACTICAL TREATISE on MEDICAL DIAGNOSIS. By JOHN H. MUSSER, M.D., Assistant Professor of Clinical Medicine in the University of Pennsylvania; Physician to the Philadelphia and the Presbyterian Hospitals. Royal 8vo, Cloth, pp. viii., 881. Illustrated with 162 Woodcuts and 2 Coloured Plates. Price 24s. (1894.)

MALIGNANT DISEASE of the THROAT and NOSE. By DAVID NEWMAN, M.D., Laryngologist to the Glasgow Royal Infirmary; Assistant Surgeon to the Western Infirmary; Examiner in Pathology in the University of Glasgow. 8vo, pp. xvi., 212, with 3 Illustrations. Price 8s. 6d. (1892.)

TEXT-BOOK of OPHTHALMOLOGY. By W. F. NORRIS, A.M., M.D., and C. A. OLIVER, A.M., M.D. Royal 8vo, pp. viii., 622, Illustrated with 5 Coloured Plates and 357 Woodcuts. Price 25s. (1893.)

LEAD POISONING, ACUTE AND CHRONIC. BEING THE GOULSTONIAN LECTURES DELIVERED AT THE ROYAL COLLEGE OF PHYSICIANS. By THOMAS OLIVER, M.D., F.R.C.P., Physician Royal Infirmary, Newcastle-on-Tyne; Professor of Physiology, University of Durham; Honorary Physician, Newcastle-on-Tyne Dispensary and Industrial Schools. 8vo, Cloth, pp. xii., 121, with Coloured Illustrations, Price 10s. 6d. (1891.)

THE PRINCIPLES and PRACTICE of MEDICINE, DESIGNED FOR THE USE OF PRACTITIONERS AND STUDENTS OF MEDICINE. By WILLIAM OSLER, M.D., F.R.C.P., Professor of Medicine in the Johns Hopkins University, and Physician-in-

Chief to the Johns Hopkins Hospital, Baltimore. Second Edition, thoroughly Revised and partly Re-written. Large 8vo, Cloth, pp. xvi., 1080, Illustrated with Charts, Price 24s. (1895.)

THE SCIENCE and ART of OBSTETRICS. By THEOPHILUS PARVIN, M.D., LL.D., Professor of Obstetrics and Diseases of Women and Children in Jefferson Medical College, Philadelphia, and one of the Obstetricians to the Philadelphia Hospital. Third Edition, thoroughly revised, large 8vo, Cloth, pp. 701, with 269 Wood Engravings, and 2 Coloured Plates, Price 18s. (1895.)

BERI BERI : RESEARCHES CONCERNING ITS NATURE AND CAUSE AND THE MEANS OF ITS ARREST. By C. A. PEKELHARING, Professor in the Faculty of Medicine, University of Utrecht ; and C. WINKLER Lecturer in the University of Utrecht. Translated by JAMES CANTLIE, M.A., M.B., F.R.C.S. 8vo, Cloth, pp. xvi., 160, Illustrated with full-page Coloured Plates from Original Drawings. Price 10s. 6d. nett. (1893.)

PRACTICAL LESSONS IN NURSING :

A Series of Handbooks.

Crown 8vo, Cloth, each 4s. 6d.

THE NURSING and CARE of the NERVOUS and the INSANE. By CHARLES K. MILLS, M.D., Professor of Diseases of the Mind and Nervous System in the Philadelphia Polyclinic and College for Graduates in Medicine ; Lecturer on Mental Diseases in the University of Pennsylvania.

MATERNITY, INFANCY, CHILDHOOD: HYGIENE OF PREGNANCY ; NURSING AND WEANING OF INFANTS ; THE CARE OF CHILDREN IN HEALTH AND DISEASE. By JOHN M. KEATING, M.D., Lecturer on the Diseases of Women and Children, Philadelphia Hospital.

OUTLINES for the MANAGEMENT of DIET : OR, THE REGULATION OF FOOD TO THE REQUIREMENTS OF HEALTH AND THE TREATMENT OF DISEASE. By E. T. BRUEN, M.D., Assistant Professor of Physical Diagnosis, University of Pennsylvania, one of the Physicians to the Philadelphia and University Hospitals.

REPORTS from the **LABORATORY** of the **ROYAL COLLEGE OF PHYSICIANS, EDINBURGH.** Edited by J. BATTY TUKE, M.D., G. SIMS WOODHEAD, M.D., and D. NOEL PATON, M.D.

VOLUME FIRST, 8vo, Cloth, pp. 212, with 23 full-page Plates, and 19 Engravings, Price 7s. 6d. nett.

VOLUME SECOND, 8vo, Cloth, pp. xiv., 280, with 43 full-page Plates, consisting of Lithographs, Chromo-Lithographs, and Micro-Photographs, Price 10s. 6d. nett.

VOLUME THIRD, 8vo, Cloth, pp. xii., 304, with 11 Plates and Folding Charts, Price 9s. nett.

VOLUME FOURTH, 8vo, Cloth, pp. xii., 254, with 25 Plates and Folding Charts, Price 10s. 6d. nett.

PEDIATRICS: THE HYGIENIC AND MEDICAL TREATMENT OF DISEASES IN CHILDREN. By THOMAS MORGAN ROTCH, M.D., Professor of Diseases of Children, Harvard University. Two vols., large 8vo., pp. 1124, with 450 Illustrations in the Text, and 8 full-page Coloured Plates, Price 25s. nett. (1896.)

DISEASES of the MOUTH, THROAT, and NOSE, including RHINOSCOPY AND METHODS OF LOCAL TREATMENT. By PHILIP SCHECH, M.D., Lecturer in the University of Munich, Translated by R. H. BLAIKIE, M.D., F.R.S.E., formerly Surgeon, Edinburgh Ear and Throat Dispensary; late Clinical Assistant, Ear and Throat Department, Royal Infirmary, Edinburgh. 8vo, Cloth, pp. xii., 302, with 5 Wood Engravings, Price 9s. (1886.)

ELEMENTS of PHARMACOLOGY. By Dr. OSWALD SCHMEDEBERG, Professor of Pharmacology, University of Strasbourg. Translated by THOMAS DIXSON, M.B., Lecturer on Materia Medica in the University of Sydney, N.S.W. 8vo, Cloth, pp. xii. 223, with 7 Illustrations, Price 9s. (1887.)

MANUAL of CLINICAL DIAGNOSIS. By Dr. OTTO SEIFERT, Privat Docent in Wurzburg; and Dr. FRIEDRICH MULLER, Assistent Der II. Med. Klinik in Berlin. Third Edition, revised and corrected. Translated with the permission of the Authors by WILLIAM B. CANFIELD, A.M., M.D., Chief of Clinic for Throat and Chest, University of Maryland. Crown 8vo, Cloth, pp. xii., 173, with 60 Illustrations, Price 5s. (1887.)

SURGICAL ANATOMY. A MANUAL FOR STUDENTS. By A. MARMADUKE SHEILD, M.B. (Cantab.), F.R.C.S., Senior Assistant Surgeon, Aural Surgeon and Teacher of Operative Surgery, Charing Cross Hospital. Crown 8vo, Cloth, pp. xvi., 212, Price 6s. (1891.) (*Pentland's Students' Manuals.*)

MEDICAL GYNECOLOGY: A TREATISE ON THE DISEASES OF WOMEN FROM THE STANDPOINT OF THE PHYSICIAN. By ALEXANDER J. C. SKENE, M.D., Professor of Gynecology in the Long Island College Hospital, Brooklyn, New York. 8vo, Cloth, pp. vi., 530, with Illustrations in the Text, Price 21s.

ILLUSTRATIONS of ZOOLOGY, INVERTEBRATES AND VERTEBRATES. By WILLIAM RAMSAY SMITH, B.Sc., and J. STEWART NORWELL, B.Sc. New and Cheaper Edition. Crown 4to, extra Cloth, gilt top, with 70 Plates, exhibiting over 400 Figures, Price 7s. 6d.

DISEASES of the DIGESTIVE ORGANS in INFANTS AND CHILDREN. WITH CHAPTERS ON THE INVESTIGATION OF DISEASE AND ON THE GENERAL MANAGEMENT OF CHILDREN. By LOUIS STARR, M.D., late Clinical Professor of Diseases of Children in the Hospital of the University of Pennsylvania; Physician to the Children's Hospital, Philadelphia. Second Edition, Post 8vo, Cloth, pp. 396, with Illustrations, Price 10s. (1891.)

EPIDEMIC OPHTHALMIA: ITS SYMPTOMS, DIAGNOSIS, AND MANAGEMENT. By SYDNEY STEPHENSON, F.R.C.S. Ed., Surgeon, Ophthalmic School, Hanwell. 8vo, Cloth, pp. xvi., 278, Illustrated throughout the Text. Price 9s. nett.

APPENDICITIS and PERITYPHLITIS. By CHARLES TALAMON, Physician to the Tenon Hospital, Paris. Translated from the French by RICHARD J. A. BERRY, M.B., C.M., late President of the Royal Medical Society, Edinburgh. Crown 8vo, Cloth, pp. viii., 239, Price 6s. (1893.)

THE PATHOLOGY and TREATMENT of VENEREAL DISEASES. By ROBERT W. TAYLOR, M.D., Clinical Professor of Venereal Diseases at the College of Physicians and Surgeons (Columbia College) New York; Surgeon to Bellevue Hospital; and Consulting Surgeon to the City (Charity) Hospital, New

York. Royal 8vo, Cloth, pp. 1002, Illustrated with 230 Engravings in the Text, and 7 Coloured Plates, Price 22s. nett. (1896.)

MINOR SURGERY and BANDAGING. INCLUDING THE TREATMENT OF FRACTURES AND DISLOCATIONS, ETC. ETC. By HENRY R. WHARTON, M.D., Demonstrator of Surgery and Lecturer on Surgical Diseases of Children in the University of Pennsylvania. Post 8vo, Cloth, pp. 496, with 403 Engravings. Price 12s. 6d. (1891.)

OUTLINES of ZOOLOGY. By J. ARTHUR THOMSON, M.A., Lecturer on Zoology, School of Medicine, Edinburgh. Second Edition, Revised and Enlarged. Crown 8vo, Cloth, pp. xx., 820, with 266 Illustrations in the Text, Price 15s. (1895.)

(Pentland's Students' Manuals.

CLINICAL TEXT-BOOK of MEDICAL DIAGNOSIS, BASED ON THE MOST RECENT METHODS OF EXAMINATION. By OSWALD VIERORDT, M.D., Professor of Medicine at the University of Heidelberg. Translated, with additions from the second enlarged German edition, with the Author's permission. By FRANCIS H. STUART, M.D., Member of the Medical Society of the County of Kings, New York. Large 8vo, Cloth, pp. xvi., 700, with 178 fine Engravings, many in Colour, Price 18s. (1891.)

PRACTICAL GUIDE to MEAT INSPECTION. By THOMAS WALLEY, M.R.C.V.S., formerly Principal of the Edinburgh Royal (Dick) Veterinary College; Professor of Veterinary Medicine and Surgery, &c. Third Edition, thoroughly Revised, pp. xvi., 198, with 44 Figures, mostly in Colours, Price 10s. 6d.

ECTOPIC PREGNANCY. By J. CLARENCE WEBSTER, M.D., F.R.C.P.Ed., Formerly Assistant to the Professor of Midwifery and Diseases of Women and Children in the University of Edinburgh. 8vo, Cloth, pp. xvi., 374, with 22 pages of Plates and Figures throughout the Text, Price 12s. 6d. nett. (1895.)

RESEARCHES in FEMALE PELVIC ANATOMY. By J. CLARENCE WEBSTER, B.A., M.D., M.R.C.P.Ed., Demy 4to, Cloth, Illustrated with 26 full-page Coloured Plates from Original Drawings. Price 30s. nett. (1892.)

TUBO-PERITONEAL ECTOPIC GESTATION. By J. CLARENCE WEBSTER, B.A., M.D., M.R.C.P.Ed. Demy 4to,

Cloth, Illustrated with 11 full-page Plates, several Coloured, exhibiting numerous Figures. Price 16s. nett. (1892.)

PRACTICAL and OPERATIVE GYNECOLOGY. By J. CLARENCE WEBSTER, M.D., F.R.C.P.ED., formerly Assistant to the Professor of Midwifery and Diseases of Women, University of Edinburgh. Crown 8vo, Cloth, pp. xvi., 296, with 54 Illustrations. Price 7s. 6d. (1896.) (*Pentland's Students' Manuals.*)


TEXT-BOOK of OBSTETRICS, INCLUDING THE PATHOLOGY AND THERAPEUTICS OF THE PUERPERAL STATE. DESIGNED FOR PRACTITIONERS AND STUDENTS OF MEDICINE. By Dr. F. WINCKEL, Professor of Gynæcology and Director of the Royal Hospital for Women. Translated under the supervision of J. CLIFTON EDGAR, A.M., M.D., Adjunct Professor of Obstetrics, University of the City of New York. Royal 8vo, Cloth, pp. 927, Illustrated with 190 Engravings, mostly Original, Price 28s. (1890.)

PRACTICAL PATHOLOGY. A MANUAL FOR STUDENTS AND PRACTITIONERS. By G. SIMS WOODHEAD, M.D., F.R.C.P.ED., Director of the Laboratories of the Royal Colleges of Physicians (London) and Surgeons (England). Third Edition, Revised and Enlarged, 8vo. Cloth, pp. xxiv., 652, with 195 Coloured Illustrations, mostly from Original Drawings, Price 25s. (1892.)

THE JOURNAL of PATHOLOGY and BACTERIOLOGY. Edited, with the collaboration of distinguished British and Foreign Pathologists, by GERMAN SIMS WOODHEAD, M.D., Director of the Laboratories of the Royal Colleges of Physicians (London) and Surgeons (England). Assisted in special departments by SIDNEY MARTIN, M.D., Lond. (*Pathological Chemistry*); G. E. CARTWRIGHT WOOD, M.D., Edin. (*Bacteriology*); C. S. SHERRINGTON, M.D., Cantab. (*Experimental Pathology*); S. G. SHATTOCK, F.R.C.S. (*Morbid Anatomy and Histology*). Issued at Quarterly Intervals. Subscription 21s. per annum (in advance) post free.

YOUNG J. PENTLAND,
EDINBURGH: 11 TEVIOT PLACE.
LONDON: 38 WEST SMITHFIELD, E.C.

3210
2-12





COLUMBIA UNIVERSITY LIBRARIES

This book is due on the date indicated below, or at the expiration of a definite period after the date of borrowing, as provided by the rules of the Library or by special arrangement with the Librarian in charge.

DATE BORROWED	DATE DUE	DATE BORROWED	DATE DUE
MAY 13	17		
C28(1141)M100			

QM23

Cunningham

C912
1896

v.1

Copy 1

COLUMBIA UNIVERSITY LIBRARIES (hsl.stx)

QM 23 C912 1896 C.1 v 1

Manual of practical anatomy



2002174235

