



This is a digital copy of a book that was preserved for generations on library shelves before it was carefully scanned by Google as part of a project to make the world's books discoverable online.

It has survived long enough for the copyright to expire and the book to enter the public domain. A public domain book is one that was never subject to copyright or whose legal copyright term has expired. Whether a book is in the public domain may vary country to country. Public domain books are our gateways to the past, representing a wealth of history, culture and knowledge that's often difficult to discover.

Marks, notations and other marginalia present in the original volume will appear in this file - a reminder of this book's long journey from the publisher to a library and finally to you.

Usage guidelines

Google is proud to partner with libraries to digitize public domain materials and make them widely accessible. Public domain books belong to the public and we are merely their custodians. Nevertheless, this work is expensive, so in order to keep providing this resource, we have taken steps to prevent abuse by commercial parties, including placing technical restrictions on automated querying.

We also ask that you:

- + *Make non-commercial use of the files* We designed Google Book Search for use by individuals, and we request that you use these files for personal, non-commercial purposes.
- + *Refrain from automated querying* Do not send automated queries of any sort to Google's system: If you are conducting research on machine translation, optical character recognition or other areas where access to a large amount of text is helpful, please contact us. We encourage the use of public domain materials for these purposes and may be able to help.
- + *Maintain attribution* The Google "watermark" you see on each file is essential for informing people about this project and helping them find additional materials through Google Book Search. Please do not remove it.
- + *Keep it legal* Whatever your use, remember that you are responsible for ensuring that what you are doing is legal. Do not assume that just because we believe a book is in the public domain for users in the United States, that the work is also in the public domain for users in other countries. Whether a book is still in copyright varies from country to country, and we can't offer guidance on whether any specific use of any specific book is allowed. Please do not assume that a book's appearance in Google Book Search means it can be used in any manner anywhere in the world. Copyright infringement liability can be quite severe.

About Google Book Search

Google's mission is to organize the world's information and to make it universally accessible and useful. Google Book Search helps readers discover the world's books while helping authors and publishers reach new audiences. You can search through the full text of this book on the web at <http://books.google.com/>


LANE


MEDICAL



LIBRARY

LEVI COOPER LANE FUND





MANUAL OF OPERATIVE SURGERY

BY
JOSEPH D. BRYANT, M.D.

PROFESSOR OF ANATOMY AND CLINICAL SURGERY, AND ASSOCIATE PROFESSOR
OF ORTHOPEDIC SURGERY, BELLEVUE HOSPITAL MEDICAL COLLEGE; VISITING
SURGEON TO BELLEVUE HOSPITAL, AND CONSULTING SURGEON TO
THE NEW YORK LUNATIC ASYLUM AND THE OUT-DOOR
DEPARTMENT OF BELLEVUE HOSPITAL

WITH ABOUT 800 ILLUSTRATIONS

VOLUME I



BERMINGHAM & COMPANY

28 UNION SQUARE, EAST
NEW YORK

1884

K

20 KING WILLIAM ST., STRAND
LONDON

WASHERS

Copyright, 1888, by BIRMINGHAM & Co.



WASHERS

WASHERS


M32
B915
V.1
1884

TO
STEPHEN SMITH, M.D.,
AND
To my Preceptor,
GEORGE W. AVERY, M.D.,

THIS VOLUME IS RESPECTFULLY INSCRIBED,

THOUGH BUT A MEAGRE RECOGNITION OF THE
MANY KINDNESSES SHOWN
BY THEM TO

THE AUTHOR.



PREFACE.

THE frequent request on the part of those whom it has been my pleasure to instruct in operative surgery during the last few years, to make a book based somewhat upon the plan employed in teaching this subject, has been the principal incentive to my action. The field of operative surgery is too well cultivated already for one in this brief space to hope to do more than to aid the student in acquiring established facts, rather than to add to the art itself. The works of Ashhurst, Gross, Erichsen, Holmes, Packard, Smith, Esmarch, Stimson, and others, have been fully consulted, and in some instances their language has been employed or paraphrased. The illustrations, which are numerous, have been in most instances selected from the works of the authors just mentioned, although a considerable number of original cuts have been introduced. The author desires to acknowledge the aid derived from the sources mentioned, and trusts that the reader will find something to commend in the pages that are to follow. The operations peculiar to the female, and the eye and ear, have not been considered, since they are, in the opinion of the author, entitled to a far more extended consideration than the intentional scope of this work will admit of.

J. D. BRYANT.

66 WEST 35TH ST., NEW YORK, December, 1883.

The first part of the document discusses the importance of maintaining accurate records of all transactions. It emphasizes that every entry should be supported by a valid receipt or invoice. This ensures transparency and allows for easy verification of the data.

In the second section, the author outlines the various methods used to collect and analyze the data. This includes both primary and secondary data collection techniques. The primary data was gathered through direct observation and interviews, while secondary data was obtained from existing reports and databases.

The third section details the statistical analysis performed on the collected data. It describes the use of descriptive statistics to summarize the data and inferential statistics to test hypotheses. The results of these analyses are presented in a clear and concise manner, highlighting the key findings of the study.

Finally, the document concludes with a discussion of the implications of the findings. It suggests that the results have significant implications for the field of study and provides recommendations for further research. The author also acknowledges the limitations of the study and offers suggestions for how these can be addressed in future work.

OPERATIVE SURGERY.

OPERATIVE surgery treats of the manual procedures necessary to properly accomplish the surgical object in view. The operation to be done is the execution upon the part of a verdict that is, or should be, based upon surgical principles and laws in a comparative sense of legal proceedings in the Courts of Justice. The surgeon, in most instances, however, holds the threefold position of judge, jury and executioner. It is, therefore, very essential for the welfare of the patient that he properly interpret the surgical laws and principles relating to the case, in order that the verdict to follow may be just, and its execution cast no opprobrium upon himself or his profession. To be able to operate understandingly requires not only a thorough knowledge of the principles of surgery, but a fair knowledge of the ways and means of accomplishing the desired purpose.

It is not enough to be able to remove, in a scientific manner, an offending member or disease, but it is equally important for the surgeon to so prepare the patient and himself that no unanticipated complication can occur immediately prior to, during, or subsequent to the operation.

Regarding the principles of surgery proper, the reader is referred to the many works upon that subject; since it is not the intention of the author to intrude upon this department of surgery, except, in so far as it may be found expedient to apply them to the immediate safety of the patient during and subsequent to the operation.

Prior to an operation, especially if it be one of any magnitude, it is essential that the following facts be ascertained:

First. The physical condition of the heart, lungs, kidneys, brain and great vessels.

Second. If there be an acute surgical or other complica-

tion of the essential organs of the body, joints, serous cavities, etc.

Third. If the patient be suffering from shock.

Fourth. If the patient be anæmic or scorbutic. If he has syphilis, phthisis, epilepsy, diabetes, or be in danger of delirium tremens.

Fifth. If he be willing and ready for the operation.

Upon the healthful condition of the heart, lungs, brain, etc., may depend the expediency of giving an anæsthetic, and the choice between them. If the kidneys be diseased, it may be inadvisable to operate upon the urethra or bladder, or even to give an anæsthetic; if the great vessels be dilated or atheromatous, much discretion must be employed in its selection and administration. It should not be forgotten, however, that the mental emotion and physical suffering attendant upon an operation, when performed without anæsthesia, may be of greater moment than with its use.

If the injury demanding an operation be recent, and the patient be suffering from a severe shock, it should be deferred until reaction is established. If the shock be out of proportion to the visible injury, a careful examination of the patient must be made to ascertain its cause. If a complicating injury be discovered, which of itself imperils the life of the patient, all idea of an immediate operation must be deferred. These thoughtful attentions lessen the righteousness of the oft-repeated satirical expression, "The operation was successful, but the patient succumbed."

If the patient be already anæmic, or scorbutic, the loss of blood added to the shock of the operation may expose him to greater dangers than if the operation be postponed. Unfortunately, however, in a majority of cases, the conditions calling for operative interference are the prime factors which determine the degree of the blood changes, and will not, of themselves, admit of any delay.

The existence of syphilis, phthisis, diabetes, etc., exert a marked influence on the recovery, and their importance must not be underestimated in connection with this fact. If a patient be addicted to the continuous use of intoxicating beverages, and worse still, if he receives an injury during a prolonged debauch, it seriously complicates his case, not only directly from the previous effects upon his *bodily vigor*, but from the impending danger of delirium tremens.

It is not necessary to the successful issue of an operation that the patient be ready and willing; yet, if such a fortunate combination be present, it will weigh heavily in favor of ultimate success. It is prudent, however, that he should be ready in a legal sense; that is, that his consent be gained.

If the operation be a *dernier ressort*, he should be given the opportunity of adjusting his business and spiritual affairs. If they be prematurely adjusted—if such be possible—the knowledge of it, and the quiet of mind resulting therefrom, will become valuable aids to his recovery.

SEASON OF THE YEAR.—Autumn and spring are the best seasons for operating. Still it is not always practicable to render this knowledge available. It is best to avoid, as far as possible, extremes of temperature. Fair weather with an ascending barometer is more propitious than the reverse.

Time of day should be such as to secure a good light until the completion of the operation.

The surroundings of the patient subsequent to the operation are to be studied with great care. The sick room should be commodious and sunny, and when possible be on the second floor with a southern exposure, and with the door and windows so arranged that it can be easily ventilated without exposure to improper air-currents. All sewer-connected wash-basins or other receptacles of waste must be excluded from the room. The plainer the walls and ceilings the better; for, if the patient become delirious, the outlines and figures of modern decorations may invite, and form the basis of exciting delusions. It is better at all times, for hygienic reasons, that the room be as plain as possible, and that all unnecessary articles be removed therefrom, especially when it is to be reoccupied for a similar purpose. During convalescence, and after all dangers from septic influences are passed, objects of interest may be placed upon the mantels and walls, which can be varied from time to time to please the fancies of the patient.

The *temperature* of the room should be maintained at about 70 degrees Fahrenheit. Pure air is quite as essential to a rapid recovery as good food. It should be thoroughly ventilated at least once each day; this can be readily done by opening the windows and doors, thereby creating a *through-and-through* current, at the same time using cau-

tion that the patient be protected from direct draughts, and be well covered till the temperature shall have resumed a suitable standard. The presence of flowers and other odoriferous agents are not to be encouraged in the sick room, although they may exert a good moral influence, in that they remind the patient of the existence of sympathizing friends without. It must always be made as cheerful as possible, consequently all annoyances are to be removed whenever the fancies of the patient indicate their presence.

Place for an Operation.—The office of the surgeon is not a proper place to do operations of any magnitude, or even those requiring the use of an anæsthetic, because the rest and quiet that should follow the former cannot be had if the patient be removed; and, moreover, anæsthesia is often followed by persistent nausea and vomiting, and not infrequently by prolonged noisy delirium.

Nursing.—All who require the services of a nurse should, if possible, secure those of an experienced and professional one. The well-intended attentions and observations of solicitous friends are often burdensome to the patient and misleading to the surgeon, and are as apt to be controlled by their sympathy for the patient as by the desire to consult the express wishes of the medical attendant. It is well to remember, however, that a discreet friend is a far better attendant than a garrulous self-sufficient nurse. The attendant who proffers his views and experience in the sick-chamber, hoping thereby to honestly impress all present with his worth, is as detrimental to the moral atmosphere of the room, as closed windows and doors are to the physical.

Preparatory Treatment.—This should be directed to the improvement of the patient's general condition, also, to directly combating the constitutional diseases which may effect the ultimate result.

Diet.—Precisely the variety and amount of food to be given, are matters which must be determined by the requirements of the individual cases. Milk, eggs, milk-punch, stimulants, etc., are stereotyped articles, the usefulness of which is well established. They should not, in any instance, if it be possible to avoid it, be substituted by the traditional beef tea, and more elaborate chemical extracts with which the market is cloyed. The requirements necessary to secure satisfactory results in surgical operations may be divided into the essential and precautionary.

The essential requirements consist of such implements, agents and information as are necessary to the proper performance of an operation, as well as to a due consideration of the result. *The precautionary* are those which are useful in the various emergencies that may complicate an operation; and it is necessary, if they are to be of practical utility, that they should be at hand and be prepared for immediate use.

ESSENTIAL REQUIREMENTS.

First. A knowledge of the usual result of the operation about to be performed.

Second. A practical knowledge of the anatomy of the parts involved in the operation.

Third. Anæsthetics; proper means of administering, and their dangers.

Fourth. The necessary implements and a knowledge of their use.

Fifth. Suitable trays to hold instruments.

Sixth. Operating table, sponges, empty vessels and antiseptic solutions.

Seventh. Agents for controlling hemorrhage.

Eighth. Assistants of suitable number and proficiency.

Ninth. A patient properly prepared for the procedure.

Tenth. Proper materials for dressing wounds and a knowledge of their use.

A knowledge of the usual result of the operation about to be performed, is one of the chief factors to be employed to determine its propriety; and is, therefore, entitled to be first considered. This knowledge can be gained from only two sources: First, the personal experience of the operator and of those from whom he may be able to receive an opinion. Second, the recorded experience of the profession. The first implies the calling of a consultation, which should always be done whenever a doubt exists in the mind of the operator; such a course not only offers to the patient every available chance, but in unfortunate results, frequently serves to soothe the feelings of disappointment experienced by all concerned. If a consultation be not feasible, the surgeon must then rely upon the recorded practical knowledge of the profession.

A practical understanding of the anatomy of the part involved in an operation is always essential to the comfort of

the operator, and often to the safety of the patient. This knowledge is somewhat difficult to obtain and is always of uncertain tenure. In the case of the general practitioner, it consists chiefly of that which can be gleaned from text-books and anatomical plates; often called, "Flat Anatomy," added to the anatomical knowledge retained since graduation. Those who reside in large cities can avail themselves of the ample opportunities afforded, to rehearse important operations. When the dead can be made generally subservient to the welfare of the living, then all medical men can avail themselves of the only means of becoming fully able to surgically, "Do unto others as they would be done by."

Anæsthetics.—The anæsthetics in established use are ether, chloroform, and nitrous oxide or laughing-gas. The first is employed far more in surgery, than the others combined. The chief objections to its use are its pungency; the liability of nausea and vomiting; inflammability, and the production of cerebral excitement.

Its disagreeable *pungency* can be lessened, in fact, almost entirely obviated, by allowing a good volume of air to mingle with it during the first moments of its administration. One has but to cover his own face with the well-charged ether cone in common use, to realize the sense of impending suffocation, which is experienced by the unwary patient, whose struggles to resist it are often violent, and suggestive of the belief that, upon his part, the struggle is for life. Scenes of this kind should always be avoided, more especially when the patient is suffering from any complications which will expose him to an additional peril. The nausea and vomiting following, are not of sufficient importance to contra-indicate its use, except in such cases as it would be otherwise objectionable.

The resultant vomiting is chiefly dangerous, where solid food has been recently taken, often causing suffocation by its entering the larynx and trachea.

Inflammability.—This is only to be regarded while operating in the presence of artificial light, or with the actual cautery. There is, however, but little danger, since the weight of the vapor causes it to create a downward current, thereby tending to remove it from contact with the igniting agent. It is safer, however, for all concerned, to treat it on such occasions as if it were only awaiting the slightest opportunity to assert its power. The strong cerebral excitement which often precedes complete anæsthesia may be due to

an idiosyncrasy, or be excited by surrounding circumstances. The patient should be assured that no harm will attend its administration; it should be given in a gentle manner, slowly in the beginning, that the mucous membranes may not suffer too great irritation; and complete quietude on the part of all present should be maintained, since talking often serves to excite the inebriated fancies, and forms the basis of disorderly actions. The handling of the part to be operated upon, prior to complete insensibility, is a fertile source of annoyance, and is often suggestive to the patient of the impending operation. These are precautions which



FIG. 1.—CHLOROFORM INHALER. (Esmarch.)

should be observed during the administration of all anæsthetics.

Chloroform is more dangerous than ether, and should not be used, unless the contra-indications to the use of ether are exceedingly strong. Although it has a pleasant odor and is devoid of pungency, less liable to induce vomiting and cerebral excitement, non-inflammable and quicker of action than ether, yet these facts weigh but little as against the additional dangers incurred by its use. At the present time its application as an anæsthetic is almost entirely limited to children, and to obstetrical practice. Chloroform can be administered by pouring a few drops on a napkin which is held at a short distance from the nose, or by the agency of an inhaler figured by Esmarch (Fig. 1), which consists simply of a properly shaped wire

framework, covered by flannel and fastened to the head. Nitrous oxide is the most agreeable and least dangerous of the anæsthetics in general use. Its employment is limited to operations of short duration. It cannot be classed as a practical anæsthetic, since its expense, the cumbersome apparatus for administration, and transient effects unfit it for general use. It is, however, often employed where the presence of cardiac or other organic diseases contraindicate the use of ether or chloroform.

Inhalers.—The variety of inhalers for administering anæsthetics is large. It is no part of my intention to discuss the comparative virtues of the various forms; but rather to select those in common use, so that the general practitioner residing at a distance from the basis of surgical supplies, can be able to extemporize at least one of the many which will meet the pressing indications.

The simplest method of administering any anæsthetic, and the one generally employed with chloroform, is upon a towel or napkin. In the case of ether, this is very unsatisfactory; inasmuch as it involves an unnecessary expenditure of time and ether, and produces a less satisfactory anæsthesia than any other method. There are other pertinent objections to it, but those already mentioned are of sufficient weight to dismiss its further consideration.

The simplest form of ether cone, or inhaler, is the one that has been for a long time in common use in many of the hospitals of this city.



FIG. 2.

The method of its construction is simple and the materials employed are always accessible. A sheet of paper of strong texture, or three or four layers of an ordinary newspaper, two feet in length and eighteen or twenty inches in width, together with a strong piece of cloth, the dimensions of which shall exceed those of the paper two or three inches, and a dozen ordinary pins, are all that is required to construct it. Place the cloth—a towel is usually employed—and the paper on a table, with the paper uppermost; fold them in the centre of their long diameter, which will bring the cloth on the outer surfaces and the paper within. Then fold them in the short diameter, the length of the fold corresponding to the distance

from the lower border of the symphysis mentis to the root of the nose of the patient; when thus folded, pin the outer and inner extremities firmly through the whole texture of the sides, using care that the pins be so placed that they will not stick the patient's face, or the hands of the one administering the anæsthetic. Several pins are now to be passed through all the textures in various situations to hold them firmly together. One end of this tube must now be closed, which is easily and quickly accomplished by turning inwards its borders, and securely pinning them to each other. It is better to close the end corresponding to the free extremities of the material, thereby giving a firmer basis to the cone. Into the top of the cone is then crowded a good-sized sponge, or a piece of coarse-textured cloth, always observing that it be beyond the reach of the nose and face of the patient. Absorbent cotton or several layers of muslin may be interposed between the surfaces of the upper end, instead of their being closed by turning and pinning as just described. If this material be now confined in position by means of pins and the end covered with a layer of thin gauze, the ether can then be poured upon the interposed material and administered without removing the cone from the face. It likewise admits the requisite amount of air. The advantages which this simple affair possesses over the permanent and more expensive ones, are quite numerous. It cannot be damaged by the patient, nor will the face be bruised by its borders during his struggles; it is a temporary affair, and therefore need never be used a second time—a fact which is obviously of considerable importance in a fastidious and hygienic sense. It does not, however, admit of the easy regulation of the amount of ether to be given, or the amount of air to be admitted; it is also liable, unless care be used in replenishing it with ether, to permit the anæsthetic to flow into the eyes and upon the face of the patient; yet these are objections which can be easily surmounted by a requisite amount of caution. The amount of ether required with this apparatus is less than if a napkin be used alone, while it exceeds that employed in the more perfect inhalers.

Allis' inhaler, which consists of a penetrated metallic framework for the support of cloth partitions, surrounded by an adjustable leather or rubber covering, is simple, efficient, *portable*, and can be quite easily cleansed (Figs. 3 and 4). *Its advantages*, briefly stated, are the following:

It allows a free admission of air from above, which becomes saturated with ether, the evaporating surface is great, causing thereby a rapid vaporization, which hastens anæsthesia and saves ether. The ether can be replenished

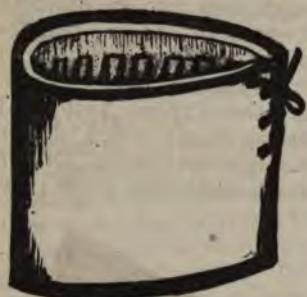

FIG. 3.

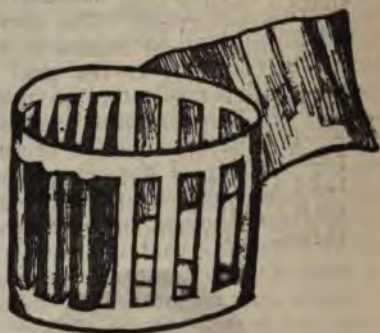


FIG. 4.

ALLIS' INHALER.

through the top, which obviates the necessity of removing the inhaler and interrupting the administration.

The cloth partitions can be readily changed whenever propriety and cleanliness demand it.

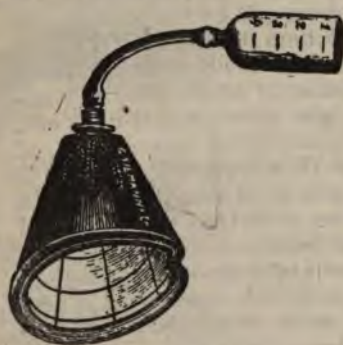

FIG. 5.—LENTE'S INHALER.

The inhalers of Lente, Squibb, Noyes, Chisholm, and others, are all serviceable, and whoever possesses either of them can, so far as the apparatus is concerned, administer ether with safety. It is not necessary to the safety of the patient that either of them be employed. It is, however, necessary to the safety of the patient, no matter which one be employed, that the giver of the anæsthetic shall rely more upon his knowledge of the principles governing its administration than upon the mechanism of the apparatus. With a proper knowledge of these principles, it matters but little whether one or another form of inhaler be used.

Lente's Inhaler (Fig. 5).—The construction of this apparatus is so simple that space is not necessary to describe it. The modified inhaler has additional advantages, however. Either answers the purpose admirably.

Squibb's Inhaler (Fig. 6).—This consists of an hour-glass-shaped muslin bag, one end of which is cut off to fit the face of the patient. The narrow portion is made to receive a tin tube several inches in length and two in diameter; the round end serves the purpose of an air-chamber. When the bag is to be used it should be wetted with water and thoroughly squeezed, to render it only partially pervious to the passage of air or other vapor. Into the tin tube a piece of flannel and blotting-paper rolled together, each about six inches wide and eighteen inches long, are thrust, after which they are saturated with ether; or it



FIG. 6.—SQUIBB'S INHALER.

may be done before the introduction. The open end of the apparatus is then placed over the mouth and nose of the patient and the administration commenced. One to two and a half ounces are quite enough to properly anæsthetize the patient.

Noyes' Inhaler (Fig. 7).—This apparatus is simple of construction. It consists of a flexible air-chamber at one end and a face piece at the other. Between the two is a small tin chamber to contain the ether. The bag or air-chamber is perforated by a small hole, which allows the entrance of a sufficient amount of air, which enters the lungs along with the ether at each effort of inspiration. The amount of ether with this is about the same as with the preceding.

The amount of ether required to produce insensibility depends upon several conditions, the most important of which are, the susceptibility of the patient, the manner of administering, and the purity of the anæsthetic. Some persons

can be completely anæsthetized by an ounce, and even less, if it be not wasted; on the other hand, those are occasionally met with who "take ether badly," and cannot be rendered quiet unless a large amount be given; rarely, a



FIG. 7.—NOYES' INHALER.

case is encountered which will not yield to its influence, and the surgeon is forced to desist, from fear of destroying the patient. It is not prudent to determine in advance the definite amount that will be used, except possibly in some peculiar cases. Anæsthesia is never to be attempted unless the surgeon can be certain he has a sufficient amount to



FIG. 8.—CRISHOLM'S INHALER.

complete the operation, for nothing can be more humiliating than to be obliged to discontinue an operation for the purpose of procuring additional ether. It is not politic to begin an operation that requires much time and care, without at least one pound of ether be at hand.

Purity of the Anæsthetic.—It is important that the anæsthetic be pure, in order that the amount taken may be suitably judged, and a proper interpretation placed upon the effect produced. Those manufactured by Squibb, of Brooklyn, are generally considered to be of a superior quality.

Dangers from the Use of Ether.—The dangers attending the use of anæsthetics may be reduced to a minimum, provided proper attention be given to the physical conditions recognized as contra-indicating or requiring caution in their use, together with a display of ordinary care in administering. Before giving it, the heart, lungs, brain, and kidney vessels, etc., should be interrogated, even though there be no apparent evidences of disease. If they have undergone organic changes, or, if the patient have laryngeal obstruction from any cause, bronchitis, or be pregnant, the greatest caution must be employed in the administration even if it be given at all. The degree of the disease, and the condition of the patient dependent thereon, together with the necessity of an immediate operation and its severity, must determine the advisability of its use. If the patient have advanced heart and kidney disease, phthisis, or aneurism, it is better to use nitrous oxide; chloroform, even, has been used under such circumstances instead of ether, on account of its causing less excitement and vomiting. The danger from a full stomach is great, especially if the ingesta be solid; since, if vomiting occur, the food may be sucked into the larynx and trachea, causing death by suffocation; moreover, nausea and vomiting are more frequent and persistent when the stomach is partially filled with food. It is impracticable to lay down all the important relations existing between the use of an anæsthetic and the various complications that may exist as contra-indications. The surgeon must be largely controlled by the circumstances surrounding the individual case. If it be determined to administer ether or chloroform to a patient suffering from a debilitated heart, the latter's action must be strengthened by the administration of digitalis some days prior to the operation, as well as by stimulants during it. If the patient have laryngeal obstruction, from spasm of the glottis or other causes, the pungency of the ether, and spasm of the respiratory muscles, when added to the already lessened area of the respiratory chink, and the diminished æration of the blood resulting therefrom, may be often sufficient to produce rapid unconsciousness and impending death from asphyxia.

In my opinion, chloroform is the better anæsthetic under such circumstances.

How to Prepare a Patient for Anæsthesia.—First. Inform yourself of the state of the brain, heart, lungs, kidneys, vessels, etc.; if disease be found, inform the patient or the friends of the additional dangers incurred.

Second. Count the pulse and respiration, noting the character of each, and making due allowance for the excitement dependent upon surrounding circumstances. These observations will be far more valuable if they have been taken some time prior to the immediate operation.

Third. See that no solid food has been taken for at least six to eight hours before; if so, evacuate the stomach by means of a simple and rapid emetic. The practical way of having the stomach in a proper condition is to omit the meal preceding the operation. If the time be too long for this, a glass or two of milk three or four hours before will meet the indications.

Fourth. Remove all false teeth from the mouth, or whatever else might fall into the larynx.

Fifth. Loosen all constricting bands which surround the abdomen, chest, and throat.

Sixth. Cause the evacuation of the contents of the bladder and rectum; this will often prevent the soiling of the clothes and patient.

Seventh. Place the patient upon the back with the head and shoulders slightly raised; neck not bent.

Eighth. If the patient have a beard, wet it to prevent the rapid escape of the ether through it.

Ninth. Adjust windows and doors to admit fresh air, without exposing the patient to a draught.

Tenth. Disarm the patient of all fears of danger attending its use.

The one who is to administer the anæsthetic should have at his convenience a basin, towel, and a tenaculum or forceps. The first for the reception of the dejections from the stomach; the towel to remove the saliva, etc., from the mouth and face; the tenaculum or forceps, to pull forward the tongue if it fall backward over the glottis.

It is recommended, and with much force, to administer hypodermically or otherwise a dose of morphia an hour or so before anæsthesia is to be commenced. It quiets the nervous excitement of the patient, reduces the amount of ether otherwise necessary, and prolongs its effect; lessens

the tendency to nausea and vomiting, and diminishes shock. Moderate inebriation has been produced immediately in advance of an operation by giving brandy or whisky, and for substantially the same reasons.

Method of Administering Ether.—Commence by pouring a small amount, an ounce or so, into or upon the inhaler, and adjust it so that a good volume of air shall mingle with the ether, for the first few moments of the administration. After the sense of pungency has somewhat subsided, the patient should be told to "cough," "breathe deeply," at the same time the fresh air is to be quite rapidly excluded. The patient soon becomes oblivious, and may be fully anæsthe-

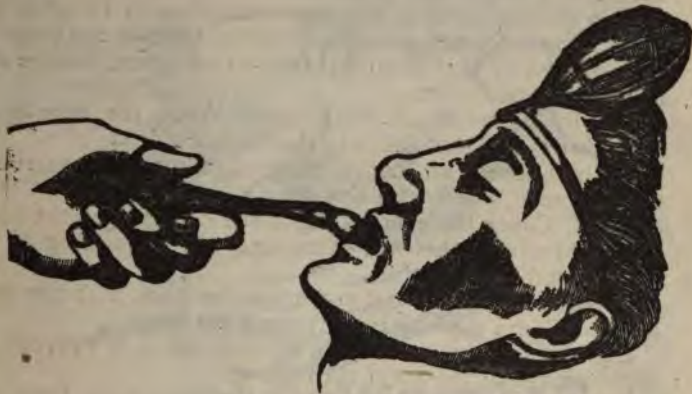

FIG. 9.—DRAWING THE TONGUE FORWARD. (Esmarch.)

tized without further trouble. This is recognized by the insensibility of the conjunctiva, or, what is better, a relaxed muscular system, which is ascertained by noting the absence of any resistance to flexing or extending the extremities. If an extremity be raised from the bed, it will fall directly downward and lie motionless. Stertorous breathing is likewise a concomitant of complete anæsthesia. More often, however, the patient will be seen to pass through the three distinct stages of anæsthesia, which will vary in their length and manifestations, according to his peculiarities. *The attention of the giver of the anæsthetic should always be directed to the character of the respiration and pulse,*

the color of the surface and its temperature. The respiration is often temporarily stopped or impeded by the tonic stage, causing marked cyanosis. This is quite readily relieved by making sudden and forcible pressure in the epigastrium, or slapping the chest with the naked hand or a wet towel. The respiration may be obstructed or prevented, at any period of anæsthesia, by foreign bodies in the larynx and trachea; such as false teeth, vomited matter, etc. In complications of this character the obstructing agent must be removed immediately or death will ensue, unless tracheotomy be performed. The glottis may become stopped by the falling backwards of the tongue; this usually occurs during the stage of complete anæsthesia, and is to be in-




FIG. 10.—PUSHING THE JAW FORWARD. (Esmarch.)

stantly remedied by drawing the tongue forward by the aid of a tenaculum or dry towel or forceps.

If the jaw be pressed forward during the administration of the anæsthetic, by the one giving it (Fig. 10), the muscular attachments of the base of the tongue are separated, and its base depressed and drawn forward.

The treatment for the relief of poisoning, due either to an overdose of ether or chloroform, is substantially the same. Successful treatment will depend not only upon the presence of mind of the surgeon, but upon the precautionary preparations which have been made for such a contingency, *as well as the rapidity and force with which the remedies are applied.*

The anæsthetic must be stopped at once; the head lowered and the tongue pulled forward; windows and doors opened to admit fresh air; artificial respiration (Figs. 11 and 12); flagellation of the face and chest by towels wet with cold water; hypodermic injections of brandy, whisky, or ammonia; inhalation of nitrite of amyl, and the use of electricity. It is not intended that these remedies shall be used in the order mentioned; but the surgeon and his as-

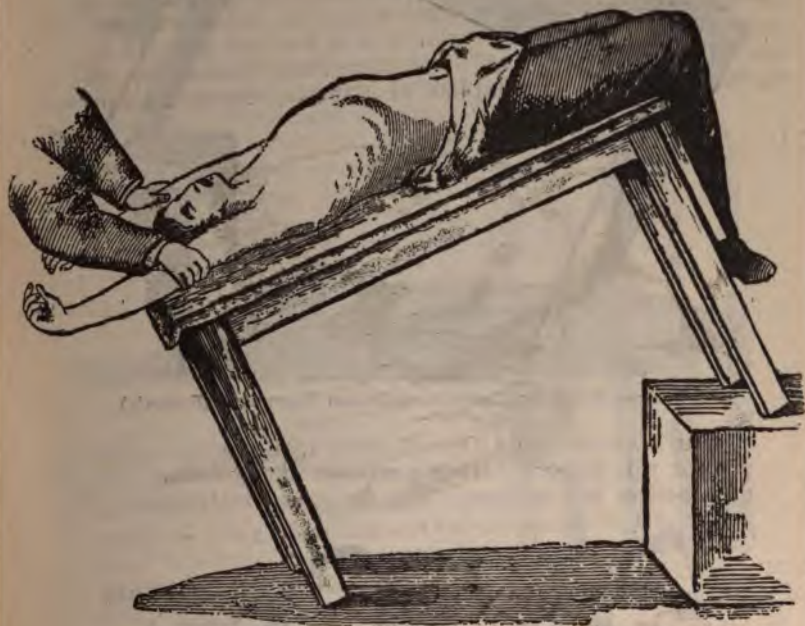

FIG. 11.—ARTIFICIAL RESPIRATION—FIRST MOVEMENT. (Esmarch.)

sistants will find their time and thoughts occupied in carrying them into execution—such of them as may admit of instant application. Under no consideration must the efforts of resuscitation be allowed to flag, or be stopped, until every hope of saving the life has some time since passed.*

* In performing artificial respiration the movements should be done slowly and with a regularity similar to the normal act of respiration.

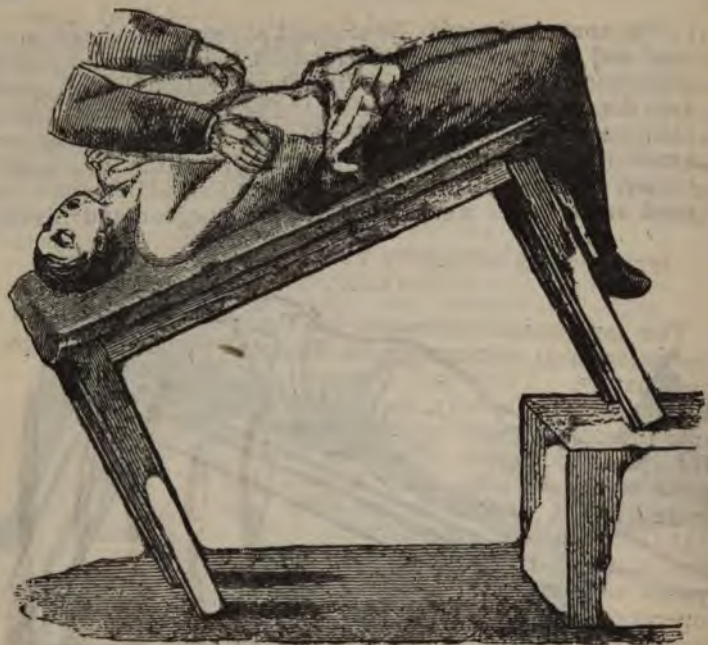

FIG. 12.—ARTIFICIAL RESPIRATION—SECOND MOVEMENT. (Esmarch.)

Local Anæsthesia.—Although there are numerous agents in use for this purpose, ether possesses the greatest number of practical advantages. The following instrument (Fig.



FIG. 13.—RICHARDSON'S SPRAY.

To move the arms upward and downward with the rapidity of a pump-handle is irrational and inoperative; yet under the influence of exciting surroundings such a manner is not infrequently to be seen,

13) is the one commonly used for purposes of local anæsthesia, and is employed in those minor operations which can be quickly done. The pain that follows the return of sensibility to the benumbed parts is often more severe and prolonged, than the immediate suffering from the operation without its use. The tissues should not be frozen, but be numbed; since to freeze them increases the pain and retards repair.

INSTRUMENTS NECESSARY FOR THE PERFORMANCE OF OPERATIONS.

The instruments necessary for the performance of an operation must, of necessity, be regulated by its magnitude and nature. They can, however, for the sake of brevity, be divided into those in general use and those for special purposes. The ones in general use include scalpels and bistouries of various forms (Fig. 14), thumb forceps, grooved directors, and scissors. Those for special purposes are used in performing the operations which, in most instances, caused their creation. These will be considered in connection with the operations to which they are particularly adapted.

Method of holding the Scalpel.—Three positions are commonly recommended, each of which is subdivided into two. The basis of the positions rests upon the manner of holding the ordinary table knife, the pen, and violin bow.

Figs. 15 and 16 represent the subdivisions of the first



FIG. 14.
SCALPELS AND BISTOURIES.



FIG. 15.

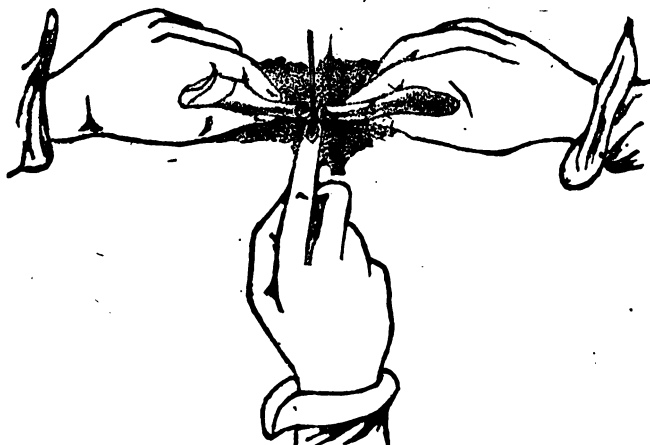


FIG. 16.



FIG. 17.

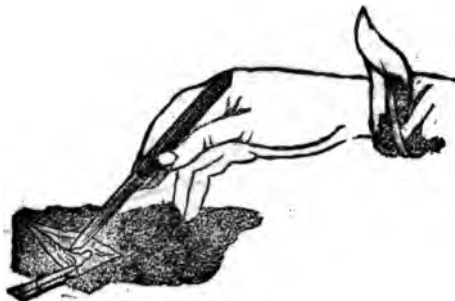

FIG. 18.

position; they indicate that force or firmness are desired. Figs. 17 and 18 represent the subdivisions of the second

positions; these are taken when quick, delicate and precise movements are required. Figs. 19 and 20 are the subdivisions of the third position, and are employed when caution is used in conjunction with delicacy in cutting.

These positions are more essential to graceful, than to successful operating.

Thumb forceps (Fig. 21) are used in connection with the



FIGS. 19 and 20.

scalpel or scissors. They are employed to pick up tissues, like the fascia, etc., which are to be incised at the point grasped for the purpose of inserting the grooved director. The scalpel or bistoury should be held at nearly an angle to the forceps when the incision is made, especially when important structures lie immediately beneath (Fig. 22).

The grooved director (Fig. 23) is used to raise the tissues



FIG. 21.—THUMB FORCEPS.

which are to be divided with caution. It should be five or six inches in length, depending upon the length of the incision and the depth of the wound into which it is to be inserted; flexible, with a broad extremity to grasp, and a pocket at the end of the groove to arrest the point of the knife or scissors. It should not be pushed beyond the extremities of the external incision because of the danger of making pockets in the soft parts, which will impede drainage. *The tissues raised upon the director must not*

be divided beyond the angles of the external incision. Care should be taken when the director is passed between a serous membrane and its superimposed fascia that the membrane does not fold over the advancing extremity, thereby causing it to be punctured or divided by the knife or scissors.

The Scissors.—They are used as a substitute for the scalpel in incisions of great depth, combined with limited



FIG. 22.—NICKING FASCIA.

space and a necessity for caution. Less hemorrhage follows their use than from the scalpel, owing to the crushing nature of their force. They should be more or less angular, to accommodate them to the depth of the operation wound (Figs. 24 and 24a).

Incisions.—The varieties of incisions are numerous, and are named from the shape which they take. The outlines of incisions are controlled very largely by the underlying anatomy; the desire to secure good drainage, and to avoid *disfiguring* the patient. There is a greater danger of making an incision too short than too long; and of the two, the

former is the greater evil. A long, deep, clean-cut incision will drain better and heal more quickly than a short deep one, bounded by tissues which have been disturbed by the efforts to accomplish a definite purpose within a too limited space. The various forms of incisions will appear in connection with the operations to which they are applicable.




FIG. 23.



FIG. 24.



FIG. 24a.

Instruments should be Plain.—All instruments associated with surgery should, when practicable, be constructed in a plain and substantial manner. The handles and shanks of the knives should be smooth and closely fitted. The inequalities of instruments tend to catch impurities, and

should never be tolerated when they but serve to embellish the implement.

Receptacle for Instruments.—It is better that all instruments be made aseptic before they are used; for this purpose, a shallow tray of suitable dimensions should be filled with an aseptic fluid, and the instruments be immersed therein for an hour or two before they are used. This tray, with the contents, should be placed at a convenient distance, in order that the instruments may be taken directly from it when needed. If they are to be again required, they should be returned to the tray as soon as used.

Operating Table.—The patient should always be placed upon a genuine, or an extemporized table, of sufficient height to suit the convenience of the surgeon. To operate upon a bed or lounge, as is often done, not only cripples the resources of the surgeon, but robs him, too often, of a suitable light, to say nothing of the soiling of the bedding. There are numerous styles of operating tables, many of which are of very ingenious construction; they are, however, much better suited for hospital than private practice. The ordinary table, covered by an old quilt and rubber cloth, will meet all common indications.

Empty Vessels.—There should always be a good supply of empty pails and basins to receive the waste-water, soiled linen, amputated parts, etc. At least one empty basin should be provided to receive the soiled sponges, otherwise they may fall upon the floor or table, and be stepped or pressed upon, or lost. A pail or two each of water, hot and cold, should be provided to wash the sponges during, and the hands and instruments after, the operation; for the latter purpose hot water is better.

Clean Towels and Old Linen.—An abundance of these should be at hand, and for obvious reasons. However, if the operation is being conducted on strict antiseptic principles, they must not be used until after the wound is dressed; unless they be, at first, saturated with the antiseptic solution.

Antiseptic solutions must be abundantly provided and be used in the place of water, by all who are obliged to handle the undressed wound, or the instruments which are to be brought in contact with it. Carbolic acid is more often used than all the others combined. It is cheap, efficient, and easily obtained. Two solutions are commonly employed: one, called the weaker, and the other the stronger

solution. The latter can be made in the following manner:

Carbolic acid crystals.....	1 part.
Alcohol	1 "
Water.....	20 parts.

This is employed to wash the wound before and subsequent to an operation. It is used with the spray, and to purify all the instruments; it may be used to wash the hands prior to operating, but this strength is objectionable, since it often benumbs the keen sense of touch and otherwise causes them to feel disagreeable. The weaker solution is made by taking—

Carbolic acid crystals.....	1 part.
Alcohol	1 "
Water.....	40 parts.

This is employed for general purposes of cleanliness, and has, therefore, a somewhat more extended range of usefulness.

Carbolic acid is often combined with oleaginous substances in the proportions of one to five or ten. Ligatures may be soaked in these preparations, and lint be saturated with them and applied directly to the granulating surfaces. The objections to carbolic acid are its offensive odor, and liability to produce poisoning. The former can be tolerated, while the latter can be prevented in nearly all instances by not allowing the strong solution to become confined within the tissues. Solutions of the chloride of zinc (1-15); sulpho-carbolate of zinc (1-80); bichloride of mercury (1-2000), and a saturated solution of boracic acid, pure or diluted (1-2); sulphurous acid; a saturated solution of iodoform and ether, are employed as washes, or modified applications for wounded surfaces. The objectionable odor of iodoform may be improved by adding to it one tenth its weight of thymol, Tonka bean, or balsam of Peru.

Sponges.—The variety known as “surgeon’s sponges” are the best, although expensive. The larger sponges of a proper texture can be cut into pieces of a suitable size, thoroughly cleansed and disinfected, when they will answer all purposes. No sponge of whatever quality should be used till it has been thoroughly deprived of all foreign

matters and disinfected. It is a good practice to select and cleanse a number of sponges, and keep them in a closed jar containing a strong solution of carbolic acid, until needed. They should not be repeatedly used; it is far more consistent with careful surgery to get a new supply in each individual case, than to use them, even a second time, under the most favorable circumstances.

Agents for controlling Hemorrhage.—The agents that arrest hemorrhage are multifarious and suited to all of its phases. They may be divided into the natural and artificial, each of which may be subdivided into the temporary and permanent. A natural agent is one interposed by nature; one which results as a natural consequence, from an interference with the inherent tendencies or endowments of the vessels and blood. The principal temporary natural hemostatics consist of the contraction and retraction of the inner coat of a divided or ligatured vessel, accompanied by the formation of a blood clot within it. The contraction and retraction, if perfect, require that the coats of the vessels be not diseased; and that they be properly constricted by the ligature, or other force. The formation of the internal clot requires that a suitable distance, depending upon the size of the vessel, shall exist between the ligature and the collateral branches; also, that the coats of the vessel be not greatly diseased.

These points are of importance in determining the site and feasibility of an operation. The permanent natural agent is the organization and contraction of the clot; thereby completely occluding the artery; this result will depend largely upon the condition of the coats of the vessel, and has a very important bearing upon the possibility of that much to be dreaded sequel of an operation, secondary hemorrhage.

Artificial Hemostatics.—This class is always temporary. The following are the well-recognized ones in constant use: Cold, styptics, position of injured part, bandages of various forms, digital and instrumental pressure; also, pressure by a simple or graduated compress; acupressure, torsion, forceps, serresines, compressors, cautery, etc.; finally, and best of all, the ligature.

Styptics, such as liquor ferri sub-sulphatis, tannin, etc., are frequently employed to check oozing; hot water being especially indicated when the patient is debilitated, or suffering from severe shocks. Liquor ferri sub-sulphatis is

decidedly objectionable where union by first intention is desired, but is very serviceable when an antiseptic styptic is required.

Position.—Elevation or flexion of a limb serves to impede its circulation, and thereby lessens the tendency to hemorrhage. The reverse of this principle directs us to lower the head in prostration from loss of blood.

Bandages.—These may be divided into two distinct classes, the inelastic and elastic. The inelastic, or ordinary roller, can be used to check capillary and venous oozing by applying it firmly over the bleeding part.

Elastic Bandage—of which Esmarch is the projector—is made of elastic webbing the width of an ordinary roller,



FIG. 25.

and of sufficient length to meet the requirements (Fig. 25). It is to be applied in a spiral manner to the limb, firmly from the distal extremity upward (Fig. 26) to a good distance above the point to be operated upon, where it is supplemented by a rubber cord, or strap, passed firmly around the limb at this point, and fastened by a clasp or hook adapted to that special purpose (Figs. 27, 28 and 28a). The bandage is then removed by unwinding it from above downward; the clamp devised by Langenbeck (Fig. 29) can be applied to the upper turns of the bandage, which is then removed from below upward, or to an independent cord or strap as in the preceding instances. After the removal of the bandages the limb will have a cadaverous aspect, being entirely devoid of blood; and the necessary operation can be per-

formed and the wound dressed even without the least hemorrhage. This, like many other useful agents, has objectionable features. Its removal is often followed by a large amount of persistent oozing; its application may force into the circulation deleterious elements which will form the

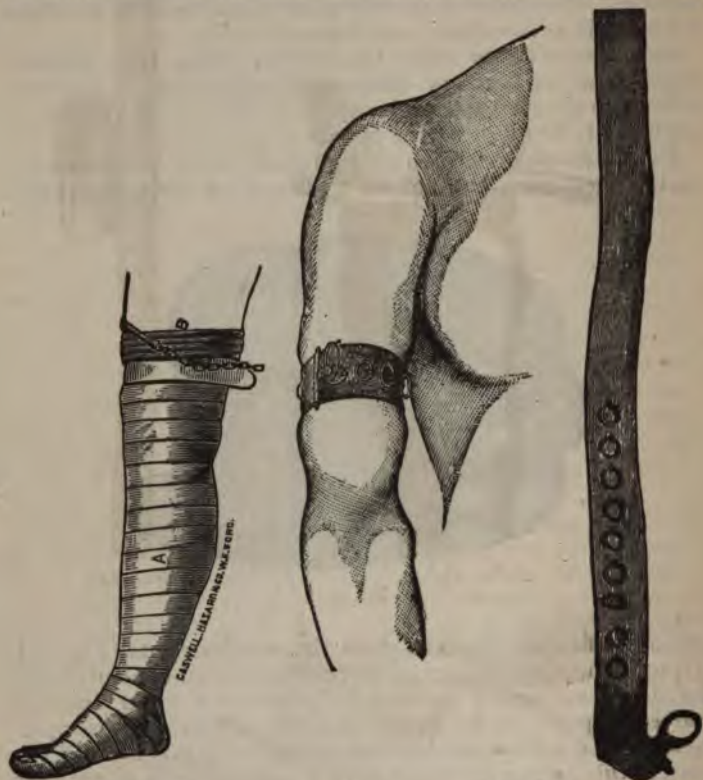

FIG. 26.

FIG. 27.

basis of disease; it has temporarily paralyzed the part to which it was applied, and caused transient disturbances of the general circulation. These latter are not, however, sufficiently important to contra-indicate its use. The tendency to severe oozing is an objection which must stand *against it*; but its power to force improper products from



FIG. 28.



FIG. 28a.



GASHWELLHAZARD, & CO. W.L.F. FORD,

FIG. 29.

diseased or injured parts into the general circulation can be *obviated* by omitting its application to those parts; that

is, by raising the limb and holding it till well depleted by the force of gravity, then applying it to the sound parts, above the seat of injury or disease, and using the rubber band as before. The elastic bandages can be made to serve another, and very important purpose; that of forcing into the circulation of the trunk the blood in the extremities in cases of extreme prostration from hemorrhage. Martin's bandage (Fig. 30) is simply a rubber roller, and is used to



FIG. 30.

meet the same indications as the former. It can be, however, more readily cleaned than a webbed one, and in this particular is preferable to it. Solid rubber rings of suitable size to pass firmly over an extremity have been used as a substitute for the rubber bandage. In connection



FIG. 31.



FIG. 32.

with the digits, and even the foot, hand and wrist, they act quite well, but have not as yet gained the support of the profession.

Compresses.—Two kinds of compresses are in common use; the simple and the graduated. The former consists only of two or three thicknesses of cloth, or other suitable substance, folded into small dimensions and placed over the vessel, or upon the part which it is desired to compress,

and held in position by a tightly drawn bandage or strip of adhesive plaster.

The graduated compress may be of the form of an inverted




FIG. 33.

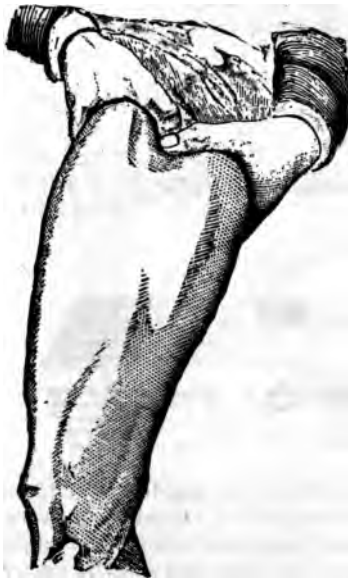

FIG. 34.

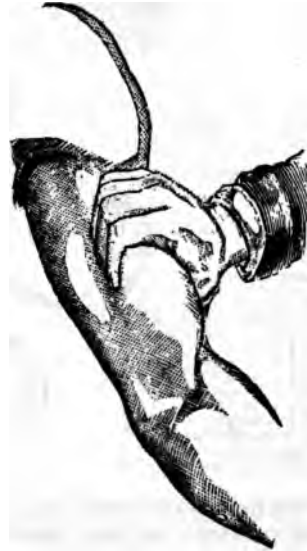

FIG. 34a.

pyramid or cone, and oblong (Figs. 31, 32, and 33). Its apex should be firm and unyielding, to give an equal and constant pressure. The whole structure can be made of *superimposed layers of cloth, antiseptic gauze, or adhesive*

plaster, of a size and shape to symmetrically form its structure. It is employed to press upon the deep-seated vessels of the soft parts, and to arrest hemorrhage from within a deep wound or cavity. Care must be employed in properly adjusting it, else it may impede venous return, or cause pain by pressing upon large nervous trunks.

Digital pressure is the most available of all the pressure hæmostatics. It is constantly at hand, and often intuitively seeks to arrest the flow of blood. It is necessary only to add to a sensitive finger and a sensible brain a knowledge



FIG. 35.

of where and how to apply the force, to render this form of pressure of inestimable value. The vessel should be pressed against some resisting part; as, where it lies in contact with bone. If the bone be deeply seated, the vessel must always be pressed towards it; unless, as is done in many cases, the limb be grasped so as to bring the ends of the fingers against the vessel (Figs. 34 and 34a). If blood flows from an open wound, direct pressure must be made upon the bleeding points with one hand, while the other hastens to compress the main artery above the point

of hemorrhage. It is not necessary to use great force to interrupt the blood current; moreover, to do so tires the arm and hand, and causes the patient much pain; use just force enough to interrupt all blood flow. The thumb of the right hand is the best digit to apply at first; afterwards it may be relieved in various ways by the aid of the fingers and thumbs of those in attendance. If secondary hemorrhage be anticipated, or have occurred, the proper point for pressure must be indicated by some indelible



FIG. 36



FIG. 36a.

substance so that in case of a sudden flow any attendant can arrest it; with this object in view, all of the attendants must be instructed in the details of making it, and be thoroughly impressed with the necessity of instant action.

Vessels that are inaccessible to digital compression can be controlled often by the handle of a key or a short crutch; the applied extremity of either should always be covered by some soft material to prevent injuring the vessel.

Instrumental Pressure.—Under this heading is included the

various forms of tourniquets and such other devices as are not directly connected with the adjustment of ligatures to bleeding vessels. The one in common use was devised by Petit, and is no doubt familiar to all (Figs. 35, 36, and 36a). It should be cautiously applied, and so directed that the pressure will compress the vessel against the bone, when possible. A simple and effective tourniquet can be extemporized by placing a roller bandage over the site of the vessel, confining it in position by a handkerchief passed around the arm. If the handkerchief be then tied, and twisted by a stick the circulation will be effectually stopped (Fig. 37).



FIG. 37.

Davy's Lever is an implement devised by the surgeon whose name it bears. It is employed for the especial purpose of controlling hemorrhage in amputations at the hip-joint. It is passed up the rectum in the direction of that canal a sufficient distance to make pressure on the common iliac artery, on the side from which the limb is to be removed. The upper extremity is then carried to the right sufficiently to lie between the bodies of the lumbar vertebrae and the *posas magnus* muscle. The lower extremity must then be raised sufficiently to bring the requisite pressure upon the vessel (Fig. 38).

It has been employed by its designer and other surgeons with signal success. It can be more safely applied to the

left than the right side on account of the left iliac artery being nearer to the rectum than the right. Its introduction must be preceded by an injection of sweet-oil, after

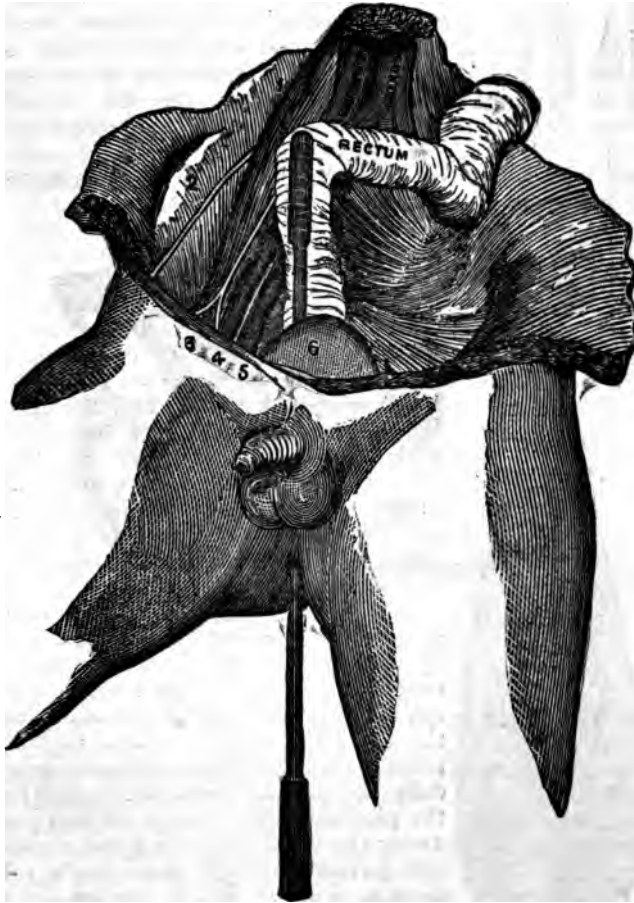


FIG. 38.

which it must be cautiously introduced, and held in position by a gentle, though firm pressure. If unnecessary force be used it may tear or perforate the gut. The in-

strument in question is round, turned from ebony, and from eighteen to twenty inches in length. The surface is smooth, and its extremities rounded; its largest diameter is about five eighths of an inch. It can be graduated so that the surgeon will be able to estimate the exact extent of its entrance to the bowel. Its shape has been variously modified to meet the requirements suggested by its more extended use.

Trendelenburg's Rod.—This is likewise used for the same purpose, but in an entirely different manner (Fig. 39). It is passed through the soft parts at such a depth as to include the whole thickness of the proposed flap. A stiff rubber cord is then passed over its extremities with sufficient force to compress the vessel in the tissues above it. The flap can then be made and the vessels ligatured without loss of blood, after which the rod is withdrawn and the remaining portion of the operation completed in a similar manner. The principle is a feasible one, but it has not yet been enough practiced to become an established method.

Acupressure.—This plan, as a means of controlling hemorrhage, was devised by Sir James Y. Simpson, and is used much less in this than foreign countries. It is variously modified to meet the common indication; the modifications may, however, be reduced practically to two in number: one, where the pin is carried through the soft parts under the vessel, and the point elevated and pushed through at an angle sufficient to cause it to close the tube of the canal (Fig. 42).

If this be not effective, additional pressure can be made by passing beneath each extremity of the pin several turns of cotton yarn or ordinary silk ligature. This method is often



FIG. 39.

employed to arrest hemorrhage from small branches in the palm of the hand and similar situations, and should be supplemented by Buck's pin conductor (Fig. 43), which is passed beneath the vessel and out through the integument, when the pin is inserted into its open extremity and



FIG. 40.



FIG. 41.



FIG. 42.

carried through by withdrawing the needle. The second method is the reverse of the first (Figs. 40 and 41), the pin resting upon and pressing the vessel downward upon the deep-seated tissue, instead of upward against the superficial. The distance from the end of the vessel at which the press-



FIG. 43.

ure is applied depends upon its size; if large, within one half inch; if smaller, the distance can be lessened proportionately to its size.

Circumclusion, torsocclusion, and retroclusion are variations of the method of pin-pressure produced either by

twisting or compressing the calibre of the vessel. These various methods seem to possess but one distinct practical advantage over the occlusion of the same channels by cat-gut ligature; they can be more safely applied to vessels with brittle coats due to atheromatous and other changes. The minute descriptions of the various modifications of acupressure can be found in the various text-books of the day. The pins are made of gold, silver, steel and iron; are of various lengths; having glass heads and variously shaped points. A further description or an illustration is not nec-




FIG. 44.

essary, since they can be satisfactorily ordered. Shawl-pins, ordinary pins and needles, can be substituted, if the exigencies of the case require it.

Torsion.—This is not as modern a procedure as its limited employment would warrant the belief. It consists in thoroughly isolating and drawing down the vessel, seizing it firmly by a pair of forceps, about one half inch above its extremity, and twisting the end several times till its resistance is overcome (Fig. 44); care being taken to not *twist it off*. The blood is then allowed to impinge upon *the twisted portion* before the vessel is released, to test the

completeness of the occlusion. The twisting produces a mutilation and breaking up of the coats of the vessel, which occludes its calibre, and causes a rapid formation of the internal clot. It is evident, if the coats be diseased



FIG. 45.

and brittle, that much caution is necessary in twisting them, else a good basis for the occurrence of secondary hemorrhage will be established. Torsion-forceps, which combine in one instrument the holding and twisting forceps,



FIG. 46.

are far more convenient (Fig. 45). Torsion as a substitute for the ligature is not considered with much favor in this country, except in individual instances. It is commonly




FIG. 47.

employed, however, to check the small bleeding points seen on the surface of freshly cut wounds.

Forceps, Serrefines and Tenacula.—Since these instruments are closely associated in common usefulness,

can be best spoken of in connection with each other. The spring-catch fenestrated forceps are the better. There are two patterns of these, the common (Fig. 46), and those devised by Prof. Hamilton (Fig. 47).

The expansion of the fenestrated extremity carries the ligature around the vessel, and it is practically impossible



FIG. 48.

to tie the end of the instrument, as in the case of the simple Liston forceps (Fig. 48).

Liston's forceps, while they are not suitable for the common purpose of catching bleeding points, are nevertheless of great service by securing bleeding points on flat surfaces.




FIG. 49.

The serresfine are of great utility to control bleeding points during an operation. They can be easily and quickly adjusted, and by their pressure on the coats of the small vessels, the necessity of using a ligature thereafter may be obviated. They can be used to catch and control bleeding points to which the application of a ligature is impossible, and even be allowed to remain upon the vessel till all danger of bleeding has subsided. There are several varieties of these instruments. The forcep-serrefine, which is the largest (Fig. 49); the angular and straight, and those of Langenbeck. The first are admirably adapted to controlling large vessels, and by their grasping and self-retaining forces can be employed in connection with other tissues. Dr. J. L. Little, of this city, has devised a forcep-serrefine having a fenestrated biting extremity, resembling in all practical respects the extremity of the fenestrated artery forceps. The one devised by Gross (Fig. 52) can be attached to the bleeding point, handle unscrewed, and the blades permitted to remain until all danger of bleeding has ceased.

The smaller ones (Figs. 50 and 51) are employed to catch small bleeding points.



FIG. 50.




FIG. 51.



FIG. 52.

Milne's compressing forceps (Fig. 53) are closely allied in principle to the serrefine; they are, however, used to compress the smaller arteries in their course through the soft tissues, as the coronary arteries in the operation for hare-lip.



FIG. 53.

Tenaculum (Fig. 54).—This is used to pick up and draw



FIG. 54.

vessels from the soft parts. If a vessel be too short to be ligatured by the aid of forceps, it can be transfixed along with a small portion of the contiguous soft parts by the tenaculum, and a ligature thrown around the combined tissues (Fig. 56*a*.) If a niche be made in the tissues raised by the tenaculum at either side, the ligature can be more securely applied and the vessel more firmly grasped.

Prince's tenaculum forceps combine the principles of both instruments, and can be used with advantage (Fig. 55).

The arterial compressor of Spier, of Brooklyn (Fig. 56), is an instrument of undoubted efficacy, but the advantages

which it is said to possess over the ordinary ligatures are not of enough importance to commend it to general use.

A small portion of the vessel is isolated and its hook-like extremity passed around it, the handle is then turned until the coats are compressed sufficiently to divide the innermost, as in the tightening of the ordinary ligature.

Cautery.—This remedy, once a universal means of controlling hemorrhage, has now but a limited application. There are three varieties of cautery in common use: the actual, the thermo, and galvano cauteries. The first requires the cautery irons (Fig. 57), which should be accompanied by the blow-pipe (Fig. 58), although they can be heated by ordinary means. The blow-pipe is far better, since, during the summer months,



FIG. 56.




FIG. 56a.




FIG. 57.

or in unfavorable situations, when great haste is necessary, the domestic means of heating them will be inadequate.

The irons can be made incandescent, or of a dull red color; the latter is the better, since it burns more deeply and is less liable to be followed by secondary hemorrhage.

Thermo-cautery.—The instrument designed by M. Paquelin for this purpose is exceedingly ingenious. It consists of a thoroughly isolated hollow handle, provided with



FIG. 55.

three movable platinum cauteries, into which, after they have been heated in the flame of a spirit lamp, a stream of benzine vapor is introduced by the means of a spray bulb connected by a tube with the bottle containing it (Fig. 59); this brings the cauteries quickly to the required temperature, which can be maintained for an indefinite length of

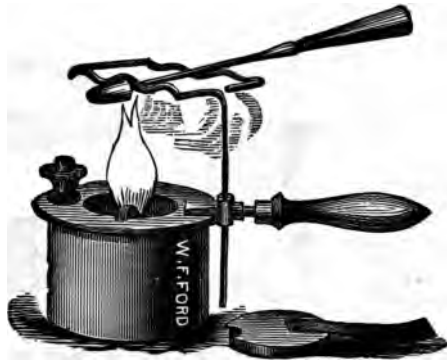

FIG. 58.

time by squeezing the rubber bulb. The range of the usefulness of this instrument is more extended than the former. It is used not only for the same purposes, but can be employed as a cutting implement for the removal of morbid growths, etc., when union by first intention becomes a lesser consideration than the annoyance from primary hemorrhage.

Galvano-cautery.—This method is chiefly employed in connection with uterine surgery, although it is a proper expedient in connection with all operations where the use of the ecraseur is admissible.

Ligatures.—The ligature is by far the best general agent for controlling hemorrhage. It can be readily applied, is easily portable, and can always be obtained in some form. Ligatures may be classified according to their nature into organic and inorganic. The latter are very frequently used, and then in the form of fine silver or



FIG. 59.

iron wire, which is looped rather than tied around the vessel. The organic comprise the hemp, silk, and catgut varieties, which should be made at least from twelve to sixteen inches in length, depending somewhat on the depth of the wound into which they are to be applied. They must be of sufficient strength to withstand the traction necessary to cause complete occlusion of the vessel; also, their size must depend somewhat upon the force to be employed in tying. The requisite force to properly occlude a vessel cannot be estimated by ounces or pounds, but is large-

ly a matter of experience. The traction should be made steadily, and over the ends of the forefingers or thumbs without disturbing the relations of the vessels to its surrounding parts (Fig. 60). The giving away of the inner




FIG. 60.

coat of a vessel indicates that the ligature is drawn sufficiently tight. This cannot be felt, however, except in connection with the large vessels. Great caution is to be exercised to prevent any tissues other than the walls of the vessel being included in the grasp of the ligature. If a nerve be seized the patient will be tormented by constant pain, which may not cease even with the disappearance of the constricting agent. All tissues other than the coats of the vessel not only cause additional irritation, but delay the separation of the ligature.

The Knots.—The variety of the knot tied exercises an important influence in the security of a ligature. The surgeon's knot is tied by making two turns of the ligature at first, instead of one (Fig. 61); it will not slip when drawn




FIG. 61.

tightly, and should always be employed when the knot beyond the sight of the surgeon, otherwise the first haul of it may slip without his knowledge, thereby resulting

an imperfect ligaturing of the vessel. It sometimes happens, owing to the ligature becoming soaked, that it cannot be drawn as tightly as one with a single turn. If it




FIG. 62.

binds in this manner, the tying of the second part will leave the whole very insecure.




FIG. 63.

The Reef or Square Knot.—Either this or the preceding must always be employed in tying a vessel. The reef-knot

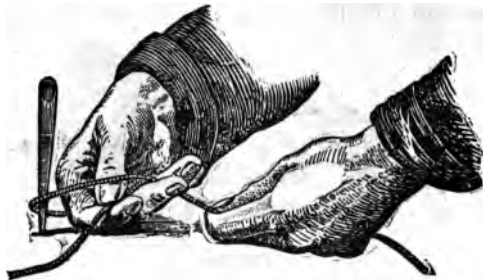

FIG. 64.

(Fig. 62) is easily confounded with the "granny knot" (Fig. which is insecure. The following description of the

method of tying the reef-knot, taken from Heath, is too graphic to be substituted by another. "The ligature is to be



FIG. 65.

held in the palm of the right hand between the thumb and finger; the end is then to be thrown around the forceps



FIG. 66.

closely and caught with the left hand, and carried across the right thumb and inserted between the third and fourth

fingers of the right hand (Fig. 64). The left at the same moment seizes the other end, and the ends of the threads are drawn out as is being done in Fig. 65. There will now be no difficulty in drawing the knot thus formed tight with the forefingers, or, if preferred, with the thumbs (Fig. 66). To complete the knot by making another tie, the same manoeuvre is to be affected, taking care always to begin with the opposite hand to that which began before. It is quite immaterial which hand begins the first part of the knot, so long as the opposite one always begins the second part; in this way with a little practice the reef-knot may be unerringly tied with the greatest rapidity." When the knot is completed, it will be seen that the ends of the ligatures lie parallel with and in contact with the portion of the ligature which surrounds the vessel. (See Fig. 62.)

The silk and hemp ligatures should be well purified before their application by a strong solution of carbolic acid, or other suitable disinfectant. If both ends are to be cut short and the ligature allowed to remain in the wound, they should have been soaked for some time—eight or ten days at least—in a solution of bichloride of mercury (1:1000). If they be thus treated in a strong solution of carbolic acid their strength may be impaired. If uncarbolicized, they should be freshly waxed. After tying, one end may be cut short and the other allowed to hang from the wound.

Carbolized catgut ligatures are now an established fact in surgery; they, like other ligatures, vary in size and strength, and a selection must be made in accordance with the purpose in view. If a proper choice be made they can be relied upon to fulfil the ordinary indications of the silk ligature. The requisite sizes can be obtained of the surgical instrument-makers of this city. Catgut can be tied by the surgeon's, or the reef-knot; but is less secure than silk. A third tie should always be added to whichever of the two is employed. The ends are cut close to the point of tying, and the wound closed irrespective of the presence of the ligature.

Chromacized catgut is thought by some to be superior in many respects to the carbolicized. It is more flexible, and can be carried and used like the ordinary silk ligature, requiring only to be moistened in some aseptic fluid before it is applied.

de catgut can be purchased of those who deal in

surgical supplies, and aseptacized to suit the fancy of the surgeon.

A good plan, however, is that recommended by Lister in his inaugural address of June 28, 1881.

"Dissolve one part of chromic acid in 4000 parts of distilled water, and add to the solution 200 parts of pure carbolic acid; into this liquid immediately put catgut equal in weight to the carbolic acid. At the end of forty-eight hours it is sufficiently prepared. Then it is to be removed from the solution, dried, and placed in one-to-five carbolized oil. It is then fit for use."

Assistants.—The number of efficient assistants necessary to conduct an operation with ease is modified by its character.

To one must be intrusted the giving of the anæsthetic, and watching the pulse, respiration, and circulation of the patient. By combining these duties the giver of the anæsthetic becomes the immediate observer of its effects, and he must always be prepared to carry into execution the various expedients that are recommended in the complications attending anæsthesia. If the temporal and radial pulsations be compared before its administration, the assistant will be able to judge of one from the character of the other. He can then give the anæsthetic, hold forward the lower jaw to prevent swallowing the tongue (see Fig. 10), and with the finger on the temporal artery, he will be able to attend to the cares of the case without any interruption.

To a second should be assigned the care of the instruments; giving them to the surgeon when asked for, and returning them to a place of safety after being used.

To a third may be intrusted the care of the sponges; he must always observe that a suitable number be well squeezed and placed at the convenience of the operator.

To a fourth the ligatures should be given. He should first hold the limb, after which he may either sponge or ligature the vessels, as best suits the circumstances of the case or the fancy of the operator. The securing of the bleeding points and the necessary sponging are best done by the operating surgeon; however, these are matters which will become self-regulating as the operation progresses. All assistants must be proficient, especially the one who ligatures the vessel and administers the anæsthetic. When the surgeon is not able to avail himself of a suitable number of assistants, he must then draw upon his own resources. *This can be done by placing the sponges and instru-*

ments where they can be conveniently reached, when he can sponge, secure, and tie the vessels. If the circumstances demand it, he can at the same time control the giving of the anæsthetic. *The patient should be prepared for the operation.* The physical, legal, and spiritual aspects of a prepa-

ration have been heretofore considered under various headings, consequently little remains to be done other than to properly cleanse and shave the part to be operated upon.

The proper materials for uniting and dressing wounds and a knowledge of their use must always be had.

As soon as the operation is completed the wound should be washed thoroughly with the strong solution of carbolic acid or other antiseptic, which not only purifies it, but serves to check the capillary oozing of the cut surfaces. The proper securing of the cut surfaces and the dressing of the wound involve three important considerations: (1) The retentive coaptation of the divided tissues; (2) perfect drainage; (3) the application of some suitable protective dressing. If union by first intention be a desideratum the cut surfaces must be kept in a perfect coaptation. For this purpose there are numerous means employed. The part bearing the wound may be so placed as to avoid all muscular contraction, or undue tension of the soft parts. Strips of adhesive plaster with or without roller bandages or simple compresses may meet the indications. These agents constitute the common dressings of a

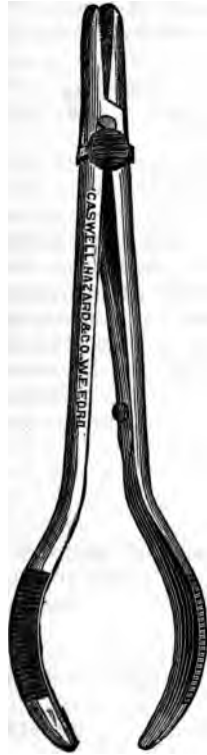

FIG. 67.

less recent date, and are at the present time open to the strong objection of interfering with union by first intention, except they be of an antiseptic nature.

Sutures may be classified with reference to their composition or method of arrangement. They are of either organic or inorganic nature.

*Those of an organic nature are most commonly used; which of these is the better is more a matter of personal
ence than a surgical requirement. The silk, hemp,*

catgut and horse-hair sutures belong to this class, and are respectively employed as best suits the preference of the surgeon. The silk and the hemp varieties are constantly employed, and if they are carbolized they cause but little irritation, and can be removed without pain. The proper introduction of sutures under all conditions requires needles of various shapes and sizes. The curved, straight;



FIG. 68.

those with round and edged extremities. These are too familiar with all to require other than a passing mention. The curved are used in cavities and depressions; the straight on plain surfaces. Those with an edged extremity cut the tissues they pass through, while the smoother separate the tissues and avoid the hemorrhage that so often follows the track of the former. The latter are, however, inserted with greater difficulty. *Needle forceps*, or holders (Figs. 67, 68, and 69), should always be at hand to aid




FIG. 69.

in conducting the needles steadily through the tissues. The instrument bearing the artery forceps at one end and the holder at the other (Fig. 70) is an admirable and compact implement.

Horse-hair.—When carbolized these cause but slight irritation, and are admirably adapted to those cases requiring but little force to maintain coaptation and where scarring from sutures is to be avoided.

Catgut as a suture possesses the same special advantages that belong to it as a ligature. It rarely produces irritation, and if allowed to remain will become absorbed without ulceration. If, however, much force is required to unite the wound, the catgut is less reliable than the silk ligature.

Inorganic or Metallic Sutures.—Those in common use are

the silver and iron wire. They can be retained *in situ* longer than the uncarbolic silk or hemp, with less danger




FIG. 70.

from ulceration. Their application and removal, however, are attended with more pain than either of the others. The silver wire is more expensive than the iron; aside from this it matters little which be used. The depth to which all sutures should be passed, the distance between them and their tension, depend upon the depth of the wound and the tendency of its lips to separate. The object of all sutures is to hold the surfaces of wounds in close

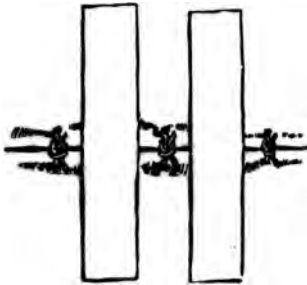


FIG. 71.

contact until union occurs. To accomplish this they must be carried to that depth and be placed at such distances from each other as will best accomplish the purpose. They can be supplemented by strips of adhesive plaster passed between them (Fig. 71). They must not be drawn too tightly, or the tissues within their grasp will be strangulated, causing ulceration and disfigurement.

If the integument within the grasp of the suture remain white after it is tightened, the suture must be loosened before the final dressing is completed. The length of time they should remain is to be governed by the danger of ulceration and disfigurement, also the tendency of the wound to open. In exposed portions of the body they should be removed as soon as notable irritation is observed. The rapidity and extent of the ulcerative process can be lessened by relieving any undue traction upon them by means of adhesive plaster or other restricting influences.

Variant Forms of Sutures.—The interrupted, continuous, *d*, hare-lip, etc., are the forms in common use. The

special varieties for intestinal sewing will be shown in connection with operations upon the intestines.

The interrupted suture is the one in every-day use, and has a more general application than the other form (Fig. 72). It is made by passing a needle armed




FIG. 72.

with a well-prepared suture through the integument from a line to a third of an inch or more from the borders of the wound, depending upon its size, depth, and retractive force. The ends should then be united by a reef-knot drawn with sufficient force to oppose the surfaces without puckering the skin (Fig. 73.) The ends of the suture can be united in alternate sides of the wound or at one of its points of exit alone. The latter is the better, since, if the dressings cling to




FIG. 73.

the extremities, their removal is less liable to interfere with the line of coaptation.

The continuous suture, sometimes called the glover's (Fig. 74), is used to unite superficial wounds and such others as require little force to secure a proper adjustment of the divided surfaces. This is made by passing the needle diagonally from one side of the wound over to the other.



FIG. 74.

The Quilled Suture.—This is made by passing several strong double threads through




FIG. 75.

the lips of the wound a half an inch or so apart, and tying them over quills, wood, etc., while they lie parallel with the cut (Fig. 75). This is used about the vagina, perineum, etc., when deep gaps are to be closed.

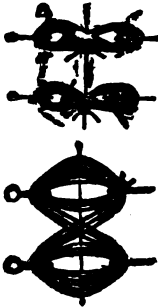


FIG. 76.

The Twisted or Hair-lip Suture (Fig. 76).— This is made by pushing a pin through the edges of the wound and passing cotton yarn around it to confine it in position (Fig. 77). The yarn should be changed as often as it becomes soiled. If it be properly carbolized before application, it lessens its tendency to cause irritation. An ordinary pin or needle can be used, although those specially adapted for the purpose are preferable (Fig. 78). They can be, if not spear-pointed, pushed or drawn through the tissues by

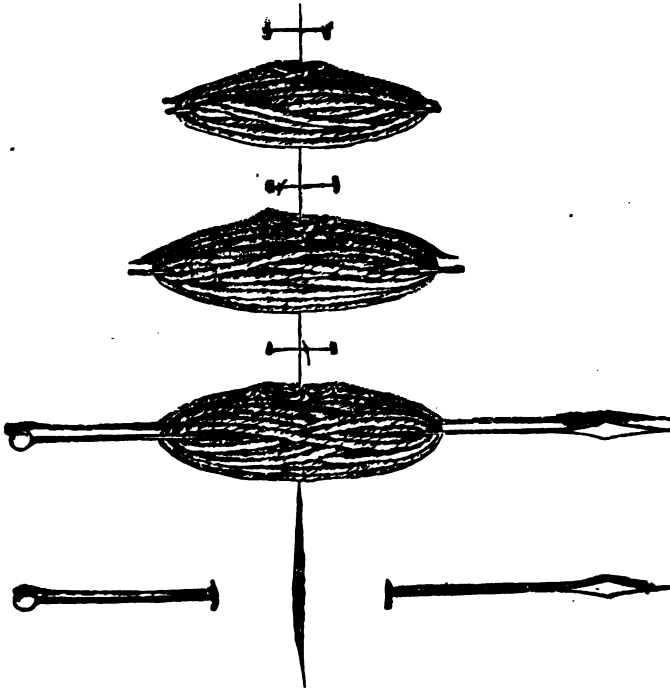


FIG. 77.

aid of Post's or Buck's needle carrier (Fig. 79). After which the points should be nipped off and separated from the skin by a small strip of adhesive plaster. Pins with adjustable spear-shaped points can be employed and be

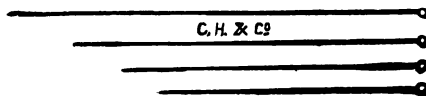


FIG. 78.



FIG. 79.

carried into position by the fingers of the operator (Fig. 80).

There are various other special forms of sutures which will be considered under their proper headings.



FIG. 80.

Drainage is not only of greatest importance in securing successful union of the divided surfaces, but also to the safety of the patient. Good drainage to a wound is as potent to its cleanliness as is the good drainage of a dwelling to the healthfulness of its occupants. No one local condition will interfere so materially with the process of healing or expose the patient to greater constitutional danger than the collection and decomposition of fluids in a wound. Drainage may be secured through dependent incisions, or, better still, by introduction into the wound of a drainage tube. Horse-hairs or threads introduced into the wound in some cases answer quite well. The long extremities of the silk or linen ligatures, if allowed to extend from its most dependent portion, will drain it, though somewhat imperfectly.



FIG. 81.

Ellis's Drainage Spiral (Fig. 81), or that which is still more practical, the rubber drainage tube (Fig. 82), will fulfil the indications more perfectly. An ordinary piece of black or white rubber tubing, of about one fourth of an inch in di-

ameter, with holes in the sides at irregular intervals, can be inserted into the bottom of the wound cavity through its most dependent portion. Another can be introduced into the upper portion of the cavity through the uppermost angle of the wound. The size should vary with the dimensions of the wound. They are more often too small than too large. They must be fastened in position, or they may slip into the wound; this can be done by passing a thread through the projecting extremity and tying it around the limb or fastening it securely by adhesive plaster. If a single tube be passed so as to protrude from both sides of the wound, it can be securely fastened by passing an ordinary safety pin through each extremity. However, it is better to use two short tubes instead of one long one; the latter introduces into the wound a superfluous amount of rubber, which does not perform a duty sufficient to compensate for



FIG. 82.

its presence. In either case it is necessary to allow for the swelling of the parts, else the pins or threads may cause constriction of the injured parts. The outer extremities should then be cut off flush with the soft tissues. The wound can be washed through the upper tube, while all discharges will pass from the lower one. The length of time they should remain must depend upon the character and amount of the discharge. If the amount be small and of inoffensive nature, they can be removed. It must not be forgotten that they, as foreign bodies, may excite the discharge for which they are retained to carry off.

Protective Dressings.—These include the ordinary dressings, such as one who is a long way from the basis of supplies, or not a believer in the modern methods, would employ; as covering the wound with a linen cloth kept moist with a weak solution of carbolic acid, or water; the application of adhesive plaster, and covering it with medicated cloths held in position by bandages or plasters. Of the modern methods, the one bearing the name of Lister, its designer, is deserving of especial mention, not only on account of its acknowledged worth, but also from the fact

that other methods involving similar principles are advocated, the result being sought by the aid of different agents.

The requirements for the Lister treatment are the atomizer, or spray, carbolic acid solution, drainage tube, protective, antiseptic gauze, McIntosh, catgut ligatures; and that everything to be brought in contact with the wound be made antiseptic by a strong solution of carbolic acid.

The Antiseptic Spray Apparatus consists of a kettle, lamp, spray tube, and a bottle to contain the solution of strong carbolic acid (Fig. 83). The spray is produced and directed



FIG. 83.

upon the site of the operation before the first cut is made. It should be continued through the whole operation, and until the wound is surrounded by the protective dressing. It is always to be used when the wound is redressed. The arteries are tied with catgut; the wound is united by the same material and washed with the carbolic solution, and the drainage tube is inserted as before described.

The protective (which somewhat resembles oiled-silk) is placed over the wound and extended an inch or so from its border, with openings for themouths of the drainage tubes. A small piece of the antiseptic gauze wet in the strong solution of carbolic acid can be laid over and beyond the protective. Numerous layers of the antiseptic gauze are then made to cover the part, their borders extending a good distance or so beyond the edge of the wound. Around the whole is wrapped the McIntosh, which is *confined in position* by bandages made of the antiseptic gauze.

This dressing can be removed on the second or third day, the wound washed out, protective and McIntosh purified, and unsoiled gauze substituted, after which it need not be examined again—other things being equal—within a week or ten days, unless the discharges soak through the dressing.

At the present time, more often than otherwise, the spray is not employed. If the spray be omitted, the surface to be operated upon should be thoroughly scrubbed with soap and water and afterwards washed with a strong solution of carbolic acid or some other suitable disinfectant, and the surfaces contiguous to it covered by towels saturated by the same disinfecting solution, which should be kept thoroughly wetted by it during the operation. The operation wound must likewise be thoroughly doused with some disinfecting fluid during the entire course of the procedure. In all other respects, however, the preceding details are carried out.

Cotton-batting Dressing.—Cotton batting, or that which is better, borated, or salicylated cotton, is frequently employed as a protective dressing in place of the antiseptic gauze. The results obtained warrant the belief that it is entitled to be considered worthy of an extended application. It exerts a very desirable uniform pressure upon the parts to which it is applied, thereby aiding coaptation and fostering union.

Iodoform Dressing.—Iodoform is dissolved in ether, and after the operation it is thrown upon the cut surface by means of an ordinary atomizer. The ether evaporates, leaving the iodoform evenly deposited over the cut surfaces.

It can be better applied if pulverized and blown into the wound by an insufflator. The wound is then closed by antiseptic sutures, drainage tubes introduced, and the whole surrounded by antiseptic gauze, upon the surface of which iodoform has been freely sprinkled, corresponding to the vacuity of the wound. This is bandaged in place and allowed to remain until the dressing becomes solid, when it is redressed as before.

The odor of the iodoform and its occasional deleterious effects upon the nervous system of the patient has made its use infrequent and cautious.

Iodoform gauze is made use of in many instances.

Peat Dressing.—Into a small carbolized gauze bag the *light peat or turf* is introduced, combined with $2\frac{1}{4}$ per cent of iodoform; over this a larger bag filled with carbolized

peat is applied, and the whole bandaged firmly in position. The fine peat serves admirably to make equitable pressure and absorb the discharges, and need not be re-applied until it has become soiled.

Bichloride of Mercury Dressing.—By this method the dangers attending the use of carbolic acid and iodoform are avoided; at the same time a cheap and inoffensive substance is utilized. It is used with the spray ($\frac{1}{1000}$) or as a wash for the wound ($\frac{1}{1000}$). Sponges, ligatures and sutures are soaked in solutions varying in strength from 10 to 75 grains to the pint of water or alcohol, the latter being used for the ligatures and sutures, in which they are kept for three or four hours, thence removed to a much weaker one. Catgut can be treated in substantially the same manner by allowing it to remain ten or twelve hours in the alcoholic solution, from which it is to be taken and introduced into a weaker one (one half of 1 per cent) containing a drachm or so of glycerine.

The protective dressing can be saturated with a strong solution (50 gr. to the pint) and applied in the same manner as before.

Instruments can be purified with it, although it lessens their cutting power.

This dressing can be recommended as one possessing efficiency and safety. Alcohol, thymol, eucalyptol, and the essential oils have been recommended as antiseptic agents, but with insufficient assurance to warrant their employment in place of the other well-established agents.

Open Dressing.—The so-called open dressing consists in washing the wound cavity with the strong carbolic acid solution at the completion of the operation, after which it is placed upon a suitable cushion of oakum, and over it is laid a thin piece of gauze, which is kept moistened with a solution of carbolic acid. The wound is washed two or three times daily by gentle irrigation with a carbolic solution, after which balsam of Peru is poured into it. All the dressings are to be kept clean.

The success which attended this method in the hands of the late Prof. James R. Wood can but cause the skeptical surgeon to wonder at the necessity of the tedious details of the Lister and other methods.

Precautionary Requirements.—These requirements, and their importance were stated some time since.

Stimulants, of which brandy, whisky, champagne, ammo-

nia, and nitrite of amyl, etc., etc., are examples, enter into common use. Some one or more of these should be at hand in all operations, irrespective of its length or requirements.

For purposes of administration the hypodermic and Davidson's syringes are most convenient. Under no circumstances must fluids be administered by the mouth, if the patient be unconscious, except by the medium of a stomach tube.

Tenaculum.—Its use has been sufficiently emphasized to render the importance of its presence evident.

Electric Battery.—This must always be thought of when the nature of the operation or condition of the patient may give rise to the subsequent failure of the circulatory or respiratory powers.

Tracheotomy Tube.—Although this is not necessary to the performance of tracheotomy or laryngotomy when indications suddenly arise calling for either, yet it is better it be at hand. The surgeon must not overlook the fact that the death of a patient due to the absence of a tube or to the loss of time consumed in seeking for one is most unpardonable, and, to say the least, entitles him to censure.

Elastic Bandages.—These are not only important in preventing the loss of blood, but, as heretofore stated, doubly important when applied to the limbs in forcing the blood contained in them into the centre of circulation, as in cases of impending death from shocks due to the loss of blood. They are, in my opinion, of greater practical utility for immediate use than the more elaborate instruments employed in transfusion. They will certainly bridge over the interval of time necessary to prepare for the use of the transfusion apparatus better than any other expedient.

Artificial Respiration.—No one can be safely intrusted to administer an anæsthetic, or to attempt any operative procedure, who is not familiar with the manipulations necessary to the proper performance of this act. It is, in fact, the only one of the requirements which can and should be continuously employed until the safety of the patient is assured, or until death is an established fact.

Finally, a surgeon should never begin an operation, be it of greater or lesser magnitude, without having carefully rehearsed its various steps in his mind, together with the possible complications that may arise and the best means of combating them.

Preparations of this kind serve to distinguish the careful and conscientious surgeon who places a proper value upon human life and a just professional reputation, from the one who operates only because the opportunity is offered, and considers the details tedious or worthless because he has not had sufficient patience or faith to practice them. He trusts to luck, and attributes his results to an inscrutable Providence ; more especially when the patient succumbs.

LIGATURE OF ARTERIES.

Arteries are ligatured in their continuity or at their divided extremities. Under this heading, however, will be considered the ligaturing in their continuity only. Nearly all arteries to which ligatures are thus applied can, from their association with the soft and hard parts, be said to possess certain guides, which, when carefully adhered to, indicate with precision their position beneath the surface.

The guides to ligaturing arteries in the living subject are practically four in number. (1) The linear guide. (2) The muscular guide. (3) The contiguous anatomical guide. (4) The pulsation and color of the vessel.

The linear guide to an artery is a line drawn upon the external surface so as to correspond with the established course of the vessel beneath. Its extremities are usually indicated by the relations which the vessel bears to fixed bony prominences.

The muscular guide is based upon the relation which the vessel bears to some portion of a well-developed superficial muscle, the outline of which can be quite readily traced if the muscle be placed upon the stretch. If the border of a muscle be given as the guide, it must not be forgotten that in case it be unusually developed, or have a broader origin and insertion than common, it will overlap the vessel, and thus may lead the surgeon astray. Under these circumstances he must direct his attention unerringly to the *contiguous anatomical guides*, which include the relations that a vessel bears to its immediate surrounding parts; and when taken in connection with its pulsation, lead directly to it. The contiguous guides may be muscular, if a muscle be ascertained to bear an established relation to it; or bony, when a bony prominence is in close contact with it; or

nervous, when a certain nerve is known to lie in a definite relation with it; or vascular, when veins of an established arrangement exist. And finally, the sheath of the vessel itself, when it is present. Some of the large vessels, of which the common carotid and femoral arteries are the most striking examples, possess well-developed sheaths. The smaller arteries are surrounded by a greater or lesser amount of areolar tissue. The larger arteries, as the popliteal, femoral, and subclavian, are each accompanied by a single vein which commonly runs in a definite relation with them. The smaller ones, those of the extremities, etc., are attended by satellite veins, known as the *venæ comites*,

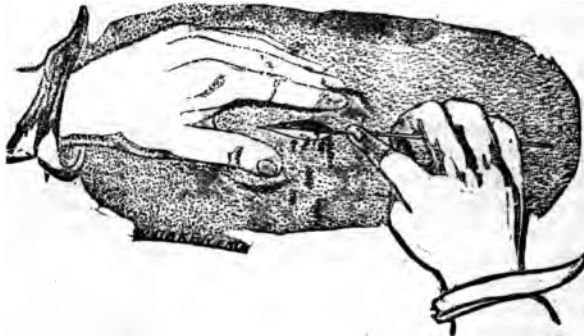


FIG. 84.

usually two in number; however, that is not invariable, since three or more are often seen. The vessels are distinguished from each other by the darker color of the veins and the lighter or pinkish color of the artery. If three vessels are seen, the middle one is almost certain to be the artery; if more than three exist, the third vein usually rests upon the artery; if pressure be made upon them, the veins are distended and the artery is collapsed beyond the point of pressure. If to these facts be now added the pulsation of the artery, its location is assured. The operator who relies exclusively upon the arterial impulse as a guide, may be led astray by the transmitted pulsations of other vessels, or by the functional movements of the parts in which the artery is located.

Having determined the anatomical details, the portion *of the body in which* the vessel is contained is placed in *position to afford* all available room and the best possible

light; the portion of the vessel is then selected at which the surgeon feels best assured of the absence of a branch of sufficient size to interfere with the formation of an internal clot. The primary incision is then made, the centre of which should, if possible, correspond to the point of the vessel to which the ligature is to be applied. The length of the incision will depend upon the depth of the vessel, and should always be of sufficient extent to afford easy access to it. If the thumb and finger be employed to make tense and to steady the integument, great care must be taken to make the traction equal on the respective sides

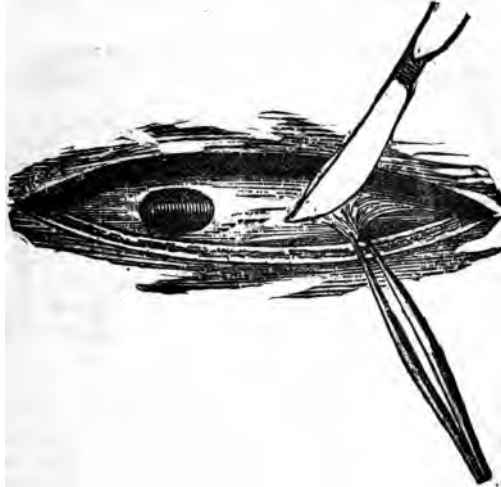


FIG. 85.

(Fig. 84). Otherwise, after the tissues are released, the cut will be outside the line of the vessel, which, if not noticed, will lead the surgeon astray; besides, its irregularity will interfere with the necessary space and light as well as the subsequent drainage. The external incision should be made with one sweep of the knife, rather than by repeated cuts, which tend to chop the tissues, increasing the danger of suppuration, and correspondingly lessening the prospects of union by first intention.

The fascia is pinched up by the thumb forceps, or tenaculum, and carefully nicked with a scalpel, after which a *grooved director* is cautiously passed beneath it, upon which

it is then divided. The fascia should not be incised the full length of the integumentary cut. The nearer the approach to the vessel, the shorter should be the line of the separation of the tissues, so that when the vessel is reached the bottom of the wound will somewhat resemble an inverted triangle, with its apex corresponding to the artery.

The tissues beneath the fascia are to be gently separated by the fingers, handle of the scalpel, or director; using the knife only when necessary, until the sheath of the vessel is reached, when a small opening is made into it—about one fourth of an inch being ample—of sufficient size to pass the needle with ease. This opening is made by picking up the sheath or condensed tissue with the thumb forceps, and with the scalpel at, or nearly at right angles with the forceps, carefully cutting out a button-hole-shaped piece of a suitable size (Fig. 85).

The borders of this opening are then to be separately raised, to inform the operator if deeper tissues still surround the vessel; if so, they should be incised in a similar manner. When the peculiar pinkish white appearance of its coats are seen, the side of the cut in the sheath nearest to the contiguous vein should be grasped and raised by the forceps, and the aneurism needle, or probe, armed with a ligature, carefully passed around the vessel, being carried from the contiguous vein (Fig. 86).



FIG. 87.

When its extremity appears at the other side the ligature is seized by the forceps and one end drawn through, while the other extremity is retained in position by the withdrawal of the needle. If the vessel be sufficiently superficial, the ligature can be passed through the eye of the needle after its passage beneath the artery (Fig. 87). If now all

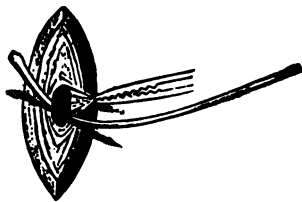


FIG. 86.

doubts be settled as to the identity of the vessel, the liga-

ture is tied by making either the surgeon's or the reef-knot. If the ligature be of catgut, cut both ends short and dress the wound; if silk, cut one extremity short and allow the other to hang from its most dependent position. This extremity should be secured, so that it will not be unneces-

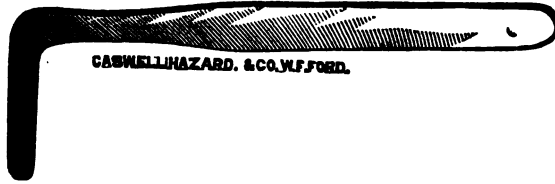


FIG. 88.

sarily drawn upon when the wound is dressed. The length of time the ligatures are to remain depends upon the size of the vessel, and will be considered in connection with the ligaturing of the individual arteries.

Instruments required to Ligature Arteries.—An ordinary scalpel, a flexible grooved director, thumb-forceps, tenacu-



FIG. 89.

la, retractors, and an aneurismal needle armed with a ligature.

Retractors vary in size and shape. The ones recommended by Profs. Mott (Fig. 88) and Parker (Fig. 89) are appropriate for all practical purposes. If neither be at hand, one



FIG. 90.

can be devised by bending the handle of the common table-spoon to the necessary angle.

Aneurismal Needle.—These vary in size, shape, and arrangement. The simplest form is combined with a director (Fig. 90); another in common use has a broader ex-



FIG. 91.




FIG. 92.




FIG. 93.

tremity with a suitable handle (Fig. 91); still another with adjustable points for the purpose of securing deep-seated vessels. The points must be securely screwed into position, else the turning and twisting of turns necessary to pass it may loosen the points, causing it to become a source of annoyance instead of an advantage (Fig. 92). Also one with a lateral curvature may be employed. Fig. 93 is a representation of the safest needle with movable points now in use. It is known as the "Movable Immovable Aneurismal Needle," and also as the "Student's Aneurismal Needle." It was devised by Dr. S. W. Fletcher, of Pepperell, Mass., while a student; hence the name sometimes given to it.

Ligature of the Abdominal Aorta.—This vessel can be liga-



FIG. 94.

tured at its lower two inches—that is, below the origin of the inferior mesenteric—by two or three methods.

Linear guide is the linea alba.

The omentum, intestines, and mesentery lie in front; the left lumbar veins, receptaculum chyli, thoracic duct, and vertebral column behind, on the right the inferior vena cava, vena azygos, and thoracic duct. At the left no structures are liable to be injured (Fig. 94).

Operation.—First method (Cooper's).—An incision is made three or four inches in length a little to the left of the umbilicus, its centre corresponding to it. (See "A," Fig. 95.) The peritoneum is divided to the same extent on a grooved

director; the omentum, mesentery, and intestines are then pushed upward, the peritoneum scratched through with the finger-nail, or a director; the finger is passed beneath the vessel, and the needle carried around it from right to left, the ligature tied and the wound closed.

Second Method (Murray's).—Linear guide: From the apex of the tenth rib to within an inch of the anterior superior spinous process of the ilium. (Fig. 95, "B").

The left ureter lies to its outer side.

Operation: Divide the various tissues on a grooved director down to the subserous tissue; the hand is then inserted,

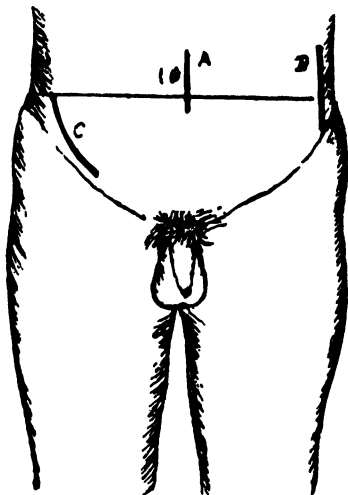


FIG. 95.

and the peritoneum, intestines, and ureter are raised upward and inward, readily exposing the vessel to view. The artery is then raised with the finger and the ligature passed as before. It can be reached through an incision extending from the end of the last rib to the anterior superior spinous process of the ilium.

Results.—It has been ligatured ten times, and in every instance has proved fatal; death occurring from within three or four hours to ten days.

Common Iliac Arteries.—These vessels average about two

inches in length, and should be ligatured at a point nearest to their middle. They commonly begin at the left of the middle of the body of the fourth lumbar vertebra, and pass downward and outward to the sacro-iliac synchondroses. A line drawn between the highest portions of the iliac crests corresponds very nearly to their point of origin. Two lines drawn a little to the left of the centre of this one, and carried downward and outward between, but a little nearer the pubes, than the anterior spinous process of the ilium, mark the course of the vessels downward.

There are two general methods of access to them; one, by entering the abdominal cavity in front, the other by raising the peritoneum through an incision made at the side of the abdomen.

First method: At this time this method is not favorably considered as a substitute for the latter, except in cases

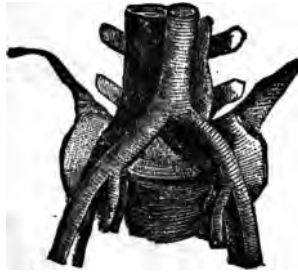


FIG. 96.

where the latter is inadmissible. If the surgeon be able to command complete asepsis, the advisability of the latter operation is greatly enhanced; if otherwise, it should not be attempted unless the situation of the disease calling for it renders the former impracticable. The outer side of the rectus muscle, or more properly the linea semilunaris, is the best superficial guide to the vessel in this method. The linea semilunaris extends from the lower portion of the seventh rib in a slightly outwardly arched direction downward to the spine of the pubes. In a normal abdomen these lines are about three inches from the umbilicus. An incision through the linea alba below and even extending a little above the umbilicus, may be employed likewise. The relations of the common iliac arteries and veins are intricate and dissimilar (Fig. 96), and should be carefully memorized.

IMPORTANT ANATOMICAL RELATIONS.

PLAN OF THE RELATIONS OF THE COMMON ILIAC ARTERIES.

<i>In front.</i>		<i>In front.</i>	
Peritoneum.		Peritoneum.	
Small intestines.		Rectum.	
Ureter.		Superior hemorrhoidal artery.	
		Ureter.	
<i>Outer side.</i>		<i>Inner side.</i>	
{ Right Common Iliac }	Vena cava	Left common iliac vein.	{ Left Common Iliac }
	Right common iliac vein.		
<i>Behind.</i>		<i>Behind.</i>	
Right and Left common iliac veins.		Left common iliac vein.	

Operation: An incision five inches in length and three inches to the left of the median line is made into the abdominal cavity; intestines are pushed aside, and a small

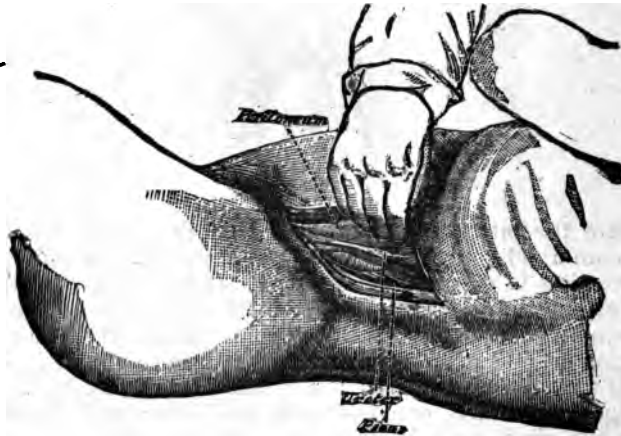


FIG. 97.

opening is scratched through the peritoneum; and the vessel ligatured by passing the needle from without inward on the right and within outward on the left side. That is to say, pass it from the veins nearest the vessel. The wound is then closed as in ovariectomy.

Results: They are thus far sufficiently satisfactory to warrant its employment when other methods are inadmissible.

Second method: Without opening into the abdominal cavity.

Linear Guide to Operation.—(1.) (Crampton.) A line drawn from the apex of the last rib, downward and a little forward nearly to the crest of the ilium, then carried forward parallel with it to the anterior superior spine (Fig. 97).

(2) Is a line drawn downward from the tip of the eleventh rib to one and a half inches within the anterior

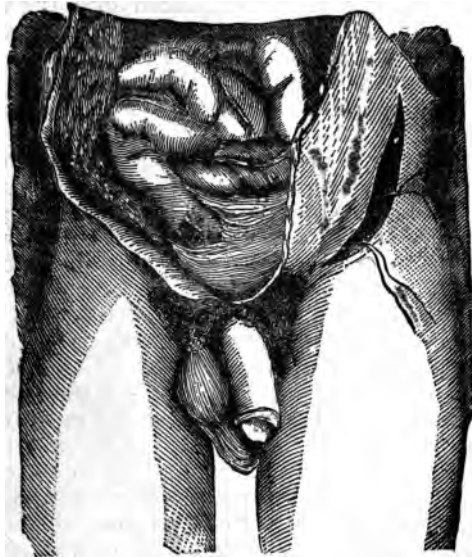

FIG. 98.

superior spine, then carried downward and forward and curved sharply upward, sharply terminating above the internal abdominal ring (Fig. 98).

Muscular Guide.—There is no superficial muscular guide except the rectus in the median operation. The inner border of the psoas magnus is, however, an undeviating and markedly prominent deep muscular guide. The contiguous anatomy in this method is indicated by the plan of the preceding.

Operation.—Place the patient on the back, inclined to the

opposite side, with the thighs flexed sufficiently to relax the abdominal walls. By repeated divisions on the grooved director, the various layers of the tissues composing the abdominal walls are divided down to the fascia transversalis, which is cautiously raised from the peritoneum at the upper end of the wound, where it is less dense and less firmly attached, and a small opening made into it, through which the finger or a large grooved director can be passed, upon which it is divided to the full extent of the wound. The hand of an assistant, who must stand on the opposite side of the body, is then introduced into the wound and the peritoneum raised gently upward and outward, while the operator by the aid of the finger or handle of the scalpel separates it carefully from the tissues beneath; when the psoas magnus is reached, the surgeon will then know the exact location of the artery. If the external iliac be first felt, it is to be followed upward to the common; when the common iliac is reached, and the areolar tissue surrounding it scratched aside by the finger or a director, the needle is passed; the one with the adjustable end being the better.

Dangers.—The dangers attending this operation are considerable. The peritoneum may be lacerated; the ureter included in the ligature; the veins punctured by the needle. The assistant who raises the membrane should keep the fingers closely approximated, using both hands, if necessary, and being careful that the fingers do not become too much flexed, else they may lacerate it. If the patient struggle, vomit, or cough, the membrane should be permitted to return to its normal site, until quiet is again restored. The traction necessary to separate and elevate it cannot be made too carefully, and it is better if it be done during the acts of expiration, since at this time less downward pressure will be made by the abdominal contents; large, broad, retractors are sometimes employed for this purpose, but they are much less reliable than intelligent hands.

The ureter passes across the artery at the point of bifurcation; it is in little danger, since it is usually raised along with the peritoneum and its subjacent tissue. The veins can be avoided by always remembering to pass the needle from them. This will be somewhat difficult on the right side, owing to the large venous trunks in close contact with it. If the vein obscures the arterial trunk, pressure upon it below the point to be ligatured will diminish its size.

Fallacies.—The external may be mistaken for the common

iliac. The relation of the sacro-vertebral prominence to the vessel should settle this doubt. The ligature may be applied too near the bifurcation, owing to the difficulty of finding it, on account of obscure light and the intimate relation of the vessels. Care only will solve this uncertainty.

Results.—This vessel has been ligatured sixty-eight times, with sixteen recoveries, giving a rate of mortality of about seventy-seven per cent.

Ligature of Internal Iliac.—This vessel is about an inch and a half in length, extending from the bifurcation of the common iliac downward and forward to near the upper border of the great sacro-sciatic foramen.

Methods of Operation.—Two or three incisions are given with a view of reaching this vessel. Either of the incisions employed in the ligature of the common iliac, will easily lead to it; or an incision five inches in length, parallel with the epigastric artery, or a semicircular one about seven inches in length, two inches to the left of the umbilicus, with its convexity outwards, and ending just external to the external abdominal ring.

This vessel possesses no practical linear or muscular guide, other than it lies to the inner side of the psoas magnus.

PLAN OF THE RELATIONS OF THE INTERNAL ILIAC ARTERY.

In front.

Peritoneum.
Ureter.

Outer side.
Psoas magnus.

{ Internal }
{ Iliac. }

Behind.

Internal iliac vein.
Lumbo-sacral nerve.
Pyriformis muscle.

Operation.—The tissues are successively divided as in the primitive iliac in the line selected for the primary incision; the peritoneum is elevated in the same cautious manner, the connective tissue scratched away, and the ligature carried from within outward, taking care to avoid the ureter, and the external iliac vein as it lies at the angle of bifurcation of the primitive iliac.

Fallacies.—It might be mistaken for the external iliac;

however, this can be quickly rectified if the course of the latter be considered.

Results of the Cases.—Eighteen terminated fatally; making a rate of mortality of about seventy per cent.

Ligature of the Gluteal Artery.—This vessel passes out of the pelvis at the upper border of the great ischiatic notch, above the pyriformis muscle.

Linear guide to the vessel is a line extending from the posterior superior spinous process of the ilium, to the trochanter major when rotated inward. The artery is beneath the junction of the upper and middle thirds of this line ("A," Fig. 99).

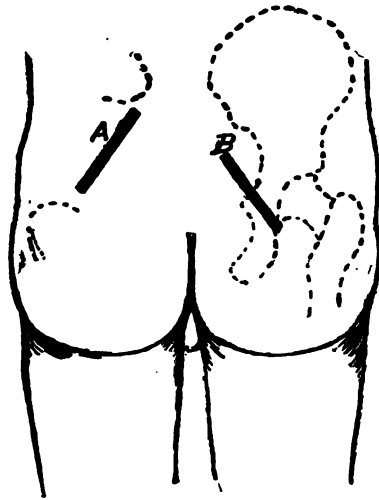


FIG. 99.

Anatomically it lies in the upper border of the notch, the concavity of which is a guide to it; it is accompanied by its venæ comites, and is covered by the gluteus maximus muscle.

Operation.—Place the patient on his abdomen, with the thigh extended; make an incision five inches in length in the course of the line indicated. The line of separation will pass between the fibres of the gluteus maximus, down to the vessel; liberate it from its accompanying

veins and pass the ligature in the most convenient manner (Fig. 100).

Fallacies.—It might be mistaken for either of its venæ comites; otherwise no fallacy will occur.

Results.—The operation itself implies but little danger to the patient.

Ligature of the Sciatic Artery.—This vessel escapes from the pelvis below the pyriformis muscle, and passes downward in the interval between the tuberosity of the ischium and the trochanter major.

Linear guides to the vessel are two in number; one of which is drawn parallel with the preceding, only about an inch and a half lower down. A second, extending from the posterior superior spinous process of the ilium to the outer side of the tuberosity of the ischium. (See B, Fig. 99.)

Its deep muscular guide is the lower border of the pyriformis, beneath which it descends from the pelvis.

Contiguous Anatomy.—It is covered by the gluteus maximus; the sciatic nerve accompanies it, and it is posterior to the pudic artery.

Operation.—An incision is made three or four inches in length on one of the lines indicated, down through the fibres of the gluteus maximus, the nerves and veins are pushed aside, and the ligature is carried around it. Care being used to avoid the vein which lies to its outer side. (Fig. 101.)




FIG. 101.

Fallacies.—This artery might be mistaken for the pudic artery, which lies internal to it; however, the direction taken by the respective vessels should make the distinction easy.

Results.—The prognosis to life is always good so far as the operation itself is concerned.

Ligature of the Internal Pudic Artery.—This vessel escapes from the pelvis through the greater sacro-sciatic foramen



FIG. 100.

below the piriformis muscle, lying internal to the sciatic artery; then enters the pelvis through the lesser sacro-sciatic foramen, and runs along the inner surface of the

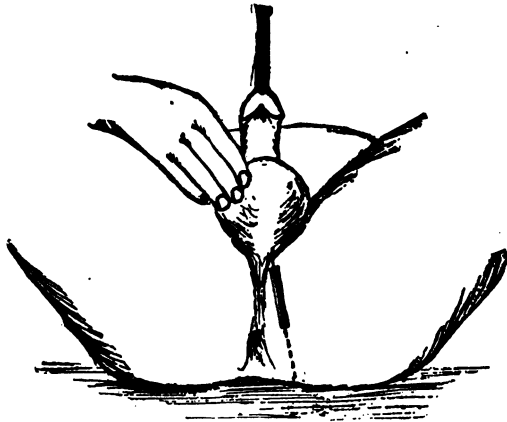


FIG. 102.

ramus of the ischium and pubes, till it divides into its terminal branches.

It may be ligatured in two situations: (1) At the greater sacro-sciatic foramen; (2) in the perineum. In the first situation the incision for the sciatic is sufficient, the pudic being found internal to that artery, and lower down accompanied by its veins and the pudic nerve. In the perineum the linear guide to the operation extends from the arch of the pubes to the inner border of the tuber ischii (Fig. 102). The artery is situated about an inch and a quarter above the margin of the tuber ischii.

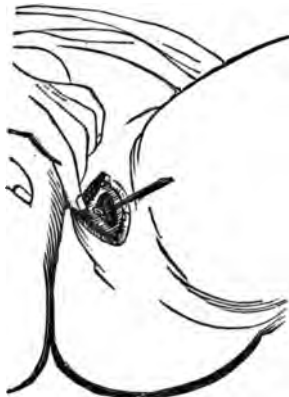

FIG. 103.

Contiguous Anatomy.—It runs along the outer side of the ischio-rectal fossa, resting upon the

obturator internus muscle, covered by the obturator fascia, and accompanied by the pudic veins and pudic nerve.

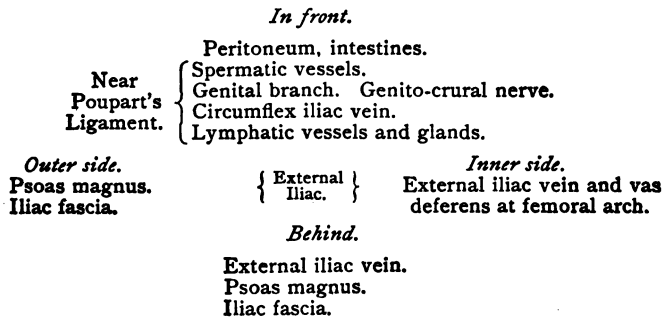
Operation.—The patient is placed in the lithotomy position and an incision is made in the course of the line indicated, the tissues are carefully divided down to the vessel, which is then isolated from its veins and nerves and tied (Fig. 103). If care be not taken the crus penis will be cut. The introduction of a sound into the urethra will so positively define its outlines that the danger of cutting will be obviated.

Ligature of the Dorsalis Penis.—This may be tied on the dorsum of the penis by making an incision an inch in length on a line corresponding to the centre of its long axis. It is superficial, and is attended by its veins and nerves, which should be carefully avoided in passing the needle.

Ligature of the External Iliac Artery.—This vessel is about four inches long and passes obliquely downward and outward, nearly corresponding to a line drawn from the left side of the umbilicus to midway between the anterior superior spinous process of the ilium and the symphysis pubis. It is ligated at about the middle of its course. It has no superficial muscular guide; however, the psoas magnus, at the inner border of which it lies, is a most important deep muscular guide.

Contiguous Anatomy.

PLAN OF THE RELATIONS OF THE EXTERNAL ILIAC ARTERY.



Operation.—Before beginning the operation evacuate the contents of the bladder and rectum of the patient, then place him in a recumbent position, with the thigh slightly flexed. A curvilinear incision is then made, with the convexity downward, beginning about an inch and a half

above Poupart's ligament, and immediately to the outer side of the external abdominal ring, and terminating on a level with, but about two inches internally to the anterior superior spinous process of the ilium (Fig. 104, C). The superficial fascia, aponeurosis of the external oblique, the muscular fibres of the internal oblique, and the transversalis are separately divided upon a grooved director. The fascia transversalis is now carefully picked up with the thumb forceps, and a small opening made through it, into which

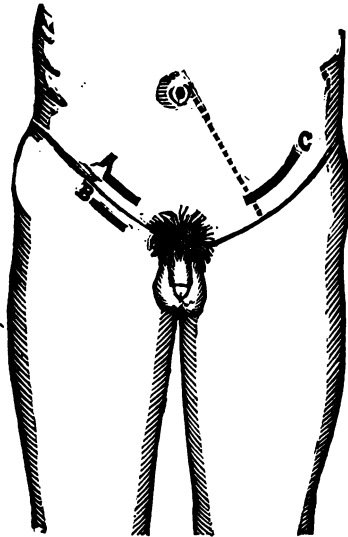


FIG. 104.

the director is inserted and the fascia divided. The peritoneum and its subserous tissue are then carefully raised from the iliac fascia, and pressed upward and inward until the outer border of the psoas magnus is ascertained, when, after a little further separation, the vessel is felt pulsating at its inner margin.

The condensed areolar tissue constituting its sheath is then opened, and the needle carefully inserted between the vein and artery, from within outward. If the incision be made about a half of an inch above Poupart's ligament it will come upon the iliac fascia without coming in con-

tact with the peritoneum, since it is reflected upward and downward into the pelvis a little above this point.

Fallacies.—The external oblique aponeurosis may be mistaken for the deep layer of fascia. The muscular fibres of the internal oblique will then be mistaken for those of the external oblique. If, however, the direction of the fibres of the respective muscles be recalled, and furthermore, that the external oblique has no muscular fibres in this situation, the mistake will be quickly rectified. The fascia transversalis may be mistaken for the peritoneum; this fallacy is easily detected by following it downward, when, if it be attached to Poupart's ligament, or passes beneath it, it cannot be the peritoneum, and must therefore be the transver-

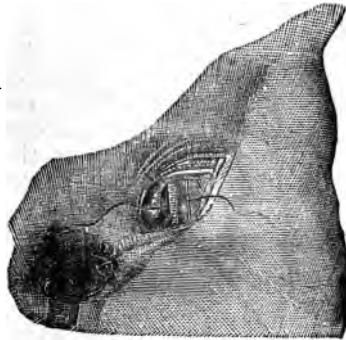


FIG. 105.

salis fascia. If its relations to the previously divided tissues be taken into account, together with its density and opacity, this mistake can hardly occur.

The iliac fascia may be mistaken for the subserous tissue, and be raised along with the peritoneum. Under such circumstances the vessel will be raised upward along with the peritoneum and iliac fascia, and will be felt pulsating in the roof rather than the floor of the operation wound. This mistake can be avoided by remembering that the iliac and psoas muscles are covered by a dense fascia, which passes out of the pelvis beneath the Poupart's ligament and is attached to it, and that the artery does not lie beneath it.

If an irreducible inguinal hernia exist, or the vein be adherent to the artery, then much difficulty may be

experienced in properly depositing the ligature without injury to the intestines or the vein. After ligation the wound must be thoroughly closed by carrying the sutures deeply down and close to the peritoneum, the superficial tissues, integument, and fascia being united separately. If this be not done the patient will be exposed to the danger of the occurrence of a hernial protrusion due to the weakening of the abdominal walls. This is a precaution which should always be taken in operations involving the separation of the peritoneum.

Results.—This vessel has been ligatured 169 times, with 61 deaths; which have arisen from various causes connected either with the operation itself, or the conditions calling for it.

Ligature of the Epigastric Artery.—This vessel is ligatured in one situation only. It arises from the lower portion of the external iliac and runs upwards toward the umbilicus, between the peritoneum and the fascia transversalis. It lies at the inner border of the internal abdominal ring.

Linear Guide.—A line extending from the umbilicus to the middle of Poupart's ligament corresponds to the course of the vessel. The guide to the first incision is the middle of the upper border of Poupart's ligament. (See A, Fig. 104.)

Operation.—An incision is made about three inches in length parallel with and about one inch above Poupart's ligament. The various layers of the abdominal wall are then divided separately upon a grooved director until the fascia transversalis is reached, which is opened over the artery, the veins separated from it, and the ligature properly placed.

The wound should then be carefully closed, and the patient kept quiet in a recumbent posture until the tissues are firmly united, else a weak point in the abdominal walls may follow.

Deep Circumflex Iliac.—This vessel may be secured in two positions: (1) At the internal abdominal ring; (2) near the anterior superior spinous process of the ilium. In the first it may be tied through the same incision as the epigastric. In the second it may be secured through an incision made parallel to Poupart's ligament and just above it, through the various tissues anterior to the transversalis fascia, which is then opened, the artery isolated and tied.

Ligature of the Femoral Artery.—The femoral artery ex-

tends from Poupart's ligament to the lower extremity of Hunter's canal, at the junction of the middle and lower thirds of the thigh, where it terminates in the popliteal. It is ligatured in three situations: (1) Just below Poupart's ligament; (2) at the apex of Scarpa's triangle, or about four inches below the ligament; (3) at its lower third, or in Hunter's canal. The most favorable situations are at the apex of Scarpa's triangle and in Hunter's canal. However, circumstances often arise which necessitate its being tied, irrespective of the stereotyped situations.

The linear guide to the artery throughout its whole

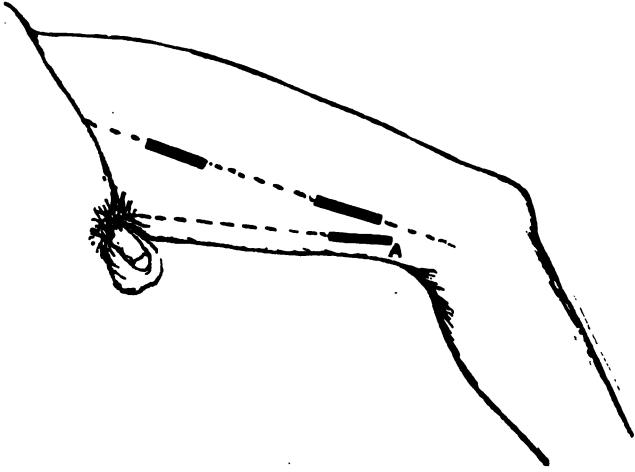


FIG. 106.

course is a line drawn from midway between the anterior superior spinous process of the ilium and the symphysis pubes to the inner condyle of the femur (Fig. 106, A).

A line drawn from the origin of the adductor longus to the insertion of the adductor magnus tendon into the internal condyle of the femur, also corresponds to the femoral at its lower third. (See Fig. 107.)

The Muscular Guide.—The sartorius is given as its muscular guide; the artery is at its inner border in the upper third, behind it in its middle, and at its outer side in its

lower third. The better muscular guide to the lower third is the inner border of the tendon of the abductor magnus.

Contiguous Anatomy.

PLAN OF THE RELATIONS OF THE FEMORAL ARTERY.

In front.

Fascia lata.
Branch of anterior crural nerve.
Sartorius (middle part).
Long saphenous nerve.
Aponeurotic covering of Hunter's canal (lower part).

Inner side.

Femoral vein (at upper part).
Adductor longus.
Sartorius.

{ Femoral }
{ Artery. }

Outer side.

Vastus internus.
Femoral vein (at lower part).

Behind.

Psoas muscle.
Profunda vein.
Pectineus muscle.
Adductor longus.
Femoral vein (middle part).
Adductor magnus.

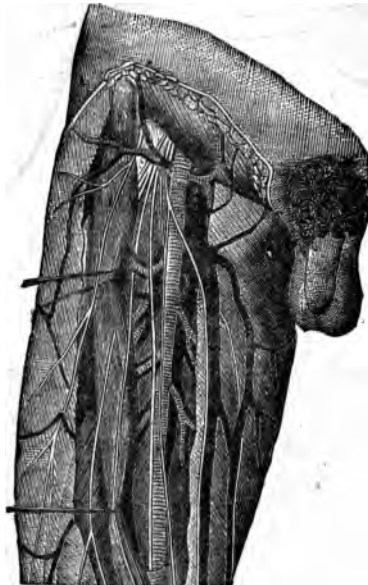

FIG. 107.

Operation.—First situation common femoral. The vessel can be ligatured immediately below Poupart's ligament through two incisions; one made in the long axis of the vessel, the other parallel with the lower border of the ligament. (See B, Fig. 104.) The former is, however, the better method. The patient is placed upon his back, and the thigh flexed and rotated outward. The pulsation of the artery noted by the finger, when an incision about three inches in length is made through the integument, and subcutaneous tissues are divided, the fascia lata is divided on a director in the usual manner, and the sheath, which is of

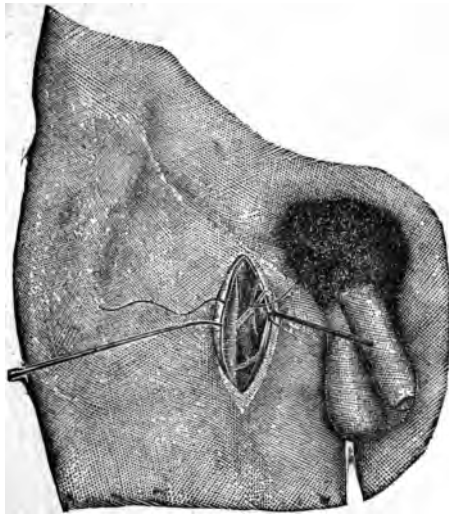


FIG. 108.

much density, is opened and the needle passed from within outward (Fig. 108). The vein will be noticed at its inner side, enclosed in a common sheath with it, but separated from the artery by a fibrous partition (Fig. 109). The attention of the surgeon should be directed to the pinkish white pulsating vessel rather than to seeking for the vein. If the attention and manipulations be directed toward the artery, the vein will remain securely within its apartment. The lymphatic glands which are encountered are drawn aside.

Second situation: At the apex of Scarpa's triangle, or

about four inches below Poupart's ligament. The saphenous vein runs along the inner side of this region; its location can be determined by pressing above, which will cause it to be distended. The limb is placed as in the preceding operation, and an incision is made about four inches in

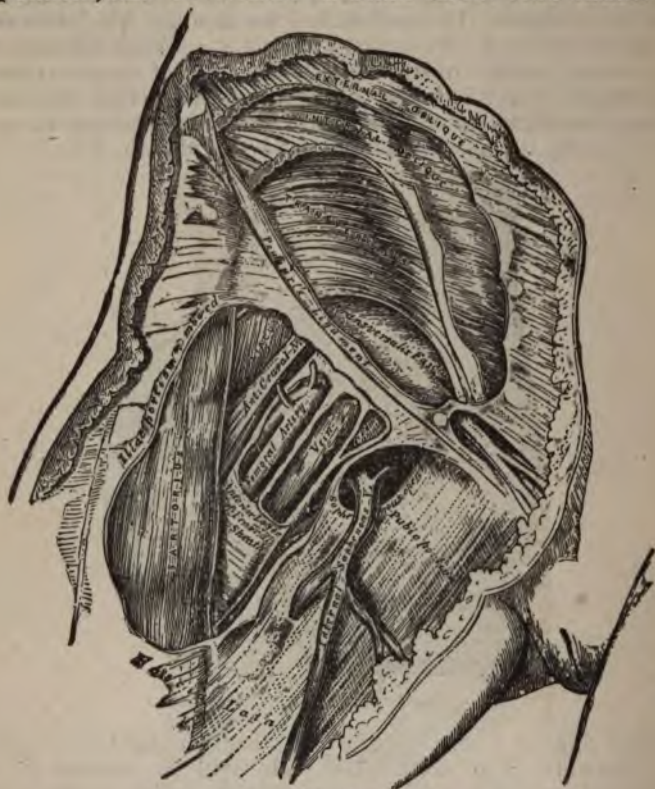


FIG. 109.

length along the inner border of the sartorius muscle; divide the tissues down to the fascia lata, draw the sartorius to the outer side, and the sheath of the vessel will be seen with the pulsations of the artery beneath it; cautiously open it, and pass the needle from within outward. *The vein lies to the inner side, somewhat more posteriorly than above (Fig. 110).*

Third situation: or in Hunter's canal. Flex the thigh on the pelvis and the leg on the thigh, with thigh rotated outward; an incision is then made along the outer border of the tendon of the adductor magnus (see Fig. 106, A), about four inches in length, down through the integument and fascia, when the tendon will be readily felt. If the sartorius be in the way it should be drawn to the outer side. Any intervening soft parts are pushed aside, which will expose the fibrous canal in which the artery is contained, the fibres of the adductor magnus with the inner

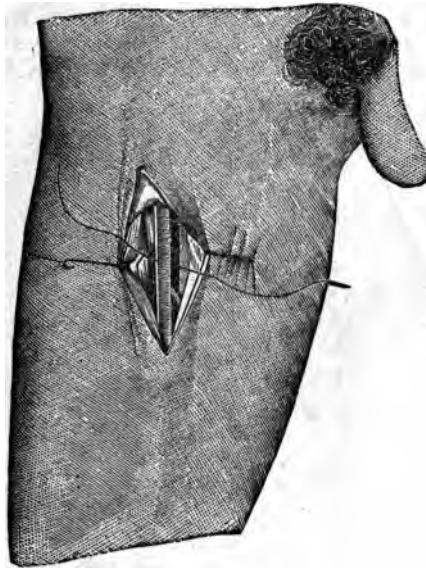


FIG. 110.

border of the vastus internus. The canal is cautiously opened, and the long saphenous nerve is seen resting upon the vessel; this is drawn aside and the needle passed from without inward; the vein now being located posteriorly and externally (Fig. 111). The vessel can be ligatured in this situation by making an incision of a similar length on the linear guide above (Fig. 106); it is not so easily secured, however, as by the method just stated.

Fallacies.—The sartorius may be mistaken for the other

muscles lying in its course. If, however, it be recollected that no other muscles run in the same direction on the anterior surface of the thigh, and that it is superficial throughout its whole course, no great confusion can arise from this fallacy. The lymphatic glands that lie over the sheath of the vessel in the upper portion of its course may be mistaken for the vessel itself, owing to their color and to the transmitted pulsation. These are irregular, movable, can be raised upward, when their apparent pulsation will cease. Moreover, the artery is beneath the fascia lata, and they are above it.

The tendon of the adductor magnus may be mistaken for tendon of the semimembranosus or semitendinosus. This mistake will be avoided if the tendon be traced by

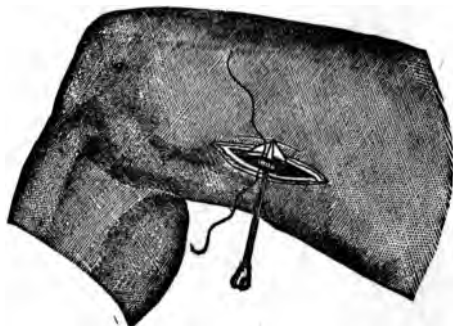


FIG. 111.

palpation downward; the latter will pass behind the internal condyle, while the former will be found inserted into it. Care must be taken in ligaturing it at the apex of Scarpa's triangle not to make the incision too low down. The width of the hand below Poupart's ligament is a good practical guide to its apex. In ligaturing it in Hunter's canal, it should be remembered that the canal is located but a little below the middle third of the thigh, otherwise the incision will be made too low down, and the upper portion of the popliteal secured instead.

In a very small number of cases (four) the femoral has been double; in a like number it passed behind instead of in front of the thigh. If it be double, the portion found will be *smaller than normal*, and the object for which the *ligature is applied* will not be accomplished. If the vessel be not

found in its common location it will be necessary to seek for it elsewhere. Deep pressure may enable one to detect the site of its deviation.

Results.—The common femoral has been ligatured eight times for aneurism, with a rate of mortality of 25 per cent. The superficial femoral has been tied 204 times, with a mortality of 50 cases.

Deep Femoral, or the Profunda.—This vessel usually comes

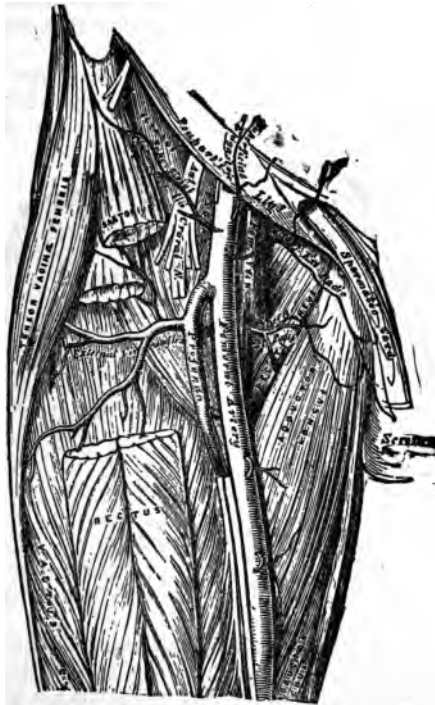

FIG. 112.

off from the common trunk one or two inches below Poupert's ligament. It may arise above or even four inches below this ligament. There is no known manner of determining its site prior to an operation. It arises from its outer side, running slightly outward, then downward and inward, passing behind the superficial femoral, accompanied by its vein, which lies in front of it (Fig. 112).

below the piriformis muscle, lying internal to the sciatic artery; then enters the pelvis through the lesser sacro-sciatic foramen, and runs along the inner surface of the

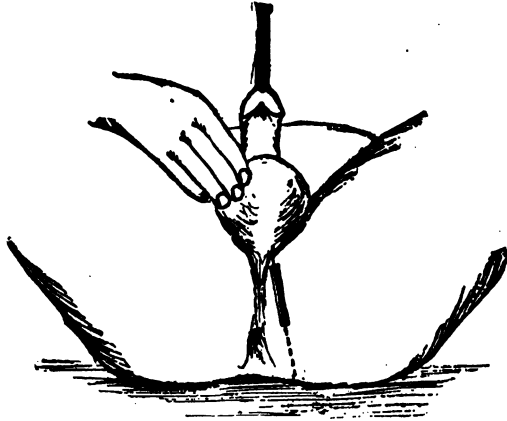


FIG. 102.

ramus of the ischium and pubes, till it divides into its terminal branches.

It may be ligatured in two situations: (1) At the greater sacro-sciatic foramen; (2) in the perineum. In the first situation the incision for the sciatic is sufficient, the pudic being found internal to that artery, and lower down accompanied by its veins and the pudic nerve. In the perineum the linear guide to the operation extends from the arch of the pubes to the inner border of the tuber ischii (Fig. 102). The artery is situated about an inch and a quarter above the margin of the tuber ischii.

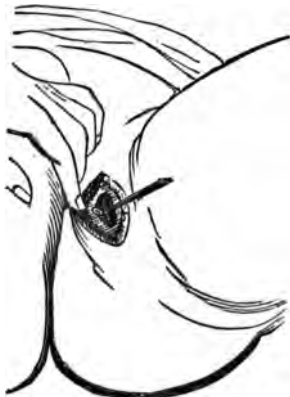

FIG. 103.

Contiguous Anatomy.—It runs along the outer side of the ischio-rectal fossa, resting upon the *obturator internus* muscle, covered by the obturator fascia, and accompanied by the pudic veins and pudic nerve.

Operation.—The patient is placed in the lithotomy position and an incision is made in the course of the line indicated, the tissues are carefully divided down to the vessel, which is then isolated from its veins and nerves and tied (Fig. 103). If care be not taken the crus penis will be cut. The introduction of a sound into the urethra will so positively define its outlines that the danger of cutting will be obviated.

Ligature of the Dorsalis Penis.—This may be tied on the dorsum of the penis by making an incision an inch in length on a line corresponding to the centre of its long axis. It is superficial, and is attended by its veins and nerves, which should be carefully avoided in passing the needle.

Ligature of the External Iliac Artery.—This vessel is about four inches long and passes obliquely downward and outward, nearly corresponding to a line drawn from the left side of the umbilicus to midway between the anterior superior spinous process of the ilium and the symphysis pubis. It is ligated at about the middle of its course. It has no superficial muscular guide; however, the psoas magnus, at the inner border of which it lies, is a most important deep muscular guide.

Contiguous Anatomy.

PLAN OF THE RELATIONS OF THE EXTERNAL ILIAC ARTERY.

In front.

Near Poupart's Ligament.	{	Peritoneum, intestines. Spermatic vessels. Genital branch. Genito-crural nerve. Circumflex iliac vein. Lymphatic vessels and glands.	
<i>Outer side.</i> Psoas magnus. Iliac fascia.	{	External Iliac.	} <i>Inner side.</i> External iliac vein and vas deferens at femoral arch.

Behind.

External iliac vein.
Psoas magnus.
Iliac fascia.

Operation.—Before beginning the operation evacuate the contents of the bladder and rectum of the patient, then place him in a recumbent position, with the thigh slightly flexed. A curvilinear incision is then made, with the convexity downward, beginning about an inch and a half

below the pyriformis muscle, lying internal to the sciatic artery; then enters the pelvis through the lesser sacro-sciatic foramen, and runs along the inner surface of the

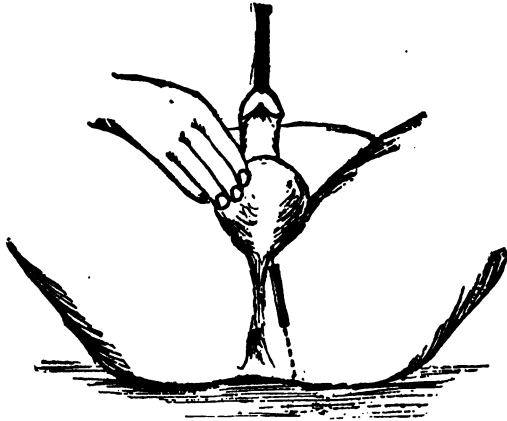


FIG. 102.

ramus of the ischium and pubes, till it divides into its terminal branches.

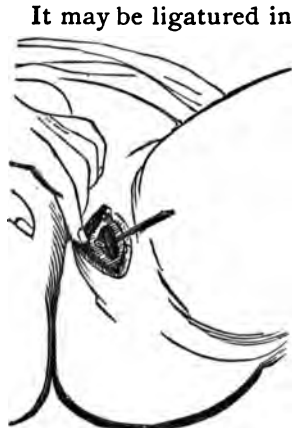

FIG. 103.

It may be ligatured in two situations: (1) At the greater sacro-sciatic foramen; (2) in the perineum. In the first situation the incision for the sciatic is sufficient, the pudic being found internal to that artery, and lower down accompanied by its veins and the pudic nerve. In the perineum the linear guide to the operation extends from the arch of the pubes to the inner border of the tuber ischii (Fig. 102). The artery is situated about an inch and a quarter above the margin of the tuber ischii.

Contiguous Anatomy.—It runs along the outer side of the ischio-rectal fossa, resting upon the *obturator internus* muscle, covered by the obturator fascia, and accompanied by the pudic veins and pudic nerve.

Operation.—The patient is placed in the lithotomy position and an incision is made in the course of the line indicated, the tissues are carefully divided down to the vessel, which is then isolated from its veins and nerves and tied (Fig. 103). If care be not taken the crus penis will be cut. The introduction of a sound into the urethra will so positively define its outlines that the danger of cutting will be obviated.

Ligature of the Dorsalis Penis.—This may be tied on the dorsum of the penis by making an incision an inch in length on a line corresponding to the centre of its long axis. It is superficial, and is attended by its veins and nerves, which should be carefully avoided in passing the needle.

Ligature of the External Iliac Artery.—This vessel is about four inches long and passes obliquely downward and outward, nearly corresponding to a line drawn from the left side of the umbilicus to midway between the anterior superior spinous process of the ilium and the symphysis pubis. It is ligated at about the middle of its course. It has no superficial muscular guide; however, the psoas magnus, at the inner border of which it lies, is a most important deep muscular guide.

Contiguous Anatomy.

PLAN OF THE RELATIONS OF THE EXTERNAL ILIAC ARTERY.

In front.

		Peritoneum, intestines.	
		Spermatic vessels.	
		Genital branch. Genito-crural nerve.	
		Circumflex iliac vein.	
		Lymphatic vessels and glands.	
<i>Outer side.</i>			<i>Inner side.</i>
Psoas magnus.	{ External }		External iliac vein and vas
Iliac fascia.	Iliac. }		deferens at femoral arch.

Behind.

External iliac vein.
Psoas magnus.
Iliac fascia.

Operation.—Before beginning the operation evacuate the contents of the bladder and rectum of the patient, then place him in a recumbent position, with the thigh slightly flexed: A curvilinear incision is then made, with the convexity downward, beginning about an inch and a half

the operation wound. Place the patient on the back with the thighs extended, the leg turned inward, and the foot forcibly extended to mark the outlines of the tibialis anticus. Make an incision four or five inches in length on the line indicating the course of the artery, down to the fascia, which is then divided on a director. The aponeurosis is divided along the line of apposition between the tibialis anticus and the extensor longus digitorum; it should likewise be divided transversely to admit of the wider

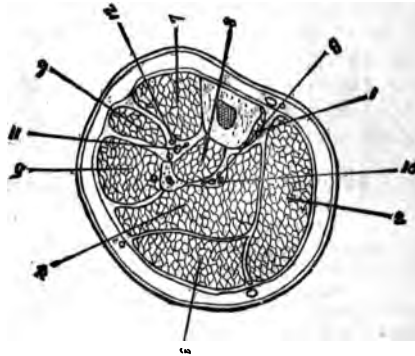


FIG. 117a.—TRANSVERSE SECTION, UPPER THIRD.

1. Popliteus. 2 and 3. Gastrocnemius. 4. Soleus. 5. Peroneus longus. 6. Extensor longus dig. 7. Tibialis anticus. 8. Tibialis posticus. 9. Posterior tibial artery and venae comites. 10. Posterior tibial nerve. 11. Anterior tibial artery and venae comites. 12. Anterior tibial nerve.

separation of these muscles. The foot is now flexed, and with the finger or handle of the scalpel the line of separation is extended directly down to the vessel; separate the surfaces of the wound with a spatula, when the artery with its nerve and veins will be seen, the nerve being in front and to the outer side; separate the veins, draw the nerve aside and pass the ligature from without inward (Fig 118.)

Operation at the Lower Third.—With the limb as in the preceding instance, extend the foot to mark the course of the tendon of the tibialis anticus; make an incision along the external border of the tendon on the linear guide, about three inches in length. Divide the fascia on a direc-

tor, and seek with the finger for the space between the tibialis anticus and the extensor proprius pollicis which has crossed to the inner side of the vessel; flex the foot, separate these muscles, and the artery will be seen accompanied by its veins and nerve; the latter lying in front and a little to the outer side; isolate the artery, and place the ligature by passing from without inward.

Fallacies.—The outer surface of the head of the tibia may

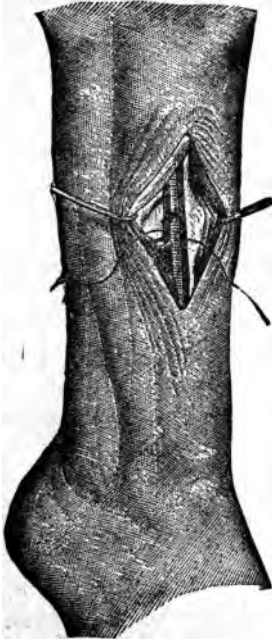

FIG. 118.

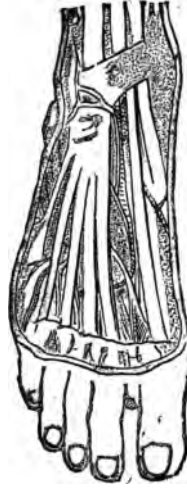

FIG. 119.

be mistaken for the head of the fibula, which will bring the linear guide too far to the inner side of the leg, and cause the incision to be made over the belly of the tibialis anticus muscle. To avoid this it must be remembered that the head of the fibula is more posteriorly, and constitutes the most external bony prominence at this joint.

The septum between the tibialis anticus and the extensor longus digitorum may be indistinct or absent; then the *outer border* of the tibialis can be determined, (1) by for-

cible extension of the tarsus; (2) by determining its limits by the resistance to lateral pressure; (3) the line indicating the interspace may be seen at the lower extremity of the cut when not visible above.

The vessel may be rudimentary or absent; it may run more superficially than common. So long, however, as it keeps in the proper line its pulsations will lead to its detection.

Ligature of the Dorsalis Pedis Artery.—This vessel is a continuation of the anterior tibial, beginning at the ankle-joint and passing downward between the metatarsal bones of the great and second toes. It is tied in one situation, and on a line which is a direct continuation of the linear guide to the anterior tibial.

The Muscular Guide is the outer border of the tendon of the extensor proprius pollicis (Fig. 119).

Contiguous Anatomy.

PLAN OF THE RELATIONS OF THE DORSALIS PEDIS ARTERY.

In front.

Integument and fascia.
Innermost tendon of Extensor brevis digitorum.

Tibial side.

Extensor proprius pollicis.

{ Dorsalis }
{ Pedis. }

Fibular side.

Extensor longus digitorum.
Anterior tibial nerve.

Behind.

Astragalus.
Scaphoid.
Internal cuneiform,
and their ligaments.

Operation.—Extend the tarsus and forcibly flex the great toe to make prominent the tendon of the extensor proprius pollicis; make an incision about three inches in length along its inner border, commencing from the bend of the ankle; divide the fascia on a director, when the fleshy under portion of the flexor brevis digitorum will be seen; this should be drawn outward when the artery and its satellite veins will be seen; separate the artery from them, and pass the needle as best suits the convenience of the operator (Fig. 120).

Fallacy.—It may pass outside of the line indicating its proper course.

Ligature of the Posterior Tibial Artery.—It is an artery of considerable size which comes from the popliteal at the lower border of the popliteus muscle, passes obliquely to the tibial side of the leg, going down between the superficial and deep layers of muscles to a point midway between the internal malleolus and inner tuberosity of the

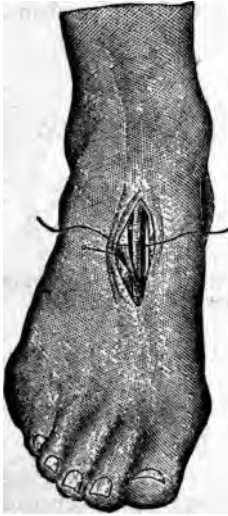


FIG. 120.

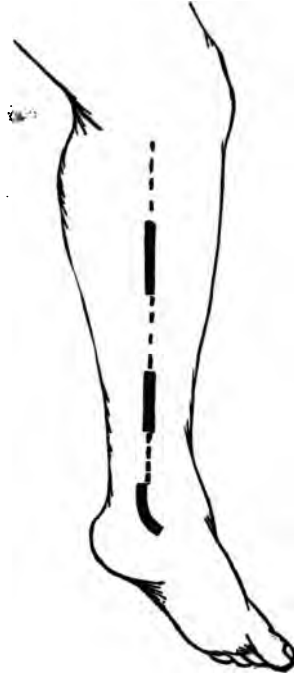


FIG. 121.

os calcis, where it terminates a little later in the external and internal plantar vessels. It may be ligatured in three situations: at its middle and lower thirds, and as it passes behind the inner malleolus.

The linear guide of this vessel is drawn from the middle of the popliteal space to midway between the inner malleolus and tuberosity of the os calcis. This guide is not a feasible one, since, to reach the artery by cutting upon

it necessitates the diversion of the fibres of the muscles of the calf of the leg.

Linear guide to the operation is made by drawing a line three fourths of an inch behind the posterior border of the tibia in the upper and lower thirds, from its upper to its lower extremity (Fig. 121).

The Muscular Guide.—At its middle third it lies beneath the soleus; at its lower third to the outer border of the flexor longus digitorum.

Contiguous Anatomy.

PLAN OF THE RELATIONS OF THE POSTERIOR TIBIAL ARTERY.

In front.

Tibialis posticus.
Flexor longus digitorum.
Tibia.
Ankle-joint.

Inner side.

Posterior tibial nerve, } Posterior }
upper third. } Tibial. }

Outer side.

Posterior tibial nerve.
lower two thirds.

Behind.

Gastrocnemius.
Soleus.
Deep fascia and integument.

Operation at its Middle Third (Fig. 122).—Place the patient on the back, flex the leg on the thigh and the thigh on the pelvis, so the leg will lie on the outer side. Make an incision on the line indicated about four inches in length; divide the deep fascia, recognize the inner border of the gastrocnemius, beneath which will be seen the fibres of the soleus, which should be divided on a director, down to the pale yellow aponeurosis on its under surface; separate the fibres of the soleus and make an opening through its aponeurosis about one inch from the inner border of the tibia, of sufficient size to expose the artery, which is found beneath, attended by its veins and the posterior tibial nerve; draw the nerve to the outer side, separate the vessel from the veins and pass the needle from without inward.

Operation at the Lower Third (Fig. 123).—Place the limb as before; make an incision in the course of the linear guide about three inches in length; divide the integument and fascia in the usual manner; separate the borders of the wound, then divide the aponeurosis which binds down the

deep layer of muscles at about one inch from the posterior border of the tibia, push aside the fat, and the vessel with its nerve and veins will be found at the outer border of the flexor longus digitorum. Separate the vessel, push the nerve to the outer side and pass the needle from without inward.

Operation between the os calcis and internal malleolus. Place the foot on the outer surface and make a curved incision about three inches in length, with the convexity uppermost, and its centre at a point midway between the malleolus and the inner tuberosity of the os calcis.

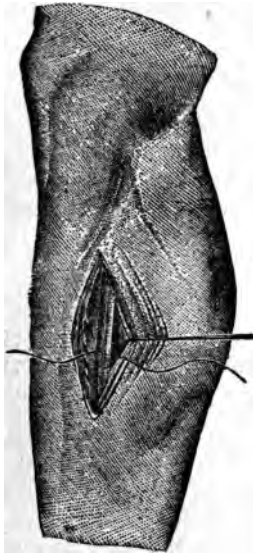


FIG. 122.

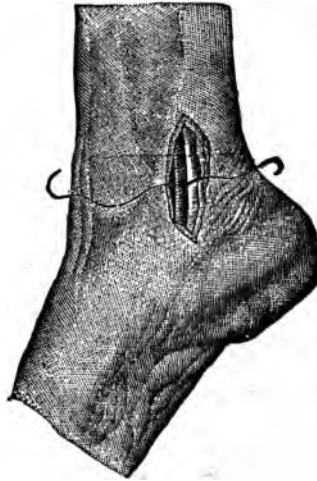

FIG. 123.

(See Fig. 121.) Divide the fascia and the internal annular ligament on a director, using caution with the latter, since the artery rests beneath it; isolate the vessel from the veins and pass the needle from without inward. In passing through the superficial tissues some small branches of the long saphenous vein may be divided, unless caution be used. In old people both these and the vena comitis often become varicose, which increase the difficulty of finding and isolating the artery. It is better not to

attempt to ligature it in this situation if evidences of varicosities exist.

Fallacies.—The posterior tibial may be rudimentary or absent. In either instance the peroneal is usually increased in size.

Ligature of the Peroneal Artery.—It arises from the posterior tibial about an inch below the popliteus muscle, passes obliquely outward to the inner border of the fibula, along which it descends to the lower third of the leg, and is finally distributed to the outer side of the ankle. It may be ligatured at the middle third of the leg.

The linear guide is a line drawn from the posterior border of the head of the fibula to the external border of the tendo-achilles at its insertion.

Contiguous Anatomy. (See Fig. 117.)

PLAN OF THE RELATIONS OF THE PERONEAL ARTERY.

In front.

Tibialis posticus.
Flexor longus pollicis.

Outer side.

Fibula. { Peroneal }
 { Artery. }

Behind.

Soleus.
Deep fascia.
Flexor longus pollicis.

Operation.—Extend the foot and make an incision about four inches in length along the line indicated, parallel with the external border of the fibula. Separate the attachments of the soleus and the flexor longus pollicis from each other, when the artery will be found at the inner side of the flexor longus pollicis close to the fibula.

Fallacies.—It may be absent: this is, however, very rare. It may be overlooked, and the posterior tibial found instead. If its close relation to the fibula be remembered, this mistake will not occur.

Ligature of the Innominata Artery.—The innominata artery arises from the beginning of the transverse arch of the aorta in front of the left common carotid, passes obliquely upward and outward to the upper border of the right sterno-clavicular articulation, where it divides into the right common carotid and right subclavian. It has no practical linear or muscular guides.

Contiguous Anatomy.

PLAN OF THE RELATIONS OF THE INNOMINATE ARTERY.

In front.

Sternum.

Sterno-hyoid and Sterno-thyroid muscles.

Remains of thymus gland.

Left innominate and right inferior thyroid veins.

Inferior cervical cardiac branch from right pneumogastric nerve.

Right side.

Right vena innominata.

Right pneumogastric nerve.

Pleura.

{ Innominate }
{ Artery. }*Left side.*

Remains of thymus.

Left Carotid.

Behind.

Trachea.

Operations.—Numerous incisions have been given for gaining access to the vessel. The one which is best calculated to afford the requisite amount of room was employed by the late Valentine Mott (Fig. 124). Place

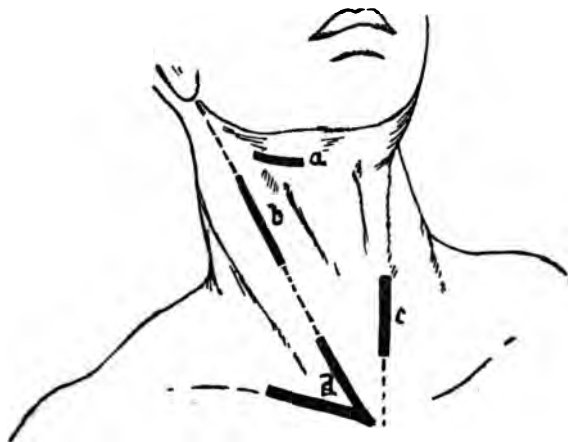


FIG. 124.

the patient on the back, with the shoulders somewhat raised and the head turned to the opposite side. An incision was then made three inches in length, extending along the upper border of the clavicle to opposite the centre of the epi-sternal notch. This is joined by another of a similar length directed along the anterior portion of

the sterno-mastoid muscle. This triangular flap, consisting of the integument, superficial fascia, and platysma, is turned upward and inward. The portions of the sterno-cleido-mastoid, corresponding to the horizontal incision, and the sterno-hyoid and sterno-thyroid muscles, are divided on a director and turned aside. The inferior thyroid veins, if they now come into view, must be carefully drawn aside, the deep cervical fascia is carefully torn or cut through, when the sheath of the common carotid artery, pneumogastric nerve, and internal jugular vein is brought into view. Open it, draw the vein and nerve to the outer side, and follow the carotid down to the subclavian, the origin of which should be exposed. The upper portion of the innominata is then to be separated from its important connections by the finger or a blunt director; the left vena innominata is depressed, and the right vena innominata, right internal jugular, and pneumogastric nerve are carried to the right, and then the aneurismal needle is passed from below upward and from behind, forward and inward, in close contact with the vessel.

Fallacies.—If the innominata be shorter than usual, the lower extremity of the common carotid may be tied instead. If the aorta arches to the right side, the innominata will be on the left side, instead of the right.

The necessity of treating all the veins and the pleura with most judicious care is emphasized by the knowledge of the fact that nearly all the fatal cases thus far have died from pleurisy or secondary hemorrhage.

Results.—This vessel has been ligatured sixteen times, with one recovery.

Ligature of the Subclavian Artery.—This vessel can be ligatured in three situations: (1) Between the inner border of the scalenus anticus and its origin; (2) behind the scalenus; (3) between its termination at the lower border of the first rib and the outer border of the scalenus anticus.

Ligature of the First Portion, Left Side.—This portion has no definite linear or muscular guide. The inner border of the scalenus anticus is of use in leading to and limiting its extent. Owing to its origin from the arch of the aorta it is of great depth, almost beyond the reach of a ligature; while its close relation to very important structures, injury to which, of itself, may be more grave than the condition for which the vessel is tied, render it exceedingly difficult to perform and of questionable expediency.

Contiguous Anatomy.

PLAN OF RELATIONS OF FIRST PORTION OF LEFT SUBCLAVIAN ARTERY.

In front.

Pleura and left lung.
 Pneumogastric, cardiac, and phrenic nerves.
 Left carotid artery.
 Left internal jugular and innominate veins.
 Sterno-thyroid, Sterno-hyoid, and Sterno-mastoid muscles.

Inner side.

Esophagus.
 Trachea.
 Thoracic duct.

{ Left Subclavian Artery. }
 { First Portion. }

Outer side.

Pleura.

Behind.

Esophagus and thoracic duct.
 Inferior cervical ganglion of sympathetic.
 Longus colli and vertebral column.

Operation.—Place the patient on the back with the head extended and turned to the opposite side; the left shoulder should be well depressed; make an incision three inches and a half in length along the inner border of the sterno-cleido-mastoid down to the sternum; another two inches and a half in length along the inner extremity of the clavicle, meeting the former near the trachea. It is seen that this incision is substantially the same as for the ligaturing of the innominate artery. The flap, consisting of the integument, superficial fascia, and platysma, is turned aside, one half of the clavicular portion of the sterno-mastoid and its whole sternal portion are then divided on a director, bringing into view the sterno-hyoid, sterno-thyroid and to the outer side the omo-hyoid. The sterno-thyroid and hyoid should be divided with great care, after being liberated from the fascia which covers them. The inner edge of the scalenus anticus muscle is now sought for; when found it will guide the finger directly to the vessel. The important contiguous structures are now drawn in, pressed away from the artery, using great caution to avoid the thoracic duct, which will be in the line of search, and the needle carefully passed from before backward. The great depth of the vessel will make it exceeding difficult to pass the needle, which should be the one with the adjustable extremity.

Results.—Tied by Dr. J. Kearney Rogers, 1845; patient died from secondary hemorrhage on the fifteenth day.

Ligature of First Portion, Right Side.—The inner border of the anterior scalenus leads to it upon this, the same as upon the left side.

Contiguous Anatomy.

PLAN OF RELATIONS OF FIRST PORTION OF RIGHT SUBCLAVIAN ARTERY.

In front.

Clavicular origin of Sterno-mastoid.
 Sterno-hyoid and Sterno-thyroid.
 Internal jugular and vertebral veins.
 Pneumogastric, cardiac, and phrenic nerves.

Beneath.

{ Right Subclavian Artery, }
 First Portion. }

Pleura.

Behind.

Recurrent laryngeal nerve.
 Sympathetic.
 Longus colli.
 Transverse process of seventh cervical or first dorsal vertebra.

Operation.—The position of the patient, primary incisions, and dissection are substantially the same as the preceding.

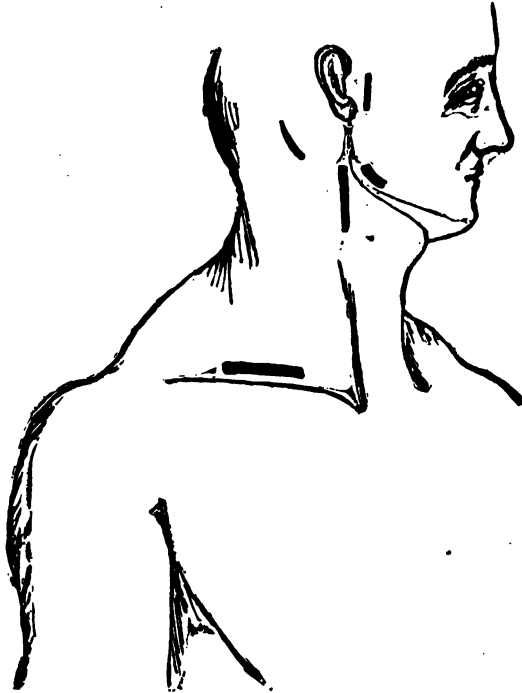


FIG. 134.

The internal jugular should be pressed aside and the needle passed from below upward and from behind forward, carefully avoiding the pleura, recurrent laryngeal, and phrenic nerves. The ligation of the vertebral and internal mammary at the same time will lessen the danger of secondary hemorrhage.

Fallacies.—This vessel may arise from the arch of the aorta, when it will be more deeply situated, often passing behind the œsophagus or between it and the trachea.

Results.—Has been ligatured thirteen times; all the cases proved fatal, of which eight died of hemorrhage.

Ligature of the Second and Third Portions.—The linear guide to the operation is drawn just above the upper border of the clavicle, extending between the posterior border of

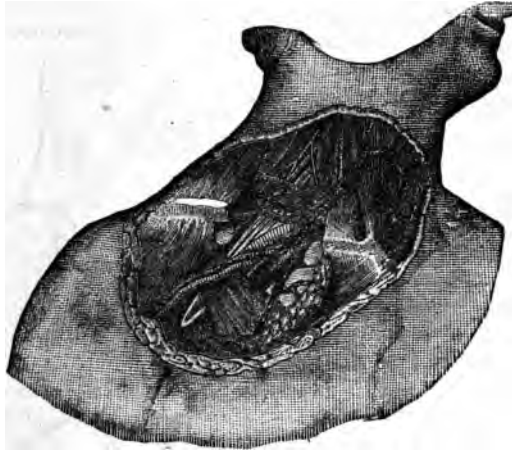


FIG. 126.

the sterno-cleido-mastoid and the anterior border of the trapezius, and should be about four inches in length. (Fig. 125.)

Muscular Guides to the Artery.—This vessel has no superficial muscular guide. The deep muscular guide is the outer border of the scalenus anticus. The posterior belly of omo-hyoid, while not in close contact with it, serves an important purpose in directing the attention of the surgeon towards it. The outer border of the scalenus anticus is well indicated by the posterior border of the sterno-cleido-mas-

toid, provided the latter muscle be not uncommonly developed. The junction of the inner two inches of the clavicle with its outer portion is a far more unvarying indication of the approximate deep location of its outer border than the former.

The tubercle on the first rib into which the scalenus anticus is inserted is the direct guide to the vessel, the artery being directly behind it. (Fig. 126.)

Contiguous Anatomy of Third Portion.

RELATIONS OF THIRD PORTION OF SUBCLAVIAN ARTERY.

In front.

Cervical fascia.
 External jugular, supra-scapular, and transverse cervical veins.
 Ascending branches of cervical plexus.
 Subclavian muscle and supra-scapular artery and clavicle.

Above.

Brachial plexus.
 Omo-hyoid.

{ Artery. }

Below.

First rib.

Behind.

Scalenus medius.

Operation: Third Portion.—Place the patient on the back with the shoulders elevated from the table, head turned backward and to the opposite side. Draw the shoulder of the corresponding side firmly downward and retain it in that position. Compress the external jugular vein above the clavicle long enough to cause its distension, thereby indicating its exact situation. The integument is then drawn evenly downward and incised upon the clavicle, which will, when allowed to retract, carry the incision upward to its proper situation—one half inch above the clavicle. The superficial fascia and platysma are then divided upon a director, being careful not to sever the external jugular, which can be either pulled aside or divided between two ligatures. The supra-scapular and transverse cervical veins should be treated in the same manner. The omo-hyoid is now sought for and drawn upward if necessary, and the supra-scapular artery avoided. The deep cervical fascia is torn asunder by the finger-nail or a director and the outer border of the scalenus anticus felt for on a line with the outer border of the sterno-cleido-mastoid, if it has not been *divided*; if so, it should be located as described under the *head of "Muscular Guides."* If the head be turned smartly

to the opposite side the scalenus anticus will be made tense and more prominent. When found it should be followed downward to its insertion, when the finger will rest upon the tubercle of the first rib, immediately behind which the pulsation of the artery will be felt. The vessel is now carefully exposed and the needle passed from before backward. (Fig. 127.) Great caution should be taken not to interfere with the subclavian vein, which lies in front of, and on a lower plane than the artery.

Fallacies.—The sterno-cleido-mastoid may have an unusual breadth of origin from the clavicle, thereby causing the incision to be made too far posteriorly. The clavicular

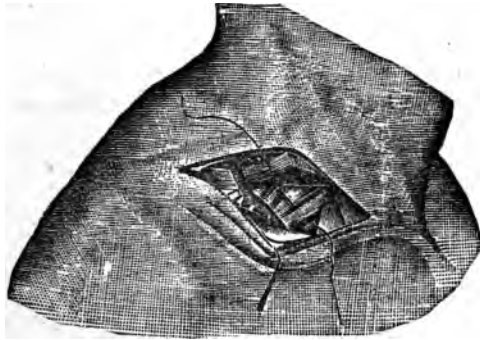


FIG. 127.

measurement will prevent this error. The tubercle on the anterior surface of a transverse process of one of the lower cervical vertebra may be mistaken for the tubercle of the first rib. This, however, is easily rectified by remembering that the rib is located downward and backward, that no contiguous pulsation is found, and that the outline of the scalenus anticus is absent. The tubercle may be absent, when the muscle inserted into the rib must be relied upon.

The artery may be in front of the tubercle and the vein behind. The pulsation as well as the anatomical appearances will determine the interchange of situation. The inner cord of the brachial plexus may be mistaken for the artery. A little attention to the distinctive physical characteristics between nerves and arteries will quickly settle *this doubt*.

Results.—Two hundred and fifty-one cases tabulated, of which one hundred and thirty-four, or fifty-three per cent, died.

Ligature of the Second Portion.—All muscular and linear guides are practically similar to those of the preceding.

Contiguous Anatomy.

PLAN OF RELATIONS OF SECOND PORTION OF SUBCLAVIAN ARTERY.

<i>In front.</i>		
Scalenus anticus.		
Phrenic nerve.		
Subclavian vein.		
<i>Above.</i>	{	<i>Below.</i>
Brachial plexus.	Subclavian Artery. Second Portion. }	Pleura.
<i>Behind.</i>		
Pleura and Middle Scalenus.		

Operation.—The proceedings essential to arrive at the proper site in this instance are not varied from those given for the third portion until the outer border of the scalenus anticus is well determined; the phrenic nerve and subclavian vein should then be pushed aside and the muscle divided (see Fig. 127), when the retraction of its fibres will expose the portion to view. The needle is then passed as before, closely hugging the artery, to avoid the pleura below and posteriorly.

Fallacies.—The vessels may be transposed.

Results.—Thirteen cases reported, of which nine, or sixty-nine per cent, were lost.

The subclavian should always be tied in the third portion when possible; if impossible, the second should be selected. The ligature of the first portion is unwarranted in view of the results heretofore gained.

Ligature of the Vertebral Artery—This artery arises from the first portion of the subclavian and passes directly upward along the anterior surface of the vertebral column to the transverse process of the sixth cervical vertebra. It may be ligatured in three situations: (1) Before entering the vertebral canal; (2) between the atlas and axis; (3) between the atlas and the occipital bone. The first situation, however, is sufficient for all practical purposes.

The linear guide to the artery is drawn from the junction of the inner fourth with the outer three fourths of the

clavicle, to the posterior border of the mastoid process. The deep guide is the tubercle of the transverse process of the sixth cervical vertebra, and the space between the borders of the longus colli and the scalenus anticus.

Contiguous Anatomy.

In front.

Internal jugular vein and its sheath.
 Aponeurosis between longus colli and scalenus anticus.
 Superior thyroid artery.
 Vertebral vein.

<i>Outer side.</i>	{	Vertebral	}	<i>Inner side.</i>
Scalenus anticus.		Artery.		Longus colli.

Behind.

Vertebral column.

Operation.—The head should be turned to the opposite side and an incision about three inches and a half in length made along the anterior border of the sterno-cleido-mastoid, terminating at the upper border of the sternum. The fascia and the connections between the sterno-mastoid and sterno-hyoid are divided and these muscles separated, which exposes the common sheath of the internal jugular vein, common carotid artery, and pneumogastric nerve. This sheath is now carefully separated from its connections to the sterno-thyroid and longus colli muscles and drawn outward. The parts are now relaxed by raising the head, the inferior thyroid artery displaced, and the aponeurosis covering the vessel torn through, the vein pushed aside, and the ligature deposited from within outward.

Results.—This vessel has been tied eight or ten times, and so far as the operation itself is concerned no ill results are reported.

Ligature of the Internal Mammary Artery.—The internal mammary arises from the first portion of the subclavian. It descends behind the internal jugular and subclavian veins to the posterior wall of the chest, resting upon the costal cartilages about one half inch from the margin of the sternum. It may be ligatured in any of the upper intercostal spaces.

Linear Guide to the Artery.—About one half inch to the outer side of the sternum is a fair indication of its locality. It has no muscular guide.

Operation.—Make an incision two inches in length along the

upper border of the costal cartilages and rib. The integument, fascia, and pectoralis major muscle are divided down to the intercostal muscles. Beneath the internal intercostal muscle, surrounded by the connective tissue, the artery, accompanied by the venæ comites, will be found. The vessel is isolated, and the needle carefully passed to avoid penetrating the pleura. If the vessel be tied in the upper intercostal spaces a single vein will attend it.

Ligature of the Inferior Thyroid.—This vessel arises from the thyroid axis, passes in a somewhat irregular course upward and inward behind the sheath of the common carotid and internal jugular vein to the thyroid gland.

The linear guide to the operation is along the anterior border of the sterno-mastoid, as in ligaturing the common carotid. The body of the fifth cervical vertebra opposite to which it enters the gland is an approximate bony guide to the vessel.

Contiguous Anatomy.—In front the common carotid sheath and its contents and the sympathetic nerve on the inner side; on the left, the recurrent laryngeal and the œsophagus; if low in the neck, carefully avoid the thoracic duct. The respective tissues are pulled aside and the needle passed. No dangers attend the ligaturing other than those incurred by the manipulation necessary to arrive at the vessel.

Ligature of the Axillary.—This vessel begins at the lower border of the first rib and extends to the lower border of the tendon of the latissimus dorsi. It may be tied in three situations: (1) Above the pectoralis minor; (2) behind; (3) below that muscle. The first and last, however, are the only ones at which the vessel can be practically secured.

First Portion.—There is no *linear guide* to the vessel. The *linear guide to the operation* is located about one half inch below the lower border of the clavicle, extending from within an inch or so of the sternal extremity, outward three or four inches.

The *muscular guides* are superficial and deep. The former is the space between the border of the deltoid and pectoralis major muscles. The latter is the pectoralis minor; its upper border corresponding to the first portion, etc., etc., as before stated.

Contiguous Anatomy.

RELATIONS OF THE FIRST PORTION OF THE AXILLARY ARTERY.

In front.

Pectoralis major.
 Costo-coracoid membrane.
 Subclavius.
 Cephalic vein.

<i>Outer side.</i>	{	Axillary Artery. First portion.	}	<i>Inner side</i>
Brachial plexus.				Axillary vein.

Behind.

First Intercostal space, and Intercostal muscle.
 First serration of Serratus magnus.
 Posterior thoracic nerve.

In this situation the artery lies very deeply, and it is better, if possible, to ligature the third portion of the subclavian.

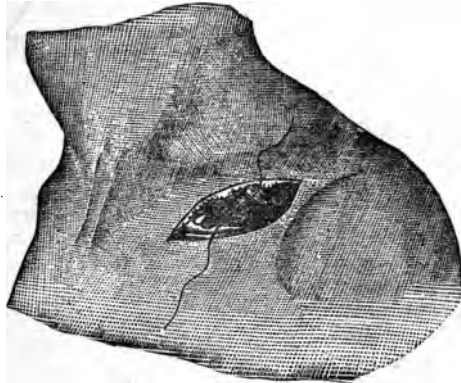


FIG. 128.

Operation (Fig. 128).—Place the patient upon the back with the head turned to the opposite side; raise the shoulder and carry the arm from the side of the chest somewhat. Make an incision about four inches in length on the line given, down through the integument, fascia, and platysma; separate the fibres of the pectoralis major, or divide them the full length of the wound; tear apart the underlying fascia, when the pectoralis minor muscle will be brought in view; bring the arm to the side to relax it, then draw it to the outer side; displace the areolar tissue carefully

with the finger or a director, when the vein will be seen, which should be carried upward and outward with a blunt hook, and the artery will be noticed beneath and above it, in close contact with the inner cord of the brachial plexus, which lies to its outer side and above. The needle is then passed from below upward. The cephalic vein which empties into the axillary vein should be cautiously avoided, as it passes between the borders of the pectoral and deltoid muscles to its termination.

Fallacies.—The inner cord of the brachial plexus may be mistaken for the artery. Before tightening the ligature pressure should be made upon the vessel, and the effect upon the radial pulse noted.

The vessel may be reached by making an incision be-

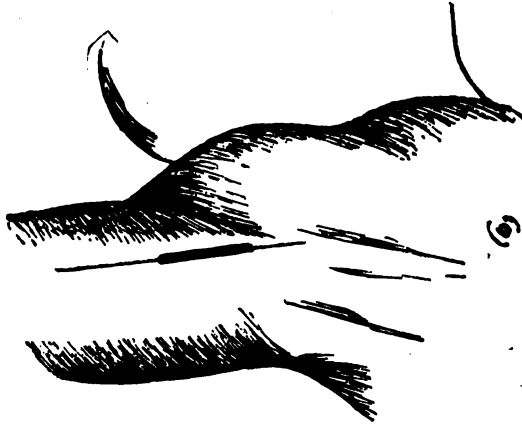


FIG. 129.

tween the borders of the deltoid and pectoral muscles about three inches in length, which shall connect with the one previously made below the lower border of the clavicle. The fat and cellular tissue can then be removed or displaced as in the previous instance.

Results.—No definite records are given of the results of the operation.

Ligature in the Third Portion.—Linear guide to the artery is a line extending upward into the axilla corresponding to the junction of its anterior and middle thirds. (Fig. 129.)

Muscular Guide.—The inner border of the coraco-brachialis.

Contiguous Anatomy.

RELATIONS OF THE THIRD PORTION OF THE AXILLARY ARTERY.

In front.

Integument and fascia.
Pectoralis major.

Outer side.

Coraco-brachialis.
Median nerve.
Musculo-cutaneous nerve.

{ Artery. }

Inner side.

Ulnar nerve.
Internal cutaneous nerve.
Axillary vein.

Behind.

Subscapularis.
Tendons of latissimus dorsi and teres major.
Musculo-spiral and circumflex nerves.

Operation (Fig. 130).—The arm should be adducted and rotated outward. Make an incision three inches in length along the inner border of the coraco-brachialis in line of the arterial pulsation, observing that its centre be above the fold of the axilla; cautiously divide the tissue upon a director, drawing the median nerve to the outer, and the veins to the inner side; pass the needle from within outward.

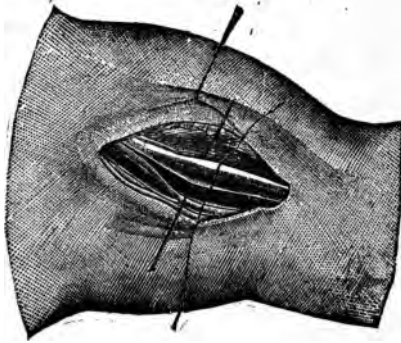


FIG. 130.

Fallacies.—Large branches may be given off at this situation, which will confuse the operator. Pressure upon the vessel prior to the tightening of the ligature will determine the influence upon the circulation beyond.

Results.—The operation implies in itself no particular danger to the patient.

Ligature of the Brachial Artery.—The brachial artery extends from the lower border of the tendon of the latissimus dorsi to about one inch below the bend of the elbow joint.

The linear guide is drawn from the junction of the middle

and anterior thirds of the axilla to midway between the apices of the bony condyles of the humerus. (Fig. 131.)

Muscular Guide.—At its upper third it lies at the inner border of the coraco-brachialis; in the middle third, at the




FIG. 131.

inner border of the biceps; in the lower third, the inner border of the biceps tendon. It may be ligatured in three situations: at its upper, middle, and lower thirds.

Contiguous Anatomy.

PLAN OF THE RELATIONS OF THE BRACHIAL ARTERY.

In front.

Integument and fasciæ.
Bicipital fascia, median basilic vein.
Median nerve.

Outer side.

Median nerve.
Coraco-brachialis.
Biceps.

{ Brachial }
{ Artery. }

Inner side.

Internal cutaneous
and ulnar nerve.
Median nerve.

Behind.

Triceps.
Musculo-spiral nerve.
Superior profunda artery.
Coraco-brachialis.
Brachialis anticus.

Operation: Upper Third.—Adduct the arm, and rotate it outward; make an incision about three inches in length along the inner border of the coraco-brachialis. The artery being very superficial is quickly reached. The median nerve is drawn to the outer, and the ulnar nerve and ba-

silic vein to the inner side; separate it from the vein, and pass the needle from within outward.

Operation in the Middle Third (Fig. 132).—Place the arm as before; make an incision three inches in length along the inner side of the biceps muscle. The median nerve is found lying upon and a little to its outer side; push it aside, isolate the artery from the venæ comites, and pass the needle in the same direction as before.

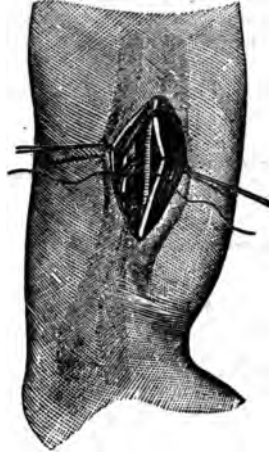

FIG. 132.

Operation in the Lower Third (Fig. 133).—Abduct the arm and supinate the forearm. Compress the arm above to distend the median basilic vein; make an incision about three inches in length along the inner border of the tendon of the biceps; draw aside the median basilic vein, when the artery will be felt pulsating beneath the bicipital fascia; a suitable sized opening is now cut through

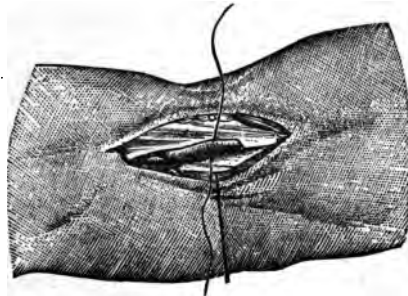

FIG. 133.

this fascia; the fore-arm partially flexed; the vessel separated from its veins, and the needle passed from within outwards.

Fallacies.—The arteries of the fore-arm may be given off from the axillary, or the brachial may bifurcate high up, thereby increasing the large vessels in the arm. This is to be told by the comparative size of the brachial, and the in-

fluence of pressure on the circulation beyond the point of proposed ligature. The brachial may run along with the ulnar nerve behind the inner condyle. If it be not in its normal site, deep pressure may detect its pulsations elsewhere; which, together with its effect on the circulation

beyond, will determine the size and site of the vessel. The incisions in the upper two thirds may be made too far inward, leading the surgeon to mistake the ulnar for the median nerve. If the forearm be flexed and traction be made upon either, its course will be determined and the mistake corrected.

The median nerve may pass behind the artery instead of in front; when, if the circulation from above be obstructed, the artery may escape notice.

Anomalous muscular slips and unusual muscular development may obscure the artery in its normal course. In such instances the pulsation will determine its location.

Occasionally, especially in female subjects, when the extremity is markedly concave on its outer surface, due to an unusual length of the internal condyle, the primary incision may be made to the outer side of the vessel. If, however, it be made midway between the tips of the bony condyles, irrespective of the overhanging soft parts, this error will not arise.

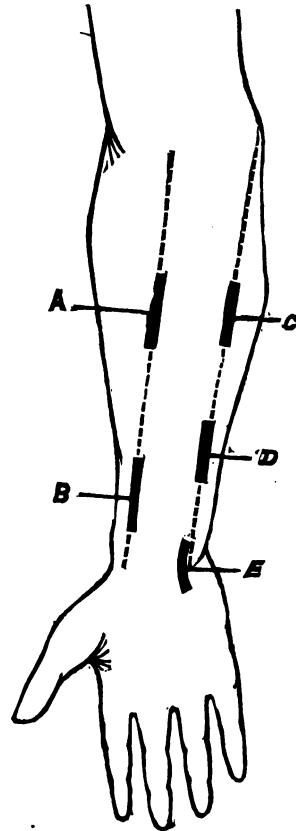


FIG. 134.

Results.—It has been ligatured seventy-six times for hemorrhage, with fifty-five recoveries.

Ligature of the Radial Artery.—This artery arises from the brachial, is an apparent continuation of it, and is *superficial* in its entire course. It may be ligatured in any *portion* of its course: it is, however, usually ligatured in

three situations: at the upper and lower thirds, and at the wrist.

The linear guide (Fig. 134) to this vessel is drawn from midway between the tips of the bony condyles of the humerus to the inner side of the extremity of the styloid process of the radius. *The muscular guide* is the inner border of the belly of the supinator longus muscle.

Contiguous Anatomy.

PLAN OF THE RELATIONS OF THE RADIAL ARTERY.

In front.

Integument—superficial and deep fasciæ.
Supinator longus.

Inner side.

Pronator radii teres,
Flexor carpi radialis.

{ Radial }
Artery in }
Forearm. }

Outer side.

Supinator longus.
Radial nerve (middle third).

Behind.

Tendon of Biceps.
Supinator brevis.
Pronator radii teres.
Flexor sublimis digitorum.
Flexor longis pollicis.
Pronator quadratus.
Radius.

Operation: Upper Third (Fig. 135).—Supinate the forearm; press upon the arm above to distend the superficial veins; make an incision about three inches in length along the linear guide to the vessel. After going through the fascia, the inner edge of the supinator longus will be found extending beyond, *overlapping* the line; separate and pull this outward, when the artery will be seen lying between its veins, with the nerve to the outer side; separate the artery, and pass the needle from without inward.

Operation in the Lower Third (Fig. 136).—In this situation the vessel is very superficial; its well-known pulsation being the best guide to it; with the arm placed as in the preceding position, make an incision two inches in length along the course of the vessel. After the division of the integument and fascia, the artery will be seen surrounded by loose areolar tissue, accompanied by its veins, and lying to the inner side of the tendon of the supinator longus. Separate and ligature it, passing the needle from the nerve.

Operation at Apex of Styloid Process.—In this situation the vessel is found in a triangular-shaped space bounded ante-

riorly by the tendon of the extensor primi internodii pollicis; externally by that of the secundi internodii pollicis, and the base corresponding to the apex of the styloid process of the radius. If the thumb be forcibly extended the outlines of the space will be well marked.

Operation.—Place the hand midway between the supination and pronation, and having ascertained the exact situ-

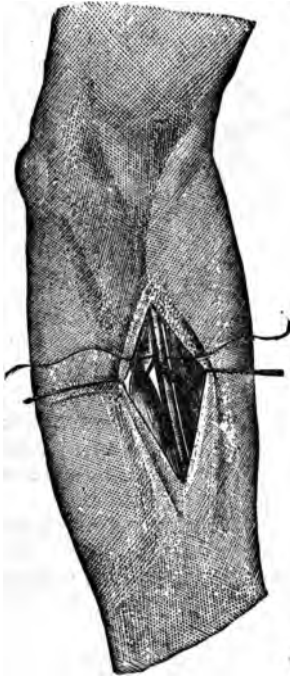


FIG. 135.

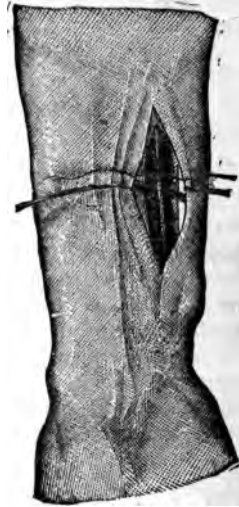


FIG. 136.

ation of the tendon of the extensor primi internodii pollicis, make an incision along its outer border about an inch in length; use care not to divide the superficial veins. The areolar tissue and the extensor primi internodii pollicis are pushed aside and the vessel found somewhat deeply situated. The needle can be carried in either direction. (Fig. 137.)

Fallacies.—The radial artery may be upon the fascia and supinator longus instead of beneath them; it may pass over the extensor tendons of the thumb instead of beneath them.

Results.—During the late war it was tied twenty times; four died.

Ligature of the Ulnar Artery.—This vessel is larger than the radial. It is given off from the brachial about one inch below the bend of the elbow, passes obliquely inward and downward deeply beneath the superficial flexors of the

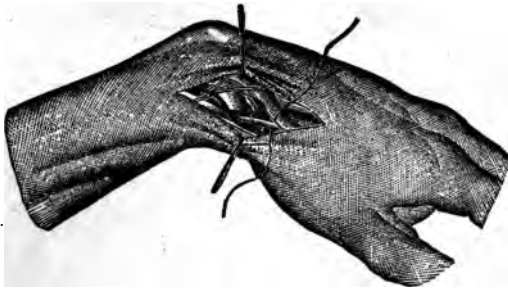


FIG. 137.

forearm, and gains the ulnar side a little above its middle; becoming superficial, passes along the outer side of the flexor carpi ulnaris to the radial side of the pisiform bone, where it terminates in the superficial palmar arch. It may be ligated in three situations.

The linear guide is drawn from the extremity of the internal condyle to the pisiform bone. (See Fig. 135.)

The muscular guide is the outer border of the flexor carpi ulnaris.

Contiguous Anatomy.

PLAN OF RELATIONS OF THE ULNAR ARTERY IN THE FOREARM.

In front.

Superficial layer of flexor muscles.	} Upper half.
Median nerve.	
Superficial and deep fasciæ.	

Inner side.

Flexor carpi ulnaris.	} Ulnar Artery in Forearm. }
Ulnar nerve (lower two thirds).	

Outer side.

Flexor sublimis digitorum.

Behind.

Brachialis anticus.
Flexor profundis digitorum.

*Operation: Junction Middle and Upper Third (Fig. 138).—*Supinate the forearm and make an incision about three inches in length, beginning about four finger-breadths below

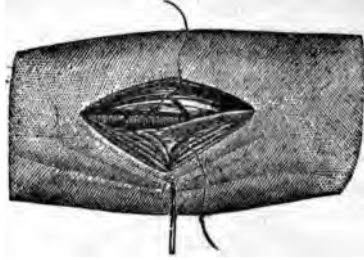


FIG. 138.

the internal condyle, on the linear guide to the vessel. Divide the fascia on a director; seek for the line of connection between the borders of the flexor carpi ulnaris and the

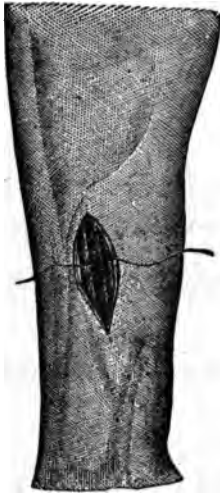

FIG. 139.



FIG. 140.

flexor sublimis digitorum. It is of a yellowish-white color. Divide it on a director, and pull the muscles apart, when the ulnar nerve will be seen, to the outer side of which will

be found the artery with its accompanying veins; separate the artery and pass the needle from within outward.

Operation in the Lower Third (Fig. 139).—Place the arm as in the preceding operation; extend the hand to make the tendon of the flexor carpi ulnaris tense; make an incision about three inches in length along the radial border of this muscle down to the fascia, which should be divided on a director, exposing the tendon of the flexor carpi ulnaris, which should be drawn inward, and the artery is seen beneath it. Isolate the vessel from its veins and pass the needle from within outward.

Operation at the Wrist (Fig. 140).—Place the hand on its dorsal surface and make a curved incision about two inches in length along the radial side of the pisiform bone, with its convexity outward; carry it downward along the side of that bone through the fascia and fatty tissue to the vessel. Flex the hand and pass the ligature from within outward.

Fallacies.—In the upper third the interspace between the flexor carpi ulnaris and flexor sublimis may be mistaken for the one between the flexor carpi radialis and the palmaris longus or flexor sublimis digitorum. If the hand and fingers be moved alternately, the proper muscles can be ascertained.

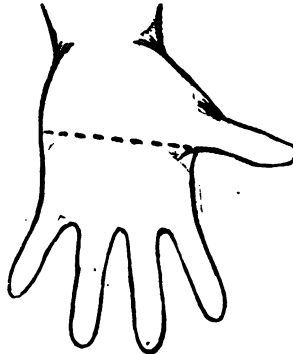


FIG. 142.

The artery may run beneath the fascia, or otherwise vary in its course; if not in its normal situation, deep pressure may define it.

Results.—The ulnar artery was ligatured during the war ten times, with three deaths.

The Superficial Palmar Arch can be tied at the seat of injury. It must be remembered, however, that beneath it lie the tendons of the flexors of the fingers and the divisions of the median and ulnar nerves.

Linear Guide (Fig. 141).—Extend the thumb at a right angle to the carpus, and draw a line transversely across it corresponding to its palmar border; this will denote the lower limit of the arch.

Ligature of the Common Carotid.—The right common

carotid comes from the innominate artery, and the left from the arch of aorta. The left is consequently longer and more deeply situated in the chest. The left after leaving the aorta passes obliquely upward to a point opposite the left sterno-clavicular articulation; and, from this point upward the right and left common carotids maintain substantially the same course to the upper border of the thyroid cartilage, where each divides into the internal and external carotids.

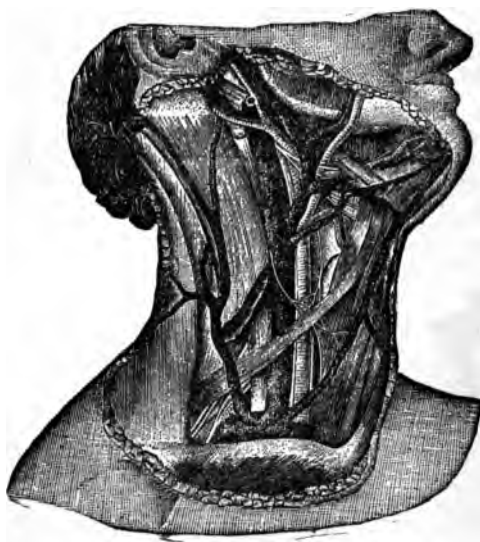

FIG. 149.

Each vessel may be ligatured in three situations: (1) At the root of the neck; (2) below the omohyoid muscle; (3) above that muscle. The last two are the situations commonly selected, the first not being employed except under forced circumstances. (Fig. 142.)

The linear guide to the vessel is a line drawn from the sterno-clavicular articulation to midway between the angle of jaw, and mastoid process. (See Fig. 125.)

The muscular guide to the operation is the anterior border of the sterno-cleido mastoid.

Contiguous Anatomy.

PLAN OF THE RELATIONS OF THE COMMON CAROTID ARTERY.

In front.

Integument and fascia.
Platysma.
Sterno-mastoid.
Sterno-hyoid.
Sterno-thyroid.

Omo-hyoid
Descendens noni nerve.
Sterno-mastoid artery.
Superior thyroid, lingual, and facial veins.
Anterior jugular vein.

Internally.

Externally.
Internal jugular vein.
Pneumogastric nerve.

} Common }
} Carotid. }

Trachea.
Thyroid gland.
Recurrent laryngeal nerve.
Inferior thyroid artery.
Larynx.
Pharynx.

Behind.

Longus colli.
Rectus capitis anticus major.
Recurrent laryngeal nerve.

Sympathetic nerve.
Inferior thyroid artery.

Operation below the Omo-hyoid. (Fig. 143.)

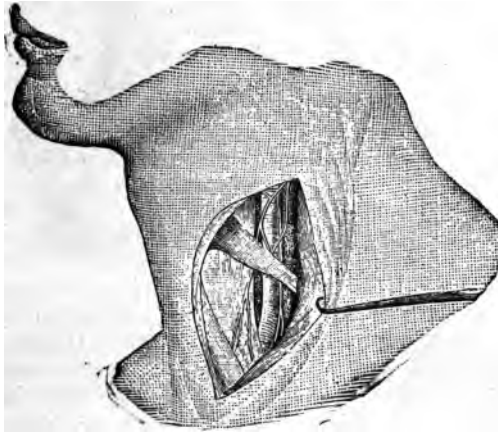


FIG. 143.

Place the patient on the back, with the shoulders slightly elevated, and the head turned to the opposite side; make an incision three inches in length, beginning a little above

the cricoid cartilage, on the line stated, and carry it downward along the anterior border of the sterno-mastoid; divide the superficial fascia, platysma, and deep fascia on a director, thus exposing the anterior border of the sterno-mastoid. If the sterno-mastoid artery be divided, ligature it. If otherwise, push it aside, together with the thyroid veins; draw the sterno-mastoid outward, and the sterno-thyroid and hyoid inward, when the lower border of the omo-hyoid will be seen above; divide the fascia beneath these muscles and draw it apart, when the descendens noni nerve will be seen resting upon the inner portion of the common sheath of the carotid, internal jugular vein, and the pneumogastric nerve: the artery being to the inner side, the nerve behind and between the two and out of sight. Place the finger upon the sheath, to ascertain the exact location of the artery; raise a portion of the sheath at its inner side corresponding to the site of the artery with a tenaculum or the thumb forceps, cut a small opening into it, and pass the needle from without inward, cautiously insinuating it between the vessel and its sheath. This manipulation should be carefully done, else the vein, pneumogastric, and recurrent laryngeal nerves may be implicated.

Operation above the Omo-hyoid.—The vessel is more superficial in this situation; which is sometimes denominated "the site of election." (See Fig. 125*b*.)

Place the patient as before, and make an incision along the anterior border of the sterno-mastoid, beginning at about the angle of the lower jaw, and extending it a little below the cricoid cartilage; divide the superficial fascia, platysma, and deep fascia on a director, carefully avoiding the small veins; expose the anterior border of the sterno-mastoid and slightly flex the head to relax the tissues of the neck; draw the edges of the wound apart, and the artery will be felt pulsating in its sheath. If the jugular vein overlap it, it should be emptied by pressure above and below, and be pressed outward; then carefully open the sheath as before, avoiding the descendens noni nerve; pass the needle carefully from without inward. It is well to observe the upper border of the omo-hyoid muscle before opening the sheath, that the exact location to apply the ligature be assured.

Fallacies.—The artery may bifurcate at the cricoid cartilage, and even lower; however, this is extremely rare;

under such circumstances both branches should be secured. If the vessel be pressed upon before the ligature is tied, it will determine the influence of the ligaturing upon the branches above.

The jugular vein may be much dilated, lie over and receive the impulse of the artery, hence be mistaken for it. This fallacy may be determined if that vessel be emptied of its blood in the manner before described. The thyroid gland may be enlarged and obscure the artery by displac-

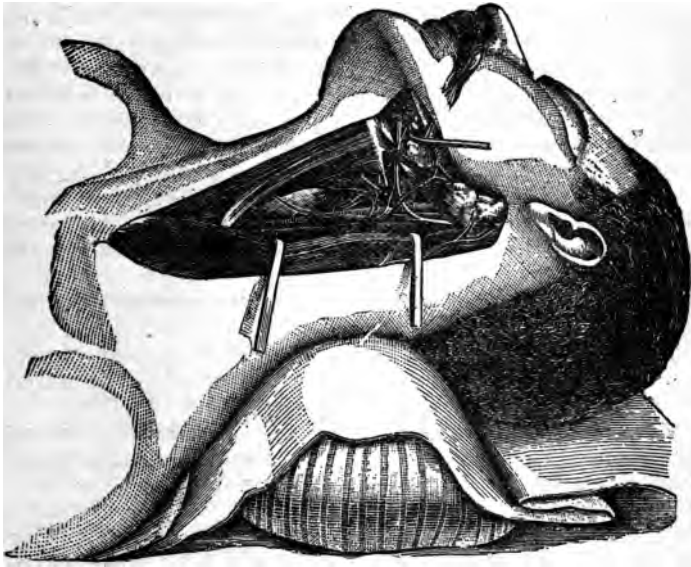


FIG. 144.

ing or overlapping it. Under these conditions it should be pushed aside. It is reported that the omo-hyoid muscle has been mistaken for the artery; the fact of its being muscular, taken in connection with the direction of its fibres, together with other obvious reasons, should eliminate any danger of this mistake. If branches arise from the main trunk, it may be mistaken for the external carotid. The comparative size of the vessel and the influence of pressure on the circulation of the internal carotid will effectually solve the question. If branches be given off from the com-

mon carotid near the site of the proposed ligaturing, they should be tied also.

Results.—This vessel has been tied 789 times for various reasons, of which 323, or about 41 per cent, have perished.

Ligaturing of both common carotids, either simultaneously or at variable intervals, has been done 36 times. The shortest interval between the operations in which recovery has taken place is four and one half days. Instances where the interval varied from thirteen to thirty days are reported, with recovery of the patients.

Ligature of the External Carotid.—This artery arises from the common carotid at or just above the upper border of the thyroid cartilage. It ascends in a slightly curved course, with the convexity forward, to a point midway between the neck of the condyle of the lower jaw and the external auditory meatus. The upper part of its course lies in the substance of the parotid gland (Fig. 144).

This artery may be tied in two situations: (1) Between the posterior belly of the digastric and its origin; (2) above the belly of the digastric. The former situation is the one to be selected, if possible.

The *linear* and the *muscular guides* are substantially the same as for the common carotid.

Contiguous Anatomy.

PLAN OF THE RELATIONS OF THE EXTERNAL CAROTID.

In front.

Integument, superficial fascia.
 Platysma and deep fascia.
 Hypoglossal nerve. } External }
 Lingual and facial veins. } Carotid. }
 Digastric and stylo-hyoid muscles.
 Parotid gland, with facial nerve and
 temporo-maxillary vein in its sub-
 stance.

Behind.

Superior laryngeal nerve.
 Stylo-glossus.
 Stylo-pharyngeus.
 Glosso-pharyngeal nerve.
 Parotid gland.

Internally.

Hyoid bone.
 Pharynx.
 Parotid gland.
 Ramus of jaw.

Operation.—Below the digastric muscle, with the patient on the back, head slightly extended and turned to the opposite side, make an incision along the anterior border of the *sterno-mastoid*, beginning opposite the angle of the *lower jaw*, and carry it downward to a point opposite the

cricoid cartilage. Divide the superficial fascia, platysma, and deep fascia on a director; expose the anterior border of the sterno-mastoid. The edges of the wound should be well drawn apart, when the hypoglossal nerve and the digastric and stylo-hyoid muscles will come into view.

The end of a grooved director should now be employed to separate and push aside the lingual and facial veins, together with the areolar tissue and lymphatic glands that rest upon the vessel. Expose the artery and pass the ligature from without inward. The internal jugular vein oft-times overlaps the vessel, and should be carefully drawn aside, or treated as recommended in ligaturing the common carotid.

Before the ligature is tied the following facts should be carefully observed: (1) If it be the external carotid around which the ligature is passed, this can be told by pressing upon the vessel and observing its effect upon the circulation of the facial; (2) the distance of the seat of the ligature from collateral branches; this can only be determined by carefully exposing the vessel for half an inch above and below the seat of the ligature. If vessels be found within this extent, they too should be ligatured to destroy the possibility of any interference with the formation of the internal clot; (3) that the ligature be not carried around both the external and internal carotid at or just above their point of bifurcation; if it be around both, pressure will check the pulsation of both; if but one it will have a like effect on its circulation.

Other Fallacies.—Enlarged lymphatic glands resting on the vessel may be mistaken for it. They need cause but momentary thought, since their circumscribed outline and mobility will determine their nature. If large they should be removed, otherwise they can be pushed aside. The superior thyroid branch may be confounded with the lingual. If the course of the respective vessels be observed they can be readily told apart; the superior thyroid arises nearest the bifurcation, arches upward and forward, then passes quite directly downward. The lingual does not arch downward, but passes upward and inward to gain the upper border of the greater cornu of the hyoid bone, which can be easily outlined by the finger.

Operation above the Digastric.—Make an incision from the lobe of the ear to the greater cornu of the hyoid bone, *along the anterior border of the sterno-mastoid.* Divide

the superimposed tissues as before down to the digastric muscle; pull it, along with the stylo-hyoid, downward, and the jugular vein outward, if it be in the way, and pass the ligature from without inward.

Results.—The external carotid has been ligatured seventy-one times, with three deaths.

Ligature of the Superior Thyroid Artery.—This vessel comes from the external, or from the common carotid near the point of its bifurcation. It passes upward and forward at first quite superficially, then runs downward and less superficially to enter the thyroid gland.

Operation.—Make an incision about three inches in length along the anterior border of the sterno-mastoid, its centre corresponding to a point opposite the thyro-hyoid space. The carotid sheath should be exposed as in the ligaturing of that vessel, and the artery sought for along its inner border.

Ligature of the Lingual Artery.—This vessel arises from the external carotid opposite the hyoid bone, and runs upward and inward to about one quarter of an inch above the upper border of its greater cornu, and passes horizontally parallel with it, resting upon the middle constrictor of the pharynx, and being directly covered first by the digastric and stylo-hyoid muscles, and more internally by the hyo-glossus. It then ascends between the hyo-glossus and genio-hyo-glossus muscles and terminates in the ranine artery.

It has no superficial muscular guide; a *linear* guide may be drawn parallel with, and a fourth of an inch above the greater cornu of the hyoid bone; practically, however, the upper border of the greater cornu of the hyoid bone marks its situation. It may be ligated in three situations: (1) At apex of greater cornu; (2) between that cornu and the posterior belly of the digastric; (3) in the triangle made by the digastric, mylo-hyoid, and hypo-glossal nerve.

Operation between the digastric and the greater cornu. Place the patient on the back, and turn the head to the opposite side; carefully define the greater cornu of the hyoid bone. If the neck be fleshy, this will be somewhat difficult. It can be made more prominent on the side of the operation by pushing against its body on the opposite side, being careful to press it directly towards that point, otherwise it may mislead the operator. After the patient is thoroughly anæsthetized to prevent spasmodic movements

of the hyoid bone, make an incision about two or three inches in length parallel with the upper border of the cornu, which should pass downward and outward to nearly the anterior border of the sterno-mastoid (see Fig. 125*a*). Divide the superficial fascia, platysma, and deep fascia on a director; draw upward the sub-maxillary gland and divide the deep aponeurosis, and the digastric and stylo-hyoid muscles, and the hypoglossal nerve will be exposed. Accurately locate the greater cornu with the finger, draw up the digastric and the stylo-hyoid muscles, and hypoglossal nerve with a blunt hook, push aside the lingual vein if seen, and pick up the fibres of the hyo-glossus with a pair of forceps, and incise them in the direction of the external

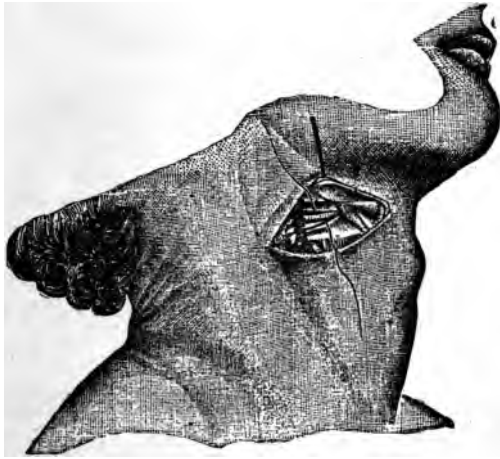


FIG. 145.

incision about one quarter of an inch above the greater cornu; beneath them will be found the vessel, sometimes accompanied by the lingual vein (Fig. 145). Pass the needle from the vein. Before tying the ligature, ascertain if pressure will stop its pulsation.

Ligature in the Third Situation.—This is often called the place of election. Make an incision transversely two inches long, concavity upward, and its centre just within the middle of the cornu of the hyoid bone. Divide the integument,

superficial fascia and platysma, carefully avoiding the superficial veins; divide the deep fascia and pull upward the sub-maxillary gland, when the posterior belly of the digastric will come into view; also the posterior border of the mylo-hyoid and the hypoglossal nerve, accompanied usually by the lingual vein. Carefully outline the triangle before mentioned, pinch up the fibres of the hyo-glossus, and divide them midway between the hyoid bone and the nerve, when the artery will be seen beneath. Separate it from the vein, if it has not been seen before, and deposit the ligature (Fig. 147).

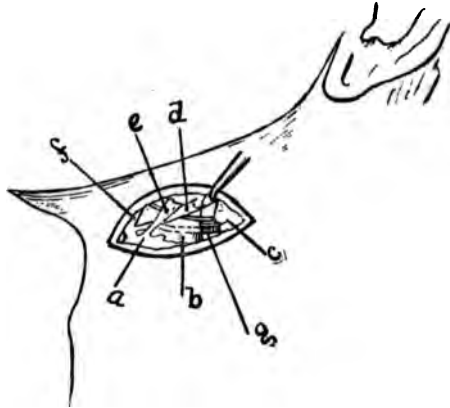


FIG. 146.

a. Hyoid Bone. b. Hyo-glossus Muscle. c. Sub-maxillary Gland. d. Digastric Muscle. e. Stylo-hyoid. f. Mylo-hyoid. g. Lingual Artery passing Beneath the Hyo-glossus Muscle. Its course beneath it is indicated by dotted lines. The hypoglossal nerve and lingual vein are seen above the artery, the nerve passing upon and the vein beneath the muscle (the latter is unusual). h. Hypoglossal Nerve.

Ligature of the First Portion.—In this situation the vessel is tied between the point of its giving off and the tip of the greater cornu of the hyoid bone.

Operation.—Make an incision three inches in length running obliquely downward and backward, its centre corresponding to the greater cornu. The various tissues are carefully divided as before, the ninth pair of nerves exposed. The numerous veins located in the course are now pushed aside and the artery carefully sought for at the point of the *cornu*, and ligatured. This operation, on account of the *absence of a definite deep guide to the location of the vessel*

and the uncertainty of its point of origin, together with the great number of large veins in the course of the search, is much less feasible than either of the other two.

Fallacies.—The hypo-glossal nerve may be mistaken for the artery. The nerve rests on the hyo-glossus; the artery runs beneath it. This, together with the pulsation of the artery and other distinctive anatomical features, should render the discrimination easy. It is well to know, however, that the movements of the tissues dependent on the acts of respiration make it somewhat difficult and often impossible to detect the arterial impulse. If, however, the supposed artery be carefully isolated, ligature passed around it, and a good light thrown into the wound, its tortuous outline will be noticed with each pulsation. The pulsation can be seen the best in the interval of the respiratory acts, when the tissues are quiet.

The lingual vein may be mistaken for the artery. This vessel sometimes runs with the artery behind the hyo-glossus; more frequently, however, it rests on this muscle. It has the characteristic color of a vein, and is larger than the artery. After the division of the fibres of the hyo-glossus, the search for the vessel must be conducted cautiously to avoid opening into the pharynx.

Results.—It has been tied repeatedly for the purpose of controlling hæmorrhage from the tongue, and delaying a morbid growth of the same, and with great advantage.

Ligature of the Facial Artery.—The facial is one of the large branches of the external carotid. It arises from it just above the tip of the greater cornu, or about one inch from the bifurcation of the common carotid, passes forward and upward beneath the ramus of the lower jaw, going through the substance of the sub-maxillary gland, and gains the external surface of the ramus at the anterior inferior angle of the masseter muscle, lying in a groove in the outer border of the bone. The masseter muscle, therefore, becomes its muscular guide in a portion of its course. It may be ligatured in two situations: in the neck, and as it crosses the ramus of the jaw; this being the better. In the former, the head is turned to the opposite side and an incision of about three inches in length is made obliquely downward and forward a little in front of the anterior border of the sterno-mastoid, its centre being at a point about one fourth of an inch above the tip of the *greater cornu*. The dissection is carefully made as in the

preceding instance, pushing aside the facial and other contiguous veins, drawing up the digastric and passing the ligature.

Operation on the Ramus of the Jaw.—Place the patient as before, draw the skin upward over the ramus, so when retraction occurs the scar will be beneath the jaw; make an incision about two inches in length along the border of the jaw, divide the tissues on a director (Fig. 125), down to the vessel; isolate it and pass the ligature. If a resulting scar be of no moment, the primary incision can be made in the long axis of the vessel along the anterior border of the masseter muscle. (Fig. 147.)

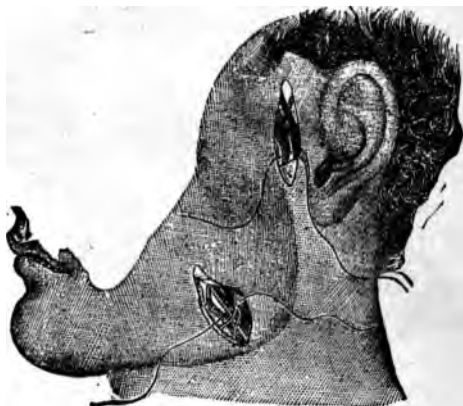

FIG. 147.

Fallacies.—At its origin this vessel may be mistaken for the lingual. Interruption of the circulation will easily determine the difference.

Ligature of the Temporal Artery.—The temporal is one of the terminal branches of the external carotid. It begins in the substance of the parotid gland between the neck of the lower jaw and the external meatus and passes upward across the root of the zygoma, subcutaneously where its pulsation can be distinctly felt; about two inches above the zygoma it divides into its terminal branches.

The Zygoma is the guide to it.

Operation (see Figs. 125 and 147).—Make an incision in the line of the vessel, as indicated by its pulsation, about one fourth of an inch in front of the tragus, and

one inch in length; divide the skin and fascia; expose the vessel and pass the needle so as to avoid the vein and nerve.

The Ligation of the Occipital Artery.—This artery arises from the external carotid a trifle above the facial, passes upward and outward between the transverse process of the atlas and the mastoid process of the occipital bone. It then passes over the posterior portion of the skull midway between the external occipital protuberance and the mastoid process. (Fig. 126.) It has no muscular guide. It may be tied at its origin or behind the mastoid process.

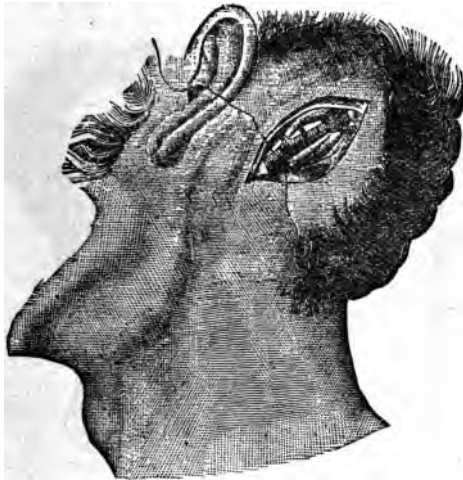

FIG. 148.

Operation at its origin.—Make an incision along the inner border of the sterno-mastoid, about three inches in length, its centre corresponding to a point a little above the apex of the greater cornu of the hyoid bone. Divide the superficial tissues carefully on a director; separate the areolar tissue with the blunt end of a director; push aside the veins and find the posterior belly of the digastric. A little below this will be seen the ninth pair of nerves, winding around the object of search. Pass the needle from the nerve.

Operation Behind the Mastoid Process (Fig. 148).—Make an incision about two inches in length one half inch behind

and a little below the mastoid process. Divide the integument, and attachments of the sterno-mastoid and the splenius muscles, feel the pulsation at the bottom of the wound. Isolate the artery and pass the ligature.

LIGATURING OF VEINS.

Veins, like arteries, may be ligatured in their continuity or at their divided extremities. Large venous trunks, when divided in the course of an operation, should always be tied, otherwise they may give rise to an objectionable amount of oozing, which will interfere with the rapidity of the union of the divided surfaces, and possibly require the re-opening of the wound to secure the bleeding points. If a large vein be nicked during an operation—as the internal jugular—during the removal of growths from the neck, ligatures may be thrown around it, above and below the nick, rather than to tie the nicked portion. The latter procedure is liable to be followed by secondary hemorrhage. The practice of ligating the nick, or of sewing its divided borders by fine catgut, is strongly extolled by many writers. If it be determined to tie the vessel, it should be done above and below the cut, else the return circulation will cause secondary hemorrhage. If it be possible to surround the patient with the degree of surveillance necessary to detect and treat secondary hemorrhage at the onset, I am of the opinion that the practice of sewing the cut with the continuous or other suitable form of suture offers the better opportunity for rapid recovery. Aside from the ligaturing of veins on account of traumatism, they are ligated in their continuity for the purpose of causing their occlusion in those cases where they are in a dilated or varicose condition.

OPERATIONS FOR VARICOSE VEINS.

When the veins of the lower extremities become too much distended to be amenable to palliative measures, it is often necessary to resort to operative interference, which has for its object the occlusion of the distended canals. Injection, acupressure, and ligation are the common means employed.

Injection.—The vein is compressed above and below the proposed point of injection by the fingers, leaving an intervening space of an inch or less, or by small pads con-

fixed in position with adhesive plaster; the latter being the better. The isolated portion is then slowly injected with twenty or thirty drops of a twenty per cent solution of liq*u*o-ferri subsulphatis and water. Almost immediately the contents of the vessel will become coagulated, when the pressure can be removed. The limb should be kept quiet for a few days; and any tendency to undue inflammation combated. The results of this operation, while not so favorable as other expedients, are, nevertheless, very satisfactory. Of the 103 cases, some time since reported, 79 were cured, one perished, and, of the remainder, 16 were failures.

Acupressure.—There is substantially no difference between this method and the application of the same means for arresting the circulation of arterial trunks. (See Fig. 43.) It consists simply of carrying a thoroughly purified needle or pin, which may or may not have been constructed for the purpose, beneath the vein at various situations, and compressing the intervening tissues by means of a carbolized thread of silk or cotton yarn. The pins are removed on the sixth or seventh day, depending on the degree of ulceration produced. Caution should be observed that the pins be not passed through instead of beneath the vein, otherwise a serious phlebitis may follow.

Subcutaneous Ligation.—This is accomplished by passing a carbolized needle, armed with a fine wire or catgut ligature, in front of and across the vein; after which the direction is changed so as to carry it beneath the vessel and out at the point of entrance. The wire is then twisted and cut short, and the opening closed antiseptically. If catgut be employed, it is to be tied and cut in the same manner. Three or four of these constrictions may be applied at intervals of an inch. If the blood in the intervening spaces becomes necrosed, giving rise to fluctuation, it should be evacuated; since absorption is then impossible.

A varicose condition of the hemorrhoidal veins causes a disease denominated hemorrhoids, or piles; for the cure of which various radical measures are recommended. The patient is prepared by a saline cathartic, followed by an injection, a few hours prior to the operation. He should then be etherized, placed upon a table of suitable height, with the buttocks drawn down to the edge; the thighs are then elevated, drawn apart, and the nates separated. If the *growths be of the external variety, and not inflamed, they*

can be nipped off with a pair of scissors; being careful not to cut them too closely, else the resulting cicatrization may cause a narrowing of the anal orifice. Local anæsthesia is sufficiently potent to meet the indications of the operation. If the hemorrhoid be distended, tender, and painful, it may be necessary to employ general anæsthesia. The tumor should then be taken between the thumb and finger, raised up, drawn out, transfixed near the base, and cut outward; the pressure will then evacuate its contents, after which a pellet of fine oakum saturated with balsam of Peru should be placed in the bottom of the sack, and the operation is completed. When the transfixing incision is made, it should be done in the direction of the radiating folds of the anus, to facilitate union.

Operations for internal hemorrhoids are quite numerous, but the following are believed to secure the best results:

Excision.—This method is reckoned among those which

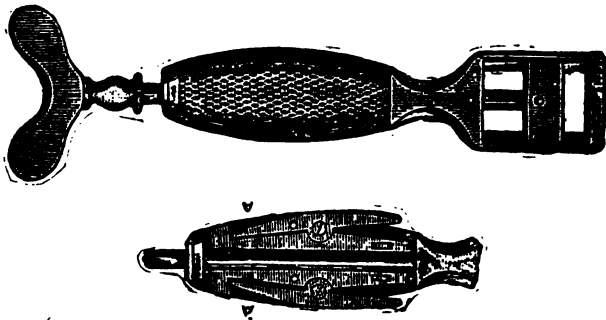


FIG. 149.

secure the best results in selected cases. It causes little after pain, and recovery takes place within a week or ten days. It is applicable to those cases where but three or four tumors exist, which are not very large, and have well defined bases. The sphincter should be well dilated and the anus opened with a speculum or retractor. The pile is then seized at the base with a vulsellum, and cut off with a pair of scissors above the point grasped, which should be held till all arterial hemorrhage is stopped by twisting the *bleeding points*. After it has ceased a pledget of lint saturated with tannin and water, or with liquor ferri subsulpha-

tis, is applied to the cut surfaces, and the patient kept quiet for twenty-four to forty-eight hours.

This operation has been frequently performed, and with eminent success.

Crushing.—This method consists in crushing the pedicle of the growth in the instrument especially constructed for that purpose (Fig. 149). It is not suitable for universal application, but rather to those tumors which possess well-defined bases. If the integument be connected with the tumor it should be incised, otherwise too great pain is caused. The patient being prepared as in the preceding instance, the pile is pulled between the bars of the instrument by the aid of a hook or a volsellum, after which the screw is turned tightly against it. The projecting portion is then cut off. The instrument is retained in position for half a minute or so, to insure against the danger of hemorrhage. While this method may be classed among the satisfactory ones, it possesses no superiority over the treatment by ligature; and as a rule causes more pain, less speedy recovery, and exposes the patient to the probable danger of subsequent hemorrhage.

Ligation.—This method may be employed with or without incision. The latter being far preferable. The treatment without incision is to pass a needle, armed with a double ligature of stout carbolized silk, through the base of the growth, tying each half separately; after which the pile is cut off below the ligature. If strong catgut be used, the ends should be divided close to the pedicle; while with silk one end may be allowed to hang from the anus.

Ligature with incision consists in drawing down the tumors by aid of forceps or volsellum to the anus, or beyond it, and with a pair of curved scissors dividing them from their connection with the sub-mucous membrane from below upward, parallel with the bowel, far enough to leave the pile connected only by a slim pedicle, around which a strong ligature should be cast and securely tied. The ligature portion is thus cut off and the parts returned. The vessels connected with the growth enter it from above downward, parallel with the gut, and are therefore secure from injury, if ordinary caution be taken. The injection of carbolic acid and astringent agents, together with the application of caustics, is hardly entitled to the dignity of being considered an operation. Nor are the results, notwithstanding *the claims of some to the contrary, on the whole better than*

by ligature, either with or without incision. The occasional severe inflammatory reaction, often followed by abscesses and gangrene, detract from that which might otherwise become an extremely satisfactory remedy. The full explanation of these methods can be found in systematic treatises upon the subject.

Varicocele.—This is caused by a varicose condition of the spermatic veins (Fig. 150). The treatment of the varicose

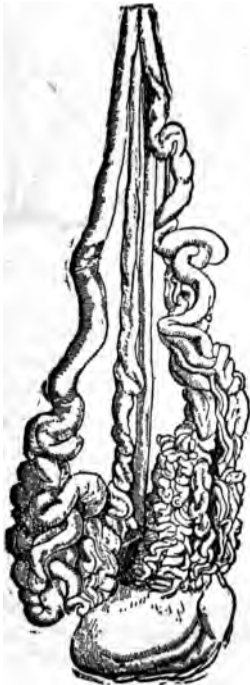

FIG. 150.

veins of the cord, like that in other situations, is divided into the palliative and radical methods; the object of the latter being to obliterate the lumen of the vessels. The same dangers appertain to operations upon these veins, as upon those of other portions of the venous system. Erysipelas, phlebitis, pyæmia, to which may be added a consequent atrophy of the testicle depending upon the occlusion of the vein and artery, may follow; therefore radical measures directed to the vessels should not be entertained until the disease becomes a source of great discomfort and even distress. The palliative treatment consists in shortening the cord by raising the scrotum and its contents, which lessens the weight of the column of blood contained in the vessels. This is achieved by the various forms of suspensories, as Morgan's (Fig. 151), and the one in ordinary use. Should these serve to relieve the urgent symptoms, the patient may not deem it desirable to submit to an operation of any kind. If, however, the characteristic symptoms

recur or continue, then the palliative operation for shortening the scrotum should be done.

Excision of the Scrotum.—The instruments required for this simple operation are the scrotal clamp—the one devised by Dr. Henry being in every way suitable (Fig. 152)—a sharp bistoury, needles armed with silver wire, or carbolized silk, artery forceps, and catgut ligatures. The scrotum

should be thoroughly cleansed and the patient anæsthetized; the clamp is then applied to the side afflicted by drawing the bottom of the scrotum between the blades, which should be applied as nearly as possible parallel with the raphé; all danger of including the testicle is obviated by pressing it upward to the external abdominal ring. When a sufficient amount of tissue is grasped to meet the indication, the blades are tightened to cut off all circulation, at the same time securely holding the scrotal tissues; the protruding portion is then transfixed, on a level with the adjustable bar (Fig. 152-2), by a sharp and narrow-bladed scalpel, and cut off. Before the blades are loosened it is better to pass the sutures, which should be at least ten inches in length, through the divided borders. Having adjusted them, remove the clamp, tie the bleeding points, and close the wound. Caution must be taken always to stop all bleeding points before the edges of the wound are united; else, owing to the looseness of

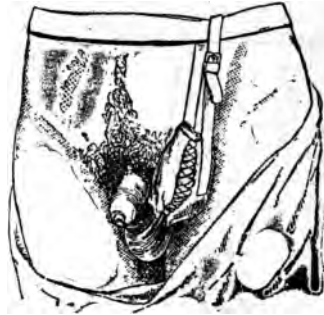

FIG. 151.

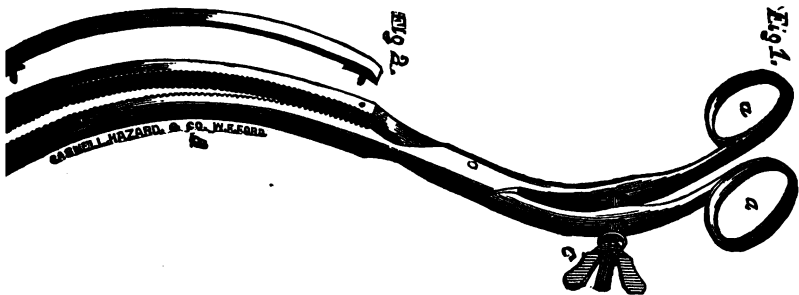


FIG. 152.

the scrotal tissues, an ordinary oozing may cause the formation of large bloody clots, which must be removed. If a drainage tube be introduced throughout its course and allowed to protrude at its most dependent extremity, this danger will be avoided. Place the patient in bed, elevate

the scrotum, and dress the wound antiseptically. It usually heals quickly, and affords sufficient relief to amply recompense the patient for the annoyance incurred. If the instrument just described be not at hand, the operation should not be delayed for this reason. A clamp of great practical utility may be extemporized from long-bladed forceps, or by adjusting to the scrotum two narrow bars of metal or stiff wood, the extremities of which can be firmly held by the hands of an assistant.

Radical Treatment for Varicocele.—The means employed to obliterate the dilated vessels are quite numerous. They all, however, accomplish the result by compression. Only such as are considered practically consistent with the safety of the patient are here described. In all the operations



FIG. 153.

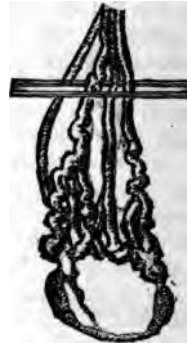

FIG. 154.

great care must be exercised to avoid the vas deferens and artery. They lie posteriorly to the enlarged and worm-like congeries of vessels, around which the compression is to be applied. If the patient be caused to lie down with the hips elevated, the blood will return from the varicose veins into the general circulation, after which the vas deferens and artery can be easily isolated and pulled aside. If the patient then assume an erect position the veins will again become distended, when, if pressure be maintained upon the cord at the external ring, the vessels can be distinctly outlined if the patient be placed in the recumbent position. *The operator having thus carefully located the vas deferens, the patient can be etherized and the operation be proceeded with.*

Compression by Pins (Fig. 153).—This consists simply of passing a strong pin in front of the vas deferens and artery, and throwing around its protruding extremities an elastic ligature, or cotton yarn, drawn sufficiently tight to cut off the circulation. This should be duplicated at about one inch from the first application. The pins can be withdrawn at the end of three or four days.

Compression by Wires (Videl's).—This is done by passing a stout wire either in front of or behind the veins, prefer-



FIG. 153.

ably the latter, then passing a second but thinner one at the opposite side, but through the same opening in the integument (Fig. 154). They are then twisted together till the veins are thoroughly compressed and rolled around them (Figs. 155 and 156).

Subcutaneous Ligation.—This is accomplished by carrying a needle armed with silver wire between the veins and cord, returning it at the point of entrance, going in front of the veins. The wire is then twisted firmly. A strong silk ligature can be applied in similar manner. However, the amount of tissue in their grasp renders the separation somewhat tedious. The process of separation can be hastened by tying the ligature over a small cylinder of elastic tubing, the resistancy of which will exercise a constant traction (Fig. 157). If this be done, a button should be introduced between the tissues and tubing to protect the skin.



FIG. 156.

A strong catgut ligature can be carried around the dilated veins and caused to emerge at the point of entrance by means of a curved needle, tied, ends cut short, and permitted to remain until it is absorbed, which will take place in five or six days. This is, in my opinion, the safest and simplest method and equally efficacious.

The Double-Loop Compression of Ricord (Fig. 158).—This is an excellent plan, and can be readily done by passing

a needle armed with a silk ligature between the veins and the vas deferens; to this is fastened a double ligature,

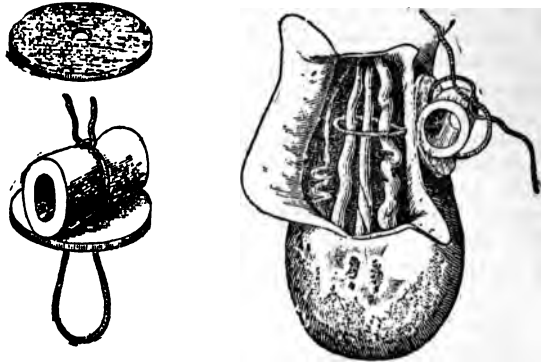


FIG. 157.

which is drawn through and left in position. The needle with its silk ligature is then passed in front of the veins in the opposite direction, entering and emerging at the points previously made. A second double ligature is then drawn through and left in position. The extremities on the respective sides are now tucked through the loops on the



FIG. 158.

same side and drawn tight, and tied over a narrow roller or piece of elastic tubing. The ligatures will cut a way through in five or six days. The methods of exposure, division, and exsection of the vessels are more dangerous, and not infrequently result in death from pyæmia.

Venesection.—While the withdrawing of blood from a vein can hardly be classed as an operation of much moment in a surgical sense, yet the infrequency of its employment at the present time is quite apt to render the details connected therewith somewhat uncertain in the minds of a majority of the practitioners of the present generation. The veins selected for the procedure are the internal saphenous at the ankle, median basilic, median cephalic, and external jugular. The instruments required are the ordinary thumb lancet, or a curved or sharp-pointed bistoury, the first, however,

possessing the greater number of traditional virtues. If these be not at hand, either of the others can be used as satisfactory substitutes. If the region of the elbow be selected, the median cephalic is preferred on account of its greater distance from the brachial artery. The arm should be constricted by a bandage drawn sufficiently tight to obstruct venous return, without interfering with arterial circulation: this will cause the veins to become prominently distended, unless the patient be very fleshy. The veins should be well defined by the finger, and held in position by the thumb or finger placed just below the point for incision, which is made obliquely to the transverse diameter, and of sufficient depth to freely open the vessel, without severing it (Fig. 159). The flow may be increased by causing the

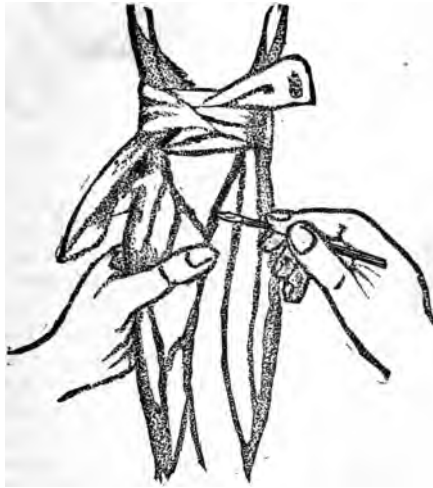

FIG. 159.

patient to firmly grasp a stick or broom-handle; it may be impeded by the interposition of the subcutaneous fat, which should be pushed aside. The amount drawn will be governed by the strength of the patient, as well as his position. If standing or sitting its effects will be sooner felt than if in a recumbent posture. Usually, however, from half a pint to a pint will suffice. The flow is stopped by removing the bandage above and applying the finger to *the bleeding point*; after which a small compress is placed

over the incision, and confined in position by adhesive plaster, so arranged as not to impede the venous return.

These directions will apply with equal force to venesection in all situations other than of the external jugular. If this vein be selected, the compress is placed just above the clavicle, and confined in position by a bandage carried under the opposite axilla. The finger is then placed above

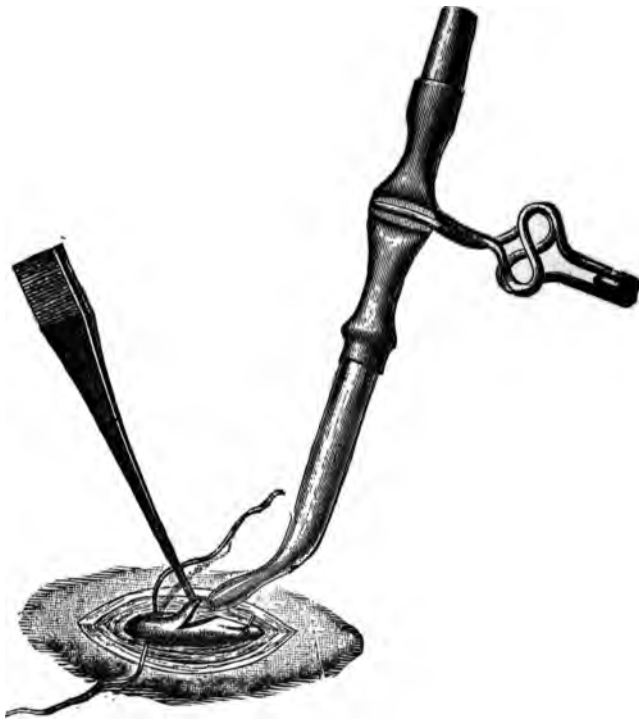

FIG. 260.

the point of proposed incision, and the vessel opened at right angle with the fibres of platysma myoides muscle. The finger must always be placed on the opening before the compress is removed, in order to prevent the entrance of air into the circulation.

Transfusion.—This is a means sometimes employed to

overcome the exhaustion produced by disease, or loss of blood; the latter being the only condition to which it can, thus far, be said to be practically adapted. It consists in conveying the blood from one person to another, either directly, or by collecting it in a suitable receptacle, removing the fibrin, and introducing the resulting blood plasma and corpuscles. The dangers to be avoided, are, the introduction of air, blood clots, and too great a quantity of blood, which might overpower an already weakened heart. From six to eight ounces are usually sufficient, and it should be thrown slowly and carefully, watching its effects upon the circulation, respiration, and sensorium of the patient. If its introduction causes a depression of the pulse, or gives rise to nervous tremors, or difficulty in breathing, it should cease at once. The blood, to be transfused, should be

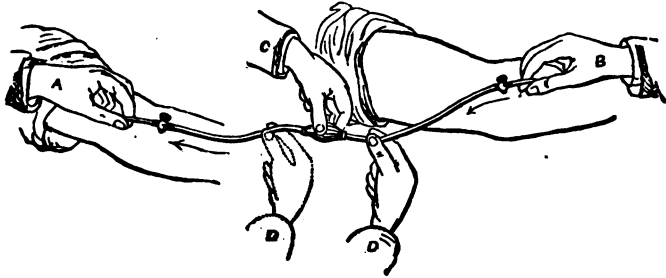


FIG. 161.

taken from a person of strong physique, and free from any constitutional taint.

Direct Transfusion from arm to arm. The requirements for this are, an apparatus for the transmission of the blood, together with a pair of forceps and a scalpel to open the vessels. A basin of water or saline solution at a temperature of about 100° F., into which the instrument should be laid to impart to it the requisite degree of warmth, and to exclude the air. The arm of the donor and receiver are constricted above the point for incision, as in phlebotomy; the skin covering the distended vessels is pinched up, transfixed, and cut out, leaving the veins exposed at bottom of the wounds; they are then seized with a pair of forceps, and a V-shaped opening made with the scissors (Fig. 160). The tube A (Fig. 161) is then taken from the bottom of the basin, and with the thumb applied

to its larger extremity to keep it filled, is inserted into the opening in the vein of the receiver; the tube B is inserted in like manner into the vein of the donor (Fig. 161), after which the propelling power of the apparatus, likewise filled with fluid and kept so by turning the stop-cocks, is attached to the two tubes; the cocks are now opened, and the fluid contained in the instrument is thrown into the circulation by squeezing the bulb C, while the tube D is compressed (Fig. 161). After the bulb C is emptied, and before it is permitted to expand, the compression should be changed from *d* to *d'*. If the bulb be now allowed to expand it will become filled with the blood of the donor, which can be pushed into the circulation as in the preceding instance. The bulb should be allowed to fill slowly, and the amount

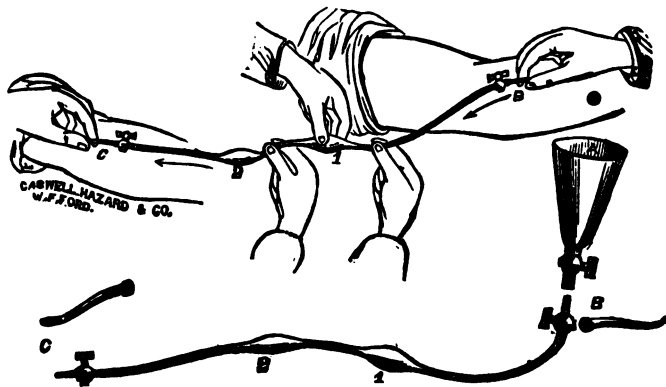


FIG. 162.

introduced is estimated by counting the number of times it is emptied. After the operation is completed, the incisions are treated the same as in phlebotomy. The instrument devised by Fryer (Fig. 162) differs from the former in being cast whole, with an additional bulb, which does away with the metallic couplings, and presents a continuously smooth surface to the blood current; and, moreover, the additional bulb saves time by producing an almost continuous current. It will be seen that a funnel is added to this instrument which allows it to be employed in mediate transfusion.

Mediate transfusion is collecting the blood from the arm



FIG. 163.



FIG. 164.

of the donor and injecting it into the circulation, either with or without the removal of the fibrin. For this purpose the instrument devised by Collins (Fig. 163) can be especially recommended. It consists of a pump attached to a funnel, in such a manner as to carry the blood easily, and without danger of coagulation, or the introduction of air. It can be used equally well with the defibrinated and with the unwhipped blood: in the latter it is particularly convenient, since the blood can be caught in the funnel and injected while flowing from the donor; this saves time, and avoids the blood changes induced by its exposure. In the use of this, and all other implements brought in contact with the blood, the temperature of the instrument, and of the blood injected, should be kept at about 100° F. by means of water, or a saline solution.*

If defibrinated blood be employed, it should be prepared by agitation, after being collected in a vessel of the temperature stated (Fig. 164), then strained (Fig. 165) into the funnel of the instrument and pumped into the system.

The introduction into the funnel, or into the bulbs, of two or three ounces of the saline solution; or of a carbonate of ammonia solution, four to six grains to the ounce, prevents the entrance of air to the instrument, and also has a stimulating effect upon the patient.

Intra-venous injection of milk has been done to counteract the conditions similar to those calling for the use of blood. The milk should be freshly drawn from the cow and covered with fine gauze; the carbolized being the better, through which it is strained into a transfusion instrument, which can be extemporized by joining to one end of a rubber tube a glass funnel, and to the other a small conducting canula.

If the canula be introduced into the vein, and the funnel be raised after having been filled with six or eight ounces of milk, the force of gravity will become the propelling agent.

Arterial transfusion has been advocated on the basis that

* R Chloride of Sodium.....	3 i.
Chloride of Potassium.....	gr. vi.
Phosphate of Soda.....	gr. iii.
Carbonate of Soda.....	3 i.
Aqua.....	℥ xx.
℞—Heat to 100 F.	

it conveys the blood more equably to the heart, with less danger of exciting undue disturbance of the circulation. The admission of a small amount of air does no harm, and the danger of phlebitis is avoided. The vessels selected are the radial, or the posterior tibial at the ankle, which is exposed, and three ligatures are placed around it; the proximal one is tied, and the distal tightened sufficiently to cut off collateral circulation. The vessel is then opened,



FIG. 165.

the tube inserted, and tied in position by the middle or third ligature; the distal one is then relaxed and the blood forced into the circulation. As soon as this is completed the distal ligature is tied, and the intervening portion of the vessel removed with the tube. The vein may be tied in venous transfusion by placing two ligatures. Tie the distal one, open the vein, introduce the tube, then tie the proximal one; this will prevent all loss of blood.

Capillaries.—This system of vessels, like the venous, may

undergo dilatation of sufficient size to create distinct but slowly developing and painless deformities, or tumors. The morbid process may be, and usually is, limited entirely to the capillaries of the integument; however, the larger vessels are not infrequently involved, in the beginning, or during their development; they likewise vary in size, shape, and color. The simplest form is known as the "mother's mark," "birth-mark," etc.

A birth-mark can be treated by pressure, caustic, hot needles, vaccination, etc., depending upon its size and situation. It is not well to interfere with them at all except by simple means, unless they increase rapidly in size. The majority of these growths will disappear of themselves before their presence will become a source of annoyance or regret to the possessor. There are, however, several simple means which will often hasten their departure. The use of simple compresses, repeated application of collodion, vaccination, if it be located suitably therefor. The method introduced by Squire some time since, which bade fair at one time to meet the desired end, can be employed.

The "mark" is frozen with an ether spray, and numerous parallel incisions are made about one sixteenth of an inch apart, and extending the same depth, and the whole covered with blotting-paper, held upon it with sufficient force to prevent any gaping of the cuts and escape of blood; after fifteen or twenty minutes the paper is thoroughly wet with water and removed. Sometimes a thin underlying clot of blood will be found; this must be carefully washed away with water and a soft brush. It is sometimes necessary to repeat the operation, when the incisions should be made in the opposite direction. If proper care be taken, in suitable cases a perfect cure is secured without any scarring. The injection of ergot, liquor ferri subsulphatis, and various other astringents, have been recommended. They are, however, uncertain in their action, and are liable to be followed by inflammation, ulceration, and sometimes by embolism. The solutions can be injected by aid of the ordinary hypodermic syringe, three or four drops at a time, in various portions of the growth, or hot needles can be introduced at various points. The application of red heat around the base and over the surface of the growth by *means of the Paquelin cautery* is an admirable method, *provided it involves the skin alone, or only the capillaries in the tissue immediately beneath it.* It is usually followed

by more or less disfigurement, depending upon the extent of the cautery.

If it be of large size, persistent, of a dark color and markedly elevated, it is suitable for subcutaneous ligation. This is done in several ways, depending upon the size and shape of the tumor, and fancy of the operator.

(Fig. 166.) This represents a simple method. In it the needle, armed with a strong, well-carbolized hemp or silk ligature, is thrust through the integument at its base, and carried as far as possible around the base, and passed out, to be again introduced at the point of exit, and carried still further around, and pushed through as before, and so on until it is caused to emerge at the first point of insertion; the ends are then tied in a firm, hard knot.



FIG. 166.

(Fig. 167.) In this a double ligature is carried through the base and divided; each portion is then carried around its half of the base as before, and tied. This is applicable to those having a larger base. Fig. 168 represents the ap-



FIG. 167.



FIG. 168.

plication of the ligature to quarter-sections of the base. It is employed when the growth is large. Pass a double ligature through the centre of the base, cut the loop near to its centre, leaving one end of the divided thread in the eye of the needle; then, after threading the needle with the other end of the portion of the ligature which was liberated by the division of the loop (Fig. 169), pass the needle through the base at right angles to its primary course. The ends are then to be firmly tied after the integument has been incised, to allow the ligature to sink deeply into the base, as well as to avoid the pain and ulceration incident to the constriction of the integument (Fig. 170). It will simplify the selection and uniting of the proper extremities if one half the ligature be colored before its primary introduction.

Fig. 171 represents the ligation of a growth with an elongated base. In this the double ligature is required, and should be colored as before; pass it through the base from side to side, commencing and terminating just outside of the extreme limits of the growth; if the white loops be now divided on one side and the black on the other, independ-



FIG. 169.



FIG. 170.

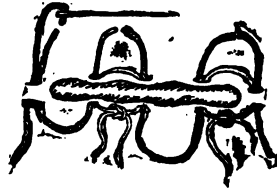


FIG. 171.

ent sets of ligatures will be had, which should be tied; the skin coming within the grasp of each ligature is incised as in the preceding instance. The separation of the growth is hastened by the use of an elastic or rubber ligature, applied in a similar manner.

NERVOUS SYSTEM.

The brain, spinal cord, and the nerves arising from the cerebro-spinal axis, owing to the various morbid processes and injuries to which they, together with their coverings, are subjected, are often the seat of common and yet important surgical procedures.

Hydrocephalus.—Tapping for the removal of the superfluous fluid is the only practical surgical procedure to which this condition is amenable. This may be done with a small aspirating trocar, or, what is better, with an aspirator. In either instance the puncturing agent is introduced through the anterior fontanelle, close to its outer border, and passed perpendicularly into the fluid accumulation. The fluid must be slowly withdrawn, accompanied by moderate and equable pressure upon the external surface. Whenever any manifestations referable to the circulatory or nervous centres appear, the needle should be withdrawn

and the puncture carefully closed. Often the removal of less than three or four ounces will cause feebleness of the pulse, contraction of the pupil, and evidences of approaching convulsion. After the withdrawal of the fluid, gentle and universal pressure should be maintained by aid of bandages, adhesive plaster, or tightly-fitting perforated rubber cap. Care is necessary, else the combined pressure of re-accumulating fluid and external dressing will cause alarming symptoms.

Meningocele is a protrusion of the meninges of the brain, caused by an accumulation of hydrocephalic fluid within the cranium, and must of necessity occur before the closure of the fontanelles. It may be present at any point of separation between the cranial bones, although more frequently at the posterior fontanelle than elsewhere. As a rule, little can be done, other than to protect the tumor from external irritation. If it have a well-defined pedicle, it can be clamped and the fluid withdrawn, either by incision, or with a small trocar. The clamp must be applied with caution, else the pressure caused by tightening of its blades may produce convulsions or other nervous phenomena. If it be determined to puncture it, a small amount of fluid may be withdrawn, when the clamp can be the more readily adjusted. As long as the pedicle is open, any operative interference is liable to be followed by death from a resulting meningitis. If the pedicle be occluded, incision may be done and the tumor removed. In all instances where it is removed, sufficient integument should be left to insure a complete and proper closure of the divided surfaces.

Hydro-rachis.—This is a congenital defect, comprising a cleft in the laminae of the vertebrae, and a protrusion of the membranes of the spinal cord. It occurs more frequently in the lumbar region, although it is found in the other portions of the spinal column. Various operative expedients have been employed to cure the defect, nearly all of which have, at one time or another, resulted in isolated cures.

The two methods which have secured the best results are: 1. Repeated punctures with a small needle at various intervals through the sides of the sack, followed by gentle and uniform pressure to the surface. 2. Consists of injecting into the sack, which should be partially emptied of its fluid, one or two drachms of the iodo-glycerine solution, which is made by dissolving ten grains of iodine and thirty

grains of iodide of potassium in one ounce of glycerine. Exercise caution that none of the fluid escapes after the operation. This must be repeated from time to time, always allowing the irritation due to the previous operation to subside before it is again repeated. This method has been very successful. Of forty-four cases treated, thirty-five were cured.

Trephining the cranium is an operation which is, without doubt, performed more frequently than the requirements of the majority of cases will warrant. In every instance, before attempting it, the indications should be most carefully studied.

The special instruments required for the operation are the trephine (Figs. 172, 173, 174), the conical being by far the safer; an elevator (Figs. 175, 176, 177) and rongeur (Fig. 178), sequestrum forceps (Figs. 179 and 179a), gouges and mallet (Figs. 180, 181, 182, 183, 184). The traditional tooth-pick, and the brush, to remove the dust from the track of the trephine, while not absolutely necessary, have, nevertheless, especially the former, become so closely associated with the operation as to be entitled to a most respectful consideration. The patient is



FIG. 172.



FIG. 173.



FIG. 174.

prepared by shaving the head for a considerable distance around the seat of the proposed operation. If unconscious, an anæsthetic is unnecessary.

Operation.—Make an incision through the scalp down to the bone of a size and shape as to best expose the portion of bone to be attacked, and at the same time to avoid large vessels and to secure good drainage. Lay back the integumentary flap, along with the periosteum covering the portion of bone to be removed. Lower the centre-pin a little *below teeth* of the trephine, and fasten it firmly in position *by means* of its adjusting screw; place the point of the *centre-pin* as nearly as practicable upon that portion of

TREPHINING.



W.F.FORD,
FIG. 175.



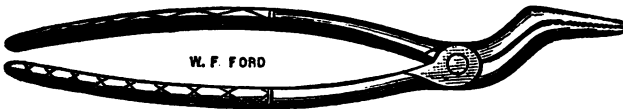W.F.FORD,
FIG. 176.



FIG. 177.




CASWELL, HAZARD & CO. W.F.FORD,
FIG. 178.



W. F. FORD

FIG. 179.



CASWELL, HAZARD & CO. W.F.FORD.

FIG. 179a.



CASWELL, HAZARD & CO. W.F.FORD.

FIG. 180.



FIG. 181.




FIG. 182.




FIG. 183.

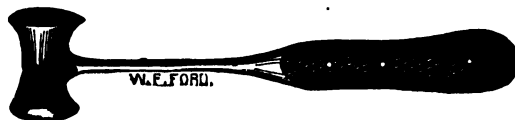

FIG. 184.

the solid and undepressed bone which, when removed, will allow the best opportunity of elevating that which is depressed; provided, however, that it be not placed over the course of the middle meningeal artery, or a large sinus (Fig. 185). The trunk of the middle meningeal artery is located an inch and a half behind the external angular process of the frontal bone, and the same distance above the zygoma. The median line of the skull from the root of the nose to the occipital protuberance corresponds to the superior longitudinal sinus. The course of the lateral sinus is indicated by a line drawn from the occipital protuberance to the anterior border of the mastoid process. Bear firmly upon the instrument, at the same time turn it *quickly from right to left*, till a suitable track is established *to retain it in position* (Fig. 186). The centre-pin is then

withdrawn, and fastened in place, otherwise it may perforate the membranes.

The instrument must be held perpendicularly to the point of section, and the pressure evenly distributed; if not, one side will be penetrated more quickly than the other, thereby endangering the laceration of the membranes. During the process, the trephine must be frequently raised from the track, that it may be cleared of bone-dust, the color of which should be carefully noticed; at first it is of a pale white, but as soon as the *diplœ* are reached it becomes reddened; from this time on the tooth-pick must be frequently used to clear out the track as well as to detect the first point of complete section. But little pressure is now allowable, since to use it might force the crown of the instrument

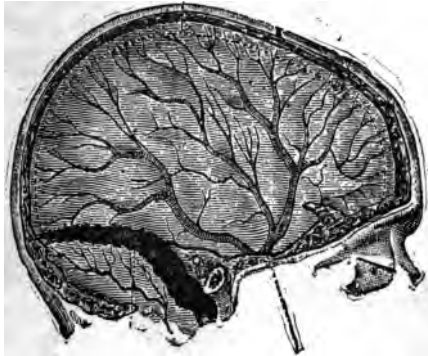


FIG. 185.

through the membranes and the brain structure itself, especially if it be of a horizontal pattern. If the button of bone be percussed with the handle of a scalpel or forceps, it will emit a low pitched sound, and vibrate when a considerable portion of the circle is divided; moreover, it can, probably, be raised from its bed at this time by the aid of the elevator. As soon as the button is removed, the elevator is inserted beneath the depressed portion, and it is raised to its proper level.

This is sometimes difficult to accomplish, owing to the dovetailing of the fragments. The solid bone is used as a fulcrum, when much force is necessary. If great force be used, and a fragment be suddenly loosened, its sharp or

jagged border may cut through the membranes; it is therefore necessary that force be used in a guarded manner.

All loose fragments are to be removed; those that will retain their position when replaced, owing to continuity of structure, may be allowed to remain. All projecting points of bone must be cut away, else the pulsation of the brain

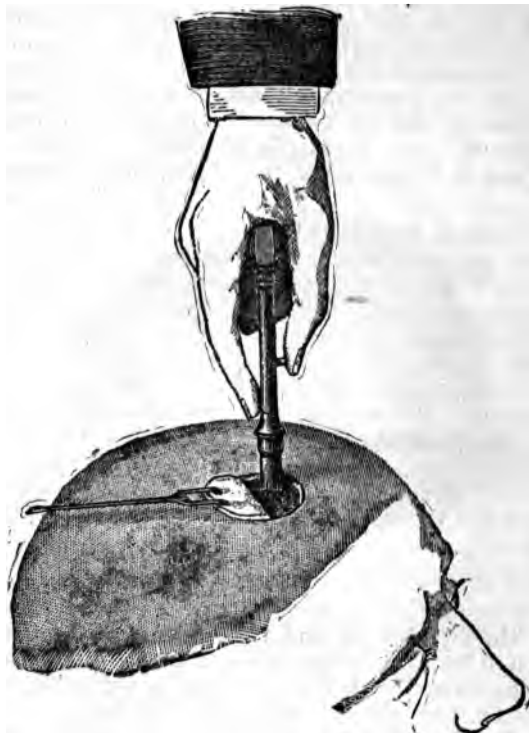


FIG. 186.

may cause them to perforate the dura-mater. Clots of blood and pus are likewise to be cleared out. If the compressing agents be below the dura-mater it may be opened sufficiently to admit of their escape; before it is done, however, their presence should be clearly established. If *the dura-mater* be lacerated, it may be closed by fine *cat-gut sutures*, especially when the opening is large enough

to endanger the formation of hernia cerebri. If the meningeal branches be divided or a sinus opened, the hemorrhage is controlled by antiseptic compresses, so applied as not to exert undue pressure on the brain. If the membranes be lacerated, the fragments of bone removed must be fitted to each other, in order that the absence of any osseous portion may be ascertained and sought after.

The wound should now be thoroughly cleansed with carbolic acid, the flaps adjusted, suitable drainage established, and the antiseptic dressing applied. It is often possible to elevate the fragments without the use of the trephine, an expedient that should always be tried, if any reasonable prospect of success be apparent.

Nerves of the Cerebro-Spinal Axis.—Owing to neuralgia, spasm, tremor, etc., it may become necessary, after all ordinary means have failed, to operate upon the trunk of the nerve involved, either by division, excision, or stretching. The first method can afford but temporary relief, since the divided extremities will speedily unite.

If *excision* be done, not less than two inches, if possible, should be removed from the continuity of the trunk, otherwise at a greater or lesser period the extremities will become united. If the nerve be a small one, the tendency to union is less; but the rule to remove a long piece must not be deviated from. *Stretching* consists in cutting down on the affected nerve, seizing it with the fingers, and making firm and steady traction for a minute or two. This is applied more properly to the large nerves, and those which cannot be divided without the sacrifice of important functions.

Supra-Orbital Nerve.—This may be divided or excised at its exit from the supra-orbital foramen or notch. Locate the notch by the fingers of the left hand, then pass the point of a narrow bistoury beneath the integument, from its inner to its outer side; turn the edge backward, and cut firmly down and across the opening upon its inferior wall.

Resection.—This can be done by elevating the brow, and making an incision between it and the lid, one inch in length, down upon the site of the nerve; its branches are then sought for, and excised or stretched, as seems better. The nerve may be pulled out with a small blunt hook from the roof of the orbit, and excised before it enters the foramen; or, it may be stretched and allowed to remain.

The infra-orbital nerves are the terminal branches of the

supra-maxillary division of the fifth pair: they escape from the infra-orbital foramen.

The infra-orbital foramen is about four lines below the lower edge of the orbit, and nearly on a line extending from the bicuspid teeth to the supra-orbital foramen. The nerve may be divided through the mouth by first recognizing the location of the foramen, and placing the finger upon it; then make a narrow incision, beginning at the fold of the cheek and maxilla, carrying it upward in the line before indicated, till within a short distance of the foramen, when with a sharp-pointed pair of scissors the nerves are divided as they emerge. They may also be divided through an external incision made directly down upon the foramen.

The Superior Maxillary Nerve.—This may be *excised, divided, or stretched* in its course along the floor of the orbit, or at its exit from the foramen rotundum. It may be attacked on the floor by passing a tenatome about two thirds of an inch backward in the line of its course, turning the edge downward, and cutting upon and through the thin floors of the orbit. Its terminations at the infra-orbital foramen, are then exposed, and the several portions pulled out. Through a narrow incision of the soft parts in this situation a blunt hook can be introduced, the nerve caught up and stretched. The whole of the nerve can be removed from the canal, and sometimes further posteriorly if an incision be made about an inch and a half in length along the lower border of the orbit; the tissues raised and the nerve isolated from the artery, raised on a hook and divided; or by pulling out the central portion, either by a ligature previously applied, or with a pair of forceps. If the more formidable operation of its division, as it escapes from the foramen rotundum, be attempted, the initiatory incision through the soft parts should be of a shape and extent to best expose the site of the proposed operation; the V, +, U, - shaped ones are selected, according to the fancy of the operator. In either instance, its central portion should correspond as nearly as possible to the infra-orbital foramen. After the flap is raised the crown of a small trephine or drill is applied to the bone so as to open into the antrum along the course of the nerve, which is carefully followed backward to the sphenomaxillary fossa by cutting away the floor of the canal with a small sharp chisel. It is then carefully isolated from the tissues

in the fossa back to the foramen of exit, and divided with a pair of curved scissors; the internal maxillary artery runs through the fossa, and should be carefully avoided. If it be cut, it should be ligated if possible; not infrequently firm pressure will check the hemorrhage.

The Inferior Dental Nerve.—This nerve may be *divided, excised, or stretched* before it enters the jaw; in its course through it, and at its exit from the mental foramen. In the first situation, an incision is made about an inch and a half in length along the anterior border of the ramus of the jaw, within the mouth, down to the anterior fibres of the internal pterygoid muscle; the connective tissue between this muscle and the inner surface of the ramus is now pushed aside, and the nerve detected as it enters the canal. The small spine surmounting the opening for the entrance of the vessel and nerve can be quite readily detected, and will be a valuable guide to the nerve as it enters the dental canal. It can now be isolated, hooked up, and divided. About an inch and a half can be easily excised in this situation, if after its isolation a strong ligature be thrown around it and tied. It can then be divided by curved scissors as it enters the canal; traction by means of the ligature can then be made which will not only draw the nerve down to admit of the division of one, but also aid the good that may be derived from stretching process.

It may be approached in this situation from without by making an incision from the sigmoid notch to the angle of the jaw, the parotid gland is turned aside, and the masseter muscle detached from the ramus sufficiently to allow the application of a trephine. When the button of bone is removed, about one half an inch of the nerve can be isolated, exposed, and excised. However, this is not a suitable substitute for the internal method.

The nerve may be exposed in its course through the body of the jaw, by raising the soft parts upward, and making an incision through them, about two inches in length, beginning in front of the facial artery. After the bone is thoroughly bared, a trephine is applied in two or more situations, and the bone removed down to the canal, when the intervening portions may be chiselled out, and the whole nerve removed; or it may be resected at each opening.

The former is the surer course. It may also be divided as it emerges from the mental foramen, by turning the

lower lip outward, and making an incision at the junction of the buccal fold, about an inch in length, in the line of the bicuspid teeth downward, three fourths of an inch, when a careful search will disclose the filaments as they escape from the opening. Seize them with the forceps, draw them slowly and carefully out, and cut them off.

The Lingual Nerve.—This may be reached in two situations: 1. As it passes just below the insertion of the pterygo-maxillary ligament. 2. Beside the tongue and sublingual gland. In the former, the mouth is opened widely, and the fold of mucous membrane covering the ligament is readily seen behind the last molar tooth. The nerve can be felt just below the insertion of the ligament, and close to the tooth. Make an incision backward from the tooth over the course of the nerve, about one inch in length, carefully push aside the submucous tissue, and the nerve will appear in the wound, when it can be raised and cut. It has been successfully divided on several occasions near this situation by entering the point of a curved bistoury, three fourths of an inch behind, and below the last molar, cutting downward and outward to the bone in an imaginary line, extending from the angle of the jaw to the last molar tooth. In the second situation, the tongue should be drawn forward, and to the opposite side, and an incision made about one inch in length, parallel with the tongue, and one fourth of an inch from the attachment of the mucous membrane to it; push aside the submucous tissue, and the nerve will be readily seen.

Brachial Plexus.—It may become necessary on account of a severe neuralgia involving the branches of this plexus, or located in a painful stump, to exsect, or stretch the cords near their origin. It is best done prior to its division into its three terminal cords; that is, where only two cords are found. Place the patient upon the back, raise the shoulders, and turn the head backward and to the opposite side. The course of the external jugular is determined by pressure, just above the clavicle. Make an incision along the posterior border of the sterno-mastoid, three inches in length, extending down to the clavicle; a second incision of the same length is now made from this point, along the upper border of the clavicle, carefully avoiding the external jugular; turn the flap upward and seek for the posterior belly of the omo-hyoid; when found, draw it upward with a hook or ligature, push aside the loose con-

nective tissue, and the two cords will appear located above and to the outer side of the third portion of the subclavian artery, which should be carefully avoided. The inner cord is cautiously hooked up, and a ligature applied to it, by which it can be raised from its bed and divided with a pair of scissors near the outer border of the scalenus anticus muscle; being careful to avoid the muscle and the phrenic nerve. If gentle traction be made upon the ligature the distal extremity will be raised, and can be again divided an inch or so from the point of the first section, and removed. The second or outer cord is then divided in the same manner.

Musculo-cutaneous Nerve.—Make an incision two and one half inches in length, between the biceps and the supinator longus, through the integument, fascia, and aponeurosis; separate the muscles and the nerve will be readily seen.

Musculo-spiral Nerve.—This can be exposed in two situations. 1. By making an incision about four inches in length, between the outer border of the triceps and the brachialis anticus muscles, beginning it two and one half inches above the external condyle. Divide the fascia on a director, separate the connective tissue with the handle of a scalpel or by the finger, and the nerve will be easily found. 2. Make an incision, three inches in length, in the space between the supinator longus and the brachialis anticus muscle; divide the fascia, separate the connective tissue beneath it, and the nerve will be quickly found.

Median Nerve.—It can be easily exposed in its course along the arm and lower one half of the forearm by modifying either of the incisions for ligaturing the brachial to correspond to the relations of the nerve to that vessel.

In the forearm, by making an incision about three inches in length, along the inner border of the tendon of the flexor carpi radialis, beginning about two inches above the wrist joint. Divide the tissue in the usual manner. Separate the tendons of the flexor carpi radialis and palmaris longus, when the nerve will be discovered emerging from beneath the fleshy fibres of the flexor sublimis digitorum.

The Radial and Ulnar Nerves—like the median in the arm—can be reached readily through the same incisions employed to ligature the vessels referred to above.

Great Sciatic Nerve.—This is best exposed just after its escape beneath the lower border of the gluteus maximus. Place the patient on the abdomen and make an incision

three or four inches in length, beginning at the gluteal fold, at a point midway between the tuber-ischium and trochanter major; divide the integument and fascia on a director, separate the connective tissue with the fingers and handle of the scalpel down to the nerve. It can then be stretched by passing one or two fingers around it, and making firm and steady traction upon it for a minute or so. Division or exsection can be done easily through the same opening. The wound should be carefully closed and dressed under antiseptic precautions.

Internal Popliteal Nerve.—This can be reached by the same method and with the same caution as the popliteal artery. It is, however, less deeply situated and somewhat nearer the centre of the popliteal space than the vessels. Extreme caution should be exercised in operating upon it, on account of its nearness to the popliteal vein, which lies beneath it and to its inner side.

External Popliteal Nerve.—It can be easily reached by making an incision, two or three inches in length, along the inner side of the tendon of the biceps cruris, when the nerve can be readily found beneath the fascia, surrounded by fat.

The Small Sciatic, Anterior and Posterior Tibial Nerves can be exposed through the incisions adopted in ligaturing the vessels of the same name.

Internal Sphenous Nerve—is given off from the anterior crural and supplies the inner surface of the leg. It is accompanied by a vein of the same name in its course along the leg. It can be reached easily in many situations, but practically, however, it is best exposed at the inner side of the knee, where it escapes beneath the sartorius, and in the middle of the leg. In the former situation recognize the tendon of the sartorius. Press upon the internal saphenous vein above this point to distend it, make an incision two inches in length close to and parallel with the vein, draw it aside, and the nerve will be found emerging from beneath the tendons of the sartorius and gracilis. In the middle of the leg make an incision three inches in length, parallel with the properly distended vein, which should then be pulled aside, and the nerve is found beneath it.

The External Saphenous Nerve arises from the internal popliteal, escapes between the heads of the gastrocnemius, pierces the fascia below the middle of the leg and becomes subcutaneous, passes down on the fibular side of the poste-

rior surface to the malleolus, accompanied by the external saphenous vein. Distend the vein by pressure, make an incision close to and parallel with it, near the border of the tendo-Achillis; pull the vein aside, and the nerve will be seen beneath.

The Plantar Nerves.—These are the terminal branches of the posterior tibial, and are given off just after the nerve winds around the internal malleolus. They can be exposed by making an incision about three inches in length, beginning just in front of the centre of a line extending from the anterior border of the internal malleolus to the inner tuberosity of the os-calcis, and extended forward along the external border of the abductor pollicis. If the space between the short flexor and the abductor be now opened at the posterior portion, the nerves will be found accompanied by the arteries of similar name.

Perineal Nerve.—This may be exposed in the perineum of the male by making an incision along the rami of the pubes and ischium, in the same manner as directed for ligaturing the pudic artery at this situation. In the female perineum the nerve may be exposed either by an incision made without or within the vagina. In the former, make it through the superficial tissues, about three inches in length, in the groove between the labium and the perineum, just inside the rami of the pubes and ischium. The nerve is surrounded by connective tissue, and it is difficult to find it in this situation; however, if the blade of the knife be turned inward and the outer coats of the vagina be divided down to the inner one, the nerve will not escape section.

It is more easily severed from without the vagina. If the finger be introduced an inch or more, and lateral pressure be made, the nerve will be felt, cord-like in character and sensitive to touch. Make a vertical incision through the coats of the vagina, and the nerve will be exposed for division or excision.

TENOTOMY.

Tenotomy consists in making a subcutaneous division of the tendons of muscles to overcome or alleviate a defor-

mity. In order to accomplish this successfully, the exact location of the offending structure must be known, together with its important contiguous vessels, nerves, etc. Many of the large tendons are easily located by their natural prominence.

Others that ordinarily lie concealed become apparent if contraction has occurred, and still more conspicuous if they be placed upon the stretch. The principles governing tenotomy should be well considered ere a tendon be divided, otherwise an expedient of great good becomes mischievous and even destructive in its results. Muscles and fascia, either singly or conjointly, are also the direct causes of, or may be indirectly connected in causing deformities. They, too, are amenable to similar treatment.



FIG. 186a.

The instruments employed are few in number and simple in character. Figure 186a represents the tenotomes devised by Dr. L. A. Sayre. They are excellent instruments for the purpose.

(Fig. 187.) This represents the ordinary tenotome found in the pocket-cases of the day. It is too fragile to be safely



FIG. 187.

employed in the division of tissues requiring any outlay of force. A detailed description of either is unnecessary, since they can be ordered from the instrument-maker by simply naming the designer.

The blade of the tenotome used for dividing fascia and muscles (Fig. 188) is of necessity much longer than either of the former; the principles embodied in it, however, are substantially the same. An observance of the fol-

Following simple rules will obviate the possibility of doing violence to other than the tissues directly concerned in the operation: 1. Mark the handle to indicate the direction towards which the cutting edge looks. 2. Carefully note the length of the blade, that it may be inserted only far enough to divide the contracted tissues. 3. Place the structure to be divided upon the stretch (Fig. 189). Pinch up, or press aside the skin over the part to be cut, so that when it is released, after the completion of the operation, the opening will not correspond to the divided tissues. 4. The blade should be made aseptic before being used. 5. Pass the knife blade from important vessels and nerves. 6. Insert the blade on the flat, closely to the surface of the tissue to be divided; turn the edge towards it, and carefully sever it by a guarded sawing motion, aided by pressing the tendon upon the cutting surface of the knife. If unguarded force be used, the tendon and its superimposed tissues may be divided, which will seriously complicate the recovery. 7. Withdraw the blade upon the flat, following it by firm pressure upon the parts with the thumb, which should finally rest upon the incision; this will press out all blood and exclude the air. 8. Seal the wound carefully with adhesive plaster or collodion; or, stitch it with asepticised silk, and apply the antiseptic dressing. 9. Rectify the deformity and confine the part to which the tendon is attached until repair shall have commenced. 10. Avoid the division of a tendon as it passes through its sheath, if possible. 11. Divide the offending tissue at the point of greatest forced prominence; provided, it be consistent with its relation to important structures. If reflex spasm results from "point pressure" the tendon should be divided; and, at the pressure-point inciting the reflex action.

Tenotomy of Upper Extremities.—The tendons of the flexors sublimus and profundus digitorum may be divided by a transverse, subcutaneous incision carried through them down to the bone, at about the middle of the first row of anatomical phalanges. Antiseptic precautions should be observed care-



FIG. 188.

fully in this instance, otherwise severe inflammation of the tendons of the sheath may follow. After the division of the tendons reduce the deformity and keep the parts quiet for five or six days, till the danger from inflammation has subsided, when they may be cautiously extended.

Extensor Communis Digitorum.—The tendons of this muscle can be readily divided as they pass along the carpus or upon the dorsum of the phalanges. In the former instance, pinch up the skin, pass the knife beneath the tendon as before directed, and cut towards the surface. They may be divided by passing the blade above the tendons and cutting down upon the bone. On the dorsum of the phalan-

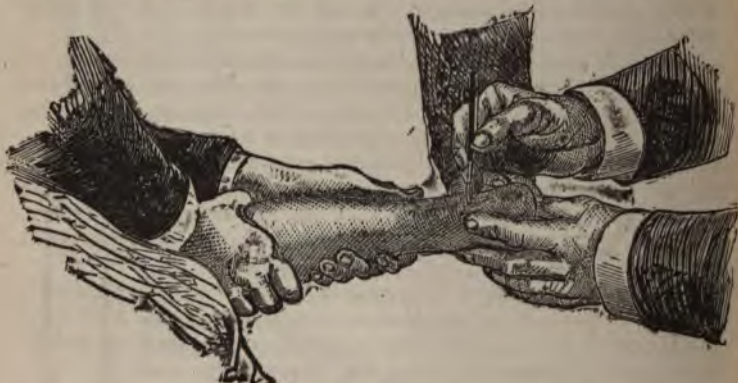

FIG. 189.

ges the blade should be passed beneath the skin, and the tendons divided upon the bone. In the division of the tendons of both flexor and extensor muscles, the joints and palm of the hand above the transverse line should be avoided, also the course of the veins and the spaces between the metacarpal bones.

Extensors primi, secundi, and ossis, metacarpi pollicis tendons can readily be made prominent by forcible extension of the thumb in the living subject, with the forearm midway between supination and pronation. The *primi* and *ossis* tendons form the inner boundary of the "snuff-box" at the apex of the styloid process of the radius, the *ossis* being the innermost of the two. The tendons of the extensor *secundi* form its outer boundary. They can be divided

in this situation by first making them as prominent as possible, then introducing the knife beneath from the anterior surface of the wrist and cutting towards the integument. The radial artery is to be avoided as it passes beneath them, and likewise the radicle of the radial vein as it crosses the intervening space.

Flexor Carpi Radialis.—The tendon of this muscle is situated immediately to the inner side of the radial artery, at the lower third of the forearm, and can be readily divided by passing the knife from the artery beneath the tendon.

Flexor Carpi Ulnaris.—This is the most internal tendon on the anterior surface of the forearm, and has the ulnar artery at the outer border. It can be easily cut by passing the knife beneath it, from without inward.

Biceps Muscle at the Forearm.—The tendon of insertion of this muscle may be divided either above or below the giving off the bicipital fascia. The former being the safer. Make the veins in the region prominent by constricting the arm above, extend the forearm to make the tendon prominent and tense; enter the knife at its inner border, pass it cautiously between it and the brachial artery, and cut upward, being careful not to injure the distended veins.

Latissimus Dorsi.—The tendon of this muscle may be divided separately at the lower border of the axilla, or conjointly with that of the teres major, a short distance below their insertion into the humerus.

In either instance the arm is forcibly raised to render them tense and prominent, and a long narrow-bladed tenotome is inserted along the anterior border, and they are carefully severed by a sawing motion.

It may likewise be divided at the lower angle of the scapula. Make the muscle tense as before, pass a long strong tenotome beneath it, and cut carefully outward; close the opening with a compress.

Tenotomy in the Lower Extremities: Tibialis Posticus.—The tendon of this muscle is intimately associated with the deformity talipes varus. It runs along the inner border of the tibia, behind the internal malleolus, in a separate sheath; being the innermost tendon at this situation, after leaving the internal malleolus, it goes beneath the calcaneo-scapoid articulation to its insertions.

In the normal foot it lies well concealed within its closely

fitting groove; it can be readily outlined between the tip of the malleolus and the calcaneo-scapoid articulation.

In talipes varus it is raised from its groove and becomes more prominent above the tip of the internal malleolus, as well as below it. It can be divided in either situation, but is better done at a point about one and a half inches above the tip of the malleolus in the adult, and one inch in the child or infant. The tendon is made tense by strongly abducting the foot, and the knife is passed with the usual precautions between the posterior border of the tibia and the tendon; the division is made by cutting outward.

The section between the tip of the malleolus and the calcaneo-scapoid articulation is not advised, on account of the contiguity of the ankle-joint and the internal plantar artery; if, however, it be thought advisable to operate at this situation, the foot should be strongly abducted, and the point of the tenotome carefully insinuated beneath the tendon, and between it and the internal plantar artery; the handle is then depressed so as to carry the point away from the joint, and the section be made from within outward.

Flexor Longus Digitorum.—The tendons of this muscle are sometimes productive of contraction of the toes, after the correction of the deformity of the tarsus caused by the tibialis posticus. It lies immediately posterior to the tendon of the muscle, behind the internal malleolus, and is often divided by the same cut which severs this tendon. It can, however, be divided independently.

If, after the division of the posticus tendon, the influence of the flexor longus digitorum be objectionable, it may be divided by introducing the tenotome beneath it through the same incision, and cutting towards the surface as before. The posterior tibial artery and its venæ comites, which in the adult are often varicose, in this situation must be carefully avoided by pressing them outward with the finger. If from contraction of the toes, unassociated with deformity due to the tibialis posticus, it be deemed advisable to sever its tendon, the posterior tibial vessels must be first detected, pushed outward by the thumb, which should then be pressed firmly between them and the tendons at the inner side; pass the tenotome perpendicularly through the integument, midway between the posterior margin of the tibia, and the end of the thumb; carefully insinuate it between the tendons of the posticus and the flexor longus

digitorum down to the bone, turn the edge upward, and carefully divide it towards the surface.

Flexor Longus Pollicis.—It may become necessary to divide the tendon of this muscle, on account of the crippled action of the foot in walking, dependent upon undue flexion of the great toe.

The toe should be forcibly extended, and the knife carefully inserted beneath it at the point of its greatest prominence, which will be at the anterior and inner side of the foot. The instrument must always be passed from the planter artery.

Tendo-Achillis is the most prominent tendon of the human system, and is divided at its narrowest portion. The posterior tibial artery is at the front and inner side, but sufficiently remote to be secure, if ordinary care be exercised. The short saphenous vein lies superficially and closely to its outer border.

It can be readily divided if the foot be forcibly flexed, to render it tense; pinch up the skin, push it outward to protect the vein, enter the knife beneath it from within outward, turn the edge towards the tendon and carefully sever it with a sawing motion while the foot is firmly flexed and the tendon pressed upon the edge of the knife by the finger. Great care is necessary, else a sudden giving away of the tendon may cause the knife to sever the superimposed tissues. All the precautions enjoined in tenotomy should be carefully observed in this instance.

Peroneus Longus and Brevis.—Their tendons pass in a common groove behind the external malleolus, and are enclosed by the same sheath; the latter being the most anterior. It leaves its fellow after passing behind the malleolus, and is inserted into the base of the metatarsal bone of the little toe on the outer side. The longus, after passing behind the malleolus, gains the sole of the foot, enters the calcaneo-cuboid groove, and is inserted into the base of the metatarsal bone of the great toe at its outer side. The tendon of either may be divided in two situations: (1) About one and one half inches above the tip of the malleolus: (2) three-fourths of an inch in front of it. It is commonly divided in the first situation. They can be severed connectedly or singly in either situation.

If it be decided to sever both simultaneously above the malleolus, seek the anterior and external border of the *fibula*, about an inch and a half above its tip, pass the knife

between the bone and the tendons, turn the edge outward and cut towards the surface. The short saphenous vein should be pushed inward to avoid injury.

If either be divided separately, push the integument backward with the thumb, to protect the vein, then push the thumb firmly down to the bone behind the tendons; pass the tenotome perpendicularly midway between the end of the thumb and the external border of the fibula, carefully insinuate it between the tendons, after which it is passed outward or inward, as the case may be, beneath the tendon to be severed, the edge turned upward, and the division made as in the preceding instances.

If the division be made below the malleolus, make the tendons tense, enter the knife about one half or three fourths of an inch in front of the tip of the malleolus, between the tendons, when either or both may be divided.

Tibialis Anticus.—This muscle, like the posticus, is of importance in connection with the deformity of talipes varus.

It is the innermost tendon of the leg and foot on its anterior surface, and can be easily outlined unless the foot be fat and chubby, when some difficulty may be experienced.

In well-marked cases of talipes varus it is displaced considerably to the inner side, and if the foot be abducted will become quite prominent. It is best divided about one inch above its insertion into the internal cuneiform bone. Make the tendon tense, pass the knife from without inward, to avoid the dorsalis pedis artery.

Extensor Proprius Pollicis.—As it passes across the dorsum of the foot, it can, like the preceding, be quite easily distinguished. It may become necessary to divide it after the division of the extensors of the tarsus, on account of its causing undue extension of the great toe. The toe should be forcibly flexed, and the tenotome carried beneath it from without inward, to avoid the dorsalis pedis vessels.

Extensor Longus Digitorum.—The tendons of this muscle may not only cause an obstinate extension of the toes, but aid in maintaining the tarsus in a state of forced flexion. They can be divided separately, as they pass along the dorsum of the foot, provided either require it. If all be cut at once, it is done by flexing the toes, entering the knife beneath them, a little below the bend of the ankle, from within outward, to avoid the dorsalis pedis vessels.

Proncus Tertius.—This may be divided along with the

extensor longus digitorum, of which it is a part, as before described; or it can be done separately before its insertion into the dorsum of the metatarsal bone of the little toe, by extending the tarsus, and passing the knife beneath it, from without inward. It is the most external tendon on the dorsum of the foot, in front of the external malleolus.

Biceps of the Leg.—This tendon forms the *external hamstring*, and is inserted into the head of the fibula and tuberosity of tibia. The external popliteal nerve is located immediately at the inner side. To divide it, the leg should be extended, and the tenotome passed from within outward, beneath the tendon about an inch and a half above the head of the fibula.

The inner hamstring tendons are the *semi-tendinosus*, *semi-membranosus*, *gracilis*, and *sartorius*; the two first, however, are the ones principally concerned. The tendon of the semi-tendinosus is felt as the longest, smallest, and nearest to the median line of the popliteal space; that of the semi-membranosus is internal to it, somewhat less superficial, and runs parallel with it. Either of these tendons can be divided by extending the leg to make it tense, and entering the knife beneath and from the outer side, at the most prominent portion, and cutting towards the surface. Their division to relieve forced flexion will not always admit of complete extension, due, among other things, to the contraction of the heads of the gastrocnemius, which are inserted into the condyles of the femur. The forced extension of the leg under these circumstances, often causes a tearing asunder of the attachments of this muscle, especially the inner head, which is larger, stronger, and inserted higher than the external. The hemorrhage resulting therefrom may be severe enough to infiltrate the calf of the limb, even extending throughout the popliteal space. The liability to this rupture and consequent bleeding may be lessened, if not obviated, by first dividing the tendo-Achillis; or, which is perhaps better, by first dividing the hamstring tendons, when, if the foot becomes extended, on attempting to straighten the limb, the tendo-Achillis can then be divided.

The Gracilis and Sartorius.—They may be divided, after forcible extension of the leg. Pass the tenotome close at the inner side of the tendon of the semi-membranosus, between it and the gracilis, depress the handle outwards or inwards as the case may be and divide these structures *towards the skin*.

Quadriceps Extensor Tendon may be divided above the patella, by making an incision down to the tendon and parallel with it, entering the point of the knife above it, cautiously and with a sawing motion divide the tendon. A careful and continuous attempt should be made to flex the leg while the tendon is being cut, that its deepest fibres may be ruptured, thus avoiding the possibility of entering the synovial extension of the knee-joint, which lies beneath it. However, the limb should not be flexed further than is necessary for this purpose, and after the division should be placed in a comfortable position till repair is well advanced.

Pectineus.—This muscle, which acts as a flexor and adductor of the thigh, may require division on account of malposition of the limb. The pelvis is steadied, thigh extended and adducted, which causes the fibres to become tense and prominent. A long-bladed tenotome is then introduced at the outer border, about an inch below its origin, and carried inward and upward, till the division is complete. The internal circumflex artery, which runs between the psoas magnus and the outer border of the pectineus, is the only vessel of any size exposed to injury. The danger to this is obscure, unless it arises higher than usual.

Adductor Longus is situated further to the inner side of the thigh than the preceding, forming the inner border of Scarpa's triangle. It is, however, located on about the same plane as the pectineus. It is tendinous at its origin from the pubes, and can be easily divided, when made tense, by passing the knife beneath its outer border, and cutting upward and inward.

Tensor Vaginæ Femoris can be severed without difficulty, by introducing a long-bladed tenotome beneath it, from either border of the muscle, about an inch below its origin, and cutting towards the surface.

Sartorius forms the outer boundary of Scarpa's triangle, and can be divided by making its fibres tense, by strong abduction; then introducing a long tenotome beneath it, by way of its anterior border, two or three inches from its origin, and cutting upward towards the surface.

Multifidus Spinæ lies on either side of the spinous processes, in the groove formed by the spines and transverse processes, from the sacrum to the axis. It is quite superficial in the sacral region, opposite to the posterior superior

spinous process of the ilium. Raise a fold of skin parallel with the long axis of the muscle; pass a long-bladed tenotome from the spine outward to the outer border of the muscle, and cut towards the spine.

Erector spinæ forms the principal portion of the muscular prominences on either side of the spine, to be seen in the lumbar region. It is a thick, strong muscle, which arises from the sacrum and contiguous structures, and divides at the lower border of the last rib, into the *longissimus-dorsi* and *sacro-lumbalis*, which are inserted into the angle of the ribs and the transverse processes of the dorsal vertebræ. The *erector-spinæ* can be divided by a long tenotome passed from within outward, to the outer border of the muscle, just below the last rib, and carried downward and inward towards the spine.

Trapezius.—This is a muscle possessing an extensive origin. The portion which arises from the inner third of the superior curved line of the occipital bone is often divided, on account of deviations of the head.

This is readily accomplished by making the muscle tense, and severing it with a tenotome entered beneath it, and below the occipital protuberance; the edge turned towards the integument.

Sterno-cleido-mastoid.—Division of this muscle is often necessary in cases of wry neck, dependent upon abnormal muscular force. It is divided at its lower extremity, either at its sternal or its clavicular attachment; often at both. For the division at either, the muscle is put on the stretch by turning the head, and a blunt-pointed tenotome passed beneath it from the outer side, about a half inch above its insertion, and divided towards the surface. The division of the clavicular portion may be ample to correct the deformity; if not, the sternal portion should be severed in the same manner. It is necessary to closely hug the under surface of the portions to be divided, else the deep seated and important vessels may be injured. It is not safe to attempt a subcutaneous section of the muscle above this point, on account of its relation to the common carotid artery, and the internal jugular vein.

Plantar Fascia.—This tissue is an exceedingly dense, white fibrous membrane of great strength, with the fibres arranged longitudinally. It is divided into three portions: the middle and two lateral. The former is the one especially concerned in those deformities requiring division.

It is narrow behind and attached to the inner tubercle of the os-calcis. Broader and thinner in front, and divides into five processes opposite the middle of the metatarsal bones; being one for each of the toes. Each of these processes divide opposite the metatarso-phalangeal articulations into two slips, which embrace the sides of the flexor tendons, and are inserted into the sides of the metatarsal bones and the transverse ligament. It likewise sends prolongations between the groups of the plantar muscles. This fascia serves the important function of assisting in maintaining the integrity of the plantar arch.

It is divided by placing it upon the stretch, and passing a tenotome beneath the inner border of the most prominent portion, and cutting towards the sole. The deformity is then overcome as much as is practicable; and the foot is placed and fixed in the corrected position.

Palmar Fascia.—Like the plantar fascia, this is divided into three portions: two outer and a middle part; the middle division being the one of special significance. It is narrow above, and attached to the lower border of the annular ligament; below it is broad and thinner, and opposite the heads of the metacarpal bones divides into four slips, one for each finger. Each slip subsequently subdivides into two processes, which enclose the tendons of the flexor muscles, and are attached to the sides of the first phalanx, and to the glenoid ligament. This fascia is intimately connected with the integument of the palm, and sends vertical septa between its muscles. From various causes it may undergo structural changes, which result in contractions of the fingers on the palm, as well as shortening of the palm itself. The anatomical arrangement of the fascia fully explains the mechanism of the deformity. It must be carefully diagnosed from paralysis of the extensors, also, contraction of the common flexors. The contracted bands are divided, by placing them on the stretch, and passing a narrow bladed tenotome beneath, and cutting towards the surface. The deformity is then reduced, and the rectified part placed in a fixed position until danger of inflammation has subsided.

The fascia in other situations may become contracted, as the fascia lata, at its upper or lower extremities. Whenever these contractions cause a persistent deformity they *should* be divided, and upon the same principles as like tissues in other portions of the body. The employment of

an anæsthetic is advisable in tenotomy, especially when the section is to be extensive or contiguous to important structures.

OPERATIONS ON BONES.

The injuries and diseases to which bones are liable, although not differing in any essential particular from the same conditions, when occurring to the soft parts, require an independent consideration, on account of their dissimilarity of function and structure. Tendons, muscles, nerves, and fascia are divided and resected; so is bone. The integument and soft parts generally, become the seat of inflammation, ulceration, and gangrene. Bony tissue is likewise preyed upon by the same morbid processes; named, however, quite differently: ulceration of the soft parts being comparable to caries of bone; necrosis of bone finds its synonym in gangrene of soft parts. To preserve the function of a tissue unimpaired, is the greatest end that can be attained. To relieve a patient of the local effects of an injury, or disease, and keep him in possession of his natural endowments, constitutes conservative surgery in its fullest sense.

The functions of bones being, in a practical sense, to support the body, protect important organs, and act as levers for purposes of prehension and locomotion, we have but to act with a knowledge of these facts, and of the methods to maintain them, to give to the patient the full benefit of our art.

The operations upon bone are denominated, gouging, sequestrotomy, exsection, osteotomy, and osteoplasty.

Gouging is applied to the removal of carious bone, and should not be attempted until the process has become chronic.

The instruments required to meet the exigencies of a case are gouges (Figs. 189a, 190, 191, and 192), scoops, and chisels (see Figs. 180, 181, 182, and 183), of various sizes and shapes, together with a suitable mallet.

Operation.—Having arranged the patient suitably for the convenience of the operator, administer an anæsthetic, apply the elastic bandage, carrying it lightly over the site of

the disease, make a free incision down upon the carious bone, separate the soft parts with retractors; and, with the drills, gouge, etc., remove all the diseased structure.

It is important to be able to determine the line between the healthy and diseased bone; and this is often very difficult. If the portions removed, when washed, present a



FIG. 189a.

FIG. 190.

FIG. 191.

FIG. 192.

whitish, grayish, or blackish appearance; are porous and fragile, instead of being vascular, red, and tough, then the operation should be continued. If the gouged surfaces bleed freely from numerous points, and have a normal firmness and color, then the operation should cease.

It is important in gouging the extremities of bones to use extreme caution, or the joint cavity may be opened

directly, or become secondarily involved. After the removal of the elastic constriction, all bleeding should be stopped; the wound washed thoroughly with a suitable antiseptic solution, good drainage secured, the parts united, and dressed antiseptically.

 SEQUESTROTOMY.

This operation is employed to remove dead bone *en masse*, therefore applicable to necrosis. The additional instruments necessary, are small crowned trephines, bone-cutting forceps of various shapes (Figs. 193, 194 and 195), gnawing




FIG. 193.



FIG. 194.



FIG. 195.

forceps, small saws, (Figs. 196 and 197), periosteal elevator, (Fig. 198), etc. There are two methods employed, depending on the nature of the case, viz.: direct and indirect.

The Direct.—Having detected the situation of necrosed

bone, and being satisfied, either from the long course of the disease, or by movement of the dead portion, that detachment has occurred, apply the elastic bandage, using care not to force deleterious matters into the circulation, select a strong knife (Fig. 199), and connect the fistulous openings with each other, down to the bone; selecting such openings, of course, as will cause the connecting incision to be consistent with good drainage, easy access to the dis-



FIG. 196.




FIG. 197.




FIG. 198.

eased parts, and safety to the underlying structures. The surfaces of the incision should now be separated with retractors, to fully expose the openings in the involucrum (Fig. 200). If the sequestrum can be drawn out of the opening with suitable forceps, it should be done carefully; otherwise the reparative tissue upon which it rests will be injured, and the process of recovery deterred. If it be too large, or be interlocked with healthy bone, the opening must be enlarged sufficiently to admit of its withdrawal; or,

if this be impracticable, an incision through the periosteum should be made, corresponding to the long axis of the sequestrum. The periosteum should be carefully raised upon either side of the incision sufficiently to permit the application of a small crowned trephine, with which the involucrum should be perforated a sufficient number of times, to admit the easy removal of the dead portion; either with or without the chiselling away of the irregular borders.

The gnawing forceps (see Fig. 179), chisels, and mallet,




FIG. 199.

FIG. 199a.

FIG. 200.

and even the small saws may be used in lieu of, or in conjunction with the trephine.

If there be but one sinus, and evidences of disease exist above and below it, the centre of the incision should correspond to the sinus, if the anatomical relations will admit of it. Much caution is often essential in making these incisions in the vicinity of joints, or their synovial pouches will be opened. After the removal of the dead bone, the wound, through its whole extent, should be thoroughly cleansed, suitable drainage provided, the lips of the wound closed, and antiseptic dressing applied; or, after washing it can be lightly filled with oakum saturated with balsam of

Peru, or carbolic acid and oil, and the whole confined in place by a mass of carbolized oakum, held in position by a roller bandage. In the latter instance it should be dressed frequently to secure proper cleanliness. If the antiseptic plan be employed, the rules applicable to the method should be carried out. When the portion of bone removed is large, or the remaining part is small and fragile, the limb must always be supported by a splint; otherwise it may bend or break, and thereby complicate the ultimate prognosis.

If the sequestrum be as yet unseparated from the healthy bone, it should be allowed to remain until the process of separation is completed, when it can be removed.

The indirect method is preferable when the bone is superficial and its disease progressive, as in periostitis of the lower jaw, clavicle, bones of the arm, forearm or tibia; in fact, all the long and many of the flat bones can be reproduced by this method. It consists in making a free incision down upon the diseased bone, through the surrounding periosteum, and separating the membrane by means of the handle of a scalpel, spatula, periosteal elevator, or any instrument of a like character. This must be done at intervals, and not extend beyond the diseased portion; the length of the intervals will depend entirely upon the rapidity of the morbid process. This plan is necessarily tedious, both in detail and in time; yet sooner or later the dead bone can be raised from its new osseous trough, which will soon become filled, and serve the purposes of its predecessor. The free incision necessary to expose the dying bone will provide good drainage; other than this, it should be kept clean by ordinary means.

Excision.—Excision of bone is a conservative operation, directed to the extraction of such portions of it as are inconsistent with its future usefulness or the symmetry of the patient, together with the removal of the condition directly demanding the operation. It is employed in lieu of the more radical measure—amputation. It may be directed to the articular extremities or to the shaft of a bone; and, in either instance, it may be *partial* or *complete*. The articular extremities or joints are excised on account of injury, disease, or ankylosis in a faulty position. In estimating the prognosis for life, the surroundings of the patient, his previous habits, present condition, and the *existence of constitutional taints*, must be considered; also, the *nature and extent of the cause demanding it*. The prospec-

tive usefulness of the limb will depend on the ability to leave the muscular attachments intact; also the condition of the nerves that animate, and the blood-vessels that nourish them. If the patient be a manual laborer, or be one oversensitive of a deformity, it is well then to consider if additional advantages can be derived from artificial limbs and appliances; when, it may be deemed the wiser to relegate the offending member to the relief afforded by amputation. The incision preparatory to the necessary exposure of the parts to be removed should be free, and, when possible, be made in the long axis of the bone. They are often, however, varied, to suit the peculiar demands of the individual cases. They are likewise varied for the different joints, being in one instance longitudinal, in another U, H, or — shaped, according to the proposed extent of the operation and the contiguous anatomy of the part. In every instance, however, they should be made with view to good drainage, when the same incision will render the parts accessible, and not expose adjacent important structures to unwarranted danger. The future usefulness being one of the most important factors to be gained, the insertion of all muscles, having especially defined functions, as flexion or extension, must be religiously respected. If it be necessary to divide tendons, it should be done obliquely; the better to facilitate subsequent union. If it be necessary to remove the bony surfaces, into which they, or the ligaments are inserted, the periosteum covering these surfaces should be carefully peeled off, along with the tendinous attachments. All diseased and loose pieces of bone should be removed, together with irregularities and isolated portions of articular cartilages. The synovial membrane should be preserved, unless it be diseased; and its diseased portions be cut or scraped off. The removal of the entire shaft of a bone may be necessary on account of injury or disease, notably the latter. In such cases the incision should be a free one, and be made over its most superficial aspect, provided that important structures do not intervene; the periosteum is then removed proportionately to the extent of the disease, gradually or rapidly, as the circumstances indicate, and the diseased bone removed, leaving, if possible, the epiphyseal extremities. If the epiphyseal cartilage be destroyed the growth of the bone in its long axis will be interrupted. This is very important to observe in *operations upon the bones of adolescents, since to destroy*

this cartilage will cause a subsequent shortening of the limb. The consultation of any standard work on anatomy will enable the surgeon not only to accurately locate the epiphyseal junctions, but likewise inform him of the age at which the shafts become united to their epiphyses.

The time of operating must be governed by the condition of the patient, and also the part to be operated upon. If the patient be suffering from shock, reaction should take place prior to operative interference. If inflammation of the bone occurs, good drainage should be established, and the operation deferred until it subsides. If for necrosis, the diseased bone should have separated before the attempt is made.

The instruments required for resection are varied in number and shape, and must be selected according to the peculiarity of the case. The knives should be broad and strong (see Fig. 199). The retractors (see Fig. 200) must likewise be strong and possess a hook-like curve, otherwise they will slip from the wound. A sharp-pointed one may be employed (Fig. 201). The periosteotome, or elevators (Fig. 202), vary in shape; but should possess a blunt, non-cutting edge; if compactness be desired, it may be connected with the handle of the knife (see Fig. 199a). However, it is not so handy or efficient as the independent instrument. They must be used with care, otherwise the function of the periosteum will be destroyed, and may even be followed by sloughing. The bone-cutting instruments are forceps, saws of various sizes and shapes. The straight bone forceps are the most available for general purposes. The blades should fit accurately, and be sufficiently sharp to make as clean a cut as possible. In order that bone intricately located may be reached, the blades are bent at various angles. The gnawing forceps or rongeur are of inestimable value in removing bony projections.

Bone-holding Forceps (Fig. 203) vary much in their grasping and holding powers; consequently, the surgeon will be governed in his selection of an instrument by its



FIG. 199. FIG. 200.



FIG. 203.

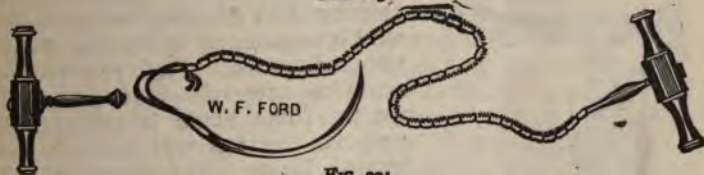


FIG. 204.

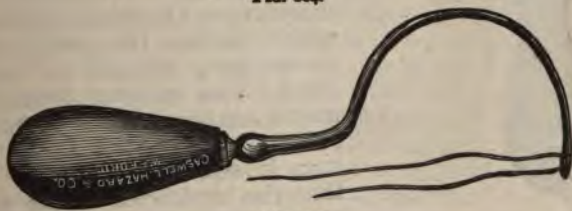

FIG. 205.



W. F. FORD

FIG. 206.

suitability for the purpose. The varieties of saws are numerous, among which are the chain saw (Fig. 204), the straight saw, with an adjustable back (Fig. 206);

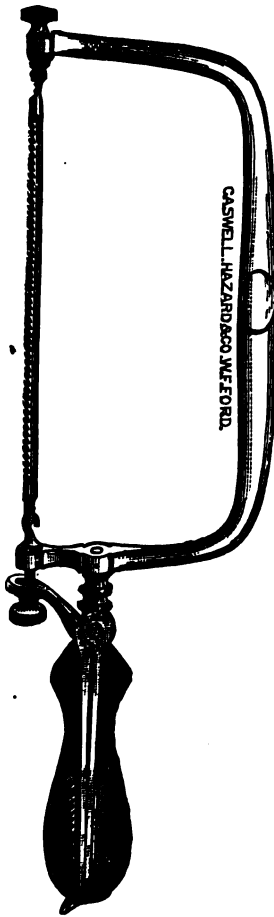


FIG. 207.

and the curved, for right and left sawing. These are of use in removing portions of thin bones from flat surfaces. The chain saw, as the name indicates, is composed of numerous links or sections, having attached to each extremity a handle for working it. To apply the saw, remove the handle from the hooks and carry it beneath the bone by means of a thread and curved needle, with the cutting edge upward, or an instrument known as the "chain-saw carrier" may be employed instead (Fig. 205), readjust the handle, and draw it from side to side at an angle of about 45° with the bone. It should not be jerked, or be allowed to kink, for fear of clamping or breaking it. This instrument is employed in dividing those bones which are nearly surrounded by the soft parts. Fig. 207 represents a saw of great practical worth. The blade is adjustable, and its cutting surface can be turned in any direction; it has therefore a universal application, which renders it superior to the chain saw, except in isolated cases. The gauges, chisels, and mallet are required to thoroughly remove all diseased bone. They vary in size and shape, in order that the intricacies of the wound may be reached. The instruments to seize the fragments of bone are also variously turned, to be better able to grasp them.

Treatment of excision wounds is in nearly all instances

substantially the same. Rest and thorough drainage, together with strict antiseptic measures, constitute the basis of the future treatment. Rest can be secured by the various forms of splints, either movable or immovable in character. The common dressing of the wound consists of oakum, lint, marine lint, or a fine silken oakum, either with or without saturation with carbolic acid and oil, or balsam of Peru. The wounds should be dressed with sufficient frequency to prevent any septic infection, once daily being usually enough. If the antiseptic methods be adopted, the rules governing their readjustment should be enforced.

Excision of the Upper Jaw.—This operation is done for various purposes, connected either with the bone structure itself or the cavities with which it is associated. In all instances the periosteum should be preserved, except in such as are associated with malignant diseases.

The special instruments requisite, in addition to those already enumerated for exsections, are a trephine, or a bone drill and a strong pair of forceps to turn out the bone, together with forceps to draw the teeth in the line of section. The patient is anæsthetized and placed upon the back, either with the head slightly raised or markedly depressed. In the latter the blood does not escape into the larynx, but into the upper and posterior part of the pharynx. This position, however, impedes respiration by undue stretching of the tissues of the anterior cervical region. However, this may be obviated in a great degree, if the front of the table be raised, as in the reduction of the abdominal contents by taxis. If the head be elevated, the blood can, with care, be kept from the larynx, either by constant sponging or tamponing the pharynx around a large catheter or rubber tube, or allowing the patient sufficient consciousness to dislodge it. Still another method is to confine the patient in a rocking-chair, which can be tipped forward or backward as circumstances require. The surest of all is to perform a preliminary tracheotomy, and then close the floor of the pharynx. This is not as a rule necessary, unless the operation be complicated with a very vascular morbid process requiring a separate removal. If the important associated anatomy be carefully considered before beginning the operation, it will save much time and not a little amount of blood.

In complete removal, the bony connections which must be divided are: 1. With the malar, below the outer angle of

the orbit; 2. with the fellow of the opposite in the roof of the mouth; 3. the nasal process of the bone, with its body below the inner angle of the orbit; 4. the slight connection between it and the palate bone and pterygoid processes of the sphenoid. The internal maxillary in the sphenomaxillary fossa and the branches of the facial running through the external soft parts are the only vessels that will cause troublesome hemorrhage. Steno's duct must be avoided, as it runs from the parotid gland to empty into the mouth opposite to the second molar tooth, on a line extending



FIG. 208.

from the lobe of the ear to midway between the border of the lip and the ala of the nose. The superior branches of the seventh pair may be divided unnecessarily, if the course or extent of the incisions be too great. No anticipated complication should be permitted to occur. Loss of blood, however, is the only one outside the common shock of all operations that requires close attention. Hæmorrhage from the facial and internal maxillary, while often profuse, can be easily controlled.

The Lines of Incision.—They may be made within or without the buccal cavity.

To attempt the removal from within is too tedious, the room being limited and the ability to control hemorrhage entirely inadequate. At the present time the external incisions are the only practical ones. These can be classed as outer and median. The former commencing at the angle of the mouth and passing in a curved course upward and outward to the malar process; this exposes Steno's duct and the branches of the seventh nerve to injury, and is followed by a conspicuous scar (Fig. 208, A). The latter is made at the middle of the upper lip, and following the furrows between the cheek and nose, terminates about one half an inch below the inner angle of the eye (B). To this may be added an incision of an inch or so in length, extending outward half an inch below the orbit, and at a right angle with the vertical one. In this incision the coronary and angular arteries only are divided.

Operation by the median incision, with removal of the whole bone. The middle incisor tooth corresponding to the side to be operated upon is drawn, and the facial artery compressed on both sides by an assistant. The incision is begun at the border of the lip, but not carried through it until later, to prevent blood entering the mouth; from the upper attachment of the lip, through the remainder of the course, the incision is rapidly made down to the bone, and the flap dissected outward as far as the malar bone above, and the tuberosity of the maxilla below; during the dissection the bleeding points are controlled by the fingers of the assistant or by the serrefine forceps. They should be ligated with catgut before the bone is moved. The cartilage of the *nose* is separated from the bone and turned inward, the edge of the orbit gained, and the periosteum on the floor separated, and pushed backward and upward by means of an elevator or handle of a scalpel to the border of the speno-maxillary fissure. The malar process is now divided by sawing, or cutting through it with bone forceps, from the outer extremity of the speno-maxillary fissure. The thin floor of the orbit is divided with a scalpel from the speno-maxillary fissure obliquely forward and inward, and the nasal process severed with forceps. The mucous membrane of the roof of the mouth is then divided transversely from the centre inward, on a line with the last molar tooth, then from the centre forward, in the median line, to the incisor teeth. The hard palate is divided at the side of the septum, corresponding to the bone to be removed,

by a saw or bone forceps, and the bone seized and pressed downward to break up its posterior connections, after which it is raised and twisted slightly from side to side and pulled out, bringing with it some portions of the palate and pterygoid process of the sphenoid, together with the muscular fibres connected with them. If the mucous membrane of the mouth be not diseased, it can be saved by making an incision through it along the alveolar border, and pushing it inward along with the periosteum to the median line. After the removal of the bone it can be stitched to the side of the cheeks.

Excision Below the Floor of the Orbit.—After the exposure of the external surface of the superior maxilla, as in the preceding method, perforate the anterior wall of the antrum with a drill or trephine; then with the bone forceps or saw inserted into the opening, divide the bone through into the nasal fossa, and separate it from its outer connections by sawing or cutting through the malar bone. Aside from this the steps of both are similar.

After the operation, the wound is washed with carbolic acid, and all bleeding points checked either by ligature, pressure, or cautery, the former being the best. The external incision is then closed with sutures, or pins, and readily unites in three or four days. The raw surfaces within should be kept thoroughly cleansed while repair is taking place. These cases make a satisfactory recovery from the operation, although some deformity will remain.

The stitches are removed from the soft parts the third or fourth day, union, as a rule, being complete. The results of this operation are good, so far as immediate loss of life is concerned. About one in six or seven will perish. If the removal be done for malignant growths, the prognosis for ultimate recovery is unfavorable.

Subperiosteal Excision.—This can be done with any of the median incisions, but an external one is preferred by some (Fig. 209). The external incision is made from the middle of the malar bone to a point on the upper lip, one third of an inch from the angle of the mouth. It is sometimes necessary to make a second cut from the middle of the lip upward, as in the preceding operation. The mucous membrane on the external surface of the alveolar process is divided down to the bone: beginning at the line of junction between the lateral incisor and canine teeth and carried backward to and around the posterior molar

to the inner surface of the alveolar process, forward parallel with the external incision to a point opposite the commencement of the external, then obliquely backward and inward on a line corresponding to the intermaxillary suture of that side to the median line. The anterior extremities of the external and internal incisions are now connected to each other by a transverse one, carried on a line extending between the lateral incisor and canine teeth. The periosteum is then peeled of the external and orbital surfaces of the bone, and also from the inner surfaces of the alveolar process, and the hard palate of that side. The



FIG. 209.

nasal and malar processes are divided as before, the canine tooth drawn, and the intermaxillary bone separated, together with the hard palate of the maxilla to be removed, from the contiguous bone, by a chisel, saw, or forceps. The maxilla is then twisted out, and the periosteum from the inner and outer surfaces of the alveolar process united. *The superior maxilla may be removed simultaneously by either of two methods. 1. Make an incision from each angle of the mouth to the middle of the malar bone on the respective sides (Fig. 210, A), and dissect upward the in-*

tervening flaps; or, 2, make a vertical one along the ridge of the nose through the lip, beginning at a point one fourth of an inch below the lower border of the orbit. To this may be added a transverse one extending between the middle of each orbit, one fourth of an inch below it, across the upper end of the vertical one, B; the outer bony attachments are divided as in the single operation; the nasal processes are divided either by forceps or the saw, and both bones removed at once—not separately. About fifty per cent of those perish from whom both bones are removed simul-



FIG. 210.

taneously. In all operations for the complete removal, the superior maxillary nerve should be divided as far back as possible.

Excision of the Inferior Maxilla.—The operations on the lower jaw require no additional instruments, and the precautions referrible to the patient in the former case are almost equal in importance in this, and the contiguous anatomy is even greater. The facial artery runs beneath and across its lower border and outer surface at the ante-

rior border of the masseter muscle; the parotid gland lies behind the ramus, and often sometimes overrides it. The external carotid artery, as it passes through the gland, is closely associated with its posterior border. The internal maxillary artery passes closely behind and to the inner side of the neck of the condyle. The inferior dental artery runs along the inner surface of the ramus to enter its canal. The superior division of the seventh pair of nerves pass across the outer border of the neck of the condyle. Steno's duct passes across the masseter muscle to the opening opposite the second molar tooth, on a line parallel with and a half inch below its lower border. The lingual nerve runs along the inner surface of the ramus, close to the bone just below the last molar tooth.

The genio-hyo-glossus muscle is attached to the superior genial tubercles, and if incautiously detached will permit the tongue to fall backward, and close the glottis. It is very important, when possible, to respect the attachments of the muscles of mastication, on account of their action on the resultant tissues. The operation may be directed to a complete or partial removal of the bone. A partial removal may include any fractional portion of it.

The *incisions* for the removal may be made within the mouth or on the external surface. If the whole or a lateral half be removed, an external incision must be made. The portion in front of the molar teeth, and even in front of the ramus, can be excised by internal incisions alone; the latter is, however, often attended by vexatious difficulties, and is hardly warrantable, except in isolated cases. The ramus and portions of the body behind the teeth can be removed through an external incision without opening into the buccal cavity, provided the periosteum be carefully raised from its surface. In the same manner the body, or any portion of it, can be taken away if the teeth be absent. If the teeth be present, the periosteum may be carefully detached and the bone with the teeth removed; after which the openings into the buccal cavity, caused by the withdrawal of the teeth, can be closed with sutures applied internally. If the jaw be suffering from phosphorous or a similar necrosis, it may be gradually enucleated by the indirect method, through an external opening, from its surrounding involucre, and the teeth may even remain in the new growth. Unfortunately, however, when processes of a malignant nature call for the operation, these

conservative methods are of no avail, since the operation must be directed to the removal of all the diseased tissues. When possible, the incisions in the buccal lining should be closed and the wound drained externally. This will keep the wound clean and prevent swallowing of the discharges.

Excision of the Central Portion.—Pass a stout ligature through the tongue well behind its tip, to prevent tearing out, and tie the ends to form a loop, which will be convenient for holding it. The assistant stands behind the head of the patient, holds it firmly, at the same time compressing the facial arteries where they pass across the jaw; or, seizes the lower lip at the angles between the thumbs and fingers, rendering it tense, and at the same time arresting its circulation. The operator, standing in front, makes a vertical incision through the median line down to the bone, extending it to the lower border of the symphysis mentis, raises the periosteum from its surfaces, if practicable, to the extent of the proposed section, draws a tooth at each point where the bone is to be divided, saws it at these points, and draws the fragment forward, and separates the attachments of the muscles as closely as possible to their insertion. The flaps are then united with silver wire, extending through the mucous membrane. The vermilion border of the lip is carefully adjusted, and united with pins or silver sutures. If the tongue fall backward, its severed muscular attachments can be drawn forward, and connected with the cut in the median line by a deep suture passed through the lip. The bone can be easily reached through a curved incision made along its lower border, or by an internal one corresponding to the fold of the buccal membrane: The lip is depressed over the symphysis mentis, and the bone is removed.

Excision of the Lateral Portion of the Body.—Make an external incision along the under border of the portion to be removed, down to the bone. If necessary, it may be turned upward at a right angle towards but not through the lip. If the condition of the parts will permit, the periosteum is reflected off, the bone divided in front, external to the insertion of the genio-hyo-glossis, and if possible turned outward, and the tissues separated back to the point of posterior section; it is then removed with a chain saw, and dressed as before.

Excision of Half of the Lower Jaw.—Commence the in-

cision about an inch below the arch of the zygoma, and carry it downward at the posterior border of the ramus, and around beneath the body of the jaw to the symphysis mentis, carefully exposing the facial artery and tying it. If the operation be for necrosis, this incision will be sufficient; if for other disease, the lower lip is cut perpendicularly through its centre to meet the longitudinal incision (Fig. 211). The bone is exposed in front by

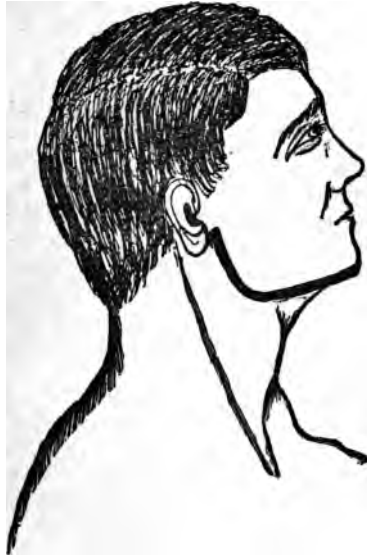

FIG. 211

peeling off the periosteum or otherwise, and sawn through just outside the insertion of the genio-hyo-glossus if possible, the end pulled outward, and the remaining attached tissues separated either by cutting or by a periosteotome, back to the beginning of the incision. Depress the fragment forcibly, and if possible detach the temporal muscle with scissors or osteotome, then turn it outward, and divide the insertions of the pterygoid muscles in the same manner, carefully avoiding cutting the lingual nerve, draw the bone forward forcibly and twist it from its socket.

If it be impossible to accomplish its removal in this manner, extend the incision upward to the neck of the

bone, avoiding if possible the division of Steno's duct and the branch of the seventh pair of nerves, and enucleate the condyle. In this situation, the condyle must be closely followed, otherwise the internal maxillary artery may be injured, as it passes immediately behind it. If the primary incision be sufficient to expose the bone above the seat of the disease, it should be sawn through at this point and the upper portion allowed to remain.

Excision of the Entire Lower Jaw.—Remove the left half first, or the right if it best suits the convenience of the operator, in the manner before described. A ligature is then passed through the tongue, given to an assistant, and the remainder excised in a similar manner. Stop all hemorrhage, and close the wounds with sutures in such a way as to accurately coapt the divided buccal borders.

In all situations, when the nature of the disease will permit, the periosteum should be reflected by a careful yet vigorous use of the elevator. The insertion of ligaments and tendons only will afford an obstacle, and these should be carefully detached by a sharp knife, that a continuity of the periosteal and fibrous tissues will remain.

The periosteum in young subjects may reproduce enough bony material to give a fair outline to the face and serve an important function in mastication.

If bone be not reproduced, the membrane will furnish a firm fibrous base, which may be utilized for artificial appliances. If the anterior portion of either or both sides be removed, the gap may be filled in by an artificial dental appliance, which will often happily maintain the symmetry of the face and become useful in mastication.

Excision of the Alveolar Process.—When the extent of the disease will permit, the alveolar process can be removed down to the body of the jaw through either an external or internal incision, the former being the better. The diseased part is then removed, and the wound closed as before. After recovery, the body of the jaw will form an excellent foundation for a compensatory dental appliance. Whenever the disease is malignant, the periosteum should be removed with the bone, and care taken that none of the diseased membrane remains in the wound. It is also necessary in such cases to remove all associated structures when diseased—such as glands, floor of the mouth, and even the tongue itself.

Results.—Out of 246 excisions in the continuity, 46 died.

Of 153 disarticulations of one half the bone, 36 died. In 20 operations for removal of the entire jaw, 1 died. It will be seen that death has followed in 20 per cent of all the cases. Pyæmia, erysipelas, and exhaustion, were the principle causes.

Operation for Anchylosis of the Inferior Maxilla.—This consists in establishing a false joint in front of the cause of the immobility which is usually dependent on cicatricial contraction, irreducible dislocation, and anchylosis. The removal of a wedge-shape piece from the lower border of the jaw has been practised; also, from the alveolar process; transverse section of the ramus with a sharp chisel introduced through the mouth, likewise, fracture of the neck when the condyle is involved.

Operation for Removal of a Wedge-shaped Piece.—Make an incision two inches in length down to the bone, along the lower border of the jaw, beginning at or in front of its angle, depending upon the location of the cause of the immobility. Avoid or tie all important vessels in the course of the incision; expose both surfaces of the bone up to the summit of the alveolar process, and pull a tooth if necessary. Divide it with a chain saw at one extremity of the exposed surface, force the other extremity through the wound, and remove the wedge-shaped piece with the rongeur or saw, the base of which should not exceed a third or half an inch. While the patient is still under the influence of the anæsthetic and before the wound is closed, ascertain the distance the liberated portion can be separated from the upper jaw with moderate force. Provide suitable drainage, close the wound, and prevent union of the bones by passive motion.

Excision of the Sternum.—No definite plan for this operation can be outlined. The form and length of the incisions must be governed by the location and extent of the disease. The diseased bone should be freely exposed, and removed in the usual manner. Care must be observed, else the pleural cavity will be opened. When possible, subperiosteal excision should be done, as the bone is quite readily reproduced.

Excision of a portion of a Rib.—This may be done for the removal of necrosed bone, or to make a permanent opening into the thorax for the escape of pus. If for diseased bone, make an incision in the middle of its long axis of sufficient length to include the diseased portion. This may be crossed

at the middle by a transverse incision. Separate the periosteum along with the superimposed tissues, liberate the bone, and raise it from its bed. If the sequestrum be not loose, time should be allowed for its separation. If the operation be for pyo-thorax, select the sixth or seventh rib; make an incision about two or three inches in length down upon its middle, through the periosteum in a line with the axilla, bisect this by a horizontal one the width of the rib, expose the bone on both surfaces by raising the periosteum along with its surrounding tissues, being careful as yet not to open into the pleural cavity; exsect one half or three fourths of an inch, dividing it with a chain saw. If the intercostal artery, which lies beneath its lower border, be cut, tie it; then make a suitable opening through the intervening structures into the pleural cavity.

It is well to make the first incision for the purpose corresponding to the long axis of the rib, and thus avoid the intercostal vessels and nerves. The wound should be dressed antiseptically.

Excision of the Clavicle.—This operation is performed for necrosis and for morbid growths. The patient is placed on the back, with the shoulders elevated from the table and head turned to the opposite side.

Contiguous Anatomy.—Its muscular and ligamentous attachments must be carefully studied, for it is by a knowledge of these that the surgeon is enabled to raise the bone from its more important relations.

In front.

Attachments of
Pectoralis major.
Sterno-mastoid.
Trapezium and Deltoid.

Above.

External jugular.
Branches of thyroid axis. { Clavicle. }
Subclavian artery.
Brachial plexus.

Below.
Cephalic vein.

Behind.

Internal mammary artery—Sternal half.
Subclavian vein artery, “ “
External jugular.
Innominate vein on the right half.
Thoracic duct on the left half.
Pleural cavity.

Its intimate association to important arteries, veins, nerves, etc., surrounds its removal with great difficulties and dangerous complications; especially, if it be attempted for a well-developed malignant, or other morbid growth. With the patient in the position assumed for the operation, the foregoing plan shows the important anatomical relations of the clavicle.

The whole or a portion can be removed. If the whole be removed, it may be raised by its scapular extremity, or divided, and each half taken away separately.

Removal of the Entire Clavicle.—Anæsthetize and place the patient in the position just described; if for necrosis, make an incision the whole length of the bone parallel with its long axis. If necessary, a short transverse incision is added; expose the bone, divide the periosteum, and with the elevator enucleate it from the surrounding tissues. It can be divided through the centre and each half removed separately, or the acromial end can be detached and the whole raised by it. In either instance the articular ends, and their connective ligaments should be preserved if possible.

If the involucrum be weak and liable to bend or break after the bone is removed, the shoulder must be held outward, backward, and upward by the methods employed in fracture of that bone. The indirect method of sequestrotomy can be employed in some instances.

If the operation be for the removal of a tumor of the bone, especially one acutely malignant, and involving any considerable portion of the surrounding tissues, it is certain to be an exceedingly tedious and bloody one.

The smaller the size of the tumor and the less its vascularity, the easier its removal. Make an incision in the long axis of the bone, from the sternal to the acromial extremity; if necessary this is crossed by a vertical one, extending from the posterior border of the sterno-mastoid to the upper third of the pectoralis major. Carry these incisions as deeply as the nature of the growth will permit, and reflect the flaps from off the tumor; separate the insertions of the deltoid and trapezius muscles on a director, cutting them either with a knife or strong curved scissors, being careful to avoid the cephalic vein which lies at the inner border of the deltoid. Divide the coraco- and acromio-clavicular ligaments; raise the acromial extremity of the clavicle, thus elevating the morbid growth, which should be separated cautiously from the surrounding tissues. The nearer the

approach to the sternal extremity, the greater necessity for caution, since the growth may be connected with the important structures there; finally, divide the sterno-mastoid insertion, the pectoralis major, and rhomboid ligament, and carefully disarticulate while the tumor is lifted upward and inward.

Either extremity may be excised by making a cruciate incision corresponding to the portion to be removed down to the bone, exposing and dividing it with a chain saw, and removing with the same precautions as before described. The results of the operation of complete excision have

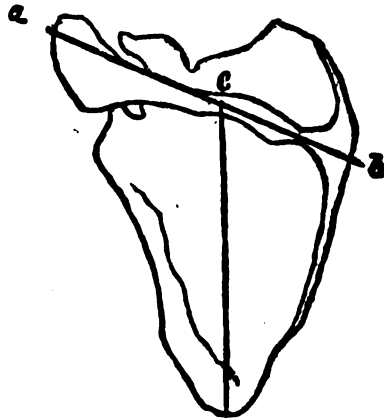


FIG. 219.

been very unfortunate, nearly all having perished from exhaustion, due to loss of blood, erysipelas, etc.

The entrance of air into the veins is especially to be guarded against, on account of their near proximity to the chest.

Excision of the Scapula.—This bone is excised on account of gun-shot injuries, necrosis, and morbid growths.

The whole bone may be removed, or its body, angles, and spines can be removed separately. Its contiguous anatomy is extensive, but not of the dangerous character found associated with the clavicle. To its spines, borders, and surfaces, are attached numerous and powerful muscles.

At the upper border are found the supra-scapular vessels and nerves; the posterior scapular passes down its vertebral

border; while at the axillary border the subscapular, dorsalis scapulæ, and even the axillary artery itself, and the brachial plexus, are in close connection with it.

Removal of the Entire Scapula (Fig. 212).—Make an incision from the top of the acromion process along the spine to the posterior border. *a, b*. Join it by a second from near its centre to the inferior angle of the bone, *c, d*; turn aside the flaps thus formed.

Separate the attachments of the deltoid and trapezius; disarticulate the acromio-clavicular articulation; secure the subscapular artery; divide the ligaments and tendons around

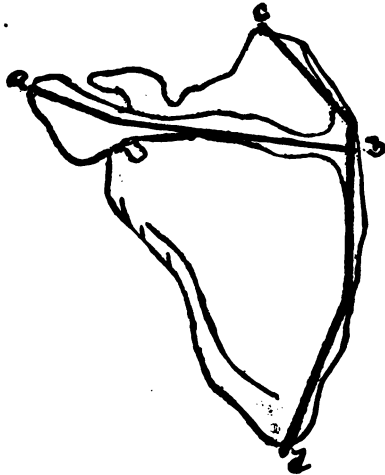


FIG. 213.

the glenoid cavity; raise up the coracoid process and carefully sever its ligaments and muscular attachments; raise the bone upward and divide the remaining muscular attachments with a knife or strong pair of scissors, carefully avoiding the subscapular and posterior scapular vessels; tie all the bleeding points; wash with an antiseptic solution; provide drainage, close the wound with suitable sutures, and dress antiseptically.

Removal of the Body of the Scapula (Fig. 213).—Make an incision the whole length of the spine, *a, b*; begin a second

at the posterior superior spine, and carry it along the posterior border of the bone to its inferior angle, *c, d*; dissect the resulting triangular flaps from their corresponding fossæ, carefully avoiding the supra-scapular artery and nerve; saw through the acromion close to the body, divide the muscles attached to the anterior and superior borders; raise the bone upward and saw through the anterior superior angle behind the coracoid process, turn the bone outward and sever its posterior connections with the knife.

Acromion Process and Angles may be separately removed. For the former, make an incision along its upper border, which may be curved, if necessary: expose this portion of

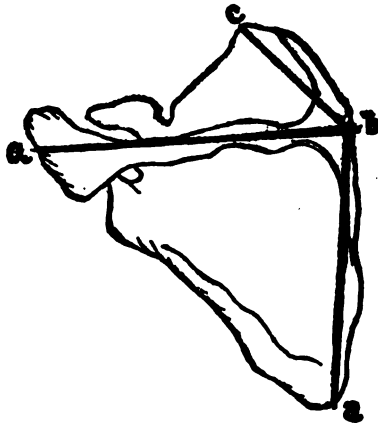


FIG. 214.

the bone, divide the muscles attached to it, and with a pair of bone forceps remove the desired amount. The acromion can be removed by making a curved or crucial incision over it; expose its upper surface, divide the muscles connected therewith, disarticulate the clavicle, and remove with a chain saw.

To remove an angle, make a V-shaped incision over it, dissect off the flaps, separate the muscles, and divide with the bone forceps.

Subperiosteal Excision of the Scapula (Fig. 215).—Make an incision from the apex of the acromion process along the spine to the posterior border of the scapula, *a, b*. Carry

a second from the posterior superior angle along the posterior border, crossing the former, to the inferior angle, *c, d*. Sever the muscular attachments to the acromion and spine; divide the periosteum at the posterior border between the attachments of the rhomboideus major and infra-spinatus, and separate it from the infra-spinous fossa. Separate the inferior angle from its muscular attachments. The periosteum is then raised from the supra-spinous fossa in the same manner; be careful to not injure the supra-scapular vessels, as they pass in close contact with the foramen; disconnect the muscles around its borders, closely hugging the bone, raise it upward by its inferior angle, denude the subscapular fossa, leaving its periosteum connected with the subscapularis; liberate the posterior border, allowing its cartilaginous border to remain—when present. Turn the bone upward and forward, and remove the remaining periosteum from its under surface to the neck of the scapula, which is divided with the chain saw. If the disease will not permit this, the neck can be enucleated, leaving the ligaments connected with the periosteum. *If the bone be removed for a malignant* or other morbid growth, make an incision from the posterior superior angle to the lower border of the tumor, carrying it downward, forward, and inward, with the convexity posteriorly. A second, beginning five inches or so in front of the preceding, carried downward and backward, crossing the other at or near its middle, and terminating at the lower border of the growth. The flaps are then reflected from the tumor, and the muscular attachments of the spine separated, and the acromion process sawn through behind the clavicle; expose the superior and posterior borders, and free them of their attachments; raise the bone upward and forward by its posterior border, and sever the serratus magnus from it; free the axillary border, and divide the neck with a saw, if practicable. When necessary, complete the entire removal by disarticulation.

It is not possible to lay down absolutely practical rules to govern the number, extent, or direction of the incisions; all this must depend on the size and situation of the growth, together with the amount of bone to be removed, and the ease and safety with which it can be done. After the removal, arrest hemorrhage, provide good drainage, unite the cut surfaces, and dress antiseptically.

The results of the operation are flattering: 27 per cent died after complete removal for injuries, and 19 per cent

when due to disease. The mortality was 26 per cent in partial excisions for disease, and about 20 per cent when done for injury.

Excision of the Humerus.—This can be removed entirely or in part.

The Important Associated Anatomy.—The insertions of the muscles acting upon the upper end of the bone, course of the superior profunda, and circumflex arteries, of the cir-

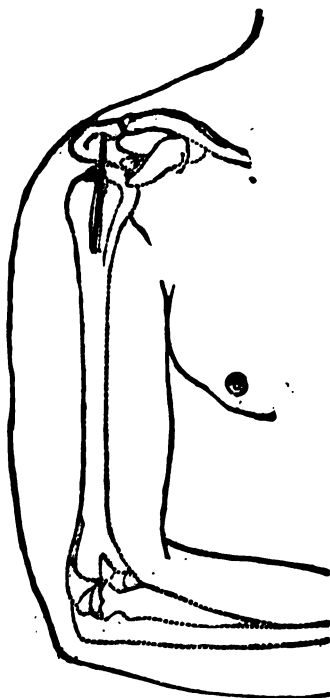


FIG. 215.

cumflex, musculo-spiral and ulnar nerves; points of insertion of the ligaments of the joints, together with the connections of the flexors and extensors, must be carefully considered before attempting the operation. This operation has been done for the relief of old dislocations, caries, necrosis, gun-shot injuries, arthritis, malignant disease, etc.

Excision of the Upper End.—Place the patient upon the

back, with the shoulders raised; make an incision from the anterior border of the acromion process, close to the articulation with the clavicle, downward, about four inches, in the line of the bicipital groove (Fig. 215). The bone at this region is quite superficial; liberate the long head of the biceps tendon from the groove, by carrying the point of the knife upward in it at the outer side, through the capsule to the acromion, and raise it out of the groove (Fig. 216); rotate the arm outward and divide the subscapularis tendon and inner portion of the capsule; then inward, cutting the external rotators and posterior portion of the capsule (Fig. 217); force the head of the bone, through the opening, seize it with a strong pair of forceps, divide the inferior portion of the capsule and remove the head of the bone with a chain or a small straight saw (Fig. 218).

Subperiosteal Excision of Head of Humerus.—Expose the bicipital groove and split up the capsular ligament as in the preceding operation. Divide and raise the periosteum from the inner border of the bicipital groove, passing inward and separating it along with the subscapularis and the fibrous capsule from the lesser tuberosity. Rotate the humerus outward and complete the separation to the required extent with the elevator and knife; rotate the arm inwards, displace the tendon of the biceps to the inner side of the head and separate the periosteum in connection with the capsule and the insertions of the external rotators, being very careful not to sever its connection with the bone below. To force the head through the external opening is practically impossible without destroying the periosteal connections; it is necessary, therefore, to divide it with a chain or narrow-bladed saw. Partial removal of the upper extremity is often necessary on account of disease or injury.

The variety and extent of the incisions to reach the part must be governed by the amount of the disease.

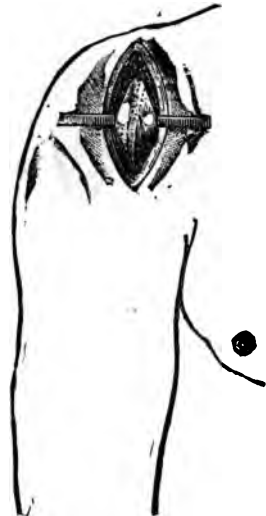

FIG. 216.

The vertical, V-, and U-shaped ones are selected as best suits the exigencies of the case.

Excision of the Glenoid Cavity.—This operation is only applicable to those conditions of injury or disease that are limited to the glenoid articular surface of the scapula. If a penetrating wound has ensued, its course should be followed to reach the bone; if not, then a curved insertion is made around the posterior border of the acromion which

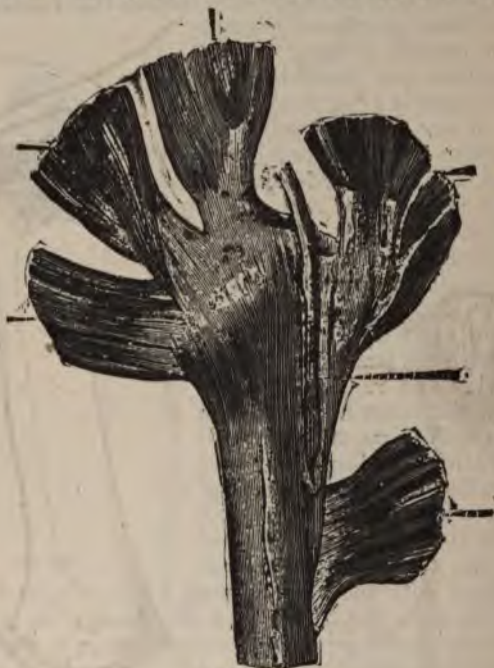

FIG. 217.

divides the fibres of the deltoid, and exposes the posterior and upper surface of the joint. A second incision is then made, commencing at the centre of this one, at the upper margin of the glenoid cavity, and, passing downward through the capsule, upon the centre of the greater tuberosity, between the supra and infra-spinatus tendons through the deltoid in the direction of its fibres (Fig. 219). *Open the wound widely by means of retractors and divide*

the tendons of the biceps at its insertion; separate the periosteum around the neck of the scapula if possible, leaving the attachments of the capsular ligament. Cut away the bone with a chain saw. The wound is then dressed as usual in such cases.

Excision of the Shaft.—Unless great caution be observed, the musculo-spiral nerve and the superior profunda artery will be injured in their course along the musculo-spiral

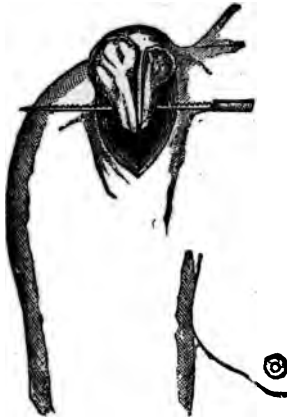

FIG. 218.



FIG. 219.

groove. The circumflex nerves and vessels also, if the incision be extended (Fig. 220) upward too far. The upper portion of the shaft is easily exposed by making an incision of sufficient length through the outer surface of the deltoid, commencing at its lower third and dividing it continuously upward, to avoid the circumflex nerve and artery; the bone is then denuded of its periosteum, or the morbid

In all the preceding operations, substantially the same after-treatment is required: stop the hemorrhage, irrigate with an antiseptic solution, provide drainage, close the lips of the wound, and surround with antiseptic dressing. Place the limb upon a splint affording an easy support at the proper angle. Extension is often necessary to main-

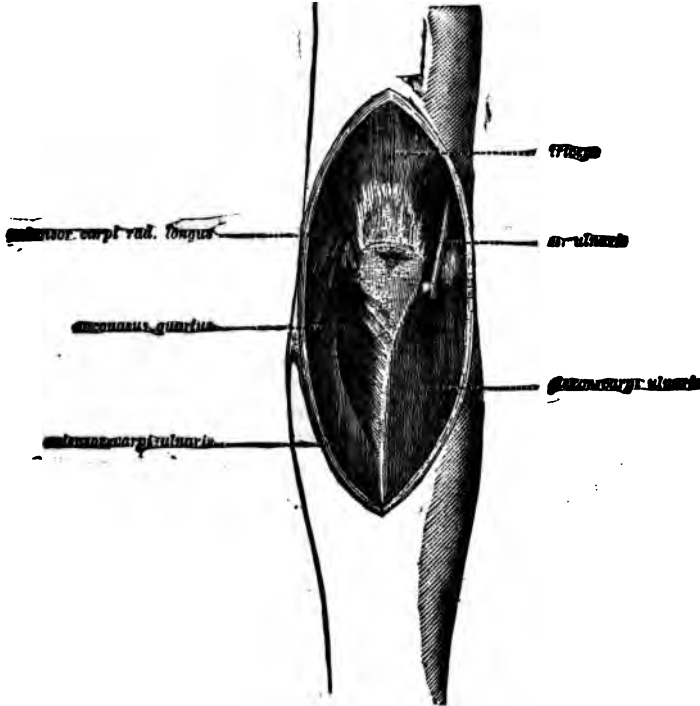


FIG. 221.

tain the limb at a suitable length during the healing process.

The results depend much upon the nature of the injury and the period of the operation. For gunshot wounds of the bone requiring excision, about 35 per cent perish. The rate of mortality being increased when the inflammatory stage exists at the time of operation.

Excision of the Elbow Joint (Hueter).—With the forearm extended make a straight incision about an inch in length

down upon the tip of the internal condyle, carefully avoiding the ulnar nerve (Fig. 221). Through this opening separate the muscular and ligamentous attachments to the condyle; make a second longitudinal incision from three to four inches in length down to the head of the radius (Fig. 222). Draw aside the soft parts and cut the external lateral and orbicular ligaments (Fig. 223). Expose the head of the radius and cut off with a saw or bone forceps. Separate the capsular ligament from its attachments on the anterior and posterior surfaces of the humerus, force the bone out of the external wound; this movement admits of its division, and at the same time raises the ulnar nerve from its bed away from the bone. Saw off the lower end of the humerus, carefully expose and remove the olecranon.

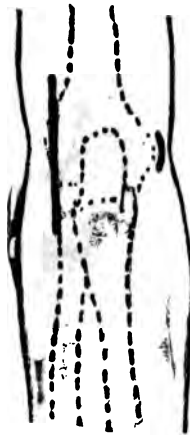


FIG. 222.

Subperiosteal Excision of Elbow (Langenbeck).—Make a longitudinal incision down to the bone, three to four inches in length, a little to the inner side of the olecranon (Fig. 224), about two thirds of its length being below the tip of the olecranon. Relieve that portion of the olecranon and ulna at the inner side of the incision of the periosteum. Separate by short parallel incisions the attachments of the inner half of the triceps tendon. Push the tissues at the internal condyle, together with the ulnar nerve inward towards the tip of the condyle, and elevate the periosteum from the inner condyle

sufficiently to separate the internal lateral ligaments and muscles from the bone, leaving them connected with the periosteum. The liberated tissues are now permitted to return to their former position, and the outer portion of the tendon is drawn outward and disconnected from the process by short transverse incisions, closely hugging the bone and allowing it to remain continuous, with the periosteum; which is reflected from the inner surface of the olecranon and shaft of the ulnar; expose the external condyle by separating the capsular ligament at its attachment, above the trochlear and capitillum, the tissues, including the detached periosteum and tendons of the biceps, are separated well from the bone by retractors. *Flex the forearm and force the extremities of the bones*

through the openings; saw off the head of the radius, lower end of the humerus and finally the olecranon process. It is important to remember that in all cases of excision about the elbow joint, to respect the insertions of important muscles, as the insertion of the brachialis anticus, biceps, triceps, etc. To unnecessarily destroy the power of one of these, is to be guilty of an unpardonable oversight. Various formed incisions, other than the longitudinal, have been employed: as the H, with the horizontal portions corresponding to the articulation; the T, with the horizontal on a line with the condyle; U-shaped or semilunar, with the convexity downward.

Excision of the Joint by the T-Shaped Incision (Liston's, Fig. 225).—Flex the elbow to an obtuse angle, the operator facing its posterior surface (Fig. 226), open the capsule between the olecranon and internal condyle by a longitudinal incision about four inches in length along the inner border of the olecranon, dissect and draw the soft parts over the internal condyle with the thumb (Fig. 226), increasing the flexion gradually till the condyle is fully exposed, divide the internal lateral ligament, extend the arm and carry a transverse incision from the point of articulation of the radius with the humerus directly across to the centre of the former incision.

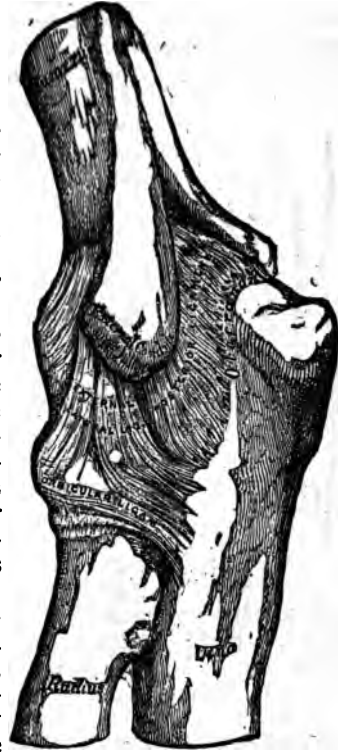

FIG. 223.

The periosteum on the inner surface of the olecranon and ulna is raised and left connected with the tendon of the triceps, which is carefully separated from the bone. Open the flaps wide and divide the external lateral ligament, flex the forearm, when the articular surfaces will

separate. Seize and saw off the lower extremity of the humerus and the olecranon process, finally the head of the radius. Dress as in the preceding instance.

Excision of the Elbow Joint has been done with such success that its rank is thoroughly established. Although when due to injury the rate of mortality is about 25 per cent, when due to disease it is less than 11 per cent. Partial excisions are followed by better results, so far as motion is concerned, than complete ones.

It would appear that the saving of the synovial mem-

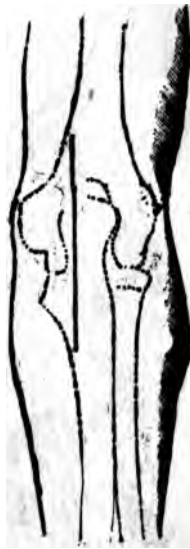

FIG. 224.

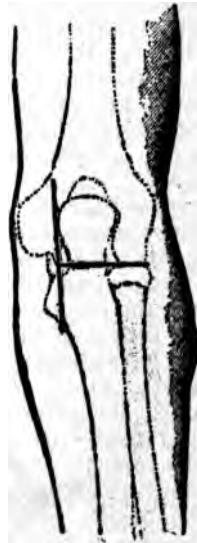

FIG. 225.

brane exerts a more conservative influence upon the usefulness of the joint than the saving of bone; provided, of course, that the bony insertions of the muscles acting directly upon the joint be respected. The amount of bone removed will determine the usefulness of the joint. If too little, the movement will be limited and insufficient; if too great, it will dangle, and be of little use except for carrying purposes. If the operation be for traumatism, remove the *fragment*; if for disease, remove only the diseased portion,

and in all, the wounds should be washed with a suitable antiseptic solution, closed with proper drainage, dressed antiseptically, and kept extended till repair is begun; when it should from time to time be placed at various angles for a day or so. By this course the newly formed



FIG. 226.

tissue will conform more readily to the various positions of the joint thereafter.

Excision of the Ulna.—An incision is made along the posterior surface of sufficient length to expose the diseased portion, the periosteum pushed aside, and section made at the requisite point and the bone removed.

on a table of convenient height for the operator and his assistant. An incision is then made through the integument, beginning at the middle of the metacarpal bone of the index finger at its ulna border, and extending longitudinally to three-fourths of an inch above the lower extremity of the radius, at its middle (Fig. 230). The deeper course of the incision passes to the radial side of the extensor indicis without opening its sheath, upward, either over the tendon of the extensor carpi radialis brevis, or to the inner side of its insertion, depending on the degree of adduction of the hand; then, if the tendons going to the index finger be pushed to the ulnar side,

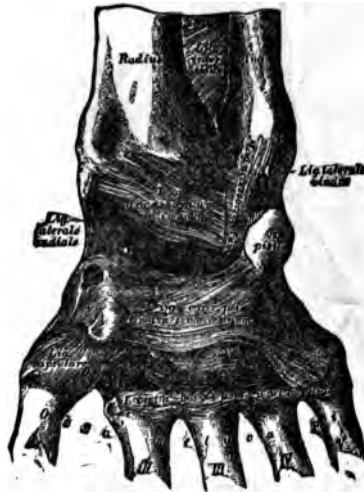

FIG. 229.

upward to the point of termination between the tendons of the extensor secundi internodii pollicis and the extensor indicis (Fig. 230), dividing the lower portion of the posterior annular ligament. Draw the tissues apart with suitable retractors and separate the fibrous sheaths of the extensors of the carpus situated on the posterior surface of the radius with a periosteal elevator, also, the insertion of the supinator longus, annular ligament, periosteum, and capsular ligament are then disconnected and drawn inward; the tendons, ligaments, and periosteum on the posterior surface of the ulna are separated in the same manner and drawn out.

ward; open well the radio-carpal joint, flex the carpus and expose the articular surfaces, and separate the bones of the first row from their connection with each other, leaving the periosteum if possible. Liberate the scaphoid from the trapezium and trapezoid, the semilunar from the

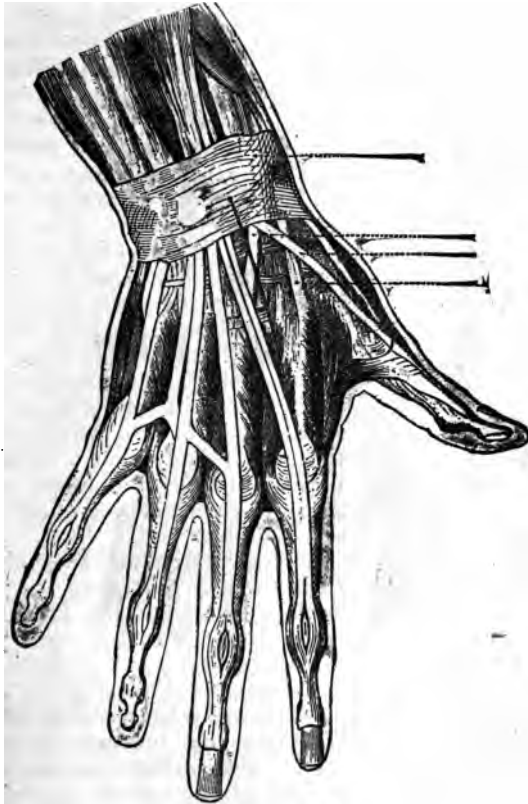


FIG. 230.

os magnum, and the cuneiform from the unciform; lift them out, leaving, if possible, their periosteum and the trapezium. The bones of the anterior row are taken out after severing the connections between the trapezium and trapezoid and the heads of the metacarpal bones. The extremities of the

radius and ulnar can now be forced through the wound, carefully stripped and sawn off, carefully avoiding the radial and ulnar vessels. The resulting wound is treated by antiseptic measures, attended when possible with extension. Continuous extension from the fingers should be early and constantly employed during the after treatment.

Excision of the Lower Extremities of the Bones of the Forearm (Bourgary).—Make an incision along the inner side of the ulnar, from just below the apex of the styloid process two inches along the inner border (Fig. 231). Divide

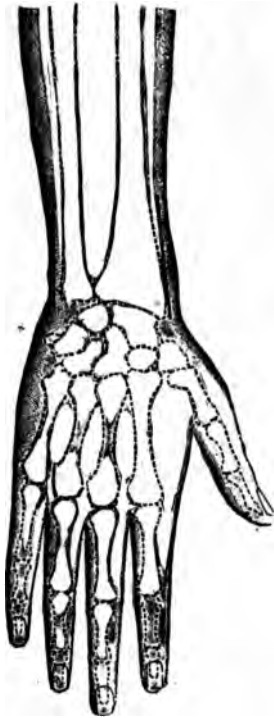


FIG. 231.

the periosteum at the interspace between the extensor and flexor carpi ulnaris in the same line, and reflect it from the bone inward to the interosseous membrane. The denuded extremity of the ulna is then removed, and a second longitudinal incision is made along the outer side of the radius from just below the apex of the styloid process two or three inches upward, divide the periosteum through the same incision, separate the attachment of the supinator longus, and raise the periosteum on the dorsal surface along with the sheath of the extensor tendons.

The periosteum is then elevated from the like portion of the palmar surface around to the interosseous membrane. Protect the periosteum and soft parts while the bone is being sawn through.

There are other incisions intended to meet the indication. 1. (Lyster). Beginning on the dorsal aspect of the radius, opposite the styloid process. Carry it towards the inner side of the metacarpal articulation of the thumb parallel with the secundi internodii pollicis (Fig. 232). When at the radial border of the second metacarpal bone, carry it along one half the length of that bone; separate the soft parts on the radial side, divide the tendon of the extensor carpi radi-

alis longior at its insertion, raise it along with the breviar and secundi internodii pollicis, open the wound well and disconnect the trapezium from the remaining bones, which are then taken away. Extend the carpus and separate the soft parts on the dorsum at the ulnar side of the incision.

Make a second incision along the anterior and internal border of the forearm inside the flexor carpi ulnaris, beginning about two inches above the styloid process and extending to the middle of the metacarpal bone of the lit-

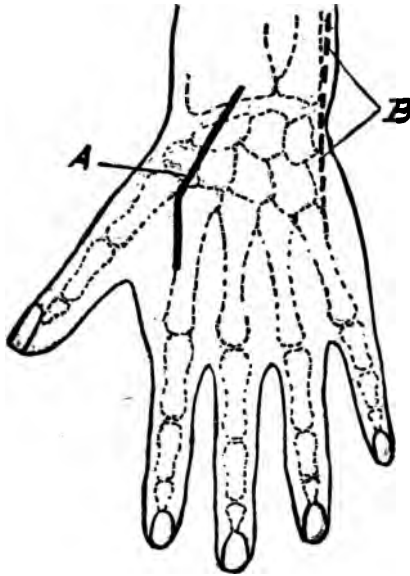


FIG. 232.

tle finger. Expose the dorsum of the ulna, divide the tendon of the extensor carpi ulnaris at its insertion, separate it from the groove in the ulna, raise the extensors of the fingers from the carpus, leaving their attachments to the radius intact; expose the entire surface of the ulna, hugging the bone closely; separate the pisiform bone with the flexor carpi ulnaris; flex the hand and separate the flexor tendons in the same cautious manner; divide the remaining ligaments connecting the bones of the forearm with the carpus.

Separate the process of the unciform bone, also the carpus from the metacarpus with cutting forceps; expose the extremities of the radius and ulna through the ulnar incision, remove with saw or forceps the diseased portions, carefully avoiding the grooves for the passage of the tendons; remove the trapezium without injury to the tendon of the flexor carpi ulnaris. All articular surfaces of bones—metacarpal bones, pisiform and between lower extremities of radius and ulna—should be removed, as well as all diseased portions of bone. Many other incisions are made to affect the removal; but only such as admit of it being done through longitudinal incisions are advisable, since transverse incisions sacrifice the tendons which impart usefulness to the remaining portion.

All hemorrhage having ceased, the wound should be closed, allowing the most dependent incision to remain open for drainage and the introduction of supporting dressings. Envelope the limb in antiseptic dressings, causing the whole to be properly supported by a splint. The subsequent treatment consists in cleanliness, extension, and passive motion.

Results.—Seven per cent die after excision for disease; 15 per cent for gunshot. In about 33 per cent of those who recover, the operation is worthless. In about 11 per cent entirely satisfactory; in the remainder, useful. The prognosis for usefulness is better when due to injury than to disease.

Excision of the Metacarpo-phalangeal Joints.—This can readily be done by making an incision about one and one half inches in length along the dorsum of the bones composing the joint at one side of the extensor tendons. The tissues in contact with the bone are carefully raised and turned aside, the joint exposed, and the requisite amount of bone removed by the chain-saw or cutting forceps.

The phalangeal articulations may be approached either through a longitudinal incision made along the side of the joint, or by a curved one corresponding to the outer surface with the convexity downward. In either instance raise the tissues by carefully clinging to the bones, which when properly exposed can be caused to protrude through the incision by lateral flexion and their extremities be removed.

The dressing consists in placing them in an immovable position properly protected by an antiseptic method,

and when repair begins passive motion must be begun and continued until the recovery is complete.

Excision of the Joints of the Lower Extremities.—The phalangeal joints of the tarsus are removed in a similar manner to those of the upper extremity.

The Metatarso-phalangeal Joints are removed through longitudinal incisions made on the dorsal surface of the bones constituting the joints at either side of the extensor tendon, which is pushed aside along with the remaining surrounding soft parts, the bones exposed, and their extremities severed by the chain-saw or bone-forceps. The removal of the metatarso-phalangeal articulation of the great toe can be and often is done differently. Make a curved incision with the convexity downward, at the inner side of the joint, its centre corresponding to the joint centre, of sufficient length to freely expose the bones to

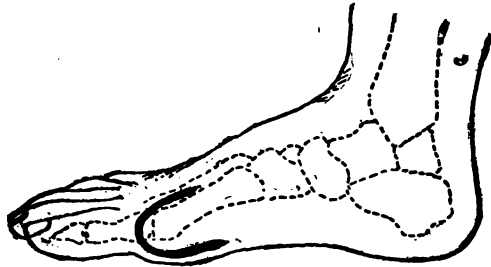


FIG. 233.

be removed (Fig. 233). Dissect the soft parts from around the bones, carefully pushing aside the tendons; expose and remove the necessary amount of bone with chain-saw or forceps. If the operation be done for the correction of the deformity caused by prominence of the head of the metatarsal bone, enough bone is removed from its extremity to permit the easy return of the displaced toe to its natural position; where it is to be retained quietly till repair is well advanced, when passive motion is commenced.

The Metatarso-tarsal Joints can be excised by raising a semilunar flap over their dorsal surface; avoiding division of the extensor tendons, which are raised and pushed aside, while the dorsal ligaments connecting the bones are divided and the joint cavity exposed by forced flexion, after

which the extremities of the bones of the distal row can be divided with a saw or bone forceps. The corresponding extremities of the tarsal bones can be treated likewise.

Tarsal Joints.—When separate tarsal joints become involved by disease or traumatic violence, they can be removed by making an incision over the injured or diseased portions, often following in the line of the course of the violence, or in the tracks of sinuses leading therefrom.

This treatment is, however, better adapted to those joints having a limited synovial membrane, than to those where that membrane extends between several contiguous bone surfaces; in the latter case it is often better to remove the bones entire by aid of the chisel, saw, or gouge. In either instance curved incisions are preferable, provided they do not divide important tendons and vessels.

Excision of the Ankle Joint.—This is a hinge-joint, having

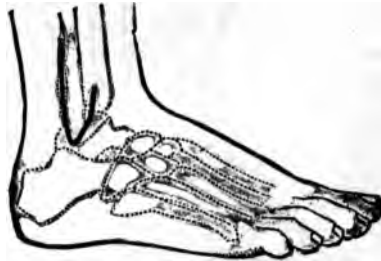

FIG. 234.

no lateral movement, except the foot be well extended, and then it is very limited. The indications calling for the operation are numerous, and should be well considered before it is attempted. As in all excisions those procedures which best preserve the tendons, vessels, nerves, and periosteum are to be adhered to, consequently those of a longitudinal character are best employed.

Operation, Subperiosteal (Langenbeck).—Make an incision down to the bone (Fig. 234), about three inches in length along the posterior border of the lower extremity of the fibula, carrying it forward in a hooked shape around the lower end and upward along its anterior border about an inch. The periosteum is reflected from the bone along with the tissues in contact with it, thereby exposing the lower extremity of the fibula without opening the tendi-

nous grooves of the peronei muscles (Fig. 235). The fibula is then divided at the upper end of the cut with a narrow saw, pulled outward, and the ligamentous attachments along its inner border and surfaces disconnected (Fig. 236), and the bone removed. An incision is then made about an inch and a half in length down to the bone, around the lower-end of the inner malleolis (Fig. 237). A second and ver-

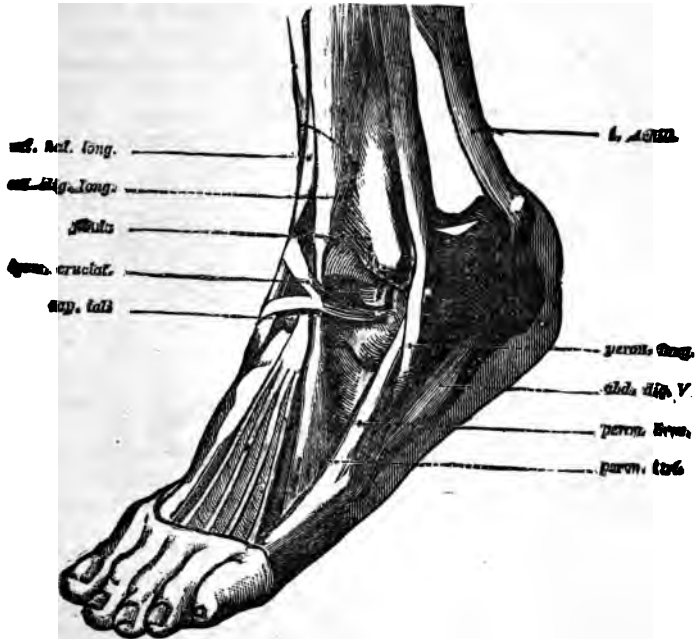

FIG. 235.

tical one is next made about two inches in length, down to the bone through the centre of tibia, connecting with the semicircular one first made. The triangular flaps are turned aside, including the periosteum, with the elevator, using care to raise the sheath of all tendons from their grooves (Fig. 238), push them aside, divide the tibia at the upper end of the cut with a chain saw; pull it outward with the forceps, free it from the interosseous membrane, as in the preceding instance, and remove the bone. If it be neces-

sary to remove the articular surface of the astragalus, it can be done through either incision; the better, however, through the internal one, on account of the greater amount of room. *Results*: About 13 per cent die from excision of

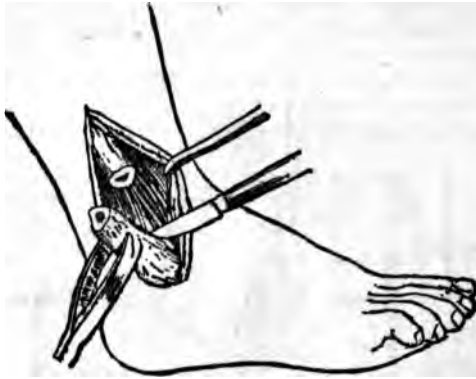

FIG. 236.

this joint; the rule of mortality being about 50 per cent greater from disease than from injury.

The prognosis for life is most favorable between one and fifteen years of age. Most unfavorable between thirty and forty. A large proportion of the recoveries from this results

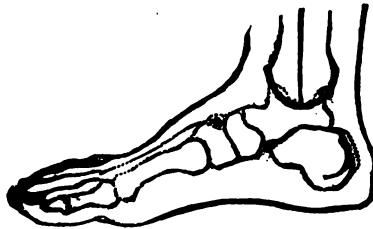


FIG. 237.

in a more or less useful limb; about 9 per cent being worthless.

The treatment consists in the immovable dressing of the joint, after the usual washing and drainage has been established.

If it be desired to remove, by section or otherwise, portions of either of the bones of the leg, the external incision is governed, as to its location and extent, by the situation and degree of the injury or disease. The bone should, however, be reached by the shortest course, which should be carried *between* the individual muscles, rather than through their structures. After its removal, which should always be subperiosteal, the limb must be so confined as to permit the new structure, when completed, to fulfil the requirements of its predecessor.

Excision of the Knee Joint.—This joint can be excised with

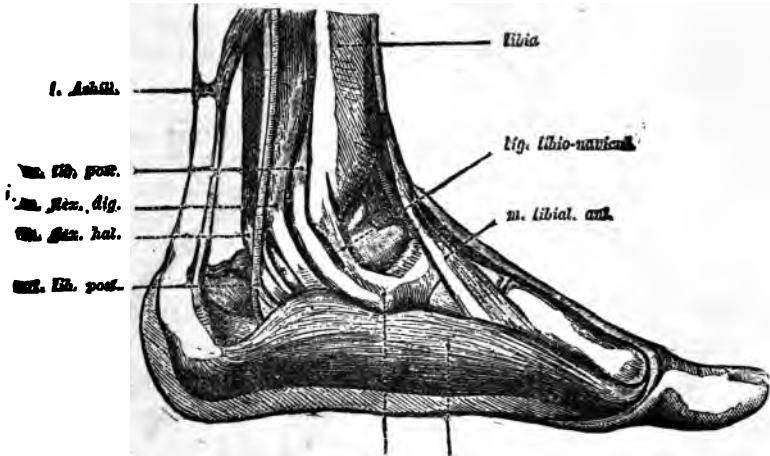


FIG. 238.

comparative safety to the patient, and with a fair prospect of recovery with a useful limb. As in the preceding, the nature of the cause demanding the operation exercises a marked influence on the result.

Results : The mortality, when due to disease, is about 30 per cent; when dependent upon injury, about 40 per cent.

If it be a gunshot injury, the mortality is increased to 75 per cent. The age of the patient is a consideration not to be underestimated; being best from five to ten years, when due to injury or disease; 15 to 20 per cent when done for gunshot wounds. Complete excision gives a higher rate than partial, when due to disease or injury. The removal of about three inches insures the best prognosis for life.

A less or greater amount increases the rate per cent. The removal of the patella, when not diseased, increases the rate of mortality slightly. The usefulness of the limb after the operation can be briefly summed up as follows:

When due to disease, 14 per cent were perfect, 42 were useful, and the remaining useless, of which 18 per cent were amputated.

For injuries about 18 were perfect, about 65 useful, and about twelve were amputated.

When due to gunshot injuries, about 60 per cent were useful, and 24 were amputated, the remaining not accounted for.

When done for deformity, 19½ were perfect, and about 68 per cent had useful limbs; the remainder not reported.

It appears that the degree of usefulness does not depend upon the amount of bone removed.

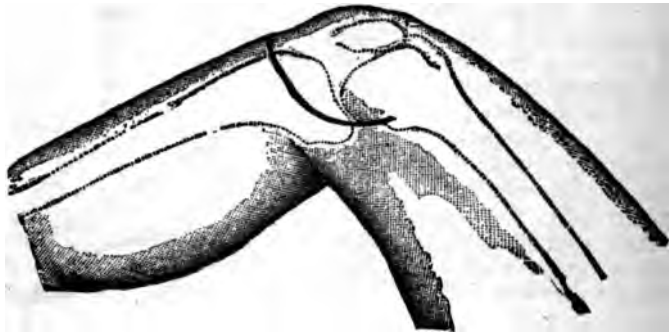


FIG. 239.

The removal of the patella increased the usefulness over the retention about 45 per cent.

Contiguous Anatomy.—The articular vessels and those which occupy the popliteal space are the ones to be avoided. The latter are separated from all danger by the dense and unyielding ligamentum posticum Winslowii. The former can be avoided by limiting the incisions to the space between the origin and insertion of the lateral ligaments. There are two well-known methods of excising this joint: 1. The non-subperiosteal, or the ordinary method; and 2, the subperiosteal. The former is employed when the tissues are too extensively destroyed, or diseased to admit of the saving of the periosteum.

Non-subperiosteal Excision of the Knee Joint.—Flex the leg to a right angle and make a curved incision, beginning at the posterior border and upper portion of one condyle, around to the same point on the outer, with the convexity downward and corresponding to the insertion of the ligamentum patella (Fig. 239). This incision divides the tissues down to and opens the anterior portion of the capsular ligament. The limb should now be still more strongly flexed and the lateral and crucial ligaments divided. A retractor is then passed between the ligamentum posticus and the posterior surface of the femur, the bone pushed forward and cut off on a line parallel with the articular surface, provided the extent of the diseased bone will admit of it. The head of the tibia is then treated in the same manner, being careful to avoid the articulation of the fibula.

In this operation it is better to remove the patella, since its means of attachment (the ligamentum patella) has been severed. All inflamed and degenerated synovial membrane should be dissected away.

The bony surfaces should now be united by passing annealed iron wire or silver, through the contiguous lateral borders; the wound is then washed with the strong carbolic solution and a drainage tube passed from side to side through the joint behind the bones; the whole enveloped in the antiseptic dressing, and the limb immovably fixed in a bracketed plaster splint, properly suspended. In sawing through the exposed extremities of either bone, the line of incision must be made to include the whole of the diseased osseous tissue. The line of section through the bone last sawn must correspond in direc-

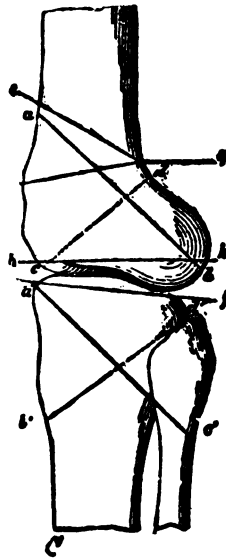


FIG. 240.

tion and be parallel with the line of section through the bone to which its sawn surface is to be applied, otherwise the union of the sawn surfaces will cause an angular deformity (Fig. 240). This applies more particularly to those cases where ankylosis in the straight position is sought. If for any reason it be thought better to ankylose

it with slight flexion, then the thicker portion should be taken from the posterior parts of the bone.

Subperiosteal Exsection of Knee Joint.—Extend the limb and make a curved incision (Langenbeck) on the inner side from six to seven inches in length, with the convexity downward, corresponding to the posterior border of the condyles and its centre to the line of articulation, commencing at the inner border of the rectus femoris and terminating below at the crest of the tibia (Fig. 241).

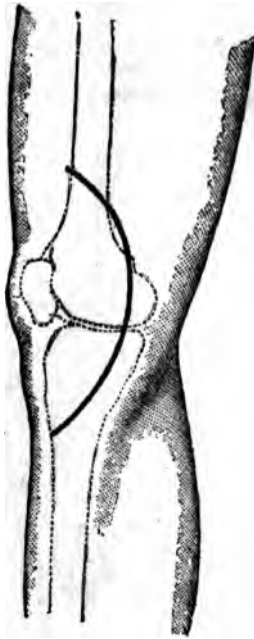


FIG. 241.

If the parts are now separated, the vastus internus muscle and the tendons of the adductor magnus and sartorius will be seen (Fig. 242), and should be carefully avoided. Divide the internal lateral ligament in a line with the articulation, with the periosteal elevator, separate the capsular ligament from the anterior surface of the inner condyle of the femur up to the vastus internus, and from the tibia forward to the median line, along with the internal alar; extend the leg slowly and at the same time dislocate the patella outward by the thumb applied to the inner border; divide the crucial ligaments, also the external lateral, and the corresponding portion of the capsular by a semi-lunar incision carried a few lines below the tip of the external condyle. Divide the posterior portion of the capsule and force the extremities of the femur and tibia successively through the wound, and saw them as before. The patella remains unmolested, except it be diseased, when the diseased portion is removed with a gouge, or the bone can be enucleated from the periosteal surroundings by the elevator and scalpel. A small opening should now be made at the outer side of the joint, for the purpose of establishing thorough drainage. A drainage tube should be passed through the upper synovial pouch, or firm compression be made thereon to prevent the collection of inflam-

matory products. It is then cleansed, all hemorrhage stopped, surrounded by antiseptic dressing, and immovably fixed till future dressings become necessary.

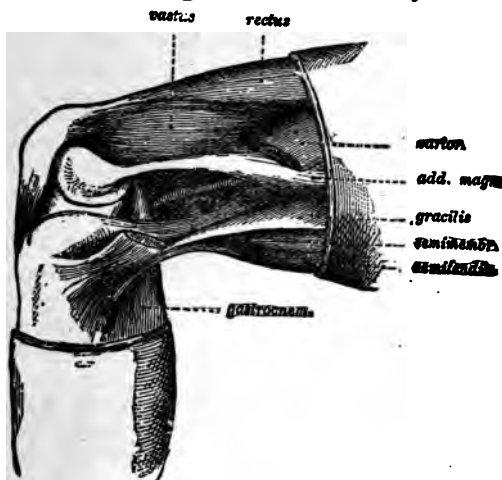


FIG. 242.

The subperiosteal of Ollier is made through an incision commencing two inches above and to the outer side of the patella, carried down to its upper and outer angle, along the outer border to the apex and outer side of the ligamentum patella below its insertion, through the superimposed tissues (Fig. 243). The outer condyle of the femur is denuded of its periosteum along with the lateral and capsular ligaments and the outer head of the gastrocnemius; the anterior surface of the femur is denuded, the crucial ligaments cut, patella displaced inward over the inner condyle, the leg is then flexed and carried inward; causing the femur to protrude, when it is isolated and sawn off. The upper end of the tibia is then denuded from above downward, pushed through the opening and likewise divided. If the patella be diseased, remove it, leaving its periosteum behind.

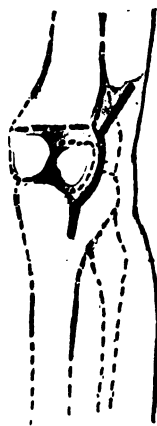

FIG. 243.

Excision of the Patella.—It may be necessary, on account of necrosis or injury, to remove the

patella independently of the tibia and femur. In such cases the deep incisions must correspond in extent to the diseased bone; for if they be greater the synovial cavity may be opened. The periosteum should be raised, dead bone carefully removed, if possible, without entering the joint. If the joint be not involved, recovery will be speedy and satisfactory under disinfectant dressing, with the limb confined in the extended position till sufficient repair has taken place to warrant flexion without fracture of the bone. *The results* in eleven cases are two deaths and nine recoveries, of which eight were complete and three partial excisions.

Excisions of the Hip Joint.—It is well before attempting this operation to give a brief survey of the important ligaments and muscular attachments to be respected. The space is too limited to describe them in detail, and even to do so would hardly be in keeping with the scope of this work.

The ilio-femoral, capsular, cotyloid, and even the teres, should be carefully considered in relation to their origin and insertion, in order that their relations with the involucrem or periosteum may be maintained. Those muscles which are connected with the trochanters major and minor, should likewise be preserved intact, in order that their association with the new bone growth may give to the new joint, so far as possible, the normal functions of the old one. *The results* of this operation are approximately as follows: 90 per cent die, when done for gunshot injuries. Of these, the greater percentage (48) followed the intermediate operation; 15 per cent the secondary, and the remainder the primary. For disease the mortality is reported variously from 15 (Sayre) to 45 per cent. Is best done from one to ten years of age; and is most favorable when it has existed from ten to fifteen months. A greater number die from complete than partial excisions. The rate of mortality is but little modified by the removal of the trochanters, and even the upper portions of the shaft, diminishing, however, from the head of the bone downward, and increasing in proportion to the extent of the disease of the ilium. About 94 per cent secure useful limbs, when excised for disease. Complete excision is followed by a more useful limb than partial.

The hip joint may be removed with or without the preservation of the periosteum; giving two quite distinct forms

erating. 1. The simple, when no effort is made to the periosteum, and the muscular and ligamentous hments are freely sacrificed. This method is applica-) malignant disease of the bone, and to injuries caus- xtensive comminution and laceration. In the latter a conscientious search will often be repaid by finding

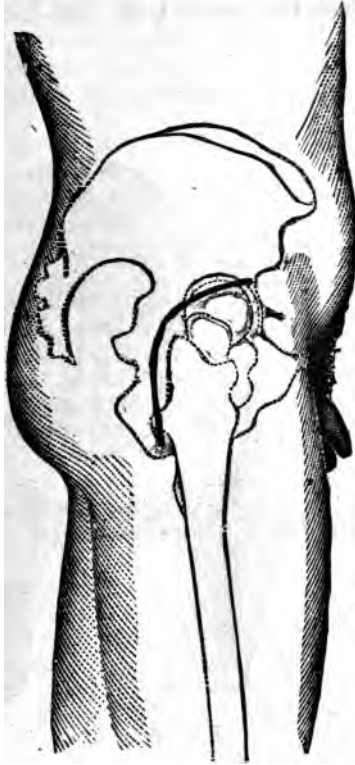


FIG. 244.

steal tissue and muscular attachments worthy of care- reservation. Under all circumstances the acetabulum ld be carefully scrutinized for the presence of dead , which should, in all instances, be removed with care, he pelvic contents may be injured.
eration (White) The simple method is done by placing

the patient on the healthy side, and making a deep curved incision (Fig. 244) commencing at a point midway between the anterior superior spinous process of the ilium and the trochanter major, and passing backward around the top of the trochanter, down its posterior border about three inches: with a stout knife divide the insertions of the muscles connected to the great trochanter (Fig. 245), draw them aside

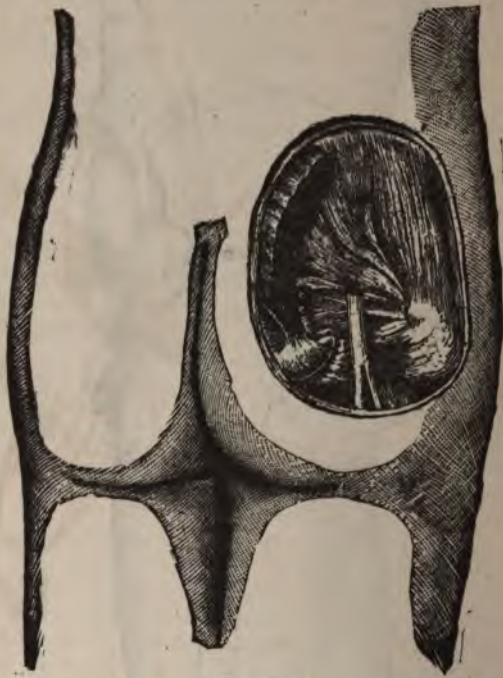


FIG. 245.

with a spatula, and expose the posterior surface of the neck of the femur and the acetabulum. The exposure will be still more complete if the femur be rotated strongly inward. If the cotyloid and capsular ligaments be now divided, and the thigh be flexed and adducted, the head of the bone will be raised from the acetabulum sufficiently to admit of the division of the ligamentum teres, when the complete escape of the head of the femur will take place. The soft parts

are then protected by the spatula, the bone exposed the required extent, and sawn off (Fig. 246).

Subperiosteal Excision of the Hip Joint (Langenbeck).—Place the patient on the sound side with the thigh flexed at an angle of 45° ; make an incision five or six inches in length in the long axis of the great trochanter (Fig. 247)

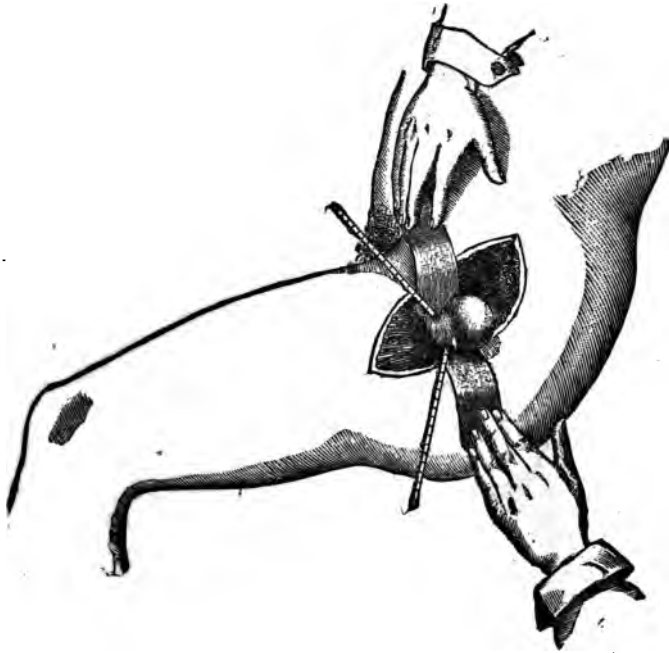


FIG. 246.

upward and backward towards the posterior superior spine of the ilium, through the fibres of the gluteus maximus, fascia lata, and periosteum of trochanter; separate the surfaces of the wound with retractors, and with the elevator and knife raise the periosteum and the attachments of the muscles inserted into the trochanter major and the contiguous surfaces, being careful to preserve their connections with each other; next make a longitudinal incision along the neck of the femur, through the capsular ligament and

the periosteum. The periosteum of the neck is then separated in connection with the attachments of the capsular ligament, and the obturator externus in the same manner as before. If a piece be now cut from the cotyloid ligament, and the thigh be rotated inward and adducted, the head of the bone will be elevated from the floor of the acetabulum sufficiently to admit of the division of the ligamentum teres, when it can be pushed through the opening and sawn off.

The following admirable method of excision is recom-

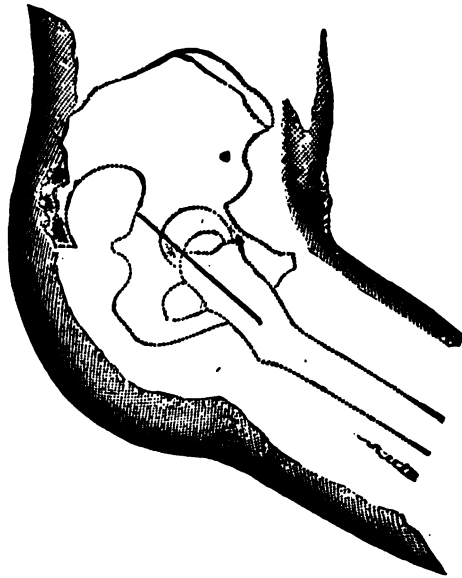


FIG. 247.

mended by Prof. Lewis A. Sayre. It is subperiosteal in all essential particulars, and possesses an advantage over the one just described in that the primary incision is better adapted to drainage. Place the patient on the sound side and introduce a strong knife down to the bone, midway between the anterior spinous process of the ilium and top of the trochanter major; carry it in a curved course upon bone to the top of the great trochanter midway between

its posterior border and centre; complete it by carrying the knife forward and inward, making the length of the incision from four to six or eight inches, depending upon the size of the thigh (Fig. 248). If it be not certain that the

periosteum of the trochanter be divided by the first incision, the knife should be carried along the same line a second, and even a third time if needs be. The soft parts are now drawn asunder, exposing the great trochanter, when, with a narrow, thick knife, a second incision is made through the periosteum only, at right angles with the first, about an inch or an inch and a half from the top of the trochanter. At the junction of the periosteal incisions introduce the blade of the elevator, and carefully peel the periosteum from either side as far as possible, together with the ligamentous attachments, until the digital fossa is reached. The insertions of the rotators into the trochanter

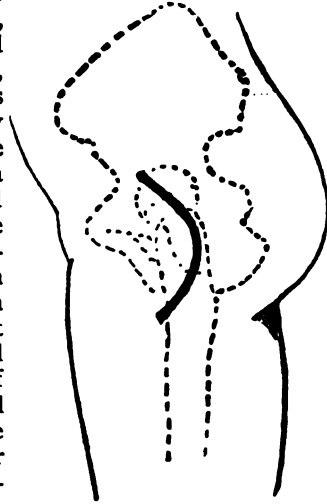


FIG. 248.

major and digital fossa are so firm that it will be impossible to peel them off; they must be carefully separated by short parallel cuts, so directed as to remove the periosteum with which they are blended. After the separation of the tendinous insertions, continue to elevate the membrane upon either side of the neck, using great care not to rupture it. Its integrity is important to prevent infiltration into the surrounding tissues, provide attachments for the important ligaments and muscles, also as the basis for the reproduction of bone which is hoped will take place; each of which will exert an important influence in the formation of a useful joint. Having separated the periosteum so far as safely can be done, adduct the thigh carefully when it will be raised from the acetabulum, and the remaining portion can be detached. Adduct and depress the femur slightly, being careful not to tear the periosteum, lift the head of the bone out far enough to admit of a division just

above the trochanter minor; care should be taken to not expose a greater surface than is necessary, since necrosis will follow and hinder recovery. It is better to remove the trochanter major, even though it be not diseased, since it will impede the escape of discharges, and is not essential to a useful limb if its periosteal covering and muscular attachments have been preserved. In all cases after the operation, the wound should be well irrigated with a strong solution of carbolic acid, thoroughly smeared with balsam of Peru, and loosely filled with fine, well-shaken oakum; good drainage provided, and extension applied to the limb either by the Buck's apparatus or the wire breeches.

Excision of the Great Trochanter.—This is occasionally required on account of caries. A longitudinal or curved incision is made down upon the bone, which is removed with the usual instruments. The circumflex branches and the capsular ligament are to be avoided.

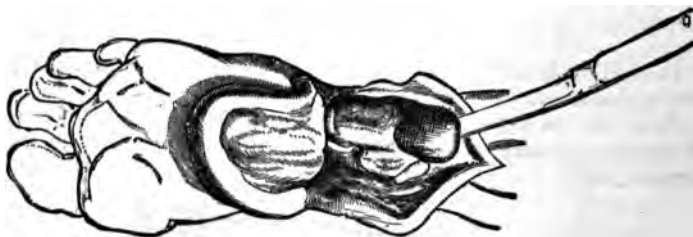


FIG. 249.

Excision of the Calcaneum.—It is important that as much as possible of the bone be saved, as it forms the posterior pillar of the arch of the foot, also the attachment of the tendo-Achilles, which exerts a powerful influence in locomotion. When gouging fails to remove the diseased tissue, excision becomes the final resort. A horseshoe-shaped incision is carried from a little in front of the calcaneo-cuboid articulation around the base along the side of the foot to a corresponding point on the opposite side. This flap, with the knife hugging the bone, is dissected up, exposing its entire under surface (Fig. 249). A second perpendicular incision about two inches in length is then made through the middle of the tendo-Achilles down to the preceding one; the resulting flaps are dissected off closely to the bone, and the posterior articulation between the cal-

caneum and the astragalus opened, the ligamentous connections severed, together with those between it and the contiguous bones, the os calcis taken away, and any additional diseased bone removed. The larger majority of cases recover with useful limbs.

Excision of the Astragalus.—This is accomplished through a semilunar opening, with the convexity downward, extending between the malleoli in front. The tendons of the extensor muscles must be carefully pushed aside; its connections with the tibia, fibula, and os calcis severed; finally, those with the scaphoid; when, with the foot extended, the bone is pulled from its site and the calcaneum placed in the resulting gap between the malleolus. About 75 per cent of these cases recover with useful limbs.

OSTEOTOMY.

In a liberal acceptance, osteotomy may be defined as a section of bone.

In a limited sense, however, it is applied to the divisions of bone that may be attempted for the relief of deformity, dependent on ankylosis, rickets, badly united fractures,

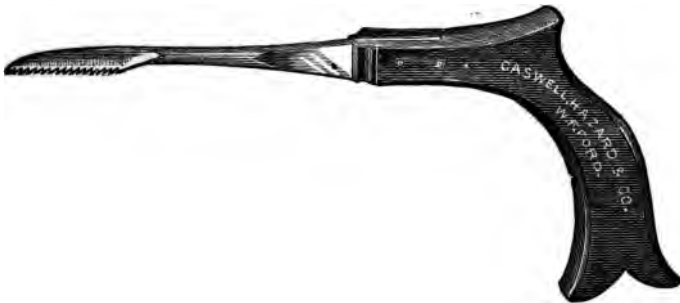

FIG. 250.

etc., etc. It may be done either with or without antiseptics. The latter, however, is by far the better plan.

The instruments employed consist of especially designed saws, chisels, osteotomes, mallets, scalpels, blunt hooks, and sand pillows.

There are various forms of saws employed, named usually after the one who designed them. Langenbeck (Fig. 250), Adams (Fig. 251). The blade is short and strong; one fourth of an inch in width and an inch and a half in length, connected to the handle by a strong shank three inches long. Deviations from this one are to meet especial indications, rather than to abrogate its use.

The objections to the use of the saw not only apply to



FIG. 251.

the danger of lacerating the contiguous tissue, but more forcibly to the retention in the wound of the bone-dust, which, failing to be absorbed, is followed by suppuration. The saw devised by Dr. George F. Shardy, of this city, is the best, and is described as follows by himself:



FIG. 252 (1, 2, and 3).

Figs. 252 and 253. The instrument consists of a trocar (Fig. 1) and a staff (Fig. 2), with a handle and blunt extremity. A portion of this shaft at a short distance from the extremity is flattened, one edge (B) being made into a knife blade, and the other (C) being provided with saw-teeth. This shaft (Fig. 2) is intended to replace the trocar in the canula after the latter is introduced. When in position (Fig. 3) either the saw (C) or the knife (B) edge of the

shaft, according to the way the latter is turned, corresponds with the opening of the canula. The saw or knife can then be worked to and fro within the canula by a piston-like movement, the canula being steadied by grasping the flange (D) at its base. If it be necessary to work the instrument as an ordinary blunt-pointed sheathed saw or knife, the shaft can be fixed in the canula, and made into one piece by a thumb-screw in the handle. The portion of the canula at the back of the opening is made extra strong, and is of the same thickness as the blade, so that in sawing there is no stoppage of the passage of the instrument through any thickness of the bone. The soft parts are protected from injury, no matter which way the instrument may be worked. The saw-blade is blunt at its extremity, and is guarded on all sides except in its limited cutting surface. The same may be said of the knife. The working of the saw to and fro in the canula is sufficient in sweep to insure the division of any bone having a diameter less than the cutting edge. Still, as this process is much slower than when the saw is used in the ordinary way, it is perhaps better to restrict its employment to operations on the smaller bones, to cramped localities, and to situations where there is special danger of wounding some neighboring vessels. All that is necessary in using this saw is to thrust the trocar and canula into the limb, the fenestrum of the canula being alongside of the bone upon which the operation is to be performed. The trocar is then withdrawn, the staff introduced in its place (Fig. 3), and worked as already described.




FIG. 253.

Since the above description was written the instrument has been slightly modified by lessening the size of the fenestrum through which the teeth of the saw are seen, which strengthens the canula and facilitates its progress through the bone (Fig. 253).

The Chisel is like that of the carpenter, but differing in its temper; it has two parallel sides extending to its cutting




FIG. 254.

edge. The cutting surface has one side straight and the other bevelled; it should be one eighth of an inch thick at the base of the bevel. If thicker, it may splinter the bone. The breadth varies according to the size of the bone, one half an inch is suitable in the majority of cases. For narrow bones one fourth inch is better (Fig. 254). The width should always be less than the bone to be attacked.

The temper of the tools of the hard-wood or ivory turner is best suited for the purpose, and its efficiency should be tested upon the thigh-bone of an ox or other animal before using.

Its edge should be sharp, leaving a smoothly cut surface. This instrument is employed only to remove a wedge-shaped piece from the bone, since the shape of its cutting extremity will, as with the carpenter's chisel, cause it to go awry if a straight section be attempted.

The Osteotome.—This instrument is bevelled on both edges (see Fig. 254), resembling a slender wedge; the handle and the blade forming one piece. The top should have a round head, against which the thumb is pressed to steady it. One border of the blade is delicately marked in inches to determine the depth of the incision. The edge should be sharp enough to cut the finger-nails, and the temper of a character to withstand the strain required. It can be tested upon the thigh-bone of the ox; when, if it neither turn nor chip, it is calculated to withstand the test of human bone. Osteotomes should vary in thickness, in order that a section begun by one of a given thickness may be continued on its withdrawal by the substitution of one of a lesser thickness.

The Mallet is made of hard wood, and can be constructed for the purpose; or, an extemporized one may be employed.

The Scalpel is an ordinary one, with a sharp point suitable for penetrating at once to the bone. Blunt hooks to draw the cut asunder are employed, without force.

The Sand Pillow.—Its dimensions should be about eighteen inches by twelve; made of stout cloth, and filled sufficiently to permit its contents being moved from one part of the bag to another, without leaving a portion empty. It should be dampened before being used, covered with carbolized cloth, and the limb laid upon, or rather embedded in it. It forms an efficient support, and prevents the force imparted to the bone by the mallet injuring the soft parts.

The opening through the soft parts leading down to the point of proposed section should be limited in extent, and so located as to avoid the division of vessels, or injury to a joint. It should be made in the long axis of the fibres of any muscle through which it passes when practicable, down to, but not through the periosteum. The scalpel should remain in the incision till the danger of muscular contraction ceases, and then the chisel or osteotome is passed into the incision

by the side of the blade, as a guide, when it can be withdrawn.

It is better that the wound be large enough to admit the finger, or even to permit inspection of the bone, than that the tissues around a small incision be treated with violence, in the effort to accomplish the purpose.

If chips of bone are to be removed, a larger incision is required than if a simple section be intended. The patient should in all instances be anæsthetized and the limb rendered bloodless by the elastic bandage of Esmarch or Martin. All cutting instruments employed must be made antiseptic, and in all other respects the operation must be performed with antiseptic care.

Subcutaneous Division of the Neck of the Femur (Adams).
—Place the patient upon the side, with the bone to be operated upon uppermost. Introduce a long slender scalpel

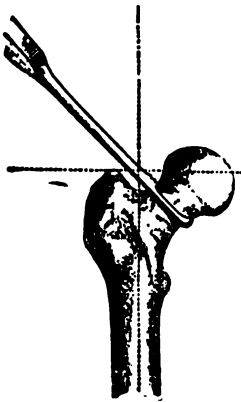


FIG. 255.

or tenatome above the top of the great trochanter, straight down to the neck of the femur; divide the muscles and open the capsule freely on the anterior and upper surface; pass the small saw by the side of the knife along the track down to the anterior surface of the neck, which is then sawed transversely through (Fig. 255) sufficiently from before backward to be easily broken. The limb is then placed in position, the wound irrigated with a solution of carbolic acid (1 to 20), to render it aseptic and wash out the bone-dust; hemorrhage checked, a small drainage tube introduced, the remaining portion of the incision closed, the whole enveloped in antiseptic dressing, and the limb placed in an im-

movable position. Such tendinous contractions as interfere with the limb being placed properly, should be severed subcutaneously.

This operation has been successful in thirty-one out of thirty-four cases.

Mauder, Billoth, and others have used the chisel with forcible fracture with good results. Another method (Volkman) consists in forming a false joint in the following manner:

Make an incision along the posterior surface of the great trochanter,* and divide the bone one inch below its upper border; fracture the interior of the neck of the femur and scoop out the acetabulum with a gouge. Round off the upper end of the femur, reducing it to the size of the shaft below, and place it in the cotyloid cavity; apply extension to the limb, and make early passive motion. Volkmann has done this operation several times, resulting in useful limbs in each instance.

Inter-trochanteric Osteotomy.—This operation consists in exposing the anterior, outer, and posterior surfaces of bone through an incision about six inches in length, beginning just above the tip of the trochanter major, and carried longitudinally through the centre of its outer surface. A short, transverse incision is then joined to the centre of the posterior lip of the first; the respective surfaces are then exposed with an elevator until the trochanter minor can be felt, when a chain saw is passed around the bone immediately above this process. The uppermost, or curved incision (Fig. 256) is made by first sawing upward and outward, until the bone is one half severed, then changing the direction downward and outward and completing the section.

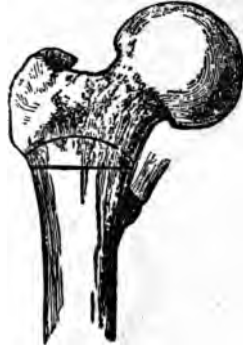

FIG. 256.

The second section is made by sawing directly through the bone in its transverse axis, removing a piece one eighth of an inch thick at its outer and posterior border, and three fourths of an inch of its central part.

The upper end of the lower fragment is then rounded to fit the concavity above. The limb is straightened out and treated like a compound fracture.

This method was practiced by Dr. Sayre some time since with eminent success.

The removal of a disk of bone in this situation has been quite frequently practiced, but with indifferent success. Out of the 17 cases reported, 7 died. While this method displayed great ingenuity and resource on the part of the

* Centralblatt Chirurgie, Jan. 31st, 1880.

originator, the fatality attending it, together with the introduction of the chisel and osteotome, render it at the present time impracticable.

The modification introduced by Völkman in 1873 consists in making an incision along the posterior surface of the great trochanter and removing the periosteum from two thirds of its circumference, when with chisels and gouges a triangular piece is taken from just below the trochanter, the bone broken, straightened, and placed in proper position until union has taken place. Of the twelve operations thus performed, all recovered.

Osteotomy for Bony Ankylosis of Knee Joint (supra-condyloid).—Make a longitudinal incision, sufficient to admit the osteotome, at the outer side of the rectus tendon, one finger's breadth above the upper portion of the outer condyle. The osteotome is introduced, and turned so its cutting surface corresponds to the transverse axis of the bone at the point to be divided; with the limb resting up on the sand-bag, the bone is two thirds divided and the remainder broken or bent. If performed from the inner aspect, the incision is made along the anterior border of the tendon of the adductor magnus, beginning one inch above the insertion. The remaining steps of the operation are similar to the preceding. It may be necessary to supplement the section of the femur with that of the tibia, in order to correct the deformity sufficiently. This is done by making an incision through the skin over the tibial crest just below the tuberosity. Through this opening, the subcutaneous and posterior surfaces of the tibia are divided sufficiently to admit of a fracture and the consequent correction of the deformity. The fibula, owing to its mobile association with the tibia, does not require division. It is often necessary, however, to cut the hamstring tendons before the deformity can be properly corrected. Supra-condyloid osteotomy has yielded most satisfactory results. In 522 operations for all causes, not a single death attributable to it has occurred. All of the patients were benefited, and many were able to take an active part in affairs from which they had been debarred.

Supra-condyloid osteotomy for Genu Valgum (Fig. 257).—In this operation care is taken to avoid the popliteal vessels, anastomotica magna, superior internal articular arteries, and the synovial pouch. The incision in the soft parts is made at the inner side of the limb, beginning a finger's

breadth above the tendon of insertion of the adductor magnus into the upper portion of the internal condyle and half an inch in front of it, and carried upward sufficiently to admit the osteotome. The course of this incision avoids as far as possible any interference with the anastomotica magna and the articular branches. The osteotome is applied to the bone transversely at the point indicated by the dotted line in Figure 258, and so directed that its course will correspond to a line extending across the posterior surface of the femur to a point one finger's breadth above the external condyle. The extent of the osseous incision depends upon the density of the bone ; if the subject be young, it can be bent or broken, if it be cut through two thirds of its diame-



FIG. 257.

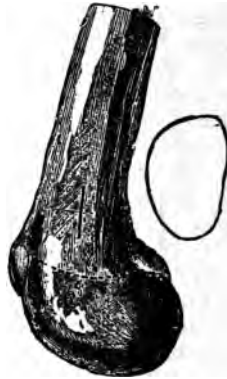

FIG. 258.

ter. If it be dense, it will be necessary to carry the incision to the outer wall. The posterior and inner surfaces of the bone are cut, if necessary, using a finer chisel to complete the operation. When the bone is sufficiently divided, the limb is straightened, all hemorrhage arrested, and the limb treated as before indicated. The following figures will aid in explaining the method :

Fig. 259 shows a long internal condyle in genu valgum ; Fig. 260 a section through about three fifths of its diameter ; Fig. 261 the appearance of the bone with the limb placed in position, showing the curvature rectified. The results of this operation, with reference to usefulness of the limb,

cure of the deformity, and danger to life, are most flattering.

Osteotomy for Genu Varum.—In this deformity the operative proceedings are directed to the outer instead of the inner side of the bones of the leg and thigh. The procedure, precautions, and treatment are similar. The division of bones through a small external opening can be applied almost indiscriminately to such as present this deformity, always remembering that thorough and complete antiseptic precautions should be taken. The results are most flattering, and commend it to the consideration and practice of the profession.

Bow-legs.—Genu varum may depend on an outward curvature of the bones of the leg, wholly or in part. In



FIG. 259.

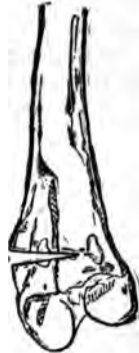

FIG. 260.

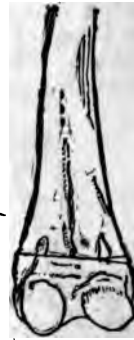

FIG. 261.

either instance the deformity can be corrected by a subcutaneous osteotomy of the tibia. If the patient be young enough a green-stick fracture of the fibula will obviate the use of the osteotome upon it.

Operation.—Make a longitudinal incision at the point of greatest curvature, an inch or so in length, midway between the borders of the subcutaneous portion of the bone. Separate the tissues, introduce the osteotome and cut the bone transversely until the remaining portion can be fractured. Cut or bend the fibula, correct the deformity, and treat antiseptically. It is sometimes necessary to divide the bone in two situations to secure good position. If so, it should be done at another time, and at the remaining point of

greatest convexity. It is much safer to cut both tibiae than to divide either in two situations at the same time.

OSTEOPLASTY,

Or transplantation of bone.

This has not gained the prominence as a surgical expedient that the knowledge of the laws governing the growth of bone bids fair to lead to.

Bone associated with its periosteal and fibrous connections, has been transferred, as in the case of the operation on the hard palate for the closure of a fissure, also the closure of the spaces between the ununited fragments of bone, by the filling of them with freshly sawn sections from the main shaft. The conditions necessary to a successful issue of this operation are exceedingly numerous and exacting.

AMPUTATIONS.

Amputation consists in the removal of a limb either in its continuity or at its articulation. The aims sought to be gained by an amputation are : 1. The saving of the life of the patient. 2. The securing of a serviceable limb.

If the prospects of recovery be annulled by the presence of a badly diseased or mangled limb, it is no opprobrium upon the Art to remove it. If a limb be so badly injured or diseased as to require removal, it is entirely proper that the ability of the designer of compensative appliances be considered, that the patient may reap the combined benefit of the art of the surgeon and the ingenuity of the mechanic. A stump, to be serviceable, should be sound, unirritable, with a good circulation and abundant leverage. The first three qualities depend, all things being equal, very largely upon its length, shape, and vascular supply of the flaps; the last one depends entirely upon the length of the bone. The flaps should be movable over the extremity of the stump after healing is completed, not tightly drawn and smooth, like a base-ball cover. Flaps tightly drawn at the initial

dressing soon become more so, on account of inflammatory action. At a later date, the normal shrinkage of the integument draws them against the end of the bone, to which they, together with the cicatrix, become immovably united, and form a good basis for a troublesome stump. The proper length of the flaps, then, becomes an important point in estimating the prospective usefulness of the limb and comfort of the patient. In cases where they can be made of similar lengths, their extent should correspond to about one fourth the circumference of the limb at the point where the bone is to be divided. If one flap only be employed, it should be



FIG. 262.

double the length of the two. Any increase in the length of one should be accompanied by a proportionate decrease in the length of the other. The shape of the flaps largely controls the site of the cicatrix. It is advisable that the cicatrix be so placed as not to be subjected to pressure or friction. If, however, the flaps be made of sufficient length to admit of the formation of a non-adherent or movable cicatrix, its location is a matter of secondary importance. The length and location of the flaps also largely controls their circulation. If they be too long, the circulation will be enfeebled; if, on the contrary, they be too short, the tension will become the greater impediment, causing a

blue, cold, and shiny surface, sensitive to the slightest injury. The circulation in the normal limb, or a portion

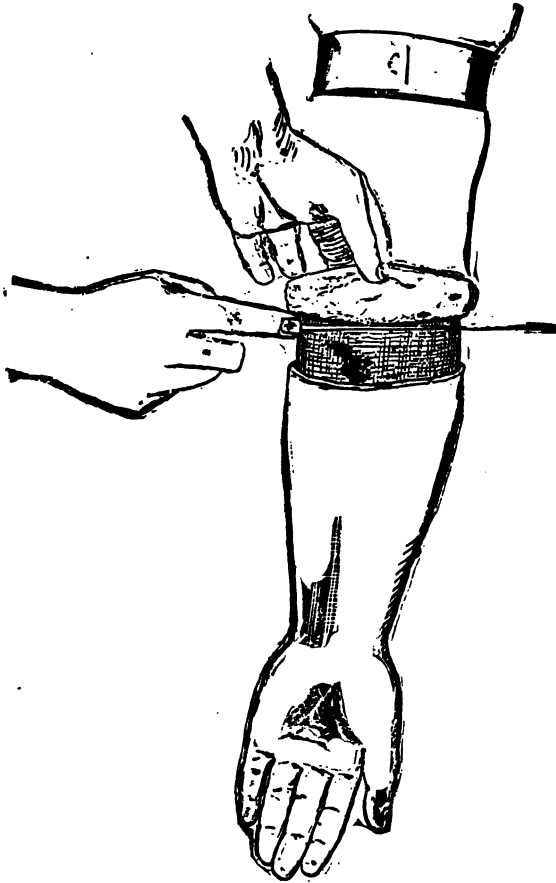


FIG. 263.

of it, may be such as to predispose to a small and sluggish blood supply in flaps constructed from it.

Flaps are classified, according to the tissues entering into them; into the cutaneous, integumentary, or skin flaps, mus-

culo-cutaneous, muscular, and periosteal. The integumentary is commonly employed in this city.

They are also classified, according to their shape, into circular, modified circular, oval, rectangular, hood, etc.

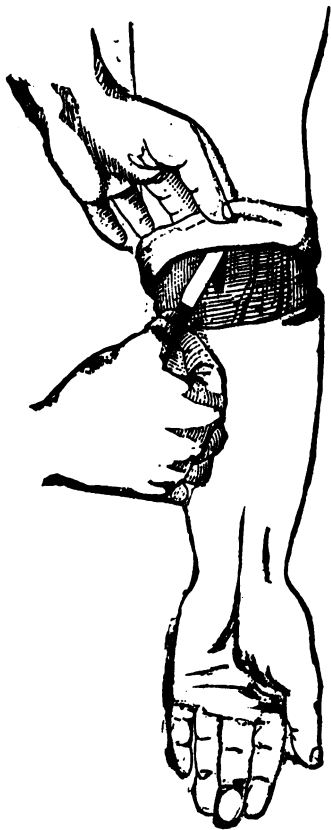


FIG. 264.

The oval may be either unilateral, bilateral, anterior, or posterior. Many of the preceding may be composed of integument alone, or, combined with muscular tissue, and even periosteum.

Circular Method (Fig. 262).—This method is followed by

an admirable stump, is easiest of performance, and consequently very frequently practised. It is done by making a circular incision transversely around the long axis

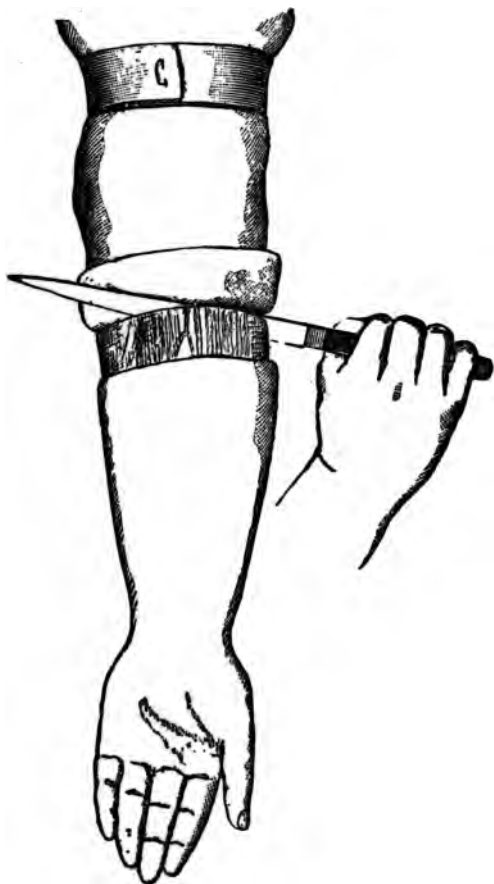

FIG. 265.

of the limb, through the integument and subcutaneous tissue down to the muscles, at a distance below the proposed division of the bone, corresponding to one fourth the circumference of the limb at that point. The flap is then dissected

up from the muscles with an ordinary scalpel; its edge being directed towards the muscles (Fig. 263) rather than parallel with them (Fig. 264), as the latter severs the capillary connection between the integument and the deeper tissues. The dissection should be done by circular sweeps, rather than mincing cuts, which hack the tissues and provoke suppuration. This careful manner of raising the flap applies equally to all of the varieties which involve the separation of similar tissues.

If the limb be conical, much difficulty will be experienced in turning over the sleeve of integument, which can be ob-




FIG. 266.

viated by making a longitudinal cut at the most dependent portion.

The flap should be turned upward to the point where the bone is to be divided; then with the catling make a circular division of the muscles down to the bone (Fig. 265); beginning far enough below the reflection of the flap to allow for the retraction for the divided muscles. No definite law can be assigned to this element, although they will contract according to their size, length, degree of irritability, etc. The suitable point of section will appear in connection with the description of the special amputations.

Not infrequently the muscles are cut just below the reflection of the flap, as in Fig. 267; this is not, however, as good a plan as the former, since sensitive stumps are more liable to result therefrom. The bone is sawn at the highest point of exposure.

Modified Circular Method (Fig. 267).—This plan was suggested by Mr. Liston, who made semilunar flaps, which he dissected up to their point of junction with each other, when the muscles and bone were divided, as in the circular method. This was afterward modified by Mr. Symes, who dissected the flaps a short distance above their point of

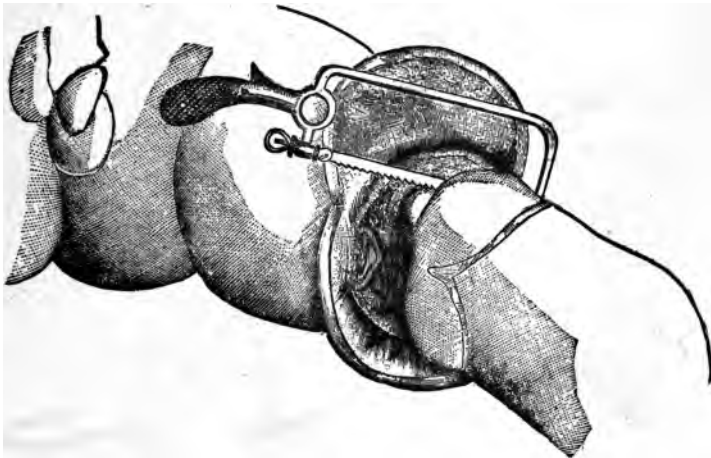


FIG. 267.

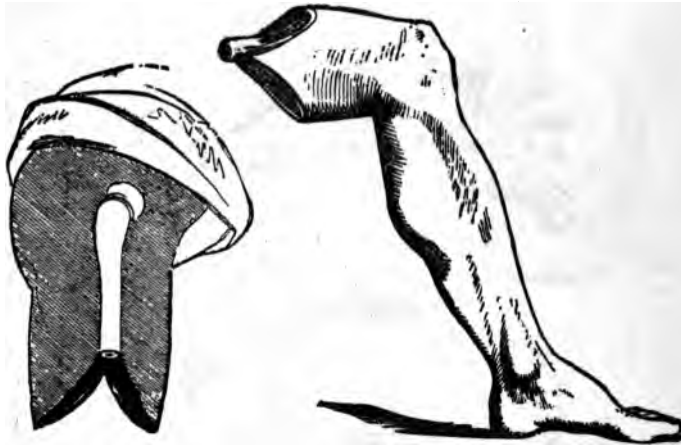
junction, and divided the muscles and bone, as before. In either instance, however, it amounts to slitting up the cuff of a circular flap, and trimming off the angles caused thereby.

Oval Method is in reality a modified circular, slit up at one side and the angles trimmed off. It is employed principally in disarticulations, and will be described in connection with those operations.

Single Flap Method.—This is adapted to those cases where the tissues of one side of the limb only, are suitable for the purposes of a flap; as, in the case of unilateral lacerations, ulcerations, etc. This flap is composed of the muscular tissues and integument, and can be made either

by transfixion or division from without. If possible, a short convex flap is made on the opposite side of the limb.

Double Flap Operation is made by transfixion, and includes the muscles down to the bone on either side of the limb (Figs. 268 and 269). The tissues to be transfixed are raised slightly by the left hand of the operator, who then enters the point of the knife at the side nearest himself; pushing it through slowly, in close contact with the anterior surface of the bone, slightly raising the handle as it passes, thereby causing its point to emerge at the opposite side of the limb at a point exactly opposite to its entrance; the flap is then made by cutting obliquely upward with a sawing motion.

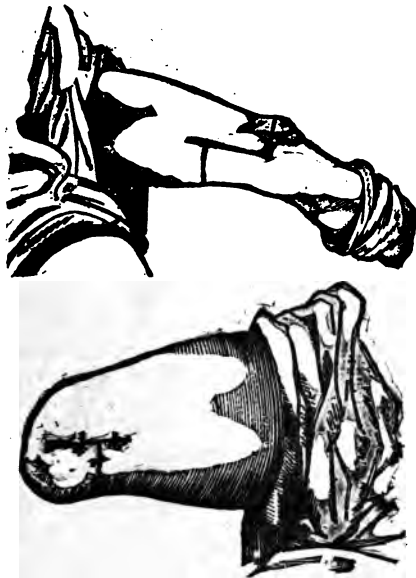


FIGS. 268 and 269.

It is pulled backwards by an assistant, and the knife is reinserted at the original point of entrance, carried behind the bone, handle depressed to cause the point to emerge at the same situation as at the anterior transfixion, and the posterior flap made by cutting obliquely downward. Each flap should correspond to at least one half the diameter of the limb. The retractor is then applied, and all the soft tissues are drawn well upward; the remaining fibres in contact with the bone are severed, and the bone carefully sawn through. If lateral flaps be made, the outer should be formed first. The flap containing the large vessels is to be last divided.

The Mixed Double Flap is a modification of the preceding, and sometimes called Sedillot's method. The flaps are made by transfixion, as before, but are more superficial; the knife not being brought in contact with the bone. The remaining muscles and vessels are divided by a circular incision, and the rest of the amputation is done as before described. In this instance the flaps are thinner and shorter than in the preceding.

Langenbeck's Method.—This differs from the last only in the manner of obtaining the result; the flaps being cut from without inward, which affords a better opportunity



FIGS. 270 and 272.

to shape them. Another combination of the method is made by cutting the anterior flap from without inward, and the posterior by transfixion.

The Rectangular, or Teale's Method (Figs. 270 and 271).—In this two rectangular flaps are employed; one being four times longer than the other; both flaps include the structures down to the bones. The longer flap is taken from the side of the limb, where the bone is the most superficial. The shorter contains the important vessels. The length and breadth of the long flap corresponds to half the circumfer-

ence of the limb at the point of proposed amputation. The width of the short flap is a half, and its length an eighth of the circumference of the limb. Both flaps should be carefully marked out before beginning the operation. This method makes an admirable stump, but sacrifices fulcrumage, and brings the bone section nearer the body than is consistent with the additional dangers incurred. Mr. Lister recommends that the longer flap be made a third and the shorter flap a sixth of the circumference of the limb, which brings the cicatrix at the edge of the stump. Also that the posterior flap consist of the integument and subcutaneous tissues alone. This, like Teale's, may be employed when the loss of tissues is greater upon one side than upon the other.

The Hood Flap.—There is no substantial difference between this and the oval method, when the latter is slit up at the most dependent part. This form meets the indications requisite to form a good stump as well as any other variety.

Equilateral Flaps (Fig. 272) consist of equilateral skin flaps, oval in outline, the posterior incision being made further up the limb, to improve the drainage. The bone is divided above the anterior point of junction of the flaps, and the muscles by a circular sweep at a suitable distance below the point of reflection of the integumentary flaps.

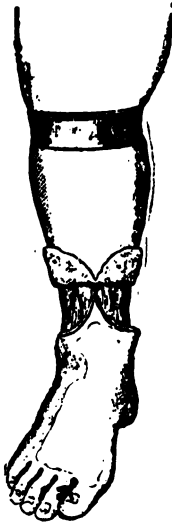


FIG. 272.

Periosteal Flap.—This consists in raising the periosteum in conjunction with the tissues which rest upon or are attached to it sufficiently to cover the end of the divided bones; when, it is allowed to fall into place. It is best adapted to those bones subcutaneously located; like the tibia, and will be again referred to in connection with amputations of the leg.

A periosteal flap will, if it becomes adherent to the end of the bone, preserve it from atrophy, and lessen the danger of the formation of a conical stump; it likewise prevents the adhesion of the cicatrix to the stump, thereby forming the basis for a movable scar.

If the patient be young, new bone may be developed, which lessens the sensibility and increases the usefulness

of the stump. It is claimed by some that bony spicula often shoot into the soft tissues on the end of the stump, and require a second operation for their removal. It is my opinion, however, that if the membrane be removed entire and in connection with its superimposed tissues, and be so placed that the force of gravity will aid in holding its bone-producing surface in contact with the divided extremity, that this danger will be obviated.

Comparative Merits of different Forms of Flaps.—The ends sought to be gained in making flaps are: 1. To secure good drainage. 2. To make them of suitable length that the circulation and movement of the cushion at the end may be free. 3. To place the cicatrix beyond the point of friction, and prevent its adhesion to the end of the bone. 4. To guard against any danger of undue sensibility, by making the flaps of proper length, and by drawing down and cutting off the cutaneous and other nerves of larger size that may exist in them. With these ends in view, it will be seen that the old-fashioned circular flap affords equal advantages with the others, and is further commended by its simplicity. It is true that in this method the scar will fall on the end of the stump, but with proper precautions as to the length of the flaps and suitable attention any danger from this source is reduced to a minimum.

Agents required for Amputation may be classed as those for arresting hemorrhage; for the division and trimming of the bone and soft parts, and, those for uniting and dressing of the wound. The preparation of the patient for the operation; the agents for controlling and arresting hemorrhage, together with the various methods of securing and maintaining the coaptation of the cut surfaces, drainage, and various forms of dressing, antiseptic and otherwise, have herein been previously considered; therefore, there remains to be enumerated, under this heading only those instruments especially adapted to the requirements of the procedure.

Amputating Knives (Fig. 273).—The modern amputating knives can be used for circular flaps, or for those made by transfixion. They should be double edged for an inch or two from the point. The length selected will depend upon the size of the limb to be operated upon, and should be about one and one half times its diameter. It may be inconsistent with good taste, but it is entirely consistent with good judgment and economy to amputate an arm or fore-

arm with the catling intended for the thigh, and the rest will be equally satisfactory. The manner of holding the catling, prior to and during the division of the soft part adds much to the optical effect of the operation. It should be, at first, lightly grasped between the thumb and tw




FIG. 273.

FIG. 274.

first fingers, with the edge forward, near enough to the shank to admit the upper end of the handle to play between the heads of the metacarpal bones of thumb and finger when it is swung backward and forward (Fig. 274). There are two methods employed of carrying it entirely around

the limb. Stand with the left side toward the patient, seize the limb above the point of intended operation with the left hand, an assistant holding its distal extremity; place the left foot forward, slightly bend the right knee, and with the catling held by the right hand, as before described, stoop downward and forward sufficiently to carry the knife and arm under, and the knife over the limb, placing its heel as near to the upper surface of the limb as is convenient, when, with a sawing motion, it is drawn toward the operator beneath the limb, then upward between it and the operator, and so on around, until it joins the beginning of the cut, making a complete circle (Fig. 275).

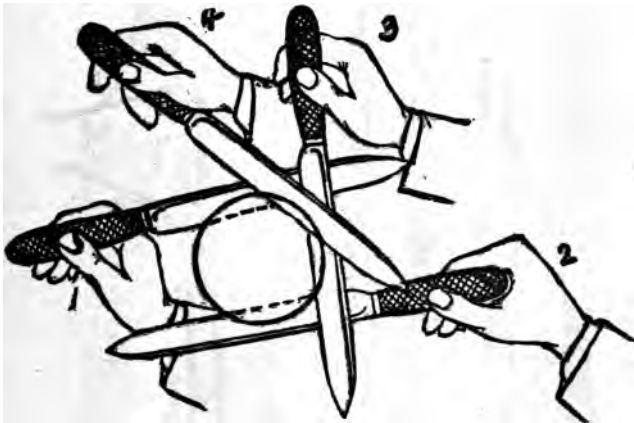


FIG. 275.

If the knife be properly grasped it will pass readily between the thumb and forefinger, as the hand passes around the limb; enabling the surgeon to make the section with perfect ease, and without the least manifestation of the stiffness. The method may be reversed by passing the hand and knife over, instead of under the limb (Fig. 276); otherwise the manipulations are the same. The latter, however, is less natural, besides which it exposes the arm of the operator, and the integument to be divided last to the flow of blood. Still either of these methods is far superior to the one commonly employed and figured in text-books (Fig. 277).

Double-Edged Catling (Fig. 278).—This is chiefly employed to divide the tissues in the interosseous space, in amputations of the leg and forearm. It can be readily supplemented by the single-edged narrow knife, provided the latter be withdrawn to complete the division of the interosseous tissues, instead of changing the direction of the cutting edge, while it remains between the bones. The latter act will bruise and tear the tissues. To these should be



FIG. 276.

added two or three ordinary scalpels, for raising integument, flaps, etc.

A knife with a long narrow blade is the better for amputating at the phalangeal articulations (Fig. 279).

Saws.—The ordinary broad bladed saw (Fig. 280) and the bow-backed (Fig. 281) are in common use. The first meets all requirements except in certain exsections, when *the chain* or butcher's saw (Fig. 282) must be employed.

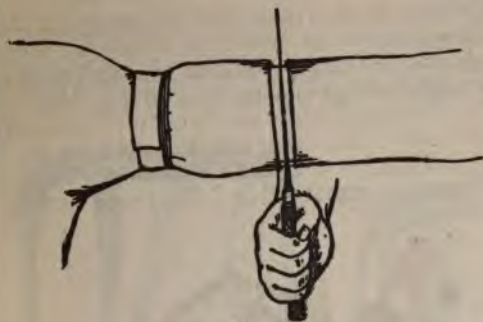

FIG. 277.



FIG. 279.



FIG. 280.



FIG. 278.

The narrow movable backed saw is of use in sawing small bones, removing spiculæ, etc.

The proper method of using a saw should be given some attention (Fig. 283). After the section of the soft parts,




FIG. 281.



FIG. 282.

the surgeon grasps the saw firmly, places its heel close to the edge of the contracted muscles, in a line made through the periosteum by the knife, and slowly and carefully draws it towards himself along the first four or five inches of its edge, raises it from the track, and places it as before; re-

peating the operation until a track of sufficient depth is made to retain it during the to-and-fro movements of sawing, which should be done by quick, sharp strokes, until



FIG. 28.

the bone is nearly severed, when care must be exercised, or the saw will be clamped and the remaining portion be broken off. If the handle of the saw be raised and the remaining

portion be divided at a different angle to the bone, the danger of breaking is lessened. When two bones are to be sawn off, the saw should be started in the one most immovable, and then turned so as to include both. If the movable one clamp the saw, cut off the more solid one first, then complete the other.

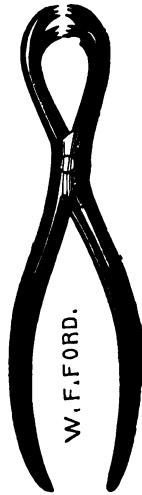

FIG. 284.



FIG. 285.

Bone Forceps.—Liston's cutting forceps (see Fig. 196) for trimming off rough prominences. Ferguson's lion-jawed (Fig. 284) and Farabeuf's forceps (Fig. 285) are excellent instruments for grasping the bone to steady the part. They are also used for removing bone by twisting, when great force is required.

How to Operate.—Before beginning an amputation, the operator should rehearse in his mind at least the entire procedure as he contemplates it; by doing this he will be confident, and be certain to anticipate the unimportant as well as the important details. The preparation of the patient and administration of anæsthesia are given on pages in the fore part of the work. The surgeon should always plan his work with careful precision, even to marking out upon the limb the outlines of the flaps, and such other incisions as may be required. I am aware that this is seldom practised,

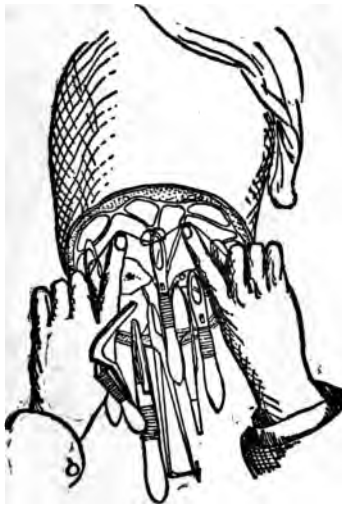

FIG. 286.

even by the most experienced surgeons; but within my own observations, had it been done more frequently better results would have been secured. The young surgeon too often fancies that to do this argues himself ignorant and inexperienced; such, however, is not always the case; it rather serves to emphasize his cautious and painstaking qualities. All operations should be done without haste, when the safety of the patient will permit; remembering it is done quickly, when done well.

The operator should stand in such a relation to the patient that the left hand can readily control any undue hemorrhage by compressing the artery or otherwise.

The primary incision should be so located, if possible, that the escaping blood will not obscure the course of the remaining ones.

The incision which will divide the important vessels should be made last.

In circular amputations the tissues should not be retracted until after the division of the integument.

In flaps by transfixion, the tissues to constitute the flap can be raised or depressed, as the case may be.




FIG. 287.



FIG. 288.

After the limb is removed, the open mouths of the vessels should be caught by serresfines, forceps, etc. The tourniquet, or Esmarch's band loosened slowly, and all bleeding points controlled in a like manner (Fig. 286). The surgeon can then proceed carefully to ligature the vessels thus secured.

The retractor is made of linen, or ordinary muslin, torn according to the size and anatomical arrangement of the *limb* to which it is to be applied. If to one with two *one* extremity should be torn into three strips (Fig.

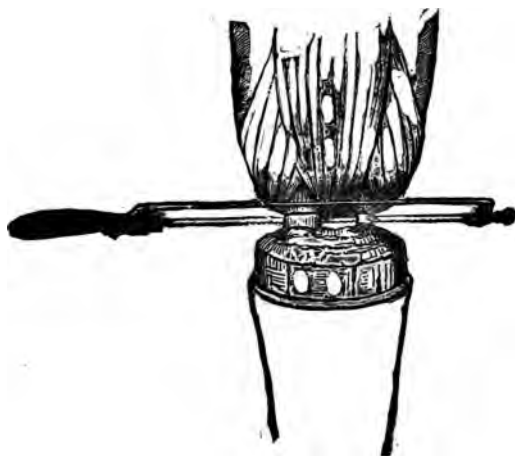

FIG. 289.

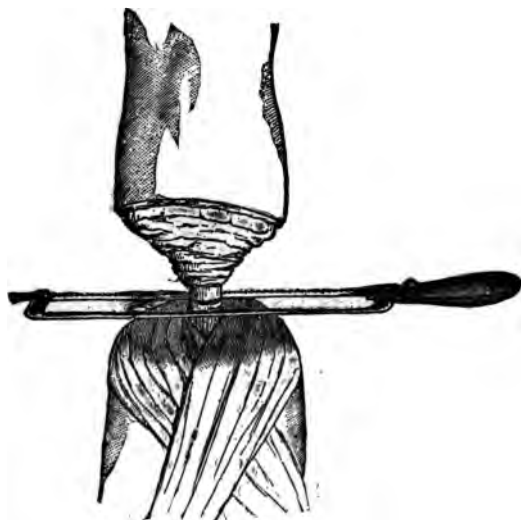

FIG. 290.

288). The middle one to pass between the bones (Fig. 289). If for one alone, it is torn partially through the middle (Fig. 287), and applied as shown in Fig. 290.

AMPUTATION OF UPPER EXTREMITIES.

General Remarks.—In all amputations of the hand and fingers, it is important to remember that usefulness and symmetry are the points sought to be gained. If strength and usefulness be a desideratum, all of those points into which the muscles and ligaments that endow the part with important functions are inserted should be preserved.

It therefore becomes imperative for the surgeon to carefully study the functions of the muscles associated with the hand; and to preserve as carefully as possible their points of insertion. It is a well-established principle that every portion of the hand of a laboring man which possesses movements and can become of service to him should be saved. In the case of one whose circumstances or avocations will permit the sacrifice of usefulness to symmetry, the movements may be sacrificed with the concurrence of the patient.

SPECIAL AMPUTATIONS OF HAND AND FINGERS.

Amputation at the Inter-Phalangeal Articulations.—The first row of surgical phalanges is flexed by the terminal insertion of the flexor profundus digitorum. The second by the flexor sublimus digitorum. The third by the preceding, through the *vincula accessoria tendinum*; by dense fibrous bands connecting the tendons of the flexor sublimus, with the distal extremity of that phalanx as it passes across it; also by the secondary action of the lumbrical muscles (Fig. 291). The terminal phalanx is amputated by seizing and flexing it at right angles with the second (Fig. 292); a transverse incision is then made on its dorsal surface, on a line corresponding to the centre of the long axis of the second phalanx,

which will open the joint; divide the lateral ligaments with the point of the knife, separate the articular surfaces, and pass the blade between them along the under surface of the phalanx to be removed, close to the bone (Fig. 293) far enough to make a palmar flap of sufficient length to easily cover the end of the bone (Fig. 294). If the attached extremity of the flap be commenced by dividing the tissues at each side of the phalanx for three or four lines, down to the bone, the knife can then follow its under surface with-

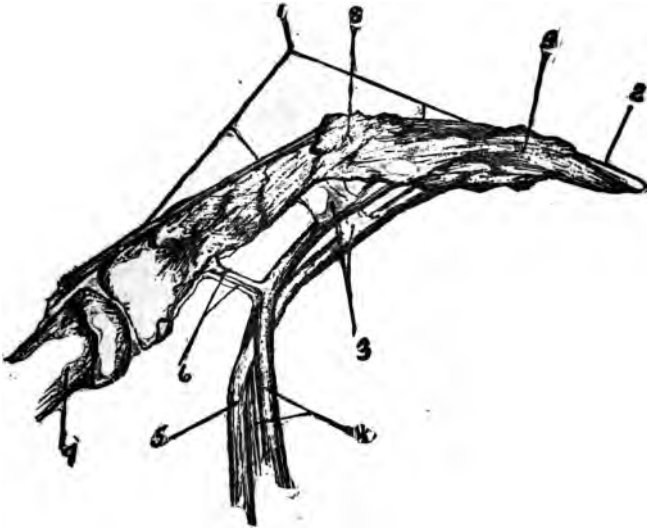


FIG. 293.—1. Extensor communis digitorum. 2. First surgical phalanx. 3. Fibrous bands between common flexor tendons and distal extremity of the third surgical phalanx. 4. Tendons of flexor sublimus digitorum. 5. Tendon of flexor profundus digitorum. 6. Vincula accessoria tendinum. 7. Head of metacarpal bone. 8. Joint between second and third surgical phalanges. 9. Second surgical phalanx.

out the danger of making the attached end of the flap too narrow, owing to the extremities of the phalanges being thicker than their bodies. The rule previously given regarding the length of flaps will enable the operator to meet this requirement. If any of the tissue of the flexor tendon be in the flap, it should be removed. Tie the vessels, place and hold the flap in position by two or three fine sutures and adhesive strips; or dress antiseptically.

Amputation of the Second Row can be done in precisely the same manner as at the first, or by making a palmar-flap first by transfixion with the finger extended, through the palmar surface opposite the joint and cutting downward until a well-rounded flap is formed (Fig. 295). Then carry the knife between the articular surfaces and through the soft parts on the dorsum (Fig. 296).

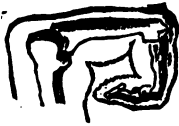

FIG. 292.



FIG. 293.



FIG. 294.

Either of the phalanges may be amputated at the centre, by a short posterior and a long inferior or palmar flap. If the third surgical (first anatomical) phalanges be amputated at the centre, the power of flexion is limited to the lumbrical muscle, and the vincular tendons connecting it with the flexor sublimus digitorum. In all cases where symmetry is a subsidiary consideration, this amputation

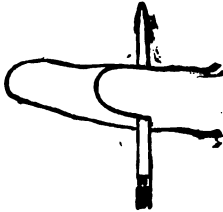


FIG. 295.

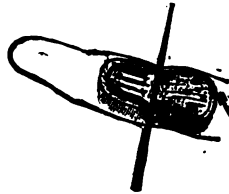


FIG. 296.

may be made. In the case of the index and little fingers, and thumb, everything possible adding to length should be saved, as the range of motion of the thumb and little finger is more extensive than the others, and the presence of the index or its stump aids the crippled thumb in performance of its functions.

Amputation at the Metacarpo-phalangeal Articulations.—It is recommended by some that this operation be done in lieu

of amputation at the middle of the third phalanges (surgical) of the second and third fingers, or even disarticulation between their second and third phalanges. I am satisfied, however, that the hand will be far stronger if the stumps be allowed, since they soon become easy of flexion and extension, and the continuance of these movements serves to stimulate and nourish the common muscles engaged in



FIG. 297.

them, thereby strengthening the power of the remaining fingers.

Amputation of the Second or Third Finger.—This is done by the oval flap, which ought to be marked out before the operation is commenced (Fig. 297). The flaps must be taken from the finger to be removed, and should be of generous dimensions. The limit of the incision above corresponds to the head of the metacarpal bone; the

lower limit, to the transverse line joining the fingers to the web. Separating widely the contiguous fingers, the surgeon seizing the condemned finger, extends it well and carries his incision transversely along the line beneath, then in a curved direction upward, along the side of the finger to the head of the metacarpal bone. This incision is repeated on the opposite side; the tissue carefully dissected up, ligaments and tendons carefully divided, and the finger removed (Fig. 298).

Lateral Flap Operation.—This is best adapted to the thumb, index, and little fingers (Fig. 299); it can, however, be employed at the ring and middle fingers. The limit of



FIG. 298.

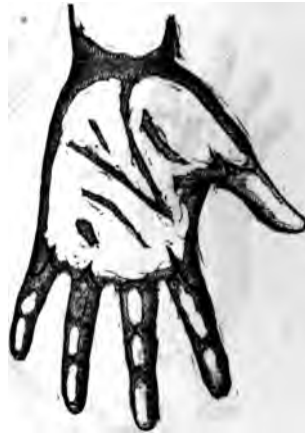

FIG. 299.

the incision of the dorsum is the same as in the preceding. The lower limit after crossing the transverse line of the web extends towards the palm about a third of an inch. The flaps are taken from the sides of the finger to be removed.

In the case of the middle and ring fingers they should be equilateral. For the thumb, index, and little finger, that portion of each against which pressure is most liable to be brought should be covered by a longer flap, which is taken from the outer surface of the dorsum of the index and little fingers and from the palmar aspect of the thumb, the base being on a level with the joint. This is dissected off,

after which the smaller one is made; divide the ligaments and tendons, and remove the member.

Amputation of the Thumb at the Carpo-metacarpal Joint (oval method, Fig. 300).—This can be employed equally well upon the thumb, index, and little fingers. The limit of the dorsal incision in either instance is the proximal extremity of the metacarpal bone to be removed. Its palmar limit is the transverse line at the junction of the finger with the palm. Begin the first incision at the base of the metacarpal bone of the thumb, carrying it along in a slightly curved direction to the outer side of the metacarpophalangeal articulation; then inward through the line of

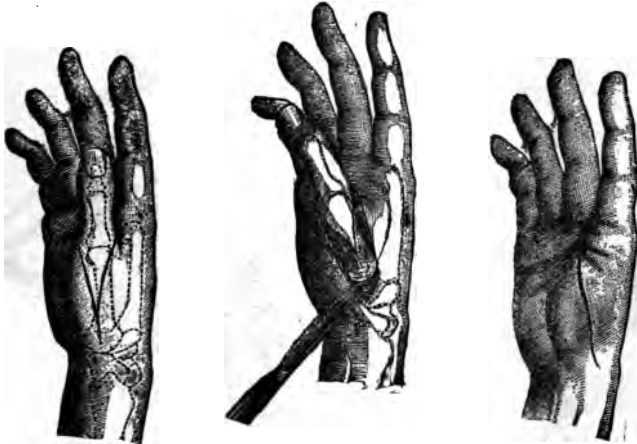

FIG. 300.

FIG. 301.

FIG. 302.

the web. The second one joins the first near the base of the bone, and takes a corresponding course along its inner side, meeting the former at the inner extremity of the transverse line of the web. The flaps are dissected off, and the articulation between the metacarpal bone and the trapezium is opened from the ulnar side, to avoid injuring contiguous joints (Fig. 301). The union of the flaps leaves a linear cicatrix (Fig. 302).

The Lateral Flap Method (Fig. 303).—This method can be more quickly and easily performed than the former, but leaves the cicatrix in a less advantageous situation. Abduct the thumb and enter the knife between the first and

second metacarpal bones; carry it up between them with a sawing motion, till the head of the first is reached. Cautiously disarticulate it from within outward; increase the abduction, and carry the blade through the joint and along the outer side of the metacarpal bone, making the outer flap, which should terminate opposite the web of the thumb (Fig. 304).

The description of the oval method as applied to the thumb is equally applicable to the index and little fingers, if an interchange of digits be made. The lateral flap method is not advised except in connection with the thumb.



FIG. 303.

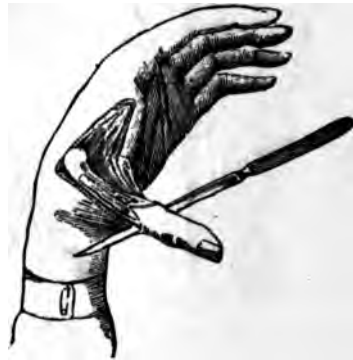

FIG. 304.

The bases of the metacarpal bones of the index, middle, and little fingers should be preserved in all possible instances, as they afford attachment to the important extensor and flexor muscles of the carpus.

Amputation through the Metacarpal Bones.—In amputation through two or more of these bones, the principal flap should be taken from the palmar surface. If but one be removed, the incisions are the same as those made for amputation at the metacarpo-phalangeal articulation by the oval method, only their upper limit will correspond to the point of proposed section of the bone (Fig. 305). The

bone in this instance is to be sawn through with a chain or metacarpal bone saw. If neither of these be convenient, the cutting bone forceps (Liston) can be used, although with some risk of splitting the bone. This operation is often performed in preference to disarticulation at its head, in order to give symmetry to the hand.

The division of the transverse ligament, which extends between the heads of the metacarpal bones, lessens the strength of the grip. This operation is, therefore, not to be recommended except in those of sedentary habits.

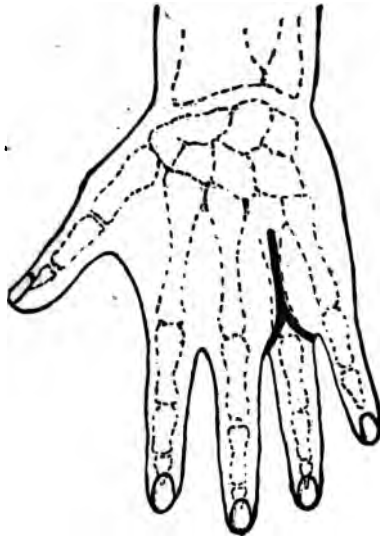

FIG. 305.

Amputation (Disarticulation) of the Last Four Metacarpal Bones (Fig. 306).—Make a semilunar flap from the palm by a curved incision, beginning at the web of the thumb and terminating at the ulnar border of the fifth metatarsal bone. This flap can be made by transfixion, if desired (Fig. 307). The dorsal incision (Fig. 308) begins at the same point of the web of the thumb, and is carried to the upper third of the metacarpal bone of the index finger, and from there transversely across until it meets the ulnar extremity of the first incision. The flaps are now reflected from the carpo-

metacarpal joint, the hand strongly abducted, and the carpo-metacarpal articulation opened from the ulnar side, using great caution not to injure the trapezium and the

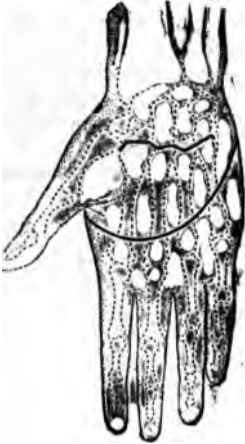

FIG. 306.



FIG. 307.

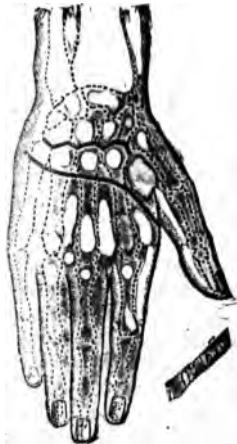

FIG. 308.



FIG. 309.

metacarpal bone of the thumb. Without the thumb, this operation would be of little avail in securing a useful

stump. Unite the flaps with interrupted sutures, introduce a drainage tube (Fig. 309), and treat antiseptically. *The results* of amputations of the thumb and fingers are favorable, three to six per cent only perishing.

Amputation of the Wrist (Disarticulation).—The bones entering directly into this articulation are the radius, scaphoid, and semilunar. The location of the joint can be determined (1) by forcibly bending the carpus backward, when the summit of the angle on the dorsal surface formed by the hand and forearm indicates the radio-carpal joint; (2) by drawing a line transversely from one styloid process

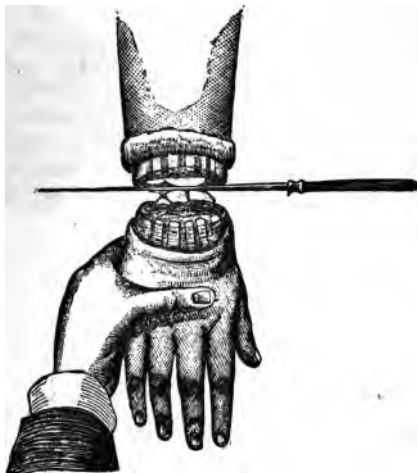

FIG. 310.

to the other—the joint is about one fourth of an inch above it. This operation can be done by the circular method, single palmar, or radial flap, and the double flap.

Circular Method.—Ascertain one fourth of the circumference of the articulation. Measure this distance downward from the articulation, and divide the tissues at that point by a circular incision; dissect up the sleeve of integument until opposite the joint; pronate and forcibly flex the carpus, and open the wrist joint on the dorsal surface by an incision extending between the styloid processes; divide the lateral ligaments, pass the blade through the articula-

tion, and sever the remaining structures (Fig. 310). Unite the flaps in the long axis of the joint, introduce drainage tubes and sutures, and dress antiseptically (Fig. 311).



FIG. 311.

Flap Method (Double).—Mark out the distal limits of the flaps as in the circular method; flex and pronate the hand; carry a semilunar incision over its dorsum, beginning at the styloid process of the ulna and extending to the circular line indicating the dorsal extent of the flap, terminating at the radial styloid process (Fig. 312). Dissect up the flap, allowing the tendons to remain, flex the carpus firmly, and open the articulation, as in the circular method; carry the blade of the knife through the articulation (Fig. 313) and make the anterior flap by cutting outward.

Single Palmar Flap.—This method is easily performed,



FIG. 312.

and makes as serviceable stump as any. Mark out a flap on the palmar surface, semilunar in shape, and about three and a half inches in length, its base being located just

below the apices of the styloid processes (Fig. 314); reflect it upward; divide the remaining tissues in front of the articulation, open it, passing the knife through, and making a short dorsal flap. The dorsal flap can be made first, the joint opened from behind, and the long anterior flap cut from the joint outward.

Radial Flap (Dubrueil).—Mark out a flap, semilunar in shape, the base of which shall embrace the radial third of the carpus and the ulna, corresponding to the base of the first phalanx of the thumb (Fig. 315). Separate the thumb flap, then connect the extremities by an incision carried transversely around the ulnar side, draw the skin upward, open the joint as before, remove the carpus, and properly adjust the flaps and drainage tubes (Fig. 316).



FIG. 313.

The rate of mortality in amputation at the wrist joint is about 29 per cent for gun-shot wounds, being eight per cent greater than for amputation through the forearm.

It therefore follows that amputation at the wrist joint cannot be recommended, on the ground of safety to the patient. There are other objections of less importance, which, with one just stated, should place the operation in disfavor with the surgeon. It makes a stump, which, owing to the feebleness of the circulation in the flaps, becomes cold and even chill-blained; also its extremity is bulbous, thereby preventing the application of properly fitting sockets connected with artificial appliances.

Amputation of the Forearm.—The forearm is best amputated by the circular flap method; although the equilateral skin flap and musculo-cutaneous are often employed.

Circular Amputation.—Carefully lay out the length of the proposed flap, based on a fourth of the circumference. Divide the tissues down to the fascia surrounding the muscles by a circular incision; the integumentary *cuff* is then dissected upward by repeated incisions directed towards the fascia surrounding the muscles (see Fig. 26).

If the cuff be too small to turn up readily, its most dependent part, when dressed, can be slit up. After the flap is

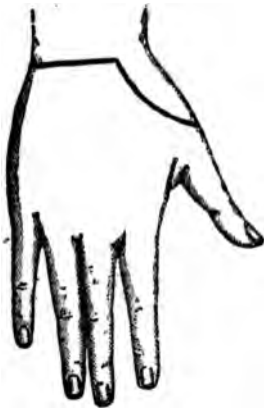

FIG. 315.



FIG. 314.

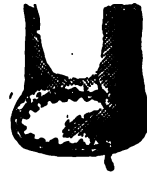

FIG. 316.

reflected sufficiently, the muscles are divided a half an inch or so below the line of its reflection by a circular sweep of the knife down to the bone, the bone sawn off, and the wound dressed in the usual manner. The interosseous membrane and its vessels should be divided a short distance below the point of proposed bone section and its borders be separated from those of the contiguous bones up to where they are to be sawn. This avoids the risk of cutting the vessels too short, as when they are divided at a level with the bones which permits them to retract above the point of easy access. These remarks apply with equal force to amputation of the leg.

The equilateral skin flaps are raised from the anterior and posterior or internal and external surfaces; the latter being by far the most frequently adopted. The length is determined in the same manner as in the circular; in fact, if the circular be first done, and its angles cut off down to near the site of the muscular section, the lateral flaps will be formed. It is better, however, to mark out their outlines before beginning them; since, to make each with the same curve and same breadth of base is not an easy

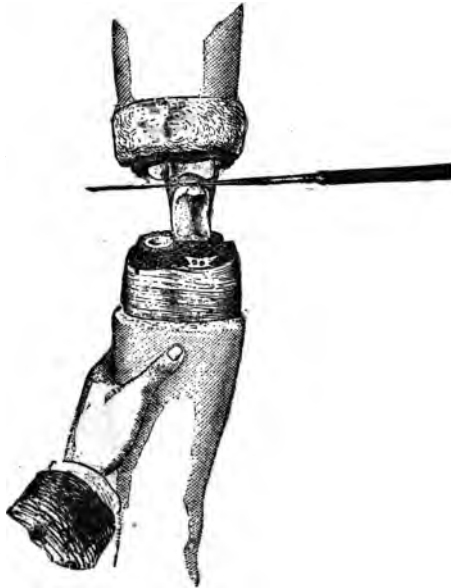


FIG. 317.

task without this precaution. The remaining procedures are the same as those of the circular method.

Musculo-cutaneous flaps are made by transfixion and cutting outward; in other respects the steps do not differ from the preceding operation. The rate of mortality in amputation of the forearm is about 21 per cent for all causes.

Amputation at the Elbow Joint (Disarticulation).—The methods commonly employed are the circular and the single flap ones. Before operating carefully define the most prominent

portions of the condyles. Just below the outer, is felt the movable head of the radius; about an inch below the inner, the ulna joins the inner condyle; the articulation is therefore oblique; the inner portion being about a half an inch the lower, owing to the inner condyle being that much longer than the outer.

Circular Method.—Lay out the flaps in the usual manner, measuring around the condyles. Divide the superficial tissues down to the fascia surrounding the muscles, as before; dissect the flap upward to a level with the joint, the bone indications to which should be carefully determined. For-



FIG. 318.

cibly extend the arm and make an incision on the line of the articulation (oblique) down to and into it; sever the internal and external lateral ligaments, and press the arm still further backward, and draw the olecranon process forward into the wound, and sever its connection to the triceps (Fig. 317). Unite the borders of the flap as indicated in the figure (Fig. 318). The flaps can also be united from before backward; this causes the cicatrix to fall *between* the condyles, and likewise increases the drainage facilities—two very important indications.

The single flap method can be made either of integument

and subcutaneous tissue alone, or be musculo-cutaneous; and formed by transfixion. In either instance it should be taken from the anterior surface of the forearm. If by transfixion (Fig. 319) supinate and flex the forearm slightly; raise the soft parts in front of the joint, and enter the knife an inch below the internal condyle, pass it in front of the bones obliquely outward, causing it to escape about one and one half inches below the outer condyle. Cut the anterior flap downward and outward, making it about three and one half inches in length; dissect and draw the flap up to a level with the joint in front. Make the posterior flap by connecting the extremities of the first incision by a transverse one (Fig. 320), and dissect this up, after

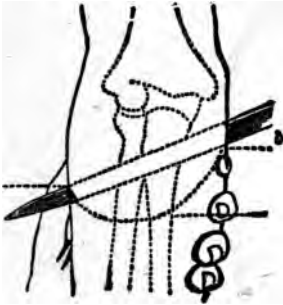


FIG. 319.

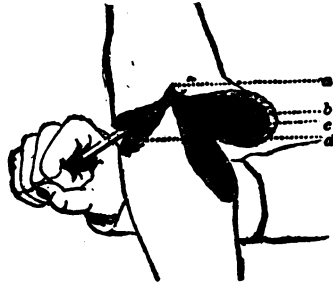


FIG. 320.

which the joint is opened from in front; the lateral ligaments divided, olecranon process displaced forward, and the triceps cut off. It is advisable, when possible, to saw off the olecranon, allowing it to remain with the triceps attached. The stump will be stronger if it be possible to sever the ulna below the insertion of the brachialis anticus, allowing the fragment to remain along with its muscular attachments. In amputations near the elbow, the tubercle of the radius, along with the biceps tendon inserted into it, should be carefully preserved. The deaths from this amputation vary from 17 to 30 per cent. In the latter rate, the operation was done for gunshot injuries.

Amputation of the Arm.—Either the circular, double flap, or the single circular incision method can be employed. The former is usually preferred. In the second the flap

may be anterior, posterior, or lateral; integumentary alone, or combined with muscular tissue. The single circular operation is seldom employed.

Circular Flap.—Plan the length of the flap upon the cir-

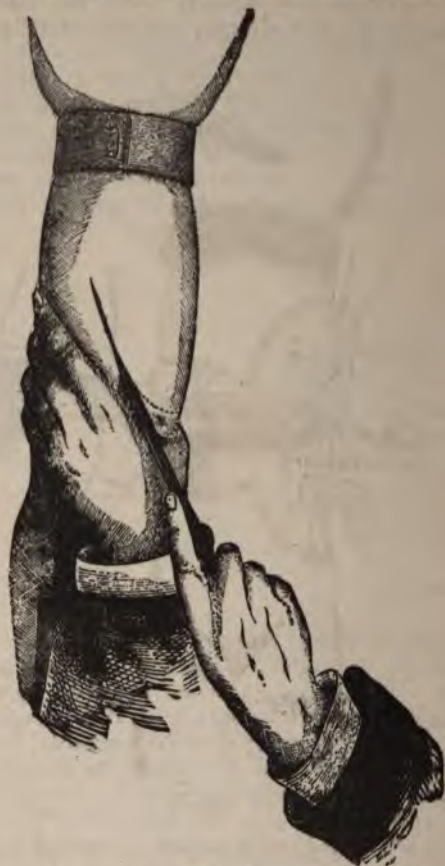

FIG. 321.

cumference of the limb at the point of proposed section. Divide the superficial tissues down to the muscular fascia, and turn the flap up as elsewhere; then divide the muscles down to the bone, about one inch below the reflection of

the flaps. Apply the two tailed retractor, saw off the bone, and unite the flaps in the direction best calculated to provide dependent drainage.

Double Flap Method.—If skin alone be used the flaps should be carefully mapped out upon the integument of the arm, in the general manner before described. Dissect

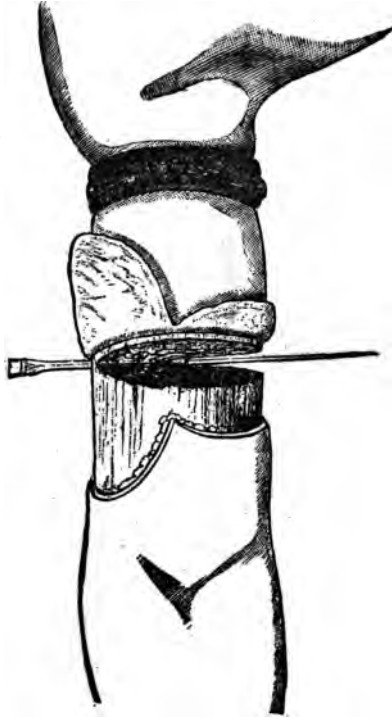


FIG. 322

them up and make a circular section of the muscles down to the bone; unite the flaps, and dress the stump as before.

If *musculo-cutaneous flap* (Langenbeck) be desired, they can be made from within outward by transfixion, or from without inward, with a scalpel. The latter plan secures the more uniformity of outline in the flap. If they are to be made from without inward, first mark them out carefully,

then with a sharp scalpel form them as planned (Fig. 321); when dissected up the desired distance, complete the operation by dividing the muscles as before.

Large anterior and small posterior skin flaps are sometimes made (Fig. 322), also a large anterior one, with a posterior circular incision (Fig. 323). They possess the

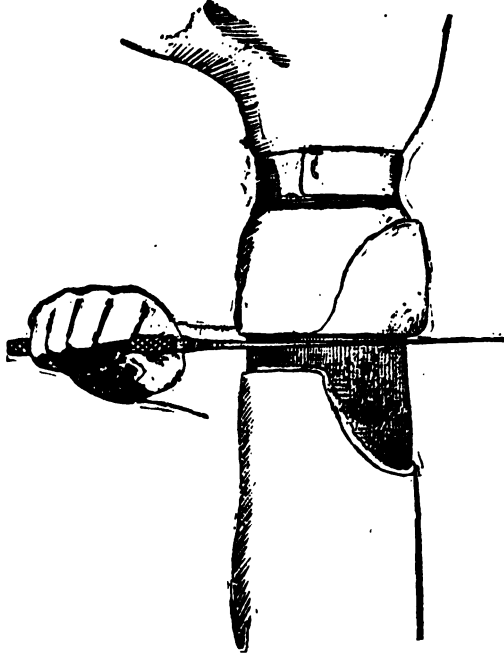


FIG. 323.

advantage of good drainage, and placing the cicatrix where it is well removed from irritation. The outline of these flaps can be easily estimated on the same basis as if they were to be equal in length, viz., if one be proportionately increased in length, the other is to be shortened. The death rate from amputation of the arm is over 27 per cent. Being greater than for excision of the elbow joint.

Amputation at the Shoulder Joint (Disarticulation).—There are various methods recommended for amputation at this

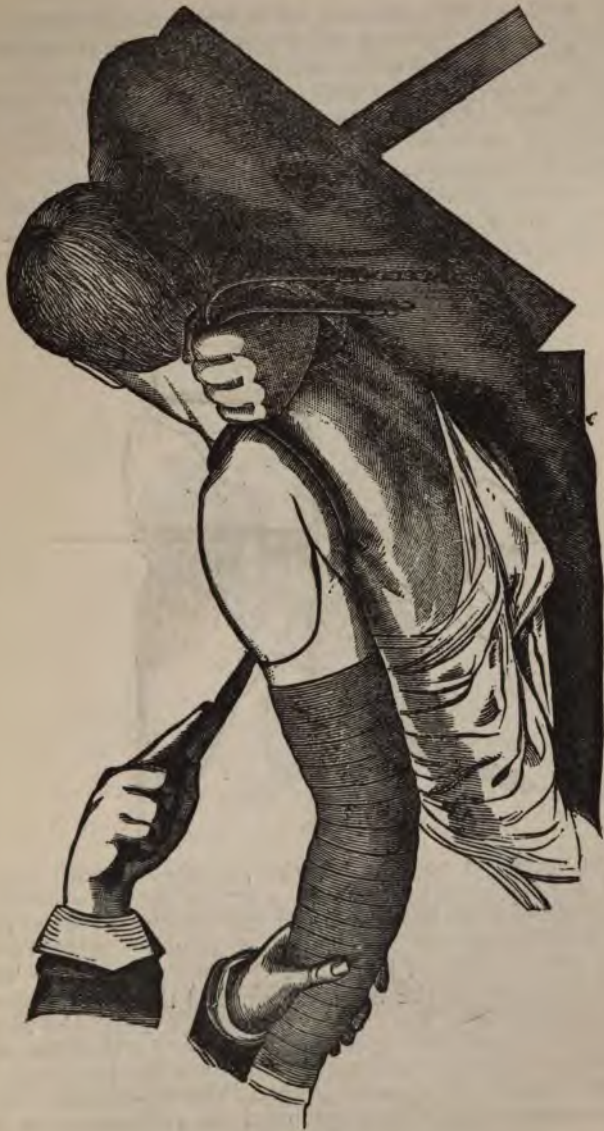

FIG. 324.

joint. It is hardly necessary to enter into the details of more than two or three of those commonly recognized and employed. The remainder, while ingenious in many instances, do not present differences of enough practical worth to be introduced into a hand-book of operative surgery.

Amputation by Internal and External Flaps.—Place the patient on the edge of the table, partially upon the healthy side, with the body raised. An external oval flap is made by an incision extending from the coracoid process down-

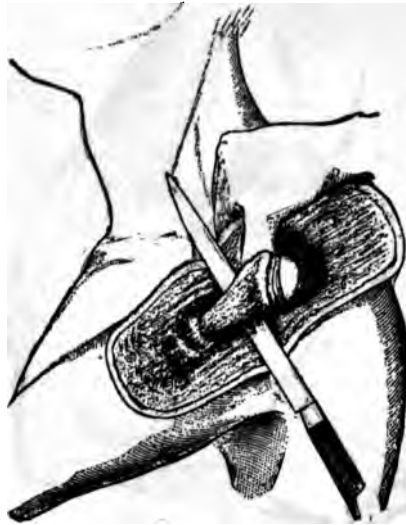

FIG. 325.

ward and outward to the insertion of the deltoid; then upward and backward, terminating at the junction of the acromion process with the spine of the scapula (Fig. 324). The flap including the deltoid muscle is now raised as far as the acromion, turned back, and the capsule of the joint exposed, the head of the humerus pushed upward, capsule divided above; then the arm is rotated outward and the subscapularis severed, followed by the rapid division of the external rotators attached to the greater tuberosity. While the arm is rotated internally, the capsule is still further divided, along with the tendon of the long head

of the biceps, the head of the humerus tilted outward, and the blade of the knife passed beneath it (Fig. 325), the head of the humerus seized and drawn outward, and the knife carried along its inner surface until within about four inches below the axillary fold, when its edge is turned inward and the flap completed. The last sweep of the knife severs the principal vessels, and this flap should be seized by an assistant and tightly grasped before it is completed. The vessels in this operation are controlled by either pressure upon the third portion of the subclavian, or by the elas-

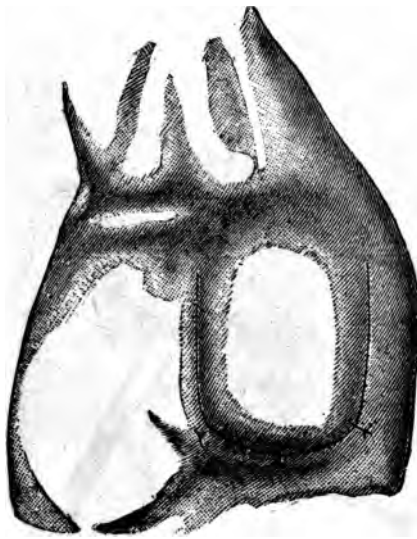


FIG. 326.

tic band arranged as shown in the illustration. The appearance of the wound after the operation is shown in Fig. 326.

Amputation by Circular Incision.—Control the circulation as before. Abduct the arm and make a circular incision entirely around it through all the tissues, down to the bone, at a point corresponding to the insertion of the deltoid. Saw off the bone and ligature the vessels. Make a second incision longitudinally, from the anterior border of the acromion, the whole length of the stump, down to the bone. The bone is then held firmly and the soft parts separated

near the middle of the vertical cut, one on the anterior and the other on the posterior aspect of the limb; which, when carried through the structures composing the anterior and posterior walls of the axilla, to the lower border of each, divides their attachments to the humerus (Fig. 329). The soft parts on the inner side of the humerus still remain undivided. The lips of the wound are now drawn apart,

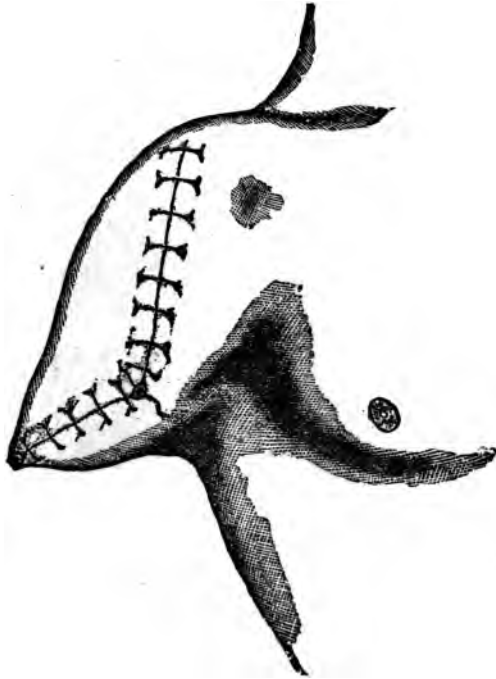

FIG. 328.

the joint exposed and opened above; the bone drawn downward to separate the joint surfaces, and the blade of the knife passed between them, behind the luxated bone, and the operation completed by cutting the remaining tissues at the inner side of the humerus intervening between the lower extremities of the incisions previously made (Fig. 330).

Spence's Method has attracted some considerable attention, and is certainly entitled to additional consideration.

It does not possess any advantages over the method by single circular incision. It is done in the following man-

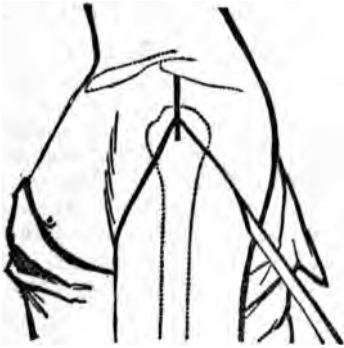

FIG. 329.

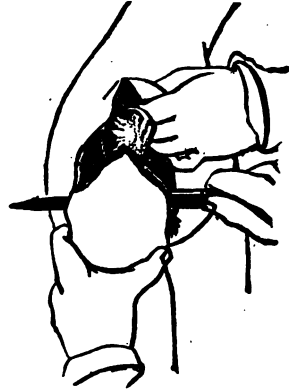


FIG. 330.

ner: Abduct the arm slightly; rotate the humerus outward; cut down upon the head, beginning immediately external to the coracoid process, thence directly downward through the fibres of the deltoid and pectoralis major

to the lower border of the latter, which is divided; carry the incision with a gentle curve across and through the lower fibres of the deltoid, to, but not through, the posterior border of the axilla (Fig. 331). Begin the inner incision at the lower extremity of the vertical one, carry it around the inner side of the arm, through the skin and fat only, to meet the one made at the outer side. If the fibres of the deltoid have been thoroughly divided, the flap, together with the posterior circumflex artery can be easily separated by the finger, from the bone and joint, drawn upward and backward until the head of the bone is exposed; when the

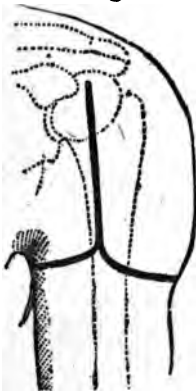

FIG. 331.

ligaments and muscular attachments are divided, and

disarticulation accomplished, the remaining soft parts at the axillary aspect are divided.

In very muscular subjects, a redundancy of that tissue in the flap can be avoided by dissecting upward, a short distance, the integument and subcutaneous tissues over the deltoid, and dividing its fibres high up.

The rate of mortality varies from 37 to nearly 50 per cent.

Amputation above the Shoulder Joint.—It may become necessary on account of malignant growths to amputate the scapula along with a portion or the whole of the clavicle.

The operation is often tedious and attended with great loss of blood. Inasmuch as the situation of the disease or injury calling for it will modify the location and direction of the incisions, no definite plan can be prescribed. However, the aim should be to always save enough healthy integument to cover the wound and to avoid hemorrhage.

Fifty-one cases are reported, with a mortality of 25.5 per cent.

Amputation of the Forearm.—The forearm is best amputated by the circular flap method; although the equilateral skin flap and musculo-cutaneous are often employed.

Circular Amputation.—Carefully lay out the length of the proposed flap, based on a fourth of the circumference. Divide the tissues down to the fascia surrounding the muscles by a circular incision; the integumentary *cuff* is then dissected upward by repeated incisions directed towards the fascia surrounding the muscles (see Fig. 26).

If the cuff be too small to turn up readily, its most dependent part, when dressed, can be slit up. After the flap is



FIG. 315.



FIG. 314.

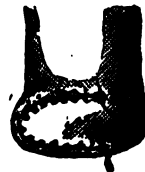

FIG. 316.

reflected sufficiently, the muscles are divided a half an inch or so below the line of its reflection by a circular sweep of the knife down to the bone, the bone sawn off, and the wound dressed in the usual manner. The interosseous membrane and its vessels should be divided a short distance below the point of proposed bone section and its borders be separated from those of the contiguous bones up to where they are to be sawn. This avoids the risk of cutting the vessels too short, as when they are divided at a level with the bones which permits them to retract above the point of easy access. These remarks apply with equal force to amputation of the leg.

The equilateral skin flaps are raised from the anterior and posterior or internal and external surfaces; the latter being by far the most frequently adopted. The length is determined in the same manner as in the circular; in fact, if the circular be first done, and its angles cut off down to near the site of the muscular section, the lateral flaps will be formed. It is better, however, to mark out their outlines before beginning them; since, to make each with the same curve and same breadth of base is not an easy

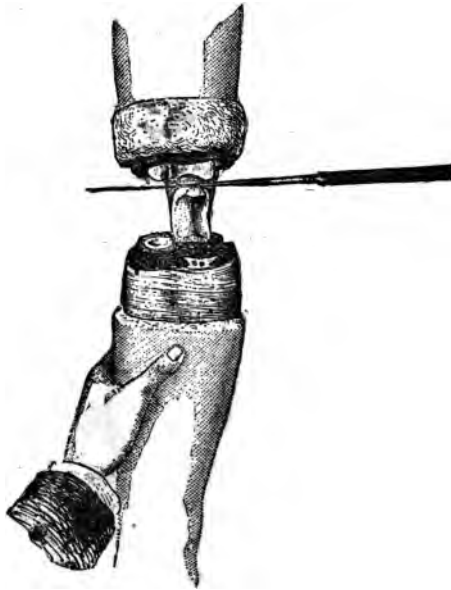


FIG. 317.

task without this precaution. The remaining procedures are the same as those of the circular method.

Musculo-cutaneous flaps are made by transfixion and cutting outward; in other respects the steps do not differ from the preceding operation. The rate of mortality in amputation of the forearm is about 21 per cent for all causes.

Amputation at the Elbow Joint (Disarticulation).—The methods commonly employed are the circular and the single flap ones. Before operating carefully define the most prominent

portions of the condyles. Just below the outer, is felt the movable head of the radius; about an inch below the inner, the ulna joins the inner condyle; the articulation is therefore oblique; the inner portion being about a half an inch the lower, owing to the inner condyle being that much longer than the outer.

Circular Method.—Lay out the flaps in the usual manner, measuring around the condyles. Divide the superficial tissues down to the fascia surrounding the muscles, as before; dissect the flap upward to a level with the joint, the bone indications to which should be carefully determined. For-



FIG. 318.

cibly extend the arm and make an incision on the line of the articulation (oblique) down to and into it; sever the internal and external lateral ligaments, and press the arm still further backward, and draw the olecranon process forward into the wound, and sever its connection to the triceps (Fig. 317). Unite the borders of the flap as indicated in the figure (Fig. 318). The flaps can also be united from before backward; this causes the cicatrix to fall *between* the condyles, and likewise increases the drainage facilities—two very important indications.

The single flap method can be made either of integument

and subcutaneous tissue alone, or be musculo-cutaneous; and formed by transfixion. In either instance it should be taken from the anterior surface of the forearm. If by transfixion (Fig. 319) supinate and flex the forearm slightly; raise the soft parts in front of the joint, and enter the knife an inch below the internal condyle, pass it in front of the bones obliquely outward, causing it to escape about one and one half inches below the outer condyle. Cut the anterior flap downward and outward, making it about three and one half inches in length; dissect and draw the flap up to a level with the joint in front. Make the posterior flap by connecting the extremities of the first incision by a transverse one (Fig. 320), and dissect this up, after

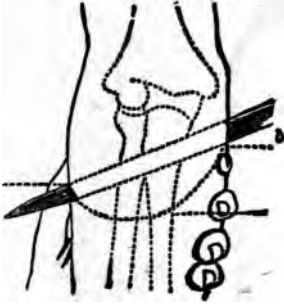


FIG. 319.

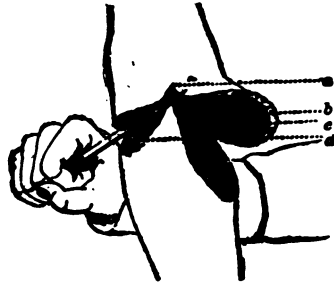


FIG. 320.

which the joint is opened from in front; the lateral ligaments divided, olecranon process displaced forward, and the triceps cut off. It is advisable, when possible, to saw off the olecranon, allowing it to remain with the triceps attached. The stump will be stronger if it be possible to sever the ulna below the insertion of the brachialis anticus, allowing the fragment to remain along with its muscular attachments. In amputations near the elbow, the tubercle of the radius, along with the biceps tendon inserted into it, should be carefully preserved. The deaths from this amputation vary from 17 to 30 per cent. In the latter rate, the operation was done for gunshot injuries.

Amputation of the Arm.—Either the circular, double flap, or the single circular incision method can be employed. The former is usually preferred. In the second the flap

may be anterior, posterior, or lateral; integumentary alone, or combined with muscular tissue. The single circular operation is seldom employed.

Circular Flap.—Plan the length of the flap upon the cir-

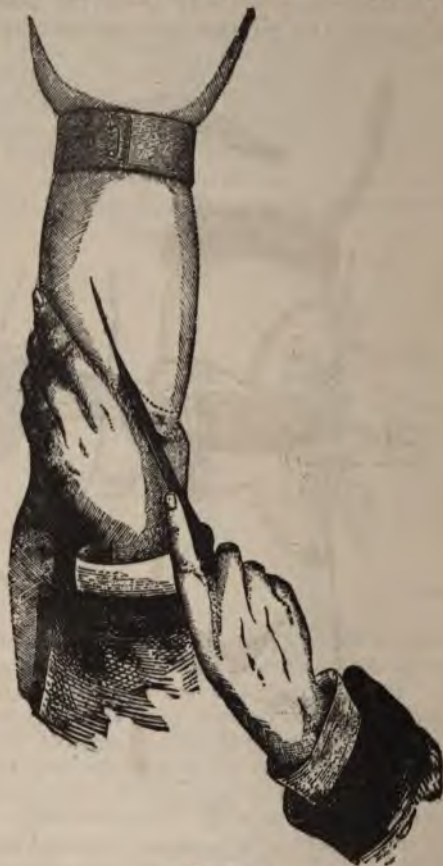

FIG. 321.

cumference of the limb at the point of proposed section. Divide the superficial tissues down to the muscular fascia, and turn the flap up as elsewhere; then divide the muscles *down to the bone*, about one inch below the reflection of

the flaps. Apply the two tailed retractor, saw off the bone, and unite the flaps in the direction best calculated to provide dependent drainage.

Double Flap Method.—If skin alone be used the flaps should be carefully mapped out upon the integument of the arm, in the general manner before described. Dissect

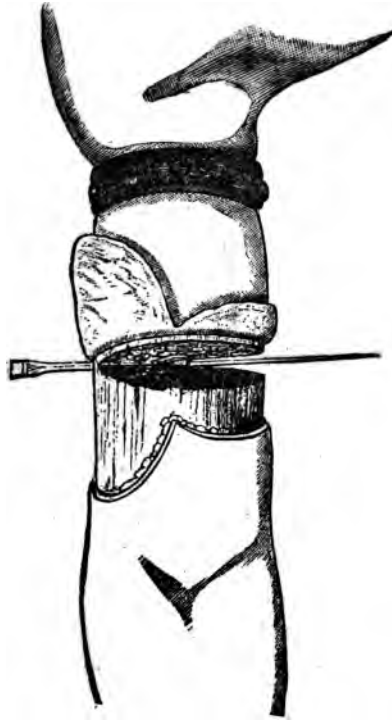


FIG. 322

them up and make a circular section of the muscles down to the bone; unite the flaps, and dress the stump as before.

If *musculo-cutaneous flap* (Langenbeck) be desired, they can be made from within outward by transfixion, or from without inward, with a scalpel. The latter plan secures the more uniformity of outline in the flap. If they are to be made from without inward, first mark them out carefully,

